

A guide to the dissection of the dog / by O. Charnock Bradley.

Contributors

Bradley, O. Charnock 1871-1937.

Publication/Creation

Edinburgh : W. Green, 1919.

Persistent URL

<https://wellcomecollection.org/works/geshndy3>

License and attribution

Conditions of use: it is possible this item is protected by copyright and/or related rights. You are free to use this item in any way that is permitted by the copyright and related rights legislation that applies to your use. For other uses you need to obtain permission from the rights-holder(s).



Wellcome Collection
183 Euston Road
London NW1 2BE UK
T +44 (0)20 7611 8722
E library@wellcomecollection.org
<https://wellcomecollection.org>

IED



22500545602

Med
K51537

UN

Tl
 wl

$\overline{\hat{z}}$

\hat{u}

A GUIDE
TO THE
DISSECTION OF THE DOG

A GUIDE
TO THE
DISSECTION OF THE DOG

BY
O. CHARNOCK BRADLEY

M.D., D.Sc., F.R.S.E., M.R.C.V.S.

PRINCIPAL OF THE ROYAL (DICK) VETERINARY COLLEGE, EDINBURGH ; LECTURER
ON COMPARATIVE ANATOMY, UNIVERSITY OF EDINBURGH

WITH 69 ILLUSTRATIONS



EDINBURGH AND LONDON
W. GREEN & SON, LIMITED
PUBLISHERS

1919

All rights reserved

20556732

WELLCOME INSTITUTE LIBRARY	
Coll.	WelMOMec
Coll.	
No.	V

27191

PREFACE

DURING recent years the feeling that there was room for a book in English dealing with the anatomy of the dog has been steadily gaining ground. Doubtless, in the opinion of many, the gap can be adequately filled only by a systematic treatise similar to the classic 'Anatomie des Hundes' of Ellenberger and Baum. Until some such work makes its appearance, perhaps the present publication may serve as a temporary means of supplying the deficiency.

For several reasons it was decided to introduce the subject of canine anatomy to the English reader in the form of short notes planned to aid him in his desire to obtain first-hand knowledge by dissection. Herein are given directions which experience has shown will help the student to display the various organs and structures in an orderly and profitable manner. The descriptions which follow are purposely given in the briefest possible form, in order that the dissection of the whole animal may be accomplished within a reasonable length of time.


While primarily intended for the guidance of the student who proposes to join the ranks of a profession which already contains a fair number of specialists whose work necessitates a close knowledge of the anatomy of the dog, it is hoped that these notes may be of some service to the student of comparative anatomy who wishes to gain an acquaintance with the structure of an easily obtained mammal.

The nomenclature herein employed is that which may be called the Baden and Stuttgart modification of the B.N.A. of the human anatomist; and, if not perfect, is infinitely better than the nondescript nomenclature, crowded with synonyms, formerly found in works on comparative anatomy.

My thanks are due to my colleague, Mr. W. M. Mitchell, M.R.C.V.S., for assistance in many directions; and to the publishers for the cordial manner in which they have met my suggestions.

O. CHARNOCK BRADLEY.

EDINBURGH : *June* 1912



Digitized by the Internet Archive
in 2017 with funding from
Wellcome Library

<https://archive.org/details/b29820054>

COLOURED ILLUSTRATIONS IN TEXT

FIG.	PAGE
1. Dissection of the Pectoral Region	3
8. Diagram of the Cranial Mesenteric Artery	26
13. Cœliac Artery	39
14. Portal Vein	41
16. Medial Surface of the Right Lung	43
18. Medial Surface of the Left Lung	45
23. Diagram of the Thoracic Duct	60
24. Diagram of Part of the Sympathetic Nervous System	61
28. Diagram of the Urinary Organs of the Male	69
29. Superficial Dissection of the Inside of the Thigh	76
30. Dissection of the Inside of the Thigh	78
31. Superficial Dissection of the Gluteal Region and Thigh	81
32. Dissection of Gluteal Region and Lateral Aspect of the Thigh	84
33. Deep Dissection of the Gluteal Region	87
34. Diagram of the Arteries on the Dorsum of the Pes	88
35. Diagram of the Nerves on the Dorsum of the Pes	90
36. Dissection of the Lateral Aspect of the Leg	91
37. Dissection of Origin of Tibial and Common Peroneal Nerves	93
38. Dissection of the Medial Aspect of the Leg	95
39. Superficial Dissection of the Sole	98
40. Diagram of the Plantar Nerves of the Pes	100
41. Diagram of the Plantar Arteries of the Pes	101
42. Diagram of the External Iliac and Hypogastric Arteries	111
44. Superficial Dissection of the Shoulder and Neck	117
45. Dissection of the Shoulder	119
46. Dissection of the Medial Aspect of the Shoulder, Arm, and Forearm	121
47. Dissection of the Lateral Aspect of the Shoulder, Arm, and Forearm	125
48. Dissection of the Arm	127
49. Dissection of the Medial Aspect of the Forearm	131
51. Diagram of Nerves on the Dorsum of the Manus	133
52. Diagram of Nerves on the Volar Aspect of the Manus	138
53. Diagram of the Arteries on the Dorsum of the Manus	139
54. Diagram of the Volar Arteries of the Manus	140
55. Dissection of the Side of the Neck and Thorax	147

FIG.		PAGE
56.	Superficial Dissection of the Face	157
57.	Dissection of the Tongue, Pharynx, etc.	162
58.	Dissection of the Larynx	177
59.	Dissection of the Larynx	178
60.	Dissection of the Orbit	185
61.	Dissection of the Orbit	186
64.	Arteries at the Base of the Brain	208

BLACK AND WHITE ILLUSTRATIONS IN TEXT

2.	Diagram of the Brachial Plexus	9
3.	Position of the Abdominal Viscera	16
4.	Extent of the Abdominal Muscles	17
5.	Transverse Section of the Abdomen	20
6.	Transverse Section through the Abdomen	21
7.	Transverse Section of the Abdomen	22
9.	Transverse Section of the Thorax	32
10.	Transverse Section of the Thorax	33
11.	Outline of the Spleen	36
12.	Outline of the Stomach	37
15.	Lateral Surface of the Right Lung	42
17.	Lateral Surface of the Left Lung	44
19.	Diaphragmatic Surface of the Lungs	46
20.	Outline of the Heart as seen from the Left	49
21.	Outline of the Heart as seen from the Right	50
22.	Diagram of the Branches of the Bronchi	58
25.	Outline of the Diaphragmatic Surface of the Liver	63
26.	Outline of the Visceral Surface of the Liver	64
27.	Diagram of the Gall-bladder and its Associated Ducts	65
43.	Plexus of Lumbar and Sacral Nerves	113
50.	Tendons on the Dorsum of the Manus	132
62.	Transverse Section of the Spinal Cord	204
63.	Transverse Sections of the Spinal Cord at Different Levels	204
65.	Lateral Surface of the Cerebral Hemisphere	212
66.	Dorsal View of the Cerebral Hemisphere	213
67.	Medial Surface of the Cerebral Hemisphere	214
68.	Dissection to show the Floor of the Lateral Ventricle	216
69.	Lateral Aspect of Hind-brain and Mid-brain	220

DISSECTION OF THE DOG

THE dissection of the dog is best begun with the animal lying on its back. If the subject is a female, the mammary glands should be examined as far as possible before any dissection is carried out.

MAMMÆ.—The mammary glands of the dog are eight to ten in number, arranged in a double row—often asymmetrical—along the ventral aspect of the thorax and abdomen. When ten glands are present, they can generally be designated as four thoracic, four abdominal, and two pubic.

Though nipples are present in both sexes, mammary glands, as such, are seldom demonstrable in the male. Even in the female, except during the period of lactation, the mammæ do not generally form very distinct projections.

Each *nipple* (*papilla mammæ*) is conical in form, covered with hairless skin, and pierced at its apex by numerous (eight to twelve) openings. Each small orifice leads to a *milk canal* (*ductus lactiferus*), which traverses the length of the teat from a *milk sinus* (*sinus lactiferus*) at its base.

Dissection.—Make a longitudinal incision along the mid-ventral line from the middle of the neck to near the external genital parts, and a transverse incision from the medial aspect of one elbow to a corresponding point on the opposite limb. Two short and two long flaps of skin should now be reflected. In doing this, be careful to avoid removal of the mammary glands. On arriving at the base of the nipple, make a circular cut through the skin so as to leave the teat uninjured and attached to its gland. In turning outwards the flaps in the neck, avoid removal of the cutaneous muscle which here forms a thin layer of transverse fibres.

If the mammary glands are not active the gland-tissue will be scanty and form merely a thin layer under the skin. Generally the thoracic glands are separate from each other, while those over the abdomen are continuous. The character of the glands is much more obvious during lactation, when they form a continuous, lobulated sheet stretching from the oral border of the pectoral muscles to the neighbourhood of the external genital parts.

Dissection.—Remove the thoracic mammary glands and define the pectoral muscles. Then proceed with the dissection as in the male.

Dissection of the Male.—If the subject be a male, make an incision along the mid-ventral line from the middle of the neck to the prepuce. Then make a transverse incision from the medial aspect of one elbow to a similar point on the opposite limb. Turn back four flaps of skin. In doing so, an extensive but thin subcutaneous muscular sheet—*m. cutaneus*—will be exposed in the neck, where its fibres are transverse, and over the abdomen, where they are oblique.

Define the pectoral muscles.

In clearing the fascia from the pectoral muscles note small vessels and nerves (about six), which appear close to the mid-ventral line and proceed laterally over the surface of the muscles. These vessels are the perforating branches of the internal mammary artery. In the xiphoid region an artery and vein (branches of the cranial epigastric vessels) appear from under the border of the deep pectoral muscle, and run obliquely in caudo-lateral direction to supply the mammary region. These are larger in the female.

M. PECTORALIS SUPERFICIALIS.—In the main the fibres of the superficial pectoral muscle run transversely to the long axis of the body. The origin of the muscle is from the first two segments of the sternum and from the septum between it and its fellow muscle, and its insertion—hidden as yet by the brachio-cephalic muscle—is to the line on the humerus running distalwards from the tuberculum majus.

Crossing the superficial pectoral muscle close to its insertion, and lying in a narrow space bounded by this and the brachio-cephalic muscle, are two vessels: namely, a communicating branch from the cephalic vein to the external jugular vein, and the deltoid ramus of the thoraco-acromial artery.

Dissection.—Reflect the superficial pectoral muscle by cutting across it close to its origin, and notice in doing so that the muscle increases in thickness towards its cranial border. Clean the surface of the deep pectoral muscle and dissect out the various structures lying in a triangular space at the root of the neck. In reflecting the superficial muscle observe its nerve of supply (from the brachial plexus) bending round the cranial border of the deep pectoral muscle, accompanied by the pectoral ramus of the thoraco-acromial artery and its satellite vein.

M. PECTORALIS PROFUNDUS.—The deep pectoral muscle is much more extensive than the superficial member of the same group. Consequently, a considerable extent of it is visible before the superficial muscle is reflected. Its fibres are disposed with a varying degree of obliquity. The most caudal fibres are the most oblique. The caudal border of the muscle is rendered somewhat indefinite from the presence of a narrow band sometimes isolated, and always separable, from the rest.

The origin of the muscle is from the sternum from the level of the second costal cartilage to the xiphoid process. Its insertion is into the medial tubercle (tuberculum minus) of the humerus, and, by means of a thin tendon which crosses the origin of the biceps, to the lateral tubercle (tuberculum majus)

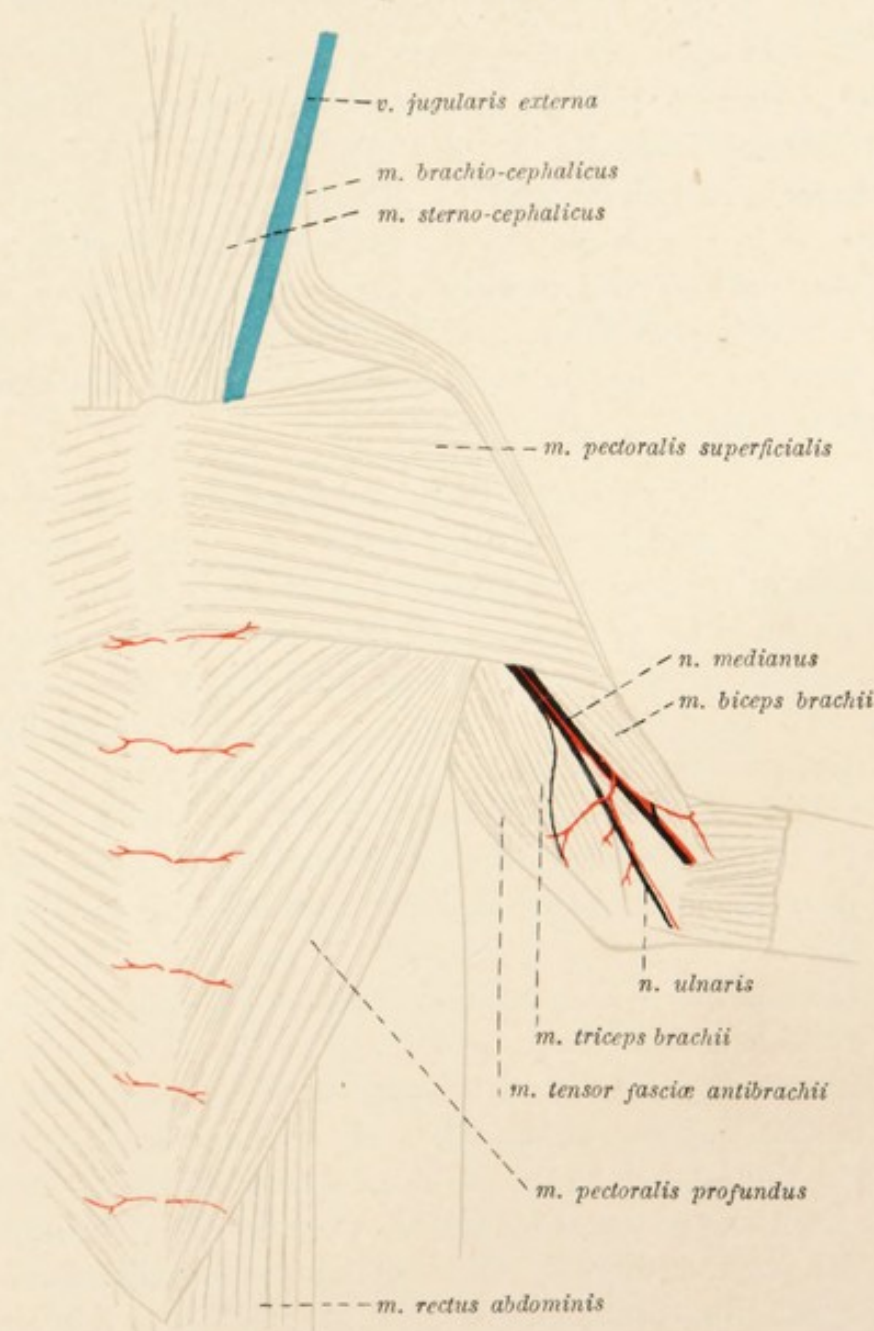


FIG. 1.—Dissection of the pectoral region.

also. The most caudal fibres of the muscle are connected with the cutaneous muscle of the abdomen.

At the root of the neck is a triangular space of some moment on account of the structures contained therein. The lateral limit of the space is formed by the brachio-cephalic muscle. Medially the sterno-cephalic muscle forms its boundary; while its base—caudal in position—lies at the edge of the pectoral muscles.

Within the space will be found the external jugular vein, the communicating branch from the cephalic vein, the omo-cervical arterial and venous trunks, and the nerves to the superficial pectoral and brachio-cephalic muscles. In the depths of the triangle is part of the brachial plexus of nerves.

All these structures will be more fully exposed during the dissection of the axillary space.

Dissection.—Reflect the deep pectoral muscle by cutting through it a short distance from its origin. This exposes the axillary space, the structures in which should be cleaned with great care. In reflecting the muscle, a lymph-gland (the axillary gland) will be found lying over the distal part of the teres major and between this and the pectoral muscle. Branches from the brachial plexus of nerves should also be noted bending round the axillary vessels to sink into and supply the deep pectoral muscle.

AXILLA.—The axillary space is bounded laterally by the scapula and the subscapular muscle, and medially by the chest-wall and the muscles clothing it. In the natural condition the space can scarcely be said to exist except as a narrow chink filled by areolar and fatty tissue; but on dissection its medial and lateral walls are separated from each other and a definite space is produced. Dorsally the two walls meet at a very acute angle; ventrally, however, they diverge slightly, and the floor of the space is defined by the pectoral muscles. Cranially the axillary space communicates with the neck; whereas caudally it is closed in by the latissimus dorsi and cutaneous muscles. The principal contents of the space are the axillary vessels and the brachial plexus of nerves.

V. ET A. AXILLARIS.—The axillary vessels are among the structures first exposed on reflecting the deep pectoral muscle. The vein drains the blood from the limb, and joins the external jugular vein at the entrance to the chest, thus constituting one of the roots of the innominate vein. Its collateral tributaries are the lateral thoracic, subscapular and omo-cervical veins, and small vessels from the pectoral muscles. Occasionally the omo-cervical venous trunk joins the jugular direct. Of the tributaries the subscapular vein is by far the largest, its volume depending mainly upon the circumstance that it continues the cephalic vein.

The axillary artery is a continuation of the subclavian artery. Commencing on a level with the first rib, it runs down the limb as far as the tendon of insertion of the teres major muscle. Most of its branches will be examined in connection with the scapular and arm regions, but two should now be noted as supplying the pectoral muscles and their neighbourhood. These are the thoraco-acromial and lateral thoracic arteries.

A. THORACO-ACROMIALIS.—The thoraco-acromial artery soon divides into two branches, a *ramus deltoideus* and a *ramus pectoralis*. Both of these have

been already noted in connection with the dissection of the pectoral muscles. Very commonly the deltoid ramus arises from the omo-cervical trunk.

A. THORACALIS LATERALIS.—The lateral thoracic artery arises some little distance from the border of the first rib, supplies the pectoral muscles, runs along the deep face of the deep pectoral muscle in company with the nerve to the latissimus dorsi, and ends in the cutaneous muscle over the abdomen.

TRUNCUS OMO-CERVICALIS.—The omo-cervical trunk is a branch of the subclavian artery. Arising within the first rib, it passes medial to the axillary artery and the brachial plexus to divide before long into the ascending cervical and transverse scapular arteries.

The *ascending cervical artery* (a. cervicalis ascendens) runs for a distance on the medial surface of the brachio-cephalic muscle, and finally enters the substance of this muscle.

The *transverse scapular artery* (a. transversa scapulæ) passes towards the cranial border of the subscapular muscle and divides into several branches, the main one of which accompanies the suprascapular nerve.

N. PHRENICUS.—The phrenic nerve will be found between the axillary vein and artery dorsal to the omo-cervical arterial trunk. It arises by three roots from the ventral divisions of the fifth, sixth, and seventh cervical nerves, and leaves the present dissection by entering the thorax. Later, it will be traced to the diaphragm to which it carries motor impulses.

Dissection.—Cut across the axillary vessels, close to the first rib. This allows of a more complete inspection of the brachial plexus.

PLEXUS BRACHIALIS.—The brachial plexus is a somewhat complex arrangement of nerves formed by branches from the last three cervical and the first two thoracic nerves. It is placed between the axillary vessels and the scalenus muscles.

Its branches are : *Nerve to the brachio-cephalic muscle, n. suprascapularis, n. subscapularis, n. musculo-cutaneus, n. axillaris, n. radialis, n. medianus, n. ulnaris, n. thoraco-dorsalis, nn. thoracales ventrales, and n. thoracalis longus.*

Most of these will be examined in the dissection of the limb ; but the following points should be noted at the present moment. The ventral thoracic nerves (nn. thoracales ventrales) are mainly distributed to the pectoral muscles. One of them supplies the skin and cutaneous muscle on the side of the chest and abdomen. The thoraco-dorsal nerve (n. thoraco-dorsalis) supplies the latissimus dorsi muscle.

If the subject is a male the external genital organs should next be dissected.

PARTES GENITALES EXTERNÆ.—The male external genital parts consist of the scrotum, the penis, and the prepuce.

The *scrotum* is a membranous bag with a double cavity in which the testes

are lodged. It lies between the thighs, and forms a rounded prominence crossed in a cranio-caudal direction (generally obliquely) by a shallow groove in which a faint line, the *raphe scroti*, may be detected. The skin of the scrotum is thin and provided with comparatively few hairs.

Dissection.—Make an incision through the skin along the raphe of the scrotum, and expose the underlying tissues.

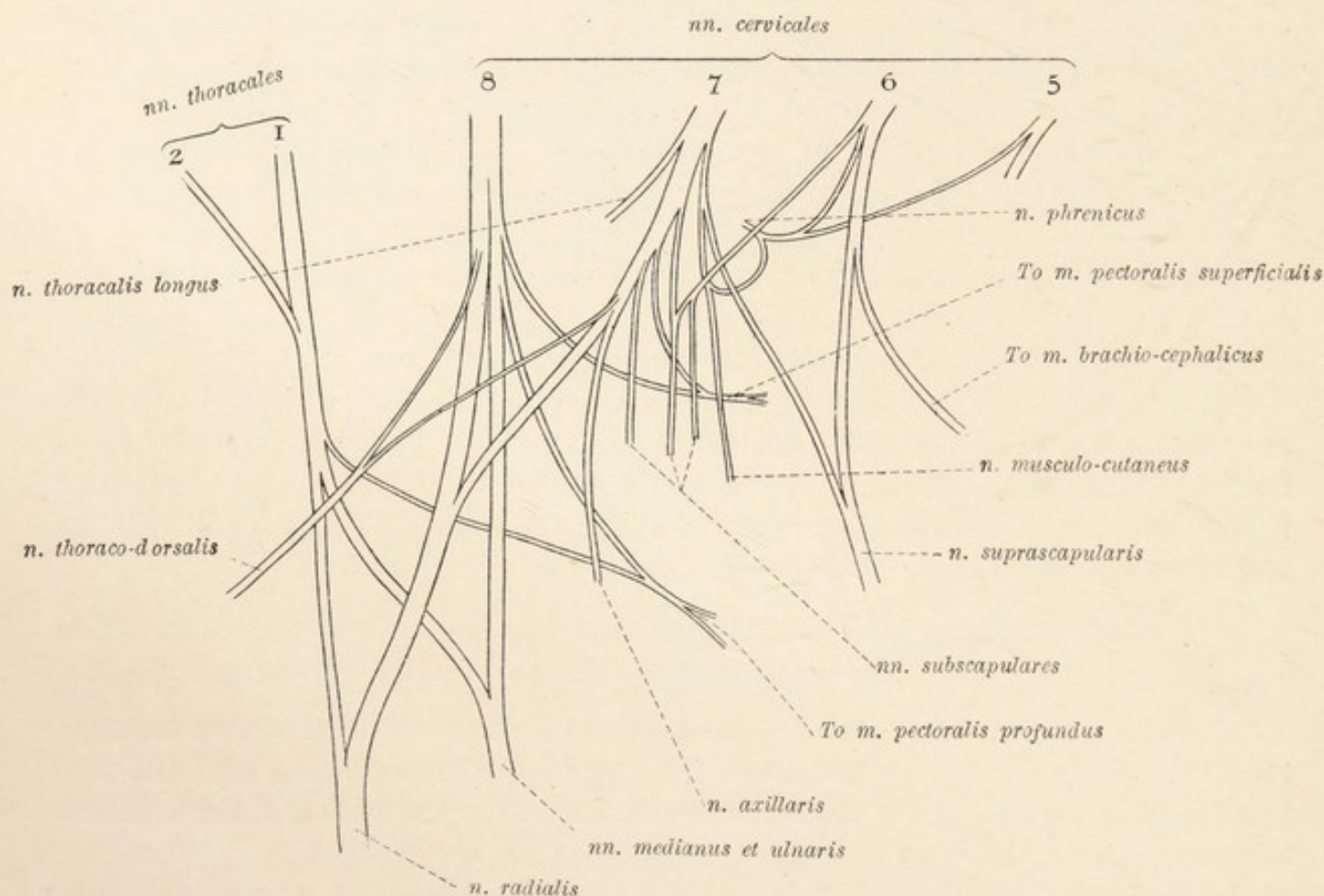


FIG. 2.—Diagram of the brachial plexus.

The wall of the scrotum can be resolved into three layers. Of these the most superficial consists of skin. Under this is a fibrous tissue known as the *tunica dartos*, which, with its fellow of the other side, forms the median septum between the two scrotal cavities—the *septum scroti*.

Removal of the dartos exposes the third layer composed of a fascial tunic lined within by a serous membrane. The fascia is continuous with that covering the deep face of the transverse abdominal muscle, and is in the form of a pear-shaped sac the narrow end of which is connected with the superficial end of the inguinal canal. Along the dorsal side of the narrower part of the sac there is a muscular slip, the *external cremaster muscle* (*m. cremaster externus*), associated with the internal oblique muscle of the abdominal wall, on the one hand, and terminating, on the other hand, in an aponeurosis within the substance of the wall of the scrotum.

TUNICA VAGINALIS.—The tunica vaginalis is a serous membrane continuous, through the inguinal canal, with the peritoneum. Like other serous membranes it is composed of a parietal and a visceral part. The parietal portion lines the interior of the scrotum and is continuous with the visceral part in the caudo-dorsal region of the scrotal cavity. The visceral part of the tunic will be displayed after an examination of the testis and its surroundings has been made.

Dissection.—Cut through the parietal tunica vaginalis with a pair of scissors, and examine the contents of the cavity of the scrotum.

TESTIS ET EPIDIDYMISS.—The testes are two oval organs, slightly flattened laterally (especially on the medial surface), each lodged in its own compartment of the scrotum. The long axis of each testis is oblique, and runs caudo-ventral. The two surfaces, medial and lateral, are smooth and convex, as is also the ventral border. The dorsal border and the two extremities are connected with the epididymis.

The epididymis of the dog is relatively large. It consists of an elongated, laterally compressed mass formed by the tortuous windings of a long tube held together by dense connective tissue and covered by the tunica vaginalis. The *body* (corpus epididymidis), or main part of the structure, lies dorsal to the testis. The cranial and caudal ends, known respectively as the *head* (caput epididymidis) and the *tail* (cauda epididymidis), are adherent to the extremities of the testis. The cauda is also firmly bound to the wall of the scrotum. From the cauda the *ductus deferens* takes origin. The duct runs cranialwards dorso-medial to the testis, at first somewhat convoluted but afterwards straighter, and passes into the inguinal canal.

FUNICULUS SPERMATICUS.—The spermatic cord consists of the ductus deferens and certain blood vessels, nerves, and lymphatics. The vein within the cord is richly coiled and forms a prominent object, extending from the head of the epididymis into the inguinal canal. Partly buried within the venous mass is the internal spermatic artery (a. spermatica interna).

The visceral part of the tunica vaginalis may now be followed. It is applied closely to the testis and epididymis, and dips in between these two organs to form a cavity, the *sinus epididymidis*, the entrance to which is lateral in position. Continued towards the inguinal canal, the tunic encloses the spermatic cord, from which and from the epididymis it is reflected as a mesentery containing fine nerve filaments. It will be observed that the deferent duct and the external spermatic artery are enclosed in a special sheath of the tunic which is an offset from the covering of the other constituents of the spermatic cord.

PRÆPUTIUM.—The prepuce is a tubular sheath of integument enclosing the glans of the penis, and, in the retracted state of this organ, circumscribing a cavity which communicates with the surface by a slit-like orifice. The prepuce

consists of two layers : a double parietal layer, and a visceral layer intimately adherent to the glans penis. The superficial sheet of the parietal layer is composed of skin differing little from that of the neighbourhood. This should be reflected by making a longitudinal incision from the preputial orifice to the scrotum. Care must be taken to preserve the preputial muscle (*m. præputialis*) which, as a flattened band, springs from the abdominal aponeurosis in the xiphoid region, and runs immediately under the skin to form a loop round the orifice of the prepuce.

If the deep sheet of the parietal layer be now slit open with a pair of scissors, its resemblance to mucous membrane will be manifest. The surface looking towards the penis is longitudinally folded and studded with irregular rows of flattened, rounded elevations caused by masses of lymphoid tissue. The membrane is directly continuous with the visceral layer of the prepuce, which extends over the glans penis to the urethral orifice where it meets the urethral mucous membrane.

It should now be noted that the prepuce is supplied with blood by the external pudendal artery.

Dissection.—The penis should now be freed from its surroundings as far as its root. In cleaning the organ, note the presence of a narrow, pale muscle, the retractor of the penis, running along its urethral surface from the anus to the vicinity of the glans. Preserve also the dorsal vessels and nerves which will be found on the opposite surface.

PENIS.—The penis consists of a middle part (its *body* or *corpus penis*), a *root* (*radix penis*) attached to the arch formed by the two ischial bones, and a free extremity (*glans penis*) of considerable length.

The term *dorsum penis* is applied to that aspect of the organ which is in contact with the abdominal wall ; whereas the opposite aspect is called the *urethral surface* (*facies urethralis*).

The body of the penis lies in the middle line, dorsal to the testes and crossed laterally by the ductus deferens. It is composed of three bodies running parallel to each other.

The *corpora cavernosa penis* are two rods of erectile tissue surrounded and bound together by a dense fibrous envelope, the *tunica albuginea* [*corporum cavernosorum*], and separated from each other by a fibrous septum (*septum penis*). In the ischial region the two corpora diverge, each forming a *crus penis* which is attached to the border of the ischium. From about the middle of the penis, the corpora are continued onwards as a bone, the *os penis*. This may be considered as formed by two narrow plates joined dorsally and diverging ventrally to enclose a groove in which the urethra lies. The caudal end of the bone is truncated. The cranial end is more pointed, and to it is appended a curved process composed of fibrous tissue of cartilage-like density.

The third erectile body of the penis is the *corpus cavernosum urethræ*,

associated, as its name indicates, with the urethra, and lodged in a groove on the urethral surface of the penis.

The two crura penis, forming the radix penis, are covered by the ischio-cavernous muscles. In the middle line, between the crura, the corpus cavernosum urethræ forms a double expansion, the *bulbus urethræ*, also covered by a muscle, the *M. bulbo-cavernosus*.

The glans penis of the dog is of considerable length. Thinnest about the middle, it expands into a swelling at each end. The caudal expansion known as the *bulbus glandis* is the larger, and is developed on the dorsal side of the os penis. From it the dorsal veins of the penis take origin.

The smaller expansion of the glans forms the free extremity of the penis and is more cylindrical in form than the bulbus glandis. Its terminal part is pointed and has the urethral orifice at its apex. Running along the urethral surface of the glans is a feeble fold of prepuce known as the *frænulum præputii*.

VV. DORSALES PENIS.—The two dorsal veins of the penis arise in the erectile tissue of the bulbus glandis. Running along the dorsum of the penis to its root, they bend round the border of the ischia and form the main roots of the internal pudendal veins.

AA. DORSALES PENIS.—The dorsal arteries of the penis lie lateral to the veins of the same name. Each forms the largest terminal branch of the internal pudendal artery of its own side, and, leaving the pelvis by curving round the border of the ischium, can be readily followed to the glans penis.

NN. DORSALES PENIS.—The dorsal nerves of the penis, branches of the internal pudendal, accompany the dorsal vessels, each nerve lying lateral to the artery which it follows.

Dissection.—Cut through the roots of the brachial plexus and clean up the ventral and lateral aspects of the thorax and abdomen. In doing this, first define the extent and attachments of the cutaneous muscle as far as the present dissection permits. Preserve the branches of the intercostal and lumbar vessels and nerves which appear about midway between the mid-dorsal and mid-ventral lines of the trunk. Observe that the branch from the third or fourth intercostal nerve is of good size and crosses the border of the latissimus dorsi muscle to reach the lateral aspect of the arm. It is connected with a ventral thoracic nerve from the brachial plexus.

In removing the remains of the prepuce of the male, or the mammæ of the female, take care not to destroy the external pudendal vessels and the external spermatic nerve which may be found embedded in an accumulation of fat in the inguinal region. The artery and vein can generally be traced to an anastomosis with branches from the cranial epigastric vessels.

A group of lymph-glands will also be found in the inguinal region. Several vessels and nerves pierce the abdominal wall. Of these the circumflex iliac vessels and the lateral cutaneous femoral nerve are the most conspicuous. They appear close to the angle of the ilium and are distributed in the cutaneous muscle of the abdomen and in the skin over the lateral proximal part of the thigh. A little cranial to the point of appearance of the circumflex iliac vessels, the phrenico-abdominal artery pierces the oblique muscle of the abdomen. Branches of the ilio-inguinal and ilio-hypogastric nerves should also be noted and preserved.

A. PUDENDA EXTERNA.—The external pudendal artery is generally a branch of the deep femoral, but it may arise from a common trunk from which springs the caudal epigastric artery as well. The origin of the vessel cannot be examined at present. Crossing the spermatic cord medially, the artery runs towards the umbilicus and supplies the inguinal lymph-glands, the prepuce, and the surrounding skin. In the female it is larger and furnishes blood to some of the mammary glands.

N. SPERMATICUS EXTERNUS.—The external spermatic nerve is a part of the genito-femoral nerve. Appearing through the abdominal wall along with the external pudendal vessels, it crosses the spermatic cord and is expended in the external genital parts, or the mammary glands, and the skin of the inner part of the thigh. It is sometimes connected with the ilio-inguinal nerve.

M. OBLIQUUS EXTERNUS ABDOMINIS.—The external oblique is the most superficial muscle of the abdominal wall. Its origin is by digitations from the ribs from the fifth or sixth to the last, and from the lumbo-dorsal fascia. The muscular fibres run in a caudo-ventral direction as far as the border of the straight abdominal muscle. Here they give place to an aponeurosis which is attached to the linea alba. An important part of the aponeurosis stretches from the lateral angle of the ilium to the pubis near the symphysis. This constitutes the *inguinal ligament of Poupart* (ligamentum inguinale [Pouparti]), in association with which is the superficial opening of the inguinal canal. Opposite this opening the pectineus muscle takes part of its origin from the inguinal ligament. At the same point a thin reflection of the aponeurosis to take part in the formation of the scrotum should be noticed. Medial to the inguinal canal, i.e. in the pubic region, the aponeurosis is thin and mixed with fibres from the other abdominal muscles.

From the aponeurosis of the oblique muscle a thin, ill-defined sheet is reflected onto the medial aspect of the thigh.

M. LATISSIMUS DORSI.—As its name indicates, this is a very broad muscle covering the dorso-lateral part of the thorax. Its origin is from the lumbo-dorsal fascia, by means of which it is attached to the spinous processes of the last seven thoracic vertebræ, and by fleshy strips from the last two or three ribs. Its insertion is by a flattened tendon into the crista tuberculi minoris of the

humerus. The whole of the muscle cannot be conveniently examined at the present stage of the dissection.

M. TRANSVERSUS COSTARUM.—This is a small, thin, irregularly triangular muscle placed over the union of the bony and cartilaginous segments of the first two or three ribs. Its origin is from the first rib, and its insertion, by means of a thin and not very definitely bounded aponeurosis, is into the sternum from the third to the fifth or sixth costo-sternal joint.

Dissection.—Until such time as the inguinal canal has been examined the abdominal wall should be dissected on one side only. Reflect the external oblique abdominal muscle after making two incisions. The first incision should be longitudinal and through the aponeurotic tendon of the muscle a short distance from the fleshy margin. The second incision must be transverse and through the fleshy part of the muscle about midway between the thigh and the last rib. Now turn the aponeurosis as far towards the middle line as possible. Note that, forming the medial boundary of the superficial opening of the inguinal canal, there is a stout band connected with the origin of the pectineus muscle. This is formed by a blending of the aponeuroses of the two oblique and the transverse abdominal muscles. Immediately cranial to this the external oblique aponeurosis can be reflected to the middle line (linea alba), but as the xiphoid region is approached the reflection becomes less and less complete owing to a fusion with the internal oblique aponeurosis.

M. OBLIQUUS INTERNUS ABDOMINIS.—Many of the fibres of the internal oblique muscle of the abdomen run in a cranio-ventral direction, but towards the region of the groin they become more and more transverse. The margin of the fleshy part of the muscle forms a sinuous curve, the most caudal part of which is superficial to the rectus muscle. The muscle has a dorsal attachment to the lumbo-dorsal fascia, the inguinal ligament, and the last two ribs. Ventrally it is continued as an aponeurosis in which two layers can be demonstrated.

The superficial layer assists the aponeurosis of the external oblique muscle in the formation of the superficial sheath of the rectus muscle, and thus reaches the linea alba. The fibres of the two aponeuroses become interwoven medial to an oblique line stretching from the middle line of the body near the pubis to about the middle of the breadth of the rectus muscle at the costal margin.

The deep layer of the aponeurosis is incomplete and does not exist caudal to the umbilicus. As will be seen later, it blends with the aponeurosis of the transverse muscle of the abdomen to form the deep sheath of the rectus muscle.

Dissection.—Make a longitudinal incision through the superficial sheath of the rectus muscle along a line a few millimetres within the lateral edge of the muscle. The incision should be made with care as the sheath is not very thick. Turn the sheath towards the middle line, and in

doing so observe its firm attachment to the tendinous intersections of the underlying straight muscle. Cut across the fleshy part of the internal oblique muscle in the same manner as was done with the external oblique. Reflect the transverse muscle of the ribs.

M. RECTUS ABDOMINIS.—The fibres of the straight muscle of the abdomen run parallel to the middle line of the body. Generally six tendinous intersections cross the muscle in an irregularly oblique manner. Of these one occurs on a level with the umbilicus; two are caudal, and three are cranial to this point. As has already been seen, the superficial sheath of the muscle is firmly adherent to the intersections.

The cranial attachments of the rectus muscle are by means of a thin aponeurotic tendon (partly covered by the expanded insertion of the m. transversus costarum) from the cartilage of the first rib, and from the sternal end of the cartilages of the ribs from the second to the seventh. In addition fleshy slips leave the sternal ends of the eighth and ninth ribs.

Caudally the muscle is attached to the border of the pubis.

Dissection.—Reflect the straight muscle by a transverse incision about the middle of its length, and thus expose the cranial and caudal epigastric vessels as well as certain intercostal and lumbar nerves and vessels.

A. EPIGASTRICA CAUDALIS.—The caudal epigastric artery either arises independently from the deep femoral artery, or it has an origin in common with the external pudendal. The artery lies on the deep face of the rectus muscle of the abdomen and runs in a cranial direction. It is accompanied by the caudal epigastric vein (v. epigastrica caudalis).

A. ET V. EPIGASTRICA CRANIALIS.—The cranial epigastric vessels appear between the xiphoid process of the sternum and the ninth or tenth costal cartilages; that is, not far from the middle line. They follow a slightly oblique direction on the deep surface of the rectus muscle. Superficial branches, piercing the muscle or crossing its medial border in the xiphoid region, have already been noticed.

NERVES OF THE ABDOMINAL WALL.—Lying deep to the internal oblique and rectus muscles on the one hand, and superficial to the transverse muscle on the other, are branches of the last five thoracic and the first two lumbar nerves.

The last four *intercostal nerves* are derived from the ventral primary divisions of the ninth, tenth, eleventh, and twelfth thoracic nerves. They appear from beneath the costal arch, cross the surface of the transverse muscle, and disappear under the rectus. The *last thoracic nerve* is similarly disposed.

The *ilio-hypogastric* and *ilio-inguinal nerves* arise from the ventral primary divisions of the first two lumbar nerves.

N. ilio-hypogastricus.—The ilio-hypogastric nerve divides into lateral and

medial branches ; the former piercing the two oblique muscles to pass ventralwards on the surface of the external oblique about midway between the last rib and the ilium. The medial branch is disposed between the internal oblique and the transverse muscles in the same manner as are the thoracic nerves.

N. ilio-inguinalis.—The ilio-inguinal nerve has a distribution very similar to that of the ilio-hypogastric.

M. TRANSVERSUS ABDOMINIS.—As the name suggests, the fibres of the transverse muscle of the abdomen run, for the most part, in a direction at right angles to the long axis of the body. Towards the inguinal region, however, the fibres assume a caudo-ventral obliquity. The margin of the fleshy part of the muscle is mainly continued towards the middle line dorsal to the rectus muscle, but about midway between the umbilicus and the pubis the margin of the transverse overlaps the ventral surface of the straight muscle.

The fibres of the transverse muscle arise from the extremities of the transverse processes of the lumbar vertebræ, and from the medial surface of the last four or five ribs and their cartilages.

The aponeurotic tendon which succeeds the fleshy part of the muscle, and by which it finds attachment to the linea alba, is blended with the deep layer of the internal oblique aponeurosis cranial to the umbilicus. Thus it shares in the formation of the deep sheath of the rectus muscle. Caudal to the umbilicus the aponeurosis becomes thin, and, about midway between the umbilicus and the pubis, suddenly changes from the dorsal to the ventral side of the rectus.

VAGINA M. RECTI ABDOMINIS.—The constitution of the sheath of the straight muscle can now be fully determined. The superficial or ventral layer of the sheath is mainly formed by the aponeuroses of the external and internal oblique muscles ; but, in the inguinal region, to these is added the aponeurosis of the transverse muscle. The superficial layer, therefore, is complete and of considerable stoutness. The deep or dorsal layer of the sheath, on the contrary, is incomplete. Where the straight muscle lies over the costal cartilages no sheath interposes. From the region of the xiphoid process to a variable distance from the umbilicus the sheath is formed by the aponeurosis of the transverse muscle and the deeper layer of the aponeurosis of the internal oblique muscle. Caudal to this the transverse aponeurosis alone forms the sheath to a point about midway between the umbilicus and the pubis where, the aponeurosis passing ventral to the rectus, the deep sheath becomes deficient.

Where the sheaths of the two recti muscles meet in the middle line a strong cord is formed. This is known as the *linea alba*, and stretches from the xiphoid process of the sternum to the symphysis pubis. Composed of interlacing and decussating fibres derived from the aponeuroses of the oblique and transverse muscles, it is broadest in the xiphoid region, gradually narrowing towards the pubis. At a point on the linea alba, generally about two-thirds of the distance from the pubis to the xiphoid, is a scar, the *umbilicus*, marking the point of attachment of the umbilical cord of embryonic life.

CANALIS INGUINALIS.—The inguinal canal is a passage through the abdominal wall in which lies the spermatic cord of the male or the round ligament of the female. In the male, moreover, the testis descends into the scrotum by way of the canal. The canal is lined by a tubular connection between the peritoneum of the abdomen and the tunica vaginalis of the scrotum. In direction it is oblique; its superficial extremity (*annulus inguinalis subcutaneus*) being caudal and medial to its deep extremity (*annulus inguinalis abdominalis*).

The canal should be examined on that side of the abdomen where the muscles are yet intact. Introduce a probe or glass rod into the canal, and clean, in the first place, the subcutaneous ring. This is, speaking generally, an oval opening in the aponeurotic tendon of the external oblique muscle of the abdomen. The lateral boundary of the ring is formed by the stout part of the aponeurosis connected with the origin of the pectineus muscle. The medial boundary is formed by the combined aponeuroses of the external and internal oblique and the transverse muscles.

The canal itself has a length of some 30 mm. and crosses the lateral border of the rectus muscle obliquely. Near the subcutaneous ring, it runs along the grooved surface of the inguinal ligament (Poupart's ligament). The canal may be considered as possessing a ventral and a dorsal wall. The ventral wall throughout the whole of its extent is formed by the aponeurosis of the external oblique, and, throughout the greater part of its extent, by the fleshy part of the internal oblique muscle also. Close to the abdominal ring, some fibres of the transverse muscle may assist in the formation of this wall, but more commonly the abdominal ring occurs solely in the fascia of the transverse muscle. The dorsal wall, close to the subcutaneous ring, is formed for a very short distance by the combined oblique and transverse aponeuroses. For the greater part the wall is constituted by the fascia of the transverse muscle covered internally by the peritoneum.

In the female, the inguinal canal contains a funnel-shaped cavity continuous with that of the peritoneum. Outside its serous lining there is a considerable accumulation of fat.

In intimate association with the inguinal canal are the external pudendal and caudal epigastric vessels. The external pudendal artery and vein cross the medial aspect of the spermatic cord at the subcutaneous ring. The caudal epigastric vessels also cross the medial side of the canal, but they do so obliquely and at a variable point in its length. Running for a distance parallel to the inguinal canal, and in its dorsal wall, is the external spermatic nerve.

Dissection.—Open the abdominal cavity by making an incision along the whole length of the linea alba, and a transverse incision on each side through the transverse muscle and the peritoneum. This having been done, a fold of peritoneum will be discovered passing along the linea alba to the urinary bladder. In this fold there is frequently a considerable accumulation of fat.

CAVUM ABDOMINIS.—The bony boundaries of the abdominal cavity are incomplete. Dorsally, the lumbar and sacral vertebræ with their transverse processes are covered by the thick muscles of the back. At the cranial end of the cavity some of the ribs and their cartilages form a girdle round the abdomen, while the pelvic bones serve the same purpose at the caudal end. Otherwise the lateral and ventral walls are formed by soft structures only. The ventral wall, much longer than the dorsal, slopes downwards from the pubes to the xiphoid process of the sternum, the steepness of the slope differing in different breeds.

For descriptive purposes it is necessary to divide the general abdominal cavity into the *pelvic cavity* and the *abdomen proper*. The plane of separation is on a level with the promontory of the sacrum, the ilio-pectineal lines and the cranial border of pubes. It is, therefore, oblique to the long axis of the abdomen proper, inasmuch as it slopes caudalwards from the sacrum to the pubis.

Though of questionable utility, the abdomen proper may be subdivided into nine regions by four imaginary planes—two transverse to the long axis of the body and two parallel to the median plane. One of the transverse planes cuts the abdomen on a level with the most caudal part of the twelfth rib. The second transverse plane is parallel to the first and is taken on a level with the lateral angle of the ilium. Thus the abdomen is divided into three transverse zones which may be named subcostal, umbilical, and hypogastric.

The two longitudinal planes of subdivision are parallel to the median plane of the body and are imagined as occurring on a level with the mid-point of the distance between the lateral angle of the ilium and the symphysis pubis. The longitudinal planes subdivide each transverse zone into three regions as follows :

Subcostal zone.	{ Right hypochondriac region. Epigastric region. Left hypochondriac region.
Umbilical zone.	{ Right lumbar region. Umbilical region. Left lumbar region.
Hypogastric zone.	{ Right iliac region. Hypogastric region. Left iliac region.

CONTENTS OF THE ABDOMEN PROPER.—The organs lodged within the abdomen are numerous and serve widely different physiological purposes. They may be tabulated as follows :

(1) Alimentary organs.	{ Stomach. Small intestine. Large intestine. Liver. Pancreas.
------------------------	---

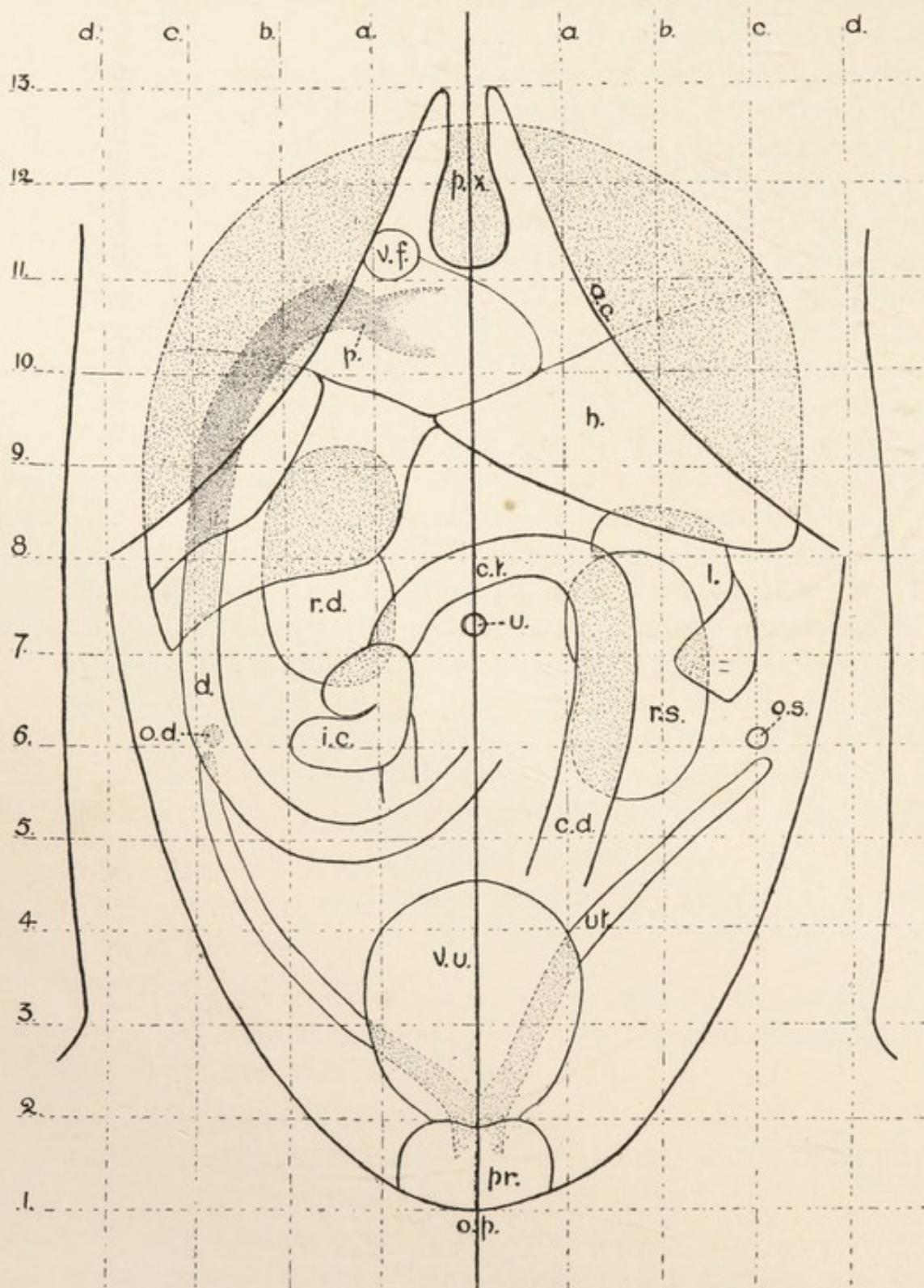


FIG. 3.—To show the position of the abdominal viscera in relation to the exterior. p.x., xiphoid process of sternum; a.c., costal arch; v.f., gall-bladder; p., pylorus; h., liver; r.d., right kidney; c.t., transverse colon; l., spleen; u., umbilicus; d., duodenum; o.d., right ovary; i.c., caecum; r.s., left kidney; o.s., left ovary; c.d., descending colon; v.u., urinary bladder; ut., uterus; pr., prostate; o.p., pubic bones.

(This figure is reproduced by permission of Messrs. Baillière, Tindall & Cox.)

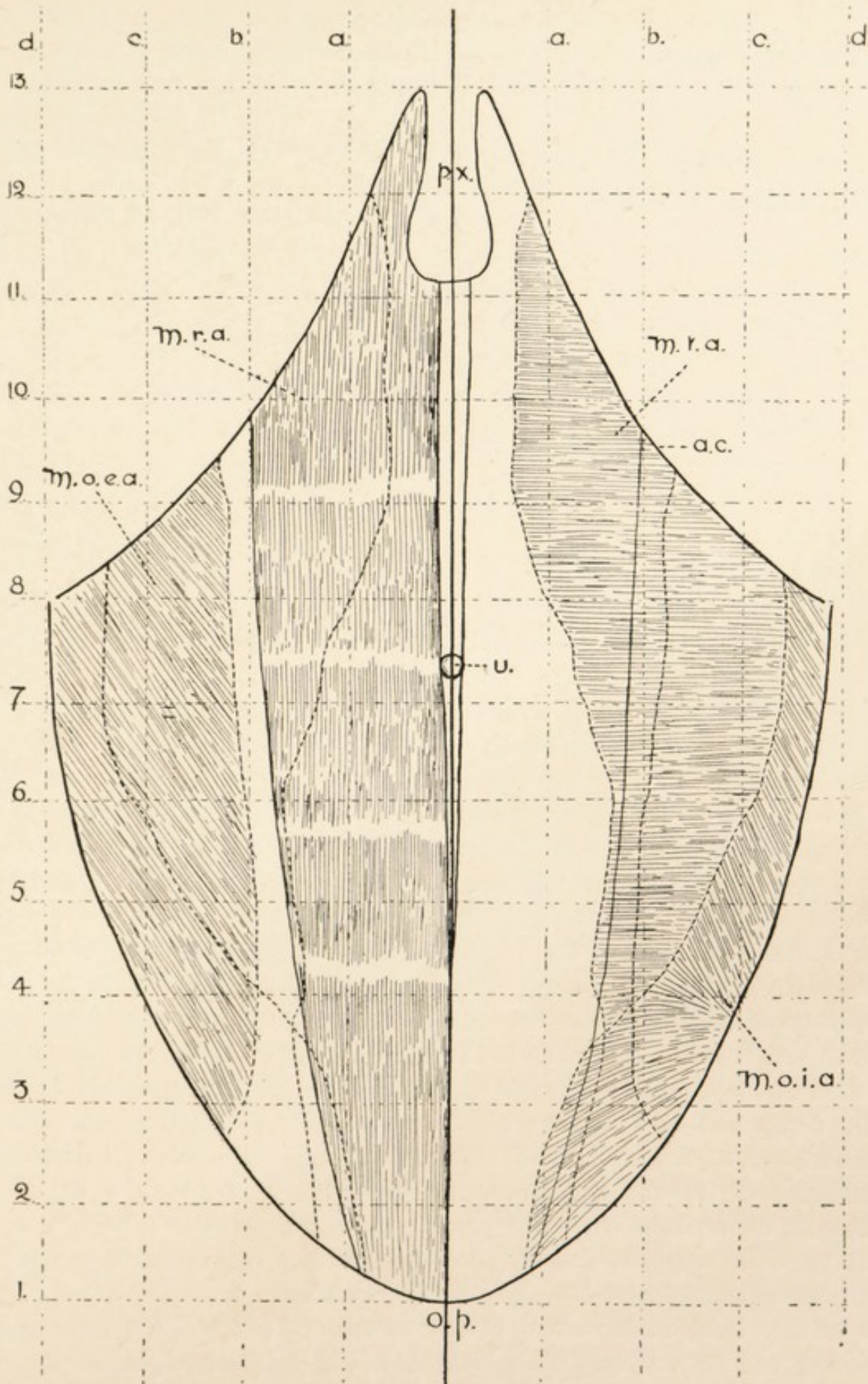


FIG. 4.—To show the extent of the fleshy part of the abdominal muscles. p.x., xiphoid process of sternum; a.c., costal arch; m.r.a., straight muscle of abdomen; m.t.a., transverse muscle; m.o.e.a., external oblique muscle; u., umbilicus; m.o.i.a., internal oblique muscle; o.p., pubic bones.

(This figure is reproduced by permission of Messrs. Baillière, Tindall & Cox.)

- | | |
|--------------------------|---|
| (2) Urinary organs. | { Kidneys.
Ureters.
Bladder. |
| (3) Reproductive organs. | { Deferent duct and prostate in the male.
Ovaries, uterine tube of Fallopius and uterus in the female. |
| (4) Ductless glands. | { Spleen.
Adrenal glands. |
| (5) Arteries. | { The abdominal aorta and its various branches. |
| (6) Veins. | { The caudal vena cava and its tributaries. The portal vein and its tributaries. The commencement of the vena azygos. |

(7) Lymph-glands and lymphatic vessels including the cisterna chyli and the commencement of the thoracic duct.

(8) The abdominal part of the sympathetic nervous system.

(9) The peritoneal lining of the cavity and investment of the organs contained therein.

It is of the utmost importance to the surgeon that he should be familiar with the positions of the main abdominal organs in relation to each other and to the surface of the body. In the accompanying figures (figs. 3 and 4), the disposition of the muscles forming the wall of the abdomen, and the position of the underlying viscera, are indicated. Both diagrams are divided into equal squares in order that a ready comparison may be made.

On first opening the abdomen only a few of the contained organs are brought to view. On turning aside the walls of the abdomen, indeed, little can be discovered but a double fat-laden membrane, the *greater omentum* (omentum majus), composed of four layers of peritoneum and containing, as will be explained later, a part of the peritoneal cavity called the *omental bursa* (bursa omentalis). On raising the omentum from the underlying coils of small intestine its connection with the greater curvature of the stomach, and its continuity with a peritoneal duplicature passing from the stomach to the spleen (ligamentum gastro-lienale), will be revealed.

Projecting from under cover of the costal arch, the sharp ventral border of the liver will be visible. This border, it will be noticed, is deeply cut by fissures, in association with one of which the broad end of the gall-bladder can generally be seen.

The ventral extremity of the spleen lies immediately caudal to the liver

on the left side of the abdomen. Not infrequently the visible part of the spleen is more caudal in position and extends farther than usual towards the middle line. This depends partly upon the size of the spleen, but largely upon the amount of distension of the stomach.

If the stomach is empty, possibly no part of it will be visible; but when distended a considerable extent of the sac may protrude beyond the border of the liver.

On turning the omentum over the ribs as far as possible, other organs will be exposed. Coils of small intestine occupy the greater part of the field of view; but close to the pubis the urinary bladder may form a conspicuous object if it happens to contain much urine. Sometimes part of the descending colon can be detected; and, if the subject be a female, part of the uterus may also be exposed. It will be observed that the interior of the abdominal wall, as well as the surface of the organs contained therein, is smooth and shiny. This is due to the presence of a serous membrane, the *peritoneum*, of which the greater omentum is a part.

INTESTINUM TENUE.—The small intestine is a long, smooth tube, measuring about five times the length of the body; and extending from the pylorus, in the epigastric region—where it is continuous with the stomach—to a point slightly caudal to the umbilicus and a short distance to the right of the median plane, where it ends by joining the cæcum. The small intestine is divided into: (1) The *duodenum*; (2) the *jejunum* (intestinum jejunum), and (3) the *ileum* (intestinum ileum). The coils of the jejunum and ileum are freely movable, since they are suspended from the dorsal wall of the abdomen by a fold of peritoneum, known as the *mesentery* (mesenterium), by way of which the blood-vessels, nerves, and lymphatics gain access to the intestine. The duodenum is not so mobile, as will be seen at a later stage of the dissection. To expose this part of the alimentary tube, it may be necessary to turn the rest of the small intestine to the left. This having been done, a portion of the duodenum will be found running along the right side of the abdomen. A second part passes in the opposite direction and ends at an abrupt ventral flexure not far from the pylorus. A closer examination of the duodenum is better left until later. In association with the duodenum one of the two limbs of the pancreas will be observed.

The terminal part of the ileum can generally be easily recognised as it travels cranialwards from somewhere near the pelvic inlet to its point of termination in the cæcum.

INTESTINUM CRASSUM.—In calibre the large intestine of the dog does not differ from the small intestine so much as it does in the other domesticated mammals. In length it falls very far short of the small intestine, measuring only about one-sixth of the length of the whole intestinal tube.

For descriptive purposes, the large intestine is divided into the cæcum, the colon, and the rectum.

INTESTINUM CÆCUM.—The cæcum is a short spiral or bent tube, the free blind end of which points towards the pelvis. There is considerable variation

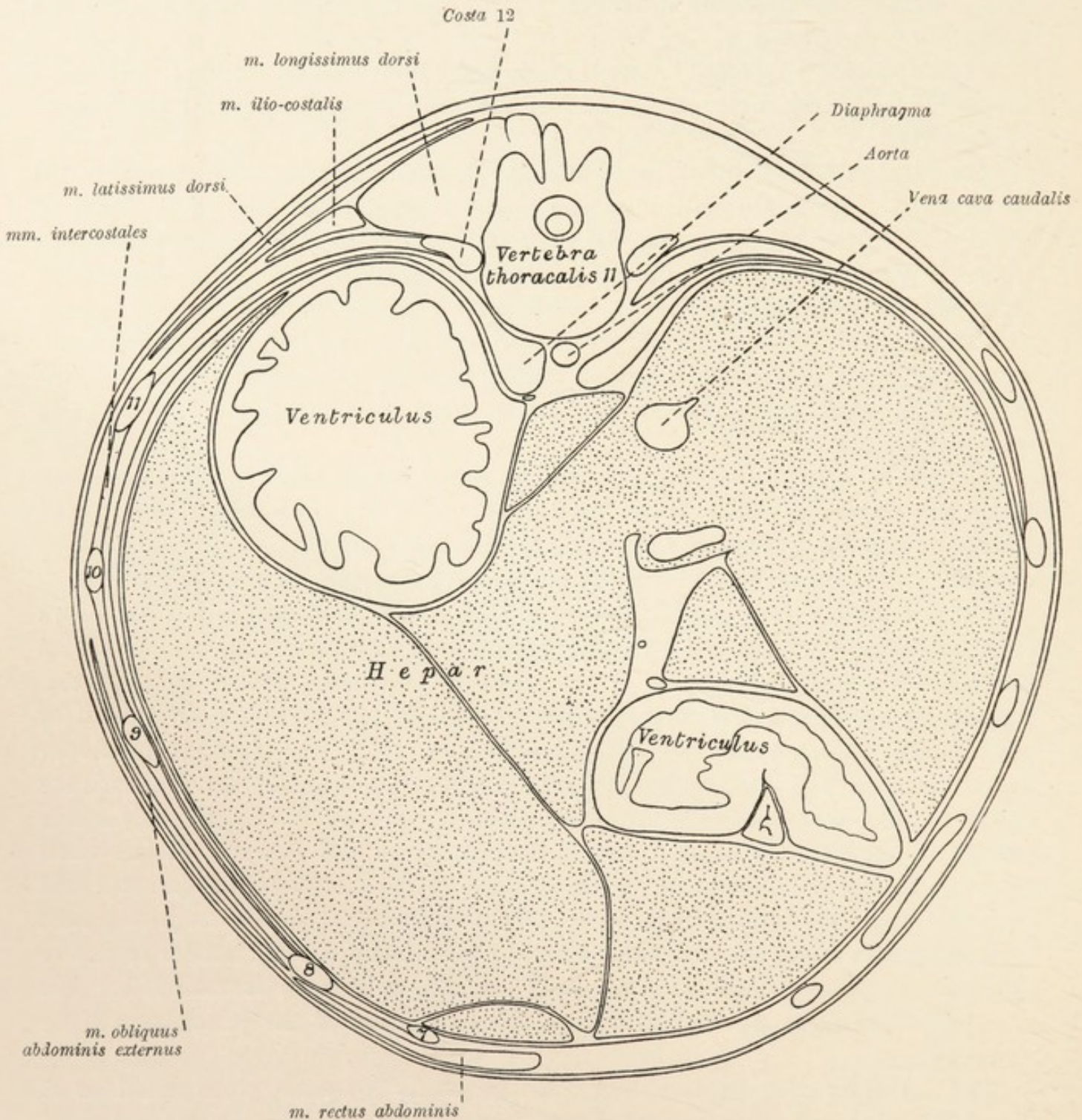


FIG. 5.—Transverse section of the abdomen on a level with the eleventh thoracic vertebra.
7, 8, 9, 10, 11 = seventh, eighth, ninth, tenth, and eleventh ribs.

in the length of this part of the intestine, and also in its form. It lies to the right of the median plane in the umbilical region.

COLON.—The colon is divided into three parts: (1) The *ascending colon* (colon ascendens) leaves the cæcum and runs cranialwards to the right of the median plane for a short distance and then turns to the left, thus forming the

right colic flexure (*flexura coli dextra*) ; (2) the second part of the colon, the *transverse colon* (*colon transversum*), like the first, is generally very short. It crosses the median plane immediately cranial to the root of the mesentery, and, arriving on the left side of the abdomen, curves in a caudal direction at the left colic flexure (*flexura coli sinistra*) ; (3) the *descending colon* (*colon descendens*)

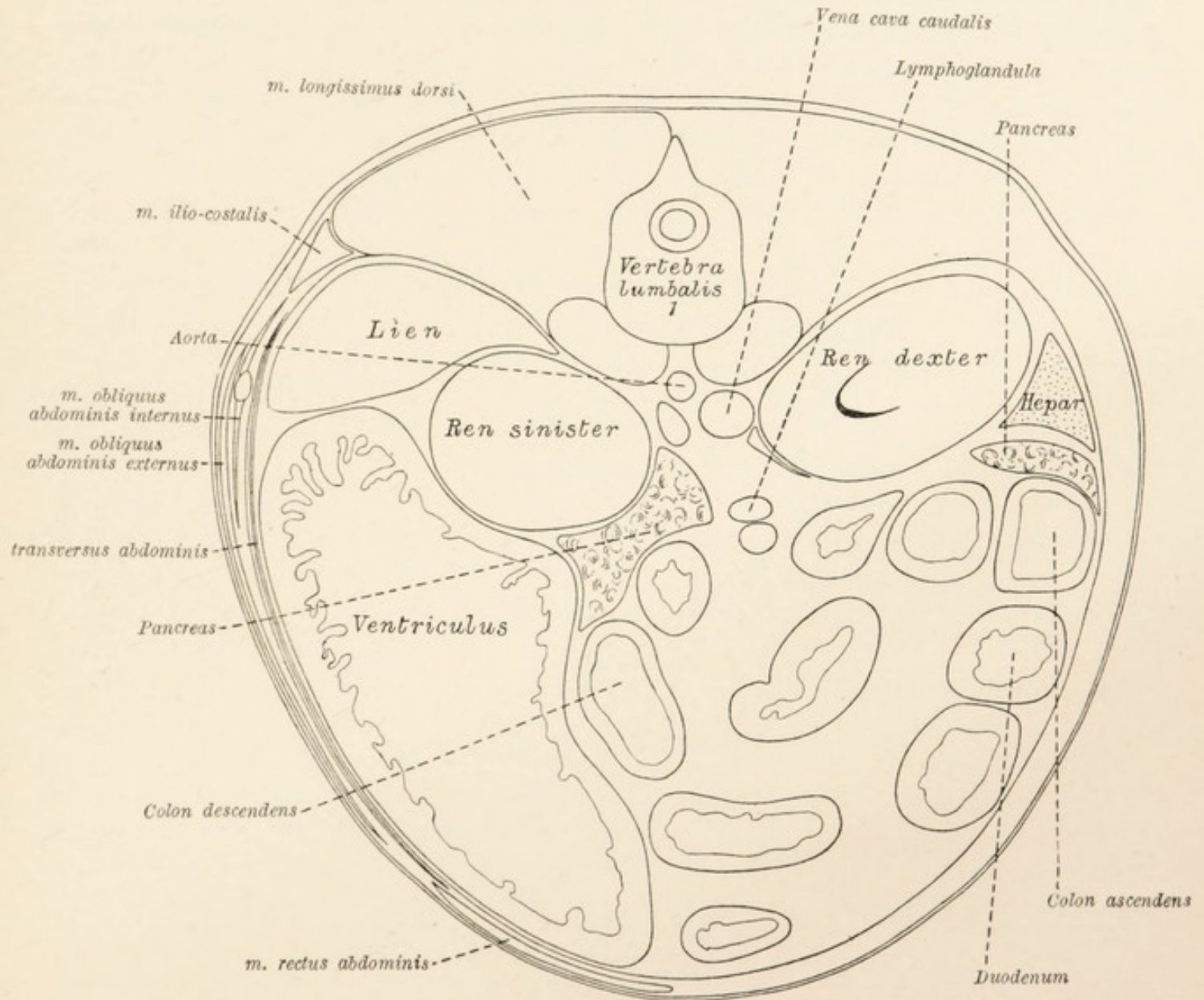


FIG. 6.—Transverse section through the abdomen on a level with the first lumbar vertebra. Sections of small intestine are not named.

forms by far the greater part of the whole tube. In order to expose it, it is necessary to turn the mass of small intestine over to the right. The descending colon will then be revealed to the left of the median plane in the form of a fairly straight tube running towards the pelvis from the left colic flexure. On approaching the pelvis, a gradual slope towards the right causes the intestine to disappear into the pelvic cavity about the middle line. In the female the colon gains the pelvis by passing dorsal to the uterus ; in the male, dorsal to the urinary bladder.

It will be observed that the whole length of the colon is provided with a short mesentery (mesocolon) which is not entirely independent of the mesentery of the small intestine. The cæcum, unlike the rest of the large intestine, does not possess a mesentery. Peritoneum is reflected from it onto the terminal part of the ileum, to the side of which it is closely applied.

PERITONÆUM.—The interior of the abdominal wall and the surface of the abdominal viscera are covered more or less completely by a serous membrane

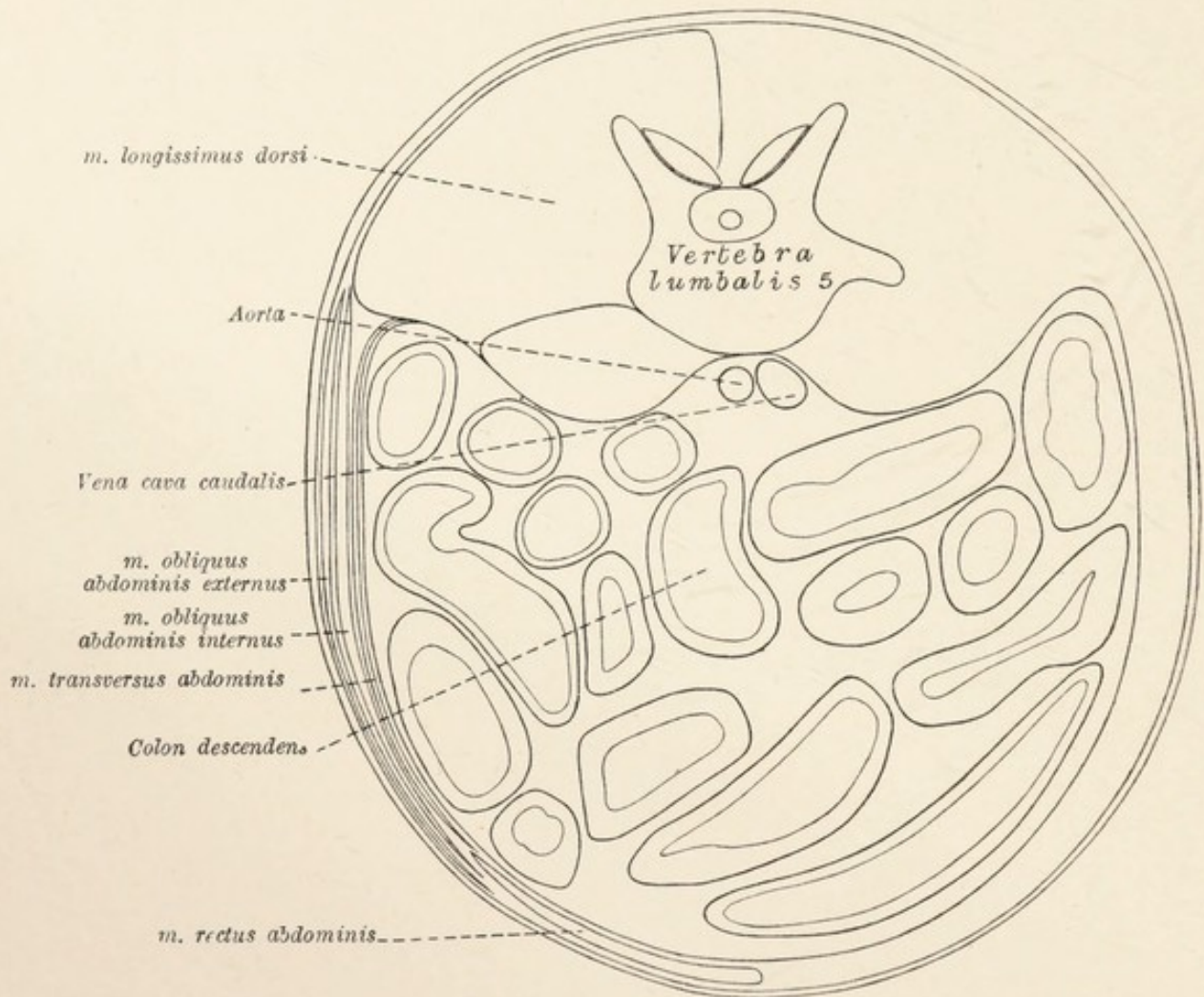


FIG. 7.—Transverse section of the abdomen on a level with the fifth lumbar vertebra. Sections of the small intestine are not named.

known as the *peritoneum*. Like the other serous membranes of the body, the peritoneum is a completely closed sac in the male. In the female, a small opening at the abdominal end of the uterine tube establishes an indirect communication between the peritoneal cavity and the exterior. As in the case of serous membranes in general, the peritoneum consists of a part lining the wall of the cavity—the *parietal peritoneum* (peritonæum parietale)—and a part covering the viscera contained within the cavity, the *visceral peritoneum* (peritonæum viscerale); but, unlike other serous membranes, the visceral peritoneum and its connections with the parietal peritoneum is very complicated because of the number and disposition of the abdominal organs.

It is best to commence the examination of the peritoneum where its disposition is simplest. This will be found to be the case in the more caudal part of the abdomen. If, then, the arrangement of the peritoneum be followed in a transverse direction a short distance from the entrance to the pelvis it will be found that the ventral, lateral, and dorsal walls of the abdomen are clothed by parietal peritoneum. This is reflected from the dorsal wall along a line a little to the left of the median plane, in order that the descending colon may be encircled. The membranous double layer which connects the descending colon to the abdominal parietes is named the *descending mesocolon* (mesocolon descendens), and is continued as a similar duplicature associated with the transverse colon, the *transverse mesocolon* (mesocolon transversum), and beyond this again on to the terminal part of the ascending colon as the *ascending mesocolon* (mesocolon ascendens).

The peritoneum should now be followed in a transverse direction at a level nearer the diaphragm; opposite, let us say, the commencement of the ascending colon. Beginning on the left side of the abdomen, the parietal peritoneum lines the lateral and dorsal walls of the cavity as far as the margin of the kidney, where it is continuous with the base of the descending mesocolon. Here it is diverted in a ventral direction in order to enclose the spleen. The membrane from the base of the mesocolon to the spleen is a part of the greater omentum. From the right face of the descending mesocolon a double layer of peritoneum extends over to the right side of the abdomen and encloses the various parts of the duodenum, the pancreas, and the commencement of the ascending colon. The jejunum and ileum are suspended from the dorsal wall of the abdomen by the *mesentery* (mesenterium), a double fold of peritoneum, fan-shaped in form.

The peritoneum should now be followed in a longitudinal direction beginning with the very obvious *greater omentum* (omentum majus). On first opening the abdomen, the greater omentum is revealed covering the whole of the intestinal mass, and extending from the stomach and spleen, on the one hand, to the pelvic entrance on the other. A careful examination of the omentum discloses the fact that it is formed by two membranes; or, rather, by one membrane folded on itself, so that the folded margin lies in the region of the pelvis and the right side of the abdomen. Still closer examination shows that there are really four layers of peritoneum in its constitution. Two ventral layers are closely applied to each other, and two dorsal layers are similarly intimately related. Between the united layers there may be a considerable accumulation of fat.

If the two ventral layers of the omentum are followed to the stomach they will be found to separate at the greater curvature of this organ so as to form serous coverings for its two surfaces. At the lesser curvature they again come together and form a thin membrane, the *lesser omentum* (omentum minus), which extends from the lesser curvature of the stomach to the margins of the

porta of the liver. Here once again the layers separate, this time to form the serous investment of the liver. The continuation of the most ventral layer of the lesser omentum follows the caudal surface of the liver, crosses its ventral border and proceeds to the diaphragmatic surface, from which it is reflected onto the diaphragm, and thence can be followed along the ventral wall of the abdomen to the pelvis. The more dorsal of the two layers of the lesser omentum, in like manner, is continued onto the liver and from this organ to the diaphragm and the dorsal wall of the abdomen.

If the two dorsal layers of the greater omentum are followed towards the dorsal wall of the abdomen, they will be found to enclose the left limb of the pancreas before arriving at the wall itself. On the wall the two layers separate. One becomes confluent with the continuation of the more dorsal layer of the lesser omentum. The other passes into the transverse mesocolon; that is to say, it leaves the dorsal abdominal wall, surrounds the transverse colon and again returns to the wall of the abdomen. Here it is continuous with the *root of the mesentery* (*radix mesenterii*).

Beyond this point the peritoneum proceeds along the abdominal wall into the pelvis and finally becomes that part of the membrane already followed along the ventral abdominal wall.

From what has just been said, it is clear that a compartment of the peritoneal cavity is enclosed within the greater omentum. Consequent upon its associations, this is known as the *omental bursa* (*bursa omentalis*). The communication between the main peritoneal cavity, entered when the abdomen was first opened, and the omental bursa, is by means of a comparatively small orifice, the *epiploic foramen of Winslow* (*foramen epiploicum [Winslowi]*). To find the foramen, pull the duodenum over towards the left and look for the caudate process of the liver, which will be readily recognised as that part of the liver which is in contact with the right kidney. If now the index finger of the left hand be passed along the caudate process towards the middle line it will enter the epiploic foramen. The right hand should be introduced into the omental bursa through an opening in the omentum, and the epiploic foramen sought from the left side.

The greater part of the omental bursa is contained in that part of the greater omentum which covers the intestine. The rest of it is continued dorsal to the stomach, and between this organ and those two dorsal layers of the omentum which contain the left limb of the pancreas. The boundaries of the bursa are formed as follows: Ventrally, by the ventral layers of the omentum, by the stomach, by the lesser omentum, and by the omental process of the liver; dorsally, by the dorsal layers of the greater omentum and the pancreas; on the left, by the spleen and the gastro-lienal ligament (*ligamentum gastro-lienale*) which connects the greater curvature of the stomach and the hilus of the spleen, and is directly continuous with the ventral layers of the greater omentum.

The disposition of the peritoneum in connection with the liver cannot be adequately studied at this stage of the dissection: it will be better, therefore, to postpone its examination until the liver itself can be displayed completely.

RECESSUS DUODENO-JEJUNALIS.—If the mass of small intestine be turned over towards the right and an examination be made immediately caudal and to the left of the root of the mesentery where the abrupt curve of the intestine marks the junction of duodenum and jejunum, the opening of the small duodeno-jejunal recess will be disclosed. The depth of the recess varies. It may extend along the right side of the ascending part of the duodenum to the second flexure of this tube.

A. MESENTERICA CRANIALIS.—The cranial mesenteric artery should be looked for at the root of the mesentery about the point at which the transverse colon crosses the middle line. In exposing it, it will be necessary to remove a large lymph-gland, the largest in the body, which lies at the root of the mesentery and is associated with the commencement of the portal vein. This corresponds to the separate lymph-glands of the stomach, liver, and spleen, and some mesenteric glands of other animals. The commencement of the mesenteric artery has a *mesenteric sympathetic ganglion* (ganglion mesentericum craniale) related to it. Nerves from the ganglion form the cranial *mesenteric plexus* (plexus mesentericus cranialis) and accompany the branches of the artery.

The cranial mesenteric artery is a branch of the abdominal aorta. It soon divides into (1) a main continuation from which arise the *intestinal arteries*, and (2) the common trunk of the *middle colic*, *right colic*, and *ileo-cæco-colic arteries*.

AA. INTESTINALES.—About fifteen intestinal arteries arise at intervals from the main continuation of the mesenteric artery and run down the mesentery to the small intestine, but before reaching the alimentary tube each artery divides and the adjacent branches anastomose. Thus a series of arterial arches are produced. Along the side of the mesenteric artery opposite to that from which the intestinal arteries arise, a small group of mesenteric lymph-glands will be found. The first of the intestinal arteries supplies a considerable amount of the duodenum and anastomoses with the duodenal branch of the pancreatico-duodenal artery; and the last artery similarly anastomoses with the iliac branch of the ileo-cæco-colic artery.

A. COLICA MEDIA.—The middle colic artery leaves the common trunk early and is the largest branch of the trunk. It supplies the transverse colon and a considerable stretch of the descending colon.

A. COLICA DEXTRA.—The right colic artery, a comparatively small vessel, supplies the ascending colon.

A. ILEO-CÆCO-COLICA.—The ileo-cæco-colic artery divides into three branches which supply the ileum, cæcum, and the commencement of the ascending colon. The iliac branch anastomoses with the last intestinal artery.

It is noteworthy that there is a series of anastomoses along the course of the colon between the ileo-cæco-colic, right colic, and middle colic arteries.

A. MESENTERICA CAUDALIS.—The caudal mesenteric artery can be most readily found by dissecting between the two layers of the descending mesocolon about the level at which the duodenum crosses the middle line. Very much smaller than the cranial mesenteric artery, it leaves the aorta opposite the fifth or sixth lumbar vertebra. From its point of origin the artery runs towards the pelvis in the attached border of the mesocolon and divides into two branches—*left colic* and *cranial hæmorrhoidal arteries*.

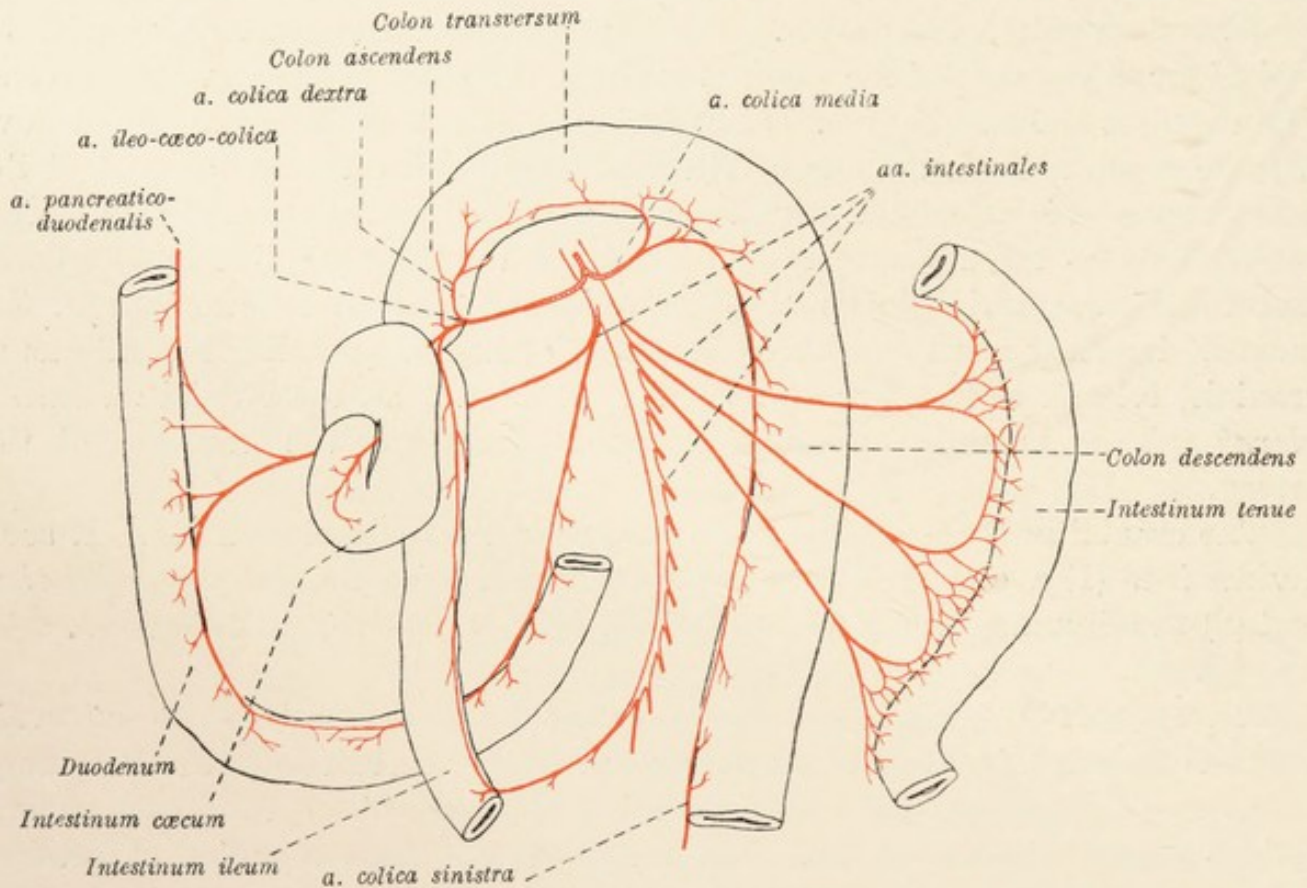


FIG. 8.—Diagram of the cranial mesenteric artery.

A. colica sinistra.—The left colic artery runs towards the thorax along the descending colon. This it helps to supply, and finally ends by anastomosing with the middle colic artery.

A. hæmorrhoidalis cranialis.—The cranial hæmorrhoidal artery follows the direction of the parent vessel and ends in the pelvis where it supplies the terminal part of the colon and anastomoses with the middle hæmorrhoidal artery.

GANGLION MESENTERICUM CAUDALE.—As was seen to be the case with the cranial mesenteric artery, so in association with the root of the caudal vessel of the same name a small sympathetic ganglion is developed. From this filaments arise which follow the mesenteric artery, so forming the *caudal mesenteric plexus* (*plexus mesentericus caudalis*).

LYMPHOGLANDULÆ.—A few small lymph-glands are lodged between the two layers of the mesocolon.

Dissection.—Apply a couple of ligatures a little distance apart around the colon where it is entering the pelvis, and the same at the junction of the duodenum and jejunum. Cut between the ligatures and take away all the intestines, except the duodenum and the terminal part of the colon. Remove them to a sink and slit up the entire length of the tube with scissors, cutting along the line of attachment of the mesentery. Wash away the contents, and examine the interior.

INTERIOR OF THE INTESTINES.—The interior of the intestines is lined by a soft, slimy, mucous membrane, generally more or less folded longitudinally. The folds, however, are not permanent, but may be obliterated by distension. In the small intestine, and more particularly in the ileum, elongated oval areas of mucous membrane can generally be distinguished as differing from their surroundings. These are the *aggregated lymph-nodules of Peyer* (noduli lymphatici aggregati [Peyeri]). Sometimes they are difficult to demonstrate, in which case they may be discovered by holding the intestine between the eye and a good light.

In the cæcum and in the commencement of the colon are numerous large *solitary nodules* (noduli lymphatici solitarii) composed, like the aggregated nodules, of lymphoid tissue.

The termination of the ileum should be specially examined. The orifice by which the ileum communicates with the commencement of the colon is narrow, and, viewed from the colon side, is surrounded by a low ridge of mucous membrane, the *valve of the colon* (valvula coli). Immediately adjacent to the iliac aperture is a constriction marking the junction of cæcum and colon.

STRUCTURE OF THE INTESTINES.—A piece of intestine should be pinned out on a sheet of cork with the mucous membrane downwards. The thin serous membrane (tunica serosa) should now be dissected off the underlying muscle. It will be noticed that the serous covering of the intestine is thinner than the membrane forming the mesentery with which it is continuous. Now turn the piece of intestine over and examine the mucous membrane (tunica mucosa). If the intestine be sunk in water and the surface thoroughly cleared of mucus, it will present a velvety appearance—most marked in the jejunum—from the presence of delicate projections, the *villi*. A pocket lens facilitates the examination of these. The mucous tunic should now be removed. In doing so, the connective tissue between the membrane and the muscular coat of the intestine—the submucous tissue (tela submucosa)—will be noted as being of somewhat loose texture. An examination of the muscular coat (tunica muscularis) of the tube shows that the fibres are not all disposed in the same direction. The outer, more superficial fibres run longitudinally; whereas

the inner fibres are circular in direction. The circular fibres form a somewhat thicker layer in the ileum than in the jejunum.

Dissection.—Turn to the wall of the thorax, and clean up the scalenus and ventral serratus muscles.

M. SCALENUS.—The scalenus muscle cannot be completely exposed at present, since its origin lies in the neck. The part which is to be examined now is applied to the chest-wall dorsal to the transverse muscle of the ribs.

The scalenus is divisible into three parts, the insertions of which are as follows: (1) The most dorsal is inserted to the cranial border of the third and fourth ribs. (2) The middle part of the muscle is attached to the fifth, sixth, seventh, and eighth ribs. (3) The most ventral part of the muscle is the shortest and reaches the first rib only. It should be noted that a satisfactory differentiation of the dorsal and middle portions of the muscle is frequently impossible.

Dissection.—Cut across the scalenus muscle on a level with the second rib and remove the part inserted into the ribs.

M. SERRATUS VENTRALIS.—The ventral serratus muscle is extensive and powerful. Part of it is in the neck and cannot be examined at the present moment. The thoracic portion of the muscle, now exposed, arises by digitations from the first seven or eight ribs. The last two or three digitations are related to the origin of the external oblique muscle of the abdomen. The converging bundles of fibres are inserted into the vertebral border and a roughened area on the costal surface of the scapula.

The nerve supply of the ventral serratus muscle—the *long thoracic nerve* (n. thoracalis longus)—is derived from the brachial plexus (from seventh and eighth cervical nerves); but, instead of accompanying the rest of the branches of the plexus, the nerve runs along the deep face of the scalenus muscle.

Between the last cervical and the first thoracic digitations of the serratus muscle, the transverse artery of the neck (a. transversa colli) and its companion vein should be noted. The vessels disappear under cover of the serratus.

Dissection.—Liberate the ventral serratus muscle from all the ribs except the first and turn it outwards. Then clean up the spaces between the ribs as far in a dorsal direction as the attachment of the dorsal serratus muscle, a level generally marked by the appearance of branches from the intercostal vessels. The external oblique abdominal muscle should be detached from the ribs. Observe the extent of the external intercostal muscles. Remove the external muscle from one or two interspaces as far as the attachment of the dorsal serratus muscle, in order to show the underlying internal intercostal muscles.

MM. INTERCOSTALES EXTERNI.—On each side of the chest there are twelve external intercostal muscles. Each muscle passes from the border of one rib to the adjacent border of the next, with fibres running in a caudo-ventral direction. It will be observed that the first seven muscles terminate about the level of union of the bony and cartilaginous segments of the ribs. Frequently the eighth muscle proceeds farther and may almost reach the sternum. The remaining muscles are also continued between the rib-cartilages, but generally there is an interruption in their continuity at the end of the bony segment of the rib.

In a dorsal direction the external intercostal muscles reach the vertebral column, but this cannot be determined as yet.

MM. INTERCOSTALES INTERNI.—The twelve internal intercostal muscles differ from the external intercostals in that their fibres pass in a ventro-cranial direction, and each muscle is continued along the entire length of an intercostal space. In the neighbourhood of the sternum, therefore, the internal muscles can be seen before the removal of the external intercostals.

Dissection.—Now carefully remove an internal intercostal muscle in order to demonstrate the intercostal vessels and nerve. These will be found lying along the caudal border of the rib, between the internal intercostal muscle and the lining membrane of the chest.

AA. INTERCOSTALES.—There are twelve intercostal arteries on each side of the chest. At the present stage of dissection, the origin of the arteries cannot be determined, but will be revealed when the wall of the thorax is examined from within. Nor can the division of each artery into a dorsal and ventral branch be exposed. At the present time it will be sufficient to note that the vessel now displayed is the ventral branch (*ramus ventralis*) of an intercostal artery. It travels down the caudal border of the rib between the corresponding vein, which is cranial in position, and the intercostal nerve.

The arteries of the first seven or eight intercostal spaces terminate by anastomosing with branches from the internal mammary artery. The rest anastomose with the musculo-phrenic artery, or are continued into the wall of the abdomen.

Lateral cutaneous branches (*rami cutanei laterales*) of the intercostal arteries become superficial by piercing the overlying muscles about the middle of the length of each interspace.

VV. INTERCOSTALES.—Intercostal veins accompany the intercostal arteries and are to be sought between the artery and the rib.

NN. INTERCOSTALES.—Intercostal nerves course along the aboral border of the arteries of the same name. Each constitutes the ventral branch (*ramus ventralis*) of a thoracic spinal nerve. A *lateral cutaneous branch* (*ramus cutaneus lateralis*) leaves each nerve at the same point as does the like-named branch of the artery.

The first eight nerves end a short distance from the sternum by dividing into (1) a *ventral cutaneous branch* (*ramus cutaneus ventralis*), and (2) a smaller branch for the transverse thoracic and internal intercostal muscles. The ventral cutaneous ramus becomes superficial about the termination of the external intercostal muscle.

The last four intercostal nerves are continued beyond the costal arch into the wall of the abdomen, where they have already been found between the internal oblique and transverse muscles.

Dissection.—Remove the intercostal muscles from all the interspaces on both sides of the chest from the sternum to about the middle of the length of the interspace. The internal intercostal muscles should be removed with the greatest care, so that the endothoracic fascia between the ribs may be preserved.

In the region of the sternum a muscle, the transverse thoracic, and an artery and a vein, the internal thoracic or mammary, are exposed on each side.

A. MAMMARIA INTERNA.—The internal mammary artery is a branch of the subclavian, and pursues an oblique course in the mediastinum to gain the ventral surface of the transverse thoracic muscle. Here the artery runs along in the region of the joints between the costal cartilages and the sternum, until it reaches the eighth cartilage, where it divides into the *cranial epigastric* and *musculo-phrenic arteries*.

The following are the collateral branches of the artery: (1) Two *intercostal branches* (*rami intercostales*) are distributed to the ventral end of each of the first seven intercostal spaces. These anastomose with the termination of an intercostal artery. (2) *Sternal* and *perforating branches* (*rami sternales et perforantes*) supply the transverse thoracic and pectoral muscles. (3) *Thymic arteries* (*aa. thymicæ*). (4) *Anterior bronchial arteries* (*aa. bronchiales anteriores*). (5) *Anterior mediastinal arteries* (*aa. mediastinales anteriores*). (6) *Pericardio-phrenic artery* (*a. pericardio-phrenica*). With the exception of the first two, these branches are distributed to structures within the thorax, and, consequently, are not accessible at present.

A. MUSCULO-PHRENICA.—In order to examine the termination of the internal mammary artery properly, it may be necessary to cut away a part of the eighth costal cartilage. The musculo-phrenic artery runs along the border of the diaphragm, and is, at first, under cover of the eighth costal cartilage. The artery supplies the diaphragm, and anastomoses with some of the intercostal arteries.

A. EPIGASTRICA CRANIALIS.—The cranial epigastric artery has already been examined as it runs along the deep face of the straight muscle of the abdomen. A considerable branch has also been noted as becoming superficial, close to the xiphoid process of the sternum. There only remains to examine

its origin as one of the two terminal branches of the internal mammary artery, and to note that it gains the abdominal wall by piercing the edge of the diaphragm.

M. TRANSVERSUS THORACIS.—The transverse muscle of the thorax arises from the third or fourth to the seventh segments of the sternum and from the ninth costal cartilage. Its insertion is to the ribs and their cartilages from the second or third to the seventh or eighth, and to the endothoracic fascia of the intervals between the ribs.

CAVUM THORACIS.—It is necessary that the dissector should have, at least, some general idea of the thoracic cavity and the organs contained therein before he proceeds with their examination. The thorax is a cavity with a bony wall formed by the thoracic vertebræ, the ribs, and the sternum. It resembles a laterally flattened cone, with a sloping base bounded by the diaphragm, which forms the thin, muscular partition between the thorax and the abdomen. The diaphragm being markedly concave when viewed from the abdominal side, it is important to remember that the cavity of the thorax is not so spacious as an examination of the skeleton would lead one to imagine.

Between the first pair of ribs, i.e. at the apex of the cone, numerous structures pass to and from the neck. The chief organs contained within the chest are the heart and the two lungs. The heart lies between the lungs and is enclosed in a fibro-serous sac, the *pericardium*. The lungs are lateral to the heart and fill the greater part of the thoracic cavity. Except where it is connected with the heart by large blood-vessels, and where it is joined to the trachea by the bronchus, each lung lies free in its own side of the thorax. A serous membrane, the *pleura*, covers each lung and lines the corresponding part of the thoracic wall. Where the two pleuræ come into contact with, or approach each other in, or near the median plane, they form the *mediastinal septum* (septum mediastinale), a partition in which all the thoracic contents, with the exception of the lungs, are contained. Part of the septum and some features of the pleural cavity must now be displayed. That part of the pleura which covers the lungs is known as visceral: the rest of the membrane is the parietal pleura.

Dissection.—Carefully free the pleura from the ribs from the second to the seventh, and divide these ribs about the middle. Cut through the sternum between the first and second and between the seventh and eighth costal cartilages. Remove the sternum and portions of ribs so isolated.

The detached part of the sternum and the costal cartilages articulating therewith must be laid aside for the subsequent examination of the joints.

The dissection leaves the pleural sacs intact, with the costal pleura (that part of the pleura originally attached to the ribs) lying loose upon the lungs. The interior of the pleural cavities should now be exposed by making an incision through the costal pleura on each side close to the cut ends of the ribs, and a second incision at right angles to the first.

PLEURA.—The disposition of the pleura must now be examined. Two

costalis). If this be traced in a ventral direction, it will be found to reach the middle line of the sternum, where it meets its fellow membrane of the opposite side. From the sternum the two pleuræ are reflected dorsalwards

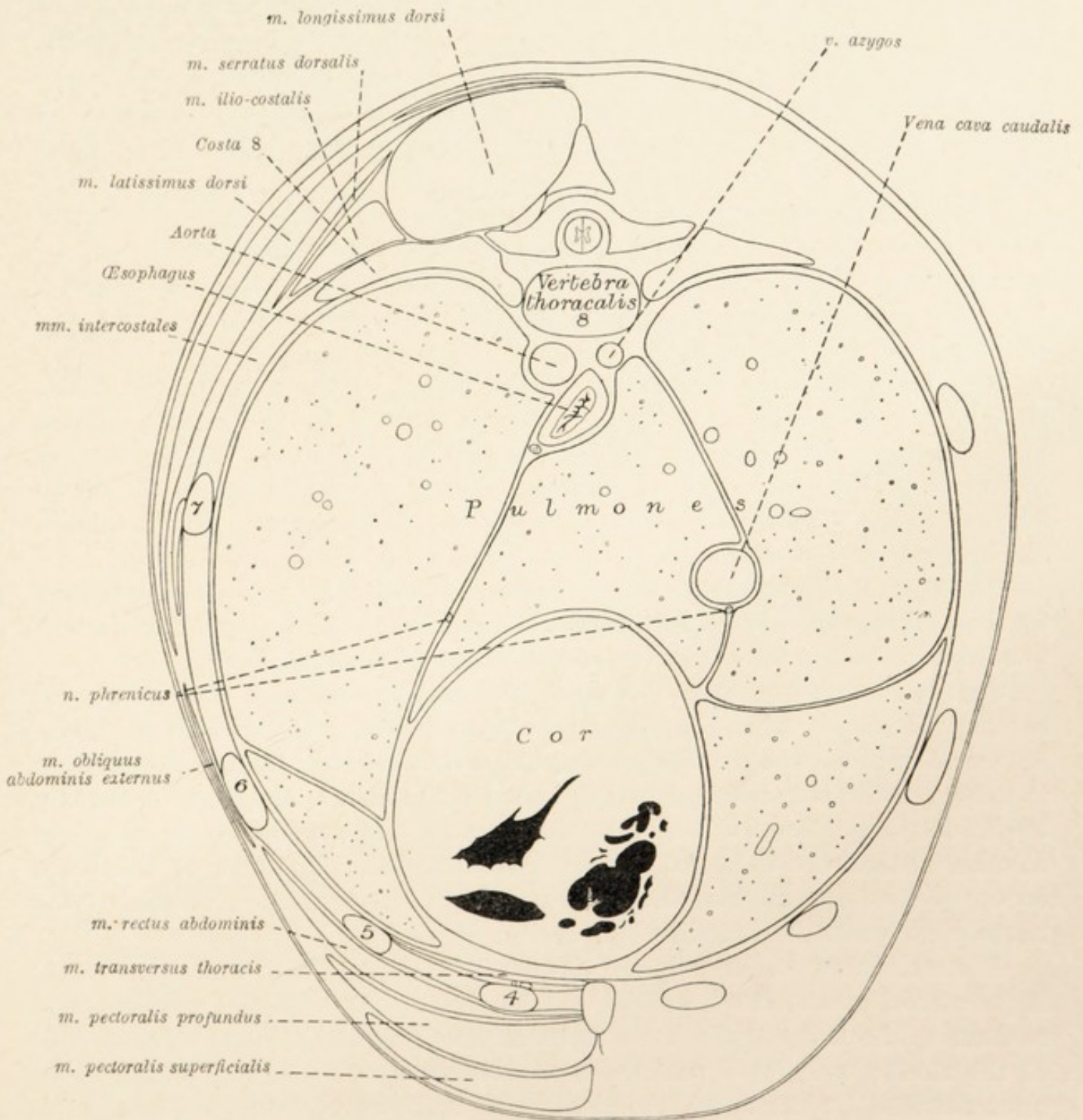


FIG. 10.—Transverse section of the thorax on a level with the eighth thoracic vertebra.
4, 5, 6, 7=fourth, fifth, sixth, and seventh ribs.

as the *mediastinal pleura* (pleura mediastinalis). Close to the sternum the two pleuræ are intimately associated and a thin double membrane is produced. Soon, however, the heart intervenes between the two mediastinal pleuræ [here specifically known as the *pericardiac pleura* (pleura pericardiaca)], with

the result that an extensive mediastinal space is formed. Followed over the heart—or more correctly, the pericardium—it will be discovered that the pleura is reflected over the root of the lung to the lung itself; that is, the parietal pleura here becomes continuous with the visceral or *pulmonary pleura* (pleura pulmonalis). Caudal to the root of the lung the reflection of mediastinal pleura does not cease but is continued as far as the diaphragm in the form of the *pulmonary ligament* (ligamentum pulmonale). The ligament runs obliquely from the root of the lung to the dorsal border of this organ, along which it is then continued to its termination.

Now trace the costal pleura in a dorsal direction. On reaching the vertebral column the membrane is reflected ventralwards as the mediastinal septum (mediastinal pleura), in which the œsophagus and aorta are conspicuous objects. Again the mediastinal pleura is continued onto the surface of the lung by way of the root of the lung and the pulmonary ligament.

Now investigate the disposition of the pleura at the apex of the chest. Here it will be found that each sac ends blindly in the *cupula pleuræ* extending for a short distance beyond the first rib, and supported, in part, by the origin of the sterno-thyroid muscle. Finally the costal pleura should be followed to the diaphragm—where it forms the *diaphragmatic pleura* (pleura diaphragmatica)—and from this once again to the mediastinal septum.

On the right side of the thorax the arrangement of the pleura is complicated by the presence of a fold which leaves the diaphragm and passes dorsalwards to surround the caudal vena cava and the right phrenic nerve.

SEPTUM MEDIASTINALE.—The mediastinal septum between the two pleural cavities is formed, as has been seen, by the apposition of the two pleural membranes at or about the median plane. The space between the two membranes is known as the *mediastinum* or *mediastinal cavity*, and is bounded laterally by the mediastinal pleuræ, ventrally by the sternum, and dorsally by the vertebral column. Since the unpaired, more or less median structures of the chest occupy a position therein, the greater part of the dissection of the thorax takes place within the mediastinal cavity.

For convenience of description the cavity is divided into three parts: (1) A *precardial mediastinum*, cranial to the heart; (2) a *cardial mediastinum*, containing the heart and other structures occupying the same transverse zone of the chest; and (3) a *postcardial mediastinum*, of triangular outline and circumscribed by the heart, the diaphragm, and the vertebral column. The precardial and cardiac mediastina are median; but the postcardial mediastinum is pushed over to the left by the accessory lobe of the right lung.

The precardial mediastinum contains the large blood-vessels connecting the heart with the head, neck, and thoracic limbs, the terminal part of the thoracic duct, the vagi, recurrent, phrenic, sympathetic, and cardiac nerves, the œsophagus and trachea, and the thymus and lymph-glands.

The cardiac mediastinum contains the heart and its enveloping pericardium,

the commencement of the arterial and the end of the venous systems, the œsophagus, the termination of the trachea, the vagi, left recurrent, phrenic, cardiac, and pulmonary nerves.

The postcardial mediastinum contains the aorta, the azygos vein, the vagi, left phrenic and sympathetic nerves, the thoracic duct, and the œsophagus.

ARTICULATIONES STERNOCOSTALES.—Nine of the thirteen ribs on each side articulate with the sternum by means of their cartilages. The end of the rib cartilage is received into a concavity on the lateral surface of the sternum and articulates therewith by a diarthrodial joint. Each articulation is enclosed by a *joint-capsule* (capsula articularis) and is provided with a synovial membrane. On each side of the joint the capsule is thickened to form the *radiate sterno-costal ligaments* (ligg. sternocostalia radiata).

The cartilages of the tenth, eleventh, and twelfth ribs do not reach the sternum, but each is bound by fibrous tissue to the cartilage preceding it. The cartilage of the last rib is generally quite independent of the second last.

SYNCHONDROSES INTERSTERNALES.—The eight bony segments of the sternum are joined to each other by cartilage, and the union is strengthened by an *internal proper sternal ligament* (lig. sterni proprium internum). Strong and well marked, the ligament is narrow over the first two or three segments of the sternum, but later it increases in width.

Dissection.—It will facilitate the further dissection of the thoracic contents if the fragment of the sternum and portions of the last few ribs be removed. This should be done by cutting through the ribs in a line with the level at which the other ribs were divided previously. The attachment of the diaphragm to the ribs and sternum must be noted and then severed. This dissection allows of the examination of the liver, stomach, spleen, and pancreas, which was not readily possible earlier.

HEPAR.—The liver is a large, solid, glandular organ of chocolate colour, closely applied to the abdominal face of the diaphragm. Approximately central in position, it lies partly under cover of the ribs, but generally a considerable proportion of its bulk projects beyond the costal arch.

The liver may be described as presenting two surfaces and a circumferent edge. The cranial surface is applied closely to the diaphragm and part of the wall of the abdomen, and upon these it is moulded. It is consequently convex in all directions, and, when the organ is *in situ*, slopes dorso-ventrally and cranialwards in its dorsal half and caudalwards in its ventral half.

The caudal surface is, in the main, concave; but, owing to the influence of adjacent hollow viscera, not regularly so. The organs with which it is in contact are the stomach, intestines, pancreas, and the right kidney. The amount of intestinal contact naturally depends largely on the degree of distension of the stomach.

The margin of the liver is sharp ventrally and laterally, but blunt and

notched dorsally. The dorsal portion of the margin cannot be satisfactorily examined at present. The ventral border, however, is readily examined, and will be seen to be interrupted by deep incisions which divide the organ into lobes.

VESICA FELLEA.—A detailed examination of the gall-bladder and its associated ducts is more easily carried out after removal of the liver from the body; but at the present time certain features should be observed.

The gall-bladder is a pear-shaped sac lying in a deep depression on the caudal surface of the liver and generally in contact with the pyloric part of the stomach. The broad *fundus* of the sac (*fundus vesicæ felleæ*) is close to

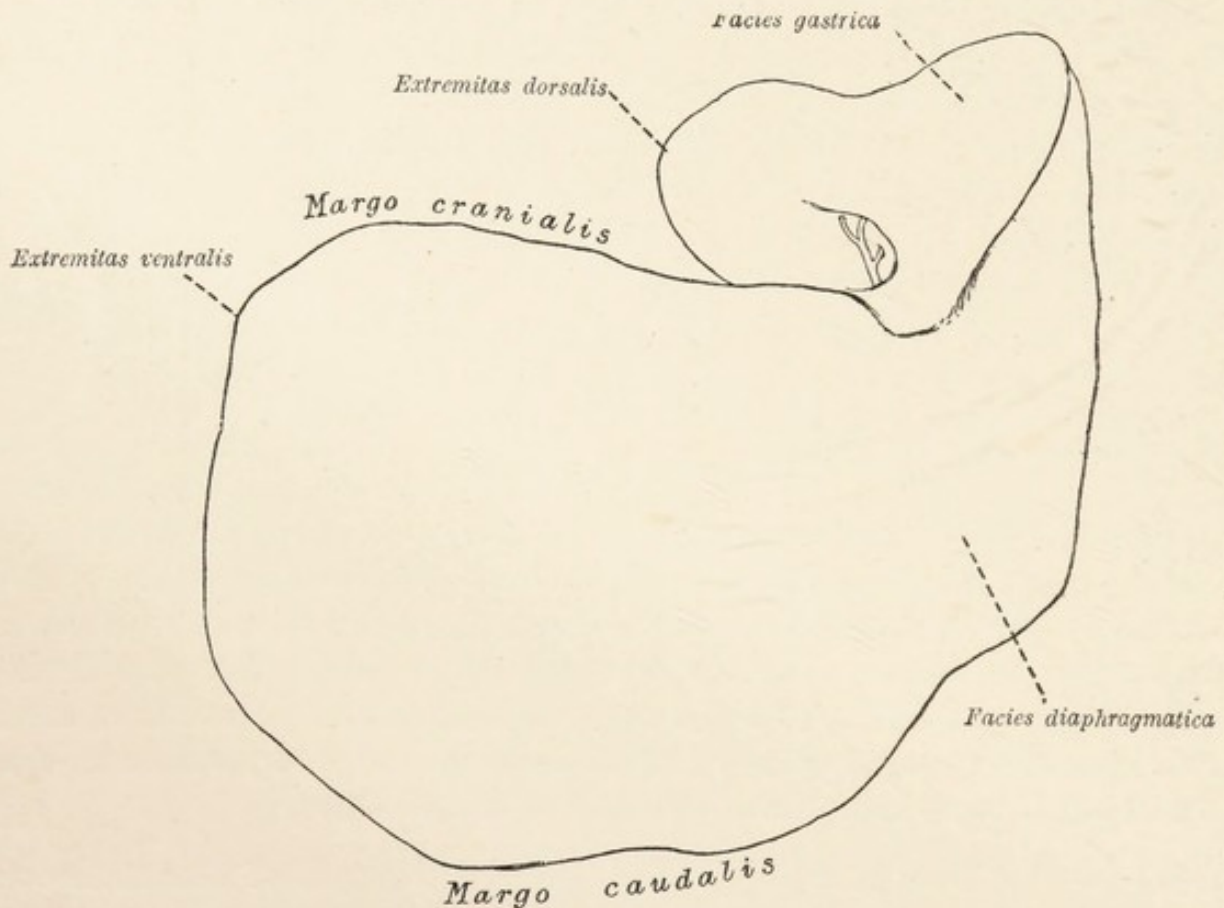


FIG. 11.—Outline of the spleen.

the costal arch a short distance to the right of the median plane, and can mostly be seen as soon as the abdomen is opened. From the narrow dorsal end of the bladder springs a short *cystic duct* (*ductus cysticus*) which communicates with the *common bile-duct* (*ductus choledochus*). The common bile-duct should be traced to the duodenum. In order to reach the intestine it has to run between the two peritoneal layers of the lesser omentum, where it is closely related to the hepatic artery and the portal vein. Of the three structures the duct is to the right, the artery to the left, and the vein intermediate and dorsal to the others. The three structures are immediately dorsal to the pylorus.

LIEN.—The spleen is one of the ductless glands of the body. It is a solid organ, deeply placed within the left side of the abdomen, extending from the vertebral region to the costal arch. Generally its ventral extremity

reaches somewhat beyond the edge of the ribs, and is, therefore, visible as soon as the abdomen is opened.

The spleen may be described as possessing three surfaces, three borders, and two extremities. The lateral surface is applied to the abdominal wall and is consequently convex in a dorso-ventral direction. Since the dorsal part of this surface fits into the groove formed by the vertebral bodies and the ribs, the convexity is most marked in this region. The other two surfaces look towards

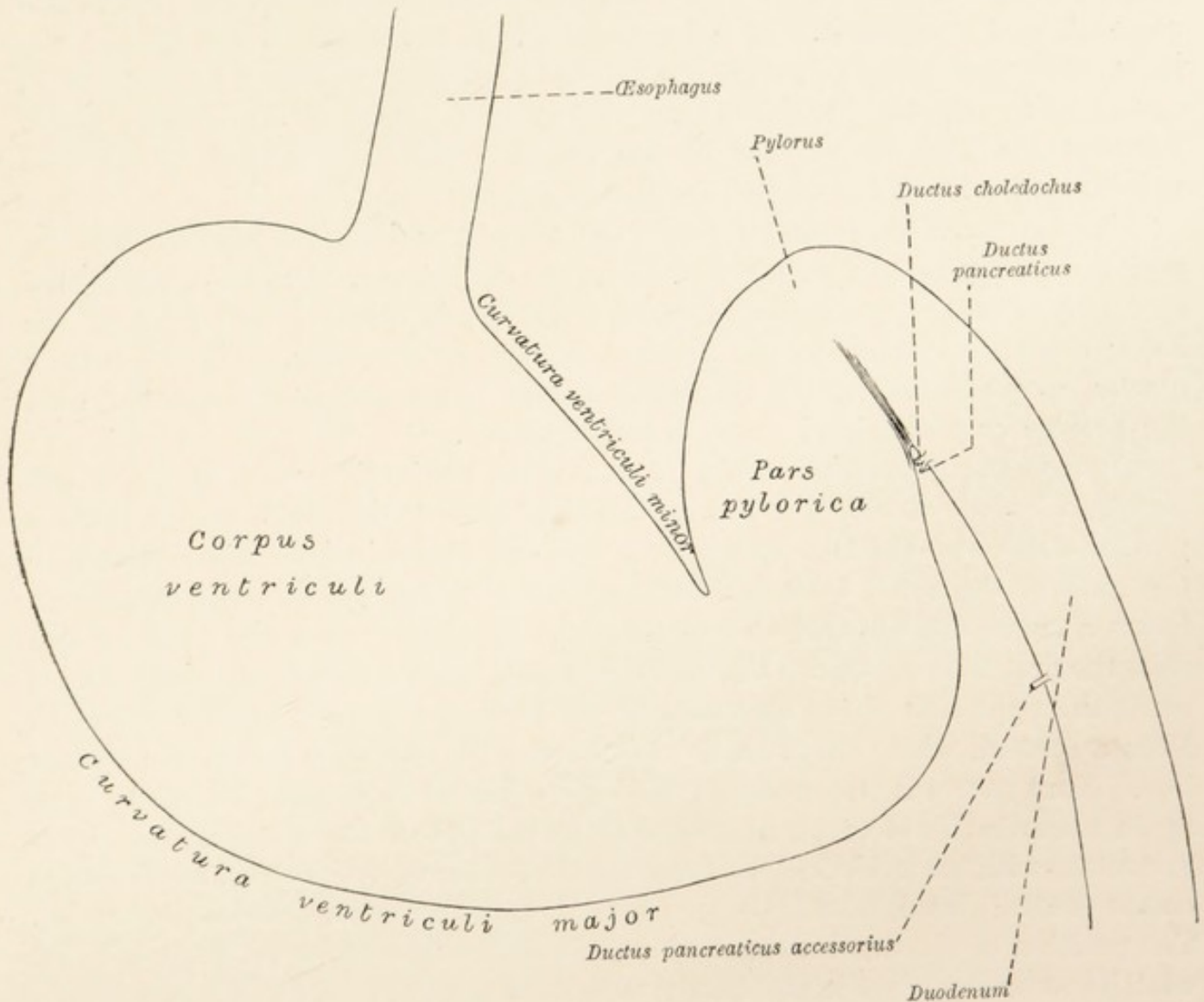


FIG. 12.—Outline of the stomach.

the median plane and are concave. The more cranial is applied to the stomach; whereas the more caudal is in contact with the left kidney and the intestines.

The cranial and caudal borders, bounding the lateral surface, are thin. The medial border is much less prominent, but is important since it is the seat of the *hilus of the spleen* (hilus lienis), by which the blood-vessels and nerves enter the organ. This border, moreover, has the *gastro-lienal ligament* (lig. gastro-lienale) attached to it.

VENTRICULUS.—The stomach is a saccular dilation of the alimentary canal

intervening between the œsophagus on the one hand and the small intestine on the other. That part of the stomach connected with the œsophagus is distinguished as the *cardia*, to the left of which is the rounded *fundus*. When moderately distended the stomach is readily distinguished as composed of two parts: a rounded, wide *body* (*corpus ventriculi*) on the left, into which the œsophagus opens; and a narrow tubular *pyloric portion* (*pars pylorica*) communicating with the duodenum to the right. The position of the *pylorus* is indicated on the exterior by a faint circular constriction at the junction of the stomach and duodenum. It is in contact with the right central lobe of the liver, and, very generally, with the gall-bladder also. Referred to the surface of the abdomen, the pylorus is immediately to the right of the median plane, between the xiphoid process of the sternum and the costal arch. The pyloric orifice looks towards the vertebral column.

The two surfaces of the stomach are smooth and convex and covered by peritoneum. The borders are known as the curvatures. Of these, the dorsal or *lesser curvature* (*curvatura ventriculi minor*) is concave and from it the lesser omentum passes to the visceral surface of the liver. The ventral or *greater curvature* (*curvatura ventriculi major*) is convex and connected with the greater omentum and gastro-lienal ligament.

DUODENUM.—The duodenum is the most distinctive part of the small intestine. Most of the tube lies on the right side of the abdomen, in contact with the right lateral lobe of the liver and the abdominal wall, and dorsal to the bulk of the small intestine. Commencing at the pylorus, the duodenum forms a curve dorsalwards and to the right in contact with the liver. From this, the first flexure, begins the *descending part* (*pars descendens*) which passes along the right side of the abdomen to the level of the sixth lumbar vertebra. Here a second, wider curve to the left carries the intestine across the middle line. Next succeeds the *ascending part* (*pars ascendens*) which, travelling back again towards the stomach immediately to the left of the median plane, ends in contact with the left kidney and close to the root of the mesentery, at an abrupt caudo-ventral bend, the *duodeno-jejunal flexure* (*flexura duodeno-jejunalis*). The position of the duodenum is subject to only slight variation from the fact that its ascending part is intimately connected with the descending mesocolon. The caudal limb of the pancreas is closely associated with the concave side of the descending part of the duodenum.

PANCREAS.—The pancreas of the dog is an elongated, lobulated gland presenting an appearance very similar to that of the salivary glands. It consists of two limbs diverging from the region of the pylorus. The left limb (*cauda pancreatis*) extends across the ventral aspect of the vertebral column in the dorsal wall of the omental bursa and dorsal to the stomach. Its left extremity is commonly in contact with the left kidney. The right limb (*caput pancreatis*) is contained within the mesentery of the duodenum and reaches from the pylorus almost to the point at which the duodenum bends to the left.

The pancreas has two ducts. One, the *pancreatic duct* of Wirsung (ductus pancreaticus [Wirsungi]), drains the left limb of the gland, and opens into the duodenum in company with the common bile-duct. The second duct, the *accessory duct* of Santorini (ductus pancreaticus accessorius [Santorini]), carries away the secretion from the duodenal or right limb, and opens independently into the duodenum a short distance (30 to 50 mm.) caudal to the orifice of Wirsung's duct. The two ducts intercommunicate in the interior of the gland.

In order to expose the ducts of the pancreas and the termination of the bile-duct, the stomach should be pulled over to the left as far as possible and the duodenum to the right. A dissection must then be carefully conducted between the pancreas and duodenum, in the angle formed by the stomach

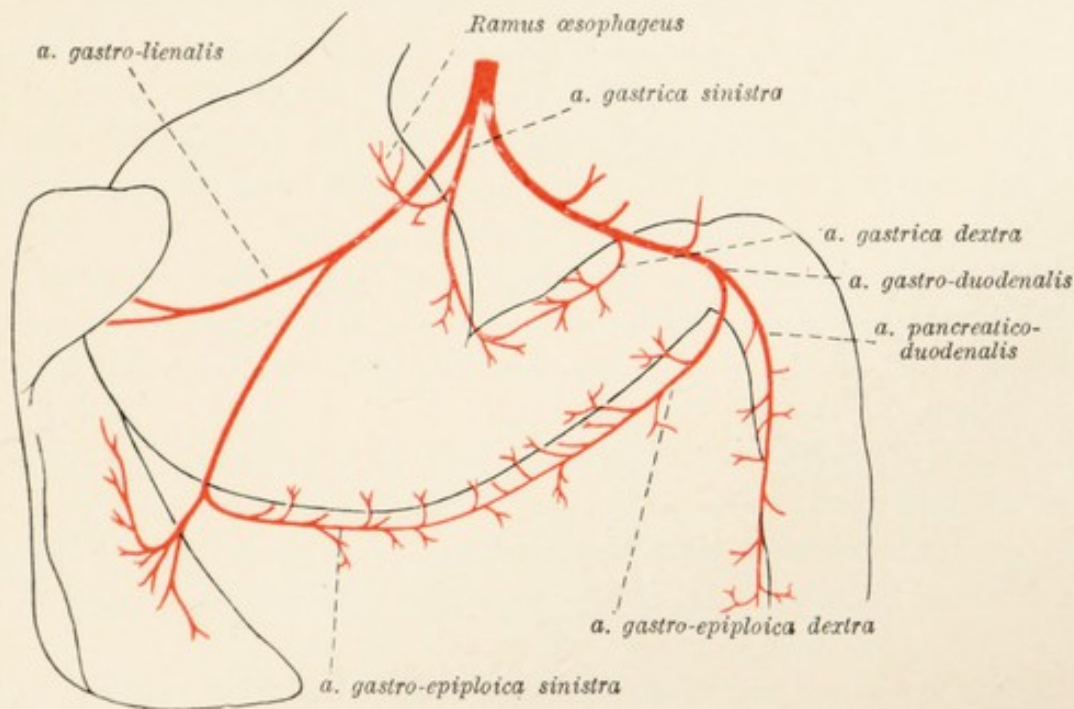


FIG. 13.—Celiac artery: semi-diagrammatic.

and the adjacent part of descending duodenum. This will also expose the pancreatico-duodenal artery and vein.

It will be noticed that the ductus pancreaticus is generally quite small, whereas the ductus pancreaticus accessorius is large. Occasionally the ductus pancreaticus opens into the duodenum independently, immediately distal to the orifice of the common bile-duct.

A. CÆLIACA.—The celiac artery is dorsal to the left limb of the pancreas, and is difficult of dissection from its association with the celiac ganglia and plexus of the sympathetic nervous system. Possibly the easiest way to find the vessel is by following the already isolated hepatic artery.

The celiac artery is a very short vessel which leaves the aorta between the two lumbar parts of the diaphragm. Its branches are the *hepatic*, *left gastric*, and *splenic arteries*; the two last-named generally arising at the same point or even from a short common trunk.

A. HEPATICA.—The hepatic artery is far from being exclusively devoted to the supply of the liver. Indeed, the greater part of the blood which it carries is destined for the stomach, the duodenum, and the pancreas. Passing in a cranial and ventral direction, the artery reaches the porta of the liver, where it furnishes a variable number (2–5) of *proper hepatic arteries* (aa. hepaticæ propriæ) to the liver. Soon after the origin of the last branch to the liver, it contributes a *right gastric artery* (a. gastrica dextra), which anastomoses with the left artery of the same name on the lesser curvature of the stomach. About the same point there is commonly a pancreatic branch.

The hepatic artery continues from the porta in the lesser omentum and arrives in the neighbourhood of the pylorus, where it terminates as the *gastro-duodenal artery* (a. gastro-duodenalis), which, in its turn, ends by dividing into *right gastro-epiploic* (a. gastro-epiploica dextra) and *pancreatico-duodenal* (a. pancreatico-duodenalis) arteries. The former supplies numerous branches in the region of the pylorus and then follows the greater curvature of the stomach in the ventral layer of the greater omentum, to anastomose with the left gastro-epiploic branch of the splenic artery.

The pancreatico-duodenal artery, somewhat larger than the gastro-epiploic, follows the lesser curvature of the duodenum. It supplies the duodenum and the adjacent limb of the pancreas, and ends by anastomosing with the first intestinal artery.

A. GASTRICA SINISTRA.—The left gastric artery is mainly concerned in the supply of the left part of the stomach. One of its branches follows the lesser curvature and anastomoses with the right gastric branch of the hepatic artery. Another branch passes along the œsophagus (ramus œsophageus) into the thorax.

A. LIENALIS.—The splenic artery runs towards the left, dorsal to the pancreas, and in the dorsal layer of the greater omentum. Its terminal branches supply the ventral extremity of the spleen, and its collateral branches of moment are two in number, the *gastro-lienal* and the *left gastro-epiploic* arteries. The former (a. gastro-lienalis) terminates in the dorsal end of the spleen and contributes twigs to the stomach. The left gastro-epiploic artery (a. gastro-epiploica sinistra) ramifies over the greater curvature of the stomach and finally anastomoses with the right artery of the same name.

The splenic artery supplies several branches (rami pancreatici) to the left limb of the pancreas.

VENA PORTÆ.—Since it drains the intestines, stomach, spleen, and pancreas, the portal vein is a vessel of great importance. Found ventral to and to the right of the origin of the cœliac artery, the vein is formed by the union of two venous trunks of considerable size. One of these results from the junction of the splenic and gastric veins, which, in the main, are satellites of the arteries of the same name. The other trunk is produced by the union of the cranial and caudal mesenteric veins, also satellites of the homonymous arteries.

Thus constituted, the portal vein makes directly for the porta of the liver, and has been previously seen in relation to the hepatic artery and the bile-duct. Close to the porta it is joined by the gastro-duodenal vein, and generally also by a fair-sized vessel from the pancreas.

Within the liver the portal vein comports itself after the manner of an artery; that is to say, it repeatedly divides and finally ends in capillary spaces, or sinusoids, between the microscopic cells of the liver.

Dissection.—Strip the mediastinal pleura from the surface of the pericardium and expose the phrenic nerves. At the same time the fat lying in the precardial mediastinum should be removed, in order that the entire length

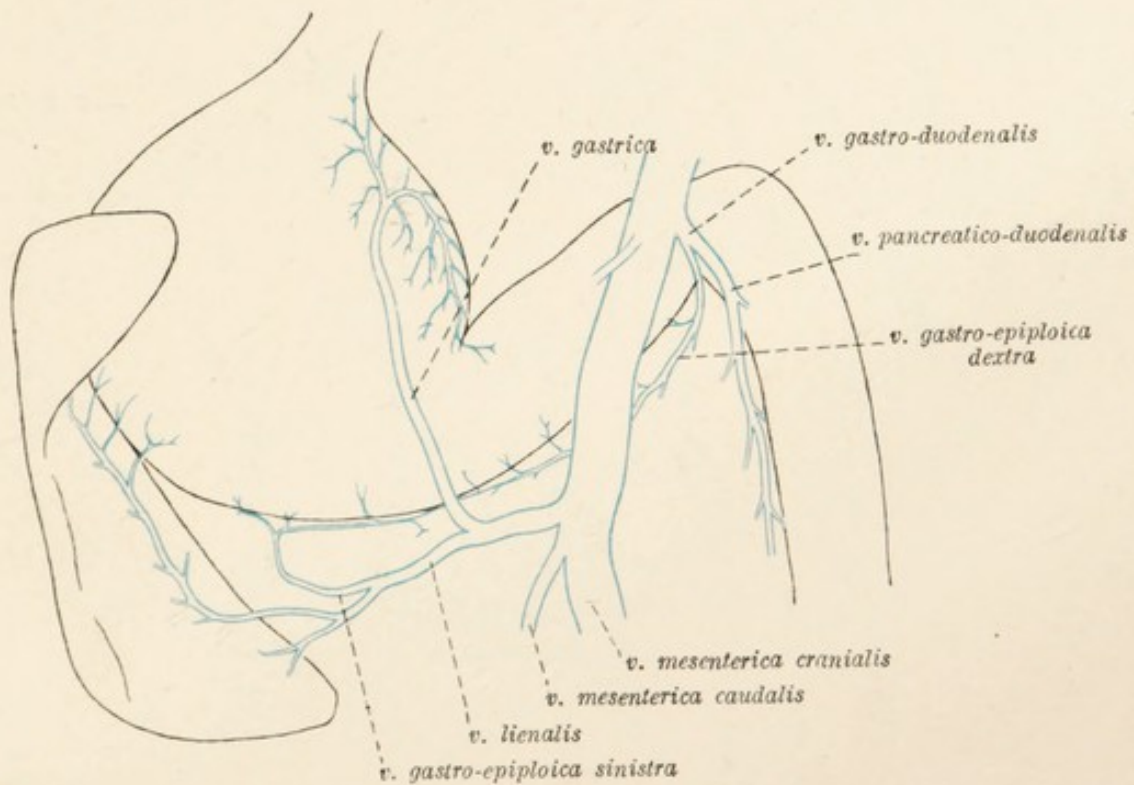


FIG. 14.—Portal vein: semi-diagrammatic.

of the phrenic nerves may be demonstrated. If the subject be a young one, the thymus should be found in this position. Other structures to be sought are the pericardio-phrenic, thymic, and mediastinal branches of the internal mammary artery.

A. MAMMARIA INTERNA.—The greater part of the internal mammary artery has already been examined. Its origin, the first part of its course, and some of its earlier branches remain for consideration. The internal mammary is a branch of the subclavian artery and arises at the first rib. From this point it runs obliquely in a caudal and ventral direction in the precardial mediastinum, and thus reaches the sternum, where its relationship to the transverse thoracic muscle begins. The collateral branches now to be dissected are as follows:

(1) The *pericardio-phrenic artery* (a. pericardio-phrenica) is often very

small. It follows the phrenic nerve as far as the pericardium. (2) Branches to the thymus (aa. thymicæ) are naturally most easily demonstrated in the young. (3) Several small arteries are distributed in the precardial mediastinum (aa. mediastinales anteriores).

V. MAMMARIA INTERNA.—The internal mammary vein is a satellite of the artery of the same name and receives tributaries equivalent to the branches of the artery. The mode of termination of the vein is subject to some variation. It may open into the innominate vein of its own side, or into the cranial vena cava.

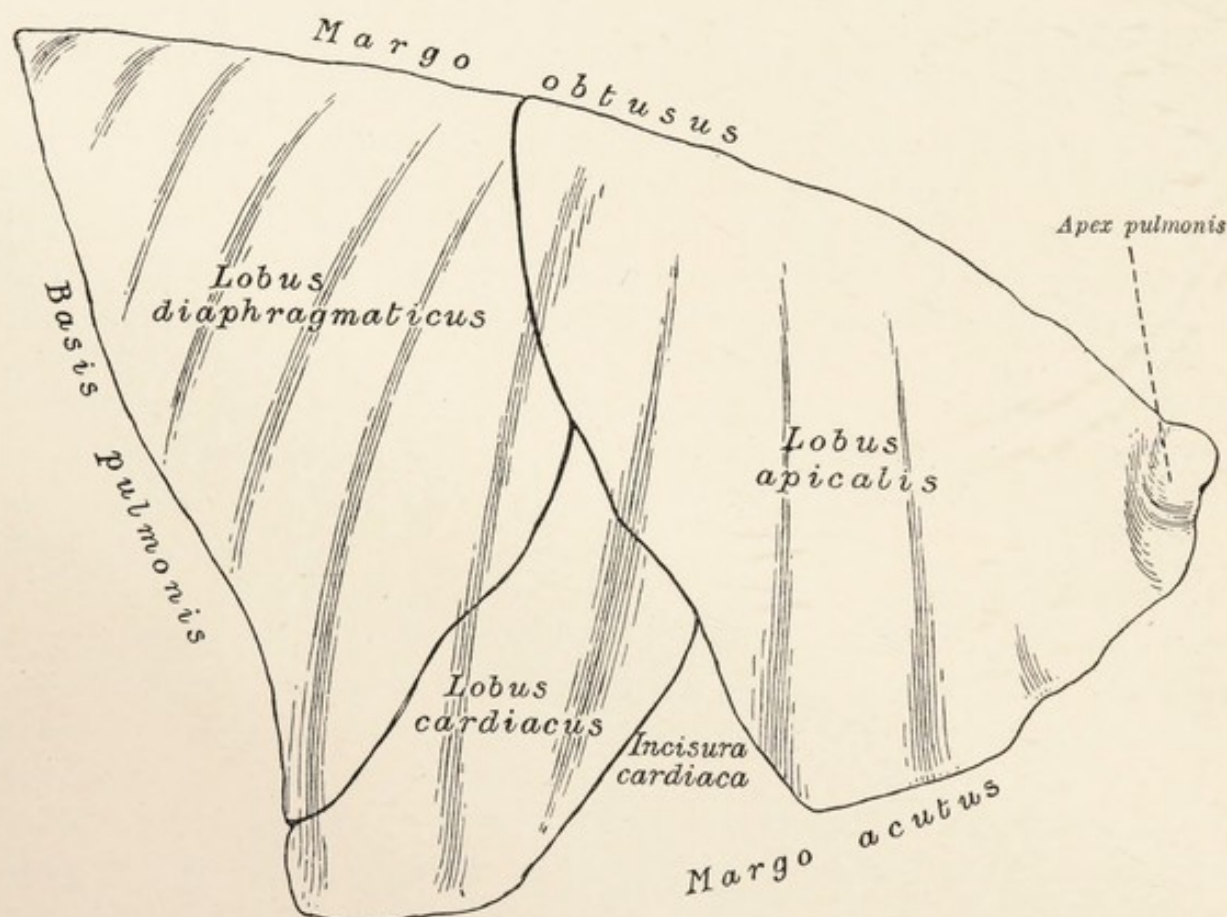


FIG. 15.—Lateral surface of the right lung.

THYMUS.—If the animal be more than two or three years old, there is little chance of seeing more than the merest trace of the thymus. When present and of good size, the organ is a greyish lobulated body lying in the precardial mediastinum, and flattened laterally in conformity with the place of its location. At its maximum development the thymus extends a little beyond the first rib on the one hand, and overlaps the heart slightly on the other.

PULMONES.—Each lung is a soft, spongy organ occupying a considerable part of one side of the thoracic cavity and, as has been seen, in intimate association with the pleura of that side. With the exception of attachments by its *root* (radix pulmonis) and the pulmonary ligament, each lung lies free. The lungs of the dog are frequently of a greyish colour due to pigmentation.

Lobi pulmonis.—Deep fissures, cutting the substance of the organ to its root, divide each lung into lobes. The left lung is completely divided into two parts, of which the more cranial is, in its turn, partially subdivided. The completely isolated lobe is basal in position and is related to the diaphragm—the *diaphragmatic lobe* (lobus diaphragmaticus). The imperfectly separated lobes may be known as *apical* (lobus apicalis) and *cardiac* (lobus cardiacus) from their position and relations.

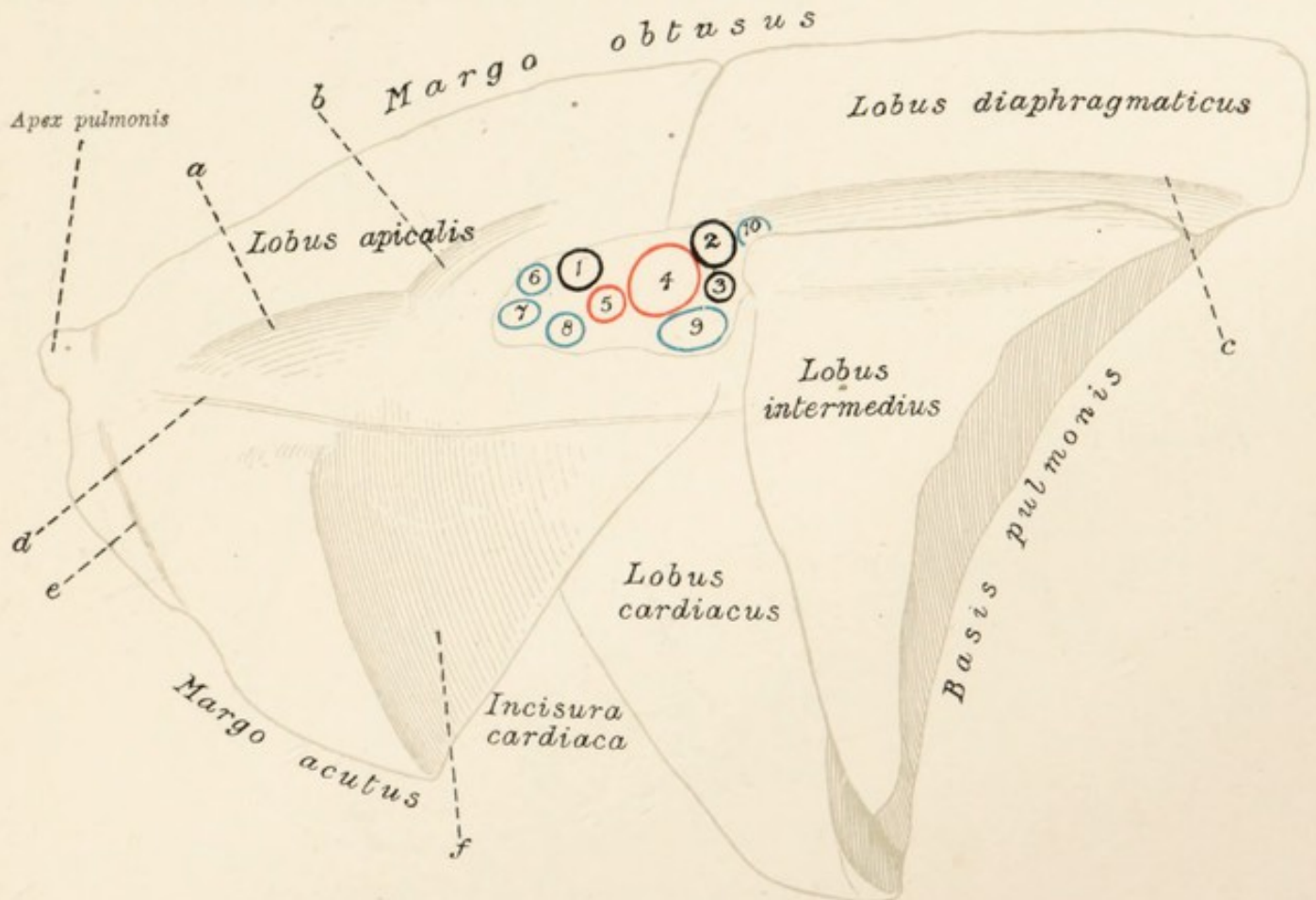


FIG. 16.—Medial surface of the right lung. *a*, Groove for cranial vena cava; *b*, groove for vena azygos; *c*, groove for oesophagus; *d*, groove for phrenic nerve; *e*, groove for internal mammary artery; *f*, depression for heart. 1, Bronchial ramus for apical lobe; 2, bronchial ramus for diaphragmatic and intermediate lobes; 3, bronchial ramus for cardiac lobe; 4, branch of pulmonary artery for cardiac, diaphragmatic, and intermediate lobes; 5, branch of pulmonary artery for apical lobe; 6, 7, 8, pulmonary veins of apical lobe; 9, pulmonary vein of cardiac lobe; 10, pulmonary vein of diaphragmatic and intermediate lobes.

The right lung has apical, cardiac, and diaphragmatic lobes completely separated from each other, and, in addition, an *intermediate lobe* (lobus intermedius) occupying the space between the diaphragmatic lobes of the two lungs, the heart, and the diaphragm. The intermediate lobe is irregularly pyramidal, with its base applied to the diaphragm. At its ventral angle there is a deep, rounded notch, in which are lodged the caudal vena cava, the right phrenic nerve, and the fold of pleura associated with these structures.

The *lateral* or *costal surface* (facies costalis) of each lung is smooth and glistening from the presence upon it of visceral pleura. Being applied closely

to the wall of the chest, the surface follows the curve of the ribs and is, therefore, convex dorso-ventrally. When the lungs have been satisfactorily hardened by preservative before the chest is opened, the surface is generally marked by grooves which indicate the position of the ribs.

The *medial* or *mediastinal surface* (facies mediastinalis) is of much smaller extent owing to the fact that the diaphragm encroaches more upon the thorax medially than laterally. The presence of the heart produces a deep depression on this face. Immediately dorsal to the depression for the heart is the *hilus*

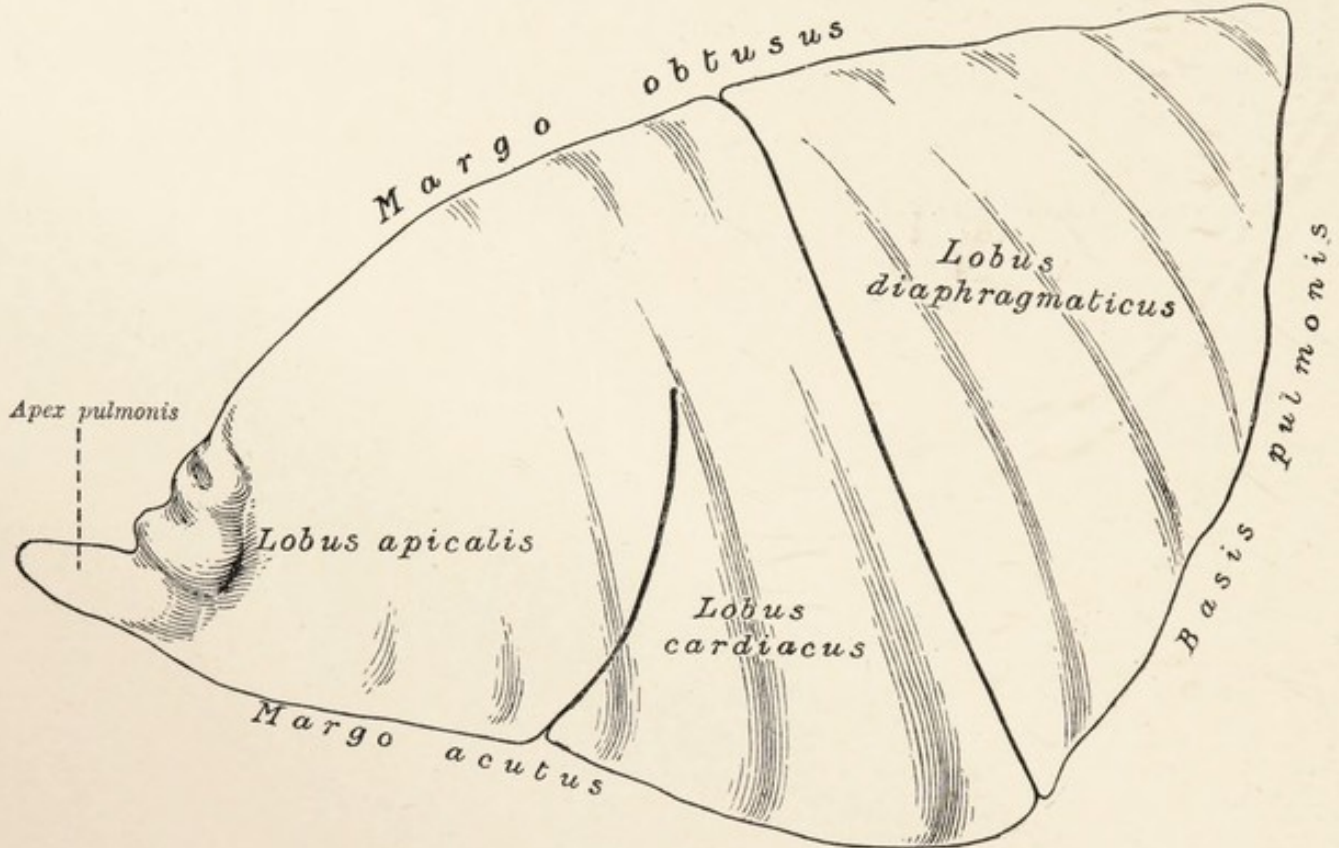


FIG. 17.—Lateral surface of the left lung.

pulmonis—that is, the point of attachment of the root. Cranial to the cardiac depression, each lung, if well hardened, shows a curved groove for the internal mammary artery. Though these are the general features of the mediastinal surface, there are certain points of dissimilarity in the two lungs. In addition to the cardiac depression, the left lung possesses a deep groove, dorsal to the hilus and the pulmonary ligament, in which lies the aorta. The rest of the surface is flattened.

The mediastinal surface of the right lung has an extensive cardiac depression, in the formation of which the intermediate lobe plays a part. Running from the neighbourhood of the lung apex is a broad groove for the cranial vena cava; and dorsal to the hilus there is a deep, slightly curved channel connected with the groove for the vena cava. The second of these grooves is produced by the vena azygos. Caudal to the lung root and partly formed by the

intermediate lobe, there is a broad groove for the œsophagus. The intermediate lobe itself forms a prominent, pointed projection on the surface. Sometimes the cardiac depression is crossed by a narrow, shallow groove caused by the right phrenic nerve.

The *dorsal* or *obtuse border* (*margo obtusus*) of the lung is adapted to the channel formed by the ribs and the vertebræ, and consequently is thin at the apex, but becomes thick and rounded towards the base of the organ.

The *ventral* or *acute border* (*margo acutus*) is much shorter and thin

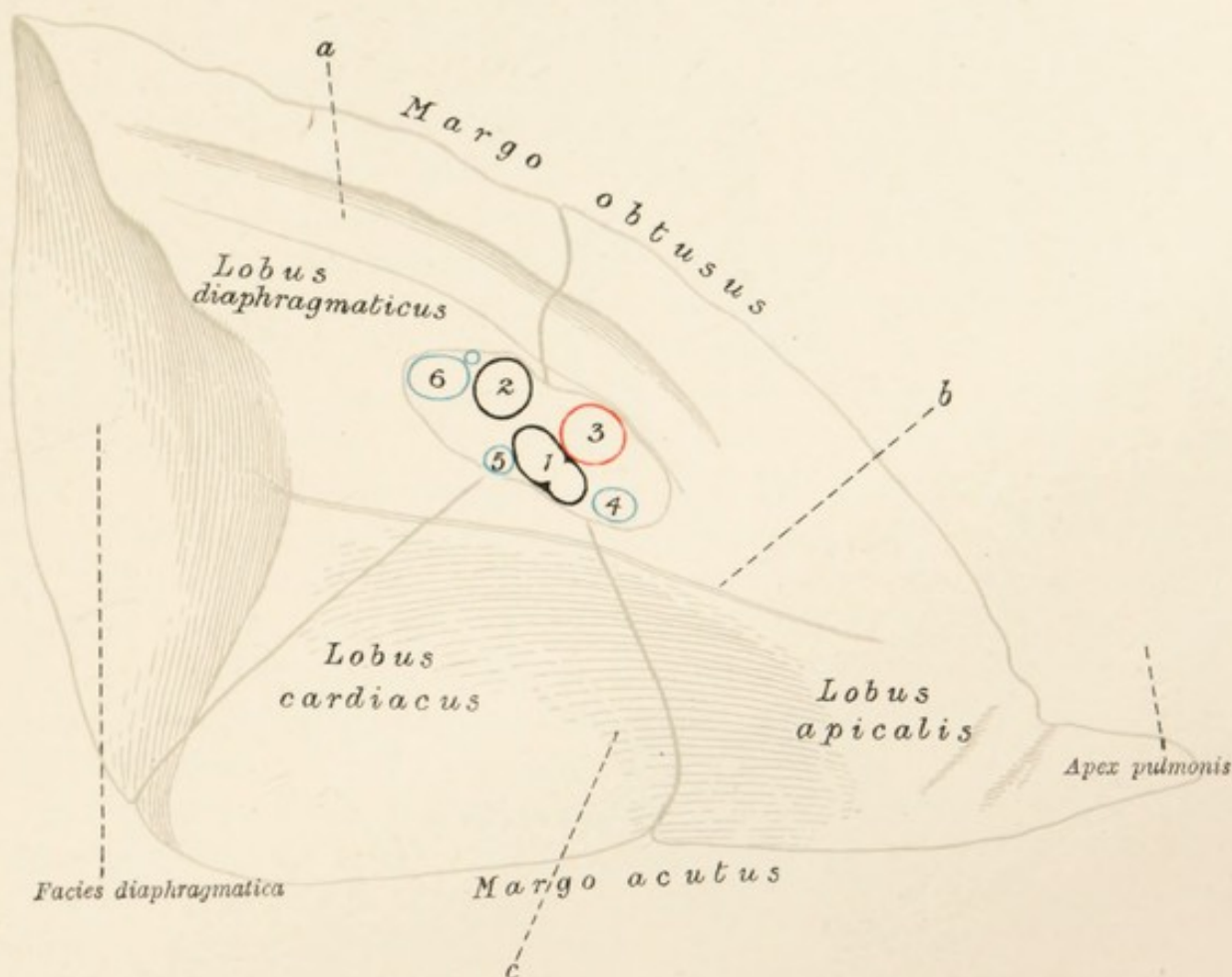


FIG. 18.—Medial surface of the left lung. *a*, Groove for aorta; *b*, groove for phrenic nerve; *c*, depression for heart. 1, Bronchial rami for apical and cardiac lobes; 2, bronchial ramus for diaphragmatic lobe; 3, pulmonary artery; 4, pulmonary vein of apical lobe; 5, pulmonary vein of cardiac lobe; 6, pulmonary vein of diaphragmatic lobe.

throughout. It occupies the narrow space (*sinus costo-mediastinalis*) between the ribs and the mediastinal septum, and is notched for the accommodation of the heart (*incisura cardiaca*). The cardiac notch is much deeper in the right lung than it is in the left; consequently more of the heart is uncovered by lung on the right side of the chest than on the left.

The *apex* (*apex pulmonis*) of the lung is free, blunt, and laterally flattened. The *base* (*basis pulmonis*), being applied to the diaphragm, possesses a concave surface (*facies diaphragmatica*) which slopes in a caudal and lateral direction.

Except medially, the border circumscribing the base is sharp and fits into the narrow space between the diaphragm and the ribs (sinus phrenico-costalis).

It will be noticed that the two lungs differ in two conspicuous respects.

- (1) The incisura cardiaca is deeper in the right lung because the more bulky part of the heart, the base, inclines towards the right side of the body.
- (2) The right lung is the larger and possesses an extra (intermediate) lobe.

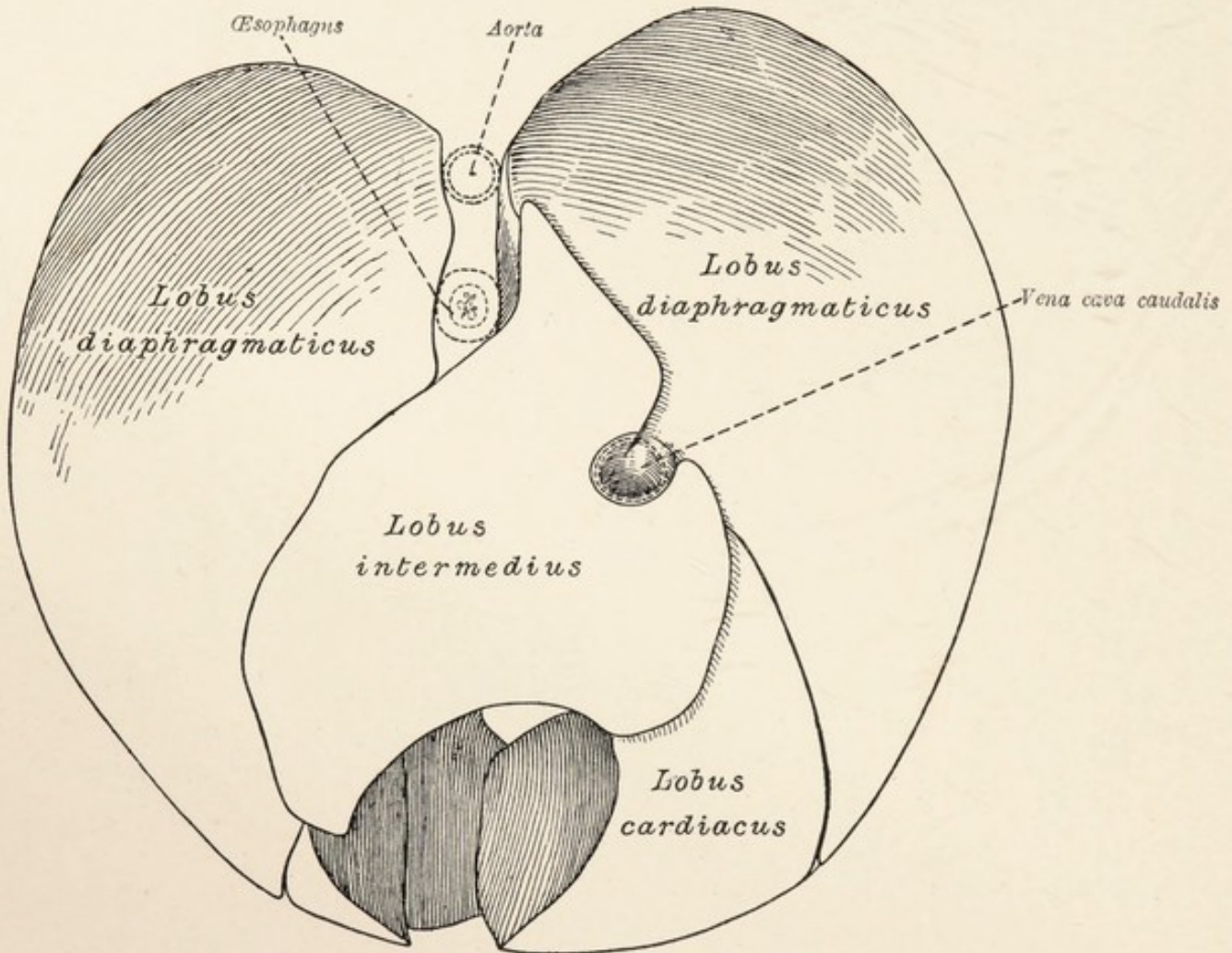


FIG. 19.—Diaphragmatic surface of the lungs.

Dissection.—The constituents of the root of the lung should now be isolated.

In removing the pleura and the fatty connective tissue, great care should be exercised not to injure the pulmonary plexus of nerves which is cranial to the root. The plexus is more accessible on the left side, the vena cava interfering with its dissection on the right. The various structures should be followed into the interior of the lung, in order that their manner of branching may be observed.

RADIX PULMONIS.—The root of each lung contains the following structures :

- (1) Several pulmonary veins conveying blood from the lung to the heart. Although it is difficult to indicate the relative position of the root constituents precisely without making the account of undue length, it may be said that,

speaking generally, the pulmonary veins are most ventral. (2) Pulmonary artery distinguished from the veins by the greater thickness of its wall, and by a somewhat more dorsal position. (3) Bronchus, a large air-tube produced by the division of the trachea. The bronchus occupies the dorsal part of the lung root. (4) Bronchial vessels of small size. (5) Nerves in the form of the pulmonary plexus, which is produced by the intercommunicating branches from the vagus and sympathetic nerves, and is connected with the cardiac plexus. (6) Lymphatic vessels.

Each root has certain structures closely related to it. The vena azygos curves round the root of the right lung; and the aorta is similarly disposed on the left side. Both roots are crossed by the vagus nerve; and the phrenic nerve, though not in contact with, is ventral to the root. Both roots, moreover, have a pulmonary ligament continued towards the diaphragm.

N. PHRENICUS.—The origin of the phrenic nerve by three roots from the fifth, sixth, and seventh cervical nerves has already been noted. Both right and left nerves enter the thorax ventral to a subclavian artery and pass through the precardial mediastinum. They then cross the pericardium ventral to the roots of the lungs. The left nerve continues through the post-cardial mediastinum to the diaphragm, but the right nerve courses along the lateral aspect of the caudal vena cava and is therefore not contained within the mediastinal septum, but in the special fold of pleura provided for the caval vein. There is a further difference in the relations of the two nerves. The left crosses the commencement of the aortic arch and the pulmonary artery, the pericardium intervening; whereas the right lies along the lateral face of the cranial vena cava.

PERICARDIUM.—The pericardium is a fibro-serous sac somewhat loosely enveloping the heart. It is conical in form with the base of the cone looking towards the vertebræ and the entrance to the chest. The apex points towards the sternum and the diaphragm. Between the pericardium and the sternum there is no attachment; but the apex of the sac is connected with the fleshy part of the diaphragm by a strong, flattened ligament. The outer face of the pericardium is covered by pleura (pleura pericardiaca), and, as has just been noticed, is crossed by the phrenic nerves.

The outer layer of the pericardium is composed of fibrous tissue, and is continued, as tubular investments, onto the large vessels associated with the base of the heart.

Dissection.—Make a crucial incision through the pericardium and examine its interior.

Within the fibrous pericardium is a serous membrane disposed after the customary manner of its kind: that is to say, the parietal part of the membrane lines the fibrous pericardium, and is reflected along the great vessels onto the heart itself as the visceral portion or *epicardium*. It will be

observed that the aorta and pulmonary artery are enclosed within a common tubular sheath of the serous pericardium. Dorsal to these vessels is a passage, the *transverse sinus of the pericardium* (sinus transversus pericardii).

The serous membrane endows the fibrous pericardium and the surface of the heart with a smooth glistening appearance, and, like all other serous membranes, is always moist.

VENA CAVA CRANIALIS.—The cranial vena cava is a large vessel formed, on about the level of the middle of the first sternal segment, by the union of the right and left innominate veins. Each innominate vein (v. anonyma) in its turn results from the junction of the jugular and subclavian veins of its own side. As collateral tributaries, each innominate vein has the internal mammary vein and a common trunk formed by the vertebral and costo-cervical veins flowing into it. Any of these, however, may join the vena cava itself.

The cranial vena cava lies in the precardial mediastinum ventral to the trachea, and pierces the pericardium to the right of the aortic arch. The vein terminates by opening into the right atrium of the heart.

During the process of cleaning the vena cava, several *mediastinal lymph-glands* (lympho-glandulæ mediastinales) will be revealed. Some of these are ventral to the vein: others are between the vein and the trachea.

VENA AZYGOS.—The azygos vein begins in the abdomen and drains a considerable proportion of the wall of the chest. At the present moment only its terminal part can be examined. The vein joins the cranial vena cava just as this is entering the heart, or it may open into the right atrium itself.

VENA CAVA CAUDALIS.—The caudal vena cava begins on a level with the last lumbar vertebra, and enters the thorax by the foramen venæ cavæ of the diaphragm. The thoracic part of the vein, which is all that should be examined now, lies in a notch in the intermediate lobe of the right lung, enclosed in a fold of pleura. The vein passes through the pericardium and opens into the right atrium of the heart.

The right phrenic nerve, as has already been said, lies lateral and ventral to the vein.

Dissection.—In order to give more room for the dissection of the heart, etc., the lungs may now be removed.

COR.—The heart is a hollow muscular organ in the form of an irregular cone placed so obliquely in the chest that its *base* (basis cordis) looks slightly towards the vertebral column, but mainly towards the entrance to the thorax. The blunt *apex* (apex cordis), on the other hand, is directed mainly towards the diaphragm, but also towards the ventral aspect of the body and slightly towards the left.

The heart of the dog is flattened in an oblique dorso-ventral direction, so that it presents convex sterno-costal and diaphragmatic surfaces and thick right and left borders.

The exterior of the heart is divided into areas corresponding to the four cavities in the interior. Forming the base are the two atria, separated from the much larger ventricles by the *coronary sulcus* (sulcus coronarius), which is continuous round the whole heart except where interrupted by the pulmonary artery. Owing to the presence of fat and blood-vessels, the depth of the sulcus cannot be properly estimated in the undissected heart.

Externally the distinction between the right and left atria is very im-

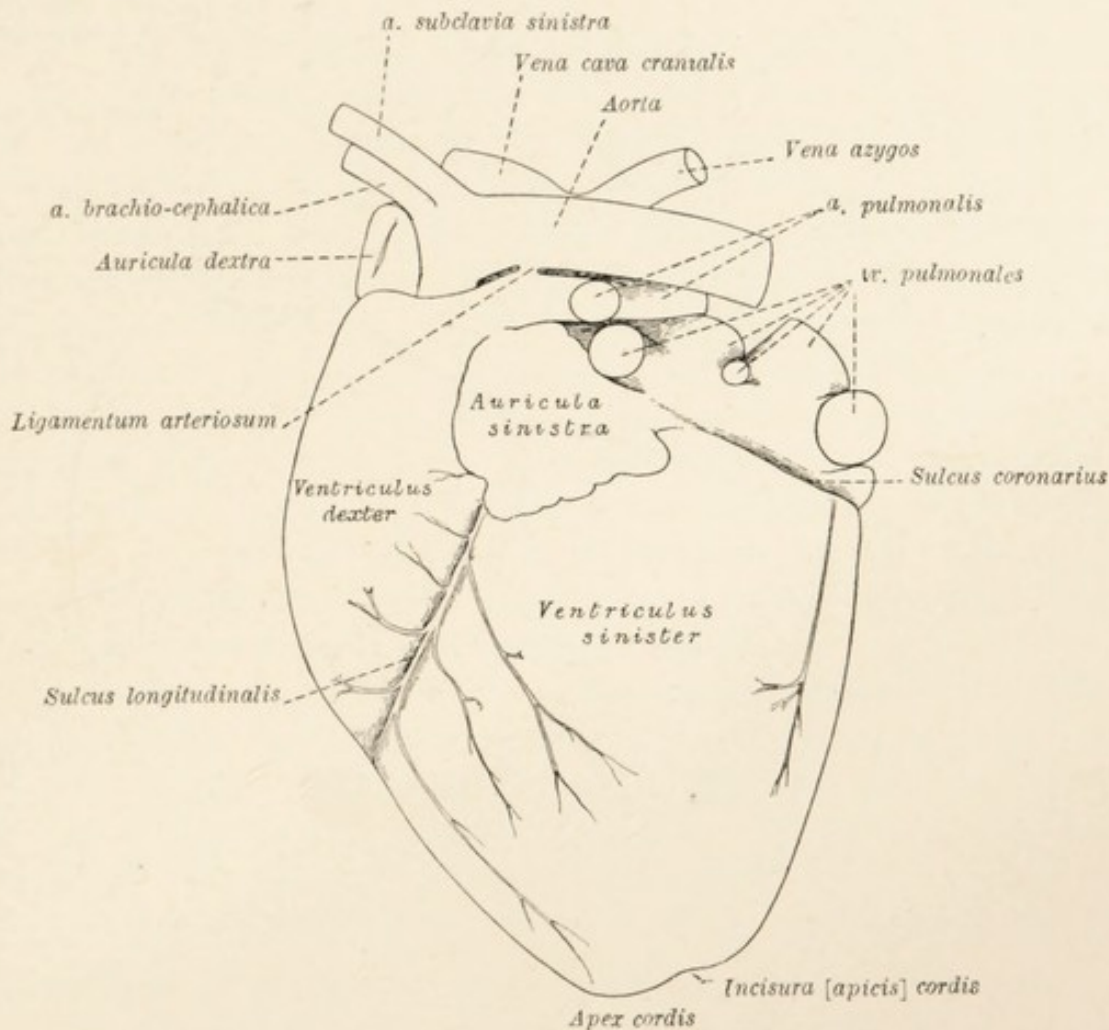


FIG. 20.—Outline of the heart as seen from the left.

perfectly marked, except on the left side. Caudally there is only a faint line of demarcation between the two chambers in the form of a shallow groove between the pulmonary veins and the caudal vena cava. Consequently the common atrial mass is crescentic in form, the horns of the crescent being two free projections, the *auriculæ cordis*, separated from each other by the pulmonary artery and the aorta.

The ventricular part of the heart is responsible for the conical shape of the organ as a whole. Its base is connected with the atria, while its apex forms the apex of the entire organ. The common mass of the two ventricles presents two surfaces and two borders. The sterno-costal face (facies sterno-

costalis) is convex and is crossed obliquely by a furrow, the *ventral longitudinal sulcus* (sulcus longitudinalis ventralis), which commences at the root of the pulmonary artery and extends as far as the right border. The diaphragmatic surface (facies diaphragmatica) differs in being not so convex

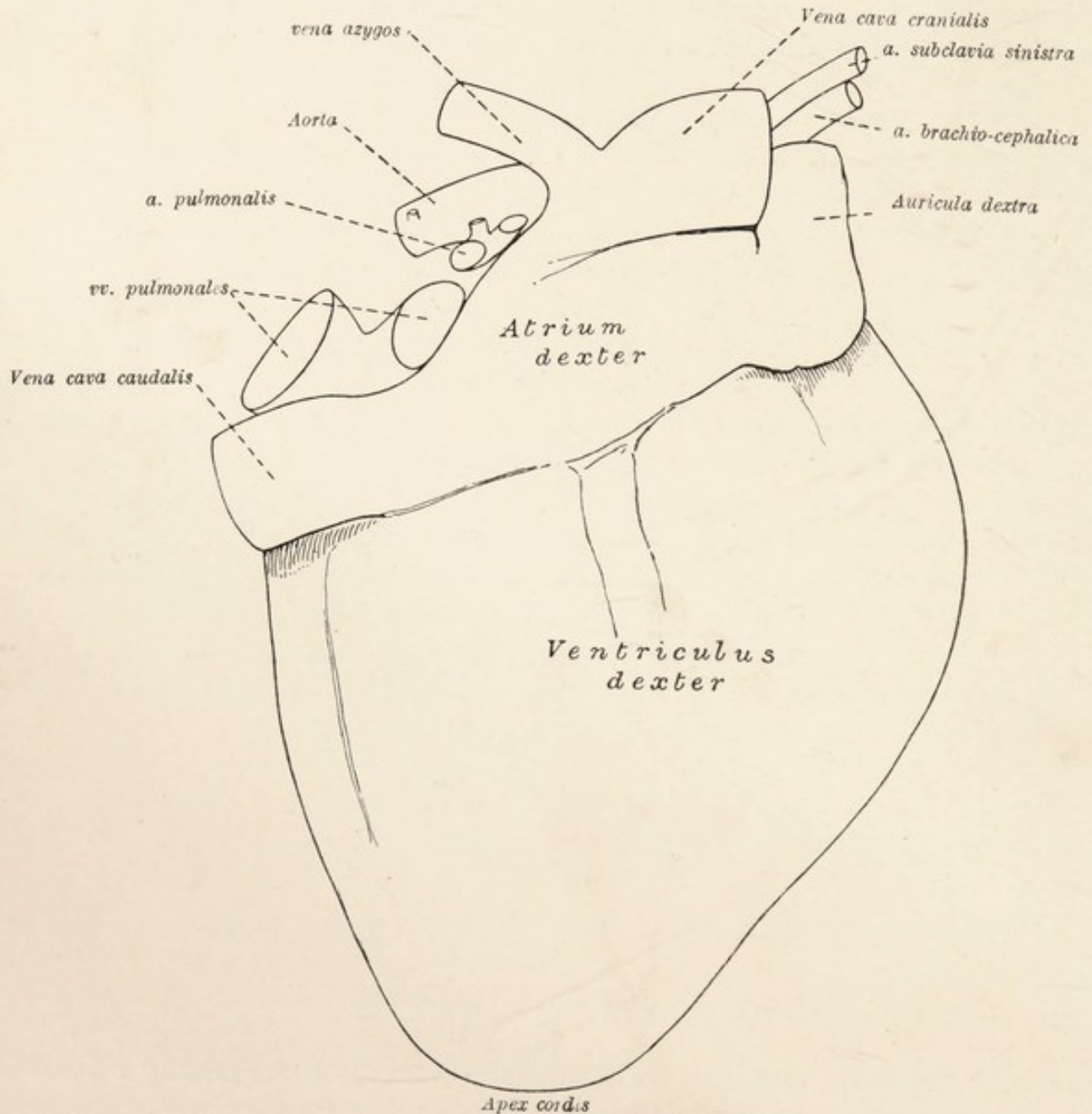


FIG. 21.—Outline of the heart as seen from the right.

and of much smaller extent. It is traversed by a *dorsal longitudinal sulcus* (sulcus longitudinalis dorsalis), which begins at the coronary sulcus opposite the terminal part of the caudal vena cava, and ends by joining the ventral longitudinal sulcus at the right border of the heart. The two grooves indicate the position of the septum between the two ventricles.

The borders of the heart differ considerably. The right is the longer, the

more convex, and much the sharper, and is notched where the two longitudinal grooves join a little to the right of the apex.

Dissection.—The vessels and nerves which supply the substance of the heart should now be examined. In order to do this it is necessary to remove the epicardium and subjacent fat from the grooves. The remains of the pericardium should also be cleared away.

The wall of the heart is supplied with blood by the two coronary arteries, right and left.

A. CORONARIA DEXTRA.—The right coronary artery leaves the aorta behind the right valve which guards the exit of this vessel from the left ventricle. From this point it runs along the right part of the coronary sulcus to the diaphragmatic surface of the heart, where it gives off a descending branch (*ramus descendens*) which traverses the dorsal longitudinal sulcus.

A. CORONARIA SINISTRA.—The left coronary artery is much larger than the right, and leaves the aorta behind its left valve to pass backwards to the right of the pulmonary artery. Its circumflex branch (*ramus circumflexus*) runs along the coronary sulcus to the diaphragmatic surface, where it ends close to the termination of the right artery. Numerous branches ramify over the surface of the left ventricle, but the largest (*ramus descendens*) leaves the coronary artery very early and follows the ventral longitudinal sulcus. Another descending branch of smaller size leaves the coronary artery close to its termination, and is distributed over the wall of the ventricle.

Vv. CORDIS.—An examination of the coronary sulcus on a level with the pulmonary veins and the caudal vena cava will reveal a large venous trunk of no great length. This is the *coronary sinus* (*sinus coronarius*) in which the large vein of the heart (*v. cordis major*) ends. By means of the sinus the bulk of the blood from the wall of the organ is transferred to the right atrium. In addition, there are numerous small veins which open directly into the atrium.

Dissection.—Now proceed to examine the interior of the heart, beginning with the right atrium. In order to open this cavity most advantageously, it is necessary to make two incisions. (1) Enter the knife at the termination of the caudal vena cava and carry it in a straight line to the point at which the cranial vena cava joins the heart. (2) From the middle of the first incision carry a second to the tip of the auricle of the atrium.

ATRIUM DEXTRUM.—As an examination of the exterior of the heart has shown, each atrium is divisible into a main part intimately connected with the other atrium and the ventricle of its own side, and a freer auricle (*auricula cordis*).

Like all the cavities of the heart, the interior of the right atrium is lined by a smooth, glistening membrane, the *endocardium*; but the wall of the auricle and the right wall of the main cavity are rendered uneven by the presence of reticulate muscular ridges known as the *musculi pectinati*. The ridges end at

a prominent, semilunar crest, the *crista terminalis*, which corresponds in position to a shallow and sometimes very imperfectly defined groove, the *sulcus terminalis*, on the exterior of the atrium.

The openings by which blood enters the atrium are as follows: (1) The opening of the caudal vena cava; (2) the opening of the cranial vena cava; (3) the opening of the coronary sinus; (4) the foramina of the small veins of the heart (foramina venarum minimarum [Thebesii]).

The caval openings occupy the caudal and cranial ends of the atrium. Between them is a semilunar ridge projecting from the wall of the cavity, and known as the *intervenous tubercle of Lower* (tuberculum intervenosum [Loweri]). The coronary sinus opens immediately ventral to the caudal caval opening, and between this and the orifice which leads from the atrium into the right ventricle. A variable fold of endocardium and subendocardial tissue, the *valve of the vena cava* (valvula venæ cavæ [Eustachii]), exists between the mouth of the coronary sinus and the caval opening. The foramina of the small cardiac veins are scattered over the wall of the atrium.

The blood passes from the atrium into the right ventricle by a large, rounded orifice, which occupies the whole of the floor of the main part of the atrium.

The septum between the right and left atria (septum atriorum) is not equally thick throughout. The thinnest part is at the bottom of a poorly defined depression, the *fossa ovalis*, which marks the position of an embryonic connection between the two cavities.

Dissection.—The right ventricle must now be opened. Make an incision through the wall of the ventricle parallel to, and a short distance from, the coronary sulcus. Care must be taken not to insert the knife too deeply, or the tricuspid valve may be injured. The incision should be carried well towards the commencement of the pulmonary artery. A second incision must begin where the first finished, i.e. near the pulmonary artery, and should be carried parallel to, and a short distance from, the longitudinal sulcus as far as the right border of the heart.

VENTRICULUS DEXTER.—The cavity of the right ventricle has a triangular outline. The base of the triangle is formed by the right border of the heart, and its apex by that part of the ventricle which is known as the *conus arteriosus* from its conical shape and from its communication with the pulmonary artery. The cavity of the ventricle does not reach the apex of the heart, but stops short on a level with the point at which the longitudinal sulcus of the exterior crosses the right border.

It will be noticed that the septum between the two ventricles (septum ventriculorum) is convex towards the right, thus causing the cavity of the right ventricle to present a crescentic outline were a transverse section to be made.

The whole of the interior of the wall of the ventricle is irregular owing to the presence of fleshy ridges (trabeculæ carneæ) of variable size and form.

These are least well marked in the conus arteriosus. Some of the trabeculæ are ridges simply ; others are in the form of cords attached at their two ends ; whereas three or more projections are of considerable size and are attached to the wall of the cavity by one extremity only. These conical, muscular processes are known as the *musculi papillares*, and have filamentous *tendinous cords* (*chordæ tendineæ*) attached to their apices. One or more slender, and often branched, muscular cords pass across the cavity of the ventricle from the septum to the outer wall.

The opening (*ostium venosum*) from the atrium into the ventricle is guarded by the *tricuspid valve* (*valvula tricuspidalis*), composed of three triangular, membranous cusps. The bases of the cusps are attached to the margin of the atrio-ventricular orifice, and each cusp has *chordæ tendineæ* affixed to its margins and ventricular surface. Most usually smaller cusps, of similar form, intervene between the three major cusps.

The exit from the ventricle, i.e. the opening (*ostium arteriosum*) into the pulmonary artery, is provided with three pocket-shaped semilunar valves so arranged as to prevent the backward flow of blood from the artery into the ventricle, but offering no obstacle to the passage of blood from the ventricle into the artery. Of the three valves, one is cranial, one is to the right, and one is to the left. By slitting open a part of the pulmonary artery the character of the valves may be more easily observed. Each segment has an attached convex border and a concave free margin looking towards the pulmonary artery. Behind each valve there is a slight bulging of the wall of the artery, which is here thinner than in other parts of the vessel.

Dissection.—Now proceed to examine the left side of the heart, commencing with the left atrium. To open this chamber it is only necessary to make one incision, beginning far back and cutting forwards to the extremity of the auricular appendage. The incision should be made at no great distance from the coronary sulcus, in order to avoid injury to the terminations of the pulmonary veins.

ATRIUM SINISTRUM.—In its outward characters the left atrium differs somewhat from the corresponding chamber on the right side of the heart. The auricle is more ventral in position, blunter at its tip, and more or less dentated along its border. In the interior of the cavity the wall is smooth, except in the auricle, in which part alone are there *musculi pectinati*. The number of openings from the pulmonary veins into the atrium is variable (three to five). The atrio-ventricular orifice (*ostium venosum*) is oval in outline and somewhat smaller than the corresponding opening in the right chamber.

Dissection.—In order to open the left ventricle an incision should commence near the coronary sulcus and be carried parallel to one longitudinal sulcus, round the apex and up the other side parallel to the other longitudinal sulcus.

VENTRICULUS SINISTER.—The left ventricle differs from the right in its general shape. It is conical in conformity with the general form of the ventricular part of the heart, and its apex is continued to the apex of the heart as a whole. Owing to the thickness of its wall, coupled with the fact that the inter-ventricular septum is concave towards the left, a transverse section of the left ventricle would present an oval or rounded outline.

Generally the trabeculæ carneæ are less conspicuous than in the right ventricle; and the papillary muscles are larger and only two in number.

The atrio-ventricular opening (ostium venosum) is provided with a valve of two cusps (valvula bicuspidalis), each being larger and stronger than the segments of the tricuspid valve. As on the right side, there are generally smaller cusps intervening between the major segments.

The exit from the ventricle is by way of the aortic opening (ostium arteriosum), around which are arranged three semilunar valves similar to those guarding the entrance to the pulmonary vein, but stronger in structure. The three semilunar segments are arranged so that one is caudal, one to the right, and one to the left.

AORTA.—The aorta—the main artery of the body as a whole—leaves the left ventricle. The first part of the vessel forms an arch which may be divided, for descriptive purposes, into (1) the ascending aorta, and (2) the aortic arch proper. The ascending portion is short and runs in a cranio-dorsal direction and towards the left (to the middle line). From it arise the two coronary arteries for the supply of the substance of the heart.

The aortic arch has its convexity looking dorso-cranial and towards the left. From the convex side of the arch spring two vessels, the *brachio-cephalic* and *left subclavian* arteries. The concave side of the arch is closely related to the pulmonary artery, with which it is connected by a fibrous cord, the *ligamentum arteriosum*, representing an embryonic communication between the two vessels.

Dorsally the aortic arch is related to the trachea and oesophagus. The left vagus, cardiac, and recurrent nerves cross the ventral surface of the arch near its termination.

Dissection.—The vessels leaving the aortic arch should be followed to the entrance to the chest. This is facilitated by cutting through the cartilages of the first pair of ribs just where they join the bony segment of the rib. The first segment of the sternum, with the cartilages attached, may now be turned over towards the head. The cranial vena cava should also be cut across. In cleaning the arteries great care must be taken to preserve intact the numerous nerves—some of them small—which are related to the vessels.

A. BRACHIO-CEPHALICA.—The brachio-cephalic artery is the larger of the two vessels arising from the aortic arch, and is the first to take origin therefrom.

It leaves the arch about the middle line and passes towards the thoracic inlet immediately ventral to the trachea. The brachio-cephalic artery gives origin to the *left common carotid artery*, and shortly afterwards terminates by dividing into the *right subclavian* and *right common carotid* arteries.

A. CAROTIS COMMUNIS SINISTRA.—The left common carotid artery begins ventral to the trachea and travels to the thoracic inlet by running obliquely across the ventral face of the œsophagus.

A. SUBCLAVIA DEXTRA.—The right subclavian artery curves lateralwards to the cranial border of the first rib. Ventral to it are the right innominate vein, the right phrenic, and vagus and sympathetic nerves. The right recurrent nerve (a branch of the vagus) bends round the caudal border of the artery. The branches of the right subclavian artery are : (1) *Vertebral artery* ; (2) *costo-cervical trunk* ; (3) *internal mammary artery* ; (4) *omo-cervical trunk* ; (5) *axillary artery*.

A. CAROTIS COMMUNIS DEXTRA.—The right common carotid artery passes to the thoracic inlet by crossing the ventral surface of the trachea with a slight degree of obliquity.

A. SUBCLAVIA SINISTRA.—The left subclavian artery leaves the aortic arch some little distance to the left of the point of origin of the brachio-cephalic artery, and at a more dorsal level. It gains the thoracic inlet by running along a groove formed by the œsophagus and the longus colli muscle. The left phrenic and vagus nerves lie ventral to the artery. Its branches are the same as those of the right subclavian artery.

A. VERTEBRALIS.—The vertebral artery is of large size, and on the right side crosses the lateral surface of the trachea to disappear between the scalenus and longus colli muscles, and so reach the foramen in the transverse process of the sixth cervical vertebra. Its subsequent course through the foramina of the rest of the cervical vertebræ will be exposed at a later stage in the dissection. The left vertebral artery crosses the œsophagus instead of the trachea.

TRUNCUS COSTO-CERVICALIS.—The costo-cervical trunk is a large branch of the subclavian artery running towards the vertebral column within the first rib. Its branches are three in number, namely, the *deep cervical*, *supreme intercostal*, and *transverse cervical* arteries.

A. CERVICALIS PROFUNDA.—Part of the course of the deep cervical artery has been noted in connection with the serratus ventralis muscle. There only remains to observe its origin and the initial part of its course round the border of the first rib dorsal to the attachment of the scalenus muscle.

A. INTERCOSTALIS SUPREMA.—The supreme intercostal and transverse cervical arteries generally leave the costo-cervical trunk as a short common vessel. The supreme intercostal runs along under the necks of the second and third ribs, and contributes the second, third, and possibly also the fourth intercostal arteries.

A. TRANSVERSA COLLI.—The transverse cervical artery pierces the vertebral extremity of the first intercostal space.

TRUNCUS OMO-CERVICALIS.—The omo-cervical trunk, arising from the subclavian within the first rib, at once leaves the thorax and has been followed in the triangular space at the root of the neck, where it divides into *ascending cervical* and *transverse scapular* arteries.

A. MAMMARIA INTERNA.—The internal mammary artery leaves the subclavian at the same level as the omo-cervical trunk, but from the opposite side of the artery. The whole of its course has now been exposed.

Dissection.—In order to examine the cardiac and pulmonary nerve-plexuses in their entirety, the arch should be cut at its two ends. Then, if the ligamentum arteriosum be also cut, the aortic arch can be turned forward, thus exposing the trachea, œsophagus, and left recurrent nerve.

PLEXUS CARDIACUS ET PLEXUS PULMONALIS.—These two plexuses are intimately connected with one another. They are formed by intercommunicating branches from the sympathetic (ganglion thoracale primum), the vagus, and the recurrent nerves. More or less independent branches (rami bronchiales) leave the vagus about the level of the tracheal bifurcation and pass into the hilus of the lung as constituents of its root. Nerves from the cardiac plexus pierce the pericardium in the neighbourhood of the pulmonary artery and the aorta.

Dissection.—Remove the heart from the thorax. The vena azygos and the caudal vena cava will be the only vessels requiring division. The aortic valves should be displayed by slitting open the commencement of the aorta. In doing so the cut should be made between two cusps so as to avoid undue injury.

VALVULÆ SEMILUNARES.—The *aortic semilunar valves* (valvulæ semilunares aortæ) are constructed on the same principle as those at the entrance to the pulmonary artery, but, owing to the circumstance that they have to withstand a greater pressure of blood, they are stronger. The valve segments are three in number—right, left, and caudal—and are pocket-shaped or semilunar, with the mouth of the pocket directed towards the aorta. A sinus occurs behind each segment as is the case in the pulmonary artery, and in two of the sinuses the openings into the coronary arteries will be seen about on a level with the free edge of the valve segments. The left coronary artery leaves the left sinus, and the right coronary artery leaves the right sinus.

About the middle of the free edge of each segment a small fibrous nodule can be demonstrated. The valve consists of a double layer of endocardium with interposed fibrous tissue. This tissue, however, is not uniformly distributed. A firm cord lies in the free edge of each cusp, and fibrous strands are numerous throughout the valve.

The segments of the *pulmonary semilunar valves* (valvulae semilunares a. pulmonalis) are right, left, and cranial in position. They are the same in general character as those of the aortic valve, but are sometimes destitute of fibrous nodules in their free edge. The sinuses behind them present no orifices leading into arteries.

STRUCTURE OF THE WALL OF THE HEART.—By far the greater part of the thickness of the wall of the heart is composed of muscular tissue constituting the *myocardium*: much more abundant in the ventricles than in the atria. On careful dissection it is possible to show that the muscular fibres are disposed in indefinite layers, and run circularly and obliquely in direction.

At the junction of the ventricles and the atria are two fibrous rings, surrounding the atrio-ventricular orifices, and affording attachment to the bicuspid and tricuspid valves. Smaller rings of fibrous tissue surround the pulmonary and aortic orifices, and give attachment to the valves of these openings.

Covering the heart externally is the visceral portion of the serous pericardium, the *epicardium*, between which and the myocardium is a greater or less amount of fat, particularly obvious in the grooves.

The interior of the heart is lined by a smooth, shining membrane, the *endocardium*, continuous with the lining of the blood-vessels.

ARRANGEMENT OF THE CARDIAC ORIFICES.—If the atria be removed the relationship of the openings into and out of the ventricles will be evident. Most cranial and towards the left is the pulmonary opening. Immediately caudal to this and slightly to its right is the orifice leading into the aorta. The right and left atrio-ventricular openings are not on the same transverse level; the left opening being the more caudal.

Dissection.—Carefully clean the trachea, the bronchi, the œsophagus, and the vagus nerves. In doing so bronchial lymph-glands (lymphoglandulae bronchiales) will be observed in the neighbourhood of the termination of the trachea, more especially between the diverging bronchi.

TRACHEA ET BRONCHI.—The trachea or tube by which air passes to and from the lungs begins in the neck, passes through the thoracic inlet and terminates in the two bronchi immediately dorsal to the commencement of the aorta. The thoracic portion of the trachea is not exactly in the middle line except at its termination. The presence of the œsophagus causes it to incline to the right.

The main ventral relations of the trachea in the chest are the two innominate veins, the cranial vena cava, the right subclavian artery, the right and left common carotid arteries, the brachio-cephalic artery, and the aortic arch. Along the left ventral border runs the left recurrent nerve. To the left the trachea is related to the œsophagus, and to the right to the right phrenic and vagus nerves. Dorsally it is in contact with the longus colli muscle, except close

to its bifurcation, where the œsophagus, inclining towards the right, intervenes.

Of the bronchi, the right is the larger and is in contact with the vena azygos; the left bronchus is crossed dorsally by the œsophagus.

N. VAGUS.—The right and left vagus nerves descend the neck in intimate association with the right and left sympathetic nerve cords, and enter the thorax between the innominate vein and subclavian artery of their own side. The close relationship of the vagus and sympathetic nerves ceases within the first rib or the first intercostal space.

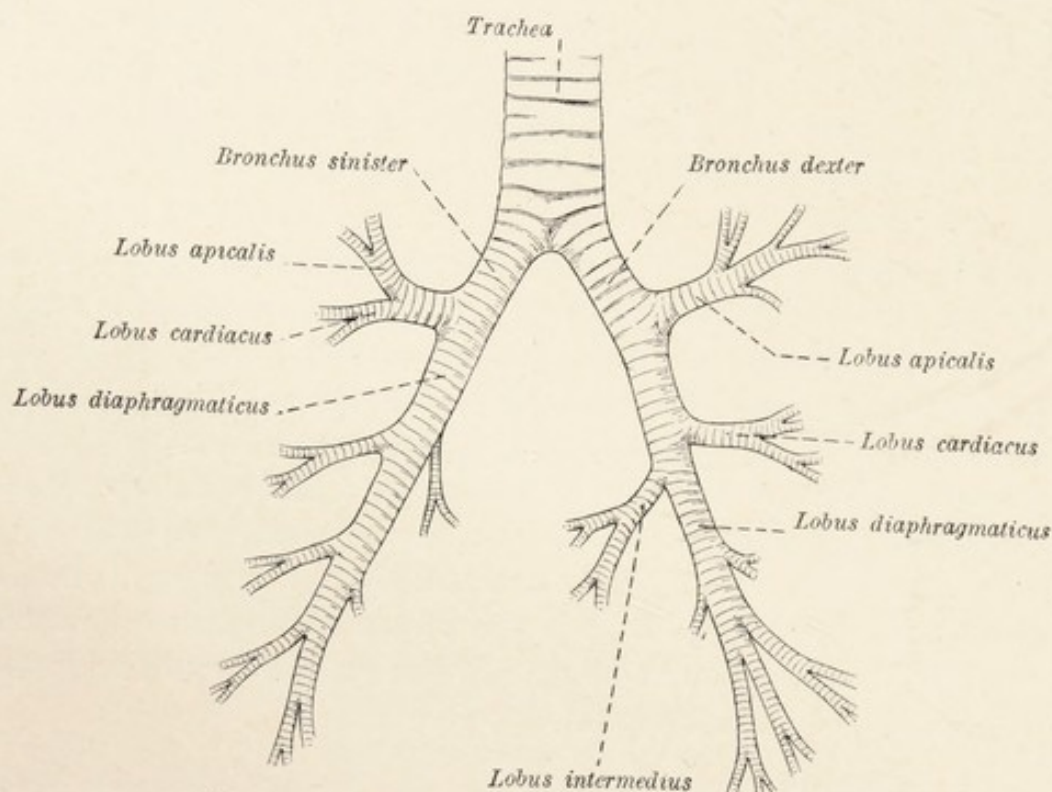


FIG. 22.—Diagram of the branches of the bronchi, indicating to which lobes of the lungs they are distributed.

In the precardial and cardial mediastina the two vagus nerves have different relations. The right nerve is at first lateral to the trachea. It then passes within the vena azygos and across the dorsal aspect of the root of the right lung, and thus reaches the œsophagus. The left nerve arrives at the œsophagus by crossing the lateral face of the aorta obliquely and the dorsal aspect of the root of the left lung.

On the gullet each vagus nerve divides into a *dorsal* and a *ventral branch* (*ramus dorsalis et ramus ventralis*). The ventral branches of the right and left nerves unite just beyond the base of the heart, and form the *ventral œsophageal trunk* (*truncus œsophageus ventralis*). The dorsal branches similarly join to form the *dorsal œsophageal trunk* (*truncus œsophageus dorsalis*), but do not do so until they arrive close to the diaphragm. The two œsophageal nerve trunks leave the thorax by accompanying the œsophagus through the diaphragm.

The branches derived from each vagus nerve while within the chest are cardiac nerves, a recurrent nerve for the larynx, bronchial branches for the lungs, and small branches for the œsophagus.

N. RECURRENS.—The right recurrent nerve turns round either the commencement of the right subclavian or the termination of the brachiocephalic artery, gains the side or the right ventral border of the trachea, and passes to the thoracic inlet dorsal to the right carotid artery. The left nerve winds round the aortic arch, and lies at first along the ventral border of the trachea. At the entrance to the chest it is placed in a groove formed by the trachea and œsophagus. *Pulmonary* and *cardiac branches* (rami pulmonales et rami cardiaci) arise from the recurrent nerves. *Bronchial branches* (rami bronchiales) leave the vagus just aboral to the aortic arch, and enter the lung along with the other constituents of the root.

ŒSOPHAGUS.—The œsophagus enters the chest along with and to the left of the trachea. This relationship is maintained for some distance, but later the œsophagus, inclining to the right, crosses the left bronchus and so reaches the median plane. After this there is a very slight deviation again to the left. The aortic arch traverses the left face of the œsophagus, and the thoracic aorta runs for a short distance in the same relation, but gradually becomes dorsal. The gullet and the vagus nerves are intimately related the one to the other.

Dissection.—Cut across the œsophagus a short distance before it pierces the diaphragm, and turn the cut ends as far apart as possible. Some idea of the structure of the tube may be obtained from an examination of the cut surface. Now clean the thoracic aorta and the vena azygos, taking particular care not to destroy the narrow, thin-walled thoracic duct which lies between them.

STRUCTURE OF THE ŒSOPHAGUS.—A naked-eye examination of a transverse section of the œsophagus shows that, like other tubular parts of the alimentary system, its wall is constructed in layers. On the outside of the tube is a loose areolar covering by which, in the thorax, the mediastinal pleura is attached to the œsophagus. A considerable proportion of the thickness of the wall is formed of muscular tissue (tunica muscularis), red in colour in the fresh state and with fibres coursing in various directions. The interior of the œsophagus is lined by a thick, pale mucous membrane (tunica mucosa), thrown into longitudinal folds when the tube is not distended. The mucous membrane is attached to the muscular coat by a loose submucous tissue (tela submucosa).

AORTA.—The thoracic part of the aorta as it continues the aortic arch onwards, is at first in contact with the longus colli muscle and decidedly to the left of the median plane; but, gradually inclining to the right as the diaphragm is approached, it finally travels along the middle plane of the body.

The œsophagus is at first to the right of the aorta, but later it becomes ventral in position. To the right also are the vena azygos and the thoracic duct.

Dorsally in contact for the greater part of its course with the bodies of the thoracic vertebræ, the aorta is ventrally in successive relation to the root of the left lung, the pericardium, and finally the diaphragm.

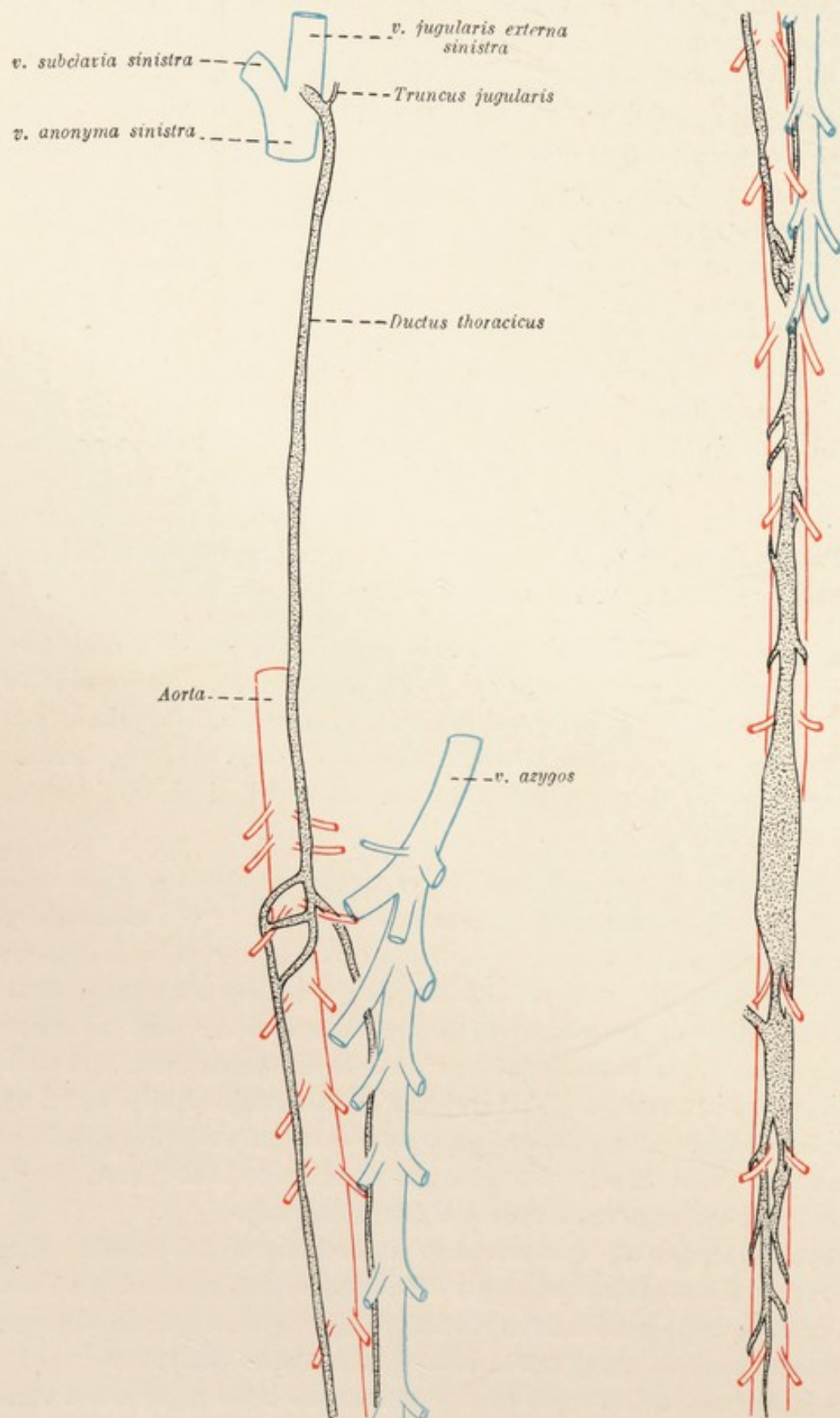


FIG. 23.—Diagram of the thoracic duct.

The branches of that part of the aorta now under consideration are as follows: (1) Nine or ten *intercostal arteries* arising from its dorsal aspect; (2) two or three small *bronchial arteries* arising either from the aorta itself or from the first intercostal artery, and supplying the bronchial lymph-glands and the œsophagus; (3) two or three small *œsophageal arteries* leaving the ventral aspect of the vessel.

DUCTUS THORACICUS.—By means of the thoracic duct the lymph from the whole body, with the exception of that from the right side of the thorax, the

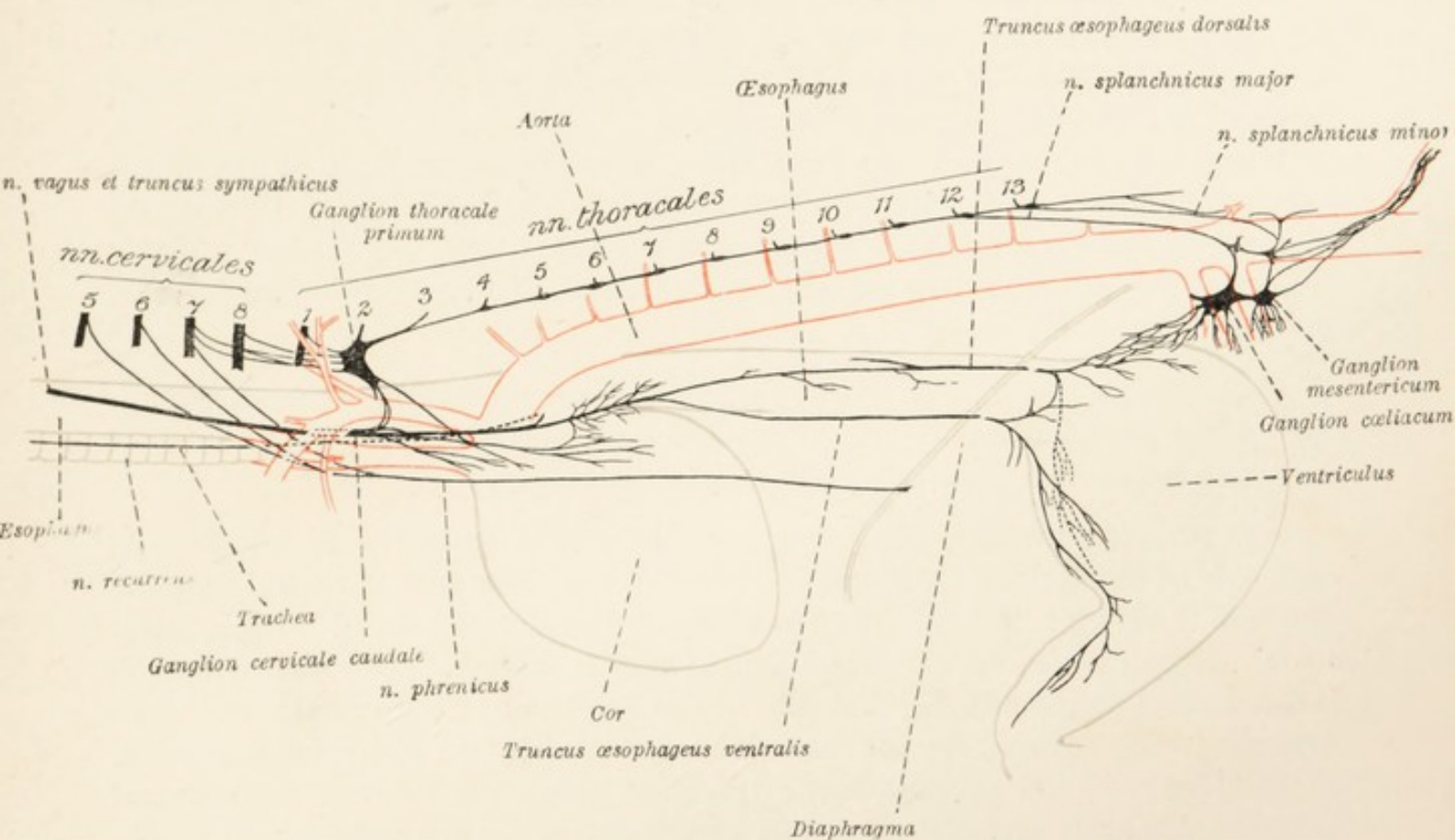


FIG. 24.—Diagram of part of the sympathetic nervous system.

right thoracic limb, and the right side of the head and neck, gains the venous system. The thoracic duct begins in the abdomen between the lumbar parts of the diaphragm, as a dilation known as the *cisterna chyli*. It enters the thorax on the right side of the aorta, between this vessel and the vena azygos.

Variable as is its thoracic course it may be said generally that, inclining slightly towards the left, the duct passes for some distance through the chest dorsal to the œsophagus. Afterwards it crosses the œsophagus on the left, and finally opens into the left innominate vein.

The duct is nearly always double for a greater or shorter part of its course, frequent intercommunications existing between the two vessels.

PARS THORACALIS SYSTEMÆ SYMPATHICI.—A large, elongated ganglion, the *first thoracic ganglion* (ganglion thoracale primum), lies between, the longus

colli muscle on the one hand, and the first intercostal muscle and the second rib on the other. Communicating branches connect it with the last two cervical and the first three or four thoracic spinal nerves. A filament passing between the seventh cervical nerve and the ganglion arises in common with the nerve which supplies the thoracic part of the longus colli muscle. By means of the *ansa subclavia* [*Vieussenii*] a connection is established between the first thoracic and the caudal cervical ganglia. One or two cardiac rami (accelerator to the heart) leave the ganglion.

A nerve cord leaves the first thoracic ganglion and can be followed along the dorsal wall of the chest into the abdomen. At first the cord occupies a deep groove to the side of the longus colli muscle, but later it runs across the heads of the ribs and the intercostal vessels.

Ganglia on the cord, at first small but afterwards larger, begin at the fourth intercostal space, and continue, one at each intercostal space, throughout the rest of the thorax. Each ganglion is connected with the ventral primary branch of the corresponding spinal nerve by means of a communicating branch, the *ramus communicans*.

Dissection.—The wall of the thorax should now be examined from within.

Strip the pleura and follow the intercostal vessels. The arrangement of the intercostal muscles may be again examined.

AA. INTERCOSTALES.—The intercostal arteries are twelve in number on each side of the body. Of these, the first three or four arise from the supreme intercostal artery: the rest are branches of the thoracic aorta. Each intercostal artery divides into a dorsal and a ventral branch. The *ramus dorsalis* is distributed to the muscles and skin of the back and to the spinal cord. The *ramus ventralis* runs along the caudal border of a rib (in the sulcus costalis), at first between the two intercostal muscles, and then between the internal intercostal muscle and the pleura in association with the corresponding vein and nerve, and ends by anastomosing with the intercostal or musculo-phrenic branches of the internal mammary artery. In its course along an interspace, several small branches leave the intercostal artery and cross the inner surface of the rib.

VV. INTERCOSTALES.—The intercostal veins are disposed after the manner of the arteries, but all except the first two or three terminate in the vena azygos.

V. AZYGOS.—The vena azygos begins in the abdomen by the union of the first, or first and second lumbar veins. Entering the thorax to the right of the aorta, it passes along the vertebral bodies to the right of the median plane as far as the fifth or sixth thoracic vertebra. Finally, curving towards the heart, the vein opens into the cranial vena cava, or possibly into the right atrium itself. The vena azygos drains much the greater part of the wall of the thorax.

NN. INTERCOSTALES.—Running along the intercostal spaces caudal to the vessels, the intercostal nerves are derived from the ventral primary divisions of the thoracic spinal nerves. Each nerve supplies a lateral cutaneous branch, which was encountered about midway between the vertebral column and the sternum when the thoracic wall was examined from the outside. The termination of each nerve as a ventral cutaneous ramus has also been displayed.

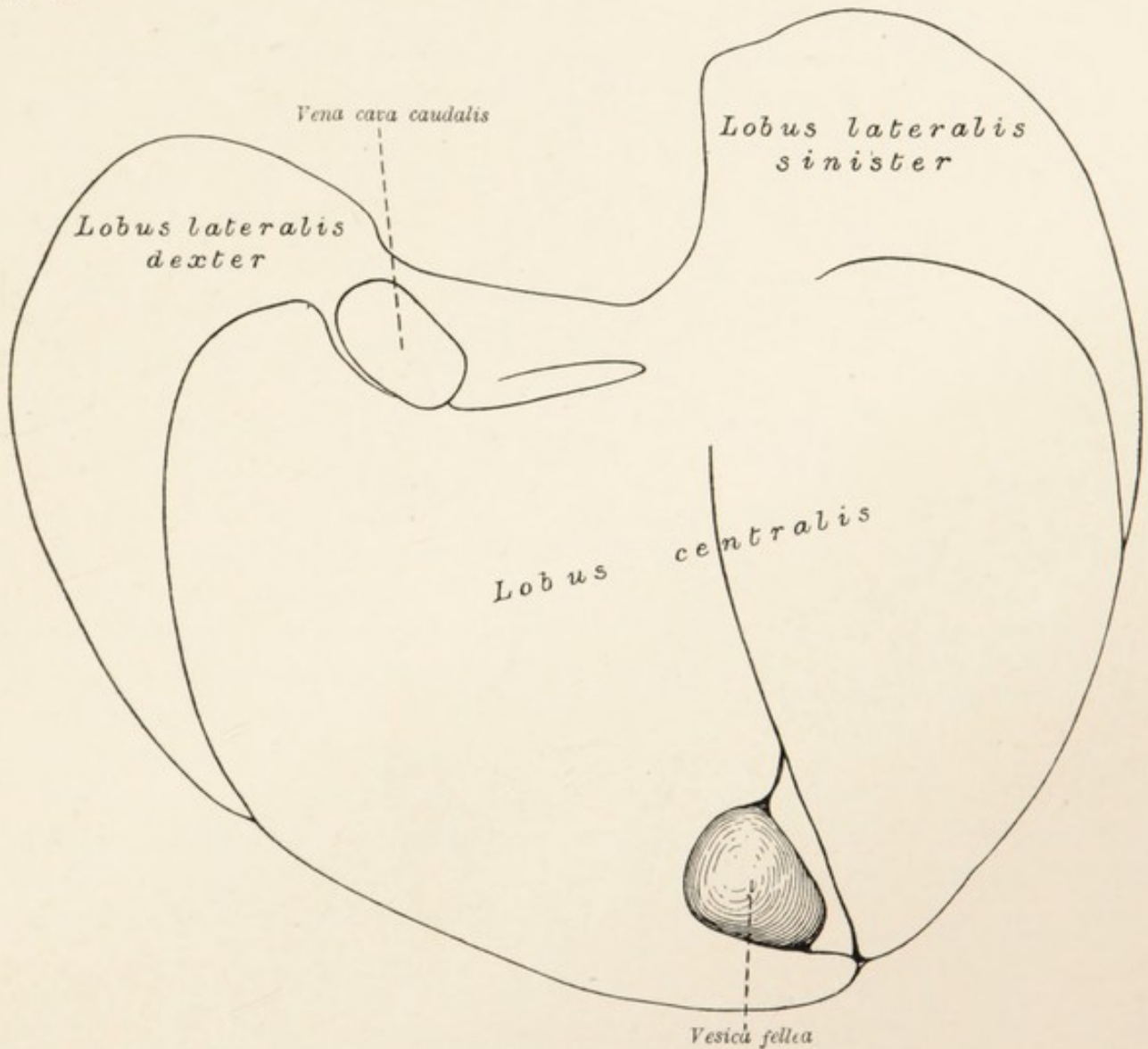


FIG. 25.—Outline of the diaphragmatic surface of the liver.

Dissection.—The liver may now be removed, but before doing this its lobes and the arrangement of the peritoneum in association with it should be examined. In removing the liver preserve the vena cava as far as possible.

LOBI HEPATIS.—Two deep fissures divide the substance of the liver into three main lobes: a central and two lateral. The *central lobe*, readily distinguished by its position and the presence of the gall-bladder in association

with it, is subdivided into right and left parts by a fissure of considerable depth known as the *umbilical fissure* from the circumstance that the umbilical vein lies in it during embryonic life. The right part of the central lobe carries the gall-bladder lodged in a deep depression, the *fossa vesicæ felleæ*.

The two lateral lobes are unequal in size, the *left lateral lobe* being generally the larger. In addition it is distinguished by being the simpler, for to the

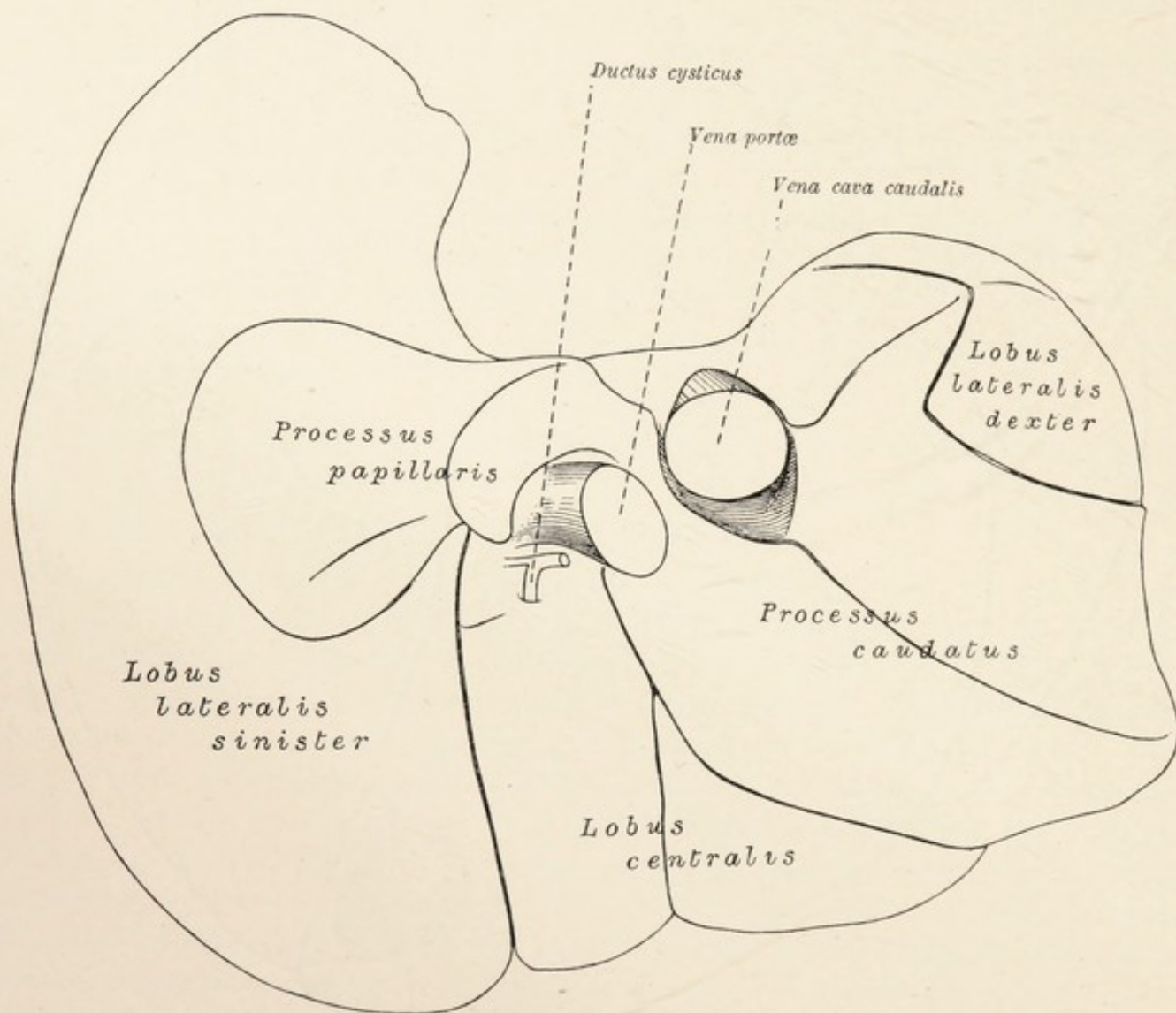


FIG. 26.—Outline of the visceral surface of the liver.

right lateral lobe are appended two processes : caudate and papillary or omental. The *caudate process* is the larger, and assists the right lateral lobe in forming a fossa for the reception of the right kidney. In the dorso-medial part of the process is a deep groove or canal in which the vena cava lies ; and in the ventro-medial border of the process is a notch for the portal vein. The *omental process* lies to the left of the caudate process, and is in intimate relation to the lesser omentum, hence its name.

VESICA FELLEA, ETC.—A more complete view of the gall-bladder and its associated ducts may now be obtained.

Leaving the narrow neck of the gall-bladder (*collum vesicæ felleæ*) is the *cystic duct* (*ductus cysticus*), to which are joined *hepatic ducts* (*ductus hepatici*) from the central and left lateral lobes. The result of this union is the production of the *common bile-duct* (*ductus choledochus*) which opens into the duodenum. Mostly, the hepatic duct from the right lateral lobe joins the common bile-duct independently.

Arrangement of the peritoneum in connection with the liver.—Like other abdominal organs, the liver is covered by visceral peritoneum, which gives its surface a smooth, shining appearance. The visceral peritoneum becomes continuous with the parietal peritoneum of the diaphragm by reflection along the vena cava, which lies in a deep groove (*fossa venæ cavæ*) on the diaphragmatic surface of the liver. Lateral to the vena cava on each side is a double fold of peritoneum connecting the right and left lateral lobes to the diaphragm—the *right* and *left triangular ligaments*—and connected with the right ligament is an offshoot binding the caudate process to the right kidney.

On the visceral surface of the liver is a transverse depression, the *porta hepatis*, from the margins of which the peritoneum is reflected onto the lesser curvature of the stomach in the form of a thin membrane, the *lesser omentum*.

PORTA HEPATIS.—The porta of the liver is in the deepest part of a depression circumscribed by the central lobe and the caudate and omental processes, and is the place of entrance of the portal vein and the hepatic artery, and for exit of the hepatic ducts and lymphatic vessels.

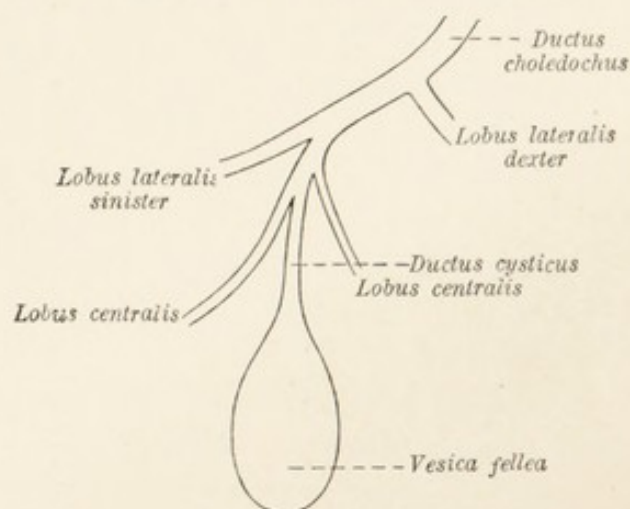


FIG. 27.—Diagram of the gall-bladder and its associated ducts. The names of the lobes of the liver are included in order to indicate the drainage-area of each hepatic duct.

Dissection.—Follow the œsophageal nerve trunks through the diaphragm into the abdomen. The ventral nerve will be found to terminate over the stomach, especially in the region of the lesser curvature and the cardia whereas the dorsal nerve will lead to the cœliac plexus and ganglia.

TRUNCUS ŒSOPHAGEUS VENTRALIS.—The formation of the ventral œsophageal trunk has been seen to result from the union of the ventral branches of the two vagus nerves. Following the œsophagus into the abdomen, the nerve divides into many small branches which form a plexus chiefly disposed over the cranial surface and cardia of the stomach. The larger filaments of

the plexus follow the lesser curvature of the stomach almost as far as the pylorus. Some hepatic filaments reach the liver.

TRUNCUS ŒSOPHAGEUS DORSALIS.—The fusion of the dorsal branches of the vagus nerves has been seen to produce the dorsal œsophageal nerve trunk. Like the ventral trunk, this enters the abdomen and forms a plexus. The fine filaments of the plexus lie mainly along the lesser curvature and caudal surface of the stomach; and many of them are connected with the cœliac plexus.

The two great plexuses formed by the œsophageal trunks are connected with each other in the region of the cardia of the stomach.

GANGLIA CŒLIACA.—The cœliac ganglia, right and left, are placed ventral to the aorta, between the origins of the cœliac and cranial mesenteric arteries. The right ganglion is the larger. Radiating from the ganglia are anastomosing filaments constituting the *cœliac plexus* (plexus cœliacus) with which gastric, hepatic, and splenic plexuses are associated.

GANGLION MESENTERICUM.—A ganglion of fair size, connected by filaments with the much larger cœliac ganglion, should be found about the root of the cranial mesenteric artery. Numerous filaments from the mesenteric ganglion follow the branches of the artery and form the *mesenteric plexus* (plexus mesentericus).

Connected with both the cœliac and mesenteric ganglia is another small ganglion, or possibly more than one, related to the adrenal gland.

Dissection.—Remove the stomach and duodenum from the abdomen and examine their structure and the interior of their cavities. In the first place they should be moderately distended with water.

STRUCTURE OF THE STOMACH.—Like the other parts of the alimentary tract within the abdomen, the wall of the stomach is composed of four layers: (1) An external serous tunic derived from the peritoneum; (2) a muscular tunic; (3) submucous tissue; and (4) a mucous membrane.

The serous covering is complete except along those narrow areas following the curvatures by which vessels and nerves gain access to or egress from the wall of the organ. The muscular tissue is disposed in three strata. When the serous membrane has been removed, longitudinal fibres, most numerous along the curvatures, are exposed. Over the surface of the right half of the sac the fibres are oblique rather than longitudinal.

The superficial fibres should now be carefully removed and a stratum of circular fibres displayed. The circular stratum is more or less complete over the whole stomach, but near the pylorus it is thicker than it is towards the right. At the pylorus a double sphincter is produced by a marked thickening of the circular fibres. The two sphincters are separated on each side by a thin area in the middle of which is a large vein proceeding from the underlying

submucous tissue. Around the vessel the fibres are disposed in loops; and between the two areas and along the greater curvature, longitudinal fibres connect the two sphincters.

The deepest fibres, oblique in direction, are best examined from within. To do this the stomach must be turned inside out, and the mucous membrane examined and removed. The mucous lining is in the form of a soft membrane, in the main similar to that of the intestine. It may be divided into three areas. A small *cardiac portion* at the œsophageal opening is somewhat pale and moderately smooth. The *fundus portion* lines the rest of the body of the stomach and is markedly rugose and dark red in colour. The *pyloric area* is smoother and paler. The three areas distinguishable by the naked eye correspond to the distribution of microscopic glands of different character.

Now remove the mucous membrane and observe the loose and highly vascular submucous tissue, beneath which is the third stratum of muscle. The deep, oblique muscular fibres are most plentiful about the cardiac orifice, where they form an elongated horseshoe-like loop.

INTERIOR OF THE DUODENUM.—The duodenum should be opened by an incision along its greater curvature. The wall of the tube has a structure similar to that of the rest of the small intestine. The mucous membrane has a markedly velvety appearance due to the presence of innumerable delicate filiform *villi*, and is longitudinally folded. Pass a probe along the bile-duct and observe how obliquely it passes through the wall of the duodenum to open on a broad blunt papilla surmounting one of the longitudinal folds. While within the substance of the duodenal wall, the duct is included between the longitudinal and circular layers of the muscular coat.

The opening of the ductus pancreaticus accessorius will also be found on the summit of a blunt papilla.

Dissection.—If the subject be a female those reproductive organs which are contained within the abdomen must now be examined.

The female reproductive organs consist of the two ovaries, each with a uterine tube by which the ovum travels to the uterus, the uterus, the vagina, the urogenital sinus, and the vulva and external genitals. Of these, the vagina, urogenital sinus, and vulva, fall to be considered with the pelvis; but the other organs above named are contained in the abdomen.

UTERUS.—The uterus can generally be seen, in part at least, as soon as the abdomen is opened and before the intestinal mass is disturbed. It consists of a single portion, the *body* (corpus uteri), in the form of a short tube placed between the bladder and the rectum, and two *cornua*. The pelvic end of the body, connected with the vagina, is known as the *neck* of the uterus (cervix uteri); whereas the cranial end forms the *fundus* of the uterus (fundus

uteri). From the fundus spring the two *cornua*, in the form of two slightly curved, diverging tubes which reach almost to the kidneys.

Suspending the uterus are two broad duplicatures of peritoneum—the *broad ligaments* (ligamentum latum uteri)—reflected from the sublumbar region onto the dorsal borders of the cornua and the lateral borders of the body. The broad ligaments are divergent and bound a peritoneal cavity, the *recto-uterine excavation* (excavatio recto-uterina [Cavum Douglassi]), in which the terminal part of the colon is lodged. The ligaments, continued beyond the extremities of the uterine cornua, are associated with the uterine tubes and the ovaries. The terms *mesometrium*, *mesosalpinx*, and *mesovarium* are applied to the parts of the ligament connected with the uterus, tube, and ovary respectively. The lateral surface of each broad ligament bears a secondary peritoneal duplicature, in the free edge of which is a feeble fibrous cord, traceable into the inguinal canal, and known as the *round ligament of the uterus* (ligamentum teres uteri). If the round ligament be followed down the canal, it will be found to end in the region of the vulva by blending with the skin.

OVARIUM.—Seeing that this organ is completely enclosed within the *ovarian bursa* (bursa ovarii), the examination of the ovary necessitates a certain amount of dissection. The mesovarium appears to continue the mesometrium to the end of the kidney. If the medial and ventral part of the membrane is examined, a narrow and short slit-like opening, leading into the ovarian bursa, will be found. Bounding the opening there are two folds, the medial of which is traceable to the kidney. The lateral fold is attached to the convex border of the kidney and the last rib.

The ovarian bursa should be opened up and the ovary exposed. Each ovary is a flattened, oval body, placed on a level with the third or fourth lumbar vertebra. Owing to the difference in the level of the two kidneys, the left ovary is often close to the kidney of its own side, but a space nearly always intervenes between the right ovary and the corresponding kidney. Connecting the ovary to the end of the uterine cornu is a ligamentous band, the *proper ligament of the ovary* (ligamentum ovarii proprium).

TUBA UTERINA.—The uterine or Fallopian tube is nearly straight. Its wide ovarian end is funnel-shaped (infundibulum tubæ uterinæ) and opens into the peritoneal cavity by the *ostium abdominale tubæ*. The margin of the abdominal ostium is fringed by irregular processes, the *fimbriæ tubæ*. The narrow uterine extremity penetrates the wall at the end of the cornu of the uterus and communicates with the uterine cavity by the *ostium uterinum tubæ*.

The examination of the interior of the uterus had better be postponed until the interior of the vagina can be exposed.

If the subject is a male, the distribution of the constituents of the spermatic

cord at the abdominal ring of the inguinal canal should now be noted. The ductus deferens, enclosed in a fold of peritoneum, at once turns into the pelvis. The internal spermatic vessels proceed towards the vertebral column and the median plane within a peritoneal fold which can be followed to the kidney.

RENES.—The kidneys are placed against the dorsal wall of the abdomen and are embedded in loose areolar tissue generally containing a considerable quantity of fat. In clearing away the fat, care must be taken not to destroy the ureter and the adrenal gland.

Each kidney is bean-shaped and presents two surfaces, two borders, and two extremities. The dorsal surface is flattened and applied to the sub-lumbar muscles; whereas the ventral surface is markedly convex and covered by peritoneum. While the lateral border is convex, the medial border is straighter and notched by the *hilus*, in association with which are the renal vessels and the ureter. The extremities are rounded.

The two kidneys differ in position and relations. In regard to position, the right organ is more cranial than the left. This may be indicated by saying

that the cranial end of the left kidney is on a level with the hilus of the right organ. The ventral surface of the right kidney is in contact with the liver, the pancreas, and the cæcum; while the corresponding surface of the left kidney is related to the descending colon. The dorsal surface of both organs is applied to the lumbar part of the diaphragm and the psoas muscles. The adrenal gland, the ureter, and the renal vessels are related to the medial border of both kidneys. The right kidney is within a short distance of the vena cava; and the left, of the aorta. Sometimes the right organ touches the vena cava.

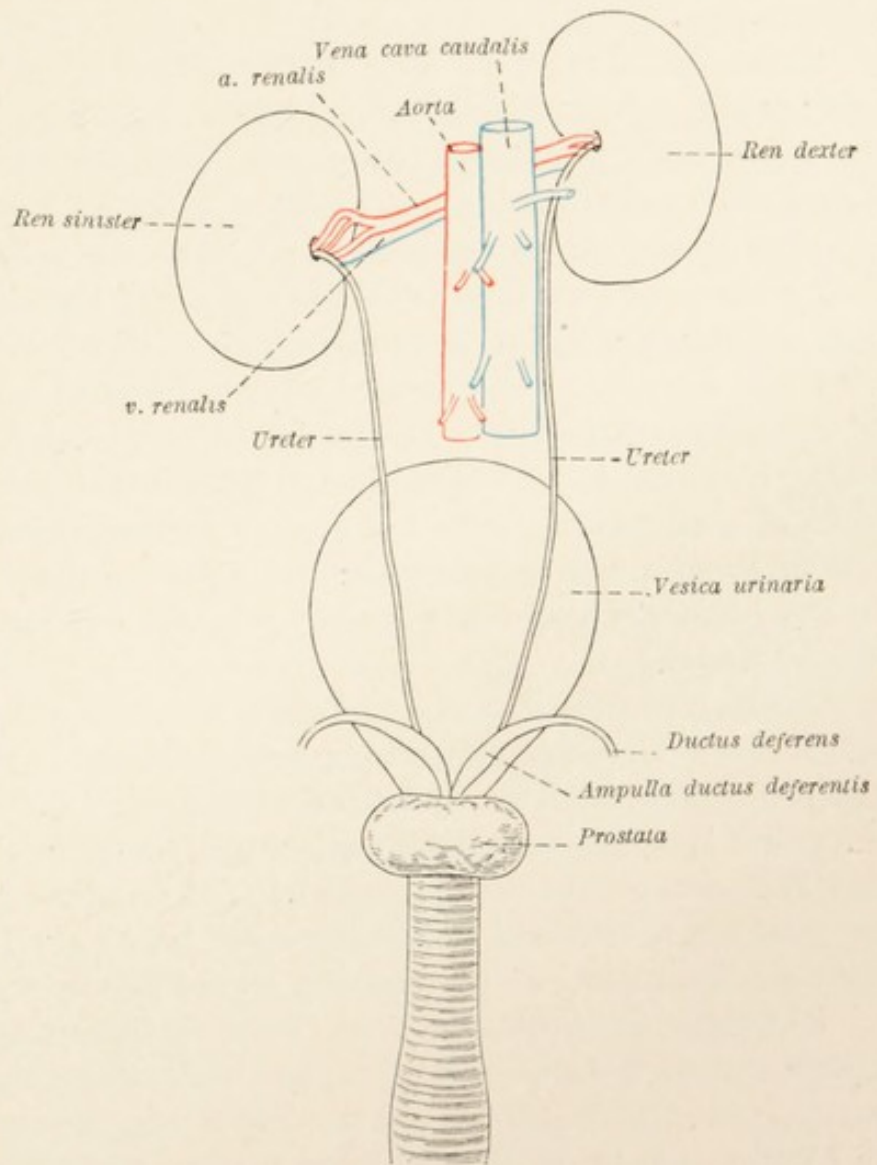


FIG. 28.—Diagram of the urinary organs of the male.

The duodenum runs along the lateral border of the right kidney, and the spleen comes into contact with part of the corresponding border of the left organ. Cranially the right kidney fits into a deep fossa formed by the right lateral lobe and the caudate process of the liver; the left kidney is embraced by the dorsal end of the spleen.

In the male the caudal end of each kidney is related to the small intestine. In the female this end is connected with the ovary by means of the mesovarium.

HILUS RENALIS.—The hilus of the kidney affords a means of entrance and exit for the various blood-vessels, nerves, and lymphatics, and the ureter. Of the three main structures connected therewith, the renal artery is the most dorsal, the renal vein the most ventral, and the ureter between the two. The lymphatics and nerves are mainly dorsal to the vein.

INTERIOR OF THE KIDNEY.—The surface of the kidney is covered by a strong fibrous capsule, which can be readily stripped off except where it is continuous with the sheaths of the several structures entering the organ at the hilus.

A section of the organ should be made by entering the knife at the lateral border and carrying it to the hilus. When this has been done, the two portions of kidney substance, *cortex* and *medulla*, are revealed. The cortical substance presents a granular appearance; whereas the medullary substance is striated. In the boundary zone between the two, the cut ends of numerous large vessels will be noted.

The innermost part of the medullary substance is paler in colour than the rest and forms a curved ridge running longitudinally to the long axis of the kidney and projecting into a cavity known as the *pelvis* (*pelvis renalis*). The cavity of the *pelvis* is elongated in conformity with the general form of the kidney itself, and has a crescentic outline, each horn of the crescent being abruptly recurved to produce a *terminal recess* (*recessus terminalis*). In the concavity of the crescent is a funnel-shaped portion of the *pelvis* leading into the ureter.

URETER.—Immediately upon its exit from the hilus of the kidney, the ureter curves towards the *pelvis* and runs along the *psoas* muscles under the peritoneum. Crossing the ductus deferens in the male close to the pelvic inlet, or piercing the broad ligament of the uterus in the female, the ureter ends by obliquely piercing the wall of the neck of the bladder.

GLANDULÆ SUPRARENALES.—The adrenal or suprarenal glands are two irregularly triangular objects found in the neighbourhood of the hilus of the kidney. The ventral surface of each is crossed by a deep groove in which the phrenico-abdominal vein is lodged. On section, the organs reveal a pale cortical substance, and a darker, more vascular, and somewhat softer, medullary substance.

Dissection.—With great care remove the fat which lies dorsal to the kidneys and about the aorta as it passes through the diaphragm. The greater

and lesser splanchnic nerves are to be sought bending round the dorsal border of the diaphragm, between this and the psoas minor muscle.

N. SPLANCHNICUS MAJOR.—The greater splanchnic nerve arises from the twelfth thoracic sympathetic ganglion, enters the abdomen between the lumbar part of the diaphragm and the psoas minor muscle, and joins a small ganglion dorsal to the celiac ganglion.

N. SPLANCHNICUS MINOR.—The lesser splanchnic nerve may be double, or even treble. It leaves the last thoracic and first lumbar ganglia, and ends in a plexus about the adrenal gland.

DIAPHRAGMA.—The diaphragm forms a dome-shaped, muscular, and tendinous partition between the cavities of the thorax and abdomen. Viewed from the abdominal side, it is concave in all directions, and a little more so on the right than on the left. The partition, as a whole, has a marked slope in a ventral and cranial direction.

The diaphragm is described as consisting of a tendinous centre around which are grouped lumbar, costal, and sternal muscular portions.

Centrum tendineum.—The tendinous centre of the diaphragm of the dog is relatively small in extent and ventral in position. In outline it is somewhat heart-shaped with the base dorsal; and has a curved continuation from each side of the base running in a dorsal direction towards a tendinous area separating the lumbar and costal muscular parts of the diaphragm.

Pars lumbalis.—The lumbar part of the diaphragm consists of muscular fibres arising from two tendons. The right tendon, the thicker and stronger, is attached to the bodies of the third and fourth lumbar vertebræ. The thinner left tendon generally arises from the body of the third lumbar vertebra only, though it may have attachment to the fourth vertebra also.

Each tendon divides into a medial and a lateral portion. The medial divisions of the two tendons unite ventral to the aorta, and thus form an arch over which this vessel passes. The two lateral divisions—slenderer than the medial—are attached to the transverse processes of the first lumbar vertebra. In this way three tendinous arches are produced, and from them right and left muscular fibres spring. These, when followed into the main part of the diaphragm, are found to decussate both dorsal and ventral to the opening by which the œsophagus gains the abdomen.

Pars costalis.—The costal part of the diaphragm arises from the ribs, from the eighth to the thirteenth, close to the point of union of their bony and cartilaginous segments. It is, therefore, evident that the diaphragm is not attached to the costal margin itself, but slightly within it.

Pars sternalis.—The sternal origin of the diaphragm is from the xiphoid process and the adjacent part of the sternum.

Openings in the diaphragm.—There are numerous openings in the diaphragm, but most of them are of small size and of little importance. Three openings,

however, are of moment. (1) The *aortic hiatus* (hiatus aorticus) between the vertebral column and the middle of the three arches formed by the tendons of the pars lumbalis. Through this pass the aorta, the vena azygos, and the thoracic duct. (2) The *caval foramen* (foramen venæ cavæ) in the right part of the tendinous centre, for the passage of the caudal vena cava. (3) The *œsophageal hiatus* (hiatus œsophageus) between the right and left muscular fibres of the pars lumbalis. This transmits the œsophagus and the œsophageal nerve-trunks.

AORTA.—The last part of the aorta, namely that which is found in the abdomen, has now to be examined. The abdominal aorta continues the thoracic aorta from the aortic hiatus of the diaphragm to the seventh lumbar vertebra, where it ends by dividing into four large vessels, the two hypogastric and the two external iliac arteries.

The abdominal aorta is not precisely in the median plane, but inclines a little towards the left except at its termination. Lying to the right is the vena cava; and between the aorta on the one side, and the right lumbar origin of the diaphragm and the sublumbar muscles on the other, is the delicate-walled cisterna chyli in which the thoracic duct has its origin. The cisterna and the duct must be carefully preserved during the removal of the fibrous tissue and fat from around the aorta at its entrance into the abdomen.

To the left of the aorta are the left adrenal gland, the left kidney, and the left ureter; but the kidney and ureter are generally not in actual contact with the artery.

Ventrally the aorta is covered by a plexus of sympathetic nerves; while dorsally it is in contact with the tendinous origin of the diaphragm and the psoas muscles.

The branches of the abdominal aorta may be divided into two groups, according as they are paired or single, as follows:

<i>Paired.</i>	<i>Single.</i>
Phrenic arteries.	Coeliac artery.
Phrenico-abdominal arteries.	Cranial mesenteric artery.
Renal arteries.	Caudal mesenteric artery.
Internal spermatic arteries.	Middle sacral artery.
Lumbar arteries.	
Deep circumflex iliac arteries.	

A. PHRENICA.—The phrenic artery, destined for the diaphragm, generally arises with the phrenico-abdominal artery, and runs ventralwards, a little to the side of the hiatus œsophageus, to the tendinous centre.

A. PHRENICO-ABDOMINALIS.—The phrenico-abdominal artery leaves the aorta beyond the origin of the cranial mesenteric artery, and runs in a lateral direction across the psoas muscles, at the lateral margin of which it meets the

ilio-hypogastric nerve. The artery pierces the transverse abdominal muscle, and is mainly expended between this and the internal oblique muscle. Collateral branches are contributed to the fat about the kidney, the adrenal gland, and the sublumbar muscles.

It will be observed that the phrenico-abdominal artery crosses the dorsal face of the adrenal gland, while the corresponding vein occupies a groove on the ventral face of the gland.

A. RENALIS.—The renal artery is relatively large. The right and left arteries do not always leave the aorta at the same level. The right artery generally arises before the left, and crosses the dorsal face of the caudal vena cava. The renal artery soon disappears into the hilus of the kidney.

A. SPERMATICA INTERNA.—The internal spermatic artery is small and takes origin from the aorta at a variable point cranial to the caudal mesenteric artery. After an oblique course within a fold of peritoneum which also contains the corresponding vein, the spermatic artery enters the inguinal canal and there forms one of the constituents of the spermatic cord.

The corresponding artery of the female (a. ovarica) supplies the ovary, the uterine tube, and the extremity of the uterine cornu.

AA. LUMBALES.—The lumbar arteries arise in pairs from the dorsal side of the aorta. In all there are seven pairs, but the last springs from the hypogastric artery and not from the aorta direct. Each artery disappears almost at once under the psoas muscles, and therefore cannot be followed at present.

A. CIRCUMFLEXA ILIUM PROFUNDA.—The deep circumflex iliac artery leaves the aorta at a right angle. Having crossed the psoas muscles and come into company with the lateral cutaneous femoral nerve, the artery becomes subcutaneous in the region of the angle of the ilium. Its terminal branches are distributed superficially over the cranial aspect of the thigh and the adjacent part of the abdominal wall.

In cleaning the origin of the circumflex iliac artery, a group of lymph-glands will be observed lying along the side of the aorta.

VENA CAVA CAUDALIS.—This large vein begins at the seventh lumbar vertebra slightly to the right of the median plane, where it is formed by the union of the two common iliac veins which drain the limbs and the pelvis. The vessel runs along the right side of the aorta for some distance; but the right lumbar part of the diaphragm ultimately separates the vein from the artery. The last part of the abdominal course of the vena cava is between the diaphragm and the liver. Thus the vein reaches the foramen venæ cavæ of the diaphragm, and, by it, enters the thorax.

The tributaries of the caudal vena cava are as follows: (1) *Common iliac veins* (vv. iliacæ communes); (2) *lumbar veins*, six or seven (vv. lumbales); (3) *circumflex iliac veins* (vv. circumflexæ ilium profundæ); (4) *spermatic veins* (vv. spermaticæ)—the left may join the renal vein of that side instead of opening into the vena cava directly; (5) *renal veins* (vv. renales); (6) *phrenico-abdominal*

veins (vv. phrenico-abdominales) ; (7) *hepatic veins* (vv. hepaticæ) ; (8) *phrenic veins* (vv. phrenicæ).

With the exception of the two last named, all these veins are satellites of the corresponding arteries. The *hepatic veins* are numerous ; two to four are large, and the rest are small. They join the vena cava as it runs along the diaphragmatic surface of the liver.

VV. PHRENICÆ.—The dorsal part of the diaphragm is drained by phrenic tributaries of the phrenico-abdominal veins ; but a right and a left vein, in addition, open into the vena cava as it pierces the diaphragm.

VENA AZYGOS.—Almost the whole of the vena azygos has been examined during the dissection of the thorax. It remains for the commencement of the vein in connection with the first and second lumbar veins to be looked for dorsal to the aorta close to the hiatus aorticus.

DUCTUS THORACICUS.—The commencement of the thoracic duct in the *cisterna chyli* must also be examined at this stage of the dissection. The cistern is a mere dilatation of the duct and lies to the right of the aorta on a level with the origin of the renal arteries. It occupies a cleft bounded by the aorta to the left, and by the lumbar origin of the diaphragm and the lesser psoas muscle to the right. The cranial vena cava is ventral to the cistern. From the cistern the thoracic duct passes into the thorax to the right of the aorta.

Sublumbar muscles.—In the sublumbar region there are three muscles : namely, psoas minor, ilio-psoas, and quadratus lumborum, arranged in this order from the middle line outwards.

M. PSOAS MINOR.—The lesser psoas muscle arises from the bodies of the last two or three thoracic vertebræ and from the bodies of the first three or four lumbar vertebræ. Its insertion is into the psoas eminence of the hip bone.

M. ILIO-PSOAS.—The ilio-psoas muscle consists of two parts : namely, *m. psoas major* and *m. iliacus*. Of these the greater psoas muscle alone can be properly examined at present.

The origin of the psoas major muscle is from the bodies of the last three or four lumbar vertebræ. Its insertion into the lesser trochanter of the femur will be dissected in connection with the thigh.

M. QUADRATUS LUMBORUM.—This muscle has an origin in common with the psoas minor from the last two or three thoracic vertebræ. It also arises by separate bundles from the last rib and the lumbar transverse processes. Its insertion is into the lumbar transverse processes, and into the ilium in the neighbourhood of the sacro-iliac articulation.

Dissection.—Some of the lumbar spinal nerves (seven in number) may now be examined. Certain derivatives of these are visible without further dissection. Between the psoas minor and quadratus lumborum muscles appear the ilio-hypogastric and ilio-inguinal nerves ; and between the

psoas minor and ilio-psoas muscles the lateral cutaneous femoral nerve makes its exit from the sublumbar muscular mass. A small nerve, the genito-femoral, runs obliquely across the surface of the psoas minor muscle; and along the medial border of the same muscle the lumbar part of the ganglionated cord of the sympathetic nerve should be found. After the foregoing nerves have been recognised, they should be followed to their several origins. This must be done by removing the psoas minor and psoas major muscles piecemeal.

N. ILIO-HYPOGASTRICUS.—The ilio-hypogastric nerve, the ventral branch of the first lumbar spinal nerve, pierces the quadratus lumborum muscle and, accompanying the phrenico-abdominal vessels, crosses the aponeurotic origin of the transverse abdominal muscle to dip into the fleshy part where it divides into two branches.

N. ILIO-INGUINALIS.—The ilio-inguinal nerve is derived from the second lumbar nerve. After having pierced the quadratus lumborum muscle, it has a course similar to that of the preceding.

N. GENITO-FEMORALIS.—The origin of the genito-femoral nerve is irregular. Generally it arises by two roots from the third and fourth lumbar nerves, and, running almost directly towards the pelvis, comes into contact with the external iliac artery. Following the external pudendal vessels, its termination, as the external spermatic nerve, is in the skin of the penis, scrotum, and medial aspect of the thigh.

N. CUTANEUS FEMORIS LATERALIS.—The lateral cutaneous femoral nerve may arise by one or two roots from the third and fourth lumbar nerves. It either pierces the psoas minor muscle, or appears between the two psoas muscles. Crossing the psoas major and quadratus lumborum the nerve perforates the transverse muscle of the abdomen in company with the circumflex iliac vessels.

N. FEMORALIS.—The femoral nerve is larger than the foregoing, and is formed mainly by roots from the fourth and fifth lumbar nerves. The third nerve, however, assists. The femoral nerve passes through the psoas major muscle, to which it supplies branches, and ends, as will be seen later, in the muscles in front of the thigh.

Dissection.—Follow the external iliac artery into the thigh. Examine the fat-laden fascia of the inner side of the thigh and note its continuity with the fascia of the abdomen.

A. ILIACA EXTERNA.—The external iliac artery leaves the aorta on a level with the sixth lumbar vertebra. It runs obliquely across the tendon of the psoas minor and the ilio-psoas muscles, and ends on a level with the brim of the pelvis by becoming the femoral artery.

A short distance from its termination, the external iliac gives off the common trunk of origin of three arteries, viz. the caudal epigastric, external pudendal,

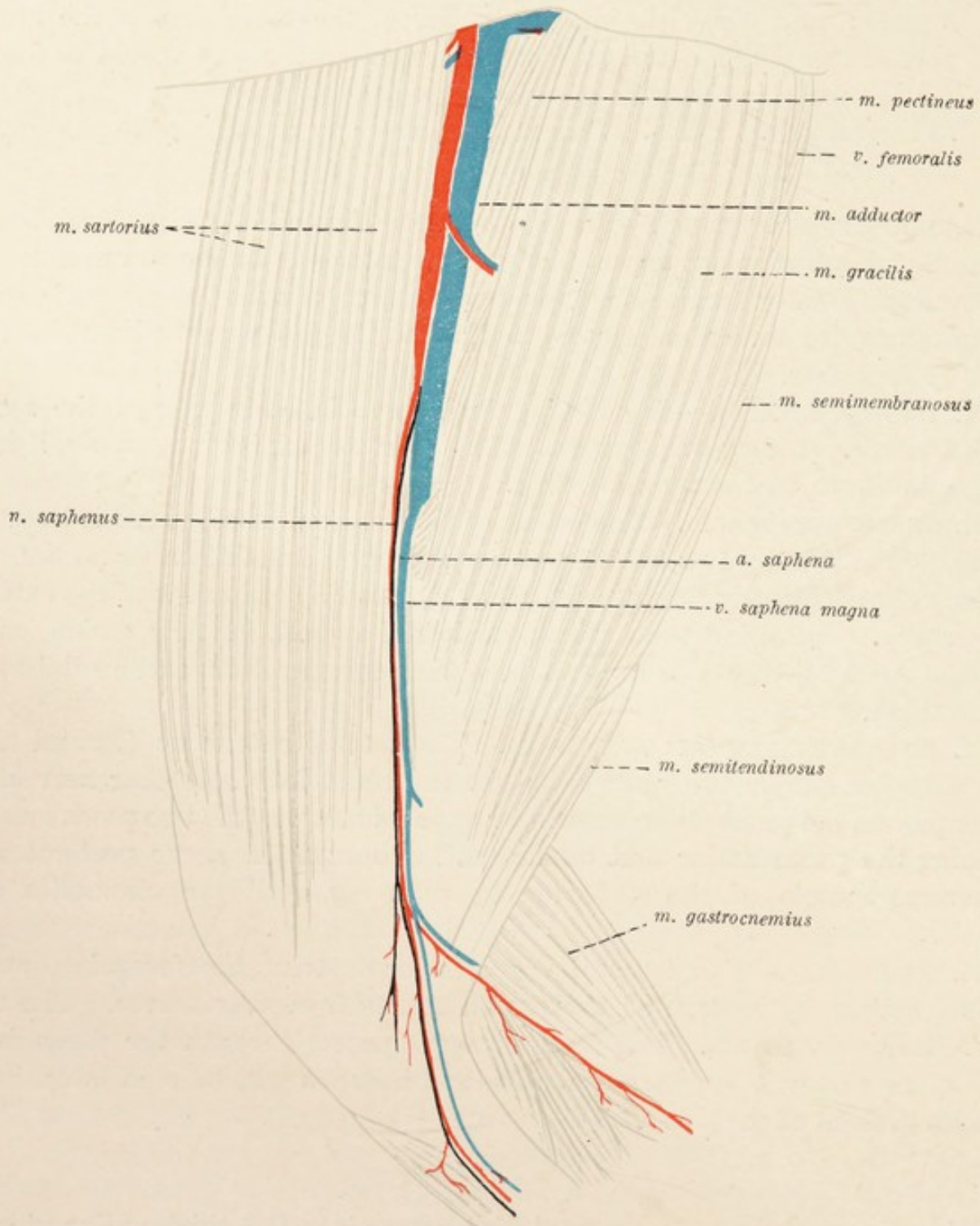


FIG. 29.—Superficial dissection of the inside of the thigh.

and deep femoral. The first two belong to the abdominal wall. The deep femoral artery disappears almost at once under the pectineus muscle.

V. ILIACA EXTERNA.—The companion vein of the external iliac artery lies on

its medial side, and receives tributaries corresponding to the branches of the artery. It assists the hypogastric vein in the formation of the common iliac vein.

A. SAPHENA, V. SAPHENA MAGNA, ET N. SAPHENUS.—About the point at which the borders of the gracilis and sartorius muscles meet, three structures make their appearance. These are the saphenous artery, vein, and nerve; of which the nerve is most oral and the vein most aboral. Running immediately underneath the fascia, they are continued from the thigh into the leg. A branch from each of the three passes across the medial aspect of the joint between the femur and the tibia to supply the skin in this region.

M. GRACILIS.—The oral part of the gracilis muscle is very thin, but its aboral border is of considerable thickness. The origin of the muscle is mainly from the tendon of the adductor of the thigh and from the gracilis muscle of the opposite side. In addition a part of the muscle arises from the symphysis ischii and the border of the ischium. The insertion is to the anterior tibial crest by means of a broad, thin tendon blended with the tendons of the sartorius and semitendinosus muscles.

The main nerve of the gracilis (a branch of the obturator nerve) appears between the pectineus and adductor muscles, crosses the surface of the latter, and then enters the deep face of the gracilis.

M. SARTORIUS.—The sartorius muscle lies oral to the gracilis, and is clearly divided into two parts: (1) The oral portion arises from the lateral angle of the ilium, and is inserted into the patella by a flattened tendon partly blended with the common insertion of the muscles of the front of the thigh; (2) the aboral portion has origin from the ventral border of the ilium. Its tendon partly joins that of the gracilis, but is also partly attached to the medial surface of the tibia.

A. FEMORALIS.—The first part of the femoral artery lies in a triangular space, the *femoral triangle* (trigonum femorale), bounded by the sartorius and pectineus muscles and the inguinal ligament of Poupart. The branches which arise from this part of the artery are: (1) The *lateral circumflex artery*; (2) the *anterior femoral artery*; and (3) small *muscular branches*. The first and second branches may leave the femoral artery either separately or in common. In any case their origin only can be seen at present. Leaving the femoral artery just as it crosses the border of the ilio-psoas muscle, they immediately disappear under the aboral part of the sartorius muscle.

Of the small muscular branches the largest arises close to the apex of the femoral triangle and is mainly concerned in the supply of the gracilis.

Dissection.—Reflect the gracilis and sartorius muscles by cutting across them about the middle of their length. In turning upwards the proximal part of the sartorius be careful to preserve the nerve to the muscle (ramus anterior of the femoral nerve) and the lateral circumflex artery.

The second part of the femoral artery begins at the apex of the femoral triangle and extends down the medial side of the thigh, under cover of the aboral portion of the sartorius, to disappear in the interval between the adductor

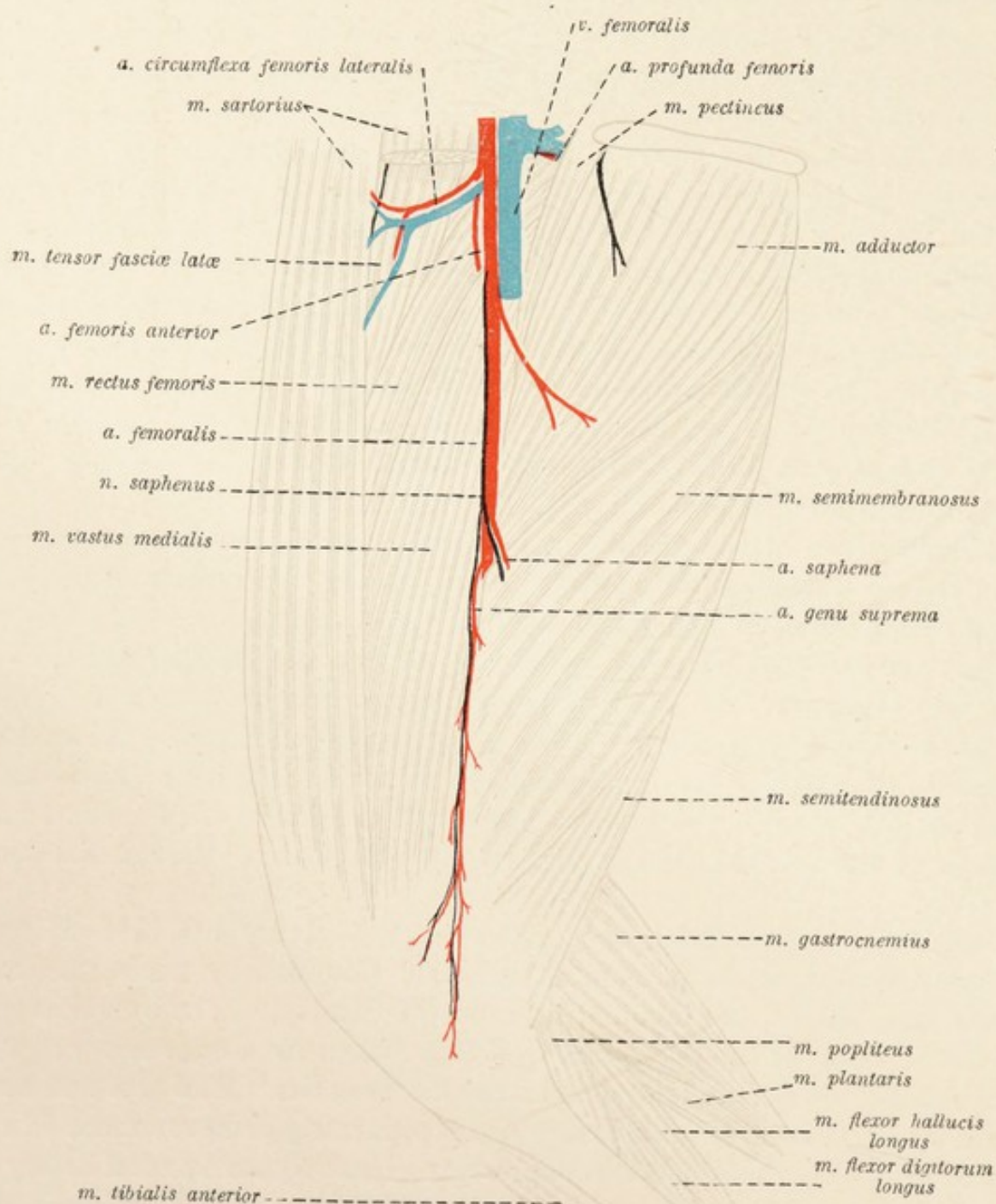


FIG. 30.—Dissection of inside of the thigh after removal of the gracilis muscle.

and semimembranosus muscles. The artery lies in a passage or canal which is triangular in section. The medial wall of the canal is formed by the sartorius muscle; the cranio-lateral boundary is the medial vastus muscle, and the caudo-lateral wall is formed by the pectineus and adductor muscles.

Small *muscular branches* arise from this part of the femoral artery, as do also the *saphenous* and *articular arteries*.

V. FEMORALIS.—The femoral vein lies along the medial and aboral side of the femoral artery, and receives tributaries which are the satellites of the branches of the artery.

N. SAPHENUS.—The whole course of the saphenous nerve in the thigh is now exposed. A branch of the femoral nerve, it runs along the oral side of the femoral artery in the first part of its course, crossing the artery medially on a level with the border of the semimembranosus muscle, about which point it contributes a twig to accompany the articular branch of the femoral artery.

A. GENU SUPREMA.—The articular branch of the femoral artery leaves the parent vessel as this disappears under the semimembranosus. It travels in a groove formed by the semimembranosus and medial vastus muscles, accompanied by a vein and a small branch of the saphenous nerve.

Certain muscles are now exposed. These, enumerating them in order and beginning with the most oral, are: Medial vastus, pectineus, adductor, semimembranosus, and semitendinosus.

M. VASTUS MEDIALIS.—The medial vastus is one of a group of three powerful muscles clothing the oral surface of the femur. Its origin, which cannot be properly examined until the adductor muscle has been reflected, is from the femur close to the head and from the proximal third of the medial lip of the linea aspera. The insertion is into the patella in common with the other muscles of the same group.

M. PECTINEUS.—The pectineus muscle is rather narrow and rounded, and lies immediately aboral to the medial vastus. Its origin is blended with the attachment of the abdominal muscles, and extends from the ilio-pectineal eminence to the symphysis of the pubis. The insertion of the muscle is by means of a thin tendon to the distal part of the medial lip of the linea aspera, and along with the semimembranosus to the medial epicondyle of the femur.

M. ADDUCTOR FEMORIS.—The adductor of the femur is a powerful muscle placed aboral to the pectineus. Its more distal part is covered by the semimembranosus. The origin of the muscle is from the ventral surface of the pubis and ischium. It has a fleshy attachment to the whole of the linea aspera and a little of the popliteal space of the femur; and a tendinous attachment, partly fused with the tendon of the pectineus, to the medial lip of the linea aspera.

M. SEMIMEMBRANOSUS.—The semimembranosus muscle is long and thick, and partly hidden by the adductor. Two parallel parts can be readily separated towards the insertion of the muscle.

Their common origin is from the medial part of the sciatic tuber. The oral portion is inserted into the medial epicondyle of the femur and the sesamoid bone in that neighbourhood. The aboral part is inserted into the articular margin of the tibia.

M. SEMITENDINOSUS.—This is a long and fleshy muscle lying aboral and lateral to the semimembranosus, with an origin from the lateral part of the sciatic tuber; its insertion is by a strong tendon to the medial surface of the tibia and the anterior tibial crest in line with the insertion of the gracilis.

Dissection.—Cut across the semimembranosus muscle about its middle, and reflect towards its origin and insertion. In turning upwards the proximal part look for the nerve to the muscle, as well as for that for the semitendinosus.

The distal part of the femoral artery will be exposed as it lies in a triangular channel formed by the vastus medialis, adductor, and semimembranosus muscles.

In the depths of the groove formed by the semitendinosus, adductor, and biceps muscles the sciatic nerve will be found. This divides unequally into the tibial and common peroneal nerves.

Now reflect the adductor and pectineus muscles by cutting them across not far from their origins. Thus will be revealed the branches of the obturator nerves supplying the adductor and pectineus, the deep femoral artery, the insertion of the ilio-psoas muscle, and the external obturator and quadratus femoris muscles.

A. PROFUNDA FEMORIS.—As has previously been noted, the deep femoral artery arises from the external iliac artery in common with the caudal epigastric and external pudendal arteries. Immediately after its origin the artery pierces the tendinous aponeuroses of the abdominal wall and arrives between the ilio-psoas and pectineus muscles. From this point the artery continues between the adductor and external obturator muscles. A branch passes through the obturator foramen, and others supply the various adjacent muscles.

N. OBTURATORIUS.—The obturator nerve comes out of the pelvis by the obturator foramen, and appears in the thigh by crossing the oral border of the external obturator muscle. It immediately divides into branches for gracilis, adductor, and pectineus muscles.

M. ILIO-PSOAS.—The insertion of the ilio-psoas muscle into the lesser trochanter of the femur is now exposed, and the origin of its iliac portion from the medial surface of the ilium and the tendon of psoas minor can be examined.

A. CIRCUMFLEXA FEMORIS LATERALIS ET A. FEMORIS ANTERIOR.—The lateral circumflex and anterior femoral arteries may arise either together or separately from the femoral artery about the point at which this vessel crosses the ventral border of the ilio-psoas muscle. The lateral circumflex artery runs in a cranial and lateral direction between the sartorius medially and the rectus femoris and tensor fasciæ latæ muscles laterally. It supplies these and the gluteal muscles. The anterior femoral artery is much larger than the preceding, and disappears almost at once between the rectus femoris and the medial vastus muscles.

N. FEMORALIS.—Piercing the ilio-psoas and the tendons of the abdominal muscles, the femoral nerve enters the thigh between the femoral artery and the ilio-psoas muscle. At once the saphenous nerve and the nerve to the sartorius leave the main trunk. The former has been followed down the thigh in company with the saphenous artery. The nerve to the sartorius follows the lateral circumflex artery.

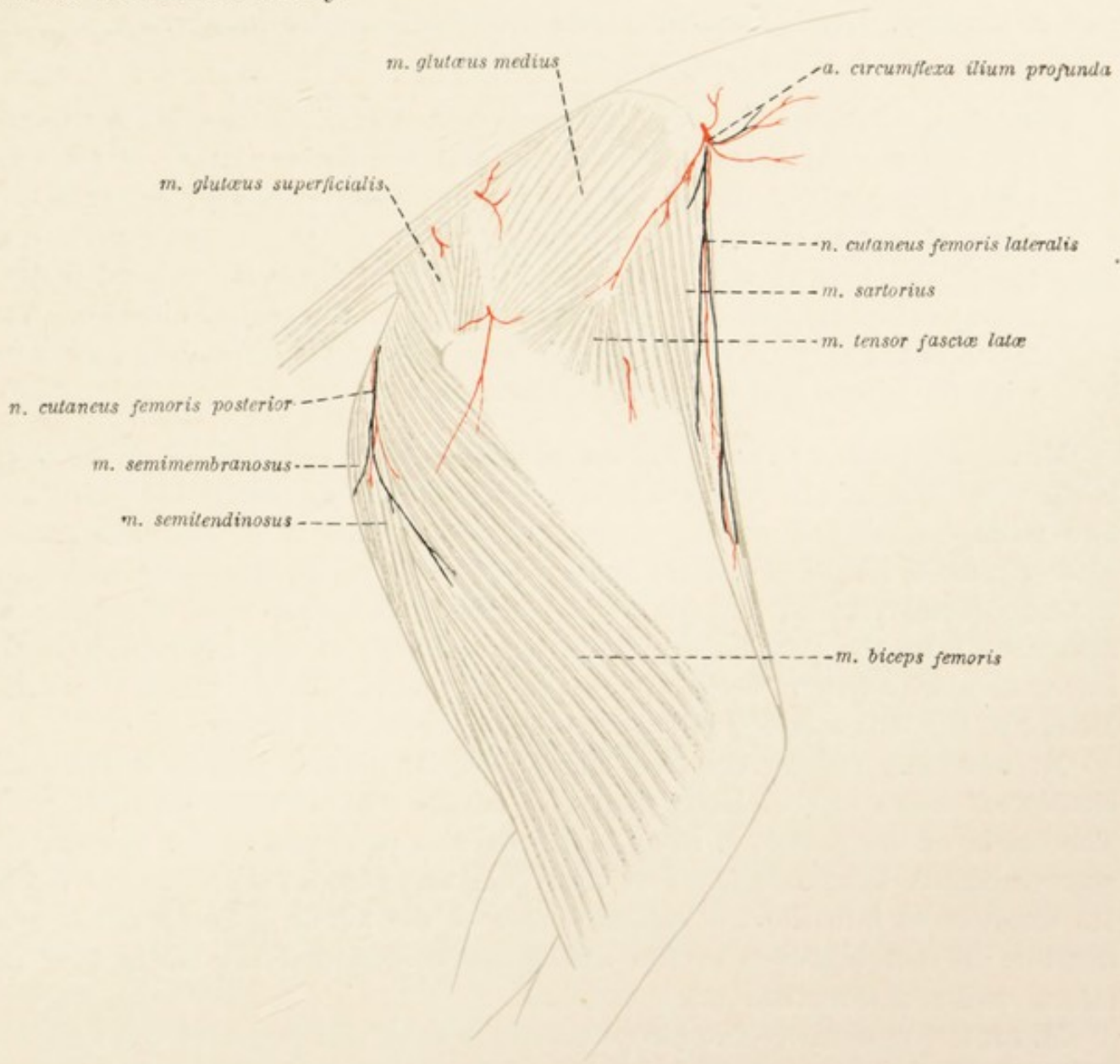


FIG. 31.—Superficial dissection of the gluteal region and thigh.

The femoral nerve accompanies the anterior femoral artery into the gap between the origins of the medial vastus and rectus femoris muscles, to which and to the lateral vastus it is distributed.

A. FEMORIS POSTERIOR.—The posterior femoral artery, the last collateral branch of the femoral artery, takes origin on a level with the medial head of the gastrocnemius muscle. Branches from it supply the semitendinosus, biceps, gastrocnemius, and the neighbouring flexor muscles of the digits.

M. OBTURATOR EXTERNUS.—The external obturator muscle covers the ventral aspect of the obturator foramen. Its origin is from the ventral surface of the pubis and ischium about the margin of the foramen. The fibres of the muscle converge laterally to be inserted into the trochanteric fossa.

M. QUADRATUS FEMORIS.—The quadrate femoral muscle is short and thick. Arising from the ventral surface of the sciatic tuber, it is inserted into the distal part of the trochanteric fossa on a level with the lesser trochanter.

Dissection.—Remove the skin and fascia from the gluteal and thigh regions.

Observe the thickness of the fascia and the accumulation of fat connected therewith. When all the fat has been removed, an extensive sheet of fascia, covering the gluteal muscles and the anterior surface of the thigh, is revealed. Removal of the gluteal fascia is rendered tedious from the fact that its deep face affords origin to the gluteal muscles. The fascia of the thigh is known as the *fascia lata* and is intimately connected with the biceps and tensor fasciæ latæ muscles.

M. TENSOR FASCIÆ LATÆ.—The tensor muscle of the broad fascia of the thigh is the most oral of the group now exposed, and can be readily separated into two parts. Arising from the ventral border of the ilium and the middle gluteal muscle, its fibres radiate and give place to an aponeurosis which joins the superficial gluteal, biceps and quadriceps muscles, thus obtaining an attachment to the patella. In addition, some fibres are inserted into the intermuscular septum between the biceps and lateral vastus muscles. Medial to the tensor fasciæ latæ is the lateral circumflex artery.

M. GLUTÆUS SUPERFICIALIS.—The superficial gluteal muscle is not sufficiently extensive to completely hide the middle gluteal upon which it rests. The origin of the muscle is from the transverse processes of the sacrum, the sacro-tuberous ligament, the first coccygeal vertebra, and the gluteal fascia. Its insertion is into the trochanter tertius of the femur. Some of its aponeurotic tendon blends with the tensor fasciæ latæ and the fascia over the lateral vastus and rectus femoris muscles.

M. BICEPS FEMORIS.—The biceps muscle is thick and powerful, covering the greater part of the lateral aspect of the thigh. It arises by two heads. A large fleshy head springs from the sacro-tuberous ligament and the sciatic tuber. A much smaller and tendinous origin is from the tuber medial to the first-mentioned origin. The muscle is inserted into the patella, patellar ligament, anterior tibial crest, fascia lata, and fascia of the leg.

Dissection.—Reflect the superficial gluteal muscle so as to expose the middle gluteal completely.

N. CUTANEUS FEMORIS POSTERIOR.—Leaving the pelvis in company with the

caudal gluteal vessels, the posterior cutaneous femoral nerve runs parallel to the sacro-tuberous ligament as far as the border of the superficial gluteal muscle. Here it becomes superficial, and passes along the groove between the biceps and semitendinosus muscles to supply the skin over the back of the thigh. Large *perineal branches* (rami perineales) supply the region of the anus.

M. GLUTÆUS MEDIUS.—The middle gluteal muscle is strong and thick, and occupies the depressed lateral surface of the ilium. Its origin is from the iliac crest and the fossa on the lateral surface of the ilium. Some fibres also arise from the tendon of origin of the shorter belly of the tensor fasciæ latae. The muscle is inserted into the trochanter major of the femur.

Dissection.—Reflect the biceps muscle about the middle of its length. In doing so, observe a thin, narrow band of muscle crossing its deep face somewhat obliquely. This is the *m. abductor cruris posterior*, which takes origin, by means of a feeble tendon, from the sacro-tuberous ligament. The distal part of this little muscle forms the apparent caudal border of the biceps, with which the abductor finally blends.

Observe lymph-glands (lympho-glandulæ popliteæ) lying on the gastrocnemius between the abductor cruris posterior and the semitendinosus muscles.

Under the biceps there is a strong intermuscular septum attached on the one hand to the linea aspera of the femur, and continuous on the other with the fascia lata of the thigh. This will require to be reflected so that the lateral vastus muscle may be clearly demonstrated.

In order to adequately expose the deep gluteal structures it is necessary to remove the greater part of the middle gluteal muscle. This must be done with great care.

M. GLUTÆUS PROFUNDUS.—The deep gluteal muscle lies close upon the hip-joint. Its fibres arise from the sciatic spine and the adjacent part of the lateral surface of the ilium. The insertion of the muscle is into the trochanter major of the femur.

M. PIRIFORMIS.—This muscle is immediately behind the deep gluteal. Taking origin from the lateral border and the ventral surface of the sacrum, its insertion is into the trochanter major close to, or blended with, the insertion of the middle gluteal muscle.

MM. GEMELLI.—Though named in the plural there is really only one muscle, the origin of which is from the lateral surface of the ischium, and the insertion into the trochanteric fossa of the femur.

M. VASTUS LATERALIS.—The lateral vastus muscle is the most powerful member of the quadriceps group. It arises mainly from the anterior surface of the femur immediately distal to the greater trochanter. A small proportion of the muscle also arises from the lateral lip of the linea aspera. Joining

the other members of the quadriceps group, the lateral vastus is inserted into the patella.

Dissection.—Reflect the piriformis in order to expose the full length of the sciatic nerve.

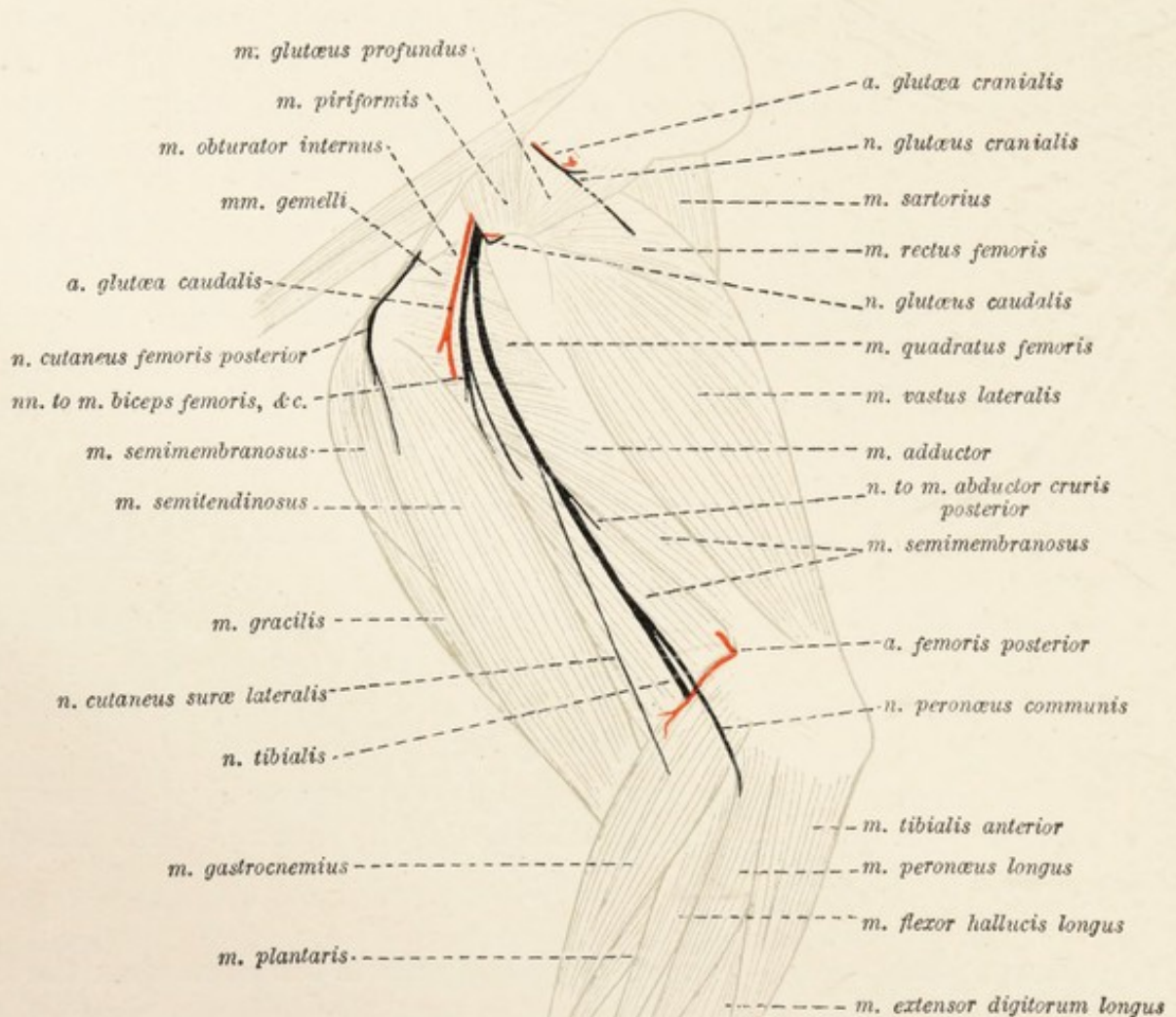


FIG. 32.—Dissection of gluteal region and lateral aspect of the thigh after removal of the superficial and middle gluteal muscles and the biceps.

N. ISCHIADICUS.—The sciatic nerve is formed by roots from the last three lumbar and the first sacral nerves. Leaving the pelvis by the greater sciatic foramen in company with the gluteal nerves and the caudal gluteal vessels, it reaches the region of the hip-joint where it turns into the thigh, and ends about the distal third of this segment of the limb by dividing into two branches of unequal size—the tibial and common peroneal nerves. The exact point of division of the sciatic nerve is very variable, being occasionally as early as the point at which the hip-joint is passed.

In its course the sciatic nerve lies in succession on the deep gluteal muscle, the tendon of the internal obturator, the gemelli, the quadratus femoris, the adductor and (possibly) the semimembranosus muscles. It is covered by the piriformis, middle gluteal and biceps; and the abductor posterior crosses it obliquely in the proximal third of the thigh. As it curves round the region of the hip-joint the nerve lies on the oral side of the caudal gluteal vessels.

The branches of the sciatic nerve are as follows: (1) A branch arising before the sciatic leaves the pelvis, and dividing into twigs for the piriformis, internal obturator, and gemelli muscles; (2) nerves to the biceps, semitendinosus, semimembranosus, and quadratus femoris muscles. These leave the sciatic in the form of a large common trunk, springing from the parent nerve on a level with the highest part of the trochanter major; (3) a small nerve to the posterior abductor muscle of the leg; (4) *lateral cutaneous nerve of the leg* (n. cutaneus suræ lateralis). The two last-named branches leave the sciatic about the same point, this varying from just beyond the trochanter major to about the middle of the thigh. If the sciatic nerve divides unusually early, the nerves to the abductor and the cutaneous nerve are branches of the common peroneal nerve. The cutaneous nerve gains the leg by running between the semimembranosus, semitendinosus, and abductor muscles medially and the biceps muscle laterally.

N. GLUTÆUS CRANIALIS.—The cranial gluteal nerve is formed by branches from the sixth and seventh lumbar nerves (possibly also from the first sacral). It leaves the pelvis by the greater sciatic foramen, passes out between the piriformis and deep gluteal muscles, runs between the deep and middle gluteals supplying both, and ends in the tensor fasciæ latæ, mainly in the longer, oral part of this muscle.

N. GLUTÆUS CAUDALIS.—This rises from the seventh lumbar and the first sacral nerves. It accompanies the sciatic nerve on the medial face of the piriformis, where it divides into two branches to end in the superficial and middle gluteal muscles.

AA. GLUTÆA CRANIALIS ET CAUDALIS.—Both the cranial and the caudal gluteal arteries are branches of the parietal ramus of the hypogastric artery. Leaving the parent vessel opposite the oral border of the piriformis muscle, the cranial gluteal artery accompanies the nerve of the same name into the gluteal mass of muscles. Very much larger, and virtually the terminal branch of the parietal ramus of the hypogastric, the caudal gluteal artery accompanies the sciatic nerve to the region of the hip-joint, and ends in the biceps and semitendinosus muscles.

M. OBTURATOR INTERNUS.—The origin of the internal obturator muscle is within the pelvis, and, consequently, cannot be examined as yet. Its insertion into the trochanteric fossa of the femur, however, should now be determined.

Dissection.—Reflect the deep gluteal muscle, and so expose the origin of the rectus femoris and capsularis muscles.

M. QUADRICEPS FEMORIS.—Although named the quadriceps muscle of the thigh, only three heads can be satisfactorily demonstrated in the dog. These are the two vasti muscles (*m. vastus medialis* and *m. vastus lateralis*) already dissected, and the straight muscle of the thigh (*m. rectus femoris*) now to be examined. It seems possible that the fourth head (*m. vastus intermedius*) is blended with the lateral vastus muscle.

M. RECTUS FEMORIS.—The rectus femoris muscle is the middle member of the quadriceps group, and clothes the anterior aspect of the femur. Its origin is from an eminence on the cranial edge of the acetabulum and its insertion is into the patella.

M. CAPSULARIS.—The capsular muscle is small and flat and lies on the lateral face of the capsule of the hip-joint.

Dissection.—Cut across the sciatic nerve on a level with the sacro-tuberous ligament, and the femoral vessels at the hip-joint. Remove the remains of those muscles which are attached in the close vicinity of the hip-joint, and clean the outer surface of the joint-capsule.

ARTICULATIO COXÆ.—The *joint-capsule* (*capsula articularis*) of the hip-joint is in the form of a roomy, double-mouthed sac, one end of which is attached to the margin of the acetabulum and the fibrous appendage thereto, and the other is fixed to the neck of the femur a little distance from the articular margin. The strongest part of the capsule is lateral and oral.

Dissection.—Cut through the joint-capsule and examine its contents.

The joint is formed by the acetabulum and the head of the femur. The whole of the acetabulum is not articular, inasmuch as its medial half contains a depressed non-articular *fossa acetabuli*. Opposite the fossa the continuity of the cavity is broken by the *incisura acetabuli*. Surrounding the acetabular margin is a ring of fibro-cartilage, the *labrum glenoidale*, continued across the incisura acetabuli by a ligamentous bridge, the *transverse ligament* (*ligamentum transversum*).

Passing from the fossa acetabuli to the non-articular and slightly depressed area on the head of the femur is the strong *round ligament* (*ligamentum teres*). When this is divided by the dissector the limb will be separated from the body.

Dissection.—The examination of the limb should be continued by the dissection of the regions in front of the tibia and about the fibula. With this it is necessary to combine the dissection of the dorsum of the pes. Before proceeding to an examination of the deep fascia and muscles of the leg, it is well to follow the superficial structures of the metatarsus and digits. The removal of the skin must be conducted with great care.

VEINS OF THE DORSUM OF THE PES.—On the dorsal aspect of each digit two veins are to be distinguished, the *dorsal digital veins* (vv. digitales dorsales). These join to form three or four *common dorsal digital veins* (vv. digitales communes) which, in their turn, form the radicles of one large *dorsal metatarsal vein* (v. metatarsæ dorsalis). This single vein crosses the

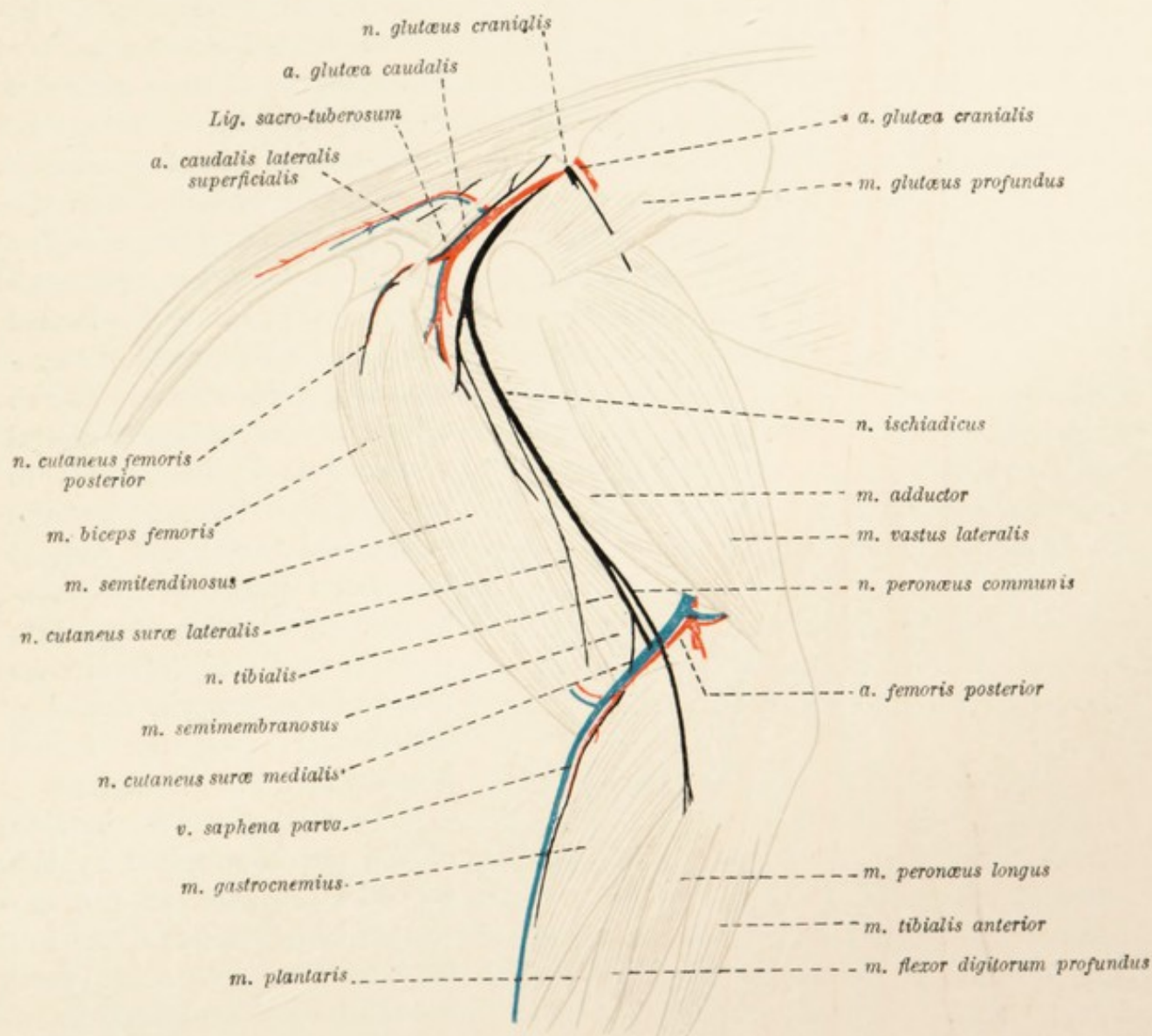


FIG. 33.—Deep dissection of the gluteal region and the lateral aspect of the thigh.

flexor aspect of the tarsus, where it communicates with the large saphena vein, then passes obliquely over the lateral face of the leg and disappears medial to the biceps muscle to become the *small saphenous vein* (vena saphena parva), which finally ends in either the femoral or the popliteal vein.

The medial side of the metatarsus and tarsus is drained into the large saphenous vein (vena saphena magna).

ARTERIES OF THE DORSUM OF THE PES.—The arteries dorsal to the

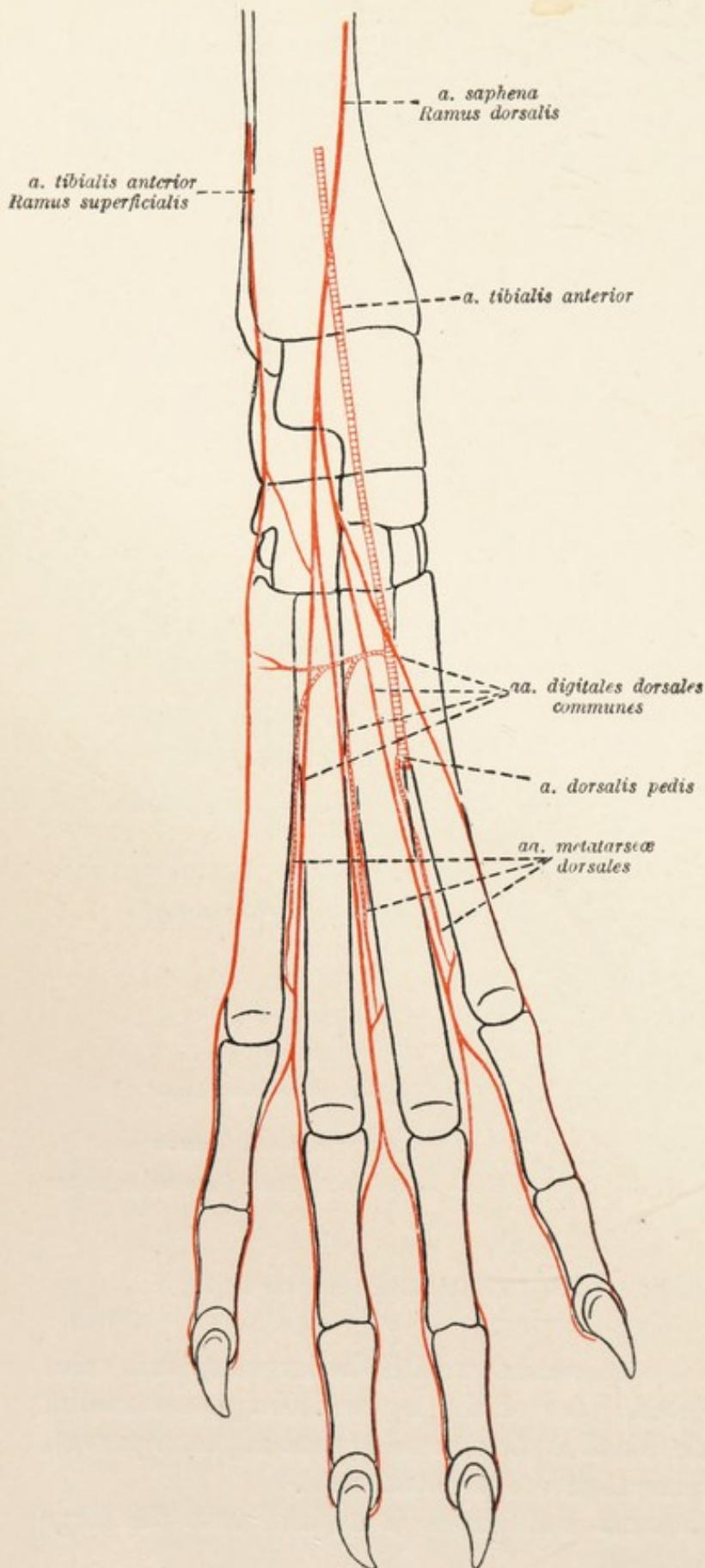


FIG. 34.—Diagram of the arteries on the dorsum of the pes.

metatarsus and digits are derived from two sources, the saphenous and anterior tibial arteries.

The saphenous artery (*a. saphena*) divides into plantar and dorsal branches. The dorsal branch arrives at the flexor aspect of the tarsus and there divides, in its turn, into medial and lateral branches. The medial branch forms the *second dorsal common digital artery* (*a. digitalis communis dorsalis II*); and the lateral branch furnishes the corresponding third and fourth arteries. The common digital vessels travel distalwards in the grooves formed by the metatarsal bones and end, at the distal part of the metatarsus, by dividing each into two *proper digital arteries* (*aa. digitales propriæ dorsales*) distributed along the dorsal borders of adjacent digits.

The skin on the fibular side of the pes is supplied by the superficial branch of the anterior tibial artery. A full consideration of this vessel should be deferred until later.

NERVES OF THE DORSUM OF THE PES.—The nerves of the region are derived from the superficial and deep peroneal nerves. The *superficial peroneal nerve* (*n. peronæus superficialis*) appears by piercing the deep fascia in the peroneal region a little above the tarsus. It supplies the *medial dorsal*

cutaneous nerve (n. cutaneus dorsalis medialis) to the first digit, and then the *second, third, and fourth dorsal digital nerves* (nn. digitales dorsales II, III, et IV) which accompany the corresponding arteries.

N. PERONÆUS PROFUNDUS.—The *deep peroneal nerve* cannot be satisfactorily followed at the present stage of dissection, but may be found lying medial to the tendons of the long extensor muscle at the distal end of the tibia. A large artery, the *a. dorsalis pedis*, runs medial to the nerve.

FASCIA.—The deep fascia on the lateral aspect of the leg is thick, especially in the proximal part of the region where it is connected with the aponeurotic tendon of the biceps muscle. Close to its attachment to the anterior border of the tibia, longitudinal fibres give strength to the fascia. Intermuscular septa are projected between the several muscles of the region.

In the distal third of the leg the tendons of the anterior tibial muscle and the long extensor of the digits are bound to the tibia by a band-like specialisation of the fascia, known as an *annular ligament*. One end is attached to the tibia, the other to the line of union of the two bones of the leg.

Two other annular ligaments occur in the front of the tarsus. One binds down the tendon of the extensor digitorum longus. The other, at the same level, is provided with two compartments; one containing the tendons of the extensor digiti quinti and peronæus brevis, the other the tendon of the peronæus longus. Yet another annular ligament fixes the tendon of the peronæus longus muscle in the groove on the lateral malleolus.

The muscles in the region now being examined are seven in number, namely: mm. tibialis anterior, extensor digitorum longus, peronæus longus, extensor digiti quinti, peronæus brevis, extensor hallucis longus, and extensor digitorum brevis.

M. TIBIALIS ANTERIOR.—The anterior tibial muscle, as its name indicates, lies in front of the tibia, and is the largest and most medial of the group of muscles in this region. Its origin is from the lateral condyle (a small origin) and the lateral surface of the anterior crest of the tibia. About the junction of the middle and distal thirds of the leg a rounded tendon begins, and, passing under the annular ligament, crosses the tarsus obliquely to be inserted into the rudimentary first metatarsal bone (or the proximal end of the second metatarsal bone).

M. EXTENSOR DIGITORUM LONGUS.—The long extensor of the digits lies partly under cover of the anterior tibial muscle and partly to its lateral side. It takes origin by means of a rounded tendon from a rough depression between the lateral condyle and the patellar surface of the femur. Running down a groove between the lateral condyle and the tuberosity of the tibia, the muscle lies on the surface of this bone. In the distal third of the leg the fleshy belly gives place to a strong round tendon, which, passing under the annular ligament, divides into four parts at the tarsus. These are finally inserted into the terminal phalanges of the digits. Each tendon becomes expanded over the metatarso-

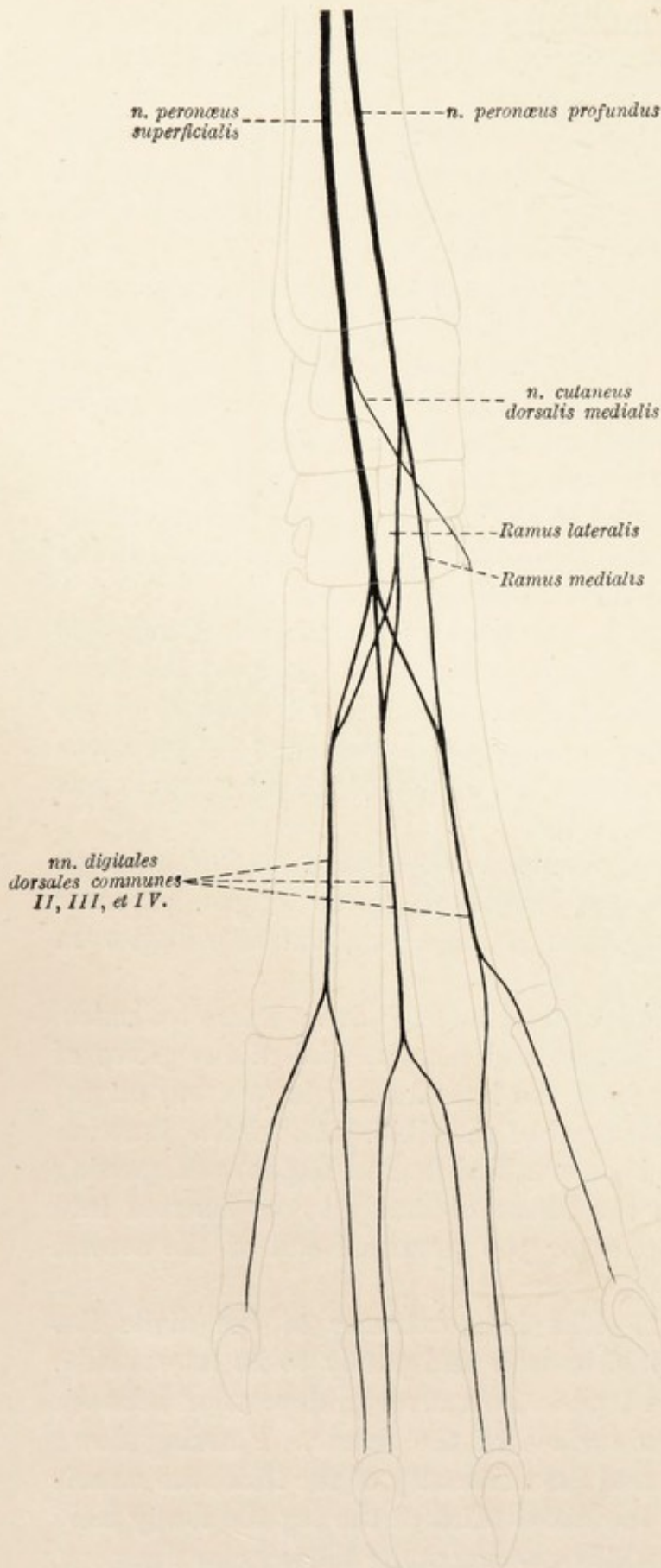


FIG. 35.—Diagram of nerves on the dorsum of the pes.

phalangeal articulation. Here the most lateral tendon is joined by the tendon of the extensor of the fifth digit; the others by the tendons of the extensor digitorum brevis. The tendons are connected with the capsules of the metatarso-phalangeal and interphalangeal joints, and on a level with the first phalanx are joined by slips from the tendons of interosseous muscles.

M. PERONÆUS LONGUS.—Placed to the lateral side of the foregoing, the long peroneal muscle has origin from the lateral collateral ligament, the lateral part of the proximal end of the tibia and the head of the fibula. Its tendon runs over the lateral malleolus, across the back of the tarsus in a groove on the cuboid bone, and is inserted into the base of the first or second metatarsal bone.

M. EXTENSOR DIGITI QUINTI.—This is a slender muscle partly buried between the long peroneal muscle and the deep flexor of the digits. Its origin is from the proximal half of the border of the fibula. A thin tendon passes down the leg in company with that of the long peroneal muscle, crosses under this tendon just beyond the lateral malleolus, and finally joins that slip from the common extensor of the digits which goes to the fifth digit.

M. PERONÆUS BREVIS.—The short peroneal muscle arises from the distal half or two-thirds of the fibula, and is inserted into the base of the fifth metatarsal bone.

M. EXTENSOR DIGITORUM BREVIS.—The short extensor of the digits is confined to the dorsum of the pes. Its three heads arise from the calcaneus and the anterior ligament of the tarsus. Of its three tendons, the most lateral goes to the fourth digit; the middle one to the third and fourth digits; and the medial tendon to the second and third digits. Their union with the tendons of the long extensor is blended with the tendons of the interosseous muscles.

M. EXTENSOR HALLUCIS LONGUS.—This is a thin muscle arising from the lateral surface of the fibula about the junction of the proximal and middle thirds. It lies, at first, between the long extensor and the tibia, then between the anterior tibial and the long extensor muscles, and has a variable insertion. It may end on the rudimentary first metatarsal bone.

Dissection.—The dissection of the common peroneal nerve and its branches and the anterior tibial vessels will be facilitated by the reflection of the long peroneal muscle. The muscle should be cut across about the middle of its fleshy belly.

To follow the deep peroneal nerve and the anterior tibial artery, it is necessary to reflect the short extensor muscle also.

N. PERONÆUS COMMUNIS.—The common peroneal nerve is the smaller of the two terminal branches of the sciatic. Beginning about the middle of the thigh, it crosses the gastrocnemius and deep flexor of the digit under

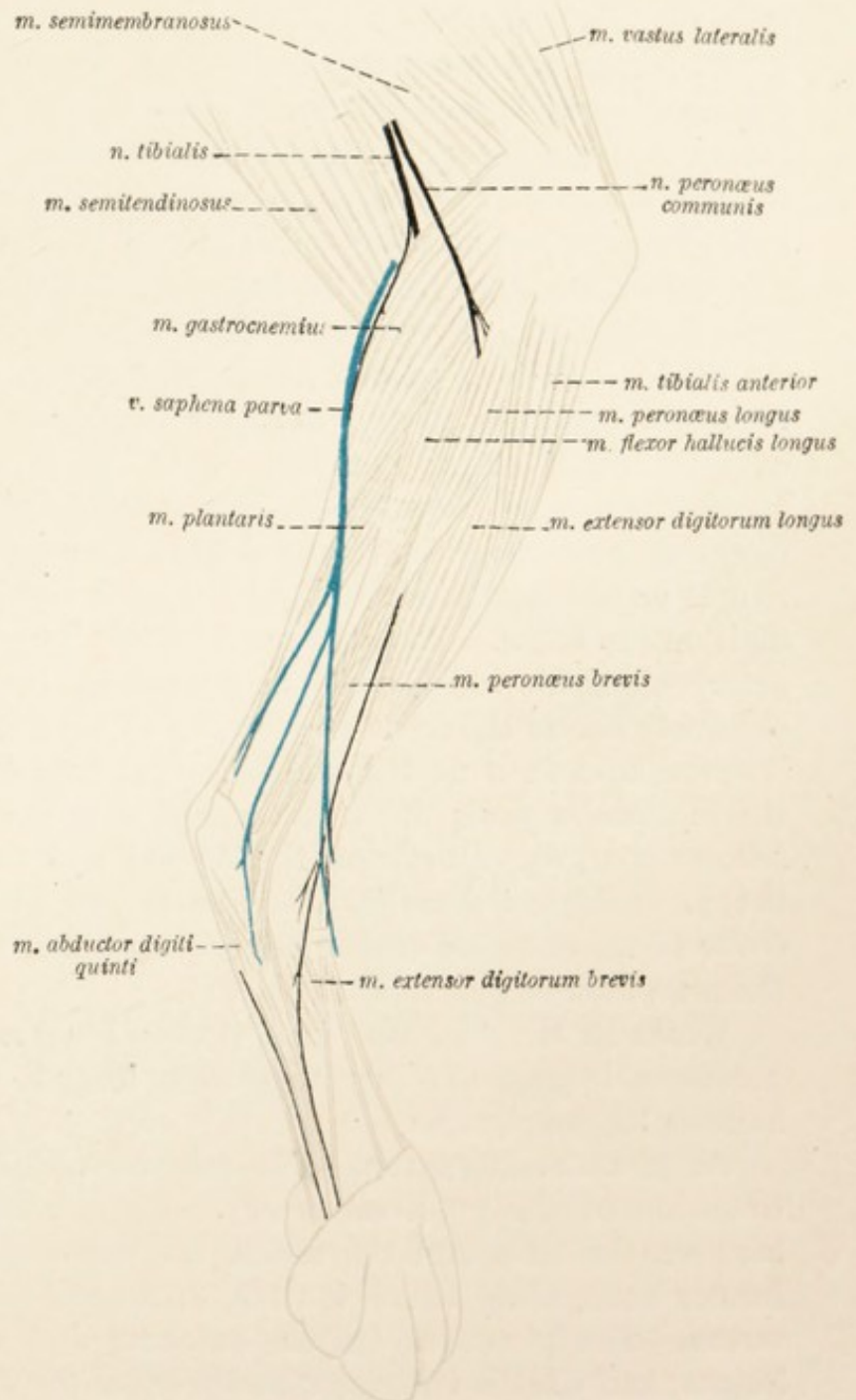


FIG. 36.—Dissection of the lateral aspect of the leg.

cover of the biceps muscle. Disappearing between the long peroneal and deep flexor muscles, it divides in the proximal half of the leg into deep and superficial branches (n. peronæus profundus et n. peronæus superficialis).

Before its division the common peroneal nerve supplies a branch to the long peroneal muscle.

N. PERONÆUS SUPERFICIALIS.—The superficial branch of the common peroneal nerve is included for a time in the septum between the peronæus longus and the extensor digiti quinti muscles. Piercing the deep fascia over the lateral aspect of the leg some little distance proximal to the tarsus, it becomes subcutaneous, and has been followed over the dorsum of the pes where it supplies a dorsal cutaneous nerve of the first digit, and the second, third, and fourth common dorsal digital nerves distributed to the second, third, fourth, and fifth digits.

While still deep to the fascia of the leg, the superficial peroneal nerve furnishes branches to the extensor digitorum longus, peronæus brevis, and extensor digiti quinti muscles.

N. PERONÆUS PROFUNDUS.—From the point at which it leaves the common peroneal nerve, the deep peroneal branch runs obliquely between the peronæus longus on the one hand, and the extensor digiti quinti and deep flexor of the digit on the other. Thus the nerve comes into contact with the anterior tibial artery, alongside which and its continuation (the a. dorsalis pedis) it runs very obliquely across the front of the tibia to the flexor aspect of the tarsus, where it terminates in a medial and a lateral branch. The medial branch follows the a. dorsalis pedis until that vessel disappears from the region, and then follows the groove between the second and third metatarsal bones to form the *n. metatarsæ dorsalis II*. The lateral branch crosses the tarsus under cover of m. extensor digitorum brevis, which it supplies, and then furnishes the *nn. metatarsæ dorsales III et IV*.

While in the leg, the deep peroneal nerve contributes branches to the peronæus longus, extensor digitorum longus, tibialis anterior, and extensor hallucis longus muscles.

A. TIBIALIS ANTERIOR.—The anterior tibial artery is practically the continuation of the popliteal artery. By piercing the interosseous membrane between the tibia and the fibula, the artery gains the lateral surface of the former bone, along which it runs, with some degree of obliquity, towards the tarsus. The peronæus longus, extensor digitorum longus, extensor hallucis longus, and tibialis anterior muscles cover the artery in succession.

Opposite the joint between the tibia and the talus, the anterior tibial artery changes its name to that of *dorsal artery of the pes* (a. dorsalis pedis), which crosses the flexor aspect of the tarsus, between the tendons of the anterior tibial and long extensor muscles, to disappear into the space between the bases of the second and third metatarsal bones. Before disappearing, the a. dorsalis pedis supplies the *second, third and fourth dorsal metatarsal arteries* (aa. metatarsæ dorsales II, III, et IV).

Dissection.—Attention should now be directed to the structures behind the tibia. The disposition and strength of the fascia over this part of the leg calls for remark. In the proximal third of the leg, where the

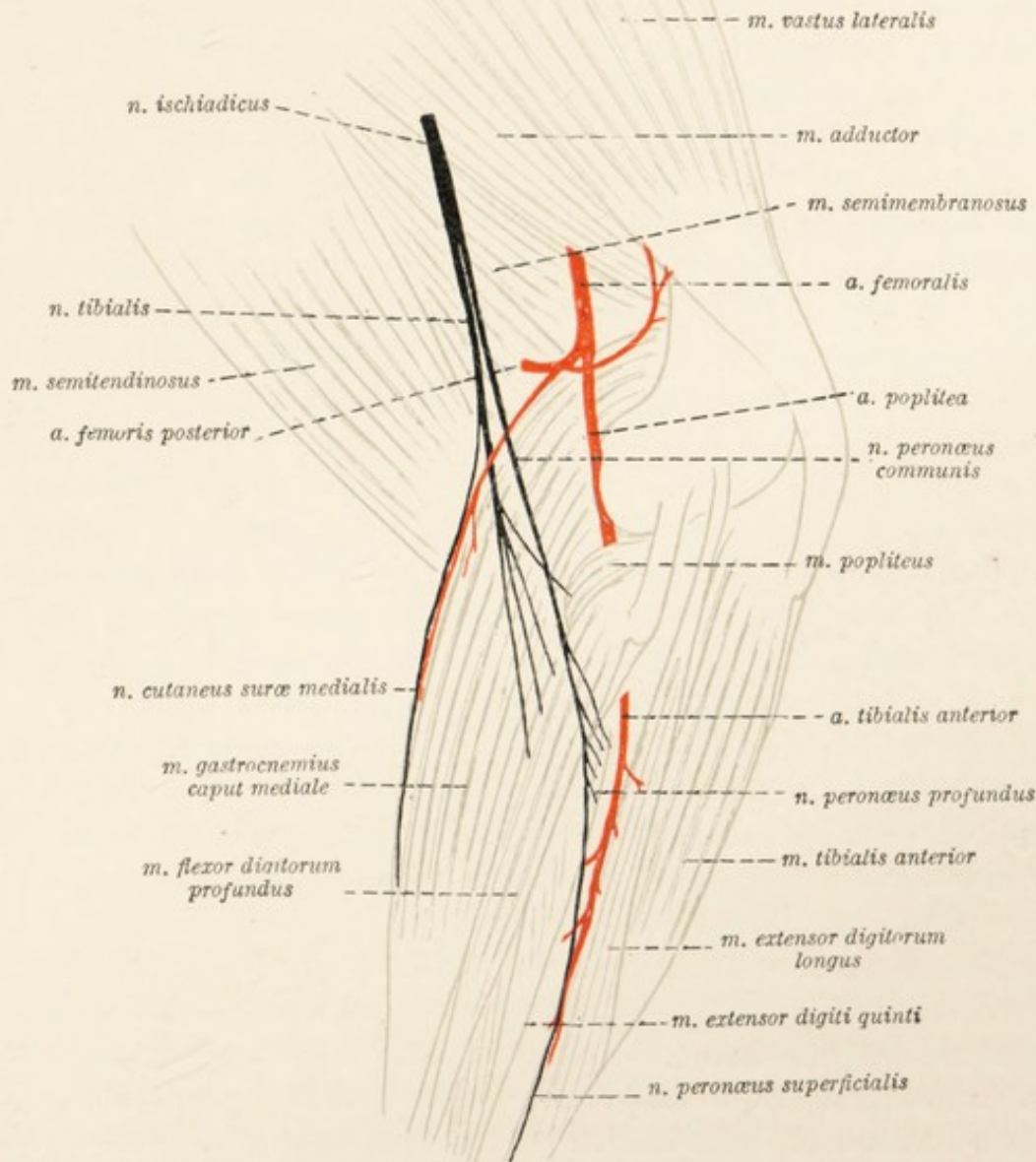


FIG. 37.—Dissection of origin of tibial and common peroneal nerves.

calf muscles are covered by the hamstring muscles, the fascia is not notably strong ; but in the distal half of the region it is thick, strong and tendinous, especially over the *tendo-calcanæus* [*Achillis*] (the combined tendons of gastrocnemius and plantaris muscles). In front of the tendon there is a thick tendinous cord inserted into the calcaneus.

The small saphenous vein may be again examined and its termination noted. Examine the cutaneous nerves of the region.

THE CUTANEOUS NERVES OF THE BACK OF THE LEG are derived from the saphenous, peroneal, and tibial nerves. The saphenous nerve supplies the medial aspect of the leg and pes. The lateral cutaneous of the calf (n. cutaneus suræ lateralis) has been previously noted as arising either from the sciatic or from the peroneal nerve. It becomes superficial at the border of the biceps and supplies the skin of the posterior and lateral parts of the leg.

N. CUTANEUS SURÆ MEDIALIS.—The medial cutaneous nerve of the calf is a branch of the tibial nerve, and arises a little distance before this nerve sinks between the two heads of the gastrocnemius muscle. Crossing the surface of the gastrocnemius slightly obliquely, along with a branch from the posterior femoral artery and the small saphenous vein, the nerve divides into two branches about the middle of the leg. These immediately pierce the deep fascia and become superficial. The posterior (plantar) branch runs along the lateral side of the tendo-calcaneus [Achillis] and supplies the skin about the tarsus. The anterior (dorsal) branch runs obliquely between the tendo-calcaneus and the deep flexor of the digits, is connected with the tibial nerve, and ends in the skin of the distal part of the leg, the tarsus and the metatarsus.

A. SAPHENA.—The origin of the saphenous artery from the femoral was noted in the dissection of the thigh. Crossing the surface of the gracilis and semitendinosus muscles subcutaneously, it arrives in the leg and immediately divides into anterior (dorsal) and posterior (plantar) branches. The anterior branch passes down the leg in association with the large saphenous vein and has been examined in connection with the dorsum of the pes.

The posterior branch, much the larger, descends upon the deep flexors of the digit in a special compartment of the deep fascia which also contains the corresponding vein and the tibial nerve. A little proximal to the tarsus it supplies the *lateral tarsal artery* (a. tarsea lateralis) and is continued into the pes, where it will be followed subsequently.

M. GASTROCNEMIUS.—This powerful muscle arises by two heads. The lateral head takes origin from the lateral sesamoid and from the lateral border of the planum poplitæum of the femur. The medial head arises from the medial sesamoid and the medial border of the planum poplitæum.

The two heads soon join, and the common muscle thus formed gives place to a strong tendon about the middle of the leg. The insertion is into the tuber of the calcaneus.

Dissection.—Cut across the gastrocnemius muscle just where its two heads are about to join. The process of reflecting the lateral head is made a little difficult by its close connection with the underlying plantaris muscle.

M. PLANTARIS.—The plantaris muscle arises in common with the lateral head of the gastrocnemius from the lateral sesamoid bone and the lateral lip of the planum poplitæum. In the distal third of the leg the fleshy belly of the

muscle is replaced by a strong tendon closely associated with that of the gastrocnemius, the two together forming the so-called *tendo-calcaneus* of Achilles. At first the plantaris tendon is the deeper of the two ; but, by

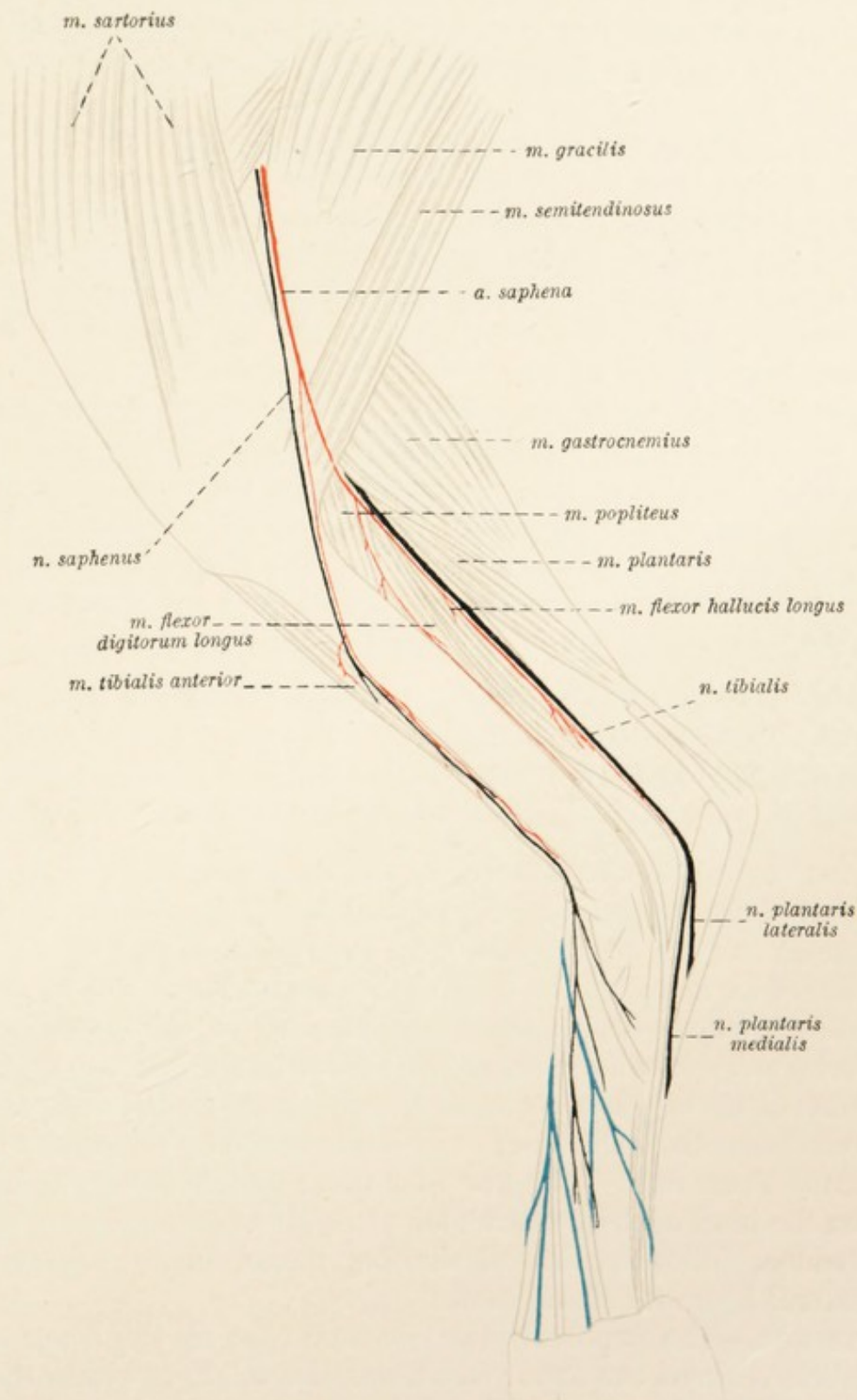


FIG. 38.—Dissection of the medial aspect of the leg.

gradually passing on the medial side of the gastrocnemius tendon, it ultimately comes to be the more superficial.

Two slips attach the plantaris tendon to the side of the tuber calcanei, from which point there is an apparent direct continuation of the tendon into the pes. This appearance, however, depends upon a modification of the short flexor of the digits (*m. flexor digitorum brevis*), which will receive consideration later.

N. TIBIALIS.—The larger of the two terminal branches of the sciatic, the tibial nerve accompanies the peroneal nerve for a little distance, and then enters the gap between the two heads of the gastrocnemius muscle. Following the border of the plantaris muscle underneath the medial head of the gastrocnemius, the nerve comes into relation with the posterior branch of the saphenous artery; and in the distal part of the leg it becomes associated with the deep flexor of the digits which it accompanies to the tarsus.

The branches of the tibial nerve are as follows: (1) *Medial cutaneous nerve of the calf* (*n. cutaneus suræ medialis*), which has already been examined; (2) branches (*rami musculares*), large and numerous, for the supply of all the muscles behind the tibia; (3) *medial plantar nerve* (*n. plantaris medialis*); (4) *lateral plantar nerve* (*n. plantaris lateralis*). The medial and lateral plantar nerves form the terminal branches of the tibial, and are distributed in the sole of the pes, where they will be examined at the proper time.

Dissection.—Reflect the plantaris muscle and expose the deep muscles of the leg. These are three in number. The most lateral really consists of two muscles—*m. flexor hallucis longus* and *m. flexor digitorum longus*—but will be more conveniently referred to as the deep flexor of the digits.

M. FLEXOR DIGITORUM PROFUNDUS.—The deep flexor of the digits arises from the head of the fibula and the proximal half of the border of this bone, from the lateral condyle of the tibia, from the proximal part of the posterior surface of the tibia, and from the interosseous membrane. The tendon of the *m. flexor hallucis longus* begins about the junction of the middle and distal thirds of the leg and passes down the groove formed by the calcaneus. The much smaller tendon of the *m. flexor digitorum longus* is more medial and passes down the groove on the medial malleolus, in which it is bound by an annular ligament.

M. TIBIALIS POSTERIOR.—The posterior tibial muscle is very rudimentary. Arising from the head of the fibula under cover of the long flexor of the digits, its feeble tendon, following that of the long flexor, finally blends with the medial collateral ligament of the tarsus.

M. POPLITEUS.—The popliteal muscle covers part of the flexor aspect of the articulation between the femur and tibia. Its origin is within the capsule of the joint from the lateral condyle of the femur (sesamoid). The fibres of the muscle spread out to find attachment to a triangular surface on the proximal posterior part of the tibia.

A. POPLITEA.—The popliteal artery continues the femoral between the two heads of the gastrocnemius muscle, and insinuates itself between the popliteal muscle and the joint-capsule of the articulation between the femur and tibia. In order to follow the artery to its termination it is necessary to reflect the popliteal and long flexor muscles. This having been done, it will be found that the popliteal ends by dividing into the anterior and posterior tibial arteries. The latter is so small that, to all intents and purposes, the anterior tibial is the direct continuation of the parent vessel.

A. TIBIALIS ANTERIOR.—The anterior tibial artery soon pierces the ligamentous membrane between the tibia and fibula and thus gains the anterior tibial region, where its further course has been previously noted.

THE SOLE OF THE PES.—Before any dissection is performed, five areas of modified skin should be noted. These are in the form of distinct, callous, hairless projections; one of them, the largest, lies in the hollow of the digits. Its form is that of a heart with the apex distal. The four smaller callosities lie over the joints between the second and third phalanges of the second, third, fourth, and fifth digits.

The skin over the sole should now be removed and the structure and connections of the callosities determined. Each callosity consists of a fibro-fatty basis with which thick, horny, papillated skin is intimately connected. The callosities are joined to the sheaths of the flexor tendons by strong ligamentous bands. This is more particularly noticeable in connection with the large callosity, which also receives a bifurcating band from the tendon of the deep flexor muscle.

MUSCLES AND TENDONS OF THE SOLE.—The muscles and tendons of this part of the pes are arranged in the following layers:

1st Layer.—M. flexor digitorum brevis, m. abductor digiti quinti.

2nd Layer.—Tendon of the m. flexor digitorum profundus, mm. lumbricales, m. quadratus plantæ.

3rd Layer.—M. adductor digiti quinti, m. adductor digiti secundi, mm. interossei.

4th Layer.—Tendon of m. peronæus longus.

In the dissection of the most superficial layer an examination must be made of the sheaths of the flexor tendons. The sheaths assist the bones of the digits in the formation of osseo-membranous tubes in which the flexor tendons are contained. The dorsal wall of the tube is formed by the metatarsal sesamoids and the phalanges; while the plantar portion of the tube is formed by the flexor sheaths which are attached to the margins of the above bones. The sheaths are not of uniform strength throughout. On a level with the sesamoid bones, and opposite the distal end of the first phalanx, a considerable accession

of transverse fibres contributes great strength to the sheaths. In cleaning the fascia from the surface of the short flexor of the digit, the medial plantar nerve which runs along the medial border of the muscle must not be injured.

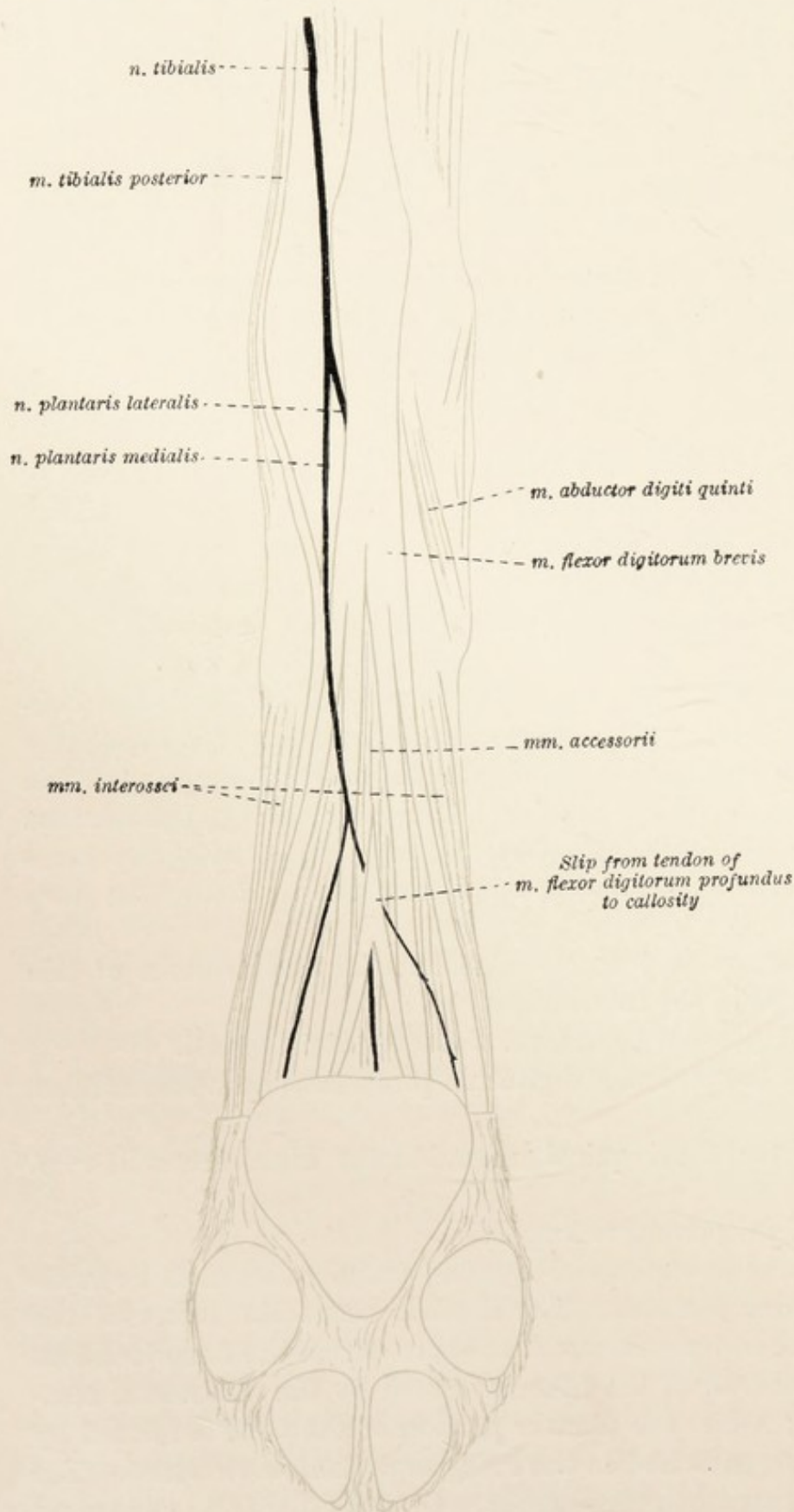


FIG. 39.—Superficial dissection of the sole.

nerve which runs along the medial border of the muscle must not be injured.

M. FLEXOR DIGITORUM BREVIS.—This was mentioned in the dissection of the leg as forming the direct continuation of the plantaris muscle into the sole. Almost the whole of the muscular tissue of the short flexor has been replaced by tendon. Continuous with the plantaris tendon at the tuber calcanei, the flattened tendinous band runs down the plantar aspect of the tarsus to the proximal part of the metatarsus, where it divides into two branches, each branch again dividing about the middle of the metatarsus. The initial part of the muscle is intimately connected with the fascia in the region of the tarsus. The four terminal tendons enter the flexor sheaths, divide into two slips which form a ring through which the deep flexor tendon passes, and end by becoming

attached to the proximal part of the second phalanges of the second to fifth digits.

M. ABDUCTOR DIGITI QUINTI.—The abductor of the fifth digit is very rudimentary and somewhat variable. Two parts can be distinguished : (1) In the form of a tendinous band passing from the proximal part of the calcaneus to the base of the fifth metatarsal bone ; (2) either with the same origin as the first part, or as an offshoot therefrom, as a feeble fleshy belly continued by a thin tendon to the first phalanx of the fifth digit.

Dissection.—Cut across the short flexor close to its commencement ; cut its connections with the fascia and turn it downwards as far as possible. In performing this dissection care must be taken to preserve the two plantar nerves—terminal branches of the tibial nerve—and the plantar branch of the saphenous artery.

M. FLEXOR DIGITORUM PROFUNDUS.—The strong tendon of the m. flexor hallucis longus runs along the groove on the calcaneus where it is bound down by a strong annular ligament, and is joined by the much smaller tendon of the m. flexor digitorum longus which has traversed a groove on the medial malleolus. The powerful deep flexor tendon so formed divides into four parts, one for each of the digits (second to fifth). Each tendon enters a flexor sheath, pierces the ring formed by a tendon of the short flexor, and is finally inserted into the terminal phalanx.

MM. LUMBRICALES.—Three rather feeble lumbrical muscles arise from the plantar surface of the deep flexor tendon. Their thin tendons are traceable to the proximal end of the first phalanx of the third, fourth, and fifth digits. Occasionally small tendinous slips may join one or more of the tendons of the short flexor of the digits.

M. QUADRATUS PLANTÆ.—The quadratus muscle is very small and thin, and arises from the distal extremity of the calcaneus and the lateral collateral ligament of the tarsus. Its fibres join the deep flexor tendon.

N. TIBIALIS.—The tibial nerve follows the tendon of the m. flexor hallucis longus to a level with the joint between the tibia and the talus, where it divides into the medial and lateral plantar nerves.

The *medial plantar nerve* (n. plantaris medialis) is the smaller, and runs along the medial border of the m. flexor brevis to the middle of the metatarsus, where it ends in two branches. The more medial of the two is continued onwards as the *n. digiti plantaris communis I*. The more lateral branch crosses the plantar aspect of the short flexor muscle and divides into *nn. metatarsi plantares II, III, et IV*, which join the common plantar digital nerves. The *lateral plantar nerve* (n. plantaris lateralis) is much larger. Placed between the superficial and deep flexor tendons, it disappears from view between the origins of the most lateral interosseous muscle and the adductor of the fifth

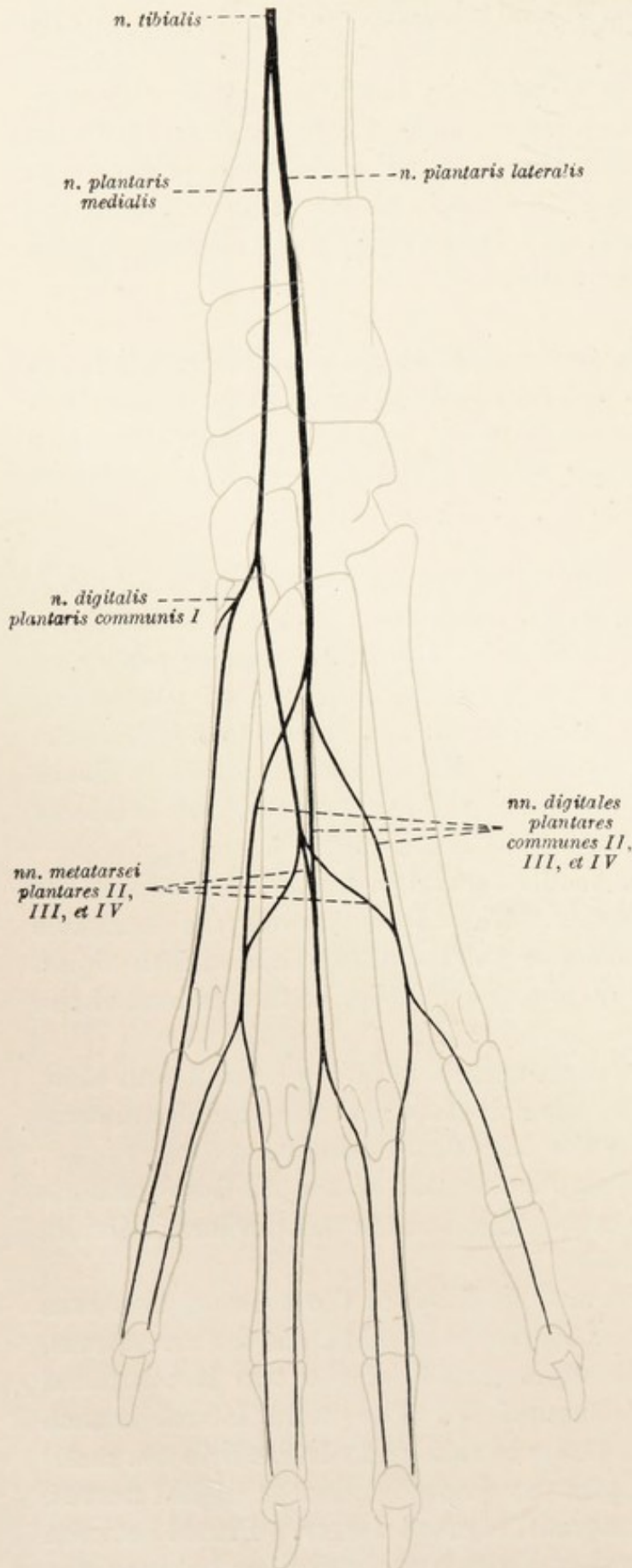


FIG. 40.—Diagram of the plantar nerves of the pes.

digit. It cannot be followed satisfactorily until the deep muscles have been examined.

Dissection.—Reflect the deep flexor tendon.

M. ADDUCTOR DIGITI QUINTI.—The adductor of the fifth digit arises by a flattened tendon from the plantar surface of the tarsus. Crossing the sole somewhat obliquely, it dips in between the interosseous muscles of the fourth and fifth digits, and is inserted into the fifth metatarsal bone and the first phalanx of the fifth digit.

M. ADDUCTOR DIGITI SECUNDI.—A smaller muscle than the preceding, its origin is between that of the adductor of the fifth digit and the interosseous muscle of the second digit. Running distalwards between the interosseous muscles of the second and the third digits, it is inserted into the first phalanx of the second digit.

MM. INTEROSSEI.—The interosseous muscles are four in number. Each takes origin from the tarsus and the proximal end of the metatarsal bones and divides into medial and lateral parts to be attached to the sesamoid bones.

Dissection.—Reflect the adductor muscles of the fifth and second digits and the interosseous muscle of the second digit. Follow the plantar ramus of the saphenous artery in the ligamentous tissue on the flexor aspect of the tarsus, and

then between the interosseous muscle of the second digit and the adductor digiti quinti, until it joins the a. dorsalis pedis in the formation of the plantar arch.

A. TARSEA MEDIALIS.—

The plantar ramus of the saphenous artery is continued, as the *medial tarsal artery*, along the medial side of the flexor aspect of the tarsus, and forms the *arcus plantaris* along with the dorsalis pedis artery. The medial tarsal artery then continues to the distal part of the metatarsus and divides into the second, third, and fourth plantar metatarsal arteries (aa. metatarsi plantares II, III, et IV), which join the common plantar digital arteries.

A. DORSALIS PEDIS.—

The continuation of the anterior tibial artery appears deep in the sole between the second and third interosseous muscles and under cover of the origin of the m. adductor digiti quinti. Anastomosing with the plantar branch of the saphenous artery it forms the *plantar arch* (arcus plantaris), from which arise the *second, third, and fourth common plantar digital arteries* (aa. digitales plantares

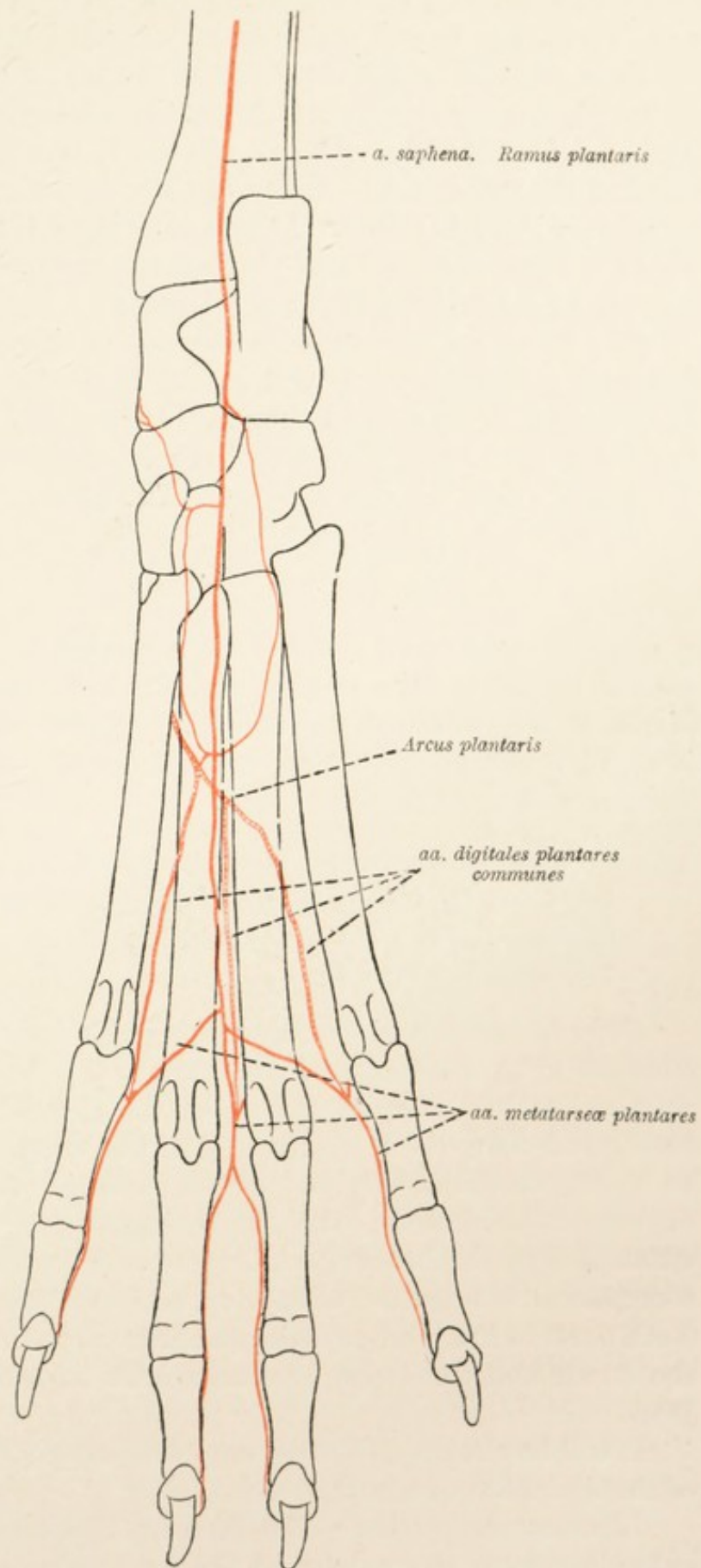


FIG. 41.—Diagram of the plantar arteries of the pes.

communes II, III, et IV), which run between the second and third, third and fourth, and fourth and fifth metatarsal bones.

N. PLANTARIS LATERALIS.—This, the larger of the two terminal branches of the tibial nerve, has been followed to its disappearance under the m. adductor digiti quinti. It will now be seen to end in several branches about the proximal third of the metatarsus. Some of these branches are distributed to the small muscles of the sole; three of them, the *second, third, and fourth common plantar digital nerves* (nn. digitales plantares communes II, III, et IV), follow the corresponding arteries of the same name.

M. PERONÆUS LONGUS.—The tendon of the long peroneal muscle has been followed as far as the lateral aspect of the tarsus. It can now be examined as it lies in the groove in the cuboid bone and crosses the plantar aspect of the tarsus to its insertion into the rudimentary first metatarsal bone (or, in its absence, into the second bone). The tendon is enclosed in a strong fibrous sheath which must be opened.

ARTICULATIO GENU.—This joint is formed by the condyles and patellar surface of the femur, the patella, and the articular surface at the proximal end of the tibia. Although the adaption of the bony surfaces is indifferent, the joint, in virtue of the character and number of the ligaments in association therewith, is strongly constituted.

Dissection.—Clear away the remains of the muscles about the joint, but leave the tendons of origin of the popliteus muscle and the long extensor of the digits. Clean the surface of the joint-capsule and define the collateral ligaments.

Capsula articularis.—In describing the joint-capsule, it is convenient to consider it as divided into two parts: (1) The anterior part is roomy and attached to the condyles and about the margin of the patellar surface of the femur and along the articular edge of the tibia. The patella may be regarded as a bony island in this part of the capsule. On each side of the patella the capsule is thickened; the thickenings being connected with cartilaginous extensions of the bone. (2) The posterior portion of the capsule is much less roomy, and is attached about the articular margins of the femur and tibia. Both parts of the joint-capsule are adherent to the edges of the menisci between the femur and tibia, and are continuous with the collateral ligaments of the joint.

It will be observed that the origins of the popliteus muscle and long extensor of the digits are within the capsule.

Ligamentum patellæ.—The patellar ligament is a strong flattened band extending from the patella to the tuberosity of the tibia. A pad of fat is interposed between the ligament and the joint-capsule, and a small synovial

bursa intervenes between the ligament and the smooth proximal part of the tibial tuberosity.

The patellar ligament is, strictly speaking, the tendon of insertion of the quadriceps muscle of the thigh, and the patella is a sesamoid bone developed therein.

Ligamentum collaterale tibiale.—The medial collateral ligament passes from the condyle of the femur to just beyond the condyle of the tibia. The ligament is attached to the margin of the medial meniscus.

Ligamentum collaterale fibulare.—The lateral collateral ligament passes from the lateral condyle of the femur to the head of the fibula.

Dissection.—Open the joint by making a transverse incision through the capsule just proximal to the patella and a longitudinal incision along each side of this bone. The patella with the patellar ligament may then be turned downwards. Observe the synovial fringes in the interior of the joint, and the cartilaginous extensions of the patella.

Dissect away the posterior part of the capsule and examine the crucial ligaments and the menisci of cartilage interposed between the femur and the tibia.

Ligamentum cruciatum anterius.—The anterior cruciate ligament passes obliquely from the anterior intercondyloid fossa of the tibia to the medial face of the lateral condyle of the femur.

Ligamentum cruciatum posterius.—Not quite so strong as the anterior, the posterior cruciate ligament runs from the popliteal notch of the tibia to the lateral surface of the medial condyle of the femur.

Menisci lateralis et medialis.—The poor adaption of the femoral and tibial articular surfaces is partly compensated by the presence of two crescentic, cartilaginous pads of which the lateral is somewhat the larger. The convex edge of each meniscus is thick; whereas the concave edge is thin and directed towards the intercondyloid eminence of the tibia.

The convex border of the lateral meniscus is crossed obliquely by a deep groove for the reception of the tendon of origin of the popliteus muscle. ★

Each meniscus is attached in front by ligamentous tissue to the anterior intercondyloid fossa of the tibia, and in addition there is a *transverse ligament* (lig. transversum genu) running from one meniscus to the other across the tibial attachment of the anterior cruciate ligament.

Behind, the medial meniscus is attached to the posterior intercondyloid fossa of the tibia. The lateral meniscus has two posterior attachments; one to the tibia just beyond the articular margin and lateral to the popliteal notch; the other by a strong ligament which crosses the posterior cruciate ligament obliquely to end on the medial condyle of the femur.

Dissection.—Now proceed to the examination of the joints between the

tibia and fibula. All remains of the muscles will require to be cleaned away.

There are two joints between the tibia and the fibula: a proximal *tibio-fibular articulation* (articulatio tibio-fibularis), and a distal *tibio-fibular syndesmosis* (syndesmosis tibio-fibularis). Between these joints the *interosseous membrane of the leg* (membrana interossea cruris) unites the two bones. Very commonly the distal third or more of the tibia and fibula are joined together by bone.

Articulatio tibio-fibularis.—The tibio-fibular articulation is surrounded by a *joint-capsule* (capsula articularis).

Syndesmosis tibio-fibularis.—The tibio-fibular syndesmosis is very strong and provided with an anterior and a posterior ligament (lig. malleoli lateralis anterior et lig. malleoli lateralis posterior) which bind the malleolus of the fibula to the distal end of the tibia.

Dissection.—Remove all tendons, annular ligaments, and muscles from the tarsus, metatarsus, and digits.

Articulatio talo-cruralis.—The talo-crural or ankle-joint, formed by the two bones of the leg and the talus, is a strong articulation provided with conspicuous ligaments. The *joint-capsule* (capsula articularis) is attached to the articular margins of the tibia, fibula, and talus. On the medial side of the joint the *deltoid ligament* (ligamentum deltoideum) arises from the medial malleolus, and, by diverging bundles, passes to the scaphoid, talus, and sustentaculum tali of the calcaneus. Laterally there are three ligaments running from the end of the fibula to the talus and calcaneus. The *posterior talo-fibular ligament* (ligamentum talo-fibulare posterius), the most proximal of the three, joins the lateral aspect of the trochlea of the talus. The *calcaneo-fibular ligament* (ligamentum calcaneo-fibulare) is the strongest and best defined member of the group, and finds attachment to the lateral surface of the calcaneus. The *anterior talo-fibular ligament* (ligamentum talo-fibulare anterior) is very rudimentary and attached to the neck of the talus.

Ligaments connected with the talus.—A number of ligaments, some of them feeble, hold the talus in position. The *posterior talocalcanean ligament* (ligamentum talo-calcaneum posterius) is rudimentary and is placed at the most proximal point of contact of the talus and calcaneus. A very poorly represented *lateral talo-calcanean ligament* (ligamentum talo-calcaneum laterale) unites the lateral surfaces of the two bones. The *medial talo-calcanean ligament* (ligamentum talo-calcaneum mediale) is much stronger than the preceding, and is partly covered by the deltoid ligament. It runs from the tubercle on the medial surface of the talus to the sustentaculum tali. A *dorsal tarsal ligament*

(ligamentum tarsi dorsale) joins the neck of the talus to the cuboid and third metatarsal bones. A small *anterior talo-calcanean ligament* (ligamentum talo-calcaneum anterius) will be found in the depths of the groove between the two bones with which it is associated.

Dissection.—Remove the talus. This is rendered difficult from the presence of a strong interosseous ligament.

Ligamentum talo-calcaneum interosseum.—The talo-calcanean interosseous ligament passes between the two bones, and is attached to the grooves between their articular facets.

Ligaments connected with the calcaneus.—Removal of the talus exposes both surfaces of the strong *plantar calcaneo-navicular ligament* (ligamentum calcaneo-naviculare plantare), which passes from the sustentaculum tali to the navicular bone. Part of the cavity in which the head of the talus rests is formed by this ligament. The *long plantar ligament* (ligamentum plantare longum) is powerful and runs from the plantar surface of the calcaneus to the tubercle on the cuboid and on to the tubercle at the proximal end of the fifth metatarsal bone. Partly under cover of, and much shorter than, the preceding is the *plantar calcaneo-cuboid ligament* (ligamentum calcaneo-cuboideum plantare), which joins the calcaneus to the cuboid only. On the dorsal and lateral part of the joint between the calcaneus and cuboid is a *short dorsal calcaneo-cuboid ligament* (ligamentum calcaneo-cuboideum dorsale), which may be regarded as a thickening of the capsule of the joint.

Ligaments connected with the navicular.—A short *dorsal cuboideo-navicular ligament* (ligamentum cuboideo-naviculare dorsale) joins the cuboid and navicular on the dorsal aspect of the joint between the two bones. The navicular and lateral cuneiform bones are united by a small *dorsal navicular-cuneiform ligament* (ligamentum naviculari-cuneiforme dorsale), and a much stronger *plantar ligament* (ligamentum naviculari-cuneiforme plantare) joins the navicular and the medial cuneiform bones. The latter is continued to the first and second metatarsal bones.

Dissection.—Remove the calcaneus and the plantar calcaneo-navicular and plantar navicular-cuneiform ligaments.

The dissection exposes a short *plantar cuboideo-navicular ligament* (ligamentum cuboideo-naviculare plantare) uniting the plantar aspects of the navicular and cuboid bones.

Articulationes tarso-metatarsecæ.—The metatarsal bones articulate with the cuboid and the three cuneiform bones, with which they are connected by dorsal, plantar, and interosseous ligaments. The dorsal ligaments are flattened bands of no great strength. The interosseous ligaments should be examined along with the interosseous tarsal ligaments.

Dissection.—Separate the remaining bones of the tarsus in order to demonstrate the interosseous ligaments.

Ligamenta tarsi interossea.—One of the interosseous ligaments—the talocalcanean—has already been studied. Others will now be found joining the navicular to the cuboid, the cuboid to the lateral cuneiform, and the three cuneiform bones.

Articulationes intermetatarseæ.—Weak *dorsal* and *plantar* ligaments unite the bases of the metatarsal bones. The rigidity of the intermetatarsal joints depends upon strong *interosseous ligaments*.

Articulationes metatarso-phalangeæ.—The metatarso-phalangeal joint is formed by four bones; namely, the metatarsal bone, the first phalanx, and two sesamoid bones. The joint is enclosed by a *capsule* connected with the extensor tendons in front. On each side of the joint is a *collateral ligament* which joins the head of the metatarsal bone to the first phalanx and one of the sesamoid bones.

The sesamoid bones are firmly united to each other by a strong interosseous ligament, and are further attached to the proximal part of the first phalanx by ligaments on each side of the joint as well as on its plantar aspect.

Articulationes digitorum pedis.—The joints between the first and second, and second and third phalanges are provided with capsules and collateral ligaments. In addition, the joint between the second and third phalanges has two dorsal ligaments, which spring from the sides of the proximal end of the second phalanx and are attached to the proximal end of the third phalanx.

PELVIS.—The pelvis is a cavity bounded by the sacrum and the two hip bones, and differing in its contents dependent upon the sex. It is convenient to suppose that the subject being dissected is a male. The contents of the female pelvis will be considered later.

The contents of the male pelvis may be tabulated as follows:—

Viscera.	{	Rectum.
		Possibly a small part of the prostate.
		Prostatic and membranous parts of the urethra.
		Deferent ducts.
Blood-vessels.	{	Hypogastric vessels and their branches.
		Middle sacral vessels.
Nerves.	{	Pudendal nerve.
		Sacral plexus and its branches.
		Obturator nerve.
		Sacral part of the sympathetic nervous system.

Before any dissection is effected, it is well to examine, as far as possible, the general disposition of the viscera and the arrangement of the peritoneum in the pelvis.

At the inlet to the cavity the urinary bladder and part of the colon will be encountered. The urinary bladder is pear-shaped with its narrow end directed towards the pelvis. When entirely empty the bladder is small in size and firm to the touch. When distended with urine it projects for a variable distance towards the umbilicus, and is generally pushed more or less to one side by the neighbouring intestines.

The peritoneal covering of the bladder is reflected from the organ in the form of three sheets. One of these (*plica pubovesicalis*) is ventral in position, triangular in form, extensive and thin. The other two are lateral in position (*plicæ vesicales transversæ*), are also triangular, and contain the ureters.

The two deferent ducts in their course from the abdominal ring of the inguinal canal lie dorsal to the neck, or narrow pelvic end, of the bladder. Each duct is contained in a fold of peritoneum, and the two ducts are united dorsal to the bladder by a triangular peritoneal fold with a free cranial base. Close to its termination each duct is crossed laterally by the ureter.

The terminal part of the colon is dorsal to the bladder. The peritoneal investment is more extensive on the dorsal aspect of the bladder—where it is reflected onto the termination of the colon—than it is ventral to this organ. About the pelvic inlet the peritoneum generally covers a considerable accumulation of fat, on the removal of which the prostate is exposed.

Dissection.—Clean the muscles away from one hip bone. Liberate the root of the penis from the ischium. Cut along the symphysis of the ischia and pubes, and snip through the ilium immediately cranial to the acetabulum. This will isolate a piece of bone consisting of ischium, pubis, and part of the ilium. Remove this carefully. In doing so it will be necessary to cut through the origins of the levator ani, coccygeus and ischio-urethral muscles. Stumps of these should be left attached to the bone for examination at the proper time. Now clean the lateral surface of the pelvic organs, preserving the vessels and nerves and observing the arrangement of the peritoneum.

M. COCCYGEUS.—The coccygeus muscle is the most lateral of a group contained within the pelvis. From their origin from the margin and medial aspect of the sciatic spine, the fibres of the muscle run towards the tail, diverging somewhat as they go, and are inserted into the transverse processes of the coccygeal vertebræ from the second to the fifth.

INTESTINUM RECTUM.—The last part of the large intestine is a short and approximately straight tube continuing the colon through the pelvis and terminating at the anus. Externally the tube is even, and shows the course of longitudinal muscle fibres. Suspended from the mid-dorsal line by a narrow

mesentery continuous with the mesocolon, the rectum has its dorsal surface covered by peritoneum to a level slightly caudal to the acetabulum. The line of peritoneal reflection slopes obliquely across the lateral face of the tube in such a manner that the ventral surface has scarcely any peritoneal investment.

The terminal opening of the intestine, the *anus*, is surrounded by thick skin provided with a somewhat scanty supply of short fine hairs. Close to the line of junction of skin and mucous membrane is a small opening on each side leading into a sac, from a hazel-nut to a walnut in size, known as the *para-anal sinus* (sinus para-analis). The sinus lies between the external sphincter muscle of the anus and the longitudinal muscle of the rectum, and has a lining membrane provided with glands which produce a thickish, strong-smelling secretion.

M. LEVATOR ANI.—The levator muscle of the anus of the dog is relatively large but thin. Triangular in form, it lies over the lateral face of the rectum. Since it is medial to the coccygeus muscle, this has to be turned aside in order that the full extent of the levator may be exposed. The levator ani arises from the symphysis of the ischia and pubes, from the oral border of the pubis, and from the medial surface of the ilium. Some of its fibres blend with the sphincter ani, and some end on the first vertebra of the tail.

M. SPHINCTER ANI EXTERNUS.—The external sphincter surrounds the anus as a ring. It consists of three portions more or less blended together, and is attached to the aponeurosis of the tail. The oral portion is poorly developed. The middle portion is connected with the m. bulbo-cavernosus, and the aboral portion with the retractor muscle of the penis.

M. SPHINCTER ANI INTERNUS.—The internal sphincter muscle is merely a thickening of the circular muscle of the rectum.

It should be noted here that the longitudinal muscular fibres of the rectum send a well-defined band to the ventral aspect of the first few coccygeal vertebræ.

VESICA URINARIA.—Although not a pelvic organ in the dog, it is convenient, because of its connections, to study the urinary bladder here rather than with the abdominal viscera. An ovoid sac with a strong muscular wall, the bladder is divided, for descriptive purposes, into a main portion or *body* (corpus vesicæ); a blunt cranial end, the *vertex* (vertex vesicæ); and a narrow pelvic extremity, the *neck* (collum vesicæ), continuous with the urethra.

Ventrally the bladder lies on the abdominal wall, the great omentum sometimes intervening. Dorsally it is in contact partly with the colon, partly with coils of the small intestine. Dorsal to the neck are the deferent ducts. On each side the bladder is in relation to the small intestine and the ureter.

Naturally the relations of the vertex of the bladder depend materially upon the amount of distension of the viscus. When the sac is moderately full it may touch the ileum. At all times the vertex is in contact with some part of the small intestine.

Dissection.—Open the bladder by making an incision along the mid-ventral line from the vertex to the neck.

The interior of the urinary bladder is lined by a mucous membrane of distinctly rugose character ; but towards the neck the rugæ are generally less prominent than over the rest of the interior.

In the dorsal part of the neck the openings of the ureters will be found, and if a probe be passed along a ureter, its oblique passage through the wall of the bladder can be demonstrated. The term *trigone of the bladder* (*trigonum vesicæ*) is applied to that triangular area whose angles are denoted by the openings of the ureters and urethra.

Structure of the bladder.—From a naked-eye examination it is evident that the wall of the urinary bladder is composed of the four layers customarily found in connection with hollow viscera of a like nature. A serous coat is derived from the peritoneum. A muscular tunic contains fibres running in different directions and arranged in rather ill-defined strata. The superficial stratum contains fibres mainly longitudinally disposed. A middle stratum has circular, and a deep stratum oblique and longitudinal fibres. The oblique and circular fibres form a *sphincter vesicæ* muscle at the neck of the bladder.

A submucous tela unites the lining mucous membrane to the muscular tunic.

PROSTATE.—The prostate is a rounded, lobulated, yellowish mass completely surrounding the first part of the urethra, and imperfectly divided into two lateral lobes by a shallow median longitudinal groove. The surface is thinly covered by longitudinal muscular fibres continued from the bladder. Generally only a very small portion of the organ lies within the confines of the pelvis.

The two deferent ducts insinuate themselves close together between the prostate and the neck of the bladder.

URETHRA.—The male urethra is a tube concerned in the transmission of both urine and semen, and extends from the neck of the bladder to the free end of the penis. In the female it is much shorter and purely urinary in function.

The tube is divisible into three portions : (1) *Pars prostatica* surrounded by the prostate ; (2) *pars membranacea* extending to the bony arch formed by the borders of the ischia ; (3) *pars cavernosa* within the corpus cavernosum urethræ of the penis.

The pelvic portion (consisting of *pars prostatica* and *pars membranacea*) runs along the middle line immediately dorsal to the symphysis of the pelvis and ventral to the rectum. This portion of the urethra is surrounded by the *urethral muscle* (*m. urethralis*). A branch of the pudendal nerve destined for the prostate will be found running along the ventral face of the *pars membranacea*.

If the pelvic portion of the urethra be opened by continuing the mid-ventral incision of the bladder backwards to the bony arch formed by the ischia, it will be evident that the lumen of the prostatic part is narrow, whereas that of the

membranous part is wider. On the dorsal wall of the prostatic part, moreover, an elongated ridge, the *crista urethralis* and *colliculus seminalis*, will be noticed; and on each side of the ridge the opening of the ductus deferens and the numerous openings of the ducts of the prostate will be found.

M. ISCHIO-CAVERNOSUS.—The ischio-cavernosus muscle is short and broad, and covers the crus penis. Its fibres arise from the dorsal aspect of the medial angle of the sciatic tuber, and are spread out over the expanded portion of the corpus cavernosum penis.

M. BULBO-CAVERNOSUS.—The bulbo-cavernosus muscle of the dog is well developed. It consists mainly of transverse fibres covering the bulbus urethræ, and is connected with the middle part of the sphincter muscle of the anus.

M. RETRACTOR PENIS.—The long, pale retractor of the penis leaves the aboral part (possibly also the middle portion) of the sphincter ani, and runs along the urethral surface of the penis towards the glans.

M. ISCHIO-URETHRALIS.—The ischio-urethral muscle is rather small, and springs from the dorsal aspect of the medial angle of the sciatic tuber. The fibres of the muscle pass to the symphysis of the ischium and are inserted into a fibrous ring through which pass the dorsal veins of the penis.

M. URETHRALIS.—As has already been mentioned, the pelvic portion of the urethra is surrounded by a circular muscle, which can now be demonstrated as continuous with the bulbo-cavernosus muscle.

A. HYPOGASTRICA.—One of the terminal branches of the abdominal aorta, the hypogastric artery pursues an oblique caudo-lateral course across the brim of the pelvis. Between it and the middle sacral artery is a group of lymph-glands (lymphoglandulæ iliacæ). Scarcely has the hypogastric artery reached the pelvic cavity than it divides into two parts, which may be called, from their distribution, the one visceral, the other parietal.

The artery crosses the ventral aspect of the common iliac vein obliquely. The ilio-psoas muscle lies on its lateral side, and ventrally it is separated from the terminal part of the colon by peritoneum only.

A. UMBILICALIS.—The only collateral branch of the hypogastric is the umbilical artery, which proceeds towards the side of the vertex of the bladder in the lateral peritoneal fold connected with this viscus. A *cranial vesical artery* (*a. vesicalis cranialis*) arises from the umbilical, and supplies both the bladder and the prostate. A small branch, the *a. deferentialis*, follows the deferent duct for some distance.

A. PUDENDA INTERNA.—The visceral part (*pars visceralis*) of the hypogastric artery consists solely of the internal pudendal artery, which travels at first alongside the rectum—from which it is separated by peritoneum—then across the lateral face of the coccygeus and levator ani muscles within the sciatic spine, to bend round the arch formed by the ischia, and, finally, to be continued as the dorsal artery of the penis.

The following are the branches of the internal pudendal artery: (1) The

umbilical artery (a. umbilicalis) very often arises from the visceral part of the hypogastric artery instead of from the main trunk; (2) the *middle hæmorrhoidal artery* (a. hæmorrhoidalis media) for the supply of the rectum and the region of the anus; (3) the *perineal artery* (a. perinei), a small branch ending in the perineum; (4) arteries to the penis: (a) the *dorsal artery of the penis* (a. dorsalis penis) follows the dorsal vein and nerve along the dorsum of the penis to the glans; (b) the *deep artery of the penis* (a. profunda penis) enters the corpus cavernosum penis; (c) the *artery of the urethral bulb* (a. bulbi urethræ)—the largest of the three—sinks into the corpus cavernosum urethræ.

The parietal part (pars parietalis) of the hypogastric artery is larger than the visceral division of this vessel, and passes along the wall of the pelvis

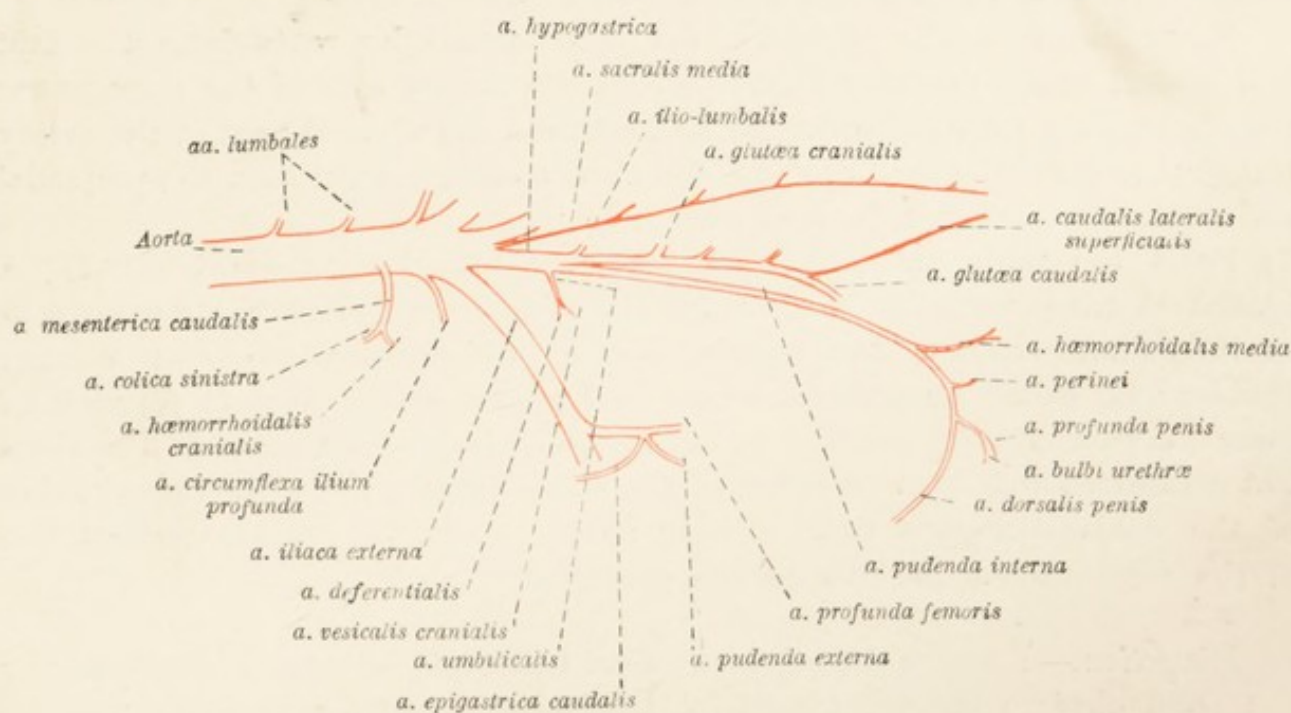


FIG. 42.—Diagram of the external iliac and hypogastric arteries.

at a more dorsal level. Crossing first the medial face of the ilium and then the medial face of the piriformis and superficial gluteal muscles, it ends as the caudal gluteal artery previously examined in connection with the other deep gluteal structures.

The vessels arising from the parietal part of the hypogastric artery are the following: (1) The *ilio-lumbar artery* (a. ilio-lumbalis) arises close to the origin of the pars parietalis, or even from the main stem of the hypogastric artery itself, and is expended in the psoas minor, ilio-psoas, sartorius, tensor fasciæ latæ and middle gluteal muscles; (2) arising at the oral border of the piriformis muscle, the *cranial gluteal artery* (a. glutæa cranialis) passes into the gluteal region along with the sciatic nerve; (3) branches are contributed to the internal obturator, levator ani, coccygeus and piriformis muscles (rami musculares); (4) the *superficial lateral caudal artery* (a. caudalis lateralis

superficialis) has been noted before as supplying branches to the gluteal, gemelli, internal obturator, quadratus femoris, adductor, biceps, semitendinosus and semimembranosus muscles.

V. HYPOGASTRICA.—The hypogastric vein differs from the artery of the same name in not having distinct parietal and visceral parts. It has two main tributaries, viz. the caudal gluteal vein and a common vessel formed by the union of veins from the penis (dorsal and deep), the perineal vein, and the middle hæmorrhoidal vein.

The hypogastric vein thus formed lies lateral to, and midway between, the parietal and visceral parts of the artery. Its collateral tributaries are the cranial gluteal (often double), cranial vesical and ilio-lumbar veins corresponding to the arteries with the same names.

N. PUDENDUS.—The pudendal nerve is formed by roots from the first and second sacral nerves. These join on the medial side of the hypogastric vessels, and the nerve so produced accompanies the visceral part of the artery (internal pudendal artery). There is a close connection between the pudendal and posterior cutaneous femoral nerves.

From the pudendal nerve the following branches take origin: (1) A branch running vertically in a ventral direction from the parent nerve close to its commencement, and supplying the urethra, prostate, and urinary bladder; (2) *middle hæmorrhoidal nerve* (n. hæmorrhoidalis media); (3) *perineal nerve* (n. perinei); (4) *dorsal nerve of the penis* (n. dorsalis penis). The three last mentioned follow the arteries of the same name. From the dorsal nerve of the penis springs a twig, already noted, which follows the ventral face of the membranous urethra to the prostate.

Dissection.—Remove the pelvic organs. Cut open the rectum longitudinally and observe the transverse folds of mucous membrane, which become longitudinal as the anus is approached. The lumen of the tube will be noted as greater than that of the colon. Cut open the para-anal sinus.

Clear away the fat from that pelvic wall which is yet intact. By removal of the levator ani muscle, the internal obturator muscle will be exposed. Determine the constitution and branches of the sacral plexus.

M. OBTURATOR INTERNUS.—The internal obturator muscle is thin, and lies on the ventral wall of the pelvis over the obturator foramen. Its origin is from the pubis and ischium as they form the margin of the foramen. The muscular fibres converge to a flat tendon which lies upon the gemelli muscles and is attached to the femur within the trochanteric fossa.

NN. LUMBALES ET NN. SACRALES.—The seven lumbar and three sacral spinal nerves form a plexus which is simple at the commencement of the lumbar region, but becomes increasingly complicated towards the sacral

region. The constitution of the nerves arising from the lumbar and sacral plexus may be summarised in this place.

N. ilio-hypogastricus is formed by the first lumbar.

N. ilio-inguinalis consists mainly of fibres derived from the second lumbar nerve, but has, in addition, a reinforcement from the first lumbar.

N. genito-femoralis generally contains fibres from the third and fourth lumbar nerves, but occasionally those from the fourth are absent.

N. cutaneus femoris lateralis is mainly formed by the fourth lumbar nerve, but it also receives a branch from the third.

N. femoralis is constituted by the union of two main roots from the fifth and sixth lumbar nerves, with an occasional thin root from the fourth nerve in addition.

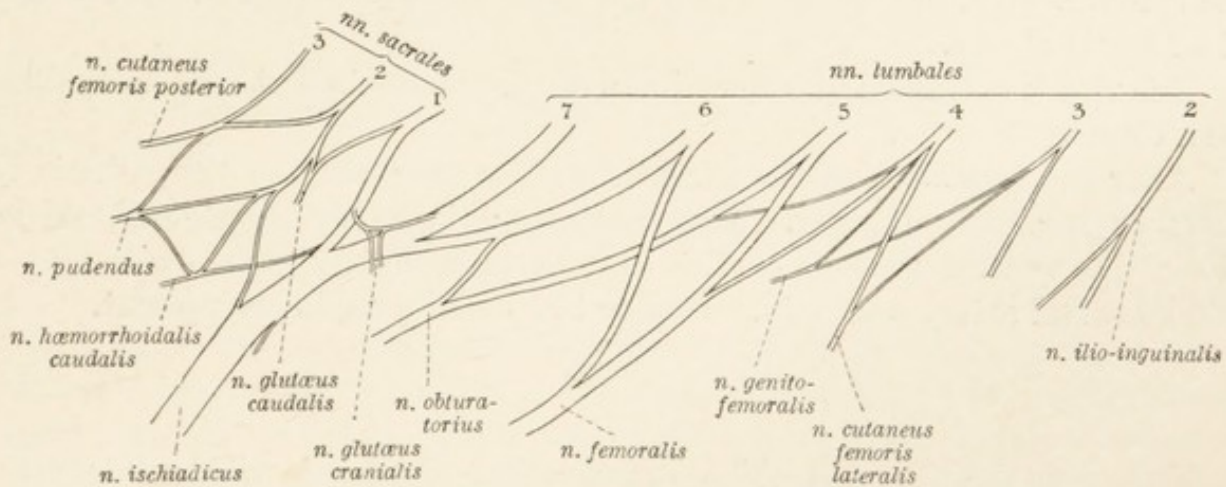


FIG. 43.—Plexus of lumbar and sacral nerves.

N. obturatorius results from the conjunction of three roots: namely, from the fourth, fifth, and sixth lumbar nerves.

N. ischiadicus is formed by the fusion of large roots from the sixth and seventh lumbar nerves, and a smaller root from the first sacral nerve.

N. glutæus cranialis receives its fibres from the same spinal nerves as does the sciatic nerve.

N. glutæus caudalis contains fibres contributed by the first and second sacral nerves.

N. pudendus has roots from the first, second, and third sacral nerves.

N. cutaneus femoris posterior is formed by the second and third sacral nerves.

N. haemorrhoidalis caudalis is composed of fibres derived from the first and second sacral nerves.

With the exception of the obturator and caudal hæmorrhoidal nerves, all the above have been examined.

N. OBTURATORIUS.—The obturator nerve is of considerable size, and is formed by roots which join medial to the ilio-psoas muscle. The nerve crosses the medial surface of the ilium and enters the obturator foramen by insinuating

itself between the pubis and the internal obturator muscle. Entering the thigh, it lies between the pectineus and adductor muscles.

N. HÆMORRHOIDALIS CAUDALIS.—The caudal hæmorrhoidal nerve supplies branches to the bladder and rectum.

A. SACRA MEDIA.—The middle sacral artery arises from the end of the aorta in the angle formed by the two hypogastric arteries, and runs along the mid-ventral line of the sacrum into the tail.

PARS ABDOMINALIS ET PELVINA SYSTEMÆ SYMPATHICI.—The sympathetic system is continued from the thorax into the abdomen and onwards into the pelvis. The abdominal part is connected with a chain of seven lumbar ganglia which will be found deep down in the narrow chink between the two psoas minor muscles. The ganglia have the usual communications with the spinal nerves, and filaments arising from them take part in the formation of an aortic plexus.

The various plexuses in connection with the abdominal viscera have already been examined.

After the formation of the seventh lumbar ganglion, the sympathetic cord becomes markedly thinner. The sacral part is feebly developed and runs along the ventral surface of the sacrum immediately dorso-lateral to the middle sacral artery and vein. One or two small ganglia are present.

THE FEMALE PELVIS.—The examination of the female pelvis follows the same lines as those laid down for the pelvis of the male. The first thing to be done is to make a general examination of the disposition of the pelvic organs so far as is possible before any dissection has been carried out.

The pelvic inlet is occupied by the urinary bladder, the vagina, and a part of the colon. Thus the entrance to the female pelvis contains practically the same organs as are associated with the male cavity, with the addition of the vagina.

The general form of the bladder agrees with that of the male organ, but there are no deferent ducts associated with its neck. As in the male, the peritoneum is reflected from its mid-ventral and lateral aspects onto the abdominal wall in the form of three membranous sheets. In the female, the peritoneum associated with the bladder does not extend into the pelvis but is reflected ventrally and laterally onto the abdominal wall about the brim of the pelvic inlet. From the dorsal side of the neck of the bladder peritoneum is continued to the vagina.

The vagina occupies a position dorsal to the bladder and ventral to the termination of the colon. Lateral folds of peritoneum—continuations of the broad ligament of the uterus—connect the vagina with the wall of the cavity. Dorsally the peritoneum is carried back for some distance into a pouch (the

recto-uterine excavation of Douglas) which intervenes between the vagina and the colon, and in which the colon hangs by its short mesentery.

Dissection.—Proceed as in the dissection of the male pelvis.

INTESTINUM RECTUM.—The description as given for the male rectum applies also to the female. Ventrally, the rectum is related to the uro-genital sinus.

The levator ani, and external and internal sphincter muscles, as well as the longitudinal muscular fibres of the rectum, have the same general disposition as in the male.

VESICA URINARIA.—The description of the urinary bladder as given in connection with the male pelvis applies here, with the difference that there are no deferent ducts or prostate related with the neck, and the dorsal surface is in contact with the vagina. The presence of longitudinal muscular fibres continued from the neck of the bladder to the wall of the uro-genital sinus should be noted.

Dissection.—Open the bladder and urethra by making an incision along the mid-ventral line.

URETHRA.—The female urethra is shorter than the corresponding canal of the male, and is purely urinary in function. Running ventral to the vagina it opens into the uro-genital sinus just beyond the margin of the ischium.

ORGANA GENITALIA MULIEBRIA.—The reproductive organs of the female consist of the two ovaries with their associated uterine tubes of Fallopius, the uterus, the vagina, the uro-genital sinus, and the external genital parts. Of these the ovaries, uterine tubes, and uterus are abdominal in position. The ovaries and uterine tubes have been described earlier.

UTERUS.—The uterus consists of two long, tubular, divergent *cornua* (cornua uteri) and a short *body* (corpus uteri). The cornua are suspended in the sublumbar region by duplicatures of peritoneum known as the *broad ligaments* of the uterus (ligamenta lata uteri), and are connected with the cranial end, or *fundus uteri*, of the body. The pelvic extremity of the body is called the *neck* (cervix uteri) and is in continuity with the vagina.

If the cornua be opened by a longitudinal incision, the longitudinally folded character of the mucous membrane lining the interior will be revealed. The cavity of the body of the uterus is small, and the part joining the vagina is much constricted to form the *canal of the cervix* (canalis cervicis uteri). The canal opens, on the one hand, into the body of the uterus by means of the *internal orifice* of the uterus (orificium internum uteri); while, on the other hand, it communicates with the vaginal cavity by the *external orifice* of the uterus (orificium externum uteri).

VAGINA.—The vagina is a long tube extending from the neck of the uterus

to just beyond the margin of the ischium, where it is continuous with the uro-genital sinus.

The interior should be exposed by making a longitudinal incision in the mid-ventral line. When this has been done, there will be no difficulty in determining the extent of the vagina, for its conspicuous longitudinal folds of mucous membrane cease abruptly at the junction of the vagina and the uro-genital sinus.

The projection of the *vaginal portion* (*portio vaginalis*) of the cervix of the uterus into the vaginal cavity should be noticed.

SINUS URO-GENITALIS.—The uro-genital sinus is a short tube with a comparatively smooth interior. Just about the point of junction of the vagina and uro-genital sinus, the ventral wall of the latter is pierced by the *external opening of the urethra* (*orificium urethræ externum*).

PARTES GENITALES EXTERNÆ.—The external opening of the genital canal or *vulva* is in the form of a vertical slit with a rounded dorsal and a sharp ventral commissure. The margins of the opening are formed by prominent, rounded *labia pudendi*.

Immediately within the ventral commissure is the *clitoris*, the homologue of the male penis.

Muscles of the external genital parts.—The sphincter ani muscle is divisible into two parts, both more or less continuous with muscular fibres of the perineum.

The oral part of the sphincter is continued almost completely towards the vulva as an *ano-vulvar muscle*. The aboral portion of the sphincter is only partially continuous with a perineal muscle also running to the vulva.

The vulva is provided with a constrictor muscle connected with the two perineal slips just mentioned and consisting of external (aboral) and internal (oral) parts.

A. HYPOGASTRICA.—The hypogastric artery has the same origin and the same general disposition as has the corresponding vessel of the male. Naturally, however, there are certain differences dependent upon the differences in the organs of the two sexes.

From the *ramus visceralis* (internal pudendal artery) springs a large branch from which the uterine and the cranial and caudal vesical arteries arise. The *uterine artery* (a. uterina) follows the body and cornua of the uterus. The *cranial vesical artery* (a. vesicalis cranialis) supplies the bladder mainly, but in addition sends twigs to the vagina. The *caudal vesical artery* (a. vesicalis caudalis) is mainly concerned in the nourishment of the vagina and the uro-genital sinus.

The terminal branches of the internal pudendal artery are concerned in the supply of blood to the uro-genital sinus and the vulva.

The *ramus parietalis* of the hypogastric artery comports itself as in the male.

The rest of the dissection of the female pelvis proceeds on the lines given for the male.

Dissection.—Remove the skin from the side of the neck, shoulder, and trunk. Preserve the cutaneous nerves, the largest of which are derived from the second, third, and fourth cervical spinal nerves.

M. CUTANEUS.—On the removal of the skin from the neck, thorax, and abdomen, a muscular sheet, the cutaneous muscle, is revealed. This is divisible into two parts: (1) the cutaneous muscle of the face and neck, and (2) the cutaneous muscle of the thorax and abdomen.

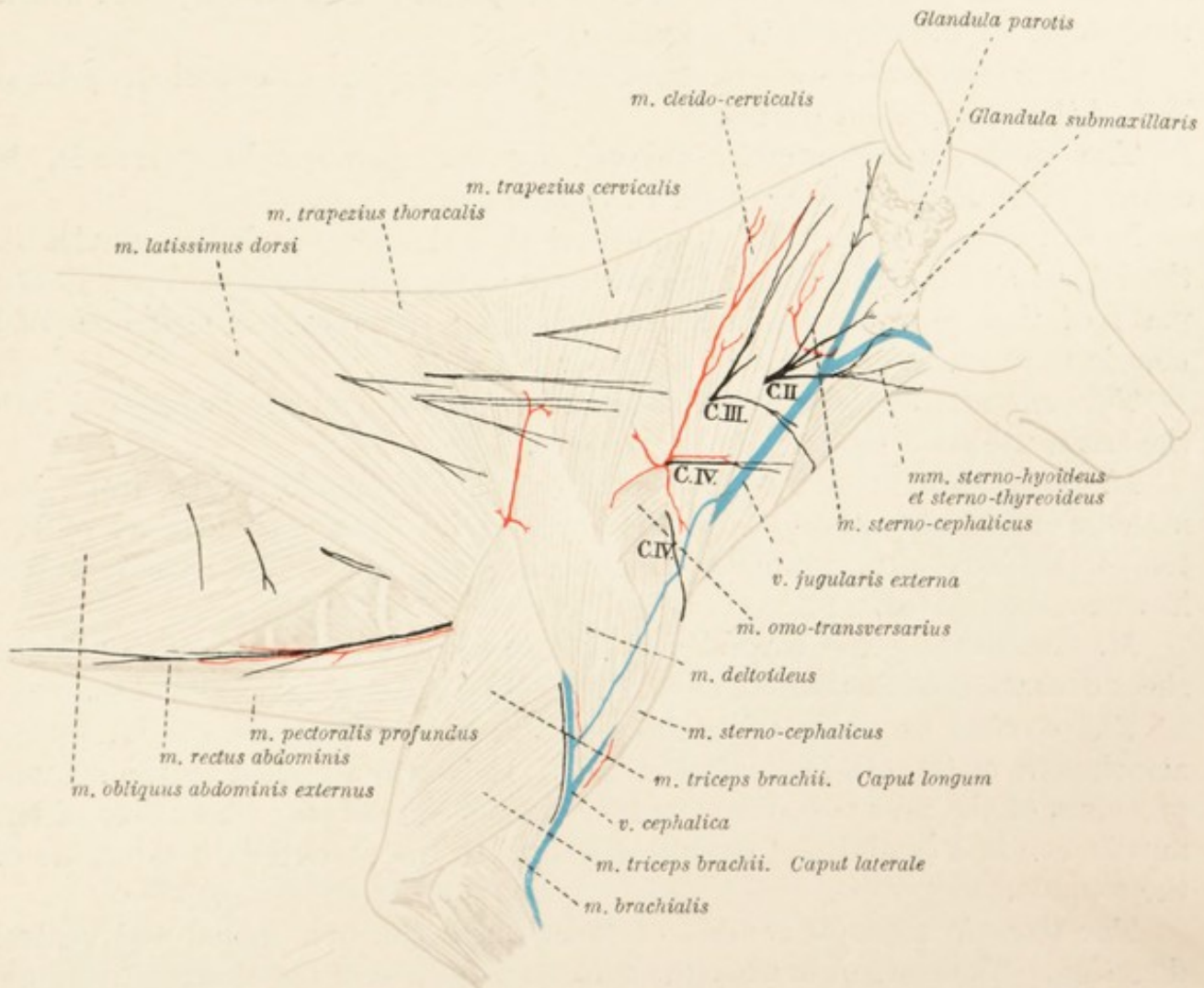


FIG. 44.—Superficial dissection of the shoulder and neck.

(1) *M. cutaneus faciei et colli.*—In the neck the cutaneous muscle is arranged in two strata, the deeper of which consists of transverse fibres and extends from the manubrium sterni to the larynx. The superficial stratum contains fibres which run obliquely ventro-orally, and is continued to the face. In the face itself there is a third, still deeper layer confined to the region of the chin, where it forms the *submental muscle*.

(2) *M. cutaneus abdominis et pectoris.*—Covering the whole of the lateral aspect of the abdomen and thorax caudal to the scapula is an extensive sheet

of fibres running cranio-ventral in direction and converging upon the axilla, where a tendon connects the cutaneous with the deep pectoral muscle.

Two muscles, the brachio-cephalic and the sterno-cephalic, are more or less blended, and together form a muscular sheet of no great thickness covering the lateral and ventral aspects of the neck.

M. BRACHIO-CEPHALICUS.—The brachio-cephalic muscle is divisible into two parts, cleido-cervical and cleido-mastoid, joined together in the region of the shoulder joint and continued to the arm as a single muscle. The place of union of the two parts is marked by a transverse tendinous line, with which the vestige of the clavicle is associated.

The *cleido-cervical muscle* is attached to the occipital bone and the cranial half of the ligamentum nuchæ.

The *cleido-mastoid muscle*, covered by the sterno-cephalic muscle, is connected with the mastoid part of the temporal bone.

It will be noted that the cleido-cervical and sterno-cephalic muscles in the lateral and dorsal parts of the neck are in the same plane and practically parts of the continuous thin muscular sheet; whereas the cleido-mastoid muscle is much thicker and in a deeper plane.

The common aboral part of the brachio-cephalic muscle is inserted into the crista tuberculi majoris of the humerus.

M. STERNO-CEPHALICUS.—The sterno-cephalic muscle arises from the manubrium of the sternum, and is inserted into the mastoid part of the temporal bone. Its intimate connection with the cleido-cervical muscle has just been noted.

M. TRAPEZIUS.—The trapezius muscle forms a thin irregularly triangular sheet over the scapular region, and consists of two parts—cervical and thoracic.

The *cervical trapezius* arises from the ligamentum nuchæ caudal to the attachment of the cleido-cervical muscle. It is also attached to the spinous processes of the first two, three or four thoracic vertebræ. The fibres of the muscle run in a caudal and ventral direction to be inserted into the spine of the scapula.

The *thoracic trapezius* consists of fibres which run in a cranial and ventral direction. Their origin is from the spinous processes of the thoracic vertebræ from the third or fourth to the ninth or tenth, and also from the lumbo-dorsal fascia. The insertion of the muscle is to the dorsal third or so of the spine of the scapula.

Dissection.—Cut through the trapezius and cleido-cervical muscles close to their dorsal attachments, and turn them downwards. In doing so, note the presence of lymph-glands (lympho-glandulæ cervicales profundæ) between the two muscles and under cover of the cleido-cervical and omo-transverse muscles. In the same neighbourhood, the superficial cervical branches of the transverse scapular vessels and the accessory

nerve are to be found. The muscles exposed are the three rhomboids, the omo-transverse and the latissimus dorsi.

M. RHOMBOIDEUS CERVICALIS.—The cervical rhomboid takes origin from the ligamentum nuchæ as far towards the head as a level with the second or third cervical vertebra, and from the spinous processes of the first two or three thoracic vertebræ. It is inserted into the medial face of the cranial angle of the scapula.

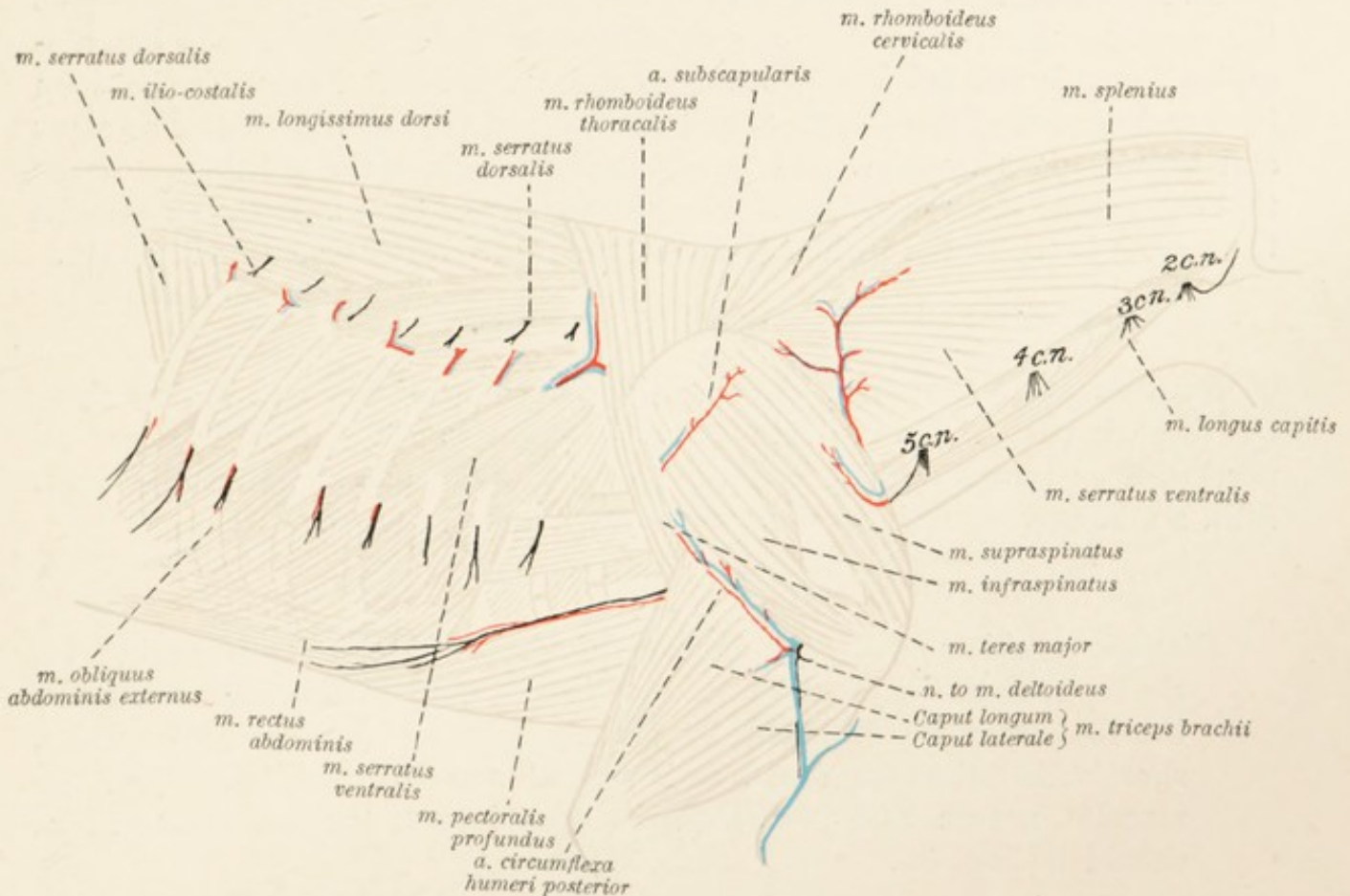


FIG. 45.—Dissection of the shoulder after removal of the more superficial muscles.

M. RHOMBOIDEUS CAPITIS.—This might reasonably be described as a part of the cervical rhomboid, since the two blend towards a common insertion. The muscle consists of a thin strip arising from the occipital bone.

M. RHOMBOIDEUS THORACALIS.—The thoracic rhomboid is a very much shorter and feebler muscle than the cervical rhomboid. It arises from the spinous processes of the fourth to the sixth or seventh thoracic vertebræ, and is attached to the scapula immediately caudal to the insertion of the cervical rhomboid.

M. OMO-TRANSVERSARIUS.—The omo-transverse is a band-like muscle running from the wing of the atlas to the distal part of the spine of the scapula and the fascia over the deltoid.

M. LATISSIMUS DORSI.—The latissimus dorsi muscle has already been partly exposed in the dissection of the ventral aspect of the thorax and the axilla, and its insertion into the crista tuberculi minoris of the humerus has been examined. At the present stage of the dissection the origin of the muscle by a tendinous expanse from the lumbo-dorsal fascia, by means of which it is connected with the last seven thoracic and all the lumbar vertebræ, is to be examined. It will be found further that there is a fleshy origin from the last two ribs.

N. ACCESSORIUS.—The accessory or eleventh cerebral nerve passes towards the shoulder ventral to the wing of the atlas, under cover of the brachio-cephalic muscle and between this and the omo-transverse. It then lies between the cervical part of the trapezius and the cervical part of the ventral serratus and supraspinous muscles, and finally disappears into the substance of the thoracic part of the trapezius. During the passage of the accessory nerve down the neck it is connected with the cervical nerves from the second to the fifth.

Dissection.—Reflect the omo-transverse muscle.

M. SERRATUS VENTRALIS.—During the dissection of the wall of the chest the thoracic part of the ventral serratus muscle was examined. The cervical portion of the muscle, arising from the transverse processes of the third, fourth, fifth, sixth, and seventh cervical vertebræ, is now exposed.

Dissection.—After noting the presence of a small communicating vein from the cephalic to the jugular on the surface of the brachio-cephalic muscle, the limb may be removed by cutting through the brachio-cephalic, rhomboid, latissimus dorsi, and ventral serratus muscles. Then the muscles, nerves and vessels on the deep face of the scapula and arm should be cleaned.

M. SUBSCAPULARIS.—The subscapular muscle is broad and fan-shaped and occupies the whole of the subscapular fossa of the scapula. Its fibres are separated into five or more portions by tendinous bands which converge towards the shoulder-joint. The origin of the muscle is from the subscapular fossa, and its insertion is into the tuberculum minus of the humerus.

M. TERES MAJOR.—A powerful muscle placed immediately aboral to the foregoing, the origin of the teres major is from the axillary border of the scapula, the angle separating the axillary and vertebral borders of this bone, and the subscapular muscle. The insertion of the muscle is in common with that of the latissimus dorsi to the crista tuberculi minoris of the humerus.

M. BICEPS BRACHII.—The biceps muscle runs parallel to, and to the medial side of, the humerus. Arising from the coracoid process of the scapula, the strong tendon of origin is bound down in the intertubercular sulcus of the

humerus by a transverse band of fascia and is surrounded by a synovial prolongation from the shoulder-joint.

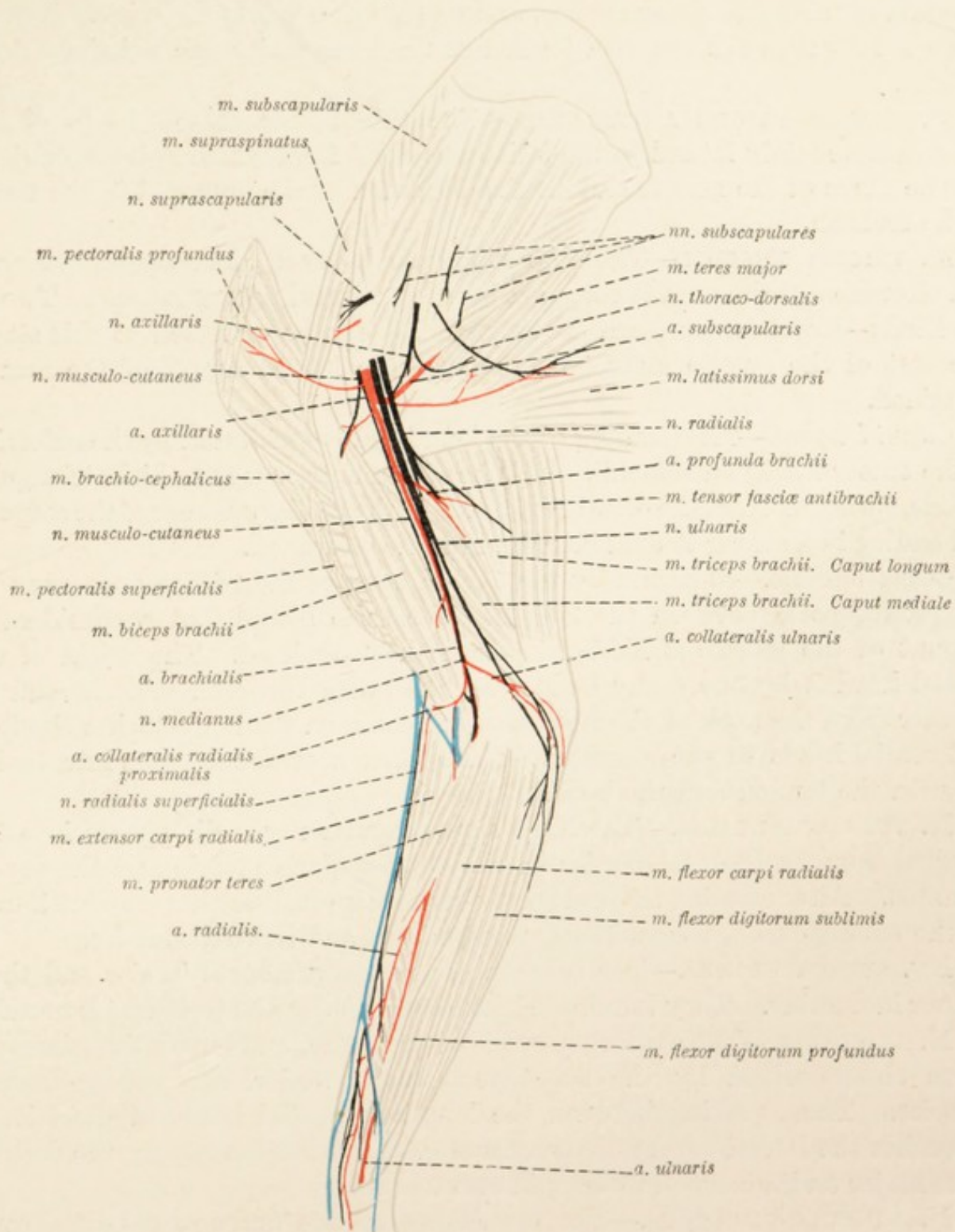


FIG. 46.—Dissection of the medial aspect of the shoulder, arm, and forearm.

The tendon of insertion of the biceps is double. The stronger part is attached to the tuberosity of the ulna; the weaker to the tuberosity of the radius.

M. CORACO-BRACHIALIS.—This is a small muscle lying in a depression

bounded by the subscapular, teres major, and biceps muscles. It arises from the coracoid process by a long, narrow, flattened tendon which crosses the insertion of the subscapular muscle, and its insertion is into the crista tuberculi minoris, lateral to the common tendon of the teres major and latissimus dorsi muscles.

M. TENSOR FASCIÆ ANTIBRACHII.—The thin tensor of the fascia of the forearm lies mainly lateral to the latissimus dorsi from which it takes origin.

The fibres of the muscle end on the olecranon of the ulna and in the fascia of the forearm.

M. TRICEPS BRACHII.—The triangular gap between the scapula, humerus, and olecranon of the ulna is occupied by the powerful triceps muscle. Two of the heads—caput longum and caput mediale—can be dissected at this stage. The rest of the muscle must be left until the lateral aspect of the arm is examined.

Caput longum.—The cleaning of the long head is facilitated by the reflection of the tensor fasciæ antibrachii. This head of the triceps is a thick, triangular muscle, springing from the distal two-thirds of the axillary border of the scapula, and ending in a strong tendon inserted into the olecranon.

Caput mediale.—Superficially the medial head of the triceps appears as an elongated muscle between the long head and the biceps, but a considerable amount of the muscle is hidden beneath the long head. The origin of the medial head is by one fleshy band from the crista tuberculi minoris, and by another from the neck of the humerus. A common tendon attaches the long and medial heads to the olecranon of the ulna, a synovial bursa intervening between the tendon and the bone.

N. SUPRASCAPULARIS.—The large suprascapular nerve disappears into the interval between the oral border of the subscapularis muscle and the supraspinatus. After crossing the oral border of the scapula, branches are contributed to the supraspinous, infraspinous, teres minor, and deltoid muscles.

NN. SUBSCAPULARES.—The subscapular nerves are small in size and three or four in number. They terminate in the subscapular and teres major muscles.

N. AXILLARIS.—The axillary nerve is of large size, and enters the triangular space circumscribed by the subscapular, teres major, and coraco-brachial muscles. Then, passing between the long and medial heads of the triceps, it reaches the lateral aspect of the shoulder. Its branches supply the deltoid, teres major and minor, and infraspinous muscles.

N. MUSCULO-CUTANEUS.—The musculo-cutaneous nerve passes distalwards between the axillary artery and the coraco-brachial muscle, and then accompanies the brachial artery, lying oral to the vessel. The terminal part of the nerve runs between the radius and the biceps. Branches are given to the biceps, coraco-brachial, and brachial muscles.

In the distal third of the arm a communicating branch joins the median nerve, and a short distance distal to this the *n. cutaneus antibrachii lateralis* arises.

N. MEDIANUS.—At its origin the median nerve is closely connected with the ulnar and radial nerves. All three accompany the axillary and brachial arteries as far as the origin of the deep artery of the arm where the radial nerve leaves the other two. The median and ulnar continue onwards in company with each other and the brachial artery as far as about the junction of the middle and distal thirds of the arm, where the ulnar parts company with the median nerve and the artery. The median nerve accompanies the artery into the forearm.

N. RADIALIS.—The radial nerve is generally the largest of the branches of the brachial plexus. As previously stated, it accompanies the median and ulnar nerves for some distance. At the distal border of the teres major the nerve sinks into the interval between the long and medial heads of the triceps.

N. ULNARIS.—The ulnar is as large as, or possibly larger than, the median nerve, by the side of which it runs as far as beyond the middle of the arm. Coursing, from this point, along the face of the medial head of the triceps, it passes into the forearm under cover of the antibrachial fascia.

In the distal third of the arm the ulnar nerve contributes a *palmar cutaneous branch* (ramus cutaneus palmaris), which reaches the forearm by first running obliquely between the medial head of the triceps and the tensor of the antibrachial fascia, and then across the medial face of the olecranon of the ulna.

A. AXILLARIS.—The mode of origin and some of the branches of the axillary artery have been examined during the dissection of the axilla. The further course of the artery is first across the medial aspect of the shoulder-joint, and then over the coraco-brachial muscle and the tendon of insertion of the teres major. On a level with the distal border of the last-named muscle the axillary artery becomes the brachial.

The only branch which belongs properly to the limb is the subscapular artery.

A. SUBSCAPULARIS.—The subscapular artery is the largest branch of the axillary; indeed it is larger than the continuation of the parent trunk, a circumstance which has led to the conception that the axillary artery terminates at this point by bifurcation.

The subscapular artery passes along the axillary border of the scapula between the subscapular and teres major muscles and on the medial face of the origin of the long head of the triceps. The full course of the vessel cannot be followed without reflection of the teres major; but this dissection had better be postponed for a little.

The following vessels are branches of the subscapular artery:

(1) Branches (rami musculares) to the subscapular, teres major, trapezius, deltoid, supraspinous, and brachio-cephalic muscles.

(2) *A. circumflexa humeri anterior*.—In many cases the anterior circumflex humeral artery arises directly from the axillary. Crossing the surface of the coraco-brachial (or teres major) muscle, the artery divides into two twigs, of

which one disappears into the biceps muscle. The other travels towards the shoulder-joint, and finally anastomoses with the posterior circumflex artery.

(3) *A. circumflexa humeri posterior*.—The posterior circumflex humeral artery accompanies the axillary nerve round the back of the proximal part of the humerus. In the dissection of the lateral aspect of the shoulder it will be found under the deltoid muscle.

(4) *A. thoraco-dorsalis*.—Arising close to the commencement of the subscapular artery, the thoraco-dorsal artery crosses the medial face of the teres major—to which it gives a branch or branches—and ends in the latissimus dorsi and cutaneous muscles and in the skin.

(5) *A. circumflexa scapulæ*.—The circumflex scapular artery is a small vessel which pierces the origin of the long head of the triceps and ramifies in the infraspinous muscle. From it springs the nutrient artery of the scapula.

A. BRACHIALIS.—From its origin at the distal border of the teres major, the brachial artery runs distalwards in a groove formed by the biceps and the medial head of the triceps. Crossing the flexor aspect of the elbow-joint, it enters the forearm in company with the median nerve. The musculo-cutaneous nerve follows the oral, and the median nerve the aboral, border of the artery.

The following branches leave the brachial artery while it is still in the arm :

(1) *A. profunda brachii*.—The deep artery of the arm leaves the brachial close to its origin, and, accompanied by the radial nerve, enters the chink between the long and medial heads of the triceps.

(2) *Ramus muscularis*.—A branch to the biceps leaves the brachial in the distal third of the arm.

(3) *A. collateralis ulnaris proximalis*.—The proximal ulnar collateral artery takes origin from the aboral side of the brachial almost opposite the artery to the biceps. Crossing the face of the medial head of the triceps in company with the palmar cutaneous ramus of the ulnar nerve, it is expended in the region of the elbow-joint and the ulnar aspect of the proximal half of the forearm.

(4) *A. collateralis radialis proximalis*.—The proximal radial collateral artery arises from the brachial about the same level as the origin of the ulnar collateral, but from the oral border of the parent vessel. After passing in succession over the communicating branch from the musculo-cutaneous to the median nerve, the medial face of the biceps, and the flexor aspect of the elbow, it reaches the forearm.

(5) *A. collateralis radialis distalis*.—The distal collateral radial artery leaves the brachial artery close to the elbow-joint. Running lateralwards, almost at right angles to the parent vessel, it lies between the biceps and the brachialis muscles on the one hand and the humerus on the other. The artery thus comes into relationship with the deep radial nerve, which it accompanies into the forearm.

Dissection.—Proceed to the examination of the outer aspect of the shoulder and arm. Remove the remains of the trapezius and omo-transverse muscles. Observe the termination of the subscapular artery and the

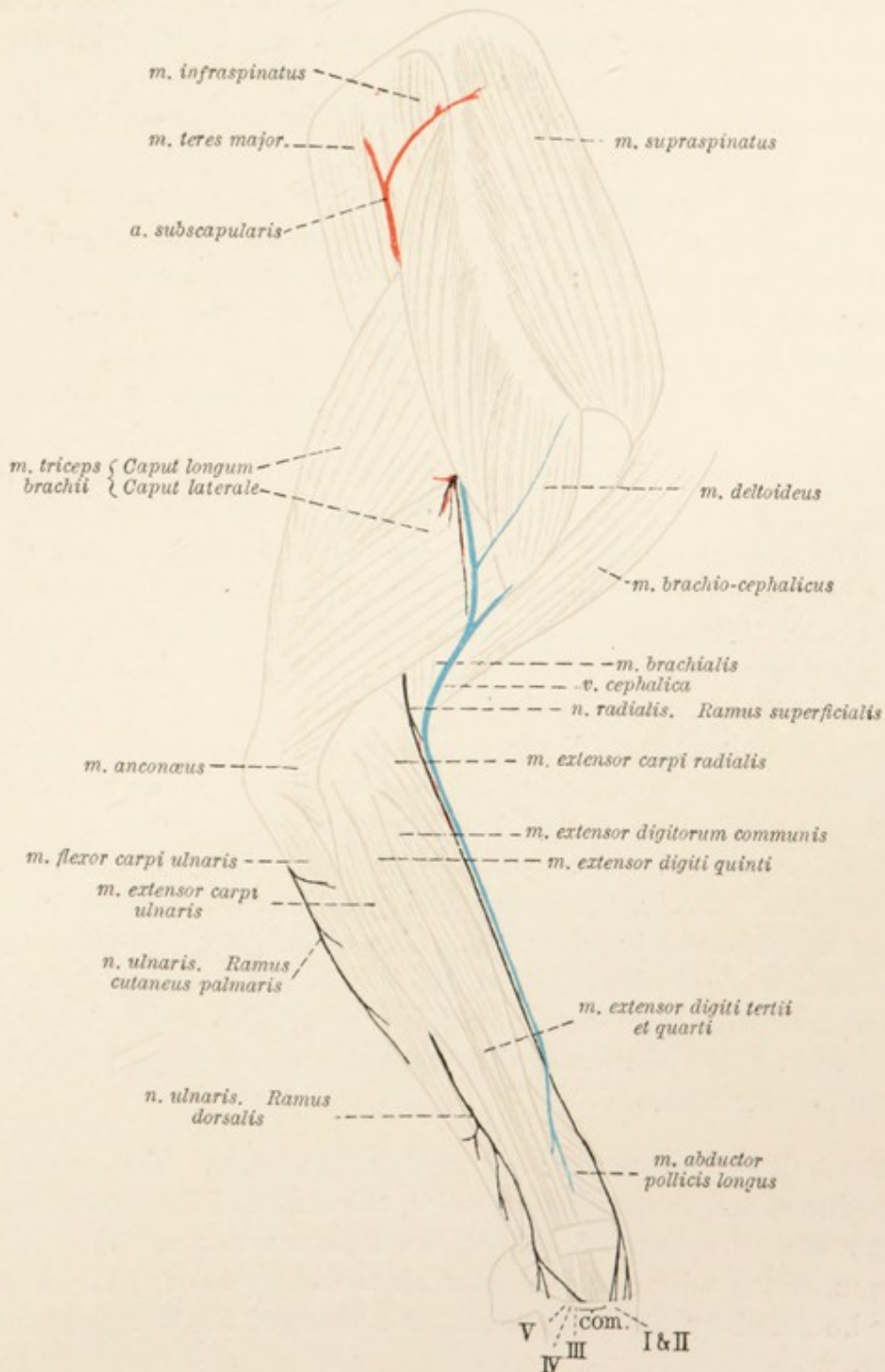


FIG. 47.—Dissection of the lateral aspect of the shoulder, arm, and forearm.

Com. = tendons of the common extensor of the digits; I, II, III, IV, and V = tendons of the extensors of the first, second, third, fourth, and fifth digits.

commencement of its companion vein. The artery appears at the axillary border of the scapula in the interval bounded by the teres major, infraspinous, and long head of triceps muscles. Crossing the infraspinous muscle and the aponeurotic origin of the deltoid, it ends in the trapezius.

M. SUPRASPINATUS.—The supraspinous muscle fills the whole of the supraspinous fossa of the scapula from which it takes origin. In addition, some of its fibres arise from the subscapular muscle.

Its insertion is into the greater tubercle of the humerus and into the insertion of the deep pectoral muscle.

M. DELTOIDEUS.—Irregularly triangular in outline and placed in the angle formed by the spine of the scapula and the humerus, the deltoid muscle can be divided into two portions: (1) arising from the spine of the scapula by aponeurosis; (2) taking origin from the acromion. The two parts blend into a common insertion to the deltoid tuberosity of the humerus.

Veins of the arm.—The main veins of the arm begin as superficial veins in the forearm.

V. MEDIANA CUBITI.—The median vein of the forearm divides, on a level with the tendon of insertion of the biceps, into a median basilic and a median cephalic. The *median basilic vein* (v. *mediana basilica*) crosses the medial face of the biceps and, receiving the ulnar vein or veins, becomes the *basilic vein* (v. *basilica*). This follows the brachial artery to the distal border of the teres major muscle, where it receives the deep humeral vein and becomes the *axillary* (v. *axillaris*).

V. MEDIANA CEPHALICA.—The median cephalic vein runs in a groove formed by the brachio-cephalic and brachialis muscles, receives the radial vein, and becomes the *cephalic vein* (v. *cephalica*). After a short single course the cephalic vein becomes double. One of its parts, the original vein, travels along the groove between the superficial pectoral and deltoid muscles and finally joins the external jugular vein. The other part, generally the larger, follows the border of the deltoid, and disappears between the lateral and long heads of the triceps to join the subscapular vein. Before its disappearance a small twig leaves it to cross the brachio-cephalic muscle superficially and enter the external jugular vein.

Dissection.—Reflect both parts of the deltoid muscle. This will expose the infraspinous and teres minor muscles, the origin of the lateral head of the triceps and the termination of the axillary nerve. The last named appears, along with the posterior circumflex vessels, from a triangular space bounded by the long and lateral heads of the triceps and the teres minor.

M. INFRASPINATUS.—The infraspinous muscle occupies the fossa of the same name. Its origin is from the whole extent of the fossa and in addition

from the aponeurotic origin of the deltoid and from the long head of the triceps. On the lateral aspect of the shoulder-joint the muscle gives place to a flattened tendon which is attached to a ridge on the lateral face of the tuberculum majus after having played over a smooth area covered by cartilage, a

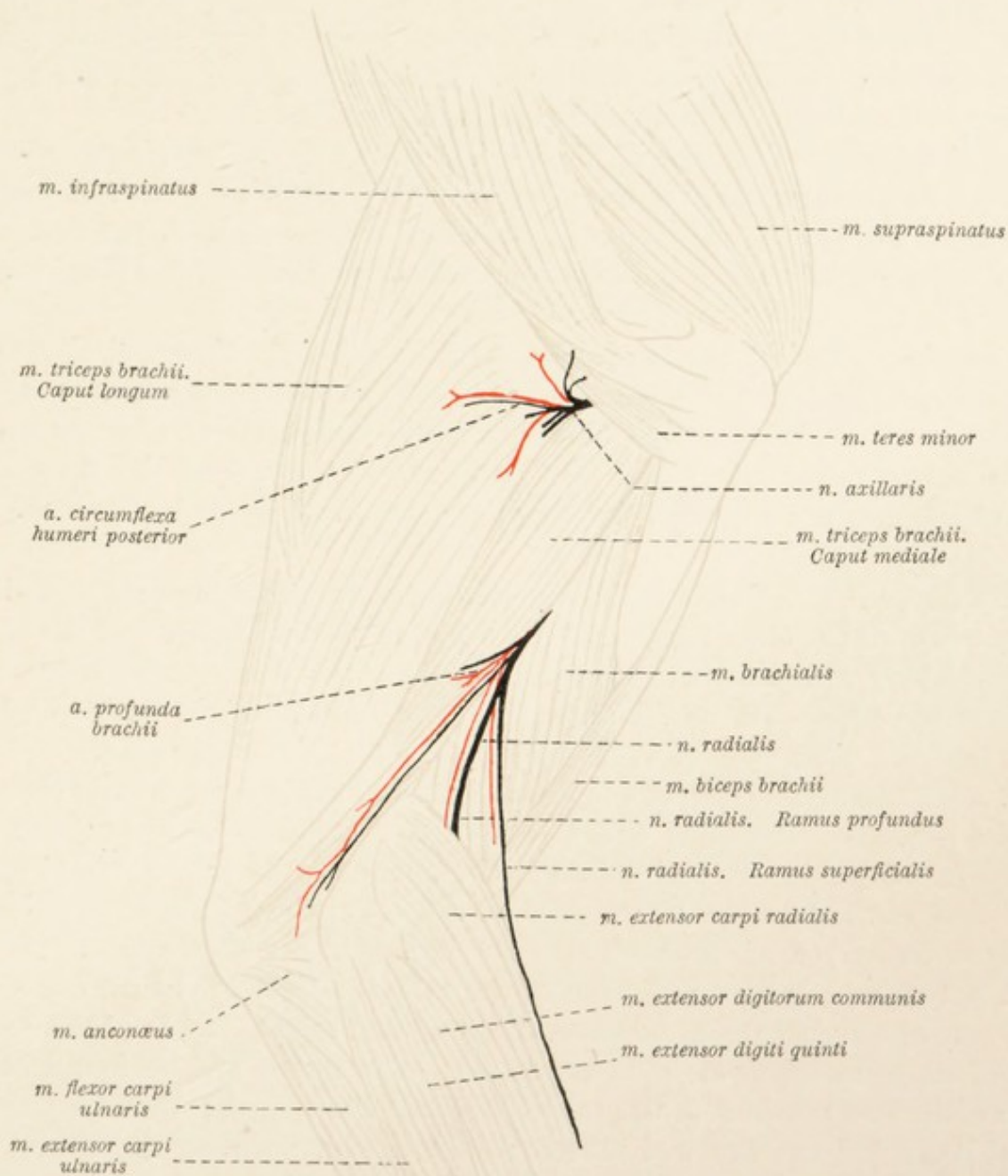


FIG. 48.—Dissection of the arm after removal of the deltoid and the lateral head of the triceps muscle.

synovial membrane further reducing the friction. Demonstrate this arrangement by cutting the tendon across close to its commencement, and turning back the two ends. This has the further advantage of showing a greater amount of the teres minor muscle.

M. TERES MINOR.—The narrow, and somewhat rounded, teres minor lies

along the aboral border of the infraspinous muscle. Its origin is from the distal third of the axillary border of the scapula and particularly from a rough elevation close to the glenoidal margin. The insertion is to the crista tuberculi majoris between the attachment of the infraspinous tendon and the origin of the lateral head of the triceps.

M. TRICEPS BRACHII.—Two heads—caput longum and caput mediale—of the triceps have already been examined. It will be noticed that the long head is included in both the medial and lateral aspects of the arm.

Caput laterale.—The lateral head arises from the crista tuberculi majoris of the humerus under cover of the insertion of the deltoid. The main insertion of the head is into the olecranon of the ulna in common with the rest of the triceps. In addition there is a connection with the fascia of the forearm.

Dissection.—Reflect the lateral head of the triceps. This will allow of an examination of the lateral part of the medial head which has origin close to the head of the humerus. The brachial and aconeus muscles and the radial nerve are also exposed. A branch of the deep artery of the arm accompanies the nerve and follows it into the forearm.

M. BRACHIALIS.—The brachial muscle has its origin immediately medial to the insertion of the teres minor and the origin of the lateral head of the triceps. Running along the humerus in a spiral manner, the muscle crosses the flexor aspect of the elbow-joint and ends in two tendons which join the two tendons of the biceps. Thus it obtains insertion into both radius and ulna.

M. ACONÆUS.—The aconeus is a small muscle lying between the olecranon and the humerus. Its chief origin is from the lateral epicondyle; but some fibres come from the lateral collateral ligament of the joint. The insertion of the aconeus is into the lateral face of the olecranon of the ulna. Some of the fibres, moreover, are inserted into the capsule of the elbow-joint.

N. RADIALIS.—In the dissection of the medial aspect of the arm the radial nerve was observed to pass between the long and medial heads of the triceps. More of its course may now be examined. The nerve will be found at first between the two portions of the medial head of the triceps; then between the medial head and the brachial muscle; and, lastly, between the lateral head and the brachial muscle. Here the nerve divides into deep and superficial branches, both of which proceed into the forearm.

The *superficial branch* (ramus superficialis) of the radial nerve is subcutaneous and accompanies the radial vein. The *deep branch* (ramus profundus) follows the brachial muscle.

Dissection.—Remove the skin from the forearm and the dorsum of the manus. In the superficial fascia blood-vessels and nerves should be discovered.

V. MEDIANA CUBITI.—The median vein begins by draining the first digit. After crossing the medial aspect of the forearm it comes to occupy the groove between the extensor and flexor mass of muscles. The termination of the vein on the flexor aspect of the elbow-joint has already been examined.

V. RADIALIS.—The large radial vein commences as the dorsal veins of the second to the fifth digits. Just above the carpus a considerable augmentation of volume results from the reception of a large branch from the median vein. The radial vein now follows the anterior border of the forearm, and ends by assisting the median cephalic vein in the formation of the cephalic vein.

VV. ULNARES.—One or two small ulnar veins will be found over the posterior and medial part of the proximal third or so of the forearm. They may join the basilic vein.

A. RADIALIS COLLATERALIS PROXIMALIS.—The proximal radial collateral artery, a branch of the brachial, enters the forearm by crossing the surface of the biceps muscle. A division into two branches takes place. The more lateral and larger of the two passes into the metacarpus and terminates as three *common dorsal digital arteries* (aa. digitales dorsales communes II, III, et IV) which lie in the grooves between the second and third, third and fourth, and fourth and fifth metacarpal bones.

N. CUTANEUS ANTIBRACHII LATERALIS.—The lateral cutaneous nerve, a branch of the musculo-cutaneous, enters the foramen between the biceps and brachialis muscles, and then follows the median vein.

N. RADIALIS.—The superficial branch of the radial nerve travels down the forearm in company with the radial vein. About the level of the elbow it divides into medial and lateral branches. The *medial branch*, the smaller of the two, accompanies the communicating vein from the median to the radial vein and ends as the dorsal nerves of the first and second digits.

The *lateral branch* crosses the extensor aspect of the carpus and terminates as dorsal nerves of the second, third, fourth, and fifth digits.

DEEP FASCIA.—The deep fascia of the forearm is strong and thick. It forms a sheath for all the muscles and passes between them as intermuscular septa. At the borders of the limb it is attached to the radius and ulna, and at the distal end of the radius forms an annular ligament by which the tendons of the extensor muscles are retained in place.

Dissection.—The deep fascia must be removed in order to allow of the examination of the anterior and lateral regions of the forearm and the dorsum of the manus. The annular ligament, however, must be left in position for the present.

It is convenient to note here that the annular ligament has bony attachments at five places. The result is that four passages in which tendons are

lodged are produced. The arrangement of the tendons may be summarised in the following manner :

ULNAR.						RADIAL.
	M. extensor digiti quinti.		M. extensor digitorum communis.		M. extensor carpi radialis.	
	M. extensor digiti tertii et quarti.		M. extensor pollicis longus et indicis proprius.		M. abductor pollicis longus.	

The muscles in front and on the lateral aspect of the forearm are arranged in two layers, superficial and deep. The superficial layer contains the mm. brachio-radialis, extensor carpi radialis, extensor digitorum communis, extensor digiti tertii et quarti, extensor digiti quinti, and extensor carpi ulnaris—in this order from the radial to the ulnar border of the forearm.

M. BRACHIO-RADIALIS.—The brachio-radial muscle is very often exceedingly rudimentary or even absent, and lies immediately under the skin superficial to the radial extensor.

The origin of the muscle is from the proximal part of the ridge above the lateral epicondyle of the humerus, and its insertion is into the medial border of the radius.

M. EXTENSOR CARPI RADIALIS.—This, the most bulky muscle in front of the forearm, has origin partly from the lateral epicondyle of the humerus, but mainly from the ridge proximal to the eminence. The fleshy belly of the muscle lies lateral to the brachialis and is imperfectly divided into two layers. The superficial layer gives place to a flattened tendon which is inserted into the base of the second metacarpal bone (m. extensor carpi radialis longus). The deep part of the muscle, larger and longer than the preceding, is succeeded by a strong tendon which terminates at the base of the third metacarpal bone (m. extensor carpi radialis brevis). The two tendons are crossed obliquely in the distal third of the radius by the abductor pollicis longus, and are held down in a broad groove at the distal end of the radius by the annular ligament.

M. EXTENSOR DIGITORUM COMMUNIS.—The common extensor muscle of the digits is lateral to the foregoing, with which it is intimately connected at its origin from the lateral epicondyle of the humerus and from the septum

between the muscles. Four tendons leave the tapering end of the muscle, play through a groove at the distal end of the radius, and spread out on the dorsum of the manus. The tendons are finally inserted into the terminal phalanges of the second, third, fourth, and fifth digits.

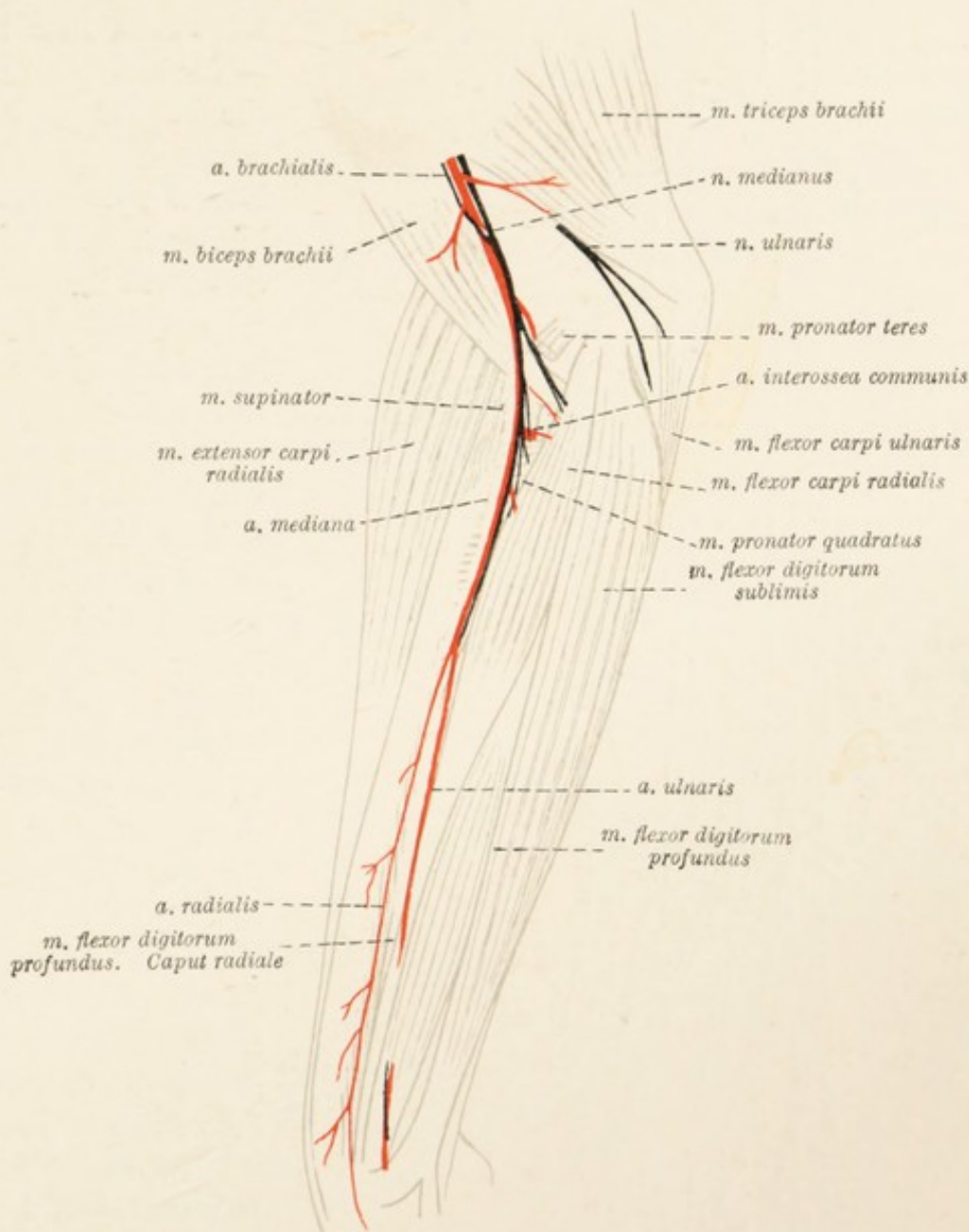


FIG. 49.—Dissection of the medial aspect of the forearm.

Each tendon expands over the metacarpo-phalangeal articulation, with the capsule of which it is closely connected, and has a sesamoid bone over the proximal interphalangeal joint. In the neighbourhood of the joint between the metacarpal bone and the first phalanx, each tendon is joined by the tendon of one of the smaller extensors of the digit—extensor indicis proprius, extensor digiti tertii et quarti, and extensor digiti quinti. At the distal end of

the first phalanx, each tendon is further joined by the slender tendon of an interosseous muscle. The short extensor and interosseous tendons may blend before they unite with the common extensor tendons.

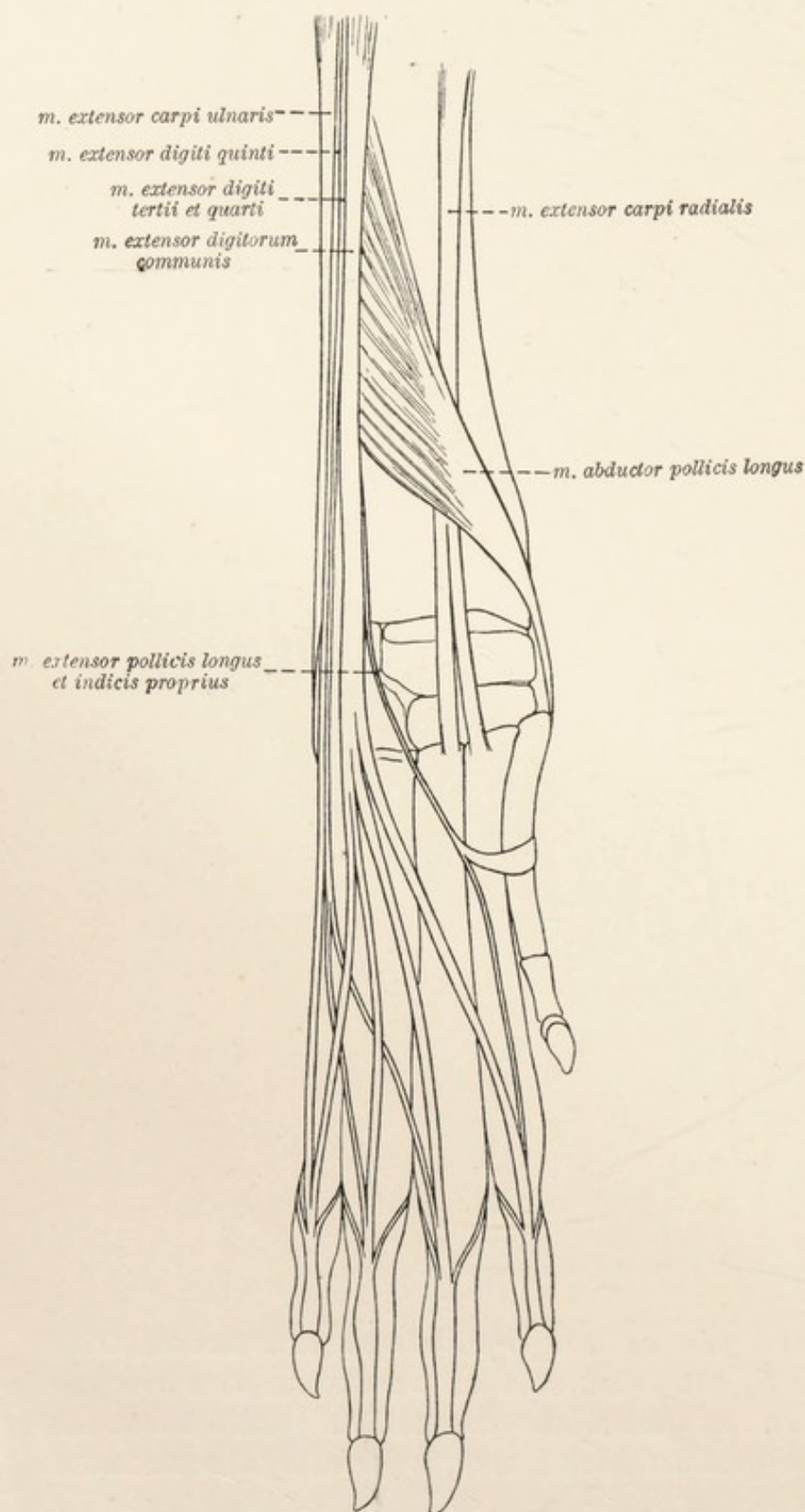


FIG. 50.—Tendons on the dorsum of the manus.

M. EXTENSOR DIGITI TERTII ET QUARTI: M. EXTENSOR DIGITI QUINTI.

—These two extensors of the digits arise as a common muscle from the lateral epicondyle of the humerus and the lateral collateral ligament of the elbow-joint. In the proximal third of the forearm, the common mass divides into two fleshy bellies, of which that of the extensor of the third and fourth digits is the longer. The tendon in which the longer belly terminates divides as the carpus into two parts, which join those tendons of the common extensor destined for the third and fourth digits. The very much stronger tendon of the extensor of the fifth digit, in like manner, joins the common extensor slip belonging to that digit.

M. EXTENSOR CARPI ULNARIS.—The ulnar extensor of the carpus forms the extreme ulnar border of the forearm. A flattened and partly tendinous belly takes origin from the lateral epicondyle of the humerus, where it is closely associated with the anconeus.

The strong flattened tendon of the muscle is inserted into the base of the fifth metacarpal bone. An additional connection of the tendon is with the annular ligament of the carpus and with a broad band of fascia crossing the pisiform bone. Between the band and the bone there is a synovial bursa. It should be noted that, unlike the tendons of the other extensors, the tendon of the ulnar extensor is not enclosed in a synovial sheath at the carpus.

The deep layer of muscles in front of the forearm includes the mm. extensor pollicis longus et indicis proprius, abductor pollicis longus and supinator. The two first mentioned can be completely exposed by cutting that part of the annular ligament which binds down the tendons of the common extensor muscle of the digits. To expose the supinator muscle, it is necessary to reflect the radial extensor of the carpus and the common extensor of the digits.

M. EXTENSOR POLLICIS LONGUS ET INDICIS PROPRIUS.—The extensor of the first and second digits is a small muscle lying under cover of the common extensor, with an origin from the middle third of the lateral border of the ulna. The small tendon

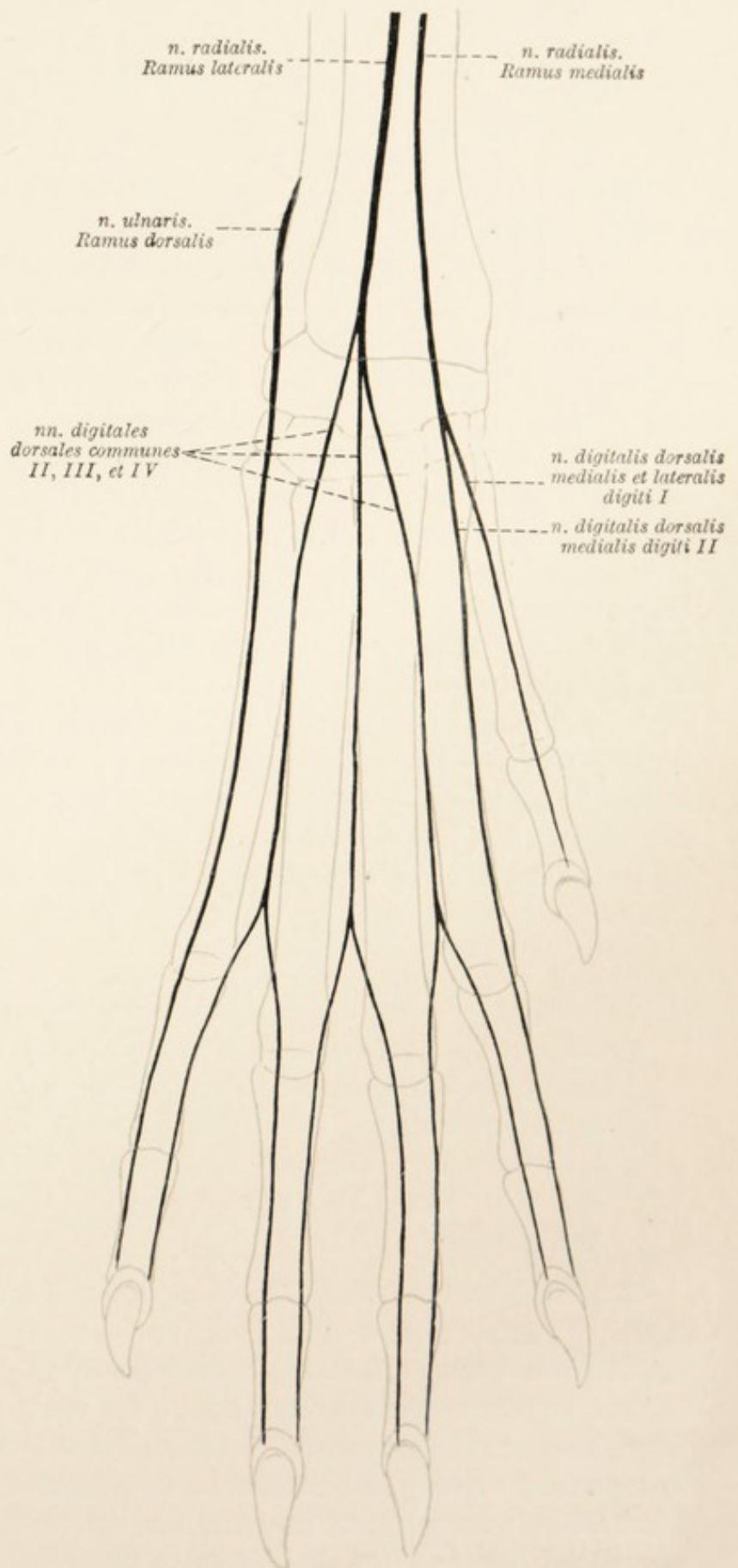


FIG. 51.—Diagram of nerves on the dorsum of the manus.

of the muscle passes down that groove of the radius in which the common extensor tendons lie. In the metacarpal region it divides into two parts: one (inconstant) joins the first digit (m. extensor pollicis longus); the other fuses with that slip of the common extensor which goes to the second digit (m. extensor indicis proprius).

M. ABDUCTOR POLLICIS LONGUS.—The abductor of the first digit is distinctly semi-penniform. Its origin, partly under cover of the foregoing muscle, is from the middle two-fourths or more of the adjacent borders of the radius and ulna and the intervening interosseous membrane. The tendon runs along the medial border of the muscle, crosses obliquely over the tendon of the radial extensor, and ends on the base of the first metacarpal bone. A sesamoid bone is associated with the tendon at its insertion.

M. SUPINATOR.—The supinator muscle is small, flat, and irregularly triangular, and lies on the proximal fourth of the radius. Arising from the lateral epicondyle of the humerus and the lateral collateral ligament of the elbow-joint in association with the common origin of the extensors of the third, fourth, and fifth digits, the muscle is inserted into the anterior surface and medial border of the radius partly under the insertion of the pronator teres muscle.

N. RADIALIS PROFUNDUS.—In the dissection of the arm it was seen that the radial nerve divided into deep and superficial branches. The deep radial nerve crosses the flexor aspect of the elbow-joint under cover of the radial extensor and supinator muscles. Inclining laterally, it then passes between the radius and the extensors of the third, fourth, and fifth digits to end in the ulnar extensor of the carpus.

Dissection.—Before removing the skin from the palmar aspect of the manus, observe the presence of callosities similar in position and form to the five eminences encountered in the pelvic limb. In addition there is a sixth callosity present in a line with, but immediately distal to, the prominence caused by the pisiform bone. When the callosities have been examined the skin should be removed and the characters and connections of the fascia noted.

FASCIA.—The fascia at the back of the forearm may be divided into two layers. The more superficial of the two is the looser, and is continuous with the fascia of the arm. The deeper and denser layer is more limited to the forearm itself. It forms a tough investment for the muscles of the region, and sends septa between the individual members of the group. The fascia of the forearm is especially strong and tendinous in character close to the carpus. Here a band of it passes under the annular ligament (from the carpus to tendon of superficial flexor of the digits) and is partly attached to the medial border of the carpus and partly continued to the dorsal aspect of the manus. Over the

projecting extremity of the pisiform bone it forms a transverse band associated with the tendon of the ulnar extensor. Between the fascia and the bone there is a synovial membrane, already mentioned.

The fascia of the palmar aspect of the manus is connected intimately with the various callosities and with the annular bands of the flexor tendons.

SUPERFICIAL VEINS OF THE PALM.—The proper digital veins unite with a venous arch at the distal part of the metacarpus. From the radial end of the arch there arises a large vessel which forms the root of the ulnar vein and one of the roots of the radial vein. At the ulnar extremity of the arch the superficial veins communicate with the deep vessels.

As in front, so at the back of the forearm the muscles are arranged in two layers. The superficial layer contains four muscles which, enumerated from the medial towards the lateral side, are as follows: *Mm. pronator teres, flexor carpi radialis, flexor digitorum sublimis, and flexor carpi ulnaris*. Strictly speaking, however, the ulnar flexor has only one of its heads, and that the smaller, in the superficial layer. The humeral head of the muscle really forms an intermediate layer, and is to be sought for underneath the superficial flexor of the digits.

M. PRONATOR TERES.—The round pronator is placed on the medial side of the elbow-joint, and, with the supinator muscle, circumscribes a triangular space the base of which is proximal. In the triangle are found the insertions of the brachial and biceps muscles, the median and deep radial nerves, and the brachial vessels.

The pronator teres muscle has origin from the medial epicondyle of the humerus, and is inserted about the middle of the medial border of the radius superficial to the attachment of the supinator.

M. FLEXOR CARPI RADIALIS.—The radial flexor of the carpus is a relatively small muscle arising from the medial epicondyle of the humerus between the pronator teres and the flexor digitorum profundus. About the middle of the forearm the muscle is succeeded by a thin rounded tendon which, after crossing the flexor aspect of the carpus, divides into two parts to be inserted into the bases of the second and third metacarpal bones. A reinforcing band leaves the middle of the medial border of the radius and joins the tendon of this muscle.

M. FLEXOR DIGITORUM SUBLIMIS.—The superficial flexor of the digits is a large flattened muscle separated from the foregoing by a narrow strip of the deep flexor. Its origin is from the medial humeral epicondyle. In the distal part of the forearm a strong tendon passes over the flexor aspect of the carpus just medial to the pisiform bone. Arriving in the palmar region this divides into four parts, each of which, after splitting for the passage of the deep flexor tendon, finds insertion into the second phalanx of a digit.

At the carpus three strong fibrous bands join the superficial flexor tendon. The first passes from the medial border of the carpus ; the second is derived from the pisiform bone ; and the third from the sesamoid at the medial side of the carpus connected with the tendon of the abductor pollicis longus.

In the palm the flexor tendons are contained in flexor sheaths comparable to those of the pes.

Slips to the callosities of the digits leave the tendons on a level with the metacarpo-phalangeal joint. Close to the carpus a separate tendinous and feebly muscular slip branches off from the lateral border of the flexor tendon of the fifth digit and ends in a transverse thickening of the flexor sheath opposite the metacarpo-phalangeal joint.

M. FLEXOR CARPI ULNARIS.—This really consists of two separate muscles. The more superficial and the weaker head (*caput ulnare*) arises from the olecranon and is inserted into the pisiform bone by a thin flattened tendon which begins about the middle of the forearm. The deep, strong humeral head (*caput humerale*) lies mainly under cover of the flexor digitorum sublimis. It arises from the medial epicondyle of the humerus, and is inserted into the pisiform bone by a very short, strong tendon.

The humeral head is anterior to the ulnar at its origin ; but the ulnar head passes obliquely across the lateral surface of the humeral head, with the result that the small ulnar tendon is inserted into the pisiform in front of the stout humeral tendon. At their insertion a small synovial bursa intervenes between the two tendons.

The deep layer of muscles consists of *mm. flexor digitorum profundus* and *pronator quadratus*.

Dissection.—In order to follow the deep flexor tendons it is necessary to cut across the superficial flexor about the end of its fleshy belly. Liberate the tendon from its accessory slips derived from the carpus, and turn it downwards. At the carpus the superficial and deep flexor tendons are separated by a strong transverse band passing from the pisiform to the medial border of the carpus. This must be divided. Reflect the two heads of the flexor carpi ulnaris.

M. FLEXOR DIGITORUM PROFUNDUS.—The deep flexor of the digits has three independent fleshy bellies. The largest, the humeral head, arises from the medial epicondyle of the humerus. The ulnar head—second in point of size—has origin from the proximal half of the ulna. The radial head is slender and springs from the middle two-fourths of the medial border of the radius. The tendons of the three heads join a short distance proximal to the carpus. The common tendon passes down the flexor side of the carpus, and, arriving in the palm, divides into four parts, each inserted into the terminal phalanx of a digit.

A very small, variable muscular slip, sometimes difficult of demonstration, leaves the humeral head of the deep flexor in the distal third of the forearm and has been considered as homologous with the *m. palmaris longus* of man. Its very thin tendon soon divides into two parts which accompany the common tendon of the deep flexor into the palm, and terminate at the metacarpophalangeal joint by uniting with the superficial flexor tendons of the third and fourth digits.

M. PRONATOR QUADRATUS.—The quadrate pronator muscle consists of transverse fibres crossing from the radius to the ulna and filling the interosseous space except at its ends.

N. MEDIANUS.—The median nerve enters the forearm by passing between the pronator teres and the proximal end of the radius. It follows the humeral head of the deep flexor, and is related superficially to the flexor carpi radialis. In the distal half of the forearm the nerve occupies a groove formed by the humeral and radial heads of the deep flexor. Finally, crossing the flexor aspect of the carpus, between the tendons of the superficial and deep flexors, it ends as the volar metacarpal nerves (nn. metacarpei volares) of the first, second and third digits, which gain these by coursing between the first and second, second and third, and third and fourth metacarpal bones.

The following arise from the median nerve: (1) A branch is contributed to the pronator teres just before the median passes under this muscle. (2) Under the pronator teres a large nerve arises for the supply of the radial flexor of the carpus, the superficial flexor of the digits, and the humeral head of the deep flexor. (3) A small branch accompanies the common interosseous artery for a short distance, and terminates in the pronator quadratus and radial head of the deep flexor of the digits. (4) A small branch supplies the muscular slip which has been thought homologous with the *m. palmaris longus* of man.

N. ULNARIS.—The ulnar nerve gains the forearm by traversing the interval between the two heads of the flexor carpi ulnaris. It then travels towards the carpus on the deep flexor of the digits (humeral head) and under cover of the humeral head of the ulnar flexor of the carpus. Gaining the metacarpus by crossing the medial aspect of the pisiform bone, the ulnar nerve ends by dividing into a superficial and a deep branch.

The branches of the nerve are as follows: (1) As the ulnar nerve is entering the forearm it gives off a bunch of branches to the flexor carpi ulnaris and the humeral and ulnar heads of the deep flexor of the digits. (2) A *dorsal branch* (ramus dorsalis) arises in the proximal third of the forearm, becomes superficial on the ulnar border of the limb just above the carpus, runs along the lateral border of the carpus and metacarpus, and ends over the fifth digit. (3) *Terminal branches.* Of these, the *deep ramus* (ramus profundus) disappears from view almost at once, and must, therefore, be followed later. The *superficial branch* (ramus superficialis) passes along the lateral border of

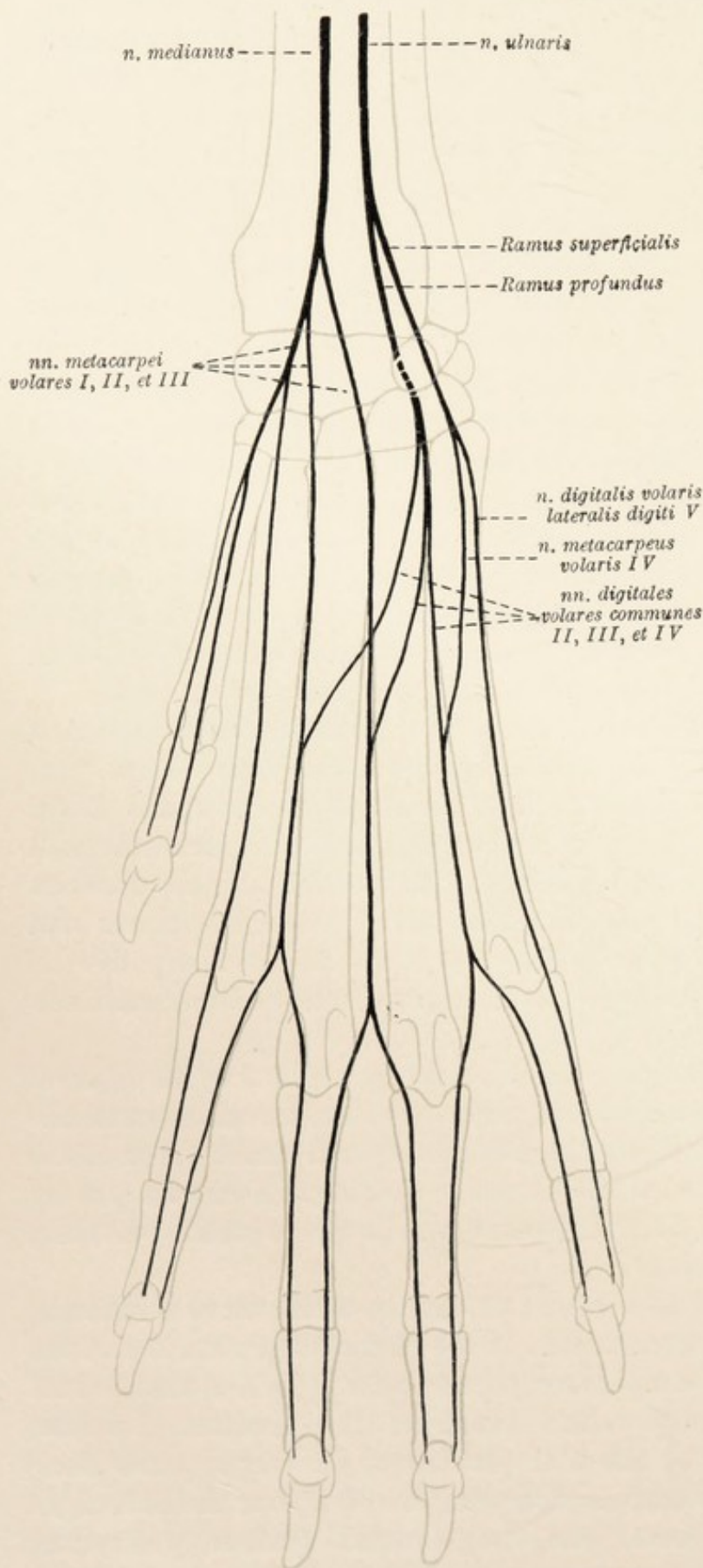


FIG. 52.—Diagram of nerves on the volar aspect of the manus.

the flexor tendons and divides into two parts, of which one supplies the fifth digit, and the other follows the groove between the fourth and fifth metacarpal bones to join a part of the ramus profundus.

A. MEDIANA.—The brachial artery proceeds from the arm into the forearm by following the median nerve under the pronator teres, and so becomes the median artery. About the junction of the proximal and middle thirds of the forearm the median terminates by dividing into two vessels of unequal size—the *radial* and *ulnar arteries*.

The collateral branches of the median artery are (1) articular to the elbow-joint; (2) muscular to the flexors; and (3) the *common interosseous artery* (a. interossea communis).

The common interosseous artery leaves the median a short distance distal to the elbow-joint and soon divides into a dorsal and a volar branch. The *dorsal interosseous artery* (a. interossea dorsalis) at once pierces the interosseous membrane between the radius and the ulna, and thus gains the dorsal aspect of the forearm. Here it is continued distalwards between the extensor carpi ulnaris and the exten-

sor digiti quinti towards the carpus, where it assists the proximal collateral radial artery and the radial artery in the formation of the *rete carpi dorsale*.

The *volar interosseous artery* (*a. interossea volaris*) is much larger than the dorsal artery of the same name, and follows the interosseous space under cover of the pronator quadratus muscle. Just above the carpus a moderately large branch is contributed to the *rete carpi dorsale*. In the region of the carpus the artery comes into relationship with the ulnar nerve, and medial to the pisiform bone it contributes a superficial branch which runs along the fifth digit. The continuation of the artery sinks into the deeper structures and will be followed later as the main contributor to the *deep volar arch* (*arcus volaris profundus*).

A. RADIALIS. — The radial artery is much the smaller of the two terminal branches of the median. Following first the radial head of the deep flexor and then the medial border of the radius, it terminates just proximal to the carpus by

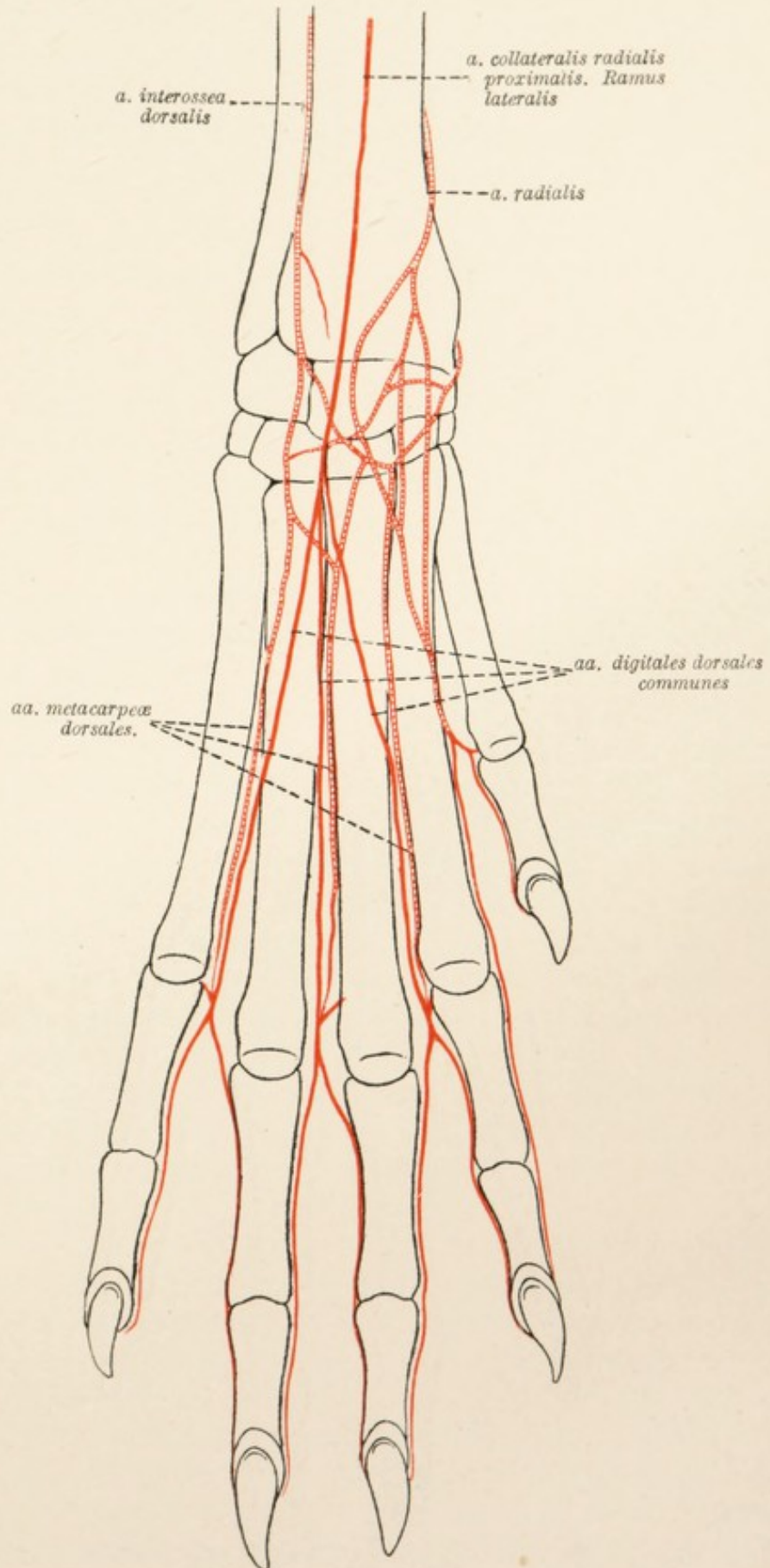


FIG. 53.—Diagram of the arteries on the dorsum of the manus.

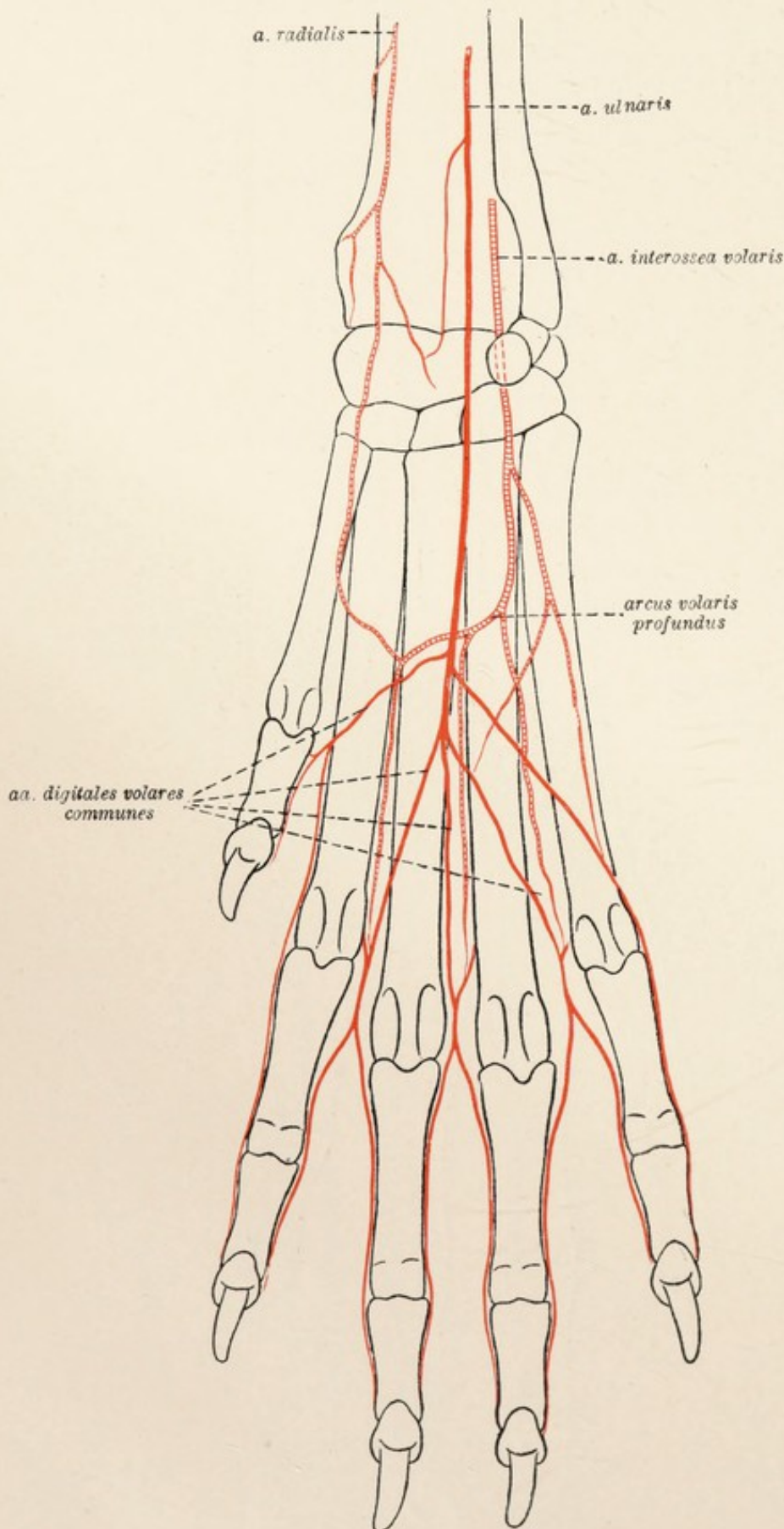


FIG. 54.—Diagram of the volar arteries of the manus.

dividing into a dorsal and a volar branch. The former assists in the formation of the rete carpi dorsale; and the latter is concerned in the production of the deep volar arch.

A. ULNARIS.—The ulnar artery is so much larger than the radial that it might be regarded as the direct continuation of the median. It follows the median nerve along the medial border of the deep flexor, and crosses the flexor aspect of the carpus into the metacarpus between the superficial and deep flexor tendons. Just above the carpus there is a slender communication between the ulnar and radial arteries. In the metacarpus the ulnar artery contributes a *common volar digital artery* to the first digit; and then ends about the middle of the metacarpus by dividing into *common volar digitals* for the second, third, and fourth digits (*aa. digitales volares communes* II, III, et IV). Each common artery is joined by a communicating branch from the dorsal common digital artery, and then divides at the end of the metacarpus into two

branches for the adjacent borders of neighbouring digits (aa. digitales volares propriæ).

MM. LUMBRICALES.—Three slender lumbrical muscles arise from the palmar aspect of the deep flexor tendon and lie between the tendinous slips belonging to second, third, fourth, and fifth digits. The middle muscle of the three is the best developed. Their fine tendons are inserted into the radial side of the proximal end of the first phalanx of the third, fourth, and fifth digits.

Dissection.—Cut across the deep flexor tendon on a level with the carpus.

This will allow of the dissection of the deep muscles, etc., of the palm.

MM. INTEROSSEI.—There are four fleshy and moderately large interosseous muscles lying over the second, third, fourth, and fifth metacarpal bones and in the grooves between them. They arise from the volar aspect of the distal row of the carpus and from the proximal end of the metacarpal bones. Each muscle divides into medial and lateral parts and is inserted to a pair of metacarpal sesamoid bones. In addition tendinous cords are continued to the common extensor tendon.

SHORT MUSCLES OF THE FIRST DIGIT.—Three small, short muscles are connected with the first digit. The most medial, *m. abductor pollicis brevis et opponens pollicis*, is rudimentary and arises from the band which leaves the sesamoid bone at the medial side of the carpus to join the tendon of the superficial flexor. The abductor and opponens muscle is inserted into the distal part of the first metacarpal bone and the proximal phalanx of the first digit. *M. flexor pollicis brevis* is better developed than the foregoing, to the lateral side of which it lies, and arises from the volar aspect of the carpus. The muscle is inserted into the proximal phalanx of the first digit. The third short muscle of the pollex, *m. adductor pollicis*, is the largest of the three. Its origin is from the volar surface of the carpus between the foregoing and the interosseous muscle of the second digit, and its insertion is into the lateral face of the proximal phalanx of the first digit.

M. ADDUCTOR DIGITI SECUNDI.—The adductor muscle of the second digit is thin and narrow. Lying along the lateral border of the interosseous muscle of the second digit, it has origin from the volar face of the carpus, and is inserted into the first phalanx of the second digit.

SHORT MUSCLES OF THE FIFTH DIGIT.—Four short muscles are connected with the fifth digit. One of these, the interosseous, has already been described.

M. adductor digiti quinti arises from the flexor aspect of the carpus close to the origin of the adductor of the second digit. Crossing the interosseous muscles of the third and fourth digits obliquely, it gains the first phalanx of the fifth digit by sinking between the fourth and fifth interosseous muscles.

M. abductor digiti quinti.—The abductor is the largest of the three muscles now under consideration. It lies immediately under the skin on the lateral border of the carpus. The relatively thick fleshy belly arises from the pisiform

bone and gives place to a thin tendon at the proximal part of the metacarpus. The insertion of the abductor is into the lateral aspect of the base of the first phalanx of the fifth digit, and into the lateral sesamoid bone.

M. flexor digiti quinti brevis.—The short flexor lies medial to the abductor, and has origin from the strong ligamentous band which joins the pisiform bone to the third and fourth metacarpals. Its slender tendon joins that of the abductor.

Dissection.—The deep vessels and nerves of the palm must now be examined.

The continuation of the ulnar artery runs under the ligamentous band which joins the pisiform to the third and fourth metacarpal bones, and then under the short flexor of the fifth digit. To follow it, it is necessary to reflect the adductors of the second and fifth digits as well as the interosseous muscle of the second digit. This dissection will also expose the continuation of the ulnar nerve.

ARCUS VOLARIS PROFUNDUS.—The deep volar arch is formed under the short muscles of the digits in the proximal third of the metacarpus, by the union of the continuation of the ulnar artery and the termination of the radial artery. The radial artery gains the arch by passing under the short muscles of the first digit.

From the arch arise *volar metacarpal arteries* (aa. metacarpeæ volares II, III, et IV) which run distalwards between the second and third, third and fourth, and fourth and fifth metacarpal bones. The third artery is the largest and most superficial.

At the distal end of the metacarpus the volar metacarpal arteries are connected with the common dorsal digital arteries.

RAMUS PROFUNDUS OF THE ULNAR NERVE.—The deep branch of the ulnar nerve follows the ulnar artery into the palm and is there related to the deep volar arch. Filaments are supplied to the deep muscles of the palm, and three *common volar digital nerves* (for the second, third, and fourth digits) are also furnished. The common volar nerves follow the arteries of the same name, and, at the distal end of the metacarpus, divide into the *proper digital nerves* (nn. digitales proprii) for the adjacent sides of neighbouring digits.

Dissection.—It now only remains to examine the various joints of the limb.

Remove the muscles and remains of fascia, etc., and begin the dissection of the articulations with the shoulder-joint.

ARTICULATIO HUMERI.—The necessity for many or powerful ligaments in connection with the shoulder-joint is obviated by the numerous strong muscles closely surrounding the articulation. Indeed there is only a *joint-capsule* (capsula articularis) attached to the margin of the glenoid cavity of the

scapula and to the head of the humerus. Strengthening bands leave the base of the coracoid process of the scapula and proceed to the tuberculum majus and tuberculum minus of the humerus. It will be noticed that a membranous ligament stretches from the acromion to the capsule.

The capsule should be opened in order to allow investigation of the synovial membrane down the intertubercular sulcus in connection with the biceps tendon of origin.

ARTICULATIO CUBITI.—The term ‘elbow-joint,’ strictly speaking, includes three joints: the humero-radial articulation (*articulatio humero-radialis*), the humero-ulnar articulation (*articulatio humero-ulnaris*), and the proximal radio-ulnar articulation (*articulatio radio-ulnaris proximalis*).

Capsula articularis.—The joint-capsule, surrounding all three components of the elbow-joint, is strong in front where it is associated with the annular radial ligament, but weak and roomy behind where it is supported by the triceps and anconeus muscles.

Ligamentum collaterale ulnare.—The ulnar collateral ligament springs from the medial epicondyle of the humerus and divides into two parts. One limb is attached to the border of the radius, while the other is connected with both radius and ulna.

Ligamentum collaterale radiale.—The radial collateral ligament leaves the lateral epicondyle of the humerus and, like the ulnar ligament, divides into two portions. One of these, the shorter and the stronger, ends on the lateral part of the head of the radius. The other, longer, weaker and more diffuse, joins the border of the ulna.

Ligamentum annulare radii.—The radial annular ligament is essentially a thickening of the joint-capsule on the flexor aspect of the articulation. Attached to the lateral part of the head of the radius, it crosses over to unite with the tendons of insertion of the brachial and biceps muscles by which it is fixed to the ulna. From the middle of the ligament an offshoot, firmly adherent to the capsule, proceeds in a proximal direction to the humerus.

Membrana interossea antibrachii.—The interosseous membrane consists of short fibres passing between the two bones of the forearm.

ARTICULATIO RADIO-ULNARIS DISTALIS.—The joint between the distal end of the radius and ulna is enclosed in a joint-capsule which consists mainly of ligamentous bands on the dorsal and volar aspects of the joint.

ARTICULATIO RADIO-CARPEA.—Uniting the bones of the forearm to the

proximal row of carpal bones are four ligaments which together close in the joint on all sides and form a capsule.

Ligamentum radio-carpeum dorsale.—The dorsal radio-carpal ligament is thin and membranous, and passes from the dorsal aspect of the distal end of the radius to the cuneiform and scapho-lunar bones.

Ligamentum radio-carpeum volare.—The volar radio-carpal ligament, disposed similarly to the dorsal ligament, is thick and strong. In association with it there are two definite bands. One runs from the radius to the scapho-lunar bone: the other, very oblique in direction, unites the ulna to the scapho-lunar. Small bundles of fibres also end on the pisiform bone.

Ligamentum collaterale carpi ulnare.—A not very well defined ulnar collateral ligament joins the ulna to the cuneiform. A few fibres may be continued to the fifth metacarpal bone.

Ligamentum collaterale carpi radiale.—Much better marked than the ulnar ligament, the radial collateral passes from the styloid process of the radius to the tubercle on the scapho-lunar.

ARTICULATIO OSSIS PISIFORMIS.—The pisiform bone is held in position by five bands which connect it with (1) the ulna; (2) the scapho-lunar; (3) the cuneiform (*ligamentum piso-hamatum*); (4) the fifth metacarpal bone (*ligamentum piso-metacarpeum*); and (5) the third and fourth metacarpal bones.

LIGAMENTA INTERCARPEA.—The individual bones of the carpus are joined together by dorsal, volar, and interosseous intercarpal ligaments.

The *dorsal ligaments* (*ligamenta intercarpea dorsalia*) are six in number. One joins the scapho-lunar and cuneiform, and three unite the members of the distal row of bones. Of the remaining two, one runs from the cuneiform to the unciform; the other from the scapho-lunar to the trapezoid.

The *volar ligaments* (*ligamenta intercarpea volaria*) are also six and have the same connections as the dorsal ligaments, except that the more medial of the two joining the two rows of bones passes from the scapho-lunar to the magnum and trapezoid.

The *interosseous ligaments* (*ligamenta intercarpea interossea*) are concerned with the union of the different members of the same row of bones; that is, there are no interosseous ligaments running from one row to the other.

ARTICULATIONES CARPO-METACARPEÆ.—The four members of the distal row of carpal bones are joined to the bases of the five metacarpal bones by dorsal and volar ligaments.

The remaining articulations of the manus are similar to the corresponding joints of the pes.

Dissection.—Clean up the dorsal part of the chest wall and the lumbar

region. Note the cutaneous branches of the intercostal nerves and the vessels accompanying them.

The two dorsal serratus muscles demand first attention.

M. SERRATUS DORSALIS CRANIALIS.—The cranial dorsal serratus muscle springs by a broad, thin aponeurosis from the ligamentum nuchæ and the spinous processes of the first six or seven thoracic vertebræ. The fibres run in a ventral and caudal direction to be inserted by digitations into the ribs from the second or third to the ninth or tenth.

M. SERRATUS DORSALIS CAUDALIS.—The caudal dorsal serratus muscle arises from the dorso-lumbar fascia. Its fibres have the same direction as those of the internal oblique muscle of the abdomen, with which it appears to be continuous. The insertion of the muscle is into the last three ribs.

Dissection.—Reflect the dorsal serratus muscles.

M. LONGISSIMUS DORSI, ETC.—A powerful muscular mass lies in the groove formed by the transverse and spinous processes of the lumbar vertebræ. On a level with the last rib the mass divides into three muscles: ilio-costalis, longissimus dorsi, and spinalis dorsi et cervicis.

M. ILIO-COSTALIS.—The ilio-costal muscle leaves the common mass about the last rib, and has attachments by independent tendons to the ribs about their angles and the transverse processes of the last two or more cervical vertebræ. Each tendon passes over one or two ribs before finding insertion. Slips from all the ribs except the first four or five join the muscle as it runs along the wall of the chest.

M. LONGISSIMUS DORSI.—The fibres of this powerful muscle arise from the ventral surface and crest of the ilium, and are attached to the transverse processes of the lumbar, thoracic, and last cervical vertebræ, to the spinous processes of the lumbar and thoracic vertebræ, and to the ribs.

M. SEMISPINALIS DORSI ET CERVICIS cannot be completely examined at the present time.

Dissection.—Remove the longissimus dorsi muscle. In doing so, observe the muscular branches of the dorsal rami of the intercostal and lumbar arteries.

M. MULTIFIDUS.—A series of small muscles, larger in the lumbar than in the thoracic region, arise from the sacrum and the articular and transverse processes of the lumbar and thoracic vertebræ, and are inserted into the spinous processes of these vertebræ. Each muscle passes over one spinous process before its insertion.

M. SUBMULTIFIDUS.—In the thoracic region it is customary to find yet shorter muscles underneath the multifidus. The bundles of the submultifidus muscle pass from the transverse process of a vertebra to the spinous process of the one immediately preceding it.

MM. LEVATORES COSTARUM.—The levators of the ribs are a series of small muscles arising from the transverse processes of the thoracic vertebræ. The fibres of each muscle run in a caudal and ventral direction to be inserted into the cranial border of the rib succeeding the vertebra from which they have taken origin.

Dissection.—The muscles of the tail should now be cleaned and examined.

MM. SACRO-COC CYGEUS DORSALES.—The dorsal sacro-coccygeal muscles are two in number, a medial and a lateral. The medial muscle arises from the spinous processes of the lumbar, sacral, and first coccygeal vertebræ, and is inserted into the dorsal surface of the coccygeal vertebræ.

The lateral muscle springs from the articular processes of the last three lumbar and all the sacral vertebræ, and from the transverse process of the first coccygeal vertebra. Rounded tendons pass over several vertebræ and are inserted into the dorsal aspect of all the bones of the tail.

M. SACRO-COC CYGEUS ACCESSORIUS.—The accessory sacro-coccygeal muscle may possibly represent the intertransverse muscles of other regions. It is a rounded muscle lateral in position to the preceding and with origin from the dorsal border of the ilium, the lateral border of the sacrum, and the transverse process of the first coccygeal vertebra. The insertion is into the side of the tail vertebræ.

M. COCCYGEUS.—The coccygeal muscle has already been examined.

MM. SACRO-COC CYGEUS VENTRALES.—As on the dorsal, so on the ventral side of the tail, there are medial and lateral muscles.

The lateral ventral sacro-coccygeal muscle arises from the ventral face of the last lumbar vertebra, the sacrum, and the transverse processes of coccygeal vertebræ. By long tendons the muscle is inserted into the ventral surface of the bones of the tail.

The medial muscle springs from the ventral surface of the sacrum and the first coccygeal vertebra, and is inserted into the corresponding aspect of the tail vertebræ.

Dissection.—Reflect the skin from the ventral side of the neck and the mandibular region. Secure the previously detached manubrium of the sternum and the first costal cartilage, so as to keep the ventral cervical muscles on the stretch. Then clean up the external jugular vein on the side from which the limb has been removed.

V. JUGULARIS EXTERNA.—The external jugular, much larger than the internal vessel of the same name, is the main vein of the neck. Formed at the aboral border of the submaxillary gland by the union of the external and internal

maxillary veins, the external jugular crosses the surface of the sterno-cephalic muscle to assist the subclavian in the formation of the innominate vein.

The following tributaries join the jugular at different points in its course : (1) Small veins from the skin ; (2) a large and a small communicating branch from the cephalic vein of the arm ; (3) the companion vein of the ascending cervical artery ; (4) the companion vein of the transverse scapular artery.

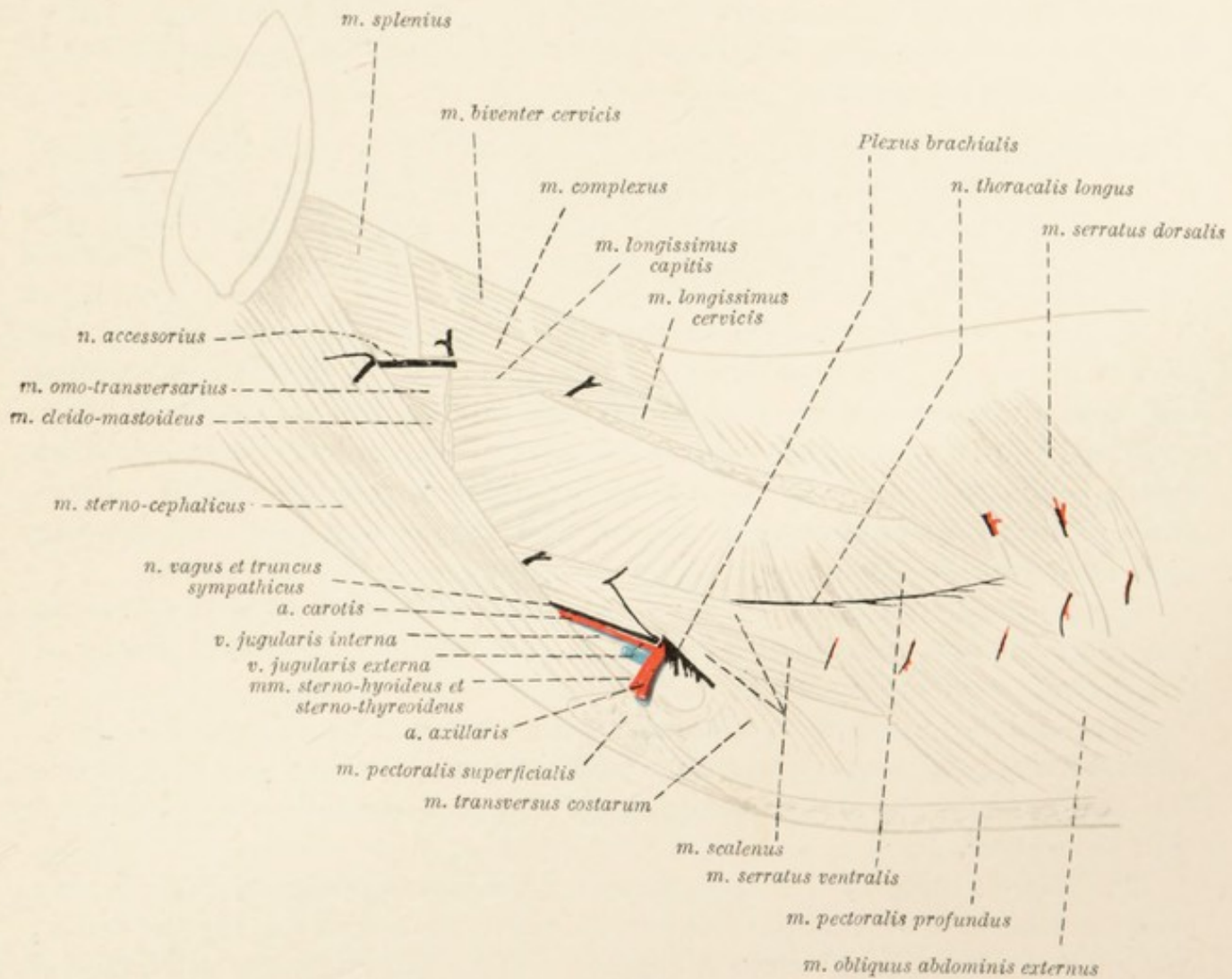


FIG. 55.—Dissection of the side of the neck and thorax.

Very commonly the two last named unite to form an omo-cervical trunk which, in its turn, joins the jugular.

V. MAXILLARIS EXTERNA.—The external maxillary vein drains the blood from the face, the tongue, and the mandibular region. The main root is formed by the common facial vein which will be found in the groove between the masseter and digastric muscles. About the ventral border of the sub-maxillary gland the facial vein receives the common trunk formed by the union of the lingual and sublingual veins, and then changes its name to that of external maxillary vein.

The lingual vein appears in the angle formed by the borders of the mylohyoid and digastric muscles, and is at once joined by a transverse vessel which passes across from one lingual vein to the other.

A group of lymph-glands (lympho-glandulæ submaxillares) are present about the point of junction of the facial vein and the common trunk of the lingual and sublingual veins.

V. MAXILLARIS INTERNA.—The internal maxillary vein is formed under cover of the parotid gland, and is only visible, at the present stage of the dissection, as it runs along the aboral border of the submaxillary gland to unite with the external maxillary vein.

Dissection.—Cut across the sterno-cephalic muscle a little distance from its sternal attachment and turn it aside. This will permit of the demonstration of the common carotid artery, the internal jugular vein, the vagus and sympathetic nerves, as well as certain muscles.

M. STERNO-HYOIDEUS.—The sterno-hyoid muscles of opposite sides of the neck lie in contact with each other in the middle line. Each takes origin from the manubrium of the sternum and is inserted into the body of the hyoid bone.

M. STERNO-THYREOIDEUS.—In the region of the sternum the sterno-thyroid muscle is almost completely covered by the preceding; but, owing to a divergence of the two sterno-thyroid muscles they are exposed more and more in their course to the larynx.

The sterno-thyroid muscle has origin from the manubrium of the sternum and from the first costal cartilage, and is inserted into the aboral border of the thyroid cartilage about its middle.

It should be noted that, a short distance from their origins, the above muscles are crossed transversely by a tendinous intersection; and that at this line the two muscles of the same side of the neck are intimately connected with each other.

The nerve supply of the sterno-hyoid and sterno-thyroid muscles is largely from the ventral division of the first cervical nerve; but with this the descending branch of the hypoglossal nerve is blended. The composite nerve will be found along the lateral border of the muscles.

V. JUGULARIS INTERNA.—The internal jugular vein is a vessel of small and variable size lying, in the main, lateral to the common carotid artery. Not only does the size of the vein vary in different animals, but the two vessels of the same animal are not necessarily of the same calibre. The origin of the internal jugular may be traced to the occipital and cerebral veins.

Accompanying the common carotid artery, the vein is close to the trachea on the right side of the neck, and to the œsophagus on the left. It ends by joining either the innominate vein or the external jugular of its own side. The internal jugular receives the cranial and caudal thyroid, muscular, tracheal, and œsophageal veins.

A. CAROTIS COMMUNIS.—The two common carotid arteries leave the brachiocephalic at no very great distance from each other. The right artery runs obliquely lateralwards across the ventral surface of the trachea, and then along the lateral face of this tube. The left artery has a similar relation to the trachea about the thoracic inlet, but in the neck it is in contact with the œsophagus. Each artery is in relation dorso-laterally with the combined trunk of the vagus and sympathetic nerves.

On a level with the wing of the atlas the common carotid artery divides into external and internal carotid and occipital arteries. The collateral branches of the artery are: (1) The *caudal thyroid artery* (a. thyreoidea caudalis), a small vessel arising at the entrance to the chest and accompanying the recurrent nerve up the neck to end in the thyroid gland; (2) the *cranial thyroid artery* (a. thyreoidea cranialis), an artery of some size supplying the thyroid gland and contributing the *ascending pharyngeal artery* (a. pharyngea ascendens), *muscular* (rami musculares) and *glandular* (rami glandulares to the submaxillary gland) branches; (3) the *laryngeal artery* (a. laryngea), a small vessel ramifying in the larynx.

N. VAGUS ET TRUNCUS SYMPATHICUS.—The thick nerve cord lying dorsal and lateral to the common carotid artery is formed on a level with the wing of the atlas by the union of the vagus nerve and the cervical cord of the sympathetic. These are bound together by strong connective tissue.

N. RECURRENS.—The recurrent nerve, a branch of the vagus already encountered in the chest, follows the lateral aspect of the trachea and ends in the larynx. In the neck the nerve supplies branches to the trachea and œsophagus (rami tracheales et œsophagei).

M. MYLO-HYOIDEUS.—Lying in the space between the two halves of the mandible, the mylo-hyoid is a flat, broad, thin muscle composed of transverse fibres arising from the mylo-hyoid line close to the alveolar border of the mandible. The fibres join a raphe in the middle line, as well as the symphysis of the mandible and the body of the hyoid bone.

Dissection.—Turn the manubrium of the sternum, with the muscles attached thereto, as far as possible towards the head, and so expose the trachea and œsophagus.

TRACHEA.—The trachea is an almost cylindrical tube extending from the larynx to a point opposite the fourth rib, where it divides into the two bronchi. The lumen of the tube is not quite uniform on account of a certain amount of narrowing from the larynx to the thoracic entrance. Nor is the trachea absolutely in the middle line since there is some degree of inclination towards the right. At its commencement the windpipe is in contact dorsally with the œsophagus, but later this relation is exchanged for one with the longus colli muscle.

The skeleton of the trachea consists of a variable number (thirty-five to forty)

of incomplete rings of cartilage (cartilagine tracheales) joined together by membranous annular ligaments (ligamenta annularia). The interruption in the continuity of each ring is placed at the dorsal part of the tube, where transverse muscular fibres occur. The interior of the trachea is lined by a mucous membrane.

ŒSOPHAGUS.—The œsophagus is that part of the alimentary canal which intervenes between the pharynx and the stomach. For descriptive purposes it is divided into cervical, thoracic, and abdominal parts (*pars cervicalis*, *pars thoracalis*, et *pars abdominalis*). In the earlier dissections the thoracic and abdominal parts have been exposed and examined.

The cervical part is at first in the middle line and immediately dorsal to the trachea, but an inclination towards the left soon becomes noticeable. At the entrance to the chest the œsophagus may be at a level even ventral to that of the trachea.

GLANDULA THYREOIDEA.—One of the ductless glands, the thyroid consists of two *lateral lobes* connected ventral to the trachea by an *isthmus* of variable dimensions. Frequently the isthmus is absent; but when present, it connects the more caudal part of the two lateral lobes. Each lobe is elongated, with narrow oral and aboral extremities, and lies on the lateral face of the trachea immediately aboral to the larynx (over six or seven tracheal rings). The lateral surface of each lobe is covered by the sterno-cephalic muscle, and its ventral border is in contact with the sterno-thyroid muscle.

In association with the thyroid gland are two or more small *parathyroids*.

Dissection.—Remove the skin from the ear and the parotid region. Clean up the auricular nerves, vessels, and muscles.

AURIS EXTERNA.—Before commencing the dissection of the muscles of the external ear, it is necessary to have some knowledge of the cartilages to which they are attached.

The cartilages of the external ear are three in number—conchal, scutiform, and annular. The *conchal cartilage* or *auricula* is the largest, and forms the projecting, conspicuous part of the ear. Its form varies greatly with the breed of the dog; but, generally speaking, it may be said to have a funnel-like or trumpet-shaped outline. The wide free part of the cartilage has two borders—cranial and caudal—meeting at the tip of the ear. At the base of the cranial border is an irregular projection known as the *helix*. At the lateral part of the narrow, basal portion of the cartilage is a curved, plate-like projection, the *tragus*; and immediately caudal to this an irregular process, the *anti-tragus*.

The *scutiform cartilage* is in the form of a plate of irregular outline, and lies on the temporal muscle oral to the base of the conchal cartilage.

The *annular cartilage*, as its name implies, is ring-like in form, and is adherent to the margin of the external acoustic meatus of the temporal bone.

M. SCUTULARIS.—Medial and oral to the base of the ear is a thin sheet of muscle, the scutular muscle, divisible into two portions: (1) the *m. fronto-scutularis*, springing from the zygomatic process of the frontal bone and from the orbital band; (2) the *m. interscutularis*, thinner than the preceding and continuous with the corresponding muscle of the other ear.

The two muscles are inserted into the scutiform cartilage.

Mm. auriculares anteriores.—There are three auricular muscles lying mainly to the nasal side of the base of the ear. The uppermost (most dorsal) continues the fronto-scutularis from the scutiform cartilage to a fold of skin at the base of the oral border of the conchal cartilage. The middle muscle of the group is very short, and connects the scutiform and conchal cartilages. The lowest (most ventral) muscle has a broad tendinous origin from the fronto-scutularis, sometimes also from the zygomatic muscle, and is inserted into the antitragus.

M. AURICULARIS INFERIOR.—The inferior auricular muscle is narrow and long, and lies over the parotid and submaxillary glands. Arising from the fascia over the region of the larynx, its insertion is into the conchal cartilage close to that of the lowest anterior auricular muscle.

MM. AURICULARES POSTERIORES.—Three muscles fall within this group. One of them is the long levator; the others are the long and short abductors. The *long levator* rises from the mid-dorsal line of the neck, and is inserted into both conchal and scutiform cartilages. The long levator is aboral to the interscutular muscle and in the same plane, and the two muscles are more or less continuous.

Dissection.—Reflect the scutular and long levator muscles.

MM. AURICULARES SUPERIORES.—The superior group of muscles contains a short and a middle levator. The *short levator* arises from the scutiform cartilage and passes to the conchal cartilage. The *middle levator* lies under cover of the interscutular and long levator muscles, and takes origin from the sagittal crest. The muscle divides into two parts, and its fibres are partly inserted into the conchal and partly into the scutiform cartilage.

The *long abductor* muscle arises from the ligamentum nuchæ, and is inserted into the lateral aspect of the conchal cartilage.

Dissection.—Reflect the middle levator and long abductor muscles.

The *short abductor* takes origin from the occipital bone, and passes to the medial side of the base of the conchal cartilage.

MM. AURICULARES PROFUNDI.—The deep auricular muscles consist of two rotators—long and short—placed underneath the scutiform cartilage and running from this to the conchal cartilage.

M. TRAGICUS.—The tragicus muscle is divided into two parts—lateral and medial.

M. tragicus lateralis springs from the border of the mandible between the condyloid and angular processes.

M. tragicus medialis joins the tragus to the base of the conchal cartilage.

M. HELICIS joins helix and antitragus.

M. TRANSVERSUS AURICULÆ.—The transverse muscle is a band of fibres lying on the conchal cartilage close to the insertion of the long levator.

M. ANTITRAGICUS consists of a few fibres placed immediately aboral to the attachment of the inferior auricular muscle, and runs from the tragus to the antitragus.

A. AURICULARIS POSTERIOR.—The main artery of the external ear is the posterior auricular, a branch of the external carotid. Commencing on a level with the hyoid bone, this artery runs to the base of the ear underneath the parotid gland, and is distributed to the aboral and medial portions of the ear.

A. AURICULARIS ANTERIOR.—The anterior auricular artery is a branch of the superficial temporal from which it is derived on a level with the zygoma. The vessel ramifies over the oral and medial parts of the external ear.

N. AURICULARIS POSTERIOR.—The posterior auricular nerve leaves the seventh cerebral nerve under the parotid gland and divides into branches which follow those of the posterior auricular artery.

N. AURICULARIS INTERNUS.—Also a branch of the seventh cerebral nerve, the internal auricular pierces the deep lateral part of the conchal cartilage in the interior of which it is distributed.

The temporal division of the auriculo-palpebral branch of the seventh nerve supplies the oral part of the ear.

The auricular branch of the second cervical nerve is distributed over the lateral and aboral part of the ear; and the occipital branch of the first cervical nerve spreads out over the medial surface.

M. OCCIPITALIS.—Although not belonging to the ear, the occipital muscle may be examined at this stage of the dissection. The muscle is a narrow, thin band running longitudinally from the superior nuchal line of the occipital bone and the sagittal crest of the parietal into the fascia which is blended with the periosteum of the frontal bone.

The muscles of the dorsal part of the neck must now be examined.

M. SPLENIUS.—The splenius muscle is triangular, with its apex caudal and its base at the occipital bone. The origin of the muscle extends as far caudal as the fifth or sixth thoracic spinous process, and is continued along the middle dorsal line throughout the cervical region. At first the origin is aponeurotic, but from the first or second thoracic spine onwards it is fleshy. The insertion of the muscle is into the occipital bone and mastoid part of the temporal bone.

About the level of the atlas the fibres of the splenius are closely connected with the tendon of the longissimus capitis muscle.

M. LONGISSIMUS CERVICIS.—This muscle is immediately ventral to the splenius, and intimately connected with the longissimus dorsi. With an origin from the transverse processes of the first five or six thoracic vertebræ, its insertion is into the transverse processes of the last four or five cervical vertebræ.

Dissection.—Reflect the splenius by cutting through the entire length of its origin. Observe the branches of the cervical nerves. Then reflect the longissimus cervicis by a transverse incision about the middle of the muscle.

M. LONGISSIMUS CAPITIS ET ATLANTIS.—These two muscles are readily separated, but are better considered together. The *longissimus capitis* muscle arises from the transverse processes of three or four thoracic vertebræ and from the last three or four cervical articular processes. By union with the splenius the muscle obtains an insertion into the mastoid part of the temporal bone.

The *longissimus atlantis* is a very much smaller muscle than the preceding, and passes from the third, fourth, fifth, and sixth cervical articular processes to the wing of the atlas.

M. SEMISPINALIS CAPITIS.—Dorsal and medial to the preceding in position, the semispinalis muscle of the head consists of two parts—*m. biventer cervicis* and *m. complexus*. The former is readily distinguished by the presence of four oblique tendinous intersections. This muscle arises from the spinous processes of the second to the fourth or fifth, and from the transverse processes of the fourth, fifth, and sixth thoracic vertebræ, as well as from the ligamentum nuchæ. The complexus muscle has its origin from the transverse processes of the first two or three thoracic vertebræ, and from the articular processes of the last five cervical vertebræ.

The two parts of the semispinalis muscle may or may not join about the level of the atlas. In any case they are inserted into the occipital bone.

Two branches of the second cervical nerve are associated with the biventer cervicis muscle. A large branch pierces the muscle close to its insertion and proceeds to the ear. A much smaller nerve either pierces the muscle close to the middle line, or appears between the muscle and the ligamentum nuchæ, and ramifies in the skin medial to the base of the ear.

Dissection.—Cut across the complexus muscle on a level with the joint between the atlas and the epistropheus. Free the biventer cervicis muscle from its origin and turn it towards the head. In reflecting these two muscles the large dorsal primary divisions of the cervical nerves will be observed between the complexus and multifidus muscles.

M. SEMISPINALIS DORSI ET CERVICIS.—This muscle, as has previously been noted, is continuous with the longissimus dorsi. It receives a bundle of

fibres from the first thoracic vertebra, and is attached to the articular and spinous processes of the last six cervical vertebræ.

M. MULTIFIDUS CERVICIS.—The multifidus of the neck is a continuation of the already examined multifidus muscle of the back, but is much better developed. In position lateral to the semispinalis and underneath the complexus, the muscle consists of four or five bundles which run from the articular processes of the last four or five cervical vertebræ to the spinous processes of the second, third, fourth, and fifth vertebræ of the neck.

The dorsal divisions of the cervical nerves appear at the lateral border of the muscle and lie on its superficial surface.

MM. INTER-TRANSVERSARI.—The intertransverse muscles of the neck are double, with the ventral primary divisions of the cervical nerves passing between their dorsal and ventral portions.

LIGAMENTUM NUCHÆ.—The ligament of the nape of the neck is in the form of a flattened, elastic cord extending from the spinous process of the epistropheus to the tip of the spinous process of the first thoracic vertebra, where it is continuous with the supraspinous ligament. By careful examination, the dissector can satisfy himself that the ligament consists of right and left halves.

Immediately behind the occipital bone there is a group of muscles, the straight and oblique muscles of the head, which connects the atlas and epistropheus to the skull. The occipital nerve (a branch of the second cervical nerve) and branches of the occipital vessels cross the muscles superficially.

M. RECTUS CAPITIS DORSALIS MAJOR.—The larger dorsal straight muscle of the head is flat and in contact with its fellow of the opposite side. With an origin from the spinous process and possibly also from the adjacent part of the caudal articular process of the epistropheus or second cervical vertebra, its insertion is into the occipital bone immediately ventral to the insertion of the semispinalis capitis.

A separable part of the muscle (*m. rectus capitis dorsalis medius*) arises from the oral extremity of the spinous process of the second cervical vertebra.

Dissection.—Reflect the rectus capitis dorsalis major muscle.

M. RECTUS CAPITIS DORSALIS MINOR.—This is a small muscle passing from the oral border of the dorsal arch of the atlas to the occipital bone.

M. OBLIQUUS CAPITIS CAUDALIS.—Of the two oblique muscles of the head the more caudal is the larger. A powerful muscle springing from the whole of the spinous process of the epistropheus, its fibres run obliquely oral and lateral to be inserted into the wing of the atlas.

M. OBLIQUUS CAPITIS CRANIALIS.—Smaller than the preceding, this muscle arises from the oral and lateral border of the wing of the atlas, runs obliquely orally and medially, and is inserted into the mastoid process of the temporal bone.

Dissection.—Reflect the longissimus capitis et atlantis muscles. Remove the caudal oblique muscle of the head and the intertransverse muscles in order to show the vertebral vessels and the second cervical nerve.

A. VERTEBRALIS.—The vertebral artery is a branch of the subclavian. After leaving the chest, the artery enters the interval between the longus colli and scalenus muscles and gains the transverse foramen of the sixth cervical vertebra. After traversing the foramina in the transverse processes of the cervical vertebræ from the sixth to the first, a union is effected under the wing of the atlas with a branch of the occipital artery.

The dissection of the face should be commenced by an examination of the external parts of the eye.

PALPEBRÆ.—The eyelids, using the term in the more usual sense, are two in number: upper (palpebra superior) and lower (palpebra inferior); but to these may be added a much less obvious third eyelid (palpebra tertia). The upper and lower eyelids may be described as membranous curtains arranged for the protection of the eye. The upper lid is the larger and the more movable, and is provided with a special muscle, the *m. levator palpebræ superioris*, by which it is raised. Each lid has an outer surface (facies anterior palpebræ) covered with hair-bearing skin, and an inner surface (facies posterior palpebræ) applied to the eyeball and rendered smooth by the *conjunctiva*, a membrane continued from the lid over the front part of the eyeball.

The free borders of the lids (limbi palpebrales) bound the palpebral fissure (rima palpebrarum), which is in the form of a narrow slit when the lids are closed, but assumes an elliptical outline when the eye is open. The free border of the upper eyelid carries a row of long and strong hairs. The two lids are joined at the lateral and medial commissures (commissuræ palpebrarum lateralis et medialis). Both are acute, and in the neighbourhood of the medial commissure the eyelids circumscribe a space (lacus lacrimalis) in which is a rounded body, the *lachrymal caruncle* (caruncula lacrimalis). On the margins of the lids near the medial commissure are the small *puncta lacriminalia*, upper and lower, leading into the *lachrymal ducts* (ductus lacrimales), by which the tears are drained from the eye.

Each eyelid contains a framework of fibrous tissue, the *tarsus*, much better developed in the upper than in the lower lid. A sphincter muscle (*m. orbicularis oculi*) is associated with the eyelids, and can be exposed by the removal of the skin over them. In addition, the upper lid and the region of the eyebrow contain muscular fibres which corrugate the eyebrow (*m. corrugator supercilii*).

The third eyelid consists of a pigmented semilunar fold of conjunctiva, the *membrana nictitans*, easily demonstrated near the medial commissure, and a

piece of cartilage (cartilago palpebræ tertiae) which will be examined along with the other contents of the orbit.

Dissection.—Remove the skin from the face and proceed to examine the underlying muscles. The nerves and vessels of the face must be carefully preserved.

M. ZYGOMATICUS.—A narrow, band-like muscle arising from the scutiform cartilage of the ear, the zygomatic crosses the face obliquely and is inserted at the angle of the mouth.

M. RISORIUS.—The risorius muscle is merely that portion of the cutaneous muscle of the face which lies in the region of the angle of the mouth and is inserted close to the termination of the zygomatic muscle.

M. QUADRATUS LABII SUPERIORIS.—Covering the side of the nose, the quadrate muscle is divisible into three parts: (1) *M. nasolabialis*, with fibres arising from the maxillary and frontal bones in the neighbourhood of the medial commissure of the eye, and from the frontal fascia, to end in the substance of the upper lip; (2) *m. malaris*, thin and connected with the foregoing at its origin, where it blends also with the orbicular muscle of the eye, and confused with the buccinator muscle at its insertion; (3) *m. levator labii superioris proprius*, with an origin from the maxillary bone in the region of the infra-orbital foramen, and an insertion about the nostril.

M. CANINUS.—Ventral to the proper levator of the upper lip in position, the canine muscle arises close to the infraorbital foramen and from the canine fossa of the maxillary bone. Its insertion is into the upper lip.

M. BUCCINATOR.—The buccinator muscle consists of two strata: (1) The more superficial stratum contains fibres running obliquely from the alveolar border of the maxilla to the lateral face of the mandible; (2) the deeper fibres run obliquely downwards and forwards from the maxilla on a level with the last two or three cheek-teeth to the lateral face of the mandible.

M. ORBICULARIS ORIS.—A sphincter muscle contained in the lips, the orbicular muscle of the mouth, provides a means by which the lips are approximated and the entrance to the mouth is closed.

MM. INCISIVI LABII SUPERIORIS ET INFERIORIS.—The upper and lower incisive muscles are best demonstrated by removing the mucous membrane from the inside of the lips. In dissecting the upper incisive muscle of each side a large branch of the infraorbital nerve is exposed.

The muscles consist of bundles of fibres passing into the lips from the incisive bone and the mandible on a level with the second and third incisor and the canine teeth.

M. MASSETER.—The masseter muscle is powerful and lies over the mandible ventral to the zygomatic arch. A complete examination should be postponed.

GLANDULA PAROTIS.—The parotid gland of the dog is relatively small.

Irregularly triangular in outline, with a base notched and embracing the auricle and an apex overlying the submaxillary gland, it is lodged in a depression bounded by the base of the external ear, the masseter muscle, and the wing of the atlas. The lateral surface of the gland is covered by the cutaneous and inferior auricular muscles; while its deep or medial surface covers the facial nerve, the internal maxillary vein, the base of the external ear, part of the digastric muscle, and part of the submaxillary gland. The great auricular vein runs along its aboral border.

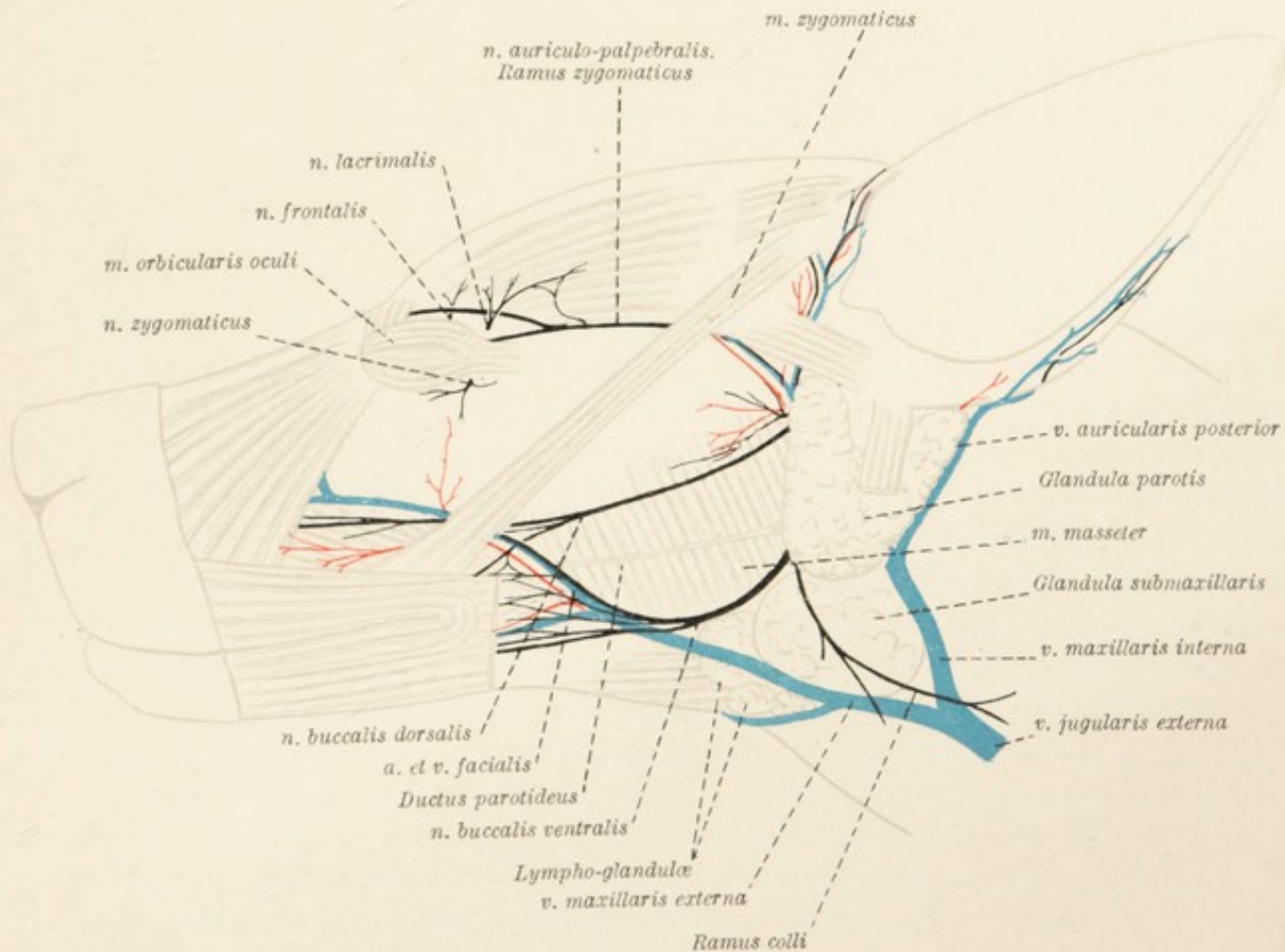


FIG. 56.—Superficial dissection of the face.

Commencing at the oral border and close to the apex of the gland, and formed by the union of a number of smaller ducts, the *parotid duct* (ductus parotideus [Stenonis]) crosses the surface of the masseter muscle, pierces the cheek, and opens into the mouth on a level with the third maxillary premolar tooth.

The nerves of the face are derived from two sources: namely, the fifth and the seventh cerebral nerves.

NERVUS FACIALIS.—The facial, or seventh cerebral nerve acquires a superficial position by emerging between the border of the mandible and the parotid

gland. The following are its superficial branches : (1) The *auriculo-palpebral nerve* (n. auriculo-palpebralis), which divides into a temporal ramus (ramus temporalis), supplying the front part of the ear, and a zygomatic ramus (ramus zygomaticus). The latter crosses the zygomatic arch, furnishes twigs to both eyelids, and ends on the side of the nose, where it arrives by curving round the medial side of the eye. (2) The *dorsal buccal nerve* (n. buccalis dorsalis) crosses the surface of the masseter muscle and ends in the upper lip ; while (3) the *ventral buccal nerve* (n. buccalis ventralis) follows the ventral border of the muscle and ends in the lower lip. A considerable amount of intercommunication takes place between branches of the two buccal nerves. (4) The smallest superficial branch of the facial nerve—the *cervical branch* (ramus colli)—pierces the parotid gland and joins the superficial cervical branch of the second spinal nerve.

N. TRIGEMINUS.—The trigeminal, or fifth cerebral nerve, has not long left the brain before it divides into three parts—the ophthalmic, maxillary, and mandibular nerves—all of which supply branches which should be sought at this stage of the dissection.

N. ophthalmicus.—Two branches of the ophthalmic nerve become superficial about the eye : (1) The *frontal nerve* (n. frontalis) leaves the orbit by bending round the orbital band—a fibrous cord stretching from the zygomatic to the frontal bone—and is expended in the upper eyelid and its neighbourhood, where it assists in the formation of the anterior auricular plexus ; (2) the *infratrochlear nerve* (n. infratrochlearis) appears medial to the eye.

N. maxillaris.—The maxillary nerve furnishes four branches—two small and two large—to the face : (1) The *lacrimal nerve* (n. lacrimalis) leaves the orbit lateral to the point of exit of the frontal nerve, and plays a part in the formation of the anterior auricular plexus ; (2) the *zygomatic nerve* (n. zygomaticus) is quite small, emerges from the orbit close to the lateral commissure of the eyelids and ends mainly in the lower eyelid ; (3) the two large *infraorbital nerves* (nn. infraorbitales) leave the foramen of that name and spread out in the substance of the upper lip and nose. They will receive further attention at a later stage.

N. mandibularis.—The mandibular nerve contributes three branches to the face : (1) The *superficial temporal nerve* (n. temporalis superficialis) bends round the border of the mandible and divides into auricular and temporal branches ; (2) the *mental nerve* (n. mentalis) leaves the foramen of the same name and supplies the lower lip ; (3) the *buccinator nerve* (n. buccinatorius) becomes visible at the oral border of the masseter muscle and ends in the cheek and lower lip, some of its branches joining the plexus formed by the buccal nerves derived from the seventh cerebral nerve.

A. FACIALIS.—The facial artery will be found in a groove bounded by the masseter and digastric muscles. Its branches are the *inferior labial artery* (a. labialis inferior), the *angular artery of the mouth* (a. angularis oris), and the

superior labial artery (a. labialis superior), which ramify in the parts indicated by their names.

A. INFRAORBITALIS.—The infraorbital artery leaves the homonymous foramen along with the large nerves of the same name, and terminates in *dorsal nasal* (a. nasi dorsalis) and *lateral nasal* (a. nasi lateralis) branches.

A. TRANSVERSA FACIEI.—The transverse facial artery, a branch of the superficial temporal, is generally a very small vessel which crosses the surface of the masseter muscle.

V. FACIALIS ET V. MAXILLARIS EXTERNA.—The facial vein is formed by the union of the angular vein of the eye and the dorsal nasal vein. Running down the face, it receives the superior labial, reflex, buccinator, and inferior labial veins, and becomes the external maxillary vein on a level with the inferior border of the mandible. Instead of joining the facial vein directly, the buccinator may unite with the inferior labial.

The external maxillary vein will be found in the groove between the masseter and digastric muscles. It runs backwards ventral to the submaxillary gland, and ends by uniting with the internal maxillary vein to form the external jugular. The main collateral tributaries of the external maxillary vein are the deep facial and the lingual. The former appears at the oral border of the masseter muscle. The lingual vein joins the external maxillary just before this flows into the jugular. A transverse vessel, on a level with the body of the hyoid bone, forms a link between the lingual veins of the two sides of the head.

Dissection.—The parotid gland must now be removed with great care. When this has been done, the origin of those branches of the facial nerve which have recently been examined in connection with the face will be exposed.

M. MASSETER.—The powerful masseter muscle completely fills the considerable depression ventral to the zygomatic arch. Very tendinous in structure, its origin is from the whole of the ventral border and the immediately adjacent medial surface of the zygomatic processes of the zygomatic and temporal bones. On account of a difference in the direction of its fibres at different depths, the muscle may be divided into three imperfectly separated strata. The most superficial fibres are caudo-ventral in direction; the middle stratum has practically vertical fibres; and in the deepest stratum their direction is ventral and oral.

The masseter muscle is inserted into the whole of the fossa on the lateral surface of the mandible, the ridges bounding the fossa, the angular process, and a ridge continued in an oral direction from this process.

In the dissection of the masseter muscle care must be exercised to preserve its nerve of supply—the masseteric nerve (n. massetericus)—a branch of the mandibular nerve, which reaches the muscle by way of the mandibular notch, and is most easily found between the middle and deep strata of the muscle.

Dissection.—The temporal muscle is covered by a strong temporal fascia

attached to the margins of the temporal fossa, and particularly thick at its attachment to the zygomatic arch. Make an incision along the border of the arch, and turn the fascia upwards. In doing this, some fibres of the muscle which arise from the deep face of the fascia will have to be divided. The fascia should be removed completely. The superficial temporal vessels will be exposed in the process.

With bone forceps snip through the zygomatic arch close to the mandibular articulation, and at its other end as close as possible to the orbit. The piece of bone, with the remains of the masseter muscle attached thereto, must be removed.

M. TEMPORALIS.—The powerful temporal muscle, mixed with much tendinous tissue, arises from the whole of the temporal fossa, which it fills completely. In addition to the bony origin, some fibres spring from the orbital band and the temporal fascia.

The insertion of the muscle into the coronoid process of the mandible is rendered somewhat indefinite by confusion with the masseter.

A. TEMPORALIS SUPERFICIALIS.—The superficial temporal artery is one of the two terminal branches of the external carotid. Crossing the aboral end of the zygomatic process of the temporal bone, it pierces the temporal fascia and runs towards the frontal bone approximately parallel to the zygomatic arch and in close relationship with the temporal muscle. Terminal twigs supply the frontal region and both eyelids.

The collateral branches of the artery are as follows: (1) *Transverse facial artery* (a. transversa faciei), a small vessel already encountered on the surface of the masseter muscle; (2) *anterior auricular artery* (a. auricularis anterior), leaving the parent vessel as this crosses the zygomatic arch, and terminating in the muscles and skin over the medial and oral parts of the external ear; (3) in addition, there are small branches which end in the parotid gland, the masseter and other muscles, and the skin.

V. TEMPORALIS SUPERFICIALIS.—The superficial temporal vein is arranged in conformity with the artery.

Dissection.—The following dissection must be performed on one side of the head only. With a saw or bone-forceps separate the coronoid process from the rest of the mandible, and then cut through the bone on a level with the first premolar tooth. Liberate the insertion of the digastric muscle from the bone, and carefully pass the knife through the muscles, etc., attached to the medial surface of the mandible, keeping the edge of the knife as close to the bone as possible. Disarticulate the mandibular joint, bearing in mind the close relationship which exists between the joint and the internal maxillary artery. Remove the piece of mandible which the foregoing operations have isolated.

This dissection involves the partial destruction of the pterygoid muscles and

the inferior alveolar vessels and nerve; but the dissector will have an opportunity later of examining these on the other side of the head.

Note the presence of the mylo-hyoid nerve—a branch of the mandibular nerve—and the sublingual vessels.

Now turn the mylo-hyoid muscle downwards as far as possible.

GLANDULA SUBMAXILLARIS.—The submaxillary gland is a rounded, yellowish object, placed between the digastric muscle and the wing of the atlas on a level slightly deeper than that of the parotid gland. While being the least distinctly lobulated of all the salivary glands, the submaxillary, in consequence of a strong fibrous capsule, is the most definite in form.

In contact with the lateral surface of the gland are the narrow, ventral end of the parotid, the inferior auricular and cutaneous muscles, the cervical branch of the facial nerve, and the superficial branch of the second spinal nerve. This surface, moreover, is not infrequently traversed by a shallow groove in which the internal maxillary vein is lodged. The medial surface is moulded upon the sterno-cephalic and digastric muscles.

The *submaxillary duct* (ductus submaxillaris [Whartoni]) leaves the medial surface of the gland and crosses the surface of the digastric muscle under cover of the sublingual gland. Then, accompanying the larger sublingual duct over the stylo-glossal muscle, it finally opens into the mouth on a poorly marked elevation—the *sublingual caruncle* (caruncula sublingualis)—by the side of the frænulum of the tongue.

GLANDULA SUBLINGUALIS.—The sublingual gland is elongated, narrow, reddish in hue, and stretches from the submaxillary gland, with which it is in intimate contact, to about the level of the third premolar tooth. Two parts are readily distinguished: (1) a larger, thicker aboral portion; and (2) a much smaller, thin and narrow, oral part.

The aboral portion (gl. sublingualis grandicanalaris) lies between the digastric, pterygoid, and masseter muscles and a part of the mandible. Its duct (ductus sublingualis major) runs along the surface of the stylo-glossal muscle, in company with and somewhat dorsal to the submaxillary duct, in common with which it opens into the mouth.

The feebly developed oral portion of the sublingual gland (gl. sublingualis parvicanalaris) lies between the mylo-hyoid muscle and the mucous membrane of the mouth, and is occasionally slightly overlapped by the aboral portion, from which it can only be distinguished by its slightly paler colour. The lingual nerve crosses the lateral surface of this part of the sublingual gland obliquely. There are several (eight to twelve) smaller sublingual ducts (ductus sublinguales minores).

Dissection.—Remove the submaxillary and sublingual glands and clean the muscles, vessels, and nerves on the side of the tongue, pharynx, and larynx.

M. DIGASTRICUS.—Inasmuch as this muscle has only one fleshy belly in the dog, the name ‘digastric’ is apt to mislead. The strong muscle arises from the jugular process of the occipital bone, and is inserted into the medial surface and ventral border of the mandible.

M. STYLO-HYOIDEUS.—A thin and narrow fleshy slip crosses the surface of the digastric muscle. This is the stylo-hyoid muscle, which has an attenuated

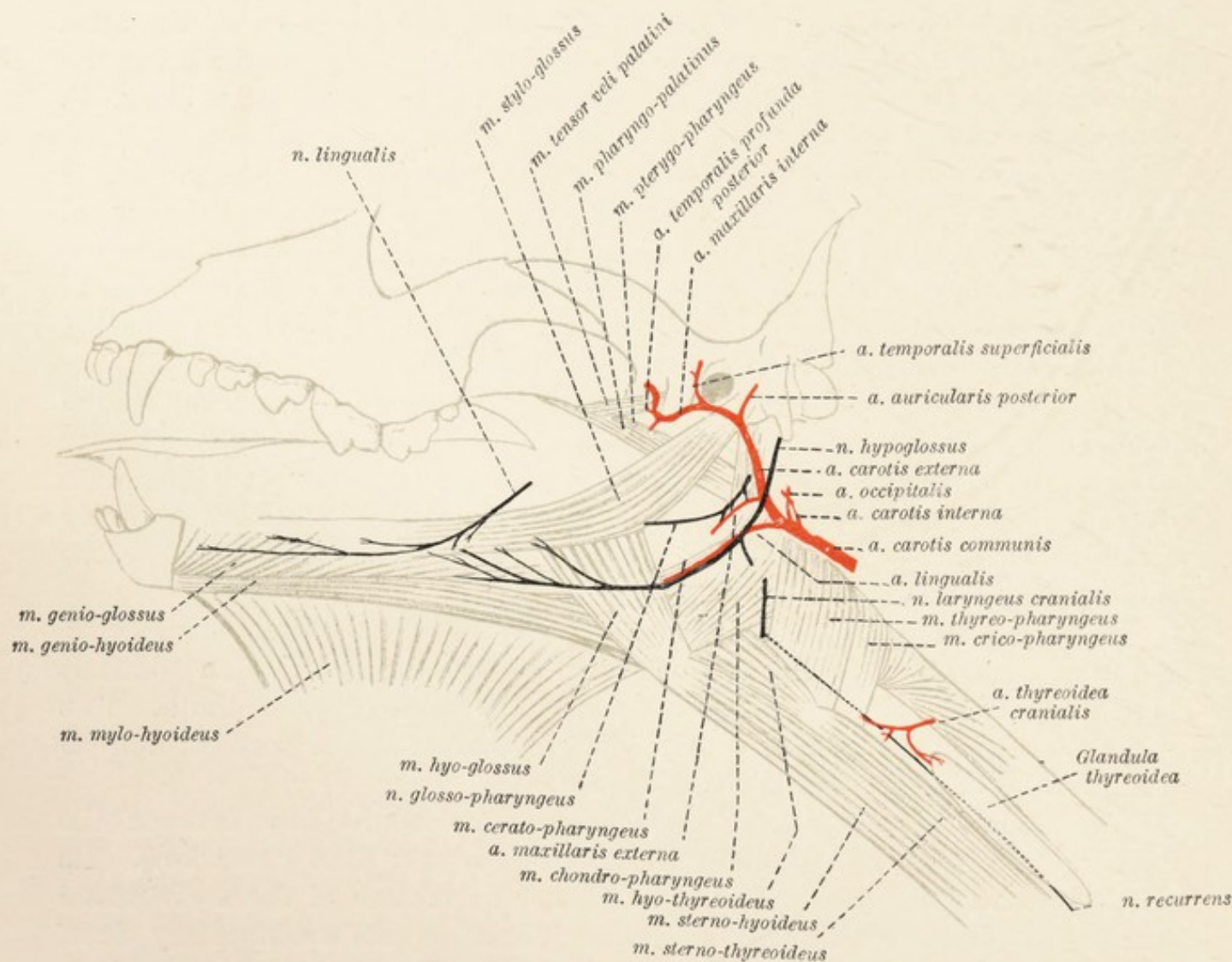


FIG. 57.—Dissection of the tongue, pharynx, etc.

tendinous origin from the point of union of the stylo-hyal with the temporal bone, and an insertion into the body of the hyoid bone.

M. STYLO-GLOSSUS.—Long and flat in form, the stylo-glossal muscle will be found medial to the digastric muscle and along the side of the tongue. Arising from the stylo-hyal bone, its fibres are lost in the substance of the tongue.

M. GENIO-GLOSSUS.—The right and left genio-glossal muscles are in contact with each other in the median plane of the head. The ventral border of each muscle extends from the symphysis of the mandible to the body of the hyoid bone, and from it the fibres radiate into the substance of the tongue.

A better opportunity for examining the hyoid attachment will be afforded at a later stage of the dissection.

M. HYO-GLOSSUS.—The hyo-glossal muscle is flat, and lies on the side of the base of the tongue, lateral to the genio-glossal and genio-hyoid muscles. Arising from the lateral surface of the thyro-hyal and the end of the body of the hyoid bone, its fibres run dorsalwards and towards the tip of the tongue, medial to those of the stylo-glossal muscle.

M. GENIO-HYOIDEUS.—The genio-hyoid muscle has its origin in the neighbourhood of the symphysis of the mandible, and its fibres run longitudinally to the body of the hyoid bone, into which they are inserted.

M. THYREO-HYOIDEUS.—The thyro-hyoid muscle springs from the thyro-hyal bone and is inserted to an oblique line on the lateral surface of the lamina of the thyroid cartilage.

N. LINGUALIS.—Since it is the largest branch, the lingual may be regarded as one of the terminals of the mandibular nerve. Its fibres reach the mucous membrane of the tongue by crossing the pterygoid muscles in the first place, and then the stylo-glossal muscle, the submaxillary and major sublingual ducts, and the oral portion of the sublingual gland. Laterally the nerve is covered by the mylo-hyoid muscle.

N. HYPOGLOSSUS.—After leaving the cranium by the hypoglossal foramen, the hypoglossal or twelfth cerebral nerve is connected for a distance with the accessory nerve. Medial to the origin of the digastric muscle, it crosses the external carotid artery laterally and comes into contact with the lingual artery. The nerve and the artery travel together as far as the border of the hyo-glossal muscle, where they part company for a time; the nerve continuing lateral to the muscle, the artery disappearing medial to it. Having passed the muscle, the two structures (as well as the lingual vein) once again come together and travel side by side towards the tip of the tongue.

The following are the branches of the hypoglossal nerve: (1) Filaments connecting the nerve with the pharyngeal plexus, the cranial cervical sympathetic ganglion, the plexus nodosus, and the pharyngeal branch of the vagus nerve; (2) a descending branch (*ramus descendens*) leaving the parent nerve immediately it has crossed the external carotid artery, to run obliquely over the pharynx and larynx and join the ventral branch of the first cervical nerve. Filaments are contributed to the thyro-hyoid, sterno-hyoid, and sterno-thyroid muscles; (3) terminal branches of the hypoglossal nerve supply all the muscles of the tongue.

A. CAROTIS COMMUNIS.—The common carotid artery terminates on a level with the thyroid cartilage by dividing into three vessels of unequal size, namely, the occipital, the internal carotid, and external carotid arteries. The occipital and internal carotid arteries are much smaller than the external carotid, which, from its size and the direction it takes during the first part of its course, appears to be the direct continuation of the common carotid.

A. CAROTIS EXTERNA.—The external carotid artery continues the direction of the common carotid for a short distance along the side of the pharynx, and then forms a curve round the medial and oral sides of the digastric, and between this and the stylo-glossal muscle. The curve brings the artery to a more superficial level, and it ends just aboral to the post-glenoid process of the temporal bone by dividing into the superficial temporal and internal maxillary arteries. At no great distance from its commencement, the external carotid artery is crossed laterally by the hypoglossal nerve. Its collateral branches are the lingual, external maxillary, and posterior auricular arteries.

A. LINGUALIS.—The lingual artery leaves the external carotid about the aboral border of the digastric muscle and pursues a course towards the side of the tongue, being accompanied by the hypoglossal nerve as far as the border of the hyo-glossal muscle. After crossing the medial face of this muscle, it enters the tongue in company with its satellite vein and the hypoglossal nerve. In order that the full course of the artery may be satisfactorily demonstrated, it is well to reflect the hyo-glossal muscle. The terminal branches of the artery are lost in the substance of the tongue. One collateral branch—the *hyoid branch* (ramus hyoideus)—should be noted as arising where the lingual artery crosses the hyoid bone, and terminating in the basal part of the tongue. The largest twig of the hyoid branch follows the genio-hyoid muscle towards the tip of the tongue.

It will be observed that the lingual vein ceases to accompany the artery about the aboral border of the hyo-glossal muscle, and becomes superficial in order to flow into the external maxillary vein.

A. MAXILLARIS EXTERNA.—As the external carotid artery crosses the hyoid bone, and as it lies between the digastric and stylo-glossal muscles, it gives origin to the external maxillary artery. Travelling along the dorsal and medial border of the digastric muscle, this vessel reaches the groove between the masseter and digastric muscles at the ventral border of the mandible, and here becomes the facial artery, the course of which has already been traced.

The collateral branches of the external maxillary artery are: (1) Arteries to the submaxillary and sublingual salivary glands; (2) branches to the digastric, stylo-glossal, and pterygoid muscles; (3) the *sublingual artery* (a. sublingualis), which follows the border of the digastric muscle, and then runs between the mylo-hyoid muscle and the mandible.

A. AURICULARIS POSTERIOR.—The great or posterior auricular artery leaves the external carotid close to the origin of the digastric muscle and between the muscle and the hyoid bone. The artery, as its name implies, is distributed over the aboral part of the ear, which it reaches by bending round the digastric muscle and running upwards under cover of the parotid gland.

The following branches should be observed: (1) One or more small vessels spread out over the sterno-cephalic and cleido-mastoid muscles and supply the parotid and submaxillary glands; (2) a branch of small size—the *stylo-mastoid*

artery (a. stylo-mastoidea)—enters the stylo-mastoid foramen of the temporal bone; (3) an anterior auricular branch supplies the front of the ear and anastomoses with the anterior auricular artery.

A. MAXILLARIS INTERNA.—From the circumstance that it passes through the alar canal of the sphenoid bone, the internal maxillary artery may be divided into two parts, namely, (1) a part before the canal is entered, and (2) a part after the canal has been traversed. The first portion of the artery is now exposed, and will be observed to take a curved course towards the median plane of the head, and in an oral direction, ventral to the mandibular articulation.

From the first part of the internal maxillary artery three important vessels arise: (1) The *inferior alveolar artery* (a. alveolaris inferior) crosses the external pterygoid muscle and enters the mandibular foramen. Within the bone this artery contributes twigs to the teeth, and the *mental artery* (a. mentalis), which leaves the bone by the mental foramen and assists in the supply of blood to the lower lip; (2) the *posterior deep temporal artery* (a. temporalis profunda posterior) leaves the internal maxillary about the same place as does the inferior alveolar, and curves round the oral side of the mandibular joint to reach the temporal fossa, where it is expended in the muscles therein contained. One of its branches accompanies the masseteric nerve through the mandibular notch; (3) just before the internal maxillary enters the alar canal it gives origin to the *middle meningeal artery* (a. meningea media), which at once enters the cranium by the oval foramen.

N. TEMPORALIS PROFUNDA.—The deep temporal nerve, a branch of the mandibular, accompanies the deep temporal artery into the temporal muscle.

Dissection.—Remove the remains of the digastric and pterygoid muscles. Sever the stylo-glossal muscle a short distance from its origin, and turn it down as far as possible. Cut through the stylo-hyal bone about its middle, and disarticulate its distal portion. Then carefully clean the structures lying in the neighbourhood of the base of the skull and the pharynx. The structures to be examined are a number of small muscles, the commencement of the extra-cranial course of the last four cerebral nerves, the ventral branch of the first spinal nerve, a part of the sympathetic nervous system, the occipital and internal carotid arteries, and the commencement of the internal jugular vein.

M. TENSOR VELI PALATINI.—The tensor muscle of the palatine velum, that is of the soft palate, lies medial to the pterygoid muscles. Arising from the muscular process of the temporal bone, the muscle becomes tendinous on the lateral face of the pterygoid and bends round the free border of this bone to end in the soft palate.

M. LEVATOR VELI PALATINI.—The levator of the palatine velum arises in

common with the tensor and crosses the medial surface of the pterygo-pharyngeal muscle to reach the soft palate.

M. PTERYGO-PHARYNGEUS.—The pterygo-pharyngeal muscle has its origin from the hamulus of the pterygoid bone, from which it passes in a caudal direction to reach the raphe of the pharynx.

M. PHARYNGO-PALATINUS.—Partly blended with the foregoing, the fibres of the pharyngo-palatine muscle stretch from the free border of the palatine bone to the pharynx.

M. JUGULO-HYOIDEUS.—If sufficient care be exercised, the very small jugulo-hyoid muscle may be discovered crossing the narrow interval between the jugular process of the occipital bone and the cartilaginous connection of the stylo-hyal with the temporal bone.

M. STYLO-PHARYNGEUS.—The stylo-pharyngeal muscle arises from the proximal part of the stylo-hyal bone, and terminates, under cover of the hyo-pharyngeal muscle, in the wall of the pharynx.

M. HYO-PHARYNGEUS.—The hyo-pharyngeal muscle consists of two parts, both of which end in the wall of the pharynx : (1) The more superficial part of the muscle (*m. chondro-pharyngeus*) is much the more extensive, and arises from the thyro-hyal bone and possibly also from the adjacent portion of the hypo-hyal ; (2) the deeper part of the muscle (*m. cerato-pharyngeus*) is in the form of a narrow band springing from the cerato-hyal bone.

M. THYREO-PHARYNGEUS.—The thyro-pharyngeal muscle passes from the oblique line on the lamina of the thyroid cartilage to the raphe of the pharynx.

M. CRICO-PHARYNGEUS.—Disposed in the same manner as the foregoing, the crico-pharyngeal muscle arises on the lateral surface of the cricoid cartilage.

M. CERATO-HYOIDEUS.—To display the cerato-hyoid muscle properly it is necessary to reflect the hyo-pharyngeal muscle. When this has been done a mass of muscular fibres will be found attached to the whole length of the thyro- and hypo-hyal bones and the adjacent part of the cerato-hyal.

N. GLOSSO-PHARYNGEUS.—The glosso-pharyngeal or ninth cerebral nerve leaves the cranium by the jugular foramen and soon divides into two branches : (1) The *lingual branch* (*ramus lingualis*) is much the larger, and, crossing the lateral surface of the stylo-pharyngeal muscle, passes between the stylo-glossal, stylo-pharyngeal, and hyo-pharyngeal muscles to reach the mucous membrane of the tongue ; (2) the *pharyngeal branch* (*ramus pharyngeus*) is much smaller and is joined by a twig from the superior pharyngeal branch of the vagus nerve.

N. VAGUS.—The vagus or tenth cerebral nerve comes out of the cranium by way of the jugular foramen in company with the glosso-pharyngeal and accessory nerves. Two ganglia augment the volume of the nerve at different points. The *jugular ganglion* (*ganglion jugulare*) is formed on the nerve while it is within the jugular foramen ; and the *nodose ganglion* (*ganglion nodosum*) when it has become free from the cranium. The latter ganglion is long and fusiform,

and lies alongside the cranial cervical sympathetic ganglion. It will be found on the surface of the ventral straight muscle of the head, and has the occipital and internal carotid arteries on its lateral surface.

The vagus nerve enters the neck by running beneath the wing of the atlas, and, immediately beyond the nodose ganglion, is joined by the sympathetic nerve-cord. The combined nerve has already been examined during the dissection of the neck.

The following branches leave the portion of the vagus nerve which is now under examination: (1) A small *auricular branch* (ramus auricularis) leaves either the jugular ganglion or its immediate neighbourhood and enters the facial canal of the temporal bone. (2) Two *pharyngeal branches* (rami pharyngei): (a) the first arises from the vagus between the jugular and the nodose ganglia, and, traversing the side of the pharynx, crosses the superior laryngeal nerve medially to end in the crico-thyroid muscle of the larynx. Close to its origin it contributes a twig to the second pharyngeal ramus. (b) The second ramus takes its main origin from the nodose ganglion, and is reinforced as just stated. The ramus passes over the surface of the thyro- and crico-pharyngeal muscles—to which it supplies twigs—joins the recurrent nerve and supplies the thyroid gland. (3) The *superior laryngeal nerve* (n. laryngeus superior) arises from the nodose ganglion, crosses the thyro-pharyngeal muscle and disappears into an interval between the hyo-pharyngeal, thyro-pharyngeal, and thyro-hyoid muscles. The termination of the nerve in the mucous membrane of the larynx, and its connection with the recurrent nerve, will be revealed during the dissection of the larynx. Branches from the superior laryngeal nerve pass to the adjacent sympathetic ganglion, to the first pharyngeal branch of the vagus, and to the hyo-pharyngeal muscle.

N. ACCESSORIUS.—Like the two preceding nerves, the accessory or eleventh cerebral nerve makes its exit from the cranium by the jugular foramen. The nerve crosses the surface of the ventral straight muscle of the head and then, after supplying the sterno-cephalic muscle, reaches the side of the neck, where it has already received attention. Branches connect it with the nodose plexus of the vagus and the adjacent sympathetic ganglion.

N. HYPOGLOSSUS.—The disposition, course, and distribution of the hypoglossal or twelfth cerebral nerve were considered earlier.

At the present stage of the dissection it is convenient to examine the ventral branch of the first spinal nerve, which runs alongside the vagus and accessory nerves for a short distance. It is connected with the sympathetic and vagus nerves, and also with the descending branch of the hypoglossal nerve.

GANGLION CERVICALE CRANIALE.—The more cranial ganglion of the cervical part of the sympathetic nervous system lies by the side of the nodose ganglion of the vagus nerve, where it is crossed by the occipital artery. The ganglion is elongated, fusiform, and greyish in colour, and from its caudal extremity proceeds a nerve-cord which soon becomes almost inseparably joined to the vagus.

A. OCCIPITALIS.—One of the two smaller terminal branches of the external carotid which arise about the aboral border of the digastric muscle, the occipital artery crosses the internal carotid artery, the superior laryngeal nerve, the nodose ganglion, and the cranial cervical sympathetic ganglion to reach the surface of the ventral straight muscle of the head, where it is crossed in its turn by the hypoglossal nerve.

In order to follow the further course of the artery, it is necessary to remove the remains of those muscles attached to the occipital bone which were dissected in connection with the neck.

In the neighbourhood of the jugular process of the occipital bone the artery makes a curve which brings it to a level with the lateral border of the process. This the vessel follows underneath the posterior straight muscles of the head, thus arriving at a groove between the two nuchal lines of the occipital bone.

During its course the occipital artery contributes several branches : (1) Numerous small twigs leave it close to its commencement and are expended in the wall of the pharynx and surrounding muscles ; (2) at a point before the occipital artery curves round the jugular process, the *condyloid artery* (a. condyloidea) takes origin. This vessel divides into several branches, some of which end in the anterior straight muscles of the head. One enters the jugular foramen, while another—which may be regarded as the main continuation of the parent artery—enters the condyloid foramen ; (3) while in the groove between the two nuchal lines of the occipital bone, the occipital artery gives origin to the *posterior meningeal artery* (a. meningea posterior), which at once enters the cranium by a neighbouring foramen ; (4) the *cerebro-spinal artery* (a. cerebro-spinalis) enters the vertebral canal by the intervertebral foramen of the atlas, and, joining a branch from the vertebral, forms the basilar artery of the brain.

A. CAROTIS INTERNA.—Like the occipital, the internal carotid artery is small. From its origin immediately aboral to that of the occipital artery, the internal carotid runs in a dorsal and oral direction within the occipital artery and the hypoglossal nerve and lateral to the superior laryngeal nerve and the nodose ganglion. After crossing the ventral straight muscle of the head, the artery enters the carotid canal and so gains the interior of the cranium.

V. JUGULARIS INTERNA.—In the region of the basilar part of the occipital bone, the internal jugular vein is formed by the union of the inferior cerebral, the occipital, and a number of small veins. By crossing the side of the pharynx the vein gains the ventral border of the common carotid artery and so travels down the neck.

Dissection.—Make a longitudinal incision close to the middle line through the wall of the pharynx and the soft palate.

PALATUM MOLLE.—In the dog the soft palate forms a long and broad

moveable partition between the mouth and the pharynx. One border is attached to the margin of the bony palate ; while the other border, which forms the dorsal boundary of the isthmus faucium (the opening from the mouth into the pharynx), is free, and, in a state of rest, is in contact with the epiglottis of the larynx. Of the two surfaces, the dorsal is continuous with the floor of the nasal cavity and is slightly convex. The ventral surface, which continues the hard palate, is correspondingly concave.

Prolongations of the mucous membrane of the soft palate pass to the tongue and the pharynx in the form of folds known as the *glosso-palatine* and *pharyngo-palatine arches* (arcus glosso-palatinus et arcus pharyngo-palatinus). The pharyngo-palatine arch really consists of two diverging folds, the more dorsal of which is the better developed and ends on the dorsal wall of the pharynx. The other fold of the arch passes to the epiglottis.

Between the glosso-palatine and pharyngo-palatine arches is a deep depression, the *tonsillar sinus* (sinus tonsillaris), bounded by prominent folds of mucous membrane, and containing the *palatine tonsil* (tonsilla palatina), an elongated eminence composed mainly of lymphoid tissue. Immediately dorsal to the tonsillar sinus there is a shallow *supratonsillar fossa* (fossa supratonsillaris).

Structurally the soft palate may be described as composed of four layers : (1) Mucous membrane continuous with that of the hard palate ; (2) a layer of glandular tissue, thickest towards the free border of the palate ; (3) an aponeurotic and muscular layer containing the pharyngo-palatine muscles and the muscles of the uvula ; (4) mucous membrane continuous with that of the nasal cavity. Naturally the mucous membrane on the two surfaces is continuous round the free border of the palate. The pharyngo-palatine muscle has already been examined.

M. UVULÆ.—The muscle of the uvula is a rounded strip running from the margin of the palatine bone to the free edge of the soft palate. The muscles of the two sides are close to each other and are generally blended at their termination.

MOUTH.—The mouth is the initial part of the alimentary canal and occupies the more ventral part of the face. Its cavity comprises two parts : (1) a *vestibule* (vestibulum oris) and (2) a *proper cavity* (cavum oris proprium).

The vestibule of the mouth consists of a narrow space between the lips and the cheeks on the one hand and the teeth and the gums on the other. The mucous membrane reflected from the lips and cheeks to the maxillary and mandibular bones forms its upper and lower boundaries. In front and to each side the vestibule communicates with the exterior by an elongated fissure-like opening (*rima oris*) between the lips. Communication between the mouth cavity proper and the vestibule is effected by irregular openings between the teeth of the opposed jaws and behind the last cheek-tooth. Into the vestibule, on each side, open the ducts of the parotid and buccal glands.

The mouth cavity proper is contained within the dental arches, by which, and the gums connected therewith, it is bounded in front and on each side. Behind, it communicates with the cavity of the pharynx through the *isthmus faucium*. The roof of the cavity is formed by the hard and soft palates, while the floor is formed by the tongue and the mucous membrane extending therefrom to the mandible. Into this part of the mouth open the ducts of the submaxillary and sublingual glands.

LABIA ORIS.—The two lips are not alike. In all dogs the upper lip is the better developed and the more moveable, and overhangs the lower lip. In some breeds the overlapping is considerable. The upper lip, moreover, is marked in the middle line by a deep, vertical groove, the *philtrum*; and in some breeds there is, in addition, a notch of greater or lesser depth indenting its free edge in the middle line.

Behind the level of the canine tooth the free margin of the lower lip is generally sharp and dentated.

Each lip may be regarded as containing four layers: (1) The outer surface is covered with skin provided with hair except over a small, triangular, median area of the upper lip. The hairs are of two kinds. The most numerous are variable in length—depending upon the breed—and relatively fine. Longer and stronger tactile hairs are fairly abundant on the upper lip, but more scanty on the lower; (2) a muscular layer composes the greater part of the entire thickness of each lip, and consists of a sphincter muscle (*m. orbicularis oris*) and the terminations of such other muscles as converge upon the oral fissure; (3) small collections of labial glands constitute an imperfect third layer; (4) the inside of each lip is clothed by mucous membrane continuous with that lining the rest of the mouth cavity. In the median plane the mucous membrane is raised into a small fold, the *frænulum of the lip* (*frænulum labii*). Skin and mucous membrane meet at the margin of the lips.

BUCCÆ.—The cheeks, which form the lateral boundary of the mouth cavity, have the same general structure as the lips. The glands (*glandulæ buccales*) are arranged in two groups—an upper and a lower. The former group is considerable in volume and disposed below the orbit, where it will be examined at a later period. The lower glands, less voluminous and more diffuse, extend along the cheek in a line with the alveolar border of the mandible, and are continuous with the glands of the lower lip.

Each cheek is pierced by the parotid duct, which opens into the mouth on the summit of a low elevation, the *salivary papilla* (*papilla salivalis*), about the level of the third maxillary cheek-tooth. The ducts of the buccal glands also open on the surface of the mucous membrane.

DENTES.—A tooth consists of a *crown* (*corona dentis*) visible above the gum, a *neck* (*collum dentis*) embraced by the gum, and a *root* or *roots* (*radix [radices] dentis*) embedded in the bony tooth cavity (*alveolus dentalis*). The crown of the tooth has a chewing surface (*facies masticatoria*), a surface covered

by the lips or cheek (*facies labialis*, *facies buccalis*), and a surface looking towards the tongue (*facies lingualis*). Generally a tooth touches its neighbour by a surface of contact (*facies contactus*). All except old teeth contain a cavity (*cavum dentis*) entered by an opening at the apex of the root (*foramen apicis dentis*) and containing the tooth pulp (*pulpa dentis*).

With the naked eye it is possible to distinguish three tissues forming a tooth. *Dentine* (*substantia eburnea*) constitutes the greater part of the structure. *Enamel* (*substantia adamantina*) forms a porcelain-like white cap covering the crown; and *cement* (*substantia ossea*), a bone-like tissue, covers the roots and possibly also parts of the crown.

Teeth are classified from before to behind as *incisors* (*dentes incisivi*), *canines* (*dentes canini*), *premolars* (*dentes præmolares*), and *molars* (*dentes molares*). When complete, the dentition of the adult dog comprises forty-two permanent teeth (*dentes permanentes*), of which twelve are incisors, four canines, sixteen premolars, and ten molars. The permanent dental formula of the dog is $\frac{3}{3} \frac{1}{1} \frac{4}{4} \frac{2}{3}$, from which it is evident that the upper and lower rows of teeth are not numerically equal. Each maxillary bone carries only two molars, whereas each half of the mandible has three.

The incisor teeth are placed close together and increase in size from the first to the third. The mandibular teeth are smaller than those in the incisive bones. The crown of each incisor presents three projections, and on the lingual surface there is a curved ridge, the *cingulum*, close to the neck.

The canine teeth are large, with conical, curved crowns. A *cingulum* is present, as it is on all the teeth. The upper tooth is separated by a gap from the third incisor, and a similar interval separates the lower canine from the first premolar. These gaps receive the opposed tooth when the mouth is closed.

The premolar teeth increase in size from the first to the last. The first is small and has only one root. The second and third in the maxilla, and the second, third, and fourth in the mandible have two roots. The last premolar in the maxilla is much larger than the others and has three roots. It is distinguished by the name of *sectorial* or *carnassial* tooth.

The two molar teeth in the maxilla have broad, irregularly triangular and tubercular chewing surfaces, and each has three roots. The second tooth is much the smaller.

The first mandibular molar is much larger than its neighbours and forms the sectorial tooth of the lower row. Its crown is similar to that of the last upper premolar. The second and third mandibular molars have tubercular chewing surfaces, and the third is smaller than the second. The first and second molars have two roots, but the last has only one.

PALATUM DURUM.—The hard palate consists of a dense mucous membrane, with a very vascular deep layer, attached to the periosteum of the palatine, maxillary, and incisive bones. An indifferently marked median, longitudinal

raphe, which ends in front at a four-sided *incisor papilla* (papilla incisiva), divides the surface into two lateral halves. Each half is raised into some nine or ten curved transverse *palatine folds* (plicæ palatinæ transversæ), each with its convexity turned forwards. The whole surface is covered with small, low, blunt papillæ.

FLOOR OF THE MOUTH.—When at rest, the tongue forms the floor of the proper mouth cavity, but the term 'floor of the mouth' is commonly used to express a narrow area exposed when the tongue is raised.

Continuation of the mucous membrane from the inner surface of the mandible to the tongue results in a degree of fixation of the greater part of this organ. In the anterior part of the mouth, however, the disposition of the mucous membrane permits of a greater amount of freedom. If the free portion of the tongue be raised, a prominent median fold of mucous membrane, the *frænulum of the tongue* (frænulum linguæ), is disclosed, as is also the rudimentary, flattened elevation, the *sublingual caruncle* (carunculus sublingualis), on which open the ducts of the submaxillary and aboral sublingual salivary glands. In the narrow groove between the tongue and the mandible are the openings of the smaller sublingual ducts.

LINGUA.—The tongue is an organ concerned in mastication, deglutition, and taste, and consists mainly of a mass of muscular tissue partially covered with mucous membrane. In its anterior half the tongue is very decidedly flattened, but posteriorly it is so thickened that a transverse section presents a triangular outline. The broadest part of the organ is within a short distance of the anterior extremity—roughly on a level with the first maxillary premolar tooth. The main mass of the tongue is known as the *body* (corpus linguæ); the *tip* (apex linguæ) is the blunt free extremity; and the *root* (radix linguæ) is that part which is attached to the hyoid bone and the mandible.

Dorsum linguæ.—The term dorsum is applied to that surface of the tongue which, when the organ is at rest, is in contact with the hard and soft palates. The dorsum is divided longitudinally into two lateral halves by a groove (sulcus medianus linguæ), shallow towards the tip, but becoming much deeper as it proceeds backwards. The whole of the dorsum is thickly studded with elevations of the mucous membrane, the *lingual papillæ* (papillæ linguales), of which five kinds can be distinguished, namely, filiform, conical, fungiform, vallate, and foliate.

The *filiform papillæ* (papillæ filiformes) are much the most numerous and occupy the greater part of the dorsum. In the anterior half of the tongue they are small, but posteriorly they become larger and finally merge into the next group. The *conical papillæ* (papillæ conicæ) are arranged in rows—as, indeed, are all the lingual papillæ—running backwards and towards the median groove. Each elevation is sharply pointed and directed backwards. It will be noted that the conical papillæ are continued somewhat beyond the posterior limits of the tongue.

The *fungiform papillæ* (papillæ fungiformes), though less numerous, are distributed over the same area as the filiform papillæ, but do not occur among the conical papillæ in the most posterior part of the dorsum. They can be distinguished readily by their rounded form and pale colour.

The *vallate papillæ* (papillæ vallatæ) are generally four in number, two on each side of the median sulcus, arranged along a V-shaped line, the point of the V being directed backwards. Their position is about the line of transition of filiform into conical papillæ. Each vallate papilla is large, with a slightly constricted base and a flattened crown which reaches somewhat above the general level of the mucous membrane. Around a papilla is a circular fossa with an outer wall, known as the *vallum*, slightly raised above the surrounding level.

The *foliate papillæ* (papillæ foliatæ) are two in number. One occurs on each side immediately in front of the point of attachment of the glosso-palatine arch to the tongue, and has the form of an oval area crossed transversely by six to eight ridge-like elevations.

The mucous membrane of the tongue is continuous with that lining the interior of the mouth generally. Over the dorsum it is thick, dense, covered with papillæ, and firmly adherent to the underlying fibrous and muscular tissue. Beneath the tongue it is much thinner, smooth, and not so adherent to the subjacent tissues. Posteriorly the *glosso-epiglottic fold* (plica glosso-epiglottica) connects the tongue and epiglottis. On each side of the fold is a depression known as the *epiglottic vallecula*.

MUSCULI LINGUÆ.—The muscular tissue of the tongue is divisible into that which belongs to extrinsic muscles and that which is intrinsic to the tongue itself. The extrinsic muscles—stylo-glossal, hyo-glossal, and genio-glossal—were examined earlier in the dissection. The intrinsic muscular fibres are longitudinal, transverse, and vertical in direction.

In the dog a thin layer of loose connective tissue in the median plane and separating the muscles of the two halves of the organ, is all that represents the *lingual septum* (septum linguæ).

If the mucous membrane immediately underneath the tip of the tongue be incised longitudinally, an elongated condensation of fibrous tissue, the *lyssa*, will be disclosed.

PHARYNX.—The pharynx is a muscular and membranous tube succeeding the mouth and reaching from the level of the mandibular articulation to about the joint between the atlas and epistropheus when the head is extended. Functionally the pharynx belongs to the respiratory as well as the digestive system, since through it pass both air and food. Dissection of the wall of the tube reveals three layers, namely, a layer of muscular tissue, an aponeurotic layer, and a lining of mucous membrane. The muscles of the pharynx have already been considered, and it will have been noticed that the majority of them are so disposed as to act as constrictors of the cavity. The aponeurotic layer, the submucous tela, is intimately connected with the muscles, and

gives attachment to some of their fibres. It is continuous with the periosteum covering the bones of the base of the skull and with the other connections of the pharynx.

The mucous membrane of the pharynx is moderately thick and contains collections of lymphoid tissue. In the dorsal part of the tube it is redder in colour and somewhat softer than in the more ventral and caudal portion. The junction of the pharynx with the œsophagus is well defined by a transverse mucous fold.

The *cavity of the pharynx* (cavum pharyngis) is divisible into dorsal and ventral portions. The dorsal part communicates with the nasal cavities by the posterior nares, and is co-extensive with the soft palate. It is respiratory only. The ventral part of the cavity is both respiratory and alimentary in function, inasmuch as it communicates with the mouth and nose in the one direction, and with the œsophagus and larynx in the other.

In the cavity seven openings must be sought. Of these, the opening from the mouth, the opening into the larynx, and the continuation of the cavity into the œsophagus, are single and median. Two paired openings, namely, from the nasal chambers and from the Eustachian tubes, are present in the dorsal part of the cavity.

TUBA AUDITIVA [EUSTACHII].—The auditive or Eustachian tube is a short passage leading from the middle ear to the dorsal or nasal part of the pharyngeal cavity. It should be looked for medial to the tensor muscle of the soft palate. That part of the tube which is nearest the middle ear has a bony wall formed by the temporal bone, and opens into the ear by the *tympanic opening* (ostium tympanicum). The remainder, and greater part, of the tube is provided with a cartilaginous medial and a membranous lateral wall. The pharyngeal end of the cartilage produces a ridge-like projection of the mucous membrane of the pharynx, medial to which the *pharyngeal opening* (ostium pharyngeum) of the tube will be found.

Dissection.—The tongue, the pharynx, and the larynx should now be removed, in order that an examination of the last named may be proceeded with.

LARYNX.—The larynx is a tubular organ situated behind the root of the tongue and ventral to the pharynx. On each side and ventrally it is related to the constrictor muscles of the pharynx and to the thyro-hyoid, sterno-thyroid, and sterno-hyoid muscles. The organ is provided with a skeleton of cartilages, upon which muscles act in such a way as to cause variations in the character of the interior. The interior itself is lined by mucous membrane continuous, on the one hand, with that of the pharynx, and, on the other, with the lining of the trachea or windpipe.

It would be well that the student procure a set of disarticulated laryngeal cartilages in order that he may familiarise himself with their peculiarities before commencing the actual dissection of the organ. Seeing that it is well-nigh impossible to obtain an intelligent grasp of the arrangement of the muscles, etc., without knowing something of the parts with which they are connected, an account of the laryngeal cartilages is given here instead of later.

CARTILAGINES LARYNGIS.—The larynx of the dog contains three single cartilages—thyroid, cricoid, and epiglottis; and three paired—arytenoid, corniculate, and cuneiform.

Cartilago thyreoidea.—The thyroid cartilage is the largest and consists of two laminae meeting and fusing in the mid-ventral line at the *laryngeal prominence* (prominentia laryngea). The dorsal border of each lamina terminates in two projections or *cornua*, the oral of which (cornu craniale) is connected with the thyro-hyal bone, while the aboral (cornu caudale) articulates with the cricoid cartilage.

The oral border of the two laminae is connected with the hyoid bone by the *hyo-thyroid ligament* (ligamentum hyo-thyreoideum). Aborally the laminae bound a notch (incisura thyreoidea caudale) and are joined to the cricoid cartilage by the *crico-thyroid ligament* (ligamentum crico-thyreoideum). The lateral surface is crossed by a faint *oblique line* (linea obliqua) to which the sterno-thyroid and thyro-hyoid muscles are inserted.

Cartilago cricoidea.—The cricoid cartilage is placed aboral to the thyroid, by the laminae of which it is partially covered laterally. In form it has some resemblance to a signet ring, and may be divided into a ventral *arch* and a broader dorsal portion or *lamina*. In the middle line of the oral border there is a shallow notch, and on each side of this an oval, convex facet for articulation with an arytenoid cartilage (facies articularis arytenoidea). On the dorsal surface of the lamina there is a median ridge.

Cartilagines arytenoideae.—Resting on the oral border of the lamina of the cricoid cartilage are the two irregularly pyramidal arytenoid cartilages. The apex of each is directed oralwards and is continued by a curved piece of elastic structure which constitutes the *corniculate cartilage* (cartilago corniculata). The base of the arytenoid cartilage has a prominent ventral angle, the *vocal process* (processus vocalis) to which the vocal fold is attached, and a lateral angle, the *muscular process* (processus muscularis), on which certain muscles terminate. A small, nodular *interarytenoid cartilage* lies over the narrow gap between the two arytenoid cartilages.

Cartilago epiglottica.—The epiglottis is a four-sided plate of elastic cartilage connected with the thyroid by a narrow stem (petiolus epiglottidis). The oral angle of the plate is free and projects towards the base of the tongue; while the lateral angles form marked projections connected, by means of folds of mucous membrane, with the cuneiform cartilages. Of the two surfaces the dorsal is entirely free and covered by mucous membrane. The ventral

surface also is largely free, but gives attachment to the glosso-epiglottic fold of mucous membrane and the hyo-epiglottic muscle.

Cartilaginee cuneiformes.—The cuneiform cartilages are relatively large and of an irregularly triangular outline. The laterally flattened base of each is intimately associated with a corniculate cartilage, while the apex forms an elongated curved projection.

CAVUM LARYNGIS.—If the interior of the cavity of the larynx be regarded it will be observed that its lumen is constricted opposite two lateral folds of mucous membrane. These are known as the *vocal folds* (plicæ vocales) and form sharp and prominent ridges running from the angle of convergence of the two thyroid laminae to the vocal processes of the arytenoid cartilages. The folds are close together at their ventral ends, but diverge dorsally. The interval between the folds is known as the intermembranous part (pars intermembranacea) of the *glottis* (rima glottidis): its continuation between the arytenoid cartilages being the intercartilaginous part (pars intercartilaginea) of the glottis. Immediately lateral to each vocal fold there is a slit-like depression, the *ventricle of the larynx* (ventriculus laryngis). The depression or opening has two lips, of which one is formed by the vocal fold; the other by a very inconspicuous *ventricular fold* (plica ventricularis).

Oral to the vocal folds the cavity of the larynx is more spacious and is distinguished as the *vestibule* (vestibulum laryngis). Its boundaries are formed mainly by the epiglottic and arytenoid cartilages and the folds of mucous membrane which connect them with each other.

The entrance to the vestibule from the pharynx should receive attention. The prominent epiglottis, which forms the anterior boundary of the entrance, is connected with the tongue by the glosso-epiglottic fold of mucous membrane, to the side of which is the *epiglottic vallecula*, a deep and somewhat triangular depression. Joining the lateral angles of the epiglottis to the apices of the arytenoid and corniculate cartilages are the two *ary-epiglottic folds*. Each of these may be considered as divided into two parts. The first part is prominent and transverse in direction, passing from the epiglottis to the cuneiform cartilage, which forms a distinct projection. Then follows a much more feeble part, sagittal in direction, and running from the cuneiform to the corniculate cartilage. Between the ary-epiglottic fold and the lamina of the thyroid cartilage is a rather shallow *pyriform sinus*.

Beyond the vocal folds the cavity of the larynx is roomy, somewhat compressed laterally, and directly continuous with the lumen of the trachea.

The mucous membrane (tunica mucosa laryngis) lining the cavity of the larynx is continuous in one direction with that of the pharynx, and in the other with the mucous membrane of the trachea. It is firmly adherent to the dorsal surface of the epiglottis, and very thin over the vocal folds.

Dissection.—Remove the remains of the pharyngeal, the sterno-hyoid,

sterno-thyroid, and thyro-hyoid muscles. Take care to preserve the laryngeal nerves and vessels. Now examine the structures on the ventral aspect of the larynx.

LIGAMENTUM HYO-THYREOIDEUM.—The connection of the hyoid bone and the thyroid cartilage is established by a continuity of the extremities of the thyro-hyals with the oral thyroid cornua, and by the presence of a membranous hyo-thyroid ligament. This ligament, which fills the gap between the hyoid bone and the thyroid cartilage, is attached on the one hand to the body and thyroid processes of the hyoid bone, and on the other to the oral border of the thyroid laminae. Strongest in the middle line, it becomes thinner laterally where it is pierced by the superior laryngeal nerve.

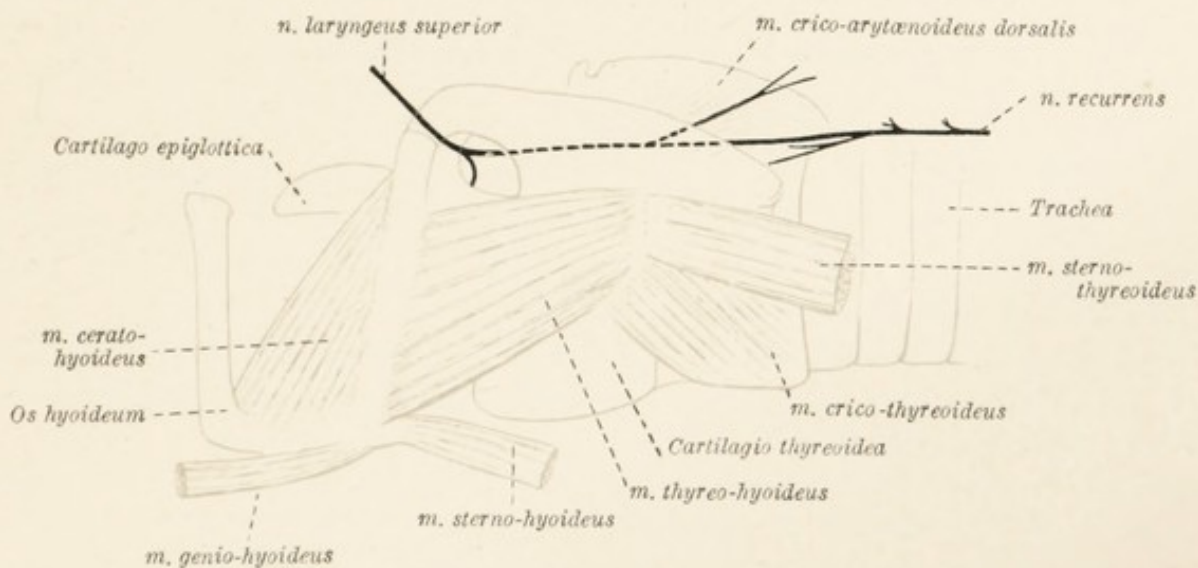


FIG. 58.—Dissection of the larynx.

M. CRICO-THYREOIDEUS.—The crico-thyroid muscle lies on the side of the cricoid arch, from the aboral border and the lateral surface of which it takes its origin. The insertion of the muscle is into the aboral border and immediately adjacent parts of both surfaces of the lamina as well as the aboral cornu of the thyroid cartilage.

LIGAMENTUM CRICO-THYREOIDEUM.—In the triangular gap between the two crico-thyroid muscles a strong ligamentous band, the crico-thyroid ligament, will be observed. The broader end of the ligament is attached to the margins of the shallow caudal thyroid notch, while the narrower end is fixed to the mid-ventral part of the cricoid cartilage. Laterally the ligament is continuous with a thin membrane which will be exposed later.

The articulation between the thyroid cornu and the cricoid cartilage should be looked at now, but its complete examination may be deferred until the dissection of the larynx nears completion. The joint is a diarthrosis provided with the usual joint-capsule attached round the articular margins of the two cartilages.

Dissection.—Now turn to the dorsal part of the larynx. Remove the mucous membrane from the cricoid, arytenoid, and corniculate cartilages, taking care not to destroy the superior laryngeal and recurrent nerves and the connection between them. The origin of the longitudinal muscular fibres of the œsophagus from the median ridge of the cricoid lamina will be noted. The dorsal layer of the ary-epiglottic fold should be removed. Define the dorsal crico-arytenoid and arytenoid muscles.

M. CRICO-ARYTÆNOIDEUS DORSALIS.—The dorsal crico-arytenoid muscle arises from the dorsal surface and median ridge of the lamina of the cricoid cartilage. From this extensive origin the muscular fibres converge and are

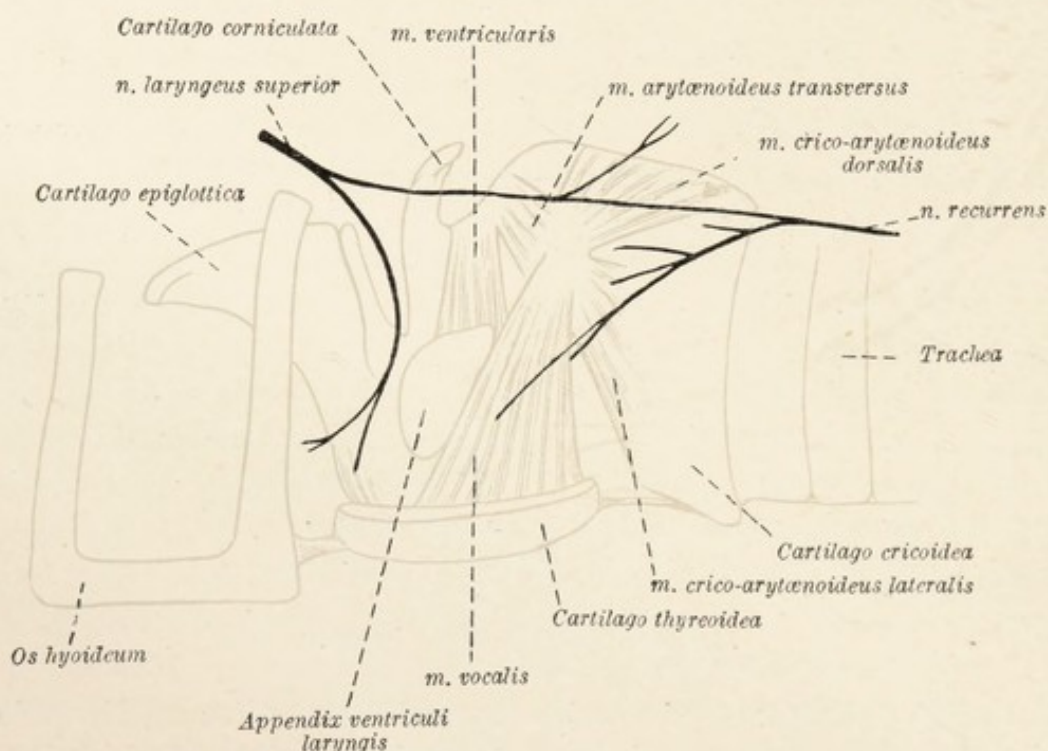


FIG. 59.—Dissection of the larynx after removal of the lamina of the thyroid cartilage.

inserted into the muscular process of the arytenoid cartilage. It follows that all the fibres will not possess a like degree of obliquity, nor will they all be of the same length. The more oral are the most nearly transverse and are shortest; the aboral fibres are longest and most nearly longitudinal; whereas the intermediate fibres are oblique.

M. ARYTÆNOIDEUS.—The arytenoid muscle of the dog is neither very well developed nor very distinct. Its fibres arise from the arytenoid cartilage in the region of the muscular process, and are inserted, along with the bulk of the ventricular muscle, into the inter-arytenoid cartilage. Thus the cartilaginous nodule forms a connection between the muscles of the two sides.

Dissection.—The dissection of the remaining muscles should be confined, for the time being, to one side of the larynx; the other side being reserved

for later examination. Sever the union of one thyroid cornu with the hyoid bone, and cut through the hyo-thyroid ligament on the same side as far as the middle line. Disarticulate the aboral thyroid cornu from the cricoid cartilage and make a longitudinal incision through the thyroid lamina a little distance from the middle line. Cut across the crico-thyroid muscle. Now carefully remove the isolated piece of thyroid cartilage. Clean the three muscles thus exposed to view, and define the appendix of the laryngeal ventricle.

M. CRICO-ARYTÆNOIDEUS LATERALIS.—The lateral crico-arytenoid muscle is much smaller than the dorsal muscle of the same name. Triangular in form, its origin is from the oral border of the arch of the cricoid, and its insertion into the muscular process of the arytenoid cartilage.

M. VOCALIS.—Running parallel to the vocal fold is the thick vocal muscle. The fibres composing it arise from the medial surface of the thyroid lamina close to the middle line, and from the strong crico-thyroid ligament. They are inserted into the muscular process and lateral surface of the arytenoid cartilage, some of them being apparently continuous with the dorsal crico-arytenoid muscle.

M. VENTRICULARIS.—The ventricular muscle is oral to and shorter than the preceding. The fibres of the muscle pass from the broad basal part of the cuneiform cartilage to the arytenoid and inter-arytenoid cartilages.

If the vocal muscle be released from its thyroid attachment and turned aside, a thin membrane connected with the oral border of the cricoid cartilage will be exposed. The membrane ventrally is continuous with the crico-thyroid ligament, and dorsally reaches the vocal process of the arytenoid cartilage. Its oral border joins the *vocal ligament* (ligamentum vocale), a definite band stretching from the angle of union of the laminae of the thyroid cartilage to the vocal process of the arytenoid cartilage. The vocal ligaments are covered by the vocal folds of mucous membrane already examined in connection with the interior of the larynx; and, like the folds, are close together at their ventral ends, but diverge towards their arytenoid attachments.

APPENDIX VENTRICULI LARYNGIS.—The appendix of the laryngeal ventricle is a spacious blind diverticulum which will be found oral to the vocal ligament, and between the thyroid lamina and the vocal muscle laterally and the cuneiform and arytenoid cartilages and the ventricular muscle medially. The appendix generally extends as far as the oral border of the thyroid lamina.

Dissection.—An examination may now be made of the lateral wall of the cavity of the larynx. This is rendered easier by the removal of that part of the ary-epiglottic fold which joins the cuneiform cartilage to the epiglottis.

The ventricle of the larynx can best be studied at this stage of the dissection.

It is an elongated depression, bounded aborally by the vocal fold and

orally by the ventricular fold and the base of the cuneiform cartilage. The ventricular fold forms only a short ventral segment of the oral boundary; or, in other words, it forms a boundary to the entrance to the appendix of the ventricle. It should be noted that the fold has, as a basis, a fibrous band, the *ventricular ligament* (lig. ventriculare), reaching from the basal part of the cuneiform cartilage to the thyroid and epiglottis. If the glosso-epiglottic fold of mucous membrane be removed, the underlying hyo-epiglottic muscle will be revealed. At the same time the hyoid attachment of the genio-glossal muscle will be made more clear than was previously possible.

M. HYO-EPIGLOTTICUS.—The two hyo-epiglottic muscles arise independently from the body of the hyoid bone, but blend as they proceed towards their insertion, by a common tendon, into the middle line of the lingual surface of the epiglottis.

Dissection.—Clean up the nerves and vessels on the intact side of the larynx.

The nerves are the superior laryngeal and the recurrent. The former pierces the hyo-thyroid ligament close to the oral thyroid cornu in company with the superior laryngeal vessels. The recurrent nerve runs up the neck along the dorsal border of the trachea.

Dissection.—Strip the mucous membrane from the interior of the larynx, and remove the remains of the muscles. Care must be exercised in the removal of the membrane from the epiglottis, cuneiform and corniculate cartilages, as these are fairly readily torn. The description of the various cartilages, already given, should be again gone over.

The connections of some of the cartilages have been described as the dissection proceeded, but there still remains to be discussed the attachment of the epiglottis to the thyroid, the articulation between the arytenoid and cricoid cartilages, and the union of the two arytenoids.

The petiolus of the epiglottis is attached to the thyroid cartilage by the *thyro-epiglottic ligament* (lig. thyreo-epiglotticus), which, in conjunction with the elasticity of the epiglottis itself, allows of free movement.

Now that the restraining muscles have been removed, it is easy to demonstrate that the movement between the thyroid cornua and the cricoid cartilage is mainly rotatory about a transverse axis running between the two joints.

The crico-arytenoid joint is also diarthrodial, enclosed in the customary joint-capsule. Movements are gliding in various directions, and rotatory about a longitudinal axis.

The two arytenoid cartilages are united by fibrous tissue, which is sufficiently loose to allow of the necessary rotation in the crico-arytenoid joint.

Dissection.—The dissector should now turn to those muscles which lie ventral to the thoracic and cervical vertebræ.

M. LONGUS COLLI.—This composite muscle, the long muscle of the neck, stretches from the sixth or seventh thoracic vertebra to the atlas. It is decidedly complicated in the arrangement of the numerous bundles which compose it, and may be divided, for convenience of description, into thoracic and cervical portions. The distinction of the two parts is readily made; for, though all the bundles of fibres pass in a cranial direction, those of the thoracic portion slope lateralwards, while those of the cervical portion incline towards the median plane.

The bundles of the thoracic part arise from the ventral aspect of the bodies of the first six or seven thoracic vertebræ, and are inserted into the transverse processes of the last two cervical vertebræ. The fibres of the cervical part spring from the transverse processes of the cervical vertebræ from the sixth or seventh to the third, and are inserted into the ventral ridge of the vertebræ and the ventral tubercle of the atlas.

M. LONGUS CAPITIS.—The long muscle of the head arises from the transverse processes of the cervical vertebræ from the sixth to the second, and also occasionally from the lateral part of the aboral border of the wing of the atlas. From this diffuse origin the fibres are gathered together and inserted into the ventral surface of the basilar part of the occipital bone.

M. RECTUS CAPITIS VENTRALIS.—The small ventral straight muscle of the head lies dorsal to the foregoing, which should be reflected by making a transverse incision on a level with the joint between the atlas and the occipital bone. The origin of the straight muscle is from the ventral surface of the atlas, and its insertion is into a depression on the occipital bone immediately aboral to the insertion of the preceding muscle.

M. RECTUS CAPITIS LATERALIS.—Of about the same size as, and parallel to, the ventral muscle, the lateral straight muscle of the head springs from the ventral surface of the wing of the atlas, and is inserted into the jugular process of the occipital bone. The occipital artery curves round its insertion.

Dissection.—An examination of the pterygoid muscles and associated structures should now be made on that side of the head on which the mandible has been left intact.

M. PTERYGOIDEUS INTERNUS.—The internal pterygoid muscle forms a considerable mass, the fibres of which pass from the pterygoid, palatine, and sphenoid bones to the medial surface of the mandible ventral to the mandibular foramen. At its insertion it is partly confused with the masseter muscle.

Dissection.—The internal pterygoid muscle should be removed in order that the external muscle of the same name may be examined. By this

dissection the termination of the mandibular nerve, with its inferior alveolar, lingual, and mylo-hyoid branches, will be displayed from the inside. At the same time the dissector will note a part of the internal maxillary artery and its inferior alveolar branch.

M. PTERYGOIDEUS EXTERNUS.—The external pterygoid muscle, much smaller than the internal muscle of the same name, takes origin from a fossa on the lateral face of the pterygoid and palatine bones, and is inserted into a rough area on the medial surface of the mandible ventral to the condyloid process.

Dissection.—Remove as much as possible of the zygomatic bone without injuring the orbit, and open up the infraorbital canal. The full extent of the zygomatic gland will be exposed.

GLANDULA ZYGOMATICA.—The distinctly lobulated zygomatic gland lies under cover of the oral end of the zygomatic arch. Its deep face is in contact with the pterygoid muscles, the periorbita, the internal maxillary artery, and the maxillary nerve. The main duct of the gland is of some size and opens into the mouth near the last molar tooth. In addition, there are generally several smaller but inconstant ducts.

The gland must be removed in order to allow of the examination of the internal maxillary artery and the maxillary nerve.

A. MAXILLARIS INTERNA.—As previously stated, the passage of the internal maxillary artery through the alar canal permits of its division into two parts. That part of the vessel which occurs before its entrance into the canal has already been examined. The second part, that is to say the part after the artery has traversed the canal, now falls to be discussed.

From the oral end of the canal the internal maxillary artery pursues a course over the surface of the pterygoid muscles in company with the maxillary nerve. The temporal muscle and the zygomatic gland form its lateral relations. Having arrived close to the entrance to the infraorbital canal, the vessel divides into the infraorbital artery and a common stem from which the sphenopalatine and greater palatine arteries arise.

The following branches leave the second part of the internal maxillary artery: (1) The *ophthalmic artery* (a. ophthalmica) leaves the parent vessel immediately this emerges from the alar canal. A short length of the artery may now be disclosed between the temporal muscle and the periorbita, but its further examination should be deferred. (2) The *buccinator artery* (a. buccinatoria) accompanies the buccinator nerve across the pterygoid muscles towards the last molar tooth, and ends in the component parts of the cheek. (3) The *lesser palatine artery* (a. palatina minor) crosses the pterygoid muscle, to which it supplies one or more branches, and ends in the soft palate. Small twigs also go to the hard palate. (4) The *infraorbital artery* (a. infraorbitalis)

traverses the infraorbital canal, during which it supplies vessels to the teeth, and ends on the face as the dorsal and lateral nasal arteries. (5) Generally arising from a stem which also gives origin to the spheno-palatine, the *greater palatine artery* (a. palatina major) runs along the palatine canal into the hard palate. Here it is continued towards the incisor teeth, behind which it ends by anastomosing, in the form of an arch, with its fellow. Twigs anastomose with branches of the lesser palatine vessel, and a branch of some size passes through the palatine fissure into the nose. (6) The *spheno-palatine artery* (a. spheno-palatina) at once enters the nasal cavity by way of the spheno-palatine foramen. As will be seen later, the main branches of the artery ramify on the lateral wall of the nasal cavity, while smaller branches supply the mucous membrane of the ethmoidal cells and the nasal septum.

N. MAXILLARIS.—The maxillary nerve—a division of the fifth cerebral nerve—leaves the cranium by the foramen rotundum and accompanies the second part of the internal maxillary artery across the pterygoid muscles. The nerve is medial and somewhat dorsal to the artery.

The following are the branches of the maxillary nerve: (1) The *lacrimal nerve* (n. lacrimalis) and (2) the *zygomatic nerve* (n. zygomaticus) leave the stem of the maxillary at its exit from the foramen rotundum, and soon pierce the periorbita. Their terminal filaments were examined in connection with the face. The middle part of their course will be disclosed during the dissection of the contents of the orbit. (3) The largest branches of the maxillary nerve are the two *infraorbital nerves* (nn. infraorbitales). These accompany the artery of the same name along the infraorbital canal. Immediately on their emergence from the canal, they divide into several large branches, which, after further division, arrange themselves in a dorsal and a ventral group. (4) The dorsal nerves—the *external nasal branches* (rami nasales externi)—spread out over the side of the nose. (5) The ventral and larger nerves—the *superior labial branches* (rami labiales superiores)—supply the upper lip, and more particularly the tactile hairs thereof. While within the infraorbital canal, the more ventral infraorbital nerve contributes filaments to the teeth, the *dental branches* (rami dentales). (6) The *spheno-palatine nerve* (n. spheno-palatinus). The dissection of this nerve and its branches is facilitated by the extraction of the last two cheek teeth and the removal of the lateral wall of their alveoli. The spheno-palatine nerve, as such, has only a short course, inasmuch as it soon divides into three parts, the lesser palatine and the greater palatine nerves, and nasal branches: (a) The *lesser palatine nerve* (n. palatinus minor) accompanies the artery of the same name into the soft palate; (b) the *greater palatine nerve* (n. palatinus major) also follows the vessel of the same name; (c) the *nasal branches* (rami nasales posteriores) enter the nasal cavity by the spheno-palatine foramen.

GANGLION SPHENO-PALATINUM.—Lying on the pterygoid muscle, and generally underneath the infraorbital nerves, is the spheno-palatine ganglion,

an elongated object of greyish colour connected by fine filaments with the spheno-palatine nerve. The Vidian nerve of the pterygoid canal joins the aboral extremity of the ganglion.

N. MANDIBULARIS.—The opportunity should now be seized to again examine the mandibular nerve—the most ventral division of the fifth cerebral nerve—as it leaves the cranium by the oval foramen and lies alongside the first part of the internal maxillary artery, ventral to the mandibular joint and lateral to the pterygoid muscles. The various branches of the nerve are the deep temporal, the masseteric, the buccinator, the superficial temporal, the pterygoid, the lingual, the inferior alveolar, and the mylo-hyoid nerves, all of which have been described as the dissection proceeded.

GANGLION OTICUM.—Close to the foramen ovale, the small otic ganglion lies on the mandibular nerve, with which it is connected by fine filaments. A small bundle of fibres forms a link between the ganglion and the tympanic nerve.

The orbit and its contents now claim the attention of the dissector. The bony boundaries of the orbit of the dog are very imperfect, the medial wall alone being represented in the macerated skull. Of such bony wall as exists the frontal bone forms by far the greater part. The lachrymal bone assists, as does also a narrow strip of the palatine above the crest limiting the depression from which the pterygoid muscles have their origin. Moreover, the entrance to the orbit from the face is not completely encircled by bone. Only some three-fourths of it is formed by the frontal, lachrymal, and zygomatic bones. The rest is completed by the *orbital band*, a strong fibrous cord bridging the gap between the rudimentary zygomatic process of the frontal and a small projection on the zygomatic bone.

PERIORBITA.—An exact definition of the orbit is produced by the stout, conical, fibrous periorbita, the apex of which is adherent to the bone in the neighbourhood of the optic foramen, while the base is fused with the orbital band and the periosteum of the bony orbital margin. The periorbita, therefore, forms a definite separation between the orbit and the temporal and pterygo-palatine fossæ, and contains the eyeball and its various accessory structures.

The axis of the orbital cavity is not parallel to the long axis of the head; nor are the two orbital axes parallel to each other. Each axis runs in a dorsal, lateral, and oral direction from the optic foramen.

Dissection.—In order to effect a proper exposure of the contents of the orbit it is necessary to remove the coronoid process of the mandible and the temporal muscle attached thereto. For convenience the orbital band and as much as possible of the periorbita should also be taken away. In the removal of the periorbita care must be exercised not to injure the structures lying close to its deep face.

GLANDULA LACRIMALIS.—The lachrymal gland will be found under the orbital band and over the dorsal and lateral part of the eyeball. Flat in form and curved conformably to the structures with which it is in contact, the gland is pale-red in colour and distinctly lobulated. Generally its numerous ducts, which open into the superior fornix, are too small to be satisfactorily dissected.

Previously the two ends of the lachrymal and zygomatic nerves have been examined. The middle part of their course is now revealed. These two nerves—branches of the maxillary nerve—lie immediately under the periorbital, and run together, or a very short distance apart, on the surface of the lateral

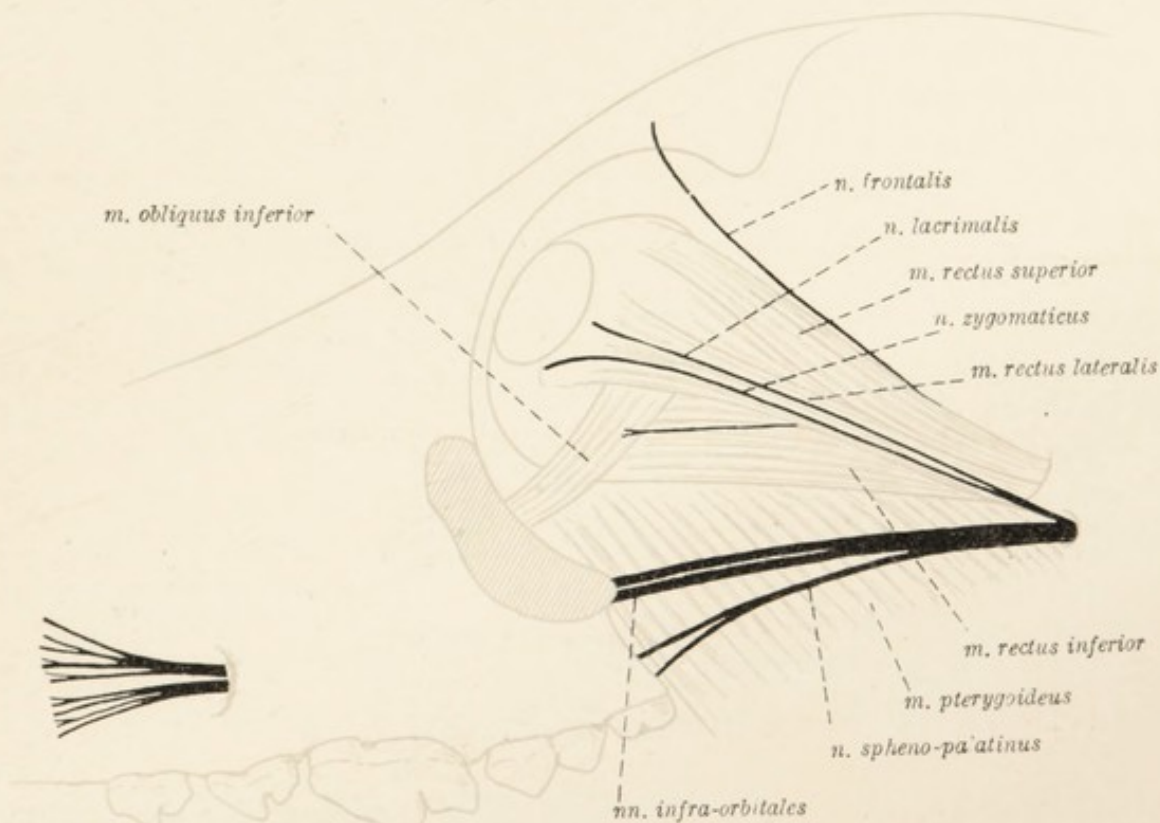


FIG. 60.—Dissection of the orbit.

straight muscle of the eyeball, towards the entrance to the orbit. The lachrymal nerve is the more lateral and gives branches to the lachrymal gland. The zygomatic nerve pierces the orbital band in order to reach the lower eyelid.

N. OPHTHALMICUS.—The ophthalmic nerve—the most dorsal division of the fifth cerebral nerve—enters the orbit at its apex, and should be looked for between the origins of the superior and lateral straight muscles of the eyeball. It divides into the frontal, infratrochlear, and naso-ciliary nerves. Of these the first named can be examined at once, but the dissection of the others should be deferred for a little.

N. FRONTALIS.—The frontal nerve lies just within the periorbital, and will be found running obliquely across the levator of the upper eyelid and the superior straight muscle of the eyeball to the point of attachment of the orbital

band to the zygomatic process of the frontal bone. Its distribution is to the upper eyelid and the adjacent part of the side of the nose.

M. LEVATOR PALPEBRÆ SUPERIORIS.—The thin, narrow levator muscle of the upper eyelid is dorsal to the eyeball and just underneath the periorbita. Its origin is from the margin of the optic foramen, and its expanded insertion is into the upper eyelid.

M. OBLIQUUS SUPERIOR.—Of the two oblique muscles of the eye, the more superior arises from the medial side of the optic foramen. Under the zygomatic process of the frontal bone, the fleshy belly of the muscle gives place to a thin rounded tendon, which, playing through a pulley, forms an angle with the rest

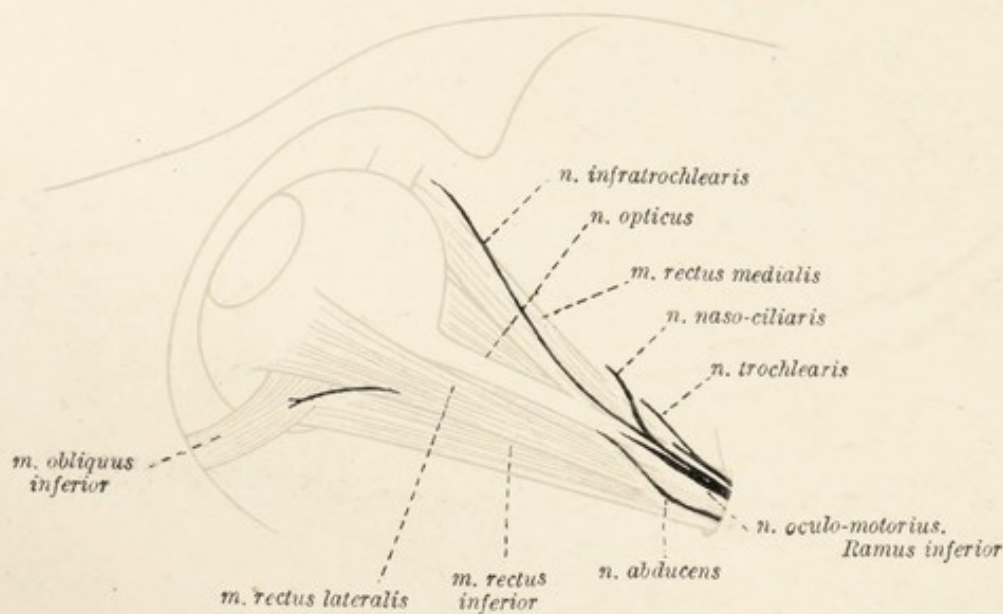


FIG. 61.—Dissection of the orbit.

of the muscle and is attached to the sclera after passing under the tendon of insertion of the superior straight muscle.

N. TROCHLEARIS.—The trochlear or fourth cerebral nerve lies lateral to the superior oblique muscle, which it enters after a very short intraorbital course.

N. INFRATROCHLEARIS.—The infratrochlear branch of the ophthalmic nerve may now be examined. The nerve is at first between the medial and superior straight muscles, but later it passes towards the entrance to the orbit between the medial straight and the superior oblique muscles. In order to gain the skin medial to the eye, the infratrochlear nerve passes below the trochlea of the oblique muscle, whence it derives its name.

N. NASO-CILIARIS.—The naso-ciliary nerve generally arises from a common stem along with the infratrochlear nerve. In order to reach the ethmoidal foramen, by means of which it leaves the orbit, the nerve turns round the edge of the medial straight muscle and then passes between the medial straight and superior oblique muscles.

MM. RECTI OCULI.—There are four straight muscles of the eyeball, namely, superior, inferior, medial, and lateral. They all arise in the neighbourhood of the optic foramen and are inserted by flattened tendons into the fore part of the eyeball.

N. OCULO-MOTORIUS.—The oculo-motor or third cerebral nerve enters the orbit at its apex and supplies all the muscles of the eyeball with the exception of the superior oblique and the lateral rectus.

Two main divisions of the nerve may be distinguished. Of these the upper (ramus superior) supplies branches to the retractor and superior straight muscles of the eyeball and the levator of the upper eyelid. The lower division (ramus inferior) is larger and travels between the inferior and lateral straight muscles to end in the inferior oblique. In addition it furnishes nerves to the inferior and medial straight muscles and to the retractor of the eyeball.

The small *ciliary ganglion* (ganglion ciliare) lies between the origins of the nerves to the inferior oblique and inferior straight muscles. Two or three *short ciliary nerves* leave it to accompany the optic nerve into the eyeball.

N. ABDUCENS.—The abducent or sixth cerebral nerve will be found running along the border of the lateral straight muscle, into which it disappears at a point about the middle of the length of the muscle.

M. OBLIQUUS INFERIOR.—The inferior oblique muscle is ventral and lateral to the eyeball, and differs from the other muscles in not having its origin in the vicinity of the optic foramen. The origin is close to the lachrymal fossa, from which place the muscle passes under cover of the lateral rectus to be inserted into the sclera.

M. RETRACTOR OCULI.—Composed of four distinct parts (superior, inferior, lateral, and medial) which all arise about the optic foramen, the retractor of the eyeball lies and is inserted into the sclera within the four straight muscles.

N. OPTICUS.—The thick, rounded, cord-like optic or second cerebral nerve forms a conspicuous object in its transit from the optic foramen to the back of the eyeball.

A. OPHTHALMICA.—As has been seen, immediately the internal maxillary artery emerges from the alar canal it gives off the ophthalmic artery. This pursues a somewhat circuitous course round the structures at the apex of the orbit in order to gain the ethmoidal foramen, which it enters as the ethmoidal artery.

The branches of the ophthalmic artery are as follows: (1) Close to its origin an anastomotic branch leaves it to enter the orbital fissure and join the internal carotid artery within the cranium. (2) There are generally two main muscular branches (rami musculares) which supply not only the ocular muscles but also the fat within the orbit, the periorbita, and the lachrymal gland. (3) The *lachrymal artery* (a. lacrimalis) is a small vessel accompanying the nerve of the same name and terminating in the lachrymal gland and the

upper eyelid. (4) The *frontal artery* (a. frontalis) courses along the lateral border of the superior straight muscle to reach the upper eyelid, where it anastomoses with the superficial temporal artery. (5) Two *posterior ciliary arteries* (aa. ciliares posteriores) accompany the optic nerve into the eyeball. (6) The continuation of the ophthalmic artery, the *ethmoidal artery* (a. ethmoidalis), traverses the ethmoidal foramen and gains the interior of the cranium, where it divides into meningeal and nasal branches.

A. CENTRALIS RETINÆ.—The small central artery of the retina arises from the anastomotic branch of the ophthalmic which joins the internal carotid artery. The vessel enters the eyeball within the optic nerve and is distributed over the anterior surface of the retina.

PALPEBRA TERTIA.—On making an examination of the undissected orbit, a prominent fold of conjunctiva will be observed medial to the eyeball. This is the *membrana nictitans* or free edge of the third eyelid, the basis of which is formed by a roughly triangular plate of cartilage (cartilago nictitans). The deeper part of the cartilage is surrounded by a reddish glandular mass (glandula palpebræ tertiæ [Harderi]).

Dissection.—Before entering on the dissection of the eyeball (bulbus oculi), it is well that several specimens be secured. Some of these should be examined in the fresh condition; others should be hardened in a formol solution preparatory to their dissection. From all of them the muscles should be removed. When doing this notice the exit of the vorticosse veins about the equator of the eyeball, and the entrance of the optic nerve and the posterior ciliary arteries.

In the first place the dissector should gain some idea of the general structure of the eyeball by making sections of two specimens. One should be cut in a vertical, antero-posterior direction; the other in the plane of the equator.

GENERAL CONFORMATION AND STRUCTURE OF THE EYEBALL.—Although more spherical than in other domestic animals, the eyeball of the dog is not a perfect sphere, as is shown by certain proportions given by Koschel. According to this observer the average transverse, vertical and antero-posterior diameters are in the proportion of 19·7, 18·7, and 20 in small dogs, and 24, 23, and 24·2 in large dogs. The excess in the antero-posterior diameter depends upon the bulging of the cornea, a part of a sphere with a shorter radius than that of the sclera by which the greater portion of the curve of the eyeball is determined.

It is found convenient to employ certain descriptive terms in the consideration of the eyeball. The *anterior* and *posterior poles* (polus anterior et polus posterior) are the central points of the anterior and posterior curvatures respectively. They are joined by an imaginary line, known as the *optic axis* (axis optica),

the shortest distance between the two poles, and by *meridians* (meridiani) which follow the surface of the eyeball. The *equator* (æquator) is a line drawn equidistant from the two poles cutting the meridians at right angles.

The eyeball is composed of three concentric tunics enclosing three refracting media. The tunics are: (1) An outer, dense, fibrous coat (tunica fibrosa oculi) consisting of the posterior opaque *sclera* and the anterior transparent *cornea*; (2) a middle vascular and pigmented envelope (tunica vasculosa oculi) comprising a posterior and most extensive portion, the *choroid* (chorioid), an intermediate *ciliary body* (corpus ciliare), and an anterior diaphragm, the *iris*; and (3) an internal and thin nervous tunic, the *retina*.

The refracting media are: (1) The most posterior and most voluminous, the *vitreous body* (corpus vitreum), of jelly-like consistence; (2) the *crystalline lens* (lens crystallina), the most dense of the media; and (3) an aqueous humour which occupies the most anterior part of the eyeball.

Dissection.—In order that a complete examination may be made of the sclera and cornea it is necessary to separate them from the structures within. With great care make an incision with a knife through the sclera at the equator. The underlying choroid must not be injured; therefore the incision must stop as soon as pigment becomes visible. Now complete the incision round the equator by means of scissors. The separation of the sclera can be very readily effected, except at the junction of the sclera and cornea and at the entrance of the optic nerve. In the former position resistance is offered by the attachment of the ciliary muscle, but can be easily overcome by using a pair of closed forceps or similar blunt instrument. The optic nerve must be severed immediately it has pierced the sclera. The fibrous tunic of the eyeball is now divided into two parts. The rest of the specimen must be preserved for future examination.

SCLERA.—The sclera is a dense, resisting, white tunic, of considerable thickness in the neighbourhood of the optic nerve, and fairly thick close to the margin of the cornea. The intermediate part, however, is relatively thin, so much so, indeed, that generally the shimmer of the dark underlying choroid imparts a bluish colour to this part of the sclera.

The free anterior margin of the sclera (rima cornealis), with which the cornea is connected, is almost perfectly circular. The point of entrance of the optic nerve is not quite at the posterior pole of the eyeball, but slightly ventral and lateral to it. Here the fibrous sheath of the nerve—derived from the dura mater of the brain—is continuous with the sclera, and bundles of nerve-fibres pass through small orifices in the sclera. The area so pierced is known as the *cribrose lamina* of the sclera (lamina cribrosa scleræ).

Between the sclera and the choroid is the *perichoroideal lymph space*

(spatium perichorioideale), crossed by the fine ciliary vessels and nerves and a loose network of pigmented connective tissue known as the *lamina fusca*.

CORNEA.—The cornea is transparent, of great density, and nearly circular in outline. Its thickness is greatest in the central part and becomes less towards the periphery. The edge of the cornea is overlapped by the sclera in much the same manner as a watch-glass is overlapped by the metal rim into which it fits.

CHOROID.—The choroid forms the greater part of the middle tunic of the eyeball, and is thickest about the entrance of the optic nerve. If the choroid be viewed from the front, a triangular or crescentic area, beginning either above or medial to the entrance of the optic nerve, is readily distinguished from the rest. This is the *tapetum*, and the peculiar appearance of the choroid in this position is caused by the presence of a number of superposed layers of cells (*tapetum cellulosum*). In the dog the tapetum has a metallic lustre and is often of a golden colour with a whitish or bluish periphery.

The main thickness of the choroid consists of two layers of blood vessels. The more superficial layer, the *lamina vasculosa*, contains the larger vessels; while the inner layer, the *lamina choriocapillaris*, is composed of a network of capillaries. The tapetum occurs between the two laminae.

Dissection.—In order to display the ciliary body an eyeball should be cut across a little distance in front of the equator, and the vitreous body and crystalline lens carefully removed from the anterior segment.

CORPUS CILIARE.—The ciliary body consists of the ciliary processes and the ciliary muscle. The *ciliary processes* (*processus ciliares*) are some seventy to eighty radially arranged ridge-like thickenings of the body; each ridge becoming taller from the periphery centralwards and ending abruptly as a slightly expanded prominence. A portion of the *hyaloid membrane* (*membrana hyaloidea*), which surrounds the vitreous body, is applied to the ciliary processes, and is radially thickened and folded, so as to present grooves and elevations intimately connected with the processes and the depressions between them. Immediately behind the ciliary processes there is a circular area, almost entirely smooth, known as the *orbiculus ciliaris*, which, however, is very narrow or even absent in the medial half of the eye.

M. CILIARIS.—The ciliary muscle consists of involuntary fibres arranged, for the most part, in a meridional or radiating manner. Some fibres, however, are circular in direction. In a sagittal section of the eyeball the ciliary muscle forms a triangular mass in the neighbourhood of the junction of the sclera and cornea. The radiating fibres arise from the sclera close to the rima cornealis and are attached to the ciliary processes and the orbiculus ciliaris.

Dissection.—The iris must now be examined. Its posterior surface can be studied in the preparation used to show the ciliary body. To reveal its anterior surface the cornea must be removed from another eyeball.

IRIS.—The iris is a muscular diaphragm placed immediately in front of the crystalline lens. About its centre is an almost circular opening, the *pupil* (pupilla), which varies in size during life to regulate the amount of light entering the eye. The variations in the size of the pupil are governed by muscular fibres within the substance of the iris. Some of these are disposed in a circular manner and act as a sphincter (m. sphincter pupillæ).

The iris has two margins. One (margo pupillaris) circumscribes the pupil. The other (margo ciliaris) is connected with the ciliary body and, by the *pectinate ligament* of the iris, with the posterior lamina of the cornea.

Dissection.—The retina may be demonstrated in several ways. By carefully removing the vitreous body from the eyeballs which have been sectioned sagittally and transversely, a good view of the retina from within can be obtained. It may also be studied in the specimen in which the sclera and cornea have been removed for the exhibition of the vascular tunic. In this specimen the choroid, ciliary body, and iris must be cautiously removed bit by bit.

RETINA.—The pigmentary (outermost) layer of the retina is so closely adherent to the deep face of the choroid that it is removed with this tunic. The rest of the retina consists of nervous and connective tissue. Within the nervous layers of the retina the fibres of the optic nerve have their origin, a circumstance which accounts for the gradual increase in the thickness of the membrane as its point of connection with the nerve is approached.

At an indistinct line, the *ora serrata*, close to the margin of the ciliary body, the nerve elements cease, and the retina suddenly becomes thinner. From this line the membrane is continued to the ciliary body as the ciliary part of the retina (pars ciliaris retinæ).

When the retina is viewed from within, the entrance of the optic nerve is distinguished as a slight, round or triangular elevation, the *optic papilla* (papilla nervi optici), lying a little below and lateral to the posterior pole of the eyeball. Three or four small arteries, branches of the central artery of the retina, with their satellite veins, radiate from the papilla.

Dissection.—To obtain the isolated vitreous body and crystalline lens, the method suggested by Anderson Stuart should be followed. An eyeball is allowed to lie untouched for some time—one to three days according to season. An incision is then made along the equator through the three tunics, and the two halves of the eyeball gently separated. If this is properly done, the vitreous body and lens may be allowed to drop entire into water, or still better into a stain in which they may remain for some minutes. If stained, the specimen should be well washed before examination.

CORPUS VITREUM.—The vitreous body is a transparent, jelly-like substance

occupying the posterior part of the cavity of the eyeball, and intervening between the crystalline lens and the retina. In front, adaption to the lens necessitates the presence of a concavity, the *hyaloid fossa* (fossa hyaloidea). The rest of the surface of the body is convex and applied to the retina (optic and ciliary parts), but is not in any way connected with this tunic of the eyeball, except at the entrance of the optic nerve.

The surface of the vitreous body is covered by the delicate *hyaloid membrane* (membrana hyaloidea), which, over the ciliary body, is thickened by the accession of radial fibres. This thickened part of the membrane is known as the *ciliary zonule* (zonula ciliaris), and is firmly adherent to the ciliary processes to which it is adapted by a series of radial folds and grooves. Close to the margin or equator of the crystalline lens the zonule splits into two layers. The thinner of the two lines the hyaloid fossa; while the much thicker anterior layer is connected with the capsule of the lens, and thus forms its suspensory ligament.

Running through the vitreous body from the optic papilla to the back of the lens is the minute *hyaloid canal* (canalis hyaloideus) marking the line of the embryonic *hyaloid artery* (a. hyaloidea), a branch of the central artery of the retina. The canal cannot be detected in adult material unless the vitreous body has been stained.

SPATIA ZONULARIA.—If a blow-pipe be introduced through the suspensory ligament, a varicose canal surrounding the equator of the lens can be inflated. This is formed by the zonular spaces, bounded in front by the suspensory ligament and behind by the hyaloid membrane covering the vitreous body.

Dissection.—Separate the lens from the vitreous body by cutting through the suspensory ligament.

LENS CRYSTALLINA.—The transparent and biconvex crystalline lens lies between the iris and the vitreous body. It should be noted that its surfaces in the dog are not so convex as in other domestic mammals. A zone between the extreme periphery and the centre of the anterior surface (facies anterior lentis) is in contact with the iris; whereas a variable amount of the central part of the surface coincides with the pupil. The posterior surface (facies posterior lentis) has a greater curve than the anterior and is received into the hyaloid fossa of the vitreous body. The central points of the surfaces are known as the *anterior* and *posterior poles* of the lens (polus anterior lentis et polus posterior lentis). Joining the two poles is the *axis* of the lens (axis lentis). In accordance with the comparative flatness of the surfaces, the margin or *equator* (æquator lentis) is moderately sharp.

If the lens be held up to the light, fine radiating lines may be detected spreading out from the central point of each surface. These indicate the planes of contact of the ends of the fibres (fibrae lentis) which compose its intimate structure. Covering the surface of the lens is a homogeneous

membrane, the *capsule* (capsula lentis), much thicker over the anterior than over the posterior surface.

If a fresh lens be crushed between the fingers, the peripheral part will be found to be much softer than the more central part. A hardened lens also should be broken by pressure, in order to demonstrate the concentric disposition of laminae of fibres which compose it.

CAMERÆ OCULI.—Between the cornea in front and the iris and central part of the lens behind is the *anterior chamber of the eye* (camera oculi anterior). Within the angle formed by the cornea and iris, the *angulus iridis*, the aqueous humour finds its way into the spaces of Fontana (spatia anguli iridis [Fontanæ]). The *posterior chamber of the eye* (camera oculi posterior) is a circular interval bounded by the iris, the peripheral part of the anterior surface of the lens, and the projection produced by the anterior extremities of the ciliary processes.

Dissection.—Remove all the muscles, etc., from about the joint between the mandible and the temporal bone on that side of the head which is yet more or less intact.

ARTICULATIO MANDIBULARIS.—The mandibular articulation occurs between the mandibular fossa of the temporal bone and the condyloid process of the mandible. The two bony surfaces, however, are not in contact, for between them is an *articular disc* of cartilage (discus articularis) moulded upon the bony articular areas.

The joint is enclosed by a *capsule* (capsula articularis) attached around the articular surfaces of the two bones and also to the circumference of the articular disc. Thus it comes to pass that there are in reality two joint-cavities : one between the temporal bone and the disc, the other between the disc and the condyloid process of the mandible. Each cavity has its own synovial membrane. In general the capsule is strong, but the presence of the *temporo-mandibular ligament* (lig. temporo-mandibulare) makes it especially so laterally.

From the conformation of the bony surfaces, the only movements possible in the joint are such as result in depression and elevation of the mandible.

Dissection.—As a preliminary to the removal of the brain, the remains of the muscles, etc., should be cleared away from the cranial bones. That part of the mandible which is still in position should also be taken away, as well as the zygomatic arch of that side. The cranial bones must now be cut away piecemeal with the bone forceps down to the level of the zygomatic arch. This must be done very cautiously, in order that the fibrous membrane covering the brain, the dura mater, may escape injury. It will be observed that the dura is closely applied to the inner surface of

the cranial bones, and that it is particularly adherent along the line of sutures. Some difficulty will be experienced in the removal of the bony tentorium, but this may be overcome by the gradual stripping of the membrane from the bone.

In the region of the foramen magnum the bone between the two occipital condyles should be removed. As this means partial destruction of a connection between the occipital bone and the atlas, note should be taken of the presence of the *dorsal atlanto-occipital membrane* (*membrana atlanto-occipitalis dorsalis*), a strong membrane passing from the edge of the arch of the atlas to the margin of the foramen magnum.

It will be noticed that the dura mater is firmly attached to the edge of the foramen magnum.

DURA MATER ENCEPHALI.—The brain is enclosed within three membranes, or meninges, of which the outermost, and at the same time the thickest and strongest, is the dura mater. The function of this membrane is a double one. In the first place it affords protection to the brain, which it completely surrounds. In addition it constitutes the periosteum of the inner surface of the cranial bones, as evidenced by the appearance of the membrane when it is stripped from the bones. The exposed surface of the dura in the specimen now being examined presents a more or less ragged appearance, due to the presence of stumps of vessels ruptured during separation of bone from membrane.

Consequently, the dura mater within the cranium may be regarded as composed of two layers: (1) an endocranial or periosteal layer, and (2) a supporting layer applied to the brain and forming folds between certain parts of this organ. In certain regions the two layers are separated by channels containing venous blood, the blood-sinuses of the dura. One of these sinuses, the *sagittal sinus* (*sinus sagittalis*), is easily recognised as it runs in a longitudinal direction in the middle line. At the osseous tentorium the sagittal sinus divides into right and left *transverse sinuses* (*sinus transversi*), which are mainly contained in the temporal meatus, and consequently suffer considerable injury during the removal of the bone.

A much smaller sinus, the *occipital* (*sinus occipitalis*), sometimes difficult of demonstration, lies in or about the middle line behind the tentorium, that is to say, over the cerebellum.

Dissection.—Raise the dura mater from the underlying brain and make as long an incision as possible through it on each side of and parallel to the sagittal and occipital sinuses. At right angles to the first incisions, and from about the middle of their length, make an incision on each side as far as the cut edge of the cranial bones.

CAVUM SUBDURALE.—The subdural cavity—a space between the dura and the arachnoid mater—is now opened. It will be observed that the

opposed surfaces of the two membranes are smooth and glistening, and moistened by a small quantity of a serous fluid.

FALX CEREBRI.—The falx cerebri is one of the folds of the supporting layer of the dura mater. It lies in the median plane between the two cerebral hemispheres, and in form resembles a sickle with a gentle curve. The convex border is attached to the middle line of the cranial vault from the crista galli to the osseous tentorium, and contains the sagittal sinus. The concave border is inferior and free.

Dissection.—The falx cerebri should now be cut across as close as possible to its anterior end, and turned backwards. When this has been done, veins from the interior of the brain will be noted joining the system of blood-sinuses at the tentorium. The deep veins join to form a *straight sinus* and this, in its turn, joins the sagittal sinus. The converging point of the sinuses is known as their confluence (*confluens sinuum*).

The brain must now be removed. Begin by cutting across the medulla oblongata on a level with the foramen magnum. At the same level cut the basilar artery, which will be found immediately ventral to the medulla, and the spinal roots of the accessory nerves, which run lateral to the medulla. Now introduce the handle of the knife under the medulla and gently raise the brain from the base of the cranium. If the head be placed in a vertical position, with the nose resting on the table, the removal of the brain will be facilitated. The nerves and vessels associated with the base of the brain are thus put on the stretch, and should be severed one by one. In cutting the cerebral nerves it is well to divide them close to the dura on the one side, and close to the brain on the other. The last eight nerves are fairly close together, but may be distinguished by differences in size and mode of exit from the cranium. The twelfth nerve alone leaves by the hypoglossal foramen. Then comes a group formed by the eleventh, tenth, and ninth, which leave by the jugular foramen. The eighth and seventh nerves enter the internal acoustic meatus in company. The sixth, a small nerve, and the fifth, the largest of the cerebral nerves, pierce the dura mater close together at the medial border of the temporal bone. At this stage notice that a small lobule of the cerebellum is lodged in a depression of the temporal bone. A little care is necessary to remove the lobule without injury.

The fourth nerve is the smallest of all the cerebral nerves and appears round the side of the cerebral peduncle. The third nerve is much larger. The next structure interfering with the removal of the brain is the infundibulum, a hollow, median connection between the tuber cinereum and the hypophysis. Just in front of the infundibulum, and only a little distance from the median plane, are the two internal carotid arteries.

A little farther forward and about the same distance from the median plane are the optic or second cerebral nerves.

The last connection of the brain is that of the olfactory nerves as they pierce the ethmoid bone. It is generally very difficult to extract the olfactory bulbs, from which the nerves arise, without injury.

If the brain when removed is not sufficiently hardened to allow of satisfactory dissection, it should be placed in a 5% solution of formaldehyde. In any case its dissection is better postponed.

It will now be well to examine the dura mater and the other structures at the base of the cranium. The dura mater covering the basal bones of the cranium is removed with difficulty, thus differing from that part of the membrane which lines the bones of the cranial vault. Not only is the dura adherent to the bones; in addition it forms sheaths for the various cerebral nerves, and is continuous, through the foramina of the cranium, with the periosteum of the exterior.

One of the folds of dura mater, the falx cerebri, has been examined. There remain two others: the tentorium of the cerebellum and the diaphragm of the sella turcica.

TENTORIUM CEREBELLI.—The tentorium is interposed between the cerebral hemispheres and the cerebellum, and, in the dog, contains an extensive central bony portion. The lateral membranous part is attached to the projecting border of the temporal bone. The free edge of the partition bounds an opening by which the middle and posterior cranial fossæ communicate with each other, and can be traced forwards as far as a small projection of the sphenoid overhanging the orbital fissure.

DIAPHRAGMA SELLÆ.—A rudimentary circular fold of dura mater surrounds, and in a manner defines, the sella turcica. By means of the diaphragm the hypophysis is firmly retained within its bony bed.

NERVI CEREBRALES.—Each cerebral nerve, on its exit from the cranium, is provided with a sheath derived from all three cranial meninges. With the exception of the optic nerve, however, the identity of the three membranes is soon lost because of the disappearance of the arachnoid and the subsequent blending of the dura and pia mater.

The numerous small olfactory nerves leave the cranium at once by the foramina of the ethmoid bone. The optic nerve also makes a rapid exit by the foramen which bears its name. The oculo-motor nerve, on the contrary, travels for some distance within the substance of the dura mater before it reaches its point of exit, the orbital fissure. The course of the nerve can generally be seen without dissection as it follows a line crossing, very obliquely lateralwards, the continuation of the free margin of the tentorium cerebelli. The trochlear nerve will be found just under the free edge of the tentorium in a shallow groove on the anterior surface of the temporal bone close to its apex. Thence it runs in a slightly curved manner to the orbital fissure.

To follow the trigeminal nerve, a certain amount of dissection is needed. The nerve has two roots : a large, loosely coherent, *sensory root* (portio major), and a much smaller *motor root* (portio minor). Soon after the nerve leaves the brain it passes through a short canal in the temporal bone. In order to follow the nerve satisfactorily it is necessary to strip the dura mater from the bone, and snip away the wall of the canal. Immediately the sensory root has left the canal its volume is considerably increased by the presence of the Gasserian or *semilunar ganglion* (ganglion semilunare [Gasseri]), from which arise the three main divisions of the nerve, namely, the ophthalmic, maxillary, and mandibular nerves. To obtain an adequate view of the ganglion and the nerves arising therefrom, the dura mater must be raised from them. Very great care is needed in doing this, since the membrane is intimately adherent to the ganglion and the nerves. The relatively small ophthalmic nerve (n. ophthalmicus) has an intracranial course along the side of the cavernous blood-sinus to the orbital fissure. The maxillary nerve (n. maxillaris) travels to the foramen rotundum parallel to the ophthalmic nerve, but on a slightly lower level. The mandibular nerve (n. mandibularis), immediately on leaving the semilunar ganglion, traverses the foramen ovale and gains the exterior of the cranium. The small compact motor root of the trigeminal joins the mandibular nerve, and will be found underneath the semilunar ganglion.

The abducent nerve pierces the dura mater just below the point at which the trigeminal nerve enters the canal in the temporal bone, and runs to the orbital fissure medial to the ophthalmic nerve in the wall of the cavernous blood-sinus.

The exits of the remaining cerebral nerves from the cranium were noted during the removal of the brain. A closer inspection of them may profitably be made at this time.

SINUS DURÆ MATRIS.—The sagittal, transverse, and occipital sinuses have already been examined. There still remain for dissection the cavernous and petrosal sinuses, and the basilar plexus.

The *cavernous sinus* (sinus cavernosus) lies to the side of the sella turcica, and is connected with its fellow sinus behind the infundibulum. Posteriorly the cavernous sinus is continuous with the *inferior petrosal sinus* (sinus petrosus inferior) which lies between the apex of the petrosal bone and the body of the sphenoid, and is thence continued into the venous canal between the petrosal bone and the basilar part of the occipital. There is a transverse connection (plexus basilaris) between the two inferior petrosal sinuses just behind the dorsum sellæ.

The *superior petrosal sinus* (sinus petrosus superior), running along the projecting border of the temporal bone and communicating with the confluence of the sinuses, is of small size in the dog.

A. CAROTIS INTERNA.—The intracranial course of the internal carotid artery should now be followed. Entering the cranium by emerging from the

carotid canal at the apex of the petrous part of the temporal bone, the artery pursues a course in the cavernous sinus, at first sinuous, but afterwards more direct. Close to the orbital fissure, the artery pierces the dura mater and proceeds to divide into branches which supply blood to the brain.

The branches at present available for examination are one or two small twigs which anastomose with the middle meningeal artery, and a larger anastomosis with the ophthalmic artery.

A. MENINGEA MEDIA.—The middle meningeal artery has been observed to leave the first part of the internal maxillary artery and enter the cranium by the foramen ovale. Within the cranium the artery lies between the parietal bone and the dura mater, occupying a deep groove in the bone. An anastomosis is effected with the internal carotid artery.

N. PETROSUS SUPERFICIALIS MAJOR.—A very minute nerve, the larger superficial petrosal, should be looked for underneath the semilunar ganglion. Arising from the geniculate ganglion of the facial nerve, it enters the cranium by way of the carotid canal and is joined by the deep petrosal nerve from a plexus surrounding the internal carotid artery. The compound structure thus formed, known as the *Vidian nerve* (n. canalis pterygoidei [Vidii]), finally joins the sphenopalatine ganglion.

Dissection.—The cavity of the nose must next be examined. In order to expose the interior of the cavity the skull should be sawn across on a level with the sella turcica, and a sagittal section then made by sawing parallel to and slightly to the side of the median plane. Thus the septum of the nose will be preserved intact on one side of the plane of section.

Next examine the entrance to the nasal cavity. Observe the area of pigmented skin surrounding the nostrils. The area is covered with depressed papules, is free from hairs, and in a state of health is moist and cold. The cartilages associated with the nostrils must also be displayed.

CARTILAGINES NASI.—The cartilaginous skeleton of the nose is mainly composed of offshoots from the cartilaginous septum of the nasal cavity. This projects above and beyond the incisive bones and has its dorsal and ventral borders prolonged to such an extent and in such a manner that they meet in the lateral wall of the nasal cavity. In addition to the dorsal and ventral processes of the septum, there is an independent lateral cartilage of roughly triangular form.

SEPTUM NASI.—The composition of the septum between the two nasal cavities will be disclosed by stripping off the mucous membrane covering it. The septum is partly bony, partly cartilaginous. By far the greater portion of the *bony septum* (septum nasi osseum) is formed by the vomer and the perpendicular plate of the ethmoid, but ridges projecting from the frontal and nasal bones play an auxiliary part.

The *cartilaginous septum* (septum nasi cartilagineum) fits between the two plates of the vomer, and fills the interval between this bone, the perpendicular plate of the ethmoid and the nasal bones. As already stated, the cartilaginous septum is continued forwards above the incisive bones, where it is more or less moveable (septum mobile nasi).

Dissection.—By the exercise of a reasonable amount of care, the septum may be removed bit by bit in such a way that the mucous membrane clothing its opposite side is left intact. This permits the dissector to examine the blood-vessels and nerves of the partition. In removing the posterior part of the septum a horizontal plate of bone, the transverse lamina of the ethmoid, will be observed to cut the nasal cavity into upper and lower divisions.

In common with that of the nasal cavity generally, the mucous membrane covering the septum is richly supplied with both vessels and nerves. The vessels are derived from the ethmoidal branch of the ophthalmic artery which ramifies over the upper area of the septum, and the nasal branch of the sphenopalatine artery which supplies the lower region.

The nerves are derived from two sources: (1) The olfactory nerves are distributed over the dorsal and posterior part of the septum and also supply the vomero-nasal organ (of Jacobson); (2) the trigeminal nerve contributes branches from both its ophthalmic and its maxillary divisions. The ethmoidal branch of the ophthalmic nerve terminates over the dorsal part of the septum, and the nasal branch of the sphenopalatine nerve supplies the lower part.

Dissection.—With a pair of scissors cut along the upper border of the septal mucous membrane, and so obtain a view of the interior of the nasal cavity.

CAVUM NASI.—Each nasal cavity is narrow and elongated, but its relative length in the dog is largely dependent upon the breed. The narrow dorsal boundary or roof of the cavity is formed by the nasal and frontal bones, while the palatine, maxillary, and incisive bones enter into the composition of its floor. The nasal septum constitutes the medial wall. The lateral wall is very uneven as the result of the projection of the turbinated bones and the ethmoidal cells into the cavity. The dorsal turbinated bone (concha nasalis superior) is relatively much narrower and has a smoother surface than the ventral turbinated bone (concha nasalis inferior). The ethmoidal cells form an elongated triangular mass insinuated between the posterior ends of the two turbinated bones.

The intrusion of the turbinated bones divides the nasal cavity into passages, the *meatus nasi*. The *upper meatus* (meatus nasi superior) is narrow and shallow; the *middle meatus* (meatus nasi medius) is short and narrow and divides posteriorly into two parts; and the *lower meatus* (meatus nasi inferior) is

narrow in front but becomes more spacious behind. These three passages are put into communication with each other by the *common meatus* (meatus nasi communis), a cleft-like channel intervening between the turbinated bones and the nasal septum.

As was observed during the removal of the septum, the posterior part of the cavity of the nose is divided into two parts by the transverse lamina of the ethmoid which joins the vomer. The dorsal and more extensive portion is olfactory in function, the lower is respiratory.

The most anterior part of the nasal cavity, i.e. that part corresponding to the moveable septum, forms the *vestibule* of the nose (vestibulum nasi) and contains two mucous folds continuous with the two turbinated bones. The dorsal fold as such soon disappears, and its place may be said to be taken by two short, oblique folds. The ventral fold expands anteriorly and ends abruptly. Close to the floor of the vestibule, and on a level with the end of the ventral mucous fold, is the opening of the *naso-lachrymal duct* (ductus naso-lacrimalis) by which the tears reach the nose.

ORGANON VOMERO-NASALE [JACOBSONI].—If a fine probe be introduced into a small opening at the side of the incisor papilla, it will traverse the *naso-palatine duct* and appear in the floor of the nasal cavity close to the septum and on a level with the canine tooth. Into the naso-palatine duct opens the tubular vomero-nasal organ of Jacobson. The organ is enclosed in the *vomero-nasal cartilage* (cartilago vomero-nasale) situated along the base of the nasal septum, and is innervated by the olfactory and the nasal branch of the sphenopalatine nerve.

SINUS MAXILLARIS.—It is best to open the maxillary sinus from the outside. As a preliminary step the infraorbital canal should be opened up and cleared of its contents. The inner wall of the canal is formed by a thin plate of bone which may be fairly easily removed without injury to the underlying mucous lining of the sinus. The bony opening may be enlarged as much as desired and the mucous membrane should then be incised to such an extent as to allow of a good view of the interior.

The maxillary sinus has an oval outline and coincides in extent with the last four maxillary teeth. It will be noted that the communication between the sinus and the nasal cavity (aditus naso-maxillaris) is large and oval, but is not in the lowest part of the sinus. The aditus opens into the nasal cavity close to where the ventral limb of the middle meatus joins the inferior meatus.

SINUS FRONTALIS.—When the skull was sawn longitudinally one of the frontal sinuses was opened. The dimensions of the sinus should be ascertained. It is generally of good size, and more or less perfectly divided into two or more parts, but in this respect much depends upon the breed of the dog which is being dissected. The sinus opens into the ethmoidal meatus of the nasal cavity.

If the mucous membrane covering the lateral wall of the nasal cavity be examined it will be found that a certain zone of the lining of the vestibule is

distinguished by the possession of pigment. The rest of the mucous membrane of the lateral wall, like that of the septum, is divided into an upper olfactory (regio olfactoria) and a lower respiratory region (regio respiratoria). Though the olfactory mucous membrane is thicker than that over the rest of the wall, the limits of the regions are not recognisable with the naked eye. The nerves supplying the lateral wall of the cavity are similar in origin to those of the septum.

Dissection.—Remove the muscles which still remain attached to the spinous and transverse processes of the vertebræ. Then open the vertebral canal by cutting through the arches of the vertebræ just within the articular processes. Those parts of the bones which are now removed must be left attached to each other: in other words, the ligaments connecting them must be preserved intact for future study.

This dissection will expose the spinal cord within its membranes, the roots of the spinal nerves, and certain blood-vessels.

Little difficulty will be experienced in demonstrating a series of spinal veins emerging from the vertebral canal by the intervertebral foramina; and, if the spinal cord be raised somewhat from the bodies of the vertebræ, their connection with a longitudinal vein on each side will be seen. Into the longitudinal vessels open veins which drain the bodies of the vertebræ.

Unless the subject be well injected it will be difficult to detect the small spinal arteries which enter the vertebral canal by the intervertebral foramina. These are derived from the vertebral, intercostal, lumbar, and sacral vessels, and are distributed to the spinal cord, the spinal meninges, and the bodies of the vertebræ.

MENINGES.—Surrounding the spinal cord are three membranous envelopes—the meninges—continuous with those which cover the brain.

DURA MATER SPINALIS.—A certain amount of soft fat covers the outermost of the spinal meninges and must be removed before a satisfactory examination can be made.

The spinal dura mater is in the form of a dense, fibrous tube, continuous with the cranial dura mater at the foramen magnum and extending into the sacrum. The tube is of uneven calibre. Wide in the cervical and lumbar regions, it is narrower and much more closely applied to the spinal cord in the thoracic region. Aborally it tapers rapidly to its sacral termination. Along each side the roots of the spinal nerves pierce the wall of the dural tube, and in doing so derive a thin fibrous sheath therefrom.

Dissection.—The dura mater should now be carefully slit along the middle line. This having been done, the smooth nature of the interior of the tube will be manifest. The interval between the dura and the arachnoid is known as the *subdural cavity* (cavum subdurale).

It is obvious that differences exist between the dura mater covering the brain and its continuation over the spinal cord. The cranial dura mater is closely adherent to, and forms the periosteum of, the cranial bones. The spinal dura mater is separated from the vertebræ by a space in which is a certain amount of fatty tissue. The cranial dura mater consists of two layers, from one of which membranous partitions are formed. The spinal dura mater corresponds to the inner of these two layers only. Venous sinuses are present in the cranial dura mater, while the corresponding membrane of the spinal cord is devoid of them.

ARACHNOIDEA SPINALIS.—This, the second, tubular investment of the spinal cord is very delicate and transparent. Continuous at its cranial end with the arachnoid of the brain, caudally it forms a loose investment for the cauda equina and ends by joining the other meninges. Between the arachnoid and the pia mater is the *subarachnoid space* (cavum subarachnoidale).

Dissection.—Remove the arachnoid mater from a length of the cord and so expose the pia mater.

PIA MATER SPINALIS.—The pia mater is a tough vascular membrane closely applied to the surface of the cord and continued into the ventral median fissure.

LIGAMENTUM DENTICULATUM.—Connecting the pia mater with the dura mater and suspending the cord in the dural sheath, the denticulate ligament is attached continuously along the lateral border of the spinal cord. Its connection with the dura mater, however, is interrupted and in the form of pointed teeth, which reach the dura mater between the apertures of exit of successive spinal nerves.

MEDULLA SPINALIS.—The spinal cord is a bilaterally symmetrical cylindrical mass of nerve matter extending from the foramen magnum, where it is continuous with the medulla oblongata of the brain, to the seventh lumbar vertebra. Its caudal extremity rapidly tapers, thus forming the *conus medullaris*, beyond which is the *filum terminale*. The last named is a thin, thread-like structure, mainly composed of pia mater, but containing some small amount of nervous tissue.

A certain degree of dorso-ventral flattening is observable in most of the spinal cord. This, however, is infinitesimal in the thoracic region. The thickness of the cord is not uniform. Those parts are thickest from which spring the nerves forming the limb-plexuses. Thus it comes to pass that there are two enlargements, a *cervical swelling* (intumescentia cervicalis) and a *lumbar swelling* (intumescentia lumbalis). The longest stretch with uniform diameter is the thoracic part of the cord.

NN. SPINALES.—Leaving each side of the spinal cord are thirty-four or thirty-five spinal nerves, classified according to the vertebræ caudal to which they leave the vertebral canal. The number of nerves agrees with the number

of vertebræ in the thoracic, lumbar, and sacral regions; but in the cervical region there are eight nerves, the first leaving the vertebral canal by the intervertebral foramen of the atlas. The number of coccygeal nerves is three or four.

Each spinal nerve is formed by the union of two roots, a dorsal and a ventral. Each root in its turn is compounded of a number of rootlets which leave the lateral aspect of the cord. The rootlets of the dorsal root leave the cord along a definite line; but those of the ventral root emerge from a narrow longitudinal area. The two roots pierce the dura mater separately, though close together, and join to form the mixed spinal nerve within the intervertebral foramen, except in the sacral and coccygeal regions, where union takes place within the vertebral canal. Immediately before the union is effected the dorsal root expands into an oval grey swelling, the *spinal ganglion* (ganglion spinale).

Because of the disparity in the length of the spinal cord and the vertebral canal which contains it, and because the spinal cord only reaches as far as the seventh lumbar vertebra, it follows that all the spinal nerves do not leave the cord on a level with their foramina of exit. In other words, it is necessary that most of the nerves must travel, for a longer or shorter distance, within the vertebral canal before gaining egress. Only the first six nerves pass straight and immediately from the spinal cord to the intervertebral foramina. At the seventh cervical nerve commences an obliquity which gradually increases to such a degree that the terminal part of the spinal cord is surrounded by a cluster of nerve roots known as the *cauda equina*.

Dissection.—The spinal cord should now be removed from the vertebral canal. Cut the spinal nerves at the intervertebral foramina, when the cord and its membranes can be raised by pulling upon the dura mater. The membranes should be re-examined at this stage by pinning the specimen out in a cork- or paraffin-lined tray. If the specimen be well injected, the ventral spinal artery will be noted. When this is done, the membranes must be removed, so that the exterior of the cord itself may be studied.

By examination of the exterior of the spinal cord the dissector may readily satisfy himself as to its bilateral symmetry. A deep *median fissure* (fissura mediana ventralis) runs the full length of the ventral aspect and, in conjunction with a faint *dorsal median groove* (sulcus medianus dorsalis), divides the surface into two symmetrical halves. Each half is subdivided into three *funiculi* (ventral, lateral, and dorsal) by the *dorsal* and *ventral lateral grooves* (sulcus lateralis dorsalis et sulcus lateralis ventralis) along which the dorsal and ventral rootlets of the spinal nerves emerge. Of the two, the dorsal lateral groove is the more definite, and persists on the conus medullaris after the ventral lateral groove has disappeared. In the cervical region, a *dorsal*

DISSECTION OF THE DOG

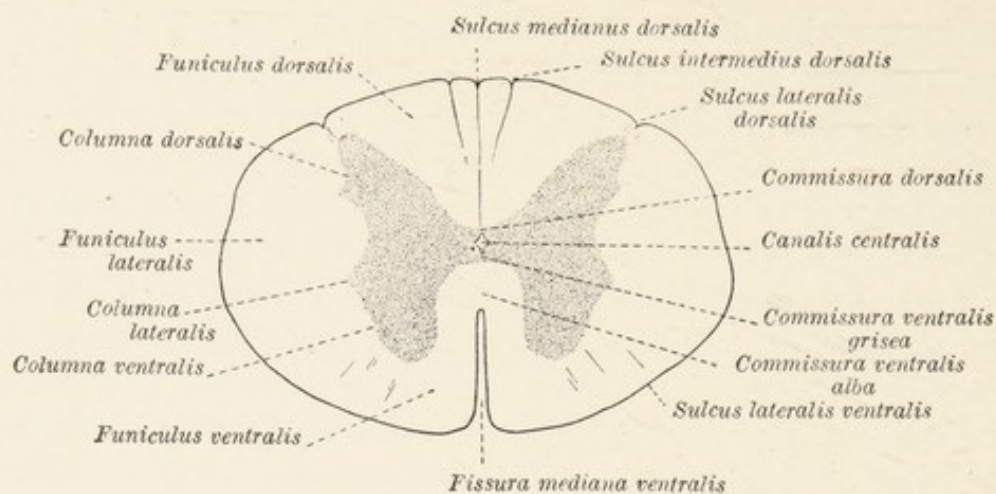
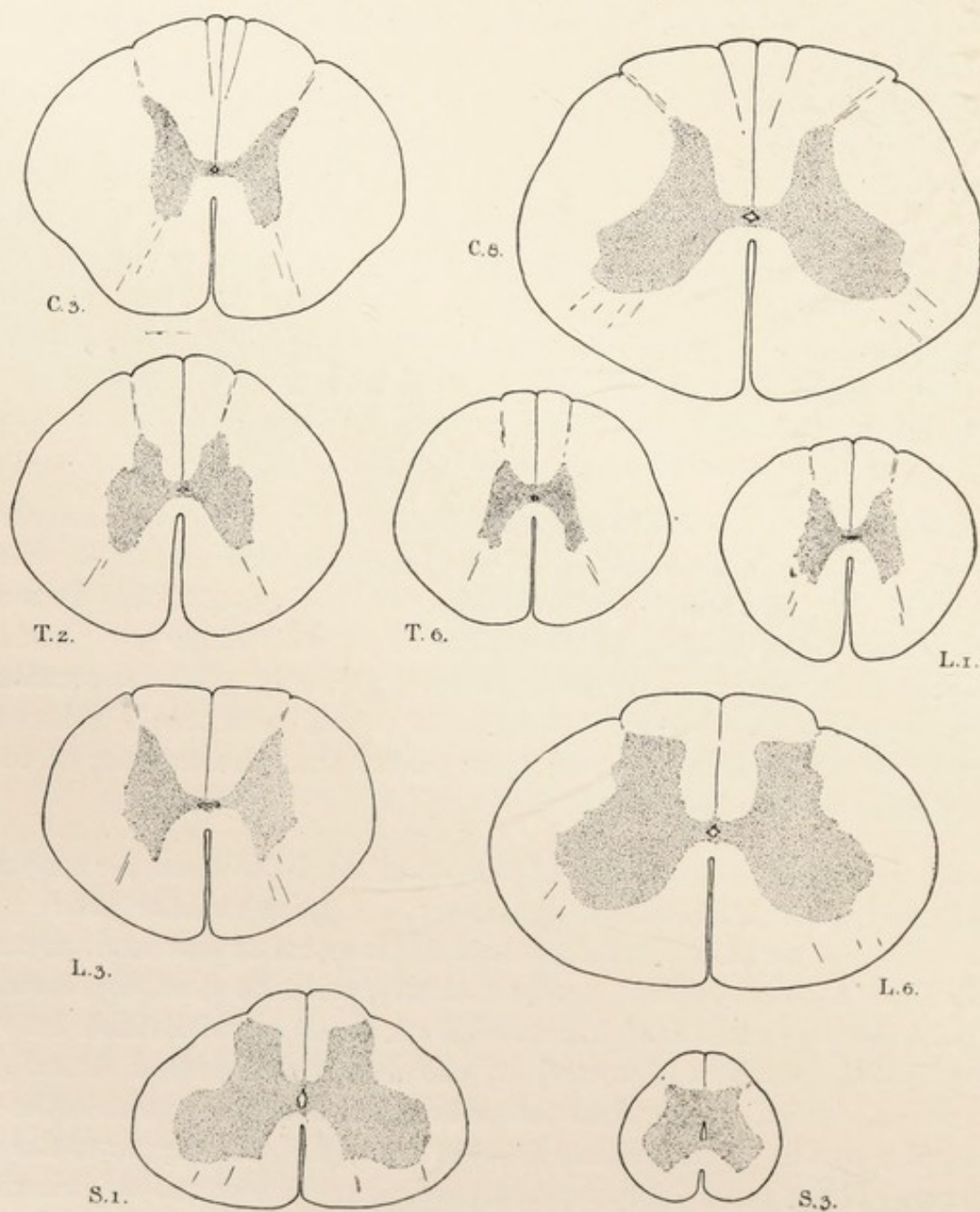


FIG. 62.—Transverse section of the spinal cord.

FIG. 63.—Transverse sections of the spinal cord at different levels, drawn to scale.
C. 3, etc., indicate the segments.

intermediate groove (sulcus intermedius dorsalis) divides the dorsal funiculus into a medial *fasciculus gracilis* of Goll and a lateral *fasciculus cuneatus* of Burdach. Goll's fasciculus is much the narrower.

In the cervical and thoracic regions, moreover, a longitudinal groove runs along the side of the spinal cord midway between the dorsal and ventral lateral grooves.

SECTIONES MEDULLÆ SPINALIS.—Sections should be made across the cord in different regions and the cut surfaces studied. The bilateral nature of the cord is obvious. The ventral median fissure cuts into it to a considerable depth, and a *median septum* (septum medianum dorsale) continues the dorsal median groove into the interior. Each half contains grey and white matter; the former more deeply placed and in the form of a curved or comma-shaped mass. The grey matter is continued from one side of the cord to the other by the *dorsal* and *ventral grey commissures* (commissura dorsalis grisea et commissura ventralis grisea), between which is the *central canal* of the cord (canalis centralis) surrounded by the *central grey matter*.

The exact shape of the sectional area of the grey matter varies considerably in different regions, but in the main it may be indicated by saying that it resembles the capital letter H; the cross-bar of the letter being represented by the grey commissures. Each half of the cord contains a *dorsal* and *ventral column* of grey matter (columna dorsalis et columna ventralis). Of these the ventral is the larger, and terminates bluntly some distance from the surface. The dorsal column approaches the surface very nearly, and terminates in a pointed apex.

Occasionally a slight constriction, the *neck of the dorsal column* (cervix columnæ dorsalis), marks off this column from the rest of the grey matter. The apex of the dorsal column is covered by a particular kind of grey matter called the *gelatinous substance of Rolando* (substantia gelatinosa [Rolandi]) from its semi-transparent character.

The grey columns are largest in the cervical and sacral regions and particularly so on a level with the origin of those nerves which form the limb-plexuses; while they are smallest in the thoracic and early lumbar regions.

The white matter is disposed external to the grey columns, and consequently is divided into three funiculi. A *dorsal funiculus* (funiculus dorsalis), triangular in section, lies between the dorsal grey column and the dorsal median septum. A *lateral funiculus* (funiculus lateralis) occupies the concavity lateral to the grey columns. A *ventral funiculus* (funiculus ventralis) fills the interval between the ventral grey column and the ventral median fissure. The two ventral funiculi are connected across the bottom of the fissure by the *white commissure* (commissura ventralis alba). From the circumstance that the ventral grey column does not reach the surface, it is obvious that the lateral and ventral white funiculi are only imperfectly separated.

In the cervical region the dorsal funiculus is divided into a *fasciculus gracilis* [Golli] and a *fasciculus cuneatus* [Burdachi].

ENCEPHALON.—It is best to begin the examination of the brain by a general inspection of its external conformation. The brain in its entirety has an ovoid shape, the broader, caudal end being formed mainly by the medulla oblongata and the cerebellum, but partly also by the cerebral hemispheres. The compressed oral extremities of the cerebral hemispheres, capped by the olfactory bulbs, constitute the narrow end of the ovoid. Of all the component parts of the organ, the cerebral hemispheres are far and away the most bulky, and it is these which contribute the greatest transverse diameter.

When the brain is viewed from the dorsal aspect little more than the hemispheres is visible, though a part of the cerebellum may be seen as well as a small section of the medulla oblongata. A *longitudinal fissure* (fissura longitudinalis cerebri) separates the two hemispheres, while a transverse fissure divides the hemispheres and the cerebellum from each other.

On looking at the brain from the ventral aspect a considerable number of structures are distinguishable. Of these, the most important only need be mentioned here. The rest will be examined in the proper place. Continuing the spinal cord at the aboral end of the brain is the *medulla oblongata*, a dorso-ventrally flattened column somewhat similar to the spinal cord in external appearance. Immediately in front of the medulla there is a broad, transverse band, the *pons*, which can be readily followed laterally into the cerebellum. Appearing at the oral border of the pons are two thick, rounded cords, the *cerebral peduncles*, which, after a diverging course, disappear into the cerebral hemispheres. Between the two peduncles is a depression, the *interpeduncular fossa* (fossa interpeduncularis [Tarini]), containing a white eminence, the *mammillary body*, and a grey prominence, the *tuber cinereum*. With the latter, the hypophysis is connected by the hollow stalk-like infundibulum. The optic tracts approach each other and finally blend at the *optic chiasma*, which lies immediately in front of the tuber cinereum. The rest of the ventral view is occupied by parts of the cerebral hemispheres.

A lateral examination of the brain reveals little more than the hemispheres of the cerebrum, with partial views of the cerebellum, pons, and medulla oblongata.

MENINGES.—Of the three membranous coverings of the brain, the dura mater has already been examined.

ARACHNOIDEA ENCEPHALI.—Continuous with, and structurally similar to the corresponding membrane of the spinal cord, the arachnoid of the brain is, for the most part, closely related to the pia mater. It does not, however, follow the pia into the fissures of the cerebrum, and at the base of the brain the relation of the two membranes is much less intimate than elsewhere.

CAVUM SUBARACHNOIDALE.—Over the summit of the cerebral convolutions the arachnoid and pia mater form practically one membrane, but in other situations the two membranes are separated by a subarachnoid cavity of variable depth, across which passes a felt-work of fine fibres. In some situations, for example at the base of the brain, the subarachnoid cavity is considerable and forms what are known as the *subarachnoid cisterns* (cisternæ subarachnoidales). A cistern of some magnitude exists between the dorsal surface of the medulla and the cerebellum (cisterna cerebellomedullaris). Another lies over the interpeduncular fossa (cisterna interpeduncularis). A third is related to the optic chiasma (cisterna chiasmatis), and is continuous on each side with a small cistern in the Sylvian fissure (cisterna fossæ lateralis cerebri [Sylvii]).

PIA MATER ENCEPHALI.—The thin pia mater of the brain follows all the inequalities of its surface, and is highly vascular since the smaller branches of the chief cerebral arteries ramify in it preparatory to entering the substance of the brain. Consequently, when the membrane is raised, its deep surface is rough and shaggy from the presence of minute ruptured vessels.

Dissection.—Cautiously strip the arachnoid from the base of the brain, and follow the arteries thus exposed as far as possible without injury to the brain tissue.

The brain is supplied with blood from three main sources, namely, the single basilar artery and the two internal carotid arteries.

ARTERIA BASILARIS.—The basilar artery is formed within the vertebral canal by the union of branches of the right and left cerebro-spinal arteries. The single, median vessel, so formed, enters the cranium by the foramen magnum and runs ventral to the medulla and pons to end by dividing into right and left branches slightly aboral to the mammillary body. In its course the basilar artery contributes a number of small branches to the medulla and pons, and about its termination a multitude of fine branches leave it to enter the apertures of the posterior perforated substance between the cerebral peduncles.

In addition the basilar artery has branches of larger size and specific name. (1) The *posterior cerebellar arteries* (aa. cerebelli posteriores) arise close to the foramen magnum and run, right and left, round the lateral margins of the medulla oblongata to be expended in the cerebellum. (2) The *internal auditory arteries* (aa. auditivæ internæ) are branches either of the basilar or of the posterior cerebellar arteries. Each enters a temporal bone along with the auditory nerve and ends in the tympanum. (3) The *anterior cerebellar arteries* (aa. cerebelli anteriores) leave the terminal branches of the basilar artery. Bending round the lateral border of the mid-brain, and following the pons, they terminate chiefly over the oral surface of the cerebellum. (4) After the origin of the anterior cerebellar arteries, the two terminal branches of the basilar may be regarded as becoming the *posterior cerebral arteries* (aa. cerebri posteriores).

Each of these is joined by the posterior communicating branch of the internal carotid artery, and then disappears from the present dissection by passing between the cerebral hemisphere and the cerebral peduncle. The posterior cerebral arteries are chiefly concerned in supplying the posterior part of the cerebral hemispheres.

ARTERIA CAROTIS INTERNA.—The termination of the internal carotid artery will be found immediately lateral to the optic chiasma. About this

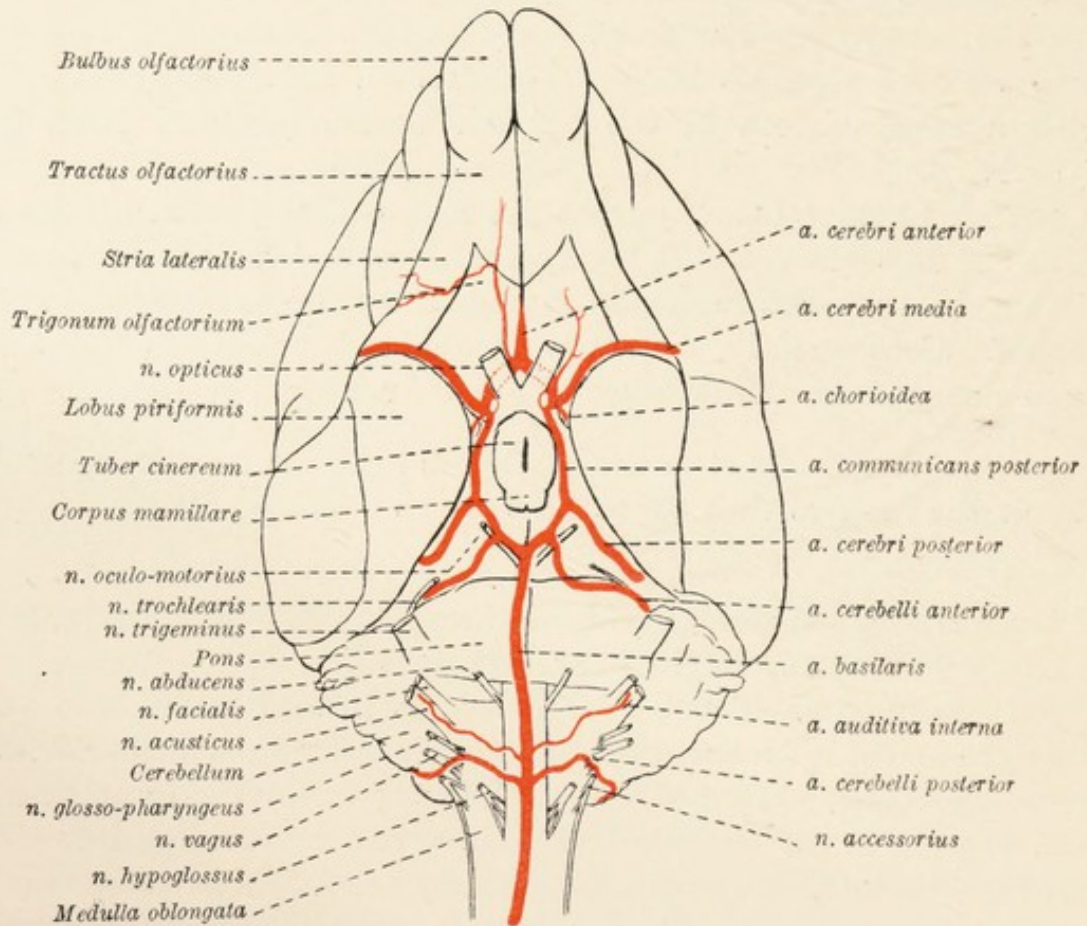


FIG. 64.—Arteries at the base of the brain.

point the artery contributes a *posterior communicating* branch (*a. communicans posterior*) to the posterior cerebral artery, and then immediately ends by dividing into the middle and anterior cerebral arteries.

The *middle cerebral artery* (*a. cerebri media*) gains the Sylvian fissure, and spreads out over almost the whole of the lateral surface of the cerebral hemisphere. A small *choroidal artery* (*a. chorioidea*) leaves the middle cerebral close to its commencement, and follows the optic tract to end in the choroid plexus of the lateral ventricle.

The *anterior cerebral artery* (*a. cerebri anterior*) passes dorsal to the optic nerve, and converging upon the median plane, either fuses with its fellow artery of the other side of the brain, or is joined to this by a transverse *anterior communicating artery* (*a. communicans anterior*). The anterior cerebral artery ramifies over the medial surface of the hemisphere.

CIRCULUS ARTERIOSUS [WILLIS].—The anastomoses, mentioned above, result in the production of the arterial circle of Willis, which lies in the depressed area in front of the pons. Anteriorly the circle is formed by the direct or indirect (by the anterior communicating artery) union of the anterior cerebral arteries. Laterally the posterior communicating arteries link the anterior to the posterior part of the circle, which is completed behind by the two terminal branches of the basilar artery.

Dissection.—Remove the membranes and vessels from the base of the brain. This must be done with the utmost care in order to avoid injury to the brain tissue generally, but especially to prevent tearing away the roots of the several cerebral nerves. The relation of the pia mater to the nerve roots is so intimate that it is probably safest to cut the membrane with scissors around each root.

It is well to preface the detailed examination of the brain by a cursory inspection of certain structures at its base.

The ventral aspect of the medulla oblongata is divided into two lateral halves by a *median longitudinal fissure* (fissura mediana ventralis) continuous with the ventral fissure of the spinal cord and bounded on each side by a prominent white strand, the *pyramid* (pyramis), which disappears under the pons. The median fissure terminates abruptly at the *foramen cæcum*, a blind depression close to the pons. Lateral to the pyramid, and separated from it by a shallow groove, is the oval *facial tubercle* (tuberculum faciale). Immediately oral to this is a transverse prominence, the *corpus trapezoideum*. The prominent pons forms a convex elevation, and is continued laterally into the cerebellum. The broad rounded *cerebral peduncles* appear oral to the pons and, diverging somewhat, disappear into the cerebral hemispheres. Consequent upon their divergence, a depressed area, the *interpeduncular fossa* (fossa interpeduncularis) is produced. The oral boundaries of the fossa are formed by the *optic tracts*—white cords appearing at the edge of the pyriform lobe of the cerebrum—and the *optic chiasma* produced by the union of the two tracts. The aboral part of the fossa is formed mainly by the *posterior perforated substance* (substantia perforata posterior), which derives its name from the presence in it of numerous small openings by which blood-vessels reach the deeper brain tissue. The oral portion of the fossa is occupied by the *mammillary body* and the *tuber cinereum*. The mammillary body (corpus mamillare) is a prominent white object, frequently showing indications of its double nature, connected with the two columns of the fornix. A grey elevation of somewhat less prominence intervenes between the mammillary body and the optic chiasma. This, the tuber cinereum, is connected by means of a hollow stalk, the infundibulum, with the hypophysis, which, as a rule, is left behind in the removal of the brain from the cranium.

On a level with the interpeduncular fossa, the cerebral hemisphere is raised

into a *pyriform lobe*. A small oral continuation of the lobe is separated from the main mass by a deep transverse depression in which the middle cerebral artery lies. Oral to the depression is the *olfactory lobe* (*lobus olfactorius*), consisting of the *olfactory bulb* (*bulbus olfactorius*) from which arises a flattened white band, the *olfactory tract* (*tractus olfactorius*). At its posterior extremity the tract divides into *medial* and *lateral striæ*; the former disappearing into the fissure between the two hemispheres; the lateral coursing, as a white band, across the surface of the oral prolongation of the pyriform lobe, and finally disappearing in the prominent part of this lobe. Between the two striæ is a grey eminence, the *olfactory tubercle* (*tuberculum olfactorium*), the greater part of which is pitted with holes and thus constitutes the *anterior perforated substance* (*substantia perforata anterior*).

NERVI CEREBRALES.—Twelve cerebral nerves arise from each half of the brain. These are either named numerically or are given names signifying their function or distribution :

First cerebral nerve	Nervus olfactorius.
Second „ „	„ opticus.
Third „ „	„ oculomotorius.
Fourth „ „	„ trochlearis.
Fifth „ „	„ trigeminus.
Sixth „ „	„ abducens.
Seventh „ „	„ facialis.
Eighth „ „	„ acusticus.
Ninth „ „	„ glossopharyngeus.
Tenth „ „	„ vagus.
Eleventh „ „	„ accessorius.
Twelfth „ „	„ hypoglossus.

Each cerebral nerve is connected with cells in the interior of the brain, from which it can be traced to some definite point on the exterior where it has what is generally called its ‘superficial origin.’ The superficial origins of the various nerves should now be determined.

N. OLFACTORIUS.—Numerous small olfactory nerves leave the olfactory bulb and immediately enter the foramina of the ethmoid bone. They are generally left behind when the brain is removed.

N. OPTICUS.—The optic nerve is a large round cord leaving the optic chiasma.

N. OCULOMOTORIUS.—The oculomotor nerve has origin from the cerebral peduncle about the middle of its length and towards its medial border.

N. TROCHLEARIS.—Since the origin of the trochlear nerve is from the anterior medullary velum, it cannot be demonstrated at present. The nerve itself, however, will be found curving round the lateral border of the cerebral peduncle, in the interval between this and the cerebrum and cerebellum. The trochlear is the smallest of the cerebral nerves.

N. TRIGEMINUS.—The trigeminal is the largest of the cerebral nerves and arises by two roots from the lateral part of the pons. Of the roots, the larger (portio major) is sensory in function; while the much smaller medial root (portio minor) is motor.

N. ABDUCENS.—The abducent nerve has its origin from the most anterior part of the groove forming the lateral limit of the pyramid of the medulla oblongata.

N. FACIALIS ET N. ACUSTICUS.—The facial and acoustic nerves arise together from the lateral extremity of the corpus trapezoideum. The facial is the more medial, and slightly the smaller.

N. GLOSSOPHARYNGEUS, N. VAGUS, ET N. ACCESSORIUS.—From the lateral border of the ventral surface of the medulla, a series of nerve rootlets take origin. These join to form the glosso-pharyngeal, vagus, and accessory nerves. The accessory nerve, in addition to its medullary roots, contains fibres derived from the cervical part of the spinal cord. The spinal roots of the accessory unite as a single cord, which enters the cranium by the foramen magnum and joins the medullary roots to form the complete nerve.

N. HYPOGLOSSUS.—The hypoglossal nerve arises by several rootlets from the aboral portion of the groove lateral to the pyramid.

Dissection.—As a preliminary to the examination of the surface of the cerebral hemispheres, they must be carefully denuded of the covering formed by the pia and arachnoid. Since the whole of their surface cannot be examined without the separation of the two hemispheres from each other, it is well to procure two brains. One of these should be left intact; while the cerebellum, medulla oblongata, and pons of the other should be separated from the cerebrum by a transverse incision made just in front of the pons. The two hemispheres of this specimen may now be isolated by an incision in the plane of the great longitudinal fissure.

HEMISPHERIA CEREBRI.—The two cerebral hemispheres form the greater part of the bulk of the brain. Each is flattened laterally in a certain degree, and so possesses two surfaces—lateral and medial. The lateral surface, for the main part convex, is applied to the walls of the cranium. The medial surface, on the contrary, is flattened, and much of it faces the corresponding surface of the opposite hemisphere; but the more aboral portion, faintly concave, joins the rest at an angle and is separated from the cerebellum by the tentorium only.

If, in the intact specimen, the hemispheres are separated as far as possible by opening the longitudinal fissure between them, it will be found that they are connected by a broad commissural band, the *corpus callosum*. It will be observed, moreover, that the width of the commissure is not as great as

the length of the hemisphere; i.e. the corpus callosum does not reach the frontal and occipital poles of the hemisphere.

The surface of the hemisphere is sculptured by lines, known as *fissures* (fissuræ) and *sulci*, which separate winding ridges referred to generally as *convolutions* (gyri).

Lateral surface.—A fissure of great fundamental importance—the *rhinal fissure* (fissura rhinalis)—separates the olfactory and pyriform lobes from the rest of the lateral surface. That part which is dorsal to the rhinal fissure is covered with convolutions, rising tier above tier, and arranged in a curved manner about a short straight fissure of considerable depth, the *lateral cerebral fissure* of Sylvius (fissura cerebri lateralis [Sylvii]). The Sylvian fissure occurs

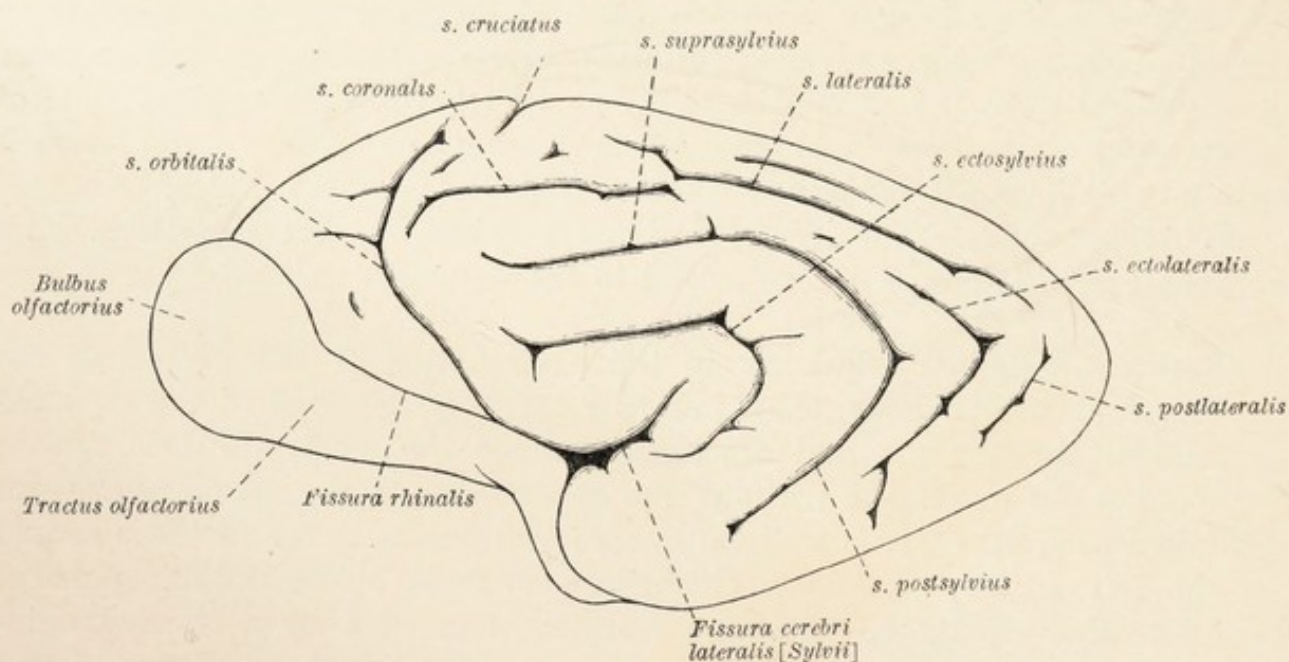


FIG. 65.—Lateral surface of the cerebral hemisphere.

on a level with that transverse depression which crosses the pyriform lobe. In the depths of the fissure, and in the natural condition hidden from sight, are several short convolutions composing the *insula*.

Bent round the Sylvian fissure is a convolution bounded on the other side by a sharply curved *ectosylvian sulcus* (sulcus ectosylvius). More dorsal in position is a sulcus comprised in reality of two parts, though in the majority of specimens its double character is not apparent. The oral segment is one of the deepest of the several cerebral sulci, and is known as the *suprasylvian sulcus* (s. suprasylvius). Continuous with this, and united to it at an angle, is the *post-sylvian sulcus* (s. postsylvius). The area between the suprasylvian sulcus and the dorsal margin of the hemisphere is cut by the *lateral sulcus* (s. lateralis) generally, but not always, continuous anteriorly with the *coronal sulcus* (s. coronalis). The coronal can be distinguished from the lateral sulcus by its greater distance from the margin of the hemisphere. Small sulci of

little moment—*ectolateral* and *post-lateral*—indent the surface of the hemisphere in the neighbourhood of the occipital pole. Consequent upon the lateral inclination of the coronal sulcus, an area of cerebral cortex, roughly quadrilateral in form, is isolated. In this area is the *cruciate sulcus* (s. cruciatus) which crosses the border of the hemisphere and is continued onto its medial surface. In the oral part of the lateral surface is the long, curved *orbital sulcus* (s. orbitalis), one end of which lies close to the cruciate sulcus, while the other joins the rhinal fissure.

Medial surface.—The cruciate sulcus is prolonged, as has been said, to the medial surface of the hemisphere, where it is very generally continuous with the *intercalary sulcus* (s. intercalaris), so named because of its interposition between the cruciate sulcus on the one hand and the calcarine sulcus on the other.

The *calcarine sulcus* (sulcus calcarinus), one of the most important of the cerebral grooves, forms an angle with the intercalary sulcus with which it is continuous, and is confined to that part of the medial surface in contact with the tentorium of the cerebellum. Between the margin of the hemisphere and the intercalary and calcarine sulci are one or two secondary grooves of no great depth and inconstant in disposition. The medial surface of the hemisphere oral to the cruciate sulcus is also indented by a number of grooves of no great moment.

A fissure of fundamental importance—the *hippocampal fissure* (fissura hippocampi)—forms the medial boundary of the pyriform lobe.

Dissection.—Part of one cerebral hemisphere should be removed to a level with the corpus callosum. This must be done by making a succession of slices in planes parallel to that of the corpus. The specimen in which the two hemispheres have been separated by a longitudinal incision, is of service in acting as a guide to the direction and depth to which the slices should be removed. As soon as the corpus callosum can be plainly seen, it is well to remove the remains of the convolution

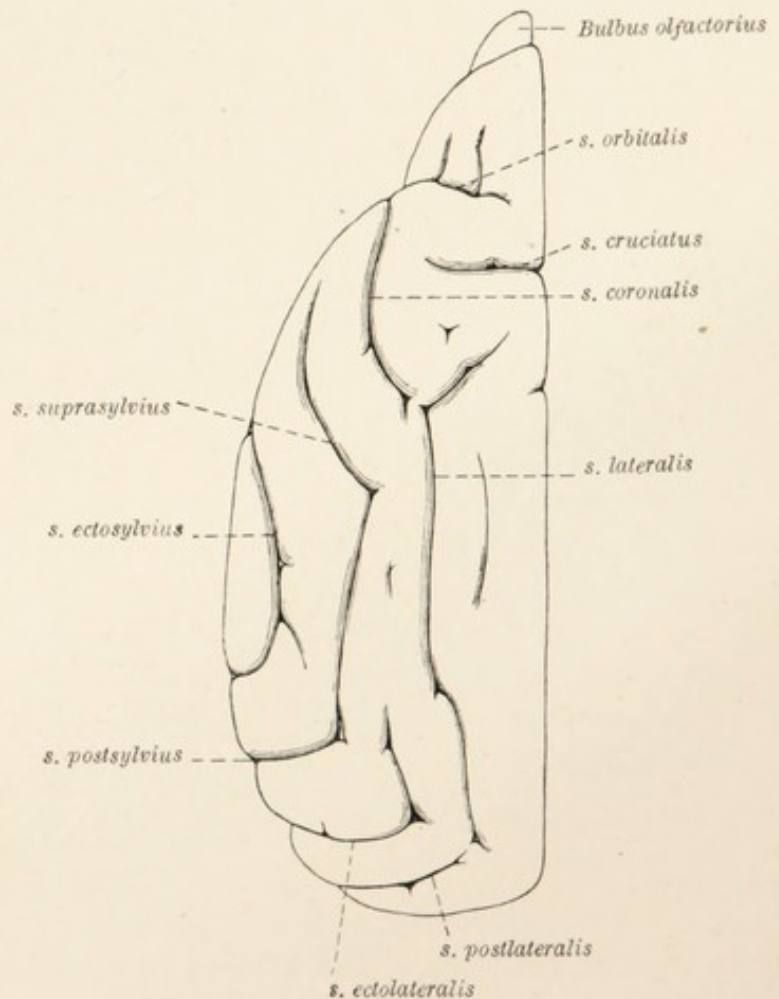


FIG. 66.—Dorsal view of the cerebral hemisphere.

immediately dorsal to it by tearing rather than cutting. This is necessary because the lateral ventricle, a cavity roofed over by the corpus callosum, projects above the level of the medial part of the body. There is, therefore, danger of opening the ventricle if the slicing process is continued. When sufficient of one hemisphere has been removed the other should be treated in the same way.

In the process of this dissection some features of the inner structure of the cerebrum will be revealed. The depth of some of the sulci will be demonstrated, and the fact that the convolutions are composed of an outer rind of grey matter enclosing a core of white matter will be disclosed. As the sections become deeper the white cores of the convolutions

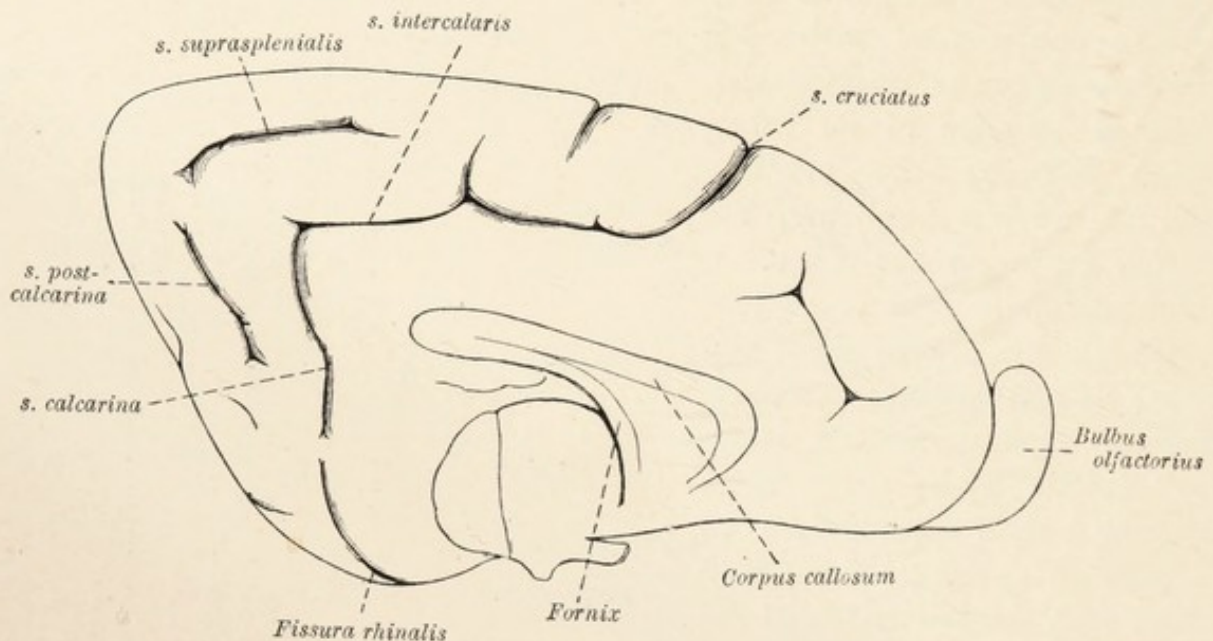


FIG. 67.—Medial surface of the cerebral hemisphere.

become confluent. Finally a large island of white matter occupies the central part of the section of each hemisphere, and is connected by the corpus callosum with a similar island in the other hemisphere.

The study of the corpus callosum is best carried out by an examination of the hemi-sected brain in conjunction with that of the specimen just dissected.

CORPUS CALLOSUM.—The corpus callosum is a broad transverse band mainly concerned in connecting the two hemispheres with each other. It will be noted that it is not co-extensive with the hemisphere, but that it coincides roughly with the middle two-fourths of the length of that structure.

The dorsal surface of the corpus callosum is flat or has a slight convexity. Numerous transverse lines (*striae transversae*) denote that the body is mainly composed of commissural fibres. In addition, faint longitudinal markings, equivalent to the *striae longitudinales* of the human brain, may be detected.

The ventral surface forms the roof of the lateral ventricles, and in the median plane is connected with the *septum pellucidum*, a partition separating the cavities of the two ventricles. The lateral boundaries of the corpus callosum are lost in the white substance of the hemispheres.

The main part of the corpus callosum is known as the *truncus corporis callosi*. Its aboral end is thickened and forms the *splenium corporis callosi*. On examination of the sagittal median section of the brain, the oral end of the body will be seen to make an abrupt bend. This is the *genu corporis callosi*, from which is a recurved, tapering (in section) *rostrum corporis callosi* connected in its turn with the *lamina terminalis*.

Dissection.—It is now necessary to expose the interior of the lateral ventricles. Make a longitudinal incision through the corpus callosum about three or four mm. from the middle line. Then remove that part of the body which is lateral to the incision by tearing it away with either forceps or the end of the handle of the scalpel. When both ventricles have been opened in this manner a narrow strip of the corpus callosum will be left undisturbed. From the main part of the ventricle so exposed two cornua proceed. One of these is anterior in position and can be followed to its termination without difficulty. The other (inferior) cornu must be followed by the piecemeal removal of portions of the hemisphere. Previous to doing this, however, it will be well to note that the cornu is at first directed in a lateral, backward and ventral direction. Later its course is medialwards and forwards.

A proper understanding of the lateral ventricle and its boundaries will be facilitated by dissection from the medial side. To do this, remove the corpus callosum and the immediately adjacent part of the hemisphere from the hemi-sected brain. Though the anterior cornu may be completely investigated in this specimen, it is better to do no more than expose the first part of the inferior cornu.

VENTRICULUS LATERALIS.—The lateral ventricle represents the cavity of the vesicle from which the cerebral hemisphere originally developed, and is in communication with the third ventricle by way of the *interventricular foramen* of Monro (foramen interventriculare [Monroi]), a small opening immediately beneath the fornix. Generally the cavity of the ventricle is not spacious, since its roof and floor are mostly in contact.

For descriptive purposes the lateral ventricle is divided into three parts—a central part, an anterior cornu, and an inferior cornu. The *central part* (pars centralis) has a roof formed by the corpus callosum, and a medial wall, by which it is separated from the other ventricle, consisting of the *septum pellucidum* and the fornix. There is no lateral wall, because the roof and floor meet and thus form the lateral boundary.

The floor of the central part of the ventricle is formed by several important

objects. Of these the most anterior is a pear-shaped grey eminence, the *caudate nucleus* (nucleus caudatus), the narrow end of which is continued into the inferior cornu. Along the medial border of the caudate nucleus runs a vascular fringe, the *choroid plexus* (plexus chorioideus ventriculi lateralis). The appearance of the plexus might lead to the assumption that it is actually within the ventricle. It is, however, excluded from the cavity by a thin

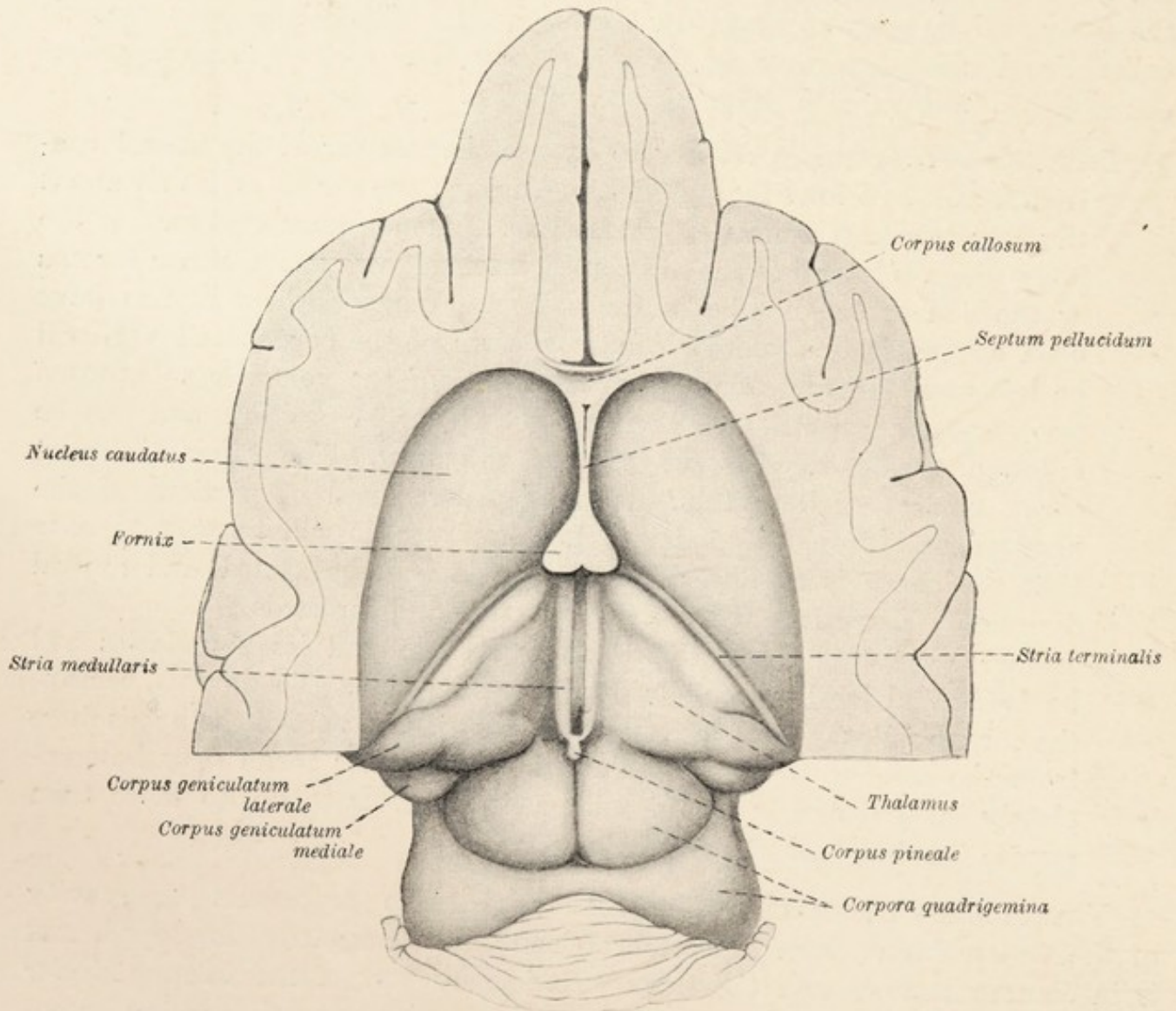


FIG. 68.—Dissection to show the floor of the lateral ventricle and the dorsal part of the mid-brain.

cellular investment, the *ependyma*, continuous with that lining the whole of the interior of the ventricle. Parallel to, and partially covered by, the choroid plexus, is the edge of the *fornix* and its backward prolongation, the *fimbria hippocampi*. The last named is a white hem appended to the greyer, rounded, ridge-like eminence, the *hippocampus*, with the mention of which the list of components of the floor is completed.

The *anterior cornu* (cornu anterius) of the ventricle is, strictly speaking, a mere extension of the central part beyond the level of the foramen of *Monro*.

It inclines in a ventral direction and, in the dog, ends blindly about the level of the tuberculum olfactorium. In many mammals the cornu is continuous with the cavity of the olfactory bulb.

The *inferior cornu* (cornu inferius) is a tapering curved prolongation of the ventricle traceable into the pyriform lobe, where it ends on a level with the point at which the optic tract makes its appearance on the surface of the brain. The cornu contains the tail of the caudate nucleus (cauda nuclei caudati) reduced to a narrow grey ridge, and the diminished continuations of the choroid plexus, fimbria, and hippocampus.

SEPTUM PELLUCIDUM.—A thin medial partition separates the anterior part of the pars centralis of the two ventricles, and fills in the triangular gap between the corpus callosum and the fornix. This is the septum pellucidum, in reality composed of two thin laminae with a narrow chink-like cavity intervening.

Dissection.—The fornix must now be exposed as completely as the present stage of the dissection permits. Cut across the remains of the corpus callosum about the genu, and remove it from this point to the splenium. Its connection with the septum pellucidum is necessarily destroyed in the proceeding.

The hemi-sected brain affords much assistance in the study of the fornix, which there appears as a curved white band, ventral to the corpus callosum.

FORNIX.—The fornix consists of two bands of longitudinal fibres pursuing an arched course and intimately connected with each other at one place. The united bands constitute the *body* of the fornix (corpus fornicis) and are related to the corpus callosum and the septum pellucidum. At each end of the body the two constituent parts of the fornix separate. At the anterior end the separation is not very great and results in the production of the *columnae fornicis*, two rounded white cords which curve ventralwards in front of the foramen of Monro. Continuing to the base of the brain the columns form the prominent mammillary body, the double character of which is thus explained. From the posterior end of the body of the fornix arise two *crura fornicis*. These, widely diverging, are at first connected with the corpus callosum. Soon they form the white hem—*fimbria hippocampi*—adherent to the hippocampus; and, as such, are continued down the inferior cornu of the lateral ventricle. Some fibres of the crus fornicis are spread out as a white layer (alveus) on the surface of the hippocampus.

Dissection.—Cut across the fornix about the point where the crura are leaving the body. Now, with the utmost care, remove the isolated aboral part of the hemispheres; i.e. the hippocampus and adjacent part of the wall of the inferior cornu of the ventricle.

This is a convenient opportunity to study the association of the hippocampal fissure of the exterior with the hippocampus in the interior. It will be observed that the two coincide in position; indeed, the fissure causes the elevation of the hippocampus. Between the hippocampal fissure and the fimbria hippocampi is a narrow, somewhat corrugated strip, the *fascia dentata hippocampi*.

TÊLA CHORIOIDEA VENTRICULI TERTII.—The choroid tela of the third ventricle is a triangular double fold of pia mater containing a layer of arachnoid and some blood-vessels. It is interposed between the fornix and part of the hippocampus on the one side and the thalami on the other. The apex of the triangle lies at the foramen of Monro. Each of its sides is bounded by the choroid plexus of the central part of the lateral ventricle. At its base the tela divides into its two component sheets of pia mater continuous with the pia covering the surface of the brain generally.

The cleft into which the choroid tela and the choroid plexuses of the inferior cornua of the lateral ventricles are insinuated, is known as the *transverse cerebral fissure* (*fissura transversa cerebri*).

Dissection.—Seize the apex of the choroid tela with forceps and strip it from the surface of the thalami upon which it lies. As this is done the cleft-like third ventricle will be exposed.

THALAMUS.—The thalamus is an oval mass of grey matter separated from the caudate nucleus by an oblique groove containing a narrow white band, the *stria terminalis*. The dorsal surface of the thalamus is convex in the main and bounded medially by a prominent border formed by a longitudinal ridge, white in colour, known as the *medullary stria* (*stria medullaris*). The anterior end of the stria appears to join one of the columns of the fornix, while posteriorly it is apparently connected with the pineal body. The medial surfaces of the two thalami are flattened and form the lateral walls of the narrow third ventricle. Crossing the ventricle and uniting the two thalami is a thick, rounded grey bridge of tissue, the *intermediate mass* (*massa intermedia*). The lateral and ventral surfaces of the thalamus cannot be demonstrated at present, as they are in connection with other parts of the brain. The lateral surface is in contact with a band of white matter known as the *internal capsule*. The ventral surface rests on the dorsal or tegmental part of the cerebral peduncle (the hypothalamus).

CORPUS PINEALE.—In the middle line where the posterior part of the two thalami are in contact, the small and inconspicuous pineal body will be found. The base of the body contains one of the recesses of the third ventricle.

VENTRICULUS TERTIUS.—The third ventricle is the narrow space between the two thalami. The choroid tela forms the roof of the ventricle, while its floor corresponds to the tuber cinereum, mammillary body and the posterior perforated substance. Anteriorly the cavity is bounded by the terminal lamina,

the columns of the fornix, and the anterior commissure. The ventricle communicates with the lateral ventricles through the foramen of Monro, and posteriorly an *aditus* (*aditus ad aquæductum cerebri*) gives access to the aqueduct of Sylvius.

The regularity of the contour of the cavity is broken by several recesses. Among these is the *recess of the infundibulum* (*recessus infundibuli*) extending into the hypophysis. The *optic recess* (*recessus opticus*) is just dorsal to the optic chiasma. In the base of the pineal body is a small *pineal recess* (*recessus pinealis*), and above it a much more extensive *suprapineal recess* (*recessus suprapinealis*).

COMMISSURA ANTERIOR.—The anterior commissure is a transverse band of fibres readily demonstrated in the hemi-sectioned brain. If such a specimen be examined, the commissure will be seen in section as a small oval white object, immediately in front of the columns of the fornix. In the specimen from which the structures overlying the thalami have been removed, a glimpse of the commissure may be obtained between the slightly divergent columns of the fornix.

COMMISSURA POSTERIOR. — The posterior commissure consists of a narrow white strand crossing the brain transversely at the base of the pineal body. It is best demonstrated in a median longitudinal section.

Dissection.—This is a convenient time at which to make a complete examination of the mid-brain. Strip the membranes from the corpora quadrigemina, aboral to the thalami in position, and from the adjacent parts of the cerebellum. Be careful to preserve the small trochlear nerve to be found deep down in the depression between the cerebellum and the corpora quadrigemina.

MESENCEPHALON.—The mid-brain is the short and narrow segment joining the pons and cerebellum on the one hand with the cerebrum on the other. It has a dorsal part formed by the *corpora quadrigemina*, and a larger ventral portion consisting of the *peduncles of the cerebrum*. In the intact brain the corpora quadrigemina are completely hidden by the cerebral hemisphere. Running through the mid-brain is a passage, the *aqueduct of Sylvius* (*aquæductus cerebri* [Sylvii]), which connects the third and fourth ventricles.

CORPORA QUADRIGEMINA.—These are four rounded elevations lying between the thalami and cerebellum and arranged in two pairs. The anterior elevations (*colliculi anteriores*) are somewhat more clearly defined, and are closer together than the posterior colliculi. These latter are separated from each other by a wide and shallow groove, from which a thin thread-like *frænulum veli* runs into the anterior medullary velum. The two colliculi of the same side are separated by a narrow but not very deep transverse groove.

Laterally each colliculus is continued by a *brachium*. The brachium of the anterior colliculus (*brachium quadrigeminum anterius*) is scarcely demonstrable,

since it becomes buried immediately on leaving the colliculus. The brachium of the posterior colliculus (*brachium quadrigeminum posterius*), on the contrary, is easily traced as a rounded ridge-like eminence, running in a ventral and nasal direction to disappear under an oval white eminence, the *medial geniculate body*.

CORPORA GENICULATA.—The geniculate bodies, medial and lateral, are intimately connected with the thalamus and the corpora quadrigemina. The *lateral geniculate body* (*corpus geniculatum laterale*) is closely applied to the

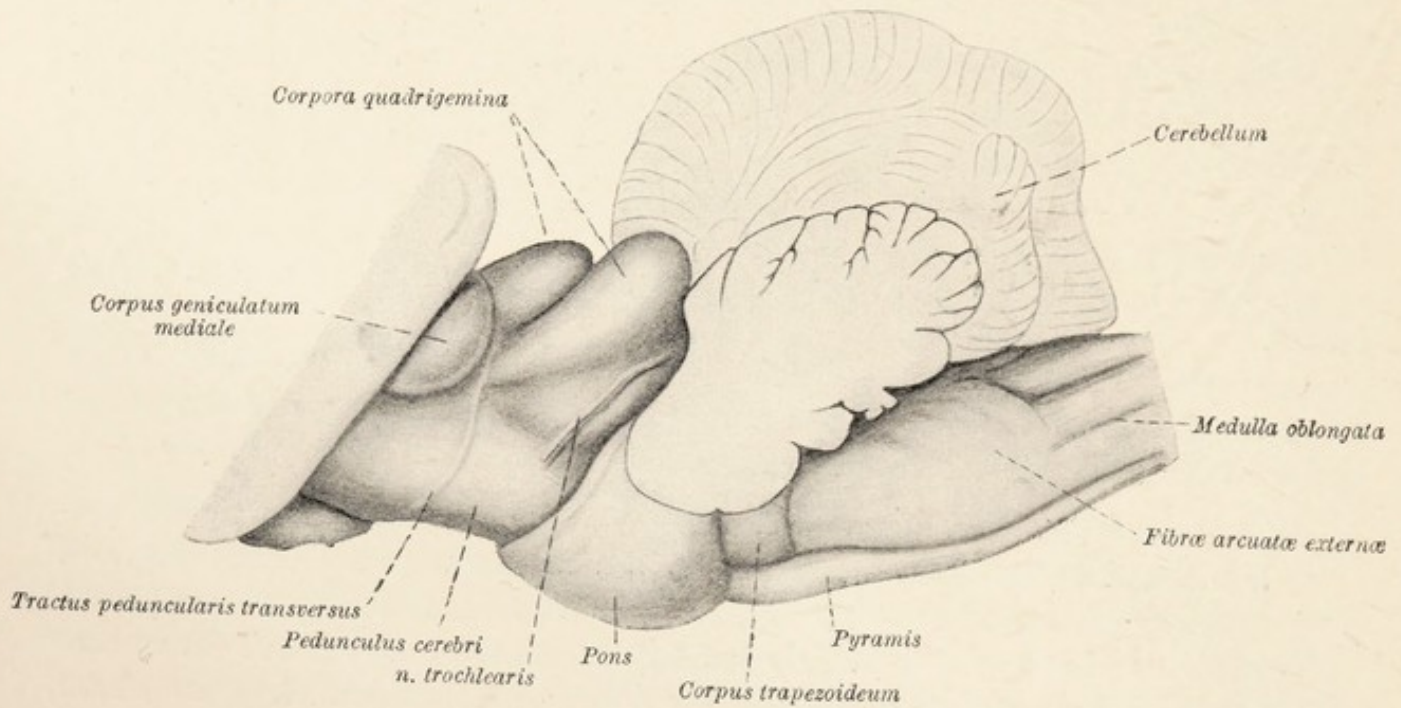


FIG. 69.—Lateral aspect of hind-brain and mid-brain.

posterior part of the thalamus, and from it the optic tract appears to arise. The *medial geniculate body* (*corpus geniculatum mediale*) is an oval eminence between the optic tract and the brachium of the posterior colliculus.

TRACTUS OPTICUS.—The optic tract, in the form of a white band, curves obliquely round the lateral part of the cerebral peduncle. To the naked eye it appears to commence in the lateral and medial geniculate bodies. Microscopically, however, its fibres are connected with the lateral geniculate body, the anterior colliculus and the thalamus.

PEDUNCULI CEREBRI.—Forming the ventral part of the mid-brain, each cerebral peduncle is divisible into two portions—the *tegmentum* and the *basis pedunculi*. Of these, the basis pedunculi is the smaller and the more ventral. The superficial distinction between the two parts is indicated by two grooves. The *lateral groove* (*sulcus lateralis*) is visible when the mid-brain is viewed from the side, and runs from the pons to the medial geniculate body. The extent of the basis pedunculi in a medial direction is marked by a groove from which the roots of the oculomotor nerve take origin—the *sulcus nervi oculomotorii*.

An indistinct narrow ridge of fibres winds round the cerebral peduncle beginning at the brachium of the anterior colliculus and ending vaguely about the mammillary body. This is the *transverse peduncular fasciculus* (fasciculus peduncularis transversus [Guddeni]).

Dissection.—Cut across the mid-brain, making the section through the anterior colliculus but not so far forwards as to injure the geniculate bodies.

An examination of the cut surface of the mid-brain reveals the aqueduct of Sylvius, which places the third and fourth ventricles in communication with each other. In general the outline of the aqueduct is lozenge-shaped, and around it is a mass of grey nerve matter.

The differentiation of the tegmentum and basis pedunculi can readily be made by an observation of the position of the two grooves already noted on the surface. In addition, a stratum of nerve tissue of somewhat different colour lies between the two structures.

Dissection.—By a median incision separate the two halves of what remains of the cerebrum. Of one half, make a series of horizontal sections about two or three mm. thick. The other half should be cut into slices by vertical transverse incisions. In making these sections it is well to use a broad-bladed knife or a razor.

CORPUS STRIATUM, ETC.—The so-called basal ganglia of the cerebral hemisphere consist of masses of grey matter separated by intervening strata of white matter. The ganglia are the caudate and lentiform nuclei of the corpus striatum, the claustrum, and the amygdaloid nucleus.

NUCLEUS CAUDATUS.—A partial examination of the caudate nucleus was made after the lateral ventricle had been opened. The nucleus consists of a mass of grey matter of curved pear-shaped form. The *head* (caput nuclei caudati) is thick and forms a projection in the anterior cornu of the ventricle. From the head the nucleus tapers somewhat rapidly to a *tail* (cauda nuclei caudati), which follows the inferior cornu of the ventricle to end in the *amygdaloid nucleus* (nucleus amygdalæ) in the roof of the extremity of the cornu. From what has previously been seen and from the sections now under examination, it is manifest that two surfaces of the caudate nucleus may be described. A free ventricular surface is covered by the ependyma of the lateral ventricle. A deeper surface is embedded in the substance of the cerebral hemisphere, and is mainly in contact with the internal capsule.

NUCLEUS LENTIFORMIS.—The lentiform nucleus is an irregularly lens-shaped mass of grey matter placed lateral to the caudate nucleus and the thalamus. Smaller than the caudate nucleus, it is connected with this by strands of grey matter which cross the intervening white stratum. In addition the

two nuclei are connected with each other and with the grey matter of the surface of the hemisphere at the olfactory tubercle.

CLAUSTRUM.—The claustrum is a very thin layer of grey matter lateral to the corpus striatum and very nearly co-extensive with the insula, i.e. the convolutions hidden in the Sylvian fissure.

CAPSULA INTERNA.—The term internal capsule is applied to the white matter separating the caudate nucleus and the thalamus on the one side from the lentiform nucleus on the other. The continuity of the capsule is much interfered with anteriorly by the grey strands crossing from one nucleus to the other. In horizontal sections the capsule is bent opposite the stria terminalis at what is known as the *knee* of the internal capsule (*genu capsulæ internæ*). The limb in front of the genu may be designated the *frontal part* (*pars frontalis capsulæ internæ*), and the limb behind the genu the *occipital part* of the capsule (*pars occipitalis capsulæ internæ*).

The internal capsule is of great importance since it contains fibres derived from or passing to various parts of the cerebral cortex. The divergence of the fibres dorsal to the capsule is referred to as the *corona radiata*.

CAPSULA EXTERNA.—The term external capsule is applied to the layer of white matter between the lentiform nucleus and the claustrum.

RHOMBENCEPHALON.—Attention must now be directed to the hind-brain composed of the medulla oblongata, the pons, and the cerebellum.

MEDULLA OBLONGATA.—An arbitrary limit to the spinal cord is made on a level with the foramen magnum; but when the brain and cord have been removed from the body, it is difficult to say exactly where the cord ends and the medulla oblongata begins. The medulla extends as far in a nasal direction as the pons. At first it has the same general form as the spinal cord; but soon it becomes dorso-ventrally flattened and expanded laterally. The increase in width is associated with the opening out of the central canal (continued from the spinal cord) into the fourth ventricle.

The bilateral character of the medulla oblongata is made manifest on the surface by the presence of ventral and dorsal median fissures continuous with the like land-marks of the spinal cord. While the *ventral median fissure* (*fissura mediana ventralis*) can be traced as far as the pons, where it terminates abruptly at the *foramen cæcum*, it is not of uniform depth throughout. About the aboral end of the medulla oblongata numerous fibres pass from one side to the other (the decussation of the pyramids) and cause the fissure to be very shallow at this point. The *dorsal median fissure* (*fissura mediana dorsalis*) is not so extensive. It is continued only to the extremity of the fourth ventricle, where it apparently widens out in conformity with the lateral divergence of the two halves of the dorsal portion of the medulla oblongata.

Along each side of the ventral median fissure is a very definite strand of nerve fibres known as the *pyramid* of the medulla oblongata (*pyramis [medullæ oblongatæ]*). Followed towards the cerebrum, the pyramid disappears

under the pons. Research has shown that the fibres composing the pyramid are derived from nerve cells in the grey matter of that part of the cerebral cortex which lies in the neighbourhood of the cruciate sulcus. From their origin these fibres, which are motor in function, pass by way of the corona radiata and internal capsule into the basis of the cerebral peduncle and so through the pons into the pyramid of the medulla oblongata. Close to the foramen magnum the fibres cross over from one side to the other (decussation of the pyramids) and travel along the *crossed pyramidal tract* of the opposite side of the cord.

Lateral to the pyramid is a groove, of no great depth, from which the rootlets of the abducent and hypoglossal nerves arise. The groove separates the pyramid from an elevation known as the *facial tubercle* (*tuberculum faciale*). In an adult dog the tubercle is not very conspicuous, because its surface is crossed by the *external arcuate fibres* (*fibrae arcuatae externae*) which traverse the lateral border of the medulla oblongata obliquely. Behind the facial tubercle the medulla oblongata resembles the lateral part of the spinal cord, and to the naked eye it appears as if the lateral columns of the cord were merely prolonged into the medulla. This appearance is, however, contrary to fact. The lateral column of the cord contains fibres not present in a similar position in the medulla, e.g. the crossed pyramidal tract.

On each side of the dorsal median fissure is a very narrow strand of fibres forming the *funiculus gracilis*, which deviates from the middle line when the end of the fourth ventricle is reached and expands slightly to form the *clava*. Lateral to the gracile funicle is the much wider *funiculus cuneatus*. This also diverges laterally on reaching the ventricle and forms the eminence called the *tuberculum cinereum*. The gracile and cuneate funicles form the direct continuation of the dorsal column of the spinal cord. The clava and tuberculum cinereum contain collections of nerve cells (*nucleus funiculi gracilis et nucleus funiculi cuneati*) in association with which the fibres of the dorsal column of the cord end.

A third band of white matter lies lateral to the funiculus cuneatus. This is known as the *funiculus of Rolando* because it is produced by the substantia gelatinosa [Rolandi] of the cord coming towards the surface when the medulla oblongata is reached.

A superficial naked-eye examination of the medulla oblongata leads to the conclusion—an erroneous one—that the three funicles just mentioned are continued forwards as the *restiform body* (*corpus restiforme*), a thick strand which, after forming a floor for the lateral prolongation of the fourth ventricle, turns abruptly dorsalwards and enters the cerebellum. It will be observed that the external arcuate fibres enter largely into the formation of the restiform body.

PONS.—The pons is a transverse prominence between the medulla oblongata and the cerebral peduncles. Its ventral surface is convex from side to side

with a very shallow antero-posterior groove in the middle line. The dorsal surface assists in the formation of the floor of the fourth ventricle, and will be examined later. On each side the pons is continued into the cerebellum as the *brachium pontis*.

A superficial examination of the pons suffices to show that it is composed largely of transverse fibres. The greater part of these are superficial to the pyramids. Some, however, cross the dorsal aspect of the pyramids, and, since they are more caudal than the superficial fibres, form an elongated transverse area, the *trapezoid body* (*corpus trapezoideum*) on the surface of the brain. From the lateral part of this body the facial and acoustic nerves have their superficial origin.

Dissection.—The course of the pyramids should be followed through the pons. This can be done by making a longitudinal incision across the middle of the pons, and a similar incision just medial to the origin of the trigeminal nerve. Now, with a pair of forceps, tear away the superficial transverse fibres of the pons until the pyramid is exposed. The continuity of the pyramid with the basis pedunculi can thus be demonstrated.

CEREBELLUM.—The cerebellum, a transversely elongated, rounded mass, forms the dorsal and more bulky part of the hind-brain. For descriptive purposes three parts may be distinguished, namely, a central vermis and two hemispheres. The *vermis* is the most prominent part of the organ, and projects beyond the level of the hemispheres as a rounded ridge, more sharply defined in its caudal and ventral parts than elsewhere. The *hemisphere*, lateral in position, is narrow anteriorly but rapidly widens. A small lateral appendage is conspicuous when the brain has been removed from the cranium, and is received into a depression in the temporal bone when the parts are in their natural position. It is with the hemisphere that the restiform body, the *brachium pontis*, and the *brachium conjunctivum* are connected; that is to say, access to the vermis is only obtained by way of the hemisphere. The restiform body and the *brachium pontis* have been mentioned in connection with the medulla oblongata and pons respectively. At the present stage of the dissection the *brachium conjunctivum* cannot be seen in its entirety, but a glimpse of it is obtained between the *brachium pontis* and the posterior colliculus of the corpora quadrigemina.

The surface of the cerebellum is beset with narrow ridges or *folia* separated by *fissures*. Deeper fissures cut the cerebellum into *lobes*, the disposition of which can be more easily studied in sections, as will be done presently. It should be observed, however, that the most lateral part of each hemisphere is separated from the rest by a fissure running in a sagittal direction. The portion so defined is composed of the *paraflocculus* and *flocculus*. The *paraflocculus* consists of two rows of *folia* from the more ventral of which projects the *petrous lobule* (*lobulus petrosus*), so named from its location in a fossa of

the petrous portion of the temporal bone. Into the depths of the fissure between the paraflocculus and the rest of the hemisphere the brachium pontis can be followed. Between the paraflocculus and the origins of the facial and acoustic nerves is the *flocculus*, a small collection of folia separated from the paraflocculus by a fissure of considerable depth.

Dissection.—Make a median sagittal section through the vermis of the cerebellum and the two medullary vela—thin membranes forming the roof of the fourth ventricle. By separating the two halves of the cerebellum a view of the floor of the ventricle may be obtained. The cut surface of the vermis should be examined and the arrangement of the lobes and fissures noted.

ARBOR VITÆ.—A sagittal section of the vermis of the cerebellum reveals in a very striking manner the peculiar arrangement of grey and white matter. The grey matter forms a continuous layer on the surface of the organ. The white matter within, as a consequence of the presence of numerous fissures, presents a tree-like appearance in sections, and therefore goes by the name of arbor vitæ. From the central mass of white matter various branches radiate. Of these, two are conspicuously large and form the core of the two largest lobes of the cerebellum separated from each other by the deepest of the cerebellar fissures.

BRACHIUM CONJUNCTIVUM.—Two of the connections of the cerebellum, viz. the restiform body and the brachium pontis, have previously been examined. Up to the present, however, the third connection—the *brachium conjunctivum*—could not be examined in its whole length. If the two halves of the cerebellum be separated as much as possible the brachium will be seen connected with the hemisphere immediately within the brachium pontis. Followed towards the mid-brain, each brachium runs in a slightly medial direction to disappear under the posterior colliculus of the corpora quadrigemina.

MEDULLARY VELA.—Ventral to the cerebellum, and connected round the ends of the vermis with the white matter of this organ, are two thin membranes which form the roof of the fourth ventricle. The *anterior medullary velum* (velum medullare anterius) is a triangular membrane filling the space between the two brachia conjunctiva. The base of the triangle bends round the end of the vermis and is continuous with its white core.

The *posterior medullary velum* (velum medullare posterius) is somewhat more complicated. Its cerebellar attachment stretches from the median plane—where it has a connection similar to that of the anterior velum—to the flocculus. The velum soon loses its nervous elements and gives place to a very thin translucent membrane composed of pia mater lined internally with ependyma. This completes the posterior part of the roof of the fourth ventricle and is attached to the margins of the cavity.

VENTRICULUS QUARTUS.—The fourth ventricle represents the cavity of

the original vesicle from which the hind-brain developed. Consequently it is in communication with the central canal of the spinal cord at the one end and with the cavities of the rest of the brain at the other. The opening of the central canal into the ventricle has already been commented upon. If the anterior medullary velum be raised the communication with the aqueduct of Sylvius—and through this with the third ventricle—will be revealed.

In outline the cavity is rhomboidal; hence the name *fossa rhomboidea* as applied to its floor. From the narrow caudal part—*calamus scriptorius*—it widens to the level of the place where the restiform bodies turn up into the cerebellum. Here the transverse diameter is materially increased by the presence of *lateral recesses* (*recessus laterales*), which curve round the caudal aspect of the restiform bodies. In front of the recesses, the ventricle narrows to the entrance of the aqueduct of Sylvius.

The roof or dorsal wall of the ventricle is formed by the two medullary vela and the thin pial continuation of the posterior velum. Seen in sagittal section, the roof is somewhat tent-like, being continued into a recess, the *fastigium*, between the vermis attachments of the two vela. The roof, moreover, is rendered irregular on a level with the lateral recesses by an invagination produced by the *choroid plexus* (*plexus chorioideus ventriculi quarti*). That part of the plexus which is related to the recesses can readily be seen in the intact brain as a vascular tuft occupying an angular depression formed by the cerebellum and medulla oblongata.

The membranous roof is defective at the extremity of the lateral recess, where a small irregular opening, the *lateral aperture* (*apertura lateralis ventriculi quarti*), places the cavity of the ventricle in communication with the subarachnoid space.

The floor of the ventricle is formed by the medulla and pons. Divided into two lateral halves by a median longitudinal groove, the floor is further subdivided into areas. A longitudinal *limiting groove* (*sulcus limitans*) forms the lateral boundary of an elongated and narrow medial area. The limiting groove is quite shallow, but deepens a little at two places known as the *anterior* and *posterior foveæ*. A prominent *medial eminence* (*eminentia medialis*) occurs about the middle of the length of the strip demarcated by the median and limiting grooves. A triangular area, the *hypoglossal trigone* (*trigonum nervi hypoglossi*) intervenes between the posterior fovea and the median groove, while lateral to it is the grey *ala cinerea*. An elevated *acoustic area* (*area acustica*) forms a conspicuous object lateral to the limiting sulcus and opposite the recess of the ventricle.

Dissection.—It is now necessary to remove the remains of the muscles attached to the vertebral column, the ribs, the pelvis, and the occipital

bone, in order that the ligaments connected with these parts of the skeleton may be examined.

The bodies of adjacent vertebræ are connected by discs of fibro-cartilage (fibrocartilagine intervertebrales). If two vertebræ be separated from each other, it will readily be seen that the connecting cartilage is composed of a peripheral fibrous portion (annulus fibrosus) and a much softer central part (nucleus pulposus). Assisting in the firm union of the vertebræ are two longitudinal bands. The *ventral longitudinal ligament* (lig. longitudinale ventrale) is attached along the ventral aspect of the vertebral bodies from the sacrum to about the fifth thoracic vertebra, where it materially diminishes in volume. The *dorsal ligament* (lig. longitudinale dorsale) is more sharply defined. Running along the ventral wall of the vertebral canal from the sacrum to the dens of the epistropheus, it has the form of a band of unequal width. At each intervertebral fibro-cartilage the ligament widens somewhat, to become narrow again on a level with the vertebral body.

Yellow ligaments (ligamenta flava) bridge the narrow gap between neighbouring vertebral arches. In the thoracic region these ligaments are narrow, but are considerably wider in the cervical region. The joint-cavities between contiguous articular processes of the vertebræ are enclosed by *joint-capsules* (capsulæ articulares) with the customary attachment around the articular surfaces, and possessed of the usual synovial lining.

Forming the bond of union between the vertebral spinous processes are the supraspinal and interspinal ligaments. The *supraspinal ligament* (lig. supraspinale) is a strong cord-like object attached to the summits of the processes from the sacrum to about the first thoracic vertebra, where it is continuous with the ligament of the nape. The *interspinal ligaments* (ligg. interspinalia) fill the intervals between the spinous processes, and are confined to the thoracic and lumbar regions. In the lumbar region *intertransverse ligaments* (ligg. intertransversaria) connect the transverse processes.

ARTICULATIO ATLANTO-OCCIPITALIS.—The articulation between the atlas and the condyles of the occipital bone has a cavity continuous with that between the atlas and the epistropheus, and is enclosed by a *joint-capsule* (capsula articularis) on each side. An extensive *ventral atlanto-occipital membrane* (membrana atlanto-occipitalis ventralis), disposed on the ventral side of the joint, closes in the interval between the atlas and the occipital bone; while a *dorsal membrane* (membrana atlanto-occipitalis dorsalis), also extensive but rather stronger than the ventral membrane, bridges the space on the dorsal aspect of the articulation. The union of the two bones is finally effected by the presence of a *lateral atlantal ligament* (lig. laterale atlantis) on each side. This is connected with the joint-capsule, and runs from the edge of the atlas to the jugular process of the occipital bone.

ARTICULATIO ATLANTO-EPISTROPHICA.—The joint cavity of the atlanto-epistrophic articulation, continuous as previously stated with that of the foregoing joint, is enclosed by the customary joint-capsule. Intimately connected therewith, and passing between the arches of the atlas and epistrophæus, is a *tectorial membrane* (*membrana tectoria*), from which an *interspinal ligament* (*ligamentum interspinale*) may be separated with difficulty. Associated with the dens of the epistrophæus are *alar* and *transverse ligaments*. The former (*ligamenta alaria*) spring from the tip of the dens, and diverging proceed forwards to be attached within the occipital condyles. The transverse ligament (*lig. transversum dentis*), along with the atlas, forms a ring within which the dens rotates.

ARTICULATIONES COSTO-VERTEBRALES.—Since a rib is in contact by its head with the bodies of two vertebræ, and by its tubercle with the transverse process of the more caudal of the two vertebræ, it follows that there are two joints between a typical rib and the vertebral column.

The *capitular articulation* (*articulatio capituli*) possesses two joint-cavities, corresponding to the two vertebral bodies with which the head of the rib is in contact, and separated from each other by an interarticular ligament to which the two joint-capsules are attached. The *interarticular ligament* (*lig. capituli costæ interarticulare*) springs from the depression on the head of the rib, and passes to the middle plane of the body where it is continuous with the same ligament of the corresponding joint of the other side of the body. Broad at its attachment to the head of the rib, the ligament narrows as it lies under cover of the dorsal longitudinal ligament of the vertebral column. There is a slight connection between the ligament and the intervertebral fibro-cartilage. On the ventral aspect of the joint is the *radiate ligament* (*lig. capituli costæ radiatum*) with fibres extending, in a radiating fashion, from the neck of the rib to the bodies of the vertebræ and the interposed intervertebral fibro-cartilage.

The *costo-transverse articulation* (*articulatio costo-transversaria*) between the tubercle of the rib and the transverse process of the vertebra, is provided with the customary joint-capsule. In addition there are a *dorsal ligament* and the ligament of the neck. The former (*lig. costo-transversaria dorsale*) passes from the vertebral transverse process to a point on the rib immediately lateral to the tubercle. The *ligament of the neck* (*lig. colli costæ*) runs between the vertebra and the dorsal aspect of the neck of the rib.

ARTICULATIO SACRO-ILIACA.—The slightly moveable articulation between the sacrum and the ilium is provided with a very short joint-capsule. Ligaments disposed in the vicinity of the joint all tend to restrict its range of movement.

The *ventral sacro-iliac ligament* (lig. sacro-iliacum ventrale) consists of short fibres joining the sacrum and ilium, and lies, as its name indicates, ventral to the joint. *Short and long sacro-iliac ligaments* (lig. sacro-iliacum dorsale breve et lig. sacro-iliacum dorsale longum) connect the ilium with the spinous processes and the lateral border of the sacrum respectively.

At some distance from the sacro-iliac joint, but conveniently considered in this place, is the *sacro-tuberous ligament* (lig. sacro-tuberosum), which stretches in the form of a stout cord from the edge of the sacrum to the sciatic tuber of the ischium.

SYMPHYSIS PELVIS.—The two pubes and the two ischia join in the median plane at the symphysis of the pelvis. Occasionally in old animals the union becomes bony. A few transverse fibres, crossing the ventral aspect of the symphysis, constitute the *arcuate ligament* (lig. arcuatum).

ORGANON AUDIUS.—It now remains for the dissector to complete the dissection of the organ of hearing by an examination of the internal ear and the cavity of the tympanum. To do this with any degree of satisfaction, it is necessary to have several specimens, so that sections across some of them may be made with a fine saw, while one at least is examined after piece-meal removal of parts of the bone.

Prior to commencing the dissection of the internal ear and the cavity of the tympanum, it would be well that the student have some general idea of the auditory apparatus as a whole. The organ of hearing is naturally divided into three parts: an external ear or auricle (auricula), a middle ear or cavity of the tympanum, and an internal ear. An examination of the cartilages of the external ear and the muscles concerned in the production of their movements was conducted at an earlier stage of the dissection. The canal circumscribed by the external ear is known as the *external acoustic meatus* (meatus acusticus externus) and is partially bounded by the temporal bone. The meatus terminates at the *membrane of the tympanum* (membrana tympani), by which its cavity is separated from that of the tympanum.

The cavity of the tympanum, or middle ear, is a space within the temporal bone connected with the interior of the pharynx by the *auditory tube* of Eustachius (tuba auditiva [Eustachii]). Crossing the cavity from the membrane of the tympanum to its inner-wall is a chain of three auditory ossicles by way of which vibrations of the tympanic membrane are transmitted to the internal ear. The air-containing cavity of the osseous bulla of the temporal bone is in free communication with the tympanic cavity.

The internal ear consists of a series of spaces and canals within the temporal bone, to which is given the collective name of *osseous labyrinth* (labyrinthus

osseus), containing membranous sacs and tubes—the *membranous labyrinth* (labyrinthus membranaceus). The central space of the osseous labyrinth, the *vestibule* (vestibulum), in the dried skull communicates with the cavity of the tympanum by an oval opening, the *fenestra of the vestibule* (fenestra vestibuli). In the fresh state and in the living animal the fenestra is occluded by the base of the stapes, one of the auditory ossicles. In the posterior part of the vestibule are fine openings leading into the three *semicircular canals* (canales semicirculares ossei), while in the lower and anterior part of the cavity is an opening into the spiral canal of the cochlea. The *cochlea* itself resembles the shell of a snail, and consists essentially of the spiral canal wound round a central column of bone designated the *modiolus*. The spiral canal ends blindly at the apex of the cochlea, where it forms the *cupola* (cupula). Into the canal a *spiral lamina* of bone (lamina spiralis ossea) projects for some distance from its inner (modiolar) wall; thus the canal is partially divided into two compartments; one of which, the *scala vestibuli*, communicates with the vestibule, the other, the *scala tympani*, in the macerated bone opening by a small rounded aperture—the *fenestra of the cochlea* (fenestra cochleæ)—into the cavity of the tympanum. In the fresh condition the fenestra is closed by a membrane.

The membranous labyrinth consists of the saccule, the utricle, three semicircular ducts and the cochlear duct. The *saccule* (sacculus) and the *utricle* (utriculus) are lodged in the vestibule, and are placed in indirect communication with each other by means of the *endolymphatic duct* (ductus endolymphaticus). The *semicircular ducts* (ductus semicirculares) occupy the three bony semicircular canals and are in communication with the utricle.

The *cochlear duct* (ductus cochlearis) is attached, on the one side to the outer wall of the spiral canal of the cochlea, and on the other to the edge of the bony spiral lamina. At the base of the cochlea the duct is connected with the saccule by a narrow *uniting duct* (ductus reuniens). The blind apical termination of the duct does not quite reach the cupola of the cochlea, thus allowing a communication between the scala vestibuli and the scala tympani.

Dissection.—As previously stated, it is scarcely possible to make a complete dissection of the ear on one specimen only. In order to examine the cavity of the tympanum the lower part of the osseous bulla should be removed bit by bit, a ring of bone being left round the external acoustic meatus. In order to demonstrate the tympanic membrane properly, it is necessary to remove the cartilages of the auricle. It will be observed that the cavities of the tympanum and of the osseous bulla communicate with each other by a wide opening bounded by the serrated edge of a thin plate of bone.

CAVUM TYMPANI.—The tympanic cavity is a narrow, air-containing chamber between the internal ear and the end of the external acoustic meatus. Its outer wall is formed almost entirely by the thin, translucent *tympanic*

membrane (membrana tympani). On the inner wall, which separates the cavity from the labyrinth of the internal ear, is a well-marked projection, the *promontory* (promontorium), above and slightly in front of which is the fenestra of the vestibule. Below the promontory is the fenestra of the cochlea. Leading from the anterior part of the tympanic cavity is the narrow opening of the auditory tube of Eustachius.

Dissection.—Snip all round the outer wall of the tympanum, so that it may be removed. In the process an irregular space, the *epitympanic recess* (recessus epitympanicus), containing the incus and the head of the malleus, will be revealed in connection with the roof of the tympanic cavity.

OSSICULA AUDITUS.—The auditory ossicles are three in number, namely, the malleus, the incus, and the stapes. The *malleus* is the outermost and the largest of the three bones. It consists of a large upper part or *head* (capitulum mallei), below which is a *neck* (collum mallei), and a *manubrium* (manubrium mallei) and two processes. The head carries an articular surface for contact with the incus. The manubrium is attached to the tympanic membrane, as is also the *lateral process* (processus lateralis). The *anterior process* (processus anterior) is extremely slender, and is attached by ligament to the wall of the tympanic cavity.

The *incus* bears some resemblance to a human bicuspid tooth, and possesses a body and two crura. The *body* (corpus incudis) carries a saddle-shaped surface for articulation with the head of the malleus. The *short crus* (crus breve) is movably connected with the wall of the tympanum; while the *long crus* (crus longum) articulates with the head of the stapes.

The *stapes*, a stirrup-shaped bone, consists of a *head* (capitulum stapedis), two *crura* (crus anterior et crus posterior), and a base. The *base* (basis stapedis) is in the form of an oval plate lodged in, and so connected with the margin of the fenestra vestibuli that some amount of movement can take place.

MUSCULI OSSICULORUM AUDITUS.—Connected with the auditory ossicles are two small muscles. The *tensor muscle of the tympanum* (m. tensor tympani) is short and conical, with an origin from a depression just anterior to the epitympanic recess. A slender tendon connects the muscle with the manubrium of the malleus close to its root. The *stapedius muscle* (m. stapedius) is inserted into the head of the stapes.

CANALIS FACIALIS.—The dissector should open up the whole length of the facial canal, beginning at the stylomastoid foramen and working toward the internal acoustic meatus. He will then find that the canal curves round the base of the cochlea and the posterior part of the internal wall of the tympanum.

INDEX

- ABDOMEN, 15
 Accessory pancreatic duct (of Santorini), 39
 Acoustic area (of fourth ventricle), 226
 Aditus of aqueduct of Sylvius, 219
 Aggregated lymph-nodules of Peyer, 27
 Ala cinerea, 226
 Amygdaloid nucleus, 221
 Annular cartilage, 150
 Anterior commissure, 219
 fovea, 226
 medullary velum, 225
 perforated substance, 210
 Aortic semilunar valves, 54
 Appendix of laryngeal ventricle, 179
 Aqueduct of Sylvius, 219, 221
 Aqueous humour of eyeball, 189, 193
 Arachnoid, 202, 206
 Arbor vitæ, 225
 Arrangement of cardiac orifices, 57
 Arterial circle of Willis, 209
 ARTERIES :
 Angular, of mouth, 158
 Anterior auricular, 160
 bronchial, 30
 cerebellar, 207
 cerebral, 208
 circumflex humeral, 123
 communicating, 208
 femoral, 77, 80
 mediastinal, 30, 42
 tibial, 92, 97
 Aorta, 54, 59, 72
 Artery of urethral bulb, 111
 Articular artery (from femoral), 79
 Ascending cervical, 5, 56
 pharyngeal, 149
 Axillary, 4, 123
 Basilar, 207
 Brachial, 124
 Brachio-cephalic, 54
 Bronchial, 61
 Buccinator, 182
 Caudal epigastric, 12
 gluteal, 85
 mesenteric, 26
 Arteries : Caudal thyroid, 149
 Central, of retina, 188
 Cerebro-spinal, 168
 Choroidal, 208
 Circumflex scapular, 124
 Cœliac, 39
 Common carotid, 55, 149, 163
 interosseous, 138
 Condylod, 168
 Costo-cervical trunk, 55
 Cranial epigastric, 12, 30
 gluteal, 85, 111
 hæmorrhoidal, 26
 mesenteric, 25
 thyroid, 149
 vesical, 110, 116
 Deep artery of arm, 124
 penis, 111
 cervical, 55
 circumflex iliac, 73
 femoral, 80
 volar arch, 139, 142
 Deferential, 110
 Distal radial collateral, 124
 Dorsal arteries of penis, 9, 111
 digital, 88, 129
 interosseous, 138
 metatarsal, 92
 nasal, 159
 Dorsalis pedis, 92, 101
 Ethmoidal, 188
 External carotid, 164
 iliac, 75
 maxillary, 164
 pudendal, 10
 Facial, 158
 Femoral, 77
 Frontal, 188
 Gastro-duodenal, 40
 -lienal, 40
 Greater palatine, 183
 Hepatic, 40
 Hyaloid, 192
 Hypogastric, 110, 116
 Ileo-cæco-colic, 25
 Ilio-lumbar, 111

- Arteries : Inferior alveolar, 165
labial, 158
Infraorbital, 159, 182
Intercostal, 29, 61, 62
Internal auditory, 207
carotid, 168, 197, 208
mammary, 30, 41, 56
maxillary, 165, 182
pudendal, 110
spermatic, 73
Intestinal, 25
Lachrymal, 187
Laryngeal, 149
Lateral circumflex femoral, 77, 80
nasal, 159
tarsal, 94
thoracic, 5
Left colic, 26
coronary, 51
gastric, 40
gastro-epiploic, 40
subclavian, 54, 55
Lesser palatine, 182
Lingual, 164
Lumbar, 73
Medial tarsal, 101
Median, 138
Mental, 165
Middle cerebral, 208
colic, 25
hæmorrhoidal, 111
meningeal, 165, 198
sacral, 114
Musculo-phrenic, 30
Occipital, 168
Oesophageal, 61
Omo-cervical trunk, 5, 56
Ophthalmic, 182, 187
Pancreatico-duodenal, 40
Pericardiac-phrenic, 30, 41
Perineal, 111
Phrenic, 72
Phrenico-abdominal, 72
Plantar arch, 101
digital, 101
metatarsal, 101
Popliteal, 97
Posterior auricular, 164
cerebellar, 207
cerebral, 207
ciliary, 188
circumflex humeral, 124
communicating, 208
deep temporal, 165
femoral, 81
meningeal, 168
Proper digital, 88
Proximal radial collateral, 124, 129
ulnar collateral, 124
Radial, 139
Renal, 73
- Arteries: Right colic, 25
coronary, 51
gastric, 40
gastro-epiploic, 40
subclavian, 55
Saphenous, 77, 80, 94
Spheno-palatine, 183
Splenic, 40
Stylo-mastoid, 164
Sublingual, 164
Subscapular, 123
Superficial lateral caudal, 111
temporal, 160
Superior labial, 159
Supreme intercostal, 55
Thoraco-acromial, 4
-dorsal, 124
Thymic, 42
Transverse cervical, 28, 56
facial, 159, 160
scapular, 5, 56
Ulnar, 140
Umbilical, 110, 111
Uterine, 116
Vertebral, 55, 155
Volar digital, 140
interosseous, 139
metacarpal, 142
- ARTICULATIONS:
- Atlanto-epistrophic, 228
-occipital, 227
Carpo-metacarpal, 144
Costo-vertebral, 228
Digital, 106
Elbow-joint, 143
Hip-joint, 86
Humero-radial, 143
-ulnar, 143
Intermetatarsal, 106
Intersternal synchondroses, 35
Knee-joint, 102
Laryngeal, 180
Mandibular, 193
Metatarso-phalangeal, 106
Pisiform, 144
Radio-carpal, 143
-ulnar, 143
Sacro-iliac, 228
Shoulder-joint, 142
Sterno-costal, 35
Symphysis of the pelvis, 229
Talo-crural, 104
Tarso-metatarsal, 105
Tibio-fibular, 104
Vertebral, 227
Ary-epiglottic folds, 176
Arytenoid cartilages, 175
Auditive tube of Eustachius, 174, 229
Auditory ossicles, 231
Auricles of heart, 49
Axilla, 4

- BASIS PEDUNCULI, 220
 Bicuspid valve, 54
 Brachia of quadrigeminal bodies, 219
 Brachium conjunctivum, 224, 225
 pontis, 224
 Brain, 206
 Bronchi, 157

 CÆCUM, 20
 Calamus scriptorius, 226
 Canines, 171
 Capsule of lens, 193
 Cartilages of the nose, 198
 Cauda equina, 203
 Caudate nucleus, 216, 221
 Cavity of the nose, 199
 Central canal, 205
 grey matter, 205
 Cerebellum, 224
 Cerebral hemispheres, 211
 peduncles, 206, 209, 219, 220
 Cervical enlargement (of spinal cord), 202
 Chambers of the eye, 193
 Cheeks, 170
 Chordæ tendineæ, 53
 Choroid, 190
 Choroid plexus, 216, 226
 tela, 218
 Ciliary body, 190
 processes, 190
 zonule, 192
 Cisterna chyli, 74
 Claustrum, 222
 Clava, 223
 Clitoris, 116
 Cochlea, 230
 Cochlear duct, 230
 Colon, 20
 Columnæ fornicis, 217
 Columns of spinal cord, 205
 Common bile-duct, 36
 Conchal cartilage, 150
 Conical papillæ, 172
 Conjunctiva, 155
 Conus arteriosus, 52
 medullaris, 202
 Cornea, 190
 Corniculate cartilage, 175
 Corona radiata, 222
 Coronary sulcus, 49
 Corpora quadrigemina, 219
 Corpus callosum, 211, 214
 striatum, 221
 trapezoideum, 209, 224
 Cricoid cartilage, 175
 Crossed pyramidal tract, 223
 Crura fornicis, 217
 Crystalline lens, 192
 Cuneiform cartilages, 176
 Cupola, 230
 Cystic duct, 36

 DECUSSATION of the Pyramids, 223
 Deferent duct, 7
 Diaphragma sellæ, 196
 Ductus reuniens, 230
 Duodeno-jejunal flexure, 38
 recess, 25
 Duodenum, 19, 38
 Dura mater, 194, 201

 EAR, 150, 229
 Endocardium, 51
 Endolymphatic duct, 230
 Ependyma, 216
 Epicardium, 47
 Epididymis, 7
 Epiglottic vallecula, 173, 176
 Epiglottis, 175
 Epiploic foramen of Winslow, 24
 External acoustic meatus, 229
 arcuate fibres, 223
 capsule, 222
 ear, 150
 Eyeball, 188
 Eyelids, 155

 FACIAL canal, 231
 tubercle, 209, 223
 Falx cerebri, 195
 Fascia of forearm, 129, 134
 leg, 89
 Fasciculus cuneatus, 205, 206
 gracilis, 205, 206
 Fastigium, 226
 Female genital organs, 67, 115
 Femoral triangle, 77
 Fenestra cochleæ, 230
 vestibuli, 230
 Filiform papillæ, 172
 Filum terminale, 202
 Fimbria hippocampi, 216, 217
 Fissures of medulla oblongata, 222
 Flocculus, 225
 Foliate papillæ, 173
 Foramen cæcum, 209, 222
 Fornix, 217
 Fossa ovalis, 52
 rhomboidea, 226
 Fourth ventricle, 225
 Frænulum of the lip, 170
 tongue, 172
 Frænulum veli, 219
 Frontal sinus, 200
 Fungiform papillæ, 173
 Funicles of spinal cord, 205
 Funiculus cuneatus, 223
 gracilis, 223
 of Rolando, 223

- GALL-BLADDER, 36, 64
 GANGLIA :
 Caudal mesenteric, 26
 Ciliary, 187
 Celiac, 66
 Cranial cervical, 167
 mesenteric, 25, 66
 First thoracic, 61
 Gasserian, 197
 Jugular, 166
 Nodose, 166
 Otic, 184
 Spheno-palatine, 183
 Spinal, 203
 Gelatinous substance of Rolando, 205
 Geniculate bodies, 220
 Glosso-epiglottic fold, 173
 -palatine arch, 169
 Glottis, 176
 Greater omentum, 18, 23
 Grey commissures (of spinal cord), 205
 Grooves of spinal cord, 203
- HARDER'S Gland, 188
 Hard palate, 171
 Heart, 48
 Hepatic ducts, 65
 Hilus of kidney, 70
 Hind-brain, 222
 Hippocampal fissure, 213
 Hippocampus, 216
 Hyaloid canal, 192
 fossa, 192
 membrane, 190, 192
 Hypoglossal trigone, 226
 Hypothalamus, 218
- ILEUM, 19
 Incisor papilla, 172
 Incisors, 171
 Incus, 231
 Inguinal canal, 14
 Insula, 212
 Inter-arytenoid cartilage, 175
 Interior of the duodenum, 67
 intestines, 27
 kidney, 70
 Intermediate mass, 218
 Internal capsule, 218, 222
 Interpeduncular fossa, 206, 209
 Interventricular foramen of Monro, 215
 Iris, 191
 Isthmus faucium, 170
- JEJUNUM, 19
- KIDNEYS, 69
- LACHRYMAL caruncle, 155
 ducts, 155
 gland, 185
 Lamina chorio-capillaris, 190
 fusca, 190
 terminalis, 215
 vasculosa, 190
 Large intestine, 19
 Laryngeal prominence, 175
 Larynx, 174
 Lateral aperture (of fourth ventricle), 226
 groove (of mid-brain), 220
 recess (of fourth ventricle), 226
 ventricle, 215
 Left atrium of heart, 53
 ventricle of heart, 54
 Lentiform nucleus, 221
 Lesser omentum, 23
 LIGAMENTS :
 Alar, 228
 Arcuate, 229
 Broad (of uterus), 68
 Calcaneo-cuboid, 105
 -fibular, 104
 -navicular, 105
 Collaterals of carpus, 144
 Crico-thyroid, 175, 177
 Cruciate, 103
 Cuboideo-navicular, 105
 Deltoid, 104
 Denticulate, 202
 Dorsal atlanto-occipital membrane, 194, 227
 costo-transverse, 228
 longitudinal, 227
 tarsal, 104
 Fibular collateral, 103
 Gastro-lienal, 18
 Hyo-thyroid, 175, 177
 Inguinal (of Poupart), 10
 Interarticular, 228
 Intercarpal, 144
 Internal proper sternal, 35
 Interosseous membrane (of forearm), 143
 (of the leg), 104
 tarsal, 106
 Interspinal, 227, 228
 Intertransverse, 227
 Lateral atlantal, 227
 Ligament of neck of rib, 228
 Ligamenta flava, 227
 Ligamentum nuchæ, 154
 Long plantar, 105
 sacro-iliac, 229
 Navicular-cuneiform, 105
 Patellar, 102
 Pectinate of iris, 191
 Pisiform, 144
 Plantar, 105
 Pulmonary, 34
 Radial annular, 143
 collateral, 143, 144
 Radiate, 228

Ligaments: Radiate sterno-costal, 35
 Radio-carpal, 144
 Round (of hip), 86
 (of uterus), 68
 Sacro-tuberos, 229
 Short sacro-iliac, 229
 Supraspinal, 227
 Suspensory of lens, 192
 Talo-calcanean, 104, 105
 -fibular, 104
 Tectorial membrane, 228
 Temporo-mandibular, 193
 Thyro-epiglottic, 180
 Tibial collateral, 103
 Transverse (of dens), 228
 (of hip-joint), 86
 Triangular (of liver), 65
 Ulnar collateral, 143, 144
 Ventral atlanto-occipital membrane, 227
 longitudinal, 227
 sacro-iliac, 229
 Ventricular, 180
 Vocal, 179
 Limiting sulcus, 226
 Linea alba, 13
 Lingual papillæ, 172
 septum, 173
 Lips, 170
 Liver, 35
 Lobes of liver, 63
 Longitudinal fissure (of brain), 206
 groove (of heart), 50
 Lumbar enlargement (of spinal cord), 202
 Lungs, 42
 Lymph-glands, 4, 10, 25, 27, 48, 73, 83, 110, 148

MALE external genital parts, 5
 Malleus, 231
 Mammary glands, 1
 Mammillary body, 206, 209
 Maxillary sinus, 200
 Meatus nasi, 199
 Medial eminence (of fourth ventricle), 226
 Median fissure (of spinal cord), 203
 longitudinal fissure (of medulla), 209
 septum (of spinal cord), 205
 Mediastinal septum, 31, 34
 Medulla oblongata, 206, 222
 Medullary striæ, 218
 vela, 225
 Membrana nictitans, 155, 188
 tympani, 229, 230
 Membranous labyrinth, 230
 Menisci, 103
 Mesentery, 19, 23
 Mesocolon, 23
 Mesometrium, 68
 Mesosalpinx, 68
 Mesovarium, 68
 Mid-brain, 219

Modiolus, 230

Molars, 171

Mouth, 169

MUSCLES:

Abductor of the fifth digit, 99, 141
 pollex, 134, 141
 Adductor of the femur, 79
 fifth digit, 100, 141
 pollex, 141
 second digit, 100, 141

Anconeus, 128

Ano-vulvar, 116

Anterior tibial, 89

Antitragicus, 152

Arytenoid, 178

Auricular, 151

Biceps brachii, 120

 femoris, 82

Biventer cervicis, 153

Brachialis, 128

Brachio-cephalic, 118

 -radial, 130

Buccinator, 156

Bulbo-cavernous, 9, 110

Canine, 156

Capsularis, 86

Cerato-hyoid, 166

Ciliary, 190

Cleido-cervical, 118

 -mastoid, 118

Coccygeus, 107, 146

Common extensor of the digits, 89, 130

Complexus, 153

Coraco-brachial, 121

Corrugator of eyebrow, 155

Crico-pharyngeus, 166

 -thyroid, 177

Cutaneous, 117

Deep flexor of the digits, 96, 99, 136

 gluteal, 83

 pectoral, 2

Deltoid, 126

Diaphragm, 71

Digastric, 162

Dorsal crico-arytenoid, 178

 serratus, 145

 straight (of the head), 154

Extensor of the fifth digit, 90

Extensors of third, fourth and fifth digits, 132

External cremaster, 6

 oblique abdominal, 10

 obturator, 82

 pterygoid, 182

Gastrocnemius, 94

Gemelli, 83

Genio-glossal, 162

 -hyoid, 163

Gracilis, 77

Helicis, 152

Hyo-epiglottic, 180

 -glossal, 163

 -pharyngeus, 166

Muscles : Iliacus, 74

Ilio-costalis, 145

-psoas, 74, 80

Incisive, 156

Inferior oblique (of eye), 187

Infraspinous, 126

Intercostal, 29

Intermediate vastus, 86

Internal oblique abdominal, 11

obturator, 85, 112

pterygoid, 181

Interosseous, 100, 141

Intertransverse, 154

Ischio-cavernous, 110

-urethral, 110

Jugulo-hyoid, 166

Lateral crico-arytenoid, 179

straight muscle of the head, 181

vastus, 83

Latissimus dorsi, 10, 120

Levator ani, 108

of soft palate, 165

of the upper eyelid, 155, 186

lip, 156

Levators of the ribs, 146

Lingual, 173

Long abductor of the pollex, 134

extensor of the digits, 89

hallux, 91

pollex, 133

flexor of the digits, 96

hallux, 96

Longissimus capitis et atlantis, 153

cervicis, 153

dorsi, 145

Long peroneal, 90, 102

Longus capitis, 181

colli, 181

Lumbrical, 99, 141

Malar, 156

Masseter, 156, 159

Medial vastus, 79

Middle gluteal, 83

Multifidus, 145, 154

Mylo-hyoid, 149

Naso-labial, 156

Oblique muscles of the head, 154

Occipital, 152

Omo-transverse, 119

Opponens pollicis, 141

Papillary (of heart), 53

Pectinate (of heart), 51

Pectineus, 79

Pharyngo-palatine, 166

Piriformis, 83

Plantaris, 94

Popliteal, 96

Posterior tibial, 96

Preputial, 8

Pronator quadratus, 137

teres, 135

Muscles : Proper extensor of the second digit, 133

Psoas major, 74

minor, 74

Pterygo-pharyngeus, 166

Quadrate of upper lip, 156

Quadratus femoris, 82

lumborum, 74

plantæ, 99

Quadriceps femoris, 86

Radial extensor of the carpus, 130

flexor of the carpus, 135

Rectus femoris, 86

Retractor (of eye), 187

of the penis, 110

Rhomboid, 119

Risorius, 156

Sacro-coccygeal, 146

Sartorius, 77

Scalenus, 28

Scutular, 151

Semimembranosus, 79

Semispinalis capitis, 153

dorsi et cervicis, 145, 153

Semitendinosus, 80

Short extensor of the digits, 91

flexor of the digits, 98

fifth digit, 142

pollex, 141

peroneal, 90

Sphincter of the anus, 108

eyelids, 155

lips, 156

pupil, 191

vulva, 116

Splenius, 152

Stapedius, 231

Sterno-cephalic, 118

-hyoid, 148

-thyroid, 148

Straight abdominal, 12, 13

muscles of the eye, 187

Stylo-glossal, 162

-hyoid, 162

-pharyngeus, 166

Submultifidus, 145

Subscapular, 120

Superficial flexor of the digits, 135

gluteal, 82

pectoral, 2

Superior oblique (of eye), 186

Supinator, 134

Supraspinous, 126

Temporal, 160

Tensor fasciæ latæ, 82

of the fascia of the forearm, 122

soft palate, 165

tympani, 231

Teres major, 120

minor, 127

Thyro-hyoid, 163

-pharyngeus, 166

- Muscles:** Tragicus, 151
 Transverse abdominal, 13
 costal, 11
 thoracic, 31
 Trapezius, 118
 Triceps, 122, 128
 Ulnar extensor of the carpus, 132
 flexor of the carpus, 136
 Urethral, 109, 110
 Uvulae, 169
 Ventral serratus, 28, 120
 straight muscle of the head, 181
 Ventricular, 179
 Vocal, 179
 Zygomatic, 156
Myocardium, 57

NASO-LACHRYMAL duct, 200
 -palatine duct, 200
NERVES:
 Abdominal part of the sympathetic, 114
 Abducent, 187, 211
 Accessory, 120, 167, 211
 Acoustic, 211
 Ansa subclavia, 62
 Anterior auricular, 152
 Auriculo-palpebral, 158
 Axillary, 5, 122
 Brachial plexus, 5
 Buccinator, 158, 184
 Cardiac plexus, 56
 Caudal gluteal, 85, 113
 haemorrhoidal, 113, 114
 mesenteric plexus, 26
 Cerebral, 196, 210
 Common peroneal, 91
 Cranial gluteal, 85, 113
 mesenteric plexus, 25
 Deep peroneal, 89, 92
 radial, 134
 temporal, 165, 184
 Dental, 183
 Dorsal buccal, 158
 digital, 89
 metatarsal, 92
 nerves of penis, 9, 112
 oesophageal trunk, 58, 66
 External nasal, 183
 spermatic, 10, 75
 Facial, 157, 211
 Femoral, 75, 81, 113
 Frontal, 158, 185
 Genito-femoral, 75, 113
 Glosso-pharyngeal, 166, 211
 Greater palatine, 183
 splanchnic, 71
 superficial petrosal, 198
 Hypoglossal, 163, 167, 211
 Ilio-hypogastric, 12, 75, 113
 -inguinal, 13, 75, 113
 Inferior alveolar, 184

Nerves: Infraorbital, 158, 183
 Infratrochlear, 158, 186
 Intercostal, 12, 29, 63
 Internal auricular, 152
 Lachrymal, 158, 183
 Lateral cutaneous femoral, 75, 85, 113
 (of calf), 94
 (of forearm), 122
 plantar, 96, 99, 102
 Lesser palatine, 183
 splanchnic, 71
 Lingual, 163, 184
 Long thoracic, 5, 28
 Lumbar, 112
 Mandibular, 158, 184
 Masseteric, 159, 184
 Maxillary, 158, 183
 Medial cutaneous (of calf), 94, 96
 dorsal cutaneous, 88
 plantar, 96, 99
 Median, 5, 123, 137
 Mental, 158
 Middle haemorrhoidal, 112
 Musculo-cutaneous, 5, 112
 Mylo-hyoid, 184
 Naso-ciliary, 186
 Obturator, 80, 113
 Oculo-motor, 187, 210
 Olfactory, 210
 Ophthalmic, 158, 185
 Optic, 187, 210
 Pelvic part of the sympathetic, 114
 Perineal, 112
 Phrenic, 5, 47
 Plantar digital, 99, 102
 metatarsal, 99
 Posterior auricular, 152
 cutaneous femoral, 82, 113
 nasal, 183
 Pudendal, 112, 113
 Pulmonary plexus, 56
 Radial, 5, 123, 128, 129
 Recurrent, 59, 149
 Sacral, 112
 Saphenous, 77, 79, 94
 Sciatic, 84, 113
 Short ciliary, 187
 Spheno-palatine, 183
 Spinal, 202
 Subscapular, 5, 122
 Superficial peroneal, 88, 92
 temporal, 158, 184
 Superior labial, 183
 laryngeal, 167
 Suprascapular, 5, 122
 Sympathetic trunk, 149
 Thoracic part of the sympathetic, 61
 Thoraco-dorsal, 5
 Tibial, 96, 99
 Trigeminal, 158, 211
 Trochlear, 186, 210

- Nerves : Ulnar, 5, 123, 137, 142
 Vagus, 58, 149, 166, 211
 Ventral buccal, 158
 œsophageal trunk, 58, 65
 thoracic, 5
 Vidian, 198
 Volar digital, 142
 metacarpal, 137
 Zygomatic, 158, 183
- OCULO-MOTOR groove, 220
 Œsophagus, 59, 150
 Olfactory bulb, 210
 lobe, 210
 tract, 210
 tubercle, 210
 Omental bursa, 18, 24
 Optic chiasma, 206, 209
 papilla, 191
 recess, 219
 tracts, 209, 220
 Ora serrata, 191
 Orbiculus ciliaris, 190
 Orbit, 184
 Orbital band, 184
 Osseous labyrinth, 229
 Ostium arteriosum (of heart), 53, 54
 venosum (of heart), 53
 Ovarian bursa, 68
 Ovary, 68
- PANCREAS, 38
 Pancreatic duct (of Wirsung), 39
 Paraflocculus, 224
 Parotid duct, 157
 gland, 156
 Pelvis (female), 114
 (male), 106
 of kidney, 70
 Penis, 8
 Pericardium, 31, 47
 Perichoroidal lymph-space, 189
 Periorbita, 184
 Peritoneum, 22, 65
 Petrous lobule, 224
 Pharyngo-palatine arch, 169
 Pharynx, 173
 Philtrum, 170
 Pia mater, 202, 207
 Pineal body, 218
 recess, 219
 Pleura, 31
 Pons, 206, 223
 Porta of liver, 65
 Posterior commissure, 219
 fovea, 226
 medullary velum, 225
 perforated substance, 209
 Premolars, 171
 Prepuce, 7
 Promontory, 231
- Prostate, 109
 Pubo-vesical fold, 107
 Pulmonary ligament, 34
 semilunar valves, 53
 Puncta lacriminalia, 155
 Pylorus, 38
 Pyramid, 209, 222
 Pyriform lobe, 210
 sinus, 176
- RECESS of the Infundibulum, 219
 Recto-uterine excavation, 68
 Rectum, 107, 115
 Restiform body, 223
 Retina, 191
 Rhinal fissure, 212
 Right atrium (of heart), 51
 ventricle (of heart), 52
 Rima cornealis, 189
 Root of lung, 46
- SACCULE, 230
 Salivary papilla, 170
 Scala tympani, 230
 vestibuli, 230
 Sclera, 189
 Scrotum, 5
 Scutiform cartilage, 150
 Sections of spinal cord, 205
 Semicircular canals, 230
 ducts, 230
 Semilunar valves, 56
 Septum of the nose, 198
 pellucidum, 215, 217
 ventriculorum, 52
 Sheath of straight abdominal muscle, 13
 Sinuses of dura mater, 194, 197
 Small intestine, 19
 Soft palate, 168
 Sole of the pes, 97
 Solitary lymph-nodules, 27
 Spermatic cord, 7
 Spinal cord, 202
 Spiral lamina, 230
 Spleen, 36
 Stapes, 231
 Stomach, 37
 Stria terminalis, 218
 Structure of the bladder, 109
 intestines, 27
 œsophagus, 59
 stomach, 66
 wall of heart, 57
 Subarachnoid cisterns, 207
 space, 202, 207
 Subdural cavity, 194, 201
 Sublingual caruncle, 161
 ducts, 161
 gland, 161
 Submaxillary duct, 161
 gland, 161

- Sulci of brain, 212
 Suprapineal recess, 219
 Suprarenal glands, 70
 Supratonsillar fossa, 169

 TAPETUM, 190
 Tarsus (of eyelid), 155
 Teeth, 170
 Tegmentum, 220
 Tentorium cerebelli, 196
 Terminal crest (of heart), 52
 groove (of heart), 52
 Testis, 7
 Thalamus, 218
 Third ventricle, 218
 Thoracic duct, 61, 74
 Thorax, 31
 Thymus, 42
 Thyroid cartilage, 175
 gland, 150
 Tongue, 172
 Tonsil (palatine), 169
 Tonsillar sinus, 169
 Trabeculæ carneæ, 52
 Trachea, 57, 149
 Transverse cerebral fissure, 206
 peduncular fasciculus, 221
 sinus of pericardium, 48
 vesical folds, 107
 Tricuspid valve, 53
 Tuber cinereum, 206, 209
 Tubercle of Lower, 52
 Tunica vaginalis, 7
 Tympanic cavity, 230

 UMBILICUS, 13
 Ureter, 70
 Urethra, 109, 115
 Urinary bladder, 108, 115
 Uro-genital sinus, 116
 Uterine tube, 68
 Uterus, 67, 115
 Utricle, 230

 VAGINA, 115
 Vallate papillæ, 173
 Valve of the colon, 27
 vena cava, 52
 VEINS :
 Axillary, 4, 126
 Basilar plexus, 197
 Basilic, 126
 Buccinator, 159
 Cephalic, 126
 Caudal epigastric, 12
 gluteal, 112
 vena cava, 48, 73
 Cavernous sinus, 197
 Common iliac, 73
 Cranial epigastric, 12
 gluteal, 112
 vena cava, 48
 Veins : Cranial vesical, 112
 Deep circumflex iliac, 73
 facial, 159
 Dorsal digital, 87
 metatarsal, 87
 veins of penis, 9
 External iliac, 76
 jugular, 146
 maxillary, 147, 159
 Facial, 159
 Femoral, 79
 Great saphenous, 77
 Hepatic, 74
 Hypogastric, 112
 Ilio-lumbar, 112
 Inferior labial, 159
 Innominate, 48
 Intercostal, 29, 62
 Internal jugular, 148, 168
 mammary, 42, 148
 Lingual, 159
 Lumbar, 73
 Median basilic, 126
 cephalic, 126
 (of forearm), 129
 Middle hæmorrhoidal, 112
 Occipital sinus, 194
 of heart, 51
 penis, 112
 Phrenic, 74
 Phrenico-abdominal, 73
 Perineal, 112
 Petrosal sinuses, 197
 Portal, 40
 Radial, 129
 Reflex, 159
 Renal, 73
 Sagittal sinus, 194
 Small saphenous, 87
 Spermatic, 73
 Spinal, 20
 Superficial temporal, 160
 Superior labial, 159
 Transverse sinuses, 194
 Ulnar, 129
 Vena azygos, 48, 62, 74
 Ventricle of larynx, 176, 179
 Ventricular folds, 176
 Vestibule of the ear, 230
 larynx, 176
 nose, 200

 Villi, 27
 Vitreous body, 191
 Vocal folds, 176
 Vomero-nasal cartilage, 200
 organ, 200
 Vulva, 116

 WHITE commissure (of spinal cord), 205

 ZONULAR spaces, 192
 Zygomatic gland, 182



PRINTED BY
SPOTTISWOODE AND CO. LTD., COLCHESTER
LONDON AND ETON

