Surgical diseases of the mouth and jaws / by Earl Calvin Padgett ... with 334 illustrations.

Contributors

Padgett, Earl Calvin, 1893-1946.

Publication/Creation

Philadelphia ; London : W.B. Saunders company, 1938.

Persistent URL

https://wellcomecollection.org/works/bv9ac88k

License and attribution

Conditions of use: it is possible this item is protected by copyright and/or related rights. You are free to use this item in any way that is permitted by the copyright and related rights legislation that applies to your use. For other uses you need to obtain permission from the rights-holder(s).

wellcome collection

Wellcome Collection
183 Euston Road
London NW1 2BE UK
T +44 (0)20 7611 8722
E library@wellcomecollection.org
https://wellcomecollection.org

22101905033

H. K. LEWIS & CO. LTD.
MEDICAL & SCIENTIFIC BOOKSELLERS.
NEW AND SECOND HAND.
136 GOWER ST., LONDON, W.C.1.

Donated by H. Ryder

Med
K49224

45/- net
65/-
Digitized by the Internet Archive
in 2017 with funding from
Wellcome Library
https://archive.org/details/b29819672

SURGICAL DISEASES

of the

MOUTH AND JAWS

By

EARL CALVIN PADGETT, B. S., M. D., F. A. C. S.

Associate Professor of Clinical Surgery, University of Kansas School of Medicine, Kansas City, Kansas; Associate Professor of Oral Surgery, Kansas City Western Dental College, Kansas City, Missouri

WITH 334 ILLUSTRATIONS

PHILADELPHIA AND LONDON

W. B. SAUNDERS COMPANY

1938

2368815

Copyright, 1938, by W. B. Saunders Company

All Rights Reserved
This book is protected by copyright. No part of it may be duplicated or reproduced in any manner without written permission from the publisher

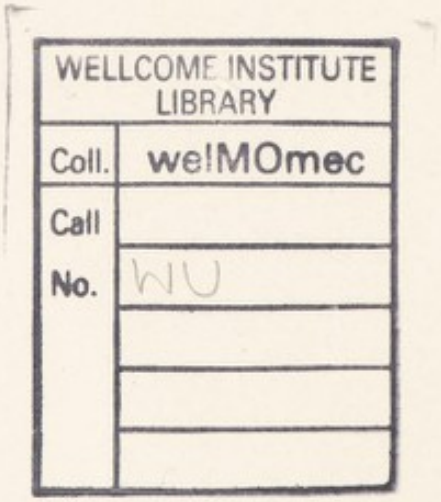

MADE IN U. S. A.

PRESS OF
W. B. SAUNDERS COMPANY
PHILADELPHIA

PREFACE

Both the dental and the medical professions have made and are making many contributions to the subject of oral surgery. Thus, in the field of surgical diseases to which the mouth and jaw are heir, there is considerable overlapping of interests between the two professions. Besides the more time honored etiologic, pathologic and therapeutic contributions, the prevention of many of the more serious diseases of the oral cavity, as for instance cancer, is at present more than ever assuming a position of very great importance. In the field of preventive medicine both the dental and the medical professions have opportunity to offer a service of the highest type.

The student of oral surgery should approach the subject, I believe, from the standpoint of broad surgical principles and from the viewpoint of general pathology. If he does not develop this broader outlook his understanding of the subject is likely to be too limited for his therapeutic results to be on a par with those obtained elsewhere in the body by the other more or less regional specialists. In addition to a basic general knowledge, certain special information is necessary. Thus, certain phases of dentistry and roentgenology become from necessity a component part of the subject.

In a textbook on oral surgery, most teachers insist that considerable emphasis be placed upon the diagnosis of the ordinary surgical conditions encountered in everyday practice. To this viewpoint I adhere. But it would seem that with the addition of a few chapters the care of the major surgical situations which may be encountered in this region also can be presented. Thus, I have hoped a rather complete book would be of value to several general groups of men—the dental student, the medical student, the general dentist and physician, and the surgeon. Besides attempting to appeal to these more general groups, I have made an effort to present material which would be of interest to certain special practitioners such as the "nose and throat" specialist, the dermatologist or the radiologist who see conditions which in certain instances overlap from their field into that of oral surgery.

In writing this book I have attempted to cover all of the headings suggested in the report of the Curriculum Committee of the American Association of Dental Schools made in 1935. In some of the chapters, however, as those on fractures, congenital malformations and malignant tumors, I have gone into the matter more extensively than the outline recommends. I consider this material of sufficient importance—especially to the oral or general surgeon—to merit a rather detailed discussion since the surgeon who wishes to use this book as a guide probably would not consider that a superficial résumé was sufficient to give him the information for which he is seeking. I have gone into the pathology at considerable length as I believe that no one can treat certain lesions in this region unless he understands pathology. The chapter on anatomy is inserted because in no other

region of the entire body is it more essential to "know one's way about," so to speak, in carrying out a diagnostic or an operative procedure. I know of no book on oral surgery *per se* which has as yet gone into the principles of radiation therapy. But it seems that the advances made in this field during the past few years have made a section on radiation therapy an essential part of a book which presumes to cover the whole field of oral surgery.

In writing an oral surgery, the question of grouping and naming the chapters is a very difficult one to decide. Almost any method that one adopts when he begins to place the material in its proper category for one reason or another sooner or later does not seem to fit. For instance, in a regional classification he finds repetition in the discussion. If one adopts a pathologic classification there are certain diseases and infections which do not fall readily into any particular category. After considerable thought, I have decided rather arbitrarily to relegate a few of the preliminary chapters which are pertinent to the whole field, to the first part of the book and then to group the remainder of the chapters according to the following scheme: (1) Wounds and injuries of (*a*) soft tissues, (*b*) hard tissues. (2) Inflammations and unclassified diseases. (3) Acquired malformations. (4) Congenital malformations. (5) Tumors of the soft tissues, (*a*) benign, (*b*) malignant. (6) Tumors of the hard structures, (*a*) benign, (*b*) malignant. (7) Restoration of deformities. Certain chapters which have to do with the treatment of conditions in chapters immediately preceding are interspersed because they would seem to fall naturally into such a position.

I am indebted to Dr. Don Woodward for writing the original outline for the chapter on the removal of teeth. Also before this chapter was placed in its present form, I received much valuable advice from Dr. R. W. Edwards, Dr. C. W. Keeling and Dr. G. Farrell Webb. Dr. Copeland Shelden wrote the paragraphs on the orthodontic management of Class II and Class III (Angle) cases. With Dr. Shelden and Dr. Louis James there took place considerable discussion concerning the dividing line between those cases which should be submitted to the orthodontist and those cases which should be managed by the oral surgeon. Dr. Don Mosher not only read the paragraphs concerning pyorrhea but to a certain extent rewrote the section on treatment of that disease. Dr. C. W. Keeling and Dr. Claude O'Dell were kind enough to read and criticize the chapter on "Inflammations and Diseases of the Soft Structures of and about the Teeth." I am very much indebted to Professor Martin F. Palmer who devotes his time to "speech training" for writing the subject matter concerning this phase of the cleft palate problem. The majority of the drawings were made by Mr. Ted Bloodhart but Dr. S. J. Conrad and Miss K. Bell also made a considerable number. To my secretary, Miss Opal M. Quick, I am particularly indebted for doing the required typing. Lastly, I am indebted to the publishers who have made every effort to bring the book up to the high standard comparable with their other publications.

EARL C. PADGETT.

KANSAS CITY, MISSOURI,
January, 1938

CONTENTS

PAGE

CHAPTER I

Study and Diagnosis 17

CHAPTER II

Anatomic Considerations Related to Examination and Treatment 24

CHAPTER III

Asepsis and Materials of Surgery 51

CHAPTER IV

Wounds of the Soft Tissues 60

CHAPTER V

The Complications of Wounds 71

CHAPTER VI

Injuries of the Bony Framework 90

CHAPTER VII

Injuries of the Teeth and the Alveolar Processes 100

CHAPTER VIII

Fracture of the Upper Jaw and the Neighboring Bones 103

CHAPTER IX

Fractures of the Lower Jaw 119

CHAPTER X

Methods of Fixation for Fractures of the Lower Jaw 127

CHAPTER XI

Dislocation of the Lower Jaw 147

CHAPTER XII

Inflammations and Diseases of the Soft Structures of and about the Teeth. 155

CHAPTER XIII

The Removal of Teeth and Related Matters 198

CHAPTER XIV

Inflammations and Diseases of the Face and Lips 229

CHAPTER XV

Acute Inflammations and Diseases of the Buccal and Pharyngeal Cavities. 241

CHAPTER XVI

Chronic Inflammations and Diseases of the Buccal and Pharyngeal Cavities. 259

CHAPTER XVII

Inflammations and Diseases of the Antrum 272

CHAPTER XVIII

Inflammations and Diseases Involving the Neck 281

CHAPTER XIX PAGE

Inflammations and Diseases of the Jaw Bones 294

CHAPTER XX

Inflammations and Diseases of the Temporomandibular Joint 312

CHAPTER XXI

Inflammations and Diseases of the Salivary and Lachrymal Glands 321

CHAPTER XXII

The Neuralgias and Motor Derangements Affecting the Face, Mouth and Jaws 336

CHAPTER XXIII

Malrelations of the Teeth and the Jaw Bones 351

CHAPTER XXIV

Facial Clefts—General Considerations 378

CHAPTER XXV

Historical Development of the Surgery of Cleft Lip and Palate 388

CHAPTER XXVI

The Treatment of the Bony Cleft and the Neighboring Soft Tissues 398

CHAPTER XXVII

The Repair of a Cleft Lip 410

CHAPTER XXVIII

General Considerations in Cleft Palate Surgery 431

CHAPTER XXIX

Operations for the Repair of the Palate Proper 452

CHAPTER XXX

Other Anomalies, Sinuses, Cysts and Benign Tumors of Congenital Origin. 482

CHAPTER XXXI

Benign Tumors of the Soft Tissues 502

CHAPTER XXXII

Malignant Neoplasms of the Soft Tissues 525

CHAPTER XXXIII

The Principles and the Application of Irradiation in the Treatment of Malignant Neoplasms 569

CHAPTER XXXIV

Operations for Malignant Neoplasms of the Soft Tissues 602

CHAPTER XXXV

The Management of the Lymphatic Areas Tributary to Epidermoid Carcinoma 639

CHAPTER XXXVI

The Selection of Therapy and the Prognosis for Malignant Neoplasms of the Soft Tissues 656

CHAPTER XXXVII

PAGE

Maxillary Tumors of Dental Origin (The Odontomas) 670

CHAPTER XXXVIII

Other Benign and Malignant Tumors Primary in the Bones of the Face and Jaw 689

CHAPTER XXXIX

Resections of the Jaw Bones 714

CHAPTER XL

Surgical Restoration of Deformities 722

CHAPTER XLI

Prosthetic Restoration of Deformities 761

CHAPTER XLII

Anesthesia 773

Index 791

Surgical Diseases of the Mouth and Jaws

CHAPTER I

STUDY AND DIAGNOSIS

Fitz quotes Thomas Sydenham as follows: "It is likely in every case to prove true, that those who have devoted their eyes and their mind, the most accurately and diligently, to the natural phenomena of diseases, will excel in eliciting and applying the true indications of cure."

Before good treatment can be rendered, a correct diagnosis in most instances has to be made. Without a sound knowledge concerning the actual lesion to be treated one is only reverting to guesswork and empiricism—two very inaccurate tools to use in the therapy of disease. To make a correct diagnosis, an accurate history of the course of the condition is often just as essential as an accurate physical examination. The ideal history "taker" is the one who knows the most medicine and surgery and the history will very often be an index to whether or not one has such knowledge. One of the main reasons for this book is to present the knowledge required to take a history. Thus, to a certain extent when we present history taking and examination first, we have the "cart before the horse"—but such has been custom. Besides knowledge, there is an art in history taking which one develops to its highest only if he has that innate understanding, "common sense," intuitiveness, and experience which only the rare individual has. There are, of course, many methods of taking a history—any one of which in the hands of an expert is good. But for the student in his early days, it is well to tie to some form, one of which will be outlined here. Later if he wishes to modify it when he develops the art and has the experience and knowledge, certainly, more power to him!

The History Form.—A uniform type of case history for all patients is highly desirable. There are many good history forms. Almost every hospital of high standard and almost every well-known clinic of caliber has considered the point of enough importance to go to considerable trouble in the organization of a history and physical examination form. Many of the patients seen by an oral surgeon are seen at his office. A form used in an office should be inexpensive, in one sheet, and should contain all the data necessary to give one an adequate record of the case. One need not fill out all of the form unless it seems necessary. In such a case one loses little if only the data pertinent to the case are filled in.

As many cases with dangerous oral lesions will be submitted to a serious operative procedure, not only does one have to understand the local lesion but he certainly should know something of the patient's general history and condition.

One of the purposes of a good history is to record one's own clinical experience. Statistics of various sorts may prove valuable. Such simple information as age, sex, birthplace, and occupation, of a group of unusual

or even common cases has been known to cause an observing clinician to find out something concerning a disease syndrome or to prove a new fact of the greatest interest not only to himself but to society as a whole. The early continuous taking and keeping of complete history forms has been an important reason for many a man gaining a reputation of much

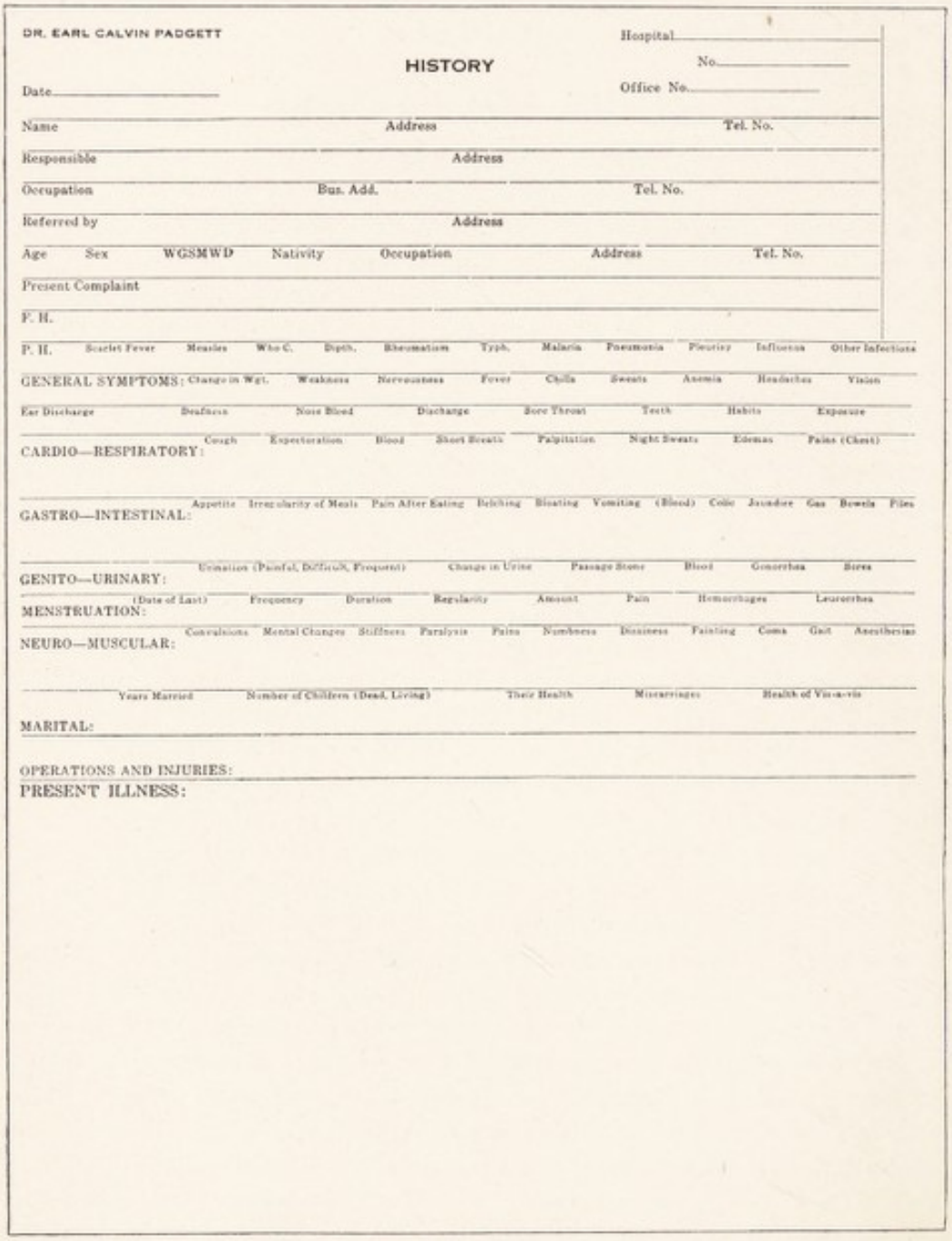

DR. EARL CALVIN PADGETT

HISTORY

Hospital_____

No._____

Office No._____

Date_____

Name Address Tel. No.

Responsible Address

Occupation Bus. Add. Tel. No.

Referred by Address

Age Sex WGSMWD Nativity Occupation Address Tel. No.

Present Complaint

F. H.

P. H. Scarlet Fever Measles Whp C. Diph. Rheumatism Typh. Malaria Pneumonia Pleurisy Influenza Other Infections

GENERAL SYMPTOMS: Change in Wgt. Weakness Nervousness Fever Chills Sweats Anemia Headaches Vision

Ear Discharge Deafness Nose Bleed Discharge Sore Throat Teeth Habits Exposure

CARDIO—RESPIRATORY: Cough Expectoration Blood Short Breath Palpitation Night Sweats Edemas Pains (Chest)

GASTRO—INTESTINAL: Appetite Irregularity of Meals Pain After Eating Belching Bloating Vomiting (Blood) Colic Jaundice Gas Bowels Piles

GENITO—URINARY: Urination (Painful, Difficult, Frequent) Change in Urine Passage Stone Blood Gonorrhea Sores

MENSTRUATION: (Date of Last) Frequency Duration Regularity Amount Pain Hemorrhages Leucorrhea

NEURO—MUSCULAR: Convulsions Mental Changes Stiffness Paralysis Pains Numbness Dizziness Fainting Coma Gait Anesthesias

MARITAL: Years Married Number of Children (Dead, Living) Their Health Miscarriages Health of Husband

OPERATIONS AND INJURIES:

PRESENT ILLNESS:

Fig. 1.

greater import than it would have been possible for him to have done without adequate records which when taken may have seemed irrelevant to the situation in hand.

A goodly amount of any history form is to aid the inexperienced in arriving at a diagnosis. The irrelevant questions asked one hundred times may yield something in 1 or 2 per cent of the cases.

The experienced man usually asks enough questions to get on the right path and examines the presenting lesion. Often he is able to arrive at the diagnosis then and there but on the other hand, if there is something not true to form about the picture, he begins to gather additional evidence for and against and begins to eliminate as closely as he can or if the lesion


PHYSICAL EXAMINATION Appearance Height Weight Temp. Pulse Resp.

HEAD:
Eyes
Ears
Nose
Mouth

NECK:

CHEST: Heart
Vessels
B P
Lungs

ABDOMEN:

EXTREMITIES:

NERVOUS SYSTEM:

GENITALIA:

LABORATORY FINDINGS: Haemoglobin Clott. Time Urine Color Sheeds Sugr. React. Alb. Sug. Microscopic
Cast
X-Ray

Photograph

Provisional Diagnosis

Recommend

Fig. 1.—*Continued,* reverse side.

appears to be one in which other procedures must be carried out before a positive diagnosis can be made, he does them or recommends that they be done. But for the inexperienced man all teachers recommend that he start the other way around. Although not the fastest method, it may be the most thorough and is the most fool proof.

The form we use is inserted for your perusal (Fig. 1). Additional data could be inserted in this form if one wished. In the case of the special

lesion such as cleft lip and cleft palate, we have used a form made for that particular purpose. The dentist may desire to insert diagrams concerning the teeth (Fig. 2). An ordinary sheet of paper is used for progress notes. The name, address, who is responsible, occupation, age and sex, by whom they are referred, are filled in by the secretary before the case is seen. Although they are almost obvious points, the occupation, the age and the sex may form an important clue to the diagnosis.

Present Complaint.—It is well to ask the patient immediately what his version of the reason for coming to you is although every once in a while, he is likely to tell you that is the reason he came to you, to find out. The first question then is "Why did you come to me for an examination?" Frequently, the complaint is pain, or a swelling. Less often an ulceration, a discharge, or bleeding is the complaint. It is obvious, of course, that there are almost as many presenting symptoms as there are diseases. Again, one must emphasize that the importance a good man will attach to a present-

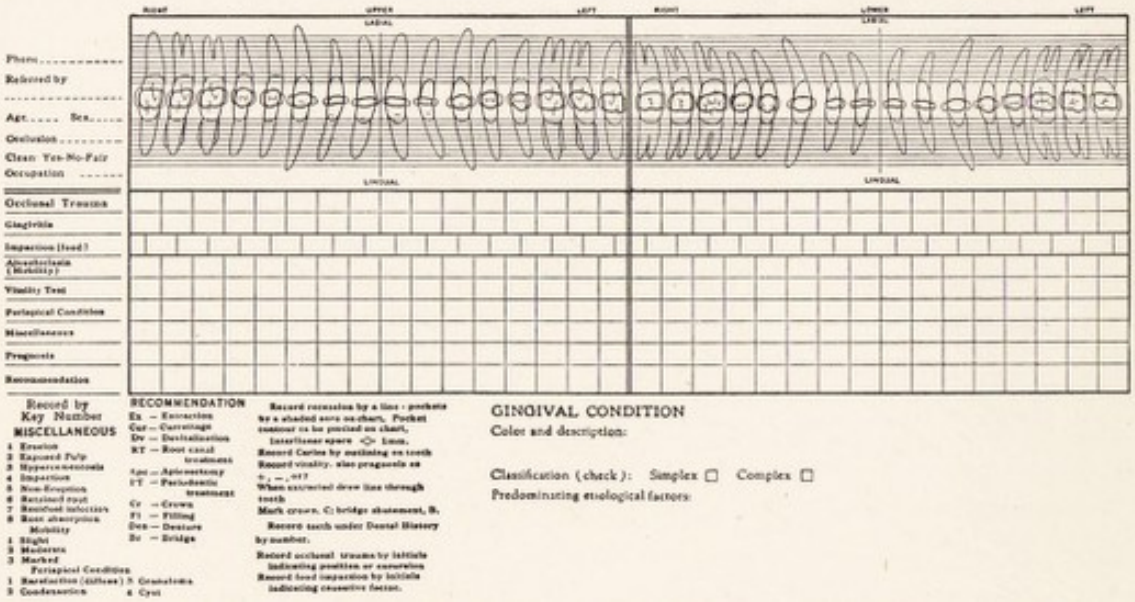

Fig. 2.—Part of a history form taken from S. D. Miller. (Oral Diagnosis and Treatment Planning, P. Blakiston's Son and Co., Inc., Publishers.)

ing symptom is directly proportional to the fund of his knowledge. When the patient is very ill and the reason for it is known, it may be good sense and courtesy to get only a short history.

Family History.—Whether or not the parents are living or at what age they died and with what may be of importance. Such information may aid in the diagnosis or if it does not give one a clue to the diagnosis, it may be suggestive when therapy is carried out. The same applies to the information concerning sisters and brothers. Information of this type concerning such diseases as tuberculosis and syphilis is obviously important. In hemophilia, a bleeding tendency is the usual history and one that should make the prospective surgical case a matter of further study as to clotting time and so forth.

It must be admitted that often a family history yields little information of value. But often while obtaining it, one learns something concerning the personality and mentality of the patient. It is often well to know from

what stock a patient springs. This knowledge is always easily obtained and lends a tinge of background to the clinical picture.

Past History.—The previous medical history is always important. Such a history is best obtained by asking the patient specifically if he has had any of the common infectious diseases or any peculiar general symptoms such as an unusual loss of weight. Then so that no information of general value is missed, one should begin with the head and work downward in a regional fashion seriatim and ask specifically whether or not there has ever been any trouble or whether or not he has ever had any of the common diseases which may affect that region. For example, Have you ever had any trouble with your heart? or Did you ever have pneumonia? The history form with its tabulated words will offer suggestions. Finally, the question should be asked, Have you ever had any serious diseases in your life? Such a question may call to mind something of importance that has slipped from memory. One may not be able to obtain the history of venereal disease from women and in certain types of women at least it is best to obtain it indirectly by discreetly questioning concerning their marital history, the number of miscarriages, or stillbirths, type of pelvic operations or a leukorrhea with a history of frequency. Men very often frankly admit a venereal history. Nowadays one sees a considerable number of patients who have sustained an injury. Some question should be asked concerning the seriousness of the injury and the course of the convalescence to see if it has any bearing on the patient's condition. Some questions concerning whether or not the patient is trying to collect any indemnity for an accident may aid one in judging certain subjective complaints. Habits are important and many persons are very evasive about certain habits that may have a bearing on the case. What medicines have been taken previously may be worth a question. The character of a previous operation may give some light.

All of these preliminary studies give a good deal of miscellaneous information which when fitted together properly will allow a fairly accurate idea of the extent which environmental factors, hereditary factors, and the various happenings of fate may have influenced the present situation.

Present Illness.—To more accurately delineate the present trouble, the patient should be questioned as to when and how the complaint began, whether it is getting better or worse, and if painful the type and location of the pain should be carefully asked about. If the complaint is some new swelling or an old swelling which is growing, the rate of growth is important and whether or not it is tender, has discharged any secretion, is fixed or movable, is soft or hard, or is ulcerated. At first it is advisable to let the patient describe his own symptoms as he chooses. Usually this pleases him. After the patient ceases to describe his symptoms in his own fashion, the complaint should be elaborated further by a series of direct questions which seem pertinent to the examiner. In general one builds up as clear-cut a picture of the patient's complaint as he can from a painstaking cross examination. One must be on guard, however, and realize that the complaint may have little relationship to the underlying disease. General complaints are rather notorious for this defect. All the while one is taking the history he should be studying the patient. The manner

in which a patient describes his symptoms may be of greater import than the symptoms.

Examination of the Affected Part and Adjacent Regions.—When one gets a good view of the affected part, the appearance alone to the experienced leads to certain surmises or even to a diagnosis. The affected part may be swollen, or red. There may be a sinus discharging pus. Ulceration may be present. If so, what is the character of the edges and the base? Is the ulceration of a multiple type? Does the ulcer bleed easily and what is the character of its granulations? The size, shape and color of any mass should be noted. By palpation the consistency and the outlines of a mass are determined. Is it hard or soft? Does it feel elastic or does it fluctuate? Is fluid present and what is its probable type? Is there a feeling of tenderness or warmth? If possible, determine the origin of a sinus. The state of the tributary lymphatics may be very important.

General Examination of the Teeth and the Tissues About Them.—The gums should be carefully examined for evidence of traumatic injury, congestion of the gingival margin, gum recession, abnormalities of the interdental papilla, the presence of bleeding or pus. All pockets should be probed and their depth and outline recorded. The teeth should be examined for vitality and whether or not pulp inflammation is present. They should be tested for mobility. A radiographic examination of all teeth often is necessary. The occlusion of the teeth should be noted. Study casts may aid one to estimate the possibilities of balancing the occlusion or improving the alignment. All cavities should be explored. Dr. Samuel Miller in his Oral Diagnosis and Treatment has inserted a chart used by him to tabulate these data. It is reproduced here (Fig. 2).

General Physical Examination.—Although in the routine practice of oral surgery as seen in the office, it may not be necessary to do a general physical examination, a general physical examination starting with the head and routinely examining each region and system to the feet may throw a great deal of light upon the nature of an otherwise obscure local mouth condition. The appearance of an acutely ill or a fatally ill person is often noted by even the untrained. The cachexia of rather late malignant disease is suggestive. The unhealthy appearance of a patient with a leukemia may suggest to one the advisability of a blood examination. Old scars—such as the scars and marks of syphilis—may put one on the correct path. Tuberculosis of the mouth is practically never primary. Evidence of the general disease should be looked for if one suspects the local lesion as being tuberculous. The value of taking the pulse rate and the temperature is so well known that it hardly needs to be mentioned. A brief survey of whether or not a person's reflexes are normal may be instructive. A blood pressure examination with a hurried examination of the heart, lungs, and abdomen does not in the true sense of the word constitute a physical examination. A patient has to be stripped for a complete physical examination.

After a history and a complete physical examination have been completed, in the great majority of cases a correct diagnosis will have been arrived at but not uncommonly various laboratory methods are necessary for confirmation, or even may suddenly bring light into the darkness by giving the diagnosis after these other methods have failed.

Laboratory Examination.—As an aid to diagnosis, the various laboratory procedures may be of the greatest aid and sometimes are entirely indispensable. In this sense, the roentgenogram and the biopsy are most often absolutely necessary. In practically all lesions involving the bones a radiographic examination is necessary. Certain new growths and ulcerations with a questionable clinical diagnosis must be subjected to biopsy before a positive diagnosis can be made and certain types of malignancies should have biopsy before treatment is instituted. Bearing directly on the diagnosis of certain lesions within the mouth, smears and cultures studied from the bacteriologic standpoint may determine the nature of the causative agent.

Besides the blood and the urine, the stool, the sputum, the spinal fluid, the basal metabolic rate, the phthalein test, the chemistry of the blood and other laboratory tests in cytologic and bacteriologic fields are indicated in studying specific cases and gaining as accurate a conception of the disease as is possible to gain. Nowadays most hospitals and certain clinical laboratories are equipped to do this special type of work when the clinician himself does not have the necessary training, the equipment, or the time.

Before an operation of any severity, the urine should be examined, a blood count made, and when any abnormality is found the relationship of the abnormality to the matter under consideration should be carefully evaluated in the light of whether or not the original plan should be changed.

Importance of Thoroughness.—The importance of thoroughness in examination cannot be overemphasized. It has been said that one of the greatest fascinations in the field of medicine and surgery is that every dentist, physician, and surgeon becomes an investigator when he undertakes the responsibility of treating a case. It must be remembered that the clinical records represent the scientist's notebook, should form the basis for collateral reading, be a postgraduate teacher, and should improve clinical work.

Bibliography

Blair, V. P.: Surgery and Diseases about the Face, Mouth and Jaws, C. V. Mosby Co., St. Louis, 1917.

Fitz, Reginald: Diagnostic Methods, Dean Lewis' System of Surgery, Hagerstown, Maryland, W. F. Prior Co., Chapter II, **1:** 1–12, 1933.

Miller, S. D.: Oral Diagnosis and Treatment Planning, Phila., P. Blakiston's Son and Co., 1936.

Sydenham, Thomas: Quoted by Fitz, Reginald.

CHAPTER II

ANATOMIC CONSIDERATIONS RELATED TO EXAMINATION AND TREATMENT

PROBABLY in no other field of surgery is a good working knowledge of the essentials of the anatomy of the region more important than that about the face, mouth and jaws.

MOUTH CAVITY

The face as a whole consists of a variously shaped network of bony partitions, covered with skin, mucosa, subcutaneous tissue, and muscles attached to the forepart of the skull. The bony partitions enclose spaces which either contain air or special soft organs. The mouth is one of these cavities and is a part of the face viewed from this standpoint. Also it is the beginning of the alimentary tract and acts in case of obstruction or inadequacy of the nasal passages as an accessory air passage. Within it are the organs of mastication, taste, and to a certain extent articulate speech. Just without the mouth proper is an external space called the *vestibule*. The teeth, gums and alveolar ridges separate the two cavities. The roof of the mouth is formed by the palate, the anterior five eighths of which centrally is composed of bone. Normally, the palate separates the nasal fossae and the nasopharynx from the mouth. In some instances the palate also separates a part of the maxillary sinuses from the mouth. The upper mouth is bounded laterally and anteriorly by the upper teeth and alveolar ridges of the upper jaw, and the lower mouth is bounded similarly by the lower teeth, alveolar ridges and the upper part of the body of the mandible. Posteriorly the mouth communicates with the faucial space which passes directly into the oropharyngeal space.

Most of the upper and the lateral walls of the mouth are unyielding tissues. Thus, when the mouth is closed any adjustment of capacity must needs be accomplished through the floor of the mouth.

Floor of the Mouth.—The floor of the mouth is mostly a muscular plane of a fanlike shape. This partition is held up anteriorly by the mandible and is supported posteriorly by the upper part of the neck. All the structures lying above the muscular plane, mucosa, submucosal tissue and glands are spoken of as the floor of the mouth (Fig. 3). The muscular partition, made up of the fan-shaped mylohyoid muscle and the geniohyoid muscles, stretches between two concentric bony arches—the concavity of the body of the mandible and the convexity of the body of the hyoid. Posteriorly and to a certain extent within the concavity of the hyoid, the air passages and the tube for the transportation of food proceed downward from the oropharynx into the neck. The tongue is not in contact with the floor of the mouth save at its point of attachment to the centrally located geniohyoglossus muscles. Coronal and sagittal (Fig. 4) sections show this quite plainly. Thus, the space between the body of the tongue and the floor

is in most of its extent divided into two compartments by these two muscles and each of the lateral spaces is limited below by the muscular floor, laterally by the body of the mandible and superiorly by the mucosa of the under surface of the body of the tongue. Within the walls of these com-

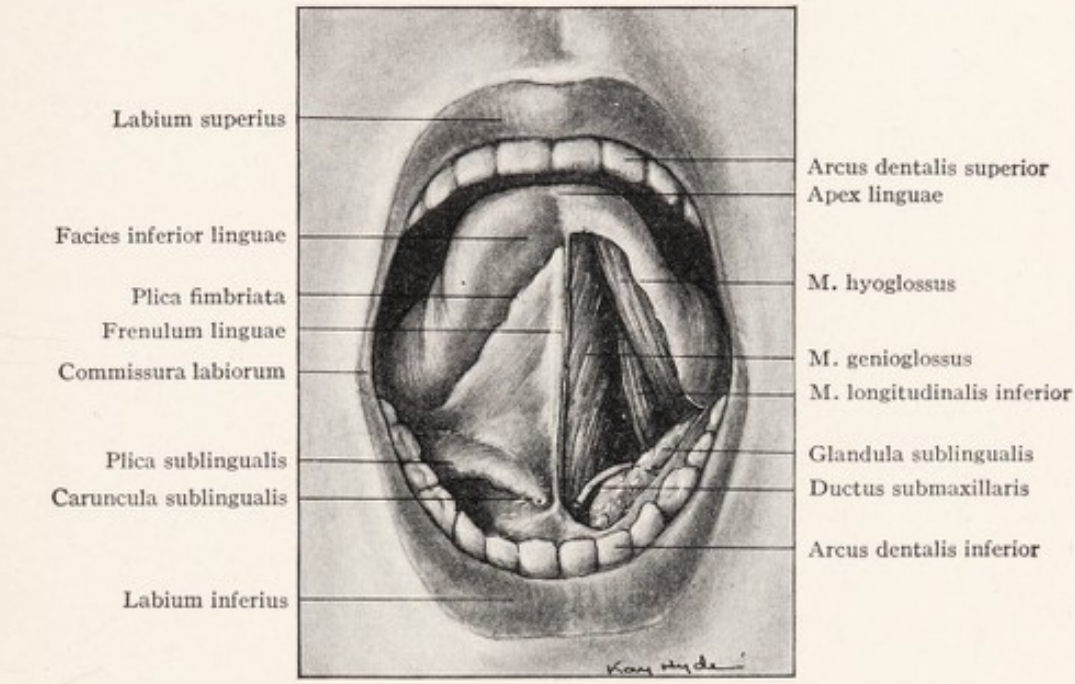

A

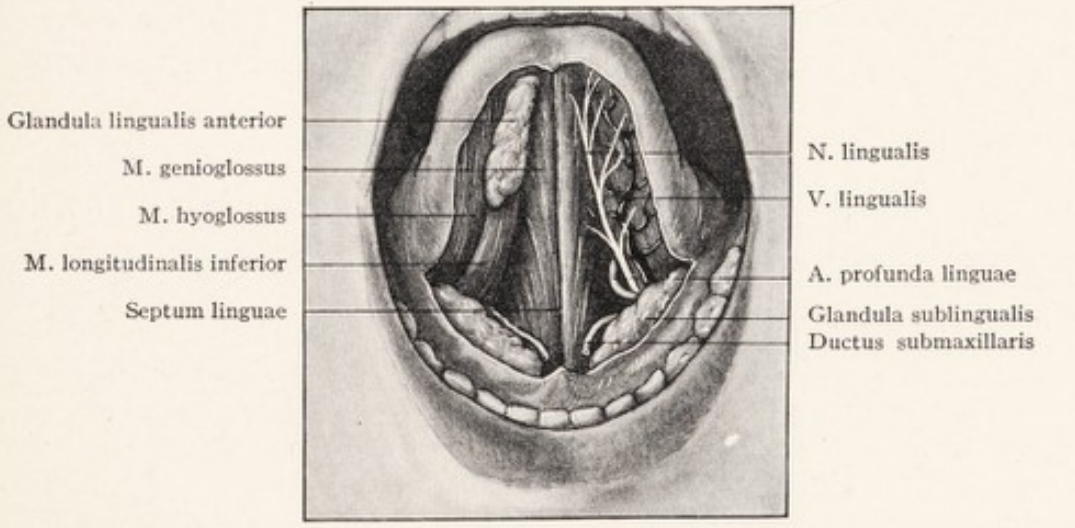

B

Fig. 3.—Superficial and deep structures in the sublingual region. *A,* The mucosa is left intact on the right side; on the left the region has been cleared of the vessels and nerves. *B,* The vessels and nerves have been removed on the right side; and on the left, the vessels and nerves are *in situ.* (Callander, Surgical Anatomy.)

partments are the structures spoken of as lying in the floor of the mouth. Anteriorly these spaces are limited by the mental portion of the mandible. Posteriorly between the root of the tongue and the angle of the jaw they communicate with the intermuscular spaces of the neck. The intermuscular spaces posteriorly offer a passageway for the vessels, nerves and ducts

which lie in the floor of the mouth. Thus, within the floor of the mouth lie the lingual nerve, the lingual vein, and the submaxillary duct (Fig. 5).

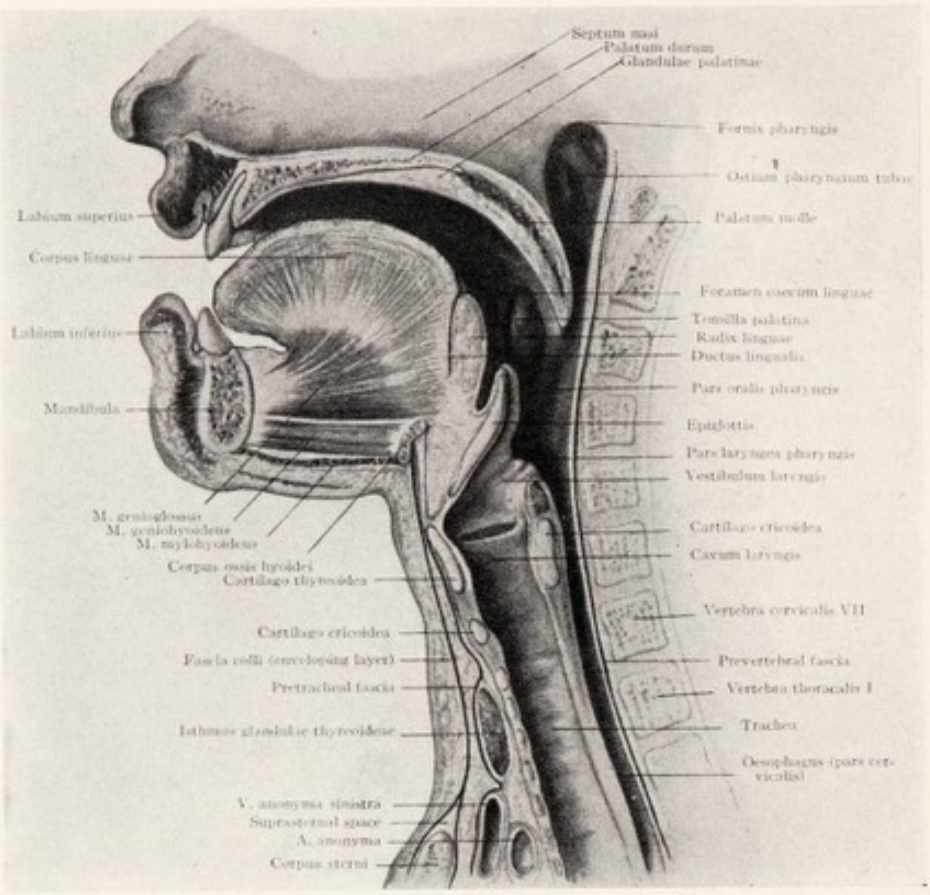

Fig. 4.—A median sagittal section of the viscera of the head and neck. (Callander, Surgical Anatomy.)

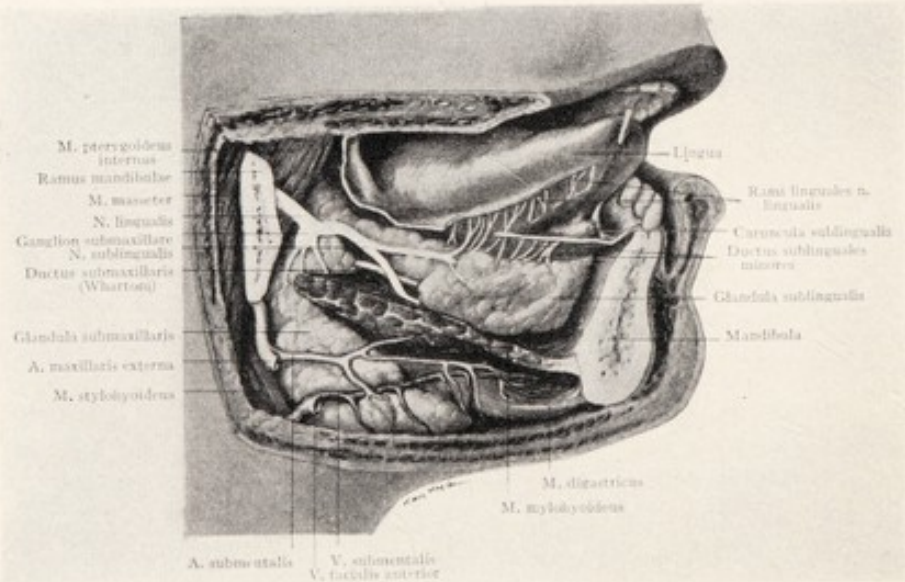

Fig. 5.—Lateral view of the sublingual region. The body of the mandible has been removed. (Callander, Surgical Anatomy.)

The lingual artery is buried in the tongue. Within the floor of the mouth and on the under surface of the tongue are the glands of Nuhn and Blandin,

the incisive glands, Bochdalek's glands, the sublingual glands and part of the submaxillary glands.

Glands of Nuhn and Blandin.—Blandin described two mucous glands each of which have one or two excretory ducts opening on the inner surface of the tongue. The glands are about the size of an almond. One lies in each side of the midline on the under surface near the tip of the tongue. Very rarely, cysts, neoplasms and stones have been described as occurring in these glands.

Incisive Glands.—Suzanne and Merkel described a group of mucous glands on each side of the midline in the anterior floor of the mouth which lie in front of the salivary caruncle and immediately behind the periosteum of the mandible. Besides these glands Tillau and Fleishmann described an inconstant sublingual bursa, one on either side of the midline between the geniohyoglossi muscles and the mucous membrane which are located midway between the frenum and the sublingual gland. Anterior small ranulas have been thought to arise from these bursae. However, Merkel and other equally authoritative anatomists have denied the existence of such a bursa. Probably the latter opinion is nearer the truth.

Bochdalek's Glands.—Bochdalek's glands are thought to be remnants derived from the thyroglossal duct tract. They are stated to be lined with ciliated epithelium. Obstruction of the excretory duct of one of these glands has also been advanced as a possible cause of ranula. (See Ranula, Chapter XXX.)

Sublingual Glands.—The sublingual salivary glands lie in the floor of the mouth beneath the duct of the submaxillary gland (Fig. 5). At the bottom of the sulcus between the mucosa of the under surface of the tongue and the floor of the mouth on either side of the frenum are two elevated ridges of mucosa under which lie the sublingual glands. Upon the crest of this ridge of mucosa the sublingual ducts open. These ridges are called the *plicae sublinguales*. Beneath and just medially to the sublingual gland lies the duct of the submaxillary gland. The lingual nerve enters the mouth posteriorly just to the inner side of the body of the mandible and can be felt with the finger when it is pressed against the mandible below the last molar tooth. On bimanual palpation the sublingual gland can be distinctly outlined with the fingertip unless the patient is too fat.

Submaxillary Glands.—The submaxillary glands lie mostly outside the floor of the mouth curving around, behind and below the mylohyoid muscle. Externally the gland lies under the body of the mandible. The gland is enclosed in a complete capsule (Fig. 5). The external gland can usually be palpated provided there is not too much fat. The facial artery enters its deep surface. The facial vein crosses the gland superficially. The sheath of the gland contains lymph nodes—usually only those of the superficial layer (Blair). The lip, middle dorsum of the tongue, and the floor of the mouth drain lymph into these nodes. Stones, neoplasms, and lymph node enlargements may involve the submaxillary duct and gland. The anterior part of the gland and the common excretory duct lie within the floor of the mouth, bend around and above the posterior edge of the mylohyoid muscle and pass forward above the muscle. The duct continues forward above the mylohyoid muscle and the sublingual gland. The excretory duct opens in a small *papilla* located to one side of the juncture of the frenum

with the tongue. The papilla is easy to see—about the size of a pinhead. The submaxillary duct may be probed by inserting a small lachrymal duct probe into the opening of the papilla. As previously mentioned, on bimanual palpation the whole of the submaxillary gland can be rather accurately outlined in the normal individual. The duct itself, however, cannot be palpated when in its normal condition. However, a stone or an inflammatory thickening can be outlined. When the floor of the mouth is examined in this manner, the head should be bent forward to relax the muscles of the floor of the mouth. As the connective tissue of the floor of the mouth is very loose, inflammatory conditions very rapidly cause a marked edematous swelling of the loose tissue which causes the mucosa to bulge upward beneath the tongue. However, this edema usually tends to subside as rapidly as it appears.

TONGUE

Tongue.—The body of the tongue occupies the upper portion of the cavity of the mouth. The dorsal surface presents an anteroposterior convexity that might approximate a semicircle. On opening the mouth the

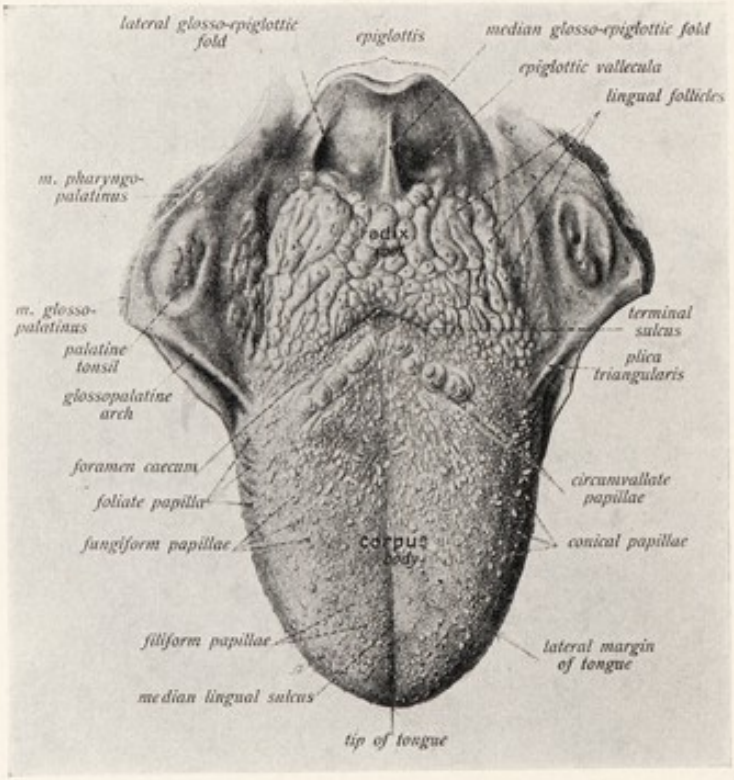

Fig. 6.—View from above of the tongue removed from the body. (Sobotta and McMurrich.)

body of the tongue must necessarily follow the movement of the anterior part of the lower jaw. The anchorage points of the tongue are relatively small ones both anteriorly and posteriorly. The posterior attachment is to the body of the hyoid bone and the anterior attachment at the midpoint of the mandible at the symphysis. Besides its muscular anchorage the mucous reflections and some intrinsic muscles limit to a certain extent its excursion and determine its shape. No ligament supports and no liga-

ments are attached to it. The tongue has an increased mobility because of the fact that the hyoid bone is not a fixed bone but lies between two muscular groups which are elastic and freely movable.

On the surface of the tongue posteriorly is the *sulcus terminalis,* a faintly visible V-shaped furrow which runs from the anterior faucial pillar on either side backward and centrally to the foramen caecum (Fig. 6). This structure marks the beginning of the thyroglossal duct tract. Anteriorly and parallel with the sulcus terminalis is a V-shaped row of large taste papillae called the *circumvallate papillae.* The nerve supply to these papillae is supplied by the glossopharyngeal nerve. Morphologically the structures are related to the pharyngeal portion of the gullet.

The portion of the tongue behind the sulcus is called the *root* and is anatomically related to the pharynx. The portion of the tongue anterior to the sulcus is derived from the primitive buccal cavity. The root of the tongue makes up the anterior wall of the pharynx. The mucous covering of the root of the tongue continues into the fauces and lateral pharyngeal walls. Below, it continues on to cover the epiglottis and centrally it forms the middle glosso-epiglottic fold. This part of the tongue mucosa is quite sensitive so that a tongue depressor touching it in the unanesthetized individual causes gagging. In the submucosal tissue of the root of the tongue are numerous mucous glands and lymphoid islands. This lymphoid tissue is called the "lingual tonsil." The lingual tonsil with the faucial tonsils proper and the adenoids (pharyngeal tonsil) form a complete ring of lymphoid tissue encircling the entrance of the pharynx. About the sulcus terminalis, the lateral borders and the dorsum of the tongue are located other mucous glands. From these glands may arise retention cysts, benign or malignant new growths. Ewing states that transitional cell epithelioma sometimes may arise from the mucous glands.

Anterior to the sulcus terminalis over the dorsum of the tongue the mucosa is studded with *taste papillae* (taste buds) which normally give the tongue a rough appearance. When inflamed and the papillae are swollen, this appearance may be quite exaggerated. Beneath the tongue the mucosa is smooth. As previously mentioned in describing the floor of the mouth, the mucous covering of the dorsum of the tongue is reflected around the sides to the inferior surface of the body and covers a large part of the inferior surface of the tongue before it is reflected over the floor of the mouth which it covers. The mucosa is reflected to the border of the glosso-alveolar sulcus in a double fold with a free border anteriorly. Laterally and anteriorly the mucosa passes into the gums. Posteriorly this fold forms the posterior limit of the glosso-alveolar sulcus and becomes continuous with the lower gum and the anterior faucial pillars behind the third molar tooth when the latter is present. Between and beneath the anterior part of this fold there is little save some loose connective tissue but posteriorly the geniohyoglossi muscles are interposed. When this septum is grasped between the fingers, the anterior border of the geniohyoglossi muscle can be outlined. The *frenum* is the anterior nonmuscular portion of the septum. An abnormally short frenum causes the condition of tongue-tie. Too great laxity of the frenum has been reported in an instance or two. Two somewhat raised ridges may be seen on the under surface of the tip. They converge at the tip and indicate the position of the ranine

arteries. The termination of the ranine veins are also seen with ease. Conditions resembling varicosities of these veins have been described.

The part of the dorsum of the tongue somewhat anterior to the circumvallate papillae is the least movable portion of the tongue. It is therefore more apt to become coated. Unilateral furring is occasionally seen in connection with painful conditions of the fifth nerve which supplies this area. The condition is due to an involuntary spasm or voluntary immobilization of one half of the tongue. In tic douloureux the condition may be present or it may accompany a severe toothache. The mucous membrane of the tongue is subject to a variety of lesions a description of which forms several of the succeeding chapters.

As previously stated, the body of the tongue is made up almost entirely by intrinsic muscles. An incomplete median raphe separates the two halves of the tongue. This fibrous septum in the anterior portion to a considerable degree separates the lymphatic system into two parts. The lymphatic channels of the tongue (Fig. 6) are large and numerous and are drawn into the submental, submaxillary and inferior and superior deep cervical nodes. One node situated at the bifurcation of the common carotid artery is finally a central focus for nearly all the streams of lymph flow just mentioned. The tongue has a good blood supply from the lingual arteries. These arteries are said to have but a scanty intercommunication.

The hypoglossal nerve is the motor nerve of the tongue. When this nerve is paralyzed the tongue deviates to the opposite side when protruded. The sensory nerves of the tongue for both taste, and ordinary tactile, pain and pressure sensations are numerous. The tactile sensation at the tip is especially acute. The glossopharyngeal nerve is the sensory nerve of the circumvallate papillae and the tongue posterior to them. These fibers originally are derived from the nucleus of the fifth nerve. The fifth nerve supplies the part of the tongue anterior to the circumvallate papillae by fibers which are carried by the lingual nerve. The fibrils for the taste papillae of the tip, sides and dorsum are carried through the lingual and chorda tympani nerves. Irritative diseases of the tongue may cause referred pain through this connection of the fifth with the seventh cranial nerve and be felt about the meatus of the ear and spasmodic contraction of the muscles of mastication may result from the same connection.

PALATE

In the midline of the palate is a median raphe which terminates anteriorly at the incisive papilla (Fig. 7). This marks the position of the anterior palatine fossa. In infants without teeth this papilla connects with the frenum of the lip. This midline bony raphe of the palate is sometimes thickened by a ridge of bone—the *torus palatinus*. A small pit can sometimes be seen on either side of the midline behind the incisive papilla which corresponds to the openings of Stensen's canals. At the juncture of the hard and soft palates on either side of the raphe are often seen small pits—the *foveolae palatinae*—wherein the secretory ducts of several palate glands open.

On the ventral surface of the hard palate, the soft tissue is thrown into irregular, more or less parallel ridges.

The palate is made up of two parts, the hard and soft palate, and is covered on both surfaces by mucous membrane. The soft tissues of the hard palate consist of mucous membrane, the submucous tissue containing some mucous glands, lymphoid tissue, blood vessels, nerves and periosteum which all fuse together and form an inseparable layer which is, however, rather easily detached from the bone. The soft tissues of the hard palate are continuous through the gums in the edentulous jaw with the mucosa of the mouth. The interdental portions of the gingiva when the teeth are present connect the vestibule mucosa with the palatal mucosa. The prin-

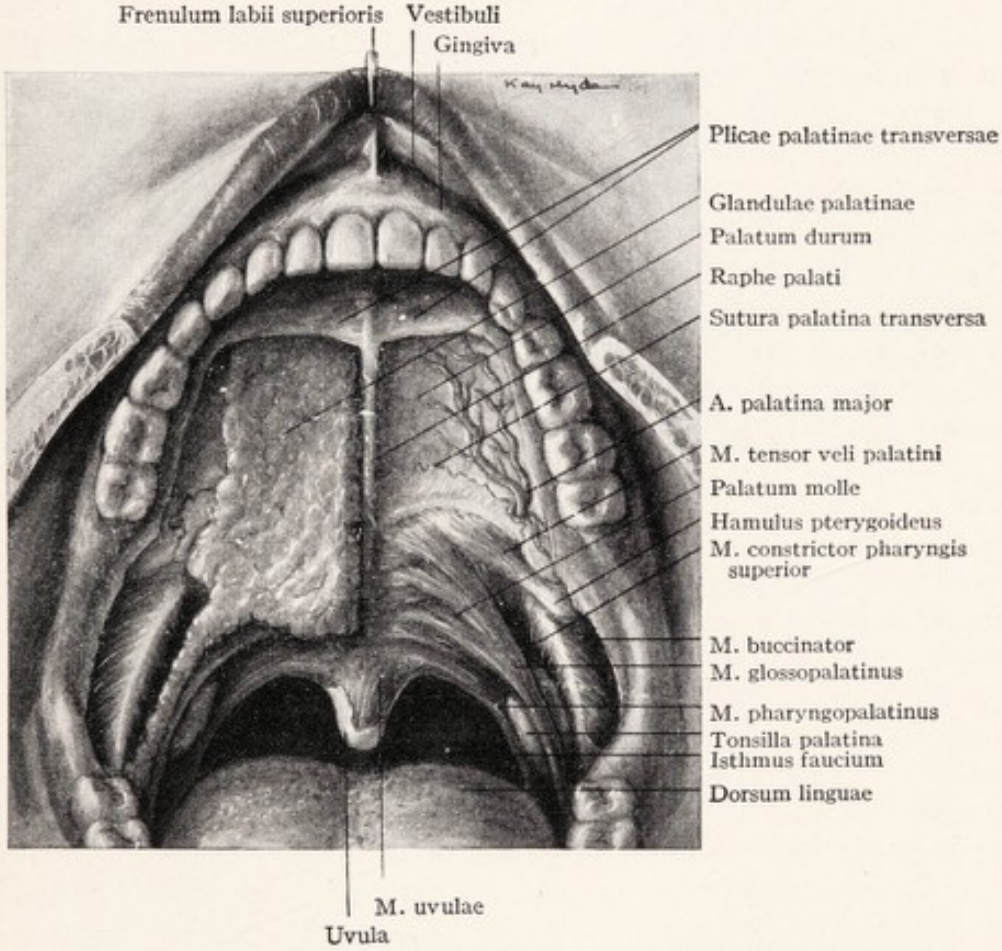

Fig. 7.—View of the oral cavity and palate after dividing the cheeks. The mucous membrane of the palate has been partly removed on the right side to show the palatine glands and on the left side the glands have been removed to show the inner relation of the muscles of the velum palatinum. (Callander, Surgical Anatomy.)

cipal blood supply of the mucoperiosteum of the hard palate is given by the posterior palatine artery which emerges into the palatal soft tissues through the greater palatine foramen at the outer border of the hard palate close to the alveolar process and at the level of the posterior border of the last molar tooth. The artery is a continuation of the descending palatine artery. Branches of the descending palatine artery turn posterior and add to the blood supply of the soft palate. The anterior palatine nerve emerges along with the artery through the same canal and passes forward. The strength of the nerve makes it possible to not tear the artery in the von Langenbeck type of operation.

There are a few accessory foramina through which small nerves—the middle palatine—pass and also supply the palatal tissues. Through the incisive foramen at the junction of the premaxillary with the palatal plates, the sphenopalatine artery whose branches enter the palate from the nasal septum, emerge along with the nasopalatine nerve and supply the anterior mucoperiosteum of the hard palate. In double cleft palate they supply only the soft palatal tissue of the premaxilla.

The prominence at the posterior end of the superior alveolar ridge is called the *maxillary tubercle* and posterior and slightly internal to the tubercle can be palpated the tip of the hamular process of the internal plate of the ptgeryoid process of the sphenoid bone. The posterior palatine nerve descends through the pterygopalatine canal and through an opening behind the greater palatine foramen and supplies the soft palate, tonsil, and uvula. The middle and posterior palatine nerves form a plexus along with branches of the ninth nerve about the tonsillar region. The ascending palatine artery enters the soft palatal tissues about 1 cm. posterior to the hamular process and runs beneath the oral mucosa.

The soft palate is firmly attached to the posterior edge of the palatal plates by an aponeurosis. The palatoglossi and palatopharyngei muscles, which form the anterior and posterior tonsillar pillars respectively, extend upward into the soft palate. Also the termination of the levator palati and the tensor palati muscles enters the soft palate from above after arising from the base of the skull and encircling the lateral wall of the nasal pharynx. These four muscles are immediately connected in the soft palate with the palatal aponeurosis. The tensor palati muscle lies between the internal and external pterygoid plates. At the tip of the internal pterygoid plate, the tendon of the muscle turns at a right angle inward over the hamular process and then the muscle spreads out fanlike in the soft palate. The fifth cranial nerve furnishes its motor nerve supply and the branch enters its posterior border. It is thus not in danger of being cut during a palate operation. The levator palati muscle lies posterior to the tensor, ends in the posterior part of the soft palate, and descends from the base of the skull. The pharyngeal eustachian tube separates the two muscles just described. The motor nerve supply of the levator palati is uncertain. Some anatomists state that the nerve supply comes from the eleventh cranial nerve through the pharyngeal plexus while others state that it is derived from the fifth cranial nerve through a branch that passes posterior from the large palatine nerve just after it enters the palate, from the posterior palatine canal. Rich states that the tensor palati muscle is supplied by the bulbar root of the spinal accessory nerve which contains the inferior rootlets of the pneumogastric nerve. Preservation of the nerve supply to this muscle conserves good palatal function so lack of exact knowledge as to its innervation is of more than passing importance. However, it is usually not necessary to interfere with the nerve whatever its situation in the usual palate operation.

In cleft palate the mucosa of the roof of the mouth is continuous with that of the floor of the nose and nasopharynx on one or both sides according to whether the cleft is double or single. In single clefts the mucosa of the nasal septum is often continuous with the mucosa of one palatal plate as the septum is attached to the palatal plate on that side. The nasal and oral vessels anastomose freely around the border of the cleft.

TEETH

The teeth which penetrate and rise above the gums are divided into incisors, cuspids, bicuspids, and molars. The incisors present a sharp cutting edge for incision and cutting. The cuspids are used for prehension and are conical shape with a pointed crown. The bicuspids are located distally to the cuspids. The bicuspids have a function somewhat intermediate between that of the cuspids and molars. Late in life after the incisors are worn down, some grinding surface may gradually appear and when the molars are lost this function may be of considerable aid in chewing.

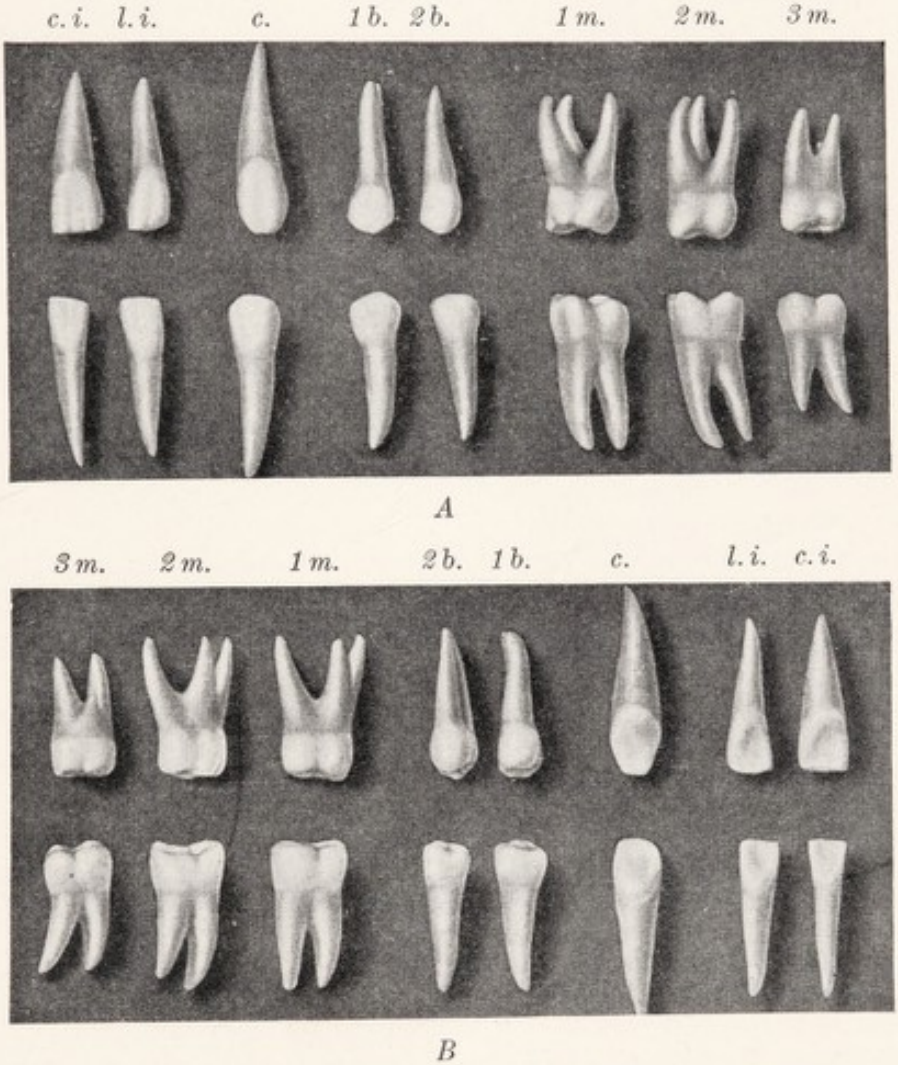

Fig. 8.—*A*, The upper and lower teeth from the labial or buccal surface. *B*, The upper and lower teeth seen from the lingual surface. *c. i.*, Central incisor; *l. i.*, lateral incisor; *c.*, cuspid; *1 b.*, first bicuspid; *2 b.*, second bicuspid; *1 m.*, first molar; *2 m.*, second molar; *3 m.*, third molar. (Sobotta and McMurrich.)

Posterior to the bicuspids are located the molars. They have a somewhat broad occlusive surface and are used for grinding.

Man possesses two sets of teeth, the deciduous and the permanent. In the permanent set are four incisors, two cuspids, four bicuspids, and six molars in each jaw—32 in all. In the deciduous set are two incisors, one cuspid, and two molars in each jaw—20 in all (Figs. 8 and 9).

Each tooth is made up of enamel which covers the crown, dentine which forms the body of the crown and the root, the cementum which

covers the dentine of the root, and the internal pulp tissue which fills the pulp canal. The peridental membrane is attached to the cementum. The pulp cavity contains connective tissue, blood vessels, lymph vessels, and nerves. The root may be divided into three parts: the gingival portion or that part above the alveolus, the alveolar portion or that portion extending from the rim of the alveolar process to practically the end of the root, and the apex or the extreme end of the root. The somewhat constricted part of the tooth at the junction of the crown and the root is spoken of as the

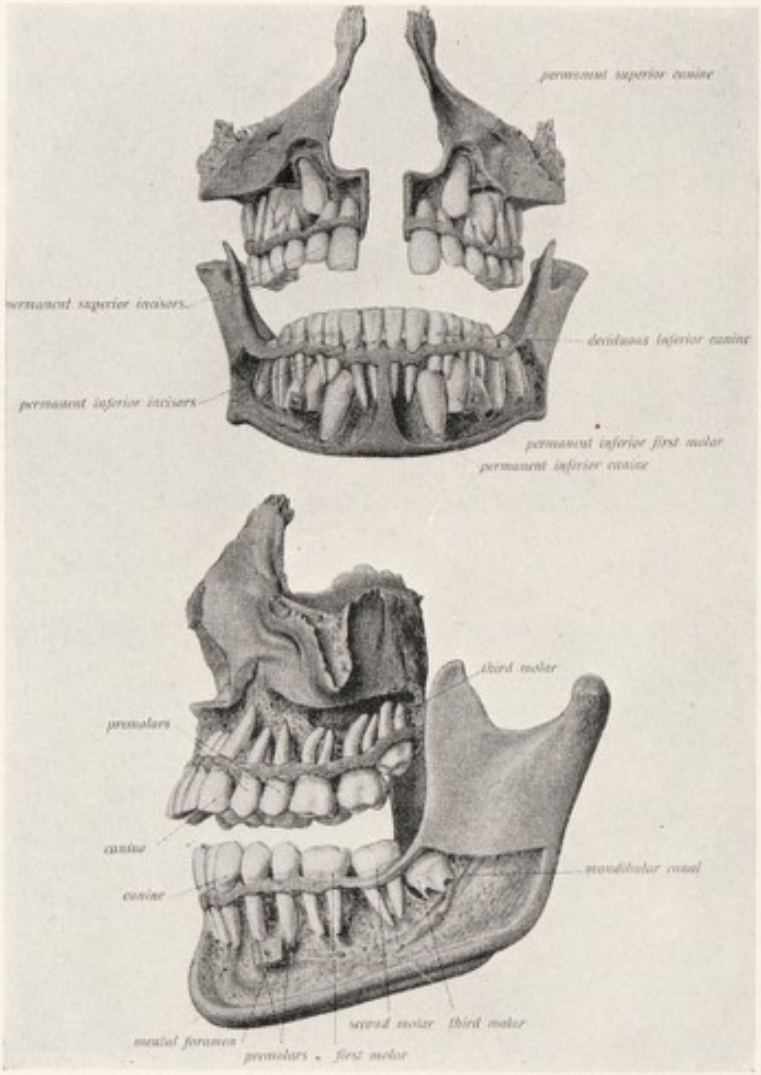

Fig. 9.—Upper illustration: skull of a five-year-old child with the deciduous and permanent teeth seen from the front. The permanent teeth and the roots of the deciduous teeth have been exposed by chiseling away the anterior alveolar wall. Lower illustration: the upper and lower jaws of a twenty-year-old man similarly prepared. (Sobotta and McMurrich.)

neck. The portion of the crown near the neck is called the gingival portion of the crown. The junction of the crown and the root is generally surrounded by a ridge in the enamel known as the *gingival ridge*. The crowns of the incisors and cuspids have a cutting edge and four surfaces, buccal (labial), lingual, mesial, and distal. The bicuspids and molars have five surfaces, buccal, lingual, mesial, distal, and occlusal.

From the median line the *four incisors* are the first and second teeth respectively in the dental arch. The upper central incisor is the longest of

the incisors and the most conspicuous. The lower central incisor is not only the smallest of the incisor teeth but the smallest of all the teeth. The *cuspid* is the third tooth from the median line. The cuspid presents the same surfaces as the incisor. The incisal edge is characteristic. It is divided into a mesio-incisal and disto-incisal portion and terminates as a cusp. The root of the upper cuspid is the longest found in the human mouth. The average length is about 18 mm. The pulp cavity follows the outline of the root and is the largest of any of the single-rooted teeth. In contradistinction to the lower central incisor there is little danger of drilling through the side of the cuspid except near the apex. The cuspid because of its length contributes more to the formation of the shape of the mouth and influences facial expression more than any other tooth. It is a favorable tooth for anchorage of bridges and removable dentures. The *bicuspids* are eight in number. The lower first bicuspid is the smallest of the bicuspids and the upper first the largest. The chewing surface is broad, uneven, and rounded off quadrangularly and is divided by a groove running mediodistally into a larger buccal cusp and a smaller lingual cusp as a rule (except the second upper bicuspid). In the upper arch the bicuspids possess two cusps—therefore the name—but in the lower there is a tendency for the first to develop but one cusp while the second lower bicuspid may have three cusps. As a rule, the root is single and curved distally. The root is flattened mediodistally, presents grooves on the medial and distal surfaces, and may be divided for a third from the apex toward the gingiva. The *permanent molars* are twelve in number. They have very broad occlusal surfaces and present a number of cusps not found on other teeth. The lower first molar is generally the largest of the series. The upper third is the smallest. The roots of the upper molars are three in number and have been described as "straddling the jaw"—two on the buccal side and one on the lingual. The roots of the lower jaw are two in number and have been described as "lying in cross section to the jaw"—one mesially and one distally.

For minute anatomic description of the separate teeth, the student should consult a textbook on dental anatomy.

Occlusion.—The teeth in each jaw form an arch—a half ellipse. When the occlusion is correct the edges of the upper incisors overlap the edges of the lower incisors producing a scissors action (Fig. 10). The upper central incisors are wider than the lower. This causes each succeeding tooth in the upper jaw to fall about one half tooth behind its corresponding lower tooth. Therefore, every tooth in the upper jaw except the last molar is in relation with two teeth in the lower jaw. Thus, any tooth cusp of the lower jaw is slightly in advance of any corresponding tooth cusp in the upper jaw. The buccal cusps of the molars of the lower teeth rest in the grooves forward between the buccal and lingual cusps. Marked variations from this arrangement as to position may be seen and also as to the shape of the teeth themselves. Nutritional diseases are the principal offending diseases in this respect. Congenital syphilis also may be an etiologic factor.

Deciduous Teeth.—Previously it has been mentioned that man has two sets of teeth, the permanent and the deciduous (Fig. 9, *a*). During early life the deciduous teeth aid in mastication and also stimulate growth of the jaw. As the permanent teeth erupt the roots of the deciduous teeth

are absorbed. This process begins at about the seventh and ends at about the fourteenth year.

The deciduous central and lateral incisors and cuspids have the same general form and lobe construction as the permanent teeth but are smaller. The deciduous molars are replaced by the bicuspids. The deciduous second molar of both the upper and lower jaw very closely resembles the upper and lower first permanent molar but the deciduous first molars do not resemble any of the permanent teeth.

Eruption of the Deciduous and Permanent Teeth.—The time of the eruption of the teeth is of interest. It is as follows for the deciduous teeth: central incisor from the sixth to the eighth month, lateral incisor from the eighth to the twelfth month, cuspid from the sixteenth to the

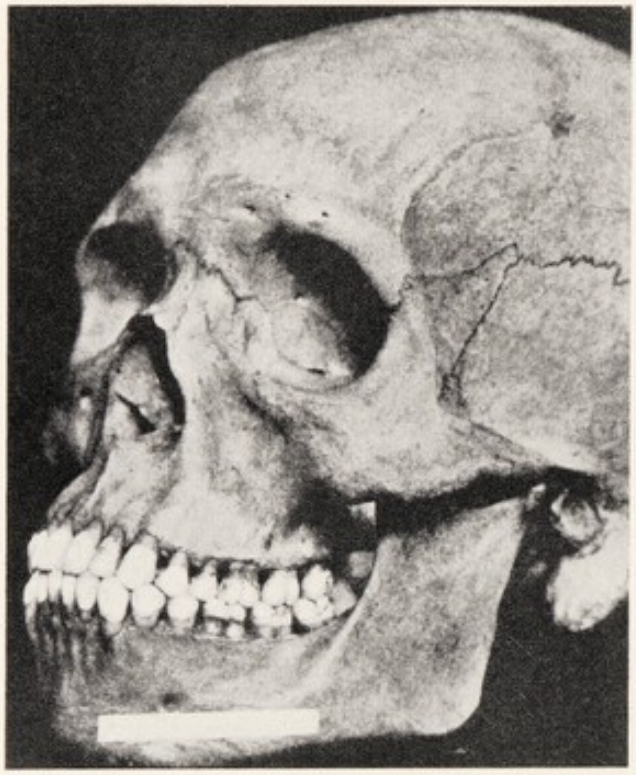

Fig. 10.—Skull which shows normal occlusion. The "Old Glory" of orthodontia. (A skull owned by Richard Summa. After Strang, Textbook of Orthodontia, Lea and Febiger, Publishers.)

twentieth month, first molar from the twelfth to the sixteenth month, and the second molar from the twentieth to the thirtieth month. The order of succession mediodistally is 1—2—4—3—5. For the permanent teeth the time of eruption is as follows: central incisor from the sixth to the ninth year, lateral incisor from the seventh to the tenth year, cuspid from the ninth to the fourteenth year, first bicuspid from the ninth to the thirteenth year, second bicuspid from the tenth to the fourteenth year, first molar from the fifth to the eighth year, second molar from the tenth to the fourteenth year, third molar from the eighteenth to the fortieth year. The order of succession mediodistally is 2—3—5—4—6—1—7—8.

GUMS

The gums are made up of mucoperiosteum which resembles the soft tissues of the hard palate. They surmount the alveolar processes of the jaw.

The gums contain a good many large mucous glands which are more numerous near the necks of the teeth. Around the neck of each tooth the mucoperiosteal tissue rises on the neck of the tooth and forms a type of collar for the margin of the gingiva. The lateral upper part of the crowns of the teeth come into contact but toward the neck, the crown decreases in circumference leaving a slight space between each tooth into which the gingiva extends and forms the *interdental papillae*.

The periosteum of the alveolar ridge extends down into the tooth socket as the *peridental membrane* which is attached to both the tooth and the socket in the alveolar ridge. The peridental membrane holds the teeth in position in an almost but not quite completely rigid manner. Inflammation causes the membrane to become edematous and thickened and the teeth to loosen slightly and protrude somewhat from the socket. Tartar collecting about the necks of the teeth may irritate the gingival margin about the tooth setting up an inflammatory reaction which results in destruction of the attachment of the peridental membrane to the tooth. When such a condition happens the gum retracts and if the depth of the separation of the peridental membrane is sufficient a pocket which fills with pus results. Certain mucosal poisons may act in a similar fashion. The various acute and chronic inflammatory conditions and neoplastic conditions which may be seen in the remainder of the buccal cavity may also involve the gum.

VESTIBULE OF THE MOUTH

The vestibule of the mouth is a space bounded by the lips and cheeks externally and the alveolar ridges and gums internally (Fig. 7). It is lined with smooth mucous membrane which is reflected on the alveolar ridges. In the midline the reflection is drawn into a fold connecting the upper lip and the gum somewhat more closely. This fold is the *frenum of the lip*. In infantile life it reaches to the incisive papilla. Usually in adult life it lengthens and assumes a higher position. When the frenum retains the infantile arrangement, the upper central incisors are separated somewhat. In the midline of the lower jaw, opposite the upper frenum, there is a frenum of less definiteness. With the teeth in contact, posteriorly there is a space behind the third molar and the maxillary tubercle about 6 mm. or more in diameter by which the vestibule communicates with the mouth cavity. When the patient opens his mouth widely the pterygoid maxillary ligament can be felt stretching from the hamular process of the sphenoid bone to the inner side of the ramus of the mandible. To this ligament is attached the superior constrictor muscle of the pharynx, which loops backward around the pharynx from pterygomaxillary ligament to pterygomaxillary ligament. The buccinator muscle of the cheek attaches to the anterior part of the ligament. Between the right and left buccinator muscles lies the orbicularis oris muscle. Thus, the orbicularis anteriorly, the buccinator laterally and the superior constrictor posteriorly serve to make a continuous muscular band which encircles the vestibule and the mesopharynx. External to the pterygomaxillary ligament may be felt the anterior border of the internal pterygoid muscle, the anterior border of the ramus of the mandible and its coronoid process and the anterior border of the masseter muscle. In the upper fornix of the vestibule above the

first molar tooth may be palpated the malar process of the maxilla. Anterior to this prominence is the *canine fossa,* a point often selected through which to open the antrum. Just about opposite the second molar tooth is the papilla through which the parotid duct opens. A small probe can normally be passed into the duct. The normal tone of the buccinator and orbicularis oris muscles holds the cheeks against the teeth and alveolar ridges and prevents food from falling into the lower fornix when chewing. When the seventh nerve is paralyzed this function is lost.

The mucosa of the cheek is rather closely adherent to the underlying muscles. This prevents it from being caught between the teeth. Within the mucosa are a good many mucous glands. They may be felt with the tongue and are especially numerous in the neighborhood of the last molar tooth. Various retention cysts, benign and malignant tumors may originate from these glands or from the normal squamous epithelium of the cheek.

FAUCES AND PHARYNX

With the mouth open widely, the tongue somewhat depressed, the soft palate slightly raised, and the pillars separated, one gets a clear view of the superficial anatomy of the fauces and the oropharynx (Fig. 6). On a cross section specimen, it is to be noted that the arch of the atlas is on about the same level as the hard palate and the body of the axis holds a similar position of relationship with the soft palate. In adults the upper four vertebral bodies can be palpated and in children even more of the bones.

The pharynx forms an elongated flattened tube about 5 inches in length. Its walls are made up of fibrous tissue, muscular tissue and a lining made up of mucous membrane. The tube is much wider from side to side than from the front backward. At its widest part about the level of the greater cornu of the hyoid it is about 5 cm. in width and at its narrowest part at the level of the cricoid cartilage, it measures about 2 cm. in width (Fig. 11). Posterior to the nasal fossae, the upper edge of the muscular bag is attached to the base of the skull just anterior to the vertebral column. The bag becomes continuous with the esophagus at the edge of the cricoid cartilage. It is larger above and becomes somewhat smaller from above downward. Posteriorly and laterally the muscular walls of the bag are complete but anteriorly they are lacking. The anterior deficiency is partly filled by the pharyngeal surface of the tongue, and the body of the larynx. Four anterior openings are present, the openings of the two nasal fossae, the buccal cavity and the larynx. Posteriorly the walls lie adjacent and in close relation to the upper six cervical vertebrae and the great vessels of the neck, separated only by layers of the deep cervical fascia, and at certain areas by a few muscles. There is no direct attachment to the secondary structures; areolar tissue is interposed. Most of the muscles are constrictor muscles and are active in deglutition, phonation and respiration. The mucous lining is continuous with that of the buccal cavity. The three pharyngeal constrictors attach to the openings into the buccal cavity at the lateral border of each of the openings. Thus, the anatomical and physiologic relationship of the two cavities is maintained. The pharynx anteriorly has a muscular attachment to the pterygoid process and to the pterygomaxillary ligament, the hyoid bone and the thyroid cartilage. Anatomically the pharynx is divided into three parts which correspond to the

three openings, the nasopharynx, the oropharynx and the laryngopharynx or hypopharynx.

Thus, the nasopharynx is situated above the palate which separates it from the mesopharynx during the act of swallowing, respiration and talking This flat valve action is accomplished partly by elevation of the velum and partly by constriction of the superior constrictor muscles of the pharyngeal muscular tube. Anteriorly the nasopharynx is open and communicates directly with the nasal fossae through the posterior nares. On each lateral wall at about the level of the middle turbinate lies the eustachian cushion and the opening of the eustachian canals. The tubopharyngeal folds pass downward on each side of the pharynx. This fold of mucosa covers the

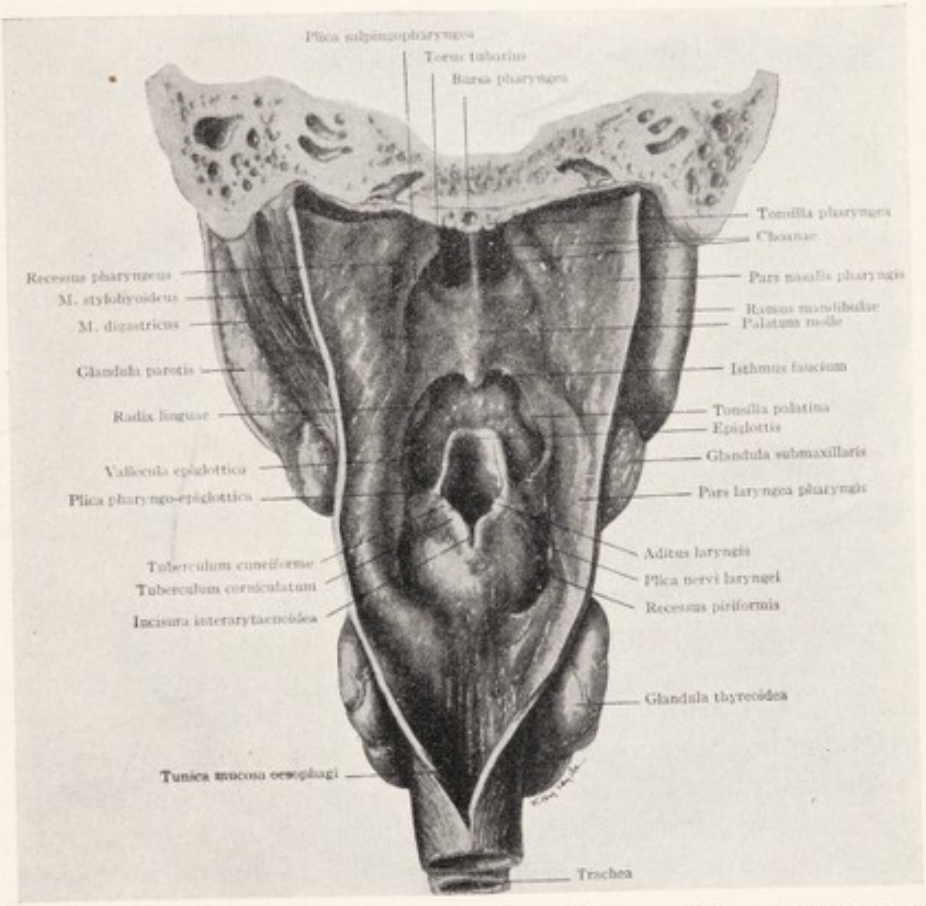

Fig. 11.—Posterior view of the pharynx and esophagus. The posterior wall of the pharynx is opened. (Callander, Surgical Anatomy.)

levator palati muscle (salpingopalate fold). Posterior to each eustachian cushion is a depression of some depth—the fossa of Rosenmueller or the pharyngeal recess. In the mucosa of the roof of the nasopharynx is a collection of lymphoid tissue—the *pharyngeal tonsil* (adenoids).

The *mesopharynx* extends from the level of the palate to the hyoid bone Anteriorly it is continuous with the buccal cavity through the isthmus of the fauces which is bounded above by the palate, below by the tongue and laterally by the anterior and posterior pillars. Between the two pillars on either side are the two tonsillar sinuses which hold two collections of lymphoid tissue—the tonsils. The faucial, pharyngeal and a collection of lymphoid tissue at the root of the tongue form a ring of lymphoid tissue known as *Waldeyer's ring*. Lymphoid tissue is found in smaller amounts

in Rosenmueller's fossa and in the posterior pharyngeal wall—the so-called *lymphoid follicles*. This ring of lymphoid tissue almost completely surrounds the nasal and oral openings of the pharynx.

As stated previously, the tonsils are situated between the anterior and the posterior pillars and lie on the superior pharyngeal constrictor muscle. They vary considerably in size. In children they are apt to be large and somewhat superficially located with relation to the pillars. In adults the tonsils tend to be smaller in relationship to the size of the fauces and they often sink farther back between the pillars. The tonsils also vary much in size according to whether or not they are inflamed. The tonsillar tissue not infrequently undergoes malignant change.

The lymphatics of the tonsils drain into the deep cervical lymph nodes. One lymph node situated just behind the angle of the jaw is so constantly enlarged in tonsillar inflammations that it has been called the tonsillar node. The lymphatics from the palate and upper pharynx drain to the lateral pharyngeal and retropharyngeal nodes and thence directly to the superior cervical nodes. The pharynx is often subjected to acute inflammatory attacks. It may be injured and is also fairly prone to involvement with chronic ulcers of both the inflammatory and neoplastic types.

The base of the tongue is connected to the esophagus by a median line of mucous membrane which has on either side a fossa known as the vallecula.

The *hypopharynx* begins at the hyoid bone and extends to the lower border of the cricoid cartilage where it joins the esophagus. The anterior wall of the hypopharynx is formed by the laryngeal box. The hypopharynx communicates with the larynx through the glottis. The glottis is demarked from the mesopharynx by the epiglottis. From the epiglottis on each side to the lateral border of the base of the tongue are two mucosal folds—the pharyngeal epiglottic folds. The opening of the glottis is bounded laterally by the aryepiglottic folds and lateral to these on either side are two pockets—the recessus pyriformes. All these structures and spaces can be seen with the laryngoscope mirror or on direct laryngoscopy or can even be felt with the finger. The ascending palatine branch of the external carotid and the ascending branch of the facial artery, and a few branches of the internal maxillary artery give arterial supply to this region.

LARYNX AND TRACHEAL TUBE

The laryngotracheal tube is made up of the larynx and the cervical trachea. Both have considerable mobility. The chief support of the larynx is the hyoid bone which is connected to it principally by the thyrohyoid muscles and the thyrohyoid membrane. The laryngeal box is a series of cartilages adapted for phonation. The cervical trachea measures about 6.5 cm. in length, is made up of a series of three quarters circular cartilaginous rings and is flattened on its posterior surface because of the deficiency in these cartilaginous rings. Within the larynx lie the thyroid and cricoid cartilages and three sets of paired cartilages—the arytenoids, corniculates and cuneiforms. The *thyroid cartilage*—the largest cartilage—affords valuable protection to the structures of the larynx and forms a box triangular in shape—the so-called "Adam's apple" of the neck. The *cricoid cartilage* is a modified tracheal cartilage with the narrow part of its arch

in front. It forms a signet, the upper angles of which support the arytenoid cartilages. The interval between the cricoid and the thyroid cartilages is bridged by the *cricothyroid membrane*. The arytenoids furnish attachment for the intrinsic muscles of the larynx which govern the tension of the vocal cords. The *corniculate cartilages* (of Santorini) surmount the arytenoids and to either side of these lie the *cuneiform cartilages* (of Wrisberg). The mucosa of the larynx is continuous with that of the pharynx and trachea.

The interior of the larynx is divided into three compartments by two paired folds of mucosa within which lie the aryepiglottic muscles stretched anteroposteriorly from the arytenoid cartilages to the thyroid cartilages which lie below the epiglottis. The folds project medially from the lateral walls of the larynx. The superior folds form the *false vocal cords* and the inferior folds the *true vocal cords*. On either side of the laryngeal opening is a pharyngeal recess termed the *pyriform sinus*. The entrance of the larynx is triangular in shape with the base toward the epiglottis. The supraglottic compartment (vestibule) extends from the inlet to the false vocal cords. The middle compartment (glottis) is the recess between the true and false cords. The infraglottic compartment extends from the true vocal cords to the first tracheal ring.

Inflammations and tumors involving the vocal cords tend to produce hoarseness or later even respiratory obstruction. Cancer of the true vocal cords is not uncommon. Cancer of the vestibule of the larynx is usually secondary from extension of cancer primary in the pharynx.

LIPS

The lips encircle the entrance of the vestibule. Their covering is a modified mucous membrane which, along a line posteriorly to the margins which meet in normal contact, gradually changes to mucous membrane of the type which covers the vestibule. The lip mucosa proper is studded with simple vascular papillae in which are nerve endings. Therefore, the lip is very sensitive to pain. No hair follicles are present but about the skin line are numerous sebaceous glands which occasionally become cystic. The layers of the lip are as follows: skin, fatty fibrous tissue, the orbicularis oris muscle, submucous tissue, and mucous membrane. The angles of the mouth where the two lips converge are located opposite the first bicuspid teeth. The size of the rima oris varies in different individuals. It has been stated that the size is related to the size and prominence of the teeth.

The *orbicularis oris muscle* encircles the opening of the mouth. It is a muscle with slight bony attachments but it receives fibers from and is an insertion focus of every muscle of the face that converges to the mouth. These various muscular attachments account for the various contortions and variety of expressions of which the mouth opening is capable. The remarkable facility with which the lip swells is accounted for by the considerable amount of loose connective tissue it contains. The general elasticity of the lips allows a considerable amount of manipulation so that operations of a plastic nature are relatively successful.

The main arteries of the lips are the coronary arteries which form an elliptical anastomosis about the mouth. The artery lies about $\frac{3}{16}$ inch deep to the surface and its pulsations may be palpated. The lips are easily cut by the teeth and when this happens are prone to bleed quite profusely.

Various congenital malformations, both acute and chronic inflammatory lesions, cysts, and benign and malignant neoplasms may occur in the lips.

Facial Vein.—The facial vein is continuous through the orbit with the ophthalmic vein. The vein has no valves so that an infected thrombus has an unimpeded pathway to the interior of the cranium. Infections of the upper face and nose are therefore likely to have serious consequences because of this anatomic peculiarity.

MANDIBULAR JOINT

If one presses the finger along the lower border of the zygoma, the condyle of the mandible may be felt just in front of the external ear. When the mouth is opened slowly the condyle will be felt to travel downward and forward for a part of its arch of movement and then finally straight forward as it travels on and across the articular eminence.

If the mouth is opened slightly beyond its normal range of excursion, a clicking or cracking sound is heard and the condyle may even lock itself in a position of subluxation. When the condyle falls forward far enough to drop into the pterygoid fossa, a complete dislocation is present. With the mouth entirely open a depression instead of a prominence may be felt at the position of the condyle when the mouth is closed.

In addition to injuries causing fracture, fracture and dislocation, or dislocation alone, the joint may be subject to inflammations which limit the joint somewhat and produce an ankylosis, either complete or partial. Growth of the mandible tends to be retarded on the side of the ankylosis when it occurs in childhood. Suppuration tends to spread anteriorly or posteriorly as the joint capsule is thinner in these positions. Muscle spasm or a paralysis of surrounding muscles also may contribute to the disability of the joint. The anatomy about the joint is discussed further in the chapter on Dislocation of the Mandible.

JAWS

Fracture of the maxilla may cause injury to the superior maxillary nerve, the nasal duct, and branches of the internal maxillary artery and the line of fracture may extend into the oral, orbital, or nasal cavities. In the chapters (Chapters IX and XI) on Fractures and Dislocations of the Jaw the anatomy of practical importance is discussed. It is of interest that both of the jaw bones can be palpated over most of their area. All the borders and most of the surfaces of the mandible may be palpated save the sigmoid notch. The maxilla and the malar bones are also almost entirely accessible to the palpating finger.

MAXILLARY SINUS—THE ANTRUM

Within and occupying most of the body of the superior maxillary bone is a more or less triangular, pyramidal, pneumatic space, the antrum of Highmore. The mucosal lining is a continuation of the mucoperiosteum of the outer posterior wall of the nasal chamber and it is covered with ciliated columnar epithelial cells. The cilia move toward a small exit in the nasal cavity in the hiatus semilunaris located beneath the middle turbinate bone (Fig. 12). The floor of the orbit is formed by the same

bony plate as the superior wall of the antrum. The superior wall is nearly a smooth plane and may be very thin or even show a dehiscence of bone. Thus, when the exit of the antrum is blocked, the orbit may be invaded by pus. The inner wall also forms the lateral nasal wall and is more or less imperfect. The external wall is concave within and its external wall forms the facial surface of the maxillary bone. It extends forward from the body of the malar bone to the median line at the anterior nasal aperture and is the thickest of the walls described. The apical part of the imperfect pyramid extends to and into the base of the alveolar process. The size of the antrum varies considerably in different individuals and the cavity may extend into the malar bone or the palate bone. Rarely the cavity has been found to be divided by an incomplete vertical septum. As the opening into the nasal cavity is in the upper part of the sinus cavity, fluid cannot drain out unless the head is held downward and to the opposite side.

The roots of the molar teeth, and the bicuspid teeth are in rather close relation with the floor of the sinus. Sometimes even the cuspid

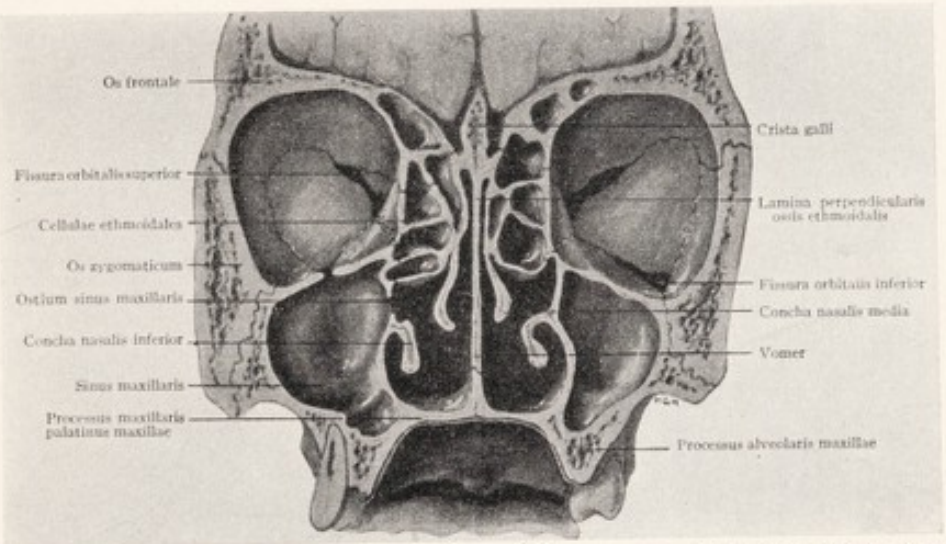

Fig. 12.—Frontal section through the brain, orbits, paranasal sinuses, and nasal fossae to show their interrelations. (Callander, Surgical Anatomy.)

tooth is also in close relationship to the sinus. The relationship may be so intimate that the roots of the teeth cause the mucosa to bulge upward into the sinus. The nasolachrymal duct lies in the inner wall running from the inner canthus of the eye to the inferior meatus of the nose. The infra-orbital nerve enters the soft tissues of the face through the infra-orbital foramen which lies in the maxillary bone just above the antrum. The anterior and middle dental nerves run through the external wall of the sinus to the upper teeth. The sensory nerve to the mucosal lining of the antrum is supplied by the second branch of the fifth nerve. It may be blocked in the pterygomaxillary fossa by local anesthesia.

At about the twelfth year the antrum is supposed to have obtained the greater part of its complete development. At birth the cavity is present but extremely small.

MUSCLES OF MASTICATION

The masseter muscle on the external surface of the mandible can be palpated easily. When the teeth are firmly pressed together the temporal

muscle readily may be outlined. The anterior border of the internal pterygoid muscle cannot be palpated. The four muscles of mastication—the temporal, the internal pterygoid, the external pterygoid and masseter muscles—are innervated by the motor division of the fifth nerve. Paralysis may result therefore from injury to this branch of the nerve. Irritative, toxic or painful sensory stimulation factors may produce spasm of the muscles.

SALIVARY GLANDS

The sublingual and submaxillary glands have already been alluded to in this chapter.

Parotid Gland.—The parotid gland is the largest of the salivary glands and lies in front of the ear, overlaps the ramus of the mandible and a part

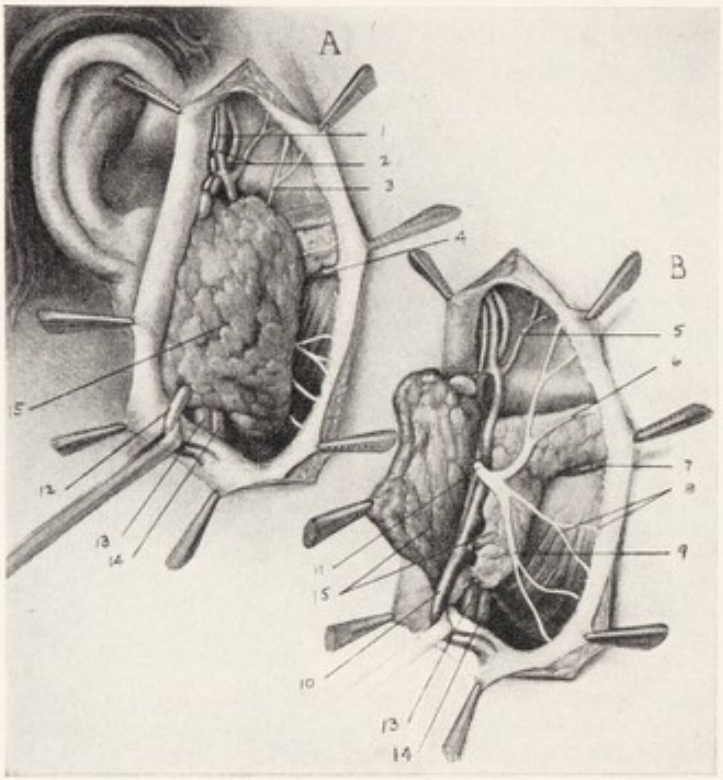

Fig. 13.—Superficial and deep dissections of the parotid region. In B, the outer part of the parotid gland is retracted to show the vessels and nerve which traverse it. 1, N. auriculotemporalis; 2, A. et V. temporalis superficialis; 3, ramus temporalis N. facialis; 4, ductus parotideus; 5, V. temporalis media; 6, ramus zygomaticus N. facialis; 7, ductus parotideus; 8, rami buccales N. facialis; 9, ramus marginalis mandibulae N. facialis; 10, V. jugularis externa; 11, N. facialis; 12, V. jugularis externa; 13, A. carotis externa; 14, V. facialis posterior; 15, glandula parotis. (Callander, Surgical Anatomy.)

of the masseter muscle extends slightly downward into the upper neck and around the posterior and anterior border of the ramus (Fig. 13). In its normal condition the substance of the gland cannot be felt with precision. A heavy fascia encases the gland externally and below but medially only on the lower part. Thus, the medial layer part of the capsule is lacking and here the parotid space therefore communicates with the deep connective tissue spaces of the pharynx. The duct of the parotid gland (Stensen) runs through the cheek about 2 cm. below the zygoma, and turns into the mouth at the anterior border of the masseter muscle. The duct can be

distinctly felt when the masseter muscle is made tense. It enters the mouth opposite the upper second molar tooth.

The seventh nerve passes through and branches in the parotid gland. The auriculotemporal branch of the fifth nerve and filaments of the great auricular nerve of the cervical plexus also lie within the gland. Also within the parotid gland are a number of lymphatic nodes into which the eyelids, eyebrows, root of the nose, upper part of the cheek, the frontal and temporal part of the scalp, the outer ear, the tympanum and possibly some of the mucosa of the nose, the posterior alveolar region of the superior maxilla and the soft palate, drain. The efferent lymph channels pass to the cervical nodes.

THE LYMPH NODES

The superficial lymph nodes of the neck and the face are numerous and if enlarged are often palpable. Some of the deeper more centrally located nodes are rarely palpable. In most instances the lymphatics are sec-

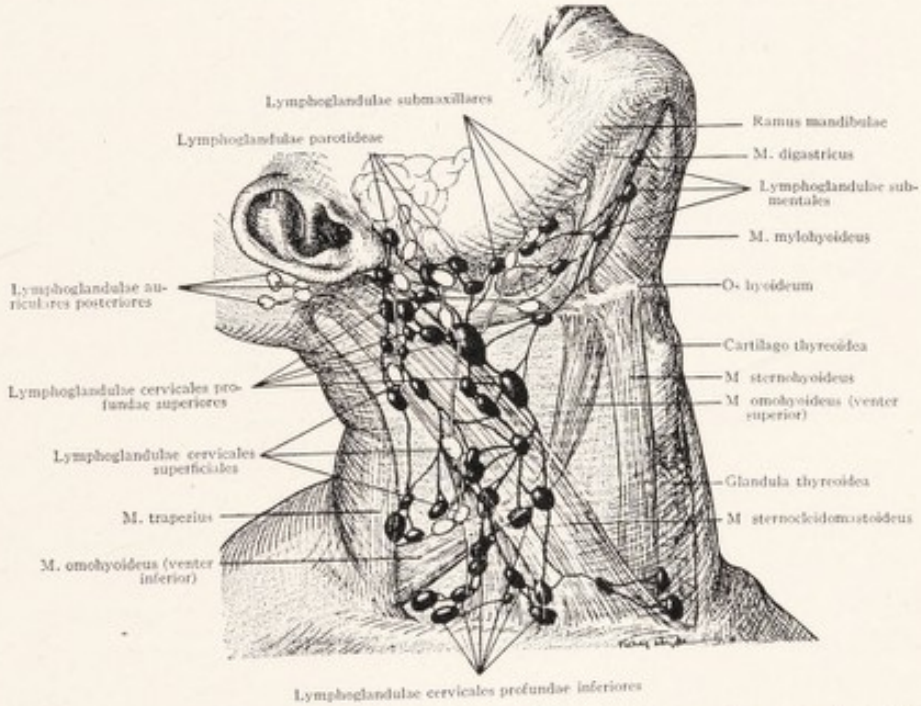

Fig. 14.—Surface anatomy of the lateral region of the neck showing the distribution of the superficial and the deep cervical lymph glands. (Callander, Surgical Anatomy.)

ondarily involved on account of either infections or neoplasms of a metastatic nature. One may group the lymph nodes of this region for descriptive purposes, somewhat as follows (Fig. 14):

1. Between the geniohyoid muscles about the mylohyoid muscles are one or two lingual nodes which are rarely palpable.

2. Beneath the chin at the anterior end of the digastric muscle are located the submental nodes. Into them drain the tip of the tongue, midgums, midfloor of the mouth and midpart of the lower lip and chin. Their efferent channels run partly to the submaxillary nodes and partly to a node situated in the anterior surface of the internal jugular vein, at the level of the cricoid cartilage.

3. In front of the deep jugular vein between the vein and the omohyoid muscle and above where the muscle crosses the carotid sheath are the infrahyoid nodes in which the frenum of the tongue drains quite directly.

4. Superficial to the submaxillary gland lie the submaxillary nodes. A rather large node is usually situated near the facial artery. These nodes receive channels from the nose, the upper lip, the outer part of the lower lip, the anterior third of the lateral tongue, the gums and teeth, the sublingual glands, and the floor of the mouth. Their afferent channels discharge into the upper deep cervical nodes in the neighborhood of the bifurcation of the common carotid artery.

5. Behind the nasopharynx are a few retropharyngeal glands. They receive lymph from the nasal cavities, the accessory air sinuses, the nasopharynx and the eustachian tube. They are not ordinarily palpable.

6. Along the internal maxillary artery is situated a variable number of lymph nodes. Their afferent channels come from the orbital cavity, the zygomatic and temporal fossa, the cerebral meninges, the nose, and the

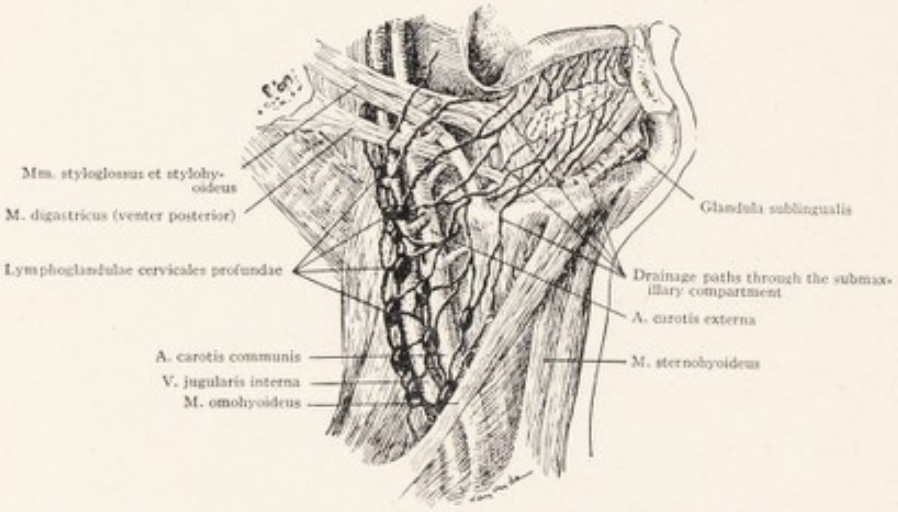

Fig. 15.—Lymphatic drainage from the tongue. (Callander, Surgical Anatomy.)

palate. Their afferent channels discharge into the upper deep cervical nodes. They are seldom if ever palpable.

7. Superficial to the superficial fascia of the cheek and superficial to the fascia of the parotid gland there are a few lymph nodes. Into them drain the upper part of the face and ear. Their efferent channels go to the superficial and deep cervical glands.

8. Cunningham describes a lateral nasal node situated between the nose and the cheek.

9. Embedded in the deep cervical fascia along the course of the external jugular vein lie the superficial cervical lymph glands. Into them drain the superficial tissues of the neck, the superficial parotid and submaxillary nodes. Their efferent channels connect with the deep cervical nodes.

10. The deep cervical nodes are arranged in two groups (Fig. 15). One lies along the common carotid artery and internal jugular vein—the true deep cervical group. Second, the group found in the posterior triangle of the neck behind the sternomastoid muscle—the supraclavicular group. The efferent channels of these two groups all finally empty into the general

blood stream at the juncture of the internal jugular and subclavian veins. These supraclavicular glands if slightly enlarged are readily palpable. The deep jugular glands are difficult to palpate on account of the overlying sternomastoid muscle.

While the preceding description represents the normal course of the lymph stream for this region, it is conceivable that when one group of glands or channels becomes obstructed by various pathologic lesions the pathway of lymph flow may be diverted through a more circuitous route.

Most, Cuneo, and Greene, in particular, have studied the lymphatic system of the larynx. Briefly the situation is as follows:

1. The cavity of the larynx is divided into an upper and a lower lymphatic area. These two areas are almost completely separated except posteriorly where there is an anastomotic connection in the posterior wall.

2. The lymphatics of upper area (false cords, sinus of Morgagni, sides and posterior surface of the epiglottis) collect from the epiglottis, near the aryepiglottic folds and leave the larynx through the pharyngo-epiglottic folds and the thyrohyoid membrane.

3. The lymphatics of the lower area pass through the cricothyroid membrane and communicate with the tracheal lymphatics. In the midline of the larynx, communication is free to either side, to the trachea, to the pharynx and to the esophagus.

4. The upper area drains mainly to the glands along the internal jugular vein by way of the superior thyroid vessels. Most found a small gland below the digastric tendon at its attachment on the lateral border of the thyrohyoid muscle. A gland was also found in the thyrohyoid membrane also one or two along the upper edge of the thyroid gland.

5. The subglottic area sends its lymph through the cricothyroid membrane to one or two glands anterior to the larynx which may communicate with the thyroid glands and the deep cervical glands. Back of the vocal cord and the posterior laryngeal surface the channels pass through the cricotracheal membrane, to the glands situated between the trachea and esophagus. These may communicate with the supraclavicular glands.

The relation of the lymphatic system of the larynx to the spread of laryngeal cancer is of particular significance.

THE LOCATION OF THE NERVES

By judicious planning and selection along with a knowledge of the course of the sensory nerves, there is hardly any operation about the face, mouth and jaws, that cannot be carried out successfully under local anesthesia if one deems it advisable (Fig. 16). The nasal nerve can be located with a needle before it leaves the orbit by the anterior ethmoidal foramen. The nerve is encountered at a depth of from 18 to 22 mm. from the bony ridge that may be palpated in the inner border of the orbit. The supra-orbital nerve emerges from the supra-orbital notch which can be felt at the juncture of the inner with the outer two thirds of the upper border of the orbit. The supratrochlear nerve emerges just under the inner end of the supra-orbital ridge. As it emerges it is in close relation with the periosteum and the tendon of the superior oblique muscle. The infra-orbital nerve emerges from the infra-orbital foramen, situated 6 mm. below the middle of the lower border of the orbit. One can palpate the foramen

with the finger. The orbital branch of the superior maxillary nerve emerges in the floor of the orbit or in the sphenomaxillary fissure and finds an exit by one or two foramina located near the juncture of the floor with the lateral wall of the orbit—4 to 8 mm. from the border. The nerve divides into two branches—a temporal branch which enters the temporal fossa and a malar branch which emerges in the facial aspect of the malar bone. Not always is the nerve constant in its size, mode of exit, and area of distribution. A branch of the ophthalmic nerve may replace it. The auriculotemporal nerve crosses the root of the zygoma. The nerve lies behind the temporal artery; the pulsation of the artery serves as a guide. The mental branch of the inferior dental nerve emerges from the mental foramen located on the external surface of the mandible below the second bicuspid. When

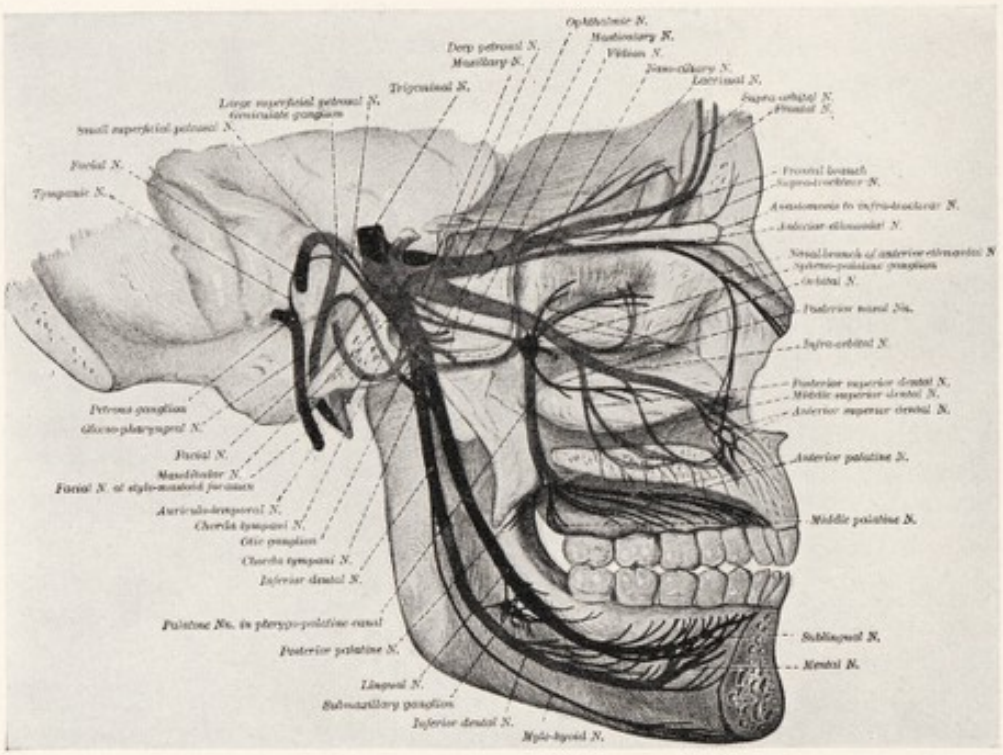

Fig. 16.—Distribution of the fifth, or trigeminal nerve. The black lines indicate the branches embedded in the soft tissues, the gray lines those embedded in bony tissue. (Sobotta and McMurrich.)

the teeth are present the foramen lies slightly nearer to the lower edge of the bone than the alveolar border. When the alveolar process has been absorbed the foramen lies higher. When the mouth is opened widely, a triangular space is visible behind and above the last molar which is directly in front of the anterior borders of the pterygoid muscle. The border of the ramus is external. One may identify these structures with the finger. To strike the region of the inferior dental nerve, a needle should pierce the mucosa of this space near its median border and about 5 mm. above the occlusal plane of the lower teeth. The needle is then driven through the tissue in an outward and backward direction to a depth of about 1½ cm. along the inner side of the ramus through the internal pterygoid muscle. The lingual nerve lies near the ramus of the mandible slightly forward to the inferior dental nerve. The descending palatine nerve emerges from the

posterior palatine canal in the sulcus between the palate and the alveolar process opposite the last molar. The nerve runs forward. The nerves which supply the mucosa of the soft palate emerge close by the opening of the posterior palatine canal and run backward. The palatine branches of the nasopalatine nerve emerge from the incisive foramen which is situated posterior to the incisive papilla just posterior to the central incisor. The long buccal nerve is to the medial side of the coronoid process. When the mouth is opened with a gag and the coronoid process is located, the nerve may be located as it lies between the buccinator and the insertion of the temporal muscle. The mandibular division of the fifth nerve may be reached below the level of the zygoma at a point midway between the posterior border of the condyle of the lower jaw and the angle between the temporal and zygomatic borders of the malar bone. At a depth of 40 to 60 mm. the external plate of the pterygoid process lies. Posterior to the upper part of the plate is a space through which a needle may be inserted so that its point will lie at or near the foramen ovale which gives exit to the third division of the fifth nerve. The superior maxillary division of the nerve may be reached by inserting a needle below the zygoma at the juncture of the anterior with its posterior two thirds just posterior to the coronoid process when the mouth is held open. At a depth of about 43 cm. the external pterygoid plate is encountered. The point of the needle is pushed forward and upward until it drops into the sphenomaxillary fossa where it will be close to the nerve and also to the sphenopalatine ganglion. The ophthalmic division of the fifth nerve is so located that it is difficult to reach for the purpose of injection. The sensory nerves of the neck emerge from behind the sternomastoid muscle about midway between its origin and insertion. They may be reached for the purpose of injection along the posterior border of the sternomastoid muscle at a depth of about 1 cm. subcutaneously.

Bibliography

References Quoted in Text

Blair, V. P., and Ivy, R. H.: Essentials of Oral Surgery, St. Louis, C. V. Mosby Co., 1926.

Blandin: Quoted by Blair, V. P.: Surgery and Diseases of the Mouth and Jaws, St. Louis, C. V. Mosby Co., 2d ed., 1913.

Callander, C. L.: Surgical Anatomy, Phila., W. B. Saunders Co., 1933.

Cuneo: Gazette des Hôpitaux, No. 141, 1902.

Cunningham, D. J.: Textbook of Anatomy, New York, William Wood and Co., 4th ed., 1913.

Ewing, James: Neoplastic Diseases, W. B. Saunders Co., Phila., 3d ed., 1928.

Greene, D. C.: Trans. of Amer. Laryngol. Assoc., p. 63, 1906.

Merkel: Quoted by Blair, V. P.: Surgery and Diseases of the Mouth and Jaws, St. Louis, C. V. Mosby Co., 2d ed., 1913.

Most: Deutsche Zeitschrift für Chirurgie, No. 56.

Sobotta, Johannes, and McMurrich, J. Playfair: Atlas and Textbook of Human Anatomy, Phila. and London, W. B. Saunders Co., 1911.

Spalteholz, Werner: Human Anatomy, Phila., J. B. Lippincott Co., 3d ed., 1903.

Strang, R. H. W.: A Textbook of Orthodontia, Phila., Lea and Febiger, 1933.

Suzanne and Merkel: Quoted by Blair, V. P.: Surgery and Diseases of the Mouth and Jaws, St. Louis, C. V. Mosby Co., 1913.

Tillau and Fleischman: Quoted by Blair, V. P.: Surgery and Diseases of the Mouth and Jaws, St. Louis, C. V. Mosby Co., 1913.

Ziegelman, Edward F.: The Inverted T Shaped Incision with Block Anesthesia in Radical Surgery of the Maxillary Sinus, Western Jour. of Surg., Obst. and Gynec., Feb., 1934.

Supplementary References

Black, G. V.: Descriptive Anatomy of the Human Teeth, Phila., The Wilmington Dental Mfg. Co., 1890.

Deaver, John B.: Surgical Anatomy of the Human Body, Phila., P. Blakiston's Son and Co., 1926.

Dewey, Martin: Dental Anatomy, St. Louis, C. V. Mosby Co., 1928.

Diamond, M.: Dental Anatomy, New York, The Macmillan Co., 1929.

Gould, A. Pearce: Elements of Surgical Diagnosis, New York and London, Cassell and Co., 1919, pp. 111–115.

Gray, Henry: Anatomy of the Human Body, 21st ed., Phila., Lea and Febiger, 1924.

Piersol, George Arthur: Human Anatomy, Phila., J. B. Lippincott Co., 1907.

Prinz, Hermann: Dental Materia Medica, St. Louis, C. V. Mosby Co., 6th ed., 1926.

Treves, Sir Frederick: Surgical Applied Anatomy, London, Cassell and Co., 9th ed., 1934.

CHAPTER III

ASEPSIS AND MATERIALS OF SURGERY

The original experimental work (1879) of Pasteur (1822–1895) when put into practical application by Lister (1827–1912) allowed aseptic surgical technic to reach its present state of perfection. Lister developed the so-called "antiseptic surgery" under the whirling carbolic spray. A later development was the so-called "aseptic surgery"—surgery in which the bacteria on all objects coming in contact with the wound have been killed by heat. Halstead's introduction of the rubber glove in 1890 into this country had far-reaching results in attaining this final goal.

Sixty years ago operations on the internal organs were unknown. Exposed parts of the body only were accepted as offering possibilities of alleviation or cure by operation. The mouth, of course, is an exposed surface and to a certain extent operations in this region did not have to await the advent of asepsis.

The majority of intra-oral surgery cannot be done under aseptic conditions in the true sense of the word. If one does not take this into consideration and provide drainage compatible with possible contamination when operating within the mouth, he courts the danger of an infection developing. A relative asepsis for the moment may be obtained if one paints the mucosa with any one of the good antiseptics but as soon as one makes an incision through the mucosa, it probably makes little difference whether an antiseptic solution was applied to the mucosa or not as almost immediately the wound is contaminated with the various organisms always present in secretions of the mouth. The wisdom of applying locally some antiseptic solution before inserting a needle is a somewhat different matter. A contaminated needle may carry bacteria along its pathway. On the other hand, when a noncontaminated needle is withdrawn, the hole of its insertion is so small, especially if a little time is given for the coagulating mechanism of the blood and tissue juices to function, it is unlikely that contaminating bacteria will be allowed to pass beyond the mucosa.

The era of aseptic surgery in contradistinction to the era of antiseptic surgery does not mean that antiseptics have been discarded entirely. Antiseptics are usually used in securing surgical cleanliness of instruments which are destroyed or damaged by boiling. Antiseptics are also used to secure surgical cleanliness of the skin or mucous membrane. Antiseptics will usually only partially remove infectious organisms from involved tissues. When they are used in sufficient strength to destroy bacteria in the tissues, they also destroy tissue cells. This fact has been demonstrated repeatedly.

Wright and Fleming made a study of the effects of antiseptics on wounds and drew the following conclusions: (1) antiseptics are diluted quickly by tissue juices to a point where they no longer kill bacteria. (2) Antiseptics cannot reach bacteria in tissue spaces. (3) Antiseptics will not act in the presence of slough and have little action in serous discharges or in the presence of blood. In 1919 Fleming showed that the antiseptics then in

use killed leukocytes and inhibited their movements. To an open wound one should favor mild antiseptics if any are used (gentian violet and dahlia).

As asepsis began to be adopted in preference to antisepsis it began to be realized that ordinary clean air carries potentially infecting micro-organisms only so rarely that the point may be disregarded. Secondly, it began to be realized that spore-bearing organisms may not be killed by antiseptics. The agents of infection have been shown by the bacteriologist to be those things which come into contact with the wound which carry micro-organisms. Among these conveyers are the surgeon's and staff's garments, their hands, and the instruments, the linen, and the sutures. The proper method of preparation and sterilization of operating paraphernalia, the surgeon's and his assistants' hands must be understood.

Besides the various architectural qualifications of an operating room, an adequate "scrub room," instrument room, linen room, and anesthesia room which all may be varied according to taste or space, are adjunct requirements of an operating room. The surgical nursing staff prepares the operating room (Fig. 1). When preparing for an operation at least one sterile nurse is assigned to the room who prepares the linen "set-ups," instruments, suture material, etc. An unsterile nurse fetches and carries, opens packages and hands sterile odds and ends that may have been placed in an antiseptic solution because they would not stand boiling.

PREPARATION AND DRAPING OF THE PATIENT

According to the type of operation, sterile sheets and sterile towels are used. Often the whole body is covered if possible save the actual field of operation (Fig. 17). Towel clips are used to hold the towels in place. When the patient is under an anesthetic, the towels may be clipped to the skin.

Scrubbing the skin with soap and water only removes the bacteria which inhabit the surface. Organisms in the sweat glands and hair follicles are not reached by an antiseptic. Therefore, tanning or fixing agents with an antiseptic action are useful after the use of some fat solvent to dissolve the fat. The incision is made and the skin edges if possible are curtained away by means of towels held by clips. As much of the contents of the hair follicles and sweat glands as possible are isolated from the wound by such a technic. Tinker and Sutton who thoroughly studied certain skin antiseptics came to a conclusion which is pertinent: "For the present, at least, it would seem wiser not to discard the old method of soap, water and 95 per cent alcohol, followed by the relatively efficient antiseptics now generally employed."

PREPARATION OF THE SURGEON AND HIS ASSISTANTS

For most operations both head and face coverings (Fig. 17) should be worn in the operating room. For the relative sterilization of the surgeon's and assistant's hands and arms, the method usually employed is: cleanse beneath the nails well with a nail file. For ten minutes scrub the hands, arms and elbow region with liquid soap and water, then dip the hands and arms in 70 per cent alcohol for three minutes. Next, a sterile gown is put on. The hands are dried, powdered with sterile talcum, and

encased in dry sterile rubber gloves. The gloves are held open by the nurse so that the outside is not touched in any part by the other hand of the surgeon. Many hospitals use some additional antiseptic besides alcohol

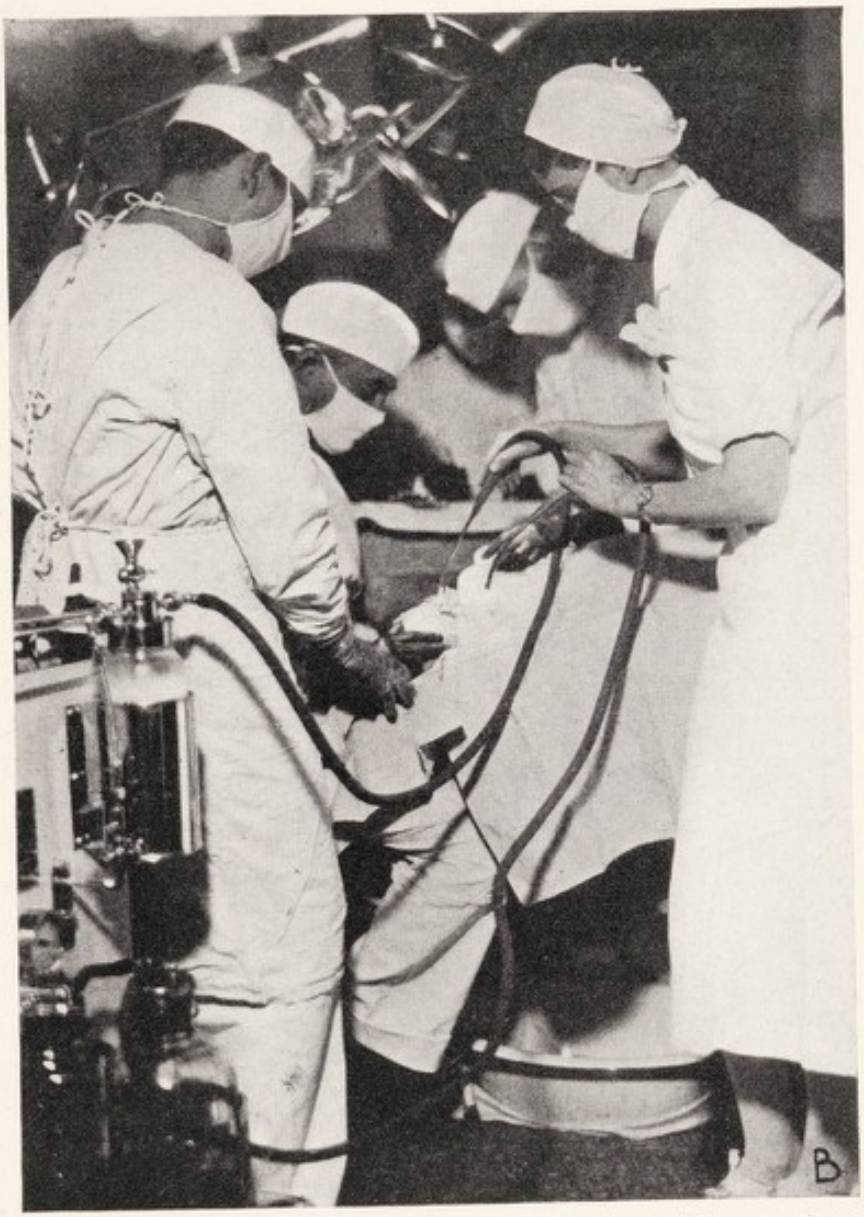

Fig. 17.—Position of a baby for a cleft palate operation. The anesthetist is holding one tube in her right hand for the purpose of blowing vaporized ether into the mouth of the patient and in her left hand she holds another tube for suction. The surgeon sits on a stool at the patient's head. There is a Lane gag in the mouth of the baby. The head of the table is broken so that the occiput falls fairly well back and the body is on a slight downward grade. The first assistant stands at the left. The instrument table is seen directly in front of the operating nurse (it is a little too high as it was raised to show in the photograph). The ether machine stands at the left hand corner. A good light properly directed is shown in the upper left hand corner.

such as permanganate of potash decolorized by a solution of saturated oxalic acid, cyanide of mercury, or bichloride of mercury.

PREPARATION OF INSTRUMENTS, LINEN AND SUTURES

After each operation the instruments are washed, reboiled, dried, oiled, and placed in a case. Just before use they are boiled for twenty minutes.

Cutting instruments such as scissors, knives, and the needles ordinarily are placed in a 20 per cent solution of carbolic acid for thirty minutes and then rinsed in 95 per cent alcohol.

Nonabsorbable sutures such as silk, linen, celloidin, horsehair, silver wire, silkworm-gut may be wound on bobbins and boiled. Absorbable suture, usually catgut, is sealed within glass tubes in an antiseptic solution by the manufacturer. The glass tubes may be sterilized by submerging in any appropriate antiseptic solution.

Dressings, gauze sponges, towels, and linens are sterilized in wrapped packages or in metal drums by steam under pressure in sterilizers made for that purpose. A vacuum is produced in the sterilizer and then live steam is allowed to penetrate under 15 to 20 pounds for twenty minutes which gives a temperature on an average of 255° F. Finally, a vacuum is again created to aid in drying the material. Occasionally the sterilizer is checked by bacteriologic methods.

Certain special instruments, rubber tissues, etc., are sterilized in antiseptic solutions. Hypodermic syringes and needles are boiled with the instruments.

THE UNDERLYING PRINCIPLES OF ASEPTIC SURGICAL TECHNIC

Throughout any operation, gentleness is essential. Slipping, clawing retractors, rough manipulations tend to lower the resistance of the tissue and the tissues are unable to overcome the small number of organisms ordinarily of relatively nonpathogenic type and proportions which are usually present in any operative wound.

The surgeon and his assistants must develop an aseptic conscience. Strict attention to the operation so that the work is facilitated is wise. Asepsis depends upon a chain of persons all of whom are aseptic conscious and the chain is not stronger than its weakest link. The technic with the provisions previously outlined should aim toward simplicity. The rôle of foreign bodies and dead spaces (see Chapters IV and V) should be known to all men who presume to operate.

INSTRUMENTS—DRAINS

In oral surgery as in general surgery the background of an instrument set-up is a group of instruments spoken of as a dissecting outfit which simply means that sufficient scissors, scalpels, retractors, tissue forceps, and hemostatic forceps are gathered together so that one can cut, dissect, and catch the bleeding points in a given procedure. The number of hemostatic forceps laid out will depend upon the size of the operation. When work on the bone is contemplated, chisels, rongeurs, curets, and sequestrum forceps are in order. The size and shape of these instruments will depend upon the location and magnitude of the procedure. Besides these basic instruments, needles, needle holders, and sutures will be needed if closure of the wound is contemplated. When closure is not planned as a part of the operation, it may be that a gauze pack will be used to hold the wound edges open and at the same time prevent excessive oozing or contamination by food particles if the wound be in the mouth. When drainage is necessary rubber dam, small rubber tubes, or even a gauze wick may be of use.

To wash pus or blood out of a cavity, an irrigating syringe may be useful. A catalog-like description of the instruments of surgery is of no particular value to the modern trained student. As he comes up through his various courses, he can hardly miss having such information become an integral part of his groundwork. If one's curiosity is purely academic, the instrument catalog of any supply house will graphically inform one concerning these matters to an extent which space forbids herein. In the chapter on extraction of teeth an everyday working set-up for extraction is named and depicted.

SOLUTIONS USED IN SURGERY AND ORAL SURGERY

The student should be familiar with some of the solutions more commonly used in surgery.

Normal Salt Solution.—Normal salt solution contains salts in about the same proportion as the blood plasma. That is, it is isotonic. This solution is an indispensable one at the time of operation and often postoperatively. The solution causes little or no irritation to the tender body cells, does not upset their physiochemical metabolism and may be placed in the blood stream without destructive effect upon the corpuscles, white blood cells and platelets. Normal salt solution is used to moisten sponges, to keep tissue from becoming dry. In dehydrated states or when some loss of fluid has occurred, or is likely to occur, it is used for hypodermoclysis or it is not uncommonly given intravenously directly into the blood stream. Tablets are prepared commercially a certain number of which will prepare a liter of the solution. The solution must, of course, be sterile.

Mercury Solutions.—Various strength solutions of bichloride of mercury have been used in the past and still are commonly used in the operating room. Sometimes a weak solution of bichloride of mercury is used to moisten a dressing. The solution is a fatal poison if used internally and is somewhat irritating to external tissues if used in a fairly high concentration. It also tarnishes instruments very quickly. At the present time there are several antiseptic solutions with a mercury base alleged by commercial houses to be as potent bactericidally as mercury bichloride but less irritating to the external tissue. Mercury cyanide is one of these commonly used preparations. Many operating rooms routinely use two solutions to pass the hands through before putting on gloves and gowns—one of mercury cyanide and finally one of 70 per cent alcohol. Merthiolate is another mercury preparation more recently placed on the market. An alcoholic solution of merthiolate is often used as an antiseptic for local preparation of the skin. Mercurochrome nowadays is a commonly used mercury base antiseptic. It is mentioned separately below. Almost every commercial drug house now has some mercury solution which is sold under a trade name. Of those sold in this country until the stamp of approval of the Committee on Drugs and Chemistry of the American Medical Association has been obtained, one would probably be wiser in abstaining from their use.

Mercurochrome.—Within recent years mercurochrome—a mercury base solution—has been used to a considerable extent as a local antiseptic to supplant iodine. The solution is less irritating than iodine and is thought to be efficient when used in 2 to 5 per cent strengths. Mucous membrane

will tolerate from 1 to 2 per cent. It has been used intravenously—a practice which at the present time is not regarded with as much favor as a few years back.

Iodine.—Official tincture of iodine has a strength of 7 per cent. This strength has represented a standard type of drug for skin preparations before operation for years. On the face or about rather tender, moist mucous surfaces, a solution of one half to one third strength is often used. After application to the skin alcohol often is used to remove a good share of the iodine either to prevent the marked discoloration or to prevent the chance of a slight burn. One should never place a moist dressing over a surface covered with iodine as the tendency to blister is increased very markedly thereby. Similarly if one places adhesive over a surface covered with iodine, a blister probably will develop.

Ether.—Besides being used as an anesthetic—its best known use—ether is often used as a solvent to clean the skin before applying an antiseptic solution. It will also remove residue of adhesive tape. During the late war ether was not uncommonly used to flush out a wound or a joint cavity.

Phenol Solution.—On the market are a great many antiseptic solutions with a phenol base. Carbolic acid in solutions of 1:20 to 1:40 is the oldest of these preparations and probably the most useful. Tubes of catgut are often kept in such solutions. Just before using they are rinsed in alcohol which "cuts" the carbolic acid. Lysol is a commonly used solution with a phenol base. If the newer preparations made in this country are used in substitution for these older solutions, they should have the approval of the Committee on Drugs and Chemistry of the American Medical Association. Such a course will prevent the use of some unreliable preparations.

Boric Acid Solution.—For general usefulness as a solution to moisten a dressing saturated boric acid solution has few equals. It is mildly antiseptic and only very slightly irritating. It is often used as an irrigating fluid for wounds. It is especially useful as an eye wash. For routine use especially in office practice or out-patient work the solution is ideal. One only has to tell the patient to buy ¼ pound of boric acid crystals and place enough crystals in a pint or a quart of water so that some lie on the bottom of the container. This gives a saturated 4 per cent solution. After standing for a time the solution will be sterile.

Dakin's Solution.—Carrel during the late war devised a new technic for the use of Dakin's solution. At that time a great deal of experimental work was carried on to develop an ideal irrigating fluid for infected wounds. One was needed which was harmless to the body tissues but had a high antiseptic titer. Dakin's solution probably more nearly fulfils these conditions than any other irrigating fluid when it is used as originally recommended, when it is prepared correctly and is fresh. Carrel used small tubes with holes in the sides near the tip which was tied off. About the tubes gauze was packed to hold the tubes in place and to prevent direct contact with the granulating surface of the wound. To the outer ends of the tubes was connected a glass tube with as many nozzles as tubes. The connecting tubes are then attached to an irrigating can. The fluid flow was regulated by a drop mechanism. In this manner the wound was continuously irrigated and bathed in the antiseptic solution. Bacterial counts of smears made from the wound showed a rapid decrease in the number of

bacteria. The skin surrounding the wound was protected by gauze impregnated with vaselin as the fluid irritates the skin slightly. This method of treatment is applicable to all infected wounds and cavities, but about the face, mouth and jaws it is seldom necessary. Dakin's solution has been used as a mouth wash in diluted form but is unpleasant. Other solutions are as efficient and more pleasant.

Mouth Irrigants and Washes.—A simple nonirritating mouth wash is 1 teaspoonful of table salt and 1 teaspoonful of baking soda to 1 glass of warm water. To decrease odor potassium permanganate in dilution 1: 3000 is sometimes useful to irrigate a malodorous wound in the floor of the mouth. The solution is poisonous enough to make swallowing of it dangerous. When the odor is quite marked after an operation in the floor of the mouth as in advanced cancer, one can temporarily change the permeating aroma after applying a weak solution of cocaine (2 per cent) by irrigating with a 1 per cent formalin solution. This treatment is somewhat drastic but is effective. The eyes should be covered thoroughly before the irrigant is used.

There are a number of commercial preparations on the market which when diluted from one half to one third with water make fairly efficient mouth washes after ordinary operations. Many of them contain a fair percentage of alcohol. Others contain a small proportion of phenol which in inflammatory conditions may be soothing as phenol is a mild anesthetic. Direct application of finely powdered aspirin is soothing to acute inflammations of the pharyngeal mucosa as is also local application of a ferric chloride solution, a prescription for which follows:

Potassii chlorati	gr. xx
Tincturae ferri chloridi	ʒ iii
Glycerini	ʒ iv
Aquae	ʒ ii—M.

Sig.—Apply locally.

Dobell's solution is a time-tried gargle of value. Hydrogen peroxide 1: 4 is an efficient mouth wash and especially so when one desires to remove pus or blood.

The time-honored irrigating solutions are usually spoken of as alkaline antiseptic solutions. A solution of alkaline antiseptic of the pharmacopeia diluted one half represents such a solution. It may be gargled warm. Its odor is pleasant, the color is pleasing, and it is harmless. A 10 per cent solution of boric acid in glycerin is also a soothing mouth wash.

In gingivitis, tincture of iodine, chromic acid (5 per cent) or silver nitrate (5 to 10 per cent) have been used for ages. In Vincent's disease arsphenamine in 5 to 10 per cent strength in glycerin or water has been recommended. For the same disease, another arsenic preparation recommended is Fowler's solution used as an undiluted wash every three or four hours. Potassium chlorate solution in some cases of ulcerative stomatitis acts almost as a specific. For an adult about 4 to 5 grains in dilute solutions every four hours can be recommended.

LIGATURE AND SUTURE MATERIAL

In surgery some material which brings divided tissues into apposition and holds them is a prime requisite. Besides sutures, there is also needed

ligature material to tie off blood vessels so that hemorrhage is controlled. The ligature material in use today falls into two classes, absorbable and nonabsorbable. Most commonly absorbable ligature and suture material is used when buried beneath the skin. When the asepsis is definite, buried silk—a nonabsorbable material—may be used to great advantage. Nonabsorbable material is used almost exclusively for skin sutures and they are removed as soon as union of the skin is moderately firm. A few words concerning some of the more commonly used ligature and suture materials may be of advantage.

Catgut.—Probably the most widely used suture and ligature material is catgut (so-called)—a material from the submucosa of sheep's intestines, especially cleaned, treated and twisted. There are six standard sizes running from 000 to 3, with triple 0 being the smallest size. For tying ordinary blood vessels probably size 0 plain is most generally used. For subcutaneous sewing both the plain and chromicized catgut are commonly employed. Plain catgut is supposed to remain in the tissues ten days before absorption but probably is effective as suture material for a lesser number of days. Chromicized catgut has been subjected to the action of chromic acid and according to varying degrees of hardening is made so that theoretically it is useful as suture material from ten to sixty days.

Twenty-day chromic catgut is most commonly used when a suture material is needed that withstands absorption for longer than ten days. Catgut is sterilized, prepared, and placed in glass tubes in the laboratories of the commercial houses. The sterilization is a long and laborious process and is repeatedly checked for asepsis. Infection of a wound with catgut occurs only with the greatest rarity nowadays. For special purposes catgut may be bought already threaded on an appropriate needle. Within the mouth, catgut may be used to draw the mucosa together but ordinarily it is not used as a skin suture. Catgut like all suture material acts for a time as a foreign body. The greater the amount of catgut in a ligature or suture the greater the immediate reaction and the more prolonged. Therefore, one tries to use the finest catgut that will hold the tissue and to place as few knots as possible. When a ligature is tied, catgut may slip so that one dares not to cut down as close to the knot as is possible when using silk. If a microscopic section is taken from next to a catgut ligature buried in tissue, a considerable amount of polymorphonuclear infiltration along with a considerable fibroblastic reaction is noted. Catgut causes more reaction within uninfected tissues than silk.

Silk.—In some clinics silk is used both as ligature and suture material. When used beneath the surface perfect asepsis is necessary. The material is nonabsorbable and will act as a foreign body if it becomes infected. In the mouth it is not used as a buried suture. Almost any size of silk is now prepared, from the very finest to the coarsest. When properly braided even fine silk has a considerable tensile strength. Very fine silk is used for blood vessel, nerve, and tendon suturing. The finer the silk the less the reaction of the tissues about the suture. As silk stays tied well, it may be cut almost directly on the knot. Small silk ligatures and buried sutures do not cause as much reaction beneath the tissues as one would expect. A microscopic section from about a silk suture shows only a slight increase of lymphocytes and some endothelial proliferation and a

slight fibroblastic reaction. As previously mentioned, the reaction about catgut is considerably greater. Silk is more difficult to use than catgut. It takes considerably more experience to learn to tie it easily without breaking. The heavier grades of silk are used only when considerable permanent tensile strength is required. Silk is a good skin suture and is probably the skin suture most commonly used.

Silkworm-gut, Dermal.—Besides silk, silkworm-gut and horsehair are used for skin sutures. Silkworm-gut is prepared by drawing out the silk secretion of the silkworm in one piece without weaving. It is strong, can be sterilized by boiling and is used where tension is necessary to hold the skin edges together. Silkworm-gut is rather irritating to the tissue and is always removed as soon as its purpose is served. Dermal, a Japanese silk preparation, is strong and more flexible than silkworm-gut. It may be used as a substitute for silkworm-gut.

Horsehair.—Horsehair is a good skin or mucous membrane suture where little tension is required. Horsehair sets in the tissues with less reaction than any suture. This is especially true where the sutures are continually moist as after a cleft palate operation. In moist areas, silk has a capillary attraction which within a few days causes a little halo of necrosis immediately surrounding the suture. Horsehair does not have this reaction.

Silver Wire—Kangaroo Tendon—Live Fascia.—Where strength and considerable permanency are essential as between the ends of a bone difficult to hold in position, silver wire and kangaroo tendons have been used. But if the fracture is a compound one, usually silver wire will eventually act as a foreign body and will have to be removed and kangaroo tendon may be absorbed before its purpose is served. Recently live fascia has been considered a suture of choice in such situations. It has strength. It usually will heal in and if it does not, it will be absorbed and not necessitate a second operation.

Bibliography

Bibliography Quoted in Text

Carrel, A., and Dehelly, G.: The Treatment of Infected Wounds, P. B. Hoeber, New York, 1917.

Halsted, W. S.: Quoted by Garrison, F. H.: An Introduction to the History of Medicine, W. B. Saunders Co., Phila., 1929 (Halsted, pp. 730–731).

Lister, Lord: On the Antiseptic Principle in the Practice of Surgery, Lancet, pp. 11, 95, 353, 1867.

Pasteur, Louis: Études sur le vin, Paris, 1866.
Études sur les maladies des vers à soie, Paris, 1870.
Études sur la bière, 1876.

Tinker, Sutton, Wright and Fleming: Quoted by Maes, Urban: Aseptic Surgical Technique, Dean Lewis' Practice of Surgery, Hagerstown, Maryland, W. F. Prior Co., Chapter VII, **1:** 1–21, 1933.

Supplementary References

Kieffer, Richard F.: Materials of Surgery, Dean Lewis' Practice of Surgery, Hagerstown, Maryland, W. F. Prior Co., Chapter VI, **1:** 1–35, 1933.

Maes, Urban: Aseptic Surgical Technique, Dean Lewis' Practice of Surgery, Hagerstown, Maryland, W. F. Prior Co., Chapter VII, **1:** 1–21, 1933.

CHAPTER IV

WOUNDS OF THE SOFT TISSUES

A FAIR estimate of a surgeon's general ability can be made from judging his methods of handling wounds. One of the first requisites of a surgeon is an accurate knowledge of how, when and where to start and to continue the treatment of a wound. And the most important information of all is the converse of the preceding, that is, when and where not to interfere with a wound.

In the maxillofacial region as elsewhere, injuries may vary from slight scratches to total destruction of the tissues. To gain a conception of the whole picture, the word tissue has to be taken to mean both the soft tissues and the underlying or contained bone. Often the injury to the bony tissue requires attention and mechanical fixation at the same time that the soft tissues are given the preliminary or final care. However, to facilitate the description of the subject, the treatment of bony injuries is taken up separately in Chapters VI to X. Only injuries and the wounds of the soft tissues per se will be considered in this chapter.

WOUNDS

Definition.—A wound may be described as any break in continuity of the external or internal tissues of the body. Clinically, wounds are open or closed. The former are open to infection and contamination and the latter are closed to direct infection and contamination. Contusions without rupture of the skin and simple fractures are examples of closed wounds. Incised, punctured and lacerated wounds and compound fractures are examples of open wounds.

General Symptoms.—The local signs of a wound are gaping and hemorrhage. Usually pain is complained of. In very damaging wounds or after considerable internal or external hemorrhage has occurred, the final symptom, "shock," may supervene.

The degree of pain depends somewhat upon the site of the injury and the susceptibility of the patient to painful stimuli. However, the character of the injury or wound probably influences pain more than the other factors. An incised wound, a bullet wound or a shrapnel wound may not be particularly painful. In the former example the sensory nerves are probably severed so quickly that pain almost fails to register while in the latter cases the numbing effect of the blow from pure molecular disintegration of nervous tissue may prevent much pain. On the other hand, a burn by irritating and uncovering large areas often causes a patient the most exquisite agony. The external face is very sensitive to pain but the gums of the alveoli and the hard palate are about as insensitive as any of the areas of the body innervated by the central nervous system.

Hemorrhage is often the most obvious sign of a wound. (See discussion of Hemorrhage in Chapter V.) If large arteries and veins are not

sharply severed, the amount of hemorrhage usually depends upon the vascularity of the tissue severed and the incisiveness of the resulting wound. A large lacerated or contused wound may bleed very little while a small incised wound usually bleeds freely. A bright red spurting stream of blood indicates that an artery of a size corresponding to the caliber of the stream has been cut. A smooth flow of dark red blood indicates that a vein of some size has been opened. The first thing to do for the injured patient is to prevent a damaging loss of blood. Digital pressure should temporarily stop the flow. When a cavity exists, if the blood is not from an artery of any great size, pressure may be obtained by gauze packing or if the wound is on a smooth surface a large gauze pack may be bandaged tightly over the wound in such a manner as to obtain adequate pressure over the wound. When an artery of some size or a large vein is cut and hemostatic clamps are available, the best thing to do is to immediately separate the edges of the wound, clamp and tie the vessel. In all operative procedures and in all wounds every effort should be made to conserve the patient's resources by preventing blood loss. Blood loss if not immediately serious inhibits the resistance of an individual to an infection that may arise during convalescence and ordinarily a wound reacts and heals quicker in the non-anemic than in the anemic patient.

Besides the obvious clinical signs another clinical syndrome may appear after extensive wounds which is of very serious import—namely, what is called for want of a better name "shock." As shock develops (see Chapter V) the patient although conscious usually becomes somewhat indifferent to what would ordinarily seem a condition that is likely to cause great pain and anxiety. The patient's skin becomes pale, cold and damp. When the pulse is felt it is rapid, thready and soft. When the blood pressure is checked, it is found to have fallen to from 70 to 85 systolic. A low blood pressure is necessary for a diagnosis of shock. The term has often been used loosely in literature without any reference to blood pressure. Every ill, pale, cold and damp patient is not in shock. The low blood pressure is only the clinical indication of a preceding and accompanying low blood volume in the "circulatory tree." When shock is present, the attention of the surgeon should be focused on its relief and the care of the primary wound or causative wound may become relatively unimportant for the time being. This criterion is so important that it can hardly be overstated.

Types of Wounds.—*The Incised Wound.*—An incised wound is characterized by sharp, clear-cut edges and usually is made by a sharp object or instrument, but may be made by a flat surface blow on the soft tissues which are superimposed upon a bony edge. The soft tissues over the supra-orbital ridge are rather often cut in this manner. The degree of gaping of an incised wound as a rule depends in its superficial parts upon the lines of cleavage of the skin and in its deeper parts upon the direction of pull of the severed muscles. In some situations gravity also may have an influence on gaping, especially if the weight of the bony fragments pull upon the soft tissues.

The Contused Wound.—A contused wound is an open wound with the neighboring tissues somewhat bruised. A blunt object strikes the soft tissues with some force causing some molecular disintegration of the soft tissues below. The tissues are bruised. The skin may or may not be

ruptured over the area. Bleeding from such a wound is usually slight but the pain is usually more marked than in incised wounds. Ecchymosis from extravasated blood is often quite startling and in most tissue swelling supervenes quite rapidly.

The Lacerated Wound.—A lacerated wound is an open wound with serrated, jagged, irregular edges resulting from tearing and crushing of the skin and underlying tissues. Any irregular or blunt object striking the soft tissues with sufficient force may produce such a wound. The wound is often not confined to the soft tissues alone. In such wounds one often observes fractures of the underlying bone and sometimes actual bone loss. Bleeding is usually not a pronounced symptom unless a large artery or vein is torn. Pain may be quite severe and the traumatization and devitaliza-

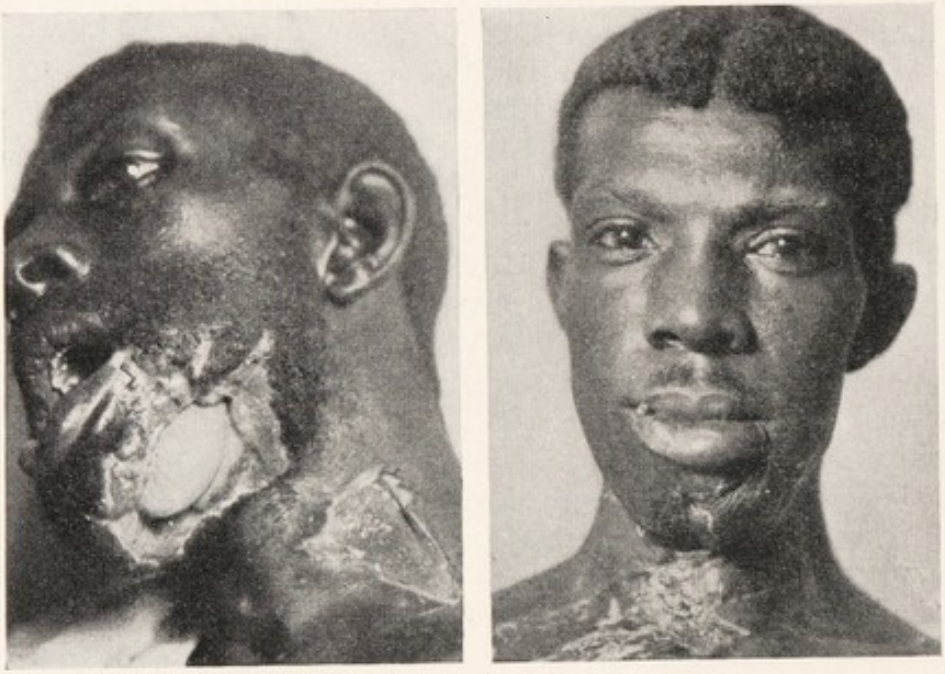

A *B*

Fig. 18.—*A,* Gunshot wound of lower jaw in which the mandible was completely destroyed. This case was repaired by a pedicled flap in which was embedded a bone graft from the clavicle. *B,* Patient after repair.

tion of the surrounding soft tissues increases the liability to infection (Fig. 18, *A* and *B*).

The Avulsed Wound.—Avulsed wounds are characterized by a tearing away and possibly a consequent loss of tissue. Stripping off of the scalp when the hair is caught in machinery is a typical example. The lack of bleeding and pain is often quite surprising. Quite often the manner in which the avulsed wounds are obtained is so generally severe that soon considerable shock appears.

The Punctured Wound.—A punctured wound has a small external opening and relatively great depth. Narrow penetrating objects cause such wounds which may include nails, stilettos, and rifle bullets. Bullet wounds are more dangerous than they appear because beneath the skin circumferentially about the tract of the wound there is usually some devitalized tissue with a central core of blood clot. Consequently, if any bacteria

or any foreign body containing bacteria—as clothing—enter along with the bullet, a deep-seated infection is likely to develop. These wounds should never be probed. A probe opens up new avenues for the extension of the infection, and traumatizes more tissue. As a rule it is impossible to trace the tract anyway because of shifting muscles and fascial planes. Deep wounds of the neck are particularly liable to serious complications because of the many vital structures found here in a comparatively small area.

GUNSHOT WOUNDS

According to Blair the following projectiles in the late World War caused face and jaw injuries in frequency in the order named: (1) shrapnel (most common), (2) machine gun bullets, (3) rifle bullets, (4) grenade, (5) trench mortar and (6) shell.

Shrapnel consists of metal casing containing numerous lead or steel bullets. The casing explodes and the bullets are scattered at varying velocities in a forward shower. Large tearing lacerated wounds are caused. The bullets may remain embedded in the tissue and when bone is struck there is shattering and comminution (Fig. 18).

An ordinary bullet fired at close range may have an explosive effect upon the tissue and cause a great amount of tissue destruction. A steel-jacketed bullet tends to pass through the soft parts leaving a narrow defined channel unless bone is struck, in which case the splintering and comminution may be quite remarkable. The shattered pieces of bone may considerably widen the area of traumatization and devitalization of the soft tissues. When soft bullets which flatten cause the wound, the circumferential area of traumatized and devitalized soft tissue is considerably wider than after steel-jacketed bullet wounds.

About a bullet wound three moderately distinct zones extending radially from their pathway have been described: (*a*) the central core of the wound containing blood clot, tissue juices, shreds of necrotic muscles, and in some cases bits of clothing and fragments of the missile. (*b*) The second layer is composed of completely devitalized muscle which if left alone sloughs off. (*c*) In the third zone is contused and disrupted tissue of uncertain vitality.

The simple rifle bullet wound was uncommon in the late war. The typical wound was a small wound of entry and a larger wound of exit. Under actual conditions of warfare, the nature of a wound is modified by very many factors. The axis of the bullet may strike the body sidewise owing to deflection from its original course by striking some intervening object. In a similar manner it may be altered in shape or it may be flattened after entering the body by striking bone. Thus the change of shape and axis may increase the amount of tissue destruction. It is axiomatic that the size and appearance of the external wounds tell one little of the amount of actual destruction of tissue beneath.

In the late war the small explosive bombs inflicted jagged, lacerated wounds of the tearing destructive type.

Explosive shells are made of steel or iron filled with highly explosive material. Large irregular fragments of metals are scattered far and wide when they explode and very extensive jagged, lacerated wounds are the rule. These are the most destructive and formidable of all war injuries.

THE HEALING OF WOUNDS

For a wound to heal hemorrhage must stop, the defect must be filled, necrotic tissue or foreign material must be disposed of, infection must be prevented or overcome, and function must tend to be restored. Surgery may aid in the first three essentials. Nature's method of obliterating a cavity in a clean wound is the formation of a blood clot. In an infected wound, the wound is closed by granulation tissue. A sterile clot if not too large is soon organized and invaded by fibroblasts. Modern surgeons in clean wounds obliterate the dead space by suturing and providing immobilization to encourage healing. When there is some question of asepsis or of whether or not the surgeon has completely obliterated a dead space, a small drain is inserted to give early drainage and to prevent the accumulation of fluid which will separate the tissues and delay union.

The human tissues may wall off an inert sterile foreign body first by granulation and later by fibrous scar. When infection is associated the natural healing mechanism shows little or no ability to cope with the situation. The healing process is usually delayed until the foreign body is extruded by one means or another. The reason for this is that the bacteria enter the foreign body and become inaccessible to the phagocytes. When the foreign material is dead tissue a line of demarcation is formed between the dead and the live tissue and the dead tissue finally separates—soft tissue like skin, fat and muscle in about two weeks and hard tissue like bone in about two months. Early careful débridement in some instances may make this prolonged process of nature unnecessary. Irrigation of a wound with various irrigating solutions like hypertonic saline, saturated boric acid solution and especially Dakin's solution may hurry this process somewhat by causing some chemical dissolution. Baer in some types of wounds has deliberately introduced maggots which ingest dead tissue.

The greatest guard against general infection when a wound is contaminated is the development of an adequate granulation tissue wall, rest of the parts, measures which increase the blood supply to the part such as hot applications and the institution of an adequate drainage which lets the toxins out, relieves tension, and thereby tends to promote a better blood supply.

After injury most tissue responds with an effort to restore function. Peripheral nerves respond after division by an outgrowth of neurofibrillae. When the severed ends are approximated accurately under aseptic conditions, there is a return of function in from six to twenty months. When blood vessels are injured or severed, thrombosis takes place supposedly in many instances up to the first branch. The branch enlarges and other collateral vessels develop. A broken bone lays down callus in which calcium is deposited and new osseous tissue is the result. A cut mucosal surface heals by epithelial and submucosal fibroblastic proliferation with little visible scar. The union of the skin is not the same as that of the subepithelial tissues. Skin heals by the proliferation of epithelial cells while the fat, fascia, and muscle heal by the formation of a fibrotic scar. The cells of the epithelium wander out onto the granulation tissue base by a type of ameboid movement (Akaiwa). A wound closes by a contraction of the granulation tissue and its fibroblastic base. This phenomenon starts about the fourth or fifth day (Spain and Loeb). Early as the

granulating surface is being covered by new epithelium, if good drainage is promoted and if the wound is kept relatively sterile by a wet dressing, epithelialization is hastened. After a superficial layer of epithelium covers the wound, the number of layers of epithelial cells increase not from the edge of the skin of the wound but from a rearrangement of the cells of the new epithelium. The increase in thickness of the epithelial scar takes place by a process of slow cornification. As previously noted, dermis, fat, fascia, and muscle are healed by the formation of fibroblastic tissue. Whether the fibroblasts are derived from the fibrin network of a coagulum; from mitotic proliferation of preexisting fibrous cells or from wandering cells is still unsettled. The healing process is a very fundamental one in both aseptic and infected wounds. In the latter case, the fibrous tissue is developed from granulation tissue and is much greater in amount than when a wound heals by first intention.

As mentioned previously, besides healing by epithelialization a part of the wound closes by contracture. The relative amount of the part closed by epithelialization or by contracture of the fibrotic base depends largely upon the underlying anatomy. Underlying, unyielding structures such as a bone without a joint limit the amount of closure by contracture. In such cases the greater part of the closure of the wound will be by epithelialization. An example of this would be granulating areas over the side of the mandible or the forehead. When the soft tissues are yielding, however, due to their natural elasticity or due to the fact that a joint can easily flex or close (lower to upper jaw) the greater part of the closure of a wound may take place by fibrosis. When such is the case fibrotic contractures result which limit function.

Carrel has shown that plasma has a tendency to inhibit cellular proliferation for wound healing. Anemia, old age, cachexia, diabetes, and any severe illness are conditions known to inhibit the healing of a wound. An anemia decreases the healing time of a wound.

DIAGNOSIS OF DAMAGE DONE

The method of examining the structures should be both anatomic and physiologic. Inspection should be as thorough as possible. It is well to remember that a severed muscle loses its ability to function, that a severed motor nerve gives paralysis, a severed sensory nerve an anesthesia, and a severed salivary duct leakage of saliva. In this manner the anatomic damage to the soft tissue is estimated. When external examination is complete, under aseptic methods, the wound edge may be separated and the examination carried further by inspection and palpation. It may be best to do this under a stream of warm irrigating fluid which tends to wash away the blood clots and external bacteria.

A Foreign Body.—One should be on guard for the possible presence of a foreign body in the depths of a wound when the history is at all suggestive. The point of a stick, knife or a lead pencil may be broken off. Fragments of broken glass from broken windshields may remain within the wound. Often cinders, gravel and other débris are ground into the lacerated tissue. When a bullet shows a wound of entrance without a hole of exit, one must conclude that the bullet lies buried some place within the tissues. Even the presence of a wound of exit does not exclude the possi-

bility of fragments of the bullet; pieces of clothing, or misplaced bone fragments still remaining somewhere within the tract. Unless careful inspection of the depths of a wound leads one to findings which indicate with certainty that no foreign body is present, localizing roentgenograms should be taken when the foreign body is of the type which will cast a shadow. Thus, its outline and location is definitely established. Even if one cannot see or palpate the foreign body, suggestive pain or discomfort caused by palpation may lead one to suspect the presence and location of the foreign body. As a general rule most foreign bodies should be removed, but when rather inaccessible their location and character will determine the operator's future course. Foreign bodies which cause wounds with little surrounding laceration of tissues and are comparatively sterile at the time of entering the soft tissues, may heal in the tissue without causing disturbances. Thus, it may be better in some cases to wait for a possible indication for their removal than to cause greater damage by an immediate attempt at removal. When an infection develops about a foreign body, it has to be removed and the wound drained.

It is often very disconcerting to attempt to remove a small foreign body without exact localization. Needle points are notoriously hard to find, and small metal fragments and small bullets may be almost as difficult.

TREATMENT OF VARIOUS TYPES OF WOUNDS

In the face and mouth the blood supply is so abundant that the resistance of the tissue to infection is relatively high. Consequently, healing takes place readily if the ordinary rules for preventing infection or obtaining union are observed.

Tattoo Marks and Powder Stains.—After injury to the face in which dirt or cinders have been rubbed into the lacerated tissues, if the wounds are allowed to heal without thoroughly cleansing and removing all of the insoluble particles, the skin may show very disfiguring tattoo marks. To prevent this, the patient is given an anesthetic and the wound thoroughly washed with soap and water using a stiff brush if necessary. If oil has been mixed in with the débris, as sometimes happens after a patient has slid across oiled pavement, a solution such as ether which will dissolve oil should be used. After the thorough scrubbing, the wound should be thoroughly débrided of all devitalized tissue and, if possible, sutured so that primary union may be gained.

Incised Soft Tissue Injuries.—Incised soft tissue injuries such as are received in automobile accidents from flying glass, when immediate closure is decided upon may be closed with an excellent chance of gaining primary union. The surrounding skin is carefully cleaned. The wound edges are separated and the depths irrigated clean of blood clot with saline solution or boric acid. All foreign bodies are removed and all devitalized tissue is excised. The wound is then carefully sutured so that the deeper structures as well as the skin edges are approximated. Primary union and a good cosmetic result generally follow such a procedure.

When the parotid duct is cut a drain should be inserted from the cut end to within the mouth. When the facial nerve is cut it should be sutured end to end with very fine silk. The branches are almost impossible to

suture as they are so small but the main trunk can be sutured with fair success.

Early Lacerated Wounds.—A lacerated wound if seen within the first few hours (Fig. 19) may for the most part be converted into an incised wound by very carefully excising the edges of the gap and subjecting it to a very careful general débridement. One should not excise tissue that will distort the face. When there is some doubt, it is best to allow the wound to heal by secondary intention. This may be done by taking a deep stitch or two to hold the tissues as nearly as possible in their approx-



Fig. 19.—This girl, four days before this picture was taken, was in an automobile accident which caved in the upper part of both antra and her nasal bones were projected back into the nasal fossa between the maxillary bones. Over the upper part of the face and nose there were a variety of lacerations through the whole thickness of the soft tissues. The bony framework of the lower orbital rims was depressed downward and backward. The point to be made here is that it is necessary immediately to remould the bony framework to as nearly normal contour as possible if one wishes to obtain a good result. The nasal bones were raised upward and both nasal fossae were packed with vaselin gauze. Both antra were entered through the canine fossa. The bones of the walls of the antra and the floor of the orbit were pushed back into as nearly normal position as possible. Both antra were packed with vaselin gauze packs to hold the shattered bones in place. The packs were removed after five days. Subsequently the nasal fossae and antra were irrigated twice daily. This girl obtained practically normal contour of the face and nose.

imate normal position. A small rubber drain is inserted to the depth of the wound or even in some cases with more gaping, one corner of the wound is gently packed with gauze to maintain free unimpeded drainage. At a subsequent time, the scar is excised and the tissues carefully coapted under conditions which will give primary union.

Wounds Seen Late.—As a general rule, when soft tissue injuries are seen twelve hours or longer after their infliction, one should not attempt to get primary union. It is wisest to clean up the wound by irrigation and to gently pack the gutter or cavity in the soft tissues and allow the wound to heal by granulation. After the wound has healed, the scar can be ex-

cised and the tissue reapproximated. A better final cosmetic result is obtained with no particular risk from infection.

The Preservation of the Bony Framework.—The literature contains reports where segments of bone had apparently been destroyed, yet with the proper care of the soft tissues and maintenance of the gap by a bridge splint sufficient regeneration of bone took place to maintain the integrity of the lower jaw. Regeneration of bone in such instances probably is due to the preservation of some of the inner periosteal layer. Therefore, no fragment of bone should be taken out unless it is certain that it has not enough soft tissue about it to remain viable. After suppuration has set in in neglected fractures, free drainage should be made from below but no bone fragment should be removed until it becomes completely detached (Fig. 19).

Gunshot Wounds.—In gunshot wounds any amount of soft tissue along with an equal amount of the bony framework may be torn away so that the face becomes a sagging, formless mass frightful to behold. Deep natural cavities may be exposed in a rather startling manner.

The records of experiences in the World War allowed Blair to summarize the following general rules in regard to the treatment of war wounds. These principles are outlined here because the general principles involved are generally applicable to severe wounds seen in civilian practice.

Wounds of the Soft Tissues Alone.—(*a*) Wounds above the lower border of the mandible: when these are seen early, they should be sewn up, possibly with the application of an antiseptic. Even where there is moderate loss of tissue, undermining of the flaps might be practiced with provision of drainage of the undermined spaces. In the section of the parotid duct provision for drainage of the saliva into the mouth must be made.

(*b*) Wounds of the neck: here there are two zones of especial danger in reference to subsequent sepsis; the deep subfascial spaces that lead from the neck to the thorax, and axilla and the carotid sheath when some branch of the carotid artery has been ligated. Superficial wounds may be sutured in any part, usually with provision for drainage. Deep wounds may be sutured in their upper part but in the lower part of the wound the deep tissue spaces that have been opened should be lightly packed off with iodoform or some other antiseptic gauze to block off communication with mediastinal and axillary spaces. These packs should not be large or tight, but should enter the deepest part of the open spaces. In wounds involving the carotid sheath or submaxillary region in which one of the primary branches of the external carotid artery has been ligated, to lessen the danger of secondary hemorrhage, drainage of the immediate area of ligature, preferably by a packing of gauze, should be done.

If the trachea or larynx is opened, the air tube may be partly closed by suture, but the part of the wound superficial to the air tube opening should be packed to encourage drainage away from and not into the air tube.

A wound of the pharynx or esophagus should be immediately sutured, and this suture line covered by some other tissue, but the fascial space should be packed in its lower part to its full depth.

Wounds involving the full thickness of the floor of the mouth should not be sutured. The part of the wound above the lower border of the mandible should where possible be closed; but below the mandible the wound in the floor of the mouth should be packed, preferably with iodoform gauze and balsam of Peru.

If the wound is of such extent as to allow the tongue to fall out of the mouth, for example, such as tearing across in front of its anterior midline connections, repair should be made in the midline, but the carotid space should be protected by packing in the lateral part of the wound. This is of especial importance where one or more of the carotid branches have been ligated. It is never wise to suture a wound through the floor of the mouth throughout its entire extent; to do so where a carotid branch has been ligated invites secondary hemorrhage.

When the antrum contains an infected blood clot, it should be opened and irrigated. Attempts should be made to prevent soft tissue infection. Frequent nasal and oral irrigation of a warm salt and soda solution will aid drainage. A forceful stream should not be used in douching the nasal



A *B*

Fig. 20.—*A,* Secondary suture of wounds. After the granulation tissue wall is formed and on the basis of smears the wound has proved to be relatively free from bacteria, the skin edges and wall of the wound are excised. *B,* The deeper tissues are approximated with sutures and the skin is closed.

cavity as it may force the infected material into uninfected cavities. The patient should lean forward and the irrigation should be done gently but thoroughly.

"Billroth made an observation that has somewhat generally been lost sight of, namely, that it is bad practice to sew up a wound in the floor of the mouth, especially one of the larger wounds that results from excision of the jaw or tongue. It predisposes to sepsis and secondary hemorrhage. Our earlier observations conform with Billroth's. For some time we have made it a practice never to sew up the floor of the mouth after a resection, but put in a Mikulicz pack of iodoform gauze and balsam of Peru, which will usually make a water-tight joint and remain in place a week or ten days without changing. If in planning, the transverse incision

is made below the level of the hyoid bone, then it is probable that the fistula will close spontaneously. If not, it is later closed by suture after dissecting out the granulating tissue. In this secondary suture there does not seem to be the same danger of severe sepsis and secondary hemorrhage as when the wound is sutured primarily.

"Extensive loss of tissue on the face is to be replaced by plastic operation. It is not necessary to wait until the wounds have entirely healed before undertaking to do this, but one should be guided by what is to be expected from the healing process, unassisted by any flap method. The defects from absolute loss of tissue become smaller as granulation and scarring progress, but undermined flaps retract so that the defect will for a time enlarge. Later these will be drawn toward but not exactly to their original position. According to the condition of the wound, the repair of these defects may be undertaken immediately, or as soon as the wound presents a clean granulating surface and the general condition of the patient warrants." *

Secondary Suture of Wounds.—Occasionally it is expedient to wait a few days before suturing a wound of the face or neck and prepare the wound for a so-called "secondary suture" (Fig. 20, *A*, *B*). For the secondary suture to be successful the wound must not be allowed to become clinically infected. Usually sterile dressings saturated in some antiseptic fluid such as Dakin's solution or boric acid solution are repeatedly applied to the wound. It is important to change the dressing several times a day and also to keep it wet. Repeated changing aids in carrying off bacteria and tissue débris. If the dressing is allowed to become dry, drainage is hindered. Thus, conditions are likely to become favorable for the multiplication of bacteria.

Bibliography

Akaiwa, Baer, Loeb, and Spain: Quoted by Martin, W.: Surgical Infections, Dean Lewis' Practice of Surgery, Hagerstown, Maryland, W. F. Prior Co., Chapter X, 1–143, 1933.

Blair, V. P.: Surgery and Diseases of the Face, Mouth and Jaws, St. Louis, C. V. Mosby Co., 1917.

Billroth: Quoted by Blair, V. P.: Surgery and Diseases of the Face, Mouth and Jaws, St. Louis, C. V. Mosby Co., 1917.

Carrel, A., and Dehelly, G.: The Treatment of Infected Wounds, P. B. Hoeber, New York, 1917.

Firor, Warfield M.: Wounds, Blood Grouping and Transfusion, Dean Lewis' Practice of Surgery, Hagerstown, Maryland, W. F. Prior Co., Chapter VIII, **1**: 1–41, 1933.

* From Blair, V. P.: Surgery and Diseases of the Face, Mouth and Jaws, 1917, C. V. Mosby Co., Publishers.

CHAPTER V

THE COMPLICATIONS OF WOUNDS

THE principal complications of wounds are the pyogenic types of surgical infection, certain special infections, hemorrhage, shock, and certain complications which may follow operative procedures such as postoperative pneumonia or a cardiorenal catastrophe.

WOUND INFECTION

Ordinarily a wound of some degree precedes infection and as a rule the mere fact that pyogenic infection is present presupposes that an avenue through the protective mucosal or skin covering of the body has been provided by a trauma sufficient to allow an ingress of the invading organism. But not always is a visible wound present.

The term surgical infection implies that a living parasite has gained a foothold and is multiplying in the tissues of the body and has set up modifications in the body structure and function.

When bacteria are lodged in a wound the three following sequences may supervene: (*a*) the bacteria may be destroyed rapidly by the body cells and fluids and no morbid manifestation is noted; (*b*) when the virulence of the bacteria is greater or the number is larger a local reaction of greater or lesser extent is manifested; (*c*) when the bacteria are of extreme virulence and the susceptibility is great, there results a general bacterial invasion with or without local reaction. Up to a certain degree, the more virulent the micro-organism the more marked the local reaction. But beyond this degree, increased virulence tends to manifest less and less local reaction until finally a point may be reached where the local defense is practically nil and little resistance is shown to general invision.

(*a*) In the first category, the bacteria cause active movement of the motile cells of the body known as *chemotaxis* (Pfeffer) of both a positive and a negative nature—both toward and away from the irritated area. Certain cells in the body have the ability to engulf certain bacteria and foreign bodies and the enzymes within these cells cause an intracellular digestion. The polymorphonuclears and certain large mononuclear cells (lining capillaries of the liver, spleen, bone marrow) and the large wandering connective tissue cells (macrophages) especially exhibit this property. The bacterium even when engulfed may not necessarily be killed—usually it is but it may remain alive and not injure the cell or it may manufacture its own toxin and kill the cell. The enzymes of the phagocytes are thrown off locally and also into the body fluids by a mechanism not thoroughly understood. But in this first category the irritation is insufficient to cause a fluid tension within the tissue, pain, heat or redness. No clinical evidence of infection is present.

(*b*) In the second category when the number is greater or both the defensive fluid accumulation and defensive cells of the body do not re-

sult in immediate death of the bacteria. The difference between the first and the second categories is one of degree. In the second situation the resistance of the defensive mechanism of the body has to be more active. The chemotactic action is more marked. The accumulation of phagocytic cells is more marked. The circulatory changes in the blood vessels and capillaries are no longer only transitory and they become dilated. Active hyperemia results. The blood stream slows. The leukocytes move slowly and adhere to the wall of the vessels, and pass through their endothelial lining. White cells, red cells, plasma cells, and blood platelets accumulate in the tissue spaces. The cells arrange themselves in a wall surrounding the bacteria. Whether or not the process spreads now is determined by the character of the tissue and the number and virulence of the micro-organisms. If the exudate is to be walled off, it is collected inside the granular barrier under tension.

(*c*) In the third category the body cells may show so little reaction that little or no local reaction results. The bacteria are carried along by the lymph or blood stream into the general body fluids and eventually may or may not be destroyed by the general defense reaction of the body fluids.

Mechanical Factors Which Influence the Local Defense.—There are certain mechanical factors which influence the local reaction to bacteria and to a certain extent these may be under the control of the surgeon. Trauma, foreign bodies, devitalized and necrotic tissues, dead spaces, and the accumulation of exudate under tension are the five important factors—purely mechanical in nature—which determine to a certain extent whether or not bacteria will gain a foothold within the tissues. At first the wall of leukocytes which forms along the edges of a wound is very friable and easily broken. The newer the wound the greater the danger of breaking this protecting wall. Any foreign body is an irritant to tissues. A silk ligature aseptically implanted causes a slight reaction. A catgut ligature aseptically implanted although eventually dissolved will set up a considerable reaction. Other factors being equal the amount of the reaction is proportionate to the amount and size of the foreign body. Any foreign body makes it more difficult for the body cells to destroy bacteria that may have been implanted at the time of the implanation of the foreign body. An infection once established about a foreign body as a rule does not terminate until the foreign body is removed.

After any trauma sufficient to sever tissue, the cells immediately surrounding the area show for a time a paralysis of cellular activity. During a varying period the capacity for resistance is at a low ebb. After a cleanly incised wound this period is short. After a bruising lacerated wound the interval is longer, the amount of tissue involved is greater and some of the tissue may never recover its vitality. Necrotic tissue besides acting as a foreign body and promoting the growth of the ordinary bacterial contaminators, may encourage the growth of certain other ordinarily saprophytic bacteria and certain anaerobic bacilli. Infection in necrotic tissue lasts until the dead tissue separates from the live tissue. The body cells act in separating the dead tissue from the live tissue. They form the granulation tissue wall on the live side of the line of demarcation between the dead and the live tissue.

Some dead space occurs in wounds no matter how painstakingly one closes a wound. When hemostasis is perfect, such spaces are filled with lymph and tissue "juices"; when not perfect, blood is extravasated in them. The bactericidal power of fresh blood is soon lost and stagnant blood soon becomes an excellent medium for the growth of bacteria.

During an inflammatory reaction the vessels are congested and cells and fluids collect in the interstitial spaces. The blood supply in the center of an inflammatory induration tends to be shut off by the accumulation of inflammatory cells and fluids. A point is reached where the tension which was at first beneficial becomes actually harmful and the local defense mechanism is interfered with. From the focus of infection toxic substances are forced into the surrounding area and further reaction is stimulated in the circumference.

General Defense Reaction.—In the liver, spleen, bone marrow, lymph glands, and so forth are certain specialized phagocytic cells belonging to the reticulo-endothelial system which have the property of removing inert particles which may be introduced into the intracellular tissues by one means or another. Microbes injected into the blood stream are deposited and detained in a similar fashion. The lymph glands act particularly from a practical standpoint in this manner. Inert particles and bacteria settle out where the circulation is slower in the network of the spaces of the lymph nodes. Bacteria may remain alive in the phagocytic cells which pick them up or the phagocytic cell may kill the organism or in other instances the ingested bacteria overwhelm and kill the cell. The reticulo-endothelial cell also has the ability when irritated of secreting certain specific substances which tend to destroy invading organisms. Thus, a mechanism is present for protecting the cells of the body against material toxic to the body cells. Foreign proteins especially tend to stimulate this latter reaction.

The hemocellular reaction to infection is so well known that mention of it is hardly necessary. The polymorphonuclears and other cells pass rapidly from the bone marrow and lymphoid structures into the circulatory blood. After invasion by bacteria soon they are in transit to the tissue area that will need them.

The nervous regulating mechanism of the temperature of the body normally remains within narrow limits. Toxic substances within the blood stream alter the relation between heat production and dissipation. It is probable that various protein substances passing into the blood during an infection cause the characteristic disturbance of the heat-regulating mechanism. Again it is possible that some of the reaction of the tissues such as phagocytosis are more active at fever temperature.

Certain factors influence the general defense reaction unfavorably such as starvation, dehydration, repeated hemorrhages, shock, cold, fatigue, and certain chronic diseases. At certain times individuals differ in their reaction to infection. Different individuals within the species vary. Under favorable circumstances the naturally immune animal may become susceptible.

It is a matter of ordinary experience that various individual types of bacteria call forth a response which has common characteristics both local and general. For example, staphylococcic pus is creamy white and

thick with a pasty odor and streptococcic pus is thinner and often slightly blood stained, pyocyaneus pus is greenish and colon pus has the fecal odor of skatol. Besides showing characteristic products bacteria may show a predilection for certain tissues. An example is the bacillus of Welch which grows under anaerobic conditions and requires fermentable carbohydrates found in devitalized muscle.

After the body has acquired the capacity of destroying a particular protein or bacterial product so that the local and general reactions are dependent upon how sensitive the individual is to that particular substance, there are not only specific reactions involved, both local and general, but a reaction may be involved due to a previous introduction of a given protein or bacterial product which has rendered the cells hypersensitive. In the sensitized individual very minute amounts of the substance to which the individual is sensitized may produce a reaction and rise in temperature all out of proportion to that found in the nonsensitized person.

Clinical Picture of Infection.—When a wound is infected a period of time elapses before symptoms appear. The symptoms of localized infection appear next in sequence. These may sometimes be followed by the symptoms of a general infection.

The incubation period is the time after germination starts and enough toxic material accumulates to give appreciable clinical signs and symptoms. It takes some time for bacteria to germinate and multiply. During this time the body is acquiring the aptitude for heightened activity and for producing antibacterial substances in quantities necessary to split the bacterial protein into irritating toxic products. The incubation period of infection in an operative wound may vary from twelve hours to two or more weeks. A short incubation period usually suggests a virulent infection.

It is important to remember that contamination of a wound does not always lead to infection. Undoubtedly only a few wounds are ever closed with complete asepsis. When conditions for healing are good, the body can take care of a few relatively near-virulent bacteria without any clinical signs of infection.

When clinical signs and symptoms appear, the period of incubation is terminated. The area about the wound becomes painful. Then there is an elevation of temperature, may be a chill, and the patient feels ill. Not uncommonly the general symptoms precede the local symptoms. At first the wound may look normal. Soon, however, redness appears about the wound and the pain becomes throbbing.

In practically all wound infections there is a local reaction and the tributary lymphatics are likely to be swollen. In the aged, however, in terminal infections, in certain chronic diseases, and in infection by very virulent organisms there may be no signs of localization at the port of entry.

When the infection is near the surface a local reaction is manifested in the skin first by redness. The venules and arterioles dilate and the tissues about become hyperemic. The surface is hot to the touch. The extravasation of fluid into the intercellular spaces makes the parts edematous. The edema is soon followed by infiltration as the cells characteristic of inflammation invade the tissue. Even from the first as the exudate collects

in the tissue, pain is present and is intense and throbbing and is dependent upon pressure within the tissues. In tissue that does not stretch easily such as about the chin it is especially severe. When the exudate is confined within bone or in a tooth socket, it is especially severe. Proof that the pain is due to pressure would seem to be given by the prompt relief afforded on incision and drainage. Any distention of inflamed tissue as with novocain will increase the pain. Accompanying the pain is soreness and tenderness. The induration which follows an infection may be of various degrees. The tissue may be so packed with cellular exudate that it feels hard. The tissues do not slide past each other in the normal way. When the multiplying organisms are sufficient in number or virulence the swelling and induration of the tissues are progressive and more and more tissue is invaded. When the body forces are more or less in command of the infection, a point is reached when the process comes to a standstill. The induration begins to subside and may return to normal or a central soft spot may develop which first is likely to pit on pressure and later to fluctuate. When untreated, by a process of pressure necrosis the overlying tissues are penetrated or if treatment is prompt, drainage is given. The pus escapes. The tension is relieved. The swelling and induration soon subside. When one studies the relation of the exudate to these developments, one notes that two processes are taking place—a progressive infiltration with exudate and a liquefaction and digestion of tissue.

The spread of the infection is interesting. As the tension increases, the extravascular exudate finds its way along the planes separated only by loose connective tissue and it percolates through the meshes of the areolar tissue. Pyogenic cocci are nonmotile and spread by multiplication but may also be carried in a floating fashion by liquid exudate. Bacteria are also carried about as a result of the tryptic action that the exudate acquires when the toxins of the bacteria predominate over the body defense mechanism. Certain bacteria also spread along paths and planes wherever they find a suitable culture medium. Besides along the areolar tissue planes the inflammatory reaction often spreads definitely along the path of lymph vessels or veins. Following many wounds small red lines are seen passing from the reddened wound toward the tributary lymph nodes for the given area. The red line is a *perilymphangitis*. The walls of the lymph channels and its perivascular tissues have been invaded. Accompanying these signs are the constitutional symptoms of infection. When the deeper lymphatics have been invaded dull pain, edema, and swelling of the regional lymph nodes are found. A *lymphangitis* may be followed by a *lymphadenitis* and the cycle from early infection to *abscess* formation may supervene, although in most instances the process is overcome and the swelling of the lymph node subsides.

If the walls of minute capillaries and veins become involved with the reaction of the tissues to pyogenic organisms, a clot forms and plugs the lumen. When the wall is eroded and the bacteria pass into the clot, an infected *thrombus* is produced. The thrombus is infiltrated with bacteria and leukocytes. Often the process is progressive and passes from branch to main veins and so forth until finally the infected thrombus projects into the lumen of a rather large vein, is broken off and swept away into the blood stream. This process is called a progressive *thrombophlebitis*.

When the infected thrombus passes into the general circulation a *bacteremia* or *septicemia* is present. Now three things may happen. The defense mechanism of the body may overcome the bacteremia. The infected clot may localize in some organ and form an abscess. Or the defense mechanism of the body may break down and the result is multiplication of the bacteria in the blood stream—a frank septicemia. If multiple abscesses develop, the patient is said to have a *pyemia*. The general symptoms—fever, leukocytosis, malaise, and so forth—are not particularly different from those of the toxins liberated at a local focus of infection. But when there is a sudden violent chill, high fever, rapid pulse, and a general appearance of illness, dissemination is probable. Positive blood cultures and the appearance of secondary foci verify the diagnosis.

Treatment of Infection.—Certain very simple mechanical procedures have profoundly altered the outcome of infection for two thousand years. Treatment consists of incision of abscesses, extraction of foreign bodies, and drainage of dammed-up exudate. The rigid walls of abscess cavities are changed to yielding walls; sloughing tissue which may become a source of secondary infection is removed. The surgeon in treating an infection should keep eight essential fundamental conditions in mind: (1) that protection of the infected area from trauma is necessary; (2) that prevention of new germs from being implanted is wise; (3) that an exit should be given to pus when it collects under tension; (4) that necrotic tissue may be produced and that a certain length of time is necessary for its separation and extrusion from the body and that the infection will continue until this occurs; (5) that a foreign body in the infected tissue will cause the process to continue until it is removed; (6) that a free exit should be provided for a discharge to allow necrotic morsels and foreign bodies to be discharged; (7) that when uncollapsible space is left, the rigidity which prevents collapse should be removed; and (8) that possibly in certain stages of an infection, it may be wise to remove the whole local focus.

Besides the observance of the preceding fundamental principles certain ancillary measures aid the local reaction and may aid in localization. Certain chemicals (Chapter III) may help in sterilizing the surface of a wound, dissolving necrotic morsels and in gaining good drainage by washing away bacteria, toxins, and particles of necrotic tissue. The production of an active passive hyperemia by the *application of heat or cold* has received almost universal approbation. *Hot moist dressings* saturated with some antiseptic cannot be too strongly recommended. All physiologic movement should be prevented by *splinting*. Recently in some instances the local focus has apparently been favorably influenced when exposed to various forms of *radiant energy*, such as sunlight, ultraviolet rays, and roentgen rays.

Ordinarily few complications follow minor operations about the face, mouth, and jaws. But certain minor procedures such as opening an infection on the upper lip, anterior face, or nose at the wrong time may be dangerous. Occasionally disastrous complications follow the extraction of a tooth when the infection about it has not become sufficiently chronic. In a later chapter these matters are more fully discussed.

Certain Specific Infections Complicating Wounds.—Besides the common pyogenic organisms are bacteria of a special nature which may also gain access through a wound.

Gas Gangrene.—Because of the profuse blood supply of this region and the absence of long muscles, only a few cases of gas gangrene are seen. Bacillus welchii, vibrion septique, and B. oedematiens are the three organisms, all anaerobic, which are principally concerned in the production of gas gangrene. As many as fifty different strains of anaerobic micro-organisms, however, have been described as producing gas in tissue.

In gas bacillus infection there is no leukocytic infiltration to retard the advance of the bacteria. A serous exudate precedes which increases the tension and decreases the blood supply. Toxins are formed and tend to cause a thrombosis of the blood vessels. The red blood corpuscles are destroyed by the toxin and the striated muscles lose their normal color and contractility. The blood supply to the muscles is cut off and gangrene is the result. The ecchymosis due to red blood cell destruction produces a brownish red color and the necrotic tissue assumes a brick red or salmon color. The gas has a characteristic sickly odor.

One of the first symptoms is a sudden increase of pain due to the outpouring of the serum. About the wound there is little redness or increased surface temperature. The discharge from the wound is a characteristic brownish color and has a sickly foul odor. Bubbles of gas are seen. Over the distended area the skin at first is white and as the edema extends, it becomes dusky and bronzed in appearance. The circulatory collapse is quite remarkable—all out of proportion to the extent of the local signs. The pulse soon becomes very fast, and is easily compressed. The temperature is not elevated in a proportion usually associated with such an elevation of pulse rate. The patient appears apathetic, weak and is very pale. He may vomit. Examination of the blood shows little change in the leukocytes but the red blood cells are quite definitely decreased when the infection is of some severity. The patients hard hit succumb within eighteen to twenty-four hours after the onset of the symptoms.

The best method of ascertaining the presence of gas in the deep tissue is by auscultatory percussion. In the roentgenogram at first a few fine streaks are seen along the course of the muscles. Later as the gas collects a definite mottled appearance is given to the film.

Polyvalent serum for these organisms has been developed (Leclainche, Valée, Weinberg, Sacquépée, Bull, Pritchett). The Fifth Interallied Surgical Congress recommended the use of the serum at the time prophylactic tetanus serum was given. For prophylactic purposes from 10 to 20 cc. was recommended.

A preliminary bacteriologic examination is recommended to identify the organisms when the serum is used for therapy. Subsequently, the specific antiserum is given for the organisms involved. Twenty to 100 cc. of the serum is recommended for curative purposes.

Although the serum is recommended as stated, general opinion probably tends now to place main reliance upon appropriate surgical treatment. By thorough prompt débridement of a wound and with the precaution of delayed primary closure and open drainage, the incidence of gas bacillus infection can be cut to practically nothing.

Van Beuren in a résumé of the subject advises early operation under nitrous oxide anesthesia. Long longitudinal incisions should be made splitting the muscle sheath. The wound is then thrown wide open. All

torn, crushed, discolored, and noncontractible muscle is excised. A search is made for foreign bodies. The wound is left wide open and Carrel-Dakin tubes are implanted through the wound in gauze.

In gas gangrene of all regions in the late war from a mortality of 52 per cent in 1916 improved methods reduced the mortality to 26 per cent.

Tetanus.—The most unnecessary complication of any wound is tetanus. The disease is caused by an anaerobic bacillus gaining entrance to the subcutaneous tissue through the broken skin. The spores of tetanus bacilli are very resistant. The bacilli produce a powerful toxin which is absorbed causing a principal effect upon the central nervous system. Originally Marie, Morax, Meyer and Ransom thought they had demonstrated that the principal path taken by the toxins is by way of the motor nerves and that after being taken up by the end-plates the toxin traveled along the axis-cylinders. But Field, Cernovodeanu, Henri, and Thiele more recently have alleged that the toxin travels by way of the perineural lymph spaces. In 1890 Behring and Kitasato demonstrated tetanus toxin and antitoxins.

About the local wound the reaction is very slight. Clinical signs may appear as early as the second day or as late as after forty days. Suppuration, pain and swelling do not occur unless other organisms are present. Usually the first sign of the disease is a spasticity of the masseter and posterior neck muscles. Soon the facial muscles tend to become involved in tonic contractions giving a rather characteristic expression which has been called "risus sardonicus." As the disease advances the muscles of deglutition are involved causing difficulty in swallowing. Later the muscles of the trunk and extremities become involved by the tonic contraction. A position of opisthotonos is assumed. Finally, general seizures of both tonic and clonic contractions become a part of the picture. The most trivial stimuli precipitate a convulsion—a noise in the street, a jar of the floor or even a draft of air. The suffering is acute. Sleep is banished. The urine and feces are retained. The mentality is alert. Finally, if death results, usually the respiratory center is paralyzed but some die of cardiac collapse, exhaustion, or an aspiration pneumonia.

Incomplete forms of tetanus are seen. In the War cephalic tetanus was seen. In this type the pharyngeal spasm may simulate hydrophobia (tetanohydrophobia). Two types occur—the paralytic and the nonparalytic. The latter results from an injury in the distribution of the fifth cranial nerve. The facial and cervical muscles show spasm. The seventh nerve is partially or completely paralyzed on the side of the injury. After injuries about the eyes, a form of tetanus may be seen in which the characteristic signs are those of oculomotor paralysis. Occasionally one sees paralysis of the muscles innervated by the hypoglossal nerve in another type.

Focal tetanus was seen during the War in a few individuals who had received tetanus antitoxin but in whom complete immunity did not develop.

As a prophylaxis tetanus antitoxin is highly effective. Repeated injections are more effective than one injection of 1500 units. Toward the end of the War the accepted method was 1000 units of antitetanic serum as the initial dose. After this a weekly injection of 500 units was given for one month.

As soon as symptoms develop tetanus antitoxin should be given. Most

of the recent literature shows a preference for combined intravenous, intramuscular and intraspinal injection. Probably a desensitizing dose of 1 cc. should be given subcutaneously. Following this one hour later an intravenous injection of from 10,000 to 20,000 units may be given and 10,000 to 12,000 intraspinally. After this 10,000 to 20,000 units are given at about eight- to twelve-hour intervals until about 200,000 are given (Dick).

Sedatives in large doses such as opiates are indispensable. A 25 per cent solution of magnesium sulfate intraspinally has been advised, as has a 1 per cent solution of phenol. The value of these agents is as yet a mooted point.

Kolmer states that the mortality in the British army dropped from 71.2 to 24.8 per cent under a type of therapy similar to the above.

GENERAL CONDITIONS WHICH MAY OVERSHADOW THE LOCAL INJURY

In concussion, loss of blood, or "shock" the patient's general condition may be rendered so serious that the local injury becomes a subsidiary condition. Thus, the chief immediate consideration is the means to be taken to prevent the general condition from becoming critical.

Cerebral Concussion With or Without Fracture of the Skull.—When unconsciousness indicates cerebral concussion to be the overshadowing injury, the jaw should be supported well forward so that there is no obstruction to breathing caused by the tongue obstructing the pharynx. The term, fracture of the skull, is misleading. The actual fracture of the skull is not the important point. The point is the amount of injury to the brain tissue and its coverings. (In the latter case whether or not the dura is torn—*i. e.*, whether or not the fracture is compounded.) Following a blow the brain is set in motion and strikes the skull. Not much protection is furnished by the cerebrospinal fluid. The end-products of trauma as elsewhere in the body are edema, hemorrhage, and destruction of tissue. Various combinations of these three are produced. The new volume of blood and edema requires extra space. Therefore, after injury to a certain extent the intracranial pressure is increased. This all is called "concussion of the brain." Hemorrhage, depending upon its amount whether it is arterial or venous, whether it is extradural or intradural, is on the whole more serious than edema.

Not uncommonly after injuries which fracture the upper maxilla or even some other bone of the face, one has to consider the chances of a fracture of the base of the skull and whether or not the fracture of the base is a compound one. If it is a compound one, very commonly a purulent meningitis will supervene with usually a fatal termination. After a crushing fracture of the nose, the cribriform plate may be crushed. A rhinorrhea should be looked for when such is suspected.

Usually in acute increased intracranial pressure the patient becomes drowsy or loses consciousness and is restless. At first during the stage when the cerebral pressure mechanism is compensating, the pulse is slow, the blood pressure near normal, the respirations are regular and the temperature remains below 102° F. When the stage during which the cerebral pressure mechanism fails to compensate is reached the pulse becomes more rapid, the blood pressure drops or raises, the rate and force of the pulse

may change, the respiration may tend to change and become more rapid, more shallow and irregular and finally if the temperature rises above 102° F. danger is suggested. The patient usually vomits and it may be projectile. Later, a certain amount of papilledema appears. The signs of local injury are judged by changes in the sensation and motor reflexes and the appearance of focal convulsion. Extradural hemorrhage is suggested when at first the patient is unconscious, then becomes conscious and later again loses consciousness. This is a characteristic sign of a middle meningeal hemorrhage.

Treatment.—There are two ways to reduce the intracranial pressure: (1) lumbar puncture; (2) intravenous injections of hypertonic salt solution, and (3) subtemporal decompression. The first two are only temporary. The cerebrospinal fluid soon reforms. When performed immediately after the injury, it may tend to increase the hemorrhage and it may produce edema. There is some danger to lumbar puncture. It may eventually tend to increase the edema and if the hemorrhage is basal or above the tentorium, it may tend to produce medullary compression. Twenty to 30 per cent of patients with severe intracranial injuries will die regardless of the treatment on account of the nature of their injury. Sixty to 70 per cent will recover if left alone regardless of their treatment. In about 10 per cent decompression is indicated. Immediately after injury they should be put to rest. Roentgenograms often can be omitted. Usually nothing should be given by mouth until they become conscious. Morphine should not be given. It depresses an already harassed respiratory center. It may, however, be necessary to use a canvas restraint sheet. After six or seven hours the hemorrhage should have stopped. After this time the question of decompression may arise. Extradural hemorrhage must be differentiated early. The treatment is immediate operation and the object is evacuation of the blood and ligation of the broken vessel.

The plan herein given is not commonly the plan followed, I well know. Most men do repeated spinal punctures and give hypertonic fluid intravenously. The plan outlined here is advised by Dandy and by Sachs and it is the plan which seems to me most rational when the physiology and pathology of the lesion are considered.

Hemorrhage.—No other occurrence is more spectacular than hemorrhage. The end-results of copious hemorrhage are always of serious enough import to cause real worry to a surgeon—especially if he be the cause of it.

When performing large operations about the face, mouth, and jaws due regard has to be given to the dangers of losing too much blood. Severe secondary hemorrhage from some cut or eroded vessel is not an uncommon occurrence following certain types of operations in this region because of the impossibility of maintaining a surgically clean wound. Often the suffering of those afflicted with a malignant tumor is terminated by a large secondary hemorrhage caused by the erosion of one of the main branches of the carotid artery.

The adjectives, arterial, venous, capillary, parenchymatous, internal, primary, and secondary have been used to describe the various types of hemorrhage. *Arterial blood* comes in tell-tale spurts and is never black unless the patient is distinctly cyanotic and suboxidated. *Venous blood* is bluish and exudes in a smoothly flowing stream. *Capillary blood* oozes.

An example of *parenchymatous bleeding* may occur when structures of unusual vascularity such as the liver or spleen are ruptured. An example of *internal hemorrhage* might occur when a vessel is ruptured into a cavity without an exit such as within the chest. *Primary hemorrhage* is a term used primarily in contradistinction to secondary hemorrhage. *Secondary* or *delayed hemorrhage* is that which appears after a period of a few or several days. It is usually due to an infective process but also may be caused by the erosion of a malignant tumor.

There are several rather evident natural mechanisms for the control of bleeding. The serum from the injured tissue contains substance that promote blood clotting. Veins tend to retract and collapse after or during a hemorrhage. As soon as the blood volume is decreased to a sufficient extent that the compensatory contractile mechanism of the "circulatory tree" fails to be sufficient, the blood pressure tends to be decreased and decreases progressively according to the degree of loss of blood volume.

When the blood pressure is decreased small arteries tend to retract and collapse as do veins. Although nature provides certain rather evident safeguards against death from hemorrhage, in the case of the severance of a main arterial branch or a very large vein such as the deep jugular vein, death may occur in a very few minutes.

A practical point of interest is the various artificial means of arresting hemorrhage the simplest of which is pressure. Pressure may be applied digitally or by means of a tightly packed gauze sponge. When the severed vessel is such that pressure would seem unsafe or unlikely to promote the degree of hemostasis considered necessary in a given situation, the most commonly used method of preventing bleeding is the clamping and tying of the bleeding vessel. The local application of arterial vasoconstrictors (adrenalin and ephedrine) or caustic preparations (ferric chloride) may be of aid in certain situations in preventing oozing from rather small vessels too small to ligate. To stop capillary bleeding a low-heat cautery or bipolar needle may be used with efficacy. Finally, in individuals with a deficiency of their natural clotting mechanism, substances may be injected into their blood stream—such as fibrinogen, calcium, or whole blood. In certain areas such as the scalp, it is difficult to clamp the vessels. Here the galea may be caught and the clamp turned over the wound edge to stop the bleeding temporarily. Temporary suturing of the tissue en masse in an encircling manner may be helpful as about a cavernous hemangioma which one wishes to excise. The reaction of different individuals to hemorrhage varies somewhat and depends upon age, sex, and state of the general health. The young, the old, and the debilitated do not tolerate hemorrhage as well as normal adults. Women sometimes tolerate hemorrhage better than men. Undoubtedly this is true after delivery. When the blood volume becomes reduced as much as 25 per cent, serious symptoms supervene and when reduced to 40 per cent death is likely to be the result. The loss of about 48 per cent of the blood plasma within a short period of time is often sufficient to cause death.

Symptoms.—Firor comments "the study of the symptoms of hemorrhage is always engaging." The symptoms and signs of hemorrhage may be summarized as syncope, occasionally nausea, dizziness, disturbed vision (black spots before the eyes), tinnitus, yawning, restlessness, great thirst,

air hunger, pallor, cold skin, perspiration, subnormal temperature, increasingly rapid pulse, and a falling blood pressure. The whole symptomatology is due to the signs caused by a lessened blood volume with a resultant decreased oxygen carrying capacity of the fluid content of the "circulatory tree."

In the past often following an operation or an injury in which the extent of the blood loss was uncertain, the question arose whether the patient's condition was due to hemorrhage or shock. Evidence is tending at the present time (Phemister and Blalock) to show that what was called traumatic shock is, principally at least, due to a "concealed hemorrhage" within the tissues themselves. That is, sufficient blood plasma is lost from the "circulatory tree" into the extravascular spaces to make the situation practically one of hemorrhage within the body itself. The symptoms of severe hemorrhage and the condition formerly called "secondary shock" are often practically the same. Certain changes in the capillary red cell count have been thought in the past to be of diagnostic aid in distinguishing hemorrhage from "secondary shock" but now it is thought that the same changes occur, at first at least, in both conditions, namely, a concentration of the red blood cells within the capillaries.

Treatment.—After severe hemorrhage three types of therapy are considered to be indicated. First, sufficient sedatives to allay restlessness and conserve the patient's energy; second, by one means or another such as hot-water bottles, blankets, and electric-light tents one should add sufficient heat to compensate for the loss of body heat; third, an effort should be made as soon as possible to replace by substitution the lost blood plasma. Temporarily crystalloid solutions such as isotonic saline or 5 per cent glucose solution may aid one in replacing the lost blood volume until a blood transfusion can be given. Blood transfusion, however, is the real bulwark of treatment for hemorrhage. Thereby one replaces that which has been lost.

In the past it has been stated that fluids were taken up and retained within the "circulatory tree" much better in hemorrhage than in shock. The gist of the matter of the relative tendency to recovery after severe hemorrhage is the length of time between the hemorrhage and the replacement of that which was lost. In hemorrhage treated late as after prolonged shock, a considerable amount of damage has already been done to the outlying tissues from which the patient may not recover even with the best of treatment.

Hemophilia.—Although one rarely encounters a case in practice a man doing surgery—no matter how trivial—should be aware of certain blood dyscrasias which show a tendency to spontaneous or continued bleeding.

Hemophilia is usually a constitutional affection due to a congenital defect in the coagulating elements of the blood. More rarely a hemophilic condition may be caused by toxins or sepsis. Congenital hemophilia often may be traced back through many generations. Legg traced in the Clitherow family a history of it back for two hundred years. Very rarely the disease arises spontaneously in healthy stock. Although not wholly immune females are not often affected. Females possess a much greater ability to transmit the disease than males. Often the second generation is skipped. Usually a history of repeated and long-continued bleeding from

slight injuries is obtainable. Such a history should suggest to one that the coagulating properties of the blood be ascertained before the performance of any contemplated surgical procedure. The normal coagulation time of the blood is from four to seven minutes. In hemophilia the clotting time may be delayed from twenty to thirty minutes up to several hours. A purpuric state may simulate hemorrhage. It is well to know the bleeding time, the prothrombin time, and the number of blood platelets in differentiating between hemophilia and purpura. In hemophilia the bleeding time is generally normal but in purpura it is prolonged. In purpura haemorrhagica, the coagulation time and prothrombin time are normal while the number of blood platelets are decreased. In hemophilia the platelets are often normal and may be increased. In hemophilic conditions due to toxins or sepsis the leukocyte count generally is increased while in congenital hemophilia both the total and differential counts are normal. Temporary treatment of hemophilic conditions is blood transfusions. In the congenital type of hemophilia permanent benefit is not obtained. In such individuals any operative procedure is obviously contraindicated.

Shock.—Cowell divided shock into "primary" and "secondary shock." True *"secondary shock"* appears usually after a lapse of several hours, although it may supervene rather quickly when the damage sustained by the body is great. Recovery from true secondary shock is apt to be problematic unless treatment has been instituted relatively early.

Primary shock is that condition of collapse which appears almost immediately. Recovery from it with or without treatment is generally rapid. In primary shock the symptoms appear to be the result of a powerful stimulus of nervous tissue which results in a reflex relaxation of the vascular tree. It has been suggested that such shock is more likely to occur in the "high-strung" or in those with temperamental instability. It may be similar in nature to the conditions initiating fainting or syncope but persists somewhat longer. Primary shock is the type of shock one is likely to encounter when doing relatively minor procedures not involving any great loss of blood.

Cannon has defined *"secondary shock"* as follows: "It is characterized by a low venous pressure, a low or falling arterial pressure, a rapid thready pulse, a diminished blood volume, a normal or increased erythrocyte count and hemoglobin percentage in peripheral blood, a leukocytosis and an increased blood nitrogen, a reduced blood alkali, a lowered metabolism, a subnormal temperature, cold skin, moist with sweat, a pallid or grayish cyanotic appearance, also by thirst, by shallow and rapid respiration, often by vomiting and restlessness, by anxiety changing to mental dullness and lessened sensitivity." *

During the World War considerable evidence was accumulated which led Bayliss and Cannon and others to postulate the theory that the chief factor in the production of secondary shock was a toxin developed in damaged tissues. The toxic agent was never isolated but histamine represented an example of a protein cleavage product which would produce experimentally the classic picture of shock. Just recently, however, Phemister and Blalock have presented experimental evidence which would seem to indicate that the shock syndrome can be explained on a more mechanical basis. In their experimental work on animals which had had

* From Cannon, W. B.: Traumatic Shock, D. Appleton-Century Co., Publishers.

the thigh muscles of their legs hammered Cannon and Bayliss probably misinterpreted the amount of gain in weight in the legs traumatized. Phemister's and Blalock's work seems to indicate that these animals are actually suffering from hemorrhage into the traumatized leg—that is, that the legs gain enough weight to account for the loss of blood volume so that what the animal is really suffering from is internal hemorrhage. This conception brings up the question if there is really such a thing as secondary traumatic shock separate from hemorrhage in one form or another.

In secondary shock, as we see it in ordinary hospital work, hemorrhage, toxic agents from infection, the harmful effects of anesthesia (especially if it be ether or chloroform), and loss of water from the body of sweating or preparatory purging, all may be more or less operative.

Treatment.—The obvious points of attack in so far as treatment is concerned have been, first, to correct as quickly as possible all of the initiating factors by giving rest opiates, applying heat and stopping fluid loss. The sustaining factors are attacked by attempting to increase the blood volume, the blood pressure, and the volume flow of oxygenated blood to the outlying tissues.

To treat a patient for shock without first controlling any hemorrhage that might exist would be to neglect the most vital contributing factor. Because of the tendency to a lowered metabolism heat is very efficacious in the treatment of shock. Cold and wet clothing should be removed. Further trauma to disintegrated tissue should be guarded against. Pain and restlessness should be relieved by moderate doses of morphine and the patient should be covered with warm, hot blankets and warmed in an electric heater.

Much can be done to prevent shock. Patients with anemia or a toxemia or other conditions which lower the general bodily resistance develop shock more quickly than normal individuals. The anemia can be improved by blood transfusions before operation. Depleting purges, starvation, dehydration, and excessive anxiety should be avoided. Transfusion, hypodermoclysis of physiologic sodium chloride or infusion of glucose solution before or during shock is of value. Recently Frazier has called attention to the value of 10 per cent ethyl alcohol in 10 per cent dextrose given slowly, as much as 2 liters in twenty-four hours, as being of some value in the collapsed state. The proper selection of an anesthetic should receive careful consideration. Nitrous oxide and local anesthesia are less shocking than ether. Local anesthesia may have an additional advantage in certain operations as the blood loss is likely to be less than that under general anesthesia. Vasoconstrictor drugs are theoretically contraindicated according to Cannon. The arterial tree is already contracted down to compensate for the loss of blood volume. A greater contraction may raise the blood pressure by more vasoconstriction temporarily but the underlying condition of the patient is more likely to be hindered than improved.

Intravenous injections of crystalloid solutions (salt-glucose) have only a temporary value in severe shock but given slowly it may tide a patient over temporarily until other measures can be instituted. The blood pressure can be kept up fairly well for several hours if such a solution is given slowly and continuously. Thus, crystalloid solutions are to be recommended if a transfusion is not immediately available.

Of all the methods of intravenous treatment of shock—both from a theoretical standpoint and a practical standpoint—blood transfusion seems to be of the most value. It increases the blood volume and thereby raises the blood pressure. It also supplies a fluid capable of carrying oxygen. Mann reached the conclusion that blood was better than any of the artificial solutions although he thought a colloidal solution such as gum acacia—although sometimes dangerous—was better than crystalloid solutions.

Early cases of shock may recover without much treatment. Late cases of shock are likely to die after the best known treatment. In using intravenous therapy it is to be emphasized that too rapid an introduction of the solution is harmful and possibly may kill in itself. Prophylactic treatment and early treatment are extremely important in life saving.

Blood Grouping.—Now there is general recognition of the existence of four distinct blood groups in human beings. Unless the donor belongs to the same group or to some group in which the recipient's serum will not hemolyze the donor's red blood cells, a fatality is likely to result or even if the recipient does not die, most of the red blood cells of the donor would be destroyed and the patient would receive no benefit. Between the third and twelfth months of life the blood group to which an individual will belong becomes definite. A person's blood group is a hereditary factor and is transmitted as a dominant mendelian characteristic. Disease and time do not alter it. Before transfusion is considered, the blood group of both the donor and the recipient should be determined and in most cases the effect of the serum of both the recipient and donor on the blood cells of the other should be observed. Commonly, it is routine to run a Wassermann test on the donor and to take a careful history as to freedom from infectious disease.

Transfusion.—In the past many ways of taking blood from one individual and giving it to another have been used. All of them, however, can be divided in two groups. By one method no coagulant is used and the blood is passed unaltered from the donor to the recipient (the direct method). By the other an anticoagulant is added to the blood of the donor. Sodium citrate now is used almost universally. In 500 cc. of blood about 1.25 Gm. is used which is about one fourth of the maximum safe dose. Experience has shown that little if any outward effects result from the intravenous injection of this amount and apparently the efficiency of the blood is not materially altered. Direct methods of transfusion are often a little worrisome because of the danger of clotting which tends to interrupt the procedure. The donor has to be at the bedside of the recipient when a direct transfusion is given. A critically ill or nervous patient may be upset on this account. Unaltered blood just before clotting tends to become toxic. Therefore, if the blood is on the verge of clotting, one may be giving a fluid more or less toxic. The simplicity of the citrate method and the lack of necessity for haste so that one may precede slowly enough to anticipate reactions are points in favor of this method. Slight febrile reactions of 1° to 3° F. do appear, however, after the citrate method more often than after the use of the direct method. In about 10 per cent of the cases a fairly severe chill with a subsequent fever of from 101° to 105° F. may follow. Ordinarily these reactions are not of serious import. As the patient's coagulation time is not prolonged but is shortened after

the use of the citrate method, there are no diseases in which the method is contraindicated. For the relatively inexperienced, the citrate method is the method of choice. For the expert the use of the direct method may be desirable. In all hospitals an apparatus for transfusion with appropriate chemicals should be kept in a place of the greatest accessibility. Rarely one may see a jaundice and hemoglobinuria after a transfusion. An urticarial rash sometimes appears. Ephedrine and adrenalin aid in controlling this latter complication. Extremely rarely one hears of a death during a transfusion. Although the inaccuracy of the cross matching is always suspected in such cases, often it will prove to have been correctly done. One cannot unequivocally state that the procedure is not totally without danger. When the condition for which the transfusion is being given, however, is of some seriousness, this slight danger is insufficient for hesitation. Ordinarily the chief indication for transfusion is loss of blood. But sometimes postoperatively one may wisely order a transfusion if the patient is showing hesitation in convalescence. Normally, unless there is anemia the use of transfusions in surgical infections is probably of no value, although children with infectious disease apparently do show some signs of good effects from the procedure.

COMPLICATIONS OF OPERATION

Among the more important postoperative complications are certain cardiorenal complications, certain vascular complications and certain respiratory complications. For the purpose of emphasis, a few comments should be pertinent.

Cardiorenal Complications.—"The surest treatment of cardiac failure is prevention" (Hughson). No other type of complication is met with so often as some form of cardiovascular disorder (Hughson). In practice two types of individuals are encountered (1) those in whom the signs and symptoms of cardiac disease are evident. (2) Those in whom to all outward examination the cardiac apparatus appears normal. The first group is no great problem as almost every internist is capable of treating a frank cardiac decompensation. The real danger lies in the second group.

Toxemia, acute or chronic, may have an effect on the myocardium which is not readily observed. The electrocardiographic examination is a valuable procedure in this group of cases. The average surgeon does not use this diagnostic aid enough. Cognizance of a hypertension with its heart and kidney association should always be taken into consideration. Although hypertension in itself may not be a menace to surgery, a hypertension should warn one to study the cardiac reserve and the renal function. Possibly one should omit adrenalin when using local anesthesia when the hypertension is of marked proportions.

Occasionally for no apparent reason, postoperatively a suppression of urine follows. Large quantities of glucose solution (5 to 10 per cent) intravenously are usually effective if the kidney function were comparatively normal before operation. Obviously, if there are any cardiac symptoms, they should be adequately treated by the proper heart remedies familiar to the internist. In elderly persons and also in youthful individuals if there is anything in the history or physical examination suggestive of kidney disturbance, the phenolsulfonphthalein output should be assessed before any

operation of considerable magnitude. A phthalein output of 25 per cent or less is an almost absolute contraindication to operation. When the phthalein output is materially decreased (35 to 40 per cent) further checking on the kidney function is wise. After proper fluid therapy and possibly cardiac attention, if an operation has to be performed it may be much safer.

Vascular Complications.—Postoperative phlebitis, thrombosis, or embolism may greatly prolong convalescence, handicap permanently or even cause death. Traumatism and toxemia or bacterial invasion are causative factors. Anemia and cachexia may be contributory. Fortunately, in contradistinction to gynecologic practice, it is seldom that thrombosis of an important vein follows an operation in the oral cavity. Occasionally, however, a pulmonary infarct is seen. As is well known, the main symptoms are agonizing pain in the chest and difficulty in respiration. If the difficulty in breathing is marked, oxygen is indicated. For the pain opiates should be given. A patient with a thrombophlebitis of the leg or pelvic veins runs a certain chance of developing a fatal pulmonary embolus.

Postoperative Pneumonia.—Postoperative pneumonia is more prone to occur in the aged. The following factors may have a bearing on its development: (1) irritation from unnecessarily concentrated ether, (2) aspiration of mucus, blood, vomitus either infected or noninfected, (3) exposure or chilling during and after operation, (4) limitation of expansion of the chest either due to pain or improper position during and after operation, (5) an impaired circulation, (6) a season of the year when upper respiratory infection is prevalent. One of the most vital factors in the prophylaxis against a postoperative pulmonary complication is an adequate circulation.

In 1896 Gottstein in studying a series of von Mikulicz's cases at Breslau brought out the fact that as many cases of pneumonia followed operations under local anesthesia as after operations performed under general anesthesia. Previously, it had been considered that pneumonia postoperatively was due to the anesthetic. The point is that the majority of postoperative pneumonias are independent of the anesthetic. A concentration of such anesthesia as ether to as high as 25 to 35 per cent may be irritating to the air passage but a good anesthesia can be given with concentration of from 6 to 7 per cent which is withstood without irritation. Postoperative pneumonia may be due to emboli which have entered the circulation at the site of the operation. The time of development of symptoms varies from within the first twenty-four hours to a week or so. Pain in the chest, an elevated temperature, cough, a quick respiration and pulse throw one on guard. The aspiration of mucus or blood has to be considered as a contributory factor in lung complications. This is especially true if the operative procedure has been a severe one on the patient or if respiration is depressed either during the anesthesia or after the operation by either the nature of the operation or by the depressant drugs. Aspiration from the mouth of solid or liquid vomitus, pus, or blood all contribute a quota of lung complications.

Usually when pneumonia is suspected an internist should be consulted. The indications are good elimination, a moderate amount of sedatives to produce rest, change of position and cardiac stimulant only when there are signs of decompensation. Oxygen may be of aid, when signs of suboxygena-

tion begin to appear. Early, pneumococcic serum may be indicated after proper typing.

Lung Abscess.—Some observers hold that lung abscesses following operations about the oral cavity are of embolic origin but probably aspiration of septic material through the alveoli is the common route. Moore in an analysis of 200 lung abscesses following operations upon the upper air passages concluded that (1) the vast majority are of inspiratory origin because (*a*) the time of development, and (*b*) the involvement of the lower lobes of the lung in 60 per cent of the cases (right, 41 per cent; left, 19 per cent) are of almost the same relative incidence as in cases of inspired foreign bodies; (2) pulmonary abscess occurs once in 2500 to 3000 tonsillectomies; (3) blood stream transmission of infected material causing pulmonary abscesses occurs but in a relatively small number of cases; (4) lymphatic extension is a rare mode of infection; (5) the semirecumbent and upright positions are not so free from this complication as heretofore supposed.

Massive Collapse of the Lung.—During recent years considerable attention has been paid to this pulmonary complication. Massive collapse of a lung usually appears after an abdominal operation or is associated with a wound of the chest wall but occasionally is seen after an operation on the upper respiratory passages. W. Pasteur in 1906 first described the condition. The condition in the past apparently was confounded with postoperative pneumonia or pulmonary embolus. Within a few days after operation a febrile complication arises and is accompanied by a unilateral pulmonary consolidation and displacement of the heart to the affected side. The chest is asymmetrical, the respiration unilateral, and there may be cyanosis. The roentgenogram shows an area of increased density with the heart and mediastinal tissue displaced toward the affected side, while in the affected side the diaphragm is elevated. In about two weeks the collapse disappears. So few cases have died that there is practically no autopsy material available for study. C. Jackson has bronchoscoped some cases with the idea of aspirating a plug of mucus from the bronchus if this be the etiologic factor.

Bibliography

Bibliography Quoted in Text

Applemanns, R.: Les injections isovisquérises dans le sang, Arch. internat. de méd. exp., **2:** 3, 1925.

Bayliss, W. M.: Acacia for Transfusion, J.A.M.A., **68:** 1885, 1922.

Intravenous Injection in Wound Shock, Brit. Med. Jour., London., **1:** 553–556, 1918.

Behring, E. von, and Kitasato, S.: Ueber das Zustandekommen der Diphtherie-Immunität und der Tetanus-Immunität bei Thieren, Deutsche Med. Woch., **16:** 1113, 1890.

Blalock, Alfred: Experimental Shock: Cause of Low Blood Pressure Produced by Muscle Injury, Arch. Surg., **20:** 959–996, 1930.

Bull, C. G., and Pritchett, I. W.: Inoculation against Bacillus Welchii, Jour. Exp. Med., **26:** 119, 1917.

Cannon, W. B.: Traumatic Shock, New York, D. Appleton-Century Co., 1923.

Cannon, W. B., Fraser, J., and Cowell, E. M.: Report of Shock Committee, English Medical Research Committee, Dec., No. XXV, 1917.

The Preventive Treatment of Wound Shock, Medical Research Committee, London, 1919, Special Report Series, **25:** 125–134.

Cannon, W. B., and Cattell, McK.: Experimental Traumatic Shock, Critical Level in a Falling Blood Pressure, Arch. Surg., **4:** 300–323, 1922.

Cornioley and Kotzareff: Serologic Research on Traumatic Shock, Rev. de chir., **54:** 233, 1921.
Cowell, E. M.: Initiation of Wound Shock and Its Relation to Surgical Shock, Lancet, **11:** 138, 1919.
Initiation of Wound Shock, J.A.M.A., **70:** 607, March 2, 1918.
The Initiation of Wound Shock, Med. Res. Com., London, Special Report Series, **25:** 99–108, 1919.
Dandy, W. E.: The Brain, Dean Lewis' Practice of Surgery, Hagerstown, Maryland, W. F. Prior Co., Chapter I, **12:** 1–682, 1933.
Dick, George: Anaphylaxis and Serum Therapy, Dean Lewis' Practice of Surgery, Hagerstown, Maryland, W. F. Prior Co., Chapter XI, **1:** 1–37, 1933.
Editorial: Deleterious Effects of Acacia for Transfusion, J.A.M.A., **78:** 730, 1922.
Acacia and Fundamental Aspects of Intravenous Injections, J.A.M.A., **86:** 556, 1926.
Firor, Warfield M.: Wounds, Blood Grouping, and Transfusion, Dean Lewis' Practice of Surgery, Hagerstown, Maryland, W. F. Prior Co., Chapter VIII, **1:** 1–41, 1933.
Frazier, C. H.: The Modern Treatment of Surgical Shock, J.A.M.A., **105:** 1731–1733, 1935.
Gottstein: Quoted by Herb, I. C.: General Anesthesia, Dean Lewis' Practice of Surgery, Hagerstown, Maryland, W. F. Prior Co., Chapter III, **1:** 1–88, 1933.
Henderson, Y., and Haggard, H. W.: Circulation in Man in Head-down Position, Jour. Pharm. and Exper. Ther., **11:** 196–207, 1918.
Hughson, W.: Postoperative Treatment, Dean Lewis' Practice of Surgery, Hagerstown, Maryland, W. F. Prior Co., Chapter XII, **1:** 1–41, 1933.
Jackson, C.: Quoted by Dick, George.
Kolmer, J. A.: Infection, Immunity and Biologic Therapy, Phila., W. B. Saunders Co., 1923.
Leclainche, E., and Vallée: Traitement sérique spécifique des plaies, Bull. et mém. Soc. de chir. de Paris, **17:** 1804, 1916.
Legg: St. Bartholomew Hospital Report, 1881.
Mann, F. C.: Studies on Experimental Surgical Shock, Amer. Jour. Physiol., Balt., **47:** 231–250, 1918.
The Peripheral Origin of Surgical Shock, Johns Hopkins Hospital Bull., Baltimore, **25:** 205–212, 1914.
Meyer, H., and Ransom, F.: Untersuchungen über den Tetanus, Arch. f. exp. Path. u. Pharm., **39:** 369, 1903.
Morax, V., and Marie, A.: Recherches sur l'absorption de la toxine tétanique, Ann. d. l'Inst. Pasteur, **17:** 335, 1903.
Pasteur, W.: Massive Collapse of the Lung, Lancet, **11:** 1351, 1908; Quoted by Hughson.
Pfeffer: Irritability of Plants, Cryptogams, Unters. Bot. Instit. Tübingen, I and II, 1884, 1888.
Phemister, Dallas B., and Parsons, E.: Hemorrhage and Shock in Traumatized Limbs, Experimental Studies, S. G. O. (Aug.), **51:** 196–207, 1930.
Sachs, E.: Quoted by Dandy, W. E.: The Brain, Dean Lewis' Practice of Surgery, Hagerstown, Maryland, W. F. Prior Co., Chapter I, **12:** 1–682, 1933.
Sacquépée, E.: Researches on Gaseous Gangrene of War Wounds, Presse méd., **26:** 197, April 18, 1918.
Teale, F. H., and Embleton, Dennis: The Paths of Spread of Bacterial Exotoxins with Special Reference to Tetanus Toxin, Jour. Path. and Bact., **28:** 50, 1919.
Van Beuren, F. T.: Treatment of Gas Bacillus Infection, J.A.M.A., **73:** 230, 1919.
Weinberg, M.: Bacteriological and Experimental Researches on Gas Gangrene, Proc. Royal Soc., **9:** 121, 1915–1916.

CHAPTER VI

INJURIES OF THE BONY FRAMEWORK

Injury to the bony tissues does not necessarily always result in complete dissolution or fracture. A *subperiosteal hemorrhage* without actual dissolution is occasionally seen. At first there is an extravasation of blood beneath the periosteum following the blow. An infiltration of fixed tissue cells and white blood cells follows. The periosteum is stimulated to lay down new osseous tissue. The result is a thickening and tenderness over the part of the bone which received the injury. Usually these injuries are of a more or less trivial nature when a basic blood dyscrasia does not lend a contributory hand and require no special treatment other than symptomatic care. Some few weeks or even months may be required before the thickening completely subsides. Actual dissolution of the bony tissues is of greater interest as the care of a fracture may be difficult and the diagnosis sometimes requires careful study.

VARIETIES OF FRACTURES

Various adjectives have long been used to describe a broken or fractured bone. Most of these adjectives, such as *greenstick, comminuted, impacted, depressed* and so forth, are self-explanatory to the modern student. One may point out that the preceding adjectives refer only to the bone itself and not to what has happened to the soft tissue surrounding the bone. In common usage for describing whether or not the soft tissues have been torn and lacerated and whether or not infection from the outside is possible or likely, fractures are divided roughly into two large groups, first, the *simple or closed fractures* without communication to the outer surface, and second, the *compound or open fractures* in which there is some communication, that is, the mucous membrane or the skin is torn.

The majority of fractures of the jaw bones are compound in type, that is, the fracture line communicates with a cavity in which infectious bacteria are present. In fractures of the upper jaw, the lining mucosa of the sinuses lies in close contact with the bone so that very little displacement of the fragments of bone at the time of fracture is necessary to tear the mucosa. The gum tissue which covers the alveolar ridge is in almost immediate contact with the underlying bone. Thus, here the slightest separation of the fragments may cause tearing of the mucosa even if the jaw be edentulous. Usually in the body of the jaw whether it be the upper or lower jaw, the line of fracture lies between two teeth. However, fracture back of the angle of the mandible, that is, fracture of the ramus or a condylar fracture is nearly always a simple fracture and is not likely to become infected.

Fractures of the upper jaw are often comminuted but comminuted fractures of the lower jaw are not often found in civilian practice, a linear fracture is the usual type of fracture. The so-called "greenstick fracture" is seldom found in the jaw. *Pathologic* fractures of the jaw occasionally are

seen in cases of advanced malignancy or after gross necrosis of the jaw. *Impacted* fractures are not uncommon in the upper jaw but are rare in the lower jaw.

Gunshot injuries besides being characterized by comminution of bones are also characterized by absolute loss of bones. And moreover, gunshot missiles or shrapnel often tear away a considerable amount of the soft tissues. Obviously the type and the velocity of the flying missiles have a direct bearing on the character of the resultant wound.

ETIOLOGIC FACTORS

Direct violence practically always is the cause of fracture of the jaw. There are a few cases reported in the literature of the lower jaw sustaining a fracture due to muscular contraction. At least one instance of a fracture sustained while yawning is recorded. Probably in quite a few fractures of the lower jaw the force of direct violence is augmented by muscular contraction. When the mouth is open a blow may cause sudden contraction of the muscles of mastication, sometimes without the blow even striking the jaw itself. In the upper jaw, muscular action can play no part in causing the fracture but gravity may allow a complete separation of both maxillae from the base of the skull.

The majority of fractures of the jaw occur in the active adult period of life. The elderly are less likely to receive an injury of this seriousness while children have less brittle bones which withstand a sudden force fairly well. Moreover in many of the accidents and injuries of childhood sufficient force is not delivered to cause a mandibular fracture.

Sex.—In the past a great majority of jaw fractures were seen in the male. Nowadays many fractures of the jaw are seen after automobile accidents and the automobile is about as destructive for the female as for the male. Thus, in the past possibly more than at the present, environmental factors caused the male to sustain fracture of the jaw bones oftener than the female. Fist fights still contribute a fair percentage of the fractures of the lower jaw. Horse kicks used to contribute to the incidence of upper jaw fractures as well as lower jaw fractures. Nowadays most persons do not come in contact with horses. Ivy and Curtis found that 80 per cent of their 100 fractures were found in the male sex.

GENERAL SYMPTOMS AND SIGNS OF FRACTURES OF THE JAW BONES

The general symptoms and signs of fracture are: (1) pain and tenderness, which is typically most pronounced at the line of fracture either when another part of the bone is moved or when pressure is made upon the line of fracture. (2) Disability, which varies according to the function of the broken bones. The reasons for disability are more or less obvious. (3) Swelling, which is caused first by torn lymph and blood vessels and later by the gathering products of the blood which are intended to carry on the process of repair. (4) Discoloration or ecchymosis, which is due to an infiltration of the extravasated blood beneath the surface. (5) Deformity which is due to either the primary direction and strength of the producing force or to secondary muscle spasm or both. Obviously, gravity may play a part in causing deformity. (6) Abnormal mobility which is self-ex-

planatory. It is a very distinctive sign. (7) Crepitus, which is the sensation felt in the palpating fingers on the grating together of uncovered ends of bone. This sign may be considered pathognomonic of fractures. Often, however, it is not considered necessary for this sign to be elicited for the diagnosis of fracture to be made. Unnecessary manipulation traumatizes the surrounding tissue and is often painful. (8) The roentgenogram nowadays is the final sign to be observed. It is often considered grounds for a malpractice suit if one does not avail himself of its evidence at one time or another in the treatment of a fracture. Often, however, in so far as the fracture of the jaw bone is concerned, the roentgenogram gives one little or no additional evidence if one avails himself of all the means of making a good physical examination.

GENERAL CONSIDERATIONS IN THE MANAGEMENT

Reduction and Fixation.—As a rule, the fundamental principles involved in the reduction and fixation of a simple fracture of one of the jaw bones are relatively simple and not by any means as complicated as they might appear to be at first glance. Moreover, in 90 per cent or more of fractures of this type, no complicated apparatus is necessary to obtain good union in a reasonable length of time.

Briefly, the goal to be striven for in the treatment of a fracture of the jaw is accurate replacement of the fragments so that normal occlusion is not disturbed and after which by one method or another definite fixation is provided for during a period of time sufficient for bony union to occur. Accurate approximation of the fragments of a fractured jaw is more essential than in other bones of the body as good occlusion of the teeth is necessary for proper function, *i. e.*, for the proper mastication of food. The exception to the foregoing statement is the edentulous jaw where the approximation need not be anatomically so accurate for good function to result. New dentures can be made which will compensate for a moderate malposition. The simplest principle of fixation is the use of the opposite normal jaw as a splint. When a sufficient number of teeth are present this may be accomplished simply by fastening several of the opposing occluding teeth together by one means or another. A second principle of fixation is one in which a sufficient number of the teeth in the same dental arch of the fractured bone are held firmly fixed by means of a specially constructed dental splint. In subsequent chapters (Chapters VII to XI) the application of these principles is discussed.

Dependent Drainage.—The care of the soft tissues when incised or lacerated is discussed in Chapter IV. One phase of their care should be mentioned here, for some emphasis probably should be placed upon the point. When the tissues at the line of fracture in the body of the lower jaw are considerably loosened, there is necessarily a pathway or pocket lined with more or less traumatized tissue into which the infected secretions of the mouth have perfectly free access. When dependent drainage is not present and no precaution is taken to drain such a pocket, the chances of a low-grade infection with the formation of an abscess about the line of fracture is very much increased. Besides the pain and the annoying swelling of the cheek which accompanies such an infection, osteomyelitis of the ends of the broken fragments of bone with its characteristic sequelae such

as delayed union, nonunion, or even sequestration of a piece of bone, are probable sequences (Fig. 21). It is therefore to be recommended, I believe, that in most cases of mandibular body fracture with a fair amount of tearing of the soft tissue at the line of fracture that a stab drain be



Fig. 21.—Swollen jaw when drainage was not given at the line of fracture at the proper time.

placed to the lower end of the fracture line to give dependent drainage. The small scar is insignificant and avoidance of the likelihood of complications resulting from infection more than compensates for the disadvantage of having an inconspicuous scar about 1 cm. in length beneath the edge of the jaw. Blair has always insisted that early drainage be given.



Fig. 22.—Tooth in line of fracture.

Tooth in Line of Fracture.—Another factor which always needs consideration is the likelihood of a loosened dead tooth in the line of fracture acting as an infected foreign body would in the line of fracture (Fig. 22). The tissues surrounding a loosened tooth in the line of fracture become

infected and the tooth is really isolated as is a sequestrum in an osteomyelitis. It then acts similarly. The infection about the tooth may extend to the fracture, and initiate a low-grade osteomyelitis which will prevent early union. Therefore, one may recommend that in cases where the tooth in the line of fracture has been loosened or possibly even fractured, the tooth should be removed. The exception to this principle is when the third lower molar in the line of fracture in a fracture at the angle holds the ramus backward and downward in a normal position. The advantages of holding the ramus back in this simple manner until some union occurs are greater to my mind than the advantages of removing the foreign body. In this case the tooth may preferably be removed several weeks later. When the line of fracture falls between the teeth and the roots of the teeth do not seem to be uncovered entirely, one might allow them to remain in place but a careful check should be kept for any evidence of interference with union. If infection develops above the tooth and the roentgenogram shows absorption of the dental alveolar bone between the teeth, it preferably should be extracted.

Anesthetic.—Rather often in our own cases a general anesthetic has been given. Very often there are three or four things to be done in the efficient fixation and care of a fracture such as (1) pulling a tooth, (2) giving dependent drainage, (3) wiring the teeth together, and (4) making some sort of fixation as in angle fractures or an edentulous jaw where circumferential wiring is used. This can be done in the majority of cases with local anesthetic properly applied but it is often quite a trying ordeal for the patient, especially if the fracture is not seen immediately. If the patient's stomach is emptied with a stomach tube before operation and the patient allowed to regain his swallowing reflexes before he is allowed to leave the operating room, the danger from a short ether anesthesia is almost negligible. Stomach fluid vomited without particles of food is fairly easily strained through the teeth. Often this is rendered easier because there is a tooth missing or one or two have been extracted in the line of fracture. The mechanism for fixation can be placed on the teeth and then drawn together after the anesthesia has worn off if one deems it the wiser procedure. If the mechanism for fixation is applied firmly, however, when the patient is relaxed, fixation and approximation are likely to be more accurate. With general anesthesia one also has the advantage of being able to examine the patient with all muscles completely relaxed. Muscular spasm gives little or no interference. In none of our cases have we found it necessary to cut the mechanism of fixation when we placed the teeth together before the patient was completely out from under the influence of the anesthetic.

Many men prefer local anesthesia and it must be admitted that their results justify their contention. In only 11 per cent of Ivy's cases did he deem it necessary to use a general anesthetic. The decision whether to use a general or a local anesthetic depends upon the balancing of the following factors: (1) the surgeon's cleverness in handling a local anesthesia, (2) the type of patient with whom one is dealing (in children a general anesthesia is almost obligatory), (3) the number and extent of the procedures necessary, (4) the time at which the patient is seen, whether immediately after the accident or after there has been some scar tissue formation to prevent

easy adjustment of the fragments or after there is some evidence of infection in the soft tissues. (Under the two latter conditions a general anesthetic would seem best.) (5) The amount of laceration of the soft tissues and whether or not a débridement seems indicated.

The Roentgenogram.—A good roentgenogram is advisable in most fractures of the jaw although it must be admitted that one may get most or all of the essential information by a careful examination. The films should show body, ramus and condyle. Not uncommonly the root of a tooth is seen to be fractured and another unsuspected root may be found to act as a foreign body and prevent union. When either probability seems eminent, the fragments should be removed.

Care of the Mouth.—In fractures of the jaw, there is a tendency for the teeth to get dirty, and not uncommonly the odor becomes distinctly noticeable especially when mouth splints are used or when modeling composition has been placed over wires to prevent irritation of the lips and cheeks. Decomposing food tends to collect about wires or beneath the modeling compound. The gums may also show some gingivitis if the mechanism for fixation comes in contact with them. Along the line of fracture often the soft tissues do not become clean for ten days to two weeks—until after the superficial slough has separated from the viable tissue and a granulation tissue wall has developed.

Thus, the mouth should be kept as clean as possible with a soft brush and cleansing mouth washes which deodorize as well as cleanse. When the tissues are unusually tender pledgets of cotton or gauze may be used to gently clean tender surfaces. The inside of the mouth should be douched every four hours by irrigation or by sucking the antiseptic mouth wash back and forth between the teeth. Most any of the popular mouth washes are suitable. Saturated boric acid, $\frac{1}{3000}$ potassium permanganate solution, Dakin's solution, or even a plain salt and soda solution (1 teaspoon salt and 1 teaspoon soda to a glass of warm water) may be recommended.

Dribbling of saliva is usually best caught in a large properly applied dressing. Sometimes a dam of modeling composition placed in the proper position will aid in blocking the dribbling of saliva to a considerable extent.

In some instances it is best to spend a few days cleansing the mouth before splints or wires are placed on the teeth. For the same reason deposits of tartar between the teeth are sometimes advantageously removed.

Complications.—In a general way the complications of severe injury to the bony framework are those previously described as complications of soft tissue injury—that is, local infection, general infection, hemorrhage, shock, concussion, and certain systemic complications. Severe dissolutions of the bony framework are likely to be associated with some concussion. The jaws after all attach rather directly to the cranial "box" and force is rather directly transmitted to the rather friable contents of the cranial cavity.

After transverse fracture of the upper jaw, the maxillary bone tends to drop down. The palate presses against the tongue. As hemorrhage and swelling are likely to block the nasal air passages, the immediate indication is some simple means of giving a free airway to prevent suffocation. Temporarily a large rubber tube placed in the mouth over the back of the tongue will give relief. Also after a fracture of this type sometimes

the amount of blood loss from torn vessels in the nasopharynx may be considerable. The insertion of a nasopharyngeal pack by the method described in Chapter XXXIII may be of aid when this appears to be a dangerous complication.

In simple fractures of the mandible the dental artery may be torn. Seldom does this cause bleeding sufficient to cause worry. When the fragments are adjusted the bleeding will cease as a rule. A hot-water bottle or an ice-bag for a few days over the site of the fracture will often tend to reduce the pain and cause the swelling to subside somewhat quicker. When swelling of the tongue or soft tissues about the pharynx develops, breathing may be difficult. A tracheotomy is not necessary except in the most unusual injuries. A free airway can be provided by drawing the tongue forward and maintaining or inserting a large rubber or a Connell tube posterior to it. When there is uncertainty whether or not adequate airway has been provided by these simpler methods, a tracheotomy may be considered.

Among the annoying complications is the development of a low-grade osteomyelitis. Fortunately this complication usually tends only to involve compound fractures of the body of the lower jaw. If drainage is not good at the dependent point of the line of fracture in such a fracture there may be pocketing of infection with induration of the cheek or even an extension to the upper neck.

Union usually occurs fairly promptly if the fixation has been good, dependent drainage given, and if no foreign body remains in the line of fracture, such as a tooth root or a piece of dead bone. The older writers were prone to comment upon the rareness of nonunion.

As previously mentioned, an unconscious state with or without a skull fracture is more commonly found in association with fractures of the upper jaw. When there is coma, however, with fracture of the mandible and especially so if there are multiple fractures of one or both sides, there is a tendency for the tongue to fall backward, obstruct the pharynx, and fall in the way of the larynx, thereby producing dyspnea or even suffocation. Immediately some method must be used to pull the jaw forward.

Emphysema.—Emphysema is best combated by insuring free ingress and egress of air through the nose. Blair has plugged the posterior nares in a rapidly spreading emphysema with some success. Cool moist applications will aid somewhat in preventing swelling and edema. When the nasal meatus is blocked, a vasoconstricting solution of adrenalin or ephedrine may aid in giving a free airway.

Delayed Union.—Union may be retarded by lack of a good blood supply to the fragments, lack of proper fixation, by the interposition of spicules of bone, a tooth, or a foreign body, by infection, by a sequestrum or by a general lack of healing effort on the part of the patient. An anemic patient usually shows less of a healing tendency than a patient with a normal blood picture. Undoubtedly, general disease which lowers the patient's general vitality may tend to lengthen the time of union of a fracture. Among such diseases is tuberculosis. Syphilis probably does not inhibit union as much as has been thought in the past.

The blood supply of the upper jaw is so well developed and secondary infection is so uncommon that delayed union ordinarily does not have to be considered. A nonunion of the mandible without any explainable cause

should not be said to exist until several months have elapsed. After several months have elapsed without union, eburnated ends or fragments should be refreshened so that actual bone comes in contact with bone and the fixation should be reapplied.

If union should fail after the procedure above, after at least six months have elapsed, a bone graft might be inserted across the line of nonunion under aseptic conditions.

Stiffness of the Jaw Muscles After Fracture.—When the jaw bones have not been used for several months, movement at the temporomandibular joint may be considerably restricted because of a disuse atrophy or a fibrosis of the muscles of mastication. When there is no restriction due to cicatricial contracture of the soft tissues of the mouth and face, as a rule, the restriction of movement is soon overcome. Stretching the muscles by

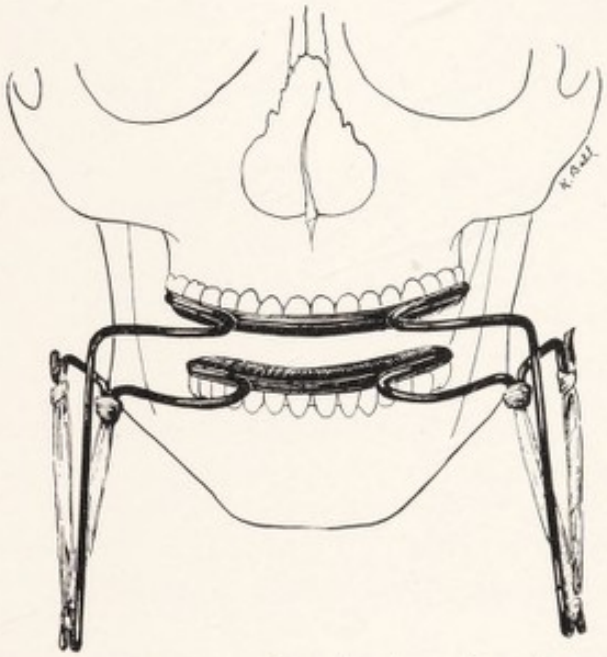

Fig. 23.—Apparatus used by Ivy when the jaws do not open freely. The wires are attached to dental trays which are cemented to the teeth. Rubber bands are placed so there is a constant tendency for the lower jaws to be pushed downward and the mouth opened. This application of dilating force was originated by Darcissac.

placing a rubber cork as far back as possible between the teeth may help. The trismus apparatus described by Darcissac and modified by Ivy may be of value (Fig. 23). In extreme cases forcible stretching under anesthesia plus blocking open the mouth for ten days or two weeks may be helpful.

Bandaging.—The modified Barton bandage described on page 128 is the most helpful type of bandage. If one desires an elastic or crinoline bandage it can be used. An elastic sling made of rubber dam is sometimes more effective than the simple bandage alone. The bandage is then placed over the rubber dam sling to hold it in place.

The Period of Fixation.—The time required for union depends principally upon the amount of blood supply to the fragments, the amount of infection, whether or not any foreign body is present or becomes present (as a sequestrum) in the line of fracture, and finally the general reparative effort of the individual. Although the same amount of union may occur as

quickly in comminuted and multiple fractures as in simple fractures, fixation is necessary for a longer time in the former because union does not have to be more than moderately firm in the simple fracture while it has to be definitely bony in the multiple fracture.

In simple fractures of the mandible with early approximation, good fixation, little or no infection, fairly good union is present in four weeks. This will not, of course, be strong bony union but position at least will be maintained without splints. In comminuted double fractures the tendency to displacement is greater than in simple fractures so that firmer bony union is necessary before fixation can be dispensed with. Such fractures usually need fixation for six weeks. Suppurating fractures and fractures with loss of bone usually need fixation for a longer period of time. The roentgenogram is valuable in estimating the amount of bony union. Ivy and Curtis in 100 cases of fractures of the mandible found the average number of days for fixation to be thirty-one and one-half. The shortest period was fourteen days and the longest was wired seventy-five days. The latter case was a double fracture wired after one month. When fibrous union of suffi-

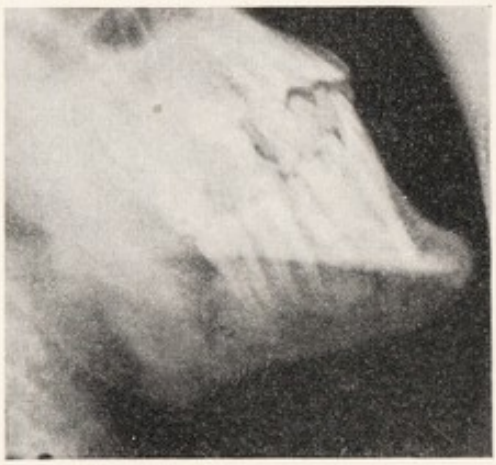

Fig. 24.—Old fracture with nonunion.

cient strength to preserve alignment of the fragments has occurred, removal of the wires or splints may encourage union by the stimulation accompanying the slight movements. Nonunion is exceedingly rare without an explainable local cause (Fig. 24).

On the whole, fractures of the upper jaw tend to unite somewhat quicker than fractures of the lower jaw. Drainage about an upper jaw fracture line tends to be more adequate than about a lower jaw fracture. The upper jaw is a membranous bone. Membranous bone such as the nose becomes fixed notoriously quickly. The union does not necessarily have to be a complete bony one for fixation to be adequate if chewing of hard food is prohibited.

Feeding During Treatment of a Fracture of the Jaw.—When an interdental splint has been used, soft foods or chopped meat can be taken from the first. But when the teeth have been wired together, the diet must be restricted to fluids or semifluid mixtures. With these primary restrictions in mind, the diet should be planned to contain about 3000 cc. or more of fluids per day and 3000 calories per day.

The following foods are useful: cooked cereals such as cream of wheat, rolled oats, or rice with milk or cream and sweetened with sugar, mashed potatoes thinned with milk or cream and flavored with butter, ground peas and beans made into a thick soup, boiled eggs with butter and seasoning, finely ground meats thinned with soups, all thick soups, a certain amount of olive oil to increase the caloric value of the foods, cocoa made with milk or cream and sugar, ice cream made with cream, jellies and custards, milk and cream, an ounce or so of whisky occasionally, orange juice and lemon juice with sugar, tea and coffee with cream and sugar.

Usually after a short time sweet mixtures have to be eliminated. The patient tires of them. All foods should be well seasoned. As a rule, to get the required amount of calories, it is necessary to feed the patient as often as every four hours. Every two hours is usually too often as the patient's digestive apparatus is apt to be upset.

It is not necessary to extract a tooth for the passage of food when the upper and lower teeth are wired together. There is always sufficient space either between the teeth, through the places where teeth were previously lost or behind the last molar.

One of the following methods of administering food should be applicable to all types of injuries encountered:

1. Plain sucking through the teeth from a cup.
2. Sucking through a porcelain goose-necked feeder.
3. Funnel with tube through mouth to the pharynx.
4. Duodenal tube or catheter (No. 24 F) through the nose, pharynx and esophagus.

Bibliography

Bibliography Quoted in Text

Blair, V. P.: Injuries of the Teeth and Alveolar Process, Surgery and Diseases of the Mouth and Jaws, C. V. Mosby Co., St. Louis, 1917.

Blair, V. P., Padgett, E. C., and Brown, J. B.: Surgery and Diseases of the Face, Mouth and Jaws, Graham's Surgical Diagnosis, Phila., W. B. Saunders Co., **2:** 318–329, 1930.

Darcissac, M.: Physiological and Permanent Mobilization of the Lower Jaw, Dental Cosmos, **64:** 356, 1922

Ivy, Robert, and Curtis, Lawrence: Fractures of the Jaws, Phila., Lea and Febiger, 1931.

Supplementary References

Braun, H.: The Advantage of Local Anesthesia for the Reduction of Fracture and Dislocation, Deutsche med. Wchnschr., **38:** 17, 1913.

Desault: Treatise on Fractures and Luxation, Phila., 1805.

Scudder, C. L.: The Treatment of Fractures, Phila., W. B. Saunders Co., 7th ed., 1911.

Stimson, L. A.: Practical Treatise on Fractures and Dislocations, Lea and Febiger, New York and Phila., 6th ed., 1910.

Wilson, P. D., and Cochran, W. A.: Fractures and Dislocations, J. B. Lippincott Co., Phila., 2nd ed., 1928.

CHAPTER VII

INJURIES OF THE TEETH AND THE ALVEOLAR PROCESSES

ALTHOUGH both the upper and the lower alveolar processes are obviously a part of their respective jaw bones, in clinical practice there is often a rather close association between a mechanical disturbance of the teeth and an injury of the alveolar process. Consequently, injury of the teeth and the alveolar processes very conveniently may be discussed under a common heading.

MECHANICAL ABRASIONS OF THE TEETH

All occluding teeth eventually show evidence of the "wear and tear" consequent to the grinding of food. Two counterbalancing factors foretell the amount of wear which a tooth is likely to show—the amount of mechanical friction to which a tooth is subjected and the ability of the anatomic structure of the tooth to withstand that friction. The latter varies considerably and depends upon general metabolic factors about which we know too little to become specific.

Persistent tobacco chewers, betel nut chewers, those who subsist on coarse, tough foodstuffs and those who live in an atmosphere of sand and grit, such as workers in glass factories or the Bedouins of the desert, are likely to show a more marked degree of mechanical abrasion than other individuals.

When the enamel is slowly worn off the mechanical irritation tends to stimulate the pulp to produce a secondary dentine which is laid down in advance of the ever-wearing enamel structure. As the pulp chamber is encroached upon by the secondary dentine the pulp tends to disappear.

As the process progresses, rather surprisingly little hypersensitiveness is caused.

In certain instances it may be considered wise to cap the abraded surface and prevent a continuation of the dissolution. Should hypersensitiveness of the pulp become pronounced, the same methods may be applied to the tooth as if it were carious.

LOOSENING OR AVULSION OF THE TEETH

During an extraction an adjacent tooth may be moved enough to damage the blood supply which enters the apex of the tooth and consequently the pulp may die. Orthodontists have to work with a great deal of care as movements may place too great tension on the apical vessels and cause them to become thrombosed. Any blow which loosens a tooth is likely to cause the blood supply to the tooth pulp to be cut off.

A loosened tooth even though there is slight fracture of the alveolar process usually becomes solid without treatment. It is best, however, to allow only soft food for a week or two. A greater degree of tooth displacement without absolute avulsion can usually be satisfactorily treated by slipping a metal band or a loop of wire about the tooth. The loose tooth is then fastened by a fine wire to the adjacent solid tooth. It is even possible but not always wise to reimplant teeth completely avulsed if it is done immediately.

FRACTURE OF THE TEETH

Decay may weaken the crown of a tooth sufficiently for a considerable piece of the enamel to be rather easily broken off. Even a perfectly normal tooth is sometimes broken off by what seems to be a comparatively slight blow if the contact is with a hard object. The only evidence of spontaneous repair in a tooth by natural process is the tendency to secondary dentine deposition when slight irritation is prolonged for some time. Overwhelming irritation simply causes death of the dental pulp. Dentine production then abruptly stops.

The diagnosis of fracture of the root of a tooth may be made with the aid of a dental film.

Treatment.—The artificial substitutes commonly used for filling the cavities in carious teeth may also be used to repair a tooth with a part of its crown broken off. When a root is fractured and the remainder of the tooth remains fairly solid and no particular symptoms follow one might consider it a justifiable procedure to keep the patient under observation and not extract the tooth immediately, for there is a slight tendency for a type of callous union if the pulp does not die. Such a tooth should be checked occasionally by *x*-ray, as eventually the probabilities are in favor of signs arising which would indicate extraction.

IMPLANTATION OF TEETH

Isolated instances often have been reported of good service being rendered by a tooth after reimplantation. However, the knowledge of local cellular reaction to foreign bodies, the likelihood of chronic inflammatory processes about the roots of damaged teeth and finally the relationship of these local cellular reactions to general systemic damage has taken most of the enthusiasm out of the advocates of the procedure.

The implantation of a normal tooth into a new socket as advocated by Younger of San Francisco in 1889 is passé. Younger drilled a socket for the reception of the root. Greenfield advocated the same method except the tooth was artificial. The root was made of platinum upon which was mounted a porcelain crown. No lasting successes were achieved. Only one without a fundamental knowledge of cellular pathology would expect a lasting result from such a procedure.

Transplantation of a tooth from one socket to another is possible but is practically never practiced nowadays. The only possible indication would be where a healthy tooth has been lost through accident. The reasons for throwing a good tooth after one already lost would hardly be evident.

An exceptional case might arise where reimplantation would be advisable, such as when a normal tooth is dislodged by traumatism or accidentally removed during an extraction. However, the patient should be kept under observation from time to time. In such cases reimplantation is all too often done more to save the operator's face than for any benefit that might be derived by the patient from the procedure. Certainly when the tooth is the seat of chronic periapical disease, the best practice would be not to attempt reimplantation.

Technic of Reimplantation.—The pulp chamber of the tooth is opened under aseptic precautions and the canal filled. The tooth is then placed

in an antiseptic solution. One per cent mercurochrome is supposed to fulfil this condition. A very small part of the apex of the tooth is removed to allow the tooth to be reinserted into the socket. The socket is gently swabbed out with some of the antiseptic solution. The tooth is inserted into the socket and some type of splint is applied to hold the tooth firmly in position for several weeks.

FRACTURE OF THE ALVEOLAR PROCESS

When fracture of the alveolar process is not associated with fracture of the body of the jaw bone, it is usually due to displacement of a tooth or occurs during the extraction of a tooth. In all probability the alveolus is splintered rather often when a tooth is loosened or extracted. But usually such a happening is of small consequence and passes unnoticed. However, when quite a large section of the alveolar process in which one or several teeth are imbedded is detached from the body of the jaw, some special attention is demanded. The alveolus of the upper jaw is more frequently fractured in this manner than that of the lower jaw as the bone is of a softer nature.

The separation of large fragments of an alveolus is generally the result of some undue force of a similar nature to that which has already been described in the chapter "Injuries of the Bony Framework." At the same time some of the teeth in the fragment are likely to be dislodged. On the other hand, a large fragment of the alveolus may be broken off from the body of the bone and the teeth still remain imbedded in the process. When this latter condition is present, the roots of the teeth are very likely to be fractured, and at any rate if not fractured, the blood supply and nerve supply to the apex usually suffer permanent injury.

Diagnosis.—The diagnosis is simple. On examination the alveolus will be found to be movable according to the extent of the bone broken off from the body of its respective jaw. When teeth remain in the bony fragment, a dental film should be made to check the condition of the roots—to verify whether or not a fracture of the tooth root is present. Periodically, about every six months after union is firm, a dental film should be taken to note, in so far as a roentgenogram will indicate, what the subsequent effects of their dislodgment are going to be. By electric stimulation one can tell whether or not the tooth is devitalized. Eventually a devitalized tooth may require extraction.

Treatment.—As a rule, all attached fragments of the alveolar ridges should be replaced. The blood supply of the alveolar process is abundant—especially in the upper jaw—and union occurs quite readily. As commonly is the case with the larger fragments, the contained teeth can be used as a fulcrum of attachment to the adjacent solid teeth. A dental splint or a simpler encircling small wire may be utilized for this purpose. (See method of wiring teeth together under fractures of the jaws.)

When the teeth have been dislodged from the fragment simple replacement of the bone in its proper position is usually sufficient as the soft tissues tend to hold it in place.

Bibliography

Greenfield: Quoted by Blair, V. P.: Surgery and Diseases of the Mouth and Jaws, St. Louis, C. V. Mosby Co., 1917.

Younger: Quoted by Blair.

CHAPTER VIII

FRACTURE OF THE UPPER JAW AND THE NEIGHBORING BONES

MALGAIGNE in his "Treatise on Fractures," published in 1859, suggests that for clinical purposes the upper jaw comprises the majority of the bones of the cranium and the face except the skull bones. Cryer much later draws attention to the fact that surgically the maxillary bones include the malar, the palate, the inferior turbinates, the lachrymal, the nasal, the lateral masses of the ethmoid, and the nasal septum as any or all of these are likely to be involved in injuries characterized as fractures of the maxillary bones. For descriptive purposes, however, some separation is considered necessary. This is the plan followed in the following paragraphs.

FRACTURE OF THE UPPER JAW PROPER

Richard Wiseman is supposed to have described the first case of complete fracture of the superior maxilla in the literature (Malgaigne).

The most common type of fracture of the upper jaw is a fracture of a part of the alveolar ridge. Somewhat less commonly a part of the body of the bone is broken off along with a part of the alveolar ridge. In fact, all degrees of fracture are seen even to the transverse complete separation of all the upper facial bones from their attachment to the cranial base. Direct crushing violence is by all odds the most common means of fracture of the upper jaw but the bone has been fractured by a transmitted force from a blow on the lower jaw. Commonly the lines of fracture tend to radiate from the point of the applied force. The cheek is most often the focus of the impact and although the malar bone is seldom fractured, it may be driven backward and downward into the maxillary antrum causing the body of the maxilla to be comminuted. When severe force is applied from the front in an upward direction, the maxilla may be driven in toward the base of the cranium with comminution and impaction. In these severe crushing fractures there is not uncommonly an associated fracture of the base of the skull. Also a considerable laceration of the overlying soft parts is prone to occur.

The Displacement.—The displacement is due to the original force, as muscle pull plays no part. Of pathologic but of little practical interest is the type of fracture caused by the firing of a pistol within the mouth with a view of suicide. The force then acts from within outward. No greater variety of comminution ever takes place than is usual after this injury.

Symptoms, Signs and Diagnosis.—Alveolar fractures are usually evident on inspection but careful palpation may be necessary to give an idea of the extent of the fracture. The line of the teeth is changed and abnormal mobility or crepitus is obtained. When there is a considerable swelling such a fracture as a depressed malar bone may be overlooked but if one palpates very carefully with thumbs and forefingers and com-

pares the bony contour of the opposite uninjured side of the face with the injured side, some change in the contour usually can be made out if there is any displacement present. Localized tenderness referred to a constant point is most suggestive. No difficulty will be experienced in diagnosing a transverse fracture below or through the orbits as lateral mobility is quite definite. Crepitus is usually present and often the upper face sags until the upper jaw is contacted by the lower jaw. Slight lateral deviation may be ascertained by drawing a line between a central point on the forehead and the chin. The roentgenogram may be of value (Fig. 25) but quite often more information is obtained by a careful inspection and digital palpation of the facial landmarks and the bony contours within the mouth than can be given by even the best of films.

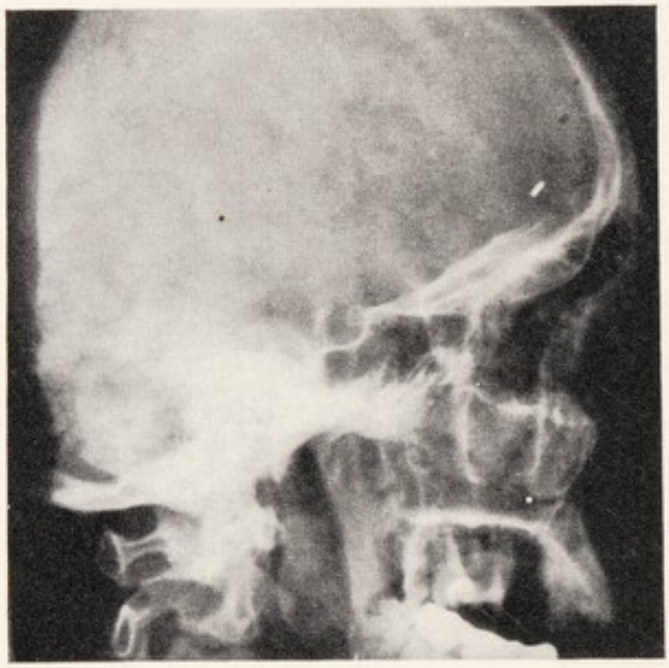

Fig. 25.—Complete fracture across the maxillary bones. Film shows line of complete separation through the midpart of the maxillary bones. This is somewhat lower than the usual fracture found when the maxillary bones are completely separated from the base of the skull. The alveolus was also separated in the midline anteroposteriorly. The case is the same as shown in Fig. 27.

Complications.—Among the less serious complications is the usual damage to the overlying soft tissues. Evidence of these vary from only slight ecchymosis and swelling up to large incised or lacerated wounds. (See chapter on Wounds of the Soft Tissues.) Because these fractures practically always open into the nasal accessory sinuses, the nose or the mouth, there is a possibility of a sinusitis or even an osteomyelitis developing. Fortunately, as the blood supply is quite plentiful, secondary infection of any severity is rare. The infra-orbital nerve or the superior dental nerve may be injured and cause pain, numbness or complete anesthesia. Because of the swollen or edematous nasal mucosa, free breathing may be difficult and in extreme cases, especially if the patient is unconscious, a breathing tube may have to be inserted into the patient's mouth to give him a free airway. A large rubber tube or a Connell breathing tube such as used by anesthetists will answer the purpose temporarily. As soon as the bone

is pulled into its proper position and some means—although it may be only a temporary fixation—used to hold it there the patient will be able to breathe through his mouth. When swallowing is difficult, tube feeding may be necessary. But ordinarily if the patient is not unconscious, swallowing of liquids is possible.

Outstanding among the more dangerous complications are cerebral concussion and fracture of the skull. When the unconsciousness from the concussion clears soon, usually no great harm is to be feared but if the coma fails to clear up and other signs of increasing intracranial pressure are present, the situation demands the knowledge of one trained in neurologic surgery (Chapter VII—see Concussion). When besides a fracture of the skull, the dura is opened there may be a leakage of cerebrospinal fluid from the nose or ear or a fatal purulent meningitis is likely to develop by the way of the torn dura.

The Treatment of Fracture of the Upper Jaw.—When the upper jaw is crushed or an impacted fracture results every attempt should be made to restore the fragments to their former position before any union takes place. Any change in the contour of the face is quite noticeable and the less the displacement the less the likelihood of interference with the aeration and drainage of the paranasal sinuses. By early replacement quite serious trouble later may be forestalled.

Malgaigne remarks: "In compound fractures of the upper jaw, there is one principle which the surgeon can not too carefully bear in mind, that is, that all splinters becoming slightly adherent should be scrupulously preserved as they become reunited with wonderful facility." Originally Saviard and Larrey later called attention to this fact.

When the anterior part of the bone is crushed the antrum of Highmore may be opened above the canine fossa and the wall of the cavity remolded with a steel urethral sound as originally urged by Hamilton. The malar bones, the zygomatic process, or the lower border of the orbit sometimes may be manipulated into a proper position with practically no disfigurement by inserting a strong steel hook through the tissues and hooking over the edges of the bones wherever it seems most advisable. A corkscrew-like instrument may aid one. But when the crushed bone cannot be replaced by one of the preceding methods one may be forced to separate the impaction with a narrow chisel. Once replaced the deformity shows little tendency to recur in most instances but sometimes wire sutures placed at various angles may be valuable.

When the alveolar process on one side of the maxilla is fractured and the teeth and the bone of the opposite side are sound (Fig. 26), the teeth of the lower jaw and the teeth of the upper on the sound side may be wired together and thereby the lower jaw is made into a splint to hold the loose fragments of the upper jaw in place.

For transverse fractures of the maxillary bones with downward displacement, eventually the proper replacement must be obtained by some sort of constant pressure exerted in an upward direction. A bandage is useful temporarily as a partial support. Usually the patient's nasal fossae are obstructed by the swelling of the nasal mucosa and blood clots. Consequently breathing through the mouth is hindered by bandaging the lower jaw snugly up against the upper jaw. In our cases of this type, it

has been possible after waiting for about a week or ten days for the swelling of the nasal mucosa to subside to use the lower jaw as a splint and

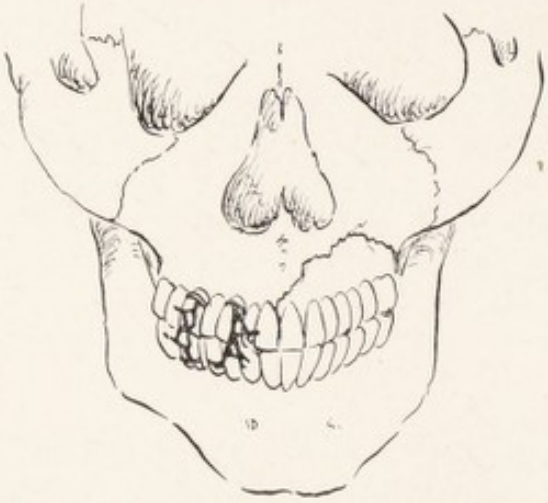

Fig. 26.—Method of supporting one side of the maxilla after a fracture through the body of the bone. In most instances one would also wire the bicuspid tooth of the fractured fragment to the corresponding bicuspid of the mandible so as to steady the fragment. However, the wire is left out so as to emphasize the essential point of the procedure.

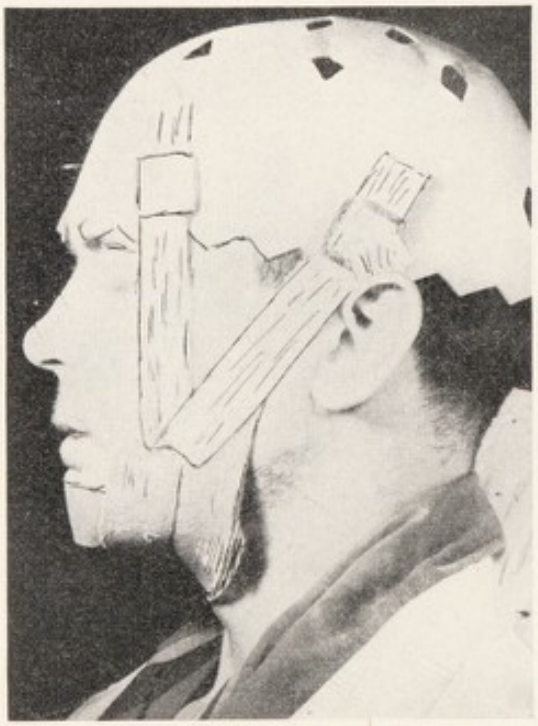

Fig. 27.—In complete separation of the upper jaw from the skull usually we have not used any of the splints described. If there is difficulty in breathing and the soft tissues do not hold the upper jaw up enough a large tube is inserted between the palate and the tongue. After about ten days when the swelling of the soft tissues has subsided and there is an air passage through the nasal fossa, the teeth of the upper jaw are wired to the teeth of the lower jaw and by using a head cap as shown in the photograph the upper jaw is pulled into the proper position for that of the closed jaw. In this manner the lower jaw is used for a splint for the upper. The method is simple and satisfactory when enough teeth are present.

bandage it upward. In the interval the nasal fossae should be irrigated with salt and soda solution to which has been added a mild vasoconstrictor

drug such as ephedrine or adrenalin. The irrigation is given every four hours with the idea of rinsing out blood clots and accumulating secretions so a free airway through each nostril is encouraged. After this is obtained the teeth of the upper jaw are wired to the teeth of the lower jaw. A snug Barton bandage with crinoline on the outside gives sufficient support to the lower jaw to hold it in its normal position and thereby good position of the upper jaw is maintained. After another week the head and jaw support shown in Fig. 27 is applied and worn for four weeks from the time of the injury. After this time has elapsed union of the upper jaw will be fairly firm and its position is maintained without further support. We have successfully handled our last four cases in which this type of fracture was present and consider this the most simple and usually the most satisfactory way of handling the injury. Good occlusion of the upper teeth with the lower teeth is obtained.

Splints for Fractures of the Upper Jaw.—When the jaw or the fragments cannot be supported sufficiently by the method just described, a splint fixing the upper jaw in the proper position may be necessary. Graefe first recognized this and constructed a splint, the principles of which are fundamental. Several modifications have been brought forward from time to time under the names of such men as Goffres in 1862, Marshall in 1888, Ombrédanne and others more recently.

Graefe Splint.—The original Graefe splint as described by Malgaigne is as follows: "A curved steel spring properly padded is applied over the forehead and kept in place by a strap buckled around the occiput. This spring has at each side a hole, with a screw for making pressure, and a steel brace, to which it affords a point d'appui for acting steadily on the dental arch. Now these braces, descending to the level of the free edge of the upper lip curve backward so as to go around the lip without wounding it, getting thus at the dental arch, they again curve so as to apply themselves to it. But as the pressure of the braces should have the effect of keeping the detached teeth in proper relation with the rest, a silver trough duly padded is made to fit over both of a sufficient length and upon this trough the braces exert their pressure. It is easy to see how, by altering their length as regards the spring over the forehead, the pressure may be regulated to the right degree."

Marshall Splint.—Marshall in 1888 described a modification of Kingsley's—a reversed Kingsley splint—dental splint which gave excellent results (Fig. 28). A Kingsley splint is applied to the maxillary teeth and a head bandage supports the splints and upward pressure upon the upper teeth. "Impressions of the upper and lower teeth were taken with the modeling compound by first molding it upon the upper teeth and while it was yet soft forcing the lower teeth upward until occlusion of the teeth was obtained. This impression was trimmed to the desired shape; a ⅛-inch steel wire was imbedded in the sides on a line with the ends of the teeth, then backward upon itself opposite the cuspid teeth, and allowed to extend outside the cheek nearly to the border of the ear. From this was constructed a hard-rubber splint, with the wires attached. This splint can be made from silver swaged over metal dies, but if a metal plate is desired, the most perfect adaption can be secured by the electro-deposit plate, the wires being attached with solder. The splint is held in position by means of double

elastic straps attached to the wire on each side and buckled to a close fitting leather or net cap, which is reinforced with leather and laced firmly on the head. This proved to be a very successful appliance, as it held the

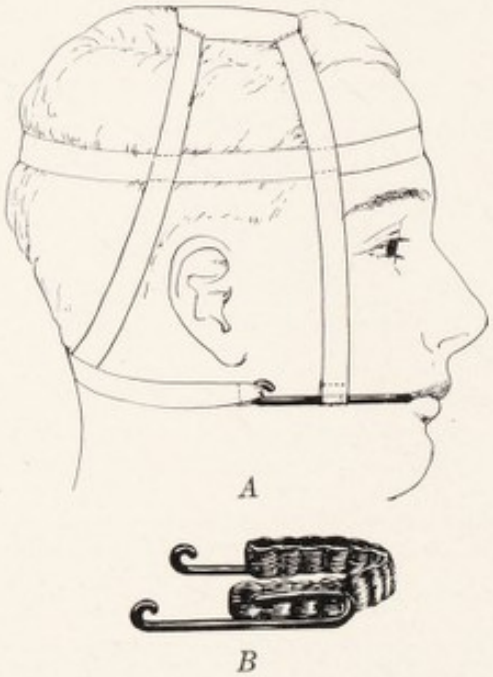

Fig. 28.—*A*, Method of using the reversed Kingsley splint. The arms protrude from the corners of the mouth and the splint is cemented to the teeth. The upper jaw is held in position by a head-gear somewhat similar to that shown in the diagram. *B*, Kingsley splint.

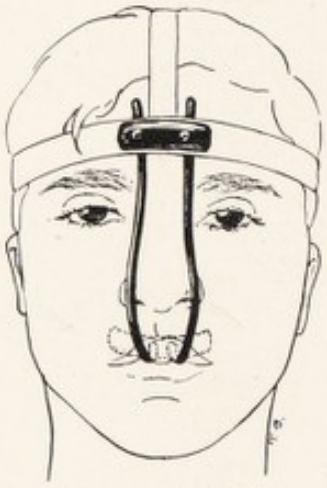

Fig. 29.—Splint which was used by Ombrédanne. This splint holds the fractured upper jaw in a rather definite relationship to the skull. Ivy used this same principle. He used an iron bar which was curved around the teeth and was wired to them. The arms were wired to the bar. Attached to the iron bar shown here is a swaged metal splint. A dental tray may also be used in a similar fashion. If one wishes to get the head piece more firm, a head cast may be placed around the head and is really quite effective. In this head cast may be placed a wire so that straps or rubber bands may be attached in the position in which it is desired to hold the upper jaw.

fractured bones in their proper position and permitted comfortable breathing and free movement of the lower jaw, which enabled him to talk and, after a few days, to masticate soft food. Deep indentations were made in the under side of the splint, in which the lower teeth fitted accurately when

the mouth was closed. The object of this was to furnish a sure guide to the normal position of the superior maxillae. Without this the correctness of the adjustment of the bones could not have been verified. Its importance therefore cannot be overestimated."

A

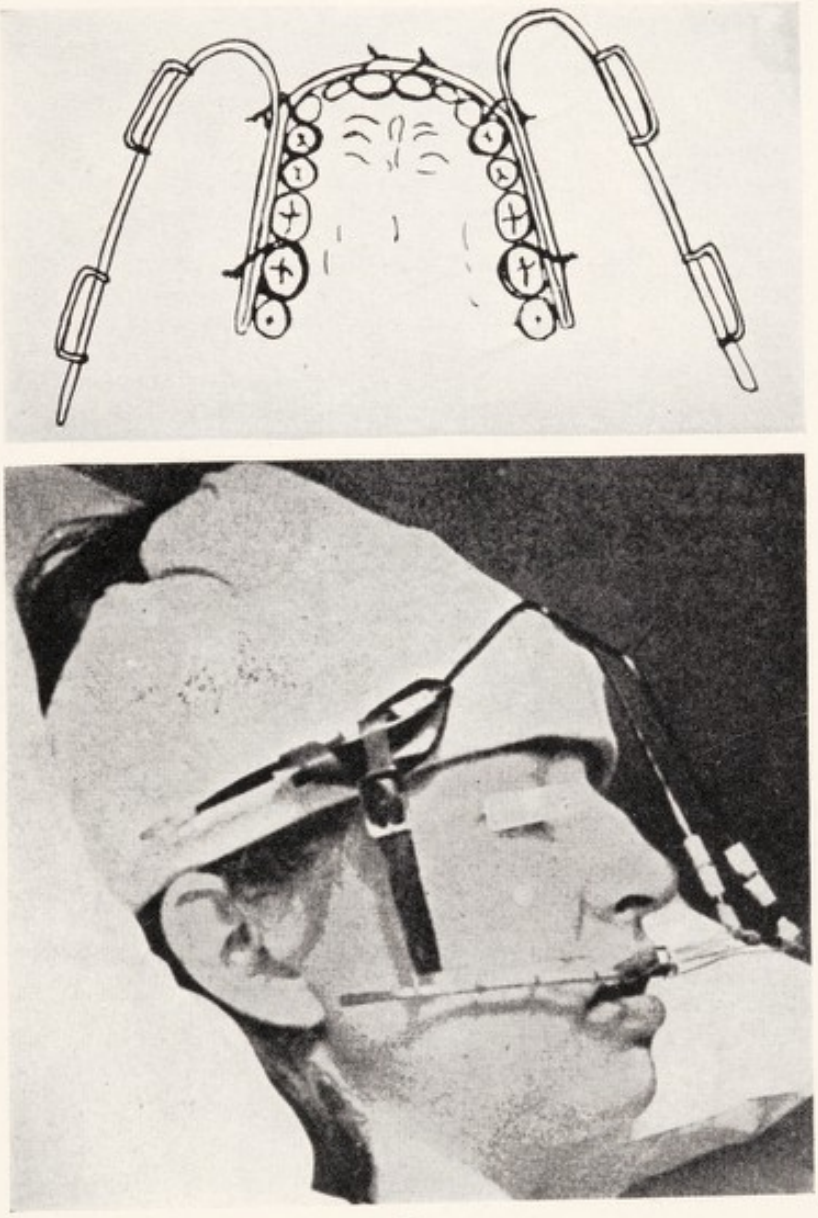

B

Fig. 30.—*A*, Heavy arch bar secured to teeth with wire ligature for treatment of fracture of the upper jaw, in connection with plaster head cap. *B*, Apparatus applied to bring about upward traction posteriorly and at the same time to draw the maxilla forward. (Blair and Ivy, Essentials of Oral Surgery, C. V. Mosby Co., Publishers.)

When the fragments of the upper jaw are not in alignment a positive reconstruction of the impression may be made which may be cut at the points of the malalignment. The parts of the positive impression are then realigned using a lower dental arch positive impression as a guide for occlusion. The splint is then made over the restored arch. If the patient should be edentulous and have an uninjured upper plate, it may be converted into a Marshall splint by attaching arms to its side.

The Marshall splint is not applicable to those cases with considerable loss or comminution of bone between the palate and the base of the skull for the upward pressure exerted by the pull of the head bands will tend to displace the body of the maxillae upward and overcorrect it, so to speak.

Ombrédanne Splint.—The principle of the Graefe splint as modified by Ombrédanne (Fig. 29) may be used in these cases with satisfaction. A metal cast is cemented to the upper teeth and attached to a fixed head cap by metal rods. The dental arch is thus held in its proper relationship to the lower jaw and at the proper distance from the skull.

Ivy and others have used a plaster cast about the head to which to attach arms of the metal cast which has been attached to the teeth. A plaster head cast offers a very firm basis of anchorage. Various methods of attachment may be used as indicated (Fig. 30).

Temporary Splints.—During the late war often the necessity arose for a temporary splint in the destructive fractures encountered. The two splints suggested below were found to be of use.

Pickerill Splint.—The Pickerill splint (Fig. 49, Chapter X) may be reversed and attached to a head cap. This is a good splint to carry in an emergency kit as its applicability is fairly wide. It can be used either on the upper or the lower jaw.

Gunning Splint.—The metal Gunning splint (Fig. 48, Chapter X) may also be useful. A bandage of the modified Barton type (Fig. 45, Chapter X) is necessary to hold the lower jaw against the upper jaw.

FRACTURES OF THE OSSA NASI

Malgaigne states that Hippocrates spoke of fractures of the nose and made the distinction between fragments being directly driven in or pushed to one side. Hippocrates and Celsus afterward (Malgaigne) used forms within the nose to hold the fragments in place. Finally Malgaigne says "I have dealt thus carefully on the therapeutics of the ancients because moderns have merely followed after them, not even meeting the indications so completely."

Direct violence from the side or the front is almost without exception the cause of fracture of the nose. The prominent and relatively exposed nasal bones are fractured more frequently than the other bones of the face, but as Hamilton emphasized nearly one half are not seen by a surgeon at the proper time to afford relief. The nature of the accident is rather frequently overlooked by the patient and sometimes by the physician. Such mistakes are explained principally by the rapidity with which swelling ensues after severe blows on the nose. Moreover, the extreme sensitiveness of an injured nose makes the examination an unpleasant episode. Children are especially difficult to examine. However, as the prominence of the nose renders a slight deformity quite evident and buckling of a snapped nasal septum may obstruct free breathing, the physician who fails to make the correct diagnosis may lay himself open for no small amount of criticism.

Fractures of the nasal bones may be classified as (1) circumferential fractures, and (2) crushing fractures.

Usually precipitated by a lateral force, circumferential fractures of the nasal bones are separated from their maxillary bone attachments at the basis of the V-shaped arch formed by the ossa nasi. As the bone is snapped

sidewise the frontal attachment is loosened and the nose takes a position toward or even beneath the opposite eye. On the other hand, in crushing fractures the force comes from the front and the nose is more or less squashed (Fig. 31). A moderate force is most likely to crush inward transversely only the lower thin edge of the nasal bones about their middle. At the same time the nasal processes of the superior maxillae may be cracked. Hamilton states that it requires as much force to fracture the upper third of the nasal bones as the os frontalis. All fractures with much crushing are accompanied by some displacement or an actual fracture of the nasal septum. The most frequent displacement of the septum is at the line of the articulation of the cartilaginous septum with the bones of the nose. Next in frequency, is the displacement produced by a fracture of the perpendicular nasal plate where it approaches the vomer. Crushing of the



Fig. 31.—Fracture of nasal bones. The fracture extends upward into the anterior ethmoidal region.

bridge of the nose necessarily causes some bowing of the septum if not an actual overlapping which tends to result in obstruction—more or less complete—of the airway through the nose. It is not uncommon to see a lateral obliquity of the external nose which dates from a septal fracture. Occasionally the nasal bones are neither broken at their lower edges nor through their central diameter but only at their lateral edges or bases. The deformity which results is a depression of the nasal bones on the maxillae. This really constitutes a dislocation. It happens oftener in childhood. Following this type of fracture the lachrymal canals are likely to be obstructed.

As the mucous membrane within the nose is usually torn, practically all nasal bone fractures are of the compound type. A clinical infection, however, usually fails to develop but occasionally if the patient blows his nose, the rent in the mucous membrane allows the development of a sub-

cutaneous emphysema with its characteristic crackling sensation on palpation, in the tissues about the nose, eyes and lower forehead.

If in an individual who has received a blow on the nose causing an epistaxis one notes through the swollen ecchymotic tissue, on palpation some displacement or change of bony contour at the line of maximum tenderness, a diagnosis of fracture is warranted. If greater displacement, abnormal mobility or crepitus is felt, the diagnosis is definite. After rinsing out the internal nose with some vasoconstrictor preparation—adrenalin or ephedrine—one may examine the internal nose and note septal displacements, the evidence of a torn mucosa or of a submucosal hemorrhage.

Treatment.—The best method of immediate treatment was known as early as the day of Hippocrates who insisted upon reduction from within and without (Fig. 32). Later Hamilton placed a blunt silver female catheter within the nose and the nasal bones were lifted from within while with the opposite hand the fragments were coapted from without. After this pro-

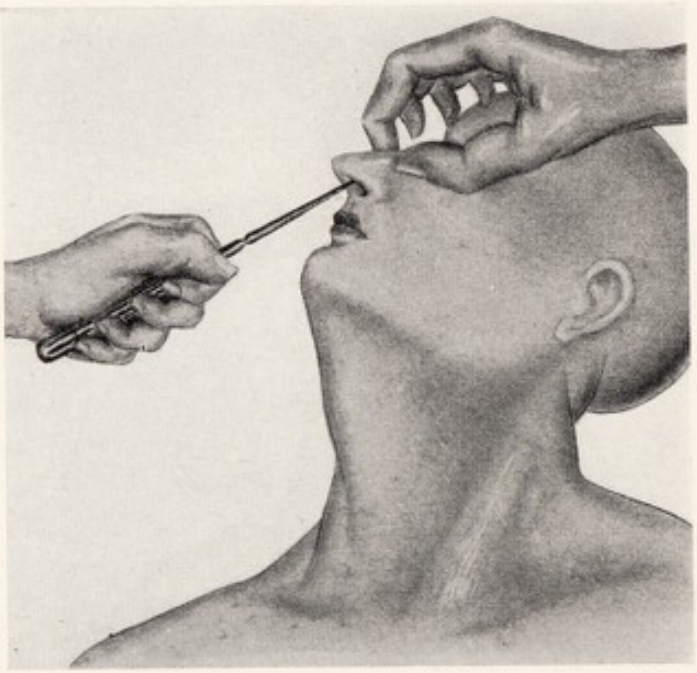

Fig. 32.—Method of replacement of fractured nasal bones.

cedure quills covered with some soft substance were used to pack the nose firmly from within. Celsus, Lafranc, Paré and Boyer used various sorts of intramucosal packs after reduction. B. Bell and Boyer placed a silver cannula along the floor of the nose for the patient to breathe through. Hamilton points out that the fragments are generally loose and easily pressed into place by the use of proper instruments. A blunt straight silver sound which is narrow enough to get well up above the nasal process of the superior maxilla is an ideal instrument. Here it is well to remember Hamilton's caution that the diameter of the meatus at the point where the instrument must touch in order to make effective pressure upon the ossa nasi is on an average of not more than two lines. After molding the contour of the nose one should rinse out the nose with a vasoconstrictor solution, ephedrine or adrenalin, and observe the septum to see if it is in the proper position. Then, the nose in its upper and forward part is packed firmly with vaselin gauze. A small rubber tube may be laid along the

nasal floor so that the patient can breathe somewhat more freely. After three days the gauze is removed, the nose irrigated, and cocainized and the vaselin pack is reinstated for two more days. Usually by this time enough cellular infiltration of the tissue about the bones has occurred so that the bones remain in their proper place. Molds which cover the nose usually defeat their purpose by pressing in the wrong direction.

Mason of Brooklyn in 1880 suggested transfixing the nose at the base of the fragments. Such a procedure is not ordinarily necessary but one need not hesitate if the necessity arises. For this purpose through and through double horse-hair sutures over tin-foil plates can be recommended.

Many writers such as Boyer and Malgaigne and even Hippocrates commented upon the rapidity of union of the nasal bones—about two weeks. The bones are membranous in origin and no provisional callus is necessary for union. The ultimate prognosis depends upon the character of the treatment. When prompt and efficient treatment is instituted, a good functional and cosmetic result should be obtained in practically all cases. Poorly treated individuals are prone to have intranasal obstruction and deformity of the external nose depending upon the position of abnormality in which the nasal bones were allowed to unite.



Fig. 33.—Method of chiseling the nasal bones free from the frontal and maxillary bones so they may be replaced in the proper position. Besides using this procedure when a nose has assumed an improper position after fracture we not uncommonly use it to repair nasal bones when they assume a lateral deformity which is characteristic of harelip in adolescents and in adults. In this latter condition usually the lower end of the septum and the nasal spine has to be removed so the columella can assume a central position without distortion.

Refracture of the Nose.—When a fracture of the nose is neglected or mistreated, the malunited bones may cause a lateral deviation which is best treated by refracture. This is done by nicking the mucous membrane of the lateral wall of the meatus just in front of the attachment of the bases of the nasal bones to the maxillary bones. A small chisel is inserted and made to separate one nasal bone from its maxillary attachment (Fig. 33). The separation is then made on the opposite side in a like manner. Then through a very small incision in the skin just slightly above and between the eyes, the frontal attachment of the nasal bones is cut with the chisel.

After this procedure the bones are pushed sidewise to a midline position. There usually remains a tendency for the bones to assume their former position unless means are taken to prevent a recurrence of the deformity.



Fig. 34.—After refracture of the nasal bones the nose may tend to assume its former position. If it does a head cast may be applied and a heavy wire placed about it as depicted in the photograph. The nose may be pushed over in a position of over correction by this method. At least it can be held in the proper position until healing is firm enough to make the position permanent.



Fig. 35.—Method of holding the nose in proper position by using a wire attached to a swaged metal form cemented to the front teeth. This method is somewhat more expensive than the head cast but may be just as effective and is somewhat more comfortable. But generally we prefer the head cast.

Fixation.—One of three methods can be used to prevent this tendency to deviation. In the first, a cast of plaster well padded with stockinet and felt in which is incorporated a loop of moderately heavy wire (Fig. 34).

This wire is bent to the proper form parallel along the side of the nose to which the deviation tends. Beneath this double wire are placed felt pads of sufficient thickness to very slightly overcorrect the deformity. In the second, a dental splint may be cast and attached to the front teeth (Fig. 35). A wire is attached to the splint and turned upward to fit into one nasal meatus, or it may also be placed externally along the side of the nose. One is apt to cause some pressure necrosis of the mucosa of the meatus if the former method is used. At least pressure necrosis should be watched for and the wires removed if such become evident. There is a third method which is fairly simple and when it holds the bones in their proper position may be useful. Both ends of a fine silver wire are passed through a small incision in the skin at the lower edge of the nasal bone through separate holes in the nasal bones. The wires are continued through the septum and out through the opposite lateral wall of the meatus beneath the opposite cheek and brought down and tied around the cuspid tooth.

LACHRYMAL BONES

Fracture of the lachrymal bones occurs in conjunction with nasal and maxillary bone fractures. The treatment is not an isolated procedure.

MALAR BONE

All authorities are agreed that fracture of the malar bone without a complicating fracture of the surrounding bones occurs extremely rarely,



Fig. 36.—When the malar bone is depressed or displaced Roberts suggested using a screw porte through a very small incision to elevate the depressed malar bone. This along with the use of a narrow chisel to loosen the line of fracture may enable one to elevate the depressed malar bone.

and therefore a fracture of the malar bone implies that other fractures exist as a complication. However, a few authentic cases of isolated fracture of the bone have come to autopsy and are listed in the literature. Hamilton saw two cases of fracture of the orbital margin. Usually what is called a

fracture is really a subluxation, *i. e.*, the malar bone is simply driven in. Great force is required to produce this fracture or subluxation. Horse kicks in bygone days produced a few as do automobile accidents nowadays.

The pathognomonic sign of fracture or subluxation is the depression of the bone but the swelling may render the diagnosis impossible. Compres-



Fig. 37.—Elevating depressed malar bone (Gillies). Incision is made through skin and temporal fascia. A thin elevator is passed downward on top of the temporal muscle until it lies deep to the displaced bone. A pad is placed on the shoulder and the handle of the lever is pressed downward. The lines of fracture may have to be separated with a chisel in old or neglected cases.

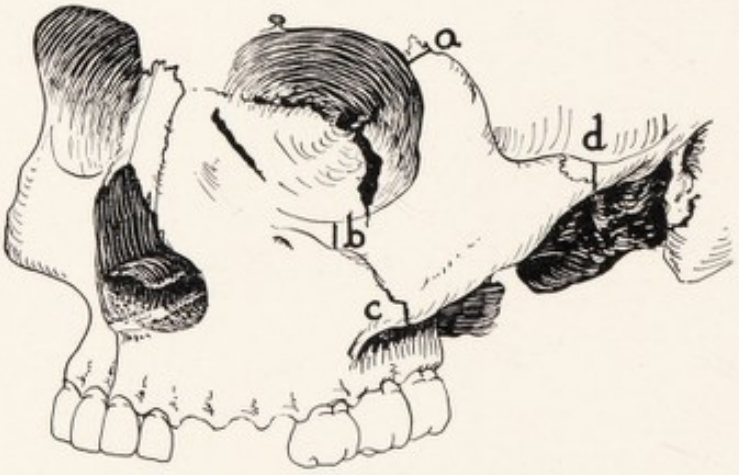

Fig. 38.—Common lines of fracture when the malar bone is depressed. *a*, Frontal process; *b*, orbital process; *c*, maxillomalar articulation; *d*, zygomatic process.

sion of the infra-orbital nerve has been observed which resulted in an anesthesia of the upper lip and a triangular area of anesthesia below the eye or the face with the apex at the infra-orbital foramen. The orbit of the eye may have its capacity changed and an enophthalmos may remain or on the other hand, the opposite may occur. Then a permanent enophthalmos results on account of an enlargement of the orbital cavity which allows the

eyeball to recede somewhat. At first, protrusion of the eyeball is produced by extravasated blood in the orbit. This, of course, gradually disappears. However, unless the contour of the orbital box is changed considerably no permanent change in the position of the eyeball remains.

Treatment.—Hamilton states that restoration is impossible because of the antagonism of the serrated margins of the intramaxillary sutures. But this is not the case at the present time. The application of the screw porte (Fig. 36) through a small skin incision may aid one in replacing the depressed malar bone. If this method or one of the methods described under fracture of the upper jaw does not suffice, it is possible to get a prying force by making a small incision in the temporal region (Fig. 37) and inserting a strong chisel through the temporal muscle in behind the zygoma and the body of the malar bone. Quite a considerable outward force may be exerted in this manner. This method, plus the use of a small short chisel if need be, in the fracture line should allow one to get replacement.

ZYGOMATIC ARCH

Fracture of the zygomatic arch is rare. Duverney (Malgaigne) was the first to speak of fracture of the zygomatic arch which was caused by a direct blow and M. Ferrier (Malgaigne) was the first to elevate a depressed fracture of the zygoma. Commonly, direct violence produced the fracture although depression of the malar bone or the forcing of foreign bodies through the mouth—indirect violence—has caused the injury. The smallest part of the process near the temporal end is the common site of the dissolution. The masseter muscle which attaches to the bone is thrown into spasm so that those suffering the injury complain of difficulty in chewing. It is usually possible to palpate the change of contour of the bone if the swelling is not too pronounced.

Treatment.—The procedure described to elevate a malar bone fracture modified to suit the case will reduce this fracture also.

HYOID BONE

During throttling there occasionally occurs a fracture of the hyoid bone from indirect pressure. The main symptoms are pain on opening and closing the mouth and moving the tongue. Swallowing is painful and there may be sufficient edema of the vocal cords to muffle the voice. A certain amount of ecchymosis and swelling of the tissues about the hyoid bone usually appear and if the mucosa is broken on the inside there may be some spitting of blood tinged sputum. Abnormal mobility and slight gritty sensation hardly sufficient to be called true crepitus establish the diagnosis. The treatment is expectant and symptomatic.

LARYNGEAL CARTILAGES

Rarely one sees a fractured voice box following throttling or a blow. Old brittle cartilages are more likely to be snapped. The thyroid cartilage is practically always the cartilage broken. The pain may be considerable and it is increased by talking and swallowing. If the swelling and edema become quite marked, the dyspnea may increase to actually dangerous proportions. Bloody sputum occurs if the mucosa behind the cartilage is

much lacerated, as may also an emphysema of the soft tissues of the neck. The diagnosis is suspected from the history and by finding abnormal mobility on palpation. A gritty sensation not so marked as in fracture of a bone is often perceptible when the cartilages are moved. The treatment is expectant and symptomatic.

Bibliography

Bibliography Quoted in Text

Bell, B., and Gunning: Quoted by Hamilton, F. H.: Practical Treatise on Fractures and Dislocations, Phila., Lea Bros. and Co., 1891.

Boyer: Lectures on Diseases of the Bones, Phila., 1805.

Cryer, M. H.: Studies of the Internal Anatomy of the Face, Phila., The S. S. White Dental Mfg. Co., 1901; University Medical Magazine, Penna., June, 1900.

Goffres: Bull. de l'Acad. de méd., **27:** 1157, 1862, from Poinset.

Graefe: Quoted by Malgaigne, J. F.: A Treatise on Fractures, Phila., J. B. Lippincott Co., 1859; also Richter's Atlas, Table IV.

Hamilton, F. H.: A Practical Treatise on Fractures and Dislocations, 1891, Phila., Lea Bros. and Co., pp. 96, 98, 102, 103, and 108.

Larrey: La Denta, A. et Delbet, P., Nouveau Traité de Chirurgie.

Malgaigne, J. F.: A Treatise on Fractures, Phila., J. B. Lippincott Co., 1859, pp. 297, 304.

Marshall: Injuries and Surgical Diseases of the Face, Mouth and Jaws, Phila., S. S. White Dental Mfg. Co., 3rd ed., 1909.

Mason: Transfixing the Nose, Annals of Anatomical and Surgical Society of Brooklyn, March, 1880.

Ombrédanne, L.: Maladies des Machoires.

Paré and Pickerill: Quoted by Blair, V. P.: Surgery and Diseases of the Face, Mouth and Jaws, St. Louis, C. V. Mosby Co., 1912.

Roberts, S. E.: Fracture of Malar Zygomatic Arch: Review of Literature, Simplified Operative Technic: Case Reports, Ann. Otol., Rhinol. and Laryngol., **37:** 826–838, Sept., 1928.

The following are quoted by Malgaigne in A Treatise on Fractures, Phila., J. B. Lippincott Co., 1859: Celsus, Duverney, Ferrier, Hippocrates, Lafranc, Paré, Saviard and Wiseman, Richard.

Supplementary Bibliography

Gillies, H. D., Kilmer, T. P., and Stone, D.: Fractures of Malar-Zygomatic Compound with Description of New X-ray Position, Brit. Jour. Surg., **14:** 651–656, 1927.

Huet, P. C.: Fractures of the Nose: Early Treatment, J. de chir., **31:** 649–658, May, 1928.

Ivy, R. H., and Curtis, L.: Fractures of the Upper Jaw and Malar Bone, Ann. Surg., **94:** 346, Sept., 1931.

Kazanjian, V. H.: Treatment of Injuries of the Upper Part of the Face., J.A.D.A., **14:** 1607, Sept., 1927.

Pont, M.: Emergency Treatment of Maxillary Fracture, Lyon Chir., **21:** 490, 1929.

CHAPTER IX

FRACTURES OF THE LOWER JAW

The lower jaw tends to act as a guard for the remainder of the face, and most any direct violence of sufficient force may cause a fracture. But incredible as it may seem, Gross is authority for the statement that muscular action has been known to cause a mandibular fracture during a paroxysm of coughing. The reception of a fist blow or a fall upon the chin is quite often the history given. Times change so that the once common fracture from a horse kick is being supplanted by the "automobile accident" fracture.

The large majority of jaw fractures still occur in the male sex but accident by automobile is changing the percentage gradually so that a constantly higher percentage of women are seen with their jaws fractured.

Type and Site.—The mandible is a hard brittle bone which fractures ordinarily in a fairly straight line with very little tendency to comminution. A greenstick fracture of the mandible is a surgical curiosity. Practically all fractures of the mandible anterior to the region of the third molar will be found to be of the compound type. Even in the edentulous jaw the gum is so firmly attached to the alveolar processes of the mandible that any displacement of the underlying bone breaks the overlying mucosal tissue. When the fracture line falls between two teeth as it usually does, there is necessarily some separation and an avenue is opened for the secretions of the mouth to seep in between the ends of the fractured bone.

Hamilton had thirty examples of fracture through the body not including fractures of the symphysis in which the line of fracture in 20 cases was at or very near the mental foramen, three times between the first and second incisors, four times behind the last molar and three times between the last two molars. In the series of 100 cases of Ivy and Curtis, 68 were single fractures. Of these 30 were at the angle and 21 at the mental foramen. Thirty-one were double fractures; and of these, 24 were fractured at the mental foramen on one side and at the angle on the opposite side. In the whole series the condyle was broken seven times. No ramus or coronoid fractures were present. One case had a fracture through both mental foramen and the symphysis and was broken seven times in all. Dean in 50 cases of mandibular fracture had 62 per cent single, 32 per cent double, and 6 per cent triple. In his 31 single fractures the location was at the angle in 18, symphysis 5, mental foramen 4, molar region 3 and condyle 1. The symphysis was fractured seven times in the 50 cases. Reiter and Ruggles show about the same relative sites. Although the statement is made in most books and by the older writers that the most common site of fracture is at the mental foramen, we conclude that in reality fracture of the angle is the most common location. The older writers such as Boyer originally stated that fracture never occurred at the symphysis. However, Smith, Lonsdale, and Gibson had authentic cases and they made the statement that it was more liable to occur in childhood. In the two recent series

of fracture published by Ivy and Curtis and Dean there were 15 fractures of the symphysis in 150 cases.

Our series of fractures of the lower jaw shows the following: 26 were single, 12 were double, 4 had loss of substance due to a gunshot wound. Of the single fractures 7 occurred at the angle, 7 in the canine region, 7 in the body, and 1 alveolar ridge was fractured, and 4 had a fracture of the neck of the condyle. Of the double fractures the angle on one side and the body on the opposite side were fractured four times, both condylar necks were fractured once, the condylar neck and the opposite body once, the ramus and opposite canine region once, and the body on both sides five times.

About one third of lower jaw fractures seen in civilian life are broken in more than one place. In Dean's series 32 per cent were double and 6 per cent triple. In Ivy's and Curtis's series 31 per cent were double and 1 per cent triple.

Two reasons probably account for the relative frequency of the mental foramen as a site of fracture. The bone is weakened here by the mental foramen itself and by the large canine tooth socket.

The coronoid process is so well protected by bony projections that it is rarely broken. In the old literature Houzelot's case is quoted. It had a fracture at both condyles and one through each coronoid process and a symphysis fracture.

Displacement.—A study of the directions of muscle pull immediately makes it obvious to one that a fracture of the mandible will disturb the normal muscular balance and certain groups of muscles will act unopposed. The transverse axis of motion in the ordinary movement of opening and closing the mouth falls at a point near the entrance of the inferior dental nerve into the mandibular bone on the inner side of the bone which is also at about the level of the occlusal plane.

When the periosteum and mucous membrane covering the bone are not torn to any great extent there may be little or no displacement. Also in certain fractures which are bevelled in such a fashion that muscle pull is counteracted, there may be practically no displacement. Often fractures near the symphysis show little tendency to displacement because the muscle pull is the same on either side of the bone.

In the beginning the displacement is produced by the original violence but the final forecast of the displacement depends on the attachment and direction of pull of the four muscles of mastication and four muscles of the floor of mouth if counteracting bevelling does not hinder.

The masseter, the temporal, and internal pterygoid muscles close the mouth (Fig. 39, *A*). The internal pterygoid muscle passes upward, forward and inward from the inside of the ramus of the mandible. The masseter passes upward, slightly forward, and outward from the outer surface of the ramus of the mandible to its zygomatic attachment. The two preceding muscles have relatively the same upward and forward pull. However, the inward pull of the internal pterygoid is more angular than the outward pull of the masseter but as the masseter is the stronger muscle of the two, the latter muscle more than counteracts the former. Thus, in fractures at the angle of the mandible unless bevelling of the bone counteracts the pull of the masseter outward, the posterior fragment shows a tendency to lie outside of the anterior fragment. Fractures of the ramus

itself as a rule show little or no displacement for two reasons. First, because of the width of the internal and external attachments of the internal pterygoid and the masseter muscles and second, because the two muscles counteract each other fairly well in this area.

The temporal muscle inserts into the coronoid process and has a fanlike attachment over the temporal fossae of the skull. Its pull is essentially upward and is fairly strong. The displacement in fractures of the angle of the posterior fragment is upward and forward unless prevented by serration of the line of fracture or the presence of occluding teeth in the posterior

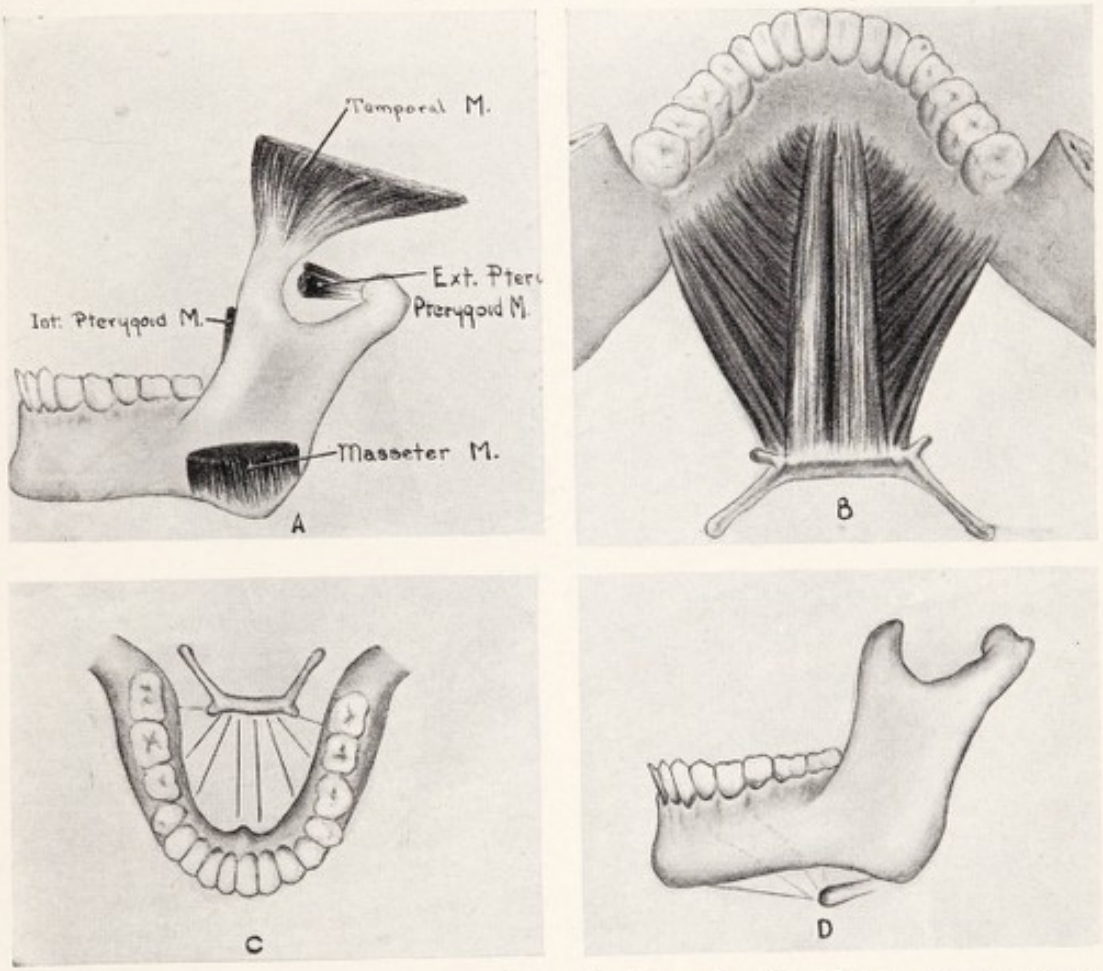

Fig. 39.—A, Insertion of muscles of mastication. B, Muscles of the floor of the mouth which bridge the space between the concavity of the mandible and the convexity of the hyoid. C and D, Showing the two components of pull of the muscles of the floor of the mouth.

fragment. Thus, two muscles, the temporal and masseter, cause the characteristic displacement of the short fragment outward, forward and upward. In fracture of the coronoid process the short fragment is pulled upward and backward so that the separation of the two fragments is quite evident.

The external pterygoid muscle is inserted into the front of the neck of the condyle and the capsule of the temporomandibular joint and passes upward and inward to its attachments to the sphenoid bone. Therefore, unless bony spicules or the periosteum prevent, the characteristic displacement of the condyle below the insertion of the external pterygoid muscle is for the condylar fragment to fall into a forward and upward position.

The muscles of the floor of the mouth are four in number, the mylohyoid, the genioglossus, the geniohyoid, and the digastric (Fig. 39, *B*). The mylohyoid, a fan-shaped muscle, is attached to the concavity of the mandible forward of the molar teeth. It is inserted into the hyoid bone below. The genioglossus, the geniohyoid, and the digastric make a fairly strong central muscular mass extending from the symphysis of the mandible to the body of the hyoid bone. The central part of the flaring muscular group is the strongest. It is readily seen that this group has essentially three components of pull, to the midline, downward and backward. The latter two are the most important, namely, the downward and the backward pull. The pull to the center of the semicircle formed by the anterior part of the mandible is caused by the relatively smaller semicircle of

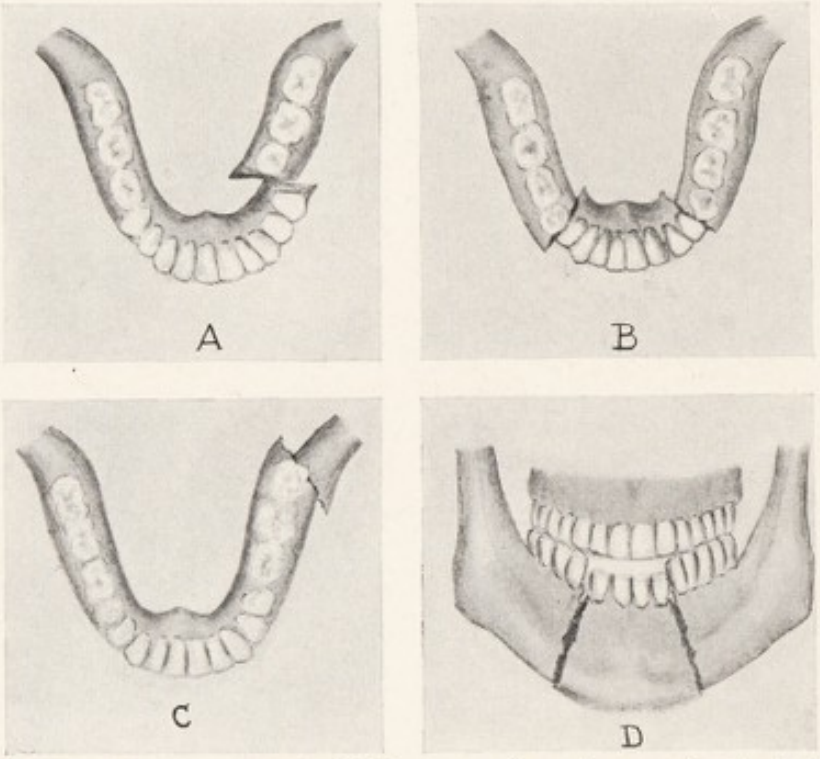

Fig. 40.—A, Probable horizontal displacement in a fracture in the bicuspid or the anterior molar region. B, Probable horizontal displacement in a double fracture in the mental portion of the body of the mandible. C, Probable horizontal displacement in a fracture at the angle of the mandible. D, Probable vertical displacement in a double fracture of the mental portion of the body of the mandible.

the hyoid bone. That is, the attachment of the muscles to the mandible forms a considerably larger semicircle than the muscular attachments to the hyoid bone. The radius of the semicircle of the mandible is about three times that of the hyoid (Fig. 39, *C*, *D*).

To make a prediction of the probable position of the fragments these anatomic facts should be taken into consideration along with the observations of Boyer and Malgaigne. Boyer stated that when fracture of the body is oblique, it usually passes downward and backward and Malgaigne pointed out that very often the fracture divides the thickness of the bone obliquely and that generally the obliquity is at the expense of the inner face of the posterior fragment and the outer face of the anterior fragment. Malgaigne stated that "for want of attention to this obliquity

some surgeons preoccupied with the idea of muscular action have carried their love of theory so far as to contradict their own facts." Thus the obliquity may be such as to cause an outward overriding of the posterior fragment which contradicts the position expected if muscular action alone were considered.

To point out some examples (Figs. 40, 41), in simple fracture of the body in the mental foramen region, the displacement of the anterior fragment will be backward, downward, and outside of the short fragment if muscle pull alone is considered because the greater part of the mylohyoid muscular fan is attached to the sound side of the body. Only the posterior part of the mylohyoid muscle is attached to the short fragment to draw it inward.

In a downward and backward fracture at the angle, the anterior fragment is pulled somewhat back and down (Fig. 41, *B*), if the obliquity of the fracture does not interfere with muscle pull. As the masseter is stronger than the internal pterygoid, the short posterior fragment rides outside of the anterior fragment. But the main muscle pull is on the short fragment

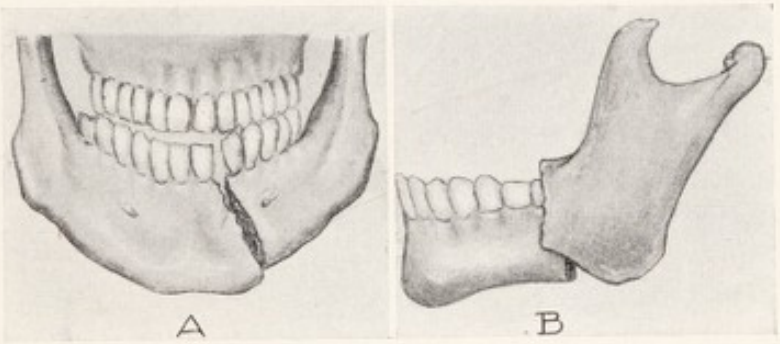

Fig. 41.—A, Fracture in the region of the cuspids showing the probable displacement. B, Probable displacement of the ramus in a fracture of the body of the mandible posterior to the third molar. When the lower molars are absent the same displacement may take place somewhat further forward.

in an upward direction so unless a third molar remains in the short fragment which will come in contact with the upper third molar, the short fragment will tend to be pulled upward and forward. The inside and outside displacement is really not very important as compared to the upward and forward displacement of the short fragment. In angle fractures some of the masseter fibers are often attached to the posterior end of the anterior fragment. This tends to depress the chin by holding the posterior end of the anterior fragment a little closer up and back than normal.

When the line of an angle fracture is downward and forward, the posterior fragment cannot be greatly displaced because the short fragment impinges immediately upon the posterior end of the long fragment.

All single fractures of the body show a tendency to downward and backward displacement of the anterior fragments both because of the downward and backward muscular pull and the influence of gravity.

Of course, multiple fractures of the body are even more influenced by the mechanics of muscle pull and gravity than single fractures.

Symptoms, Signs and Diagnosis.—The same symptoms and signs are present in fractures of the mandible as in other fractures such as sharp

pain, localized tenderness, and so forth. On attempting to open and close the mouth there is disability, some deformity, abnormal mobility and crepitus. Localized tenderness referred to a definite point may aid one in the diagnosis of fracture. Pressure on both angles of the jaw will cause pain at the point of fracture in a symphysis or fracture of the body. Similarly, if one pushes the chin backward or from one side to the other, pain is elicited at the line of fracture when angle, ramus or condyle is fractured. Inspection practically always tells one where a body fracture is located. One can see the point of rupture of the mucosa or even note a loosened tooth or teeth. Even slight displacement changes the level of the teeth. When the jaw is forcibly moved by the examiner abnormal mobility will be observed. Ordinarily it is not necessary to obtain crepitus to be certain of a fracture of the jaw. Inspection, grasping the jaw with thumb and forefinger, and gently manipulating it give one the needed information in body fractures. In fractures behind and above the angle without easily perceptible displacement, the point of tenderness will suggest a fracture but the roentgenogram may be needed to make the diagnosis positive. In fractures of the ramus or condyle, the patient may hear crepitus even when the examiner fails to obtain it.

The position of the hyoid bone is not fixed save by attachment of various muscles. Consequently, swallowing, talking, moving of the head will cause pain.

It is well to remember that in fracture of the ramus if there is any displacement that the occlusal surfaces of the upper and lower teeth on the injured side will be pulled together because of shortening of the ramus caused by spasm of the internal pterygoid and masseter muscles.

A typical history and signs of fracture of the condyloid process run something like the following: a man receives a blow on the opposite side of the chin, and there ensues a swelling with some pain in front of the ear with limitation of motion of the jaw. When the condyle is palpated it may not be felt to move with the jaw. When the middle line swing of the chin is noted very carefully it is found to swing a little to the side of the suspected fracture which is the opposite from the swing of the dislocation. Ribes (Malgaigne) first called attention to this sign. If it happens that the thin bony plate posterior to the glenoid cavity is injured, as very rarely occurs, there may be bleeding from the ear and some temporary or even permanent deafness.

Fracture of the coronoid process is suggested when it is noted that the temporal muscle is rather prominent and that it fails to contract. When palpation reveals the separation of the two fragments the diagnosis becomes a certainty. This is an extremely rare fracture.

Injury to the inferior dental nerve happens much less often in body and ramus fractures than one would ordinarily infer. Anesthesia in the chin distribution is rare although some temporary numbness may be noted.

Finally, although fracture of the jaw can be diagnosed without the aid of the roentgen ray in most cases nowadays one could not be excused for not checking his clinical diagnosis with the roentgenogram (Figs. 42, 43, 44). Additional evidence as to fragmentation and the relationship of the teeth to the fracture is usually needed to carry out proper treatment. Symphysis pictures can be obtained by inserting a film between the teeth and direct-

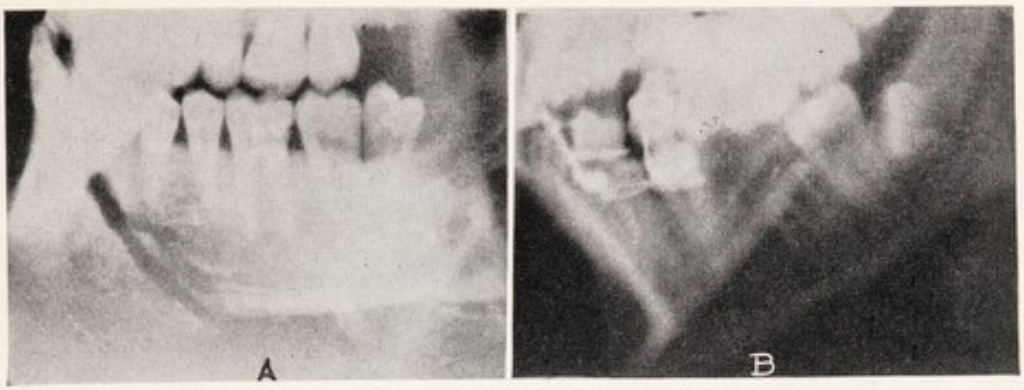

Fig. 42.—A, Fracture of the mandible in the cuspid region. B, Fracture anterior to the last occluding molar. Lower teeth simply wired to the upper teeth.

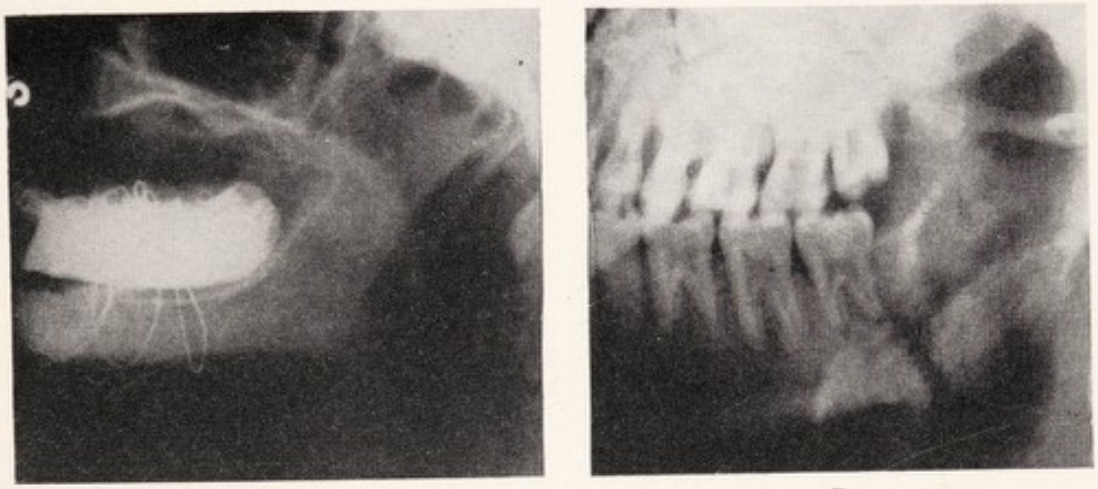

A *B*

Fig. 43.—*A*, Fracture of mandible in an edentulous jaw. The lower plate was used as a splint. *B*, Fracture of angle in which the third molar is in line of fracture and holds ramus down and back.

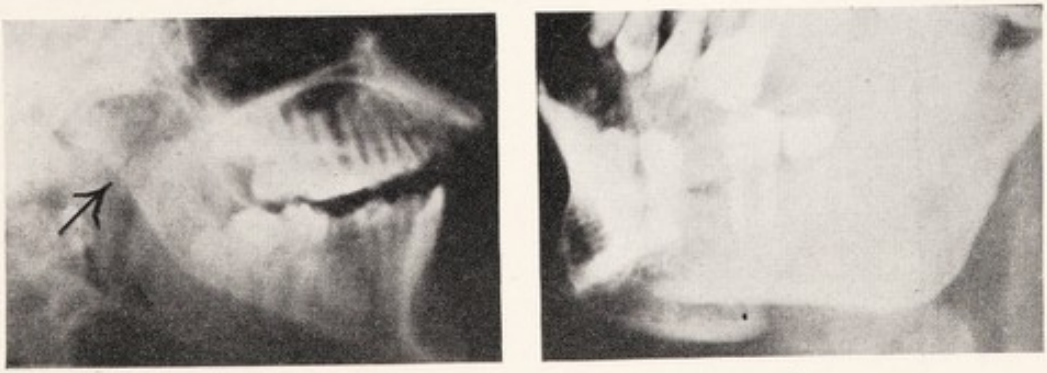

A *B*

Fig. 44.—*A*, Fracture of condylar neck with slight forward displacement. This boy had a double condylar fracture. His teeth were simply wired together. The result was good. *B*, Double fracture with a certain amount of downward displacement. As the anterior upper teeth also had been loosened at the time of the fracture the fracture was treated by putting a circumferential wire up through the palate and into the nose about the anterior part of the maxilla. The wire was brought down beneath the lips. One circumferential wire was placed in the base of each nasal opening.

ing the rays from beneath the chin. To obtain a good lateral film, it is necessary to direct the rays in an oblique direction with the chin elevated

away from the cervical vertebrae so the vertebrae do not overshadow the jaw bone or one ramus coincide with the other. An unsuspected fracture may be revealed in addition to the suspected one.

Complications.—The matter of complications likely to follow fractures of the mandible is discussed in the chapter on Injuries of the Bony Framework of the Face (Chapter VI). In the chapter on Wounds of the Soft Tissues (Chapter IV), the general complications that may follow any severe injury are described.

Bibliography

Bibliography Quoted in Text

Boyer: Lectures on Diseases of the Bones, Phila. ed., 1805.

Dean, H. T.: Fractures of the Mandible: An Analysis of 50 Cases, Jour. Amer. Dent. Assoc., **17:** 1074, June, 1930.

Gibson: Quoted by Hamilton.

Gross, S. D.: System of Surgery, 7th ed., H. C. Lea, Phila., 1872.

Hamilton, F. H.: A Practical Treatise on Fractures and Dislocations, Lea Bros. and Co., Phila., p. 118, 1891.

Ivy, R. H.: Fractures of the Mandible, **4:** 2019, 1927.

Ivy, R. H., and Curtis, L.: Fractures of the Mandible: Analysis of 100 Cases, Dental Cosmos, **68:** 439, 1926.

Lonsdale: Quoted by Hamilton.

Malgaigne, J. F.: A Treatise on Fractures, Phila., J. B. Lippincott Co., 1859, J. H. Packard Trans.

Reiter, E.: Fracture of the Mandible, Dental Cosmos, 50 Cases, **70:** 722, Aug., 1928.

Ribes: Quoted by Malgaigne.

Ruggles, S. D.: Fracture of the Mandible, Dental Summary, **34:** 641, Sept., 1919.

Smith: Fractures of the Mandible, New York Jour. Med. and Surg., Jan., 1857.

CHAPTER X

METHODS OF FIXATION FOR FRACTURES OF THE LOWER JAW

When a method of fixation is adopted for the treatment of a fracture of the lower jaw, the following factors are to be considered: (1) simplicity of application; (2) efficiency of the fixation; (3) comfort after application; (4) economic factors; (5) the state of the teeth, and (6) whether or not there is loss of bony substance.

Expedients Used to Retain the Fragments

Expedients which have been resorted to in the past to retain the fragments in place when the mandible was broken may be arranged under (1) simple bandage, (2) fastening of the teeth together, (3) metal splints of various types, (4) ligature of fragments, and (5) a combination of two or more of the preceding methods.

Few if any of the ideas are fundamentally new. Within recent years only refinement of technic has been added and rather often this has been of no great consequence.

Historical.—Hippocrates (Malgaigne) knew the principle of fastening the teeth together. He used ligatures of flaxen thread or gold wire. Alix and Ledran also used this method. Malgaigne states that wire ligatures often came off and that the method of proper application was for a considerable time apparently lost sight of. Evidently fastening the teeth together in the early days meant only the teeth of the same jaw. The lower teeth were not fastened to the upper teeth so the upper jaw could be used as a splint as is done today. Guillaume de Salicet (1859) (Malgaigne) used the principle in the middle of the past century. Chassaignac wired 4 teeth together. The dentist, Lemaire—the same man who sutured the first cleft velum together—consulted with Dupuytren and besides using Guillaume de Salicet's method, he placed cross wires, one from the wisdom tooth of one side to the bicuspid of the opposite side, a second from the first lower bicuspid on the right to the first upper bicuspid on the left and a third bound the canine teeth together on the left side. Malgaigne did not consider the wire ligature satisfactory and therefore fashioned a trough which embraced the teeth of both fragments. M. Nicole de Newberg used a similar appliance. In 1780 Chopart and Desault made and used a combination internal and external splint. In 1799 Rutenick, a German surgeon, used a similar apparatus. The upper plate of the apparatus of Chopart and Desault fitted over the teeth made of iron and cork or lead was placed directly over the teeth. A second plate of iron was placed beneath the chin. The two plates were screwed together. Such an appliance was found to be very uncomfortable and seldom gave the proper amount of fixation. Bush of England (1822) and M. Houzelot of France (1826) used splints not unlike the preceding types. A. Paré (Hamilton) recommended an external splint.

M. Baudens (Malgaigne) first ligatured the two ends of the fragments together in a compound fracture in which the two ends of the bone were exposed through the face wound. The ligatures were withdrawn on the twenty-third day.

Within recent times (1887) Gilmer repopularized the principle of using the upper jaw as a splint for the lower jaw. To obtain fixation by this method the lower teeth were wired in occlusion to the upper teeth.

A. THE USES OF THE SIMPLE BANDAGE

Historical.—Probably from the first some sort of bandage has been used to support a fracture of the mandible. Hippocrates used two straps. The fronde or four-tailed

bandage was invented by Siranus and recommended and used by Petit and Boyer. In 1878 Vander Poel used a plaster of paris cup beneath the chin and supported it to the head. M. Bousson proposed that a strip of elastic webbing be placed beneath the chin and over the vertex of the head to supplement the bandage and to overcome muscle spasm. Later a rubber dam sling was used by Aiguier in 1918.

To our mind a bandage described by Elliot-Blake in 1902 has all the essential qualifications of a proper jaw bandage and does not have the disadvantages of all the others with which we are familiar. This bandage has been called the modified Barton bandage.

Modified Barton Bandage.—In the words of the originator it is described: "Place the end of the bandage on the side of the vertex, let it pass obliquely to the left side of the head behind the left ear to below the occiput, continue it round the right half of the neck and obliquely under the chin and to the outside of the left ramus of the jaw; thence carry the



A *B*

Fig. 45.—*A,* Modified Barton bandage which is the ideal bandage for applying about the jaw. This bandage, as noted in the diagram, lifts upward and supports the mandible and it does not push the mental portion of the mandible backward. *B,* Method of placing dental wax on gutta percha over the wires on the teeth to prevent rubbing on the cheek.

bandage obliquely up to the left side of the face in front of the ear, to meet and overlie the initial end. This makes the first loop. The second loop is formed in the same way but on the other side. Thus, starting at the vertex, the bandage is continued slantingly down the back part of the head behind the right ear to below the occiput, and after crossing the first loop there, it passes round the left side of the neck, crosses the first loop again under the chin, and reaches the outside of the right ramus of the jaw, it is then carried obliquely to the right side of the face in front of the right ear to the vertex. This completes the second loop and finishes the bandage. The turns are repeated to cover any dressing" (Fig. 45).

This bandage lifts upward, does not pull backward—a point of the utmost importance in fracture of the body of the mandible—does not choke and will stay on when properly applied with the addition of two adhesive strips on each side applied in a transverse direction just above the ears.

For a temporary support of a fractured jaw this bandage may be all that is necessary but only in fractures without any tendency to displacement and not needing entire fixation would one consider it sufficient treatment for the injury.

Fixation by Bandage Only.—Occasionally no fixation will be necessary. The fragments though slightly movable maintain good position and accurate occlusion. Such patients can be instructed to adhere to a soft diet and report occasionally for observation. In these cases the displacement at the time of fracture has been slight and the soft tissues about the fracture are for all practical purposes intact. Usually the position of the fracture is such that action of the muscles of mastication tends to little or no displacement. It is only these cases which are suitable for treatment by bandaging alone.

B. INDIRECT FIXATION BY INTERMAXILLARY WIRING OF FRACTURES WITHIN THE DENTAL ARCH

As Blair notes: "It has long been recognized that where there is a full quota of teeth the dental arch of the uninjured jaw should make an ideal splint for the fractured jaw, if adequate means could be devised to hold the two arches in occlusion. The oldest method of doing this was a bandage of the Barton or four-tailed type. This was soon recognized as not being efficient in cases with any displacement. A bandage only gives a sense of security temporarily. A rubber elastic bandage or a broad strip of rubber dam passed under the chin is usually somewhat more efficient than a plain bandage or even a crinoline bandage." *

In the vast majority of fractures of the mandible good results may be obtained by holding the broken fragments in their proper relationship to the sound upper jaw and thus indirectly with each other. Gilmer emphasized many years ago the value of intermaxillary wiring in fixation of fractures of the mandible although it is probable the essence of the method dates back to Hippocrates as he seems to have recognized that when there is a complete or nearly complete number of teeth present the upper jaw and dental arch should make an ideal splint if the fragments of the lower jaw were held in apposition to the upper jaw.

In favor of the method when it is indicated may be enumerated the following: the procedure is simple; it is economical; there is little discomfort. The delay of from three to four days up to a week which will necessarily intervene before a dental splint can be made and applied is dispensed with. There is no material between the upper and lower teeth and the teeth are uncovered so that the state of occlusion is ever evident. Sometimes during the course of treatment it is necessary to open the mouth. The wires may be placed upon the teeth in such a manner that the mouth can be opened for inspection or treatment. It is much easier to cut a few wires than to remove a splint cemented to the teeth and less damage is done by disturbance of the tissues. Ivy points out that occasionally it is impossible to completely reduce the parts at the first visit and in these cases the use of wires is invaluable, for they can be tightened readily from day to day as the fragments relax.

* From Blair, V. P.: Surgery and Diseases of the Face, Mouth and Jaws, 1917, C. V. Mosby Co., Publishers.

Finally, intermaxillary wiring of the teeth is efficient in giving a good final restoration so far as occlusion is concerned. The final criteria of a good result is a movable jaw with the teeth in as good occlusion or even better occlusion than before the fracture was sustained. In the majority of instances such a result is possible by the use of this principle.

For many years Blair has used intermaxillary wiring almost exclusively. In Ivy's series of 100 cases of fracture of the mandible, he used an interdental splint only six times and then so that dental students could get the practice. In our own series (about 50 cases) at Bell Memorial Hospital no cases have been found where we thought it necessary to use a dental splint.

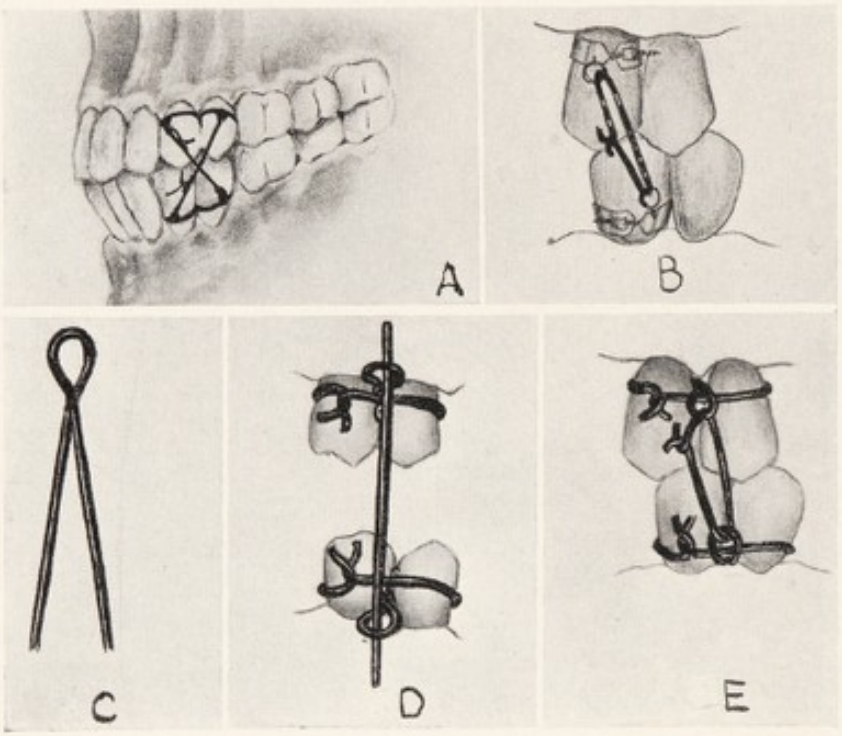

Fig. 46.—A, Gilmer method of wiring the upper to the lower teeth. The wires are placed tightly around the necks of two consecutive teeth in each jaw and then crossed as they are twisted together. B, Method of using Angle bands with lugs attached and wires between to wire the lower teeth to the upper teeth. C, Elby method of placing wires on teeth. An eyelet is made in the center of the wire before sticking it doubled between the teeth. D, Wires encircling the teeth from within outward and just above the eyelet. A third wire is placed from eyelet to eyelet. E, Shows the teeth together after all the wires have been tightened and twisted.

The Method of Gilmer (Fig. 46, A).—Soft wire (No. 24) such as is used by florists might be used but the heavy copper wire (22A or 24G) used by orthodontists is preferable. Four teeth are selected on each side of the jaws. If possible, on the side of the fracture a tooth next to the line of fracture is not selected for wiring. This avoids loosening the teeth in immediate proximity of the fracture. Each tooth is wired singly. The ends of the wire are passed between the interdental spaces at the gum margin on each side of the chosen tooth. The two free ends of the wire will project out of the mouth after encircling the tooth. Both ends of the wire are caught and twisted as tightly as possible around the neck of the individual tooth. After two upper and two lower teeth have each been encircled by separate

wire, the upper and lower teeth are brought together in pairs, but diagonally with firm pressure.

Eby in 1920 and Ivy in 1923 described a modification of Gilmer's principle (Fig. 46, B, C, D) which has the advantage of allowing the teeth to be unwired without disturbing the wire originally placed about the necks of the teeth wired together. Scudder calls this method the Oliver method.

A wire about 12 inches long of 24-gauge brass or iron is bent in the middle and twisted around an instrument to form an eyelet. Both ends of the eyelet wire are inserted from the outside through an interdental space. One end is then drawn around the tooth anterior to the eyelet and the other end is drawn around the tooth posterior to the eyelet. Both ends are twisted together just to the occlusal side of the eyelet. A towel clip may be inserted into the eyelet when tightening up the wire to prevent it from

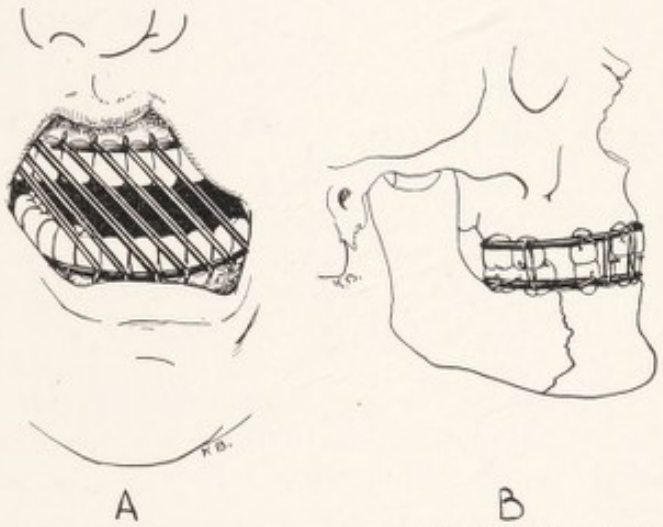

Fig. 47.—A, German silver half-round arches with fine interdental wiring are shown. Rubber bands are shown attached to the ends of the interdental bands placed in a position so that the lower jaw is pulled toward the midline. When there has been bony loss of one side of the mandible rubber bands placed in this manner may be of aid in getting or maintaining position. In the diagram a complete quota of teeth are shown. This method, however, is especially valuable when a considerable number of the teeth are missing or are unstable. Instead of the smooth German silver, half-round wires which resemble one half of a ladder may be used. The lengthwise side is bent around the teeth (modified Baker anchorage). B, Use of the Baker anchorage when some of the teeth are missing.

disappearing into the interdental spaces. At least two sets of teeth on each side of the jaw are prepared in this manner. The bicuspid teeth are often used when the fracture is of the type to make their use advantageous. Finally, a third wire is placed through the eyelets on both the upper and lower teeth. The teeth are placed in occlusion and the connecting wire is twisted tightly together.

When it is necessary to open the patient's mouth it can be done by cutting the third wires. The method, therefore, gives one the opportunity to pull a tooth if need be or to test the union of the fracture. The interdental ligation is as easily reapplied as originally.

German Silver Half-round Arch Wire.—Alternative to wiring the lower teeth to the upper teeth when the teeth are insufficient in number or stability for direct application of the wire (Fig. 47), a German silver half-round

arch wire* molded to conform to the vestibular surfaces of the teeth of both upper and lower jaws and attached to the latter with brass wire ligatures may be used very satisfactorily.

Sauer (1889) first called attention to the usefulness of this method. He ordinarily applied an arch to the mandibular teeth only. Ivy recently has recommended that the arch wire be flattened on one side and be about 2 mm. in width. He states that stability is increased by the use of a flattened arch wire next to the teeth. The modified Baker anchorage devised by Winters, described by Darnall and more recently used by Ivy has similar indications and advantages.

In marked displacement (Fig. 47) that has not been replaced immediately after fracture, gradual reduction can be obtained by elastic traction by means of small orthodontic rubber bands passed over the ends of the brass wire which fastens the arches to the teeth. These elastic bands may run in the direction of pull which tends to counteract the deformity. Hooks or lugs are not necessary to connect the rubber bands when this method is used. After reduction is accomplished the rubber bands are replaced by brass tie wires to hold the fragments in a position of permanent correction.

Several other methods of intermaxillary ligation have been devised to facilitate the fastening of the lower to the upper jaw—such as the small Angle bands with heavy knobs or spurs attached to which a wire ligature can be attached.

C. DIRECT FIXATION BY SPLINTS OF FRACTURES WITHIN THE DENTAL ARCH

The principles of dental splints for use in fractures within the dental arch without loss of substance are on an average admirable, but it goes without saying that if by relatively simple procedures a satisfactory anatomical and functional result can be obtained in most types of fractures—95 per cent or more—that the rather complicated and expensive dental splints are necessary only in a small minority of fractures of the mandible—probably less than 5 per cent.

The main advantage of the swaged metal splint or cast splint in the ordinary fracture of the body of the mandible is that sufficient fixation can be obtained and at the same time the patient can open and close his mouth. The fact that it is often easier for a man to carry on his work with a swaged metal splint in his mouth than with his teeth wired together may be a determining factor. In children the swaged metal splint may be indicated because the deciduous teeth will seldom stand the strain of being wired together.

The real indication for dental splints applies to the rare group of individuals in whom there has been loss of bone.

Dental Splints Used for Fixation of Fragments Anterior to the Last Existing Molar not Complicated by Loss of Substance

The description of splints and methods are grouped in the following résumé in a general way under the types of fractures for which they are

*Two-mm. half-round German silver wire satisfactory for this purpose is made by the Blue Island Specialty Company, Blue Island, Illinois.

considered most applicable. It is presupposed that the man who attempts to treat fractures already understands the general basic principles that govern results and that some ingenuity, leeway, and individualization may be considered advisable provided the basic principles of fracture care are not violated.

The dental splints that recommend themselves as preferable are those of the most simple construction which take up the least space in the mouth and have the requisites of strength and fixation qualities.

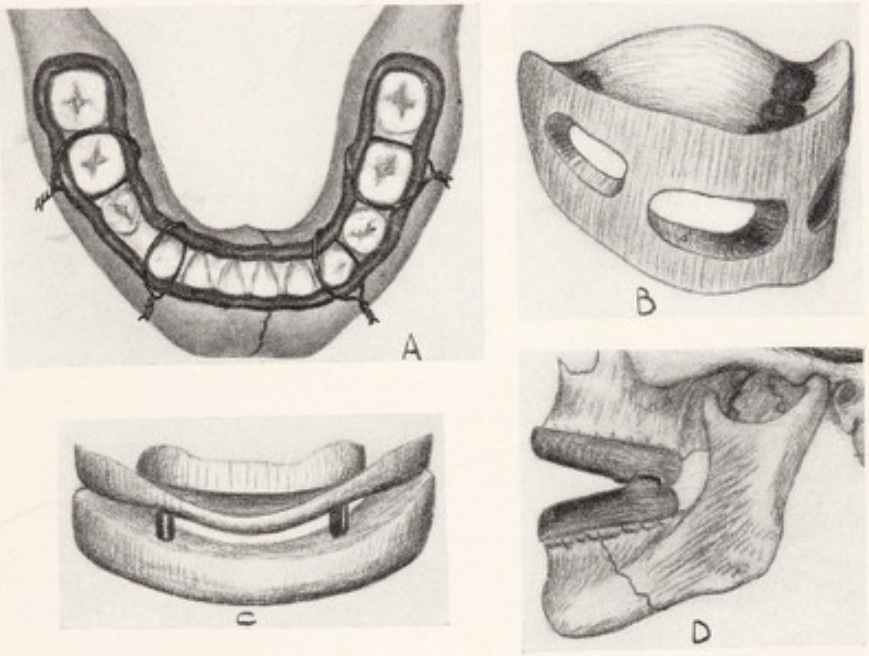

Fig. 48.—A, Old Hammond wire splint which encircles the teeth and is held in position by cross wires. B, Gunning splint. This splint was designed to treat a fracture of the mandible with the jaws separated. The splint consists of troughs somewhat separated. Modeling composition was laid in each trough. The splint was placed in the mouth and the teeth pressed down into the modeling composition after which the Barton bandage was placed around the head. This splint is valuable for temporary fixation. C, Type of Gunning splint in two sections which was used during the War for temporary fixation. The trough was filled with modeling composition and the teeth were pushed into the wax. D, Modification of the Gunning splint in place. This splint is of value when it is necessary to hold the jaws apart. It is made in two pieces which are fastened together after the splint is in place. This type of splint should not be used unless the fracture is in front of the second molars. If it is behind the third molars, the ramus cannot be controlled and a permanent open bite is likely to be the result.

Hammond Splint.—One of the first efficient splints was the Hammond splint (Fig. 48, A) which consisted of a loop of wire fitted around the whole dental arch. The inside and outside loops of wire are then wired together between and around the teeth. This splint first was used at Guy's Hospital (Jacobson).

Gunning Splint.—The Gunning splint was devised to allow the jaw to be held apart and at the same time to be fixed in a position that is anatomically correct. The splint is essentially two impression trays fixed together in a slightly open bite position (Fig. 48, B, C, D). A permanent impression may be cast for the teeth to fit into. This was the original idea of the splint. However, during the late war, stock splints were made after the Gunning idea. They were of light metal and were furnished in various sizes. This splint was applied by filling in the upper and lower grooves of each dental arch with soft modeling composition. The teeth were forced into the composition with the fragments in as near their normal relationship as possible. A bandage was

then applied for temporary fixation until permanent fixation was applied. The Gunning type splint allows free breathing through the mouth when the nose is blocked and is quite valuable.

Kingsley Splint.—From an impression of the lower dental arch, Kingsley (Fig. 49, A) constructed a vulcanite rubber case which fitted the teeth of the lower dental arch. To each side of the cast was attached a heavy steel wire which in a curving manner extended forward and protruded outside each corner of the mouth. Each wire was then bent upon itself and extended backward. A snug bandage was looped over one wire, thence downward beneath the chin and upward over the other wire. Ordinarily a Kingsley splint is not very satisfactory. It is difficult to hold in place

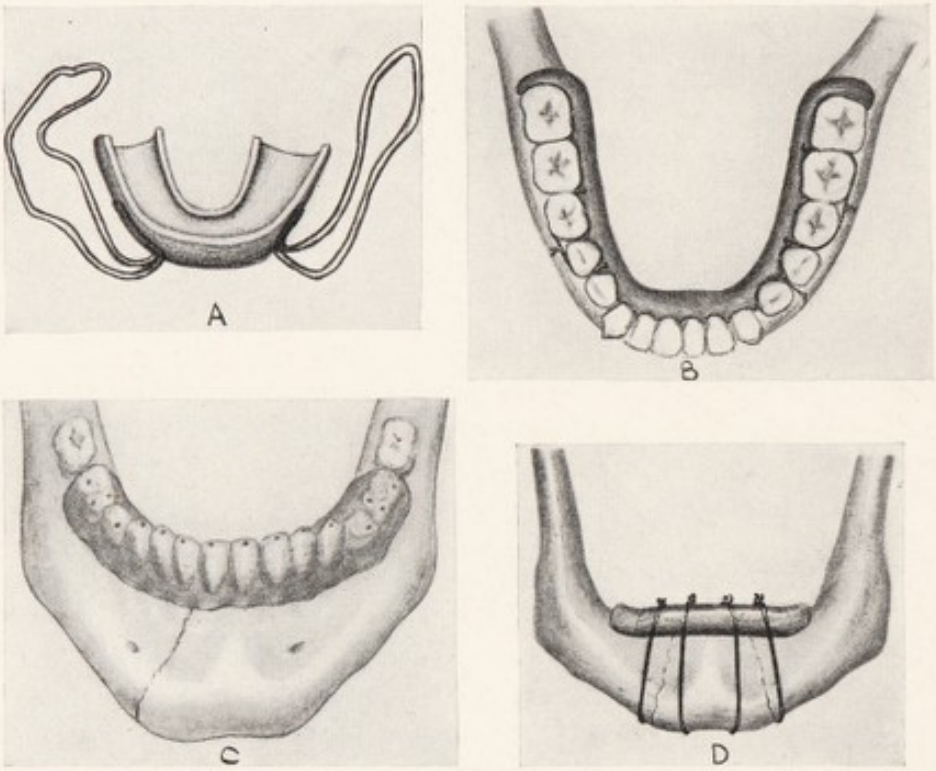

Fig. 49.—A, Kingsley splint which consists of a simple dental tray in which wires have been soldered on either side. Modeling composition may be placed in the trough of the tray and the teeth pressed down into it. This is a simple way of holding a fracture of the upper jaw in position in the manner described by Pickerill. B, Gilmer posterior band splint which is made to fit the teeth within the alveolar arch. Holes are made in this splint through which wires are run and tied around necks of teeth in appropriate places. The splint may be made of metal or vulcanite. This splint has the advantage that the mouth can be closed while it is worn. C, Hullihen swaged continuous metal splint. Fracture of the jaw held in position by a Hullihen continuous metal splint. The teeth are held in the splint with cement (after Angle). D, Vulcanite splint with circumferential wiring.

Gilmer's Posterior Band Splint.—Gilmer in 1872 used a simple splint (Fig. 49, B) which is comparatively simple in structure, is easy to apply and is fairly comfortable for the patient to wear.

Hullihen's Splint.—Hullihen constructed a continuous dental splint for a case of resection of the alveolus (Fig. 49, C). It since has been used often for the treatment of interdental fractures. It may be made of metal, vulcanite, celluloid, or hard rubber and is modeled over a plaster or metal reproduction of the dental arch. The splint should fit accurately and has to be cemented to the teeth to give rigid fixation. This is one of the best types of interdental splints.

Gilmer's Method of Reconstructing the Impression of the Deformed Arch.—Figure 50, A, B, C, depicts and the legend describes Gilmer's method of taking impressions for the reconstruction of the deformed arch. Correct impressions of both upper and lower teeth and jaws must be made. The upper may be taken in plaster alone but

the lower can be made better and more accurately by first taking it in modeling composition according to Gilmer.

Construction of Swaged Metal Splints.—Thoma described the construction of metal splints as follows: "Take impressions of both the upper and lower jaws in modeling compound softened in hot water. Models are made from these impressions in plaster of Paris. The model of the lower fractured jaw is cut apart in the exact location of the fracture and reassembled on an articulator to meet the upper teeth in normal occlusion. A piece of metal, gage 32, silver aluminum, German silver or 18 karat gold, may now be swaged over a metal die made from the model of the lower jaw. A casting can be made instead from a wax pattern constructed on the model. For reinforcement solder 18 gage wire along the border of the splint, or reinforce the entire surface. The occlusal surface is cut entirely away, which gives opportunity to observe the occlusion more correctly, when in place. Otherwise, holes must be made in the occlusal surfaces of the splint. Dry the metal and the teeth (applying alcohol and air by pressure) and keep the saliva away by the use of cotton rolls or gauze; fill the splint with thinly mixed dental cement and press it over the teeth in the proper place. The surplus cement will come out through the holes in the top of the splint. Sometimes small holes are made in the side of the splint corresponding with interdental spaces. These serve to further fixation by means of wires. These are drawn through the holes on the

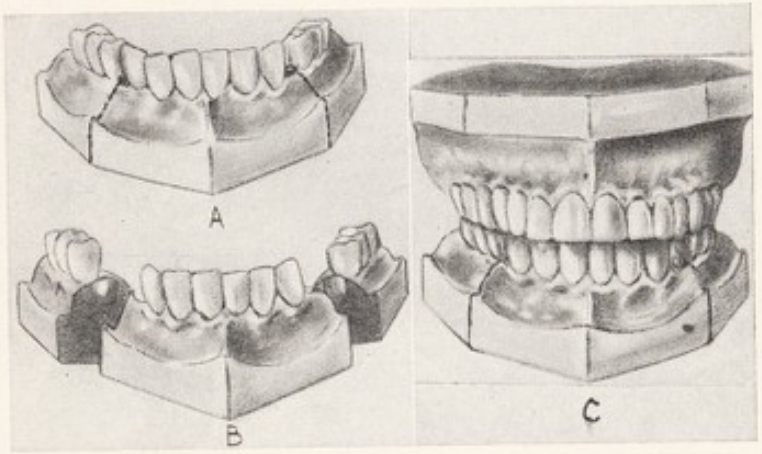

Fig. 50.—A and B, Plaster cast of dental arch and alveolar process of lower jaw. This cast was made in one piece over a fracture of the jaw which showed some displacement. At the points of displacement the cast was sawed in two so it could be readjusted. C, Complete reduction of the lower teeth in a position of their occlusion with the uppers. A swaged splint is made to hold the teeth of the lower jaw in a relative position to the upper teeth when it is applied (after Gilmer).

inside of the splint, passing through the interdental space on each side of a tooth out through holes on the external side of the splint, where they are twisted together, cut off, and bent over." (C. L. Scudder.) In applying a Gunning splint (Fig. 48, B, C, D) it is better to place the two halves of the splint in the mouth separately, get them in normal relationship to each other and then fuse the two halves together in the mouth with a hot instrument.

The Construction of Vulcanite Rubber Splints.—Vulcanite rubber splints—celluloid splints—are formed by a technic similar to that described above by Thoma. The vulcanite splint is rather bulky and not adapted to complicated cases.

Construction of Cast Splints.—The construction of a swaged metal splint consumes a considerable amount of time. Cast splints are better appearing and can be made in one third of the time it takes to construct a swaged splint. In the late war cast splints were used. An anatomic occlusion is absolutely necessary. A Gysi or other frame is used. A wax pattern is carried over the crowns of the teeth and trimmed to the gingival margin. The patterns are cast in sections, as extensive castings invariably contract. The various sections drop into position without pressure. The connections are then attached with solder. Bars and saddles are made of the same material. The thickness of the splint should be at least equal to 26 gauge to be rigid. The metal most used for castings is an alloy known as maxillar (French) containing 80 parts of

silver and 20 parts of copper. After the use of a bandage for one or two days to gain firm sealing the casts are cemented to the teeth. Locking devices with removable pins may be found advantageous for examination and when cleansing is desired. In case of vomiting, devices constructed in this manner can be detached temporarily.

The Saddle Vulcanite Plate for the Edentulous Jaw.—It has often been recommended that for edentulous cases full upper and lower vulcanite dentures be inserted, fastened together, and held in place with a tight bandage. Ordinarily this does not give efficient fixation.

Black (Gilmer) suggested a plan which is ordinarily efficient and not particularly complicated. A vulcanite splint is made to saddle the lower alveolar ridge (Fig. 49, D). If the patient has an unbroken lower vulcanite denture, this may be used. Circumferential wires are inserted which surround the denture and the mandibular bones. The number and position of these wires depend upon the site of the fracture. A small incision is made through the skin and subcutaneous tissue just beneath the mandibular edge cutting all tissue down to the periosteum of the bone. A large one-third curved cutting needle is passed next to the bone from within the mouth downward to the small incision. The wire is then passed back into mouth in the same manner in which it was passed out. After the proper number of wires necessary to give adequate fixation of the fragments are put in place, the ends of each wire are pulled tight and twisted together over the denture. The small incisions—¼-inch incisions—are left open for drainage. This procedure can be done under local anesthesia. The circumferential wires are fairly well tolerated and are left in place until union has occurred. In cases of double fracture in an edentulous jaw, the method is the one par excellence.

LIGATURE OF THE BONE

Methods of direct uniting of the fragments by means of silver wire are sometimes useful. In a fracture of the angle where simpler means are not efficient, this procedure still is used sometimes (Fig. 51), but silver wire suturing of the fragments has two distinct disadvantages. The first is that about a fracture—a compound fracture especially—silver wire has a tendency to act as a foreign body and a discharging sinus is apt to result. This necessitates the removal of the wires which, however, is not a difficult procedure. The second disadvantage is that there is apt to be some sequestration of the bone between the wires in a compound fracture. This may interfere with early union which will not occur until after the small sequestrum and the wire are removed. In some badly comminuted cases transplantation of bone or bone sliding, or wiring together of the fragments may be a necessity. Fascia usually will heal in normally. Absorbable sutures have a tendency to be absorbed before the length of time needed for fixation has elapsed. Fixation by wiring or plating, as a rule, should not be attempted in recent fractures which communicate with the mouth. The wires or plates practically always work loose. In late cases of nonunion, when the soft tissues have closed the cavity between the ends of the fragments and when some of the teeth are available for additional fixation, external exposure and wiring of the fragments may be justifiable.

The Operation.—An incision is made under the border of the lower jaw at least 5 cm. long. At the angle region care is taken not to endanger

the facial nerve which crosses the posterior border of the ramus at the level of the lower border of the lobe of the ear. The incision extends down to the lower edge of the bone. Arteries and veins in the pathway are caught and tied. When the incision is made crosswise of the pathway of the facial artery and vein, it is best to dissect out the artery and vein so that they can be doubly clamped before they are cut. The muscles and other soft tissues are cut from the periosteum of the bone without removing the periosteum from the underlying bone. Denuding of the bone of the periosteum increases the chances of sequestration as the periosteum carries the blood supply of the outer cortex. The most advantageous position for the drill holes is selected according to the direction of the line of separation of the two bony fragments. The drill holes should not be closer to the ends of the fragments than 5 mm. and in a general way the wire should cross the line of contact of the separated fragments at a right angle. Strong lion wire forceps are used to hold the fragments while they are being drilled. A flat spatula should be placed beneath the fragment that is being drilled

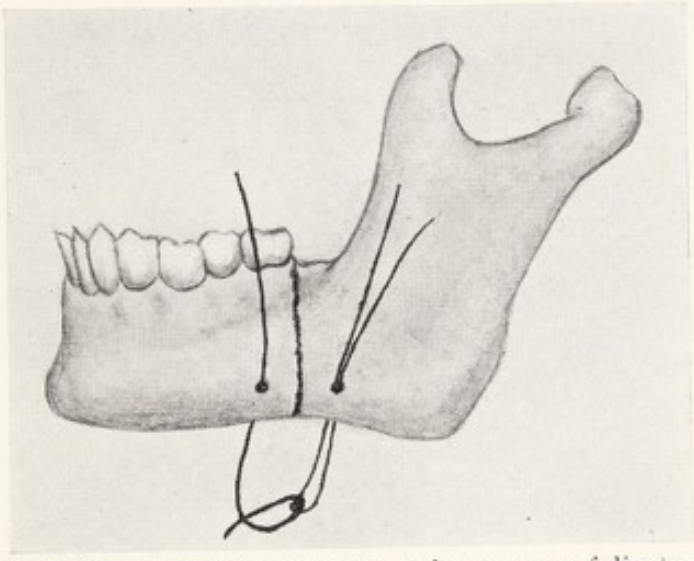

Fig. 51.—Method of directly uniting fragments by means of ligature of the bones.

so that when the drill passes through the bone, the underlying soft tissues are not deeply pierced. This carelessness has caused penetration of a large vessel. When one hole is drilled the wire should be immediately inserted; otherwise the hole may be lost to view. The drill holes must be large enough to admit a double soft silver wire, of about No. 20 caliber. Through one hole a single wire is passed and through the other a double wire. The single wire is passed through the loop of the double wire like a thread in a needle. The doubled wire is then pulled back through its hole (Fig. 51). Thus a single wire is looped through the holes in each fragment of bone. The fragments are then adjusted and the single wire is tightened, twisted tightly together, cut about ¼ inch long and bent down flat with the bone. The wound is then closed with an interrupted catgut suture or two. A small piece of rubber dam drain is inserted into the line of fracture.

Several figure-of-eight horse hair interrupted sutures close the skin and immediate subcutaneous soft tissues. The drain is sutured to the skin edge. If there happens to be no connection with the inside of the mouth, the drain would not be necessary.

CARE OF FRACTURE AT THE ANGLE

In fracture at the angle of the jaw if the fracture line extends forward from above downward, there may be no upward displacement if the fragments are properly adjusted and the anterior fragment held fixed by intermaxillary wiring of the teeth. The upward pull of the muscles of mastication is counteracted by the angle of the fracture line. However, as a rule, the fracture line extends from above downward and backward and unless the posterior fragment has the third molar tooth in it which will prevent displacement by coming into contact with the upper third molar tooth, the short posterior fragment is pulled upward and forward (Fig. 52, A). The lateral displacement depends upon the obliquity of the fracture as a rule and is not so very important.

When a lower third molar comes in contact with the upper third molar in a fracture at the angle, the lower third molar very often can be used

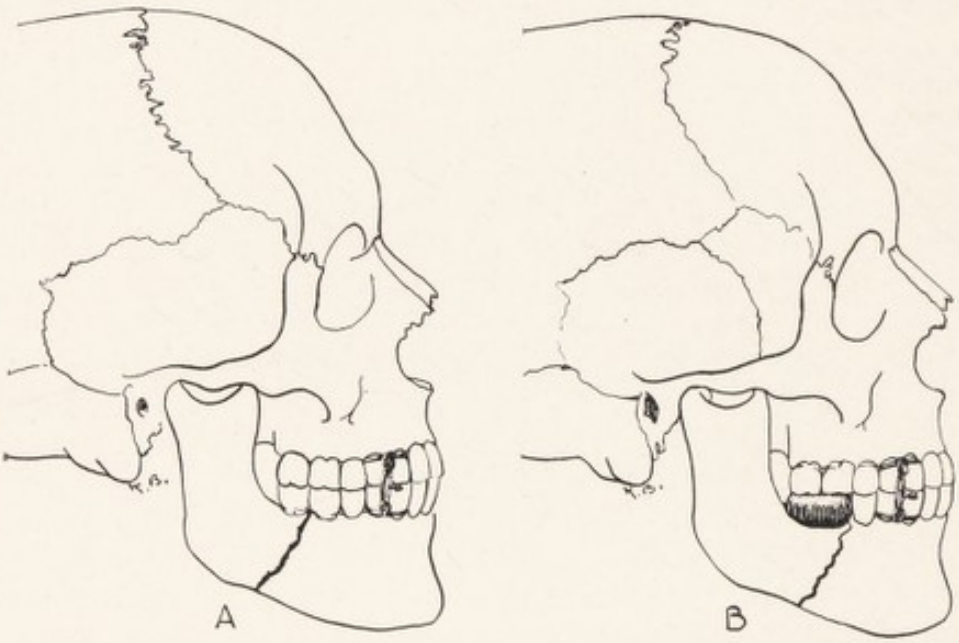

Fig. 52.—A, Fracture of the third molar in distal fragment. B, Holding the distal fragment down and back with modeling composition wedge.

advantageously to hold the posterior fragments down and back (Fig. 52, B). If the tooth suffices for this purpose it is by far the simplest method of retaining the posterior fragment in position. After two or three weeks—I usually make it at least three weeks—the tooth may be extracted. By the end of three weeks or more the soft tissue infiltration about the fracture has become firm enough to hold the two fragments from slipping past each other. By that time, the upward pull due to the muscles of mastication is less, *i. e.*, the original muscular spasm has subsided somewhat. Thus, the fragments maintain a good position and union is obtained. During this period of about three weeks, however, if there is evidence that there is much infection about the tooth, it should be extracted and some other means used to keep the posterior fragment in place.

When it is necessary to extract the third molar before sufficient time has elapsed for the posterior fragments to be fixed by development of firm fibrous tissue or partial bony union, when the third molar is absent either

from being extracted previously or at the time of the fracture or when the fracture line is such that the third molar does not suffice to hold the ramus back and down, one of four methods of retaining the posterior fragment in position has been recommended: (1) retention of the posterior fragment by means of a wire loop through the ramus with attachment to a plaster skull cap; (2) direct ligature of the two ends of the bone; (3) intermaxillary splint with a jack screw impinging upon the anterior ramus; (4) and fixation of the coronoid downward by means of a nail.

Direct ligature of the two ends of the bones has been described previously. A description of the other three procedures follows:

Retention of the Posterior Fragments by means of Wire Loop Through the Ramus with Attachments to a Plaster Skull Cap.—Figure 53, *A*, shows the essentials of a procedure used and recommended in fractures at the angle back of the posterior molar in which the posterior fragment

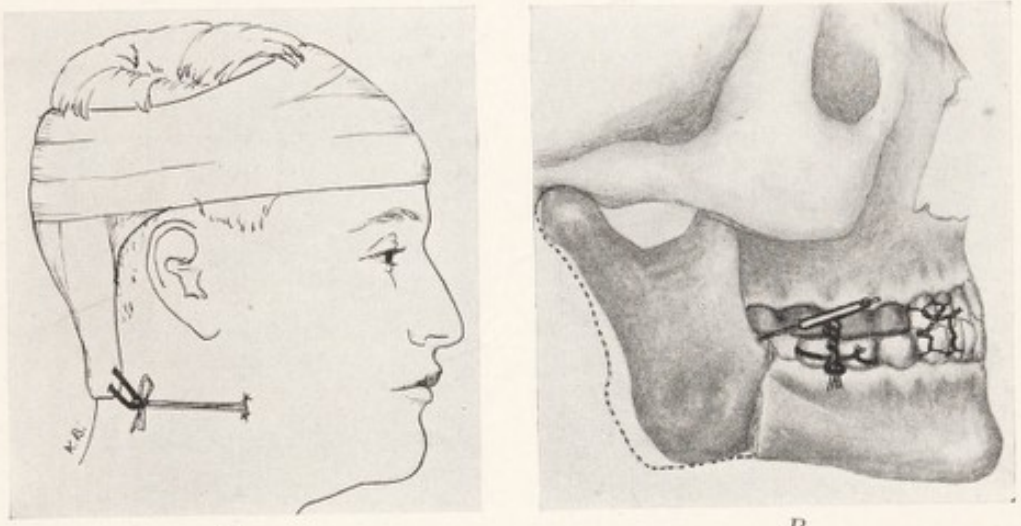

A *B*

Fig. 53.—*A*, Holding the ramus down and backward without having to wire the two fragments together. Plaster cast is placed over the head and a wire is placed through a hole in the posterior part of the angle. *B*, Intermaxillary splint with jack screw. A method of pushing the ramus backward by means of a screw pivot. The appliance is fastened to the upper molars and the pivot impinges upon the anterior borders of the ramus. As the arm is screwed downward, the ramus is pushed backward.

is pulled upward and forward. External incision under local anesthesia is necessary. The incision need not be more than 1 inch in length. The periosteum of the posterior border of the ramus is exposed. With a drill a small hole is made in the ramus. A silver wire is passed through the hole. A plaster head cast is applied and the silver wire attached. Another heavy wire loop is built in the head cap at a point on the lower occipital region. The ramus is held back efficiently by this procedure and the wire of course does not tend in any way to interfere with union of the fracture. The disadvantage is the discomfort of wearing a plaster skull cap for over three weeks. All in all, this manner of handling a fracture of the angle posterior to the last molar in which the last lower molar does not serve to hold the ramus down and back is the preferable one in my opinion.

Intermaxillary Splint with Jack Screw.—In a complicated fracture near the angle with the line of fracture running down and back, the following

device has been used by Blair to prevent an upward displacement of the short fragment. A metal or vulcanite splint is cast and attached to the dental arch of the upper jaw on the side of the fracture. To the splint is attached a jack screw which, through a small incision in the mucosa and submucosa is allowed to bear down upon the ramus in the region of the first molar triangle (Fig. 53, *B*). This procedure should prevent lateral displacement as well as upward displacement. The jack screw is gradually lengthened and the short fragment is forced backward. Instead of a silver point, a vulcanite saddle has been used (Blair, Eby and Herpin). After the posterior fragment is forced into position, the anterior fragment is placed in position and held there by interdental wiring to the upper teeth. This is quite efficient. The main disadvantages are that the splint is not a comfortable one for the patient to wear and that difficulty is likely to be encountered in making the splint and also in making it effective.

Coughlin's Method.—A small incision is made parallel with the facial nerve at the lower edge of the zygoma directly over the coronoid process which can be located by sounding with a straight needle. Closed pointed scissors are placed close to the zygoma and down through the masseteric fascia and muscles until the coronoid is felt. The scissors are opened and two small retractors inserted. An assistant passes his fingers into the mouth and reduces the fragments. The operator drills a hole through the coronoid as close to the edge of the zygoma as possible. An ordinary nail 1½ inches long is then inserted into the hole until its flat head contacts the skin. The point of the nail impinges on the base of the skull and the neck of the nail on the zygoma. After four weeks the nail is removed.

CARE OF FRACTURES AT THE RAMUS

It is seldom that one sees a fracture of the ramus. The muscle attachment on both sides of the ramus of the mandible tends to maintain good position—at least when the teeth are in occlusion. Intermaxillary fixation holds the body and the angle of the mandible in correct position. Thus, no overlapping occurs at the line of fracture. Adjustment of the fragment plus intermaxillary wiring of the teeth is all that is necessary. As a rule in edentulous jaws, an interdental splint the width of the upper and lower teeth plus the application of a snug bandage to hold the chin and body of the mandible lightly against the upper jaw answers all the requirements.

CARE OF FRACTURES OF THE CONDYLE

The tendency in a fracture of the condyle is for the short fragment to be pulled forward by the external pterygoid muscle. In some cases, however, if the lower jaw is manipulated carefully under a general anesthetic to get relaxation with the mouth open and the ramus on the side of the fracture pushed upward so that roughened edges of the bone may come in contact, there will be enough serration of the fractured ends to push the condyle backward. If the lower teeth are wired to the upper teeth the condyle will stay in fair position. This procedure is worth a trial.

When the condyle lies almost entirely forward, an open operation may be advisable. But the condyle can be partially forward and still a good result can be obtained. In most instances if the condyle is not turned more

than one third of a right angle forward, a good functional result will be obtained.

Exposure of the Condyle.—The condyle is exposed through a semilunar incision running in front of the ear and upward into the hair line and curving slightly forward. With a periosteal elevator one may be able to throw the condyle back and when the teeth are placed in occlusion, it maintains its normal position because of some interlocking of uneven serration of bone. In such a case intermaxillary wiring of the teeth would possibly be sufficient. However, when the fragment does not stay back, the external pterygoid muscle can be cut from its attachment to the condyle.

Although it is rare, one undoubtedly sees instances of considerable disability or even fixation of the joint after fractures of the condylar neck. In our series of patients referred because of a partial ankylosis of the temporomandibular joint, we have two who gave a history of having had a fracture of the condylar neck. A complete or almost complete ankylosis was present in each case with a marked increase of bone formation about the head and neck.

FIXATION IN FRACTURES OF THE CORONOID PROCESS

This fracture is a very rare one. All that is necessary is fixation of the lower jaw to the upper until the swelling, soreness and pain are relieved. The temporal muscle pulls the short fragment upward and away from the ramus. If there should be disability afterward from overproduction of bone, one should remove the coronoid process.

FIXATION OF FRAGMENTS COMPLICATED BY LOSS OF BONY SUBSTANCE

Fractures in which a segment of bone has been lost present a considerable list of problems to be solved. When the loss does not involve the full width of the body no great problem is presented as sufficient bone usually fills about the fragments until strong union occurs. A dental splint may be necessary to strengthen the weak places. Blair advises that when the complete loss is not greater than 1 cm. and is situated behind the bicuspid by removing all the teeth from the posterior fragment and allowing the latter to tilt forward until it comes in contact with the anterior fragment, one may be able to get bony contact. The anterior fragment is held in its proper place until bony union is obtained.

When some of the teeth remain solid in each fragment after loss of bone or comminution of bone in the submental region, the band and wire splints of Hayes, Cryer (Fig. 54, A, B, C), and Kazanjian (Fig. 54, D) will give fixation until the time of repair. In such fractures not seen immediately after there has already been some pulling to the midline, if the two posterior fragments are bound by cicatricial tissue, the sectional metal jacket with jack screws are applicable. They give fixation and by their proper use the fragments are returned to their normal position.

The final repair may be made by one of two methods. First, a sliding bone graft from one of the immediate fragments may be used. This type of bone replacement does not absolutely demand a sterile field because the bone is not separated from the soft tissue from which it derives its blood supply. Any depressions of the contour of the external face are filled in

later by cartilage transplantation. Second, a free bone graft from the tibia, ilium or rib may be implanted into the defect. In this method a sterile field is required. Therefore, enough soft tissue has to be about and between the end of the fragments to allow the bone graft to be inserted without breaking the mucosa of the inside of the mouth. Before these conditions are obtained it may be necessary to transplant an epithelial flap into the mouth to give lining, or a skin flap may be necessary to fill in the gape in the soft tissue externally.

Splints for Bony Defects Anterior to the Last Existing Molar.—The Hullihen idea may be modified for use in fracture with loss of bone as was

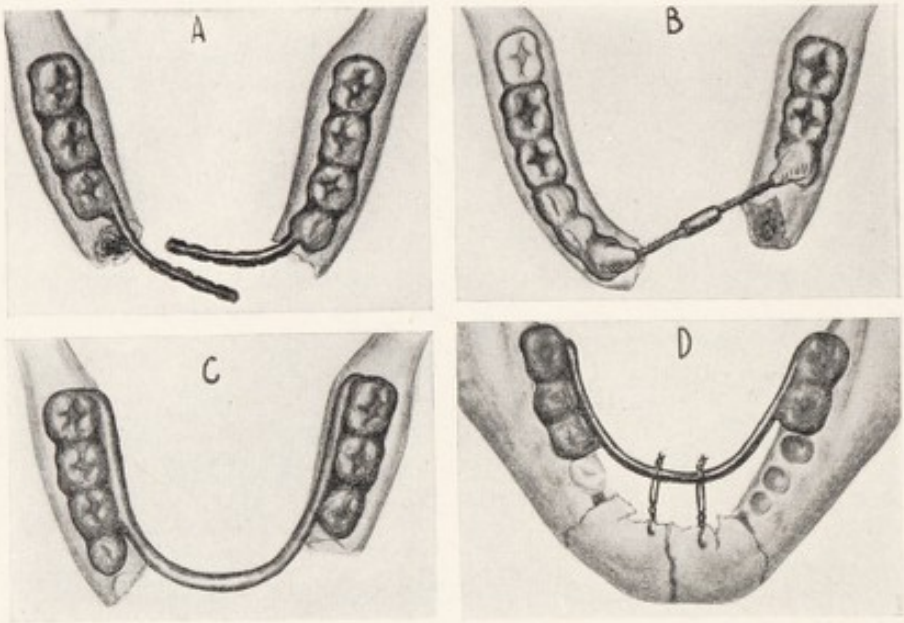

Fig. 54.—A, Swaged metal splint used in fractures with loss of substances in which the arms across the bony loss are roughened so the position of fragments may be changed. The roughened arms are held together by wrapping fine wires around the two arms. Hayes described this type of splint. B, Swaged metal splint with two screws across the bony loss. By turning the nut between the screws the two ends of bone can be forcibly separated. The joint of attachment of the screws to the metal splint should be movable. Hayes and Kazanjian have both described this type of splint. C, Swaged metal splint placed upon a fracture of the jaw in which there has been a loss of substance. The teeth are held in the splint with cement. This splint is appropriate for holding the fragments in proper position while plastic procedures are being carried out. Cryer described a splint of this type. D, Swaged metal splint with cross arms, showing a method of holding comminuted fragments in position in a relatively proper relationship with the distal bony fragments. (After Kazanjian.)

done by Cryer and Hayes (Fig. 54, A, B, C). These latter splints have to be cast from metal as the gape has to be bridged by a heavy wire or bar. Instead of the rigid wire or bar to bridge the gape the splint may be fitted with an extension jack screw apparatus so that a gradual widening of the gape may be forced.

Kazanjian and Hayes (Fig. 54, D) have described a further modification. The splint is made in two sections in the same manner as the preceding splint. Each section is provided with a heavy corrugated wire to bridge the gape. The wires overlap each other. Each side of the splint is cemented to the teeth separately. Finally, the overlapping wires are joined to each other with a brass ligature wire. This type of splint is

particularly applicable in cases in which it is desired to gradually expand the gape as the cross arms of the splint can be wired and unwired as often as desired.

When the anterior part of the jaw is broken in numerous small pieces which may contain no teeth, the application of the methods described may be impossible. Kazanjian described a combination maxillary splint and sutures through the bone. The first step is the construction of a splint which holds the rami in position. A curved board or rod passes from the swaged metal caps made to fit the remaining molar teeth on each jaw in a curve the circumference of the original jaw bone. The splint is cemented to the remaining molars. Holes are drilled in the comminuted fragments through which silver wires are passed. The silver wires are looped over the metal band and are held in a fairly normal position.

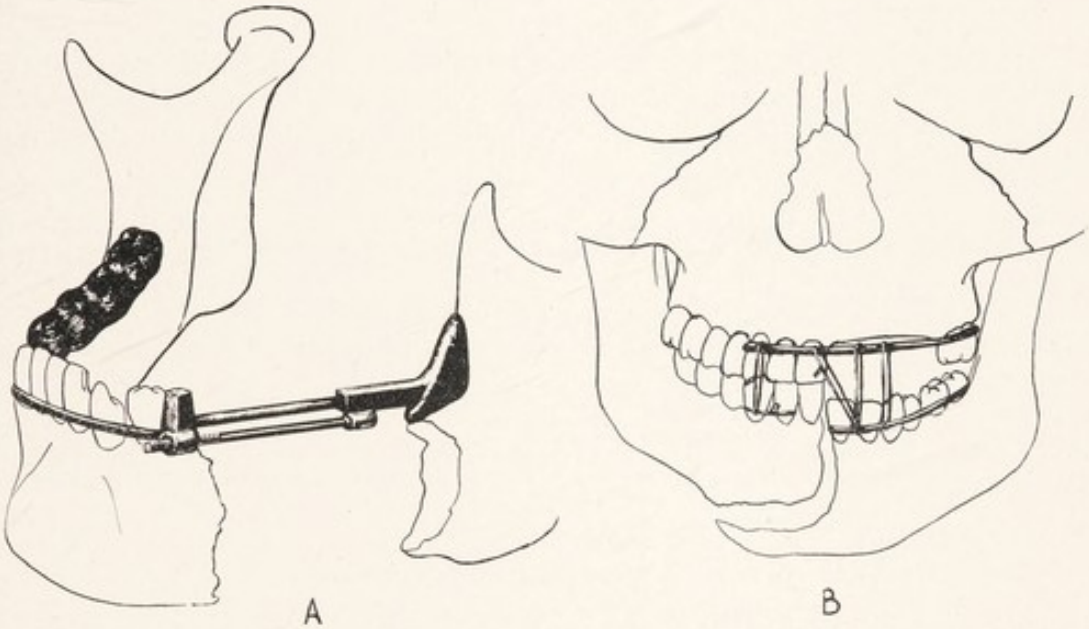

Fig. 55.—A, Herpin splint. This splint was designed to push the ramus down and back when there was loss of bony substance immediately anterior to it. A wedge pushed the ramus backward and a turn screw is used to gradually force a separation of the anterior and posterior fragments. B, Showing use of Baker half-round splint and wires on orthodontic rubber bands to readjust fragments by traction when there is displacement of some days' or weeks' standing.

Lugs and Incised Planes.—In cases with bony loss where there is a tendency to lateral displacement, lugs and incised planes may be attached to metal splints to engage with the opposing jaw. Thus, the mouth can be opened and closed and still the fragments are held to their normal plane. Such lugs may also aid in holding the fragments apart or in partially filling in gapes which later will be reconstructed by transplanted soft tissue or bone.

Prosthetic Replacement.—A metal or vulcanite form may be used to fill a bony loss after the defect has been lined with epithelium either by scarring or in most cases by plastic repair. These sections fill the defect, tend to hold the remaining hard structures in position and mold the external soft tissues so that a normal contour is obtained. These forms are attached to the remaining teeth for stabilization.

Blair states that "the use of such appliances is restricted as a rule to cases where the amount of bone lost precludes the probability of new bone formation, though they may be employed to maintain separation at the upper portion of the gape with the view to regeneration of the lower border of the bone."

Splints for Loss of Bone at and in Front of the Angle.—*Herpin Splint.*—When the bony defect is behind the last available molar, Herpin designed a splint to apply the bridge method of maintaining a gape and still allow the mouth to open. A metal cast is fastened to the teeth anteriorly (Fig. 55, A) and a metal arm extends backward to a vulcanite saddle which embraces the border of the ramus of the jaw.

Davenport Splint.—Davenport described a similar apparatus, the arm of which extends back and can be fitted with a jack screw extension apparatus so that the ramus can be gradually forced back if forward dislocation is present. The splint of Davenport with a jack screw has the advantage that pressure necrosis of the mucosa over the ramus is limited. As the sharp point of the jack screw impinges on the anterior border of the ramus the screw does not slip off the bone. The splint efficiently pushes the ramus backward.

OLD FRACTURES OF THE MANDIBLE WITH NONUNION OR MALUNION

Large loss of bony substance as seen in gunshot fractures more commonly cause nonunion. About 11 per cent of gunshot fractures (Blair



Fig. 56.—Method of doing an osteotomy of the mandible when malunion has developed after a fracture. A Gigli saw cuts through the old fracture line. The teeth are placed in normal occlusion and wired together.

and Ivy) result in nonunion. In such cases bone grafting with a sliding pedicled flap retaining the blood supply of the newly replaced bone, or by an osteoperiosteal graft or by a thick graft, is indicated. The tibia, rib, or crest of the ilium is the site most commonly used for the removal of bone grafts.

In early malposition a great deal can sometimes be accomplished by springy wire or intermaxillary rubber bands used within the mouth.

Pronounced malunion may be corrected by cutting through the original line of fracture, reducing the fragments and establishing proper fixation by the wiring of the teeth or by the use of interdental splints (Fig. 56). A Gigli saw may be used to cut through the line of fracture. If splints are to be used for fixation they should be made in sections and cemented to the teeth before the operation. After reduction of the malunion the splints are locked in position with lock pins.

OPERATIVE TREATMENT OF NONUNION OR MALUNION

In old fractures of the mandible with nonunion or malunion the ends of the bones should be separated by knife or the Gigli saw if necessary (Fig. 56). The eburnated ends of the bones should be refreshened, the fragments placed in the proper position and fixation given by one of the methods described above. If nonunion persists without evident reason after many months or if the gape caused by the bone loss prevents union, bone grafting may be considered. In the former case the operation might be considered with the idea of stimulating new bone production by an osteo-periosteal graft and in the latter case actually to replace the amount of bone needed to fill in the gape.

Orthodontic Splints.—Cases having a lesser degree of displacement or where operative methods cannot be considered for some reason may be improved by orthodontic appliances which put a constant pull or push in the direction in which it is desired to shift the fragment. The forms of apparatus most commonly used for this purpose are sectional band splints (Fig. 54, A, B, C, D, and Fig. 55, B), jack screws (Fig. 53, *B*), lugs and inclined planes.

Bibliography

Bibliography Quoted in Text

Aiguier, J. E.: Aiguier Headgear, Dental Cosmos, **60:** 602, 1918.

Baker: Quoted by Ivy.

Blair, V. P.: Surgery and Diseases of the Mouth and Jaws, St. Louis, C. V. Mosby Co., 3rd ed., 1918.

Blair, V. P., and Ivy, R. H.: Essentials of Oral Surgery, St. Louis, C. V. Mosby Co., 2nd ed., 1936.

Black: Quoted by Gilmer: Lectures on Oral Surgery, Chicago, 1901.

Blake, Elliot: A New Head and Neck Bandage, etc., Lancet, **2:** 940, 1902.

Boyer: Lectures on Diseases of the Bones, Phila. ed., 1805, trans. by M. Farrell.

Bousson: Annales de la chirurgie, **8:** 472, 1843.

Cryer, M. H.: University Medical Magazine, Penna., June, 1900.

Studies of the Internal Anatomy of the Face, The S. S. White Dental Mfg. Co., Phila., 1901.

Darnall, W. L.: Modified Baker Anchorage in Naval Dental Service, U. S. Naval Med. Bull., **19:** 42, 1923.

Davenport: Dental Cosmos, October, 1916, p. 1136.

Desault: Treatise on Fractures and Luxation, Phila., 1805.

Eby, J. D.: Internat. Jour. Orthodont., **6:** 273, 1920.

Gilmer, T. L.: Lectures on Oral Surgery, Northwestern University Dental School, Chicago, 1903.

Archives of Dentistry, Sept., 1887.

Oral Surgery, p. 105–109, 1907.

Guilford, D.: An Articulator for Normally Posing the Mandible in Cases of Fracture, Dental Cosmos, **58:** 524–528, May, 1916.

Hullihen, S. P.: Amer. Jour. Dent. Sci., **9:** 157, 1849.

Hammond: Quoted by Pick: Fractures and Dislocations.
Quoted by Hamilton, p. 123 (Guy's Hospital).
Hamilton, F. H.: Buffalo Med. Jour., **14:** 148, 1859.
A Practical Treatise on Fractures and Dislocations, Phila., Lea Bros. and Co., 1891.
Hayes: Dental Cosmos, Oct., 1916, p. 1148.
Herpin: Gaz. hebd. de la soc. de méd. de Bordeaux, **38:** 43–45, 1917.
Ivy, R. H., and Curtis, L.: Fractures of the Jaws, Phila., Lea and Febiger, 1931.
Operative Treatment of Losses of Substance of the Mandible with Special Reference to Fixation of Edentulous Fragments, Surg., Gynec. and Obst., **52:** 849–854, 1931.
Ivy, R. H.: Practical Method of Fixation in Fractures of the Mandible, Surg., Gynec. and Obst., **34:** 670–673, 1922.
Fractures of the Mandible, J.A.M.A., **80:** 295–297, 1922.
Surgical Treatment of Accident Wounds of the Mouth and Face with Special Reference to those Complicated by Bone Injury, J.A.D.A., **17:** 967, 1930.
Kazanjian, V. H.: Wounds of the Face and Jaw, Brit. Jour. Surgery, **5:** 126, 1917.
Jour. Allied Dental Societies, **12:** 27, 1917.
Lemoire: Quoted by Dupuytren: Jour. univ. des Soc. médicales, **19:** 77, 1820.
Malgaigne, J. F.: A Treatise on Fractures, Phila. and London, J. B. Lippincott Co., 1859, J. H. Packard Trans.
Muys: Quoted by Malgaigne, J. F.: Praxis rationale decad., **12:** 3.
Oliver, Robert: A Method of Treating Mandibular Fractures, J.A.M.A., **54:** 1187, 1910.
Pickerill, H. P.: Dominion Dental Jour., **29:** 217, 1917.
Sauer: Deutsch. Monatschr. f. Zahnheilk., **7:** 381, 1889.
Scudder, C. L.: The Treatment of Fractures, Phila., W. B. Saunders Co., 1911.
Thoma, K. H.: Clinical Pathology of the Jaws, Springfield, Ill., C. C. Thomas, 1934.
Vander Poel: Arch. Clinical Surg., Jan., 1878.
Winters, J. C.: Quoted by Ivy and Curtis: Fractures of the Jaws, Lea and Febiger, Phila., 1931.
The following are quoted by Blair, V. P., in Surgery and Diseases of the Mouth and Jaws, St. Louis, C. V. Mosby Co., 3rd ed., 1918: Coughlin, Kingsley, Hippocrates, Lane, and Thomas.
The following are quoted by Hamilton, F. H., in A Practical Treatise on Fractures and Dislocations, Phila., Lea Bros. and Co., 1891: Hippocrates, Jacobson, Paré, and Gunning, J. B.
The following are quoted by Malgaigne, J. F., in A Treatise on Fractures, Phila., J. B. Lippincott Co., 1859: Alix, Ledran, Baudens, Barton, John R., Bush, Chassaignac, Chopart, Guillaume de Salicet, Hippocrates, Houzelot, Newberg, M. Nicole, Patet, Rutenick, and Soranus.

Supplementary References

Dean, H. T.: Fractures of the Mandible: Analysis of 50 Cases, J.A.D.A., **17:** 1074–1085, June, 1930.
Fry, W. K.: Fractures of the Mandible in and Posterior to the Molar Region, Proc. Royal Soc. Med., London, **22:** 37–45 (Sect. Odont.), March, 1929.
Goodsell, J. O., Jr.: Treatment of Fractures of Edentulous Jaw, Dental Cosmos, **72:** 385–389, April, 1930.
Risdon, F.: The Treatment of Fractures of the Jaw, Canadian Med. Assoc., **20:** 260–262, March, 1929.

CHAPTER XI

DISLOCATION OF THE LOWER JAW

NORMALLY the condyloid process of the lower jaw fits into that portion of the glenoid fossa anterior to the glenoid fissure and rises forward onto the articular eminence. In this manner the temporomaxillary articulation is formed (Fig. 57, *A*, *B*). The capsular ligament holds the condyle in position. The stronger part of the ligament is to the outer side and posteriorly and the weaker portion is to the inner side and anteriorly. The oblique outer fibers of the capsular ligament extending from the root of the zygoma to the neck of the jaw have been termed the external lateral ligament. Internal to the joint and not related to it is a loose fascia-like band extending from the spinous process of the sphenoid bone to the inner

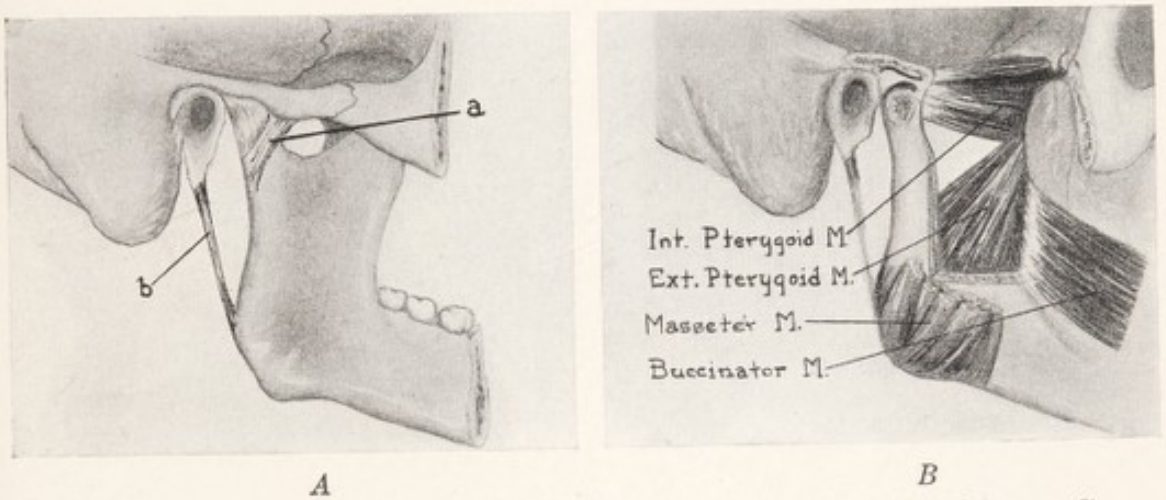

A *B*

Fig. 57.—*A*, Temporomandibular joint viewed from the external surface. *a*, Capsular ligament; *b*, stylomandibular ligament. *B*, Insertion of muscles of mastication about the joint.

margin of the posterior dental foramen. This ligament is called the internal lateral ligament. The stylomaxillary ligament also tends to strengthen the joint. Within the joint cavity is an intra-articular disk of fibrocartilage with two synovial sacs on either side. The intra-articular disk is elliptical in form. Its under surface is in the form of a concavity for the reception of the head of the mandible. Above and in front there is another cavity into which fits the articular eminence. Behind the cartilage is thicker and slightly convex where it fits into the glenoid cavity. The upper synovial sac is the larger of the two and the less fixed. The two sacs not infrequently communicate through a small perforation in the center. The movements of the joint are two: a to and fro swinglike motion which occurs when the mouth is opened and closed and a lateral movement that may be used, when food is to a certain extent ground between the molars. When the jaw is rather completely depressed the condyle glides forward upon the articular eminence but normally in ordinary small movements it maintains a position within the glenoid fossa. Posterior to the glenoid fossa

is the thin tympanic plate of bone which separates the fossa from the external ear canal. The roof of the fossa is also a thin bony plate.

VARIETIES OF DISLOCATIONS

Dislocations of the mandible may be divided into (1) forward dislocations (usual type); (2) upward dislocations; (3) backward dislocations; (4) outward dislocations, and (5) inward dislocations. All of the varieties of dislocations except the forward type are accompanied by fractures of either the condylar neck, the ramus, the base of the skull or the tympanic plate. Thus, they are fracture dislocations and not simple dislocations.

Upward Dislocation.—When the thin roof of the glenoid fossa is fractured by an upward force, the head of the mandible may be dislocated upward. According to Blair, Le Fevre has reported such a case. The condition is so rare that it would rank as a surgical curiosity. A blow on the chin or on the angle of the mandible if the molar teeth were absent might conceivably produce such a fracture. After such a fracture dislocation the movement of the jaw is limited and the ramus of the jaw apparently shortened. The condyle cannot be felt in its normal position. A roentgenogram shows the condyle pushed upward through the base of the skull. A stereoscopic roentgenogram allows one to judge the exact extent of the fracture and the position of the fragments.

Backward Dislocation.—When the mouth is closed a strong force on the chin may produce a backward dislocation of the condyle. The tympanic plate is fractured and the tissues pushed backward into the external auditory canal. The chin recedes somewhat. When the dislocation is only unilateral the chin will deviate to the affected side. When the epithelial lining of the ear is broken, bleeding from the external ear is a symptom. The obstruction of the canal can be noted by use of an ear speculum. The condyle is felt posterior to its normal position. An *x*-ray should be taken to determine the exact position of the fragments and the condyle.

Outward Dislocation.—Accompanying this type of dislocation of the condyle a fracture of the ramus occurs. The deformity of the condyle can be felt exterior to the zygoma. The *x*-ray aids one in visualizing the exact location of the fragments. Roberts reported a case in which the body was fractured in front of the angle, and the condyle was to the outer side and above the zygoma.

Inward Dislocation.—This rare type of fracture dislocation I have seen once. The condylar head was dislocated inward from the glenoid fossa and the condyle neck was fractured. The mandible was fractured on the same side in the canine region, low down involving a part of the ramus. The roentgenogram shows the exact location of the fragments.

Forward Dislocation.—About two thirds of the cases of forward dislocation of the condylar head are bilateral. The type of dislocation is more frequent in women than men while the preceding types are more frequent in men as in the latter instances trauma is the decisive factor while in the former case, the strength and tenseness of the ligaments and muscles about the joint are of more importance. In extreme old age and in infancy one seldom sees a forward dislocation. In a difficult labor where the device of placing the finger in the mouth is used, it may occur. Nélaton attributed its more frequent occurrence in middle life to the greater length and strong

anterior inclination of the coronoid process (Hamilton). In the majority of instances, however, the direct cause is sudden muscular tension. In 25 of the 40 cases Malgaigne found muscular tension to be the decisive factor. Of the 25, 15 occurred during yawning, 5 during convulsions, 4 during vomiting, and 1 in a rage. When direct violence causes the dislocation some foreign body is often within the mouth, as in pulling of a tooth. A blow on the chin when the mouth is open will also at times produce the dislocation.

ANATOMY AND MECHANISM

The lower jaw is held up in position by the normal muscular tension of the temporal, masseter, internal pterygoid, and also by a small part of the external pterygoid muscle. Most of the pull of the external pterygoid muscle is a forward pull on the upper condylar neck. However, the alternate action of the internal and external pterygoid muscles may tend to move

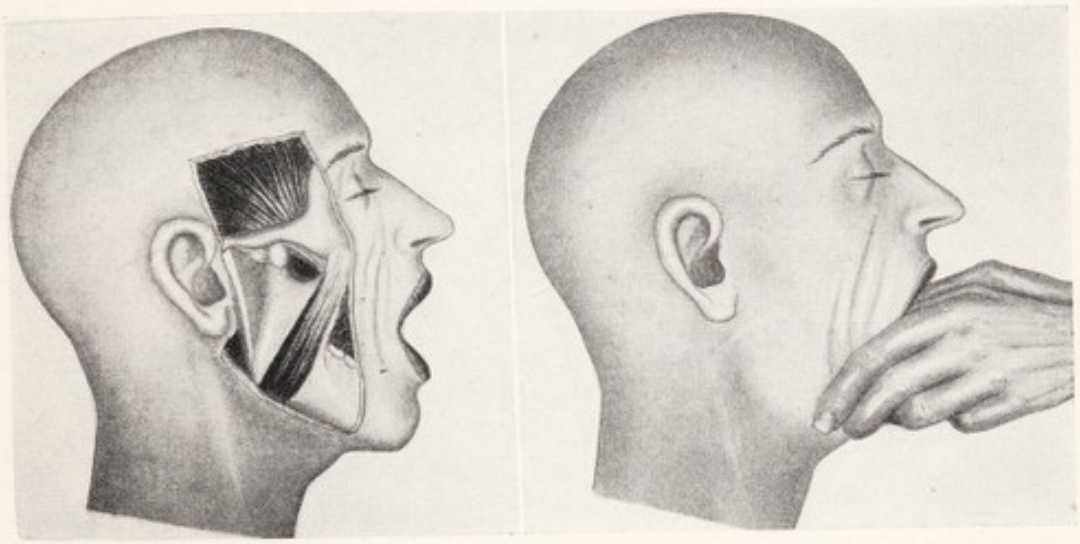

A *B*

Fig. 58.—*A*, Condyle forward of articular eminence in a position of forward dislocation. *B*, Method of replacement of displacement with the thumbs on the molars.

the jaw laterally and back. The muscles of the floor of the mouth pull downward and backward.

On opening the mouth fully, the condyle slips forward, rises on the articular eminence until it rests upon its summit. Hamilton was of the opinion that in most individuals the condyle even passed the summit of the articular eminence when the mouth was fully opened. If Hamilton was correct, the capsule only needs to be relaxed to cause a dislocation allowing the condyle to slide forward and occupy a position directly in front of the eminence (Fig. 58).

The external lateral ligament is very important in maintaining the head of the condyle in its dislocated position. The other ligaments also aid. The direction of pull of the external lateral ligament when the condyle is in its normal position is upward and backward. When the condyle moves forward the lower attachment of the ligament falls directly beneath the upper attachment. Because of the articular eminence the ligament does

not become slack. After the head travels still further forward, the axis of motion which is normally near the opening of the inferior dental canal changes somewhat and takes a point at the insertion of the external lateral ligament beneath the neck of the condyle. On this new axis the head tilts forward and the lower attachment of the ligament is carried forward of the upper attachment and it therefore still remains taut. Now, the muscles of mastication are unable to throw the head backward as normally they do because the head is thrown backward against the anterior surface of the articular eminence. The external lateral ligament is now the fulcrum and the temporal, internal pterygoid and anterior part of the masseter pull on the long handle of the lever. The stylomandibular and internal ligaments aid also in holding the abnormal position. As a rule, the ligaments are not ruptured in an anterior location. But the capsule is often torn especially if the head originally travels well forward of the articular eminence, at the primary dislocation. The meniscus is thought to go forward with the condyle as the external pterygoid muscle is attached to the meniscus as well as the condyle.

The combined action of the two pterygoids in complement with the action of the masseter may produce a forward dislocation when the mouth is widely opened. A slight blow with the mouth open may contribute an additional factor causing the muscles to contract just as the condyle is well forward of the eminence. After the dislocation has occurred, the condyle is drawn upward and forward by the two pterygoid and the temporal muscles. The coronoid process rests back of the superior maxilla or against the malar bone at the point of its junction with the superior maxillary bone. The chin remains in a descended position with the mouth open. The temporal, the masseter, and the two pterygoid muscles are stretched considerably if not possibly lacerated.

SYMPTOMS AND DIAGNOSIS

When the dislocation is bilateral the mouth is held open and the jaw is nearly fixed. The chin cannot be elevated as the coronoid process is resting on the maxilla and the malar bone. The mandible is slightly advanced. A depression can be felt in the position normally occupied by the condyle in front of the auditory canal while a slight fulness is made out in the temporal fossa and also on the side of the cheek in the region of the masseter muscle. The condition is very painful and articulation is interfered with.

Unilateral dislocation causes nearly the same symptoms but the signs are only on one side, the mouth is not opened so widely as in bilateral dislocation, and the jaw is not so fixed. On the side of the dislocation, the condyle can be felt anterior to the articular eminence. A depression can be made out at the normal position of the condyle. The chin deviates to the side opposite the dislocation and will be found to be a little forward.

TREATMENT

In an **upward dislocation,** treatment consists of pulling the condyle from the middle cerebral fossa. Under a general anesthesia, this should be possible ordinarily without operation. However, it is conceivable that opera-

tive approach and removal might be necessary. The same approach can be used as for ankylosis of the joint (see Chapter XX).

In a **backward dislocation** treatment will consist of drawing the jaw forward and retaining it by wiring the lower teeth to the upper teeth for about three weeks. An attempt to remold the external auditory canal so that it will not be blocked is advisable also.

In **outward dislocation,** under a general anesthesia the ramus is pushed outward until the condyle is freed from the zygoma, after which the angle is pushed downward and into its normal position. The teeth are then wired together for three or four weeks.

In **internal dislocation,** a general anesthesia is given and by manipulation with the finger of one hand inside of the mouth and finger of the other hand over the condylar region an attempt is made to throw the condyle into its proper position. In our case this was possible. The upper and lower teeth are then wired together for about four weeks. It is conceivable that operative interference might be necessary in some instances. After manipulation the position is checked by the roentgenogram. In the preceding type of dislocation one has to consider the fracture as well as the dislocation so that in the treatment a logical combination of the procedures used in fracture treatment as well as those used to replace or hold the dislocation are necessary. Under fracture of the jaw, these procedures are more fully described.

Anterior Dislocation.—The treatment consists in reducing the dislocation and retaining the condyle in its normal position, while the torn or stretched ligaments are uniting or regaining their tone. There are two methods of obtaining reduction: (1) by traction, which causes the ligaments and the muscles to relax sufficiently to allow the condyle to pass the obstruction and slip into the glenoid fossa, and (2) by manipulation which brings the condyle in reverse order into the various positions through which it traveled as it left the glenoid fossa. The later procedure is the preferable one. It requires less force and gives less pain. The former may inflict more damage than has already occurred.

Hippocrates thought that reduction was prevented by the coronoid process impinging on the malar bone. Thus, in order to free it, he depressed the chin and pushed the jaw backward at the same time encouraging the patient to relax this muscle. Galen and others followed this method. For a time this method was lost sight of and force was used to overcome the muscular and ligamentous resistance. Maisonneuve (1862) after a careful study concluded that the spasm and resistance of the muscles and ligaments prevented reduction and that these could be overcome best by direct backward propulsion after opening the mouth more widely.

Stimson has reported a case where the meniscus became detached and folded up in the glenoid fossa and prevented reduction. In such a case the joint should be exposed and the meniscus removed.

Reduction by Traction.—The body of the jaw is grasped on each side with the thumbs on the occlusal surfaces of the molars (Fig. 58, *B*). Downward traction is made on the ramus and at the same time an attempt is made to raise the chin and push the condyle or condyles backward into the glenoid fossa. When one does this the thumbs should be protected with some type of padding. Otherwise when the jaws snap together on reduction the thumbs

are likely to be pinched. This reduction is much facilitated by an anesthesia to relax the muscles. Gilmer suggested placing a wedge of wood in the region of the posterior molars to use as a fulcrum against the upper jaws.

Reduction by Manipulation.—An anterior dislocation has been known to reduce itself spontaneously. Stimson pointed out that the most gentle methods are those in which the condyle is carried back through the position in inverse fashion to those assumed at the time of dislocation. The mouth is opened more widely to relax the spasm of the muscles. The theory is that as the chin is depressed, the lower end of the rami travels upward and backward which relaxes the ligaments and disengages the condyle from the articular eminence. Then, the backward pressure is made on the ramus, causing the condyle to glide over the articular eminence after which reduction is complete.

Retention.—Some means of preventing a recurrence of the dislocation must be provided. The condyle does not rise up on the articular eminence until the mouth has been opened at least 1 cm. The point is to prevent the mouth from opening too much for several weeks. There are several ways to do this. The simplest is the Barton head-to-chin bandage but the patient may not find it convenient to wear a bandage. The neatest and less handicapping procedure is to place a gold band about the upper bicuspid and a lower bicuspid and pass a strand of braided silk between the two in such a way that the jaw can only open to a distance of about 1 cm. Three weeks is usually sufficient time for fixation for an acute dislocation.

UNREDUCED DISLOCATIONS

Both condyles have been excised for an old unreduced dislocation (Mazzoni) with an ultimate good functional result. Ordinarily such a drastic procedure is unnecessary. Under an anesthesia the jaw is replaced and the teeth wired together for about a month or five weeks. The condyle and the ligaments adapt themselves to their new position. In some instances, if the reduction fails to remain, it might be wise to explore the fossa and clear out any tissue obstructing the reduction.

CHRONIC DISLOCATION AND SUBLUXATION

Chronic dislocation and partial subluxation are degrees of the same malady, the former being the more pronounced degree of the latter.

Occasionally when a dislocation is repeated it becomes chronic. The condyles slip forward at almost any time the mouth is widely opened.

Subluxation is a partial dislocation of the condyle or condyles. The condition occurs as a rule in young individuals with atonic muscles and relaxed ligaments. The condition is rare. The relaxation of the ligaments is the factor of most importance. On yawning or even on eating there is a sudden arrest of motion of the jaw and the mouth hangs open half way. The chin deviates as described under unilateral dislocation when the condition is unilateral. The patient complains of pain. Usually on manipulation the condyle falls back into its proper position easily. The condyle or condyles can be palpated forward of the normal position.

There is a less pronounced form of this condition in which either the joint and the teeth or both snap because of an atonic condition of the

temporomandibular joint capsular ligament (see Chapter XX on Snapping Jaw).

Treatment.—Nieden has advised reinforcement of the lateral ligaments of the joint with a fascial band from the temporal muscles (Fig. 59). Annondale advised turning the meniscus forward and suturing it to the condylar neck.

Konjetzny also opened the mandibular joint, severed the meniscus at its posterior and lateral attachments, and after the insertion of the external pterygoid muscle was severed, the meniscus was rotated at right angles and sutured in front of the condyle. The lateral and medial portions of the attachment of the meniscus to the joint capsule were left attached. Again, more recently (Morris) it has been recommended that the meniscus be folded upon itself and stitched over the articular eminence (Fig. 59, A, B). Axhausen and Dufourmentel have advised removal of the meniscus. The

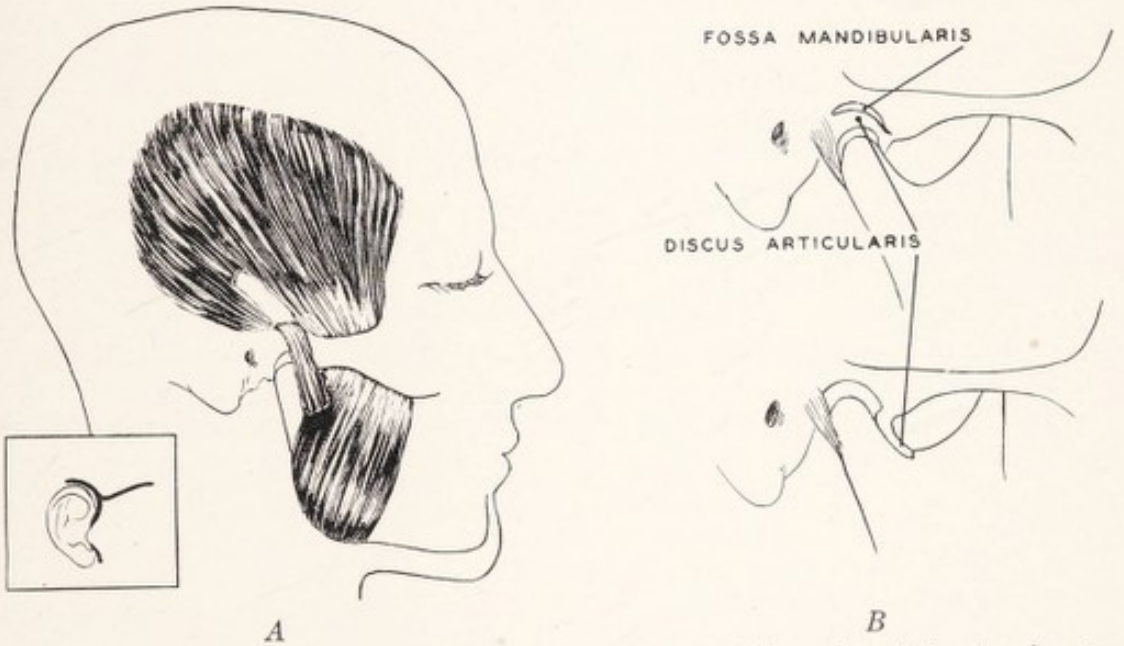

Fig. 59.—*A*, Nieden's method of preventing chronic dislocation of the jaw by turning fascia down and stitching it to the ramus. *B*, Preventing chronic dislocation of the jaw by turning the meniscus forward and suturing it to the condylar neck.

operation of Nieden is simpler. It seems logical. Open operation ordinarily should be reserved for those patients with persistent repeated catching of the jaw.

A simple procedure that should be tried first but one not always particularly curative is to have the patient continuously wear the gold band silk strand appliance previously described under treatment of anterior dislocation.

Bibliography

Bibliography Quoted in Text

Annondale, T.: Displacement of the Interarticular Cartilage of the Lower Jaw and Its Treatment by Operation, Lancet, **1**: 411, 1887.

Axhausen, G.: Pathology and Therapy of the Temporomandibular Articulation, Fortschr. d. Zahnheilk., **7**: 199, 1931; **8**: 201, 1932.

Blair, V. P.: Surgery and Diseases of the Mouth and Jaws, C. V. Mosby Co., 1917, St. Louis.

Blair, V. P., and Ivy, R. H.: Essentials of Oral Surgery, St. Louis, C. V. Mosby Co., 2nd ed., 1936.
Blair, V. P., Padgett, E. C., and Brown, J. B.: Graham's Surgical Diagnosis, vol. 2, W. B. Saunders Co., Phila., 1930.
Dufourmentel, L.: Chirurgie de l'articulation temporo-maxillaire, p. 83, Paris, Masson et Cie, 1929.
Temporomandibular Crepitus Treated by Resection of the Meniscus, Bull. et mém. Soc. de chir. de Par., **16:** 389, 1924.
Treatment of Temporomandibular Ankylosis, Paris chir., **16:** 300, 1924.
Gilmer, T. L.: Lectures on Oral Surgery, 1901, Chicago.
Archives of Dentistry, **4:** 388, 1887.
Hamilton, F. H.: A Practical Treatise on Fractures and Dislocations, 1891, Lea Bros. and Co., Phila.
Konjetzny, G. E.: Arch. f. klin. Chir., **116:** 681, 1921.
Le Fevre: Journal Hebdomadaire, **3:** 133, 1934.
Malgaigne, J. F.: A Treatise on Fractures, Phila., J. B. Lippincott Co., 1859, J. H. Packard Trans.
Morris, J. H.: Chronic Recurring Temporomaxillary Subluxation, Surg., Gynec. and Obst., **50:** 483–491, 1930.
Nélaton: Quoted by Hamilton.
Nieden, H.: Ueber operative Behandlung habitueller Kieferluxationen, Deutsche Ztschr. f. Chir., **183:** 358, 1923.
Roberts: Arch. gén. de méd., 1845.
Stimson, L. A.: Practical Treatise on Fractures and Dislocations, Lea and Febiger, New York, 6th ed., 1910.
Galen, Hippocrates, Maisonneuve, and Mazzoni: Quoted by Blair, V. P.: Surgery and Diseases of the Mouth and Jaws, St. Louis, C. V. Mosby Co., 1917.

Supplementary Bibliography

Kappis, M.: Fracture Dislocation of the Condyle of the Jaws, Zentralbl. u. Chir., p. 814, 1934.
Mayer, L.: Recurrent Dislocation of the Jaws, Jour. Bone and Joint Surg., **15:** 889, 1933.
Orlowitch, Wolk: The Results of Konjetzny Operation in Habitual Luxation and Subluxation of the Jaw, 1928, Dissertation, Kiel.
Schmidt, G.: Operative Treatment of Unusual Types of Dislocations of the Jaw, Deutsche Ztschr. f. Chir., **233:** 536, 1931.
Staplemohr, S. von: Crepitation of the Temporomaxillary Articulation and Habitual Luxation of the Jaw, Acta Chirur. Scand., **65:** 1, 1929.
Wakeley, C. P. G.: The Causation and Treatment of Displaced Mandibular Cartilage, Lancet, **217:** 543, 1929.

CHAPTER XII

INFLAMMATIONS AND DISEASES OF THE SOFT STRUCTURES OF AND ABOUT THE TEETH

Diseases of the teeth and the parodontium are very often of an inflammatory nature and therefore fall in the field of surgery or if such in the strict sense is not the case, some familiarity with their characteristics is necessary for diagnostic purposes.

Gingivitis

A gingivitis is an inflammation of the gingiva proper. At times the term "ulitis" has been used. Very often a gingivitis merges rather indefinitely into a stomatitis—an inflammation of the oral mucosa in general. Into the group of terms used to describe the various types of gingivitis common usage has lent some definiteness to a variety of terms not exactly conforming to a classification from any one standpoint such as regional terms (marginal), etiologic terms ("cotton roll"—"pregnancy"), various anatomic terms (atrophic, hypertrophic), and various pathologic terms (desquamative—ulceromembranous—gangrenous).

The reason for this state of affairs is twofold. First, the exact etiology of a considerable number of the inflammations of the gingiva is not known. Second, it is probable that an indefinite pathologic terminology sometimes has caused different stages of the same inflammatory disease to be described as separate disease entities.

MARGINAL GINGIVITIS

(Simple, Traumatic, Toxic, Idiopathic, Gingivitis Calculosa, etc.)

Marginal gingivitis is an inflammation of the gingival margin and papilla. The difference between the acute, subacute, and chronic forms is purely a quantitative one. The following factors have been considered of importance in its initiation and propagation: food débris, highly spiced or tempered foods, condiments, stimulants, calcareous deposits, tobacco, betel nut chewing, caries, faulty dental restoration, toothbrush bristles, cement dust, sand blower's dust, chemical irritants, etc. An idiopathic type has been described. Besides these local factors, a lessened resistance of the gums due to a constitutional malady, such as diabetes, leukemia, scurvy, etc., sometimes may be the basic cause.

Pathology.—Early there is a mild succulent increase in the volume of the gingival margin within the so-called "annular ligament." There may be some superficial excoriation and exudation. The papillae are enlarged and edematous and may be lifted from the interdental spaces. On smear the increased material in the gingival crevice and a marked increase of the various organisms ordinarily found in the mouth are noted. The spirochete and fusiform bacillus and the Endamoeba buccalis often are present. An edentulous mouth, of course, does not have the disease.

Clinical Picture.—The gingival margin and the interdental papilla become red, thick and swollen, engorged and bleed easily. A mild type of parodontitis may be present. The teeth feel more elongated than normally. No pain is felt but mastication is not pleasant. The disease may be confused with the so-called "acute ulcerative gingivitis" (Vincent's disease). The greater severity of the symptoms and a smear showing a predominance of the spirochete and fusiform bacillus should aid one in making the distinction.

A localized inflammation of the gingiva sometimes follows prolonged contact of cotton rolls (*cotton roll gingivitis*) as used by the dental practitioner to keep the operative field dry. The surface shows the appearance of the inflammation the following day. The epithelium may desquamate. This is especially likely if caustic drugs have been used during the operation. To prevent this type of gingivitis, a thin coat of

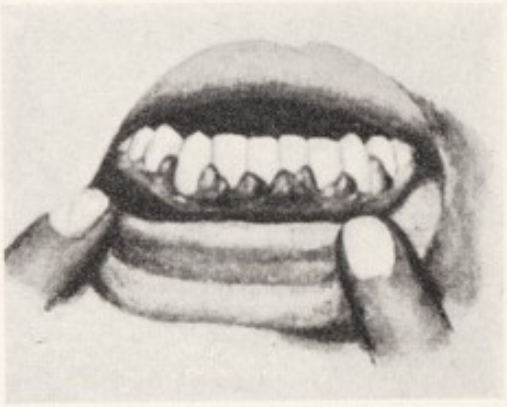

Fig. 60.—Proliferative marginal gingivitis in pregnancy, labial aspect. (Monash, Surg., Gynec., and Obst.)

petrolatum is placed over the gingival surface prior to the insertion of the cotton roll.

Within the labial region of the lower anterior teeth or less frequently lingually or sometimes about the upper teeth, *during pregnancy* (Fig. 60) a mild type of chronic marginal gingivitis is occasionally seen. This type of gingivitis usually starts during the first or second month of pregnancy. Besides the relatively mild affection there may appear during pregnancy a rapidly progressing dental caries, a considerable hypertrophy of the gingival tissue, exacerbation of any disease processes in the parodontal tissues or tendency of hypertrophy of the gums, and fungoid growths of the papillae. The development of such a new growth as epulis is enhanced at this time. The tendency is for these lesions to clear up after delivery and unless mastication is interfered with need not be removed until that time.

The *treatment* should be threefold: first, wash the gums and mouth with a mild antiseptic solution and then remove all solid deposits with instruments. Mild alkaline astringent such as a weak boric solution combined with hydrogen peroxide is of value.

Often the patient should be checked over generally to rule out some general disease of which the marginal gingivitis may be only a local manifestation.

PYORRHEA ALVEOLARIS—PARODONTITIS (Praeger)

Definition.—Prinz has described pyorrhea alveolaris as a mechanical interference of the physiologic absorption of the parodontium accompanied by excessive proliferation of the external epithelial enamel cuticle at the point of its union with the epithelium of the gum tissue which is known as the epithelial attachment.

Pierre Fauchard in 1746 under the term "scurvy of the gums" described a lesion of the gums which did not heal and terminated in the loss of the teeth. In 1867, John W. Riggs of Hartford described the disease as a suppurative inflammation of the gums with absorption of the alveolar processes and attributed the disease to local cause. During this century many workers have studied the pathologic anatomy of the disease (Talbot, Hopewell-Smith, Box, Gottlieb, Weski, Broderick and others) and a great many clinicians have studied the disease with great care at first hand.

Etiology.—The six principal factors which have received attention are: the factor of salivary calculi, of infection, abnormal occlusal stress, constitutional disturbance, diet, and alveolar atrophy.

Factor of Salivary Calculus.—The presence of salivary calculus has always attracted attention in pyorrhea, and the so-called "serumal type" in the past has been given credit for the causation. But probably all dental calculi are formed from saliva and its contents. Possibly when such elements are present in the saliva, they may act in a contributory way. Most observers while admitting that subgingival calculus is practically always present, agree that it is not the cause of the formation of pus pockets but in reality represents the sequence.

The Factor of Infection.—Without infection and ulceration pyorrhea does not exist. But as in so many other diseases the difficulty is to distinguish primary invading organisms from secondary invading organisms. Starting with Gallippe in 1894 many attempts have been made to isolate a specific organism as the sole causative agent of pyorrhea. About 1914 Smith and Barrett, Bass and Johns, isolated Endamoeba buccalis from the pockets of pyorrhea alveolaris. But soon it was shown that the Endamoeba buccalis was only an incidental secondary invader and when the parasite is eliminated the progress of the disease remains unaltered. More recently Kolle and Beyer (1918) have shown some data which to them appeared to be indicative of a specific bacillus.

All research along this line has resulted in collateral data of a more or less uniform nature, that is, that the infection is a mixed one. The ordinary pyogenic organisms ever present in the mouth and on the skin are the ones cultivated. Most men have concluded that the infective process is a secondary affair.

The Factor of Occlusal Stress.—In 1894 Karolyi insisted that malocclusion of the teeth with the resultant abnormal occlusal stress was an etiologic factor of importance in the causation of pyorrhea alveolaris. During the past quarter of a century, this conception has been much discussed. In 1915 the Hungarian Dental Society investigated the matter. They concluded by referring to a number of positive factors which favored the conception of abnormal occlusal stress as a dynamic factor in producing pyorrhea but on the other hand, an equal number of negative factors spoke against the theory. Although many more recent articles pro and con

might be cited, the matter rests now somewhat as it did in 1915. In certain individuals who develop pyorrhea alveolaris, abnormal occlusal stress is a factor of importance.

The Factor of Constitutional Disturbances.—The relationship of constitutional disease has been stressed but the evidence is indefinite and of a clinical character. Those with clinical experience often have commented upon the fact that conditions which interfere with the health of an individual over a long period of time seem to predispose at times to diseases of the parodontium. Diseases which have been accused of contributing are diabetes, gout, chronic nephritis, chronic cirrhosis, anemia, leukemia, certain endocrine diseases, and certain chronic infectious diseases. Aside from the supposition that in certain instances such diseases may predispose, no positive information is available. The possibility of auto-intoxication from the gastro-intestinal tract has been stressed by some. The acid-base balance of the body is, however, a fairly definite protective mechanism.

The Factor of Diet.—Recent animal experiments point toward general diet factors as being of importance. Mellanby believes the structures of the periodontal membrane are controlled by diet as are those of the teeth. His experiments suggest that the problem of periodontal disease is fundamentally a problem of nutrition. Periodontal disease is most likely to occur in individuals deficient in vitamin A (growth factor) and vitamin D (antirachitic) according to Mellanby's experiments, and he found the diet factor more important in the young. According to him, if the diet is correct in early life the tissues are much more resistant in later life. In animals even in later life, however, he finds that the diet has an influence upon the onset and progress of the disease especially when the periodontal tissues are imperfectly developed.

The Factor of Alveolar Atrophy.—Principally, Gottlieb but also others during the past two decades have furnished histologic proof when teeth are erupted that the continuous separation of the external enamel epithelium from the remaining Nasmyth's membrane takes place coincidently with the recession of the alveolar process and when the cemento-enamel junction is approached by the retracting gingival trough, there is a proliferation of the epithelial attachment into the periodontal space. This normally is a harmonious occurrence but a disruption of this involuntary process is conceived by these workers as being the principal etiologic factor in the production of pyorrhea alveolaris.

At present the factor of alveolar atrophy combined with other contributory factors is favored by many authorities as being the most plausible explanation of pyorrhea alveolaris.

Discussion.—It is probable that the disease is a manifestation of a more general defect in its onset at least and that local factors do play a contributory part—secondarily. Probably in some way an ill-nourished gingival tissue is subjected to some chronic irritation and the cells are no longer able to cope with the aggressive action of the pyogenic organisms of the mouth because of some constitutional deficiency. At present deficiency of vitamins A and D has the backing of some recent experimental evidence.

Pathology.—In pyorrhea alveolaris one of the most outstanding pathologic characteristics is the eventual absorption of the alveolar process.

Probably localized increased circulation is necessary to its purpose. The rarefaction within bone caused by any type of granuloma is an example.

Within the gingival trough, débris, calculi, and bacterial organisms collect and the underlying connective tissues become infected—a cellulitis of the gingivae results. An ulcer is formed with granulation tissue base. Finally, the underlying bone is involved and rarefying osteitis involves the alveolar process. Coincidently with the preceding occurrences the epithelium which lines the gingival trough proliferates, shows hyperplasia and appears to penetrate into the parodontal space working toward the apex of the root of the tooth. Sections taken at the beginning of the process through the fibers of the circular ligament show projections of sprouting epithelium crawling downward in the form of spurs. Later the "spurs" show an increased growth laterally. The parodontal space is enlarged. The overlying gum is swollen and hypertrophied. A pocket is thus formed which has inadequate drainage. Sticky adhesions, food débris and subgingival calculi all tend to aggravate the original damage.

Noyes demonstrates that the perivascular lymphatics of the blood vessels of the peridental membrane which run principally parallel with the tooth root encourage the spread of infection along the peridental membrane. Thus, the lymphatic anatomy is such that the infection may spread along the tooth instead of around the teeth. The principal fibers of the peridental membrane, which attach it to the cementum of the tooth tend to be destroyed. The cementum continues to act as a denuded foreign body. Reattachment of the peridental membrane does not occur. Thus, finally the peridental membrane becomes converted into a granulation tissue wall and the cavity between the cementum and the granulation tissue becomes a pocket for the accumulation of pus. After the process is well developed there is a tendency for it to continue and involve the whole of the peridental membrane of the tooth and adjacent teeth, unless adequate treatment halts and heals the diseased tissues. As the alveolus is absorbed the gum contracts and rolls inward as the scar tissue on the outer wall of the loosened gum pulls it inward. Finally, the teeth become loosened and seem as if they would fall out of their sockets.

Specificity of any particular organism has not been demonstrated. All the organisms found in the mouth have been cultivated including the Endamoeba buccalis and fusiform bacilli and spirochetes. As many as 20 organisms have been cultivated from 1 case.

Symptoms and Signs.—Pyorrhea is essentially a chronic disease. Instances of fairly rapid course are seen, however, and acute exacerbation of chronic disease is also observed. In women during menstruation or pregnancy an exacerbation may be seen.

From the clinical standpoint one may divide pyorrhea alveolaris in two broad types: (1) the horizontal type and (2) the vertical type.

Horizontal Type.—The great majority of sufferers from the disease are of the horizontal type (90 per cent, Prinz). Although rarely seen in the adolescent, this type is not entirely restricted to middle age. Cases appearing in children are reported by Hopewell-Smith (aged ten years), Miller (eight to nine years), and Kranz (aged ten to twelve years).

Typically the horizontal type of pyorrhea attacks either several adjoining teeth, the teeth on one side, or even all of the teeth. Early the gum

margins show a thickening and rounding of the margin and cease to be attached firmly about the neck of the tooth. The gum is hypertrophic and red. The odor of the breath becomes tainted. As the disease advances some complaint is likely to be made of tenderness on mastication. This is the picture of chronic marginal suppurative gingivitis. Although fairly early rarefaction of the alveolar margin may be found, loosening of the teeth does not begin to develop until late in this type of the disease. Bone resorption tends to be greater along the outer plate in the maxilla while in the mandible the entire alveolar process tends to be resorbed in a more even manner.

Following this marginal inflammation, the gingival trough deepens and a shallow pocket develops with particular definite location about the tooth. Usually the depth of the pocket is more or less uniform and reaches to the marginal edge of the resorbed alveolus. The connective tissue is exposed, becomes infected and suppuration follows. Commonly large quantities of friable supragingival calculus which tend to penetrate into the pocket are found to be deposited on the crowns of the affected teeth. The apical

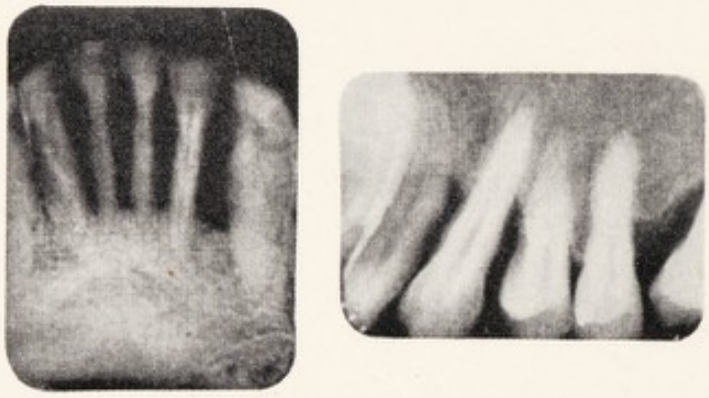

A *B*

Fig. 61.—*A*, Typical horizontal pyorrhea. *B*, Typical vertical pyorrhea. (Prinz and Greenbaum, Diseases of the Mouth and Their Treatment, Lea and Febiger, Publishers.)

end of the teeth remains firmly implanted in the remaining alveolus. In the roentgenogram a typical case of the marginal type of pyorrhea alveolaris shows a horizontal type of resorption of the edges of the alveolar plate with little enlargement of the peridental space (Fig. 61, *A*). The tributary lymph nodes are ordinarily not clinically involved.

Vertical Type.—The vertical type is really the genuine type of pyorrhea. Very fortunately it is far less common than the preceding type (10 per cent, Prinz). The disease is seldom observed before twenty-five years of age or after sixty years of age. It is essentially a disease of early middle life with the greatest age incidence in the third and fourth decades of life. Some observers (Tomes, Arkoevy) state that the disease occurs slightly more commonly in men. Others find no difference in the sex incidence.

As a rule, the disease tends to be more or less restricted to isolated teeth. When a group of teeth are involved, it is more commonly the four lower incisors. The next group in frequency are the lower molars. No definite rule can be laid down as to the frequency of involvement of an isolated tooth but Prinz has stated that "in point of frequency the upper incisors

and cuspids, the lower bicuspids, the upper biscuspids, the upper molars and finally, the lower cuspids follow in routine sequence."

Pierce pointed out that the earliest sign of a vertical pyorrhea is a diffuse redness of the labiobuccal gum tissue with some recession of the interdental papillae in the affected area. At first subjective symptoms are practically nil. Later if a diffuse alveolar atrophy should supervene, pain may appear after mastication. Patients with a pronounced vertical pyorrhea who grind their teeth when asleep may complain of some discomfort on awakening. Manifestations of a chronic marginal gingivitis are often of only a slight degree or even practically nil. As the dentine of the roots of the involved teeth is exposed to fruit acid, sugar, and rapid changes in temperature may elicit considerable hyperesthesia. Lateral movement of the loosened teeth causes pain only late in the disease. Thus on the whole, genuine pyorrhea is ordinarily a painless disease. Roemer has stated that pyorrhea teeth usually contain atrophic, less reactive pulps. In advanced cases on awakening the patient complains of a bad taste in the mouth and, as a rule, has a mildly offensive mouth odor.

A characteristic clinical sign of pyorrhea alveolaris is separation and migration (Gottlieb) of the upper central incisors as they become loosened. The continued impact of the lower teeth on the posterior surface of the upper teeth exacerbates the process and causes deviation in a lateral and labial direction. When the separation between the incisors is considerable, the condition has been termed by Arkoevy as "pathological diastema." The anatomy of multiple-rooted teeth precludes migration as a rule. The process advances very slowly, but it is a pathognomonic sign of a diffuse alveolar atrophy.

The most characteristic sign of a vertical pyorrhea is the pocket which tends to form rather late in the disease. It is, as a rule, restricted to one side of the tooth and most commonly is the mesial or distal surface. The pocket varies greatly in size and depth. Although the shape is by no means always uniform, it often represents an inverted cone. One side of the pocket becomes lined with granulation tissue in the more advanced cases and, because of poor drainage, the pocket becomes filled with pus. Pressure of the finger over the pocket toward the crown of the tooth causes a droplet of yellowish, usually odorless, pus to appear at the gingival margin. Sometimes a bleb of pus will appear spontaneously.

Pocket formation is often not possible in a site directly over teeth with prominent roots which consequently have a very thin layer of alveolar bone. Resorption of the overlying gums and the alveolar bone takes place coincidently. Examples of such a site are the labial surfaces of the canines and the palatal surfaces of the upper molars.

The normal depth of the gingival trough according to Orban is about 1 mm. A depth of 2 mm. is of rare occurrence. Any depth greater than 2 mm. is to be regarded as of diagnostic value when accompained by other suspicious signs. Black devised a special millimeter gauge to ascertain the correct depth of the pocket—a very serviceable instrument.

Practically always some salivary calculus is present in a moderately advanced case of vertical pyorrhea, and as a rule, the deposit is of the subgingival type. The incrustations encircle the neck of the tooth below the detached annular ligament and they extend downward on the root

surface of the tooth into the pocket. Calculi are considered the sequence of the pocket and not the cause. They do, however, act as foreign bodies and encourage repeated flare-ups of infections.

Pericemental (interradicular) abscesses are found occasionally on the roots of teeth affected with vertical pyorrhea. Such abscesses have no connection with a dead pulp. They are the result of an inflammation of the pericemental tissue from a pocket deeper seated than the gingival trough.

When there is considerable infection in vertical pyorrhea, the tributary lymph nodes rarely may swell and become tender.

A tooth affected with vertical pyorrhea on percussion sounds duller than normal. This effect is due to the presence of the granulation tissue which replaces the alveolar bone and its alveolodental periosteum. Also if the tip of the finger is placed over the apex of the affected tooth during percussion, a vibration may be felt known as percussion fremitus. This abnormal peculiarity is caused by the progressive loosening of the tooth in its socket. In chronic apical pericementitis the same sign may be noted but then some pain is also present and in the latter case the pulp of the tooth is dead.

The roentgenogram of vertical pyorrhea is so characteristic that a diagnosis from the roentgenogram alone is rarely misleading (Fig. 61, *B*). But notwithstanding the roentgenogram should be used as only one sign of the disease. A careful clinical examination also should be made. Typically at the periodontal space is seen a diffuse line of bone rarefaction which becomes enlarged in width and dips in the shape of a cone into the alveolus. Weski suggested that if one wishes to observe the depth of a labial and lingual pocket that gutta-percha points be placed in the pocket before the roentgenogram.

It might be assumed from the foregoing description that only two distinct types of pyorrhea exist. Such, however, is not the case. Clinically, numerous combinations of both the horizontal and vertical varieties are observed. Also in connection with diffuse alveolar atrophy, numerous combinations of both the horizontal and vertical varieties are observed.

Diagnosis.—In the incipient stage the diagnosis is difficult. Early about the only recognizable sign is hyperemia of the labiobuccal gingivae and more or less atrophy of the interproximal gum papillae. The age of the patient has something to do with judging the situation; when he is in the later third decade the hyperemia may indicate a beginning senile atrophy of the alveolar bone. When he is in the fifth decade, this atrophy is probably of the physiologic senile type. The roentgenogram may verify clinical suspicion by showing horizontal atrophy of the edge of the alveolus which is recognized by the gradual exposure of the roots of the teeth (Fig. 62). Either pathologic or physiologic senile atrophy may be present, however, without pyorrhea being present.

If a marginal atrophy, diffuse, inflamed, hypertrophic, bleeding gums, subgingival and supragingival calculus, pockets containing pus, a foul breath, some pain during mastication, caries, and a generally dirty mouth are present, the diagnosis of horizontal (marginal) pyorrhea is clear.

On clinical examination, the outlining of a pocket with granulation tissue lining and purulent contents along with calcareous deposits on the

tooth is pathognomonic. The shifting of the anterior teeth, loosening and mobility of the bicuspid and molars are characteristic signs. Dental caries in many instances is absent. If the patient complains of pain on awakening, he possibly grinds his teeth when asleep due, in part, to a locked bite, or faulty occlusion.

Treatment.—The pathologic disturbance in pyorrhea alveolaris is primarily confined to the supporting structures of the teeth. The tooth is necessary to the entity of the parodontium. When the tooth is lost, the parodontium is absorbed and any diseased condition that existed, heals.

After pyorrhea alveolaris becomes progressive, an abnormal occlusal stress usually is present and causes an overstrain and disintegration of the supporting structures.

The best results in clinical treatment are obtained by applying the proper methods to the case in hand after correctly interpreting the causative factors. Pyorrhea alveolaris has not been cured by a specific drug or vaccine; it is not a disease caused by a specific organism but it is a condition where may be found various organisms as a result of and not

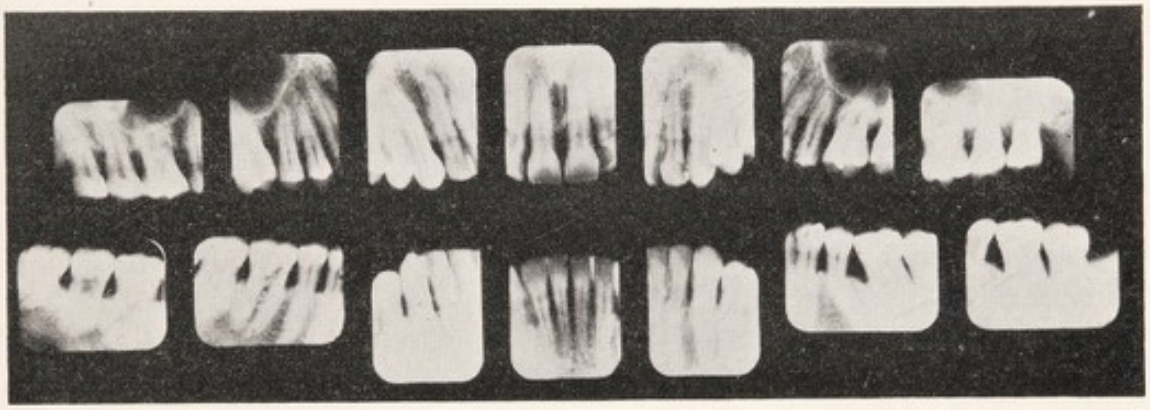

Fig. 62.—Showing destruction of the alveolar marginal bone about the teeth in chronic suppurative pericementitis.

the cause of the condition. Drugs, however, may be used as an adjunct but of themselves will not result in a cure.

Specific Instrumentation.—As subgingival calculi act as a continual irritant of the foreign body type, all calculi should be removed. This is done by the use of a special set of instruments which, according to the form of their cutting edges, are designated as scalers, planes, curets, and files. The selection of the proper instrument depends upon the personal equation of the operator and the case in hand. To facilitate the disintegration of the calculi on the surfaces of the roots, certain acids and salts may be used.

Local Medical Treatment.—The object of medical treatment is the examination of certain contributory factors, such as gingivitis, secondary infection with Vincent's organism or other local inflammation. Some men make an attempt to eliminate the ever present Endamoeba buccalis with a 1 per cent mixture of urea hydrochloride and quinine. The drug is applied in the form of a paste by means of a metal applicator after the pocket has been dried. Petrolatum may be used to seal the outlet of the pocket for a few minutes to allow the drug to act. The drug also acts as a mild local anesthetic so that drugs of a caustic nature, such as silver nitrate (10 per cent), zinc chloride (8 per cent), or copper sulfate (in the form of a paste

using 8 per cent zinc chloride solution as a vehicle) may be inserted to cauterize the granulations.

Hecker (1913) recommended a phloroglucin sulfuric acid compound for cauterizing granulations and sterilizing infected areas around the teeth and Prinz stated it had been satisfactory. About this time, Hecker also made one small cutting instrument with which he resected loose, flabby gum tissue.

When medical treatment would appear to be inadequate to cause obliteration of the pocket, surgical procedures for its removal are in order.

Correction of Abnormal Stress.—A kind of disarticulation is necessary in lessening abnormal occlusal stress. After a careful study of articulated models, the procedure most likely to give the desired results is adopted. Among the first procedures used was that of grinding the occlusal cusps of the offending teeth and this still is the simplest and most commonly used. Care, however, must be exercised not to grind too much as this would have a tendency to close the bite. In extreme cases, restorations or orthodontic appliances may be necessary to increase the vertical dimensions to permit the lateral shifting of the mandible and relieve the strain on the anterior teeth. When grinding the teeth, one should start cautiously with the molars, then the bicuspids, then the cuspids and finally, the anterior teeth. The final goal is perfectly balanced articulation or occlusion to allow for smooth forward, backward and lateral movement of the mandible and the relief of all existing abnormal stress on the individual teeth. The new alignment should be carried out to completeness of a balanced occlusion. Partial adjustment is likely to be productive of greater harm than good.

*Surgical Treatment.**—Medical treatment and instrumentation have often failed to bring about the obliteration of the pocket and restore a healthy mouth condition. When the pocket is more than 5 mm. deep, it likely will be found a physical impossibility to secure adequate drainage. To eliminate a pocket and any loose tissue around the tooth for which medical treatment has been ineffective, resection by means of the scalpel or the cautery is used. The operation may properly be referred to as gingivectomy in milder cases. In the more severe cases the operative procedure is somewhat more extensive than a simple gingivectomy.

It is interesting to note that fifty years ago Riggs performed an operation essentially of the nature of what is being done today but probably without the refinements that make up the present technic. As mentioned previously, this condition was for a long time known as "Riggs' disease." Arthur Black, Ward and others introduced and demonstrated what is now called the "surgical eradication of pyorrhea." This operation often has been referred to as "radical," but really is not as it consists only of thoroughly removing all diseased, loose, unattached gum and smoothing of the underlying bone or process.

The principle of the operation of gingivectomy is simple. Suppurative detachment of the dental periosteum from the cementum is permanent. The pocket which is formed along the side of the tooth affords a convenient incubator for the growth of organisms of the mouth. Dependent drainage

* Dr. Don Mosher, Kansas City, Missouri, rewrote most of the matter pertaining to surgical treatment.

is not obtained. These pockets can be eliminated by the removal of the overlying detached soft tissues with a scalpel or with the diathermic cutting needle. As the root is usually denuded to a lower level than the overlying bone, it may be necessary to trim off the edge of the alveolus in order to remove the granulation wall to the full depth of the pocket. The inner granulating wall is removed and drainage is given. The systemic danger is eliminated.

Opinion varies considerably as to the indications for gingivectomy. Some men state that in over 90 per cent of the patients in whom a surgical eradication of a pyorrhea is indicated, this operation is the only operation necessary (Mosher). Other men (Miller) state that the procedure should be resorted to only in lower molars in exceptionally well-kept mouths when the bifurcations are involved by the infective process and it is necessary to save the teeth for abutments or to preserve arch continuity.

Gingivectomy.—It is assumed that, previous to the operation (Fig. 64, *A, B*), any active infection of the mouth and exposed calculi have been removed and any occlusal stress corrected. Any necessary tooth extractions may be done before, at the time of the operation taking advantage of the anesthetic or afterward, depending upon the judgment of the

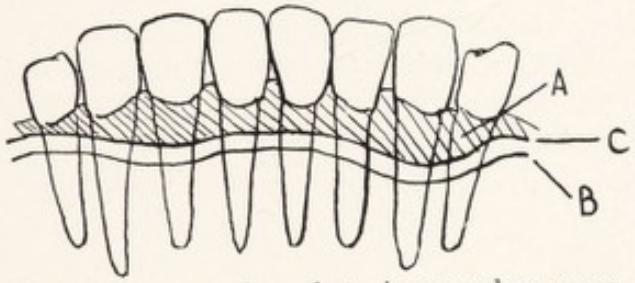

Fig. 63.—A, Position of gum and pockets in pyorrhea cases suitable for surgical treatment. B, Level of destruction of bone and line of incision for removal of infected tissue. C, Approximate amount of gum tissue which is restored in healing in advance of the first incision.

operator. The gum tissue to be excised is anesthetized with novocain-adrenalin solution (2 per cent) and by means of a sharp scalpel of proper design, and other instruments necessary to do a finished piece of work, the gum is removed down to the alveolar process on both buccolabial and palatolingual sides. The same thing applies to the interproximal spaces.

The amount of gum tissue to be removed is decided upon after careful clinical examination and the roentgenogram study is completed. These roentgenograms, to give a complete survey of the mouth, should include bite-wing films which give a more direct view of the interproximal spaces and at least 14 intra-oral films (Fig. 63).

In most cases it is best to operate upon one side of the mouth at a time. Usually, first the upper, then the lower teeth on one side are operated on at separate sittings. When healed, the procedure is repeated on the opposite side of the mouth, thus allowing one side for mastication throughout the operations.

The amount of destruction of the supporting structure can be definitely determined by the roentgenograms and the depth of the pocket can be definitely established making a sharp incision interproximally down to the alveolar process. The loose gum tissue is then removed, the alveolar

process at the bottom of the pocket is smoothed and all calculi removed. Postoperatively, the interproximal spaces and all areas which have been resected should be packed with gauze saturated in some antiseptic (10 per cent protargol is one) or, better, one of the newer medicated cement packings, which in addition to its germicidal effect forms a protective shield against irritation from the tongue, mouth, food and drink.

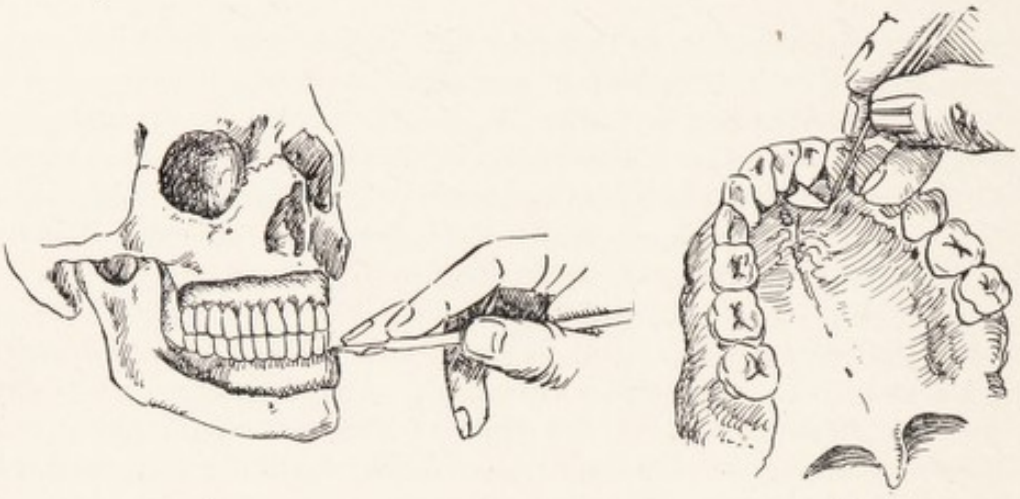

A *B*

Fig. 64.—Surgical treatment of pyorrhea (modeling composition has been laid around the teeth to imitate the gum structure). With approximal curet cut through the approximal gum adjacent to the distal surface of the right central until the resistance of healthy bone is felt which is the base of the pocket. Remove the curet and repeat the procedure on the mesial surface of the lateral incisor. Lift out the severed gum with point of the curet. Reverse the curet, that is, turn the teeth upward and use it to remove the calculus. Repeat this procedure on all approximal surfaces until the distal of the second bicuspid is reached. Proceed as on anterior teeth, except use contra-angle curets; push and pulls on molars and bicuspids. Use push curets except where teeth are in close contact, in which case first open the way with the pull curets.

Force the high point of the labial gum knives into the gum at the base of absorption indicated by the lowest point of incision made by approximal curets. Detach the labial gum at this point by working the instrument around the tooth. Scrape the surface of the cementum with the same instrument, proceeding to the second bicuspid.

Remove the gum tissue at a point a trifle lower than the incision made by approximal curet on molars and bicuspids with molar gum knives.

From a position directly behind the patient, remove lingual gum on anteriors with lingual gum knife.

Finish off the alveolus, labial and lingual surfaces with bone hoes. Pack over blood clots with thick mix of wondrpak, always packing toward contact points. *Leave pack in ten days or until alveolus is entirely covered with new tissue.* (Explanation for technic from Postoperative Care in the Surgical Treatment of Pyorrhea, by A. W. Ward, D.D.S. Reprinted from Jour. Amer. Dent. Assoc., April, 1929.)

In from two to three weeks, the teeth will be surrounded by new, thinned, scarred gum tissue.

Recently, the bipolar electrode has been used to excise the gum tissue (Webb). In using the bipolar cold cutting electrode, the hemorrhage is less than when a scalpel is used. But the principle of this operation in removing the tissue is in no way changed by using a different method for cutting purposes.

The Flap Operation.—Widman, in 1911, advocated a different surgical procedure than the simple gingivectomy as just described. More recently Kirkland has discussed the flap technic. As the detachment from the root

in advanced pyorrhea is usually deeper than the destruction of the overlying bone, it becomes necessary, if surgical treatment is to be effective, to trim off the edge of the alveolus in order to remove the soft tissues to the full depth of the pocket. The operation is used for the elimination of a pocket or pockets in single multiple teeth in which gingivectomy would seem an insufficient procedure or when for esthetic reasons objection is raised to considerable destruction of the gum. The flap operation sometimes may result in deficient drainage, and defeat its own end. The entire involved gum tissue on both sides of the teeth is lifted up; the edge of the alveolar process is removed, the granulations excised, the calculi on the surface of the roots are cleared away, and the gum flap is then replaced and held with a few sutures.

The mouth is placed in a hygienic condition. Novocain-adrenalin by infiltration or conduction is used for the anesthetic. The area to be operated is cleansed with an antiseptic solution. A flap of the width required to give the necessary exposure is raised by making two slightly oblique incisions. The incisions start at the apical region of the gum and they are carried to the cervical margin on either side of the involved area. The incision severs the mucosa, the submucosa, and the periosteum. The interstitial gum is separated with a special triangular pointed knife. The full thickness of the flap is raised from the bone with a flat elevator, and it is retracted back. The diseased tissue is exposed. All the granulation tissue between and surrounding the roots is removed. With a small chisel and round burr the rarefied alveolar overhang is cut away from the denuded roots. The calculus is scaled off after which the roots are polished. The flap is replaced and held by a few sutures at each end of the incisions and between the teeth. The part of the free edge of the flap which will not be needed to cover the alveolar bone may be cut away with scissors. It has been stated that new bone formation takes place around the roots. Although this probably does not occur when the flap becomes bound down with scar tissue, the loosened teeth are held much more firmly. After five or six days the sutures are removed. The patient is then treated in a way to promote a general state of good health.

Postoperative Care After Operations for the Eradication of Pyorrhea.—Experimental evidence suggests the importance of getting the patient on a diet containing adequate amounts of the vitamins A, C and D. The calcium-phosphorus ration should be adequate.

After therapy as soon as possible gum massage with a brush three times daily is to be recommended.

In some cases cutting away of the gum may be contraindicated for cosmetic reasons.

Extraction.—In the decision of whether or not to remove the teeth, their value for purposes of mastication should be weighed against the systemic danger of their retraction. When a tooth is loose and radiographic evidence also shows that a sufficient amount of the alveolar ridge has been destroyed about the tooth to render it permanently unstable, the tooth should be removed. See indications for extraction of a tooth (Chapter XIII).

Prognosis.—Usually a fairly favorable outlook can be forecast in horizontal pyorrhea alveolaris when proper care is instituted. On the

contrary, in the vertical type of pyorrhea alveolaris, a guarded prognosis should be given and all the more so when diffuse atrophy of the alveolar process is present. The operator has to be mindful of the unalterable fact that a completely resorbed alveolar process, a destroyed cementum, and a pericementum do not regenerate and that the retracted gum remains a retracted gum. He may, however, be able to check the progress of the disease and gain some tightening of the loosened teeth. If there has not been too much of the supporting structure destroyed and the work is carried out properly in every detail a good result plus a healthy mouth can be promised.

ATROPHIC GINGIVITIS

Partsch introduced the term "gingivitis atrophicans" to designate an atrophic condition of the gingivae which follows an inflammation of the margin of the gum including the papillae. Prinz states that literature concerning atrophy of the gingivae is very meager. The papillae become slightly shriveled but the gingival margins are thickened, red and somewhat retracted from the teeth. Brownish subgingival calculus encircles the teeth. Subjective symptoms are absent as a rule. Primarily the disease is observed in neglected mouths.

HYPERTROPHIC GINGIVITIS

Hypertrophic gingivitis is ordinarily a chronic painless increase in the bulk of the gingivae (Fig. 65). Sometimes the affection may be moderately

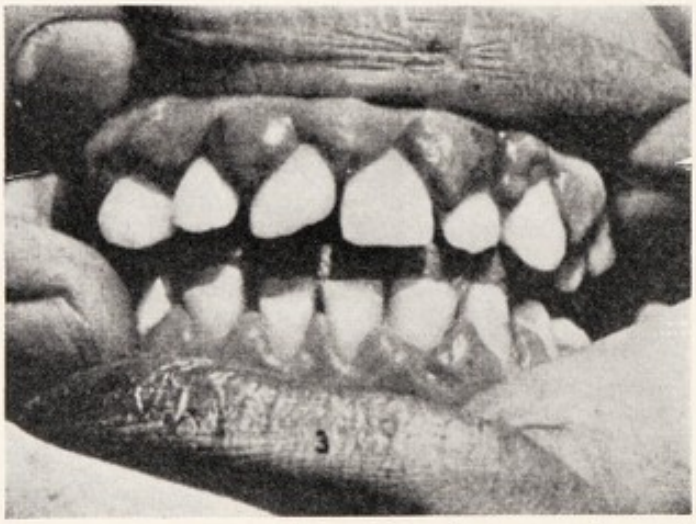

Fig. 65.—Permanent hypertrophic gingivitis. Note the separation and protrusion of the teeth by the growth. (Bunting, Oral Pathology, Lea and Febiger, Publishers.)

acute. The condition is primarily restricted to the gingival margin and the interdental papillae. Two types are found: the inflammatory and the idiopathic (endogenous) types. The inflammatory type occurs in mouths in which the oral hygiene has been defective. Any of the various local irritants of this type may be guilty. The idiopathic type apparently is restricted to the mouths of asthenic children, young girls, or young pregnant women. In the inflammatory type the marginal gum tissue and the papillae become painlessly enlarged, bluish red in color and bleed

readily. Usually the disease is localized to small sections of the gum tissue where the traumatic factor is operative. In the idiopathic type the distribution of the hypertrophy is more uniform and the rounded, "grapelike" enlarged papillae surround the entire dentures. There is a tendency for the disease to be more pronounced in the upper jaw. The tendency to bleed is only slight. Usually the teeth are well cared for. The inflammatory type heals when the local cause is removed. The idiopathic type is not particularly influenced by local treatment. For the treatment of the disease after local causes are removed, copper sulfate in the very finest powder form freshly made into a paste with 8 per cent zinc chloride solution has been recommended. An iridioplatinum loop is used to apply it below the papilla. A 50 per cent solution of trichloracetic acid may be used as a caustic and applied very cautiously. In protracted cases excision of the papillae furnishes the only permanent remedy.

DIFFUSE FIBROMATOSIS OF THE GINGIVAE

The etiology of diffuse fibromatosis of the gingivae is questionable. Whether it should be grouped with the inflammatory lesions or the neoplastic lesions is debatable. As the lesion is not always confined to the gingivae, it has been found convenient to describe the lesion in the chapter devoted to lesions of the oral cavity in general.

CHRONIC DIFFUSE DESQUAMATIVE GINGIVITIS

The term "chronic diffuse desquamative gingivitis" nearly defines itself. Besides being characterized by desquamation of the epithelium of the papillae and adjacent gingivae, the gingivae are covered with sticky mucoid deposits and the uncovered connective tissue bleeds with the greatest of ease. Magitot, who first described the affection in 1868, called it "gingivite fongeuse." The exact etiology is unknown. Middle-aged females near the menopause are more frequently affected. It is possible that the disturbance is a hormonal deficiency. On section the stratum corium is seen to be almost completely desquamated. In the deeper layers of the mucosa are found plasma cells and cells of a chronic inflammatory type. The principal signs noted clinically are an excessive fungoid growth of the papillae, scarlet red gingivae, a red circular ligament, and redness of the mucosa of the labiobuccal surface of both jaws. The tips of the interdental papilla are bluish red, excoriated, and they bleed very easily. The breath is characteristically mildly offensive. The mandibular lymph nodes are often slightly enlarged. Subjectively the patient complains of a burning sensation after solid or hot food. The presence of teeth is necessary for the disease to develop. The disease runs a very chronic course from one to several years. Mild cases may be improved by the use of local astringents such as copper sulfate and zinc chloride but in well-established cases local therapy does little good. A great many types of therapy have been tried—vaccines, foreign proteins, arsenicals, mercury, carbon-lamp exposure, salt-free diet, all without any marked effects. Surgery usually will effect a cure. All useless teeth and roots are extracted. The affected gum tissue and papillae are excised and all tartar removed from the teeth. The operative procedure is somewhat similar to that recommended for the horizontal type of pyorrhea alveolaris.

ACUTE ULCEROMEMBRANOUS GINGIVITIS (PLAUT-VINCENT INFECTION), TRENCH MOUTH, AND GANGRENOUS GINGIVITIS (NOMA)

To avoid repetition, we have chosen to discuss these diseases more completely in Chapter XV under stomatitis (Fig. 66, *A*, *B*).

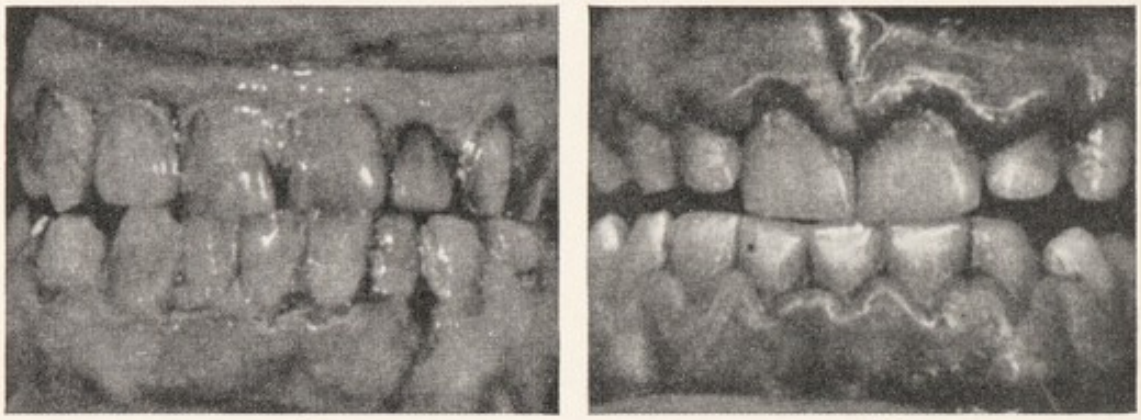

A *B*

Fig. 66.—*A*, Acute destructive Plaut-Vincent's infection. When the necrotic interproximal papillae, especially in the lower jaw, are wiped away, the gingiva has a punched-out apppearance. There is marked hemorrhage, especially on the left side. Blood may be seen oozing from between the lower left lateral incisor and the cuspid. *B*, Acute hypertrophic Plaut-Vincent's infection. In contrast to the destruction seen in *A*, there is hypertrophy of the entire gingiva, which was tender and bled easily. A thin gray necrotic line may be seen along the margin of the upper gingivae (the other white markings are merely high lights produced in making the photograph). The hypertrophy was one of recent onset and disappeared with the other symptoms in response to treatment. (Hirschfeld, Jour. Amer. Dent. Assoc.)

ALLERGIC GINGIVITIS

Localized areas of swelling and redness of the gingivae which show some connection with a particular food, contact with some animal, and mineral sensitization have been described. The diagnosis depends upon clearly establishing the causative agent and proving it by obtaining a cure by its elimination.

Diseases of the Dental Pulp

Most of the diseases of the dental pulp are of an inflammatory nature following a dental caries which, causing dissolution of the protective encasement, allows an ingress of bacteria to the connective tissue structure. Save for a few unique characteristics due principally to a peculiar anatomic housing, the injuries and infections which affect the dental pulp produce reactions similar to connective tissue structures elsewhere in the body.

When applying treatment for an inflammation of the pulp along the same lines as is customary elsewhere in the body, the following handicaps at once become evident: (1) the pulp is encased in a hard capsule of dentine; (2) possibly no lymphatics are present in its structure; (3) it is difficult to establish drainage; (4) it is difficult to gain ready access to the diseased tissue to apply remedial measures. Complete vascular stasis is

always likely to follow an inflammation of the pulp. The apical foramen offers little chance for the development of a collateral circulation. When one compares the small size of the apical foramen with the large bulk of the dental pulp in an adult tooth, one may well wonder that any pulpitis ever undergoes resolution.

Secondary Dentine.—Secondary dentine occurs in teeth which have a caries of a mild degree or teeth in which the crowns are worn off and its deposition decreases the size of the pulp cavity. It is a compensating process which tends to ward off exposure of the pulp by an increase in the thickness of the dentine from within as the outer dentine is destroyed.

It is quite generally admitted that the new formation of dentine is caused by abnormal irritation transmitted through Tomes' fibers by way of the dentinal tubules to the odontoblasts. Such an irritation may be set up by the exposure caused when the alveolar process is destroyed in pyorrhea but usually a dental caries in the crown is the etiologic factor. There is also a physiologic (senile) formation of dentine which may result in nearly total occlusion of the pulp canal in elderly individuals. The amount of secondary dentine may be even greater than the original dentine and may even fill the pulp chamber. Usually the dentine is perfectly adherent but sometimes free bodies are formed (pulp stones). The formation of secondary dentine is relatively frequent in permanent teeth but exceedingly rare in deciduous teeth. It is said to develop earlier in incisors and canines and later in premolars and molars. The circumscribed adherent masses of dentine are called "denticles" or "pulp stones."

Howe and Wolbach have insisted that when the diet is deficient in vitamin A, the odontoblasts revert to osteoblasts and that osteoblasts may lay down bone. (A different etiology for "pulp stones" is suggested if this observation be true.)

Roundish bodies composed of irregular dentine and embedded in the normal dentine of the root have been found—the so-called "interstitial denticles" (Wedl). Denticles may be either solitary or multiple and histologically the regular arrangement of dentinal tubules is observed. The dentinal tubules of the dentine are irregular and spirally curved, and run vertically to the lamellae and branch centrally.

THE GENERAL ETIOLOGY OF THE VARIOUS AFFECTIONS OF THE DENTAL PULP

The causes of disease of the dental pulp correspond with those responsible for the production of disturbance in other soft tissues of the body. They may be mechanical, thermal, electric, or parasitic in nature. The vast majority of disturbances find their origin in a direct or indirect association with infective processes of the hard structures of the tooth, *i. e.*, dental caries followed by secondary mixed infection.

Mechanical causes of pulpitis are represented by a blow, a fall, or being hit on the tooth by some solid object. The upper front teeth are more subject to such accidents. Fracturing of a tooth during extraction may also be a mechanical cause. In the aged particularly mechanical destruction of tooth structure through abrasion is observed. When the posterior teeth are lost, the incisors may be called upon to do the work of the molars. Active abrasion results. The teeth are worn down to the dentine. The

production of new adventitious dentine may be insufficient to keep pace with the rapid process of abrasion, so that the pulp finally becomes involved. Occupations such as sand blowing, glass cutting, tool grinding may cause abrasions of the tooth structure. Typical examples of localized abrasions are "pipe stem hole" and the "blow hole" of the glass blower. Large fillings in cavities may irritate the pulp. Too rapid movement of the teeth in orthodontic work has often caused death of the pulp of a tooth.

Among the causes of a chemical nature are acids, and protoplasmic poisons. It is a common observation that a pulp may die beneath a deep-seated filling. Thus, the orthophosphoric acid of cement fluid may cause the death of a pulp. Arsenic is intentionally applied to destroy the pulp.

Metallic fillings are good conductors of thermal changes. Dental cements when setting evolve heat and a sufficient amount has been known to have been given off to kill a pulp. Electric shocks have been reported as causing death of the pulp.

The most common cause of pulp death, however, is infection by bacteria which in the great majority of cases occurs directly from a carious process or indirectly by the way of the pericementum near the free margins of the gum tissues.

Secondary pulpitis occurs sometimes as a consequence of a local or general disease. Many of the acute infectious diseases have been accused on rare occasions of having an etiologic relationship to a secondary pulpitis. The evidence, however, is largely of an indirect nature. Longcope years ago was able to demonstrate petechial hemorrhage after certain of the severe childhood infectious diseases. An antritis is possibly most often the local cause. Prinz states that an acute temporomandibular arthritis may bring about a secondary pulpitis in the lower jaw.

HYPERSENSITIVE DENTINE

Because of the absence of enamel, exposed dentine of a vital tooth may become responsive to mechanical, chemical, thermal or electric irritation. Caries, erosion, abrasion or trauma, incomplete calcification or premature atrophy of the alveolar process and its cementum all may cause a hypersensitive dentine. Whether or not the dentine contains actual nerve fibers is a debatable question. The men who favor noninnervation hypothesis attribute the changes in surface tension, etc., to a mechanism whereby impulses are carried to the pulp by the dentinal fibrils. Hypersensitive dentine is thought to represent a state of irritation of the odontoblasts of the dental pulp which are in direct contact with the nerve fibers of the plexus of Boll—the anatomic threshold of sensation.

Symptoms—Treatment.—More or less pain is the subjective symptom of hypersensitive dentine. It is not continuous but lasts only as long as the irritant is present. No changes in the color of the tooth, percussion, or palpation are noted and the roentgenogram is normal.

In the prevention of pain when working on the teeth, sharp instruments aid one. As hypertension tends to cause the pain, removal of moisture from the tubules reduces the pain. Such a drug as benzyl alcohol possesses the combined property of acting as a partial local anesthetic and as a dehydrating agent. Oil of cloves is also a time-honored obtundent for dentinal sensitiveness but on a thick layer of dentine it is of little value.

Exposure of a Healthy Pulp.—An exposed healthy pulp is in reality a wound and as with wounds elsewhere in the mouth, such a wound must be looked upon as a contaminated one.

Pulp capping is the process of applying a protective medium to the exposed pulp and it is an operation of chance. In certain instances, however, the procedure may be indicated. Pfaff in 1756 first described the procedure. Only perfectly healthy exposed pulps which are only slightly wounded should be "capped." Temporary or permanent teeth with roots not fully completed offer the best chance for capping.

PULPITIS

A classification of pulpitis into clinical entities such as acute simple pulpitis, acute suppurative pulpitis, secondary pulpitis, chronic ulcerative pulpitis, degeneration of the dental pulp, devitalization of the dental pulp, mummification of the dental pulp, necrosis and gangrene of the dental pulp must seem to one trained in the general reaction of tissues to infection as splitting the matter down to a fine point as the various names represent only a different degree of inflammation. A terminology of this type is used for clinical discussion among the members of the dental profession. For convenience such a terminology is used in the following paragraphs.

Etiology.—Heat, cold, progressing tooth decay, and large fillings may only stimulate the odontoblastic layer to the formation of protective dentine. The most common cause of inflammation of the pulp tissues is progressive tooth decay which allows bacteria to gain access to the pulp cavity. The bacteria enter by way of the dentinal tubules. Pulpitis rarely may be caused by extension of peridental membrane inflammation by way of the apical foramen of the tooth. A blow on the tooth may rupture the apical vessels and cause either atrophy of the pulp tissue when no secondary infection occurs or when secondary infection occurs a gangrenous or putrescent pulpitis.

Pathology.—The first stage of pulpitis is active hyperemia. Transudation and infiltration with the cellular products of inflammation follow. The final outcome is analogous to inflammation elsewhere in connective tissue. When the injury, infective or otherwise, is not too severe, and the resistance of the patient is good, the pulp may be restored to health. When the infective process is more severe, the pulp may go on to complete destruction because of complete blockage of its blood supply. In less active infections the process may be circumscribed or not involve the whole of the pulp. Again multiple or single abscesses may be formed. When the blood supply is cut off from the tooth and secondary infection does not supervene, the pulp becomes atrophic. When the blood supply is cut off and the dead tissue becomes secondarily infected, a putrescent gangrene supervenes. If the resistance of the pulp tissue is relatively high and the infecting organism is not very virulent, the defense mechanism may be shown by regressive changes such as fatty degeneration, hyalinization, and eventually calcification. Thus, some of the stony denticles or pulp stones found in the pulp cavity are only calcified masses.

Bacteriology.—Mayrhofer found the following bacteria in 53 cases of open root canals: streptococci 70, streptococci and rods 44, streptococci and staphylococci 14, streptococci, staphylococci and rods 10, streptococci and

yeast cells 5, streptococci, rods and yeast cells 3, staphylococci 3, staphylococci and rods 1, and rods 2. In 51 cases of closed canals he found streptococci in 31, staphylococci and rods 6, streptococci and staphylococci 1, staphylococci 2, rods 6. The harm caused by the bacteria is due to the chemical and toxic products of their metabolic processes.

Clinical Features of Pulpitis.—The tooth in most instances shows a carious defect or some form of deep-seated abrasion. Generally speaking, the outstanding feature of a pulpitis is pain which is more prone to occur in the evening and at night. The patient, as a rule, can point out the offending tooth. A pulp may be diseased, however, and die without the slightest sensation. As the result of general disease pulps may die without manifesting pain (secondary acute simple pulpitis).

Hyperemia of the Dental Pulp.—Hyperemia of the pulp is the initial inflammatory response to an irritation. Such a change is likely to follow any type of work on the tooth which generates too much heat as polishing, grinding, etc. Clinically, hyperemia may be suspected when hot or cold fluids, or cold air produces a more or less sharp pain. The tooth may have recently been filled or some structural defect of the enamel may be present. Atrophy of the alveolar process may cause the roots of the teeth to be abnormally sensitive to thermal changes. Chronic irritation of the pulp may activate the odontoblasts to a deposition of calcium salts which by pressure may lead to complete atrophy. Early hyperemia of the pulp usually responds favorably to treatment and filling.

Acute Simple Pulpitis.—Theoretically, the initial picture is one of a partial pulpitis—possibly one horn. Theoretically, the pain of a partial pulpitis is supposed to last for a shorter time and appear at longer intervals than in a total pulpitis. In a more complete involvement of the pulp, localization by the patient of the offending tooth is progressively more difficult after reflex disturbances are manifested to complicate the picture.

Acute Suppurative Pulpitis.—Usually this type of infection is restricted to filled teeth of the permanent set. Typically, the patient suffers excruciating intolerable pain. The pain is not localized and is of a boring throbbing character. Localization of the affected tooth by the patient is difficult or impossible as a rule. Heat increases the pain. Cold in many instances temporarily seems to palliate the pain. General constitutional symptoms of infection appear—chills, elevated pulse rate, and a leukocytosis. Often the patient becomes weak from pain and lack of sleep. The condition is really an abscess of the pulp which may be single or multiple or nearly complete.

Secondary Pulpitis.—The clinical picture varies widely and depends upon the underlying disease. When the disturbance is of a local character, the affection manifests itself as an acute simple pulpitis or as an acute suppurative pulpitis. In general diseases the patient may complain of pain of a dull continuous character without being able to localize the tooth. Usually the teeth are intact. In locomotor ataxia a secondary pulpitis may develop and the entire pulp degenerate without pain and finally it is only accidentally or intentionally discovered when the pulp canal is entered. A maxillary sinusitis is one of the commonest causes of a secondary pulpitis. A dull painful sensation about the teeth and the bony region of the affected side is characteristic (see Chapter XVII on Maxillary Sinusitis).

Chronic Ulcerative Pulpitis.—When a chronic ulcerative type of inflammatory disease has developed in the pulp, the affected tooth usually has a deep cavity or leaking filling which allows drainage around it. The subjective symptoms are only mild or are absent. Real pain is rarely felt unless débris is crowded into the cavity, after which a paroxysm appears and lasts for some minutes or until the pressure is removed. When the cavity is explored or the filling removed, granulation tissue is found and within it often is an adventitious deposition of dentine and pulp nodules.

Chronic Hyperplastic Pulpitis (Pulp Polypus).—Chronic hyperplastic pulpitis presents a clear clinical picture characterized by a polypus of deep red granulation tissue within the cavity ranging in size from 1 to 7 or 8 mm. The condition is comparatively rare. After fracture of a tooth a fungoid growth of the exposed pulp is occasionally observed. The growth may pulsate. Subjective symptoms are largely lacking, but are sometimes described as unpleasant. A slight wound of the mass causes it to bleed.

Necrosis and Gangrene of the Dental Pulp.—True necrosis without infection if the tooth appears sound externally presents practically no signs or symptoms. Often after necrosis occurs secondary putrefaction changes develop, due to protein cleavage products. When the products of putrefaction are forced by their own pressure into the periapical tissues, a periapical inflammatory reaction is evoked of either subacute or chronic type. On exposure of the pulp chamber, the putrefaction reveals itself by a foul odor and a bad taste. When the reaction is a mild one, the disturbed pericementum institutes an active battle of defense and a chronic proliferating pericementitis results—a granuloma.

Degeneration of the Dental Pulp.—Degeneration of the dental pulp is rather commonly found in the aged. Clinically the practitioner cannot diagnose atrophy of the pulp. The subjective symptoms are nil.

Diagnosis of Diseases of the Dental Pulp.—The history is important. The manifestation of pain as subjectively noted by the patient provides the diagnostician with considerable reliable information concerning the nature of the ailment. The quality, intensity, duration and the exact location should be inquired into. The radiation of the pain is important. A careful examination of the teeth by inspection first and exploration second should be made. The color of the tooth may give one a clue as death of a pulp usually produces various shades of darkening of a tooth. Transillumination of a tooth furnishes a fairly well-outlined shadow of its pulp. When a dead pulp is present the light is diffused. The method is more valuable in the anterior teeth. The reaction to temperature conditions may be revealing. A suppurating pulp often registers quickly to a temperature above normal. On the other hand, an acutely inflamed pulp may sometimes be recognized by the application of cold—water, ether or ethyl chloride.

Percussion and palpation may give valuable information. The peculiar dulness of a suppurating or dead tooth is often evident. When the finger is placed over the apical region of a tooth afflicted with a marked apical absorptive area and it is tapped with a steel instrument, fremitus is imparted to the fingertip. In a normal tooth fremitus is absent.

Roentgenogram should be insisted upon in cases of doubtful diagnosis and in many others for study of probable changes. Early acute periapical disturbances are very likely to show little change. Some time is necessary

for the density of the afflicted bone to be changed. Thus, the diagnosis of an inflamed pulp should always be supplemented by a differential diagnosis in regard to a concomitantly existing disturbance of the peridental membrane of the affected tooth or of a general disease.

Electrical examination often gives important information. A vital tooth gives a pronounced reaction when a weak faradic current is passed through it and the body. The result obtained by the faradic current is stated by Prinz to be so very superior to all diagnostic procedures that its use for such purposes deserves to be highly recommended.

Treatment.—In an acute simple pulpitis the indications for therapy depend upon whether or not, in the judgment of the operator, an attempt should be made to treat conservatively an inflamed pulp or to destroy it at once. In either instance the carious cavity is excavated, sterilized, and a sedative antiseptic is sealed into it for twenty-four hours at least. In case the pulp is to be devitalized, it is opened, anesthetized, and the cavity is dressed. In acute suppurative pulpitis, the pulp chamber is drained by penetration with a bur.

In secondary pulpitis the treatment depends upon whether or not the pulpitis was due to a local infection or a general disease. The treatment of a secondary pulpitis due to a general disease constitutes a situation requiring the cooperation of both the dentist and the physician. The treatment of chronic ulcerative pulpitis is no different from that of acute suppurative pulpitis. In chronic hyperplastic pulpitis the treatment consists of removal of the granulation tissue and destruction of the remaining pulp. When degeneration of the pulp is present and one opens the pulp canal by intent or accident the indications for treatment are the same as after infection of the dental pulp.

Prognosis Following Pulpitis.—Acute pulpitis offers an unfavorable prognosis for the preservation of the involved pulp. In total pulpitis the destruction of the pulp is always indicated. Recovery of a pulp affected by suppurative pulpitis is not to be expected. Removal of the pulp is always indicated. In secondary pulpitis the prognosis depends upon the cause. The pulpitis may subside when it is due to local disease and the local disease is cured. Usually injury to the pulp from the toxins of general infection or disease is largely overcome. In chronic ulcerative pulpitis, in chronic hyperplastic pulpitis, in necrosis and gangrene of the pulp, the pulp cannot be preserved. But removal of the pulp and subsequent treatment of the root usually restore the tooth to normal function. The same is also true after the removal of an atrophic pulp.

Diseases of the Pericementum

Inflammations of the peridental membrane may spread from a starting point over the entire structure. But because of the rich vascularity of the structure an inflammation is prone to become localized at the point of entry of the infection.

HYPERCEMENTOSIS

Hypercementosis usually affects practically only the apical portion of the root but it may affect practically the entire area of the root of the tooth. The etiology is thought to be due to a prolonged irritative process insuf-

ficient to cause degeneration of the cells of the periodontal membrane and its connection with the cementum. The source of irritation is probably both infective and mechanical but a constitutional factor has also been suggested. Among the mechanical probabilities are improper pressure on a tooth due to an improper position, to general malocclusion, stimulation by improper fillings or subgingival calculi. The fact that hypercementosis happens to be found about apices of roots in just the position of a chronic dento-alveolar abscess might possibly be the evidence of the effects of an irritative low-grade infection about the tooth.

Clinical Features.—No discomfort ordinarily is felt and usually the patient's attention is called to the defect by the dentist after a radiograph. More rarely some pain calls attention to the offending tooth. By a process of exclusion the discomfort may be attributed to hypercementosis which the radiograph verifies. The radiograph which shows the enlargement of the root caused by abnormal amount of cementum confirms the diagnosis. The treatment is discussed under Chronic Periapical Infection.

PERICEMENTITIS

Acute or chronic inflammation of the pericemental or peridental membrane per se is really nonexistent. The surrounding bone is always more or less involved in the inflammatory process and all save the relatively mild inflammations tend to cause more or less destruction of the natural attachments of the pericementum to the cementum. Once the cementum has the pericementum entirely detached and the area is bathed in the products of infection, the cementum acts as a foreign body in a manner similar to a sequestrum. When it is remembered that a chronic inflammatory process may lie buried so to speak and give no symptoms immediately pointing to the involved tooth, and that such foci quite generally are recognized to cause serious disability of a general nature in a varying percentage of instances, the importance of the various inflammations of the pericementum becomes evident.

Etiology.—Diseases of the pericementum may be caused by mechanical, thermal, or electrical injuries or by bacterial invasion. The latter factor is of the greatest importance.

Mechanical Causes.—After a fall, a blow, food trauma, or force applied during dental work, if the disturbance is not severe, recovery follows. The importance of calcareous deposits about the necks of teeth should be stressed particularly in connection with pyorrhea. The importance of poor fillings and poorly fitting plates is discussed under the etiologic factors concerned in the cause of epidermoid carcinoma.

Injudiciously placed root canal fillings may cause a severe inflammation of the apex of the tooth. Abnormal occlusion stress may enlarge the peridental space and cause a chronic pericementitis.

Chemical, Thermal and Electrical Causes.—Arsenic, mercury, phosphorus are all well-known responsible factors in producing a pericementitis. Various other chemicals such as bismuth, lead, antimony, and other metals may also be the basic cause of a pericementitis. All of these factors are more fully discussed under stomatitis caused by these chemicals. The thermal and electrical causes of a pericementitis are not so decisive or common.

Bacterial Causes.—Pericementitis having its origin at the apex of a tooth is exceedingly common and is next to pulpitis the most frequent and one of the most serious ailments of the soft structures about the teeth. The point of injury prior to the ingress of bacteria may be the periapical region or the gingival margin of the pericementum. In either case later a spreading inflammation may involve the whole pericementum or it may localize and form an abscess. Usually an acute apical pericementitis is caused by the invasion of a streptococcus and other organisms arising from a more or less housed-in gangrenous pulp. In the majority of instances a carious dentine allows ingress of the infecting organism. The agents responsible for the death of the pulp, however, have little influence on the resulting inflammation of the peridental membrane. The mode of passage of the bacteria through the apical foramen follows the general laws of the spread of infection in connective tissue and by vascular and lymphatic channels. Very much more rarely bacteria gain entrance through the pericementum alongside the tooth and extremely rarely the blood stream may carry bacteria directly.

Bacteria of Periapical Infections.—The flora of periapical infection may be of either the aerobic or the anaerobic type or both. The similarity between the flora of pulpitis and the periapical lesion is definite. Monier and Idman found anaerobes almost routinely present but routine examinations at present usually ignore these micro-organisms.

Haden found out of 346 positive broth cultures which were transferred to blood agar plates from individuals showing evidence of a chronic pericementitis that 302 showed a pure culture—usually of nonhemolytic streptococci. In only 3 instances were hemolytic streptococci found. Forty-four of the cultures showed a mixture of organisms. But Streptococcus faecalis, S. mitior, and S. salivarius were the common types grown.

Etiology of the Various Clinical Types of Pericementitis.—*An acute marginal pericementitis* is caused usually by traumatic insult primarily with an infective element contributing secondarily. Among the traumatic factors calcareous deposits, occlusal stress, the stress of ill-judged dental technic, overhanging fillings and so forth are predisposing. Careless dental technic may allow drugs such as arsenic, caustics, and phenol to precipitate a marginal gingivitis.

In the great majority of instances an *acute suppurative pericementitis* originates from an acute apical pericementitis and the same organisms are involved.

Acute interradicular pericementitis is caused by the entrance of some of the micro-organisms of the oral cavity through a wound within the dental trough. Some writers have claimed a hematogenous origin for interradicular pericementitis but no definite proof can be presented to substantiate this conception.

Chronic apical suppurative pericementitis often follows an acute infection of the apical tissues. Rarely, it may result from the relighting of an infection of a granuloma.

Chronic proliferating pericementitis is caused by bacterial invasion of the periapical tissue. Either the resistance of the patient is good or the infecting organisms are relatively avirulent or few in number. Consequently, only a granuloma is produced instead of a suppurative process. The pres-

ence of epithelial cells in the granuloma is thought to present the etiologic factors necessary for the formation of a radicular cyst.

Pathology.—In acute apical pericementitis about the apical tissues hyperemia, serous effusions and round-cell infiltrations are seen early and as the process develops the polymorphonuclears predominate. Finally, the surrounding blood vessels become thrombosed. The bony trabeculae are absorbed and replaced by the cellular products of inflammation with the central necrotic area characteristic of abscess formation.

In the milder types only a granuloma forms (Fig. 67, *A*, *B*, *C*). Either an actual abscess with pus in it does not develop or if it has formed, the pus is absorbed and replaced by fibroblastic tissue. In the more acute forms the inflammatory process does not halt and the central area of necrosis increases in size. The presence within the abscess causes the pus to go in the direction of the least resistance through the medullary spaces of the alveolar bone. Thus, a large area of absorption of the bony trabeculae is produced and eventually even the compact bone is perforated, the peri-

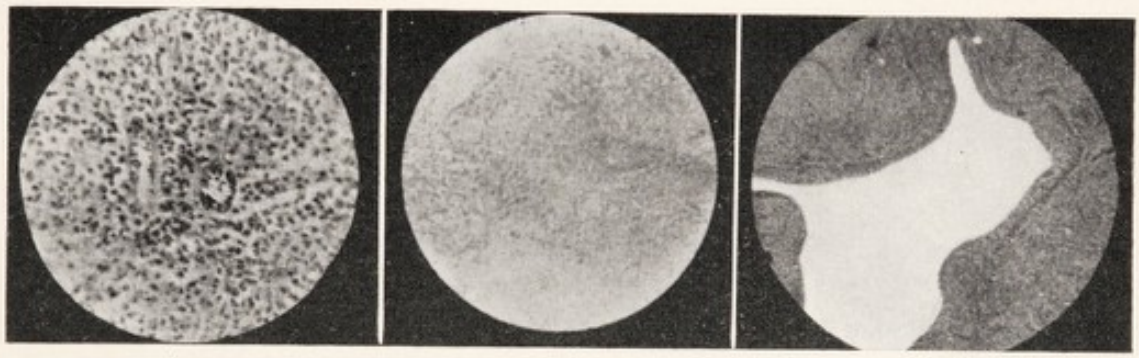

A *B* *C*

Fig. 67.—*A*, Chronic type of periapical inflammation. Preponderance of small, round cells. Capillary blood vessels are seen, establishing a connection between the focus of infection and the general circulation. *B*, Masses of squamous epithelial cells (débris épithéliaux paradentaires) embedded in chronic periapical inflammatory tissue. *C*, Early stages of cyst formation, showing cavity lined with several layers of epithelium, with chronic inflammatory tissue at the periphery. (Blair and Ivy.)

osteum is undermined, and if not immediately perforated by abscess, a considerable area of bone may be denuded. Sooner or later the abscess perforates the periosteum and invades the soft tissues about the alveolar ridge or perforates into the mouth. Operative drainage artificially accomplishes and hurries this final stage.

Within the center of a granuloma—so-called—one finds fibroblasts, plasma cells, lymphocytes, newly sprouting vascular tissue and the various other cells characteristic of granulation tissue (Fig. 67, *A*). Besides the cells of fibroblastic and granulation tissue, a granuloma may or may not present in a certain percentage of instances certain epithelial cells—the "paradental débris" of Malassez (Fig. 67, *B*). When these cells proliferate, the granuloma may develop the qualities of an epithelium-lined cyst (Fig. 67, *C*). Anyway whether or not the epithelial cells develop in such a manner that a cyst tends to be formed, the epithelial cells within the granuloma may proliferate and add a factor which is ordinarily not present in a simple granuloma in so far as treatment is concerned. Thus, to eliminate all possibility of the eventual development of a cyst, the epi-

thelial cells should be removed after extraction of the pulpless tooth. If one could be certain whether or not the granuloma was definitely made up of granulation tissue alone, this would not be necessary. A simple granuloma, of course, has no potential radicular cyst possibilities, while on the other hand, if the granuloma is of the so-called "epithelial type," it has potentially the ability to become a radicular cyst (Fig. 67, *C*).

About the circumference of a granuloma the fibroblastic tissue is much denser and more fibrillar. Within the center there is often a considerable accumulation of lipoid material within which is a gutter or cavity containing some albuminous fluid. Into this cavity projects the apex of the affected tooth. Degenerative changes in the vascular system of the granuloma are usually present and hemorrhagic infarcts in various stages of resolution are seen. When the granuloma is in this stage not uncommonly the contents prove sterile on culture but a certain tendency is always present for infection to occur or to be reactivated and appear definitely as an infective process. When this flare-up is pronounced, an acute type of the disease is the result. These granulomas vary in size from a few millimeters to 1 or more cm. in diameter. Frequently when the tooth is extracted the granuloma is removed with the tooth and is observed as a solid red sac adhering to the apex of the tooth.

The bacteriology of chronic peridental infections has been studied more than that of the acute dento-alveolar abscess because of the very nature of the condition. Haden cultured a great many radiographically positive chronic periapical abscesses. Three hundred and ninety were found to contain streptococci alone, usually of the nonhemolytic type. Staphylococci alone were found in 2, staphylococci and streptococci in 1, gram-positive bacilli in 7, gram-positive bacilli and streptococci in 21, and gram-negative bacilli in 1.

As previously mentioned, the pathogenesis and the pathology of radicular cysts are all well-established at the present time. Their etiology for the past two hundred years has received extensive attention. Actual cysts of the jaw have been grouped and discussed in Chapter XXXVII with tumors of epithelial origin where they belong but their association with the infected granulomas is so close that it would seem pertinent here at least to emphasize this relationship. The epithelial cells present about the region of the apex are unabsorbed remnants of the epithelial sheath of Hertwig. Some observers have stated that very rarely epithelial remnants from the maxillae or the oral mucosa itself might be at fault but little evidence of importance has been produced to substantiate any such pathogenesis.

No definite figures are available as to the percentage of granulomas which are simple and the percentage which are epithelial in character. Sometimes the proliferating epithelial cells are quite definite while on the other hand often it is not possible always to distinguish between cells which are epithelial or mesothelial in character. Certain cells in a simple granulation may resemble epithelial cells and still be of mesothelial origin and have none of the potential functional characteristics of epithelium. Interradicular abscess runs through the same inflammatory stages of hyperemia, infiltration with the cells of acute inflammation, and finally, central liquefaction as do periapical abscesses. After actual abscess formation sometimes organization occurs. But if the injecting organism is of a rather virulent

nature or if the forces of resistance are low or if some of the cementum has been denuded so as to henceforth act as a foreign body the abscess increases in size. The bone is rarefied either gradually or rapidly. The abscess ruptures spontaneously. Such abscesses are most commonly found between the roots of the molar teeth.

The various stages of chronic periapical disease may be summed up as: (1) chronic proliferating pericementitis which signifies only a slight thickening of the peridental membrane. (2) Chronic rarefying osteitis with granuloma. In this stage there is a slow disintegration of the bone about the apex of the tooth. The tooth apex may present an enlargement due to hypercementitis but usually only projects as a shortened or roughened foreign body into the cavity. (3) Chronic rarefying osteitis with suppurative or chronic abscesses. In this group the space at the apex of the tooth is filled with pus which may or may not have an opening to the gum. The necrotic cementum is filled with pus. The peridental membrane is destroyed. (4) Chronic rarefying osteitis with cyst formation. This stage succeeds the granuloma. The fluid is clear. The process may continue after the removal of the teeth.

Clinical Picture of Pericementitis.—The classification suggested by Prinz has certain clinical advantages. The dental profession is accustomed to its nomenclature. Therefore, it is used although the terminology may seem a little complicated to the general pathologist or surgeon.

Acute Apical Pericementitis—Acute Alveolodental Abscess.—The clinical symptoms and signs of acute apical pericementitis differ in respect to the stage and severity of the infection. Possibly with some convenience three stages may be described. In the stage of hyperemia and serious exudation, the tooth feels big, one is aware of it and can scarcely resist biting down upon the tooth as mild pressure temporarily affords relief. As the inflammatory exudate accumulates at the apex, there is a tendency for the tooth to be slightly raised. Then the pain is increased if the teeth are occluded or the tooth is percussed. In the stage of early purulent accumulation the preceding symptoms and signs are increased. The sensitiveness becomes markedly increased and as the meshes of the pericementum are infiltrated the tooth begins to loosen in its socket. The gum becomes red and swollen and the pain of the boring, throbbing, continuous fashion develops. On assuming the recumbent position the pain is exaggerated. Salivation is increased, the tongue becomes coated and the breath foul. The general constitutional symptoms and signs of a purulent infection make their appearance. The temperature may range from 101° to 104° F. and the pulse rate is correspondingly increased. Chills may be complained of. Early in the stage of abscess formation, the face begins to swell about the area in the neighborhood of the involved tooth. If an upper jaw tooth is the one affected, the eyelids may be nearly closed by edema. If a lower jaw tooth is affected, the swelling is greatest in the floor of the mouth and along the lateral border of the mandible, as a rule. The pus by a process of pressure necrosis begins to find its way through the bone. A subperiosteal abscess is formed (Fig. 68, *A*, *B*). Before the periosteum is perforated the pain may be terrific. Finally, either the periosteum is perforated and the pus is allowed to flow into the subcutaneous soft tissues or if incision releases the tension and the internal pressure is released, al-

most immediately the pain is diminished. After perforation into the soft tissues the swelling tends to increase and the pain to diminish. In the meantime, the tributary lymphatics more than likely have become tender, swollen, and painful to palpation. This whole process of the pointing of an abscess may require from three days to a week. Most frequently the pus finds its way to the surface on the buccal side of the jaw nearly opposite the apex of the involved tooth. After the pus is discharged into the soft tissues if the tension is not too great, soon fluctuation is felt beneath the tensely stretched gum or below the facial soft tissues beneath the skin of the face. Before the periosteum of the bone is perforated in some cases considerable of it may be stripped from the bone from a rather large subperiosteal abscess. After drainage by incision or perforation and release of the confined pus, immediately and within a period of three or four days the swelling largely subsides. The amount of drainage decreases. Al-

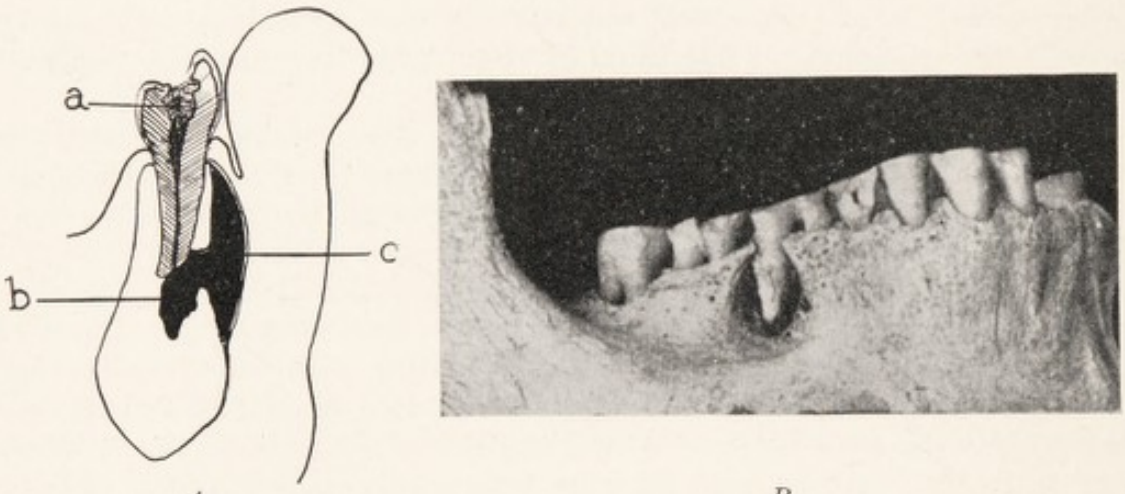

A *B*

Fig. 68.—*A*, Acute alveolar abscess of a lower tooth in which the pus has raised the periosteum from the labial plate of the mandible. The periosteum has not been penetrated. *a*, Cavity in tooth; *b*, subperiosteal cavity filled with pus; *c*, periosteum. *B*, Lower jaw of a flat-head Indian from Columbia River, Oregon, showing destruction of bone by a chronic alveolar abscess about the distal root of the first molar. The bone about the first molar of the opposite side is in practically the same condition. This is typical of the injury which occurs. (G. V. Black.)

though a discharging fistula remains for a variable time, the tooth becomes firm in its socket. The acute apical pericementitis passes on into a chronic apical pericementitis.

The appearance of the swelling varies somewhat with the seat of the dental involvement. Upper incisor abscesses cause the upper lip and floor of the nose to swell. Upper cuspid and bicuspid involvement often causes the tissues about the eye, angle of the mouth and upper lip to swell. Upper molar infections cause the most swelling in the tissue about the eye. Infections of the lower teeth usually cause some swelling of the submental and submaxillary regions according to which region the tooth is nearest. The third lower molar involvements are especially likely to cause trismus, as the inflammation involves the masseter and internal pterygoid muscle. Muscle spasm causes the jaw to be fixed in a closed position. When the abscess burrows lingually, it is almost impossible to examine the patient properly and thus mistakes may be made.

The routes traveled by the pus are often interesting. Gingival abscesses are rather common and usually they will perforate spontaneously. In the upper jaw, possibly the most important possible involvement is the antrum, usually caused by the proximity of an involved premolar or a molar. Occasionally the palate is invaded. The peculiar construction of the palatal tissue allows little edema or change of color but after a time, the swelling fluctuates and is somewhat sharply demarcated from the surrounding tissue. Upper incisor abscesses have formed sinuses in the floor of the nose. When pus reaches the periosteum above the attachment of the buccinator muscle, it may perforate the cheek as it may also when above the nasal muscles below the inner canthus of the eye. In the lower jaw pus from the molar region has burrowed beneath the deep cervical fascia and followed the sternomastoid muscle downward. Perforation to the lingual side of the mandible may result in a swelling of the floor of the mouth below the attachment of the mylohyoid muscle.

Unless the acute process has been preceded by a chronic dento-apical abscess, the radiograph will show little in the early stages.

Acute Marginal Pericementitis.—The objective features of acute marginal pericementitis are easy to recognize. The margin of the gum presents a cyanotic, turgid, easily bleeding, rounded border. The gingival trough is deepened to a pocket and incrustations are usually found about the neck of the tooth. As the edge of the inflamed pericementum is touched pain is elicited. A stripping pressure toward the crown of the tooth may cause a droplet of pus to appear at the margin of the gum. Usually more than one third of the pericementum is involved in the more acute part of the inflammation. In mild cases the patient may not be aware of the disturbance save during mastication. In severe inflammations the tooth "feels sore." The tooth does not become elongated and percussion or lateral pressure causes no pain. Seldom are the tributary lymphatics involved.

Acute Diffuse Suppurative Pericementitis.—The disturbance begins as a circumscribed inflammation and spreads as a cellulitis until the whole of the peridental membrane is involved. The edema and the infiltration is so intense that the circulation is cut off from a lesser or greater part of the peridental membrane. The tooth becomes very loose and elongated and is movable. Although the gum is swollen and red early, its margin is not much disturbed. Early the tributary lymphatics show signs of toxic absorption. Early in the disease the tooth is very sore and no pressure can be borne upon it. Later as the pericementum is destroyed, the soreness and pain decrease. Finally, the gum becomes more turgid and red and on pressure near the root pus appears about the gingival margin. The breath becomes foul. A moderate amount of constitutional reaction is the rule but it may be quite pronounced.

Paradental Abscess—Acute Interradicular Pericementitis.—Acute interradicular pericementitis is a paradental abscess upon a tooth with a living pulp. The term "paradental" was introduced by French authors in 1885. The etiology is somewhat different from an acute apical pericementitis which is invariably dependent upon a disturbed pulp. In paradental abscess the point of entrance of the infecting organism is the gingival trough. As a rule, the abscess is located near the lower third of the root of the tooth. After going through the various stages of infiltration and central

necrosis, the pus has a fairly early path of exit through a fistula into the gingival trough. Seldom does the pus penetrate the alveolar plate and the gum. In multirooted teeth the abscess tends to be located near the bifurcation of the roots. The pocket of an erupting lower third molar is a common site for the encouragement of the formation of a paradental abscess. Paradental abscesses are not common and are usually found in those past middle age. No difficulty is experienced in locating the tooth by the subjective type of continuous annoying pain complained of. The gum does not swell much. Percussion and palpation are not complained of. The tooth is not elongated or movable. On careful examination with a steel probe a deep pocket or a fistula is located which leads to the abscess cavity. Calcareous deposits are common. Pressure often causes a droplet of pus to appear.

A paradental abscess about an erupting third molar often gives a rather characteristic picture—rather severe pain, trismus of the mandible, swelling of the gum about the tooth, some swelling of the cheek at the angle of the jaw, some tributary lymphatic involvement and constitutional symptoms of a moderate or even a severe degree. Usually within a few days the abscess finds an exit about the tooth.

Chronic Dento-alveolar Abscess—Chronic Apical Suppurative Pericementitis.—Three well-defined types of chronic dento-alveolar abscess are found: (*a*) the type discharging through a fistula to the surface, (*b*) the type discharging through a root canal, and (*c*) the type in which no free exit is present—the so-called "blind abscess."

(*a*) In the first type the pathognomonic sign is the fistula discharging through the gum or upon the surface of the face or neck. Usually the fistula leads fairly directly to the apex of the offending tooth but sometimes the point of discharge may be considerable distance from the offending tooth. Characteristically, the discharge is intermittent in character. During quiescent periods one sees only a pin-point granuloma at the mouth of the fistula. Not much pain accompanies the cycle as a rule. Usually the offending tooth is painless. Most commonly the fistulous exit is on the gums over the apex of the offending tooth but sometimes it is more or less hidden in the gingival trough. Variable amounts of alveolar bone are destroyed.

In the second type, the root canal acts as the fistulous tract. The clinical manifestations outside of the fistulous tract do not differ from type one. Occasionally if the root becomes clogged, an abscess develops at the apex of the tooth with its characteristic train of symptoms.

In the third type no visible outlet for the discharge is to be found. This type is observed principally at the apex of teeth in which the root canals are filled. Some of this type of abscess have been accused of not being entirely local affairs. In certain states of decreased vitality there is a tendency for a pulpless tooth with an inactive infection to show signs of an active infection.

In either of the three types of chronic apical suppurative pericementitis the tooth because of the extensive bone absorption at the apex may become somewhat loosened. Palpation with the fingertip over the apex may outline a soft area. As a consequence of the dead pulp the crown of the offending tooth is often discolored. In the third group—the blind abscess

type—the clinical symptoms are vague although pressure over the apical area may reveal slight tenderness.

Simple Granuloma and Epithelial Granulomatous Cyst—Chronic Proliferating Pericementitis.—The term "chronic proliferating pericementitis" is applied to two conditions: (1) a circumscribed mass of granulation tissue usually located at the apex of the tooth, or (2) a granulation tissue mass most commonly located at the apex of a tooth which also contains epithelial cell rests which may be the precursor of a radicular cyst. Both lesions are the result of a chronic inflammation of the pericementum. Partsch called a granuloma a "catch basin." That is, the lesion represents the mechanism of defense applied by the body cells to the invasion of bacteria and their products. More than one granuloma may be present about one root of a tooth. Simple granulomas are very common about the roots of pulpless teeth.

Radicular cysts according to Becker (University of Berlin) were seen in 2 per cent of the patients admitted to the surgical clinic of the University of Berlin (Prinz). The two sexes are about equally affected with possibly a slight majority in the female sex. The upper jaw is affected about five times more frequently than the lower (Prinz). The greatest age incidence falls in the third or fourth decade of life, but are occasionally seen in the second decade and up to the seventh. It is only very rarely that radicular cysts are encountered in connection with the deciduous teeth. Becker records their frequency in regard to the individual teeth as follows: upper jaw, second incisors, premolars, first incisors, molars, cuspids, and lower jaw, first incisors, premolars, molars, second incisors and cuspids.

The size of a granuloma varies from a few millimeters to a centimeter. The usual granuloma enlarges very slowly and no pain accompanies its increase in size as a rule. Ordinarily there is no visible discharge from the root canal. Outside of a pulpless tooth, objective signs are usually absent. It is only when the area of rarefaction reaches considerable size that a softening is felt at the apex. The shadow cast on the roentgenogram is, however, quite characteristic and definite. At the apex of the affected tooth is a rarefied area with an indistinct and hazy outline (Fig. 69, *A, B, C*). No clinical symptoms are present during the early stages of the development of a radicular cyst. Dentists sometimes accidentally discover an early one when a broach is passed beyond the foramen of a tooth during the treatment of a root canal. A mucous fluid may exude after the broach is removed. Later as the cyst grows sometimes there is distortion in the alignment of the teeth or else some bulging begins to be evident along the alveolus and eventually as the bone is thinned, pressure may cause an eggshell crackle sensation or sound. The mandible resists pressure to a greater extent than the upper jaw. Therefore, in the upper jaw the signs of bulging and thinning of the bone are evident oftener and sooner. Ordinarily it is not necessary to make a trial aspiration for diagnosis but when this is done usually a thick glairy fluid will be obtained. When for some reason these cysts become secondarily infected, the clinical picture may be much obscured and the pain, tenderness and discharge which are ordinarily considered the symptoms and signs of an abscess are superimposed upon those of a simple cyst. When a cyst ruptures into the antrum or the nose the difficulty in diagnosis is considerably increased.

Typically, in the roentgenogram a radicular cyst shows a dark circular defect with a rather indefinite demarcation of the edges of the bony wall. The roots of the teeth penetrating in the cyst are often clearly visible. Sometimes solid concretions may be seen in the cystic cavity.

The Relationship of Chronic Pericementitis to Focal Infection.—As a chronic pericementitis of some type is necessary if the teeth are to be blamed for a systemic damage of the focal infection type, some mention of this much discussed and rather hackneyed subject is pertinent.

Definition.—Focal infection is the term applied to general or local systemic disease which results from a focus of infection when bacteria or their toxins spread to other areas by way of blood or lymph stream.

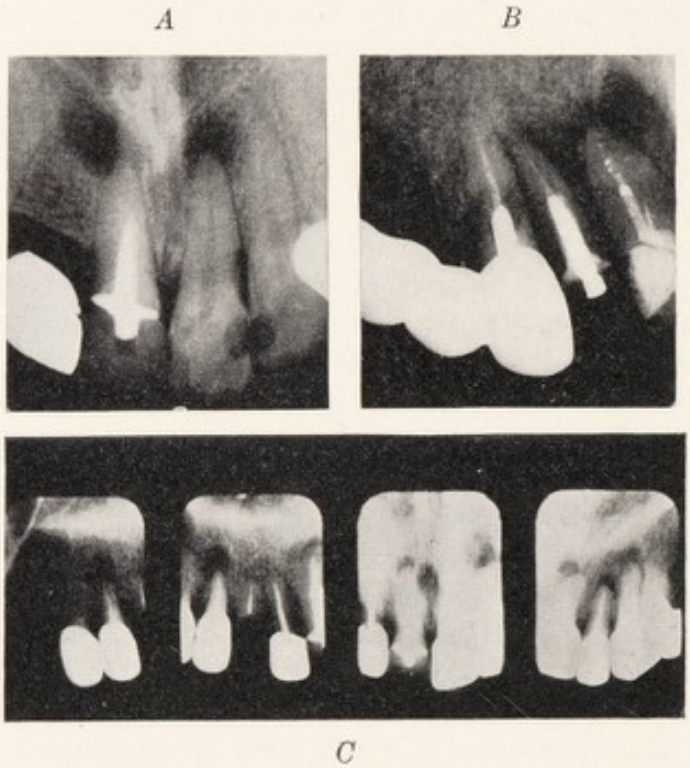

Fig. 69.—*A*, Chronic apical pericementitis about the two central upper incisors. *B*, Chronic pericementitis of the upper central incisors. *C*, Upper anterior teeth showing crownless tooth roots and multiple chronic pericementitis.

The primary foci may be divided into the active and the inactive. The active foci affect the body either generally or locally at some distant region. The inactive foci harbor bacteria but cause no evident symptoms for the time being but may spring into activity—especially if the tissues harboring the bacterial invader are interfered with. The active foci may be divided into the active and the chronic types. Active acute primary foci are oftentimes rather quickly or even almost coincidently followed by secondary foci.

The effects of a nidus of infection—acute or chronic—are thought to be due to the transportation of bacteria or their toxins by either the blood or lymph streams from a primary focus in the body to a secondary situation and results often in more or less damage to the secondary situation. Either with or without the local drainage there may or may not be noticeable general constitutional symptoms.

Although the general recognition in medicine of focal infection as a factor in systemic disease has been a rather recent development, as early as 1818 Benjamin Rush connected systemic diseases with focal infection and Black mentions articles published in 1842 relating dental disease to lesions of the eye. Garrettson in 1890 and Miller in 1891 also had an inkling of the conception. William Hunter of England in 1898 began to call attention to the importance of dental infection. The broader conception of focal infection was really originated by him. Soon after this Billings became interested in the importance of focal infection and with the aid of the researches of Rosenow drew the attention of the dental and medical profession to our modern conception of focal infection.

Elective Localization of Bacteria from Dental Foci.—Rosenow postulated the theory in 1915 that organisms concerned in chronic infection, principally streptococci, tend to have an affinity for certain organs or tissues from which they are isolated. His interpreted findings indicate that organisms removed from foci of infection of which those about the teeth were in the majority from patients suffering from diseases such as rheumatic fever, ulcer of the stomach, myositis, endocarditis, and epidemic parotitis, etc., tend to reproduce in animals the lesions from which the patient suffered. A great number of workers, however, have failed to verify Rosenow's findings but a few workers, notably Haden working independently under similar conditions, have obtained essentially the same results. The tendency to specific localization if such exists possibly depends upon local conditions at the site of the focus and also upon properties peculiar to the tissues and fluids of the host.

The Cultural Findings of Extracted Teeth.—Haden made 2000 apical cultures of teeth and divided the teeth cultured into three groups (1) vital, (2) pulpless and negative in the roentgenogram, and (3) pulpless and positive in the roentgenogram. The cultures of 400 vital teeth were used as controls to give an estimation of the technical error incident to the study, and 85.5 per cent showed no growth in the agar tube and 45 per cent were sterile in broth culture. Five hundred radiographically positive pulpless teeth were cultured. Seventy three and four-tenths per cent showed one or more colonies in the agar tube. Nine per cent were negative in broth. This group constitutes the most important group but it was rather surprising to find 600 pulpless teeth with negative radiographs showing 56.7 per cent with one or more colonies in the agar tube. The noteworthy finding was in the radiographically negative group which shows the incidence of infection to be nearly as high as in the radiographically positive group.

Types of Systemic Disease Associated with Chronic Dental Infection.—Acute rheumatic fever is probably never caused by dental infections but other types of acute infectious arthritis are often due to foci of infection. Barker thinks that the majority of cases of infectious arthritis in middle and later life are caused by dental foci of infection and Wilcox expresses the opinion that 90 per cent of all cases of chronic arthritis are caused by dental infection. Cecil and Archer estimated that 93 per cent of their cases of chronic infectious arthritis were caused by dental infection. However, there is still some difference of opinion as to the etiologic classification of chronic arthritis. Some cases may be of metabolic origin as Pemberton has emphasized.

Occasionally dental infection may be the focus for a glomerulonephritis or even a nephrosis or a chronic diffuse nephritis. Meisser experimentally has shown that pyelonephritis sometimes may be produced by bacteria from areas of dental infection.

Acute endocarditis is caused by bacteria from some focus of infection—usually in the young from tonsils or other adenoid tissue but in older individuals dental infection may cause an endocarditis—especially in the subacute form. This condition is usually ultimately fatal. Chronic myocarditis may be the result of an acute infection which becomes chronic and the heart muscle is replaced by fibrous tissue. But in some instances the damage possibly is caused by the absorption of toxins for a period of years from some chronic focus of infection which quite possibly may be of dental origin. Some of the arrhythmias of the heart such as transient auricular fibrillation and paroxysmal tachycardia sometimes do have a relationship to focal infection. There is some evidence of both an experimental (Rosenow, Nakamura) and clinical nature that in certain cases at least focal infection has a casual relationship to peptic ulcer and the work of Bargen is interpreted by him to indicate that chronic ulcerative colitis may be due to a nonhemolytic streptococcus which he believes may frequently be recovered from foci about the teeth. It is possible that some cases of appendicitis and cholecystitis may be attributed to distant foci of infection.

Uveal tract infection by many observers is thought to be due frequently to foci of infection about the teeth. Butler decided that about 12 per cent of uveal tract infection was caused by oral foci, and de Schweinitz considers that there is no better established etiologic relationship than that between septic foci in dental areas and certain diseases of the eye, especially those of the uveal tract.

In oral sepsis there is not rarely a secondary anemia. The relationship of pernicious anemia to oral infection has been suggested, but it is very doubtful if the disease is ever caused primarily by focal infection. Probably neuritis of various nerves is not infrequently initiated by dental foci of infection and the symptom-complex called neurasthenia may occur in the debilitated condition which sometimes follows prolonged absorption of toxins from septic foci.

Viewpoint Regarding Focal Infection.—As the question is continually arising in the minds of both the physician and the dentist whether or not systemic absorption is originating from dental disease, a sound viewpoint is quite necessary to both professions. From the standpoint of systemic disease, only the presence of bacteria is important. It is impossible to say positively that changes in the roentgenogram mean the presence of bacteria. On the other hand, it is also true that the presence of bacteria cannot always be ruled out on radiographic evidence alone. Haden explained his findings in pulpless teeth radiographically negative by saying that "The organisms commonly are of a low grade of virulence, so might well be present in the periapical tissues for a long time without producing radiographic evidence of bone destruction." He considers the radiographically negative and radiographically positive pulpless teeth as being approximately equal in importance from the standpoint of the systemic disease. Haden expresses the opinion that "It seems most probable that pulpless teeth which show no evidence of resistance and yet harbor bacteria at the apex are more

apt to be a focus of systemic disease since there is no barrier to the entrance of bacteria and their products into the blood and lymph channels."

Thus, many internists aware of the results of cultural results from areas of residual infection and aware of certain clinical evidence often feel warranted in suggesting the removal of a suspicious tooth although they admit that undoubtedly many individuals carry infected teeth throughout life without showing any manifest evidence of focal infection. On the other hand, they point out that long absorption of bacterial poisons probably does injury to vital organs that often does not manifest itself in the early stages of the disease. Late the removal of the foci of infection often does little to correct the damage already done, although in some cases, good results do follow. Thus, many internists believe that all evidence points to the wisdom of the elimination of foci of infection before systemic disease occurs. The ideal condition they believe is to remove all dental infection but to determine in any given individual how completely this should be done requires common sense and a sound knowledge of all the pros and cons of the situation. And they admit that the frequent examples of the reckless removal of teeth, the frequent ascribing of conditions to focal infection when initiated by entirely different causes and the careless promise of relief after the removal of foci of infection may very well cause the sound careful student to become more cautious with his advice and performance.

The preceding statement in a way outlines the thought in so far as the less conservative internist is concerned. On the other hand, the following quotation from Prinz probably will give a résumé of the position taken by a dental practitioner of the conservative school: "In simple granuloma the extraction of the tooth which usually carries with it the attached granulation tissue completely eliminates the cause and the effect of the disease plus the future service of the respective tooth. This procedure is very rarely indicated at present although at times it may be necessary. Certain faddists still insist upon the radical elimination of the periapical foci of infection by this method of treatment. At present these men are fortunately in the minority among dental practitioners. On the other hand, the proper treatment and filling of the root canals by approved methods which must include established asepsis of the periapical tissues will, in the majority of cases, eliminate the disease by a process of resolution of the pathologically altered pericementum and will insure the future service of the involved tooth as a useful masticatory organ. The writer can testify from carefully kept records of many hundreds of clinical cases covering a period of over ten years that in 95 per cent of such cases permanent results, *i. e.*, results that clinically show no pathologic manifestations, are obtained."

In all probability like so many debatable questions, there is something to be said in favor of each position. The individual who very carefully follows a middle pathway will not be far from being sound.

Treatment of Pericementitis.—It is important that every possible effort be made to prevent infection of the peridental membrane. Dental caries should be prevented if possible. When present, the disease should be treated so that the highest conservation of pulp tissue will supervene. Cooperation between the dentist and patient is necessary for this to be the result.

Acute Apical Pericementitis.—The type of treatment of an *acute pericementitis* as in other pyogenic infective processes depends upon the stage

of the disease. The primary object at first is to relieve the pain. Anyone who has felt the immediate relief to be given in this condition by an appropriate dose of morphine hypodermically will always appreciate the possibilities of this drug in such a condition. And later if the practitioner decides to use a revolving engine burr to open the root canal, the patient again will be doubly impressed with the possibilities of this drug.

Very active operative procedures at this time are contraindicated as it would be in an acute osteomyelitis. The danger of kindling the infection into one of a spreading nature should be stressed.[1] No chances should be taken which violate this principle. Sometimes sufficient drainage can be instituted by opening the root canal to be of some value. Simply opening the root canal offers no possibility of spreading the infection. When this is done it is well to give the patient a sedative and to stabilize the tooth as the vibration may be excruciatingly painful in the face of the existing pericementitis. The drainage instituted by opening the root canal if the infection is fairly active is usually only partial and more or less insufficient. It may be sufficient, however, to partially relieve the pressure and the severer part of the pain.

During the developmental stage of the inflammation or after instituting drainage through the root canal two types of therapy are of value, heat therapy and appropriate sedatives. To aid the resolution of the inflammation a type of therapy which increases the blood supply to the region is advisable. Heat either in the dry form or the wet form is a time-honored method of doing this. Besides tending to limit the spread of the infection the counterirritant factor is important in alleviating pain. Usually it will be found that large continuous hot wet packs over the affected areas is a most effective aid in the therapy of the more acute types of this inflammation. But in some instances an ice-bag over the jaw is more comfortable than a hot application. In such cases if the infection is one of moderate degree an ice-pack should be prescribed because eventually the reaction from the cold pack is the same as the reaction from heat, *i. e.*, a vasodilation of the covered area.

As to sedatives, there are many on the market which have the necessary qualifications of relieving mild pain or causing sleep. The barbital compounds (veronal, 9 grains, sodium medinal, 10 grains, etc.) in appropriate dosages are quite effective when the pain is not too severe. Codeine sulfate (1½ grains) along with pyramidon (5 grains) or acetylsalicylic acid (10 grains) will relieve a more severe pain. When the pain is excruciating, as previously mentioned, morphine (⅙ to ¼ grain) is the most effective drug.

One of the many reasons for emphasizing such nonactive type of therapy as the use of sedatives and heat applications is to stress the point that during the active stage of the infection no active operative procedures such as the extraction of the tooth are indicated. It is not only not indicated but in many instances such a procedure is a very dangerous one as the infection may be spread locally or generally thereby. Either a greater amount of local destruction is promoted or else a general infection is stirred up which may actually result in death by ill-judged operative activity. The time to pull the tooth if such is indicated, is after the acute inflammation has subsided and the process has become a chronic one.

Prinz dogmatically states "a tooth affected with acute suppurative pericementitis should be extracted at once." In acute inflammations elsewhere in the body the bulk of good surgeons of the world would severely criticize any surgeon who took such a stand. It violates the fundamental principles of the treatment of an acute inflammation which has been developed down through the ages. Why should the principle be changed when the infection is located at the apex of a tooth?

When the inflammation is an active one, after a variable period of time an abscess as a rule develops which begins to seek an outlet along the paths of least resistance. In the great majority of instances sooner or later the abscess will tend to point upon the labial or buccal surface of the gum. Abscesses of the second upper incisors and the palatal roots of the upper molars, however, most frequently select the palatal side as the point of discharge. Sometimes an abscess of the upper incisor may discharge into the antrum. An abscess of the lower third molar often tends to burrow into the soft tissues up above the angle of the jaws. Rarely the pericementum is loosened and the discharge occurs alongside the root.

An acute alveolar abscess progresses by the same means and the principles of treatment are the same as those for any other abscess. Good drainage is necessary to relieve the pressure and the pain. When fluctuation can be made out, an incision should be made to evacuate the pus. Usually the incision should be made within the mouth. When it is necessary to make the incision in the lingual aspect of the mandible posterior to the premolar tooth it is well to remember the close proximity of the lingual nerve. The incision should not only cross cut the mucosa but the periosteum as well, and the center of the incision should be placed at the point of maximum tenderness. When pus is not seen to flow after the incision the knife should be inserted again in the middle of the wound and the periosteum incised in the lower jaw to the alveolar border of the jaw. Both cuts of such a crucial incision should not miss a subperiosteal focus. The most virulent infections are sometimes characterized by well-marked indurations without actual pus formation. It is best and safer as a rule to incise such an induration unless the case is seen late and the symptoms are already subsiding. Though such an incision may temporarily stir up some reaction the final outcome as a rule is the initiation of convalescence. Occasionally the infection continues to spread in spite of drainage. The incision ordinarily should be free enough so that no drain is necessary or would not remain in place if inserted. When dead or diseased bone is already present a sinus will persist. Usually the offending tooth is not worth saving and eventually it should be extracted—after the acuteness of the infection has subsided.

When early incision of an acute dento-alveolar abscess is made within the mouth, often one may prevent the pointing externally on the face or the neck. Probably poultices—hot or cold—as has often been stated, have little to do with the location of pointing of an abscess. When the case is seen late, and external pointing has already occurred, cosmetic considerations must give way to the consideration of the patient's safety. An incision large enough to evacuate the pus should be made but one can use some judgment as to the location of the incision. It is not always necessary to select the most direct avenue to drainage if cosmetic considerations dictate a scar at a less conspicuous point.

Nitrous oxide is often the best anesthetic in operating on an acute dento-alveolar abscess. Sometimes ethyl chloride used as a general anesthetic will fulfil all the indications of the situation. Local anesthesia is usually contraindicated.

Acute Marginal Pericementitis.—Acute marginal pericementitis is treated by removal of the cause and the prevention of its return. Talbot's iodine-zinc iodide solution as a local application is a favorite with many dentists as a medicinal application.

Acute Interradicular Pericementitis.—Misplaced or partially infected lower third molars are more often affected with *acute interradicular pericementitis* than any other of the teeth. As surgical elimination of the pocket is often difficult or impossible and medicinal treatment offers little or nothing, it is usually advisable to extract the tooth. The treatment of an ordinary case of acute interradicular pericementitis is the same as that just outlined. The deep pocket present is drained by incising the gum flap in such a manner as to obliterate the recess.

Chronic Proliferating Pericementitis.—Once it was customary to extract all teeth affected with chronic apical suppurative pericementitis. At present extraction is not always done.

Chronic Granuloma.—The treatment of chronic granuloma, of chronic abscess and of dental root cyst is eradication together with the removal of the associated diseased tooth structure. The form that treatment takes depends upon the extent and the amount of involvement of the peridental membrane and necrosis of the root of the tooth, the position of the tooth, the value of the tooth to the patient, and the general systemic condition of the patient.

Whether to treat teeth showing evidence of periapical infection conservatively or radically possibly should first of all be decided by taking into consideration the general health of the patient. In those patients with systemic disease one's attitude should be more radical than that adopted in patients having no physical disease. So far no reliable or definite preoperative means of proving the connection between suspected areas and systemic condition is definitely known. The sacrifice of an occasional tooth is often only a small matter when weighed against the general health of the patient.

Three surgical procedures are used in these cases: (1) sterilization and filling of the root canal, (2) extraction with surgical eradication of the diseased area, (3) sterilization and root canal filling followed by removal of the necrotic end of the tooth plus surgical eradication of the diseased periapical tissue.

Group I.—Cases suitable for this treatment should show no denudation or necrosis at the apex of the root of the tooth. When the root canal can be sterilized quickly, one may eventually fill it. When prolonged treatment is necessary the tooth should be sacrificed. Only when the patient is healthy should conservative treatment of this type be tried.

Some dentists maintain (Prinz) that resolution of the granuloma in chronic proliferating pericementitis takes place after the granulation tissue has become relatively sterile. They state that the granulation tissue is absorbed, that new bone is laid down, and that the pericementum becomes thickened and that finally a deposit of secondary cementum is observed.

This takes place in from three to twelve months as portrayed by a series of roentgenograms. If it is not going to occur, however, as shown by the roentgenogram over this period of time surgical removal of the root end and the granulation tissue often furnishes a satisfactory method of treating the involved tooth.

Group II.—The following damaged teeth should be placed in the group for extraction.

(*a*) The tooth with a large periapical area of granuloma, suppuration or cyst in which as much as one fourth of the peridental membrane has been lost and in which the cementum is eroded and absorbed.

(*b*) A tooth which has the side of the root perforated and there is infection of the peridental membrane with bone destruction.

(*c*) Upper molar teeth and most lower molars with fairly extensive granuloma, cystic areas with or even without evidence of root absorption. The location of these teeth is not favorable to conservative surgery.

(*d*) The tooth from which a sinus opens onto the skin, into the mouth or into the antrum.

Group III.—The percentage of cases in which this procedure is successful is not at present definitely known.

The treatment applies to the upper incisors, cuspids, and premolars and possibly the lower incisors with periapical granuloma, suppuration or cysts, with roughening or absorption of apical cementum not involving more than one fourth of the root. Prinz considers, however, that the operation is applicable to all teeth but the third molars and states that in multirooted teeth the operation is frequently materially simplified by excising the entire involved root. When there is any evidence of serious systemic infection, teeth falling in this class should be extracted after three months if there is no evidence of obliteration of the periapical areas.

Technic of Root Resection.—Removal of the diseased root ends of a tooth and the involved periapical tissues surgically was suggested by J. S. Smith in 1871. Following this several men (Farrar, 1880, Rhein, 1890, and Lodge, 1897) described methods of its application. Partsch in 1896, however, gave the most satisfactory systematic description of the procedure. During the last quarter of a century the literature concerning the subject has become voluminous. The operation has been recommended for certain cases of (1) chronic apical suppurating pericementitis with or without fistula, (2) chronic proliferating pericementitis, (3) radicular cysts, (4) deep fractures and perforations of the roots, (5) hyperplasia of cementum, (6) foreign bodies in root canals (broken instruments).

In considering the advisability of performing this operation in preference to extraction the position of the tooth in the mouth is of importance. The upper teeth are more suitable for the procedure than the lower teeth. The lower teeth have a thick external bony plate and the saliva is more likely to infect the wound.

The roentgenogram should be studied carefully when one considers the operation with regard to the position and shape of the root, its proximity to maxillary sinus or nasal fossa, the extent of the apical abscess, and the length of the root filling. The root canal should be treated and filled as thoroughly as possible to the apex of the tooth. When the tooth already contains a root canal filling, this should be removed, the root canal treated

and refilled. Oxychloride of zinc carried on a gutta-percha point is the most suitable filling. It hardens and is not disturbed when the root end is cut across.

All effort should be made to wall off the field in such a manner as to prevent external bacterial contamination. When one follows the principles of asepsis, the chances of early healing are increased.

Either nerve blocking or infiltration anesthesia may be employed or a combination of the two might be used. After anesthesia is obtained the patient is draped. A large pad of gauze is placed between the teeth, the lip is raised with a retractor, and the gums and crowns of the teeth are painted with a tincture of iodine. A curved incision from ¾ to 1 inch in length is made over the root to be resected with the base of the incision away from the gingival margin (Fig. 70, *A*, *B*, *C*). The convexity of the incision comes within about ¼ inch of the gingival margin. The ends of the incision overlie the roots of the adjacent teeth. In the case of the central incisor the frenum is divided. With an appropriate periosteal elevator the mucoperiosteum is separated from the underlying bone to a

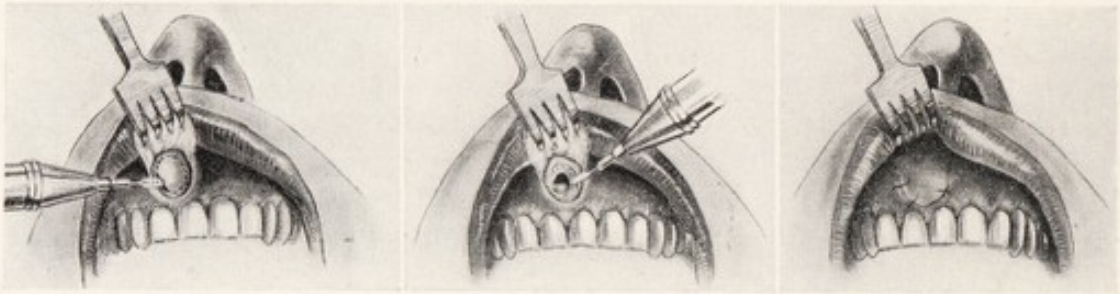

A *B* *C*

Fig. 70.—Technic of root resection. *A*, Shows gum flap turned up and the outer layer of the bone exposed. The window in the bone outlined with a Fisher burr. *B*, The window has been completely removed with the burr and the apex of the root has been removed. The periapical area is curetted. *C*, The flap is thrown down and a few sutures are placed to hold it. It is often well to stitch a roll of gauze over the flap for the purpose of pressure to prevent formation of dead spaces.

point slightly above the apex of the tooth. The mucoperiosteal flap is then retracted upward. Pressure is used to control the bleeding which is only slight. An oval groove is made in the bone with a small fissure burr of a diameter great enough to give a good exposure of the root. The button of bone is then freed with a small chisel. The apex of the root is thus exposed down to the point at which the resection is to be made. With the same fissure burr the root end is cut across and loosened by inserting a narrow chisel in the groove. The root end is examined to see if the root canal filling extends to the apex. A culture is taken if desired. All inflammatory tissue, cyst wall or foreign body is removed until healthy bone is exposed. The root is smoothed over with the fissure burr. It is important to avoid reinfection of the apical area from the root canal. Certain substances of a foreign nature have been recommended for this purpose. It is probably better not to use such substances. All that can be done is the application of some antiseptic such as 10 per cent silver nitrate to the apex of the tooth. This tends to seal the open tubule of the bare root. The retractor is removed. The flap is sutured in place with two or three horse-

hair or silk sutures. If one can by some method or other press the flap into the cavity so that no dead space remains, healing will be facilitated. This can be done by stitching a wad of marine sponge over the flap so that it is pressed snugly up against the cavity behind. The incision should heal by first intention. If suppuration should occur beneath the flap, the sutures should be removed and the cavity packed with gauze and allowed to heal by granulation from the bottom. When suppuration is found to be present at operation, the wound should not be sutured but packed with gauze. After root resection the tooth should be studied by roentgenogram about every three months to follow the progress of the regeneration of bone. Ivy states that if no progress is seen after three months the tooth should be extracted.

The Partsch operation for the treatment of radicular dental cyst is described in Chapter XXXVIII which takes up tumors of epithelial origin.

Bibliography

Bibliography Quoted in Text

Arkoevy: Oesterr.-Ungar. Vierteljahrsschr. f. Zahnheilk., 1897, p. 40.

Arkoevy, J.: Kritische Bemerkungen zu den jüngsten Veröffentlichungen über die sogenannte Pyorrhoea alveolaris, Oesterr.-Ungar. Vierteljahrsschr. f. Zahnheilk., **10:** 194, 1894.

Bargen: Etiology of Chronic Ulcerative Colitis, J.A.M.A., **83:** 332, 1924.

Barker: Oral Sepsis and Internal Medicine, Jour. Den. Research, **2:** 43, 1920.

Barrett, M.: Dental Cosmos, Aug., 1914.

Bass and Johns: Alveolo-dental Pyorrhea, J.A.M.A., **64:** 553, 1915.

Becker, E.: The Significance of the Teeth Regarding the Utilization of Foodstuffs, etc., Berlin and Leipzig, Walter de Gruyter, 1926.

Billings, F.: Focal Infection, New York, Appleton and Co., 1917.

Black, A. D.: Roentgenographic and Microscopic Studies of Tissue Involved in Chronic Mouth Infection, J.A.M.A., **69:** 599, 1917.

Treatment of Chronic Suppurative Pericementitis, J.A.D.A., Feb., 1920.

Black, G. V.: Spec. Dental Pathology, Chicago Medico-Dent. Pub. Co., 1915.

Blair, V. P., Padgett, E. C., and Brown, J. B.: Diseases of the Face, Mouth and Jaws, Graham's Surgical Diagnosis, W. B. Saunders and Co., Phila., **2:** 209, 1930.

Blair, V. P., and Ivy, R. H.: Essentials of Oral Surgery, St. Louis, C. V. Mosby Co., 1924, pp. 85–88.

Box, H. K.: Studies in Periodental Pathology, Canadian Dental Research Foundation Bull., p. 7, May, 1924.

Broderick, F. W.: Dental Medicine, St. Louis, C. V. Mosby Co., 1928.

Butler: Etiology of Iritis, Brit. Med. Jour., **1:** 804, 1911.

Cecil and Archer: Classification and Treatment of Chronic Arthritis, J.A.M.A., **87:** 741, 1926.

Cecil: Discussion, Jour. Dent. Research, **2:** 830–831, 1931.

Fauchard, Pierre: Chirurgie Dentist, **1:** 1742, 1746.

Gallippe: Die infectiöse orthio-dentäre Gingivitis, Berlin, 1880.

Gottlieb, B.: Tissue Changes in Pyorrhea, **14:** 2178, 1927.

Wchnschr. f. Zahnheilk., No. 2, 1920.

Schmutzpyorrhöe, Paradentalpyorrhöe und Alveolaratrophie, Vienna, Urban und Schwartzenberg, 1925.

Garrettson: Oral Surgery, Phila., Lippincott and Co., 1890, p. 1364.

Gilmer, T. L., and Moody, A. M.: A Study of the Bacteriology of Alveolar Abscess and Infected Root Canals, J.A.M.A., **63:** 2023, 1914.

Gilmer, T. L.: Chronic Oral Infection, Illinois Med. Jour., **21:** 275, 1912.

Haden, R.: Dental Infection and Systemic Disease, Lea and Febiger, Phila., 1928, p. 25.

Harris, D. Fraser: Transactions of the Nova Scotian Institute of Science, vol. 4, p. 47.

Head, Henry: Distribution of Sensation with Special Reference to the Pain of Visceral Diseases, Brain, **3:** 1894.

Hecker, F.: Pyorrhea Alveolaris, St. Louis, 1913.
Hopewell-Smith, A.: The Normal and Pathological Histology of the Mouth, Phila., 1918.
Howe, P. R.: Practical Nutritional Suggestions for Dentists, J.A.D.A., **17:** 2140–2143, 1930.
J.A.M.A., **15:** 1673, 1929.
Hunter, John: Oral Sepsis as a Cause of Disease, Brit. Med. Jour., **2:** 215, 1900.
Karolyi, M.: Beobachtungen über Pyorrhoea alveolaris und Caries dentum, Oesterr.-Ungar. Vierteljahrsschr. f. Zahnheilk., **18:** 520, 1902.
Kirkland, Olin: The Suppurative Periodontal Pus Pocket; Its Treatment by the Modified Flap Operation, J.A.D.A., August, 1931.
Kranz, P., and Falk, K.: Alveolarpyorrhöe, Berlin, 1922.
Magitot: Quoted by Endleman, Dental Pathology, St. Louis, C. V. Mosby Co., 1927.
Mayrhofer: Principien der Pulpagangrän, 1909.
Mellanby, May: Experiments on Dogs, Rabbits, and Rats and Investigations on Man Which Indicate the Power of Certain Food Factors to Prevent and Control Dental Disease, J.A.D.A., **17:** 1456–1480, 1930.
Miller, S. C.: Oral Diagnosis and Treatment Planning, Phila., P. Blakiston's Son and Co., 1936.
Miller, Joseph L.: Dental Infection as a Cause of Systemic Disease, **17:** 1598, Sept., 1930.
Miller, S. R.: Blood Chemistry and Periodental Problems, **17:** 459, 1930.
Miller, W. D.: Dental Cosmos, The Human Mouth as a Focus of Infection, **33:** 689, 1891.
Mosher, D. F.: Personal communication to author.
Moral, H.: Die Chirurgie der Weichteile des Mundes, in Handbuch der Zahnheilkunde, 4th ed., Munich, J. F. Bergmann, 1932, vol. I.
Noyes, F. B.: Studies of the Pathology of the Periodental Membrane, Jour. Nat'l Dental Assoc., p. 375, April, 1917.
Orban, B.: A Contribution to the Knowledge of the Physiologic Changes in the Periodental Membrane, J.A.D.A., **16:** 389–404, 1929.
Partsch, C.: Deutsch med. Wchnschr., 1904, No. 39.
Pemberton: Significance and Rôle of Diet in Treatment of Chronic Arthritis, N. Y. State Med. Jour., **26:** 668, 1926.
Pfaff, Philipp: Abhandlung von der Zähne des menschlichen Körpers und deren Krankheiten, Berlin, 1756.
Praeger, W.: Zahnaerzt. Rundschau, **39:** 2261, 1930.
Prinz, H.: Disease of the Soft Structures of the Teeth and Their Treatment, Lea and Febiger, Phila., 1928.
Dental Materia Medica and Therapeutics, 6th ed., St. Louis, C. V. Mosby Co., 1926.
Prinz, H., and Greenbaum, S. S.: Diseases of the Mouth and Their Treatment, Phila., Lea and Febiger, 1935.
Rhein, M. L.: Dental Cosmos, **36:** 779, 1894.
Riggs, J. M.: Suppurative Inflammations of the Gums and Abscription of the Gums and Alveolar Process, Penn. Jour. Dent. Soc., Lancaster, Pa., **3:** 99, 1876.
Roemer, C.: Periodentitis und Periostitis alveolaris, Schaff's Handbuch der Zahnheilkunde, **2** (part 1): 576, 1909.
Roemer, O.: Periodontitis und Periostitis alveolaris, Schaff's Handbuch der Zahnheilkunde, Vienna, 1924.
Rosenow, E. C.: Elective Localization of Bacteria, Jour. Dent. Res., **1:** 205–247, 1919.
Sachs, H.: Paradentitis und Paradentose, Partsch Handbuch der Zahnheilkunde, Munich, 1924.
Schreier: World's Columbian Dental Congress, 1893.
Schweizer: Quoted by Hopewell-Smith.
Smith, E.: Quoted by Ruffner, M. A.: Studies in Paleopathology of Egypt, Univ. Chicago Press, p. 293, 1921.
Talbot, Eugene S.: Dental Caries, Pulpitis, Periodentitis, and Dental Sepsis, Interstitial Gingivitis and Pyorrhea Alveolaris, Nelson's Loose Leaf Living Medicine, **5:** 20.
Etiology and Treatment of Interstitial Gingivitis, J.A.M.A., 68–420, Feb. 10, 1917.
Tomes, C. S.: Manual of Dental Anatomy, Phila., P. Blakiston's Son and Co., 1914.

Tomes, J., and Ch. S.: Dental Surgery, 4th ed., London, J. and A. Churchill, p. 638, 1897.
Webb, G. F.: Personal communication to author.
Weld: Dental Cosmos, p. 397, 1897.
Weski, H.: Deutsch. Monatschr. f. Zahnheilk., **38:** 557, 1920.
Widman, L.: The Operative Treatment of Pyorrhea Alveolaris, Stockholm, 1918.
Wilcox: Infective Arthritis and Allied Conditions with Special Reference to Etiology and Treatment, Brit. Med. Jour., **1:** 805, 1921.
Wolbach, S. B.: Jour. Med. Res., p. 415, Oct., 1909.

The following are quoted by Prinz, H., and Greenbaum, S. S., in Diseases of the Mouth and Their Treatment, Phila., Lea and Febiger, 1935: Beyer, Farrar, Kolle, Pierce, Smith, J. S., and Wood.

CHAPTER XIII

THE REMOVAL OF TEETH AND RELATED MATTERS*

INTRODUCTION

GENERALLY speaking, one can summarize largely the causes which may lead to the removal of a tooth as follows (see Chapter XII): (1) the destruction of a tooth by dental caries to an extent beyond repair, (2) an advanced disease of the pericementum, (3) a severe destructive infection of the tooth pulp, (4) an impaction of a tooth, (5) a malposition of a tooth not amenable to orthodontic reposition (instances which require removal of the teeth preparatory to correction of a deformity of the jaw bone fall into this category), (6) a severe injury to the tooth or to the surrounding structures or both, (7) to provide access for the adequate removal of a tumor. This summary applies to the deciduous teeth as well as the permanent teeth. The caution, however, should be made that irrational extraction of deciduous teeth frequently predisposes to irregularities of the permanent set which may be difficult to correct. The orthodontist stresses the factor of premature removal of deciduous teeth in the production of the various types of irregularities of the permanent teeth and resultant malrelation of the jaws.

Besides the removal of teeth for the reasons just enumerated one often has cause to remove a tooth from the line of fracture of the jaws. When a tooth is out of position so that its function is nil it may be wise to remove it. Sometimes one removes healthy normal teeth because they are not sufficient in number to be of value after the other worthless teeth have been removed.

Study of Factors Present.——Before attempting to remove a tooth, the operator should make a careful physical examination of not only the teeth but also the neighboring structures. He should have an adequate idea of the type of patient with whom he is dealing. Among the factors to be considered are the following: (1) the form of the face (square and ovoid types have, as a general rule, heavier jaws which may increase the difficulty of the operative procedure); (2) the size and shape of the alveolar structures (when thick, prominent buccal ridges are encountered removal of the tooth may be more difficult); (3) the presence or absence of marked gingival infection; (4) accessibility (it frequently determines the type of operative procedure); (5) the temperament of the patient (in neurotic and highly nervous individuals it may be difficult to use successfully local anesthesia even after the patient has been given a preliminary sedative.

* In writing this chapter, I have become greatly indebted to several of my friends who to a certain extent specialize in the removal of teeth for writing and reading the copy and offering suggestions. This is true especially of Dr. Don Woodard and also of Dr. R. W. Edwards, Dr. C. W. Keeling and Dr. G. F. Webb, all of Kansas City. Several of the illustrations are those of Dr. Woodard to whom credit is given. Dr. Woodard originally wrote a part of the chapter in outline form. From this form I rewrote the chapter and added about one half of the chapter as it stands at present.

In most instances roentgenograms should be made of the teeth to be extracted. From them the operator is able to obtain much useful information as to the size, shape and number of the roots and of their degree of curvature and relationship to the surrounding structures. The presence of malformation of the structures can be noted. The presence or absence of such conditions as hypercementosis, granuloma, and cyst is information of value. The density of the surrounding osseous structures may be observed. The proximity of the tooth to important structures such as nerves, the antral cavity, and adjacent teeth can be estimated.

Selection of the Anesthetic.—The anesthetic appropriate to the facilitation of the removal of teeth is a matter of some importance. A considerable number of factors may be involved. Among these one may categorically mention the age and temperament of the patient, the difficulty likely to be encountered in carrying out the operative procedure and the length of the operative time, the presence of local infection, and the general condition of the patient.

Dogmatic statements either for or against either local or general anesthesia often are incorrect. A great deal depends upon the expertness of the anesthetist and the operator. When one has an expert anesthetist and is an expert operator, undoubtedly gas anesthesia may be very pleasant for the patient and postoperatively on an average probably one encounters less soreness and possibly less of a tendency to low-grade infective complications. At least some of the older more expert operators argue along these lines. At the present time, however, there is a trend among dentists toward the recommendation of local anesthesia for the usual operative procedures. The very best operator should be equipped and able to use both general and local anesthesia properly selected for the individual case. For a considerable number of operations the selection of the type of the anesthesia will make no great difference. In others the indications are more definite.

Sometimes a general anesthetic is preferable to a local anesthetic when there is some low-grade infection about the teeth to be removed. It is a general rule of surgery that one should not introduce any fluid under pressure into acutely inflamed tissue. The result may be an exacerbation of the tendency of the infection to spread or even a slough may develop. In certain situations, however, proper blocking can be accomplished without the needle traversing infected tissue.

Besides the group of individuals in which infection may contraindicate local anesthesia, there is a group of nervous individuals in whom the use of local anesthesia may be difficult or even almost impossible. Usually in children it is quite difficult or impossible to use local anesthesia. The wisest choice in these groups is a general anesthesia.

Aged patients and those affected with arteriosclerosis, hypertension, hyperthyroidism, endocarditis, decompensation, etc., must be handled very carefully under any anesthetic. The wiser dentist will handle this type of patient in conjunction with an internist after a careful evaluation of all the factors connected with the situation in so far as the general condition of the patient is concerned. The extent of the operative procedure contemplated in this group assumes an increased importance and should be evaluated by both the internist and the dentist.

Local anesthesia may have certain advantages over gas anesthesia. It may avoid a certain amount of inconvenience. The necessity of obtaining an anesthetist and preparing the patient is dispensed with. Although ordinarily gas anesthesia causes no nausea or vomiting, one cannot be absolutely certain that some postoperative nausea or vomiting will not occur. Local anesthesia does not have this defect except in the rarest of instances. With local anesthesia unless the operator is unusually expert, a less obstructed field often is obtained. The conscious cooperation of the patient may be advantageous in performing certain types of operative procedures. The advantage of encountering less blood in the operative field when local anesthesia is used may be a determining factor in its selection.

Thus, many dentists prefer local anesthesia for the removal of both excementosed and impacted teeth, for root resection, operations for small cysts, alveolectomy, for the removal of small tumors and for small plastic operations.

Local Anesthetic Solutions.—A 2 per cent solution of novocain in normal saline is commonly used for local anesthesia within the oral cavity. A drop of 1:1000 solution of adrenalin to about 4 cc. of a solution is about the correct amount to obtain the proper vasoconstriction to prolong anesthesia. Recently, for individuals rather hypersensitive to adrenalin such as those suffering from some hyperthyroidism, a solution of novocain containing cobriform has been found of use. Besides novocain a considerable number of substitute local anesthetics are on the market and in the hands of certain dentists have been used successfully. Recently ethycain borate has been studied by Daily and Benedict as a drug rivaling or surpassing novocain in effectiveness. Freeman has recommended the drug as being less toxic, giving a quicker anesthesia and as a drug never producing postoperative pain. If Freeman is correct, it is possible that ethycain borate may have some advantages over novocain.

Syringes and Needles.—A 3-cc. Luer syringe is satisfactory. If one objects to the needle not being attached to the ordinary Luer syringe, the Luer-Lok syringe, a modification of the Luer to which the needle may be firmly attached by a half turn of the hub, may be found more satisfactory. For deep injections a 1½-inch 22-gauge needle is satisfactory. For infiltration a 24-gauge needle ½ inch in length is efficient. A steel needle is about as efficient as an iridioplatinum needle.

Position of the Operator.—Equally expert operators do not always advocate the same positions of the patient or the operator. Preference as to position of the patient and stance of the operator will depend somewhat upon early training and whether or not the operator prefers some particular type of instrument.

Winters describes two positions for the removal of the lower teeth which vary according to the type of forceps used or the preference of the operator. For the left lower molars he recommends a standard type of molar forceps and for the remaining lower teeth a standard type of a premolar forceps. When using those styles of forceps the operator takes his position to the right and behind the patient. The jaw is supported with the fingers of the left hand. When removing the right first and second bicuspids and the right lower molars, the index finger is used to retract the soft structures. The thumb is used to protect the tongue. When the anterior lower

teeth, the left cuspid and bicuspids and molars are being removed, the arm supports the head of the patient and the thumb of the left hand is used to retract the lip.

When the Cryer universal forceps (No. 151) is used for the removal of the lower teeth, the operator stands in front of the patient. The thumb and index finger of the left hand are used to retract the soft structures and the remaining fingers to support the jaw. Force is applied outwardly unless it is found that the lingual plate offers the least resistance.

For the removal of the upper left bicuspids and upper left cuspid, the operator stands in front of the patient, the soft tissues of the lips and cheeks are retracted by the thumb on the right side and the index finger on the left side. The palm of the hand rests in front of the face. For the removal of the upper central and lateral incisors, the upper right bicuspids, the upper right molars, the upper left first, second and third molars, the operator stands behind and to the right of the patient and the fingers of the left hand retract the soft tissues.

Instruments.—Ordinarily instrument requirements should be kept to the minimum needed. The wise operator strives for proficiency with a few instruments rather than many. Vague familiarity with an impressive array is not conducive to real efficiency. On the other hand, he should not become so narrow as not to recognize the advantages of different technics and should conscientiously strive to improve his technic by an intelligent application of their principles. Some operators stress the use of exolevers, others of chisels and others of burrs. Probably they all have their place in technical proficiency and the operator may do well if he follows a course which recognizes this and uses the advantages of each.

Forceps.—Forceps are designed for and used to grasp the tooth and supply a sufficient means of leverage and traction to remove it from its socket. They should be so designed that when applied to the tooth properly the tooth in a sense becomes a part of the instrument and the force is applied to the long axis of the tooth (Fig. 71). There are many types of dental forceps on the market. Some men pride themselves upon simplicity and use only one forceps for the extraction of all upper teeth and roots. The Cryer universal upper forceps No. 150 has been recommended highly as a most useful forceps for this purpose (Fig. 71) by Ivy. He also recommends for the extraction of all molar teeth and roots the English "hawk-bill forceps" pattern No. 74.

Elevators.—Elevators are designed for applying leverage to teeth or tooth fragments so that they may be elevated from their sockets. Elevators improperly and injudiciously used can apply damaging stress to the osseous structures or adjacent teeth. Roughly, elevators have a straight handle which may be either small or large as the case may be. There are many designs from gouges to angles (Fig. 71). Crossbar elevators have a crossbar handle which fits the hand and provides maximum control and sensitivity. They should not be used in the maxilla. Exolevers come in the classification of more specialized technic.

Chisels.—Chisels are indispensable to a complete armamentarium. They are used to remove bone and to section teeth. Much has been said about the sectioning of teeth by the use of chisels. The technic is one which can be mastered by practice.

Bone Burrs and Drills.—Bone and tooth substances can frequently and efficiently be removed by the use of bone burrs and drills. The bibeveled drill is the most efficient drill in that the areas of bone to be removed can be easily and quickly outlined with a minimum of trauma and lapse of time. They do not clog and of all types of burrs, probably cause less heating and condensing of the bone tissue.

Surgical Accessories.—A dissecting outfit which includes hemostatic forceps, tissue forceps, scissors, sutures and needles are all a necessary

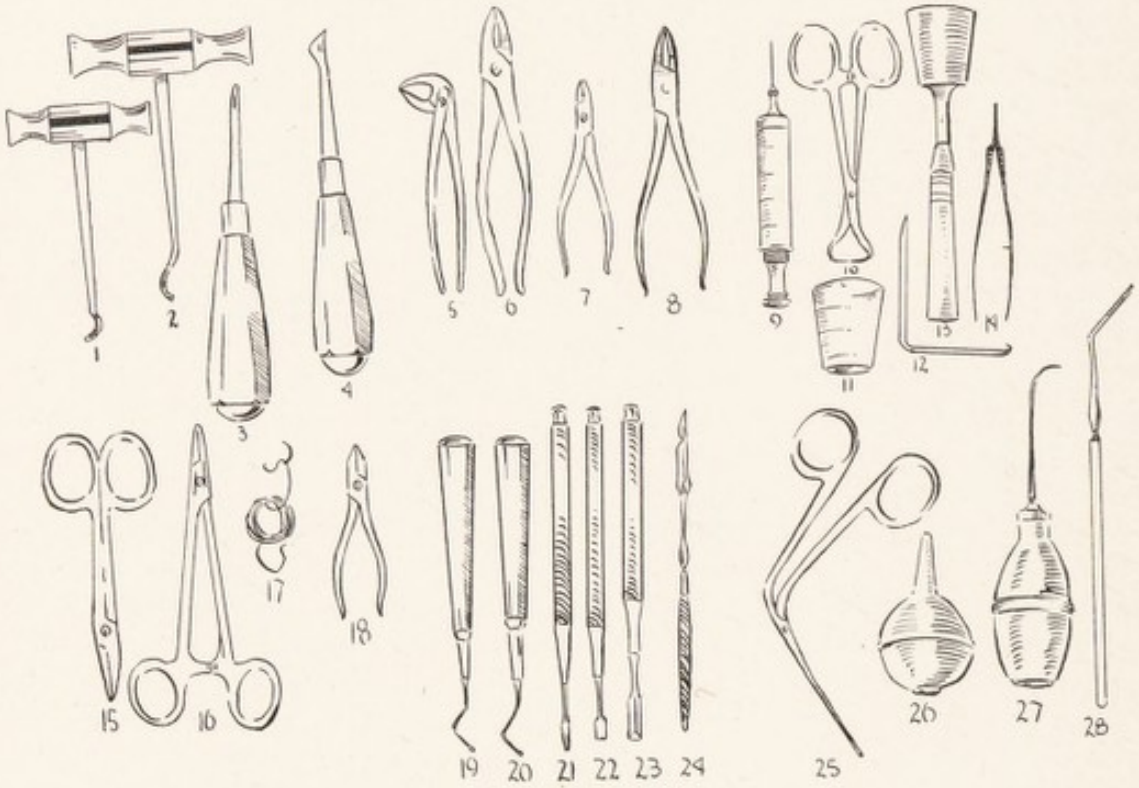

Fig. 71.—Typical set-up for the extraction of a tooth. 1, Right elevator (Winter); 2, left elevator (Winter), 3, Crane pick; 4, Cryer right elevator; 5, hawk-bill forceps; 6, large rongeur; 7, small rongeur; 8, upper universal forceps; 9, Luer syringe and 24-gauge needle; 10, towel clip; 11, medicine glass; 12, cheek retractor; 13, mallet; 14, anatomic forceps; 15, tissue scissors; 16, Kelly hemostat; 17, curved needle and suture; 18, wire cutter; 19, left apical curet (Molt); 20, right apical curet (Molt); 21, narrow chisel; 22, wide chisel; 23, Gardner bone chisel; 24, scalpel; 25, nasal dressing forceps; 26, ear and ulcer syringe; 27, chip blower; 28, explorer.

adjunct. Besides these certain bone files, curets and rongeurs may be of considerable advantage.

Premedication.—Frequently it is advisable in oral operations to premedicate the patient. Usually this is resorted to to relieve apprehension, nervousness, and to assure a cooperative patient. At other times it is necessary because of systemic complications. In systemic diseases it is advisable to seek the advice of the patient's physician regarding appropriate premedication.

In cases of nervousness on the part of the patient, the night prior to the operation some of the barbital preparations such as sodium medinal (10 grains) may promote sleep. Sodium amytal has few contraindications and is said to be especially indicated in novocain sensitivity. Administered in 3-grain doses the night before and one-half hour before operation, it

usually assures a quiet cooperative patient. In hospital practice a hypodermic of morphine (1/6 to 1/4 grain) and atropine (1/150 grain) not only makes the operation easier for the patient but also limits to some extent the flow of saliva providing a clearer operative field. In the majority of cases there is certainly no contraindication to making the operative ordeal as easy as possible for the patient.

Technic of the Induction of Local Anesthesia

In Chapter II the location of the sensory nerves and the area which they supply is considered. A knowledge of this anatomic data is absolutely necessary if one wishes to use local anesthesia with success.

INFILTRATION ANESTHESIA

In many injection procedures the local anesthetic to be effective must be carried through the outer cortical bone to the cancellous bone through

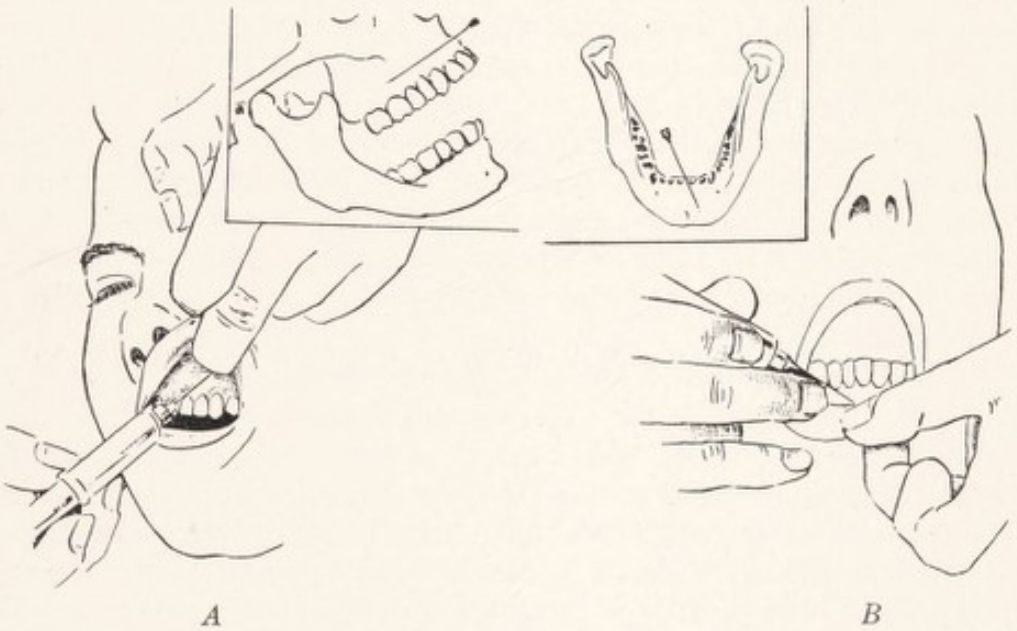

A *B*

Fig. 72.—*A,* Maxillary infiltration. Point of insertion of needle. The diagram of the skull at the upper right corner shows the relative position of the needle to the bony structures as it is inserted. *B,* Incisive fossa infiltration. Position of the needle and syringe for injection of the incisive fossa. The diagram of the mandible and the needle at the upper left corner shows the relative position to the bony structure when the solution is deposited.

the minute channels which traverse cortical bone from the periosteum to the central spongy bone. Generally speaking, more of these canaliculi are present in the maxilla than in the mandible. This fact renders infiltration anesthesia more effective on the whole in the maxilla than in the mandible. In the anterior portion of the mandible about the region of the incisor, the cuspid, and the bicuspid teeth the cortical bone is not so thick as about the molars. The dental alveoli are made up principally of a rather cancellous type of bone. The external wall of alveolar bone has many small perforations which permit rapid diffusion of an infiltrating solution so that the nervous structures of the peridental membrane may be rendered anesthetic without difficulty.

Under moderate pressure by means of *periosteal infiltration* a limited area of the alveolar process may be anesthetized. The sensory nerve endings are rendered functionless after about five minutes and the anesthesia is present for about one-half hour. For the extraction of all individual teeth save the lower molars this type of anesthesia is quite effective. A short needle should be used, and it is inserted into the gum at almost a right angle with the bevel facing the bone. From 1 to 2 cc. of the solution is injected under as little pressure as is actually required to introduce the fluid. Slight massage of the area will encourage diffusion.

Although infiltration anesthesia may be used and may be effective, in most procedures it is not the method of choice.

Maxillary Infiltration.—Several teeth in the maxilla may be infiltrated at one time. Too many puncture wounds should be avoided. The insertion of the needle is made high up in the buccal fold near the apex of the cuspid tooth. The needle should enter the gum at about the juncture of apical and middle thirds of the roots of the tooth. The syringe and needle are held parallel to the occlusal surfaces of the teeth. The bevel of the needle faces toward the bone. The needle may then be advanced and about 1 cc. of the solution is deposited over the apices of each of the several teeth to be anesthetized (Fig. 72, *A*).

When one is anesthetizing for the purpose of removing a tooth, the lingual alveolar plate and its coverings must also be anesthetized. To avoid the use of an excessive amount of solution and numerous puncture wounds, the posterior palatine foramen and nasopalatine foramen injections often are made instead of a single infiltration for each tooth.

CONDUCTION ANESTHESIA

When an anesthetizing fluid is injected near a sensory nerve trunk the solution penetrates the perineurium and enters the nerve substance. The result is an anesthesia of the peripheral area supplied by the nerve. The conductivity of the nerve is eliminated. It is really a perineural form of anesthesia as the nerve sheath is not ordinarily punctured by the needle.

Conduction anesthesia may have the following advantages over local injection. A more complete anesthesia over a wider area is obtained. Fewer injections are necessary. A less amount of anesthetic is used. The anesthetic is more prolonged. The psychologic effect on the patient is better, as most of the injections are made in tissues which are not taut and the pain of insertion of the needle is less. Finally, very often it is possible to avoid an infected field.

In the use of conduction anesthesia asepsis, a knowledge of important anatomic parts, a knowledge of technic, an adequate knowledge of pathology, and good surgical judgment are necessary. The solution should be isotonic and of a temperature nearly that of the body. The injection should be made slowly. Finally, sufficient anesthetic has to be given for anesthesia to be obtained.

Conduction Anesthesia of the Maxilla.—In the upper jaw one encounters two nerve loops—the outer and the inner. The outer is formed by the infra-orbital and superior alveolar or superior dental nerves. All of the teeth of the upper jaw, the mucosa of the antrum, the buccal gum and the periosteum are supplied by this loop. The inner loop is made up of the

anterior palatine and nasopalatine branches from Meckel's ganglion. By the latter loop the sensory supply of the hard palate and its mucosal covering is supplied on one side.

The Tuberosity Injection.—This injection is used to block the posterior alveolar nerves. These fibers are given off from the maxillar division of the fifth nerve in the sphenomaxillary fossa and pass downward and forward over the zygomatic surface of the maxilla, entering the bone about ¾ to 1 inch above and slightly posterior to the last erupted tooth.

To make the injection, the second molar ridge is palpated with the index finger. The needle is inserted high up in the buccal fold above the distobuccal root of the upper second molar (Fig. 73, *A*). The syringe is held at an angle of approximately 45 degrees to the occlusal plane of the upper teeth and the needle is passed backward, upward and inward about 1 inch. The syringe should be held as far externally as the angle of the mouth will permit but the needle should be kept as close to the slightly convex tuberosity as possible. The injection is made slowly and cautiously. As the needle progresses through the tissues, a few drops of solution are deposited periodically. When a depth of about 1 inch is reached, the balance of the solution is deposited. The area anesthetized includes the upper, second and third molars, their buccal alveolar plate, periosteum and mucous membrane. When the first molar is to be removed, a few drops of solution is injected to the mesiobuccal root of this tooth to anesthetize the overlap of the fibers of the middle superior alveolar nerve and the posterior superior alveolar nerve. When the first, second and third molars are to be removed, the area about the posterior palatine foramen should be infiltrated to anesthetize the palatal mucosa and underlying structures.

The Posterior Palatine Foramen Injection.—The anterior palatine nerve enters the oral cavity through the posterior palatal foramen. This foramen is located approximately 5 to 6 mm. anterior to the junction of the hard and soft palates, and about two thirds of the distance laterally from the median line to the gingival border of the last erupted tooth. On each side and in a line or a trifle posterior to the palatine root of the upper second molar, there is a very slight depression. The needle is inserted through the mucosa of this depressed area (Fig. 73, *B*). The needle is then advanced into the posterior palatine foramen. Several drops of the anesthetizing solution then are deposited. The palatal alveolar plate and the mucous membrane of the palate to the midline and as far forward as the second bicuspid where the branches of the anterior palatine nerve anastomose with the nasopalatine nerve are anesthetized by this injection.

The Infra-orbital Injection.—An imaginary line may be passed through the supra-orbital, infra-orbital and mental foramina. Usually the infra-orbital foramen lies about 0.5 to 1 cm. below the infra-orbital ridge. For the removal of teeth, the dentist usually uses the internal approach to the foramen. The technic of this approach is as follows: the foramen is palpated with the index finger. The lip is held upward with the thumb. The needle is inserted high up in the buccal fold above the apices of the upper bicuspid teeth in a direction toward the pupil of the eye and directed in such a manner as to arrive under the palpating finger. Keeling has stated that in the study of skulls he has found the foramen opening more in line with the lateral incisor than with the bicuspid teeth. He believes

a more direct entrance is obtained when the needle and syringe are directed from this angle (Fig. 74, *A*). A few drops of anesthetizing fluid are

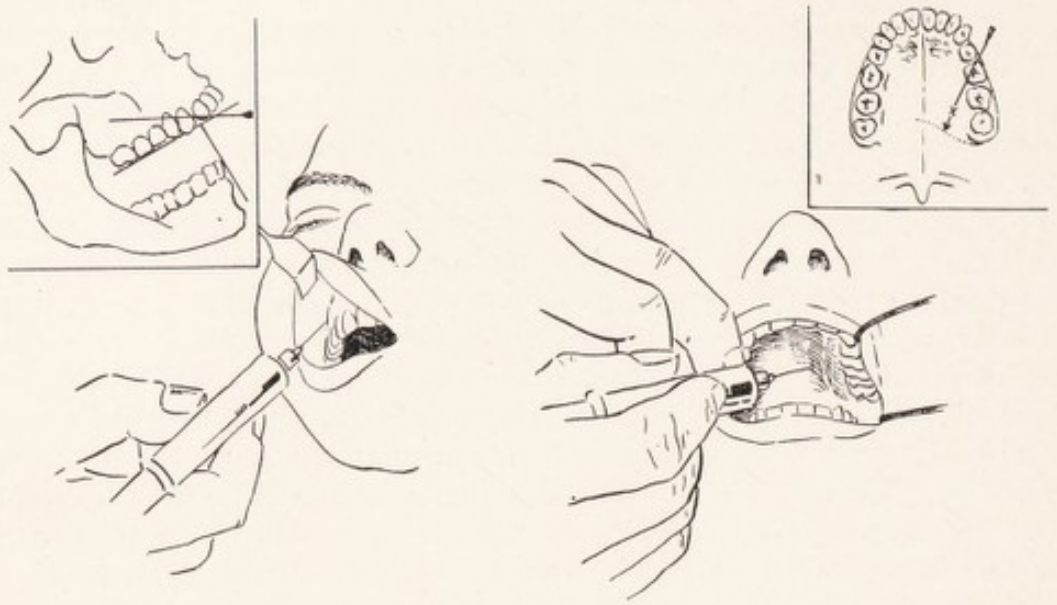

A *B*

Fig. 73.—*A*, Tuberosity injection. Direction and point of insertion of the needle for tuberosity injection. The insert shows the relative position of the needle to the bony structures when the solution is deposited. *B*, Posterior palatine injection. Point of insertion of the needle for the posterior palatine injection. The needle is then swung over to the right to the alveolar ridge and is pushed backward somewhat. The diagram in the insert shows the position of the needle at the time the fluid is deposited.

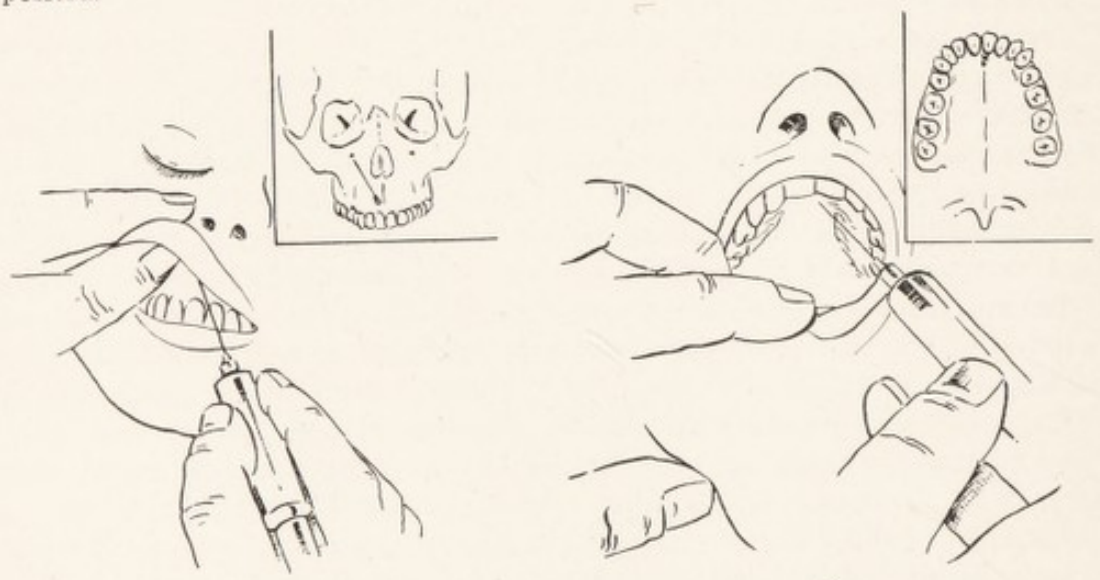

A *B*

Fig. 74.—*A*, Infra-orbital injection. Position of the point of insertion for the needle and the position of the finger when one wishes to inject the infra-orbital foramen from within the mouth. The skull in the insert depicts the relative position of the needle to the deeper structures and the infra-orbital foramen when the fluid is injected. *B*, Anterior palatine injection. Position of the needle and the direction of the needle to inject the incisive foramen. The diagram at the upper right hand corner shows the position of the incisive foramen.

injected in the region of the foramen after which a careful hunt is made for the opening of the foramen. When this opening is located the needle

is inserted and several drops of anesthetizing fluid are injected directly into the canal.

This injection provides anesthesia of the anterior and usually the middle superior alveolar nerves supplying the bicuspids, cuspids, and incisors. If the central region is to be removed, it is necessary to give an infiltration in the midline, due to anastomotic fibers from the nerves of the opposite side. To anesthetize completely the tissue about the second bicuspid infiltration is sometimes necessary over the tooth on account of overlapping of the posterior superior alveolar nerve.

The Anterior Palatine Injection.—The opening of the anterior palatine foramen corresponds to a little elevation of the mucosa slightly posterior to the median space between the two central incisors. This elevation or papilla is rather sensitive; hence, the insertion of the needle directly into it is painful and should be avoided (Fig. 74, *B*). Thus, first the needle is inserted laterally to the papilla to avoid giving the patient unnecessary pain and a few drops of solution deposited. After a lapse of about a minute the needle is inserted in line with the two central incisors, the syringe being held parallel to the labio-alveolar plate, and the anterior palatine foramen is sought. This is entered for a short distance and a few drops of the solution are deposited. This injection anesthetizes the nasopalatine nerve which supplies the palatal alveolar plate and the mucous membrane as far back as the first bicuspid tooth (both sides). It must be remembered that there is an anastomosis of the nasopalatine and the anterior palatine nerves so that if a cuspid is to be removed, it is advisable to make a lingual infiltration opposite the tip of the root of the tooth rather than to make the anterior palatine injection.

Conduction Anesthesia in the Mandible.—Conduction anesthesia has its greatest field in operations upon the mandible.

Conduction Anesthesia for the Lower Six Anterior Teeth.—Conduction anesthesia for the lower six anterior teeth may be accompanied by depositing the solution in the incisive fossa (Fig. 72, *B*).

The needle is inserted in the median line as low as possible in the reflection of the labial mucosa. The left fossa is sought first by directing the needle downward and backward (Fig. 72, *B*). The fossa will be found at a depth of 1 to 1.5 cm. One cc. of solution is here slowly injected. The needle is then withdrawn to the point of insertion but not removed from the tissue and, after swinging the syringe to the opposite side, the right fossa is injected in a like manner. After completing the injection the chin should be massaged in order to force the solution through the foramina into the cancellous structure of the bone. When removing the incisors lingually a small quantity of novocain is injected behind the central incisors in the line of the long axis. Likewise, when removing the cuspid and first bicuspid, a small quantity of the anesthetizing fluid is injected lingually to the tooth. This injection anesthetizes the filaments of the lingual nerve which innervate the gum.

The Mandibular Injection.—Blocking of the mandibular nerve produces anesthesia of the teeth, alveolar process, and mucosa of one half of the lower jaw with the following exceptions: (1) an area of gum tissue on the buccal side of the lower molar teeth which is partially supplied by the long buccal nerve, (2) the mucous membrane on the lingual side of the

jaw which is largely supplied by the lingual nerve, and (3)) an anterior portion of the mandible, including the incisor teeth, which is supplied in part by the overlapping fibers of the nerve from the opposite side.

If one examines the bare mandible he may observe the following landmarks: (1) at the lower part of the ascending ramus there is an outer

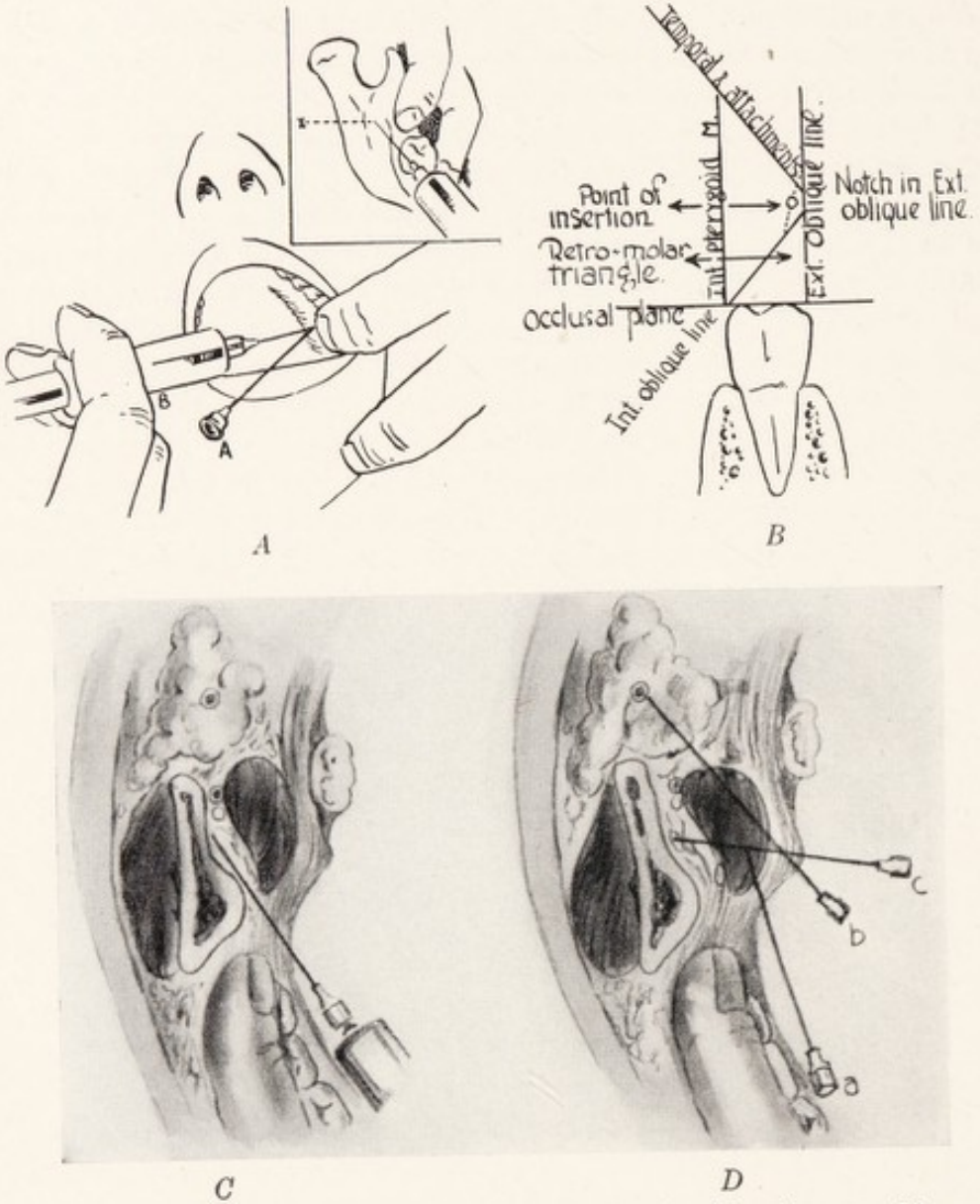

A B C D

Fig. 75.—*A*, Insertion of the needle for mandibular injection. B, Shows second position as the needle is inserted and feels its way along the inner side of the mandible. The needle should be about ½ inch above the occlusal plane of the lower molars. The inset shows the position of the inferior dental foramen. *B*, Approximate point of insertion and landmarks for mandibular injection, anterior view. *C*, Cross section view of mandibular injection, anterior view. Correct method. *D*, Common errors in mandibular injection. (Woodard.)

ridge on the bone, the so-called "external oblique line." This ridge of bone becomes continuous above with the anterior edge of the coronoid process, (2) about 0.5 cm. inward and back of this outer ridge is a second ridge—the so-called "internal oblique line." This ridge also gradually loses itself in the coronoid process. These two ridges of bone and the third molar tooth in front outline a more or less triangular area called the "retromolar

triangle." This retromolar triangle is useful as a guide to the insertion of the needle for injection in the region of the opening of the mandibular canal which lies approximately 0.5 to 1 cm. above the occlusal plane of the molar teeth and at a point near the center of the ascending ramus. Thus, with the index finger over the retromolar triangle as a guide, the needle is inserted at a point about 1 cm. above the occlusal plane of the molar teeth. At a point where the intra-oral oblique line tapers off into ascending ramus, the point of the needle is inserted through the mucosa. It is then directed toward the foramen. The point of the needle is then kept in close relation to the bone until a depth of about one half of the width of the ramus is reached. The main injection, however, is not made until the needle point rests upon the surface of the ramus at its midpoint horizontally. When this point is reached, the syringe will be resting on the occlusal surfaces of the opposite lower bicuspid teeth. If one deposits solution imme-

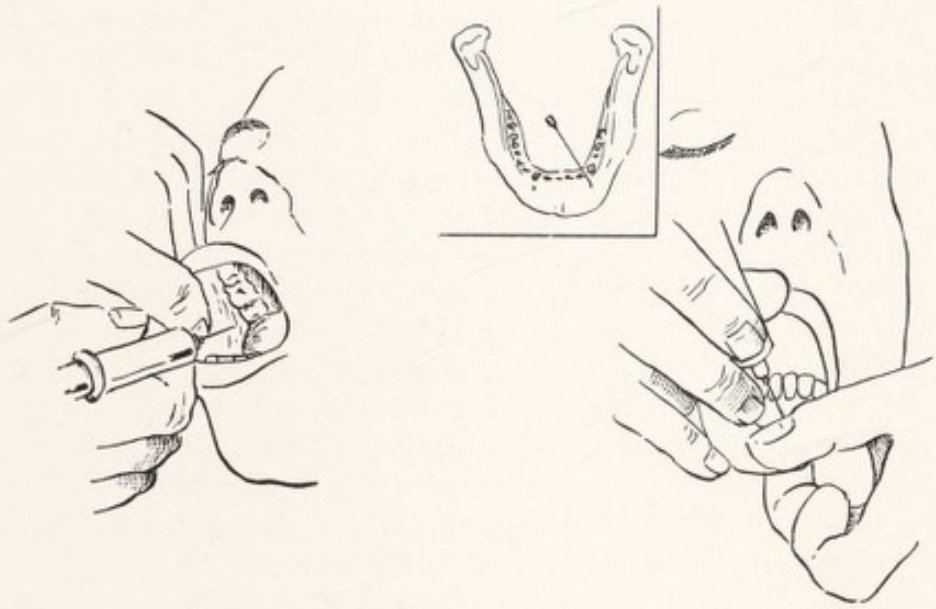

A *B*

Fig. 76.—*A,* Position of needle for long buccal nerve injection. *B,* Direction of needle for injection of the mental foramen. The insert of the mandible shows the position of the mental foramen.

diately after penetration of the mucous membrane and injects as the needle is carried inward, usually the lingual nerve will be anesthetized.

The Long Buccal Injection.—When the posterior teeth are to be extracted, it becomes necessary to make a long buccal injection. This is accomplished by infiltration of the buccal mucosa posterior to the area of operation (Fig. 76, *A*). Many men do not use it but use a buccal infiltration instead.

The Mental Injection.—The mental foramen is usually located at a point midway between the lower border of the mandible and the alveolar margin in the region of the apices of the bicuspid teeth (Fig. 76, *B*). To inject an anesthetizing solution in the neighborhood of the mental foramen one visualizes its position at the same time palpating immediately above it, with the index finger. The nedle is inserted at this point and a small amount of solution is deposited in the neighborhood of the opening of the foramen. The needle can then be used in an exploratory manner

and when the point is found to drop in the foramen sufficient of the anesthetizing solution is injected to produce anesthesia. The objection to the foramen injection is the variability of the foramen and failure to anesthetize the lingual surface of the mandible. Therefore, usually most men use the inferior dental injection for the same purpose.

Sterilization of the Field.—Prior to an operative procedure in the region of a tooth, the field should be as nearly sterilized as possible with some antiseptic solution. Dilute tincture of iodine, mercurochrome 2 per cent, or merthiolate solution answers the purpose in so far as painting the immediate mucosal surfaces are concerned. A suitable dilute tincture of iodine is composed of tincture of iodine, 1 part and ether, 1 part. Such a solution does not burn the gums and dries almost immediately.

Extraction Technic

Simple extractions may be classed as those extractions in which, after a careful study has been made of the roentgenograms and existing conditions, no difficulties are anticipated and wherein the removal may be carried out by forceps technic alone without undue damage to the supporting structures. When it is found that in spite of this deduction the tooth cannot be removed without undue trauma, some modification of technic as outlined under complicated extractions then becomes a necessity.

Operative Rules of Value.—If one observes the following rules when removing teeth, his general results will be improved: (1) the needles should be sharp if local anesthesia is used, (2) the force applied to elevators should be applied slowly, carefully and steadily with a definite purpose in mind. Don't just dig. (3) Force applied with forceps should be applied slowly, carefully and steadily with a compensating force applied with the left hand to the supporting structures. This is especially applicable in the lower jaw, where unless the jaw is properly supported, pain and injury to the articulation may result. (4) When a tooth cannot be dislodged with moderate force, its supporting structures should be relieved before further attempts are made. Tugging, yanking, and pulling are a mark of incompetence. (5) One should give careful consideration to the effects of trauma upon the tissues.

Simple Removal of Teeth

In applying forceps to a tooth, one beak is placed on the lingual (palatal) side. The handle of the forceps is slightly closed and the instrument is pushed up or down as the case may be as far as possible on the tooth under the gum. The sharp edges of the beak may be pushed slightly up or down under the edges of the alveolar process. A firm grasp of the root is thus obtained. When the crowns are weak from decay or partially destroyed this may be especially important. One should, of course, take care not to grasp the alveolar process with the forceps for besides interfering with extraction of the tooth, damage to the jaw bone may cause more after-pain and some delay in healing. If the crown is weak from decay, and it alone is grasped, it is very apt to be crushed. The extraction of the root or the roots is thus made doubly difficult. When the crown is used for a guide in placing the forceps on the root, success in extracting the tooth with ease is the usual occurrence.

After the forceps have been placed properly, an effort is made to loosen the tooth by rotating it slightly or by using a slight lateral motion according to the position of the roots and their number. Rotation of a single conical tooth is sufficient to loosen it. Teeth without conical roots and multirooted teeth usually require a definite lateral motion, often first inward and then outward. The final force is applied in the direction of least resistance. Lateral force sufficient to break the tooth should not be applied. The object of the lateral motion is to loosen the attachment of the peridental membrane to the tooth so that it can be lifted out of its socket without undue force. The removal of a tooth is not a matter of crude strength. Delicate movements carefully planned so that the force is efficiently used should be the aim.

In the removal of deciduous teeth as a rule difficulty is not to be anticipated unless the crown is destroyed by decay. Then in the removal of the roots of deciduous teeth, great care should be exercised not to disturb the tooth buds of the permanent teeth.

The roots of the first upper bicuspid may be broken during the removal of the tooth as they are usually double rooted and rather thin and flat. A moderate palatine and buccal movement is necessary to loosen the upper first and second bicuspids and the extraction itself is made in a downward and outward direction. Because of the firmness of attachment of the cuspid within the jaw due to its long and large single root, considerable force may be necessary to extract it. The upper first and second bicuspids ordinarily are removed in a buccal direction. The maxillary sinus lies directly above the upper bicuspid and the first and second molars. Care must be taken not to force a broken root into it.

To remove the lower incisors they are firmly grasped and rotated labially. Very little force is required as the labial alveolar plate is rather thin. A slight lingual and labial movement ordinarily frees them. The lower molars are loosened similarly. A normally placed third molar is not, as a rule, difficult to extract. But often the roots are fused and turn distally. When it is necessary to use an elevator care must be taken not to injure the second molar if one uses this as a fulcrum. In multirooted teeth if a fracture occurs at the neck in the process of removal often it is good judgment to separate the roots by means of a fissure burr or chisel and then dislodge each root separately with a forceps or elevator.

Broken Roots.—Broken roots usually may be considered as complicated extractions. Frequently, however, they can be removed easily, especially when the roots are those of the upper central or lateral incisors, single roots of the upper molars and single roots of the lower molars. Roots of the upper central and lateral incisors and of the upper and lower molars can frequently be dislodged by labial application of gouge elevators between the roots and the bone, by the use of biscuspid bayonet forceps or Winter type elevator. But when simple technic will not dislodge the root, it may be wiser to eliminate the chance of mutilation and proceed with a flap operation.

COMPLICATED OR SURGICAL EXTRACTIONS

Complicated extractions may be classed as those extractions in which, after a careful study of the roentgenograms and the anatomic conditions

present, it is decided that some difficulty will be encountered in the removal of the tooth. In this group may be found certain pulpless teeth with granulomas, certain teeth with malposed roots, teeth with marked hypercementosis of roots, teeth surrounded by an unusually heavy alveolus, root fragments and impacted or malposed teeth.

The usual cause of failure of the operator to remove this type of tooth is that he fails to recognize the difficult factors beforehand. The operation of the removal of any tooth should be thoroughly planned out in advance and the possibility of failure must be taken into consideration and steps taken whereby it can be avoided. Wherein the diagnosis of a simple extraction has been made and failure ensues, the operator should take immediate steps to institute other principles which will assist in the removal of the tooth. This in a broad sense reduces the matter to a so-called "surgical removal." This means that one lays back a flap and removes a sufficient amount of superimposed or impinging bone to facilitate the removal of the tooth. The factors which defeat the easy removal of the teeth are superimposed bone, excementosis, impingement of other teeth, badly broken-down teeth and in a few instances inaccessibility. Thus, in such cases it may be better or even necessary to incise and reflect the mucoperiosteum to provide access to the bone which hinders removal so that the bone can be removed to provide access to the tooth.

Root Fragments and Foreign Bodies

The successful removal of root fragments buried within the alveolus depends first upon an accurate radiographic interpretation of the position of the buried root. This may be accomplished by the application of the rule illustrated in Fig. 77, *A, B, C, D*. Once the location is accurately determined, the approach is made by designing a flap large enough to extend well beyond the edge of the window in the alveolar plate. The flap is retracted. Occasionally the location of the root can be determined by a sinus which may be present in the bone. Rarely the fragment is partially exposed but usually it is completely buried. In the latter case, its position must be estimated and a window made through the alveolar plate, preferably by cutting the bone with bibeveled drills. The segment so outlined is removed and the root fragment is searched out, loosened and removed through the window. The flap is sutured back in place and a small wick drain is instituted for forty-eight hours. The most important factors are accurate approach and sufficient access. Once located, these fragments are usually easily loosened.

The Care and Removal of Impacted Teeth

The etiology and symptomatology of impacted teeth are discussed in Chapter XXIII—Malrelations of the Teeth and Jaw Bones.

It is not always necessary to remove an impacted tooth when no special symptoms are present. All of those teeth which communicate with the mouth cavity and are malposed, however, probably should be removed, in that they predispose to chronic gingival infection, decay of the adjacent teeth and may disturb the interdental relationship. One is justified in removing an impacted tooth in the face of more serious disease such as persistent headache without any cause or nervousness even though there is

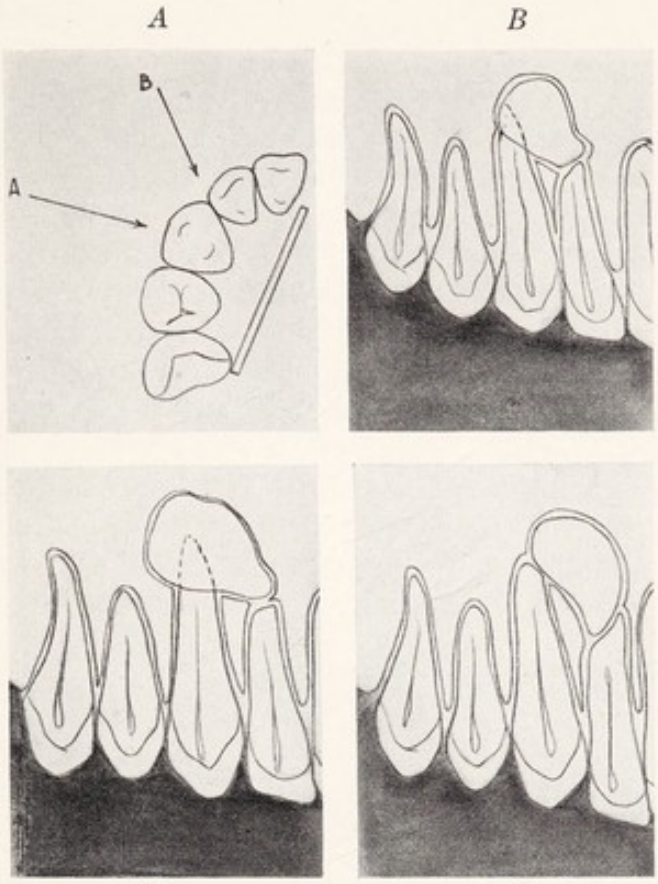

Fig. 77.—*A,* (A) Normal angle of ray; (B), mesial angle of ray. *B,* Supernumerary tooth discovered, angle A. *C,* If the result of angle B shows that the supernumerary tooth has moved distally in its relation to the cuspid tooth, the supernumerary tooth will be found labial to the cuspid because as the angle of the ray is advanced mesially any object on the labial will move distally in direct proportion to its distance from the known object. *D,* If the result of angle B shows that the supernumerary tooth has moved mesially in its relation to the cuspid, the supernumerary tooth will be found lingual to the cuspid tooth because as the angle of ray is advanced mesially an object on the lingual will move mesially in direct proportion to its distance from the known object. This rule is applicable to any hidden body in the dental arches provided that a known object is present normally or is artificially introduced for diagnostic purposes. (Woodard.)

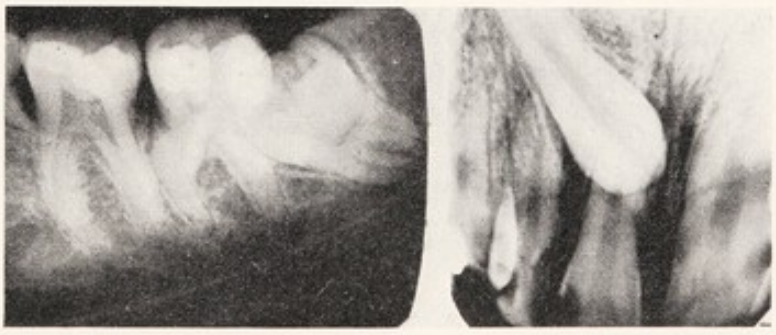

Fig. 78.—*A,* Impacted lower third molar. *B,* Impacted cuspid.

grave doubt whether or not the impacted tooth is at fault. The orthodontists in some instances are able to bring an impacted tooth such as a cuspid into its correct position. In such case removal of the tooth may not be the wiser procedure.

The roentgenogram is indispensable in accurately localizing and determining the shape, size and position of the crown and roots and the relationship to the neighboring teeth (Fig. 78, *A*, *B*).

When the patient presents himself with definite symptoms such as infection of the flap over the tooth or infection of a pocket around the tooth, the infection should first be controlled and all symptoms allowed to subside before operative interference is instituted. The pocket should be cleaned out as thoroughly as possible and an antiseptic solution applied. Home treatment should consist of frequent hot copious saline irrigations. One very good method of applying irrigations is by the use of an enema or douche bag. The rubber tube should be boiled, the bag filled with water as hot as the patient can tolerate, and a level tablespoon of salt added. The bag is hung above the level of the patient's head, the end of the tube is placed over the infected area and the entire contents of the bag allowed to irrigate it and then flow out of the mouth into a basin. This,

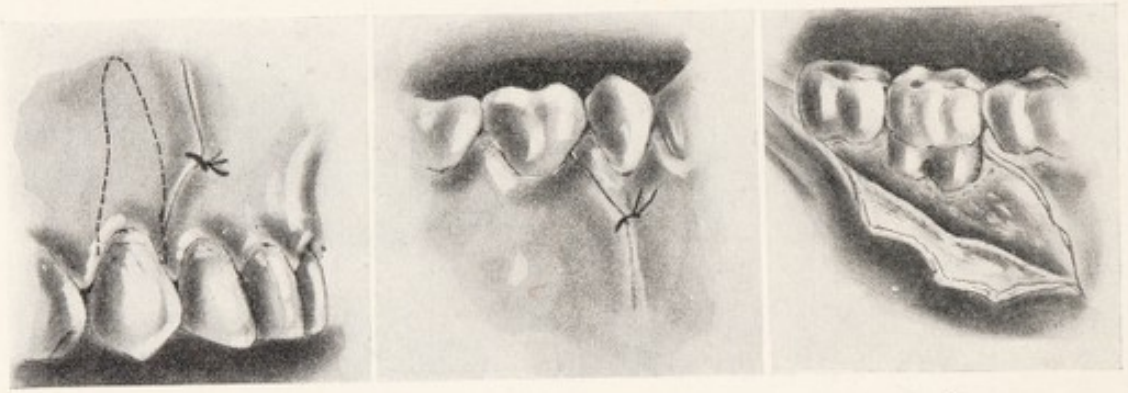

A *B* *C*

Fig. 79.—*A*, Angular flap incision designed to expose the root region of the upper cuspid, premolar, anterior molar, lower premolars and anterior molars. *B*, The angle of the flap may be made to point distally instead of mesially if one prefers. *C*, Flap design for fairly extensive exposure of the lower first and second molar region.

repeated every two to three hours, will give considerable relief and will assist greatly in the control of the infection.

The Formation of the Flap for Exposure.—The design of the flap may be an important factor in the ultimate success of the operation. Improperly designed flaps, though they may provide access to the osseous structure, frequently cause unnecessary complications. Numerous types of flap designs have been recommended from time to time to expose the superimposed bone about a buried tooth. But many of them have been more characterized by their unnecessary bizarreness than by desirable simplicity.

The few simple principles of flap design to which to adhere are briefly as follows: the flap should be wider at its base than at any other point. A wide base will serve to provide an adequate blood supply. It is wise in operations necessitating a palatal flap to consider the midline, though not incised, as one border of the flap because the anastomosing blood supply across this area may be rather meager. If this factor is overlooked, a slough may ensue. Scar tissue must also be regarded in a similar light. Although the blood supply of the mucoperiosteal tissue is ordinarily sufficient, if ordinary precautions are taken for its preservation it may be

well in some instances to outline the flap in line with its greatest blood supply. The flap must be so designed that it is large enough, first, to give an unobstructed field and, secondly, to be retracted from the operative field so that it is not traumatized during the manual procedures. A flap should be so designed that it can be returned and cover the exposed operative field (Fig. 79, *A, B, C,* and Fig. 80, *A, B*). Finally, when outlining the flap one should consider the possibility of the resultant scar at its borders causing some interference with a subsequent denture. With these principles in mind, the operator can construct adequate flaps which will assist him greatly in removing certain teeth and which will further assist in maintaining the contour of the alveolar ridge. The operator, as just mentioned, ordinarily should not lose sight of the fact that ultimately the edentulous ridge may be called upon to support the artificial restoration. The end-result is the trade-mark of the operator's surgical care.

Removal of Overlying Bone.—As the flap is designed and raised, it then becomes necessary to remove a sufficient amount of the alveolar bone

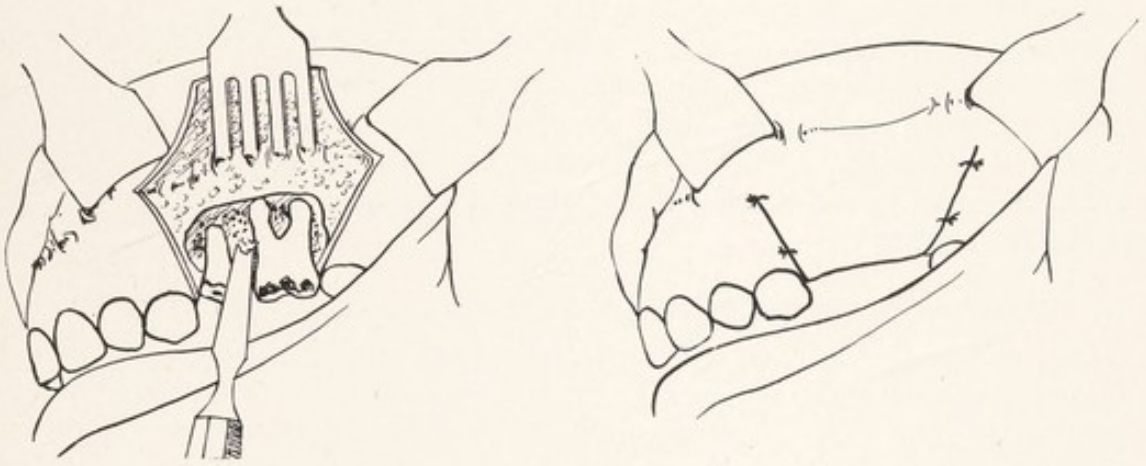

A *B*

Fig. 80.—*A,* Rectangular flap for fairly extensive exposure of upper first and second molar regions. Flap is raised. Buccal plate is removed. The first molar roots are removed. The second molar with hyperecementosis is removed. *B,* The flap is replaced.

to allow for the removal of the tooth. When the buccal plate is to be removed, as it is in the majority of cases, many men prefer to use a chisel (Fig. 80, *B*). But other men prefer to use a burr mostly. The use of a burr obviates a certain amount of jarring. The bone should be severed in line with the long axis of the tooth. When using a chisel the bone should be removed cleanly. Chipping of the bone in too large pieces is evidence of poor technic. Whatever technic is used—burr or chisel—care should be taken to remove sufficient bone at the mesiobuccal and distobuccal angle of the tooth. When a sufficient amount of bone has been removed, the tooth should be tested to see if it can be tipped out of its socket. Rather than to use undue stress, more bone should be removed.

Sectioning of the Tooth.—Frequently it is found that because of the size and position of the tooth, far too much bone must be sacrificed to facilitate its removal. The operator may then section the tooth by the use of a chisel and mallet or by the use of a surgical burr if one prefers

this technic, and remove the tooth without the sacrifice of an undue amount of overlying bone. After the crown is removed, it is much easier to separate the roots and remove them separately rather than to remove them intact.

When using a chisel to section a tooth, one should select one with a long bevel and it should be sharp. The tooth to be sectioned must not be loose and when the tooth is struck, the chisel must be firmly seated against the tooth at as near a right angle as possible. The blow must not be directed toward fragile supporting structure and it should be rather quick and sharp. In mesio-angular impactions of the mandibular third molar, the tooth can frequently be cut through the long axis into several segments and these segments easily removed. It is easier to cut the crown occluso-gingivally than to sever it at the dentino-enamel junction. This technic may be applied to practically any lower impacted tooth.

Once the removal is effected, the remnant of the enamel organ or the sac found around the crown of the tooth should be removed and the cavity thoroughly cleaned of all débris. Unattached bony fragments tend to prevent early healing.

In all surgical removals, the operative area should be packed off with gauze and the field contaminated as little as possible. Aseptic operations cannot be performed in the mouth except in rare instances, but this factor should not allow the operator to become careless in his technic. On the whole, the less the socket is contaminated, the greater the possibility of an uneventful recovery.

Examples of Typical Operative Procedures for Impacted Teeth

For purposes of illustration the technic for the removal of a few of the most typical types of impacted teeth are selected. For a more complete dilatation of the subject, the student should consult a textbook on exodontia.

The dental literature abounds with technics for the removal of impacted teeth. For example: Winter advocates a technic in which elevators—many of which he has originated himself—play a prominent part. Gardner has developed a technic in which the use of a chisel which sections the tooth is an outstanding feature. And again Cogswell has developed a technic in which the dental burr plays a prominent part for both the removal of overlying bone and sectioning of the tooth if necessary.

Technic of Removal of Impacted Mandibular Third Molar.—The most common position for the impacted third molar to assume is a mesio-angular one but they may be entirely horizontal, or vertical, or the crown may point toward the ramus or even be completely embedded within it. The roots may be straight, curved separately or fused. All data of this nature should be carefully determined from the roentgenogram as the position and the shape of the component parts of the tooth should be known to the operator before he attempts to expose the tooth. Such information will greatly facilitate removal when the proper advantage is taken of it.

Winter divides impacted mandibular third molars into two main groups —tissue impactions and bony or true impactions. The latter group is further divided into (1) those above the superior border of the mandible where the anterior portion of the crown is exposed and the distal part is covered with overlying bone and (2) those below the border of the mandible

which are completely covered by bone. This latter type calls for extensive removal of osseous tissue.

Entrance to the unerupted third molar should always be gained from the buccal or superior surface of the ridge. As a rule, it should never be attempted from the lingual side as the chance of injuring the lingual nerve is considerable. In removing an impacted mandibular third molar the position of the inferior dental nerve within the bone must be considered. Severe traumatization or severance of the nerve will result in anesthesia of the distal area supplied by the nerve. Finally, one should guard against injury to the second molar.

In some instances extensive removal of the buccal osseous tissue for the purpose of exposure of the crown should be avoided. A technic which allows extraction of the tooth without extensive osseous removal is the ideal.

Elevator technic (Winter) briefly is as follows: an incision is made along the center or slightly lingual of the center with a slight turn downward and buccally. When the impaction is a tissue impaction, a spear-pointed elevator is inserted into the opening and passed along the mesiobuccal surface of the impacted tooth. The external wall of the mandible is used as a fulcrum. The leverage is governed by the curvature of the roots as depicted by the extra-oral plate and the position of the tooth as depicted by the bite film.

Winter described the principles of leverage recommended by him as follows: "The most common type is where the roots are completely distal. In such instances direct the force backward, turn the elevator backward and upward, and the tooth will rise out of its socket.

"Where the mesial root is curved distally and the distal root is straight, just enough leverage must be applied to control the curvature of the mesial root; then, having the grooved buccal plate between the tooth and the external oblique line, use the elevator buccally and direct the force upward. Where the roots are vertical, use upward leverage for obvious reasons.

"Where the mesial root is curved distally and the distal roots are curved mesially, a septum will be found between the roots which will offer great resistance. In order to overcome this factor, place a spear-pointed elevator on the mesial buccal surface of the third molar and with a few blows of a mallet, the septum will be fractured. Then use force directed upward, of course presuming all resistance has been relieved.

"Horizontal types where roots are straight and thin are very liable to be fractured. In these instances apply direct force upward.

"Where the crown of the tooth is directed upward into the ascending ramus, relieve the bone distally to gain entrance for the elevator of the Cryer type, having first relieved the bone mesially. Using the ascending ramus as a fulcrum, direct the force upward, groove the buccal plate inside the external oblique line, and direct the force according to the curvature of the roots. In this type we often find the roots of the second molar destroyed due to close contact of the third molar roots.

"Sometimes we find the roots curved mesially. This type of impaction fortunately is not common; it presents great difficulty, and unusual care should be taken to remove all resisting osseous structure prior to the application of the elevator, in order to prevent its being fractured.

"When the tooth is standing alone, drive down mesially with a spear-pointed elevator and direct the force according to the curvature of the roots.

"In edentulous mouths, use burs for removing bone and be careful in applying force because of the danger of fracturing the mandible.

"In rare cases where the crown of the tooth is directed completely toward the lingual side, the method of determining the position of the roots would be to take a radiogram in keeping with the technic used in the upper molar, directing the rays downward." *

In the true bony impactions Winter states that even though the radiologic findings disclose the presence of a portion of bone distally, the latter need not necessarily be removed in order to luxate the tooth as this overlying bone is of varying consistency. When it is of the honeycomb variety, it yields readily to the force exerted by the elevator. Winter deplores the idea which he considers erroneous, namely, that in these bony impactions the entire buccal plate must be removed to luxate the tooth. In very deep-seated impactions he suggests the following technic: "knowing that the outer layer of bone is at most not over ⅛ inch in thickness, and that the inner layer of bone is of a cancellous consistency, and having made an incision and elevated the mucoperiosteal flap, the operator with a spear-pointed bur, just distally to the second molar, makes a groove down to the spongy portion on the occlusal surface to a point where resistance has been eliminated. He then grooves down on the buccal aspect, just below the center of the tooth, and then connects the two grooves mesially and distally. Thereupon placing a gouge on the buccal aspect, he directs a few blows of the mallet downward when the section will come away, or at least a greater portion of it, en masse. When the operator desires to eliminate entirely the use of gouges and mallet force, the bone may be removed by the use of surgical burs. In cases of fracture of the crown of the tooth where a portion of the root remains, the following technic should be employed: where there is a bifurcation on the crown portion, together with a multirooted tooth, it is necessary to reach the bifurcation by aid of a spear-pointed bur; thereupon separate the roots, insert the elevator in the space created by the bur, and loosen one root; then placing the elevator into the socket of the root elevated, break the interposing septum and loosen the other root.

"In fused rooted teeth the buccal plate must be grooved lingually to the external oblique line, relieving bone distally, and a spear-pointed elevator should be inserted in this particular space and the root loosened up out of position. In cases where just the apical portion remains, an attempt should be made by means of Ivory Elevators to luxate this particular portion. In a majority of cases the use of this instrument will bring about the desired result; however, cases will present themselves where this particular apical portion will appear to be fused directly with the surrounding bone. To remove this apical portion, it is necessary to groove the immediate surrounding bone and lift out the apex by the aid of a hooked instrument. The entire outer plate of bone covering this portion need not be disturbed in order to effect the removal of the tooth."

* From Winter, A Textbook of Exodontia, Oral Surgery and Anesthetic, 1931, C. V. Mosby Co., Publishers.

The *chisel and burr technic* briefly is as follows: an incision is made at the angle of the ramus distal to the second molar (Fig. 81, *A, B, C, D, E*). The flap is dissected loose and a suture is placed in its tip which is retracted back exposing the bone. Just enough of the coronal third of the tooth is exposed with chisel or by use of multiple burr holes (Cogswell) to permit severing of the crown at the cemento-enamel junction. The crown may then be severed or split, mesiodistally or buccolingually, dividing the crown into two pieces. The crown is then removed with curets or elevators, leaving the roots which may be elevated according to their

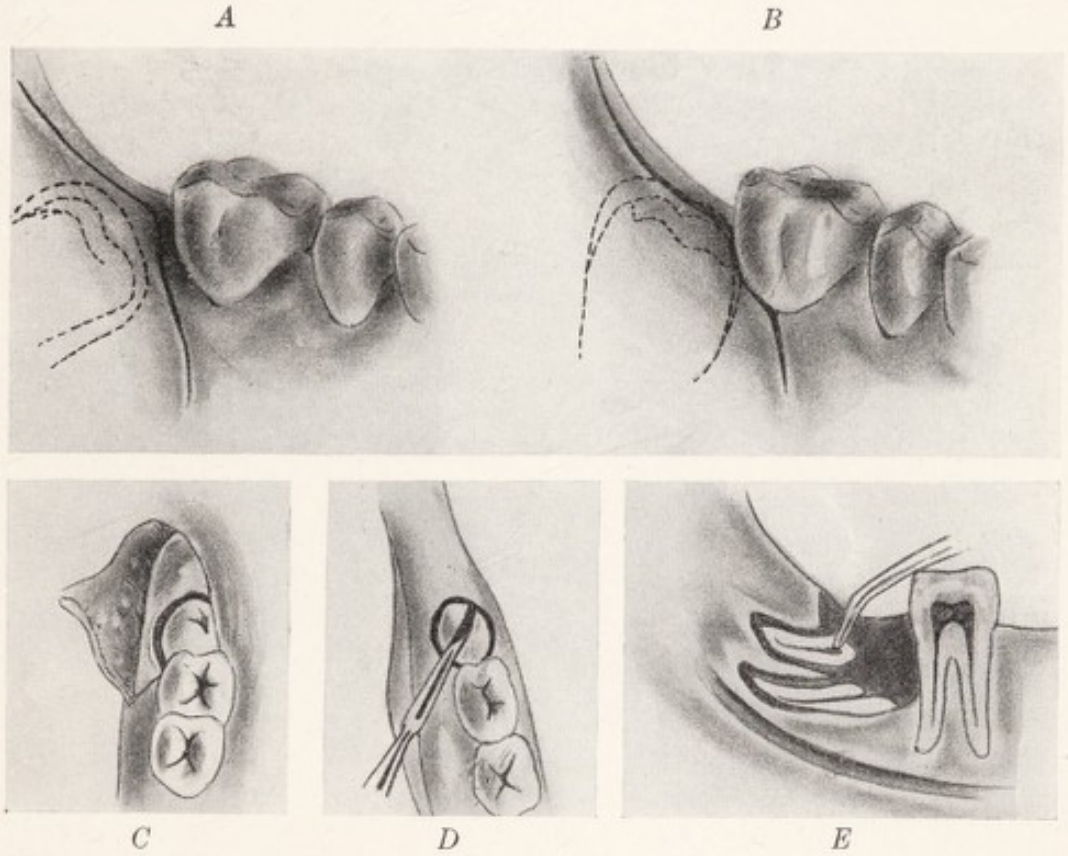

Fig. 81.—*A,* Flap incision for exposure of impacted lower third molar. When the impacted third molar is not in contact with the second molar its gingiva may be left intact. *B,* When the impacted molar comes into contact with the second molar the gingiva about the second molar is elevated. *C,* Correct exposure of the crown of an impacted third molar. An elevator is used to attempt to elevate the tooth using the outer plate as a fulcrum. When difficulty is encountered the crown may be separated from the roots with a chisel if one prefers. *D,* Method of dividing the crown with a chisel if the whole tooth cannot be easily removed by an elevator. *E,* Removal of superior root by the use of round point elevator or with a pick elevator.

curvature. Cogswell divides the crown angularly. Entrance to the crown is made distally with a No. 703 crosscut fissure straight hand piece burr. The burr starts at the cemento-enamel juncture and the cut in the crown is made toward the operator. Sometimes it is necessary to split the roots at the bifurcation, removing each root separately. When the curvature of the roots prevents their extraction with ease, Cogswell advises making a slanting hole in each root with a burr after which traction is made on the root with a small round pointed elevator which is introduced into the hole. This technic may be applied to practically any lower impacted tooth. The idea of sectioning a tooth into different pieces is to remove a small portion

at a time so that enough space is created to remove the remaining part of the tooth.

Removal of Impacted Upper Third Molar.—Impacted maxillary third molars occupy many and varied positions. The roentgenogram must be studied carefully. As a rule, all impacted third molars should be removed from the buccal aspect. In removing the upper impacted third molar, it is unnecessary to split the tooth. To avoid the serious accident of forcing the tooth into the antrum of Highmore never should a forceps be shoved up to obtain a better hold on the crown without observing the nature of the obstruction. One will be able to remove the tooth by relieving the bony process buccally and distally and elevating the tooth with an elevator or even removing it with a forceps.

A proper flap is raised. The overlying bone is removed by a chisel or surgical burr. The crown is exposed. A spear-pointed elevator is inserted

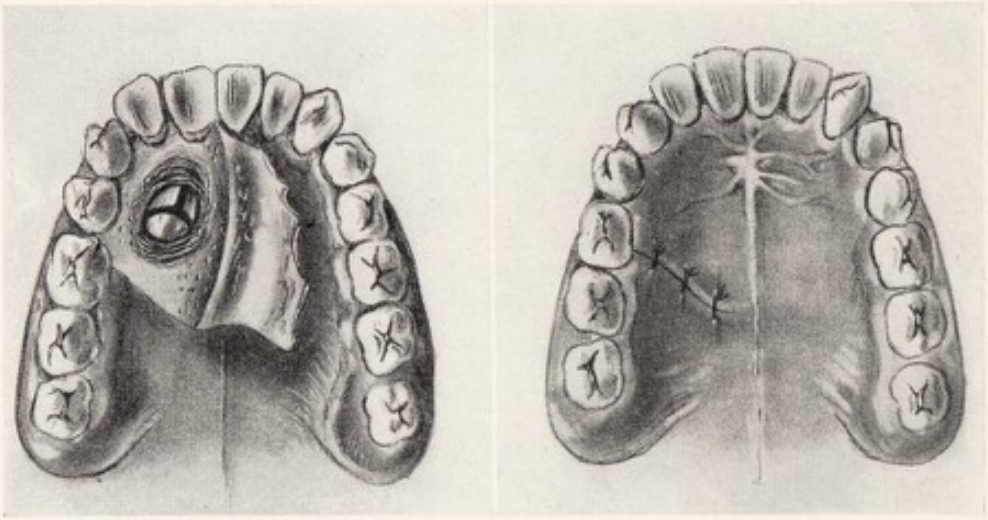

A *B*

Fig. 82.—*A*, Removal of impacted cuspid. Flap outlined. The overlying bone has been removed above the tooth and the tooth has been sectioned with a chisel and burr. *B*, A few stitches have been taken. The flap is thrown back in its former position. If a tooth is absent stitches may be taken across the gum. When the teeth are present no stitches are taken across the alveolar ridge.

into a space between the crown of the impacted tooth and the alveolar process. Using the maxilla not the adjacent teeth as a fulcrum an attempt is made to luxate the tooth. If difficulty is encountered an endeavor is made to ascertain the cause of the obstruction. It is better to remove more bone than to break off the crown as this may cause considerable difficulty in removing the roots.

Removal of the Impacted Upper Cuspid.—Roughly an impacted upper cuspid, provided the mouth is not edentulous, falls into 3 classes: (1) the crown palatally and lying close to the gingival margin, (2) the crown situated palatally and lying at a distance from the gingival margin and (3) either of these two preceding classes may be bilateral. The first step in the removal of an impacted upper cuspid is accurate localization by means of proper roentgenograms.

When the tooth lies close to the gingival margin (Fig. 82, *A*, *B*) and is unilateral, an incision including the gingival margin is made. An

incision beginning posterior to the opposite lateral incisor is extended directly posteriorly to approximately the level of the second bicuspid (Winter). The flap is elevated and held out of the field of operation by sutures fastened to a molar tooth. The overlying bone is removed by chisel or burr. When an elevaor is to be used to elevate the tooth the overlying bone is removed for approximately two thirds the length of the tooth commencing at the coronal end. When the tooth is to be sectioned with chisel or burr, it is not necessary to remove quite so much of the overlying bone. When an elevator is to be used a fine spear-headed one is selected and it is inserted under the crown and gently struck with a mallet. If resistance is met, more bone is removed. Leverage is made on the process of the maxilla.

When the crown lies at sufficient distance from the gingival margin a semilunar incision may be made parallel with the gingiva but a sufficiently broad band of tissue must be allowed between the incision and the gingiva. When the incision is made it must be considered beforehand whether or not it will allow an unobstructed view of the crown after the overlying bone is removed and whether or not one may suture the flap in place without destroying the tissue between the incision and the necks of the teeth.

Incision for the removal of an impacted canine in the edentulous mouth should cause little difficulty as one does not have the interrupting factor of the teeth in the mucoperiosteal layer.

The incision for bilateral impaction is similar in type to that described for unilateral impaction but the vertical incision which extends posteriorly is thrown somewhat more laterally on one side than on the other. Anteriorly it starts at about the anterior edge of the first bicuspid tooth and extends directly posteriorly to about the level of the first molar. When this flap is elevated the palatal bone over a bilateral cuspid impaction will be uncovered. Subsequently the technic of removal of a bilateral impaction differs in no way from the technic of the removal of a unilateral impaction except that the procedure is bilateral instead of unilateral.

In all instances following the successful extraction of the tooth and the proper cleaning and preparation of the operative field, loose suturing of the mucoperiosteal flap so that it will be retained in the position previous to the operation, is the final step in the operative procedure.

Many men more or less routinely prefer to section the tooth with either chisel or burr at the cemento-enamel juncture. An elevator is then placed beneath the crown and it is removed. Some more bone is removed from about the root, or if that is not convenient the root is split with the chisel lengthwise down the center and one fragment at a time is removed until the tip is reached or a burr hole is made in it so that traction may be made upon the root. In carrying out these latter technics it must be remembered that when the apex of the root lies adjacent to the antrum, one should not attempt to split the root. If one does so, he may drive the root into the antrum.

Technic for Impactions Less Commonly Encountered.—In textbooks on exodontia technics for the removal of less commonly impacted teeth are more minutely covered. The preceding types of impacted teeth are those most commonly encountered. If one understands the principles of the removal of the preceding impactions, the removal of the less commonly

encountered and, as a rule, more easily accessible impactions or malposed teeth, should not in any way involve principles other than those which have been covered. For exposure of the overlying bone in general, principles of flap design discussed elsewhere in this chapter should be followed. The most direct approach should be decided upon after a careful study of the location of the tooth in the roentgenogram. The method of removing the overlying bone will depend upon location and the particular preference of the operator.

CARE AFTER THE REMOVAL OF THE TOOTH

After the removal of the tooth, the care of the operative area may only partially be completed.

Eradication of Diseased Periapical Tissue After the Removal of Teeth.—Very often the extraction is only a part of the operation. The tooth extracted is often only the original cause of the injury to the underlying peridental membrane and alveolar bone. When the roentgenogram gives evidence of a granuloma or cyst (see Chapter XII) extraction should be followed by gentle curettement.

Every granuloma has cystic potentialities. One cannot forecast which granuloma will eventually require a secondary operation, before the diseased area is eradicated. Certainly a definite percentage of granulomas do not disappear after extraction alone. The operator in deciding on the extent of the procedure should be guided by the extent of the disease shown in the roentgenogram.

When there is evidence of acute infection, no curetting should be done even if it has been considered wise to extract the tooth. The likelihood of spreading the infection is a very considerable factor. For the ordinary small granuloma gentle curetting with an ordinary chalazion curet is sufficient. When the lining of the rarefied area cannot be removed adequately by simple curettement, surgical exposure of the diseased area so that the lining of the cavity can be removed and the overhanging bone edge rounded off is indicated. The hurry sometimes considered necessary and the increased hemorrhage which may be associated with a nitrous oxide anesthesia may serve to prevent proper attention to the diseased bone or fail to allow proper regard for the surrounding soft tissue to be taken. As a rule, under local anesthesia, the field of vision is not obscured. Thus, any redundant alveolar process may be trimmed. The ragged edge of the gum may be evened up and loosely approximated as needed by stitches.

The matter of root resection and the reasons for the eradication of the diseased periapical area is discussed further in Chapter XII. The treatment of frank cysts is considered in Chapter XXXVII.

Closing the Operative Field After Removal of the Teeth.—When closing the operative field after the removal of a tooth, one should be sure that no particle of tooth or bone fragment remains in the socket. The socket should be perfectly clean. Edges of the flaps if traumatized or irregular should be trimmed to present a healthy and even suture line.

Frequently after removal of a mandibular third molar, an excess of soft tissue is encountered after removal of the overlying bone and the tooth. The flap should be trimmed to eliminate this excess. Whenever possible, a flap for the removal of a mandibular third molar should be so designed

that in closing, it may be sutured distal to the second molar with an opening at the distal end of the incision. All treatment then is carried out distally to the part of the incision sutured together. This tends to eliminate to a great degree the formation of a pocket and to prevent further denudation of the cementum of the second molar.

Operative areas should never be completely closed. Drainage always should be given. Often following operations for impaction, drainage is best accomplished by gently inserting a ¼-inch iodoform gauze wick between sutures.

LOCAL COMPLICATIONS OF EXTRACTION

Dry Socket.—"Dry socket" is the term used to designate a socket in which either the clot has failed to form or once formed, has necrosed and sloughed out. "Dry socket" really means that the socket has become infected. Frequently the patient will have an uneventful course until about the fourth or fifth day when he will report that the area pained him during the night and there seems to be a dull, boring ache present. On examination of the socket, it will be noted that the clot is black and foul smelling or a portion of it has sloughed out. A "dry socket" is characterized by deep boring pain. Sometimes the patient also manifests some of the signs of a low-grade infection or a toxic absorption and may complain of considerable malaise.

The reason for the deep pain is the irritation of the highly sensitized nerve endings in the bony wall of the socket from the inflammatory process.

In treating a "dry socket" first one should thoroughly clean out the remnants of the infected clot, dry the socket and desensitize the painful nerve endings by appropriate medication. Some form of beechwood creosote preparation is often used. An anesthetic as well as an antiseptic preparation usually is necessary each day. The socket is thus gently treated and protected until granulation tissue springs out from the bony wall. This is first indicated by the wall turning a pale pink. This is best accomplished by the use of medicated pastes and gauze.

Later, sometimes portions of the bony wall may sequestrate. Then the granulation tissue may fill up and extrude from the socket. The protruding granulation tissue then assumes a bright red color and bleeds at the slightest touch. When sufficient time has elapsed for the dead bone to separate from the live bone—six weeks to two months—careful exploration of the granulations will usually disclose a small fragment of bone, the removal of which leads to a termination of the symptoms.

Postoperative Hemorrhage.—Rarely after extraction a hemorrhage of severe proportion develops. When a cotton compress between the teeth fails to check the hemorrhage one may be forced to pack the tooth socket itself. If a small pack of the finest gauze is forced in the socket under pressure the bleeding will be allayed unless the patient is a *hemophiliac.* In Chapter V this condition is discussed. The pack should be removed in twenty-four hours.

Infection and Sloughing.—Following the injection of local anesthetic, some error in technic may cause an infection or a slough. Lack of sterility of the needle or solutions may cause infection (Fig. 83, *A*). Occasionally one sees an instance of the injection of a wrong corrosive solution by mis-

take. More commonly injudiciously the anesthetic solution is injected into a focus of infection and an exacerbation of the process is caused with the various complications that may follow an infection.

Breaking the Needle.—During mandibular injection this accident occasionally occurs. The broken portion of the needle may disappear into the tissues (Fig. 83, *B*). A faulty needle or a sudden movement of the patient is the usual reason for this accident. To guard against such a mishap, care should be taken that the needle is not rusty or bent.

The needle should be removed. The operation may not be an easy one. Preliminary to operation the needle should be accurately localized by anteroposterior and lateral roentgenograms or stereoscopically. A useful trick to aid one is to insert a second needle and compare its position in the radiogram with the broken needle. An incision then should be made if possible at a right angle to the needle so that the knife blade will contact



A *B*

Fig. 83.—*A*, Woman who had a corrosive fluid injected into the soft tissues about the jaw for the purpose of extracting a tooth. She developed an osteomyelitis and necrosis of the soft tissues of the cheek and side of the nose. *B*, Needle in region of the pillars in the muscles of mastication on the inside of the mouth. This illustrates one of the accidents which might happen and should be guarded against.

the needle. After recovery of the needle a loose stitch is taken to draw the wound together or it is packed open according to the dictates of the situation.

Unusually Prolonged Anesthesia.—This complication usually is to be ascribed to injury of the nerve during injection. Occasionally if the syringe is kept in alcohol, all of the solution is not washed out of the syringe. Sufficient alcohol injected near a nerve may produce an anesthesia of several months' to even several years' duration.

ALVEOLECTOMY

Alveolectomy is the operation of excising a portion of the alveolar process for the correction of a deformity or for improving the dento-alveolar ridge for the reception of a denture. Individuals with hyperostosis or exostosis characterized by hypertrophy of the alveolar process may be much improved by this procedure. In some patients "undercuts" may be

eliminated. When the ridges are prominent and the bite is short, the esthetics may be much improved.

Care must be taken not to remove too much of the alveolar process or flattened arches will result and the stability of the denture will be interfered with. Much harm has been done in the past by certain operators by the removal of too much of the bony alveolar ridge. A certain amount of bony absorption is certain to take place later and an allowance for this must be made when the operation is performed.

Heretofore most technics for alveolectomy have overlooked certain basic principles of soft tissue surgery which have to some extent defeated consistent good end-results. When the buccal flap is raised, the mucosa contracts to some extent and the flap is consequently not so long as it originally was after healing in its new position. Coincident with the contractures of the soft tissue there is some loss of bone substance. The operator, after raising the buccal flap and trimming the alveolar bone, and suturing the buccal and lingual flaps together, often found that the bony atrophy plus contraction of the soft tissues frequently caused a lowering of the buccal sulcus, sometimes as much as one third of its depth. Consequently, the operation sometimes resulted in a mouth less favorable to the reception of dentures than if the operation had not been done.

It has been contended that one may largely prevent such a defective result, if the soft tissue attachments are well freed from the crest of the alveolar ridge, if the deeper soft tissues are coapted when suturing and splints are used postoperatively to aid in maintaining the depth of the sulcus. It is probable, however, that dependence upon such a procedure may overlook the fundamental factors—the removal of too much of the alveolar crest and subsequent atrophy of the underlying soft and hard structures (see Chapter XL—Surgical Preparation for Artificial Dentures).

Alveolectomy in the true sense of the term immediately after the extraction of the teeth in normally well-proportioned jaws is not indicated. Normal jaws do not require more than slight trimming of the sharp bony edges—possibly slight trimming of the lacerated uneven edges of the gum and loose suturing. In malproportioned jaws, however, some trimming of the alveolar ridges to establish normal proportions for esthetic or for mechanical reasons may be advantageous. The mouth in these cases should be studied by means of carefully articulated models to determine just how much tissue it is advisable to remove. Alveolectomy conservatively performed is a desirable procedure for the care of abnormally prominent alveolar ridges.

The Operation.—The operation of alveolectomy fundamentally consists of the raising of a buccal flap throughout the operative area, the removal of interfering buccal alveolar bone to facilitate tooth removal, the trimming of the alveolar bone to a smooth U-shaped contour, eliminating undercuts and sharp edges and the reposition of the soft tissues (Fig. 84, *A, B, C*).

In the operation if gingival incisions are to be made (as in the cuspid region in full uppers), it is better that they are made over interproximal bone and not over the socket to allow for table bone to support the line of incision. The lingual tissue should be slightly freed to allow for the clipping of the interproximal eminence of bone and to assist in suturing.

Triangular pieces of mucosa may be removed distal to the last remaining tooth to allow for proper adjustment of the mucosa. Sutures should be placed over septal bones and not over the socket. A much smoother result is given thereby. They should be interrupted. The trimming should be done conservatively. The crest is brought up to a U form by very conservative lingual and labial-buccal plate trimming and rounding off. Possibly postoperatively splints aid in holding the flap up in position and in this manner aid in maintaining depth of the buccal sulcus. Dentures should be inserted almost immediately. When the dentures are inserted early, considerably better results are obtained than after the surrounding alveolar bone structures have contracted.

Postoperative Care After the Removal of Teeth and Alveolectomy.—Every patient should be carefully instructed in the postoperative care of the operative field. The patient is instructed not to rinse the mouth out for at least six hours. Such a procedure tends to reduce the incidence of so-

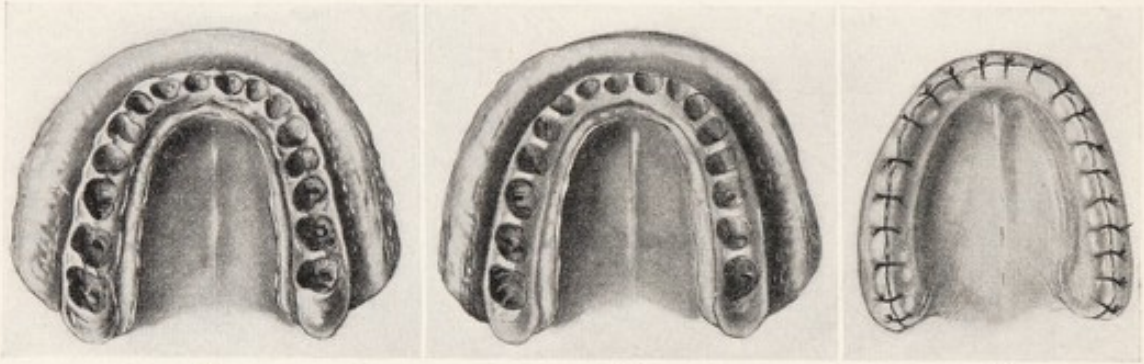

A *B* *C*

Fig. 84.—Alveolectomy. *A,* Upper arch with teeth removed and flap deflected. *B,* The alveolar crest has been slightly reduced. Considerable care should be taken not to remove too much. The buccal prominence is reduced somewhat. The lingual plate is rounded off. The interproximal and alveolar septa are somewhat reduced. The alveolar ridge is brought up in a more or less U shape and made smooth. Marked care should be taken not to overdo the reduction. *C,* The mucoperiosteum is replaced and interrupted sutures are taken. If possible the suture line is thrown inside of the line of the tooth sockets. After the mucoperiosteum has been trimmed to fit, interrupted sutures are taken to close the flaps.

called "dry socket." After six hours the patient is instructed to rinse the mouth with a hot normal salt solution. Thus, the wound is very gently bathed. In most oral operations save possibly the simplest removal of a tooth, the patient's recovery will be materially hastened by at least twelve hours' rest in bed immediately following the operation. Frequently exertion and disregard of the operative area is a causative factor of postoperative hemorrhage and of dry socket after extraction. In more extensive cases it is good treatment to keep the patient in bed twenty-four to forty-eight hours, depending upon the amount of operative interference. In such cases, under no circumstances should patients be allowed to come out in inclement weather to be treated at the office. It is better to go by and see the patient. A certain number of infectious complications are prevented by such a procedure.

There is considerable controversy over the use of hot and cold applications but eventually the end-results are probably somewhat the same. That

is, the capillaries are dilated and a better blood supply is given to the area. The intermittent application of an ice-bag on the face over the operated areas tends to reduce edema and frequently allays pain. The application of a large continuous wet hot pack undoubtedly is a superior external application when there is considerable inflammatory reaction. Resolution is hurried and, as a rule, the pain is somewhat allayed.

Liquid diet should be prescribed for at least twenty-four hours. Mild cathartics in the evening following operation may be a good thing.

As a rule, the patient should be provided with some type of mild sedative to control postoperative pain, such as phenacetin (10 grains) or even codeine sulfate (1 grain).

One should instruct the patient to place a cotton compress over the socket if a postoperative hemorrhage occurs, to put pressure upon it by closing the teeth against it and to hold the jaw set for fifteen minutes to one-half hour. At the same time an ice-bag may very well be applied to that side of the face. If that does not control the hemorrhage, the patient should be instructed to call for further treatment.

Most dentists believe that when the patient returns for treatment in forty-eight hours, the socket and surrounding teeth should be gently sprayed and cleaned and an antiseptic should be applied.

SERIOUS GENERAL COMPLICATIONS OF INJUDICIOUS REMOVAL OF TEETH

It seems wise to emphasize that it is an almost universal rule in surgery not to do anything during the acute stage of an infection which may tend to break the cellular wall which the natural defense mechanism of the body throws down to attempt to prevent the ingress of bacteria into the body generally. In the experience of every oral surgeon and in the literature many experiences are to be found of deaths following removal of a tooth, most of which were the result either of extracting a tooth or teeth during the acute stages of an infection or of removing a tooth in a patient with some blood dyscrasia. For a long time it has been noted by both physician and dentist that there is a frequent association between the various types of stomatitis and certain blood diseases. Probably in every case of stomatitis there should be a complete history taken, a general physical examination made, and a careful examination of the blood.

Kuhn, Helwig and Webb have alluded to some of the major tragedies that may follow injudicious tooth removal. They have described disastrous results following ill-advised removal of teeth in individuals with acute thrombotic vascular complications, regional inflammatory complications, blood dyscrasias and remote latent infections. Most of the cases which may be classified as resulting in acute thrombotic complications involve the facial branches of the angular vein or the deep branches of the internal jugular vein. From the facial veins the spread of the thrombotic process is to the cavernous sinus and death is caused by a meningitis or a septicemia or both. Acute swellings in the floor of the mouth not rarely follow the ill-advised removal of a lower tooth and occasionally death follows the so-called "Ludwig's angina" which may ensue.

After removal of foci of infection for therapy in certain diseases commonly thought to be caused by focal infection, such as a certain type of

arthritis, and so forth, it has been noted that frequently there may be a sudden exacerbation of the symptoms. When such exacerbations occur, the attempted cure may be as bad as the disease. Opinion differs as to the rôle focal infection plays in such lesions as endocarditis, gastric ulcer, various types of stones in the gallbladder or kidney and so forth.

Any practitioner of wide experience can remember examples of cases in which the question arose whether or not he would have been wiser if he had not at the particular time selected advised against an extraction which later proved to be rather closely associated with the undoing of the patient.

Bibliography

Bibliography Quoted in Text

Benedict, H. C.: Studies in Local Anesthesia, Dental Cosmos, **71:** 861, 1929.

Benedict, H. C., Dailey, H. T., and Armin, S. S.: Studies in Local Anesthesia, Dental Cosmos, **71:** 866, 1929.

Cogswell, W. W.: Dental Oral Surgery, Press of the Out West Printing and Stationery Co., Colorado Springs, 1932.
Also Dental Digest Publishing Co., Pittsburgh, Pa.

Dailey, H. T., and Benedict, H. C.: Studies in Local Anesthetics, Dental Cosmos, **71:** 704, 1929.

Dailey, H. T.: Studies in Local Anesthetics, Dental Cosmos, **71:** 945, 1929.

Freeman, C. W.: Studies in Local Anesthetics, Dental Cosmos, **71:** 949, 1929.

Gardner: loc. cit.

Ivy, R. H.: Quoted by Blair, V. P., and Ivy, R. H.: Essentials of Oral Surgery, St. Louis, C. V. Mosby Co., 2nd ed., 1936.

Keeling, C. W.: Personal communication to author.

Kuhn, H. P., Helwig, F. C., and Webb, G. F.: Major Tragedies Following Extraction of Teeth: A Clinical and Necropsy Study with Report of Ten Cases, J.A.D.A., **10:** 2155–2162, 1933.

Winter, Leo: A Textbook of Exodontia, Oral Surgery and Anesthetics, St. Louis, C. V. Mosby Co., 2nd ed., 1931.

Supplementary References

Bauer, W.: Fatal Osteomyelitis of the Mandible Following the Extraction of Teeth, Vierteljahrsschr. f. Zahnheilk., No. 2, 1930.

Berger, A.: Principles and Technique for the Removal of Teeth, Dental Items of Interest Publishing Co., 1929, Brooklyn, N. Y.

Braun, H.: Local Anesthesia, Phila., Lea and Febiger, 1914.

Ernst, F.: Plastic Operation on the Gums, Zentralbl. f. Chir., **52:** 464, 1925.

Fischer, G.: Local Anesthesia in Dentistry, Phila., Lea and Febiger, 1933.

Goblirsch, A. W.: A Study of the Third Molar Teeth, Mayo Clinic, **17:** 1849, Oct., 1930.

Smith, Arthur E.: Block Anesthesia and Allied Subjects, St. Louis, C. V. Mosby Co., 1920.

Woodard, Don C.: A Simplified Outline of Conduction Anesthesia, Dental Cosmos, Jan., 1931.
Surgery of the Soft Tissues of the Mouth, J.A.D.A., Sept., 1936.

CHAPTER XIV

INFLAMMATIONS AND DISEASES OF THE FACE AND THE LIPS

ALTHOUGH certain regional characteristics do appear, the skin and subcutaneous tissues of the face in a general way are subject to the same inflammations and diseases as are these tissues elsewhere.

INFECTIONS OF THE FACE AND LIPS

Cellulitis of the Face.—The face is a common site for erysipelas—a streptococcic cellulitis of the skin and subcutaneous tissue. The skin becomes a bright red, is indurated, smarts and is tender. The infection usually runs a self-limited course of from five to ten days but recently the course has been thought to have been shortened by the use of mild exposure by the roentgen ray. By others antistreptococcic vaccines have been considered beneficial. Few conditions in medicine have had as varied types of therapy advocated from time to time. As elsewhere in medicine, where the types of therapy advocated are diverse, none of those advocated are startlingly successful. On the whole probably as many cases will recover and just about as quickly if large moist packs—either hot or cold, whichever is the more comfortable—are applied constantly over the area.

Recently para-aminobenzenesulfonamide by mouth in doses of 0.3 to 0.9 Gm. at four-hour intervals until the temperature falls to normal has been highly recommended for beta hemolytic streptococcic infections. Prontosil, a derivative, may be given intravenously, 100 cc. of 2.5 per cent per dose for an adult. An editorial in the Journal of the American Medical Association, October 2, 1937, however, warns that this drug may have certain toxic effects.

Furuncles and Carbuncles of the "Butterfly Area" of the Face.—It is quite generally recognized that furuncles and carbuncles are more likely to occur in the diabetic. In some instances skin infections such as impetigo, sycosis, or acne pustules, and so forth, may precede. Furuncle of the chin is said to precede osteomyelitis of the lower jaw occasionally. Special mention should be made concerning furuncles and carbuncles of the interior of the nose, upper lip (Fig. 85) and the cheeks below the eyes as these lesions have a more serious prognosis in this region than elsewhere in the body. Extension of the inflammatory process is likely to cause a thrombosis of the vein which runs up from the angle between the nose and the cheek and communicates with the superior ophthalmic vein which empties into the cavernous sinus. A virulent spreading inflammation in this region has a mortality of nearly 50 per cent. The cause of death is a cavernous sinus thrombosis and a resultant purulent meningitis. An infection of the carbuncle type is more serious than a small furuncle. The clinical and pathologic characteristics of a furuncle or carbuncle described in all surgical textbooks in this locality present no variation other than the one mentioned. Dittrich reported a mixed series of 112 cases of carbuncle of the face at the Breslau Clinic of which 50 per cent in the upper lip had mortality of 8.8 per cent. Another mixed series (Dittrich) varied from 100 per cent

(8 cases, Lenhartz) to 5.4 per cent mortality (Bier, Hofman—92 cases). Roedelius had 80 cases with 30 per cent mortality. When a régime of strictest surgical noninterference is followed along with bed rest and hot fomentations, the mortality is less than after early surgical interference. Early surgical interference is likely to cause the infection to extend. Any trauma may cause extension. Therefore, any manipulation such as squeezing should be tabooed. After complete localization has occurred, it may be advantageous to aid nature by the institution of a drainage pathway. The cautery knife is thought to cut tissue with less likelihood of causing the infection to spread.

Noma or Cancrum Oris.—Noma is the common name applied to a fulminating gangrene of the mouth primarily characterized, as a rule, by eventually perforating the cheek (Fig. 85, *B*).

Etiology.—The disease attacks the debilitated and the youthful most commonly. Between the ages of three and ten the majority of cases are seen. The disease usually accompanies or follows some debilitating disease



A *B*

Fig. 85.—*A,* Carbuncle of lip. *B,* Noma. (Blair, Padgett, and Brown.)

such as measles, scarlet fever, whooping cough or pneumonia. Very rarely in institutions, however, the condition has assumed epidemic characteristics. Considerable evidence has been presented that the fusiform bacillus along with the spirochete of Vincent's angina causes the thrombosis of the blood vessels (Davis and Pilot). Certainly if not the primary cause these organisms are secondary invaders. The organisms are found between the living and the necrotic tissue in large numbers (Tunnicliff). Apparently the spirochetes go in advance of the bacilli. Tunnicliff, along with others, suggested the conception that the fusiform bacillus and the spirochete may be the same organism at a different stage in its life cycle. Dewey states: "The spirochetes settle in the tissue which still possesses nuclei, whereas the fusiform bacilli advance as far as the border line of the necrotic area." The true rôle of the spirochete and fusiform bacillus is still uncertain.

Most students of the disease hold to the conception that several different organisms may enter into the picture, such as various types of streptococci, staphylococci, pneumococci and certain anaerobic organisms. Rarely the Klebs-Loeffler bacillus has seemed to play a rôle.

Clinical Picture.—In an individual debilitated by some severe disease, especially a child, an indurated mass appears usually in the cheek near the commissure of the lips. But the gums or alveolar ridges may be involved first, especially in adults. In adults a leukemic blood picture is not uncommonly present. The question then arises whether the leukemic picture is a precursor or only accompanies the slough. The induration at its center soon turns to a livid slough. Phlyctenules appear in the surrounding mucosa which break down. The ulceration progresses rapidly. The walls of the ulcer become jagged as it widens and the base becomes sanious and greenish-black. Salivation is marked. The odor is fetid. Soon, a dark red spot appears on the skin of the cheek which shortly turns dark. Perforation of the cheek soon follows (Fig. 85, *B*). When the condition involves the alveolar ridge the bone is soon bared. The tongue is rarely involved. Early in the disease the tributary lymph nodes become enlarged and tender.

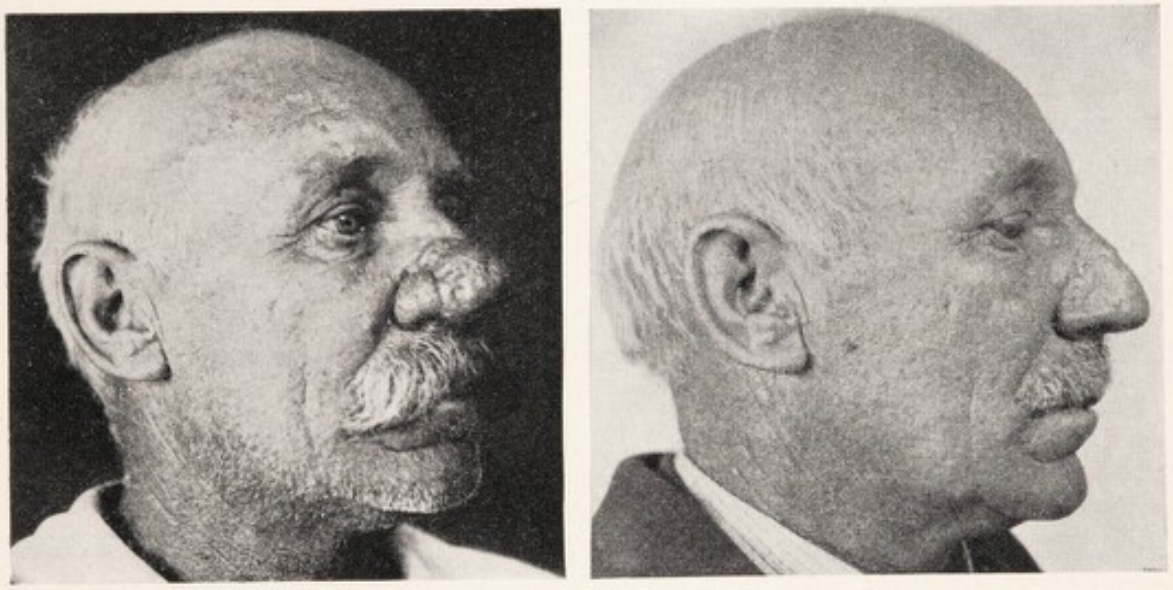

A *B*

Fig. 86.—*A*, Rhinophyma when patient was first seen. *B*, Six weeks after excision and after application of stent graft.

The constitutional reaction of the patient gives all the signs of an overwhelming severe toxemia from the beginning. Although the temperature in some cases may not be high, the pulse will be found to be rapid and soft. Toward the end, coma often supervenes. A severe anemia often precedes and accompanies the condition.

Diagnosis.—When the preceding symptomatology is called to mind, the diagnosis becomes evident.

Prognosis.—The mortality runs from 75 to 95 per cent. Death is due to exhaustion from the toxemia, a septicemia, or possibly a terminal pneumonia. Blair remarked that when early perforation of the cheek occurs, a better prognosis is offered.

Treatment.—Every effort should be made to bolster up the patient's resistance. Blood transfusions may aid. Salvarsan both locally in a 5 to 10 per cent solution and intravenously have been used. Its value is questionable. In some instances it may be wise to excise the indurated gangrenous area with a cautery knife. Usually, however, the questionable value

of such a procedure and the illness of the patient preclude such active treatment.

Rhinophyma.—When the sebaceous glands of the nose become markedly hypertrophied, the condition is called "rhinophyma." Leading dermatologists state that the condition is an advanced stage of acne rosacea. Persistent hyperemia and irregular periodic aggravation of the disease cause the sebaceous glands to hypertrophy and form first gelatinous nodules which later become more fibrous. The connective tissue shows a red hyperplasia. The tuberous, irregular, porous, pimplish, red overgrowth of the tip of the nose is quite characteristic and is not likely to be mistaken for anything else. The treatment is excision to the proper shape for a good appearing nose with an immediate skin graft. In two weeks the nose is healed and the cure permanent if the excision has been complete (Fig. 86, *A*, *B*).

Lupus Vulgaris.—Lupus vulgaris is the most common form of tuberculosis of the skin. The disease occurs in young persons and about 75 per cent of the cases seen occur on the face. The lips and particularly the nose may also be involved. In advanced instances of the disease even the mucosa of the mouth and gums is invaded. The highest incidence is between the second and tenth years. The tubercle bacilli reach the skin either through the blood vessels or the lymphatics. The pathology differs not greatly from that of tuberculosis elsewhere. The essential lesion is the "tubercle" of the corium. The epidermis is involved secondarily.

Clinically, lupus vulgaris is characterized by the presence of small, soft "apple butter-like" tubercles, which may undergo absorption or may ulcerate and then finally heal with some scarring. The disease invades new areas by the formation of nodules which coalesce and form irregular plaques. The nodules vary from the size of a pin-head to that of a pea. Although the disease is usually progressive, regressions with subsequent atrophy may take place here and there. When the disease involves the lips, the involved part of the lip thickens into an "elephantiasis-like" edematous swelling. As the vermilion border of the lip is destroyed, the mouth slit is narrowed by the cicatricial contracture.

When secondary extension occurs to the mouth, as it may later in the process, the gums, the alveoli, and the palate even may be involved, so that a necrosis of the palate bone similar to that of syphilis may eventually be encountered. The involved gingiva becomes soft, dark and bleeds easily. The regional lymph nodes often are enlarged. Finally, the diagnosis is proved when scrapings from the ulcerated surface show tubercle bacilli.

Treatment.—Ordinarily the most efficient method of treatment of the larger patches is roentgen therapy. Good results have also been reported by heliotherapy and phototherapy by means of the Finsen lamp. Sometimes it is best to excise small patches and cover the area with full-thickness skin grafts. In several instances we have obtained good results by this method. Hygienic measures are important, such as sunshine and good food. Tuberculin has been used with some success. But in spite of all types of therapy, the disease is prone to relapses and recurrences.

Lupus Erythematosus.—This disease is a subacute inflammatory one characterized by the appearance of pinkish-red patches which as they subside leave a thin atrophic scar. Usually the lesion is circumscribed but a more disseminated form is sometimes seen. The cause for lupus

erythematosus is not known. The greatest majority of cases reported have been in women as a rule and between the second and fourth decades of life. The pathologic lesions of the disease are confined mainly to the corium. Robinson suggested that the disorder is an infective process closely connected with the lymph channels while Fordyce and Holder found the primary changes to be located in the blood vessels. At first the sebaceous glands are hypertrophied but later the sebaceous and the coil glands show atrophic changes.

Usually the lesions are well-defined macular pinkish-red patches which vary in size from a centimeter to several centimeters in diameter. The lesion ordinarily is slightly elevated and covered with small grayish scales. The "flush area" of the face is the most common site but it may occur elsewhere. The skin is only slightly infiltrated and in long-standing patches the area sometimes becomes atrophic. The inflammation is principally marginal. According to Smith, the mucous membrane may be involved in about 25 per cent of the cases.

Treatment.—Irradiation therapy by means of both roentgen ray and radium has been used with success in certain cases and solid carbon dioxide suggested by Pusey has been found effective in the hands of some men. On account of the relative inefficacy of most therapeutic measures we have not hesitated in a few cases to totally excise the lesion and cover the area with a full-thickness skin graft.

Actinomycosis of the Soft Tissues of the Face and Neck.—Actinomycosis, a disease which somewhat rarely affects man but more commonly domestic animals, especially cattle, is due in man to a specific micro-organism—Actinomyces hominis. An infective granuloma is produced. About 60 per cent of individuals affected with actinomycosis show the lesions about the head and neck and in from 15 to 20 per cent the condition follows the extraction of teeth. Hazen points out that Actinomyces bovis tends to produce lesions in bone while Actinomyces hominis rarely, if ever, does. Most probably the Actinomyces hominis is present in normal mouths and infection takes place only when opportunity is presented. A tooth socket after extraction provides in its depth an ideal situation for the growth of the anaerobic fungus. However, any break in the mucosa may serve as a portal of entry for the infection. It now seems fairly definitely established that the types of actinomyces found in the grasses do not produce the disease. However, one cannot help but speculate why it is that farmers (91 out of 1163) are so often affected.

"Lumpy jaw" was recognized in cattle in 1826. In 1877 Bollinger described the parasite more fully. He showed the causative organism to be Actinomyces bovis. In 1878 Israel described the disease in man. In 1885 Murphy described the first human case in America.

Pathogenesis.—Wright who has written extensively on the subject regards the widely accepted idea that Actinomyces bovis is carried by grains and vegetables as erroneous. He states that Actinomyces bovis does not have the same biologic characteristics as Actinomyces hominis. He believes the organisms exist normally in the mouth and gastric intestinal tract. Lord produces the disease in guinea-pigs by intraperitoneal inoculation of scrapings from carious teeth, the tongue and crypts of the tonsils. Transmission of the disease from animal to man has no experimental proof. There is only some indirect evidence to suggest the possibility, namely, the

greater prevalence of the disease among farmers. On the other hand, some authors state that the incidence of the disease is greater in the city than in the country.

The organisms gain access to the soft tissues and spread by direct continuity. The lymphatic system peculiarly is not involved. The size of the filaments is probably a factor. Occasionally due to rupture of an abscess into a vein general metastasis occurs by way of the blood stream but such a complication is rare.

Bacteriology.—The fungus may be seen microscopically in the tissues in the form of yellowish colonies which have been designated as "sulfur granules." Under anaerobic conditions with special media one may cultivate the organism. When the granules are examined microscopically a central mass of branching, interlacing filaments which extend out and away from the central nucleus is seen. At the periphery of the filaments closely set hyaline, refringent, club-shaped bodies of varying size and thickness

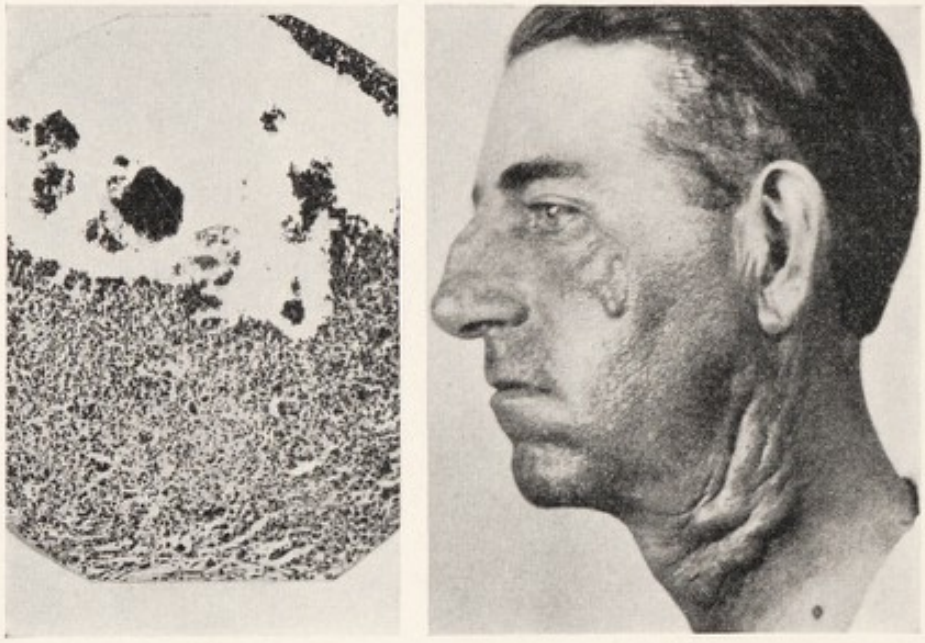

A *B*

Fig. 87.—*A,* Actinomycosis. *B,* Patient with actinomycosis of the neck.

are found. These club-shaped bodies develop out of the filaments. All transitions between filaments and club-shaped bodies are seen. The clubs may degenerate and various atypical shapes are then encountered. Spores have been described as being formed by segments of some of the filaments. The filaments and spores are gram-positive and the clubs gram-negative. Wright has regarded the amount of club formation as of some significance in judging the progress of the disease. When the progress of the disease is slow club formation is less pronounced.

Pathology.—Microscopically there is seen a new formation of granulation and fibrous tissue (Fig. 87, *A*). The appearance of the granuloma varies principally depending upon whether or not suppuration has occurred. When suppuration has not developed many lymphocytes are seen. Polymorphonuclears predominate after suppuration. A great amount of overproduction of fibroblastic tissue is the outstanding characteristic of the lesions. The mycelium is not often noted in sections.

Clinical Features.—In the soft tissues about the jaw bone, the gum and the cheek a firm spreading tumefaction slowly develops which sooner or later—but sometimes not for several months—tends to soften and finally to break down and rupture, thereby evacuating the central necrotic contents of the induration, after which a more or less permanent sinus persists. New has reported several cases in which only the tongue was involved. The tendency to multiple sinus formation is one of the characteristics of the disease. Occasionally the progress of the disease is rapid so that an abscess forms within a few days but ordinarily at least six weeks or longer is required for central necrosis to develop. The overproduction of fibrous tissue causes stiffness and induration. When the process is in the temporal or parotid regions the disease may manifest itself by ankylosis of the jaws. If and when the sinuses heal puckered scars remain. Pain is seldom severe and often is almost entirely absent. The whole picture, as a rule, is one of chronicity. Cases are observed with repeated flare-ups which have a history of a course of from ten to twelve years (Fig. 87, *B*).

Connective tissue and muscles are destroyed and replaced by fibroblastic tissue as the disease progresses. Ordinarily bone is not invaded as may be shown by the roentgenogram. The body of the bone tends to pass through the inflammatory mass with little or no erosion. Sometimes, however, the bone shows rarefaction and destruction (case of Thoma). After the soft tissue about the jaws is involved there is a tendency for extension to the neck. As the infection nears the skin it assumes a purplish, mottled appearance and the underlying fibrous tissue often pulls the skin into ridges and corrugations between and about the sinuses. In older areas the tendency to heal is spontaneous.

Lesions of the tongue are nodular and are slow to break down. Actinomycosis of the tongue is particularly likely to be mistaken for a neoplasm or a gumma. New and Figi in 1922 collected 49 cases of actinomycosis of the tongue. Leith's statistics (1910) state that the tongue is involved in about 4 per cent of the cases.

Diagnosis.—Actinomycosis may be suspected in a case in which there has been a slowly developing inflammatory process about the face or neck. When suppuration occurs, the pus from a freshly opened abscess should be carefully examined for the characteristic sulfur granules. Often a fresh abscess is not present when the case is first seen. Therefore it may be necessary to keep the patient under observation for some time to prove or disprove the presence of the organism.

A good method of examining the granules has been recommended by Colebrook. A few drops of pus are collected in a test tube half full of water. The test tube is fitted with a cork and shaken vigorously. The pus is emulsified. The granules are not broken up but sink to the bottom of the tube and are easily recognized. By means of a capillary pipet the granules are transferred to a slide, crushed beneath a coverglass and examined unstained.

Treatment.—Four principal measures are of value: (1) radiation by radium or roentgen ray which hastens the process of localization and suppuration, (2) drainage as indicated laying all pockets open and packing them with iodoform gauze, (3) the use of potassium iodide in increasing

doses up to the limit of tolerance, and (4) the application of heat to the affected area. About six months are required to cure the average case.

Prognosis.—To actinomycosis about the head and neck has been commonly ascribed a mortality of from 8 to 10 per cent but in a recent series of 143 cases in all of which the treatment was satisfactorily carried out, there was only one death (Havens).

Blastomycosis.—Blastomycosis is a chronic infection caused by a fungus —the blastomyces gaining entrance by means of a skin wound. Males are more frequently attacked. It may be seen in infants. The disease may attack the skin of the face and neck. It begins as small pin-head or pea-sized papule or papulopustule which gradually enlarges by peripheral extension or the development of new foci. Crusting is present from the start. Beneath the crusts and scales are reddish, purplish, irregular, papillomatous masses bathed in a seropurulent liquid. Centrally the patch tends to heal with the formation of whitish atrophic scars. Some itching and burning are the subjective symptoms. The diagnosis is made by finding the organisms in smear or by biopsy.

When suspended in a 10 per cent potassium hydrate solution, the fungi appear as double-contoured, refractile bodies many of which contain granules or shining sporelike bodies. A few are vacuolated. The parasite occurs in varying numbers in the cutaneous abscesses.

Montgomery and Ormsby have written an admirable article on the subject.

Treatment.—Potassium iodide in large doses and irradiation give the best results.

THE LIPS

Scars.—Fine radiating scars about the angles of the mouth extending to the buccal surface are suggestive of an old syphilitic ulceration and infiltration. Perlèche must be differentiated. It is an acute lesion.

Lip Cracks and Chaps.—Lip cracks and chaps most often are found at the angles of the mouth or at the midline of the lower lip. Syphilitic infection in children may cause chronic fissures at the corner of the mouth. Single acute cracks especially of the midportion of the lip are prone to occur on exposure to inclement weather. Their recurrence is in some persons quite periodic and distinctly annoying. When such cracks tend to recur in children, a permanent lymphoid hyperplasia of the lip has occasionally developed causing a permanent hypertrophy of the lip. The midline crack of the lower lip is often quite persistent and may become sufficiently indurated to simulate an early malignancy. The anatomic configuration and the type of mobility of certain lips is an important factor in the origin and chronicity of midline fissured ulcer. On spreading the crack too energetically it oozes blood which later may form a crust. On removal of the crust the vicious circle is again started. As the weather becomes pleasant or exposure to it ceases, the usual tendency is for the crack to close. A soothing ointment is efficacious as temporary treatment. When chronicity is a marked characteristic, the fissure should be excised and the freshened edges united by suture.

Simple Hypertrophy.—It has been suggested that lip sucking may cause a simple hypertrophy of either offending lip. Malocclusion and certain types of jaw deformities certainly may lead to the appearance of lip

hypertrophy. Such lip hypertrophy is sometimes more one of appearance than actuality. The protruding lower lip appearance seen accompanying a tight upper lip after a harelip repair is a common example. Occasion-

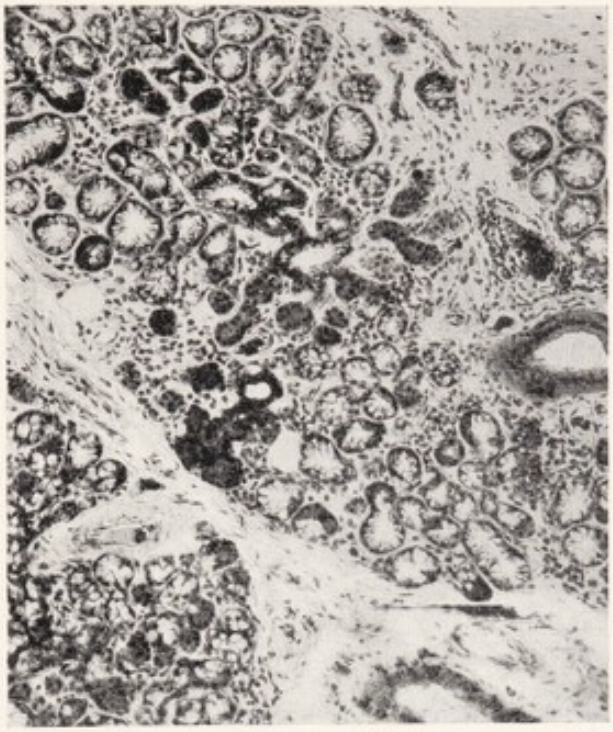

Fig. 88.—Hypertrophy of labial glands.

ally enlargement of the lip is caused by a hypertrophy of the labial gland (Fig. 88).

Macrocheilia.—As mentioned, a large lip may be caused by a chronic lymphangitis following the entrance of infection through fissures or cracks.

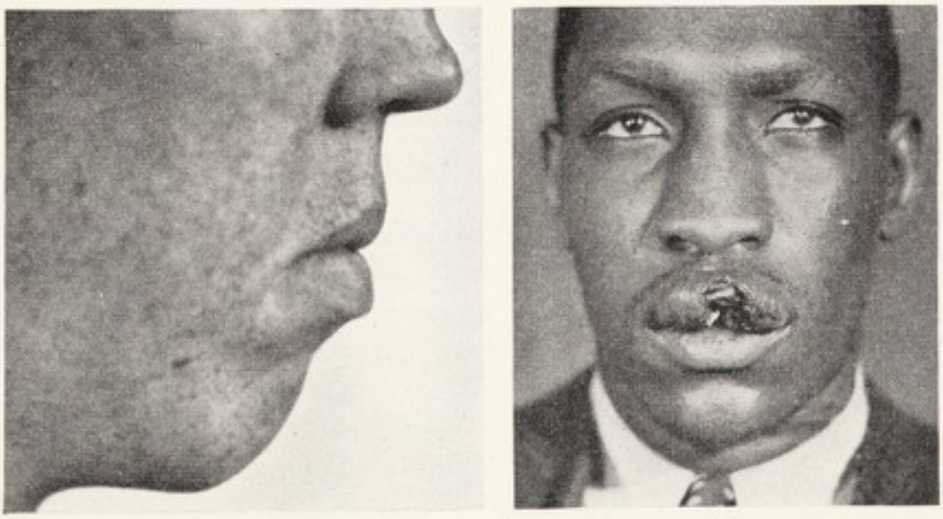

A *B*

Fig. 89.—*A*, Hypertrophy of lip. *B*, Excavating chancre of the lip.

The resultant lymphoid hyperplasia and fibrosis may cause some permanent enlargement of the lip (Fig. 89, *A*). Now and then one sees a macrocheilia which is lymphangiomatous in nature. Under lymphangioma of the face

and also of the tongue, the basic pathology is described. The course, the pathology, the signs and the diagnosis are essentially the same for the lip as elsewhere. Rarely syphilis in both children and adults has caused a more or less persistent hypertrophy of the lip. In infants a diffuse infiltration of the borders of the lips is occasionally seen.

Perlèche (A dialect form of pour lécher—to lick).—In children there occurs a mildly contagious lesion at the commissures of the mouth characterized by an area covered with a whitish slightly wrinkled loosely attached pellicle beneath which are shallow radiating fissures. This clinical entity is called perlèche. Lemaistre, of Limoges, described the condition in 1885. Lay inhabitants have probably known the condition for a much longer time. He described a streptococcus which he regarded as the specific bacterium. But at present this organism is not regarded as specific.

Etiology.—The infection runs a self-limited course and is thought to be caused by a streptococcus or a staphylococcus. Perlèche epidemics have occurred in schools and so forth. The transmission is through the use of towels or by contact such as kissing. Excessive moisture at the angle of the mouth is thought to be the main predisposing cause.

Clinical Features.—The fissures resemble a bird's claw extending outward. In contradistinction to syphilis the fissures do not extend into the inner mucosa. About the fissures there is very little inflammatory reaction. Accompanying the infection is a slight burning sensation which leads the child to lick the corners of the mouth causing periodic moistening of the skin. This irritation encourages a continuation of the disease. Crying or yawning causes slight distress. In from four to six weeks the infection usually subsides. Recurrence after apparent healing is not uncommon. For several months after healing the involved areas remain white and smooth but no permanent scarring results.

Diagnosis.—The mucous patch or the "split papule" of syphilis has to be differentiated from perlèche. Syphilis is excluded by the lack of the other general signs of the disease, a negative Wassermann and the absence of the Spirochaeta pallida on dark-field examination. In perlèche the radiating grooves do not extend to the inner mucosa and no scar is left after healing. Both of these facts are in contradistinction to a syphilitic lesion at the corners of the mouth.

Treatment.—Ten per cent xeroform or 5 per cent ammoniated mercury in vaselin are useful in the treatment of the disease. The ointment is applied to the mouth corners several times daily until healing has occurred. A 10 per cent solution of silver nitrate daily or touching with a copper sulfate stick is also effective fairly promptly.

Fordyce's Disease—Pseudocolloid of the Lips.—Pseudocolloid disease of the lips is characterized by small discrete yellowish slightly elevated nodules of pin-head or smaller size beneath the mucosa of the lip on the inner surface of the vermilion border. Fordyce, in 1896, described the affection and found it relatively common. Blocked aberrant sebaceous gland is thought to be the cause of the masses. The appearance is characteristic. The duration of these harmless lesions is indefinite and, consequently, the diagnosis offers no difficulties. Treatment is usually unnecessary but eradication may be effected by sticking a red-hot needle into each mass after novocain infiltration.

Cheilitis Glandularis Apostematosa.—Volkmann, in 1870, described a rare type of chronic affection of the mucous glands of the lip in which there is a retention of whitish débris somewhat resembling pus. The name "cheilitis glandularis apostematosa'" has been applied to this condition. The condition may be congenital. The orifices of the glands are dilated, patulous and filled with a yellow material and the lip may be covered with a crust. The lower lip is the usual site but rarely the upper lip is also involved. It has been pointed out that an excessive amount of glandular tissue may be found in the mouth, pharynx, and nose as associated lesions and these structures may be mildly inflamed as well as hypertrophied. Pathologically, there is dilatation and hypertrophy of the mucous glands and ducts, with a thickening of the walls. Besides the mucous cells some serous cells are seen in the acini.

Alterations in the corium are not marked. The elastic fibers are increased both in size and number, and the interacinal connective tissue is thickened. When palpated a "shot bag" resistance is given to the finger. On compression a serous fluid is squeezed out. By using a small cautery needle the lesion may be largely obliterated. Potassium iodide was used by Volkmann but other observers have not found it to be efficacious.

Cheilitis Exfoliativa.—Rayer described a chronic disorder of the lips to which later Stelwagon applied the name "cheilitis exfoliativa." The condition is rare and is characterized by a chronic inflammatory process involving the border of both lips with the formation of slight, dry, adherent scales or crusts. The bright redness, itching and liquid exudation distinctive of eczema is wanting. The condition is probably a seborrheic dermatitis.

It is quite rebellious to treatment and recurs. Radium exposures have been tried. Stelwagon used a sulfur ointment compounded with a resorcin lotion.

Eczema.—Eczema of the lip especially in children may occasionally be seen and may be quite persistent. A band of the vermilion border with the superficial epidermis absent which weeps, forms crusts, itches, with here and there small vertical fissures characterizes the disorder. Besides the vermilion border at times the cutaneous border is also affected. During the day, lotions containing aluminum acetate, 2 to 5 per cent, may be helpful. During the night, a mild tar ointment is useful. Roentgen-ray therapy has been used as in almost everything else.

Syphilis.—The lips may be the site of luetic lesions characteristic of all stages of syphilis.

Chancre.—Extragenital chancres make up from 3 to 6 per cent of all chancres. The lip is more often affected than other regions in and about the mouth (Fig. 89, *B*). The tonsil ranks next and the tongue third. Most commonly the middle of the vermilion border of the lower lip is affected. The incidence is somewhat higher in the female. Clinically a small superficial erosion appears which soon is likely to be slightly elevated. The lip becomes somewhat swollen and edematous. In lip chancre often there is considerable tendency to ulceration although the appearance of the lesion is quite variable in this location. Sooner or later the characteristic induration of the base tends to appear. The tributary lymph nodes especially and the others also to a lesser extent show discrete rubbery enlargement

not tender to palpation. The diagnosis is suspected on the history including the age and character of the ulcer, and the lymph node enlargement, but finally is made definite on the demonstration of the Spirochaeta pallida in the dark field. Soon the secondary skin lesions of the disease clinically make the diagnosis definite. The treatment is more fully discussed under Syphilis of the Mouth (Chapter XVI).

Bibliography

Bibliography Quoted in Text

Bier, Hofman, Lenhartz, and Rodelius: Quoted by Dittrich, R.: Furuncle of the Face, Beitr. z. klin. chir., **132:** 671, 1924.

Blair, V. P.: Surgery and Diseases of the Mouth and Jaws, St. Louis, C. V. Mosby Co., 1918.

Bollinger and Israel: Quoted by Jacobson, H. P.: Actinomycosis, A Clinical, Pathological and Bacteriological Study, Med. Jour. and Rec., **132:** 342–346, 1920.

Colebrook, L.: Mycelial and Other Micro-organisms Associated with Human Actinomycosis, Brit. Jour. Exper. Path., **1:** 197–212, 1920.

Actinomycosis of the Jaw, Proc. Roy. Soc. Med., **23:** 861, 1929–1930.

Davis, D. J., and Pilot, I.: Studies of Bacillus Fusiformis and Vincent's Spirochete. I. Habitat and Distribution of these Organisms in Relation to Putrid and Gangrenous Processes, J.A.M.A., **79:** 944, 1922.

Dewey, K. W., and Moorehead, F. B.: Pathology of the Mouth, Phila., W. B. Saunders Co., 1925.

Dittrich, R.: Furuncle of the Face, Beitr. z. klin. chir., **132:** 671, 1924.

Fordyce, J. A.: A Peculiar Affection of the Mucous Membranes of the Lips and Oral Cavity, Jour. Cutaneous Diseases, **14:** 413, 1896.

Fordyce: Quoted by Reclus: Deux nouvelles observations d'épitheliomes en surface, developpes sur une muqueuse leucoplasique, L'odont., **18:** 261, 1908.

Havens, F. Z.: Actinomycosis of the Head and Neck, J.A.D.A., **20:** 478–480, 1933.

Lemaistre: Prog. Med., 2nd ed., **4:** 597, 1886.

Jour. Soc. de méd. et de la pharm. Haute, Vienna, **1:** 44, 55, 74, 1886.

Leith: Quoted by Prinz and Greenbaum: Diseases of the Mouth and Their Treatment, Phila., Lea and Febiger, 1935, p. 359.

Montgomery, F. H., and Ormsby: Blastomycosis and Coccidioidal Granuloma, Arch. Int. Med., **11:** 1, 1908.

New, G. B., and Figi, F. A.: Actinomycosis of the Tongue, Amer. Jour. Med. Sci., **163:** 507, April, 1922.

Pusey: Quoted by Sutton.

Rayer: Quoted by Besnier-Besnier, Doyan's Trans. Kaposi's Lehrb. d. Hautkrankheiten, Paris, **1:** 664, 1891.

Stelwagon: Cheilitis Exfoliativa, Jour. Cutaneous Diseases, **18:** 268, 1900.

Thoma, K. H.: Clinical Pathology of the Jaws, Chas. C. Thomas, Springfield, Ill., 1934.

Wright, J. H.: Biology of Micro-organisms of Actinomycosis, Jour. Med. Res., **13:** 349–404, 1905.

Rep. Mass. Gen. Hosp., 1905.

Tunnicliff, Ruth: Identity of Fusiform Bacilli and Spirilla, Jour. Infec. Dis., **3:** 1, 1906.

The Microscopic Appearances in Ulceromembranous Tonsillitis (Vincent's Angina), Jour. Infec. Dis., **25:** 132, 1919.

Volkmann: Virchow's Arch., **1:** 142, 1870.

Supplementary References

Bull, Engelsted R.: Radium Treatment of Actinomycosis of the Face and Neck, Norsk Mag. f. Laegevidensk., **93:** 161, 1932.

Desjardins, A. N.: Radiotherapy in Actinomycosis, Radiology, **11:** 321, 1928.

Jurgen, H. J.: The Deadly Upper Lip Infection, Illinois Med. Jour., **55:** 273, 1929.

Long, P. H., and Bliss, E. A.: Para-aminobenzenesulfonamide and its Derivatives, Arch. Surg., **34:** 351, 1937.

Naeslund, Carl: Studies of Actinomycosis from Oral Cavity, Acta Path. et Microbiol. Scand., **2:** 110–140, 1925.

CHAPTER XV

ACUTE INFLAMMATIONS AND DISEASES OF THE BUCCAL AND PHARYNGEAL CAVITIES

The classification of many of the acute inflammations of the mouth is at the present time rather unsatisfactory as it is largely symptomatic. The classification followed here takes up first those diseases without known specific cause and secondly those oral lesions of known etiology.

STOMATITIS—GROUP I. CHARACTERIZED BY AN INDEFINITE ETIOLOGY (SYMPTOMATIC)

Simple Catarrhal Stomatitis.—Most frequently simple catarrhal stomatitis is found in children. As initiatory causes erupting teeth, rough or jagged teeth should possibly be taken into consideration in some instances. Most prone to the disease are individuals in a state of malnutrition. Chlorosis, secondary anemia, diabetes, nephritis, and so forth may initiate the subnormal resistance to infection. The inflammation may originate about the gums, in the larynx, pharynx or nose and spread to the oral mucosa. In the acute exanthemata a catarrhal stomatitis is quite often seen and may be a part of the disease. Women during pregnancy may be victims and in some rare instances the menstrual period may be sufficient to precipitate an attack.

At first the oral mucosa becomes red, tender, and dry and soon a more or less indistinct whitish filmy change of color is seen. Desquamation may follow after which a very bright red excoriation appears. Soon the breath becomes fetid, the tongue furred, and in pronounced examples the oral and labial mucosa becomes quite edematous and swollen. According to the intensity of the inflammation the sense of taste is progressively diminished and salivation progressively is increased. Ordinarily, except in babies, the constitutional reaction is slight. The tributary lymphatics become swollen in the more severe types.

Simple mouth washes make the patient more comfortable. The patient's general resistance ordinarily overcomes the disease unless the underlying cause is an incontrollable or fatal disease. When a general disease is the underlying cause, the treatment appropriate for the disease should be the fundamental care.

Aphthous Stomatitis.—The suggestion has been made that aphthous stomatitis is entirely a contagious disease. It is probably rather often an acute infection stimulated by a gastro-intestinal upset. Following whooping cough, measles, or scarlet fever examples are seen. Both a diplococcus and a streptococcus have been accused of being the specific organism but the proof for such is very questionable. Most commonly the lesion is seen in children.

Microscopically the small vesicular yellowish or grayish elevated lesions show simple epithelial cells with fibrin and round-cell infiltration. A fibrinous exudation within the epithelium apparently causes the lesion.

In a typical example there appears one or many small yellowish or grayish vesicles of about a 2- to 4-mm. diameter surrounded by a reddish inflammatory halo. The lesions are more plaquelike than vesicular but there is some exudate within the lesion and as it is discharged a very superficial ulceration appears. This round or oval lesion has either a red or a little later a grayish base. Although some authors comment on the lack of discomfort as being a diagnostic symptom, not uncommonly slight pain is present. The gums, the lips, vestibule, and under surfaces of the tongue are customary sites for the lesion to be seen. Successive crops of the lesion appear during the first few days but usually within a period of ten days they have ceased to appear and are largely healed without a scar. The gums especially are affected in children but in adults the cheeks, lips, pillars, and soft palate are also quite often involved. The fetor of the breath is quite a noticeable feature. Salivation is slight. Some regional lymph node enlargement is usual. As a rule, only slight constitutional symptoms are present but in children, especially, slight fever may be registered.

Mild mouth washes make the patient more comfortable. When the practitioner has a propinquity for treatment whether or not it is necessary, no harm is done by touching the areas with some astringent of a caustic or antiseptic nature. Thus, the patient may feel that the treatment is more likely to end well. An 8 per cent solution of zinc chloride has been recommended for this purpose.

Ulcerative Stomatitis.—When the teeth are present ulcerative stomatitis may develop in both children and adults. A good many of these cases fall in the category to be described as "Vincent's Disease," "Trench Mouth," or "Ulceromembranous Stomatitis." Because of lowered general resistance or poor oral hygiene or both, infection of the gums is initiated. In scurvy, purpura, the hemophilias, and the leukemias, the disease may appear. In other instances, the disease seems to assume a mild epidemic character. Osler stated that in some instances an exanthem may accompany the affection similar to exanthem of measles—presumably a toxic rash.

The inflammation starts at the margin of the gum which becomes soft and red. At the edges of the gum slight ulceration soon appears. A dirty white more or less adherent membrane covers the bases of the ulcers. The inflammation extends along the gum margin of both the upper and lower teeth. The mucosa of the lips, cheeks, and tongue becomes somewhat swollen and may also rarely show evidence of breaking down and tendency to ulceration. About the teeth the peridental membrane finally becomes involved, and causes the teeth to loosen and fall out. In the final picture even the alveoli may necrose. Fetor of breath, salivation, painful mastication, lack of appetite, and general malaise are all present. Especially in children but also in adults the temperature and pulse show an elevation, and the regional lymph nodes may become swollen and somewhat enlarged. A smear of a culture may aid in the diagnosis.

When a constitutional malady is found, the treatment of stomatitis is largely the treatment of the fundamental disease. The local application of a fairly strong antiseptic about the gum margins once or twice a day possibly aids nature in resisting the infection.

Potassium chlorate, 10 grains to the ounce, hydrogen peroxide, 1 to 5 per cent aqueous solution or potassium permanganate has also been recom-

mended. Cotton pledgets saturated in hydrogen peroxide may be used advantageously to swab about the teeth every four to six hours. After the treatment the mouth should be rinsed with hydrogen peroxide.

Gangrenous Stomatitis.—Gangrenous stomatitis is only an advanced stage of ulcerative stomatitis. The same individuals are affected. The disease entity called noma is a gangrenous stomatitis. Vincent's disease may also take the form of a gangrenous stomatitis. (See Noma, and Vincent's Disease.)

In the vestibule of the mouth from an ulcer there develops a slough which soon becomes a foul, yellowish, gray, stringy mass. As the severity of the infection increases the local and constitutional symptoms become more pronounced. Bone may be invaded and caused to sequestrate. About one half of the pronounced cases die.

The treatment is the same as for ulcerative stomatitis. When a slough loosens it should be clipped off to aid drainage.

STOMATITIS—GROUP II. CHARACTERIZED BY A MORE OR LESS DEFINITE ETIOLOGY

Erysipelatous Stomatitis.—Erysipelatous stomatitis is a very rare form of stomatitis caused by a streptococcic invasion of the oral mucosa and is analogous to cutaneous erysipelas. Intense diffuse redness and swelling of the oral mucosa is characteristic. The soft palate, the uvula, and the pharyngeal tissue become quite edematous. The mucosa is dry and tender. The edema tends to spread downward and involves the spaces of the neck and the larynx. A laryngeal edema with respiratory obstruction may develop.

The treatment is symptomatic. Soothing hot mouth washes, rest in bed, and sedatives to give rest and sleep are in order. Hot fomentations about the upper neck may possibly be of value.

Gonorrheal Stomatitis.—Gonorrheal stomatitis is seldom seen, but rarely it does affect the newborn. Most likely the mucosa of the mouth is injured so that if the birth canal is infected with the gonococcus, the infection is given a port of entry. Soon the tongue and oral palate become covered with yellowish-white patches, but the constitutional symptoms are slight. The diagnosis is made by smear and culture. The finding of a gram-negative diplococcus in the exudate should lead one to the correct diagnosis. One or 2 per cent silver nitrate or 2 per cent protargol is used in the treatment. The prognosis is good. A conjunctivitis should be guarded against by binding the baby's arms down to the sides.

Vincent's Disease—Trench Mouth—Ulceromembranous Stomatitis.—During the late World War ulceromembranous stomatitis was common among the troops. The disease was then called "trench mouth." Probably most of the ulcerative and gangrenous types of stomatitis which in the past have been classified simply by the symptomatologic name were in reality Vincent's disease. That is, the organisms of Plaut and Vincent are found accompanying the affection. Plaut and Vincent described a spindle-shaped fusiform bacillus and a spirochete which are present in association and are now generally thought to cause the most common form of ulceromembranous stomatitis. In many instances these organisms are found in the mouth as saprophytes. Stookey found as high a percentage as 70 of

the more or less normal mouths examined at the Kansas City General Hospital. Under unfavorable conditions it is thought that these organisms become pathogenic and the clinical form of the disease develops. Distinct epidemics occur. The disease is thought likely to be spread through the common use of drinking cups, kissing, etc. Poor hygienic conditions and overcrowding seem to encourage outbreaks. Locally within the mouth lack of oral hygiene and irritating conditions about the teeth are predisposing factors. The disease is seen commonly in adolescence.

In regard to the organism, it has been suggested that the two organisms do not live in true symbiosis but that the two forms encountered on smear are different stages in the life cycle of one organism. Tunnicliff demonstrated spiral forms within the bacillary filaments and observed various transition forms from granules to definite spiral forms. The Bacillus fusiformis is a slender bacillus and measures from 4 to 12 microns in length. The cross section width is from 0.7 to 0.9 micron. The organism is gram-negative, nonmobile, anaerobic, and the aniline dyes stain the bacillus in such a way that a granular appearance is given. The better known Spirochaeta pallida is a much smaller spirochete than Vincent's spirochete and has more spirals.

In the mouth there are found several sizes of spirochetes. Different names such as Spirochaeta buccalis, S. medium, S. dentium, and S. pyorrhoeae. These spirochetes are of various sizes and all possess long slender flagella. In all the spirochetes are found granules termed "polar ends" said to be better seen after salvarsan treatment. Gande suggested that these granules represent disintegration products or that they represent a phase in the life cycle of the spirochete similar to Much's granules in the tubercle bacillus. The spirochete of Vincent is stained with the aniline dyes such as gentian violet, somewhat more lightly than the bacillus. At times on smear only spirochetes are found, the bacillus apparently being absent. Also associated with the spirochete and the bacillus are a great number of cocci of different varieties (Davis and Pilot). Various streptococci, staphylococci and pneumococci and rarely the Klebs-Loeffler bacillus all may play an important rôle in the disease. It is difficult to estimate the exact rôle of the primary debilitated state, the fusiform bacillus and spirochetes of Vincent and the other pathogenic organisms—which is primary and which is secondary.

Clinical Picture.—Preceding the onset of the stomatitis a feeling of malaise prevails and there is some salivation, a fetid breath, and slight elevation of temperature and pulse rate. A few days later the gums become red, tender and soon bleed easily. The gum margin becomes rolled, soft and tends to recede from the teeth. Later the edge ulcerates and a grayish-yellow adherent membrane lines the border. The membrane is easily removed and leaves a bleeding gum with an irregularly shaped, denuded ulcerous base. The gum edges and the interdental septa slough. As the disease progresses the constitutional symptoms become more pronounced and locally the teeth become tender, loose and sharp pains shoot along the jaws. The fever ranges from 101° to 103° F. and the pulse rate is correspondingly elevated. The leukocyte count is not very high—about 10,000 to 12,000 white blood corpuscles. The fetor of the breath increases and becomes quite repulsive. Mastication becomes nearly impossible. The

gums of the molar region are usually most definitely involved and in the third molar region extension to the cheek may appear. Extension posteriorly to the tonsil region and upward to the soft palate is also seen in the more virulent cases. The submental and submaxillary lymph nodes become moderately enlarged and tender. Although fairly prompt recovery is the usual course, in the more extensive and more severe types of the infection a fatal outcome is sometimes unavoidable.

In clinical cases of stomatitis, the diagnosis is made by demonstrating in a smear a preponderance of fusiform bacilli and the spirochete of Vincent.

Treatment.—Hydrogen peroxide makes a satisfactory local cleansing fluid. Pledgets of cotton are dipped in the solution and the gum margins carefully swabbed every three or four hours. A cleansing mouth wash of potassium permanganate about 1:3000 in the intervals also is useful. After

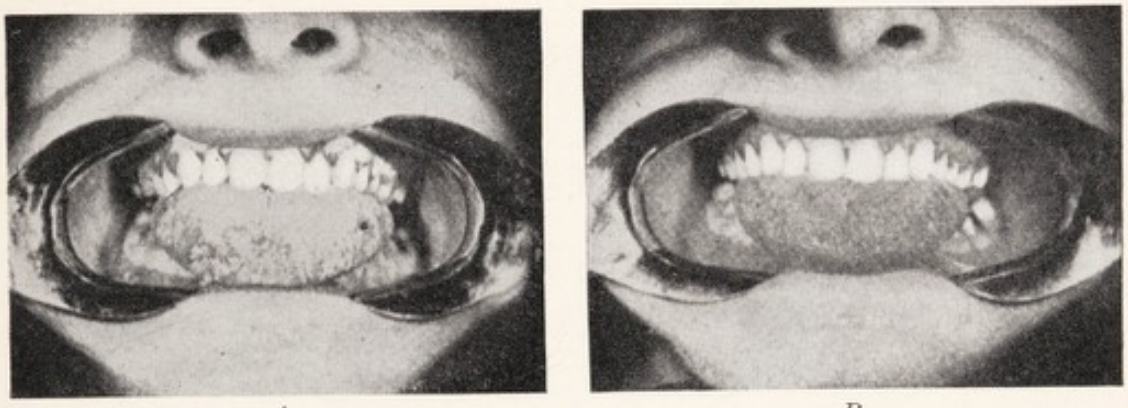

A *B*

Fig. 90.—*A,* Mouth of acute ulcerative gingivitis patient showing inflammatory involvement of tongue, extending almost to entire oral cavity with canker sores in numerous places. The tongue is markedly swollen. Temperature, 104° F. *B,* Mouth and tongue one week later. The tongue is normal in size and free from membrane. Hanke states: "Citrus fruit juice is definitely antagonistic to gingivitis if enough of the juice is administered. It is, however, sometimes possible to reduce the dose to eight or even to four ounces a day after the condition has improved, without incurring a relapse. The curative dose is larger than the maintenance dose in some cases which agrees perfectly with observations that have been made on animals." (After Hanke.)

the use of hydrogen peroxide the gums may be painted with some antiseptic such as mercurochrome 2 per cent. Ten per cent salvarsan in glycerin has been highly recommended. Hanke has recommended citrus fruit juice (Fig. 90, *A, B*).

Generally the patient is cared for according to the severity of the general symptoms. Attention is paid to the diet so that it is soft and easily masticated and nourishing. Fruit juices and vegetables should be given freely.

Thrush.—A fungus, Oidium albicans, may cause in the ill-nourished a mild stomatitis. Usually, only infants are affected, but cachectic adults may also be victims of the disease. Babies suffering from a cleft palate defect are thought to be slightly more prone to the affection. The infection may be contagious and may spread quite rapidly if precautions are not taken to sterilize nipples, bottles and pacifiers. Histologically the spores are found to lie on or between the epithelial cells. Wagner and

Huebner state that they may also invade blood vessels and be carried to distant places.

Either preceding or accompanying the infection, a gastro-enteritis is likely to be present. First, a spot about the size of a pin-head appears most often over the anterior part of the tongue, the gums and the cheeks. These small areas soon spread and coalesce and form an adherent whitish or cream-colored layer attached to an erythematous base. In more pronounced infections, the whole of the tongue, the palate and the pharyngeal mucosa become involved. The patches are adherent and when rubbed off leave a bleeding base.

As the stomatitis clears up, the involved areas become yellowish brown and soon begin to peel off. Some soreness accompanies the infection and feeding may be somewhat interfered with on account of it. As a rule, recovery is prompt and seldom is life endangered.

Diagnosis.—The coherent, slightly elevated, coalescing layer of creamy or glazed white, which if removed reforms, is rather pathognomonic. The fungus is easily demonstrated under the microscope when a smear is made. When the membrane is at all suggestive of a diphtheroid membrane a culture should be taken.

A mild nonirritating alkaline mouth wash such as borax, sodium bicarbonate (10 per cent) or a saturated solution of boric acid applied every four hours will aid recovery.

Foot and Mouth Disease.—Although foot and mouth disease is primarily a disease occurring in cattle, hogs, sheep, goats, etc., man is occasionally attacked. A virus present in the fluid of the vesicles transmits the disease. Inoculations occur when the skin or mucosa is abraded and may follow the ingestion of contaminated milk. The incubation period is from two to five days in man but rarely may be as long as ten days.

As a rule, the constitutional symptoms are of moderate severity. Slight fever, anorexia, and nausea and a feeling of burning or dryness of the mouth appear. The buccal mucosa becomes congested and swollen after which within two or three days clear vesicles (3–10 mm. in diameter) develop on the lips, tongue, and cheek and pharyngeal wall (Fig. 91, *A*). Besides the mouth the nasal mucosa may also be involved. The vesicles after twenty or thirty-six hours begin to turn milky in appearance. After two or three days more the vesicles rupture spontaneously leaving tender, reddish ulcers which heal rather quickly without scar. A sensation of burning, soreness, paresthesia, and salivation accompany the lesion. The regional lymph nodes become tender and swollen. Besides the mouth the extremities are likely to be attacked in the more severe forms of the disease. Very rarely the eruption becomes generalized. The cutaneous lesion pursues a course similar to the mucosal lesion just described. Only a few fatalities have been reported. Usually the course is relatively mild in man.

Treatment.—The treatment is mainly symptomatic. Mild antiseptics and astringent washes are recommended. In the mouth potassium chlorate, alum and such washes have been used. On the general surface calamine lotion or a weak ammoniated mercury ointment aid in healing the eruption.

Scorbutic Stomatitis (“Moeller-Barlow Disease”).—Scorbutic stomatitis is caused by a deficiency of the antiscorbutic vitamin commonly found in fruit juices and vegetables. The absence of the antiscorbutic foods,

such as fruit juices, fresh meats, and milk is the causative agent. Pathologically, the characteristic lesions are hemorrhages beneath the periosteum of the bones and in the marrow and elsewhere in the body such as the gums. The blood-forming elements of the marrow disappear, the epiphyseal cartilages become irregular, and the zone of ossification is distorted. Osseous tissue is inefficiently laid down.

The most profound disturbance takes place in the osseous system in both the bony structure and the marrow but in the mouth the chief symptom of scurvy is a gingivitis. As a rule, the mucosa of the remainder of the mouth is not particularly involved. The gums become soft, spongy, and bleed easily. The edges become dark red and beneath the mucosa small hemorrhages are noted.

The child is restless and irritable and handling causes pain and discomfort. The various joints of the body may be somewhat swollen. Anemia and wasting in the more pronounced cases is definite. The *x*-ray discloses



A *B*

Fig. 91.—*A*, Foot-and-mouth disease. Vesicles on the lips and tongue on the seventh day. The mucous membrane showed an intense dusky red color. (Clough, Johns Hopkins Hosp. Bull.) *B*, Pemphigus of the pharynx. Note the fibrinous exudate over the palate and pharynx, and the 2 bullae on the left soft palate and the anterior pillar. (New, Arch. Otolaryngol.)

the subperiosteal hemorrhage and the distortions of the epiphyseal plate. The Trummer zone is seen, a band in the metaphyseal region several millimeters from the epiphyseal plate. It is associated with degenerative changes and deposition of calcium salts. Later when organization of a hemorrhage takes place or ossification, the deformity may simulate sarcoma of the bone. Scurvy usually shows bilateral lesions. No leukocytosis or fever accompanies the disease. Hemorrhage from the bowel may be an important symptom. In the diagnosis the lesions elsewhere than in the mouth should be considered and studied with the roentgen ray.

Orange juice, lemon juice, fresh vegetables, fresh meats, and milk supply the necessary vitamins and chemical agents and when the proper amounts are supplied, recovery takes place. Surgery is concerned in differentiating scurvy from conditions that may need surgical interference.

Diphtheria.—Primary diphtheria of the oral cavity is extremely rare. A diphtheritic infection primary in the pharynx or nose may extend to the soft palate or faucial pillars and in severe cases the gums and oral mucosa

are involved. A dirty grayish adherent pseudomembrane forms which on detachment leaves a bleeding erosion. When not possible by clinical examination the disease is differentiated by smear and culture from Vincent's angina. Occasionally the two diseases are both present at the same time. A twelve-hour culture or blood agar should allow one to make the diagnosis. The treatment is that of diphtheria elsewhere.

MINERAL STOMATITIS

Stomatitis Mercurialis.—Mercurial stomatitis may develop in an individual who has absorbed for one reason or other a considerable quantity of mercury. The victims give a history of overdosage in the treatment of some disease such as syphilis or exposure to mercurial vapors in certain occupations. Makers of mirrors, those working in mercury mines and those in contact with the fumes in the making of certain alloys are especially exposed. Apparently poor oral hygiene causes a predisposition to the disease. As the treatment for syphilis has become better understood, mercury in sufficient quantity to be dangerous is not often given. In the trades mercury may enter the body either through the digestive tract or the respiratory tract. The reason for the pronounced effect on the gums is that an "excretory" stomatitis is set up. The mercury is excreted by the saliva, the oral mucosa is injured and becomes apparently more susceptible to infection by organisms not ordinarily pathogenic. Almkvist has stated that the hydrogen sulfide produced by food decomposition in the mouth causes a precipitation of mercuric sulfide in the capillaries of the gingival mucosa which causes a thrombosis of the vessels with subsequent necrosis and secondary infection. On the other hand, Blair and Ivy state "mercury is not excreted by the saliva."

Early the mouth feels dry and a metallic "taste" appears. Soon the gingiva becomes red, swollen and tender and the teeth become tender on pressure and the quantity of saliva is greater. The lower incisors, the canines, about the posterior half of the third molars or about a carious tooth are locations most susceptible (Fig. 92, *A*). As the process continues the vessels of the gingival margin are thrombosed and marginal necrosis and ulceration become evident. The breath now is fetid. Later the mucosa, the lip, and the tongue may all become involved. Redness, edema, and tenderness are the local signs of wider involvement. In extreme instances it may be impossible to close the mouth on account of swelling and in rare instances even the tongue has become gangrenous. As the inflammation extends the vessels leading to the alveolar ridges are involved, the teeth loosen and the blood supply to the alveolar ridge may be cut off causing it to necrose. The affected individual becomes anemic. Gastrointestinal disturbances occur. A diarrhea is almost always present at one time or another.

For purposes of prophylaxis, before administering mercury all deposits should be removed from the teeth, carious teeth should be filled and all old roots removed. During the course of treatment the mouth and gums should be kept clean. When tenderness occurs on bringing the teeth together, the dosage should be cut abruptly and if the tenderness does not subside, the treatment should be discontinued. After the disease is established the treatment should be eliminative generally and locally cleansing

and nonirritating. Warm baths and saline cathartics may aid elimination; 1:2000 potassium permanganate has been suggested as a valuable mouth wash to aid in both treatment and prophylaxis. Potassium iodide in 10- to 15-grain doses may be given internally to aid in elimination. Sodium thiosulfate is also of aid in causing elimination of the metal.

Bismuth Stomatitis.—Clinically practically the same sequence of symptoms is produced in a stomatitis caused by an overdosage of bismuth as with mercury (Fig. 92, *B*). In bismuth stomatitis, however, the gums about the teeth show a bluish black discoloration instead of the red found after mercurial poisoning. As the gingival crest is discolored in lead poisoning, to differentiate the two a careful history is necessary. In lead poisoning the red blood cells show stippling. The injection of bismuth paste into sinus tracts or cavities was at one time the most common cause of bismuth poisoning. The treatment is similar to that outlined under Mercurial Stomatitis.

Stomatitis of Lead Poisoning.—Lead poisoning is not uncommonly found in individuals working in such trades. Painters, potters, storage battery makers, electricians, plumbers, printers, and pile cutters are some

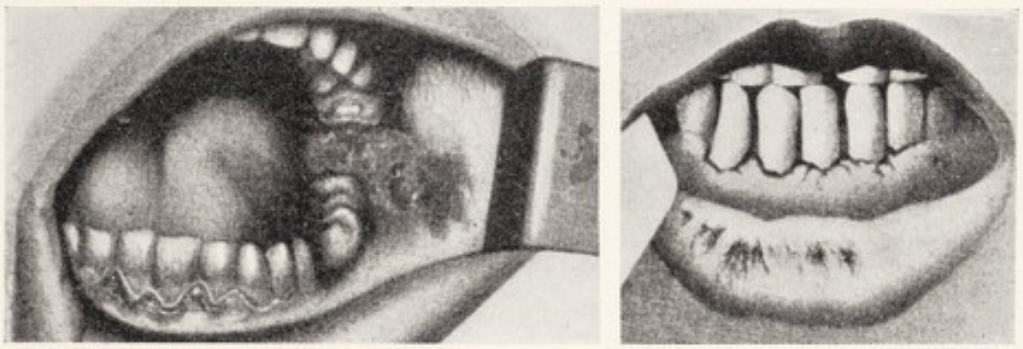

A *B*

Fig. 92.—*A,* Mercurial stomatitis. (Mikulicz and Michelson.) *B,* Bismuth stomatitis. Bluish-gray bismuth deposits within the marginal gum line and in the mucous membrane of the lower lip. (Moral.)

of the workers that may be exposed. Lead may also be ingested from certain drugs, water from lead pipes, hair dyes and certain cosmetics.

Lead poisoning does not of itself produce a marked stomatitis but slight gingivitis is the characteristic inflammatory reaction in the mouth. The gingivitis may either precede or follow the general symptoms of lead poisoning. Characteristic of the gingivitis is the development of a bluish black line on the crest of the gums. The black is caused by the deposition of lead sulfate in the endothelium of the capillaries of the papillae of the gingiva. The lead line is "tattooed" so to speak. Among the more general symptoms encountered in lead poisoning are anemia and gastro-intestinal symptoms, with colic and constipation. A peripheral neuritis frequently accompanies the disease. Wrist drop due to weakness of the radial nerve is a characteristic syndrome. The red blood cells show decrease of hemoglobin, basophilic degeneration and a stippling which is largely pathognomonic.

The treatment is generally eliminative and locally cleansing. The same treatment is recommended as that described under Mercurial Poisoning.

Sodium thiosulfate has been highly recommended as aiding in elimination of the metal.

Stomatitis from Arsenic, Copper and Silver Poisoning.—Following the ingestion of large amounts of either arsenic, copper or silver, an ulcerative gingivitis may be produced which in more pronounced instances may extend and produce a general stomatitis. In a gingivitis following the ingestion of copper, the so-called "copper line," a greenish-red line may be seen at the gingival crests. In silver poisoning the grayish-black spots may be noted in the oral mucosa. Chromium salts have been accused of producing ulcers in the palate resembling those following the evacuation of a gumma. The treatment is similar to that described under mercurial poisoning.

Stomatitis of Phosphorus Poisoning.—A quarter of a century ago workers in match factories and makers of phosphorescent dials and so forth not uncommonly suffered from phosphorus poisoning. A gingivitis first occurs as a manifestation of oral damage. When the inflammation progresses, the alveolar periosteum is involved and an acute alveolodental periostitis supervenes. The blood supply of the alveolus and surrounding bone is cut off and the alveolus and a greater or less amount of the mandible becomes necrotic and eventually forms a sequestrum (see under Osteomyelitis of the Jaw). The treatment does not differ from that of the other mineral poisons.

Stomatitis of Radium Poisoning.—Those who work with luminous paints or ingest radioactive substances in other ways may develop a very resistant gingivitis and stomatitis which may in pronounced instances involve the underlying structures sufficiently to cause the teeth to loosen, or even the bone of the jaw to necrose. The only known treatment is to remove the individual from a possibility of contact with radioactive substances. Some years ago quite a few individuals lost their lives from careless exposure to radioactive substances before proper methods of screening were known.

MISCELLANEOUS LESIONS OF THE BUCCAL MUCOSA

Bednar's Aphthae.—On the posterior part of the hard palate or the mucosa over the pterygoid process in infants, there sometimes appear small whitish spots, excoriations or even definite ulcers. They are symmetrically placed as a rule and may tend to spread toward the median line thus simulating a butterfly shape. The causative agent is thought to be pressure of the tongue or nipple, or injury while cleansing the mouth. The treatment is avoidance of trauma, with possibly a mild antiseptic mouth irrigation.

Epithelial Pearls.—Epstein has described in infants before the sixth week of life hard round nodules pin-head in size located in the median palate raphe. The structure is that of an epithelial pearl. Treatment is not necessary.

Chronic Aphthae.—In anemic or chlorotic women in rare instances chronic recurring aphthae may appear. The small vesicles rupture after which the small ulcerated area may be quite sensitive. The periodic recurrence of these lesions is most annoying. Some relationship to the menstrual period or a digestive upset is thought to be suggested. The ulcers soon heal spontaneously. The treatment is difficult. Every effort should be made to correct and regulate the general health.

Tropical Aphthae.—In the tropics associated with a chronic enteritis and anemia, aphthae similar to those just described may be encountered.

Peridentitis Mucosae Necrotica Recurrens.—This rare affection was first described by Loblowitz. A nodule appears beneath the mucosa of the lip, cheek or tongue, increases in size for several days and then gradually shrinks leaving a crateriform depression. At the end of a week it has healed and a thin pliable scar remains. During development and healing the area is tender and sore and the regional lymphatics become slightly enlarged and tender. Treatment influences the disease but little.

Pemphigus.—Pemphigus may be either a chronic or acute disease and is characterized by successive crops of bullae which may be accompanied by constitutional symptoms of varying intensity. The cause of pemphigus is not known. Bacteriologic studies have shown nothing definite. Pathologically, the papillae are swollen and edematous with capillary dilatation and perivascular exudation. The bullae are epidermal and in most instances lie just beneath the stratum corneum although they may be separated from it by a few loosely adherent prickle cells (Sutton). The first manifestations of this rather fatal disease are quite often noted in the oral cavity. New emphasized the fact that quite a large percentage of patients with pemphigus first consult a laryngologist. Mouth lesions may precede the cutaneous lesions by weeks or months. In New York City the disease is prevalent among the Russian, Polish, and Galician Hebrews (Wise and Parkhurst). Superficial bullae on red bases appear which soon rupture or more rarely deflate without rupture (Fig. 91, *B*). After rupture, covering the red base, the thin pellicle of wrinkled dead epithelium is at times plainly visible but usually the pellicle is lost and the red base is evident with possibly epithelial shreds hanging attached to the margin. After twenty hours a red areola surrounds the bullae. The erosions heal eventually but in the meantime the breath is foul from fermentation and necrotic débris. The disease is characterized by the occurrence of successive crops of bullae. Lesions may be present practically all the time or outbreaks may occur alternately with periods of comparative quiescence. The bullae vary from ½ to 5 cm. in diameter. Usually true cases of pemphigus are eventually fatal.

The general health of the patient should receive attention. Tonics of cod liver oil, iron, quinine and strychnine have been recommended. Arsenic in the form of Fowler's solution is supposed to be beneficial. Likewise, arsphenamine intravenously has been used. Autogenous vaccines have been tried.

ACUTE INFLAMMATIONS OF THE TONGUE

Acute inflammations of clinical significance do not commonly involve the tongue but like all other parts of the body, the tongue does not enjoy complete immunity to infection. Single papillae even become infected and stick up above their fellows. Acute papular glossitis is a rare disease of obscure etiology but is occasionally seen. Several papular nodules about 4 to 6 mm. in diameter appear on the tongue and eventually become shallow erosions which heal in two to three weeks. Superficial abrasions and fissures of course are rather common. Simple traumatic ulcer of the tongue may arise from any one of many causes and become more or less infected. A sharp, jagged tooth, a rough denture or bridges, biting of the tongue, friction (as a whooping cough), hot foods or a newly erupted tooth, all may damage the tongue sufficiently to cause superficial epithelial necrosis.

Traumatic ulcers as would be expected are usually on the tip or the border of the tongue.

A diffuse cellulitis of the tongue is seldom seen. Infection probably enters from a crack or ulcer. In most instances streptococci are the invaders as has been demonstrated in the tongue muscles. Staphylococci much more rarely have also been the pathogenic organisms (Fig. 93). The onset is rapid. Tenderness on movement first is felt. The movements of the tongue are somewhat limited. Swelling develops rapidly and within a few hours the tongue may be too large for the mouth and begin to protrude. The pain increases. Salivation becomes pronounced. Swallowing is difficult or becomes impossible and breathing even may be embarrassed. The tributary nodes enlarge and become tender. A temperature of from 101° to 103° F. develops. The pulse rate is increased. A moderate leukocytosis is found. In severe infection the tongue has sloughed. However, this is a very rare complication. Suppuration with scattered abscesses occasionally develops or a Ludwig's angina. But the usual course is for the swelling to begin to subside in three to four days and within a week very

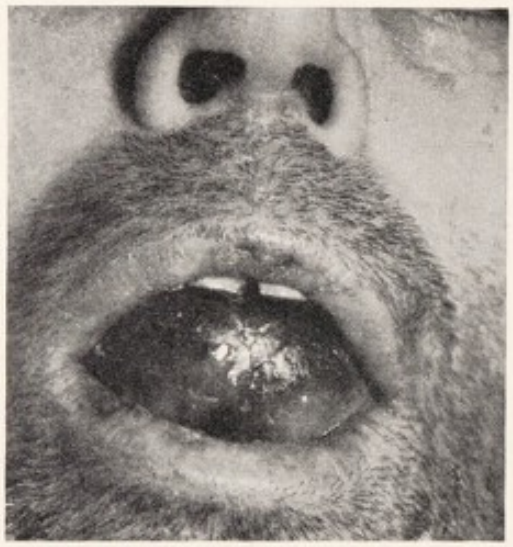

Fig. 93.—Acute hemorrhagic cellulitis of the tongue.

little induration remains. The treatment is generally largely symptomatic. A large hot wet pack about the neck may make the patient more comfortable. Sedatives should be given if required. After localization, incision and drainage should be practiced. Acute localized abscess of the tongue is most frequent near the base as the condition usually follows acute lingual tonsillitis, but localization is rather slow.

As a rule, within a week or ten days if the source of irritation—tooth, plate, bridge, etc.—is removed, the ulcer heals if it is benign. When it does not heal or the induration increases, it should be excised completely and subjected to a microscopic examination.

Instances of involvement of one half of the tongue with an acute cellulitis have been described (Wormer and Bercher, 1922).

SPECIAL INFECTIONS AND DISEASES

Anthrax.—Anthrax is rare in man but not uncommon in the herbivorous animals. The disease is caused by the spore-forming Bacillus anthracis. Man is infected through the skin (malignant pustule), the respiratory tract

(woolsorter's disease) and the intestinal tract. A few years ago a few cases of anthrax were traced to shaving brushes not properly sterilized. Three to six days after external inoculation a small pimple is noted which rapidly becomes a vesicle the fluid of which on smear shows the characteristic large, thick, blunt-ended, gram-positive bacillus. The vesicle never contains pus (Boyd). It soon ruptures and discharges a clear or blood-stained fluid after which a black slough remains. New vesicles develop about the slough. About the base of the vesicles and surrounding them there develops a brawny induration which is purplish in color and tends to be centrally depressed. When the vesicles rupture there is some burning but pain is not a pronounced characteristic of the infection. The tributary lymphatics enlarge. Marked constitutional symptoms soon develop. Fever and chills appear. Death is caused by an anthrax septicemia. About one fourth of the individuals infected in the past have died.

Anti-anthrax is the treatment to be depended upon. After reviewing 51 cases at the Massachusetts General Hospital Scholl concluded that expectant treatment is to be recommended. Of 9 treated surgically 4 died. Of 42 treated nonsurgically only 3 died. Anti-anthrax serum can be obtained from the Bureau of Animal Industry at Washington, D. C. Locally a 1 per cent lysol solution has been recommended. Lienhardt saw a number of cases at Camp Merritt. He recommends the actual cautery for the local lesion and anti-anthrax serum 100 to 200 cc. intravenously.

Glanders.—The Bacillus mallei causes a disease primarily in horses but the infection may be conveyed to man. The incubation period is from several days to three weeks. A papule appears first which later develops into a pustule. The single pustules are followed rapidly by a crop of pustules which become secondarily infected and break down to form irregular ulcers. The nasal fossa is most commonly affected and not only the soft tissues but bone becomes involved. In the acute form a septicemia soon follows. In the chronic form the disease may last several years. The mortality is about 50 per cent. The diagnosis is made by injecting the discharge of the diseased tissue into the peritoneal cavity of a guinea-pig. Within twenty-four to forty-eight hours an acute inflammation of the tunica vaginalis develops. The fluid from the tunica is aspirated and a potato culture medium is inoculated. The Bacillus mallei produces a transparent growth which after three days has a "yellowish honey-like appearance." This test is called the Strauss reaction. The test is pathognomonic. Mallein, a preparation corresponding to antitoxin, has been used by Bonome. In addition surgical measures are employed.

Agranulocytic Angina—Agranulocytosis.—Roberts and Kracke believe that agranulocytosis is a definite disease entity. The disease is characterized by a bone marrow onset followed by a gradual disappearance from the blood stream of granulocytes. Following this appear symptoms such as weakness, fever, exhaustion, delirium and finally septicemia, necrosis, hemorrhage and death. Kracke presented some evidence which might incriminate certain drugs related to the benzamines as being etiologically responsible for the disease. Amidopyrine has caused the disease as shown by Madison and Squires.

At autopsy, both cellular hypoplasia and hyperplasia are seen in the bone marrow. The bone marrow, however, is consistently deficient in cells

of the myelocytic series. Thrombophlebitis involving the iliac, axillary and pelvic veins is seen. The mucosa of the stomach and gastro-intestinal tract shows congestion. The heart shows pathology of a secondary toxic nature. The liver shows enlargement and cloudy swelling, and congestion. The kidneys are swollen and show albuminous degeneration and swelling of the glomeruli. The adrenals show a moderate cloudy swelling. The ulcers may be described as having successive developmental phases, starting out as a hyperemia, on which appears a tenacious, slightly elevated, grayish-green membrane. The membrane may change in color and has been described as even pink. It may be shed and then a red granular tone is seen. The vessels on the red area become thrombotic and a slough develops. The ulcers tend to erode and extend. The ulcers may extend to the larynx or the esophagus.

The circulatory leukocytes in 76 cases studied by Norris averaged 850 cells and the neutrophils were usually lacking—only lymphocytes remaining.

Twenty-seven of the 76 cases studied by Norris showed a positive blood culture. Pneumococci, Bacillus pyocyaneus, staphylococci, colon, paratyphoid and gas bacilli, and streptococci were found. As a rule, those affected die from an absence of leukocytes and the effect of a profound toxemia of the toxic type. Pneumonia develops in some.

Jaundice is observed in about one quarter of the patients. In about one sixth of the cases petechiae and hemorrhage into stomach, vagina, rectum, throat, etc., are noted. The spleen is enlarged in 30 or 40 per cent of the patients. About one half of the patients show enlarged glands in the cervical or retromandibular region. The gland response is rapid and acute and is felt as firm resistant nodules but suppuration only rarely occurs. The enlargement occurs simultaneously with or before the appearance of an oral ulcer or tonsillar necrosis. Little pain is complained of, although ulceration may appear elsewhere. The most important ulceration seen appears in the pharyngeal and buccal cavities. Over one half of the cases present ulcers in the tonsils. The entire tonsil may be destroyed. About one third present ulcers in the gum margins or elsewhere in the buccal cavity. About one tenth present ulceration in the pillars or fossa of the pharynx. Norris found the mortality in 76 cases to be 85 per cent. In acute cases, death occurs from four days to four weeks. In chronic cases, death occurs after a period of several months.

Blood transfusions have been given repeatedly with some temporary but little permanent success. Pentnucleotides, fetal spleen, and fetal liver have been tried with an occasional success reported.

General Diseases Which Present Oral Manifestations.—The following skin diseases may involve the oral mucosa: simple herpes, herpes zoster, lichen planus, lichen ruber acuminatus, porokeratosis, scleroderma, vitiligo, mycosis fungoides, xeroderma pigmentosum, molluscum contagiosum, xanthoma, impetigo herpetiformis, erythema multiforme, Addison's disease and rhinoscleroma. Verruca peruviana, gangosa, espundia, yaws, and "oriental sore" in the tropics may present mouth manifestations. Anthrax of the mouth is extremely rare. Among the fungi which may involve the mouth are Monilia candida, actinomyces, blastomyces, and sporotrichum. The parasitic diseases such as echinococcus, cysticercus, Filaria medinensis and

Trichina spiralis have been known to invade the mouth. Pellagra victims may present a stomatitis and glossitis. In sprue sensitive individual superficial erosions are found in the mouth. In pernicious anemia burning sensations in the mouth are not uncommon. Leprosy may invade the oral cavity late in the disease (Prejean). In typhoid and paratyphoid fevers oral ulcerations may appear which are said to be suggestive of "mucous patches." The strawberry tongue of scarlet fever should not be forgotten. In diabetes mellitus a gingivitis and a catarrhal form of stomatitis may occasionally develop. Chancroid of the mouth is very rare but occurs. The lesions resemble the "soft chancres of the genitalia." The Ducrey bacillus must be demonstrated to make the diagnosis.

ACUTE INFECTIONS OF THE PHARYNX

Acute cellulitis of the pharyngeal mucosa and acute tonsillitis due to various types of bacterial invaders are quite common. Following a tonsillitis rarely a tonsillar abscess develops which eventually ruptures. All of these infections are accompanied by the general constitutional signs of a pyogenic infection. The diagnosis is ordinarily quite obvious on examination and the treatment is symptomatic.

Peritonsillar Abscess.—Following a tonsillar infection the purulent material may rupture through the tonsillar capsule and infect the peritonsillar areolar tissues. The anterior pillar and the adjacent part of the soft palate and uvula become red, swollen, and edematous. From one third to one half or even more of the faucial isthmus is encroached upon. However, the tonsil itself may show only slight swelling. Soon the upper deep cervical nodes begin to show some enlargement and tenderness. Swallowing, speaking, or even breathing is interfered with as the inflammatory process increases. The pain is very distressing. Sedatives become necessary. Seldom does one have a peritonsillar abscess and not remember the pain for many a day. Finally on palpation, a point of maximum tenderness points to the focus of suppuration. Later some softening is felt. Eventually if evacuation is not done by surgical means the abscess ruptures spontaneously usually with inadequate drainage. Instances occasionally are reported in which the abscess burrows into the retropharyngeal space or along the perivertebral space. In the latter case the mediastinum may be endangered. The internal carotid artery or one of the branches of the internal maxillary artery may be eroded and the secondary hemorrhage has been fatal. It is not unlikely that an aneurysm of the internal carotid artery would be confused with a peritonsillar abscess. Stranger things have happened. The point is that an incision into a supposed abscess that turns out to be a mass due to an arterial or a venous dilatation usually suddenly places one in a very embarrassing situation.

During the period of cellulitis without localization, watchful waiting is the best régime. Too early drainage is dangerous. During this period hot packs to the side of the neck, hot gargles, and sedatives should be given. When, on palpation, a point of maximum tenderness which shows increasing resistance is found, the time for drainage has arrived. Evidence of localization of pus should develop before drainage is attempted.

When drainage is decided upon, it should be complete. In an adult it usually can be done under local anesthesia. Ordinarily the local anes-

thesia is not to be recommended in infections, but in this instance the anesthesia need only be injected just beneath the mucosa. When local anesthesia seems out of the question nitrous oxide anesthesia with the head turned in the Rose position is to be recommended. A mouth gag is placed and a tongue depressor holds the tongue in the proper place. Usually the point of maximum swelling and softening is in the anterior pillar region extending upward into the soft palate region. An incision (Fig. 94, A) just through the mucosa is made just lateral to the upper part of the anterior pillar and up onto the velum. A curved blunt pair of pointed scissors is then plunged backward and laterally so that the point goes just behind the tonsillar capsule. The prongs of the scissors are then opened and withdrawn while open. This is all done in one movement and when done properly the tonsil is about half thrown out of its bed. This gives complete drainage and relief as a rule within a few hours. When only local anesthesia is used, the patient

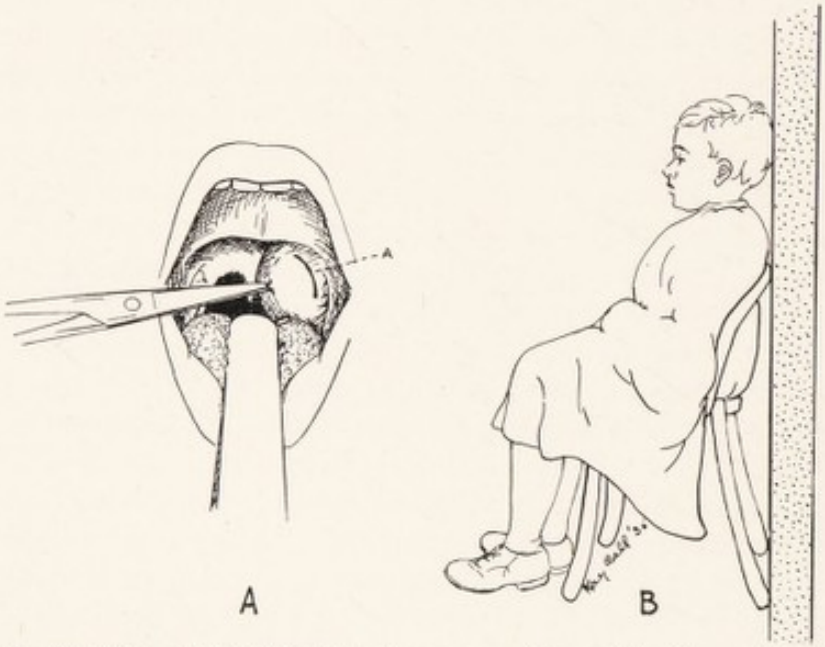

Fig. 94.—A, Opening of peritonsillar abscess. A, Shows the line of incision through the mucosa before the blunt scissors are inserted in behind the tonsil and opened. The scissors in the diagram are pictured as being straight curved scissors but blunt ones are easier to handle. B, The ideal position of the patient when the abscess is opened—with the head against the wall.

should be in a chair (Fig. 94, B) with the head against an immovable object.

Retropharyngeal Abscess.—A retropharyngeal abscess arises subsequent to a tonsillitis, a pharyngitis or a middle ear infection. Rarely an abscess of the parotid or even suppuration of the temporomandibular joint may extend to the retropharyngeal space. In children less than five years of age, a few lymph nodes are present in the prevertebral areolar tissue. Later these glands tend to atrophy. Therefore, in children a lymphadenitis of one of these glands may be the cause of the abscess. When a retropharyngeal abscess follows an otitis media it is thought that the pus burrows along the tensor tympani muscle. A lymphadenitis of the deep cervical nodes may result in extension of the burrowing pus to the retropharyngeal space or it may even be possible for a Ludwig's angina to cause a retropharyngeal abscess. Staphylococci and streptococci are the usual organisms

but any pyogenic organism may be the offender. The possibility of a retropharyngeal abscess being of tuberculous origin should always be borne in mind. Such an abscess follows a tuberculous caries of one of the cervical vertebrae. As the treatment is very different, the diagnosis between a tuberculous and a pyogenic retropharyngeal abscess should always be made before any radical treatment is instituted.

The severity of the local and constitutional symptoms depends upon the virulence of the infection. Malaise, fever, elevations of pulse, pain, especially on swallowing, are all noted. The blood picture corresponds to that of a pyogenic infection in general. Some swelling and tenderness in the upper deep cervical region are usually present. Breathing may become embarrassed because of encroachment of the edema about the larynx. The pain and inability to coordinate the pharyngeal and laryngeal musculature are likely to cause regurgitation of fluid with coughing when attempts to swallow are made.

On examination within the mouth, the posterior pharyngeal wall is found to be a dark dusky red and the pharyngeal wall bulges forward. A viscid mucus often covers and clings to the mucosa. The bulging area is often somewhat unilateral and although ordinarily in the direct line of vision, it may be quite low and require the use of a laryngeal mirror to be visible. Palpation gives more exact information in regard to the tenderness, induration, localized softening or fluctuation.

Those abscesses of slow insidious onset without marked general symptoms need very careful study. They are likely to be of tuberculous origin. If the cervical vertebrae are involved, the neck usually shows rigidity from muscle spasm. In such cases a roentgenogram is imperative. A tuberculin test may aid in the diagnosis. Ordinarily the diagnosis if suspected is then proved without great difficulty.

An abscess of pyogenic origin should be opened through the pharyngeal wall provided it has not begun to point in the neck. Under the latter condition drainage externally through the neck may be the better procedure. These abscesses may contain considerable pus so that there is some danger of strangulation by aspiration of the pus. Usually a general anesthesia of gas, ethyl chloride or ether is necessary. A mouth gag should be inserted to gain control of the jaws. The Rose position for the head will largely prevent aspiration of pus. An aspirating tube will aid in sucking up the discharge of pus and blood. The incision in the pharyngeal wall should be free and low enough to prevent pocketing. The opening should be large enough to admit the finger. The cavity is then explored generally to see that all pockets drain freely. Within a period of a few hours after opening the abscess, the swelling and edema largely subside. One should not do a tracheotomy unless forced to by edema of the larynx. But when such a complication arises one should not procrastinate until too late. When there is evidence of some respiratory distress constant attendance with all necessary equipment for a tracheotomy is absolutely imperative.

A tuberculous abscess is but an incident in tuberculosis of the cervical vertebrae. The abscess should never be opened through the pharynx. External drainage through the neck is to be deplored as tuberculosis of the bone secondarily infected does not do well. But aspiration of an old abscess may be indicated in certain instances.

Bibliography

Bibliography Quoted in Text

Almkvist: Pathology of the Mouth, Moorehead, F. B., and Dewey, K. W.: W. B. Saunders Co., Phila., 1925.

Blair, V. P., and Ivy, R. H.: Essentials of Oral Surgery, C. V. Mosby Co., St. Louis, 1926.

Bonome: Deutsche med. Wchnschr., p. 703, 1894.

Boyd, William: Surgical Pathology, Phila., W. B. Saunders Co., 1925.

Davis, D. J., and Pilot, I. S.: Studies of Bacillus Fusiformis and Vincent's Spirochetes, Habitat and Distribution of these Organisms in Relation to Putrid and Gangrenous Processes, J.A.M.A., **79:** 944, 1922.

Epstein: Quoted by Lexer.

Gande, B.: Die Spirochäten der menschlichen Mundhöhle, Diss., Berlin, 1919.

Lienhardt: Quoted by Sutton.

Loblowitz: Quoted in Nelson's Loose Leaf Surgery, edited by Wise and Parkhurst.

Norris, J. C.: The Pathology of Agranulocytosis, South. Med. Jour., **28:** 504–509, 1935.

Madison, F. W., and Squires, T. L.: The Etiology of Primary Granulocytopenia, J.A.M.A., **102:** 755–759, 1934.

Osler, William: Principles and Practice of Medicine, New York, D. Appleton-Century Co., 1935.

Plaut, H. C.: Studien zur bacteriellen Diagnose der Diphtherie und den Anginen, Deutsche med. Wchnschr., **20:** 920, 1894.

Prejean: Oral Aspects of Leprosy, J.A.D.A., **17:** 1030, 1930.

Roberts, S., and Kracke, R.: Further Studies on Granulopenia with Report of Twelve Cases, Ann. Int. Med., **8:** 129–147, 1934.

Scholl, A. J., Jr.: Anthrax: Comparison of Surgical and Nonsurgical Methods of Treatment, J.A.M.A., **74:** 1441, 1920.

Stookey, P. F.: Vincent's Angina, Jour. Iowa Med. Soc., **19:** 49, Feb., 1929.

Strauss: Quoted by Zilz, J.: Deutsche zahnärztl. Zeitung, 2, No. 1, 1912.

Sutton, R. L.: Diseases of the Skin, St. Louis, C. V. Mosby Co., 1921.

Tunnicliff, Ruth: The Identity of the Fusiform Bacillus and Spirilla, Jour. Infec. Dis., **3:** 148, 1906.

Vincent, M. H.: Recherches bacteriologiques sur l'angine à Bacillus fusiformis, Ann. l'inst. Pasteur, **13:** 609, 1899.

Lancet, London, **1:** 1260, 1905.

Ann. l'inst. Pasteur, Paris, **10:** 488, 1896.

Wagner and Huebner: Quoted by Faber, H. K., and Clark, E. B.: Amer. Jour. Dis. Child., **34:** 408, 1927.

Wise, Fred, and Parkhurst, A. J.: Nelson's Loose Leaf Living Medicine, **5:** 53–67.

Wormer and Bercher: Quoted by Wise and Parkhurst.

Supplementary References

Bloodgood, J. C.: Oral Lesions Due to Vincent's Angina, What Every Physician and Dentist Should Know About Its Recognition and Treatment, J.A.M.A., **88:** 1142, 1927.

Fox, C. C.: Pemphigus of the Mouth and Pharynx, Laryngoscope, **36:** 676, 1926.

New, G. B., and O'Leary, P. A.: Pemphigus from the Laryngologist's Standpoint, Arch. Otolaryngol., **1:** 617, 1925.

New, G. B., and Childrey, J. H.: Primary Blastomycosis of the Tongue, Arch. Ophth., **12:** 184, 1930.

Noguchi, H.: Culture Studies in Mouth Spirochaetae, Jour. Exper. Med., **15:** 81, 1912.

Sampsell, T. L.: Vincent's Infection, U. S. Naval Med. Bull., **22:** 450, 1925.

Schomalter, A. M.: Vincent's Angina, Virg. Med. Month., **56:** 192, 1929.

Sutton, R. L., and O'Donnell, A.: Foot and Mouth Disease in Man, J.A.M.A., **66:** 947, 1916.

Urban: The Question of Noma, Wien. klin. Wchnschr., **1:** 453, 1930.

CHAPTER XVI

CHRONIC INFLAMMATIONS AND DISEASES OF THE BUCCAL AND PHARYNGEAL CAVITIES

Some familiarity with the chronic inflammations and diseases is necessary to the oral surgeon for purposes of diagnosis even if they are not strictly of a surgical nature.

"Smoker's Patch."—Not rarely one sees a form of chronic superficial glossitis, especially among pipe smokers but also more rarely among cigar smokers, which was called by Butlin "smoker's patch." On the middle dorsal tongue where the end of the stem of the pipe or where the smoke strikes, the first changes are noted. The color of the mucosa becomes red or livid. The size and shape of the area are often about that of a navy bean. Here the surface of the tongue loses its papillae and appears a little depressed in the midst of the surrounding furred papillae. Crusts may tend to form on the involved area, which appear dirty yellow or dirty brown in color. The crusts peel periodically and leave reddish spots exposed. Another type of smoker's patch also occurs and appears as a bluish or pearly patch, smooth, oval and well defined.

These patches in certain individuals spread over most of the tongue and even to the oral mucosa. Eventually the affection assumes the characteristics of true leukoplakia. No subjective symptoms ordinarily accompany the lesion. The treatment is discontinuance of the source of the irritation.

"Leukoplakia" (**Leucoma—Hutchinson**) (**Leukoplakia—Schwimmer**) (**Ichthyosis—Julke**).—Two clinical forms of leukoplakia are encountered. Most probably the etiologic factors are the same and the pathologic picture varies only in the variation of cornification of the epithelium. Many gradations are seen between the two forms so that the clinical distinction is not clear-cut in all instances—even in the same individual. Butlin questions whether the two varieties are stages of the same disease.

Etiology.—Etiologically, smoking and the use of tobacco in other ways are thought to be the most important etiologic factors, but examples are seen where tobacco has never been used. In some of these latter cases, syphilis, alcohol, irritating foods, carious teeth, tooth plates, and gout have been thought to contribute to the affection. However, one sees instances in which the history is absolutely negative for all of these suggested irritative factors. Although syphilis might be placed as second to tobacco as a cause of the condition it is by no means of any great diagnostic significance. Certainly leukoplakia in a nontobacco user does not necessarily mean syphilis was ever present. A congenitally delicate skin may be a factor.

Leukoplakia is not really a common disease and in women it is very rare. Before the age of thirty years it is practically never seen. In the past tobacco has been used more frequently by man. It will be interesting to watch the results of changing customs in our women.

Clinical Picture.—In type one, the affected area becomes nearly smooth and the papillae disappear. The color becomes bluish white and the

mucosa appears so thin that the red color of the tissues beneath shows through the thinned epithelial covering. Often the edge fades into the surrounding mucosa but in some examples the definition is more clear cut and may appear more opaque and terminate distinctly with a dirty whitish dentated margin. Periodically raw areas are found within the affected area with a surrounding inflammatory area. When palpated, the involved area is fairly soft and pliable. Subjectively very little annoyance is the rule. On extension of the lesion, the whole of the oral mucosa including the cheeks, lips, palate, and even the sides of the tongue may show involvement.

In type two, an opaque whitish, or bluish, or dirty yellowish area is encountered (Fig. 95, *A*). The whole of the patch but especially the center, is likely to be slightly elevated and the outline is quite well defined and

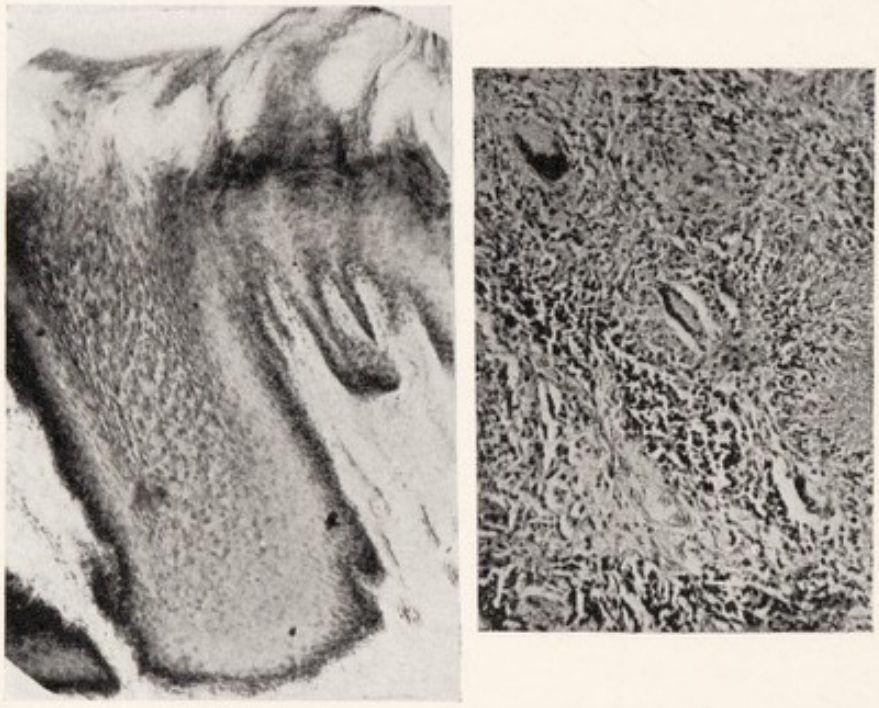

A *B*

Fig. 95.—*A,* Leukoplakia of tongue. Section shows excessive thickness of the epithelial layers. *B,* Tuberculosis of tongue. Giant cells, with multiple nuclei at the periphery, small round cells and early caseation. (Blair, Padgett, and Brown.)

may be dentated. Furrows and cracks cross the patch and the whole of it is stiffer, drier and firmer than the surrounding mucosa. Excoriated areas are common within the thickened area and these may be tender and sore. Crusts which alternately form and are shed often accompany this type of leukoplakia. Thirstiness, a sense of dryness, soreness or stiffness are the subjective symptoms complained of. (See Relation to Epithelioma, Chapter XXXII.)

Treatment.—Favorable reports have been presented after the use of radium but in our own experience radium has done little good and often has made the area more sensitive. The best treatment in the generalized type I believe is a moderate sparking of the whole area with the high frequency current. When the area is only localized one may destroy the epithelium more thoroughly without fear of cicatricial contracture. Local anesthesia

usually is sufficient. If one is careful with this type of therapy, the lesion can be destroyed without causing enough scarring to interfere with function. We usually advise the discontinuance of all irritating factors and periodically observe the lesion, unless it has been totally destroyed, the remainder of the patient's life because of the likelihood of epitheliomatous degeneration.

The Influence of Electric Potential in the Oral Mucosa.—Lain has recently attempted to measure the electrolytic current in mouths with metallic dentures. Seventy-one per cent showed electrolytic phenomena. He lists the clinical symptomatology that may be caused as metallic taste, salivation, mucous patches, erosions, leukoplakia, nerve shock, burning tongue, indigestion, and nervous irritability. Positive cases are relieved by removing the denture and restoration with dentures that are of uniform electropotentiality.

Tuberculosis of the Mucous Membrane of the Mouth.—Rarely tuberculosis of the mucous membrane of the buccal cavity proper is encountered. Three clinical types are known to occur. Lupus vulgaris may extend to the mucosa of the mouth. As a rule, active ulceration is not present. Miliary tuberculosis is a second type of tuberculosis of the oral tissue. It is encountered very rarely. This type of infection is blood borne. The cheek, the palate, the pharynx, and the lips may be studded with tubercles. The third and the usual type may involve any part of the mouth and rather often begins at several different points which may be distinctly separated from one another. After a nodular stage, definite ulceration of a type characteristic of tuberculous ulceration occurs. This type of tuberculous ulcer is practically always secondary to tuberculosis of the lungs. Although a few authentic cases are listed in the literature (Clark and Sahilperowitch) primary oral tuberculosis practically is never seen. A more complete discussion of the pathology and clinical features of this latter type follows under the heading of tuberculosis of the tongue.

Tuberculosis of the Tongue.—Tuberculosis of the tongue is rare. In 1804 Portal described the first case and in the American literature Toland reported the first case in 1859. The existence of primary tuberculosis of the tongue has been questioned but Clark and Sahilperowitch present two cases in which postmortem examination revealed no evidence of tuberculosis elsewhere. Ordinarily the infection is thought to follow a break in the continuity of the tongue mucosa which allows the tubercle bacilli to enter. A few cases may be blood borne—in miliary tuberculosis. Lymph-borne infection is also a possibility. About 3 men to 1 female are affected by the disease. It has been suggested that the male tongue is more prone to slight injury than the female tongue—a questionable explanation. Children are seldom affected. The type secondary to lupus vulgaris is more likely to occur in females but it is extremely rare to see the tongue involved by this approach.

Pathology.—Although there are some slight variations from tuberculosis elsewhere when it is encountered in the tongue, they are not important (Fig. 95, *B*). The usual tubercle formation with characteristic epithelial cells, giant cells of tuberculosis, plasma cells, small round cells, and fibroblasts are all seen. It has been suggested that giant cells are not so common in tongue tuberculosis as in the infection elsewhere.

Clinical Picture.—In the tongue, clinically, three groups of tuberculous lesions may be described: (1) A nodular type without ulceration. It may be superficial or deep and caseation may have occurred. (2) A papillomatous or warty variety, which has a little more induration than ordinarily seen in a tuberculous lesion of the tongue. It is the rarest form. (3) The ulcerative form, which may be superficial or fairly deep. This variety is the most common type.

Nodules are an earlier form of the infection and are seen especially in miliary tuberculosis. Caseation without ulceration may be present for a time but finally characteristic ulceration occurs. The more superficial the nodules, the earlier the caseation and ulceration. At first the ulcer may be small. The base is characteristically uneven, pale, and covered with a yellowish mucus. The edges are well defined, possibly sinuous and a little elevated, everted and undermined. The induration is slight. The shape is not characteristic but often a somewhat ovoid outline is found. Small yellowish tubercles in the edges are quite pathognomonic. Tuberculous fissures have margins a little more indurated than the superficial ulcers. Such fissures are usually located at the tip or sides of the tongue. When spread apart, it will be observed that the fissures go down to the vascular tissue beneath. The tuberculous papilloma is an exaggeration of the tuberculous fissure and the corrugated epithelium is crossed by short fissures. The corrugations are infiltrated with small tubercles. The tip and lateral surfaces of the tongue are the commonest points of involvement but the dorsum may also be infected or even more rarely the under surface. Before ulceration develops there is likely to be little or no pain or stiffness of the tongue but after ulceration has progressed for a time, the pain may be quite excruciating, the mobility of the tongue is decreased and the whole is accompanied by considerable salivation.

In the diagnosis the characteristics of a carcinomatous ulcer and a luetic ulcer should be considered. A biopsy should be taken when there is a question.

Treatment and Prognosis.—Primary tuberculosis of the tongue or tuberculosis of the tongue in persons in good condition, if fairly well localized, may well be excised or destroyed with a cautery. Persons in poor condition from tuberculosis elsewhere are probably best treated by hygienic care generally and if possible the application of heliotherapy. Small doses of radium have been of some value recently and may be the treatment of choice in most cases. All in all, the prognosis of tuberculosis of the oral mucosa as a whole is bad. The pain and discomfort aggravate the fundamental disease elsewhere.

SYPHILIS OF THE MOUTH AND TONGUE

Undoubtedly, syphilitic lesions of the mouth taken all in all are frequent but the majority heal rather completely when medical treatment is given. Although the oral manifestations of syphilis are seen commonly by the syphilologist, the oral surgeon does not see them as commonly as the inexperienced might suspect.

Chancre.—The primary sore, of course, rarely is seen in the mouth but now and then one is encountered. Points of easy contact such as the lips,

tongue, palate and tonsil are the usual sites. The lips, however, are the most frequent site. Chancres are practically always single. Young adults naturally show the greatest frequency.

Three clinical types of chancre may be described: (1) The smooth form which presents an excoriated surface, oval, or circular, sharply defined, nearly on a level with the surrounding surface, a smooth reddish base covered with grayish mucopus and a definite well-marked induration of the base and edges. (2) The ulcerated type which shows more involvement of the deeper structures, a greater concavity of the base, sloping edges and possibly more induration than the first form. In the folds of the tongue, a fissured ulcer may be found, a subvariety of this form. (3) The diffuse type with more widespread induration. Most chancres in the oral region present a characteristic induration of the base and edge—cardboard-like hardness—which has caused the name "hard chancre" to be applied to the primary sore of syphilis. With "hard chancre" present the tributary lymph nodes are enlarged, elastic, and rubbery. The ulcerated type and the diffuse type may be somewhat painful and the salivation may be quite marked. Dark-field examination is required to confirm the suspected diagnosis. An experienced observer is required to differentiate Spirochaeta pallida from S. microdentium.

The Secondary Lesions of Syphilis.—*Mucous patches*—a secondary manifestation of syphilis—are common in the mouth and pharynx. The inner surface of the lip, the cheeks, the palate, the tonsil, the pharynx, and the tip and sides of the tongue may show them. The lesions are usually observed in the middle or late secondary stages of the disease but rarely they are seen in the tertiary stage. Occasionally in congenital syphilis they are present. The lesions are multiple. As to incidence the male sex is slightly more favored. In areas not rubbed by the teeth or food one sees typical examples. The patches are smooth, round or oval, grayish white, very slightly elevated, and sharply defined with a slightly wavy border and no circumferential inflammatory areola. On the under surface of the tongue the lesions are whiter and more elevated. In this location, condylomas are also seen. Condylomas have a constricted base and a warty cauliflower-like elevation with an inflammatory circumferential areola. In areas irritated by friction, the tip or borders of the tongue for instance, the patches are often ulcerated and then usually a surrounding inflammatory areola is present. The border becomes more notched and the ulceration may become quite deep.

The Tertiary Syphilitic Lesions of the Mouth and Pharynx.—Gumma and gummatous ulceration are not uncommonly seen on the palate, in the nose, and in the pharynx. In the nose and in the palate the bone is commonly involved with a resultant necrosis. In Chapter XIX the result of luetic infection of the bone is described. In the pharynx syphilitic ulceration results sometimes in a stricture of the region of the juncture of the naso- and oropharynx. In the following three subheads the tertiary lesions of the tongue are given special discussion for two reasons. First, the tongue reacts rather uniquely at times to syphilis. Second, the description of gummatous ulceration of the tongue may be applied as more or less typical for gummatous involvement of the remainder of the oral and pharyngeal soft tissues.

Syphilitic Sclerosing Glossitis—Tertiary Plaques.—This condition is very rare. Fournier in 1887 described the lesion. Butlin later described 2 cases. Fournier explained the condition on the basis that a cellular luetic infiltration of the tongue first occurred which in the course of time subsided with a resultant contraction so that the tongue tissues became atrophic, strangulated, and a sclerosis was produced. Two clinical types are described—a superficial sclerosing form and a deep parenchymatous type.

The superficial sclerosing glossitis shows superficial, smooth, uniform, slightly raised dermal plaques. The plaques are often not well defined, but are irregularly rounded, firm, parchment-like and deep cherry red. The plaques may coalesce in some instances, become continuous and cover the greater part of the tongue. Ulceration of the areas quite often occurs and when the ulcerations heal, milk-white patches of scar remain. The course of the disease is very slow and usually little or no subjective discomfort is complained of.

The deep parenchymatous form is usually limited principally to the deeper structures of the tongue. The dorsal surface of the tongue becomes swollen. Later as atrophy follows, the surface of the tongue becomes lobulated, and resembles a cirrhosis of the liver. The mucous membrane becomes smooth without papillae and assumes a color called by Butlin "a morbid redness of vinous hue." Butlin says this condition is practically pathognomonic of syphilis. In this form also ulceration is prone to develop but as a rule healing is fairly prompt.

Syphilitic Macroglossia.—A rare form of syphilitic macroglossia is also described in which the whole tongue is enlarged and firm.

Gummas of the Tongue.—Gumma commonly is seen as a part of the picture of a tertiary syphilis but extremely rarely one resulting from congenital syphilis is seen. Two clinical types of gumma may be described, a superficial form in the mucosa and submucosa and a deep type in the muscular substance of the tongue. Males are for the most part the victims, but less commonly women are affected. The lesion is not unknown in childhood.

The superficial form appears most commonly on the dorsum of the tongue as multiple, rather small, indolent, poorly defined nodules which slowly approach the surface, become softer and finally rupture through the mucosa, leaving multiple small punched-out ulcers. The tip and border of the tongue are not immune to the lesion. When rupture is eminent the superimposed mucosa becomes redder and smoother from loss of the papillae. The size of the nodules varies from 2 or 3 mm. to 1 or 2 cm. in diameter. As a rule, within a few weeks rupture takes place. On the other hand, more rarely several months may be required. The depth of the ulcer varies according to the size of the nodule.

The deep parenchymatous type is poorly defined because of the depth within the muscular substance of the tongue. The mass when felt presents itself principally on the dorsal aspect of the tongue whether in the midline or nearer the border. In size each mass varies from about 1 cm. in diameter to 2 or even 3. Seldom is only one nodule present. The size increases slowly, and by a process of pressure necrosis of the superimposed tissue indolently nears the surface of the dorsum of the tongue. As rupture be-

comes imminent the mucosa becomes bared of papillae, perfectly smooth, and redder. No fluctuation may be felt. Several of the nodules make the outline somewhat lobulated. Several months or even a year may pass before deep gummas reach the stage of rupture. Ordinarily there is no pain. Although instances have been recorded where the swelling of the tongue was quite diffuse, as a rule, the swelling is quite well localized to the immediate vicinity of the lesion.

As an aid to diagnosis usually the Wassermann reaction will be found to be positive and if one does not wait too long it is safe to try the therapeutic test, but an uncertain type of mass in the tongue which does not get smaller when antiluetic therapy is given should be subjected to biopsy.

Gummatous Ulceration of the Tongue.—Ulcer formation is due to the rupture of either a superficial or a deep gumma. Upon rupture a cavity remains in the tongue of a size according to the diameter of the original necrotic center of the lesion. The rupture occurs first through a comparatively small hole which is only gradually enlarged. Immediately or relatively soon after evacuation of the contents of the gumma the walls of the cavity are lined with ragged sloughing granulations. Later the granulations become cleaner. The typical round ulcer characteristically found elsewhere on the body is not common on the tongue. The walls of the gumma although moderately indurated fall together and a fissure results which is quite angular and irregular. The resulting ulcer becomes very chronic and when it heals a deep furrow with puckering and round edges remains.

The ulcer has to be differentiated from a tuberculous ulcer and from epithelioma. The prevalent situation—on the dorsum of the tongue is not typical enough of either of the ulcers to be of practical diagnostic importance. All three of these ulcers are more common in males. The history and age may aid one if the ulcer occurs early in life. The general signs of syphilis do not aid one much. They may be present and an epithelioma present also. In gumma the ulceration is generally deeper than in tuberculosis or epithelioma. Epithelioma shows the most induration of the three. Undermined edges do not suggest either an epitheliomatous or a gummatous ulcer. The softness, the undermined edges and the small tubercles in the edge, in a person with tuberculosis, are fairly definite for a tuberculous ulcer. But after all the various clinical signs are enumerated and evaluated, one should have definite evidence and definite proof. A biopsy gives it. Antiluetic treatment (mercury, salvarsan, bismuth and iodides as indicated) then can be instituted immediately. If the lesion is of luetic origin, it will heal within a few weeks.

MISCELLANEOUS CHRONIC AFFECTIONS PECULIAR TO THE TONGUE

Glossodynia Exfoliativa.—In 1885 Kaposi described a peculiar tongue affection which he called glossodynia exfoliativa. The disease occurred in the neurotic—usually women. The sole lesions are spots somewhat redder than the rest of the tongue with the superimposed papillae somewhat enlarged. Accompanying the objective findings are complaints of burning pain often, according to the patient, quite unendurable. Eating and speaking aggravate the symptoms. The papilla shows an increased lymphocytic infil-

tration. The disease may continue for years with periodic remissions. The treatment is not satisfactory. In instances of considerable severity, passing a cautery over the surface may give relief. Local anesthesia may be used to do this.

Raw Tongue (Dyspeptic Tongue).—The dyspeptic tongue is characterized by denudation of the epidermis with practically no depth to the ulceration and as a rule is associated with some derangement of the digestive apparatus. The denuded areas appear raw, red and smooth. The filiform papillae are absent. The margins are definite. Any amount of the tongue may be involved but usually rather large areas of the anterior dorsal surface are denuded. In the diagnosis, the dyspeptic tongue must be differentiated from excoriations due to hot food. When the digestive derangement is remedied the tongue returns to normal.

Erythema Migrans Linguae, Geographical Tongue, Wandering Rash.—In 1872 Bridou described the disease. The affection is rare and practically limited to the mouths of children. The etiology is not known. However, debilitated individuals seem more prone to the disease. The affection is characterized by reddish, smooth spreading patches, with slightly elevated yellowish borders which spread over the dorsal surface of the tongue. The central part of the patch appears to be on about the same plane as the tongue. Filiform papillae are absent but the fungiform may be present. The patches spread in irregular rings and bizarre shapes appear—hence the term "geographical tongue" applied by the Germans. A patch reaching the border of the tongue creeps on around the edge to the ventral surface. Often when two rings encounter each other one stops advancing and the other gains at the expense of the first. Slight itching is the only subjective symptom and it is not usually present. As the disease subsides, the areas contract until they disappear and the tongue is left slightly redder and smoother than before. The diet should be regulated. Hartzell found arsenic of value. Various local ointments have been suggested among which are boric acid and balsam of Peru in a paraffin base. Relapses are likely and the malady may be quite persistent.

Smooth Tongue (Moeller's Glossitis).—Moeller in 1851 described a rare type of chronic superficial glossitis. The disease is characterized by superficial, irregular, more or less sharply defined desquamations which are smooth, bright or bluish red, neither raised nor depressed. On microscopic examination the epidermis is found to be thinned and the intermediate layer of cells is missing. The downward prolongation of the epithelium between the papillae is less than normally found. The corium is thickened, somewhat vascular and shows lymphocytic infiltration. Absence of filiform papillae causes the smoothness. Fungiform papillae may still be present and even hyperemic and swollen. On palpation, the tongue is smooth and soft, but movement is annoying and the patient describes the tongue as being stiff. Whenever exacerbation of the inflammation occurs, irritating foods aggravate the lesion and considerable distress is caused. The condition is chronic, and more or less permanent. Once established, the areas show little tendency to advance. Besides the tongue the lip, cheeks, and palate may be sites for the disease. Treatment is ordinarily not satisfactory. Engman and Weiss cured one patient by removing two infected teeth. It is possible that radium may aid in the treatment of the disease.

Ichthyosis.—In 1861 Hulke described a condition of the tongue which he termed ichthyosis. The affection is characterized by hypertrophied, hard, sometimes quite horny papillae. The condition is more warty than leukoplakia. Epitheliomatous degeneration is the danger. The treatment is the same as for leukoplakia.

Black Tongue or Hairy Tongue.—In 1835 Rayer described black tongue. The condition is rare—about 50 cases being described in the literature (Sutton). The filiform papillae hypertrophy at first on the posterior mid-dorsal surface of the tongue. Later the affection may extend and cover most of the tongue. The overgrown papillae resemble black or brown hairs. The color is probably caused by chromogenetic bacteria clinging to the papillae. Cianglinski, Hewelke, and Sandiak cultivated a black mold but their observation was not confirmed. No inflammatory changes are noted in the mucosa. The disease usually disappears spontaneously within a few months. It is not of any great clinical importance so far as is known. A 10 to 15 per cent solution of salicylic acid in alcohol and glycerin may be applied followed by swabbing with H_2O_2 after several minutes.

Superficial Cerebriform Hyperplasia of the Tongue.—In 1922 Brocq described 4 cases which he called superficial cerebriform hyperplasia of the tongue. On stretching the tongue a multitude of depressions are found but, preceding the objective findings for several years, burning and lancinating pains are complained of. When the mucosa is allowed to retract, it folds up like a fan and appears smooth. As the edges of the furrows of the epithelium are whitish, the epithelium shows little change microscopically. The tongue is somewhat thickened and may seem a little indurated. Scrotal tongue has to be differentiated from it. The treatment is unsatisfactory.

Glossitis Rhombica Mediana.—Brocq and Pautrier first described a rare affection which is characterized by a rhomboidal shaped lesion in the middle of the tongue with long axis anteriorly and posteriorly. The filiform papillae are absent and the mucosa is redder than normal in the area. Slight induration is present. No subjective symptoms are complained of. The condition shows little tendency to heal. Treatment is not very satisfactory. Radium has been suggested.

Muscular Macroglossia.—Muscular macroglossia is not inflammatory in origin. The muscles hypertrophy, sometimes unilaterally. Wise and Parkhurst state the patients are usually mentally defective and short lived.

Scrotal Tongue, Lingua Plicata.—Scrotal tongue is a condition in which the tongue is larger than normal, causing the mucosa to become plicated. Therefore, the term "scrotal tongue." Normal papillae cover the elevations but the sides of the depressions may be devoid of them. The tongue shows no induration and is soft and pliable. Varying degrees of enlargement are seen. Usually, the condition is congenital and often favors children. Certain cases, however, apparently are acquired. It persists throughout life. The only danger is the collection of food in the crevices which may irritate the tongue and eventually tend to malignant degeneration.

Atrophic Tongue.—Hutter, Middleton, and Steenbock have described glossitis with atrophy of the lingual papillae and have emphasized that the condition constitutes a manifestation of a number of diseases among which are the following: pernicious anemia, achlorhydric anemia, anemia of pregnancy, pellagra, sprue, Plummer-Vinson syndrome, malnutrition at-

tended by dysentery and anemia, intestinal stricture, pyloroplasty complicated by peritonitis, tapeworm infestation and achlorhydria. In 1900 Hunter noted the relationship of achlorhydria to glossitis. Because sprue and pellegra have been included among diseases accompanied by atrophic tongue, a vitamin deficiency was suggested as an explanation for the symptoms of the entire group. Strauss and Castle have concluded that the extrinsic factor concerned in certain anemic disease "may now be defined as a substance closely related to vitamines B_2, if not vitamine B_2 itself." It is of interest that Gerstenberger had previously observed a favorable response of aphthous and ulcerative stomatitis to water-soluble vitamin B. In two of his cases with an acute glossitis improvement was also shown under such therapy.

Actinomycosis of the Tongue.—In Chapter XIV, actinomycosis of the soft tissues of the face is discussed and mention is made that actinomycosis may involve the tongue.

PHARYNGEAL CAVITY

Strictures of the Pharynx.—Strictures may be seen (1) in the neighborhood of the velum which occlude to a lesser or greater extent the communication between the oropharynx and the nasopharynx, (2) in the faucial isthmus, which lessen the size of the communication between the mouth and the pharynx, and (3) in the hypopharynx which lessen the caliber of the lower end of the hypopharynx.

Simple ulceration might possibly cause a minor degree of cicatricial contracture. The extensive and deep ulceration of tertiary lues is the usual cause of a marked cicatricial contracture of this region. Tuberculosis seldom is a cause. In the hypopharynx region strong chemicals may cause ulceration which is followed by stenotic constriction. Children in earlier days not uncommonly drink lye water and cause this particular type of stricture.

The type and extent of constriction depends upon the location and the amount of the superficial epithelium which is destroyed by the ulcerative process. Any disease or injury which destroys epithelium may cause an adhesion of one soft part to another or a contracture deforming or narrowing the region.

Operative procedures for malignant lesions not uncommonly leave the faucial isthmus moderately constricted. The elasticity and mobility of the mucosa of this region plus the mobility of the muscles underlying the mucosa all tend to lessen cicatricial contracture so that the amount of destruction or contraction of sufficient extent to give symptoms has to be considerable.

When the upper surface of the soft palate and the surface of the pharyngeal wall are destroyed, the nasopharynx tends to be closed off from the oropharynx. In ulceration of the soft palate, normal contour and mobility are interfered with and when the ulceration involves the openings of the eustachian tube, some deafness may result. When the nasopharynx is more or less separated from the oropharynx, mouth breathing becomes necessary and when complete the nose, of course, cannot be blown and nasal secretions collect above the soft palate. This is uncomfortable for the patient and the offensive odor may be embarrassing. Some modification of the voice may also result.

Contractures at the fauces are usually only partially deforming and obstructive on one side. Swallowing may be interfered with or the tongue may be bound to the lateral pharyngeal wall in such a manner that its movements are hampered. Mucous collections within the mouth may be annoying and the speech shows some inpediment.

Contractures in the hypopharynx interfere with swallowing and the amount of interference, of course, depends upon the degree of constriction.

Treatment.—Adhesions due to agglutination of mucous surfaces probably do not form in the pharynx. The muscular movement beneath is too energetic.

Dilators are only temporary. They may stretch the scar for a time but it will tend to contract down again. In some instances dilators have to be used because no other means are available. They are often useful in hypopharyngeal strictures.

In the nasopharynx two methods are available—the application of a stent graft (Thiersch) about a form or the rotation of a mucosal flap from the pillar region upward over the raw edges of the incised opening. It is difficult to get a "stent" graft to take in the nasopharynx. If sufficient tissue for correction can be obtained from the mucosa of the pillar region, it is the simplest method but the mucosa in this region may be so inadequate that a mucosal flap of sufficient length and width to alleviate the defect is unobtainable.

For the correction of a hypopharyngeal stricture, it is possible to turn a neck flap into the stricture such as that used by Trotter after the excision of a postcricoid carcinoma (see Chapter XL).

Pharyngeal or Esophageal Diverticula.—An uncommon diverticulum is seen rarely at the junction of the esophagus and the pharynx; usually the lesion is found in the male sex after the third decade of life. The etiology is not exact but two factors have been blamed for the development of the defect—(1) congenital weakness of the pharyngeal wall, and (2) prolonged increased pressure within the pharynx. The second factor is probably the most important. The fact that no cases have been seen in childhood tends to lessen the importance of the first factor. Probably an incoordinate action of the two movements of the pharyngeal musculature (propulsive and sphincteric action) tends to cause an increased intrapharyngeal pressure and the posterior pharyngeal mucosa is pushed between the oblique and transverse fibers of the cricopharyngeus muscle. Moreover, because of the somewhat forward position of the upper esophageal opening there is a tendency for the food to be directed posteriorly and this tends to enlarge the diverticulum once it starts to form. The sac thus extends downward posteriorly to the esophagus. Obviously, as the sac fills with food, swallowing will be interfered with. After the sac is filled, an ill-defined swelling may appear in the neck, and pressure in the region of the neck fulness may cause the sac to empty. After the sac is emptied the dysphagia tends to disappear. The diagnosis is suggested by the history of dysphagia increasing during a meal, which disappears after regurgitation. The diagnosis is confirmed by giving a bismuth meal and seeing its outline in the fluoroscope or on the roentgenogram.

Treatment.—The procedure of establishing a fistula was proposed by Bell in 1830. Nicoladoni in 1877 practiced the procedure. Later, the idea

of excision was first done by Niehaus in 1884. Goldman in 1909 first practiced the two-stage operation. The generally accepted treatment is surgical excision in two stages (Fig. 96, A, B, C, D, E, F). In the first stage the sac is isolated but not opened until the surrounding tissues are matted together by fibroblastic reaction. After a period of seven days or longer the sac is extirpated and the neck allowed to close by granulation.

The two-stage operation has provided a method by which a hitherto hazardous surgical procedure may be made much more safe, eliminating the danger of a cellulitis of the neck and a mediastinitis. The skin incision is made just above the level of the cricoid cartilage. The sternomastoid

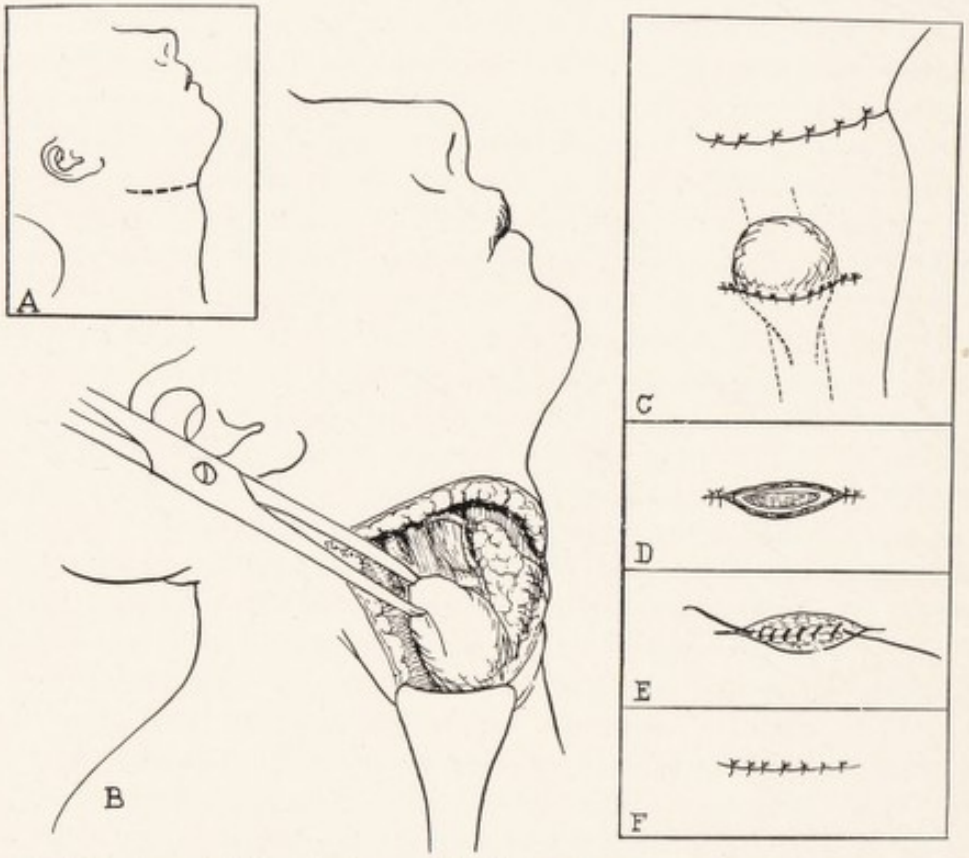

Fig. 96.—Esophageal diverticulum. A, Line of incision for exposure of esophageal diverticulum. B, Diverticulum being isolated. C, The wall of the diverticulum is stitched to the skin with an opening at a point lower than the original incision. D, After ten days or two weeks the diverticulum is cut off the neck and the neck is turned in and sutured. E, Shows suture of the tissue about the neck of the diverticulum which has been closed. F, Skin sutures.

muscle is retracted backward and the lobe of the thyroid gland to the midline. The middle thyroid vein from the internal jugular is ligated. The upper part of the trachea and thyroid cartilage are exposed. When the posterior belly of the omohyoid interferes with exposure it is cut. When the sac is small it is found lying behind the esophagus—usually slightly to the left of the midline. The sac is freed. When the sac is large, with each act of swallowing its large domelike top will bulge out of the mediastinum. The operation is made much easier by the use of novocain anesthesia.

The sac is sewed to the edges of the wound and left unopened. The stitches must not penetrate the sac wall. A cigaret drain is placed toward

the mediastinum. Ten to twelve days later the sac is removed. The patient may have to be fed through a nasal catheter for a few weeks.

Recently Shallow of Philadelphia advocated a one-stage operation for pharyngeal diverticula and reports 76 patients operated upon with only 2 deaths, one of which was due to a renal complication. There was a recurrence of the sac in two patients. Shallow carefully closes the neck of the sac with sutures and brings the surrounding muscles over the suture line. Shallow's operation possibly has certain advantages over the two-stage operation depicted above.

Bibliography

Bibliography Quoted in Text

Bell, Sir Charles: Quoted by Lahey, Frank H.: The Technique of the Two-Stage Operation for Pulsion Oesophageal Diverticulum, Surg., Gynec. and Obst., **43:** 359, Sept., 1926.

Bridou: Thèse de Paris, 1872.

Butlin, H. T., and Spencer, W. G.: Diseases of the Tongue, Phila., P. Blakiston's Son and Co., 3rd ed., 1931.

Engman, M. F., and Weiss, R. S.: Arch. f. Derm. und Syph., **1:** 119, 1920.

Gerstenberger: Quoted by Hutter, Middleton and Steenbock.

Goldman, Edwin: Quoted by Lahey, F. H.: The Technique of the Two Stage Operation for Pulsion Oesophageal Diverticulum, Surg., Gynec. and Obst., **43:** 359, 1926.

Hartzell: Med. News London, London, **51:** 502, 1887.

Hutter, Middleton and Steenbock: Vitamine B Deficiency, Atrophic Tongue, J.A.M.A., Oct. 21, 1933.

Kaposi: Quoted by Blair, Padgett and Brown.

Lain, E. S.: Chemical and Electrolytic Lesions of the Mouth Caused by Artificial Dentures, Arch. Dermat. and Syph., **25:** 21–31, Jan., 1932.

Electrogalvanic Lesions of the Oral Cavity, Produced by Metallic Dentures, J.A.M.A., **100:** 717–720, 1934.

Moeller: Deutsche Klin., **3:** 273, 1851.

Nicoladoni, Karl, and Niehaus: Quoted by Lahey.

Prejean: Oral Asepsis of Leprosy, J.A.D.A., **17:** 1030, 1930.

Rayer: Traité théoretique et pratique des maladies de la peau, Paris, **3:** 573, 1835.

Shallow, T. A.: Combined One Stage Closed Method for Treatment of Pharyngeal Diverticula, Surg., Gynec. and Obst., **62:** 624, 1936.

Strauss and Castle: Quoted by Hutter, Middleton and Steenbock.

Thiersch: Quoted by Blair.

Thoma, K. H.: Clinical Pathology of the Jaws, Chas. C. Thomas, Springfield, Ill., 1934.

Trotter, Wilfred: Operations for Malignant Disease of the Pharynx, Brit. Med. Jour., **16:** 485, Jan., 1929.

Wise, Fred, and Parkhurst, A. J.: Nelson's Loose Leaf Living Medicine, New York, Thomas Nelson and Sons, **5:** 53–67.

The following are quoted by Butlin, H. T., and Spencer, W. G., in Diseases of the Tongue, Phila., P. Blakiston's Son and Co., 3rd ed., 1931: Fournier, Hulke, Hutchinson, Julke, and Schwimmer.

The following are quoted by Finney and Finney in Tuberculosis of the Tongue: Clark, Portal, Sahilperowitch, and Toland.

The following are quoted by Parkhurst and Wise: Brocq, Ciaglinski, Hewelka, Hulke, Hutchinson, Pautrier and Sandiak.

Supplementary References

Gilmer, T. L.: Some Diseases of the Soft Tissues of the Mouth, J.A.D.A., **14:** 767, 1927.

Figi, F. A.: Stenosis of the Nasopharynx, Arch. Otol., **10:** 480, 1929.

Finney and Finney: Tuberculosis of the Tongue, Surg., Gynec. and Obst., 1923.

Friedlaender, Ruth: Electrolytic Manifestations in the Oral Cavity in the Presence of Two or More Metals, abst., Monatschr. f. Zahnheilk., Aug. 15, 1932.

Lahey, F. H.: The Surgical Management of Pharyngo-Oesophageal Diverticulum, Surg., Gynec. and Obst., **51:** 227, 1930.

CHAPTER XVII

INFLAMMATIONS AND DISEASES OF THE ANTRUM

To gain a clear idea of what may be expected in antral disease, the anatomy should be familiar to one (see Chapter II).

Inflammations of the Antrum.—There are two ways for infectious organisms to gain entrance to the antrum—(1) by the way of the nose and (2) by an alveolar inflammation at the apex of the contiguous tooth root.

Tooth Antritis.—All gradations of infection may be encountered, but the typical form of antral infection developing from a tooth is a subacute or chronic type. Probably about 15 to 25 per cent of the subacute and chronic types of maxillary sinusitis are caused by inflammations at the apex of the adjacent teeth (Fig. 97, A, B). More extreme authors have placed the incidence as high as 50 per cent.

Nontooth Antritis.—No one, of course, can estimate the number of times the antral mucosa shows signs of inflammation because coincident with inflammation of the nasal mucosa there is a more or less similar reaction of the antral mucosa. Thus, in the "common cold" the antral mucosa necessarily shows some involvement. When the inflammation is severe enough to cause sufficient swelling of the mucosa of the antral aperture, lack of proper drainage aggravates the inflammation (Fig. 98, *A*, *B*). An acute antritis may be caused by entrance of infectious material from the nose or by extension by way of the lymphatics from the originally inflamed nasal mucosa. And as just mentioned, an adjacent infection of a tooth or tooth socket, or a compound fracture which opens the avenue for infectious material to gain access to the interior of the antrum, all may cause an acute infection of the antrum. Tuberculosis and syphilis have rarely involved the antral wall in a manner similar to the way such diseases affect the palate.

Pathology.—In the earlier stages of an acute inflammation, the antrum is likely to contain only serum and seropus. Later, and especially so if the drainage is insufficient, the fluid thickens to frank pus. A continued inflammation tends to injure, or even destroy the mucosal lining. The least that can happen is infiltration of the mucosa with chronic inflammatory cells and thickening with fibroblastic overproduction. All of this may be somewhat temporary if adequate therapy is instituted in time but if not the injury tends to be permanent. When the infection is severe enough to cause denudation or necrosis, the epithelium may be destroyed in certain areas, and a granulation tissue lining is the result which if healing ever occurs must necessarily be a cicatricial epithelium. Cellular hyperplasia of the mucosa may produce polypi or obstruction of the mucous glands may cause mucous cysts. In inflammation caused by an infected tooth, small sequestra of bone may form and until the sequestrum is removed, or exfoliates, the disease continues.

Clinical Features.—In acute maxillary sinusitis, the patient notes first a sensation of fulness and discomfort in the nose and face region. This discomfort increases progressively to one of considerable pain varying ac-

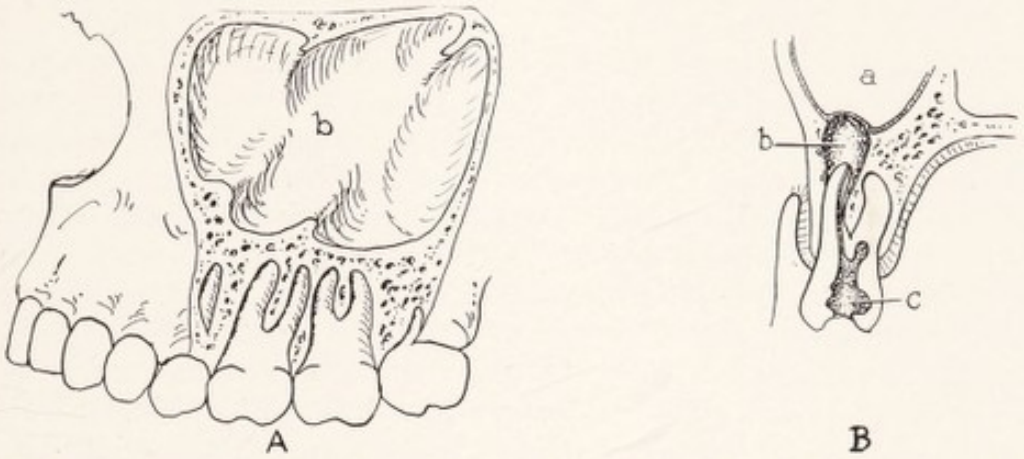

Fig. 97.—A, Relationship of the molars to the antrum. B, Carious teeth below the antrum with an apical abscess. *a,* Antrum; *b,* apical abscess below antral mucosa; *c,* hole extending into the pulp cavity.

cording to the acuteness of the process and the amount of drainage present. Fever, general malaise, and an increased white blood count are present.

In chronic sinusitis, the degree of discomfort and pain depend upon the amount of impairment of drainage which is present.

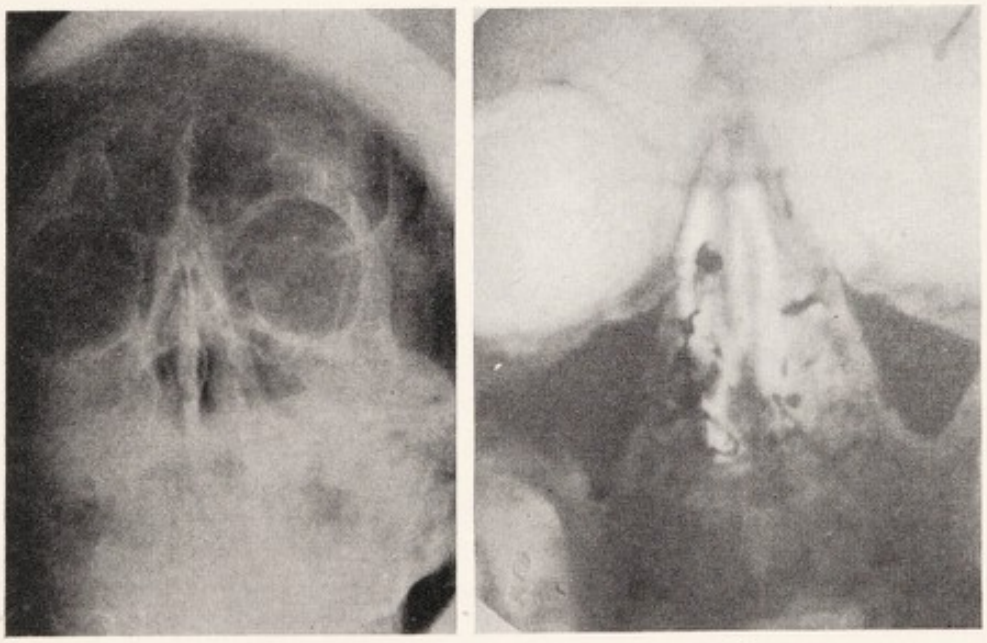

Fig. 98.—*A,* At time of blockage of right antrum. The antrum is cloudy, nearly opaque. *B,* Lipiodol injection for outlining the antrum. (Gilliland.)

A subacute sinusitis, where the drainage is only partially blocked, is often accompanied by a dull headache and a feeling of pressure between the eyes. The type of headache is not specific. It is similar to the headache of a frontal or ethmoidal sinusitis or even a sphenoidal sinusitis. A frontal

sinusitis is more often accompanied by a frontal headache but either a maxillary or a sphenoidal sinusitis may produce a frontal headache. An occipital headache is thought to more often accompany a sphenoidal sinusitis. Orbital pain is thought to be somewhat characteristic of an ethmoidal sinusitis.

Sensitive, tender upper premolar or molar teeth are suggestive of an acute maxillary sinusitis. Tender teeth do not indicate that the condition is due to infection of an adjacent tooth but the teeth should be examined carefully to see if they might have infected apices when the reason for the sinusitis is not clear. In a severe maxillary sinusitis, the tissue anterior to the antrum is often tender and it may be edematous and red. Within the nose one finds evidence of inflammation on the diseased side. Because of mucosal swelling the nostril tends to be blocked on the side of the antral infection. A unilateral discharge is likely to be present in the nose.

Diagnosis.—If one applies a 1 per cent solution of cocaine in 1:10,000 adrenalin solution to the nasal mucosa, pus appears in the middle meatus which indicates that the infection is either in the frontal sinus, the anterior ethmoidal or the maxillary sinus.

Transillumination of the various sinuses gives additional information. In a darkened room a small intense light is placed in the mouth and a comparison made of the amount of light transmitted through the maxillary sinuses. Normally the cheek transmits some light and a red crescent of light is seen through the lower lid. The patient is also aware of the light subjectively and can to a certain extent estimate the varying degrees of light intensity. A growth in the antrum or fluid in the antrum lessens the intensity of the transmission of the light. One antrum may be normally thicker than the other. This fact should be taken into consideration in judging the diagnosis.

In the diagnosis of maxillary sinusitis, the roentgenogram often gives important information. The infected antral cavity is likely to be more opaque than the opposite. When there is any bony destruction, its extent and degree can be estimated.

After a careful examination of the preceding data, if the diagnosis is still not clear, the antrum may be punctured through the nasal wall beneath the inferior turbinate bone.

Treatment of Acute Antral Infections.—For a few days or a week during the acute stage, the patient should be put to bed with hot wet packs over the front of the face. Within the nose twice a day should be dropped a solution of ephedrine in oil to shrink the mucosa and unblock the aperture for normal drainage.

Treatment of Acute and Subacute Antral Infections of Dental Origin.—After the acute stage has subsided somewhat, if a tooth is the etiologic factor, it should be removed. Conservative treatment of the tooth should not be attempted. Sufficient drainage cannot be obtained through the root canal and the periapical tissue can never be put in a permanently healthy condition. If it is thought necessary for the purpose of drainage, after extraction of the tooth, the opening can be made into the antrum by drilling through the tooth socket with a surgical burr. The antral cavity should then be irrigated with a mild antiseptic solution or possibly better normal saline solution, once or twice a day until the signs of suppuration have dis-

appeared. To keep particles of food from blocking the entrance of the hole or from getting into the antrum, a small piece of gauze can be inserted into the tooth socket. If one inserts a drainage tube it is likely to keep up the infection by acting as a foreign body in the antrum. A subacute antral infection may drain for a month and a half to two months. After this period has elapsed, if the drainage fails to cease, the infection may be regarded as a chronic one and permanent drainage through the nose will be indicated in most instances. But before this is done, it should be ascertained whether or not the other upper paranasal sinuses are infected. If they are, the downpour of pus from them may keep up the antral infection if the normal opening into the nose is patent. In case these sinuses are infected, appropriate treatment should be instituted to clear up the possible factor before radical surgery is performed to give permanent drainage into the nose. If a sequestrum is thought to be present, it should be removed if possible in such a manner that no hole will be left through the alveolar ridge. When the infection of the antrum is associated with other intranasal diseases or diseases of the other nasal sinuses, these conditions

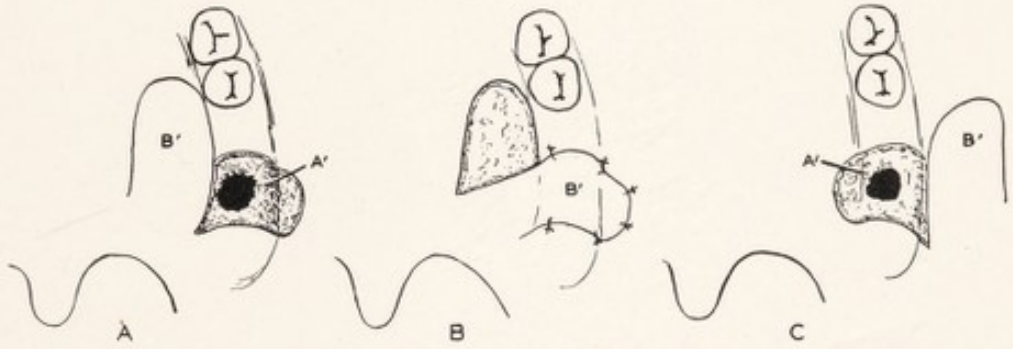

Fig. 99.—Closing a fistula between the antrum and the mouth. Sometimes after extracting a tooth or entering the antrum through the alveolar ridge a fistula remains. A, Outlined flap from the palate. B, Flap turned across the fistula after excising the mucosa about the fistula. C, Shows how one might obtain a flap from the buccal mucous membrane in a similar manner.

as well as the antral infection must be adequately treated or healing is not to be expected.

Occurrence of a Sinus into the Antrum After a Molar is Extracted.—Occasionally after a molar is extracted a hole is broken into the antrum through the alveolus which is large enough to cause a permanent fistula. To close such a fistula a flap of mucosa from either the palatal mucoperiosteum or the mucosa of the alveolar cheek sulcus may be used to crosslap the fistulous opening after a fairly wide area is denuded of mucosa about the fistulous opening (Fig. 99, A, B, C). The two principles of the operation necessary to obtain are a wide overlap of raw tissue with the flap and to make the base of the flaps of sufficient width to get a good blood supply. The flap is stitched carefully into its new position.

Treatment of Chronic Antral Infections.—It has been found that chronic suppurative disease of the antrum is only given permanent relief when the hypertrophied and diseased tissue is removed and permanent drainage given.

As yet the profession is somewhat divided as to the relative merits of conservative and radical methods. But as better trained surgeons are de-

veloped, the antrum is approached with more courage and success. There can be no question, however, of the viewpoint which stresses the respect for tissue. When one approaches these radical procedures, it is presupposed that a good knowledge of the embryology, the anatomy, the bacteriology, the pathology, and the physiology of the mucous membrane of the nose and sinuses is a part of the surgeon's equipment.

Attempts to establish a permanent draining sinus into the buccal cavity have largely been discarded as unsound. The drainage tube tends to re-infect the sinus and after the drainage tube has been removed, the sinus tends to close. The nasal route for drainage probably more clearly approaches the correct physiologic and anatomic conditions. The operations which provide permanent drainage fall into two classes: (1) those which produce permanent intranasal drainage, and (2) those which furnish free access to the cavity so that diseased tissue may be removed. In most

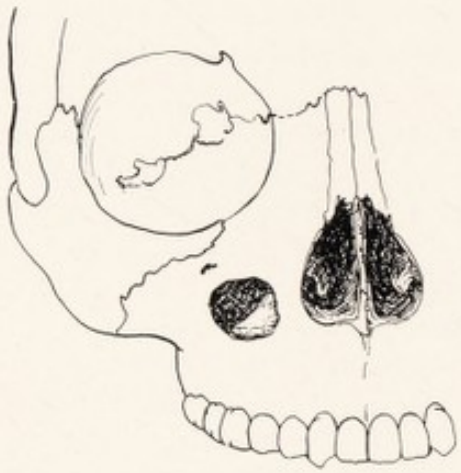

Fig. 100.—Showing point of opening the canine fossa from a point beneath the lip for exploration of the antrum. This is also the point where one enters the antrum when he wishes to pry a fragment of the antral wall forward.

instances permanent relief follows one of the operations which establishes permanent drainage of the antrum into the nose. The group of operations may be collectively styled of the Mikulicz's type. However, Schaeffer was the first to describe the method and the principles. Sluder has described a most effective operation. This operation gives a fairly large opening and at the same time preserves the inferior turbinate. Access for curetting the sinus, however, is not given but curetting should seldom be done. Polypi, dead bone, and heavy coarse granulations may be removed but actual tearing of the mucous membrane from the bone can only be the source of more trouble. When the mucosa is only denuded, eventually cicatricial epithelial tissue will recover it. When the mucous membrane is entirely destroyed a flap of mucosa transplanted from the nose aids relining of the cavity. Operations of the stent-graft type are theoretically of value but it is difficult to get a stent graft to take on a dirty granulation tissue base. In event that a flap is not available, the stent graft may be tried and will sometimes "take." When free drainage is given, the foreign body will be thrown off. Polypi will tend to cease to grow as they are growths whose continuation depends upon inflammatory conditions.

Kuster Operation.—The Kuster operation is the older radical operation which consists of entering the antrum through a large opening made in the canine fossa (Fig. 100). The operation allows one to explore if malignancy is suspected, to remove granulations, to remove polypi, to remove dead bone and to pack or treat the cavity for a time. Finally, the opening is allowed to close. Later, if necessary, the operation may be supplemented by an intranasal opening for permanent drainage.

A description of the Kuster operation is as follows: an incision is made down to and up over the bone in the canine fossa of the upper fornix. The periosteum and the soft tissues are raised upward. With a chisel the anterior wall is opened. With a rongeur the hole in the bone is enlarged. The antral cavity is inspected and, if need be, palpated. The diseased tissue may be removed, a biopsy taken, or radium inserted in a case of early malignancy. The cavity is loosely packed or possibly drained with a tube



Fig. 101.—The Denker operation. A, Amount of removal of bone from the front view. B, Shows the permanent opening between the antrum and the nasal fossa through the inferior meatus. The upper dotted line indicates the height to which the lateral wall is removed, but from this view most of the wall is hidden by the turbinate bone.

and subsequently irrigated, according to the indications. Finally, the sinus is allowed to close.

Caldwell-Luc Operation.—Under the name of the Caldwell-Luc operation, the Mikulicz operation and the Kuster operation have been combined. This operation is a radical procedure; it gives both access to the antrum and permanent drainage into the nose. The diseased tissue may be removed if necessary. The mucous lining of the inferior meatus of the nasal cavity is turned over onto the floor of the antrum. The opening into the canine fossa is immediately sutured. Any further treatment may be carried on through the nasal fossa. The anterior inferior angle of the antrum is somewhat difficult to reach even by this procedure.

Denker Operation.—The difficulty of reaching the anterior inferior angle of the antrum is overcome by the Denker operation. This operation gives free access to the antrum, provides permanent drainage intranasally (Fig. 101, A, B). Its performance does not require the technical skill which is required for an intranasal operation.

The operation may be done under either a local or a general anesthesia. Under local anesthesia, the second division of the fifth nerve is blocked

in the pterygomaxillary fossa. Under general anesthesia the Rose position is a good one. An incision is made in the labiogingival sulcus to the midline. The soft tissues with the periosteum are elevated. The antrum is opened in the canine fossa. The lower part of the bridge of bone between the antral opening and the nasal opening is removed. A strong biting forceps is required to do this. After this is accomplished, the whole antrum is accessible. A mucous flap may be turned from the nose to floor of the antrum if required. All mucous membrane should be removed from the floor before this is done.

The second step is to free the mucoperiosteum from the bony wall of the inferior meatus and from the under surface of the inferior turbinate bone. After incising the mucoperiosteum a flap is formed which will finally be laid in the floor of the antrum. The bony wall of the inferior meatus is then removed, including the mucous covering of the antrum. The flap of nasal mucoperiosteum is then laid on the antral floor. Gauze is packed into the antrum to hold the flap in place. It is removed in about forty-eight hours. The end is left protruding from the nostril. The wound in the buccal cavity is then closed. The inferior turbinate bone need not be sacrificed in this operation. Ballinger has stressed the objection to removing this functional structure. The lower part of the nasal duct may be injured in this operation if care is not taken. It opens below the attachment of the inferior turbinate about 30 to 35 mm. from the posterior border of the nostril, which is about at the juncture of the anterior and middle thirds of the bone.

Pansinusectomy.—Wagner (1934) has recently advocated an operation for chronic pansinusitis which consists of the removal of the contents of all sinuses on one or both sides. The operation combines several operative procedures to which are added some facilitating measures. The contents of the frontal, maxillary, ethmoids and sphenoids are exenterated. An open approach is afforded to the spheno-ethmoid region from above through an external incision and below through the antrum. It offers a patient with a pansinusitis a cure in one operation. He has performed 11 operations and considers it the best procedure for the treatment of nonspecific pansinusitis of the nonrecuperable metaplastic, degenerative, atrophic and mixed types. All sinuses on one or both sides should be involved in the process and beyond aid of nonsurgical (palliative and conservative), constructive surgical (submucous resection of the nasal septum, infraction of the turbinates) and minor surgical procedures (naso-antral, nasofrontal, sphenoidal openings) for the operation to be indicated.

"The operation is divided into two approaches. The external radical fronto-ethmosphenoid approach outlined by Lynch is carried out first, followed by the transantral spheno-ethmoid approach through the canine fossa. The frontal incision is made through the eyebrow and curved from its horizontal plane to the vertical plane down the side of the nose at the bridge to the inner side of and in front of the anterior lacrimal crest . . . (Fig. 102, *A*, *B*). The lower lip of the incision is elevated, separating the periorbita from the bony orbital wall until the anterior ethmoidal vessels are visible, at which point they are ligated and severed from the foramen. The periorbita is retracted as far as the posterior ethmoid vessels. . . . The sinuses are entered by gauging at the "T" suture landmark formed by the

articulation of the nasal process of the superior maxilla and lacrimal bone below with the frontal bone above. . . . After removing the bony floor of the frontal sinus and being particularly sure to avoid injury of the frontal plate, the entire mucosa is extirpated. Attention is then devoted to the ethmoids and sphenoid; the lamina papyracea or orbital plate of the ethmoid is removed, consistent with thorough removal of the ethmoids overlying the orbit. The lower orbital cells are considered in the second approach through the antrum. . . .

"The second approach is carried out through the antrum, which is opened at the gingivolabial junction through the canine fossa as in the usual Caldwell-Luc. After thoroughly eradicating the antrum mucosa, the remaining infra-orbital anterior and posterior ethmoid cells not easily accessible through the external approach above are exenterated through the antrum. . . . Through these two approaches every sinus is accessible. Therefore, there is no reason why any cell or sinus should be overlooked or its



A *B* *C*

Fig. 102.—*A,* The incision is carried through the eyebrow to the inner corner of the orbit and curved downward on the lateral wall of the nose at the bridge. The curved portion is crossed by a superficial incision bisecting the wound incision in the region of the contemplated skin incision. This marker is made before the skin is incised. *B,* Lateral view. All ethmoids are removed, including the lamina papyracea, as far posterior as the optic foramen. Both anterior and posterior ethmoidal foramina have been removed and ethmoidal vessels ligated. *C,* Bilateral pansinusectomy. Note the almost invisible scars. (After Wagner, courtesy of Jour. South. Med. Assoc., April, 1935.)

mucosa unsatisfactorily exenterated, not excepting any abnormalities such as extension of the sphenoid sinus into the pterygoid process, and so forth. The naso-antral wall of the inferior meatus is resected and packed. The end of the pack is brought through the naso-antral opening and placed into the inferior meatus, where it may easily be found on removal. The frontal wound is packed from the nose and sutured. . . .

"After recovery the patients are symptomatically well. There is no deformity and the cosmetic result is excellent . . ." (Fig. 102, *C*).*

Bibliography

Bibliography Quoted in Text

Ballinger, W. L.: Diseases of the Nose, Throat and Ear, Medical and Surgical, Phila., Lea and Febiger, 1930.

Caldwell-Luc: Quoted by Blair, V. P.: Surgery and Diseases of the Face and Mouth, C. V. Mosby Co., St. Louis, 1917.

* Wagner, W. A.: Jour. South. Med. Assoc.

Denker, Kuster and Shaeffer: Quoted by Blair.
Lynch: Quoted by Wagner.
Mikulicz: Langenbeck's Arch. f. klin. Chir., vol. 34.
Sluder, Greenfield: A Modified Mikulicz Operation, Laryngoscope, **19:** 904, Dec., 1909.
Wagner, W. A.: Pansinusectomy, Jour. South. Med. Assoc., April, 1935.

Supplementary References

Harter, J. H.: Chronic Supppuration of the Maxillary Sinus, Including Oral Fistula, Arch. Otolaryngol., **8:** 823, 1928.
Schultz, Louis: Maxillary Sinus Infection, Etiology, Diagnosis and Treatment, Dent. Items Int., **49:** 977, Dec., 1927.
Consideration of the Maxillary Sinus in Relation to the Practice of Dentistry, J.A.D.A., **17:** 453, 1931.
Shambaugh, G. E.: Infection of the Maxillary Antrum, J.A.D.A., **16:** 773, May, 1929.

CHAPTER XVIII

INFLAMMATIONS AND DISEASES INVOLVING THE NECK

PRACTICALLY all of the infections of the floor of the mouth and neck have a primary focus of entry above in the mouth, pharynx or nose. The focus may be a small abrasion or an ulcer in the mucosa, an infected tooth, a tonsillitis or a pharyngitis. Almost any infection may at times be guilty of being the source of a spreading cellulitis or a lymphangitis. As a rule, the infecting agent is transplanted by the way of the lymphatic channels. In rarer instances the infection may spread along cellular planes. Extremely rarely an infection of the metastatic variety develops, being carried by the blood stream. (The anatomy of the cervical lymphatics is outlined in Chapter II.)

Acute Lymphadenitis of the Neck.—Probably the staphylococcus is the invading organism more often than the streptococcus. But certainly the more virulent types of acute lymphangitis and lymphadenitis are of streptococcic origin. Certain other pyogenic organisms such as the pneumococcus may also produce an acute lymphadenitis. In many other diseases, such as diphtheria, typhoid fever, acute syphilis of the mouth, scarlet fever, German measles, and so forth, the regional lymph nodes show acute inflammatory changes. The neck has an abundant lymphatic apparatus. Its work is done efficiently on the whole as most infections are limited and held relatively local. The upper lymph nodes are usually the first to be involved. All grades of reaction to the invading organisms are seen from slight hyperemia and transient enlargement to complete destruction of the glandular structure by necrosis and suppuration. The original focus or source of infection in some instances may hardly be evident while again the lymphadenitis is but a minor additional feature of a severe infection in nonlymphatic structures. The lymph nodes of the neck during one's lifetime are subjected to repeated minor irritations and infections but in the vast majority of instances the disease is overcome without leaving any very marked permanent effect and it is seldom on a percentage basis that the invading organism causes actual suppuration.

Pathology.—Microscopically, at first, a hyperemia plus a proliferation of lymphocytes is seen. Later, polymorphonuclears crowd in and often suppuration follows. In certain rather severe inflammations, fibrin is deposited in the lymph spaces. Because of blood vessel thrombosis, focal necrosis may develop. In typhoid fever the endothelial proliferation is quite marked and in pneumonia and diphtheria fibrin formation tends to be prominent.

Clinical Features.—An acute or subacute lymphadenitis is characterized by constitutional symptoms of a severity varying from only a malaise to a marked reaction with high fever and pulse rate and by local signs varying from a slight swelling and tenderness to marked swelling, excruciating tenderness, the fixation of a periadenitis and the induration and fluctuation of abscess formation. When the lymphadenitis is mild, the

enlarged gland is fairly freely movable and only slightly tender. When the severity increases, a perilymphadenitis begins to develop which limits movability and tends to cause fusion. The enlargement is increased and the tenderness becomes more pronounced.

When the inflammatory process is severe enough to cause necrosis and suppuration, the periadenitis extends and the products of the inflammation involve the surrounding tissues in a cellulitis. The suppurating glands along with the swelling and induration of the surrounding tissues form at the time a large, red, hard, tender, completely fixed mass. Finally, as the induration tends to break down more tissue, tender areas of softening or even fluctuation announce nature's attempt at resolution—the formation of the abscess. Abscess formation within the gland at times probably occurs without immediate rupture of the capsule of the gland, but in the more virulent infections the gland capsule soon ruptures and the contained pus is liberated into the surrounding tissue planes. The liberated pus is usually fairly well localized to the immediate region but in other rarer instances may travel a considerable distance provided drainage is poor and sometimes even if it is good. The localized abscess if not drained tends to rupture spontaneously eventually by a process of pressure necrosis toward the skin surface provided the patient survives a sufficient length of time. The diagnosis is not difficult if one takes into consideration the quick onset, the local evidence of acute inflammation and the general constitutional signs.

Treatment.—Sedatives for the relief of the local and general discomfort are in order. When fever is present, the patient should be put to bed. The local treatment par excellence is continuous large wet hot packs over the area of tenderness and also over a goodly area of the surrounding tissues. The general circulation of the inflamed area is improved. The heat also lessens the pain. This type of treatment is continued until the infection is overcome, *i. e.*, the swelling subsides spontaneously, or until it becomes evident that suppuration with localization is present. When localization has occurred, as evidenced by the maximum point of tenderness, by softening or by fluctuation, the abscess should be drained in an effective manner. Thus, besides the evacuation of the pus and necrotic débris, the tension of the tissues about the abscess is relieved and the circulation improved thereby, so that the tissues not too greatly damaged may return to a normal or near normal state.

Glandular Fever—Pfeiffer's Disease.—This clinical syndrome occurs most commonly in children. The disease seems to be contagious and is often epidemic. Fever and swelling of the cervical lymph nodes occur. The liver and the spleen usually become palpable. In about 40 per cent the mesenteric lymph nodes are also enlarged. The pharyngeal mucosa is reddened. The course of the disease is from four to seven days. No specific organism has been connected with the disease. In sporadic cases the diagnosis from an ordinary acute pyogenic lymphadenitis is difficult. In epidemic the differentiation is not difficult. The treatment is symptomatic.

Infectious Mononucleosis.—This disease is principally characterized by an increased white cell count and a relatively large increase in young mononuclear cells. Although the adenitis is a general one, the enlargement

of the cervical glands may be the first to attract attention. Along with the glandular signs is a general malaise. The disease resembles somewhat the common respiratory infections. The treatment is symptomatic.

Ludwig's Angina.—Ludwig, in 1936, described this condition and called it "gangrenous induration of the neck." "Ludwig's angina" is a clinical term applied to an acute spreading infection—an acute cellulitis—of the tissues of the floor of the mouth. The infection is characterized by a marked edema, infiltration, and induration of the tissues of the floor of the mouth, submental and submaxillary regions and upper portions of the neck. The tissue planes are involved so rapidly that the lymphatic involvement is overshadowed.

Bacterial Invader.—No specific organism is found. Usually the infection is due to a streptococcus but a staphylococcus alone or streptococci and staphylococci or pneumococci or even certain bacilli may all add their share to the process. The infection resembles certain of the anaerobic infections but no mention is made in the literature of the cultivation of such organisms. The bacteria enter the tissues of the floor of the mouth by way of an abrasion, ulceration, a carious tooth, an osteomyelitis of the jaw, and so forth. A suppurating lymph node in the floor of the mouth is likely to be the starting focus. Blair mentions a case which had its origin in an ulcerated tooth which involved the cheek and the floor of the mouth successively, a second case in which the infection started from a sarcomatous ulcer of the lower jaw, and a third case which had its origin from an abscess under the thyrohyoid ligament.

Clinical Features.—In the beginning only a subacute swelling may be present which after a period of days suddenly becomes active, but in the vast majority of instances the infection is active from the beginning and the edema, infiltration and induration of the tissues spread rapidly so that within twenty-four to forty-eight hours the whole of the floor of the mouth, the submaxillary regions and the upper neck regions are involved to a greater or less extent. Often, early, the edema is so intense that the skin becomes pale, does not pit and becomes immovable. Later or even at first the usual redness or purplishness of an inflammation is seen. The indurated area is tender and painful. Within the mouth the mucosa is swollen and bulges upward in a pinkish grayish roll. The tongue is pushed upward and there is a tendency for the mouth to hang open and dribble saliva. Swallowing and speech are embarrassed. When the inflammatory edema continues even dyspnea may occur from a perilaryngeal or a laryngeal edema. A semireclining position is usually the most comfortable one. By bimanual palpation the extent of the induration and tenderness becomes evident. The floor of the mouth often seems fixed within the arch of the mandible. It is not unusual to find the temperature and the pulse rate not so disturbed as one would suspect from the extent of the local evidence of involvement. However, in other instances a temperature of 103° or 104° F. is found with a corresponding elevation of the pulse.

Treatment.—Spontaneous resolution may begin at almost any time but the tendency is toward a continuing extension if adequate relief of tension and drainage are not given to the infiltrated tissue. Even partial gangrene may finally result. While waiting to determine whether or not resolution is possible, large hot wet packs should be placed about the neck and chin

region and mild sedatives given to relieve the distress. But when the treatment is of the procrastinating indifferent type, the mortality may run as high as 40 per cent. Pneumonia is not an infrequent complication. Suffocation has rarely occurred. Prompt rather radical incision will reduce such



Fig. 103.—Ludwig's angina. Incision and the manner in which tissues turn out after incision.

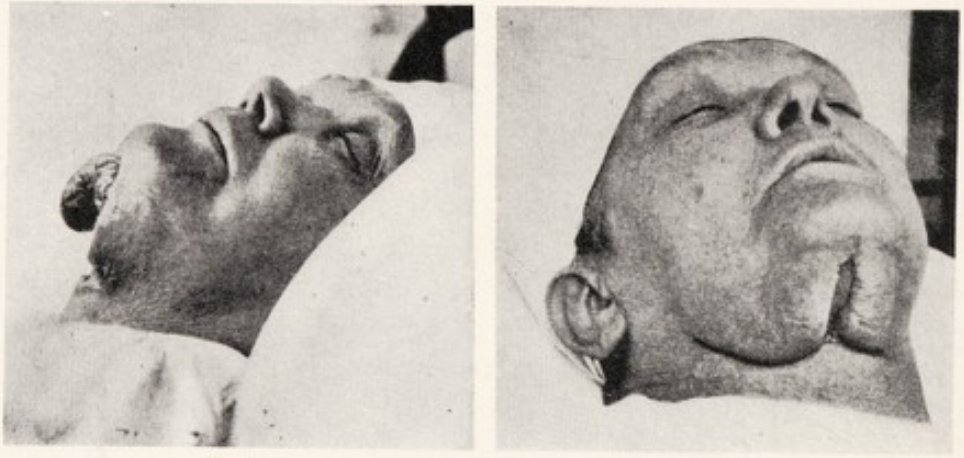

A *B*

Fig. 104.—*A*, Lateral view of patient recently operated for Ludwig's angina, further illustrating how the tissues open up. *B*, Patient shown in the preceding figures, eight days after operation. As soon as the induration subsides, the flaps drop back in their normal positions. (Blair, Surgery and Diseases of the Mouth and Jaws, C. V. Mosby Co., Publishers.)

a high mortality rate quite markedly (Figs. 103 and 104, *A*, *B*). An incision through the skin, subcutaneous tissue, through the mylohyoid muscle in the form of a right angle running from a midsubmental point to a point about ¾ inch above the hyoid bone; at this point the incision

is turned at a 90 degree angle toward a point about 1 inch below the lobe of the ear and extends from 1 to 2 inches according to the amount of induration and to the side of the greatest induration. Often little or no actual pus is encountered. The principal object of the incision is to relieve tension and limit further extension to the neck. Because of the edema, after such an incision the bleeding is slight. The tissues point outward and the incision immediately opens widely. The tongue and tissues of the floor of the mouth dip downward. More space is given within the mouth. The wound is packed wide open. Hot packs are continued. Usually within a few days the swelling has decreased to a remarkable extent. The wound heals by secondary intention and the incision is such that the permanent scar shows but slightly when healing has become complete.

CHRONIC INFLAMMATIONS OF THE FLOOR OF THE MOUTH AND NECK

Chronic Cellulitis or "Woody Phlegmon" or "Holz Phlegmon."—This condition was described by Rebus in 1894. The infection has the same etiologic factors as Ludwig's angina. The organisms are less virulent or the resistance of the patient to bacterial invasion is more marked than in the acute Ludwig's angina. Both staphylococci and streptococci have been isolated. Debilitated patients or those affected with syphilis also are more likely to develop this clinical condition. Locally, the neck and floor of the mouth show a hard infiltration, which may be quite sharply limited in some instances. The induration may be present for months with only slight change. There is little or no pain. There is little tendency to suppuration. The lateral aspect of the neck is more often involved. Some difficulty may be experienced in swallowing because of the inflammatory invasion of the muscles which limits their free movement. The skin assumes a dark red or violet color and is edematous. On section the tissue shows an overproduction of fibroblastic tissue beside the usual cells of a low-grade inflammation. If suppuration develops, incision and drainage is indicated. Usually it does not. Mild exposures to the *x*-ray are sometimes of value.

Actinomycosis—Blastomycosis.—(See Actinomycosis and Blastomycosis in Chapter XIV.)

Chronic Lymphadenitis (Nonspecific).—The various staphylococcic and streptococcic infections cause by far the most common type of chronic lymph node enlargement in the neck. The particular group involved depends upon the location of the primary lesion above. Two rather typical sequences of events precede a chronic enlargement of a lymph node. In the first instance, the hyperplasia and enlargement take place slowly, supposedly due to repeated assaults of either a toxic type or the irritation caused by bacteria of a type not sufficiently virulent to cause actual suppuration of the gland. In the second instance, an acute swelling of the gland has preceded the chronic smaller enlargement and resolution is not complete as yet or else is never complete. The diagnosis is made by ruling out specific lymph node infections and the generalized lymphatic node diseases such as Hodgkin's disease, the lymphatic leukemias and lymphosarcoma. When, after the source of the infection is removed, as it should be, the enlargement fails to disappear or if the glands enlarge

to a greater degree, either tuberculosis, Hodgkin's disease, lymphatic leukemia or lymphosarcoma becomes a probability. Then, excision of a lymph node for diagnosis is in order.

Syphilitic Lymphadenitis.—The spirochetes of syphilis reach their final destination through the perivascular lymphatics. At any stage in the disease the lymph nodes may show evidence of the disease. The cervical nodes are no exception to the rule and especially is this true when primary, secondary, or tertiary lesions are present in the oral cavity. Thus, cervical primary syphilitic lymphadenitis is indicative of a buccal location of the primary sore. The tributary glands are filled with spirochetes and the enlargement is principally due to an endothelial proliferation of the cells lining the lymph sinuses. The enlarged nodes are not tender, are moderately firm, and do not decrease in size for several months.

After the generalized infection of the blood stream occurs—during the secondary stage—the lymphadenitis becomes a general one. All the lymph nodes of the body are likely to show some changes. At this time the lymph node enlargement is not so great but the firmness of the glands is greater. They become somewhat "shotty." When secondary lesions are present in the mouth, the tributary neck nodes assume a picture more nearly corresponding with the enlargement found in the neighboring glands when the primary lesion is still present. During the secondary stage, the spirochetes still remain in the glands. The pathologic picture is similar to that found in the primary stage save that a more chronic picture is presented.

When a gumma appears in the buccal cavity, the tributary lymph nodes are not changed from their previous state unless the gumma ruptures. After this some of the signs of secondary pyogenic irritation may be added to the original picture. The lymph nodes then are enlarged from a more acute irritative process and may be tender.

In the diagnosis of the case, the Wassermann should not be neglected. The treatment is that of the primary disease.

Tuberculous Lymphadenitis.—Probably in over 90 per cent of the cases tubercle bacilli gain access to the lymph glands by route of the lymph channels. In possibly less than 10 per cent access to the glands is gained via the blood stream. Harbitz has pointed out that in a more or less general lymph node infection, it is necessary to look upon the infection as being a blood-borne one. Direct lymphatic extension is by far the most common method of extension to the original lymph node focus and also to nearby lymph nodes. Herring and MacNaughton suggested that tubercle bacilli are acted upon by phagocytic cells as are minute solid particles such as India ink or carmine and are then carried by the phagocytes to the lymph nodes and are then caught up and held. Bacilli carried by way of the lymph channels are most likely to be deposited in the periphery of the gland because the lymph channels enter the gland through the cortex. On the contrary the bacilli carried by the blood are most likely to be deposited in the center of the gland and the principal artery passes centrally and branches centrally.

Children are decidedly more often affected with lymph gland tuberculosis than adults. The disease is principally one of childhood. A factor possibly predisposing to infections but probably a very minor one, is

trauma. Malnutrition along with repeated pyogenic infections of the glands are thought to be the most important factors in the predisposition to tuberculous infection of the glands. "Scrofula," a term used by Laënnec, Virchow, and Czerny with somewhat different meanings, has long been associated with a chronic lymphadenitis and in the minds of the medical profession, the condition is also rather closely associated with a tuberculous lymphadenitis.

In cervical tuberculous lymphadenitis, the tonsils, adenoids, carious teeth, and sometimes the middle ear, are thought to furnish a portal of entrance for the bacilli. The frequency of each site is believed to decrease in the direct order just named. Clinically, the tissues named are seldom involved with a tuberculous process. When the tonsils are examined microscopically usually one does not find evidence of a tuberculous infection. Mitchell found 38 per cent of tonsils, examined when tuberculous



A *B*

Fig. 105.—*A,* Gross appearance in caseous tuberculosis of the cervical lymph gland. (Blair, Padgett and Brown.) *B,* Tuberculosis of upper cervical lymph gland, showing caseation, giant-cell and round-cell infiltration characteristic of the lesion.

cervical lymph nodes were present, to show evidence of tuberculosis and Boyd states that in apparently healthy individuals about 5 per cent of the tonsils examined show some evidence of a tuberculous infection. It is thought that chronic granulation at the apices of carious teeth are a more important portal of entrance than has been suspected in the past.

Both human and bovine tubercle bacilli play a rôle. Apparently, the variation in incidence of the two types depends upon the condition prevalent in the community. In many communities where the herds are rigidly inspected, the incidence of bovine tuberculosis of the lymph nodes is low. On an average Griffith has estimated that over 40 per cent of cervical tuberculous lymphadenitis is due to bovine type of tubercle bacilli. This preventable source of infection is important.

Pathology.—On section the enlarged glands show translucent grayish areas which later, after necrosis and caseation have developed, change to

a more opaque yellowish granular appearance (Fig. 105, *A*). The first change noted, microscopically, is a proliferation of the lymphocytes and the endothelial cells which line the lymph sinuses. Soon centrally in the tubercle necrosis appears and surrounding the necrotic area there is an infiltration and proliferation of lymphocytes, endothelial cells, foreign body giant cells and fibroblasts (Fig. 105, *B*). This is nature's defense against the invading organism. When the defensive mechanism is effective, the tubercle becomes a fibrous tissue nodule. Finally, there may also be some calcification due to a deposit of lime salts in the caseous center.

Chronic Hyperplastic Tuberculous Lymphadenitis.—There is a rare form of tuberculosis of the lymph nodes—called "chronic hyperplastic tuberculous lymphadenitis"—in which the glands are enlarged and firm. The inflammatory signs are slight and no caseation develops. The condition simulates Hodgkin's disease rather closely. The cellular hyperplasia is principally confined to the endothelial cells which form small nodules within the nodes.

In both types of tuberculous lymphadenitis described the tubercle bacilli can be stained and identified in microscopic sections properly prepared.

Clinical Features of Tuberculous Lymphadenitis.—The affection is primarily a disease of childhood and adolescence. Rarely does one see the disease after the age of thirty. The younger the child, the greater the tendency to an acute form. In children of one year or less, the disease is quite typically acute. The disease at times appears to subside for a time and then continues its progress. In rare instances, the affection seems to run an acute course from the beginning or starts to run an acute course after a chronic course has been run for some time. In both cases it seems that the defensive mechanism of the body is overcome. In the vast majority of cases, a slow course without very marked general symptoms seems the typical course. There is no local tenderness or pain and the enlargement of the glands is fairly slow. In this more typical form, the temperature is more than normally sensitive to exertion or local manipulation of the glands. Some anorexia, pallor, loss of weight, and lack of energy is present in most instances. When there is some fever, night-sweats are usually present. In acute cases all the general signs of an acute tuberculous infection develop. The temperature is elevated, the child loses weight, sweats, gets weak, becomes anemic, and locally the glands enlarge. The common blood changes are a mild secondary anemia. In the more marked forms there may be present an increase in both the small and the large mononuclear lymphocytes.

Locally, the typical findings are that a small mass appears in the upper cervical or submaxillary region which enlarges slowly. Within a short time, other nodules appear in more or less proximity to the original enlarged nodes. At the first the nodes remain discrete but as the disease progresses, there is an increasing amount of perilymphadenitis with consequent fusion and matting of the glands. The outline of the fused mass becomes somewhat lobulated. The whole jugular chain of nodes may enlarge on one side of the neck. In rarer instances, the affection is bilateral. When fusion of the cervical nodes is rather complete, the surrounding tissue becomes matted to the nodes and more or less fixed. After the mass or masses attain a size of 4 or 5 cm. or more, caseation with softening is common. In other

instances oven after the mass has attained this size, resolution may supervene. As softening sets in, the so-called "cold abscess" develops. These abscesses always have a tendency to rupture through the skin by a process of pressure necrosis when treatment is delayed. When sinuses form they persist for months or years and may even heal and reappear at a subsequent date. Commonly in untreated cases, successive glands are involved which successively caseate and rupture with the formation of multiple sinuses.

In those glands which enlarge rapidly, there is commonly a definite tenderness and some slight pain with stiffness of the neck and difficulty in swallowing.

Rarely secondary pyogenic infection changes the picture to that of an acute pyogenic absces.

In chronic hyperplastic tuberculous lymphadenitis the clinical picture is very similar to that of Hodgkin's disease. The glands remain fairly discrete, rarely break down, and the inflammatory signs are slight.

Diagnosis.—As a rule, when the chronicity of the picture is considered with little signs of acute inflammation, the diagnosis is suspected. After study of the blood picture to rule out the leukemias, one is warranted in removing an enlarged gland to confirm the diagnosis. In the advanced cases, the diagnosis is almost evident. Often one can by aspiration with a long needle, prove the diagnosis. Aspiration should not be done through an area where the skin is thin but off to one side so that a sinus is prevented.

Treatment.—The original port of entry should be removed. The patient should be placed under good hygienic conditions, given rest and good food and sunshine. Formerly, many cases were treated by surgical excision of the diseased nodes. At present most cases are best treated by mild doses of irradiation. In children and also in adults the great majority of tuberculous lymphadenitis will regress over a period of several months. Large cold abscesses should be repeatedly aspirated while treatment is going on. Usually sinuses will heal under sunshine and irradiation therapy.

There are two types of cases where surgical excision may still be indicated: (1) on an adult where the neck involvement is unilateral, fairly well localized and without signs of tuberculous activity elsewhere, who has an economic responsibility in which the factor of time is important. In such cases it may be a procedure of wisdom to remove the involved nodes surgically and then follow the excision by irradiation therapy. A considerable amount of time is saved by this procedure. (2) In those cases with sinuses which show little signs of healing, excision of the involved sinus tracts and the glands at their base may be necessary to obtain complete and permanent healing.

Prognosis.—As to prognosis, tuberculous lymphadenitis properly treated usually has a favorable outcome. Notwithstanding this tendency, infection does at times spread to more vital organs. A tuberculous gland may rupture into the blood stream and cause a rapidly fatal miliary tuberculosis. Boyd says "a tuberculous gland must be regarded as a sleeping volcano."

Recently Stanton and Richards gave the prognosis on 115 cases of tuberculous cervical adenitis, most of which were treated surgically. The group had been followed by Stanton for many years—an average of twelve years. Four of the 107 traced patients died subsequently of pulmonary

tuberculosis. Of 99 cases, who came without demonstrable active pulmonary tuberculosis, none developed a serious form of pulmonary disease. Twenty per cent still presented evidence of nonpulmonary tuberculous infection in the form of sinuses or demonstrable glandular enlargement in some part of the body. The age of the patients when they came under observation was as follows:

At 5 years or under	15
From 6 to 10 years	23
From 11 to 15 years	16
From 16 to 20 years	16
From 21 to 25 years	15
From 26 to 30 years	9
From 31 to 40 years	6
Over 40 years	5
No age given in histories	10

OTHER CHRONIC PROGRESSIVE LYMPH GLAND ENLARGEMENTS OF THE NECK

Lymph gland enlargements of the chronic progressive type may be largely of a chronic pyogenic origin, or of syphilitic origin but the usual types showing progressive enlargements are tuberculous lymphadenitis, Hodgkin's disease, chronic lymphatic leukemia and aleukemia, chronic lymphoblastic leukemia and aleukemia, lymphosarcoma and metastatic enlargements. Most instances of lymphosarcoma proceed rather too rapidly to be rightfully classed under chronic progressive lymph node enlargements. Lymphadenitis of infective origin has just been described. Lymphosarcoma and metastatic enlargements are described in the chapters on malignant neoplasms of the buccal and oral cavities. In the following brief résumé only diagnostic data with a few words in regard to treatment are presented. A complete presentation of these conditions belongs in the realms of a medical treatise. Bunting's terminology is used in presenting the leukemias.

Hodgkin's Disease.—In youth, second to tuberculous lymphadenitis, Hodgkin's disease is the most common cause of a chronic progressive lymph node enlargement. In about 65 per cent of the cases of Hodgkin's disease the first nodes to be involved are the cervical nodes (Fig. 106). The disease is about twice as common in the male as the female.

Pathology.—On section the involved nodes have a medullary appearance with a moist surface with bands of fibrous tissue interlacing through the gland. Microscopically, a lymphocytic hyperplasia is noted with proliferation of the reticulo-endothelial cells, and fibroblasts and giant cells are formed. The giant cells have a single, bilobular, or a multilobular nucleus in which the nucleolus is very prominent. These large cells (Dorothy Reed cells) are very characteristic. Some eosinophilic leukocytic infiltration is also usually present in a typical case. Soon the normal structure of the node is lost. In the latter stages of the disease, the lymphocytes tend to decrease in number and fibroplastic proliferation becomes quite pronounced. Small areas of necrosis may be present especially when the case is progressing rapidly.

Clinical Features.—Along with some lassitude and malaise, a painless lymph node enlargement is the first sign noted. Sometimes it seems that the gland or glands increase in size faster than during more stationary

intervals in the same individual. Usually the glandular enlargement is unilateral at first. A single gland or a group of glands only enlarge when the disease remains fairly well localized from one to several months. In other cases the progress of the disease is more rapid. Sooner or later the opposite side of the neck becomes involved. Pressure symptoms and limitation of movement of the neck develop as the disease progresses. In the final stages of the disease a secondary anemia develops and periodic febrile attacks of several days' duration are common.

The glands in Hodgkin's disease are oval, elastic, and fairly discrete. Early the glands are rather soft but later they are firmer. Only in a late stage of the disease do they mat together as in tuberculosis of the lymph nodes. In about 75 per cent of the cases the spleen and also the liver will be found eventually to be enlarged.

Diagnosis.—Bunting maintains that the blood picture aids in differential diagnosis. Most other men find little of diagnostic significance in



Fig. 106.—Patient with Hodgkin's disease. (Major.)

the blood smear. Bunting finds that in Hodgkin's disease, there is a picture of lymphocytic destruction quite in contrast with the picture of lymphocytic stimulation in early tuberculosis. In early Hodgkin's, he finds a constant decline in lymphocytes until the cells represent only about 15 per cent of the count. A gradual eosinophilia develops. There is a slight increase of basophilic cells and the large mononuclear cells increase to 10 per cent of the total white count. Later in the disease, Bunting believes the blood smear pathognomonic in the absence of suppuration in the body. The picture then shows an increase in the total leukocytes to about 20,000 or more, a decrease in the lymphocyte percentage to 5 per cent or less, the polymorphonuclear and the transitional cells exceed the lymphocytes in number and remain at approximately the high percentage of the early cases and the eosinophils and basophils are now absent. In both early and late Hodgkin's disease there is a secondary anemia present.

Tuberculous lymphadenitis of the hyperplastic form especially may simulate Hodgkin's disease very closely. The early stage of tuberculous

lymphadenitis before fusion or caseation has occurred is the only time that the differentiation between tuberculous glands and Hodgkin's may become difficult. In chronic hyperplastic tuberculosis the blood picture is similar to that of Hodgkin's disease. When the diagnosis is in doubt, one should resort to excision of a gland for microscopic study. Thus, confirmatory evidence of the clinical diagnosis is established.

Treatment.—Yates for some time did a dissection of the lymph nodes when the disease seemed fairly well localized and considered that he prolonged life by the procedure. Most men consider irradiation therapy as offering the best palliative treatment.

Prognosis.—Hodgkin's disease finally leads to a fatal outcome. The course varies from a few months in acute cases to as long as seven or eight years or even longer in the more chronic cases.

Chronic Lymphocytic Leukemia and Aleukemia.—Most of the individuals suffering from chronic lymphocytic leukemia are seen in the third decade of life. Cabot's cases presented 80 per cent under fifty years of age. The sex ratio is ordinarily found to be about three females to one male. The glandular enlargement may simulate Hodgkin's disease but the blood picture is totally different. The white count ranges in the ordinary case from 80,000 to 150,000 cells of which from 90 to 99 per cent are small lymphocytes. Very few or no myeloblasts are seen as in the acute leukemias.

Pathology.—On section an involved gland presents a medullary appearance. Hemorrhagic dots or more rarely small opaque necrotic areas are seen. Under the microscope the tissue is seen to be made up of small lymphocytes among which are interspersed large endothelial cells. Mononuclear giant cells may also be present. Eosinophils, however, are absent. The capsule of the lymph glands may be infiltrated and the infiltration may even extend out into the periglandular tissue. The normal architecture of the gland is usually largely destroyed.

The aleukemic form of the disease may be diagnosed as Hodgkin's disease if one's experience is not mature. The distinction must be made on the more general lymph node enlargement in aleukemia, on the greater age of the patient, and the difference in the blood picture. In aleukemia the total lymphocyte count is nearly normal but there is an increased percentage of lymphocytes (50 per cent or more), the polymorphonuclear neutrophils are relatively decreased and the large mononuclear percentage is nearly normal. On the other hand, in Hodgkin's disease a relative lymphemia is characteristic (Bunting) instead of the relative increase of lymphocytes in a chronic aleukemia.

Treatment.—The treatment is unsatisfactory. Hygienic measures are first insisted upon. Benzol often produces temporary improvement although it is not free from dangerous toxic properties. Arsenic increased to the point of tolerance has been used. Stengel and Pancoast state the best results have been attained by irradiation methods. Radiotherapy has been combined with benzol therapy. (See a medical treatise for a complete discussion of the best medical therapy.)

Prognosis.—Within from two to three years or even before most individuals affected with lymphatic leukemia die.

Lymphoblastic Aleukemia and Leukemia.—In this type of the disease the blood smear shows small lymphocytes to be distinctly in the minority.

The characteristic cell is large and has a reticular nucleus with little protoplasm.

The sex incidence and the age incidence varies in no distinct way from the small cell type of chronic leukemia.

Pathology.—On section the glands have a medullary appearance with slight nodular appearing areas. Under the microscope a proliferation of the lymphoblastic cells of the germinal centers is noted. The germinal centers are seen to be enlarged. In advanced examples the architectural structure of the gland is completely destroyed as the infiltration with this type of cell becomes more complete. The cell is large, has a reticular nucleus and little protoplasm. The small lymphocytes are distinctly decreased.

Clinically, the disease simulates Hodgkin's disease and lymphocytic leukemia. The blood smear shows a decrease of lymphocytes with an increase of large mononuclear cells. In early Hodgkin's disease this may also occur. In lymphocytic aleukemia there is a high percentage of lymphocytes in most cases. The final diagnosis from other types of chronic lymph node enlargements had best always be confirmed by microscopic examination of an involved gland.

Treatment.—The treatment is the same as that outlined under chronic lymphocytic leukemia and aleukemia.

Prognosis.—The disease terminates fatally in from several months to three or four years.

Bibliography

Bibliography Quoted in Text

Blair, V. P., Padgett, E. C., and Brown, J. B.: Graham's Surgical Diagnosis, Diseases of the Face, Mouth and Jaws, W. B. Saunders Co., Phila., 1930.

Boyd, William: Surgical Pathology, W. B. Saunders Co., Phila., pp. 611–629, 1925.

Bunting: Nelson's Loose Leaf Medicine, **3:** 347–368, New York, Thomas Nelson and Sons.

Cabot: Quoted by Blair, V. P., Padgett, E. C., and Brown, J. B.: Graham's Surgical Diagnosis, Phila., W. B. Saunders Co., p. 356, 1930.

Herring, P. T., and MacNaughton, F. G.: The Lymphatics and Lymph Glands: Their Rôle in Absorption of Foreign Particles and Tubercle Bacilli, Lancet, **1:** 1081, 1922.

Hodgkin, Thomas: Some Morbid Appearances of the Absorbent Glands and the Spleen, Med. Chir. Tr., **17:** 68, London, 1832.

Ludwig, D.: Med. Correspondenz-Blatt, p. 21, Stuttgart, Feb., 1836.

Mitchell, A. P.: Primary Tuberculosis of the Faucial Tonsils in Children, Jour. Path. and Bacteriol., **21:** 248, 1917.

Rebus: Quoted by DaCosta.

Reed, Dorothy M.: On The Pathological Changes in Hodgkin's Disease, with Special Reference to Its Relationship to Tuberculosis, Johns Hopkins Hosp. Reports, 133, 1902.

Stanton, E. MacD., and Gomer, Richard: Tuberculous Cervical Adenitis: A Study of Post Operative End Results, J.A.M.A., **102:** 1214–1216, April 14, 1934.

Stanton, E. M., and Richards, G.: Tuberculous Cervical Adenitis, J.A.M.A., **102:** 1215, 1934.

Stengel and Pancoast: Quoted by Stevens, A. A.: A Practice of Medicine, Phila., W. B. Saunders Co., 1926.

Yates, J. L., and Paine, F.: Quoted in Graham's Surgical Diagnosis, Phila., W. B. Saunders Co., **3:** 415–450, 1922.

The following are quoted by Boyd, William: Czerny, Griffith, Harbitz, Laënnec and Virchow.

CHAPTER XIX

INFLAMMATIONS AND DISEASES OF THE JAW BONES

THE acute inflammatory diseases of the peridental tissues and jaw bones are not always clearly defined. Both acute and chronic dento-alveolar abscess represent in reality a form of osteomyelitis of the jaw of a small degree.

Besides the acute inflammations of the jaws there are many chronic inflammations which are sometimes difficult to interpret. The incidence and the course of the infections of the bones of the jaw differ somewhat from that found in other bones principally because of the tooth buds and the teeth.

OSTEOMYELITIS OF THE JAW BONES

Definition.—Periostitis per se is a misnomer. Osteitis is in the same sense also a misnomer. In a way even the term "osteomyelitis" itself is a misnomer. The term should apply to an inflammation of the marrow cavity. It is quite impossible for an acute inflammation to be confined to the marrow of the cancellous bone or to any one point of the bone in view of the easy communication by means of the haversian canals and in long bones of the para-epiphyseal line. However, by common usage the convenient term "osteomyelitis" has come to mean an inflammation of all the structures going to make up a bone. The soft parts of a bone really take part in the inflammation—the marrow and its extension into the bony spaces, the blood vessels, the fibroblastic tissues and the periosteum. The mineral part of the bone only modifies the inflammatory process.

Thus, four main groups of infection may be recognized in the jaw bones as elsewhere—infection from without, infection from contiguous tissue, infection carried by the blood stream, infection of the jaw bones as a complication or a part of certain severe acute illnesses or primary blood diseases.

Infections from Without.—In an open wound without fracture the periosteum may be involved primarily although some inflammatory exudate travels along the blood vessels into the cortex. However, the bone may show little gross evidence of the infection and because the blood supply is not sufficiently damaged, there may never be any sequestration but on the contrary an actual thickening of the bone.

Infection from without may result from an open wound, following a compound fracture or after an operation—such as tooth extraction. The location and the reason for the infection are obvious.

In fractures of the jaw bones, as a rule, little of the bone is actually denuded of its soft tissue and because of the abundant blood supply of the soft tissues covering the bones in this region, there is seldom devitalization of a noticeable amount of bone save possibly in the lower jaw if dependent drainage is not given.

Fortunately, the course of infection about an extracted tooth, as a rule, is relatively mild provided no active infection is present about the tooth at the time of extraction. In the latter case, however, when the tooth is

pulled at the time that the focus is at its apex, a very severe and virulent osteomyelitis of the jaw bone is likely to be initiated.

Infections from Contiguous Tissue.—In many cases of osteomyelitis of the jaw the condition is the result of extension of the infection along vascular channels from an area adjacent to the bone.

Infections of a tooth pulp chamber are usually followed by a secondary involvement of the jaw bone by extension of the inflammatory process through the apex of the tooth into the cancellous tissue of the bone.

Zarble has reported a group of infections of the dental sacs in nurslings. An erysipelas was the etiologic factor in some of the cases. In such types an abrasion of the gum mucosa allows an alveolar ridge infection to develop which extends to the bone.

The ulcerative condition of the cheek known as "noma" may extend and devitalize the jaw bones and if the child lives, eventually cause an exfoliation of a part of the bone.

Poisons or mineral irritants such as mercury, phosphorus, arsenic, bismuth, cocaine, the rare "pearl worker's" disease, may cause in some instances an inflammation of the peridental membrane and periosteum of the jaw bones. Eventually the devitalized structures become secondarily infected and a rather extensive necrosis of the jaw bones is caused which fortunately is confined to the alveolar ridges.

Pearl worker's disease is an inflammation of the metaphysis or the periosteum. Although the disease is more apt to affect other bones than the jaws occasional examples have been observed of a low-grade osteomyelitis with this etiology. Fortunately, if the patient gives up his work, a spontaneous cure is the usual outcome.

Certain constitutional diseases caused by deficient vitamins such as scurvy may predispose to secondary infection of the jaw bones with a resultant osteomyelitis.

Necrosis of the jaw has been observed in workers who use radium paint. Small amounts of radioactive substances get into the mouth and about the teeth of the workers who wet with their tongues the small brushes which they use.

Infection Through the Blood Stream.—In this type of infection such conditions as tonsillitis, a boil or some exanthematous disease serve as a source for the blood stream infection. Because of some trauma, decreased resistance or some as yet unexplained factor, bacteria may localize in the jaw bones and cause a virulent osteomyelitis. It is a metastatic lesion developing during the course of a bacteremia resulting from an acute bacterial lesion on the surface of the body.

Infection of the Jaw Bones as a Complication of a Severe Acute Illness or a Primary Blood Disease.—It has been shown by Longcope that during an acute illness, there may occur at times areas of necrosis in the bone marrow. Such areas might conceivably predispose to infection. In this manner severe illnesses such as typhoid fever, smallpox, measles, diphtheria, scarlet fever, may lower the vital resistance of the tissues of the bone, and encourage infection to be initiated. Rather often an agranulocytic angina is accompanied by a necrosis of one or both of the jaw bones (see Agranulocytic Angina) and it is not uncommon for a leukemia to be accompanied by jaw bone necrosis.

Incidence.—Mentioned in order of decreasing frequency the bones most commonly involved in osteomyelitis are the femur, tibia, humerus, radius, ulna, vertebrae, os calcis and mandible (Wilensky). In 450 cases of acute and chronic osteomyelitis at Mt. Sinai Hospital (1924–1930) the jaws were involved in 39 instances.

A pulpitis is the most common forerunner and cause of osteomyelitis of the jaw bones and especially is this true if all the apical involvements are included under the term "osteomyelitis." Under alveolar abscess a more complete account is given of this particular type of osteomyelitis.

The incidence of associated dental trauma as Blair, Brown and Moore have emphasized is quite high. In 39 cases of osteomyelitis seen by them 31 were associated with extraction during an acute stage of a peridental infection. Of the 31, 2 followed devitalization of a pulp with arsenic and 1 followed the application of phenol to the pulp chamber. Formerly peridental infection due to an overdose of mercury in the days of calomel dosing and early days of syphilitic treatment was quite common but nowadays the condition has become rare. The older mineral irritants such as phosphorus, lead, bismuth, and arsenic are rarely seen. "Pearl worker's disease" is extremely rare. Although infection through the blood stream represents the most common type of acute osteomyelitis in other bones of the body, the jaw bones are but rarely affected in this manner. In 942 cases of acute osteomyelitis Heinomen had only 2 cases of blood-borne osteomyelitis of the jaw bones (0.29 per cent). Osteomyelitis of the jaw bones as a complication of acute illnesses and the acute exanthemata is occasionally seen. Out of 39 cases Blair, Brown and Moore had 4 that would be considered as falling under this category. A few cases of involvement of the jaw accompanying such primary blood diseases as agranulocytic leukemia and an ordinary leukemia are seen. There are not many statistics available on the relative percentage. Zarble collected 12 cases of acute infection of the dental sacs in nurslings from the literature in which erysipelas was the primary cause.

Age.—Osteomyelitis occurs at all ages but osteomyelitis of definite bacterial origin is most common in childhood or adolescence.

Ratio of Lower to Upper Jaw Osteomyelitis.—In a series of 69 cases reported by Blair, Brown and Moore, the mandible was involved eight times more frequently than the maxilla. Wilensky in 39 cases of osteomyelitis of the jaws found 8 in the upper jaw and 29 in the lower jaw. In young children the upper jaw is involved more frequently than the lower jaw. Later the difference no longer exists.

Organisms.—Streptococci, as a rule, cause the fulminating extension of infection following the extraction of a tooth during the acute stage of a peridental inflammation. This particular type of osteomyelitis differs from the usual osteomyelitis in other bones of the body in that the blood stream may be infected secondarily to the bone infection. In osteomyelitis of the other bones of the body directly the opposite course of events is characteristic. The blood-borne type of osteomyelitis is thought to be caused most commonly by the Staphylococcus aureus. Gilmer and Moody, Rosenow and Haden present evidence to show that the common organism in the acute alveolar abscesses is the Streptococcus haemolyticus and that less commonly the staphylococcus or a mixed infection also occurs. The types of osteo-

myelitis caused by secondary invasions are infected by the mixed group of organisms commonly found in the mouth.

Pathology of Osteomyelitis of the Jaw Bones.—Bone is a fibroblastic tissue which differs principally from ordinary connective tissue only in that lime salts are deposited in the ground substance. It reacts to an inflammation as does connective tissue.

These changed conditions call forth a cell about whose origin and function there is a difference of opinion. This cell was called by Kölliker an "osteoclast" and in the past according to the osteoclastic theory this cell has been considered a specific type of cell having to do with the advent of the inflammatory cells and the coincident increased vascularization. With the appearance of the so-called "osteoclasts," bone resorption and rarefaction begins and progresses.

When the infection is an avirulent one or the resistance to infection is relatively high, the inflammation may subside, rarefaction ceases, and the fibrous tissue is recalcified forming new bone. When the infection is more virulent the blood exudation and the proliferation of the usual cells of the acute inflammation (fibroblastic polymorphonuclear cells, etc.) cause a blockage and cutting off of the blood supply to the given area of bone. In the center of the cellular infiltration an abscess forms containing pus which because of the resistant character of bone is under an unusual amount of tension. Within twenty-four to forty-eight hours a definite microscopic change is present in acute cases. Already there is some destruction of the bony trabeculae. With the development of pus the tendency is toward new inflammatory involvement of tissue in the path of least resistance. When the area is involved quite suddenly and is of more than microscopic extent, gross death of bone results from lack of blood supply. Eventually, pressure of the contained exudates of the inflammation within the bone and the rarefying tendency of the process cause the products of inflammation to break through to a surface outlet which anatomically is the least resistant. As the inflammation approaches the surface, the periosteum is involved and if it is not penetrated immediately to give free exit to the contained inflammatory products it may be and usually is raised up. A greater or lesser extent of the bone is thus stripped. In this manner a considerable amount of the blood supply of the cortex is cut off and when, as is often the case, the internal source of the blood supply is inadequate or not available because of vessel thrombosis, death of the bone occurs which corresponds to the amount depleted of its blood supply. A bone which derives a considerable part of its central blood supply from a single nutrient artery such as the inferior dental artery suffers a large amount of bone devascularization if the artery becomes thrombosed from infection. Thus, when the infection is more or less overwhelming the blood supply may be cut off by thrombosis from within and from without by a stripping of the periosteum after pus burrows through the cortex. When such factors are at work all or practically all of a given bone may be devitalized.

Following the acute stage of an acute osteomyelitis, there is a reactive stage when the tension of the exudate is relieved either by rupture of the periosteum or surgical interference by incision. As time goes on in a long bone such as the mandible, new bone is laid down under the raised periosteum. But in the membranous bones such as the maxilla there seems to

be little or no tendency for the generation of new bone beneath an elevated periosteum. This new bone laid down beneath an elevated periosteum is called the "involucrum." As long as sequestra are present openings through the periosteum persist as cloacae through which drain pus and bone débris. While the process of new bone formation is going on by the action of the phagocytes of a developing layer of acute granulation tissue, a line of demarcation is being formed between the live bone and the dead bone. The dead bone is gradually separated from the living bone and becomes sequestrum. If the sequestrum is small it may possibly be dissolved in time but if it is of some size it will have to be removed before healing will occur.

The mechanism of the cementum of an adult tooth acting as a foreign body when denuded of peridental membrane has been mentioned previously. The products of inflammation about a tooth cause the fibrillar connections between the peridental membrane and the cementum of a tooth to be disrupted. The cementum once denuded remains denuded. The peridental membrane does not reattach itself. As the cementum has no blood supply, it does not exfoliate. The uncovered cementum acts as a nonviable irritating substance. Thus, the infective process continues until the affected tooth is removed. The action of the uncovered cementum of a tooth is thus similar to a sequestrum.

Before the teeth are erupted the dental sacs may be involved in the inflammatory process and the unerupted tooth surrounded by pus. In such case, the tooth is isolated, becomes nonviable and acts as a mechanical irritant until it either falls out or is removed. Thus, the action of an infected unerupted tooth is also similar to that of a sequestrum.

It is possible for the new bone to wall off a pus pocket forming a cyst-like cavity, the so-called "Brodie's abscess." Bacteria in these cavities have been known to lie inactive for years. There is, however, a distinct tendency for these cavities to sterilize themselves.

Symptoms.—Severe, aching, throbbing, deep-seated pain is the outstanding characteristic of an acute osteomyelitis of bone wherever it may be found because of the tension under which bone retains inflammatory exudates. The pain is worse in the prone position and consequently the symptom of "night pain" has been stressed. Although often the application of heat increases the subject's comfort, the opposite may be the case. Percussion of the bone is painful and even when the characteristic redness, bluishness, and the swelling of the overlying mucosa and soft tissues are as yet absent, tenderness is present. Within a few hours after the onset of the pain the tissues surrounding the infected areas begin to swell. The swelling increases and extends to neighboring sites. As the bony cortex is perforated, the periosteum becomes elevated. Whether or not the fusiform swelling can be separately distinguished by palpation depends upon the thickness of the overlying tissues. Whether or not fluctuation can be distinguished depends upon the tension within the abscess cavity on the one hand and the thickness, the amount of infiltration and edema of the overlying tissues on the other. All the while the pain is excruciating. But as soon as the periosteum perforates, whether the pus is evacuated into the surrounding soft tissues or into the mouth, the pain lessens. But although the pain tends to lessen, the swelling and induration increase very markedly when the pus is evacuated into surrounding soft tissues and further drainage is not immediately possible.

When the induration extends into the attachment of the muscles of mastication, pain and muscle spasm prevent the mouth from opening. In the lower jaw infections, instances are occasionally seen where the pus has extended down into the deeper tissues of the submaxillary region, the upper deep cervical region or on the inside into the tissues of the anterior pillar region, so that swallowing is impeded. In osteomyelitis of the upper jaw the pus sometimes invades the tissues of the hard and the anterior soft palate. When the soft tissues of the hard palate are undermined there may be no particular redness on account of the compact structures of the soft tissues of the hard palate. In fact, the tissues may actually be pale but a sense of fluctuation usually appears within a few days.

The constitutional symptoms depend upon the virulence of the infection. A fever of 104° or 105° F. with a corresponding rise in the pulse



Fig. 107.—Woman who had an acute osteomyelitis a few weeks previously due to extraction of a third molar. She became acutely ill. At the time of this photograph about six weeks later she had just had a sequestrum removed from the angle of the ramus. Note the characteristic swelling after an osteomyelitis in this region.

rate is not uncommon. The leukocyte count of the blood in different subjects varies from 15,000 to 35,000 cells per cubic centimeter.

In the blood-borne type of infection a septicemia may precede or a septicemia may follow the local focus of infection. In the latter case death is common but in the former case if the organism disappears from the blood stream within a few days, recovery is probable.

In the lesser types of alveolar infection often if the abscess is not incised it ruptures spontaneously into the mouth, most often on the buccal side where the bone is thinner, and single or multiple sinuses persist.

As soon as thorough drainage has spontaneously taken place or has been given by incision, the pain and the constitutional symptoms tend to subside and remain at a low level as long as the drainage is good. The sinus or sinuses persist as long as the dead bone or dead tooth structure remains in the depths of the involved bone. The persistence of such a discharging sinus is always evidence of the presence of a foreign body. The opening of such a sinus appears as a pouting projection of granulation tissue.

As almost immediately some of the periosteum has been loosened from the bone which is nonviable one may pass a hard instrument and get the characteristic feel of uncovered bone.

After a variable time (from six weeks to three months) the dead bone becomes loosened from the live bone and is sequestrated (Fig. 107). After a time—six weeks to two months—in an extensive necrosis of bone, the superimposed gum tends to separate. Infection then reveals bare uncovered bone in the depths of the gutter. In the upper jaw the tendency is for the areas of bony necrosis to be of smaller size on account of the abundant blood supply.

Not all cases of osteomyelitis of the jaw bones result in sequestration. Some show only areas of slow absorption of bone. From this low degree of bony death, one sees progressively greater and greater degrees of sequestration until instances of sequestration of the whole mandible are encountered. So far no absolute reason is given in some instances for total

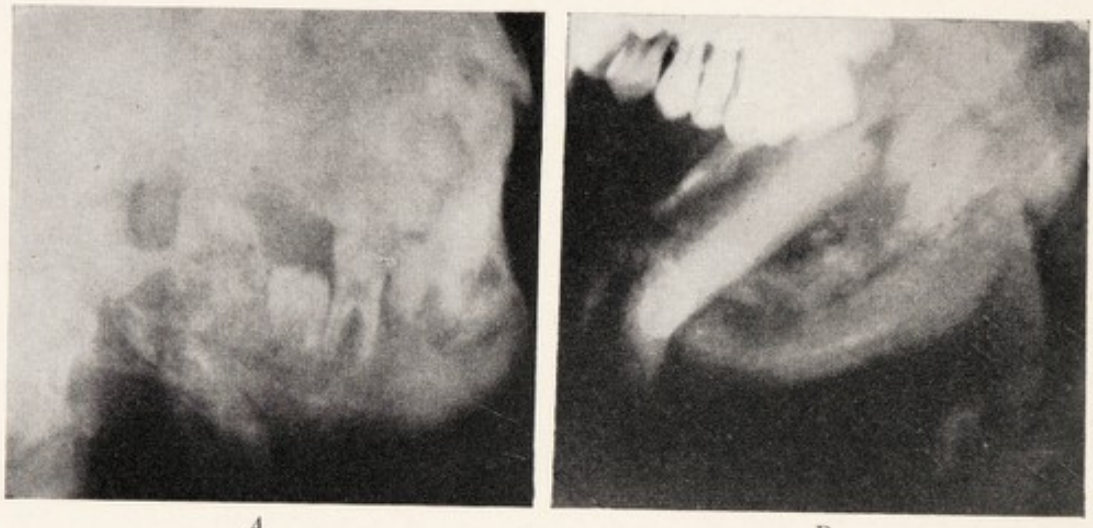

A *B*

Fig. 108.—*A*, Boy about thirteen years old with an osteomyelitis which shows a sequestrum of the ramus and in the body of the mandible. *B*, Osteomyelitis in a boy about fourteen years of age. He had already had his teeth removed when the roentgenogram was taken. He has a sequestration of the alveolar ridge and a part of the mandible.

necrosis. Blocking of the inferior dental artery is of course to be considered but the surrounding periosteum should give considerable blood supply to the cortex. Most probably both external and internal damage to the blood supply has occurred in those cases showing almost total loss of the jaw bone. One may assume that a rather diffuse virulent inflammation would probably cause thrombosis of the internal blood vessels after which the pus erodes through the cortex, lifts the periosteum from the bone, and in this manner the total blood supply is cut off.

Dead bone is not distinctly visible in the roentgenogram for several weeks as sufficient changes in the density of the bone may not have had time to occur. However, some mottling of the bone may be present in the first weeks. Usually the process of absorption between the dead bone and live bone has progressed sufficiently after six or seven weeks for one to have some idea of the probable amount of sequestration. The roentgenogram gives a hazy, moth-eaten, uneven outline at the edges of the live bone (Fig.

108, *A*, *B*). The sequestrum shows as an irregularly shaped piece of bone lying in a cavity surrounded by either uninvolved bone or new bone. Later the sequestrum loses some of its density. On those cases in which the necrosis is the full thickness of the jaw, the roentgenogram aids in judging the extent to which the involucrum or new bone has formed. Repeated roentgenograms over a period of six to nine months may be necessary before there seems to be sufficient new bone to not jeopardize the contour of the lower face when the sequestrum is removed.

Bonner in discussing osteomyelitis of the upper jaw in infants states that the first symptom is often swelling about the eyelids and that pus often pouts to the side of the inner canthus of the eye and practically never in the nose. Osteomyelitis of the jaw in children shows no essential difference from osteomyelitis near puberty or in later life. Osteomyelitis in nurslings owes its peculiar course to the anatomic location of the infection. It is characterized by the relatively large extent of the subsequent necrosis.

In the bone necrosis seen accompanying a primary blood disease, the soft tissues about the necrotic bone usually show only slight reaction. The constitutional symptoms tend to be more severe than the local condition would lead one to suspect. The general appearance of an adult—rather pale and yellow—and the fact that no other obvious etiology seems to be present suggests to one immediately that a blood smear is advisable.

When a child is seen with evidence of a bone infection in the region of the epiphyseal cartilage of the condyle rather often it is difficult to be certain whether or not one is dealing with a purulent arthritis of the temporomandibular joint or a true blood-borne osteomyelitis of the type more commonly seen in the other long bones. The region in front of the ear is swollen and tender and in either case great difficulty is experienced in moving the lower jaw. The roentgenogram is often of no great value. The joint cannot be aspirated well. The only possible distinguishing signs are that the swelling and the point of maximum tenderness should be lower in an osteomyelitis and less difficulty should be experienced in moving the lower jaw. Early careful exploration may solve the dilemma and also give drainage at a time when it is most needed to prevent further damage. Later in the disease the condyle and a varying amount of the upper part of the ramus may necrose in either condition so that just what the primary condition was may remain a guess.

Treatment.—Drainage of the early products of the inflammation should be established with the minimum of operative trauma. External incision should be made through the soft parts to provide drainage of the abscess when internal incision would not seem to give adequate drainage or would cause a pocket which would not drain in the proper manner.

In the case of an alveolar abscess which has not yet perforated the periosteum, an incision should be made through the periosteum where the pus seems to be pointing. The periosteum should be stripped as little as possible. At times, however, the necessity for exposure may require a slight periosteal stripping.

After the preliminary abscess drainage, the operator should wait until the virulence of the infection has subsided, the sequestrum formed and separated and a sufficient amount of new bone has formed to maintain the continuity of the jaw bone before radical removal is attempted. This period

of separation averages from about three months in infants. But in cases with only a limited amount of sequestration six weeks or two months may be a sufficient interval to wait for separation. In gross sequestration of the whole thickness of the lower jaw it may be necessary to wait from six months to nine months to allow sufficient new bone to form to maintain the contour of the lower face. Although the sequestrum may seem almost ready to fall out it may be necessary to maintain the form of the face until sufficient new bone is formed. During this period every effort should be made to maintain the patient's general health by good food and good hygienic conditions. When anemia is pronounced a blood transfusion is advisable. During the interval of waiting secondary incision through the soft parts for drainage is often necessary.

Finally at the proper time, all of the dead bone should be removed with a minimum damage to the living bone and the periosteum surrounding it. However, the procedure should be radical enough to gain approach to the dead fragments and therefore, may necessitate a considerable external incision to allow retraction of tissue for exposure. Some removal of overlying viable bone is often necessary. A cavity along the side of the bone should be "saucered out" without overhanging edges to allow the soft tissues to fall into the groove. Provision for drainage is necessary. As soon as all the dead bone is removed the wound heals completely in from three to four weeks. Most writers favor this conservative plan.

Early bone-cutting operations have few arguments in their favor. A high percentage of osteomyelitis of the jaw follows too early or too zealous activity in suturing up tissue already inflamed.

Prognosis.—Following dental trauma unless the patient develops a septicemia as may happen—especially after ill-advised extraction of a tooth during an acute inflammatory exacerbation—with the proper care, most cases of osteomyelitis of the jaw recover. Death from starvation and exhaustion is not an uncommon sequela of an extensive jaw necrosis from phosphorus, mercury or bismuth. Zarble collected 12 cases of nurslings with osteomyelitis with infection of the dental sacs of which 11 died. Upper jaw osteomyelitis in small children from antral inflammation is likely to be fatal. Osteomyelitis as a complication of a primary blood disease is as fatal as the primary blood disease—about 100 per cent. Infection of the jaw bones as a complication of an acute illness has a high mortality because the osteomyelitis is not likely to occur unless the original disease has almost completely destroyed the resistance of the patient. Most of the other less severe types of osteomyelitis, however, recover.

INFLAMMATIONS OF THE JAW BONES CAUSED BY SPECIFIC INFECTION

The clinical course of the various types of osteomyelitis of the jaw caused by various organisms of a specific type is quite different from a true pyogenic osteomyelitis.

Syphilitic Disease of the Jaw Bones.—The objective signs of syphilis met with in the bones are the result of an inflammation caused by the Spirochaeta pallida. The outcome of the disease is the development of granular tissue which differs from the granulation of acute inflammatory bony disease in that the leukocytes are chiefly lymphocytes. The specific granulation tissue may undergo resolution (especially is this so after anti-

luetic treatment) or organization if resolution is delayed a sufficient length of time for a considerable amount of fibrous tissue to be formed.

Congenital Syphilis.—Alaroze (1929) divided congenital syphilis into parasyphilitic hereditary or true syphilitic heredity. The parasyphilitic stigmata are underdevelopment of the dental arch and of the maxilla which show a high glottic arch (Fig. 109, *A*). True hereditary syphilis affecting the facial and jaw bones has been described by Burkhardt (Thoma). Champret *et al.* (1929) described 2 cases of necrosis of the mandible due to congenital syphilis and stated that only 5 such cases could be found in the literature. Schlager (1928) described changes due to syphilitic osteochondritis in the condyle of the mandible. It has been stated that congenital absence of the teeth may be caused by congenital syphilis. Kranz has attributed the so-called "Hutchinson teeth" to the disturbance of the glands of internal secretion in congenital luetics. Boyle found histologic changes in the developing teeth in the congenitally luetic very similar to the findings



A *B*

Fig. 109.—*A,* Saddle nose in adolescent due to congenital luetic infection. He had a perforated septum. *B,* Patient with complete atrophy of the lower jaw. Lateral view with finger pressed back of the chin. (Thoma, Clinical Pathology of the Jaws, courtesy of Charles C. Thomas, Publisher, Springfield, Ill.)

in the teeth of vitamin-deficient rats. Baur, however, found spirochetes by special staining methods in the enamel organ, the enamel epithelium, the dental papilla, and the dentine. He believes the tissue change is due to direct action of the spirochete.

Acquired Syphilis.—For the purpose of description acquired syphilis of the bone may be divided into (*a*) periosteal and (*b*) osteomyelitic (gummatous).

(*a*) Periosteal involvement with thickening may begin at any time after a year and a half after the infection. At first there is a subperiosteal exudate which causes more or less severe pain and is often noticed more at night. In the latter stages there tends to be in some cases bony deposits in the old granulation tissue or in other cases rarefying osteitis may be present.

(*b*) The osteomyelitic form of syphilis usually begins as periosteal gumma and localized swellings are felt in the bone. At first the skin or mucosa is unchanged, but later it becomes adherent and red and finally necrotic.

Characteristic reniform ulcers appear. Underneath the involvement the bone is invaded, producing rarefaction, discernible in the roentgenogram. When invaded at several points, mottled appearance is given. The whole picture is not one of destruction. Hand in hand with the destruction is some true proliferation. In the center of the gummatous process is found a generalized necrosis in which the nuclei of the cells are not well preserved. When membranous bone is involved the proliferative tendency is largely lost. Surrounding the necrotic center is a layer of fibroblasts, infiltrated with lymphocytes, and a few giant cells are seen. The blood vessel walls are usually considerably thickened by endothelial proliferation.

In both forms the pathologic picture shows perivascular formation of granulation tissue about the periosteal vessels and the haversian canal vessels. The haversian canals are eroded and widened by inflammatory tissue which gives moth-eaten appearance to the bone. In some areas after treatment the osteoblasts lay down new bone and as healing results there may be an actual sclerosis instead of rarefaction. Membranous bones, however, do not show the reaction to new bone formation as do the long bones. Finally, in the center of an involved area an obliterating endarteritis causes central necrosis and the gumma is formed which softens centrally and as the superimposed mucosa or skin is involved finally ulcerates through to the outside. Thus, the typical gummatous ulcer is formed. In syphilitic osteomyelitis with necrosis of the bone, the separation of the sequestrum is often unusually slow because of the decreased vascular supply which the endoarteritis produces.

Clinical Features.—The bones of the face, the head, and also the frontal, ethmoidal, nasal, palatal and maxilla offer rather commonly a site for a syphilitic inflammation. Both the periosteal form and the osteomyelitic form are seen. Clinically at least, the mandible is rarely affected. Involvement of the palate is manifested by a smooth painless swelling which tends to soften and ulcerate with exposure of dead bone. In the end the dead bone is thrown off as a sequestrum and causes the characteristic palatal perforation. The nasal cartilages as well as the nasal bones may be involved. The septum and sometimes the nasal bones show an end-result similar to that of the palate, namely, a perforation. In the latter situation, the vomer, the turbinates, and the surrounding soft tissues are included in the inflammatory process and after the dead tissue has sloughed out there is usually considerable permanent scarring and contraction of the soft tissues. During the period of ulceration a foul nasal discharge is present—the luetic ozena. Often a sufficient involvement of the nasal bones occurs to cause the cicatrix within the nose to distort the contour of the bridge of the nose and cause the characteristic "saddle nose."

In syphilitic inflammations about the mouth and nose, not only do areas with the bone near the surface tend to be involved but the ulceration may spread to the soft tissues of the palate, the nasopharynx or to the buccal pharynx. In these latter locations when the ulceration has been allowed to involve an area of some extent, almost complete obliteration of the normal passages is likely to result from cicatricial contracture.

In the mandible, which is rarely affected, a periosteal thickening may arise on the surface as a firm, fusiform swelling accompanied by little pain. Night pain may be complained of.

A tendency to recession of the gum with loosening of the teeth has been described as a syphilitic manifestation. This has been stated to be more commonly observed in the upper jaw.

Diagnosis.—The diagnosis is made on the history, the general findings indicative of a syphilitic infection, the Wassermann reaction and the response to treatment after malignant disease if at all suggested has been ruled out by biopsy.

Treatment.—The treatment is fairly intensive antiluetic therapy, with repair of the deformity after complete healing has been present for a period of about six months or more.

Tuberculosis of the Jaw Bones.—Tuberculosis of the bone is always secondary to a tuberculous lesion elsewhere—generally in the lymph nodes in children and the lungs in adults. Two types of tuberculous bacilli infection occur in the human—the bovine (from cow's milk) and the human. Thus, the incidence as to type depends largely upon the hygienic conditions under which the supply of milk is obtained. For instance, up to eight years Fraser (Edinburgh) found the bovine tubercle bacilli type about twice as numerous as the human (39 to 19). After eight years the proportion fell slightly but of the 70 cases twelve years of age or under, 41 were of the bovine, 26 human and 3 both bovine and human.

Incidence.—Tuberculosis of the bones of the jaw is rare and an infection of epiphysis of the mandible corresponding to the type of infection common in the long bones is extremely so. Kremer (1930) with a large experience in a tuberculosis sanatorium states that tuberculosis of the jaws is very rare and tuberculosis of the temporomandibular joint almost unknown. Sir Watson Cheyne and Stanley Bond in 602 cases had 5.5 per cent involving the bone of the skull and face. Axhausen (1931) also found the disease rare. Gross (1922) states that in the upper jaw the infra-orbital margin is most commonly affected. In 1930 Chapotal stated that but 50 cases of tuberculosis had been recorded in the literature before 1922.

Forms in which Tubercle Occurs.—Apart from scattered miliary tubercles which may be met with in acute miliary tuberculosis, Knaggs divided the forms in which tubercle occurs in the bones into (1) soft deposits often caseating, (2) deposits with sclerosis of bone and the formation of sequestra, (3) diffuse tuberculous osteomyelitis, (4) a surface infection which includes tuberculous periostitis and caries of an articular surface, and finally (5) caries sicca or caries without suppuration (Volkmann's Inflammatory Atrophy of Bone).

Pathology.—The tubercle bacilli which cause a chronic osteomyelitis are carried by the blood stream in most instances. The tubercle bacilli find lodgment in the bone, the bacilli and the toxin cause irritation, and a miliary tubercle is formed composed of a mass of granulation tissue infiltrated with endothelial cells and lymphocytes. During the first few days of the infection the polymorphonuclears are said to be as numerous as the lymphocytes but soon the former are largely replaced by the latter. A typical miliary area has a classic histologic picture, giant cells with the multiple peripherally located nuclei, round cells, and endothelial cells about a caseated center. Later the fibroblastic tissue of the wall of the tubercle becomes adult connective tissue and tends to form a limiting tissue and prevents to a certain degree extension of the process. This is nature's attempt

at healing and in some areas it is successful. Although the vessels may show endarteritis the perivascular infiltration so characteristic of syphilis is not present. The action of the osteoclasts and the granulation tissue tends in tuberculous infection to rarefy and destroy. Tuberculosis is characteristically a destructive process in bone and very little tendency to bony proliferation is shown but occasionally about the periosteum a certain amount of the cancellous type of bone may be laid down.

Clinical Features.—The observation has been made that tuberculosis of the jaw bones increases in virulence and aggressiveness in direct proportion to its distance from the orbit. Pain is slight. The lymph nodes are secondarily involved rather early. Tuberculosis of the upper and lower jaws runs a somewhat different clinical course. Tuberculosis of the lower jaw is an aggressive disease. Tuberculosis of the upper and lower jaws runs a somewhat different clinical course. Tuberculosis of the lower jaw is an aggressive disease. Tuberculosis of the upper jaw often runs a relatively mild course. Palatal tuberculosis and upper alveolar process tuberculosis are said to run a middle course in aggressiveness. Infection of the lower jaw which causes a thickening and involvement of the muscles of mastication causes trismus. The caries causes any fistulae which develop to drain periodically. Sequestration is as a rule very slow. When ulceration is present very small miliary tubercles may be seen in the walls. The granulations are characteristically pale and the edges undermined and overhanging.

Diagnosis.—Because secondary infection occurs early in tuberculous disease of the jaw, it is often difficult to prove that the disease is actually tuberculosis. When secondary glandular involvement is present, the evidence may be fairly conclusive. Oftentimes the microscopic examination of the débris removed at operation fails to be conclusive. The general appearance of chronicity and the fact that the disease is not ordinarily a primary one should put the surgeon on his guard. Guinea-pig culture may be of aid in puzzling cases.

Treatment.—As a rule, conservative measures should be employed. Drainage of an abscess when indicated along with the removal of any loose fragments or spicules of bone should be done. General hygienic measures, sunlight and light may be of value.

Unusual Organisms.—The jaw bones are probably not involved by typhoid bacillus. No cases of pneumococcal osteomyelitis have been reported as occurring in the jaw bones (Knaggs). Actual involvement of the jaw bones by the gonococcus has not been reported. Blastomycotic osteomyelitis has not been reported in the jaw bones. The bone lesion of coccidioidal infection is similar to that of tuberculosis. The endosporulating organism would have to be isolated for a diagnosis.

Actinomycosis.—Very rarely the fungus of actinomycosis involves the jaw by the avenue of a carious tooth. The cortical layers of the bone may be rarefied and minute abscesses formed with little pus. Often the roentgenogram of actinomycosis of the jaw reveals the bone running through the lump with little or no involvement. However, when the infection develops centrally a localized area of rarefaction or even an expanding lesion of the bone may be the result (see Actinomycosis of the Soft Tissues of the Face).

Yaws.—Yaws is a disease of tropical countries with a strong likeness to syphilis. Its causal organism is Spirochaeta pertenuis. Maul in Manilla in

100 cases of yaws found 20 which presented bone lesions. A periostitis manifested by a nodular type of swelling on the surface of the bone was noted in some cases. A diffuse osteitis was also found. Rarefied areas with well-defined borders and their long axis parallel to that of the bone may be found in the interior of the bone and at the surface. An epiphysitis and a destructive lesion of the joint surfaces exposed to injury are also seen. The rarefied areas according to Maul rapidly disappear after salvarsan treatment. They mark the situation of small granulomatous masses. The lesions tend to multiplication, and widespread destruction and frequent implication of the interior of the bones.

Leontiasis Ossea.—*Definition.*—This expression has been employed to designate those individuals with a hyperostosis of the bones of the face and skull whose nature was not understood. Virchow suggested the term but had in mind a condition in which new connective tissue developed in the skin and subcutaneous tissue. He considered the bone condition analogous. McCusker, Messonger and Thoma have recently described cases of leontiasis. No sure ground exists for differentiation of the disease from osteitis deformans which Paget described in 1876. At the present time most observers believe that this disease is not entitled to be regarded as a clinical entity, but the disease is a localized form of osteitis deformans or Paget's disease.

Incidence.—The disease in the past called leontiasis ossea starts in childhood usually but is seen in adults. It is very rare. Most men have never seen a case.

According to Knaggs the majority of cases fall into two groups: (1) cases of very chronic periostitis spreading from bone to bone—creeping periostitis of the bones of the face and skull, and (2) cases of diffuse osteitis of the bones of the face and skull. This diffuse condition may be (*a*) general, (*b*) circumscribed, or (*c*) local.

Pathology.—A marked disturbance in the structure of the bones occurs with a general thickening. The subperiosteal layer is irregularly thickened producing a rough external contour. The cortex is often perforated by new blood vessels and cystic areas may be found scattered here and there in the changed bones. The blood-forming elements of the bone marrow are lost and replaced by a rich vascular fibrous and soft osseous tissue.

(1) *Periostitic Form.*—The involved bone is grossly of the cancellous type and it extends through both the original bone and periostitic deposit. There is no outer layer of compact tissue. Often no trace of the original bone can be found.

The periostitic form of leontiasis ossea is remarkable for the great exuberance of the subperiosteal deposit and the slow manner in which the inflammatory process creeps from bone to bone until the whole face and skull are involved. In most cases the disease begins in the nasal fossae or sinuses and in early cases the fossae may be blocked by the bony growth. Later the superior maxillae show the first visible signs of bony hypertrophy. In some instances the disease is almost limited to these bones and in advanced cases the most marked overgrowth is seen in the maxillary bones. The alveolar processes are often not involved or are involved relatively late in the process. From the maxillae the affection spreads to the frontal bones by way of the frontal processes and diffuses widely over that bone

until it reaches the parietals and then the occipitals. Laterally it spreads to the malar bones and passes beneath them around the external aspect of both upper jaws to the pterygopalatine fossae. From here it passes upon the greater wing of the sphenoid into the temporal fossae and joins the affection of the frontal bone. The orbits are likely to be invaded.

The hyoid bone has been involved. One of the earliest signs is a nasal obstruction. Trouble with lachrymal apparatus from stenosis or obliteration of the nasal duct is also to be expected. With involvement of the orbits, the eyes suffer and proptosis and exophthalmus eventually are produced. Knaggs described 13 cases of this type of the disease which were collected from the records and museums.

(2) *Diffuse Osteitic Form.*—The complete absence of any periosteal bone deposit is the most striking feature of this type. The bone becomes enormously enlarged and distends its periosteal envelope so that fossae are filled and sharp ridges and elevations rounded off. In its early stages the bone is vascular and soft. In later stages the bone is firmer but still softer than normal. In some areas the compact bone is not replaced but the innumerable apertures of most of the surface represent a cancellous bone of new formation which has taken place of the original bone. Little buds of osteogenic tissue protruding from the foramina may ossify giving a mammillated surface. The cranial bones may be enormously thickened—as much as 3 inches in thickness. The inner and outer tables are indistinguishable.

Those affected seldom live to be over thirty years of age. Deep irradiation therapy has been suggested as of value in the therapy. But no treatment has been particularly satisfactory. In one case of Paget's disease I removed one parathyroid and a half on the advice of Ballin. No parathyroid adenoma was found. I am inclined to believe that Paget's disease is not generally benefited by this treatment although this particular patient showed considerable improvement.

Schüller-Christian's Disease.—Schüller-Christian's disease is an osseous form of xanthomatosis and shows particularly an involvement of the skull but the jaw bones also may show the characteristic changes. The disease is stated to be congenital. Hebrews are predominantly affected, as is the male sex. The disease is essentially a disease of childhood but rarely adults are affected. Schaeffer and Williams (1932) reported a case affecting the mandible and femur in a woman thirty years of age.

Among others Sosman (1932), Griefenstein (1933), and Pick (1933), have reported cases since Christian's (1919) description of the disease. Christian noted at that time the syndromic triad of diabetes insipidus, exophthalmus and defects in the membranous bones. The first two may or may not be present and in the early stages are not considered essential to diagnose the disease. Among the other symptoms are gingivitis and stomatitis, cessation of growth, lack of gain in weight, malnutrition, anemia, dwarfism, adiposogenitalia, and sometimes jaundice. The spleen, kidneys, liver and lymph nodes may be enlarged. The skin of the entire body may be stained a diffuse yellowish brown. Occasional xanthomatous patches are seen about the eyes. The maxilla and the mandible show consistent involvement. The teeth may loosen and fall out. The defects of the skull, however, are the most characteristic features of the bony changes.

The disease is caused by a disturbance in the fat embolism. The involvement of the pituitary with foam cells is regarded as the cause of the diabetes insipidus and in children of the adiposogenital type. The exophthalmus is caused by a fatty bursa behind the eye (Horax). Cholesterol is deposited in the granulation deposits. The typical cell is a histiocyte filled with lipoid (foam cell). Possibly the lipoid substances in the body fluids become pathogenic for the organism. Irritation of the vessel walls develops, then perivascular infiltration and the lesion increases as a result of blockage of the reticulo-endothelial system. First, lymphoid cells appear, then by rupture of the vessel walls fusiform cells and finally multinuclear xanthoma cells are found.

Granulomatous osteolytic defects develop in the membranous bones. The granulomatous areas are made up of mononuclear and eosinophilic cells and masses of foam cells. In sections prepared in the ordinary way the cholesterol is largely dissolved out leaving vacuoles—the so-called "foam cells."

In the roentgen examination the skull and other bones involved show round or oval or irregular defects. The larger the defects the greater the tendency to irregularity. The defects have sharp margins. In extensive involvement the typical effect has been called the geographic skull. The defects in the maxilla and the mandible appear as large and small cysts. Teeth may appear to float in the space.

When the exophthalmus becomes of serious proportions a decompressive operation on the orbit is to be considered. Pitressin has ameliorated the diabetes insipidus somewhat. Treatment generally has been unsatisfactory. Rowland reported 14 cases, 7 of which died. The other 7 were surviving at the time of the report.

Marble Bone Disease (Osteosclerosis Fragilis Generalisata).—The disease is generalized osteosclerosis which affects the whole skeleton. The chief clinical symptoms are an abnormal fragility of the bones which heal normally, however. A severe anemia accompanies most cases. Atrophy of the optic nerve has been described and other changes in the eye muscles. The sella turcica shows somewhat characteristic bony changes.

The etiology of marble bone disease is not known, but it is transmitted by inheritance. The disease has its onset as early as the beginning ossification. Clairmont and Schinz, Karshner, Lorey and Reye and Thoma have reported cases and discussed the disease. Dentition is delayed and the teeth are faulty and of poor structure—decaying easily. Lorey and Reye reported cases with necrosis of the mandible which resulted in death. The disease affects the osteoblastic activity of the bone and an osteoid hypertrophy of the endosteum and spongiosa is produced. No new periosteal bone is present. In an occasional case studied the blood phosphorus has been found to be increased but ordinarily the blood calcium and phosphorus are within normal limits. The jaws have been reported underdeveloped. The roentgen-ray picture shows a radiopaque bone with the normal architecture of the spongiosa missing. The sella turcica shows a club-shaped thickening of the clinoid processes. The jaws may show complete sclerosis. A severe osteomyelitis of the jaws may develop after tooth extraction.

Osteomalacia.—The cranium and the jaws are rarely affected in osteomalacia. Thoma describes a case which he calls a bone atrophy in which

the mandible, maxilla, palate bone and a part of the sphenoid bone became involved in an obscure process of bone resorption resembling in many respects osteomalacia. After pregnancy, pains in the pelvis, back and sacro-iliac region developed.

The roentgenogram shows a thickening of the cortex and a disappearance of the bony trabeculae in the spongiosa. The disease generally affects the entire skeleton. Cures have recently been reported with cod liver oil concentrate and irradiated ergosterol (Goldstein, 1929), and Gargill, Gilligan, and Blumgart (1930).

Atrophy of the Jaws.—Atrophy due to pressure, atrophy due to disease and senile atrophy has been alluded to as has also neurotrophic atrophy first described by Virchow. Lehmann (1917) and Goring (1924) discuss certain phases of trophic function of the nervous system. Romberg in 1857 described a unilateral atrophy of the face. The bones and muscles become smaller in the disease. The subcutaneous fat disappears, the skin becomes white and the hair is said to have a tendency to fall out. Two main theories have been brought forward to explain acute atrophy, the reflex neurotrophic theory—Vulpin (1869), Paget (1873), Schultze (1924), Muller (1924) and Goring (1924)—and the vasomotor theory. The men arguing for the vasomotor theory say that no proof has been given of the presence of trophic fibers in the bone. Such men believe that the atrophy is due to a nutritional disturbance which may be caused by a variety of conditions but principally by a disturbance of the sympathetic nervous system, causing a vasotonus with vasoconstriction and undernourishment. Thoma has presented one of the most unique examples of complete atrophy of the mandible yet described in the literature (Fig. 109, *B*). The entire mandible including the rami and the condyles was absorbed. The patient was a woman thirty-six years of age. The other bones were normal. The soft tissues of the chin could be pushed back to the pharynx. Later the maxilla showed resorption in the posterior part. Also evidence of resorption of the pterygoid plates and the hamular process was shown. The condition was observed four years and was apparently progressive.

Bibliography

Bibliography Quoted in Text

Alaroze: Semaine dent., **11:** 10–247, 1929.

Axhausen, G.: Pathologie und Therapie des Kiefergelenkes, Fortschr. d. Zahnheilk., **7:** 199–202, Nov., 1931.

Ballin, M.: Parathyroidism in Reference to Orthopedic Surgery, Jour. Bone and Joint Surg., **15:** 120, 1933.

Ballin, M., and Morse, P. F.: Parathyroidism and Parathyroidectomy, Ann. Surg., **94:** 592, 1931.

Parathyroidism, Amer. Jour. Surg., **12:** 403, 1931.

Bauer, W.: Wien. klin. Wchnschr., **11:** 879–882, 1931.

Osteomyelitis of Mandible after Extraction of Teeth Ending in Death, Vierteljahrsschr. f. Zahnheilk., **46:** 194–206, 1930.

Blair, V. P.: Editorial, Surg., Gynec. and Obst., **37:** 847, 1923.

Blair, V. P., Brown, J. B., and Moore, Sherwood: Osteomyelitis of the Jaw, Jour. Mo. State Med. Assoc., **27:** 173, 1930.

Blair, V. P., Padgett, E. C., and Brown, J. B.: Diseases of the Face, Mouth and Jaws, Graham's Surgical Diagnosis, Phila., W. B. Saunders Co., 1930.

Bonner, H.: Osteomyelitis of the Jaw in Infants, Beitr. z. klin. Chir., **133:** 163–183, 1925.

Champret, L., and Dechaume: Zahnärzt. Rundschau, **38:** 790, 1929.
Chapotel: Rev. odontol., **51:** 444, 1930.
Cheyne, W.: Tuberculous Diseases of the Bones and Joints, 1895.
Christian, H. A.: Contribution to Med. Research, New York, Paul B. Hoeber, Inc., 1919.
Clairmont, P., and Schinz, H. R.: Arch. f. klin. Chirurgie, **135:** 347, 1929.
Gargill, S. L., Gilligan, D. R., and Blumgart, H. L.: Metabolism Treatment of Osteomalacia, Arch. Int. Med., **45:** 879, June, 1930.
Goldstein, J.: Wien. klin. Wchnschr., **42:** 202, 1929.
Goring, D.: From L. R. Müller's Die Lebensnerven, 2nd ed., Berlin, 418, 1924.
Griefenstein, A.: Arch. f. univ. Heilk., **132:** 337, 1932.
Gross, H.: Berberick: Lehrbuch der Mund- und Rachenkrankheiten, Leipzig, Georg Thieme, 1932.
Haden, Russell: Dental Infections and Systemic Disease, Phila., Lea and Febiger, 1928.
Heinomen: Acta Chir. Scand., **58:** 289–304, Nov., 1925.
Hertzler, A. E.: Surgical Pathology of Diseases of the Bones, 1930. (Published by the author.)
Karshner, R. G.: Osteopetrosis, Amer. Jour. Roentgen., **16:** 405, 1926.
Knaggs, R. L.: Diseases of the Bone, New York, Wm. Wood and Co., 1926.
Kranz, P.: Wien. klin. Wchnschr., **2:** 879, 1931.
Kremer, W., and Wiese, O.: Die Tuberkulose der Knochen, Berlin, Julius Springer, 1930.
Lehmann, W.: Med. Klinik, No. 23, 1917.
Lorey and Reye: Fortschr. a. d. Geb. d. Roentgenstr., **30:** 35, 1923.
Maul, H. G.: Phil. Jour. Sci., **13:** Sec. B63.
McCusker: Rhode Island Med. Jour., **13:** 84, 1930.
Messonger, H. C.: Deutsche Ztsehr. f. Nervenheilk., **105:** 35, 1930.
Müller, L. R.: Die Lebensnerven, 2nd ed., Berlin, 1924.
Paget, Sir James: Trans. Med. Chir. Soc., **60:** 37, 1877.
Lancet, **2:** 511, 1873.
St. Barthol. Hospital Reports, **10:** 83, 1874.
Rowland, R. S.: Xanthomatosis and the Reticulo-endothelial System, Arch. Int. Med., **42:** 611, 1928.
Schaeffer, J. E., and Williams, R. E.: Schüller-Christian Disease, Dental Cosmos, **74:** 879, 1932.
Scheider, O.: Ztschr. f. Stomatol., **29:** 80, 1931.
Schlager, G.: Pathologische Histologie der Mundhöhle, Leipzig, S. Hitzel, cit. from Siegmund and Weber, 1926.
Schulze: Münch. med. Wchnschr., **18:** 494, 1924.
Sosman, M. C.: Xanthomatosis (Schiller-Christian's Disease: Lipoid Histiocytosis), J.A.M.A., **98:** 110, 1932.
Thoma, K. H.: Clinical Pathology of the Jaws, Charles C. Thomas, Springfield Ill., p. 223, 1934.
Oral Abscesses, Ritter and Co., Boston, 1916.
Virchow: Pathology of Tumors, French Trans. Arohnsson, **2:** 22, 1869.
Vulpin: Arch. de phys. norm. et path., p. 558, 1869.
Wilensky, A. O.: Osteomyelitis of the Jaw, Arch. Surg., **25:** 183, 1932.
The Association of Osteomyelitis of the Skull and Nasal Accessory Sinus Diseases, Arch. Otol., **15:** 805, 1932.
Osteomyelitis of the Jaws in Nurslings and Infants, Ann. Surg., **95:** 33, 1932.
Zarble: Ztschr. f. Kinderheilk., **25:** 266, 1920.

The following are quoted by Blair, V. P., Padgett, E. C., and Brown, J. B.: Graham's Surgical Diagnosis, 1930: Rosenow, Longcope, Gilmer and Moody.

The following are quoted by Knaggs, R. D.: Diseases of the Bone, New York, Wm. Wood and Co., 1926: Bond, S., Cheyne, W., and Fraser.

The following are quoted by Thoma: Boyle, Burchardt, and Horax.

CHAPTER XX

INFLAMMATIONS AND DISEASES OF THE TEMPOROMANDIBULAR JOINT

THE temporomandibular joint in a general way is subjected to the same diseases as other joints of its kind in the body.

ACUTE INFECTION OF THE TEMPOROMANDIBULAR JOINT

An acute purulent infection of the temporomandibular joint occasionally accompanies or follows a septicemia.

The following case is an example: child shown in Fig. 110 had a septicemia following pharyngitis during the course of which he developed a painful swollen area over the right temporomandibular joint which eventually subsided, after which he was never able to open his mouth. The jaws



Fig. 110.—Ankylosis of the jaw. Result three months after excision of condyle.

were forcibly separated a time or two during the following year and held open with a block of wood but to no avail.

An osteomyelitis of the condyle, a rare type of osteomyelitis, may extend to the temporomandibular joint. When the ramus originally is the site of an osteomyelitis, the condyle and finally the joint may be invaded. Gonorrheal arthritis of the joint is not unknown. A tuberculous arthritis of the joint is a surgical curiosity. In hypertrophic arthritis the temporomandibular joint may be affected in a manner similar to that which occurs in other joints.

Clinical Features.—In acute temporomandibular arthritis, the symptoms vary with the virulence of the infection. The severity of the constitutional symptoms depends both on the virulence of the local infection and the general infection if one be present. Surrounding and above the

joint, redness of the skin, swelling and tenderness point to the location of the infection. Movement of the mandible is almost impossible due to the pain and muscle spasm. The pain extends over the whole side of the face and often also extends to the ear. Eventually the inflammation subsides with partial or complete ankylosis or the condyle sequestrates.

The location of the point of maximum tenderness along with extreme pain on attempting to move the jaw is important. The tenderness and the other signs of inflammation are located somewhat above that of an acute pyogenic parotitis and in the latter infection movement of the jaw is not so greatly impeded. The maximum swelling in a parotitis conforms pretty well to the location of the parotid gland itself. Rarely one sees a case of abscess beneath the subtemporal muscle. When such is the case there is some impediment to movement of the jaw due to temporal muscle spasm, but the maximum tenderness and swelling is somewhat higher than in a temporomandibular joint infection. When the diagnosis is uncertain and

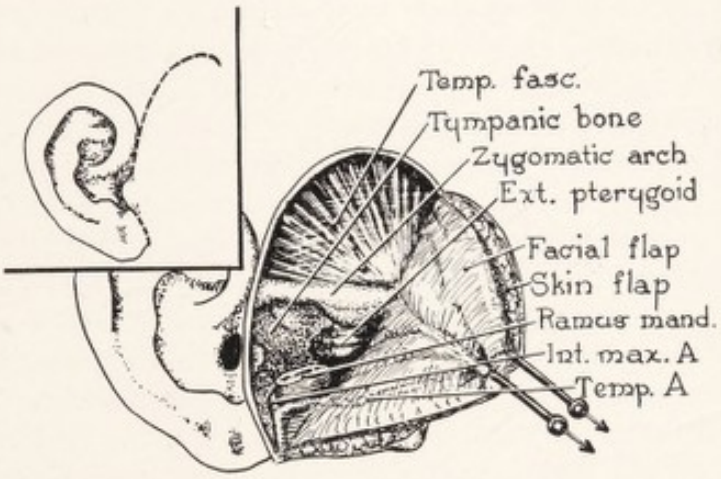

Fig. 111.—Incision and exposure for excision of the condyle of the mandible. A facial flap is shown separated for the purpose of turning to the bottom of the cavity.

it is deemed that the needle will not pass through infected tissue, the introduction of the aspirating needle may give one some additional information.

The usual result of a purulent arthritis is ankylosis. The structure of the joint is changed into dense eburnated bone and the affected portion of the mandible becomes massive and hypertrophic—from two to three times the normal size.

Treatment.—The details of the operative approach to the joint are outlined under the treatment of ankylosis of the joint (Fig. 111).

Early in the acute and the subacute inflammation the most effective treatment is rest and the application of heat—a treatment that is easily adapted to the joint. In acute process no one need caution the patient to keep his jaw still.

In chronic affections the condyle may be confined to the posterior part of its fossa by limiting the amount that the mouth can be opened. Thus, the damage to the joint is lessened and the ligaments about it given a chance to recover. A silk cord between two bands, one on an upper and one on a lower tooth is at times useful for this purpose. Temporarily a head-chin bandage may be used for the same purpose.

HYSTERICAL CLOSURE OF THE JAW

One of the manifestations of hysteria may be inability to open the jaws. A careful clinical history along with no signs of a definite lesion together with other hysterical phenomena are the criteria on which one bases the diagnosis. Young women are usually the victims. In some instances the attack has lasted for weeks. From day to day it may be noted that the amount of opening the jaws varies. The treatment consists of general treatment of the patient, encouragement and assurance that the disability is not permanent. (See textbooks on functional neurological diseases.)

IRRITATIVE CLOSURE OF THE JAWS

The close sensory nerve connections besides the actual limitation caused by infiltration of muscles and other tissues cause inflammatory lesions in the cheek, larynx, external auditory canal, temporal region and parotid gland reflexly to tend to limit jaw movement.

After a lower third molar extraction especially if some infection follows or accompanying an osteomyelitis of the angle of the ramus one almost invariably observes some signs of limitation of jaw movement. An old fracture or ulcer of the tongue or even soreness in the region of the upper posterior molars may cause some limitation of jaw movement. The muscles of mastication are thrown into a reflex spasm which may almost completely fix the jaws. The spasm has been entirely involuntary without pain in the initial lesion in some rare instances. One or several of the muscles of mastication may be involved or the attacks may appear periodically until the source of irritation is removed. A tonic spasm of the muscles of mastication is an early symptom of tetanus. Imbert and Real described a muscular contracture (hypermyotonia) which was characterized by appearing immediately on receipt of the wound or following a rather insignificant lesion. They stated that four tenths of all the cases of contracture of the jaws following war wounds were of this type. Vitality tests and roentgenograms of the posterior molars may aid one in clearing up an obscure case. The treatment is either symptomatic or elimination of the cause.

CONTRACTURAL CLOSURE OF THE JAWS

Severe infection accompanied by gross slough of tissue such as in noma, destructive operations or injuries, is often an obvious cause of limitation of movement of the jaw. The fixation of the jaw is permanent and not relatively transitory as in hysterical closures and closures caused by muscle spasm. A pseudo-ankylosis is caused when the contracture is sufficient to cause absolute fixation of the lower jaw to the upper. In some instances the difficulty in distinguishing a false ankylosis of the joint may be considerable. A good roentgenogram should show whether there is actual bony union or not. In rare instances examination under anesthesia along with the use of jaw dilators or possibly the severance of suspicious bands becomes necessary before the true part the joint plays in limitation of movement is determined.

Gunshot injuries in the region of the ramus of the mandible not rarely cause a limitation of motion due to the formation of cicatrices. The application of radium to the angle of the cheek for carcinoma may result in sufficient fibrosis to more or less fix the lower jaw.

Treatment of Trismus Due to Muscular Contracture.—The treatment of trismus caused by muscular contracture consists of forcibly separating the jaws by means of special instruments introduced between the teeth for this purpose. Frequently the resistance of the muscles are overcome without an anesthetic. Herpin suggested a simple jaw dilator, which consists of two pieces of hardwood 30 cm. in length fastened together by means of a simple hinge which permits opening the jaws of the instrument to an extent of 5 cm. The handles serve as levers. Notches are cut in the handle throughout half its length. These notches hold rings of rubber which regulate the opening of the jaws of the instrument more or less according to the distance of the application of the elastic traction from the hinge. The external and internal surfaces of the jaws of the dilator are covered with a piece of German silver. One introduces the instrument between the teeth and opens with a moderate but sustained pressure. Two or three daily seances are given after the first successful opening. Between treatments the mouth may be kept open with wedges of wood placed between the teeth. Later gum chewing is recommended.

Colyer described an instrument for gradual forceful opening of the jaws. With his apparatus the force is evenly distributed over several teeth. The apparatus consists of two curved metal plates which crown the occlusal surfaces of the teeth. Between the ends of each plate are screws which are gradually tightened. This gag may be worn at night.

Brown constructed an apparatus with upper and lower vulcanite plates which fitted over the gums. Between these plates a small thick-walled rubber bag was fitted. The rubber bag was attached to an air pump and dilatation accomplished by forcing air into the bulb.

In attempting to stretch adhesions, brutality gains nothing permanent. What cannot be gained by gentle means cannot as a rule be gained by excessive force. When the teeth are not present or are loose, these dilators are not of great use.

An ordinary rubber bottle stopper repeatedly inserted between the teeth may be useful in stretching adhesions. The patient can aid himself considerably by conscientiously using such an aid to forceful opening of the jaw.

Operative Treatment of Contractures Limiting Jaw Movement.—Scar bands that bind the jaw together may be situated any place between the symphysis and the temporomandibular joint. Simply cross cutting a scar contracture will not relieve the deformity. When the wound heals the defect will be the same as before. To relieve the contracture it is necessary to recover in some way the resulting raw surface with skin. The less the skin contracts after the wound is resurfaced, the more permanent the correction of the defect. A mucosal or skin flap of sufficient width turned crosswise of the wound will relieve the contracture. Another effective way of relieving scar contracture is to cross cut the contracture and lay a skin graft about a stent in the resulting raw surface. When a correction is made by this method, it must be remembered that the defect has to be overcorrected as the graft will eventually contract about 50 per cent or even more.

When the whole of the inner lining of the cheek has been destroyed it may be necessary to turn a pedicled flap from the neck to get the proper amount of relining. Before the prepared flap is turned into the cheek, the

scar is excised so that the natural depths of the cul-de-sacs are restored when the mouth is opened. When the flap is turned from the neck the cheek skin and the soft tissues are incised at the lower border of the mandible and dissected from the mandible. Through the incision the flap may be turned upward to reline the cheek.

ANKYLOSIS OF THE TEMPOROMANDIBULAR JOINT

Ankylosis of the temporomandibular joint practically always is caused by a pyogenic infection of the joint. An osteomyelitis may involve the condyle or the ramus and extend to the joint (Fig. 110).

The structure of the bone is changed. The affected portion of the mandible becomes massive and hypertrophic. The joint is obliterated. Often the condyle becomes continuous with the temporal bone. Sometimes an infection of the extra bony structures may involve the periarticular structures causing strong fibrous adhesions which limit the movement of the joint without producing an actual bone ankylosis.

In ankylosis, the mouth cannot be opened. There is, of course, difficulty in eating and some interference with speech. The teeth cannot be cleaned well. Thus, there is a tendency for considerable oral sepsis. Differentiation between the affected and the unaffected side is not always easy. Usually the affected side of the jaw is the smaller of the two. When there is any motion and movement of the jaw is attempted the chin moves to the unaffected side. Movement in the normal joint may be made out by palpation. When both sides of the joints are ankylosed, of course, no movement can be observed. The degree of joint destruction can be judged fairly accurately before operation by the use of a roentgenogram. Two views of the jaw should be taken, anterior, posterior and semilateral. In taking the picture, the head must be placed so that the rays will penetrate the point at the proper angle without other bony shadows superimposing.

Treatment.—The disability is so marked and embarrassing and the results of the operation so satisfactory that all cases should be subjected to arthroplasty of the temporomandibular joint. Very briefly, the history of arthroplasty is as follows: Esmarch of Kiel suggested in 1851 taking a wedge-shaped piece from the condyle. The condyle was removed for arthritis by Humphrey of Cambridge in 1856. Verneuil in 1860 according to Campbell did the first arthroplasty and it was of the temporomandibular joint. Rizzoli first simply cut the ramus for ankylosis. In 1864 Hearth did the operation suggested by Esmarch and removed ⅞ inch of bone and in 1880 the patient was known to have good function. More recently Blair and Murphy in this country did work in perfecting the operation.

Arthroplasty of the Temporomandibular Joint.—The operation may be done under local or general anesthesia. The hair should be shaved from the area about the skin incision and the skin properly prepared. The skin incision (Fig. 111) is from in front of the lobe of the ear upward immediately in front of it to a point 1 cm. above its upper free border. From here it curves forward and then to a point about 2½ cm. directly in front of the upper attachment of the ear. The incision is carried only through the skin and immediate subepithelial tissues, and the skin flap is dissected downward. The superficial fascia is then incised downward to the temporal and parotid fascia and the zygoma along the line of the skin cut. Only three fourths of

the incision in the superficial fascia is made first as the anterior end of the incision may cross a branch of the seventh nerve that supplies the anterior belly of the occipitofrontalis muscle. This flap contains the temporal artery which insures its vitality. The posterior part of the masseter muscle is freed from the zygoma and the muscle is pulled downward and forward with a small retractor. The site of the joint is now exposed. The condyle is resected with the aid of biting forceps and a chisel. About ½ to ¾ inch of the condyle is removed. A true ankylosis often obliterates the sigmoid fossa and involves the coronoid process and the coronoid may have to be removed. When it is possible the insertion of the temporal muscle is preserved. The jaw is opened by means of the strong dilator.

The location of the internal maxillary artery and part of the third division of the fifth nerve which lies subjacent to the condylar neck should be kept in mind during the operation. The flap of superficial fascia previously described is sutured to the bottom of the defect which is left after the

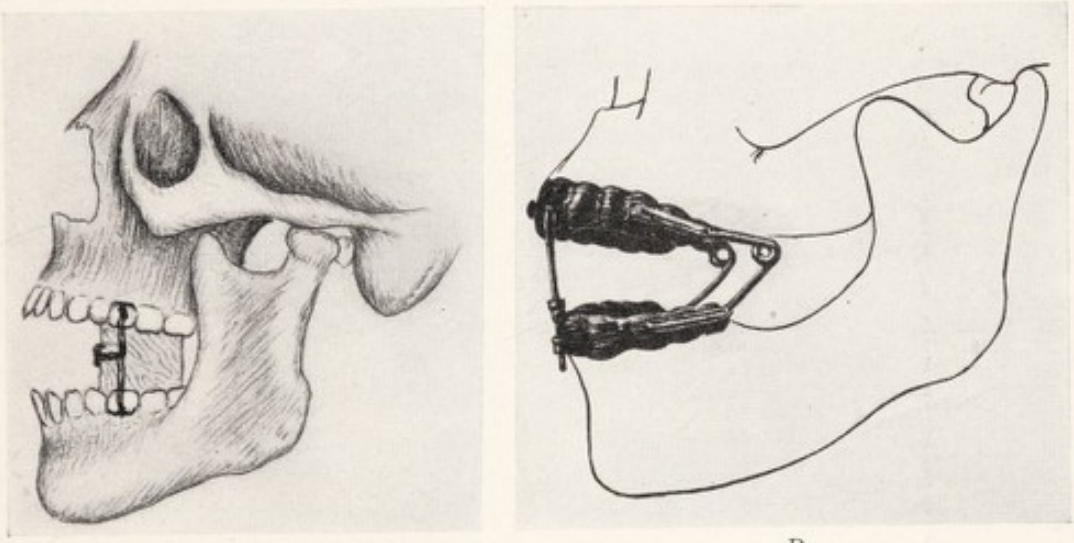

A *B*

Fig. 112.—*A*, Method of inserting a wedge between the teeth when it is considered necessary to keep the jaws separated for a time. *B*, Apparatus constructed by Ivy to aid in obtaining separation of the jaws in muscular stiffness or partial ankylosis.

condyle has been removed. The skin is then sutured and a pressure sponge placed over the skin flap in such a manner that some of the dead space is obliterated.

When difficulty has been experienced in getting the mouth open, it may be well to fix the mouth wide open by wiring a wedge-shaped block between the teeth (Fig. 112, *A*). This is left a week or more according to the amount of difficulty in getting the mouth open that one finds at operation. In most instances, however, no difficulty is experienced in opening the mouth after the condyle is completely removed and therefore a wedge between the teeth is not necessary.

When there is marked retraction of the chin that often accompanies an early ankylosis, the ramus on the sound side may be sectioned. The body of the mandible is then drawn forward and held forward by wiring the lower teeth to the upper teeth.

Murphy advocated the use of a flap of fascia over the temporal muscles. Other men have used a free fascial transplant. Others have used a fat

transplant. However, as Henderson has demonstrated, interposition of any material is unnecessary. Success from this operation is obtained on account of mechanical reasons. The raw bony surfaces between the temporal bone and the mandible do not become approximated. Articulation of the mandible with the superior maxilla holds the mandible down in place. The essential of the operation is really excision—not arthroplasty.

When the ankylosis is bilateral, both sides are operated at the same time. After the operation gravity may cause some separation. But soon the muscles of mastication become rebalanced and the position of the lower jaw becomes about normal.

Active motion is started as soon as the pain and tenderness has disappeared. Chewing gum is a satisfactory exercise, if there is a tendency to a recurrence. The use of dilators of the various types previously described may be useful (Fig. 112, *B*).

SNAPPING JAW

An appropriate term, "snapping jaw," has been applied to a certain group of functional derangements of the temporomandibular joint. This disturbance has been attributed to an abnormal periarticular relaxation which permits excessive mobility of the condylar head within the glenoid fossa. The condition is not at all infrequent. Malgaigne in 1855 collected a series of 76 cases of "snapping jaw," 54 of which were bilateral. The common age incidence was between twenty and thirty years.

Pringle, Ashhurst, Blake, Perthes, Loessl, Podlaka and Schnitzler have described cases. In 1822 Astley Cooper directed attention to the possibility that relations intermediary between normal and complete dislocation might exist between the condyle and the glenoid cavity. According to his conception, the causative factor comprised the separation of the meniscus from the condylar head followed by the riding forward of the latter minus the meniscus upon the articular eminence. Pringle offers an alternative theory that internal pterygoid muscles may act to displace the loosely applied cartilage so that the thick central ridge lies obliquely instead of transversely so that the cartilage assumes the rôle of a foreign body in the joint. But whatever may be the exact mechanism, a certain degree of periarticular relaxation probably is contributory.

Clinical Features.—No pain or discomfort ordinarily is felt but the victims of the condition are often subjected to a constant annoyance as a result of a more or less definite snapping noise when eating or even when talking or yawning.

Axhausen states the condition is usually unilateral but most of the patients with snapping jaw whom we have seen were affected bilaterally. He describes two forms: first, the snapping occurs during the opening of the mouth (intermediary snapping), and second, the snapping occurs at the termination of the opening movement (terminal snapping). Intermediary snapping is usually the result of an arthritis of the joint analogous to that found in other joints. Terminal snapping is usually the result of a habitual subluxation of the joints. (See Partial Subluxation, Chapter XI.) Rarely overstretching of the capsule of the joint as that which follows the insertion of a mouth gag has been thought to be of etiologic significance in terminal snapping.

Treatment.—Perthes injected 0.75 cc. tincture of iodine about the joint and secured a cure. In another case he excised a portion of the joint capsule. Nieden turned a fascia strip down from the temporal fascia to reinforce the joint capsule. Morris concludes that the operation of Nieden is based upon sound surgical principles. A more lengthy discussion of operative procedures used when this condition is very marked is given under partial subluxation which is described in Chapter XI.

A SYNDROME OF EAR AND SINUS SYMPTOMS DEPENDENT UPON DISTURBED FUNCTION OF THE TEMPOROMANDIBULAR JOINT

Costen has recently called attention to the possibility of headache and ear symptoms dependent upon disturbed function of the temporomandibular joint. He presents several examples attributed to evulsion of the condyle from overbite which when corrected by appropriate dentures had their symptoms relieved. Hearing tests showed in some a mild catarrhal otitis with eustachian-tube involvement attributed to pressure on the anterior membranous wall of the tube. Attacks of dizziness described as being present in these cases were attributed to changes in the intratympanic pressure. He attributed the symptoms as being due to overaction of the joint which as time went on became more and more loose and showed evidence of absorption of the meniscus, condyles and the surrounding bone. The prognosis depended upon the accuracy with which the abnormal pressure on the joint was relieved, by the refitted dentures and the extent of the actual injury to the joint.

Bibliography

Bibliography Quoted in Text

Ashhurst, A. P. C.: Annals of Surgery, **73:** 712, 1912.

Axhausen, G.: The Pathology and Therapy of the Temporomandibular Articulation, Fortschr. d. Zahnheilk., **7:** 199, 1931; Lancet, **1:** 411, 1887.

Blair, V. P.: The Consideration of the Contour as Well as Function in Operations for Chronic Ankylosis of the Lower Jaw., Surg., Gynec. and Obst., **46:** 167, 1928.

Blake, J. B.: Recurrent Dislocation of the Lower Jaw, Trans. Amer. Surg. Assoc., **36:** 350, 1918.

Brown, J. A.: Quoted by Blair, V. P.: Surgery and Diseases of the Mouth and Jaws, 1912, St. Louis, C. V. Mosby Co.

Campbell, W. C.: Dean Lewis' System of Surgery, W. F. Prior Co., Inc., Hagerstown, Maryland, vol. 2, Chapter 5.

Arthroplasty of the Hip, Surg., Gynec. and Obst., **43:** 9, 1926.

Colyer: Jour. R. A. M. C., p. 597, 1926.

Cooper, A.: Treatise on Dislocation, B. B. Cowper, p. 393, 1842.

Costen, J. B.: A Syndrome of Ear and Sinus Symptoms Dependent Upon Disturbed Function of the Temporomandibular Joint, Ann. Otol., Rhin. and Laryng., **43:** 1–15, 1934.

Henderson, M. S., and New, G. B.: Ankylosis of the Jaws, Surg., Gynec. and Obst., **27:** 451, 1918.

Herpin: Presse méd., May 8, 1916.

Imbert and Real: Revue neurol., **23:** 942, Paris, 1916.

Loessl, J.: Nieden's Operation for Habitual Dislocation of the Mandible, Zentralbl. f. Chir., **53:** 1749, 1926.

Malgaigne, J. F.: Cited by Lexer, Manuel de médicine opératoire, p. 462, Paris, 1916.

Morris, J. H.: Chronic Recurring Temporomaxillary Subluxation, Surg., Gynec. and Obst., **50:** 483–491, 1930.

Murphy, J. B.: Bony Ankylosis of the Jaw with Interposition of Flaps of Temporal Fascia, Surg. Clin. of John B. Murphy, **2:** No. 4, 1913.

Nieden, H.: Ueber operative Behandlung habituelle Kieferluxation, Deutsche Ztschr. f. Chir., **183:** 358, 1923; Photo., Surg., Gynec. and Obst., p. 490, Feb., 1930.
Perthes, G.: Die Verletzungen und Krankheiten der Kiefer, Deutsche Chir., **33:** 40, 1907.
Pringle, J. H.: Displacement of the Mandibular Meniscus and Its Treatment, Brit. Jour. Surg., **6:** 385, 1919.
Schnitzler, J.: Zur Frage nach der Existenz eines Kapselrisses bei der Kieferluxation, Zentralbl. f. Chir., p. 889, 1891.
Verneuil: Quoted by Campbell.
Esmarch, Hearth, Humphrey, Rizzoli and Podlaka: Quoted by Erickson, E. E.: Science and Art of Surgery, vol. 2, Lea Brothers and Co., Phila., 1885.

CHAPTER XXI

INFLAMMATIONS AND DISEASES OF THE SALIVARY AND LACHRYMAL GLANDS

Pyogenic infection occurs in all three of the salivary glands and their ducts. But the acute virulent type is almost always seen in the parotid glands while the chronic obstructive type of infection is most common in the submaxillary gland. Most commonly a salivary gland stone is found in the submaxillary gland.

Clinical Classification of Pyogenic Parotitis.*—Cases of pyogenic infection of the parotid gland fall for the greatest part into two broad groups: (*a*) one in which an acute inflammation of the gland is the first and predominant symptom; (*b*) the other presenting primarily recurrent symptoms of duct obstruction but added to the symptoms of duct obstruction there may be any grade of inflammation of the gland or duct. Cases of the first group are commonly characterized by a sudden onset and a rapid course, with pain and swelling in the gland region and general symptoms of a severe infection or, less often, a slight swelling and a mild rise in temperature are the only symptoms observed. Cases of the second group of parotid infections seem to be related to no preceding illness or injury and show a very distinct tendency to recurrent symptoms. They are usually characterized by recurrent exacerbation of moderate pain and swelling in the gland region, often more pronounced when food is taken, and with or without the general symptoms of a mild infection. Rarely, the exacerbation develops all the acute signs found in cases of the first group.

Included in the group of acute and subacute inflammations in which spontaneous resolution takes place, there is a type of case whose course is characterized by exacerbations of slight pain and moderate swelling with, or sometimes without, the general symptoms of a mild infection. The question arises as to whether these do not belong to the second group, the obstructive cases. Clinically, the differentiation is sometimes difficult.

ACUTE PYOGENIC PAROTITIS

Acute suppurative parotitis was described in the earliest medical records. The Lancet of 1828 and 1829 contains a description of a case of acute parotitis at the Hôtel Dieu which resulted in gangrene. Brodie (1834) described accurately the clinical course and the gross pathologic picture. It seems that because of the known tendency of an orchitis to follow epidemic parotitis, an association was suspected very early between the parotid gland and the female pelvic organs, especially the ovaries. Munde (1878), Moeriche (1880), Goodell (1881), and Paget (1886) described and reported the earliest cases following ovariotomies. Hanau (1889) and Pilliet (1890) suggested that parotitis could occur as secondary infection from Stensen's

* The material used herein was taken after some rearrangement from an article written by Blair, V. P., and Padgett, E. C.: Pyogenic Infections of the Parotid Glands and Ducts, Arch. Surg., **7**: 1–36, 1923.

duct by mouth organisms. Bucknell described microscopic sections of the acutely inflamed parotid gland which showed polymorphonuclear leukocytes, and the usual cells of acute inflammation immediately surrounding and within the ducts. Since the tissues immediately surrounding these blood vessels were comparatively free of infiltration and the lumina of the blood vessels were not involved, it was therefore assumed by Bucknell that the blood vessels were not usually the primary source of entrance for the infecting agent.

Pathogenesis of Pyogenic Parotitis.—It is now generally accepted that at least the great majority of pyogenic inflammations of the salivary glands are due to an ascending infection, that is, that the infection travels along the lining mucosa of the excretory duct. The cases in which an inflammation of the duct can be demonstrated are to be classified most probably as ascending infections. There is also evidence to warrant the belief that a blood-borne infection is an occasional cause of acute suppurative inflammation of the salivary glands.

Analogy would suggest the possibility of infection being borne by the lymphatic channels. As far as we know, there are no definite cases although we have one case in which such an etiology was suspected.

The most common infecting organism is a staphylococcus. Cases showing a streptococcus are of the greatest virulence clinically. Certain cases show a pneumococcus and other organisms are found.

Clinical Features.—Acute pyogenic parotitis usually follows as a complication of a postoperative state, of an infected wound, or of an acute infectious disease, or as a part of the terminal condition. In certain instances, it seems to follow an acute form of pharyngitis. Occurrence is most frequently in adults, especially in the third decade of life, but may occur in adolescence, childhood or infancy. Of our cases, 39 in number, 30 adult cases occurred after the third decade of life and cases in the females were slightly in the majority. Thirty-four of the 39 of our cases occurred within the winter period.

Pneumonia was present in nearly one third of the cases. About one eighth had a definite history of a sore throat or a preceding "cold." About one fifth of the cases were bilateral.

The symptoms may be mild with little fever, with mere discomfort or moderate pain and slight swelling limited to the parotid region or they may be extremely severe from the first with all the clinical symptoms and laboratory findings of a severe infection, including great pain in the gland, chills, high fever, and marked swelling first in the gland and later a rapidly spreading cellulitis of the neck, head and face.

As the infection spreads, edema sometimes closes the eye and may involve the neck down to the clavicle or even the breasts, or they may extend backward over the mastoid region (Fig. 113). The swelling rarely extends into the pharynx to threaten the airway. Death has occurred during a period of acute swelling and has suggested the possibility of edema of the glottis.

The duct in the mouth in the majority of cases, shows signs of inflammatory reaction as manifested by a pink or red swollen papilla with, when most pronounced, a partially everted duct mucosa. Usually saliva flowing from the duct will vary from the faintest cloudiness to frank pus. In

certain of our cases of the more severe type which were suspected of being blood borne but in which laboratory evidence was not complete enough to be convincing, no evidence of duct infection of infected saliva was found. Certain patients, preceding onset, complained of pain in the ear or the back of the neck. Often patients become delirious and there may be convulsions, especially in children. Spasms of the muscles of mastication and pain may prevent opening of the mouth. Very rarely a seventh nerve weakness is noted.

Treatment.—The evident mild cases are given no special treatment other than possibly the application of heat or cold, while in the more severe cases, when not unmistakably a part of a terminal condition, the patients are operated as soon as it appears probable that the gland infection will not subside spontaneously. We have followed the rule of opening the gland in all doubtful cases not later than within the second twenty-four hours and we believe that it is a more serious error to delay too long than to

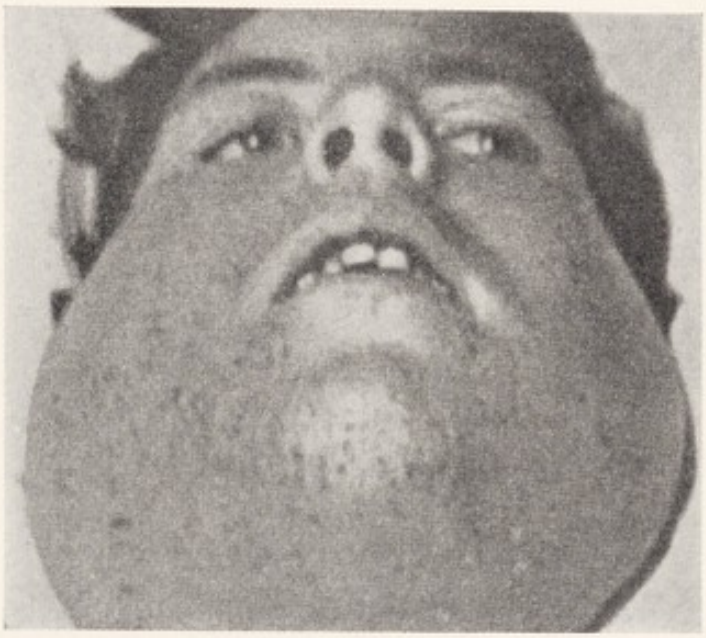

Fig. 113.—Bilateral parotitis. (Blair, Padgett and Brown.)

incise the gland unnecessarily. The local changes in the gland that operation seeks to prevent are gangrene and suppuration. The latter is often of a diffuse miliary type. The operation, therefore consists of exposing the gland by splitting the capsule and also puncturing the parenchyma for drainage (Fig. 114). Noticeable scarring is prevented by placing the greater part of the skin incision in the angle at the junction of the cheek with the ear. Free access is obtained by exposing the whole gland and the motor facial nerve is safeguarded by puncturing the gland with blunt forceps. The incision starts 2 cm. in front of the zygoma and at the lower border, running back to the ear and then downward, to behind and below the angle of the jaw. This incision which is made with one sweep of the knife goes to, or just through, the capsule of the gland. Along this line the facial nerve lies quite deep. A flap of skin and superficial fascia is stripped forward with sharp retractors; the capsule is stripped off the whole gland and its parenchyma is punctured and torn in numerous places. It is

important that the whole gland be exposed and explored. Usually the parts behind the lobe of the ear and along the origin of Stensen's duct are the ones missed. We have had to reoperate in certain cases on this account. The wound is packed wide open with gauze and bandaged with some pressure. Spontaneous closure of the wound with a very slight scar follows, with the recovery of the patient.

Direct incision of the gland may be followed by a salivary fistula.

Recently in certain of the less fulminating types of pyogenic parotitis, roentgen-ray therapy has been recommended as giving quite satisfactory results.

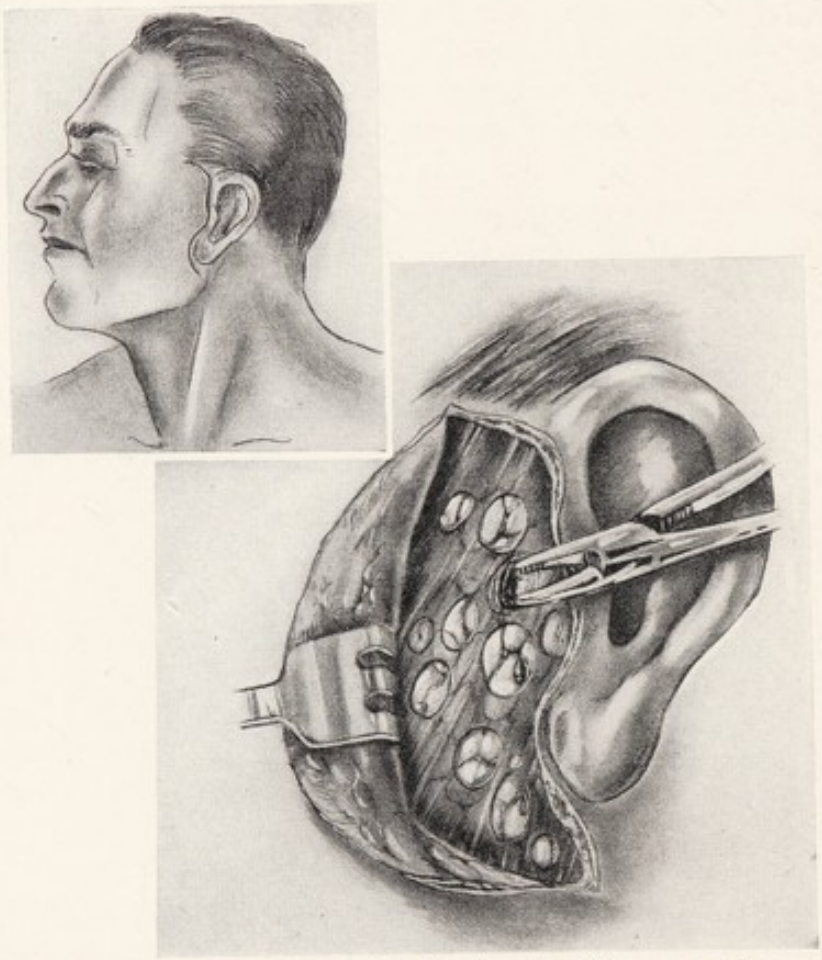

Fig. 114.—Exposing the parotid gland when involved by an acute pyogenic inflammation. The capsule is then torn with a Kelly forceps here and there to give drainage. This method guards one from injuring the facial nerve. Insert shows the line of incision.

Prognosis.—Naturally, cases in which the parotid infection is but one evidence of a terminal condition in an essentially fatal malady are not favorably influenced by any form of treatment. Out of our 39 cases, 18 were operated on and 5 died before the parotid wound was healed. Thirteen of the 18 cases survived. Of these, 4, it is believed, were saved by operation, while in the other 9, convalescence was materially hastened.

PAROTITIS ASSOCIATED WITH OBSTRUCTION

The Lancet for 1827 and 1828 described a case at the Hospital of Surgery, Panton Square, St. James, which was probably an obstructive parotitis. It is said that in 1856, Dermarquay described a case in which Stensen's

duct was blocked with pus and distended with gas and secretion, and that a report embodied in an anonymous communication to the Medical Times and Gazette of November 1, 1868, gave the first complete history of the lesion. Kussmaul, in 1879, records a case of salivary tumor recurring at intervals of almost six months which had resulted from fibropurulent inflammation of Stensen's duct. The fibrous nature was verified microscopically by Friedländer and von Recklinghausen. In 1881, Stiller of Budapest reported a similar case. Hutchinson in 1893 was the first to describe xerostomia (dry mouth) according to Rhodes.

Johnson, in 1896, appears to be the first man to emphasize an obstructive parotitis of other origin than calculus. In 1913, Howlett reported a case of "bacterial intermittent swelling of the parotid gland due to infection of Stensen's duct" and discussed the condition.

Etiology.—In this group of cases are those in which something suggests that the trouble is associated with or dependent on partial obstruction of the duct, and that when suppuration occurs, it is secondary to the obstruction. The obstructive agent might be simply the swelling and the thickening of the mucosa, a plug of mucosa lodged at the meatus, some inflammatory obstruction, or a stone formed anywhere within the duct.

The cases of chronic obstructive parotitis occur at any age without a preceding or accompanying severe or debilitating illness. In some patients there is a history of a "cold" preceding the exacerbation of swelling. In others the swelling has followed the extraction of a tooth, tonsillitis, or a tonsillectomy. It seems likely that an acute infection in the pharynx, mouth or nose has more than coincidental relation to the exacerbation of swelling.

Clinical Features.—Obstruction to the outflow of saliva is manifested by recurrent swelling, usually associated with some slight discomfort or even pain, most pronounced in the majority of cases when food is taken. Added to this there is usually some inflammatory disturbance of the duct and the gland, although not necessarily. In cases where stone formation is the cause of the obstruction, the area about the stone or stones is commonly indurated and tender as calculi commonly lie in a bed of granulation tissue.

It is not usual for stone cases to present themselves to the surgeon with a clinical picture resembling that of the acute pyogenic parotitis with the exception that, as a rule, more of a tendency to localization and abscess formation is shown. In the parotid gland calculi are very often multiple and quite small. The history of successive swellings of the gland or a chronically tender or indurated area or areas in the gland should suggest the possibility of a calculi even in the face of a clinical picture of an acute generalized inflammation of the gland.

Diagnosis.—Although one should not probe the duct in the face of an acute infection, in the chronic cases showing little evidence of inflammation certain very suggestive information may be obtained. In the cases with stone the probe may strike the calculus, and the diagnosis is made. All cases in which the question of the presence of an obstruction arises should have the advantage of a roentgenogram which will reveal a calculus in the majority of cases although a few stones, especially small ones, cannot be identified. There is a fairly constant symptom present that is of a good deal of value in making the diagnosis of salivary gland stones. There

occurs during each meal an increase in the size of the swelling behind the obstruction, due to the increased output of saliva, and this swelling subsides at a rate compatible with the degree of obstruction of the duct.

Treatment for Parotitis Associated with Obstruction.—Treatment should vary with the type of cases. Control of infections might tend to prevent exacerbations of swelling in the duct. Surgical treatment has for its primary object the relief of the obstruction, to free the flow of saliva. When due to stones their removal is followed by complete subsidence of all obstructive symptoms and of the induration of the gland. Obstructions due wholly to acute swelling of the mucous lining of the duct or to plug of mucus engaging the meatus might be relieved temporarily at least by passage of a dilating probe into the duct. We have seen quite severe reactions or extensions of infections following the use of probes in some cases.

Some strikingly good results have followed slitting of the contracted meatus of the duct in chronic obstructive inflammation of the duct without stones. This contraction of the outlet of the duct is thought to be a protective mechanism, but if the duct does become infected, it is then liable to obstruct drainage. We are just now inclined to slit the meatus of the mouth in every case of chronic infection of the duct or gland in which a stone cannot be demonstrated and in which dilation with a probe fails to give permanent relief. The operation should not take over fifteen or twenty minutes even for the inexperienced. A probe or probed scissors are passed into the opening and the duct is slit for ¼ inch. Three stitches of fine silk are usually sufficient, one at the apex of the slit and one on each side.

SUBMAXILLARY GLAND AND DUCT INFECTION

Cases of acute virulent submaxillary gland infection are very rare, but do occur. The etiology is the same as in the acute pyogenic parotitis so far as is known.

Submaxillary gland inflammations with obstructive symptoms also have a similar etiology to those of the parotid gland and are fairly common. Salivary calculi have their most common location here. Their history, clinical features, and the diagnosis are similar to those of the parotid gland. Of course, it is evident that the location of the submaxillary gland and the fact that its duct can be palpated throughout its length in the floor of the mouth cause an anatomic variation in signs.

The submaxillary gland duct, being dependent and longer than the parotid gland, is more liable to have foreign bodies such as small seeds, fish bones, and bristles, enter the meatus. Acute obstruction is possible from this cause but undoubtedly is extremely rare. A sudden painful swelling caused by dammed-up saliva occasionally results which subsides on relief of the obstruction. The diagnosis will depend on the history, touching with finger or probe or expressing the foreign body. Infection sooner or later develops, if the foreign body is not removed. When the foreign body is left in place for some time, lime salts may be deposited on it and form the nucleus of stone.

Treatment.—About 15 per cent of the cases in which simple removal of the stone through the mouth is done show exacerbations of symptoms. In the submaxillary gland cases the treatment advisable is removal of the entire gland when exacerbation continues after the removal of the stone

or the slitting of the duct plus dilation have failed to give relief. In those individuals with a considerable amount of infection in the gland and a long history of recurring suppuration, it is usually not to be expected that this will entirely clear up by the removal of the obstructing agent alone. In this type of case the entire gland had better be removed. In certain acute phlegmons of the submaxillary gland or of the Ludwig's syndrome with regional cellulitis which started from a submaxillary gland infection, it is imperative to give adequate and complete drainage from the outside (see Treatment of Ludwig's Angina).

FOREIGN BODIES AND STONES IN THE SALIVARY DUCTS AND GLANDS

Although it would not seem possible, foreign bodies, such as pieces of grain, small seeds, bristles and such have been known to find their way into and to cause obstructive symptoms in both the submaxillary and the parotid ducts. However, on account of its small caliber only very small or slender bodies can enter the parotid duct. Sooner or later if the foreign body is not dislodged, some inflammatory reaction develops locally about it. When the blockage is complete, acute obstructive symptoms with pain and swelling supervene which pass off as soon as the blockage is removed. Sooner or later the inflammatory reaction about the foreign body plus the stasis of saliva sets up an ascending duct inflammation and more or less involvement of the whole gland follows, depending upon the amount and type of the infecting obstructing organism. In time some foreign bodies of this nature become coated with lime salts after which it appears to be a salivary calculus.

A few cases of calculi in Blandin's glands are recorded in the literature.

In the literature up to 1926 Harrison found about 400 cases of salivary calculi reported. He reports an example of one in a three-week-old baby. Wakeley reported the incidence according to gland as submaxillary 63.2 per cent; parotid 20.6 per cent; and sublingual 16.2 per cent. He found 3 cases in which calculi were present in more than one duct or gland in the same person. The right submaxillary is affected about twice as often as the left. Twice as many males as females are affected. The condition occurs principally in middle life. New and Harper report about 110 cases of nonspecific inflammation of the salivary glands in which 70 had salivary calculi as the background.

Etiology.—Formerly it was thought that salivary calculi start their formation because of the presence of bacteria, which in some manner influence a change in the mucus secretion to start the matrix of a stone. After the matrix has formed, it is considered that the same conditions continue as cause the deposit of tartar on the teeth. Some of the stones undoubtedly have a foreign body for a matrix and the deposit of lime salts is secondary. The stones in the gland would not seem to be difficult to explain because bacteria, salivary stasis, and metabolic influences all enter the picture in some way at one time or another. Wakeley found that salivary calculi were 75 per cent calcium carbonate and 10 per cent calcium phosphate. Tartar usually forms about the lingual surface of the lower anterior teeth and it is probable that the same factor produces stones in the submaxillary glands. Analogously there is not a great difference between stones of the kidney or gall ducts and stones well up in the salivary glands.

Söderlund of Sweden (1919) first definitely associated salivary calculus formation with the presence of actinomycosis. He reports 41 cases in which he found actinomycosis in all. He and Naeslund (50 cases—actinomycetes found in all) believe the cause in some cases is saphrophytic actinomycetes in the mouth while in others the organisms are derived from outside the mouth. Lime salts are deposited around the colonies of the organisms.

Frequency—Location—Number.—Ivy and Curtis (1932 to 1936) recently studied 115 cases of salivary calculi. They found 106 connected with the submaxillary salivary apparatus and 9 with the parotid salivary apparatus.

Salivary calculi are much less frequent than stones of the kidney or gall duct. The most common location of salivary calculi is the submaxillary duct. They are more frequent in the submaxillary duct than in all the other locations combined. Men are more frequently affected than women or children (2:1). It is stated that they have been congenital (Blair). In the submaxillary duct or gland one stone is usually the limit in number. In the parotid gland more than one may be found. An ordinary stone in the submaxillary duct is usually about the size of a pea or smaller but larger

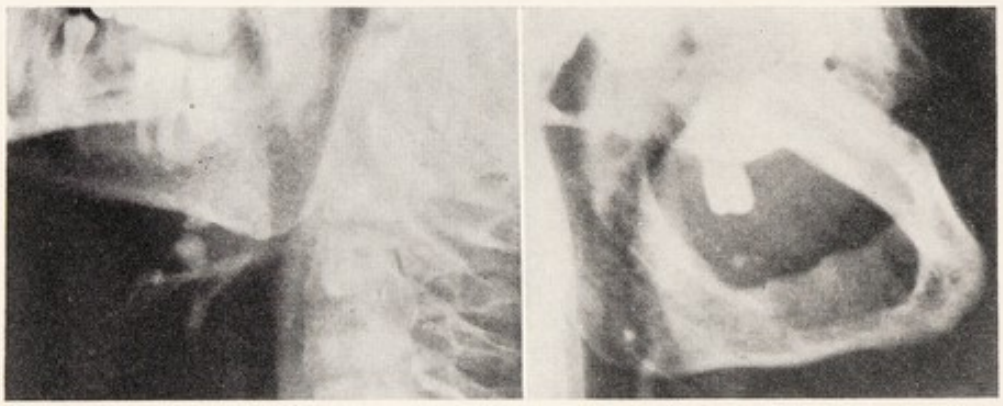

A *B*

Fig. 115.—*A*, Stone in submaxillary duct. *B*, Stone in parotid duct.

stones have been found (Fig. 115, *A*). Orth described a stone weighing 70 Gm. and Noehren reported a case of 14 stones in Wharton's duct and Söderlund found 30 in the submaxillary duct. Stones of the parotid duct or gland are usually about one third the size of a pea or even smaller (Fig. 115, *B*).

Pathology.—Henke and Lubarsch describe the pathology encountered. In the duct obstruction petechial hemorrhages are caused. The stones cause erosion and ulceration, which continuing leads to fibrosis and more complete obstruction. The intralobular ducts become congested and dilated and finally atrophy of the gland tissue follows. Accompanying the obstruction periodic flare-ups of infection result in more or less phlegmon in the gland and surrounding structures. Sometimes, the stones are extruded by the formation of a fistula. Four cases of external fistula were noted from submaxillary stone in the Mayo series of 70 cases of salivary calculi.

Clinical Features.—A foreign body or stone in the duct of a salivary gland causes little or no symptoms unless partial obstruction is caused. When an infection of the periductal tissues is started, inflammatory signs are added to the obstructive signs caused by the inflammatory edema.

Pain and tenderness in the floor of the mouth and a tender enlargement of the submaxillary gland which is exaggerated when eating are the signs of submaxillary duct obstruction with secondary infection (Fig. 116). When the gland is diffusely involved with a more virulent type of infection, a diffuse cellulitis may extend and involve the tissues surrounding the gland and the duct. The clinical syndrome of Ludwig's cellulitis of the floor of the mouth may be set up by a spreading infection starting in the submaxillary gland. The general symptoms of an acute pyogenic infection such as fever, elevation of pulse and malaise supervene in direct proportion to the virulency of the infecting organism. As a result of one or repeated exacerbations of inflammations the stones may come to lie in an abscess, in the bottom of a sinus or in a bed of fungating granulations surrounded by scar tissues. The latter picture to the uninitiated may be suggestive of a malignant growth. When untreated, a stone may lie in



Fig. 116.—Swelling in neck due to submaxillary stone. (Blair, Padgett and Brown.)

its bed for a long time. After repeated ulcerative flare-ups, a stone may erode its way through the tissues into the mouth and be extruded. By carefully palpating the region over and along the duct in the floor of the mouth usually the stone or the fibrous reactive tissues about it can be palpated as a hard mass. In 92 per cent of Mayo's series pus could be expressed from Wharton's duct. The opening of the duct was usually thick and red. It is seldom that a stone or stones in the parotid duct or gland can be palpated.

The obstructive symptoms found in the parotid duct or gland stones are analogous to those of the submaxillary gland and duct save for the variations due to the anatomy of the regions. The clinical picture of parotitis due to the obstruction by stones is given under that subject in this chapter.

The roentgen ray is positive in from 75 to 85 per cent of salivary duct stones.

Hickey described a good technic for visualization of submaxillary duct stone. The patient is allowed to lie supine on the table with the head projecting over the edge. A large film is placed in the mouth and held in position by the closed teeth. The roentgen rays are directed from above downward, with the central rays passing through the center of the mouth.

After injecting the mucosa over a suspected mass with a little novocain solution, the needle of the syringe may be used as an exploratory instrument, or a small probe may be passed into the duct. Often the exploring instrument will contact the foreign body and give an unmistakable grating sensation.

Treatment.—All salivary calculi and foreign bodies should be removed in the most expeditious manner. When there is an acute infection, the use of hot applications is advisable until the acute symptoms subside. Probing of the duct should never be done when there is acute inflammation in the tissue. It may increase the cellulitis. Simple removal of the stone does not always clear up the condition of the gland because of the very nature of the duct apparatus of the gland itself and the possibility of multiple pockets of inflammation throughout the gland.

Stones in the floor of the mouth in front of the molar teeth can be removed, as a rule, under local anesthetic. A gag is placed in the mouth, and the cheek and tongue are retracted in an opposite direction. After the stone is located, it is pushed upward into the mouth by placing the fingers over the gland under the jaw. After a sufficient infiltration of the novocain solution an incision is made down to the stones. By touch the stone is located and enucleated from its bed. The freeing of such a stone may be more difficult than one would at first suspect. A bistoury knife cutting about the stone aids one in loosening it. Finally, an elevator or curet may be needed to complete the extraction. After the removal, the incision is packed with a gauze wick for two to three days. Following this, a mouth wash ordinarily is all that is needed.

A stone in the anterior oral part of the parotid duct is removed in a similar fashion to that of a submaxillary duct stone. For a stone too far back in the duct to make the intra-oral approach seem wise, a small incision from without is the method of choice. The stone is removed and after passing a probe along the duct from within the mouth to be sure the duct is patent, the wound is sutured to its full depth and snugly approximated to prevent a salivary fistula. Multiple stones should be removed similarly.

When the submaxillary gland contains multiple stones and is considerably damaged by inflammatory flare-ups, it may be wisest to remove the gland from the outside. The operation can be done very nicely under local anesthesia also.

In New and Harper's series of 70 cases of submaxillary stone it was deemed good surgical judgment simply to remove the stone from the duct in 30 cases. In 13 cases it was simply removed from the gland. In the remaining 27 cases on account of the situation of the stone and the amount of infection present, it was thought best to remove the entire gland. There was a recurrence of symptoms in 4 per cent of those removed from the duct and in 3 per cent of the cases in which it was removed from the body of the gland.

Sialography.—Until recently roentgenologic study has been of value only in the study of the stones. By the injection of an opaque medium, it is possible to outline the ducts of the gland. Barsong in 1925 was the first to do this. Since 1925 Carlsten, Keith, Wiskosky, Barsky, and Silberman have published reports. Barsong used a 20 per cent potassium iodide solution which was painful. At present lipiodol is used and is injected into the duct (Fig. 117, *A*). The procedure is not to be done in the face of an active infection but otherwise it seems safe and it may be of aid in studying parotid fistula or in determining the anatomic state of the ducts of the gland in chronic obstructive conditions of the ducts. Exposures have to be made immediately after the injection of the opaque medium. To interpret the film, a knowledge of the normal anatomy of the gland is required. Sialography demonstrates abnormalities, dilatations, and ob-

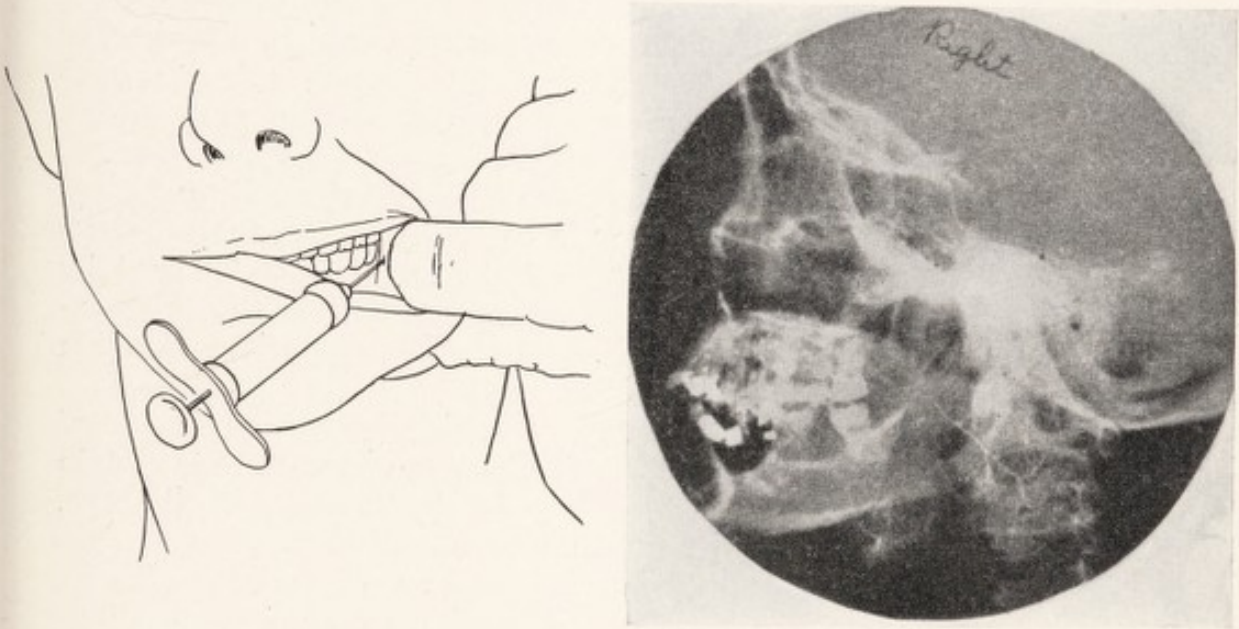

A *B*

Fig. 117.—*A,* Inserting blunt, rounded-point needle into parotid duct to inject lipiodol for sialograph. *B,* After injection of lipiodol. (After James J. Quiney.)

struction of the larger and smaller salivary ducts. Sialography may aid in the exact location of intraglandular parotid stones in particular.

MIKULICZ'S DISEASE

By Mikulicz in 1888 was described a rare chronic, symmetrical painless enlargement of the lachrymal and salivary glands. About 100 cases have been reported since that time. Some infectious agent of unknown type appears to precipitate the affection. Howard in 1909 and Thursfield in 1914 pointed out that besides the cases of true Mikulicz's disease, there were also cases with lymphatic and hematopoietic system involvement. More recently Schopper and Jacobsen have written about the Mikulicz syndrome. The disease occurs at any age of life and is almost twice as frequent in males as in females. Certain cases have shown a general glandular enlargement and others a definite leukemic blood picture. Bunting has suggested that the disease shows a close relationship to chronic lymphatic aleukemia.

An infiltration or a hyperplasia of the preexisting lymphoid cells of the salivary and lachrymal gland is found. Beside the round cells, epithelioid cells and giant cells may be seen. There is also an overgrowth of fibrous tissue. Eosinophils also may be present. Changes in the epithelium when found are secondary and degenerative in type.

Clinical Features.—Increased lachrymation is usually the first symptom observed. But soon there appears a painless enlargement of the lachrymal gland—the main characteristic of the disease—which may eventually cause ptosis or an exophthalmia. Later the salivary glands are affected and become enlarged. Although, as a rule, the glands are rather firm, this is not universally true. Finally, the salivary secretion decreases and the mucous membrane becomes dry. Ordinarily for a time, the general health remains good unless there is an extension of the picture to the general lymphatic system with resulting general glandular enlargement. Very rarely a splenic enlargement develops. In some cases the involved glands enlarge for a time and then remain stationary; in some instances, they recede. Heerfordt described a syndrome in which iridocyclitis is accompanied by enlargement of the parotid and sometimes other salivary glands. Howard analyzed a group of cases. Fifty-five showed a benign course, 20 tended to general lymphatic involvements and 5 developed a leukemic blood picture. The majority of cases die within two years. The characteristic painless symmetrical enlargements of the lachrymal glands followed by salivary gland involvement should make one suspect the disease. Eventually microscopic examination may be essential when there is a question of the diagnosis.

Treatment.—Some good results have been reported following the use of arsenic and potassium iodide. Total excision has been resorted to in certain appropriate cases which show interference of the function of the eye. Irradiation therapy will decrease the glandular enlargement.

MISCELLANEOUS INFECTIONS OF THE SALIVARY GLANDS

Tuberculosis of the salivary glands has been stated to occur but it is extremely rare. Usually it is a contained lymph gland that is involved, and really not the salivary gland itself. The swelling is diffuse, comes up slowly, and there are little or no subjective symptoms. The diagnosis is finally made certain when confirmed by microscopic examination.

Manifestations of spirochetal involvements of the salivary glands are not common. In secondary syphilis there is occasionally an enlargement of the glands with slight discomfort due to increase of tension. In tertiary syphilis the lesion is either a gummatous mass or an interstitial fibrous overgrowth. When a luetic lesion is suspected the diagnosis has to be made by a rapid disappearance of the lesion under antiluetic treatment or by biopsy.

Actinomycosis may be primary in the gland itself after gaining entrance through the duct, but usually it is secondary to involvement of neighboring infected tissue. The diagnosis and treatment are discussed under Actinomycosis of the Soft Tissues (Chapter XIV).

EPIDEMIC PAROTITIS (MUMPS)

Epidemic parotitis is a contagious, nonsuppurating disease of one or several salivary glands. Kermorgant has produced some evidence that the disease is due to a spirochete but his work has not been generally accepted. Occasionally, salivary glands other than the parotid are involved and it is possible for the parotid glands not to be affected. A swelling appears which gradually increases for a period of from three to six days. It is accompanied by moderate fever, malaise, and often a headache or if in a child, possibly vomiting, and pain at the angle of the jaw or in the parotid region. For some reason the left gland is affected more often than the right. During the latter days of the swelling the superimposed skin becomes red and edematous. The parotid duct exudes unclouded saliva and the papilla of the duct remains normal or nearly normal in appearance. Usually when one gland is involved first, within a day or two the opposite gland becomes affected. Feiling states that in mumps there is a slight incease in the total number of leukocytes with a relative or absolute lymphocytosis.

The diagnosis from pyogenic parotitis is usually easy but in the early stages in children and in adolescents it may be difficult. In pyogenic parotitis in contradistinction to "mumps" the saliva exuding from the parotid duct is cloudy and purulent and the duct has a red pouting appearance. Pyogenic parotitis shows a rather marked increase of leukocytes with a relative increase of the polymorphonuclears—a picture characteristic of a purulent infection.

Treatment.—The treatment of epidemic parotitis is nonsurgical and palliative. It is claimed that the incidence of orchitis can be lowered by injection of convalescent serum if given early in the disease.

UVEOPAROTITIS

Originally Heerfordt recognized and named the syndrome. Cohen and Rabinowitz have recently called attention to a combination of uveitis and parotitis either with or without nerve palsies and skin eruption. In the literature about 65 cases have been reported. Ophthalmologists apparently see most of the cases.

The etiology of the syndrome is in controversy. Tuberculosis has been suggested but there is no indisputable pathologic or clinical evidence to support this idea. The majority of cases give negative tuberculin reaction. That the condition is a deficiency syndrome has been suggested. Because of the eosinophilia and a skin rash an allergic state has been suggested. But the organism producing this state has never been isolated.

In those cases from which biopsy material for study was obtained, the excised lymph nodes showed an increase of epithelial cells and giant cells but no caseation or tubercle bacilli. The parotid gland showed no tubercle bacilli, giant cells or caseation.

Clinical Features.—The parotid glands are usually involved early. First one and then the other gland is affected. The gland becomes swollen, hard, not painful and never suppurative. The swelling lasts for several months or even a year or so. After the swelling disappears, shotlike nodules remain. The submaxillary, cervical and supraclavicular lymph nodes are often enlarged but are not tender.

Both eyes are always involved—first one and then the other. Misty vision and pain in the eyeballs are complained of. The pupils become irregular, dilated and may not react to light. Keratitis, ciliary congestion and nodules in the iris appear and the vitreous shows opacities. Synechiae, optic neuritis and atrophy may cause permanent visual defects.

One third of the cases show facial paralysis. One or both sides may be affected and the palsies take several weeks to clear up. Occasionally other nervous system involvement is noted.

A rash over the body, arm and legs of an erythematous type may be present during the acute systemic involvement.

Fever as high as 103° F. has accompanied the infection. An eosinophilia of 3 to 20 per cent is usually found. The white blood count is not necessarily changed.

There are only three recorded deaths. The usual defect may be permanent. The nerve palsies clear up.

Treatment.—Foreign protein has been suggested as the logical approach to therapy. The ophthalmologists have used tuberculin therapy. Radiotherapy has also been used. The disease is self-limited no matter what the therapy.

Bibliography

Bibliography Quoted in Text

Anonymous Communication to the Medical Times and Gazette of November 1, 1868.

Barsong, T.: Klin. Wchnschr., **52:** 2500, 1925.

Blair, V. P., and Padgett, E. C.: Pyogenic Infections of the Parotid Glands and Ducts, Arch. Surg., **7:** 1–36, 1923.

Barsky, J. A., and Silberman, H.: Ann. Surg., **95:** 46–51, 1932.

Brodie, B.: Lancet, **1:** 450, 1834. Quoted by Blair, Padgett, and Brown.

Bucknell: Moynihan's Abdominal Surgery, Phila., W. B. Saunders Co., 1916.

Bunting, C. H.: Nelson's Loose Leaf Living Medicine, **3:** 364, 365.

Carlsten, D. B.: Acta Radiol., **6:** 221, 1926.

Cohen, S. J., and Rabinowitz, M. A.: Uveoparotitis, J.A.M.A., **105:** 496, 1935.

Feiling: Lancet, London, July 12, 1913.

Friedländer: Quoted by Kussmaul, Berl. klin. Wchnschr., No. 15, 1879.

Goodell: Med. Times and Gazette, **2:** 290, 1881.

Hanau: Beitr. z. path. Anat. u. z. allg. Path., **2:** No. 5, 1889.

Howard, C. P.: Internat. Clinic., **1:** 30, 1909.

Harrison, G. R.: Calculi of the Salivary Glands and Ducts, J.A.M.A., **43:** 431–435, 1926.

Heerfordt, C. F.: Ueber eine Febris uveoparotidea subchronica, Arch. f. Ophth., **70:** 254, 1909.

Henke, F., and Lubarsch, O.: Handbuch der speziellen pathologischen Anatomie und Histologie, Berlin, Julius Springer, **2:** 61–73, 1929.

Hewlett, A. W.: Bacterial Intermittent Swellings of the Parotid Glands Due to Infection of Steno's Duct, Jour. Mich. Med. Assoc., **12:** 664, 1913.

Hickey, P. M.: Amer. Jour. Roentgen., **2:** 776, 1915.

Hutchinson, J.: Quoted by Rhodes.

Ivy, R. H., and Curtis, L.: Salivary Calculi, Ann. Surg., **96:** 979, 1932.
Salivary Calculi, Internat. Jour. Orthodont., **22:** 179, 1936.

Johnson, P.: Arch. Surg., London, **3:** 343, 1892.
Some Unusual Cases of Swelling of the Parotid Gland, Lancet, **1:** 1056, 1896.

Keith, H. M.: Jour. Amer. Med. Assoc., **90:** 1270, 1928.

Kermorgant: Amer. Inst. Pasteur, **39:** 565, 1925.

Kussmaul: Berl. klin. Wchnschr., No. 15, 1879.
Lancet, **2:** 540, 1828–1829; **1:** 538, 1844; **13:** 830, 1827–1828.

Mayo, W. J.: Co-Ordination of Human Vegetative Functions, Surg., Gynec. and Obst., **38:** 312, 1924.

Mikulicz, J.: Berl. klin. Wchnschr., **25:** 759, 1888.

Moeriche: Quoted by Wagner: Ueber postoperative Parotitis, Wien. klin. Wchnschr., **17:** 1407, 1904.
Munde: Quoted by Wagner.
Naeslund, C.: Acta Path. et Microbiol. Scand., **6:** 78, 1929.
New, G. B., and Harper, F. R.: Chronic Inflammations of the Salivary Glands With or Without Calculi, Surg., Gynec. and Obst., **53:** 456, 1931.
Noehren, A. H.: Multiple Calculi in Stensen's Duct, J.A.M.A., **80:** 25, 1923.
Orth, Johannes: Lehrbuch der speciellen pathologischen Anatomie, Berlin, A. Hirschwald, **1:** 629, 1887.
Paget, S.: Secondary Inflammation of the Parotid, Lancet, **1:** 732, 1886.
The Relation of the Parotid Gland to the Generative Organs, Lancet, **1:** 86, 1886.
Pilliet: Bull. Soc. anat. d. Paris, p. 182, 1890.
von Recklinghausen: Quoted by Kussmaul: Berl. klin. Wchnschr., No. 15, 1879.
Rhodes, G. B.: Intermittent Swelling of the Salivary Glands, Lancet, Clinic, Cincinnati, **113:** 248, 1915.
Schopper, A., and Jacobsen, A. W.: Amer. Jour. Dis. Child., **34:** 327, 1927.
Söderlund, G.: Die Speichelsteinkrankheit ("Sialolithiasis") und ihres Verhalten zu den primären und duktogenen Speicheldrüsenaktinomykose, Acta Chirurg. Scand., **63:** 1–237, 1927.
Stiller: Wien. med. Wchnschr., 1881.
Thursfield, H.: Quart. Jour. Med., **7:** 237, 1914.
Wakeley, C. P. G.: The Formation of Salivary Calculi and the Method of Treatment, Lancet, **1:** 708–711, 1929.
Tumors of the Salivary Gland, Surg., Gynec. and Obst., **48:** 635, 1929.
Wiskosky: Ann. des mal. de l'oreille, **46:** 76, 1927.

CHAPTER XXII

THE NEURALGIAS AND MOTOR DERANGEMENTS AFFECTING THE FACE, MOUTH AND JAWS

The Neuralgias

Little is known concerning the cause of neuralgia—a loose term used to designate a recurrent localized pain without objective findings. The pains which arise on account of affections of the teeth, bones and accessory sinuses are discussed in their respective sections.

MAJOR TRIGEMINAL NEURALGIAS; TIC DOULOUREUX

This disease is characterized by recurring attacks of severe paroxysmal pain in the distribution of one of the three bundles of the fifth nerve.

John Locke, physician and philosopher, in letters to Dr. Mapleoft gives the first description of the disease. Nicholas André in 1756 in a treatise on urethral disease apparently first used the term "tic douloureux." Fothergill in 1776 described the condition. Oliver Wendell Holmes in 1838 published the first monograph on neuralgia. In 1884 Mears suggested excision of the gasserian ganglion, in 1898 Spiller suggested cutting the sensory root and in 1901 Frazier performed the first successful division of the root.

As to the etiology numerous theories have been advanced, but there is no convincing evidence for any of them. The incidence shows no peculiarities as to climate, race, sex or occupation. Attacks may occur any time. Most cases have their onset between the ages of forty and sixty. About 4 or 5 per cent are bilateral. The right side is involved about twice as often as the left. Patients afflicted with the disease usually appear late in hospitals as they suffer with the disease for many years ordinarily before finally submitting to a definite radical procedure. The ophthalmic division of the fifth nerve is seldom involved. The third or mandibular branch is the branch most frequently involved.

No definite pathologic lesion can be found. In young subjects, no pathology is found. In old subjects the lesion in the nerve or the gasserian ganglion are only those consistent with old age.

Clinical Features.—The typical onset is a sudden, shooting, stabbing pain felt in the upper jaw, lower jaw, cheek, lip or most rarely in and about the eye. No prodromal symptoms are present. The pain disappears but may recur at any time. No soreness follows the pain and all objective symptoms are negative. As the disease progresses the intervals between the pain become shorter and shorter. As many as four years have passed between the first and the next pain but, as a rule, within a few hours the pain recurs. For several days this is repeated. Then a period of freedom intervenes for about four weeks to months but almost daily pain may rarely be experienced from the onset. The pain is characteristically noted in individual flashes—not continuous (Fig. 118). This is important in the diagnosis. The function of the nerve is not changed.

The anatomic distribution of the pain is definite (Fig. 119), usually in the second or third division of the nerve. When a second branch becomes involved, it is always an adjacent one. Bilateral trigeminal neuralgia is rare. Unilateral pain is the typical type. One nerve trunk of one branch of the



A *B*

Fig. 118.—Two common attitudes assumed by patients during a paroxysm of trigeminal neuralgia. (Peet, Dean Lewis' System of Surgery, W. F. Prior Co., Inc., Publishers.)

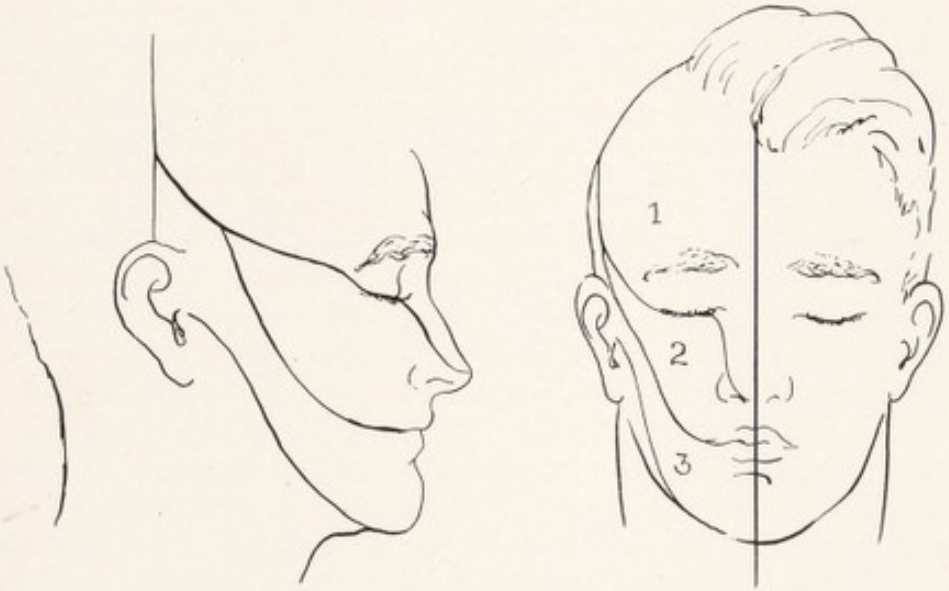

Fig. 119.—Areas of skin innervated by the three branches of the fifth nerve.

nerve may be all that is involved but the pain always extends to the midline. The pain is always felt on the surface, never deep or throbbing. The pain is often induced by talking, eating, swallowing, smiling, the irritation of a breeze, shaving, or touching the face. Many have dolorogenic areas

or trigger zones and they may not be situated in the distribution of the branch involved but in adjacent areas. Patients soon learn not to touch or move in such manner that the paroxysm is initiated. Some of the cases exhibit a typical facial spasm during the paroxysm. Others hold themselves immobile. Others clutch the hand to the cheek. The tears may flow and the eyes may become reddened. The diagnosis is made on the history and the exact localization and description of the pain.

Treatment.—The treatment is directed to the relief of symptoms. Extraction of diseased teeth will not cure trigeminal neuralgia. Countless sound teeth have been sacrificed on the altar of this forlorn hope. Infections of the sinus play no rôle in the etiology. Two types of treatment are useful: (1) alcohol injection of the gasserian ganglion; and (2) avulsion of the root. The latter is ordinarily curative.

Alcohol Injection of the Fifth Nerve.—For the mandibular division, all injections are directed to the foramen ovale. The subzygomatic route is

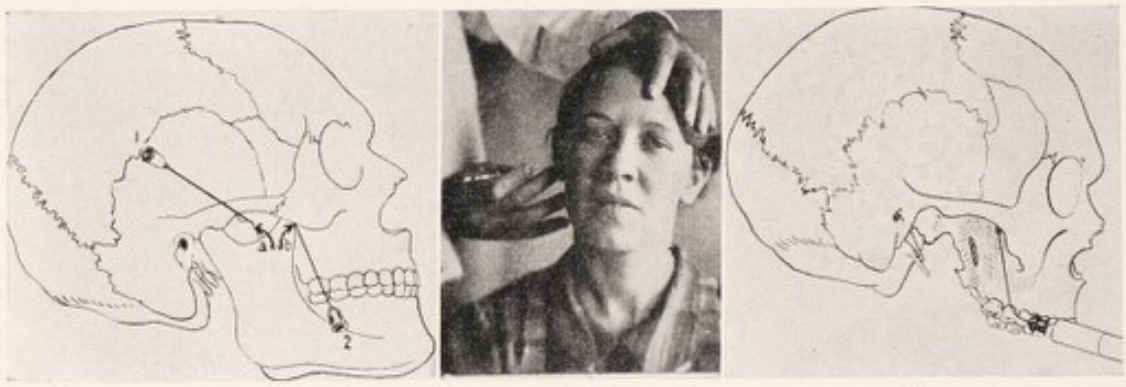

A *B* *C*

Fig. 120.—*A*, 1, Position of needle to strike the pterygoid plate. The needle can then be shifted slightly backward and dropped a little deeper so that one approaches the foramen ovale. As you shift forward it is possible to place the needle near the foramen rotundum. 2, The needle is placed in position to strike near the first division of the fifth nerve at a little different angle. *B*, Needle being inserted in the region of the foramen ovale to strike the third division of the fifth nerve. *C*, Inserting needle toward the foramen rotundum from within the mouth through the buccal mucosa.

considered the safest. Local anesthesia is used for the skin. A special needle about 12 cm. long and 1.75 mm. in diameter is best. The needle should have markings to indicate the depth of insertion.

At the inferior surface of the zygoma below the notch, the needle is inserted and slowly pushed inward to the depth of 4 or 4.5 cm. When the patient immediately complains of pain in the lower jaw or lip all well and good. If not, the needle is moved somewhat posteriorly and if no pain is elicited, next somewhat anteriorly until pain in the distribution of the nerve is elicited. Pain referred to the ear is indicative of the needle being too far posteriorly. Two cc. of 95 per cent alcohol is injected (Fig. 120, *A*, *B*, *C*).

The second branch is injected at the foramen rotundum. The needle is inserted beneath the anterior end of the zygoma anterior to the coronoid process. Then the needle is pushed inward and upward. At about 5 cm. it should reach the maxillary division of the nerve, but the depth varies from 4 to 6 cm. in various individuals (Fig. 120, *A*, *B*). About 2 cc. of

alcohol is injected slowly after evidence of pain in the distribution of the second division of the fifth nerve is given.

The duration of relief from alcohol injection varies from six months to one year and relief may persist for several years in rare instances. The injections may be repeated. Usually most patients choose to be operated upon after from two to three injections as the procedure is quite painful. The relief given often after each successive injection is of shorter duration. Some complications may occur after alcohol injections.

Operation for Trigeminal Neuralgia.—Section of the sensory root offers permanent relief and the operation is really indicated in almost all cases of major trigeminal neuralgia. The mortality in proper hands is very low even in the aged. Spiller suggested the operation which Frazier first performed successfully. Local anesthesia along with a preliminary sedative

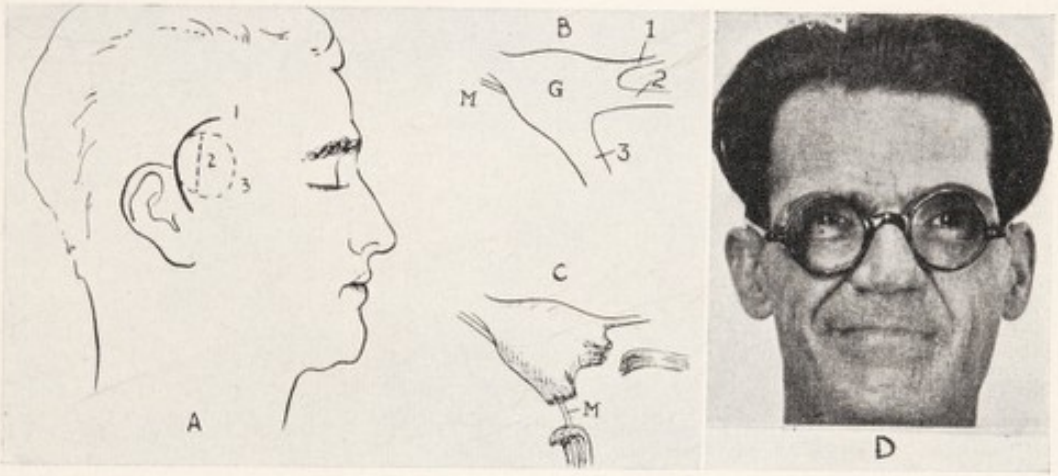

Fig. 121.—A, Skin incision for tic douloureux. 1, Skin incision; 2, dotted line shows incision through fascia; 3, circular dotted line shows amount of bone removed from the temporal fossa. B, Gasserian ganglion with its motor root which comes in from underneath and runs behind the ganglion and along the third sensory division of the fifth nerve. C, Shows how the sensory part of the third division can be divided without dividing the motor root. D, Three years after bilateral section of sensory roots of the gasserian ganglia. Both motor roots were preserved, hence there was no atrophy of the temporal and masseter muscles and no impairment of mandibular action. Glasses have celluloid shields to protect the cornea from windblown dirt. (Peet, Dean Lewis' System of Surgery, vol. 12, W. F. Prior Co., Inc., Publishers.)

is satisfactory. The temporal fossa is entered through an incision just in front of the ear and about the zygoma (Fig. 121, A, B, C, D). In experienced hands this is not a difficult operation but, in inexperienced hands, there are many pitfalls detrimental to the patient.

Lingual Spasm After Operation for Trigeminal Neuralgia.—Cobb and Mixter in reviewing their series of atypical trigeminal neuralgia found 3 cases which were relieved temporarily of their pain by an operation on the gasserian ganglion but who later developed a spasmodic contraction of one half of the tongue. This is apparently a rare complication. Mixter cut the lingual nerve on the side of the spasm and entirely cured the lingual spasm.

TIC CONVULSIF OF THE PAINFUL TYPE

In this type of the disease a spasmodic contraction of the facial musculature occurs which is accompanied by severe neuralgic pains. The cause

is unknown. The disease is very rare. Cushing described a case. In his case pain appeared about the eyes and extended later to the cheeks and finally involved the whole trigeminal region. The painful tic is always started by motor spasm, while in tic douloureux the pain precedes the motor spasm.

Treatment.—The treatment is not successful. Cushing cut the facial nerve, destroyed the geniculate ganglion and did a spinofacial nerve anastomosis. Dandy suggests that if the disease is due to a lesion of the geniculate ganglion, section of the pars intermedia should result in a cure.

NEURALGIA OF THE SEVENTH NERVE

This is characterized by neuralgia of the sensory distribution of the geniculate ganglion. It is decidedly rare. Mills does not believe the geniculate ganglion to be at fault. Hunt has been the chief exponent of the geniculate ganglion hypothesis. Dandy states that at least some forms of otitic neuralgia should be accredited to this ganglion. Without relation to other disease the onset is sudden. The pain may be either of the intermittent or the constant type and is always located in some portion of the ear and may in certain instances also spread over the trigeminal field or to the cervical region. If the pain is intermittent to start with, the attacks become more frequent and of longer duration until finally they occur many times daily. The pain may closely simulate a trigeminal neuralgia.

Treatment.—Dandy has advised section of the pars intermedia for its relief. He says the operation is comparatively safe as the exposure is extradural.

GLOSSOPHARYNGEAL NEURALGIA—TIC DOULOUREUX OF GLOSSOPHARYNGEAL NERVE

Weisenburg in 1910 first described the symptoms of glossopharyngeal neuralgia but his case was due to an intracranial tumor. In 1920 Sicard and Robineau first described true glossopharyngeal neuralgia. In 1923 Doyle published the first report in this country. Dandy described the first intracranial section of the root in 1927.

The disease is characterized by excruciating stabbing pain located in the sensory distribution of the glossopharyngeal nerve. The etiology is unknown. In 22 cases the average time of onset was forty-nine years (Peet). The youngest was twenty-one and the oldest seventy-five years of age (Peet). Only 29 cases are recorded in the literature. No pathologic studies have been made of the nerve or nerve ganglion.

Clinical Features.—Without prodromal symptoms, a sudden knifelike pain is felt in the base of the tongue, the tonsillar region, the posterior pharynx, or about the ear. Not uncommonly, the attack appears while talking or drinking. Each painful attack is of short duration, but it soon recurs and soon becomes a series of paroxysms. A period of hours or days follows the attack in which there is a complete freedom from the pain. The painful periods may last several weeks. The interval of freedom varies from weeks to several months. Three and one-half years has been recorded as a period of freedom. The pain is always unilateral, tends to

appear in approximately the same location but in rarer instances there is a distinct tendency to radiation. Swallowing, coughing, yawning, and so forth, tend to precipitate an attack. A "trigger zone" is often present. The slight touch on the area of the trigger zone during the periods of attack is followed by excruciating pain. The diagnosis is made on the history of repeated sharp stablike excruciating pain localized in the distribution of the glossopharyngeal nerve. No other form of neuralgia has the same distribution. Intracranial tumors have produced pain similar to glossopharyngeal neuralgia as reported by Weisenburg and Harris. The possibility of an intracranial tumor should be considered.

Treatment.—The only treatment is actual section of the glossopharyngeal nerve. Alcohol injection near the jugular foramen has been suggested and attempted by Harris. The procedure is too dangerous because of the structures near by—the internal carotid artery, internal jugular vein, spinal accessory, vagus, and cervical sympathetic nerves—to be considered. The nerve is sectioned by the intracranial approach. Adson has done the intracranial section on 4 cases and Dandy on 2. Peet has 5 cases. A cerebellar approach is necessary.

After operation the patient is given complete relief. A unilateral loss of taste on the posterior third of the tongue and anesthesia of the soft palate, uvula, tonsillar region, base of tongue and pharynx is produced. The pharyngeal muscles of the soft palate are not paralyzed and the isolated paralysis of the stylopharyngeal muscle is not demonstrable.

SECTION OF THE GLOSSOPHARYNGEAL NERVE FOR PAIN DUE TO MALIGNANT GROWTHS IN THE TONGUE AND PHARYNX

The operative procedure is similar to the one just described. However, it would seem to me that the indications, namely, excruciating pain from malignant lesions in the area, or after radiation of malignant tumors, would seldom arise to justify the operation. Usually the patient is in a hopeless condition in which it is only a matter of a few weeks or a month or so until the end. Opiates are usually sufficient to allay this type of pain.

SPHENOPALATINE NEURALGIA

Greenfield Sluder first called attention to this syndrome. The neuralgia is caused most likely by some lesion in the sphenopalatine ganglion. The etiology is obscure. It has been suggested that the pain may be a sequela of sinus disease. No pathologic lesion has been definitely demonstrated in the ganglion.

Clinical Features.—Sluder's own description of the syndrome follows:

"One of the most striking manifestations of disturbance in the sphenopalatine ganglion is the wide and characteristic distribution of pain along definite lines. These neuralgic manifestations can be evoked by mechanical irritation of the ganglion, by the faradic current, and by therapeutic injections of alcohol. The neuralgia is described as a pain at the root of the nose, sometimes also in and about the eye, taking in the upper jaw and teeth; sometimes also the lower jaw and teeth, and extending beneath the zygoma to the ear to take on the form of earache. It is emphasized at the mastoid, but is nearly always severest at a point about two inches posterior to the mastoid, thence reaching backward by way of the occiput and neck; and it may extend to the shoulder blade and shoulder, and in severe attacks to the axilla, arm, forearm, hand, and fingers. Sometimes the patient complains also of a 'stiff' or 'aching' throat,

without inflammation; of pain, or oftener of itching, in the roof of the mouth; or of pain inside the nose.

"Along with the pain there is, also, on the affected side, slight anesthesia of the soft palate, and of the pharynx as far down as the lower part of the tonsil, and also in the anterior lower part of the nose.

"In a large percentage of cases, the neuralgia is accompanied by motor disturbance, affecting the configuration of the soft palate. The palatine arch on the affected side is often higher than on the well side, and during movement, the median raphe is deflected from the affected side. Taste is usually less acute on the dorsum of the affected side."

Treatment.—Sluder injected the ganglion through the nose with alcohol and obtained relief for a few months to several years in most cases. The procedure requires a special heavy needle to pierce the thin bony shell overlying the ganglion. Cocaine anesthesia to the mucosa of the nose or light gas anesthesia is used.

GLOSSODYNIA

Glossodynia is only a symptom. Kaposi has referred to the disease as glossodynia exfoliativa, a disease in which the tongue is hyperesthetic, and Morelli has described a glossodynia of a similar nature. Glossodynia should be described as a psychopathic neurosis. It may be associated with a trigeminal neuralgia or with neuralgia of the glossopharyngeal nerve. There has been an idea that the disease is definitely associated with abnormal function of the stomach with a hypo-acidity or at times a complete achylia gastrica. Very often in women it has some relationship to the menstrual period and would suggest possibly a relationship of an endocrine nature.

The symptoms of the disease are characteristic burning sensations of the anterior third or the tip of the tongue and is especially prominent near its borders. Rarely the hyperesthesia extends to the soft and hard palate or even to the vermilion border of the lower lip. Usually the pain is described as being of a burning character but sometimes only of an itching character. The pain ordinarily is more or less constant. As a rule, the patient shows some neurotic tendencies and very often seems to be somewhat depressed. The pain is usually increased when the tongue is brought into contact with liquid or solid foods and very often between meals the patient complains of a dryness of the mouth. When the conversation is animated or the patient's attention is distracted, very often no complaint is made. Usually the papillae of the tongue are slightly enlarged. Practically all of the patients are over thirty-five years of age, and of the female sex. A good many of the patients really have some fear of a malignant disease. At least, it seems that their minds are altogether too much concentrated on the matter. The patient tends constantly to inspect his own tongue and is apprehensive in regard to ordinary anatomic conditions which the physician would consider largely normal.

Although these cases may be very stubborn as far as treatment is concerned, if the patient's attention can be transferred to some other matter, they very often forget about the condition. In the treatment one makes every effort to eliminate any general causes like gastric disturbances or a general disease.

Sluder is said to have controlled some cases of glossodynia by cocainization of Meckel's ganglion. Not all cases, however, will be controlled by

injections which knock out the sensation of Meckel's ganglion. A description of the method of injection is given under Sphenopalatine Neuralgia.

Motor Nerve Derangement

The motor nerve derangements of this region may be divided into two types, namely, the spasmodic and the paralytic.

A. Spasmodic Derangements:

Two types of spasmodic tic may be distinguished, one, those more or less under control of the volition and two, those not under control of the volition, *i. e.*, completely involuntary and uncontrollable. Facial tic is a common example of the latter. An example of the former is tetanic contracture of the jaws due to a hyperirritability of the motor nerve to the muscle of mastication.

FACIAL SPASM

Facial spasm is a true spasm of the facial muscles. It is always unilateral. The etiology is unknown. The condition is not to be confused with facial tic or habit spasm. In true spasm there is no voluntary or involuntary control. The movement cannot be imitated. Speech is definitely interrupted. The disease usually starts in one portion of the muscle, usually the orbicularis palpebrarum. Gradually the remainder of the muscle in which the spasm starts is involved and finally the remainder of the muscles supplied by the seventh nerve. According to Head (Blair) facial spasm is more likely to develop in an individual of neurotic temperament.

Treatment.—The treatment has not been any too satisfactory. One method of treatment tried has been to stretch the seventh nerve until it was paralyzed, but with return of function, the spasm usually returns. Patrick suggested the injection of alcohol about the nerve. This prevents a return of the spasm until some time after the facial paralysis has disappeared. The nerve is struck just at the stylomastoid foramen and 1.5 cc. of 70 per cent alcohol injected. When the injection has struck the nerve immediate facial paralysis results. Some months elapse before the return of voluntary motion.

B. Paralytic Derangements:

Electrical Test for Paralysis.—Considerable information as to the state of a nerve or muscle can be obtained by electrical stimulation. Once a nerve has degenerated there will be no response from the faradic current. In using the galvanic current a contraction of the muscle supplied by the nerve is obtained when the current is turned on and also when it is turned off. In health the contractures are sharp and abrupt. In disease of the nerve or muscle, the contracture may be altered quantitatively or qualitatively.

When a motor nerve is severed, within a short time degeneration of the axis-cylinders begins to take place. The nerve soon fails to respond to electrical stimulation and soon the muscle fails to respond. It is during these periods of degeneration of the nerve and atrophy of the muscles that the reaction of degeneration appears. This includes a series of changes: (1) with the faradic current no response is obtained. (2) With the galvanic current both quantitative and qualitative changes occur. The quantitative changes are that the muscle will respond to a weaker current than is normally required. Among the qualitative changes are a more sluggish con-

traction and in most cases the anodal closing contraction is obtained with a weaker current than is cathodal closing contracture. About a week after severance of the nerve, the reaction of degeneration is established. After about three days the nerve is less sensitive. After about two years the muscles will cease to respond to stimulation. The reaction of degeneration only occurs when the nerve is severed between its muscles and its peripheral ending. In complete section of an important motor nerve, direct nerve suture, transplantation or grafting should be resorted to as soon as possible.

PARALYSIS OF THE MOTOR FIFTH NERVE

The fifth nerve besides carrying sensory fibers to one half of the face carries the motor fibers to the muscles of mastication. Paralysis of the muscles of mastication on one side causes no great inconvenience and is only slightly noticeable. The masseter and the temporal muscles do not contract on the side of the paralysis. This is not difficult to determine by palpation. In a unilateral paralysis the chin deviates toward the paralyzed side when the mouth is opened, because of the unopposed action of one external pterygoid muscle. The mouth could not be closed if the paralysis were bilateral.

PARALYSIS OF THE FACIAL NERVE

The facial nerve has both a motor and a sensory root. The sensory root is known as the pars intermedia called by some the thirteenth nerve. The motor cells arise in the facial nucleus. The motor root traverses the geniculate or sensory ganglion and connection is made with the sphenopalatine (Meckel's) ganglion by means of the great petrosal nerve. The sensory portion finally emerges in the fallopian canal as the chorda tympani which joins the lingual nerve and carries the sense of taste to the anterior two thirds of the tongue. Supranuclear paralysis is usually caused by tumors located in the cortex or along the pathway of the nerve to its nucleus. Middle meningeal or cerebral hemorrhage often causes a supranuclear paralysis. Nuclear paralysis may be caused by anterior poliomyelitis, syphilis, diphtheria, parotid tumors, and so forth. Peripheral paralysis is the most common type of paralysis of the facial nerve and the most common type of peripheral paralysis is the so-called "Bell's palsy" produced most likely by an inflammation or edema of the nerve within the fallopian canal. The history is usually elicited that the sufferer slept in a draft, washed the hair or suffered some such exposure. Hunt has advocated the view that Bell's palsy is due to inflammation of the geniculate ganglion in which the herpes is absent. Trauma reasons for a peripheral facial paralysis are fracture and operations. Otitis media may cause the lesion. A neurofibroma of the acoustic nerve may produce the paralysis.

Clinical Features of Peripheral Paralysis. (See a textbook on neurologic diagnosis for the symptoms of supranuclear paralysis and nuclear paralysis of the nerves.)—Briefly, supranuclear paralysis is characterized by a paralysis of the lower part of the nerve but as the upper part of the nerve has a cross innervation, the ability to close the eye and wrinkle the forehead is retained (Fig. 122). Nuclear lesions and peripheral lesions result in a paralysis of all of the muscles of one side of the face. A lesion of the

pars intermedia alone does not impair taste. A lesion in the fallopian canal between the geniculate ganglion and the point of branching off of the chorda tympani results in loss of taste. A lesion below the chorda tympani results in simple muscular paralysis.

In oral surgery one is concerned only with the peripheral type of paralysis. Both voluntary and involuntary motion is lost and also muscle tone is lost in complete peripheral paralysis of the nerve.

Treatment of Facial Paralysis (Peripheral).—Mechanical support should be supplied to aid the paralyzed muscles. This may be done by attaching an adhesive strap to the cheek and attaching it by a hook in the hair or to a head band. This is worn until voluntary motion returns.

Surgical relief of a permanent facial paralysis consists of end-to-end suture of the divided nerve, anastomosis of the proximal end to a less important proximal end of another motor nerve and the application of fascial bands to hold the cheek in a normal position when it is in a position of rest.



A *B*

Fig. 122.—Patient with a seventh-nerve paralysis of long standing. *A*, Before fascial strands were placed through the cheek. *B*, After.

Duel and Ballance after doing considerable work with transplantation of segments of nerves from other parts of the body have come to the conclusion that the best way to repair a sectioned facial nerve is to cut a section of some other peripheral nerve and leave it in position for a while—until the axis-cylinders degenerate and then to transplant it between the two ends of the facial nerve end-to-end. They state that the axis-cylinders of the divided facial nerve will migrate down the small tubules of the delayed nerve graft and that eventually the facial nerve will functionate. They show some cases which would lead one to think that there might be some basis of fact for their conclusion. If this is the case, however, it is rather contrary to the work concerning the regeneration of nerves which has preceded.

Operative relief is indicated when it is evident that the facial nerve has been completely divided or is not going to regenerate. Within six months some evidence of regeneration should be present if it is going to occur. The

percentage of recoveries are much greater if surgical intervention is undertaken within a year. If the galvanic current will not produce contraction of the muscles, they have become fibrotic and nerve suture or anastomosis is useless. Rarely, when the evidence points to a constricting scar, exploration followed by a neurolysis of the nerve may give improvement.

1. End-to-end Anastomosis of Divided Nerve.—Ney in 1922 published a technic for suture of the nerve within the canal. Bunnell in 1927 reported a performed operation with fairly complete recovery. End-to-end suture between the stylomastoid foramen and the point of division into its major peripheral divisions has been performed with some success a number of times. The lower part of the mastoid process may be removed and a part of the canal to give more space for work and mobility to the nerve.

2. Anastomosis of the Distal End of the Facial to the Proximal End of a Less Important Motor Nerve.—Both the hypoglossal and the spinal accessory nerves have been used to anastomose to the distal end of the facial nerve. Both nerves are easily exposed. The hypoglossal nerve is closer to the facial nerve. The movements of the face and tongue are somewhat synergistic. On these grounds the hypoglossal might seem preferable. Whether the spinal accessory or the hypoglossal nerve is used, one can also anastomose the descendens hypoglossi to the distal end of either the eleventh or twelfth nerve and largely prevent complete sternomastoid and trapezius paralysis in the first instance or atrophy of the tongue in the second instance. Most men now perform the hypoglossofacial anastomosis.

Technic.—Exposure of Facial Nerve.—The incision begins about a finger-breadth above the mastoid tip, and is carried downward and a little forward toward the hyoid bone. The parotid gland is retracted upward and the facial nerve is located before it passes into the capsule. The nerve courses backward and upward and disappears beneath the upper part of the digastric muscle. The posterior auricular artery is encountered here and should be ligated and cut. The nerve is exposed to the stylomastoid foramen.

Exposure of the Hypoglossal Nerve.—The anterior edge of the sternomastoid is retracted backward. The posterior belly of the digastric is retracted upward. The hypoglossal nerve lies on the external carotid artery. It hooks around the occipital artery and curves forward beneath the digastric muscle. As the hypoglossal nerve crosses the internal carotid, it gives off the descendens hypoglossi. This latter nerve courses vertically downward. The hypoglossal nerve is well freed.

Exposure of the Spinal Accessory.—The sternomastoid muscle is retracted posteriorly. The posterior portion of the digastric is elevated. The spinal accessory nerve lies on or just in front of the transverse process of the atlas covered by a layer of deep fascia which is incised. The nerve is isolated up to its entrance into the sternomastoid muscle.

3. Anastomosis of the Hypoglossal to the Facial and the Descendens Hypoglossi to the Distal End of the Hypoglossal.—The hypoglossal nerve is cut at a point which will give sufficient length so that the distal end of the hypoglossal nerve can be approximate to the proximal end of the facial which is also cut at a point near the stylomastoid foramen so that the proximal stump is as long as possible (Fig. 123, *A*). The hypoglossal can be carried either over or under the digastric muscle. Fine in-

terrupted silk is used for suturing. The incision should be obtained without tension. The descendens hypoglossi is cut low and the distal end brought up to the proximal end of the hypoglossal nerve. The two ends are then sutured in an end-to-end anastomosis as above.

4. Anastomosis of the Spinal Accessory to the Facial and the Descendens Hypoglossi to the Spinal Accessory.—The same procedure can be carried out of cross anastomosing the descendens hypoglossi to the

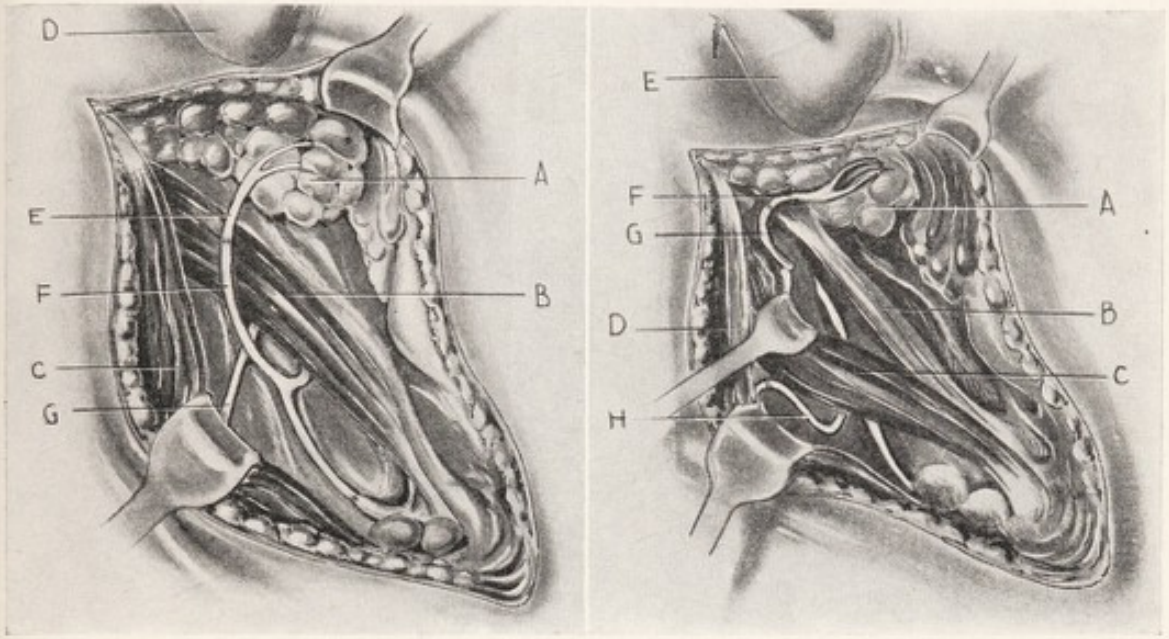

A *B*

Fig. 123.—*A,* Hypoglossofacial anastomosis. The proximal end of the hypoglossal has been carried over the digastric muscle and sutured to the distal end of the facial nerve, and the descendens hypoglossi has been sectioned and its proximal end sutured to the distal end of the hypoglossal nerve. The spinal accessory nerve is seen passing from in front of the transverse process of the atlas backward to enter the median surface of the retracted sternomastoid muscle. A, Parotid gland; B, digastric muscle; C, sternomastoid muscle; D, lobe of the ear; E, distal end of facial nerve; F, proximal end of hypoglossal nerve; G, spinal accessory nerve.

B, Diagram of spinofacial anastomosis. The proximal end of the spinal accessory has been sutured to the distal end of the facial nerve. The proximal end of the descendens hypoglossi is then sutured to the distal end of the spinal accessory. The proximal end of the latter nerve is carried upward beneath the digastric muscle which is seen retracted downward. The sternomastoid muscle is retracted to expose the distal end of the spinal accessory nerve. A, parotid gland; B, stylohyoid muscle; C, digastric muscle; D, sternomastoid muscle; E, lobe of the ear; F, distal end of the facial nerve; G, proximal end of spinal accessory nerve; H, distal end of the spinal accessory nerve.

distal stump of the spinal accessory when the proximal stump is used to suture to the distal segment of the facial nerve (Fig. 123, *B*).

Prognosis.—Within from six months to a year after the anastomosis muscle tone usually returns. Some voluntary control is usual. The percentage of recoveries depends upon the length of time the paralysis has been present and the longer the time after one year, the less likelihood of improvement. After three years, operation is usually without benefit (Dandy). When the spinal accessory is used, contraction of the facial muscles is associated with movements of the shoulder. When the hypoglossal

nerve is used, contraction of the facial muscles coincides with movements of the tongue. In many cases these are pronounced but later they tend to diminish. Involuntary expression is completely lost.

5. Operative Technic of Implanting Fascial Bands in the Face for Facial Paralysis.—In a facial paralysis of long standing in which the chances of relief by nerve transplantation are slight or hopeless, the appearance of the face when at rest can be made nearly normal by running doubled fascial strands through the soft tissues of the face. And on smiling the paralyzed side of the face is not pulled over to the normal side; it is



Fig. 124.—Placing fascial strands. With a long, curved needle which pushes the fascia through the soft tissue, the fascia is inserted and then looped back so that the two ends can be knotted and then fixed with a silk suture. A small incision is made in the skin to facilitate insertion of the needle and the end of the fascial strands. From 3 to 4 strands are inserted and are run down near the corner of the mouth to a point which seems to need retraction and fixation. The upper ends of the fascia are fixed rather high up above the tissue of the zygoma where there is not much elasticity of tissue.

held fixed (Fig. 124). The importance of this fixation to the appearance is quite marked. The method has also been used to keep the facial muscle from being overstretched in conjunction with nerve transplantation which will eventually give muscular tone. The firm tissue near and about the zygoma region is used for the purpose of securing a tissue which will not give under a slight tension. The strands are placed running downward to appropriate points from above in the zygoma region and then reversed on themselves to a point near the one of the start of the insertion. From three to four or even five double strands are used—as many as are necessary to fix the side of the face in a normal contour when at rest.

The fascial strips are taken from the fascia lata of the outside of the thigh. They should be a little less than ¼ inch in width and about 1 foot long. The fascia lata should be closed by suture so that the muscle of the thigh does not herniate outward. The whole procedure may be done under local anesthesia.

6. Operation of Eden—Masseter Muscle Transplantation.—The masseter muscle is exposed and a strip detached at the lower end which is transplanted into the lower end of the angle of the mouth. The upper end remains attached to the zygoma. Usually the result is inferior to fascial band transplantation. The operation has the advantage of being somewhat similar in execution.

JUGULAR FORAMEN SYNDROME

Peet has given a good résumé of the literature of this syndrome. Paralysis of the ninth, tenth and eleventh nerves has been called the jugular foramen syndrome. Jackson described in 1864 combined paralysis of the tenth, eleventh and twelfth nerves. In 1915 Collet designed complete paralysis of the last four cranial nerves as glossoscapulopharyngeal hemiplegia. In 1917 Sicard applied the name of the syndrome of the condyloposterior lacerated foramen to the condition. Villaret in 1917 described the syndrome of paralysis of the last four cranial nerves and also the cervical sympathetic. Trauma has produced the syndrome but tumors of either the intracranial type or the extracranial type are a more important cause. Tuberculous adenitis, gummas and aneurysms in the jugular foramen region have produced the syndrome. Cerebellar and extracerebellar tumors sometimes cause this clinical picture. Peet in 6 cases operated found the following as the cause: (1) metastatic carcinoma of the spinal accessory nerve at the jugular foramen, (2) rare chondroma arising from the basilar portion of the occipital bone, (3) inflammatory plaques at the jugular foramen, (4) and (5) acoustic neurofibromas with extension to the jugular foramen, (6) myxo-endotheliomas of the gasserian ganglion with extension to internal auditory meatus and the jugular foramen.

VAGUS NERVE TUMORS

Primary tumors of the vagus are exceedingly rare but do occur. Sekiguchi and Oije have reviewed the literature. Their case had a tumor of the upper cervical region and was a neuroma with sarcomatous degeneration and was successfully excised.

BILATERAL RECURRENT LARYNGEAL PARALYSIS

This very serious condition may be benefited by anastomosing the phrenic or the descendens hypoglossi to the distal end of the nerve. Frazier and Lahey in this country and Ballance in England have reported favorable results.

Bibliography

Bibliography Quoted in Text

Adson, A. W.: The Surgical Treatment of Glossopharyngeal Neuralgias, Arch. Neurol. and Psychiat., **12**: 487, 1924.

André, Nicholas: Observations pratique sur les maladies de l'urèthre et sur plusieurs parts convulsive, Paris, p. 323, 1756.

Ballance, Sir C.: Anastomoses Between the Recurrent Laryngeal and Phrenic Nerves, Brit. Med. Jour., **1:** 746, 1928.

Blair, V. P.: Notes on the Operative Treatment of Facial Palsy, South. Med. Jour., **19:** 116, 1926; Abst. July, 1926.

Bunnell, S.: Suture of the Facial Nerve Within the Temporal Bone., Surg., Gynec. and Obst., **45:** 7, 1927.

Cobb, S., and Mixter, W. J.: Lingual Spasm, Ann. Surg., **101:** 49–55, 1935.

Collet: Quoted by Peet: The Cranial Nerves, Dean Lewis' Practice of Surgery.

Cushing, Harvey: The Varieties of Facial Neuralgia, Amer. Jour. Med. Sci., **160:** 157, 1920.

Dandy, W. E.: Glossopharyngeal Neuralgia, Arch. Surg., **15:** 198, 1927.

Lewis' Practice of Surgery, The Cranial Nerves, Chapter 2, **12:** 53–67, 1932.

Duel, A. B.: The Operative Treatment of Facial Palsy, Brit. Med. Jour., **2:** 1027, 1934.

Fay, T.: Intracranial Division of Glossopharyngeal Nerve Combined with Cervical Rhizotomy for Pain in Inoperable Carcinoma of the Throat, Ann. Surg., **84:** 466, 1926.

Fothergill, J.: Of a Painful Affection of the Face, Medical Observations and Inquiries, **5:** 129, 1776.

Frazier, C. H., and Spiller, W. G.: A Further Report Upon the Treatment of Tic Douloureux by Division of the Sensory Root of the Gasserian Ganglion, Phila. Med. Jour., **10:** 594, 1902.

Frazier, C. H.: The Treatment of Paralysis of the Recurrent Laryngeal Nerve by Nerve Anastomosis, Ann. Surg., **79:** 161, 1924.

Harris, W.: Persistent Pain in Lesions of the Peripheral and Central Nervous System, Brain, **44:** 557, 1921.

Head, Henry: Distribution of Sensation with Special Reference to the Pain of Visceral Diseases, Brain, III, 1894.

Holmes, O. W.: Boylston Prize Dissertation for the Years 1836 and 1837, Neuralgia, Boston, Chas. C. Little and J. Brown, p. 135, 1838.

Hunt, J. R.: The Sensory System of the Facial Nerve and Its Symptomatology, Jour. Nerve and Mental Dis., **36:** 321, 1909.

Jackson, J. H.: Illustrations of Diseases of the Nervous System, Clinical Lectures and Reports by the Medical Staff and Surgical Staff of the London Hospital, **1:** 337, 1864.

Kaposi: Quoted by Prinz and Greenbaum: Diseases of the Mouth and Their Treatment, Phila., Lea and Febiger, 1935.

Lahey, F. H.: Suture of the Recurrent Laryngeal Nerve for Bilateral Abductor Paralysis, Ann. Surg., **87:** 481, 1928.

Locke, John: A Letter to Dr. Mapleoft dated "Paris 4 Dec., 1677," European Magazine and London Review, **15:** 273, 1789.

Mears, J. E.: Study of the Pathological Changes Occurring in Trifacial Neuralgia, Ann. Surg., **2:** 469, 1884.

Mills, C. K.: The Sensory Function Attributed to the Seventh Nerve, Jour. Nerv. and Ment. Dis., **37:** 273 and 355, 1910.

Morelli, G.: Ztschr. f. Stomatol., **26:** 692, 1928.

Ney, K. W.: Facial Paralysis and the Surgical Repair of the Facial Nerves, Laryngoscope, **32:** 327, 1922.

Patrick, H. T.: The Technique and Results of Deep Injections of Alcohol for Trifacial Neuralgia, J.A.M.A., **58:** 155, 1912.

Peet, M. M.: The Cranial Nerves, Dean Lewis' Practice of Surgery, Hagerstown, Maryland, W. F. Prior Co., **12:** 1–102, 1932.

Sekiguchi, S., and Oije, T.: Beiträge zum Vagustumor, Arch. f. klin. Chir., **143:** 113, 1926.

Sicard, R., and Robineau: Communications et presentations. I. Algie vélo-pharyngée essentielle, Traitement chir., Rév. neurol., **36:** 256, 1920.

Sluder, Greenfield: Etiology, Diagnosis and Prognosis and Treatment of Sphenopalatine Ganglion, Neuralgia, J.A.M.A., **61:** 1201, 1913.

Villaret: Quoted by Peet: The Cranial Nerves, Dean Lewis' Practice of Surgery.

Weisenburg, T. H.: Cerebello Pontile Tumor Diagnosed for Six Years as Tic Douloureux: The Symptoms of Irritation of the Ninth and Twelve Cranial Nerves, J.A.M.A., **54:** 1600, 1910.

CHAPTER XXIII

MALRELATIONS OF THE TEETH AND THE JAW BONES*

The dentist in general practice, the oral plastic surgeon, and the orthodontist all will be consulted by individuals with growth deformities of the teeth and jaws who desire advice as to what can or should be done to prevent additional deformity or to correct that which is already present.

The Mode of Growth of the Lower Jaw.—Hunter in his "On the Natural History of the Human Teeth" was the first to show by comparison of four half jaws at different ages that the mandible grows principally at the posterior border (Fig. 125).

By means of madder feeding, which colors new-formed bone, Duhamel verified Hunter's contention. He also verified the principle of the growth in thickness by simple addition beneath the periosteum and discovered that absorption also takes place at the surface. In 1864 Humphrey added experimental proof to these already ascertained facts by inserting metal rings in the rami of young pigs. A ring fixed to the front of the coronoid was

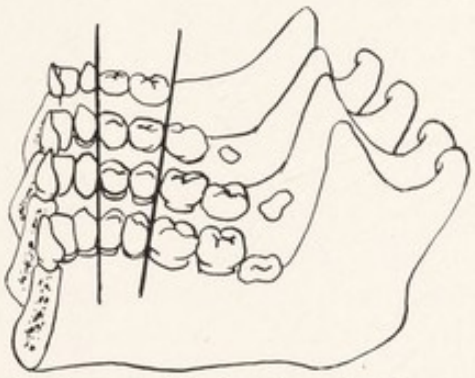

Fig. 125.—John Hunter's diagram illustrating what he considered to be the normal growth of the mandible. The bicuspid teeth occupy less space than did the deciduous molars which they replace. The extra space is used partly by the permanent cuspids and partly by the first permanent molar moving forward. If the teeth are not crowded into this space, bicuspid internal spaces may result. In the younger bones it will be seen there is quite a space between the ramus and the last occluding tooth.

freed as the result of natural absorption. A ring fixed to the back of the ramus became imbedded in the bone. Brash (1924) has by means of madder feeding in pigs restudied the whole matter. Externally in a twenty-week-old pig that has been fed madder, a noncolored area is situated in front of and below the condyle extending across the coronoid to its anterior border. There is also a small noncolored area above the mental foramen. These areas represent absorptive areas. The remainder of the external surface of the bone is colored by madder and represents a deposition of new bone. On the medial aspect a large white area is found on the ramus in its upper two thirds. The area extends into the dental foramen and below along the mylohyoid groove and upward in front of the condyle. From this aspect there is also a small white area in the front of the coronoid extending downward to the crypt in which the second molar

*To Dr. Copeland Shelden I am indebted for the paragraphs outlining his viewpoint on the case management of Class II and Class III malocclusion, and the dangers which accompany the various types of tooth movement. Dr. Shelden also furnished several of the illustrations for which credit is given.

lies. There is another large white area on the inner aspect of most of the body as far back as the last deciduous molar. There is also a small area of absorption on each side of the middle of the symphysis. The areas showing addition of newborn show that the mandible grows in all directions except along the anterior border of the coronoid. The extension backward of the ramus and upward of the condyle is definite as well as addition to the lower border and alveolar ridge. The latter grows upward and forward.

The ascertained fact that the foramina of the bone are not stationary must be considered in selecting a point for measurements of growth. The inferior dental foramen moves backward by progressive addition to its sharp anterior aspect and simultaneous absorption of the posterior aspect. It cannot therefore be selected as a fixed point. A similar process affects the mental foramen. It moves backward during growth.

The Mode of Growth of the Upper Jaw and the Face as a Whole.—A long and laborious investigation would be required to determine exactly how much growth of the skull depends upon suture expansion and how much upon surface expansion. But one of the aspects of the mode of production of normal and deformed jaws is undoubtedly bound up in this problem. In the pig skull Brash found surface addition taking place over the malar and lachrymal bones. The nasal, maxillary, and premaxillary bones were found to be growing only moderately on the surface but additions are very obvious along the suture lines joining them at the frontonasal suture.

On the external surface of the maxilla the chief absorption areas were found to be located in front of the maxillary lachrymal malar articulation. The medial aspect showed absorption over the inner surface of practically the whole of the nasal cavity and its extensions. The tuberosity of the palatal bone and the internal pterygoid plate grow rapidly by addition to their edges. In the palatal bone, although there is a small amount of growth in length of the hard palate at the front, the chief point is the obvious addition to its under surface which amounts to almost half the thickness of the palatal bone. There is also active growth at the median palatal suture. On the upper surface of the palate is an area of absorption. In applying these facts to the human face in correlation with the measurements of Keith and Campion, Brash concludes that the forward growth of the maxilla is essentially due to increase of its body in both directions associated with its simultaneous excavation by the expanding antrum and a downward and forward growth of the alveolar border carrying the teeth. The determination of the more forward position of the whole bone is brought about by suture growth which takes place at its articulation but that this is secondary to the general growth of the surface of the bone.

The Growth of the Alveolar Bone.—The alveolar bone is accessory to the teeth and its existence depends upon the presence of the teeth. The teeth and the alveolar bone constitute a functional unit as Hunter originally pointed out. Alveolar bone is produced as the teeth develop but not always is it exactly proportional to the requirements of the teeth. The general increase of alveolar bone takes place by apposition on the surface. Madder specimens do not bear out the supposition that the alveolar process grows higher at the expense of the body of the jaw. The increase of alveolar

bone in the maxilla leads to a strong downward, outward and forward growth and in the mandible similarly in the opposite direction but of less extent. The alveolar ridges are important in the addition to the height of the jaws, in relation to the eruption of the teeth and other changing forms of the alveolar arches.

When the milk teeth are shed there is a destruction of the alveolar edge and the socket for the permanent teeth have to be rebuilt but accompanying this temporary diminution there is a continuous addition to the alveolar edge. In the upper jaw this is important for the increase of the depth of the bone as the increase in the length of the antrum is almost entirely at the expense of the alveolar bone.

In madder specimens it is noted that the bone around erupting teeth is more active than around the fully erupted teeth. Alveolar growth is seen to be a part of a general growth by means of which the alveolar process deepens all along. The teeth rise with the growth of the alveolar margin. Increase of the width of the alveolar margin occurs and the teeth move outward. However, part of the outward growth in the upper jaw may be due to suture growth but in the mandible it is due only to alveolar change. It has been postulated that there is a forward movement of the molars and this has been given as a cause of forward crowding of the teeth. However, madder specimens provide no unequivocal evidence of such a movement (Brash).

The incisors, the cuspid, and the bicuspids to a less extent, however, do move forward relative to the molars but the separation is explained simply by the fact that in this region the alveolar border is obliquely set and not by movement of these teeth, in alveolar bone or "interstitial growth."

The question of the movement of the first permanent molar is important from the viewpoint of having a fixed point in the anterior-posterior direction from which to compare and measure the alveolar arches. It undoubtedly moves upward in the alveolar border and also laterally. Although as yet it cannot be definitely stated to be a fixed point even in the anterior-posterior direction, it remains the best available point when considering the relation of deciduous teeth and permanent arches.

IMPACTED TEETH

An impacted malposed tooth is one type of irregularity in growth and position of a tooth which may or may not have a relationship to occlusion or malocclusion.

A tooth is said to be impacted or imbedded when its eruption is partially or wholly obstructed by bone or some other teeth or tooth. The mandibular third molar is the tooth most frequently found impacted but in frequency it is closely followed by the maxillary third molar and the maxillary canine. Other teeth may also be impacted but are found much less frequently.

Etiology.—Conceivably, a variety of pathologic conditions might bring about retarded eruption, displacement, or the impaction of a tooth. Most frequently the final cause is explained as a mechanical affair due to lack of space in the arch.

Usually one does not obtain a history which would explain the preliminary cause for the noneruption of a tooth. Of the various reasons that

have been suggested as conceivably being an etiologic factor to explain the occurrence of impacted teeth as a group, many will not bear the test of true scientific skepticism. Still almost any disease or injury of the formative jaw bone or a hereditary factor of growth in the jaw which interferes with the normal movement of the teeth might cause impaction by limiting the normal space provided for the tooth. Thus, the frequency of impaction of the third molar is explained by the assumption that as the tooth is the last in the series, anything which tends to lessen the space provided for the molars may leave insufficient space for this tooth between the ramus and the second molar. A cuspid conceivably may be held from erupting and caused to be impacted by the lack of sufficient space being provided for it in the development of the arch. Of the anterior teeth, the cuspid erupts last and the tooth frequently is crowded out of normal line. The multiplicity of factors which enter into the question are possibly somewhat analogous to those of malocclusion of the jaws.

Sometimes a history may be obtained which would seem to be clear cut enough to explain an impaction. Local increase in the density of the alveolar bone does sometimes follow acute infection of the peridental membrane. An infection about the tooth following caries of the first permanent molar soon after its eruption has been stated to be a cause of impaction of the third molar and more especially may this be true if the first molar is treated and retained in the jaw. It has been stated that early removal of the first molar is rarely followed by third molar impaction.

Symptoms.—Impacted teeth frequently lay dormant in the jaws for a variable length of time. Sometimes even after the loss of the adjacent teeth or late in life, the tooth sometimes starts to erupt and causes pressure changes due to absorption of the overlying bone. Such a tooth may cause pain of either a local or a referred character. Rarely large cysts of the enamel organ develop. When the tooth partially erupts, because of the existing pocket around the crown, infection tends to develop. This is especially true of the lower third molar. An infected third molar pocket is to be suspected in a person with swelling and tenderness in the region of the molars and inability to open the mouth from inflammatory muscle spasm. When the tooth is partially erupted, the diagnosis is almost always evident on inspection.

An impacted tooth may press against the crown of an adjacent tooth and encourage decay. The root of the tooth pressed upon may undergo pressure absorption and in pronounced instances, the pulp may be exposed. Pressure of the roots of an impacted tooth on the inferior dental nerve may cause a neuralgia of that nerve.

Various positions are assumed by impacted teeth and frequently they are malformed. An impacted lower third molar most frequently lies in the mesio-angular position. However, it may be found in any number of positions and not uncommonly is found to point backward toward the ramus. The upper third molar is usually impacted with its crown pressing on the second molar. When the cuspid fails to assume its position in the tooth series, it is more frequently found on the lingual aspect with its angle toward the midline.

Diagnosis.—Absence of any tooth from the tooth series, without history of removal, should be investigated as it frequently means that the tooth

is impacted. It is, however, stated that absence of a lateral incisor, in counterdistinction to the cuspid, is usually indicative that the lateral incisor has never developed. In edentulous cases, the first indication of an erupted tooth is usually the appearance of soreness and a lump under the denture.

Besides detecting a suspected unerupted tooth, the roentgenogram is indispensable in accurately localizing and determining the shape, size, and position of the crown and roots and relation to neighboring teeth.

Treatment.—The indications for removal and the technic of the removal are discussed in Chapter XIII (The Removal of Teeth and Related Matters).

Normal Occlusion and Malocclusion

Definition of Normal Occlusion.—Strang states that "normal occlusion of the teeth is the normal relationship of the so-called "occlusal planes" of the teeth when the jaws are closed, accompanied by the correct proximal contacts and axial positioning of all teeth, and the normal growth, development, location and correlation of the various associated tissues and parts" (Fig. 10, p. 36). It has been pointed out, however, that normal occlusion in a general sense does not imply exact resemblance to other normals and does not exclude variation and individuality. There is implied, therefore, some variation "within the normal."

Malocclusion.—Malocclusion, a perversion of the normal, presents itself in many forms. Individual teeth may occupy any one or as many as five of the following malpositions: labial or buccal to the line of occlusion; closer to the median line than its normal mesio-distal relation; further away from the median line than its normal mesio-distal relation; rotated upon its vertical axis; when it has failed to erupt sufficiently; when it has erupted beyond its normal plane; when its vertical axis is not on the line designated to be its correct vertical axis.

Classification of Malocclusions of the Teeth and Malrelation of the Jaws

The oral surgeon who is called upon to treat marked deformities of the jaws is inclined to name the gross deformity which is present in some

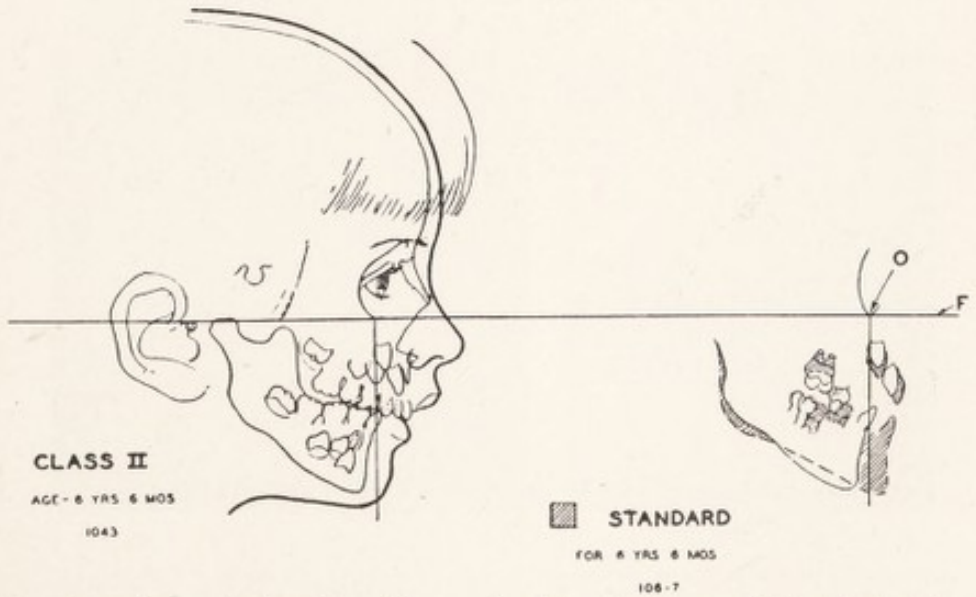

Rig. 126.—Superimposed drawings illustrating the locations of the lack of growth in Class II, Division I, malocclusion. (Broadbent.)

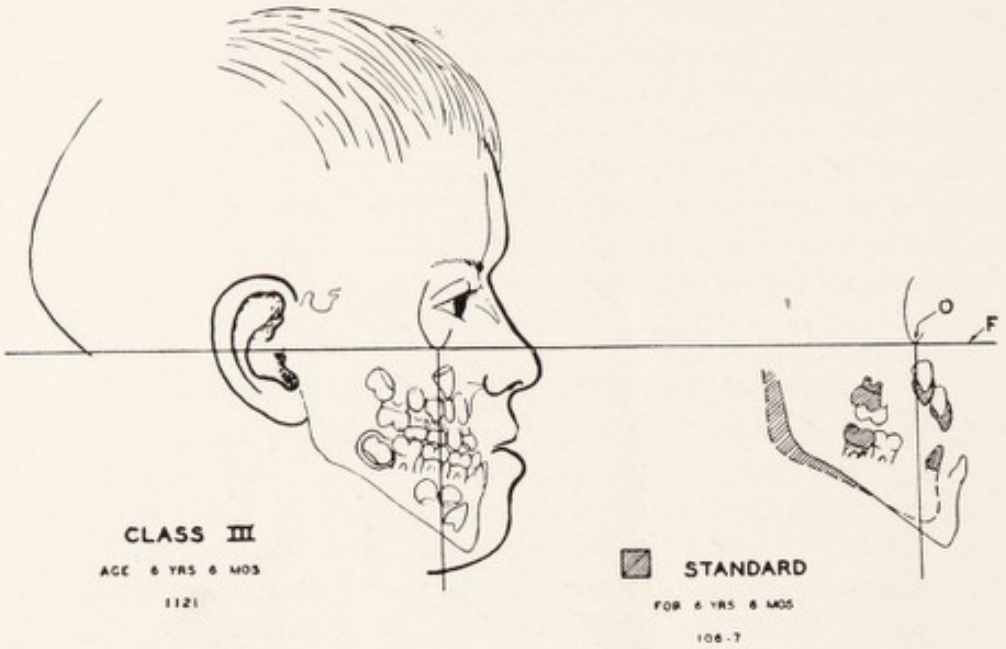

Fig. 127.—Superimposed drawings, illustrating the locations of the deformity in Class III malocclusions. (Broadbent.)

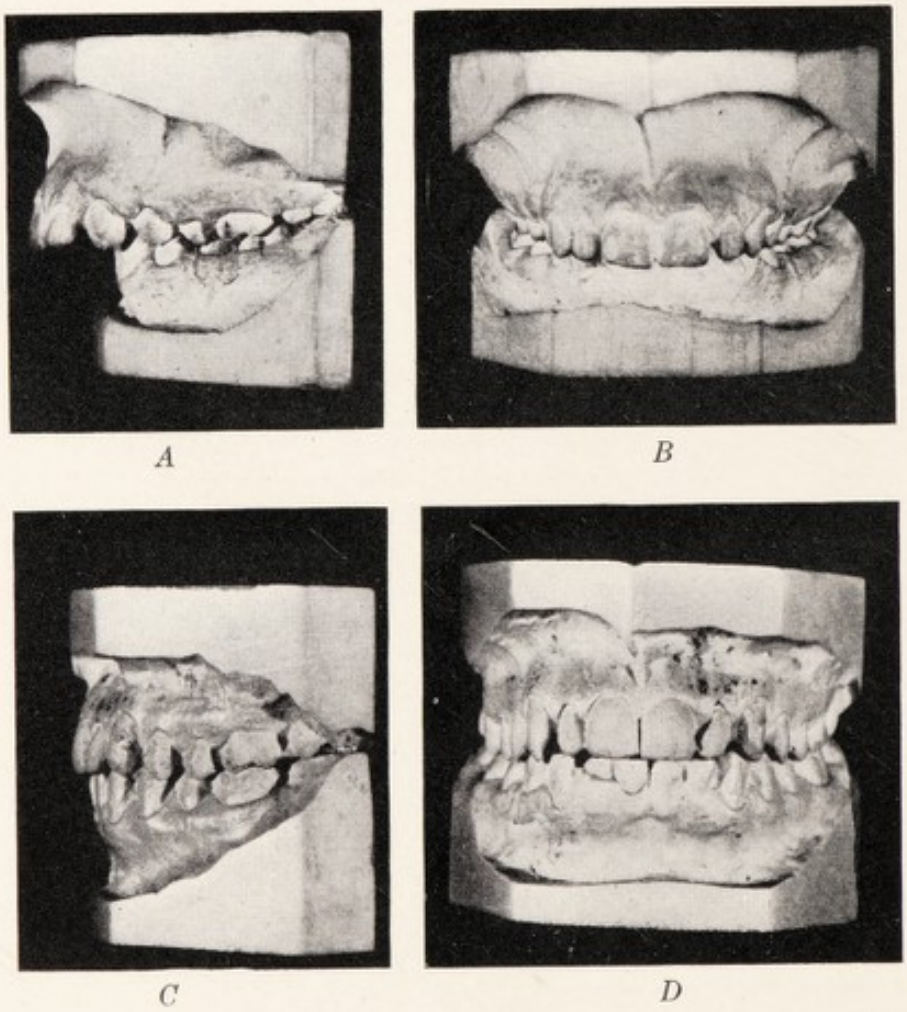

Fig. 128.—*A* and *B*, Cast of Class II malocclusion, age thirteen years—before treatment, lateral and front views. *C* and *D*, Eighteen months after treatment was started, lateral and front views. (Shelden.)

such manner as the following: (1) simple irregularity of the teeth alone, (2) retrusion of the mandible—unilateral or bilateral, (3) protrusion of the mandible or prognathism, (4) mandibular curvature—"open bite," (5) a recessive or narrowed maxillary alveolar arch (cleft palate), (6) secondary deformities of either jaw (disease or trauma).

The orthodontist, however, has ordinarily approached the matter of malocclusion of the teeth and malrelations of the jaw in their less pronounced forms with a different classification and for the orthodontist the Angle



A *B*



C *D*

Fig. 129.—Preceding patient (Fig. 128) from whom the casts were made. *A* and *B*, Before operation, front and lateral views. *C* and *D*, After operation, front and lateral views. (Shelden.)

classification has been rather commonly used. Angle's classification is not based upon the true nature of the condition but what the originator considered should be done to remedy the situation. In Class I (Angle) the lower dental arch and body of the mandible are in normal mesio-distal relationship to the upper dental arch and skull anatomy, but the individual teeth are in malposition. In Class II (bilateral retrusion of the lower jaw) (Angle) the lower dental arch and body of the mandible, either on one side or both, are in distal relation to the upper arch and skull anatomy (Figs. 128, 129). In Class III (Angle) (mandibular prognathism) the lower arch

and body of the mandible, either on one side or both, are in mesial relation to the upper arch and skull anatomy (Fig. 130). Class II may be divided in two divisions: (1) in which the upper incisors manifest labial axial perversion, and (2) a division in which the upper incisors manifest lingual

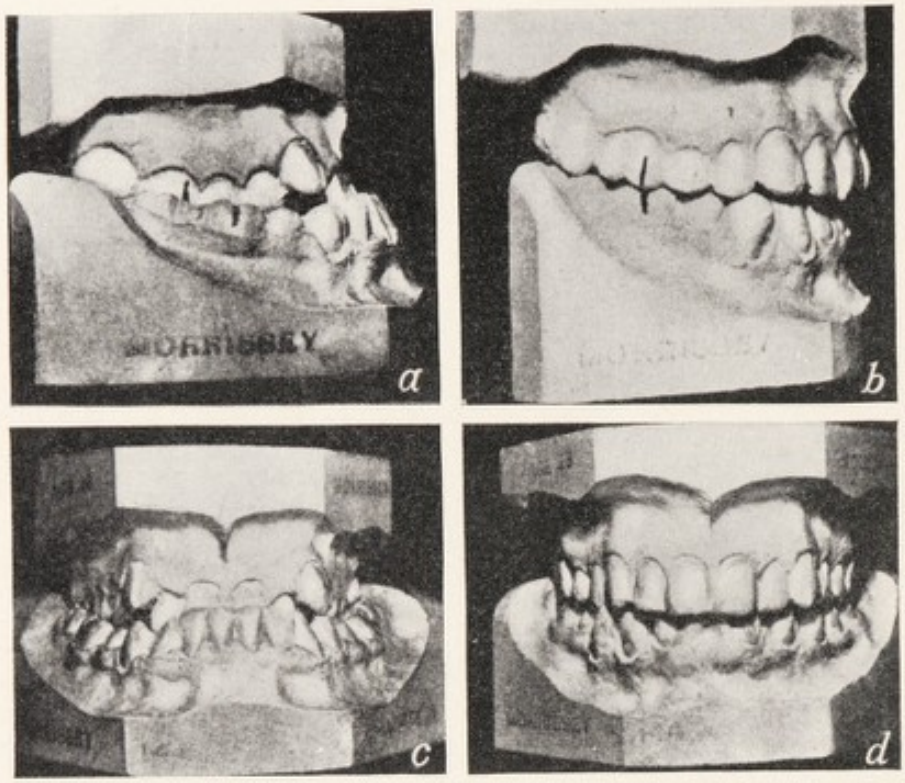

Fig. 130.—*a* and *c*, Complicated case of Class III malocclusion. Age, nineteen years. *b*, Models of the case in (*a*) taken four years after all appliances had been removed from the mouth. Age, twenty-eight years. *d*, Front view of the model at age twenty-eight years—four years after removal of appliances. (After Strang, A Textbook of Orthodontia, Lea and Febiger, Publishers.)

axial perversion. Subdivisions of both Class II and Class III cases are noted when the malrelation to skull anatomy is evident on one side only.

GENERAL ETIOLOGIC FACTORS CONNECTED WITH MALOCCLUSION OF THE TEETH AND MALRELATION OF THE JAWS

The various conceptions which have been brought forward from time to time in an attempt to explain the occurrence of malocclusion and the grosser deformities of the jaw bones largely fall under three headings, namely: (1) inheritance as a factor, (2) physiologic and pathologic conditions of growth, (3) functional change as a factor in the control of the direction of growth.

The Factor of Inheritance.—After surveying our imperfect knowledge of the incidence, distribution, the age of determination of irregularities of the teeth and malocclusion, Brash has concluded that "the evidence concerning the early origin of these conditions is of fundamental importance, *i. e.*, the frequent evidence of the presence of malocclusion in the deciduous dentition, the evidence that malocclusion of the permanent dentition is frequently foreshadowed in the deciduous, the evidence of variations in the jaws, before the erupting of teeth. All this evidence not merely narrows the main field to a question of which may be briefly characterized as one of

Nature or early Nurture but in fact strongly points to Nature rather than to Nurture. That it is prevalent but not universal in certain races and communities, that it is infrequent but not absent in other races and other communities, that it has increased in degree and also in extent in the evolution of the higher races of mankind, also within historical time, and that similar conditions are found to affect lower animals, and even to be distinguishing marks of particular breeds—all these facts may be consistent with an environmental origin, but they are certainly also consistent with the suggestion of genetic origin that is contained in the evidence of the age of onset."

Physiologic and Pathologic Conditions of Growth.—Concerning the conception that environmental factors are capable of producing structural alterations in the teeth and jaws which have to be designated as "abnormal" in the past there has been a great deal of speculation and much confident statement but not much real evidence. Deficiencies and faults in nutrition have been blamed for defective teeth and jaw bones. In general malnutrition no evidence is given that there is a particular selective action on the growth of the jaws. During the World War the privations suffered by children in the Central European countries seemed not to have increased the incidence of malocclusion. No correlation between artificial feeding or malocclusion has ever been shown to exist. There is little evidence that vitamin deficiency is a factor of proved importance in the causation of anomalies in the size and structure of the jaws. Along this line Mellanby's work is best known. After reviewing the evidence of the relation of human rickets—a disorder of calcium and phosphorus metabolism along with a deficiency of vitamin D—to the form of the jaws and the position of the teeth critical examination of the question has always resulted in the conclusion that only in exceptional instances is there any essential relation between rickets and the form of the jaws and the position of the teeth.

Jansen of Leiden has advanced the conception that various "nocive" factors, among which were exhaustion of the mother and certain antenatal poisons, may depress the growth impulse which may lead to deformity. This whole conception has not been accepted as in any way proved or as offering a general scientifically satisfactory etiologic point of view. No association between severe illness and malocclusion has ever been definitely proved (Hellman).

Although it is generally known that hormonal defects may influence bony growth in general and that of the jaw bones in particular, it is accepted that hormonal deficiencies probably have no relationship to the ordinary run of irregularities of the teeth and malrelationship of the jaws.

Thoma discusses the effect of such conditions as osteogenesis imperfecta, achondroplasia, dysostosis craniofacialis (Crouzew's disease) and congenital ectodermal dysplasia with complete anodontia upon the development of the jaws and the teeth and gives the clinical records of illustrative cases. Possibly a discussion of this phase of imperfection in jaw development is beyond the scope of this book. The abnormal development of the jaw is only incidental to the general condition.

It might be worth mentioning that conditions causing an abnormal skull such as oxycephalus, acrocephalus, a condition of deficient ossification,

macrocephalus, hydrocephalus, and microcephalus may influence the growth of the jaw as a part of the general condition.

Local trauma and disease do affect the growth of the teeth and the jaw bones. External scars of the soft tissues may exert sufficient pull on the growing jaw bone to cause a growth deformity of a type according to the direction of the pull.

The premature removal of the deciduous and permanent teeth and the too long retention of deciduous teeth are etiologically factors of considerable importance as they derange the natural spacing of the teeth. The result of either of these undoubtedly disturbs the forces of occlusion so that conditions of shifting of the teeth are initiated. Experimental and clinical data show that in mutilation such as removal of the nasal septum, the tooth germs do not greatly affect the growth of the jaws but the growth of the skull will show some adjustment to removal of the muscles on one side, the grinding down or the extraction of teeth. But in so far as the general cause of the ordinary run of irregularities and malocclusions of the teeth are concerned, such data add little additional light.

Functional Changes as a Factor in the Control of Direction of Growth.—No convincing evidence has been produced that the individual size of the jaw is greatly influenced by the amount of activity of the muscles. It is probable that there is a wide range of activity within which growth proceeds normally and that it requires a very exceptional degree of lack of use amounting nearly to cessation of use to affect to any great degree the growth of bone. On the other hand, no amount of exercise will cause bone to develop to a degree beyond the limit preordained by congenital factors.

The question of the mechanical influence of the size of the tongue on the growth of the lower jaw and whether or not this may be the cause of mandibular prognathism or Class III malocclusion was discussed a quarter of a century ago and more recently by Schendel (1903), Angle (1903) and others in its relation to Class III malocclusion. Cryer, Wallace and Brash have discussed the matter.

Undoubtedly, there is a correlation between the growth of soft parts and the growth of bones but probably in most instances neither is determined by the other.

Comparative dental anatomy, crowding of the teeth in dwarfs, and spacing of normal sized teeth in the jaws of giants furnish evidence that there is no direct relation between number and size of teeth and size and form of the jaws although no doubt there is a correlation between the teeth and the jaws. The presence of a full set of teeth does not necessarily imply that the jaws are capable of carrying them without crowding and irregularity. On the other hand, the presence of teeth do exert an influence on the growth of the jaws, mainly on the alveolar process. The change which occurs when the teeth are lost makes this point clear. They exercise a local influence although they probably do not influence the fundamental form and the primary mode of growth of the jaws. Busch (1886), Tomes, McQuillen, and Brash (1929) have discussed the effect of anomalies in the number of teeth—both temporary and permanent.

Certain habits that cause prolonged local and direct pressure on the teeth may by inducing abnormal movement of the teeth cause an irregular

arrangement. However, before one establishes the reasonable probability of the causal relationship of a habit to a given case of irregularity of the teeth, it should be shown that the habit is definite and continuous and that the result stands in recognizable relationship to its cause. The mechanism must be demonstrated. The history alone of a habit is not sufficient. There is no evidence that purely muscular habits such as lip and tongue sucking have an effect on the growth and form of the jaws as a whole but there is evidence that individual teeth sometimes may be influenced as to position. Apparently sometimes muscular habits such as thrusting forward the lower jaw and the adoption of the "bite of convenience" are a part of a mechanism by which a slight malocclusion may become worse and finally quite definite. Although the position of individual teeth possibly may be influenced in certain instances, the evidence that such habits have an effect upon the form of the jaw is vague. Habits combining muscular activity and the insertion of thumb or forefinger in the mouth (thumb sucking) appear probable on the basis of continuous local pressure on individual teeth. Here the hooking pull of the thumb itself is an additional factor. It is certain, however, that in most instances thumb sucking causes no derangement of the teeth. The intensity of the habit is probably the point. Lewis has shown that many cases showing a marked habit such as thumb sucking as a causative factor can be arrested, and often will afford nature an opportunity to correct them if the habit is broken at an early age.

In the past probably the most discussed habit has been the effect of mouth breathing and associated conditions of nasal obstructions on retrusion of the mandible. Although somewhat generally accepted, critical opinion has always cast doubt upon this conception. Within recent years there has been a tendency to reopen the question. In this conception enters the question of the importance of muscular counterbalance. Many absurd explanations of the mechanics of high palate and forced changes in growth of the maxilla have been offered. The most plausible explanation probably is that habitual opening of the mouth produces abnormal "pressure" upon the teeth and sides of the jaws by dragging on the cheeks and lips while the mandible is depressed or by direct muscular action. Others would add to this the absence of counterpressure of the tongue as a factor. Probably the aspect of this conception that deserves the most serious consideration is the possibility of an effect upon the rapidly growing alveolar margins of the jaw. There has never been any proof that there is an increased lateral pressure when the mouth is open. Examples of nasal atresia due to causes other than adenoids do not provide much support for the hypothesis that nasal breathing is essential to the proper growth of the jaws Ballantyne (1904), Schwalbe (1913). McKenzie in 1908 analyzed 222 cases of adenoids and concluded that the pressure of adenoids does not necessarily affect the form of the palate.

In 1914 the Committee's report of the British Society for the Study of Orthodontia in an inquiry to discover "the relationship between contracted dental arches and complete or partial nasal obstruction and the local or constitutional factors which produce obstruction" contains this conclusion: "Taking all the facts together, we are bound to admit that there is but little evidence of a causal relationship between adenoids and the type of jaw deformity which used to be ascribed to the tension of the lips and cheeks on the dental arch as a result of mouth breathing" (Wallace).

Comment on the Etiology of Malocclusion and Malrelations of the Jaws.—Although a considerable array of isolated facts is known, the genesis of irregularities and malocclusions of the teeth and deformities of the jaw bones and the interrelationships between the two is rather nebulous. Many aspects of the situation are purely speculative. Certainly careful sifting of the evidence concerning the matter will show that the problem is a many-sided one.

In the matter of the true nature of malocclusion there is now a reaction toward a wider anatomic and developmental conception. Brash observes that "the more and more certain recognition that irregularity and malocclusion may be, and in the majority of cases are in fact, determined at a very early age and secondly, the increasing interest in problems of the growth of the jaws and the face as a whole which has led to a general opinion that an exact knowledge of the way in which the jaws grow is essential to an understanding if not of the origin, at least of the way in which malocclusion develops, and may progress or spontaneously improve." Throughout the growth period, evidence at present indicates the erupting and erupted teeth are constantly changing their positions. Thus, occlusion seems to be only an expression of the relative position of the teeth which are changing their position slowly in three directions. This conception has a bearing on both the etiology of malocclusion and the treatment.

MECHANISM OF PRODUCTION

Retrusion of the Lower Jaw.—In the development of retrusion of the lower jaw or Class II malocclusion, according to the Angle conception, some factor initiates a malocclusion and when mandibular molars fall into distal occlusion with the maxillary molars the groundwork is laid for the forces of occlusion to influence and tend to push the mandible backward into an abnormal position of distal or mesial relationship to the remainder of the skull anatomy. Angle insisted that the malocclusion is the initiating and the continuing force. Modern data do not entirely substantiate this opinion.

Several observers have found that in retraction of the lower jaw, a relative shortness of the ramus may be partly responsible.

For the upper jaw to move downward, the body of the lower jaw has to move downward. For this to happen and for a proper relationship of the upper to the lower jaw to be maintained, the ramus of the jaw must elongate. In most cases the proponents of this hypothesis have not been able to offer any proved cause for the limitation of growth of the ramus. In other cases, the etiology is quite definite. There are several diseases which may produce a failure of growth of either one or both rami.

Direct evidence of an actual abnormal size and form of the jaw bones has recently been presented by Broadbent and Oppenheim. By radiographic methods they found that in retrusion of the mandible in Class II malocclusion, the posterior location of the mandibular denture to the normal anatomy of the skull is due to a lack of forward growth of its basal bone—the mandible. According to them this error in growth is probably more marked in the body of the mandible than in the ramus (Fig. 126).

Mandibular Prognathism.—According to Angle in the development of prognathism of the lower jaw or Class III malocclusion, the mechanism

for the production of a prognathous lower jaw is that due to some perverted muscular action the mandibular molars fall into mesial occlusion with the maxillary molars, the forces of occlusion tend to force the growing mandible into a mesial relationship with the remainder of the skull anatomy. The inferior incisors fail to lock behind the superior incisors. A forward protrusion starts and the angle straightens when not restrained by proper interlocking of the teeth and the jaw tends to push forward and possibly to separate from the upper jaw. His school (Angle) insists that the malocclusion is the initiating and continuing factor. As previously mentioned, that malocclusion represents the sole continuing factor, is disputed by the data which present day research presents.

Proponents of the conception that mandibular prognathism is primarily a disturbance in the growth of the mandible point to the greatly enlarged and thickened body of the mandible and the greatly enlarged and thickened tongue occasionally found in advanced examples as having a meaning which an initiating malocclusion can not entirely explain. When a growth error is the basis of the deformity the malocclusion is only a natural incidence. A type of mandibular prognathism is encountered where the two alveolar arches are of about a corresponding size but the lower as a whole is in a mesial position compared to the upper. Some observers have maintained that protrusion of this type is sometimes accompanied by a comparative overgrowth of the ramus. Again, a study of the anatomy of the mandible suggests that a gradual opening of the angle of the two arms, which are formed by the ramus and the body of the bone, may be the cause of forward progression of the body of the mandible. Accompanying the condition either as a cause or as a result, the ramus may be lengthened. A change in the angle of the jaw might be either a contributing cause or a result. There is a type of prognathous jaw which shows a wide premolar interdental space, the lower incisors fall into mesial occlusion preventing them from locking behind the upper incisors, *i. e.*, the lingual inclination is increased (Fig. 134, *A*, *C*). Therefore, when such spaces occur the lower jaw tends to project forward. Cryer possesses a skull which shows a forward position of the condyles with this type of prognathism.

In some recent work (1931) by means of radiographic studies Broadbent and Oppenheim in mandibular prognathism or Class III malocclusion found an excessive forward growth of the symphysis of the mandible, a reduction in the vertical growth at the angle of the mandible, and a retardation of the forward growth of the maxilla. No forward displacement of the condyle was noted (Fig. 127).

Mandibular Curvature.—"Open bite" or mandibular curvature (Federspiel) which may be classified as either Class I, II or III under the Angle classification is a deformity of the jaw bones in which the angle of the mandible is increased and the body of the mandible curves abnormally upward in the molar region. The lower teeth in the bowed section on attaining full eruption are on a plane above that of the normal. These lower teeth come into contact with the upper teeth first and open bite is caused at the anterior part of the jaws. Sometimes some definite local cause such as a cicatrix explains the genesis of the deformity.

In certain instances maldevelopment of the anterior alveolar ridge has been stated to be associated with the abnormal mandibular curvature.

Several observers have contributed the primary etiology of some of these cases to rickets (Blair, Lischer). A pitting and malformation of the crowns of the permanent incisors is said to be frequently present. Although as a rule, rickets has little or no relationship to malocclusion and malrelation of the jaws in general, it is possible in rare instances that the disease might possibly cause a jaw deformity. In most cases the evidence of rickets, however, is absent. Theoretically, the explanation given for the mechanism of production of the deformity when rickets is a causative factor is as follows. In severe rickets the bones may become abnormally soft. Thus, it is conceivable that normal muscular pull might cause them to bend. As the acquired deformities are not corrected in subsequent hardening and growth of the bone, the deformity, once started, not only may persist but might progress. Theoretically, it is possible that if rickets occurred at about the second year and were accompanied by softening of the bones, that if the crowns of the lower permanent incisors occluded behind the upper incisors and thus prevented the body of the mandible from moving forward, the posterior unsupported part of the body of the mandible would bend upward by the pull of the masticatory muscles and that later the mandible might harden in an abnormal position. When the sixth-year molar erupted it would protrude to a higher level than the bicuspids and would prevent the lower bicuspids from coming into contact with the upper bicuspids. As rickets usually occurs early in life, this factor plus some local factor such as thumb sucking possibly might make rickets and habit a simultaneous etiologic factor.

Recessive Narrowed Upper Jaw.—The oral surgeon sees this deformity most often after early wiring operations on a cleft alveolar ridge. The condition also is seen less rarely after a cleft-palate operation when no operative interference with the alveolar ridge has been a part of the procedure. A syphilitic ulceration of the palate in a growing child often causes a deformity of the upper jaw characterized by a recessive upper jaw with a narrowed dental arch. Scar contracture evidently causes the defect in growth. In congenital syphilis one is likely to see a depression of the upper jaw bone in the region of the alar base which is quite characteristic.

ORTHODONTIA IN TREATMENT OF MALRELATIONS OF THE JAWS

From the standpoint of the oral surgeon the most important question which arises concerning the orthodontist's rôle is how much the growth and the shape of the bones of the jaw can be influenced by a correct type of orthodontia. It is generally admitted that the position of the teeth and the alveolar ridges can be changed and often somewhat permanently in the young, and the teeth certainly and to some extent the alveolar ridges in the young adult. But many men have questioned whether or not the growth of the jaw bones themselves can be materially influenced by appliances attached to the teeth. The experimental evidence is in favor of the view that the natural growth stimulus of the bones of the jaws is more active than any resistance that can be applied to influence the position of the teeth and the alveolar ridges. However, there is considerable clinical evidence which both the orthodontist and the surgeon see such as the influence of scar contracture and so forth, which may lead even a skeptical mind to doubt the view of the experimental school in its entirety.

The viewpoint of Angle that certain untreated malocclusions tend to be progressive when not corrected cannot be entirely ignored. I favor the viewpoint personally that to a certain extent growth may be influenced by mechanical appliances so that to some extent the final form and shape of the jaw bones may be influenced in certain cases. However, in the great majority of instances all the orthodontist can be expected to do is to change the position of the teeth and the supporting bone of the alveolar ridges. When this change would seem insufficient to correct reasonably the malrelation of the jaw bones, I am inclined to believe at the present time that in the large majority of instances the case will be found to be beyond the control of the orthodontist. At the present time good orthodontists frankly admit a certain percentage of failures in treatment even when treatment was instituted at the opportune time and continued over the required period of time. Some types of malocclusion are simple to correct at almost any age. On the other hand, others approach the impossible and this is especially so as the individual passes into later adolescence.

Case Management

By Dr. Copeland Shelden

As the first responsibility may rest upon the practitioner who discovers the patient's condition, some knowledge of the usual effective orthodontic procedures may be illuminating, although he may not presume to consider himself capable of directing the therapy.

A. Management of Class I Malocclusion.—The management of Class I malocclusion is omitted. The orthodontist has little difficulty in correcting irregularities of the teeth without malrelation of the jaw bones.

B. Management of Cases Falling in Class II (Angle Classification).—In the treatment of cases falling into this class, a perfect relation of the inclined planes of the teeth and the normal functions of the forces of occlusion are the final objects of treatment. It has been argued by one group that the individual teeth in the maxillary and mandibular arches should be placed in the proper line of the arch and the patient then taught to thrust the mandible forward until the proper inclined-plane relationship is established. But this procedure is extremely difficult and it is virtually impossible to accomplish the normal, for the forward thrust of the mandible so perverts the forces that proper balance can never be reached or maintained. Better results are to be obtained by the distal tipping of the maxillary molars, bicuspids, and cuspids and the lingual moving of the maxillary incisors until the proper inclined-plane relationship of maxillary to mandibular teeth is attained. This then brings into play forces by the constant use of which the mandibular development is controlled. Individual tooth positions such as perverted axial inclinations, elongation and rotation, along with the perverted curve of Spee and the closed bite are corrected as the upper teeth are being moved distally (Figs. 128, *A, B, C, D* and 129, *A, B, C, D*).

It must be remembered that we do not want to move the teeth of the mandible forward, and therefore, fairly stationary anchorage must be obtained in the mandibular teeth. Ordinarily this is accomplished by an arch wire passing through brackets on bands attached to the tooth which allows no tipping. When anchorage is good, rubber bands are placed from

the fore part of an upper arch wire to the hind part of a lower arch wire. When the individual bands are placed properly on the upper arch, the maxillary teeth move distally. The controlling bracket on each tooth makes possible the correct positioning of each individual tooth; when the arch wire is properly formed and placed, the teeth take their places according to the relation of the arch wire as it passes through the brackets. By this method the *curve of Spee* tends to be changed and the closed bite is opened.

C. Management of Cases Falling in Class III (Angle Classification).—In the cases of Class III malocclusion an attempt is made to carry the entire mandibular denture distally and lingually. It is therefore necessary to create as nearly stationary anchorage as possible in the maxillary arch. Often this is done by the use of the tie bracket bands on all the maxillary incisors, cuspids, and bicuspids, and clamp bands on the maxillary first molars with the rectangular sheath flattened on the buccal side. When using this method, an upper edgewise arch wire is formed and placed. A mandibular arch wire is prepared in the same manner. When fairly stationary anchorage is obtained in the maxillary arch, rubber elastics are put to work from the anterior of the lower arch wire to the posterior ends of the upper arch wire (Fig. 130, *a, b, c, d*).

Dangers that Accompany Various Types of Tooth Movement.—Minor orthodontic treatment consists of tooth tipping, tooth elongation, and tooth rotation. Major orthodontia refers to the moving of teeth bodily and to depressing teeth in their alveoli.

The tipping of teeth, tooth elongation and tooth rotation are more or less simple changes and can be accomplished with the Jackson removable, the lingual arch, and round labial expansion arch—less efficient appliances. Bodily tooth movement, however, and the depressing of teeth are difficult changes and demand a rather efficient appliance. The ribbon arch and the edgewise arch mechanism are usually effective.

There is little danger of degenerative or inflammatory changes in the simple movements of tipping, elongation or rotation of teeth, but the bodily movement of teeth and the depression of teeth place considerable strain on the structures and utmost care and careful technic must be employed by the operator practicing such movements.

The devitalization of the pulp may result from too great a force being used to depress the teeth, in which the blood supply of the tooth is affected to such an extent that the tooth may die. Destruction of bone of the alveolar process was noticed in certain cases shortly after root moving appliances were introduced. A recession of the gingival tissues and the exposing of a portion of the root of the tooth was caused due to the exaggerated force used in attempting root movement. Some cases were reported in which the teeth were moved to a position labial of buccal to the line of occlusion and sufficient bone was not present to cover the abnormal position. Other cases of root resorption reported may have been the result of trauma set up by an unskilfully adjusted appliance. Other cases of root resorption were noticed when the movement of teeth in patients of advanced age was attempted. As a rule, the resorption of root apices has been blamed to a great extent upon the movement of teeth bodily. In certain instances, however, root resorption in permanent teeth that have

had no orthodontic treatment has been noted. Marked muscular hypertonicity has been suggested as a cause of root absorption. Root absorption sometimes seems to result from movement or from fixation of teeth by retaining bands over too long a period.

Most orthodontists at the present time believe that, when the condition dictates the necessity for the major operations of orthodontia, these operations are indicated. In the great majority of instances when proper care is used, these movements may be made without apparent harm either to the teeth or to their supporting structures.

OPERATIVE CORRECTION OF MALRELATIONS OF THE JAWS

Naturally operative interference is not to be chosen if the deformity is amenable to correction by orthodontic means. In the selection of cases to undergo surgical correction, often the fullest cooperation between surgeon and orthodontist is necessary. For the surgeon to do his work correctly, it is necessary that he have at least a theoretical knowledge of the possibilities of orthodontic procedures.

In most cases of malrelation of the jaws which develop during adolescence, the first indication is a malocclusion of the teeth which usually is best treated by the orthodontist. When certain forms of malocclusion are allowed to progress or do progress in spite of orthodontic treatment, a deformity sometimes develops by the time adolescence is reached which is beyond correction by orthodontic appliance but which at least could have been alleviated somewhat if treatment had been instituted at an early time.

In rather definite unilateral mandibular deformities, as a rule, it is useless to depend solely upon orthodontic methods.

Fairly marked examples of "open bite" respond very poorly to orthodontic measures. Many of the upper-jaw deformities that one very often encounters following operative procedures for cleft palate certainly are beyond the control of orthodontic measures. The deformities of the jaw which follow infection or trauma also ordinarily do not respond favorably to traction methods alone.

A few of the more marked growth deformities of the lower jaw bone itself and deformities following such diseases as osteomyelitis, arthritis, or scar contractures can be corrected only by surgical means.

Although occlusion of a passable character is the goal immediately it is ordinarily not possible by a bone-cutting operation. As a rule, when the cooperation of the orthodontist is desirable to obtain a good final result, it seems most practical for the orthodontist to plan the extent of the treatment he is to render after the operation instead of before. Although sometimes well-planned orthodontic treatment of the maxillary teeth before operation may be highly desirable, generally it is not practical.

Normal Facial Outline.—Besides the relative correction of the deformity of the jaw with most cases a second issue at stake is the facial outline—the lateral breadth as well as the profile. In the correction of facial outline, the normal should be roughly approached. The statement has been made that the septolabial angle should be about 90 degrees and that the distances between the hair line and the root of the nose, between the root of the nose and the sublabial angle and between the sublabial angle and

the tip of the chin should all three be nearly equal. Finally the upper lip should be slightly in advance of the lower.

Bringing the Lower Jaw in Relation with the Upper Jaw.—The upper jaw is a cubical mass well fixed in its position. Whether it is in position or out of position, it is nearly impossible to move it to any great extent. The lower jaw, however, is an altogether different structure—a "hoof" of bone. By removing or adding a section it is possible to give it almost any given shape. In the correction of gross malrelations between the upper and lower jaws, the lower jaw necessarily has to be brought into conformity with the position of the upper jaw.

For a long time surgeons feared to cross cut the mandible. Necrosis and nonunion were spoken of as bugbears which contraindicated the procedure. Now it has been shown that neither of these possible complications is at all probable. No harm is done by cutting the inferior dental artery.

The inferior dental nerve does not always regenerate as has been stated. There is no way for it to do so when the cross cut canal in the bone is moved enough to make the ends some distance apart—especially if the movement is up or down.

The operations which plan to section the ramus have the advantage of being performed in a clean field so that primary union of the operative wounds ordinarily should follow. In such operations bony union is somewhat more certain and occurs several weeks earlier—an advantage worth due consideration if the ultimate result is to be equally good.

In the operation of oblique vertical ramus section, the nerve supply to the teeth may be preserved. The disadvantage of these operations is the difficulty that may be encountered in controlling the distal fragment after the proximal fragment is moved into its new position.

Operation for Retrusion of the Lower Jaw.—Marked bilateral retrusion of the lower jaw presents some interesting problems. It is comparatively rare. Some are undoubtedly congenital in origin but the majority are due to infection or to trauma in early childhood. Some of the cases are associated with bilateral ankylosis of the temporomandibular joint. In a marked simple case of retrusion of the lower jaw, subcutaneous section of the rami with drawing of the body forward to a normal position gives an acceptable result. Kazanjian shows acceptable results in this type of deformity by sectioning the body of the mandible in an L-shaped fashion and sliding the symphysis forward. When the chin is recessive, a cartilage transplant may be added to the procedure.

When a unilateral retraction of the mandible follows the ankylosis of one temporomandibular joint, the condyle on that side should be resected and the joint reconstructed and the ramus or the body is also cross cut so the body of the mandible can be brought forward on that side to its proper position. The same procedure is necessary on both sides if the ankylosis is double and the deformity of the jaw is bilateral. The teeth are wired together to hold the new position until union occurs.

The Operation of Ramus Section.—Blair has stated that the rami should not be cross cut until after the second permanent molar has erupted. Resection of the condyle has to be done without regard to time so that the mouth may be opened. An incision about 2 cm. in length is made through the skin over the posterior border of the mandible. A special large, curved

needle is passed behind the ramus and the internal pterygoid muscle and emerges through the cheek just anterior to the ramus (Figs. 131, *A*, *B* and 132, *A*, *B*). The needle, of course, does not enter the mouth. A Gigli saw is pulled back through the needle pathway. It is necessary to avoid

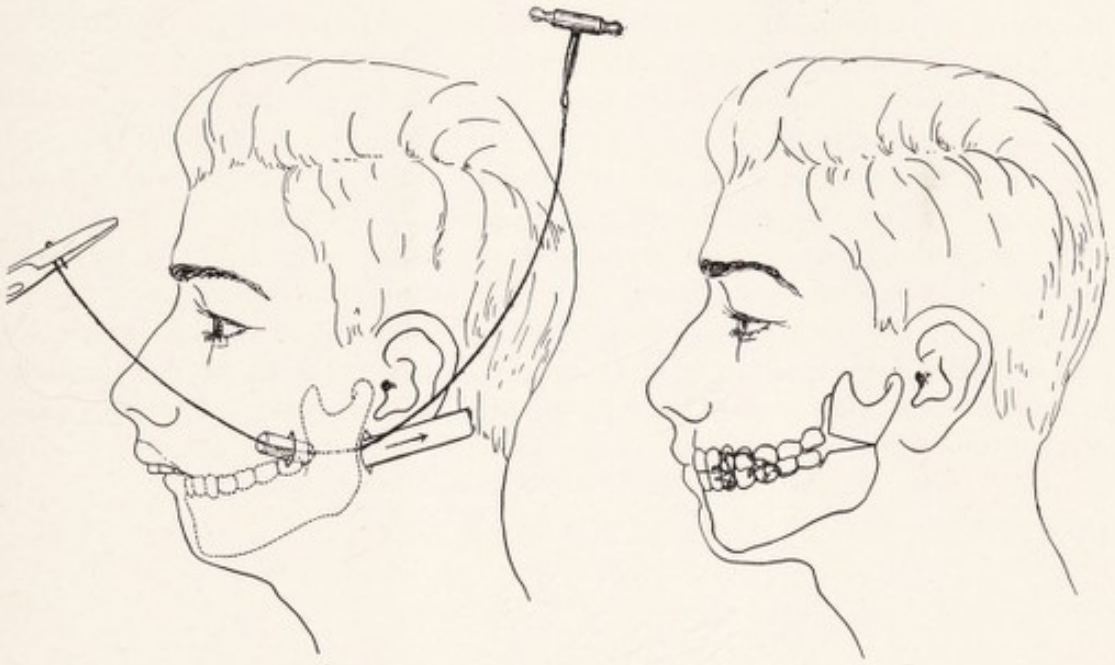

A *B*

Fig. 131.—*A*, Subcutaneous resection of the ramus, showing the points of entrance and exit of the wire saw. *B*, Jaw wired in its new position after section of the ramus.

the parotid gland and the cervicofacial division of the facial nerve. Each is retracted out of the way. To prevent damage of the skin by the saw, a short small steel tube is passed over the ends of the saw. After the bone

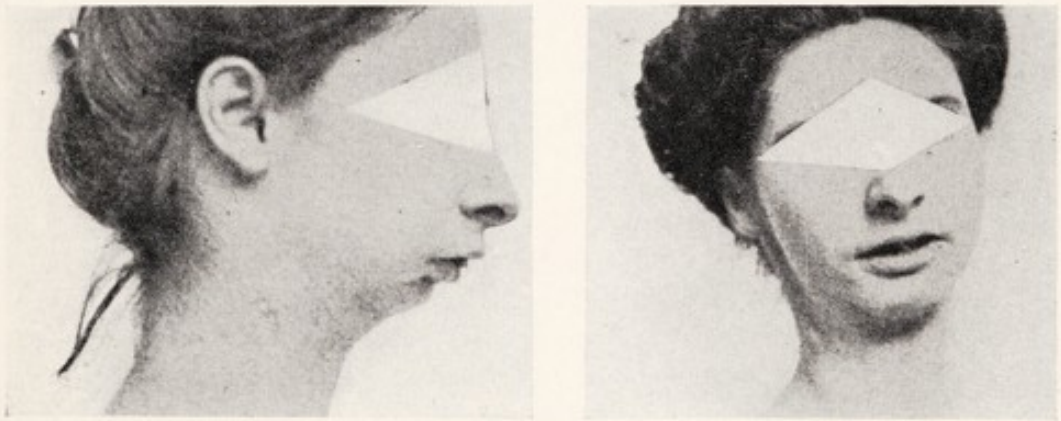

A *B*

Fig. 132.—Patient in whom the rami were cut and the mandible moved forward. *A*, Profile view before operation. *B*, Shows patient after bringing the body of the jaw forward and transplanting costal cartilage into chin. (Blair, Surgery and Diseases of the Mouth and Jaws, C. V. Mosby Co., Publishers.)

is cut the jaw is pulled forward in its new position and fixed. As the posterior part of the occlusal plane of the molars inclines upward and backward, the obliquity allows the lower jaw to be brought forward only by lengthening of the ramus. Theoretically, the line of the saw cut

according to Blair should be slightly downward and forward—about 5 mm. lower in front than behind to allow the body to be moved downward as well as forward. But practically this seems to make no great difference. The masseter and internal pterygoid muscles must be stretched in order to lengthen the ramus. This may be done by inserting a block of wood between the posterior molars and pushing the chin upward. By means of this lever action the muscles are slowly stretched until the jaw can be moved forward. The chin should be brought to the midline if possible. The general contour of the face has to be considered as well as the occlusion. The occlusion can be changed somewhat at the time by grinding the molars or later by orthodontic appliances, if necessary.

To hold the jaw forward, firm wiring of the lower to the upper teeth has been found the most satisfactory. The upper first and second bicuspids are wired to the last available molar to put the pull in the line of correction. The lower canines and bicuspids are used to hold the mental part of the mandible in position. Quick setting cement may be placed between the occlusal surfaces of the teeth to aid in maintaining position.

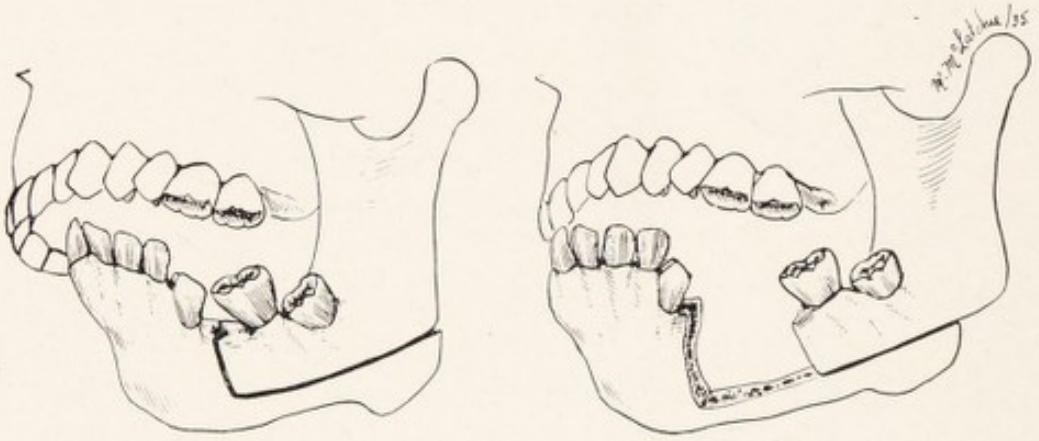

Fig. 133.—Method of elongating the mandible. (After Kazanjian, Internat. Jour. Orthodontia and Oral Surg., March, 1936.)

Usually these cases present an obliquity of the chin which detracts from the result unless corrected.

The Operation of Mandibular Section for Retrusion.—An incision about 6 cm. (Fig. 133) is made under the lower border of the mandible. With an Albee saw an L-shaped incision is made beginning about 5 mm. above the lower border of the angle horizontally forward to the bicuspid region where the incision is carried vertically to the alveolar ridge. The same procedure is carried out in the opposite side. The loosened anterior part of the mandible is then pulled forward until the anterior teeth of the mandible fall into good occlusion and are held there by dental splints fastened to the mandibular second molars, cuspids and bicuspids. The anterior maxillary and mandibular teeth are then wired together.

Correction of Obliquity of the Chin.—This deformity is most satisfactorily and easily corrected by the implantation of a rib cartilage cut to the correct thickness and shape (Fig. 132, *A, B*). The cartilage is inserted subcutaneously across the chin, after the soft tissues are freed with scissors through a small incision 1.5 cm. in length just below the mandible and to

one side of the chin. Cartilage is permanent, not injurable, and the scar is not seen when properly placed and sutured.

Three types of patients with mandibular prognathism are suitable for operative measures. The first group has a normal maxillary bone and dental arch. The facial outline is good save for an extreme prognathism. In the second group there is not only an extreme prognathism but the maxillary development and the upper facial outline are deficient. The maxillary teeth tend to be crowded and the palatal vault is high. The third group has a marked prognathism and an "open bite" with crowding and irregularity of the teeth. The first group of cases obtain the best results.

Roughly two types of operative procedures have been used commonly to correct extreme mandibular prognathism: (1) resection of a measured section from each side of the body of the mandible preferably in the first molar region, (2) horizontal section of the ramus of the mandible above the occlusal plane. More recently a temporomandibular joint arthroplasty for prognathism has been suggested.

CORRECTION OF MANDIBULAR PROGNATHISM

In December, 1897, Blair (Fig. 134, *A, B, C, D*) corrected the first case of pronounced prognathism by removing a section of the body of the mandible anterior to the first molar on either side. Since that time an occasional similar operation has been done by various operators (Ballin, Willett, Kazanjian, Padgett, Schultz, Pichler, Henschen and Swarz). In carefully selected cases the results have been satisfactory enough to make the operation worth while.

Plaster models and the roentgenogram are used to determine the length and shape of the sections of bone to be removed to allow the mental fragment to assume a backward position as near normal as possible. The facial outline also has to be considered as well as the occlusion. A chin which balances with the remainder of the face should be given.

The section of bone is removed at or just anterior to the first premolar. In some instances a tooth may have to be removed. The tooth should be removed and the socket allowed to heal over before the wedge of bone is removed.

Through a short incision about 2.5 cm. in length just below the area of the mandible selected to be excised, the lower border of the mandible is exposed. From this point two types of approach have been used—a submucoperiosteal one and transmucoperiosteal one. In the transmucoperiosteal approach the sawing may be more accurately done if a straight saw is used. A Gigli saw is necessary to cut the bone in the submucoperiosteal approach. Usually it will be found that through accident a communication between the mouth and the wound is established anyway so the theoretical advantage of not entering the mouth cavity is usually lost.

Transmucoperiosteal Approach.—In the transmucoperiosteal operation the tissues are dissected from the outer surface of the jaw bone without injury to the periosteum and the dissection is continued upward until the mouth is opened through the bucco-alveolar sulcus. The mucosal covering of the gum is left intact. A small straight bone saw is used to cut the bone. A Gigli saw is equally useful. The type of saw is solely a matter of preference. Before the bone is cut entirely across, a hole is made in

both ends of the fragments of the bone near the lower edge with a small drill. The wedge of bone is then removed by completing the saw cuts. Through the drill holes is threaded a small silver wire. The same procedure is performed on the opposite side. The mental fragment is thrown into position. On each side around the second tooth back from the line of bone section, a wire is looped in a manner as to wire the teeth in the proximal and distal fragments in apposition. The lower teeth of the mental

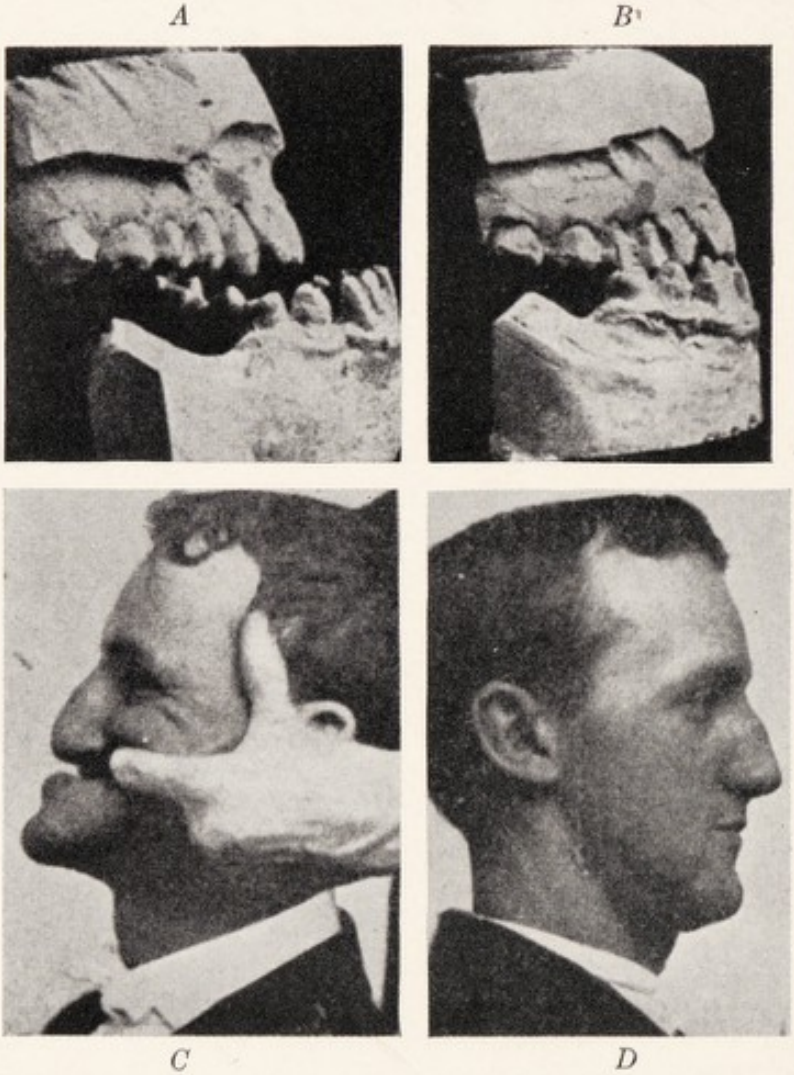

Fig. 134.—This represents the first case operated on by radical methods for a mandibular protrusion. (Blair, December, 1897.) *A,* Extreme protrusion due to interdental spaces and forward position of the body. *B,* Adjustment obtained by submucous resection of the body. *C,* Profile view with the upper lip drawn back and the jaws "closed" as far as the soft tissues will permit. This position was obtained without pushing the condyle forward. *D,* Profile view after operation. (Blair, Internat. Jour. Orthodontia, **1:** 395, 1915.)

fragment are then wired securely to the upper teeth of the maxilla by one of the methods commonly used in fracture of the jaw. The wires through the drill hole in the lower edge of the mandible are drawn tight, twisted, and cut. The wound is closed with two sutures and a small rubber tube drain is placed at the midpoint. To give additional support, a firm Barton bandage is applied beneath the jaw and over the head. As in fracture of the jaw and as was suggested by Angle, a metal dental splint in three sections might be advantageous if the bones were cut accurately enough.

The use of a swaged metal splint fastened to the teeth would allow the mouth to be opened. But ordinarily the fixation would probably not be entirely adequate.

Submucoperiosteal Approach.—In the submucoperiosteal operation every effort is made not to enter the mouth cavity. The soft tissues are dissected from the periosteum half way up the inner and outer surfaces of the body of the jaw (Fig. 135, *A*, *B*, *C*). From then on the dissection is subperiosteal up and over the alveolar ridge. This is theoretically possible but practically it often fails. After the periosteum is loosened, a blunt needle with a heavy braided silk suture on it is passed over the alveolar border of the jaw in such a fashion that it does not penetrate into the mouth. A Gigli saw is pulled over the border following the braid silk suture. As one usually breaks into the mouth, the submucoperiosteal operation often fails to give the one reason for the operation—a sterile field uncontaminated by mouth secretions. On the other hand, the loosening of the periosteum from the ends makes some necrosis of bone, a slightly

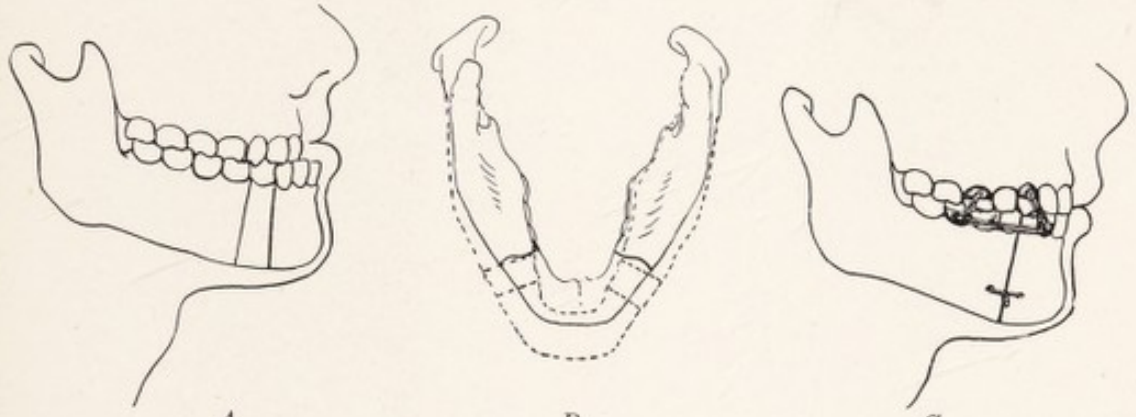

A *B* *C*

Fig. 135.—Partial resection of the lower jaw on both sides for marked prognathism. *A*, Shows section of bone to be removed from lateral view. *B*, Shows section of bone to be removed from the superior view. *C*, Shows the lower jaw and upper jaw after section of bone has been removed with the mental segment wired to the body of the mandible and the lower teeth wired to the upper teeth in a position of relative occlusion.

greater hazard. All in all, the transmucoperiosteal operation is the most expedient.

Cross Section of the Ramus for Protrusion of the Lower Jaw.—When the protrusion is caused solely by a sliding forward of the body of the jaw and there are no abnormal interdental spaces or supernumerary teeth, Babcock proposed in 1909 that the ramus be cross sectioned above the angle and the body of the mandible pushed back into place. Pichler, Bruhn, Kostečka, Ivy and Blair have reported successful cases. The operation is done best with a Gigli saw. The mouth is not entered. The operation has the advantage of being a clean one. After the operation the lower teeth are fixed to the upper teeth until union is present. If possible, the teeth are made to interlock to prevent the jaw from pushing forward again.

Arthroplasty for Prognathism.—Pettit and Walrath have recommended that, in certain extreme cases of prognathism not amenable to orthodontic correction, an additional joint in the condyloid process be constructed similar to that done in the present-day operations for arthroplasty for ankylosis of the temporomandibular joint (Chapter XX). They conclude

that because of its advantages the procedure would seem to supplant the former type of jaw resections. They stress that the nerve and blood supply of the teeth is preserved, that no teeth or bones are lost, that no foreign body is necessary to hold the fragments and that there is no danger of infection. Their only case was a unilateral prognathism. Most of the cases of prognathism would require a bilateral arthroplasty as one side is affected as much as the other. Dufourmentel in 1921 advocated the removal of both condyles. The disadvantage of Dufourmentel's operation is that it is frequently followed by "open bite."

Operation for "Open Bite."—(1) *Section of the Mandibular Body.*—Three types of operations have been recommended for the correction of this deformity: (*a*) sectioning of the mandibular body; (*b*) section of the ramus above the occlusal plane and (*c*) vertical section of the ramus.

Preoperative study usually shows that the anterior part of the mandible can be elevated by removing a V-shaped section with the base at the alveolar ridge anterior to the site of the deciduous molars. The oversized tongue may after this procedure fill the oral cavity to overflowing, so to

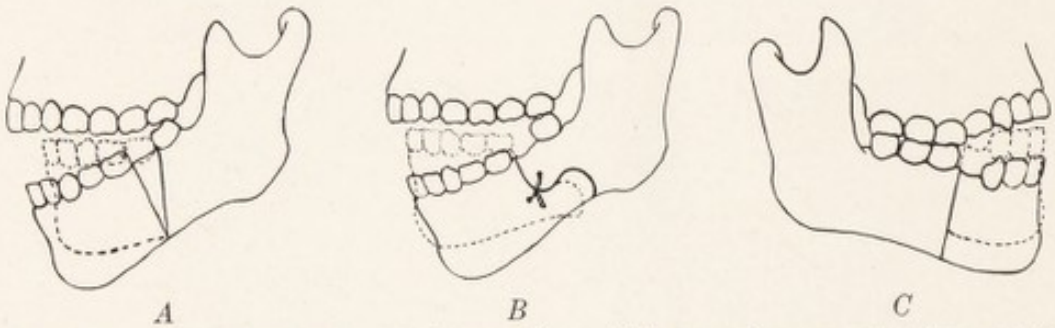

Fig. 136.—*A*, A Case of marked open bite which may be corrected by resecting a V-shaped segment of the mandible. *B*, A marked case of open bite which may be corrected by resection of the body of the mandible as shown in the figure. The lower teeth are wired to the upper teeth in both instances. *C*, Reconstruction of an open bite by simple section of the body of the jaw on each side.

speak, and the jaw is shortened somewhat. All of this must be considered before operative interference. A curved cut in the mandible as shown in Fig. 136, *B*, has been recommended for the correction of the deformity but probably the most promising excision is that shown in Fig. 136, *A*. Of course, the point of the correction depends somewhat upon the point forward at which the open bite starts. Sometimes malunion of a fracture may cause this deformity. In such a case the mandible should be refractured and given adequate fixation to hold it in place until union has taken place.

The principle in operation is section of the jaw on both sides in front of the first tooth that occludes with those above, provided the lower jaw is not too long after the mental fragment is fixed anteriorly. The fragment is a V-shaped one, and it should be removed with the base upward at the alveolar ridge (Fig. 136, *A*). The cutting of bone is done best probably with a Gigli saw. The exposure is the same as that previously described under operation for prognathism of the lower jaw. In Fig. 136, *B*, *C*, the jaw is not shortened. It is only elevated in the submental region. In Fig. 136, *A*, the jaw is shortened. The operation to be selected depends upon the case.

(2) *Section of the Ramus Above the Occlusal Plane.*—This is described under retrusion of the mandible.

(3) *Vertical Section of the Ramus.*—Coster of Brussels has recently recommended the operation of vertical section of the ramus and states that in his opinion the majority of surgeons operate on the mandible by osteotomy either of the vertical ramus like Limberg or of the condyle like Dufourmentel. An operation of the type depicted in Fig. 137, *A*, *B*, he considers a logical procedure. An incision is made anterior to the ear. At the upper end the incision curves forward about 1 inch almost to the zygoma. The parotid fascia and the gland are pushed forward. The base of the zygoma is exposed. The ramus is exposed. Care is taken not to drop downward so that the facial nerve is jeopardized. The sigmoid notch is located. With a dental burr the ramus is split vertically just posteriorly

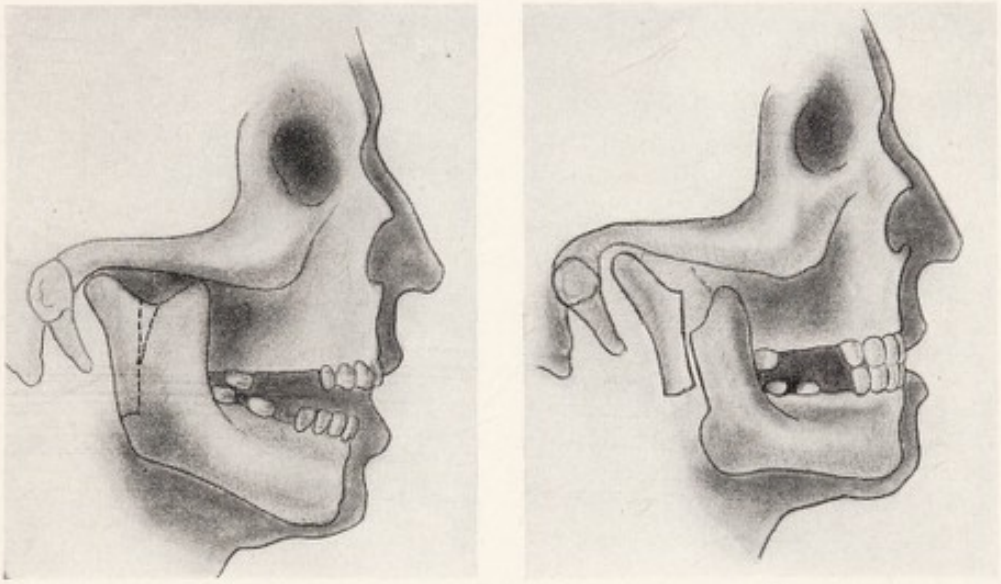

A *B*

Fig. 137.—Method of sectioning ramus vertically for the correction of an open bite.

to the inferior dental canal. Thus, the condyle with a section of the ramus is detached.

The posterior fragment of the ramus should approach 1 cm. in width and have sufficient length to obtain a wide overlap after the teeth of the anterior fragment of the mandible are brought into occlusion with the maxillary teeth. The wound may be closed without drainage in the ordinary manner.

Fixation.—In the chapter on wiring together of the teeth in fracture of the jaw is described the interwiring of the teeth. When the teeth in the chin fragments are poor, circumferential wiring of the fragments may be necessary. The pull of the digastric and the geniohyoid muscles is considerable. The fixation has to be forward and adequate. In a bilateral fracture of the mandible in 1 case we passed a wire up through the palate into the nasal fossa and over the maxilla in a circumferential manner after a circumferential wire had been passed about the mandible. The fixation was adequate and harmless. Kazanjian has described a dental splint which he constructed and which gave adequate fixation in his cases. As a rule, I believe the simpler method of fixing the lower to the upper teeth will be more satisfactory in the hands of most men.

Atypical Deformities.—All of these deformities do not run true to any classification so far laid down. Convenience only has governed the preceding grouping, but by the grouping it is hoped that the principles have been laid down. After all, the etiology is only of scientific interest after the cause has ceased to function. It has been mentioned that scar contracture of the neck and chin can cause "open bite" deformity of either a unilateral or a bilateral nature. The contracture of the soft tissues should be operated upon early enough during the growing period to prevent contracture of the soft tissues from interfering with a subsequent operative attempt for correction of the malformed bony structures. In such cases contractures are corrected along the lines described under the correction of soft tissue deformities and later the deformity of the jaw is corrected along the lines laid down under the preceding headings. In all of these deformities the surgeon must make himself thoroughly familiar with the anatomic condition which he is called upon to treat—whether of the soft tissues or the hard tissues or both.

Postoperative Treatment.—The principles of postoperative treatment are discussed in the chapters describing the care of fractures of the jaw bones.

Bibliography

Bibliography Quoted in Text

Angle, E. H.: Double Resection for the Treatment of Mandibular Protrusion, Dental Cosmos, 1903.

Treatment of Malocclusion of the Teeth, 7th ed., Phila., 1907.

Babcock, W. Wayne: Items of Interest, June, 1910.

Ballantyne, J. W.: Manual of Antenatal Pathology Hygiene, The Embryo, Edinburgh, W. Green and Sons, 1904.

Ballard, T.: On the Constitutional Ill-Effects of Fruitless Sucking, and the Diagnostic Value of Deformed Jaw in Relation Thereto, Trans. Odont. Soc., **4:** 147, 1863–1865.

Ballin, Max: Double Resection for the Treatment of Mandibular Protrusion, Items of Interest, **30:** 422, 1908.

Blair, V. P.: Instances of Operative Correction of Malrelation of the Jaw, Internat. Jour. Orthodont., **1:** 395, 1915.

Brash, James: The Growth of the Jaws and Palate, The Dental Board of the United Kingdom, Lectures in 1924, p. 23.

Broadbent, Holly: Quoted by Strang.

Bruhn, Christian: The Surgical Orthopedic Removal of Deformations of Jaws, Int. Orthodont. Cong., **1:** 245, 1927.

Busch: Deutsch. Monatsschr. f. Zahnheilk., 1886–1887.

Campion, G. G., Chapman, H., and Spiller, J. E.: Report of the Committee (of the Brit. Soc. for the Study of Orthodontia) on the Normal Arch, Dent. Record, **29:** 398, 1909.

Costen, L.: Open Bite, Internat. Jour. Orthodont., **22:** 912, 1936.

Cryer: Quoted by Blair.

Duhamel: Sur le developpement et la crue des os, Mem. l'Acad. sci., Paris, 1742–1743.

Dufourmentel: Surgical Treatment of Prognathism, Presse méd., **29:** 235, 1931.

Dufourmentel and Darcissac: An Attempt to Treat Inferior Retrognathism, Bull. et mém. soc. chir. de Paris, **20:** 750, 1928.

Federspiel, M. N.: Surgical Procedures which Extend the Field of Dental Facial Orthopedics, Jour. Amer. Dent. Assoc., **14:** 2143, 1927.

Proc. Amer. Soc. Orthodont., 1923.

Franke, F.: Über Wachstum und Verbindung des Kiefers und des Nasenscheidewandes, auf Grund vergleichender Kiefermessungen und experimenteller Untersuchungen über Knochenwachstum, Leipzig, 1921.

Hatfield, H. K.: A Preliminary Study of the Effect of Rickets on the Jaws, Internat. Jour. Orthodont., **5:** 367, Jan., 1919.

Hellman, Milo: Studies on the Etiology of Angle's Class II Malocclusal Manifestations, Internat. Jour. Orthodont., **8:** 129, June, 1922.

Nutrition, Growth and Dentition, Dent. Cosmos, **65:** 34, 1923.

Henschen, C., and Swarz, R.: Chirurg., **1:** 56, 1928.

Humphrey, G. M.: A Treatise on the Human Skeleton, Cambridge, 1858.

On the Growth of the Jaws (Read Nov. 9, 1863), Trans. Cambridge Phil. Soc., **11** (part 1): 1, 1866.

Hunter, John: Experiments and Observations on the Growth of Bones (from the papers of the late Mr. Hunter by Everard Home, 1798), Collected Works, Palmer's edit., **4:** 315, 1837.

Ivy, R. H.: Surgery of the Mouth and Jaws in Nelson's Loose-Leaf Surgery, vol. 2, Chapter XI, New York, 1927.

Jansen, Murk: Some of the Life Properties of Bone Substance, Dent. Record, **5:** 306, 1925.

Kazanjian, V. H.: Surgical Correction of Deformities of the Jaws and Its Relation to Orthodontia, Internat. Jour. Orthodont. and Oral Surg., **22:** 259–282, 1936.

Keith, Sir Arthur: Concerning certain Structural Changes which are taking place in our Jaws and Teeth. The Growth of the Jaws, Normal and Abnormal, in Health and Disease, Dent. Board United Kingdom, p. 133, 1924.

Kostečka, F.: Zahnärztl. Rundsch., **40:** 670, 1931.

Facial Symmetry Due to Irregular Position of the Lower Jaw, Bratisl. lekar. listy, **7:** 327, 1927.

Lewis, S. J., and Lehman, I. A.: Observations on Growth Changes of the Teeth and Dental Arches, Dent. Cosmos., **71:** 480, 1929.

Limberg, A.: The Treatment of Open Bite by Means of a Plastic Oblique Osteotomy of the Ascending Rami of the Mandible, Dent. Cosmos, **67:** 1191, 1925.

A New Method of Plastic Lengthening of the Mandible in Unilateral Microgenia and Asymmetry of the Face and Jaws, J.A.D.A., **15:** 851, 1928.

Lischer, B. E.: Principles and Methods of Orthodontics, Lea and Febiger, Phila. and New York, 1912.

Mellanby, M.: Diet and the Teeth: an Experimental Study. Part I. Dental Structure in Dogs, Med. Research Council Special Report Series, No. 140, 1929.

McKenzie, D.: Adenoids, Deformities of the Palate, and Artificial Infant Feeding. An Analysis of 222 Cases, Brit. Dent. Jour., **30:** 159, 1909.

McQuillen, J. H.: Hereditary Transmission of Dental Irregularities, Dent. Cosmos, **12:** 27, 73, 193, 1870.

Northcroft, George: The Teeth in Relationship to the Normal and Abnormal Growth of the Jaws, Dent. Board United Kingdom, p. 107.

Oppenheim, A.: Dent. Cosmos, Nov., 1928.

Tissue Changes, Particularly of the Bone Incident to Tooth Movement, Oester.-Ungar. Vierteljahrsschr. f. Zahnheilk., vol. IV, 1911.

Pettit, J. A., and Walrath, C. H.: A New Surgical Procedure for Correction of Prognathism, J.A.M.A., **99:** 1917–1919, 1933.

Pichler, H.: Double Resection of the Mandible, in Cases of Very Marked Progenia, Brit. Dent. Jour., **41:** 463, 1920.

Schendel: Deutsch. Monatsch. f. Zahnheilk., 1903.

Schultz, L.: Bilateral Resection of Mandible for Prognathism, Surg., Gynec. and Obst., **45:** 370, 1927.

Schwalbe, E., and Joseph, H.: Die Cyclopie. Schwalbe's Die Morphologie der Missbildungen des Menschen und Tiere, vol. 3, part 1, Fischer, Jena, 1913.

Strang, R. H. W.: A Text Book of Orthodontia, Lea and Febiger, Phila., 1933.

Limitation of the Lingual Appliance, Dent. Cosmos, Jan., 1922.

Thomas, A.: Facial Development, Internat. Jour. Orthodont., **11:** 705, 1925.

Tomes, Chas. S.: Studies on the Growth of the Jaws, Trans. Odont. Soc. Great Brit., **24:** 143, 1891–1892; Brit. Jour. Dent. Sci., **35:** 433, 1892.

Wallace, J. Sim: A Note on the Normal Development of the Jaws, **31:** 216, 1911; **35:** 138, 1915.

Whitaker, W. R., and Rollinson, H.: The Relationship of Nasal Obstruction to Contracted Arches and Dental Irregularities, Dent. Record, **31:** 425, 1911; Brit. Dent. Jour., **32:** 537, 1911.

Willett: A Case Report, Trans. First Internat. Orthodontic Congress, C. V. Mosby Co., St. Louis, p. 485, 1927.

CHAPTER XXIV

FACIAL CLEFTS—GENERAL CONSIDERATIONS

VERY often because of a related pathogenesis, the subjects of cleft lip and cleft palate have been discussed together.

Morphology.—Possibly all clefts seen clinically are present in every embryo. For some reason the processes which normally unite fail to come together in cleft lip or cleft palate and the tissues reach the age of infancy still out of contact. The study of the formation of the clefts occurring during normal development of the embryo furnishes the key to the understanding of this abnormality as far as we know at the present time. At about the fifteenth day after conception, the cavity from which the future nasal and buccal cavities will develop is bounded by a tubercle (the frontonasal tubercle) projecting forward and downward from the anterior part of the head. Laterally on each side lies one of the two maxillary processes, and below lie the two mandibular processes, which unite about the fifth week to form the future lower jaw. The maxillary processes do not meet in the midline. Each maxillary process remains wedged between the frontonasal process and its corresponding mandibular process. Before the seventh week 3 tubercles are developed on the frontal process, which remain separated by the 2 nasal grooves, or the olfactory pits. Thus, one tubercle lies in the center (processus nasalis medius) and to each side lie the lateral tubercles (the 2 processus nasales laterales). Then later the central process (processus nasalis medius) divides by an incisure into 2 parts—the 2 globular processes (Fig. 138, *A*).

At this time within the mouth the maxillary process is separated from the frontonasal process (including the 2 lateral nasal and the 2 globular processes) by the orbital fissure, in the upper part of which the eye is developed. Below its midpoint the orbital fissure is joined by the lateral nasal groove and together they form a Y-shaped cleft (Merkel). The lower limb of the Y cleft enters the mouth. The upper external arm extends in the direction of the eye while the upper median arm is the lateral nasal groove. When there is a failure of closure of any part of the upper external arm of this Y-shaped fissure, the extremely rare so-called "facial cleft" may be produced.

The Fate of the Lateral Nasal Process.—In the past there has been a considerable amount of conjecture concerning the fate of the lateral nasal process. The earlier conception originally sponsored by Goethe, and later by A. and Th. Kölliker and A. Dursy, assumed that the lateral nasal processes do not develop downward nearly as far as the middle nasal process and that, consequently, the lateral nasal process does not enter into the formation of the upper lip or the corresponding portion of the upper jaw—the intermaxillary. According to the older conception, the middle nasal process and the maxillary process join directly (Fig. 138, *B, C*). Somewhat later, in 1879, Albrecht advanced the theory that the lateral nasal process is also concerned in the formation of the normal lip and inter-

maxillary process—that the former actually gives rise to the outer part of the intermaxillary process, the corresponding superimposed part of the lip, and also finally gives origin to the lateral incisor teeth. Thus, according to Albrecht (Fig. 138, *B, D*) one has to recognize 4 intermaxillary processes, and consider that the philtrum and the central part of the upper lip originate from the central process; that the external process gives rise to a small part of the upper lip; and that the ala nasi and nostril represent the remains of the lateral nasal groove. Thus, Albrecht asserted that the maxillary process had nothing to do with the formation of the cleft in the lip and alveolar ridge, but that it is concerned with the oblique facial

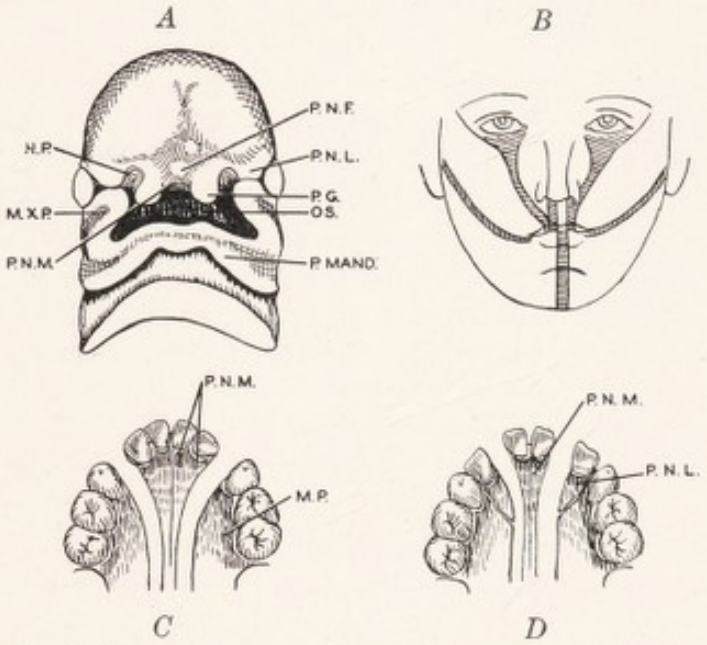

Fig. 138.—*A,* Head of fetus at about the seventh week. The mandibular processes have united. P.N.F., Frontonasal process; P.N.L., lateral nasal process; P.G., globular process attached to the nasal part of the frontonasal process; M.X.P., maxillary process; P.N.M., medial nasal process; P.MAND., mandibular process; O.S., mouth cavity; N.P. (nasal pit), lateral nasal groove which represents the anterior nares. *B,* Modified from Merkel showing the plan of a facial cleft. Right side of diagram represents Albrecht's conception, *i. e.,* the lateral nasal process comes down to form a lateral part of the premaxillary tissues. The left side interprets Kölliker's conception, *i. e.,* that the medial processes of the frontonasal process unite directly with the maxillary process. *C,* The formation of the premaxilla and lip according to the conception of Kölliker. P.N.M., Medial nasal process; M.P., maxillary process. *D,* Formation of the premaxilla and lip according to the conception of Albrecht. P.N.L., Lateral nasal process; P.N.M., medial nasal process.

clefts, which in turn are due to a failure of the lateral frontal (nasal) process to unite with the superior maxillary process.

Merkel in a schematic representation gave an outline of the most important factors according to Kölliker and Albrecht of embryonal clefts (Fig. 138, *B*).

Still another conjecture was suggested by Biondi who put forward the idea that the external portion of the intermaxillary process which Albrecht had described actually originated not from the lateral process but from the maxilla itself. The theory of Albrecht and also that of Biondi have largely succumbed for want of evidence. Proof that each half of the pre-

maxilla develops from two distinct centers is lacking. Kölliker's views have the support of most embryologists.

Thus, it is most likely that the cleft in the alveolar process lies between the intermaxillary process (arising from the two medial globular processes and the superior maxillary process) and that the two lateral (nasal) frontal processes have no share in the formation of the upper lip. Decades ago Merkel, according to Lexer, after a critical examination of the question concluded that "the lateral nasal processes under normal conditions remain entirely shut out from the formation of the lip and the intermaxillary process." No adequate evidence to the contrary has been offered up to the present time. But in oblique facial cleft the cleft lies between the lateral (nasal) frontal process and the superior maxillary process.

The Fate of the Teeth.—Albrecht accounted for the occasional appearance of two incisors in the premaxillary process as an atavistic development of a third incisor. But it is the central incisor that we are thought to have lost. A cleft behind the canine finds no place in Albrecht's hypothesis. If such a condition occurs it has been explained either by the supposition that an amniotic band cut the maxilla behind the canine or that the canine developed from that part of the dental ridge attached to the premaxilla. Little or no evidence has been brought forward to support the probability of either explanation.

Clinical cases, however, are stated to have been noted where the cleft passed between the two incisor teeth. At first thought the explanation of Albrecht seems to fit the situation in such cases. Very often there are instances without an incisor bordering the site of the cleft. To explain this, Sir William Fergusson suggested the probability of its becoming lost in the cleft. Cases are seen where the tooth buds protrude into the cleft or are suspended by a slender pedicle. Warnekros noted that an incisor is occasionally missing in the cases of cleft lip that apparently do not involve the alveolar ridge. This he explained on the basis that the tooth lies hidden in an occult bony cleft not actually involving the bony structure.

Keith who devoted especial attention to the subject sums up the fate of the lateral incisor as follows: "The germ of the lateral incisor although carried by the medial nasal process is laid down in the cleft between the maxillary and premaxillary (mesial nasal) processes. In cases of cleft palate during the middle and latter months of fetal life, the processes move apart under the strain of growth. Three fates then overtake the bud of the lateral incisor—it may be destroyed, it may remain attached to the premaxillary process, or most frequently it moves outward attached to the maxillary process. I have not seen it stranded on the bridge of tissue between the processes, or loosely attached, at one side or the other."

The Cleft Within the Mouth.—The anterior portion of the palate from the incisive foramen forward is triangular in shape, and is formed by the frontonasal process. The maxillary processes by the horizontal plates extend to the midline to form the roof of the mouth and the base of the nasal fossa. The palate, therefore, is made up of three parts, the intermaxillary part and the two lateral palatal processes which at one time have been separated by a Y-shaped fissure. When a complete fissure is present, the vertical stem of the Y lies posterior between the two maxil-

lary halves. The short arms lie anterior and each short arm separates the frontonasal portion from the adjacent maxillary process part of the palate. Complete failure of fusion gives the so-called "double cleft palate" which is practically always accompanied by a double cleft lip. It is evident, therefore, that a cleft palate is always central behind the anterior palatine fossa, but lateral in front of it on account of failure of the globular processes to fuse—a very rare condition.

Thus, the name "double" or "bilateral cleft" can be misunderstood. The name is given because of the relationship of the cleft to the intermaxilla. When no union of either maxillary process with the premaxillary process occurs, it is a double cleft. When no union of one maxillary process to the premaxillary process occurs, it is a single cleft. The cleft of the posterior part of the hard palate and the soft palate is always single and median.

As the septum and the intermaxillary structures are both derived from the frontonasal process these are always continuous. The fusion of the nasal septum with the palatal ridge does not take place in double cleft palates. But in unilateral cleft palate, it usually fuses to the palatal ridge opposite the unilateral cleft. From a clinical standpoint, a greater development of the palatal ridge on the uncleft side is often seen which at first glance makes a cleft of the palate appear to be to one side. However, from an embryologic standpoint this cannot occur. Normally, in the fetus the anterior portion of the palate closes before the posterior part. At the end of about the ninth week of fetal life the whole process is normally completed.

CLINICAL TYPES OF FACIAL CLEFTS

Median—Upper Lip (Fig. 139, *A*).—The median cleft arises from failure of the two processus globulares to fuse. It occurs with extreme rarity.

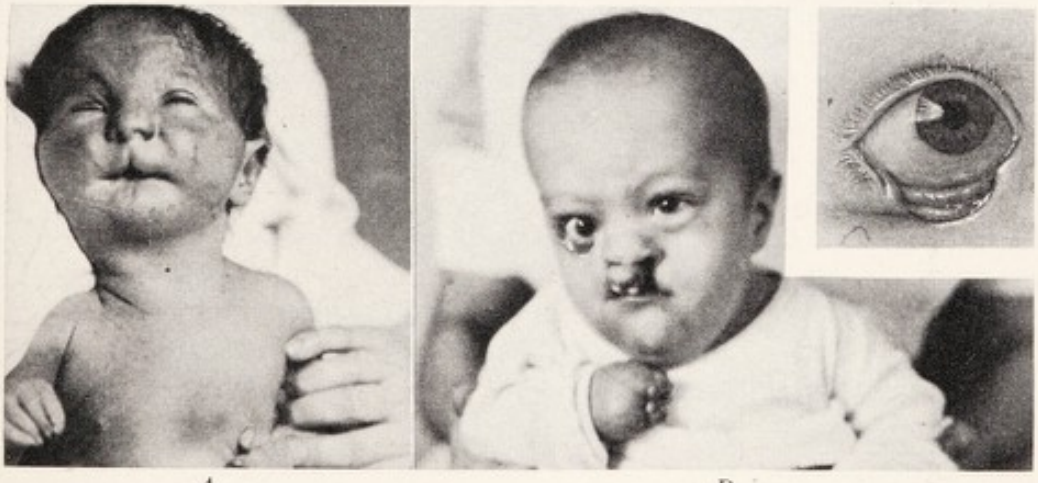

A *B*

Fig. 139.—*A*, Median cleft of the lip. *B*, Cleft of the lower eyelid. There is also a double cleft of the lip and palate present.

Defects ranging from the least degree of cleft of the lower border of the lip to complete fissures which separate the two intermaxillaries even into the nasal septum have been described (M. B. Smith, Lannelongue, Witzel). Complete absence of the middle philtrum and intermaxilla has also been seen (Sec. in the Royal College of Surgeons' Museum, London).

Single Lateral Cleft of Lip.—The most common form of cleft is the lateral which occurs in all degrees; partial or complete, with or without cleft of the palate (Fig. 140, *A*). The so-called "strips" of scar tissue which occur in the lip in partial clefts do not apparently show scar tissue on histologic investigation and thus the theory of subsequent partial intra-uterine healing of the cleft has no support. The partial harelip is a cleft extending toward the nostril floor and practically always the floor of the nostril is somewhat widened and the ala on that side flares slightly. A narrow bright glistening piece of skin is often continued from the apex of the indentation into the nostril. The U notch is lined with vermilion border. In complete one-sided harelips the whole lip is clefted and each side of the cleft is lined with vermilion border. The alveolar ridge is also cleft and a cleft palate represents the continuation of the defect in a horizontal direction within the mouth. The alveolar ridge cleft may vary from a mere notch to a width of 2 cm. In complete alveolar ridge clefts



A *B*

Fig. 140.—*A*, Typical complete single cleft lip with cleft palate. *B*, Complete double cleft of the lip with moderate projection of the premaxilla.

the alae on the side of the cleft are attached to the maxillary process. It is pulled outward and its base is externally rotated on a vertical axis. The tip of the nose is flattened on the cleft side and the cartilages are pulled downward, thus slightly increasing the length of the nose on that side. The intermaxillary process often projects toward the side which is not cleft, in case the lateral support to the vomer is wanting. The apex of the nose and septum are deflected somewhat to the sound side.

Double Lateral Cleft of the Lip.—In double lateral cleft both fissures may be complete or one or both may be only partial as described under partial cleft lip. The double total cleft lip and palate (Fig. 140, *B*) represent the greatest extent of cleft formation possible as a result of a failure of the lateral borders of the central frontal process to join with the maxillary processes. The projection of the intermaxilla is not restrained by lateral connections, and the vomer may grow forward in double-sided cleft lip and cleft palate to form a clinical picture that has been described

as the "pope's nose"—not without some levity one may suspect. This projection of the intermaxilla is often even beyond the apex of the nose. The columella may be practically absent. The nose is flattened. The small area of skin above the intermaxilla is surrounded with a rim of vermilion border. The cleft in the alveolar ridge curve may vary from 0.5 to 2.5 cm.

Cleft of the Nose.—The most severe degree is represented by a broad median groove which divides the nose into more or less symmetrical semiparts and extends up to the vomer through the septum. Below there is a median cleft of the upper lip and intermaxilla back into the palate forming an incomplete cleft palate. The two eyes, the frontal process of the superior maxilla and the alae nasi are more widely separated from each other than normal. By splitting the cartilaginous septum both nasal cavities may appear as cartilaginous tubes. The nasal bones may be absent. One nostril may be only rudimentarily developed as the two halves of the nose are not symmetrically divided. Congenital median fistulae and dermoids are to be considered also as the last remains of the median groove.

Lateral nasal cleft is less frequent than the medium. Infrequent examples are described in the literature (Broca, Kredel, Madelung, Lexer, Augerer, Leukart, Landow, Nash). Trendelenburg and Merkel have ascribed this type of cleft formation as a continuation of the lateral labial cleft—the middle nasal process being separated from the lateral in its entire length, but this explanation does not satisfactorily explain those clefts passing above the nose (Landow). Such a fetal cleft is not known to exist.

Oblique Facial Cleft (Meloschisis).—Usually anomalies of the brain also accompany this extremely rare anomaly and few are born alive. An oblique cleft passes through the upper lip to the eye or beyond. Varying degrees of cleft may be present. The slightest form is represented by a simple indentation of the upper lip, joined by a web of scarlike tissue to a wedge-shaped defect of the lower eyelid (coloboma). The cleft may involve only the soft tissues of the face or the bones may also be penetrated and in some severe cases the very broad and deep cleft continues into the maxillary palate. Morian has studied this type of cleft and he states that three forms are noted and that either the theories of Kölliker or Biondi (external maxilla is approximated to the superior maxillary process) are needed to explain the first type. The second variety which passes laterally to the nasal opening was explained by Morian as an example of Albrecht's stomato-orbital groove. In a third variety the cleft of the soft parts was thought to begin at the angle of the mouth, and by cutting the alveolar ridge external to the canine tooth, it extended up to the infraorbital foramen. Morian suggested that pressure of the amniotic bands might explain this variety of cleft as its course is not typically that of any known embryologic fissure.

Cheek Clefts (Macrostomia).—Cheek clefts correspond to the embryonal fissure between the superior maxillary process and the first branchial arch. The normal fusion to form the closed cheek fails in such cases. Milder degrees are simply a widened mouth that may in addition show a scarlike strip extending as far as the front of the ear at the tragus (Fig. 141). Usually the lack of fusion ends at the masseter muscle.

Median Cleft of the Lower Lip and Jaw.—Very rarely a median fissure has been observed in the lower lip and alveolus. The best explanation seems to be failure of union between the two inferior maxillary arches. In described cases the extent of the defect has varied from a simple central cleft of the alveolar ridge or lip to complete lack of fusion of the lower jaw, or even a cleft of the floor of the mouth and the tongue.

Abnormalities in the Region of the Fetal Clefts.—It is of interest before passing on to call attention to a few unique or uncommon types of congenital malformations which have been described in the literature, such as atresia of the nostril (Maisonneuve) and defective formation of the eyelid (Fig. 139, *B*). Amniotic bands are supposedly closely adherent to the cornea of the eye, which projects somewhat in early embryonic life. Such bands might conceivably be stretched over the eyelids and affect their formation. Colobomata of the lower lid are found in connection with tear duct anomalies and partial oblique facial clefts. Congenital fistulae corresponding to almost all the fetal clefts have been found—*i. e.*, upper lip (Freurer), nose (Beely), cheek fistula (Trendelenburg, Lannelongue,



Fig. 141.—Baby with left unilateral macrostomia.

Kroske). In our records are two examples of nose fistula and two of cheek fistula.

Ritchie Classification.—Ritchie has attempted to simplify the terminology of congenital clefts of the lip, alveolar ridge, and palate. He points out that many different terms appear in the literature. Partial, complicated, double, complete, first degree, second degree, third degree, bipartite, tripartite have been used in many combinations, primarily or secondarily to the lip or the palate or in combination. Using the alveolar ridge as a foundation for a grouping of the cases, he offers the following classification. Prealveolar clefts (harelips) are placed in group I, postalveolar clefts in group II, alveolar process clefts unilateral and bilateral in group III. The alveolar process is viewed first in this grouping. If normal, the case is thrown in group I or II but if cleft, it falls in group III and is labeled either unilateral or bilateral as the case may be.

Incidence of Various Forms.—It has been estimated (J. S. Davis) that 1 out of about every 2500 babies born has a cleft lip or cleft palate. Others have estimated the incidence as about half or even less than half of that figure (W. B. Davis). I am inclined to believe the latter figure the nearest to the correct one. Muller in 270 cases of cleft lip found 170 in boys and

100 in girls. Single cleft lip occurred 142 times on the left and 62 times on the right. Ritchie took 100 of his cases selected serially and found: (*a*) 11 prealveolar clefts (group I), of which all happened to fall on the left side, (*b*) 15 postalveolar clefts (group II) of which 7 involved only the soft palate and 8 involved besides the soft palate some of the hard palate, and 76 alveolar clefts (group III) in which 66 were unilateral and 10 were bilateral. In group III (unilateral clefts), 36 were on the left and 19 were on the right side. Eleven of these (9 left and 2 right) had normal palates. Of the bilateral clefts (group III) 2 had normal palates. In this series of 100 cases Ritchie considered 2 cases in two different groups, thus accounting for the total of 102 cases in the above grouping.

Davis (W. B.) in 1928 presented 325 cases of harelip and cleft palate with incidence similar to those just quoted. He found a positive family history in 57 per cent and only 1 negro was in the group. In one third or more of cleft-palate cases one is able to obtain a positive family history.

THEORIES CONCERNING THE FAILURE OF THE CLEFT TO CLOSE

Historical.—Fortunius Licetus in the seventeenth century attributed these anomalies to diseases of the fetus, maternal impressions, superfecundation and nutritional disturbances of the fetus—in other words to those things about which little is known. To some extent this attitude has been carried over in the literature to the present day. Soon after (1690) Pierre Sylvian Regis is said to have first called attention to the important rôle of heredity. Later Winslow, Haller and Merkel also emphasized the heredity factor. Geoffrey St. Hilaire proposed that mechanical influences were the important factors. Panum and Dreste attempted to support Hilaire's views by experimentation. Dreste incubated eggs on one end and Panum painted eggs with varnish and produced deformities in chicks. Vrolik and Nicati held that cleft palate was due to increased development of the tongue. Ahfeld called attention to hydrocephalus as an occasional factor in these cases and Fein called attention to the adenoids and their mechanical influence (adenoids, however, do not appear in the fetus until the third month of intra-uterine life). Warnekros showed supernumerary teeth by roentgenogram and ascribed the cleft to their presence. (The presence of these teeth is probably only an incident.) Schorr spoke of architectonic and vegetative factors. Syphilis was first suggested as a factor by Bumba, and Rokitansky (1885) suggested that an arrest of development due to some abnormal disturbance caused cleft palate, and that factors producing the deviation were unknown.

Heredity.—I suspect that everyone who sees a considerable number of congenital malformations of the face and jaw will be struck with the tendency for such deformities to run in certain families. I know of few reliable statistics on this question but it is not unusual to see several members of a family afflicted with harelip or cleft palate either in the immediate or collateral branches. Several children of the same family are occasionally afflicted and it is not unusual to see father and mother transmit the defect to one of their children. The occurrence usually is not serious enough to preclude reproduction, but occasionally families are seen where because of the occurrence of the malformation in the first two children, no more children are thought advisable. I have in mind two doctors with such a transmission in their families and neither the father nor mother had any malformation but on one side of the family in each case there was a distant record of the deformity. I have also in mind several instances of direct transmission from parent to child. It is not uncommon to see several children of the same family afflicted. Haentzchel (1935) has discussed the

eugenic significance of congenital clefts of the lip, jaw and palate in 128 cases. In 20.4 per cent the inheritance factor in ascent or descent could be demonstrated. Thirty-five and one-tenth per cent showed other congenital deformities and 11.7 per cent showed a slight grade of congenital feeblemindedness. At the end of 1936 I had records of about 350 clefts of the lip. I was able to trace some record of someone on one or the other side of the family who had had either a congenital cleft of the lip or the palate in about one fourth of these cases.

Mechanical Causes.—Lexer speaks of the rôle of the amnion in the causation of congenital malformations in general. He points out the reports of observers concerning the presence of remains of amniotic adhesions found in the cleft itself and its neighborhood (cases of Hoppe, Nasse, Lexer). The factor of traction disturbing the union of the two embryonic processes might deserve consideration in some cases but it is difficult to understand why most of these malformations run true to a definite embryologic cleft if bands and adhesions of the amnion were a factor in causation.

In some instances it has been suggested that tumors play a rôle. Broca and Lannelongue are responsible for reporting cases in which a tumor may have prevented union of the embryonic processes. It is possible that when formed early a tumor might be a factor but the usual case has no evidence of tumor formation.

Supernumerary teeth by requiring more spaces have been attributed by Warnekros as a cause. He found that many cases of cleft had supernumerary teeth showing in the mouth or buried in occult bone clefts. But Warnekros seems not to have taken into consideration the fact that the dental ledge first shows signs of separate tooth papillae at the ninth week. Zuckerkandl first pointed out that the alveolar processes close at a period considerably earlier than the ninth week.

The tongue has been considered by Dursy as in certain instances preventing the perpendicular plates of the palate from descending to a horizontal position and the influence of pressure upon the under jaw due to an unfavorable position of the hands has been considered. However, no mechanical factor is known which seems adequate to account for the failure of approximations of the embryonic processes.

Maternal Impressions.—No evidence is available to warrant these folk myths. Whatever might operate in this fashion would usually have to operate very soon after and perhaps before the woman knew she was pregnant. Usually the history of "an impression" is much later.

Injury.—No evidence is available to suggest that injury in the specific sense of a blow, etc., plays a rôle.

Infection.—Although infection of the chronic type has been suggested, no one at the present time can furnish reliable evidence of any connection. Congenital syphilis does not appear in cleft palates more often than in other children.

Malnutrition.—As we come to know more about the various lesions of malnutrition, their effect upon bones and upon teeth, our curiosity is aroused concerning the possibility that a malnutritional defect not now understood might be influential in the failure of the embryonic processes to close normally. Congenital malformations of the face and jaws seem to occur more often in the lower strata of society. This observation is quite

a universal one. However, heredity factors might be a factor complicating this observation. There seems to be no direct evidence to support a nutritional theory. The supposition is therefore purely speculative in nature.

Location.—No explanation has ever been offered for the fact that cleft lip and palate occur about twice as often on the left side as on the right side. This is a fact that seems established although the significance is not understood.

Other Deformities.—One occasionally encounters other congenital anomalies in children with clefts of the lip or palate such as umbilical hernia, an ear deformity, or some deformity of the fingers and toes, such as webbing. One case I have in mind had a cleft palate, a median cleft upper lip, a deformed lower jaw, a deformed tongue, and webbing of both the fingers and toes with one additional finger. Other congenital malformations are found slightly more often in those afflicted with congenital facial clefts than in other children.

Bibliography

Bibliography Quoted in Text

Ahfeld: Die Missbildung des Menschen, Leipzig, F. W. Grunow, 1880.

Albrecht: Die morphologische Bedeutung der Kiefer-, Lippen- und Gesichtspalten, Langenbeck's Arch., vol. XXI.

Biondi: Verhandlungen des XV. Chirurgen Congress, 1886, quoted by Tillmanns, pp. 183–201.

Brophy, T. W.: Oral Surgery, P. Blakiston's Son and Co., Phila., 1915.

Bumba, Josef: Monatschr. f. Ohrenh. u. Laryngo-Rhinol., **56:** 225, 1922.

Davis, John Staige: The Incidence of Congenital Clefts of the Lip and Palate, Ann. Surg., **80:** 363–374, 1924.

Davis, W. B.: Harelip and Cleft Palate, Ann. Surg., **87:** 536–554, 1928.

Fein, Johann: Wien. klin. Wchnschr., **12:** 76, 1899; **9:** 982, 1896.

Fergusson, Sir William: Quoted by Blair, V. P.: Surgery and Diseases of the Mouth and Jaws, St. Louis, C. V. Mosby Co., 1918.

Goethe: Quoted by Sir William Turner: Jour. Anat. and Physiol., vol. XIX.

Haentzchel, K.: The Eugenic Significance of Congenital Clefts of the Lip, Jaw and Palate, Leipzig Dissertation, 1935.

Kölliker: Zur Odontologie der Gaumenspalte, Centralbl. f. Chir., **15:** 1890.

Ueber das Os Intermaxillare des Menschen, Nova Acta Leopold, Carol. Akad. der Naturforsch., **43:** 1882.

Keith, A.: Certain Factors in Tooth Eruption, Trans. B. S. S. O., p. 45, 1913.

Lexer, E.: Malformations, Injuries and Diseases of the Face, v. Bergmann's System of Practical Surgery, Lea Bros. and Co., Phila., vol. I, Chapter 10, 1904.

Merkel: Handbuch der topographischen Anatomie, Vieweg, **1:** 401, 1885.

Zuckerkandl: Quoted by Lexer, pp. 411–458.

His, W.: Anatomie menschlicher Embryonen, Leipzig, 1880.

Rokitansky, Carl: A Manual of Pathological Anatomy, Phila., **2:** 17, 1885.

Schorr, Goethe: Virchow's Arch. f. path. Anat., **197:** 16, 1909.

Warnekros: Verhandlungen der Deutschen Odontologischen Gesellschaft, vol. VII, Schaff's Handbook.

Arch. f. Laryngol. u. Rhinol., 1909.

Licetus, Fortunius; Winslow; Pierre Sylvian Regis, and Haller: Quoted by Tirifahy, S.: Jour. de méd. e. chir. et de pharmacol., **37:** 335–422, 1863.

Broca, Dursy, Freurer, Madelung, Maisonneuve, Morian, Nash, Hoppe, Nasse, Kredel, Kroske, Lannelongue, Leukart, Witzel, and Smith, M. B.: Quoted by Lexer, E.: Von Bergmann's System of Practical Surgery, Phila., Lea Bros. and Co., Malformations, Injuries, and Diseases of the Face, Chapter 10, **1:** 411–458.

Dreste, Geoffrey St. Hilaire, Nicati, Panum, and Vrolik: Quoted by Kramer, Josephy: Ueber Wolfsrachen und frühzeitige Uranoplastik, Inaug. Diss. Kiel, 1900.

Augerer, Beely, Landow, Muller, Madelung, Morian, Trendelenburg: Quoted by Tillmanns: Textbook of Surgery, New York, D. Appleton Co., **2:** 183–201, 1897.

CHAPTER XXV

HISTORICAL DEVELOPMENT OF THE SURGERY OF CLEFT LIP AND PALATE

Preliminary to a discussion of present methods of repairing clefts of the lip, alveolar ridge, and palate, an historical résumé of the development of the subject is pertinent as well as interesting. Perspective and balance of judgment are gained by understanding the reasons for the gradual discarding of certain procedures and the retaining of others which appear to be essential.

HISTORICAL SKETCH OF OPERATION FOR HARELIP

The early operations for harelip consisted of simple denudation of the cleft lip edge. Velpeau is authority for the statement that Celsus and other ancient surgeons pared and sutured harelip and even made relaxing incisions on the inner surface of the cheek. It seems that this knowledge became obscure and late in the eighteenth century, various make-shifts for raw surface to raw surface approximation without suturing such as escharotic plasters, clamps, and bandages were tried. Franco in 1561 recommended that, prior to the closure of the lip cleft, the posterior surface of the lip be separated from the maxillary bones. Later Pointe in 1825 and Mannoir of Geneva revived and emphasized this recommendation which is a basic procedure today. According to Lexer, Graefe in 1825 attempted to overcome the notching of the lip by curving the incisions (Fig. 142, A, B). Husson in 1936 (Blair) recommended that the denuding incisions be made concave to gain length of lip after suturing the cleft soft tissue. This principle is basic today. Angular incisions to gain the same result was described by Malgaigne in 1844 (Fig. 142, C, D). Nélaton described a method for use in partial lip which is of value at times (Fig. 142, E, F). The flap operation of Mirault (Fig. 142, G, H) was described in 1844 and aided in giving the shorter side of the lip more length. But apparently it was only used to give proper length and fulness to the lower part of the lip.

Plessier has looked up the original Mirault description of the operation which in this country has his name attached. It seems that Mirault had only operated 2 cases when he described his first method (Fig. 142, I, J). In this method the flap is taken from the long side of the lip. Apparently for some reason, probably because of the obscurity of his description, most later authors have shown the flap as coming from the shorter side of the lip. Hallington Smith in 1852 in his Surgery shows the first record of this change. Mirault a short time later described his second method (Fig. 142, K, L) as being better than his first. Thus, the excellent operation rather generally attributed to Mirault was probably never performed by him. The procedure of Meleux published by his intern Verrier in 1880 (Fig. 142, M, N) who succeeded Mirault in the chair of clinical surgery at l'École de Médecine d'Augers, is similar to the second procedure of Mirault.

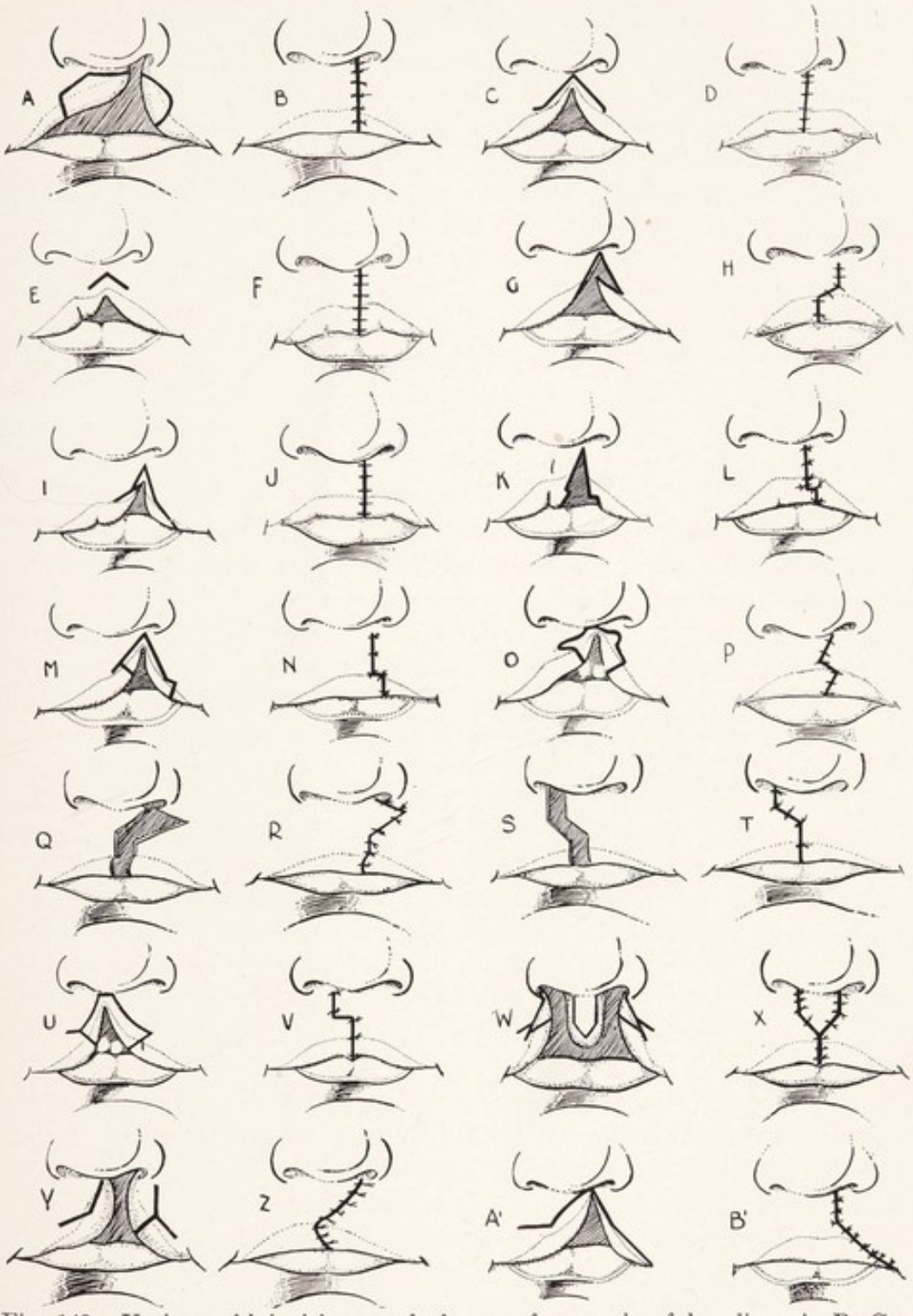

Fig. 142.—Various old incisions and closures for repair of harelip. A, B, Graefe's incision and closure of cleft lip. C, D, Malgaigne's incision and closure of cleft lip. E, F, Nélaton's incision and closure of cleft lip. G, H, Mirault's flap operation for harelip according to H. Smith. I, J, Mirault's incision and closure for cleft lip—"première méthode" according to Plessier. K, L, Mirault's incision and closure—second method according to Plessier. M, N, Meleux's incision and closure for cleft lip. O, P, Jalaguier's incision and closure for cleft lip. Q, R, Giraldes' incision and closure of cleft lip. S, T, König's incision and closure of cleft lip. U, V, Hagedorn's incision and closure for single harelip. W, X, Hagedorn's incisions and closure for double harelip. Y, Z, Colles' incision and closure for cleft of lip. A′, B′, Owen's operation for single cleft of lip.

Jalaguier about the same time as Meleux developed a somewhat similar operation (Fig. 142, O. P). These operations are liable to give a lip which

is too long as the flap is taken from the long side of the lip. The operations to which the name of Mirault is attached as used in this country today is shown in Fig. 155, Chapter XXVII.

Other modifications of the flap operation were invented and recommended but the basic principles of the Graefe and Mirault type of operation have largely withstood the test of time. Giraldès (Fig. 142, Q, R) and König (Fig. 142, S, T) and Hagedorn (1884) (Fig. 142, U, V, W, X) presented modifications. The Graefe-Husson principle is today probably the most widely used type of operation although several operators have developed the Mirault procedure to a high point of excellence. Either principle can be applied to a double harelip. Blair gives B. Bell credit for recognizing the necessity of extending the incision up into the nostril in incomplete harelip. The first operation which emphasizes the principle of turning a flap into the nostril to build a floor to the nostril is the Colles operation (Binnie). It is of the Mirault type plus the flap reversal to form the floor of the nostril. Also it internally rotates the alae by taking a point at the alar base to sew to the tissue at the base of the columella.

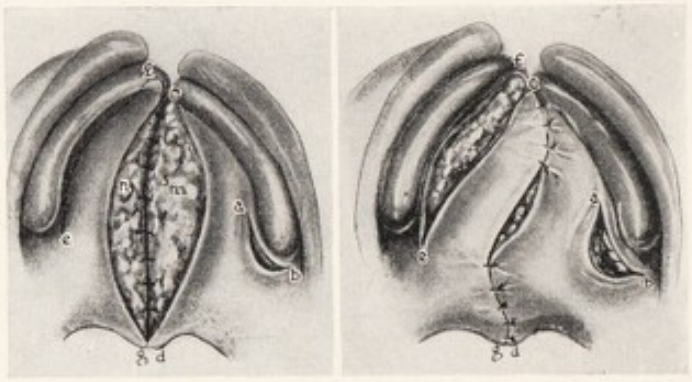

A *B*

Fig. 143.—Davies-Colley flap operation. *A*, Flaps *m*, *n* are turned over backward like the leaves of a book. Flap *e*, *f*, *g* is loosened and made to crosslap to opposing flap. *B*, Along line *c*, *d*. Lateral relaxing incision made at *a*, *b*.

Clamps such as hemostats were used rather early to prevent bleeding. Such a clamp is depicted in the 1858 edition of Erichsen's Surgery.

The Colles operation embodies most of the principles of the Mirault-Blair operation (Fig. 142, Y, Z), which in certain surgeon's hands has become the most efficient operation for complete single cleft of the lip. Owen used the flap principle of Mirault but cut his flap from the long side of the lip as did Giraldès (Figs. 142, 143). It does not give so satisfactory a lip as the Mirault operation. In 1925 Veau published an operation using the flap from the shorter side of the lip. He has since abandoned this technic according to Plessier. Since this time Veau has developed a different technic (Fig. 162, Chapter XXVII), which discards use of a flap of skin from the short side of the lip.

Supplementary Supports.—After closure of the lip by suture, supplementary supports of several types have been suggested. Roux used a support of threads crossing the suture line and attached to pieces of adhesive. A spring compressor which pushes the cheek forward is depicted by Erichsen. The modern supplementary support is best represented by the type used by Logan (Fig. 173, Chapter XXVII).

HISTORICAL SKETCH OF OPERATION FOR THE REPAIR OF CLEFT PALATE

In 1764 Le Monnier, a French dentist, reported the first successful repair of a cleft velum. Later, his success was followed by von Graefe of Germany in 1817, Roux of France in 1819 and Warren of America in 1820. But it remained for Dieffenbach to report the first successful closure of both the hard and the soft palate in 1834. Baizeau in 1853 and von Langenbeck in 1861 claimed originality for the operation of Dieffenbach with its lateral incisions. But even today the operation often bears the name of von Langenbeck (Fig. 177, Chapter XXIX). Warren of Boston (1842) is sometimes given credit for the first closure of both the hard and the soft palate but Dieffenbach seems to have preceded him by about eight years. Warren did not use the lateral incisions and that type of operation is still known by his name. Mütter (1843) reported 21 cases operated by the Warren method so both Warren and Mütter must have used it for some time previously. Both Warren's and Dieffenbach's operations are now in general use. To obtain relaxation Dieffenbach in 1826 did an osteotomy of the horizontal plates of the maxillary process and in 1834 advocated cutting the palate muscles. Later Fergusson was generally credited with both of these procedures. Billroth in 1861, suggested early operation for cleft palate, but according to Heitmüller, Velpeau made the same suggestion. Later J. Wolff advocated operation between one and two years of age which was earlier than the operation had been done before. In 1861 Reeves (Blair) at autopsy observed that most of the tissue that goes to make up the normal palate was present and that the width of the cleft depended mostly upon the fact that the maxillary bones were spread apart.

Fergusson has generally received credit for first advocating the severance of the palatal muscles (1845) and also with osteotomy (1873) of the horizontal processes of the palatal bones for relaxation. It appears, however, that Froriep first carried out the former procedure in 1823, and Dieffenbach the latter procedure in 1826. Billroth in 1861 made the suggestion that the hamular processes be fractured to relieve tension. The use of the mucosal flap from the septum to aid in the repair of the fissure was done first by Lannelongue in 1877. The "'criss-cross" operation of Davies-Colley (Fig. 143, *A*, *B*) for closure of the hard palate appeared in 1890. In 1893 Brophy suggested the wiring operation (Fig. 146, Chapter XXVI) for bringing the separated alveolar ridges together at an early age. Finally, in 1902, the Lane operation (Fig. 144, *A*, *B*) appeared which was an extension of the principles of the Davies-Colley flaps to both the hard and the soft palate.

Efforts to lengthen the atrophic shortened soft palate that often follows these more routine procedures started with Passavant in 1865 who connected the uvula to the posterior pharynx. Schoenborn (1876) extended the procedure somewhat. Several men including von Kuster (1893), Dorrance (1925) (Chapter XXVIII), Limberg (1927) and Lvoff (1928) have developed operations that attempt to obtain length of palate using a pharyngeal flap. Rosenthal (1928) used modifications of Schoenborn's operation and von Langenbeck's operation which attempt to overcome the shortening of the palate which follows the von Langenbeck operation alone. Padgett (1930) (Chapter XXVIII) has published a modification of Schoenborn's operation which uses a pharyngeal flap to augment the soft palate in those

cases which have had a large part of the soft palate destroyed by previous operations. Various external flap operations (Chapter XXVIII) for the repair of palates after nearly complete loss of both the hard and soft palatal tissues were originated first by Blasius and later by Thiersch in 1867, and Rotter in 1869. Recent modifications of the method have been published by von Eiselsberg (1901), Blair (1911) and Padgett (1930, 1936).

Retention Devices for Holding the Palatal Flaps.—Dudon (1887) of Bordeaux gives credit to Sédillot for the idea of using tapes drawn through the lateral incisions to support the palate flaps. Dudon used them with freshening the middle edges and Fergusson passed wires around his flaps (1873). The use of the many devices has been suggested such as the old quill and lead plate suture (Fillebrown and Brophy), the vulcanite plate, crosswise wires or a cross tape (Mayo). But now, a supplementary means of protecting the suture line such as sutures through the lead plates has

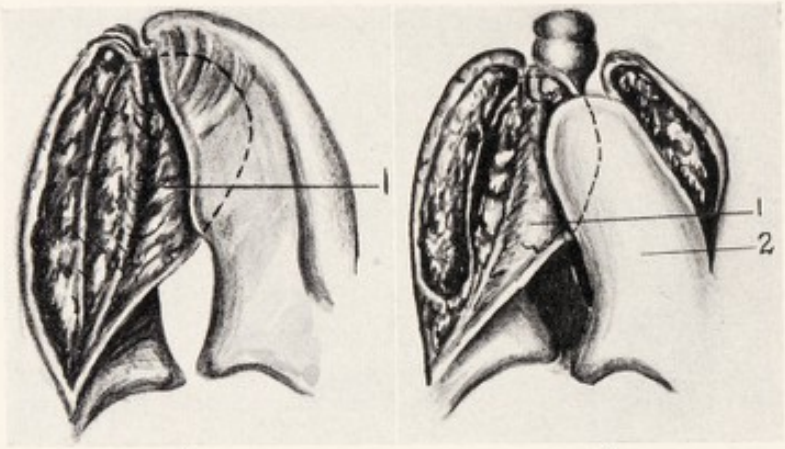

A *B*

Fig. 144.—Lane operation for unilateral and double cleft. In *A* a flap was outlined from the short side and turned over like a book is opened. The palatine artery was left intact in the flap. The mucoperiosteal flap from the long side was raised from the horizontal plate of the palatal bone. The flap from the short side was cross-lapped up above the flap from the long side. *B*, For a double cleft the principle of the operation was the same as for a single cleft. 1, Turned-over flap; 2, loosened upper mucoperiosteal flap.

been largely abandoned because of a tendency to cause sloughing, and dependence is placed upon relieving tension, getting accurate approximation and maintaining blood supply. There is no efficient way of guarding against tongue pressure but when relaxation is thorough, coughing and vomiting strain is largely guarded against. The palatal flaps may at times be aided in uniting when stabilized and held toward the center by lateral gauze packs properly placed.

Methods of Forcibly Approximating the Alveolar Processes.—Reeves in 1861 advocated the use of a clamp on the gums to obliterate the maxillary cleft. The elder Sayre discussed such a possibility in his clinical lectures (Blair). The original Hammond clamp modified by Roberts is interesting. The clamp has three teeth on each arm which projects on the upper alveolar ridge. A screw attachment allows one to close the arms by a gradual turning of the screw. Several of the old operators tried these but as Roberts remarks "Theoretically, the old method is valuable but its prac-

tical usefulness has not yet been established." If the clamp did not fret the baby too much or damage the soft tissues over the bones, the principle would seem fairly good. The clamp was put on under an anesthetic and tightened a little each day. Brophy made one and discarded it but at that time the disadvantages of the wiring operation were not so well known. He concluded that as the wires were more efficient, they were preferable. Brophy started to do his wiring operation some time before 1891.

Methods of Handling the Premaxilla and Its Vomerian Support.—Blandin cut the vomer and Partsch (Fig. 145, B) took a V-shaped piece out of it, after which they pushed the premaxillary bone backward. Krönlein pushed the intermaxilla back after the method of v. Bardeleben (1868) and held the freshened intermaxilla in place by means of a lead plate

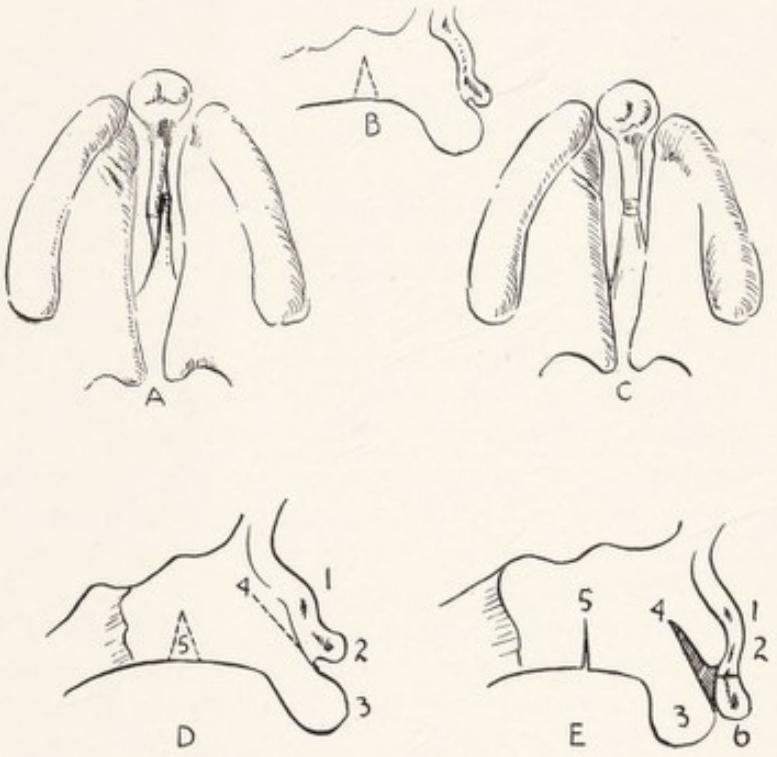

Fig. 145.—Methods of handling the vomer when the premaxilla projects forward. A, Von Bardeleben's method of sectioning and crosslapping the vomer. B, C, Partsch method—removal of V-shaped wedge. D, Reich's operation. 1, Tip of nose; 2, philtrum; 3, premaxilla; 4, oblique section of septum; 5, wedge of septum removed. E, Position for Reich's operation of parts after adjustment.

which passed through the region of the nasolabial folds and over these behind the philtrum. Lexer (1904) felt that in older children bony union was possible by this method but in younger children such a result was exceptional. Firm union seldom occurs between the portions of the vomer pushed by one another after the method of von Bardeleben (Fig. 145, A). Experience teaches that in both situations the union is by firm connective tissue. Lane (Binnie) disproved of these methods of replacing the premaxilla. Thiersch advocated simple pushing back and said that it could be obtained in about eight weeks (Lexer). He used a metal band "Thiersch butterfly"; von Esmarch used this method by adding a night cap. Simon utilized the soft tissues first for this purpose. Wolff also used the method without the mutilating incisions used by Simon. Finally in 1911

Reich described a method which attempted to overcome the "blunt and bulldog nose" that occurs by the methods described previously (Fig. 145, C, D).

Ideas on Palate Lengthening.—In 1876 Schoenborn advocated the use of a flap from the posterior pharyngeal wall. In 1878 Passavant tied the uvula to the posterior pharyngeal wall by turning small flaps so that raw surface would be to raw surface.

Again, recently Rosenthal and Padgett (Fig. 189, Chapter XXIX) have utilized a flap from the posterior pharyngeal wall to aid in repairing the velum. Von Kuster's lengthening operation by means of a portion of the detached edge of the cleft also belongs to this group.

In 1922 Blair performed an operation in which flaps from the cheek were outlined and turned in through the lateral incisions on the upper raw surface of the palate. In 1925 Dorrance described an operation for the lengthening of the palate in which the soft tissues of the hard palate and the raphe of the soft palate are loosened from the horizontal plates of the palatal bones. An encircling incision was made within the alveolar margins and both the hard and the soft palates were displaced backwards. Again, Limberg in 1927 and Lvoff in 1928 presented operations based upon a somewhat similar principle.

Morestin in 1910, Helbing in 1912, and Makuen in 1915, in discussing a paper by Emerson, referred to Brophy as having used the posterior pillars to lengthen the shortened velum. Just recently Blair has recommended the procedure after using it for some years (Fig. 178, Chapter XXIX).

Advancement of the Pharyngeal Wall.—Von Gaza in 1926 advised the implantation of fat and fascia into the retropharyngeal space. Recently Wardill has developed an operation to increase the thickness of the soft tissue of the pharyngeal wall. In one case (1930) we implanted cartilage in the posterior pharynx beneath the mucosa and superior constrictor muscle to supplement a short velum. In our case we had no difficulty but we were aware of the danger. The speech seemed to be improved somewhat.

Gersuny in 1900 suggested the use of paraffin in the posterior wall of the pharynx. In 1902 Eckstein used the method. Woods in 1927 injected paraffin into the retropharyngeal space and reported improvement in speech. He also tried to produce a scar of the pharynx by diathermy similar to the procedure of Rubenberg.

Repair of a Palate by Means of an Extrapalatal Flap of Skin.—The idea of the repair of a palatal defect by a flap elsewhere than inside the mouth is rather ancient. It was first unsuccessfully attempted by Blasius by the use of a flap from the neck. Thiersch in 1867, and Rotter in 1869, used the principle successfully. Later the method was successfully used by von Eiselsberg, Blair, and Padgett (Figs. 191, 192, 193, Chapter XXIX).

Bibliography

Bibliography Quoted in Text

Billroth, T.: Ueber Uranoplastik, Wien. klin. Wchnschr., **2**: 241, 1889.

Blair, V. P.: Personal communication to the author.

Congenital Facial Clefts, Surg., Gynec. and Obst., **37**: 530, 1923.

Mirault Operation in Surgery and Diseases of the Face, Mouth and Jaws, St. Louis, C. V. Mosby Co., 1917.

Operative Treatment of Difficult Cases of Palatal Defects After Infancy, Surg., Gynec. and Obst., **12:** 289, 1911.
Blair, V. P., and Brown, J. B.: The Dieffenbach-Warren Operation for Closure of the Congenitally Cleft Palate, Surg., Gynec. and Obst., **59:** 309–320, 1934.
Blasius: Quoted by von Eiselsberg, F.: Zur Technik der Uranoplastik, Arch. f. klin. Chir., **64:** 509, 1901.
Brophy, T. W.: Oral Surgery, Phila., P. Blakiston's Son and Co., 1915.
Fundamental Principles and Recent Conclusions in the Surgery for Cleft Palate, Internat. Jour. Orthodont., Oral Surg. and Radiology, **10:** 548, 1924.
Celsus: System of Surgery, Trans. by Smith, **11:** 31, 1847.
Colles: Cited by Binnie, J. F.: Operative Surgery, 1921, P. Blakiston's Son and Co., Phila.
Davies-Colley, T. N. C.: On A Method of Closing Cleft of the Hard Palate by Operation, Brit. Med. Jour., **11:** 950, 1890.
Dieffenbach, J. F.: Chirurgie Erfahrung, **324:** 168, 1834.
Die Operative Chirurgie, Leipzig, F. A. Bockhaus, **1:** 856, 1845.
Dorrance, George M.: Lengthening of the Soft Palate in Cleft Palate Operations, Ann. Surg., **82:** 208–211, Aug., 1925.
The Operative Story of Cleft Palate, Phila., W. B. Saunders Co., 1933.
Dudon, E.: Bull. et mém. soc. d. chir. Paris, **13:** 48–52, 1887.
Rev. de chir., **8:** 30–43, 1888.
Emerson: Quoted by Makuen.
Eckstein: Berl. klin. Wchnschr., **39:** 315, 1902.
Erichsen, John: Science and Art of Surgery, 1858, vol. 2, Lea Bros. and Co., Phila.
Fergusson, William: A New Operation for Cleft Palate, Lancet, **2:** 784, 1873.
Successful Treatment of Four Cases of Cleft in the Hard Palate by a New Operation, Lancet, **1:** 298, 1874.
Fillebrown, T.: A Study of Harelip and Cleft Palate, Proc. of Mass. Dental School, **33:** 68, 1897.
Froriep: Nottizen chirurgische Kupfertafln, Landes-Industrie Comp., Wiemar, 1823.
Heitmüller: Corresp.-Bl. f. Zahnärzte, **33:** 1.
Helbing, Carl: Ueber Uranoplastik, Allg. med. Centr.-Ztg., **81:** 21, 1912.
Berl. klin. Wchnschr., **39:** 980, 1912.
Jalaguier: Presse méd., Nov. 5, 1910.
König, F.: Lehrbuch der speciellen Chirurgie, Berlin, August Hirschwald, 1898.
Lane, W. A.: On Cleft Palates, Lancet, **11:** 433, 1902.
The Modern Treatment of Cleft Palate, Lancet, **1:** 6, 1908.
Lannelongue: De l'uranoplastik ostéo-muqueuse, Bull. et mém. soc. de chir. de Par., **111:** 467–468, 1877.
Operation by a Nasal Flap, Bull. de la soc. chir., p. 472, 1877.
Le Monnier: Quoted by Robert: Mémoires sur different objet de médecin, Paris, Masson et Cie, 1764.
Quoted by Verneuil, A. S. S.: Mémoires de chirurgie, Paris, Masson et Cie, **1:** 506, 1877–1878.
Quoted by Velpeau.
Lexer, E.: von Bergmann's System of Practical Surgery, Lea Bros. and Co., pp. 411–458, 1904.
Limberg, A.: Innovations in Operative Methods, Zentralbl. f. Chir., **54:** 1745–1750, July 9, 1927.
Logan, W. H. G., and Kronfeld, R.: Development of the Human Jaws and Surrounding Structures from Birth to the Age of Fifteen Years, Jour. Amer. Dent. Assoc., **20:** 379–427, 1933.
Lvoff, P. P.: Operation for Lengthening Palate, Vestnik khir., **13:** 212–221, Nos. 37–38, 1928.
Malgaigne, J. F.: Manuel de médecine opératoire, Paris, p. 462, 1861.
Mayo, C. H.: Cited by Binnie: Discussion of Brophy's Paper in Tr. Sect. Surg., Gen. and Abd., A.M.A., p. 30, 1918.
Makuen: Quoted by Dorrance.
Morestin, H.: Opération complémentaire de l'uranostaphylorraphie, amélioration phonétique considerable obtenus par l'allongement de piliers postérieurs, Bull. et mém. soc. de chir., **36:** 621, 1910.
Mirault: Malgaigne's Jour. de chir., p. 257, Sept., 1849, and p. 5, January, 1845.

Mütter, T. D.: Report on Operations for Fissure of the Palatine Vault, Phila., 1843. Amer. Jour. Med. Sci., 1837–1838.
Nélaton, A.: Elements der pathologie chirurgicale, Paris, **4:** 497, 1876.
Owen, Edmund: Cleft Palate and Harelip, Burghard's Operative Surgery, vol. 2, London, 1904.
Cleft Palate and Harelip, 1904 (Med. Monograph Series).
Surgery of the Mouth, Teeth and Jaws, Keen's Surgery, **3:** 614, 1908.
Padgett, Earl C.: Repair of Cleft Palates Primary Unsuccessfully Operated Upon, Surg., Gynec. and Obst., **63:** 483–496, 1936.
Passavant, G.: Ueber die Beseitigung der nasalden Sprache bei angeborenen Spalten des harten und weichen Gaumens, Arch. f. klin. Chir., **6:** 333, 1865.
Plessier, Paul: Traitement du bec-de-lièvre unilatéral, Procédé du Dr. Veau, Masson et Cie, Paris, 1931.
Reeves: Med. Record Australia, June 15, 1861, quoted from Owen in Burghard's System of Operative Surgery, 2nd ed., **11:** 145.
Reich, A.: Zentralbl. f. Chir., p. 859, June 24, 1911.
Ritchie, H. P.: Cited in Dean Lewis' Practice of Surgery, vol. 5, Chapter IX, W. F. Prior Co., Inc., Hagerstown, Maryland, 1930.
Congenital Cleft Lip and Palate, Ann. of Surg., **84:** 211–222, 1926.
Roberts, J. B.: Surgery of Deformities of the Face, 1912, William Wood and Co., New York.
Trans. Phila. Acad. Surgery, Ann. Surg., p. 110, January, 1918.
Rosenthal, W.: Pathologie und Therapie der Gaumendefekte, Fortschr. Zahnheilk., **4:** 1021, 1928.
Rotter, Julius: Deckung eines Defectes im harten Gaumen mittels eines Sternlappens, Münch. med. Wchnschr., **36:** 535, 1889.
Roux, Joseph P.: Mémoires sur la staphylorraphie, Arch. gén. de méd., **7:** 516–538, 1825.
Rubenberg, D. C.: Wien. med. Wchnschr., **26:** 815–839, 862, 1876.
Schoenborn: Ueber eine neue Methode der Staphylorraphie, Arch. f. klin. Chir., **19:** 528–531, 1876.
Sédillot, C.: Quoted by Heath, Christopher, in Ashhurst, John: The International Encyclopedia of Surgery, New York, William Wood and Co., **4:** 911, 1889.
Smith, H. H.: Operative Surgery, Lippincott, Grambo and Co., Phila., 1852.
Thiersch, C.: Verschluss eines Loches im harten Gaumen durch die Weichtheile der Wange, Arch. f. d. Heilkunde, **9:** 159–164, 1868.
Veau, Victor: Division Palatine, Anatomie, Chirurgie, Phonétique, Masson et Cie, Paris, 1931.
Velpeau: New Elements of Operative Surgery, 2nd edit., p. 329, 1847; **3:** 485–507, 1839.
Verneuil, A. S. S.: Mémoires de chirurgie, **1:** 506, 1877, Masson et Cie, Paris.
Verrier: Quoted by Plessier.
Von Eiselsberg, F.: Zur Technik der Uranoplastik, Arch. f. klin. Chir., **64:** 509–529, 1901.
Von Kuster: Die Operation der complizierten Hasenscharte, Zentralbl. f. Chir., **32:** 713, 1905.
Ueber die operative Behandlung der Gaumenspalten, Arch. f. klin. Chir., **46:** 215–229, 1893.
Von Graefe, C.: Die Gaumennaht, ein neuentdecktes Mittel gegen angeborene Fehler der Sprache, Jour. d. Chir. u. Augenheilk., **1:** 556, 1820.
Von Langenbeck, B.: Operation der angeborenen totalen Spaltung des harten Gaumens nach einer neuen Method, Deutsch. Klin., **12:** 231, 1861.
Weitere Erfahrungen im Gebiete Uranoplastik mittelst Ablösung des mucoperiostalen Gaumenüberzuges, Arch. f. klin. Chir., **5:** 1–170, 1864.
Wardill, W. E. M.: Cleft Palate, Brit. Jour. Surg., **16:** 127, July, 1928.
Warren, J. Mason: New England Quart. Jour. Med. and Sci., April, 1842.
Warren, John C.: On an Operation for the Cure of Natural Fissure of the Soft Palate, Amer. Jour. Med. Sci., **3:** 1, 1828.
Waterhouse, H. P.: Afflictions of the Mouth, Palate, Tongue, Tonsil and Pharynx, in Treves, F.: System of Surgery, **2:** 450.
Wolff, J.: Ueber fruehzeitige Operation der Gaumenspalte, Samml. klin. Vortr., p. 167, 1901, cited by Lexer.
Verhandl. d. deutsch. Gesellsch. f. Chir., **14:** 387, 1885; **23:** 461, 1894.

Woods, Sir Robert: Aids to Palatal Sufficiency After Cleft Palate Operations, Brit. Med. Jour., **1:** 371–372, Feb. 26, 1927.

B. Bell, Husson, Hammond, Krönlein, Sayre, von Eiselsberg: Quoted by Blair, V. P.: Congenital Facial Clefts, Surg., Gynec. and Obst., **37:** 530–535, 1923.

Baizeau: Quoted by Verneuil, A. S. S.: Mémoires, Paris, Masson et Cie, **1:** 506, 1877.

Franco and Pointe: Quoted by Velpeau: New Elements of Operative Surgery, 2nd ed., p. 329, 1847; **3:** 485–507, 1839.

Von Bardeleben, von Esmarch, Simon, Partsch, Meleux, Hagedorn, and Gersuny: Quoted by Lexer in von Bergmann's System of Practical Surgery, Lea Bros. and Co., pp. 411–458, 1904.

CHAPTER XXVI

THE TREATMENT OF THE BONY CLEFT AND THE NEIGHBORING SOFT TISSUES

In all discussions of the treatment of cleft lip and cleft palate, the treatment of the alveolar cleft assumes an important position. The most prominent advocate of the forcible closure of the alveolar ridges was Brophy who in 1890, in carrying out his method, inserted wires over lead plates through the alveolar ridges.

The method of using the soft tissues of the lip or anterior palate or both to draw the alveolar processes together was developed early along with the various operations for the repair of cleft lip and cleft palate. P. Broca (Lexer) and von Langenbeck first freshened the bony side of the alveolar cleft to encourage union between the ends of the alveolar ridge. Later, Lane used soft tissue flaps from the alveolar ridges and palate to bridge the alveolar defect soon after birth.

FORCIBLE APPROXIMATION OF THE ALVEOLAR PROCESSES IN SINGLE CLEFT

Recently Logan, who was a student of Brophy's, has presented the case of forcible closure in the light of modern experience and research on the position of the tooth buds and teeth at various ages. Logan argues that upper jaw deformities occur even when the bones are not interfered with. Instances are cited by Logan in which upper jaw deformities occurred without any operation on the alveolar ridges of the palate following simple closure of the bone, due to pull of the soft tissues, without wiring. He still remains convinced that the principle of the direct application of force through the medium of silver wires and lead plates on the buccal side of the alveolar ridge is the best treatment for wide clefts. After sectioning jaws at various ages, he shows the exact position of the deciduous teeth in relation to the germs of the permanent teeth between birth and six months and calls attention to the position of the deciduous teeth at this age. They are to the lingual side save the bicuspid "buds" which are to the occlusal side of the erupting deciduous first and second molars. He advocates the passing of silver wires above the deciduous buds which he states does not damage the permanent buds which are lingual and occlusal (Fig. 146, *a*, *b*).

Logan and Kronfeld draw conclusions in regard to the calcification of the teeth which vary from those on which the standard accepted tables are based. As far as cleft palate surgery is concerned, they summarize their conclusions as follows:

"At the time when wiring through the upper jaw is preferably performed (between the second and fourth months), the tooth germs are lying in the jaw in such a crowded position that passing wires between them, as originally suggested by the advocates of the direct application of force, is now known to be impossible. It is possible to pass wires or other suture material

through the maxilla above certain germs, at a point mesiad from the cuspid eminence and distad from the deciduous and permanent central incisor germs, or immediately above the deciduous lateral incisor. A second point of entry is located in the field between the cuspid eminence and the zygomatic process above the first deciduous molar germ. If the points of entry for the wires are high enough and at the exact landmarks specified, the only possibility of injury to the germs is that which confronts the operator when sufficient care has not been exercised in the location of the very definite anatomic landmark described.

"Attention of all members of the profession who perform surgical operations for the closure of complete congenital clefts or those clefts which extend to the maxillary ridge is invited to the necessity of obviating the making of incisions through the attached overlying soft tissues on the lingual aspect of the maxillary ridge for any considerable distance from the border of the cleft on either the long or short fragment for the purpose of elevating the periosteum for coaptation in the median line. Nor should

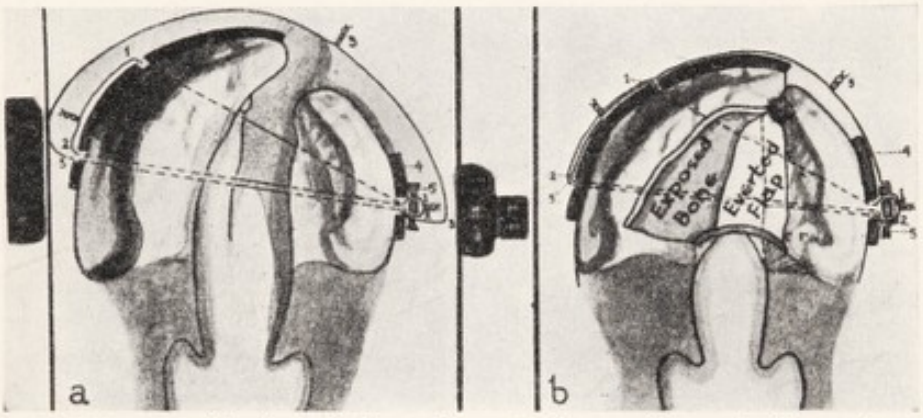

Fig. 146.—Direct application of force through the medium of silver wires and lead plates, and the recommendation of the adoption of an everted flap for the closure of the cleft extending through the anterior part of the hard palate in early infancy, as set forth by Logan. *a*, 1, Anterior wire; 2 and 3, posterior wires; 4, lead plates; 5, uranoplastic button. *b*, 1, Anterior wire; 2 and 3, posterior wires; 4, lead plates; 5, uranoplastic button; 6, silk sutures.

such incisions be made for the purpose of everting or transferring of this tissue toward the center of an open cleft until the patient is at least one year of age, for the germ of the permanent lateral incisor is encased in the fibrous tissue of the maxillary ridge during this period. Furthermore, the germ of the permanent incisor is not yet within the bone of the ridge in the first six months."

Logan and Kronfeld (1933) in a study of the development of the teeth and jaws arrived at the conclusion that caution must be taken not to pass elevators or knives through the fibrous tissue overlapping the anterior part of the maxillary ridge until after one year of age for the germ of the permanent lateral incisor is encased in fibrous tissue of the maxillary ridge and not within the bone during this period and the germ of the permanent central incisor is not within the bone during the first six months. Laterally and posteriorly in the field of the occlusal surface of the deciduous molars or to the immediate lingual aspect the same caution is necessary prior to a date somewhere between the second and third year, for during this time

the germs of the bicuspid teeth are passing from the occlusal aspect of the deciduous molars to their lingual side and have not entered the bone in the majority of instances prior to two years for the first bicuspids, and three years on an average for the second bicuspids.

Brophy Procedure for Closure of the Alveolar Cleft.—The Brophy procedure for closure of the alveolar cleft was neither an operation for cleft lip nor for cleft palate but only a procedure for closure of the open alveolus.

Brophy's method was applied with the idea of getting bony union of the alveolar process and proper contour of the alveolar ridge. The operation was considered applicable to children under six months of age. In Brophy's hands the operation had little mortality. He operated 211 cases without a death. Other men were not so fortunate, however. Brophy stated that there was surprisingly little shock to his procedure and that little blood was lost by tears.

Brophy preferred to operate on the alveolar bones and anterior hard palate within the first three months of life and to do the operation on the lip from six weeks to three months subsequently. He felt that the correction of the lip could best be accomplished by first closing the bones which to some extent corrects the defect of the nose, tending to bring it into the median line of the face.

Brophy presented diagrams showing the alveolar arches are separated considerably in cleft palate and are wider proportionately to the width of the cleft. The evidence to support this conception was contradicted by Thompson and others. Brophy failed to take into consideration that the palatal processes have an increased verticality in cleft palate. Most likely the arches are separated somewhat but how much is another question.

Brophy evidently thought he obtained bony union of even the hard palate because he states when speaking of the Lane operation, "While he succeeds in closing the cleft, it would seem that the open fissure is covered only by the soft parts with no prospect of bony union whereas the bringing of the edges of the bone into contact after my own method of practice, insures the union of the plates of the hard palate, thus establishing a substantial bony arch." The bones of the upper jaw including the palatal bones are membranous bones. As far as I know, it has never been established that membranous bone lays down new bone like long bones.

Brophy claimed for his early closure of the soft palate that muscular atrophy was presented and normal speech resulted. Still in the later years of his life, he did not close the soft palate at an earlier age than those using the other methods. Judging from the cases that it has been my privilege to observe, the soft palate is no longer or more mobile in those cases subjected to the Brophy procedure than in the others.

Good speech usually comes from having a palate of normal length and mobility so that the flap valve action of the soft palate cuts the nasopharynx off from the oropharynx. It is granted, I believe, that the ideal would be closure of the palate at birth which would probably tend to prevent muscular atrophy of the soft palate and would probably draw the palatal process above the hard palate into a horizontal position while the bones were pliable. But the risk of real early operation on the palate has as yet prevented operation as early as it should be performed from the standpoint of physiology.

The Logan Operation.—Recently Logan and Kronfeld have shown that when one passes wires through the jaw at the time when the procedure is preferably performed (two to four months) the tooth germs are lying in the jaw in such a crowded position that passing wires between them, as originally suggested by the advocates of the direct force, is now known to be impossible but it is according to them possible to pass wires through the maxilla above certain germs at a point mesial to the cuspid eminence and distal to the deciduous and permanent central incisors. A second point of entry is located in the field between the cuspid eminence and the zygomatic process above the first deciduous molar germs. When the points of entry of the wires are high enough and the exact landmarks are specified, they consider that the only possibility of injuring the germs is that which confronts the operator when sufficient care has not been exercised in the loca-

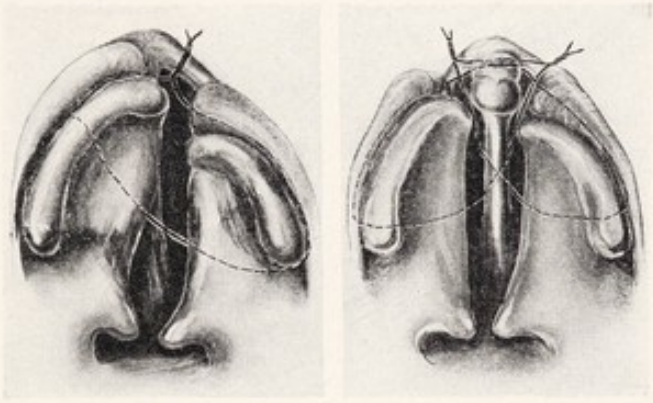

A *B*

Fig. 147.—*A,* Ritchie's method of placing the wires in a single cleft. It will be noted that in placing the wires in a single cleft the wire does not pass through the alveolar ridge but on the short side of the palate goes around behind the alveolar ridge and above the palatal horizontal plates, crosses, goes through the septum and above the horizontal palatal plate on the longer side of the alveolar ridge. *B,* Ritchie's method of placing the wires in a double cleft. In a double left the wires are placed similar to the manner in which they are placed in a single cleft. Two wires are placed instead of one. The premaxilla is fixed in between the two wires and held in place in that manner.

tion of the very definite landmarks described. Nevertheless, they believe that the most uniform development of the upper jaw may be influenced by the establishment of a relatively normal nasal floor and, therefore, they favor the early closure, not only of the cleft through the maxillary ridge but also through the hard palate for at least its anterior three fourths with everted flap (Fig. 146, *a, b*), by preference some time between the second and fourth months. Besides the use of wires as depicted in the diagram (Fig. 146, *a, b*) Logan uses a small flap of the Lane type to gain closure of the alveolus and the anterior palate.

Other Methods of Placing the Wires.—Another example of the present-day wiring operation is exemplified by the Ritchie method of passing wires around the alveolar ridges for the most part (Fig. 147, *A, B*). Ritchie aims to interfere with the tooth buds as little as possible. Davis uses a somewhat similar method.

NONFORCIBLE CLOSURE OF THE ALVEOLAR PROCESSES IN SINGLE CLEFT

The adherents of the viewpoint which opposes forcible approximation of the alveolar processes maintain that forceful closure of the alveolar cleft is an unnecessary procedure and that better results are obtained if one does not forcibly close the cleft. Over one half of the American surgeons and the majority of the European surgeons favor this conception.

In single cleft of the lip early closure of the soft tissues of the lip over the open cleft causes the cleft to come together within a few months. Even in older children closure of the lip causes the alveolar ridge to tend to approximate the ends of the cleft alveoli and even if the cleft does not entirely close, as soon as the permanent teeth are available, orthodontic procedures can be used to supplement the pull of the soft tissues. Closure of the palate supplements the pull caused by the scar beneath the lip after the closure. The closed lip and the scarred upper surface of the hard palate act somewhat like a rubber band on a stretch.

Reasons for Nonforcible Approximation of the Alveoli.—In a certain percentage of the cases (to say how great is difficult) a deformity of the upper jaw is seen in children with a history of having had a wiring operation done. The deformity is apparently caused by interference with the tooth buds. Particular damage is caused to the first and subsequent derangement or a possible loss of the second teeth rarely may also occur.

When the normal growth sequence of the tooth buds and teeth is prevented or delayed, it is very likely to be manifested later in childhood by a recessive superior maxilla. Not only does normal forward projection fail but the alveolar arch may become more angular and narrower. Normal occlusion of the teeth is prevented and a relatively prognathous lower jaw results. In some cases the lower alveolar arch may be from ½ to ¾ inch in advance of the upper alveolar arch. The upper lip lies back of the lower lip and a facies is caused which may be described as "dish face."

In single cleft of the alveolar ridge certainly without approximating the alveolar ridges forcibly, excellent results (that is, a pleasing nose and lip and fair occlusion of the teeth) are shown which in a series of cases we believe surpass the results of those shown after the use of forcible approximation. Of course, the artistry of the technic of some surgeons may add to the favorable results in either case.

Early Alveolar Ridge Closure Without Forcible Approximation in Single Cleft.—In single cleft in common use at the present time are two methods of obtaining alveolar ridge closure without resort to the methods of forcible approximation with wires or clamps.

In the first the lip is simply repaired over the alveolar cleft and the cleft in the alveolus is by this procedure alone caused to close during a period of some months, before the age arrives which is considered appropriate for the plastic operation. Between the ages of five and nine months the separated alveolar ridge ends practically always approximate but, of course, do not unite because of the mucosal covering. When the palate operation is done at about a year of age or later, the mucosa is raised off the end of the approximated alveoli and sutured across the cleft. Ordinarily no hole remains if sufficient mucosa is turned downward where it curves over the alveolar ends. To make palate operation easier later, a second plan has

been advocated. This procedure may have the disadvantage of adding another operation to the series of operations necessary to repair the deformity completely. With some plans this disadvantage (Veau) is overcome if the child is older and is in good enough condition so that both the alveolar plastic and the lip repair may be performed at the same time. It must be admitted that the probability of complete closure of the palate when the anterior palate has been closed is increased somewhat because only about the posterior two thirds of the palate remain to be closed.

Veau as a rule repairs the anterior palate and the lip when the baby is about four or five months of age. He thereby eliminates the disadvantage of running in a third operation.

Personally in the past we have favored the "one-two" type (lip-palate) of operation for the usual complete single cleft. We are confident that the lip can be successfully repaired over the opened cleft at the first operation in almost all instances. When it is successfully closed, the separated alveolar ridges are pulled together by the closed lip. The alveolar ridges gradually approximate within the next eight or nine months. Then, at the age of a year or a little more, the palate may be repaired by the Dieffenbach-von Langenbeck procedure or some modification of it (Axhausen). In more than 80 per cent of the cases of total single cleft a complete closure should be the result if that operation is done thoroughly and correctly. In less than 20 per cent there will remain a hole some place along the line of closure or even a complete breaking down of the palate. However, the hole is most often at the juncture of the hard and soft palate. As a result of this sequence in more than 80 per cent of the cases of single cleft, the lip and palate can be closed in two operations. In the remaining less than 20 per cent a secondary operation of lesser or greater extent is necessary to close the defect.

METHODS FOR EARLY CLOSURE OF THE ALVEOLAR RIDGE IN SINGLE CLEFT

Simple Coaptation of the Anterior End of the Mucoperiosteal Flaps.—The first type simply entails bringing the anterior palatal flaps together as one would in the ordinary von Langenbeck operation after they have been thoroughly mobilized from the palatal bones and alveolar ridges. Special elevators aid one in loosening the mucosa about and within the alveolar ridge ends. It would seem that this procedure might be practical when the ends of the alveolar ridges are in apposition or near apposition. Otherwise, the likelihood of union would be decreased or if some union occurred, an anterior hole would follow due to the natural narrowness and insufficient length of the palatal flaps. Kirkham states, however, that the flaps practically always unite after this operation.

Types of Turn-over Flap Operations for Closure of the Alveolar Cleft.—The second type of operation is represented by that of Veau of Paris. Logan also at the present time (Fig. 146) uses a turn-over flap of the hard palate at the same time he forcibly closes the anterior alveolus by the means of wires. The original operation of this type designed primarily to gain early closure of the alveolar cleft and the anterior palate were the Davies-Colley and the Lane operations although later the posterior palate closure was added to the original principle.

Davies-Colley and Lane Operations.—Historically, these operations are important but at the present time they are seldom used. Davies-Colley recommended the turn-over flap method in those cases where the ordinary operation had failed—in infants or where the cleft of the hard palate was too wide to be closed by ordinary methods. In the Lane operation no attempt was made to narrow the bony cleft, but the defect was closed entirely by flaps formed of soft tissue. Advantage was taken of the fact that, no teeth being present to interfere, the surgeon could go past the gums and onto the cheeks to obtain extensive flaps. These flaps were made in several different ways. At first Lane performed his operation in two stages. Later he performed the operation at one sitting. In constructing the new palate, the nasal as well as the oral surface was covered with mucous membrane, and everywhere broad denuded surfaces were approximated. Wide clefts could be bridged by the Lane procedure but the operation had serious defects. The turn-over flap was likely to slough and leave a defect very dif-

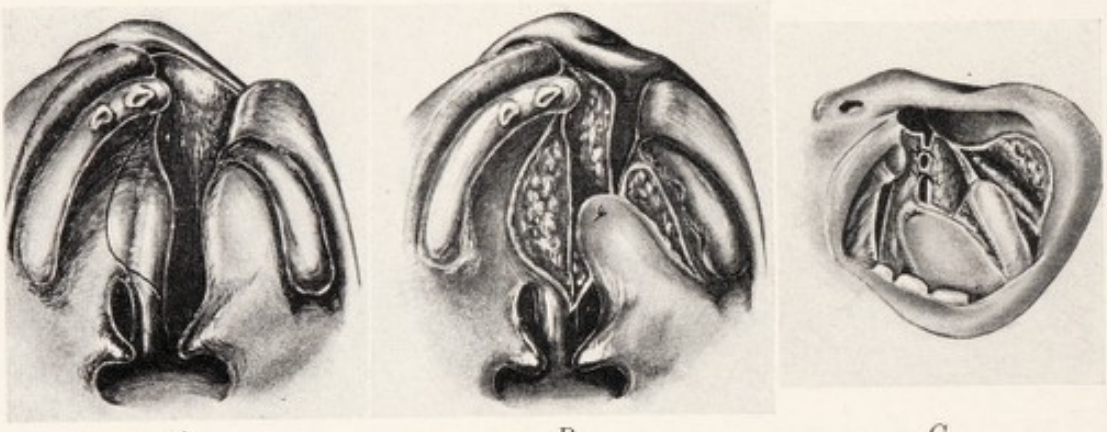

A *B* *C*

Fig. 148.—Veau's operation for single cleft. *A,* Line of incision. *B,* Elevation of the mucosal flaps and cross lapping of the septal periosteal flap with the mucoperiosteal flaps of the hard palate from the opposite side. *C,* Nasal mucosa on the short side of the palate brought over to the septal mucosa. The mucosa of the lip and the lateral nose is then cross lapped across the nasal mucosa and septal mucosa when the lip is repaired.

ficult to close. In the soft palate, although the turn-over flap method did not interfere with the muscles, the denudation of the mucosa on one side caused scarring and contracture. Therefore, the palate was likely to be shortened and not freely movable even if a good closure were obtained. Thus, the functional results were not so good as anticipated. The mortality was high in most operator's hands—even when performed in two stages—as the first operation at least was done on young infants before the teeth erupted. Lane, however, did emphasize that the alveolar ridges will come together if the soft tissues are closed early and he also emphasized that a cleft palate operation can be done at a much earlier age than had been thought possible prior to that time.

The Veau Operation for Single Cleft.—Veau's operation really falls in the classification of early plastic procedures for obtaining closure of the anterior palate and the alveolar ridges, as a second operation is necessary to close the posterior part of the hard palate and the soft palate. The main essential of the operation in so far as the palate is concerned consists of

taking a flap from the hard palate and the vomer which is turned to the opposite side—the side of the cleft—like the leaf of a book (Fig. 148, *A, B, C*) to make the nasal lining. Then a palate flap from the cleft side is raised and carried over to the under surface of the flap from the vomer and held there with a suture or two.

In single clefts Veau (Fig. 148, *A, B, C*) outlines and loosens a narrow flap on the mucosa of the hard palate. The flap has the base attached to the mucosa of the nasal septum and the mucosa of the end of the alveolar ridge. The septal mucosa is freed as shown. The flap is turned across the cleft and sewed to the nasal mucosa of the floor of the nose. A flap of palate tissue on the short side of the palate is outlined, raised, and cross lapped across the preceding suture line. The flap is held in place with a suture or two. A flap is raised in the alveolar lip sulcus and, when the lip is closed, is drawn across the nasal suture line to cross so that a small part of the anterior nasal suture is overlapped. The operation is done within the first month or two of life.

Principles Advocated by Veau.—Veau emphasizes the desirability in his opinion of suturing the nasal mucosa together. He objects to loosening of the aponeurosis from the posterior edges of the palate plates. He states that it is not necessary and that the innervation to the palatal muscles is destroyed so that speech is not so good as if the aponeurosis were not separated. (When one studies the anatomy of the palate carefully it would seem that Veau's contention that those men using the Dieffenbach procedure interfere with the muscles and their innervation is not borne out by obvious anatomic facts.) At the latter operation when the soft palate is closed Veau insists upon muscular coaptation as well as mucosal coaptation of the soft palate.

The Problem of the Premaxilla in Double Cleft.—Common agreement is given to the dictum that it is never essential to remove the projecting premaxilla. At one time, especially when the premaxilla projected as a snout, some operators just removed the premaxilla. Soon, however, it was found that the deformity of the upper lip and jaw which this causes is very unsatisfactory.

At the present time two methods for the handling of the premaxilla are used.

The first and most commonly used at the present time is the removal submucously by one method or another of a wedge-shaped piece of cartilaginous septum. The method of Reich (Fig. 145, C, D) is an example. The premaxilla and the ends of the lateral alveolar process are denuded. The premaxilla is then fixed in proper relation and held by suture of the soft tissues or by means of wires encircling the premaxilla and attached to the lateral processes in one way or another. Fibrous union in the correct position without much damage to the tooth buds is the goal. The procedure may have any one or all of the following disadvantages. First, bony union is improbable. Second, the difficulty of holding the premaxillary bone at the right angle so that the teeth come in at the proper angle is greater than it appears to be. Third, if wires are used, injuring the bones and the tooth buds, the upper jaw is likely not to develop as far forward as it should—a deformity which becomes more pronounced in later childhood. Fourth, if fairly firm union of the premaxilla to the lateral alveolar ridges fails to

occur, the premaxillary bone may wobble from lack of fixation as the edges of the several vomerian cartilages unite only by fibrous tissues. When this occurs, the central incisors are not of value for chewing purposes. Most of the disadvantages enumerated in the majority of instances can be overcome if the procedure is performed with care at the right time.

The second method is one of noninterference with the vomerian support of the premaxilla, and dependence is placed upon the pull of the repaired lip over the premaxilla after remolding to overcome the projection of the bone by the time one desires to repair the palate. The disadvantages of carrying this idea into operation for those cases with a marked projection of the premaxillary process are two. First, some curvature of the nasal septum may result which may interfere with breathing later. Second, after the premaxilla is pushed somewhat backward and downward and the lip repaired over the premaxilla, besides a tendency toward buckling of the septum, the premaxilla may tend to lie crosswise of the defect between the lateral alveolar ridge processes.

Discussion.—Probably the majority of men favor the removal of a triangular piece of the vomerian support by the submucosal route in those in-



Fig. 149.—Veau's operation for double cleft of palate. Veau operated one side of the palate and one side of the lip at the same time.

dividuals in whom the projection of the premaxilla is unusually marked and in those individuals in which it appears that, if the premaxilla were bent back, the chances of getting a buckled septum or a twisted premaxilla are likely. Recently, however, I have leaned toward the position of not interfering with the vomerian support of the premaxilla. Certainly when the premaxilla is only moderately forward it is not necessary to section the vomer. Better position of the premaxillae and better support is given if early suture of the lip across the projecting premaxilla is the method used.

Operation of Vomerian Section and Replacement of the Premaxilla.—The lip having been repaired previously over the projecting premaxilla, the mucosa along the lower border of the thickened vomerian support is incised and raised from the septal cartilage with an elevator similar to the ones used for the operation of a submucous resection. (If the instrument is bent at a right angle near the elevator end, this procedure is greatly facilitated. A right and left instrument is necessary.) The mucosa is loosened well up and well forward on both sides. As we usually bring the anterior palate flaps together as in Fig. 150, A, at the same time, the mucosal freeing is carried straight forward so as to denude as much of the

premaxilla of mucosa as possible. This allows the mucosa of the nose and the premaxilla to be turned away from the vomer and to be sewed above the anterior palatal flaps. After freeing of the vomerian mucosa a V-shaped section is carefully removed from the vomerian support after a careful estimation of the proper size of the V. One needs a slender-pointed pair of small Lister type of forceps to do this neatly. Usually the scissors are not strong enough and an ordinary small Lister forceps is too broad.

The V-shaped piece of the vomer should be removed well back. When it is removed close to the premaxilla it may become completely free from its vomerian support and great difficulty may be experienced in getting it fixed again in any way. Care must be taken also not to take away too large a wedge of bone. The premaxilla should set just anterior to the lateral

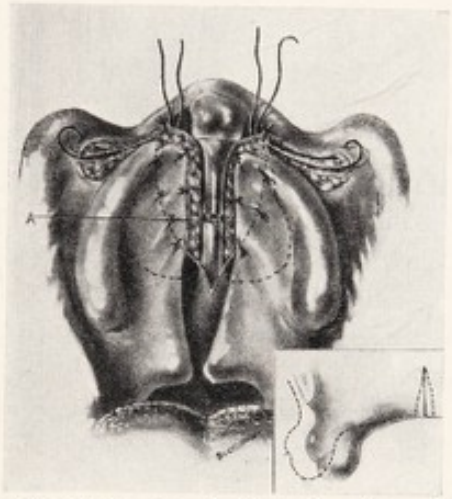

Fig. 150.—Preliminary procedure for double alveolar cleft closure. The V-shaped piece of cartilage from the septum often is not removed. A, Depicts defect in the nasal septum after the wedge-shaped piece of cartilage has been removed. As mentioned previously, ordinarily we do not interfere with the bone. None of the septal mucosa is removed. It is dissected free from the septum and is turned outward above the mucoperiosteal flaps of the hard palate. If it is deemed wise to remove a wedge-shaped piece from the vomer, it is removed at a later time after the anterior ends of the lateral alveolar ridges approximate sufficiently to prevent the premaxilla from dropping in between them. The premaxilla should sit in front of the anterior ends of the lateral alveolar ridges.

alveolar processes and in such a position that when the teeth erupt they do not turn backward like those of a rabbit but protrude slightly forward.

The Problem of the Anterior Palate and the Alveolar Ridge in Complete Double Cleft of the Palate.—It is difficult to gain complete closure of a double cleft of the palate at one operation by the use of any of the usual operations for cleft palate. Not uncommonly one fails to get complete closure at the anterior end after the Dieffenbach-von Langenbeck procedure. Sometimes if one loosens the mucoperiosteal flaps sufficiently toward the anterior end of the cleft to suture them in the midline either the blood supply to the flap may be endangered or if a slough does not actually occur, union may not follow. Therefore, we believe as do many others that in many cases of double cleft of the palate the logical plan is one which does not attempt to close the whole of the palate in one operation. Moreover, when the anterior palate has been closed first the likelihood of successfully closing the posterior palate is greatly increased.

The following methods are used which have as their object the early closure of the lip, a fairly good placement of the premaxilla, and early closure of the anterior palate.

1. *Methods Favored Personally.*—During the past year (1937) the following operation has been used. It is still too early to pass upon its advantages and disadvantages with finality. Prior to this, although the principle of the operation was the same as the one to be described immediately, the sequence and time of essential steps varied somewhat as will be described subsequently (Fig. 146, *b*).

(*a*) Within the first few days or weeks when the child is in normal condition, the mucosa is freed from the vomer well forward so that the lateral edges of the premaxilla are denuded. The anterior ends of the mucoperiosteal flaps are raised from the horizontal palatal plates and the rounded ends of the lateral alveoli are denuded. A very slight lateral incision is made to allow the anterior ends of the mucoperiosteal flap to come slightly toward the midline. The septal mucosa is then stitched up above the mucoperiosteal flap as shown in Fig. 150. This procedure can be carried out in ten minutes when the lip cleft is still open. The vomer is not sectioned. The pull of the lip and the cicatrix which develops about the vomer as the mucosal flap scars up to the bone is used to mold the premaxilla and the lateral alveolar ridges to a better position which ordinarily is preferable to the one that may be obtained with early closure and later vomerian section. The premaxilla is not pushed back for fear of breaking the bone and interfering with the blood supply of the bone. If sequestration should occur, the bony foundation of the premaxilla would be destroyed.

The lip is then closed over the projecting premaxilla. Thus, in one operation the anterior palate and the lip are closed. When the child is not in good condition, however, the anterior palate operation is performed alone and the lip is closed later. Within the next few years we hope to determine whether this sequence is preferable to the one described in the next paragraph.

(*b*) Up until the past year we closed the lip first and at a second operation, some months later, the anterior palate procedure was done as previously described along with a removal of a V-shaped section from the vomer if such seemed necessary. The argument in favor of this sequence is that when the lip is closed early, the pressure of the cheek forces the anterior ends of the lateral alveolar arches medially, so that they can be used to support the premaxilla well forward. The premaxilla then will not tend to drop too far posteriorly if it is deemed advisable to remove a wedge from the vomerian support. This sequence has the disadvantage, however, that after the lip is closed the anterior palate closure may be quite difficult. Moreover, three operations are involved. The opposite approach, if all goes well, allows one to close the lip and anterior palate at one operation and the posterior palate at a second operation.

2. *Method of Veau.*—Veau's method for double cleft is similar to his method for single cleft. He considers this step of great importance in the closure of the double cleft. He loosens the mucosa from the vomerian support as shown in Fig. 149. He only does one side at a time, however. He also repairs the lip on the same side of the cleft at the time of the anterior palate closure. A few months later at a second operation the other part of the anterior palate is closed and the other side of the lip.

Lengthening of the Short Columella Accompanying a Double Cleft.—The question of the lengthening of a short columella is discussed in the next chapter on "The Repair of a Cleft Lip."

Bibliography

Bibliography Quoted in Text

Broca, P.: Quoted by Lexer.

Brophy, T. W.: Oral Surgery, P. Blakiston's Son and Co., Phila., 1915.

Dieffenbach, J. F.: Chirurgie Erfahrung, **324:** 168, 1834.
Die Operative Chirurgie, Leipzig, F. A. Bockhaus, **1:** 856, 1845.

Kirkham, H. L. D.: Preliminary Paper on Improvement of Speech in Cleft Palate Cases, Surg., Gynec. and Obst., **44:** 244, 1928.

Lane, W. A.: On Cleft Palates, Lancet, **11:** 433, 1902.

Lexer, E.: In von Bergmann's System of Practical Surgery, Lea Bros. and Co., pp. 411–458, 1904.

Logan, W. H. G., and Kronfeld, R.: Development of the Human Jaws and Surrounding Structures from Birth to the Age of Fifteen Years, Jour. Amer. Dent. Assoc., **20:** 379–427, 1933.

Reich, A.: Zentralbl. f. Chir., p. 859, June 24, 1911.

Ritchie, H. P.: Cited by Dean Lewis: In Practice of Surgery, vol. 6, W. F. Prior Co., Inc., Hagerstown, Maryland, 1930.

Thompson, J. E.: Simplification of Technique in Operations for Harelip and Cleft Palate, Annals of Surgery, **74:** 394, 1922.

Veau, Victor: Division Palatine, Anatomie, Chirurgie, Phonétique, Masson et Cie, Paris, 1931.

Von Langenbeck, B.: Operation der angeborenen totalen Spaltung des harten Gaumes nach einer neuen Methode, Deutsch. Klin., **12:** 231, 1861.

CHAPTER XXVII

THE REPAIR OF A CLEFT LIP

A good repair of a cleft lip and the accompanying nasal deformity is a work of art and, of the two, the correction of the nasal deformity is fully as important in relation to ultimate end-results and often the most difficult to accomplish. Certainly the operation does not attain the dignity of an art until the nostrils are similar and properly balanced although the lip may be a perfect cupid's bow.

The General Preoperative Care of Cleft Lip.—The infant of twelve to twenty-four hours of age stands operative trauma fairly well although it is probable that this point might be overstressed. Such a baby has a hemoglobin of about 120 to 140 per cent and a good blood volume according to its body weight. The main reason for advocating early repair is that the parents are saved considerable heartache when the lip is repaired early.

Preoperatively, the patient should present a good "bill of health," so to speak. The operation is not an emergency operation and should not be performed with any such idea in mind and it is doubtful if it is even necessary to do the operation with the idea that the child's health will be greatly improved by the operation. The older operators had some such idea, but modern feeding experience leads to the conclusion that proper care of the child should precede any operation when the child is in questionable condition.

Immediately preceding the closure of the lip infants taking milk only are fed up to within about two and one-half or three hours before the operation. Infants taking soft food or children on ordinary diet should have no soft foods given at the period just preceding the last feeding. At the last feeding period within two and one-half or three hours of the time of operation, liquids only are allowed and encouraged. In children several years old, breakfast is simply omitted on the morning of the operation.

Ordinarily no preoperative injection of opiate or atropine is given before operation in an infant. When the child is over six months old, ordinarily a small dose of morphine or atropine according to age is given about forty-five minutes before operation. In the infant no preoperative enema is given or thought to be necessary. In children of six months or more, eating soft foods, and in adults, a preoperative enema is given.

No local preparation of the lip is considered necessary, except washing off of the lip with an alcohol sponge just as the operation is started.

The Nasal Deformity.—A cleft lip, partial or complete, on one side or on both sides, always presents a characteristic deformity of the nose—a deformity that, in the past, as a general rule was not corrected. In a single cleft of the lip, the nose points somewhat tangentially to the side opposite the cleft and in individuals not properly repaired during infancy, the nasal bones eventually deviate quite noticeably. The ala on the side of the cleft is pulled outward from the premaxillary process onto the maxillary process. The statement has been made that the nasal deformity is due

mostly to an actual change in the relation of the soft tissue and cartilage to the bone and comparatively little to the bony displacement. This is only partially true but it is true that with sufficient undermining of the soft tissues, they can be shifted far enough to compensate for both the soft tissues and the bony displacement. The apex of the nostril on the side of the cleft has become lower at the tip of the nose than on the opposite side. The tip of the nose on the side of the cleft is flattened and the lateral side of the nose is often a little longer in the crosswise direction. Not only the soft tissues are deformed but the elastic tendency of the nasal cartilage to assume the correct shape of a nostril is changed and thereby the scaffolding of the nose is rendered asymmetrical. Very important in the repair is the recognition of the fact that besides the outward displacement of the ala, it is also rotated externally on an axis perpendicular to the face. Thus, in the repair of a cleft lip, if one concentrates on the correction of the nasal deformity first and is successful, the correction of the deformity of the lip is not so difficult (Figs. 152, A, B, C, D; 153, *A, B, C;* 154, A, B).



Fig. 151.—A, Amount of undermining of soft tissues necessary in partial cleft of the lip. B, Amount of undermining of soft tissues considered necessary in single complete cleft of the lip. C, Amount of undermining of soft tissues considered necessary in double cleft of the lip.

Undermining of Cheeks.—To bring the nose into position on the short side of the lip, wide undermining of the lip, alae and cheek from the maxillary bone in single cleft or bones in double cleft is necessary and also some undermining is advisable in most instances beneath the columella and beneath the opposite side of the lip in single cleft and alae (Figs. 151, A, B, C, and 152, A, B, C, D). This allows the lateral soft tissues of the lip to be brought up as a bridge over the open cleft. The nose should be brought to the midline and the normal relation of the labial end of the columella to the labial end of the ala maintained. The nostrils must be made symmetrical. Simply narrowing the circumference of the nostril without restoring vertical height of the low nostril does not correct in many cases the lateral flattening of the tip of the nose. (Later two methods are advised to overcome this defect.) In wide open clefts part of the lining of the vestibule is pulled downward and outward. The lining not only appears to be greater than normal but in most instances actually is too plentiful. With the lining the lateral cartilage of the nose is pulled somewhat downward and will remain somewhat distorted unless replacement is carefully made.

Normal Lip.—A good lip on cross section from the base to the nose should be triangular in shape with the base of the triangle downward and the lip should be moderately short in length. On a profile view the upper lip normally projects somewhat beyond the lower lip. One should strive, therefore, to make a lip which projects forward at the base and is not stretched tightly over the alveolar arch. A moderately short loose lip with the vermilion border rolled slightly upward into a cupid's bow is aesthetically the most pleasing.

Different Operation for Different Type of Lip.—On those lips with more than a usual amount of tissue on the short side of the lip, an operation of the Rose or Husson type plus the addition of a flap for the floor of the nostril, somewhat similar to the type used in the Mirault-Blair technic will give a well-formed lip. All of this may be especially true in some of the instances where a secondary repair is being done on a previously poorly repaired lip. The vermilion border may be best shaped, we believe, by

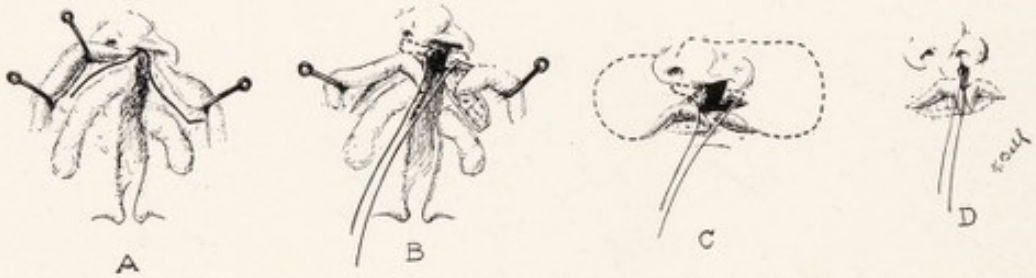

Fig. 152.—Depicting the reasons for and the amount of undermining beneath the lip. A, Lines of incision beneath the lip. B, Lines of incision beneath the lip and in front of the alveolar ridges. Also shows the catgut suture which is placed at the alar bases after the lip and the alae have been completely freed and the tip of the nose undermined. C, Shows a front view of the same as B and also shows the amount of undermining between the external skin and the cartilage and the internal lining about the ala on the cleft side and the tip of the nose. D, Shows how the nose is brought into normal position by the placing of the catgut sutures as shown in B. As a matter of fact, to get this normal-shaped nose, the internal skin with the cartilage of the nose attached has to be readjusted and held in place with sutures as shown in Fig. 153, which shows the excision of a semilunar piece of tissue from the tip of the ala to balance it.

cross-lapping angular flaps. A more perfect contour has seemed to us thereby to be made possible.

On the usual lip which seems to be characterized by less lip length on the short side, we find the Mirault-Blair operation more capable of giving a satisfactory result than the other types of operation. Possibly because this is the first operation we learned we have more than a normal preference for it. It seems to us, however, that the principles underlying the operation are sound. Some type of curved or angular incision is necessary to gain length on the short side of the lip in most instances. In the repair of poorly repaired lips a variety of procedures may be necessary—depending upon the deformity present—varying from simple excision of the scar on the upper lip to transplantation of a flap from the lower lip to the upper lip. Some idea of the conditions to be overcome may possibly be derived from the simple summary of the procedures used in our secondary lip operations, which include routine Mirault-Blair procedure (Figs. 155, 156), routine Rose-Husson-Thompson procedure (Figs. 159, A,

B; 160, A, B, C), simple plastic operation on the lip, advancement operation of Blair (Fig. 168), Gillies' "cupid bow" operation (Figs. 171, 172), Abbe's operation—transplantation of flap from lower to upper lip (Figs. 169, A, B, C; 170, A, B, C), cartilage transplant to bring the base of the nose forward, stent inlay graft beneath the lip to give place for prosthesis, and prosthesis cases to hold the upper lip forward (Fig. 103).

The Correction of the Nasal Deformity.—In the correction of a nasal deformity as a rule, but not always, most of the vestibule lining should be preserved. When too much of the internal lining is removed, obstruction of the nostril is likely to result and must be thought about if any tissue is removed. However, as the lateral nasal cartilage is pulled downward and outward somewhat and as the skin covering is stretched into a larger area than normal, simple twisting of external ala into a proper position even with undermining and separation of the internal from the external lining, practically always will result in a thickened corded band of tissue within



A *B* *C*

Fig. 153.—*A,* Placing through-and-through sutures to hold internal lining of nostril in proper relationship with the external lining. The nostril is also packed with gauze. *B* and *C,* Excision of crescent-shaped piece of tissue from tip of nostril. This procedure is used in babies.

the nostril which tends to obstruct the upper third of the vestibule. The thickened tissue is the redundant vestibule lining within which lies a certain amount of the buckled lateral cartilage. At present, therefore, we refit the internal lining and cartilage to the circular, newly shaped vestibule and turn a V-shaped flap backward out of the vestibular lining, which is manifestly redundant so that a properly fitting lining is obtained. In other words, we do not entirely trust to nature for the readjustment when it appears that the internal tissue lining has become distorted to an extent sufficient to render the probabilities of readjustment without surgical aid unlikely. With scissors the skin covering of the ala on the cleft side of the lip is undermined to and about the tip of the nose. Between the lining and the covering of the outer part of the flattened ala is a wedge of thickened tissue. This is removed subcutaneously to facilitate the molding of the nostril when the lip flap is used to supplement the floor of the vestibule. A suture—catgut (Fig. 152, B, C, D)—is passed through the tissue at the base of each ala and drawn up across beneath the columellar base in such

a position that both alae come into position to form a symmetrical nose base. The flap turned into the vestibule is stitched with horsehair to the mucosa previously loosened at the columella base on the cleft side. To hold the vestibular lining in its proper place two or three through-and-through horsehair sutures (Fig. 153, *A*) are taken through the lateral wall of the nose to bring the lining into contact with the covering and the nostril is lightly packed with gauze. This rounds out the nostril and aids in preventing any tendency to nasal obstruction. The floor of the nostril, the base of the columella and the alae having been given the proper shape, it is usually noticed that there is a downward droop of the inner half of the affected nostril. In infants this can be corrected by removing a crescent-shaped piece of skin above the cartilage just above and at the inner corner of the lower nostril (Fig. 153, *B, C*). Plessier states that Ombrédanne first suggested this procedure. In older children and in adults, a simple semilunar excision of the rim of the lower nostril at the tip is insufficient and, consequently, it is necessary to split (Fig. 154, A, B) the columella in the midline and free the lower half and the adjacent nasal

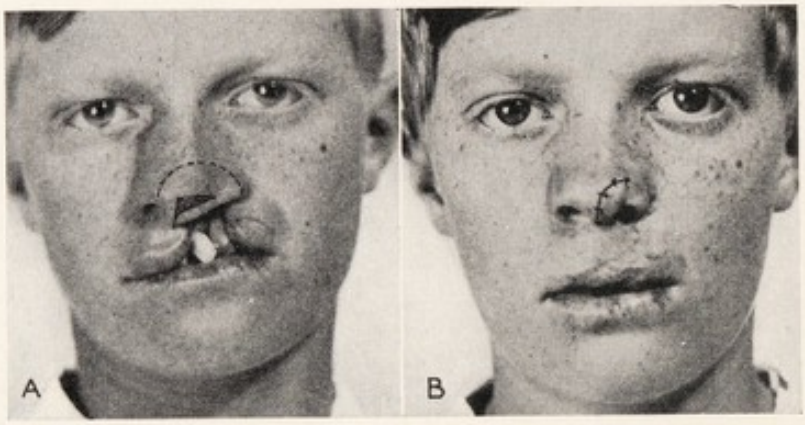

Fig. 154.—Method of splitting the columella and raising the lower nostril to a level with the upper nostril. This procedure is used in adolescents and adults. The crescent-shaped excision alone (Fig. 153, *B, C*) is insufficient.

mucosa from the septum. After undermining the skin at the tip of the nose, the low side of the columellar tissue is moved upward raising the low nostril opening to a level with the opposite normal nostril. The two halves of the columella are then sewed together in such a manner that the upper level of the corrected nostril is on a level with the opposite nostril or even slightly overcorrected. The redundant skin at the tip of the nose is excised in a V-shaped piece in sufficient amount to round off the tip of the nose and give it a normal contour. Erichsen, according to Brophy, first conceived this procedure. Blair independently, I believe, did both the Ombrédanne and Erichsen procedures.

In adolescent to nearly adult age and in adults one not uncommonly encounters a deviation of the bony structures of the nose toward the maxilla of the uncleft side. A procedure is described in Chapter VIII, Fig. 32, which allows one to correct the bony deformity. Besides the removal of a part of the anterior cartilaginous septum, usually the attachment of the septum to the maxilla should be rongeured away to allow the septum to swing to the midline.

Useful Operations for Cleft of the Lip

Here it seems necessary to present only four types of procedures for the correction of unoperated single cleft of the lip: (1) the Mirault operation as developed by Blair; (2) the Rose-Husson operation; (3) the Thompson operation; (4) the later operation of Veau. For the Rose-Husson-Thompson operations, the nasal flap and angular incisions of the vermilion border will be briefly discussed as suggested additions. The Thompson operation is only a modification of the Rose-Husson type of operation. As Thompson carefully measured his incisions, his operation is described more fully. The two operations are practically the same in principle.

For the double cleft lip three useful operations also will be presented: (1) the operation we use; (2) the Rose operation; (3) the Thompson operation. These three are presented because they embody the principles in common use today.

As one encounters a considerable variation of deformity in lips that require secondary correction at a later age, this phase of harelip surgery also will be discussed briefly.

SINGLE CLEFT OF THE LIP

1. **The Mirault-Blair Lip Operation.**—The principle of the Mirault-Blair operation on the lip is best understood by observing the illustrations and studying the legends. Figures 151 to 156 are diagrammatically illustrative.

Before undermining (Fig. 151, A, B, C), the points ABC and A′B′C are pricked on the lip (Fig. 155, 1, 2, 3). A is placed in the mucocutaneous

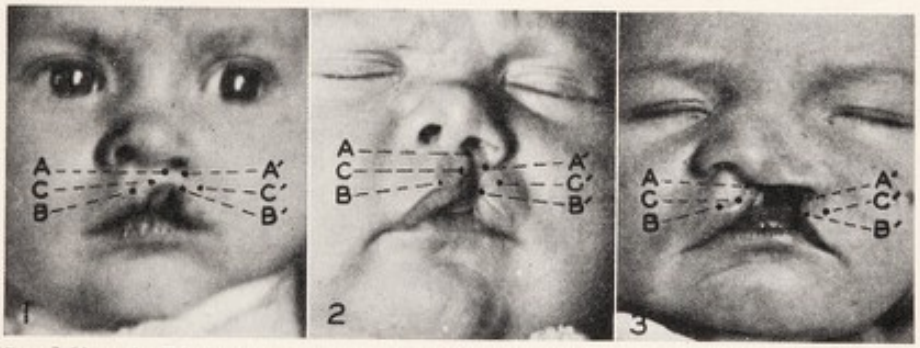

Fig. 155.—Mirault-Blair procedure, the dots between which the incision is made.

border at the base of the columella. B is placed on the mucocutaneous borders which the opposite philtrum joins. C is placed halfway between A and B. A′ is placed where the alar base passes into the lip when on a stretch. C′ is placed under and a little internal to A′. A′C′ has to equal AC and the incision may have to be angled or curved to make it do so. B′ is in the mucocutaneous line at a distance from C′ to equal B′ to B. The vermilion border of the short side of the lip is cut from B′ toward the angle of the mouth on the short side in a slanting downward direction about to a point where the lower lip normally touches the upper lip (Z, Fig. 156). To locate the incision B′Z′ accurately the sides of the two vermilion flaps are grasped with forceps and drawn across each other (Fig. 156, A). The flaps are not put on much tension. The incisions are made a little closer to the distal end of the flap than apparently is necessary. The incision goes through the mucous membrane on the anterior surface of the flap only—the distal part

not being entirely detached (Fig. 156, B). The direction of the incision is then reversed in the opposite direction but still slanting downward. The vermilion border of the long side of the lip is fitted in this Z-shaped cut (Fig. 156, C). The zigzag in the vermilion border allows one to make a lip without a thick place or an indentation. Beneath the lip the mucosa is tightened somewhat by paring some of it away on each side before it is sutured. Deep and superficial sutures then are taken through the mucosa



Fig. 156.—Localization of incision on the anterior vermilion border surface. A, Cross cutting the vermilion border flap so as to estimate where the zigzag incision is to be made. The dotted lines from the edge of the vermilion border to Z′ show the place to make the incision. B, Incision on the upper lip flap made down to Z′. The lower flap has been cut to correspond. C, Lower part of the incision completed from Z′ down to the point of contact of the upper with the lower lip. The flap is sewed into place as shown in the diagram.

and muscle of the lip so that the lip is tightened from beneath to throw the base of the lip well forward. The retention sutures are of doubled horsehair and placed in from beneath the lip so as to deeply coapt mucous membrane and muscle wall up to the skin surface. A nostril retention suture (Fig. 157, A, B) of the through-and-through type through flat thin lead plates at each end is placed through from the labial crease of the ala of the

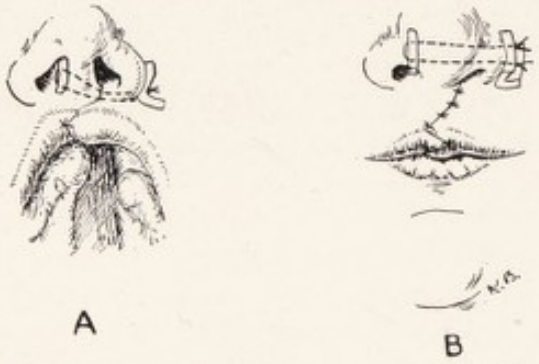

Fig. 157.—Through-and-through retention sutures over tin-foil plates. A, From below. B, Front view.

cleft side through beneath the nostril floor through the columella into the sound nostril and back again. The plate in the sound nostril is left flat. The plate in the nasolabial crease is bent to fit the nasolabial crease (Fig. 157, A, B). Sometimes it may appear wise to place a small gauze pack beneath the lip to prevent bleeding. Often this is not necessary. To prevent bleeding heavy Crile blood vessel clamps with short teeth in them are useful while cutting and suturing the lip. The diagram (Fig. 161, B, C) shows

the method of using. If external support of the lip seems necessary, the Logan clamp with adhesive fixation to the cheeks may be used. Usually this is not a necessary adjunct.

The operation does not reproduce the philtrum on the cleft side but otherwise, when properly performed, the restoration is almost perfect (Fig. 158, A, B, C, D).

2. The Rose Operation for Single Cleft Lip.—This operation (Fig. 159, A, B, C) consists of the removal of a semi-oval piece from each side of the lip so that length is given to the lip at the site of the cleft when the two concave raw surfaces are pulled straight and approximated. When performed exactly correctly, the lip notch is obliterated. It is especially appropriate for partial clefts. The virtue of simplicity is given. The full thickness of

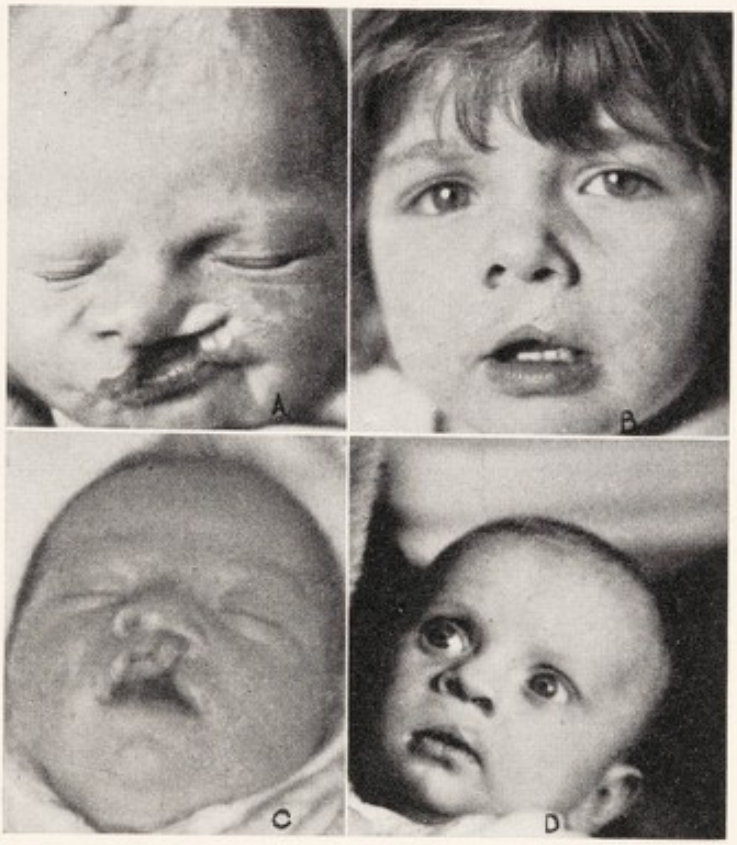

Fig. 158.—Repair of complete single cleft of the lip by Mirault-Blair procedure. A, Before operation. B, One year after repair. C, Patient before operation. D, Six months after repair.

the lip is incised. As originally performed the incision traversed the vermilion border of the lip at a place where full normal breadth was present. As often in the lip notch the vermilion border is narrower than elsewhere, the convexity of the lip incisions on each side of the cleft must extend laterally as far as the widest part of the cleft. Originally it was stated that when the lip was completed there must be a teat at the lower end of the suture line to allow for scar contracture. Considerable experience with giving contour to the vermilion edge of a lip leads us to believe that this is just what you should not do. It should be given the proper contour at the primary operation. The angling and cross lapping of the vermilion border flaps as described under the Mirault-Blair procedure will give the proper contour. The same principles of closure with sutures are used as in the

more fully described Mirault operation. Often the Rose operation is particularly adapted for a secondary repair of a preceding poorly performed operation.

3. **The Thompson Operation for Single Cleft Lip.**—Thompson laid particular emphasis on accurate measurements with a compass (Fig. 160, A, B, C); whether or not this is necessary depends upon the man operating. Some surgeons can shape a good lip by eye as an artist draws a picture.

At A and A′ the boundary between the cleft and the margin of the nostril is marked by a sharp projection or shoulder. A pair of sharp-pointed compasses, regulated with a screw are used, and a measurement



Fig. 159.—Incisions of the old Rose-Husson type of operation.

(YZ) taken from the level of the opposed corners A and A′ directly downward, of such length that Z would lie on an imaginary line KL which would complete the natural curve of the upper lip. The points of the compasses are now fixed apart at this distance (YZ) and measurements are taken in the lip on each side of the cleft (Fig. 160, A, B, C) commencing at A and A′ respectively and passing to B and B′. The points B and B′ are each close to the junction of the skin with the red line of mucous membrane, and are so placed that AB is equal in length to A′B′ and each one is the same length as YZ. The points B and B′ are permanently fixed by pricking the skin with the points of the compasses until blood appears.

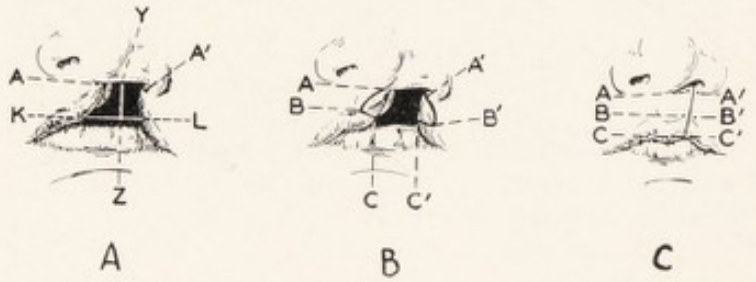

Fig. 160.—Thompson operation (see text for description).

The compasses are now readjusted and a measurement BC is taken, the point C being on the free margin of the lip. The angle which BC makes with AB is usually about 60 degrees but varies somewhat. It must always be less than 90, if a projecting prolabium is to result from the complete operation. A similar point C is taken on the other side of the cleft. Both C and C′ are pricked with the points of the compasses. Being now ready to denude the sides of the cleft the operator passes a retaining stitch of horsehair through each side of the mucous membrane of the lip close to, but below, C and C′. The lip is transfixed with a narrow-bladed knife at B, and the knife is carried with a sawing sweep in a slight curve to A, where

it emerges exactly at the shoulder. The lip is then divided along the line BC and the tissue outlined by ABC is removed. The same maneuver is carried out on the opposite side of the cleft, the knife passing along the line A′B′C′.

As a result we now have two raw surfaces opposed to one another, the corresponding sides of which are equal in length. Thus, AB is equal to A′B′, and BC is equal to B′C′.

If A be united to A′, and B to B′ and C to C′, the sides of the wound between these points can be brought into apposition with accuracy and a perfect lip will result.

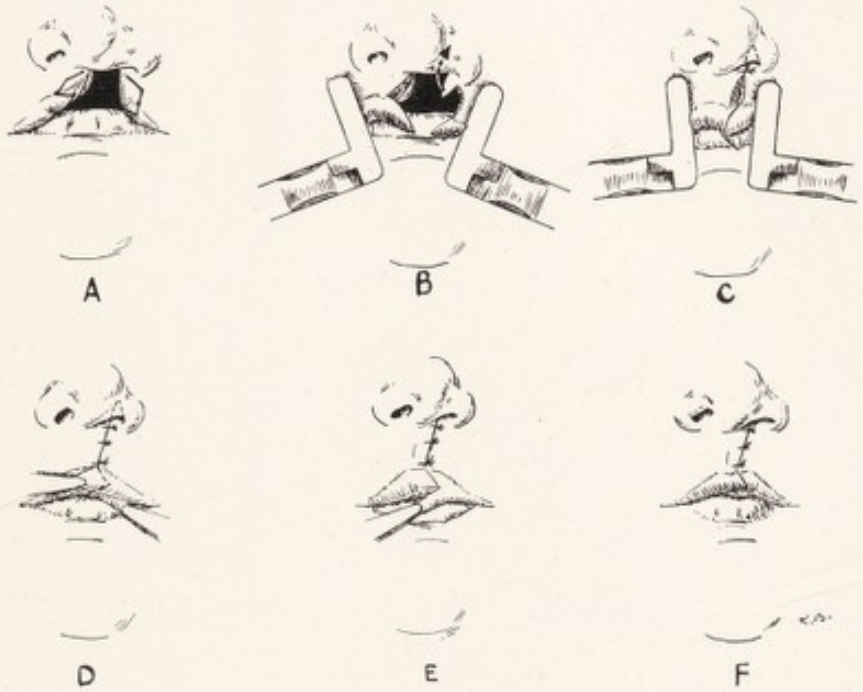

Fig. 161.—A and B, Incisions of the Rose-Thompson-Husson operation modified by a flap turned into the floor of the nostril. A larger curve has to be taken for the short side of the lip. C, The ala has been internally rotated and the flap turned into the floor of the nostril and the vermilion border flap pulled down. D, The vermilion border flaps are then cross lapped to give an estimate of the amount to be pared away. E, The upper flap has been cut downward and outward toward the angle of the mouth. F, The completed operation.

In this country, Thompson operation is quite popular although several men have adopted the Mirault-Blair procedure instead within very recent years.

Suggested Modifications of the Rose-Husson-Thompson Type of Operation.—(*a*) If the nose and nostril are built as described in the preceding Mirault procedure, and (*b*) the vermilion border also is given contour as described in the preceding Mirault procedure, the operation assumes a logical position in alignment with modern procedures and in many cases it may be used with extremely satisfactory effect—possibly more perfectly than the Mirault procedure in some cases (Fig. 161, A, B, C, D, E, F). There is a tendency to get a lip a little too long but sometimes if the effect is not pronounced this gives a most satisfactory appearance.

4. **Veau Operation.**—Veau of France who has had a large experience in this type of surgery presents an operation devised and used since 1926. In

his monograph he speaks of it as his later method (Fig. 162, A, B, C). He states that by its use he can obtain a well-balanced lip with the philtrum largely preserved or imitated. By turning a flap of vermilion border exactly in the midline he gives a central fulness to the lip which closely imitates the central fulness of the normal lip. He evidently obtained length on the short side of the lip by angulating the incision in a direction opposite



Fig. 162.—Later operation of Veau. A, The line of incision. B, The redundant tissue removed. C, The various incisions as they appear when sutured together in the proper way.

to the angulations of the preceding operations. He also uses a flap at the alar base, internally rotates the ala, and turns the flap up to the columellar base to cover the floor of the nostril. The photographs in Veau's monograph show some moderately good lips but not so good as one obtains fairly routinely when the operation described as the Mirault-Blair operation is performed well.

USEFUL OPERATIONS FOR THE REPAIR OF DOUBLE CLEFT OF THE LIP

The present-day operations are modifications of the Graefe, König and the Hagedorn operations. The older operators did not take into considera-

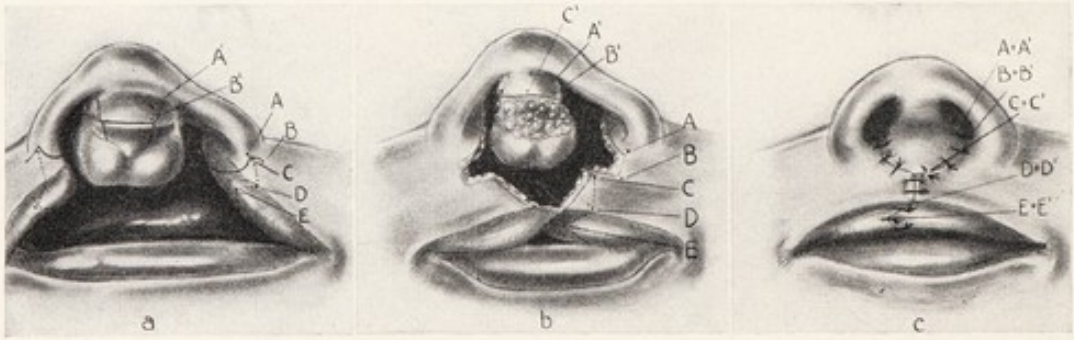

Fig. 163.—Operation for double cleft lip. *a, b, c,* When the columella is not to be lengthened or is to be lengthened at a subsequent date, the incision on the premaxillary soft tissues and the lip is depicted by the two diagrams *a* and *b*. *c,* The appearance of the lip after closure.

tion the necessity of internally rotating the alae and also of building a floor to the nostril which has been described in the Colles and in the Mirault-Blair operations. In a double harelip the necessity for this procedure is not so great as it is in a single harelip for the simple reason that if neither side is entirely corrected, the final result is not so noticeable because after all the nostrils are symmetrical although not directed correctly forward.

Three operations for double harelip are described. The first (Fig. 163, *a, b, c*) we ordinarily use. The other two operations often used at the present time are the Rose and Thompson operations.

Operation Favored Personally.—When closing the lip one has to be careful and not make CD (Fig. 163, *a, b, c*) too long as a long lip gives a lip of poor appearance. The length of the lip will depend upon the angulation of CD toward the corners of the mouth. When the lip has been repaired previously, and one wishes to advance the columella, the incision AB is made very short to correspond with A′B′. The bulk of the lip is formed from the lateral tissues of the lip. The incision CD starts out somewhat more toward the corners of the mouth so that CD, which will come to C′D′, is almost the length of a normal lip without its normal vermilion border. The operation when combined with columella lengthening, no matter what the relation of sequence of the lengthening may have been to the repair of the lip, gives only one midline scar in the lip (Fig. 164, C), a more pleasing scar than the Y-shaped scar, which is obtained when all of the premaxillary soft tissues remain in the new-formed lip. The flaps of the vermilion



Fig. 164.—Advancement of columella after lip has been repaired for some time. A, Before operation. B, Profile view after operation. C, Front view after operation.

border are zigzagged as in the Mirault-Blair operation for single cleft of the lip. The principle of the Blair advancement operation (Fig. 168, A, B) is added when one closes the vermilion border and the muscles from beneath the lip. That is, the whole lip is brought well forward and the mucosa is tightened beneath the lip so that the lower part of the lip is thickened somewhat and thrown well forward.

A suture which catches the superficial mucosa and then takes a second whip through the deep tissues of the lip is used. Very little dependence is placed upon the vermilion border flaps of the premaxilla. Occasionally we have tried some experimental use of them to determine whether they are of value to cross lap the suture line posteriorly. As yet, however, no decision has been reached.

Usually when the premaxilla projects rather markedly, the lip is repaired over the premaxilla without section of the vomer. As a rule, the anterior palate is closed at the same time the lip is repaired but, when the child is deemed not to be in the best of condition to withstand both the anterior palate closure and closure of the lip, the two procedures are separated. The traction of the repaired lip and the cicatrizing anterior palate as a rule

brings the premaxilla in fair position by the time the child is seven or eight months of age.

The inside of the nostrils are reshaped as described in the Mirault-Blair operation for single cleft of the lip.



Fig. 165.—Double cleft of the lip with projecting premaxilla. Operation shown in Fig. 167 was used. A, Front view before operation. B, Lateral view before operation. C, Front view two weeks after operation. D, Lateral view two weeks after operation.

In all complete double cleft lips a through-and-through suture of double horsehair through tin-foil plates is placed at the alar bases. Depending upon the amount of dead space or the tendency to bleed, a small gauze pack may be placed between the cheek and maxilla. For two days each nostril is packed. Horsehair is used for sutures.

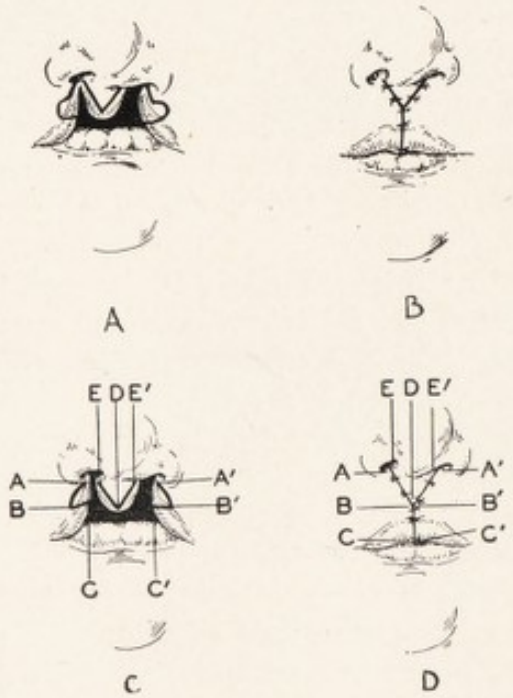

Fig. 166.—A and B, Lines of incision for double harelip operation as described by Rose. C and D, Lines of incision for double harelip operation as used by Thompson.

Rose Operation for Double Harelip.—The incision of the operation for a single harelip is made bilaterally and a Y-shaped suture line is obtained (Fig. 166, A, B). The premaxillary soft tissues are pared into a triangular shape. The diagrams are largely self-explanatory.

Thompson Operation for Double Cleft of the Lip.—The shoulders marking the margins of the nostrils are shown at A and E, and at A′ and E′ (Fig. 166, C, D). The triangle E′DE shows the line of incision by which the central piece of skin covering the intermaxillary bone is pared. E and E′ are placed on the inner margins of the nostrils. The sides DE and DE′ are usually equal in length to one another, and their length varies ac-



Fig. 167.—A, Poorly repaired harelip with nasal deformity. B, Repaired lip with nose correction by splitting the columella and Mirault-Blair type of lip operation.

cording to the depth of the central pieces of skin. It must never be greater than AB and is usually much less. The points A, B and C and A′, B′ and C′ are chosen as described previously in the operation on single harelip. Figure 166, D shows the final appearance of the lip when the flaps have been cut and the parts approximated. The point A is in contact with E; A′ with E′; the apex D of the triangle E′DE lies somewhere along the line AB; the point B is in contact with B′, and C with C′.



Fig. 168.—Patient in whom Blair's advancement procedure was carried out. A, Before operation. B, After operation.

Two essential points must be emphasized: under no consideration must the circumference of the nostril be encroached upon. The shoulders that represent the margins of the nostril must be accurately approximated. The points B and B′ must be as close to the red line as possible, and must always be on the skin (upper side) of this line.

Question of Columellar Lengthening in Complete Double Cleft.—When the premaxilla projects rather markedly, the columella may be very much shortened or even partially absent. If this defect is not corrected the tip of the nose will be pulled into a broad-tipped, flattened shape. To correct this, one can advance the premaxillary soft tissues upward and rebuild the columella.

Usually if the projecting premaxilla is extreme, one is wise to content himself with gaining firm union of the lip across the premaxilla for the time being. There is some subsequent readjustment of the nose after the lip is repaired and the premaxilla takes a better position. Later, one may advance the columella and do any plastic repair of the lip that is necessary.

Some discussion of the best time to do this lengthening may be pertinent. When one loosens the mucosa from the vomer and readjusts the anterior premaxillary soft tissues at the same time, one would expect that some of the blood supply might be cut off from the premaxillary process. Therefore, it is unwise to lengthen the columella if the anterior palate and the lip are to be repaired at the same time. The disadvantage of lengthening the columella at the time of the original repair of the lip is that the incision line between the lip and the columellar tissue does not tend to unite well—especially is this true in small babies.

The anterior palate and the lip having been closed successfully, the optimum time for closure of the palate is considered to be at about fifteen months. At this time if the columella needs lengthening, provided the child is in good condition, usually it will not be too great an operative strain to lengthen the columella after the operation on the posterior palate.

We favor the foregoing sequence but not uncommonly, due to factors not entirely within our control, the sequence of operations is varied. The result obtained because of the change of sequence is not as a rule particularly inferior.

Method of Lengthening the Columella.—All of the premaxillary soft tissues are loosened from the premaxillary process and the cartilage of the septum is exposed. With the scissors the skin of the old columella with its cartilage is cut upward toward the tip of the nose. The premaxillary soft tissues are then advanced toward the tip of the nose and refashioned into a columella of the required length (Fig. 163, *d*). Excess skin and subcutaneous tissue have to be removed from the advanced premaxillary tissue on each side of the columella so as to build the lower part of the columella into one of normal shape and contour. This allows the tip of the nose to elevate itself. The procedure is similar to the one of raising the tip in the Joseph's operation (Chapter XL). When this procedure has been done thoroughly most of the premaxillary soft tissues are eventually found to be used in building the new columella. The new lip is formed from the lateral parts of the lip. The final result shows only a midline central scar in the lip.

The Re-repair of a Poorly Repaired Lip and Nose.—A fair percentage of cleft lips which present themselves for correction of an obvious deformity of the nose and lip are individuals more or less unsuccessfully repaired at some earlier date (Fig. 167).

To give an outline of the methods of approach to re-repairs of the lip is difficult as great variation is exhibited, according to the original procedure attempted and its variable degree of success. The repair of the lip itself is

usually not the greatest problem. One of the operations previously described can be reapplied to the lip, which (with the addition of a little ingenuity in angles of incision, suture lines and possibly piecing out, so to speak, with appropriate flap shifting where needed) can produce a well-formed lip. Ordinarily in the reconstruction of such a lip, the principal idea is to get a lip that appears normal. The muscle function seems to pretty well take care of itself. The patient is principally interested in the way the



Fig. 169.—A, Incision for flap of the lower lip with pedicle on the left and incision on upper lip in the midline. B, Flap has been turned into the upper lip and stitched in place. C, The stitches have been removed after the flap has healed in and the pedicle has been snipped across. A faint scar line is shown.

lip "looks." Uneven scars are excised. Care is taken not to make the lip too tight. Much aid can be obtained in preventing the appearance of a tight upper lip by two procedures each of which is carried out beneath the lip. The first consists of advancing the mucous membrane beneath the lip along its reflection from the maxillary bones as advocated by Blair (Fig. 168, A, B). To do this the soft tissues are loosened from the maxillary bones through an incision in the alveolar buccal sulcus. The mucosa and



Fig. 170.—Transplantation of flap from lower to upper lip. A, Front view before operation. B, Profile view after operation. C, Front view after operation.

the soft tissues are then slipped forward and resutured in an advanced position. In old double lip repairs when the columella is pulled down, the whole may be raised by cutting the columella loose from the septum and stitching it to a higher point on the cartilage. The broad tip of the nose may be narrowed somewhat by taking a piece of lateral cartilage out from below so that the tip becomes narrowed.

In the extremely tight lip the transplantation of a small triangular flap from the lower lip to the upper lip (Abbe) serves two purposes (Fig. 169, A,

B, C). It makes the redundancy of the lower lip less marked in comparison and it adds width and fulness to the upper lip. When this procedure is carried out with finesse in the proper cases, the result is all that one desires (Fig. 170, A, B, C).

In some of these cases, it is almost impossible to give a properly curved shape to the attachment of the vermilion border to the skin of the upper lip due to the old scars of former incisions. The vermilion border may not be exposed sufficiently, its juncture with the skin may not be even, or the length of the lip may not be so great that shortening is required. In the latter case in several instances we have removed a semilunar piece of the



Fig. 171.—Gillies' procedure of excising an uneven piece of skin from the lower edge of the lip.



A *B*

Fig. 172.—*A*, Poorly repaired and badly scarred harelip. *B*, Lip repaired by various incisions that allowed the excision of the scar and reshaping of lip. A routine operation is of no great value in the repair of such a lip. Gillies' procedure was used for the edge of the lip.

lip at the columellar base but the result leads us to believe that it is better to remove the tissue from the lower edge of the lip than at the columellar base. The method of excising the skin along the entire edge of the lip (Fig. 171), curving the incision to give a normal curve to the mucocutaneous juncture of the lip, is quite satisfactory under the conditions outlined above (Fig. 172). The vermilion border of the lip is reshaped and stitched to the reshaped cutaneous edge of the lip. The scar does not show because its color blends perfectly with the vermilion border. The name of Gillies is attached to this procedure and it is logical provided the indications are not extended too greatly.

As has been mentioned in the description of the primary repair of the cleft lip, in secondary repairs the reshaping of the nose and floor of the nostril is fully as important as the proper shaping of the lip. Most individuals who present themselves for re-repair need reshaping of the nose and ala on the side of the cleft as well as re-repair of the lip. In many of these cases it is best to split the columella as previously described and elevate the low nostril to a level with the high nostril (Fig. 154, A, B). In those with badly deformed nose tips, it may be necessary to take out a section of the nasal cartilage at the tip besides the triangle of redundant skin which becomes present at the upper end of the incision which splits the columella. In some instances this cartilage removal can be done from within the nostril so that no scar appears. However, this trick had probably best not be recommended to those not familiar with cosmetic surgery of the nose as one is likely to be surprised by what he did not or did do to the shape of the nose. The nose should be reshaped before one starts to reshape the lip as it is almost impossible to estimate the lip incisions until it is seen what influence the reshaping of the nose has upon them.

In some adolescents and adults where the nose deviates to one side, if a good correction is to be given, the nose must be fractured—that is, the nasal bones are separated from the maxillary bones with a chisel and pushed into a position of correction or overcorrection.

Often the attachment of the anterior end of the nasal septum to the alveolar process has deviated to the uncleft side to such an extent that its lower anterior end has to be either separated or resected through a lateral columella incision. Not only is the nose held from falling into the midline when this septal deviation is marked but the lower septal end may protrude in the uncleft nostril and block it to a greater or less extent. Although this may appear to be a considerable amount of reshaping, the operation is withstood very well and the result compensates for the difficulties of the correction.

Some method of maintaining the refractured nose in position of correction until union occurs is sometimes but not always necessary. One can attach a dental splint to the front teeth with a heavy wire attachment which protrudes outward between the lips and then curves upward along the side of the nose. Ordinarily we have used a head cast (Fig. 33, Chapter VIII) with a wire attachment projecting downward along the side of the nose. A piece of felt is placed between the wire and the nose. Although this apparatus may be none too comfortable, it handles the necessities of the case well and is inexpensive.

A deformity is not uncommonly encountered, due to an early forcible coaptation of the alveolar processes by wires, in which the upper alveolar arch is considerably narrower. When this deformity is moderate and adult growth is not yet attained, orthodontic procedures are of aid, or the advancement of the mucosa of the cheek may be sufficient. But in more marked deformities in adults, some prosthetic substitute for the inadequate bony framework is often the most logical procedure to use. Of course, in childhood the growing face makes the construction of a prosthesis rather impractical because of the necessity of rebuilding it from time to time. But when the age of adolescence is reached a plate may be fitted over the alveolar ridge and remaining teeth. The teeth are used to attach clasps

to so that the body of the plate is anchored securely. The artificial teeth in the new plate should be set well forward in order to give normal occlusion with the teeth of the lower jaw. The flange denture is fitted well up beneath the upper lip. Thus, the upper lip is thrown well forward so that it takes a more or less normal position. The profile view then becomes a normal one instead of the "dish face" profile with the upper lip behind the lower lip and a complete new line of upper artificial teeth is then exhibited beneath the upper lip. Biting force is fairly good if the posterior and lateral anchorage is firm. We have used a prosthesis in cases for this purpose (Chapters XXIX and XLI). When insufficient mucosa is normally present beneath the upper lip, it may be necessary to add to the mucosal lining beneath the lip by laying in a Thiersch stent graft to give a deepened sulcus for the prosthesis beneath the upper to lie in (Fig. 326, Chapter XL). In other instances the operation of Abbe of transplanting a flap from the lower to the upper lip may seem the most efficient. A considerable amount of mucosa can be gained if necessary by this procedure.

In three cases with the columella absent and a deficiency of mucosal lining beneath the lip, a pedicled flap was used to build the columella. The flap was cut long and its tail split. With the two tails the buccal alveolar sulcus was reconstructed. The thickness of the flap does much to push the lip forward but if the flap is insufficient a prosthesis may be built in such a manner that an additional amount of projection of the upper lip is maintained.

We have used successfully still another procedure to give a normal profile when the alar bases set too far posteriorly or the upper part of the upper lip slants backward too greatly. A cartilage transplant can be laid into the upper part of the upper lip and it can be cut in such a manner that the alar bases are surrounded and brought forward. Most of the necessary undermining can be done through a small incision at the alar base. Through this incision the cartilage is inserted. The nasal fossa is entered during the procedure, so that infection about the transplant is not likely. In three cases we have used this procedure successfully to gain normal contour about the upper part of the upper lip and the alar bases due to maldevelopment of the underlying bone. But in two of these patients the maldevelopment was due to congenital syphilis.

POSTOPERATIVE CARE OF CLEFT LIP

Retention Sutures.—After the operation proper is finished, we consider it essential in some complete single and in all complete double cleft lips to use a fixing through-and-through suture at the alar base through thin lead foil plates bent to fit the contour and alar labial grooves (Fig. 157, A, B). The suture holds the alae in place for the first twelve days after which it is removed.

Retention Clamp.—Ordinarily we do not use a retention clamp for the cheeks save in the double clefts of the lip and ordinarily it is not necessary in them unless there is considerable tension of the soft tissues because of a projecting premaxilla. The Logan clamp (Fig. 173, A) is probably the best type of retention apparatus when properly applied. It aids in pulling the cheeks forward without putting any pressure on the stitched lip.

Especially after the repair of a double cleft lip but also occasionally after the repair of a single cleft lip because for the time being the upper

lip is somewhat tight and the tissues by the recent suturing are somewhat distorted, the baby may tend to suck its lower lip in beneath the upper lip in such a manner that breathing is interfered with. In Fig. 173, B, C, is shown a method of cutting and preparing a small rubber tube which may be placed between the lips and held in place by adhesive strips over the ends which project onto the cheek. This simple device is to be advised in all cases where it is noticed that there is a tendency for the lower lip to be sucked in beneath the upper lip and thus perform a valve action which may interfere with the normal intake of air.

Dressing and Care.—As a rule, no dressing is placed upon the lip but in a hospital where we are a little dubious about the attention the lip is likely to receive, a small roll of gauze may be sewed over the suture line by placing two sutures deeply through the lip and then tying them over the gauze roll. This prevents the formation of crusts if the early care of the

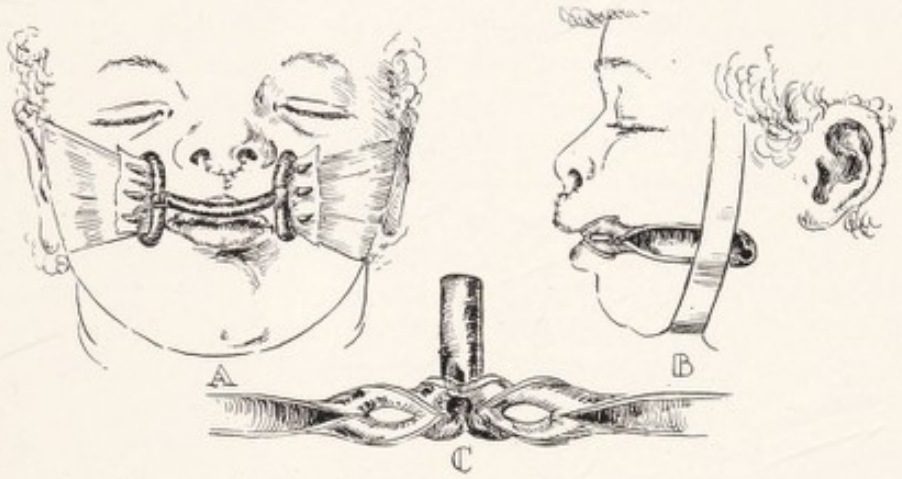

Fig. 173.—Appliances of value in postoperative care. A, Showing use of Logan clamps for external support of cross tension. Breathing tube made of rubber tubing to prevent the lower lip from being sucked in beneath the upper lip in such a manner that the intake of air is interfered with. Usually adhesive is used to hold it in place. B, The tube in place. C, The breathing tube made from rubber tubing.

lip is likely to be haphazard. This dressing is removed within two days and the remainder of the care of the lip proceeds as if no dressing had been applied.

But as previously stated, usually no dressing is applied. The lip is left uncovered but the nurse is instructed to clean the lip thoroughly with pledgets of gauze saturated in a solution of half alcohol and half boric acid. After a few hours this is not necessary more than four or five times a day, as the lip is dry and only needs the removal of dried blood or crusts. No crusts are ever allowed to form. As an aid to the prevention of blood and discharge running down over the lip for the first two or three days, we generally pack the nostril on the side of the sewed cleft with a small pledget of gauze. This acts as a stopper and also acts as an approximator of the internal nose lining to the external tissue of the nose. In the operation that we perform, the internal lining is separated from the external lining by undermining with the scissors as described in the Mirault operation. This gauze pack should be removed within three days or it may interfere with union in the nostril base if it becomes soaked with pus. Ordinarily it remains fairly dry.

On the fifth day the sutures which were placed in the skin of the lip and

external vermilion border are removed. The sutures beneath the lip are not removed until about the time the child goes home—ten days to two weeks.

When the alveolar ridge is not cleft, the baby is allowed to nurse within forty-eight hours and sometimes we allow the first feeding after the operation to be given by bottle or from breast. The lip sutures are solid at this time and there is little danger of disturbing them. One good feeding starts the child off well after operation. When the alveolar ridge is cleft the child is fed by a medicine dropper or a spoon for about one week after operation. After five to seven days, a nipple may be used if the lip union appears firm. A baby with a cleft palate does little real sucking anyway. The milk runs into the mouth mostly by gravity. When both nostrils are occluded as is usual after a double operation until the through-and-through sutures and retention plates are removed on about the twelfth day, the child will probably be unable to use the nipple even when it is given because of difficulty in breathing. With a double lip repair one is usually so concerned about good union that little chance is taken by feeding experiments with the nipple until union is a certainty.

When a pack is placed beneath the lip to prevent bleeding, where it is loosened from the maxillary bone, it is removed in about forty-eight hours.

The other postoperative care is carried on without routine and indications are met according to general surgical principles. Hypodermoclysis and blood transfusion are to be used whenever they are indicated.

Bibliography

Bibliography Quoted in Text

Abbe, R.: Harelip and Cleft Palate, Post Graduate, **10:** 15, 1895.
Med. Rec. New York, April 2, 1898.

Binnie, J. F.: Operative Surgery, 1921, P. Blakiston's Son and Co., Phila.

Blair, V. P., and Brown, J. B.: Mirault Operation for Single Harelip, Surg., Gynec. and Obst., **51:** 81–98 (Supplement), 1930.

Erichsen, John: Science and Art of Surgery, **2:** 1858, Lea Bros. and Co., Phila.

Esser, J. E.: Studies in the Plastic Surgery of the Face, Ann. Surg., **35:** 297, 1917.

Fry, W. K.: Dental Aspects of Treatment of Congenital Cleft Palates, Proc. Royal Soc. Med., **14:** 57, 1921.
Treatment of Cleft Palate, Lancet, **2:** 1081–1082, Nov. 22, 1924.

Gillies, H. D., and Fry, W. K.: A New Principle in Surgical Treatment of Congenital Cleft Palate and its Mechanical Counterpart, Brit. Med. Jour., **1:** 335, March 5, 1921.

Lexer, E.: In von Bergmann's System of Practical Surgery, Lea Bros. and Co., pp. 411–458, 1904.

Mirault: Malgaigne's J. de chir., p. 257, Sept., 1849, and p. 5, Jan., 1845.

Mirault Operation: Smith, H. H.: Operative Surgery, 1852, J. B. Lippincott Co.

Ombrédanne, L.: Reconstruction of Nostril in Simple Harelip, Presse méd., **29:** 703, 1921.

Padgett, E. C.: The Repair of Harelip and the Accompanying Nasal Deformity, Jour. Kansas State Med. Soc., **30:** 143–147, May, 1929.

Plessier, Paul: Traitement du bec-de-lièvre unilatéral, Procédé du Dr. Veau, Masson et Cie, Paris, 1931.

Rose Operation: Nitch, C. A. R.: Malformations of the Face, Lip and Palate, Choyce's System of Surgery, 1912, Funk and Wagnall's Co., New York.

Thompson, J. E.: Simplification of Technique in Operations for Harelip and Cleft Palate, Ann. Surg., **74:** 394, 1922.

Veau, Victor: Division Palatine, Anatomie, Chirurgie, Phonétique, Masson et Cie, Paris, 1931.

Brophy, T. W., Colles, von Graefe, Hagedorn, Husson, König and Logan: Quoted in Chapter XXV—see bibliography.

CHAPTER XXVIII

GENERAL CONSIDERATIONS IN CLEFT PALATE SURGERY*

THE anatomy of the palate should be familiar to one interested in the surgery of cleft palate (see Chapter II).

The Relation of the Alveoli and the Palatal Tissues to the Normal.—If there are factors which cause the upper alveolar ridges to assume an abnormal position they become important when procedures for repair and correction of cleft palate are contemplated. The question has been a subject of prolific discussion with not possibly so much accurate research as might have been done. Quantitative studies of the growth and of the amount and disposition of the tissue in the cleft palate are meager and many of the opinions are based purely on clinical observation or on the writings of others. Peyton, Keith, Kirkham, Thompson, Winternitz, Wardill, Veau, Ruppe and others have contributed to the subject.

Keith has expressed the following opinion: "I agree with you that in the majority of cases of complete cleft of the palate, there is no deficiency of tissue at birth nor for some time after birth. I also agree that the cleft, however wide, is not due to a deficiency of tissue in the several elements which go to form the palate, but is entirely due to the fact that when the various embryonal parts or elements are developed and come together in the second month of development, the process of union by first intention, is delayed and does not take place, hence the several palatal elements, being in coordinated union, tend to separate as growth occurs, the cleft increasing during each month of growth. The exact cause of the separation of the parts and the enlargement of the cleft is probably due to several factors, tongue pressure, muscle traction, and also the independent process of growth in each individual part."

Peyton comparing normal children and those afflicted with cleft palate came to the following conclusions:

1. The size of the head is approximately the same for the normal as for the maldeveloped material.

2. It is doubtful if there is a significant difference in the surface width of the palate in the normal and maldeveloped children. (Veau has expressed the opinion that the parts are normal or if less than normal that they have between them the ability to reproduce the normal amount of tissue. If any abnormal amount is present it is because of lack of coalescence.)

3. Definite growth and also significant difference in the surface width transverse diameter between the normal and the cleft palate are indicated. If the material is representative, growth is toward the midline since for cleft palate no spread or increase of the width of the maxillae during the period of study was noted. This would lead one to expect that the cleft would become narrower as growth occurred in the palate. The width of the palate was measured and the measurements confirmed this supposition. This was the most unexpected and remarkable observation of the study.

4. That cleft palate is definitely higher than the normal palate.

* The latter half of this chapter on Speech Training Following Operation for Cleft Palate was written by Professor Martin F. Palmer.

5. Growth in length of the alveolar arc of the normal palate was approximately 5 mm. during the period of the study. On the whole, the growth of maldeveloped children was slightly above that of the normal children.

6. During the first year the widest transverse direction of the palate showed an increase of 7 mm. and no increase in the dimension of the cleft palate during the same time. It should follow that the cleft becomes smaller and more narrow during the period of growth.

Thompson in 1921 presented a series of cases to add proof to the argument that the increased separation of the upper alveolar ridges over the lower alveolar ridges in cleft palate in the anterior part was due to pressure of the tongue. The increased projection of the premaxilla in both single and double clefts of the palate, he also ascribed to this factor. The increased verticality of the palatal plate—especially the smaller side in the single cleft—he also ascribed to the tongue thrust. He did not find the posterior part of the alveolar ridges much increased in separation, in fact, no greater than those of the mandible. He thought the force of the tongue, being greatest at the tip, explained the greater growth of the separation toward the anterior part. In the middle part of the alveolar arch he found the separation usually about 2 mm. and at most about 3 mm. The cleft alveolar ridge varied within great limits—often being 10 mm. and sometimes 15 mm. He concluded that the statement made by Brophy—the conception which stimulated the development of his operation—and others, that the width of the cleft is the true measurement of the extent of the separation of the maxillae, is not supported by facts. The estimate of the width of the cleft is gained by taking the sum of two measurements: (1) the lateral displacement of the maxilla, and (2) the vertical deviation or slant of the lateral plate. The question of whether or not the posterior part of the alveolar process including the hamular processes has a wider separation in cleft palate, has probably been more vigorously discussed than the other points. Ruppe and Wardill studied 16 skulls—the same group of material. Ruppe (1928) concluded that we have little anatomic proof of the separation of the maxillary tuberosities in complete cleft. Veau (1931) after perusing Ruppe's study and cross sectioning a four-month fetus with cleft palate states that the separation of the maxillary tuberosities is neither the cause nor the consequence of cleft palate.

Disadvantages to Health Connected with Cleft Palate.—The deficient separation of the nasal and buccal cavities has dependent upon it disturbances of sucking, swallowing and later, of course, phonation. The uncleanliness and possibly abnormal cooling of the mucosa of the open nasopharynx probably promotes to a certain extent many kinds of inflammations of the mucous membranes of the nose and the eustachian tube. The same factors cause the lymphatic tissue of the pharynx to be more liable to inflammatory flare-ups. Middle ear infections—supposedly by a secondary eustachian tube infection—are thought to be more common in children with cleft palates and subsequently the consequences of such infections, that is, slight or even pronounced deafness, are more common.

Feeding offers considerable difficulties. Breast nursing is largely impossible. The milk has to be brought to the posterior part of the tongue in some way without sucking as sucking requires the ability to close off the nose from the mouth. Usually artificial feeding can be given successfully

by enlarging the hole of the nipple until the milk runs out by gravity. Nowadays infant feeding knowledge is fairly common knowledge so that the malnutrition states are not so common as at one time. Still quite often it is evident from the child's appearance that proper nutrition is not present. The fat, too pale baby is often seen.

In going over our cases of cleft palate we find that at about one year of age children are often anemic. The hemoglobin is often below 60 per cent and in some cases it is as low as 45 per cent. We have not seen this emphasized before. But it is certain that operative risk on a child with a secondary anemia is increased. Besides this tendency to an anemia it is known that the blood volume in children is less according to body weight than in adults. This physiologic condition also adds to the risk. The interesting question is the cause of this low hemoglobin. We have attributed it to two factors: feeding difficulties and the increased likelihood of nasopharyngeal infection. In all likelihood the two go hand in hand and after the anemia is pronounced, a vicious circle is established. Proper feeding methods cannot be too strongly emphasized. No individual with a low hemoglobin stands operation well and undoubtedly he is more liable to postoperative infection. And healing of the postoperative wound, even without infection, is possibly delayed somewhat or, with infection, is more likely never to occur.

Preferable Age at Which to Operate.—Two situations—the ideal and the surgically probable—are to be balanced in selecting the preferable age at which to operate.

Up until about the last decade of the last century, cleft palates were operated after the child was several years of age and had learned to talk. Treves recommended the age of five, and earlier surgeons waited to as late as the age of twelve years and thought that age preferable. At this late age there was thought to be a relatively large amount of tissue in proportion to the cleft to be bridged as the alveolar ridge was thought to come together somewhat and the arch of the palate became relatively high. Furthermore, it was argued that the desire for relief by the time this age was reached aided in obtaining a good result. Later it was argued that the nasopharynx, nasal cavities, and the tongue developed abnormally in the unclosed cleft palate and that the imperfect speech is never corrected after such a late restoration of the palate. The question of function brought up a new point. It was soon fairly well established that on an average the later the operation the poorer the function. However, even at the present time Axhausen maintains that the optimum age for a cleft palate operation is about three years and that function is not decreased by the longer wait. Lane and Brophy developed their procedures in the last decade of the past century. As it was at that time theoretically assumed at least that the sooner the cleft palate was closed (provided the risk was not prohibitive) the nearer the approach to normal function, they had a strong argument in favor of earlier closure, which they advocated. Lane closed the deformity almost immediately after birth. Brophy closed the alveolar cleft as soon after birth as possible and the cleft palate at five or six months when his wiring operation was first presented. Lane and Brophy were impressed with the fact that although the cleft is fairly wide at birth, all the structures are nearly normally developed.

Of interest in this connection are the present-day statistics of Veau and Borel who claim 70 per cent normal phonation in children operated within the first year, 69 per cent in the second year, and 26 per cent in the third year.

The question on the other side is the operative mortality. It increases as the age decreases. Veau's mortality is: in the first year 86 cases—9.4 per cent; in the second year 122 cases—5.7 per cent; in the third year 72 cases—2.7 per cent.

Veau believes that the optimum time is between the twelfth and the twenty-fourth months. It is the time when his mortality is 5.7 per cent and the proportion of normal phonation is 69.6 per cent.

Blair has for many years considered the optimum time for operation at about twelve to fourteen months provided the child was in good condition. We have followed this dictum in our cases with the opinion gradually forming that, with the use of modern knowledge such as the liberal use of blood transfusion and isotonic crystalloid solutions plus an increasing dexterity in performing the operation, we are possibly justified in doing the operation in the easier cases at least at an age earlier even than one year. In those cases with partial cleft of the palate, we have in several instances performed the operation at eight or nine months with the idea that earlier function of the soft palate muscles increases very considerably the chances of proper phonation later.

On the other hand, in double cleft of the palate we have been inclined to wait until the child is over fifteen months of age before closing the palate in those cases wherein the greater part of the palate is to be closed at one operation. In all instances, however, when the child is not in good condition or is rather small for its age additional time is given—as many months as are needed for the child to be put in good condition. We consider that the factor of time is not so important as the factor of increased danger from the operation or the factor of an increased chance of not getting good union.

Preoperative Care of the Cleft Palate.—The child should be fed correctly for several months prior to operation. The feeding necessarily has to be artificial during the early months. Before the operation the child should have learned to eat without the bottle as after operation the child cannot use the bottle until the palate is healed. Consequently, the baby does better if it has learned to drink and take liquids from a spoon. All evidence of a nasopharyngeal infection should be eliminated. This is probably the one greatest "bugaboo" to the surgeon. A child with any evidence of a nasopharyngeal infection should not be operated. The surgeon who fails to heed this advice will have untold operative grief. Even if a very serious illness is avoided, the palate will more than likely separate. Consequently, in certain months of the winter and spring, very often it is wisest not to try to operate cleft palates—at least in temperate climates. "Colds" are too prevalent among children.

If the child is anemic the operation has a greater risk and the likelihood of nonunion is increased. Therefore, by feeding methods if feasible and by transfusion if necessary the blood is brought to a normal condition as far as the laboratory is concerned. Iron, copper, and liver are used over a period of time in the first case and in the second citrated blood, properly matched, in amounts of about 150 to 200 cc. at one time is given.

The morning of the operation a low enema is given. Liquids are given within two or three hours of the operation time. Thirty minutes before operation a very small dose of atropine and a small dose of morphine may be given hypodermically.

Thus, after a day or two in the hospital to check against evidence of a nasopharyngeal infection and provided the laboratory work, blood and urine, gives normal values the patient is prepared for operation the following morning. Breakfast is omitted. Just before starting the anesthetic, the patient's arms are wrapped within a snug sheet pinned about the shoulders and the body.

Thymic Deaths.—Although there has been much discussion concerning the advisability of giving the child an anesthetic without ruling out an enlarged thymus, ordinarily we do not get a roentgenogram of the chest unless something in the history or physical findings seems suspicious. In a considerable experience we have had no fatalities that we could attribute to an enlarged thymus solely. In 1 case in which the thymus weighed 35 Gm. at autopsy which died at the finish of the operation, we lost more blood from a torn alveolus than we should have—90 to 100 cc.—and the child was somewhat anemic before the operation started. The blood was being picked up by a nasal catheter and the quantity being lost was not noted quickly enough. As the child was well nourished, the operation was not hurried and extended out over an hour—about twice the usual time taken. We attributed this death to our own carelessness and we believe that, if the operation had been finished in the usual time and the hidden open blood vessel had been noted, all would have been well and we would not have known that the child had an enlarged thymus. Speaking generally we believe that, on looking up the facts, most so-called "thymic deaths" occur in the hands of poor operators or inexperienced anesthetists. Veau, however, tabulates two of his deaths as "thymic deaths." The amount of blood he lost would be interesting to know.

Shock.—Modern work on "shock" seems to indicate that in the past we have paid too little attention to the loss of blood from the "circulatory tree" and especially is this true in operating on children. Relatively, their blood volume is less than that of an adult. They stand bleeding poorly. In our experience the length of time under an anesthetic is more important in a child than in an adult. The mortality goes up as the amount of bleeding increases and the duration of the operation increases.

We consider the less perspiration and the less mucus lost at operation, the better. Work during the war with lung secretions after "gas" poisoning would indicate that the serum loss is similar in composition to blood serum. The less lost, the better. The place for serum of the protein composition of blood serum is in the "circulatory tree," not in the suction bottle. In one other place, only, is it worse to have mucus or blood serum—in the lungs.

Anesthesia.—Ether vapor anesthesia is used and no more than is necessary is given. After the preliminary induction, the vapor is blown over either through a small catheter passed through one nostril and back to the nasopharynx or through a curved tube held over the patient's open mouth by the anesthetist.

Position for Operation.—After induction, the Lane mouth gag and tongue suture are placed in position, and the patient is placed in the Rose

position (Fig. 17, Chapter III) with the head turned back into the operator's lap as he sits upon a stool. The Rose position with the head hanging over the end of the table resting on a pillow or the sitting surgeon's knees keeps the blood away from the larynx better than other positions and gives the surgeon ready access to the palate. The pad on which the patient lies should extend beyond the table so that the neck will be protected. A single pillow beneath the neck is unsatisfactory. It does not stay in place. The instrument table is brought up to the side of the operator. The table stands between the operator and the assistant. The anesthetist stands on the opposite side. The light must be good and must fall at the right angle. Modern operating rooms reflecting lights can now be used without the necessity of the surgeon wearing an electric head light unless he desires.

Instruments and Material Needed for Cleft Palate Surgery.—The following special instruments are advantageous for cleft palate work:

(*a*) A gag. Lane's gag is simple and easily adjusted (Fig. 174, A). Along with it a stout suture is placed through the median raphe of the tongue in such a manner that the upper exit of the suture is back almost to

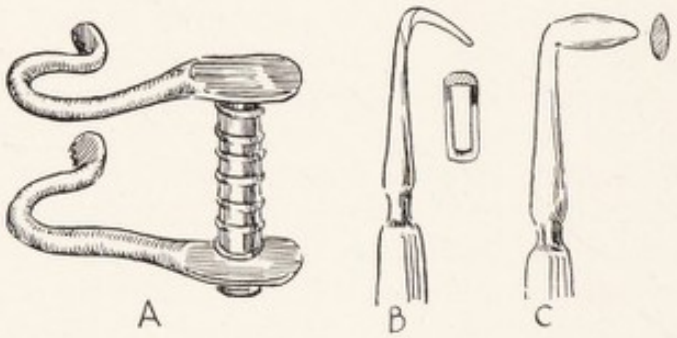

Fig. 174.—Instruments of value in cleft palate surgery. A, Lane gag. B, Brophy elevator. C, Modified Fergusson elevator.

the midpoint of the tongue. This suture with a clamp on it controls the tongue for both operator and anesthetist.

(*b*) Three sharp knives, one right-angled knife, one of the straight bistoury type and one ordinary scalpel.

(*c*) Four to 6 cleft palate elevators—one of the Fergusson type (Fig. 174, C), one of the Brophy modification (see Fig. 174, B), and one of the Durham raspatory type.

(*d*) Two long-handled, sharply curved scissors.

(*e*) Eight or 10 Lane cleft-palate needles.

(*f*) Two long dissecting forceps with teeth.

(*g*) Two types of suture: (1) heavy horse hair and (2) moderately fine waxed silk.

(*h*) Six towel clips.

(*i*) Eighteen straight Kelly clamps.

(*j*) Two special mucosal elevators with neck bent into a right angle (right and left) for elevating the mucosa on the vomer in double cleft.

(*k*) Rather narrow slender Liston-type forceps for cutting the vomerian support in double clefts if one considers the procedure indicated (see discussion in the preceding chapter).

(*l*) Two nasal submucous elevators, right and left, with angled necks.

Sutures.—Good heavy horse hair is a good suture for cleft palate suturing. It sets in the tissue with little reaction. Horse hair, however, does break easily and needs to be tied with five or six knots or it may untie. In the aponeurosis and on the upper surface of the palate, we occasionally resort to fine woven waxed silk which is easier to handle than horse hair and does not break so easily. Several of the artificial sutures of the prepared silk type are useful but expensive. Fine silver wires were once used but they are difficult to insert and have no advantage over the sutures mentioned.

Needles and Holders.—Small half-curved Lane needles clamped in straight Kelly hemostats for needle holders make an efficient and adept way of sewing in difficult holes. Small needle holders are likely to have such a broad point that they break the needles on account of their curve.

Sponges and Suckers.—Nowadays the suckers on the ordinary vapor ether machine make a great deal of the sponging with gauze unnecessary. A small catheter may be placed in one nostril and run back into the nasopharynx to suck up any accumulation of blood draining to this dependent pocket. Often clots tend to clog such a sucker and it may be almost as much of a nuisance as an aid. The assistant can aid most materially in most stages of the operation if he is an adept at sponging quickly and accurately with a gauze sponge which is not too large. He is often less likely to get in one's way than the anesthetist is with his long metal sucker.

POSTOPERATIVE CARE OF CLEFT PALATE

Some years ago after the von Langenbeck procedure a thin gauze pack saturated with some antiseptic solution was laid in through the lateral incisions, one end above the artery and one posterior to it, and sometimes at present when it is thought necessary to guard against oozing of blood, or to fix and stabilize the free mucoperiosteal flaps, a gauze pack is used. However, as it was found that packing sometimes interferes with breathing during the first night, at present it is seldom that a pack is placed through the lateral incision. When it is used if a child is doing well, the packing is left in place from two to four days depending upon the object in mind when it was inserted.

Immediately after returning from the operating room, before the child is entirely out from under the influence of the anesthetic, it is best to turn him face downward so that the blood is not aspirated or, if any bleeding is present, it can run out and be seen instead of swallowed.

Any signs of collapse or too much loss of blood should be combated by a mild opiate, heat, and fluids subcutaneously or intravenously as indicated. Usually an isotonic solution is sufficient but if there is any question of condition a blood transfusion is given. A child may "go to pieces" very fast. Sometimes crystalloid solutions will improve the condition for a few hours and give one spurious signs of fair condition only to have them suddenly disappear later. The child may die at such a time before a transfusion can be given.

As soon as the anesthetic wears off, fluids by mouth may be given freely with a spoon or medicine dropper. Nothing but fluids is given for the first two weeks after operation. No soft food is allowed until the third week. During the first two weeks high caloric liquids are forced and at all times

a fluid intake chart is kept so that dehydration is not allowed to interfere with the child's recovery. Thus, sufficient fluids with a sufficient number of calories is the goal in correct feeding of the recently operated palate case. After three weeks ordinary food is allowed as before operation.

A mild saline nasal irrigation is sometimes used in those cases exhibiting an unusual amount of nasal discharge. When these irrigations are given carelessly or after a struggle with the child, they are as likely to be harmful to the new palate as to be of benefit.

In some cases an antiseptic nose drop is placed in each nostril every four hours for the first week. Whether or not such treatment does good is a question.

The palate is inspected only for some definite reason and then very carefully and only by some one who is well aware of the damage one may do with a tongue depressor in a struggling, gagging child. Ordinarily, we restrain our curiosity as much as possible. The die is cast after a palate operation and unless some evidence of a complicating disease intervenes, there is little reason for complete inspection. A partial view is obtained usually when the child opens its mouth voluntarily for one reason or another.

Postoperative Hemorrhage.—Very rarely quite severe hemorrhage may follow several days after the operation. The blood usually comes from the posterior palatine artery and is due to the fact that it was severed at the original operation, or secondary infection causes its wall to slough. Usually after bleeding once or twice, the bleeding ceases and usually it is not severe enough to cause a serious condition of affairs. Serious bleeding is best combated by repacking. Usually a slight anesthetic is the best method of approach. A mouth gag is placed and it takes just a second to place the packs through the lateral incision. By being very careful, it is not necessary to interfere with the suture line. In 1 case in an adult, packing failed to prevent bleeding. The hemorrhage was controlled by placing a plug of orange wood in the palatine foramen.

Nonunion.—The ordinary palate operation has an innate defect so far as union is concerned. In no other place would we expect flaps to unite in an infected field with one surface raw and without any great overlap. Tension on the flaps, poor blood supply to the flaps, and infection are the main causes of nonunion. Usually if union is going to fail some separation is present by the fifth postoperative day and when the temperature stays above 102° F. until about the fifth day, one is likely to have either a partial or total nonunion.

Reoperation.—When nonunion occurs, it has been our habit to send the child home and allow the flaps to heal entirely before attempting closure.

Ordinarily the reason for failure of union in the first place is still present, so that secondary repair within the next few weeks is usually not successful.

Between the years 1927 and 1935 inclusive, our series shows 284 different individuals operated upon for cleft palate. One hundred and twenty-six of these palates had been operated upon by other surgeons before we saw them. Fifteen of the palates were re-repairs of our own cases. These 141 cases are discussed in the next chapter as they present problems somewhat different from those encountered in individuals not previously operated upon. One hundred and forty-three of the partial unilateral clefts had not

been previously operated upon. Nineteen of the preceding individuals were of the double type of cleft. As some experimentation in regard to sequence of stages has gone on in this group, discussion of this group is somewhat premature and is therefore omitted.

Anatomic Results.—In 67 individuals who survived the operation with complete unilateral cleft in 53 instances complete union was obtained at the first operation (80 per cent), in 6 a small inter- or retro-alveolar or velopalatal hole remained (8.9 per cent), in 5 (7.4 per cent) a fairly large hole remained, and in 2 there was complete nonunion (3 per cent). For the partial clefts of the hard palate in 22 cases, 19 primary closures were obtained (86 per cent), 1 small velopalatal hole, 1 complete nonunion, 1 large hole of the hard palate in cleft of the "zona pellucida" type. Three of these clefts were of the type with deficient horizontal palatal plates and soft tissue of the "zona pellucida" type which according to Ritchie and Veau is the most difficult type of cleft palate to close. For the soft palate clefts in 31 individuals, 29 were closed (93 per cent) at the first operation and in 2 small velopalatal holes remained.

Veau's results are interesting for comparative purposes. In 194 complete unilateral clefts of the palate he had 10.8 per cent showing partial separation ("échecs"), in 154 partial clefts of the hard palate he had 20 per cent showing partial separation ("échecs"), and in 104 clefts of the velum there remained 3.7 per cent showing partial separation ("échecs"). Veau did not count as "échecs" small inter- or retromaxillary holes or small velopalatal holes because ordinarily he did not advise a secondary operation. In his group of 500 cases he had 26 inter- or retromaxillary holes and 24 velopalatal holes. In this group of small holes 48 were bilateral clefts. Veau's results are better in his last 300 cases—for instance in 115 unilateral clefts he had 7 "échecs" (6 per cent).

If we subtract our small holes in unilateral clefts 88.9 per cent were closed, in the partial hard palatal clefts 91 per cent and in clefts of the velum 100 per cent.

Number of Planned Operations for Closure.—The Dieffenbach-von Langenbeck operation for single cleft is planned for one operation to give closure. In certain other technics two interventions may be planned to give closure. The morbidity at least and possibly the mortality is influenced by multiple intervention. In 194 unilateral clefts Veau in 84 instances closed the anterior palate first, making 276 interventions. At the present time Veau, I believe, does the anterior palate and the lip operation at the first sitting. In his original cases this was not the case.

Secondary Operations.—The number of operations following an earlier primary operation is of interest. This matter is discussed in Chapter XXIX.

MORTALITY

Up to January, 1936, in the group of individuals not previously operated upon with complete unilateral clefts, partial clefts of the hard palate and cleft of the soft palate alone—126 in number—death had followed operation in 4 instances—an average mortality of 3.1 per cent for the group. One death was due to a hospital catastrophe. This baby, aged fourteen months, fell out of bed and struck its head the night before operation. No report was made by the nurse. The baby was operated and after six hours be-

came unconscious and died twelve hours later. At autopsy an intracranial hemorrhage was found. Another baby died with a meningitis two days after operation. On one boy, aged eight years, both the lip and the palate were done at one operation as he was assumed to be a good risk. Some difficulty was encountered with the anesthetic and the operation. He died of shock a few hours after the operation. This death can be attributed to an error in operative judgment. The fourth child, aged fifteen months, was known not to be in very good shape. One month previously we had postponed the operation because of a throat infection. The child died of shock a few hours after operation. Although no difficulty was encountered at operation, this child should not have been operated so soon after a somewhat general infection. We have not seen an operative death in which the death was considered to be due to an enlarged thymus. In a case of harelip which died the thymus was enlarged but when we took ourselves to task, it was found that the operation was prolonged more than usual and that more blood was lost than usual. This has been our experience in other operations on children which have resulted in operative catastrophes of this type.

Veau had a mortality of 3 per cent in 194 unilateral clefts of the palate, 5.8 per cent in 154 clefts of the hard palate, and 1.9 per cent in 104 clefts of the velum—an average of about 3.9 per cent for the group.

Relationship of the Season to the Result.—Besides errors in operative technic and provided the child is in good condition the most certain condition to influence the result is a nasopharyngeal infection. When present not only is the anatomic result jeopardized but the hazard is definitely increased in so far as complications such as otitis media and its sequelae or even a pneumonia are concerned. It is seldom that we advise an operation in December, January, February, and early March and this has more than likely influenced our results as to season.

Relationship of Postoperative Fever Period to the Result.—In our group of cases with complete single cleft of which 37 (average hemoglobin 69 per cent) showed complete closure, the average postoperative temperature was four days. A temperature of 103° or even 104° F. is almost to be considered normal the first afternoon following the operation in babies from ten months to twenty months of age but it should subside within a twenty-four to forty-eight-hour period to 102° or 101° F. or else all is not likely to be well. In the 12 of our cases (average hemoglobin 51 per cent) which developed holes or failed to unite, the average postoperative temperature period was eight and one-half days.

Relationship of Weight to the Result.—When the weight is distinctly abnormal the operation was postponed but in a survey of our results no absolute direct relationship of weight to the result was noted in our cases.

The Effect of Weaning on the Result.—Whether or not the baby has been taught to drink from a cup previously or to take liquids from a spoon may be of importance. An operation accompanied by weaning from the bottle with its concomitant change of habit may be sufficient to add a handicapping factor when the load is already too heavy to be withstood with ease.

The Factor of Anemia.—We attach considerable importance to a factor which ordinarily we have not seen emphasized. A few years ago in going

over the records of the children about one year of age suffering from complete cleft of the palate, it was noticed that on the average their hemoglobin and red cell readings did not compare favorably with normal children of a comparable age. These children although not particularly underweight often have a noticeable pallor. A higher postoperative temperature is likely and the postoperative results are influenced definitely in the wrong direction.

In all of our cases the hemoglobin standard used was the Haden standard of 15.6 Gm. per 100 per cent hemoglobin blood. Both the grams and the percentage of the hemoglobin were registered. As to normal readings for children the figures of Elvehjem in the Madison survey are useful. Elvehjem shows that the hemoglobin content of the blood of infants is high at birth (22 Gm.) but falls to a low point within eight to twelve weeks (11.7 Gm.). Between the age of twelve to twenty-four weeks there was a decrease and thereafter a slight decrease with the hemoglobin remaining between 11 and 12 Gm. until the infants reached about two and one-half years, while even at five years the average reached only 12.5 Gm.

Speech Training as Early as the Midpart of the Last Century.—A. H. Gutzman according to Kuster had remarkable success with speech training after cleft-palate operations. Not uncommonly children who have had cleft palates are found to be hesitant in exhibiting their speech defect. For instance, one patient of our own could not be made to say more than "yes" and "no" at the age of seventeen. This difficulty with speech may impede progress in school although the mentality is normal. Playmates are cruel in their corrections or imitations of defects and often elders are little better. When it is possible, careful training in enunciation does a great deal for the average individual with a cleft palate.

Mr. Palmer has had the responsibility of the training of several of our patients following operation for cleft palate. In the following paragraphs he has briefly discussed the practical phases of speech retraining.

SPEECH RETRAINING FOLLOWING OPERATIONS FOR CLEFT PALATE

By Martin F. Palmer, M.A., Sc.D.*

It is assumed that the subject will have been operated successfully. It is further assumed that the subject does not present any speech defects other than those which normally follow cleft palates (stuttering, etc.). The excessive nasalization and poor enunciation are occasioned by the fact that the oronasal valve is nonexistent, and thus the flow of air from the trachea and the larynx cannot be cut off between the nasal and oral cavities.

Consonantal System.—The consonantal system is especially poor since most of the consonants depend on explosive or semiexplosive puffs of air for their auditory values. The location and type of closure of the modified peristaltic tube differentiates these puffs of air. During the production of an initial consonant such as p, the lips are closed, the oronasal valve is closed, and air pressure is built up behind the lips. The opposing longitudinal fibers (represented in the modified peristaltic tube by quadratus

* Associate Professor and Chairman, Department of Speech Sciences; Director of Flo Brown Memorial Laboratory for Research in the Speech Sciences and Correction of Speech Defects, University of Wichita, Wichita, Kansas.

(The author acknowledges his indebtedness to Dr. J. H. Muyskens through whose kind permission much of this material is used.)

labii superioris and inferioris; zygomaticus major; triangularis; incisivus; anterior belly of the digastricus, etc.) are suddenly contracted, and a puff of air is released, forming the p. It is readily seen that individuals with cleft palates cannot build up the requisite air pressure as the air escapes through the nasal passages. Thus the auditory value of p is lost. Similarly the entire consonantal system is muffled by this nasal escape of air, and a peculiar and offensive speech results which is practically incomprehensible.

Compensatory Type of Speech.—Since the ability to occlude the oronasal port is lost, and with it the ability to produce a specific consonantal system, most of these individuals develop compensating types of speech, which are, unfortunately, hardly more intelligible than ordinary cleft-palate speech. These substitutions may occur as occlusions of other parts of the peristaltic tube, in the effort to check the flow of air somewhere, or they may be constrictions which produce sounds analogous to the normal. For example, the phenomenon of glottal stop, which is a vigorous occlusion of the laryngeal valve and a distinctly audible click as they fly apart again. The normal occlusion for the desired consonant may or may not be made, but the result is the same, since the flow of air is cut off in the larynx itself. The lips may close for p, for example, but no air pressure is built up behind them, as the laryngeal valve occludes synchronously with the lip occlusion. The click substitutes for the puff of air as the lips open. Glottal stop is developed from the normal adjunctive activity of the laryngeal valve, which tends to close when any portion of the cephalic part of the peristaltic tube closes—a deglutitive reflex. During normal speech, there is a tetanic contraction of the laryngeal sphincter in sonant consonants and vowels; in all other sounds, the occlusion is incomplete. The phenomenon of glottal stop, then, should be regarded simply as a substitution for the normal occlusion.

Other types of substitutions are: (1) snoring seems to be a fluttering of the back of the tongue with the velum or the posterior wall of the pharynx. It generally occurs in substitution for, or in conjunction with the fricative consonants, w, wh, f, v, th, s, z, sh, zh, ch, j. (2) Gutturals. These sounds are slightly different from snoring, occurring lower in the pharynx and being more of a continuant nature, but serving the same purpose, and substituting for or occurring with the same consonants. (3) Substituting an audible stream of air through the nose for the fricatives. (4) Substitutions of consonants for each other. Postoperatively, some consonant may be developed, such as p or t, and these will then be substituted for other consonants. (5) Laterals. This type of movement is the surd analogue of (1), and is not found in English, except in speech defectives. The apex of the tongue is placed against the alveolar ridges, leaving a space between the lateral edges and the upper lateral gingiva. The air, instead of being blown along a median groove of the tongue to impinge upon the lower medial incisors, is blown over the edges of the tongue, giving a sloshy effect often accompanied by sprays of saliva, as the air blows it out through the sides of the mouth. This phenomenon occurs often among cleft-palate subjects due to the fact that more space is allowed orally for the air to escape in this type of production than in the normal type.

If it is recognized that these symptoms are not entities in themselves, but are merely the result of a more or less conscious attempt to produce

normal speech, it will be seen that their correction lies in substituting normal movements and habits for them.

Vowel System.—The vowel system suffers in two ways: (1) the leakage of air through the nose gives a nasal quality. (Rarely this nasal quality may be of the nature of closed rhinolalia, but this is more generally due to adenoid vegetations than to a nose obturated by operation. Prospects of normal speech from closed rhinolalia are not good if the defect arises from these causes. Borel cautions against the removal of adenoidal vegetations which have appeared after completion of cleft-palate resection.) (2) Many individuals are unable to perform those vowels which lie in the tongue-raising scale—or rarely because the defect has retarded the development of speech, do not perform any of the vowels. The reason for the failure to perform the tongue-raising scale (see below) is the fact that these particular vowels depend for their auditory values on an adjunctive approximation of the posterior portion of the tongue with the posterior portion of the hard palate and the velum. (Adjunctive, since the laryngeal sphincter is minimal.)

Oronasal Valve.—The oronasal valve may be considered as essentially sphincteric in function—the superior constrictor drawing the walls of the upper pharynx forward and medially to meet with the velum, which has been raised vertically by the combined contraction of the tensor veli palatini, the levator veli palatini, and the azygos uvulae. (The uvula is of negligible value in this occlusion.) The position of the velum during the moment of occlusion is roughly a horizontal continuation of the hard palate, with the posterior portion hanging a little inferior to the remainder. A cleft-palate operation for good speech then should give an approximation of this position of the velum, for it is clearly seen that most of the work in closure will have to be undertaken by the superior constrictor. Of interest in this connection is the cushion by Passavant. The mobility of the reconstructed velum is not so important as its length.

When it is Impossible to Gain Closure of the Oronasal Valve.—In cases where it is found impossible to secure a closure of the valve for one reason or another, a readily understood speech may be attained by careful training of the nasalis muscles, thus making a valve of the nostrils. This vicarious function in the alar muscles can be readily built up. This function may develop without training in individuals with cleft palates. These subjects grimace in efforts to close the alar valve. When the operation is successful, the trainer should attempt to remove these grimaces. It will be found in most instances that after good surgical reconstructions and careful training, a successful closure of the nasopharyngeal valve can be made.

First Step.—The first stage of retraining consists of two parts:

1. *To Increase Contractural Ability of the Superior Constrictor.*—In general, any reflex that occasions a contraction of the superior constrictor will be found of value in early training. "The object is to aid the subject in selecting from a mass of general sensory control data coming into attention from function, a specific kinesthetic sensation which is the index of a specific contraction. Thus, the subject is aided in training for speech and exactness in muscle functions which were vegetatively poorly trained for the selective movements" (Muyskens).

(*a*) Yawning.

(*b*) Peristaltic reflexes: speech is the modification of the vegetative reflexes of chewing, sucking, and swallowing. Thus, a course of hard food orientation is advisable—zwieback, crackers, meat, hard candy, etc. The bolus is swallowed without liquids. There is often in these cases a gross inertia of the tongue, evidenced by transverse and longitudinal furrows on the blade, occasioned by the failure of development of the vowel and consonantal system, which is best corrected by hard food orientation. The procedure affects three phases of the speech process: (1) increases function of the superior constrictor; (2) flexes and massages the repaired palate; (3) lays the foundation for a sharper vowel and consonantal system by exercising and training the muscles of the tongue, lips, jaws, pharynx and larynx.

(*c*) Gag reflex: within very narrow limits, the gag reflex may be resorted to when other methods fail.

2. *To Increase Vital Capacity.*—The consonantal and vowel system may suffer through the failure of air pressure sufficient to make these sounds clearly audible. Tests of vital capacity may be made with the spirometer, or with the manometer devised by Mme. Borel. A crude measurement is the following test: "To have sufficient air for speech (not necessarily normal vital capacity) the subject should be able to maintain a rather loud ä for at least fifteen seconds. Failing this, drill should be instituted on this function until the subject is able to achieve it. Calisthenics and gymnastics may be of benefit to the subject. If a spirometer is available, daily practice with it is helpful. At first, the leakage of air may be such that the subject cannot blow it at all, and in this case, it is permissible to allow him to hold his nose, but when a closure can be made, this should no longer be permitted. Where a kymograph and pneumographs are available, they should be used to slow and deepen the subject's breathing.

Second Step.—If and when motion is observable in the superior constrictor, without discontinuing the above exercises (especially the peristaltic reflexes) an attempt should be made to obtain a specific closure of the valve. For this purpose all sorts of toys which can be blown, such as horns, balloons, etc., are used. Mme. Borel suggests practice with soap-bubble pipes, since this game requires a slow, controlled expiration. Blowing out candles is excellent for younger children, and other games can be devised along this line. Work should be commenced with those toys which are easy to blow, and can be considered complete when the subject is able to blow up a balloon, and maintain it full of air for a short period of time, by the control of the expiratory muscles and the new sphincter. *Neither at this time nor later should holding the nose with an instrument or the fingers be allowed, as this common practice defeats the purpose of the entire training procedure.*

Third Step.—Certain general suggestions should be made before the question of specific speech drill is discussed. For the teaching of vowels and consonants, a small hand mirror in which the subject can check his movements will be of assistance.

Repetition of wrong movements will lead only to wrong movements, and thus correct production is essential before the subject attempts to make habits of the new articulations. The trainer in the first stages will actually say the sound many more times than the subject. A good procedure is to repeat the sound carefully five times, pausing between repetitions. The

timing will work out best if the trainer takes the subject's pulse and counts one beat for the sound, one beat for the pause. Allowing one pulse beat to elapse after five repetitions; the trainer then asks the subject to repeat the sound. If the subject is in error, repeat the procedure. If after many trials he still fails, then his error should be explained to him in terms of muscle movement. (E. g., "You held your tongue too high. Try again.") This failing, take a tongue blade or applicator and lightly tickle the areas of the speech organs that should contact, instructing the subject to put the touched areas together.

When correct articulation appears, then it is necessary to repeat this articulation until it is fluent, made without hesitation or conscious effort. Let the subject take an isolated sound which he has just learned correctly, and have him repeat it at about the rhythm of his pulse beat, over and over again, until he can repeat it at least forty or fifty times in succession, and without error.

In working with either the vowel or consonantal systems, ascertain first of all which vowels or consonants are missing. Then work from those which are correctly pronounced to those which are missing, but which are made similarly as p-b, t-d, etc.

Thus, the *third step* consists of formation and drill of the vowels, if any of these are missing. They are classified on a physiologic basis into two scales: (A) the tongue-raising scale, in which the posterior portion of the tongue by gradual approximation to the hard and soft palates determines the auditory character of the vowel. These vowels are (diacritical markings) ä, ă, ĕ, ā, ĭ, ē. The trainer should commence with the lower positions and work to the higher positions. (B) The lip-rounding scale, in which the jaws are gradually approximated while the lips protrude and approximate. These vowels are ä, ŭ, ô, ō, o͝o, o͞o. Commence with ä and work toward o͞o (1, 9).

In drilling both vowel scales be sure to teach from as many senses as possible: sight, hearing, kinesthesis, and touch will all be found useful. The glottal stop at the commencement of the vowel will have to be avoided. This can be done by placing an h before each vowel, or exhaling audibly, gradually allowing the vowel to take shape as the laryngeal valve occludes.

All other vowels will be found to lie in combinations of these two scales, as ouch, boy, I, pupil, etc.

Fourth Step (Consonantal System).—The consonants should be learned and drilled in the peristaltic order (*e. g.,* w-wh, m, p, b, f, v, th, n, t, d, sh, zh, s, z, ch, j, x, nk, ng, k, g, l, r). This is probably the order of normal development in infancy. Commence with those known, and follow the determined order, working from analogous movements to analogous movements (p-b).

These consonantal movements should be made as rapidly as possible. Rapid production leads to a sharper sound which will deceive the listener's ear, even if the newly functioning valve does not work perfectly. Usually 0.08 to 0.10 second is required by these subjects for consonants, where only 0.04 to 0.06 second is normal. As the consonants in accented syllables are shorter than in unaccented, drill will be commenced on accented syllables, and an attempt made to retain this faster production in unaccented syllables later.

Any consonant consists of three essential movements: (1) a period of constriction of the tube (the make) as the lips moving together for the position of p. (2) A period in which the tube is constricted (the tenure). (3) A period during which the tube is opened (the break), as the lips being pulled apart to permit the explosion of p. All three of these will need to be speeded up.

Consonants occur at the beginning, the middle, and the end of words. It will be necessary to drill consonants in these positions in order to assure perfect usage in running conversation. After the correct movement for the consonant has been learned, or even before it is completely assured, some apparatus will be of help. A rubber tube is fitted with a Y tube and two nasal olives at one end, and the other end is supported by a ring stand in such a way that a discharge of air from the tube will make the flame of a candle flicker, which has been placed 1 inch from the end of the tube. The subject articulates and if there is considerable leakage of air, he can see the candle flicker and attempt to correct himself. Several modifications of this principle may be used—recording end of a tube to a tambour or the end held to the ear, etc.

When a subject is able to produce the desired consonant satisfactorily when it is isolated, the vowel should be attached to it. The glottal stop may have to be avoided here. In order to accomplish this, the first consonants are drilled in this manner: the consonant is allowed to explode, and then the ensuing vowel is spoken with an h before it. Since all consonants are followed in English by a small indeterminate h, this drill is physiologically sound. Gradually the time of the h is lessened, until the consonant seems to impinge directly on the vowel (p-h-h-h-h-ä). Also, in placing the vowel before the consonant, an analogous procedure should be followed (ä-h-h-h-p-h-ä). When correct production has been secured with ä, it is necessary to drill each consonant with all the vowels in every conceivable relation to it, as each vowel necessitates a different muscular motion. (Compare pä, pōō.)

It is best to do this drilling systematically. First, drill the consonant in the final position (äp), placing all the vowels before the consonant. Then drill the consonant in the initial position, placing all the vowels in turn behind the consonant. Then commence with äpä′, then äpŭ′, äpô′, etc., through the lip-rounding scale, then the tongue-raising scale. Then change the vowel in the initial to ŭ, and go through both scales again, Then change the initial vowel again, etc. This drill will be considered complete when all the vowels have been used before the consonant, and all the vowels after the consonant in all possible combinations.

It will usually be found that the surd consonants (unvoiced, as p), will be learned more readily. To arrive at a sonant from a surd, allow the subject to palpate your larynx as it vibrates, and compare it with his own. Start with a vowel and tell him to keep humming while he makes the movement for the consonant.

Below is a list of consonants, the most important factors in their production, and some helps for teaching them which have been found valuable in experience. Remember imitation is tried first. It will be noted that some alphabetic consonants do not appear, as c and x. We are not

concerned with spelling here, but actual sound productions. X, for example, is equivalent to ks.

1. (wh) Blown through partially closed lips; the oronasal port is closed.

2. (w) Same as above, with phonation occurring before, during, and after the consonant.

(*a*) Have subject say $\overline{oo}$ before the word.

3. (h) A simple exhalation of air preceding a vowel, during which the oronasal port is closed, and the larynx occludes slightly, and then completely for phonation.

(*a*) Suggest that the subject blow loudly.

(*b*) Hold a mirror before mouth so subject can see the condensation of air.

(*c*) Suggest whispering a vowel sound.

4. (m) The lips occlude; the oronasal port is open; the laryngeal vibrations course through the nose.

(*a*) Suggest humming and then closing the lips.

(*b*) Touch upper and lower lips with tongue depressor or applicator, instructing subject to place touched areas together.

(*c*) Hold a tongue depressor between the lips lengthwise and crosswise.

(*d*) Spread syrup or candy along edges of lips (for young children).

(*e*) Place stick of candy in child's mouth, and let him suck on it while pulling it out of his mouth.

(*f*) Tap the lips several times with the tongue depressor, the direction of tapping being away from the desired occlusion.

5. (p) Lips, oronasal valve closed, air pressure built up. Upon sudden contraction of longitudinal fibers, there is an explosion of air. (In the final consonant, there is no explosion, the lips occluding on the air stream giving the auditory value.)

(*a*) With the exception of humming, same general technic as for m.

(*b*) Blowing spit bubbles, blowing with mouth under water.

(*c*) Exhale audibly. Suddenly close the lips and open them while still exhaling.

(*d*) Explode a p on the inside of subject's wrist. Allow the subject to imitate this on his own wrist.

6. (b) The same as p with phonation occurring before, during, and after the occlusion. The note on final consonants applies to all explosive consonants.

(*a*) Have subject palpate instructor's larynx and his own, during instructor's production and the subject's.

(*b*) Have subject palpate instructor's lips during an extended tenure.

(*c*) Exaggerate the tenure of b.

(*d*) Same general technic as for p, with humming.

7. (f) The posterior upper surface of the lower lip is placed lightly against the superior teeth, the oronasal valve is closed, and a stream of air blown through the constriction.

(*a*) Suggest biting the lower lip lightly and blowing.

(*b*) Protrude the upper lip, and blow.

(*c*) Allow subject to feel the air stream of a normal f on the inside of his wrist. The subject then tries to produce the same sensation on his own wrist with his f.

(*d*) Stroke the contact points of the lower lip with an applicator, and tap the superior incisors.

8. (v) The same as f with phonation occurring before, during, and after the constriction.

(*a*) Same general technic as for f while humming.

(*b*) Saying f with a vowel very rapidly.

9. (th) (throw) There are many English methods of production, the one which is easiest taught being: the apex of the tongue is placed between the teeth, and very lightly bitten; the oronasal valve is occluded; air is blown above and below the tongue, much of it being emitted through the interdental spaces.

(*a*) Suggest biting the tongue lightly and blowing.

10. (th) (the) The same, with phonation occurring before, during, and after the construction.

(*a*) Same as above, with humming.

11. (t) The usual English pronunciation: apex of the tongue placed just above the superior medial incisors, while the lateral edges completely occlude the upper dental circle; the oronasal valve is closed; the blade and center of the tongue are lowered to provide a cavity in which air pressure may be built up. Upon contraction of the opposing longitudinal fibers, a puff of air escapes giving t its characteristic auditory value. As a final there is no puff.

(*a*) Touch the apex of the tongue and the alveolar ridges just above the superior medial incisors, and instruct subject to place these two areas together. Then tell him to blow while still holding the tongue in place, and not allowing any air to escape; then he depresses the tongue suddenly.

(*b*) Compare the puff to p.

(*c*) Show by illustration with the hands how the consonant is made. Allow the fingers of one hand to be the tongue, while the curved other hand represents the palatal arch.

12. (d) The same as t with phonation occurring before, during, and after the consonant.

(*a*) Same general technic as for t, while the subject tries to keep humming during the entire motion.

13. (n) The same as d with the oronasal valve open.

(*a*) Same technic as for t with the exception of the explosion. Allow subject to palpate the instructor's nose, then he attempts to produce the same sensation in his.

(*b*) Suggest humming with lips parted, and tongue touching the alveolar ridges.

14. (s) This consonant demands a thin stream of air, which must course across the upper gingiva, then downward behind the superior incisors in such a way as to impinge upon the inferior medial incisor's cutting edges. There are 3 general methods of production in English: (1) the apex of the tongue grooved inward at the median line is placed against the rugae, its inferior border being just above the superior medial incisors. The oronasal port being closed, a stream of air is blown through the groove in such a direction as to impinge upon the lower medial incisors, giving the characteristic hissing. (2) The apex of the tongue is placed against the inferior medial incisors, and the longitudinally grooved blade is placed against the rugae, and a similarly directed air stream ensues. (3) The apex of the tongue assumes a position midway between the teeth, although it is not protruded, and the blade is again grooved and placed against the rugae.

(*a*) Teach the first position first, if this fails try the others, using the following technic in each attempt:

(*b*) Suggest whistling with the tongue, the teeth closed.

(*c*) Draw with an applicator the desired contact points along the gingiva, being sure to omit the anterior point which the tongue will not touch, and through which the air will pass.

(*d*) Thrust the tongue out, curl it longitudinally, draw it in, still trying to retain the groove while blowing.

(*e*) Close the teeth and blow, parting the lips in a half smile.

(*f*) Draw, with an applicator, a line on the lower lip postero-anteriorly in the center of the superior surface. Ask the subject to close his teeth and try to blow air over the line.

(*g*) Hold the applicator close to the teeth, and suggest to the subject that he hit the point with the air.

(*h*) Pronounce f. While still blowing, pull the lower lip away quickly.

(*i*) Blow a normal s on inside of subject's wrist, and have him do the same on his wrist.

15. (z) Same as s with phonation occurring before, during, and after the constriction.

(*a*) Pronounce s while humming.

(*b*) Try to buzz like a bee.

16. (sh) Pronounced similarly to s except that the groove is broader, and jaws are not closed quite so tightly, and the lips tend to pout instead of smile.

(*a*) Draw the contact areas with an applicator.

(*b*) Pout the lips with the teeth closed, and blow.

(*c*) Pronounce s, and suggest to subject that he pull his tongue backward in the mouth while still blowing.

17. (zh) (Pleasure) Same as sh with phonation occurring before, during and after the consonant.

(*a*) Suggest humming while producing sh.

18. (ch) The apex of the tongue occludes as for t, the oronasal valve is closed, and the opening movement explodes as for sh, the groove of the tongue being quickly formed.

(*a*) Suggest sneezing.

(*b*) Suggest sound made by a locomotive, the lips tending to pout.

(*c*) Produce t then sh, then have subject try to produce them rapidly together.

(*d*) Touch upper gingiva with applicator.

19. (j) The same as ch with phonation occurring before, during, and after the constriction.

(*a*) Produce ch while humming.

(*b*) Produce d and zh together.

20. (l) This consonant also is produced in a variety of ways. It demands that a semiocclusion be made with the tongue against the hard palate, while the lateral edges of the tongue do not contact the sides of the oral cavity, thus allowing the voice to escape over the sides of the tongue. The most common production is achieved by placing the apex of the tongue against the alveolar ridges just above the superior, medial incisors, while phonation occurs before, during, and after this motion. The consonant has no sure analogue in English.

(*a*) Draw contact area with applicator.

(*b*) Hold lips apart and away from the teeth while trying to say the sound. (Since the fault here is likely to be a substitution of w for l.)

(*c*) Place a tongue depressor in the mouth, instructing to hold it in place with the tongue while humming.

(*d*) Teach final l first, then allow it to break into a vowel.

21. (r) This consonant also is produced in a variety of ways in English. According to West and Kantner there are 9 distinct methods of production. The following are probably the most common productions; if teaching methods fail with one of these, then attention should be paid to another type of production. (1) The fricative r, characterized by friction noises produced by the passage of the air stream through a narrow orifice formed between the tip of the tongue and the anterior hard palate. (2) The inverted r, made with the tip of the tongue curled upward and backward toward the posterior hard palate. (3) The back r, made with the tip of the tongue down, while the back is elevated toward the posterior hard palate. (4) The velar fricative r in which the back of the tongue is raised toward the soft palate and occasions a friction sound. In all of these movements, phonation occurs before, during, and after the consonant. Possibly all individuals with normal speech use all of these motions according to the surrounding movements in the normal speech continuity (*e. g.,* grape, tree). It has, however, seemed sufficient in experience to teach only one of these.

(*a*) Use the mirror to check the movements.

(*b*) Tell subject to hold upper and lower lips away from the teeth while attempting to produce the sound.

(*c*) Place an applicator between the teeth, locating its point near, but not at, the hard palate, at the point where it is desired the tongue shall remain for the production in order to develop kinesthetic appreciation of the extent of movement.

(*d*) Draw the applicator the desired lateral contacts.

(*e*) Produce zh, tell subject to draw tongue backward while still humming.

22. (ng) (Si*ng*) The blade of the tongue near the radix is raised to contact the palate, in the region of the third molar. The oronasal port remains open, allowing the sound to course through the nose. Phonation occurs before and during the occlusion.

(*a*) Teach ng before proceeding to nk, k, and g.

(*b*) Touch the contact areas with the applicator.

(*c*) Instruct subject to put apex of tongue below the inferior medial incisors, and open mouth widely.

(*d*) Allow subject to palpate instructor's nose.
(*e*) Touch sides of neck at the angle of the mandible.

23. (k) Similar to ng, with the oronasal port closed, and an explosion.
(*a*) Same general technic as for ng plus an explosion.
(*b*) Suggest blowing up the tongue behind the throat.
(*c*) Suggest coughing.
(*d*) Teach from nk, as nk can sometimes be learned before k.

24. (g) Similar to k, with phonation occurring before, during, and after the occlusion.
(*a*) Produce k while humming.
(*b*) Drill ng preceded and followed by a vowel, gradually shifting accent to the following vowel, then try to get a conscious closure of the oronasal port.

25. (nk) This is a combination of ng followed quickly by k. The oronasal valve closes quickly to allow for a brief explosion.
(*a*) Pronounce ng followed by k.

Consonants are also produced in combination with each other, and these combinations should also be checked following correct production and drill on each. The following is not an exhaustive list but is suggestive: mp, md, mbl, mbr, ml, pd, pr, pl, ps, bd, br, bl, bz, bs, fm, ft, fd, fl, fr, fs, vd, vl, vr, vz, thr, tm, tl, tr, ts, dm, dl, dr, dz, ndl, nz, ndz, lm, lp, lb, lf, lv, lt, ld, ln, ls, lz, lj, rm, rp, rb, rf, rv, rth, rt, rd, rn, rl, rs, rz, rj, rk, rg, sm, sp, spr, spl, st, str, stl, sk, skl, skr, sd, sz, sht, cht, jd, kt, kl, kr, ks, gd, gr, gl, gz, ngg, etc. When drilling these consonantal combinations it is important to note the following variations: in br, bl, pr, pl, kr, kl, etc., the movement for the l or r is commenced before the other consonant, thus allowing the two sounds to appear almost in unison (*e. g.*, in making kl: raise the apex of the tongue as for l, then the posterior part of the blade for k, without losing the l position. Now forget about the l, and sound the k. A perfect combination should result).

Fifth Step.—When the subject begins to show proficiency in the use of the consonants, it is time for practice material. This can be begun before all the consonants are learned, provided the practice material contains no sounds which have not yet been learned. First present the subject with lists of words which contain the sounds which he has learned and no other. These lists can be culled from the dictionary and other sources. Next is the use of jingles and rhymes. Careful attention should be paid, not only to enunciation, but to meaningful expression. Children should read slowly, carefully, while still retaining the natural rhythms of the language. Finally, exercises in extempore speaking and conversation are given. If the subject hesitates at any time over any phonetic combination, return immediately to the drill on that combination.

If the rest of the training procedure has been successfully completed, the subject will already have a kinesthetic appreciation of the movements involved in the valve closure and should be able to imitate the trainer. The trainer should say a vowel normally, and then nasally, repeating each five times according to the law of repetition and imitation that has already been quoted. Commence with ä and work with it until good, and then proceed along both vowel scales. Generally, little needs to be done following the other training procedures, but this additional drill will make for better quality. When the subject says all the vowels normally, give practice material.

PROGNOSIS FOR GOOD SPEECH

Prospects for good speech are better when the subjects are between five and twelve years old. These are the most successful ages for teaching. After twelve years of age the drill is not so successful in overcoming vicious habits. Before five years of age, the subject does not have sufficient comprehension, although good work may be done at any time following the normal onset of speech. It is to be hoped that, in the future, improved

technic will raise the possibilities of a success still more, but the present technics offer good assurance of success.

Length of time required for such training cannot be predetermined, as the progress of the subject is the criterion. Some go very rapidly but the usual time is from two to four months of daily lessons. Parts of these lessons, those of applying the practice material, need not necessarily be given by an expert, unless the parents or the subjects desire not to stop taking lessons until the speech is perfect.

Obturators.—In Chapter XLI a discussion of the construction of obturators is given.

Bibliography

Bibliography Quoted in Text

Axhausen, G.: Technique and Results of Cleft Palate Surgery, Leipzig, Thieme, 1936.

Blair, V. P.: Surgery and Diseases of the Mouth and Jaws, St. Louis, C. V. Mosby Co., 1918.

Borel, Mme. S.: Phonétique, in Veau, Victor: Division Palatine, Anatomie, Chirurgie, Phonétique, Masson et Cie, Paris, 1931.

Brophy, T. W.: Oral Surgery, Phila., P. Blakiston's Son and Co., 1915.

Keith, A.: On Congenital Malformations of the Palate, Face, and Neck, Brit. Med. Jour., **2:** 312, 1909.
Quoted by Brophy.

Kirkham, H. L. D.: Preliminary Paper on Improvement of Speech in Cleft Palate Cases, Surg., Gynec. and Obst., **44:** 244, 1928.

Lane, W. A.: On Cleft Palates, Lancet, **11:** 433, 1902.
The Modern Treatment of Cleft Palate, Lancet, **1:** 6, 1908.

Peyton, W. T.: The Dimensions and Growth of the Palate in the Normal Infant with Gross Maldevelopment of the Upper Lip and Palate, A Quantitative Study, Arch. Surg., **22:** 704, 1931. (Abst., Oct., 1931.)

Rich, A. R.: Bull. Johns Hopkins Hosp., **31:** 307, 1920.

Ritchie, H. P.: Cited by Dean Lewis: Practice of Surgery, vol. 6, W. F. Prior Co., Inc., Hagerstown, Maryland, 1930.

Ruppe, Charles, and Veau, Victor: Results of Treatment of Cleft Palate, Rev. de chir., **60:** 81–99, 1922.

Thompson, J. E.: Thompson Operation, Ann. Surg., **76:** 394–425, 1921.
Surg., Gynec. and Obst., p. 498, May, 1912.

Treves: Quoted by Tillmanns.

Von Langenbeck, B.: Operation of Congenital Total Cleft of the Hard Palate According to a New Method, Deutsch. Klin., **13:** 231–232, 1861.

Wardill, W. E. M.: Brit. Jour. Surg., **16:** 127, 1928.

Winternitz: Quoted by Blair.

Veau, Victor: Division Palatine, Anatomie, Chirurgie, Phonétique, Paris, Masson et Cie, 1931.

Selected Bibliography of Practical References Concerning Speech Training (Dr. Palmer)

Muyskens, J. H., Associate Professor of Phonetics, Director of the Research Laboratories of Phonetics and General Linguistics, University of Michigan, Ann Arbor, Michigan.

Russell, G. Oscar: Personal comm., Univ. Ohio State, 1928.

Stoddard, Clara B.: 1. Pupil's Guide for Speech Correction. 2. Individual Reading to be used in Speech Improvement Classes. 3. Course of Study in Speech Improvement. Part IV, pub. Detroit Board of Education, Detroit, Mich., 1933 (3 pamphlets).

Travis, E.: Speech Pathology, D. Appleton and Co., New York, 1931.

Veau, Victor: Division Palatine, Anatomie, Chirurgie, Phonétique; Avec la Collaboration de Mme. S. Borel. Part III et seq., Masson et Cie, Paris, 1931.

Wood, Alice L.: The Jingle Book for Speech Correction, Dutton, New York, 1934.

Young, Edna Hill: Overcoming Cleft Palate Speech, pub. Hill-Young School, Los Angeles, Calif., 1928.

CHAPTER XXIX

OPERATIONS FOR THE REPAIR OF THE PALATE PROPER

A GREAT many surgeons while recognizing the innate defects of the Dieffenbach-von Langenbeck principle for the closure of a cleft palate have nevertheless considered its principles as the standard which has withstood the test of time. Within recent years other methods have been advocated in a way which has tended to throw one using the standard classical operation for single complete cleft of the palate somewhat on the defensive.

With recent years Veau of Paris has originated a procedure combining the principles of Lannelongue and Davies-Colley and Lane for the hard palate and the Dieffenbach-Warren operation for the soft palate. Veau has also stressed the advantages of utilizing the nasal mucosa for closure of the nasal floor and eliminating the dead space between the nasal mucosal layer and the mucoperiosteal layer of the hard palatal soft tissues. He has reported rather good results. Now, at the present time, the operation of Veau is tending to draw certain new adherents.

Other operations of a more radical nature, entailing the principle of stitching the palate backward, such as those of Halle and Limberg with their long lateral incisions and thorough loosening of the anterior pharyngeal muscular ring anteriorly and Dorrance's "push back" operation which in the complete single cleft palate to be effective entails two operations, are being recommended by isolated operators. The various operations entailing plastic procedures on the posterior or lateral pharynx hardly allow these procedures to be adapted as a routine measure with the exception possibly of the operation of Wardill which makes an effort to increase the bulk of Passavant's pad. It is probably the simplest of the group.

For the completely cleft palate some of the operations which tend to place the soft palate in a more posterior position either tend to fail to accomplish their object, or entail a greater risk on account of the increased amount of surgery or they add an additional operation or finally, although their object may be accomplished, are likely to leave a hole in the anterior palate which has to be filled with a prosthesis.

Principle of the Usual Operative Procedures.—Generally speaking, the operations developed to close the usual open cleft of the palate depend upon three types of palatal flaps. In the first, the border of the cleft is taken as the base of the flap with blood supply coming from the nasal vessels, and in a certain type of the procedure (Lane) the flap is pivoted in such a manner that also the posterior palatine artery and nerve enter a corner of the flap. In the old Lane procedure when the mouth was edentulous the flaps were made large, if necessary, and sometimes they extended across the alveolar ridge to the cheek. On rotating the flap, the raw surface was toward the mouth and its mucosa was toward the nose. In the Davies-Colley operation, this principle was also utilized as it is today in the operation of Veau. Although these operations at the present time have largely

passed out of use, the principle is used sometimes to close a hole in the palate or to close over the cleft in the alveolar ridge at the time of the lip repair (see Fig. 187).

In the second type of operation flaps may be formed by incising the mucoperiosteum at the border of the cleft and raising the soft tissues from the palatal plates as far laterally as the alveolar process. In the past, when the teeth were absent, even a part of the gum has been utilized in this flap. The flap is left attached at both the anterior and the posterior extremity, and the posterior palatine artery is not severed as its blood supply is needed to nourish the flap. A parallel incision may or may not be made parallel to the alveolar ridge. To free the flap entirely at the posterior extremity the aponeurosis attaching the soft palate to the palatal plate and the superimposed nasal mucosa was usually severed to convert the soft palate and the hard palate soft tissue into a continuous flap. A good many modifications of this procedure are in use. The Warren operation and the Dieffenbach-von Langenbeck operation are representative.

In the third type of operation, flaps have been used including the soft tissues of the hard palate, the horizontal plates of the maxillae and the superimposed nasal mucosa. Fergusson used a chisel to sever the bone within the lateral alveolus and to obtain relaxation for midline closure. Brown in this country has used this type of operation. The remainder of the operation is similar to the Dieffenbach-von Langenbeck operation.

Functional Considerations.—While it has been rather generally agreed that hygiene of the mouth, nose or middle ear and the later facilities of dental prosthesis are probably sufficient reasons in themselves for closure of an open cleft of the palate especially within recent years it has been pointed out that after all one of the most important reasons for the repair of a cleft palate was the improvement of speech which should be but is not a constant accompaniment of midline closure. Aside from its function of forming a diaphragm between the nasopharynx and the oropharynx in the act of swallowing, the palate normally should be able to form a "flap valve" between the resonating cavities of the nose and the mouth at the moment of the proper articulation of a great many of the consonants—all except m, n and ng. In "cleft palate" speech some of the air which in the articulation of nearly all consonants ought to be expelled through the mouth escapes through the cleft into the nose, where it vibrates in the nasal cavity and finally escapes through the anterior nares. The oral consonants are converted into the voiced nasal consonants and cannot be voiced so loudly, so clearly or so forcibly as they should be.

Passavant long ago called attention to the hypertrophy of the superior constrictor muscle of the pharynx in individuals who attempt to compensate for a deficient velum. Overdevelopment of the muscle was explained on the basis of its being a muscle not directly involved in the defect but still one which has to function directly for correct speech. Thus, one of the outstanding needs in surgical intervention of the cleft palate today is a workable procedure which effectually lengthens the soft palate.

Common Defects.—Practically all of the common operations for the repair of complete cleft palate, such as the operations of Warren, von Langenbeck, Brophy, Veau, and Axhausen, have a more or less common fundamental defect. They tend to give too short a palate.

The position of the palatal plates in clefted palate causes the roof of the mouth to form an incomplete gothic arch. In other words, the two sides are raised up in the nasal fossa like the two sides of a drawbridge. When the mucoperiosteum of each side is loosened from the palatal plates and brought down to the midline, the distance which the palatal flaps have to bridge when approximated centrally between the alveolar ridges becomes a straight line instead of a semicircle. This gives an apparent gain of tissue to stretch across the cleft. When lateral parallel incisions are made, an additional apparent gain of tissue is obtained. When the repair is performed according to the Dieffenbach-von Langenbeck technic, provided that union occurs in the midline; it is probable that the upper surface of the flap granulates up to the bone from which it was removed. Possibly also the bone is pulled down somewhat although the greatest tendency is for the mucoperiosteal flaps to be pulled back against the palatal plates. The final defect of the Dieffenbach-von Langenbeck operation is twofold. First as the mucoperiosteal flaps granulate on the upper surface the aponeurosis of the soft palate is drawn up and forward into the V formed by the pos-

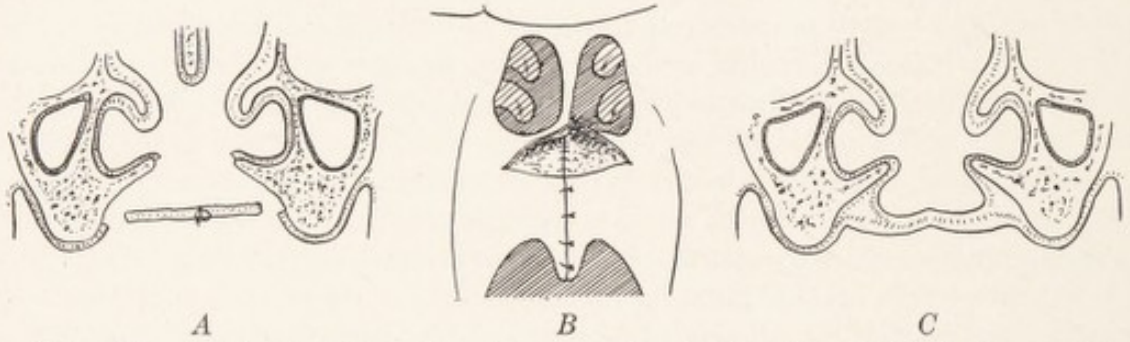

A *B* *C*

Fig. 175.—*A*, Showing how the flaps are placed after the Dieffenbach procedure with lateral incisions. *B*, View of the upper part of the palate from the back showing the diamond-shaped raw area left behind the horizontal palatal plates. This raw surface will scar up and pull the soft palate upward and forward. *C*, Illustrates how the flaps heal and pull up somewhat.

terior ledges of the palatal plates (Fig. 175, *A*, *B*, *C*) and, second, when the palate operation is done after one year of age, as it is customary nowadays, there is some disuse muscular atrophy of the soft palate. Both of these factors tend to give a short palate although midline union has been perfect at the time of the first operation. The ideal operation would be some operation which gives an epithelial covering to the upper surface of the hard palate, at least the posterior part and the ideal time to do such an operation would be immediately after birth if mortality were not prohibitive. As yet such an operation has not been perfected to meet these requirements.

In Veau's and Axhausen's operations no effort is made to obtain a longer soft palate. In the former operation the aponeurosis is not freed. In the latter it is loosened but the unsevered nasal mucosa does not allow the aponeurosis to fall back or down.

RECONSTRUCTING THE PALATE FROM PALATAL FLAPS

In a cleft which is particularly wide an estimate of the available tissue should be made and a comparison made between the width of the two mucoperiosteal flaps and width of the base of the palatal arch. The width of

the arch is measured from the proposed site of one lateral incision to the other. The amount of tissue that can be used is the sum of the two measurements from each lateral incision to the edge of each cleft. The sum of the available tissue should equal five sevenths or more of the width of the arch between the two lateral incisions. A palate is likely to be difficult to close when the proportion of palatal tissue is less than 5 to 7. However, it is seldom that one sees a single cleft which has had the lip closed early that has not enough available tissue to bridge the cleft. In double cleft the available tissue is less and if no preliminary anterior closure has been done usually it is difficult to get the whole length of the flaps together in one operation without running the risk of sacrificing blood supply or else having too great tension. In most of the double clefts better results will follow if the anterior palate is closed prior to the posterior palate. It has been suggested that the flaps be raised in difficult cases and packed to the midline and, after a few days when the tissues have become swollen and edematous, that the midline paring and suturing be done. In some cases this is a help but one is likely to encounter difficulties if a nasopharyngeal infection has been stirred up by the loosening of the flaps. In such a predicament it may be impossible to continue with the operation or if one does go on, union may not be obtained.

In the past two of the most commonly used operations for the closure of the usual case of cleft palate were the Warren operation and the von Langenbeck operation originally performed by Dieffenbach. Both of these operations withstood the test of time for a number of years. The Warren operation can usually be used after the forcible pressing toward the midline of the alveolar ridges as recommended by Brophy. The Dieffenbach-von Langenbeck operation with its lateral incisions was the most useful for the closure of the usual type of case. In those individuals with a fairly wide cleft it is of especial value. When the cleft involves only the soft palate, the operation is much simplified.

One of the principal defects of the classic operation is its failure to eliminate the "dead space" above the mucoperiosteal flaps of the hard palate and the horizontal palatal plates. Just recently Axhausen of Berlin has advocated modification of the Dieffenbach-von Langenbeck procedure to eliminate this defect. In the operation the nasal mucosa is stitched together separately from the oral mucosa as in the operation of Veau.

Both the Warren operation and the Dieffenbach operation may be used for double clefts as well as for single clefts. However, not uncommonly, neither operation will be successful in complete closure of a double cleft palate by one stage. Therefore an additional procedure which gives closure of the anterior end of the palate and the alveolar ridge cleft usually is advisable in double cleft of the palate.

The Warren Operation.—Warren (Fig. 176, *A*, *B*) did not use lateral relaxing incisions curved laterally about the posterior end of the alveolar ridges as did von Langenbeck. The mucoperiosteal flaps were raised from the palatal bones from within outward. The raphe at the posterior end of the palatal plates was loosened. No particular emphasis was laid upon the necessity for preserving the posterior palatal artery to each hard-palate flap. The soft-palate mucosa was pared or split at the cleft edge. Raw tissue was brought to raw tissue in the midline and sutured.

Brophy who always used the Warren type of operation used reinforcement of silver wire through lead plates to act as stay sutures. Brophy (as Veau does at the present time) argued against using lateral incisions and expressed the fear that when they were used there might be some interference with the musculature of the palate.

The Dieffenbach-von Langenbeck Operation.—An incision is made in the side opposite the gag through the mucoperiosteum down to the bone commencing opposite the cuspid tooth position (Fig. 177, A, B, C, D, E, F), just within the alveolar ridge elevation and extending posteriorly and then curving externally behind the posterior part of the alveolar ridge and extending in a diagonal direction externally backward and outward to a point outside of the hamular process and nearly to the anterior pillar of the tonsil. An elevator of the Fergusson type is inserted in the incision first in front of the posterior palatine artery and nerve and the mucoperiosteum is raised from without inward from the palatal plate. The elevator is then inserted

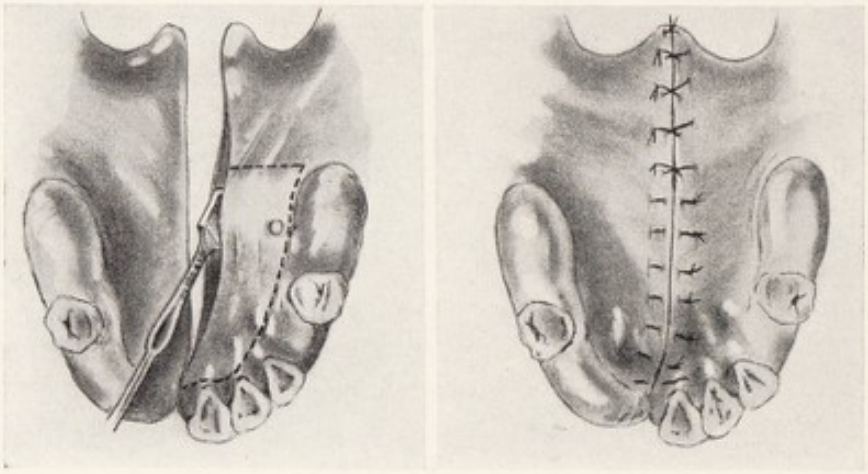

A *B*

Fig. 176.—*A*, Loosening the flaps in the Warren operation. No lateral incisions are made. The palatal flaps are loosened from the inner side. *B*, The dotted lines show the extent of the separation of the mucoperiosteal flaps from the horizontal bones and the raphe between the hard and soft palates is separated.

through the incision behind the artery and nerve and the tissues are loosened from the lateral posterior part of the palatal plate. Care is taken not to cut or rupture the posterior palatine artery as it leaves its foramen to run forward in a slanting direction to be distributed in the flap of the hard palate. This usually can be done without great difficulty. The modified Brophy elevator is then inserted beneath the flap from the medial side and the loosening is continued. After the anterior part of the flap is well loosened from the bone, the medial edge of the flap is caught with a hooked needle and, with curved scissors or a right-angled knife, the attachment of the soft palate to the posterior ledge of the palatal bone is completely cut. In some cases sufficient relaxation is now obtained to allow the flap to come past the midline without tension. When insufficient relaxation is obtained, the mucosa and muscles of the nasopharynx—above the soft palate—are relaxed by cutting outward, upward, and backward in a slanting direction toward the opening of the eustachian tube. Usually sufficient relaxation is obtained by this procedure; if not, the hamular process may be broken

inward with a small chisel. A gauze pack is now packed in through the lateral incision above the flap both in front and behind the intact artery and nerve which lie free between the bone and the flap for a distance of

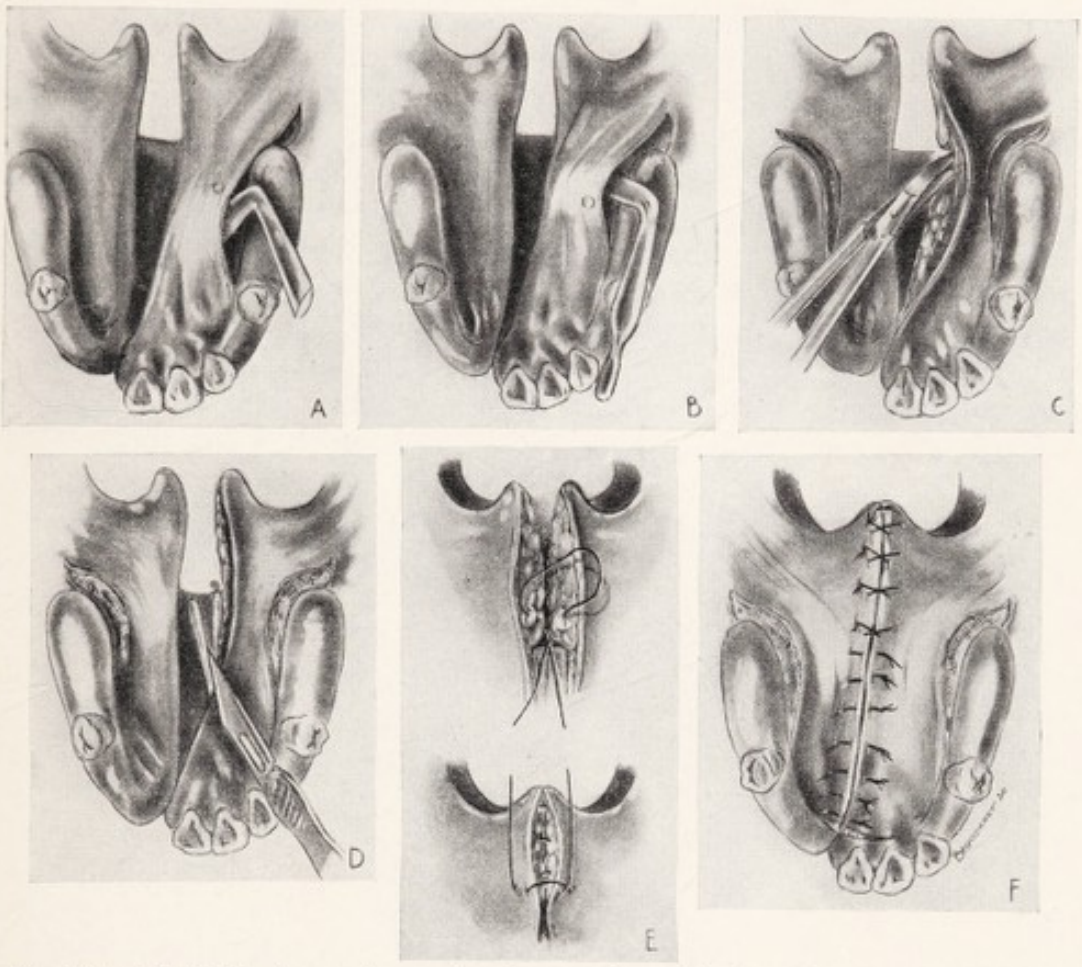

Fig. 177.—Dieffenbach-von Langenbeck operation with lateral incisions. A, Method of using the elevator to raise the mucoperiosteal flaps of the hard palate from the horizontal plates of the palatal bone. The elevator is first inserted anterior to the palatine artery, which one recognizes by the dimple as shown in the diagram. B, The elevator next is inserted posterior to the palatine artery. C, Then the raphe on the upper surface of the palate between the hard and soft palates is cut. D, A pack is placed in the lateral incisions to prevent bleeding while the medial edge is being pared. The soft palate is split at the medial edge so that one may suture the upper mucosal surface to the opposite side separately from the lower mucosal surface. The edges of the hard palate are pared so that an even raw surface is given on either side. E, The first suture taken is in the firm, soft tissues of the raphe and is taken in such a manner that the knot falls upon the upper surface of the palate. Such sutures may be taken in the raphe to draw the palate together. When one comes to the uvula it is pulled forward by a suture placed so that one may take interrupted sutures on the upper surface of the palate back midway of the soft palate. Some cases may have some tension when the soft palate is brought together in the midline. One may clip the posterior pillars to gain relaxation if necessary. F, A double whipping suture which coapts the superficial and the deep tissues of the soft palate is used to bring muscle layer to muscle layer. Interrupted Lembert sutures are then taken in the hard palate up to the incisor region. This completes the routine Dieffenbach-von Langenbeck operation.

about ¼ inch. The gag is changed to the opposite side of the mouth. The same procedure is repeated on the opposite side. In wide single cleft of the palate and when the nasal septum is attached to one side of the hard

palate between ⅛ and ¼ inch of it may be borrowed from the lower end of the septum and left attached to the palatal flap on the side to which the nasal septum is attached. To loosen this nasal flap only requires a lengthwise incision along the lower edge of the septal base and the flap is loosened along with the palatal flap from the inside. With the bistoury knife, the mucosa is split along both edges of the soft palate from the raphe back to and including the uvula. The uneven edges at the internal edge of the flaps from the hard palate are trimmed away. Care is taken that no bony flakes remain attached to the under surface of the flaps at the medial side. The first suture is then placed on the upper surface of the palate in the firm tissue of the raphe. The suture also includes the edge of the mucosa on the upper surface of the palate. It is placed so that the knot falls on the upper surface of the palate. Usually moderately heavy silk is used for this suture as it does not break so easily as horsehair. Just posterior to this suture and still on the upper surface of the palate a second similar suture is placed. These sutures draw the raphe and the

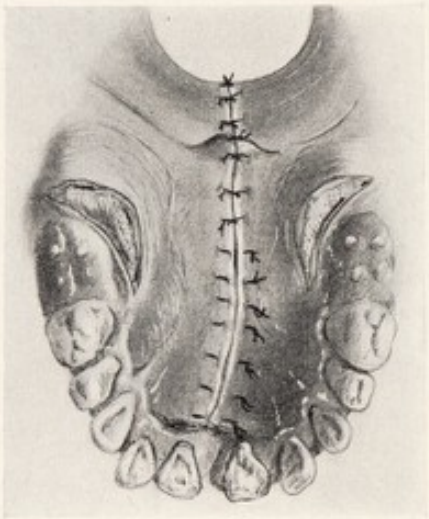

Fig. 178.—Uniting posterior pillars. One may gain ½ to ¾ inch by using this method. Cut the posterior pillars back near the lateral wall of the pharynx when tension is too great to make midline coaptation easy.

nasal palatal soft tissues together. The tissues of the soft palate should fall together without tension. Henceforward only horsehair sutures are used. They are all put in as interrupted Lembert sutures. The soft palate is sutured first and as one goes posteriorly the uvula is pulled forward by each succeeding suture and finally two or three sutures are placed upon the upper posterior surface of the soft palate. The hard palate flaps are sutured with Lembert sutures so that raw surface is to raw surface with 2 to 3 mm. of coaptation.

Usually when the lip has been repaired previously the alveolar ridges are in contact or nearly so. The firm mucoperiosteum partially encircles the two ends of the cleft alveolar ridge. If one uses a sharp cutting instrument and cuts the mucoperiosteum well up nasalward about ½ to ¾ cm. below the blunt turned mouth end of the ridge and then with a Brophy type elevator elevates the mucosa—unfolding it—a considerable amount of tissue is gained in a place where one hardly suspects it to be. Besides gaining tissue so that the alveolar cleft may be bridged with soft tissue, the ends

of the alveolar ridges are denuded of mucosa so that fibrous union between them may be obtained. This is probably the only union membranous bone ordinarily gives anyway and is sufficient in this situation.

The gauze packs placed in the lateral incisions are removed, new ones are prepared and wet with an antiseptic solution and carefully replaced. When the packs are too thick, they impede breathing but if none at all are packed in the lateral incisions, some bleeding is likely. It is also probable that the fixation and steadying influence of the lateral gauze packs aid union.

In this operation we consider the preservation of the posterior palatine arteries of considerable importance. Moreover, the operation will certainly be unsuccessful if all cross tension on the flaps is not relieved. The suturing has to be done with the utmost care. The sutures should give as wide raw contact as possible, *i. e.*, close enough together to prevent secretions from passing through but not so close together as to interfere with the blood supply of the edge. They should be tied just tight enough to get good approximation but without strangulation of tissue. In the region of the soft palate the suture is whipped in a fashion so that the mucosa is caught superficially and the second loop is carried well out through the muscles so that both superficial and deep approximation are obtained.

Lengthening of the Soft Palate by Sewing the Posterior Pillars Together.—When the Dieffenbach-von Langenbeck procedure apparently is going to give a palate which is so short that the oral pharynx will not be closed off from the nasal pharynx, it has been suggested that one continue the palate backward by denuding and sewing the posterior faucial pillars together (Fig. 178). When union occurs after this procedure the opening between the naso- and oropharynx can be made much smaller. Thereby the loop of muscle which surrounds the opening between the naso- and oropharynx is considerably tightened. When the tissues hold, the operation improves function to a certain extent.

Modification of the Dieffenbach Operation.—Very often when the cleft is particularly wide or the cleft in the palate is that type of partial cleft with very thin mucoperiosteal flaps (zona pellucida) and occasionally if the child is two or three years old, we add a supplementary flap from the cheek through the lateral incision. The flap is thrown above the palate just anterior to the nasal mucosa of the soft palate and posterior to the mucosa covering the posterior end of the palatal plates. The flap is taken from the side of the cheek in the alveolar buccal sulcus and has its base opposite the posterior part of the palatal plate. It is thrown through the lateral incisions and across the opposite side and stretches to the edge of the opposite lateral incisions. The original idea was to get palate length by covering the upper surface with additional mucosa so that the mucosa of the soft palate would not scar up again to the place from which it had been loosened at the original operation (Fig. 179). Such being the case, speech should be improved. However, it was found that the cross-lapping flap added considerable to the likelihood of complete closure in certain types ordinarily most difficult to close.

Possibly to a certain extent the procedure accomplishes the purpose of allowing the soft palate to fall down and back but its most useful purpose is to give a cross flap which stabilizes and covers the upper surface at a

place in the palate which is the one most likely to break down after the Dieffenbach operation. As it only takes a second to get the flap and as it increases the chance of permanent closure and probably allows the palate to fall down and back somewhat, the operation is of value when one is dubious about the probability of closure at the soft palate-hard palate juncture.

The Operation of Axhausen.—Axhausen of Berlin has attempted to meet the essential requirements of a palate operation as laid down by a modified von Langenbeck technic and states that his results are superior to those of Veau. He considers the essentials in cleft palate surgery to be three in number: (1) an epithelial covering on the nasal side as well as on the palatal side of the flaps; (2) obliteration of the dead space above the palatal flaps, and (3) avoidance of muscle injury and union by suture of the divided palatal muscles. Axhausen takes the stand that by means of bridge flaps these requirements can be met. He operated between the second and the third years by preference. The technic (Fig. 180, *A*, *B*, *C*, *D*) is

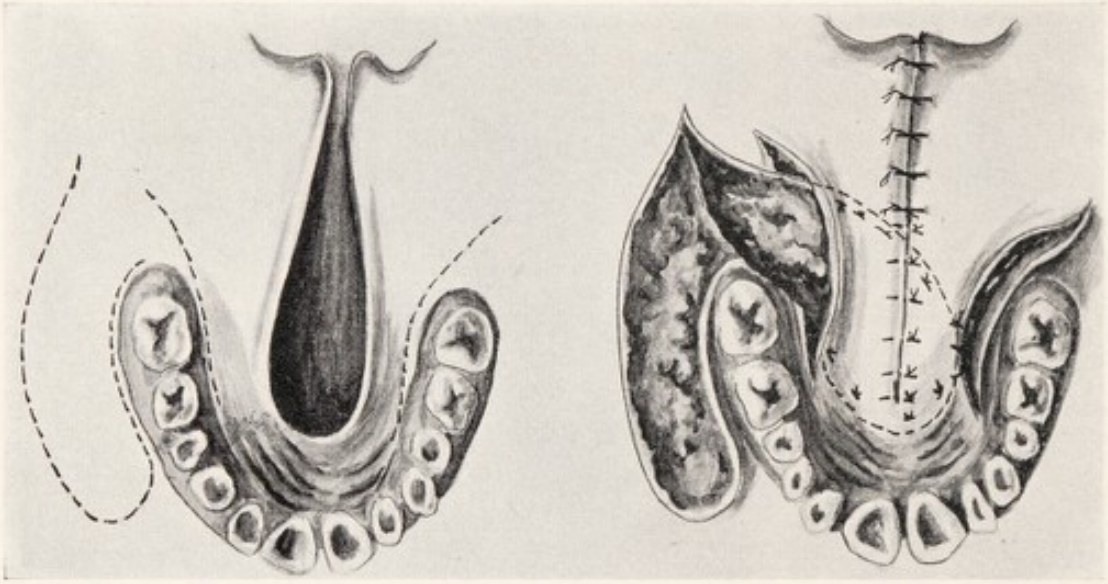

Fig. 179.—Incisions necessary to throw a mucosal flap above the palate.

similar to the Dieffenbach-von Langenbeck operation. Through a long lateral incision the hamular process is exposed and severed and the palatine artery is isolated, severed and tied. Besides this he separates the nasal mucosa from the palatal plates above. He does not cut the nasal mucosa through together with the aponeurosis at the posterior border of the palatal plates but the posterior bony edge is carefully freed of soft tissue submucously. The nasal mucosa is sutured across the cleft in a continuous layer from the tip of the uvula to the anterior margin of the cleft. The muscles of the soft palate are then united in the median line with catgut sutures. The oral mucosa from front to back is then sutured in a separate layer. A previously prepared celluloid plate fitting over the teeth is fitted to hold the flaps in contact with the bone. He reports 100 cases, of which 54 were new and 46 were failures from previous operations. Of the 54 new cases, the soft palate alone was involved in 8 and both the hard and the soft palates were involved in 46. In all of these cases the results were good, but small openings remained in 2 per cent. Of the total number of cases, small openings remained in 4 per cent. One was a failure. These results are very unusual.

Dorrance Operation.—Dorrance (Fig. 181, *A*, *B*) who has been endeavoring to overcome the defect of shortness after the usual palate operations has presented an operation applicable to those partial palatal clefts which show muscular atrophy and in which a short palate seems the rule after the usual midline closure operations. The soft tissues of the palate are loosened and pushed back. He claims considerable increase in length after this procedure. Nothing is done to the raw surface left above the palate. Presumably it scars up. One might suspect that the palate might be pulled, partially at least, back to its former position by the cicatrix just posterior to the hard palatal bones and anterior to the loosened mucosa of the soft

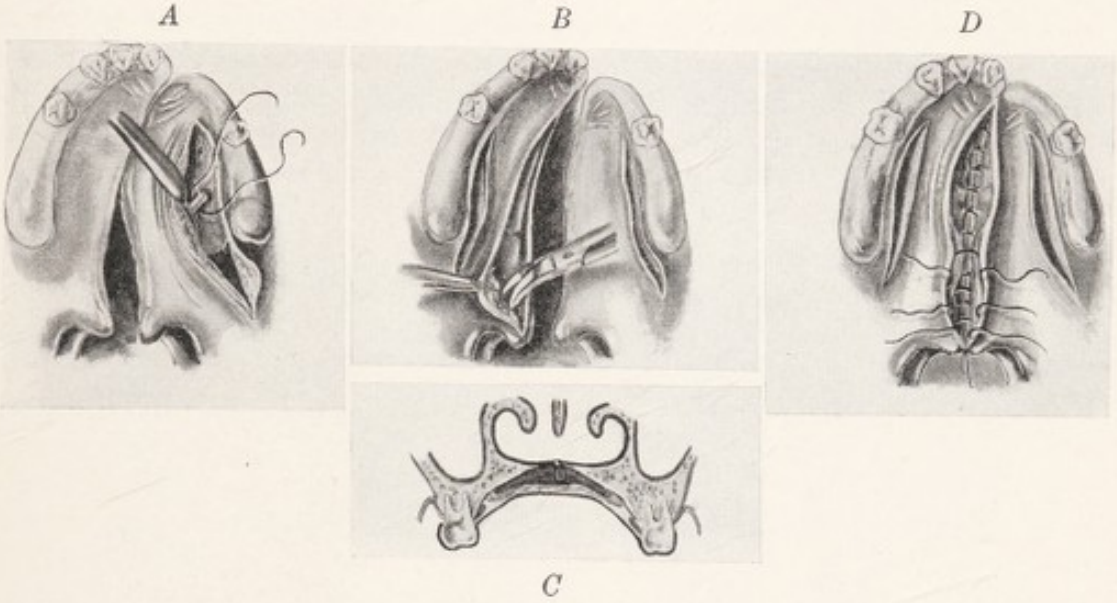

Fig. 180.—Axhausen's modification of the Dieffenbach-von Langenbeck procedure. *A*, Lateral incision is made on each side of the hard palate close to the teeth from the tuberosity forward, and the mucoperiosteum is separated from the bone almost to the margin of the cleft. *B*, The hamular process is exposed in the lateral incision and separated with a chisel to allow the tendon of the tensor palati to be carried toward the median line. The palatine artery is isolated near its emergence from the foramen, tied and severed. *C*, Cross section of the soft palate showing the three layers—nasal mucosa, muscle and oral mucosa—which are isolated. It then becomes possible to suture the nasal mucosa across the cleft in a continuous layer from the tip of the uvula to the anterior margin of the cleft. *D*, At the cleft margin the nasal mucosa is carefully separated from the bone to form a free flap of this tissue on each side. At the posterior edge of the hard palate, instead of cutting the nasal mucosa right through together with the aponeurosis, the continuity of this mucosa over the soft palate is carefully preserved, but the posterior bony edge is carefully freed of soft tissue submucously. (After Axhausen, Internat. Abstract of Surg.)

palate. Recently Brown also has used this operation on partial cleft of the palate. Again more recently Wardill has described good functional results from a special type of push back operation along with a pharyngoplasty which narrows the loop of the superior constrictor.

Veau's Operation.—In Chapter XXVI the operation of Veau is described as it is first of all an operation which closes the alveolar cleft and the anterior part of the hard palate. The closure of the posterior part of the palate does not differ greatly from these operations just described.

Critical Discussion of the Routine Operations for Cleft Palate.—Within recent years the principles of the Dieffenbach-von Langenbeck operation

have been subjected to searching criticism—some of it justified. First, a certain amount of dissatisfaction with the anatomic results was registered but a more persistent and definite note is now being struck against the functional results even when the anatomic results seem fairly good. So far as the classic procedure is concerned, the pertinent question which arises is: is there any other operation which may be used as a routine one for the ordinary cleft palate which on the whole will give as good or better anatomic results and better functional results after considering the number of operations involved and the mortality? Veau and Axhausen have made such claims for their operations. Some discussion of the matter would seem to be of interest.

So far as the soft palate is concerned one is a little puzzled to understand the essential difference between the operation of Veau and the classic operation. Veau emphasizes muscular coaptation of the velum. In this country at least, both the mucosal and muscular approximations are striven

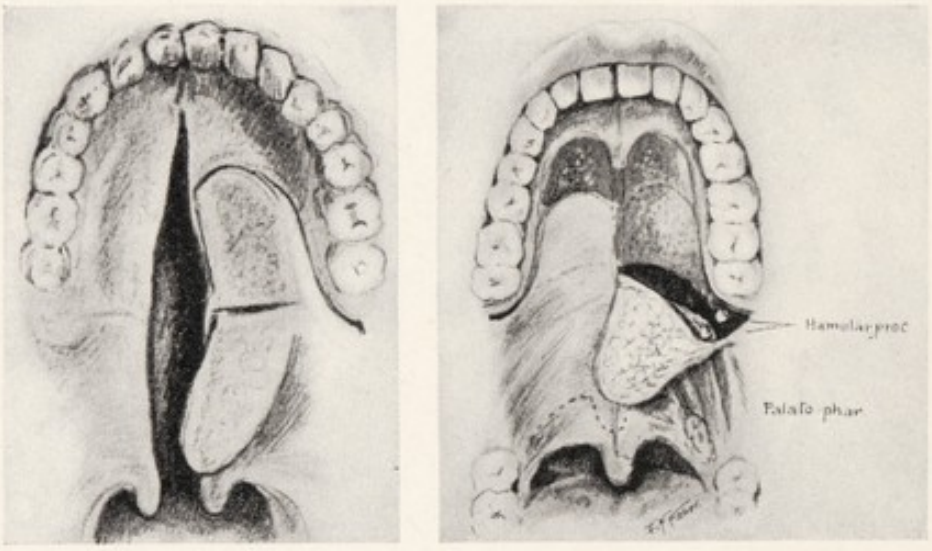

A *B*

Fig. 181.—Dorrance's push-back operation. *A*, Palatal flap raised. *B*, Hard palate completely exposed. (Dorrance, Annals of Surgery.)

for, as a matter of course, simply as a surgical procedure to increase the chance of union, to decrease the amount of scarring and to as nearly as possible approximate the normal. Within reason, the type of suture one uses is probably not fundamental to the principle.

Criticism has been leveled at those who loosen the raphe from the posterior border of the palatal plates. No essential muscle or nerve is severed. Undoubtedly, when a wound above the palate heals, epithelial surface tends to approach epithelial surface if hard structures do not impede. If the epithelial surface is traumatized or destroyed or all the available mucosa is not carefully sutured above the velum one could understand an increased tendency for scar contracture. Elsewhere in the body the degree of scar contracture depends upon the amount of epithelial surface destroyed unless the scar becomes keloidal. If the mucosa is simply cut, not traumatized or destroyed, and then carefully reapproximated why should it be different above the palate?

Concerning the drawbridge slant of the horizontal palatal plates, there is no particular evidence that unless they are broken down that one operation changes this more than the other.

The velum usually is atrophic because this depends as much as anything upon a disuse atrophy which, other factors being equal, probably is somewhat proportional to the age at which the velum is repaired.

The lateral incision commonly made in the Dieffenbach-von Langenbeck procedure for the purposes of obtaining relaxation toward the midline when placed properly has little or no likelihood of interfering with the muscular performance of the palate and the innervation to the muscles of the palate. Very often in secondary operations a number of months after the first so far as the lateral incisions are concerned one can hardly tell that a previous operation has been performed.

So far as ultimate function is concerned, it probably makes little difference whether one separates the raphe or makes lateral incisions, provided the raphe is separated with care and the lateral incisions are properly placed to avoid interfering with the muscular innervation of the soft palate.

As for the hard palate the classic operation creates a condition after the mucoperiosteal flaps are loosened from the bony palatal plates which violates a general surgical principle which one would avoid elsewhere in the body. In an unclean field experience has shown generally that the chances of primary union are decreased when the two flaps are sewed together with a raw surface on one side. As a plastic procedure such a situation is not ideal but in this region there is to a certain extent an unusual type of tissue to be sutured together—firm mucoperiosteum. Although the principle is wrong, the type of tissue is as good as can be found for proving an exception to a rule. If the palate were so constructed that a wide cross lap of raw surface were easily and practically obtainable certainly this would be a point to be driven for. Veau in his operation attempts to do this with rather inadequate material—rather friable nasal mucosa and from the very nature of the lesion a rather insufficient mucoperiosteal flap causing at the close of the operation an area where the sutured nasal mucosa anterior to the "cross-lap" mucoperiosteal flap is uncovered. Two flaps are sutured together with a raw surface on one side—the same defect in principle but smaller in extent as is presented in the classic operation.

In the operation of Veau for complete unilateral cleft if the lip-palate operation is made in a "one-two" procedure the anterior palate has to be closed at the same time as the lip. This necessitates waiting until the baby is three or four months of age or the mortality rate is likely to be rather high. Esthetic reasons alone make early closure of the open lip quite desirable. But besides the preceding reason it is known that early closure of the lip is an important factor in molding the spread bony structures of the face back into a position approaching that of normal. In the classic operation the lip is closed early. Anteriorly the open cleft is closed by gentle traction. The aim is for the lip-palate operation to be completed in two stages in the majority of instances.

There is a need, therefore, in surgery of the cleft lip and palate for a workable procedure that allows one to repair the lip, gain early closure of the floor of the nose, obtain early alveolar ridge coaptation and obtain

union of some of the anterior palate in one operation with a fair degree of certainty during infancy without materially increasing the mortality. Early union of a part of the anterior palate certainly tends to make closure of the remainder of the palate nearly always possible in one operation. Closure of the posterior palate being thus made a somewhat less formidable procedure, possibly one would be warranted in performing the second operation at a somewhat earlier age—thereby preventing some of the disuse atrophy of the soft palate.

Thus, finally in selecting a routine operative procedure for both the anatomic and the physiologic standpoint eventually it becomes a matter of balancing one defect against another and selecting the lesser.

THE REPAIR OF CLEFT PALATES PRIMARILY UNSUCCESSFULLY OPERATED*

Every surgeon who performs a fair number of operations for cleft palate encounters a good many individuals in whom the original was or the succeeding operations were unsuccessful in that part or the whole of the palate failed to unite. In some cases undoubtedly the operation was improperly performed and thereby union was prevented or even an absolute slough of tissue was caused. In other instances some factor beyond the control of the surgeon may have caused simple failure of union or even a slough. In our series of about 300 different individuals operated for cleft palate, 141 individuals were found to have been operated before, the majority had been operated more than once and some of the individuals gave a history of as many as five unsuccessful operations. The average number of unsuccessful operations for the group averaged 2.3 times. Fifteen cases of the group were primarily unsuccessful cases of our own and 126 had previously been operated by other surgeons. All of the cases who presented themselves were accepted for re-repair when the age was judged to be correct for the procedure required. In only a few instances was the principle of the operative procedure or procedures used entirely new but in most instances the technic of the procedure was not that more or less routine with most surgeons and as we gained more experience with the procedures used, or a defect became evident, the various procedures underwent at least a certain amount of refinement or even change.

For purposes of discussion these cases are primarily divided into two large groups: (*A*) the group with little or no loss of tissue, and (*B*) the group with a definite loss of tissue.

Group Without Absolute Loss of Tissue.—When no absolute loss of tissue was encountered as is the usual case after failure of a properly performed routine operation for cleft palate, the problem of re-repair is only slightly more complicated than the original operation. Usually the repair of a small midline defect without apparent loss of tissue in either the hard or soft palate is a relatively simple matter when the surgical fundamentals are observed.

The principle of the Dieffenbach-von Langenbeck operation is in most instances the most applicable to the group with little or no loss of tissue. The lateral incisions of the operation, the loosening of the raphe and the

*Taken from an article published in Surg., Gynec. and Obst., **63:** 483–496, Oct., 1936, in almost verbatim form.

complete freeing of the mucoperiosteal flaps of the hard palate are capable of allowing a considerable relaxation toward the midline. Although we believe it is important to preserve the posterior palatine artery at a primary operation, at later operations usually this will not be found to be of great importance.

When the cleft tends to be unduly wide or the palate unduly short, sectioning of the hamular process which loosens the tension of the tensor palati muscle, along with an extension of the lateral incisions both forward and backward and outward toward the anterior pillars, aids in obtaining relaxation and possibly tends to cause an eventual slight lengthening of the palate in a backward direction. With this operation some plastic variation to meet the demands of the particular defect often aids one in gaining an easy closure and is advantageous to ultimate function if not absolutely essential in gaining midline closure.

When the palate appears to be unusually short but sufficient tissue is still available to gain good midline closure, the principle of going on backward and uniting the posterior pillars will prove of value and often in using

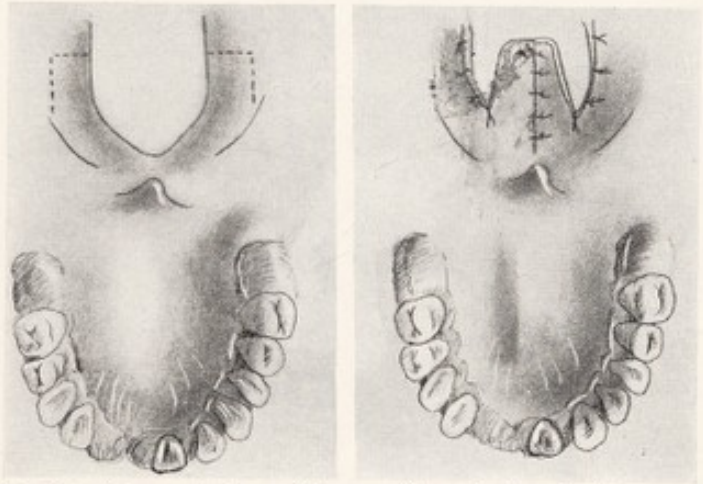

Fig. 182.—Suturing the posterior pillars with relaxing incisions on the sides.

the Dieffenbach-von Langenbeck procedure as the essential procedure this addition may be added to the standard operation (Fig. 178). Morestin in 1910 and Helbing in 1912 and Makuen in 1915 in discussing a paper by Emerson referred to Brophy as having used the posterior pillars to lengthen the shortened velum. Just recently Blair has recommended the procedure after using it for some years. The posterior pillars will be found to be progressively easier to sew together in individuals beyond three years of age. In our experience although usually the pillars stay together when properly sewed, because of the tension there is a certain amount of tendency for separation to occur. A certain amount of this, however, can be eliminated by cross cutting the posterior pillar at its base (Fig. 182). Such incisions, however, add the factor of severance of the palatopharyngeal muscle which probably interferes with function and elevation of the velum is possibly somewhat impeded. In 15 out of 19 cases in which it was deemed advisable to stitch the posterior pillars together, the pillars stayed together.

Not uncommonly a defect between and back of the cleft alveolar ridges is encountered. A flap from the lip with the base at the midline and raw

surface toward the mouth will be found to be of value in closing this type of defect. We try to get a fairly wide base and after raising the anterior hard-palatal mucoperiosteal covering from the ends of the alveolar ridges to turn the lip flap up above the mucoperiosteal flaps in such a manner that

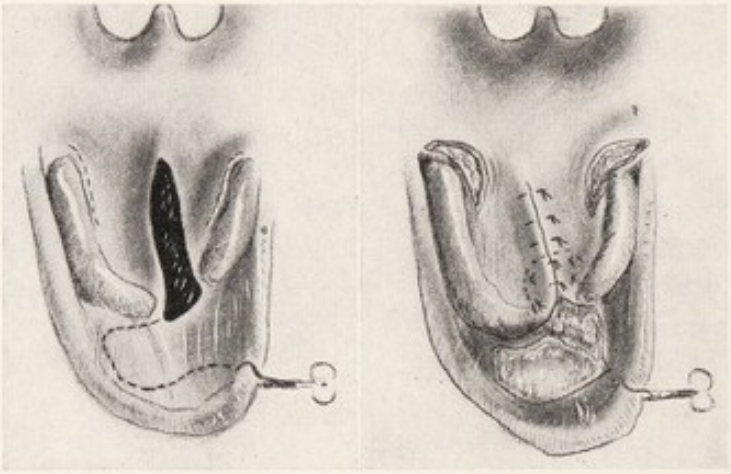

Fig. 183.—Turning an anterior flap of mucosa from the lip-alveolus sulcus above the anterior ends of the elevated mucoperiosteal hard palate flaps. The mucosal covering of the flap faces the nasal cavity. The flap is cut so that a good base is obtained and a sufficient width is given so that viability of the flap is assured and a wide overlap obtainable in all directions.

a wide overlap of raw surface to raw surface is obtained after careful resuturing (Fig. 183). Our exact figures of the number of times a small anterior flap has been used are not available as often the addition of a small anterior flap is made in the purely routine operation, but in 9 in-

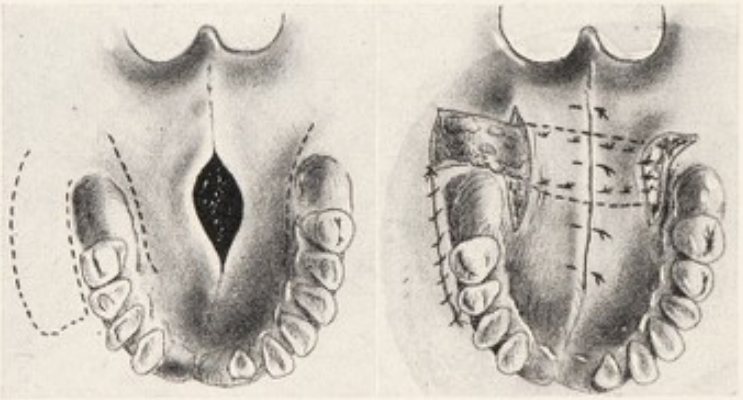

Fig. 184.—The use of a flap from the cheek which is turned in through a lateral incision above the mucoperiosteal palatal flaps so as to cross lap a large defect and to give additional support. A hole is less likely to occur and possibly the palate is somewhat lengthened as it prevents the tendency of the mucosa of the soft palate to draw back to the mucosa of the floor of the nasal cavity as is the case when a raw surface is left above the palate in this area.

dividuals in which a somewhat larger flap was used, 7 seemed to have the defect closed successfully.

When a second operation is necessary on that type of partial palate which has originally a very thin area about the midline of the hard palate, the operation which utilizes a cheek flap of mucosa which entirely overlaps the defect in the midline will be found to be a procedure of value (Fig.

184). This operation was originally designed to give more length to the palate although it was concluded that for this purpose, the procedure was of only relative value. As a plastic procedure to supplement the likelihood of union, it is worth while.

Group With Loss of Tissue.—In the group of individuals with more or less absolute loss of tissue the defects will be found to be quite variable and quite unique problems are presented when a repair is effected successfully. Very roughly these individuals present defects which fall into one

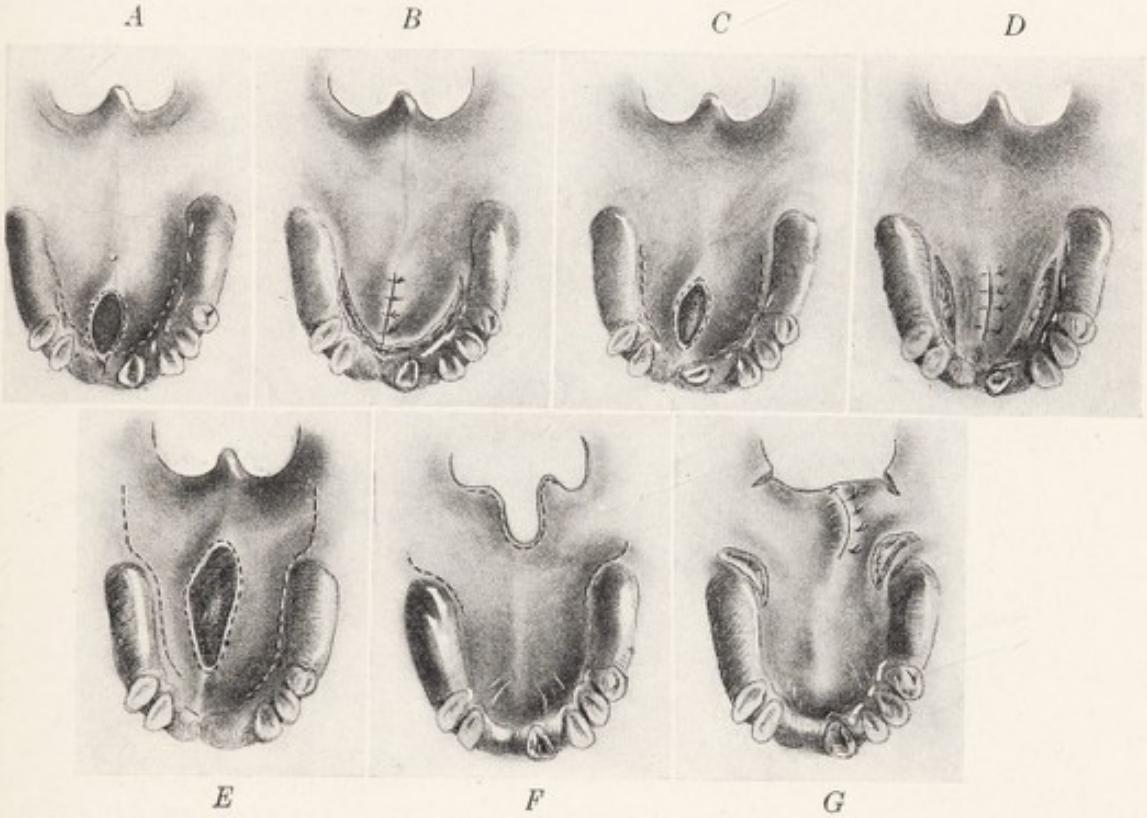

Fig. 185.—Midline hole in the anterior palate region corrected by a modification of the Dieffenbach-von Langenbeck principle. *A* and *B*, Mucoperiosteal flap detached anteriorly. When this is done it is usually wiser to add the additional support of an anterior mucosal lip-cheek flap (Fig. 183) or one will more than likely get a hole next to the alveolar defect. *C* and *D*, Midline anterior defect closed by use of long lateral incisions without detaching the anterior extremities of the mucoperiosteal flaps of the hard palate. *E*, Extending the lateral incisions to give additional relaxation to the midline and possibly some additional length. When a lateral cheek flap cross laps the middle of the upper surface as shown in Fig. 184, greater length is likely to be the final outcome. The cross lapping flap also reinforces the midline suture line. *F* and *G*, Method of using the velum of the normal or nearly normal side to fill in a defect of the velum on the opposite side.

or two or even three of the following groups: (1) a large midline loss in the central part of the hard palate; (2) a loss of a part or most of one of the flaps of the hard palate; (3) a hole in the anterior palate or lateral palate which was adjacent to the alveolus from which the mucoperiosteal covering has been lost; (4) a large defect at the hard palate-soft palate juncture; (5) a considerable loss of soft-palate tissue, and (6) an almost complete loss of the tissues of the hard palate.

1. *Large Midline Loss in the Hard Palate.*—When the midline loss is only of moderate proportions it will be found possible to use a modifica-

tion of the Dieffenbach-von Langenbeck operation with a fair degree of certainty of obtaining closure. When the hole is anterior, an anterior flap from the lip or cheek with mucosal surface turned toward the nasal cavity is of value, especially if it was necessary to loosen both ends of the hard palatal flap anteriorly (Figs. 185, *A, B;* 183). Usually, we consider it much better if possible to close an anterior midline defect without detaching the hard palatal flaps at the extreme anterior end (Fig. 185, *C, D*). When the hole is unilateral, it is sometimes advantageous to loosen one flap well forward anteriorly—even completely if the situation demands it. Often by making long lateral incisions next to the alveolus, sufficient relaxation will be obtained to allow closure of a hole of considerable size (Fig. 185, *E*). When the likelihood of union seems particularly dubious, reinforcement of the suture line by cross lapping a cheek flap above the palatal flaps will add certainty to a successful outcome (Fig. 183). In 15 cases in which a lateral flap of the cheek was added to supplement the likelihood of union, closure was obtained in 13 instances. When a part or one side of the velum has been lost another variation of the Dieffenbach-von Langenbeck principle

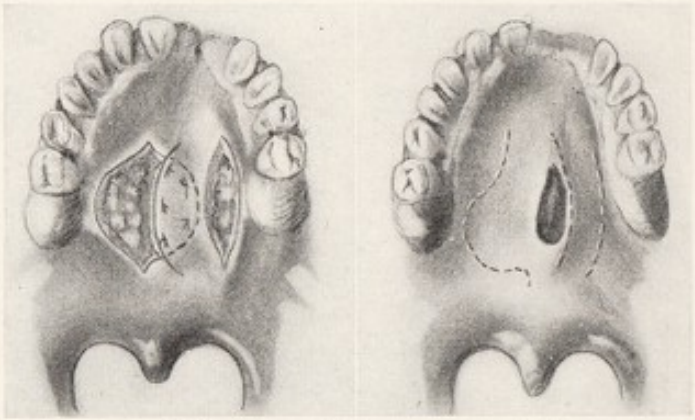

Fig. 186.—Closing a lateral hole in which one can obtain some mucoperiosteal flap on the short side with which to get a fairly good overlap of the turn-over flap. When this cannot be done, the chance of gaining closure is practically nil.

is advantageous in closing a unilateral posterior defect of the velum. The method consists of pulling the nearly normal side of the posterior velum over to the defective side after which the normal side is sewed up onto and backward of the defective side toward the lateral pharyngeal wall (Fig. 185, *F, G*).

In an occasional case, especially when the hole is somewhat lateral, the principle of the Lane operation very occasionally offers advantages (Fig. 186). As is well known, in the Lane principle a flap is outlined and turned over beneath an opposite flap. When this principle is used successfully it will be found that a good blood supply at the base of the turn-over flap has to be present and sufficient width and length so that a wide overlap is gained.

2. *Loss of a Part or Most of One of the Mucoperiosteal Flaps of the Hard Palate.*—Only occasionally is an individual encountered in whom the only essential defect is a slough of one of the flaps of the hard palate. Usually when this defect is found, the posterior part of the palate also has sustained severe damage. When only the mucoperiosteal flap of the hard palate is absent a repair with a fair type of success is one operation that will

be found to be possible by using a relatively long and broad cheek flap (Fig. 187, *A*, *B*). Whether the flap is turned from before backward or from the posterior end forward depends upon where the maximum defect is encountered. Ordinarily we believe, when an anterior flap is indicated, that

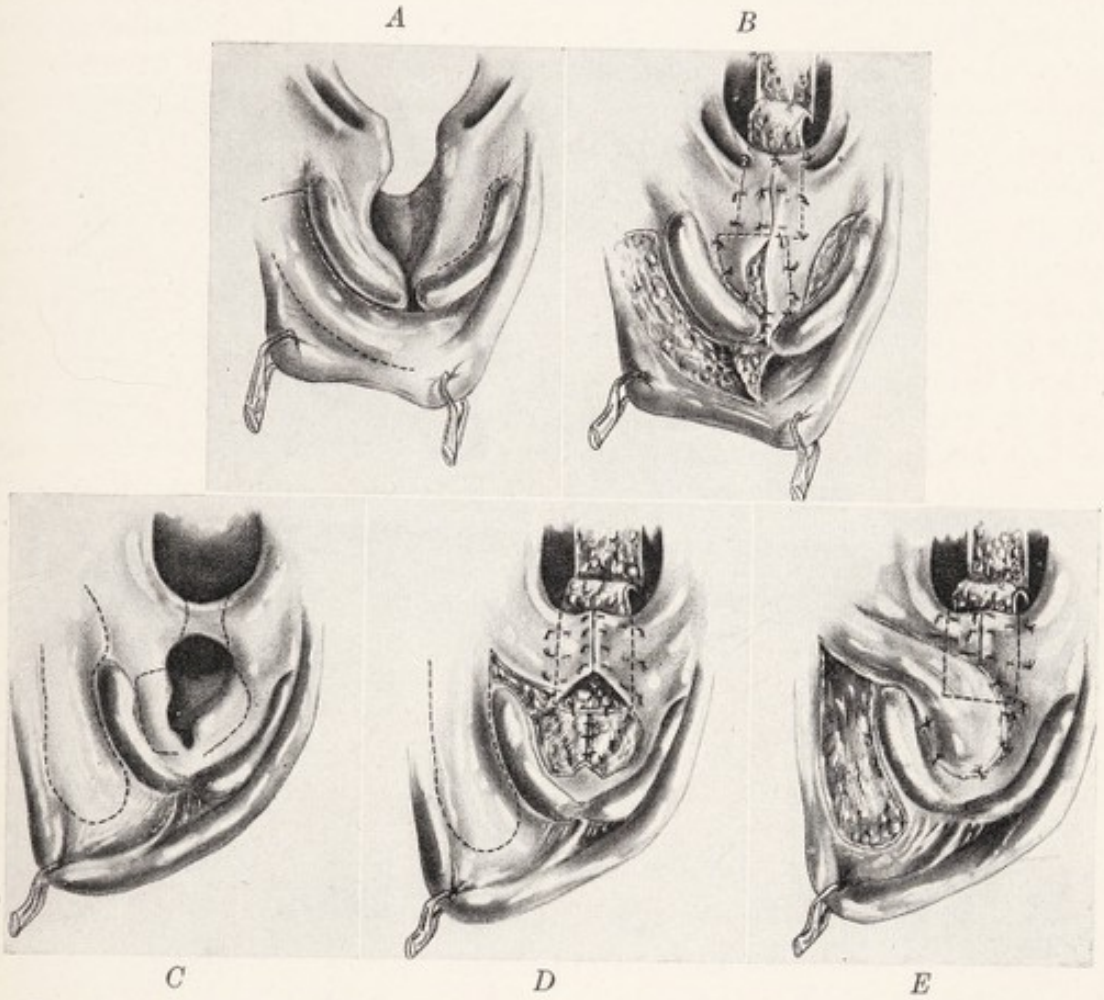

Fig. 187.—Methods of using cheek flaps to close a large or total defect of one mucoperiosteal flap of the hard palate. *A* and *B*, Repair used in a case where the anterior defect was a loss of the anterior two thirds of the left mucoperiosteal flap. This case also had sustained a loss of about two thirds of the soft palate. An anterior lip-cheek flap was turned above what one could raise of the mucoperiosteal flap on the defective side. The normal mucoperiosteal flap was brought as far to the defective side as possible. Besides this a posterior pharyngeal flap was used to supplement the defective soft palate. The two flaps met in the midline lengthwise above the palate tissue. With the greatest care the flaps were sutured with mucosa to mucosa when possible and in such a manner that a wide overlap of raw surface was obtained at the midline when the remaining palatal tissue was brought together. *C*, *D* and *E*, Repair used in a case of loss of the posterior part of the mucoperiosteal flap of the hard palate. Lane flaps were turned inward to give covering to the upper surface of the defect. A lateral cheek flap was then cross lapped over the Lane flap with as wide an overlap of raw tissue as possible to suture to. A posterior pharyngeal flap may be used to supplement the soft palate if it is found defective, as was the case in this instance.

greater likelihood of union will be obtained if the mucosal side of the flap is turned toward the nose. When using this procedure it is considered essential that a fairly broad base and as broad an overflow of raw tissue as possible should be obtained. The flap is then sewed into place with the greatest of care. When the posterior part of the lateral mucoperiosteal flap

of the hard palate is absent, flaps of the Lane type may be turned to the center of the defect. A lateral cheek flap is then cross lapped over the raw defect. Every effort is made to obtain wide apposition of raw surface when the cross lap is made (Fig. 187, *D, E*).

When a defect of the soft palate is a complicating factor to the loss of one hard palate flap, we have succeeded in 5 cases in obtaining a good palate in one operation by either turning a cheek flap before backward or using a lateral cheek flap along with a posterior pharyngeal flap turned forward above the palate. After the child has attained the age of eight or ten years by cutting an anterior flap and a posterior pharyngeal flap properly, the flaps can be made to meet at their respective tip ends. The ends are then stitched together and both flaps are sewed in carefully above the remnants of palatal tissue which are present (Fig. 187, *A, B*). If the cheek flap is cut too narrow the procedure seldom will be successful. When the base is made anteriorly, due regard should be paid to the scar if the lip has been repaired previously. When the lateral cheek flap is used care should be taken not to remove too much mucosa near the posterior angle of the cheek. It will be found that one can remove a considerable width of mucosal flap lengthwise of the cheek without noticeable impairment in opening the mouth. Later the base of the flap should be rearranged when necessary. When the cheek flap is cut if width is an absolute necessity, to assure an adequate blood supply or to obtain a wide overlap when the defect is closed, we ignore the papilla of the parotid duct. No ill effects after its removal have been observed. The combination of an anterior cheek flap or a lateral cheek flap along with a posterior pharyngeal flap offers a one-stage procedure which is useful in the middle adolescent period in obtaining closure in one operation of a large defect of both the hard and the soft palates.

When cheek flaps of these types were used to bridge a rather large gap, the flaps closed the hole in 7 out of 9 cases, but in only 2 cases was all of one mucoperiosteal flap absent.

3. *A Hole in the Anterior Palate or Lateral Palate Which is Directly Adjacent to the Alveolus.*—In a few instances this type of hole will be found to be impossible to close. When the hole is not too large it will be found possible sometimes to gain closure by cutting a thin lengthwise flap from the wider and thicker of the two palatal flaps. This flap should include only one half the thickness of the palatal flap. The upper flap is then slid over to the remnant of a flap raised from the alveolus. In those instances when an attempt is made to close a defect by one type of plastic or another, but when one is unable to raise sufficient mucoperiosteum from the alveolus to get a ledge of tissue to sew to, the procedure will not be successful ordinarily. Therefore, in such a situation a prosthesis to plug the hole is to be recommended (Fig. 188, *A, B, C, D*). In 3 of our cases such a prosthesis was considered necessary to plug a hole of no great size. Very often a bridge is necessary when alveolus is cleft anyway.

4. *A Large Defect at the Hard Palate-Soft Palate Juncture.*—By making long lateral incisions and extending them well back and thoroughly freeing the lateral palatal flaps a rather large defect at the hard palate-soft palate juncture usually can be closed without undue tension at the midline (Fig. 185, *E*). Generally the hamular processes have to be broken inward to

obtain all the relaxation toward the midline possible to gain. As an addition to the preceding operation, in children after four or five years of age, especially when the palate is short or there is some question of union, a unilateral cheek flap will be found of value. The cheek flap is drawn through the lateral incision and cross lapped above the palate. The

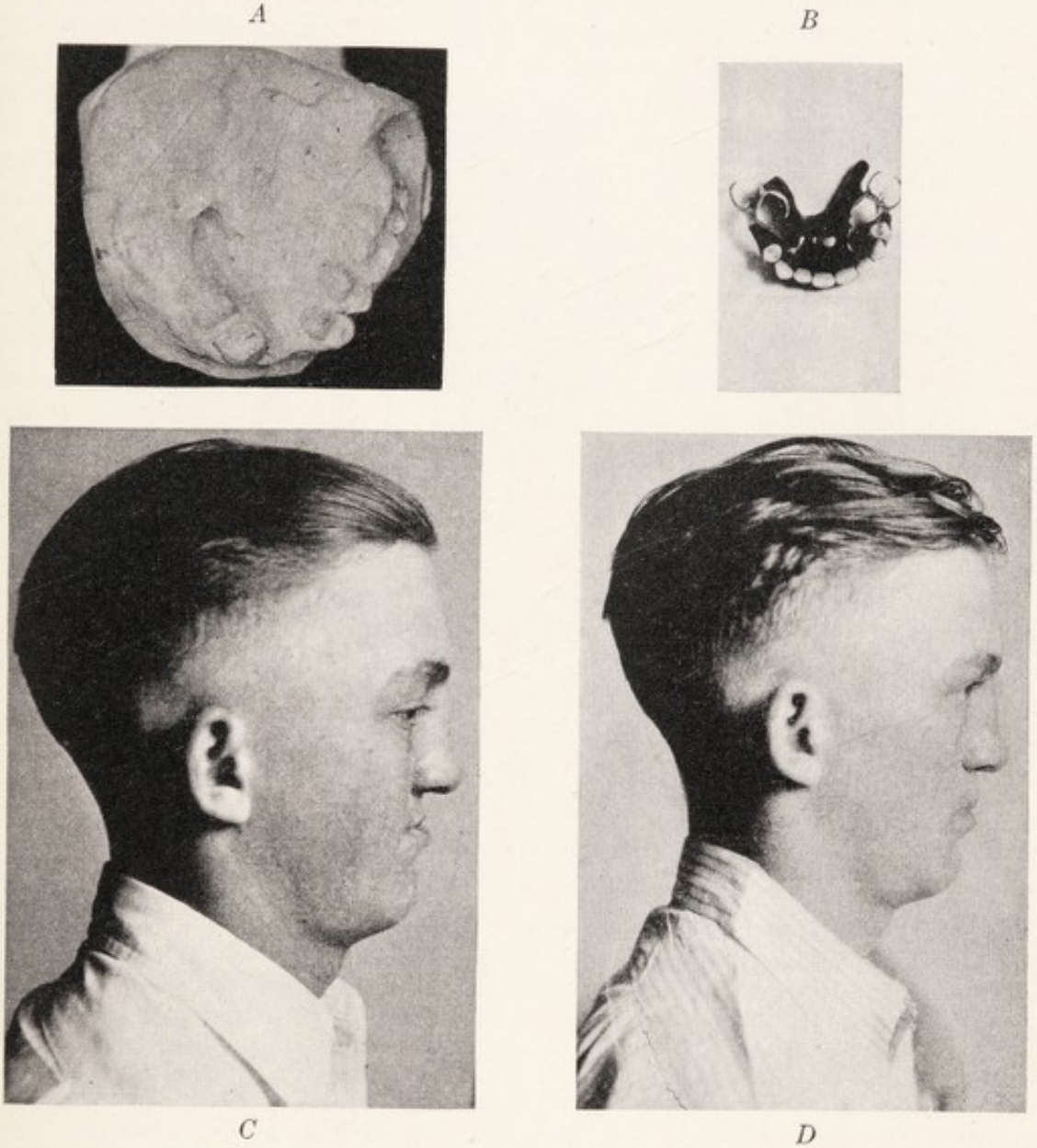

Fig. 188.—*A*, Cast of upper jaw and palate with hole anterior and next to the alveolar ridge. *B*, Plate made to plug the hole with clasps attached to the teeth. *C*, Lateral view of patient without plate in mouth. *D*, Lateral view of patient with plate in mouth. The plate is built somewhat forward of the upper alveolar ridge so that the upper row of teeth fall forward of the lower row. The upper lip is held forward by the prosthesis, giving a normal profile relationship to the two lips. (Padgett, Surg., Gynec. and Obst.)

end of the flap is sewed to the outer edge of the opposite flap. The flap is very carefully sutured in position so that the whole width and length are utilized by through-and-through sutures. Thereby the midline suturing is reinforced by cross-lapping the flap above. When lateral incisions have been made at some previous time the base of the flap is cut a little further

from the alveolar cheek sulcus. A lateral flap of this type was used in 15 instances to overcome this situation and in 13 the hole was closed. This procedure seems to be of particular value in this special type of defect.

Use of Dieffenbach-von Langenbeck Operation for Reoperation.—A brief summary of 63 cases in which the Dieffenbach-von Langenbeck principle was used as the basis of secondary repair; 39 were original single clefts, 15 were double clefts and 9 were partial clefts. In 18 individuals a secondary

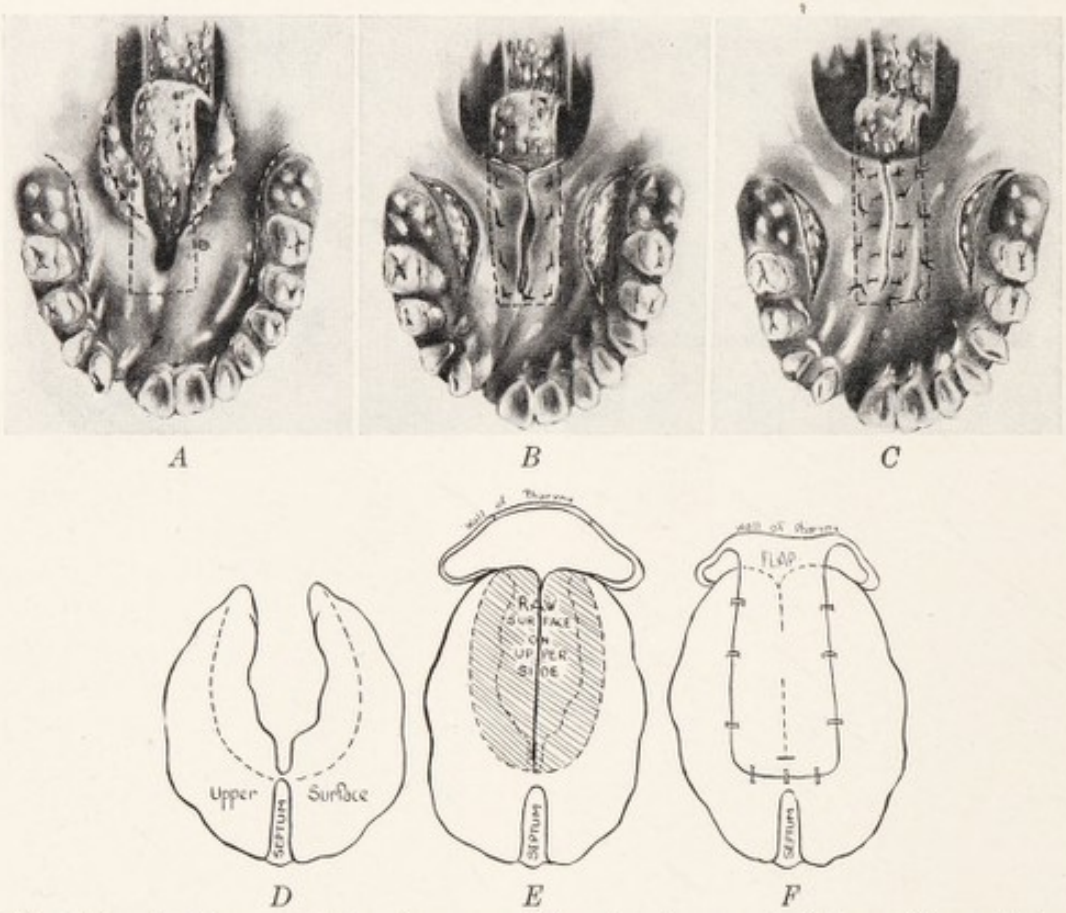

Fig. 189.—*A,* The posterior pharyngeal flap has been raised from the midline of the posterior pharyngeal wall with the base just below the adenoid region and tip downward near the level of the larynx. Lateral incisions of the von Langenbeck procedure are made. Shelf flaps from above the soft palate are turned medialward with the mucosal side to the mouth. A raw area remains above the soft palate into which is carefully stitched the posterior pharyngeal flap as shown in *B*. *B,* If the mucosal ledge around the lateral pharynx can be caught in an adequate manner, mucosa of the lateral pharynx is stitched to the mucosa of the flap or if this seems impossible through-and-through stitches are used. *C,* The flap has been stitched above the soft palate. The shelf flaps of the soft palate have been sutured in the midline. *D, E* and *F,* Diagrams of upper surface of soft palate, showing method in which shelf flaps are turned medialward and position of pharyngeal flap after it is thrown into raw area on upper surface of palate.

operation was necessary. In 2 cases a third operation was done before closure was finally complete. In 3 cases the hole was deemed impossible to repair because no mucoperiosteum remained next to the alveolus.

5. *Considerable Defect in the Soft Palate.*—Whenever enough soft palate tissue remains available, the Dieffenbach-von Langenbeck principle plus the suturing of the posterior pillars is considered an operation advisable if union seems at all probable by its use (Fig. 182). A necessary

amount of tissue will be found to be a prerequisite for a successful outcome after this operation if one is to run a fair chance of obtaining permanent closure as the tissues in this region are somewhat frail and friable.

In the individuals who had been operated several time previously and in which the soft-palate tissues have sloughed or are so deficient and atrophied that midline closure by use of the Dieffenbach-von Langenbeck principle appears in the face of the situation to be altogether unlikely or hopeless, a posterior pharyngeal flap can be used with advantage to obtain union and to build up a fairly long soft-palatal diaphragm (Fig. 189, *A*, *B*, *C*, *D*, *E*, *F*). Originally Passavant in 1865 and Schoenborn in 1876 tried a type of pharyngeal flap operation. In 1924 Rosenthal in Germany proposed an operation similar in type to the preceding operation. Rosenthal performed the operation for a much wider group of cases than we have found it useful for, including almost all cases with atrophic soft-palatal tissue. Rosenthal made his pharyngeal flap rather narrow with the base downward and used an arrow-shaped flap which narrowed toward the tip. In experimenting with the flap operation we have found that when the base is downward one can get very little length to the flap as it recedes away from the palatal position as it is made longer. Neither can the flap be thrown far enough forward to be effective for the purpose for which it is most useful. Nor is a narrow flap wide enough. Therefore, in the operation which we have used the base of the flap has been placed upward near the adenoid region and the flap made somewhat wider and longer than that shown by Rosenthal. The location of the base is thereby made near to the region to which one wishes to apply the flap. By this means it is possible to obtain a flap long enough to go forward slightly past the hard palate-soft palate juncture when such is necessary to aid in closing a hole. Somewhat more difficulty will be experienced in sewing the flap in above the soft palate but after doing the operation a few times the difference is one of only a slight degree. For the purpose of closing a soft-palatal loss which is not likely to be closed in any other manner, we have found the operation to be an unusually efficient one. After a few weeks the pedicle of the flap rolls into the form of a tube and breathing is not impeded as a rule. Ordinarily the pedicle is left attached for a variable period of time and then cut. But in 3 instances in which we cut the pedicle away from the pharynx, we were asked to reattach it as speech seemed to be better with the pedicle attached. By the use of a right-angled knife and any short general anesthesia, or in an adult local anesthesia, the flap will be found to be easy to cross cut.

The disadvantage of leaving the pedicle attached will be found to be most noticeable during an acute cold. By the use of saline nasal irrigation morning and evening the tendency for the accumulation of nasal secretions in the nasopharynx is minimized to cause only the slightest of noticeable symptoms. Sixty-eight posterior pharyngeal flap operations for the purpose of closing this type of defect have been performed. In a few instances the operation was done in children as young as three years plus, but the average age was eleven years plus. In 7 a cheek flap was deemed necessary to supplement the primary posterior flap procedure. In 52 cases complete closure was obtained. In 3 the palate broke down, in 4 one side partially broke down, and in 7 there appeared at the soft palate-hard palate juncture a

hole but the posterior part of the palate was closed. A lateral cheek flap we believe would have supplemented and added to the chance of union in those cases but at that time we did not appreciate the uses of a cheek flap. Two cases died, one of pneumonia with the onset ten days after the operation, and one of an edema and cellulitis of the pharynx twenty-four hours after operation. The latter death occurred in a child about three years of age and warned us to be careful with the operation at this age. The functional results were quite good. In 10 the speech was remarkably improved to nearly normal, in 27 the speech was fair, in 18 it was improved and in 4 it was unimproved.

This operation has been criticized, first, on the basis that the scarring up of the posterior pharynx interferes with the function of Passavant's pad and the action of the superior constrictor muscle of the pharynx and, secondly, because it prevents adequate drainage and ventilation of the nasopharynx. In the type of case for which we have used the operation the advantages of soft-palate closure in an efficient manner have proved to be considerably



A *B*

Fig. 190.—*A*, Typical case in which the posterior pharyngeal flap operation is indicated. *B*, Patient after use of posterior pharyngeal flap. (Padgett, Surg., Gynec. and Obst.)

greater than the disadvantages of interfering with the function of the upper part of the superior constrictor muscle.

In evaluating the position of the operation we believe that it has only one useful function. It is not of much value for the atrophic palate. The operation offers a one-stage procedure that will allow one to close successfully a defective soft palate that one can hardly hope to close otherwise (Fig. 190, *A*, *B*). When distinctly held to this position, although it may be physiologically the ideal procedure, it will allow one to close a very large defect of the soft palate in the majority of cases and, when the extent of the defect is considered, will result in a surprisingly good functional result. The practical effects of the disadvantages of the operation are not very important in comparison with the advantages of the operation.

In our series are no records of a sinusitis being aggravated by the operation. Middle-ear infection was not noted to have been increased. When there was evidence of interference with free breathing or of insufficient drainage of the nasopharynx the pedicle of the flap was severed, after which these

symptoms would disappear. In a good many others, although these symptoms are not complained of, the pedicle should be cut to be on the safe side.

6. *Almost Complete Loss of Both the Hard and Soft Palates.*—In our series are 9 individuals in whom both the hard and the soft palates were lost almost completely and who were considered old enough to withstand without too much danger a repair by the use of extrapalatal tissue. Seven out of the 9 of this group had double complete cleft of the palate. In 8 the palate was successfully rebuilt. In 1 the soft palate alone was rebuilt. In 6 both the hard and the soft palates were rebuilt. In 2 the soft palate was rebuilt by the means of a posterior pharyngeal flap and the hard palate was rebuilt by the use of an extra-oral tissue. In one the flap remained attached to one side only and the attachment to the opposite side has not as yet been completed. In another case—a tenth case—this was attempted when our experience had been very meager and largely at the insistence of the parents. The child was two and one-half years old. A jump flap was turned from the neck up beneath the upper lip. The child died two weeks after the flap was turned into the palate. For this operation the child undoubtedly was too young.

The idea of the repair of a palatal defect by a flap from elsewhere than inside the mouth is rather ancient. It was first unsuccessfully attempted by Blasius by the use of a flap from the neck. Thiersch, in 1867, and Rotter, in 1869, used the principle successfully. Later the method was successfully used by von Eiselsberg and Blair. Coughlin also has repaired a hard palate defect of this type by the use of a cartilage transplant.

As our experience has increased with operations using extrapalatal tissue, our opinion as to the indications for the operation has undergone somewhat of a transition. Controversy as to whether or not one is justified in building in a defective palate with extra-oral tissue naturally tends to make one view the results with a highly critical attitude. As only a few of these operations have been performed in the past, before the procedure can be judged on its merits a certain amount of experience along with a refinement of technic would appear to be necessary (Figs. 191, *A, B, C;* 192, *A, B*). The mere operation although a tedious one is not particularly dangerous when one is capable of its execution. The main danger was found to be difficulty in swallowing of the saliva which may result in respiratory aspiration during the first forty-eight hours. This danger can be largely eliminated by not stitching too thick, too wide, or too long a flap too far back into the pharynx and by being careful about propping the mouth too widely open to keep the flap from being bitten in two. Patients with the mouth propped open too widely swallowed with difficulty. Often this difficulty will not be encountered because practically all of the cases will be found to have double cleft of the palate and the premaxillary teeth are in such a position or condition that the danger of biting the flap in two is negligible. In the earliest cases the mistake was made of tubing the part of the flap which was to be inserted into the mouth. Such a flap was too thick for the best ultimate result and much more difficult to sew into the palatal ledges. A flat flap with a skin graft in the opposite surface was easier to sew in place with the required width of raw overlap necessary. Up to the mouth the flap should be tubed so that a flap long enough with a good blood supply is obtained.

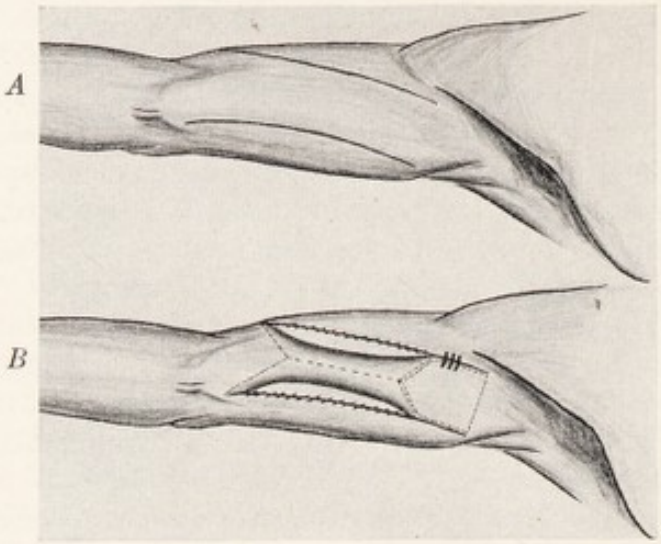

Fig. 191, *A* and *B*.—*A*, Lines of incision on arm before the flap is raised and tubed. *B*, The flap has been raised and tubed. A full-thickness skin graft has been removed from the abdomen and stitched in the raw defect save at the upper end of the flap. Beneath the upper end of the flap a nearly square, flat, thin wax stent of modeling composition has been shaped. A "split" graft from the thigh has been draped over both sides of this stent. The stent is then sewed beneath the upper end of the flap so that an epithelial covering is given to the under surface of the upper end of the flap. The raw surface of the arm beneath the upper end of the flap is also epithelialized in a similar way. The stent is removed in six or seven days. Adequate vaselin gauze dressing is placed in the position of the stent and changed daily. About three weeks after this operation, using a little local anesthesia, the upper end of the flap is cut and restitched in place. As soon as the viability of the flap is certain one may go on and transfer the flap to the mouth. (Padgett, Surg., Gynec. and Obst.)

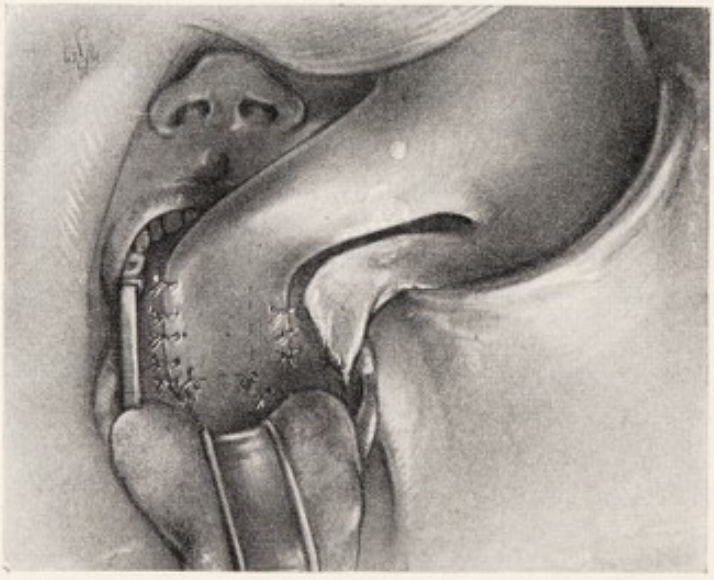

C

Fig. 191, *C*.—Lateral shelf flaps are raised. A part of the skin graft is cut away at the sides of the flap. The flap is transferred to the mouth and very carefully stitched by double whipping interrupted stitches so as to obtain deep and superficial approximation of raw surface. In the posterior palate region, especially, an effort is made to get a wide cross lap of raw surface so that the flap will not be pulled out. In a few instances a wedge may have to be placed between the teeth to prevent biting of the flap. In most instances, however, as these are usually double clefts, the upper teeth are so imperfect or so situated that there is little danger. (Padgett, Surg., Gynec. and Obst.)



D

Fig. 191, *D*.—Plaster head-arm cast. An adequate amount of felt may be placed about the head and a hole made in it to prevent pressure on the ears. (Padgett, Surg., Gynec. and Obst.)

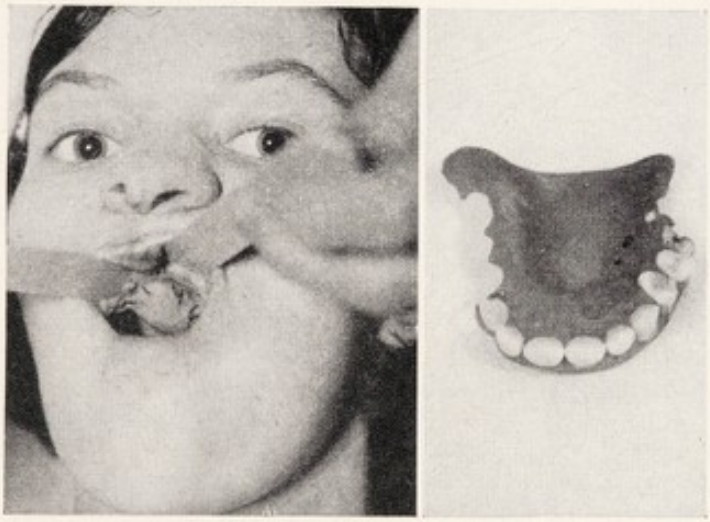

A *B*

Fig. 192.—*A*, Patient after flap has been cut from the arm and stitched to the lip mucosa. In this patient some one has removed the premaxilla at an earlier operation. *B*, Dental plate built to hold the upper lip forward and to give a normal line of teeth in the same patient. (Padgett, Surg., Gynec. and Obst.)



Fig. 193.—Patient in whom a prosthetic denture was used to hold the upper lip forward. A, Before operation, front view. B, Before operation, profile view. C, After operation, front view. D, After operation, profile view.

In 2 of our 6 cases in which the whole palate was rebuilt the functional result was improved to nearly normal (Fig. 193, *A, B, C, D*) and in 4 the functional result was considered fair.

As experience was gained in using the posterior pharyngeal flap operation to aid in closing a large loss of the tissues of the soft palate, the possibility of a combination of the posterior pharyngeal flap procedure for the soft palate when sufficient tissue was present and an extra-oral flap with which to build in the hard palate occurred to us (Fig. 194, *A, B, C, D*). In 2 recent cases this has been the procedure used. The use of the extra-oral tissue for building in the hard palate alone is a much less severe procedure than for building both the hard and the soft palate. The soft palate is built in at the same time the extra-oral flap is prepared—several weeks

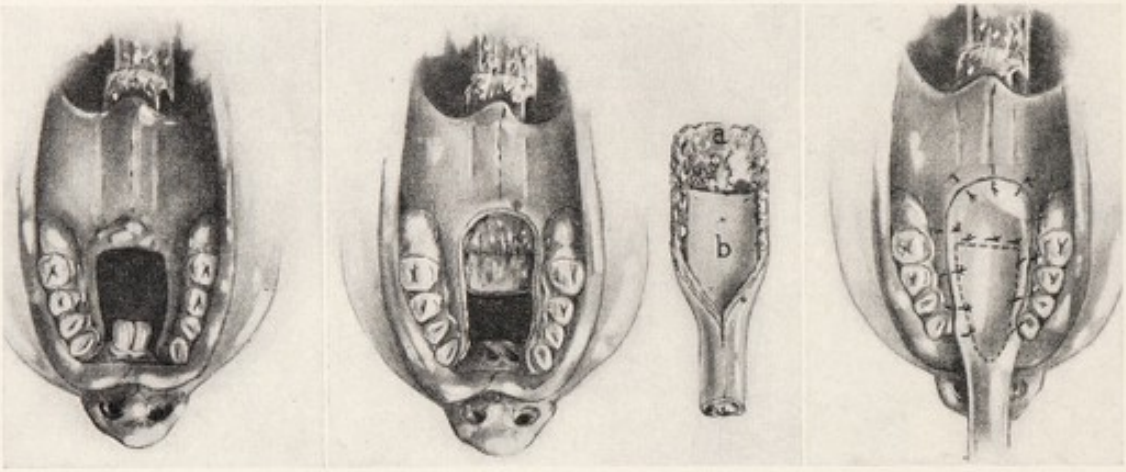

A *B* *C* *D*

Fig. 194.—Method using a posterior pharyngeal flap in combination with an extrapalatal flap. *A,* The posterior palate has been repaired by the use of the posterior pharyngeal flap method. The flap to be used, whether a jump flap from the abdomen or an arm flap, is prepared when the posterior palate is repaired. After three weeks the extrapalatal flap is thrown into the anterior palate. *B,* A ledge is turned forward from the soft-palate tissue so as to obtain a wide overlap. The remaining hard-palate mucoperiosteal flap is elevated from within outward. *C,* Flap after it is cut before being stitched into the defect. *a,* Raw surface; *b,* split graft. *D,* The flap has been stitched into the defect. Every attempt is made to get wide approximation of raw surfaces. A split graft covers the upper surface. When the patient needs relaxation in the lip-alveolus sulcus so that a prosthesis can be fitted to give a normal row of teeth and hold the lip forward, the tail end of the flap when it is cut from its base can be used for this purpose.

prior to placing the flap in the mouth. After this procedure the patient swallows easily immediately and has no difficulty with respiration. The only discomfort is due to the head cast and the fixed arm.

The operation of first "jumping" a flap beneath the upper lip was used in two instances and it will be found to be less trying on the patient than building in the palate directly (Fig. 195). In 1 case it was necessary to release the upper lip so as to obtain an epithelial lined wall anyway for the purpose of inserting a prosthesis which could be used to hold the lip forward. In the other case, the flap failed to unite within the mouth and pulled out. The flap was immediately stitched in under the upper lip, and at a later period was reversed into the mouth and thereby the day was saved.

Bitter criticism has been leveled at the operation which uses extrapalatal tissue for the reconstruction of gross palatal defects. Veau states that such operations are never indicated and has called them "surgical monstrosities." He has also stated that the defect corrected is of less consequence than the defect left after the reconstruction and finally that a prosthesis is preferable to any extra-oral tissue reconstruction. Dorrance takes a somewhat similar position.

Since plastic surgery has undergone the development it has in more recent years, operations similar in principle are of common occurrence in the hands of good plastic surgeons. The repair of gunshot defects or defects after operations for malignancy no worse than this congenital defect, when repaired by these methods are pointed to with pride.

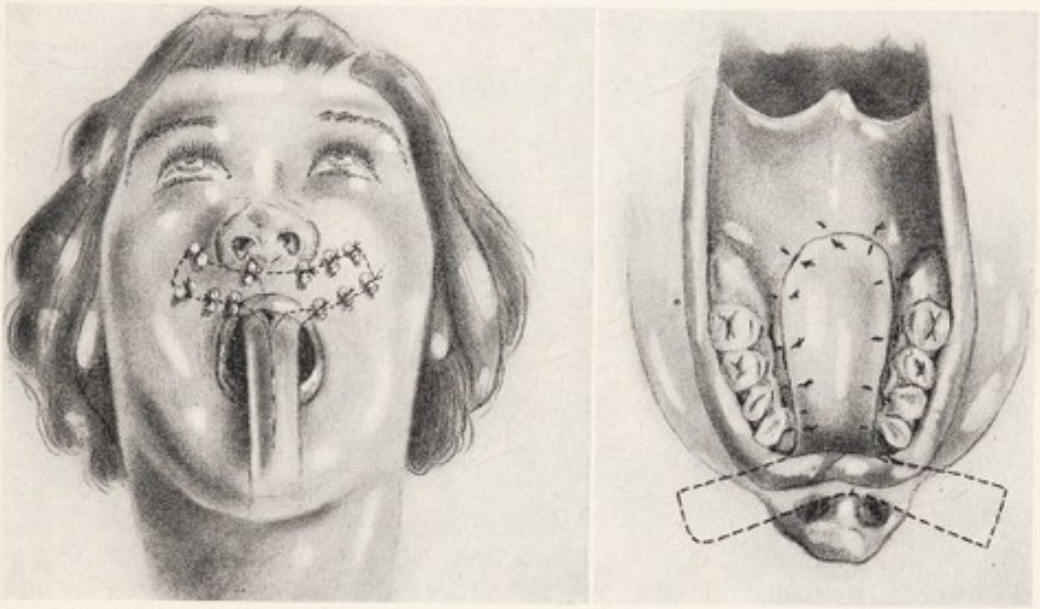

Fig. 195.—When it is necessary to free the lip from the alveolus so that a prosthesis may be used to hold the upper lip forward to improve the appearance, one may jump the flap beneath the upper lip first and later turn it backward into the anterior palatal defect. Also if for any reason the flap originally stitched into the mouth does not hold, one can immediately stitch it beneath the upper lip and then later jump the flap back into the palatal defect. The most common reason for an extrapalatal flap being torn from the mouth is too much tension either from shortness of the flap or improper application of the arm-head fixation. In one of our patients who was an epileptic, and it was unknown to me, a flap was pulled out during a "fit."

The defect that remains after an arm flap is used is negligible when the flap is taken from the medial side of the arm and a good "take" of the skin graft is obtained. In the female, if one desires, because of the scarring of the arm, a jump flap from the abdomen may be used which does not leave an arm scar, but one more operative step is entailed when this method is used.

Complete prosthesis for the unfortunate victim of cleft palate is not as a rule satisfactory. Our series contains 9 examples in which the prosthesis was either built for us or was built by various dentists before we saw the patient. In none of them has the prosthesis been satisfactory and in only 2 of them was the prosthesis used more or less continuously. Prosthesis to plug the gap of a hard-palate defect alone after the soft palate was built in can present a much stronger argument as to efficacy than can prosthesis in a total defect of the palate. However, the 2 cases in which

we have reconstructed the hard palate with extrapalatal tissue after building in the soft palate with intra-oral tissue have been happy with the result. Usually the efficiency of the prosthesis is somewhat directly proportional to the size of the defect which it closes. Prosthesis to plug a small hole is more efficient than prosthesis for placing a diaphragm across a large defect. The advantage of having a permanent diaphragm of living tissue between the nose and the mouth and of not having food pass into the nose is considerable, notwithstanding the fact that a prosthesis for a defect in the hard palate alone may aid defective speech as much, or almost as much as a permanent soft tissue diaphragm.

Conclusion.—In conclusion one might say that it is extremely rare that an individual with cleft palate unsuccessfully operated is seen, who (if proper time is selected for the operation which is indicated in a given condition) cannot be offered a good deal of improvement, and in some cases the final result will be found to be about as good as if he had gained primary union at the first operation. The problem is to individualize the patient and the condition found, and to select that procedure which when all factors are considered, such as the age of the patient, likelihood of union, number of operations required, and the size of the defect, offers the most reasonable and the nearest to the ideal anatomic and functional repair under the conditions encountered. The posterior pharyngeal flap operation is a satisfactory operation when used to aid in obtaining union and giving length to a soft palate in which the tissue loss has been considerable. As far as the proposition of prosthesis versus the transplantation of extrapalatal tissue is concerned, the question may be decided when two conditions are fulfilled: first, whether or not the patient or those responsible wish the palate built in after the advantages and disadvantages of both methods have been explained and, secondly, if the operation is decided upon, whether or not the operator can do the operation. The procedure is certainly not one to be recommended to all surgeons with whole-heartedness, but in good hands it is not at all an unjustifiable procedure. Usually it is in the individual where the damage has been considerable, and where the palate has been repaired just barely acceptably but too well to justify more radical methods, that one really sees the poorest functional results.

Bibliography

Bibliography Quoted in Text

Axhausen, G.: Technique and Results of Cleft-palate Surgery, Leipzig, Thieme, 1936.

Blair, V. P.: The Dieffenbach-Warren Operation for Closure of the Congenitally Cleft Palate, Surg., Gynec. and Obst., **59:** 309–320, 1934.

Brophy, T. W.: Oral Surgery, Phila., P. Blakiston's Son and Co., 1915.

Brown, J. B.: Elongation of the Partially Cleft Palate, Surg., Gynec. and Obst., **63:** 768, 1936.

Blasius: Quoted by von Eiselsberg, F.: Zur Technic der Uranoplastik, Arch. f. klin. Chir., **64:** 509, 1901.

Coughlin, W. T.: Reconstruction of Hard Palate with Cartilage Transplant, J.A.M.A., **75:** 1781, 1920.

Davies-Colley, T. N. C.: On a Method of Closing Cleft of the Hard Palate by Operation, Brit. Med. Jour., **11:** 950, 1890.

Dieffenbach, J. F.: Chirurgie Erfahrung, **324:** 168, 1834.

Die operative Chirurgie, Leipzig, F. A. Bockhaus, **1:** 856, 1845.

Dorrance, George M.: The Operative Story of Cleft Palate, Phila., W. B. Saunders Co., 1933.

Lengthening of the Soft Palate in Cleft Palate Operations, Ann. Surg., **82:** 208, 1925.
Congenital Insufficiency of the Palate, Arch. Surg., **56:** 1186, 1930.
Emerson: Quoted by Makuen.
Halle: Verhandl. d. Gesellsch. Deutsch. Hals-, Nasen- u. Ohrenärzte, May 28, 29, 30, 1925.
Helbing, Carl: Ueber Uranoplastik, Allg. med. Centr. Ztg., **81:** 21, 1912.
Berl. klin. Wchnschr., **39:** 980, 1912.
Lane, W. A.: On Cleft Palate, Lancet, **11:** 433, 1902.
The Modern Treatment of Cleft Palate, Lancet, **1:** 6, 1908.
Lannelongue: De l'uranoplastik ostéo-muqueuse, Bull. et mém. Soc. de chir. de Paris, **111:** 467, 1877.
Lexer, E.: In von Bergmann's System of Practical Surgery, Lea Bros. and Co., 1904, pp. 411–458.
Limberg, A.: Innovations in Operative Methods, Zentralbl. f. Chir., **54:** 1745, 1927.
Makuen: The Operative Story of Cleft Palate: Quoted by Dorrance.
Morestin, H.: Opération complémentaire de l'uranostaphylorraphie, amélioration phonétique considérable obténue par l'allongement de pilièrs postérieurs, Bull. et mém. soc. de chir., **36:** 621, 1910.
Padgett, Earl C.: The Repair of Cleft Palates After Unsuccessful Operations, Arch. Surg., **20:** 453–472, 1930.
The Repair of Cleft Palates Primarily Unsuccessfully Operated Upon, Surg., Gynec. and Obst., **63:** 483–496, 1936.
Passavant, G.: Ueber die Beseitigung der naselden Sprache bei angeborenen Spalten des harten und weichen Gaumens, Arch. f. klin. Chir., **6:** 333, 1865.
Rosenthal, W.: Pathologie und Therapie der Gaumendefekte, Fortschr. Zahnh., **4:** 1021, 1928.
Rotter, Julius: Deckung eines Defectes im harten Gaumen mittelst eines Sternlappens, München. med. Wchnschr., **36:** 535, 1889.
Plastische Operation an der Mundhöhle und in der Nase, Verhandl. d. Deutsch. Gesellsch. f. klin. Chir., **64:** 509, 1901.
Schoenborn: Ueber eine neue Methode der Staphylorraphie, Arch. f. klin. Chir., **19:** 528, 1876.
Sédillot, C.: Quoted by Christopher Heath in The International Encyclopedia of Surgery, **4:** 911, edited by John Ashhurst, New York, William Wood and Co., 1889.
Thiersch, C.: Verschluss eines Loches im harten Gaumen durch die Weichtheile der Wange, Arch. f. d. Heilkunde, **9:** 159, 1868.
Veau, Victor: Division palatine: anatomie, chirurgie, phonétique, Masson et Cie, Paris, 1931.
Von Eiselsberg, F.: Zur Technik der Uranoplastik, Arch. f. klin. Chir., **64:** 509, 1901.
Von Langenbeck, B.: Operation of Congenital Total Cleft of the Hard Palate According to a New Method, Deutsch. Klin., **13:** 231–232, June 15, 1861.
Further Experiences in the Domain of Uranoplasty, Arch. f. klin. Chir., **5:** 1–170, 1864.
Jacobsen's Operations of Surgery, 6th ed., The Macmillan Co., 1915.
Wardill, W. E. N.: Technique of Operation for Cleft Palate, Brit. Jour. Surg., **25:** 117, 1937.
Warren, John C.: On an Operation for the Cure of Natural Fissure of the Soft Palate, Amer. Jour. Med. Sci., **3:** 1, 1828.

CHAPTER XXX

OTHER ANOMALIES, SINUSES, CYSTS AND BENIGN TUMORS OF CONGENITAL ORIGIN

THE complicated manner in which the various structures which finally make up the face, mouth, and neck are joined together or attain their final position leaves the possibility of some defect due to failure of completion of the normal cycle. On this basis the origination of many curious anomalies, sinuses, cysts and tumors found in this region are explained. The embryology of the facial clefts has been adequately discussed under that heading (Chapter XXIV). Remaining to be discussed is the relationship of the branchial clefts to other anomalies, sinuses, cysts, and tumors. For the most part, these lesions develop from mishaps occurring in the development of the tissues which are formed from the second to the fifth branchial arch.



Fig. 196.—Congenital lip pits in a man aged twenty-one years. He also had a partial cleft palate. He had a brother and a sister each of whom had a cleft palate.

Congenital Lip Pits.—Lateral lip pits occur as one of the rarest anomalies of the human body (Fig. 196). Hilgenreimer states that 51 cases have been recorded in the literature up to 1924. The lesions present themselves at one side of the midline as slight depressions on the vermilion border of the lower lip or as small teats and may rarely secrete thin fluids. Keith made the suggestion that the anomaly is an atavistic one—a reversion. Mucous glands normally appear in the lip of the shark. Dursy explained these fistulae as developmental arrests on the basis of the embryologic discovery that a central position of the lower lip is formed by two small prominences. Madelung showed the canals of these pits to be lined with mucous membrane. The anomaly has also been described by Richet, DePaul and others. Hilgenreimer in an article written in 1924 concluded that the lesion is inherited, is found more often in females, and is frequently associated with bilateral harelip or cleft palate. The pits are usually bilateral and equidistant from the midline. The treatment is excision if the deformity is noticeable.

Macrostomia.—Macrostomia has been described in conjunction with facial clefts.

CONGENITAL ANOMALIES OF THE TONGUE

An arrest of or a deviation from the normal course of development supposedly may produce congenital deformities of the tongue as elsewhere in the body.

Partial Ankyloglossia ("Tonguetie").—The most common deformity of this type is a shortened frenum beneath the tongue which produces the condition commonly called "tonguetie" (partial ankyloglossia). Normal protrusion and mobility are hindered. In definite examples of the condition the tip of the tongue will not protrude beyond the gums or teeth. On attempting to touch the chin with the tip of the tongue, the tip is curved inward and a marked notch or groove in the dorsal midline is evident. Butlin says the condition is very rare but it is probable that he has overstressed the rarity of the condition.

Treatment.—Simple clipping of the frenum is not sufficient to mobilize a definite example. Later when the raw area following the frenal clipping cicatrizes, the tip of the tongue will be pulled back to nearly its former position. Besides clipping the frenum of the tongue, a mucosal flap should be thrown across the denuded area to prevent immobility. The base of the flap is downward and the lengthwise portion is taken from one side or the other of the sublingual mucosa with the apex toward the tip. The mucosa on either side where the flap is removed is stitched together in a lengthwise fashion. The flap is half turned crosswise at the base of the cross cut frenum.

Jussieu has described absence of the tongue. Deplong has recorded fusion of the tongue with the floor of the mouth and Petit and Fairbairn described cases of excessive mobility of the tongue which sometimes caused tongue swallowing. This latter deformity has caused death from suffocation. After the operation for "tonguetie" difficult respiration from tongue swallowing may develop.

Long Tongue.—A few instances of extreme length of the tongue are recorded.

Bifid Tongue.—Bifid tongue is seen occasionally. The anterior part of the tongue is cleft in the midline to a variable degree. Cleft lower lip may be associated with bifid tongue. In our series of mouth deformities, there is 1 case of bifid tongue and 1 case in which most of the anterior part of the tongue was absent. In both of these cases the anterior part of the lower alveolus was poorly developed but there was no absolute cleft. Bifid tongue can be fairly satisfactorily repaired in a manner similar to that of denuding and suturing a cleft of the palate.

CONGENITAL CYSTS AND TUMORS OF THE PALATAL REGION

Incisive Canal Cysts.—Palatal cleft cysts have been described by Grünwald (Thoma). They have also been described by Schroff as nasopalatine duct cysts. In the adult the nasopalatine duct occasionally remains open or the lumen of the duct closes leaving an impervious cord of epithelium. Most commonly, however, it is completely obliterated. Rawengel after making serial sections (19 newborn and 8 adults) found 5 patent

canals in the newborn, in 3 adults no patency, in 14 cases a blind sac from the nasal side, and in 4 cases a blind sac from the mouth side.

The etiologic factors in the formation of a cyst in this region are possibly trauma, extension of an infection about the central incisors and nasal infection.

Clinically the patient gives a history of repeated swelling in the region of the palatine papillae. Sucking of the enlargement may give a salty taste. The roentgenogram is an important part in the working up of a case. The exact midline cysts are not connected with the teeth as radicular cysts are.

Fissural Cysts.—Cysts developing from retained epithelial nests at the point of fusion of the various processes of the jaws during embryonic development are interesting. Facial cleft cysts were described first by Zuckerkandl in 1882. Recently Klestadt, Huizenza, Doring, Schroff, and Schmidt have described examples of these cysts.

A swelling appears in the anterior part of the nostril or wing of the nose. The cysts have more of a tendency to be on the bone than in the bone. The paramount location is where the maxillary and globular processes and the middle and palatal nasal processes fuse. Other sites are at the alveolopalatine fissure and the lateral nasal fissure. The cysts are lined with cylindrical epithelium and contain a thin mucoid material.

CONGENITAL CYSTS AND TUMORS OF THE FLOOR OF THE MOUTH

Ranula.—The term "ranula" is applied to cysts in the floor of the mouth. The exact origin of the cysts is uncertain. Probably the origin varies. Most of them have been considered in the past to be retention cysts, *i. e.*, of a mucous gland, or a salivary gland in the floor of the mouth. But I am inclined to agree with Thompson (Fig. 197) that some of the larger ones are congenital in origin, *i. e.*, develop from remnants of branchial cleft. Anatomically, if the retention cyst viewpoint is held, three structures might offer a very plausible source: (1) the incisive glands of Suzanne and Merkel, (2) the sublingual glands, (3) Bochdalek's glands. Ordinarily the submaxillary duct is not incriminated as saliva may be seen to issue from the duct freely. Wharton's duct is apparently always patent. Tilleux described a sublingual bursa which could possibly give rise to a cystic formation. Butlin, however, denies the existence of this bursa.

Thompson in 1923 presented anatomic and other evidence that certain large ranulae which extend well downward and backward into the lateral upper neck originate from remnants of the branchial clefts. His hypothesis is interesting and may possibly be correct. Blair and I have had cases of this nature. In these cases the styloid process could be felt in contact with the posterior wall of the cyst. The anterior part of the cyst presented beneath the tongue and connected with the posterior prolongation.

Probably the sublingual gland is given credit at the present time for formation of most ranula. Morestin presented a dissection showing the lobes of the sublingual gland extending through the mylohyoid muscle and appearing on its under surface. This would explain certain ranulae that bulge through the mylohoid muscle beneath the chin. The rarest form possibly arises in the midline behind the incisor teeth and is thought to originate from the incisive glands of Suzanne and Merkel.

Pathology.—On microscopic examination about one half of the cases show either columnar or cuboidal epithelium some (Fig. 197, *B*) place in the cyst wall. The other half of the cases have apparently lost all of the epithelial lining due to a pressure atrophy. Some instances of ciliated epithelium have been recorded. The only ciliated epithelium normally found in this locality is in the thyroglossal duct tract or its remnants, as the gland of Bochdalek. The fluid contained within the cyst is a brownish serum and may contain crystals.

Clinical Picture.—A painless, slowly growing, bluish gray, tense or possibly fluctuating mass appears beneath the tongue behind the incisor teeth in the floor of the mouth. While the mass may be located in the midline, as a rule it is to one side. The mass is movable, well circumscribed and

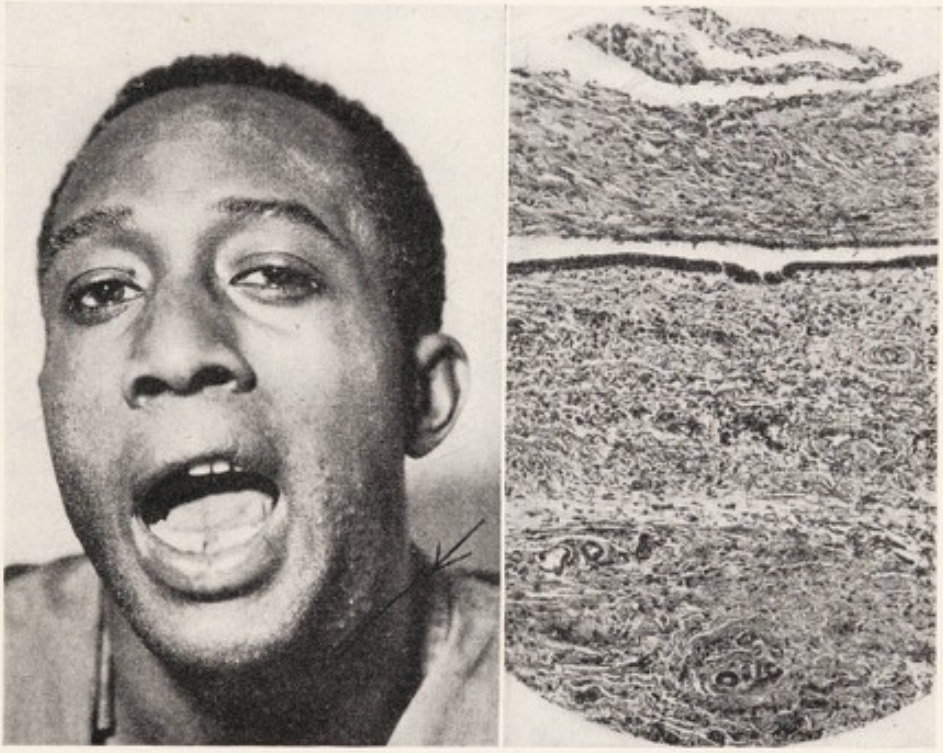

A *B*

Fig. 197.—*A,* Ranula, Thompson type. *B,* Ranula of the Thompson type showing columnar cellular wall in woman twenty-four. The tumor had been partially removed twice previously. Each time they had failed to remove the submaxillary projection of the epithelial wall.

the mucosa about it is free. According to the size of the mass, the anterior part of the tongue is elevated. The diameter varies from 2 or 3 cm. to 7 or 8 cm. in those which have backward prolongations (the Thompson type). The shape is usually more or less sausage-like and not entirely spherical unless small. In the Thompson type when pressure is made upon the cystic mass in the floor of the mouth, there is a bulging in the submaxillary region in the upper part of the neck, or if pressure is made in the submaxillary region, the mass beneath the tongue enlarges quite markedly. A growth deformity of the lower jaw is said to have been caused by such cystic masses developing in childhood and being neglected. On aspiration the characteristic yellowish brown fluid is obtained. When stuck with a knife and evacuated, it will be found that they soon refill. Like all cysts it is possible to infect them secondarily.

Treatment.—Silver wire has been passed through the cyst wall with temporary relief and evacuation of the contents. Usually permanent relief is not obtained until the whole cyst wall has been dissected out. A pair of sharp-pointed dissection scissors aids one in the dissection (Fig. 198, A, B, C). This is not difficult and offers, if the cyst wall is completely removed, a permanent cure. In the larger ranulae which go back to the styloid process, an incision is necessary in the submaxillary region to entirely remove the posterior part of the cyst. The submaxillary triangle is opened as in a neck dissection of that region (Chapter XXXV) save that a smaller skin incision is sufficient for exposure. When the cyst is removed from within the mouth, the cavity is packed loosely with gauze. If a submaxillary incision is necessary the incision is closed with interrupted sutures and a rubber dam drain inserted for a few days to allow drainage of the serum.

Dermoid Cysts of the Floor of the Mouth.—The common explanation for the origin of congenital dermoid cysts is that at the time of closure of the embryonic fissures, epithelial tissue is sequestrated or included in the

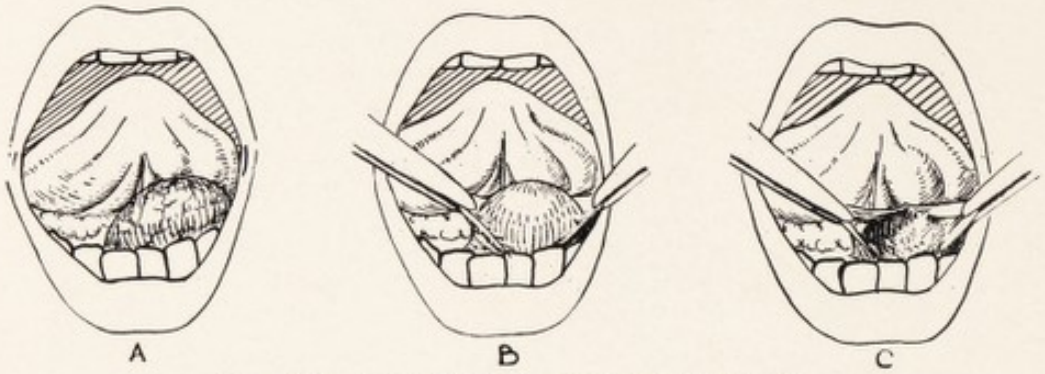

Fig. 198.—Dissection for removing a ranula.

mesodermal tissue. Such cysts are found occasionally in the floor of the mouth.

Structure.—The wall of the cysts is composed of a stratified epithelial lining which is surrounded by dense connective tissue. The epithelium has a papillary arrangement similar to normal skin (Fig. 199, *A*). Sweat glands and hair follicles also may be present. The sebaceous gland secretes cheesy content found within the cystic cavity.

Situation.—In the floor of the mouth dermoids occur in three situations: (1) in the midline beneath the skin (Fig. 199, *B*), (2) between the geniohyoid muscles or (3) to one side below the angles of the jaw. The lateral dermoids probably were once centrally located but have shifted their position. Branchial cleft cysts are not included in this third category. Cysts found just anterior to the epiglottis may have had a more anterior position at first but possibly most of these are from pathologic remains.

Clinical Picture.—Although the inclusion of epithelial elements occurs in embryonic life, it is usually not until late in childhood that the mass becomes evident. Between the ages of ten years and twenty-five years characteristically a slow-growing, smooth, painless mass makes its appearance. On palpation the mass is found to be smooth, circumscribed, and of a consistency varying from toothpaste to that of a hard-boiled egg. The surrounding structures are not attached closely. On pressure the mass may

pit perceptibly. As time goes on the mass slowly attains the size of a golf or tennis ball and usually there is a tendency for some shift to one side or the other. Externally, there is a visible bulge beneath the chin and from within the mouth the floor of the mouth appears full and the tongue is pushed upward. Through the mucosa in the floor of the mouth the mass

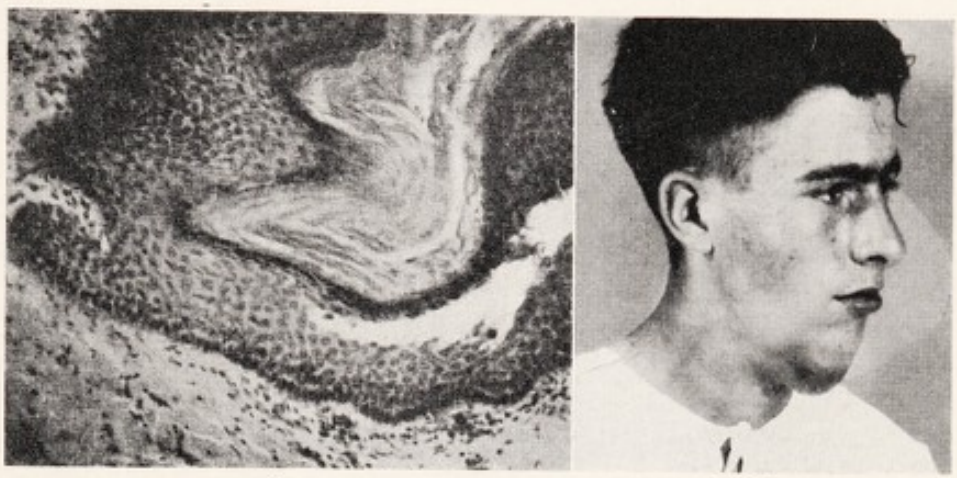

A *B*

Fig. 199.—*A*, Dermoid cyst of floor of mouth. Shows squamous-cell epithelial lining. (Blair, Padgett and Brown.) *B*, Boy with a large dermoid cyst of floor of the mouth which is mostly beneath the mylohyoid muscle.

appears whitish yellow in color. As the enlargement increases deglutition or even breathing may become hampered.

Occasionally, such a lesion may become secondarily infected after which the clinical picture may simulate that of a Ludwig's angina with fever, tenderness, edema, and induration in the floor of the mouth.

Diagnosis.—Tumors situated deeply in the region of the hyoid bone may be difficult to diagnose clinically from misplaced thyroid tissue without

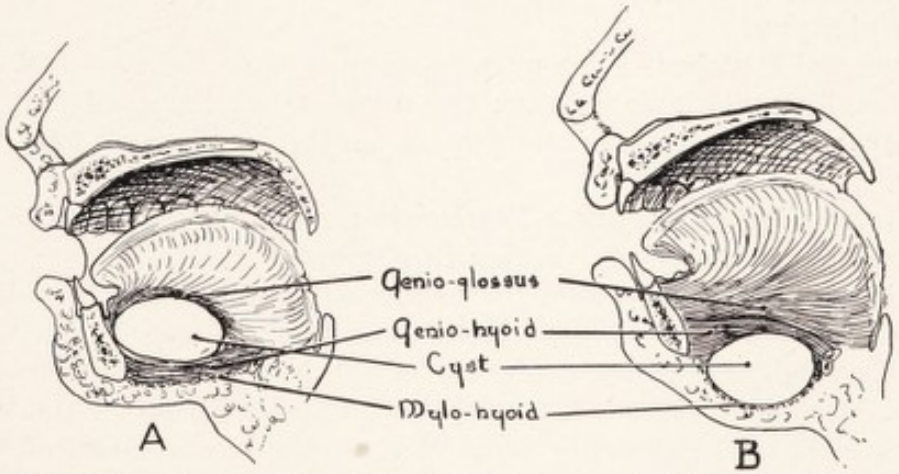

Fig. 200.—Dermoid cyst. A, Above mylohyoid muscle. B, Below mylohyoid muscle.

exploration. Ranulae are bluish gray, elastic, or semifluctuant. Aspiration with a large needle may aid in making the diagnosis when other means fail.

Treatment.—The treatment is enucleation through the most appropriate incision that would appear to give adequate exposure. These tumors, as a rule, shell out without difficulty when the dissection scissors are inserted

just without their fibrous tissue wall and pressure is made in a manner to throw the mass to the surface of the incision. When it is possible to use local anesthesia, the lines of cleavage are somewhat clearer. As many of them, however, are seen in children, local anesthesia is for this reason hardly feasible.

CONGENITAL LESIONS OF THE PHARYNX

The pharynx holds a close anatomic, pathologic and physiologic relationship with the buccal cavity.

Congenital Malformations of the Pharynx.—Other than cleft velum, congenital malformations of the pharynx are seldom seen. Atresia of the posterior nares may be congenital. I have seen 2 such cases. It is due to lack of obliteration of the oral plate, that early in embryonic life separates the primitive buccal and nasal cavities. The condition causes complete or almost complete nasal obstruction. The nasal septum has in rare instances extended back to the nasopharynx. Unilateral and bilateral small clefts have been seen at the side of the velum. Failure of union of the first branchial arch might account for this anomaly. The tensor palati muscle belongs to the first branchial arch and the anterior faucial pillar to the second branchial arch. However, Bruck states that such lateral clefts may be acquired after syphilis or diphtheria and not be of congenital origin.

Pharyngeal Branchial Fistula.—Branchial fistula is discussed under congenital malformations of the soft tissues of the neck (this chapter) where the embryologic explanation of their formation is discussed. Internal failure of obliteration of a branchial cleft explains the internal fistula.

Wenglowski in 1912 published a study of 78 embryos serially sectioned, 140 children and 59 adult cadavers, and 21 cases of neck fistulae and cysts, and concluded that in man branchial clefts and grooves are never patent. Still in the case shown in Fig. 205, *A*, the sinus connected on both sides with the pharynx.

Pharyngeal Pouches.—The mucous membrane of the pharynx is said to bulge laterally sometimes between the muscles. It has been inferred that these may represent incomplete fistulas that communicate only with the pharynx.

Teratoma of the Pharynx.—Teratomas are rarely found in the pharynx. They practically always are benign in character but the embryomas most commonly and the others less so may show malignant characteristics. They consist of tissues derived from more than one embryonal "germ layer." Probably at the time of segmentation of the ovum a misplacement of one of the blastomeres occurs. The degree of differentiation of the structures making up the tumor possibly depends upon the relative age of the ovum when the misplacement happens. Early misplacement would tend toward a more complex structure. When the growths are less complex they are termed teratoids. The tumors consisting of epithelium and its appendages such as hair, teeth, sebaceous glands and sweat glands are called dermoids. Borst has divided teratomas into three groups: (*a*) monodermal teratomas which may contain any of the structures which may develop from the mesenchyme, (*b*) bidermal teratomas which contain structures derived from two embryonic cell layers as from the ectoderm and the mesoderm, (*c*) tri-

dermal teratomas in which all three layers are represented. Blastomatous teratomas show an embryonic undifferentiated cell structure.

When dermoids are seen in the nasopharynx they are usually lined with cylindrical or ciliated epithelium and the walls may contain lymphoid tissue, cartilage or bone. They are thought to develop from the branchial clefts and are really branchiogenic cysts. Another type of endodermal cyst may develop from the remnants of the thyroglossal duct. These also are lined with cylindrical or ciliated cylindrical epithelium. These tumors arise at the base of the tongue or deeper toward the thyroid region. The symptoms are mechanical, *i. e.*, nasal obstruction. The treatment is excision.

Hairy Polypi.—"Hairy polypi" are solid skin-covered tumors usually pedunculated from which grow a lanugo-like hair. They are genetically related to the first branchial cleft. Their principal tissue is an adipose connective tissue but they also contain striated muscle, osseous tissue, cartilaginous tissue and sometimes tooth material. As a rule they are not large and are rather pear shaped. Usually the growths arise from about the middle of the nasopharynx. Tumors of a similar character may be sessile or be deeper and even project upward through the floor of the sella turcica. Although these tumors are congenital by nature, symptoms may not be noted until adult life or even in middle age. The symptoms are mechanical in nature.

Pharyngeal Goiter.—A mass of thyroid tissue has been described as lying behind in the lower part of the pharynx. Bruch, Braun, Hajek and Wolfler have described such cases. Such a location is explained either on the basis that a supernumerary thyroid gland might arise from the lateral lobe of the main thyroid gland or by the aberrant gland. The tumor ordinarily has about the consistency of the thyroid gland. The mass on examination with esophagoscope can be seen to move up and down with the swallowing motion. If it is attached to the lateral lobe, movement away from the thyroid gland is limited. By pressing on the mass from within, a bulging may be noted at the level of the thyroid cartilage in the neck. The final diagnosis can only be made after removal of the growth. Provided there are distressing symptoms and the remainder of the thyroid gland is present, excision is to be considered.

CONGENITAL MALFORMATIONS OF THE SOFT TISSUES OF THE NECK

Occasionally one sees instances of webbing of the soft tissues of the neck. I have seen three examples. Two of the patients were brothers (Fig. 201, *A*, *B*). The explanation of this deformity is rather obscure. The treatment is transplantation of crosswise flaps in such a manner that the defect is eliminated. Various sinuses, cysts and tumors of congenital origin may develop. But before discussing these lesions, it may be well to recall a few pertinent facts concerning the embryology of the branchial apparatus from the first branchial arch to the fifth branchial arch.

Embryology of the Branchial Apparatus.—It will be remembered that in the early weeks of intra-uterine life four arches are present on the external lateral neck and six arches are present internally. Internally between these six arches in the lateral wall of the anterior foregut is a depression known as the pharyngeal pouch. Externally opposite these depressions are

grooves. The mesodermal layer is very thin between these internal and external grooves, and in places is absent or nearly so. Thus, the ectoderm and the endoderm almost fuse to form a thin membrane between the interior of the gut and the exterior. In gill-bearing animals the two layers of membrane actually rupture and form the gill slits. Later, the mesoderm between the endoderm and the ectodermal layer thickens and within it in the arches is laid down cartilage.

The first mandibular arch grows rapidly and the second almost as rapidly. Soon each mandibular arch divides. The upper part forms the maxillary process and the lower part the mandibular process. The cheeks, the lateral upper lip and the maxillary bone develop from the maxillary process. The lower lip, chin, the mandible, the muscles of mastication and the anterior tongue develop from the mandibular process. The cartilaginous bar of the mandibular process is known as Meckel's cartilage, which extends from the capsule of the ear to the symphysis menti. The ventral part of the cartilage enters into the formation of the part of the mandible which

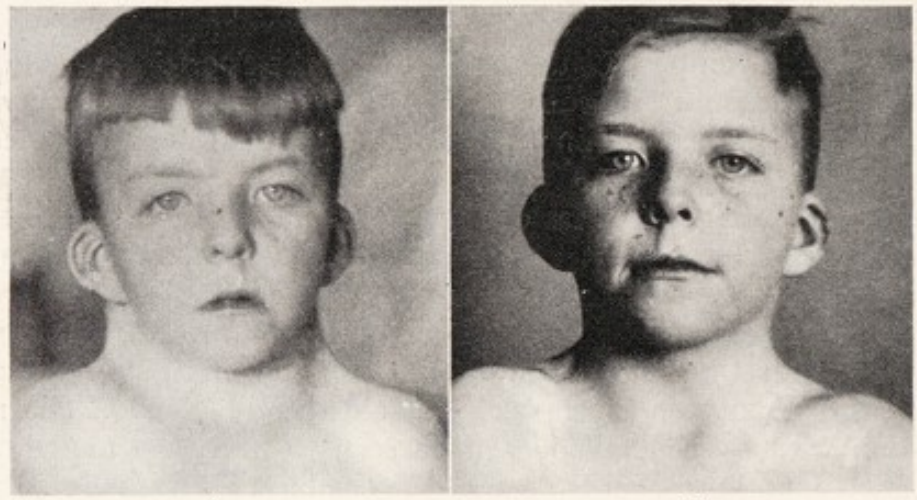

A *B*

Fig. 201.—Congenital webbing of neck. This boy had a brother with the same deformity. *A*, Before operation. *B*, After operation.

will contain the incisor teeth. The dorsal part of this cartilage enters into the formation of the malleus of the ear. The intervening part of the cartilage all disappears save a part adjacent to the malleus which forms the sphenomandibular ligament.

The second hyoid arch and the third arches form the lateral and ventral portions of the neck and also the styloid process, the body and horns of the hyoid bone and the posterior part of the tongue. The fourth and fifth arches form the thyroid cartilage. The sixth arch forms the cricoid, the arytenoid and the cartilages of the trachea.

Each arch originally has a vascular arch taking its origin from a ventral aortic trunk. The first two vascular arches disappear. The ventral aortae persist as the external carotid arteries. The third vascular arch forms the internal carotid arteries. The fourth arch on the right forms the right subclavian artery and on the left the arch of the aorta. The fifth and sixth vascular arches are ultimately lost. A remnant of a branchial cleft higher than the third arch must therefore pass superior to the internal carotid artery. A remnant of a branchial cleft below the third arch must

pass inferiorly to the junction of the internal and the external carotid arteries.

The right and left lateral pharyngeal pouches are separated anteriorly by a ventral groove—the ventral pharyngeal groove. The pouches between the second and third arches deepen more than the others. If the deepening is too marked, it is possible that the closing membrane may rupture and thus a fistula may result and persist.

As the mandibular arch especially and the second also grow more rapidly than the others, these two soon tend to overlap the remaining arches. A deep depression beneath them is produced, the precervical sinus. The precervical sinus is at first open laterally but as the second or hyoid arch grows down over the opening (the cervical duct) the opening is finally forced to close. A sac is then left lying lateral to the third pouch which is connected with the second and fourth pouches of the external clefts which have been pulled into long canals. But these do not persist. The lumen soon disappears and the epiblastic cells of the sac normally disintegrate and

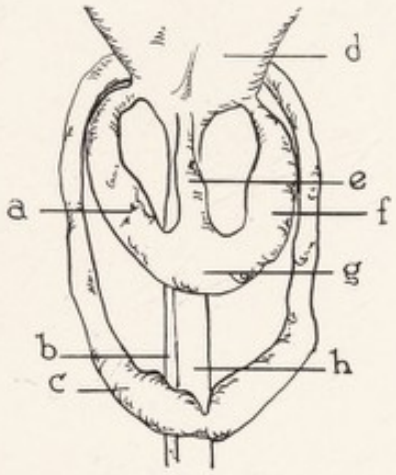

Fig. 202.—Model of pharynx and trachea and the organs from them in a 14-mm. embryo. *a*, Lateral thyroid lobes; *b*, esophagus; *c*, thymic duct; *d*, pharynx; *e*, thyrolingual duct; *f*, lateral thyroid lobes; *g*, thyroid lobes; *h*, trachea.

disappear. Any failure of regression of these epiblastic cells may leave epithelial remnants buried and thus it is thought an etiology is given for the various epithelial tumors arising in this region.

From the first groove is formed the acoustic apparatus. The external part forms the external auditory canal and so forth. From the internal part is formed the eustachian tube and tympanic membrane. The closing membrane forms the tympanic membrane. The second, third and fourth branchial grooves disappear (Fig. 202).

From the inner part of the second pharyngeal pouch the sinus tonsillaris is developed. The tonsil develops in it. Above it a trace of the sinus persists as the supratonsillar fossa. Some regard the fossa of Rosenmüller as a remnant of the second pharyngeal pouch. From the third pharyngeal pouch arises an endodermal diverticulum from which the thymus is developed. From the fourth pouch a small diverticulum is formed which becomes embodied in the thymus gland. The parathyroid gland arises from a diverticulum of the third and fourth pharyngeal pouches. From the fifth pharyngeal pouch, the ultimobranchial bodies develop. These bodies are enveloped by the lateral prolongation of the medial thyroid rudiment but they form no true thyroid tissue.

Branchiogenic Cysts and Sinuses.—Under congenital malformations of the pharynx, branchial cysts and fistulae are discussed briefly.

Wenglowski argues that most lateral neck fistulae arise from the "thymus anlage of the third pharyngeal pouch." According to the older conceptions lateral neck fistulae and cysts arose from the second gill cleft and pharyngeal pouch. The main proof in favor of Wenglowski's conception is the course of the fistulae, which pass under the glossopharyngeal nerve. Against the old theory, is the fact that fistulae are usually situated in relation to the stylopharyngeal muscle which arises from the body of the third branchial arch. Branchial fistulae pass below the muscle (stylopharyngeal) and usually open to the exterior on its posterior margin. Thus, he believes that most neck fistulae belong to the third and not the second gill cleft. Moreover, the explanation of the fact that most neck fistulae are covered with pavement epithelium offers many difficulties. Pavement epithelium is

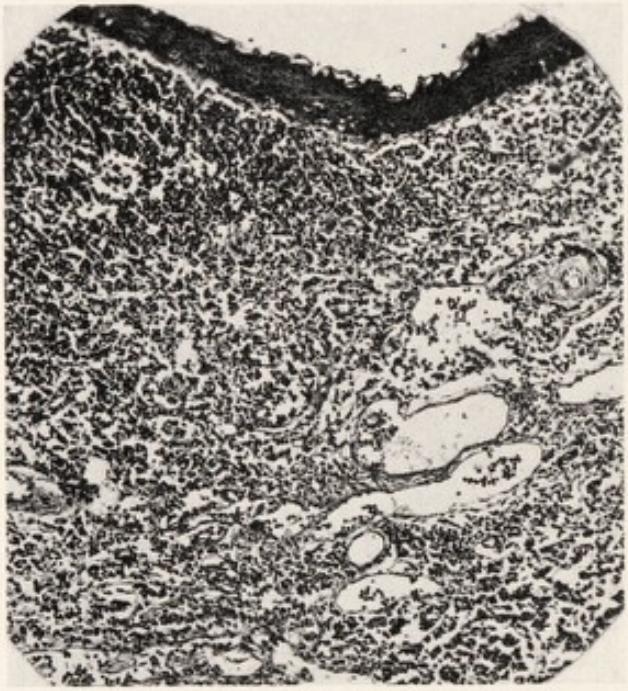

Fig. 203.—Lining of branchiogenic cyst.

supposed to belong to the third pharyngeal pouch and flat epithelium to the gill cleft. He finds external incomplete fistulae with pavement epithelium and internal fistulae with flat epithelium (Fig. 203). He argues that there is little likelihood of the arch of the pharyngeal pouch reaching down to the suprasternal fossa while the gill arches between which the pouch is situated should retain their position unchanged. Moreover, the inner opening of the fistula usually lies behind the pharyngeal arch or in the lower posterior corner of the "Mandelbucht" and, therefore, in the dominion of the third and not the second pouch and finally the course of the fistulae and their position with relation to the external carotid does not correspond to an origin from the second branchial pouch or gill cleft. I believe, at present, that Wenglowski's ideas are accepted.

Clinical Features.—The external evidence of the cyst or sinus appears on the upper part of the neck (Fig. 204, *A*, *B*). Branchiogenic fistulae or cysts are always found above the level of the hyoid bone. They are always

lateral. The cystic mass may appear beneath the sternomastoid muscle but the sinuses, whether congenital or appearing after ill-advised incision and drainage, are found laterally or just anterior to the sternomastoid above the hyoid bone or about the region of the external ear.

Diagnosis.—The diagnosis of the branchiogenic sinus is made on the location and the history of the persistence of a sinus either present since birth or present after the incision of a cystic mass. The lateral high location is characteristic.

A branchiogenic cyst, however, may be more difficult to classify if the cystic contents are not fairly definite. By aspiration one might gain some information as to the character of the tumor mass. The cystic wall moves from side to side but usually up and down movement is impeded as the cyst tends to have an attachment to its tract in the neighborhood of the carotid bifurcation. Usually it is evident that the mass, whatever it is, is one to be removed. During the enucleation of the mass its nature becomes

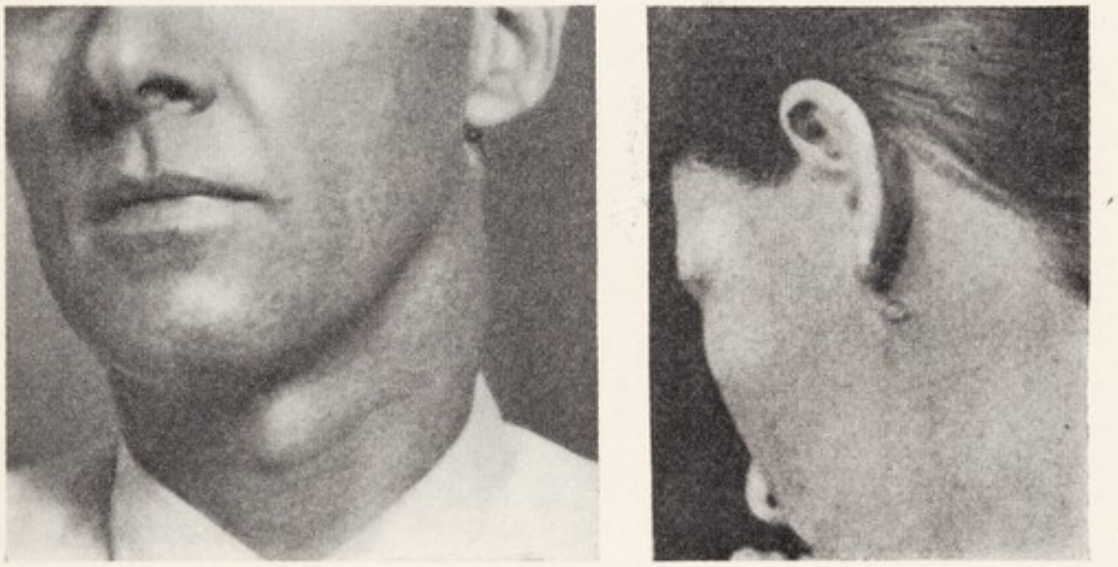

A *B*

Fig. 204.—*A*, Branchiogenic cyst. *B*, Branchial cleft fistula. (Blair, Padgett and Brown.)

evident if a diagnosis has not been made previously. If the mass should prove not to be a cyst but some type of neoplasm, the procedure would depend upon its character and the difficulty that might be encountered in its complete removal.

Treatment.—The treatment is complete excision of the cyst or sinus tract. No other method of treatment will result in a cure. An incision is made preferably over the cyst or about the sinus tract in the line of the neck wrinkles. It should be sufficiently long so that adequate exposure is possible. The sternomastoid muscle is retracted backward. In the case of a cyst, enucleation is ordinarily not difficult.

Considerable difficulty may attend the complete excision of a branchial fistula. When the pocket is a blind one, excision is easy, but a complete fistula is hard to follow as the tract may be quite delicate and identification becomes uncertain at its inner end. One is seldom fortunate enough to be able to pass a probe. The injection of methylene blue into the tract may aid one in following the tract.

According to the embryology of the branchial arches, if a fistula developed from the second gill cleft, it would run between the stylohyoid muscle and the ligament in front and the internal carotid and stylopharyngeus muscle behind. If the fistula developed from the third gill cleft, the tract would run between the stylopharyngeus and superior constrictor muscles and internal carotid above and the middle constrictor below.

When working in the neck and attempting to follow a branchial sinus, almost any structure except the common and carotid arteries, the superior laryngeal, vagus, glossopharyngeal and hypoglossal nerves may be divided if necessity so dictates. The stylohyoid and the digastric muscles may be divided and resutured. The fistula must be followed to the pharynx and the inner end of the tract removed.

Thymic Tract Sinus.—Those rare lower fistulae seen near the suprasternal notch are probably due to remnants of the tract resulting from the descent of the thymus gland from the third pharyngeal pouch. The patho-

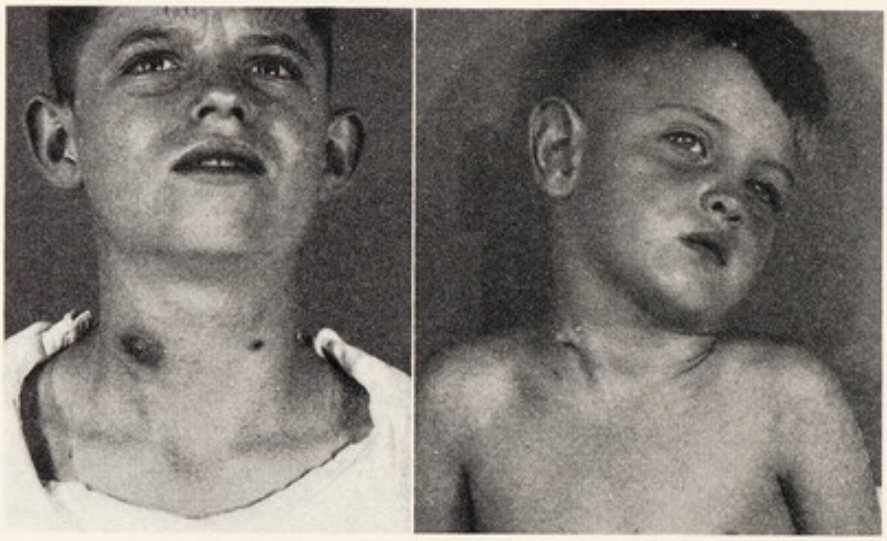

A *B*

Fig. 205.—*A*, Boy with bilateral thymic duct sinus. *B*, Boy with a cartilaginous protuberance at site where one very often finds a thymic duct sinus.

genesis, histology and pathology are similar to that of the branchial tract lesion just described.

Clinical Features.—Thymic tract fistulae have their external opening along the anterior border and below the midportion of the sternomastoid muscle. They are quite rare (Fig. 205, *A*, *B*). The clinical course of the cysts and sinuses is the same as in branchial cleft save that the external opening of the fistulous tract is at the opposite end of the neck length.

Diagnosis.—The diagnosis of the fistulae of the thymic gland tract is not difficult when the embryology is known and the location and history are considered.

Treatment.—To excise fistulae appearing in the lower neck which arise presumably from the thymus gland tract off of the third pharyngeal pouch, an incision of the type for the higher neck fistulae is insufficient (Fig. 206, A, B). An extension downward above the anterior border of the sternomastoid muscle will most likely be necessary.

Tumors and Cysts of the Thyroglossal Tract.—His demonstrated a peculiar tract of tissue extending from the foramen caecum of the tongue to

the pyramidal lobe of the thyroid gland. This tract since has been shown to be the only permanent vestige of the path traversed by the thyroid gland when it descends into the neck in embryonic life. The presence of this tract explains the tumors and cysts which in rare instances may be found between the thyroid gland and the foramen caecum. These new growths contain cells similar to those of the thyroid gland.

Bertwistle and Frazer studied a series of these lesions and stated that in their opinion "thyroglossal remnants above the hyoid are few and if present are usually either near the foramen or near the hyoid" but "below the hyoid the tract is present completely in many cases and incompletely, *i. e.*, partially in others" and "the complete infrahyoid tract extends from the

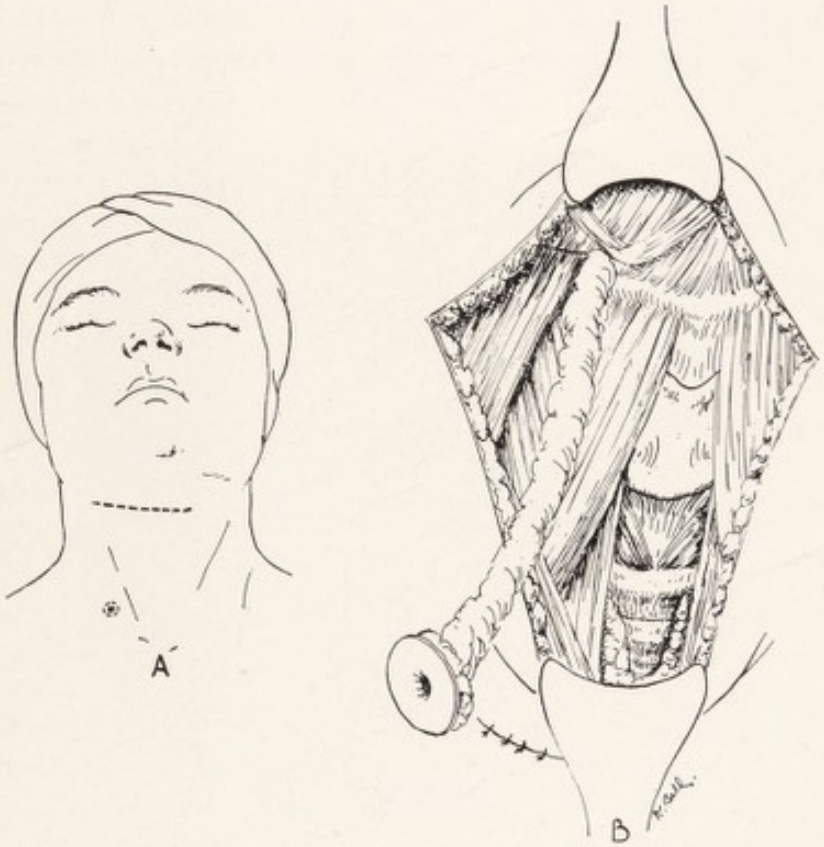

Fig. 206.—A and B, Lateral cervical fistula operation. Incisions, one about the fistula and one above the fistula. This prevents an up and down scar. Through the upper incision one might dissect out a lateral cervical fistula of a branchiogenic cyst. In this diagram a lateral cervical fistula is depicted.

hyoid (usually folded up behind it from below) to the thyroid glands either centrally or on one side." They continue and state "it is possible that some cells of the tract may become separated and ledged below the level of the glands. If this is true these cells are liable also to take on further development. Certain continental embryologists about thirty or forty years ago maintained that median fistulae, etc., found low in the neck arise from remnants of the pre-cervical sinus, a view strongly supported by Kantack. This view would not receive extensive support from embryologists today" and "cysts lying superficially below and behind the foramen caecum may possibly originate from a space included between the two halves of the developing hinder part of the tongue and may not be connected with the thyroglossal tract."

Bailey collected 117 cases of thyroglossal cysts and fistulae from the London Hospital. Seventy-five per cent of these were found in the female sex. Thyroglossal duct cysts are most commonly seen in infants. However, in 19 of Bailey's cases no evidence of the cyst was shown until after the twentieth year. Bailey emphasized the association of an inflammatory stimulus as causing their first appearance. The lymphatic tissue which surrounds the sinus tract is liable to infection. In 4 of Bailey's 19 adult cases the tumor appeared after an attack of pharyngitis or tonsillitis and in several of the others a sore throat preceded the appearance of the lesion. For instance he mentions a baby which was admitted with an infection of the foot and developed a thyroglossal cyst which suppurated.

Bailey states "there is evidence, both clinical and histological, that thyroglossal cysts are frequently the site of inflammation." In 31 fistulae (Bailey) only two were present at birth and of those not present at birth,



Fig. 207.—Thyroglossal duct sinus tract.

their appearance varied from the third week to the thirty-first year. Bailey's series of 117 cases of cysts (86) and fistulae (31) are valuable when one considers location. He found 3 cases beneath the foramen caecum, 6 in the floor of the mouth protruding beneath the chin, 12 cases along the thyroid gland, 23 cases in the thyroid cartilage or membrane, 7 cases at the level of the cricoid cartilage, and 4 in the suprasternal notch. (It would occur to me that these latter might have been of thymic tract origin.)

Thyroglossal Tract Tumors Near the Foramen Caecum.—Tumors which may be soft or solid, within the tongue or even sessile, contain multiple cysts, and may vary in size from 1 cm. to 5 cm. in diameter, usually present at birth but sometimes developing insufficiently to cause symptoms until puberty or later, are found in rare instances near the foramen caecum (Fig. 207). Under the microscope the principal cell is seen to be more or less typical cuboidal ciliated epithelium arranged in alveoli resembling

somewhat the normal thyroid cell. Through the mucosal covering of the tongue, the growths appear dark in color. They are rather vascular and hemorrhage from the mouth not rarely calls attention to the growths. When large, there is a mechanical interference with swallowing. The diagnosis is made on the history of a tumor of slow growth, a history of hemorrhage, the dark color, the consistency and the location of the mass. Biopsy may cause embarrassing hemorrhage because of the vascularity of the growth. Total removal may be less hazardous. Before removal, one should be certain that sufficient thyroid tissue remains to prevent hypothyroidism.

Perihyoid Thyroid Tumors, Cysts and Fistulae.—Rarely aberrant thyroid tissue may be found in the immediate neighborhood of the hyoid bone or more rarely in the tongue substance along the thyroglossal duct tract. Streckeisen described aberrant thyroid masses in this region. In hyperthyroidism these aberrant remnants of glandular tissue may enlarge and become hyperplastic.

But in this perihyoid region cysts and fistulae although rare are more common than aberrant thyroid-like tissues. The fistulae are usually due to incomplete removal of a cyst or to the results of secondary infection of a cyst which ruptures spontaneously or is opened on the basis that it is an ordinary abscess.

Tumors and cysts above the hyoid bone tend to project between the chin and the hyoid bone in the midline. More or less mechanical symptoms develop if the tumor is of considerable size. By bimanual palpation, the distinction can be made between the mass located near the skin surface and a deeper mass.

Tumors and cysts lying below the hyoid bone are usually attached to the back of the bone. Sinuses, therefore, extend up behind the bone. They pass between the bone and the thyroid ligament.

After a cyst has been drained or insufficiently removed, the wall of the fistulous tract tends to contract. Any secretion temporarily is dammed back until sufficient tension is attained for the accumulation of fluid to cause its discharge. Thus, the fistulae tend to discharge intermittently. The fluid is typically a glossy mucous type. Stasis of the fluid encourages repeated low-grade secondary infection so that about the tract is usually found considerable inflammatory tissue.

Diagnosis.—The midline location of a soft mass, a cystic mass or a fistula is important. A thyroglossal cyst moves upward when the tongue is protruded. A thyroglossal fistulous tract shows signs of tension in the tract when the tongue is protruded.

Thyroglossal cysts and fistulae are usually seen in infancy or childhood. Branchial cysts and fistulae are usually seen in early adult or adult life and are found in the lateral neck not in the midline. Suppuration of a lymph node which lies above the mylohyoid muscles might simulate an infected thyroglossal duct cyst. The infrahyoid bursa is practically never the site of an inflammatory lesion. One report is on record of a carcinoma of this tract (1926). When the excised tract is examined microscopically, ciliated epithelium may be found but often the repeated inflammatory attacks destroy the epithelium and leave only the lymphoid tissue normally found in the walls and the inflammatory tissues produced by the repeated injections.

Treatment of Thyroglossal Tract Tumors and Cysts.—The tumors located near the foramen caecum, that cause no symptoms do not necessarily require removal. They are not known to become malignant. When they bleed or cause mechanical interference with normal swallowing or speech, they should be excised. Butler has cited 2 cases of excision through the mouth. Tumors, cysts and sinuses along the lower three fourths of the thyroglossal tract should be excised. It is necessary that the retrohyoid or even the intrahyoid part of the tract be excised completely. When a thyro-

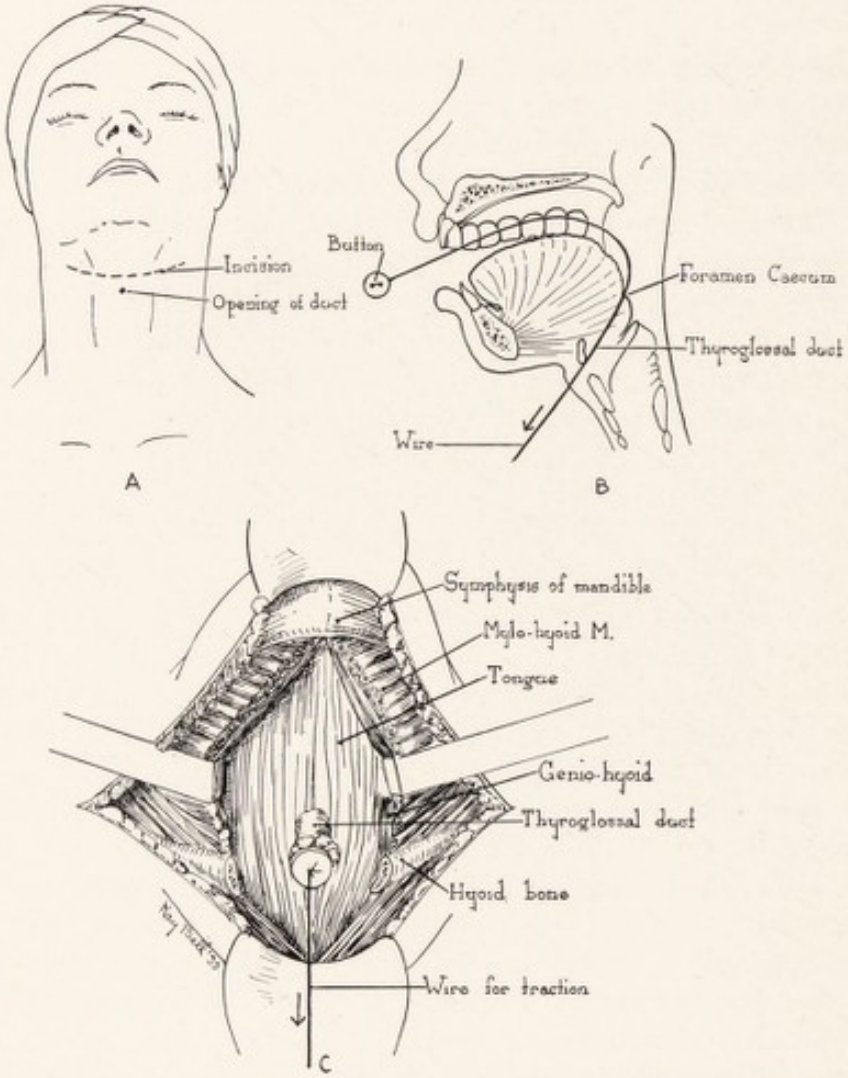

Fig. 208.—Operation for thyroglossal duct sinus. A, Shows line of incision for the thyroglossal duct sinus. B, Method of attaching the wire to the button and drawing it through the foramen caecum by means of a long curved needle down beneath the hyoid bone and out through the skin of the neck in the midline. C, Excision of the tract.

glossal duct sinus or cyst is incompletely removed, the evidence of a fistulous tract remains. Cauterization of the cyst wall or sinus tract has been attempted as a means of removing the epithelial lining but it has not ordinarily been attended by permanent success. The best way of reaching the retrohyoid part of the tract is by cutting the bone in the midline. The skin incision may be made parallel with the wrinkles of the skin of the neck but, as soon as the skin and subcutaneous tissues are cut through, the remainder of the operation and separation of the tissues is in the mid-

line. Sistrunk (Fig. 208, A, B, C) described a trick in technic which immensely simplifies the operation. The mouth is opened. With a long third-curved needle to which is attached a fine wire with a button attached to the distal end, as nearly as possible the tract of the thyroglossal duct is transfixed. The needle enters the foramen caecum and comes out below the hyoid bone. The wire is pulled through the tissues in the neighborhood of the thyroglossal duct tract. As the button is drawn against the foramen caecum and the wire is drawn taut, the tissues about the foramen caecum can be pulled toward the operator and as the tissues are separated in the midline, the bottom of the wound is always brought forward so that one does not work down in a hole. This makes the isolation of the tract fairly easy. Otherwise, the procedure is a difficult one.



Fig. 209.—This patient had a pedunculated lingual thyroid, about the size of a golf ball, that had produced marked pharyngeal obstruction. She had myxedema. Four years before the present photograph was obtained the neck was explored and no thyroid gland was found in the normal position. The lingual thyroid was dislodged from the base of the tongue and was buried in the suprahyoid region where it underwent hypertrophy, as shown in the photograph. (Case of Dr. M. B. Clopton. After Copher.)

The tract is excised up to the foramen caecum but little or none of the tongue mucosa is excised. After excision of the tract, the wound is packed lightly with a gauze wick. A few stitches bring the skin together save at the midpoint.

Before attempting to excise the tract, it may aid one to inject the sinus with methylene blue. However, it is seldom that one can inject the tract for more than a few centimeters but, nevertheless, the whole tract should be excised if one wishes to feel that the result will be permanent.

Lingual Goiter.—Some years ago Clopton (Barnes Hospital), St. Louis, excised a lingual goiter with satisfactory results (Fig. 209). The indications for the removal of a lingual goiter will depend upon whether or not obstructive symptoms are present or, if not present, upon the same indications as for the removal of a goiter when it is situated in the normal position—

i. e., toxicity. The explanation for lingual goiter is that the thyroid fails to migrate downward to its normal position. When no normal thyroid tissue can be felt in the neck or on exploratory incision, none is found to be present, only a partial excision of the lingual thyroid would seem indicated if the symptoms are not dangerous. If a total excision is necessary, and hypothyroid symptoms develop, thyroid extract in the proper dosage will keep the patient in a nearly normal state.

When the tumor is large or rather deeply situated, a very satisfactory approach can be made by splitting the hyoid bone and separating the tongue in the midline, using the method of pulling the base of the tongue toward the incision described in Fig. 208. The diathermic needle aids one in excision as the bleeding is less.

Branchiogenic Carcinoma.—Branchiogenic carcinoma because of a similarity so far as treatment is concerned is discussed in Chapter XXXII—Malignant Neoplasms of the Soft Tissues. It is accepted that the most likely origin of branchiogenic carcinoma is from epithelial inclusions which occur when the branchial clefts close.

CONGENITAL MALFORMATIONS OF THE SALIVARY APPARATUS

Congenital atresia of the duct of either salivary gland is practically unknown. However, the papilla of the parotid duct or even the whole gland may be displaced or distorted. The most conspicuous congenital anomaly of the parotid gland is one in which there is a deformity not only of the parotid gland but also one of the external ear and the corresponding side of the face. In such a malformation the mandible on that side may show an abnormal distortion and underdevelopment. Congenital aplasia of the parotid gland has been reported. Cases with congenital enlarged parotid gland without any induration have been described (Blair and Padgett).

Bibliography

Bibliography Quoted in Text

Bailey, H.: Thyroglossal Cysts and Fistulae, Brit. Jour. Surg., **12:** 579, 1925.
The Clinical Aspects of Branchial Fistulae, Brit. Jour. Surg., **21:** 173, 1933.

Bertwistle, S. P., and Frazer, J. E.: Facts and Considerations in a Study of the Thyroglossal Tract with an Account of the Embryological Condition, Brit. Jour. Surg., **12:** 561, 1925.

Blair, V. P., Padgett, E. C., and Brown, J. B.: Diseases of the Face, Mouth and Jaws, Graham's Surgical Diagnosis, Phila., W. B. Saunders Co., p. 270, 1930.

Borst, Max: Die Lehre von den Geschwülsten, Wiesbaden, J. F. Bergmann, 1902.

Bruck: Quoted from von Bergmann's System of Surgery—Kummel, vol. 1.

Braun: Quoted from von Bergmann's System of Surgery—Kummel, vol. 1.

Butlin, H. T., and Spencer, W. G.: Diseases of the Tongue, P. Blakiston's Son and Co., Phila., 3rd ed., 1931.

Clopton, M. B.: Quoted by Copher, G., and Dick, Bruce, in Graham's Surgical Diagnosis, Diseases of the Thyroid and Parathyroid Glands, W. B. Saunders Co., p. 452, 1930.

Doring, E.: Arch. f. Ohren-, Nasen- u. Kehlkopfheilk., p. 117, 1928.

Duplong: Bull. et mém. Soc. chir. Paris, **9** (new series): 457, 1883.

Dursy: Quoted by Lexer: Von Bergmann's System of Practical Surgery, Phila., Lea Bros. and Co., Malformations, Injuries and Diseases of the Face, **10:** 411–458.

Fairbairn: Quoted by Lexer and Ewing.

Grünwald: Ztschr. f. Ohrenheilk., **60:** 316, 1908.

Hajek: Quoted by Blair, Padgett and Brown in Graham's Surgical Diagnosis, p. 372. (Originally from von Bergmann's System of Surgery—Kummel, vol. 1.)

Hilgenreimer, H.: Congenital Fistula of Mucosal Pockets of the Lower Lip, Deutsch. Ztschr. f. Chir., **188:** 274, 1924.
Huizenza, E.: Acta Otolaryngol., Stockholm, **8:** 505, 1925.
Jussieu: Hist. de l'acad. des sciences, 612, 1718.
Kantack: Quoted by Blair. (Originally from von Bergmann's System of Surgery—Kummel, vol. 1.)
Keith, A.: On Congenital Malformations of the Palate, Face and Neck, Brit. Med. Jour., **2:** 310, 363, 1919.
Kledstadt: Quoted by Thoma.
Morestin: Gaz. de hôp., **70:** 529, 1897.
Petit: Mém. acad. roy. de sci., 247, 1742.
Rawengel: Anatomy, p. 97, 1933.
Schmidt: Deutsch. Zahnheilk., **81:** 50, 1931.
Schroff: Unusual Cysts of the Maxilla, Cysts of the Naso-palatine Duct: Cysts of the Facial Cleft Area (Fissural Cyst), Laryngoscope, **39:** 173, 1929.
Sistrunk, W. E.: The Technique of the Removal of Cysts and Sinuses of the Thyroglossal Duct, Surg., Gynec. and Obst., **46:** 109, 1928.
Tilleux: Quoted by Blair. (Originally from von Bergmann's System of Surgery—Kummel, vol. 1.)
Thompson, J. E.: Relationship of Ranula to Branchiogenic Cyst, Ann. Surg., **72:** 164, 1920.
Thoma, K. H.: Clinical Pathology of the Jaws, Chas. C. Thomas, Springfield, Ill., 1934.
Wenglowski, R.: Neck Fistulae and Cysts, Arch. f. klin. Chir., **100:** 798, 1913.
Wolfler, L. A.: Quoted by Ewing, James: Neoplastic Disease, Phila., W. B. Saunders Co., 1922.
Zuckerkandl: Normale u. patholog. Anatomie der Nasenhöhle. Quoted by Lexer, Leipzig, pp. 411–458, 1880.

Congenital Lip Pits

DePaul: Gaz. de hôp., **92:** 291, 1919.
Lane, W. A.: Tr. Clin. Soc., **24:** 230, 1891.
Madelung: Arch. f. klin. Chir., **37:** 271, 1888.
Richet: Gaz. de hôp., **34:** 174, 1931.

Supplementary Bibliography

Armstrong, Harold G.: Thyroglossal Cysts and Fistulae, St. Michael's Hosp. M. Bull., **3:** 90, 1923.
Christopher, F.: The Surgical Treatment of Lateral Cervical Fistulae, Surg., Gynec. and Obst., **38:** 329, 1924.
Colt, Ralph: Dermoid Cysts of the Floor of the Mouth, Surg., Gynec. and Obst., **40:** 183, 1925.
Hyndman, O. R., and Light, G.: The Brachial Apparatus, Arch. Surg., **19:** 410, 1929.
Lahey, Frank H.: Lingual Goitre, Surg., Gynec. and Obst., **36:** 395, 1923.
MacMillan, A. B.: Pouches of the Pharynx and Oesophagus, J.A.M.A., **98:** 964, 1932.
Meeker, L.: Tumors of the Nose and Throat Related to Developmental Defects, Laryngoscope, **39:** 379, 1929.
Meyer, A. W.: Congenital Cysts and Fistulae of the Neck, Ann. Surg., **95:** 1–226, 1932.
New, Gordon: Congenital Obstruction of the Larynx and Pharynx, J.A.M.A., **81:** 363 (Aug. 4), 1923.
Ziegelman, Edward F.: Lingual Goiter, Arch. Otolaryngol., **16:** 496–505 (Oct.), 1932.

CHAPTER XXXI

BENIGN TUMORS OF THE SOFT TISSUES

THE possibility if not the probability in all instances for any of the types of benign tumors derived from epidermal or mesodermal tissue to appear on the face or in the buccal and pharyngeal cavities must be considered. Many of them, however, are comparatively rare. Ordinarily no remarkable clinical variation from the usual characteristics of these tumors when found elsewhere in the body are manifested. Here, although in a general way most of the benign tumors will be mentioned along with the more common location, somewhat more complete discussion would seem appropriate to the benign new growths which are somewhat characteristic of the region.

THE FACE

Nevi (Figs. 210, *A*, and 211, *A*), warts, and other tumors common to the skin are all found on the face. A discussion of these tumors, common to the skin in general and not of particular significance in facial surgery,

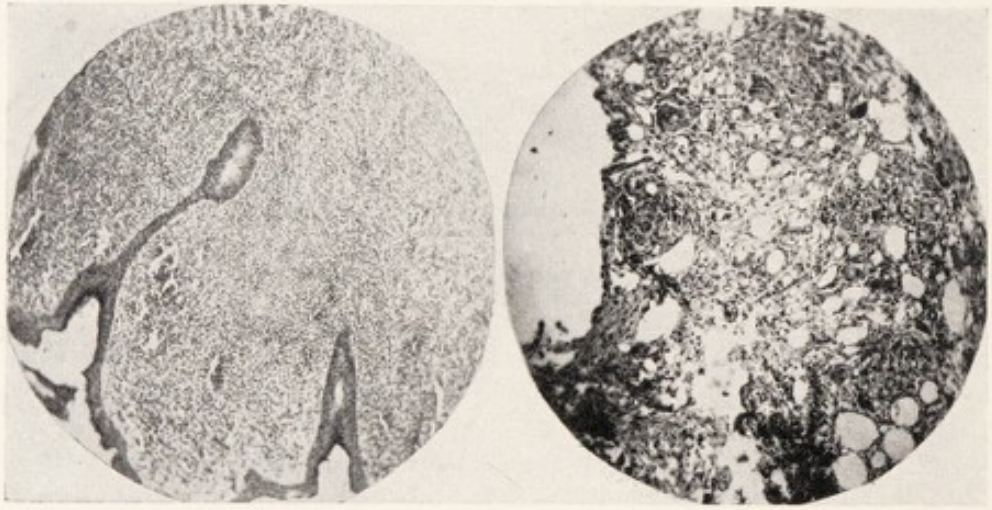

A *B*

Fig. 210.—*A*, Typical nevus. Note giant round cells which are characteristic. *B*, Lesion of paraffinoma.

may be found in appropriate texts on general pathology or skin diseases in particular.

Paraffinoma.—In a fairly large percentage of cases following the injection of paraffin beneath the skin for cosmetic purposes, a chronic granuloma develops to which the term "paraffinoma" has been applied. The tumor may not develop for a number of years—sometimes as many as twenty to thirty years elapsing. The skin is pushed up and stretched so that it becomes smooth and glossy if no inflammatory reaction is present (Fig. 211, *B*). Periodically acute exacerbations of acute inflammatory reaction appear and the whole area may become tender and the skin above red and edematous. In one of our cases the eyes were completely closed

and all of the skin of the face including the forehead was extremely red and edematous for a number of months. Pathologically, the lesion is a chronic granuloma and on cross section the tumor shows a Swiss-cheese-like appearance (Fig. 210, *B*). The growth is principally made up of connective tissue and round cells of a lymphoid type. Here and there one often sees foreign body giant cells. The paraffin apparently disappears due to a phagocytic action and thus the large cavernous spaces are left which give the Swiss-cheese-like appearance on gross section. Often the skin shares only slightly in the reaction. Rarely paraffinomas undergo carcinomatous regeneration (David). Wise presented a case which developed a sarcoma



A *B*

Fig. 211.—*A*, Nevus of the neck. *B*, Paraffinoma of forehead.

and proved fatal. The most satisfactory type of treatment is total excision. Radiation has been tried but ordinarily without much success.

TUMORS MORE COMMON ON THE FACE BUT ALSO OCCURRING IN THE BUCCAL AND PHARYNGEAL CAVITIES

The so-called "port-wine stain" is practically always found on the face and is sometimes localized in the distribution of one or more branches of the fifth nerve. Capillary hemangiomas are also usually found externally but cavernous hemangiomas often involve both the superficial and deep tissues or sometimes only the intercavity tissues.

Hemangioma.—*Etiology.*—The consensus of opinion at the present time is that hemangiomas are true neoplasms and not merely dilatations of the circulatory channels. True hemangiomas are therefore not related etiologically to vascular dilatations such as varicose veins, dilated venules and so forth. These tumors of the blood vessels are mostly congenital in origin and have appeared either at birth or do so shortly after birth. They run a benign course. As a rule, growth ceases after an initial enlargement during the first two or three months after their appearance. As to definite etiology the exact cause for the development of these anomalies is still unknown. No hereditary basis of transmission is ordinarily recognized. It has been suggested that remnants of the capillary bed may be snared off in development and that these islands of vascular tissue retain some of their primitive growth power and that function seems to keep them in retrogres-

sion mechanically (Evans). McCurdy has contended that there is evidence of new blood formation in these tumors in all cases and Moise supported this contention by demonstrating nucleated red cells in smears from angiomas of the skin, liver and testicle. Similar evidence has been presented by Pilliet and Schmieden who studied hemangiomas of the liver.

Pathology.—The simplest form of hemangioma consists of a superficial congeries of capillaries and venules not elevated above the level of the superimposed thinned epidermis—the so-called "port-wine stain." The vessels lie in the corium and are easily seen. According to injection experiments by Ribbert the neoplasm has a connection with underlying vessels but few or no anastomoses with the normal blood vessels of the overlying skin or surrounding tissues. As the "port-wine type" of hemangioma is essentially capillary in structure the appearance is characteristically red in color.

A more pronounced form of hemangioma is the so-called "strawberry mark" which is characterized by a well-defined network of dilated vessels

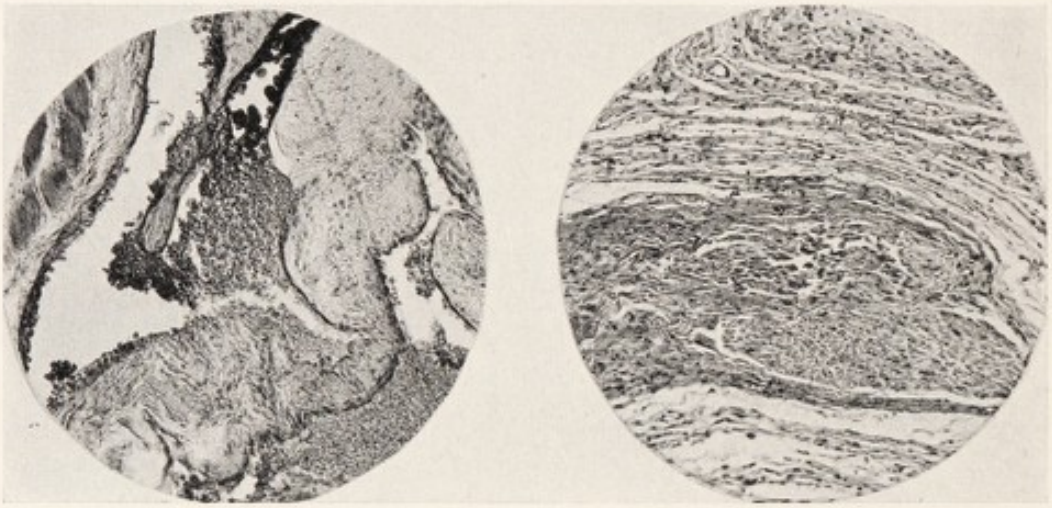

A *B*

Fig. 212.—*A*, Hemangioma of buccal cavity. Section shows blood channels with endothelial lining. *B*, Section of plexiform neurofibroma.

and which usually causes the surface to be raised and the epidermis thinned to a tense shiny covering. The more marked forms of this type may even show a surface warty in appearance and the extension may involve the deeper subcutaneous tissues. In their structure are usually a predominance of venules or arterioles on which, according to the relative amounts of each, depends the varying color—from bright red to dark purple. When the hemangioma is more distinctly subcutaneous, the overlying skin may not be affected or show much color change.

The third type of hemangioma—the cavernous hemangioma—has the largest blood spaces and sinuses (Fig. 212, *A*). The endothelium-lined walls are very thin and anastomose freely. The growth is compressible and spongy in character and the whole of it may be fed by a single artery. Thrombosis of the blood channels may occur and occasionally calcified phleboliths are a result. The skin above the sinuses often is not much affected.

Clinical Characteristics.—"Port-wine stains" appear generally at birth or shortly afterward as irregular patches colored, as a rule, bright red but

occasionally the coloring varies to a deeper red or even a bluish tinge. Although the lesions may occur on any part of the body, the head, neck and face are the most common sites. On the face and head there is a distinct tendency for the distribution to be unilateral. The size is variable from that of 1 mm. or less to half the face and neck or, in rare instances, even more of the body. Usually the blotches are single but such is not always true. About the main growth small discolored areas may be found.

The "strawberry marks" vary in appearance from a pinkish red to a deep blue. They are most common on the face, but also commonly include the eyelids, nose, ears, cheeks, neck and scalp. Often they are not large in diameter—not over 1 or 2 cm. Usually they are raised above the surface from 2 to 4 mm. The skin surface may be smooth and thinned or more irregular or even somewhat warty and thickened (Fig. 213, *A, B*). At times pulsation is a characteristic but usually the tumor is easily compressible. Crying, coughing, bending over and so forth cause engorge-



A *B*

Fig. 213.—*A,* Hemangioma of lower lip. *B,* After treatment by radium and carbon dioxide snow. (Dennie.)

ment. The thinned or roughened epidermis is easily traumatized and ulceration of the surface is quite often encountered. The resultant bleeding is not often serious but it may be. At any rate, healing is slow as the same factors that originally caused the ulceration are still operative as long as the lesion is present in its original form.

The more cavernous forms lie deeper in the tissues than the more superficial growths just described, and only when the dilated blood vessels encroach upon the surface is the skin discolored in the characteristic manner—a steely blue or a purplish flush. Commonly they appear sometime during the first year of life, sometimes following a history of injury. The scalp and face are not uncommon locations for these new growths. The whole side of the face and neck may be involved and very rarely extension to the mediastinum is also present. Cavernous hemangiomas may occur quite deep within the tissues. They may connect through a bony foramen of the skull —a part being inside and a part outside. Measures that increase the blood

pressure often cause these growths to become turgid and tense and may aid in the diagnosis.

Ordinarily the tendency is to progressive growth until encapsulation occurs. The mechanical pressure of the growth may distort cartilage and bone in which case there may be pain. Compressibility and a semifluctuant feel is characteristic of the tumor. Pulsation or even erectility may be present.

Diagnosis.—The superficial types are so characteristic that the diagnosis is largely evident. When no surface indication of their real character is evident, a hemangioma may be taken for a lipoma by the unwary. An hemangioma does not present the lobulated edge of a lipoma. A lipoma is not compressible. The diagnosis is made on the peculiar color, increase in size when the blood pressure is raised, the compressibility and elastic rebound to original size, and the pulsation. About the face, lowering of the head may bring out some of these points not otherwise obtainable.

Prognosis.—Spontaneous disappearance has been known to take place but this occurrence is very exceptional. Usually there is a rapid increase to a certain size after which the growth remains nearly stationary as a rule. In certain instances, an hemangioma remains stationary for years only to take on a new growth after injury or ineffective treatment. When ulceration occurs a very friable, vascular, fungating tumor may result which has the microscopic appearance of a perithelial round-cell sarcoma. Klinge saw widespread metastasis after local recurrence. Ewing also is authority for the statement that extremely rarely a benign appearing hemangioma may give generalized metastasis.

Treatment.—When the lesion is small and located in an area where deformity is not obtained when the skin is pulled together, excision with immediate suture gives a very excellent result. In children when the lesions are more diffuse and when eradication by methods of excision would be deforming, the proper use of radium may give a very satisfactory result. In certain small areas of discoloration the use of carbon dioxide snow may bleach the area partially at least and sometimes almost completely. Usually in children the more conservative methods should be given a thorough and careful trial. After failure of these simpler methods, more radical methods such as excision and skin grafting are to be considered. The amount of cosmetic deformity, the anatomic structures that may be injured in eradication and the final appearance of the graft all have to be evaluated. In adults with marked port-wine stains of the face, the best cosmetic result is given by complete excision and the application of a full-thickness skin graft. Radium or roentgen therapy has not been found to be so effective in adults as in children. In the adult usually a blotchy, scaly, itching, scarred skin results which in the "port-wine stain" is not to be preferred to the original mark. In 5 cases we have excised a good share of the skin of one half of the face and gained a very acceptable final result by the immediate application of a large full-thickness skin graft to the resulting raw surface. One must be familiar with the specialized technic of growing these grafts before it would be advisable to attempt so radical a step to eradicate the lesion. In cavernous growths about the cheeks, lips, within the oral cavity, about the orbit, where the incisions can be placed so that important nerves or other structures are not severed, often excision methods are the

simplest and most effective. The best treatment in a given case thus depends upon the age, the size and location of the growth, previous treatments, and the amount of cosmetic deformity. All of these factors have to be balanced and subjected to careful analysis in the selection of the method of approach. In many cases it is wise to try less radical procedures first. If improvement is not complete, it may be sufficient to be of some aid when more radical methods are considered as offering the only chance of a satisfactory result.

Lymphangioma.—Three not unusual types of lymphangioma occur about the face and in the buccal cavity. One is analogous to cavernous hemangioma—the cavernous lymphangioma. The tongue, lips, and cheek are often involved. The second form is hygroma of the neck—a cystic congenital tumor of the neck and surrounding tissues probably due to an embryonic sequestration of lymphatic tissue. Under section on the neck in this chapter this tumor is more completely described. In the third type the lymph channels are smaller and the skin and subcutaneous tissues are involved diffusely.

True lymphangiomas are neoplastic growths of congenital origin. Traumatic and inflammatory hyperplasias hardly deserve to fall in this classification. Virchow described lymphangioma first. Forty years later Wegner described the histologic structure. A striking feature in the etiology is the congenital origin. Lymph stasis, although the evidence is meager, has been suggested as a factor in the development of certain lymphangiomas. A heteroplastic formation of lymph vessels in granulation tissue has also been suggested as a factor in the occurrence of certain lymphangiomas. Here again proof is lacking. Neoplastic origin, since new formation of lymph vessels has been demonstrated, seems the most plausible explanation for these new growths. However, instances are continually being reported that have followed injury or operation.

Pathology.—Wegner originally described 3 forms of lymphangioma which may merge or all be present in the same tumor: first, lymphangioma simplex; second, lymphangioma cavernosum, and third, lymphangioma cystoides. Lymphangioma simplex presents flat and cuboidal endothelium lining anastomosing spaces and lying in a framework of fibrous tissue septa. Sometimes even the connective tissue takes part in the hyperplasia. Lymphangioma cavernosum presents a closed system of communicating spaces which may be mixed with blood vessels. Lymphangioma cystoides shows groups of cysts lined with flat endothelium. Not uncommonly associated with lymphangioma is some neoplastic activity of the blood vessels—angiomatous tissue or lymphadenomatous tissue. Inflammatory changes are prone to occur and result in an increase of fibrous tissue.

Location.—The cheeks and the lips most commonly, but the nasopharynx and the tongue also, one or all may be involved in a congenital lymphangioma. Lymphangiomatous macroglossia is described under tumors of the buccal cavity proper in this chapter.

Clinical Picture.—The structure involved is larger and softer than normal. A diffuse soft infiltrating mass with a few harder nodules here and there is observed. Superimposed skin or mucosa often lies in folds or is wrinkled and often the texture is changed to a heavier coarse type due to involvement of the subepithelial structures (Fig. 214, *A*). When it is

the function of the muscles to hold soft tissues in a normal position, either due to the weight of the tissues or the lack of muscular tone or both, the soft tissues assume distorted positions. When the neoplasm approaches the mucous membrane, small vessels, single or multiple, are usually evident. The superimposed mucosa is thinned and the vessels are therefore likely to rupture.

These growths usually appear soon after birth but may appear at almost any age during childhood. From the time of their first appearance, there is a slow increase in size. During the period of growth it is characteristic to have the clinical picture periodically modified by attacks of acute inflammation with increased swelling, redness and tenderness, which may even go on to ulceration within the mouth. With each successive inflammatory exacerbation, more fibrous tissue forms. The tumor thus develops more firmness and here and there hard knots of fibrous tissue. When cysts are



A *B*

Fig. 214.—*A,* Lymphangioma of face before excision of the new growth. *B,* Plexiform neurofibroma of right half of head.

present the fibrous tissue eventually gives them a firm wall. Any intervening muscle fibers have a tendency to be strangulated by pressure atrophy from connective tissue overgrowth.

Diagnosis.—Hemangioma and plexiform neurofibroma sometimes resemble clinically a lymphangioma. In hemangioma some evidence of the dilated blood vessels is usually a part of the clinical picture and the tumor is more easily compressed and becomes engorged on straining. In plexiform neurofibroma one can feel the coiling nerve bundles if palpation is careful enough. The tumor is not in any way compressible although it may be diffuse and soft.

Treatment.—If possible without destroying essential nerves or other structures necessary to function, the tumor should be excised. Radium and roentgen therapy have been recommended but the effect is only partially successful. The growth may be stopped and the size may decrease somewhat but sufficient shrinkage seldom occurs.

In severe lymphangiomas of the cheek we have excised the growths in toto even when we were practically certain that the facial nerve would be severed. Later fascial strands were used to give fixation to the cheek and corner of the mouth so that when the mouth was at rest a normal expression was obtained. Of course, the deformity has to be a considerable one to warrant this procedure. Often the deformity is so very striking that radical procedures are justified. On complete excision there is little or no tendency for a recurrence.

Plexiform Neurofibroma.—Rarely plexiform neurofibroma of the face is encountered. The deformity caused thereby is not unlike that of lymphangioma of the face. A bulky, ill-defined swelling in which thickened nerve trunks may be palpated is characteristic. On dissection the thickened and coiled nerve trunks are more evident. Between the nerves the blood vessels are quite often dilated and the fibrous tissue is increased. Under the microscope diffuse nodular swellings of the nerve trunks are seen. There is an increase of cells in the epineurium where also mucous degeneration may be evident. Structurally, these tumors show considerable variety. They vary from overgrowth of the medullary nerve fibers to no production of nerve fibers but cellular masses made up including mostly fibrous tissue (Fig. 212, *B*).

In our most pronounced case, the skin was hypertrophied and lax and laid in drooping folds on the side of the face. Very little muscular tissue seemed to be present (Fig. 214, *B*). Local recurrence (Ewing) is said to be likely and sarcomatous change may also occur.

The best treatment is excision and repair as just suggested under lymphangioma. In our cases some of the redundant skin near the angle of the mouth had to be excised as the face-lifting procedure was insufficient to tighten the whole face. Fascial strands from the thigh were used to hold and fix the side of the face in a normal position. Radium or roentgen ray does not affect the tumor to advantage.

TUMORS MORE COMMONLY FOUND IN THE BUCCAL CAVITY PROPER

In the buccal cavity are found several lesions more of the nature of an hypertrophy, a secondary reaction to an inflammation or an endocrine disturbance, than of a neoplastic nature. It is convenient, however, to include certain of these borderline growths under benign tumors of the soft tissues of the buccal cavity.

Hypertrophy of the Interdental Papillae.—If the teeth are rather far apart food particles and bacteria may collect between them and set up a chronic inflammation of the interdental papillae. Young girls at about the age of puberty are said to be the most commonly affected. The anatomy of the gums above the central incisors causes the interdental papillae about them to be most commonly affected. The gum about the posterior border of the third molar which is likely to overlay the tooth to a certain extent is prone to inflammatory involvement because of the accumulation of food beneath the overhanging edge and also possibly some trauma from the upper apposing tooth. In pregnancy the gingivae may hypertrophy and the hypertrophy may last well on into the lactation period.

Treatment.—When separation of the teeth is too pronounced orthodontic procedures may aid in their approximation. In the case of over-

hanging gums over the third molar, the overhanging gum may be removed. But often this does not relieve the condition as the overhang is not entirely obliterated because of the proximity of the ramus directly behind the tooth. Thus, to get relief it is often best to extract the third molar.

Hypertrophy of the Gums.—Very rarely a diffuse hyperplasia of the submucosal tissue develops. The exact etiology is obscure (Fig. 215). Several far-fetched suggestions as to cause, such as a nutritional defect or a relationship to scurvy, have been suggested. A neoplastic process has been urged as the essential factor. But the fact that the hyperplastic tissue is subject to attacks of acute inflammation is more suggestive when infection is the underlying cause. During the acute exacerbations the gums are sore and bleed slightly. The lesion is most often seen in childhood and adolescence but it is also seen during pregnancy (Brophy). Microscopically, delicate wavy bundles of fibrous tissue with interspersed areas of myxomatous degeneration are observed. The mucosa is practically normal save for a slight increase of small round cells. Clinically, the gums are



Fig. 215.—Models of teeth showing hypertrophy of gums. (Courtesy of Dr. Prinz.)

unevenly thickened and firm. Here and there nodular formations may be seen and felt. As the hyperplastic process continues, the teeth tend to appear shorter and eventually may be buried and the mouth as a whole be partially filled with the overgrowth of tissue. The treatment is thorough removal of the hypertrophied gum together with the teeth and alveolar processes. Recurrences after such treatment do not ordinarily appear.

Localized Hypertrophy of the Gums.—Localized hypertrophy of the gums results apparently from long-continued irritative processes such as carious teeth, rough crowns, ill-fitting plates, clasps, and tartar about the neck of a tooth. In the treatment the obvious causes are removed, and possibly a part of the hyperplasia excised although usually when the cause is removed, the hypertrophy tends to become thin and normal spontaneously.

Retention Cysts of the Mucous Membrane.—Retention cysts of the mucous glands are seen now and then on the inner surface of the lips and cheeks. When their situation is near the occlusal plane of the teeth such masses are likely to be injured (bitten), and thus may become ulcerated or infected. Along the edges of the upper surface of the tongue similar cystic

masses may develop. Beneath the tongue are the glands of Blandin. Rarely these may become retention cysts and attain a size of 1 cm. or more. All of the above cysts are bluish gray in color, well circumscribed, rather freely movable, and tense. Aspiration reveals the true nature when there is question. The best treatment is removal of the cyst with all of its wall. When remnants of the epithelial lining are left behind, the cyst will recur. With the use of local anesthesia and a pair of pointed dissection scissors, enucleation is fairly simple.

Lymphangiomatous Macroglossia.—The clinical picture of lymphangiomatous macroglossia is so striking that further description is interesting. Over the tongue and beneath it small vessels appear, scattered or in groups and containing a clear fluid. Between these clear vesicles are scattered capillary loops which appear as bright red dots. When the vesicles form clusters the tufts resemble papilloma. On extravasation of blood into the vesicles they appear violet or red. Because of thinning of the overlying mucosa the vesicles are prone to rupture. This gives the chance for secondary infection to enter. Attacks of inflammation are common and the tongue becomes swollen and tender at each exacerbation. Early in the disease before there is fibrous tissue overgrowth the tongue is soft; later it becomes firm. The tongue is obviously too large and, as the new growth increases in size, it begins to protrude from the mouth or cause it to be held open. When this occurs in childhood, the growth of the jaw bone is likely to be distorted.

The diagnosis depends upon the presence of vesicles and cysts associated with progressive enlargement and induration. The clear vesicles differentiate lymphangioma from hemangioma.

Treatment.—Radium should be tried. When unsuccessful, a part of the tongue should be removed—the part containing the most tumor tissue. Speech is not interfered with greatly if judgment is used in the wedge-shaped incisions necessary. After excision of sufficient tongue tissue to bring it down to normal size, the tongue is carefully sutured with interrupted silk sutures which should go deep enough to give deep approximation.

TUMORS MORE COMMONLY FOUND IN THE BUCCOPHARYNGEAL CAVITIES

Papillomas of various types, fibromas, angiomas, lipomas, myomas, and so forth occur in both the buccal and the pharyngeal cavities. Hemangiomas and lymphangiomas involve the pharyngeal region, but usually the involvement is not confined to the pharynx. The pharyngeal involvement is only a part of the tumor. True aneurysms of the internal carotid or internal maxillary artery have been described as bulging into the buccopharyngeal cavity. Varicose veins of the posterior tongue have been described, as have also varicose veins of the postpharyngeal wall. Kummel called attention to a type of lipoma and fibroma with their base originating near the laryngeal entrance which tend to grow in "finger-like" processes and may hang down into the larynx and the esophagus. This may cause dyspnea or be detached or coughed up. The diagnosis is made with the laryngeal mirror or the palpating finger.

Papilloma.—Papillomas are fairly common, and are seen most often in early adult life but are also found in children. As to location New and

Childrey found the percentage fairly evenly divided between the faucial pillars, the soft palate, the tonsil and the posterior wall of the pharynx. Papillomas are not uncommonly found on the cheek and on the anterior tongue. They are usually single, irregular, soft, pale, pink, cauliflower-like in appearance and the usual size is said to be about 1 cm. in diameter. The treatment is removal.

Fibroma.—Fibrous tumors are uncommon and are seldom entirely fibrous. Under the term fibroma is included papillary fibroma with a corrugated epithelial covering, neurofibroma, showing nerve fibers, angiofibroma with more than the normal amount of blood vessel elements and lymphangiofibroma with both blood vessel and lymphatic structures in a greater percentage than in the ordinary fibromatous new growths composed mostly of fibroblastic tissue. Often fat cells make up a part of the mass and fibrochondroma, fibrolymphadenoma, fibromyxoma, and fibromyoma have all been described as occurring. They are smooth, round and firm and may be pedunculated (Fig. 216). The treatment is surgical removal.

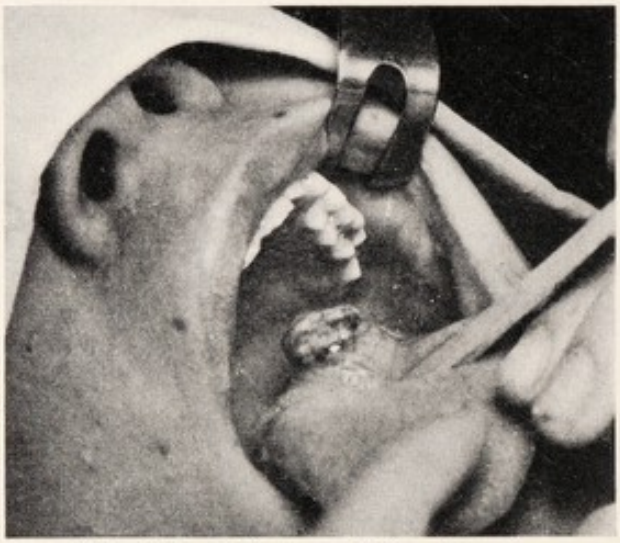

Fig. 216.—Fibroma of the tongue.

The simple fibroma is made up principally of a matrix of fibroblasts. In the hard type the matrix is likely to show some hyalinization. Within the matrix—besides the fibroblasts with their fibrils—blood, lymph and nerve tissues are found in varying amounts. When the growths are cross sectioned the appearance is that of a grayish translucent surface. When we exclude epulis and growths primary in the maxillary bones from the class of fibroma, the tongue is the most likely site in the buccal cavity. They are usually located on the dorsal surface and very often are multiple. However, the cheeks and the under surface of the tongue are not immune to these growths. Two forms occur, a soft variety that is often pedunculated and a harder type which tends to lie more within the surrounding soft tissues. The softer variety is the more common and is nearly as soft as a lipoma, but the lipoma may be distinguished by a yellowish base instead of the pinkish base of the fibroma. The harder type may be lobulated, is well circumscribed, and movable within the surrounding tissue. The later signs may be difficult to detect when the tumor lies within the tongue musculature. The life history is one of slow growth without subjective symptoms. They only cause trouble when the size interferes with function.

The treatment is excision or if the question of diagnosis arises excision should be done for diagnostic purposes in view of the possibility of overlooking a malignant growth.

Lipoma.—Lipomas are not common in the mouth. In the cheek a congenital lipoma has been described as arising from the canine fossa internal to the masseter muscle. The tumor is subcutaneous and it has been mistaken for a tumor of the parotid gland. In the tongue, lipomas are usually situated near the tip or on the ventral surface. A lipoma in the substance of the tongue may protrude beneath the tongue and give the appearance of a double tongue. Although in the tongue the tumor is usually a slow-growing single mass, multiple masses and diffuse lipoma have been described.

Lipoma of the pharynx is rare. In 1927 Figi and Hunt found 34 cases in the literature and reported an additional one. All occurred in adults. Their size causes mechanical symptoms. They have been found in the palatal, tonsillar and pharyngeal areas. They may be either sessile or pedunculated

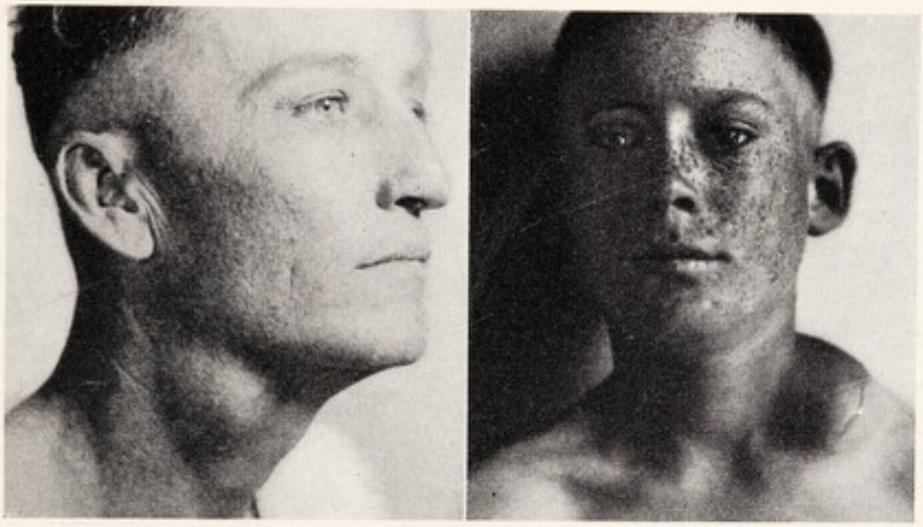

A *B*

Fig. 217.—*A*, Patient with carotid body tumor. *B*, Patient with a hygroma.

and although growth is slow, the size of a golf or even a tennis ball is obtained. The tumor is elastic. The treatment is enucleation or excision.

Because of the yellowish color and characteristic soft elastic feel, the diagnosis is usually somewhat evident. A history of slow growth, a yellowish hue, a circumscribed elastic feel, very faint lobulation and free mobility are rather characteristic. In the floor of the mouth ranulae occur but they are bluish, fluctuant and, on aspiration, a yellowish or brownish fluid is obtained.

Cystadenomas.—Cystadenomas probably arise from the muciparous glands of the mucosa. Adults are mostly affected. They are uncommon. Usually they are found on examination and are then called to the patient's attention. The hard palate is the common site. They measure from 1 to 4 cm. in diameter. They are sessile, round, pinkish, and may be soft or firm or even cystic. Ulceration seldom occurs. The treatment is thorough removal with destruction of the base. They tend to recur when removal is incomplete.

Mixed Tumors.—Under benign tumors of the salivary gland in this chapter a more complete discussion is given of this group of tumors. Since

Krompecher's work these tumors have been thought to be epithelial in origin. The cartilaginous material is thought to be only pseudocartilage developed from epithelial cells. Similar tumors also occur in the lip, the nose, the cheek, and the lobe of the ear (Kaufmann) (Fig. 218, *A*). Cell rests are supposedly left behind by an invagination of the ectoderm during embryonic development. Possibly from 5 to 10 per cent of these tumors are located elsewhere than in the salivary glands. The sexes are about equally affected. The tumors are usually seen in early adult life. About one third present no symptoms and are discovered only accidentally, but sensations of a mechanical origin eventually appear as they grow in size. In 3 of New's cases there was a jugular foramen syndrome. Microscopically, the palatal growths contain more epithelial and less cartilaginous tissue than the salivary gland growths. The diagnosis depends upon the situation, the long history and the characteristic lobulated circumscribed firm character of the growth. Some of the growths are cystic and are rubbery or fluctuate. These tumors are on the borderline between the malignant and the benign.

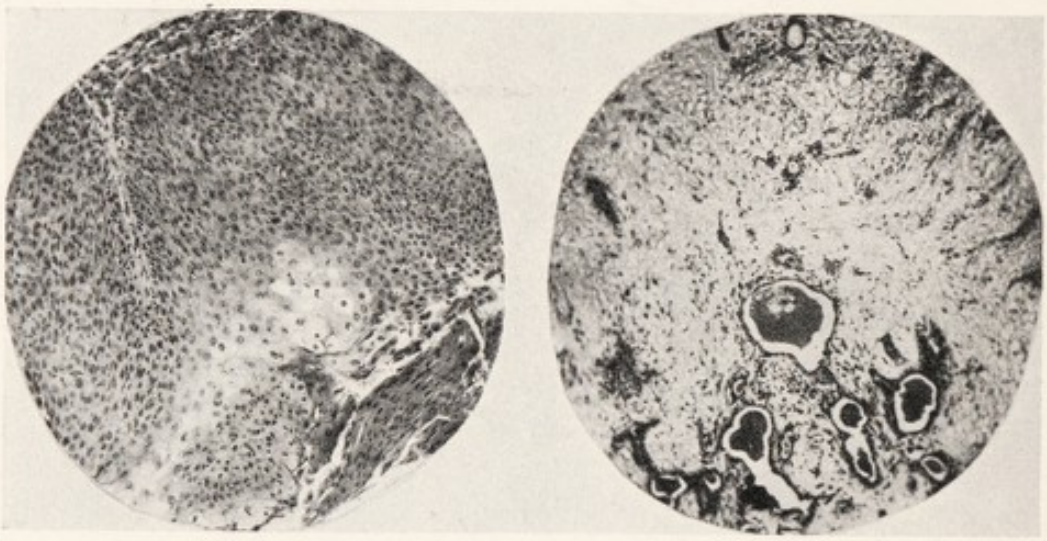

A *B*

Fig. 218.—*A*, Papilloma of the larynx. *B*, Mixed tumor of lachrymal gland.

Certainly if not completely removed, they tend to recur and, after repeated recurrence, distinct malignant characteristics are likely to be assumed.

Vascular Tumors.—Vascular tumors—lymphangiomatous tumors—have been alluded to previously in this chapter. It is only occasionally that they are seen in the buccal and pharyngeal cavities but when they do occur they are likely to be quite diffuse. Varices are seen occasionally on the posterior wall of the pharynx and at the base of the tongue in individuals with chronic pulmonary or circulatory diseases or even in individuals with no apparent cause. Usually treatment is not necessary.

True aneurysms are seldom seen about the buccal cavity. Aneurysms of the internal carotid artery may bulge into the lateral pharyngeal wall. Expansile pulsation is a characteristic of the bulging mass. The mistake not to make is to diagnose the bulging mass as a peritonsillar abscess. An incision would result in a fatal hemorrhage.

Keloid.—Keloid is a type of fibroma found only very rarely in the mouth and then usually on the tongue. The hyperplastic scar tissue should be excised and treated with small doses of radium.

Myxoma.—Pure myxoma is certainly exceedingly rare, if it is ever encountered. As pure myxoma does not exist in the adult body a primary myxoma would have to develop from embryonic mucous tissue. The typical cells are spindle or star shaped and have processes and are embedded in a basophilic matrix. Although instances of pure myxoma are described in the literature, the tumors are probably edematous fibro-adenomas which contain no mucin. Myxomatous degeneration occurs in many tumors—both benign and malignant in type.

Chondroma and Osteoma.—Supposedly fibroblasts or a process of metaplasia may produce a long body of cartilaginous tissue in the tonsillar area. These lesions are rare but may attain the size of 2 cm. The symptoms are mechanical and sometimes those of a secondary infection about the growth. The treatment is enucleation.

Polyp.—Polyp is very rare but is occasionally found springing from the pharyngeal structures. New and Childrey had 2 cases—one showing malignant degeneration.

Retention Cyst of Tonsils.—Small retention cysts are occasionally seen in the palatine tonsils. They form from obstructed tonsillar crypts. They vary in size from 0.5 to 2.5 cm. and are smooth, rounded, yellowish bluish brown and are cystic. Removal with the tonsil is usually the treatment.

Hyperplastic Lymphoid Tissue.—Hyperplastic tonsillar tissue or lymphoid tissue about the faucial entrance may cause difficulty in diagnosis from other tumors. Excision and biopsy are necessary to establish the diagnosis. Such growths become pedunculated and may be as large as $3 \times 3 \times 5$ cm. Although usually soft they may be quite firm, smooth and not ulcerated.

BENIGN LARYNGEAL NEW GROWTHS

Benign neoplasms of the larynx are not common. Fibromas, chondromas, lipomas and adenomas, all may be found in the larynx and about it. Papillomas are the most common and usually are found in children but do occur in adults (Fig. 218, *A*). Fibromas and singer's nodes ("chorditis nodosa") occupy a midpoint in relative frequency.

Ewing quotes Juracz as stating that epithelial papillomas constitute 39 per cent and Janeway and Schech as stating that the proportion varies according to histologic criteria from 8 to 59 per cent. Usually the site is the vocal cords. These papillomas tend to recur after removal. Ultimately after repeated recurrence they tend to undergo malignant change. When any of these growths attain some size, interference with respiration may occur and complete suffocation is not unheard of. The treatment of all of these tumors is removal. When the growths are large, laryngofissure is the wisest procedure. However, most benign laryngeal neoplasms may be removed safely by means of direct laryngoscopy.

Singer's nodes "chorditis nodosa" is characterized by one or more bony tumors of the vocal cords. They do not occur solely in singers. Besides singing, prolonged or faulty use of the voice is a leading cause. The patient complains usually of inability to sound middle tones. If rest fails to cure, the nodes may be pinched off.

A fibroma presents itself as an oval, smooth mass of a light pink color. Occasionally the tumor is found to be pedunculated.

Lipoma of the larynx is seldom seen. The tumor may present itself as a smooth, yellowish mass which may be pedunculated and obstruct the larynx suddenly. I have a record of 1 patient who died suddenly due to such a mishap.

Cysts of the larynx are also very rare. They are retention cysts of the mucous glands. Chondromas may very rarely be found attached to the cricoid cartilage.

ANTRUM

The antrum may contain cysts due to retention in and distention of a mucous gland. Dental cysts are described in another chapter but they may encroach upon the antral cavity. Cysts may cause pressure symptoms, and transmitted light and the roentgen ray may show obstruction. Fibromas have been described as occurring rarely in the antrum. The point is to make a positive diagnosis of the type of lesion. Exploration and biopsy are usually necessary. The treatment is excision.

NECK

As elsewhere in the body, lipomas, fibromas, angiomas, and so forth are found in the neck. Two benign tumors, a description of which follows, are rather characteristic of the location.

Tumor of the Carotid Gland.—Marchand in 1891 first called attention to this tumor. According to Reid and Andrus about 91 cases have been reported in the literature of which 84 were encountered at operation and the remainder at necropsy. These tumors are found largely in adult life. The average age is about the beginning of the fourth decade. Only 6 such tumors have been removed in patients under twenty years of age (Reid and Andrus). Sex has little or no bearing on the incidence. In two instances bilateral tumors have been found. In 60 per cent of the cases the tumor had been present over three years when operated. Three patients dated the appearance of the mass to over thirty years previously (Reid and Andrus).

Pathology.—Reid in 1920 suggested that these tumors be regarded as analogous to those of the thyroid, and considered rare bilateral tumors as diffuse hyperplasia and simple tumors as localized hyperplasia or adenomas. He considers that a large proportion of these tumors can undoubtedly be classified as adenomas but in others there is a malignant change in a benign adenoma or there is a primary malignant change in some element of the carotid gland. Cases of sarcoma have been reported (Gilford and Dobromidoff) and a few cases of carcinoma (Gilford) have been reported. Grossly, the tumors are nodular and firm. They are usually encapsulated and the cut surface is described as presenting a yellow or orange color varying to red. The adjacent lymph nodes are rarely agglomerated by the neoplasm. Under the microscope the cells are found to be polyhedral, granular and arranged in compact columns of alveolar topography. The stroma is often quite scanty. The characteristic cells are in intimate contact with the capillary endothelium.

Symptoms.—No pain is felt until the growing mass causes pressure upon the surrounding nerves or upon the pharynx or the esophagus (Fig. 217, *A*). In the tumors reviewed by Reid and Andrus the following nerves were

involved: vagus (fourteen times), hypoglossal (seven times), the glossopharyngeal (five times), and the spinal accessory (two times). In certain cases the patient complains of pain in the throat, the ear or the base of the skull. Pressure on the cervical sympathetic nerve may cause anisoconia or enophthalmus. Aphonia and dyspnea have been noted in certain large tumors. The tumors are located at the bifurcation of the carotid arteries. They are ovoid in shape, single, grow slowly, and have a long duration. The consistency is firm, and a pulsation may be transmitted. A bruit or thrill is produced in about one fourth of the cases. A bulge of the pharynx may be found. They are not painful or tender. The carotid artery is usually carried lateralward so that it lies in a groove on the lateral and anterolateral aspect of the tumor.

Treatment.—The surgical removal is difficult because the carotid artery is surrounded by the mass and consequently, complete removal necessitates the ligation or excision of the vessels. In 43 cases in which the artery was ligated for the removal of the tumor, there were 19 deaths (Reid and Andrus). Two others suffered a hemiplegia. The mortality in collected cases was about 40 per cent. The operation is usually desired for cosmetic reasons. The operative mortality is too high for so trivial a reason if one has to remove the carotid artery. When the adenoma is not malignant as is often the case, if one uses great care the tumor can mostly be dissected from the artery. The hazards of carotid artery removal are thereby eliminated which is the main cause for the high mortality.

Hygroma Colli.—Hygroma colli is the name given to a lymphangiomatous mass of the neck. The tumor has the same structure histologically as described under lymphangioma elsewhere such as under face, tongue or mouth affections. Ordinarily the neoplasm is a cavernous lymphangioma in which the lymph spaces are really converted into rather large cavities which might more correctly be termed lymphangiomatous cysts—thus the term cystic hygroma. Most commonly the neoplasm seems to arise in the neighborhood of the submaxillary region and extends forward toward the median line, backward toward the parotid pole and downward toward the clavicular fossa. In rarer instances the lesion appears to arise in the posterior triangle of the neck or in the supraclavicular fossa (Fig. 217, *B*). The diffuse growth characteristically appears at birth or soon afterward but rarely not until about the age of puberty, and it may follow the history of an injury. Growth has a tendency to be more or less progressive. On examination, a rather soft, painless, diffuse growth is found beneath the subcutaneous tissues with here and there a few indefinite scattered nodules within the mass. The cystic cavities may fluctuate and ordinarily they are not particularly tense. Since these neoplasms are of lymphatic origin they tend to suffer periodic inflammatory attacks similar to lymph nodes. The whole mass during an acute exacerbation becomes red, tender and painful. When seen during a period of swelling the diagnosis may be obscured. A shrinkage or even complete spontaneous regression has in rare instances followed an attack of acute inflammation. Suppuration with abscess formation is not common. The walls are thin and may be translucent. In size the mass varies from that of half of a golf ball to that of a grapefruit. The diagnosis is made on the history, the examination as described, and an aspirating needle may offer further evidence of the character of the growth.

Treatment.—When possible, the best treatment is rather thorough excision. If one fails to do a complete excision, what is left of the tumor tissue tends to grow. Complete excision is not easy because of the vascularity of the tissues and when one cuts across the tumor tissue with a knife, it tends to collapse, increasing the difficulty of the total excision. When the mass is rather cystic the operation is less difficult and when care is taken it may be sufficiently complete to prevent further evidence of the lesion.

Irradiation methods may be tried in the more diffuse types but ordinarily, although some decrease in size as usual, the total reduction is not sufficient.

SALIVARY AND LACHRYMAL GLANDS

Lipoma, fibroma, angioma, and lymphangioma, both of the salivary and lachrymal glands have been reported but certainly such tumors must be extremely rare. No example has ever come to our attention. Their clinical signs do not vary particularly from those when these tumors occur in other locations except as anatomic factors might influence the picture. Retention cysts due to obstruction of a duct have been reported in the submaxillary, the parotid and especially in the sublingual glands. Blockage of a sublingual duct is more likely to be encountered because of the multiplicity and small caliber of the ducts of the gland. The ordinary types of sarcoma have not with certainty been demonstrated as occurring in the salivary glands excepting lymphosarcoma which develops from the reticulum cells of the lymph follicles in the gland.

Deep orbital tumors of the basal-cell type are the most common to originate in the lachrymal gland. In 1901 Warthin collected and analyzed 132 tumors of the lachrymal gland.

Tumors derived from epithelium may be grouped as adenomas, pure carcinomas, and mixed tumors. The latter form by far the largest group. The parotid gland is affected with considerably greater frequency by these neoplasms than the remainder of the salivary glands. New growths involving the sublingual gland are extremely rare and only occasionally is the submaxillary gland involved.

Adenoma.—Although examples of adenoma have been described by Nasse, Lecene, Lexer, Wood and Kutter (sublingual adenoma) and others, most of the cases on careful analysis do not prove to be true adenoma. Warthin found 13 adenomas in 32 lachrymal gland tumors. Occasionally malignant change in adenocarcinoma is thought to have been observed. McFarland analyzed the reports of adenoma and reported one he thought possibly to be a case.

Pathology.—The microscopic section presents more or less a complete acinar reproduction in a fibrous tissue stroma. Within the lumina of some of the acini papillary projections have been observed. The mucoid and cartilage-like deposits present in mixed tumors are not found.

Clinically, a slow-growing solid tumor (four to fifteen years), well isolated and sometimes lobulated, is distinguished on palpation within the affected gland. The diagnosis is not possible until a microscopic study has been made, as a mixed tumor presents some of the same characteristics.

Mixed Tumors.—In the past a very active controversy has been waged in regard to the exact nature and origin of the so-called "mixed tumors" of

the salivary glands. At the present time, the tendency is to accept an epithelial origin as being the correct interpretation.

Origin.—At first these tumors were placed with the carcinomas. Then Kaufmann argued that they were in reality sarcomas. Warthin in 1879 attempted to demonstrate a lymphatic endothelial derivation for the group and Volkmann lent his support to this conception. Thus, in Germany the endothelial idea was quite generally accepted but in France many authorities argued for a double derivation—from both epithelial and connective tissue structures. Hinsberg then demonstrated additional epithelial characteristics and disproved certain contentions in favor of the endothelial derivation. Later, Ehrlich demonstrated that the mucus-secreting cells in the growths may produce a mucoid connective tissue from which cartilage would be formed by a peculiar metaplastic process. This conception made it unnecessary to include the theory of mesoblastic origin of the cartilage-like material. Krompecher accepted the epithelial origin and produced additional evidence that the group belongs in the class of the basal-cell epitheliomas. Fry in 1927, reviewing the subject, concluded that mixed tumors are entirely epithelial in origin, usually derived from the ducts; that the mucin material is a secretion; that no cartilage is actually present but that the cartilaginous appearing matrix is a mucinous secretion containing epithelial cells, and finally that there is no exact dividing line between the benign and malignant new growths.

McFarland has within recent years published an article discussing parotid tumors and has reviewed the literature. He presents 90 of his own cases of tumor as a basis for his discussion and favors "the theory of enclavement or accidental sequestration of embryonal cells during the early and complicated development of the face and neck." Ewing is of the opinion that "no single source of the mixed tumors meets all requirements. Some are distinctly adenomatous and probably arise from the acini and ducts of the glands in which they are well incorporated. Others are encapsulated or extraglandular and take the form of basal-cell epithelioma. These probably arise from misplaced occasional embryonal portions of the gland tissue. Branchial remnants may possibly be connected with this group."

Structure.—Grossly, section of these tumors ordinarily shows opaque cellular areas, surrounded by fibrous tissue with not unusually hyalinized areas and possibly cartilage. Some soft gelatinous tissue is often found and serum and mucus may be expressed in variable amounts. The vascularity of the tumors is usually not pronounced. Microscopically, although a rather diverse histologic structure is occasionally presented, on the whole the majority of neoplasms presents a more or less uniform picture. Derived from the acini are narrow and broad strands of small, flattened cells or masses of epithelial cells in alveolar arrangement (Fig. 219, *A*, *B*). The epithelium may be cuboidal and contain secretion, or may become flattened and spaces are then found which resemble lymph channels—thus, the endothelial theory of origin of the cells. In the smaller, firmer growths another type of cell may be seen which is presented in strands and anastomosing cords of small, dark, cuboidal or spindle-shaped cells with hyperchromatic nuclei within a hyalinized stroma. This type is regarded as a basal-cell epithelioma. Ewing speaks of a characteristic "adenoid cystic epithelioma"

which long passed as a cylindroma. This type shows masses of darkly stained cuboidal or polygonal cells with droplets or masses of mucus. This mucus is thought to be derived from the epithelial cells but in many instances may be a degeneration product of the stroma.

Even squamous cells have been seen in this tumor. They are accounted for by a process of metaplasia. Between the epithelial masses in most of these tumors is found a stroma of mucoid connective tissue or cartilage in variable amounts. Lymphoid tissue is ordinarily scattered throughout the growth. The same tumor may show all the structures that have been described in different parts but on the whole a certain uniformity as to type is found.

Recurrences as a rule exhibit the same structures as the original growth, but the cellular percentage may be more abundant and the malignant propensity is thought to be somewhat greater than that of the original tumor.

Incidence as to Gland.—About 90 per cent of the mixed tumors of the salivary glands are found in the parotid. They are not particularly rare. The majority of the remaining 10 per cent occur in the submaxillary gland.

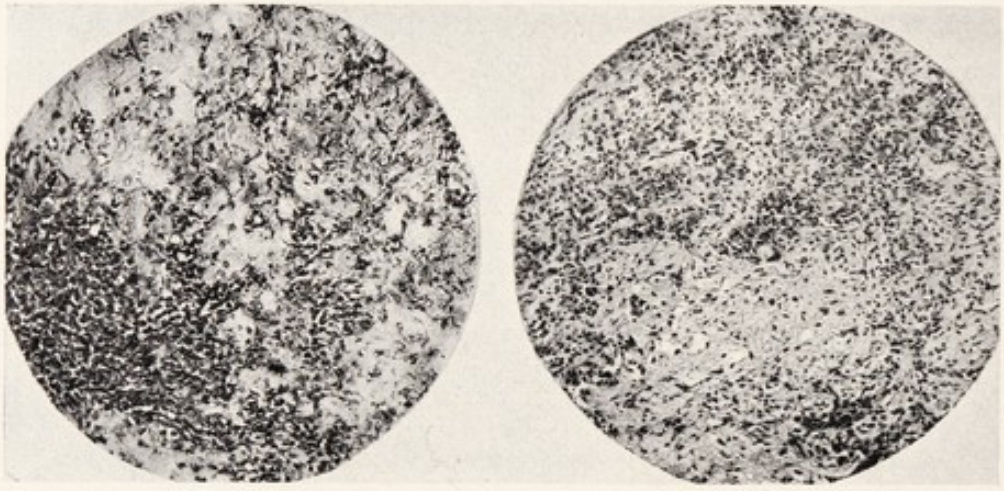

A *B*

Fig. 219.—*A*, Mixed tumor of submaxillary gland. *B*, Mixed tumor of the parotid gland

In the Benedict and Meigs series, 83 were on the right side and 78 on the left side; 110 were in males and 92 in females. A mixed tumor of the sublingual gland is rarely found. Mixed tumors are seen at all ages. The congenital ones probably remain quiescent for a time. The vast majority of individuals with mixed tumors present themselves for treatment between the second and fourth decades of life.

Clinical Features.—In the beginning at least, a mixed tumor tends to be encapsulated and is fairly sharply defined on palpation (Fig. 220). Later as the fusion of the capsule of the tumor with the fibrous septa of the gland goes on, the outline of the mass becomes less distinct. Sometimes, although the original tumor probably arose within the gland, it may free itself somewhat and become connected to the gland by hardly more than a stalk. As a general rule the consistency is firm, but in those growths which are unusually cellular or mucoid degeneration is present, and the tumor becomes somewhat softer and more elastic. Some lobulation is usually felt. When, as rarely happens, a mixed tumor develops within the ramus of the mandible, the pharynx is likely to be somewhat obstructed. When the tumor has a

chance to exert pressure on the growing mandible during childhood, a growth deformity of the jaw bone or the orbit may result. Most often throughout their course these tumors grow slowly and continuously and still in the history one rather commonly finds information concerning a quiescent period of from one to ten years followed by a period of more active growth. The tumor, when the surgeon first sees the patient, varies in size from a small nodule 1 to 2 cm. in diameter to a growth of 8 to 10 cm. Although rapid growth leads one to suspect malignant change, the latter is not common. Metastasis to the lymph nodes occurs late in those tumors showing malignant transformation. The seventh nerve is often stretched over the tumor or may even go through it. Real pain seldom is a symptom.

Diagnosis.—The supposition is warranted that a movable nodule within a salivary gland, which does not seem to be an enlarged lymph node, is probably a mixed tumor. About a stone there is usually some inflammatory thickening causing less definition.



Fig. 220.—Patient with mixed tumor of the parotid gland.

An exploratory needle or roentgenogram should reveal the true nature of a mass due to calculus. Evidence of malignant change is offered by a history of sudden rapid growth. When the mobility is impeded the evidence becomes stronger, and almost a certainty in the face of an enlargement of tributary lymph nodes. Ulceration only adds to the certainty. But although the clinical diagnosis may seem absolute, microscopic examination for confirmation is wise.

Treatment.—The treatment of mixed tumor of the parotid is local excision of the tumor mass (see Removal of Localized Mass from the Parotid Gland). When the tumor recurs, it is wisest to excise enough of the parotid gland so that one does not approach the recurring mass by less than ½ cm. This is a difficult procedure if one attempts to preserve the facial nerve which should be done if possible.

Although the consensus of surgical opinion is apparently in favor of complete removal of encapsulated tumors, there seems to be some evidence accumulating that adequate irradiation therapy favorably influences some of the mixed tumors of the parotid. All the small encapsulated tumors are still being removed surgically, but with the larger, more diffuse growths it

is not unwise to see what irradiation will do before deciding upon surgical attack. Merritt discusses the present situation from the standpoint of irradiation. Radium and *x*-rays are useful in the treatment of malignant parotid growths but usually only as palliative procedures. Excision even yet is the treatment of choice when the tumor is not inoperable. It is probably wise to give intensive irradiation before and after excision.

Prognosis.—While the tumor is still encapsulated, if the removal is complete with all the lobulations the prognosis is good as regards recurrence. But when removal is incomplete, a recurrence is the rule. It is stated that on recurrence, even if the original growth was benign, it usually becomes more cellular and active and malignant change eventually may be precipitated by repeated inadequate surgical interference. Growths with a poorly defined capsule usually recur unless the greater part of the gland is also removed.

Malignant tumors, even when the entire gland and capsule are removed with all the involved extracapsular tissue, give a poor ultimate prognosis. Death is caused usually in malignancy by recurrence rather than by general metastasis. Sistrunk reports 103 cases of mixed tumor of the parotid gland seen from 1915 to 1919. In this series 18.3 per cent had recurrences and 6.6 per cent died. Of the 40 mixed tumor cases reported by Benedict and Meigs only 1 became malignant after recurrence. Twelve (30 per cent) of the 40 had one or more recurrences. Recurrences may occur up to five years after operation.

The Removal of a Localized Mass from the Parotid Gland.—In the removal of encapsulated benign masses occurring in the substance of the parotid gland, it is necessary to guard against damaging the facial nerve. Very often it is wiser to work under local anesthesia but, whether or not local anesthesia is used instead of general, the side of the face on which one is working should be kept exposed and a careful watch made for any twitching of the facial muscles. Unless the nodule is small and superficial it is usually better to use an incision just anterior to the tragus and extend it downward behind the angle of the jaw. The incision goes down to the parotid fascia. The skin and subcutaneous tissues are then retracted forward, exposing the parotid capsule. When the tumor mass is encountered it should be removed by blunt dissection. Every bit of tissue should be examined before it is cut. Grasping the tissue sharply with an artery forceps often causes contracture of the muscles which the facial nerve supplies. The nerve spreads out and becomes superficial toward the anterior border of the gland. In the posterior part of the gland the nerve lies fairly deeply. When the right plane of cleavage is found, it is usually possible to enucleate an encapsulated mass with considerable facility. Following such an operation there may be temporary discharge of saliva, but unless a duct has been cut it ceases spontaneously after a week or so. Firm pressure on the flap for a week or ten days largely prevents the skin flap from ballooning up with saliva and aids primary union. When a large encapsulated tumor is to be removed, it is best to locate the seventh nerve at the posterior inferior border of the gland. This aids one in determining the relationship of the nerve to the mass. Sometimes, in large mixed tumors, the nerve lies anterior to the tumor and is stretched across it. In the extirpation, handling of the nerve may cause a temporary paralysis. However, if

the nerve is not severed, there will be a return of function within a few weeks.

Excision of the Submaxillary Gland.—A curved incision with convexity downward, running from a point over the anterior edge of the sternomastoid and about 1 inch below the angle of the jaw forward to above the middle of the hyoid bone, gives adequate space for exposure of the submaxillary gland. The size of the mass to be removed, of course, influences the length of the incision. The incision may or may not go through the platysma muscle. The flap over the gland is dissected upward. The incision is made deeper at the lower part of the exposure until the gland or the digastric muscle is visible. At the posterior part of the lower border of the gland, the facial vein is doubly ligated. At the upper edge of the exposure and just along the lower border of the mandible, the incision is deepened and the facial artery and vein are doubly ligated as they pass over the masseter muscle upward and forward. This allows the tissues to be freed from the lower border of the mandible. The fascia along the anterior edge of the sternomastoid muscle is cut through. The submaxillary gland is retracted upward. The facial artery is located as it enters the posterior part of the gland behind the upper border of the digastric muscle, and is doubly ligated. With gauze dissection all the gland is enucleated except its duct attachment and the prolongation onto the upper surface of the mylohyoid muscle. Slight tension is placed upon the attached portion and it is clamped across and cut at the posterior edge of the mylohyoid muscle. All vessels are tied. The wound is packed with a gauze wick. Most of the incision is closed save the inferior central part through which the gauze pack is allowed to protrude.

Excision of the Sublingual Gland.—This gland lies immediately beneath the mucosa on the anterior part of the floor of the mouth. The tongue is held to one side by a retractor after a mouth gag is inserted. Benign masses involving this gland should be removed by an incision over the most prominent portion and enucleated by dissection.

The wound is packed lightly with a gauze wick.

Malignant tumors are to be treated as cancer of the floor of the mouth (see Chapter XXXVI).

Bibliography

Bibliography Quoted in Text

Benedict, E. B., and Meigs, J. V.: Tumors of the Parotid Gland, A Study of 225 Cases with Complete End Results in 80 Cases, Surg., Gynec. and Obst., **51:** 626, 1930.

Brophy, T. W.: American Practice of Surgery, New York, Wm. Wood and Co., 1908.

Davis, E. D. D.: Specimen of Large Mixed Tumor of the Parotid Enucleated from the Soft Palate, Proc. Royal Soc. Med., Sect. of Laryngol., **18:** 26, London, 1925.

Ehrlich, E.: Beitr. z. klin. Chir., **1:** 368–496, 1906.

Evans, H. M.: Keibel and Mall, Manual of Human Embryology, **2:** 403, Phila., 1912.

Ewing, James: Neoplastic Diseases, Phila., W. B. Saunders Co., 768, 1928.

Fry, R. M.: The Structure and Origin of the Mixed Tumors of the Salivary Glands, Brit. Jour. Surg., **15:** 291–306, 1927.

Figi, F. A.: Radium in the Treatment of Multivascular Lymph Cysts of the Neck in Children, Amer. Jour. Roent., **21:** 473, 1929.

Figi, F. A., and Hunt: Quoted by New, Gordon, and Childrey, J. H.: Tumors of the Tonsil and Pharynx, Arch. Otol., **14:** 596, 1931.

Gilford, H., and Davis: Potato Tumors of the Neck and their Origin as Endothelioma of the Carotid Body, Practitioner, **73:** 729–739, 1904.

Dobromidoff: Zur Pathologie und Therapie der Tumoren des Glomus caroticum, Chir., no. 135, 1908; Zentralbl. f. Chir., **35:** 956, 1908.
Hinsberg, V.: Deutsch. Ztschr. f. Chir., **51:** 281–355, 1899.
Janeway, H. H.: Quoted by Ewing.
Ztschr. f. Krebsforsch., **8:** 403, 1910.
Jour. Cutan. Dis., **28:** 140, 1910.
Juracz: Handb. Laryng. (Heyman), 1898.
Kaufmann, Edward: Lehrbuch der speziellen pathologischen Anatomie fuer Studierende und Aerzte, Berlin, Walter de Gruyter, 463–472, 1922.
Pathology, vol. 1, P. Blakiston's Son and Co. (Reimann).
Klinge, F.: Deutsch. Zeitschr. f. Chir., 183, 195, 1923.
Krompecher: Ziegler's Beiträge, **64:** 165, 1918.
Beitr. z. path. Anat. u. z. Allg. Path., Jena, **44:** 51, 88, 1908.
Kummel: Nelson's Loose-Leaf Living Medicine, vol. 1.
Zur Chirurgie des Sympathicus, mit besonderer Berücksichtigung ihrer anatomischen Grundlagen, Beitr. z. klin. Chir., **132:** 249–323, 1924.
Kuttner, H.: Von Bergmann's System of Practical Surgery, vol. 1.
Beitr. z. klin. Chir., **16:** 181–256, 1876.
Lecene: Rev. de chir., **37:** 1, 1908.
Lexer: Von Bergmann's System of Practical Surgery, vol. 1.
Path. chir. Chevassu, Rev. de chir., **41:** 145, 1910.
Marchand, F.: Beitraege zur Kenntnis der normalen und pathologischen Anatomie der Glandula carotica und der Nebennieren, Festschr. f. Rudolph Virchow, **1:** 535, 1891.
McCurdy: Quoted by Morton, John J., in Graham's Surgical Diagnosis, The Skin and Subcutaneous Tissues, **2:** 158.
McFarland, Joseph: Adenoma of the Salivary Glands with Report of a Possible Case, Amer. Jour. Med. Sci., **174:** 362–378, 1927.
Ninety Tumors of the Parotid Region, Amer. Jour. Med. Sci., **172:** 804–848, 1926.
Merritt, E. A.: Amer. Jour. Roent., **25:** 507–511, 1931.
Moise, T. S.: Johns Hopkins Hosp. Bull., **31:** 369, 1920.
Nasse, D.: Arch. f. klin. Chir., **44:** 233, 1892.
New, G. B.: Unusual Pharyngeal Lesions, Arch. Otolaryn., **1:** 384, 1925.
New, G. B., and Childrey, J. H.: Tumors of the Tonsil and Pharynx, Arch. Otolaryngol., **14:** 596, 1931.
Adenocarcinoma of the Mixed Tumor Type, Arch. Otolaryngol., **14:** 699, 1931.
Malignant Tumors Exclusive of Adenocarcinoma of the Mixed Tumor Type, Arch. Otolaryngol., **14:** 713, 1931; Abst. April, 1932.
Pilliet, A. H.: Progrès méd., **29:** 50, 1891.
Reid, M. R., and Andrus, W. D.: Surgery of the Autonomic Nervous System, Dean Lewis' Practice of Surgery, W. F. Prior Co., vol. 3.
Reid, M. R.: Adenoma of the Carotid Gland, Johns Hopkins Hosp. Bull., **31:** 177–184, 1920.
Ribbert, D.: Virchow's Arch., 151.
Münch. med. Wochenschr., 1218, 1905.
Carc. d. Menschen., 1912.
Schech: Krank. d. Kehlk., Vienna, 1897.
Schmieden, V.: Arch. f. path. Anat., 161, 373, 1900.
Sistrunk, W. E.: Collected Papers, Mayo Clinic, **13:** 861, 1920.
Virchow: Virchow's Arch., quoted by Blair, V. P., Padgett, E. C., Brown, J. B., in Graham's Surgical Diagnosis, Diseases of the Face, Mouth, and Jaws, Phila., W. B. Saunders, vol. 2, Chapter III, 1930.
Volkmann, R.: Ueber endotheliale Geschwuelste, zugleich ein Beitrag zu den Speicheldruesen- und Gaumentumoren, Deutsch. Ztschr. f. Chir., **41:** 1, 1895.
Warthin: Arch. Ophthal., 30 (Lit.), 1901.
Wegner: Brun's Beiträge z. klin. Chir., 1894.
Wise: Quoted by Sutton, R. L.: Diseases of the Skin, St. Louis, C. V. Mosby Co., 4th ed., p. 598, 1919.
Wood, F. C.: Tumors, Nelson's Loose-Leaf Living Medicine.
Surgery, **2:** 112, 1927.
Mixed Tumors of the Salivary Gland, Ann. Surg., **39:** 207, 1904.

CHAPTER XXXII

MALIGNANT NEOPLASMS OF THE SOFT TISSUES

During the past two decades, considerable addition has been made to our knowledge of malignant neoplasms of the oral cavity in general. The use and the development of irradiation methods have markedly influenced ways of treatment. Broders' scheme of classification of epidermoid carcinoma in particular has served to emphasize the importance of studying the character of the disease as an aid in determining the prognosis. Pathologic studies along with observation of the irradiation response have been combined in recent attempts to recognize histologic criteria for grouping tumors according to their radiosensitivity. Thus, the importance of a more careful selection of the weapons for the destruction of carcinoma has become increasingly evident.

Importance of Early Diagnosis.—The importance of early diagnosis of buccal malignancies cannot be stressed too strongly. When one considers, on the one hand, the improbability of successful treatment in the late stages, the suffering of the victim, and the invariable outcome when treatment is unsuccessful and, on the other hand, the long periods of no visible evidence or perhaps even the lasting obliteration of the disease that may follow proper treatment at an early date, the importance of early diagnosis and early treatment cannot be overestimated. Nowhere else save on the skin can precancerous or early cancerous lesions be so easily observed. Dentists especially may contribute to the reduction of cancer of the mouth as most persons in this country of cancer age frequently consult their dentists. At the time most malignancies appear their teeth are disintegrating or artificial bridges and teeth are being fitted.

Warning Against the Use of Local Irritants.—A point worth mentioning is the evil effect of the use of irritants upon cancerous growths. One of the most pernicious and prevalent is the use of caustic applications. Many case histories will verify the perniciousness of an irritative type of treatment on rather indolent carcinomatous growths. By such a régime they are often stimulated to more virulent activity. A questionable lesion should never be stimulated to a quicker activity by the application of an irritant insufficient to destroy it, by insufficient excision, or even by insufficient radiation.

Importance of Biopsy.—When in doubt of the diagnosis, excision followed by microscopic examination is a reliable procedure that must be insisted upon. When the lesion is small, it should be completely excised along with a sufficient amount of surrounding normal tissue. When the lesion is of moderate or considerable size, a small wedge from the edge should be removed under local anesthesia. In oral ulcerating lesions, it is fairly well proved that a biopsy made in this manner is practically without hazard. But when a mass lies beneath an unbroken mucous membrane it

may be unwise to cut into it unless means are immediately at hand to carry out any further treatment that may be indicated.

IRRITANTS TO THE ORAL MUCOSA

Those conditions which produce a chronic inflammatory reaction or cause a chronic inflammatory reaction to continue are practically all associated with some increase in the incidence of cancer in the oral region. But considerable proof has now accumulated to show that conditions which will cause a malignant degeneration in one individual do not necessarily produce it in another. In other words, not only the irritative factor is important but the susceptibility of the individual also plays a part. As we have no yardstick for measuring either, a discussion of the exact position of these factors must necessarily be somewhat indefinite. In some instances not only the susceptibility but several of the various irritative factors all apparently contribute their part in the development of a malignant lesion.

Inclement Weather and Sunshine.—Even inclement weather has a detrimental effect on the face and the lips in many individuals. Cancer of the skin of the face is undoubtedly more common in those leading an active outdoor life. One may mention the tendency of railroad firemen and engineers to show a higher incidence of cancer of the skin of the face and the lips. Some keratotic lesion generally precedes for a considerable period of time the appearance of an actual malignant degeneration.

Basal-cell carcinoma practically never develops in normal skin. The most common dermatosis preceding the lesion is a seborrheic hypertrophy. A history of a tendency to a clinically cracked or fissured lip preceding the development of a frank malignant lesion is common. Undoubtedly, inclement weather plays a rôle in such instances. Besides wind, sunshine may tend to irritate the skin and exposed mucosa. Farmers seem to show an increased incidence of cancer of the lip. Their lips are often cracked and irritated by the rigorous outdoor life. New mentions the increased incidence in farmers when discussing the Mayo series of epithelioma of the lip. Broders estimated that in his series of cancer of the lip 63 per cent showed some type of chronic inflammation preceding the development of the malignant lesion.

The opinion is unanimous that blonds are more likely to develop malignant lesions of the skin than dark-skinned races. They are more easily affected by sunshine. Skin cancer is seldom seen in the Negro. Hazen says that the Negro does not have the senile keratosis which often precedes the disease and the American Indian, according to Lain, is practically free from the disease.

Tobacco.—Tobacco also exerts a definite influence in the development of lip, oral and laryngeal cancer. Broders, however, found only a slight difference in the incidence of lip cancer in smokers and nonsmokers. It stimulates the epithelium, produces a chronic hyperemia, local erosions, edema and lymphocytic infiltration. In smoking, heat effects may be added to those of the tobacco fumes. This is especially true of pipe smokers. Tobacco chewers are somewhat more prone to develop cancer where the quid is held against the cheek. Tobacco to a less extent affects the posterior part of the tongue, the palate, tonsils and pharynx, and the effect of excessive amounts of tobacco smoke on the larynx has long been emphasized.

Statistics in regard to the part that tobacco plays in producing cancer of the oral mucosa must necessarily be rather indefinite. Tobacco is rather commonly used in greater or less amounts. The quantity used is probably an important factor in the development of malignant degeneration. However, many individuals who have never used tobacco do develop malignant changes probably due to the factor of susceptibility plus various other irritative factors.

Alcohol.—Alcohol has been suggested as a factor. The fact that cancer of the mouth is eight times more frequent in men than in women contributed in the past to the idea that alcohol was of some importance. However, within recent years, since the use of alcoholic beverages has grown more common among women, no change in the relative sex incidence of buccal cancer has been reported. At present, however, it is thought that the effect of alcohol is ordinarily too temporary to be a factor of more than the slightest importance in increasing the incidence of buccal cancer.

Bacterial Irritation.—No one can fail to be impressed with the "dirtiness" of the teeth in the average patient suffering from cancer of the buccal cavity. There must be some relationship. Even normally the anterior half of the tongue is covered with papillae to which cling myriads of bacteria. Whether the dirtiness of the mouth somewhat characteristic of the patient with oral cancer is one of cause or effect is sometimes difficult to say. Disease conditions of the gums such as pyorrhea undoubtedly cause a "dirtier" mouth. In such individuals the evident mouth infection is probably secondary to the pyorrheic condition. But the prolonged chronic irritation of a chronic infective process possibly increases the incidence of oral cancer in such individuals.

Tartar accumulation may over a long period of time promote a low-grade inflammation of the gums. Carious, jagged teeth or poorly built dental appliances may almost constantly rub and irritate various parts of the oral mucosa. Chronically inflamed tissue and ulcerations are thus developed which may ultimately undergo malignant degeneration in the susceptible.

As to the reason for malignant degeneration of the epithelial cells of the nasal sinuses, it has long been suggested that continued sinus infection has an influence. But the evidence is only indirect. Repeated infection with possible ulceration may have something to do with a cicatricial epithelial metaplasia which allows a squamous-cell type of lesion to develop.

SO-CALLED "PRECANCEROUS" LESIONS

As the mouth cavity is examined commonly by both physicians and dentists, each group should be schooled in the recognition of the so-called "precancerous" lesions; first, because the dividing line between the precancerous and the early cancerous lesions is not always distinct clinically and, second, it is well to establish that epidermoid cancer often develops in unhealthy or abnormal epithelium. Certainly both avoidable procrastination and uninformed advice and treatment do much to keep cancer of the tongue and oral cavity a most dreaded and fatal disease.

One cannot overemphasize the importance of localized thickenings, indolent cracks and papillary structures constantly being irritated, as well as chronic ulcers, irritative appliances and generally unclean teeth.

Leukoplakia.—The importance of leukoplakia as a precursor of malignant degeneration of the oral mucosa seems definitely established in all series of cases.

Fournier and von Bergmann originally established that leukoplakia preceded about 30 per cent of cancers of the buccal cavity. No evidence has been presented to this day that would lead one to believe that these observers underestimated the importance of leukoplakia as a precursor of oral cancer. All leukoplakias should be destroyed if their diffuseness does not contraindicate such a radical procedure. In the latter case careful and prolonged observation certainly should be insisted upon, as the slightest tendency to ulceration usually means a malignant change.

Luetic Scars.—The scars of an old syphilitic infection—especially on the tongue—have been blamed for a certain percentage of carcinoma of this region. Fraser places the incidence of syphilis in cases of carcinoma of the tongue as a whole at 42.3 per cent and in carcinoma of the dorsum of the tongue at 78.3 per cent. In various series of malignancy of the mouth a percentage has been preceded by luetic scars on the mouth (Mueller 3.5 per cent, Fournier 92 per cent). Although undoubtedly the latter percentage is high, Fraser states that syphilis often precedes leukoplakia and that 90 per cent of carcinoma of the dorsum is preceded by leukoplakia. This figure again is undoubtedly exaggerated. Most observers have found that in somewhat less than one third of oral cancers some evidence of leukoplakia can be demonstrated. About 20 per cent of all leukoplakic lesions of the mouth in the series studied by Lund showed evidence of lues. When the patients without a Wassermann test were excluded the percentage was 30. Lund found in 1540 cases studied that the relationship of cancer to syphilis varies greatly according to location.

In all locations except the tongue and cheek, the presence of a positive history of syphilis or positive Wassermann test is so low that the incidence may be assumed to be close to the normal incidence in the population, considering the average age and social status of patients having cancer of the mouth. The relationship of syphilis to cancer is much more important in the tongue, falling somewhere between 17 and 32 per cent (Lund).

Another interesting feature of Lund's study is that the pathologic index or grading of the cancers of the tongue developing in syphilitic lesions indicates a higher degree of malignancy than was noted in nonsyphilitic cases. No conclusions could be reached for other locations.

Probability of an Ulcerous Lesion of the Mouth Being Due to Syphilis in Those of Cancer Age.—Of interest as to the frequency of syphilis alone when an ulcer in the mouth is found in an elderly individual and the question of diagnosis arises, are the observations of Lund from the Collis P. Huntington Hospital and the Massachusetts General Hospital. In 1548 cases with ulcerous lesions of the mouth seen in a cancer clinic only 9 were found in which the single diagnosis of syphilis of the mouth was made (Lund). These did not include leukoplakic lesions. The locations were: tongue 4, tonsil 2, palate 2, and lip 1. The types of lesions were ulcerative gumma 6, gumma 1, multiple ulcers and fissures 1, glossitis 1. The sex incidence was male 6 and female 3.

Papillomas.—Papillomatous projections of the oral mucosa, especially if subjected to trauma or prolonged irritation, for one reason or another

undoubtedly contribute to a certain share of buccal epithelioma. Butlin states that all papillomas of the mouth should be removed without procrastination because of their tendency to undergo malignant change. An indolent crack near the base of such a lesion is especially likely to be an early malignant change.

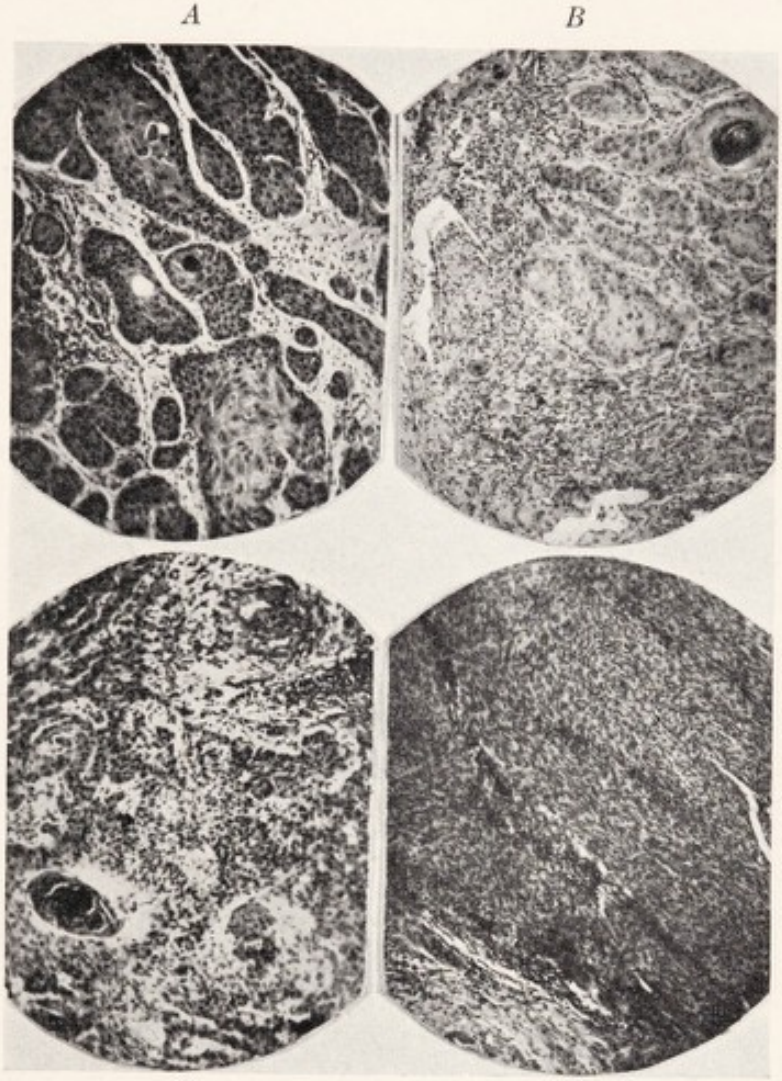

Fig. 221.—*A*, Epidermoid carcinoma showing a rather marked tendency toward adult cellular differentiation. Broders' Group I, 75 to 100 per cent adult cellular differentiation. *B*, Epidermoid carcinoma. Broders' Group II, 50 to 75 per cent adult cellular differentiation. *C*, Epidermoid carcinoma. Broders' Group III, 25 to 50 per cent adult cellular differentiation. *D*, Epidermoid carcinoma. Broders' Group IV, 0 to 25 per cent adult cellular differentiation.

Trauma and Chronic Inflammation.—Under inflammatory diseases of the tongue various chronic inflammatory diseases of that organ are described, which in rarer instances play a rôle in the incidence of cancer of that organ.

Vocal abuse was found to be important in 64.6 per cent of Jackson's 582 cases (1923) of cancer of the larynx. He regarded vocal abuse as a common cause of chronic laryngitis, keratosis, papillomas and granulomas. Less support is given to Jackson's conclusions as to the importance of vocal traumatic inflammation by the fact that 9 or 10 men to 1 woman are affected by cancer of the larynx and that cancer of the larynx is not a common but a rare disease. In some few cases syphilis of the larynx

precedes the disease. Semon, in 10,747 collected cases, did not find that the repeated removal of a benign lesion led to malignant degeneration. Jackson, however, challenges this conclusion.

Value of Histologic Prognosis in Epithelioma.—Some years ago Broders called special attention to the conception of cellular differentiation as an aid to prognosis. The idea was not entirely new but had not been emphasized. The conception is based on the theory that the more highly differentiated malignant cells are, the more nearly their appearance approaches that of a normal cell, and the lower the malignancy index should be (Fig. 221, *A, B, C, D*). Broders' work was done on carcinoma of the lip and has been quite widely accepted for lesions of the lip at least. On the other hand, some skepticism has been expressed from time to time. Plaut expressed the opinion that for practical purposes the time is hardly ripe to advocate the method for histologic prognosis in general. In criticizing Broders' data Plaut states "the microscopic picture which is supposed to warrant a favorable prognosis is found coincident with other favorable factors as smallness of the tumor and short duration." He goes on to say "The interpretation of the most used histologic features is so far uncertain. This is true of inflammation in the stroma, and also of the mass relation between epithelium and mesenchyme. Knowledge of cell division in tumors requires much more study with especial reference to the occurrence of amitosis or immediate forms of cell division and of different phases of mitosis. More problems than facts which can be used for histologic prognosis are available. Only the most careful study of individual cases can avail us in the presence of manifold histologic and clinical phases of malignant tumors. Most likely to remain are those of bad prognosis with highly irregular pleomorphic structures."

From a statistical standpoint the matter is discussed in a later chapter as it is related to therapy and prognosis. There is some evidence that the grade of the tumor is to some extent an indication of the size of the tumor and that cases tended to become of higher grade as they increased in size. Lund found that in carcinoma of the lip there was a relationship of the duration of the cases before treatment to the presence or absence of metastasis and that the relationship was different in different grades and sizes. There seemed to be a definite tendency to an increase of malignancy as the tumor developed.

My own working rule at the present time is to give about equal weight to the microscopic picture and the general clinical picture including the length of time the growth has been present and its size, the character of the growth, the age of the patient, and the rapidity of the growth. When the two disagree the clinical picture may be considered more valuable than the microscopic prognosis.

INCIDENCE OF BUCCOPHARYNGEAL CANCER

In 1929 (the last available census) in the United States about 120,000 persons died from cancer, of which about 4000 died from intra-oral cancer. Thus, it would appear that about 3 per cent of all cancers occur in the intra-oral region.

Age Incidence.—It is well known that epithelioma of the intra-oral region is most common between the ages of forty and sixty with the

maximum number falling in the fifth decade. The maximum incidence per given number falls between the seventy-fifth and the eighty-fifth years. After the sixth decade the number of cases decreases on account of the progressive decrease in the number of individuals who are living after sixty years of age. However, the incidence on a percentage basis of those living increases.

Basal-cell epithelioma of the skin is practically never seen in young people. In New's series the average age of sufferers from the lesion was fifty-six years. Epithelioma of the lip usually tends to occur relatively late in life—after the beginning of the fifth decade of life.

The age incidence of epidermoid carcinoma in the pharyngeal region is the same as for carcinoma in the anterior buccal cavity with the exception of lympho-epithelioma and adenoid cystic epithelioma which appear commonly in the adolescent period (from ten to twenty years of age).

Cancer of the larynx is most frequent in the sixth decade but it is not unknown even in the fourth decade of life. Thompson saw 2 cases in males aged twenty-three and twenty-eight years, respectively, and Figi and New record cases of fifteen years and twenty years, respectively. Postcricoid growths in women seem to appear early in life. McBride saw a case at twenty-four years and Tilly saw one at twenty-two years of age. Contrary to the age incidence in many other situations, sarcomas of the pharynx are most frequent between the ages of forty and sixty years.

Sex Incidence.—Burnam, in 165 cases of buccal cancer, had 128 of the male sex and 37 of the female sex. Piquantin (Ewing) estimated that 17 per cent of intra-oral cancer occurs in women. Roughly about 85 per cent of intra-oral cancer appears in the male sex.

The incidence of basal-cell cancer of the skin is about 3 males to 1 female. Cancer of the lip is at least twenty times more frequent in men than in women. If one included only squamous-cell epithelioma, the ratio of men to women is nearer 40:1 than 20:1. In Broders' series which included only squamous-cell epithelioma, there were 40 men to 1 woman.

Eighty-seven per cent of New and Childrey's 220 cases of pharyngeal tumors appeared in the male sex. Of the lymphosarcomas (14.5 per cent of 220 cases) 75 per cent occurred in males. Coutard estimated that carcinoma of the tonsil, hypopharyngeal larynx, occurs in the male sex in 93.3 per cent of the cases. Ledoux in a series of malignant new growths of the pharyngeal region found 54 males and 7 females.

A very remarkable characteristic of malignant epitheliomas of the laryngopharynx is that the primary seat of the tumor is somewhat determined by the sex of the patient. Postcricoid or hypopharyngeal carcinomas are practically limited to women while growths around the upper laryngeal opening show a very strong preference for men. Postcricoid carcinoma also appears at a relatively early age for carcinoma. It is estimated that the average age is at least ten years younger than the average age for carcinoma in general. Postpharyngeal carcinoma according to Trotter is analogous to the postcricoid carcinoma as to age and sex. Cancer of the larynx itself is found about ten times more frequently in men than in women.

Incidence as to Site.—In 2741 cases of intra-oral cancer cited by Quick in 1928 and seen at the Memorial Hospital, the following incidence as to site is of interest:

Lip	555
Tongue	473
Floor of Mouth	281
Mucosa of Cheek	185
Superior Maxilla	122
Antrum	103
Inferior Maxilla	149
Tonsil	318
Hard and Soft Palate	106
Pharynx	63
Intrinsic Larynx	165
Extrinsic Larynx and Epiglottis	221

1. *Basal-cell Epitheliomas.*—Basal-cell epitheliomas are most commonly found on the nose, cheek, and about the inner and outer canthi of the eyes. Broders reports that about 96 per cent appear above the clavicle.

2. *Epithelioma of the Lip.*—Statistics vary but, roughly, the incidence of cancer of the lower lip is about twenty times more frequent than cancer of the upper. An epithelioma of the upper lip is likely to be of the basal-cell type.

3. *Buccal Cavity and Anterior Tongue.*—About 10 per cent of cancers of the buccal cavity proper appear about the salivary duct in the floor of the mouth. About 68 per cent appear on the edge and 29 per cent on the dorsum of the anterior two thirds of the tongue (Fraser). About 20 per cent of buccal cancer appear in the palatoglossal sulcus (Fraser). Cancer of the tongue itself is more frequent than cancer of the floor of the mouth, gum and cheek combined.

4. *Posterior Tongue, Tonsillar Area and Nasopharyngeal Region.*—Some idea of the incidence of the various pathologic types of carcinoma in this region including lymphosarcoma may be gained from a study of Ewing's 300 cases.

He classified 300 tumors in this region and found the following:

	Posterior Tongue and Tonsil Cases 200 cases	Nasopharynx Cases 100 cases
1. Squamous	72 per cent	30 per cent
2. Transitional	14 " "	37 " "
3. Adenoid Cystic	0 " "	4 " "
4. Lymphosarcoma	9 " "	15 " "
5. Lympho-epithelioma	4 " "	11 " "
6. Adenoma Malignum	0 " "	3 " "

Berven, in reporting his malignant tumors of the tonsillar region, found 42 carcinomas, 4 lympho-epitheliomas, 35 sarcomas (lymphosarcomas), and 5 malignant mixed tumors.

New and Childrey studied 220 cases of malignant tumors of the pharynx exclusive of the nasopharynx at the Mayo Clinic during a fourteen-year period (1917–1930). One hundred seventy-four (79.2 per cent) were of the squamous-cell variety, that is, squamous-cell carcinoma was found five times more frequently than all the other malignant tumors together. They were mostly of the active type of growth. New points out that formerly many of these growths were classified as endothelioma or branchiogenic carcinoma and Americans following the lead of Ewing call them transi-

tional-cell epithelioma. Fourteen and fifty-five one hundredths per cent or 72 of this group were of the lymphosarcomatous type. Five fibrosarcomas were present in the group (2.27 per cent). Nine tumors (4.08 per cent) were classified as hemangioma-endothelioma, melano-epithelioma, myeloma, and malignant dermoid.

5. *Antrum.*—Malignant tumors of the antrum constitute a not uncommon group of neoplasms. Malignant lesions of the other nasal sinuses are considerably less frequent than those of the maxillary sinus. In 1892 cancers of all types seen at Memorial Hospital, 48 were of this region and 38 involved the antrum primarily. According to Shreiner 1.8 per cent of all cases at the New York State Institute for the Study of Malignant Diseases were of the maxillary sinus. According to Ewing 1.95 per cent of all cases of cancer admitted to the Memorial Hospital in 1916 and 1917 were cancers of the maxillary sinus. Many cancers start in the superior alveolar ridge and involve the antrum secondarily. Of 168 malignant tumors of the antrum New found 39 (1926) to have involved the antrum secondarily. Of 75 cases reported by Holmgren and Berven, 43 were primary in the antrum.

6. *Malignant Neoplasms of the Laryngopharynx and the Larynx.*—Malignant disease of the laryngopharyngeal region is fairly common. As the patients are often not submitted to an exact description of the structures involved, an exact statement of the anatomic frequency is quite impossible. In every 100 deaths due to cancer only 1.8 per cent are due to laryngeal cancer (Thomson). Jackson in 141 cases of laryngeal carcinoma found the disease intrinsic in 98. Subglottic cancer is seen less often than cordal cancer or than cancer of the laryngopharynx. Schmiegelow in 66 cases of intrinsic cancer found the cord involved in 38 cases. Thomson in 70 cases found the central portion or the anterior portion of the cord most commonly involved, and the extremities of the cord are quite often free in early cases. Cancer originating on the ventricular band or in the ventricle of Morgagni is relatively rare (Schmiegelow, Houtant). In 50 cases of intrinsic cancer of the larynx, Thomson found the subglottic area involved in 13.

7. *Intrinsic and Extrinsic Sarcoma of the Larynx.*—Molinie (Ewing) stated that sarcomas make up about 11 per cent of malignant laryngeal growths. As to site, sarcoma of the larynx may be either extrinsic or intrinsic but it is stated to be most frequent in the subglottic area.

8. *Second Buccal Cancer.*—In regard to the incidence of a second buccal cancer in the same patient, Lund found in a series of 1548 cases of buccal cancer, that it is indicated that the development of a second carcinoma of the mouth is about fifteen times as common as it would be if chance were the only factor. He also found that the development of cancer in some other organ is about twice as common as it is in the general population of the same age and sex.

9. *Malignant Neoplasms in the Young.*—In 301 malignant neoplasms of the oral cavity, Friedman and Rubenfeld (Bellevue Hospital) found 9 patients between the ages of one and twenty. Three were spindle-cell sarcomas involving the floor of the mouth, cheek and soft palate, respectively. One was a lymphosarcoma of the antrum, 3 were epitheliomas of the nasopharynx and 2 of the tonsil. Of 16,565 malignant lesions seen at

Memorial Hospital, Pack and Le Fevre found 37 instances of malignant lesions in the upper respiratory passages in patients between the ages of seven and twenty years. In 6670 autopsies at Johns Hopkins, Pearl and Bacon found 49 malignant tumors in children. Helmholz found 56 in the intra-oral region and 4 of these were squamous-cell carcinomas.

PATHOLOGY

1. FACE AND LIPS

Mesodermal Neoplasms.—A complete description of the types of malignant connective tissue new growths which rarely are encountered on the face or the lips may be left to treatises on pathology. In the literature are described a variety of malignant tumors which may be classified on microscopic study as being either of sarcomatous, endotheliomatous, or neurogenic nature.

Epithelioma of the Skin.—The two types of epithelioma most commonly occurring on the skin of the face are squamous-cell and basal-cell epithelioma.

Squamous-cell Epithelioma.—Squamous-cell epithelioma is derived from the outer layers of epidermis. The epidermal and subepidermal tissues are infiltrated by finger-like strands of epithelial cells. These projections of squamous cells extend downward and into the connective tissue below the epithelium (Fig. 221, *A, B, C, D*). The cells very often are cornified and on cross section round or oval pearly masses are therefore seen extending through the underlying connective tissue. The "pearls" are concentrically arranged groups of cells. The cells show progressive changes from the periphery to the center corresponding to changes in the normal epidermis from deep layers to the surface. As a rule, the cells are described as spindle-shaped with large ovoid nuclei and structureless protoplasm.

Basal-cell Epithelioma.—Basal-cell epithelioma is the more benign variety of epitheliomas of the skin and is thought to develop from the basal layers of the epidermis. This type is less aggressive and does not metastasize. Krompecher described this variety of carcinoma in 1900 and suggested the basal-cell origin. Prior to Krompecher's work, these tumors were regarded as having an endothelial origin by some. Fordyce asserted that the great majority of these tumors start in the epidermis covering the sheath of the hair follicles, and Mallory called them "hair matrix" cancers. Today it is generally conceded that basal-cell carcinoma arises in the basal layers of the skin in most cases but it is also conceded that certain of them may arise from fetal rests under the skin or in the hair follicles, sweat or sebaceous gland structures.

On section the surface is smooth and a limited invasion of the subcutaneous tissue is seen. The alveoli are much smaller than the squamous-cell growths and may be almost indistinguishable because of this minuteness. Microscopically, the cells partake of all the staining characteristics of the basal area of the skin (Fig. 222, *A*). The process appears to begin in the basal layer of an otherwise normal interpapillary body.

The cells are small and closely packed. The nuclei are round and elliptical. A limited amount of cytoplasm stains the latter blue. After the corium is invaded the cellular masses either remain solid or extend in branching outgrowths in the hollow columns. The mitotic figures are easily

seen. About the tumor is usually an invading walling-off process in which the smaller round cells take part. Lymphocytes, plasma cells and fixed tissue cells all enter into the reaction.

Epithelioma of the Lip.—The cellular picture of epithelioma of the lip is usually that of an acanthoma of the prickle-cell variety with intercellular bridges. "Epithelial pearls" are usually present but many varieties of detail are seen (Fig. 221, *A*, *B*, *C*, *D*). In the papillary form long papillae with or without keratosis project outward and round-cell infiltration and fibrous tissue overgrowth may hinder downward infiltration of altered papillae for quite a time. In the ulcerating form the downward invasion of the submucosal tissues is more active. In some instances the appearance of adult squamous epithelium is soon lost and the projecting columns of epithelial cells appear opaque and polyhedral. The infiltration tends to follow the lymph channels. The lymph nodes are embolically involved but in most cases are not very early.

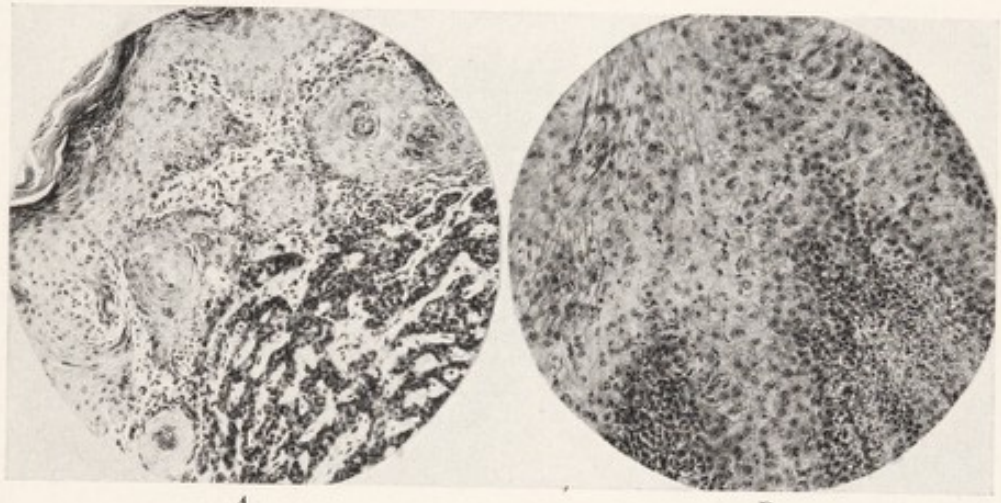

A *B*

Fig 222.—*A*, Cystic basal-cell epithelioma of side of nose. *B*, Papillomatous epithelioma of the cheek (Grade I).

It has been stated that a form of carcinoma occurs on the lips and face, having basal- and squamous-cell elements. Clinically, it is usually mistaken for a basal-cell epithelioma. Microscopic examination distinguishes the type.

Rarely one sees an instance of implantation epithelioma to the opposite lip. Supposedly an abrasion or crack in the opposite lip allows implantation of cancer cells from the active lesion to the opposite lip. However, an alternative explanation for these cases has been suggested by Ewing since both the blood and lymph vessels encircle the lips.

2. MALIGNANT NEOPLASMS OF THE CHEEK

Epithelioma of the Cheek.—Epithelioma of the cheek is ordinarily of the squamous-cell variety and fairly well differentiated. The microscopic picture is that of a somewhat more adult epithelioma than that described for anterior tongue and floor of the mouth, although the difference is not always pronounced (Fig. 222, *B*). Transitional cell epithelioma very rarely may be seen in the cheek and more rarely a basal-cell type of lesion.

Connective Tissue Tumors of the Cheek—Fissural Cheek Tumors.—Connective tissue tumors of the cheek are rarely seen. Their clinical course varies in no way from that of similar tumors in other tissues of mesoblastic origin. Rarely a mixed tumor (epithelial origin) is found in the cheek and rarely a cartilaginous nodule of congenital origin is found within the cheek. They are the remains of congenital mishaps when the maxillary and mandibular processes unite.

3. NEOPLASMS OF THE HARD PALATE

Epidermoid Carcinoma of the Anterior Palate.—Epidermoid carcinoma of the anterior palate is usually a fairly adult type of squamous-cell carcinoma. No unusual features are present because of location. It is somewhat similar to cheek carcinoma. Metastasis to the regional lymph nodes is late. The lesion is fairly radioresistant. The pathologic picture and clinical course of carcinoma of the soft palate is considerably different from

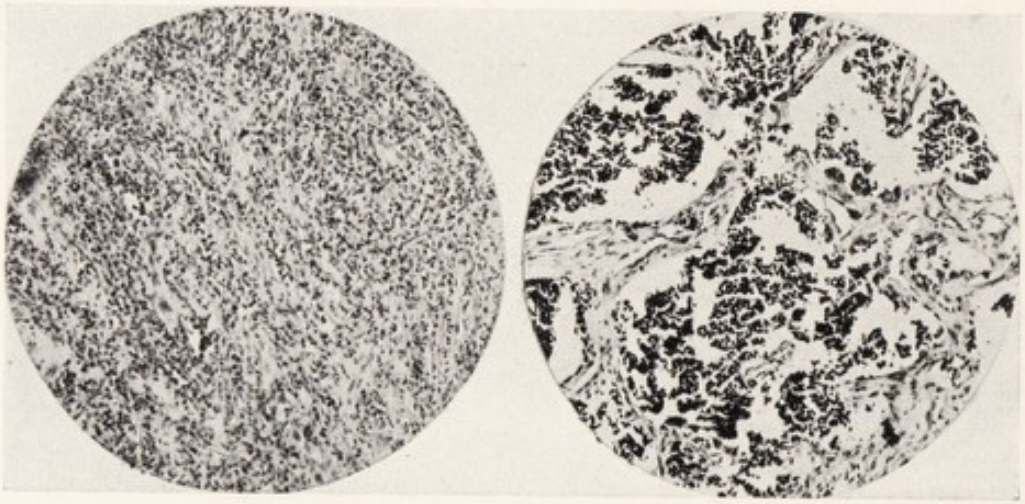

A *B*

Fig. 223.—*A*, Sarcoma of lip and cheek. *B*, Section of tumor developing at a fissural site in a baby about one month of age. It was excised. The baby is well eighteen months later. At the time of excision it was considered malignant.

carcinoma of the hard palate and is related clinically more nearly to the more anaplastic growths in the posterior parts of the tongue, in the tonsil and pharynx.

Fissural Tumors of the Palate and Connective Tissue Tumors of the Palate.—The fissural tumors described in Chapter XXXVIII are of interest when considering the anterior palate region. Some of them undergo malignant degeneration, as in Fig. 223, *B*. Sarcoma (Fig. 223, *A*) of the soft tissues has been described as developing in the palatal tissues. A few mixed tumors which rarely undergo malignant degeneration (epithelial origin) are found in the anterior palate region. (See description of clinical characteristics elsewhere.)

4. NEOPLASMS OF THE ANTERIOR TONGUE AND BUCCAL FLOOR

Epidermoid Carcinoma.—Because of a different anatomy, a greater diversity as to type of neoplastic incidence and a somewhat different reaction to treatment, tumors of the posterior third of the tongue will be dis-

cussed along with the tumors of the buccal pharynx which, pathologically and in reaction to treatment, they more nearly resemble.

The anterior two thirds of the tongue is that part of the tongue anterior to the circumvallate papillae. Many tumors of the tongue soon involve a part of the buccal floor or vice versa and the treatment often involves both areas as the pathology is similar. Therefore the two locations may conveniently be discussed under one general heading.

Microscopically, practically all epitheliomas of the anterior two thirds of the tongue are of the simple acanthomatous type. A very occasional glandular carcinoma has here and there been reported. An alveolar arrangement without squamous-cell characteristics, suggesting ducts of mucous glands, is found. From the mucous glands or the buccal mucosa of the floor of the mouth the so-called "transitional cell epithelioma" may arise. This lesion is more fully described where it is more commonly seen—under pharyngeal epithelioma. The pathology is similar whenever seen (Fig. 224, *A*, *B*). Most often acanthoma of the tongue presents fairly

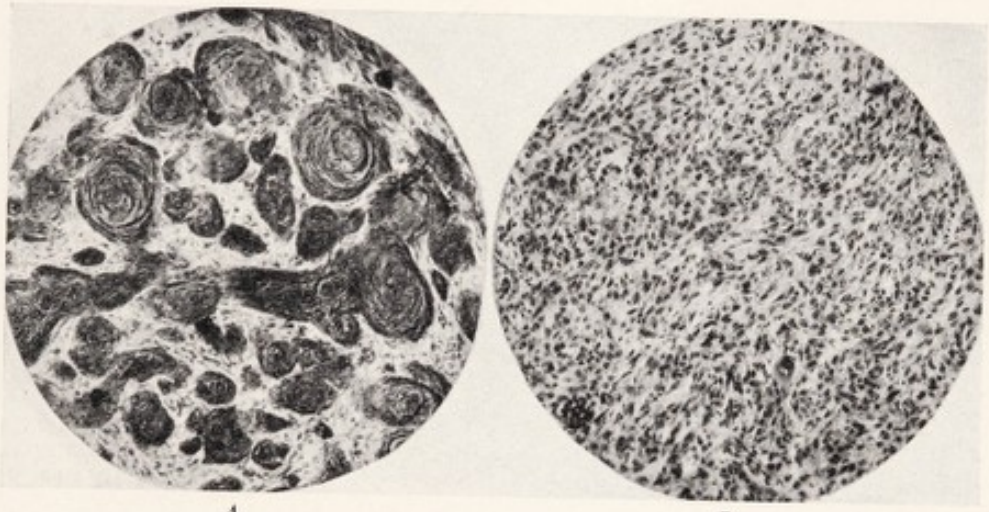

A *B*

Fig. 224.—*A*, Squamous-cell epithelioma of the tongue (Grade I). *B*, Border of the tongue (Grade II).

adult flat epithelium with hornified concentric flattened groups of cells—the so-called "epithelial pearls"—and intercellular fibrils. The less adult cells are seen in the form of cords of opaque polyhedral cells with hyperchromatic nuclei. In the more malignant type, the cells grow more diffusely (Fig. 225, *A*). However, on the whole, epithelioma of the anterior two thirds of the tongue exhibits a fairly uniform microscopic picture. The down growth of epithelium in the early stages is nearly always preceded by lymphocytic infiltration and edema of the submucosa. Soon a considerable proliferation of fibroblastic tissue develops and surrounds the invading cells. As the proliferating cells travel along the lymph channels the muscular tissue of the tongue is fairly rapidly invaded. Although metastasis usually shows about the same structure as the local lesions, anaplasia, as a rule, is more marked.

Grossly, epidermoid carcinoma of the tongue in most instances first presents itself as an indurated ulcer with hard walls. Very rarely a deeper submucous nodule may be the first evidence of the malignant growth but soon this type breaks down and produces a deep ragged exacerbation.

Epithelioma starting in a leukoplakia may at first appear as a broad, flat induration and necrosis may be relatively late. Following leukoplakia multiple areas showing carcinomatous degeneration may be found. Simple papilloma with carcinomatous degeneration or diffuse papillomatosis from which carcinoma develops in one or several foci, in the latter case at least, are rarer forms of the disease. Ewing has seen a very extensive lingual cancer without invasion of the lymph nodes in which the lesion consisted of a plexiform infolding of the entire epithelial layer without invasion by cell groups. Although, as a rule, epidermoid carcinoma of the tongue metastasizes relatively early to the tributary lymph nodes, Ewing urges that papillary plexiform, superficially diffuse and leukoplakic lesions show metastasis rather late.

Sarcoma of the Tongue.—Nonlymphoid sarcoma of the tongue may be encountered from babyhood (five months—Kaufmann) to old age. The reported cases are relatively few. The usual types are round- or spindle-celled (Kaufmann). Lymphosarcoma of the anterior two thirds of the

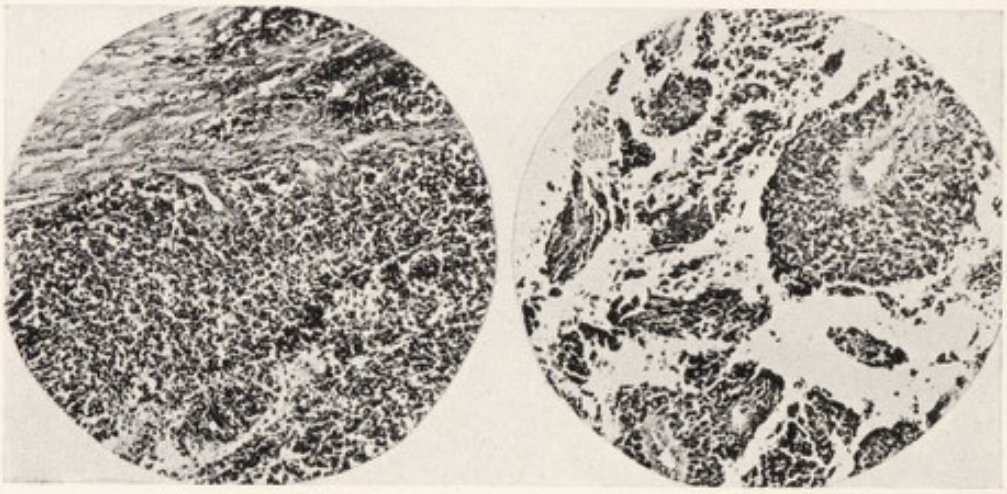

A *B*

Fig. 225.—*A*, Squamous-cell epithelioma of the posterior tongue (Grades III–IV). *B*, Section of tumor (perithelial sarcoma of the tongue).

tongue or tongue proper has occasionally been reported. Characteristically it appears more posteriorly and this is described separately. Also included in the group of connective tissue tumors are myxosarcoma and angiosarcoma (Fig. 225, *B*). In 1911 Schleinzer could only find 4 sarcomas of the tongue proper to be what he considered authentic cases. Betké (Kaufmann) found 41 cases in the literature. Fripp and Iwan collected a few cases of round-cell sarcoma and Foote described a pseudosarcoma. Kaufmann saw a hemangioma as large as a cherry at the base of the tongue. Barth (Kaufmann) reported a lymphangiosarcoma of the floor of the mouth and Schleinzer (Kaufmann) one of the tongue. Rhabdomyomas have been described. Many of the tumors of this region formerly classified as sarcomas probably were in reality carcinomas.

5. CARCINOMA OF THE JAW BONE

The term "carcinoma of the jaw bone" is usually a misnomer as far as primary squamous-cell epithelioma is concerned. However, there are certain epithelial cell rests derived from the epithelial débris of Malessez

which theoretically may undergo malignant transformation and which are located within the bone itself. The cells of such tumors generally show a tendency to differentiate toward the ameloblastic cellular form but in other instances such a differentiation may not be possible to distinguish.

Squamous-cell epithelioma of the epithelium of the gums may secondarily invade the mandible. Probably the mandible is most often invaded by epithelioma originating in the lower lip although epithelioma of the cheek and floor of the mouth frequently sooner or later secondarily invades the bone. Metastatic nodes in the submaxillary region and a metastatic involvement of the buccal gland from an epithelioma of the cheek or the skin externally on the face also not uncommonly later result in secondary invasion of the mandible after the carcinomatous cells have perforated the capsule of the enlarged lymph node. When treatment is considered, it is well to remember that the blood spaces of the bone are probably invaded by malignant cells to a greater extent than one would suspect by the appearance.

6. MALIGNANT NEOPLASMS OF THE POSTERIOR TONGUE, TONSILLAR AREA, NASO- AND OROPHARYNGEAL REGIONS

Because of some pathologic similarity and possibly a similarity in relation to irradiation, malignant neoplasms of the posterior one third of the tongue are discussed along with malignant neoplasms of the naso- and oropharyngeal regions.

The naso-, oro-, and hypopharynx present several types of epithelioma—an adult type of squamous epithelioma, transitional-cell epithelioma, schneiderian membrane epithelioma, and an epithelioma from the lining of the ducts of the mucous glands. According to Ewing, transitional-cell epithelium covers the pharynx, posterior tongue, nasopassage, a portion of the larynx and lines a portion of the ducts of the mucous glands which open on the surface. The squamous-cell carcinoma from the normal mucosal lining is the most common. Some authors classify what Ewing has termed the "transitional-cell epithelioma" as ordinary squamous-cell carcinoma of Grades III and IV (Broders').

Epithelioma of the Posterior Tongue, Naso- and Oropharyngeal Regions.—*Squamous-cell Epithelioma.*—Squamous-cell epithelioma may be either of the primary type or of the secondary type from metaplasia. The primary is generally more adult and as far as radiation is concerned more resistant than the secondary type, according to Ewing. Many of these squamous-cell types of tumors are rather anaplastic and very malignant. Often no keratin is produced and only slight desmoplastic power is retained. Usually metastasis to the upper deep cervical lymph nodes occurs quite early and the involved nodes are often multiple and may be bilateral.

Some men consider transitional-cell epithelioma, schneiderian membrane epithelioma, and lympho-epithelioma as nothing more than anaplastic, rapidly growing, squamous-cell epithelioma of Grades III and IV of Broders' classification and that all the classifications pathologically are no more than just another way and a more complicated way of expressing a conception which, if taken too wholeheartedly, tends to confuse the treatment. Following this latter idea, to a certain extent, in 174 cases of epithelioma of this region, New and Childrey found, according to Broders'

classification, 1.72 per cent Grade I, 20.6 per cent Grade II, 41.9 per cent Grade III, and 35.6 per cent Grade IV.

Transitional-cell Epithelioma.—Observers have been led to believe that because of a tendency of the tumors to subside under intensive irradiation, transitional-cell epithelioma and lympho-epithelioma are essentially different from ordinary epidermoid carcinoma. Jolly and Mollier maintained that certain lymphoid structures in mucous membrane covered with stratified epithelium develop a peculiar physiologic relation to lymphocytes, a process of symbiosis of epithelium with lymphocytes, so that the epithelium takes on some of the characteristics of the lymphocytes. Quick and Cutler used the term "transitional-cell epithelium" for this group because Regaud's contention of a specialized epithelium in the tumors he termed "lympho-epithelioma" was not regarded at that time as being fully established. Ewing also described "transitional-cell epithelioma," and according

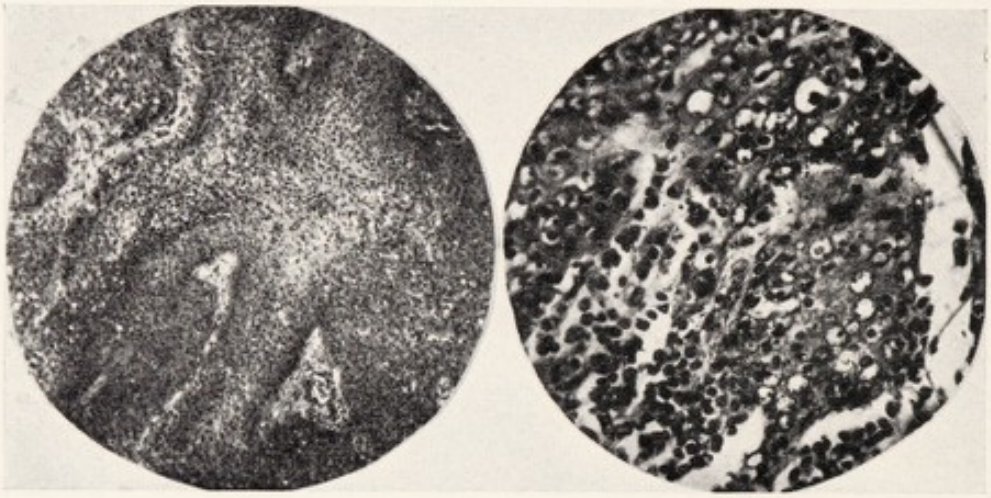

A *B*

Fig. 226.—*A,* Section of transitional-cell carcinoma of the tonsil, showing solid columnar spindle form, undifferentiated cells which have practically wiped out any remnant of tonsillar tissue. *B,* Section of lympho-epithelioma of the oral pharynx (Schmincke type). The tumor cells are seen to be widely invading lymphatic tissue and many small lymphocytes are scattered about among the masses of hypochromatic vesicular epithelial structures.

to him, Regaud calls this type of lesion lympho-epithelioma. Ewing applies the name lympho-epithelioma to slightly different types of lesions to be described separately.

Transitional-cell carcinomas probably arise from the ducts of the mucous glands of the buccal mucosa (Ewing), although their origin is not known for certain. The lining of the buccal mucosa has not been ruled out definitely as a probable origin. The tonsil, base of the tongue, and nasopharynx are covered with stratified epithelium of the transitional-cell type.

Microscopically, the tumor presents sheets or cords of cuboidal or spindle-shaped small cells without any evidence of keratin formation (Fig. 226, *A*). Flat pavement cells are seen only in areas of metaplasia. The nuclei are relatively large and hyperchromatic. The stroma is scarce. The desmoplastic reaction is not marked. Lymphatic admixture, so characteristic of lympho-epithelioma, is practically absent. Distant metastasis to the liver or the bone marrow may be explained by the plenitude of blood channels which are at times seen to be lined with tumor cells. Lympho-

epithelioma or a schneiderian membrane tumor may appear very similar so that the exact origin may be questionable. The metastasis ordinarily preserves the structure of the local lesion but in some instances if the lymphocytes of the gland are in evidence, it is not possible to distinguish the metastatic lesion of transitional-cell epithelioma from lympho-epithelioma.

Lympho-epithelioma.—Regaud and Schmincke's observations on lympho-epithelioma are of great interest. The reaction of this new growth to radiation is quite striking. Although the tumor is not very common, a great deal of attention has been paid to Regaud and Schmincke's observations. Jovin's photomicrographs show the cellular picture as containing principally large, delicate, pale-staining cells, sometimes forming syncytial masses, with indefinite cell borders and with large vascular nuclei; the field is infiltrated with many lymphocytes. Schmincke's sections depict cell groups with the epithelial cells more broken up so that their identification is not easy (Fig.

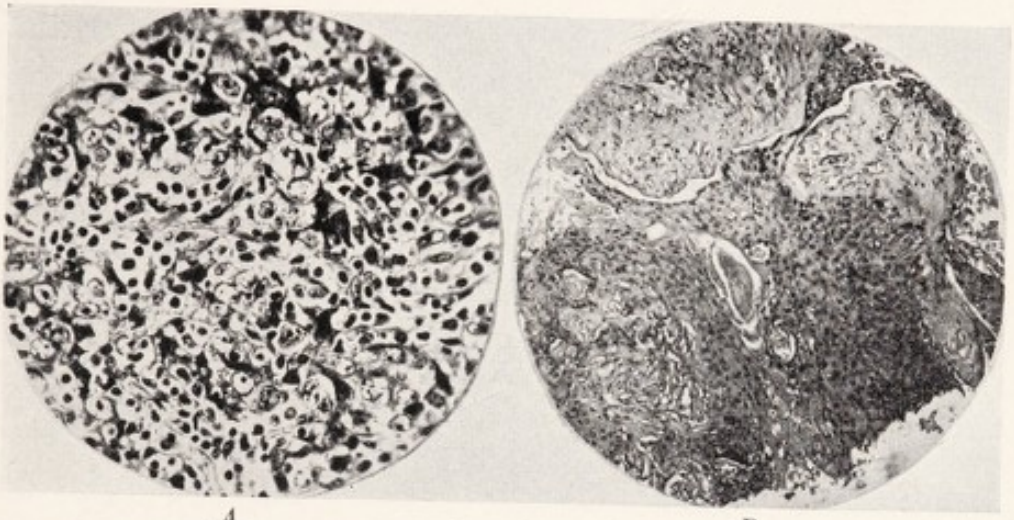

A *B*

Fig. 227.—*A*, Section of Regaud type of lympho-epithelioma from the oropharynx just behind the left tonsil, showing epithelial cells to be intimately admixed with small lymphocytes. There is some accompanying reaction of the reticuli. The atypical epithelial cells vary considerably in size, shape and staining. *B*, Section of a squamous-cell carcinoma of the pyriform sinus showing a rather diffuse infiltration of the connective tissue stroma. Epithelial cells show some tendency to keratinization and differentiation (Grades II and III).

226, *B*, and 227, *A*). The structure according to Ewing approaches that of a lymphosarcoma. Squamous and spindle cells are not present. The lymphocytic infiltration also appears in the metastasis. The picture described by Jovin is according to Ewing the more nearly correct. It is less frequent than the picture described by Schmincke which is more like the picture which Ewing classifies as transitional-cell epithelioma. Ewing believes that endothelioma of the lymph nodes should not be diagnosed until a local lesion is absolutely proved to be absent.

Schneiderian Carcinoma.—The nasal mucosa is lined with a stratified epithelium of small cuboidal or cylindrical cells—the schneiderian membrane. It is believed that the majority of nasal carcinomas arise from the transitional epithelium which lines the schneiderian membrane, the pharyngeal crypts and sinuses. Schneiderian carcinoma is very cellular and grows very diffusely. The cells are small, cuboidal, without pavement qualities, and sometimes glandular characteristics are seen. The epithelial quality of

the cells is not definite. No infiltration of lymphocytes accompanies the growth. A few tumors of the nasal mucosa are of the adenoma malignum type and a few are diffuse growths with large cuboidal cells. These have more of a tendency to metastasize to bone, liver and cervical nodes early. The typical schneiderian carcinoma suggests a special group of epidermoid carcinoma, but at present they are classified as "transitional-cell epithelioma" by Ewing.

Adenoid Cystic Carcinoma.—This peculiarly constructed growth is most commonly found in the antrum and nares. It most probably arises from the mucous glands of the regional mucosa. The cells resemble the nasal cell type. They are small and appear in sheets. As a matter of fact, Krompecher classified these growths with the basal-cell group which arises from the mucous glands of the nasopharynx. On microscopic section numerous globules and small cysts filled with mucus are seen. A resemblance to thyroid gland tissue has been suggested. The growths are very vascular and have practically no desmoplastic properties. They metastasize relatively late but quite often to the liver, lungs and bones. Metastasis to the neck appears relatively late. There is no great difficulty in separating these tumors from the other tumors of this region.

Malignant Dermoid of the Pharynx.—Although often not to be classified as invasive and distinctly of the malignant cellular type, dermoids are seen which must be classified as malignant. Dermoid of the pharynx usually is seen in stillborn fetuses but may be seen in childhood and adolescence. They arise from the hard or soft palate or in the vault of the pharynx. They contain epithelial cells derived from skin which may be hairy and contain dermal glands. Fat, fragments of striated muscle, cartilage, and bone are all found in the midportion of the tumor mass.

Juvenile Nasopharyngeal Fibroma.—Juvenile nasopharyngeal fibroma is a rare and peculiar fibromatous new growth which originates supposedly from the basilar fibrocartilages between the occipital and the sphenoid bones or "from the upper cervical vertebrae of the internal lamina of the pterygoid process." Similar growths may invade the retromaxillary space and arise from the fibrocartilage of the foramen lacertum or from the fibroblastic tissue in the sphenopalatine fossa. The cells of origin have also been thought to belong to a group of cells lying between the optic capsule and wing of the temporal bone which normally have only a transitory existence in the body and should disappear.

The basic cell is a fibroblast. A few mast cells and plasma cells may also be seen. In old growths the stroma may show hyalinization. In some of the cases fatty degenerative changes and in some necrosis may be seen. In the greatest majority of earlier growths, the blood supply is particularly abundant. Certain of the neoplasms show carcinomatous changes and then the picture rapidly changes to one of distinct malignancy with general metastasis but, as a rule, metastasis is not observed. The locally invasive character of the growth causes the symptoms.

7. MALIGNANT NEOPLASMS OF THE LARYNGOPHARYNX AND THE LARYNX

Epithelial Neoplasms.—*Extrinsic, Larynx.*—Practically all carcinomas of the laryngopharyngeal region are of the squamous-cell variety. No special description is needed. The general description of squamous-cell car-

cinoma given under Posterior Pharynx is applicable here also. A transitional-cell type of tumor may be found. Most of the growths according to Broders' classification will be graded III and IV (New) but Trotter believes that a fair percentage are not of such high grade malignancy (Fig. 227, *B*).

Intrinsic, Larynx.—Practically always carcinoma arising in the vocal cord or in the subglottic region is of the squamous-cell type, but occasionally basal-cell carcinomas are seen. Endothelioma has also been described. Basal-cell and endothelial-cell cancer are said to resemble each other clinically (Thomson). Basal cell is comparatively benign while endothelioma tends to recur. Adenocarcinoma is thought to arise in the ventricles. Mackenty's table of frequency is as follows: squamous cell 96 per cent, basal cell 2 per cent, papillary carcinoma 1 per cent, and adenocarcinoma 1 per cent.

Sarcoma of the Larynx—Intrinsic and Extrinsic.—The histologic varieties described are quite numerous. The most frequent are the spindle-celled and round-celled types. Giant cells of the tumor type may be seen. Lymphosarcoma has been described. Spindle-cell sarcomas are usually located in the cords and epiglottis. An alveolar type of sarcoma is described by Sendziak as occurring in the folds and sinuses, but Ewing questions whether the alveolar type is not in reality a carcinoma and whether many cases of sarcoma recorded in the literature are not carcinomas. Sendziak collected records of melano- and chrondrosarcomas. Turner and Menzel have described metastatic hypernephroma of the larynx. Massei observed 5 cases of skin sarcoma which had metastasized to the larynx. The first lasting success after a total laryngectomy happened to have been performed on what was diagnosed as a mixed- and spindle-cell sarcoma by Bottini.

8. LYMPHOSARCOMA OF THE BUCCOPHARYNGEAL REGION

Lymphosarcoma shows a diffuse growth of lymphoid cells embedded within reticular tissue. The structure of the organ affected is obliterated.

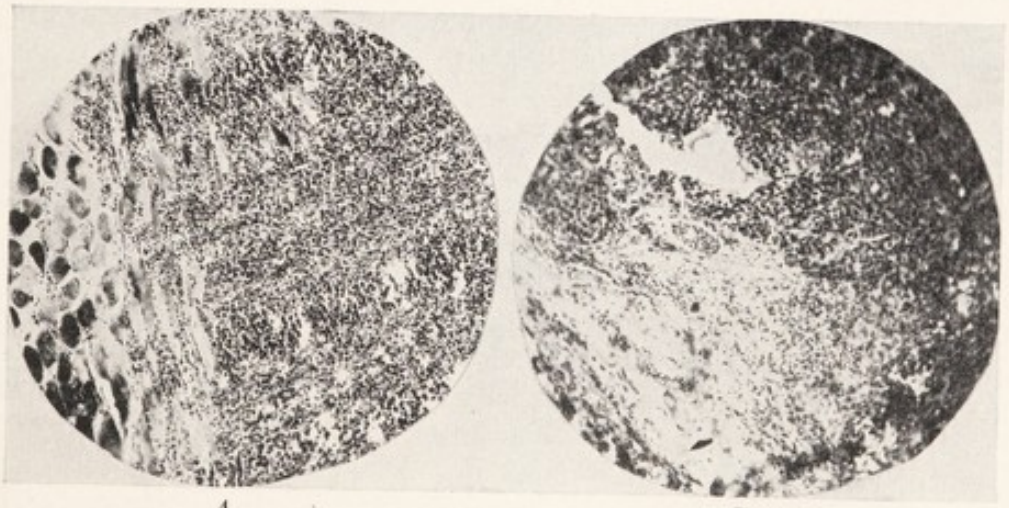

A *B*

Fig. 228.—*A*, Lymphosarcoma of tonsil. *B*, Carcinoma of the antrum.

The cells may vary considerably in size in both the same specimen and different specimens. Two different cell types may give origin to a given tumor:

(1) the reticular cell of the germ centers and (2) the lymphocyte (Fig. 228, *A*). Respectively, these give rise to two types of lymphosarcoma—reticular-cell sarcoma (large round cell) and lymphocytoma (small round cell). The local aggressive quality of this tumor is characteristic.

9. RARE MALIGNANT NEOPLASMS OF THE BUCCOPHARYNGEAL REGION

Fibrosarcoma.—Possibly 2 or 3 per cent of the tumors of the pharyngeal region may be diagnosed as fibrosarcomas. Most commonly the tumor arises in the nasopharynx and may be found to be of fibromyxosarcomatous character.

Hemangio-epithelioma.—Hemangio-epithelioma of the oral pharyngeal cavity is also a rather rare tumor. According to New, about 1 per cent of all tumors of the pharyngeal region are of this character. He found 4 such tumors in his series of 720 cases. His cases were situated in the upper pole of the tonsil and the nasopharynx.

Myeloma.—Plasma-cell myeloma has been described as occurring in the buccopharyngeal region, but it is undoubtedly a very rare lesion in this locality.

Melano-epithelioma.—The mucous membrane is capable of producing a pigment-bearing cell from the germinative layer. The palate which is derived from the ectoderm is the most likely location. New and House found 24 cases in the literature in 1921. The clinical diagnosis depends upon a rapidly growing pigmented nodular or pediculated soft vascular neoplasm with early metastasis.

10. MALIGNANT NEOPLASMS OF THE ANTRUM AND NASAL SINUSES

The embryology of this region offers considerable chance for cell rests. These, along with the normal mucosal covering of the sinuses, offer a considerable opportunity for a varied and complex group of new growths. In the old literature many of these growths were classified as connective tissue tumors but it is thought now that connective tissue tumors are exceedingly rare. Their rapid growth, vascularity and cellular anaplasia, all lead to the erroneous conclusion that the neoplasms are sarcomas. From the older literature, no true idea of the relative frequency of epithelioma and sarcoma can be obtained. Clinically, the two tumors are somewhat similar. The distinction has to be made on the basis of very careful microscopic study.

As the antrum is lined with ciliated cylindrical epithelium, the most common type of carcinoma found there is adenocarcinoma. The tumor is a rapidly growing bulky tumor with invasive qualities of a high order. Schneiderian membrane carcinoma although usually arising in the nose and secondarily invading the antrum, has been demonstrated as arising principally in the antrum. The tumor grows rapidly and is said to simulate lympho-epithelioma. It is quite vascular and infiltrates the bony walls rapidly. Squamous-cell epitheliomas not infrequently invade the antrum secondarily, and may arise from the antral mucosa by a process of metaplasia, supposedly aided by old inflammatory processes. Basal-cell carcinomas also are found. They grow slowly, are less malignant, and consequently are usually discovered late. Transitional-cell epithelioma is also found although this is not its common location (the nasopharynx).

Epithelial Papilloma.—An epithelial papilloma may rarely be found to arise in the antrum. Somewhat like laryngeal papilloma, they tend to recur after removal, especially if the base is not entirely removed. Ewing speaks of a case which recurred after several operations over a period of ten years and eventually became a frank carcinoma.

Malignant Epithelial Tumors of the Antrum.—The following types of malignant tumors may arise from the mucosa:

1. Papillary carcinoma of the type described in the preceding paragraph. The life history of this type is one of slow growth.

2. Carcinomas of the basal-cell type. They are made up of cords of small cells with relatively prominent nuclei, and with little stroma which tends to undergo hyaline degeneration. When the mucous cystic cavities are more pronounced, the structure is that of adenoid cystic epithelioma previously described under Epidermoid Carcinoma of the Pharynx. These tumors do not grow rapidly but finally invade the bone if not completely eradicated. The lymph nodes are involved late.

3. Ewing makes the statement that squamous-cell carcinoma is rarely seen in the antrum except as a secondary invader but other observers have insisted that its frequency is about as high a percentage as ⅓. It is to be pointed out that metaplasia is necessary for the occurrence of a primary squamous-cell epithelioma of the antrum. Such undoubtedly does occur but it is questionable if the frequency is very great.

4. Cylindrical-cell carcinoma is the common type of antral carcinoma. It is a bulky rapidly growing form of epithelioma. The cells are polyhedral in shape and grow in sheets. It has an adenocarcinomatous structure. All the accessory nasal sinuses (ethmoidal, frontal, etc.) may show tumors of this type. It erodes bone, ulcerates and bleeds. After operation it recurs within a few months. The nares are obstructed early.

5. Round-cell carcinomas form a group of tumors which in the past have been diagnosed as a rule as sarcomas of one type or another. The cells are round and polyhedral, mainly consisting of nuclei (Fig. 228, *B*). In the nasal passages as well as in the accessory sinuses, these tumors may be found. They have no alveolar structural tendencies but Ewing is of the opinion that the epithelial character of the tumors is quite definite. He says the existence of a mesoblastic tumor of this type has not been demonstrated.

11. MALIGNANT TUMORS OF THE SALIVARY GLANDS

Carcinoma of the Salivary Glands.—Pure carcinoma of the salivary glands is not common. Most of the cases which have been observed were in the parotid gland. Examples of carcinoma of the parotid gland have been studied particularly by Nasse, Ewing, Volkmann and Kuttner, and others have observed examples in the submaxillary gland. In a series of 225 cases of parotid gland tumors Benedict and Meigs found 30 cases of carcinoma (Fig. 229, *A*). These were verified by Mallory. In the lachrymal gland Warthin has collected 6 cases. Ewing states that most of the malignant tumors of the lachrymal gland are of the basal-cell type.

Most of these neoplasms show some trace of acinar arrangement but others grow diffusely in cellular masses and section may resemble that of a round-cell sarcoma when rapidly growing and atypical (Fig. 229, *B*). Those showing acinar arrangement often show the lumen filled with secre-

tory products—"alveolar adenocarcinomas." A papillary adenocarcinoma may rarely develop from a duct.

Sarcoma of the Parotid.—Ewing is inclined to classify all tumors of the salivary gland as epithelial tumors. But in the series spoken of above (Benedict and Meigs) there were 9 cases of sarcoma (classified by Mallory).

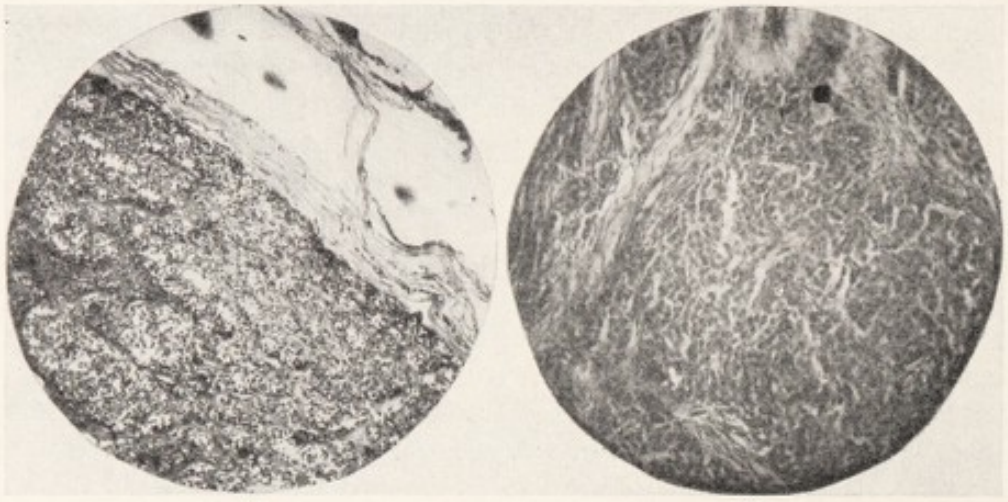

A *B*

Fig. 229.—*A*, Malignant mixed tumor of the parotid gland. *B*, Carcinoma of the parotid gland.

Three lived over five years. The lymphosarcoma metastasized by the lymphatics and the fibrosarcoma by the blood stream.

12. MALIGNANT TUMORS OF THE NECK

Branchiogenic Carcinoma.—Volkmann in 1882 gave the original explanation of deep-seated carcinomas of the neck without an evident local lesion in the buccal or pharyngeal arteries above. In 1913 Lorenz discussed rather fully the origin of the anomalies of the branchial clefts. As the derivation of carcinoma is analogous to that of cysts and fistulae, Wenglowski's conclusion that lateral fistulae are derived from the thymic pharyngeal duct is important. More recently Oliver has summarized this first thought. According to Oliver who discussed 80 cases in the pathologic laboratory at Johns Hopkins, the theories briefly are as follows: (1) the openings or rests may persist from any of the 4 clefts (von Hausinger, Bland-Sutton, His, etc.); (2) only the second cleft is at fault (Rabl, etc.); (3) the cervical sinus is responsible for the external opening or the rest (Kistaniechi, Mielecki, His, etc.); (4) the thymic stalk is also responsible (Wenglowski).

The embryology has been discussed under Lateral Cervical Fistula and Lateral Pharyngeal Fistula.

In the 80 cases reported from the Johns Hopkins laboratory by Oliver, 42 were of the solid and 16 of the cystic type. Ewing emphasized the cystic type as being the most common. Oliver divided the various histologic types into groups as follows, in 66 cases in which the microscopic sections were available: (*a*) squamous-cell forms (Fig. 230, *A*), 15 cases; (*b*) cubocell diffuse form, 23 cases; (*c*) cubo-alveolar form, 13 cases; (*d*) basocell diffuse form, 5 cases; (*e*) basocell alveolar forms, 8 cases, and (*f*) adenocarcinomatous forms, 2 cases. The majority of the cases were thus found

to be of the transitional-cell or cuboidal-cell type. The diffuse types show a sheetlike arrangement of the cells, with numerous epithelial strands and cell nests of infiltrating cells. It resembles a Grade IV Broders' classification squamous-cell carcinoma. The alveolar group show a cuboidal-cell type and the cell nests are larger or even sheets of cells may occur in which there are small areas of central necrosis or even greater cystic cavities. In a smaller group the cell resembles the rodent-ulcer or basal-cell type of skin cancer cell. Histologically, Oliver states that there is a gradual transition from the basocell type, through the cubocell type, to the squamous-cell type with little to choose from as far as prognosis is concerned.

Lymphosarcoma of the Lymph Nodes of the Neck.—Kundrat applied this term to a new growth of the lymphoid tissue. Hodgkin's disease, leukemia, and pseudoleukemia are apparently totally different affections. Kundrat and Bunting, however, have considered the disease related to Hodgkin's disease and pseudoleukemia. Metastasis seldom occurs by the blood stream but direct invasive tendencies are shown and the new growth affects successive lymph nodes by way of the lymph channels.

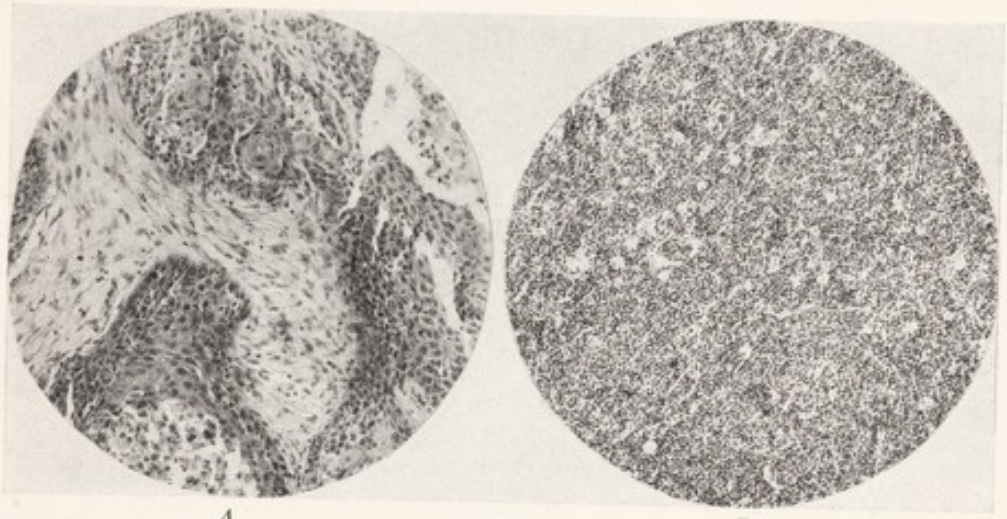

A *B*

Fig. 230.—*A*, Branchiogenic carcinoma. *B*, Round-cell lymphosarcoma of the neck.

The sex incidence shows a 4 to 1 preference for the male. The tumor is rare. The lesion is seen in childhood but is most common after the second decade of life. About one fourth or one fifth of the cases of lymphosarcoma develop primarily in the cervical lymph nodes.

The architecture of the normal gland is soon destroyed (Fig. 230, *B*). A reticular tissue within which lie lymphocytes, usually of the large type, replaces the normal structure. There has been described two varieties of the tumor—one arising from the lymphocytes and one in which the primary cell at fault is a reticular cell.

Sarcoma and Endothelioma of the Lymph Nodes.—Round-cell and spindle-cell sarcomas of the lymph nodes, if they occur, are certainly very rare types of new growth. Endothelioma of the lymph nodes, although more common, is not much more so. If one found a sufficient development of the intercellular tissue within a lymph node of the spindle-cell type, one might be justified in labeling it a fibrosarcoma. In sarcoma of the lymph nodes, the development, growth, and metastasis would be similar to that of a sarcoma elsewhere.

Endotheliomas of the lymph nodes do not differ from endotheliomas arising from the blood or the lymph endothelioma in other parts of the body. Ewing has stated that the process initiated by "the virus" of Hodgkin's disease may pass rapidly into a neoplastic process resembling lymphosarcoma —a "Hodgkin's endothelial sarcoma." Ewing described 3 general types of endothelioma of the lymph nodes: (1) diffuse, (2) plexiform or perivascular, and (3) alveolar. The neoplasm spreads as a rule within the lymphoid structure. General metastasis is not common. On the whole, the cells show only a somewhat mild invasive character.

The diagnosis is made after excision and microscopic study of tissue.

Clinical Features and Diagnosis

Basal-cell Epithelioma of the Skin.—Clinically, the growth may be flat, nodular, ulcerative or annular. In the latter case, healing may appear in the center and a progressive thickened edge about the periphery. Characteristic of the lesion is the induration and hardness of the edges (Fig. 231, *A*).

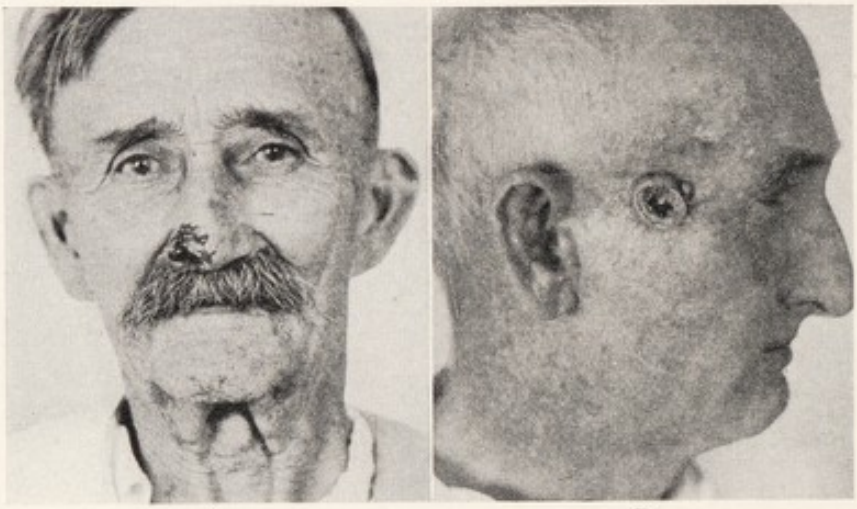

A *B*

Fig. 231.—*A*, Cystic basal-cell epithelioma of nose. *B*, Squamous-cell epithelioma of face.

Before ulceration has taken place the whole growth is thickened. Later after ulceration has taken place in the center, the edge gives a rolled, heaped-up effect. The edge often reveals translucent, pearly white nodules which are considered to be more or less pathognomonic. In the flat or nodular type large ulcers practically always follow. Over the ulcer yellowish scabs or dry crusts form which when removed show a pale, unhealthy looking, thin granulation tissue base. The annular type is the most infrequent type. There is a tendency for the basal-cell carcinoma to be multiple. No subjective symptoms accompany the lesion, at least ordinarily not until it is far advanced. Usually a patient presents himself solely to get rid of a sore which will not heal or continues to grow. The whole course of the lesion is a chronic one. It may be present for years. However, there is considerable variation in the growth in different individuals. When invasion is deep seated, neither cartilage nor bone is spared in the march of the erosion. For this reason, the term "rodent ulcer" has been applied to the growth. The question arises whether or not the basal-cell carcinoma

may be transformed into squamous-cell carcinoma. It is quite generally thought that this may occur especially if treatment is inadequate. There are 1 or 2 cases of metastasis following basal-cell carcinoma in the literature (Korbl).

The diagnosis is made from the clinical history. In most instances a biopsy should be taken although it has been stated by some that if the lesion is radiosensitive, a microscopic section is unnecessary. A slowly growing, hard, painless, white, indurated, superficial nodule or mass with a slightly ulcerating or scaling surface arising in an unhealthy skin patch on the face in an old person is more likely to be a basal-cell epithelioma than anything else.

Squamous-cell Epithelioma of the Skin.—Very early the lesion is frequently a rough and warty keratotic patch or else presents itself as a small reddish or yellowish scab beneath which or at the edge of which there may be more deeply seated nodules. By peripheral extension the neoplasm extends and centrally the tissue tends to break down. Thus, a superficial ulcer usually appears with a sharply defined, indurated base (Fig. 231, *B*).



Fig. 232.—A, Flat, indurated carcinoma starting at juncture of the skin and vermilion border of the lower lip. B, Ulcerating squamous-cell epithelioma of lip.

As the growth extends, connective tissue or periosteum or bone is attacked with equal impartiality. Secondary lymph node involvement may occur at any time but, as a rule, one does not observe this until the lesion has been present for some time or it is fairly well developed.

Besides the more rapidly infiltrating, flat clinical type, there is a papillary variety of squamous-cell carcinoma which may be papillomatous from the beginning or may develop later in the course of the type just described. The resulting lesions of this type are cauliflower-like with a broad neck and with a verrucose ulcerating surface covered with a tenacious, foul-smelling, yellowish purulent exudate.

Epithelioma of the Lip.—One clinical type of lip epithelioma starts as an indurated crack or a flat thickening at the juncture of the skin and vermilion border of the lip to one side of the midline (Fig. 232, A). The flat induration after the scales or crusts are removed shows some slight ulceration. This chronic scaly ulcer with a little induration at its base and about its edges may persist for several years without signs of much growth. In rare cases metastasis may even appear without the local lesion showing evidence of active growth. Usually, however, the local lesion is the

only lesion seen as metastasis occurs relatively late in this type of lesion. A second clinical type has more ulceration, more thickening of the borders, more induration of the base, and a tendency is shown for the lesion to run around the vermilion border and eventually the cheek may be affected. Lymph-node enlargement is relatively early for epithelioma of the lip in this clinical type and the whole course is more rapid than in the preceding form (Fig. 232, B). More rarely a third type of epithelioma of the lip is seen which begins as a papillar, wartlike growth. A slight tendency to extend and infiltrate tissue is noted and the rapidity of the general clinical course lies midway between the first and second forms described.

As mentioned, an epithelioma of the lip may appear almost healed in rare instances and then several years later be heralded by distinct evidence of cancerous involvement of the tributary lymph nodes (Fig. 233, *A*). But ordinarily, before the lymph nodes of the submental or submaxillary regions

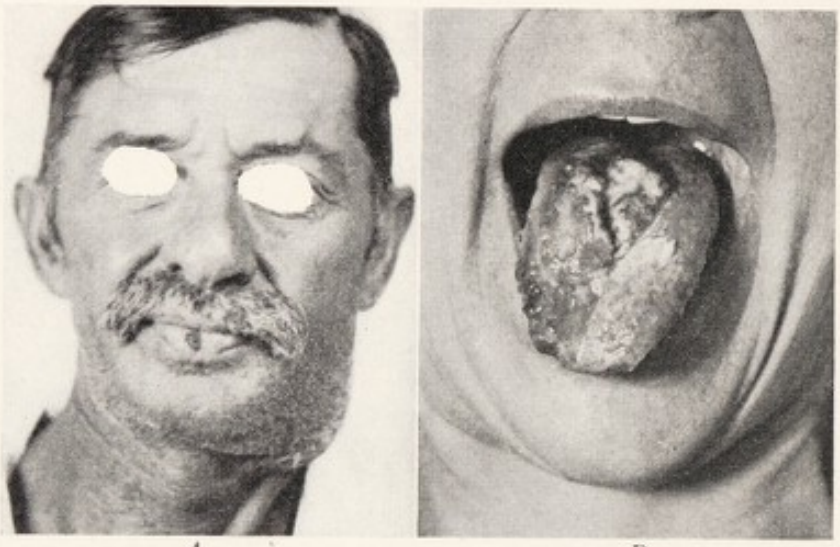

A *B*

Fig. 233.—*A*, Squamous-cell carcinoma of the lip with metastasis. Local lesion only slightly advanced. *B*, Midline carcinomatous ulceration of the tongue. There are three factors of particular interest in this patient. First, it is a carcinoma in a woman thirty-seven years of age, which is a rather early age for the appearance of cancer. Second, the lesion is located on the dorsum of the tongue which is not very common. Third, only about 15 per cent of carcinoma of the tongue appear in women.

are involved, the primary ulcer presents an unmistakable picture. In advanced cases the lip may be partially destroyed or quite widely stiffened by induration. Later, surrounding tissues (including the mandible) are invaded. In those lesions extending toward or involving the angle of the mouth, the cheek may be quite ulcerated and indurated by the invading process. In the terminal stages, as in all cancers in and about the mouth, salivation and fetor become pronounced.

Lymphatic Drainage.—A working knowledge of the lymphatic drainage of the area about the lips is pertinent. The lymphatics of the upper lip drain to the corresponding submaxillary lymph nodes. The midportion of the lower lip drains to the submental lymph nodes, while the outer part drains to the submaxillary lymph nodes. From either group of glands—the submental or submaxillary—metastatic emboli may go directly to the upper deep cervical nodes. Glandular involvement may not run true to form. The submaxillary glands may be involved before the submental or more

rarely even the upper deep cervical. Gross glandular involvement is seen, although fortunately fairly rare. The time of glandular involvement is variable. The average is from nine to twelve months. Three months is quite early and seven or eight years may intervene after the primary lesion is healed before the submaxillary nodes become involved. Twenty-eight years has been reported as intervening. Three years is not uncommon.

Metastasis.—It is well to emphasize that in the earliest stages one cannot be certain whether or not the lymph nodes are involved. Even the microscope does not always give the information early. Clinically and early it is not always possible to be accurate or positive in many cases, even after palpable lymph nodes have developed, as to whether or not the enlargement is due to inflammatory products or to malignant growth or both. Later, however, the continual growth and the hardiness make the diagnosis of metastasis rather evident to the practiced observer.

The diagnosis of epithelioma of the lip should be made early. When there is doubt, every chronic ulcer, wart, or abrasion of the lips in persons who have reached the cancer age should be excised and subjected to microscopic study. Even in younger persons, because the lesion here is more dangerous and grows more rapidly, the same procedure should be carried out. Excision and microscopic examination prove the nature of the growth and at the same time remove it.

The chronicity of the lesion is important in the diagnosis. A simple ulcer of some weeks' duration or a simple papilloma of the mucocutaneous border of the lip in a patient of cancer age, without a definite etiologic background, should be regarded as potentially malignant and be treated by excision and microscopic examination.

In advanced cases, the history, the ulceration, the induration and evidence of metastasis make up a clinical picture hardly to be compared with any other condition.

To facilitate the handling of questionable lesions of the lip, Bloodgood groups the early lesions as follows: in Group I are those lesions which are small and persist only a short time, a week or two. They imitate burns, fever blisters, vesicles, keratosis, or warts. They heal under palliative treatment in a week or two. Group II contains lesions of longer duration, such as leukoplakia or chronically chapped lips. They are usually benign. Group III contains those lesions which resemble Group I but do not disappear under palliative treatment. These lesions may be benign or malignant. Group IV contains lesions distinctly benign or definite warts. Group V contains those lesions distinctly malignant. Groups III, IV and V demand immediate excision and microscopic examination. In Group III, if a microscopic study is not permitted, a false conclusion may be reached. Often treatment by roentgen ray or radium leads one to think that an epithelioma has been cured.

Sometimes a chancre of the lip in a person of the cancer age may rather closely imitate an epithelioma. A chancre is differentiated by the rapidity of appearance, its appearance, the cardboard-base induration, and the early rubbery (not hard) enlargement of the submental and submaxillary lymph nodes and finally the dark-field examination. Somewhat later, the Wassermann test or the appearance of secondary lesions are important but the diagnosis should be made before these later manifestations appear.

Sarcoma of the Face and Lip.—Clinically the group is characterized by the appearance of a mass beneath the skin or mucosa which grows rapidly and involves and distorts the surrounding soft tissue, and tends to necrose and ulcerate. The diagnosis of the particular cell type should be confirmed by biopsy.

Epithelioma of the Cheek.—Clinically Ward and Smith describe 3 varieties, all of which may be seen: (1) a whitish papillary area with beginning induration; (2) an indurated mass in the substance of the cheek which eventually ulcerates; (3) an ulcer with hard edges infiltrating the substance of the cheek. The first type may grow rapidly, becoming papillary in form and tending to bleed easily. There are, however, at least two other clinical types of lesions which are quite characteristic: (1) a whitish, warty, thick, elevated area, with ulceration and induration in one part of it. (2) A fungating type of ulcer which projects above the cheek mucosa, with a base which is not so indurated as the infiltrating type with a hard edge described by Ward and Smith. The ulcerative type is the most common.

Metastases are only moderately early. The buccal gland in the cheek is likely to be involved. In the anterior cheek the submaxillary gland is most likely to be the site of metastasis. In the posterior cheek the upper deep cervical nodes may be involved early. Infiltrating carcinoma of the posterior cheek and gingival sulcus soon infiltrates the muscles of mastication, limiting the ability to open the mouth. After the muscles of mastication have become involved the lesion often takes on a more rapid growth. Clinically, as the location of the growth progresses posteriorly the malignancy seems to increase. Anatomic factors probably have some influence in causing this phenomena. The cheek, being of no great thickness, is likely to soon be infiltrated and the external skin involved with an ultimate perforation. This may occur fairly early but usually it is a late occurrence.

Epithelioma of the Hard Palate.—The local ulcer on the hard palate assumes clinically (1) a papillary hypertrophic form, (2) a wide serpiginous ulceration with hard ulcerated edges or, rarely, (3) a smooth globular swelling in which ulceration takes place in the center. Tumors of the anterior palate metastasize to the nodes into which the posterior palate drains.

Epidermoid Cancer of the Tongue (Anterior Two Thirds) and Floor of the Mouth.—Epidermoid carcinoma of the tongue is found most commonly along the lateral border of the tongue but not uncommonly it appears first or extends to the floor of the mouth. A carcinoma of the floor of the mouth is very likely relatively quick to invade the tongue. Carcinoma of the dorsum of the tongue is not so common and, when it appears, is likely to be secondary to a leukoplakia or a luetic scar (Fig. 233, *B*). A knowledge of the appearance of an early malignant change is extremely important. A good many years ago Butlin described 5 clinical pictures which he considered the most frequent and typical of the early forms of cancer of the tongue.

"1. A little plaque-like, hard sore, smooth and polished but neither ulcerated nor excoriated.

"2. The transformation or replacement of a simple ulcer by a cancerous ulcer, which only differs from simple ulcer by feeling a very little stiffer and a very little firmer.

"3. The transformation of an entire plaque of leukoplakia into a plaque of cancer. The difference is marked by very slight increase of induration but without excoriation or ulceration.

"4. The transformation of one small area of a leukoplakic tongue into cancer only marked by at first a very slight and superficial hardening.

"5. A white warty growth or compound wart neither broken nor ulcerated, and feeling at first as if it is fixed to the mucous membrane and quite superficial."

"Of all the actual beginnings of cancer, there is none nearly so important as a wart or warty growth, especially when this forms on the surface of a tongue which is the seat of one of the chronic conditions which predispose to the occurrence of cancer" (Butlin and Spencer).

The earliest sign of malignant degeneration is increasing induration. Ulceration is the next earliest sign and it is present in most instances so soon that it must be taken to be an almost necessary sign. The type of carcinoma that begins as a hard induration beneath the epidermis does not ulcerate immediately but the form is a rare one. Papillary growths of the warty type may also ulcerate rather late.

In the early stages growth may be quite indolent and several months may intervene with little progress shown. But the tendency to heal is not present, even after removing all evident sources of irritation, such as jagged teeth, rough bridges or crowns. Finally, at a variable period of from two to four or five months, the progressive character of the growth becomes evident. The increasing induration, the greater ulceration, and the increase in size of the whole of the lesion, are all evidence of the character of the growth in terms that are hardly to be mistaken. As the growth becomes larger, 3 or more forms are seen: (1) a form showing increasing induration and ulceration without fungation, (2) a type tending to fungation externally and less infiltration of the surrounding tissues, and (3) a form developing in a fissure or forming a fissure with an ulcerated base and induration of the walls of the fissure. The induration is a hardness, described often as stony, which is quite characteristic. In certain instances, the ulceration overshadows the induration to such an extent that the diagnosis may not be very definite clinically.

Although some discomfort is usually present, pain cannot be regarded as of much diagnostic significance. It is frequently entirely absent. Later, of course, as the deeper structures are involved, pain is quite a prominent symptom.

Sarcoma of the Tongue.—Sarcomas of the tongue start submucously and intralingually. Early no pain is felt but later when the infiltration and possibly ulceration have occurred, the symptoms are in many ways similar to an advanced epithelioma of the intra-oral cavity. As a characteristic generally of sarcoma, ulceration appears late and the mechanical interference by the infiltration and the mass is the first symptom. In lingual sarcoma there is described an interstitial variety and a tuberous, sometimes pedunculated variety. But as a rule, sarcoma first appears as a bulky, soft, vascular mass growing diffusely and expansively. As the size increases either pressure necrosis or a necrosis due to interference with the vascular supply is likely to appear. Secondary infection then occurs with its train of symptoms and signs. It is not unusual for fever to be present in sarcoma of this

region even without evident secondary infection. A specific toxic substance has been suggested as causing the reaction. The fibrosarcomas in some instances are not extremely vascular. All show evidence of infiltration along fascial planes, and blood and lymph vessels. Butlin described a "sarcoma of a relatively benign character" arising in the muscular substance of the tongue but usually the picture is that of a relatively malignant, rapidly growing neoplasm. Metastasis to the lung is of common occurrence. Always, of course, the diagnosis should be confirmed by microscopic study of a section of the tumor.

Epidermoid Carcinoma of the Posterior Tongue, Naso- and Oropharynx.—*Squamous-cell Epithelioma.*—In a way the lesion here assumes clinically an intermediate picture as to degree of malignancy between the signs of anterior tongue carcinoma and the signs of carcinoma of the pillars of the fauces and the tonsil. As to the characteristics of the local ulceration, there are roughly 3 types of ulceration: the infiltrative, the ulcerative, and the fungiform. The description of the local lesion in the anterior tongue holds fairly well for that of the posterior tongue, if one visualizes a lesion somewhat more rapid in its course. The base is hard and covered often with dirty sloughing débris. The edges are rolled and hard. The less the invasion into deeper structures and the greater the tendency to fungiform growth, the less malignant clinically the growth is likely to be. On the whole, the growth is fairly rapid and in due time there appears soreness on swallowing, and this soon increases to a marked discomfort, interference with mobility of the tongue, increased salivation, fetor and finally a definite dysphagia. As the ulceration increases secondary infection begins to play its rôle. The lingual tonsillar sulcus often is invaded by carcinomatous infiltration which later breaks down into a crateriform ulceration. Pain then tends to radiate to the jaw and ear. The upper glands of the deep cervical chin are involved quite early, but not so early as in tonsillar epitheliomas. The glandular enlargement is usually on the same side but contralateral and bilateral involvement is also seen, especially if the lesion is located rather centrally in the base.

Epidermoid carcinoma of the buccal pharynx is most commonly found on the faucial pillars or the palate rather than the tonsil or pharynx. Usually when first seen several structures are involved as growth is fairly rapid. In about 90 per cent more than one structure is involved when the patient is first seen. Low-grade lesions tend to be hard to the touch. The more active lesions are somewhat softer and of a darker, meatier appearance.

As a rule, very little attention is paid to the early lesion of the pharynx by the patient. In one half or more of the patients swelling of the lymph nodes is the first sign of the neoplasm noted by the patient. In the other half of the patients the first symptoms are noted within the pharynx. Some irritation, a sensation of fulness, a sensation as of a foreign body being present, a soreness or even pain may be felt. As the growth increases the soreness in the throat increases and the mechanical symptoms of interference with function increase. Infiltration of the palatal, glossal, pharyngeal or pterygoid muscles causes fixation of the jaw, difficulty in swallowing, difficulty in moving the tongue and so forth. Pain appears as the ulceration increases. It may be constant or present only on swallowing and usually it is referred to the affected side.

Of New's cases, 67.8 per cent showed metastatic nodes in the neck when first seen. The nodes in the neck are rather hard and nodular in low-grade epithelioma but in high-grade epitheliomas they are often softer and more bulky. But to make this distinction accurate clinically is beyond any clinician. Seven to eight months is the average duration when applying for treatment. Although as a rule growth is fairly rapid, in some instances of adult squamous-cell epithelioma several years may pass before the new growth attains a large size.

The first symptoms of nasopharyngeal squamous-cell carcinoma may be pain. Peculiar pain in an individual of carcinoma age should always warrant a thorough search for a malignant ulcer. An ulcer is probably often present for quite a time in nasopharyngeal epidermoid carcinoma without any very marked symptoms. Nasal obstruction does not occur early. Although metastasis is not so early as a rule as in carcinoma elsewhere in the pharynx, an enlarged hard lymph node in the deep cervical chain is likely to call attention to the true nature of the condition. And on search the original ulcer is seen or felt in the nasopharynx.

The posterior palate may be involved primarily or secondarily by any of the different types of epidermoid carcinoma just described as commonly affecting the posterior tongue, tonsil, or pharyngeal regions, but the great majority of the malignant lesions of the soft palate per se are moderately anaplastic and of the squamous-cell type. Lesions involving the soft palate and uvula spread to the regional lymph nodes—the upper cervical chain—comparatively early, rather often bilaterally and sometimes they multiply. Ledoux found the first glands to be invaded were the two glands situated under the head of the sternomastoid muscle. Later the glands at the bifurcation of the carotid were enlarged.

Transitional-cell Epithelioma.—Most commonly transitional-cell epithelioma develops in the base of the tongue, the pyriform sinus, the tonsil, floor of the mouth, the pharyngeal wall, nasal mucosa and nasal sinuses. In the nasopharyngeal region the transitional-cell or lympho-epithelioma may develop in young subjects between the ages of ten and twenty years. In the nasopharynx, carcinoma of this type grows slowly and the presence of the tumor is revealed by a nasal obstruction and bleeding or even swelling of the cervical lymph nodes. In the youthful, tuberculosis may be suspected. In the base of the tongue or the pharynx proper the local lesion may be small, and develop slowly (several months) beneath the mucosa.

Ulceration is thus sometimes relatively late and often cervical metastasis is the first evidence of the disease, as the local lesion produces only slight symptoms early in the disease. This typical slow-growing form may be difficult to recognize but the rapidly growing form presents very definite symptoms similar to an anaplastic rapidly growing squamous-cell carcinoma.

Lympho-epithelioma.—Lympho-epithelioma of the mucosa of the pharynx in general and of the posterior tongue region occurs most commonly from thirty to sixty years of age but may occur in adolescence from ten to twenty years. A rather small, soft, local tumor mass is characteristic. Ulceration may not be present. Characteristic locations for the low polypoid local outgrowths are the tonsil, base of the tongue, recesses of the pharynx and nasal passages. The local mass is very easily overlooked

and often the cervical metastasis which occurs is the first sign to attract attention to the lesion. The average duration is said to be about three years. Thus, on the whole, the course of the disease is slow. The tumor metastasizes to the liver and the bone marrow and, although markedly radiosensitive, usually causes death from the general metastasis. Ewing, however, reports 10 cures.

Schneiderian Carcinoma.—Clinically, schneiderian carcinoma grows slowly and produces a rather bulky soft mass. It occurs most frequently in the nares and antrum but also in the pharyngeal regions. Ewing described 2 tumors of this type in which the victims lived eleven and thirteen years, respectively. Each showed recurrences several times following various operative procedures. Because of the anatomy of the nose, obstructive phenomena are rather early when the tumor appears here. In the antrum the growth may attain considerable size before symptoms appear. As a rule, metastasis to the neck is a late phenomenon. Eventually, the bone marrow, liver, and the lungs may show metastases. Spontaneous necrosis as in sarcoma is quite common. The tumors are quite radiosensitive. The friable vascular structure may cause death by exsanguination, thus forcing a dramatic but easy way out upon the patient.

Lymphosarcoma of the Buccopharynx.—Lymphosarcoma of the tonsil may very closely resemble an hypertrophy. The tonsil appears swollen unilaterally, often to twice the normal size, is dull red and fleshy in appearance. For some time the bulky mass appears to tend to remain encapsulated. Rarely both tonsils are involved. A leukemia or a lymphatic lymphosarcomatosis should be ruled out by the blood smear.

In the pharynx, lymphosarcoma may appear as a distinct pedunculated and movable mass or as a more diffuse enlargement. The tumor is not nearly so firm as an epithelioma and ulceration appears very much later. In fact, ulceration is usually a late symptom in lymphosarcoma.

In about one fourth of them swelling of the cervical lymph nodes is the first sign of the disease. Of New's cases, 59.4 per cent showed metastasis in the neck when first seen. When involved by lymphosarcoma the lymph nodes are at first fairly discrete but soon they tend to become bulky and the capsule is infiltrated. Growth on the whole is rapid. Three to four months is the average history of duration of any noticeable sign when the case is seen first.

Fibrosarcoma of the Buccopharynx.—Early ulceration is not a characteristic. In New's cases the average age was 37.2 years, 3 out of 4 were males, and all soon became fairly good-sized tumors. The point of origin is often obscure. Tumors are seen involving the posterior pharynx, the tonsil and the nasopharyngeal region and glossal or epiglottic field. The lesions are firm, round and smooth.

Myeloma of the Buccopharynx.—The symptoms are mechanical. In 1 case described by New, the growth was an ulcerated polypoid tumor 6 by 4 cm. in the right pharynx with a metastatic mass 4 cm. in diameter in the right cervical region. The treatment is irradiation.

Hemangio-epithelioma of the Buccopharynx.—These tumors attain considerable size, and cause mechanical symptoms and also sometimes show symptoms of involvement of the nerves. The first symptoms that the patient complains of may be periodic swelling in the throat. The clinical

course in some instances is quite long (twelve years' duration in one of New's cases). Metastasis to the glands and elsewhere eventually occurs.

Juvenile Nasopharyngeal Fibroma.—Almost exclusively the male sex is affected. This fact has been explained by Bensch (Ewing) on the basis of a difference in development of the male and female face at puberty. Practically all the tumors appear at about the age of puberty. Papale and Gradenigo class the neoplasm as a familial disease of the sex-bound recessive type.

If and when adult life is reached, they tend to regress somewhat. This spontaneous recession of growth which is characteristic is explained by the fact that normal cranial development ceases at about the twenty-fourth year.

The tumor arises from the base of the skull in the form of a nasopharyngeal polyp which, as it grows, fills the nasal fossa and the nasopharynx and extends through the sphenopalatine foramen into the sphenomaxillary fossa, thence along the line of least resistance, filling the posterior part of the orbit and the zygomatic fossa. It may enter the antrum and fill this also. As the tumor grows, it forms adhesions, and it is these new attachments that render the growths very difficult to remove radically. The tumors continue to grow until the age of about eighteen or twenty years is reached, at which time growth tends to cease or the mass may recede somewhat. Occurring as they do during the period of body growth, it is easily understood how they cause deformity of the bones which bound the cavities they invade. The nose becomes broad, the eyeball protrudes, the cheek bones become prominent, and the zygoma is bowed outward. The faucial pillars may be pushed downward and inward, and a red, soft, easily bleeding mass protrudes from the nose, while the entire naso- and oropharynx may be filled to such an extent that tracheotomy is required. Schlatter stated that the alveolar arch and hard palate are not involved. In a case of Blair's, however, which was subjected to examination by Dr. Opie and was pronounced to be pure fibroma, there was destruction of the hard palate by a mass of the tumor protruding through the bone. The roots of several molar teeth became loose and painful, and when they were removed particles of the tumor were adherent. A considerable degree of vascularity characterizes the tumor and recurrence after inadequate excision tends to be more vascular than the tumor was originally.

Besides a microscopic examination, the diagnosis between the pure fibromas and malignant tumor is to be made on the history and the behavior of the growth. The nasopharyngeal fibroma, or polyp, begins with a growth in the nasopharynx or the sphenomaxillary fossa, causing partial obstruction. Nerve involvement is not a characteristic. As the tumor gradually enlarges, the bones become distorted but usually not thinned. Malignant tumors, as a rule, grow rapidly and destroy the bones they encounter. The dividing line between certain fibromas and the fibrosarcomas is difficult to establish. New has been able to hold certain of these tumors in abeyance by a judicious interuse of a diathermic loop excision along with subsequent application of radium. New and Childrey report 3 cases. One was well after six years.

Epidermoid Carcinoma of the Laryngopharynx and the Larynx.—Krishaber, fifty years ago, insisted upon the difference in clinical character

according to whether or not a carcinoma arose in the interior of the larynx (intrinsic) or around the orifice of the larynx (extrinsic). Isambert proposed the subglottic variety should form a third group. Thomson suggests, therefore, the following classification for clinical use: intrinsic, subglottic, extrinsic, and mixed. The intrinsic growths embrace those starting in the vocal cords, the ventricles, the ventricular band and the interarytenoid region. Thomson states it is unknown in his experience for cancer to originate in the posterior commissure (interarytenoid area). Extrinsic cancer includes growths involving the epiglottis, the aryepiglottic fold, the arytenoids, the pyriform sinuses and the pharyngeal surface of the cricoid cartilage (postcricoid). Subglottic cancer starts on the inner or under surface of the vocal cord or in the subglottic area, chiefly in the anterior half. In the mixed growths fall the combination of extrinsic and intrinsic or subglottic and intrinsic by extension. Many of the cases, because of late recognition, fall in this group when first seen.

Extrinsic, Larynx.—In a male of the cancer age, it may be suspected that a malignant lesion is present in the epilaryngeal portion (epiglottis, aryepiglottis, lateral pharyngeal wall and pyriform sinus) of the laryngopharynx, if any abnormal sensation is persistently felt in the same part of the throat. The sensation may be a tickling or a little difficulty in swallowing. Early pain is usually not present. Such symptoms are sufficient for one to do or advise a laryngoscopic examination. Three appearances are to be looked for: (1) ulcer which will be seen only in part, (2) a collection of mucopus which the patient fails to swallow, and (3) a fixed arytenoid. When little ulceration is seen a fixed arytenoid points to a pyriform fossa lesion.

In the Hypopharynx.—Growths arise behind the cricoid cartilage in the narrow portion of the pharynx from the postcricoid or postpharyngeal mucosa. Peculiarly, they are almost limited to the female sex. Some difficulty in swallowing may be present for many years. Definite obstructive dysphagia, slight regurgitation and chronic huskiness are the signs which make the examination imperative. By laryngoscopic examination in the early stages, one does not see the growth but in the pharynx behind the larynx there is likely to be a definite pool of mucopus which the patient fails to swallow. Later the arytenoid and interarytenoid regions swell, turn purplish and glisten because of edema. Late, the edge of the ulcer is seen. Fixation of the arytenoids is common. When one suspects a postcricoid malignant lesion, the direct laryngoscope should be used.

Speaking in general for cancer of the laryngopharynx, early symptoms are local discomfort and difficulty in swallowing the salivary secretions or food. Interference with deglutition is the fundamental symptom. Later, there is also the pain of carcinomatous infiltration and secondary infection of the surrounding tissues. Thus, the early symptoms are vague and a large gland in the neck is often the first symptom to attract attention. As the tumor increases in size and as the larynx is invaded the voice becomes muffled. Finally, dyspnea and stridor develop. The ulceration causes foul breath, salivation and sometimes hemorrhage.

Intrinsic, Larynx.—An epithelioma arising on the vocal cord tends to spread directly along the cord and further extension is across the midline anteriorly. An epithelioma in the subglottic region is likely to cause fixa-

tion soon, partial or complete, of the corresponding vocal cord and, as a rule, further extension is anterior across the midline. Thus, both cords may be affected by the tendency to horizontal extension in either type of lesion.

When the anterior commissure is invaded, the epiglottis is likely also to be invaded. A common site of extension is the anterior part of the larynx with cricothyroid membrane perforation. Subglottic carcinoma may advance downward and involve the trachea. As long as the growth is confined to the larynx proper or even possibly to the epiglottis, the jugular glands tend to remain free from metastasis.

Intrinsic carcinoma usually starts unilaterally in one vocal cord. Months or even years may elapse before it has spread to any great extent. A cordal epithelioma does not tend to spread backward onto the vocal process. Forward extension up to the anterior commissure is not impeded but spreads to the opposite cord slowly and when it does it is likely to do so from the under surface of the cord.

Cancer of the subglottic area is found in 3 different locations: (1) originating from the cord and dipping downward later, (2) inner or under surface of the cord, or (3) from below and separated from the cord sometimes as low as the cricoid ring.

In early cases of intrinsic cancer of the larynx the hoarseness is slight and insidious. Voice fatigue more nearly explains the symptoms. Huskiness for a month or two occurs. For many months there is no pain or cough and no other symptoms save the change of the voice. As the growths get larger, the hoarseness changes to an inaudible type of voice and dyspnea and stridor develop.

Of course, the symptoms vary according to the site of the disease. A small growth on the cord produces a persistent hoarseness. A growth in the aryepiglottic fold may reach considerable size and may attract attention only by a metastatic node in the neck. Small subglottic growths without cord involvement may produce little or no symptoms. Ordinarily the cervical glands are not invaded until late in the disease. Then often the larynx is tender and can be felt to be enlarged. On laryngoscopic examination in early cases, decreased mobility of the cord is not seen. Hoarseness and a cord tumor may be present for months before the mobility of the cord is decreased.

In ventricular band cancer or cancer originating in the ventricle of Morgagni because of the anatomy of the region early symptoms are absent or slight. The voice may be a little muffled but the hoarseness of cordal cancer is not present. When the neoplasm arises within the depths of the false cord only a bulging of one false cord may be noted at first with ulceration occurring later. In ventricular band carcinoma extension on the whole is rapid. The thyroid cartilage becomes infiltrated and tender. The glands tend to be invaded early and diffusely in contradistinction to vocal cord cancer.

As subglottic cancer extends from beneath the cord and may involve the cord, some cases with obscure throat symptoms and fixation of one cord may thereby be explained. Alterations of voice in cancer of the subglottic area therefore may not be present.

Chronic laryngitis, keratosis, blood clots, submucous hemorrhage, innocent neoplasms, papillomas, fibroma, angioma, enchondroma, prolapse

of ventricle, rhinoscleroma, tuberculosis, paralysis, foreign body, and syphilis all have to be ruled out in the diagnosis.

Sarcoma of the Larynx.—About 15 per cent of sarcomas invade the cervical lymph nodes (Ewing). Clinically, in the early stages, one may not be able to distinguish a sarcoma from an epithelial tumor. The growth arises submucously and of course, the tendency to ulceration is less than in epithelioma. The neoplasm grows as a bulky mass and may be somewhat polypoid. The mucosa is more vascular and tends to a darker red appearance. Ulceration sooner or later develops from trauma of one sort or another and then the clinical picture is about the same as that of a fairly well developed epithelioma. The distinction from an epithelioma ordinarily can be made only by microscopic examination.

Carcinoma of the Antrum.—The great service that the physician can offer in these cases is the early recognition of the disease. So often nasal douches and extraction of teeth have occupied the physician while the patient was passing beyond the stage of any great hope of a cure. Clinically, a tumor in this situation is often not diagnosed early. The growths spread rapidly and invade the bone and become secondarily infected but on account of the size of the cavity considerable growth is allowed before clinical symptoms become very pronounced.

Early, 2 initial sets of symptoms are prominent: (1) a purulent or bloody nasal discharge, and (2) pressure symptoms of one type or another—neuralgic symptoms or possibly a bulge. Many cases are regarded as pyorrhea, toothache, neuralgia, simple sinusitis, disorders in the development of teeth, and empyema of the antrum. The duration of the disease is from four months to two years and depends upon the type of tumor present.

Mechanical pressure symptoms usually first call attention to the disease. The probable origin of the growth is judged roughly according to the primary symptoms and signs. When it arises in the ethmoid area, the floor of the orbit is likely to be involved and ocular derangements with swelling of the lids, conjunctivitis, lachrymation, and functional ocular disorders follow. When the lesion arises from the floor of the antrum, the symptoms are dental. Later, whatever its primary location may be, the growth rapidly fills the antrum and may invade the orbit, nares, infratemporal fossa or buccal cavity. As bony erosion proceeds, fungation appears at the antral orifice, or in the bony wall of the nose or a tooth socket. The invasion is accompanied by a bony osteomyelitis and, as it develops, pain becomes a prominent feature in the distribution of the second branch of the trigeminal nerve. As the anterior wall of the antrum and floor of the orbit are the thinnest walls of the antrum, they tend to become perforated. Later features are perforation of the hard palate, posterior wall of the antrum, molar surface of maxilla into the infratemporal fossa and thence into the pterygomaxillary fissure to the base of the skull, which later may give rise to anesthesia in the distribution of the second and third branches of the fifth nerve. Later, fixation of the jaws occurs as the muscles of mastication are involved, then paralysis of ocular muscles and finally persistent headaches from meningeal involvement.

In 64 cases Windmüller found the lymph nodes involved in 19 cases. The nodes most often involved are those behind the angle of the jaw. The lymphatics of the maxillary region tend to pass posteriorly with those

of the nasal mucosa and vault of the pharynx and go to the deep cervical chain. Hepatic and pulmonary metastasis may occur even without cervical lymph metastatic evidence.

When early symptoms are present, careful nasal examination should be made. The invasion must have extended rather widely for a swelling of the face or the eyelids or the alveolar margin or into the nose to call attention to the disease. An intranasal bulging or mass may be seen or an area of mucosa which is livid, congested or even ulcerated may be seen. When seen early one has to decide whether the lesion is a chronic inflammatory one or a new growth. Exploratory puncture of the antrum with irrigation may give evidence of an infection which transillumination or the roentgenogram will not give. Martin's biopsy needle has been of value here. One must weigh the clinical evidence against the duration of the symptoms. When one cannot be certain by external examination and intranasal examination, transillumination and possibly radiographic examination in those of cancer age, an antral exploration is warranted and should be performed. Visual examination or even finger exploration usually enables one to be certain of the diagnosis. A biopsy should always be taken, however, to check the clinical judgment. No other procedure gives one the same information with the same certainty. Treatment henceforth can be carried out with the satisfaction of an accurate diagnosis at a time when it gives the best results. Later in the disease, when the malignant growth has eroded through into the nose or the maxillary bone, the diagnosis should cause no difficulty. At that time a biopsy can be taken with the greatest of ease. A rongeur forceps is valuable for this purpose as it gives a satisfactory specimen with little danger of hemorrhage.

Malignant Tumors of the Salivary Glands.—The parotid gland is the usual site of carcinoma of the salivary glands but carcinoma of the floor of the mouth may develop rarely from the sublingual gland. Although for descriptive purposes 2 clinical forms may be described ([1] a hard indurated form and [2] a softer fungating form) any gradations between these two may be seen. Typically, the hard indurated type shows marked retraction of and fixation to the surrounding tissue and the softer type, being more cellular, shows more of a tendency to fungate and ulcerate without so many of the signs of excessive stroma formation (Fig. 234, *A*).

Involvement of the lymph nodes of the upper cervical region in parotid carcinoma occurs quite early. Pain is also rather likely to be a symptom of cancer of the parotid, sometimes quite early. Later the seventh nerve is likely to be weakened or completely paralyzed.

New and Childrey report 74 cases of adenocarcinoma of the mixed tumor type seen over a period of thirteen years at the Mayo clinic. In this series of cases 16.22 per cent showed enlarged cervical nodes. In 4 of the series the noses were exposed but no evidence of metastasis was found in 3. In the one in which metastasis was found, it was of the squamous-cell type corresponding to a malignant type of degeneration found in the original tumor. In 3 others the nodes became involved following treatment.

Malignant Tumors of the Neck.—*Branchiogenic Carcinoma.*—The tumor is located usually behind and below the angle of the jaw. Besides the main tumor, there may be other cervical node enlargements. Stiffness of

the neck, headache, hoarseness, and pain are present in a variable number of instances according to the stage of the disease and the tissue involved. Males predominate in the ratio of about 9 to 1. The solid infiltrative character of the mass which grows rapidly in an elderly individual is quite impressive. A benign branchial cyst is usually present for many years. Metastatic carcinoma, it must be remembered, is much more common than primary cancer from branchial remnants. The peak of the age incidence falls in the sixth decade.

Lymphosarcoma of the Lymph Nodes.—Clinically, there is a resemblance to Hodgkin's disease or pseudoleukemia but the extension is more rapid. The capsule of the gland is infiltrated quicker and the surrounding tissues are fixed more rapidly. It seems that the stimulus to growth starts in several glands at once and not in a single gland from which the others are infected (Fig. 234, *B*). The capsule of the gland, muscle and bone are aggressively attacked. When the disease starts in the cervical glands, soon the pharyngeal wall, the neck muscles, and even the base of the skull are involved in the untreated cases. The blood picture is a little indefinite. Bunting described a reduction in the percentage of lymphocytes and a high percentage of mononuclears. Boyd states that a leukocytosis may develop suggesting a leukemia in certain cases. In the diagnosis the rapid course is suggestive. Before the infiltration is well developed, the diagnosis can be made only with the microscope after biopsy. Later, the clinical picture is fairly definite, but confirmatory biopsy should always be done before treatment is instituted.



A *B*

Fig. 234.—*A,* Squamous-cell epithelioma of the parotid gland. *B,* Boy six years of age with a large lymphosarcoma of the neck which was removed surgically and irradiated. He is well at present after almost six years (end of 1937).

Later Clinical Stages of Labiobuccopharyngolaryngeal Carcinoma.—*Midperiod.*—For convenience, a midperiod may be considered to have taken place when the diagnosis is obvious, at least to the experienced observer. The characteristics described in the first period all continue in their development. Induration and ulceration progress. Epitheliomas surrounded by a wealth of fibrous tissue may show considerable central contraction with the ulcer in depression and the edge rolled rather high and feeling stony hard to palpation. On the other hand, the progress of the ulceration may be the outstanding characteristic. The indurated wall breaks down rather

rapidly and soon a marked cavity is formed with a red, granular, ulcerated base, often superficially covered with necrotic débris. Although the induration of the base and edges is absolutely characteristic, it is not so pronounced as when the ulceration is rapid. Characteristically, in all epitheliomas of the tongue or oral cavity in general the edges are prominently rolled and are hard and not much undermined. The fungating ulcerating type is quite characteristic. The ulcerating surface projects above the surface and growth tends to be external as much as beneath the surface. However, infiltration of the base and edges is always definite even from the first and, as the tumor advances, becomes absolutely definite. This latter type of clinical growth is considered to represent a less malignant form of epidermoid carcinoma than the infiltrating form. The clinical course is somewhat less rapid. As previously stated under pathology, papillary, plexiform, superficially diffuse and leukoplakic lesions tend to run a more benign course than the deeply infiltrating and rapidly ulcerating types.

In the midperiod, evidence of metastasis appears sooner or later. In a general way metastasis appears first in the underlying lymph nodes into which the area of the tongue involved drains most directly. But it is impossible to forecast with certainty the involvement for the reason that, when one group or channel is blocked by malignant cells, it is impossible to know the changed course of lymphatic drainage. When the local ulcer is on the anterior tip, on the root (posterior third) or extends to the median line, metastasis to the lymphatic nodes of both sides may occur or rarely even when the ulcer is definitely unilateral. As a rule, however, in the anterior body, or midbody and floor of the mouth, metastasis occurs only on one side. The median raphe of the anterior two thirds of the tongue has very little lymphatic communication through it. Thus, the submaxillary lymph nodes or the upper deep cervical lymph nodes on the same side become enlarged and typically hard first as a rule in unilateral carcinoma of the anterior and midportion of the tongue. The little glands between the geniohyoglossus muscles and the mylohyoid muscles are not often evidently involved. The deep-lying position of these glands probably has something to do with this but it is also true that only a few carcinomas lie in the area which drain to them most readily.

Variations in the clinical picture in the midstage are due largely to the extent and direction of the growth. This applies to both the local lesion and the state of the tributary lymphatics. As muscular action is impeded, difficulty in swallowing and speaking increases proportionately. Of course, difficulty in eating tends to cause loss of weight. In this period a foul discharge appears and a putrid odor is added to the patient's breath.

Final Period.—In the final stage of carcinoma of the intra-oral and pharyngeal cavities, all of the symptoms and signs described for the early and midperiod of the disease become more pronounced and the surrounding tissues become more fixed according to the direction of extension. As the swallowing muscles are invaded difficulty in swallowing increases. In the neck the disease progresses from one group of glands to another and from lymph node to lymph node of the cervical chain. The involved glands are at first hard and not fixed. But eventually the metastatic cells invade and rupture through the lymph-node capsules, the surrounding tissues are in-

vaded, and the gland or glands become fixed in a diffuse hard mass of involved tissue of varying extent and size. The neck becomes almost fixed by a large, hard, diffusely infiltrating mass from parotid to clavicle and from hyoid to mastoid. As the glands enlarge or the general carcinomatous mass increases in extent, central necrosis tends to appear. Eventually, the skin is invaded, is perforated and a fungating ulcer appears. As structures containing nerves are involved, and the tissues surrounding the ulceration become secondarily infected, the pain increases. Besides local pain, pain may be referred up to the back of the neck and down the arm. The patient generally shows evidence of the toxic effect of the growing tumor. Finally, amid the stench, salivation, cancerous discharge and pain, the patient is gradually exhausted by lack of sleep, difficulty in eating, sepsis, and the absorption of toxins of the disease and as death appears, it is often welcomed with open arms. Usually a terminal pneumonia is found postmortem but not uncommonly secondary hemorrhage from one of the larger arteries abruptly puts an end to the sufferer's misery.

GENERAL DIAGNOSIS OF INTRA-ORAL AND PHARYNGEAL CAVITY CANCER

The diagnosis in the midperiod or late period is practically always evident to the experienced observer, but in most instances microscopic study as well as a study of the clinical picture aids the therapist in the proper selection of treatment. Preliminary biopsy, therefore, is recommended as a wise procedure in most situations. All questionable precancerous growths or early lesions in which the resulting deformity will be somewhat negligible are best handled by total excision and immediate microscopic examination. A very great misfortune may be suffered by the patient when a misinterpretation of what to do in a patient with a positive Wassermann or other clinical signs of syphilis is made. When the diagnosis of the local lesion is questionable clinically, a positive Wassermann or other signs of syphilis certainly do not warrant one in procrastination in trying the therapeutic test. If the patient has a carcinomatous lesion much valuable time is lost and it may well be that the only chance of the life of the patient being saved is lost while an inexperienced therapist stands by and looks on. Certainly when in doubt of the nature of a suspicious lesion, an immediate biopsy is an imperative procedure. If negative for malignancy, the patient has not been harmed and consideration may then be given to treatment of a lesion in which the factor of time is not so important.

As soon as the stage of ulceration has occurred, there are at least 4 types of ulceration which one should consider in making a clinical diagnosis of cancer of the intra-oral region, namely: simple chronic ulcers, syphilitic ulcers, tuberculous ulcers, and cancerous ulcers. Actinomycosis rarely and even other fungous infections may also enter into consideration for differentiation. Certain borderline lesions of the chronic inflammatory type tax all the diagnostic resources of the most experienced and men of a little less experience are likely to find themselves uncertain when faced with relatively typical lesions.

One may state without equivocation that simple chronic inflammatory ulcers in those of cancer age with some induration that fails to heal within two weeks following the removal of any evident sources of irritation, such as rough dental appliances or carious teeth, should be excised in toto

and subjected to microscopic study. However, when such lesions heal rather promptly, one is justified in considering the lesion benign.

The primary lesion of syphilis in those of the cancer age of course is rare. One may suspect it when a nodule appears rapidly and is followed by a painless superficial ulcer whose base is a dull red copper color with a glazed surface which exudes a watery discharge. Later the cardboard-like induration of the base and edges becomes evident and the tributary lymph nodes become characteristically elastic without any tenderness. It is not unusual for the surface of the ulcer to be covered with a grayish membrane when no friction is brought to bear directly on the base. When the lesion is the primary one of syphilis, a dark-field examination should reveal the Spirochaeta pallida. However, none but the most experienced observers can be certain, for several other spirochetes also appear in the mouth. Of course, somewhat later the secondary signs of syphilis make their appearance. The diagnosis, however, should not await the appearance of secondary lesions.

In tertiary syphilis ulceration most commonly follows the rupture of a gumma; therefore, the punched-out ulcer is found. In rarer instances ulceration follows a syphilitic glossitis. A gumma of the tongue most commonly appears on the dorsum of the tongue while an epithelioma is most commonly on the lateral borders. In a luetic ulcer the Wassermann is positive in 90 per cent—a fact which in no way rules out carcinoma. Typically, a gummatous ulcer has a so-called "washed leather" base. Early its tendency is to be punched out. Later it may be stellate and fissured. The induration of the base and edges of a gummatous ulcer is not nearly so hard or so pronounced as an epithelioma. Intra-oral syphilis is usually accompanied by other signs of syphilis elsewhere but such signs do not rule out cancer. An unbroken gumma and a deep epithelioma both present an ill-defined mass. Early it might very likely be impossible to distinguish by clinical means between the two. The diagnosis can be proved by excision and microscopic examination.

A tuberculous ulcer of the mouth is practically always secondary to tuberculosis of the lung. A primary tuberculous ulcer of the mouth is a surgical curiosity but apparently has occurred, as proved by 3 or 4 post-mortem examinations reported in the literature. A tuberculous ulcer has little or no induration. The granulations are watery and pale, not granular and red as in carcinoma. The edges are sinuous and undermined instead of rolled and indurated. Pain is a more characteristic symptom of a tuberculous ulcer than in either the carcinomatous or the luetic ulcer. About the main ulcer miliary tubercles may be seen, especially when one presses down on the area with a coverglass. The tip of the tongue is a fairly common location for a tuberculous ulcer. A tuberculous nodule rarely may be noted before the ulceration starts. When one has eliminated syphilis, carcinoma, and mycosis and taken into consideration the clinical characteristics of the ulcer and tuberculosis elsewhere, one can usually be reasonably certain of the diagnosis but final proof may await the biopsy.

Lymphosarcoma, fibrosarcoma, and mixed tumors do not ulcerate until late. In the case of the first two the mass is not hard and in the case of the latter the mass is rather definitely circumscribed and possibly lobulated and movable save at the point of attachment. Lymphosarcoma is soft and

fleshy in appearance and not definitely encapsulated while a fibrosarcoma is somewhat more firm but presents a distinctly infiltrating mass.

Bibliography

Bibliography Quoted in Text

Barth and Betké: Quoted by Kaufmann.

Benedict, E. B., and Meigs, J. V.: Tumors of the Parotid Gland, A Study of 225 Cases with Complete End Results in 80 Cases, Surg., Gynec. and Obst., **51:** 626, 1930.

Bensch, I. D.: Breslau, 1878, quoted by Ewing.

Von Bergmann, E.: System of Practical Surgery, **2:** 288–291, 1904.

Berven, E. F. G.: Malignant Tumors of the Tonsil, Clinical Study with Reference to Radiological Treatment, Acta Radiol., Supplement XI, p. 285, 1931.

Blair, V. P., Brown, J. B., and Womack, N. A.: Cancer in and About the Mouth, Ann. Surg., **28:** 705, 1928.

Bland-Sutton: Tumors, Innocent and Malignant, New York, Cassell and Co., 1901.

Bloodgood, J. C.: Cancer of the Lower Lip, Boston Med. and Surg. Jour., **170:** 49, 1914.

Bottini: Quoted by Morrell Mackenzie, Diseases of the Throat and Nose, London, **1:** 345, 1880.

Boyd, William: Surgical Pathology, Phila., W. B. Saunders Co., 1925.

Broders, A. C.: Carcinoma Grading and Practical Application, Arch. Path. and Lab. Med., **2:** 376, 1926.

Bunting, C. H.: Nelson's Loose-Leaf Living Medicine, Thomas Nelson and Sons, 1920.

Burnam, C. F.: Radium in Intraoral Cancer, Radiology, **9:** 366, 1927.

Butlin, Henry T.: The Results of Operations for Carcinoma of the Tongue, Brit. Med. Jour., **1:** 1, 1909.

Coutard, H.: Roentgen Treatment of Carcinoma of the Tonsils, Strahlentherapie, **33:** 249, 1929.

Cuneo: Gaz. d. hôp., No. 141, 1902.

Ewing, James: Endothelioma of the Lymph Nodes, Jour. Med. Res., **23:** 1, 1913.
Radiosensitivity, Radiology, **13:** 313, 1929.

Figi, F. A., and New, G. B.: Carcinoma of the Larynx in the Young, Arch. Otol., **9:** 387, 1929.

Foote: Amer. Jour. Med. Sci., **143:** 198, 1912.

Fordyce: J.A.M.A., **55:** 1624, 1910.

Fournier: Wien. klin. Rund., **14:** 996, 1900.

Fraser, John: Carcinoma of the Mouth and Tongue, Ann. Surg., **96:** 491, 1932.

Friedman, M., and Rubenfeld, S.: Malignant Neoplasms of the Upper Respiratory Tract in the Young, Amer. Jour. Cancer, **22:** 781, 1934.

Fripp and Iwan: Guy's Hospital Reports, **57:** 88, 1902.

Greene, D. C.: Trans. of the Amer. Laryngol. Assoc., p. 63, 1906.

Helmholz, H. F.: Malignant Neoplasms in Childhood, Proc. Interstate Postgrad. Med. Assoc. North Amer., pp. 209–211, 1932.

His, von Hausinger, Rabl, Kistaniechi, Mielecki: Quoted by Oliver, L. O.: Malignant Epithelial Tumor of the Neck, Amer. Jour. Cancer, **23:** 16–44, 1935.

Hodgkin, Thomas: Morbid Appearances of the Absorbent Glands and Spleen, Med. and Chir. Trans. Tr. (London), **18:** 68, 1832.

Holmgren, and Berven: Bösartige Geschwülste oberen Luft- und Speisewege, Verhandl. d. Nord. Kong. für Otolaryn., 1926, Helsingfors, Mercators Tryckeri Aktiebolag.

Houtant and Molinie: Quoted by Ewing.

Isambert: Ann. d. mal. d. l'oreille et d. larynx, p. 1, 1876.

Jackson, C.: Cancer of the Larynx: Its Curability by Laryngofissure, Surg., Gynec. and Obst., **68:** 431, 1934.
Cancer of the Larynx, Ann. Surg., **1:** 1, Jan., 1923.

Jolly, J.: La bourse de Fabricius et les organes lympho-épithéliaux, Compt. rend. de l'assoc. d'anat., **13:** 164, 1911.

Jovin, J.: Les lympho-épithéliomes du pharynx, Étude histologique clinique et radiothérapique, Ann. d. mal. d. l'oreille et d. larynx, **45:** 729, 1926.

Kaufmann: Pathology, vol. 1, translated by Reimann, Phila., P. Blakiston's Son and Co., **2:** 1145, 1929.

Krishaber: Glaz. hebd. d. méd. et d. chir., **20** (No. 34): 540, August, 1879.
Korbl, H.: Arch. f. klin. Chir, **97:** 752, 1912.
Krompecher, E.: Beitr. z. path. Anat. u. allg. Path., **28:** 1, 1900.
Kuttner: Von Bergmann's System of Practical Surgery, vol. 1.
Kundrat: Ueber Lymphosarcomatosis, Wien. klin. Wchnschr., **6:** 211–234, 1893.
Ledoux: Traitement Curie chirurgical du cancer larynge, Le cancer, **3:** 20, 1924.
Lorenz, H. E.: Das branchiogene Carcinoma, Beitr. z. klin. Chir., **85:** 599, 1913.
Lund, C. C.: Pathology of Carcinoma of the Buccal Mucosa in Relation to Results of Treatment, New Eng. Med. Jour., **209:** 126, 1933.
Second Primary Cancer in Cases of Cancer of the Buccal Mucosa, New Eng. Med. Jour., **209:** 1144, 1933.
Syphilis in Relation to Cancer of the Buccal Mucosa, New Eng. Med. Jour., **209:** 131, 1933.
Mackenty, J. E.: Laryngeal Cancer, Arch. Otolaryngol., **9:** 237, 1929.
Trans. Amer. Laryngol. Assoc., Ann. Otol., **33:** 599, 1925.
Mallory, F. B.: The Principles of Pathologic Histology, Phila., W. B. Saunders Co., 1914.
Massei: Laryngeal Complication of Cutaneous Sarcoma, Arch. ital. di laringol., Oct., 1900.
Meller: Deutsch. Ztschr. f. Chir., vol. 84, 1906
McBride, P.: Medical Chronicle, Feb., 1896.
Menzel, K. M.: Ein malignes Hypernephrom in Larynx, ein Unikum, Arch. f. Laryngol., Frankel, vol. 26, No. 1, p. 265, 1914.
Most: Deutsch. Ztschr. f. Chir., No. 56, quoted and translated by Hartley, New York Med. Jour., Dec. 11, 1902.
Nasse, D.: Arch. f. klin. Chir., **44:** 233, 1892.
New, G. B.: Malignant Tumors of the Antrum of Highmore, Arch. Otolaryngol., **4:** 201, 1926.
New, G. B.: Treatment of Malignant Tumors of the Pharynx and Nasopharynx, Surg., Gynec. and Obst., **40:** 177, 1925.
New, G. B., and Childrey, J. H.: Tumors of the Tonsil and Pharynx, Arch. Otolaryngol., **14:** 596, 713, 1931.
New, G. B., and Figi, F. A.: Malignant Diseases of the Mouth, Pharynx and Larynx—Five Year Cures, Surg., Gynec. and Obst., **60:** 483, 1935.
New, G. B., and House: Quoted by New, G. B., and Childrey, J. H.: Tumors of the Tonsil and Pharynx, Arch. Otol., **14:** 596, 1931.
Opie, Papale and Gradenigo: Quoted by Blair, V. P.: Surgery and Diseases of the Mouth and Jaws, St. Louis, C. V. Mosby Co., 1918.
Oliver, L. O.: Malignant Epithelial Tumors of the Neck, Amer. Jour. Cancer, **23:** 16, 44, 1935.
Pack, G. T., and LeFevre, R. G.: Biometrical Studies in Pathology. V. The Racial and Age Incidence of Cancer and of Other Malignant Tumors, Arch. Path., **3:** 963, 1927.
Piquantin, George: Contribution a l'étude de la langue chez la femme, Thèse de Paris, p. 174, 1905.
Plaut, A.: The Relation Between Histologic Picture and Prognosis of Tumors, Arch. Path. and Lab. Med., **3:** 240, 1927.
Quick, D.: Cancer Conference London, Report of the International Conference on Cancer, July 17–20, 1928, Wm. Wood and Co.
Quick, D., and Cutler, Max: Transitional Cell Epidermoid Carcinoma: Radiosensitive Type of Intra-oral Tumor, Surg., Gynec. and Obst., **45:** 320, 1927.
Regaud, C.: Sur la suppression définitive du tissue thymique par la roentgenthérapie, Compt. rend. soc. de biol., **72:** 523, 1912.
Schmincke, A.: Über lymphoepitheliale Geschwülste, Beitr. z. path. Anat. u. z. allg. Path., **68:** 161, 1921.
Schlatter: Quoted by Ewing.
Schleinzer, Z. C.: Quoted by Kaufmann.
Deutsch. Ztschr. f. Chir., **109:** 283, 1911.
Schmiegelow: Ann. Otol., **23:** 523, 1914.
Hospitalstidende, **63:** 385, 1920.
Sendziak: Die bösartige Geschwülste des Kehlkopfes, Wiesbaden, 1897.

Shreiner, B. F., and Matick, W. L.: Five-Year End Results Obtained by Radiation Treatment of Cancer of the Lip, Amer. Jour. Roentgenol., **30:** 67, 1933.
Thomson, St. C.: Cancer of the Larynx, New York, The Macmillan Co., 1930.
Tilly, H.: Proc. Royal Soc. Med., Laryngol. Sect., **3:** 33, Dec., 1909.
Trotter, Wilfred: Purvis Operation on the Surgery of Malignant Diseases of the Pharynx, Brit. Med. Jour., Feb. 13, 1926.
Turner, L.: Metastatic Malignant Tumors of the Larynx, Jour. Laryngol., p. 181, April, 1924.
Volkmann, R.: Das tiefe branchiogene Halskarcinom, Centralbl. f. Chir., **9:** 49, 1882.
Warthin: Endothelioma of the Lachrymal Gland, Arch. of Ophthal., **30:** 601 (Lit.), 1901.
Wenglowski: Pathogenese der lateralen Halfisteln, Bemerkungèn zu der Abhandlung von H. E. Lorenz, Das branchiogene Carcinoma, Beitr. z. klin. Chir., **88:** 604, 1914.
Windmüller, P. S.: Beiträge zur casuistik der Kiefertumoren, Kastner, 1890.
Ward, W. R., and Smith, A. J. D.: Recent Advances in Radium, Phila., P. Blakiston's Son and Co., 1933.

CHAPTER XXXIII

THE PRINCIPLES AND THE APPLICATION OF IRRADIATION IN THE TREATMENT OF MALIGNANT NEOPLASMS

At the present time after a gradual development in which empirical methods largely predominated, radiation therapy finally has reached a stage of development which allows a dosage to be prescribed with a considerable degree of accuracy.

Some of the Facts Upon Which Radiation Therapy is Based.—Bergonne and Tribondeau during the first years of the present century noted that the cells of embryonal malignant tissue were more susceptible to radiation than adult tissue. In 1912 Lazarus-Barlow demonstrated that cells in a state of mitosis are more susceptible to radiation than resting cells. These two conceptions have had particular influence upon radiation therapy.

Nearly two decades ago Broders studied a series of epitheliomas of the lip in regard to the percentage of cellular differentiation with the idea of determining prognosis. He demonstrated that, by taking into consideration the percentage of undifferentiated cells in the microscopic section, to a certain extent in some types of epitheliomas one can estimate the prognosis. The value of Broders' work has been discussed considerably. One of the most pertinent criticisms is that this conception did not entirely take into consideration the length of time the tumor had been present and the size of the neoplasm. The point was made that there is a tendency for the cellular picture to be more anaplastic as the size of the tumor increases. It has already been mentioned that in certain types of tumors the more undifferentiated the cells appear, the more radiosensitive the neoplasm is likely to be and, conversely, the nearer the cells assume the characteristic of an adult cell, the nearer the sensitivity to radiation approaches that of an adult cell of that particular type of tissue. Then following the lead of Broders, Ewing began to attempt to estimate the relative radiosensitivity of a given tumor by microscopic methods. If one takes into consideration the cells of origin—one of the most important factors to consider in estimating radiosensitivity—this conception now assumes a position of some practical value. When the pathologist takes into consideration the cell of origin, the vascular structure, the character of the tumor bed, the type of intracellular stroma, the presence or the absence of inflammatory signs and the general condition of the patient, he now is able to predict to a certain extent in certain types of tumors the degree of radiosensitivity one is likely to encounter on the application of radiation therapy.

By experimental methods Wood and Prime in 1921 presented some evidence which indicated that as far as epidermoid carcinoma was concerned 7 to 10 "threshold" skin erythema doses are required to be lethal. This showed the necessity for methods of applying a larger amount of radiation to each individual cell of the tumor. With this idea in mind, radium was applied interstitially, at first without much filtration and then later with a heavy filtration, as it was soon discovered fairly heavy filtration was necessary to prevent necrosis immediately about the implant. By the use of im-

plants, either alone or in conjunction with higher voltage roentgen ray, it is now possible to deliver a dosage of radiation that should be lethal from a theoretical standpoint. It is now recognized that when a cure is contemplated, the quantity of radiant energy which each individual cell receives is really one of the most significant factors. Thus, when a lethal quantity of radiant energy for the particular type of malignant cell is not given to all points of the neoplasm, a permanent regression is not to be expected. Martin and Quimby have termed this theoretically lethal dosage as the "tissue dosage" for the particular type of neoplasm to be treated. In cancer therapy at the present time, whether permanent regression of the neoplasm is the goal or not, this conception is to be kept in mind.

But from the practical standpoint one is always limited in radiation therapy by the fact that often the cells that one wishes to render nonviable are little if any more sensitive to radiation than the normal parent cells. Thus, the problem that one faces whenever radiation methods are to be effective is to kill or to render nonviable such malignant cells without at the same time destroying an amount of normal tissue incompatible with function or even injuring the general health of the individual beyond repair.

Within the past few years Martin and Quimby have shown that squamous-cell carcinoma developing in the lip, the cheek, the floor of the mouth, or the anterior tongue requires a dosage equivalent to about 10 "skin erythema" doses if regression is to be expected. This amount of radiation must be delivered to such tumor tissue within ten to twenty days to be lethal. Apparently metastatic squamous cells in the lymph nodes have an even higher radioresistance. Recently Martin has advocated the version that posterior to Waldeyer's ring in a region including the posterior tongue, the tonsil, the naso-, oro-, or hypopharynx, down to the ventricular folds of the larynx, even though microscopically the appearance of the tumor might be about the same as that of squamous-cell carcinoma in the anterior mouth, because of certain regional characteristics the tumor might be somewhat more radiosensitive. This idea, as yet, has not been definitely confirmed. However, there is seen in the pharyngeal region a special type of tumor (in about a proportion of 16 per cent) called the "transitional-cell epithelioma" (Ewing) or the "lympho-epithelioma" (Regaud) which seems to be definitely radiosensitive and requires only from 2 to 4 skin erythema doses of radiation delivered within ten to twenty days to be lethal.

Thus, as a principle, there are several limitations to irradiation. First, the tolerance of normal tissue may be insufficient to allow one to use doses large enough to sterilize the neoplasm. Fractionated doses to a certain extent may overcome this limitation. Another factor which always handicaps one is the fact that a dosage which kills most of the cells may not kill all the cells. Packard first brought out this point. He found that in rat sarcoma a dosage of 1450 r killed 10 per cent of the cells, a dosage of 1950 r killed 50 per cent, but 1 per cent survived 3500 r. Besides the two preceding adverse factors, there are certain uncontrollable factors which are unpredictable. For no very definite reason sometimes a cure results when less than a lethal dose is given. Sometimes a cure is believed to have been effected when only a fibrosis has penned up the cells. Ultimately they start to grow again. After initial insufficient irradiation, subsequent irradiation often is valueless. Then, the door is likely to be closed to other forms

of therapy. In his preliminary decision as to the type of therapy to be given, the radiologist may be handicapped by not being able to predict the results of therapy. But in spite of these definite limitations, radiation therapy is being used extensively with a definite increase in effectiveness.

Methods of Irradiation

Largely irradiation is used in 3 ways: (1) from the outside at a distance by using radium or roentgen rays or both; (2) by burying radioactive foci within the tumor tissue (interstitial) irradiation, and (3) by using external irradiation and interstitial or external irradiation or both plus surgical intervention at one time or another.

EXTERNAL IRRADIATION ALONE

In the external application of radiation, radium which delivers principally gamma rays, and roentgen rays which emit waves of varying lengths are used. Sometimes one is used to supplement the other. Whether one or the other is used, the principles are similar. When radium is used, however, the longer wave length of the pure gamma rays is a consideration as is the shorter wave length when roentgen rays are used.

Roentgen-ray Therapy.—Roentgen rays are applied principally in 3 ways: (1) by a large mass dosage given at one time or in one day; (2) by the saturation technic of Pfahler in which each portal is rather quickly brought up to an erythema and subsequently radiation is added at short intervals to maintain the erythema, after taking into consideration the percentage of recovery each day over a period of several weeks; (3) by the fractionated dosage method of Coutard in which a third or fourth of the erythema dose is given through each portal each day for a period of three or four weeks so as to cause an intense skin exfoliation.

Different technics apparently have different effects upon the tumor cells, the stroma, and the vascular elements. At the present time the relative effect of the various technics is being energetically studied. It is hoped that in the future considerable data of value will be accumulated.

1. *Technic of the German Mass Dose.*—The technic of the German mass dose was really the starting point of measured roentgen-ray therapy. The method came to general attention soon after the close of the war and was the first to be used with the then new "high voltage" (200 KvP) equipment. In an effort to destroy the tumor at one sitting, a much larger dosage of more penetrating radiation than had been employed up to that time was given. Soon the discovery was made, however, that a lethal tumor dose ordinarily could not be given in a single treatment without extensive and irreparable damage to the adjacent or vital tissues. Now the method to a large extent has been abandoned.

2. *The Saturation Technic of Pfahler.*—Based somewhat on Kingery's study of the relation of radiation time and tissue tolerance, Pfahler developed a technic the essential factor of which was the establishment of a definite rate at which the tissues had been observed to recover from the effects of irradiation (Fig. 235, *A*, *B*). Employment of this technic became rather widespread with the general recognition of the danger and futility of the massive dose principle.

Theoretically, by the estimation of a predetermined rate of loss of radiant energy one can at any time estimate the amount of energy still in the tissues. The method consists essentially of delivering through each portal 1 full erythema dose within 2 or 3 treatments and then maintaining that total quantity in the tissues by periodic replacement of that portion of the dosage otherwise lost by tissue recovery. The chief criticism of this method has been that the total dosage has been too low. A short time ago skin recovery was thought to vary from 5 to 9 per cent daily. Now it is known that the recovery may be as high as 60 to 70 per cent during the first twenty-four hours. This means that from a practical standpoint when the divided doses are given a much higher total amount of roentgen ray may be given. Recently Pfahler has stated that he has increased the amount of total radiation, at the same time continuing the saturation plan of therapy, and his clinical results have been improved.



A *B*

Fig. 235.—*A*, Patient with lympho-epithelioma. *B*, After treatment by irradiation. Well after five years. The tumor originated in the lateral pharyngeal region. (Dr. Tice treated this patient for me.)

3. *The Protracted Divided Dose Therapy of Coutard.*—The most revolutionary change in roentgen therapy has followed a widening appreciation of a principle generally credited to Henri Coutard of the Curie Institute of Paris. Previously Regaud, the director of the institute, in using radium interstitially came to the conclusion that by protracted irradiation the maximum effect was obtained. This conception supplied the basis of the reasoning behind Coutard's radiation technic. Coutard has found that an amazingly high total dosage will be tolerated by normal tissues if a number of relatively small treatments are given at a low rate of intensity, *i. e.*, not to exceed 5 r per minute. Apparently primarily so slow a rate of administration was found to be useful because of the fact that Coutard employed the heavy and somewhat inefficient filter of 2 mm. zinc plus 3 mm. of aluminum plus 2 cm. of wood.

Coincident with the development of Coutard's technic considerable controversy arose as to the relative importance of the various factors em-

ployed such as intensity, filtration, and voltage. Generally, it is now known that tissue will withstand a much higher total dosage when roentgen rays are given by a divided dosage technic similar to the method of protracted therapy advocated by Coutard.

The extreme opposite of the old massive dose technic is the method of *continuous radiation of Heublein.* But so far as cancer in and about the face, mouth, and jaws is concerned, it is of little interest. The tissue dose possible with external radiation alone, even after cross-firing methods, is often insufficient to be lethal in all but neoplasms confined to near the surface and those of a relatively radiosensitive type. Usually from 4 to 5 skin erythema doses and sometimes even less are all that actually may be delivered to the tumor depth from external sources of radiation alone. External radiation is used primarily to induce growth restraint without the expectation of death of all the cancer cells unless the tumor is of a particularly radiosensitive type or the location is so superficial that adequate dosage may be given by external methods alone.

In the future one of the most important problems to be determined is whether or not the use of higher voltage and thicker filters will increase the number of cures. Some men believe that by making full use of cross-fire methods the maximum dose that the human body will withstand has been approached. More optimistic observers hope that such is not altogether correct. Probably the fact that higher voltages tend to ionize atoms in a different manner deserves some attention. The essential factor is the dosage at a depth and probably a deeper penetration of the neutrons adds something to this dosage.

The Measuring of Radiation.—In the past it has been the common practice to state dosage in terms of such physical factors as the kilovoltage producing the roentgen rays or the number of milligrams of radium employed plus time, filtration, etc. Each worker, when attempting to develop a satisfactory measuring unit for radiation therapy, has contended with the difficulty that equal physical measurements did not necessarily mean an equal biologic effect which is the main end-point of radiation therapy.

The difficulties in establishing a satisfactory physical unit for roentgen rays are not so great. As for radium an accurate quantitative determination of roentgen ray intensity can be obtained by using the property of roentgen rays to ionize a gas and then measuring with standardized equipment the rate of ionization produced at a given point. The International Roentgen Ray Committee proposed in 1928 a standardized unit of ionization measurement, *i. e.,* the roentgen unit or r. This committee then defined the unit for general adoption as that quantity of roentgen radiation which, when the secondary electrons are fully utilized and the wall effect of the ionization chamber is avoided, produces in 1 cc. of atmospheric air at 0° C. and 760 mm. mercury pressure such a degree of conductivity that 1 electrostatic unit of charge is measured at saturation current. This unit has been adopted rather generally and the Bureau of Standards at Washington has constructed "standard ionization chambers." Although it still remains to be determined whether or not the ionization of air is proportionate to the biologic effect for all types of radiation and for all wave lengths, the calibration of roentgen ray equipment in terms of the r has resulted in a much greater degree of accuracy. By employing a biologic unit of measure-

ment much of this discrepancy can be avoided for most sources of radiation (radium or roentgen rays). The most practical method for determining a biologic standard is to find the amount of radiation necessary to produce an erythema of the skin of a certain intensity.

The depth dosage in terms of r at any given depth beneath the surface can be determined by passing the radiation through a phantom of some medium which has about the same density as tissue such as water, rice, wheat, etc.

The radiation at any given depth is measured by means of a submerged ionization chamber and compared to the same chamber's determination of the amount of energy striking the surface of the medium. The decrease is the result of the slight increase in distance and of penetration through a given depth of the medium. This depth dosage is usually expressed as a percentage of the surface radiation in terms of the r (physical) or the skin erythema unit (biologic).

Complete accuracy in measuring gamma rays and the radiation of radium by means of the same ionization chamber is a matter which has not been entirely worked out. The use of 8.4 r per hour has been suggested as a standard measurement of the gamma radiation reaching a point 1 cm. distant from a source of 1 mg. of radium when filtered through 0.5 mm. of platinum. To obtain this figure the r output of radium has been calculated from known physical data. The use of this means of expressing radium dosage has recently been suggested by Glasser, Paterson and Parker and others. In the near future it will probably meet with general approval. For the present, however, they have advised the use of the terms equivalent to r to designate the intensity of gamma irradiation.

External Irradiation by Radium.—Although it has been stated that the gamma rays of radium are superior to roentgen rays for therapeutic purposes, it is possible that the gamma ray might have a greater specificity for certain tumor cells.

With radium there are essentially 2 methods in use for applying external radiation: (1) by means of the so-called "radium bomb," and (2) by means of the relatively small radium pack. From 3 to 4 Gm. of radium are used in a radium bomb. Only a few fortunate institutions can afford such an expense. The small radium pack is therefore more generally used. It may be used as a means of applying external radiation to the skin or mucosal surface or from within a cavity such as the antrum. As previously mentioned for roentgen ray, external irradiation by means of radium in quantities sufficient to be lethal for relatively radioresistant lesions often cannot be given without causing irreparable damage to adjacent or intervening normal tissue.

Small radium element (radon) packs or trays may be built up for external application. For instance, at the Memorial Hospital the radon tray is built to give a dosage of about 3000 m.c. hr. It has 2 mm. brass filtration, irradiates about 24 sq. cm., and is used at a distance of 3 cm. from the skin. Such an application is used chiefly for small simple fixed recurrent nodules of cancer. Similar large plaques can be built up for any particular situation encountered, varying the filtration area and focal distance according to the dosage desired.

Within the mouth, when superficially involved by malignancy in such

situations as the mucosa of the cheek or the palate, the lesion sometimes may be treated very efficiently by an intrabuccal applicator.

Calculation of Surface Dosage for Radium or Radon.—A very complete dosage system for external irradiation by means of tubes, needles containing radium element or radon based on the measurement of gamma irradiation in terms of the r employed in radiation therapy recently has been published by Paterson and Parker (Figs. 236 and 237). Such a system is very useful. The dosage system of Paterson employed at the Radium Institute in Manchester is simple enough for routine clinical use and is applicable to all forms of radium therapy other than certain types of interstitial implantation. The erythema values may be used in a rough way as equivalents in the two systems. Thus, dosages can readily be compared. The actual means of calculation becomes a matter of secondary importance. One thousand r of the Paterson system equals approximately 1.1 erythema dose of the Memorial Hospital System (Fig. 241).

The dosage system of Paterson and Parker answers two questions: (1) how much radium is required and (2) how should it be arranged? They accept the value of 8.4 r per hour as the intensity of radiation at a distance of 1 cm. for 1 mg. point sources of radium filtered by 0.5 mm. of platinum, and the working unit selected is 1000 r. They constructed a series of graphs. The amount of radium required on flat surface applicators to give 1000 r over any area at various distances may be obtained from the area graphs (Fig. 236) in milligram hours. The tube graphs (Fig. 237) give the same data for various tubes of radium expressed in milligram hours required along the central axis to give 1000 r at the surface of the tubes. The graphs are used as follows: the dose in 1000 r is decided upon, the graph ready for area or length under consideration (to be treated) is multiplied by that number (of 1000 r) which gives the number of milligram hours required. The actual amount of radium element or radon is found simply by dividing the figure by the number of hours (element) or number of millicurie hours (radon) (Fig. 239) intended. One thousand r by this unit equals about 1.1 erythema dose by the system used at the Memorial Hospital (New York) (Fig. 241). The problem of distribution of the foci is very important. The whole system assumes that the distribution of the foci has been such that uniform or almost uniform irradiation is given through the area to be radiated. They lay down a series of rules for circles, squares, rectangles, irregular areas, convex areas, concave areas, linear or tubal applicators, and single foci (Fig. 238).

In using the circles they lay down the following rules (for discussion of other forms consult the article by Paterson and Parker): Circles: use circles whenever possible and arrange radium uniformly around the circumference. The minimum number of foci is 6. A single circle alone is sufficient where the diameter is less than three times the distance (2.83 $\times$ the diameter is ideal). When the diameter is three to six times the distance, 5 per cent of radium should be placed at the center. For larger areas use 2 concentric circles and a center spot as follows: 3 per cent of radium at the center. For the outer circle, use percentage of radium as used in this table:

Diameter divided by distance	6	7½	10
Per cent radium outer circle	80	75	70

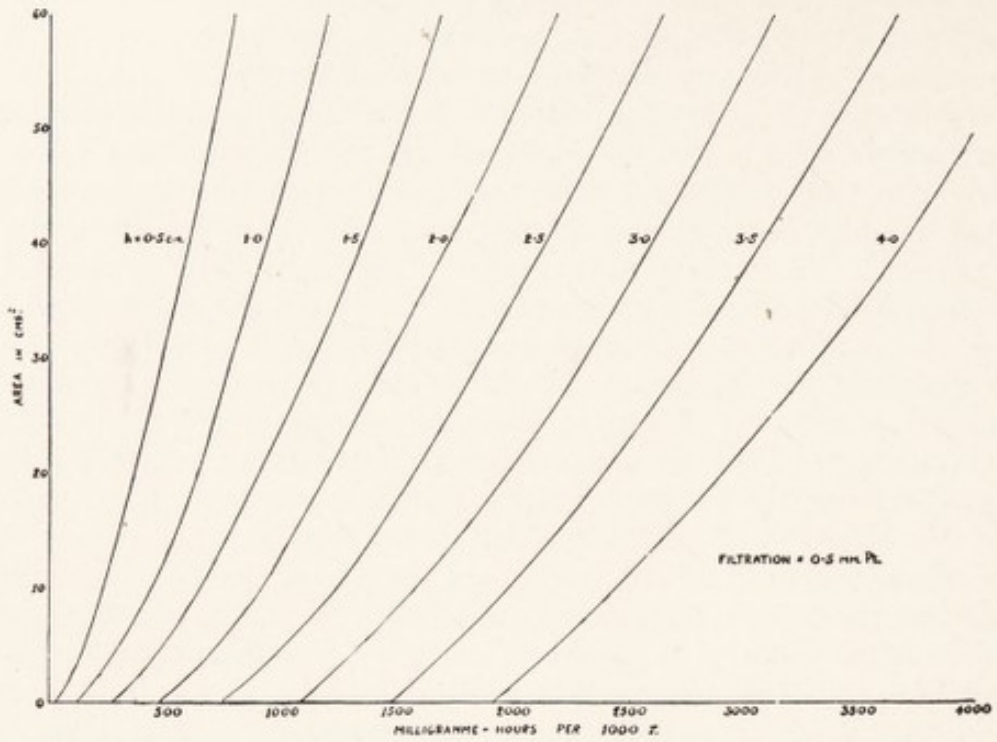

A

Dosage: small areas.

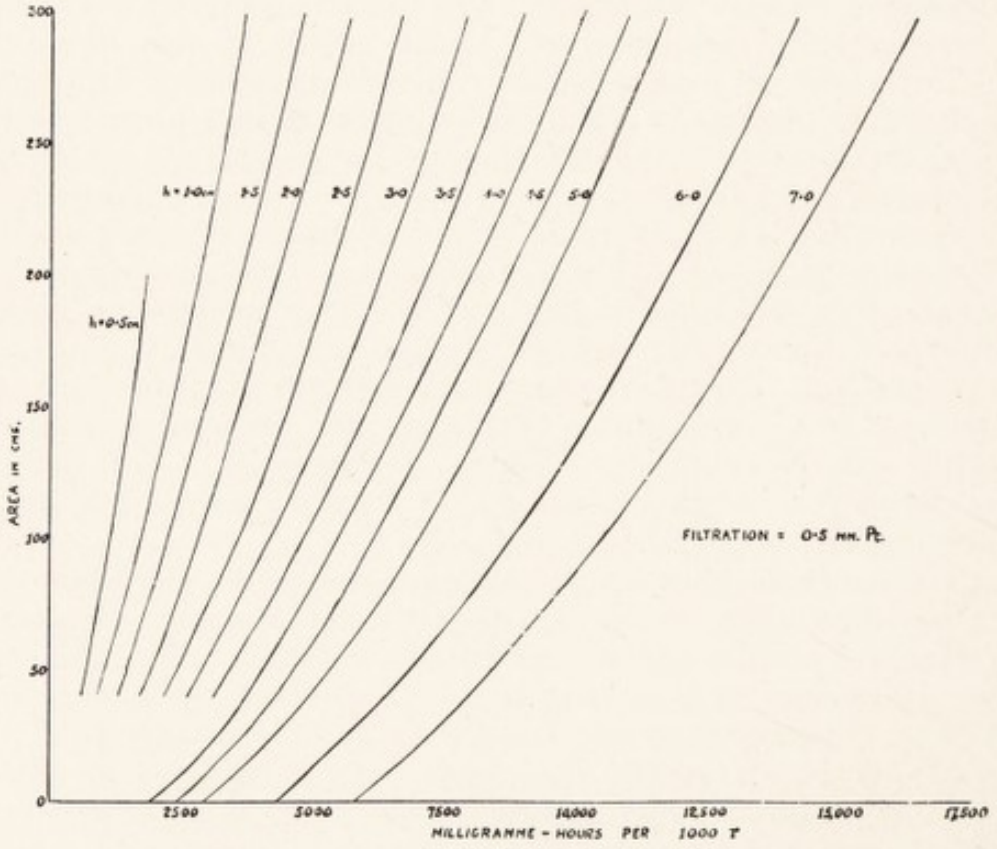

B

Dosage: large areas.

Fig. 236.—A, Dosage graph gives dose up to 60 sq. cm. at distances of 0.5 to 4 cm. B, Dosage graph giving dosage for areas up to 300 sq. cm. at distances from 0.5 to 7 cm (based on 0.5 mm. platinum filter). (Paterson and Parker.)

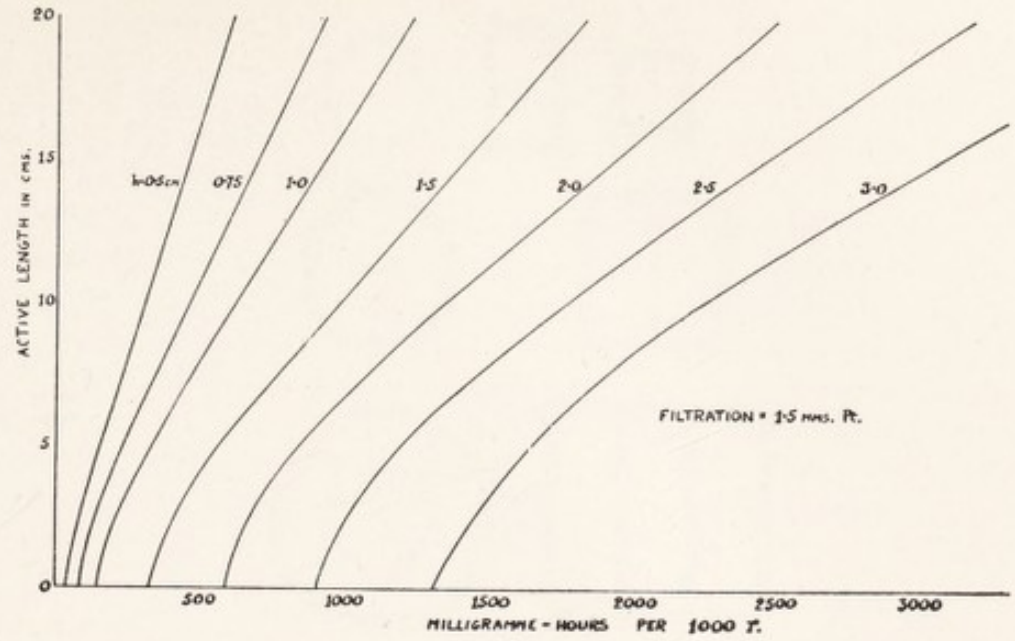

A

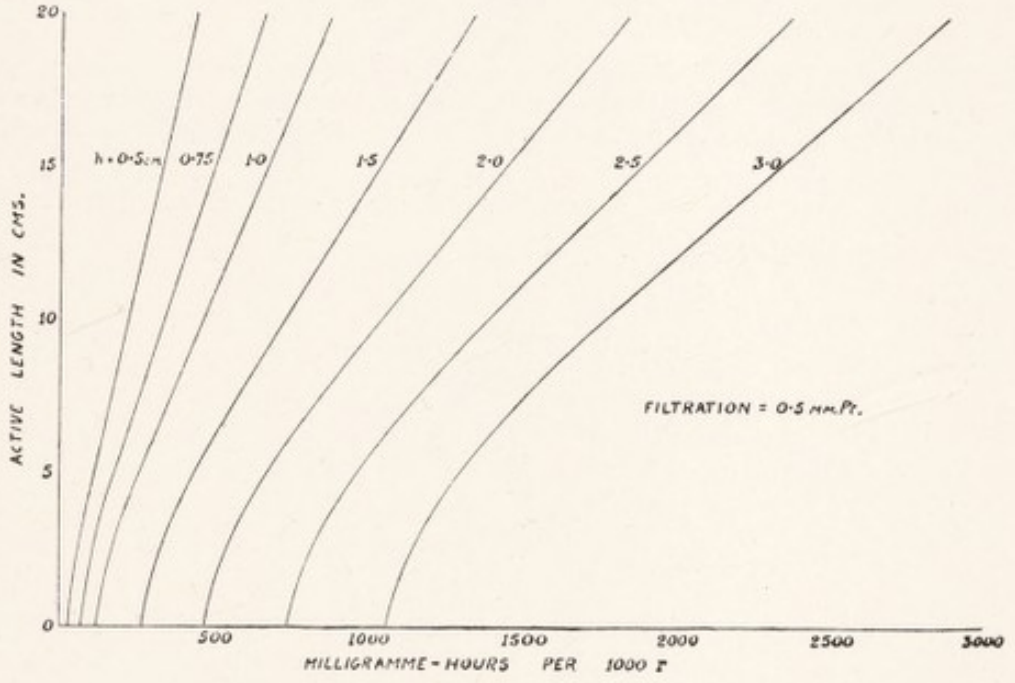

B

Add Correction for Filter

0·8	1	1·5	2
5%	10%	20%	35%

Add Correction for Rectangles

2 · 1	3 · 1	4 : 1
5%	9%	12%

Fig. 237.—A, Dosage graph (for tubes 0.5 mm. platinum filter) giving dosage at the surface of tubal applicators of lengths up to 20 cm. and for radii from 0.5 to 3 cm. B, Dosage graph for tubes (1.5 mm. platinum filter) as A but for heavier filtration. For filtration 1 mm. platinum the mean of the readings from A and B should be taken. The area graphs Figs. 236 and 237 are for 0.5 platinum filter. If other filtrations are used, the above corrections are necessary. Gold equals platinum. Lead and silver as half their thickness of platinum. Monel, brass, etc., as one third their thickness in platinum. The charts apply strictly for circles and for squares. For rectangles proceed as for squares, adding the additional lines parallel to the longer side and make correction in the direction of increased milligram hours as above. (Graphs and corrections in Figs. 236 and 237 are after Paterson and Parker.)

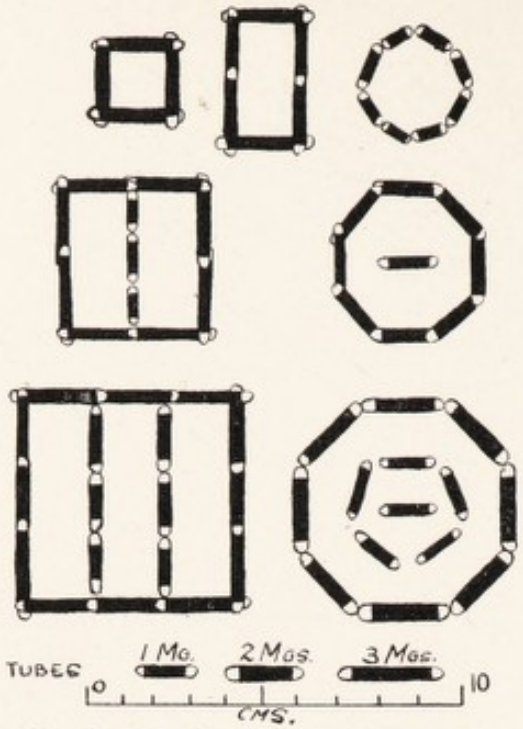

Fig. 238.—Rules for distribution depicting typical arrangement to produce homogeneity at 1 cm. distance. (After Paterson and Parker. See their article for diagram of how the system can be adapted to whatever types of radium containers are available.)

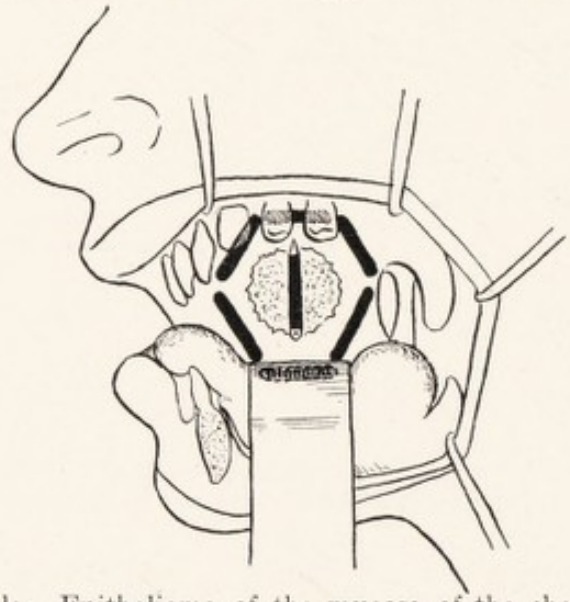

Fig. 239.—Example: Epithelioma of the mucosa of the cheek. Size of lesion, 3.5 cm. in diameter. Treatment, 0.5 cm. mold. To give 10,000 r in twenty days (mold applied sixteen hours per day).

Calculation:

Treat area 5 cm. diameter = 19.5 sq. cm.
Mold distance = 0.5 cm.
1000 r at 0.5 cm. = 400 mg. hr.
10,000 r = 4000 mg. hr.

No correction for filtration 0.5 mm. platinum.

Distribution:

$$\text{Diameter } 5 \times \text{distance}$$

Therefore single circle plus 5 per cent center spot.

Use 6–2 mg. tubes in a circle plus 1 mg. tube as center spot.

Dose at 1 cm. below mucosa.

At new distance of 1.5 cm.

1000 r = 630 mg. hr. actually used = depth dose = $\frac{4000}{630} \times \frac{1000\text{ r}}{1} = 6349$ r.

(Padgett, Principles Pertinent to the Radiation Therapy of Oral Cancer with Methods of Calculating Dosage, Internat. Jour. Orthodont. and Oral Surg., July, 1936.)

For the inner circle distribute the remainder around a circle of half diameter. For circles at small distances the last arrangement is not practical. The following is substituted:

Diameter 6 — 7 × distance = 10 per cent radium at center.
Diameter 7 — 9 × distance = 20 per cent total radium at center.

Calculation When the Growth is Sandwiched Between Two Planes Containing Radium.—Frequently, it is possible, as on the lip, cheek, and alveolus, to sandwich a growth between two molds in such a way that a fairly homogeneous dosage is given through the tissue. To do this the applicator is prepared with two molds paralleled with each other (Fig. 240). To calculate, figure dosage at successive distances for applicator A which will progressively decrease as the distance decreases. Then calculate dosage

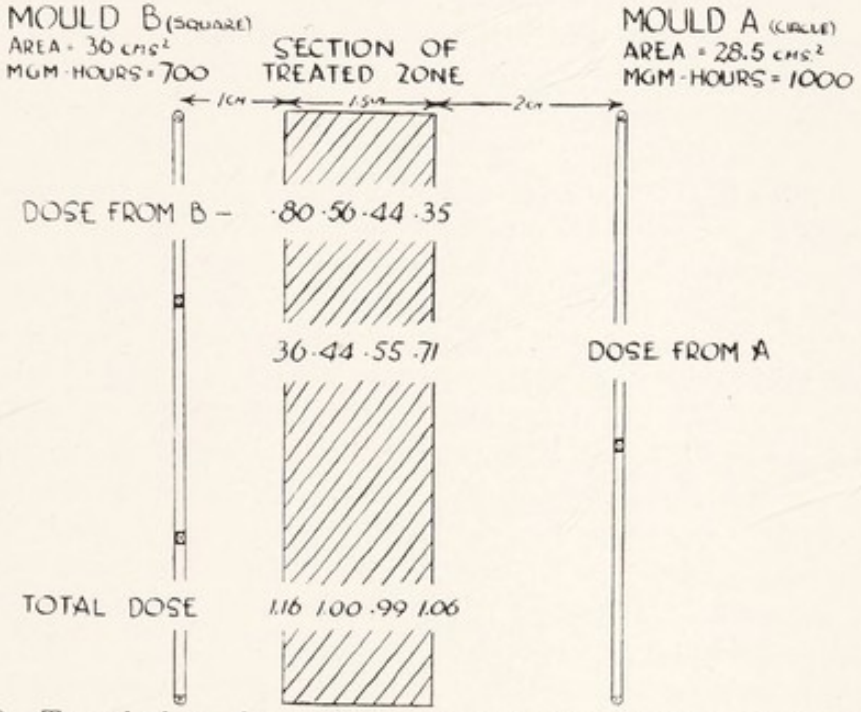

Fig. 240.—To calculate, figure dosage at successive distances from applicator A which progressively decreases as the distance decreases (latter part of legend for Fig. 239 gives example of figuring dosage at a given depth). Then calculate dosage at successive distances from applicator B which also will progressively decrease as the distance decreases but in the opposite direction. Then add A and B together as shown for total dosage at a given point. (Paterson and Parker.)

at successive distances from applicator B which also will progressively decrease as the distance decreases but in the opposite direction. Then add A and B calculation together as shown in Fig. 240 for total dosage at any given point. This dosage system provides accurate measure of actual radiation.

Dosage to be Selected.—As previously emphasized, not only is the actual dosage to be considered but the period of time over which the dosage is given is also of vast significance. The dose to produce reaction on tissue increases as the time length is increased. A standard of radiation continuous over a period of eight days was set in the transference of actual dosage to a biologic reaction of a given intensity. They found that for normal skin 3000 r gave a faint erythema, 4500 r a definite erythema, 6000 r moist desquamation, 7500 r more marked to borderline of safety,

and 9000 r resulted in a certain percentage of radium necrosis. For buccal mucosa a dosage of as high as 12,000 r usually was tolerated with eventual return to normal. For squamous-cell epithelioma 6000 r delivered to all parts of the tumor—not at surface—usually caused regression and was taken as the tumor lethal dose. For permanent response of basal-cell epithelioma about 5000 r was considered necessary.

INTERSTITIAL IRRADIATION

In the second method, interstitial irradiation, the radiant energy is applied either in the form of needles or of permanent buried radon implants. When it seems likely that the needles will not remain in situ they are held in place by sutures, and are removed after a given period of time. Radon seeds usually are buried permanently. Undoubtedly, the use of radon is one of the most efficient and practical ways of applying interstitial radiation. In a considerable number of great clinics, however, needles containing radium element are used by preference (the Curie Institute and Radiumhemmet, etc.). A continuous equal source of radiation over a period of time is thought by these workers to give better results than radon which has a half life period of a little more than three days.

One disadvantage in using needles is the necessity, as a rule, of hospitalizing the patient, which is not always the case after radon seeds are implanted. Needles are somewhat more cumbersome. Usually they have to be sewed in. The size of their puncture holes may tend to open avenues of infection. In some situations such as the oral cavity, the hypopharynx, and certain anatomic tubes, it is practically impossible to implant needles containing radium element from the inside. In such regions radon seeds may have some advantage in applicability. But often some "surgery of access" through an external incision is likely to be the most efficient way of gaining accurate implantation. The needles may be used very efficiently. Theoretically, interstitial irradiation is fraught with a slight danger of disseminating carcinomatous cells. When an error in the distribution of the foci occurs, malignant cells survive which allow an eventual recurrence of the new growth. This is one reason for postponing glandular removal until after the local lesion is eradicated.

A mere knowledge of the amount of radium, filtration, time, etc., is not sufficient when using interstitial radiation. The relative effect of radiation at varying distances from its sources must be considered. In order that a lethal quantity of energy may be delivered throughout the tumor-bearing area, the size and shape of the lesion should be known in order to plan the proper distribution of radiant sources. To fairly radioresistant neoplasms with correct introduction and spacing of radioactive foci a lethal dose can be given, unless the tumor is so large that the quantity of radiant energy necessary is incompatible with the life of the individual.

The Measuring of Interstitial Radium Dosage.—(1) Interstitial and Intercavity Measurement.—The problem of obtaining a satisfactory unit of dosage is complicated when interstitial radiation is used. No iontoquantimeter has been constructed with which one may calculate accurately dosage in terms of physical units throughout an area containing a group of interstitial implants of radium or radon. The problem has to be approached by indirect experimentation and comparison. The group of workers in the

biophysics department at Memorial Hospital (New York) have done this and for practical purposes have been able to establish a method of interstitial dosage estimation which is fairly accurate (Fig. 241). Their methods of indirect experimentation and comparison took advantage of the properties of radiation to bleach butter, to cause tissue necrosis in rabbits, and to produce an erythema of the skin in the human being. As the bleaching effect of radium upon butter is proportionate under certain conditions to the production of tissue necrosis or to the formation of skin erythema, an experimental comparison was made so that a biologic unit dosage table of some

NUMBER OF MILLIGRAM OR MILLICURIE HOURS REQUIRED
TO DELIVER SPECIFIED DOSES TO MASSES OF VARIOUS DIAMETERS

	DIAMETER OF MASS—CENTIMETERS											
	1.0	1.5	2.0	2.5	3.0	3.5	4.0	4.5	5.0	6.0	7.0	8.0
	NUMBER OF MILLIGRAM OR MILLICURIE HOURS											
1	26.0	65.0	104.0	195.0	260.0	312.0	377.0	442.0	520.0	702.0	910.0	1170.0
2	52.0	130.0	208.0	390.0	520.0	624.0	754.0	897.0	1040.0	1430.0	1820.0	2340.0
3	78.0	195.0	312.0	585.0	780.0	936.0	1131.0	1300.0	1560.0	2080.0	2730.0	3510.0
4	104.0	260.0	416.0	780.0	1040.0	1248.0	1560.0	1820.0	2080.0	2860.0	3640.0	4680.0
5	130.0	325.0	520.0	975.0	1300.0	1560.0	1820.0	2210.0	2600.0	3510.0	4550.0	5850.0
6	156.0	390.0	624.0	1170.0	1560.0	1820.0	2210.0	2600.0	3120.0	4160.0	5460.0	7020.0
7	182.0	455.0	728.0	1300.0	1820.0	2210.0	2600.0	3120.0	3640.0	4940.0	6370.0	8190.0
8	208.0	520.0	832.0	1560.0	2080.0	2470.0	2990.0	3510.0	4160.0	5590.0	7280.0	9360.0
9	234.0	585.0	936.0	1820.0	2340.0	2860.0	3380.0	4030.0	4680.0	6370.0	8190.0	10530.0
10	260.0	650.0	1040.0	1950.0	2600.0	3120.0	3770.0	4420.0	5200.0	7020.0	9100.0	11700.0
11	286.0	715.0	1144.0	2210.0	2860.0	3380.0	4160.0	4810.0	5720.0	7670.0	10010.0	12870.0
12	312.0	780.0	1248.0	2340.0	3120.0	3770.0	4550.0	5330.0	6240.0	8450.0	10920.0	14040.0
13	338.0	845.0	1300.0	2600.0	3380.0	4030.0	4940.0	5720.0	6760.0	9100.0	11830.0	15210.0
14	364.0	910.0	1560.0	2730.0	3640.0	4420.0	5330.0	6240.0	7280.0	9880.0	12740.0	16380.0
15	390.0	975.0	1690.0	2990.0	3900.0	4680.0	5720.0	6630.0	7800.0	10530.0	13650.0	17550.0

Fig. 241.—This chart has two principal uses: (1) when 2 mg. platinum covered needles containing a known number of milligrams have been introduced into a mass whose diameter has been measured to find the minimum tissue dose which has been given in terms of skin erythema tissue dose, the top row gives the diameter of the mass and in the column below is found the number of milligram hours. On the horizontal line in the first column is given the tissue dose in terms of skin erythema dose. Example: mass 3.5 cm. given 3120 mg. hr. has a dosage of 10 skin erythemas. (2) It may be used to find the number of milligram hours necessary to deliver a specified tissue dose to a mass of a given diameter or from within a cavity (such as the antrum) to the walls, figuring periphery to periphery as a sphere of a given diameter. For example: diameter of cavity 5 cm. To give eight times a skin erythema dosage, note the number of milligram hours in the intersection of the vertical column beneath 5 cm. and the horizontal column for 8 S.E.D., which equals 4160 mg. hr. (Taken from a table by Quimby and Martin and changed to milligram hours by multiplying by 130.)

accuracy for interstitial radiation in various shaped masses could be constructed. They selected as the most satisfactory unit of dosage a "threshold erythema dose" which they defined as "that amount of radiation which in 80 per cent of all cases after a single application will produce a faint bronzing or reddening of the skin in about three weeks and in the other 20 per cent will produce no visible effect." This unit is probably as satisfactory as any yet proposed. They were able to calculate the percentage of radiation delivered to any point within a given distance from the implant by means of comparative distribution of curves reduced to terms of "skin erythema" dose.

Martin and Quimby have advocated that in the use of their method of calculation each mass to be radiated by interstitial methods be carefully measured and considered as a sphere or as two more adjacent or overlapping spheres. After placing needles or radon seeds in a given tumor, each implant is considered as a point source, and the focus of any given intensity or dosage about one implant then constitutes a hypothetical sphere with the implant at its center. Since the sources would not lie in a single plane they point out that two or three implants cannot logically be placed so as to irradiate a sphere uniformly. In this connection they point out that the simplest geometrical arrangement about one point is 4 at the apices of a tetrahedron. Martin and Quimby found that a "spherical mass is equally well radiated by a given quantity of radon whether concentrated at the center or subdivided and distributed geometrically about the center, provided the implants are confined within the inner half of the radius."

When figuring the dosage quantity and implanting the implants a mass nearly spherical is taken as falling within the next larger sphere which will encompass the mass as a whole. An elliptical or rectangular mass is considered as composed of several spheres some of which may be of dif-

Voltage	150 KvP	200 KvP	250 KvP	300 KvP
	SKIN TARGET DISTANCE = 80 CM.			
Filter	Copper 0.25 mm.	Copper 0.50 mm.	Copper 2 mm.	Copper 3 mm.
Intensity on the surface	100.0%	100.0%	100.0%	100.0%
Intensity at a depth of				
2.5 cm.	87.5%	88.0%	90.0%	88.0%
at 5.0 cm.	66.3%	70.0%	73.9%	70.6%
at 7.5 cm.	56.3%	59.5%	62.1%	62.5%
at 10.0 cm.	41.6%	47.4%	50.4%	51.8%
at 12.5 cm.	33.3%	36.8%	39.3%	41.2%
at 15.0 cm.	25.8%	30.0%	32.2%	33.1%

Fig. 242.—Besides showing the depth dosage on a percentage basis, taking the surface as 100 per cent, table shows the gain in the "percentage depth dose" when heavier filters are employed at higher voltages. Our machine at present is used at 300 KvP. The increase in percentage of depth dosage is compared with other voltages.

ferent sizes. By this method, the quantity of radiation necessary for a tissue dosage is determined, or on the other hand, the dose which has been given if an empirical method was used previously (Fig. 241).

Figure 242 was worked out for the calculation of interstitial dosage by Quimby and associates at Memorial Hospital (New York). The data given were based upon radon implants 4 mm. in active length and filtered with 0.3 mm. of gold. When using small needles covered with from 0.3 to 0.5 mm. of platinum the variation in dosage due to change of filtration is not very marked. The table can be used without correction. Somewhat recently Quimby and Stewart discussed the "comparison of various sources of interstitial radiation." Space forbids a résumé of the influence of this factor.

External Irradiation Plus Interstitial Irradiation.—The third method of application—external irradiation plus interstitial irradiation—often represents the most useful method of application of a lethal tissue dosage of radiation. To obtain a lethal dose for a radioresistant lesion, the two methods may be used as adjuvant sources of radiant energy. Quimby and Pack showed that the production of a skin erythema by a half-and-half

combination of gamma (radium) and roentgen rays requires a total of 30 per cent more radiant energy than when either is used alone. Since the cancer cells as well as the skin may tolerate the increased quantity of combined radiation, it is possible that this fact, however, may not aid cancer therapy to any great extent. Several groups of workers have the distinct clinical impression that there is an advantage in combining roentgen rays with radium.

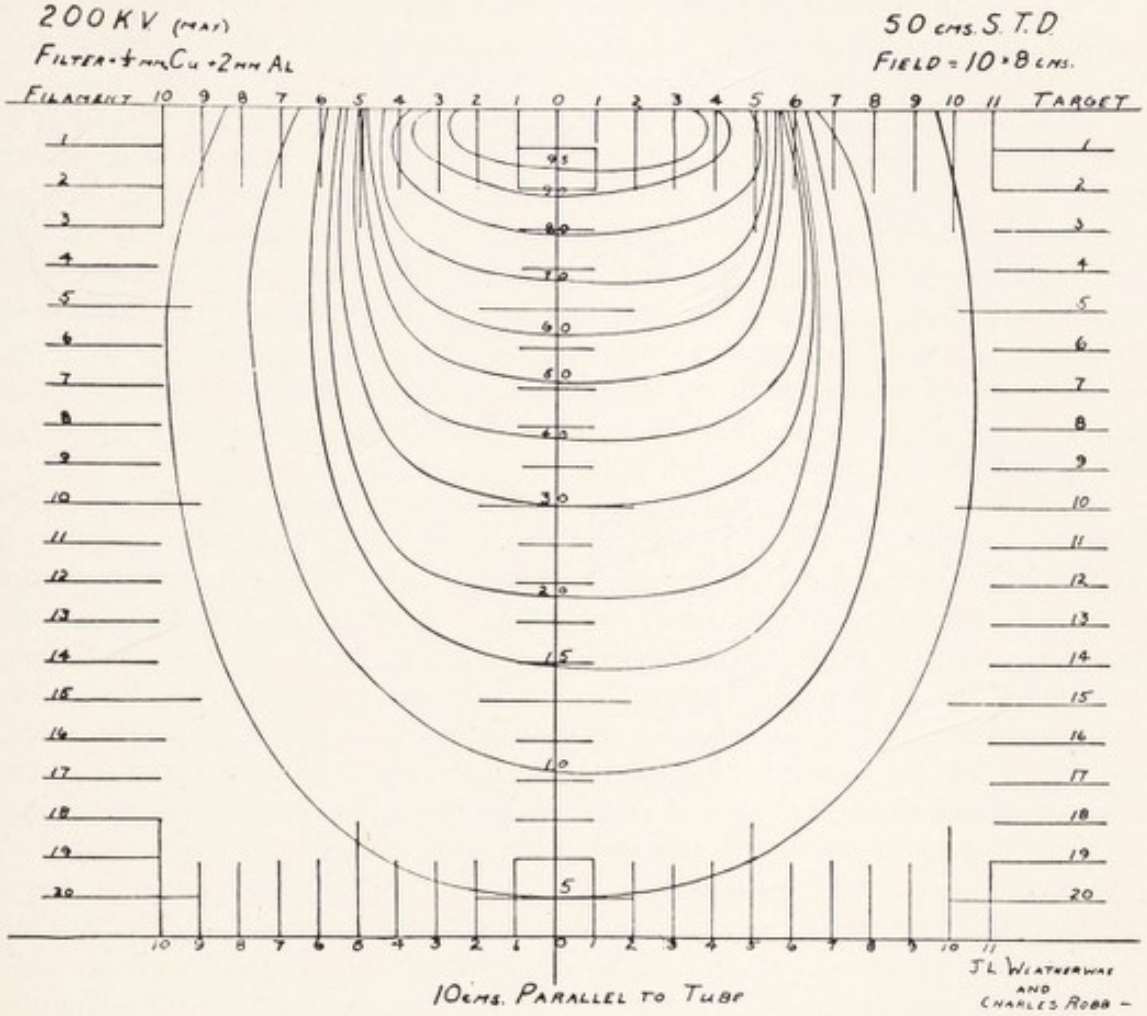

Fig. 243.—Example of isodermic depth dosage curve for 200 K.V. (max.) *x*-ray machine, filter ½ mm. Cu plus 2 mm. Al, 50 cm. skin target distance, field 10 x 8 cm. (After J. L. Weatherwax and Charles Robb, 1927.) A discussion of the effects of the size of the portal, different skin target distances, and different thickness of the filter is a treatise on the physics of radiology. My only object is to point out a general use. Obviously in calculating the total amount of effective radiation to a given point at a given depth when cross-fire methods are used, such isodose curves are necessary in the direction from each portal to gain a summation of irradiation.

The Method of Action of Radiant Energy.—In the use of radiation the question of the effect on tissue of radium or roentgen rays, respectively, is of interest. Ewing has been of the opinion that the gamma rays of radium act chiefly by direct action on the cells and that roentgen rays act chiefly by causing changes in the tissue bed about the cancer cells and further, in the case of roentgen rays, that the reaction in tissue appears later than that produced on the tumor cells by gamma rays. Although lacking confirmation, it has been stated that the roentgen ray therapy should precede the gamma ray therapy when both are used.

In determining the amount of roentgen rays given, the percentage erythema dose on the skin given at each treatment is tabulated (Fig. 242). The proper depth dosage curve is then consulted (Fig. 243). Next the percentage of surface radiation delivered at the tumor depth for each treatment is calculated. The latter percentage is multiplied by the former percentage, which gives the tissue dose for each treatment. Finally, the total tissue doses given at all treatments are added.

When a radium pack is used in conjunction with roentgen rays, the percentage depth dose for the radium pack is added to the roentgen ray percentage depth dose.

The method of calculating the tissue dosage when radium or radon is used interstitially in terms of skin erythemas has previously been given (Fig. 242). As an example of interstitial radiation plus external radiation one might prescribe to a given tumor 7 skin erythema doses by the means of interstitial radiation, and 3 skin erythema doses by means of external radiation by roentgen rays. Thereby the total tissue dosage of radiation becomes 10 skin erythema doses.

A summary of the steps in calculation of the total radiation necessary to give a specified tissue dose when using interstitial radiation in combination with external radiation follows:

(1) The tissue dose is specified; (2) the amount of radiation advisable is decided upon; (3) the distance from the depth of the lesion to each portal on the skin for external irradiation is determined. From the proper curve (either roentgen rays or external radiation) for depth dosage, the percentage of the surface radiation delivered at the given depth for each treatment is determined. The percentage for each treatment is multiplied by the calculated percentage erythema dose on the skin. This result gives the tissue dose for each treatment. (4) The tissue dose obtained is subtracted from the superficial dose (1), and the remainder given by interstitial radiation. (5) The three dimensions of the lesion are determined; (6) what sphere or group of spheres to consider as defining it are decided upon; (7) for a single sphere the larger diameter of the mass is taken and from Fig. 241 the number of milligram hours or millicuries necessary to give the dose specified in (4) is determined; (8) for a group of spheres the number of milligram hours necessary to give the dose specified in (4) from data found in the column for the diameter of one sphere of the group. This figure is multiplied by the number of spheres. The result is the dose of interstitial radiation required (Lee, Pack, Quimby and Stewart).

IRRADIATION PLUS SURGICAL INTERVENTION

The fourth method of use is radiation (external and interstitial) in combination with surgical intervention. This method represents still another combination of weapons which in certain relatively radioresistant tumors may afford a more certain method of destruction. A radioresistant tumor in an anatomic location in which surgical excision is feasible may sometimes best be excised as an additional precaution against the persistence of a viable tumor focus after thorough irradiation. Berven has obtained 15 out of 20 three-year cures of cancer of the tongue by this method. Although the series is small, results the equal of these have not been reported previously. In a large somewhat radioresistant tumor, a lethal

dose of radiation may require a dosage too great for the patient to withstand. In such a situation it may be wise to radiate the tumor by external methods and then excise it, after which interstitial radiation may be employed at suspicious points. Finally, surgery may be required so that foci of radium may be properly implanted under more direct vision. This latter method often has decided advantages and will be described later under "surgery of access."

RADIUM APPLICATION

For the treatment of malignant lesions about the face, mouth and jaws, proper radiation methods sometimes may be selected with the expectation of being of value in three types of situations. In two other situations often radiation methods are advised. But in these fourth and fifth situations the hope of benefit has fostered a type of therapy which possibly borders upon the empirical and for which as yet exact evidence is lacking which would allow one to state its value definitely. First, in relatively radioresistant but superficial epidermoid carcinoma, the local lesion in varying percentages of instances according to factors of sensitivity, extent and location may be made to disappear permanently or for the time being. This statement, however, does not mean that the use of radiation always is the method of choice, as excision may be more efficient. Secondly, when metastatic glands have advanced to such a state that complete removal is not a feasible procedure, in a varying percentage of instances, considerable palliation may be given by the use of proper methods of radiation. Then, because no other choice as to method remains, the indication is obvious. Thirdly, in certain tumors it is possible to forecast with considerable accuracy by clinical acumen and microscopic study that the local new growth and its metastasis are of a radiosensitive type. In the three preceding situations, the position of irradiation is recognized as sound. For such tumors excision is not to be considered.

In the fourth and fifth situations slightly more amplification is necessary. Fourthly, radiation methods have been advocated for the tributary lymphatic glands as a prophylactic measure when the local lesion is an adult squamous-cell carcinoma. The theory of the amount of radiation necessary for lethality argues against the conception unless the original tumor was one of a radiosensitive type. Preoperative irradiation of the tributary lymphatic areas of the type theoretically capable of being lethal for such types of malignant cells that may be present (Coutard for instance) almost fixes the tissue of the neck into a fibrous mass so that a block dissection (which is the only type of treatment proved to be of value) may be extremely difficult or practically impossible. Besides this, a thorough "coutarding" is a relatively severe ordeal in itself, so the patient may be in poor condition for a neck dissection, or, when he appears to be in condition for the operation, it may be at a much later date, at which time it may be too late for the decision to be important. Either he will have evident metastasis or he will be well with no evidence of the disease for a sufficient number of months after the local lesion has healed to make it questionable whether the benefits to be derived are worth while under the circumstances. Fifthly, radiation methods have been advocated as of use postoperatively on the tributary lymphatic areas as an additional safeguard against recurrence in these areas. The same argument as to lethality is applicable to post-

operative irradiation as is applicable to preoperative irradiation. Whether or not postoperative irradiation is of value, further therapy is not handicapped as the procedure is the final one.

Many men are aware of the truth of the preceding statements about pre- and postoperative radiation treatment to the tributary areas, and still they advocate one or the other with the idea that the patient be given every possible chance.

The Local Lesion and Radium.—The local lesion of cancer reacts better to irradiation when there is little or no secondary infection. Therefore, before applying radium, it is undoubtedly better whenever feasible to have infections about the local lesion cleaned up as nearly as possible. When applying radium in the mouth, often it is wise to have any infections about the teeth treated and if metallic fillings are rather large or metal bridges are rather near the lesion to be treated, it is a matter of wisdom to remove them to prevent the effect of secondary rays. Often carious and loose teeth should be extracted before treatment is started. When teeth have been removed to improve the condition of the mouth, one should wait about three weeks for the cavity in the gum to form a granulation tissue wall.

Carcinoma Cutis.—1. *Basal-cell epithelioma* of the skin ordinarily reacts quite favorably to the application of radium. A dosage of from 3 to 4 skin erythemas or about 4000 to 5000 r is lethal. Both the roentgen ray and radium are effective. When radium is applied the dosage may be calculated as described for surface irradiation with radium according to the method of Paterson and Parker. A somewhat empirical dosage when using radium or radon seeds of moderate filtration is 100 mg. hr. per square centimeter of tissue to be treated at about ½ cm. distance. When a basal-cell epithelioma involves bone, radiation methods are likely to prove rather ineffective. As a rule, dependence upon an excision method with possibly postoperative irradiation in a dosage not sufficient to cause necrosis of bone will prove an adequate method of therapy. To a lesser extent the same may be said when the lesion involves cartilage. With care, however, in about one half the cases on such an area as the nose, the lesion may be healed by radiation methods with a lesser amount of deformity than excision methods will entail.

2. *Squamous-cell Epithelioma.*—Squamous-cell epithelioma of the skin, although quite radioresistant, usually can be made to disappear by external radiation methods. As the lesion is on the surface, a dosage of almost a cauterizing nature can be given either with the roentgen rays or by the application of a radium pack. A dosage of from 8 to 12 skin erythemas is required to be lethal for squamous-cell carcinoma as figured by the Memorial Hospital system. The dosage calculation of Paterson and Parker previously described explains the method of calculation for radium or radon. From 7000 to 8000 r to the lesion itself is required to be lethal. A somewhat empirical dosage when using radium needles or radon seeds of moderate filtration is 200 mg. hr. per square centimeter of tissue to be treated at about ½ cm. distance. When bone is involved, this high dosage is likely to cause necrosis. Excision methods or cauterizing methods are to be advised when such is the case. As a rule, the same is true when cartilage is involved.

Epithelioma of the Lip.—When the extent of the lesion is confined to the upper third of the lower lip, in the majority of cases the local lesion in epithelioma of the lip may be treated very effectively with radium (Fig.

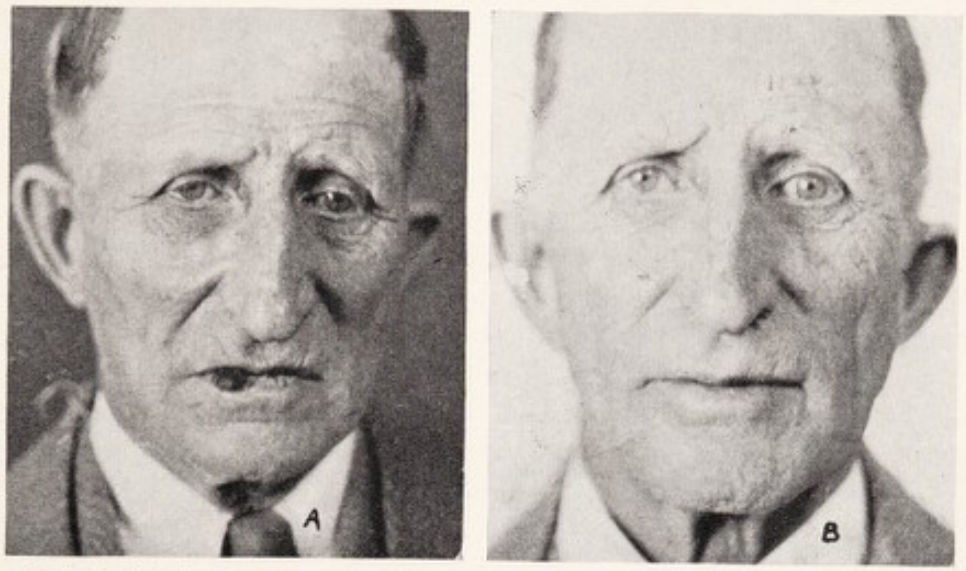

Fig. 244.—A, Patient with epithelioma of the lip before treatment. B, After treatment with radium. (Padgett, Radium Application in Oral Surgery, Internat. Jour. Orthodont. and Oral Surg., August, 1936.)

244, A, B). Both interstitial and external methods of application are used. It will be found that the lip lends itself particularly well to external application of radium unless the lesion has involved a rather large part of the

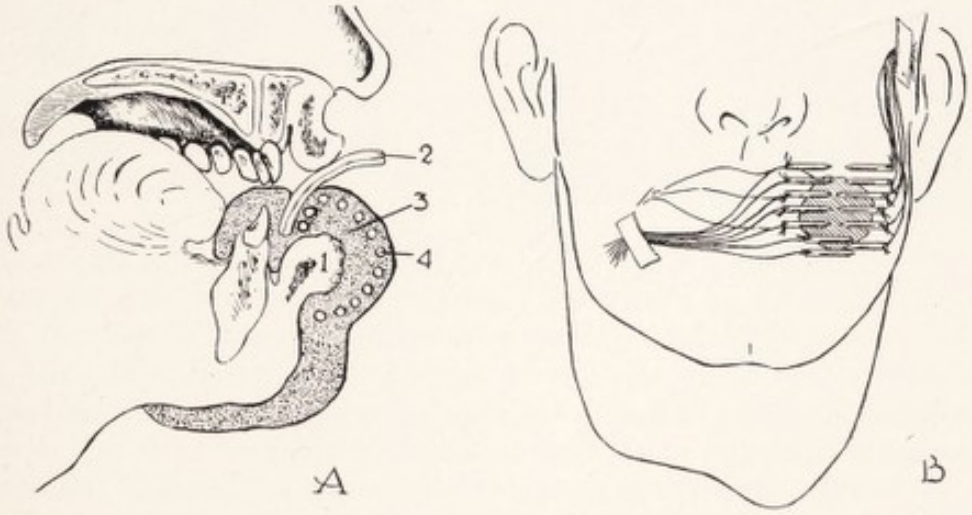

Fig. 245.—A, Sagittal section of the method of applying radium about the lower lip for epithelioma: (1) the lower lip, (2) two thicknesses of 1 mm. of lead, (3) modeling composition form, (4) tubes or needles of radium embedded in modeling composition. The needles may be somewhat closer to the lip than shown in the diagram if desired. This would depend somewhat on the filtration of the radium used. B, Diagram showing needles inserted into an epithelioma of the lower lip and the left corner of the mouth in interstitial fashion. (Padgett, Radium Application in Oral Surgery, Internat. Jour. Orthodont. and Oral Surg., August, 1936.)

soft tissues of the lip or has extended outward and involved the corner of the mouth. When radium is applied externally, the whole lower lip may be enclosed in a form (Fig. 245, A) and sandwiched between or nearly sur-

rounded by radium so that a cross firing is obtained. When radium is decided upon as the therapy of choice, radium implanted interstitially is likely to be the most effective way of making the application if the lesion involves a goodly part of the soft tissues of the lower lip or extends outward to the corner of the mouth (Fig. 245, B); but for the general run of relatively early cancer of the lip, surface radiation is regarded in most clinics as being superior to interstitial radiation.

To apply surface radiation ordinarily we pull the lip outward and surround it with a dental wax form in which the radium needles or tubes or radon seeds are embedded over the part of the impression compound which will surround the lesion. The wax is made to fit down over the lower teeth or the alveolar ridge and also to fit down over and beneath the chin. To guard the upper lip, the alveolar ridge and the tongue, two or three layers of lead 1 mm. in thickness are molded on the upper inner surface of the form.

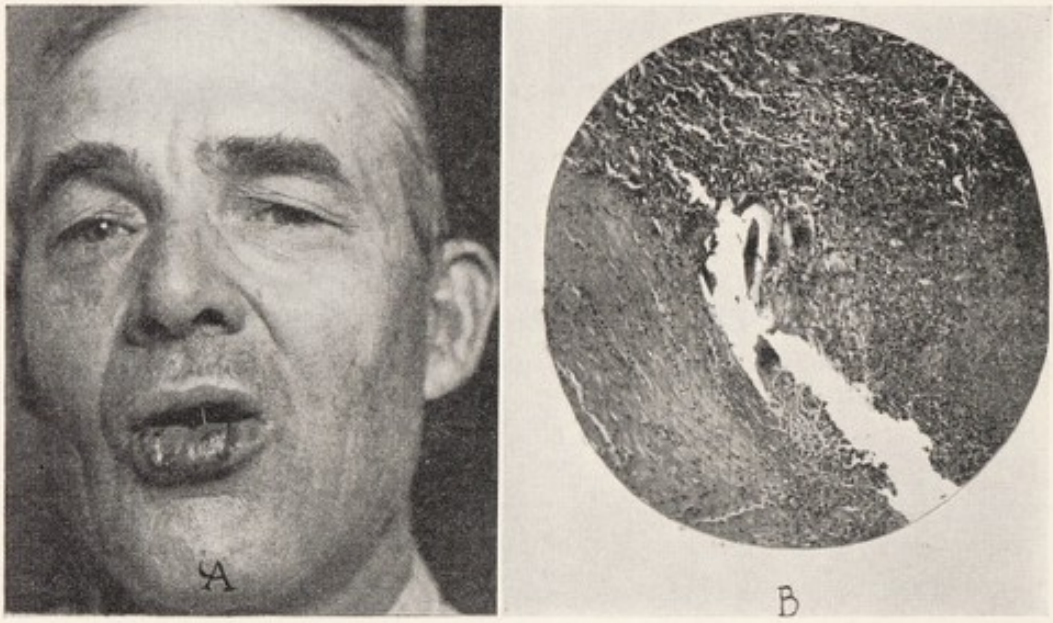

Fig. 246.—A, Patient showing a marked epithelialitis of the lip three weeks after application of radium as in Fig. 245. B, Carcinoma insufficiently treated by radium. Note the squamous epithelial cells and giant cells. (Padgett, Radium Application in Oral Surgery, Internat. Jour. Orthodont. and Oral Surg., August, 1936.)

The extension about and beneath the chin allows the form to be held securely in place by a bandage. An effort is made to get the lesion on the lip as far away from the alveolar ridge and the upper lip as possible. The calculation of a lethal dosage when the sandwich method of radiation is used was discussed in the early part of this chapter. At Memorial Hospital 80 mg. hr. per square centimeter of affected surface is given. In many instances, when platinum covered needles of moderate filtration are used, 100 mg. hr. are given per square centimeter of affected tissue.

About the lip when the interstitial radiation is used, the needles may be inserted (under local infiltration anesthesia) around and under the lesion in the normal tissues just outside the lesion as much as possible. But when the lesion is large and proper distribution of foci makes penetration of the lesion advisable, the needles should be inserted through the lesion; 0.5 mm. of platinum is an appropriate screening for needles and 0.3 mm. of gold for

the radon seeds. Usually the needles should be held in position by a passed stitch through the eye of the needle and the skin at the point of entrance of the needle. When interstitial radiation is used, calculation of dosage is made according to the method and table outlined earlier in this chapter.

The height of the radium reaction should develop in about three weeks. The lip becomes excoriated, is red and swollen. After six to eight weeks have passed most of the redness and swelling should have disappeared and the ulceration should have healed (Fig. 246, A, B). The treated tissue should be fairly normal by the tenth week. If any induration remains, or if healing is not complete after ten to twelve weeks, the lesion should be excised. In such a case, it is probable that viable carcinoma cells remain which eventually will become active.

Epithelioma of the Cheek.—The sandwich method of applying radiation treatment also is applicable to epithelioma of the cheek. Externally, radiation by either radium or *x*-rays may be used with an increase of effectiveness. Internally, either surface application (Fig. 240) or interstitial applications may be effective. When it is thought that the deeper structures of the cheek or the muscles of mastication have been involved, surface application is, as a rule, hardly adequate. Without the cheek Ward and Smith have advised that the external plaque contain 2.5 mg. per square centimeter with a filtration of 1 mm. of lead or the equivalent. They apply this at 1 cm. distance for fifteen hours on three successive days. Usually they consider a suitable plaque as being one 6 cm. in length with a total of 70 mg. distribution over its surface in such a manner as to get a homogeneous radiation. The application of roentgen rays is a very practical method of irradiating the outer cheeks. The dosage of external radiation is calculated after taking into consideration the dosage of internal radiation as described in the early part of this chapter.

When needles or seeds are used interstitially to irradiate the growth the principle is the same as that for interstitial irradiation elsewhere, but all effort should be made to protect the tongue, the alveolar ridge, and the ramus of the jaw. As a rule, the needles should be sewed in. When after careful dosage calculation such seems advisable, the needles may be left in place for a week if they are covered with 0.5 mm. or more of platinum.

Surface application of radium or radon to cancer of the cheek requires the mechanical ingenuity of a type which is especially the attribute of the dentist. The great difficulty one encounters is the construction of a mold which fits the cheek and bucco-alveolar sulci, gives the proper amount of filtration where it is needed, and at the same time within which the radium or radon can be evenly distributed over the proper area. We have used a lead form built as follows: a plaster mold or modeling composition form (Fig. 247, A, B, C) is made of the vestibule, the upper or lower alveolar ridges and the teeth. The form of plaster after it is wrapped in oiled paper surrounded by an additional thick layer of plaster is cut to allow the two halves to separate from the negative mold. After the cast dries molten lead is poured into the cavity between the two halves of the positive cast through a small hole. On the cheek side of the surface of the lead form with a knife or drill grooves are cut so that needles or seeds of the proper filtration may be distributed uniformly over and about the lesion to be treated. The lead form gives adequate filtration so that the tongue and alveolar

ridge will not react from the effects of the radium. The needles and the form are covered with shellac or bakelite. If one desires, with a metal saw he may cut off an outer layer of the lead and sandwich the radium between two layers of the lead at the proper points. The two layers of lead can be held together after being dipped in shellac. In this manner one may gain some distance and use the lead as an additional filter. The shellac also

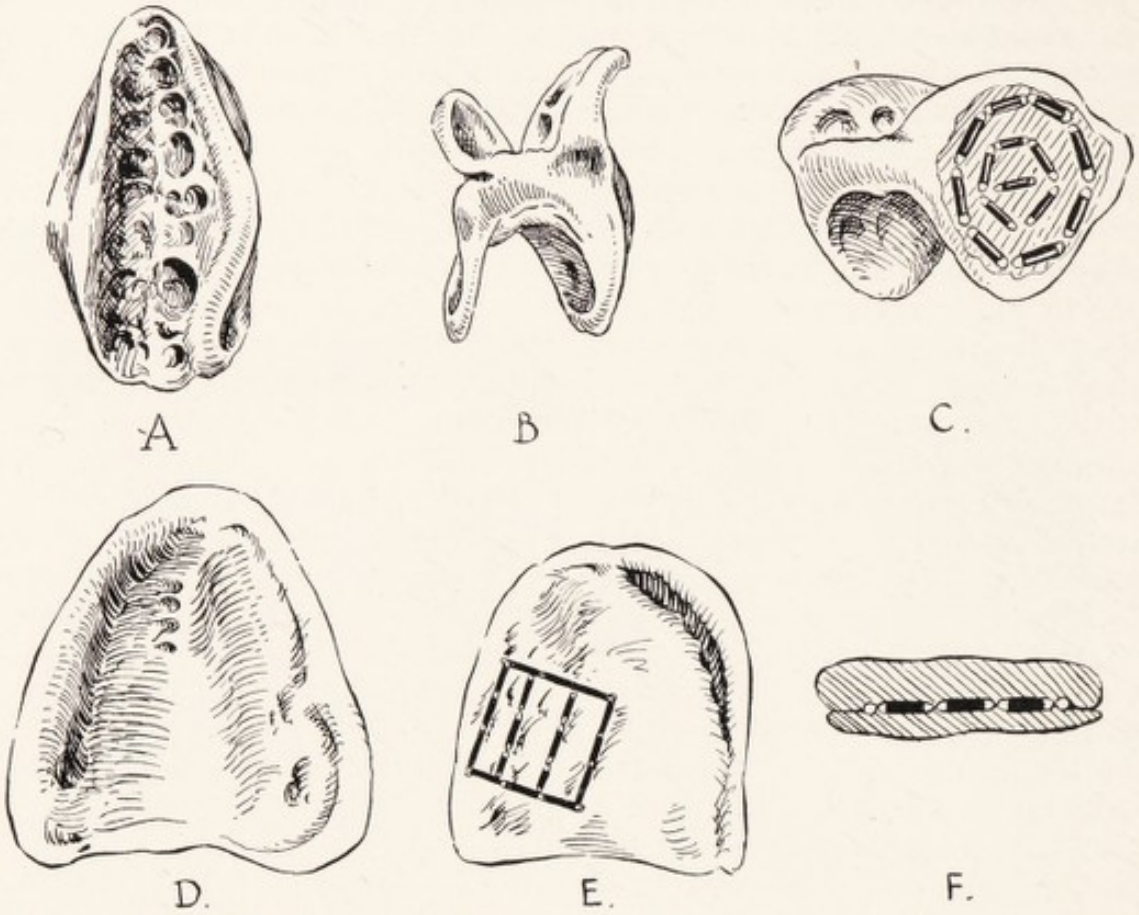

Fig. 247.—Lead form made to fit over the teeth, to conform to the vestibule, and to lie against the cheek. A, View of impression of maxillary teeth. B, Posterior view of the lead form. C, Lateral view, lateral side to cheek mucosa. Radium foci properly distributed. Foci are held in place by shellac. A small steel saw for cutting iron is used to cross cut a layer of lead from this side if one desires more filtration between the radium and the mucosa of the cheek. D, Positive of a cast of the palate. E, Thin lead plate which has been formed by tapping the lead plate with a hammer over the cast. The radium foci have been laid in their proper place in the proper distribution form. Shellac is used to hold the foci in place. F, Cross section of the lead layers with radium foci between the plates. The upper thicker layer (two 1 mm. layers) guards the tongue. (Padgett, Radium Application in Oral Surgery, Internat. Jour. Orthodont. and Oral Surgery, August, 1936.)

tends to absorb beta rays. Calculations are made as described in the first part of this chapter, for surface irradiation with radium.

After adequate treatment of the cheek the reaction should be quite severe and moderately painful. When the treatment is satisfactory, in from two and one-half to three months the growth should have completely healed. When residual ulceration or induration still is present after this period, excision is indicated.

Epithelioma of the Hard and Soft Palates.—The hard palate is covered by so little soft tissue that obviously it would be difficult to retain needles

in position for a week or longer. When interstitial irradiation is to be used, radon seeds have considerable advantage. But interstitial irradiation is not only difficult here but bone necrosis with perforation of the palate may result.

When using radiation methods, as a rule, growths of the hard palate are best treated by the external application of radium. Much less difficulty is encountered in making a lead mold which fits the hard palate than in making one to fit the cheek (Fig. 247, D, E, F). A negative impression of the palate is taken. From this a positive is made. Over the positive cast a layer of 1 mm. of sheet lead is beaten. Over the first layer a second layer is beaten and the whole is dipped in shellac or bakelite. The needles or seeds are sandwiched between the two layers of lead after grooves have been cut in one of the lead plates. Sufficient lead filter is placed on the side next to the tongue. The form is placed in the mouth as one would an upper denture.

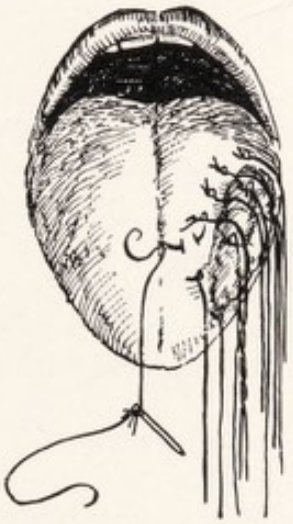

Fig. 248.—Inserting needles interstitially in malignant lesion of the tongue. The dosage would be calculated from Fig. 241. (Padgett, Internat. Jour. Orthodont. and Oral Surg., July, 1936.)

Excision by diathermy with coagulation of the underlying bone not uncommonly in our experience has been more likely to effect a cure than is the application of radium alone.

Interstitial radiation may be used to considerable advantage in the soft palate. Sufficient small needles or seeds are placed just outside and within the lesion. Care must be taken that they are not pushed into the nasopharynx. When both the hard and the soft palates are involved, a properly constructed molded intrabuccal applicator may be an efficient method of application but usually the soft palate is more efficiently treated separately by the interstitial method.

Epithelioma of the Tongue.—A general anesthetic facilitates a proper examination of the full extent of the growth in epithelioma of the tongue when the neoplasm is rather advanced or located posteriorly. In most cases the interstitial method of application of radiation is considered to be preferable to surface application. In applying interstitial radiation the proper number of needles or radon seeds are introduced around, below from the sides or through the growth so as to produce a homogeneous type of radiation (Fig. 248). When the foci are of low content, uniform distribution

is facilitated. When the growth is of some size, foci have to be interspersed within its substance and sewed in place with a separate suture besides the heavy string or fine wire placed through the needle eye to facilitate its removal or to prevent its loss. In the tongue particularly, needles are prone to become loosened during the administration of treatment.

When the involvement is well posterior, or posterior and lateral, it may not be possible to gain a correct distribution of the foci. In such a case, the foci of radiation, either needles or radon, should be inserted from below as good radium therapy depends upon accurate placement.

Also, because of the location, placement is likely to be inaccurate if made through natural anatomic channels. Some type of "surgery of access" exposure is demanded if accurate placement is to be attained. By passing a needle through the skin just above the hyoid bone, and at the same time

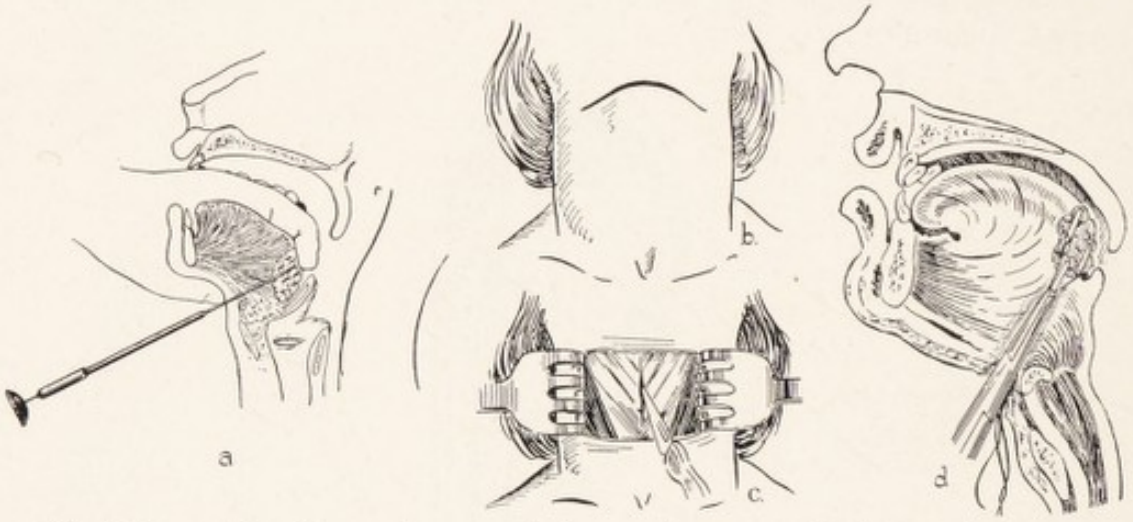

Fig. 249.—*a,* Inserting radium seeds in carcinoma at the base of the tongue. Surgery of access to the posterior tongue; *b,* crosswise incision above the hyoid bone; *c,* sagittal section in the midline of the tongue—raphe; *d,* insertion of radium needles into the area of malignant infiltration. The needles have a string attached to them and are placed in the area with the aid of a special holder which firmly holds the needle and guides it. A finger is inserted over the back of the tongue as in *a,* so that one inserts the needles by a sense of touch. After the needles are inserted, a small pack is placed in the wound, and after the needles have been in place for an adequate period of time—possibly a week—they are removed. After the pack is removed the needles are pulled out. (Padgett, Radium Application in Oral Surgery, Internat. Jour. Orthodont. and Oral Surg., August, 1936.)

with the finger in the mouth feeling where the needle will deposit the encased seeds, radon may be inserted in the posterior tongue region (Fig. 249, *a*). About 2 m.c. of radon is placed in each seed, and they are placed about 1.5 cm. apart. The filter ordinarily is 0.3 mm. of gold or its equivalent. (At the Kelly clinic a larger removable seed is used.) When one desires to use radium element in needle form (Fig. 249, *b, c, d*), by making a midline incision (crosswise in the skin and lengthwise in the tongue substance) needles may be inserted in the substance of the tongue through the incision with accuracy. The finger of the opposite hand placed within the mouth enables one to detect the location of the needle. The time of exposure is about one week when platinum-covered needles are used.

Ledoux advised a periosteal resection of the angle of the mandible with a part of the ascending ramus to aid in attaining accurate needle insertion

into the lateral tonsillar and pillar region and the posterior tongue. Ordinarily the procedure of Ledoux is hardly necessary. Ledoux recommends a filter of 0.5 mm. of platinum when radon seeds are used.

Although some workers advocate that one can insert radon seeds accurately through a direct-vision laryngoscope into lesions in this area (lower posterior tongue, lower posterior faucial pillar extending toward the pyriform fossa), in our experience accurate placement is likely not to be made. Seeds of radon are particularly advantageous about the anterior and upper part of the posterior faucial pillar and the lateral pharyngeal wall.

External radiation for the purpose of supplementing the interstitial radiation is a wise procedure in the more extensive growths. In this manner from 2 to 2½ skin erythema doses of radiant energy may be added to the dosage.

After radon is applied to the tongue, the patient is advised to stay quiet for a few days. When radium needles have been inserted the patient is hospitalized during the period that the needles are kept in the tongue. When some surgery of access has been necessary, the patient is kept in bed until a few days after the needles are removed. During treatment and for a time after, talking is discouraged, as the reaction will be fairly severe. Only fluids are given while the needles are in situ and the mouth is irrigated every four hours.

In about a week after the radium treatment, the tongue becomes coated with a yellowish diphtheroid membrane, swells and becomes red. The induration begins to diminish when a satisfactory reaction is obtained in about three weeks and after five or six weeks it should have entirely disappeared.

Too large a dosage of radiation may cause a necrosis. Syphilitic fibrotic tongues are especially liable to necrose. During and following a necrosis due to much radiation, the necrotic areas become painful. The excavation becomes covered with a dirty slough. The edges of the ulceration appear red and swollen. Then, the difficult point is to be able to distinguish between a necrotic excavation due to too much radium and a malignant ulcer which has failed to be influenced favorably by radium. In either case, it is probably best to excise the whole area with the diathermic knife. Excision gives one material for examination. If the ulcer is a radium burn, the pain tends to be relieved. In most instances a growth which does not disappear within two and one-half months should be excised by surgical means. The endothermic knife may be of material aid in excising the lesion in an efficient manner.

Epithelioma of the Jaw.—Epithelioma of the jaw itself ordinarily is due to secondary invasion. In most instances when the malignancy starts on the epithelium which covers the alveolar ridge, the bone is involved when the patient is first seen. Sometimes in metastatic carcinoma to the region of the submaxillary gland, the involved submaxillary lymph node is fixed to the periosteum of the jaw when the patient first appears for treatment. Not uncommonly the jaw bone is invaded by an epithelioma arising in the cheek or in the floor of the mouth. The bone often is invaded in advanced carcinoma of the lip.

Epithelioma involving the jaw bone almost universally fails to respond to radiation because of the nature of the tumor bed. This is the usual result

in spite of the fact that the density of the bone probably causes secondary rays to increase the local effect. Intense radiation of bone quite often results in a pain which may be quite unbearable. Besides, radiation sufficient to be lethal may cause complete necrosis.

In operable cases surgical methods which destroy a part of the bone are usually the only means offering a fair chance of a cure. In inoperable cases of epithelioma involving the jaw bones, external radiation is used for its palliative value.

Carcinoma of the Antrum.—Surgical excision for carcinoma beginning in the antrum offers little or nothing. Rarely does one see a patient live much over six months after complete excision alone. The anatomic situation of the antrum prevents adequate irradiation externally or intrabuccally. Operative approach for the purpose of insertion of radiation foci and drainage offers a comparatively good method of treatment. The

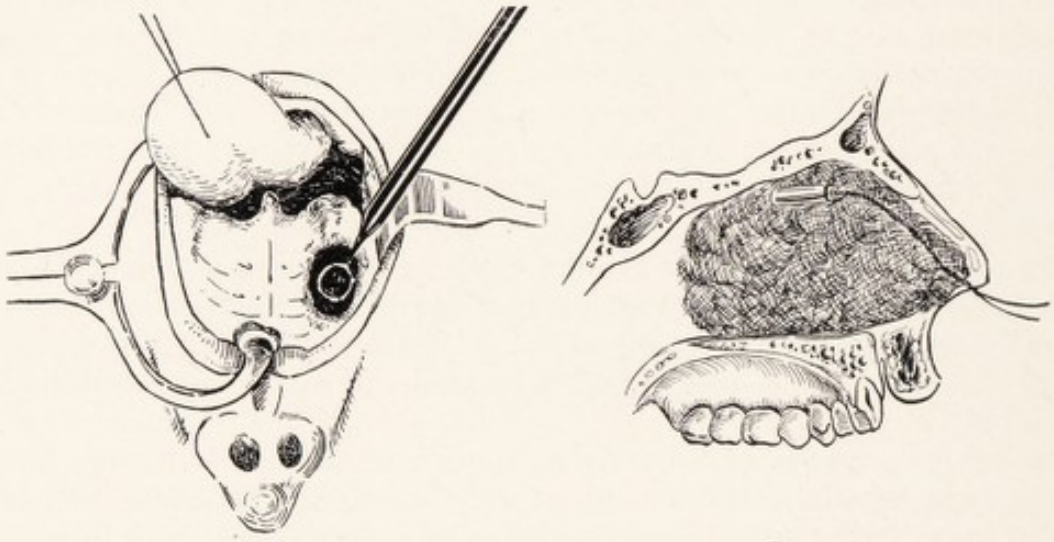

A *B*

Fig. 250.—*A,* Use of the diathermic loop to gain access to the antrum to cull out the malignant tissue in the cavity of the antrum. After this has been done, a coagulating current is turned on, and any involved bone is thoroughly destroyed by a process of coagulation. *B,* Tube of radium inserted into the nose in the ethmoid region. Gauze has been packed around the tube. The tube has been covered with rubber or aluminum foil. In antral cancer often there is an extension toward the ethmoid cells.

effectiveness of intracavity irradiation seems to be increased if a part of the total dosage delivered from the outside. In a sense neoplasms of the antrum are comparatively radioresistant. Two factors usually present have considerable bearing on this state of affairs: first, the antrum usually is secondarily infected; and secondly, the surrounding bone is involved relatively early. Moreover, besides these adverse factors, an overdose of radium in the antrum or even a lethal dose generally causes some radium necrosis of the surrounding bone.

When the tumor has not as yet shown any evidence of perforation into the mouth, a Caldwell-Luc operation may be performed (Chapter XVII). In carrying out treatment by this approach, the sequence of events is as follows: the anterior antral wall is entered, and at the same time a large opening is made into the inferior meatus of the nose. The antrum is examined. All tumor tissue that one can find is removed by the aid of the

loop diathermic knife. Radium is inserted within the antral cavity as indicated through the hole in the anterior antral wall.

Antral carcinoma tends to perforate into the mouth, through the alveolar process and the buccal alveolar sulcus of the palate. When such is the case, the following method of treatment is the most valuable one. With the diathermic knife a hole is enlarged through the site of perforation whether it be in the buccal alveolar sulcus, in the alveolus, or in the palate. With an endothermic loop, all soft carcinomatous tissue is scooped out. Some years ago a small soldering iron (Fig. 266) was often used for this purpose, but endothermic methods (Fig. 250, *A*) as developed at the present time are more graceful. The hemorrhage is less and danger of burning the inside of the mouth or tongue is less. With the endothermic loop it is much easier to see exactly what one is doing and to distinguish the line of infiltration of the tumor. When all visible malignant tissue has been completely removed, and any involved bone has been thoroughly coagulated so that it will sequestrate, radium needles or radon or radium in capsules surrounded with a gauze packing is inserted into the cavity. When the involvement extends to the ethmoidal region, it is wise to insert a tube of radium—10 mg. or so—through the nose to this region (Fig. 250, *B*). The dosage is computed according to the methods described in the first part of the chapter so that from seven to eight skin erythema doses are given from the inside, provided that it is intended two or three erythemas have been or will be given from the outside. As a matter of fact, the better plan is to give the external radiation preliminary to the internal application of radium. The external radiation is given in a dosage maximum for the skin by cross-fire methods. Harmer first stressed the value of preliminary external radiation before biopsy or internal treatment.

An adequate exposure is given by this approach. Good drainage is instituted. Although the cautery is used for destruction of a good part of the tumor, radium and *x*-ray are depended upon to kill the outlying cells. After the radium is removed, the cavity is irrigated, observed, and treated until all sequestra have separated.

Malignancy of the Nose and Nasopharynx.—The normal mucosa of the nose and the nasopharynx is very sensitive to radiation. A large dose of radium produces an atrophic rhinitis which, even if the tumor is cured, may be very disagreeable. The majority of tumors in this region are somewhat resistant. Nevertheless, the anatomy of the region handicaps adequate surgical excision so greatly that no choice remains but to depend upon radiation therapy for whatever chance of a cure the patient may have. It is probably wise to give a part of the radiation by external methods as in carcinoma of the antrum and, preferably, the external radiation should precede the application of the local radiation.

To treat a neoplasm of the nasopharynx by means of radium, either needles or cells made up into a small bundle or a small radium tube surrounded by the proper filter may be inserted up above the soft palate into the nasopharynx. A simple method of making the insertion is as follows: a catheter is passed into the nose (Fig. 251, C, D, E) back into the nasopharynx and down over the posterior edge of the soft palate until its tip is seen in the oropharynx. With forceps the tip of the catheter is caught and brought forward through the mouth. Two tapes are attached to the radium

which has been made up in a small package of the proper size and shape. The end of one tape is tied to the tip of the catheter. The catheter is then pulled out through the nose bringing the tape with it. By this means the package of radium is pulled into the nasopharynx above the palate.

When larger growths are to be treated, or when one desires a direct view of the lesion or operative attack is also planned (Fig. 251, A, B), the

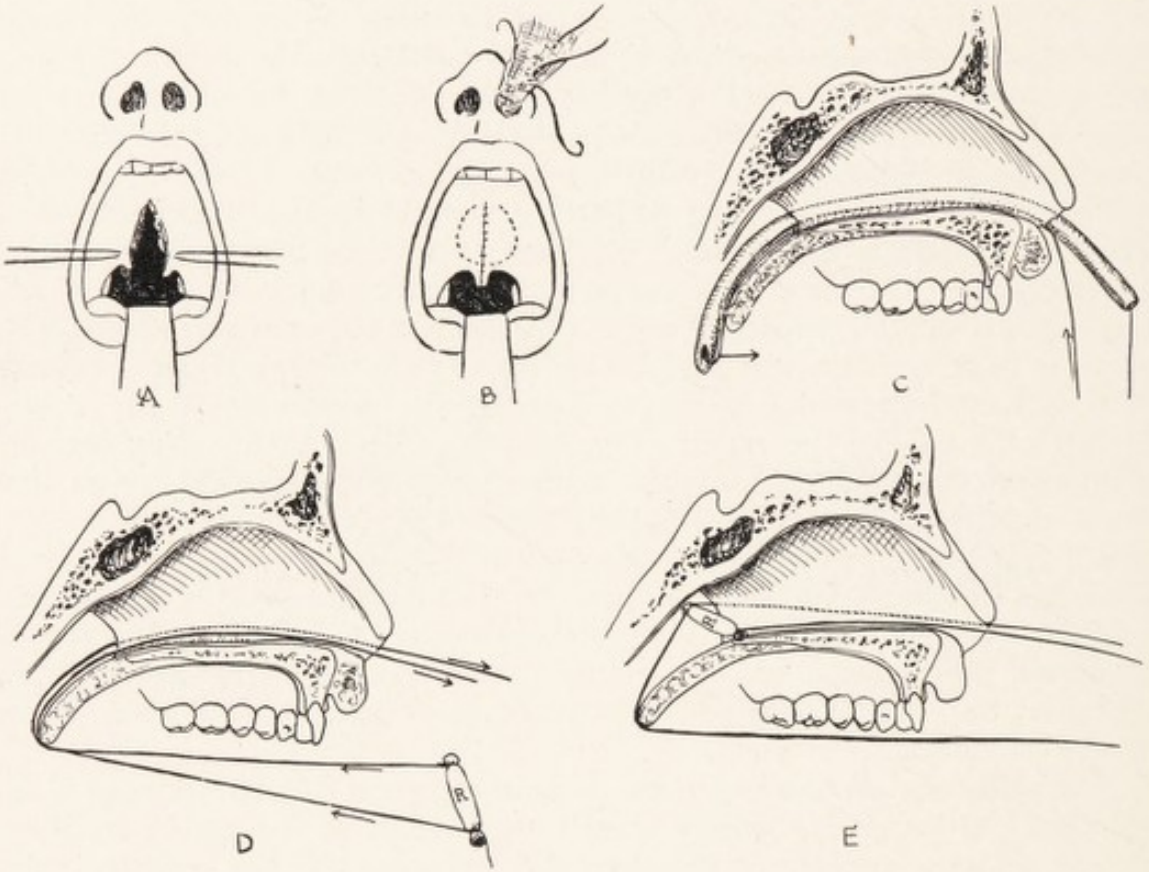

Fig. 251.—A, Method of splitting the soft palate so that direct access is given to a lesion in the vault of the nasopharynx. After access is given, the lesion may be attacked with the diathermic knife, loop, or radium foci may be inserted or laid over the lesion and held in place with a gauze pack. The strings attached to the radium needles or tubes along with the tail strip of the gauze pack are stuck out through the nostril. Several days later the two can be removed. B, Immediately after an operation or excision or the application of radium, the soft palate is carefully stitched together using suture for the mucosa above the velum and a Lembert type of suture which gives muscular coaptation as well as ventral mucosal coaptation. C, Method of placing radium tube in the nasopharynx. A catheter with a string attached is passed through the nose and pulled out through the mouth below the palate. The catheter is then pulled back out, and a radium tube attached to the string as shown in D. The string is tightened and pulled into the nasopharynx as shown in E. The string may be tied to the front of the lip if desired. (Padgett, Radium Application in Oral Surgery, Internat. Jour. Orthodont. and Oral Surg., August, 1936.)

palate may be split and the needle or radon seeds placed under direct vision. The soft palate unites well if properly repaired after this procedure. The approach allows the utmost accuracy in placement of foci of irradiation. A pack may be laid in above the soft palate to shield it somewhat. Later, it is removed through the nostril anteriorly.

Malignancy of the Tonsil, Faucial Pillar and Oropharynx.—To the tissues of the tonsillar, faucial pillar, or oropharynx region, a good part of

the requisite radiation may be delivered by external radiation. Coutard, as is well known, treats these lesions by external radiation (*x*-rays) entirely. At Stockholm, Berven uses mass irradiation (3-Gm. unit) externally and, if any residual growth remains, it is treated by interstitial irradiation or diathermy or both. Most clinics supplement the external radiation by internal radiation. This has been our plan.

When radium is to be applied internally, interstitial insertion is usually the more efficient method, although several men have devised rather complicated apparatus to give direct surface radiation from within in this region. Unless the area is definitely outlined and easily exposed so that there is no question concerning accurate distribution of the foci, one should not depend upon the internal insertion of the foci. Some surgery of access as described for the hypopharyngeal malignancy is likely to offer greater likelihood of allowing one to attain his objective, either total excision or the deliverance of a lethal dosage by irradiation methods. Ledoux of Brussels has advocated direct application of radium by access surgery after a primary resection of the angle of the jaw and part of the ascending ramus on the basis that the exposure is good and the danger of bone necrosis is eliminated.

Malignancy of the Hypopharynx.—It must be taken into consideration that the lesions in this region—especially in the pyriform fossa—are very radioresistant. Coutard's results by external irradiation for growths located in the pyriform fossa are the least favorable of any. When a cure is to be effected by radiation methods, a plan must be worked out which, theoretically at least, allows one to apply a lethal dosage as often the most intensive external radiation is insufficient and internal application of foci by interstitial methods is almost impossible because of the difficulty of gaining accurate placement.

Surgery of access may aid one in applying at least a dosage of radiation calculated to be lethal (Fig. 252). As one gains exposure of the lateral wall of the pharynx, a block dissection of the neck may be done if it is considered advisable. Often a block dissection at one time or another will be definitely indicated as not uncommonly it will be found that the glands of the neck already are involved. When neck dissection is planned, the internal jugular vein, areolar tissues, and lymphatic structures along the carotid arteries are removed from the lower neck to the mastoid process. The muscles over the thyroid cartilage and the greater cornu of the hyoid are removed. The alae of the thyroid cartilage and, if need be, the cornu of the hyoid bone are removed. By this method the danger of cartilaginous damage is eliminated and besides one comes down directly on the new growth. The mucosa beneath is palpated. When exploration would seem to offer more confirmation as to either the chances of excision or to aid in judging as to placement of the foci of radiation, the mucosa of the lateral pharyngeal wall is incised, after which a palpating finger is inserted within the pharynx. If the lesion is judged to be beyond offering a hope of cure if totally removed, the incision is closed. Needles or seeds are then laid or inserted along the side of the pharynx just external to the lesion. Until the proper time for removal, a gauze pack holds the needles in place. The main vessels are protected by the interposition of rubber.

In my experience, neither adequate knowledge of the extent of the lesion nor a proper distribution of the radon foci is obtained through the direct laryngoscope when the lesion is located in the hypopharyngeal region.

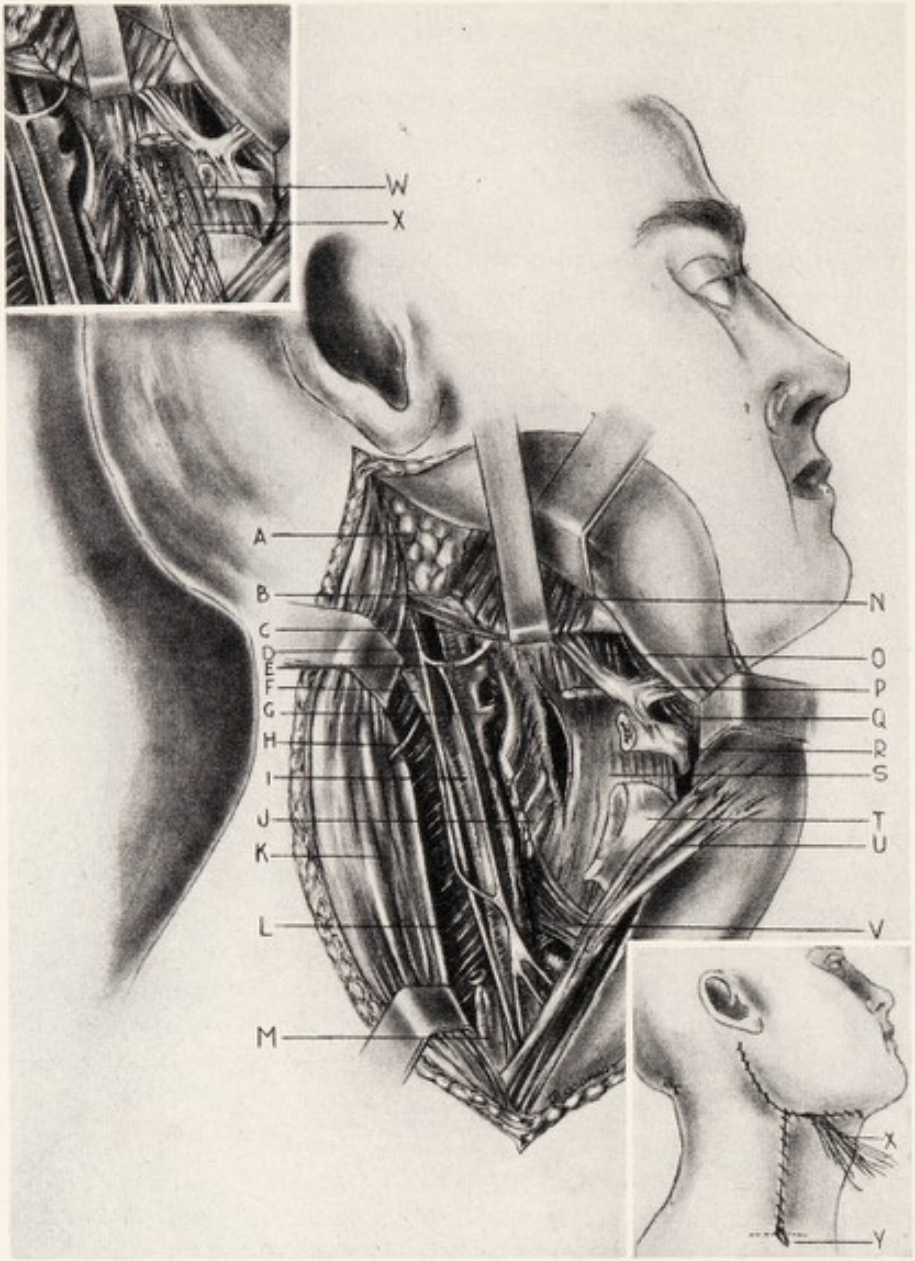

Fig. 252.—Approach to lateral pharynx. The deep lymphatic structures along with the deep jugular vein have been removed. The sternomastoid muscle has been retracted back. In the operation before the lateral pharynx is opened, the pretracheal muscles are stitched to the sternomastoid muscle. In certain patients the sternomastoid muscle is removed and a complete block dissection performed. The complete block dissection fits better with the operation in which one does not plan to open the lateral pharyngeal wall. After exploration one determines whether or not to excise the lesion. If radium implantation is decided upon, the lateral posterior part of the hyoid bone and thyroid cartilages are removed so that one can insert the seeds or needles under direct vision or by feel without fear of cartilaginous necrosis when a lethal dosage is given. The diagram in the upper left hand corner shows the needles in place with strings attached. In many cases the lateral pharynx need not be opened. The needles can be inserted by touch with one finger inside the mouth. The diagram in the lower right hand corner shows the strings of the needles projected from the incision after closure. A drain is placed at the lower end of the incision. A, Parotid gland; B, posterior belly of digastric muscle; C, external carotid artery; D, hypoglossal nerve; E, facial artery; F, internal carotid artery; G, superior thyroid artery; H, spinal accessory to the sternomastoid muscle; I, common carotid artery; J, inferior constrictor muscle of pharynx; K, sternomastoid muscle; L, deep muscles of lateral neck; M, deep jugular vein; N, masseter muscle; O, hyoglossus muscle; P, anterior belly of digastric; Q, mylohyoid muscle; R, thyrohyoid bone; S, thyrohyoid membrane; T, thyroid cartilage; U, pretracheal muscle; V, cricothyroid muscle; W, radium needles; X, strings attached to radium needles; Y, drain.

When surgery of access of the type described is contemplated as the method of caring for the local lesions in this region, it is a close question whether to give external radiation preoperatively or postoperatively. Enough external radiation to hinder the chances of implantation of loosened cancer cells but not enough to markedly fibrose the tissues of the neck is theoretically the ideal. When heavy external radiation is given preoperatively, the surgery of access may be very difficult. The wound may slough and, finally, the patient's general condition for an operative procedure possibly will have been unfavorably affected.

Malignancy of the Neck Glands.—When the lymph glands of the neck are involved by metastatic squamous-cell carcinoma and later complete removal would appear to be likely or even a possibility, as a rule they should be removed.

The matter of when to remove the lymphatic nodes of the neck and when not is discussed in a separate chapter.

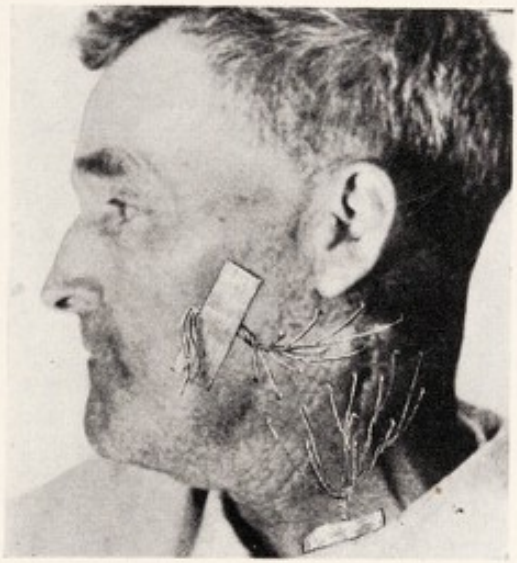

Fig. 253.—Applying interstitial radiation with radium needles to an inoperable metastatic lesion of the neck. (Padgett, Internat. Jour. Orthodont. and Oral Surg.)

When metastatic glands in the neck are beyond the possibility of a cure or even palliation by excision, the method most likely to give temporary palliation for a varying period of from six months to several years is the application of interstitial foci of radiation through the mass in a sufficient amount to be lethal from the theoretical standpoint (Fig. 253). For a part of the lethal dosage, external radiation by radium or roentgen rays may be used according to preference, the type of radiation available, and sometimes the location and extent of the lesion to be treated.

Some workers have advocated a partial exposure of the metastatic mass so that the foci could be inserted with more accuracy into the mass or laid directly upon it. Whenever it would seem that accurate localization of the foci was improbable or impossible, some surgery of access certainly would seem a wise procedure. In a considerable number of metastatic lesions of the neck, however, the size, position, and location are such that little is gained by turning back the skin or retracting a superimposed muscle.

When it is evident that the disease has advanced to a point where no hope of a long period of comparative freedom from symptoms seems probable, external radiation of a sublethal character theoretically and practically may be of some value. In such cases one hopes to make the patient more comfortable and, knowing his days are numbered, does not put him through the discomfort of the intensive radiation required when a lethal dosage for all the tumor cells is striven for.

Bibliography

Bibliography Quoted in Text

Radiation Therapy

Bergonne, Tribondeau, and Recamier: Action des rayons x sur l'ovaire de la lapine, Compt. rend. Soc. de biol., **58:** 284, 1905.

Berven, E.: Irradiation Treatment of Malignant Tumors of the Buccal Cavity, Acta Radiol., **13:** 213, 1932.

Radium Treatment of Malignant Tumors of the Oral Cavity, Deutsch. med. Wchnschr., March 4, 1932.

Broders, A. C.: Carcinoma Grading and Practical Application, Arch. Path. and Lab. Med., **2:** 376, 1926.

Cancer's Self Control, Med. Jour. and Rec., No. 3, Feb. 4, 1925.

Coutard, H.: Roentgen Therapy of Epithelioma of the Tonsillar Region, of the Hypopharynx, and of the Larynx, 1920 to 1926, Radiophys. et radiothér., **2:** 4, 1932.

Principles of X-ray Therapy of Malignant Disease, Lancet, No. 1, vol. 2; No. 5748, **227:** 1–8, 1932.

Principles of Roentgenotherapy, Lancet, **2:** 1, 1934.

Ewing, James: Factors Determining Radioresistance in Tumors, Radiology, **9:** 359, 1927.

Radiosensitivity, Radiology, **13:** 313, 1929.

Radiosensitive Epidermoid Carcinomas, Amer. Jour. Roentgenol., **21:** 313, 1929.

Glasser, Otto: The Physical Determinations of Radium Dosages, Amer. Jour. Roentgenol., **33:** 293, 1935.

Heublein: Quoted by Pack in The Principles Governing the Radiation Therapy of Cancer, Bull. New York Acad. Med., **2:** 347, 1935.

Kingery, L. B.: Saturation in Roentgen Therapy: Estimation and Maintenance, Arch. Dermat. and Syph., **1:** 423, 1920.

Lee, B. J., Pack, G. T., Quimby, E. H., and Stewart, Fred W.: Irradiation of Mammary Cancer With Special Reference to Measured Tissue Dosage, Arch. Surg., **24:** 339, 1932.

Lazarus-Barlow, W. S.: The Effect of Radioactive Substances and Radiation Upon Normal and Pathological Tissues, Tr. Internat. Cong. Med., London, August, 1913.

Martin, H. E.: Factors in Dosage Determination in Interstitial Radiation, Radiology, **13:** 338, 1929.

Martin, H. E., Quimby, E. H., and Pack, G. T.: Calculation of Tissue Dosage in Radiation Therapy, Amer. Jour. Roentgenol., **25:** 490, 1931.

Packard, Charles: Biological Effectiveness of High Voltage and Low Voltage X-rays, Amer. Jour. Cancer, **16:** 1257, 1932.

Paterson, R., and Parker, H. M.: A Dosage System for Gamma Ray Therapy, Brit. Jour. Radiol., **7:** 592, 1934.

Pfahler, G. E.: The Saturation Method in Roentgentherapy as Applied to Deep-Seated Malignant Disease, Brit. Jour. Radiology, **31:** 45, 1926.

Radiation Therapy in Malignant Disease With Special Reference to the Saturation Method, Illinois Med. Jour., **55:** 177, 1929.

Pfahler, G. E., and Vastine, J. H.: Irradiation Therapy in Cancer of the Mouth: Technique and Results, Radiology, **22:** 15, 1934.

Quimby, E. H., and Pack, G. T.: The Skin Erythema for Combinations of Gamma and Roentgen Rays, Radiology, **13:** 306, 1929.

Further Studies Upon the Skin Erythema With Combinations of Two Types of Radiation, Radiology, **15:** 30, 1930.

Quimby, E. H.: A Comparison of Radium and Radon Needles and Permanent Radon Implants, Amer. Jour. Roentgenol., **23:** 49, 1930.
Quimby, E. H., and Stewart, F. W.: Comparison of Various Sources of Interstitial Radiation, Radiology, **17:** 449, 1931.
Regaud, C.: Sur la suppression définitive du tissu thymique par la röntgenthérapie, Compt. rend. Soc. de biol., **72:** 253, 1912.
Wood, F. C., and Prime, Frederick: Lethal Dose of Roentgen Ray for Cancer Cells, J.A.M.A., **74:** 308, 1920.

Radium Application

Berven, E. G.: Development of Technique and Results of Treatment of Tumors of the Oral and Nasal Cavities, Amer. Jour. Roentgenol., **28:** 337, 1932.
Technique at Radiumhemmet in Treatment of Tumors Except Cancer Uteri, Acta Radiology, **10:** 1, 1929.
Coutard, H.: Principles of Roentgentherapy, Lancet, **2:** 1, 1934.
Roentgen Therapy of Epithelioma of the Tonsillar Regions, of the Hypo-pharynx, and of the Larynx, 1920 to 1926, Radiophys. et radiothér., **2:** 4, 1932.
Principles of X-ray Therapy of Malignant Disease, Lancet, No. 1, vol. 2; No. 5748, **227:** 1, 1932.
Harmer, D.: Radiotherapy in Cancer of the Upper Air Passages, Lancet, Nov. 14, 1931.
Diathermy Operation for Cancer of the Tongue, Brit. Jour. Surg., **15:** 661, 1928.
Radium Treatment of Carcinoma of the Larynx and Tongue, St. Bartholomew's Hospital Report, p. 113, 1927.
Radiotherapy for Cancer of the Nose and Throat (Murray), 1932.
Harmer, D., and Cade, S.: Maxillary Cancer, Brit. Med. Jour., Editorial, **2:** 496, 1933.
Harmer, D., and Finzi, N. S.: Radium Treatment of Intrinsic Carcinoma of the Larynx, Second International Congress of Radiol., Stockholm, 1928, Brit. Med. Jour., **2:** 886, 1929.
Radium Treatment of Intrinsic Carcinoma of the Larynx, Practitioner, **124:** 16, 1930.
Ledoux: Traitement Curie-chirurgical du cancer larynge, Le cancer, p. 100, 1924.
Ward, W. R., and Smith, A. J. D.: Recent Advances in Radium, Phila., 1933, P. Blakiston's Son and Co.

CHAPTER XXXIV

OPERATIONS FOR MALIGNANT NEOPLASMS OF THE SOFT TISSUES

WITHIN recent years surgery for accessible cancer in and about the oral cavity has been thrown on the defensive, but surgery still has a very definite selective place in the management of certain types of malignant conditions found in and about the oral cavity.

To facilitate description, in this chapter only the surgical treatment of the local lesion of oral cancer will be discussed. The care of the lymphatic areas to which the local lesion drains is as important a consideration as the care of the local lesion, but the discussion of their care is reserved for the following chapter.

Local Preparation of the Field.—Local preparation of the skin when excisional methods are to be practiced has been discussed in Chapter III. Preceding excisional methods in and about the oral cavity, the mouth should be placed in as good condition as is practical under the circumstances. Local tenderness may tend to preclude extensive manipulations but a brush can be used several times a day for a few days prior to treatment. Large metal fillings and bridges should be removed before radium is used. When it is considered wise to remove some of the teeth, at least two weeks should elapse before any extensive surgical procedure is attempted.

General Preparation.—Small local excisions where local anesthesia is used require no general preparation. When patients are dehydrated from lack of water and ill-nourished because of difficulty in eating, every effort should be made to correct the deficiency. Sedatives should be given when insomnia is present. When the patient is anemic, a blood transfusion or two should be routine. The patient will withstand a fairly heavy operative procedure much better if these general precautions are adhered to. Previous to operation, the usual preparatory sedatives for anesthesia, whether the anesthesia be local or general, are given as seems indicated for the procedure to be executed.

Position on the Table.—For local surface excisions the prone position with the head placed in a position which gives the operator good exposure should be used.

For small local excision in the anterior mouth the semisitting position is recommended by Whitehead. For excisions in the pharynx, very often the Rose position is acceptable. Blood tends to drain in the nasopharynx where it can be sucked away before aspiration into the trachea. For laryngectomy the chin should be well up and the head back with the patient lying prone. For lateral pharyngectomy, the prone position with the posterior shoulder slightly raised and the patient's head to one side is an acceptable position.

Anesthetic.—Lateral pharyngectomy, laryngotomy, and excision of a part of the anterior tongue, may be done under local anesthesia. In fact, almost any operation in this region can be performed under local anesthesia

and, in many instances, local anesthesia is the best. The operative mortality is less if one is an adept in using local anesthesia. In operations in the nasopharynx or where heat is used as in entering a carcinomatous antrum with a cautery, or when the patient is difficult to control, a general anesthetic is preferable and usually obligatory. When the surgeon does not have the temperament or the cleverness to give a good local anesthesia, a general anesthesia is preferable. The operations which require bone splitting or cauterizing usually require general anesthesia. Some surgeons prefer a general anesthesia of either vaporized ether alone or nitrous oxide, oxygen and vaporized ether, and believe that the results are as good as or better than when local anesthesia is used. Personally we prefer local anesthesia whenever it is possible to execute the operation with grace. The blood loss is less, tissue planes are more easily seen and defined and the patient generally gets the benefit of nourishment immediately after operation without nausea and vomiting (see Chapter XLII).

SURGICAL TREATMENT OF CARCINOMA CUTIS

Basal-cell epithelioma of the skin when located so that a disfiguring scar does not remain may be excised with very excellent results. The application of radiation when the skin alone is involved is also effective in practically all cases. The decision as to the type of treatment that is to be used depends upon the available facilities, the size, the location and the structures involved. When considering excision as a method of treatment, one must take into consideration that at least ¼ inch of surrounding good tissue in the smaller lesions should be excised. In the larger lesions at least 1 cm. of normal tissue should be excised with the lesion. When cartilage or bone has been invaded, irradiation methods are likely not to be effective. This is especially true when bone has been invaded. One sees certain individuals with involvement of the ear or the nose where the cartilage has been invaded who are apparently healed by irradiation methods. Ordinarily if the cartilage is involved, however, and especially if the disfigurement is only slight or a satisfactory plastic repair can be made, excisional methods may be considered the wisest therapy. When bone is involved it is best to use a method of complete excision or total destruction with such an instrument as the soldering iron or the coagulating diathermic electrode. In instances of bone involvement, one should not hesitate to be rather radical. The tendency is not to get entirely beyond the cancerous involvement.

Squamous-cell carcinoma of the skin also gives good results when excised widely. One should be rather radical. Radium in nearly cauterizing doses is also effective with the local lesion. About 80 per cent of the moderately early squamous-cell carcinomas of the skin and subcutaneous tissues properly treated by methods of excision or methods of irradiation are cured. When cartilage or bone is involved, irradiation methods are not to be chosen. Wide excision or destruction of the local lesion is here the treatment of choice.

Squamous-cell carcinoma of the skin does not metastasize so quickly as squamous-cell carcinoma within the oral cavity but, nevertheless, the patient runs a very definite chance of metastatic involvement. This, of course, depends upon the age of the patient and the size, duration, and location of

the lesion. Whenever possible, the tributary lymphatics should be treated on the same principles as described under the handling of the lymphatic nodes, which is completely discussed in Chapter XXXV. The tributary lymphatics should never be ignored. Whatever method of treatment is chosen, it should be based upon a consideration of all the factors in the case.

SURGICAL OPERATIONS OF VALUE FOR THE LIPS*

The statement has been made that surgery has no place in the treatment of the small or moderately-sized lesion of the lip but that extensive surgical excision of the lower lip with plastic closure must be resorted to in the bulky fungating and infected tumors which are sometimes found after neglect. The statement has also been made that V-shaped excision should never be used as the primary treatment. Although we own and use radium for the small lesions of the lip, we do occasionally do a V-shaped excision and consider that when properly done radium can in no way show a superior result. It has also been stated that in neglected massive growths where much normal tissue has been destroyed by replacement with tumor tissue, destruction of the disease by irradiation and later plastic repair is the safest procedure, and that the difficulty of plastic surgery in irradiated tissue has been overemphasized. In the former situation we believe wide operative removal and destruction are the better and more effective procedure. In the latter situation anyone who has tried to repair a defect cannot help but realize that, without interference with the blood supply of the soft tissue which either will have to be transplanted or will have to unite with other flaps, this type of surgery is tedious enough without adding anything advantageous to a procedure difficult enough at best.

The operative procedures described have all been used repeatedly in my own cases and in my hands have proved their value. Operations based upon the same principle would be applicable to the upper lip if it should be the one needing excision.

Historical.—It may be pointed out that cheiloplasty for cancer chronologically is one of the oldest operations. Celsus (born about 25 B. C.) refers to the operation. During the first half of the nineteenth century many more or less classical methods were developed. In 1859 Von Bruns described 32 methods by 52 authors (Martin). Bernard, Burrows and Saemann in 1853 described an operation in which full-thickness triangles were excised from the upper lip itself and discarded. The upper lip was narrowed thereby. The main part of the lower lip was then built by loosening and pulling the sides of the cheeks to the midline over the mandible. Stewart in 1910 modified this operation and today it goes under the name of the Burrows-Stewart operation. Usually the operation gives a very tight lower lip and the appearance as a rule is nothing to get excited about, to say the least.

In 1932 Martin described a further modification of this procedure which would appear to have the defect also of being likely to give a rather tight lower lip.

* A considerable amount of the material for surgical operations upon the lips is taken from an article published in the Journal of Orthodontia and Oral Surgery., **22**: 939–947, Sept., 1936.

V-shaped Excision.—For the small epitheliomatous ulcer, excision gives eradication of the disease locally in over 95 per cent of the cases (Fig. 254). With proper plastic repair, which is not difficult, there remains only a vertical hairline scar in the lip. The excision can be done under local anesthesia and does not necessarily have to be done in an operating room. It can be done in the office. The patient need not be confined to bed, and after a few days he may go about his ordinary work. A microscopic study of the whole of the disease can be made. The incision lines to either side of the growth should be from ¾ cm. to 1 cm. away from any sign of the disease. The incision cross cuts all layers of the lip. The coronary artery when cut is tied with fine silk or catgut. From the inside, sutures of catgut or silk are used for the mucosa and taken rather deeply so that deep approximation of the tissues is obtained. On the skin, fine silk or horsehair interrupted sutures are used, and careful approximation of the skin is obtained. A small gauze dressing may be sewed over the lip. This is removed in two days. The skin sutures are removed after five or six days. This procedure tightens the lower lip slightly but usually about 2 cm. or

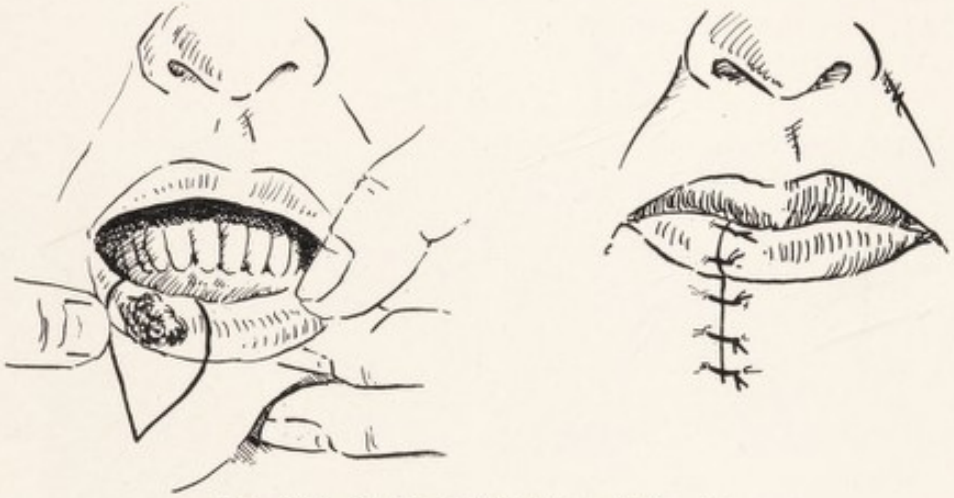

Fig. 254.—V-shaped incision of the lip.

even more of tissue can be removed in this manner without this being noticeable.

V-shaped Excision with Transplantation of a Flap from the Upper Lip.—When it is necessary to remove from one third to one half of the lower lip, it will be found that the lower lip is too tight if some additional material is not thrown into the lower lip. Estlander in 1877 described the principles of an operation which is quite applicable. A V-shaped excision may be done as described above. To fill the defect a similar flap is outlined at the outer border of the corresponding upper lip (Fig. 255, *a*, *b*, *c*) and excised in toto save for the narrow piece of tissue in which the coronary artery of the lip is located. The artery is left intact at the median corner of the flap. As the coronary artery is only about ⅛ inch from the border of the lip, practically all of the triangular piece of the upper lip is separated. The coronary artery will give a good blood supply when it is not injured. This upper triangle of lip is made about half the size of the triangle excised from the lower lip. All layers of lip are cut through. More mucosa than skin may be cut out if the lining of the lower lip appears likely to be inadequate. The upper triangle is then turned down into the lower lip and

sutured as described under V-shaped Excision. An additional tension suture is used to hold the cheek firmly to the upper lip, but it is placed in such a manner that the coronary artery which feeds the flap is not injured or constricted. The cheek may have to be reshaped to make the whole fit well. A very good appearing mouth and lip can be obtained by this procedure, and the scar is very slight. When the corner of the mouth is a little too near the midline, about twelve days later it can be extended out to the proper point by a simple outward incision. A few stitches are used



a

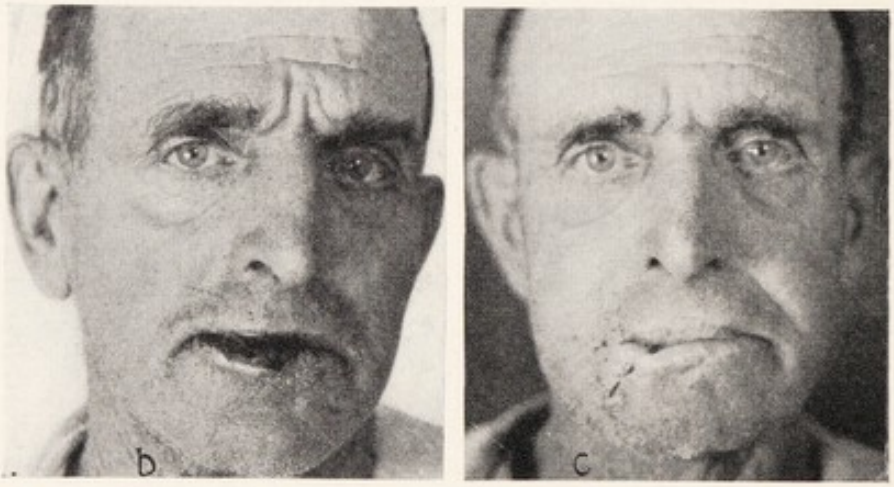

Fig. 255.—*a,* Amount of tissue excised and the amount of flap outlined in the upper lip for repair after wide excision of from one half to one third the lower lip. *b* and *c,* Patient before and after the operation shown diagrammatically in *a.* (Padgett, Internat. Jour. Orthodont. and Oral Surg., Sept., 1936.)

to draw the mucosa to the skin at the corner. The operation is done under local anesthesia as a rule, and the patient does not necessarily have to remain in the hospital more than a few days.

In Fig. 256, *A, B, C, D, E* and *F,* is shown a modification of the method of applying the principle of using an upper lip and cheek flap to aid in rebuilding the lower lip. In this second method the outer part of the lower lip is thrown toward the center of the lip to build the central part of the lip. The upper lip flap is used to build the outer corner. When the lesion on the lip is near the midline, this may be applicable.

Excision Which Removes about Three Fourths of the Lower Lip.—In case at least three fourths of the lower lip has to be removed, one flap from the upper lip will not suffice to make a lower lip of satisfactory width for good function. In several cases we have performed the following procedure (Fig. 257) which is only an extension of the preceding principle. By the use of this method in one operation a good lower lip can be built, which will appear well and function well. To build the central part of the lip the ¼ inch or so of lower lip left at each side is thrown to the midline. Then a flap is outlined at each extremity of the upper lip on both sides. The coronary artery in our cases has given sufficient blood supply for both flaps. Both of the upper lip flaps or triangles of tissue are now thrown

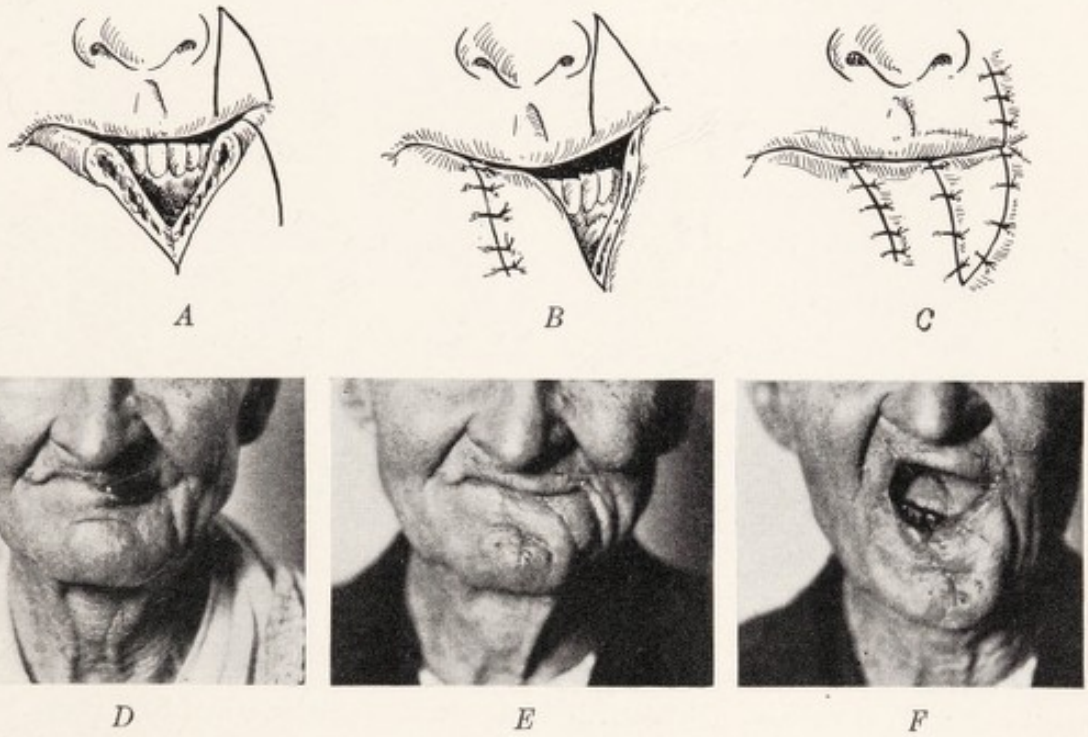

Fig. 256.—Method of repairing lip after about one half of the lip has been excised. *A,* Amount of tissue excised where flaps are shifted. *B* and *C,* Appearance of the lip and mouth after the outer part of the lip has been brought to the midline to form the central part of the lower lip, and the upper lip has been turned down to fill in the outer lower lip defect. Each flap is sutured as described in the text. *D, E* and *F,* Patient with carcinoma involving sufficient amount of lower lip to necessitate excision of one half of the lip, before and after operation shown diagrammatically in *A, B* and *C.* (Padgett, Internat. Jour. Orthodont. and Oral Surg., Sept., 1936.)

down into the lower lip region to form the outer part of both sides of the lower lip. Both the inner mucosa and the deep tissues and the skin are carefully sutured. After the operation the mouth is somewhat narrowed but, after the induration disappears, it will be found to stretch considerably. When too narrow, the mouth can be widened at the angles by an outward extension incision any time after about two weeks. This procedure has the advantage of allowing one to build a satisfactory, almost complete, lower lip in one operation. The operation is not very difficult to perform. It may be done under local anesthesia.

With this procedure an almost complete lower lip can be built (Fig. 258). When little or no part of the lower lip remains at the mouth angles, practically the whole of the lower lip may be built by bringing the two

triangular upper lip and cheek flaps down so that the two flaps are united, one with the other, in the midline without the interposition of any of the remaining lip as described in the preceding procedure.

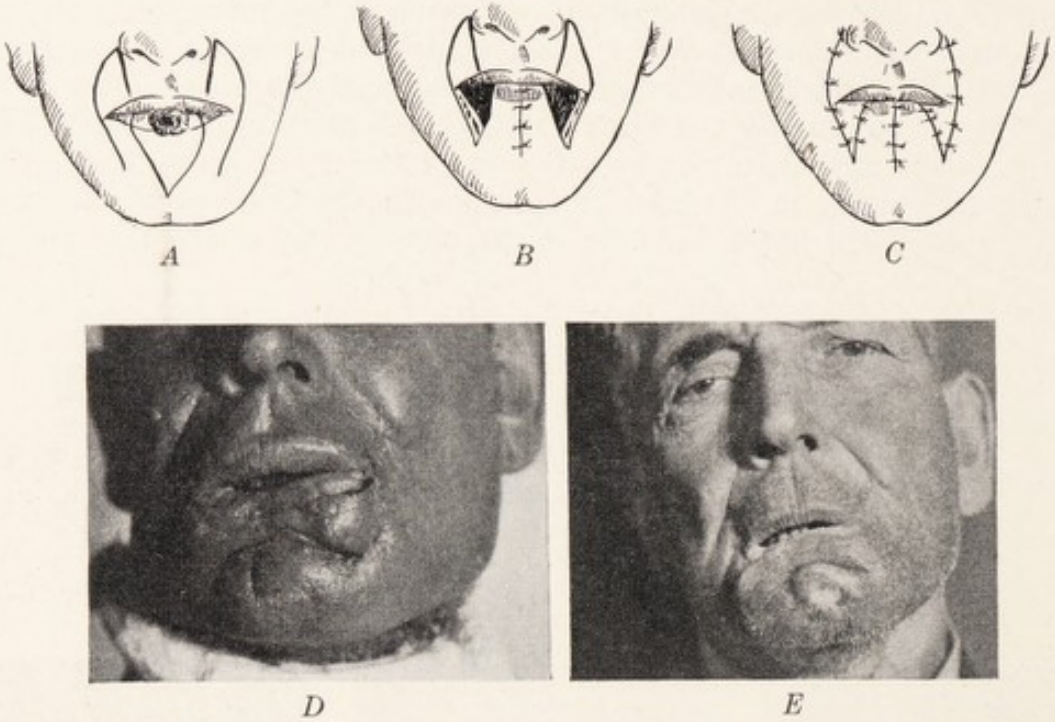

Fig. 257.—Method of repairing immediately the lower lip at one sitting after about three fourths of the lip has been excised. *A,* Lower lip shows amount excised. Upper lip shows outline of the two flaps which are to be thrown into the lower lip defect. *B,* Edges of the lower lip have been brought to the midline, but the upper lip flaps have not been thrown down. *C,* Lip and mouth after the flaps have been sutured into their proper position. *D,* Patient in whom the operation was done and from whom at least three fourths of the lower lip was excised—ten days after operation. A neck dissection was done. *E,* Same patient six months after operation. Note scar of collar incision of neck dissection. (Padgett, Internat. Jour. Orthodont. and Oral Surg., Sept., 1936.)



Fig. 258.—Method of replacing almost total lower lip by flaps from the upper lip. *A,* Outlining of a flap on the upper lip after the damaged tissue in the lower lip has been removed. *B,* Manner in which the flaps are thrown down to the lower lip and sewed in place. The deep sutures for the approximation of the deep tissue are taken from the inside presumably, and it is very important that the deep tissue be approximated.

The operation using two flaps from the upper lip to build the greater part or even the whole of the lower lip has several advantages. To us it has seemed the simplest method. No tissue is thrown away. A good lining is

given. The vermilion border is a normal one. The first time the operation was done, the question of blood supply to the flaps was considered. No difficulty from this source has arisen so far. The operation depicted in which a neck flap and a scalp flap are used is necessary for repair when the destruction has been greater than the whole of the lip.



A *B* *C*

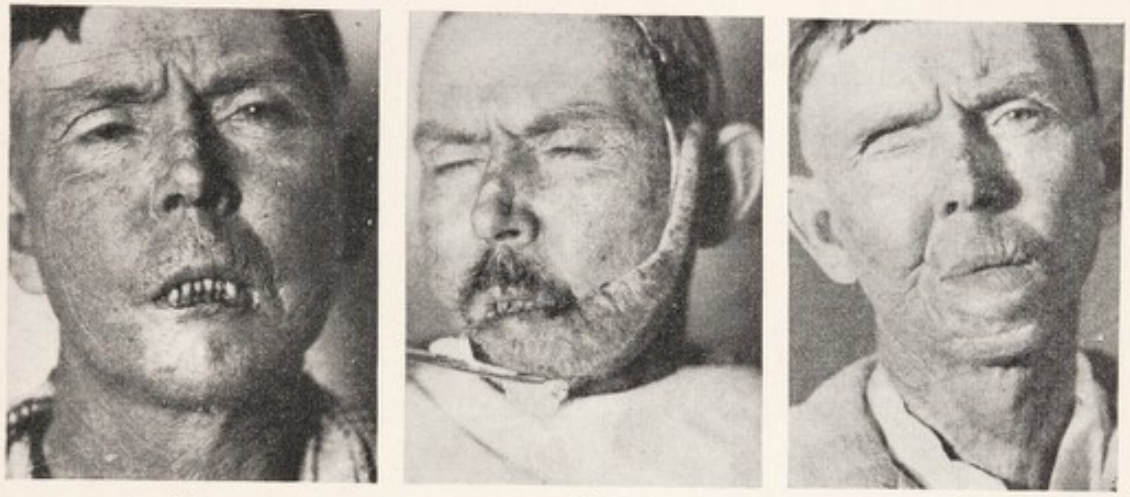

D *E* *F*

Fig. 259.—*A*, After complete removal of the lower lip with thorough cauterization of the anterior part of the mandible. *B*, Method of turning the flap from the neck behind the scalp flap to reline the lower lip. *C*, Flap turned up to reline inside of lip as shown in preceding diagram. The flap from the forehead *B* has been turned down to cross lap the flap *A*. *D*, *E* and *F*, Method of rebuilding lower lip after it has been totally destroyed. A neck flap combined with a scalp flap are used. *D*, Patient on whom cauterization was done a year after the sequestration has been removed and the chin has scarred over. The teeth ordinarily would have been removed or have been a part of the sequestrum. In this case the cauterization was done elsewhere eighteen months before the photograph was taken. *E*, Procedure when the scalp flap is thrown down to the chin. A full-thickness skin graft from the abdomen has been thrown into the defect. *F*, Patient six months after rebuilding of the whole lower lip and chin region. (Padgett, Internat. Jour. Orthodont. and Oral Surg., Sept., 1936.)

Complete Removal of Chin and Lower Lip Area and Repair.—When it is necessary to remove the lower lip, soft tissues of the chin and possibly a part of the cheek completely, it is also, as a rule, necessary to cauterize the front part of the mandible because as a rule the periosteum or even the bone is found to be invaded (Fig. 259). The coagulating diathermic current or the soldering iron as preferred is used to kill a part or nearly the whole thickness of the front of the mandible. After about two months the dead bone will have sequestrated and separated. The sequestrum is

removed by simply pulling the dead bone off with some instrument of the rongeur type, if it does not fall off by itself. Usually one should wait from six months to a year after the primary operation before starting to rebuild the lower lip to see whether there is going to be an early recurrence. There is no reason for putting the patient through such extensive reparative procedure until one is reasonably sure that local recurrences are unlikely. The lower lip is then built by using a flap of skin from the neck which has little or no hair on the part to be used, and a flap from the scalp which may have advantageously a good growth of hair. The neck flap is used for the inner lining. The scalp flap is used for the outer covering. The neck flap is tubed about two weeks before it is planned to transplant it and the scalp is outlined and resutured in place at the same time. After two weeks, the flaps are thrown into their respective positions and are well sutured. About three weeks will elapse before a sufficient blood supply is obtained so that the flaps can be cross cut and sutured in position on the opposite side of the mouth. The pedicles of the flaps at this time are sutured back into their former positions. In the area from which the scalp flap is removed, a full-thickness skin graft from the abdomen is sutured at the time the scalp flap is thrown down to the lower lip region. On the neck the skin is drawn together beneath the tubed flap at the time of tubing the neck flap. Later it is reopened partially and the pedicle of the flap resutured into its former bed.

To imitate the vermilion border of the lower lip, the neck flap must needs be turned so that a sufficient amount shows along the upper border of the new lip. The hair of the scalp prevents it from being used for this purpose. As the new part of the lip has no sphincter muscle, it will sag in the center if it is not drawn very tightly from cheek to cheek. As a rule, after a period of several months because of softening and stretching of the new tissues, some of the new lip has to be excised to make this tightening more complete. Although this operation is a large one, it should go from step to step without any mishap. It gives a satisfactory lip. If one wants to be a little fancy, mucosa from the cheek can be thrown over the upper edge of the lower lip to imitate the normal vermilion border of the lip. This little trick is not so easy as it might appear, as a rule. It is difficult to get the mucosal flaps long enough, *i. e.*, to preserve their blood supply at the distal ends. With care, it can be done, however. The flaps may have to be either delayed or tubed before final transplantation to the lip.

OPERATIONS COMMONLY PRACTICED*

Operations for Cancer of the Tongue.—At the present time, the following operations are useful in the management of cancer of the tongue: (1) V-shaped excision, (2) excision of a varying portion of the tongue through the mouth, (3) partial bilateral excision of the tongue through the mouth, (4) lateral submandibular excision of the tongue.

V-*shaped Excision.*—The so-called "V-shaped excision" of a neoplasm of the tongue is not uncommonly indicated (Fig. 260, *B*). The operation is especially useful for small and medium-sized neoplasms situated in the

*A part of the subsequent material on operations commonly practiced about the oral cavity is taken from an article published in the International Journal of Orthodontia and Oral Surgery, **22**: 1040–1053, Oct., 1936.

anterior part or on the lateral border of the tongue. The whole of the lesion is obtained for study and little or no deformity follows.

As the incision should be 1 to 1½ cm. from the outermost border of a carcinomatous growth, it is only applicable at an early stage.

The tongue is drawn forward and to the opposite side. The cheek on the side of the lesion is retracted. The proposed incision is outlined on the tongue. Heavy silk sutures taking in all layers of the tongue 5 mm. beyond the line of incision are placed as needed, crossing from one side of the proposed incisions to the other. Two long, narrow-bladed, toothed hemostats are placed in a V-shaped position, held snugly but not clamped down. The V-shaped piece of tissue is excised. The sutures are drawn together and tied.

Excision of a Varying Unilateral Portion of the Tongue Through the Mouth.—When the lesion to be excised is too large or not located in the proper position to make a V-shaped excision of the preceding type, a larger portion of the tongue may be excised along with any adjacent tissue which

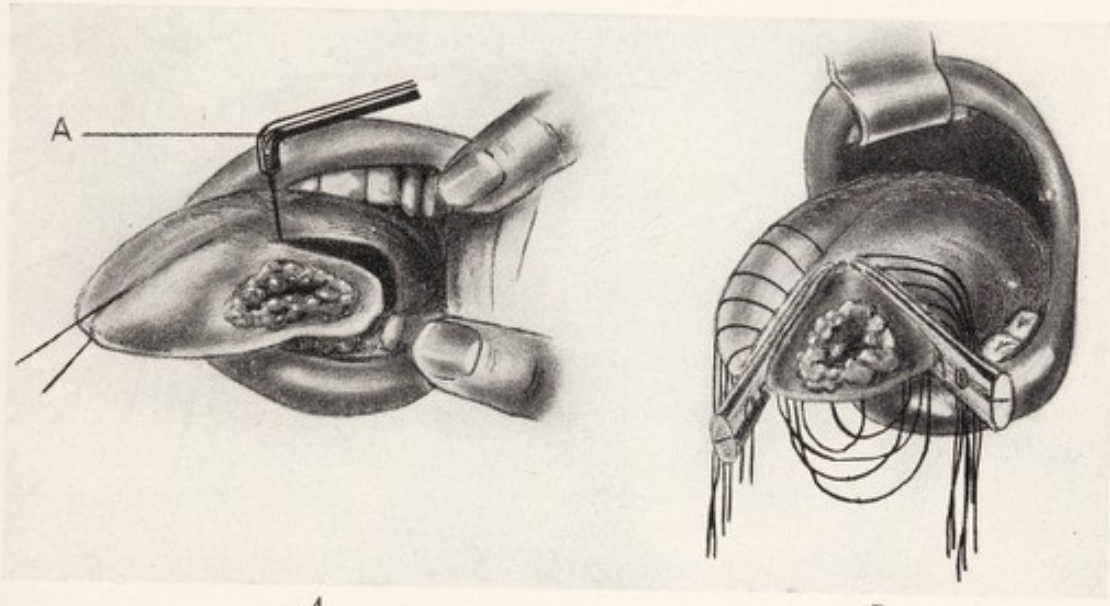

A *B*

Fig. 260.—*A*, Method of excising carcinoma at the edge of the lateral border of the tongue with a diathermic needle. *B*, Method of doing a V-shaped excision of the tongue for carcinoma.

may be involved (Fig. 260, *A*). The indications for such an excisional procedure most often follow the application of radium where one is in doubt as to the effectiveness of the previous treatment and wishes to add a local excisional procedure as an additional precaution or to excise a suspicious induration or ulceration for therapeutic purposes or for diagnosis, but it may be indicated primarily when the tongue shows evidence of an old fibrotic lesion as well as an epitheliomatous ulcer.

Of course, the greater the amount of tongue removed, the greater the resulting deformity. After more than one third of the lateral half of the tongue is removed, an increasing interference with tongue mobility is to be expected. Following an operation which approaches hemiglossectomy, the tongue becomes bound down in the floor of the mouth and interference with speech and also with swallowing is considerable. When a complete hemiglossectomy is done, the disability may be as great as after a complete glossectomy.

The Operation.—In small lesions local anesthesia is sufficient. In larger lesions intratracheal anesthetic is often preferable, as the pharynx may be packed off so that one can use the diathermic loop or the cautery knife without danger. In the large lesions the Rose position is preferable, as there is little danger of aspirating blood. A suction apparatus is used to keep the field dry.

A gag is inserted between the jaws, and the tongue is drawn forward by means of a ligature near the midline in the substance of the nondiseased half. The incision is made through the mucous membrane on the upper and lower surfaces of the tongue. The undiseased portion is pulled to the unaffected side. The diseased tissue is widely excised en bloc, cutting through the affected side posterior to the lesion. One must always take a sufficient depth—at least 1 cm. of normal tissue. The lingual artery is



A *B*

Fig. 261.—*A*, Carcinoma involving the anterior tongue and slightly into the floor of the mouth. *B*, Method of excision from within the mouth with a diathermic loop and cauterization of the inner side of the mandible in one area. If the involvement extends to the hyoglossus muscle, such an excision would be indicated. The involved tissue has been removed by a diathermic loop, coagulation current, or soldering iron. The alveolus is completely destroyed along with about one half of the mandible. Only the lower edge of the mandible remains viable.

caught and a ligature tied about it. Other bleeding points are tied. Usually it will be deemed inadvisable to attempt primary repair. Thus, as a rule, the wound is packed with gauze which may be held in place by 2 or 3 stitches over the top to whatever structures are available—tongue tissue or teeth.

Excision of Carcinomatous Mass of Tongue Through the Mouth.—Occasionally one sees a bulky infected fungating carcinoma involving the anterior part of the tongue and possibly some of the floor of the mouth where a partial bilateral excision may be of value (Fig. 261, *A*, *B*).

The operation should not be made an anatomic procedure with disregard of the pathologic involvement. What one actually does is to remove the part of the tongue involved and any of the floor of the mouth which may be involved; and, if involved tissue approaches the inner side of the mandible, it is thoroughly cauterized so that the inner part is caused to

sequestrate. The submaxillary duct is avoided if possible. First, the indurated area is outlined at least 1 cm. from the edge of the neoplasm. If one wishes to remove part of the floor of the mouth, the mucosa and subjacent tissues are pushed to the midline on either side until the outer surface of the geniohyoglossus muscle is freed as far forward as the origin of the genial tubercles at the symphysis. The lingual veins may be cut in doing this, and the lingual nerves are divided. If the mylohyoid muscle is involved, the operation is not indicated, but other tissues of the floor of the mouth such as the sublingual and intra-oral part of the submaxillary gland may be removed. The diseased tongue is now drawn upward and the geniohyoglossus muscle made tense. The muscle may be cut across close to the genial tubercles if need be. The affected part of the tongue is now drawn well forward, and the tongue is cross cut through the muscles attached to

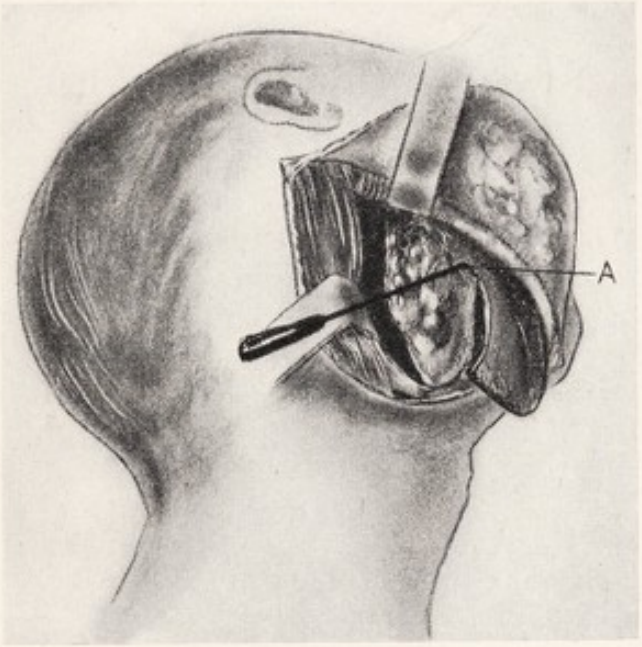

Fig. 262.—Lateral submandibular approach. (Kocher.) The oral cavity has been entered from below to the inner side of the mandible and the tongue has been pulled out through the side of the mouth so the malignant lesion can be excised. The tissues of the submaxillary triangle had been removed previously as a submental dissection en bloc has been done. A, Diathermic needle for cutting the lesion with a good margin of normal tissue of the tongue.

the base from the lower to the dorsal surface at least 2 cm. beyond the posterior border of the growth. The lingual arteries are watched for and if possible are secured before being cut. The artery lies near the midline. It should be approached by shallow cuts. All bleeding points are tied, and in some instances a row of mattress sutures across the cross cut end may aid hemostasis. Now if one deemed advisable, a pack containing radium may be inserted into the cavity.

Lateral Submandibular Approach (Kocher).—This operation is ideal from a surgical standpoint in that the closest tributary lymph glands and the local lesions are removed at the same sitting, but it has the disadvantage that the mortality is somewhat increased by the double procedure (Fig. 262). When the side of the tongue and the floor of the mouth or solely the floor of the mouth are involved in the local epitheliomatous ulcer and it lies

in apposition or is attached to the inner side of the mandible primarily, an excisional method of this type may be the better type of treatment. The operation may also be indicated subsequent to deep therapy with radium when the result is questionable or unfavorable.

When the floor of the mouth is involved as well as part of the tongue, this approach will allow adequate excision through the lateral floor of the mouth and adequate destruction of internal surface of the mandible or even excision of a section of the bone if such be required. On the other hand, the destruction of a part of the mandible involves the spontaneous separation of a sequestrum which prolongs convalescence for at least two months. Immediate resection of a portion of the mandible adds about 10 per cent more risk to the operation. When there is any evidence of metastatic involvement of the nodes other than the submaxillary nodes, the upper deep cervical nodes may be removed or the remainder of the neck dissection may be completed at a later date.

The Operation.—The operation when done under local anesthesia entails less risk for the patient. The incision begins below the mastoid and extends down along the anterior border of the sternocleidomastoid muscle and then forward below the hyoid, curving upward to the submental region. The skin flap without platysma is turned upward to the mandibular border. When the carcinoma is small, the exposure need not be more than two thirds of this incision. The tissues of the submaxillary and submental triangles are dissected upward en bloc so that the digastric and mylohyoid muscles are exposed. The facial artery and vein are ligated above the digastric tendon. The submaxillary gland is then pulled upward. The facial artery and vein are ligated as they cross the mandible above the gland. The soft tissues along the border of the mandible are freed. The outer surface of the mylohyoid muscle is exposed with its nerve lying in it. The muscle is divided parallel with the jaw. The mucous membrane up to the floor of the mouth is likewise cut parallel to the mandible. The tongue may now be dragged out of the floor of the mouth. The tumor is excised along with a border of normal tissue. When the jaw is involved, a section is removed or the inside is thoroughly cauterized with a soldering iron or diathermic plate (Fig. 261, *B*). The amount of the excision of the tongue is determined by the extent of the disease. When the submaxillary glands are involved with carcinoma, if the patient's condition warrants it, the upper deep cervical glands should also be removed by partially cross cutting the sternomastoid muscles and exposing and ligating the deep jugular vein and removing the upper part along with the areolar tissues about the carotid bifurcation and well up above the lower pole of the carotid gland. If thought advisable, the lingual artery is exposed and ligated by separating the fibers of the glossus a little about the posterior part of the greater cornu of the hyoid bone. The hypoglossal nerve and the lingual vein are preserved. When the operation extends posteriorly, a tracheotomy may be necessary either preliminary to or at the time of the operation.

The wound is packed with a Mikulicz pack with the pedicle of the pack sticking through the central part of the incision in the neck. Radium may be laid in the pack if one prefers.

Total Removal of the Tongue Through the Floor of the Mouth.—Once during the past five years a patient was seen in whom irradiation methods

had failed, and the posterior tongue and the floor of the mouth were rather widely involved without neck metastasis, and in this case we did a total removal of the tongue through the floor of the mouth. Indications for this operation at the present time will be met only in the rarest of occasions. Therefore, it is not necessary that it be described in detail. Essentially it consists of a submandibular collar incision, ligation of the branches of the external carotid and a cross section of the tongue just above the epiglottis and removal of it and all the tissues of the floor of the mouth.

OPERATIONS UPON THE LOWER JAW BONE FOR CANCER

For cancer involving the lower jaw bone, the following procedures may be indicated: (*a*) resection of a segment of the mandible; (*b*) cautery

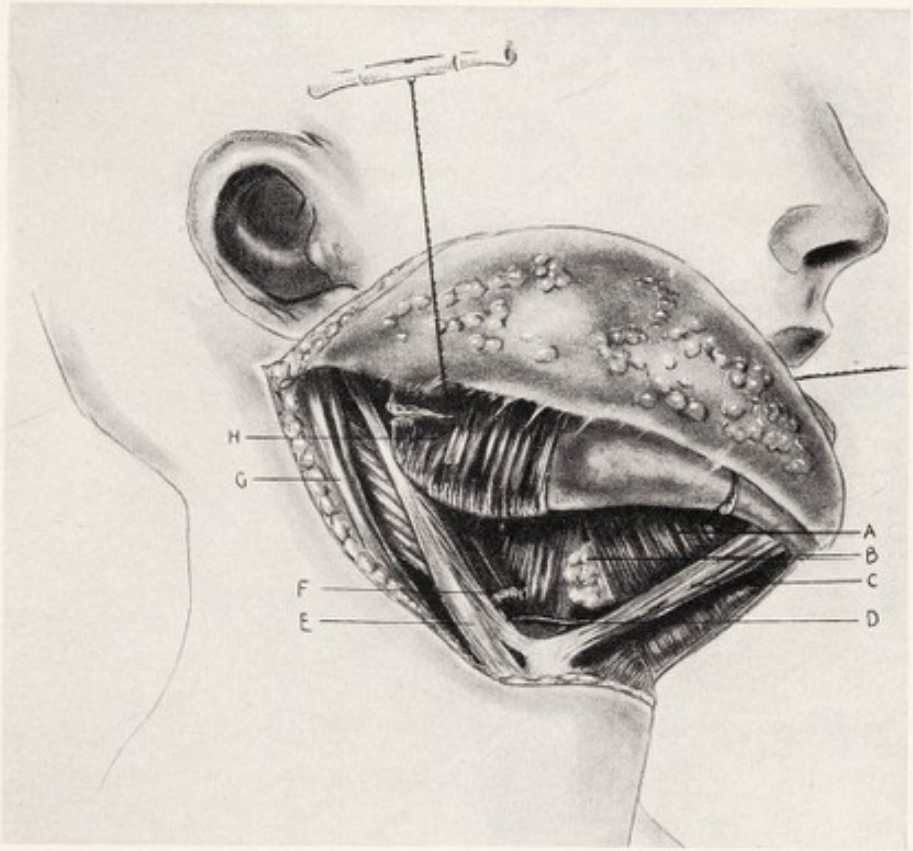

Fig. 263.—Resection of a segment of the mandible, showing the submandibular approach for a malignant lesion which has involved the mandible. A Gigli saw is used to cross cut the bone. A, Mylohyoid muscle; B, stump of submaxillary gland; C, anterior belly of digastric muscle; D, hypoglossal nerve; E, the stylohyoid muscle; F, ligated facial artery; G, sternomastoid muscle, and H, masseter muscle.

destruction of a part of the thickness of the mandible; (*c*) removal of metastatic gland in the submaxillary region with a lengthwise excision of a section of the mandible.

As a rule, radium does not favorably affect adult squamous-cell epithelioma involving bone. A large dose of radium, even if it does cause the lesion to disappear, may cause prolonged pain or else a necrosis which takes months to sequestrate and separate. Therefore, as a rule, in accessible lesions involving the jaw bone, excisional or destructive procedures are primarily indicated.

Resection of a Segment of the Mandible.—For resection of a segment of the mandible, the incision is made in a curved fashion below the mandible in the position which it is deemed advisable to excise. In some instances it may be possible to retain a portion of the lower edge of the mandible. When possible, it is well to do so. The mortality will be found to be somewhat less and little deformity of the jaw will result. When a complete resection of a part of one side of the mandible is done, the opposite side falls to the resected side to a certain extent and interferes for the first few days with swallowing of the salivary secretions and increases the tendency to postoperative pulmonary complications.

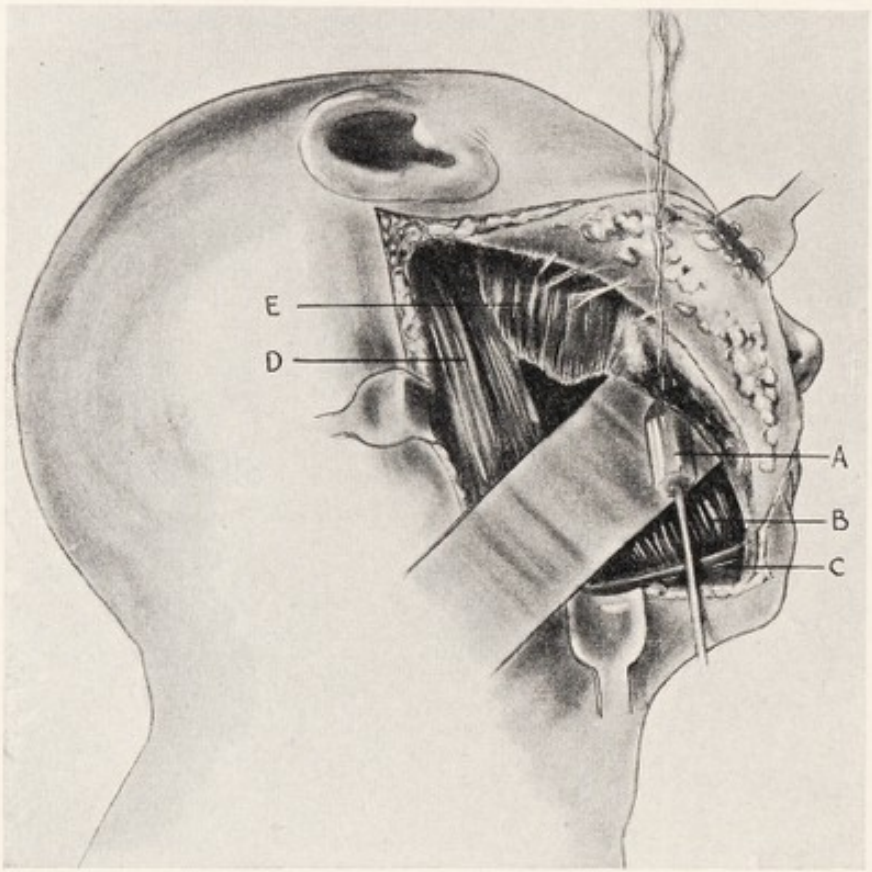

Fig. 264.—Submandibular approach for malignant lesion involving the mandible. The bone is thoroughly cauterized on the inside so that a good portion of it will sequestrate. The whole thickness of the mandible can be destroyed in this manner if the indications make it necessary. A, Soldering iron; B, mylohyoid muscle; C, anterior belly of digastric muscle; D, sternomastoid muscle; E, masseter muscle.

The soft tissues including the masseter attachment are removed from the bone externally (Fig. 263). Usually the facial artery has to be ligated as it crosses the edge of the bone in front of the masseter. When it is necessary to remove a whole section, a Gigli saw is passed behind the bone into the floor of the mouth and brought out over the top of the bone. Any teeth in the line of the saw path must be removed previously. The bone is then cut across. Access to the mouth is obtained thereby. The lesion attached to the bone is excised and the bone cut across again in a similar procedure behind the lesion. The bone may be cross cut as far back as 1 or 2 cm. about the angle. All bleeding points are ligated. The wound is packed with gauze, and the skin and platysma are loosely closed with inter-

rupted dermal suture with the tail end of the pack projecting from the skin incision at the most dependent position.

When the muscles of mastication are involved by squamous-cell epithelioma, irradiation often is not particularly effective. We believe that here excision methods are indicated primarily if a cure is sincerely to be tried for. By cutting across the ramus above the midportion, the infiltrated tissue may be removed en bloc with some chance of a cure resulting.

Resection or Destruction of a Lengthwise Part of the Mandible.—A malignant growth lying adjacent or attached to the jaw bone usually arises from a local lesion in the floor of the mouth, from the lip or from a malignant gland in the submaxillary or submental region. Many times sufficient

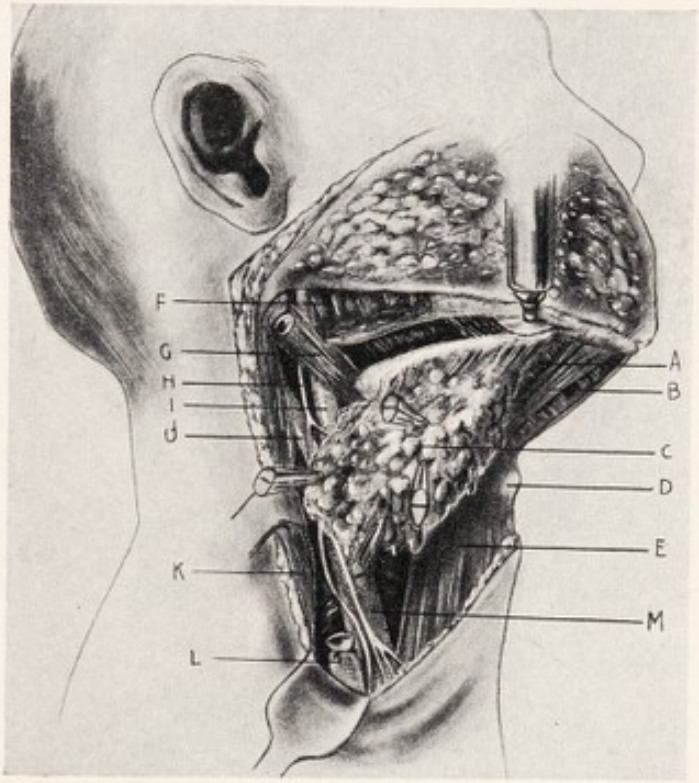

Fig. 265.—Operation on the mandible when metastatic glands are fixed to it. Removal of the upper deep cervical glands and tissues of the submaxillary triangle along with a lengthwise segment of the mandible en bloc. A, Mylohyoid muscle; B, anterior belly of digastric; C, areolar tissue of the submaxillary triangle including the submaxillary gland and a lengthwise section of the mandible; D, hyoid bone; E, pretracheal muscles; F, masseter muscle; G, posterior belly of digastric; H, hyoglossal muscle; I, internal carotid artery; J, external carotid artery; K, sternomastoid muscle; L, ligated external jugular vein; M, common carotid artery.

bone may be destroyed to accomplish one's purpose without actually removing a whole segment of the mandible. Under such conditions a satisfactory destructive procedure, with less mortality than that of the resection of a portion of the mandible, is to burn the diseased bone thoroughly with a soldering iron, killing the greater part of the thickness of it (Fig. 264). Later the sequestrum separates and can be removed, leaving a jaw which in most instances will have laid down enough bone to prevent a fracture of the bone.

Not uncommonly one sees a carcinomatous node in the submaxillary region which, although the mass is more or less attached to the mandible, is not fixed to the adjacent soft tissue. In such a situation, a satisfactory

operation is an upper cervical and submaxillary triangle neck dissection along with the removal of a lengthwise segment of the mandible—all en bloc (Fig. 265). The lengthwise segment is cut with an electric saw and more of the under surface is removed than the outer surface. The wound heals per primam in contradistinction to when the cautery is used for the same essential purpose.

One must be aware, however, in planning these procedures that malignant cells in bone always go a greater distance in canaliculi of the bone than one would suspect. The destruction or excision must be sufficient or one had better not do these operations. Properly performed they have a distinct place in the treatment of malignant disease, as irradiation in doses not sufficient to cause radiation necrosis of bone seldom cures any but the most radiosensitive lesions after they have involved the bone.

OPERATIONS ON THE MAXILLA FOR CANCER

The following operations may be indicated when cancer involves some part of the upper jaw: (*a*) cautery or endothermic enucleation of the antrum, (*b*) direct approach to the antrum with or without enucleation of the orbital contents, (*c*) partial resection and cautery destruction of the superior alveolar ridge, (*d*) partial resection and cautery destruction of the palate and alveolar process.

Resections and excisions of the maxilla as formerly practiced have almost become operations of the past. Resections of the maxilla alone have in the past given almost uniformly bad results so far as final eradication of the usual epithelial malignancies in this region are concerned. At the present time, however, one well known radium institution treats epitheliomas of the maxilla by resection and application of radium in the cavity which remains.

Cautery or Endothermic Enucleation of Antral Carcinoma.—The cautery for opening the antrum was used first by Larson in 1872. New revived the method in 1920. At present the endothermic button or loop is used on the same principle, namely, to gain access, to destroy as much of the growth as possible, and to give subsequent drainage (Fig. 250, *A*).

Previously, under Radiation Therapy of Carcinoma of the Superior Maxilla, when discussing "access surgery," a description was given of the method of largely enucleating the central tumor by cautery or endothermic electrode to give adequate drainage and central exposure of the antrum so that radium could be applied to the midportion of the tumor area. This is the present-day procedure in most clinics for the treatment of carcinoma of the upper maxilla.

When a malignant disease of the antrum has fungated through the anterior wall and involved the soft tissues of the face, the most advantageous approach for a thorough destruction of the lesion may be directly **through the anterior face.** Usually when this procedure is indicated, the floor of the orbit also has been involved by the new growth so that removal of the eye is indicated along with a thorough destruction of the orbital contents. This procedure is seemed a mutilatory one but in certain cases is quite effective (Fig. 266). The endothermic loop and coagulation electrode aid one in gaining a fairly easy approach (Fig. 250, *A*). Formerly, the soldering iron was used entirely for this procedure and yet I resort to it when I wish

to destroy the bone to a considerable depth. When one suspects an area of not being adequately removed, radium may be applied directly with little or no intervening tissue. After a year if there is no recurrence the cheek may be rebuilt by the use of an arm flap or a forehead flap (Fig. 267).

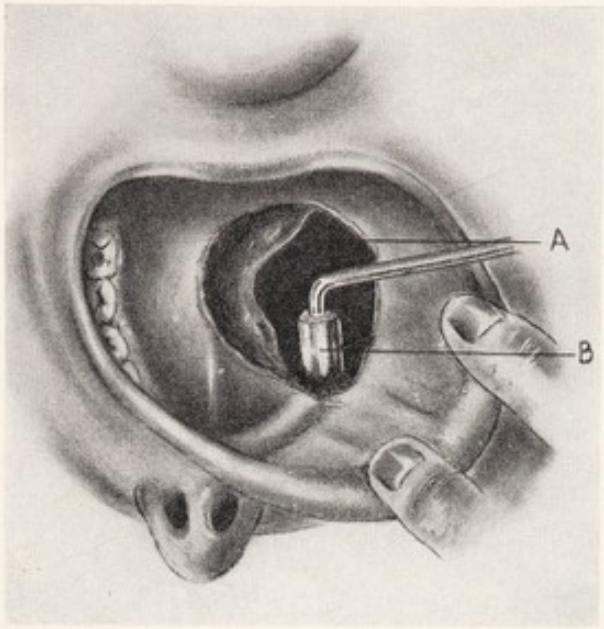

Fig. 266.—Method of using soldering iron to cauterize the inside of the antrum. A, Antral cavity. B, Soldering iron. In many cases not so much of the palatal bone would need to be destroyed as is depicted here.

Resection and Cauterization of the Alveolar Process and Palatal Plate.—As noted previously, epithelioma involving bones does not as a rule react favorably to radium therapy. Therefore, primarily it is often wiser to place main reliance on methods of excision and destruction when an adult



Fig. 267.—Advanced carcinoma of the antrum, woman aged thirty-seven. Cautery removal followed by heavy irradiation. No recurrence over five years. Plastic repair was done after two years.

squamous-cell epithelioma involves the alveolar ridges or the plates of the hard palate. When present, a tooth in front of or behind the section to be removed or destroyed is pulled. The mucoperiosteum along the lines of the proposed excision or destruction is incised to the bone. Often

partial resection facilitates the destructive procedure. If this is the case, the extremities of the part of the alveolar process to be excised are cut through by placing the edge of a thin chisel across the lower border and cutting directly upward to the depth of the base of the proposed excision. The chisel is then placed against the upper outer surface of the portion of bone to be excised, and a horizontal cut is made. With a bone forceps the block is grasped and twisted out. Considerable bleeding will be encountered, but the operation should be only a short one. The hemorrhage can be controlled by immediately turning on the coagulating diathermic current.

Very often when one wishes to destroy the alveolus and a piece of the jaw bone beneath, one does not need to resect any of the bone. After removing all the soft carcinomatous tissue with the diathermic loop so that only the involved bone is laid bare, the diathermic needle is plunged into the involved bone in first one direction and then another until the blood supply to the area of bone one wishes to destroy has been completely and thoroughly cut off. If doubt remains concerning this latter occurrence, the small hot soldering iron is used. Although the soldering iron is not nearly so graceful to use as the coagulation diathermic electrode, it is an effective weapon for the purpose of completely and totally destroying the involved bone.

When the palatal plate is involved, the soft part of the neoplasm is removed with the diathermic loop, after which the involved bone is destroyed with the coagulating current.

After such procedures the dead bone separates from the live at the end of about two months. The sequestrum then is simply pulled away from its granulation tissue base with some rongeur-like instrument, provided it does not separate spontaneously before this time.

OPERATIONS ON THE NASO-, MESO-, AND HYPOPHARYNGEAL REGIONS

Nasopharynx.—A few patients present themselves with neoplasms extending into the nasopharynx in whom it is considered that excision of the lesion is indicated. By splitting the palate (Fig. 251, A, B), exposure of the region is gained. When the tumor extends from elsewhere to this region, the extensions of the growth are followed through the palate. The endothermic loop aids one in this type of excision and destruction.

Mesopharynx.—Occasionally one sees an early epithelioma of the pillar region or the buccopharynx in which it is possible to excise adequately the local lesion through the mouth. In certain instances the splitting of one cheek is to be advised, but usually this is not found necessary. When the lesion is large enough to make this necessary, a lateral pharyngotomy is usually the only adequate way of gaining the required exposure. The mesopharynx also can be entered from beneath, the angle of the mandible retracted upward and the tongue and tonsillar area pulled downward and outward. Usually however, lateral pharyngotomy is the operation to be recommended to gain this exposure.

Technic of Local Excision in the Pillar Region.—General anesthesia is usually necessary, but in some instances local anesthesia may allow adequate access. When general anesthesia is used, the head is placed in the Rose position and sometimes intratracheal anesthesia may be the most efficient.

The mouth is widely opened with a gag. A suture is placed in the tongue. A flat retractor holds the tongue down to one side. The mucosa is incised about ½ inch from the boundaries of the lesion. Either the knife or the diathermic needle may be used for the excision. The latter is preferable because of the small amount of bleeding. The lesion is totally excised. Bleeders are caught as required. The position of the internal carotid artery must be considered. Otherwise, there is no great anatomic danger.

Hypopharynx.—Under "Access Surgery" we have described previously a method of approach for the application of radium to lesions in this area when considered of sufficient extent to make surgical excision inadvisable (Fig. 252).

Before deciding on an operative approach either for purposes of excision or for purposes of applying radium, one should determine that the patient is a good risk, the lesion should be limited, and it should be known to be an adult squamous-cell epithelioma. If glands are present, they should be movable and present only on the side of the lesion, and the mobility of the tongue should be good. Thus, it is seen that the indications for these approaches are not of common occurrence.

Provided that one had determined to expose a lesion in the hypopharyngeal region for therapy, the operator has two choices if the lesion is to be excised: to remove it in toto, or to trust to the application of radium after his "surgery of access." After the operative approach if the lesion is operable, the risk is only slightly greater if one excises the lesion in toto than if radium only is applied.

In all the removal should be adequate or it should not be done. At least 1 cm. of normal tissue in all directions is necessary and if a greater width, so much the better. When the lymph nodes are involved on both sides, it is probable the growths are not ever to be considered in the operable class. In laterally placed growths a dissection on one side of the neck gives a good result and very often may be done with the pharyngotomy.

Two forms of infection—lung and local—may cause a fatal termination after these operations. Infection of the lungs is prevented by rigid elimination of all blood and secretion from the trachea. Local anesthesia alone allows a more bloodless exposure. When a neck dissection is considered advisable as a part of the preliminary operation, at the end of it the sternomastoid is firmly stitched over the carotid vessels before the pharynx is entered, to prevent infection traveling along the deep vessels of the neck. All effort should be made to obtain water-tight closure of the pharynx after excision of the local growth. When this is not possible, it is best to sew the mucosa to the skin all about the opening. This tends to prevent extension of infection in the neck tissue. The neck wound is not tightly closed but lightly packed with gauze at a dependent point.

The Approach.—When the growth is localized to the vallecula and the epiglottis, a transhyoid approach is indicated (Fig. 268). When the lesion encroaches upon the lateral pharyngeal wall and spreads posteriorly to the pyriform fossa, a better approach is lateral pharyngotomy (Fig. 252). As a rule, a preliminary tracheotomy is advisable as a part of the transhyoid pharyngotomy and lateral pharyngotomy.

Lateral Pharyngotomy.—Trotter advises the transthyroid route (Fig. 252), because the pharynx is shielded from access laterally by the lar-

yngeal skeleton, the thyroid ala, the great cornu of the hyoid and the thyrohyoid ligament connecting them posteriorly. These structures can be removed without entering the wall of the pharynx or disturbing any growth within the pharynx. After removal of these cartilages, the tumor can be palpated and an estimation of its extent and situation made. The point to make the pharyngeal wall incision can be judged. Because of the extent, if one deems it wise to apply radium by this exposure, the application can be accurately made. The incision is made downward from a point just behind the angle of the jaw, 4 or 5 inches, and is made nearly vertical to the sternomastoid. Two incisions are advised depending upon whether or not a simple pharyngotomy is anticipated without neck dissection or whether a neck dissection is also considered advisable at the time of the pharyngotomy. When the neck dissection is not to be made, the incision made is 1 inch forward and parallel with the one first described. When the gland dissection is to be done at the lower end of the wound, the anterior edge of the sternomastoid muscle is cut transversely and the whole muscle retracted backward. The usual neck dissection is then performed without removing the sternomastoid muscle, removing the jugular vein but not, as a rule, the submaxillary gland. The superior thyroid artery is ligated well away from the carotid. The sternomastoid muscle is now stitched down over the carotid vessels and sutured to the paravertebral muscles with catgut. The deeper neck structures by this method are fairly well closed off. A drain may be placed through a puncture behind the sternomastoid muscle.

Most men prefer to remove the sternomastoid muscle as in a complete block neck dissection. Undoubtedly this is the most efficient operation for the removal of involved glands, but unless the patient is a particularly good risk, a complete neck dissection en bloc and a lateral pharyngotomy at one sitting are likely to be too much surgery. In most instances two operations will be wiser if one feels that if the sternomastoid muscle is not removed, the excision of the gland would be inadequate.

Between the anterior and posterior borders of the larynx a vertical incision is made down to the cartilage. The thyroid alae and the greater cornu of the hyoid are exposed. The superior laryngeal vessels and nerves are divided. The greater cornu of the hyoid and the thyroid cartilage are separated from the pharyngeal wall. When the growth has involved the thyroid cartilage, the alae of the thyroid cartilage should be removed en bloc with the growth. When the pharynx is free from the thyroid alae, it is divided vertically at the juncture of the anterior and middle thirds, and the alae are removed along with the thyrohyoid ligament and the great cornu of the hyoid bone, freely exposing the lateral pharynx. The pharynx is opened in such a manner that one does not cut too near or through the tumor. As soon as the pharynx is opened, the glottis is packed after cocainization. The growth is now removed, cauterized or needled with radium needles as thought advisable. Usually immediate closure is done. The incision in the pharyngeal wall is reinforced by bringing together the muscular flaps that have been turned off of the pharynx and off of the alae of the thyroid cartilage. The skin incision is closed loosely with drains. In favorable cases no leakage occurs. When the pharynx cannot be closed, it is advisable to suture the pharyngeal mucosa to the skin mucosa to prevent neck infection. Later, after three or four weeks, a plastic operation is done to close the pharyngostomy.

Some Postoperative Complications.—Removal of the epiglottis and a part of the base of the tongue abolishes swallowing for several weeks. During the interval the patient must be fed by a nasal or esophageal tube. The operation to be described for the removal of upper and lateral growths of this region needs only a small plastic operation later to gain closure. Removal of the edges of the epiglottis, the aryepiglottic fold and the anterior oral cartilage will allow almost complete recovery of the voice save a huskiness. When the epithelium over the cricoid cartilage is removed and most of the posterior part of the cricoid cartilage, a skin flap must be turned in to aid in lining the pharynx. In most instances when the growth is extensive enough to require a skin flap to be thrown into the pharynx, the local

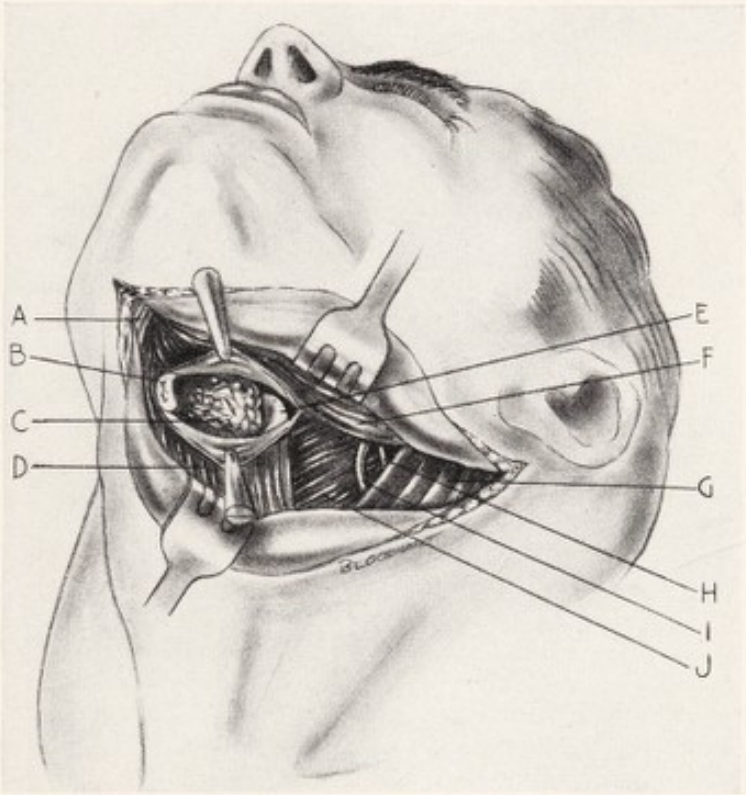

Fig. 268.—Transhyoid approach to the pharynx. This exposure allows one to expose the epiglottis and the area about it. A, Anterior belly of digastric muscle; B, cut hyoid bone; C, lesion in the pharynx; D, pretracheal muscle; E, epiglottis; F, posterior belly of the digastric muscle; G, sternomastoid muscle; H, hypoglossal nerve; I, superior thyroid artery; J, inferior constrictor muscle.

growth had best be exposed and implanted with radium. Early growths in the aryepiglottic fold or the pyriform fossa and in the lateral wall offer a fair prognosis for cure. The most favorable location is in the lateral wall.

Transhyoid Pharyngotomy.—An incision is made transversely at the level of the hyoid bone, extending from the anterior border of the sternomastoid muscle to the midline and upward to the submental region. The mylohyoid and infrahyoid muscles are exposed and detached from the hyoid bone. The hyoid is freed posteriorly and rotated medially. At the juncture of the greater cornu with the body, the bone is sectioned. The greater cornu is removed. The pharyngeal wall is incised, and the edges are retracted (Fig. 268). Now one may view the epiglottis, the base of the tongue, and the lesion. The latter may be excised if this is considered

feasible. If not, radium needles are inserted under direct vision. In either case the wound in the pharynx is lightly packed and the skin incision partly closed.

Operations for Hypopharyngeal Growths.—For growths on the posterior pharyngeal wall, as also for postcricoid growths, excision may be advisable as they are radioresistant squamous-cell carcinomas.

The posterior pharyngeal region and postcricoid region are exposed as in transthyroid lateral pharyngotomy (Fig. 252), after a transverse neck

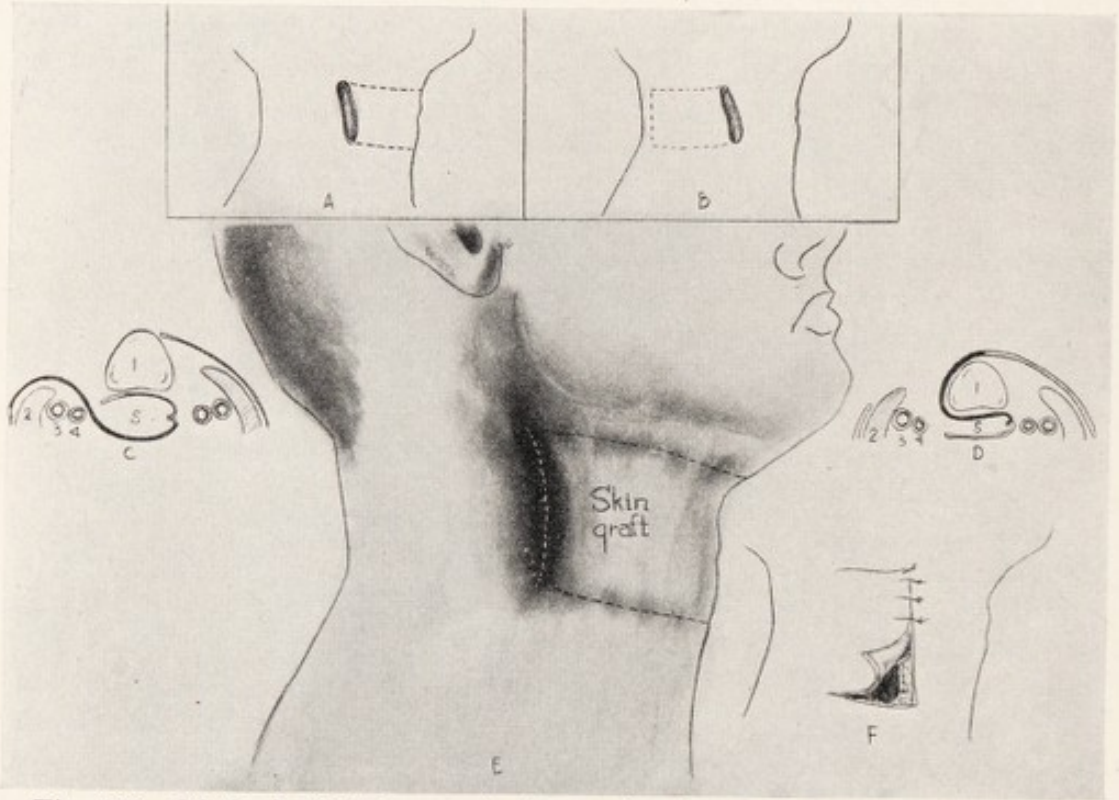

Fig. 269.—Method of doing a plastic repair when a postcricoid or a posterior pharyngeal carcinoma has been excised. Method of approach to excise posterior pharyngeal or postcricoid carcinoma. The skin flap when the carcinoma is on the posterior pharyngeal wall is outlined as in A. Before the approach to the lateral pharynx is made when the cancer lies on the anterior wall of the pharynx just posterior to the cricoid, the flap is outlined as shown in B. C, Shows cross section of neck with the skin flap turned in to cover the posterior pharyngeal wall. The flap in this case would be outlined as in A. In D the skin flap is turned to line the anterior wall of the pharynx. The skin flap would be outlined as in B. E, Shows the neck as it appears several weeks after the skin flap has been turned into the pharyngeal wall as in A and C. A skin graft has been placed over the area from which the flap was removed. F, Method of closing the defect in the lateral posterior pharyngeal wall after the flap has been grown to the posterior pharynx. The pedicle of the flap is cross cut down about ¾ inch deep and turned upward. The inner side of the lateral pharyngeal wall is then stitched together after which the flap is brought out and stitched as shown in F.

flap is outlined (Fig. 269) on the neck and raised. When the posterior pharyngeal wall is to be relined, the base of the flap is posterior over the sternomastoid muscle. On the other hand, when the postcricoid region is to be recovered the base is anterior. The flaps must be of sufficient length to fill the defect without tension, and of sufficient width to enjoy a good blood supply. In removing a postcricoid lesion care must be taken not to injure the recurrent laryngeal nerves of the crico-arytenoideus posticus muscles to prevent the development of paralysis of the vocal cords.

This method is suitable only in a quite superficial growth on the back of the larynx. After several weeks the fistula in the side of the neck is closed by severing the flap, turning into the pharynx the distal end, closing the pharyngeal structures and replacing the greater part of the flap in its original bed. When growths are in the postcricoid region or the posterior pharyngeal region, the lymphatic infection is likely to be bilateral. Therefore, to do the ideal operation, a bilateral neck dissection would be necessary—an operation which has largely been discarded because of its futility in most instances.

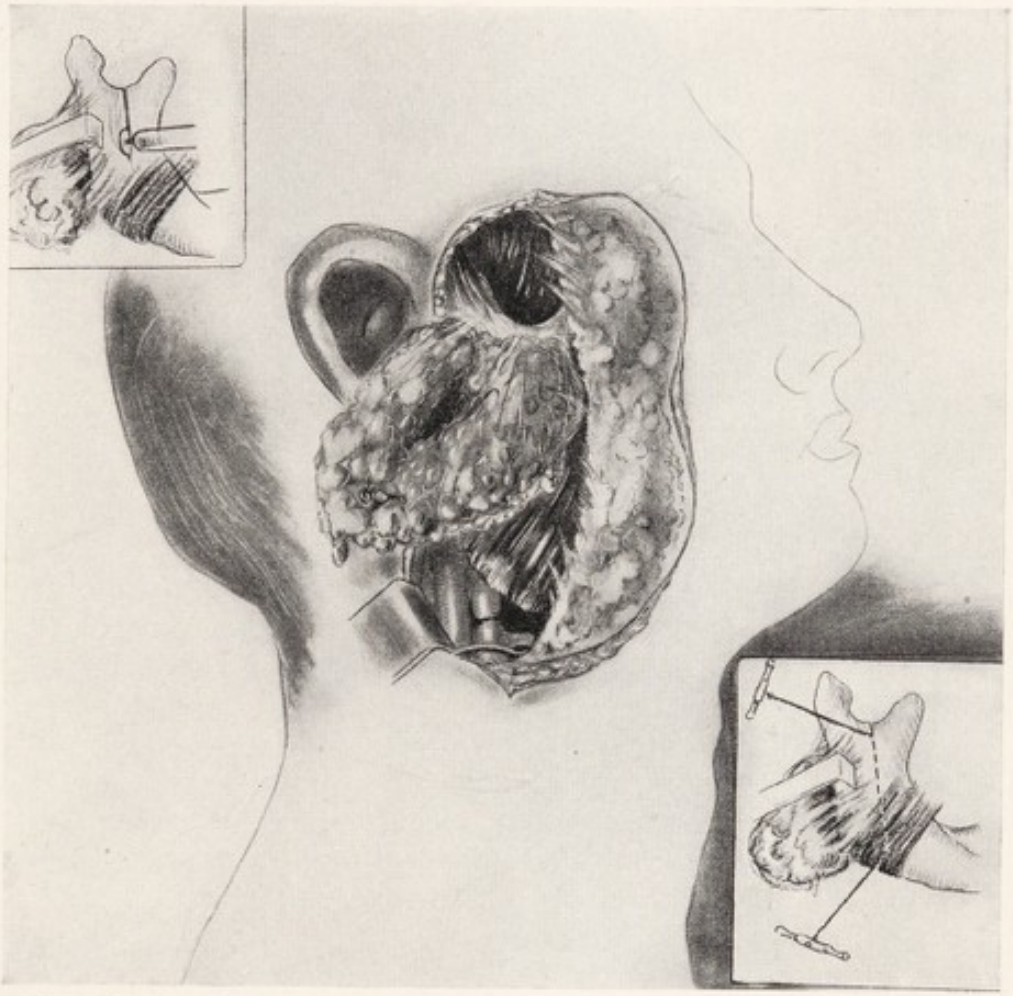

Fig. 270.—Extirpation of the parotid gland. The external carotid has been ligated, the parotid gland is isolated, the posterior half of the ramus of the mandible has to be removed so the whole of the parotid gland can be removed en bloc for part of it is beneath the mandible. The ramus may be cut across with a circular saw or a Gigli saw.

EXTIRPATION OF THE PAROTID GLAND

Ordinarily one does not consider complete extirpation of the parotid gland unless it is involved by a malignant tumor. The operation of extirpation of the parotid gland is especially indicated when the malignant degeneration is of the type which follows a so-called "mixed tumor" of the parotid and the prognosis is relatively good (Fig. 270). When the lesion is a squamous-cell carcinoma, the prognosis is usually poor. In such a situation, the preservation of the facial nerve is not an important enough consideration to influence one's conservatism. If the operation is indicated

at all one should not hesitate to act radically. The whole removal of the gland with its capsule is the ideal to be striven for. It has been stated that total extirpation of the parotid gland is impossible (Treves) but, for all practical purposes, all of it can be removed. One may have to perform a partial or even in some cases a complete resection of the ramus, however. From the middle of the lower border of the zygoma an excision is extended backward to the ear. It is curved downward in front of the tragus and around back and below the angle of the jaw. When the skin is adherent to the mass, it is left attached to the mass by using an elliptical incision. This is no disadvantage because finally it is best to remove a semilunar piece of skin to tighten the paralyzed cheek on that side. The entire surface of the gland should be uncovered.

The enucleation of the gland is usually started by dissecting up the lower pole of the gland and ligating the vessels encountered. The dissection plane is just external to the parotid capsule. For purposes of orientation the posterior bellies of the digastric and stylohyoid muscles are identified. They run downward and forward. As the posterior part of the capsule is continuous with the sheath of the sternomastoid muscle to keep from entering the parotid capsule, the sheath is cut away from the sternomastoid at its anterior edge. Just beneath the digastric and sternomastoid muscles is the external carotid artery. By drawing the muscles to one side the artery is exposed and ligated. Care is taken not to injure the hypoglossal nerve which curves over the artery. Moving upward, the temporal artery and vein are located lying just in front of the ear as it crosses the zygoma. They are also ligated. The incision is then made to surround the gland. Vessels are ligated as they are encountered. The gland is thus isolated from its bed and the ramus of the mandible is uncovered. By passing a curved Kelly clamp up behind the ramus beneath the neck of the condyle through the sigmoid fossa, a Gigli saw can be pulled back through beneath the ramus and about 1 cm. of its posterior border is cut off. The condyle is then wrenched from its socket. The inferior dental artery and the maxillary artery lie just beneath the edge of the cut ramus. This gives access to the part of the gland beneath the ramus which is connected by its capsule with the pharynx and the temporal bone. The capsule has to be carefully dissected from the internal carotid artery.

When the reason for the removal of the parotid is a carcinoma, it may be desired to remove the cervical lymph nodes at the same time.

The cavity left after extirpation of the gland is packed with gauze. The skin flap is sewed back in front of the ear. The tail of the gauze pack is allowed to protrude at the lower angle of the incision.

OPERATION OF BRANCHIOGENIC CARCINOMA

In Chapter XXXV is described the technic of radical dissection of the neck for operable cancer. The operation for the removal of a branchiogenic carcinoma is in no way different from that described for radical removal en bloc of metastatic carcinoma to the lymph nodes of the neck. The prognosis following the radical extirpation of a branchiogenic carcinoma is usually not good. The great majority develop a recurrence within six months to one year. Few if any cures, however, are obtained by interstitial radiation (Fig. 253).

When operable, it is generally considered that radical excision is to be preferred, removing the sternomastoid muscle, deep jugular vein, and all the tissues of the lateral neck save the carotid arteries and the important nerves behind the arteries. As removal of the carotid artery is so universally fatal in the elderly, it is not ordinarily a justifiable procedure. When the tumor is not free from the carotid arteries, it does not fall in the operable class. These cases usually terminate fatally. In his series Oliver reported 77 out of 80 were known to have died of the disease.

OPERATIONS NOT COMMONLY PRACTICED

In the preceding pages the operations which we consider most useful have been presented. However, it is probable that not all surgeons will agree with this more or less personal selection. For the sake of completeness a few operations not commonly practiced are outlined although the indications for their use will be found only rarely.

In the chapter on Resections and Excisions of the Upper and Lower Jaw Bones are discussed certain radical operations in which the object is to go through or to remove bone. In certain selected instances an operation of this type might be indicated in a malignancy of the soft tissues but ordinarily one would not be called upon to perform such operations, save possibly for a malignancy of the bony structures.

Excision of One Half of the Body of the Tongue.—Excision of one half of the tongue as a definite operative procedure would seldom be contemplated at present. The operation smacks of an anatomic procedure with some disregard of the pathologic involvement. The preceding operation embodies more of the principles of present thought. Thus, the operation is not often performed at the present time. Its indications would possibly be the same as the preceding operation plus a somewhat wider extension of the new growth especially to the floor of the mouth. In most instances the lateral approach of Kocher through the floor of the mouth would appear preferable, when such a condition is present. A more adequate removal of the tissues of the mouth is gained.

A gag is placed in the mouth. A retention suture is passed through the tip of the tongue on each side of the midline. The Rose position is valuable. A sucker is placed in the pharynx. The tongue is drawn forward and split with the scissors exactly in the midline to the attachment of the frenum (Fig. 271, *A*). Butlin then used the fingers of both hands to split the remaining portion of the tongue. The halves are separated as far back as the proposed excision, forward to the mandible, and downward to the inferior borders of the geniohyoglossi muscles. The two geniohyoglossi muscles are separated. The mucous membrane is incised in the floor at least 1 cm. from the edge of the neoplasm. The submaxillary duct is avoided if possible. The mucosa and subjacent tissues are pushed to the midline until the outer surface of the geniohyoglossus muscle is freed as far forward as the origin of the genial tubercles at the symphysis. The lingual vein may be cut in doing this. The lingual nerve also is divided. This operation is not indicated if the malignant lesion involves tissue near the mandible or the mylohyoid muscles. Other tissues of the floor of the mouth if partially involved may be removed, such as the intra-oral part of the submaxillary gland or the sublingual gland.

The diseased half of the tongue is drawn upward and the geniohyoglossus made tense, and is cut across close to the genial tubercle. When the entire half of the tongue is removed, the anterior pillar of the fauces is cut across. The affected part of the tongue is drawn well forward and the cross cut started through the muscles attached to the base from the lower to the dorsal surface at least 2 cm. beyond the posterior border of the growth. The lingual artery is watched for and if possible secured before it is cut. It lies near the midline. It is approached with shallow cuts. All bleeding points are cut and tied. In some instances, a row of mattress sutures across the base of the tongue may aid hemostasis.

The tongue is secured as described in a hemiglossectomy. The mucous membrane is split on both sides instead of unilaterally. Both geniohyoglossus muscles are cut from the genial tubercles, and the tongue is

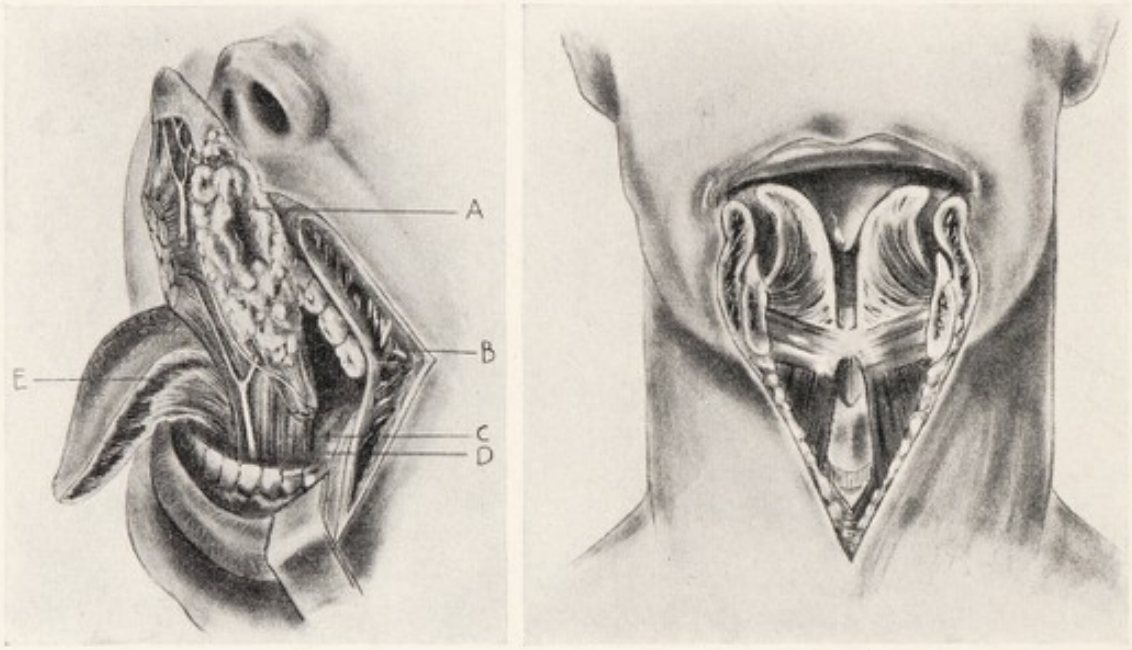

A *B*

Fig. 271.—*A*, Excision of one half of the body of the tongue, showing tongue in position for cutting it across at the base. A, Carcinomatous lesion; B, split in cheek; C, hyoglossus muscle; D, lingual artery; E, tongue is split in median raphe. *B*, Anterior translingual pharyngotomy. The epiglottis is in view. A growth in this region can now be removed.

separated back to the epiglottis. The transverse excision is made as in hemiglossectomy—only bilaterally. A ligature should be passed through the glosso-epiglottic fold when the entire tongue is removed. The ligature gives one control of the stump in case of hemorrhage or dyspnea several hours after the operation. The lingual arteries should be caught before being cut. Drainage through the floor of the mouth anterior to the stump in front of the hyoid through the myohyoid muscle is generally indicated.

Extra-oral Approaches.—*Kocher's "Normal Excision."*—Trotter in recent years has recommended this operation for growths about the epiglottic region (Fig. 271, *B*). Kocher recommended it for cancer extending as far back as the isthmus of the fauces, where it involved the arch of the palate, the walls of the pharynx, and the soft palate. The operation is a modification of the Roux and Sédillot method. The bleeding is slight and adequate

exposure is given. The incision is made through the midline of the lip. The mandible is cut through medially. The tongue is split in the midline to the epiglottis. The hyoid bone may be separated if necessary.

Total Removal of the Tongue Through the Floor of the Mouth.—Usually, after irradiation methods have failed and the posterior part of the tongue and floor of the mouth are involved widely, the only procedure that offers any hope of a cure is the total removal of the tongue and tissues of the floor of the mouth. The operation is seldom indicated but occasionally one sees a case in which it may seem best to try it. The operation has a mortality of about 25 per cent. A preliminary tracheotomy is necessary. The final result is less mutilating than a laryngectomy. The voice is fairly good, better than after a hemiglossectomy with the tongue bound down in the floor of the mouth. The patient learns to eat satisfactorily. I have seen a few of these patients living and well after many years. One, a doctor, a patient of Blair's, was carrying on his practice eighteen years later.

Blair's Operation for Removal of the Tongue.—A high tracheotomy is sometimes performed previous to the operation. A No. 6 or 7 short tube is inserted.

The operation can be performed under either local or general anesthesia. An incision is made through the skin from the mastoid tip to the opposite mastoid, curving downward to just above the hyoid bone. The flap thus outlined is raised upward to the lower edge of the mandible. The facial artery and vein on each side are isolated, ligated and cut as they cross over the lower edge of the mandible in front of the masseter muscle. Along the line of the skin incision, the subcutaneous tissues are cross cut so that the digastric tendon and hyoid bone come into view. The facial vein is cut and ligated as it enters the submaxillary triangle. The contents of the submaxillary triangles are retracted upward. As the submaxillary gland is pulled upward the facial artery is isolated, cut and ligated on either side. On either side in the triangle formed by the midtendon of the digastric and the hypoglossal nerve, a pair of forceps is stuck ¼ inch deep into the fibers of the hyoglossus muscle and the lingual artery is isolated. Both arteries are cut and ligated. Just within the rim of the mandible from beneath near the mental region one now enters the buccal cavity. The muscular attachments of the tissue of the floor of the mouth to the mandible are now severed and the tongue and contents of the floor of the mouth are pulled downward and out into the field. The tongue is cross sectioned above the epiglottis. The skin flap is turned downward and sutured into its original position by interrupted dermal sutures. A pack is placed in the mouth in the cavity which remains after removal of the tongue and contents of the floor of the mouth.

Bilateral Excision of the Tongue Through the Mouth.—Butlin preferred this operation to any other for the removal of the tongue from within the mouth, but now the operation is seldom performed. When the involvement is sufficient to warrant it, the tissues of the floor of the mouth usually need to be removed as described in Blair's operation for the total removal of the tongue. Possibly occasional patients might be seen where this operation might be indicated.

The tongue is secured as described under hemiglossectomy. The mucous membrane is split on both sides instead of unilaterally. Both genio-

hyoglossus muscles are cut from the genial tubercles. The tongue is separated back to the epiglottis. The transverse excision is made as in hemiglossectomy, only bilaterally. A ligature should be passed through the glosso-epiglottic fold when the entire tongue is removed. The ligature gives one control of the stump in case of hemorrhage or dyspnea, several hours after the operation. The lingual arteries should be caught before being cut. Damage through the floor of the mouth anterior to the stump in front of the hyoid bone through the mylohyoid muscle is generally indicated.

OPERATIONS ON THE LARYNX

The Operation of Laryngofissure (Partial Laryngectomy).—In 1851 Gurdon Buck performed the first laryngofissure for the removal of intrinsic cancer of the larynx, although Desault first performed the operation for a benign lesion. In laryngofissure, the cord is not simply removed. The approach and adequate removal may require the removal of one ala of the thyroid cartilage. At any rate the inner surface of the thyroid cartilage is laid bare and in all instances all the soft tissue lining on one side of the larynx is removed. From the upper edge of the thyroid cartilage down to the lower border of the subglottic area and from the anterior commissure in front to the arytenoid behind, the soft tissues including the internal layer of the perichondrium of the thyroid cartilages are removed in one mass. Of course, in all operations for malignancy some variation of extent of removal is required to meet the indications of the given lesion. The operation meets one of the main conditions required if surgical removal is to be successful, namely, a full-faced view of the whole extent of the disease. The operation must be thorough or it had just as well not be done. In some cases part of the opposite cord or the arytenoid may have to be removed. The operation aims to remove a malignant growth and obtain later a serviceable voice, but consideration of the voice should not influence one in favor of inadequate removal.

Indications for Laryngofissure.—The most suitable cases are those with involvement of only one cord, with both extremities free from disease and with mobility still unimpaired. It can be recommended strongly for this type of case. The operation is still suitable when the lesion involves the anterior extremities of the cord. In this type of lesion it is wise to split the arytenoid cartilage a little to one side of the midline on the unaffected side. When the disease has crossed the anterior commissure, a portion of the opposite cord and some of the soft tissues lining the opposite side of the thyroid cartilage must be removed, but success is still possible in such types of involvement.

The symptom of mobility of the cord has an important bearing on the ultimate prognosis after excision. The five-year survivals drop about one third when the cord is fixed. In instances where the disease has extended back to involve the arytenoid, the case becomes a borderline one and this exposure may not give a good result. When the arytenoid body is involved, or the movement is impaired, this operation does not give a good result and the operation is inapplicable. When the growth involves the subglottic area, and particularly if cord movement is impaired, the operation does not give good results, but in moderate involvement of such types, in some instances, a good result may be obtained. However, if the subglottic extension extends around the anterior commissure and involves the opposite cord,

the case may be considered unsuitable for laryngofissure and especially so if the opposite cord mobility is affected.

Technic of Laryngofissure.—The operation is performed under local anesthesia. The line of incision—from the hyoid bone to jugular—is infiltrated with ½ per cent novocain, with 4 or 5 drops of adrenalin added to the ounce. A preliminary hypodermic of morphine aids both the surgeon and the patient. The incision goes through the skin and superficial fascia, through the raphe between the anterior neck muscles (Fig. 272). The isthmus of the thyroid gland is divided usually and a ligature placed about each end. The fascia is cleared from the front of the trachea, the cricoid, and the thyroid cartilage up to the notch.

Novocain solution is injected between the two rings of the trachea and through the cricothyroid membrane. The trachea is opened through the second or third or even the fourth ring (in some instances of subglottic growths, below the cricoid). The rings are ovaled out a little and a good-sized short tracheotomy tube inserted. The thyroid cartilage is divided



A *B* *C*

Fig. 272.—Laryngofissure. *A*, The larynx and thyroid isthmus have been exposed anteriorly. The thyroid isthmus is being cut. Next a tracheotomy is done. A, Thyroid cartilage; B, cricothyroid ligament; C, isthmus of the thyroid. *B*, The tracheotomy tube is in position, the larynx has been split and the thyroid cartilages are separated. D, Lesion inside of pharynx. *C*, Showing coronal section of larynx to show the extent of the tissue to be removed when a malignant growth is confined to one cord. The internal perichondrium is removed.

in the middle or a little to the unaffected side. Often a saw or cutting forceps is necessary to cut the thyroid cartilage in males. Scissors are then pushed in the lumen of the larynx just below the thyroid cartilage and a cut upward is made dividing the thyroid cartilage. The larynx is opened and a piece of gauze dipped in 10 per cent cocaine and adrenalin solution is packed above the tracheotomy tube and between the two halves of the thyroid. After a few minutes, using a nasal speculum, the two halves of the larynx are separated. The upper part of the gauze is cut away and the inside of the larynx inspected. The full extent of the growth is inspected and palpated. It is usually larger than one anticipated. The decision is now made whether the partial laryngectomy is adequate to remove the involved tissue with the necessary margins of uninvolved tissue. At this time it is decided (in the case of a subglottic growth) whether the cricoid ring should be divided. When the growth is too extensive, it may be decided to either do a total laryngectomy or to depend upon radiation from the inside and outside or from the outside alone. A biopsy should be taken.

When a partial laryngectomy is decided upon, a subperichondrial removal en bloc of the diseased area with a good margin of healthy tissue is made. The perichondrium is raised from the outer surface of the affected side by a small elevator. The perichondrium is peeled back nearly to the posterior margins of the alae and upward and downward from the upper to the lower border of the thyroid alae. Next on the laryngeal surface, the perichondrium is raised in the same manner and peeled off back to the arytenoid cartilage and upward to the edge of thyroid cartilage and downward to the cricothyroid membrane. When the growth has extended more widely additional cartilage is denuded, or when downward the cricoid cartilage is similarly treated. It is difficult to get the tissue off of the cricothyroid membrane without puncturing it. The greater part of the thyroid cartilage is now clipped off posteriorly. Free access to the tissues to be excised is now given. The growth and the necessary involved tissue about the growth are removed en masse with the scissors, straight or curved as necessary, or the endothermic needle. The excision of the diseased tissues by the diathermic needle lessens the bleeding greatly and in no way hinders adequate excision. The gauze packing is removed. The wound is now closed in layers.

Treatment After Laryngofissure.—In the after-treatment only slight sedatives are given. The patient is encouraged to cough up the blood-stained mucus. Six to eight hours after operation, a few sips of water are given as a test drink. When successful, water is given freely. After twenty-four hours, ordinary food may be given if water is taken without mishaps. Very often if the taking of water is successful, the tracheotomy tube may be withdrawn in twelve hours. The external wound usually heals by first intention and the internal laryngeal wound is usually fairly well healed with secondary granulation within a period of six weeks. The voice returns slowly and in many cases almost completely, even if the disease has descended to the subglottic area in crossing.

After the operation within twenty-four to forty-eight hours, the patient is able to be out of bed part of the time and to swallow food. The mortality of Thomson was 3 in 70 cases. Jackson reports 45 cases without an operative death.

Laryngectomy.—Billroth did the first laryngectomy and reported it in 1873. Bottini performed the first operation which had a lasting success. LeBec cut the trachea across below the larynx and stitched it to the skin and then at a later time removed the larynx. Gluck (although others also performed a similar operation—Bardenheuer, Solis-Cohen, Cisneros [Thomson]) claimed the credit for introducing the principle of effecting a complete separation between the air and food passages by closing the pharynx and by fixing the orifice of the trachea to the skin.

It is the opinion of most surgeons that the operation of hemilaryngectomy need no longer be performed. The operation of laryngofissure has been made to approximate in extent so nearly the hemilaryngectomy and it has not the disadvantages of occasional stenosis and calls for no plastic repair.

Indications for Laryngectomy.—In intrinsic cancer the indications for simple laryngectomy are about as follows: when the disease has involved the cord to the epiglottis or the arytenoid, has crossed the commissure to

the opposite side, the thyroid cartilage or the cricothyroid membrane is attacked, the ventricular band is invaded, one or both cords are fixed and the glottis is blocked, the disease is subglottic or when the disease has recurred after laryngofissure.

One-stage Versus Two-stage Operation.—The question of one-stage versus two-stage type of laryngectomy is still a dispute. LeBec of France first advocated the two-stage procedure. Later Crile advocated it. Today New does the two-stage. Thomson, Looper and Jackson perform the operation in one stage.

Technic of Two-stage Operation (New).—Using a two-stage operation New has had good results in 42 cases. New states that in the two-stage operation of Crile, the patient was usually obliged to wear a tracheotomy tube. While the one-stage operation of Mackenty overcomes this objection, it requires a great deal of postoperative care from the surgeon and nurses. A midline incision is made from the symphysis of the jaw to the manubrium of the sternum. The hyoid bone is exposed and divided without entering the pharynx and the two ends are retracted laterally. The free thyroid muscles are separated from the thyroid cartilage and the isthmus of the thyroid gland is divided. The larynx and upper tracheal rings are skeletonized. The skin on both sides is sutured to the areolar tissue anterior to the second tracheal ring. The upper part of the wound is closed, leaving the trachea exposed. The trachea is not opened for several days—not until the temperature reaches normal. In the second stage, the trachea is cut across, usually above the first tracheal ring. The larynx is dissected from the pharynx from below upward. The pharyngeal opening is closed with two rows of continuous sutures. The skin is sutured above the margin of the tracheal opening and the upper part of the skin wound closed. New had 3 deaths in 42 cases. No deaths followed the second stage.

One-stage Technic of Laryngectomy (Babcock).—Jackson uses and recommends the Babcock operation—a one-stage operation—which is characterized by: (1) a high transverse collar incision just above the hyoid bone with the idea of avoiding the pouring of infective discharge into the trachea, (2) early opening of the pharynx below the hyoid to give early determination of the extent of the disease, (3) closure of the pharynx before the larynx is removed or the tracheotomy performed, and (4) the use of the cricoid cartilage through a buttonhole in the skin flap to which the trachea is sewed several inches below the crosswise skin incision (Fig. 273).

To gain early exposure of the epiglottis, a vertical incision is made in the thyrohyoid membrane from the hyoid bone to the base of the epiglottis. This incision is deepened into the pharynx and the epiglottis grasped. The incision is carried about the adjacent mucosa of the epiglottis and then about the superior and the anterior borders of the larynx to the base of the cornu of the thyroid cartilage. The base of each cornu is divided separating the pharynx and the esophagus from the larynx. The larynx is pulled forward and the attachment of the esophagus separated. The recurrent laryngeal nerves and vessels are divided. The opening into the pharynx is then closed. Jackson uses fine inverted silver wire sutures for this purpose. He considers vertical-line closure of the pharynx as preferable. The sternohyoid, omohyoid and other available muscles are used in the second layer of closure. A block dissection of the neck is done if the

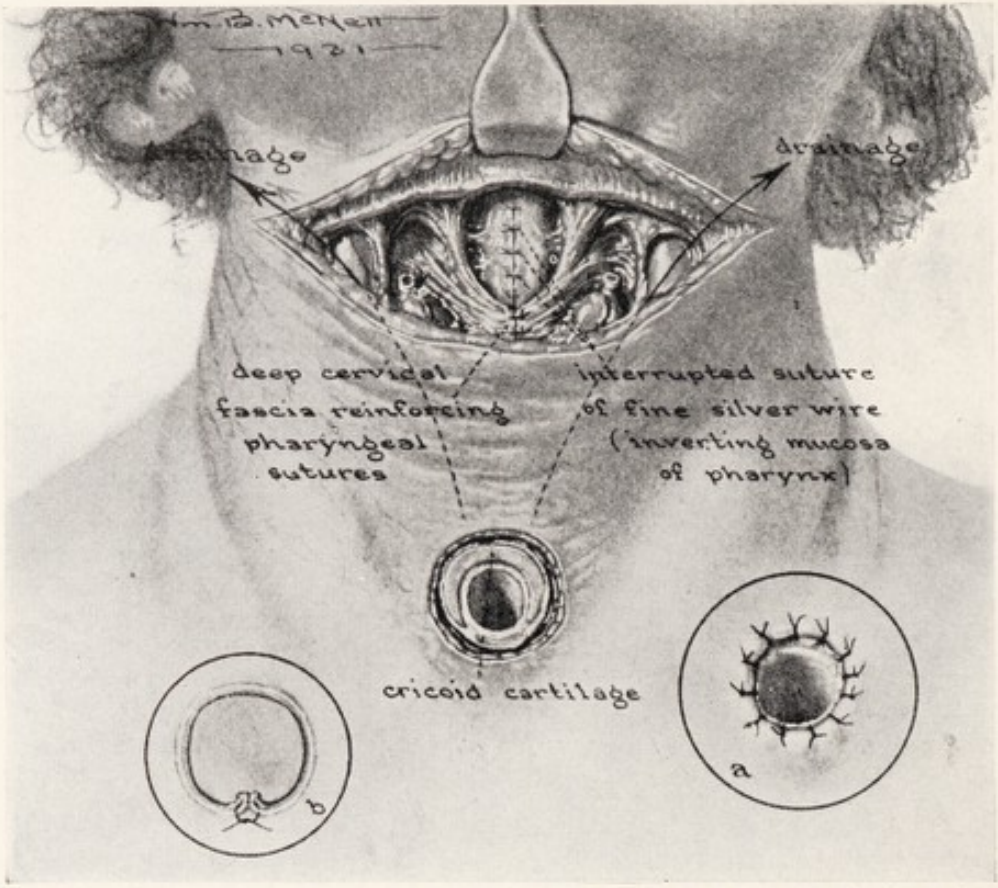

Fig. 273.—Laryngectomy. (Babcock technic.) Anterior part of the pharynx is freed showing opening through the thyrohyoid membrane exposing the epiglottis. The larynx and the upper part of the trachea are separated as far as possible and complete hemostasis is obtained before this opening in the pharynx is made. The opening in the pharynx has been closed by two rows of inverted sutures. The suture line is reinforced by uniting over it adjacent fascia or muscular tissue. The end of the trachea has been pulled through a circular opening, just above the suprasternal notch. The skin edges are accurately sutured over the exposed surface of the cricoid cartilage with the mucosa of the larynx as shown in insert *a*. The two arrows indicate the position of two small rubber drains which are brought out at the angles of the upper incision. Gauze drains are not employed. (Jackson, Dean Lewis' Practice of Surgery.)

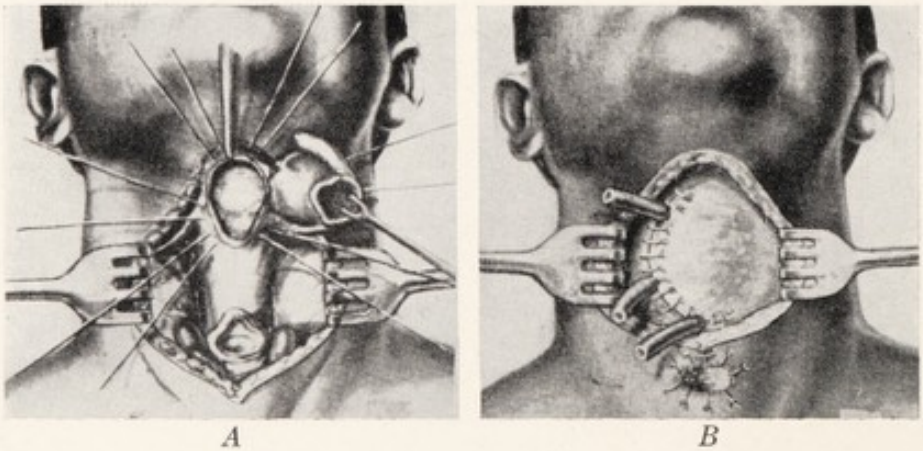

A *B*

Fig. 274.—Lateral approach for laryngectomy. *A*, Crescentic incision is used. The larynx is removed, gauze is packed into the esophagus. Mattress sutures were inserted before the larynx was cut from above. *B*, Fascia and muscles closed over. Finally the skin is closed with interrupted skin sutures. The original crescentic incision would fall nearly above the suture line for the fascia. (Looper, South. Med. Jour.)

carcinoma is extrinsic. The trachea is divided obliquely from below backward and upward through the cricoid cartilage leaving, if possible, a complete cartilaginous ring. This tracheal end is pulled through a buttonhole in the skin just above the suprasternal notch and the cartilage and the skin are sutured together. Looper (Fig. 274) recently has recommended a one-stage operation which is characterized principally by a curved lateral incision.

Pharyngolaryngectomy.—In cases of extrinsic carcinoma, a portion of the pharynx must be removed. The operation of laryngectomy is extended to include the necessary amount of pharyngeal tissue. As wide a strip of the posterior pharyngeal mucosal wall is left as is possible. The lymphatic glands on the side of the lesion may be removed at the time of the pharyngolaryngectomy but usually it is preferable to remove them later. The larynx is freed as described in one of the operative procedures for laryngectomy.



A *B* *C*

Fig. 275.—Closure of pharyngostome. *A*, Mucosal flaps dissected from each side. *B*, Mucosal flaps sutured over. Flaps outlined. *C*, Flap rotated.

The pharyngeal extension is handled according to the principles and operative procedures discussed under Hypopharyngeal Lesions.

Closure of Pharyngostome.—Although one should originally plan the incision in such a manner that a pharyngostome is not likely, one should not allow the fear of one to cause limitation of the excision of tissue when a cure seems possible, for by the transference of flaps almost any size of pharyngostome may be closed at a later period (Fig. 275, *C*).

Speech After Laryngectomy.—Solis-Cohen in 1895 had a patient who accidentally discovered a method of holding back air and ejecting it so that speech was possible after total pharyngectomy. Chiloff also studied the manner in which speech is produced after laryngectomy. When an actual voice is produced the reservoir of air is in the stomach and lower esophagus, causing the left diaphragm to rise to a higher level than the right. The air is swallowed. Speaking in this manner entails quite an effort

and to avoid strain on the diaphragm the speech is usually whispered. In this case the reservoir of air necessary does not need to be so large. The air in the hypopharynx is then sufficient. The air reaches the hypopharynx through the nose. Gluck (Thomson) and Burger have demonstrated patients who spoke well. Woods has described the education of a patient after laryngectomy as follows:

"As soon as the feeding tube is removed I begin teaching my patient the art of gulping air into his esophagus and allowing it to escape as a belch. The physical difficulty of this act is much less where the larynx has

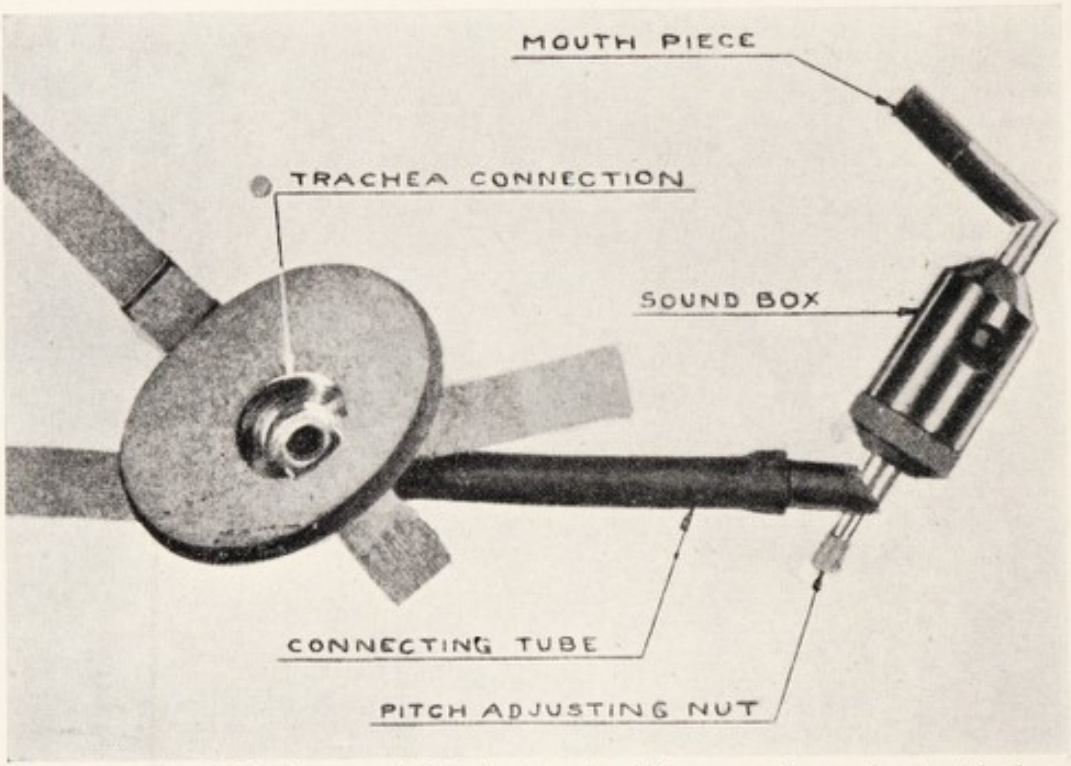

Fig. 276.—Artificial larynx of Mackenty. A rubber membrane is stretched across the inside of a hard rubber sound box. There is a pitch-regulating device which varies the tension of the rubber membrane and is externally adjusted by means of a thumb nut, a mouth piece which fits a metal stem in the top of the sound box and a flexible connection which is strapped over the tracheal opening. On using the apparatus, air is inhaled through a hole in the inside of the sound box. The air passes through a metal tube to the bottom of the sound box down through the rubber connection tube and through the tracheal connection to the lungs. When the air is exhaled, if the hole in the side of the box is closed with the thumb, it is forced out around the rubber membrane. The membrane vibrates to produce sound which passes out through the stem into the top of the sound box and the hard rubber mouth piece into the mouth to be converted into speech. (Western Electric Co.)

been removed than in normal people, because the cricoid cartilage ordinarily remains in close contact with the posterior wall of the gullet, and it requires considerable effort on the part of the mouth to overcome its resistance. With a view to giving the patient an object lesson in the art of belching to order, I sometimes administer a draught of a solution of citric acid followed by a neutralizing one of bicarbonate of soda. The carbon dioxide evolved, sooner or later escapes with a noise that makes a perfect substitute for the voice, and the patient is instructed to watch his opportunity and to form it into a vowel in its transit. When this is once accomplished it only remains for him to acquire the trick of keeping an air reservoir in the esophagus in

order that he may speak audibly and continuously. We were first instructed in the possibilities of this method in or about the year 1895, by a case in which laryngectomy had been performed by J. Solis-Cohen of Philadelphia. The patient accidentally discovered this method and cultivated it with such success that he had no difficulty in making himself heard in a room that ordinarily held three hundred people."

Artificial Larynx.—An intelligent patient and a patient physician are necessary for the development of spontaneous speech after laryngectomy. Many patients cannot or do not learn to speak. In such cases an artificial larynx is of value. Bruns in von Bergmann's System of Surgery has described a great variety of artificial larynges. He described here a simple one of his own. Some of them are very complicated. Those of Tapia and Mackenty are stated by Thomson to be the ones in ordinary use.

When a fistular communication presents itself between the neck wound and the pharynx a Braun's artificial larynx may allow the patient to speak in a loud voice. But usually the pharynx is entirely shut off and the sound is produced in a sound box and has to be conveyed to the mouth where it is converted into speech.

Tapia's instrument consists of a branched mount which fits into a tracheal tube. A rubber tube is attached between the tracheal tube and the sound box. A curved tube goes from the sounding box to the mouth. The sounding box is fitted with an exit tube across which is stretched a strip of thin India rubber which is set in vibration by the expired air. A screw-adjustable expiratory valve alters the pitch produced by the vibrating rubber band. Air is inspired by means of a tube inserted into the tracheal tube. On expiration this opening is closed with the finger which drives the air through the sound box into the patient's mouth. The artificial larynx of Mackenty is described in the legend beneath Fig. 276.

Bibliography

Babcock, W. Wayne: Quoted by Jackson, C.: Surgery of the Larynx and Trachea and Endoscopic Surgery of the Bronchi, Dean Lewis' Practice of Surgery, W. F. Prior Co., Chapter 7, **4:** 150, 1930.

Bernard, Camille: Cancer de la levre inferieure operé par un procédé nouveau, Bull. Soc. de chir. de Paris, **3:** 357, 1853.

Billroth: Plexiformes ossificierendes Condrofibrom des Oberkiefers, Arch. f. klin. Chir., **11:** 241, 1869.

Blair, V. P.: Operations for Advanced Carcinoma of the Tongue, Surg., Gynec. and Obst., **30:** 149, Feb. 20, 1920.

Bottini: Quoted by Morrell Mackenzie, Diseases of the Throat and Nose, London, **1:** 345, 1880.

Von Bruns, Paul: Von Bergmann, E.: System of Surgery, **2:** 288–291, 1904.

Buck, Gurdon: Trans. Amer. Med. Assoc., **6:** 509, 1853.

Burger: Proc. Royal Soc. Med., Laryngology Section, June, 1925, and Acta Otolaryngol., vol. 3, p. 1–2.

Burrows: Quoted by Martin, Hayes E.: Cheiloplasty for Advanced Carcinoma of the Lip, Surg., Gynec. and Obst., **54:** 914, 1932.

Butlin, Henry T.: The Results of Operations for Carcinoma of the Tongue, Brit. Med. Jour., **1:** 1, 1909.

Celsus: Quoted by Martin.

Chiloff: Étude du developpement du larynge chez les laryngectomies, Rev. de laryngol., No. 17, p. 46, Sept. 15, 1925.

Cisneros: Quoted by Thomson.

Crile, G.: Ann. Surg., **58:** 166, 1913.

Desault: Oeuvres chirurgicales, **2:** 276, 1813.

Estlander, J. A.: Methode d'autoplastie de la joue ou d'une levre par un lambeau emprunte a l'autre levre, Rev. men., med. et chir., **1:** 344, 1877.
Gluck: Handbuch der speziellen Chirurgie, Katz, Preysing und Blumenfeld, vol. 4, Curt Kabitsch, Würzburg, 1914.
Jackson, C.: Xème cong. internat. d'otol., Paris, 1922.
Kocher: Ztschr. f. Chir., **13:** 131, 1880.
Larson: Quoted by Peyton.
Laurens: Chirurgie de l'oreille, du nez, du pharynx et du larynx, p. 803, Masson et Cie, Paris, 1924.
LeBec: Ann. des mal. de l'oreille, **31:** 375, 1905.
Looper, E. A.: Laryngectomy—Improved Technic, South. Med. Jour., **29:** 1165–1169, 1936.
Martin, Hayes E.: Cheiloplasty for Advanced Carcinoma of the Lip, Surg., Gynec. and Obst., **54:** 914, 1932.
Mackenty, J. E.: Western Electric Co.: Information for the Care and Operation of the Mackenty-Western Electric I A Artificial Larynx, Copyright, 1925.
New, G. B.: Treatment of Malignant Tumors of the Pharynx and Nasopharynx, Surg., Gynec. and Obst., **40:** 177, 1925.
A Two-stage Laryngectomy, Surg., Gynec. and Obst., **47:** 826–830, 1928.
Oliver, L. O.: Malignant Epithelial Tumors of the Neck, Amer. Jour. Cancer, **23:** 16–45, 1935.
Roux: Gaz. méd., 439, 1839; Dict. de méd. et de chir. prat., **20:** 80, 1875.
Saemann, O.: Die Transplantations-Methode des Hrn. Prof. Dr. Burow, Deutsch. Klin., **20:** 221, 1853.
Sédillot: Gaz. d'Hôp., **83:** 1844.
Solis-Cohen: Trans. Amer. Laryng. Assoc., p. 132, 1918.
Spencer, Walter G., and Cade, Stanford: Diseases of the Tongue, Phila., P. Blakiston's Son and Co., 1931.
Stewart, J.: The Radical Treatment of Epithelioma of the Lip, J.A.M.A., **54:** 175, 1910.
Tapia: Xème cong. internat. d'otol., Paris, July, 1922, Rapports, vol. 1, p. 160.
Thomson, St. Clair: Cancer of the Larynx, New York, The Macmillan Co., 1930.
Treves: Quoted by Blair, V. P.: Surgery and Diseases of the Mouth and Jaws, 2nd ed., St. Louis, C. V. Mosby Co., 1916.
Trotter, Wilfred: Surgery of Malignant Diseases of the Pharynx, Brit. Med. Jour., **1:** 269, 1926.
Malignant Disease of the Mouth and Pharynx, Lancet, **1:** 1075, 1913.
Operations for Malignant Disease of the Pharynx, Brit. Med. Jour., **16:** 485, 1929.
Purvis Oration on the Surgery of Malignant Disease of the Pharynx, Brit. Med. Jour., Feb. 13, 1926.
Von Bruns, V.: Handb. d. prakt. Chir. p. 694, Tübingen, Laupp, 1859.
Woods, R. H.: Laryngectomy, Surg., Gynec. and Obst., No. 34, p. 303, 1922.

CHAPTER XXXV

THE MANAGEMENT OF THE LYMPHATIC AREAS TRIBUTARY TO EPIDERMOID CARCINOMA*

BEFORE reading the discussion of the treatment of the lymphatic areas, it may be well to review briefly a few salient anatomic facts regarding the lymphatic system of the neck (see Chapter II).

The study of the lymphatic areas is pertinent, as buccal carcinoma metastasizes principally by cell emboli, not by permeation. This opinion is supported by three lines of reasoning: first, microscopic sections between the site of the lesion and the glands do not show evidence of invasion; second, first involvement of a node may be more distant than the nearest connective one; third, the nodes may be invaded when the local lesion is still very early and small. Therefore, some knowledge of the distribution of the lymph channels and lymph nodes of the neck is germane to an understanding of metastatic cancer of the buccal, pharyngeal and laryngeal regions.

When metastasis occurs, generally the nodes into which the area involved drains show evidence of metastatic involvement first, but this is not universally true. Supposedly, a lymph channel may become blocked by malignant cells and the pathway becomes changed from the lymph drainage. The median raphe of the anterior two thirds of the tongue tends to prevent cross metastatic involvement. However, the posterior third of the tongue has no such raphe. An area near and mostly beneath the tip of the tongue and over the floor of the mouth and root of the tongue has cross connections across the midline, and metastatic nodes may appear on the opposite side of the neck to the local lesion as early as or even before the enlarged nodes appear on the same side. Likewise, the lymphatic cross connections are all too adequate about the entrance of the glottis, the postcricoid region and the posterior pharyngeal region. As a rule, however, all other areas metastasize, first at least, to the same side. The considerable variation shown in the time at which the lymph nodes are involved depends principally upon the site of the original lesion, the type of tumor, and the degree of anaplasia of the given type. The age and general condition of the patient are other factors of some importance in estimating the probable clinical course of a given type of tumor. Undoubtedly, the lymph nodes may be invaded by cell emboli a considerable time before they become palpably enlarged. As the absorption of inflammatory products also causes lymphatic nodes to become enlarged, early enlargement of the lymphatic nodes is difficult to diagnose clinically. In any series a definite percentage of error on both sides is always found. Slight enlargement of lymph nodes, whether it be from embolic cancer cells or from inflammatory products, is difficult to feel through tissues as thick as the sternomastoid muscle or to

* The greater part of the material in this chapter is taken from two articles published by the author: (1) Management of the Lymphatic Areas Tributary to Oral Cancer, Jour. Mo. State Med. Assoc., **33:** 423, 1936; and (2) Management of the Lymphatic Areas Tributary to Oral Cancer, Internat. Jour. Orthodont. and Oral Surg., **22:** 1157, 1936.

less extent through tissues about the submaxillary gland. Microscopic glandular involvement, of course, cannot be diagnosed clinically. Even several sections of the gland may conceivably fail to show malignant cells enough to ultimately cause the death of the individual. As yet, most of the factors which inhibit or allow more rapid growth in lymph nodes are unknown.

THE TREATMENT OF THE REGIONAL LYMPHATICS

At the present time, what to do with the regional lymphatics is the main point of contention in the treatment of epithelioma in and about the oral region, and this is especially true in carcinoma of the lip. The removal of the immediate tributary lymph nodes en bloc, whether the nodes were palpable or not, has been the method of treatment in most surgical clinics during the past twenty-five years. More recently the workers at Memorial Hospital have adopted what they call a more conservative method of handling the tributary lymphatic areas. They argue that, in cancer of the lip especially, a large proportion of cases seen without metastasis will remain free and that it is not justifiable to subject all patients routinely to a major operation. They do not, therefore, excise the tributary lymphatics until the lymph nodes are thought to be involved by cancer.

For purposes of discussion, one may consider the treatment of the regional glands of the neck under three headings depending on the stages of the disease: (1) when the glands are not palpable, (2) when the glands are palpable but not fixed, and (3) when the malignant cells have evidently broken through the gland capsules and have infiltrated the surrounding tissues.

When the Glands Are Not Palpable

At present, when the glands are not palpable, there is a considerable diversity of opinion as to the proper procedure to be advocated. Those adopting the so-called "conservative" attitude treat the local lesion, irradiate the neck by one type or another of external irradiation and await developments as to the glands while attempting to keep the patient under observation. When palpable nodes develop, a block dissection of the neck is performed. This group, following the lead of the workers at Memorial Hospital in New York, have maintained that up to a certain point the lymph nodes perform a conservative function and tend to limit the growth of malignant cells. The conception has, however, never been proved. They advance the argument that the disease can be dealt with as efficiently after a gland becomes palpable as before it becomes palpable. Moreover, they assume that the patient can be followed for a period of several years—sometimes an unattainable ideal. This school maintains that it is the exception rather than the rule to cure any patient with malignant cervical glands. It therefore recommends that the local lesion be treated and prophylactic irradiation be the routine when the glands are not palpable. This is recommended in the face of the evidence that it requires from 10 to 12 erythema doses of external radiation to be lethal to a fairly radioresistant malignant cell within a lymph node and that from external radiation alone no one has authentic cases of cures of metastatic squamous-cell carcinoma of the fairly radioresistant type. Thus, Shreiner has recently presented a series of cases, in one half of which prophylactic irradiation was done and in the other half

no irradiation was given. In each group the number of patients eventually showing metastasis was the same whether irradiation was given or not.

The advocates of the so-called "conservative" method of handling the glands,point to the number of operations that may be done uselessly, minimize the difficulty of following the patient for a number of years, do not stress the number of deaths due to enlarged nodes getting out from under control while a procrastinating régime is being pursued nor the number of patients that are not followed and turn up in other hands when it is too late to institute treatment with any hope of more than palliative success.

On the other hand, another group have been unable to accept this newer conception and still advocate in most instances of unilateral radioresistant squamous-cell carcinoma a block dissection of the area of the neck most likely to be involved, sometimes at the time of the destruction of the local lesion but more often after a variable period of time has elapsed.

The main points of the question that should be settled are, first, what percentage of cancer in a given situation, which heals without palpable nodes appearing, will eventually develop metastatic nodes? Second, is rather routine neck dissection in cancer a justifiable procedure in the face of the fact that a good many unnecessary neck dissections will be performed if such a procedure is adopted? Third, if the neck dissections are not performed what percentage of individuals will fail to obtain surgery soon enough to give them a chance of a cure or prolongation of life?

The facts necessary to settle this dispute are difficult to obtain. Various groups of statistics as to the percentage of metastasis that eventually appears after the local lesion is healed differ as would be expected. The rate of growth, the character and extent of the growth, and the anatomic location all have a bearing on the likelihood of metastasis eventually appearing in the neck. Even if we had exact and accurate statistics concerning the exact percentage of healed local lesions for a given region that eventually developed metastatic carcinoma, taking all patients as they come, the question of individualization of patients would enter. It is reasonable to expect the likelihood of metastasis in early relatively quiescent local lesions to be much less than in more active and more advanced local lesions. Clinical observation has always borne out this presumption.

Some discussion of the value of prophylactic irradiation is pertinent, if one advocates not performing a neck dissection until palpable nodes appear. In so far as a permanent cure is concerned it is most likely that a sublethal dose of irradiation will not produce an effect upon the ultimate recurrence rate. According to present conceptions prophylactic external irradiation is insufficient to be lethal for relatively adult squamous-cell epithelioma. Although we have little definite proof, prophylactic external irradiation probably produces changes which tend to slow up the growth of epithelioma after it has reached the lymph nodes. As advantageous as an impediment to growth may be, such is considerably different from a cure.

We have no clinical method, of course, of knowing whether or not the lymph nodes are microscopically involved. For a given lesion we can only go on probability. A node is involved with cancer cells for an indefinite period of time, depending upon the type of original lesion, before it becomes clinically palpable. Among the evidence that might guide one is the statistics of the number of patients with a given type of lesion in a given

location in which the local lesion is healed, no palpable nodes are present, but in whom eventually neck metastasis develops. There is at present a considerable amount of clinical experience, and statistical data to make available a general idea based on probabilities. The only difficulty with this line of reasoning is that when one gets the probabilities for the group down to a fair degree of accuracy, in any one case, he may be wrong. When the surgeon is wrong, the patient runs an increased risk of losing his life. On the other hand, he was not subjected to an unnecessary operation.

It seems to me that one is warranted in individualizing to a certain extent. When the chances are good that metastasis will not occur and it is certain that the patient can be followed, one is probably justified in following a conservative course. On the other hand, if the chances are relatively high that metastasis will appear and the chances of one's following the case often enough are poor, one would be justified in a more radical method of procedure.

Percentage of Cases Developing Metastasis Who Present Themselves Without Palpable Nodes.—With this line of thought in mind some study of the likelihood of metastasis in a given type of lesion becomes of immediate practical interest.

The first point to be discussed is the number of cases that do eventually show metastasis after the local lesion is obliterated in a given region.

Duffy (1927) studied the 1917 to 1924 series of cases at the Memorial Hospital. All cases were observed at least two years. In the case of carcinoma of the lip at least, this is too short a period but in some of the other situations it is significant.

Primary in	Cases admitted with no nodes.	No nodes throughout.	Percentage of cases with no nodes on entrance who did not show nodes throughout.
Lip	233	210	90.1
Tongue	194	117	60.3
Floor of mouth	77	54	70.1
Inferior maxilla	65	55	84.6
Superior maxilla	54	45	84.3
Hard palate	26	24	92.3
Soft palate	26	20	77.0
Buccal mucosa	74	59	79.7
Tonsil	56	40	71.4
Antrum	54	46	85.2
Larynx, intrinsic	77	73	94.8
Larynx, extrinsic	47	43	91.5
	983	786	79.95

Of 233 cases of lip carcinoma without palpable nodes, 210 (90.1 per cent) showed no nodes throughout the period of observation; 39 (18.6 per cent) developed nodes that proved to be inflammatory on section, and 23 (8.5 per cent) developed regional metastasis after admission.

Of 194 cases of carcinoma of the tongue, admitted free of metastasis, 117 (60.3 per cent) did not develop nodes throughout; 33 (28.2 per cent) developed inflammatory nodes, and 77 (28.7 per cent) developed metastasis after admission.

If Duffy's figures may be taken as correct, it would appear that a patient with carcinoma in or about the buccal region undergoing treatment for the local lesion and without palpable nodes in the neck has from 10 per cent chance with carcinoma of the lip to 40 per cent chance with carcinoma of the tongue of developing metastasis.

In a given case of carcinoma of the lip with a rather well-developed local lesion, however, the individual's chance of eventually developing metastasis might be greater than 40 per cent, or in carcinoma of the tongue might be greater than 60 per cent. On the other hand, a small low-grade carcinoma of the lip might have practically no chance of eventually showing metastasis and the same to a less degree may be said for a small early carcinoma of the tongue.

Percentage of Bilateral Metastasis.—Another feature of Duffy's paper worthy of our perusal is the number of bilateral metastases. They were as follows:

	Same side.	Opposite side.	Both sides.	Not stated.
Lip	40	3	9	9
Floor of mouth	42	2	24	
Inferior maxilla	21	2	5	
Superior maxilla	12	..	3	2
Hard palate	3	2	2	
Soft palate	4	..	7 (14 cases)	3
Tonsillar region	68	6	5	5
Antrum	13	..	4	
Larynx (intrinsic and extrinsic)	48	1	22	

The percentage of bilateral metastases is interesting as showing the percentage of chance a unilateral neck discussion has of not being of value in the various locations enumerated.

Results of Excision of Lymph Nodes After Involvement.—The next logical point for discussion pertains to the chances that a block neck dissection has of eliminating the lymphatic involvement if it is present. Some evidence can be presented showing the difference between removing cancerous nodes when the involvement is only microscopic in size and in removing cancerous nodes after they become palpably enlarged but before the capsule is perforated.

Blair has 20 out of 74 (27 per cent) known involvements of the cervical lymph nodes by squamous-cell epithelioma well five to seventeen years after excision en bloc (Fischel). Simmons, in 48 cases radically operated, had 23 in which the gland proved to show cancer; 17 per cent of these lived five years. Of the 25 that showed no carcinoma in the glands, 34 per cent lived five years. Of the 25 that showed no carcinoma in the glands, 34 per cent lived five years. Other series of this type can be presented to show that neck dissection properly performed is of value (see Butlin's series). Fischel recently presented a series of cases of intra-oral cancer (112 cases) with 70 per cent of the cases (including those with nonpalpable nodes—10 per cent) showing carcinoma as proved by the microscope in the lymph nodes. Neck dissections were done on all patients. He had 10 patients without palpable nodes, 7 of which showed carcinoma on microscopic examination after neck dissection; 23 per cent of these lived five years or more. Of the remainder with palpable nodes and microscopically positive, 13.8 per cent lived five years or more. This is the experience of most surgeons. Again Kennedy recently has presented a series of lip cancers, 32 of which had proved metastasis; 34 per cent of these are alive and well. Seven were alive and well over three years.

As to the value of prophylactic external irradiation, the following observations by Shreiner and Mattick are interesting as having a bearing upon the likelihood of its being of value.

Value of External Irradiation of Lymphatic Areas.—Shreiner and Mattick present some interesting statistics of nonpalpable lymph nodes treated by irradiation. They divide their cases into small and large local lesions. In one half of each group no irradiation was given to the lymphatic areas and in the other half intensive prophylactic irradiation was given. They obtained exactly the same percentage of five-year cures in the group where the lesions were treated only locally as in the group where the neck was also irradiated, namely about 85 per cent in the small local lesion group and 58 per cent cure in the large local lesion group. On the other hand, Widman presents a series of 52 patients suffering from carcinoma of the lip who had prophylactic irradiation and only 17 per cent developed metastatic nodes in the neck. In a comparable group of 72 patients suffering from carcinoma of the lip but who were given no prophylactic irradiation, 51 per cent developed metastatic nodes in the neck.

Clinical Diagnosis of Palpable Glands.—Most observers have concluded that there is a rather high percentage of inaccuracy both ways in trying to distinguish whether a palpable node in the neck is involved by cancer or is enlarged by inflammatory products. For example, Simmons in 22 cases of gland palpable clinically found that 12 proved to be cancer and 10 proved not to be. In 20 cases with no glands palpable 7 proved to be cancer and 13 proved not to be cancer when examined microscopically. Lund in 33 small gland cases found that 16 proved to be cancer and 17 proved not to be. Fischel in 112 cases had only 10 showing nonpalpable nodes and 7 of these proved to be involved by carcinoma; 24 of the 112 had palpable glands but did not prove to be involved by cancer on excision.

Microscopic Grading of the Local Lesion.—Although all observers are not agreed, the majority I believe admit that the likelihood of Group 4 (Broders') being successfully treated by radical block dissection is quite

small. For example, Simmons in 15 cases of Group IV carcinoma had no cures. Most students of the question agree that in lympho-epithelioma and transitional-cell and the various radiosensitive types of epidermoid carcinoma practically no good results are given after neck dissection. On the other hand, for the time being at least, irradiation affects such types very favorably and theoretically a sufficient dosage can be given to be lethal for metastatic tumor cells. But if the surgeon is going to place some reliance upon the cellular type and microscopic grading in so far as treatment is concerned, the pathologist must be experienced enough in the study of this type of tumor to be able to make an estimate with a fair degree of accuracy.

The Size or State of Advancement of the Local Lesion.—Besides the microscopic grading of a local lesion the size and state of advancement of the local lesion are important in the consideration of whether or not a neck dissection is indicated. All series of cases will vary according to the size of the local lesion. For example, in carcinoma of the lip treated surgically with routine neck dissections performed, Kennedy (147 cases) found that 88 per cent of the patients with lesions up to 1.5 cm., 67 per cent of those with lesions between 1.5 cm. and 3 cm. and 44 per cent of those with lesions over 3 cm. in size were alive and well.

No good statistics can be presented to compare the size of the local lesion and its state of advancement with the increased percentage of lymphatic metastasis which eventually appears. But no observer with any great experience would deny that the chances of metastasis, even if the glands are not palpable, increase proportionately as the state of advancement of the local lesion is increased.

Mortality of Neck Dissection.—The mortality of a neck dissection alone carried out under local anesthesia should not be over 2 to 3 per cent in this class of patients and in selected cases it should be lower than this. However, as cancer is a 100 per cent deadly disease, I do not believe one should select his case with an eye on his mortality statistics. In a group of cases where some chance of cure is offered one is justified in taking a chance if it is not too much of a forlorn hope.

The mortality depends to a considerable degree upon when the neck dissection is done. When one attempts to do the neck dissection at the time of excision of the local lesion, or before the patient gets in fair condition after treatment of the local lesion, the mortality will be raised. In the feeble and very old, if one leans somewhat toward the conservative side, the mortality tables for any group of cases will appear better. As cancer of the aged is not quite so malignant one may be justified in this. The submaxillary dissection used in lip carcinoma will run a lower mortality percentage than the complete unilateral block dissection. Needless to say, if one ever does a bilateral neck dissection, the patient should have completely recovered from the first operation before the second is performed.

Although the advocates of the so-called "conservative" method of handling the disease contend that, as long as the capsule of the lymph node is intact, neck dissection offers all that an operation ever offers, the evidence that can be presented would suggest that this is not entirely true. Most series of cases indirectly suggest that the earlier a carcinomatous gland is removed, the less likelihood of a recurrence, all other factors being equal.

Conclusions in Regard to Nonpalpable Nodes.—Finally after sifting all the evidence one can say, I believe, that although the number of patients without palpable nodes in the neck who will show metastasis after the local lesion is healed is smaller than once was thought, and although the percentage of cures after removal of carcinomatous glands is somewhat less than has been stated at times in the past, but considering that prophylactic irradiation in the metastatic adult squamous-cell carcinoma is as yet not of proved value along with the well known 100 per cent fatal result of uncontrolled metastasis, one is not warranted in always adopting a procrastinating régime. This régime can only be justified where the chances of metastasis are slight or where the type of local lesion suggests that the lesion is radiosensitive, and not even under these circumstances unless one has the patient under the most careful type of observation and control. When one heals the local lesion only and then allows the patient to get out from under strict observation, he has done the patient a much greater injustice than if he did a neck dissection which raised his chances of a cure from 10 to 20 per cent according to the location and type of the lesion with a risk of only 2 or 3 per cent on the operation. No doubt routine neck dissections should be discarded. Bilateral complete neck dissections in most instances should not be done. Although neck dissection when the nodes are palpable should not in my opinion be a routine procedure, neither should procrastination and prophylactic irradiation be routine. When one begins to individualize in cancer he steps out on treacherous ground and certainly the inexperienced traveler at least is going to be waylaid many times. I do believe that the experienced man can balance all factors so that the percentage of chance favors the patient. Into this consideration enters the age of the patient, his condition, the extent of the lesion, its clinical appearance, the location, the cellular type, the probable reaction to irradiation, the probable reaction to surgery and the chances for prolonged and continued observation of the given patient to whom the advice is given. The position might be described as about the "three quarter way" position from routine neck dissection of nonpalpable nodes. From routine neck dissection in adult squamous-cell epidermoid carcinoma it eliminates, on the one hand, the early small lesions with adult cellular characteristics and, on the other hand, certain rapidly growing pleomorphic anaplastic lesions which have been shown to be affected somewhat favorably by irradiation methods and unfavorably by surgical excision. This position also takes into consideration whether or not the patient will present himself for competent observation over a period of years, whether or not the patient is intelligent, and whether or not he is handicapped because of distance, economic factors or noncooperation. For example, in a large series of lip cancers treated locally by Quick by irradiation methods in a hospital with a good follow-up system, about one third soon were untraceable. When it is probable that the person will not be followed properly one is warranted in leaning more to the side of routine neck dissection. A higher percentage of lives will be saved. On the other hand, when the patient is intelligent and cooperative and realizes his condition, one may be warranted in leaning toward the side of conservatism on the basis that the neck dissection will be done immediately as soon as the smallest node appears. However, if I had a cancer of this region, I should not be inclined to take many chances with a disease

in which all too often one is forced to watch the slow disintegration of a procrastinating sufferer while standing by helpless to prevent a miserable death.

Procedure as to Location When the Nodes are not Palpable.—*Lip.*—In epithelioma of the lip without palpable glands probably about 10 to 15 per cent metastasize after the local lesion is healed. However, a larger lesion and one of more rapid growth and greater cellular activity increases the chances of the glands already being microscopically invaded by metastatic cells. An early slow-growing lesion of the Grade I type is not likely to have metastasized. It must be taken into consideration that the type of neck dissection considered adequate for carcinoma of the lip is somewhat less disfiguring and has a lower mortality than a complete unilateral neck dissection.

In the early, slow-growing, relatively benign type of lesion when the chances of following the patient are good, one may be justified in adopting a conservative procedure. But in most other instances a conservative method is hardly a justifiable one.

Tongue.—As a rule, in all save the very early epithelioma of the anterior lateral tongue expectant treatment of the glands is hardly justifiable. Metastasis is early and fairly certain. In a lateral tongue lesion, unilateral removal en bloc is sufficient. When the lesion is centrally located a conservative attitude toward the glands may be justified because one does not know on which side to do the neck dissection. Also, in the posterior tongue, the lesion may be of the radiosensitive type. When the lesion gives evidence of being of the radiosensitive type, heavy irradiation of the glandular areas may be sufficient and expectant treatment then is justified. But in all except very early adult squamous-cell lesions to one side of the posterior tongue, a conservative attitude toward the glands is not as a rule justifiable.

Epithelioma of the Mesopharynx and Hypopharynx.—In unilateral epithelioma of the adult type about the fauces, mesopharynx and hypopharynx, expectant treatment is hardly justifiable. A high percentage soon show evidence of metastasis. However, when the clinical appearance of the local growth and the microscopic study coincide and indicate that the tumor is one likely to be radiosensitive or is of an anaplastic type, external irradiation may justifiably be given and the neck treated expectantly as far as surgery is concerned.

Cheek.—Epithelioma of the cheek unless very early and of a rather benign type should not be treated expectantly as the chances of metastasis are usually sufficiently great to warrant a neck dissection.

Antrum.—Antral carcinoma metastasizes late as a rule. Usually the neck may be treated expectantly.

Prophylactic Bilateral Neck Dissection.—Prophylactic bilateral removal of the glandular area is not considered a justifiable procedure save in carcinoma of the lip where only a bilateral submaxillary and a submental removal is done.

When the Nodes are Palpably Enlarged but Freely Movable

When the lymph nodes are palpably enlarged but freely movable, most workers are agreed that the method of choice is block dissection, unless growth is thought to be clinically, or can be diagnosed microscopically, or

shown by the therapeutic test to be radiosensitive. Then excision of the glands is not justifiable. But otherwise block dissection is the method of choice.

Some conservative workers take the stand that the grade of the primary lesion in the buccal cavity should not influence the decision for or against neck dissection. Unless the work of Broders and Ewing is entirely incorrect in regard to radiosensitivity this stand is not correct. The radiosensitive types usually can be distinguished by a combination of clinical and microscopic study. In radiosensitive lesions dissection is probably of little or no value.

After block dissection, it may be advisable to lay radium in areas where one suspects the carcinomatous cells might remain. Moderate preoperative irradiation of the enlarged nodes has theoretical points in its favor. Viable carcinomatous cells possibly are not so likely to be reimplanted when a neck dissection is done. When sufficient irradiation is given to approach a lethal tissue dose (coutarding) at first the skin of the neck will not be in condition for operation and later the tissues will be fixed by a fibrosis which will make a neck dissection a practical impossibility. Although postoperative irradiation has not been proved to be of value, it is very often given after removal of the enlarged nodes. At least, no one argues that it does any harm when properly given. It may save a few cases or prolong life in other instances.

When the Malignant Cells Have Evidently Penetrated the Capsule of the Gland or the Metastases are Bilateral

When the Capsule of the Gland is Perforated by Carcinoma.—The workers at the Memorial Hospital in New York have laid down the criterion that, when there is evidence that the capsule of the lymph node is perforated, neck dissection is a useless procedure. I do not believe that this is entirely true. It must be admitted that immediately after the capsule of the gland is perforated the chances of a cure have greatly diminished, but they are not entirely gone. Whether or not a neck dissection will offer anything depends upon the type of tumor and to what it is fixed. When the metastatic mass is free from the carotid artery and has not involved bone to any great extent beyond the possibility of complete destruction or excision of all the bone likely to be invaded by cancer cells, a neck dissection may still offer the patient more than interstitial irradiation both by the way of a small chance of a cure and by the way of palliation. The mere fact that carcinomatous cells have perforated the capsule of the lymph nodes is not in our opinion a rule without exception for judging the limits of operability by neck dissection.

For those more advanced examples in which the carcinomatous glands are fixed to the carotid arteries, have involved the bone or widely invaded the soft tissues, interstitial radiation (Fig. 253), plus heavy external irradiation offers a certain amount of palliation. It is the preferable way of handling this distressing and all too common situation. When accuracy of application is desired, it may be wise to expose the glandular areas surgically and under direct vision apply the radium interstitially. The rather peculiar conception, which also has some advocates, of picking out isolated glands to insert foci of radium into seems rather far fetched. The method suggests the needle in the hay-stack aphorism.

Bilateral Glands.—Bilaterally enlarged glands are not always hopeless although usually so. We believe that here again the location and the type of the original lesion must be considered in the decision. In the more radioresistant lesions which may offer some chance when approached by operative measures, we see no reason to condemn the patient to the group listed for mere palliation until it is proved that he belongs to that category. When the original local lesion is located posteriorly in the pharyngeal or posterior buccal region, a location which tends to develop a more radiosensitive type, intensive irradiation is to be preferred as operation offers practically nothing. But in epitheliomas derived from the lip especially and sometimes from regions in the anterior buccal cavity bilateral gland removal may give the patient the only chance he has.

Thus, we believe that in this group a medium radical attitude toward the metastatic glands should be taken, making exceptions when the pathology of the region seems to indicate that the possibilities of irradiation are likely to be greater.

The evidence has not yet been produced to warrant a complete change of procedure in regard to handling the cervical lymph nodes. One goes far enough when all attempts are made to select relatively radiosensitive metastatic lesions from relatively radioresistant lesions. Many workers state that this cannot be done. But we believe that within broad limits some selection is possible and wise.

Removal of Lymphatic Tissues for Carcinoma of the Lip

Forty-five minutes before operation, the patient is given ¼ grain morphine or its equivalent. The patient is placed on a suitable table with head thrown slightly back and to one side so as to give good access to the upper part of the neck and the submaxillary, submental, and upper deep cervical regions. The neck and chin regions are prepared. One-half per cent novocain with 3 or 4 drops of adrenalin to the ounce is infiltrated along the lower border of the mandible into the skin and subcutaneous tissues. The skin and subcutaneous tissue over the submental and submaxillary areas and upper deep cervical areas are infiltrated similarly. With a longer needle the tissues deep to the skin and up beneath the mandible are infiltrated. After a few minutes (Fig. 277) an incision is outlined with the point of the knife from the mastoid process forward downward to a point ½ inch below greater cornu of the hyoid bone. From this point, the incision is continued to the midline and slightly past it upward toward the lower border of the mandible in the opposite submental region. Towels and towel clips are placed to isolate the field. The incision is deepened to just above the platysma myoides muscle. The skin flap is raised upward to just above the lower edge of the mandible. The external and anterior jugular veins and the platysma myoides are caught, cross cut, and ligated just below the original skin incision. The attachment of the digastric tendons to the hyoid is exposed. Just at the lower edge of the mandible the platysma myoides is cross cut, the facial artery and vein are caught and ligated as they cross the mandible and the anterior border of the masseter. Without injuring the periosteum the soft tissues attached to the edge of the mandible are loosened forward to past the midline in the submental region and back to the sternomastoid muscle just below the lower tip of the ear. Starting below and in front, all tissue down to and

over the mylohyoid muscle are dissected backward and upward from the submental triangle. The contents of the submaxillary triangle are dissected upward. At the posterior border of the submaxillary triangle the facial vein is encountered, caught, cross cut, and ligated. The facial artery is encountered as it enters the submaxillary gland under the posterior belly of the digastric muscle. It is caught, cross cut, and ligated. Thus, a flap is raised containing a mass of tissue normally found over and in the submaxillary triangle and, as the fascia along the anterior border of the sternomastoid muscle is freed, the contents of the submaxillary is pulled upward. The submaxillary gland and all of the surrounding tissue above

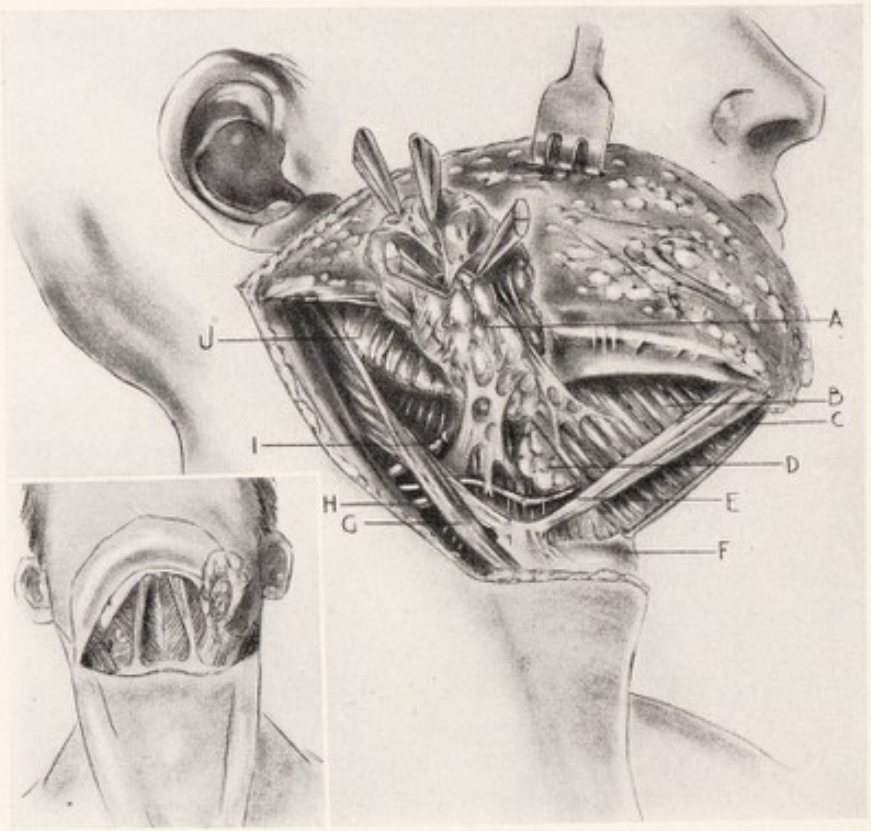

Fig. 277.—Lateral view of excision of tissue en bloc of the submaxillary and submental triangles. Insert shows anterior view of the structures. Ordinarily the operation is done bilaterally. A, Submaxillary gland and the areolar tissues of the submaxillary triangle; B, mylohyoid muscle; C, anterior belly of the digastric muscle; D, stump of the cut submaxillary gland; E, hypoglossus nerve; F, hyoid bone; G, posterior belly of the digastric muscle; H, superior thyroid artery; I, facial artery; J, masseter muscle.

and about the digastric muscle are removed and the tissue anterior to the upper part of the sternomastoid muscle is removed en bloc. The intraoral part of the gland is caught, cross cut, and ligated just where it disappears beneath the posterior border of the mylohyoid muscle. The smaller vessels of the neck which have been caught as the operation progresses are now tied. If the submaxillary lymph nodes on cross section show grossly any evidence of cancer, the sternomastoid muscle is retracted and the gland along from the bifurcation of the carotid artery upward is removed en bloc as nearly as possible (Fig. 278). If the submaxillary lymph glands show no evidence of involvement on cross section, the upper deep cervical nodes are ordinarily not removed. When the lip ulcer is near the corner of

the mouth, a unilateral neck dissection is performed. It is considered that, when the local lesion is found toward the midline, the chances of cross metastasis are sufficient to warrant removal of lymphatic structures of both submaxillary triangles. Such a bilateral removal adds little to the risk and the defect after the operation is scarcely noticeable.

The skin flap is turned down. A small gauze pack is inserted to the submaxillary space and a similar one to the upper deep cervical space where it has been entered. Silk sutures are used to close the skin. The gauze drain has its exit at a dependent position. A modified Barton bandage is

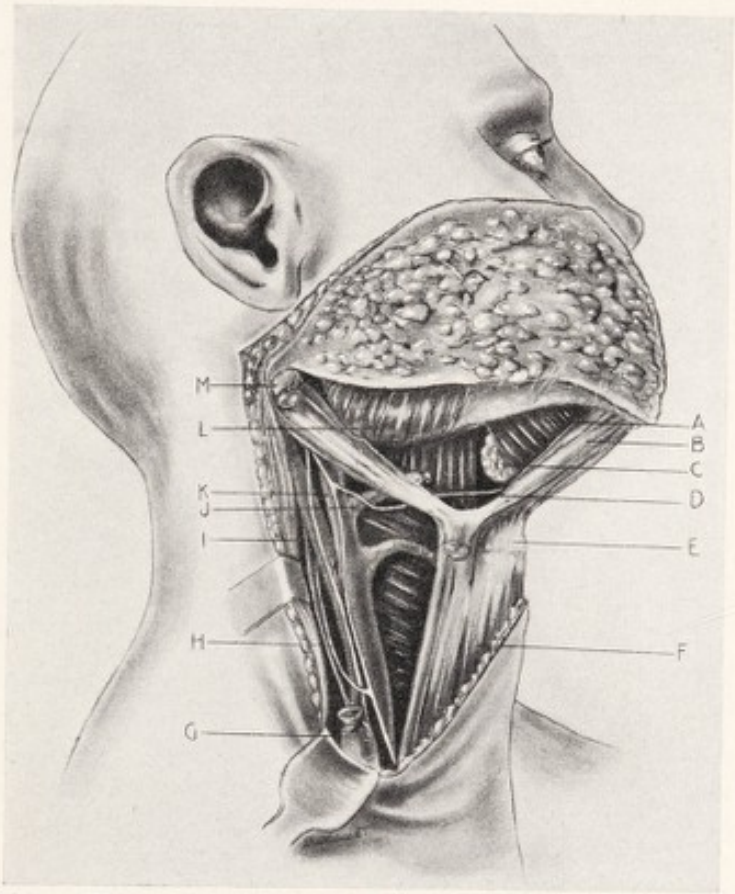

Fig. 278.—Submaxillary dissection of the upper deep cervical tissues when the submaxillary tissues show cancerous involvement of the lymphatic structures. The upper two thirds of the jugular vein is removed along with the areolar tissues which surround the carotid artery. A, Mylohyoid muscle; B, anterior belly of the digastric muscle; C, cut stump of the submaxillary gland; D, hypoglossus nerve; E, hyoid bone; F, pretracheal muscle; G, stump of deep jugular vein; H, common carotid artery; I, internal carotid artery; J, facial artery; K, external carotid artery; L, masseter muscle; M, upper stump of deep jugular vein.

used to compress tightly a fairly heavy gauze dressing. The gauze drains are removed after forty-eight hours and a dressing applied to compress the skin flap into the submaxillary space.

Local anesthesia is advantageous in comparison with general anesthesia. There is less bleeding. The exposure is easier and the patient has a happier postoperative course.

When the upper deep cervical glands are involved by cancer, a complete neck dissection en bloc should be performed.

Mortality.—This operation should not have a mortality of over 2 per cent. In good operative risks, it should not be more than 1 per cent. In

elderly persons who are evidently poor risks, often it is not necessary to do the operation as epithelioma of the lip may grow only slowly and metastizes late in elderly individuals as a rule. By the use of local anesthesia and careful selection of patients, the mortality can be kept down. In from one week to ten days the patient can be out of the hospital.

Unilateral Removal of the Lymphatic Areas en Bloc

Crile first emphasized the advantages of complete resection of the neck en bloc. His operation included the removal of the sternomastoid muscle

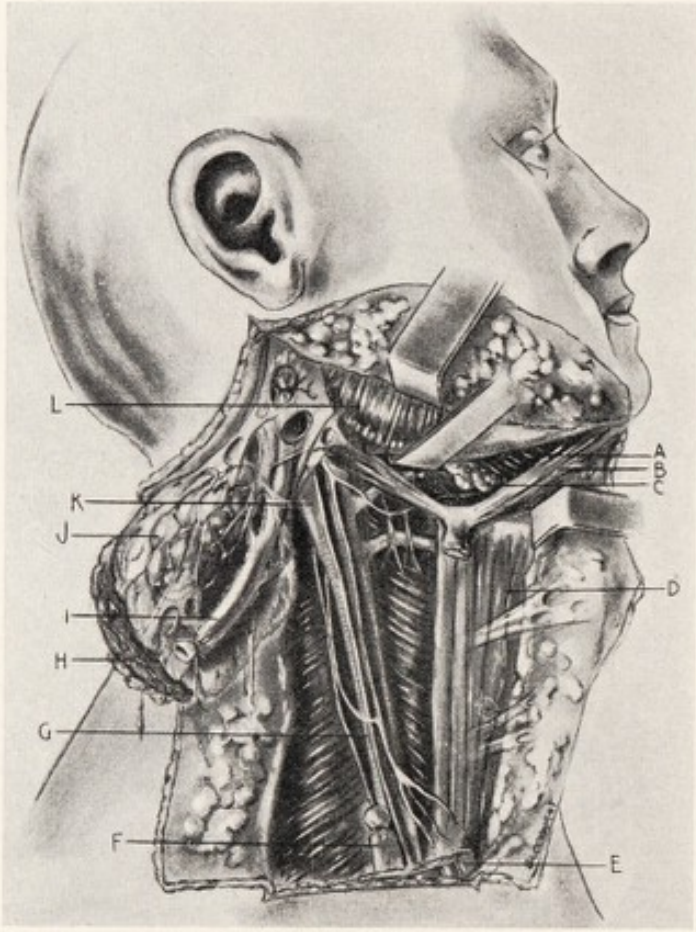

Fig. 279.—Complete unilateral bloc dissection of the neck. The areolar tissue of the submaxillary and submental triangles and the areolar tissues along the carotid vessels from the clavicle to the sternomastoid process are removed. To remove these thoroughly it is considered necessary to remove the sternomastoid muscle and the deep jugular vein. A, Mylohyoid muscle; B, anterior belly of the digastric muscle; C, cut stump of the submaxillary gland; D, pretracheal muscle; E, cut stump of the sternomastoid muscle; F, ligated stump of the deep jugular vein; G, common carotid artery; H, sternomastoid muscle; I, deep jugular vein; J, lymph nodes and areolar tissue surrounding the carotid artery; K, internal carotid artery; L, masseter muscle.

and the deep jugular vein. Kocher, Butlin, and Maitland advocated a less radical operation without removal of the jugular vein unless the glands were adherent to it. When the operation is indicated we ordinarily perform the complete operation. It is essentially as follows:

An incision is made from a point about the level of the sternomastoid process which curves downward to about the level or a little below the greater cornu of the hyoid bone (Fig. 279). The knife is then carried upward to a point a little past and below the midline submental region.

From the midpoint of the incision a second incision is made downward to a point about ¾ inch above the clavicle and to the outside of the sternomastoid muscle at this point. From this point, about ¾ inch above the clavicle the incision is turned backward and extended about 2 inches parallel with the clavicle. The upper skin flap (Fig. 279) is dissected upward to a point about ½ inch above the lower edge of the mandible. The posterior flap is dissected back until the posterior neck muscles are exposed. The anterior flap is dissected forward to within about ¾ inch of the midline. Along the lower edge of the mandible, the platysma and other subcutaneous tissue are cross cut down to the periosteum of the mandible and the masseter muscle. The facial artery and vein are caught and ligated at the anterior border of the masseter. This allows one to free the attachment of the tissue along the lower edge of the mandible. A second incision is made immediately beneath the original skin incision over and along the digastric muscle. The facial vein is caught and ligated above the digastric midtendon. The submaxillary gland is pulled upward and the facial artery caught and ligated as it passes into the posterior surface of the gland. The submaxillary triangular tissues are freed from the anterior border of the sternomastoid where this is a sort of facial raphe. The submaxillary gland and the contents of the triangles are turned upward over the edge of the mandible. The contents of the submental triangle are then dissected off of the mylohyoid muscle. The projection of the submaxillary gland above the mylohyoid muscle is pulled downward from above the mylohyoid, ligated and cut.

One then drops to the lower part of the neck and with forceps picks up the lower end of the sternomastoid muscle and cross cuts it. With dissecting scissors the deeper jugular vein is exposed. It is freed, doubled, ligated and cut and doubly tied. The fat of the triangle posterior to the sternomastoid and above the clavicle is dissected out and upward. One then exposes the deep jugular vein. Its lower part is freed, doubly ligated and cross cut. The areolar tissue of the posterior triangle of the neck is dissected free and from below upward. The carotid is exposed and the deep jugular vein, sternomastoid muscle and the areolar tissue surrounding the artery are freed from it in an upward direction. The omohyoid muscle is cut, the superior thyroid artery ligated and cut. The bifurcation of the common carotid is exposed. The occipital artery is ligated and cut. The lingual usually does not have to be ligated. The facial artery previously has been exposed, ligated and cut in the submaxillary triangle. The tissues of the lateral neck have now been freed up to the lower parotid pole. The carotid arteries lie in plain sight along with the vagus and the sympathetic nerve. All branches of the carotid artery should be ligated at least ½ inch from the main artery. The hypoglossal nerve is not molested. The spinal accessory nerve is cut as it enters the sternomastoid muscle. The superficial nerves are also cut.

Next, the sternomastoid muscle is cross cut just below the mastoid process attachment. One comes down upon the upper end of the deep jugular vein above the digastric muscle. The upper end of the vein is isolated, doubly clamped and doubly ligated. One usually cross cuts the lower pole of the parotid gland. In it lie several veins and small arteries which have to be clamped and ligated. Now the sternomastoid muscle along with the

deep jugular vein, and cervical areolar tissues and lymphatic structures have been entirely freed. They are removed.

The skin flaps are replaced to their former positions and sutured. A small pack is placed to the lower pole of the parotid, submaxillary fossa, and another just above the clavicle at the lower edge of the dissection. A large pressure dressing is placed on the neck with the bandage running up over the head.

The operation is usually done under local anesthesia. A combination of block anesthesia and infiltration anesthesia is best. The superficial cervical nerves are blocked. The inferior dental nerve is blocked by passing a needle upward inside and beneath the angle of the jaw. The remainder of the anesthesia is of the infiltrative type—both deep and superficial. With this type of anesthesia, tissue planes are easy to see. Little blood is lost. The patient should not be greatly affected by the operation. The operation takes about thirty-five minutes to complete if one is adept at doing it. The pulse should not be over 85 or 90 at its completion. Immediately after the operation the patient should be given a cup of warm coffee and placed in a semireclining position in bed. The packs are removed after three or four days. The pressure dressing is continued in such a fashion that all dead spaces are collapsed. The stitches are removed in one week to ten days.

The operation done under local anesthesia in fair risks should not have a mortality of over 3 to 4 per cent. One may, however, be justified in extending the procedure to risks that are not good when it is indicated because it may be the patient's only chance of obtaining a cure.

The diathermic knife or the cautery knife may be used for doing this operation if one prefers. However, the dissection along the artery had best be done with dissecting scissors or a scalpel in our opinion. Otherwise one runs too great a risk of damaging the artery.

Bibliography

Bibliography Quoted in Text

Blair, V. P., and Brown, J. B.: Treatment of Cancerous or Potentially Cancerous Cervical Lymph Nodes, Ann. Surg., **98:** 650, 1933.

Broders, A. C.: Carcinoma Grading and Practical Application, Arch. Path. and Lab. Med., **2:** 376, 1926.

Butlin, H. T.: An Address on the Results of Operations for Carcinoma of the Tongue With an Analysis of 197 Cases, Brit. Med. Jour., **1:** 1, 1909.

Crile, G.: Excision of Cancer of the Head and Neck, J.A.M.A., **1:** 786, Dec., 1906.

Duffy, J. J.: Conservative Treatment in the Care of Cervical Lymph Nodes in Intraoral Cancer, Amer. Jour. Roentgen., **29:** 241, Feb., 1933.

Ewing, James: Neoplastic Diseases, 3rd ed., Phila., W. B. Saunders Co., 1931.

Fischel, Ellis: Surgical Treatment of Metastasis to the Cervical Lymph Nodes for Intraoral Cancer, Amer. Jour. Roentgen., **29:** 237, 1933.

Surgery as Applied to the Lymph Nodes of the Neck in Cancer of the Lip and Buccal Cavity, Amer. Jour. Surg., **24:** 711–730, 1934.

Kocher: Ztschr. f. Chir., **13:** 131, 1880.

Kennedy, R. H.: Epithelioma of the Lip With Particular Reference to Lymph Node Metastasis, Ann. Surg., **99:** 81–95, 1934.

Lund, C. C.: Pathology of Carcinoma of the Buccal Mucosa in Relation to Results of Treatment, New Eng. Med. Month., **209:** 126, 1933.

Lund, C. C., and Holton, H. M.: Carcinoma of the Buccal Mucosa: End Results, 1919–1926, New Eng. Med. Month., **208:** 775, 1933.

Maitland, H. L.: Australian Med. Gaz., **25:** 170, Oct. 20, 1906.

Shreiner, B. F., and Mattick, W. L.: Five-Year End-Results Obtained by Radiation Treatment of Cancer of the Lip, Amer. Jour. Roentgen., **30:** 67, 1933.

Simmons, C. C.: The Treatment of Oral Cancer, Amer. Jour. Roentgen., **26:** 5, 1931.

Quick, D.: Surgery and Radium in the Treatment of Buccal Carcinoma, New York, William Wood and Co., 1928.

The Conservative Treatment of Cervical Lymphatics in Intraoral Cancer, J.A.M.A., **77:** 436, 1921.

Interstitial Radiation in Metastatic Cervical Nodes of Epidermoid Carcinoma, Ann. Surg., **93:** 380, 1931.

Widman, B. P.: Carcinoma of the Lip—Results of Roentgen and Radium Treatment, Amer. Jour. Roentgen. and Rad. Ther., **32:** 211, 1934.

CHAPTER XXXVI

THE SELECTION OF THERAPY AND THE PROGNOSIS FOR MALIGNANT NEOPLASMS OF THE SOFT TISSUES*

In foregoing chapters the various malignant new growths of the soft tissues have been described and thrown into pathologic categories which at first glance the inexperienced might judge would allow the clinician always to be certain of his diagnosis, his treatment and his prognosis. Unfortunately, such is not the case at all. The pathologists have only partially classified the subject for the therapist. A good deal of our pathologic classification, our theories as to radiosensitivity and radioresistance outline the way it should go if our theories are correct but unfortunately we sometimes can only guess before we treat and may only suspect what happens after we treat.

One should individualize in the selection of the type of therapy. To do this, the ideal therapist should have a knowledge of the pathologic and clinical course of the disease, a knowledge of the rationale and results to be obtained by good surgery, a knowledge of the rationale and results of modern radiation therapy in all its forms and, finally, not only a knowledge but the equipment and the ability to use each type of equipment.

The best method of treatment for the individual occurs when the whole clinical picture and therapeutic picture are balanced. Often, it is best to know the cellular characteristics in advance. However, although the ideal is biopsy before therapy, practicality may dictate many exceptions. One exception is the lesion, small enough and located in a region where total excision would seem wiser than the excision of a small piece of the tumor. Second, in many other locations, as the anterior tongue, the antrum, the lip, or the hypopharynx, a certain cellular type may be to a great extent prognosticated by a good clinician so that microscopic study prior to the institution of treatment is of no great advantage. A third exception may be caused by the location of the lesion and a consequent difficulty in exposure. Thus, in situations such as the hypopharynx, or sometimes the larynx, careful clinical study may be deemed sufficient to warrant a decision as to the type of therapy, biopsy being obtained in the course of procedure. The fourth exception is that considerable group of cases in which there is no question as to the advisability of operation. Then microscopic study of the case is postponed until after the operative procedure.

On the whole, when one summarizes the essentials of actual practice for neoplasms in this region a study of the microscopic grouping alone in only a small percentage of cases will materially influence the therapy. In all cases, however, where additional valuable information may be obtained in relation to the plan of attack by knowing the cellular grouping or the cellular type, time and trouble should always be taken for preliminary

* The material for this chapter is taken largely from two articles published in the International Journal of Orthodontia and Oral Surgery in the December number, 1936, and the January number, 1937.

microscopic study before treatment is decided upon. Preliminary biopsy and microscopic study aid in selecting proper therapy more in the posterior buccal pharyngeal lesions than elsewhere.

When the treatment is planned and a cure is contemplated, the scope must be sufficient to get beyond the farthest extension of the disease. It must meet the pathologic necessity of the case. When this cannot be met, the treatment is necessarily only palliative. When the treatment is necessarily only palliative, care should be taken not to interfere inadequately in such a manner that disease is encouraged to progress at an increased rate. Therefore, before treatment is started, it is usually wise to determine whether a try for a cure or only for palliation is to be made.

Although the proper selection of cases in the light of our present knowledge and the more general use of a two-stage operation in suitable cases with its tendency to a lower operative mortality will tend to throw surgery into a better light than has been the case in the past decade or so, it is not wise to subject nearly so high a percentage of advanced cases to operation as was formerly done. When surgery cannot be carried on without a fairly low mortality and not too great mutilation, radiation methods when they seem rational should be selected. In advanced cases while surgery offers little, especially in the anaplastic, more malignant grades and types, irradiation offers considerable.

One might judge that radium heals without discomfort or pain. The discomfort that follows intensive irradiation is usually as great as and in many instances considerably greater than after radical excision.

Basal-cell Epithelioma of the Skin.—Basal-cell epitheliomas, provided that cartilage or bone has not been invaded, are rather radiosensitive. But wide excision or cautery destruction also generally leads to a cure. The method of choice depends upon the facilities available and the location of the lesion. In regard to location one chooses the method which will give the best appearing result. In many areas excision allows one to get a scar which is not unsightly. In other areas, the distortion or the scar may not be satisfactory so that the scarring which follows radium is preferable. When cartilage or bone has been involved, one runs a great risk of not obtaining a cure by the use of irradiation methods. Therefore, when cartilage is involved excision is often preferable to irradiation. However, in such regions as the nose for example, in a certain percentage of cases heavy irradiation will cause a basal-cell epithelioma to heal even after there is slight cartilaginous involvement. Here often excision methods may be held in reserve until irradiation has been given a trial. Later, if necessary, the mutilation will not be much greater if radiation methods fail and one is forced to resort to wide excision. When the excision is complete the chances of a cure are good. When a basal-cell epithelioma involves bone, it is seldom that radiation is an effective mode of treatment. Usually, therefore, when bone is invaded, it is best to remove totally the diseased bone along with a moderate amount of normal bone. Around the upper face, anatomic considerations tend to handicap one in removing a sufficient amount of tissue. In such a situation supplementary irradiation may offer a somewhat greater chance of obliterating the lesion.

Squamous-cell Epithelioma of the Skin.—Squamous-cell epithelioma of the skin does not metastasize so quickly as squamous-cell epithelioma with-

in the oral cavity. The type of treatment selected should vary according to the anatomic or regional considerations. In a large series of individuals treated by surgical methods the percentage of five-year cures is about the same as in a similar series treated by radiation methods. Moderately early squamous-cell epithelioma of the skin treated by adequate methods will show in the neighborhood of 70 to 75 per cent five-year cures. In certain cases both irradiation and total excision are advisable to make one more certain of complete control. When metastases are already present some idea of the prognosis of squamous-cell epithelioma of the skin may be gained from a study of the records of cure of carcinoma of the lip with metastases. But taking all squamous-cell epitheliomas of the skin, one is not likely to find the tributary lymphatics located anatomically in a region so favorable to remove or to treat as one finds in carcinoma of the lip. Such a location may handicap effective therapy.

Carcinoma of the Lip.—In the epidermoid carcinoma of the lip, preference is given to radium if the lesion is a small local one. When the lesion is spread along a considerable length of the lip and is rather superficial, radium is also given preference. When the bone is involved, radium is not used. The local lesion is excised and a good layer of the bone destroyed with a soldering iron or endothermic button. When radium has already failed to heal the local lesion, surgery is used. This group represents a fair number of cases that one sees and does not always depend upon whether or not the original application was correctly applied. When the infiltration of the local lesion involves most of the lip, it is usually considered wiser to excise the local lip lesion if the lymphatic glands are operable.

Whenever possible after surgical excision an immediate plastic operation is done to rebuild the lip. Thus, the excision and the repair is done in one operation. If the repair entails a fair amount of surgery, the glandular region is taken care of at a separate operation as a rule. But when the patient is in good condition and the plastic repair is one that can be done quickly, in many cases the operation is completed at one sitting. When it is necessary to destroy a part of the bone, the repair of the lip is not done until the bone has had time to sequestrate and separate.

The tributary lymphatics of small early cancers of Group I (Broders') usually are treated conservatively. Unless the patient is under our immediate observation continuously, most other types of lip cancer are considered as needing a neck dissection even if the glands are not palpable. The exceptions possibly are: the rather advanced cases of Group IV (Broders'), and the cases in which the condition of the patient or the extent of the involvement contraindicates the operation. Rather advanced cases in Group IV (Broders') or recurring fixed epitheliomas are probably best treated by radium.

Prognosis of Epithelioma of the Lip.—Von Bonsdorff emphasized that in evaluating cures of epitheliomas of the lip, cures of three years' duration tell little; cures of five years are necessary as 10 per cent of the cases recur after three years.

Surgical Results.—The surgical results may be fairly accurately represented by those given by Brewer, who united the cases of several of the best American clinics. Those cases without involvement of the lymph nodes in which the lymph nodes were removed showed 92 per cent remaining

well for five years or more. In the same group if the lymph nodes were not removed the five-year cures fell to a percentage of 62 per cent. When the lymph nodes were already involved, 34 per cent remained well for five years or more.

Fischel has recently reported the five-year results in 66 cases of carcinoma of the lip with routine suprahyoid lymph node dissection. Only 2 died of local recurrence in the lip. Only 7 died with carcinoma in the cervical lymph nodes. None died of systemic metastasis. Thirty eight (57.6 per cent) were free from evidence of disease after five years; 7 died in the meantime of other causes than cancer, and 5 were not traced. In this series 37 cases had palpable nodes. After microscopic study, 27 were diagnosed hyperplastic and 10 carcinomatous. In 13 cases without palpable nodes, 2 showed carcinoma when examined microscopically. Six of 16 patients with proved metastasis of the lymph nodes (37 per cent) lived five years or more. Fischel contends that grading was of more academic and prognostic interest than of value as a guide to therapeutic effort. In Grade I, 10 cases, there were 9 (90 per cent) five-year cures. In Grade II, 38 cases, there were 22 (31 per cent) five-year cures. In Grade III, 13 cases, there were 4 (31 per cent) five-year cures. In Grade IV, 1 case, no cures. Four cases were not graded.

Irradiation Results.—The statistics that can be presented for radium might be fairly well represented by those of Regaud which were reviewed December 31, 1927, and are tabulated so that they can be reduced to five-year cures. Thirty per cent of his cases were classed as operable and 24 per cent as questionably inoperable. Twenty-eight per cent were living five years or more after treatment. Another point of interest in Regaud's cases is the percentage of clinical disappearance of primary lesions treated, which were in the inoperable cases 17.8 per cent, and in the questionably operable 91 per cent, and in the operable cases 98 per cent.

Tongue.—In carcinoma of the anterior tongue when the lesion is small, it is totally excised with the knife, endothermy needle or cautery knife. When the lesion is larger, involving as much as the greater part of the tongue, and the tendency is to extend to the floor of the mouth, radium needles are implanted so as to thoroughly irradiate all parts of the involved organ. A biopsy is taken. From 8 to 10 skin erythema doses are given to the tumor mass. The needles are left in place from four to seven days. At the end of this period, with high voltage radiation an additional 2 or 3 skin erythema doses of radiation by cross-fire methods are given to the neck and the tumor. When any thickening or residual evidence of carcinoma remains after a period of six to eight weeks, the local tongue lesion is excised or destroyed with the endothermic needle or button and usually an unilateral neck dissection en bloc is performed whether or not the nodes are palpable. Although this is generally our method of procedure at the present time, it is thought that total excision of the local lesion is just as likely to obliterate the local lesion permanently. In a considerable number of instances apparently viable carcinoma cells are found in the excised, irradiated tissue after the six- or eight-week period. When the lesion extends into the floor of the mouth or involves the jaw bone, in some instances a preliminary treatment of interstitial irradiation and external irradiation is given, but it is felt that surgery is the most valuable weapon. There-

fore, usually by the lateral Kocher approach, the tissues of the submaxillary triangle including the submaxillary gland are removed en bloc, and the mouth is entered just inside of the mandible from beneath. The local lesion is excised as widely as seems feasible and the greater part of the thickness of the jaw bone or even all of it is destroyed with a hot soldering iron when the bone is approached or invaded. It takes about two and one-half months for the destroyed part of the mandible to separate. This length of time lost is a disadvantage. However, the procedure has the advantage of not adding to the operative mortality or deformity that goes with a complete resection of a segment of the mandible. When a rim of live bone remains, the contour of the face remains practically unchanged. Some workers advise the endothermic button for destruction of a layer of bone but we have not always been able to destroy sufficient bone by this method.

When involved nodes are present in the submaxillary triangle, the upper deep cervical nodes are excised; when any of the upper deep cervical nodes show evidence of cancer invasion, a complete neck dissection is done but practically always at a later date after recovery from the wide local excision.

In carcinoma of the posterior tongue a study of the microscopic picture is necessary before or at the time treatment is started. Lympho-epitheliomas, transitional-cell epitheliomas, and lymphosarcomas should be distinguished. In lympho-epithelioma or lymphosarcoma heavy cross-fire external irradiation alone may cause a total disappearance of the neoplasm. Besides external irradiation, in the transitional-cell epithelioma interstitial irradiation also is needed.

In squamous-cell carcinoma of the posterior tongue, radium needles are inserted in sufficient numbers to give from 7 to 8 skin erythema doses to the mass. If it is thought that better distribution will be obtained, radium is inserted from below just above the hyoid bone through a skin incision. In this location if the patient can afford the additional expense, gold seeds of radon are considered to be easier to apply correctly. By cross-fire methods from 2 to 4 skin erythema doses of high voltage roentgen ray are added. When the lesion is somewhat unilateral, an unilateral neck dissection is usually done from six weeks to two months later whether the glands are palpable or not. When a palpable gland appears on the opposite side of the neck and there is no other evidence of cancer, a second neck dissection would be considered as not irrational although it is recognized that as a rule bilateral neck dissections are of no avail to the patient. When a suspicious residual thickening or hard area remains in the local lesion after two months, the lesion is removed or destroyed intra-orally.

Operation is rational and gives good results in lesions about the epiglottis.

In some instances when it is deemed necessary, very radical surgical methods are still employed as a final method. In a few instances we are pleasantly recompensed by finding that these more radical methods offer the patient the chance of recovery that he is hoping for.

When the local lesion has extended beyond any rational excision method from an anatomic standpoint or when the neck glands have perforated their capsules and have become fixed or the cervical chain of glands is bilaterally involved, radiation methods are considered the only method which offers anything.

Prognosis of Epithelioma Involving the Tongue and Neighboring Mucosa.—Obviously, end results following operation will depend upon the type of cases selected for operation. As a matter of historical interest, the statistics of Butlin may be taken as representative of about what surgery in the best hands can offer when used alone in cancer of the tongue.

Surgical Results.—Years ago Butlin in 197 tongue cases had 20 operative deaths (10 per cent) but 31 per cent of the cases lived over three years. Of 44 patients on whom gland dissections were not performed 29 per cent showed cures, and of 57 with gland resection 42 per cent showed cures. His cases were moderately advanced and spoke for gland resection. In good hands, Butlin's results can be duplicated today.

Irradiation Results Combined with Surgery for the Lymphatic Areas.—On the other hand, radium statistics may be represented by those of Regaud of Paris. His statistics for cancer of the tongue and the floor of the mouth which include all cases seen are revised to December 31, 1927. When reduced to five-year or longer "cures," they show 121 with 17.3 per cent clinical cures. His three-year cures figured on the same basis show 230 cases with 18.2 per cent (42) clinical cures. Regaud removed the lymph nodes en bloc, and as a rule intensive external irradiation is used. Thirty-six of the cases were excluded on account of death during treatment; 275 remained. About 89 were classed as inoperable. Fifty-seven died of metastasis to the regional lymphatics. Seventy-seven (28 per cent) survived for periods of from one to six years. Less than one half of these survived for three years or more. Twenty-four of the cases had no palpable glands. In 18 of these, no treatment of the glands was given and 14 were cured—a very interesting point in regard to metastasis. Six of the 24 cases received radium to the neck, and 3 remained cured. That is 21 out of 24 cases without palpable nodes did not show evidence of metastasis—a statement which argues for a conservative attitude toward the glands. The primary lesion was arrested for the time being in 43.8 per cent of the cases or less than one half of the cases.

Berven in 1932 published his results for eleven years in carcinoma of the buccal cavity. In many of his patients radiotherapy was combined with endothermic surgery. In 278 cases, 76 (27 per cent) were free from symptoms for from five to eleven years. The location and the percentage of healed cases were: sublingual, 34 per cent; mandibular involvement, 18 per cent; buccal mucosa, 26 per cent; and tongue, 32 per cent. Neck dissections were performed as indicated.

Irradiation Results Combined with Conservative Attitude Toward the Glands.—Quick (Memorial Hospital) in 1928, in 450 cases of carcinoma of the tongue had 22.4 per cent clinically free from the disease. Of these, 35 per cent were operable on admission, 50 per cent inoperable, and 15 per cent just beyond operability. Of a series of 160 cases with palpable nodes, 12 are clinically free, 103 developed under treatment or later and 16 of these are clinically free, 186 had no palpable nodes at the time of admission or during treatment. Seventy-three per cent of these had not developed clinical evidence of metastasis.

Cheek and Palate.—Practically the same treatment is used as for anterior tongue lesions; that is, excision in the smaller, less malignant types of growths, and in those with more of a tendency to infiltration, interstitial

irradiation, external irradiation and final excision or destruction with the endothermic knife, if all signs of the lesion do not entirely disappear within two months. Thus, it appears that the healing of the cheek is complete after irradiation, excision or destruction is omitted. When the lesion is somewhat advanced, a unilateral neck dissection with removal of the buccal gland is considered more safe than watchful waiting. In rather advanced cases with perforation of the cheek and extension to the jaw, radical destruction of the cheek with burning of the bone is considered a rational procedure. Later a plastic operation is performed to fill in the defect. We have a fair number of this type of case healed after five years. When the muscles of mastication are encroached upon in our experience practically nothing is to be expected by the use of radiation methods and valuable time is lost by procrastinating. But radical surgery offers a fair chance of success even when these muscles are involved. However, the operation must more than completely encompass the growth. After this operation, heavy external radiation is easily given to the open wound in doses of sufficient size to be lethal to squamous-cell lesions. When the excision is very complete, a small percentage of five-year survivals will be obtained. When there is no recurrence after one year, a skin flap is turned into the defect in the cheek and the defect is closed.

When the neck glands are fixed, the situation is handled by interstitial irradiation and external irradiation as seems indicated along the lines described under tongue carcinoma.

Prognosis in Epidermoid Carcinoma of the Cheek.—Simmons in 13 cases treated by surgery reports 48 per cent five-year cures. On the other hand, Brewer quoted 15 cases treated by radium showing 35 per cent cures for three years. Martin and Pfluger in 1935 reported 99 patients with cancer of the cheek treated at Memorial Hospital (New York). External and interstitial radiation formed the basis of the treatment. The glandular areas were treated conservatively. Thirty per cent were free of disease at the end of five years.

Carcinoma of the Lower Jaw.—When squamous-cell epithelioma lies in contact with the lower jaw itself or involves the bones, it is our practice to cauterize thoroughly and to destroy or remove totally the area of suspected involvement. It has been our experience that the extent of invasion of the bone is always greater than it appears to be. Therefore, conservative methods of removal or destruction have no place in the treatment of carcinoma involving the mandible. When the destruction or the removal is complete, the prognosis is fairly good.

New and Figi in 1935 reported the following five-year cures for carcinoma of the lower jaw. The local lesion was destroyed by surgical diathermy and the lymph nodes were removed if the mucous membrane of the cheek or the floor of the mouth was involved. Radiation was used as a supplement. Of 38 patients with nodes involved, 28.9 per cent were cured. Of 113 patients with nodes not involved, 69.9 per cent were cured. Simmons had 14 cases of carcinoma of the lower jaw. These were treated by excision; 26 per cent were well after five years.

Antrum and Paranasal Sinuses.—After radical surgical resection alone it is somewhat unusual to have a case of carcinoma of the antrum live as long

as one year. Thus, it is rather generally agreed that the best treatment is offered when free exposure and free drainage is given by surgery (Regaud, however, even resects the superior maxilla) and radium is depended upon to effect the actual cure.

In early lesions where the diagnosis is not definite, the antrum is entered through the alveolar cheek fornix above the canine fossa. Exploration is done under direct vision and a biopsy taken. When drainage is considered insufficient, a window is also made through the medial wall of the sinus into the nasal cavity. In an early lesion adequate irradiation can be given by inserting a heavily filtered radium tube surrounded with gauze through this window. When there is no question about the diagnosis, external irradiation is usually advisable before the antrum is entered.

As antral carcinomas tend to metastasize to the neck early, a policy of watchful waiting is adopted usually when there is no clinical evidence of metastases.

Prognosis for Cancer of Antrum and Paranasal Sinuses.—Hautant and Monad (Paris Radium Institute) in carcinoma of the ethmoid and orbital region in 21 cases report 38 per cent cured for from four to eleven years by the use of radium within the nose plus external irradiation.

New and Figi in 1935 reported the following five-year cures for carcinoma of the upper jaw and antrum. The growths were destroyed by surgical diathermy and subsequently thoroughly irradiated. Of 75 cases primary in the antrum, 40 per cent were cured; of 43 secondary in antrum, 53.4 per cent were cured; of 118 patients with upper jaw and palate involved, 62.7 per cent were cured.

Öhngren (1934, Stockholm) reported 38.5 per cent five-year cures of malignant tumors of the maxillo-ethmoidal region, mostly by the use of electrosurgery followed by radium.

Malignant Neoplasms of the Pharynx.—In this region a preliminary microscopic study is unusually important. When the lesion is of a radiosensitive type such as lympho-epithelioma, transitional-cell epithelioma, lymphosarcoma, a schneiderian membrane tumor, an adenoid cystic epithelioma, the procedure of treatment should be different than when one is confronted with an adult squamous-cell carcinoma. In the former neoplasms heavy irradiation externally by cross-fire methods may be all that is necessary to cause a disappearance of the neoplasm. In the transitional-cell epithelioma, however, usually and sometimes in the other types, some type of irradiation from within should be added to supplement the external irradiation. (See Chapter XXXIII.)

When the lesion is a fairly adult squamous-cell epithelioma, a much heavier irradiation dosage is necessary if any chance of obliterating the tumor is to be hoped for—10 to 15 skin erythema doses.

Often when an operative attempt is the method of treatment upon which main reliance is to be placed, a moderately intensive preliminary dose of external irradiation is given. Sometimes in squamous-cell carcinoma of the nasopharynx, if the local lesion is not too far advanced, the endothermic button may be used advantageously to destroy the lesion. The soft palate may be split to gain adequate exposure and immediately resutured after the destructive procedure.

In the oropharynx when the lesion is early and of the squamous-cell variety and located on the pillars or lateral pharyngeal wall, a local excision may be a rational procedure. But in the majority of tumors of this type, the degree or extent of infiltration is rather too great to allow an adequate excision intra-orally. A lateral high pharyngotomy may be advisable.

A transhyoid pharyngotomy (Chapter XXXIV) or a lateral pharyngectomy as previously described under "access surgery" (Chapter XXXIII) allows one to come directly down upon the lesion. At this time the decision is made whether to attempt to remove the lesion or whether to insert radium interstitially into the local lesion. The lateral pharyngeal approach allows one the choice of whether or not to remove the tributary lymphatics as indicated.

When a combination of external and internal irradiation without operative approach has been decided upon as the therapy of choice, and after two months any residual thickening or failure of the growth to heal is still noted, an operative attempt may be made. If possible, the lesion is excised intra-orally with the diathermic needle but when the lesion is too large for excision by an intra-oral approach, one sometimes may be justified in performing a lateral pharyngotomy.

Laryngopharynx.—For a squamous-cell carcinoma in the laryngopharyngeal region, when it appears that the lesion is of an insufficient extent to be thrown with the palliative group, after moderate preliminary external irradiation a surgical approach is made. The thyroid cartilage or greater cornu of the hyoid is removed if indicated. This allows the operator to come down immediately onto the pharyngeal wall. The decision then can be made whether to totally excise the lesion or to depend upon interstitial irradiation inserted through the operative exposure with or without opening the pharynx. In the latter case radium is applied directly over the lesion without the interposition of cartilage in a sufficient quantity to deliver about 8 to 10 skin erythema doses to all parts of the lesion, and an additional dosage of deep therapy may be delivered to the area if indicated.

The advocacy of this method of treatment will be disagreed upon by many, but the lesions in this location are of the squamous-cell variety. In the early and moderately advanced stages, they are amenable to surgical extirpation. But if radium is to be depended upon for the cure, it has to be given in a lethal quantity. Practically no cures are obtained by the usual methods of internal and external irradiation. As a matter of fact, it is doubtful if any cures will occur by any method of irradiation whatsoever after the cartilaginous box of the larynx is invaded by adult squamous-cell carcinoma. Proper surgery does give the patient some chance of a cure.

When all signs point to the tumor as being of an anaplastic and radiosensitive type, neck dissection is probably useless. When glands are fixed, external irradiation plus interstitial irradiation offer the most.

In 1932 Berven reported 18 patients with epithelioma of the mesopharynx treated by the new method, external mass radiation supplemented by internal surface irradiation and endothermy. Fifty-five per cent healed primarily and 39 per cent were freed from the disease for three years.

In 35 cases of sarcoma of the tonsil, Berven had 71.4 per cent primary regressions; 42 per cent remained well three years, while many died with distant metastasis. Sixty per cent of 5 malignant mixed tumors remained well three years.

Coutard in 1932 by external irradiation in 45 cases of lymphosarcoma of the mesopharynx showed 8 (17 per cent) five-year cures and 8 (17 per cent) seven-year cures. Epithelioma of the tonsillar region in 46 cases gave 13 (28 per cent) five-year cures and 8 (17 per cent) seven-year cures. A considerable palliative period with some recession may intervene before the final termination. But when the glands are not palpable and the lesion is an adult squamous-cell and unilateral epithelioma, it is probable that a conservative attitude regarding the cervical lymphatics is not justified. As a rule, palpable nonfixed glands are removed as a part of the exposure for the therapy of the local lesion. But if not, they are removed later. When it appears from the location of the lesion that most likely the metastases, when they appear, will be bilateral, a conservative attitude toward the tributary lymphatics is adopted.

Prognosis for Malignant Tumors of the Pharynx.—Harmer in 1931 was not able to find records of long-standing cures of carcinoma of the nasopharynx. He collected 63 patients with sarcoma and found 22 living and free from disease for from two to five years. He had 16 patients of this type of his own; 9 are living and 6 are free from disease after two to nine years.

1. *Surgical Results.*—The surgical results for carcinoma of the laryngopharynx are rather difficult to evaluate. New and Figi's report on laryngectomy in 73 cases showing 56.1 per cent five-year cures contains some of these cases, as certain ones had laryngectomy because of encroachment from the outside, but they have not separated them. In their opinion, epiglottic tumors are of low-grade malignancy and are best taken care of either by suspension apparatus and diathermy when small or by pharyngotomy when extending to the aryepiglottic fold and arytenoid region. Laryngopharyngeal epitheliomas (pyriform fossa and postcricoid tumors) are usually of high-grade malignancy and metastasize before they are diagnosed, they state. Early surgery they believe may offer something, but usually in their experience the patients present themselves too late for surgery to be of great value.

2. *Irradiation Results.*—The Radium Institute (London) presented 57 cases of carcinoma of the tonsillar pillars and fauces treated from 1925 to 1929 inclusive. In 1933, 5 were alive, 38 were dead, 9 untraced, and 5 untreated. Cade in 275 cases of tonsil cancer showed 187 alive and free of disease from one to seven years.

Cade was unable to show any cases of pyriform fossa cancer free from disease by irradiation methods after interstitial irradiation and external roentgen rays. At present with the addition of the radium "bomb" he has been able to heal for the time being a number of reported cases.

Recently Martin and McNatten (1934) reported 14 patients with carcinoma of the pharynx, tonsil and extrinsic larynx treated by divided doses of external radiation; 41 (29 per cent) remained free from disease one and three-fourths years to two and one-half years.

In 1932 Coutard (Radium Institute, Paris) reported on 212 patients with epithelioma of the tonsillar region, the hypopharynx, and the larynx, treated during 1920 to 1926; 157 died within the first two years, 55 (26 per cent) were healed of their primary carcinoma without any local recurrence. Twelve of 46 (26 per cent) were in the tonsillar region, 18 of 89 (20 per

cent) in the hypopharynx, 25 of 77 (32 per cent) in the larynx. Recurrence or late metastasis two years after treatment were 1 out of 12 (8 per cent) for tonsillar region, 8 out of 18 (44 per cent) for the hypopharynx, 1 of 25 (4 per cent) for the larynx. It would seem from these figures that distant metastases are not very common after the local lesion is healed in cancer of the tonsillar regions and even less common in cancer of the larynx. The results of cancer of the hypopharynx were damaged somewhat by late metastasis. Three years after treatment of the 212 patients (1920 to 1926) 50 patients remained healed, 23 per cent in all, tonsillar 25 per cent, hypopharynx 14 per cent and larynx 32 per cent. Five years after treatment of 162 patients (1920 to 1925) 16 per cent in all remained healed, 18 per cent tonsillar, 10 per cent hypopharynx, 21 per cent larynx. Since 1926 his results for cancer of the tonsil have improved. The primary and the glandular invasion has been healed in 46 per cent.

Larynx.—The results of the operation of laryngofissure are so good—about 80 per cent five-year cures—with so little operative mortality in properly selected cases that little reason remains for running the risk of failure to cure with irradiation methods even if successful. In certain cases where the information as to extent seems a point of value, a thyrotomy is done. The larynx is explored and a decision made as to the best type of treatment to be carried out.

As it is regarded that in most cases of intrinsic and extrinsic laryngeal carcinoma involving the cartilaginous box of the larynx irradiation methods are only palliative, and although recognizing that the disability is a distinct disadvantage, a complete laryngectomy is the only procedure which offers the patient in a certain stage of the disease some chance of life.

After laryngofissure and laryngectomy for intrinsic carcinoma, the glands of the neck are treated conservatively. In extrinsic carcinoma of the larynx and laryngopharynx, when an attempt at a cure is being made, removal of the tributary lymphatics is considered to be a part of the attempt at cure.

Prognosis in Epithelioma of the Larynx.—Thomson's results in 74 laryngofissures on 72 patients are as follows: 3 postoperative deaths, 11 developed local recurrences, 3 developed cervical metastases, and 2 developed metastatic lesions elsewhere; after deducting operative deaths and those who died of other diseases before three years were completed, there was a lasting cure in 76 per cent of the cases submitted to operation. Of Thomson's 11 recurrences, 8 took place within the first year. Jackson has 74 patients operated by laryngofissure over five years of which 55 were traceable (1934); 5 died with evidence of cancer; of the remaining 50, 9 died with a recurrence, 41 (80 per cent) were alive and well for periods of from five to thirty-one years.

Between 1917 and 1922 Mackenty reported 31 laryngectomies. In 24 of the traced cases the disease was arrested three years or over. New in 73 cases of laryngectomy obtained 56.1 per cent five-year cures with 1 death.

Malignant Tumors of the Salivary Glands.—Under Excision of the Parotid Gland (Chapter XXXIV) some mention is made of the results of operative interference on parotid tumors. The type of recurrence which follows excision of a mixed tumor has a relatively good prognosis after total excision. Mixed tumors of the parotid may be held in check by intensive

irradiation but ordinarily they do not entirely disappear. Usually we practice excision of the growth and follow this with the application of radium. The prognosis for adenocarcinoma of the parotid gland and sarcoma of the parotid is almost universally bad. But occasionally prompt radical excision followed by intensive irradiation may save a patient.

Benedict and Meigs in a study of 225 parotid tumors seen at the Massachusetts General Hospital from 1872 to 1930 (the end-results were studied completely) reached the conclusion that the treatment in practically all cases should be operation. Radium and roentgen ray in their experience was only palliative and never curative. In large malignant tumors in which there is no hope of a cure, irradiation is sometimes palliative and in recurrent tumors it is valuable. They point out that some surgeons have a higher regard for irradiation than they have, but they find no evidence of a single cure by the use of radium or roentgen ray. They advise in malignant tumors extensive removal of the parotid gland along with a neck dissection. The question of encapsulation is important. Such may be benign. They had only 1 case which started as a mixed tumor and recurred as carcinoma. The prognosis in carcinoma is bad. Of 30 cases operated (Benedict and Meigs) (with or without subsequent radium), only 1 was living at the time of this report (1930). I have 2 patients alive and well after five years. I had not thought that the prognosis was so grave as a rule as Benedict and Meigs' figures would indicate. Local recurrence often is very prompt. Metastases also occur in the lungs and to the bone. The length of life is from six months to two years.

The prognosis of sarcoma is nearly as bad as for carcinoma. Lymphosarcoma of the parotid may be held in check by irradiation for a time.

Lymphosarcoma of the Soft Tissues.—Lymphosarcoma is fairly radiosensitive. From 4 to 5 skin erythema doses to the tumor usually cause its local disappearance. (See methods of applying radiation therapy in chapter devoted to that subject.)

Within a few years, distant metastases have in the past caused death of the individual in from 60 to 65 per cent of the cases within from one to five years after the appearance of the disease. About 35 to 40 per cent of the patients with lymphosarcoma of the pharynx treated in the better institutions by the use of radiation methods attain five-year cures. The outlook is much better since good radiation treatment has become available. Some of the statistics for pharyngeal neoplasms in the preceding paragraphs refer to lymphosarcoma of the pharynx. Figure 234, *B*, Chapter XXXII, shows one of our cases of lymphosarcoma of the neck who is now alive and well six years after excision of the neoplasm and postoperative radiation treatment.

Excision is seldom indicated. Main reliance should be placed upon radiation methods. In the pharynx many men do not advocate biopsy. Ordinarily I always try to get microscopic evidence. On the neck also we attempt to get microscopic confirmation of the clinical diagnosis.

Endothelioma of the Soft Tissues.—When the tumor is localized, wide excision followed by intensive irradiation sometimes may be justified. When the mass is more diffuse involving structures which would render the excision not adequate from an anatomic or pathologic standpoint, radiation methods are to be depended upon. Endothelioma of the lymph nodes of the neck has a better prognosis than round-cell or fibroblastic sarcoma.

The Relationship of Microscopic Grading to Prognosis.—In Blair's cases of buccal carcinoma operated radically he obtained the following results according to microscopic grading: Grade I, 50 per cent five-year cures; Grade II, 43 per cent; Grade III, 40.7 per cent, and Grade IV, 23 per cent. In his cases the prognosis seemed to depend upon the grade only to a slight extent. On the other hand, Lund, in summarizing the cases at the Collis P. Huntington Hospital and the Massachusetts General Hospital, found that the grading of the tumor was of considerable importance. Simmons in 100 graded cases found the following: Group I, 30 cases, 20 (66 per cent) cures; Group II, 31 cases, 11 (34 per cent) cures; Group III, 24 cases, 2 (8 per cent) cures; Group IV, 15 cases, 0 (0 per cent) cures. He concluded that the grade of the tumor was the most important factor in the prognosis.

Lund in a review of 650 carcinomas of the buccal mucosa excluding lip and tonsil found that studies of the pathologic index of malignancy of carcinoma of the buccal cavity are of definite value. Two separate observers studied his material under unbiased conditions, and both arrived at approximately the same conclusion—a reaffirmation of the importance of the pathologic index of malignancy as one factor to be considered in the complete study of carcinoma of the mouth. The first observer (Simmons) found: Grade I, 49 per cent cured; Grade II, 19 per cent cured; Grade III, 7 per cent cured. The second observer (Warren) found 36 per cent Grade I cured, 21 per cent Grade II, and 0 per cent Grade III.

Results as to Permanent Healing of the Local Lesion After Radium Therapy With Primary Healing.—The results of Cade (1931) are of interest as to permanent healing of the local lesion after radium therapy. In 126 out of 169 of his cases the local lesion was healed by radium, but in 43 (about one third) eventually local recurrence appeared.

At the Radium Institute, London (1925 to 1929 inclusive), a considerable number of advanced cases are seen; 111 out of 154 had metastasis to the regional nodes. These cases were reported by Ward and Smith in 1933. In 116 instances the primary growth disappeared for the time being; 78 out of 116, however, showed a recurrence of the primary growth later; 4 of these patients survived five years, 6 for three years, 13 for two years, 47 for one year, 38 for six months, and 49 patients failed to survive six months.

Bibliography

Bibliography Quoted in Text

Benedict, E. B., and Meigs, J. V.: Tumors of the Parotid Gland, Surg., Gynec. and Obst., **50:** 626, 1930.

Berven, E. G. F.: Irradiation Treatment of Malignant Tumors of the Buccal Cavity, Acta Radiol., **13:** 213, 1932.

Malignant Tumors of the Tonsil, Clinical Study With Special Reference to Radiological Treatment, Acta Radiol., Supplement XI, p. 285, 1931.

Development of Technique and Results of Treatment of Tumors of the Oral and Nasal Cavities, Amer. Jour. Roentgen., **28:** 332, 1932.

Blair, V. P.: Discussion of Carcinoma of Lip and Cheek, by Brewer, G. E., Surg., Gynec. and Obst., **36:** 178, 1923.

Blair, V. P., and Brown, J. B.: Surgical Treatment of Cancer of the Lip, Amer. Jour. Roentgen., **29:** 237, 1924.

Blair, V. P., Brown, J. B., and Womack, N. A.: Cancer In and About the Mouth, Ann. Surg., **28:** 705, 1928.

Bloodgood, J. C.: Radiosensitive Tumors and Tumors That First Should be Subjected to Operation, Radiology, **14:** 254–262, 1930.
Brewer, G. E.: Carcinoma of the Lip and Cheek, Surg., Gynec. and Obst., **36:** 169, 1923.
Broders, A. C.: Carcinoma Grading and Practical Application, Arch. Path. and Lab. Med., **2:** 376, 1926.
Butlin, H. T.: An Address on the Results of Operations for Carcinoma of the Tongue With an Analysis of 197 Cases, Brit. Med. Jour., **1:** 1, 1909.
Cade, Stanford: Quoted by Spencer and Cade.
Coutard, H.: Radiophysics et radiothérapie, Amer. Jour. Roentgen., **28:** 313, 1932.
Roentgen Treatment of Carcinoma of the Tonsils, Strahlentherapie, **33:** 249, 1929.
Fischel, Ellis: Surgery as Applied to Lymph Nodes of the Neck in Cancer of the Lip and Buccal Cavity, Amer. Jour. Surg., **24:** 711, 1934.
Harmer, W. D.: Radiotherapy in Cancer of the Upper Air Passages, Lancet, Nov. 14, 1931.
Radiotherapy for Cancer of the Nose and Throat, Murray, 1932.
Hautant and Monad: Ann. Otol., Rhin. and Laryng., April, 1933.
Jackson, C.: Surgery of the Larynx and Trachea and Endoscopic Surgery of the Bronchi, Chapter 7, Dean Lewis' Practice of Surgery, Hagerstown, Maryland, W. F. Prior Co., **4:** 1–230, 1930.
Lund, C. C.: Pathology of Carcinoma of the Buccal Mucosa in Relation to Results of Treatment, New Eng. Jour. Med., **209:** 126, 1933.
Mackenty, J. E.: Cancer of the Larynx, Arch. Otolaryngol., **3:** 205–232, 305–337, 1926.
Martin, H. E., and McNatten, R. F.: The Treatment of Cancer of the Pharynx, Tonsil, and Extrinsic Larynx by Divided Dosages of External Irradiation, Amer. Jour. Roentgen., **32:** 77, 1934.
Martin, H. E., and Pfluger, O. H.: Cancer of the Cheek, Arch. Surg., **30:** 73, 1935.
New, G. B., and Figi, F. A.: Malignant Diseases of the Mouth, Pharynx and Larynx—Five-Year Cures, Surg., Gynec. and Obst., **60:** 483, 1935.
Öhngren, L. G.: Maxillary Tumors of the Maxillo-Ethmoidal Region, Acta Otolaryngol., Supplement 19, pp. 1–476, 1933.
Quick, D.: Surgery and Radium in the Treatment of Cancer of the Buccal Cavity, Cancer Conference, London, William Wood and Co., 1928.
Interstitial Radiation in Metastatic Cervical Nodes of Epidermoid Carcinoma, Ann. Surg., **93:** 389, 1931.
Regaud, O.: Radium Therapy of Cancer at the Radium Inst., Paris, Amer. Jour. Roentgen., **21:** 1, 1929.
Simmons, C. C.: Cancer of the Mouth, the Results of Treatment by Operation and Radium, Surg., Gynec. and Obst., **43:** 377, 1926.
Simmons, C. C.: The Treatment of Oral Cancer, Amer. Jour. Roentgen., **26:** 5, 1931.
Spencer, Walter G., and Cade, Stanford: Diseases of the Tongue, Phila., P. Blakiston's Son and Co., 1931.
Thomson, St. Clair: Cancer of the Larynx, New York, The Macmillan Co., 1930.
Von Bonsdorff, I. G.: Soc. International Chem. (Eleventh Congress), pp. 11–16, 1908.
Ward, W. R., and Smith, A. J. D.: Recent Advances in Radium, Phila., P. Blakiston's Son and Co., 1933.

CHAPTER XXXVII

MAXILLARY TUMORS OF DENTAL ORIGIN (THE ODONTOMAS)

Besides the ordinary tumors, both benign and malignant, which may arise from primary bone cells, the jaw bones are the site of several characteristic neoplasms which apparently arise from cells which are destined ordinarily to enter in the formation of the teeth.

For purposes of orientation, tumors of dental origin will be discussed under the following simple classification:

EPITHELIAL ODONTOGENIC CYSTS AND TUMORS

1. *Radiculodental Cysts—simple epithelial.*
2. *Adamantinomas or Ameloblastomas.*
3. *Follicular Cysts* (simple cysts either containing no tooth or a partially formed tooth—the so-called "dentigerous cyst").—The name suggests that the cyst develops from a tooth follicle which is not based upon definite evidence. They are thought to be derived from the enamel organ of the developing tooth. The term "dentigerous cyst" has been used quite loosely in the past and has been applied to any epithelium-lined cyst whether or not it contained an embryonic tooth.

ODONTOMAS, COMPOSITE ODONTOMAS, AND CONNECTIVE TISSUE ODONTOMAS

These embryonic mishaps show a conglomeration of the various structures which go to make up a tooth, the dental epithelium, the dental papilla or the dental follicle may all or any one or two be at fault.

Connective tissue odontomas include the fibrous odontomas and the cementomas. The occurrence of connective tissue anomalies as a separate entity has been denied by some well-informed writers. Their extreme rarity at least is certain.

Maxillary Tumors of Dental Origin.—The maxillary tumors of dental origin are a group of tumors caused by the mishaps at various stages of development of the original cells, both epithelial and mesenchymal, which make up the normal tooth and its surrounding membranes. They are practically always benign in all characteristics except the adamantinomas which show local invasive tendencies.

As these various cysts and tumors are found during the developmental stage of the tooth, young persons are the ones afflicted. The absence of symptoms, however, often prevents discovery until late in life. Adamantinomas are somewhat of an exception as far as age is concerned. They usually are seen rather late in life.

Embryology.—Unless one has some understanding of the embryology of the teeth, odontomas will in all likelihood seem rather mysterious. The few remarks concerning the embryology of the teeth may therefore be in order.

The young human embryo develops a thickening or multiplication of the epithelial cells in the location of the rudimentary alveolar processes. Next epithelial projections burrow down into the underlying mesenchymal tissue

and the tips become cup-shaped. Within the cavity of the cup-shaped projections of epithelial cells the underlying mesenchymal cells become condensed and form the mesenchymal papilla. Both the epithelial cap and the mesenchymal papilla then go to make up the dental papilla. The dental papilla then separates from the thickened epithelial dental ridge and all the structures necessary for the ultimate formation of tooth become isolated within the jaw. Thus, the first dentition of 10 milk teeth is accounted for. As the first dentition develops, the dental ridges degenerate and are converted into a network of epithelial trabeculae. Now along the lingual border of the rudimentary alveolar ridges, a ridge of epithelial cells persists from which, by a duplication of the process just described for the first dentition, a second series of dental papillae is formed from which the second dentition eventually is formed. Again when the dental papilla for the second dentition separates from the epithelium of the dental ridge, the connecting cord of epithelial cells degenerates. But according to the work of Malassez, at times at least, certain "cell rests" persist and form the "débris épithéliaux paradentaires."

The epithelial cup-shaped cap which invests the mesenchymal dental papilla from above becomes the enamel organ, and its cells differentiate into 3 layers: an outer layer of flattened epithelial cells, a middle layer of loose stellate cells, and an inner layer of columnar cells—the ameloblasts—which ultimately form the enamel of the normal tooth. A delicate cuticular zone at the central end of the ameloblasts indicates the earliest stages of the production of the enamel. The enamel organ begins to disintegrate before the final enamel is formed, and finally its degeneration becomes almost complete. A few ameloblasts, however, usually persist even in adult life about the roots of the teeth.

From the mesenchymal papilla is formed the pulp and the dentine of the tooth. The cells which surround the papilla assume a columnar form and are then called "odontoblasts;" the dentine is formed by these cells.

The tooth sac is formed from the connective tissue which surrounds the mesenchymal papilla and the enamel organ. The dental papilla, the enamel organ, and the tooth sac as a group make up the so-called "tooth follicle." The cementum which surrounds the dentine of the adult tooth is manufactured from the mesenchymal cells in a manner similar to the formation of normal membranous periosteum—a fibroblastic tissue. The peridental membrane, a mesoblastic tissue which surrounds the tooth outside the cementum and is attached to it, is continuous with periosteum of the alveolar part of the jaw bone.

Eventually the teeth of the first dentition are prepared for replacement by the teeth of the second dentition by an osteoclastic absorptive process of the roots of the teeth. This starts at the point of contact with the permanent teeth. As the roots are absorbed the pulps die, the attachments become weakened, and eventually the milk teeth practically fall out of their sockets.

Historical.—Barnes, Guzack, Delpeck, Dupuytren, Forget, and Nélaton had conceived the dental origin and probable structures of the odontomas by the middle of the nineteenth century. Broca in 1868 classified these tumors with reference to the period of their origin in the embryologic scale. Magitot in an important contribution in 1872 conceived the majority of the group as arising from dilated dental follicles. The remainder he classified

as developing from the tooth proper. Malassez in 1885 presented a study of sections of the maxillae of fetuses and found numerous groups of cells scattered in the bone about the teeth. Some of these cells were shown to persist at times in adults. He considered these groups of cell as derivatives of the epithelial cord which projects down to form the enamel organ. Malassez proposed the conception that all epithelial odontomas are derived from these cell rests. Supernumerary teeth were also suggested as originating from these vestigial alveoli. Supposedly some irritation or stimulation such as the eruption of teeth or some form of peridental inflammation starts the aberrant group of cells to forming fluid in the center and to multiplying circumferentially. When these cysts are found in connection with the dead roots of teeth, the irritative factor necessary to stimulate their growth is accounted for.

Some indefiniteness persists as to the position of the dental follicle in the formation of the odontomas. Bland-Sutton believes that these cystic odontomas simply represent an expanded tooth follicle. Malassez and Gallippe admit that certain ones may have an origin from supernumerary dental follicles. From our present evidence it seems, as Ewing suggested, that all transitions from peridental epithelium remains up the scale to true supernumerary enamel organs may be the starting point for these various odontomas. During the complex process which goes on in the development of two sets of teeth abundant opportunity is offered for abnormal growths at each step in the various evolutionary stages.

General Origin.—The basis of our knowledge concerning many of the inflammatory and neoplastic processes connected with teeth is the observations of Malassez. The cells of the epithelial débris described by Malassez about inflamed teeth tend to multiply, hypertrophy or even widen out in the tissues. Other inflammatory cells complicate the picture. In pyorrhea alveolaris this hyperplastic process participates in the explosion of the teeth. The "epithelial débris" is probably concerned in fibrous or myxomatoid growths attached to the borders of the teeth. Dilation of the lumina of such vestigial alveoli probably gives origin to the simple cysts (the radiculodental cysts). In the epulides, atrophying or proliferating epithelial cells are found which according to Ewing are probably derived from the original peridental epithelial débris. Also the cysts containing imperfect or well-formed teeth appear to be derived from the "epithelial débris" and from the mesodermal papilla. In some of the odontomas ameloblasts are seen. Malassez's conception derives these cells from the peridental structures.

The part the dental follicle plays in the formation of dentigerous cysts is somewhat uncertain. Many believe that dentigerous cysts and complex odontomas arise from original or supernumerary dental follicles. Ewing states that "it is reasonable to suppose that all transitions exist between simple groups of paradental epithelium and true supernumerary enamel organs and that the structure and contents will vary accordingly. . . . It is therefore unlikely that any simple embryonal event such as gives rise to the ordinary paradental débris is responsible for all the various clinical forms which these abnormalities present."

Recently Block-Jorgensen of Copenhagen has presented some evidence that follicular cysts are of an inflammatory genesis caused by a periodon-

titis of the deciduous teeth. He found the same bacteria in cysts as in the deciduous teeth. The pathologic examination according to him shows only old fibrous tissue instead of an epithelium-lined wall. Thoma also studied his article but was not convinced that the cases he studied were true follicular cysts. When the fact that no epithelial lining was found and that the roentgen rays were not typical were taken into consideration, he thought most of them appeared to be a granulating osteitis caused by infected deciduous teeth. Lardtschneider also has suggested that the pathogenesis of follicular cysts is that of perifollicular inflammations from neighboring teeth or organs. Fischer observed cystic formations in enamel epithelium of cats caused by artificial aseptic abscesses. Such data are of interest but proof for acceptance of the infective theory is confined to questionable findings.

As to the odontomas proper Schlossman suggested that the origin is due to a misplaced dental follicle during the early period of growth, which was especially favored in the confined quarters of the angle of the lower jaw. Broca in his embryologic classification of 4 periods in tooth development assumed that all tumors arise from the dental follicle and that the dental pulp initiated their development. Bland-Sutton used a purely anatomic classification, recognizing cementomas, dentomas, osteodentomas and mixed dentomas. Malassez attributes the majority of odontomas to proliferation of the epithelial débris. Undoubtedly, the extensive variations in the composition and relations of odontomas render the task of tracing their origin difficult.

As the first or second molar is frequently missing in odontomas, it is to be suspected that the tumors arise from structures which normally give origin to this tooth. However, the factors which initiate the abnormal growth are unknown.

Ewing is of the opinion that none of the explanations is adequate to explain all types and that several modes of origin are involved. His conception may be outlined briefly as follows: when a tooth is absent, one is probably warranted in assuming that the odontoma arose in the follicle of the missing tooth. When the growth of several teeth appears in the tumor, one might assume that all structures—especially the pulp—of the missing tooth were involved. Varying proportions of enamel, dentine, and pulp tissue do not point necessarily to different modes of origin. When all the normal teeth are present a supernumerary follicle is the logical suggested origin. Congeries of imperfectly developed teeth suggesting extensive multiplication of enamel organs and dental pulps might just as well come from a single follicle as from multiple foci of paradental débris. The case of Hildebrand is quoted as demonstrating that practically all of the follicles of both jaws may be incited to multiplication. Hildebrand's case was a boy nine years old in whose jaw were from 150 to 200 teeth, lying singly and variously fused, but most of them were well formed. After 2 thorough extirpations, the condition recurred and again the same number of teeth were removed. Cystic dilatation of the original enamel organ in the follicle according to Ewing adequately explains the dentigerous cyst with a single tooth, and pulp multiplication may be assumed where multiple teeth are observed. As the enamel organ almost caps the developing tooth, the enclosure of several odontomas in an epithelial cyst is thereby

readily explained. Cementum is only a secondary product added after the limit of growth has been reached. When extensive overgrowth of bone is encountered the periosteum is at fault.

This conception, the logic of which is agreed to by Ewing, limits the domain of the débris paradentaire to adamantinomas and cystic tumors lined by epithelium and containing only rudiments of dental structures, while the cysts with multiple well formed teeth and the various odontomas may be referred to the enamel organ and the pulp tissue.

Simple Dental Cyst, "Dental Root Cyst," Radiculodental Cyst.—*Pathogenesis.*—Radiculodental cysts are thought to arise from the paradental epithelial cells of an erupted tooth—usually a pulpless tooth. When these cysts form at the apex of the tooth, they may be classified as radicular cysts (Fig. 280). When they form along the sides they may be classified as paradental cysts. They are sometimes multiple. As stated previously,

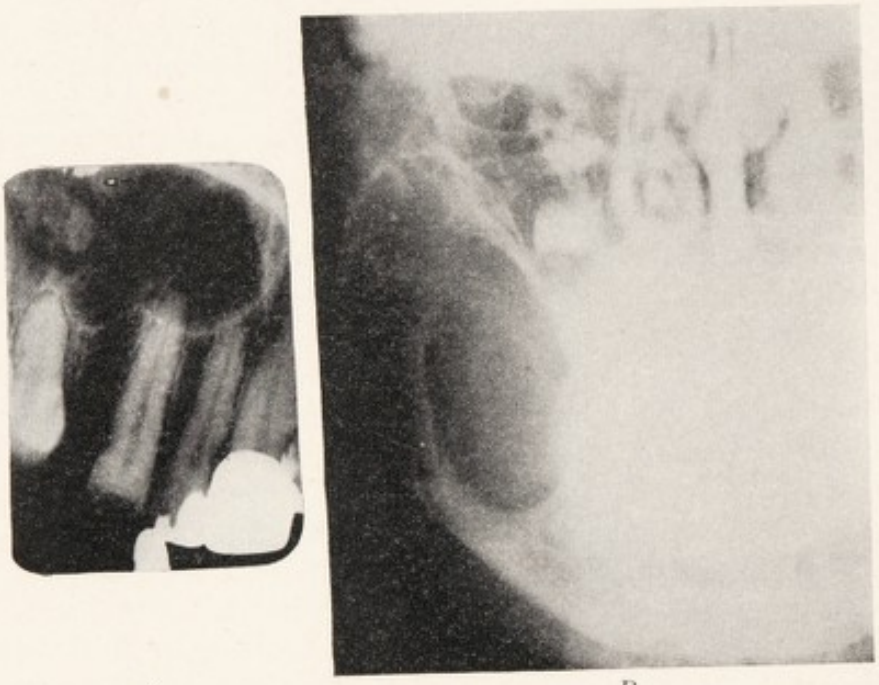

A *B*

Fig. 280.—*A*, Simple cyst in incisor region. *B*, Large cyst in ramus of mandible.

Malassez found certain aberrant cells applied to the apex of teeth and even sometimes extending into the pulp canal, which are derived from the sheath of Hertwig. Supposedly because of an irritative inflammatory process these vestigial epithelial cells are stimulated to proliferation with the formation of a lumen in which fluid accumulates as the central cells break down. Central pressure causes an enlargement of the cyst.

The fact that very few granulomas develop into cysts may be explained by the fact that not all contain epithelium (Thoma). Becker has ascribed the immediate cause of cyst formation to hemorrhage into the paradental membrane caused by instrumental, chemical or bacterial action. Grawitz, Schuster, Schloff and Counsell have argued that the epithelium of radicular cyst is derived from the mucous membrane which grows into the area through a fistula formed by a discharging periapical abscess. This hardly seems a plausible theory. There is nothing to indicate that the epithelium was not already there in the published cases.

Location.—This type of cyst and supernumerary teeth most frequently occur in the same location, which might suggest that the cysts are derived from supernumerary embryonic centers.

Scudder states that this type of cyst is found more commonly in the upper jaw in the incisor and bicuspid regions. From the Mayo clinic (New) have been reported 12 cysts of this type; 6 occurred in the upper jaw and in 6 in the lower jaw. In the lower jaw 3 occurred in the incisor region, 2 in the premolar, and 1 in the molar. Witzel found these cysts considerably more frequent in the upper than in the lower jaw (76 to 29).

Pathology.—On account of their pathogenesis, these cysts are often infected. Most commonly the organisms found are hemolytic and nonhemolytic streptococci and more rarely staphylococci.

Unless secondary infection or pressure atrophy has caused the lining of epithelial cells to disappear, the cysts are found to be lined with a flattened epithelium suggesting the squamous-cell type or cells of a more or less cuboidal shape. Very rarely the epithelial lining may be columnar indicating more clearly their paradental origin. The walls of the cysts may be quite cellular. Within the cavity is formed a brownish syrupy fluid in which floats varying amounts of cellular débris. Peter has called attention to the possibility of radicular cysts causing carcinoma of the upper jaw. When the origin seems to be within the jaws, this may be an explanation of the new growth. It is probably possible for adamantinomas to form from these cysts. Cholesterin may occur in these cysts. White (1909) and Rywkind (1932) have discussed the development of cholesterin in these radicular cysts.

Clinical Features.—For some indefinite reason these slow-growing cysts are most commonly found in the incisor and premolar regions. Practically never are these cysts seen in connection with the first dentition, but in individuals from childhood to late life. New's youngest patient was twelve years of age and his oldest seventy. Cysts without clinical signs and no larger than a pea have been reported as being pulled out of the jaw on extraction of a tooth. As soon as they attain the size of a cherry or larger, a slight smooth bulging of the normal contour of the jaw bone is usually the first evidence of their presence. Many descriptions are in the literature of cysts attaining the size of a lemon or an orange. As the cyst enlarges its cavity within the surrounding bone by a process of pressure atrophy, when pressure is made upon the mass an "egg-shell" crackle sensation is often obtained because of the thinness of the overlying bone. The fluid contents of the cyst lend often a rubbery, semifluctuating sensation on palpation. Multiple cysts are occasionally present and may become connected and form a sort of multilocular cavity. At times several roots are surrounded by a single cyst or by the fusing of multiple cysts. The mass projects through the absorbed jaw externally, or into the palatal bone or into the antrum. Secondary infection is prone to obscure the diagnosis.

A good roentgenogram, however, shows the sharply defined outline of the cavity within the bone which is distinctive (Fig. 280).

Treatment.—The principles of treatment are relatively simple. Those cysts in appropriate locations are best treated by removal of one wall, usually the outer, and total removal of the lining membrane. First, the surrounding soft tissues are incised and removed from one bony wall of

the cyst. Then with chisel and rongeur the bone is removed after which, with a periosteal elevator or curet, the lining membrane is removed in toto. No overhanging edges should be left to prevent the surrounding soft tissues from falling up against the opposite denuded bony wall. In the cavity a light strip of gauze is packed. After a few days it is removed, but ordinarily replaced daily or every other day until the granulations largely close the cavity. In the palatal region especially, the location may allow the turning back of a flap of mucosa which may be used, after the outer wall and the cyst lining have been removed, to reline the opposite inner wall with a mucosal lining (Fig. 281).* A sponge or gauze pack is sewed into the wound

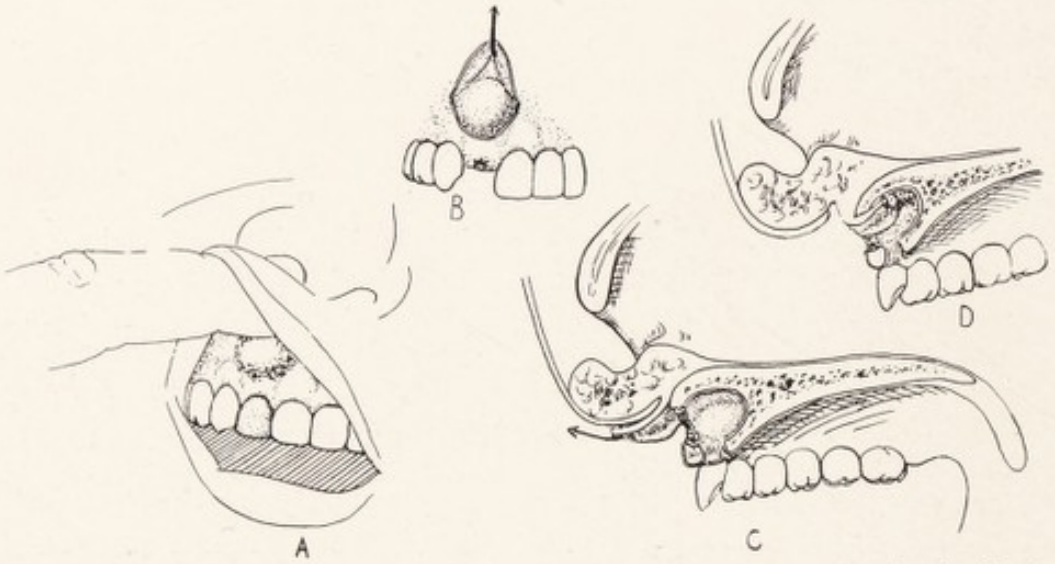

Fig. 281.—Method of removal of simple cyst (Partsch operation). A, Cyst outlined. B, Gum flap turned up exposing the bony plates over the cyst. C, Showing sagittal section with gum flap turned up. D, Bony wall of flap has been removed and the flap turned back against the cyst wall. The cavity is tightly packed with gauze.

in such a fashion as to hold the raw surface of the flap against the raw internal concave cavity of the inner denuded bony wall.

ADAMANTINOMA

Synonyms.—"Epithelial odontoma," "multilocular dentigerous cyst," "cystadenoma."

Definition.—Adamantinoma is a benign tumor but has locally invasive characteristics. The tumor shows a tendency to cystic degeneration, usually of the multilocular type. It was first described by Malassez in 1885. No enamel is found in adamantinomas as the name would imply. The tumor is one of enamel-organ epithelium.

Pathogenesis.—An adamantinoma is most generally considered as originating from the enamel organ but by Malassez it was considered to originate from the paradental epithelial débris and Ewing's conception allows the probability of adamantinoma originating from the débris paradentaire, as do Bump, Thoma and Cahn. Some of these tumors may possibly originate from oral epithelium which retains the potentiality to differ-

*The marsupialization operation of Partsch is described very well by Williger, Henschen and Schwarz.

entiate later into cells resembling those of the enamel organ (Bakey). But whether the origination is from one or the other, it is conceded to be epithelial in origin. The cells show a variety of forms. Apparently the differentiation depends to some extent on the development of the epithelium at the time when the tumor started to form. In come cases the tumor even develops characteristics of a carcinoma with epithelial pearls and prickle cells—the acanthoma type. Rare cases have simulated an adenocarcinomatous form.

Lewis collected 70 cases from the literature and found the average age to be thirty-three years. This age nearly coincided with the age of the eruption of the lower third molar. This is suggestive. The lower third molar region receives more irritation than any other locality in the mouth. It has difficulty in erupting and is often impacted. Thus, trauma, combined with tooth retention or infection, has been suggested as playing a rôle in the pathogenesis of adamantinoma. Conclusive evidence, however, of the



A *B*

Fig. 282.—*A*, Adamantinoma—fairly low power. *B*, Section of another adamantinoma—higher power.

association of adamantinomas with mishaps during eruption or with impaction or with infection is not obtainable.

A few adamantinomatous tumors also appear elsewhere in the body where there is an unusual chance for invagination of epithelium in embryonic life. Peet discussed the tumors originating from the craniofacial (hypophyseopharyngeal) duct. Fifty per cent of them are adamantinomatous in type. Deake, Zawewloschin, Feinbrunn, and Baker and Hawksley discussed the occurrence of adamantinomas in the ovary, pharynx, tibia, sacral region and so forth.

Pathology.—On gross section one finds a thin bony wall inclosing a cystic or a solid meaty growth. The cysts are often multilocular in type and are filled with a yellowish or reddish fluid which varies from the serous to mucous consistency with varying proportions of epithelial débris and possibly cholesterin particles. The cyst walls are either smooth or roughened by papillary projections. Bony and fibrous trabeculae traverse the mass. The solid portion is meaty.

Microscopically, the epithelial picture presents variations between stratified squamous epithelium and characteristic adult columnar ameloblasts (Fig. 282). Three structural groups of solid tumor are described, but different parts of the same tumor may fall into different groups: (1) the squamous type presents cords of squamous epithelium, intercellular fibrils, hornification and epithelial pearls; this type may be confused with epidermoid carcinoma of the gums; (2) plexiform adamantinoma manifests convoluted columns of epithelium surrounded by connective tissue stroma, and the epithelial cells show little or no tendency to flattening; (3) the glandular type shows a predominance of columnar ameloblasts. The columnar cells may enclose reticulated cells which may surround numerous "pearls." Secretory products in the form of droplets within cells, enamel, dentine and cementum are also noted. The stroma varies from dense or

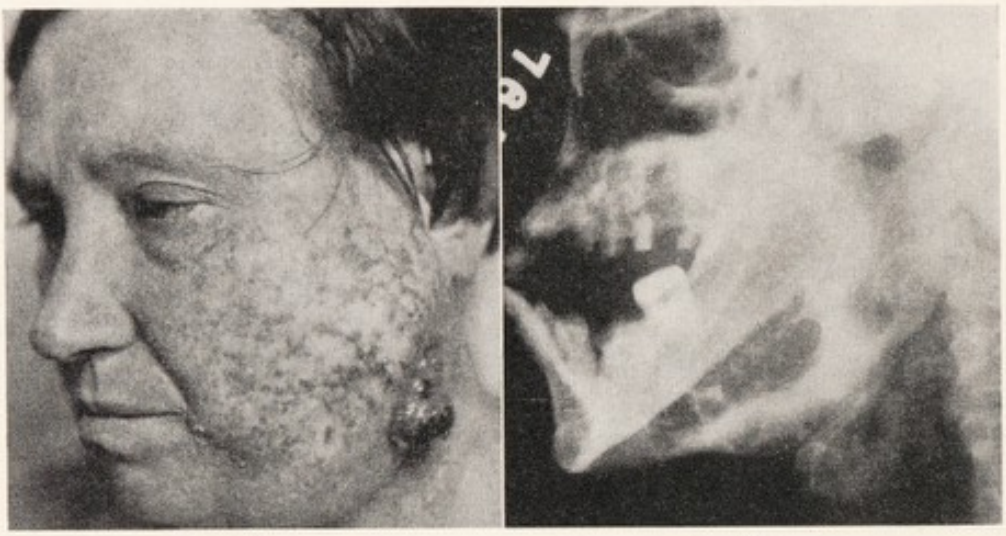

A *B*

Fig. 283.—*A,* Patient with an adamantinoma. First operation at the age of twenty-eight years. She then had deep therapy. Note telangiectasis. When we saw her she was forty-four years of age. This patient's jaw was resected. *B,* Adamantinoma. Microscopic section of tumor is shown in Fig. 282, *A*.

hyaline to a cellular overgrowth simulating sarcoma. Myxomatous degeneration is sometimes seen.

Hildebrand described an adamantinoma with branching epithelial columns, complete tooth, gums, and containing about 200 teeth. Risak, Mayer, Kallimann and Thoma describe examples of adamantinoma which changed into carcinoma. The resemblance in some cases of basal-cell epithelioma to adamantinoma has been stressed (Spring, Krompecher, Siegmund and Weber). When the stroma takes on a predominant rôle, certain adamantinomas have been classified as adamantinoma-sarcoma (Krompecher, Heath, L'Esperance, Korte, Papadimitriou).

Clinical Features.—These tumors gradually appear in early adult life, and grow very slowly. In untreated cases the growth continues without very marked symptoms other than distortions of the face due to the mass, over one third to one half of a lifetime. However, some have appeared in childhood (Massin) and others presumably have appeared in late adult life. For some unknown reason, more women are affected than men. Of the 5 adamantinomas I have operated 4 have been in women. When nerve

trunks are pressed upon or if secondary infection develops pain may be a symptom but ordinarily this symptom is not complained of. New, however, states that when they are of large size because of the pressure of the inclosed fluid, these tumors are occasionally the cause of considerable discomfort.

Although adamantinomas are found in both the upper and lower jaws, the most common site is the lower jaw near the angle (Fig. 283). Lewis states that adamantinomas are seen eleven times more frequently in the lower than in the upper jaw. Bump found the ratio of upper jaw to lower jaw to be 1:4 in 69 cases (14 in upper, 53 in lower jaw and 2 in both jaws). Schmidt collected 92 cases and found 78 in the mandible and 14 in the maxilla.

The relative percentage of solid growths is said to be higher in the upper jaw (Ewing). Although some of these tumors may originate in the premolar region they are practically never seen originating in the anterior tooth region. In 1 of our cases, however, the submental region was involved with a larger multilocular cystic adamantinoma in a Negro girl of about twenty years of age. Besides this case we have operated three located at the angle of the mandible and one in the cuspid region.

When the bulk of the tumor mass is at the angle of the jaw it tends to extend upward into the ramus and forward into the body of the bone.

Within the mouth a smooth mucous membrane is presented unless trauma causes ulceration of the overlying mucosa. In the beginning the alveolar border of the jaw is enlarged and the outer plate of the jaw is pushed outward more than the inner plate of the jaw is pushed inward. Large tumors tend to become somewhat lobulated and the thinned walls on deep pressure give an elastic sensation or possibly "egg-shell crackle." The neighboring teeth are likely to be displaced and loosened. The antrum, orbit or nasopharynx is encroached upon depending upon the size and the direction of the growth. Tumors of great size are described. For example, Bryk described a tumor extending to the sternum and weighing 3 pounds. Schmutziger also described a very large tumor. In 1 case the zygoma was eroded through (Kuhn).

Tumors of the upper jaw are somewhat more serious, as a rule because of the situation and tendency to solid type of growth. All the tumors are locally aggressive. But infiltration of the soft tissues is rare but examples are described by Spring, Heath and L'Esperance.

Although metastasis to the lymph nodes is practically unknown, Weissenfel, Simmons and Spring describe examples.

The long duration and the history of slow growth are quite characteristic. Lewis collected 70 cases in which the average duration of symptoms was eight and one-half years. Frantz and Stix have recently reported a case with a fifty-one-year history.

Diagnosis.—The diagnosis of unilocular adamantinomatous cysts may cause difficulty. Microscopic examination of the tissue, however, will prevent a mistake. The clinical picture along with the roentgenogram should make the diagnosis of multilocular adamantinoma easy.

Roentgenogram.—The roentgenogram showing a multilocular cystic cavity within the jaw bone with rather sharp bony delineations is rather characteristic (Fig. 283, *B*). However, in those neoplasms in which no

trabeculation or evidence of lobulation is seen, the roentgenogram aids one very little in determining the true character of the neoplasm.

Treatment.—Although Pichler in 1931 advised conservatism in the treatment of adamantinoma, most men consider that the best treatment is complete removal of the involved bone. However, New has advocated the destruction of the neoplasm by diathermy. In the lower jaw radical excision usually means a resection of a section of the mandible—enough to get both above and below the new growth.

The usual history is one of inadequate removal followed by a recurrence. However, in the slow-growing types the recurrence may not be rapid and a comparatively long freedom from disability is given.

Radium apparently has little effect on adamantinoma.

In removal of the angle and the ramus of the mandible, it is necessary to go through an incision just anterior to the ear which extends downward and forward below the angle of the jaw. The facial nerve can be avoided by going above and below it when the tumor is very large and extends well upward in the ramus toward the zygoma. Sufficient exposure can usually be obtained by an approach from below the facial nerve, when the soft tissues are retracted upward and away from the ramus of the mandible.

FOLLICULAR CYSTS

Dentigerous Cyst, "Odontocele," "Follicular Cyst"

Follicular cyst is inappropriate as the origin is not thought to be from the dental follicle but from the enamel organ.

The preceding cysts and tumors relate to the already erupted teeth. The remaining cysts and tumors affect the tooth before eruption and usually prevent its eruption.

Thoma calls these cysts follicular cysts and divides them into follicular cyst, simple without tooth formation; follicular cyst, dentigerous; follicular cyst with odontoma; and follicular cyst, multiple. The simple cyst contains no tooth and represents probably a very early disturbance of tooth formation. It probably takes place before the ameloblasts have differentiated from the cells of enamel organ. The result is a dilation of the inner and outer epithelial layer by accumulating fluid forming a globular cyst. The inner layer does not differentiate to form an ameloblastic layer but reacts to pressure, and forms a squamous epithelium. The follicular cyst, dentigerous (described subsequently as coronodental cyst), is formed at a later stage of development after the ameloblastic layer has produced the enamel of the tooth. Follicular cyst with odontoma (described subsequently as odontoma) differs from dentigerous cyst only in the dental product of the tooth germ in that, instead of a more or less normal tooth, a number of teeth of irregular shape or a conglomeration of tooth tissues is found. The following description of coronodental cyst and composite odontoma covers the classification of Thoma if it is considered that follicular cyst may occur without a tooth in the cyst wall or cavity. A question often arises whether a cyst is really a so-called "follicular cyst" or a radicular cyst.

Coronodental Cyst.—*Definition.*—Coronodental cyst is a benign cystic mass occurring in the jaw bones into which protrudes (or lies in the wall of) an unerupted tooth which is usually misplaced, and as a rule is only

partially developed. The fibrous capsule is commonly attached to the neck of the tooth and the root is buried in the jaw bone.

Origin.—As stated above, Thoma, accepting the lead of M. B. Schmidt and Bland-Sutton, has regarded coronodental cysts as true follicular cysts arising by dilatation of the enamel organ. Gallippe, however, explained these cysts as being caused by a stimulus exerted upon the paradental débris of the gubernaculum by an imperfectly formed tooth which becomes arrested in its course of development. Fibrosis of the gubernaculum opposing the eruption of the tooth followed by a dilatation of a mass of paradental cells would also account for most of the type encountered (Ewing).

Pathology.—Squamous-cell epithelium is the typical lining of the cavity but more rarely epithelium of the cuboidal type is found. The whole of the tooth, including the cementum and the dentine, show imperfect development. The root malformation, supposedly due to fibrosis of the pulp, is quite characteristic. Within the cavity is found a viscid, straw-colored fluid which sometimes contains cholesterin crystals. Other less typical forms are found. A supernumerary tooth has been enclosed in the cyst. Cases are described as containing masses of dentine, several roots and crowns, and some even as containing only enamel and others as containing irregular masses of dentine, imperfect pulp tissue and abnormal enamel.

Clinical Features.—At Mayo's up to 1929 (New) they had 6 of these tumors. Three were found in the upper jaw and 3 in the lower jaw. In the upper jaw one occurred in the premolar region, one in the molar region, and one was not noted. In the lower jaw one occurred in the premolar region, one in the anterior part of the jaw, and one in the molar region. These cysts occur in connection with the second dentition. When this type of cyst develops in connection with the third molar, it may develop later in life. Symptoms may not appear until in old age. In one of New's cases the patient was sixty-nine years old but he had a symptomless tumor in the lower jaw for forty-two years. But ordinarily cysts of this type are noticed in adolescent or early life during the second dentition or after it. According to Blair and Ivy only 4 cases are on record in connection with deciduous teeth. Most commonly the lower jaw is the site and the absence of a tooth in the series is of great diagnostic suggestiveness. By some authors the canine tooth is placed as the one most commonly missing, next the lower molar and next the premolars. But by Thoma the frequency is stated to be in the order named as inferior third molar, superior canine, superior third molars and the remaining permanent and deciduous teeth.

The mass heralding the development of such a cyst grows, as previously stated, very slowly and with little or no pain. First, bulging alveolus is noted. As soon as the bony wall of the jaw is sufficiently thinned the cystic mass feels springy and may give rise to the egg-shell crackle sensation. The size of the cyst is not rarely sufficient to loosen or slightly displace one or more teeth. Usually in the mandible, the outer wall becomes thin first. Cysts of the upper jaw not uncommonly depress the palate or encroach upon the antrum. Rarely a sufficient size is attained to distort the external contour of the face.

Rarely a cyst becomes infected sufficiently to cause definite signs of acute or chronic inflammation. The diagnosis may be obscured thereby. But when a roentgenogram is taken the true nature of the lesion usually is

evident (Fig. 284, *A*). The well-defined bony outline of the cavity with an unerupted tooth in the wall or projecting into the cavity is characteristic.

Treatment.—Aside from the additional necessity of removing the tooth or teeth lying in the wall of the cyst, the treatment is the same as that described under simple dental cyst.

Odontomas, Composite Odontomas and Connective Tissue Odontomas.—*Definition.*—A group of anomalies caused by an increase in number of more or less undeveloped teeth or even the hypertrophy of a single tooth is included under the heading of composite odontomas. Even the rare cases of third dentition may present a relationship. The so-called "enamel pearls" and "verrucous crowns" of Satler, which sometimes contain dentine or enamel or a part of a pulp canal, are also possibly related. Clusters of encapsulated teeth are not true examples, however. Even the dividing line between coronodental cysts and composite odontomas is indistinct.

Odontomas may be solid or cystic. The tumor classified in the preceding grouping by Thoma as follicular cyst with odontoma is the cystic type.



A *B*

Fig. 284.—*A*, Coronodental cyst. *B*, Odontoma.

Thoma has classified the solid odontomas as mature, hard odontomas, mature soft odontomas, and immature odontomas.

In the first group are thrown those odontomas consisting of the various mature parts of tooth substances. All the tooth structures may enter into the tumor. Two or more teeth may unite (geminated composite odontomas). This latter defect may involve only the crowns or the roots or both. In a second subtype (compound composite odontomas) a large number of teeth, sometimes several hundred, may be involved—the enamel organs instead of developing normally may produce many small enamel organs. Again the arrangement of the tissue may not be regular and toothlike and contain tissue in different stages of development. The fact that these tumors develop early in life, and before completion of the second dentition, indicates their probable relation to embryologic mishaps (Thoma).

In the second group are thrown a very rare tumor which is not possible to be distinguished always from true central fibroma but usually it con-

tains a scanty amount of dental epithelium on microscopic examination. The neoplastic growth affects principally the mesoderm. Siegmund and Weber show a tumor of this type.

In the third group are thrown immature tumors which tend to infiltrate, recur locally or even show distinct malignant characteristics. They, however, contain teeth or tooth particles. The adamantino-sarcoma is a variant of adamantinoma.

Origin.—The cysts with multiple well-formed teeth and the various odontomas may be referred to the enamel organ and the pulp tissue (Ewing). As the first or second molar is generally missing in odontoma it is indicated that the tumor arises in the structures which normally give origin to these teeth. Just what factors initiate this growth is obscure. Schlossman suggested that the origin might be due to a misplaced dental follicle caused by the confined quarters at the angle of the jaw during the early growth period. The variations in composition and relations of the recorded odontomas make their etiology and origination appear to be somewhat diverse.

Pathology.—Typical composite odontomas are composed of a conglomeration of imperfectly developed tooth material surrounded by a fibrous capsule which is usually lined with epithelium. Variable quantities of enamel, dentine, pulp tissue, and cementum are included. But at times enamel is missing. The fused mass, disorderly in its arrangement, presents a nodular outline because of the projection of imperfect tooth material. The mass lies in a cavity which may or may not contain fluid. There is a type which has been termed "soft odontoma" because of a composition made up chiefly of connective tissue in which, however, there may be rudimentary teeth. Early examples were described by F. S. Hunter, Hildebrand and Bland-Sutton. Virchow and Billroth described examples of hypertrophy of a single tooth. Later examples have been described by Thoma and others.

Clinical Features.—Odontomas are seen almost invariably in the lower jaw of young individuals before the age of twenty-five years. Typically an absence of one or more teeth of the molar series is observed. Thus, an irregular hard swelling appearing and growing slowly without pain in the body of the lower jaw in a young adult in the face of an absence of one or more of the molar series strongly suggests a composite odontoma. Thoma states that in his experience odontomas form a larger mass than coronodental cysts and are more liable to cause expansion of the bone than are other types of follicular cysts. The calcified masses have a tendency to erupt like teeth and at that time symptoms of discomfort are caused. When partial eruption occurs a secondary infection follows which superimposes the picture of the inflammation varying from that of the characteristic new growth. A sinus may form. In such a case a probe may aid one in ascertaining the true nature of the foreign body causing the discharge. When properly located some interference with motion of the temporomandibular joint may be observed. Infected growths near the angle of the mandible are prone to develop secondary spasm of the muscles of mastication, which interferes with opening of the mouth.

Roentgenogram.—The roentgenogram is absolutely characteristic and shows the irregular calcified mass of tooth substance lying within the jaw

bone with a sharp line of separation between the two. The roentgenogram will differentiate the condition from a necrosis of the bone (Fig. 284, *B*).

Treatment.—The treatment varies in no essential from that outlined under simple dental cyst save that the tooth-formed elements also should be removed. The principles to be observed are removal of formed tooth elements and the epithelial lining. Then one wall of the bone is saucered out so that no overhanging edges prevent the soft tissues from falling into the bony cavity.

Epulis.—Epulis is a term applied to a tumor attached to the covering of the jaw bones which Nélaton is said to have described first. The term itself is a gross clinical term applied to a group of tumors, at least most of which arise from the peridental membrane at its junction with the alveolar mucosa. Although these tumors may not be dental in origin they are placed in this group because of the suspected relationship to the paradental débris.

Etiology.—Although in the past a chronic irritation and inflammatory basis has been rather generally thought to underly or stimulate the overgrowth of new tissue which forms epulides, a few may arise from the periosteum of the alveolus. Cells of the paradental débris of Malassez have been mentioned by Ewing as being responsible for certain types of epulis. The characteristic giant cells resemble cells of the paradental débris. Possibly many extraneous lesions such as hemangioma, fibroma, and fungating ulcers are erroneously placed in this category on the insufficient grounds that they occur on the gums. The term "epulides" should be restricted to those lesions described as giant-cell and fibroid epulis. Geschickter and Copeland express the opinion that the giant-cell epulides are related to typical giant-cell tumors, and the fibrous epulides are akin to osteitis fibrosa. They see in giant-cell epulis a histology indistinguishable from giant-cell tumor, and in the fibrous variety an exact homologue of osteitis fibrosa. They also state that about the roots of deciduous teeth there is a periosteum which is normally endowed with the power of osteoclasis and after the age of five, osteoclastic hypoplasia is nature's provision for shedding the deciduous teeth. The process is analogous to the osteoclastic hypoplasia that occurs in the ends of long bones and in the cartilaginous bones of the skull.

Histology.—In many of the epulides as a group are seen atrophic and proliferating epithelial cells which have been thought to be derived from the original peridental structure. The majority of the growths are of a fibroblastic type made up from the most part of spindle cells surrounding the sinuses and blood vessels. Usually a certain degree of round-cell infiltration is present and occasionally some myxomatous degeneration is seen. Giant cells of the foreign body type with numerous nuclei are common findings (Fig. 285). A few of the growths are very vascular and numerous blood vessels are in evidence. One type has been described as an endothelioma but it is suggested that in many instances the cells that have been mistaken for epithelial endothelial cells form the peridental débris.

Clinical Features.—There arises from the margins of the gum at the neck of a tooth a small pedunculated or sessile mass, smooth and curved by unbroken mucosa, which at first sight may be taken for a "gum boil." The lesions never occur before six years of age but may occur at any time later. Seldom are they found about the molars. Most generally they correspond in location and incidence with the shedding of the deciduous teeth.

The neoplasm grows slowly and either extends along the gums and between the teeth or a stalk is developed (Fig. 286). In the former case some of the teeth may be loosened. In size the growths vary from a rather minute mass to 1 inch in diameter.

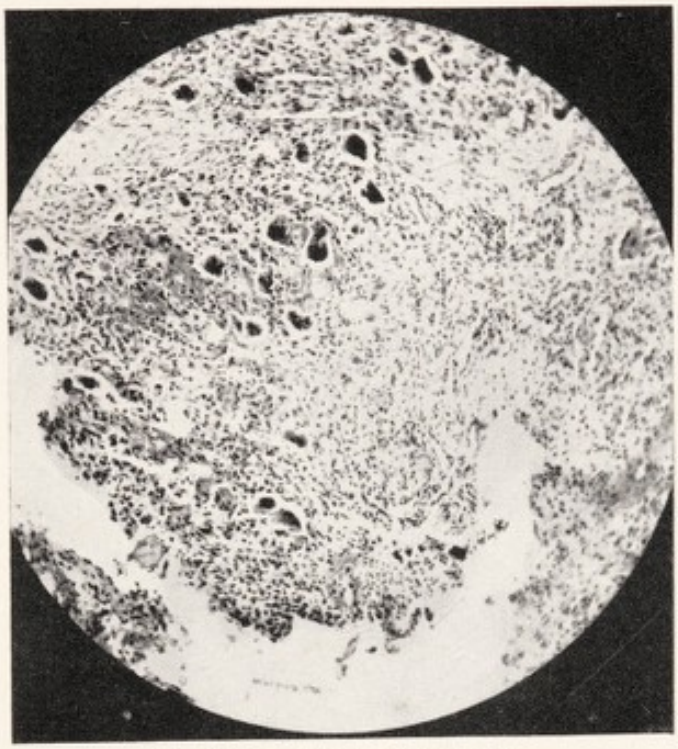

Fig. 285.—Giant-cell epulis.

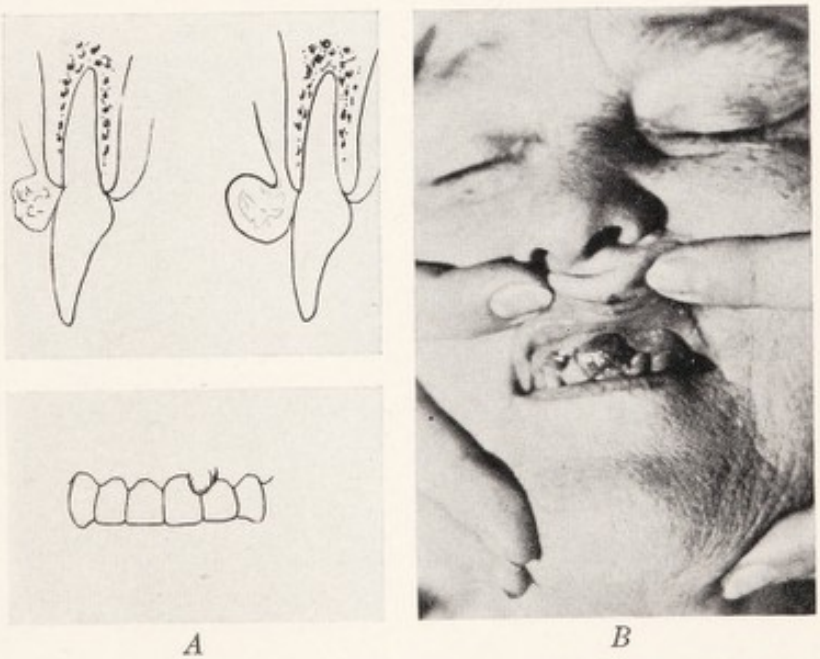

A *B*

Fig. 286.—*A*, Manner in which an epulis springs from the alveolar margin between two teeth. *B*, Patient with a fibrous epulis.

The fibrous growths are the most common and are recognized clinically by their firmness and tendency to a nodular conformation. The covering mucosa is normally red. The history of growth is slow—only a slight increase in size is shown in a year's time.

Although it is a question whether the angiomatous epulis is really a true epulis, in clinical description it may be classed as one. These lesions are rather soft and spongy and the mucosa is often dark or bluish red in color. Some of the more angiomatous types give a history of bleeding freely with slight trauma. The growth is sometimes rather rapid, a matter of months.

The giant-cell epulis is nearly as common as the fibrous epulis. It does not grow so rapidly as the angiomatous form but usually more rapidly than the hard fibrous type. A smooth soft mass is present, covered with dark red or purplish mucosa.

It is common for an epulis to show ulceration from trauma and subsequent infection.

Diagnosis.—One should not forget that epithelioma may appear at the gum margin and in some ways may resemble an epulis. However, a characteristic of epithelioma of the mucosa of the mouth wherever it may be found is early ulceration. A benign papilloma may take a form somewhat similar to that of a true epulis. A papillomatous wart is not covered with a smooth mucosa. Very rarely what was formerly a benign epulis may undergo malignant degeneration and ulcerate and start to grow rapidly. The epithelial covering of an epulis may show malignant degeneration in the elderly. A section for microscopic examination should be removed with a cautery knife when malignancy is suspected.

Treatment.—Because of a tendency to recurrence an epulis should be removed in such a fashion that the pedicle or base from which the mass springs is removed with certainty. In the past we have usually sacrificed at least one tooth and cauterized the alveolar margin including the peridental rim and gum margin with a cautery. Usually this all can be accomplished with local anesthesia but in some cases gas anesthesia may seem wisest. A more conservative treatment than the above is counseled by Geschickter and Copeland. They advise against the tooth removal although the remaining wound is cauterized. They state that epulis has never been known to undergo malignant change even if they recur after simple excision. However, in my experience, if the base from which the tumor springs is not destroyed recurrence is rather common. I believe it wisest to be radical enough so that the tumor does not reappear. If one destroys the alveolar attachment, the tooth or teeth usually suffer sufficient damage to force their removal later.

Bibliography

Bibliography Quoted in Text

Baker and Hawksley: Brit. Jour. Surg., **18:** 415–421, 1931.
Barnes: Medical Trans. London, p. 316, 1813.
Becker, E.: Cited by Blum, T.: Jour. Amer. Dent. Assoc., **15:** 1098, 1928.
Billroth: Virchow's Arch., **8:** 426, 1850.
Blair, V. P., and Ivy, R. H.: Essentials of Oral Surgery, pp. 297–305, C. V. Mosby Co., St. Louis, 1923.
Blair, V. P., Padgett, Earl C., and Brown, J. B.: Diseases of the Face, Mouth and Jaws, Graham's Surgical Diagnosis, W. B. Saunders Co., Phila., **11:** 209–237, 1930.
Bland-Sutton: Tumors, Innocent and Malignant, New York, Cassell and Co., 1901.
Correct Embryologic Classification, 1893.
Trans. Odon. Soc. Great Brit., 1867.
Block-Jorgensen, K.: Ztschr. f. Stomatol., **28:** 245, 1930.

Deutsch. Monatschr. f. Zahnh., **48:** 1416, 1930.
Dental Items of Interest, **52:** 192, 1930.
Broca, P.: Gaz. hebdom., p. 70, 1868.
Trait. de tumeurs, **11:** 35, 1886.
Rev. de mal. de l'enfance, p. 521, 1906.
Compt. rend. Soc. biol., p. 301, 1862.
Recherches sur une nouveau groupe de tumeurs designé sous le nom d'odontomas, Gaz. hebd. méd. et chir., 1868.
Bryk: Arch. f. Chir., **25:** 793, 1880.
Bump, W. S.: Adamantine Epithelioma, Surg., Gynec. and Obst., **44:** 173, 1927.
Cahn, L. R.: Case Report 48938, Bone and Radiologic Conf., Johns Hopkins, Baltimore, 1932.
Counsell, A.: Proc. Roy. Soc. Med., **25:** 201, 1931.
Deake: Amer. Jour. Cancer, **16:** 233, 1932.
Zawewloschin, Frankfurt. Ztschr. f. Path., **41:** 100–106, 1931.
Delpeck: Chir. clin., 1828.
Dupuytren: Chir. clin., 1833.
Ewing, J.: Neoplastic Diseases, W. B. Saunders Co., Phila., 1928.
Feinbrunn: Arch. f. Ohren-, Nasen- und Kehlkopfheilk., **126:** 297–299, 1930.
Fischer, G.: Deutsch. Monatschr. f. Zahnheilk., p. 29, 1911.
Forget: Thèse de Paris, 1840.
Des. anom. dent., p. 5, 1859.
Frantz, V. K., and Stix, L.: Adamantinoma, Arch. Surg., **25:** 891–896, Nov., 1932.
Gallippe: Le débris épith. parad., Paris, 1910 (Lit.), Bryck, Langenbeck's Archiv f. Chir., 25.
Geschickter, C. F., and Copeland, M. M.: Tumors of the Bones, Amer. Jour. Cancer, New York, 1931.
Gottlieb, B.: Der Epithelansatz anor. Zahn: Deutsch. Monatsch. f. Zahnheilk., 1921, No. 5, Epithelansatz.
Grawitz, A.: Die epitheal du hranden Zysten der Zahnwurzeln, Greifswald, Germany, 1906.
Guzack: Dublin Hospital Rep., p. 29, 1826.
Heath: Brit. Med. Jour., **1:** 66, 1897.
Henschen, C., and Schwarz, R.: Chirurg., **1:** 56, 1928.
Hildebrand: Deutsch. Ztschr. f. Chir., **31:** 282, 1890–1891.
200 Supernumerary Teeth, Ztschr. f. Chir., **31:** 35.
Hunter, F. J.: Deutsch. Zeitschr. f. Chir., **31:** 35, 1890, quoted by Hildebrand.
Ivy, Robert H.: Tumors and Cysts of the Jaw as Disclosed by Roentgenogram and Their Treatment, **14:** 2272, 1921.
Kalliman: Quoted by Mayer, D., 1929.
Korte: Zwei wichtige Unterkieferbeintumoren, Adamantinoma sarcomatosa u. Wurzelzyste, Inaug. Dissert., Münster, 1929.
Krompecher: Ziegler's Beiträge, **64:** 165, 1918.
Kuhn, A.: Deutsch. Monatschr. f. Zahnheilk., **50:** 49, 1932.
Kuhn, H. P.: Personal communication.
Lardtschneider, J.: Malassez So-called "Paradental Epithelial Nests," Their Biologic and Pathologic Role in the Development of Dental and Maxillary Tumors, Ztschr. f. Stomatol., **27:** 476–480, May, 1930.
Lewis, Dean: Multilocular Cysts of Jaws, Surg., Gynec. and Obst., **10:** 28, Jan., 1910.
L'Esperance, E.: Proc. New York Path. Soc., **10:** 136, 1910.
Magitot: Arch. gén. de méd., Mémoires sur les kystes, **73:** 339, 1872.
Malassez, L.: Sur le rôle des débris épithéliaux paradentaire, Arch. de physiol., Paris, **5:** 129, 1885.
Malassez, L., and Gallippe, V.: Les débris épithéliaux paradentaires, Paris, Masson et Cie, 1910.
Massin: Arch. f. path. Anat., etc., **136:** 328, 1894.
Mayer, D.: Zur Histogenese eines Adamantinomas u. seines Überganges in ein Plattenepithelcarcinoma, Inaug. Dissert., Erlangen, 1929.
Nélaton, E.: Kyste dentaire du maxillaire supérieur, Bull. soc. anat. de Par., **31:** 489, 1856.
New, G. B.: Surg. Clin. North Amer., **9:** 80, 1929.
In Engleman, Julio, Dental Pathology, C. V. Mosby Co., pp. 379–390, 1927.

New, G. B., and Figi, F. A.: Value of Roentgen Ray in Diagnosis of Tumors of the Jaw, J.A.M.A., **83:** 1555, Nov. 15, 1924.
Papadimitriou, B.: Beitr. z. klin. Chir., **144:** 556, 1928.
Peet, M. M.: Pituitary Adamantinomas, Arch. Surg., **15:** 829, Dec., 1927.
Perthes, G.: Die Verletzungen und Krankheiten der Kiefer, Stuttgart, 1907.
Ueber odontogene Kiefertumoren, München. med. Wchnschr., **52:** 725, 1905.
Peters, K.: Korresp.-Bl. f. Zahnärzte, **53:** 207, 1929.
Pichler, H.: Wien. klin. Wchnschr., **44:** 1315, 1931.
Risak, E.: Arch. klin. Chir., **144:** 441, 1927.
Rywkind, A. W.: Virchow's Arch. f. path. Anat., **283:** 13, 1932.
Schlossman: Ziegler's Beiträge, Path. Anat., **44:** 311, 1908.
Schmidt, M. B.: Ergb. d. allg. Path., Lubarsch-Ostertag, **7:** 332, 1894.
Schmidt, E.: Deutsch. Monatschr. f. Zahnheilk., **40:** 353, 1922.
Schmutziger, P.: Central Mandibular Tumors of Otogenic Origin, Schweiz. Monatschr. f. Zahnheilk., **40:** 309–370, June 30, 1930.
Schultz, L. W.: Cysts of the Mandible and Maxilla, **14:** 1395, 1927.
Odontomas: Classification, Diagnosis and Treatment, **17:** 1874, 1930.
Schuster, E.: Deutsch. Monatschr. f. Zahnheilk., **26:** 840, 1908.
Scudder: Tumors of the Jaw, W. B. Saunders Co., Phila., 1922.
Siegmund, F., and Weber, R.: Pathologische Histologie der Munderhöhle, Leipzig, S. Hirzel, 1926.
Simmons, C. C.: Adamantinoma, Ann. Surg., **88:** 693, 1928.
New York Med. Jour., **24:** 379, 1924.
Spring, K.: Wien. Zeitschr. f. Stomatol., **30:** 455, 1932.
Zeitschr. f. Stomatol., **10:** 608, 1932.
Thoma, K. H.: Clinical Pathology of the Jaws, Charles C. Thomas, Springfield, Ill., 1934.
Virchow: Virchow's Arch., **85:** 537, 1876.
Williger, F.: Zahnärztliche Chirurgie, Leipzig, W. Kleinhardt, 2nd ed., 1911.
Weissenfel, G.: Vierteljahrsschr. f. Zahnheilk., **38:** 56, 1922.
White, J.: Jour. Path. and Bact., **13:** 3, 1909.
Witzel: Monatschr. f. Zahnheilk., p. 305, 1896.
Zawewloschin: Quoted by Peet, M. M.: Pituitary Adamantinomas, Arch. Surg., **15:** 829, Dec., 1927.

CHAPTER XXXVIII

OTHER BENIGN AND MALIGNANT TUMORS PRIMARY IN THE BONES OF THE FACE AND JAW

ALTHOUGH the classifications of true bone tumors are not entirely agreed upon by equally competent authorities, rapid strides in simplification of classification were made by the Bone Tumor Registry Committee of the American College of Surgeons which was established in 1920. In the Johns Hopkins series reported by Geschickter and Copeland, an attempt is made to more specifically delineate the embryologic source and the anatomic origin than the Registry Committee believed possible at the time of its publication.

For our purposes it seems important to emphasize the relationship between normal bone development and tumor formation, as developmental factors explain why some tumors of the bone are not likely to occur in the bones of the face and jaw. It is to be emphasized that particularly in adolescence but at all ages, there are places where transitional forms between the different tissues of bone persist and that each transition represents a possibility for tumor formation, *i. e.*, that most of the neoplasms of bone are associated with the phases of osteogenesis and especially is this so where rapid change is taking place or is likely.

All components of bone are derived from preformed connective tissue which is endowed with the ability to form cartilage and bone. In membranous bones direct ossification occurs in the connective tissue. The bones of the face are mostly of the membranous type—all except the ethmoid, inferior turbinate, sphenoid, and three areas in the anterior part of either half of the mandible, an area in the coronoid and an area in the ramus extending up into the condyle.

In nonmembranous bones small rounded fetal cartilage cells precede and give rise to adult cartilage. The latter is then gradually calcified and true bone is formed. In the early stages of cartilaginous bone formation and in membranous bone there is not much of a tendency for neoplastic growth. Most commonly tumor formation appears in the bone which follows cartilage where histogenic processes are somewhat delayed until a later age. Geschickter and Copeland maintain that from an embryonic point of view "neoplasms may be divided into two large groups, those arising in connection with subsequent growth of cartilage and those arising in persisting portions of pre-osseous and pre-cartilaginous connective tissue."

Consequently, in the jaw bones when tumors of the dental structures are excepted, only rarely is a true bone tumor found. The reasons for the scarcity of true bone tumors in this region are, first, the predominance of membranous bone (the greater part of the lower jaw and the whole of the upper jaw is membranous in type); secondly, the fact that histogenic transition in all but one of the few cartilaginous areas of the lower jaw is over at an early age (the epiphysis of the condyle becomes calcified at about

fifteen years of age but the other cartilaginous areas are calcified at one year of age).

The neoplastic process observed in true bone tumors is not simply an overproduction of cells of a definite type. A sliding scale of cell differentiation is involved. This histogenic transition is a normal process and is not caused by the neoplastic process. Thus, generally only in situations and at periods of age at which normally there is going on histogenic growth in the skeleton is neoplastic growth capable of being initiated. As Geschickter and Copeland say, "this gives new importance to the skeletal and age distribution of each form of tumor and as will be shown, these two features together constitute a most important diagnostic aid. It also justifies a new approach to the clinical study of tumors of the bone, giving a new significance to the pathology of these lesions."

General Incidence.—Christensen, in a compilation of 1000 bone tumors, found the following: in the superior maxilla, 1 benign and 10 malignant osteogenic tumors; in the mandible, 2 benign and 5 malignant osteogenic tumors; 20 giant-cell tumors were noted in the upper jaw and 21 in the lower (whether or not this included epulis is not stated). Two examples of multiple myeloma were noted in the upper jaw. One endothelial myeloma (Ewing's tumor) was found in the upper jaw and 2 in the low. No metastatic tumors, periosteal fibromas or benign angiomas were listed in this group of 1000 tumors of bone.

BENIGN EXOSTOSES, CHONDROMAS, OSTEOMAS, FIBROMAS, AND MYOSITIS OSSIFICANS

Benign Exostoses and Osteochondromas of the Jaw Bones.—This group of tumors composes the largest group of benign tumors which arise from precartilaginous connective tissue. Tumors of the jaws often grouped under exostosis may be really osteomas, which represent a somewhat different type of ossification in fibrous tissue.

Incidence.—The common age incidence is between the years of ten and twenty-five. Of 262 of these types of new growths in the Johns Hopkins series, 10 occurred in the jaw bones proper, 7 in the lower jaw and 3 in the upper jaw. About twice as many males are affected as females.

Histogenesis.—Normal bones at the epiphyseal line have neither fibrous tissue nor fetal cartilage cells. The cartilage cells are in a higher state of differentiation. Thus, it has been suggested that osteochondromas are not related histogenetically to the bone nor to the epiphyseal line. Rather they are related to the articular and periarticular structures. The extraskeletal blastema, destined to form joints and the attachments of certain tendons and ligaments, goes through a slower and later embryologic development than the skeletal blastema. The extraskeletal blastemal tissue retains the ability to form cartilage and bone throughout its life. Thus, cartilage when formed does not become absorbed but is converted more directly into bone. To cause exostosis or osteochondroma in the future a disturbance or distortion of normal growth probably takes place at the tendinous attachments.

Etiology.—A considerable multiplicity of factors might be involved in tumor formation of the osteochondroma group. There is a form of congenital exostosis in which these tendencies are frequently multiple and sometimes hereditary. The effects which congenital exostosis may have upon

periosteum and cortical bone, is evidenced by the metaphyseal widening so often seen in the hereditary deforming achondroplasia. Single exostosis may arise as a result of traumatism to normal cartilaginous bone growth zones as where aberrant islands have been left behind. Some exostoses are inflammatory in origin as, for instance, "gonorrheal spurs."

Microscopic Features.—An exostosis shows the microscopic picture of bone. Osteochondromas show a typical transition from fibrous tissue to cartilage to bone. The superficial layer is hyalinized cartilaginous substance with fairly adult cartilage cells, but here and there are found islands of fetal cartilage cells. In the deeper portions this cartilage undergoes calcification and cancellous bone is formed with bone marrow within its trabeculae. Generally speaking, the microscopic picture is one of quiescence. The capsule may dip into the tumor, dividing it into lobules. Geschickter and Copeland state that many of these tumors found in the region of the jaws are more correctly classified as osteomas proper.

Gross Pathology.—An osteochondroma appears as a firm lobulated mass covered with fibrous tissue. On section the shiny surface is seen to be composed of two layers: first, a thin fibrous layer and, next, directly beneath, a translucent cartilaginous layer. Beneath this lies cancellous bone.

Clinical Features.—These tumors have a relationship to sites of tendinous attachments where there is maximal traction and where the tendons attach not to periosteum but directly to bone. Growth is slow and three to five years may elapse before a patient afflicted with one of these tumors appears for treatment. The symptoms are rather dormant. Pain is not as a rule a symptom. The ache, if there be any, is usually mild. But a complicating factor such as an inflammation from irritation of overlying soft parts may increase the discomfort. At times when growth suddenly increases the acuteness, the symptoms are likely to be correspondingly exaggerated. Despite the duration of the lesion, malignant change may take place at any time. The evidence in favor of such a change depends principally upon the sudden increase in the rate of the growth. When malignant change occurs, however, it is usually after thirty years of age. Local examination reveals a hard swelling, firmly attached to the underlying bone, with little or no tenderness and with the soft parts freely movable over the mass.

Roentgenographic Features.—A base or pedicle of bone is seen protruding through a periosteal gap, covered by a neoplastic cartilaginous cap. The bone may be differentiated into cancellous and compact portions merging into normal bone beneath. The cartilaginous cap shows varying degrees of calcification. The most important feature of the roentgenographic picture which differentiates exostosis from sarcoma is the neoplastic cartilaginous cap. As pointed out by Jansen, a widened metaphyseal zone is typical of fully developed or mild degrees of hereditary chondrodysplasia, a diffuse disease of the skeleton with which benign, single or multiple exostoses are often associated. The distinctive diagnostic features of the osteochondroma is the base or pedicle of normal bone protruding through a periosteal gap and the neoplastic cartilaginous cap which is often undergoing calcification in its deeper layers.

Treatment.—Instances of single exostosis without symptoms may be left untreated if one is certain of the diagnosis. But a careful watch should

be kept over them and an occasional roentgenographic examination made since they may undergo malignant change, especially after the age of thirty years. Simple excision with the destruction of the base usually gives a permanent cure in those instances producing symptoms or dysfunction.

Osteoma (Proper).—In the jaw bones some of the truest examples of osteomas are found (Fig. 287, *A*, *B*). It is hardly possible to define exactly the limits of osteoma as the distinction between inflammatory and neoplastic hyperplasias of bone is rather indefinite. Even microscopically, distinction between irritative hyperplastic growths of bone and true neoplasms is often not possible. The distinction, if made, is made on the gross and clinical features. A hard mass without an inflammatory beginning, a progressive history, and a circumscribed form along with active osteoblasts and a possible cartilaginous derivation are the basis for the application of the term "true osteoma."

In the maxillae hyperplastic bone formation occurs in connection with dislocated or inflamed teeth. Most of these are inflammatory hyperostoses but some may be true osteomas.



A *B* *C*

Fig. 287.—*A*, Osteoma which has a history of slowly developing for seventeen years. *B*, Preceding tumor. *C*, Typical case of torus palatinus. (Prinz.)

In the upper and inner part of the orbit osteomas arise occasionally. They arise from the ethmoid and the frontal and also from the superior maxillary bones and tend to project into the orbit, the nares or even the cranial cavity. Virchow early described 4 of these cases. Within recent years La Grange has collected 148 cases. Lesser states that they arise from embryonic cartilaginous portions of the ethmoids—even those in the frontal sinus. When projecting into the sinuses they present a covering of inflamed or even cystic mucosa. These tumors may be pedunculated or sessile in form when on the surface. Osteoma of the frontal sinus produces a swelling over the orbit and progresses slowly and steadily. Although they all grow very slowly, neglected cases may attain considerable size. No pain is felt as a rule unless there is pressure on a sensory nerve. The diagnosis is made by the roentgenogram. Exposure is made for diagnostic purposes and to alleviate symptoms.

Torus Palatinus.—Torus palatinus is an exostosis—two bony overgrowths which come in contact in the median line of the palate. When small they consist almost entirely of compact bone. The larger ones are made up of cortical bone with typical spongiosa in the center. The pedicles which

connect them to the larger of the palatine processes of the maxilla are traversed by numerous vessels. When they interfere with a plate or in other ways they should be removed (Fig. 287, *C*). Torus palatinus is a relatively rare condition.

George Carabelli in 1842 first gave a comprehensive description of this anomaly. Kupffer and Bessel-Hagen in 1879 called the lesion "torus palatinus."

Chondroma or Benign Chondromyxoma.—The Johns Hopkins series of 27 cases contains no records of a jaw tumor of the chondromatous or chondromyxomatous type.

This cartilaginous tumor is often classified with the benign exostoses. These tumors differ from the osteochondromas in having little or no osseous material and their location is more frequently central than periosteal (Fig. 288). It occurs between the ages of twenty and thirty. The hands, the

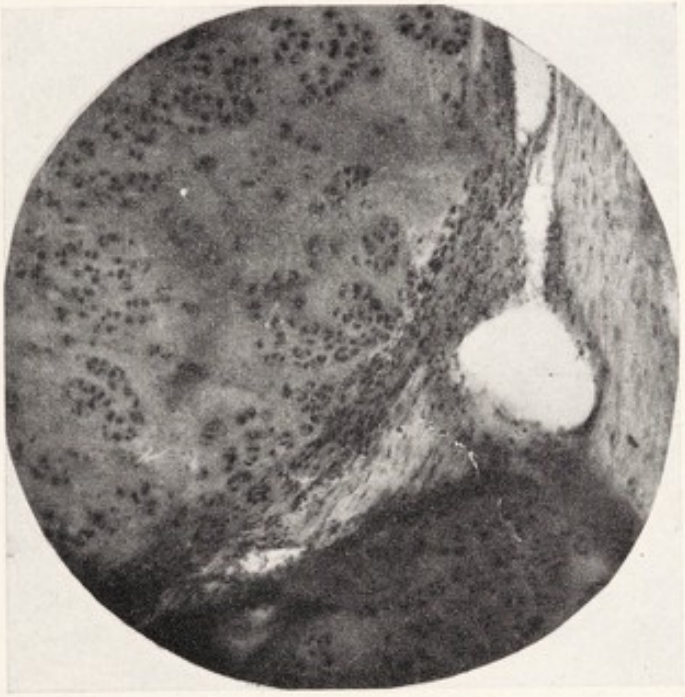

Fig. 288.—Chondroma of upper jaw.

feet, spine, ribs and sternum are the common sites. The symptoms are much the same as in osteochondroma. Although cures are usual in complete excision there is a tendency to recurrence. The soft parts are freely movable over the tumor. It is firm, smooth or lobulated to palpation and securely attached to the surrounding bone. In the roentgenogram a typical chondroma is a small translucent and rarefied area located centrally in the shaft of a bone, usually a small bone. The bony cortex is thinned and expanded. There is neither new bone formation nor calcification, although trabeculae may be seen to run transversely in some of the tumors. Sometimes the bony shell may be perforated, with extension into the soft parts.

Multiple Exostoses or Hereditary Deforming Achondroplasia.—This disease is a congenital disturbance in the perichondrium. Tags of cartilage in the tendon ends proliferate to form cartilaginous caps covering bony outgrowths. Also the disturbance in the periosteum in the metaphyseal regions leads to widening of the metaphysis and inhibition of bone growth.

The forearms and forelegs are most frequently affected. Bending of the extremities is frequent and central chondromas may be formed in the metaphysis by ingrowth of cartilaginous areas. The condition is very rare. It is congenital and is usually discovered in childhood. Little is to be found in the literature regarding the effect of the disease in the jaw bones. Presumably the epiphysis of the condyle would be the only situation that could possibly be affected. The prognosis as to life is good. No adequate form of treatment save operation to correct a deformity of considerable extent would be sensible.

Myositis Ossificans.—Myositis ossificans is a progressive ossification of one or many muscles. The condition has been observed in the muscles of mastication and the sternomastoid muscle. But in the face or neck muscles the disease is extremely rare. The muscles most commonly affected are the vastus externus and biceps muscles. The disease tends to progress until the involved muscle is completely ossified. Following a severe injury, a hemorrhage into the muscle develops. The ossification starts from the periosteum and spreads along fascia or tendon. The picture is one of a primary increase of fibrous tissue, then chondrification and finally ossification. The development of the disease leads to an atrophy of the muscle fibers. The disease occurs in young persons chiefly—most often in the third decade.

Recent experiments seem to indicate that the stimulation to ossification is chemical, causing increased calcium deposition at the local site in the presence of an injured vascular supply. A hard tumor forms and within a period of six weeks ossification occurs. Dean Lewis has emphasized that the area of ossification attains the maximum rapidly and then tends to remain stationary or to decrease.

The diagnosis of such a lesion by the roentgenogram following a history of trauma is not difficult.

Treatment.—While ossification is in progress, it is a mistake to intervene surgically—a recurrence may be stimulated. Later, if symptoms are present, surgical intervention may be considered.

MALIGNANT TUMORS PRIMARY IN THE BONES OF THE FACE AND JAWS

The true meaning of osteogenic sarcoma is a sarcomatous tumor derived from ancestors of cells which, when duly differentiated, are known as osteoblasts (Kolodny). In an osteogenic sarcoma various stages of development of osteoblasts can be seen from a simple spindle cell to mucoid cartilaginous cells, and even true bone cells. An osteogenic tumor does not necessarily produce bone. Differentiation may desert the cells midway and they remain mucoid or cartilage cells. Production of bone is a potential ability of the cells. According to the Registry, subclassification of osteogenic sarcoma is of little value and although they have subdivided them, the authors are inclined to think that the types are not really worth separate subheads. Any attempt to isolate the point of origin is, the Registry feels, usually not possible as there is both medullary and subperiosteal invasion in practically all tumors if the gross specimen or a good roentgenogram is examined, or else microscopic examination will show tumor invasion if the other methods do not.

The term "osteosarcoma" in the past included almost any malignant tumor originating in bone and one tumor at least which is supposed to arise from the outer layer of the periosteum—a nonbone-forming layer which

is to be interpreted as a fibrosarcoma proper and not a true bone tumor. Ewing originated the term "osteogenic sarcoma" as designating any malignant tumor arising from bone cells (osteoblasts) or more accurately from ancestors of cells which when differentiated are known as osteoblasts. An osteogenic sarcoma does not necessarily have to produce bone but its cells must have that potential ability. Mucoid and cartilaginous cells or even a more undifferentiated cell, the spindle cell, are seen when the ability to differentiate into true bone cells fails. Usually the more undifferentiated and the more rapid the multiplication of the cells, the more destruction there is of the surrounding normal bone. The more differentiated the cells, the greater the tendency to bone production. This conception supersedes the morphologic naming of tumors according to their predominant cellular form, as for example, round-cell, spindle-cell, or giant-cell sarcomata. It is thus to be emphasized that fibrous, osteoid myxomatous and chondromatous tissue may all be seen in osteogenic sarcomas and any one may vary predominantly.

Myxoma has been suggested by Ribbert and Bloodgood as belonging to a separate anatomic entity with a different fundamental cell origin. Geschickter and Copeland regard myxoma as a precartilaginous stage of differentiation and Kolodny has suggested that it is a degenerative stage in cartilaginous tissue.

The rare telangiectatic sarcomas are considered a type of osteogenic sarcoma with a marked overdevelopment of the vascular supply.

The term "sclerosing sarcoma" (Virchow) signifies that the intracellular substance is principally ossified. Recently Geschickter and Copeland have classified separately the form of osteogenic sarcoma of the chondromyxosarcoma type, which develops primarily and secondarily analogously to the benign exostoses and chondromas. They are made up mostly of undifferentiated cartilage cells. With all of these the main point is that the various types are probably mostly osteoblastic in origin.

Kolodny insists that there is a true angio-endothelioma of bone developing from the vascular system of bone—the endothelial vascular lining of the vessel wall. It is extremely rare.

"Ewing's sarcoma" described in 1920 is an anatomic and clinical entity formerly submerged under the diagnosis of round-cell sarcoma or myeloma. Ewing considers that the tumor originates from the perivascular endothelium, an idea not definitely settled.

Myelomas are the only true round-cell tumors occurring in bone and the specific cell is thought to be derived from bone-marrow cells of the myelocytic series.

Osteogenetic Sarcomas of the Face and Jaw Bones.—Osteogenetic sarcomas are the main group of primary malignant tumors found in the jaw bones. It is estimated that one bone sarcoma is present in 75,000 to 100,000 people and that possibly 3 per cent of the whole group occur in the jaw bones. Thus osteogenetic sarcomas of the jaw bones are rare. It is of interest here to refer back to Christensen's compilation of 1000 bone tumors. He found 10 malignant osteogenetic tumors involving the mandible and 5 involving the upper jaw in the gums.

In the other bones osteogenic sarcomas have their origin beneath the periosteum and Ewing says apparently from both sides of the shaft. The

tumor cells invade the medullary cavity and also grow beneath the periosteum which is elevated and for a period remains intact but eventually the periosteum is perforated and the soft tissues about are invaded. A part of the shaft of the bone is destroyed. Metastases are often present before an advanced stage is reached. The tumor is usually located at the end of the diaphysis in a typical long bone. In the face and jaws, there is no absolutely typical long bone, but to a certain extent the reaction of the mandible to malignant degeneration is typical of an ordinary long bone. The characteristics of osteogenetic sarcoma in other bones of the facial jaws vary principally in that membranous bones show less tendency to bony proliferation. The process is principally one of destruction beginning within the cancellous part of the bone.

General Structure.—The chief picture is one of immature and atypical bone with an intermixture of cartilage and osteoid tissue (Fig. 289). The cells are pleomorphic and hyperchromatic and their shape varies from

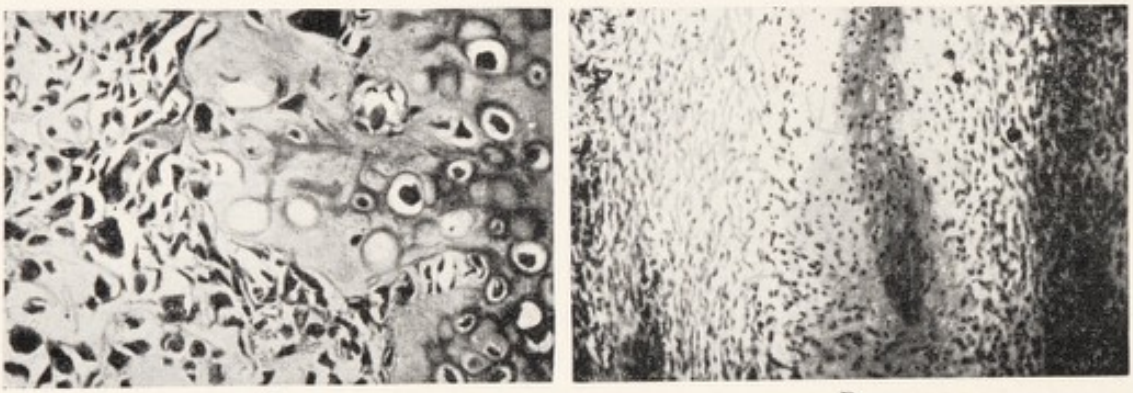

A *B*

Fig. 289.—*A*, Primary osteogenic sarcoma. One month after operation it recurred. Recurrent tumor more rapidly growing than primary tumor. (After Thoma.) *B*, Rapidly growing embryonic type of tumor, with cartilage and adjacent osteoid tissue. The cellular elevation shows low-grade differentiation. Osteogenic sarcoma. Age, twenty-five. Registry of bone sarcoma, Case No. 404. Left lower jaw is occupied by a hard mass. Roentgenogram of mandible shows some new bone formation along with bone destruction. See roentgenogram in Fig. 290, *A*.

spindle to polyhedral and rounded. There is considerable variation in the relative amount of stroma and cells. Usually it is considered that the greater the proportion of cells the greater the malignancy. Very large polyhedral cells generally go with a tendency to form cartilage (Ewing). Although the blood vessels are of the normal type, they are often lined with tumor cells, a fact which contributes to the early metastasis of the group. Giant cells of the tumor type with either single or multilobed hyperchromatic nuclei are found in many of the tumors. Foreign body giant cells may also be found about extravasations of blood.

Subgroup of Medullary and Subperiosteal Osteogenic Sarcoma.—(*a*) In the bones in general the largest group of osteogenic tumors according to Geschickter and Copeland contains principally cartilage in association with a type of myxomatous connective tissue indicatory of an analogous origin of the benign exostoses and chondromas and they believe their origin can be traced to survival points in the skeleton of primitive perichondrium and periarticular strands of precartilaginous tissue. But in the Johns Hopkins

series of 75 cases, there are only 2 cases occurring in the lower jaw. The tumors arise at the sites where tendons insert into the bone and appear between the ages of fourteen and twenty-one as a rule. They grow rapidly—six months is about the average duration. In the roentgenogram the cartilaginous neoplasm casts a fairly visible subperiosteal shadow which may be streaked by a few spicules of calcified material. The tumor involves the cortex and the medullary cavity late, after which there is bone destruction. Histologically the growth is made up of a transition of connective tissue to myxoma, to fetal cartilage, to adult cartilage, and finally to bone formation. Of the 75 examples of this type of tumor found generally over the body in the Johns Hopkins series, permanent cures were obtained in 5 per cent. Of the 2 patients with tumors of the mandible, 1 failed to survive.

(*b*) From benign osteochondromas the persistence of embryonic precartilaginous connective tissue makes possible the origin of secondary malignant chondrosarcoma which is superimposed on an original benign growth. Geschickter and Copeland, in a series of 80 cases occurring generally in the bones of the body, reported 2 such cases as developing in the lower jaw. Secondary chondromyxosarcoma may rarely also be secondary to such diseases as Paget's osteitis deformans or hereditary deforming achondroplasia. Most of these growths occur between the ages of twenty-five and fifty-five years and they grow rather slowly for malignant bone tumors. The duration averages about six years. Microscopically the cellular and abundant connective tissue strands, the malignant round cells, multinucleated cartilage cells with mitotic figures around chondral lobules distinguish the tumor and its malignancy. The roentgenogram should show a distinct evidence of the nature of the primary lesion in which the superimposed malignant change is visible as a fuzzy infiltrating periosteal shadow. Where a previous osteochondroma is present the more thoroughly ossified base or pedicle of the exostosis may persist but in advanced cases the entire tumor location becomes an infiltrating granular mass containing scattered osseous material. Later destruction of the cortical bone occurs. Permanent cures were obtained in 25 per cent of the Johns Hopkins series. Of the 2 patients with mandibular tumors, 1 survived.

(*c*) Geschickter and Copeland describe still another type of chondral tumor which arises from the cartilage cells of the epiphyseal line in adolescence. In their series are listed 24 examples, none of which occurred in the face or jaw bones. The tumor is extremely rare. Microscopically the lesions show a proliferation of chondroblasts and fragments of calcifying cartilage. At the margin of the tumor, giant cells proliferate and attempt to remove the calcification as a defensive reaction. The roentgenogram shows a definite translucent shadow with a multilocular, mottled area of bone destruction with or without an expanded bone shell, and finally there is a definite periosteal reaction zone.

(*d*) Ewing describes a fibrosarcoma which arises in a marrow cavity or on the surface of the periosteum which grows slowly and is very cellular and fibrous. The medullary type presents a bulky mass which distends and destroys the shaft. Later the periosteum is lifted and eventually perforated after which the tumors grow as encapsulated masses with little tendency to infiltration. The periosteal type grows outward and shows little tendency to involve the cortex. The radiograph shows a sharply

demarcated, solid, opaque mass destroying the bone. The main feature microscopically is the predominance of intercellular material and a low vascularity. The cells are large spindle cells. A tendency to form osteoid tissue is observed. The clinical course is slow and comparatively benign. Many surgical cures of osteogenic sarcoma are of this class.

Sclerosing Form of Osteogenic Sarcoma.—The osteoblastic sclerosing tumor represents the most differentiated malignant bone tumor and is the most pronounced bone forming tumor of the group. About 1 case in 5 according to Geschickter and Copeland shows small islands of cartilage being converted into the osteoid state. The age incidence is between ten and twenty-five years. In the earlier stages the radiograph shows only a condensation of the medullary area with only slight periosteal thickening or none at all. At this time the cuff of periosteal elevation is missing. Later the "sun ray" picture may be characteristic. On this account the tumor is familiar but it ranks third in frequency of appearance in the 360 osteogenic sarcomas in the Johns Hopkins laboratory—there being 75 cases of this type registered. No instances of this tumor are recorded in the Johns Hopkins series as being found in the jaw bones, but the Registry series shows at least one very typical roentgenogram of this type of tumor.

The tumor shows proliferation of new bone proceeding from the subperiosteal region of the metaphysis, raising the periosteum outward and inwardly infiltrating the marrow cavity. There is an exaggerated osteogenesis—many solid well-formed bony trabeculae being formed—and histologically one sees many large osteoblasts, very hyperchromatic spindle-shaped cells, derived from connective tissue with much intercellular osteoid tissue. The tumors have a rich circulation in spite of their density.

In the marrow cavity the roentgenogram shows some secondary destruction producing a mottling effect. In the cortical layer, the normal markings are obscured by osseous formation which extends both outward into the periosteal zone and inward into the medullary cavity. The periosteum is raised and a triangle of ossification occurs where it contacts the bone—the so-called "periosteal lipping." In the region of the maximal periosteal separation are radiating spicules of bones extending outward at right angles —the so-called "sun ray" appearance.

The malignancy of the tumor may be somewhat less than the other osteogenic sarcomas. The Johns Hopkins series gives permanent cures in about one fourth but Codman says the Registry series shows no evidence of the tumor not being so fatal eventually as other bone sarcomas.

Telangiectatic Osteogenetic Sarcoma.—Geschickter and Copeland describe this tumor under the name osteolytic osteogenic sarcoma. The tumor has been described variously as a malignant cyst, aneurysm of bone, or as angiosarcoma of bone. Of 88 cases in the Johns Hopkins laboratory there is no instance of this lesion occurring in the jaw bones. However, the tumor is marked by a variability of the region involved. The incidence of the lesion is maximal between the ages of ten and twenty years but the age distribution is on the whole rather wide. The lesion is a destructive tumor arising in the metaphysis and invades the marrow cavity of the shaft and also the epiphysis of the long bones.

Histogenetically, the tumor is related to the formation of cancellous bone from the endosteum which follows after the formation of calcified

cartilage. As sufficient amounts of calcified cartilage are absent, ossification is incomplete and an osteolytic tumor occurs.

Microscopically, one sees larger malignant spindle cells and osteoblasts with many mitotic figures and with only a small amount of intercellular osteoid tissue. Giant cells are present and are supposed to represent a phagocytic process which attempts to remove osteoid tissue. The neoplasm shows a tendency to produce a pathologic fracture (50 per cent of the weight-bearing long bones). The sequence of symptoms is pain, tenderness and dysfunction. A systemic reaction with slight fever and moderate leukocytosis may be observed. When the tumor reaches the epiphysis the destruction of bone may be sufficient to create a typical vascular cavity suggestive of aneurysm, and pulsation may occur. At exploration a vascular tumor mass is encountered with a thin shell of cortical bone externally. A mass resembling a blood clot or acute hemorrhage may be encountered. Always the neoplastic mass is soft and pliable.

In the roentgenogram: a central area of bone destruction which dissolves the cortex without expansion but with a definite periosteal reaction.

The prognosis is bad—6 per cent of five-year cures were obtained in the Johns Hopkins series by using radical methods. The treatment is wide excision or amputation whenever possible.

Etiology of Osteogenetic Sarcoma in General.—Little is known of the etiology of osteogenic sarcoma. Kolodny makes the statement that "whatever the personal views of the investigator as to the etiology of tumors in general may be, it can not be denied that trauma seems to be frequently associated with the origin of bone sarcoma." On the other hand, Ewing stated that the evidence that trauma leads to the development of sarcoma in previously normal bone is without satisfactory foundation.

In his examination the tumor usually has preceded the trauma. Central sarcoma arising near the epiphyseal line shows evidence of disorders of growth of bone as an origin. Periosteal sarcoma most probably arises from misplaced islands of bone-forming tissue and chronic inflammation may be contributory to capsular sarcomas.

Clinical Course of Osteogenic Sarcoma in General.—No sex predilection is observed. Most commonly an osteogenic sarcoma appears during the period of energetic skeletal growth. Thus, adolescents and comparatively young adults are usually the victims. Coley reports 4 maxillary bone sarcomas in individuals varying from seventeen months to nine years of age. The two jaws are affected about equally.

The clinical course varies considerably but on the whole accords with the histologic structure. Usually pain, tumor formation and dysfunction occur in sequence, the rapidity of which corresponds to the malignancy of the new growth. In some types, there may be some fever and when metastases occur cachexia supervenes. Dysfunction may impede the taking of food and a certain degree of inanition is then probable. The spindle-cell fibroblastic tumors tend to grow rather slowly, and the highly osteoid tumors pursue a rather chronic course (Ewing), sometimes ten to twenty years (Paget). In the soft and cellular varieties metastasis tends to develop early. The lungs are involved early. Other distant organs are reached and affected after a varying period of time. The emboli travel by the way of the blood vessels. Involved lymph nodes raise the suspicion that the new growth is really of a lymphoid or epithelial origin.

As previously stated, a gnawing pain in a bone sometimes intermittent in character often precedes the evidence of tumor formation. In most bones the pain is due, as a rule, to periosteal sensitiveness but sensory nerves traverse the jaw bones. Following the discomfort or during it a tumefaction appears. When the growth arises in the upper jaw, the paranasal sinuses (especially the antrum of Highmore), the orbital cavities and the palatal regions are liable to distortion. Even the malar bone is occasionally pushed outward. The periosteum is elevated at first, but later may be perforated after which the surrounding tissues are invaded. An osteogenic sarcoma, however, is slow to perforate epithelium. When trauma causes a break in the epithelium, secondary infection may mask the true nature of the condition. As the bony cortex is thinned, "egg-shell crackle" is noted on pressure over the tumor. Pathologic fracture occasionally occurs in the lower jaw.

Before an operative procedure is considered the chest should be pronounced clear as far as the roentgenogram is concerned. McAuliffe observed that tumor cell emboli in many organs were present at autopsy after a traumatizing operation. This should be considered.

Diagnosis.—Geschickter and Copeland emphasize the variation in the clinical course, gross anatomy and structure of osteogenic sarcomas. It is, therefore, necessary to make a very careful study of each tumor before much can be stated as to diagnosis and prognosis. The first physician often overlooks the significance of persistent, increasing, unexplained pain. More or less fixation of soft tissues is usually present as soon as the enlargement is evident. An increase of venous circulation in the skin may be noted, and even a slight elevation of temperature may be present but fever is more common in myeloma and in inflammatory conditions.

Roentgenogram.—Roentgenologically in the lower jaw, one may see a considerable amount of bone production generally radiating outward. But in the more cellular types and anaplastic types bone destruction is the predominant picture (Fig. 290, *B*). In membranous bone there is little tendency for bone production; the picture is mostly one of bone destruction. However, very few varieties of bone sarcoma show only osteolysis without any evidence of osteogenesis. Roentgenologically the anatomic varieties are to a certain extent recognizable. In nearly all osteogenic sarcoma the former bony contour is preserved to a certain extent. In the mandible most of the shaft will be found to be present. The growth is, however, seen inside and outside of the old bone. The new bone laid down outside the old bone is usually in ridges or spicules radiating away from the tumor. Where the periosteal reaction is active in nonmembranous bones (mandible) there may be "lipping" of new bone where periosteum is raised from the old bone. This has been described by Codman as the "reactive triangle." The chief features are roughening of the outer surface of the bone and lifting of the periosteum at the advancing edge of the tumor. The medullary cavity of the bone usually shows some opacity from growth of the tumor within the bone. Central sclerosing tumors may show no new bone in the roentgenogram. Medullary tumors often involve the marrow cavity far beyond the reactive triangle and in many the triangle is not present. The extraperiosteal spindle-cell sarcoma leaves the cortex or shaft of the bone intact, does not produce new bone, and forms a mass in the soft tissues.

For the diagnosis of bone tumors the pathologists should be in full possession of the complete clinical course, the roentgenologic plates or data. The predominant features are pleomorphic, hyperchromatic spindle or polyhedral cells with atypical imperfect bone, cartilage and osteoid tissue.

Therapeutic Test.—The therapeutic test by irradiation may help to establish the diagnosis, as osteogenic sarcomas resist irradiation and there is increased pain and swelling. Giant-cell tumors, although there is an increase of swelling and hyperemia immediately, show evidence of the slow reformation of bone and the pain and disability rapidly subside. The myelomas show a striking initial response to irradiation. The objection to

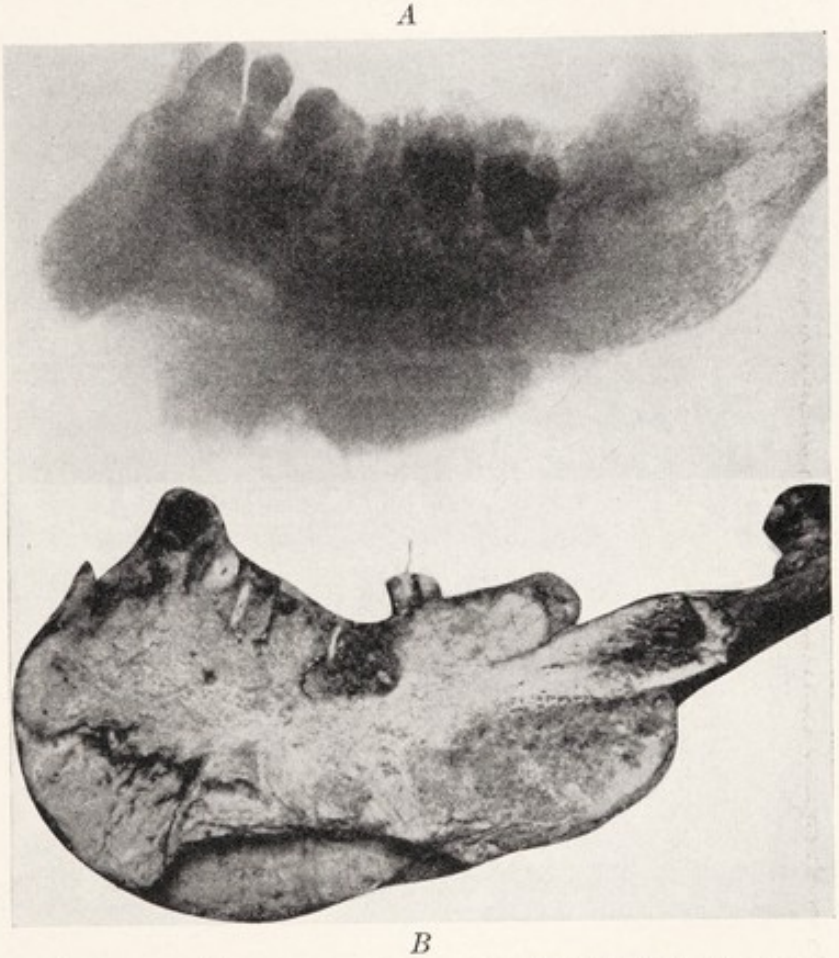

Fig. 290.—*A,* Osteogenic sarcoma in a man twenty-five years old. (American College of Surgeons, Bone Registry Plate 22, Case 404, Kolodny.) *B,* Typical specimen of osteogenic sarcoma—same as above.

the therapeutic test is the delay and it is a serious one. Some cases of osteogenic sarcoma have recovered under irradiation and in others life has been prolonged rather definitely.

Prognosis.—The prognosis varies widely and all the data, clinical and pathologic, are necessary before giving an opinion and even then the undertaking is hazardous. The age of the patient, the duration of the tumor, its present state of activity and the structure must all be considered. Finally the thoroughness with which appropriate treatment has been carried out has some influence on the prognosis. Of 200 cases (found in the bones of the body generally) of osteogenic sarcoma accepted by the Registry, 12 five-year cures were obtained and in 9 of these the structure was atypical.

Some doubt about their malignancy was expressed by some of the reviewing pathologists (Ewing). The chances of operative approach from the anatomic standpoint are obviously better in the lower than in the upper jaw and face region where often complete removal is out of the question.

Treatment.—Very few cases of osteogenic sarcoma are cured by operation even in the extremities. The regions of the face and jaws except possibly the mandible offer anatomic restrictions to radical operation which are often insurmountable as far as a cure is concerned. The usual procedure is to establish the diagnosis by roentgenograms and biopsy. When a biopsy is taken it is well to remember that unless a suitable portion of the growth is obtained an erroneous diagnosis is likely to follow. Pertinent to the biopsy it is well to know that as the structure of osteogenic sarcoma is so varied there are only a few pathologists of sufficient experience to render a competent opinion.

The records of the Registry Committee would indicate, however, that a combination of heavy irradiation followed by radical excision whenever possible will give the highest percentage of five-year cures. Preliminary irradiation tends to prevent metastasis and on this basis alone would be indicated. Neither irradiation, surgery or a combination of both give much chance of success with the more malignant varieties. During operation all rough manipulation is inadvisable as metastasis may be produced. Ewing has noted the veins are often invaded by tumor thrombi which are easily dislodged. Chondrosarcomas are very resistant to treatment of any type. The fibrosarcomas are sometimes cured by fairly conservative procedures. Coley's toxins are not thought generally to be of any particular value.

Ewing's Tumor.—Ewing first described the tumor in 1920 as a separate clinical entity. He placed this tumor among the endotheliomas but several critical observers have doubted its origin from perivascular endothelium. Geschickter and Copeland suggest that the tumor is probably a primary lymphoma of bone. Rather often a history of trauma precedes the onset. The small bones and the flat bones are affected as well as the long bones. In the long bones it generally involves the shaft. The subjects of the tumor are said rather often to be of delicate build (Ewing). At the Memorial Hospital several cases had a low blood calcium.

Incidence.—The tumor is seen principally in early life, usually in the second decade. Ninety-five per cent of the 65 cases in the Johns Hopkins series occurred between the ages of four and one-half and twenty-five years. The oldest patient was forty-four years of age. Connor, however, reported a patient sixty years of age. Ewing has observed the tumor in an eighteen-month-old child. About 15 per cent of bone tumors are of this type. The lesion is very rare in the jaw bones but the skull is invaded rather often. In 1000 cases of bone tumor collected by Christensen, 1 endothelial myeloma occurred in the superior maxilla and 2 in the mandible. The Johns Hopkins series of 65 Ewing's tumors has no cases of jaw-bone involvement.

Structure.—The process in the long bones involves a goodly portion of the shaft rather early, absorbs the cancellous tissue and displaces the weakened bone outward. New deposits of bone tend to be laid down in somewhat parallel lines. Soon the periosteum is perforated and the soft tissues are infiltrated. Some hemorrhage and necrosis are often found in the central portions.

Microscopically, sheets of polyhedral cells without intracellular material are found. The nuclei are small and hyperchromatic, the cytoplasm is clear and nucleoli are not seen. In certain areas the cells may form the walls of the blood vessels. New bone trabeculae may be found at the edges of these tumors. The cells have no noticeable osteogenic tendency.

Clinical Course.—The clinical features differ from osteogenic sarcoma in the slow intermittent onset, the fever, tendency of secondary tumors to involve the bone marrow and the tendency for the lymph nodes to be involved. Secondary tumors are observed quite early as a rule. The skull is usually involved first. Later the ribs, vertebrae, pelvis, and other bones are invaded. Sometimes it is solitary as proved by the recovery of several cases.

The usual symptoms of bone tumor are present—pain, tumor and dysfunction. The average temperature is about 100° F. but in some cases it may reach 104° F. Most of the cases show a leukocytosis of more than 10,000. The most frequent sites of metastasis are the lungs, the lymph nodes and the skull.

The roentgenogram shows irregular absorption of the shaft in long bones or of the body in the short or flat bones. The marrow cavity is widened and the periosteum is thickened and pushed outward. As the periosteum is raised an "onion peel" appearance is given by the new bone. In early cases the first evidence of the neoplasm is sometimes increased bone density. When too much of the bone is destroyed a fracture may occur (5 per cent in the Johns Hopkins series). After perforation of the periosteum a bulky tumor develops in the soft tissues. The irregular destruction of bone with the formation of bone by the periosteum suggests osteomyelitis. It is, however, more destructive of bone than is the latter. Pain is the most outstanding early symptom and was found to be present in 84 per cent of the Johns Hopkins series. The pain may be intermittent in character.

The tumor is very radiosensitive. Therefore, besides the general symptomatology and radiographic signs, the reaction to irradiation is of diagnostic importance.

Treatment.—Irradiation causes a rapid initial response, and certain cases are reported in the Registry group as cured by irradiation alone. Recurrence with a fatal termination is, however, the rule sooner or later. After irradiation local excision of the lesion would seem justifiable, especially until a larger series of five-year cures by irradiation alone are available.

Prognosis.—The younger the patient the worse the prognosis. In young children excision is hardly worth while as the recurrence is usually so rapid. In 54 cases, found generally through the bones of the body, both dead and alive, the average duration was over three years (Ewing).

Periosteal Sarcoma (Extraperiosteal Sarcoma).—Apparently from the outer layers and the central layer of the periosteum there originates a definite rare type of fibrosarcoma which grows away from and along the bone and does not erode it to any great extent, at least not until late in the disease. The cells of origin in all likelihood do not include the osteoblasts. There is little or no tendency to the production of bone. A few cases of the type have been recorded about the bones of the jaws. First, a fusiform swelling is noted about the bone. Encapsulation is found to be incomplete,

and the surrounding soft tissues are soon invaded. Grossly, the tissue is fairly firm but rather vascular. Microscopically small or moderate sized spindle cells densely packed together and showing a scanty cytoplasm are the usual picture. The roentgenogram is distinguished by practically no tendency to destruction of the cortex and marrow cavity. Surrounding the bone is the encircling tumor mass which is generally rather opaque. Radiating trabeculae are not to be seen.

Ewing describes a capsular or periosteal sarcoma which arises from the joint capsule. It does not involve the joint cavity or the bone and its malignancy is less than that of tumors of the periosteum or medulla of bone. A fusiform swelling is produced around the joint and fever is often present.

The fat tissue about joints gives origin to very malignant sarcomas which rarely are composed of large round, polyhedral or spindle cells. They have an opaque yellow color and appropriate stains demonstrate a good deal of fat.

The tendon sheaths may be the seat of a giant-cell tumor of slight malignancy.

Along the base of the skull, pharynx and nares occur tumors of osteogenic character in which the derivation from bone is only vaguely indicated by their structure (Ewing).

Treatment.—These tumors are radioresistant as a class. However, one is justified in treating them by both intensive irradiation and radical excision.

Multiple Myeloma.—Multiple myeloma is a very rare tumor which causes death and develops in multiple foci in the red bone marrow of adults—most generally in the fifth decade of life.

Eighty per cent of the cases occur between the ages of forty and seventy years. The age incidence coincides with epithelioma. Three or 4 cases have been reported in the later years of the third decade (Moore). Multiple myeloma occurs twice as frequently in males as in females. Among 400 cases of bone sarcoma at Johns Hopkins, 3 per cent were multiple myeloma. Although 20 per cent give a history of trauma preceding the onset but etiologically trauma is thought to have no direct relationship to the onset of the disease, the significance to trauma is questionable. The relationship of infection is also probably not a direct one.

The upper jaw bones may be involved along with the other bones. When the jaw is involved the skull is usually involved also. Christensen reports 2 cases of upper jaw involvement in a series of 1000 cases of malignant tumors of bone.

Structure.—Microscopically the tumors are most frequently made up of plasma-like cells—nongranular mononuclear cells. The nucleus is excentric and the chromatosomes have a spokelike arrangement. The intracellular material is scanty. The nucleus has a nucleolus which may be globular. Cells containing two or three nuclei may be seen. Theoretically a myeloma may arise from a myelocyte, a lymphocyte or a mononucleated red blood cell, *i. e.*, any of the specific red bone marrow cells. Usually the distinction is not made, as considerable special study is required. The trend of opinion is to place the origin of the plasma-cell myeloma from either the lymphocyte or from the endothelium.

Clinical Features.—When the condition is well developed pain is the outstanding symptom of myeloma but the initial symptoms are vague and indefinite, of the "rheumatic" type and often confined to the back. A sharp accentuation of the pain is caused by muscular movement and calls the patient's attention to the lesion. The attacks may be exceedingly severe. Usually an asymptomatic period follows. Tumor formation sometimes calls attention to the disease. The cardinal diagnostic point is the multiplicity of the tumors, involving the ribs, sternum, clavicles and spine. Nine out of 10 cases show the multiplicity of bony involvement fairly early. The skull and extremities, if one includes the shoulder and pelvic girdles, are involved in about one half of the cases. The tumors are elastic and a parchment-like crepitation may be elicited over the thin bone shell. In the later stages, the tumors become extremely painful, and even the touch of the clothing is unbearable. Peculiarly these tumors have a tendency to decrease in size periodically. Supposedly this is due to intratumor hemorrhage and absorption. The vascularity of the tumors rarely has been so pronounced as to cause pulsation. Deformity of the bones of the thorax and extremities has long been recognized as accompanying the disease. Pathologic fracture occurs more often than in any other bone tumor. About one half of the patients have a chronic bronchitis and emphysema. About one half show some neurologic symptoms before the termination of the disease—most often a paraplegia.

A nephrosis with albuminuria and anemia is present rather often. Bence-Jones bodies occur in the urine of about two thirds of the cases. Metastases to other organs, usually the hemopoietic tissues, are found occasionally.

In the roentgenogram multiple destruction punched-out areas, varying in size from ½ to 10 cm., are found in the sternum, ribs and spine, the clavicles, the pelvic and shoulder girdles and skull, or more rarely in the long bones of the extremities. The destruction tends to spread in a transverse direction. Bone destruction is rapid. The periosteum is pushed away from the bone and a slight amount of new bone may be laid down before the periosteum is finally perforated.

Prognosis.—The average duration of the disease is about two years although some cases live five years.

Treatment.—Deep irradiation is the most valuable treatment and brings about temporary symptomatic relief.

BENIGN GIANT-CELL TUMOR

Lebert (1845), Paget (1854) and Nélaton (1860) first described giant-cell tumors. Nélaton was the first to find out their benign character.

True giant-cell tumor is often associated with an epiphysis where osteogenesis by the way of cartilage occurs. About 40 per cent occur in the third decade of life. Typically the tumors have only benign characteristics but reports in the literature suggest the rare possibility of metastasis (Geschickter and Copeland).

Incidence.—Over a period of thirty-five years the pathologic laboratory at Johns Hopkins recorded 22 cases of giant-cell tumors occurring in the head. There were found no bone cysts. Two of the giant-cell tumors were located in the temporal fossa, 6 in the upper jaw and 14 in the lower jaw.

Christensen reports that in 1000 tumors of bone, 20 giant-cell tumors of the upper jaw and 21 of the lower jaw were found, but whether or not this includes epulis also is not stated. Of all of the cases of giant-cell tumors registered with the American College of Surgeons, the bones of the jaws were affected in 9 per cent. The distribution seemed about equal in the bones of the upper and lower jaw. The tumor was six to five times more frequent in the female. Roughly it is stated that if one includes all the bones of the body that for every 2 malignant tumors of bone, 1 giant-cell tumor is found. In the American College of Surgeons series the highest incidence occurred between the ages of sixteen and twenty-five years. This corresponds to general experience.

Etiology.—Trauma seems to be a possible etiologic factor in relation to the onset of the tumor. Gradual development of the lesion along with gradual development of areas of bone destruction as shown by the roentgenographic picture have been traced from an injury. Pathologic fracture occurs rarely.

Mallory, Codman and Barrie have suggested that the tumor may be of inflammatory origin. Mallory has maintained that the giant cells are formed from endothelial cells and are only reactive phenomena and not an essential part of the tumor. Codman has suggested the picture as one of repair following interosseous hemorrhage. In Europe, Pommer, Lubarsch, and Konjetzny are leaders in the idea that the process is essentially an inflammatory resorptive process. Among the exponents of the opinion that the tumor is neoplastic are Ewing, Bloodgood, and Geschickter and Copeland.

Their location often coincides with centers of intracartilaginous ossification. In the mandible they occur at the symphysis where Meckel's cartilage participates in the formation of bone. The others are located in the ramus where there is a separate center of ossification. In 6 lesions of the upper jaw, each lesion found its way into the antrum or into the orbital fossa.

Geschickter and Copeland argue that etiologically trauma is related to the formation of bone cyst and giant-cell tumor, and when the blood supply is disrupted an imbalance between osteoclastic proliferation in the medulla and reactive compact bone in the cortex is produced. That additional metabolic factors may enter into the production of that imbalance is shown by analysis of multiple giant-cell tumors and bone cysts in general, and studies in the serum calcium and phosphorus in parathyroid disturbances. They conclude that the age of the patient, the site of the injury, the rate or extent of cartilaginous ossification at the end of the bone and the nature of the blood supply in the affected regions are the predominant factors in the development of bone cysts and giant-cell tumors. Thus they state that "all available cases . . . support the belief that the origin of the pathologic process is at the sites of bone formed by cartilage and related to normal resorptive process of bone by osteoclasts which take place in the histogenesis of these bones. The predominant location of giant cell tumor in the epiphysis of long bones, it was seen, was in favor of this view. The fact that the membranous bones of the skull are not involved by either bone cysts or simple giant cell tumors confirms it." However, tumors of the giant-cell variety occurring in the jaws, along the alveolar border in the form of giant-cell epulis, and in the tendon sheaths and soft parts offer greater

difficulties in the establishment of their relationship to the resorption of temporary bone. To predict such a relationship for giant-cell tissue in these diverse lesions is to bring the conception of giant-cell tumor thus far advanced to a crucial test. All the available cases studied by us support the belief that the origin of the pathologic process is at the sites of bone formed from cartilage and related to the normal resorptive process of bone by osteoclasts which takes place in the histogenesis of these bones.

Pathology.—At operation the tumor bleeds easily and is very friable. Bloodgood has stated that its appearance is usually like an old bruise—every shade from red to black. Occasionally, however, it is of uniform gray color. The tumor is encapsulated by fibrous tissue at first about which lies the shell of bone not yet destroyed but centrally expanded (Fig. 291, *C*).

Microscopically two leading elements characterize the structure, the giant cells and the stroma composed of blood spaces and capillaries suspended in a net of spindle and round cells. Typically the round cells outnumber the spindle cells (Fig. 291, *B*). The round cell has a fairly large nucleus and a small amount of cytoplasm. The spindle cells are slender or oval in form with a rather definite nucleus and a moderately elongated cyto-

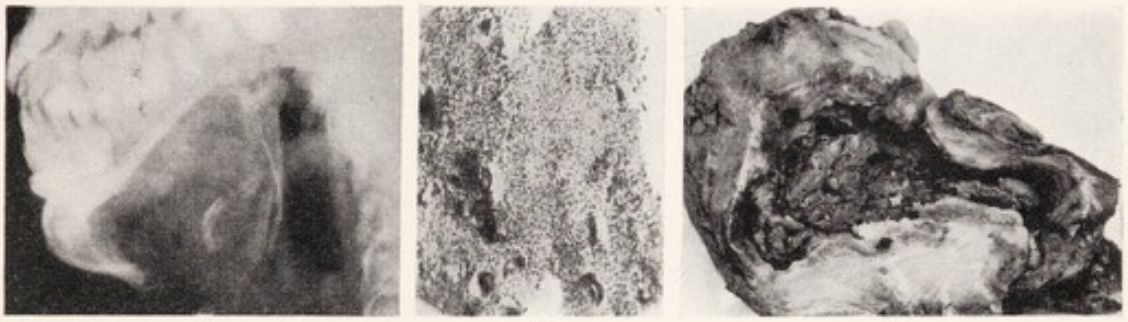

A *B* *C*

Fig. 291.—*A*, Giant-cell tumor of mandible. *B*, Same giant-cell tumor. *C*, Gross specimen of giant-cell tumor of mandible—same as *A* and *B*.

plasm. Fine fibrils surrounding these spindle cells suggest their fibroblastic character. The giant cells may contain from 15 to as many as 200 nuclei and the nuclei closely resemble the nuclei of the round cells of the stroma. On an average about 25 or 30 giant cells will be found per low-power field. They are more numerous, however, about areas of hemorrhage, bone spicules and the walls of cysts. However, as a rule, the regularity of the giant cells is a characteristic of the tumor. Hemorrhagic areas are often a conspicuous finding in the stroma.

Clinical Symptoms.—Giant-cell tumors of the lower jaw coincide in locality with centers of intracartilaginous ossification of the mandible, most frequently at the symphysis where Meckel's cartilage participates in the formation of the bone. The other giant-cell tumors are located at the ramus where there is a center of cartilaginous ossification (Fig. 292). The temporal fossae probably are to be correlated with cartilaginous centers in the sphenoid bone. The tumors of the upper jaw tend to find their way into the antrum or into the orbital fossa, and it is to be noted that the ethmoid is totally derived from cartilages in relation to both of these cavities. The true membrane bones of the skull are apparently not involved by either bone cysts or simple giant-cell tumors.

The usual clinical history has a sequence of trauma, possibly some pain, and tumor. Fracture in the jaw bones is not common. The course extends over a period of from four to fifteen months. Trauma is thought to have a rather definite etiologic bearing on their foundation, and in certain cases roentgenograms have been taken immediately after injury and at intervals thereafter and the gradual development of bone destruction traced.

In the jaw it is not unusual for a loose tooth to be pulled after which the giant-cell tumor appears and fungates through the socket. The question then arises whether the pulling of the tooth served as the antecedent local trauma or the new growth loosened the tooth. The latter is the most likely explanation. Pain is quite often present and is stated by some authorities to be more definite immediately after irradiation thereby differing from a malignant new growth. By palpation the tumefaction can be outlined



Fig. 292.—Patient with giant-cell tumor of mandible. This tumor became secondarily infected from within the mouth. On account of the resulting osteomyelitis, the greater part of the left mandible was removed.

fairly accurately. Egg-shell crackling appears when the bone becomes thin and in the very vascular types occasionally it is said a bruit is heard.

The roentgenogram emphasizes the bone-destructive qualities of this tumor (Fig. 291, *A*). The bone destruction begins subcortically and extends at the expense of the cancellous bone. Trabeculae sometimes traverse the tumor mass. The expanded mass becomes very thin and may be perforated. The bone shows no periosteal reaction, a point which aids in distinguishing these tumors from the osteolytic form of osteogenic sarcoma.

Treatment and Prognosis.—Bloodgood has been an advocate since 1912 of the conservative treatment of giant-cell tumor. In 105 cases of the Johns Hopkins series which were treated by simple curettement, 31 recurred, and 16 of these 31 were cured by a second or third curettement. Kolodny has advocated roentgen treatment more recently. In the Johns Hopkins series as a whole "excluding the alleged metastatic group, and a few isolated giant cell tumors of the skull and vertebrae (dangerous because of location) mortality either from treatment or from the tumor itself has been exceedingly rare—less than 1 per cent. Recurrence is frequently unavoidable after

curettage and occurs in about 20 per cent of all the cases treated by simple curettage alone" (Kolodny). The completeness of the curettage seems to have less to do with the absence of recurrence than one might think. Occasionally completely curetted tumors recur while incompletely curetted tumors are permanently cured.

BONE CYSTS AND OSTEITIS FIBROSA

Considerable discussion has always been prevalent as to the true nature of osteitis fibrosa and giant-cell tumor. At the present time there is a growing tendency to consider osteitis fibrosa and giant-cell tumor as pathologically related. The relationship of bone cysts and certain giant-cell tumors of the jaws to hyperparathyroidism has recently been discussed. In the past the true nature of many cases of bone cysts, giant-cell tumor formation, and osteitis fibrosa cystica has not been recognized because careful blood calcium and blood phosphorus studies were not made and the connection of hyperparathyroidism with certain of these lesions was not known. (See discussions under Hyperthyroidism, Osteitis Fibrosa Cystica, and Giant-cell Tumor.) Presumably certain of these localized cystic lesions may not be caused by either hyperparathyroidism or may not be derived from dental structure. Pommer (1920) and Schinz (1931) have held that these cysts may be produced by hemorrhage. (See Hemorrhagic Cysts below.)

Incidence.—In the Johns Hopkins series are 136 cases of solitary bone cysts. The lesion is always in the shaft side of the epiphyseal line. Only a few instances of solitary bone cyst were recognized as occurring in the jaw bones. Solitary dental cyst may be confused with the lesions. The age of a person with solitary bone cyst most commonly is between the years of six and twelve (Thoma).

Pathology.—The inside of the lesion shows fibrous tissue with new bone formation and within the cavity is old hemorrhage or straw-colored fluid. The wall of the acute cyst shows multinucleated giant cells embedded in a stroma of round cells—a tissue typical of giant-cell tumor. Geschickter and Copeland states that in the majority of solitary bone cysts (78 per cent) of the long bones there is a healed or healing giant-cell tumor.

Clinical Features.—The average duration of symptoms is about two and one-half years but many cases extend over a period of ten years or longer. About 1 case in 10 has a gradually increasing deformity. This type of case usually shows a more diffuse involvement and is more properly termed osteitis fibrosa (von Recklinghausen).

There is an acute type of cyst of about six months' duration bordering on the epiphyseal line in the ramus side which contains giant-cell areas and may be confused with giant-cell tumor. In another group there is some complicating lesion such as parathyroid tumor present. In this last variety blood chemistry shows a hypercalcemia and a lowered phosphorus content. (See Hyperthyroidism, Osteitis Fibrosa Cystica, and Giant-cell Tumor.) In other types, the blood chemistry is normal.

The roentgen ray shows a central expanding defect with a smooth, symmetrical outline. The cavity may be crossed by trabeculation. After fracture there is a tendency to union.

The treatment is similar to that of hemorrhagic or traumatic cysts. (See next heading.)

Hemorrhagic or Traumatic Cysts.—In the mandible cysts which supposedly have formed as the result of trauma have been described. Their formation has been attributed to intramedullary hemorrhage. All the cases have been found in adolescents, and a history of a blow is usually to be obtained. Because the patient is young and the bone plastic, a fracture is not sustained. Lucas (1929), Scheider (1931), Thomas (1931), Thoma (1934) and Blum (1932) have described such cases. The disease is probably related to osteitis fibrosa cystica but the surrounding bone shows little evidence of osteitis fibrosa cystica. These cysts may be found in the median line in the body of the ramus or even in more than one situation.

A blood clot forms and produces stasis. The fibrin produces sufficient irritation to cause some bony resorption of the trabeculae of the spongiosa. A cavity is produced in the bone. Usually the center is not affected or expanded. The cavity of the bone does not connect with the teeth although the roots may be secondarily involved. Within the cavity the blood decomposes and finally becomes a nearly clear serous fluid. At operation no epithelial lining is found. A dull pain which continues after a blow should suggest a roentgenogram. The typical radiographic finding is a well-defined, somewhat irregular cavity in the bone along the course of the inferior dental canine. The pulps of the teeth superimposed remain vital. Before operation a positive diagnosis from a dentoperiosteal dentigerous cyst may not be possible. At operation the absence of an epithelial lining should lead one to suspect the true nature of the case.

The treatment is similar to that of a simple dental cyst except that one need not be concerned about the epithelial lining. The overlying bone is removed through a gum flap, the fluid contents evacuated, and the cavity allowed to heal by granulation.

Hyperparathyroidism, Osteitis Fibrosa Cystica, and Giant-cell Tumor (von Recklinghausen's Disease).—Barr, Bulger and Dixon (1929) reported a case with multiple giant-cell tumors, one of them being located in the upper jaw and associated with an adenoma of the parathyroid, an increased serum calcium, a general hypotonicity and some flexibility of the long bones. Removal of the parathyroid tumor was followed by a reduction in the size of the tumors and by tightening of the teeth in the jaw. Blair and Brown later found a patient with 5 separate giant-cell tumors in the upper and lower jaw bones who was found to have a parathyroid adenoma. The patient had a high serum calcium. After removal of the parathyroid tumor, the serum calcium returned to normal. Other treatments of various types were instituted, but the final result was that the jaw tumors disappeared.

Spring (1928) describes a case of osteitis fibrosa cystica of the mandible at six years. Christeller (1916), Blum (1929) and Ivy (1927) have also reported cases. Thoma describes several cases of osteitis fibrosa cystica of the mandible.

In 1925 Hoffheinz collected the literature of 45 cases of unquestioned parathyroid enlargement and found that in 27 there were definite bone changes. In 1926 Mandl removed the first parathyroid tumor. In 1925 Collip discovered the parathyroid hormone which made it possible to study its effect experimentally. The diagnosis by duBois of the case of Captain Martel was the first clinical recognition of hyperparathyroidism in this country.

Since these earlier observations many papers have been published which would appear to establish that the clinical syndrome of hyperparathyroidism is a definite one. The lesions in the bones are apparently due to an inability of the bones to retain calcium.

Pathologic and Clinical Features.—The bony changes are general. Aub has applied the name, "osteitis fibrosa cystica generalisata" to the "full-blown" syndrome. However, in some cases the skeletal changes are entirely lacking. The formation of cysts and brown tumors in the bones appears as a late result of the decalcification and destruction of bone by osteoclasts. The normal architecture of the bone is destroyed and bone marrow is replaced by fibrous tissue—osteodystrophia fibrosa. The kidneys show calcification and diminution of renal function. The increase of the blood calcium and decrease of blood phosphorus are significant and of diagnostic import. The electrocardiogram shows characteristic changes and the nerves a general decreased excitability. Polydipsia, polyuria, loss of appetite, loss of strength, constipation, anemia and a leukopenia have been described as other clinical features of the disease. The disease is apparently a distinct disease entity with a definite train of symptoms, characteristic changes in metabolism and the presence of grossly recognizable tumor of the parathyroid bodies. Of 11 cases reported by Churchill, in only 2 was there external evidence of a tumor of the neck. Case 11 had a giant-cell tumor of the upper jaw and one in the nose among other characteristic signs of hyperparathyroidism. Extirpation of the parathyroid tumor has in every case lead to a reversal of the metabolic change.

Tumors Metastatic to the Jaws.—Secondary metastasis to the jaw bones is rarely seen. Metastasis to the jaws occurs in the same manner as to other bones. Thoma reports a case of carcinoma of the lip which metastasized to the mandible. Sonntag reported a breast carcinoma with metastasis to the lower jaw. Thoma reports a case of carcinoma of the prostate with metastasis to the jaw. Blumer stated that in 38 per cent of carcinoma of the thyroid bone metastasis developed in the bones of the cranium and face, and of the latter, 7 out of 9 went to the lower jaw. Ivy has reported such a case. According to Thoma about 20 per cent of the hypernephromas show metastasis to the bones of the skull and face. Branch and Norton reported such a case (1928). No doubt it is possible for most any of the tumors which metastasize to bone to occasionally involve the jaw bones. Pains of a rheumatoid character tend to accompany the metastatic lesions. The secondary tumor resembles the parent tumor. The diagnosis is aided by the use of the roentgen ray. Usually the tumor involvement of bone is multiple.

Bibliography

Bibliography Quoted in Text

Aub, J. C., Albright, F., and Bauer, Walter: Hyperparathyroidism, J.A.M.A., **102:** 1276–1287, April 21, 1934.

Aub, J. C.: Calcium and Phosphorus Metabolism, The Harvey Lectures, 1928–1929.

Barrie, G.: Multiple Hemorrhagic Foci in Bone, Ann. Surg., **71:** 581, 593, 1920.

Barr, D. P., and Bulger, H. A.: The Clinical Syndrome of Hyperparathyroidism, Amer. Jour. Med. Sci., **179:** 449, April, 1930.

Barr, D. P., Bulger, H. A., and Dixon, H. H.: Hyperparathyroidism, J.A.M.A., **92:** 951 March 23, 1929.

Bence-Jones: Quoted by Prinz and Greenbaum: Diseases of the Mouth and Their Treatment.
Bessel-Hagen: Quoted by Prinz and Greenbaum.
Blair, V. P., and Brown, J. B.: Quoted in Barr, D. P., and Bulger, H. A.: The Clinical Syndrome of Hyperparathyroidism, Amer. Jour. Med. Sci., **179:** 449, April, 1930.
Giant Cell Tumor of the Bone, Surg., Gynec. and Obst., **38:** 789, 1924.
Bloodgood, J. C.: Bone Tumors, Myxoma, Ann. Surg., **80:** 817, 1924.
Amer. Jour. Surg., **37:** 105–112, 1923.
The Conservative Treatment of Giant Cell Sarcoma, Ann. Surg., **56:** 210, 1912.
Blum, T.: Do All Cysts in Jaws Originate from the Dental System? Jour. Amer. Dent. Assoc., **16:** 647, 1929.
Jour. Amer. Dent. Assoc., **19:** 281–301, 1932.
Blumer, G.: Yale Med., **18:** 153, 1911.
DuBois, E. F., Hannon, R. R., Shorr, E., and McClelland, W. S.: A Case of Osteitis Fibrosa Cystica (Osteomalacia?) with Evidence of Hyperactivity of the Parathyroid Bodies: Metabolic Study, Jour. Clin. Investig., **8:** 215, Feb., 1930.
Branch, C. F., and Norton, R. H.: New Eng. Med. Jour., **198:** 11, 559, 1928.
Connor, C. L.: Endothelial Myeloma, Ewing, Arch. Surg., **12:** 789, April, 1926.
Carabelli, G.: Quoted by Prinz and Greenbaum: Diseases of the Mouth and Teeth, Phila., Lea and Febiger, 1935.
Christeller, E.: Verhandl. d. deutsch. path. Gesellsch., **21:** 7–48, 1926.
Christensen, F. C.: Bone Tumors: Analysis of 1000 Cases with Special Reference to Location, Age and Sex, Ann. Surg., **81:** 1074, 1925.
Churchill, E. D.: Parathyroid Tumors Associated with Hyperparathyroidism, Surg., Gynec. and Obst., **58:** 255–271, 1934.
Codman, E. A.: Bone Sarcoma, New York, Paul B. Hoeber, 1925.
Amer. Jour. Roentgen., **13:** 105–126, 1925.
Epiphyseal Chondromatous Giant Cell Tumors of the Upper End of the Humerus, Surg., Gynec. and Obst., **52:** 543, 1931.
Registry of Bone Sarcoma, Surg., Gynec. and Obst., **42:** 38, 1926.
Coley, W. B.: Sarcoma of the Long Bones, Surg. Clin. N. Amer., **5:** 117, 1925.
Some Problems in the Diagnosis and Treatment of Sarcoma of the Long Bone, Ann. Surg., **60:** 103, 537, 1914.
Collip, J. B.: Jour. Biol. Chem., **63:** 395, 1925.
Ewing, James: Arch. Surg., pp. 485–533, May, 1922.
Neoplastic Diseases, 3rd ed., Phila., W. B. Saunders Co., 1922.
Ewing, James, and Stone, W. S.: Arch. Surg., **7:** 280–296, 1923.
Geschickter, C. F., and Copeland, M. M.: Recurrent and So-called Metastatic Giant Cell Tumors, Arch. Surg., **20:** 713, 1930.
Tumors of the Bone, Amer. Jour. Cancer, New York, 1931.
Hertzler, A. E.: Surgical Pathology of Diseases of the Bones, Published by the Author, Halstead, Kas., 1930.
Hoffheinz: Virchow's Arch. f. path. Anat. u. Physiol., **256:** 705, 1925.
Ivy, H. H.: Arch. Surg., **17:** 27, 1927.
Ann. Surg., **94:** 437, 1931.
Jansen, M.: On Coxa Plana and Its Causation, Jour. Bone and Joint Surg., **5:** 265, 1923.
Kolodny, A.: Bone Sarcoma, Surg., Gynec. and Obst., **44:** 126, 1927.
Konjetzny, C. E.: Arch. klin. Chir., **121:** 567, 1922.
Die sogenannte "Lokalisierte Osteitis Fibrosa," Arch. f. klin. Chir., **121:** 567, 1922.
Kupffer: Quoted by Prinz and Greenbaum.
LaGrange, Felix: Tratise des Tumeurs de l'oeil, Paris, Steinheil, **2:** 346, 1904.
Lebert, M.: Physiol. Path., **2:** 121, 1845.
Lesser: Allg. Chir., **2:** 288, 1905.
Lewis, Dean: Practice of Surgery, Hagerstown, Maryland, vol. 2, W. F. Prior Co., Inc., 1929.
Lubarsch, O.: Die Bedeutung des Traumas zur Entstehung und Wachstum krankhafter Gewachse, Med. Klin., **41:** 1651, 1912.
Arch. klin. Chir., **121:** 247, 1922.
Lucas, C. J.: Discussion of paper by Blum, T.: Do All Cysts in Jaws Originate from the Dental System? J.A.D.A., **16:** 647, 1929.
Mallory, F. B.: Jour. Med. Research, **24:** 463, 1911.

Mandl, F.: Zentralbl. f. Chir., **56:** 1739, 1926.
McAuliffe: Chic. P. S., **8:** 211, 1911.
Moore: Radiology, **5:** 18, 1925.
Nélaton: Tumeurs benignes de os ou tumeurs à myeloplexis, Paris, 1860.
Paget, Sir J.: Lectures on Pathological Subjects, Lecture 28, Part I, pp. 446–455, 1854.
Pommer, G.: Zur Kenntnis der progressiven Hematom und Phlegmasieveränderungen, (H. V. Haberer's) Arch. f. Orth. u. Unfall.-Chir., vol. 17, 1920.
Pommer, G., and Hampton, H. D.: Arch. f. Ortho., **17:** 17, 1919.
Ribbert: Diss., Zürich, 1899 (Lit.).
Von Recklinghausen, F.: Die fibröse oder deformierende Ostitis, die Osteomalacie und die osteoplastiche Carcinose, in ihren gegenseitigen Beziehungen, Festschr. f. Rudolph Virchow, Berlin, George Reimer, Oct. 13, 1891.
Scheider, O.: Ztschr. f. Stomatol., **29:** 80, 1931.
Schinz, H. R., and Uehlungen, E.: Erg. Med. Strahlenforsch., **5:** 387, 1931.
Sonntag, E.: Deutsch. Ztschr. f. Chir., **223:** 236–415, 1930.
Spring, Karl: Klin. Chir., **149:** 385, 1928.
Thoma, K.: Clinical Pathology of the Jaws, Charles C. Thomas, Baltimore, pp. 608–628, 255–260, 1934.
Thomas, K. H.: Jour. Dent. Res., **13:** 1, 1931.
Virchow: Geschwülste, 2, 214.
Virchow's Arch., **52:** 504, 1871.

CHAPTER XXXIX

RESECTIONS OF THE JAW BONES

Resections and excisions of the upper jaw as formerly practiced have almost become operations of the past. Resections of the maxilla alone have in the past given almost uniformly bad results in so far as final eradication of carcinoma of the region is concerned. At the present time, however, a few men practice resection for carcinoma of the upper maxilla after which they apply radium within the cavity which remains. There are certain malignancies such as osteosarcoma and adamantinoma in which resection is indicated.

RESECTIONS AND EXCISIONS OF THE MAXILLA

Historical.—Gensoul (Smith) states that Acoluthus, a surgeon of Breslau, first removed a portion of the upper jaw in 1693. Jourdain in 1768 removed a part of the antrum. In 1824 Rogers of New York removed nearly the entire portion of both upper jaws. Lizars of England and Gensoul of France operated about 1827. But to Gensoul is generally credited the first complete resection of the superior maxilla. In 1897 Martens reported 48 resections with 19 deaths (39.9 per cent). Stein in 1902 reported 47 resections with 7 deaths (14.8 per cent). In 1901 Krönlein collected 273 total resections with 25.6 per cent operative mortality but he did 35 himself with only 1 death (1881–1901). Martens in 48 patients resected had 8 (16.6 per cent) free from recurrence at the end of three years. In 46 cases Stein has of total resection, he reports 4 five-year cures.

The cautery for opening the antrum was first used by Lawson in 1872. New in 1920 revived the method. At present the endothermic button is used on the same principle, namely, to gain access, to destroy a part of the growth and to give subsequent drainage.

Resection of the Superior Alveolar Process.—When present, a tooth in front of or behind the section to be removed is pulled. The mucoperiosteum along the lines of the proposed excision is incised to the bone. At the extremities of the part to be excised, the alveolar process is cut through by placing the edge of a thin chisel across its lower border and cutting directly upward to the depth of the base of the proposed excision. The chisel is then placed against the upper outer surface of the portion of bone to be excised and the horizontal cut is made. With a bone forceps the block is grasped and twisted out. Considerable bleeding will be encountered but the operation should only be a short one. The hemorrhage can be controlled by pressure and later by suturing the mucosa of the cheek to the edge of the palate mucosa. A wire saw can be used in the same manner as described for resecting the lower alveolar process if one prefers.

Resection of the Palate and Alveolar Process.—The mucosa of the upper buccal fornix is incised horizontally to the bone. When the mucoperiosteal covering of the palate is to be removed with the bone, the soft palate is detached from the hard palate by a transverse incision. The incision is packed

to prevent bleeding. When the mucoperiosteal covering of the palate is to be preserved, it is incised within the line of the alveolar palatal juncture. The palatal soft tissues are dissected toward the midline. The aponeurosis at the posterior border of the hard palate is freed from the bone and a transverse incision made into the nasal mucosa as in the operation for cleft palate. When the growth involves the cheek, a part of it may be excised. The bone excision with the chisel starts by placing the instrument vertically against the anterior surface of the alveolar process in the midline and driving back through the palate to its posterior border. The full thickness of the alveolar process is cut. The chisel is next placed against the front of the jaw with its edge and long axis parallel to the palate, and is driven straight back to the level of the maxillary tubercle and then, by depressing the handle, the bony mass is loosened from its posterior attachment. When this procedure fails to loosen the bone, the edge of the chisel is placed against

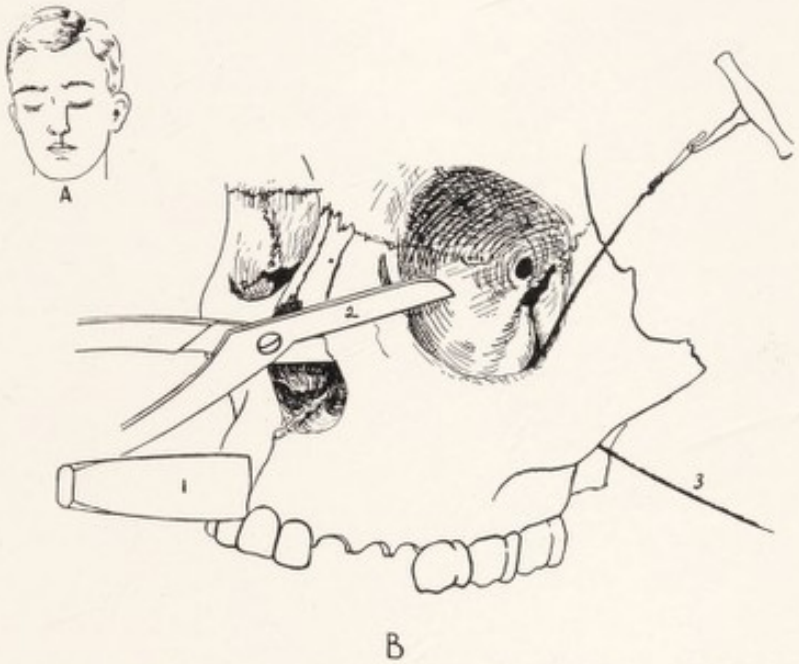

Fig. 293.—Method of excising the upper jaw. A, Weber's incision. B, 1, Chisel to separate the two maxillae in the midline; 2, Liston forceps to cut the superior process; 3, Gigli saw to cut the malar process.

the malar process of the maxilla and is then cut through obliquely upward and inward. When the bone has been weakened by disease, the maxilla is cut through the pterygoid process to obviate the chance of a fracture through the diseased part. In some instances, a part of the nasal septum also should be removed in a manner similar to that just described, by placing the chisel against the anterior superior nasal spine and cutting straight back. The whole of the maxilla beneath the orbital plate can be removed in this manner. But two transverse cuts are required in the upper part—one for the outer wall of the maxilla and one for the outer part of the nasal fossa. As the bleeding encountered is profuse, the operation must be performed quickly. A strong pair of bone forceps is needed to take a firm hold on the bony mass. As soon as the bony mass is removed, the cavity is firmly packed with gauze which can be removed after a day or two. After the pack is removed, a nasal douche of mild salt and soda water is used to cleanse the cavity.

Total Resection of the Maxilla.—Probably the most effective and the least objectionable incision is a modification of that proposed by Weber (Fig. 294). The nerve supply of the orbicularis palpebrarum is not endangered. There is a possibility of a slough of the sharp corner of the flap in the Kocher incision which, if it happens, may cause the lower eyelid to be pulled down.

Weber's incision begins immediately below the inner angle of the eye, drops downward at the line of the juncture of the soft tissues of the nose to the cheek, skirts the alae, and crosses below the nose to the midline of the upper lip (Fig. 293). A second transverse incision starts at the point of the first incision and follows the lower margin of the orbit. The skin flap is reflected outward as outlined by the incision. When the soft tissues

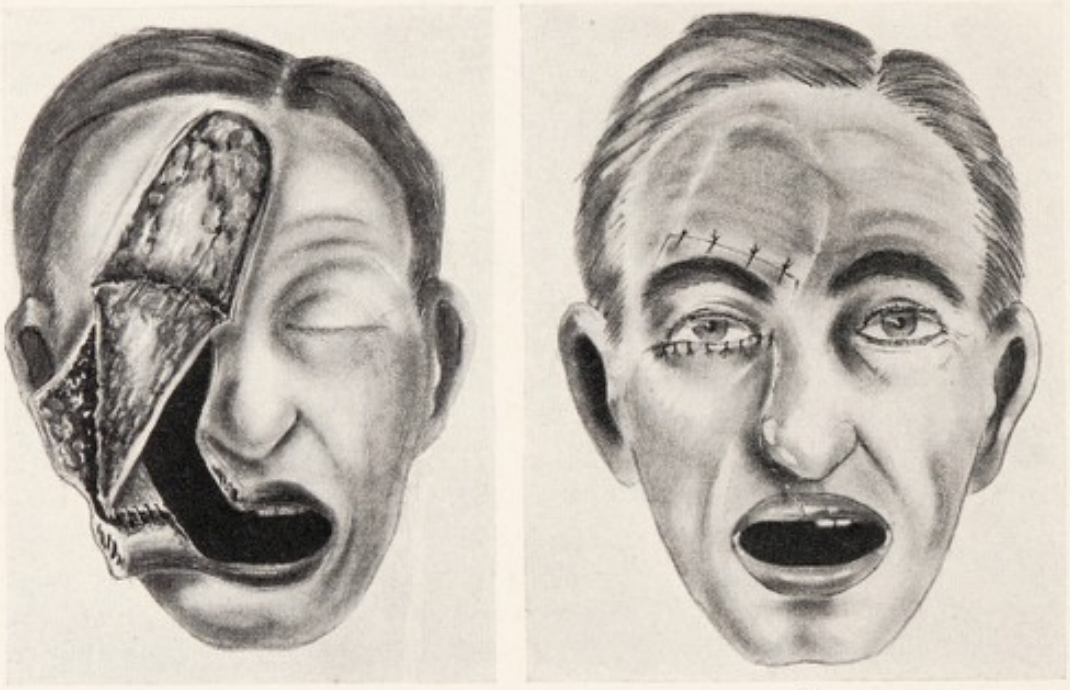

A *B*

Fig. 294.—*A*, Relining the skin flap after resection of the superior maxilla showing that a prosthesis may be laid in the cavity to hold the cheek outward and forward. A skin flap is turned down immediately after the maxilla is resected. The raw area is then covered with a split skin graft. *B*, At a second operation two weeks later the pedicle of the flap is cut across and the butt end is turned back beneath the eye to give a base to the orbit. The pedicle is readjusted on the forehead. Bardenheuer first proposed this scheme. This external incision is that of Weber.

are not involved in the malignant growth, they may be removed from the front of the bone but, when this is not the case, the involved area must be included in the excision. The face flaps are dissected back until the pyriform fossa of the nose and orbit are opened. The palatal tissues are handled as in partial resection of the alveolar ridge. When the orbital cavity is not to be removed, it is raised from the bony floor. The bony walls separating the nasal fossa from the zygomatic fossa are defined. A ⅝ circle heavily threaded needle is inserted through the anterior end of the sphenomaxillary fissure so as to protrude from the zygomatic fossa. This threaded needle is used to carry a Gigli saw through the sphenomaxillary fissure and out the zygomatic fossa so that the malar bone may be cut across. A long-bladed Lister forceps is used to cut the nasal process of the

maxilla. One blade is placed in the nose and one in the orbit. This cut also extends into the sphenomaxillary fissure. Finally, the alveolar process and the palate are cut through with a chisel or Gigli saw. A heavy forceps is used to twist the jaw out of position and the cavity is immediately packed with gauze which is left in place for one or two days postoperatively. The pack is then removed and the cavity irrigated with a mild saline and soda irrigating fluid every four hours. After this operation there is usually some luxation of the eyeball downward. Attempts to prevent this have not been entirely successful.

Bardenheuer (Binnie) has described a forehead flap operation (Fig. 294, *B*) as an addition to the operation described which relines the cheek. The floor of the orbit probably needs relining more than the cheek. In some instances, the procedure might be a useful addition. König and Hearn and Matas advise ligation of the external carotid before this operation is done. Temporary compression of the carotid may answer the same purpose.

EXCISIONS OF THE LOWER JAW

In Chapter XXXIV, under the title of Operations for Malignant Neoplasms of the Soft Tissues, the common operative procedures which are used at times in the surgical treatment of carcinoma are described. In the

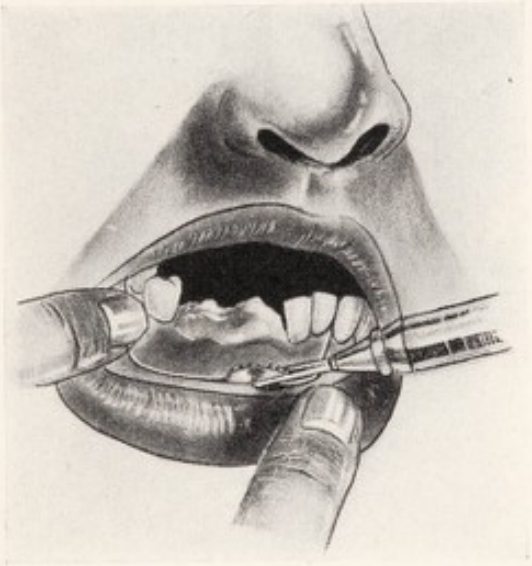

Fig. 295.—Method of removing a part of the alveolus and a section of the upper part of the mandible.

same chapter was described cautery destruction of a segment of the mandible and resection of a segment of the mandible. There are two other operative procedures, namely, resection of a segment of the inferior alveolar process and the excision of nearly all or one half of the mandible. The former operation is seldom indicated. The latter operation often is indicated when the jaw bone is involved by a malignant tumor of the bone itself.

Resections of the Inferior Alveolar Process.—In carcinoma of the alveolar process which may not extend entirely down to the floor of the mouth, it may be possible to do an adequate excision and also leave a rim of bone along the lower mandibular edge (Fig. 295). The reasons for doing this are that the mortality is less if the mandible is not cross cut and

resected and the deformity is less. Unless the lesion is fairly well forward, a lateral submandibular approach gives better exposure (Fig. 296). In this approach the soft tissues, all but the periosteum, are raised from the outer surface of the mandible, and the buccal cavity is entered through the mucosa of the alveolar cheek sulcus. We have used an Albee saw to make the parallel cut in the mandible. A bone drill is used to make a hole at each end of the parallel cut through which a Gigli saw is passed or in some cases the whole of the procedure can be done with the Albee saw. The external lateral submandibular incision is preferable to cutting the cheek.

When only the alveolar bone is to be removed, the biting forceps is acceptable, but it is rare that sufficient excision is given by this method alone.

When the lesion extends to the edge of the floor of the mouth, it can also be excised along with the upper part of the body of the mandible and still



Fig. 296.—Resection of the inferior alveolar process. It is rare that this procedure is indicated as the involvement is usually greater than it appears and if the whole bone is not resected, there will be a recurrence.

a sufficient rim of bone is left at the lower edge of the mandible to maintain the bony arch of the lower jaw.

Resection of One Half of the Mandible.—W. H. Deaderick of Rogersville, Tennessee, in 1810 excised nearly one half of the mandible which preceded by two years the excision by Dupuytren, to whom European surgeons generally assign credit for first resecting the mandible in 1812. Deaderick did not publish his work until 1823. Mott of New York successfully removed the lower jaw after ligation of the carotid in 1821. In Smith's Operative Surgery, Volume I, bibliographic indices are recorded of 23 resections by various American surgeons up until 1850. In Velpeau's Surgery he states that 160 cases of resections of the lower jaw were recorded in the literature with 40 deaths.

In removing the whole or the greater part of the mandible on one side, an incision similar to the one for partial removal is used only it is extended somewhat further backward and upward (Figs. 297, 298). Outside, the masseter is cut from the bone. The parotid gland is freed and retracted up-

ward. The jaw is cut across anterior to the lesion with a Gigli saw. The proximal fragments are pulled outward and the distal part of the jaw pulled

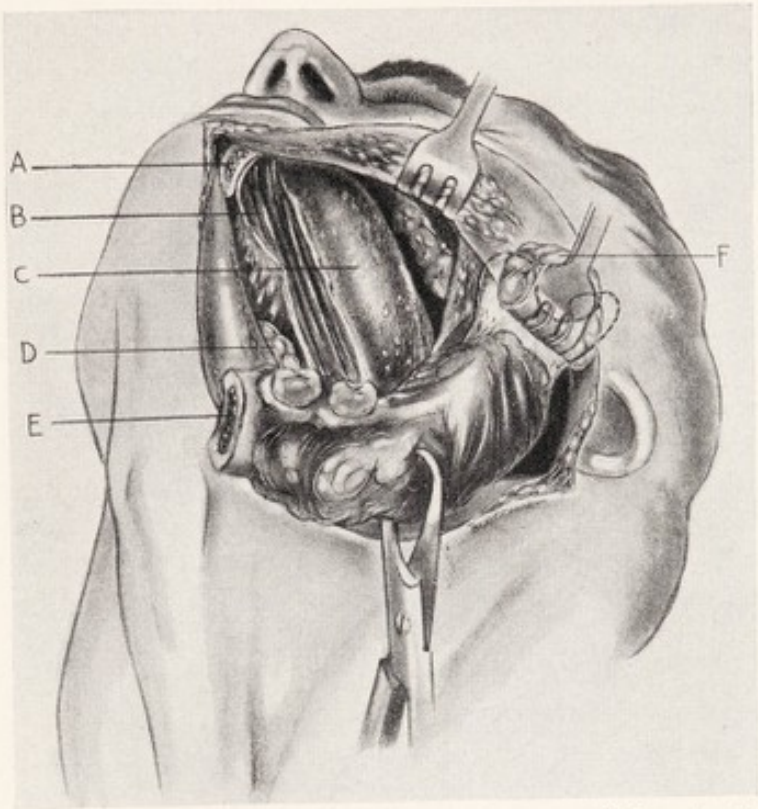

Fig. 297.—Complete resection of one half of the mandible. A, Cut end of mandible; B, geniohyoglossus muscle; C, lateral tongue; D, submaxillary gland; E, cut end of mandible; F, parotid gland retracted away from bone and upward.



Fig. 298.—This boy had a large giant-cell tumor involving the left half of his mandible. The mucosa on the inside of his mouth became eroded and the central part of the whole mass became infected and the bone necrotic. The entire left side of the mandible was therefore removed. Figure 292 shows the patient before the left half of the mandible was removed.

to the opposite side. The internal pterygoid muscle is freed from its internal attachment to the ramus. The attachment of the temporal muscle

on the coronoid is cut and the bone wrenched out of the condyle. The other ligaments and muscular attachments are cut close to the condyle. The wound is packed with Mikulicz pack and partially closed with dermal sutures. Such an operation is indicated in certain bone sarcomas or adamantinomas. The mortality of this operation in good risks is not great.

Prevention of Deformity After Excision of the Upper and Lower Jaw.—*Upper Jaw.*—After removal of the upper jaw on one side, when sound teeth are present in the remaining side, an obturator and a plate with embedded teeth can be attached to the teeth in the sound half (see chapter on Prosthetic Appliances). The cheek and orbital base should be relined if a really good result is contemplated (see method of Bardenheuer, Fig. 294).

In lesser contoural defects after excision of the upper jaw, cartilage may be transplanted to round out the face (see Chapter XL).

Lower Jaw.—After excision of a segment of the lower jaw, some steps should be taken immediately to retain the sound half of the jaw in position. One can wire the upper to the lower teeth of the sound side, temporarily at least. A useful appliance is described under dental prosthesis, in which metal bands are placed on the upper and lower teeth and the two bands are then connected by orthodontic rubber bands in a slanting direction so that the lower jaw is always pulled to the sound side. This procedure is of value in counteracting the pull of scar tissue on the unsound side and in preventing subsequent deformity.

When the anterior part of the body is removed, it is often possible to retain the two sides of the jaw in position by wiring the lower to the upper teeth. These various methods are discussed under fractures with loss of bony substance. In the manufacture of the various appliances described in Chapters X and XLI some originality and ingenuity is required. The various foreign body prosthetic forms do little to hold connective tissue parts in their correct position. As the wound cicatrizes they are pushed out of position even if they do not interfere with healing. A cavity without an epithelial lining eventually closes mostly by scar contracture and only to a slight extent by scar epithelization.

After the operative defect has healed, a bone graft may be inserted into the defect in the lower jaw. Before this procedure can be carried out, however, a good epithelial lining and covering must be present or supplied so that the bone graft will have pliable and viable tissue to surround it on all sides (see Chapter XL).

Bibliography

Bibliography Quoted in Text

Bardenheuer and Weber: Quoted by Binnie, J. F.: Manual of Operative Surgery, Phila., P. Blakiston's Son and Co., 8th ed., 1921.

Gensoul: Quoted by Rabe, L.: Deutsch. Ztschr. f. Chir., **3:** 300, 1873.

König, Hearn and Matas: Quoted by Peyton, W. T.: Tumors of the Maxillary Sinus, Amer. Jour. Cancer, **16:** 515–519, 1932.

Kocher, T.: Textbook of Operative Surgery, London, A. and C. Black, 1911.

Krönlein: Totale Oberkieferresection und Inhalationsnarkose, Arch. f. klin. Chir., **64:** 265, 1901.

Lawson: Middlesex Hospital Report, Med. Times and Gazette, **1:** 513, 1872.

Martens, Max: Zur Kenntnis der bösartigen Oberkiefergeschwülste und ihren operativen Behandlung, Deutsch. Ztschr. f. Chir., **44:** 483, 1897.

New, G. B.: Treatment of Malignant Tumors of the Antrum, J.A.M.A., **74:** 1296, 1920.

Rabe, L.: Statistische und klinische Beiträge zu der Prognose der Resectionen am Oberkiefer und den Hilfoperationen bei denselben, Deutsch. Ztschr. f. Chir., **3:** 300, 1873.
Stein, A. E.: Zur Statistik über Operationen der Geschwülste des Oberkiefers, Arch. f. klin. Chir., **65:** 490, 1902.

Historical—References Quoted in Text

Deaderick, W. H.: Amer. Med. Recorder, **6:** 516, 1823.
Gensoul: Sur les maladies du sinus maxillaire, Paris, 1833.
Mott, V.: New York Med. Phys. Jour., **2:** 157, 1823.
Smith, Henry H.: Operative Surgery, Phila., Lippincott, Grambo and Co., 1852.
Velpeau: Treatise on Surgical Anatomy or the Anatomy of Regions Considered In Its Relation with Surgery, Trans. from French by W. Sterling, New York, Wood and Co., **2:** 620, 1830.
Jourdain, Lizars, Rogers, Acoluthus: Quoted by Smith, H. H.: Operative Surgery, Phila., Lippincott, Grambo and Co., 1852.

CHAPTER XL

SURGICAL RESTORATION OF DEFORMITIES

Within the past decade marked strides forward have been made in end-results after the repair of both congenital and acquired defects. This has been especially true of the deformities of the face, mouth and jaws. Here we shall attempt only to summarize those procedures in plastic and cosmetic surgery most interesting to the oral surgeon.

The face and jaw region is particularly prone to accidental injuries which leave scars or distort either the hard or soft tissues. Not uncommonly disease processes cause a deformity or an operative procedure becomes necessary because of a disease which leaves a cicatricial deformity.

But besides those deformities caused by accident, nonmalignant diseases or surgery, radical surgery for malignancy is not uncommonly the cause of deformity for which reparative surgery is required. The well-qualified oral surgeon should, therefore, be familiar with procedures for the repair of many types of deformities.

Heavy or Deep Scars on the Face.—After deep injuries of the face have healed or after extensive grafting operations, the face may be much disfigured either by raised or depressed scars.

Keloid Scars.—When a scar shows keloid tendencies either radium or *x*-ray treatment may be valuable. But when the scar is rough and red and thick, it is better to excise the scar and obtain better approximation of the skin before radium or *x*-ray is tried if such is thought to be necessary.

Depressed Scars.—Depressed scars as a rule are best dealt with by dissecting out all of the scar tissue and, after freeing the tissues, building up the defect by approximating the walls as if one were repairing a cut by primary incision. In rare instances, where the depression in the soft tissue cannot be obliterated in the manner just shown, transplantation of fat from the abdominal wall may be resorted to, or a small piece of the subepithelial layer of the skin may be used when the defect is a shallow one. The cutaneous incision in the region of the defect should not be large, and should be placed, if possible, at some inconspicuous point. The subcutaneous tissues are separated by a knife or by tunneling with blunt-pointed scissors. After the arrest of the hemorrhage, bits of fat of sufficient size are introduced and held in the pocket by subcutaneous sutures of fine catgut. It is usually undesirable to suture the fat in position. A firm moist pressure dressing is then applied to prevent the accumulation of serum in the dead spaces. Practically all of these minor plastic operations may be done under local anesthesia.

VARIETIES OF SKIN GRAFTS

The following types of skin grafts may be of use in the repair of surface deformities about the face, mouth and jaws: the stent graft, the mucosal graft, the "pin-point" graft, the Thiersch graft, the split graft, and the full-thickness skin graft.

Stent Graft.—The stent graft is a term which designates that a form of some firm material (Fig. 299), such as modeling composition or an air-

distended rubber bag, has been used within the graft to compress it against the surrounding raw surface. Esser originally developed the principle of burying graft and stent. Later he cut down upon the stent and allowed the cavity to open. Waldron extended the principle so that the stent and graft were laid in a gutter of soft tissue and not buried—a so-called "outlay graft." This is the form of the graft in common use at the present time. A graft of the thickness of a Thiersch graft or even a full-thickness skin graft may be used to wrap about the stent. When using modeling composition for the stent, the wax is pushed into the cavity which it is desired to graft and allowed to harden in the form of the surrounding surface. The stent is then removed and is surrounded by skin after which the form and the skin graft are placed within the cavity that the stent was originally made to fit. The stent and the graft are then fixed in place by stitches.

Mucosal Graft.—A mucosal graft is useful in one situation especially—the eye socket. Although the technic for getting the proper amount of oral mucosa is difficult and in many cases impossible, it is, theoretically at least, the only type of tissue which should be placed within the "globe-lid" sulcus

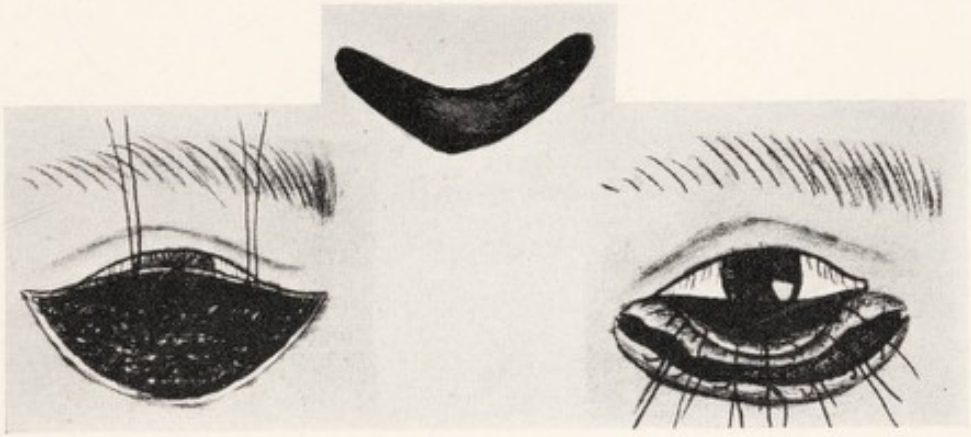

Fig. 299.—Method of using modeling composition form as a stent beneath the lower eyelid.

when the eye globe is present. A Thiersch graft placed in this situation irritates the cornea. In an eye socket with a considerable amount of conjunctiva present, the stent Thiersch graft tends to exfoliate and cause the tears to become cloudy. Thus, if it is possible to transplant sufficient mucosa—which usually is not the case—the mucosal graft is theoretically the ideal in an eye socket. The difficulty with this graft is to get a sufficient amount of it after final contraction has taken place to be of much use in the eye socket. As yet it has not been proved to be practical or satisfactory. The graft may be shaved from the inner surface of the lower lip as one would remove a Thiersch graft, or cut from the cheek lining as a full-thickness skin graft is removed. The full-thickness mucosal graft is likely not to "take" but when it does "take," there is less subsequent contraction of the graft than after the use of the thinner graft.

Pin-point Graft.—Pin-point grafts were originally originated by Davis. They are very small, about ¼ inch in diameter. Davis cuts the grafts with a sharp knife or razor after the skin is raised up somewhat by being caught with the point of a needle. The graft takes well upon a granulating surface if it is moderately clean. It is used in those cases in which resurfacing is

desired and in which the patient is too ill to have larger grafts removed. The graft is not of great value in preventing contractural deformity. When the location is such, because of the underlying bony structures, that contraction is thereby largely prevented, the graft may be of value. However, the cosmetic appearance is not good. The graft gives a rather "polka-dot" appearance which is not desirable on the face or neck.

Thiersch Graft.—The Thiersch graft is one of thin epidermis and is usually cut off the inside of the arm or the thigh with a skin-graft knife or razor. The graft will take readily on any freshly cut surface and on a granulating surface if it is moderately clean. However, although this graft has the advantage of being fairly certain to take, the tendency for ultimate contraction is considerably greater than after a full-thickness graft. The graft is useful in resurfacing granulating defects, correcting cicatricial contracture within the mouth, and repairing ectropion of the eyelids and lips. The graft has the disadvantage of appearing whiter than the surrounding skin. It also shows a marked tendency to contract, for which allowance



A *B*

Fig. 300.—Ectropion of lower eyelid corrected with a split stent graft. *A*, Before operation. *B*, After operation.

must be made. One of the main advantages of the graft is the certainty of getting a "take."

Split Graft.—"Split graft" (Fig. 300) is a term applied by Blair to a rather thick type of Thiersch graft. He and Brown have done considerable in popularizing this graft. It is removed in the same manner as the Thiersch graft but by means of a special knife and a suction apparatus to hold the skin on the stretch. One is enabled to cut a graft somewhat thicker and wider than the usual Thiersch graft and somewhat thinner than the full-thickness skin graft.

The indications for a split graft are about the same as for the so-called "thin Thiersch graft," with the exception that the thicker graft will result in somewhat less contraction and give a cosmetic result somewhat better than that of the thinner graft but not so good as that which follows a good "take" of a full-thickness skin graft.

Full-thickness Skin Graft.—The full-thickness skin graft (Fig. 301) is the thickest type of skin graft. Wolfe originated the graft in 1875. Within recent years the use of the graft has been very much extended (Blair,

Padgett). Although it may be taken from any part of the body where skin is available, it is commonly cut off the abdomen. A scalpel is used to cut the graft and one aims to section the corium at about its midline. Whenever any fat or bleeding vessels are left upon the cut surface, it is being cut too thick.

Appearance of a Full-thickness Skin Graft.—Although there is a tendency for a full-thickness skin graft to have a slightly "shiny" appearance, most grafts that have shown a good take without much superficial blistering or superficial exfoliation show grossly practically the normal skin texture of the region from which the graft was removed. Those grafts in which some superficial exfoliation occurred have more of a tendency to pigmentary changes, but in brunets pigmentation may occur in perfect "takes." Half of the brunets in our series showed slight pigmentary changes in the graft. Most of the blonds showed no pigmentation. Thus, on the face one has to consider the possibilities of getting a poor take and, if one gets a good take, of having the graft appear a little "shiny" or, in brunets, slightly pigmented.



A *B*

Fig. 301.—Patient with large hemangioma of the face. *A*, Before operation. *B*, After application of full-thickness skin graft.

The majority of hairs and hair follicles in areas that have taken will grow so that one should not use hair-bearing skin unless hair is desired.

A few cases will show a rather heavy scar at the edges, which may materially handicap the result in situations in which a good appearance is essential.

Some Late Changes After Skin Grafting.—After two or three months a thin layer of adipose tissue starts to form beneath the graft and the skin begins to loosen from the underlying tissues. A depressed area successfully grafted fills up to the level of the normal surrounding skin in from two to three months.

Beginning about two months after transplantation, a new nerve supply starts in from the edges. However, a large skin graft may never regain complete sensation, especially if the cutaneous sensory nerves have been cut in the repair or in removing a flap. The tactile sensation has not completely returned in 2 such patients who were operated on over two years ago.

Considerations in the Application of Thin and Split Skin Grafts.—On a freshly cut surface, to obtain the maximum success with thin skin grafts, the following factors are significant. A dry field with little or no oozing of blood is important. Consequently, all the vessels should be tied with the finest of suture material. When there is any question of lack of hemostasis, a hole should be made in the skin to prevent accumulation of blood serum beneath the graft. The graft must have absolute fixation, and sufficient pressure must be applied to maintain definite contact with the underlying surface.

Thin skin grafts and split grafts take well on a clean granulating surface. They are therefore very useful in getting quick resurfacing and healing after a large superficial epithelial loss has been sustained for one reason or another. Such granulating surfaces are best prepared by applying wet gauze dressings. The dressings are applied wet and kept constantly wet with a mild antiseptic solution such as boric acid, Dakin's solution, or even saline solution. The dressings should be changed at least twice a day. When the granulating surface is vermilion red and rather firm, with no evidence of pus or grayish slough, the application of a thin or a split skin graft will usually result in a total "take" if the proper precaution as to fixation and subsequent dressings is followed. Following the grafting a wet pressure dressing is placed over the graft and not changed for four days. During this time it is kept soppy wet so that good drainage is promoted.

Some Considerations in the Application of Full-thickness Skin Grafts.—Besides the above factors generally considered significant in growing thin skin grafts, it should be emphasized that full-thickness skin is not likely to "take" unless the field is sterile. The proper cutting of a full-thickness skin graft is important. The skin should be cut through the fibrous tissue layer of the corium in such a manner as to separate all the fat from the graft. The method of suturing is important. The graft should be sutured in place under moderate tension to open the endothelial spaces of the skin. The fixation and pressure must be certain. Any movement of the muscles beneath the graft or movement of the graft or the underlying tissue will result in its loss. To grow, the graft has to be in direct contact with the underlying surface even if it is an uneven one. A fairly adequate pressure dressing on a concave uneven underlying surface is provided by the damp marine sponge when it is compressed by a snug bandage as suggested by Blair. Later when the sponge dries, it stiffens and gives considerable fixation. Convex surfaces with a smooth base do not always need a pressure dressing when the graft is sutured in on a stretch. Later, after the graft has grown to the underlying bed, any superficial infection should have a type of dressing which promotes adequate drainage and tends to inhibit bacterial multiplication. Gauze saturated with a solution of boric acid does fairly well.

VARIETIES OF FLAPS

There are 5 varieties of skin and subcutaneous pedicled flaps of use in the repair of defects of the soft tissues: the sliding flap, the tubed flap of Gillies, the delayed flap, the artery flap, and the jump flap.

Pedicled flaps are especially useful in those defects which have an absence of contour as well as a surface deformity. A pedicled flap is a flap

of skin and subcutaneous tissue which obtains its blood supply from its base until it can grow into the new situation. There are at least 5 types of these flaps.

Sliding Flap.—The sliding flap is a flap from the immediate territory and is a sort of "robbing Peter to pay Paul" method, so to speak. The principle of the sliding flap is as old as plastic surgery itself. It is in certain instances very valuable in filling in defects. The skin and subcutaneous tissue is thoroughly undermined and the flaps crossed in a variety of ways to obtain the necessary relaxation or the necessary lengthening or "filling in" of a defect.

Tubed Flap.—In the so-called "tubed flap" (Fig. 302, *A*) of Gillies a rectangular area of skin and subcutaneous tissue is outlined and then sewed in the form of a tube. Each end remains attached. After a number of days—usually twelve with us—the distal end is cut across. By this time

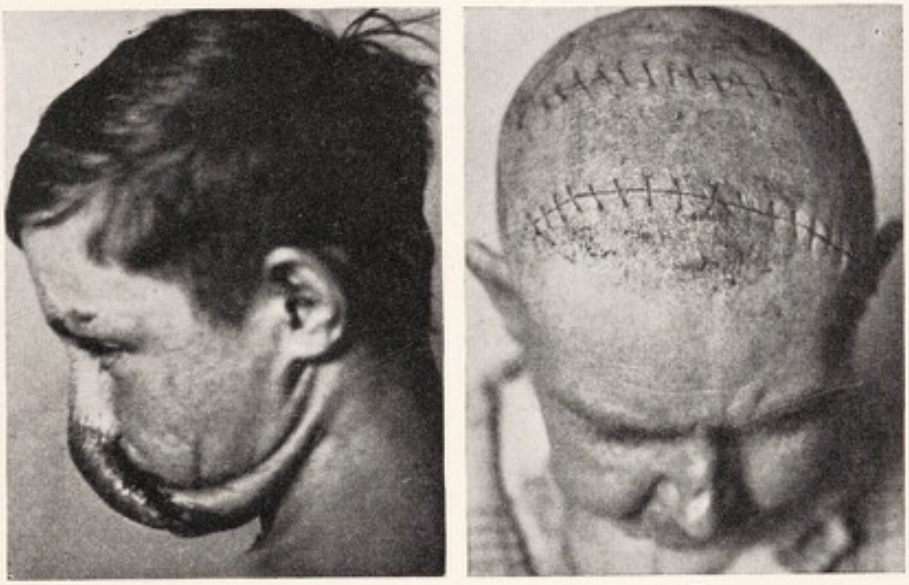

A *B*

Fig. 302.—*A*, Tubed flap attached to the nose. *B*, Showing flap outlined on scalp which has been resutured back in place. Before turning it down the distal end will be cross cut. The flap will be turned down about ten days after it was outlined.

the blood supply from the proximal end is sufficient to assure nourishment of the flap. When it is determined that the blood supply at the distal end is sufficient, the distal end is transferred to the region of the deformity to be repaired.

Delayed Flap.—The delayed pedicled flap (Fig. 302, *B*) was popularized by Blair.* A flap of skin and subcutaneous tissue is outlined and then sewed back into its original bed for ten days or so. This procedure increases the blood supply through its pedicle and should prevent damage to the flap when the pedicle is twisted on transference. In using this method it may be wise not to cut the distal end of the flap until a week after the preliminary outlining, at which time the sides and the base are separated. A week or so after this when the distal end of the flap is severed the likelihood of losing a part of the flap is greatly decreased.

* Treves described the principle of the method. Thiersch in 1876 used the method in ectopia vesicae. In 1888 MacCormac endorsed the method. Croft in 1889 used the method.

Artery Flap.—The fourth type of pedicled flap might be called the "artery flap." It is one in which a fairly large artery is kept intact to preserve nutrition to the flap as it is transferred from one place to another (Fig. 303). Esser, I believe, is generally credited with the development of this type of flap. He has insisted that it is necessary to protect not only the artery but also the accompanying veins and lymphatic vessels. The pedicle is small and therefore the flap is unusually mobile. An example is the triangular flap transfer from the lower to the upper lip. Sometimes the temporal artery has been used to supply a flap transferred from the side of the head to the face.

Jump Flap.—The fifth type of flap is the so-called "jump flap" which really is a tubed flap in which one end of the flap is transferred and grown to another part of the body such as the finger or the hand, after which the finger or hand is used to carry the flap to a totally different region. Gillies,

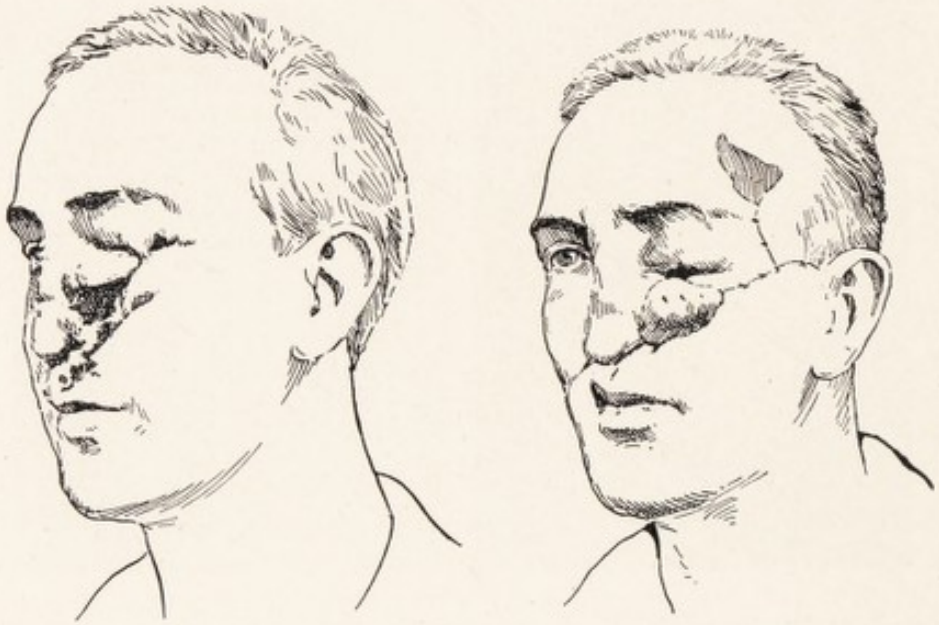

Fig. 303.—Transplantation of a forehead flap with anterior temporary artery to fill in defect of the cheek. (After Horsley.)

I believe, is accredited with the recent development of the "jump flap." Skin and subcutaneous tissue or even bone or cartilage may be transferred from the abdominal region to the face in this manner.

OTHER VARIETIES OF GRAFTS

Fat Graft.—Occasionally a fat graft may be employed advantageously in filling in soft tissues about the face. The fat may be obtained from the buttocks or the abdominal wall. Fat grafts, however, are likely to atrophy at least 50 per cent in a year or so. This has to be taken into consideration when they are transferred. A totally clean operative field and absolute hemostasis are necessary in successfully transplanting a fat graft.

Bone Grafts.—Bone grafts are used to fill in the defects of bone which require structural strength. Usually the bone is obtained from the rib, the tibia, or the iliac crest. Sufficient sound soft tissue should entirely surround the graft. The ends of the bone at either end of the bony defect to

be bridged should be freshened. Some arrangement to assure fixation is also essential. An absolutely sterile field is required, as a rule.

There is a second type of bone transplantation which is used to repair jaw defects in which a piece of bone is cut off from the jaw and then moved or slid to another location along with the surrounding soft tissues which carry the necessary blood supply. This type of bone transplant is sometimes useful even in an unclean field because blood supply is still maintained. This type of sliding transplant is, of course, a combination bone and soft tissue flap, not a true bone graft alone.

Cartilage Graft.—Cartilage grafts are used in situations where some firmness is needed to fill out contour. Cartilage always remains the same size which it was originally when transferred, if infection does not occur. It does not attach itself to the bone and lies freely movable within the soft tissue. For certain conditions where structural strength is not a necessity, such as the depressed nose or the recessive chin, cartilage is the ideal material to use.

DEFORMITIES REQUIRING RESURFACING ONLY

Commonly, there are 5 types of lesions where resurfacing only is required: (1) a granulating surface, such as that which follows an acute burn or after the loss of a skin graft; (2) after removal of a healed scar after an old burn or some other destructive incident; (3) after the removal of congenital surface lesions, such as birth marks, large moles, and so forth; (4) after the excision of some surface lesion for which there is little or no hope of cure such as lupus erythematosus and so forth, and (5) the substitution of a skin graft for destroyed mucosa within the mouth which loss resulted in a contractural deformity.

The Resurfacing of a Granulating Surface to get Early Healing.—On the face or neck two situations may arise which make early resurfacing of a granulating surface desirable solely to get a healed surface without necessarily aiming to get a permanent esthetic result. The first is following a severe burn of the third degree or a severe injury. As soon as the slough has separated from the granulating base beneath and time is given for the granulating base to be prepared, the time is at hand for resurfacing with epithelium. Contractural deformity is lessened as a heavy scar base has little time to form and the length of time during which troublesome dressings are required is cut down to a few days instead of being a matter of weeks, if the granulating base is not covered with skin. The application of wet dressings, continuously saturated with saline or boric acid and changed twice a day, within a week or ten days after the separation of all slough, will have usually cleaned the granulating base sufficiently so that a Thiersch graft or a split graft will take. The natural reaction of the tissue also plays a part in repairing the granulating base, but without proper dressing this alone will not be sufficient. In some instances the cosmetic result will be sufficiently good so that no further work will be necessary. A second indication for early resurfacing, although a rare one, may arise after the loss of a large full-thickness skin graft. After the removal, for instance, of a large hemangioma (birthmark) of the face in which a full-thickness skin graft is used for resurfacing, the chances are over 90 per cent that a good take of the full-thickness skin graft will be obtained. But if a failure re-

sulted, the question of using a thin skin graft to resurface the resultant granulating surface will arise. In none of our cases did this contingency arise, as the grafts took; the possibility was not unthought of, however.

Resurfacing of Tissue Beneath a Healed Cicatrix.—Before describing the resurfacing of tissue beneath a healed cicatrix it is pertinent to discuss the cause of deformity after loss of surface tissue. Loss of superficial tissue, unless prevented by an underlying anatomic structure which will not bend or become immovable, causes contractural deformity. The tendency to contracture of a scar can be understood fairly well if it is imagined that the scar is made of rather firm elastic rubber. That is, it pulls toward a central point or fixed point and draws tissues which will give or are movable. Thus, scars about the eyelids or lips cause contractural deformity and eversions—ectropion of the lids or the lips. About a joint, extension is limited where the scar is in the angle which must open to allow extension or, similarly, if the scar is external to the angle of flexion, extension is limited. Thus, a loss of soft tissue from inside the cheek within the angle between the upper and lower jaw will cause limited movement as the scar will fix the lower to the upper jaw depending upon the amount of mucosal and subcutaneous tissue lost originally. Again, destruction of the mucosa in the sulcus between the cheek and the alveolar ridge of the jaw will result in the soft tissues of the cheek becoming drawn and fixed to the jaw bone. When one desires to remove a surface lesion within the mouth or on the face or when an accident removes the tissue, it is necessary sooner or later to get the underlying soft tissues resurfaced with an epithelial covering by one method or another to prevent contractural deformity. More to illustrate principles than to attempt a complete discussion of this subject, situations in which epithelial resurfacing is required will be outlined briefly as well as the methods used.

On the face, following a burn or the removal of some lesion, distortion of tissue often accompanies the healing by scar of the granulating base. Over situations like the eyelids and the lips, quite marked ectropion or distortion of other types may result. Usually an alleviation of the eyelid ectropion is best obtained by the use of skin grafts of moderate thickness laid into the raw surface resulting after excision of the distorting scar (Fig. 300). To hold the graft in contact with the raw surface a modeling composition form is used and, after placing the graft about the form, the form is sewed into the raw gutter. This is termed a "stent graft." About the lip the same principle is applicable but the cosmetic result at least is better when a full-thickness skin graft is used about the stent. The contraction of the full-thickness skin graft is somewhat less than in the case of the thinner graft. Generally, in the use of both of these grafts, it is well to overcorrect the contracture as such grafts in these situations may contract from one third to one half. Elsewhere on the face and neck, the best correction, both from a function and a cosmetic standpoint after excision of large scars, is obtained by the use of a large full-thickness skin graft applied immediately to the flat surface. This is usually true on the forehead and especially so on the cheek or neck. On the forehead the anatomy of the region prevents the skin graft from contracting to as great an extent as on the neck, for instance. On the neck the contraction of a full-thickness skin graft may be as much as 50 per cent. This tendency to contraction

is taken into consideration when the graft is sewed in place and if possible by turning the skin edge back, a larger graft is obtained than would seem at first necessary. Later, the edges are trimmed.

The Resurfacing of the Underlying Tissue after the Removal of Congenital Surface Lesion.—There are several different superficial lesions, such as hairy moles and large capillary hemangiomas, which can be removed and a good cosmetic repair given after excision by the application of the proper type of skin graft. In the case of the hemangiomas, indications for removal are usually found in the adolescent or the adult. Capillary hemangiomas, at least in children, can be improved by the application of radium and also by cauterizing agents such as carbon dioxide snow. The principal necessity is to cause sufficient reaction within the capillaries to cause thrombosis and eventually obliteration of the capillaries. Children are more susceptible to this reaction than adults. Consequently, excision is reserved for those lesions which will not respond to radiation and to those in adults which would appear unlikely to obtain a satisfactory cosmetic result by any method other than total excision. The exception to the preceding is these lesions which are so small or so situated that excision and suturing without grafting can be done even in children to better advantage so far as final esthetic result is concerned. The graft which is used principally after such wide excision as about one fourth to one half of the face is the full-thickness skin graft (Fig. 301). When the take is good, the appearance resembles very closely that of the normal skin. With the proper technic the chances of losing the graft are slight. On the cases in which we have tried this method the results have been satisfactory although a second operation was necessary for the purpose of excising the scar between the graft and the normal skin.

Another type of case in which the question of resurfacing comes up is certain burns which leave such a deformity that the necessity for covering whole or half of the face with new skin becomes of vital importance. In a few such individuals we have undertaken to cover about one half to two thirds of the face with a full-thickness skin graft.

Resurfacing of the Underlying Tissue after the Removal of Diseased Skin and Subcutaneous Tissue.—In certain superficial localized diseases of the skin and the immediate subcutaneous tissues in which the chances of cure are not good or, if cure is possible, the cosmetic result will probably not be satisfactory, excision and resurfacing by skin grafts may be carried out as outlined in the preceding paragraph. A basal-cell carcinoma, lupus erythematosus, or an ulcer following a roentgen-ray burn occur to us offhand as lesions falling in this category at times.

The indication in excising an ulcer following a roentgen-ray or radium burn is to get around all the tissues harmed by the endarteritis which results, if such is possible. Where the thickness of tissue excised is considerable or else a good wearing surface is essential, it may be best to select a skin flap instead of a skin graft. A thin skin graft is even more likely to break down than the full-thickness graft, even after taking if the blood supply beneath the graft is too seriously denuded by the endarteritis. When the blood supply of the tissue beneath the graft is not good one runs the risk of a failure of the graft to take.

Resurfacing a Contracture Within the Mouth.—Within the mouth, after an injury or an operative procedure where mucosa is destroyed, the cheek, lip or tongue may be bound and fixed to the bony structures. By cross cutting the binding scar and placing a skin graft of moderate thickness about a stent modeling compound, fit to the gutter wound, in practically all cases the skin graft takes and contracture can be corrected (Fig. 331). The stent has to be fixed in place with sutures for from four to six days. In a like manner, stenotic contractures of the nasopharynx or the nostril may be corrected. This procedure properly carried out is one of the most satisfactory in corrective surgery. Grafts of moderate thickness take practically always in the unclean mouth if the raw surface is new and proper fixation and pressure is gained when the stent is fixed.

THREE-DIMENSIONAL REPAIR BY SUBSTITUTION OF SOFT TISSUES

In some situations where loss of contour has resulted from loss of deeper tissue as well as the more or less superficial tissues, a pedicled flap includ-

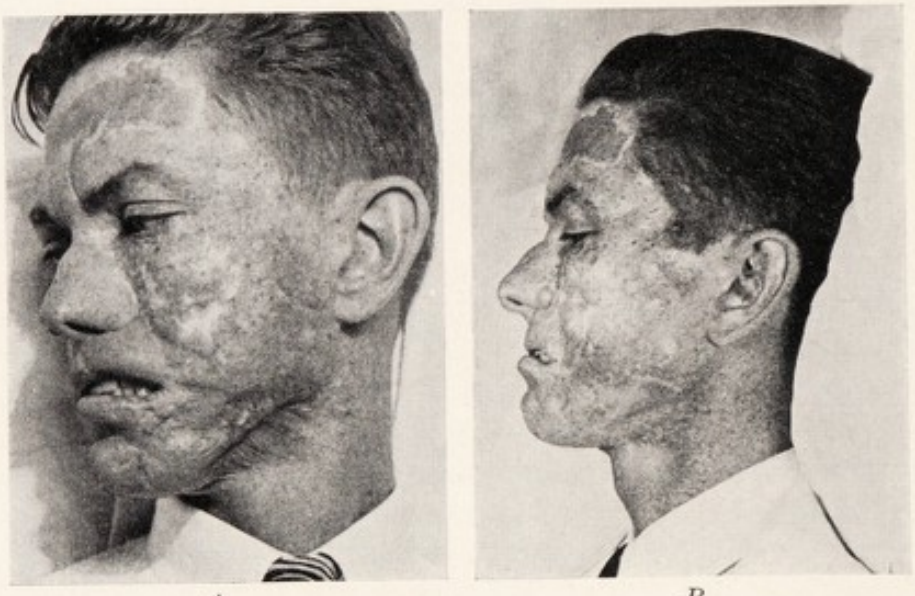

A *B*

Fig. 304.—Correction of a three-dimensional defect of the cheek by a pedicled flap taken from the neck. *A*, Before operation. *B*, After operation.

ing skin and subcutaneous tissue of varying proportion may give the best functional and cosmetic result (Fig. 304).

This type of flap requires an adequate blood supply flowing into its base when it is transferred to its new situation. Consequently, as a rule, a flap of the required size in a suitable location is outlined, or tubed from ten days to several weeks before transfer, to the final location. About three days to one week before transfer is contemplated the blood supply of the flap is tested by severance of the flap at its distal end and resuturing the end in place. In this manner the exact amount of the flap supplied by sufficient blood is definitely determined. Pedicled flaps may be undertaken in the presence of mild infections so that a clean field is not absolutely necessary for the repair of a defect. If the margins of the defect are acutely inflamed, the inflammation should be allowed to subside and healthy granulating surface should be present before an attempt is made to throw the

flap into position. Very often, following wounds both operative and traumatic, the quicker the wound is repaired, the better. Months may be saved sometimes by repairing the wound in the presence of healing granulations and not waiting until the surface is entirely epithelialized. It goes without saying that all dead bone should be removed and all exposed bone should be covered with healthy granulations. When bone is uncovered it is best to allow it to separate spontaneously. In from two to three months this will have happened. There should be no pus pockets of any type. In the case of the removal of a tumor by cautery, for instance, all slough including dead bone, if present, should be allowed to separate and a clean granulating surface should be present before repair is advised. In the case of deformity from disease such as syphilis, the patient should be thoroughly treated before any repair is undertaken.

Ordinarily when flaps are used they should be larger than at first thought would seem necessary, because in transference, especially if the transfer is delayed for any reason, they show a marked tendency to atrophy. Usually, it is best, therefore, at the time of outlining, to make them at least one quarter larger than measurement would show to be necessary. One must remember in repairing defects of the lips and cheeks that an internal lining is just as important as an external covering. A raw surface left within the vestibule is certain subsequently to cause contraction.

Motor nerves should not be endangered. For instance, motor nerves of the orbicularis palpebrum muscle should not be endangered or the eye will not close. When there has been considerable reconstruction of the side of the face, the nerve supply of the buccinator and the orbicularis oris are not so important, for after the reconstruction of the cheek and the lip they are somewhat stiff with scar tissue and the opposite side of the face does not draw the reconstructed side of the face aside as in a typical seventh-nerve paralysis. It is certain that the nerve supply of the upper part of the orbicularis oris and the muscles that raise the lips and control the nostril run deep to the zygomatic and levator anguli oris muscles so that a superficial flap can be raised from the area between the orbit and the mouth without cutting the motor supply of these muscles. In sliding flaps made from the face tissue, it is important to undermine freely but the undermining should be done superficially if possible to the muscles of expression.

For filling in large defects of the cheek or the side of the face including the lip, flaps may be transferred from the forehead, the scalp, the neck, the arm, or even a jump flap, as is thought most appropriate.

Consideration must be given to the amount of skin lining necessary, the amount of skin covering, when contour is a factor the thickness of the subcutaneous tissue, and when used externally on the face whether or not the texture and the color of the transferred skin are appropriate. Skin with hair on it should not be tranplanted to the inside of the mouth. On a man sometimes it is better to transplant skin containing hair follicles of the scalp in it so that it more closely resembles his beard. From the standpoint of operative comfort, flaps from the forehead, scalp or neck have much in their favor. The punishment entailed in the transference of an arm flap is considerable. The patient must lie with his head and arm in a plaster cast for about two weeks. When the patient is a good risk and does not want scars on the forehead, scalp or neck, the arm flap may offer advantages

that are not obtained by the other methods. The jump flap has the disadvantage of being a slower method and entailing a greater number of operations.

Ordinarily in obtaining long flaps from the neck, the platysma myoides muscle should be included. In a well-nourished adult, flaps 5 cm. in width with the base at the angle of the lower jaw can be made to include the tissue down to several centimeters below the clavicle. However, the distal end should not be severed until a week or ten days have elapsed since the primary elevation of the flap. After undermining the platysma on both sides of the defect usually the remaining skin can be brought together with sutures.

THE USE OF HARD TISSUE TO SUPPLEMENT SOFT TISSUE WHERE THREE-DIMENSIONAL REPAIR IS NEEDED

Cartilage Grafts.—Cartilage unlike bone can be trimmed and cut to any size or shape with a knife while, at the same time, it is sufficiently resistant to take the place of bony tissue in situations not requiring length

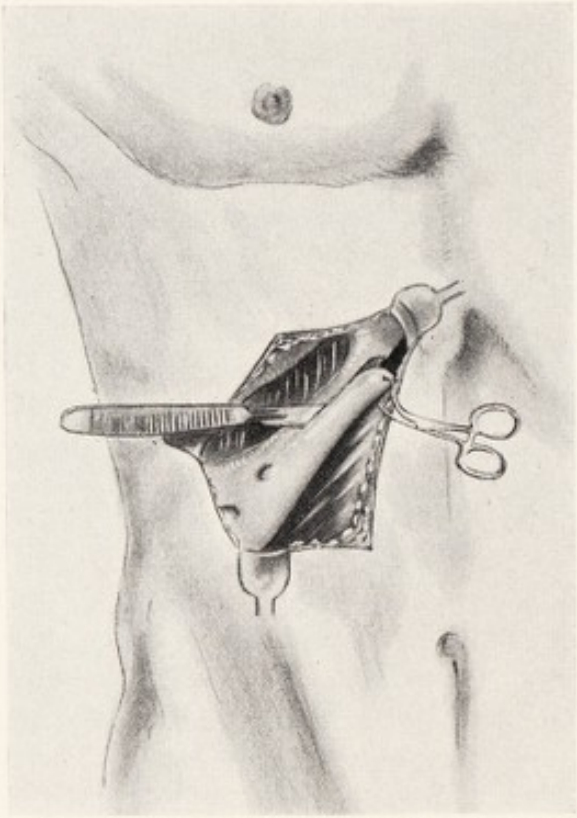

Fig. 305.—Incision and exposure for the removal of a piece of cartilage from the eighth costal cartilage. One selects the cartilage according to the shape that may be needed. Sometimes the ninth costal cartilage is used. If one is not going to remove a large piece of cartilage, an oblique incision may be advantageous in the direction of the nerves which supply the muscles of the abdominal wall. Such an incision will prevent one from injuring the nerves.

and strength. Cartilage does not unite to bone but readily becomes attached to the surrounding soft tissues. As resorption does not occur, the original size is maintained. Costal cartilage is available for use and if one studies the anatomy of the region of the seventh to tenth costal cartilages, quite a variety of shapes are offered or may be cut to pattern.

Thin layers of cartilage may be obtained from the ear through a posterior incision. In the building of a nose practically always besides the use of a flap for a lining and a covering it is necessary to use cartilage to give contour and hold the shape of the tissue near to that of a normal nose. When the supra-orbital region or the infra-orbital prominence is destroyed by injury or infection, a good permanent imitation of the original can be constructed by implanting cartilage cut to a proper form beneath the skin. Forehead depressions, receding chins, and lack of prominence at the alar bases may all be satisfactorily corrected by this method. Cartilage can be easily carved and shaped with a knife. The soft tissues grow to the cartilage and fix it permanently. There is little likelihood of a blow damaging it.

Technic of Cartilage Transplantation.—Usually the cartilage is removed from the right side of the eighth to tenth costal cartilages (Fig. 305). The cartilage most appropriate in shape is selected. In the past we have left as much perichondrium about the cartilage as possible and thought that the likelihood of a take was increased thereby. Many men, however, say that this is not only unnecessary but undesirable. They argue that cartilage has no blood supply anyway but that the perichondrium has, so that a take is more likely if one removes the perichondrium. This may be true. It is certainly easier to cut and mold the cartilage to the desired form if the perichondrium is removed. In our last few cases the perichondrium has been removed. No disadvantage has so far been noted.

The chest wound is closed as one would close an abdominal wound, in layers without drainage unless the dead space left behind is considerable or hemostasis imperfect. The depression or space is undermined with scissors or a knife through as small an incision as possible. Whenever possible, the incision is so placed that the implanted cartilage does not fall directly under it. After the skin and immediate subcutaneous tissue have been undermined sufficiently, the cartilage graft is inserted into its prepared bed. During all steps of the operation the utmost attention is paid to asepsis. Whenever possible, it is best to use a no hand touch technic. After the cartilage is transplanted in its bed, the wound is closed in layers with silk. One should attempt not to have a suture directly in contact with the cartilage. To prevent the accumulation of serum or a blood clot, after squeezing all of the fluid from around the cartilage, a damp gauze pressure dressing is applied for the first twenty-four hours at least. With good technic one is certain in over 95 per cent of the cases of the graft growing into its new bed without trouble. All is not lost if there is some infection about the graft. In several cases we have been able to save most of the cartilage even after a low-grade infection occurred. Some years ago when infection occurred, we removed the cartilage immediately. Now we provide drainage by a stab wound and within four or five weeks the wound heals usually without much liquefaction of the graft.

THE REPAIR OF DEFECTS IN SPECIFIC LOCATIONS BY THE TRANSPLANTATION OF PEDICLED FLAPS OF SOFT TISSUE ALONE

Unless a sufficient amount of bone has been lost so that new bone is required for the purpose of structural strength or skin resurfacing only is required, the majority of defects about the face, mouth and jaws are corrected by the transplantation of pedicled flaps of soft tissue. Possibly,

some more general discussion concerning certain regional restorations by this means is pertinent.

Flaps from the Forehead and Scalp.—For filling in large defects of the cheek, Horsley described the transplantation of a flap supplied by the anterior temporal artery (Fig. 303). We have never used this method, preferring to use a pedicled flap with its base anterior to the upper part of the ear. Before transplanting the flap in this situation, it is less hazardous to outline the flap and sew it back in its bed. When the flap is thrown down to the side of the face or chin its bed may be covered with a skin graft. The full-thickness skin graft is very satisfactory as it takes unusually well over the forehead. A scalp flap to cover a surface needing hair may sometimes be thrown down with a double pedicle—especially if the flap is a rather narrow one as for rebuilding eyebrows. In our experience a full-thickness skin graft from the scalp gives the best eyebrows and

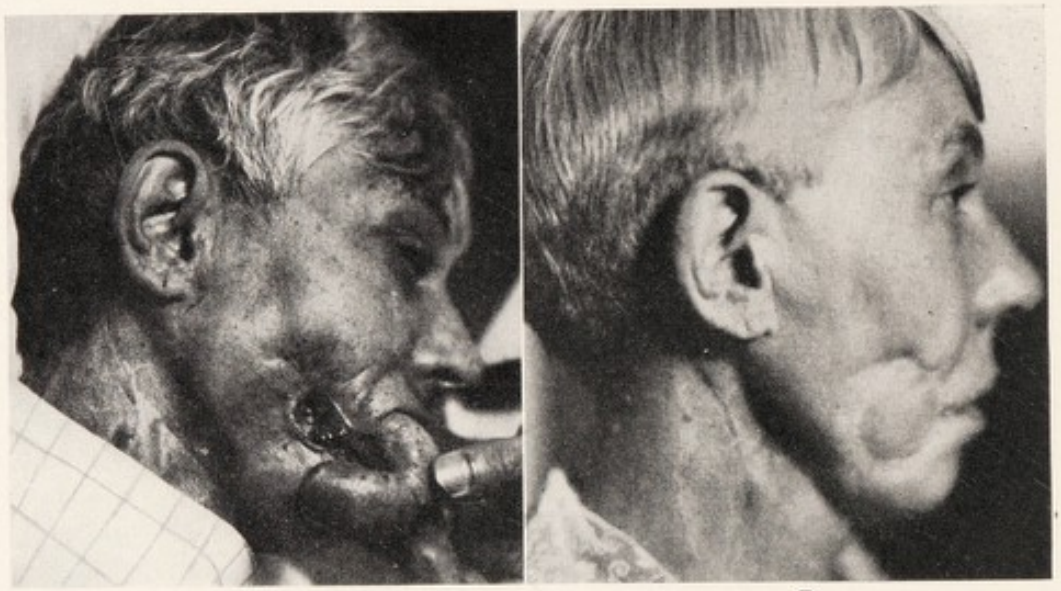

A *B*

Fig. 306.—*A*, Patient in whom a tubed flap from the arm was turned in first to make the internal lining of the cheek. This photograph shows the patient after the flap has been tubed and removed from the arm. The butt end of the flap was used for the outer part of the cheek. *B*, Final result.

the operative procedure has the advantage of comprising only one operation. On the cheek if a lining is needed, the distal end of the flap is thrown into the inside of the cheek first. Later, the flap is doubled on itself and the proximal end used for a covering (Fig. 306). This restores the epithelial lining of the cheek as well as the covering and allows the patient to open his mouth. When a scalp flap is used for a covering for the chin (Fig. 259) and lower lip, an internal lining not bearing hair should have previously been prepared on the neck.

Flaps from the Neck.—Often when a flap is obtained from the neck its blood supply is prepared by tubing the flap as described by Gillies (Fig. 302, *A*). However, the delayed method described by Blair for the forehead flap may in some cases be just as efficient. In raising these flaps the platysma muscle is taken with the flap. After undermining the platysma on both sides of the defect, unless too much fat is encountered, the remaining skin can be brought together with sutures so as to leave only a linear scar.

This scar may become a little thick and corded or it may widen and stretch making it necessary after the tissue becomes adjusted to re-excise the scar and resuture the skin edges or even to transplant a skin graft to cover the area as seems advisable for the particular case in hand. The neck flap may be extended in a downward direction so that it really becomes a shoulder, a chest or a back flap. The amount of extension depends upon the width and also the thickness of the flap needed to correct the deformity. The pedicle has to be as wide as the distal end of the flap to carry sufficient blood supply. When wide flaps are used, it will not be found feasible to draw the skin edges together. A skin graft then will be needed to cover the denuded surface. Neck flaps in men especially may be quite satisfactorily used to repair a cheek, lip, or the alae of the nose.

Flaps from the Arm.—When a flap is removed from the arm to rebuild a face it is usually tubed ten days to two weeks before it is transferred to the area (cheek, lip, face, nose, etc.) that one is reconstructing. On the arm it is impossible to approximate the skin edges beneath the tubed flap so that ordinarily either a full-thickness skin graft or a split skin graft is used to cover the defect over the biceps muscle. It is safer to sever completely the distal end of the flap and sew it back in place about three or four days before one intends to transfer the flap. This procedure prevents throwing the flap to its new field and getting a slough of the last ½ inch or so of its distal end. After the flap is transferred the arm is held to the head by a plaster cast applied snugly about each end and united. The advantage of an arm flap is that a forehead or neck scar is prevented (Figs. 191, *A, B, C;* 192, *A*). The disadvantage is the discomfort of wearing the arm in a fixed position for about two weeks. When the procedure is carried out with ease and sedatives are given as needed, patients often do not complain a great deal and many prefer the method because of saving an additional scar of the face.

Restoration of Whole Thickness of the Cheek.—There are two common methods of restoring the whole thickness of the cheek. The first is as follows: the transference of either a forehead flap which is later reversed upon itself or a neck flap, or an arm flap used in a similar manner. The second is the transference of two flaps from different areas, one for the lining and one for the covering. For large defects the latter method is usually preferable. Although the operation may be larger, a smaller number are necessary with the latter procedure.

Restoration of One Third of the Lip.—When not over one third of the lip is removed, either the lower or the upper, the easiest and the best method to use in restoration is the transference of a triangular full-thickness flap of the opposite lip into the defect. The operation is described under cheiloplasty after excision of a malignant lesion of the lip (Fig. 255).

Restoration of Two Thirds of the Lower Lip by Triangular Flaps From the Cheek and Upper Lip.—When not more than two thirds of the central part of the lower lip has to be removed or is lost, in one operation a satisfactory new lower lip can be built by moving ¼ to ½ inch of the remaining lip on either outer side of the defect to the midline. The full thickness of the lip is used so that sufficient mucosa is obtained as well as skin. The operation is described under cheiloplasty after excision of a malignant lesion of the lip (Fig. 257).

Restoration of Complete Lower Lip.—When the lower lip is completely lost, it is usually necessary to rebuild the lip from two flaps—one from the neck for the lining and, in a man, one from the scalp for the covering. In a woman the forehead is probably better. She can cover the forehead defect with her hair. The operation is described under cheiloplasty after excision of a malignant lesion of the lip (Fig. 259).

Restoration of Angle of the Mouth.—When the angle of the mouth is raised or lowered a triangular piece of the lip can be thrown to the short side from the opposite long or lower side as the case may be. Serres originally described this trick (Fig. 307). By this method the angle of the mouth can be raised or lowered. The full thickness of the cheek is used or not used, depending upon whether or not the mucosa is deficient on the inside. The principle is the same inside or outside the mouth. It is a "robbing of Peter to pay Paul" trick.

Restoration of the Upper Lip.—When more than one third of the upper lip needs restoration, it can usually best be repaired by transplanting a flap from the neck or the arm. Lining and covering must both be built in and a vermilion border, if possible, for the lower edge of the lip. Usually a

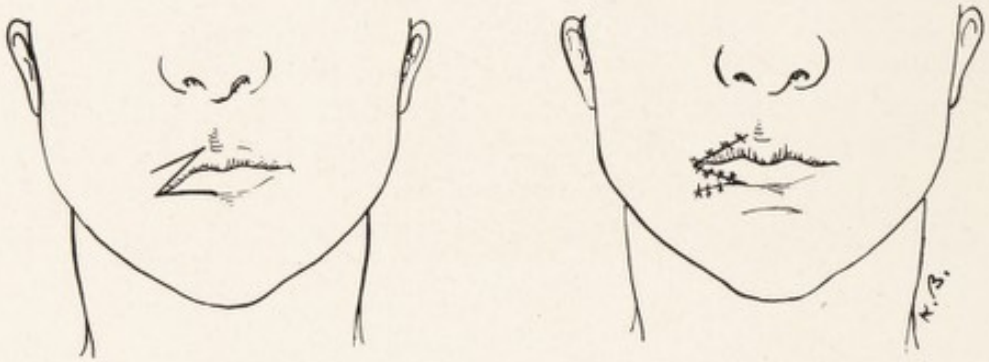

Fig. 307.—Raising the lower corner of the mouth. This method may be used for either the upper or the lower lip. (Serres.)

mucosal flap can be obtained from one cheek or the other or both, which will allow this restoration. When not more than one third is missing, a triangular flap from the lower lip gives the best restoration.

DEFORMITY REQUIRING STRUCTURAL STRENGTH

When a part of the mandible has been removed and repair is attempted, structural strength is the main object, as a rule. This requires a bone graft which will unite with the remainder of the mandible. When properly performed a free bone graft to the jaw will eventually fulfil this condition. The bone graft must be autogenous. The periosteum is probably the key to bone regeneration. The graft itself is probably replaced eventually and it is the laying down of new bone which gives a new bone structural strength. The rib, the tibia, scapula, clavicle, or crest of the ilium has been used as a site for obtaining the bone. In a consideration of the bone to use it is necessary to have in mind the shape of the part of the bone one wishes to replace. With the angle of a rib or the crest of the ilium, the contour of the angle of the jaw may be fairly closely reproduced. Sufficient soft tissue to surround the bone graft adequately inside the mouth is necessary. Often it will be found advisable to transplant a skin flap from the neck or elsewhere within the mouth for this purpose prior to the transplantation of the graft. Before the graft is transplanted, adequate time must elapse for

healing to be complete, as a sterile field is an absolute necessity if the graft is to heal by first intention.

Methods of Bone Grafting.—*Pedicled Graft from the Mandible Itself.*—Cole in 1917 first described a method of using a pedicled graft from the mandible itself (Fig. 308). Ollier originally suggested the method. Cavalié and Esser used the method at almost the same time. A semilunar flap consisting of skin only is raised. The anterior and posterior fragments are exposed. The end of the posterior fragment is freshened. A horizontal incision is then made through the soft parts which clothe the outer side of the anterior fragment at a level immediately below the buccal sulcus. The basal margin of this portion of the jaw was then cut lengthwise with a circular saw. Lateral incisions through the platysma and deep fascia



A *B* *C*

Fig. 308.—*A,* Gunshot wound of the mental region which blew away the mental part of the mandible but a fair amount of the tissues of the lower lip and chin remained. In this case a sliding bone graft from the longer side of the mandible was used to throw a piece of bone across the mental region. Roentgenogram shows long side of the mandible from which the sliding bone was taken. The lower edge of the mandible was used and the skin of the cheek was left attached to it. Dotted line shows the line of section of the mandible in the long side of the jaw. *B,* Lower edge of the mandible over the short side (opposite side to the preceding) after the lower edge of the long side of the mandible was slipped over to the short side and wired in place. The patient obtained good union of the mandible. Later a cartilage graft along the lower edge of the jaw from which the sliding bone graft was cut was used to fill in the contoural defect. *C,* Final result. Defect on short side filled in. The lower lip is a little tight. Front view was nearly normal.

are made to define the pedicle. The pedicle is then freed from the underlying structures. The anterior and posterior fragments are drilled for the passage of fine wire or fascia. The soft parts are then closed. This pedicled graft is satisfactory in cases of loss up to 3 cm. in the body or symphysis of the mandible. When the loss of substance is considerable, the amount of displacement of the soft tissues is apt to cause disfigurement or functional disability due to restriction of the movements of the tongue and floor of the mouth. It has the advantage of furnishing a piece of bone without its blood supply being totally cut off. The pedicled graft is not so likely to be lost if some infection supervenes.

In the report of the maxillofacial work done in the United States during the late World War, of 103 bone grafts 31 were done by this method with 27 (97 per cent) successes.

A sliding bone graft was used in 1 case by us (Fig. 308, *C*). The defect followed a gunshot wound. The bony defect was about 2½ inches in length at the submental region on the left side. From the long side, bone and its attached soft tissue was slid forward to bridge the gap. Later, after union, the soft tissues were moved back to their natural position. Cartilage was used to fill out the depression left over the area from which the sliding graft was removed.

Combination Flap from the Clavicular Region.—A combined bone and soft tissue graft from the clavicle and its surrounding region was used in 2 cases by us. The whole chin had been blown off by gunshot (Figs. 18, 309 and 310).

Technic.—The neck flap is extended to 10 cm. below the clavicle and in turning up the flap one half of the thickness of the clavicle with its

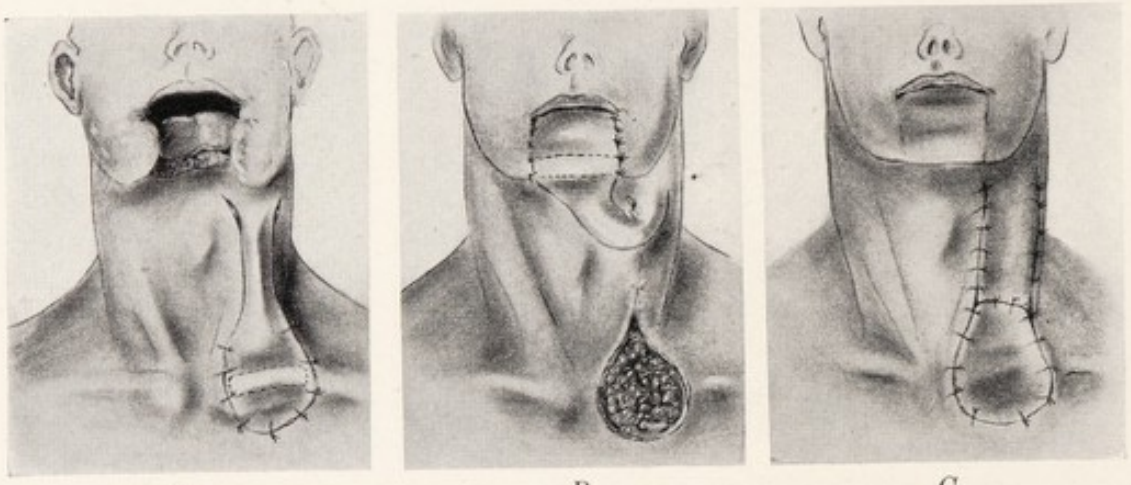

A *B* *C*

Fig. 309.—*A*, Flap from the clavicle has been outlined and the clavicle has been split longitudinally so that one half of the clavicle lies in the flap. The flap has been tubed and the skin of the neck thrown in beneath. The lower end of the flap has been sewed back in place as a delayed flap. *B*, After about two weeks the flap including the bony segment of the clavicle is thrown up into the defect in the chin and the distal end of the flap is used to throw back beneath the tongue to reline the inside of the lower lip. *C*, After about three weeks the pedicle of the flap is cut and sewed back into place. The pedicle of the tubed flap is laid back onto the neck and the granulating area is covered with a Thiersch graft.

periosteum is included (Fig. 309). A hog saw or surgical engine is used to cut the bone. The skin of the flap is turned and surrounds the bone. The skin of the flap is turned and surrounds the bone. Later the flap with the contained bone is thrown into the defect. The ends of the skin flap are opened and the bone fragment is attached to the free ends of the mandibular bone. The soft tissues are arranged so as to repair the chin and lip or cheek as the case may be. The same principle as this may be used in another way. The proper length of bone taken from elsewhere may be placed beneath a neck skin flap and allowed to heal in place. Then three or four weeks later the flap is thrown up to the jaw with its implanted bone fragment. The location in the neck into which the bone fragment is planted and the flap itself should be so planned that when finally put into its final destination the rib segment falls naturally into its new position and gives the proper contour if possible. This method can be used to bridge a large

defect and, in the case of a rib, it can be half cross cut, semibroken, and curved to imitate the shape of the anterior mandible.

Neither the sliding bone transplant nor the combination bone and soft tissue transplant need absolute asepsis for success. Otherwise the procedure could not be carried out. In most instances fine silver wire is used for fixation at the end of the fragments but if possible it is best to eliminate a foreign-body-like wire where one wishes early bony union. In some cases a circumferential wire about the transplant attached to the upper jaw can be used successfully for fixation. Avenues for drainage must be provided. Dressings should be repeated often and the head bandage must lend all the aid to fixation it is possible to get.

Osteoperiosteal Method of Delagénière.—Delagénière turned a semilunar flap upward. The gap was exposed and the ends of the fragments were



A *B*

Fig. 310.—*A,* Pedicled flap after its removal from its bed in which was embedded one half of the clavicle. This was used to throw up and rebuild the anterior part of the jaw which had been shot off. *B,* Patient after the lower lip and jaw were rebuilt. This picture was taken before the vermilion border was brought over the top of the lower lip by using a cheek flap.

freshened and a pocket prepared around the end of each fragment by stripping about 1 cm. of periosteum from the end of the fragment. Extreme care was taken not to enter the buccal cavity. The anterior surface of the tibia was then exposed. With a broad chisel periosteum and bone were raised having a thickness of 1 to 2 mm. The graft was cut into two or three pieces as desired. One piece was inserted with its end in the pockets beneath the ends of the mandibular fragments with the bony side of the graft toward the mandibular fragments. Another piece of graft was inserted in a similar manner over the fragments. The soft tissues were then sutured over the graft. The osteoperiosteal method furnished a flexible graft suitable for loss of substance of considerable extent. Theoretically, all the elements necessary for osteogenesis were present.

In cases of large loss of substance with visible deformity, this graft does not fulfil the immediate cosmetic requirements. A considerable length

of time is required for complete consolidation. Of 38 patients operated by this method in the United States Army, 27 (71 per cent) were successful. Three were partially successful and 8 were failures.

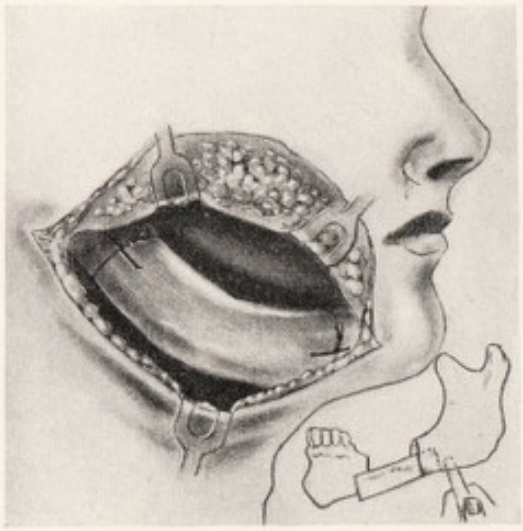

A

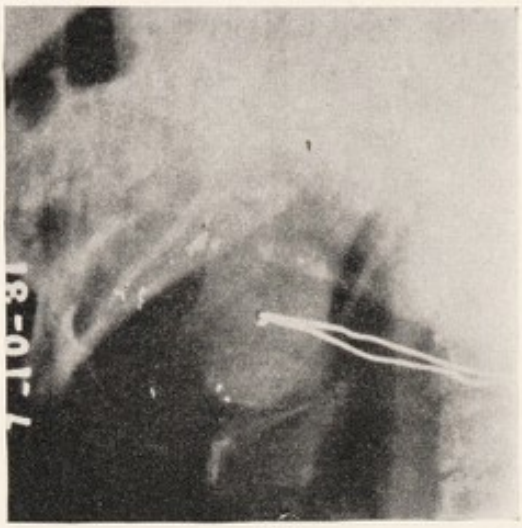

B



C



D

Fig. 311.—*A*, Inserting a bone graft in a fairly large defect of the mandible. This bone graft may either be cut from the rib, crest of the ilium or tibia. In this case a rib would probably be preferable. The insert in the lower right hand corner shows Gallie and Robertson's method of longitudinally sectioning the two fragments so a bone graft be inserted as a wedge between the two fragments. *B*, Bony defect. The ramus of the jaw had been pulled upward and forward. Therefore a hole had been drilled in the bone and a wire had been placed through the hole to pull the ramus backward. For method of gaining fixation, see Chapter X, Methods of Fixation for Fracture of the Lower Jaw. *C*, Piece of the seventh rib in the defect. *D*, Patient's appearance after the bone graft had become firm and solid. Prior to the placing of the bone graft we had prepared an adequate internal and external lining so there would be no difficulty in getting a good, soft tissue bed for the bone graft. This photograph shows external lining which was laid in from a flap from the neck. The internal lining was made from a flap turned up from the neck.

Free Graft from Cortex of Tibia, Rib or Ilium.—The ends of the mandibular fragments are exposed and prepared as described in the osteo-periosteal method with the addition that holes for the passage of some suture

material such as silver wire, kangaroo tendon, or fascia are made in the end of each fragment.

Gallie and Robertson devised a method of slitting the mandibular fragments lengthwise with a whirling saw and then wedging the bone graft into each of the V-shaped cuts made in each fragment (Fig. 311, *A*, lower right). After fixation of the ends of the grafts to their respective fragment the soft tissues are carefully stitched about the graft and the wound is closed with drainage. A marine sponge pressure dressing tends to prevent the accumulation of serum about the graft and renders the chances of infection less. When some infection does occur not always is all lost. If it is localized one may lose only a part of the graft by sequestration of a thin layer so that the result will still be satisfactory.

In many patients some difficulty may be encountered in obtaining sufficient exposure to prepare the fragments and to obtain a proper soft tissue covering for the graft. Broad bony contact is necessary between the graft and the freshened mandibular fragments. When the bony loss is only moderate and entire dependence cannot be placed on interdental splints for fixation, the cortical graft has the greatest field of usefulness.

The crest of the ilium furnishes a large thick porous piece of bone. The shape is such that the angle of the ramus and part of the body of the jaw can be closely imitated in shape. It is easily penetrated by new blood vessels. Gillies considered this the method of choice at Queens Hospital, Sidcup, England. It can be used for losses of substance of any size and is especially adapted for cases in which considerable rigidity is desired.

Generally the seventh rib is selected as the rib to be used and the periosteum is removed along with the bone. The rib is also porous and it can be made to conform to the natural contour of the jaw by producing a greenstick fracture of the graft after sawing the graft on one side.

In the United States Army as during the World War, 7 iliac grafts were used and 5 (71 per cent) were successful. One was partially successful. Seventeen patients were grafted by tibial bone. Twelve (70.6 per cent) of these were successful and 1 partially so. Six patients were grafted with rib and all were successful. In all, 103 grafts were done, and 78 (75 per cent) were successful and partial success was obtained in 8 (7.7 per cent). One case came under observation who had had a beef-bone graft. No union was present and extensive absorption was taking place.

After bone grafting, the splint has to be kept in place for a period of from three to six months. Sometimes after a month the splint may be unlocked at intervals to permit gentle exercise or to stimulate the growth of bone. Follow-up radiographs should be made once a month. After complete consolidation, the lost teeth may be replaced by prosthesis.

I have successfully used a graft from the ilium in 3 cases where the ramus, the angle and a part of the body of the mandible had been removed. In 2 of the cases the jaw was removed on account of a neoplastic process and in 1 an osteomyelitis caused a sequestration. In another patient about 4 inches of the body of the mandible was lost on account of a gunshot wound (Fig. 311). A section of rib gave a successful result.

DEFECT OF THE UPPER JAW

Defects due to loss of a part or all of the upper jaw which are large enough to cause deformities of contour are usually best corrected by adding

sufficient skin lining either by the use of a stent graft or by the use of a pedicled flap to give a space so that a prosthesis can be fitted into the defect in such a manner that the soft tissues are pushed outward to restore contour. In the prosthesis are fitted teeth to complete the restoration.

Old crushing injuries which have destroyed the symmetry of the external part of the bone are best corrected by the insertion of a piece of cartilage of the proper size and shape. A modeling composition form of the cavity is made. From this model one may cut the cartilage to the proper size and shape.

RESTORATION OF THE NOSE

The deformities of the nose are very diverse. When one considers that accidents, operative wounds, infections of both the acute and chronic types, and congenital malformations all contribute their share of peculiar distortions and deformities, it is understood very readily that an adequate systematic discussion of the subject of external deformities of the nose is



A *B*

Fig. 312.—*A*, Complete perforation of dorsum of nose, profile view. *B*, Front view after operation.

probably beyond the realms originally outlined to be covered in this book. The subject belongs rather in a textbook on plastic or reconstructive surgery proper. However, to give one a glimpse of some of the more important types of defects that have to be repaired, one might briefly outline the two following types of deformity: (1) partial or complete destruction of the nose, and (2) deformities due to an exaggeration or limitation of growth in one part or other of the nose or about the nose. Under each large heading sort many subvarieties. Probably illustrative cases will more quickly and concisely elucidate the general broad problems encountered and give an idea of the approach to a correction in an easier manner to grasp than any other.

Partial or Complete Destruction of the Nose.—1. Case of Mrs. K. (Fig. 312). The essentials of this case are as follows. As the result of a gummatous ulceration of the nasal septum and nasal bones, a perforation resulted in the dorsum of the nose as seen in the photograph. To repair this hole an epithelial lining as well as a covering and some thickness were needed. A flap was outlined on the forehead. The soft tissues about the

hole in the dorsum of the nose were undermined and freed. The flap with skin surface inside was stitched in beneath the distal circumference of the defect in the dorsum of the nose. Two weeks' time was allowed for good union of the distal end of the flap to the nose. The proximal end of the flap was then severed and the flap was reversed on itself so that the skin surface was uppermost after the flap was doubled. After stitching the proximal end of the severed flap to the distal circumferential rim of the skin of the nose, it was allowed to heal for two weeks. After this interval the proximal circumferential rim of epithelium of the nose was loosened and, after the doubled flap had been pared and all edges denuded, the skin edges of the nose and the flap were sewed together.

2. Case of Mrs. M. (Fig. 313). When no thickness is needed or is a disadvantage a more graceful way of building a part of a nose is by relining the under surface of the forehead flap with a skin graft before the flap is turned down to reconstruct the absent part of the nose.



A *B*

Fig. 313.—*A*, Defect of the nose caused by cancer healed after irradiation. *B*, Nose after it was rebuilt. The under surface of the nose is lined with a split skin graft which was placed around a modeling composition stent at the time the flap was outlined on the forehead.

3. (*a*) Case of I. D. (Fig. 314). (*b*) Case of L. K. (Fig. 315).

When the greater part of the nose has been destroyed or is so deformed that the remaining tissues are largely useless, a whole nose may be built from either a forehead flap, which is probably the most advantageous, or from an arm flap when the forehead is too narrow or for other reasons such as the preference of the patient. Technically, the forehead flap is the easier to handle and the color and texture of the resulting nose is more nearly that of the face. A disadvantage is the scarred forehead. In women the hair can be used advantageously to cover the defect. A nose built from an arm flap is a little whiter than the surrounding face, and the texture of the skin is similar to that of the arm. One has more difficulty in forming the alae and in getting the nose thin enough not to interfere with breathing.

(*a*) This girl's nose was removed and allowed to heal by second intention. After careful measurements which allowed for lining, a new columella, and a covering, a flap was outlined on her forehead (Fig. 314). The distal

end of the flap was not completely severed until a week later. Twelve days after the original outlining of the flap it was turned down for the new

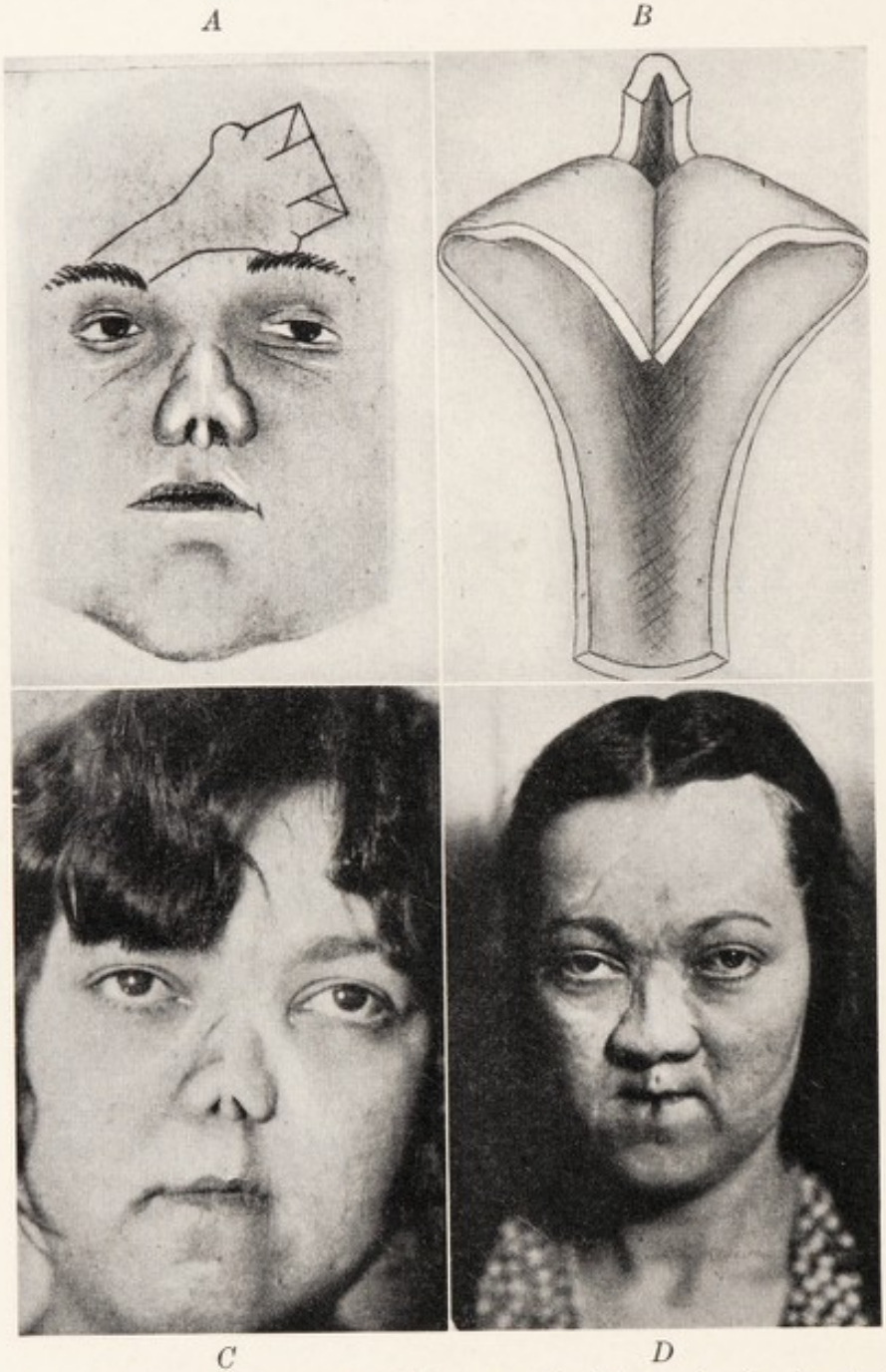

Fig. 314.—*A*, Outline of the flap which was raised from the forehead. The distal end was not cut until five days after the flap was elevated and the whole flap was not turned down until ten days after it was outlined. *B*, Showing how the distal ends were turned in to make a lining and columella. *C*, This girl shows the result of a congenital luetic infection. Note that the nose is depressed about the upper lip. This was corrected by putting a transverse cartilage in beneath the lip before the final repair of the nose. *D*, After nose has been rebuilt from a forehead flap and cartilage from the rib inserted into the newly built nose. Another piece of cartilage has been inserted beneath the upper lip to bring the upper lip forward along with the base of the nose.

nose and a full-thickness skin graft from the abdomen applied to the forehead. Later, after about three weeks, the pedicle of the flap making the nose was cut and the two severed ends of the flap were pared and rearranged

and placed in proper position. Four or five months later it seemed that a cartilage transplants would improve the appearance of the nose. A cartilage from the rib was transplanted. This procedure is described subsequently in this chapter.

(*b*) In this case the forehead was too narrow for use. An arm flap was used instead of a forehead flap. To provide a more adequate support to a tissue so very soft and pliable, a cartilage was laid in the distal end of the arm flap before it was transplanted to the nose. A full-thickness skin flap from the abdomen was used to cover the arm defect. The arm was held to the head for two weeks with a head-arm plaster case. The lining of the nose was formed from the proximal end of the arm flap after it was doubled on itself and inserted beneath the distal end of the original growth to the face to form the dorsal surface of the nose (Fig. 315).

When the columella is absent in our cases we use an arm flap for repair, as it is also necessary to gain some tissue beneath the upper lip to bring



A *B*

Fig. 315.—*A*, The flap grown to the face. *B*, The nose six weeks after the flap was reshaped. The scars as yet show up a little in the photograph but six months later they were considerably less.

it forward when the upper jaw is recessive. This can be done by growing the flap to the tip of the nose and then severing it from the arm and throwing the butt end of the flap, after splitting it, beneath the upper lip into the alveolar sulcus.

In another instance the major procedure was the building of a palate which had sloughed out. This was done from an arm flap. Then the butt end of the flap was turned up to build the new columella.

When the alae are absent a tubed flap from the neck has been used with satisfaction (Fig. 302, *A*) in several instances. But there is no reason why a forehead flap cannot be used for the same purpose.

Deformities of the Nose Due to an Exaggeration or Limitation of Growth.—When one excludes the various types of accidental deformities with scarring of the soft tissues, roughly one might divide these cases into about 6 types: (1) depressed bridge but without loss of soft tissues; (2) depressed bridge with loss of internal lining; (3) prominence of the bridge,

with or without too great length and with or without a bulbous tip; (4) a depressed tip, usually with a certain amount of recession of the upper part of the superior maxillae about the alae; (5) bulbous tip; (6) deformities of deviation of which those associated with harelip form a goodly number (they are described under the chapter on Harelip).

Depressed Bridge Without Loss of Soft Tissue.—Case 1.—M. U. (Fig. 316, *A*, *B*). As the nose was not shortened much and seemed to be deformed principally by a loss of the cartilaginous bridge, it was considered that a cartilage transplant of the proper size and shape should correct the deformity. The cartilage used was removed from the ninth rib which seemed to be of an appropriate length and shape. After cutting the cartilage down to the shape of a pattern previously fashioned from lead, an incision was made just within the left nostril. With curved scissors the soft tissues of the nose were undermined over the tip and over the bridge to a point between the inner canthi of the eyes. The cartilage was then inserted through the incision and the incision was closed by interrupted skin sutures.

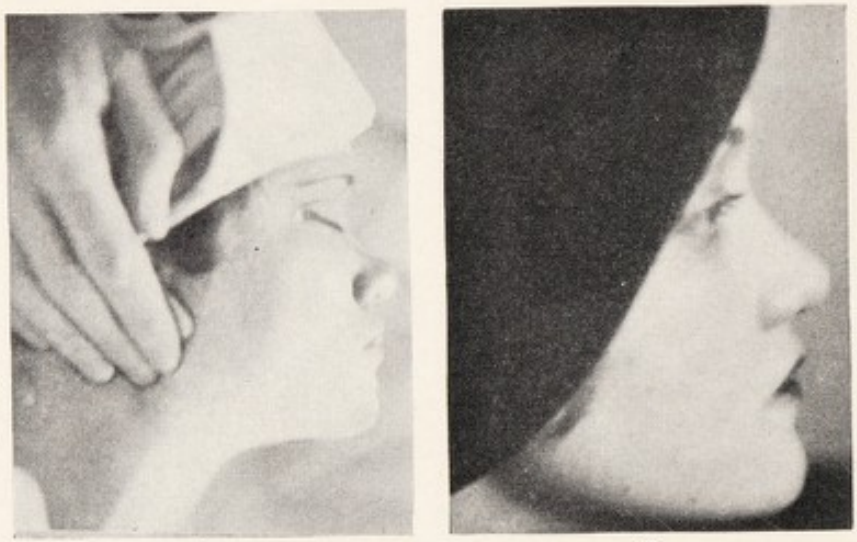

A *B*

Fig. 316.—*A*, Depressed bridge without loss of soft tissues. *B*, After transplantation of cartilage to nose.

When the tip of the nose needs little or no elevation, a cartilage of the type described in the previous paragraph is appropriate. But when the tip of the nose needs elevation, a cartilage cut so that a right angle may be formed is used. The cartilage is held at right angle by leaving perichondrium on one side and sewing the cartilage with silk across the angle. The incision in the nostril is extended downward along the side of the columella to the nostril base. In the short end of the right-angle cartilage is inserted into the columella and rests upon the maxillary prominence. The soft tissue of the columella should be sufficiently undermined so that space is given for the transplant. It is best to remove some of the columellar cartilage so that the new cartilage lies exactly in the midline and is not held to one side.

Depressed Bridge with Loss of Internal Lining and Shortening.—A simple cartilage transplant will not correct this type of deformity. One has to replace the lining originally destroyed so that the tip of the nose will be allowed to come down and sometimes the external lining is so in-

sufficient that some addition must be made to it. I have tried adding to the internal lining by bringing a flap of mucosa up from the cheek over the tip of the nose after turning back a skin flap with no great success. I be-



A *B*

Fig. 317.—*A*, Congenital luetic nose in which the internal lining as well as the external lining is deficient. *B*, Front view of nose after repair.

lieve the best procedure is to reline the nose by turning a flap down from the forehead. When the covering is deficient, it may be added to by using the tail end of the flap. The distal end of the forehead flap has to be split

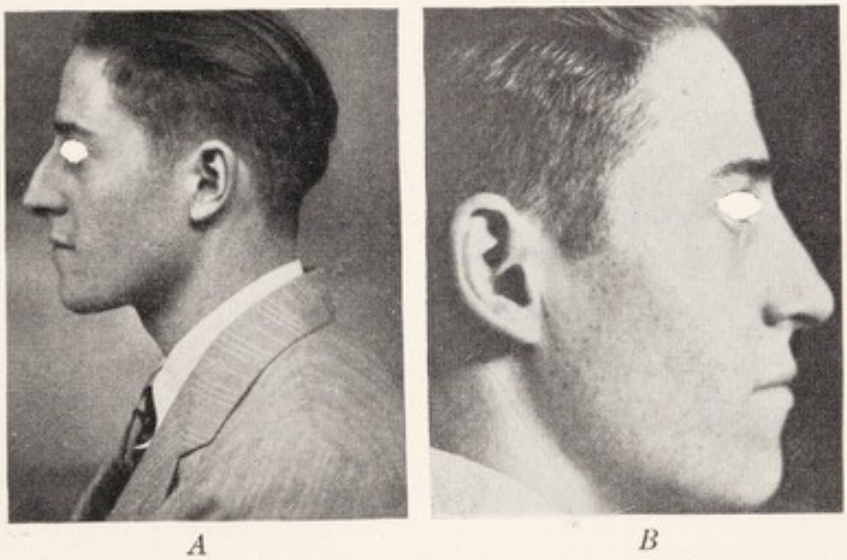

A *B*

Fig. 318.—*A*, "Humpback nose." *B*, One year after the hump was filed off the nose. If the hump is very large, when it is filed off the nose will be too wide and the skin between the mucous membrane and the bone will become blue. Therefore, unless the hump is very narrow, and not exceedingly prominent, Joseph's operation will give a better result.

and each end is cut in the shape of a triangle. First, all tissue layers of the nose are deliberately cross cut across the dorsum. The tip of the nose can then be pulled downward to a normal location. The triangular flaps are then turned with skin to the internal part of the nose and stitched in place.

Two weeks later the flap is reversed upon itself to form the covering of the nose. Two weeks later the end of the flap is shaped to its proper form and stitched to the soft tissue between the eyes (Fig. 317). The disadvantage of this procedure is the scarring necessitated. Therefore, if the deformity is not rather marked, the results will hardly justify the procedure.



A *B*

Fig. 319.—*A*, "Humpback" nose. *B*, Nose after it was corrected by Joseph's operation.

Prominence of the Bridge With or Without Too Great Length and With or Without a Bulbous Tip.—As the length of the nose and the width of the tip were not unsightly in the case of B (Fig. 318), the hump was simply removed with the nasal raspatory through an incision within the left nostril



A *B*

Fig. 320.—*A*, Bulbous tip of nose before operation. *B*, After operation.

after undermining as for a simple cartilage transplant. However, in Case X (Fig. 319) it was considered that the hump should be removed, the bridge narrowed, the nose shortened and the bulbous tip made smaller and narrower. All of this is done in one operation from within the nose (see Joseph's Operation). The hump is removed with a special saw. A V-shape

piece of cartilage is removed from the septum to shorten the nose and the lateral cartilages are removed so the tip is narrowed.

A Depressed Tip Usually with Some Recession of the Superior Maxilla about the Alae.—To correct a depression about the alae, one may lay a piece of cartilage cut to the proper shape and size on either side. This is done through a small incision at the juncture of the alae with the face. To elevate the tip of the nose, it is necessary to place at right angles a transplant of cartilage as previously described under the "depressed bridge" type of nose.

Bulbous Tip.—Case K. (Fig. 320). In this case an incision was made crosswise of the columella and just within the nostril on either side. The incision was extended upward and outward. The skin of the tip of the nose was separated from the cartilages of the nose and retracted upward and backward. An amount of each lateral cartilage sufficient to allow the skin to fall on a nonprojecting, nonbulbous scaffolding was excised on each side. The skin flap was replaced and carefully sutured.

Deformities of Deviation, of Which Those Associated with Harelip Form a Goodly Number.—In the chapter on Harelip is described the procedure for chiseling the nasal bones loose from the maxillary bone. A special type saw can be used also as used in Joseph's operation. The nasal bones are thoroughly loosened from the maxillary and the frontal bone is pushed to the midline and even overcorrected when the nose will not stay in the midline. Either a plaster head cast with a wire on it or a splint attached to the front teeth is used to maintain position.

RESTORATION OF A SEVERED SALIVARY DUCT

Because of an accident or operative interference an abnormal communication may result between the surface and a salivary gland or duct out of which saliva drips. External fistula of the parotid or submaxillary gland or duct may follow an opened abscess. Thus, ill-placed incisions, wounds and ulcerative processes (among which are noma and carcinoma) are the causative factors in producing salivary fistulae (Fig. 321). Ordinarily internal fistulae are of no surgical interest. Practically all salivary fistulae are of the parotid gland or its duct. Duphenix collected 70 Gm. of saliva from a patient in fifteen minutes. It has been estimated that about 1500 cc. of saliva are secreted by the submaxillary gland in twenty-four hours.

Diagnosis.—The diagnosis is usually evident. Saliva flows from the exit of the fistula in increased quantities during eating or when thinking of food, and the skin usually shows irritative signs where it is constantly kept moist with the secretion. If not infected, the discharge is clear. One should determine the cause of the fistula, and the exact site of the defect in the gland or duct. When the duct is at fault, the extent of the injury should be noted, and the exact distance between the external opening and the duct injury. When due to specific ulceration, this will need to be cured before any attempt is made to close a fistula. The condition of the distal end of the duct can usually be determined by placing a probe into the duct from the mouth side.

Treatment.—As to treatment, most of the fistulae close spontaneously unless the fistula is one involving the parotid duct, when closure may not take place. In gland fistulae if refreshening of the tract, followed by pres-

sure and restriction of the diet to nonappetizing unspiced foods, fails to gain closure, then the offending part should be excised after having located and freed the branches of the facial nerve.

A recent fistula to the duct if the distal end is still patent may be encouraged to heal spontaneously by such local procedures as freshening of the tract followed by firm pressure over the tract, particularly if the tract runs somewhat diagonally from the surface. In 1 case, we obtained closure in this fashion by bandaging very firmly a rubber button over the tract and its opening so that no saliva exuded for ten days. At the end of that time, the tract was closed and remained so permanently.

In a duct fistula where the external opening is situated in the buccal part of the duct near the anterior part of the masseter muscle, the external fistula may be converted into an internal one or, better, the proximal part of the duct when it is long enough may be implanted directly into the buccal mucous membrane. When the fistula is situated too far back, a tube of mucous membrane from the mouth can be turned backward and made to



Fig. 321.—Salivary fistula after incision of abscess in front of ear.

surround the duct. In some cases it may be necessary to remove a section of the masseter muscle or even a part of the anterior border of the ramus of the mandible to facilitate the procedure.

Repair of the Duct.—Nicoladoni speaks of repairing a parotid duct. When there is a lateral wound of the duct, this may not be extremely difficult. Evidence that the wound is lateral is given when a probe can be passed from the mouth beyond the fistula. The duct can then be exposed by an elliptical incision around the fistula. The edges of the lining of the fistulous tract are then turned in and sutured together to form the side of the new duct. In exposing the duct the surrounding tissues should not be stripped off entirely as it is necessary to preserve a blood supply to the new duct lining. A very fine absorbable suture is the best for suturing the duct as a nonabsorbable suture may not be thrown off and eventually will form a matrix for a duct stone. To complete the procedure, the soft tissues above the duct are brought very carefully together after all the sinus tract has been excised (Fig. 322, *A*). A drain is not advisable under ordinary circumstances. Nicoladoni also performed an end-to-end anastomosis of the

duct. A sound is passed from the mouth into the lumen of both ends of the duct to facilitate the careful suturing necessary. A temporary fistula following this operation may not mean eventual failure. Probably a good result after such an operation is aided if a small piece of urethral catheter is sewed in place to facilitate drainage during the period of swelling after the operation. When the duct is too short for the two ends to be ap-

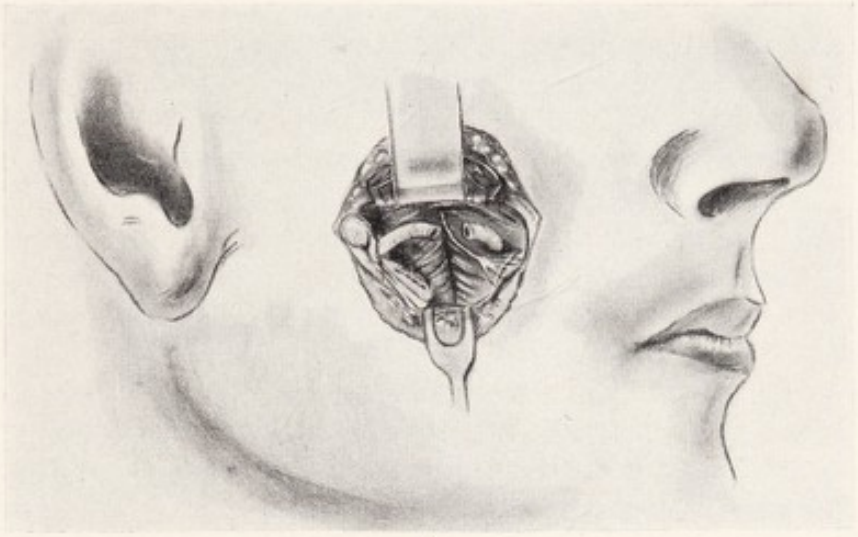

A

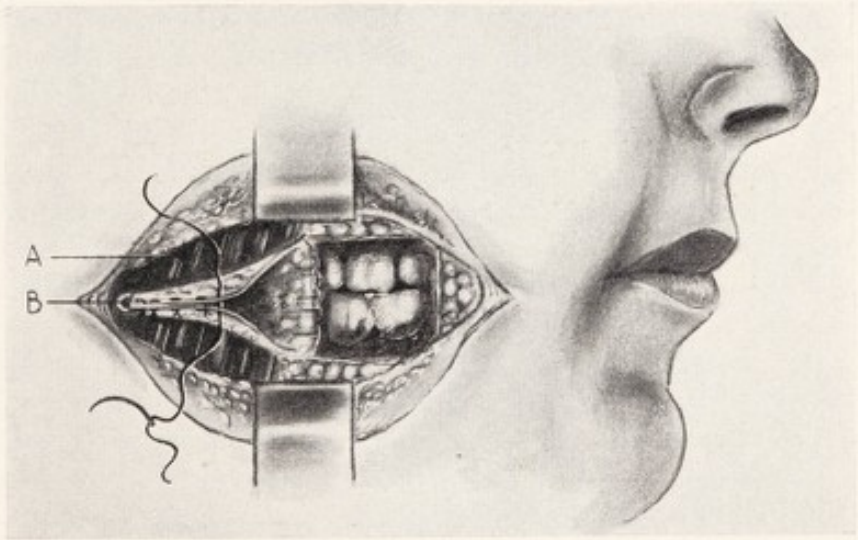

B

Fig. 322.—*A,* Nicoladoni's method of suturing the proximal end to the distal end of the parotid duct. *B,* Braun's method of building a new distal end in the parotid duct with mucosa from the cheek. The diagram is depicted with an external incision unnecessarily large for purposes of clearness. A ¾-inch external incision should be long enough.

proximated by the preceding expedient, the distal portion of the duct is exposed for its full length. Sufficient tissue is left attached to the duct to insure the blood supply. Then the outer surface of the buccinator muscle is exposed for some distance about the entrance of the duct. The natural opening of the duct is surrounded by a horseshoe-shaped incision made fairly deep so that a fair sized flap of buccinator muscle along with the superimposed mucous membrane is outlined. The flap has its base posteriorly.

By means of this amount of freeing of tissue, one is able to draw the distal part of the duct backward 1 cm. or more.

In these operations it must be remembered that in exposing the duct the surrounding tissues must not be stripped too closely or the blood supply to the duct may be insufficient.

Reconstruction of the Distal Part of the Duct from Buccal Mucosa.—Nicoladoni and Braun first presented the conception of adding to the duct by tubing a flap of buccal mucosa. This method has many advantages when the mucosa is unscarred and movable. The procedure follows: with the base at about the position of or somewhat posterior to the normal opening of the parotid duct, a rectangular flap 1½ cm. in width extending forward is outlined by incision. The flap is made long enough to overlap somewhat the proximal end of the cut duct. The mucosa is tubed inward. The proximal end of the cut duct is implanted within the end of the tubed cylinder of mucosa and is held well up on the duct by two or three sutures properly placed. A few sutures are used to close the defect in the cheek mucosa from where the flap was removed. When an external cheek incision has been made to gain exposure to the cut end of the duct, it is closed in layers so as to get primary union (Fig. 322, *B*).

Transplantation of the End of the Proximal Portion of the Duct Into the Buccal Mucosa.—Von Langenbeck did this operation and confined it to cases in which the proximal end of the duct was long enough to be inserted into the mucosa of the cheek anterior to the masseter muscle. Nicoladoni went further and excised the anterior border of the muscle to allow a short duct to be implanted more posteriorly. Blair suggested that one could go further and besides cross cutting the massseter muscle could remove a part of the ramus of the jaw. He argues that "if around the transplanted duct sufficient connective tissue is retained to insure its blood supply no infection, short of a gangrenous process, would materially influence the result, for success is in no way dependent upon primary union of the tissues." The external cheek incision necessary to give exposure to the duct over the masseter muscle is carefully closed in layers.

Conversion of an External Fistula into an Internal One.—Two old methods are described for the establishment of a new fistula: (1) by means of a seton and (2) by passing a drainage tube through the cheek at the site of the duct defect and gradually withdrawing it from the inner side allowing the external fistula to heal while the inner one remains patent (method of Kaufman). The principle is somewhat alike in both methods but it seems to us the seton method is a little more advantageous although neither method has the advantage of providing an epithelial lining for the distal end of the new pathway. Consequently, the opening is likely to contract down and tend to cause obstructive symptoms in the gland even when one is successful in getting the external wound to close by primary intention. The seton method is carried out as follows: a strip of rubber dam, about 4 mm. wide and 25 to 30 cm. in length, is threaded into an appropriate needle and inserted into the tissues at the point where the proximal end of the severed duct terminates. Both ends of the seton are then brought out through the internal cheek tissues after a small penetrating incision is made for each. About 1 cm. of tissue is left between the two points at which the dam pierces the buccal mucosa. The two ends are tied together and are allowed to protrude into the mouth.

When the fistula is well established, the seton is tightened by tying a ligature about the two ends so as to put the rubber on tension and encourage it to cut its way through the intervening tissues.

It is necessary to coapt very completely the tissues of the external cheek after refreshing the walls of the sinus tract so that primary union is obtained. Otherwise, when the internal sinus contracts down the external sinus will reopen.

SURGICAL PREPARATION OF THE MOUTH FOR ARTIFICIAL DENTURES

Within recent years considerable progress has been made in the application of surgical reconstructive operations within the mouth with the idea of rendering the prosthetic dentist's task possible or easier and also of gaining for the patient a much more efficient appliance. The prosthetic dentist has found that the use of purely mechanical contrivances alone in certain deformities has fallen short of the ideal. On the other hand, ill-advised operative procedures may do more harm than good.

Abnormalities for which operative correction may be advisable may be of either the developmental or of the traumatic type. In the first group are certain patients with over- or underdevelopment of the alveolar ridges of either a general or a localized type. Overdevelopment of the alveolar ridges tends to reduce the intermaxillary space, and may cause abnormal bulging and thus interfere with the esthetic setting of an artificial denture. Certain bony exostoses likewise may interfere with the proper setting of an artificial denture. Among these exostoses falls the peculiar condition called torus palatinus (Fig. 287, *C*) which causes a bony projection at the median raphe of the palate. Torus mandibularis—a rather prominent bony projection on the lingual aspect of the mandible—sometimes is overdeveloped sufficiently to be bothersome and likewise the tuberosity of the maxilla may be abnormally prominent. Although none of these conditions are of great significance to the patient, to the prosthetic dentist they may present distinct mechanical difficulties.

Besides these bony prominences, an excessive hypertrophy which produces a flabbiness of the mucosa or the opposite (an atrophy of the palatal mucosa) which decreases the resiliency may also present a mechanical handicap to the proper setting of a denture.

Traumatic defects may be of almost any degree of severity. The more common ones are usually produced by injury inflicted during the extraction of the teeth. Fracture of the alveolus or intentional removal of too much bone are the causes of such deficiencies of the height of the alveolar crest, and reduction of the buccal sulcus. Sharp bony ridges may result from failure to round off distinct projections at the time of the extraction.

The wearing of ill-fitting dentures or improperly balanced dentures which fall into faulty occlusion, that have not been readjusted from time to time often results after some absorption of the alveolar bone in the resulting space being filled with an hypertrophied mucosa with considerable underlying fibrosis and hypertrophy. Even after the removal of the cause of irritation, the tissue may be of sufficient extent to warrant surgical removal. Of course, not all absorptive processes in the alveolar bone are due to ill-fitting dentures. Pyorrhea may cause such a condition.

Surgical Treatment.—*Bony Projections.*—Small minor defects of the nature of exostosis or torus palatinus are repaired by incision, laying back the mucosa and removing the bony projection with a rongeur. If the superimposed soft tissue is hypertrophied, removal of some of its thickness is indicated. The incision is closed with interrupted sutures.

Abnormally Prominent Alveolar Ridges of the Upper Jaw.—In correcting abnormally prominent alveolar ridges of the upper jaw, it is necessary to preserve an adequate gingivolabial fold and a proper alveolar ridge crest.

Kazanjian recommends the following procedure to correct this deformity: "An incision is made along the prominent margin down to the bone. All tissues are carefully elevated, not only to the palatal surface but also anteriorly, well up to the anterior nasal spine and canine fossa. Extensive

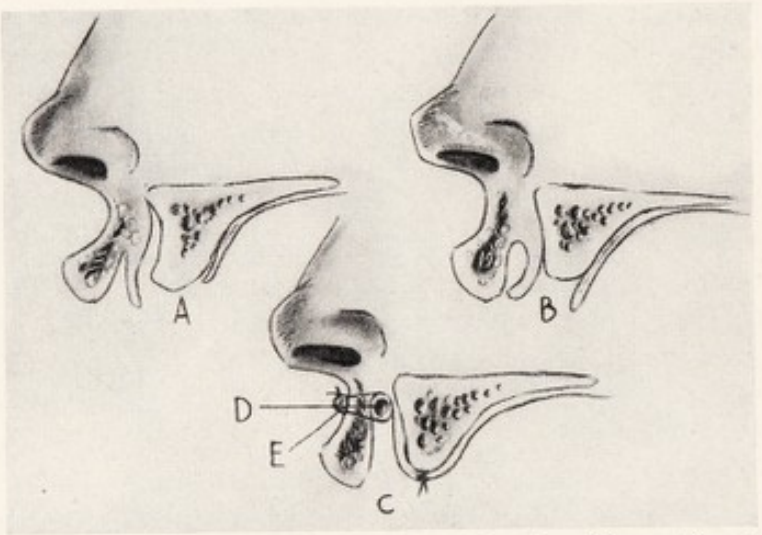

Fig. 323.—Preparing to remove a prominent alveolar ridge without sacrificing the height of the gingivobuccal fold. A, Shows point where incision is made on the upper alveolar ridge and how the mucosa is raised from the alveolus. B, Shows that a certain amount of excessive bone has been removed. C, Shows that the labial flap is carried high up and the margins are approximated by interrupted sutures. The height of the labial flap is maintained by placing a rubber tube around the lip and passing interrupted mattress sutures around it and through the lip on the face. D, Shows cross section of tube in position. E, Shows cross section of roll of gauze. (After Kazanjian.)

undermining of the tissues is important (Fig. 323, A, C). Excessive bone is removed by a rongeur (Fig. 323, B), the labial flap is carried high up, and the margins of the incision are approximated by interrupted sutures. The removal of bone allows the labial flap to slide to a higher position, which is maintained by placing a small flexible rubber tube well up under the lip and passing interrupted mattress sutures around it and through the lip on to the face as shown in Fig. 323, C. These are so placed as to create an upward tension on the mucous membrane surface. They are tied over gauze to prevent the cutting of the skin. A dressing is then placed over the lip and strapped in place with adhesive. This adhesive strap is split and one half placed over the nose for support. To help control edema, and to maintain pressure without, a double elastic band may be fastened under tension with adhesive plaster over the lip dressing. The band can be removed the next morning, but the sutures and the rubber tube should not be removed

for four or five days. The tension of the rubber tubing maintains adequate and equalized pressure on all the tissues and ensures a good gingivolabial fold, which will not close when the sutures and the tubing are removed. In operations on the anterior part of the upper jaw, it is often necessary to remove a section of the anterior nasal spine in order to allow a higher buccal sulcus."

Fibrous Bands.—A fibrous band usually may be repaired by making a horizontal incision across the band up into the buccal sulcus, undermining the buccal mucosal flaps and drawing them together by stitches. A raw surface is left on the alveolus which is allowed to cicatrize. An application of the Z incision will correct certain other types of bands. A vertical incision is made along the length of the band. The sides are then undermined. Two lateral incisions are made to form flaps. The incision appears as a letter Z. Each flap is then drawn over in place of the other and sutured in position.

Ridge Extension of the Upper or Lower Jaw.—The object of this operation is to extend the buccal and labial grooves so that the upper and lower



Fig. 324.—Various steps in the repair of fibrous adhesions covering extensive area over the alveolar ridge. Method of correction when one wishes to deepen the labial buccal alveolar sulcus. The same principle can be used for ridge extension along the lingual side of the mandible. (After Kazanjian.)

dentures will fit into a deeper resting area, with deeper residual ridges. When hypertrophy is present in addition to deepening of the sulci, some of the thickened tissue over the ridges should be eliminated.

Kazanjian recommends an operation to correct this condition. A horizontal incision, about 1.5 cm. from the alveolus, is made on the lip or cheek on a line parallel with the alveolus. The base of the mucosal flap is thus on the alveolus. The submucosal soft tissues are separated from the outer side of the periosteum. The mucosal flap is then folded down against the periosteum and sutured in place. The raw surface of the lip and cheek finally is sutured together (Fig. 324). When the amount of mucous membrane is insufficient, a skin graft is used to fill the deficiency. When the submucosal tissues are thickened and flabby they are thinned. If the nasal spine interferes, it is rongeured away. The principle of this operation may be applied to the lingual sulcus.

Excessive Amount of Submucosa.—The texture of the mucosa of the alveolus and the palate has considerable influence in the proper retention of dentures. When the entire palate and alveolus are soft and flabby, the ingenuity of the prosthodontist may be defied. Considerable benefit may be

derived from a well-planned operation. The mucous membrane is dissected free of bone and all the underlying fatty tissue is removed (Fig. 325). Ordinarily only one side of the mouth is operated upon at one sitting. A bite plate is applied immediately after the operation to get close contact between the bone and the flap.

Atrophy of the Mucosa.—When the mucosa is atrophic and adheres to the bone, very poor retention of a denture will result. Kazanjian recently has advised undermining the mucoperiosteum through appropriate incisions in a way somewhat similar to the manner in which one undermines the mucoperiosteum in a cleft-palate operation. The wound is then sutured. The theory of the operation is that blood accumulates beneath the flaps which organizes, forms fibrous tissue and finally results in an addition of resiliency to the surface. The same procedure may be applied to the alveolar ridges as well as the mucoperiosteum of the palate.

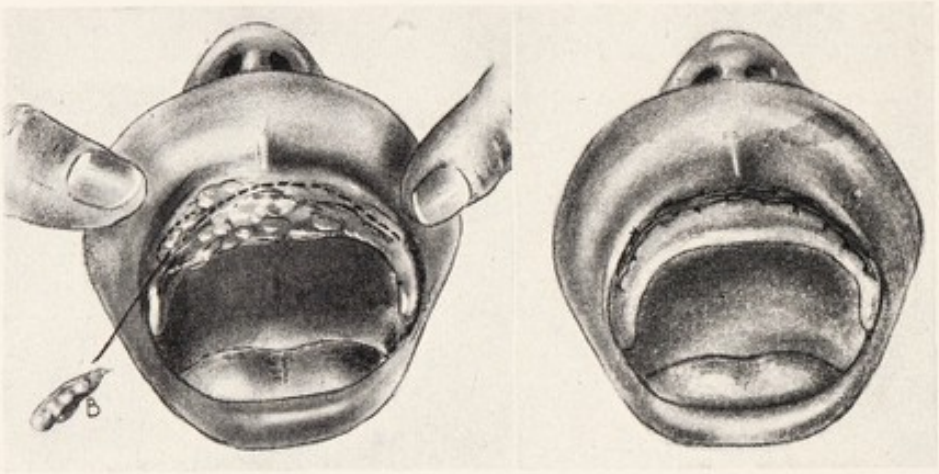

A *B*

Fig. 325.—Various steps of operation for extension of the alveolar ridge when the depth of the lingual alveolar sulcus is interfered with because of hypertrophied tissue at the anterior aspect of the upper jaw. *A,* Shows hypertrophied fibrous tissue. B, Piece excised. *B,* Shows procedure after hypertrophied tissue is removed, and the tissues are resutured. If the sulcus is quite shallow the method of Kazanjian may not be applicable. In that case, we have used a stent behind the upper or lower lip in the labial buccal alveolar sulcus for the purpose of deepening and relining the sulcus. (After Kazanjian.)

The Application of a Stent Graft to Deepen the Buccal Sulcus.—By means of the application of a split skin graft about a wax form (Fig. 326) or stent after the sulcus has been incised and adequately laid open (Fig. 325) a sulcus of almost any degree of depth may be formed. It may be necessary to cross cut partially the attachments of the various muscles of mastication or expression.

In the future the possibilities of the surgical treatment of oral conditions offering mechanical difficulties to the adjustment of artificial dentures will probably be more fully appreciated. It is a comparatively new field.

In the chapter on the extraction of teeth and related matters (Chapter XIII) some discussion is given to the question of properly rounding off the bony spicules and also to the subject of alveolectomy.

For deepening the labial buccal alveolar sulcus when the sulcus is really quite shallow, we have ordinarily depended upon a stent graft. As a rule, in such a case there is not sufficient mucosa to make the method of Kazan-

jian, just described, applicable. This method will actually allow one to rebuild a sulcus of almost any depth so that a denture or a prosthesis of almost any size which one wishes to place in the sulcus may be used. This not only gives good retention to the prosthesis or denture but also allows one to throw the face outward, if necessary, so that contoural defects of the face often are corrected.

It would be our judgment that the method developed by Kazanjian would be applicable to rather minor defects, while the more marked defects

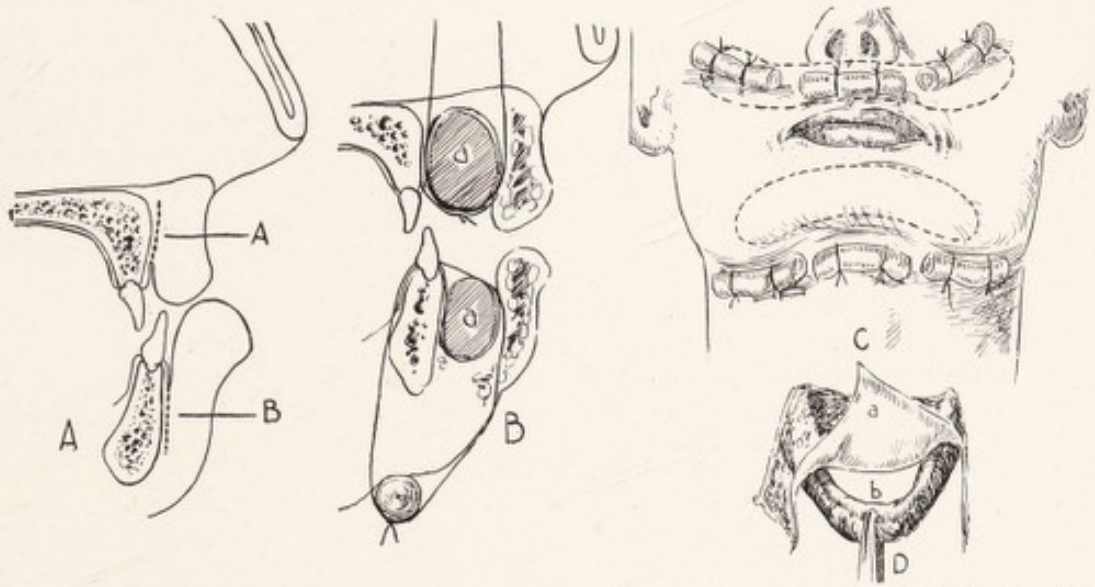

Fig. 326.—The application of a stent graft to deepen and rebuild the labial buccal alveolar sulcus. A, (A), Incision line which encircles the upper jaw; (B) incision line which encircles the lower jaw. B, *a*, Cross section of stent covered with skin which encircles the upper jaw. A heavy suture is placed around the stent and tied over a dental roll; *b*, cross section of stent covered with skin which encircles the lower jaw. A heavy suture goes around the stent and the jaw and is tied over a dental roll. C, Dotted line shows position of stent held in place by sutures tied over dental rolls. D, *a*, Stent over which a split skin graft is being draped; *b*, the stent.

would have to be corrected by the method of laying in a stent graft to actually gain more epithelial lining.

Bibliography

Blair, V. P.: Delayed Transfer of Long Pedicle Flap in Plastic Surgery, Surg., Gynec. and Obst., **33:** 261, 1921.

The Full Thickness Skin Grafts, Ann. Surg., **80:** 298–319, Sept., 1924.

Blair, V. P., and Brown, J. B.: The Use and Uses of Large Split Skin Grafts of Intermediate Thickness, Surg., Gynec. and Obst., **49:** 82–97, 1929.

Blair, V. P., Brown, J. B., and Hamm, W. G.: The Correction of Ptosis and of Epicanthus, Arch. Ophth., **7:** 831, 1932.

Braun and Duphenix: Quoted by Küttner in von Bergmann's System of Practical Surgery, vol. 1.

Cavalié: Traitement des pseudo arthroses du maxillaire inférieur, Bull. et mém. de la Soc. de méd. et chir. de Bordeaux, pp. 93–96, 1917.

Cole, P. P.: Ununited Fractures of the Mandible: Their Incidence, Causation and Treatment, Brit. Jour. Surg., Bristol, **6:** 57, 1919.

Croft: Med. Chir., vol. 72, 1889.

Determined from a study of reports and clinical records relative to maxillofacial cases received in the Office of the Surgeon-General. Reports on file, Record Room, Surg., Gynec. and Obst., 705 (name of hospital) Clinical Records on File, A.G.O.

Davis, J. S.: The Small Deep Graft, Ann. Surg., **89:** 902, 1929.

Delagénière, H.: Greffes ostéopériostiques: technique et application, Jour. de chir., Paris, **17:** 305, 1921.
Esser, J. F.: Studies in Plastic Surgery of the Face, Ann. Surg., **65:** 297, 1917.
Gallie, W. E., and Robertson, D. E.: J.A.M.A., **70:** 1134, April 20, 1918.
Gillies, H. D.: Plastic Surgery of the Face, London, Oxford Univ. Press, 1920.
Horsley, J. S.: Plastic Operations for Acquired Deformities of the Face, J.A.M.A., **66:** 411, 1916.
Kaufman and von Langenbeck: Quoted by Blair, V. P.: Surgery and Diseases of the Mouth and Jaws, St. Louis, C. V. Mosby Co., p. 422, 1913.
Kazanjian, V. H.: Surgical Preparation of the Mouth for Artificial Dentures, J.A.D.A., **22:** 566, 1935.
MacCormac: Brit. Med. Jour., Nov. 29, 1888.
Nicoladoni: Quoted by Küttner in von Bergmann's System of Practical Surgery, vol. 1.
Ollier: Bull. de l'acad. de méd., Paris, 2 series, p. 244, 1872.
Padgett, E. C.: Examples of Rhinoplasty, Bull. Univ. Kas. Med. School, **1:** 4–6, 1930.
Full Thickness Skin Grafts in the Correction of Soft Tissue Deformities, J.A.M.A., **98:** 18–22, 1932.
Is Iso Skin Grafting Practicable, Jour. South. Med. Assoc., **25:** 895–900, 1932.
Cheiloplasty for Cancer of the Lip, Internat. Jour. Orthodont. and Oral Surgery, **22:** 929, 1936.
Serre: Bull. gén. de thérap., **8:** 148, 1835.
Thiersch: Verhandl. d. deutsch. Gesellsch. f. Chir., p. 17, 1886.
Treves: Manual of Operative Surgery, Phila., Lea Bros., 1892.
Waldron, Carl: Quoted by Gillies, H. D.: Plastic Surgery of the Face, London, Oxford University Press, 1920.
Wolfe, J. R.: Brit. Med. Jour., **1:** 1882, 1875.

CHAPTER XLI

PROSTHETIC RESTORATION OF DEFORMITIES

Deformities for which prosthetic restoration is indicated may be either of congenital or acquired origin.

PALATE OBTURATORS

Greek physicians may have used obturators for closure of palate defects according to Guillemeau (1509). Alexander Petronius described an obturator early in the fourteenth century and a few years later in 1541 Ambroïse

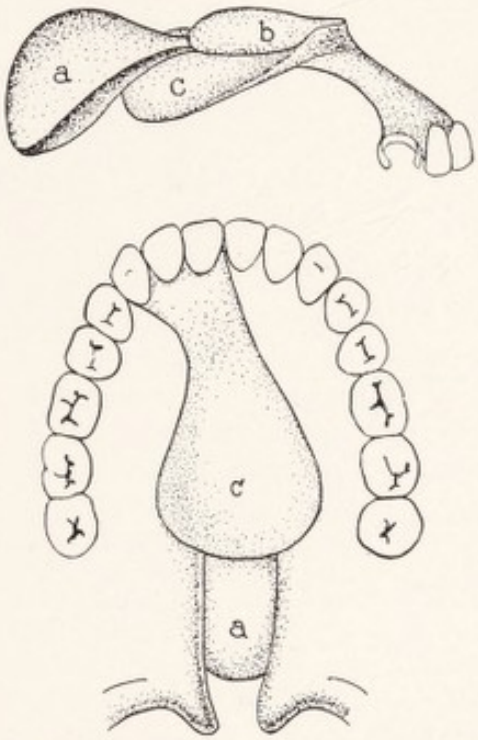

Fig. 327.—Example of mobile obturator. *a*, Mobile obturator; *b*, the part of the denture above the palate cleft; *b*, the part of the denture below the palate cleft. Kingsley shows obturators of this type.

Paré described one (Kingsley). Fifty years later Jacques Guillemeau described obturators similar to that of Paré. In 1728 Pierre Fauchard in "Le Chirurgie Dentiste" illustrated a more complicated obturator which rested upon the superior surface of the aperture to be closed. Fauchard in 1756 first recognized the advantages of arching over the vault and gaining support by attachment to the teeth. Small (1828), Powell (1841), Hullihen (1880), Buckingham (1858), White (1858), and McGrath (1860) all described obturators for various palatal defects. In 1867 Suerson of Germany described an obturator embodying a new principle for cleft of the velum. He constructed an apophysis broad enough to fill in the defect of the velum and also high enough to keep up contact between the high edges forming the sides of the apophysis and the two halves of the velum even with the levator palate in activity. M. Delaberre in 1820 in his "Mechanical

Dentistry" describes the first real artificial palate. He provided a soft flexible valve of India rubber.

Kingsley states that the artificial palate described by Dr. Stearn of Springfield, Massachusetts, a cleft palate victim, embodied most of the true principles that rendered available the muscles of the natural palate to control movements of the artificial palate (Fig. 327). Stearn worked with M. Goodyear who was experimenting with sulfur and its ability to improve rubber (Stearn gave a report of his obturator in 1845 in the Lancet). The discovery of the Goodyear process of vulcanizing rubber made it possible for Kingsley to construct an appliance from a material which by its adaptibility could be readily formed in molds made from accurate impressions of the defective parts and adjusted to them in such a manner as to be free from irritation. The form of the appliance is such that it is under complete control of the muscles of the region. Within recent time Schlitsky and J. Wolff described an elastic balloon type of obturator. The balloon was filled with air. Suerson developed an obturator of hard rubber in 1864. The soft palate had to be divided to introduce the Suerson apparatus if closure had been obtained. With Schlitsky's construction the closed velum was left untouched and the obturator only supplemented the short velum. Warnekros had considerable experience with obturators.

PALATE PROSTHESIS

Thus, an inadequate velum may be supplemented by an obturator by partially filling the space behind the velum, and it need not entirely fill the space to be somewhat effective as the superior constrictor contracts somewhat and also throws forward a cushion in the midline—Passavant's cushion. Diligent effort on the part of the patient to speak correctly was found by Kingsley to develop the action of the muscles to some extent and it was found that eventually a smaller obturator might be used.

Impartial consideration will show that operative treatment and prosthetic treatment both have their own place in the treatment of palate deformities, both congenital and acquired. In cleft-palate prosthesis several types of appliances have been made and advocated as valuable, but closer examination shows that they largely follow two distinct mechanical principles. One type is to be under the immediate control of the muscles of the soft palate. This type has at least the posterior end made of soft vulcanite rubber or "velum rubber" (Kingsley). The second type is a stationary appliance projecting from the posterior end of the appliance into the pharyngeal space, and it is shaped so that the muscles come in contact with the appliance (Suerson). Kazanjian states that for many years he has been fortunate enough to see the work of many eminent authorities in this country and abroad and that he has come to the conclusion that success depends more on the accuracy of the adaptation than on any particular design employed and that, with certain drawbacks, both movable and stationary appliances are mechanically and physiologically practical. The movable appliances cause less strain on the teeth holding the appliance but are apt to be weak at the connection with the denture and, moreover, the hinges require frequent repair. Stationary appliances are simple to make and more durable but exert a greater strain on the teeth. Therefore, if the teeth are not sound, the stationary type is not indicated.

Construction of the Denture.—Such an appliance consists of two parts: a denture covering the hard palate to which the obturator is attached, and an obturator extending from the posterior border of the denture toward the nasal pharynx. The denture may be made of gold or vulcanized rubber or any reliable material used for denture construction. The impression is usually taken in plaster and includes the teeth and the hard palate only. In cleft palate the nasal cavity should be packed off with cocainized cotton to prevent the plaster from encroaching upon the nasal cavity. It is not necessary to extend the plate into the nasal cavity. Only the cleft of the hard palate is covered. The consideration of the type of attachment to hold the obturator is important. Usually it is not desirable to vulcanize it directly to the denture. Some means by which it is possible

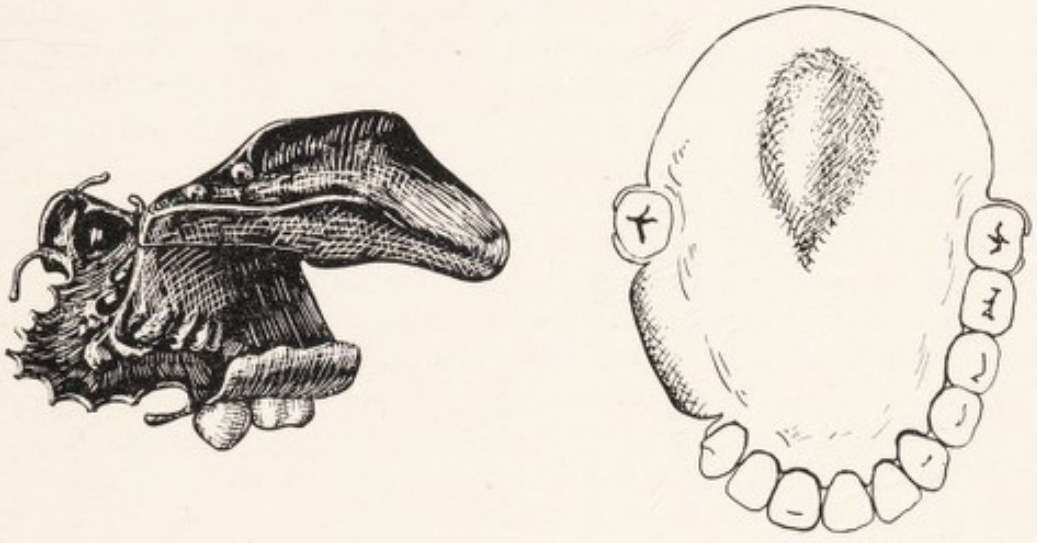

A *B*

Fig. 328.—*A*, A finished stationary plate and obturator. The denture is in one piece with two screws projecting up into the obturator. (After Kazanjian.) *B*, Denture placed over the palatal hole which the patient had refused to have closed because of several previous operations which had failed. The shaded part in the center of the denture represents the extent of the hole.

to construct each part separately is often more desirable. When finished the parts are then assembled.

The Stationary Obturator.—The construction of the obturator is the most difficult part of the procedure. The obturator, of course, is essentially a projection from the denture into the pharyngeal space which in cleft palate is surrounded laterally by the two halves of the soft palate and posteriorly by the pharyngeal wall (Fig. 328, *A*). With the soft tissues at rest and the obturator in place, the soft palate contacts the lower lateral border of the obturator. A space is then left posteriorly for free breathing. When the muscles are in action in speaking or in swallowing the soft palate is raised and lowered with no interference of action but is always in contact with the lateral walls of the obturator. The superior constrictor muscle, when in its forward contracted position, comes in contact with the posterior surface.

Modeling composition is softened and placed about a wire or bar. The modeling composition is shaped to cover the cleft of the soft palate after which it is hardened. The lateral and posterior borders are next shaped.

This is done by first softening one side over an alcohol lamp, placing the modeling composition form within the cleft and then asking the patient to swallow. When there is sufficient material to be in contact with the soft palate, the impression of the soft palate is seen in the obturator. Similarly, the opposite side is shaped. When the posterior surface fits accurately the impression of the superior constrictor muscle will be evident. Finally, a veneer of black plastic gutta-percha is added to the posterior surface of the sides to complete the shaping. After the obturator is shaped, it is best to allow the patient to use it for a time in its original state so that all necessary alterations can be made. Finally, the form is constructed in vulcanite rubber, care being taken to preserve the final shape of the obturator.

Mobile Obturator.—The mobile type of obturator, in order to be effective, must be under the control of the muscles of the soft palate (Fig. 327). Thus, it differs quite radically from the rigid type of appliance both in shape and in its position in the nasopharynx. To move freely it must be light in weight, in close contact with the sides of the velum, and the attachment to the denture must be delicate and responsive. A hinge attachment is necessary. This hinge may be made of heavy gold tubes with an inside diameter of 16-gauge wire. The tube is divided into three sections, the middle firmly fastened to the denture and the end sections attached to the obturator. The lateral borders of the obturator are fitted to the lateral and over the borders of the muscles of the soft palate. The contour of the posterior part of the oburator is fitted to the superior constrictor muscle of the pharynx. The center of the obturator may be quite thin to decrease its weight. The same technic may be used to mold the contour of the obturator as was described in the construction of the rigid type.

Very few patients are comfortable with an obturator and in children it is necessary to change them on account of their natural growth. Often a patient will not wear an obturator after it is made. Unless a patient has not been repaired up until late adult life and has become accustomed to wearing an obturator, or if he is a poor operative risk, or has been the victim of a large slough at a former operation which would render repair hazardous or nearly impossible, ordinarily there is no reason for recommending the use of an obturator. In individuals where operation is in no way contraindicated, operation should be advised. At the present time, the dispute between those who favor the use of an obturator and those who believe operative closure offers more to the patient is practically settled in favor of the latter. Years ago Gutzmann, who had unusual opportunities to observe both, came to the conclusion that operative results were the best.

Indications for the Use of Prosthetic Denture in Congenital Cleft Deformities.—In those individuals with congenital cleft deformities who leave the choice of procedure up to the surgeon—there being no contraindications as to health, age, and so forth—we have advised a prosthetic denture (Figs. 188, *B* and 192, *B*) principally in two types of cases. As an example of the first situation that may be encountered the following is fairly typical: a girl, eighteen years of age, in whom good union of the soft palate had been obtained, on one side the anterior part of the mucoperiosteal flap of the hard palate had sloughed out. A plate covering the defect in the hard palate and fastened to the teeth seemed here a procedure of some wisdom, as the

operation for building in the defect from an extra-oral skin flap was hardly possible with no soft tissue remaining along the lingual side of the alveolus.

The second situation is one in which we believe a prosthetic denture has its very greatest usefulness and one in which no other method, with or without considerable surgery, offers a satisfactory result. A considerable number of cases are seen in which the upper jaw is very much back of the lower jaw. The upper lip and the base of the nose, consequently, are from ½ to ¾ of an inch behind their normal position. Over the hard palate and the remaining teeth is molded a vulcanite denture. The denture is prolonged forward in the shape of a normal alveolar ridge in which artificial teeth are placed so that they will occlude anterior to the lower teeth. Besides protruding forward beneath the upper lip, the prosthesis is molded upward in the alveolar lip sulcus in such a manner that the upper lip is pushed forward and outward into its normal position. Gold clasps fastened to the denture surround the teeth and fix the denture securely. Properly anchored, a fair anterior biting force is obtained (Fig. 193). When the upper lip is too tight to allow it to be held forward, one of three procedures is done as seems most appropriate in the individual case: (1) the mucosa of the lip and cheek is advanced forward in the alveolar lip-cheek sulcus (this is appropriate in many cases with only a moderate lack of lip lining); (2) when the lip is very tight and the skin above is scarred and limited, the transposition of a flap from the middle of the lower lip to the upper lip relieves both the inadequacy of the lining as well as the skin covering; (3) in those rarer cases with lip lining and cheek lining very much reduced, the alveolar lip cheek sulcus may be opened and relined with a stent graft so that a prosthesis may be placed well up in the sulcus to bring the lip and cheek into a normal position. If there happens to be a hole in the lateral part of the hard palate and it appears to be a difficult one to close, and a prosthesis of the type just described is contemplated because of the recessive upper jaw and lip, an effort may not be made to close the hole as the denture will quite satisfactorily do so. Obviously, loss of teeth may make the problem of stability very difficult. Under Buccal Prosthesis, immediately below, is given a résumé suggestive to the technician.

BUCCAL PROSTHESIS

Loss of the maxilla or part of it when accompanied by loss of teeth often causes the problem of stability of the contemplated prosthesis to be paramount (Fig. 329, *A, B*). As the mass of these appliances is rather bulky and may at times have to be made in interlocking parts to facilitate introduction, bulk and weight may add considerably to the difficulty of retention. Because of these factors a brief outline of the methods of retention is pertinent.

Methods of Retention.—Adhesion by contact is the main force that retains a full denture in situ. A perforation of the palate or lack of a part of the alveolar ridge multiplies the adhesions more or less according to the degree of loss of tissue. The remaining part of the palate or alveolar ridge and the shape and surroundings of the cavity to be filled will form the foundation for support of the denture. Serviceable teeth such as the canines and the first molars greatly simplify retention. Various types of clasps are then utilized for purposes of fixation. Various spaces of the deformity

also often have to be utilized for the purpose of support and fixation. Finally, various types of spiral springs may in certain cases be advantageous for purposes of fixation. In any given case to be repaired, one or more or even all of these methods may be utilized. The entire field has to be

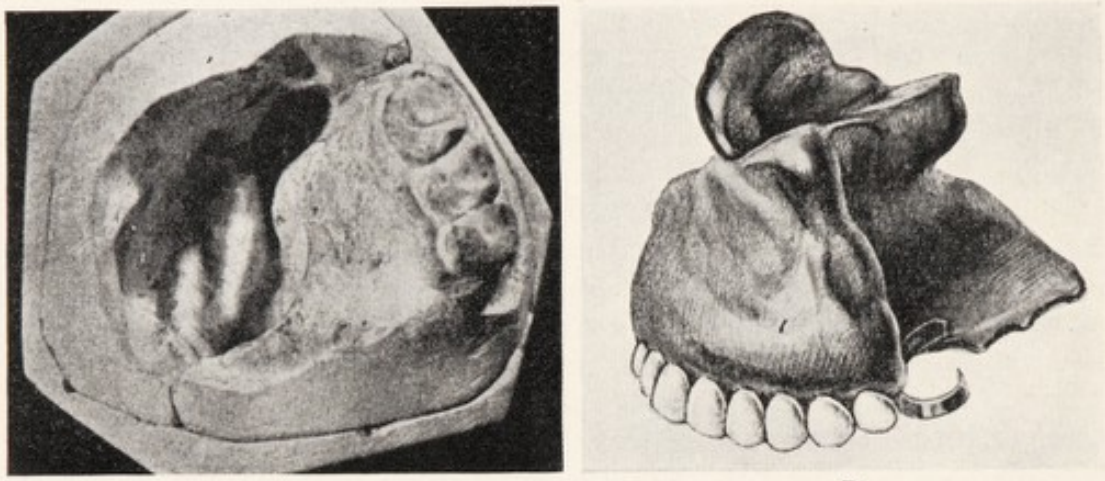

A *B*

Fig. 329.—*A*, Model showing destruction of latero-anterior portion of palate (carcinoma). *B*, Appliance used in case shown in *A*. (Retention first clasp on molar; second projections of denture covering the perforation.) (After Nichols.)

surveyed and the laws of leverage and the existing condition of the tissues all considered.

Two types of springs are in use. The first (Fig. 330, *A*) and oldest is a spring of special gold wire, about $\frac{1}{6}$ inch in diameter and 2 inches in

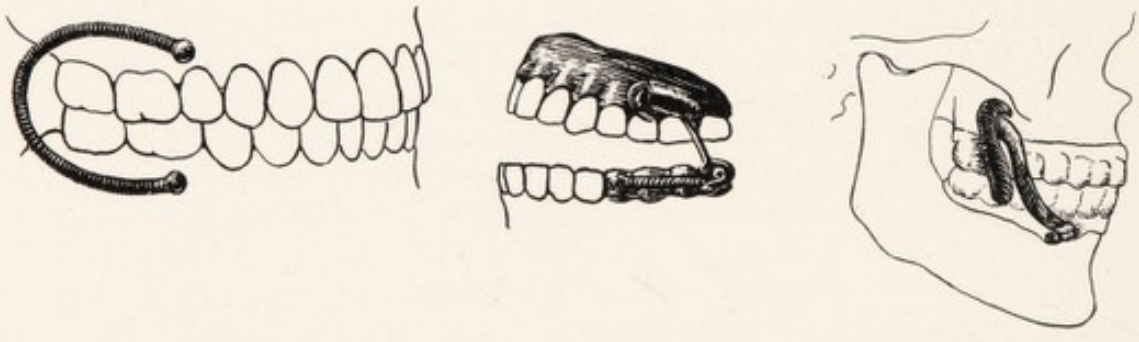

A *B* *C*

Fig. 330.—*A*, The oldest and most generally used spiral splint spring used for holding the upper denture in place. *B*, The use of a horizontal spring lever supporting the maxillary denture. *C*, Simplest type of an appliance to prevent abnormal movement of the mandible when a part of the body has been removed. A stout wire is connected to the mandibular teeth with bands or crowns which is passed from the mandible upward and backward to the buccal aspect of the third molar region where the wire ends are operated in a metal groove which is attached to a maxillary denture in a position to harmonize with the movements of the opposite temporomandibular joint. Villian made a hinge at the base where it connects with the lower teeth. Diagram of Villian's appliance.

length, which is usually attached on each side to the upper and lower dentures at or about the premolar region. When the teeth are in contact the spring is in a semicircular position and rests in grooves at the buccal side of the denture. Kazanjian in 1913 devised a horizontal spring with a lever.

Two buttons were attached to the lower plate or bridge, one at the premolar region and the other at the third molar region (Fig. 330, *B*). A horizontal spring was attached to the anterior button at one end and to the short arm of a lever at the other end, where the posterior button acted as a fulcrum for the lever. The long arm of the lever fit into a groove made in the buccal aspect of the upper plate. The tension of the spring holds the denture in position as the patient opens and closes the mouth. Spring dentures are used only in case other methods are not available. If accuracy is not used in their manipulation they do not serve their purpose. Repair may be needed often. Usually stability is not sufficient and the appliance is difficult to keep clean (Fig. 330, *C*).

Hole in the Hard Palate Including the Loss of Part of the Alveolar Ridge.—Our views as to the indications for a simple dental plate fixed to the teeth in the case of a defect of the hard palate has been outlined previously. In edentulous cases, if the hole in the palate to be covered is not over 1 cm. in diameter, adhesion of the plate to the palate and alveolar ridge is usually sufficient to retain the denture in position.

When the perforation follows the loss of one half of the palate after a cleft-palate operation, the opening is usually sufficient to require several sets of clasps to surround the existing teeth or an extension of the denture into the posterior nasal space may be advisable. If teeth should be absent, extension both posteriorly and anteriorly may be necessary or even a spring attachment may be used. Kazanjian suggested that, in order to adjust the denture successfully, the anterior attachment or extension might be made to swing on a hinge. For carcinoma of the antrum, at the present time, a hole is not uncommonly made through the alveolar ridge and posterior hard palate for the purpose of implanting radium and providing dependent drainage. Provided the carcinoma regresses a prosthesis is in order, as usually permanent repair is hardly logical even if it could be accomplished. The antrum is partially filled by the prosthesis and attachment to the teeth and other tissue follows the same principles as those just outlined for the hard palate defect (Fig. 329).

When the anterior part of the palate needs restoration the type of appliance used depends upon the extent of the nasal preparation and the number of serviceable teeth. When the destruction is not back of the first premolar area the construction is similar to that of a dental plate. When greater destruction has occurred it becomes necessary to extend the denture anteriorly and laterally to extend into the nasal spaces. In edentulous patients of this type the difficulties are increased. A spring attachment is necessary or, better, a projection from the buccal denture posteriorly toward the nasopharyngeal space and anteriorly toward the nostril.

Loss of Hard and Soft Palate.—The cases of this type encountered by us have been due to unsuccessful cleft-palate operations. When the patient is a good operative risk and a sufficient ledge of soft tissue remains at the side of the palate, we have considered that transplantation of an arm flap to rebuild the palate was indicated. Following injury such as gunshot wound or a large operative wound, following carcinoma for instance, or a sloughing type of disease such as an osteomyelitis with sequestration of a considerable part of the maxilla, prosthetic restoration may be done with great satisfaction. But in such cases a soft-tissue repair is usually neces-

sary first if the patient is not too old to make such seem advisable. For lining and covering, skin flaps or skin grafts have to be transplanted. Any surgeon caring for malignant tumors about this region will see quite a variety of cases of this type. Repair work is not started until it is evident that recurrence is not likely—a year or more should be allowed to pass without any evidence of recurrence. Retention can usually be gained by extending the denture to the maxillary space or other cavities which have been opened. The denture may be built in one or two parts to facilitate introduction. A point of resistance is necessary if mastication is to be carried on. This may be an almost unsolvable problem. Kazanjian reported a case with total loss of the maxillary bones in which he attached to the prosthesis a contrivance which gained this point of resistance from the forehead. Wires were fitted into the canine region and extended out of the mouth and upward and were attached to a form resting between the orbital ridges, which form was in turn held in place by spectacles.

PROSTHETIC RESTORATION OF DEFORMITIES OF THE MANDIBLE

Preceding prosthetic restoration of the lower face region and mandible, soft-tissue loss should be restored. After the cheeks or lips have been reconstructed usually a reconstruction of the bone itself by bone transplantation is the final goal of the surgeon. Prosthetic appliances are needed to supplement the preceding reconstruction to make normal mastication possible. In certain deformities a prosthetic appliance is advisable to push the soft tissue outward to aid in reestablishing normal contour of the face. To give the necessary elasticity to the soft tissues an adequate epithelial lining of the sulcus in which it is planned to place the prosthesis is necessary. Either a pedicled flap or a stent skin graft is used for this purpose. For simple deepening of the alveolar cheek or lip sulcus so that a prosthesis can be laid in the stent, skin has the advantage of gaining the desired end in one fairly simple operation (Fig. 331, *A*). For the relining of larger areas involving the cheeks and lips, a pedicled skin flap is usually necessary. Before one can successfully lay in a bone graft, one must be certain that sufficient soft tissue lining is present so that scar tissue does not bind the separated end of the bones out of position and also that sufficient soft tissue is present so that one does not break into the mouth when laying in the bone graft. A pedicled flap turned into the mouth is often necessary to supply the thick lining between the two ends of the bone on the inside of the mouth.

When the ramus and part of the body have been lost, the backward and lateral swing destroys occlusion of the opposite side. In this type of case it may be very advantageous to hold the mandible in its normal position to maintain as normal occlusion as possible. Among the ingenious appliances devised for this purpose are the following:

A. A heavy wire is connected to the mandibular teeth by means of bands or crowns and is passed backward and upward to the buccal aspect of the maxillary third molar region where the end of the wire operates in a metal groove attached to a maxillary denture (Fig. 331, *B*, *C*). The position of the wire and the groove must be such as to harmonize with the movement of the opposite temporomandibular joint. Villian made a hinge at the base of the wire where it connects with the lower teeth to give free lateral move-

ment. As the occlusal plane changes at different points during mandibular movement, accurate measurements must be taken to properly shape and place the groove.

B. The second appliance was designed by Kazanjian (Fig. 331, *D*) and is particularly adapted to cases with about one half of the mandible missing. Two movable joints are present—one a ball-and-socket joint at the region of the maxillary molars and the other a horizontal hinge situated on

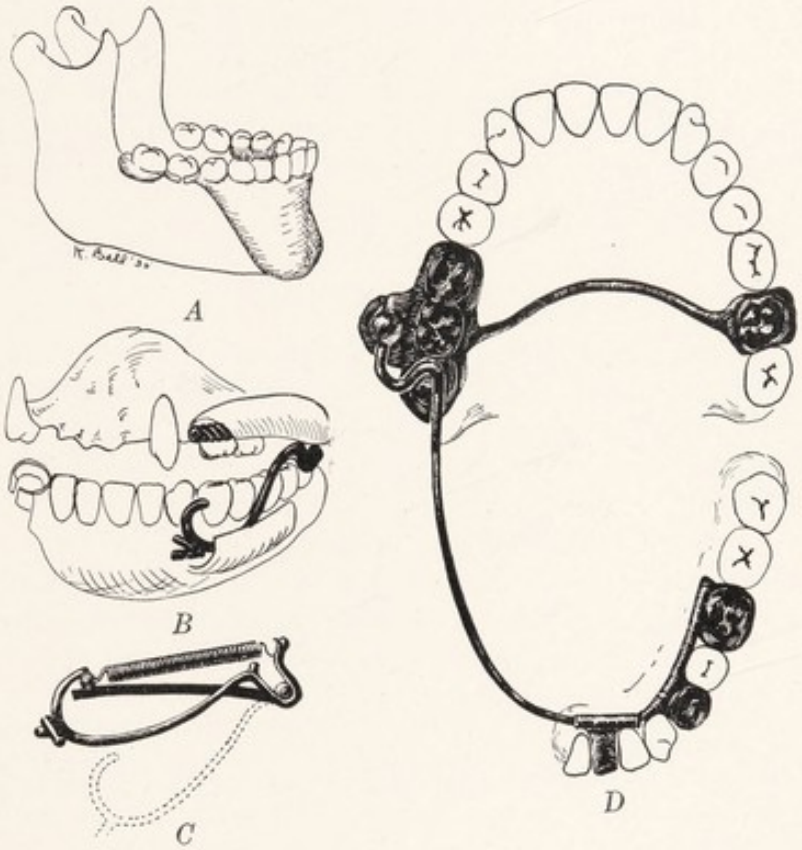

Fig. 331.—*A*, Appliance showing prolongation of denture into tissues of skin to hold them out in a normal position. Before such an appliance can be applied a stent graft or a skin flap is necessary to give a lining to the cavity. The prostheses of this type may be prolonged backward and impinge in a place just below the glenoid fossa region in the absence of one half of the lower jaw and give a fairly good contour and also serve to hold the opposite side of the jaw in normal position. *B* and *C*, The use of a horizontal spring lever supporting a mandibular denture. (After Kazanjian.) *D*, Appliance made by Kazanjian which is applicable to cases in which approximately one half of the mandible is missing. A ball-and-socket joint is placed at the region of the maxillary molars and another movable joint is a horizontal hinge situated on the lingual side of the mandibular teeth. A short wire bent to assume the desired contour extends from the ends of the mandibular stumps to the socket at the buccal side of the maxilla. The lower wire is bent horizontally to enter the denture behind the mandibular teeth.

the lingual side of the anterior mandibular teeth. The joints are fastened to selected teeth by means of crowns and bridges. A stout wire is bent to assume a curved contour and extends upward and backward from the end of the mandibular stump to the socket at the buccal side of the maxilla. The wire connecting the neck of the ball is bent slightly across inward and brought into contact with the occlusal surface of the molar teeth for the purpose of directing the force of mastication vertically to prevent lateral

pressure. The possibility of loosening the upper teeth to which this appliance is attached is considered to be less. Kazanjian lists the advantages as follows: (1) the connecting wire is easily removed and adjusted by the patient; (2) by virtue of its being double-jointed the teeth supporting bands or crowns are subjected to minimum strain; (3) no special measurements are necessary for the angle of the condyle path, thus simplifying the construction of the appliance; (4) it is possible to make an auxiliary attachment on the wire for the purpose of adding a removable denture to the missing part of the mandible which also aids in the correction of the external deformity.

Seldom does one meet a deformity that in all respects is similar to any other. Variation is the life of this type of work. Only suggestions are possible. Without originality and a knowledge of the relative possibilities of the situation, we could repair none of these cases.

NASAL PROSTHESIS

The great possibilities of proper surgery must be considered before nasal prosthesis is recommended, but the age, the physical condition, the peculiarity of the disease and the desire of the patient may modify conditions and cause prosthesis to become the method of choice. After all, nasal prosthesis or facial prosthesis, although when properly constructed they offer great possibilities, do carry with them an artificial or "false" factor which cannot be entirely satisfactory. Kingsley in his book of 1880 describes several nasal prostheses and more recently Claude Martin more completely has described the art. Kingsley used both spectacles and prolongations into the nose to hold the prosthesis in situ.

Mold.—A plaster mold of the face is taken from which a positive is made. On the positive cast a properly shaped nose is built up with clay or modeling compound, or even a lip or a part of the cheek may be built in. The cast serves as a record and also as a working model. It is probably not necessary to describe the methods of making a cast of the face completely, but, in passing, it may be well to mention that tubes must be inserted into the nasal cavities so that the patient may breathe as the plaster is placed over the face. To prevent the plaster from falling into the nasal cavities cotton wet with a mild solution of cocaine may be packed in the bases of the cavities. When it is desired to outline intranasal spaces for the projection, an attachment or form of modeling composition may be used to good advantage and added to the cast.

Materials for Construction.—The following materials have been used successfully in the construction of a nasal prosthesis: (1) vulcanite rubber, (2) copper, (3) gelatin compound, (4) bakelite. Vulcanite rubber seems to be most generally used, however. It is light in weight, easy to manipulate to the desired shape, and after the work is completed the shape may be modified. Its greatest disadvantage is that it is difficult to tint and get a good imitation of flesh color. Wood in 1916 advocated the use of copper laid down to form by electrolysis. Copper duplicates the modeled nose accurately, is light, thin and strong and parts may be easily soldered to it. The disadvantage is that an expert electroplater is required to make the apparatus and that tinting is difficult. In 1915 Ponte introduced a gelatin (50 Gm.), glycerin (150 cc.), kaolin (25 Gm.), vaselin (5 Gm.) and water

(150 cc.) compound. The mixture is heated in a double boiler and poured into a mold. The result is a tough form which holds its shape although it is quite flexible. The nose is pasted on each morning but the life of the nose is only about one week, after which the margins curl and the color changes. The patient must, therefore, be taught how to make up his own supply of noses. With proper dyeing, the result is excellent from an artistic standpoint.

Retention.—To wear a prosthesis of this type successfully the patient must be comfortable. Slight dislodgment is quite embarrassing. Proper retention is not easy. In planning the construction all available means of anchorage must be considered and often more than one must be used. The inner surface must fit the tissues accurately to assure comfort and stability. The use of spectacles is an old and common method of retention. The spectacles are fastened to the bridge of the nose, and the ears support the whole (Fig. 332). But unless other means of support are used the method

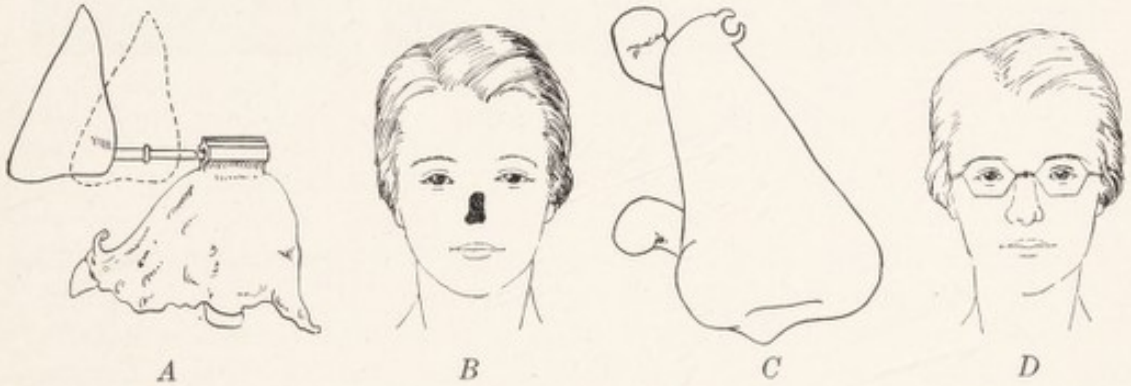

Fig. 332.—*A,* Prosthetic nose held in position by an artificial denture with the aid of a square wire and tube attachment which is made possible by a perforation extending from the mouth to the nose. (After Kazanjian). *B, C* and *D,* Nasal prosthesis. Grooves are made at the lateral aspect of the artificial nose with two extensions into the nasal cavity and one into the frontal region. The upper part of the nose is also supported by spectacles. There is another manner of supporting a nose of this type. The nose may be attached to an uppper denture behind the upper lip or alveolus.

is mechanically weak, lacks stability and tends to be dislodged. Kazanjian devised a method of focusing the pressure at the middle of the nose at its lateral aspect to aid stabilization. He used tortoise-shell spectacles, made the greatest contact at the lower point of the prosthesis and suggested that, if necessary, two fine wires extend up from the lateral sides of the nose to meet behind the lowest point of the spectacles on each side. The heavy frame hides these wires, but the prosthesis is not attached to the spectacles. The latter are used only to support the nose. Kazanjian says that, no matter how accurate the adjustment may be, spectacles will not prevent the appliance from slanting downward which is annoying to the patient. Projections into the nasal cavity are usually necessary (Fig. 332, *B*). As the mucous membrane is very sensitive any appliance must fit accurately and cover a large surface. In fitting the intranasal projection the anatomy and structural peculiarities of the case are considered. The floor of the nose often offers a desirable location for a projection. When a dental plate or a bridge is necessary the prosthesis may be anchored to the plate or

bridge. This method affords a good security. With a palatal or buccal perforation present, again the problem is simplified (Fig. 332, *A*). The nasal prosthesis is then fastened to the palatal or buccal prosthesis by an appropriate appliance. Some men have gone so far as to create an open-



Fig. 333.—Photograph of a man who had the right side of his nose removed because of carcinoma. He preferred a prosthesis rather than a plastic repair of the deformity. This was done by Dr. R. M. Seibel of Kansas City, Missouri, in the extremely efficient manner which the photographs depict. (Courtesy of Dr. R. M. Seibel.)

ing in the inner aspect of the upper lip through which a wire may be passed to fasten to an appliance attached to the teeth.

Finally, an artist is necessary to paint and tint the nose to harmonize with the face. Various oil or celluloid paints may be used. Kazanjian recommends the latter.

Bibliography

Bibliography Quoted in Text

Buckingham: Dental News Letter, 1858.

Delabarre, M.: Mechanical Dentistry, 1820.

Fauchard, Pierre: Chir. Dent., 1728.

Gutzmann, Hermann: Berl. klin. Wchnschr., **36:** 813, 1899.

Von den verschiedenen Formen des Naeselden, Halle, C. Marhold, 1901.

Kazanjian, V. H., Rowe, A. T., and Young, H. A.: Prosthesis of the Mouth and Face, Jour. Dent. Res., **12:** 651, 1932.

Kazanjian, V. H.: Dental Prosthesis in Relation to Facial Reparative Surgery, Surg., Gynec. and Obst., **59:** 70, 1934.

Kingsley: A Treatise on Oral Deformities, 1880.

Martin, Claude: Prosthèse immédiate, Paris, 1900.

McGrath: Dental Cosmos, 1860.

Ponte, M. A.: Rhinoplastic et prosthèse nasale, la restauration maxillo-faciale, vol. 1, 1915.

Schlitsky: Quoted in Handbuch der Zahner-sat by J. Parreidt, Leipzig, Arthur Felis, 1893.

Villian and Wood: Quoted by Kazanjian in Nichols, I. G.: Prosthetic Dentistry, St. Louis, C. V. Mosby Co., 1930.

White: Dental News Letter, 1858.

Warnekros: Verhandl. d. deutsch. odontol. Gesellsch., Schaff's Handbuch, vol. 2, 1913.

The following are quoted by Kingsley in A Treatise on Oral Deformities, Chapter IX, 1880: Goodyear, Hullihen, Powell, Stearn, and Suerson.

The following are quoted by Blair, V. P., in Surgery and Diseases of the Face, Mouth and Jaws, St. Louis, C. V. Mosby Co., 1913: Jacques Guillemeau, Ambroïse Paré, Alexander Petronius.

CHAPTER XLII

ANESTHESIA

Some general summing up of the more practical methods of obtaining an adequate anesthesia for a given type of procedure should be of some interest, as the proper selection of the type of anesthesia and the mode in which it is given have much to do with the successful outcome of an operative procedure. The proper use of local anesthesia depends upon an intimate knowledge of the location of the sensory nerves (Chapter II). In Chapter XXXIX some of the indications and the technic of obtaining anesthesia for the extraction of teeth was discussed.

Anesthesia falls into two large groups—local and general.

LOCAL ANESTHESIA

In 1853 Wood introduced the hypodermic syringe. This made local anesthesia possible. In 1857 Niemann discovered cocaine, but its anesthetic qualities were not known until 1884 when Koller demonstrated its local effects. Many substitutes for cocaine followed the discovery of this drug with local anesthetic powers, but none was particularly successful until the discovery of novocain by Einhorn in 1905. Braun in 1905 first tested the clinical usefulness of this drug.

Cocaine as a Local Anesthetic.—Because of its toxic properties, cocaine hydrochloride for the purposes of causing anesthesia by injection has been largely abandoned. It is still used very frequently in nasal operations and ophthalmic surgery to anesthetize mucosal surfaces by topical application.

Ethyl Chloride as a Local Anesthetic.—Pure ethyl chloride is commonly used for the local freezing of the skin and immediate subcutaneous tissues. On the skin surface about the face and jaws, when a short and not necessarily complete anesthesia is all that is desired such as in opening small infections, it may be useful. Ordinarily infiltration anesthesia is contraindicated in such conditions because of the danger of spreading the infection.

Novocain as a Local Anesthetic.—Depending upon the manufacturer, various names have been given to para-amino-benzoyl-diethylamino-ethanol hydrochloride such as procain, novocain, novol, neocain, syncain and so forth. This drug most nearly fulfils the requirements of an ideal local anesthetic. It is at least seven times less toxic than cocaine and for that reason has been substituted almost universally. Procain hydrochloride is powder which dissolves readily in water and may be sterilized by boiling. The drug is rapidly absorbed by the blood vessels and lymph channels and carried to the liver where it is broken up. The addition of a small amount of adrenalin increases its power to block sensory impulses. Adrenalin contracts the blood vessels and the effect of the anesthesia is strengthened and held for a somewhat longer time. From 3 to 6 drops of a 1:1000 solution of adrenalin to 1 oz. of novocain is sufficient and is the amount generally used for this purpose.

Novocain as an anesthesia is used in two ways: (1) for conduction anesthesia or nerve block or regional anesthesia and (2) for infiltration anes-

thesia or field blocking. In field infiltration the local anemia produced by the vasoconstrictor adrenalin aids the anesthesia.

Infiltration Anesthesia for Operations about the Mouth.—When the skin or mucosa has to be cut and block anesthesia is not considered expedient or necessary or is insufficient, infiltration is used. One half to 1 per cent strength of novocain with from 5 to 6 drops of 1:1000 adrenalin to the ounce is routine for most surgeons. When a considerable amount of the anesthetic is to be used, ½ per cent is preferable. Large areas can be infiltrated by this method. For example, complete block dissections of the neck are often performed with the bulk of the anesthesia being obtained by this method. Again, for opening the antrum for instance, one can inject the submucous and subperiosteal tissues over an appropriate area in the canine fossa. After an interval of from five to ten minutes the mucosa may be cut without pain and the bone removed from in front of the antrum. If necessary, one may supplement this injection with a nerve-block injection at the infra-orbital foramen.

In anesthetizing the skin, a fine needle is inserted obliquely into the substance of the skin. The skin turns white as the injection is made and an elevated papule with an uneven pitted surface is formed. If such elevation of the skin is produced the full length of the incision to be made, no pain is felt when the incision is made. But if the anesthetic fluid is injected beneath the skin, its appearance remains unchanged and the anesthetization is likely to be only partially complete. After the first papule the size of a dime or a nickel made with a short fine needle, a long slightly larger needle can be inserted along the proposed line of incision. As the needle is withdrawn, the novocain may be injected quite easily. Very quickly one can anesthetize a wide area of skin in this manner. The subcutaneous and deeper structures are anesthetized by inserting the needle to a depth as great as the proposed incision or excision. The tissues to be invaded are entirely surrounded by the injection. When the needle is in the neighborhood of large blood vessels, before the injection is made one should withdraw the piston of the syringe to see if any blood appears. If not, one can safely inject the novocain. Some rare instances of sudden collapse when using a local anesthetic may be due to injection of the anesthetizing fluid into a vein or artery.

Nerve Block Anesthesia.—When working upon soft tissues nerve-block anesthesia often has the advantage of causing little swelling or distortion of the tissues immediately surrounding the field of operation. As infiltration anesthesia causes swelling, nerve-block anesthesia in such a situation would be more appropriate. In other situations because of the type of tissues or the peculiar anatomic structures of the parts, as for example such a situation as one encounters when one wishes to remove a molar tooth (Chapter XIII), anesthesia by nerve block is much easier to accomplish and is more complete than that obtained by infiltration anesthesia.

For operations other than the extraction of teeth, both infiltration and nerve-block anesthesia may be used advantageously together, one to supplement or augment the other. In this manner, one may get a better anesthesia by the use of a smaller proportion of novocain than if infiltration anesthesia alone is depended upon. An example of this is encountered when doing a dissection of the neck en bloc under local anesthesia. In and about

the nose one may with advantage use cocaine by topical application to the mucous membrane, may block the nasal nerve in the orbit or the infra-orbital nerves, and may use infiltration anesthesia in the columella.

VALUABLE TECHNICS OF OBTAINING LOCAL ANESTHESIA NOT PREVIOUSLY DESCRIBED IN CHAPTER XIII

Deep Block Anesthesia of the Second and Third Divisions of the Fifth Nerve.—In certain patients, due to adverse general constitutional factors, it may be a part of good judgment not to resort to a general anesthesia. A very satisfactory anesthesia in these patients may be obtained by blocking one or both trunks with novocain at the foramina of exit from the skull of the second and third divisions of the fifth nerve as the field may require. By the use of this method radical operations for various lesions of the soft and bony structures of the face and jaws such as resection of the lower jaw, reduction and wiring of the teeth when the jaw is fractured, and bone grafting gracefully may be consummated. Preliminary medication with about ¼ grain of morphine in an adult is advisable. The technic of the injection is exactly similar to that previously described for alcohol injection of the second and third divisions of the fifth nerve (Fig. 120, *A*, *B*, *C*).

Infiltration and Nerve Block Anesthesia for Radical Neck Dissection.—For a submaxillary block dissection of the neck (a complete block dissection under the usual conditions met), local anesthesia is by far the most useful anesthetic. This is also true for the removal of certain other tumor masses in the neck where a careful dissection is necessary. A description of the injection in a routine bilateral submaxillary excision en bloc and a description for a complete block dissection of the neck should suffice for illustrative purposes. Some variation might be introduced for injections of a more unusual character.

Infiltration for Routine Bilateral Submaxillary Neck Dissection.—The skin along the line of incision (Fig. 277) from mastoid process to mastoid process is infiltrated, using ½ per cent novocain containing 5 drops of adrenalin. The skin and subcutaneous tissues along the lower border of the mandible, from angle to angle, are infiltrated. This infiltration outlines a half-moon-shaped area of skin. The subcutaneous tissues between these two lines of infiltration are then injected. Beginning about 2 inches below the angle of the mandible and working upward along the anterior edge of the sternomastoid muscle, the needle is now plunged through the skin to a depth of about ½ to ¾ inch and about 2 cc. of fluid is injected at ½-inch intervals until the lower lobe of the ear is reached. Next, a long needle is inserted from below the angle of the mandible upward beneath the ramus of the mandible to the region of the inferior dental foramen. Here about 4 cc. of the solution is injected. Then, at intervals of about ¾ inch, the needle is inserted through the skin from points below the rim of the curve of the mandible, so that the point falls back of the curve of the mandible. It is not plunged deeply enough to enter the mouth, however. About 2 cc. of the solution is injected at each insertion. The inferior dental foramen injection and the injection within the curve of the mandible should anesthetize the periosteum of the bone. Finally, in the neighborhood of the connection of the anterior and posterior bellies of the digastric muscle to the wing of the hyoid bone, the needle is plunged to a depth of about ½ to ¾

inch and 3 to 4 cc. of novocain injected. Both sides are injected similarly. After waiting about five minutes the operation may be started.

Infiltration and Block Anesthesia for Unilateral Dissection of the Neck En Bloc.—The injection as just described for the submaxillary region is made on the side to be operated. Besides the injection the skin of the line of incision for a complete block dissection of the neck is infiltrated (Fig. 279). Briefly this consists of the infiltration of a line about 1 inch above and parallel with the clavicle. This line of infiltration is then connected with the line of infiltration previously made for the mastoid to the submental region. From this line of infiltration, the subcutaneous tissue beneath the skin flaps to be laid back on each side are injected outwardly and inwardly to near the median line. The sensory nerves of the neck make their exit toward the superficial structure just posterior to the sternomastoid muscle and a little above a point midway between the mastoid process and the clavicle. The needle is inserted in this region to a depth of about ¾ inch at the same time injecting novocain rather liberally. This should block the sensory innervation of the neck. Finally, the needle is plunged through the sternomastoid muscle to a depth of about 1 inch from the lower pole of the parotid gland to the point just above the clavicle at intervals of about ¾ inch and novocain solution is injected along the pathway of the carotid artery and deep jugular vein. Before injection the piston of the syringe should be pulled backward to make certain that the solution is not injected into a vein or an artery. This is particularly a point to be observed here, but it should be done elsewhere also when injecting in the region of a fair-sized vessel.

Infiltration and Block Anesthesia for Laryngectomy.—Most surgeons use infiltration local anesthesia. The infiltration with ½ per cent novocain and 5 drops of adrenalin to the ounce is made along the line of the cutaneous incision. The cervical plexus nerves are injected at the level of the transverse processes of the third and fourth cervical vertebrae in a line taken from the mastoid processes to the sternoclavicular joint. At the juncture of the upper and middle thirds just anterior to the posterior border of the sternomastoid muscle, the needle is inserted. Deep infiltration is made laterally and just without the laryngeal box and also posteriorly by rotating the needle to fall posteriorly to the laryngeal box. Various types of skin incisions have been made.

GENERAL ANESTHESIA

The real beginnings of modern anesthesia were foreshadowed by the discovery of nitrous oxide (N_2O) by Priestley in 1772. In 1799 Davey used this gas to alleviate headaches and for the extraction of his own wisdom teeth. In 1785 Pierson of Birmingham, England, used ether (sulfuric ether) inhalations for asthma as did Warren of Boston in 1805 and 1806. Its anesthetic qualities were not known at that time. Faraday in 1818, however, pointed out that ether produced effects somewhat similar to nitrous oxide. In 1821 Stockman (Rome, N. Y.) found a young man completely anesthetized with his mouth to a faucet of a nitrous oxide gas tank, but he did not appreciate the potentialities of this accident. Hickman of England between the years 1820 and 1828 used carbon dioxide and nitrous oxide to render animals unconscious when he operated upon them.

His experiments were not accepted by his profession. Crawford W. Long in 1842 for the first time appreciated and demonstrated the anesthetic qualities of ether for operative procedures on the human. The knowledge of Long's discovery did not become generally known until several years later. By 1844 Horace Wells, a dentist, had become impressed with the belief that the administration of nitrous oxide would bring about anesthesia for the painless extraction of teeth. Colton, a chemist, was called in to administer the anesthetic to Wells and a friend, Riggs, extracted one of Wells' teeth. Morton, a former pupil of Wells, in September, 1846, produced anesthesia with ether on himself and also on a patient and later gave the first public demonstration on October 16, 1846, before the surgical and medical staffs of the Massachusetts General Hospital, Boston. Morton had no knowledge of the work of Long which was done four years earlier. Jackson, a fellow townsman of Morton's, claimed to have suggested to Morton that ether should be used for the purpose of anesthesia in surgical operations. On March 8, 1847, Fluorens suggested that chloroform and ethyl chloride had anesthetic qualities but it remained for Simpson of Edinburgh after consulting Waldie, a chemist, to produce anesthesia by the use of chloroform for the first time in a human on November 4, 1847. In 1868 E. Andrews of Chicago first reported on the use of nitrous oxide supplemented by oxygen, the way in which the gas is commonly used at the present time. Alexander Crombil of Calcutta in 1881 first advocated the use of morphine as a premedication to anesthesia. It was not until 1912 that ethyl chloride was introduced in England as a general anesthetic.

In a general way, one can say that a general anesthetic is to be chosen in preference to a local anesthetic when it is impossible to inject a local anesthetic because the tissues are inflamed, when muscular relaxation is required, and in children and nervous individuals who cannot be controlled under a local anesthesia. In extensive operations in which the area to be invaded is too great for the practical use of a local anesthetic, general anesthetics are to be recommended. In oral surgery, spinal anesthesia obviously cannot be used.

Preparation.—For a general anesthesia, the patient should be properly prepared depending upon the procedure proposed and the type of individual on whom the operation is to be performed. Usually all food and water should be out of the stomach before administration of the anesthetic is started. A sedative of some type is usually an advantage. The routine in adults is often $\frac{1}{4}$ grain morphine and $\frac{1}{150}$ grain atropine. But type and amount of preliminary sedative will have to be varied according to the condition and age of the patient, and the procedure that is contemplated. In children and infants the sedative is often omitted and it is modified in the elderly and those suffering from disease where there might be a contraindication.

Nitrous Oxide.—Nitrous oxide, ever since its introduction, has been one of the favorite anesthetics for extraction of teeth and for operations where complete relaxation is not entirely necessary. It acts on the brain cells directly and not by depriving the cells of oxygen as was formerly supposed. Unless mixed with oxygen or air, it causes considerable asphyxia. On inhalation the gas is taken up by the blood without forming a new chemical compound with the hemoglobin and without decomposition within the body.

After it has been given for some time without oxygen, it has a direct depressing effect upon the respiratory center. When properly given with a correct proportion of oxygen, nitrous oxide is a less dangerous anesthetic than ether or chloroform and has less aftereffects than either of them. The sequelae are practically nil and the gas is pleasant to take. When given alone the blood pressure tends to be increased but when given with the proper amount of oxygen the blood pressure shows little change.

Indications and Contraindications.—In young children because of their immature musculature which causes breathing into a bag to be more difficult for them, it may not be a good anesthesia. In old persons and those with sclerosed arteries or pulmonary tuberculosis, those with diseases of the heart or patients with stasis of the neck vessels, and in individuals with obstructions of the air passages the anesthetic should be used with great caution; after carefully considering all of the factors involved and then the administration should be by a skilled administrator. In large, overdeveloped individuals and in alcohol addicts nitrous oxide may be difficult to use without a considerable amount of asphyxiation.

Nitrous oxide may be a good anesthetic for short operations about the mouth such as the opening of an abscess. If the operation is to be only a short one, it is only necessary to get the patient under the anesthetic by the use of the face mask. While he is coming out from under the anesthetic, which he will do in about one-half minute, the operation can be consummated.

By the use of a nasal inhalator and a pharyngeal pack, a more prolonged operation within the mouth can be accomplished successfully. On the average, however, one encounters considerably more bleeding than with a local anesthesia and this may handicap one in performing the operation in a graceful manner. At present nitrous oxide has ceased to be anesthesia of choice for the extraction of teeth and other small intra-oral operations. It is reserved, therefore, usually for those cases in which a local anesthetic is contraindicated. Thus, if the dentist is well trained in the application of local anesthesia, it may not be necessary for him to have a nitrous oxide equipment at his immediate finger tips, so to speak. Nitrous oxide is not inflammable and sometimes can be used fairly well when using the cautery or diathermic knife in the intra-oral region.

Administration of Nitrous Oxide Anesthesia.—As a rule, rubber props should be placed between the teeth and the patient should be given instructions to take slow full breaths during the administration. At first pure gas is given without air or oxygen but as soon as a state of narcosis supervenes, oxygen is gradually added to the anesthetic. After the administration ceases, the patient regains consciousness in about three to five minutes without marked disability or aftereffects. Rarely, vomiting may occur if the anesthetic has been somewhat prolonged. Then the patient should be allowed to lie quietly until he has completely recovered.

Stages of Nitrous Oxide Anesthesia.—The following stages of gaseous anesthesia may be noted:

1. The First Stage.—This stage is characterized by numbness in the limbs and other parts of the body, and a marked feeling of exhilaration follows. The patient tends to breathe more deeply, the pulse becomes fuller and the blood pressure tends to be raised somewhat.

2. The Second Stage.—The stage of excitement begins as consciousness is lost. The thoughts become muddled and the words uttered are incoherent. Muscular movement becomes somewhat purposeless. The pulse remains full, the respiration becomes somewhat more rapid and possibly somewhat deeper than normal. The pupils tend to be dilated and the eyelids may twitch. The patient still continues to swallow. There may be some stertor, and the skin tends to be dusky.

3. The Third Stage.—This stage is usually known as the stage of surgical anesthesia and with gaseous anesthesia may be induced rather quickly. The time of introduction depends upon the quantity of gas given and the induction period. By this time the breathing should be regular. The pulse becomes full and not much increased in rapidity. The patient's skin should be fairly pink if a sufficient supply of oxygen is being given. The eyelid and corneal reflexes tend to be abolished with nitrous oxide. There is a partial relaxation and the syncope reaction should be more pronounced. The main thing in this stage of the anesthesia is to get a careful balance in the proportion of gas and oxygen. With nitrous oxide this stage usually is accompanied by a certain degree of cyanosis. If respiration becomes more steady, one might not have complete anesthesia.

4. The Fourth Stage or the Stage of Overdose.—This may intervene because of some error in technic or because not enough oxygen is given. Breathing may become embarrassed and a tendency to convulsive muscular spasm may be evidenced. At times there is excessive breathing and then breathing may become difficult. As asphyxiation is increased, there may be muscular spasm. Following this stage is a stage of muscular relaxation. The pupils become widely dilated, the reflexes inactive, the pulse becomes poor in quality, and the respiration finally ceases. Considerable cyanosis may tend to accompany this final stage.

Ethylene.—In 1918 Luckhardt and Thompson began experimenting with ethylene and in 1923 Luckhardt and Carter demonstrated its clinical value and reported 106 cases operated upon under the gas. Ethylene has the disadvantage of being very inflammable. Properly administered it is a safe and good anesthetic. It gives good relaxation and with the proper amount of oxygen the patient may be carried with a good pink color. The after-effects are about the same as those after nitrous oxide except that there is a greater tendency to vomiting (about 16 per cent). It has marked analgesic properties. An extraction can be done with ethylene before consciousness is lost. By using a nasal inhaler analgesia may be continued indefinitely with an active lid reflex and a good color. Because of its well-known inflammability, many hospitals have ceased to use ethylene.

Cyclopropane.—Freund made trimethylene (cyclopropane) in 1882. In 1929 Lucas and Henderson first demonstrated its effectiveness as an anesthetic in animals. In 1930 Waters administered the gas for the first time to human patients. Since that time a good many reports have been made concerning the efficacy of the gas (Waters and Schmidt, Griffith, Bourne, etc.). The induction is rapid. Breathing is quiet. Circulation is not depressed. Relaxation is good. Recovery is rapid. In general, the physical signs of the anesthesia produced are comparable to those of ether. The exceptions are the lack of laryngeal spasm, respiratory stimulation, and the difficulty of discriminating between the third and fourth stages of the anes-

thesia. The relaxation given is comparable to ether. The mortality following the uses of this anesthetic is less than after ether but possibly somewhat greater than after nitrous oxide. The gas is administered in a ratio of 15 per cent cyclopropane and 85 per cent oxygen. A closed carbon dioxide absorption technic is usually used.

The technic of administration is described by Waters as follows: "Administration is begun in a very rapid flow of oxygen (8 to 10 liters per minute) into the mask as it is placed on the patient's face and continued until the mask, canister and bag are sufficiently filled to accommodate completely the patient's tidal excursion. At the same time, cyclopropane is introduced at a rate of 600 or 700 cc. per minute in average cases and continued for from thirty seconds to two or three minutes. The addition of cyclopropane is then stopped completely. An interval of several minutes must intervene before complete distribution to the tissues takes place and maximum narcotic effects result. In certain resistant individuals it may be necessary to give the gas for a few seconds at a more rapid rate, and in some very susceptible ones, or those heavily dosed with nonvolatile agents, a slower flow during induction is indicated.

"During the period of maintenance, a constant slow flow of oxygen should be added, approximating as nearly as possible the metabolic demand of the patient. This usually varies between 250 and 400 cc. per minute. An air-tight contact of the mask on the face simplifies maintenance of smooth anesthesia. A few minutes of observation usually suffices to determine the optimal constant flow of oxygen for a given patient. If physical signs indicate that the degree of narcosis resulting from the mixture originally used to fill the mask, canister and bag is insufficient, the flow of cyclopropane may be resumed for a time sufficient to enrich the mixture properly. If, on the other hand, the degree of narcosis is too profound as evidenced by physical signs, a rapid addition of oxygen for a brief period will reduce the potency of the mixture inhaled. The necessity for maintenance of unobstructed respiration is quite as important as with other agents. Pharyngeal airways are frequently used for this purpose."

Cyclopropane has the potency of chloroform and is not a respiratory stimulant. Therefore, the anesthetist who gives it should be experienced.

Ether.—Ether is probably the most fool-proof general anesthetic we have. This is due to the fact that, when ether is given, the respiration will stop a considerable while before the heart stops. In oral surgery and the general practice of dentistry, it is used in hospital work for those cases which require a fairly long operative period and when it is necessary to get complete muscular relaxation. The amount of bleeding is less than that with a gas anesthesia. It is, of course, not suitable to office practice as the length of time for recovery is from twenty-four to forty-eight hours.

Ether is a rather unpleasant anesthetic in many ways. A fairly long time is required for the production of anesthesia. Ether is somewhat irritating to the respiratory tract. At first there is an increased arterial pressure. The heart is said to be somewhat stimulated by it. There is an increase in the force and a slight increase in the frequency of the pulse.

Ether safely may be administered with the patient in a sitting position and it may be administered intranasally or intratracheally. In the latter case, the pharynx may be packed off from the oral cavity with wet cotton

or gauze so there is little danger of blood getting into the trachea. This is a particular advantage in the type of case where it is necessary to use a cautery or a diathermic knife. When these remarks are made, it is not forgotten that ether is highly inflammable but by this method the ether is given in a closed circuit fashion so that the ether vapor does not come in contact with the operative field. Another way to use ether for this type of operation is to stop the administration of the ether while the actual cauterization is going on. A third way of gaining sufficient time to complete a cautery operation by the use of ether is to get the patient fairly deeply under the anesthetic by the usual mask method. The patient then is elevated into a sitting position or a semireclining position. The depth of the anesthesia plus the cerebral anemia which results from changing the position of the patient may allow one to complete an operation which may take as long as twenty minutes without the administration of more anesthetic.

Stages of Ether Anesthesia.—It has become customary to divide general anesthesia, such as with ether or chloroform, into 4 stages:

Stage 1.—On the inhalation of ether first there is considerable irritation of the mucous membranes of the throat. Sensibility becomes somewhat numb and the patient approaches a state which might be termed "semiconsciousness." A very hurried operation may be performed during this latter stage without pain.

Stage 2.—This stage is commonly known as the stage of excitement. The patient becomes somewhat delirious and may attempt exaggerated muscular movements. The muscles are rigid. Respiration becomes rapid or may cease altogether on account of spasm of the glottis. At first the skin is red or even cyanotic. During this stage the reflexes are still present and the pulse is increased somewhat in both rapidity and volume. The pupils tend to be dilated and are still responsive to light.

Stage 3.—At the beginning of this stage the patient becomes quiet, the muscles become relaxed and the reflexes are lost. The pupils contract. The breathing becomes slow, deep and regular. The pulse rate returns to normal in both rate and volume. The skin normally is pink, warm and moist. This stage is known as the stage of surgical anesthesia and may be maintained for several hours. To produce it ten to fifteen minutes are usually required.

Stage 4.—When too much anesthetic is given the patient's breathing is interfered with. Breathing becomes stertorous or the respiration may become shallow and irregular, and may altogether cease. The pupils dilate and fail to light. Finally, the pulse becomes rapid and of poor quality. The patient becomes cyanotic or lividly pale. At last the patient ceases to breathe. Respiration usually ceases before the heart ceases. Cessation of the anesthetic and artificial respiration in most cases will result in the patient's recovery.

Methods of Administering Ether.—The following methods of administering ether are used:

Open-mask Method of Administering Ether.—Administration of ether by the open-mask method is used in intra-oral operations and for short operations which can be done after removing the mask and before the patient recovers. Operations upon the neck or side of the face may be carried

out by mask anesthesia by turning the patient's head to one side so that the anesthesia is out of the field of operation. As previously noted, if the patient is fairly well under an ether anesthesia he can be put in a sitting position and the state of narcosis will last for about twenty minutes due to the anesthetic and also to the anemia of the cerebral centers. For certain short operations, especially where a cautery is being used, this may be a rather expedient way to perform the operation.

Ether Anesthesia Through an Extra-oral Tube.—For operations on the lip and palate in children, we ordinarily use ether and it is blown over through an ordinary metal suction tube which has had the cap on the end of the tube removed. The tube is held directly above the mouth. This has the advantage that only the operator's own instruments and fingers are in the mouth. Periodically a suction tube may be placed back in the pharynx to remove blood and secretions. One can keep a child under five years of age well under an anesthetic for some time by this method, and we believe it most advantageous for such operations as harelip and cleft-palate repair. In older adolescents or in adults the procedure is not so good as one has difficulty in keeping the patient under the anesthetic.

Intrapharyngeal Anesthesia.—Ether in oral surgery is very often given by the intrapharyngeal method which consists of introducing two catheters through the nose into the pharynx. Number 18 soft-rubber catheters are passed through the nostril as far back as the pharynx. These are connected with the vaporizing apparatus by means of a Y connection. The proper length of the catheter is the distance from the nostril to the external ear. This method of administering ether has the advantage that the entire face except the part to be operated on can be covered by stretching a towel across it and the field of operation can be isolated and free from the anesthetist. If the operation is in the mouth, the back of the mouth can be packed with gauze thus preventing aspiration of mucus and blood into the chest. One may use oxygen or oxygen and nitrous oxide to get the ether over. This latter method allows one to use less ether and there is less cyanosis.

Intratracheal Anesthesia.—At the present time ether alone, nitrous oxide and oxygen supplemented by ether, cyclopropane supplemented by ether, nitrous oxide and oxygen alone, or cyclopropane and oxygen are used rather extensively for intratracheal anesthesia. Often intratracheal anesthesia is particularly advantageous for operations about the face, mouth and jaws.

Dr. F. E. Davis, the anesthetist at the University of Kansas Hospital, has been kind enough to write the following brief outline of the technic of introducing an endotracheal catheter:

"In general there are two types of endotracheal catheters in use, the McGill and the woven silk or straight catheters. The McGill catheters are of fairly firm, smooth walled rubber tubing having rather thin walls to allow the lumen to be as large as possible. The catheter has a curve roughly approximating the curve through the nose, nasal and oral pharynx and vocal cords. The woven silk catheters and flexible metal catheters are straight but may be bent to some extent to allow insertion through the mouth. They are not passed through the nose."

Technic of Introducing an Endotracheal Catheter (F. E. Davis, M. D.).—Induction of anesthesia is carried out in the usual manner using

straight ether, gas-ether, cyclopropane, or avertin-nitrous oxide sequence. Anesthesia is carried down to the upper level of third plane anesthesia and if a closed technic is being employed the CO_2 is allowed to accumulate to a point where an active hyperpnea is present. If an open technic is used, CO_2 from an outside source may be used. The hyperpnea causes the cords to open widely and allows much easier passage of the tube.

In some cases a spray of 10 per cent cocaine solution or 5 per cent butyn used in the nose once or twice immediately preceding the anesthetic

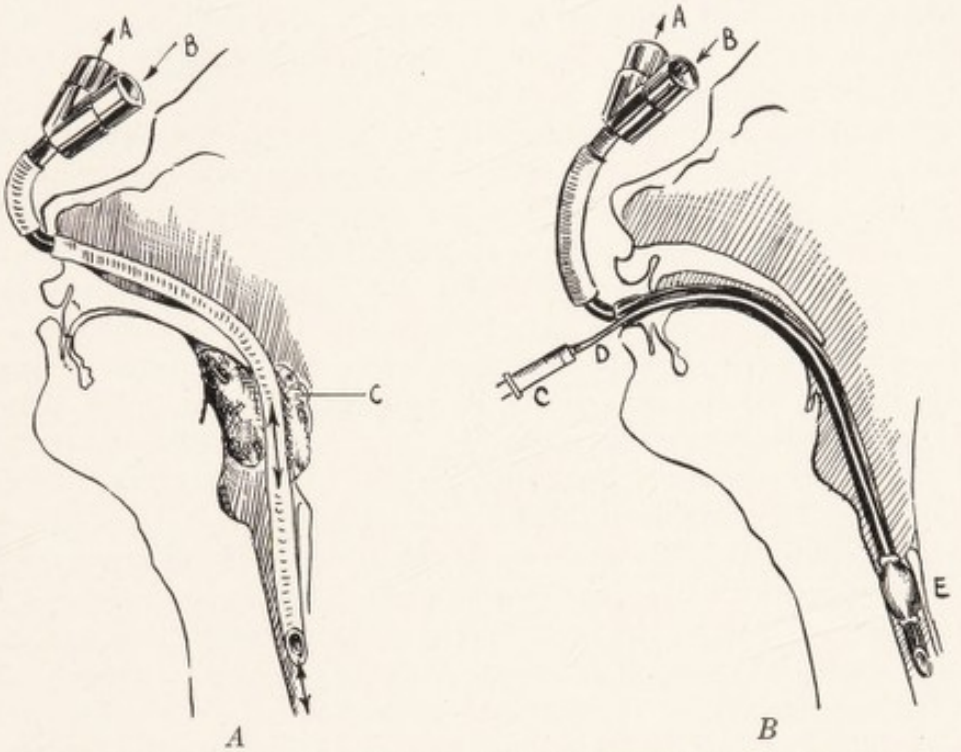

Fig. 334.—*A*, Endotracheal catheter which is inserted in through the nose. A, Outlet; B, intake; C, moist cotton or gauze packed around the catheter in the pharynx so that ether vapor does not enter the mouth or the nose. One can use a cautery in the mouth by this method during the administration of ether anesthesia. *B*, Endotracheal catheter inserted through the mouth into the trachea and made air-tight by means of a surrounding rubber balloon. A, Exit for gas or vapor; B, intake; C, syringe by means of which air is injected through the catheter (D) into a fine rubber coat which tightly surrounds the catheter giving a closed circuit. The type of mechanism was invented by Waters. E is the rubber coat into which the small catheter is inserted which is blown up with air.

will reduce the laryngeal reflex markedly and allow easier passage of the catheter.

As soon as the patient is deeply enough anesthetized, the head is elevated on a pad to about 6 to 10 cm. above the normal level and is tilted back until the mandible becomes perpendicular with the horizontal. The patient is now ready for the insertion of the endotracheal tube. Either of the following technics may then be employed.

Intubation Through the Nose.—A McGill soft-rubber catheter, as large as can conveniently be passed through the nose, is lubricated well with white vaselin and introduced into either nostril (Fig. 334, *A*) so that it passes into the nasopharynx without undue force. With the patients head squarely in the anteroposterior position the tube is advanced into the oro-

pharynx. The proximal end of the tube is held near the anesthetists ear and the tube slowly advanced; if the position is correct a hollow blowing sound will be heard indicating that the distal end of the tube is opposite the cords. As the patient inspires the tube is then advanced rapidly and in some 60 per cent of the cases it will enter easily into the trachea, the natural curve of the catheter facilitating this maneuver. The catheter should be advanced about 5 cm. or so from the cords. If the catheter is advanced too far one of the bronchi will be occluded and the breathing will become unilateral. This must always be checked by exposing the patient's chest and noting if both sides expand equally on inspiration. If a unilateral respiration is noted the condition is easily corrected by retracting the catheter a few centimeters.

In some 40 per cent of the cases the catheter will not enter the trachea but continue to enter the esophagus in spite of all the manipulation possible. In such cases a laryngoscope, preferably of the Guedel type, should be used. The laryngoscope is held in the left hand and the blade is carefully inserted in the patients mouth while the fingers of the right hand serve to spread the jaws and steady the instrument. The blade of the laryngoscope is used to depress the base of the tongue and is advanced toward the posterior wall of the pharynx until the epiglottis is visualized. The blade of the instrument is passed posterior to the epiglottis and the glottis visualized. If necessary the head may be still further extended to facilitate the exposure. The tongue is kept on the left side of the instrument as much as is possible and the upper teeth are protected from any force, otherwise they will break easily. The endotracheal tube is visualized and the end picked up with a pair of off-set forceps passed through the laryngoscope, and gently eased into the slit between the cords. Usually, immediately following the passage of the catheter the patient will hold the breath for an instant or two but this is no serious matter as long as the lumen of the catheter is open and the catheter is in the trachea.

Intubation Through the Mouth.—If it is necessary that the tube be introduced through the mouth (Fig. 334, *B*), either from choice or because of the nature of the operation, the same technic is used in introducing the laryngoscope as was described for endotracheal intubation through the nose. Usually the silk woven catheters are used in this manner. Always remember to introduce a mouth gag of some sort into the mouth so that the patient's teeth cannot close upon the tube and clamp it off after the laryngoscope is removed.

Guedel and Waters have devised a small, inflatable rubber cuff which is slipped over the distal end of the catheter. After this catheter is in position the cuff is inflated by means of a small rubber tube running parallel to the catheter. This arrangement is very satisfactory as it makes an air-tight seal in the trachea, allowing the use of the closed technic and preventing foreign material from being aspirated.

If the inflatable cuff is not used it is advisable to pack the oropharynx with moist gauze to prevent leakage of gas and aspiration of blood, etc. If blood or mucus should accumulate in the catheters it may be aspirated by means of a small catheter connected to a suction machine. This catheter is introduced through the lumen of the endotracheal tubes. Roverstine has recently invented a very fine device to facilitate this maneuver without

interrupting the closed technic. If the obstructing material cannot be removed a new endotracheal tube should be introduced; usually this is very easy and does not require a laryngoscope.

When endotracheal anesthesia is used for children, as in operations for cleft palate, harelip, etc., it is important that as much mucus be aspirated from the posterior pharynx as is possible before introducing the catheter. In children especially, as large an endotracheal catheter as possible should be used to allow free breathing. If small amounts of mucus collect in the catheter a slight increase in the pressure of the anesthetic gas or vapor will clear the tube.

Once the endotracheal catheter is in position it should be fastened with one or two narrow pieces of adhesive tape. Any technic may be used with the endotracheal catheters, probably the closed carbon dioxide absorption technic is the most satisfactory.

Chloroform Anesthesia.—Chloroform is a much faster anesthesia than ether and it is more dangerous because the heart is affected as quickly or even quicker than the respiratory center. If one understands the giving of chloroform, however, it is a very good anesthesia for certain purposes and in oral surgery it has one or two distinct indications, I believe. When one wishes a short anesthesia with fairly good relaxation and with little postoperative effect, chloroform is a good anesthetic. An example of an operation of this type is where one wishes to place radium needles or radon seeds well back in the pharynx or posterior tongue. One can get the patient moderately well under the chloroform and place the seeds or needles before the patient comes out from under the anesthetic. Afterward the postoperative effects are slight or nil. This is particularly advantageous in elderly people whom one wishes to bother as little as possible with an anesthetic.

Chloroform properly given may be a good anesthetic to use when one is using the cautery. It is not inflammable and the relaxation is good. For such operations it has certain advantages. Chloroform may be preferable to ether in patients with a chronic bronchitis or asthma.

In this country, however, at the present time chloroform is not a popular anesthetic and the majority of men use either ether or gaseous anesthesia in preference.

There tends to be a slight fall in the blood pressure when chloroform is given. It is a very pleasant anesthetic to take, it produces little excitement and little irritation to the respiratory passages. In rare instances chloroform may cause an acute atrophy of the liver after it has been given during a long operation. However, for a short operation there is little indication that these changes occur. Chloroform is given ordinarily by the open drop method and considerable care should be taken that the patient does not take a long deep inhalation during the induction when there is considerable chloroform on the mask. In the majority of cases when accidents occur from chloroform, it is during induction and is due to the fact that the patient struggles, breathes deeply and takes too much chloroform at one inhalation.

Vinyl Ether or Vinethene.—Leake and Chen first suggested vinyl ether. It is a volatile liquid. Considerable study of its anesthetic properties has been done by a number of men (Goldschmidt, Ravdin, Lucke, Müller.

Johnson and Ruigh). The anesthetic is recommended as being less of a cardiac depressant. There is less likelihood of causing liver damage than with chloroform. In comparison with ethyl chloride, it can be used over a long period of time. Anesthesia is produced with great rapidity and only a small amount is required to produce complete relaxation but some difficulty will be experienced in maintaining a smooth, long-sustained anesthetic. Its chief usefulness would seem to be for minor operations of short duration or as a supplementary anesthetic to such anesthetics as avertin. Gunter, Beach and Looby recommend the anesthetic for the extraction of teeth and in ambulatory patients.

Avertin.—Avertin (tribromethanol) within recent years has been used extensively and the literature on it is rather voluminous. In this country White and Kreiselman, and Speidel, have written articles. The anesthetic is given by rectum. Consequently, it has advantages when working around the face, mouth and jaws, especially when using a cautery, as the anesthetist is entirely out of one's way. Sometimes it is necessary to use a supplementary anesthetic such as ether, etc., by inhalation, or some local anesthesia may be used to supplement it when the anesthesia is not complete. But in many instances a complete operation can be performed without any supplementary anesthetic.

There is one disadvantage. It takes the patient a good deal of time to recover from the anesthetic. This may be a disadvantage in elderly people as the tendency for respiratory affections is likely to be increased especially when the operation has been done in the oral region. For certain operations in which the cautery is used, avertin really makes an ideal anesthetic and in certain selected cases which are likely to take a long period of time it may be advisable to use it. During the stage of recovery in oral operations, an attendant must be with the patient constantly to keep the tongue forward and to insure an open airway. One can overcome this difficulty by the insertion of a Connell tube.

Administration of Avertin.—An enema is given before the operation. One-half hour prior to the administration of the anesthetic, an ordinary dose of morphine is given hypodermically. Ninety mg. per kilogram of body weight is a good average dose. Directions for mixing the solution accompany the drug and these should be followed rigidly, as very irritating products may be liberated if the drug is not properly mixed. By means of a small rectal tube one-half hour before the operation, in the patient's room the drug is inserted into the rectum. There is no stage of excitement or muscular rigidity. The anesthetic takes effect in about twenty to thirty minutes. An operation requiring from one-half hour to two hours may be accomplished before the patient becomes restless. There is no postoperative pain or vomiting, nor other disability or aftereffect. In cases of severe diseases of the kidneys, advanced pulmonary tuberculosis, ulcerative diseases of the rectum and colon, and in acidosis, the drug is contraindicated.

Ethyl Chloride.—Ethyl chloride is a very rapid general anesthetic and leaves few aftereffects and may be employed with a fair degree of safety for a short operation. The operation is done after removing the anesthetic mask. It is doubtful whether or not such an anesthetic is justifiable when we have much safer anesthetics. Statistics show that the mortality rate from ethyl chloride is between 1 in 2000 and 1 in 3000.

Somnoform—a mixture of ethyl chloride 60 per cent, methyl chloride 35 per cent, and ethyl bromide 5 per cent—is sometimes used but the same objections are applicable as to ethyl chloride.

Evipal.—Evipal (n-methylcyclohexenylmethyl barbituric acid) produces a short anesthesia of from fifteen to twenty minutes. It is given intravenously (forearm vein) in a 10 per cent solution during a period of two minutes in sufficient dose to produce narcosis.

Although evipal (evipan) was only introduced in 1933, there is already a voluminous literature upon the subject. Reports are available on a considerable series of cases (Jarman and Abel, 2000; Brun, reported by Monod, 1500; Jentzen, 1057; Grenade, 1000, and so forth).

In a report on the clinical value of evipal soluble by the Anesthetics Committee of the Medical Research Council (British Medical Journal, July 8, 1933) it is stated that "for those who like intravenous methods it is certainly an admirable means of inducing anesthesia, all opinion agreeing as to the rapidity and pleasantness with which the patient becomes unconscious."

Evipal is a nonvolatile drug; it is detoxicated rather rapidly. The drug disintegrates in the organism. Most of it disintegrates in the liver. Only a trace of the drug is eliminated in the urine. The blood pressure is usually reduced at first by from 15 to 20 mm. of mercury. The pulse remains full and regular. When an overdose is given respiration ceases before the heart is affected. Within a few minutes after the injection, the patient becomes drowsy and falls asleep. As injection continues, twitching of the face muscles or some slight generalized movement may occur. Muscular relaxation sets in early and the jaw tends to drop. The pulse remains unchanged but may be more regular and fuller than normal.

The average patient awakens after fifteen to twenty minutes and complete recovery from the aftereffects is ordinarily strikingly rapid. In children and in some adults there may be slight postoperative restlessness or excitement.

The dosage is based on the reaction of the patient. The majority of adult patients require from 2 to 4 cc. to become unconscious. After waiting thirty seconds 1 or 2 cc. more are given. Thus, a dosage of 3 to 6 cc. is sufficient for minor procedures. Supplementary amounts are required for operations lasting from twenty to thirty minutes. The drug therefore is given in divided doses. Not more than 10 cc. should be given to an adult.

The contraindications to the anesthetic are stated to be inflammatory processes of the throat, bronchiectasis or any condition in which respiratory obstruction exists. This is due to the fact that barbituric compounds may cause spasm of the larynx. If respiration is depressed, oxygen or carbon dioxide should be given.

This anesthetic is suitable for short surgical procedures which can be done in fifteen to twenty minutes. These include incision of abscess, removing foreign bodies, reducing dislocations and possibly fractures, and the implantation of radium needles or radon seeds. Recently the Council on Chemistry and Pharmacy of the American Medical Association has reported certain fatalities when this anesthetic was used.

THE SELECTION OF THE ANESTHETIC

Thus, anesthesia for operations involving the nose, mouth and neck frequently represent problems not encountered in the usual run of operations, and special technics are of value.

By way of illustration, we might state some of our own preferences in regard to anesthesia at the present time.

We prefer to use a local anesthesia for most small intra-oral operations (see Chapter XIII). However, when the disadvantages of gas anesthesia are given due consideration for certain selected patients, it is nearly an ideal anesthetic—especially for short operations.

For neck dissection en bloc infiltration plus block anesthesia is an almost ideal anesthesia. We feel that one loses less blood, strikes tissue planes with greater ease and, on the whole, the patient is in better shape if he returns to the ward conscious, not sweating, not vomiting, and is able to sit up and swallow a hot stimulating drink.

Whenever possible for small plastic procedures on the face or nose, local anesthesia is used. Both block anesthesia and infiltration are selected as required to gain good anesthesia. In the majority of large plastic procedures on the face or within the mouth, intrapharyngeal ether anesthesia or avertin anesthesia is used. When it seems likely that some blood will trickle into the pharynx, intratracheal anesthesia with ether or preferably cyclopropane is given. This allows one to pack the pharynx and prevent the aspiration of secretions.

In some of the heavy operations upon the jaw, such as resection in an adult, local anesthesia may be quite satisfactory and is usually used if it is considered that the patient is a suitable one for local anesthesia. In those who are not, and in adolescents, ether anesthesia by the vapor method or cyclopropane is used intranasally or intratracheally.

In operations upon cleft palate, usually ether vapor is employed. As previously stated, it is blown over through a tube held in the hand of the anesthetist. In children the same method is used for operations for harelip. In adults a harelip is sometimes repaired by using block anesthesia. In an adult with a cleft palate ether is usually given intratracheally.

In wiring the lower to the upper teeth in fracture of the jaw, one can, in many cases, perform the operation very expediently without other aid than that of local anesthesia. Others, because of some manipulation or general soreness, may require an ether vapor anesthesia. Food is withheld for at least twelve hours before and after the operation and the stomach is emptied on the operating table with a stomach tube.

In operations upon the upper jaw of wide extent such as is entailed in certain types of rather advanced malignancies, either cyclopropane or vaporized ether often is given intratracheally. When the cautery or diathermic knife is used, either the ether is cut off for the time being or a closed connection is made with the trachea by means of a special intratracheal catheter and special packing of the pharynx with wet cotton or gauze. We have never had an explosion.

No anesthetic is ideal. Each has its advantage and disadvantages. Each of the commonly used general anesthetics under certain conditions has its place and may be the best under the conditions likely to be encountered. The selection of the anesthetic has therefore to take into account many

factors so variable that dogmatic statements can hold only if the many exceptions are carefully noted. Experience in surgery and the anesthesia of a given field is necessary before one will be able to select the best anesthetic for a given patient.

Bibliography

Bibliography Quoted in Text

Local Anesthesia

Braun, H.: Local Anesthesia, Phila., Lea and Febiger, 1914.
Einhorn, Niemann, Koller and Wood: Quoted by Gwathmey, J. T., in Anesthesia, New York, The Macmillan Co., 1929.

Historical Note

Andrews, Crombil, Faraday, Fluorens, Long, Pierson, Riggs, Stockman and Wells: Quoted by Gwathmey, J. T., in Anesthesia, New York, The Macmillan Co., 1929.
Colton, J. Q.: Anesthesia, Who Made and Developed This Great Discovery? New York, A. G. Sherwood Co., 1896.
Davy: Researches, Chemical and Philosophical, Chiefly Concerning Nitrous Oxide, London, 1800.
Hickman, H. H.: A Forgotten Pioneer of Anesthesia, Brit. Med. Jour., p. 843, April 13, 1912.
Morton, Wm. F. G.: J. M. Patton, Anesthesia and Anesthetics, Chicago and Cleveland Press, 2nd ed., p. 17, 1906.
Memorandum Relating to the Discovery of Surgical Anesthesia, Relation to This Event, New York, 1905.
Morton, Elizabeth: The Discovery of Anesthesia, McClure's Magazine, Sept., 1896.
Priestley: Memoirs of Joseph Priestley to the Year 1795, p. 1, 1803.
Simpson, Sir James: New Anesthetic, p. 7, 1847.
Illustrated London News, **370:** 2, Dec. 4, 1847.
Anesthesia, etc., New York, D. Appleton Co., 1872.
Warren, J. C.: The Influence of Anesthesia on the Surgery of the Nineteenth Century, 1896.

Ethylene

Luckhardt, A. R., and Carter: J.A.M.A., **81:** 1851, Dec. 1, 1923.
Luckhardt, A. R., and Carter: J.A.M.A., **80:** 765, March 17, 1923.
Luckhardt, A. R., and Carter: J.A.M.A., **80:** 1440, 1923.
Thompson: Quoted by Luckhardt and Carter.

Cyclopropane

Boure, W.: Cyclopropane Anesthesia in Obstetrics, Lancet, **2:** 20, July 7, 1934.
Von Freund, August: Ueber Trimethylene, Monatschr. f. Chemie, **3:** 625, July 13, 1882.
Griffith, H. R.: Cyclopropane Anesthesia: A Clinical Report, 350 Administrations, Canad. Med. Assoc. Jour., **31:** 157, August, 1934.
Cyclopropane Anesthesia, Anesth. and Analg., **14:** 253, Nov.–Dec., 1935.
Guedel: Quoted by Waters, R. M., and Schmidt, E. R.: Cyclopropane Anesthesia, J.A.M.A., **103:** 975, Sept. 29, 1934.
Lucas, G. H. W., and Henderson, V. E.: A New Anesthetic Gas, Cyclopropane, Canad. Med. Assoc. Jour., **21** (2): 173, August, 1929.
Roverstine, E. A.: Cyclopropane Anesthesia in Thoracic Surgery, Anesth. and Analg., **14:** 270, Nov.–Dec., 1935.
Schmidt, E. R., and Waters, R. M.: Cyclopropane Anesthesia, Postoperative Mortality in 2200 Cases, Anesth. and Analg., **14:** 1, Jan.–Feb., 1935.
Waters, R. M., and Schmidt, E. R.: Cyclopropane Anesthesia, J.A.M.A., **103:** 975 Sept. 29, 1934.

Vinyl Ether

Chen and Leake: Quoted by Blair, V. P., and Ivy, R. H.: Essentials of Oral Surgery, p. 591, St. Louis, C. V. Mosby Co., 2nd ed., 1936.
Goldschmidt, S., and Others (Ravdin, Lucke, Müller, Johnson and Ruigh): Vinyl Ether, Preliminary Report, J.A.M.A., **102:** 44, 1934.

Gunter, John H., Beach, Edward W., and Looby, J. P.: Use of Vinyl Ether as a Dental Anesthetic, Internat. Jour. Orthodont. and Oral Surg., **22:** 748, 1936.

Avertin

Speidel, F. D.: Avertin Basal Anesthesia, Amer. Jour. Surg., **9:** 73, 1930.
White, C. S., and Kreiselman, J.: Tribromethyl Alcohol (Avertin) Anesthesia, Surg., Gynec. and Obst., **51:** 361, 1930.

Evipal

Brun (reported by Monod, R.): Bull. et mém. Soc. nat. de chir., **61:** 396, No. 10, 1935.
Grenade, L.: Le scalpel, No. 4, p. 150, Jan., 1934.
Méd. d'Alsace Lorraine, No. 10, 1934.
Rev. méd. chir. Afrique du Nord, No. 263, p. 1719, 1934.
Liège méd., **27:** 438, April 1, 1934.
Jarman, R.: Proc. Roy. Soc. Med., **28:** 341, Jan., 1935.
Jarman, R., and Abel, A. L.: Lancet, **2:** 19, July 1, 1933; **1:** 510, March 10, 1934.
Brit. Med. Jour., **2:** 796, May 5, 1934.
Anesth. and Analg., **14:** 54, March–April, 1935.
Jentzen: Presse méd., No. 85, p. 1670, 1934.
Monod, R.: Gaz. d. hôp., **106:** 1474, Oct. 14, 1933.
Presse méd., **42:** 321, 1934.
Bull. et mém. Soc. nat. de chir., **61:** 396, No. 10, 1935.

INDEX

Abbe operation for tight upper lip, 425
Abrasion of teeth, 100
Abscess, 75
  lung, 88
  peritonsillar, 255
  retropharyngeal, 256
    clinical features, 256
    treatment, 256
  tonsillar, 255
Achondroplasia, deforming, 693
Actinomycosis, 233, 268
  of face, 233
  of jaw bones, 306
  of neck, 233
    bacteriology, 234
    clinical features, 235
    diagnosis, 235
    pathogenesis, 233
    pathology, 234
    prognosis, 236
    treatment, 235
  of salivary gland, 332
Acute ulceromembranous gingivitis, 170
Adamantinoma, 676
  clinical features, 678
  definition, 676
  diagnosis, 670
  pathogenesis, 676
  pathology, 677
  roentgenogram in, 679
  treatment, 680
Addison's disease, 254
Adenoma, 518
  of lachrymal glands, 518
  of salivary glands, 518
Affected part, examination of, 22
Age at which to operate for cleft palate, 433
Agranulocytic angina, 253
Agranulocytosis, 253
Alcohol injection for trigeminal neuralgia, 338
  relationship to cancer, 527
Aleukemia. See *Leukemia.*
Allergic gingivitis, 170
Alveolar bone, growth of, 352
Alveolar process
    cleft of, 398
      Brophy procedure for closure of, 400
      Davies-Colley procedure for closure of, 404
      Davis procedure for closure of, 401
      forceful approximation of in single cleft, 398
      Lane operation for closure of, 404
      Logan turn-over flap procedure for closure of, 403
      nonforcible closure of in single cleft, 402
      procedure for double cleft, 407
      Ritchie procedure for closure of, 401
Alveolar process
    cleft of, simple coaptation of anterior end of mucoperiosteal flaps, 403
      turn-over flap for closure of, 403
      Veau procedure for closure of, 404
    fracture of, 102
      diagnosis, 102
      treatment, 102
    resection of inferior, 717
Alveolectomy, 224
  postoperative care, 226
Alveolodental abscess
    acute, 181, 182, 183
    chronic, 184
Anatomy of dislocation of mandible, 149
Anemia in cleft palate, 440
Anesthesia, 773
    avertin, 786
    block, generally, 774
      for second and third divisions of fifth nerve, 775
  chloroform, 785
  cleft palate, for, 435
  conduction, for
    extraction of teeth, 205
    of mandible, 207
    of maxilla, 204, 205
      long buccal injection, 209
      lower six molars, 207
      mandibular injection, 207
      mental injection, 209
  cyclopropane, 779, 780
  ether, 780–785
  ethylene, 779
  evipal, 786
  fractures of jaws, for, 94
  general, 776
    history of, 776
    preparation of patient for, 777
  infiltration, for extraction of teeth, 199, 203
    generally, 774
  intrapharyngeal, 782
  intratracheal, 782
  local, 773
    cocaine, 773
    ethyl chloride, 773
    infiltration in, 774
    nerve block with, 774
    novocain, 773, 774
  neck dissection, for, 776
  nitrous oxide, 777–779
  novocain, 773
  selection of, for various operations, 788
  teeth, for removal of, 199
  unusually prolonged after removal of teeth, 224
  vinethene, 785
  vinyl ether, 785
Angina, agranulocytic, 253
Angina, Ludwig's, 283. See *Ludwig's angina.*

Ankyloglossia, 483
Ankylosis of temporomandibular joint, 316. See *Temporomandibular joint, ankylosis of.*
Anthrax, 253
  of mouth, 254
Antrum
  anatomy of, 42
  benign tumors of, 516
  carcinoma of. See *Carcinoma of antrum.*
  fistula of, 275
  inflammations of, 272
    tooth antritis, 272
      clinical features, 273
      diagnosis, 274
      pathology, 272
      treatment, 274
  inflammations of, chronic, 275
    operations for
      Caldwell-Luc, 277
      Denker, 277
      Kuster, 277
      pansinusectomy, 278
  management of lymphatic areas in carcinoma when glands are not palpable, 647
Aphthae, 251
  Bednar's, 250
  chronic, 250
  tropical, 250
Aphthous stomatitis, 241
Arsenic stomatitis, 250
Arthroplasty for prognathism, 373
  of temporomandibular joint, 316
Artificial dentures, surgical preparation for, 755–759
  larynx, 637
Asepsis, 51
  historical résumé of, 51
Atrophic gingivitis, 168
  tongue, 267
Atrophy of jaw bones, 310
Avertin anesthesia, 786
Axhausen operation for cleft palate, 460

Bacteremia, 76
Bacterial invasion, 71
  irritation, relationship of cancer to, 527
Barton bandage, simplified, 128
Bednar's aphthae, 250. See also, *Aphthae Bednar's.*
Benign tumors. See *Tumors, benign.*
Bismuth stomatitis, 249
Black tongue, 267
Blair advancement operation for harelip, 425
  operation for carcinoma of the tongue, 629
Blastomyces, 254
Blastomycosis, 236
  clinical features, 236
  treatment, 236
Blood grouping, 85
  vessel tumors of pharynx, 514
Bone, cysts of, 709
    coronodental, 680. See also *Coronodental cysts.*
    dental, 674. See also *Dental cysts, simple.*
    hemorrhagic, 710
    osteitis fibrosa, cyst in, 709
    traumatic, 710
Bone, growth of
    alveolar, 352
    mandibular, 351
    maxillary, 352
Bone, tumors of
    adamantinoma, 676. See also *Adamantinoma.*
    chondroma, 690
    chondromyxoma, 693
    epulis, 684. See also *Epulis.*
    Ewing's tumor, 702. See also *Ewing's tumor.*
    exostoses, 690. See also *Exostoses and Osteochondromas.*
      multiple, 693
    fibroma, 690
    giant cell tumor, 705. See also *Giant cell tumor.*
    hyperparathyroidism, 710
    metastatic tumors, 711
    myeloma, 704. See *Myeloma.*
    odontoma, composite, 682. See also *Odontoma.*
      connective tissue, 682
    osteitis fibrosa. See *Osteitis fibrosa cystica.*
    osteogenetic sarcoma, 695. See also *Osteogenetic sarcoma.*
    osteoma, 690, 692
    periosteal sarcoma, 703
Boric acid, 56
Branchial apparatus
    cysts of, 492, 493, 494
    embryology of, 489–491
    sinuses of, 492, 493, 494
Branchial fistula of neck, 489
    of pharynx, 488
Branchiogenic carcinoma, 500. See *Carcinoma, branchiogenic.*
Branchiogenic cysts and sinuses
      clinical features, 492
      diagnosis, 493
      treatment, 493
Braun operation for repair of parotid duct, 752, 753, 754
Brophy operation for closure of alveolar cleft, 400
Buccal cavity
    inflammations of, chronic, 259
    keloid of, 514
    tuberculosis of, 261
Buccal floor, carcinoma of, 536
  pharyngeal carcinoma, 530–533

Caldwell-Luc operation, 277
Cancer. See *Carcinoma* and *Epithelioma.*
Cancrum oris
    clinical picture, 230
    diagnosis, 231
    etiology, 230
    prognosis, 231
    treatment, 231
Canine fossa, anatomy of, 38
Carbuncle of face, 229
Carcinoma
  anesthesia in operations for, 602
  branchiogenic, 600
    clinical features, 561
    operations for, 626, 627
    pathology, 546

Carcinoma
branchiogenic, treatment, 626
cutis
pathology, 534
prognosis, 657
radium treatment, 586
surgical treatment, 603
therapy, 657, 658
epidermoid
of pharynx and posterior tongue, 554
melano-epithelioma of pharynx, 544
clinical features, 554
diagnosis, 554
management of lymphatic areas tributary to, 639
radium treatment, 595–597
surgical treatment, 620–626
types
lympho-epithelioma, 555
Schneiderian, 541, 556
squamous cell, 554
transitional cell, 540, 555
of antrum
clinical features, 560
pathology, 544
prognosis, 663
radium treatment in, 594, 595
therapy in, 662
of buccal floor
clinical features, 552, 553
diagnosis, 552
pathology, 536
of buccal pharynx, 530
chance of development of second cancer, 533
in young, 533
incidence, 531, 532
of cheek
clinical features, 552
pathology, 535, 536
prognosis, 661, 662
radium treatment in, 589
therapy, 661, 662
of epiglottis
Kocher normal excision for, 628
of face
clinical features, 548, 549
diagnosis, 548, 549
pathology, 534
treatment, 586
of laryngopharynx
clinical features, 557, 558, 559
incidence, 533
prognosis, 665
therapy, 664
of larynx, 538
clinical features, 557, 558, 559
laryngectomy, 632, 633, 664, 665. See *Laryngectomy*.
laryngofissure for, 630, 631, 632
operations for, 616–620
pathology, 542
prognosis, 666
therapy, 664, 665
of lip
clinical features, 549, 550, 551
operations for
complete removal of lower lip for and repair, 609
excision of three fourths of lower and repair, 607
Carcinoma of lip
operations for, historical, 604
mortality, 651
total removal of and repair, 649, 650, 651
transplant flap from upper to lower, 606, 607, 608
v-shaped excision for, 605
pathology, 535
prognosis, 658
radium treatment in, 587
therapy, 658
of lymphatic glands of neck
conclusions in regard to nonpalpable nodes, 646
diagnosis of palpable glands, 644
management of, 599
mortality of, 651
mortality of neck dissection for, 645
percentage of cases developing metastasis, 642
procedure as to location when nodes are not palpable, 647
radium treatment for, 600, 644
relationship of size or state of advancement of local lesion, 645
removal of, 649, 650, 651, 662, 663, 664
when capsule of gland is perforated by carcinoma, 648
when glands are bilaterally involved, 649
when glands are not palpable, 640, 641
when nodes are palpably enlarged but freely movable, 647, 648
of mandible
destruction of lengthwise section of, 617
incidence, 531
operations for, 649–655
pathology, 538
prognosis, 662
therapy, 593, 662
of maxilla
incidence, 531
operations for
destruction of alveolar process, 619
endothermic enucleation for, 618
pathology, 539
of mouth
clinical features, 562, 563
incidence, 552
pathology, 536, 537
treatment, 627
of nasal sinuses
pathology, 544
treatment, 595
of nasopharynx
incidence, 531
pathology, 539
radium treatment, 595, 596
treatment, 595
of neck
clinical features, 561
pathology, 547
treatment, 585, 603
of nose
radium treatment, 595, 596
treatment, 585, 603
of palate
clinical features, 552

Carcinoma of palate
prognosis, 661, 662
radium treatment, 590, 591
treatment, 661, 662
of paranasal sinuses
pathology, 539
prognosis, 554, 663
of parotid gland
clinical features, 561
operations for, 625, 626
pathology, 545
prognosis, 666, 667
of pharynx
clinical features, 562
final period, 563
incidence, 531
management of lymphatic areas, 647
operations for
hypopharynx, 621, 624, 625; mesopharynx, 620
lateral pharyngotomy for, 621, 622, 623, 624, 625
nasopharynx, 620
transhyoid pharyngotomy for, 623
pathology, 539
adenoid cystic, 542
lympho-epithelioma, 541
Schneiderian, 541
squamous cell, 539
transitional cell, 540
prognosis, 664
radium therapy, 595, 596, 597
therapy, 664
of salivary glands
clinical features, 561
pathology, 545
prognosis, 666
treatment, 625, 626
of skin
clinical features of, 548
pathology, 534
types of
basal cell, 548
squamous cell, 549
of soft tissues, 525
biopsy, 525
diagnosis, 525
relationship of
alcohol, 527
bacterial irritation, 527
chronic inflammations, 528
inclement weather and sunshine, 526
leukoplakia, 528
luetic scars, 528
papillomas, 528
precancerous lesions, 527
preparation of patient for operation for, 602
tobacco, 526
trauma, 529
value of histologic prognosis in, 530
warning against local irritants in, 525
of tongue
clinical features, 552
management of lymphatic glands of, 647
operations for
bilateral approach for removal of, 614
bilateral excision through mouth, 629
Blair operation for removal of, 629
Carcinoma of tongue
operations for excision of one-half of, 627
excision of varying unilateral portion of, 611
removal of, 614
submandibular lateral approach for excision of, 613, 614
total removal of, 629
v-shaped excision of, 610
pathology, 536, 539
prognosis, 661
radium treatment in, 591, 592, 593
therapy, 659–660
transitional cell
clinical features, 555
Cardiorenal complication following operation, 88
Carotid gland, tumor of
symptoms, 516
treatment, 517
Cartilage grafts. See *Grafts.*
Catarrhal stomatitis, 241
Cellulitis of face, 22
of neck, 285. See *Lymphadenitis.*
of tongue, 251
Cephalic tetanus, 78
Chancre of lip, 239
of mouth, 262
Chancroid, 255
Cheek
carcinoma of, 661, 662. See *Carcinoma of cheek.*
undermining of, in cleft lip operation, 411
Cheilitis exfoliativa, 239
glandularis apostematosa, 239
Chemotaxis, 71
Chloroform anesthesia, 785
Chondroma, 693
of pharynx, 515
Chondromyxoma, 693
Cicatrix, resurfacing of tissue after removal of, 730
Cleft lip
advancement operation for, 425
associated with deformity of nose, 410
correction of nasal deformity, 413
dressing after operation, 429
operations for double
method of lengthening columella, 424
operation favored personally, 420
other useful operations for, 420
Rose operation, 422
Thompson, 422
operations for single, 410–428
Gillies, 426
Mirault-Blair, 415
Rose, 417
Rose-Husson-Thompson, 419
Thompson, 418
Veau, 419
postoperative care of, 428
preoperative care of, 410
re-repair of, 424–428
retention sutures in, 428
undermining of cheek for, 411
variation in operations for, 412
Cleft palate. See also *Cleft lip* and *Facial clefts.*
anatomic results of operation, 438
anesthesia for, 435

Cleft palate
defects of usual operations, 453
functional considerations in, 453
health, disadvantages to, 432
instruments used, 436
mortality of operation, 439
nonunion after operation, 438
number of operations planned, 438
obturator for, 761–765
operations for, 452–480
after almost complete loss of both hard and soft palate, 475–480
Axhausen, 460
Dieffenbach-von Langenbeck, 456, 457, 458
Dieffenbach, modification of, 459
Dorrance, 461
Veau, 461
Wardill, 461
Warren, 455
when considerable defect of soft palate is present, 472–475
pedicled flap for closure of, 475–480
position for operation, 435
posterior pharyngeal flap for closure of, 473
postoperative care in, 437
postoperative hemorrhage, 438
preferable age for operation, 434
primarily unsuccessfully operated, 464–480
principles of usual operative procedure, 452
prognosis for good speech, 450
question of deficiency of tissue, 431
relationship of weaning to result, 440
reoperation after loss of tissue, 467–472
reoperation when no tissue has been lost, 464–467
routine operation, discussion of, 460, 461, 462, 463
anemia, 440
postoperative care, 439
postoperative fever period, 440
season, 440
weight, 440
shock, postoperative, 435
speech training following operation, 441–450
sutures used in operation, 437
thymic deaths in cleft palate surgery, 434
Cocaine anesthesia, 773
Columella, absence of, 428
lengthening in double cleft lip repair, 424
splitting of, to balance nostrils, 414
use of flap for rebuilding, 428
Concussion, cerebral, 79
clinical features, 79
treatment, 80
Conduction anesthesia for lower six anterior teeth of mandible, 207
of maxilla, 204
Condyle, fracture of, 140
treatment after, 141
Contractural closure of jaws, 314
Contracture, resurfacing after crosscutting of, 732
Copper stomatitis, 250
Coronodental cysts, 680
clinical features, 681
Coronodental cysts, definition, 680
origin, 681
pathology, 681
treatment, 682
Coronoid process, fracture of, 141
Costen's syndrome, 319
Coutard's protracted divided dose of radiation, 572
Cricoid cartilage, anatomy of, 40
Cricothyroid membrane, anatomy of, 41
Cutis, carcinoma of. See *Carcinoma cutis.*
Cyclopropane anesthesia, 779, 780
Cystadenoma of pharynx, 513
Cysticercus, 254
Cysts
of bone, 709
coronodental, 680. See also *Coronodental cysts.*
fissural, 484
floor of mouth, 484
hemorrhagic, 710
incisive foramen, 483
larynx, 515
mucous membrane, 510
thyroglossal tract, 494, 495, 496
tonsils, 515
traumatic, 710

Dakin's solution, 56
Davies-Colley operation for cleft palate, 404
Davis operation for closure of alveolar cleft, 400
Deformities
prosthetic restoration of, 761–773
repair of, by hard tissues, 738–743
by substitution of hard tissues, 734
by transplantation of soft tissues, 735–738
requiring resurfacing alone, 729–732
surgical restoration of, 722–758
three-dimensional, repair of by soft tissues alone, 732, 733
Deformity of maxilla
recessive, 751
repair of, 743
Deformity of nose, repair of
abnormal length, 750
bulbous tip, 751
depressed bridge, 748
destruction, complete, 744; partial, 744
deviation, 751
exaggeration or limitation of growth, 747
Delayed union after fracture, 96
Denker operation, 277
Dental cysts, simple, 674
clinical features, 675
location, 675
pathology, 675
treatment, 675
Dental infection, elective localization of bacteria upon, 187
types of systemic diseases associated with, 187
viewpoint regarding it, 188
Dental pulp, diseases of, 170
general etiology, 171
secondary dentine in, 171

Dental splints, 134, 135. See also *Splints for fixation of fragmented jaw bones.*
Dentigerous cysts, 680. See also *Follicular cysts.*
Dermoid cysts of floor of mouth. See *Mouth, floor of, dermoid cysts.*
of pharynx (malignant), 542
Dieffenbach-von Langenbeck operation for cleft palate, 456, 457, 458
modification of, 459
Diphtheria, 247
Diseases of face, 229
of lips, 229
periapical tissue, 184, 185, 192
temporomandibular joint, 312
Dislocation of mandible, chronic, 152
diagnosis, 150
reduction of, 152
retention of, 152
symptoms, 150
unreduced, 152
varieties, 148
Diverticula, esophageal, 269
treatment, 269
Diverticula, pharyngeal, 269
treatment, 269
Dorrance operation for cleft palate, 461
Dosage, calculation of surface dosage by radium and radon, 575–579
external, for irradiation, 579
radiation, interstitial combined with external, 582
by radium and radon, 579
Drainage after fracture, 92
of wounds, 76
Drains, description of, 54
Dry socket, 223
Dyspeptic tongue, 266

Eby's method of intermaxillary wiring, 131
Echinococcus, 254
Ectropion, skin grafting for, 724
Eczema of lips, 239
Eden's operation for facial nerve paralysis, 349
Edentulous jaw, fracture of, 136
Electric potential, effect on oral mucosa, 261
Emphysema after fracture, 96
Endothelioma of neck
pathology of, 547
Endothelioma of soft tissues in general
prognosis, 667
therapy, 667
Epidermoid carcinoma, 564. See *Carcinoma, epidermoid.*
Epiglottis, carcinoma about, 628
Kocher's normal excision for, 628
Epithelial granulomatous cyst, 185
pearls, 250
Epithelioma. See *Carcinoma.*
Epulis, 684
clinical features, 684
diagnosis, 686
etiology, 684
histology, 684
treatment, 686
Erichsen's operation for elevation of nostril in operation for cleft palate, 414
Erysipelas, 229
Erysipelatous stomatitis, 243
Erythema migrans linguae, 266
multiforme, 254
Esophageal diverticula, 269
treatment, 269
Espundia, 254
Ether anesthesia, 53, 56
intrapharyngeal, 782
intratracheal, 772
methods of administering, 781–785
through extra-oral tube, 782
Ethyl chloride, 773
Ethylene anesthesia, 779
Evipal anesthesia, 786
Ewing's tumor, 702
clinical features, 702
incidence, 702
prognosis, 703
structure, 702
treatment, 703
Examination, general physical, 22
laboratory, 22
of mandible, 717
Exostoses
multiple, 693
single, 690
External radiation therapy, 571
Extraction of teeth. See *Removal of teeth.*
Extraperiosteal sarcoma, 703. See *Sarcoma, periosteal.*

Face
actinomycosis of, 233
benign tumor of, 502–509
carbuncle of, 229
carcinoma of, 534
cellulitis of, 229
diseases of, 229
erysipelas of, 229
furuncle, 229
hemangioma of, 725
hemiatrophy, 310
inflammations of, 229
sarcoma of, 552
clinical features, 552
Facial cleft. See also *Cleft lip* and *Cleft palate.*
abnormalities in region of, 384
associated with other abnormalities, 387
cheek, 383
closure of alveolar ridge in double, 408
closure of alveolar ridge in single, 398–405
historical, 385
location, explanation for, 387
mechanical causes for, 386
medial cleft of lower lip and jaw, 384
morphology, 378
cleft within the mouth, 380
fate of lateral nasal processes, 378
fate of teeth in, 380
nose, 383
relationship of
heredity, 385
infection, 386
injury, 386
malnutrition, 386
maternal impressions, 386
Ritchie classification in, 384
types of
double lateral, 382

Facial cleft, types of
median, 381
oblique, 383
single lateral, 382
Facial nerve
paralysis of, 346–348
anastomosis of hypoglossal nerve to, 346
anastomosis with spinal accessory, 347
end-to-end anastomosis of, 346
implanting fascial bands for, 348
masseter muscle transplant for paralysis of, 349
operative technic, 348
Facial spasm, 343
tic, 339
Fauces, anatomy of, 38
Fibroma of pharynx, 512
Fibromatosis of gingivae, diffuse, 169
Fibrosarcoma of pharynx
clinical features, 556
pathology, 544
Fifth nerve, paralysis of, 344
Filaria medinensis, 254
Fixation of fractures. See *Splints for fixation of fragmented jaw bones.*
Flap operation to facilitate removal of teeth, 214
Flaps
arm, 737
arm to cheek, 737
artery, 728
combined from clavicular region, 740
delayed, 727
for restoration of lip, 727, 738
forehead and scalp, 736
including bone, 739
jump, 728
neck, 736
pedicled for repair of cleft palate, 475–480
sliding, 727
tubed, 727
Focal infection
relationship to chronic pericementitis to, 186
Follicular cysts
composite odontomas, 682. See *Odontomas, composite.*
connective tissue odontomas, 682. See *Odontomas, connective tissue.*
coronodental cysts, 681. See *Coronodental cysts.*
Foot and mouth disease, 246
Fordyce's disease, 238
Foreign body in submaxillary gland, 327
Foveolae palatinae, 30
Fracture
classification of, 90
intermaxillary wiring of teeth for fracture, 130
Eby method, 130
Gilmer method, 130
of alveolar process, 102
diagnosis, 102
treatment, 102
of condyle, 140
treatment, 141
of coronoid process, 141
Fracture
of hyoid bone, 117
of jaw bones in general, 91
anesthesia for, 96
bandaging, 98
care of mouth, 95
complications, 95
delayed union, 96
dependent drainage, 92
emphysema, 96
etiology, 96
feeding after, 98
general signs and symptoms, 91
period of fixation, 97
reduction and fixation, 92
roentgenogram, 95
sex, 91
stiffness of jaw after, 97
of jaw, edentulous, 136
of lachrymal bone, 115
of laryngeal cartilages, 117
of malar bone, 115
treatment, 117
of mandible, 119
complications, 126
diagnosis, 124
displacement, 120
intermaxillary wiring for, 129
malunion of, 145, 146
method of taking impression for reconstruction of fractured arch, 134
methods of fixation, historical, 127
by modified Barton bandage, 128
by simple bandage, 127
nonunion of, 145, 146
signs, 123
site, 119
splints for fixation of fragments, 128–144. See *Splints.*
type, 119
of mandibular angle, 138
treatment, 138
by intermaxillary splint with jack screw, 139
by nail through zygoma (Coughlin's method), 140
by wire loop, 139
by wiring both fragments together, 136
of maxilla, 103
complications, 104
displacement, 103
signs, 103
splints for, 107. See *Splints.*
treatment, 105
of nasal bones, 110, 113
classification, 110
fixation, 114
refracture of, 113
treatment, 110
of ramus, 140
of skull, 79
clinical features, 79
treatment, 80
of teeth, 101
treatment, 101
of zygomatic arch, 117
treatment, 117
pathologic, 90
Furuncle of face, 229

Gangosa, 254
Gas gangrene, 77
clinical symptoms, 77
etiology, 77
treatment, 77
General diseases which present oral manifestations, 254
Geographical tongue, 266
German mass dose of irradiation, 571
silver half-round arch wire for intermaxillary wiring, 131
Giant cell tumor, benign, 705
clinical features, 707
etiology, 706
incidence, 705
pathology, 707
prognosis, 708
treatment, 708
Gillies' operation for cleft lip, 426
Gilmer's method of intermaxillary wiring, 130
Gingivitis, 155
acute ulceromembranous, 170
allergic, 170
atrophic, 168
chronic diffuse desquamative, 169
diffuse fibromatosis, 169
hypertrophic, 168
in diabetes mellitus, 155
marginal, 155
pyorrhea alveolaris, 157
Glanders of mouth, 253
Glands
Bochdalek's, anatomy of, 27
incisive, 27
of neck, radium treatment for carcinoma of, 599, 600
of Nuhn and Blandin, 27
parotid, anatomy of, 44
sublingual, anatomy of, 27
submaxillary, anatomy of, 27
Glandular fever, 282
Glossitis, Moeller's, 266
rhombica mediana, 267
Glossodynia, 342
exfoliativa, 265
Glossopharyngeal neuralgia, 340
clinical features, 340
section of nerve for, 341
treatment, 341
Goiter, lingual, 499, 500
Gonorrheal stomatitis, 243
Grading, microscopic, relation to prognosis, 668
Grafts
bone, 728
from ilium, 742, 743
from rib, 742, 743
from tibia, 742, 743
methods of, 739–743
osteoperiosteal, 741
pedicled, 739, 740
cartilage, 729, 734, 735
technic of transplantation, 735
fat, 728
skin, 722–726
considerations in application of, 726
full thickness, 724, 725
late changes in, 725
mucosa, 723
pin point, 723
Grafts
skin, split, 724
stent, 722
to deepen buccal sulcus, 758, 759
Thiersch, 724
Granulating surface, covering of, 729
Granuloma, chronic, 184, 185, 192
Gumma of tongue, 264, 265
Gums
anatomy of, 36
hypertrophy of, 510
Gunshot wounds, repair of, 739–743

Hairy tongue, 267
Harelip. See *Cleft lip* and *Facial cleft.*
Head cap for fracture of maxilla, 106
Hemangio-epithelioma of pharynx, 556
clinical features, 556
pathology, 544
Hemangioma, 503
clinical characteristics, 505
etiology, 503
pathology, 504
prognosis, 506
resurfacing of base after removal of, 732
treatment, 506
Hemiatrophy of face, 310
of jaw, 310
Hemorrhage, 80
arterial, 80
artificial means of arresting, 81
capillary, 80
delayed, 81
hemophilic, 82
internal, 81
parenchymatous, 81
postoperative, after cleft palate surgery, 438
after removal of teeth, 223
primary, 80
secondary, 81
subperiosteal, 90
symptoms of, 81
treatment, general, 82
venous, 80
Herpes zoster, 254
Heublein's method of continuous irradiation, 573
Histologic prognosis in carcinoma, 530
History
family, 20
form, 17
past, 21
present, 20, 21
Hodgkin's disease, 290
clinical features, 290
pathology, 290
prognosis, 292
treatment, 290
Husson operation for single harelip, 419
suggested modification of, 419
Hygroma colli, 517
clinical picture, 517
treatment, 518
Hyoid bone
fracture of, 117
Hypercementosis, 176
clinical features, 177

Hyperparathyroidism
clinical features, 710
pathology, 710
Hyperplasia of tongue, 267
Hypersensitive dentine, 172
symptoms, 172
treatment, 172
Hypertrophic gingivitis, 168
Hypertrophy
of gums, 510
of interdental papilla, 509
of lips, 236
of lymphoid tissue of tonsil, 515
Hypopharynx, anatomy of, 40
Hysterical closure of jaws, 314

Ichthyosis, 267
Impacted teeth, 353
diagnosis, 354
etiology, 352
less commonly encountered, 221
chisel and bur technic, 219
elevator technic, 217
mandibular third molar, extraction of, 216
maxillary cuspid, removal of, 220
maxillary third molar, 220
symptoms, 354
treatment, 355
Impetigo herpetiformis, 254
Incisive foramen, cysts of, 483
Inflammations of antrum, 272. See *Antrum, inflammations of.*
of buccal cavity, 259
of face, 229
of lachrymal glands, 321
of lips, 229
of neck, 285
actinomycosis, 285
blastomycosis, 285
cellulitis, chronic, 285
Holz phlegmon, 285
lymphadenitis, 285. See also *Lymphadenitis.*
woody phlegmon, 282
of pharyngeal cavity, 268
of salivary gland, 321
of submaxillary glands, 326
treatment, 326
of temporomandibular joint, 312. See *Temporomandibular joint, inflammations of.*
of tongue, acute, 251
Injuries
of bony framework of face, 90
of soft tissues, 60
of teeth, 100
avulsion, 100; fracture, 100; mechanical abrasion, 100
Instruments, description of, 54
preparation of, 53
Intermaxillary wiring for fracture of mandible, 129, 130
Intratracheal anesthesia, 772
intubation through mouth, 784
intubation through nose, 783
Iodine, 56
Irritants, relationship in cancer, 526, 527

Jaw bones. See also *Maxilla* and *Mandible*
actinomycosis of, 306
anatomy of, 42
atrophy of, 310
carcinoma of, 538
cleft of, 384
closure of, 314
contractural, 314
treatment, 315
hysterical, 314
irritative, 314
muscular, 315
curvature of, 363
deformities of, atypical, 376
diseases of, 294
epithelioma of, 592, 593
radium treatment for, 592
fracture of, 91
hemiatrophy, 310
inflammations of, 294
irritative closure of, 314, 315
leontiasis ossea of, 307
incidence, 307
pathology, 307
lumpy, 233
malrelations of, 355
classification of, 355
etiology, 362
operative correction of, 367–376
orthodontic correction, 365, 366, 367
marble bone disease, 309
osteitis of, 294
osteomyelitis of, 294. See *Osteomyelitis.*
osteosclerosis fragilis generalisata, 309
Paget's disease of, 307
prognathism of, 362
recessive, 427
wiring operation for, 427
retrusion of, 362
operation for, 368
Schüller-Christian disease of, 308
snapping of, 318
clinical features, 318
treatment, 319
syphilis of, 302–305
tuberculosis of, 305
yaws of, 306
Jugular foramen, syndrome of, 349
Juvenile nasopharyngeal fibroma, 542
clinical features, 557
pathology, 542

Keloid of buccal cavity, 514
of face, 30
resurfacing of tissue after removal of, 30
scar, 722
Kocher normal excision operation, 628
submandibular approach, 613
Kuster operation, 277

Lachrymal bone
fracture of, 115
Lachrymal glands
benign tumors of, 518
inflammations of, 321
Lane operation for cleft palate, 404
Laryngeal cartilages
fracture of, 117
paralysis of, 349

Laryngectomy, 632, 633, 634, 635
indications, 632
one-stage operation, 733
speech after, 635
two-stage operation, 633
Laryngopharynx, carcinoma of, 533. See also *Carcinoma of laryngopharynx.*
Larynx
anatomy of, 40
artificial, 637
benign tumors of, 515–516
carcinoma of, 666. See *Carcinoma of larynx.*
cartilage of, 41
corniculate cuneiform, 41
cysts of, 515
operations on, 630
sarcoma of, 543. See also *Sarcoma of larynx.*
singer's nodes of, 515
Lead stomatitis, 249
Leontiasis ossea of jaw bones, 307. See *Jaw bones, leontiasis ossea of.*
Leprosy, 255
Leukemia, 292. See *Lymph glands, chronic progressive enlargements of.*
Leukoplakia, 259
clinical features, 259
etiology, 259
relationship to cancer, 428
treatment, 260
Lichen planus, 254
ruber acuminatus, 254
Ligature of bone, 136
Ligatures, 59
dermal, 59
horsehair, 59
kangaroo tendons, 59
live fascia, 59
silkworm gut, 59
silver wire, 59
Linens, preparation of, 53
Lingua plicata, 267
Lingual goiter, 499, 500
spasm after operation for trigeminal neuralgia, 339
Lip, Abbe operation for, 425
anatomy of, 41
carcinoma of, 535. See *Carcinoma of lip.*
chancre of, 239
cheilitis exfoliativa, 239
cheilitis glandularis apostematosa, 239
cleft of, 381. See *Cleft lip.*
cracks of, 236
diseases of, 229
eczema of, 239
epithelioma of, 549. See *Carcinoma of lip.*
Fordyce's disease of, 238
frenum of, 37
hypertrophy of, 236
inflammations of, 229
lymphangitis of, 237
normal, 412
pits, congenital, 482
pseudocolloid of, 238
scars of, 236
syphilis of, 239
Lipoma of pharynx, 513
Logan clamp, 429
operation for closure of alveolar cleft, 401
Ludwig's angina, 283
Ludwig's angina, bacteriology, 283
clinical features, 283
treatment, 283
Lumpy jaw, 233
Lung, abscess of, 88
Lupus erythematosus, 232
clinical picture, 232
treatment, 233
Lupus vulgaris, 232
clinical picture, 232
treatment, 232
Lymph glands
anatomy of, 45
chronic progressive enlargements of, 290
Hodgkin's disease, 290
clinical features, 290, 291
pathology, 290
prognosis, 292
treatment, 292
leukemia and aleukemia, chronic lymphocytic
clinical features, 292
pathology, 292
prognosis, 292
treatment, 292
leukemia and aleukemia, lymphoblastic
clinical features, 293
pathology, 293
prognosis, 293
treatment, 293
Lymphadenitis, 75
acute, 281
clinical features, 281
pathology, 281
treatment, 282
chronic (nonspecific), 285
syphilitic, 286
tuberculous, 286
clinical features, 288
diagnosis, 289
pathology, 287
prognosis, 289
Lymphangioma, 507–511
clinical picture, 507
diagnosis, 508
location, 507
pathology, 507
treatment, 508
Lymphatic glands, carcinoma of. See *Carcinoma of lymphatic glands.*
Lympho-epithelioma, 555. See *Carcinoma epidermoid.*
Lymphoid follicles
anatomy of, 40
Lymphosarcoma of neck, 547, 562
clinical features, 562
pathology, 547
of pharynx, 543
clinical features, 556
pathology, 543
of soft tissues generally, 667
prognosis, 667
therapy, 667

Macrocheilia, 237
Macroglossia
lymphangiomatous, 511
muscular, 267
syphilitic, 264

Macrostomia, 383
Malar bone, fracture of, 115. See *Fracture of malar bone.*
Malocclusion, 355. See *Teeth, malocclusion of.*
Malrelation of jaw bones, 351. See *Jaw bones, malrelation of.*
Malunion following fracture, 144, 145
Mandible, carcinoma of. See *Carcinoma of mandible.*
chronic dislocation of, treatment, 152
dislocation of, 147. See *Dislocation of mandible.*
fracture of, 119. See *Fracture of mandible.*
growth of, 351
mechanism of dislocation of, 149
prosthetic restoration for deformities of, 768–770
resection of, 717–720
prevention of deformity after, 720
resection of segment of, 616
subluxation, 152. See *Subluxation of mandible.*
Mandibular angle
curvature of, 363
dislocation, 147. See *Dislocation of mandible.*
fracture of, 138. See *Fracture of mandibular angle.*
joint, anatomy of, 42
nerve injection, 207
Marble bone disease of jaw bone, 309
Marginal gingivitis, 155
clinical picture, 156
pathology, 156
treatment, 156
Massive collapse of lung, 88
Maxilla, carcinoma of. See *Carcinoma of maxilla.*
deformity of, 743
repair of, 743
fracture of, 103. See *Fracture of maxilla.*
growth of, 352
recessive, 364
resection of one-half of, 718, 719
partial, 714
historical, 714
total, 716
Maxillary infiltration for removal of teeth, 204
sinus, 42. See *Antrum.*
tubercle, 32
tumors of dental origin, 670–686. See also *Dental cysts* and *Adamantinoma.*
embryology and origin, 670–672
historical, 671
Mechanism of dislocation of mandible, 149
Melano-epithelioma of pharynx, 554
Meloschisis, 383
Mental injection with local anesthesia, 209
Mercurial stomatitis, 248
Mercurochrome, 55
Mesopharynx, anatomy of, 39
Mikulicz's disease, 331
clinical features, 332
treatment, 332
Mineral stomatitis, 248
Mirault-Blair operation for single cleft lip, 415
Mixed tumors of pharynx, 514
of salivary glands, 518, 519
Mixed tumors of salivary glands, clinical features, 520
diagnosis, 521
incidence, 520
origin, 519
prognosis, 522
structure, 519
treatment, 521
Moeller's glossitis, 266
Moeller-Barlow's disease, 246
Molluscum contagiosum, 254
Monilia candida, 254
Mononucleosis, infectious, 282
Motor nerve derangements, of face, 343. See *Facial spasm, tic or paralysis.*
Mouth, anthrax of, 252
carcinoma of, 562. See *Carcinoma of mouth and carcinoma of buccal floor.*
cavity, anatomy of, 24
epidermoid carcinoma of, 564. See *Carcinoma, epidermoid.*
epithelial pearls in, 250
glanders of, 253
mucous patches of, 263
pemphigus of, 251
syphilis of, 262, 263
trench, 170, 242–245. See *Ulceromembranous stomatitis.*
washes for, 57
Mouth, floor of
anatomy of, 24
dermoid cysts of, 486
clinical picture, 486
diagnosis, 487
situation, 486
structure, 486
treatment, 487
inflammations of, chronic, 285
Muscles of mastication
anatomy of, 43
Muscular closure of jaws, 314
macroglossia, 267
Mycosis fungoides, 254
Myeloma, multiple, 704
clinical features, 705
prognosis, 705
structure, 704
treatment, 705
Myeloma of pharynx, 556
clinical features, 556
pathology, 544
Myositis ossificans, 694
Myxoma of pharynx, 515

Nasal bones, fracture of, 110. See *Fracture of nasal bones.*
sinuses, carcinoma of, 544. See *Carcinoma of paranasal sinuses.*
Nasopharynx
anatomy of, 39
carcinoma of, 595. See *Carcinoma of pharynx and nasopharynx.*
Neck, actinomycosis of, 233. See *Actinomycosis of neck.*
benign tumors of, 516, 517, 518
branchiogenic carcinoma of, 546. See *Carcinoma, branchiogenic.*
carcinoma of lymphatic nodes. 561. See *Carcinoma of lymphatic glands of neck.*
endothelioma of, 547

Neck, lymphadenitis of, 281. See *Lymphadenitis.*
lymphosarcoma of, 562. See *Lymphosarcoma.*
sarcoma of, 547
Needle, broken during local anesthesia for removal of teeth, 224
Nerves, anatomy of, 47–48
Neuralgia, 336
tic convulsif (painful type), 339
Neuralgia of glossopharyngeal nerve, 340
of seventh nerve, 340
of sphenopalatine ganglion, 341
of tongue (glossodynia), 342
of trigeminal nerve, 336
Neurofibroma, plexiform, 509
Nicoladoni operation for repair of parotid duct, 752, 753
Nieden's operation, 319
Nitrous oxide anesthesia, 777–779
Noma, 230, 243
clinical picture, 230, 231
etiology, 230
prognosis, 231
treatment, 231
Nonunion following fracture, 144
treatment, 145
Normal salt solution, 55
Nose
cleft of, 383
correction of deformity in cleft lip, 413
deformity of, associated with cleft lip, 410
prosthesis for deformity of, 770, 771, 772
radium treatment in carcinoma of, 595, 596
repair of deformity of. See *Deformity of nose.*
Nostrils, balancing of, in harelip operation, 413
Novocain anesthesia, 773

Obturator for cleft palate, 761–765
indications for, 764
mobile, 764
stationary, 763
Occlusion, normal, definition of, 355
Odontomas, 670–686
composite, 682
clinical features, 683
definition, 682
origin, 683
pathology, 683
roentgenogram, 683
treatment, 684
Odontomas, connective tissue, 682
clinical features, 683
definition, 682
origin, 683
pathology, 683
roentgenogram, 683
treatment, 684
Ombrédanne operation for elevation of nostrils in cleft lip, 414
Open bite
operations for, 374–375
cross section of ramus for, 375
section of mandibular body for, 374
vertical section of ramus, 375
Operations. See *Specific headings for.*
Operations, complications of
cardiorenal, 86
general, 88
lung abscess, 88
massive collapse of lung, 88
pneumonia, 87
vascular, 87
Operative rules in extraction technic, 210
Oriental sore, 254
Orthodontic splints following fracture, 145
Osteitis fibrosa cystica, 709
clinical features, 709–711
incidence, 709, 711
pathology, 709–711
Osteitis of jaw bones, 294
Osteochondroma, 690
clinical features, 691
etiology, 690
histogenesis, 690
incidence, 690
pathology, 691
radiograph, 691
treatment, 691
Osteogenetic sarcoma, 695–702
classification of, 695
medullary, 695–697
sclerosing, 698
subperiosteal, 695
telangiectatic, 698
clinical course, 699, 700
diagnosis, 700
etiology, 699
prognosis, 701
roentgenogram, 700
therapeutic test, 701
treatment, 702
Osteoma, 692
Osteomyelitis, 294–301
pyogenic, of jaw bones, 294
clinical features, 294, 295
etiology, 295
incidence, 296
organism, 296
pathology, 297
prognosis, 302
symptoms, 298
treatment, 301
Osteomyelitis, tuberculous, 305, 306
clinical features, 306
diagnosis, 306
incidence, 305
pathology, 305
Osteoperiosteal grafts. See *Grafts, bone.*
Osteosclerosis fragilis generalisata, 309

Paget's disease of jaw bones, 307
Palate, anatomy of, 30
carcinoma of, 661. See *Carcinoma of palate.*
cleft of. See *Cleft palate* and *Facial cleft.*
epithelioma of, 552. See *Carcinoma of palate.*
innervation of muscles of, 31, 32
nerve supply of, 31
obturators, 761–765
resection of, 714, 715
Palatine injection of maxilla, 207
Pansinusectomy, 278

Papillae
circumvallate, 29
interdental, anatomy of, 37
hypertrophy of, 509
taste, 29
Papilloma
of buccal cavity, 528
of pharynx, 511
relationship to carcinoma, 528
Paradental abscess, 183
Paraffinoma of face, 502
Paralysis of facial nerve, 344
clinical features, 344
peripheral paralysis of, 344
treatment, 345
Paralysis of motor nerve to larynx, 349
Paranasal sinuses, carcinoma of, 662. See *Carcinoma of paranasal sinus.*
Paratyphoid, 255
Parodontitis, 157. See also *Pyorrhea alveolaris.*
Parotid gland, carcinoma of, 561. See *Carcinoma of parotid gland.*
extirpation of, 625, 626
injection of duct with opaque media, 321
removal of localized mass from, 522
restoration of duct after severance, 751, 755
sarcoma of. See *Sarcoma of parotid gland.*
severance of duct
diagnosis of, 751
technic of repair, 753, 754
treatment, 751
Parotitis
chronic and associated with obstruction, 324, 325
clinical features, 325
diagnosis, 325
etiology, 325
treatment, 326
combined with uveitis, 333
epidemic (mumps), 333
treatment, 333
pyogenic, acute, 321
clinical features, 322
pathogenesis, 322
prognosis, 324
treatment, 323
Partsch operation, 675, 676
Passavant's pad, 453
Patient, draping of, 52
preparation of, for operation, 52
Pearls, epithelial, 250
Pellagra, 255
Pemphigus, 251
Pericementitis, 177
clinical picture, 181
etiology, 177
pathology, 179
treatment, 189
Pericementum, diseases of, 176–195
Peridental membrane, anatomy of, 37
Peridentitis mucosa necrotica recurrens, 250
Perilymphangitis, 75
Periosteal infiltration for removal of teeth, 204
Peritonsillar abscess, 255
Perlèche, 238
clinical features, 238
diagnosis, 238
Perlèche, etiology, 238
treatment, 238
Pfahler saturation technic of irradiation, 571
Pfeiffer's disease, 282
Pharyngeal cavity, 268
inflammations of, 268
Pharyngeal diverticula, 269
treatment, 269
Pharyngeal tonsil, anatomy of, 39
Pharyngolaryngectomy, 635
Pharyngostome, closure of, 635
Pharyngotomy, lateral, 624, 625
transhyoid, 623
Pharynx
anatomy of, 38
benign tumors of, 511–516
blood vessel tumor of, 514
branchial fistula, 488
carcinoma of, 663. See *Carcinoma of pharynx.*
chondroma of, 515
congenital malformation of, 488
cystadenoma of, 513
dermoid of (malignant), 542
epidermoid carcinoma of, 564. See *Carcinoma of pharynx.*
fibroma of, 512
fibrosarcoma of, 556. See *Fibrosarcoma of pharynx.*
goiter of, 489
hairy polypi of, 489
hemangio-epithelioma of, 556. See *Hemangio-epithelioma of pharynx.*
infections of, 255
juvenile nasopharyngeal fibroma of, 557. See *Juvenile nasopharyngeal fibroma of pharynx.*
lipoma of, 513
lympho-epithelioma of, 541. See *Carcinoma lympho-epithelioma.*
lymphosarcoma of, 556. See *Lymphosarcoma of pharynx.*
melano-epithelioma, 544. See *Carcinoma, melano-epithelioma.*
mixed tumors of, 514
myeloma of, 556. See *Myeloma of pharynx.*
myxoma of, 515
papilloma of, 511
polyp of, 511
sarcoma of, 544. See *Sarcoma of pharynx.*
stricture of, 268. See *Stricture of pharynx.*
syphilis of, 263
teratoma of, 488
Phenol, 56
Pneumonia, postoperative, 86
Polyp of pharynx, 515
Porokeratosis, 254
Posterior pharyngeal flap for closure of cleft palate, 473
Postoperative care of cleft lip, 428
Powder stains, 66
Precancerous lesions, 527–530
Premaxilla, care of, in double cleft lip, 405
operation of vomerian section and replacement of, 406
Prognathism
mandibular, 362
operations for, 371
arthroplasty, 373
cross section of ramus for, 373

Prognathism
operations for, submucoperiosteal approach, 373
transmucoperiosteal approach, 371
Prosthesis, buccal, 767
method of retention, 767
use of, in loss of hard and soft palate, 767
Prosthesis for nasal deformity, 770, 771, 772
materials for construction and retention, 771
mold, 770
Prosthetic replacement after fracture, 143
restoration of deformities, 761–772
of mandible, 768–770
Pulpitis, 173
bacteriology, 173
clinical features, 174
etiology, 173
pathology, 173
prognosis, 176
treatment, 176
Pyemia, 76
Pyorrhea alveolaris, 157
correction of abnormal stress in, 164
definition, 157
diagnosis, 162
etiology, 157
extraction for, 167
flap operation for, 166
gingivectomy for, 165
pathology, 158
postoperative care, 167
prognosis, 167
symptoms, 159
treatment, 163
Pyriform sinus, anatomy of, 41
Pyriformis recessi, 40

Radiation, external, 571. See *Roentgen ray therapy.*
external, plus interstitial, 582
by radium, 574
facts upon which it is based, 569–570
for local lesion, 586
measuring of, 573
method of action, 583
plus surgical intervention, 584
Radiation therapy. See *Roentgen ray therapy.*
Radium, calculation of surface dosage, 575
external irradiation by, 574
for local lesion, 586
stomatitis, 250
use, in carcinoma cutis, 586
of antrum, 594–595
of cheek, 589, 590
of glands of neck, 599
of nose and nasopharynx, 595, 596
of palate, 590, 591
of pharynx, 596, 597
of tongue, 591, 592, 593
in epithelioma of jaw, 593
of lip, 587, 588, 589
Radon, calculation of surface dosage, 575–579
Ramus, fracture of, 140
Ranula, 484, 485
clinical picture, 485
pathology, 485
Raw tongue, 266
Removal of broken roots of teeth, 211, 212
of alveolar process, 714, 715
of inferior alveolar process, 717
of mandible, 720
prevention of contracture after, 720
of maxilla, 714
one half, 718, 719
total, 716
of palate, 714, 715
of teeth, 210. See *Teeth, removal of.*
Retention clamps for cleft lip, 429
Retropharyngeal abscess, 256. See *Abscess, retropharyngeal.*
Retrusion of lower jaw, 362
Rhinophyma, 232
Rhinoscleroma, 254
Ritchie's operation for closure of alveolar cleft, 400
Roentgen-ray therapy, types of, 571
continuous radiation of Heublein, 573
German mass dose, 571
protracted divided dose of Coutard, 572
saturation technic of Pfahler, 571
Root canal filling following pericementitis, 148
resection, technic of, 193
Rose operation for double cleft lip, 422
for single cleft lip, 417
modification of, 419
Rose position for cleft palate operation, 435
Rose-Husson-Thompson operation for single cleft lip, 419
Rosenmüller's fossa, 40

Salivary gland, actinomycosis of, 332
benign tumors of, 518–523
carcinoma of, 561. See *Carcinoma of salivary glands.*
congenital malformation of, 500
inflammations of, 321
mixed tumors of, 518. See *Mixed tumors.*
tuberculosis of, 332
Sarcoma
of face, 560
clinical features, 560
of larynx, 560
clinical features, 560
pathology, 543
of neck, 547
of parotid gland, 546
pathology, 546
of pharynx, 544
pathology, 544
of tongue, 554
clinical features, 553
pathology, 538
osteogenetic. See *Osteogenetic Sarcoma.*
periosteal, 703
Scarlet fever, 254
Scars, 722
depressed, 722
heavy, 722
keloid, 722
of lip, 236
Schneiderian carcinoma, 556. See *Carcinoma, epidermoid, of posterior tongue and pharynx.*
Schüller-Christian's disease, 308

Scleroderma, 254
Scorbutic stomatitis, 246
Scrotal tongue, 267
Secondary suture of wounds, 70
Sensory innervation, anatomy of, 30
Septicemia, 76
Seventh nerve neuralgia, 340
Shock
  blood transfusion in, 84
  crystalloid solutions in, 84
  ethyl alcohol in, 84
  etiology, 84
  in cleft palate, 435
  morphine in, 84
  primary, 83
  secondary, 83
  treatment, 84
Sialography, 331
Silver stomatitis, 250
Simple herpes, 254
Singer's nodes of larynx, 515
Single lateral cleft of lip, 382
Sinus into antrum, 275
  of thymic tract, 494. See *Thymic tract sinus.*
  of thyroglossal tract, 494. See *Thyroglossal tract sinus and cysts.*
Skin flaps. See *Flaps.*
Skin grafts. See *Grafts, skin.*
Skull, fracture of, 79
    clinical features, 79
    treatment, 80
Smoker's patch, 259
Smooth tongue, 266
Snapping jaw, 318
    clinical features, 318
    treatment, 319
Soft tissues, lymphosarcoma of, 667. See *Lymphosarcoma of soft tissues.*
Solutions, surgical, 55
Spasm, facial, 343
    treatment, 343
Speech training following cleft palate operation, 445–450
Sphenopalatine neuralgia, 341
    clinical features, 341
    treatment, 342
Splints
  construction of, 135
  for fixation of fragmented jaw bones
      Barton modified bandage, 128
      Cast splint, 135
      Coughlin's method, 140
      Cryer splint, 141
      Davenport splint, 144
      German half round arch wire, 131
      Gilmer's posterior band, 134, 135, 136
      Graefe splint, 110
      Gunning splint, 110, 133
      Hammond splint, 133
      Hayes splint, 141
      Herpin splint, 141
      Hullihen splint, 134
      intermaxillary splints with jack screw, 139
      Kingsley splint, 134
      ligature of bone, 137
      Marshall, 110
      Ombrédanne splint, 110
Splints
  for fixation of fragmented jaw bones, Pick erill splint, 110
      plaster cast head splint, 110
      simple bandage, 128, 129
      swaged metal, 135
      temporary splint, 110
      vulcanite plate for edentulous jaws, 136
      vulcanite rubber, 135
      wire loop through ramus, 139
  historical, 127
  orthodontic, 145
Sporotrichum, 254
Sprue, 255
Stiffness of jaw following fracture, 97
Stomatitis, aphthous, 241
  arsenic, 250
  bismuth, 249
  copper, 250
  diphtheria, 248
  erysipelatous, 243
  gangrenous, 243
  gonorrheal, 243
  lead, 249
  mercurial, 248
  mineral, 248
  phosphorus, 250
  radium, 250
  scorbutic, 246
  silver, 250
  simple catarrhal, 241
  syphilitic, 248
  ulcerative, 242
  ulceromembranous, 243
Stone in submaxillary gland and duct, 327
      clinical features, 328
      etiology, 327
      pathology, 328
      treatment, 330
Strawberry tongue, 255
Stricture of pharynx, 268
    clinical features, 268
    treatment, 269
Sublingual gland, excision of, 523
Submaxillary gland
    excision of, 523
    inflammations of, 326
    stone of, 327. See *Stone in submaxillary gland.*
Surgeon, preparation of, 52
Surgical extractions, 211
  preparation for artificial denture, 755–759
  restoration of deformities, 722–759
Sutures in cleft palate operation, 437
  preparation of, 53
Syndrome, jugular foramen, 349
Syphilis of jaw bones, 302
      acquired, 302
      clinical features, 304
      congenital, 303
      diagnosis, 305
      treatment, 305
  of lip, 239
  of mouth, 262, 263
  of pharynx, 263
  of tongue, 262–265
Syphilitic scars, relationship to cancer, 528
  sclerosing glossitis, 264

Tattoo marks, 66
Teeth
abrasion of, 100
anatomy of, 33
deciduous, 33, 34, 35
permanent, 34
cultural findings in those removed, 187
eruption of deciduous, 36
of permanent, 36
examination of, 22
exposure of healthy pulp, 173
factor of functional changes in malrelations of, 360
of inheritance in malrelations of, 358
of pathologic growth in malrelations of, 359
of physiologic growth in malrelations of, 359
fracture of, 101
treatment, 101
impacted, 353
diagnosis, 354
etiology, 353
symptoms, 354
implantation of, 101
technic, 101
injuries of, 100
intermaxillary wiring for fractures, 130. See *Fracture, intermaxillary wiring of teeth for.*
malocclusion of, 355
classification of, 355
etiology, 358, 362
orthodontia in, 364, 365
occlusion of, 35
removal of
closure of field after, 222
complications following
breaking needle, 223
dry socket, 223
inadvertently entering antrum, 275
infection and sloughing, 223
postoperative hemorrhage, 223
unusually prolonged anesthesia, 223
eradication of diseased periapical tissue after, 222
after fracture, 93
impacted, care and removal of, 212
indications for, 198
instruments used, 201
local anesthesia, 200
needles and syringes, 200
after pericementitis, 192
position of operator, 200
postoperative care, 222, 226
premedication, 202
removal of root fragments and foreign bodies, 212
selection of anesthesia, 199
serious general complications, 227
surgical accessories, 202
technic of simple removal, 210
of complicated or surgical removal, 211
of conduction anesthesia, 204
of induction of local anesthesia, 203
of infiltration anesthesia, 203
Temporomandibular joint, 316
ankylosis of, 316
treatment, 316
Temporomandibular joint, arthroplasty of, 316
diseases of, 312
inflammations of, 312
clinical features, 312
treatment, 313
syndrome of ear and sinus symptoms, 319
Tetanus, 78
clinical symptoms, 78
etiology, 78
treatment, 78
Thompson operation for double cleft lip, 422
for single cleft of lip, 418
modification of, 419
Thrush, 245
Thymic cysts, clinical features, 496
embryology, 495
treatment, 496
Thymic deaths following cleft palate operation, 434
Thymic tract sinus, 494
clinical features, 494
diagnosis, 494
treatment, 494
Thyroglossal tract sinus and cysts, 494
Thyroid cartilage, anatomy of, 40
Tic convulsif, painful type, 339
treatment, 340
Tic douloureux, 336
clinical features, 336, 337
treatment, 338, 339
Tobacco, relationship to carcinoma, 526
Tongue
actinomycosis of, 268
acute inflammations of, 251
anatomy of, 28
atrophic, 267
bifid, 483
black, 267
carcinoma of, 536. See *Carcinoma of tongue.*
cellulitis, 251
dyspeptic, 266
excessive length of, 483
frenum of, 29
glossitis rhombica mediana, 267
goiter of, 499, 500
gumma of, 264, 265
hairy, 267
hyperplasia, 267
lingua plicata, 267
sarcoma of, 553. See *Sarcoma of tongue.*
scrotal, 267
smooth, 266
superficial cerebriform hyperplasia of, 267
syphilis of, 262, 264, 265
tie of. See *Tonguetie.*
tuberculosis of, 261
clinical features, 262
pathology, 261
prognosis, 262
treatment, 262
wandering rash of, 266
Tonguetie, 483
Tonsil
hypertrophy of lymphoid tissue of, 515
retention cyst of, 515
Tonsillar abscess, 255
Tooth, sectioning of, 215
Torus palatinus, 30, 692

Tracheal tube, anatomy of, 40
Transfusion, 85
  citrate method, 85
  direct method, 85
Transitional cell epithelioma, 555. See *Carcinoma, epidermoid.*
Trauma, relationship to cancer, 529
Treatment of carbuncle, face and lips, 229
Trench mouth, 170, 242–245. See *Ulceromembranous stomatitis.*
Trichina spiralis, 255
Trigeminal neuralgia, 336
    clinical features, 336
    treatment, 338
Trismus, treatment of, 315
Tropical aphthae, 250
Tuberculosis of buccal cavity, 261
  of jaw bones, 305. See *Osteomyelitis, tuberculous.*
  of salivary gland, 332
  of tongue, 261
    clinical features, 262
    pathology, 261
    prognosis, 262
    treatment, 262
Tuberosity injection of maxilla, 204
Tumors, benign
    of antrum, 516
    of lachrymal glands, 518
    of larynx, 518
    of pharynx, 511–515
    of salivary glands, clinical features, 515–521
        pathology, 518–520
        treatment, 521–523
  of bone. See *Bone, tumors of.*
  Ewing's. See *Ewing's tumor.*
  giant cell. See *Giant cell tumor.*
  metastatic to bone, 711
  of thyroglossal tract, 494–499
  of vagus nerve, 349
Typhoid, 255

Ulceromembranous stomatitis, 242, 243
    clinical picture, 244
    etiology, 244
    treatment, 245
Urticarial rash after transfusion, 86
Uveoparotitis, 333
  clinical features, 333
Uvula, anatomy of, 31

Vagus nerve tumors, 349
Vascular complications following operation, 86
Veau operation for cleft palate, 461
    for single cleft lip, 404, 405, 419
Vein, facial, anatomy of, 42
Verruca peruviana, 254
Vincent's disease, 242–245. See *Ulceromembranous stomatitis.*
Vinethene anesthesia, 785
Vinyl ether anesthesia, 785
Vitiligo, 254
Vocal cords
    false, anatomy of, 41
    true, anatomy of, 41
von Recklinghausen's disease, 710. See *Osteitis fibrosa cystica.*

Waldeyer's ring, anatomy of, 39
Wandering rash of tongue, 266
Wardill's operation for cleft palate, 461
Warren operation for cleft palate, 455
Weather, relationship to carcinoma, 526
Wounds, 61
  application of heat and cold, 76
  classification of
    avulsed, 62
    contused, 61
    incised, 61
    lacerated, 62
    punctured, 62
  clinical picture of infection of, 74, 75
  complications of, 71, 77
    gas gangrene, 77
    tetanus, 78
  diagnosis of damage done, 65
  general defense reaction after, 73
  gunshot, healing of, 64
    repair of, 739–743
  hot moist dressings for, 76
  infection of, 71
  mechanical factors which influence local defense, 72
  radiant energy for, 76
  roentgen ray for, 76
  secondary suture of, 70
  of soft tissues alone, 60, 68
      definition, 60
      general symptoms, 60
  splinting of, 76
  tattoo marks and powder stains, 66
  thrombophlebitis in, 75
  thrombus in, 75
  treatment of, 76
    early lacerated, 66
    gunshot, 68
    incised, 66
    late, 66
    preservation of bony framework in, 68

Xanthoma, 254
Xeroderma pigmentosum, 254

Yaws, 254
  of jaw bones, 306

Zygomatic arch, 117
    fracture of, 117

WELLCOME LIBRARY INSTITUTE