

Skin grafting : from a personal and experimental viewpoint / by Earl Calvin Padgett.

Contributors

Padgett, Earl Calvin, 1893-1946.

Publication/Creation

London : Bailliere, Tindall & Cox, 1942.

Persistent URL

<https://wellcomecollection.org/works/gn4caq89>

License and attribution

Conditions of use: it is possible this item is protected by copyright and/or related rights. You are free to use this item in any way that is permitted by the copyright and related rights legislation that applies to your use. For other uses you need to obtain permission from the rights-holder(s).



Wellcome Collection
183 Euston Road
London NW1 2BE UK
T +44 (0)20 7611 8722
E library@wellcomecollection.org
<https://wellcomecollection.org>



23rd
Class No. 4th P.A.D. No. 11478

The Royal College of Nursing,
HENRIETTA PLACE, CAVENDISH SQUARE,
LONDON, W.1.

❧ ❧


The Library of Nursing.
(Associated with the National Central Library)



22102343870

H. K. Lewis & Co., Ltd.
Medical & Scientific Supplies
100, Strand, London, W.C.2


Med
K43386



257
нара

Skin Grafting

from a Personal and Experimental Viewpoint



Digitized by the Internet Archive
in 2017 with funding from
Wellcome Library

<https://archive.org/details/b29817821>

Skin Grafting

from a Personal and Experimental Viewpoint

By

Earl Calvin Padgett, M.D., F.A.C.S.

Professor of Clinical Surgery,
University of Kansas School of Medicine,
Kansas City, Kansas.



1942

Baillière, Tindall & Cox

7-8 Henrietta Street, Covent Garden
London, W.C. 2

11478
2312

COPYRIGHT 1942 BY CHARLES C THOMAS
Printed in the United States of America

★ ★ ★

All rights reserved. This book may not be reproduced, in whole or in part, in any form (except by reviewers for the public press), without written permission from the publisher.

8255475

WELLCOME INSTITUTE LIBRARY	
Co.	welMOMec
Call	
No.	W0

Preface

ALTHOUGH skin grafting is one of the older surgical procedures, it is remarkable that the surgical profession generally has little knowledge of the good results which can be obtained in the alleviation of many soft tissue deformities by resurfacing the defect with a proper type of skin graft. The various specialty surgeons are more remiss in this respect than the general surgeon. Even many of the plastic surgeons—probably because of the publicity given the pedicled flap—are not always cognizant of the advantages of the usage of a properly selected skin graft.

A more or less simple surgical principle, namely, preparation of a granulating surface for the reception of a skin graft, is often neglected. The fact is lost sight of that a granulating surface has to be surgically clean if a "take" of the skin graft is to be expected and that for cleansing purposes in such instances nothing is superior to a wet antiseptic dressing changed repeatedly or immersion in an antiseptic solution followed by a moist antiseptic dressing.

If one has ever completely excised a heavy scar and noted how much larger the resultant wound is than the central scar, it is easy to understand how scar tends to contract like rubber and thereby limit movement unless prevented from doing so by underlying anatomical structures. Still much too often this simple principle is not appreciated and therefore the remedy is overlooked, namely, completely replacing the epithelium that has been lost and thereby alleviating the dysfunction. When dealing with healed soft tissue lesions often there are two reasons for hesitation, either the operator is not dexterous enough to remove a proper graft or he fears the failure of a "take."

A new epoch in skin grafting was heralded in 1929 when Blair and Brown introduced their more or less superficial intermediate skin graft—the so-called "split" graft. Their idea was that one might gain some of the advantages of the full-thickness skin graft in so far as the properties of good appearance, relative lack of contracture and fair protection were concerned and that the factor of uncertainty of a perfect "take" might be eliminated largely as it is with the so-called Thiersch graft. In other words, by cutting a graft considerably thinner than the old full-thickness graft and somewhat thicker than the type of skin graft formerly used, the good properties of each might be combined in this new type of graft and that most of the disadvantageous properties might be largely eliminated.

The ideal skin graft should be of such thinness as to assure successful

transplantation, leave the donor site capable of spontaneous regeneration and yet of such thickness as to afford adequate protection, minimum contraction and match relatively satisfactorily the surrounding skin in so far as texture and color are concerned.

However, anyone who has attempted to take an ideal piece of skin with a large knife will admit that often he does not succeed. Besides the inherent human factor and impossibility of controlling absolutely the level of a hand-held knife, much depends upon such factors as the location of the area from which the graft is being removed, the nutrition of the patient, the sex of the patient, the age and even the race. After measuring the thickness of cross sections of a large series of skin grafts taken from the adult male, cut with the large skin knife and striking an average, one must conclude that as a rule grafts cut by the hand method, even when trying for depth, vary from .008 to .016 of an inch in thickness. Full-thickness skin grafts cut by the scalpel in an adult vary from .032 to .040 of an inch in thickness.

From microscopic studies it appears that, ideally in an adult, at least one should be able to sever the skin at a level of from .020 to .024 of an inch to get sufficient thickness to approach the qualities of the full-thickness graft and still retain the two outstanding good qualities of the superficial intermediate skin, namely, comparative certainty of "take" and the retention of sufficient epithelial elements in the donor bed for reepithelization. The ideal graft, therefore, to apply on a clean raw surface is a "three-quarter thickness" skin graft cut at a level from 75 to 90 percent of the thickness of the skin.

Recently a dermatome has been constructed which, with the utmost facility and ease, allows one to remove a sheet of skin as large as the drum of the dermatome (4 x 8 inches) and to cut it absolutely of uniform thickness. The thickness can be varied and set at a predetermined level by a calibrating mechanism.

The main advantage of the "three-quarter thickness" skin graft cut with the dermatome (thickness of .020 of an inch to .024 of an inch) over the full-thickness skin graft on clinical trial has proved to be that a "take" is a practical certainty if the other factors are observed, such as proper fixation, tension, hemostasis, pressure and a clean field. Most of the inadequacy of "take" in the twenty or more percent of attempts at full-thickness skin grafting in difficult areas seems to have been eliminated.

The factor of increased certainty of "take" has allowed the surgeon to extend the indications for thick skin grafting. It has allowed him to graft successfully such areas as the dorsal and ventral surfaces of the hand, and about and between the fingers. In the correction of marked cicatricial deformity about the larger joints such as the axilla especially,

but are also in the correction of other contractures and blemishes, he can gain greater correction by the use of a "three-quarter thickness" skin graft of uniform thickness because of the certainty of a "take." The fact that one encounters few blistered areas or areas of necrosis, so that the subsequent texture and the color are as good as when one gets a partial "take," improves the functional and cosmetic result especially on the face and neck. Finally, the fact that the donor area heals within ten to fourteen days from the base is of considerable advantage.

In several situations the thinner types of calibrated grafts as removed by the dermatome, .010 of an inch (.25 mm.) to .014 of an inch (.36 mm.) in thickness, have distinct advantages over the thinner types of grafts used in the past. Foremost, it allows one to graft successfully the individual with extremely wide denuded areas—a type of case which in the past has often presented a nearly hopeless problem to the surgeon because of his inability to obtain sufficient skin to cover the denuded areas; for example, the type of case with a tremendously large denuded surface covering both thighs and legs with most of the remaining skin on the trunk. The use of the dermatome allows one to remove skin from the abdomen, the chest, the back or the buttocks. It seems that one may use a slightly thicker type of graft, .014 of an inch (.36 mm.) to .016 of an inch (.45 mm.) in thickness, on a granulating surface, so that, ultimately, the amount of contracture is less and the cosmetic appearance is better. Thus, for the routine case in which it has been customary to use successfully the types of grafts as cut with the large knife, the ease, the accuracy and the quickness of the method recommend the dermatome-cut graft as the preferable graft. In grafting a large cavity, it is particularly advantageous to have a large sheet of skin of uniform thickness to drape over the stent. On a small baby one cannot cut by hand with a skin graft knife a graft of sufficient size to be very useful if a large defect is to be covered. With the dermatome a graft of large size may be taken from either the abdomen or the chest. The same may be said for an emaciated individual such as may occur when one sees a severe burn after several months.

Further, if one can vary the thickness of the graft at will, depending upon the region to which it is to be applied and the lesion which it is aimed to correct, it should prove desirable for varying lesions, in varying locations to lean towards thickness or thinness as indicated. And again, according to the age of the patient and the particular region from which the skin is to be removed, a variation in thickness should be desirable as it is well known that the skin of children is thinner than that of adults and that the skin in certain regions, as the inner thigh of a woman, is thinner than that of the outer thigh. As previously mentioned, for certain lesions it is evident that if one could remove the skin from any area of the body,

such as the chest, the back or over the ribs, certain areas could be resurfaced in a way not possible by the use of methods commonly practiced.

Finally, and probably most important due to the invention of the dermatome, a new skin graft has become available—a “three-quarter thickness” skin graft, cut at a level from 75 to 90 percent of the thickness of the skin. This graft has advantages over the so-called full-thickness skin graft and the superficial intermediate skin graft, especially for giving adequate coverage of aseptic denuded surfaces. The ease with which a skin graft of any thickness may be removed, even from areas not previously available, simplifies the whole art of skin grafting.*

The illustrations, which I believe are very well done, are to be credited to Mr. Ted Bloodhart. I am especially indebted to Miss Opal M. Quick for the typing of the manuscript, the photography, some of the proof reading and the compilation of an index. I also want to thank Mr. Charles C Thomas for his diligent efforts in bringing the book up to a high standard from the publishing viewpoint.

E. C. P.

* The foregoing paragraphs are taken from an editorial published in *Surgery*, 1941.

Foreword

THE CLINICAL experiences on which this monograph is based now embrace a period of a decade and a half. The experimental work carried on from time to time was suggested by the obvious discrepancies in the results attained as additional clinical experience was gained. It soon became evident that many of the advantageous properties, provided a good "take" could be obtained, became increasingly maximal the thicker the applied skin graft had been cut and, on the contrary, as a rule, the disadvantageous properties save that of a certainty of a "take" increased as the skin was cut at a more superficial level. This suggested the need of attaining a skin graft cut at such a level that most of the good qualities of the thin graft and the thick graft would be embraced while the disadvantageous qualities of each would be minimized. This more or less ideal skin graft was visualized as a graft of uniform thickness cut in the last quarter thickness of the skin. In other words, clinical observations seemed to indicate that this skin graft probably would be such a graft that successful transplantation would be almost assured and yet the thickness would be such that adequate protection and minimum contraction would be attained and, at the same time, the match with the surrounding skin would be relatively satisfactory in so far as texture and color were concerned. Moreover, the donor site would be left in such a condition that it would be capable of spontaneous regeneration.

Unfortunately the mechanical means for removing such a skin graft had not as yet been developed. It was necessary therefore to invent a mechanical device capable of this. This took some eight years of more or less desultory experimentation.

Soon after it was possible to cut this new "three-quarter thickness" or deep intermediate skin graft, it became evident that not only was this skin graft proving to have the advantages predicted but that skin grafts cut with the dermatome at other thicknesses had advantages over skin grafts cut by other methods largely because one could vary the thickness of the skin graft at will and remove the skin from parts of the body and in quantities with a uniformity and facility not previously possible.

After the study and calibration as to the thickness by means of comparative crosscut microscopic sections of a considerable number of skin grafts cut by all methods from individuals of different ages, sex and race, it seemed that the whole matter of skin grafts should be reclassified from the standpoint of thickness.

These new developments were seen not only to extend the general indications for skin grafting but appeared to limit what was formerly thought to be the indications for the use of pedicled flaps.

The question of the practicability of the transplantation of homogenous skin was studied as some surgeons still insist on attempting the procedure.

Contents

PREFACE	v
FOREWORD	ix
I. HISTORICAL	3
II. HOMO- AND HETERO-TRANSPLANTATION AND PARABIOSIS.....	6
III. PRESERVATION AND HISTOLOGY	15
IV. PROPERTIES AND TECHNIQUE OF REMOVAL OF THE USUAL TYPES OF SKIN GRAFTS	19
V. SPECIAL TYPES OF SKIN GRAFTS.....	29
VI. CALIBRATED INTERMEDIATE SKIN GRAFTS AND THE NEW "THREE-QUARTER THICKNESS" SKIN GRAFT	34
VII. THE GRAFTING OF SULCI AND CAVITIES	68
VIII. SKIN FLAPS VERSUS SKIN GRAFTS	75
IX. GENERAL CONSIDERATIONS PERTINENT TO SUCCESSFUL SKIN GRAFTING	82
X. SKIN GRAFTING FOR SPECIFIC LESIONS	107
XI. TRANSPLANTATION OF MUCOSA AND DERMA	131
SUMMARY	134
INDEX	141

Skin Grafting

from a Personal and Experimental Viewpoint

CHAPTER I

Historical

A BRIEF RÉSUMÉ of some of the landmarks in the development of any phase of surgery is usually interesting and may aid one in gaining a certain judicial perspective.

Centuries ago in old records concerning the tile-maker's caste in India a description is recorded of the free transplantation of full-thickness skin from the gluteal region to the nose. Previous to transplantation the gluteal region was beaten, producing hyperemia. For the purpose of advertising an ointment early in the nineteenth century, two charlatans, one of whom was a woman, Gamba Curta, cut a piece of skin from their bodies, passed it around to spectators for inspection, then replaced the pieces on their original raw beds and applied their ointment as a dressing. It is related that the grafts "took" and healed with little scarring. Baronio (1804), a physiologist, aroused by the knowledge of this exhibition, experimented on a sheep's tail and successfully transplanted full-thickness skin from one side to the other.

As early as 1823, Bunker of Marbury successfully transplanted a free piece of whole skin from a woman's thigh to her nose and again in 1843, J. Warren Mason, one of the famous surgeons of Boston, successfully covered the alae of the nose with a bit of detached full-thickness skin from the arm.

But it was not until after Reverdin published an exhaustive paper in 1872 under the title of "epidermic graft" that the interest of the surgical profession was aroused somewhat generally. The transplanted bits were composed of the whole epidermis and a very little of the dermis. Reverdin's bits of skin measured 0.3 to 0.4 centimeter square. His method hastened healing but it was soon noted that, especially in the region of the joints, this method of grafting did not prevent contractures. Knowledge of the work of Reverdin caused Ollier to experiment with larger areas of skin 4.6 by 8 centimeters square. He used the epidermis and a portion of the dermis. Ollier apparently was not trying to produce multiple centers of epidermization as had Reverdin but to produce a complete epithelial surface by means of skin grafts. At the time, Ollier's work was not particularly noticed or appreciated.

In 1874 Thiersch transplanted skin pieces one centimeter in diameter from which the adipose tissue had been carefully removed. Later Thiersch

used larger areas of skin—large films of epidermis together with a very small portion of the dermis which he shaved off. In his report in 1886 he demonstrated that the healing of wounds of any size could be brought about quickly by covering the defects with large films of epidermis together with a small portion of the dermis. Up until 1890 this graft was placed upon an ulcer surface. But that year Halsted showed a case in which he had excised the ulcer and the graft had been placed upon the fresh fibrotic base. The Ollier-Thiersch method did not entirely prevent contractures, however, and resistance to mechanical insult was rather meager.

Netolitchi of Germany (1869), Lawson of London (1871), LeFort of France (1872) undoubtedly preceded Wolfe of Edinburgh in 1875, in the successful transplantation of whole skin. Wolfe, whose name has been connected, along with Krause of Germany, with this particular type of skin grafting, used the method for an ectropion of the eyelid. The following year, Krause (1876) reported 21 cases at the twenty-second German Surgical Congress. Now the grafts are often designated as Wolfe-Krause grafts.

Thus, although isolated records of an occasional success are found here and there in the literature many years previous to the articles of Krause, the significance of the method was not appreciated. Even these men, and of course those preceding them, used only small bits of skin and it remained for the method of successfully transplanting large areas, as large as 6 by 10 inches, to be developed as recently as the period following the late World War. Blair, Davis, Brown and Padgett were active in developing the technique of growing these larger areas of full-thickness skin.

In the recent past one of the five types of skin grafts has been used in the majority of instances. The small graft introduced by Reverdin in 1869 has always been used by some operators. Davis within the past quarter century has been responsible for popularizing the small deep graft for use on large granulating surfaces. The Ollier-Thiersch graft, first performed by Ollier in 1872 and later modified and developed by Thiersch from 1874 to 1876, has been used very commonly by many surgeons. More recently a modification of the Ollier-Thiersch graft, the "split graft" of Blair and Brown has found great favor. For the purpose of covering an aseptic denuded surface, especially since the development of a more accurate technique, the full-thickness skin graft often has been used with considerable success.

Several modifications of the method of application of the basic types of skin grafts were developed during the late World War or shortly after. Among these were the so-called "inlay" stent grafts introduced by Esser in 1917 and the "outlay" stent graft, a modification of the Esser prin-

ciple introduced by Waldron, Gillies and Pickerill in 1918. Another method of grafting skin that has acquired some utility has been called tunnel grafting. MacLennan first in 1912 and Moskowicz in 1916 and 1917 described tunnel grafting with thin skin. Parce in 1922 employed full-thickness skin to form a tunnel. In this method, after the graft has "taken" in its subcutaneous or subgranulation tunnel, the superimposed tissue was cut. Among others Keller (1930) has advocated the method after using it for ten years. The advantage claimed for the method is that a clean field for the graft is assured. The "sieve" graft described by Douglas in 1930 is another method of applying a full-thickness graft. Small interspersed areas of skin may be left in the donor area by this method. Dragstedt (1937) recently has described a graft somewhat similar to that of Douglas.

Among the less commonly used methods of skin grafting is the method of implantation of small bits of thin skin into or beneath the granulation tissue. Pollock in 1870 devised this method and in 1920 Braun revived it. More recently (1930) Wangenstein has used the method. The method is of value when the granulation cannot be cleaned up. A modification of this method is that described by Westhues in 1926. He advised that the skin be woven in and out of granulation tissue by means of a needle. Among the rarely used methods that have been suggested are those of Mangoldt, who in 1895 applied pulpified epidermis to a denuded surface and Lusk, who in 1879 advocated and used a vesicating agent to cause a blister after the use of which the elevated skin was used as a graft.

CHAPTER II

Homo and Hetero Transplantation and Parabiosis

Iso or Homo Transplantation

THE QUESTION of whether or not the transplantation of skin from one individual to another is a practicable procedure is often debated by quite well-informed surgeons.

The earlier operators made attempts to graft from other individuals, but in the second half of the last century Ollier and Thiersch observed that autotransplantation of skin was most often successful. According to Loeb, it was recognized at that time that different species and different individuals might differ in their chemical constitutions. A review of the literature of homotransplantation of skin reveals a surprising disagreement in findings.

Lexer, Freeman, Perthes, Holman and Blair have only failures to report with isodermic grafts. On the contrary, Davis, who based his statements as to the advisability of the procedure on hospital records by interns, vouches for the practical value of the procedure. Masson recommended for success the same procedure of obtaining a donor as for a successful blood transfusion, but in his report nothing is said about the length of time the case was observed. Shawan also attests to the success of the procedure when a proper blood-matched donor is used. A great many other less authentic records can be culled from the literature, the authors of which apparently thought they had had some success with homografting of skin. Usually the length of time these grafts were observed is not tabulated. In all probability this is the reason for what we believe must have been misobservations.

Experimental Results

Our own experience with homotransplantation of skin is based upon a series of 44 transplants of skin performed upon persons of varying ages (Table I). Twenty-one were free full-thickness skin grafts and 23 were thin grafts of the so-called "Thiersch" type. Grafts of a size of 1 to 2 cm. in diameter were transplanted for experimental purposes in all but 10 instances. In the latter 10 instances an honest effort was made to cover a raw area for which there was inadequate skin for autotransplantation. The first one was a case of Blair's (1921) and the second was a case of our own (1929). Both resulted in failure. The 8 other cases were done by

other surgeons and the failure was known or observed by us. These results stimulated the experimental transplantation of skin in 34 instances for our own information. As the blood group had been stated to have a determining influence upon whether or not a homotransplant "took," and whether or not it ultimately thrived, in each of our experimental cases it was determined. The blood group was also determined in Blair's case and in our own case.

The table which follows gives the date of the graft, type of graft, blood group of the donor and the recipient and the appearance of the graft as long as it remained in situ (Table I).

Four skin grafts were transplanted from one identical twin to the other and vice versa. This represents the closest possible syngenesiotransplantation (near relative, as brother to brother, mother to son) of skin at present (August 15, 1932) the grafts remain in situ, in one set of twins since August 11, 1931, and in the other since September 15, 1931. The usual type of syngenesiotransplantation is represented by three father-to-son transplants, one mother-to-daughter transplant, two brother-to-brother transplants, two sister-to-brother transplants, and one uncle-to-nephew transplant. In each case the graft "took" and remained attached and viable for three weeks at a minimum but, before the end of the fifth week, was completely destroyed. Blair's case was a Wolff graft from mother to daughter and was placed in the axilla. The opposite axilla was also grafted with an autotransplant. At the end of two weeks the homotransplant was pink with new blood and looked better than the autotransplant but, at the end of four weeks, the homotransplant had been destroyed. Our own case in which a serious attempt was made to homotransplant skin was a very severe burn of both legs and the father was used as a donor for the skin. Large Thiersch grafts were transplanted and a complete "take" was obtained. The thighs and legs were completely covered with the new skin at the end of three weeks but, at the end of five weeks, the grafts had disappeared.

Some light may be thrown upon the question of whether or not a homotransplant is more likely to "take" immediately if the blood is matched in the summary of 36 instances in which the blood group was known. In 4 instances, when the corpuscles of the donor were agglutinated by the serum of the recipient, the grafts did not "take" at any time, but in 4 other instances the grafts "took" and did as well as any of them for the first few days. In 28 instances, when the corpuscles of the donor were not agglutinated by the serum of the recipient, 27 of the grafts took temporarily, and in one instance an immediate "take" failed. Thus, a faint suggestion is given that immediate "takes" are more probable if the cells of the donor are not agglutinated by the cells of the recipient, but that finally the graft is

TABLE I

From	To	Date	Type	Blood Group Donor	Blood Group Recipient	Seventh Day	Fourteenth Day	Twenty-First Day	Twenty-Eighth Day	Thirty-Fifth Day	Forty-Second Day	Note
1. Goetz (45)	McDaniel (70)	8- 3-31	Wolff	Group I	Group IV	Gray	Separated	Separated				
2. Bradley (50)	McDaniel (70)	8- 3-31	Wolff	Group IV	Group IV	Gray	Separated	Separated				
3. Cole (40) (Negro)	McDaniel (70)	8- 3-31	Wolff	Group IV	Group IV	Pink	Separated	Separated				
4. McDaniel (70)	Goetz (45)	8- 3-31	Wolff	Group IV	Group I	Pink; take	Pigment off	Separated				
5. Bradley (50)	Goetz (45)	8- 3-31	Wolff	Group IV	Group I	Pink; take	Dark red	Separated				
6. Cole (40) (Negro)	Goetz (45)	8- 3-31	Wolff	Group IV	Group I	Pink; take	Dark red	Separated				
7. Lafferty (42)	Goetz (45)	8- 3-31	Thiersch	Group II	Group I	Pink; take	Dark red	Pink	Separated	Separated		
8. Padgett (38)	Goetz (45)	8- 3-31	Thiersch	Group IV	Group I	Pink; take	Pink	Pink	Almost gone	Separated		
9. Spangler (35)	Son (5)	-29	Thiersch	Group	Group	Pink; take	Pink	Dark red to black	Separated			
10. Lafferty (42)	Root (60)	7-15-31	Thiersch	Group II	Group IV	Gray; no take	Separated	Take	Separated			
11. Root (60)	Lafferty (42)	7-15-31	Thiersch	Group IV	Group II	Pink; take	Pink	Take	Take	Separated		
12. Ruby Tucker (19)	Nastaz (1)	8-11-31	Thiersch	Group IV	Group II	Pink; take	Pink	Take	Take	Separated		
13. Ruth Tucker (19)	Nastaz (1)	8-11-31	Thiersch	Group IV	Group II	Pink; take	Pink	Take	Separated	Separated		
14. Nastaz (1)	Tucker (19)	8-11-31	Thiersch	Group II	Group IV	Red; take	Pink	Take	Separated	Separated		
15. Nastaz (1)	Tucker (19)	8-11-31	Thiersch	Group II	Group IV	Red; take	Pink	Take	Take	Take		
16. Ruby Tucker (19)	Tucker (19)	8-11-31	Thiersch	Group IV	Group IV	Pink; take	Pink	Take	Take	Take		
17. Ruth Tucker (19)	Tucker (19)	8-11-31	Thiersch	Group IV	Group IV	Pink; take	Pink	Take	Take	Take		
18. Windley (40)	Petullo (1)	8-20-31	Thiersch	Group I	Group I	Pink; take	Take	Separated				
19. Petullo (1)	Lindley (40)	8-20-31	Thiersch	Group IV	Group I	Pink; take	Take	Separated				
20. LeClara (6)	Powell (40)	9- 3-31	Wolff	Group II	Group II	Pink; take	Take	Take	Separated			
21. LeClara (6)	Kittle (7)	9- 3-31	Wolff	Group II	Group II	Pink; take	Take	Take	Separated			
22. Powell (40)	LeClara (6)	9- 3-31	Wolff	Group II	Group II	Pink; take	Take	Take	Separated			
23. Powell (40)	Kittle (7)	9- 3-31	Wolff	Group II	Group II	Pink; take	Take	Take	Separated			
24. Kittle (7)	LeClara (6)	9- 3-31	Wolff	Group II	Group II	Pink; take	Take	Take	Separated			
25. Kittle (7)	Powell (40)	9- 3-31	Wolff	Group II	Group II	Pink; take	Take	Take	Separated			
26. F. Judd (2)	T. Judd (1 mo.)	10- 8-31	Thiersch	Group IV	Group IV	Pink; take	Take	Take	Separated			
27. T. Judd (1 mo.)	J. Judd (2)	10- 8-31	Thiersch	Group IV	Group IV	Pink; take	Take	Take	Take	Separated	Separated	
28. Potto (50)	Allison (2)	10-16-31	Wolff	Group II	Group IV	Gray; no take	Take	Take	Take	Separated	Separated	
29. Gilbreath (70)	Allison (2)	10-16-31	Wolff	Group II	Group IV	Gray; no take	Take	Separated	Separated			

Present three months
Present three months

TABLE I—Continued

From	To	Date	Type	Blood Group Donor	Blood Group Recipient	Seventh Day	Fourteenth Day	Twenty-First Day	Twenty-Eighth Day	Thirty-Fifth Day	Forty-Second Day	Note
30. Newsom (1 mo.)	Allison (2)	10-16-31	Wolff	Group IV	Group IV	Pink; take	Take	Separated	Separated	Separated		
31. Allison (2)	Pottorf (50)	10-16-31	Wolff	Group IV	Group II	Pink; take	Take	Separated	Separated	Take		
32. Allison (2)	Gilbreath (70)	10-16-31	Wolff	Group IV	Group IV	Pink; take	Take	Separated	Separated	Take		
33. Allison (2)	Newsom (1 mo.)	10-16-31	Wolff	Group IV	Group IV	Take	Take	Take	Take	Take		Present two months
34. R. Desmond (11)	F. Desmond (11)	9-15-31	Thiersch	Group III	Group III	Pink; take	Take	Take	Take	Take		Present two months
35. F. Desmond (11)	R. Desmond (11)	9-15-31	Thiersch	Group III	Group III	Pink; take	Take	Take	Take	Take		
36. Blair (45)	Daughter (5)	1921	Wolff	Group I	Group IV	Pink; take	No take	Separated	Separated	Separated		When seen, date undetermined, about 4 wks.
37. Sister (12)	Hendricks (6)	1926	Thiersch	Group	Group	Pink; take	No take	Separated	Separated	Separated		When seen, date undetermined, about 4-5 wks.
38. Sister (10)	Hendricks (6)	1926	Thiersch	Group	Group	Pink; take	No take	Separated	Separated	Separated		When seen, date undetermined, about 4-5 wks.
39. Father	Boyd (10)	9- 1-36	Thiersch									When seen, date undetermined, about 4-5 wks.
40. Mr. Fouts	Boyd (10)	9- 7-26	Thiersch									When seen, date undetermined, about 4-5 wks.
41. Father	Boyd (10)	9-16-26	Thiersch									When seen, date undetermined, about 4-5 wks.
42. Mr. Fouts	Boyd (10)	9-23-26	Thiersch									When seen, date undetermined, about 4-5 wks.
43. Mr. Clark	Boyd (10)	9-30-26	Thiersch									When seen, date undetermined, about 4-5 wks.
44. Uncle	Boyd (10)	10- 7-26	Thiersch									When seen, date undetermined, about 4-5 wks.

destroyed in any event unless the relationship is as close as that of identical twins.

Homotransplantation in Animals

Transplantation of tissues originally developed to repair surfaces denuded of skin has in recent years assumed great experimental importance. The biologist and embryologist have used the procedure to determine the extent to which development takes place by self-determination in contradistinction to inconstant environmental factors. The physiologist has used the method to determine the function of organs and of their specific excretions. By the biologist and the pathologist, growth phenomena, the origin of specific cells and the relation of normal growth to tumor growth has been studied. Among geneticists Correus has attempted to correlate the data of genetics with that of transplantation.

Rather recently the great importance of the relative nearness of the relationship between the host and the donor as the principal factor that determines the fate of the graft is being recognized in its full significance.

Leo Loeb has for a number of years carried on a painstaking investigation in various laboratory animals. His findings have in many ways elucidated the connection of the differences in genetic constitution of the host and the donor as the determinant factor which decided the fate of the graft. As his general findings are applicable for skin, a brief résumé of the sequence of events after transplantation of such an organ as the thyroid gland becomes of interest.

If the thyroid gland of a rat or guinea pig is autotransplanted, the peripheral part remains alive and the central part becomes necrotic and is replaced by fibroblastic tissue. The peripheral part is vascularized, lives permanently and about it little or no lymphocytic reaction is shown. But in homotransplantations with the same tissue, the fibroblastic reaction is more intense and replaces a larger amount of the center of the graft immediately. The fibroblasts form a dense tissue about the living acini in the peripheral zone which compresses the acini and may even destroy them directly. The lymphocytic reaction about the graft is very marked and the lymphocytes surround, invade and help to destroy the tissue. By these means, complete destruction occurs within twenty to thirty days. If, instead of transplanting thyroid tissue to another animal of the same species and variety, the tissue is transplanted to another variety (as white to hooded rats) the result is essentially the same as after homotransplantation, but the fibroblastic and the lymphocytic reaction is more marked and, by the twentieth day, the transplant is destroyed. When syngenesiotransplantation (between brother and sister, or parent and child) is done and thus the relative relationship is diminished to the

utmost nearness to that of autotransplantation, the behavior of the host towards the transplant is similar to that of autotransplantation for about five weeks, after which disharmonies between the host and the transplant develop, and the transplant is invaded by lymphocytes and eventually overwhelmed. Finally, if instead of transplanting thyroid tissue within the same species, it is transplanted from one species to another (heterotransplantation), the immediate direct injury to the transplant by the body fluids of the host is so great that marked degenerative changes are shown at the end of the first week. Not only lymphocytes but polymorphonuclear lymphocytes collect about the transplant and it is destroyed rather quickly.

Theory of Organismal Differentials

On the basis of his experimental work, Loeb proposed the theory of organismal differentials as an hypothesis to explain the findings. He states the theory as follows: "All or about all tissues in a given individual within a certain species have, in common, certain chemical characteristics which may be designated as the individuality differential; and in a similar manner all the tissues of near relatives, of different strains, varieties, species, genera and classes of animals have, in common, chemical characteristics, which may be designated as syngenesio, strain, variety, species (hetero), generic and class differentials. These differentials determine the reaction between host and donor."

After transplanting a piece of tissue of an organ into a near relative, or into an unrelated individual of the same species, or into an individual of a different species, the individuality differential comes into play and the tissues of the host assume injurious properties and toxins are set in action which destroy the graft. The relationship between the transplant determines in each case the mode of reaction of the host against the transplant.

Experimental work has shown that the substances given off by the graft probably do not act, as a rule at least, in the nature of antigens and call forth the production of secondary (immune) substances on the part of the host which cause the graft to be destroyed. If secondary (immune) reactions were important, it might be expected that the homoreaction following a second transplantation would appear more promptly, but no acceleration of time seems to occur. The evidence seems to indicate that organismal differentials in homotransplantation are shown by primary substances given off by the graft which act as toxins, and affect the cells of the host in such a manner as to cause the reaction on the part of the host as has been described previously.

The Genetic Basis of Organismal Differentials

The hypothesis that these differentials are genetically determined is suggested by the whole series of gradations in reaction found on transplanting tissues into strange hosts. The organismal differentials are more closely related within the same family or species or strain and less disharmony results after transplantation of tissues within the family, species, or strain than after transplantation without family, species or strain. Consequently, transplantations of tissue from brother to brother or brother to sister (close syngenesiotransplantation) remain viable the longest after transplantation. A slight decrease in length of time that the graft remains viable is noted in the case of transplantation of parent to child (a more distant type of syngenesiotransplantation). Experiments in closely inbred animals also show similar varying reactions according to the nearness or distance in relationship of the donor and the host.

Loeb concludes that organismal differentials are genetically determined and says that: "The conclusion that the organismal differentials are due to the genetic constitution of the organisms is based on the correspondence between the characteristics of the differentials and the relative intensity of the reaction against strange differentials on the one hand, and the genetic relationship of the organism which are the bearers of the differentials, on the other hand."

Apparently the organismal differentials depend upon the totality of genes which make up the chromosomes and which are present in the cells of the host and the donor and apparently the genes or more specifically gene derivatives determine the character of the differentials. Moreover, the relative strangeness of the genes provides the relative intensities between the tissues of the donor and the host. The Y or sex chromosome must have little to do with this reaction, as it makes little difference whether the host or the donor are of the same sex.

Blood Groups and Homotransplantation of Skin

It has been suggested and maintained by Davis, Masson and Shawan that the result of homografting of skin depends upon whether or not the red blood cells of the donor are agglutinated by the serum of the host. According to the theoretical considerations previously outlined, the improbability that the blood group of donor and host can be of any particular significance is evident. Blood groups probably depend upon a few genes and tend to throw all individuals into four groups while the individuality of organismal differential most likely is determined by all or at least a great number of genes of an individual. Thus, the theory of organismal differentials multiplies the possibilities of strangeness to an infinite number.

Skin Grafting After Parabiosis

Of interest in passing is the unique experience of uniting two animals of the same species by a surgical operation. This was performed by Bert and Sauerbruch and Heyde. But parabiosis seems not to improve the chances of transplantation of skin. The innate virility of one or the other of the animals eventually overcomes the less virile animal and its vitality is sapped progressively until death. Even at a time when both are in good health, skin transplantation from one partner to the other does not grow so well as previously and, surprising as it may seem, even transplantation of skin from one part of the animal's body to another part (autotransplantation) shows a decrease in the tendency to thrive.

Conclusions

- (1) Autotransplantation of skin usually does succeed.
- (2) Syngenesiotransplantation of skin is theoretically improbable except in identical twins where it is theoretically probable and clinically has occurred.
- (3) The experimental grafts in man herein tabulated, the experimental work performed upon animals and theoretical reasoning argue against the blood group of the individual as playing a rôle of any essential significance in the homotransplantation of skin.
- (4) Finally, the bulk of experimental and clinical experience is in agreement that for all practical purposes homotransplantation of skin may be relegated to the realms of medical mythology.

Heterografts and Zoografts

Although successful transplantations of animal to the human have been reported by Baratoux, Dubousquet, Laborderie, Cannaday, Rivin, Browning, Flegengeimer, Venable and Miles, the results of the present day experimental work would lead one to think that undoubtedly there must have been some mistake in interpretation. Zoografts disappear even more quickly than homografts. Leo Loeb, as previously mentioned, has painstakingly investigated this question. He found when, instead of tissue to another animal of the same species and variety, the tissue is transplanted to another variety (as white to hooded rats), the result is essentially the same as after homotransplantation, but the fibroblastic and the lymphocytic reaction is more marked and by the twentieth day the transplant is destroyed. When syngenesiotransplantation (between brother and sister or parent and child) is done and thus the relative relationship is diminished to the utmost nearness to that of autotransplantation, the behavior of the host towards the transplant is similar to that of auto-

transplantation for about five weeks, after which disharmonies between the host and the transplant develop and the transplant is invaded by lymphocytes and eventually overwhelmed. Finally, if instead of transplanting tissue within the same species, it is transplanted from one species to another (heterotransplantation) the immediate direct injury to the transplant by the body fluids of the host is so great that marked degenerative changes are shown at the end of the first week and not only lymphocytes but polymorphonuclear lymphocytes collect about the transplant and it is destroyed rather quickly.

Transplantation of Fetal Membranes

In 1909 and 1910 Davis experimented with amniotic sac but was unable to secure permanent results. In 1913 Sabella and Stern reported several cases in which they had successfully transplanted amniotic membrane. Since that time others have failed to obtain permanent results.

CHAPTER III

Preservation and Histology

Preservation of Skin Grafts

RARELY CAN an indication for the preservation of skin exist since the evidence indicates that successes with fresh homografts, not to mention heterografts, do not occur. However, Carrel in 1912 after preservation of skin in warm petrolatum followed by soaking in warm Ringer's solution for periods varying from twenty-four hours to seven weeks, gained the impression that skin preserved for as long as two weeks grafted as well as normal skin but after that period successes were not to be anticipated. It would appear that one might question this observation as Carrel's transplants were homografts. Present day experience leads one to believe that homografts do not remain viable even when applied immediately let alone after two weeks. It would seem probable, however, that tissue cultures of autogenous epithelium should grow after an indefinite length of time.

Recently Davis (J. S.) has stated that he has preserved autogenous deep skin grafts for several days in saline gauze in the ice box, and in vaseline in the ice box, for a week or two after which the graft "took" when they were applied to a granulating surface. It would seem from this observation that one need not be in any great hurry to transplant autogenous skin if it is carefully preserved. I am of the opinion, however, that as a rule the quicker the skin is transplanted the better. I have also observed that if one placed a skin graft in saline solution and washed out the serum from the endothelial space, the graft is less likely to "take" than if it had been placed in gauze dampened with saline which does not wash out the blood serum.

Histology of Autografts of Skin

Early in our experience, a microscopic study of a series of skin grafts at various periods after application (Fig. 1) was made. Particular attention was paid to the fate of the elastic fibers in the graft. A skin graft tends to present a shiny appearance. The thought arose that this might be due to the fact that the elastic fibers degenerated and were not replaced so that the normal corrugations of the skin remained obliterated. However, we came to the conclusion that the elastic fibers did reappear but not in the orderly manner which is characteristic of normal skin. Although the

ultimate disorderly arrangement of the elastic fibers may have something to do with the tendency toward a glistening appearance of a skin graft, it is more likely that it is the replaced fibrous tissue which tends to obliterate the normal surface corrugations in the epithelium of the graft.

After autotransplantation of skin, the repair is somewhat analogous to that of the repair of an ordinary incised wound. The graft is first fixed in place by an exudate of fibrin. Within about five hours after transplan-

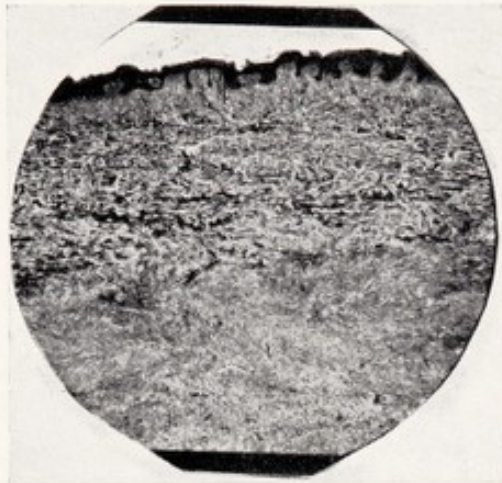

FIG. 1. This section was taken from an abdominal deep intermediate skin graft to the forehead. The skin had been in its new location for 15 days. The tissue was stained by Verhoeff's method for the demonstration of elastic tissue fibers. These can be made out vividly in the corium. Here they are represented by the short dark black appearing interlacing fibers. No special reduction in normal content is noted.

tation the graft becomes adhered to its base. The fibrin layer is soon infiltrated by leukocytes and phagocytes. A primary stage of plasmic circulation, which varies from 24 to 48 hours, temporarily preserves the viability of the graft. Soon the endothelium of the blood vessels of the host send proliferating buds toward the graft and into the graft. Some of the endothelial buds seem to connect with the endothelial spaces of the graft. The endothelial spaces of the graft, that do not connect up with endothelial sprouts from the host, show degenerative changes. The new formed vessels arise mainly by papillary budding of the endothelium developing in the fibrin layer. Davis and Traut, for instance, have noted that if the endothelial spaces of the graft are collapsed, interference with the nutrition occurs. The stage of vascularization begins at

about 18 hours and from then on is progressive. Injection experiments have demonstrated vessels in epidermic grafts on the second day and in cutis grafts on the third day. Within 65 to 70 hours definite continuity of the blood vessels of the host and those in the central part of the graft can be noted. Garré was of the opinion that the vessels had largely resumed their function by the third day. Thus, early imbibition of plasma appears to play an important rôle in the nourishment of the graft. Later success depends upon the early development of an adequate circulation of the blood. About the fourth or fifth day, the stage of organic union begins when the layer of fibrin and leukocytes begin to be infiltrated with sprouting fibroblasts. These penetrate and connect up with the fibroblastic elements of the graft. By the eighth day the blood supply is nearly com-

plete. Now grossly the graft appears distinctly pink. By the tenth day the fibroblastic connection is fairly firm and complete. This is the connective tissue which accounts for the subsequent contraction of the graft.

A question of considerable interest is the amount of degenerative change that takes place in the graft coincident with the proliferative changes just described. Early, some of the endothelial cells of the graft show some degenerative changes, but proliferating changes largely overshadow the picture. The most superficial layers of the epithelium tend to show some degenerative changes. Some exfoliation is likely to occur. The degree of exfoliation is in direct proportion to the speed of the revascularization of the graft. Within the epithelium the infiltration of round cells is often quite marked. In the middle layer of the graft a certain amount of degenerative changes are seen in both the fibroblasts and the elastic fibers—especially the latter—and considerable infiltration with leukocytes is noted. The degree of infiltration is somewhat variable, and seems to depend upon the thickness of the graft and the rapidity of its vascularization. On the whole, most of the fibroblasts seem to remain viable and the regenerative picture of replacement with new granulation tissue overshadows the degenerative changes. The elastic fibers degenerate and are replaced by fibrous tissue which appears to be derived from preexisting elements of the graft itself. The process of degeneration of the elastic fibers is rather slow. For a considerable length of time no change is shown. Regeneration of the elastic fibers occurs, and is more or less complete within one and one-quarter to one-half years after the graft has been transplanted, but never again are the elastic fibers arranged in as orderly a manner as they are in normal skin.

Briefly, some degenerative changes go on coincidentally with rapid regenerative changes and probably a good share of the cells of the graft retain their viability. At least, if they are replaced, the replacement must take place over a long period of time and is not readily discernible. The epithelium regenerates most rapidly. Later the sub-epithelial tissues regenerate and replace the granulation tissue which is converted into fibrous tissue derived from the host.

Thus, the histologic examination does not establish complete viability. Viability is most complete in the juxta-epithelial layer of the graft. The histologic picture of the full-thickness graft does not differ materially from that of thinner grafts. The process of degeneration and regeneration is slightly more rapid in the thinner grafts. Before seven days a thin graft presents rather complete regeneration and replacement of the epithelium, but in full-thickness grafts, one can still find degenerative masses in the epithelium considerably later than this.

Most of the sweat glands placed centrally in the graft show some de-

generative changes which are soon followed by proliferative changes. The hair follicles change in a similar way. The histologic evidence of how nerves regenerate in skin grafts is meager. Practically the only data available is of a clinical nature. Kadanoff transplanted skin from the sole to the snout in guinea pigs. He was able to find new nerve fibers more numerous than was normal for the foot. They frequently followed the old paths of the blood vessels. No regenerating Pacinian corpuscles were found, nor did he find degenerative changes in the sensory endings, immediately after transplantation of the graft.

Within from two to three months a layer of fat begins to develop beneath the graft, the cellular infiltration disappears, and the fibrous tissue layer decreases in width and amount. The fibroblasts begin to lengthen. The skin then gradually becomes movable and pliable on its base.

CHAPTER IV

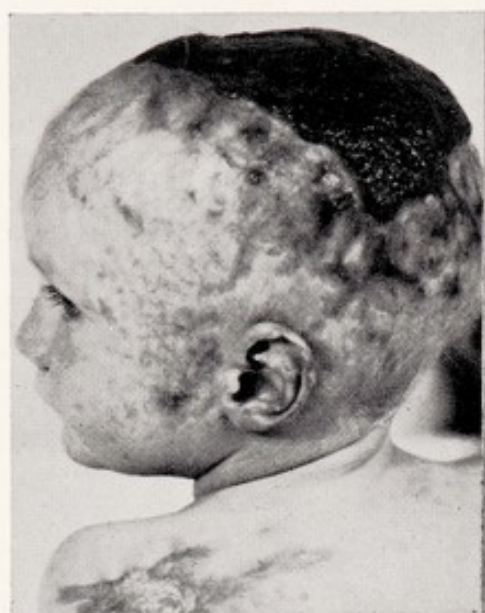Properties and Technique of Removal of the Usual Types of Skin Grafts

BROADLY speaking, in so far as the thickness of the skin grafts is concerned, the reconstructive surgeon has had in the past only two types of free skin grafts with which to repair the various defects that he encountered, for which a free skin graft was indicated: (1) the thin Thiersch, or the somewhat thicker "split" graft, removed by knife or razor from some such area as the thigh, and, (2) a thick graft (the full-thickness skin graft) which was commonly removed from the abdomen.

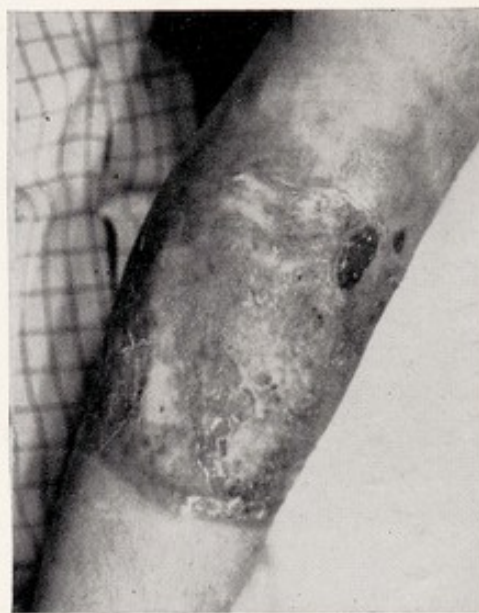My experience with these grafts up to January 1, 1938, when, for reasons to be enumerated later (Chapter VI), I began in most cases to use grafts as cut with the dermatome, was as follows: A total of 755 separate areas had been covered in 563 separate operations on 456 different individuals. Of these areas grafted: 386 were grafted by means of the Thiersch or "split" type of graft, and 369 areas were covered by the full-thickness skin graft. One hundred and forty-five of the areas covered were granulating and 610 were aseptic denuded surfaces. The 369 areas covered with full-thickness skin were all placed on aseptic denuded surfaces. Since January 1, 1938, a full-thickness skin graft has occasionally been used for the correction of web fingers or small cicatricial contractures of the fingers in children, and, occasionally, when a granulating area was small and in an inconspicuous place a "split" graft has been used as a matter of saving time.

At least three properties of skin grafts are very much dependent upon their relative thickness or thinness. First, with the exception of certain anatomic factors (the anatomy may be such that a base is formed which prevents contracture) the base on which the skin lies tends to contract in direct proportion to the thinness of the skin graft which is applied. When a skin graft is placed on a freshly made aseptic denuded surface with a movable base, such as the anterior neck, a thin graft may contract as much as 60 percent. However, if a thin graft is laid upon a freshly denuded scar or derma, periosteum or bare bone, or on areas surrounded by tense skin or scar, the subsequent contraction may be quite minimal. Second, the final appearance tends away from that of normal skin more or less proportionately to the relative thinness of the graft. That is, a full-thickness skin graft most nearly approaches the normal skin in ap-

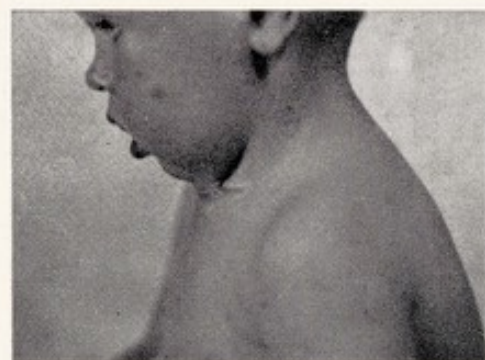pearance. Third, on an aseptic denuded surface, the hazard of not obtaining a "take" or only a partial "take" will run from one-eighth to one-third greater, varying somewhat according to the location on which the



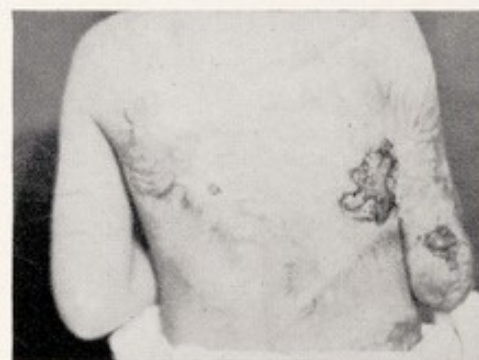A



B



C



D

FIG. 2. A, photograph of a burn, which if allowed to scar over without aid will be forced by the underlying anatomy to close principally by epithelization from the circumference. B, photograph of a burn, which, because of the anatomy of the region, has closed principally by epithelization from the circumference. C, photograph of a burn which has closed principally by the contracture of the fibrotic base. D, photograph of a burn, which, over the ribs will close principally by epithelization from the circumference and, in the axilla, principally by contractural fibrosis.

application of the graft is made when a full-thickness skin graft in contradistinction to a thinner type of skin graft is used. If a full-thickness skin graft is applied to a granulating surface, it is seldom that a "take" is obtained.

Properties of the Thiersch and "Split" Grafts

The Thiersch graft is a thinner graft than the true "split" graft. However, the two grafts fall into a group which has a certain similarity in so far as their properties are concerned.

Among the advantageous properties of the thinner types of skin grafts

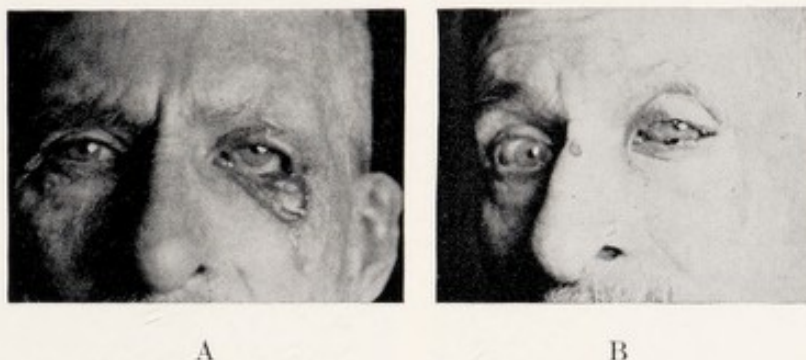

FIG. 3. Case showing ectropion of eyelids due to superficial loss of the eyelid, before and after correction by the application of skin grafts.

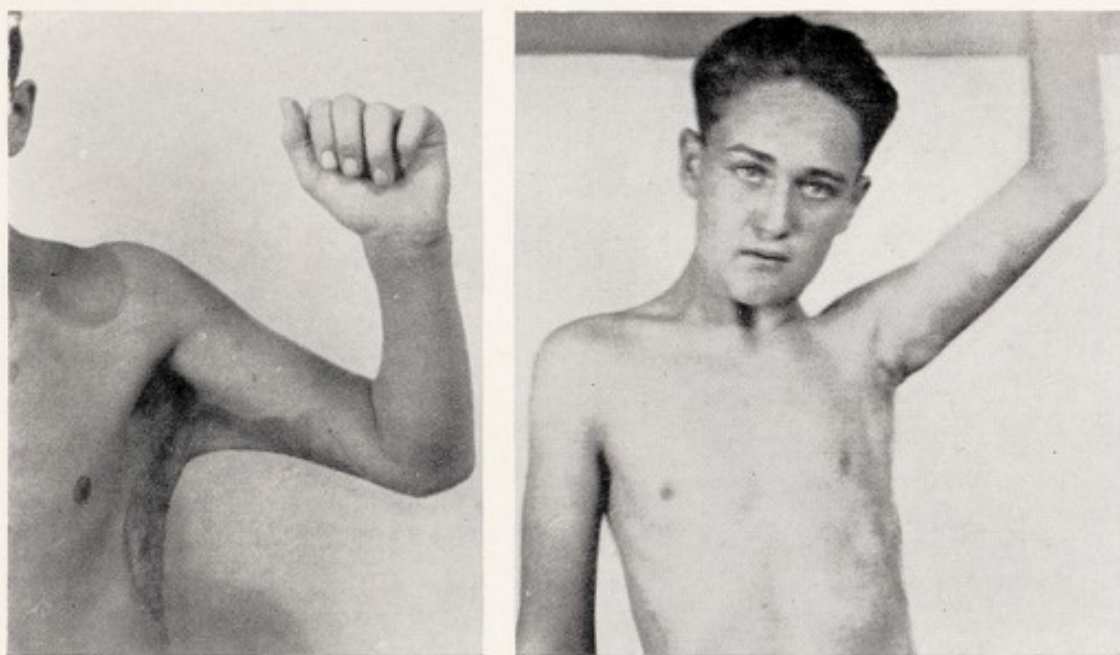
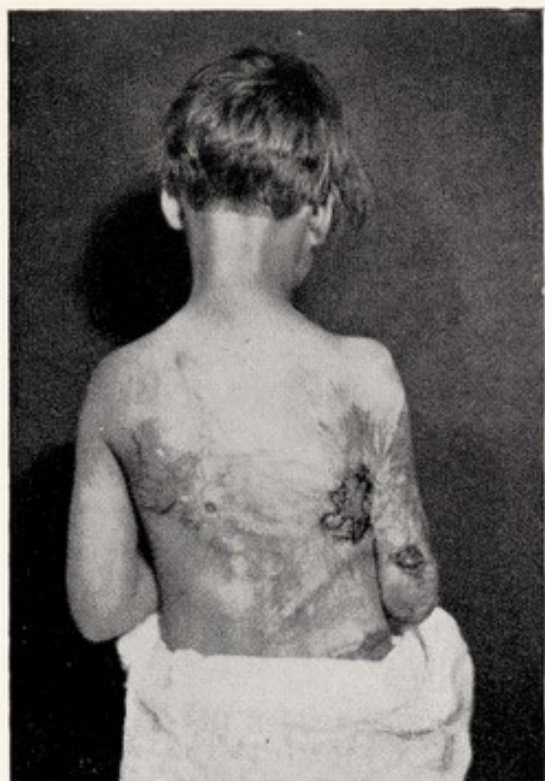
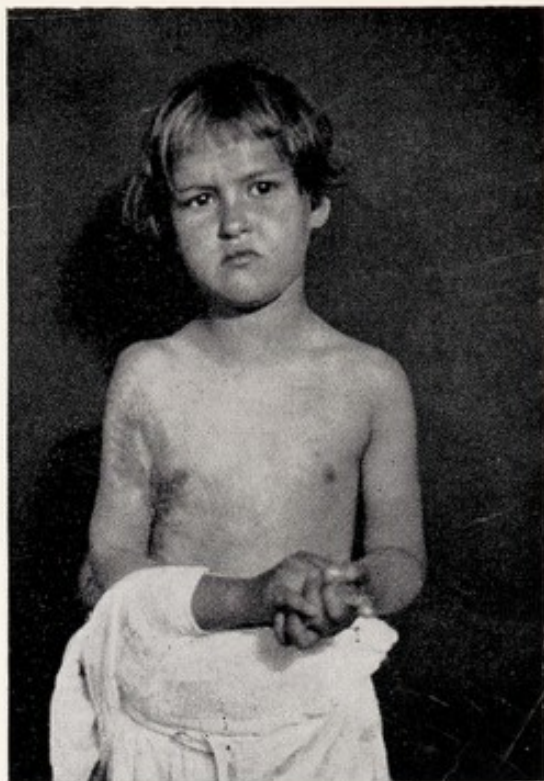
FIG. 4. This is an example, before and 3 months after operation, of a rather severe contracture of the axilla which was corrected by means of cross-cutting, removing the scar, and applying a graft as thick as could be cut with the large knife.

are the following: (Fig. 3, 4, and 5). Grafts of this type of large size can be obtained easily with relatively little damage to the area from which they are cut. A "take" is almost certain. If correctly used on surfaces where weight-bearing or repeated trauma are not factors, such a



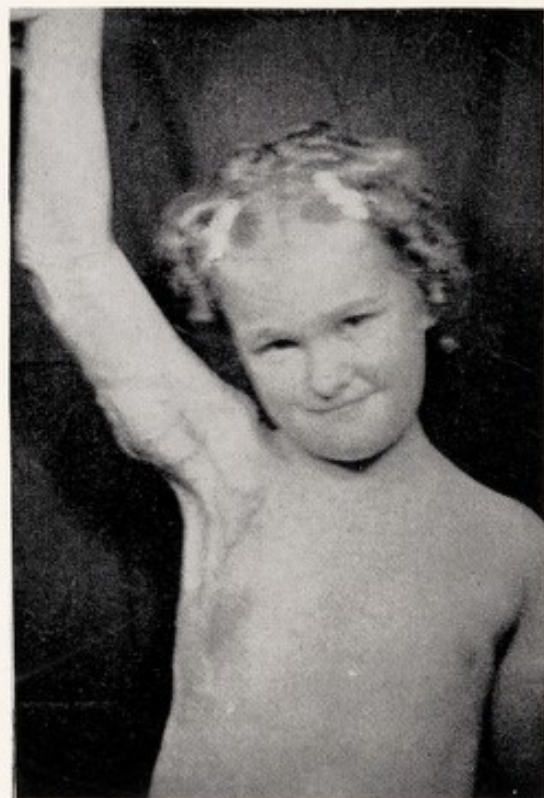A



B



C



D

FIG. 5. A, B, C, D. See next page for description.

graft may give sufficient protection. The time of healing does not depend upon the size of the graft. As a general rule, the operation can be done quickly. The donor area heals rapidly from the base and one can retake the newly formed skin after three or four weeks if necessary. The post-operative dressing period is short—from ten days to two weeks. A sufficient amount of "split" graft will correct cicatricial contractures of such areas as the axilla, the elbow region and the popliteal space. Thus, the correct application of the thinner type of grafts sometimes offers a method which in one or two operations will correct functionally a considerable contractural deformity, or adequately cover a raw area of considerable size. Thinner grafts are the grafts of choice on a fresh granulating surface and often on hidden clean raw surfaces which will resist contracture. Upon the subcuticular muscles of the face, the orbicularis oris, and the orbicularis palpebrum, the thinner types of grafts have been, in most cases, the graft of choice. Also for cavity grafting the thinner types of grafts are usually chosen. That is, for the situations and lesions mentioned, the thinner types of grafts are chosen because of the comparative simplicity of their application and the greater certainty of their "take." Among the main disadvantages of the thinner types of grafts, one may state that the appearance is not very good, that contraction is considerable and that the protection may not be sufficient.

Technique of Cutting a Thiersch or "Split" Graft: The technique developed by Blair and Brown, we believe, is the most satisfactory technique that has been presented for the cutting of a Thiersch or "split" skin graft (Fig. 6A). When the graft is cut, the skin is held tense and flat by traction pressure of small straight-edged flat pans held on either side of the knife. The knife used by Blair and Brown is 18 cm. long and 2 cm. wide. It is made of a strip of razor steel set in a stiff back. The knife is light. It can be stropped on a piece of canvas but will have to be ground occasionally. To a somewhat lesser advantage, in so far as the size is concerned, one may use an ordinary straight-edged barber's razor instead of the knife just described. The heel and the toe should be rounded and sharpened so as not to hang in the skin while being used.

The suction retractors used by Blair and Brown (Fig. 6A) are hollow

FIG. 5. A and B: A marked cicatricial contracture of the axilla with the arm absolutely fixed to the side. Posteriorly healing had not been complete about a year after the infliction of the burn. In this case the axilla was laid wide open and the arm hyperextended. Large moderately thick calibrated intermediate skin grafts were removed from the abdomen and chest and side of the thigh, and the denuded area was resurfaced. In this case after the first operation there was still some contracture. The patient returned one year later for additional release of the contracture. C and D show posterior and anterior views a year after the last operation.

brass boxes with the underneath side open. The rim that contacts the skin is bevelled. Boxes of three different lengths of openings may be obtained (4, 5, 7 and 9.5 cm.) for application to areas of different sizes. Just within the opening there is a series of transverse bars which prevent the skin from being drawn bodily up into the box. The ends are corrugated for gripping, and are 2.5 centimeters square. The tube leads from the top of the box

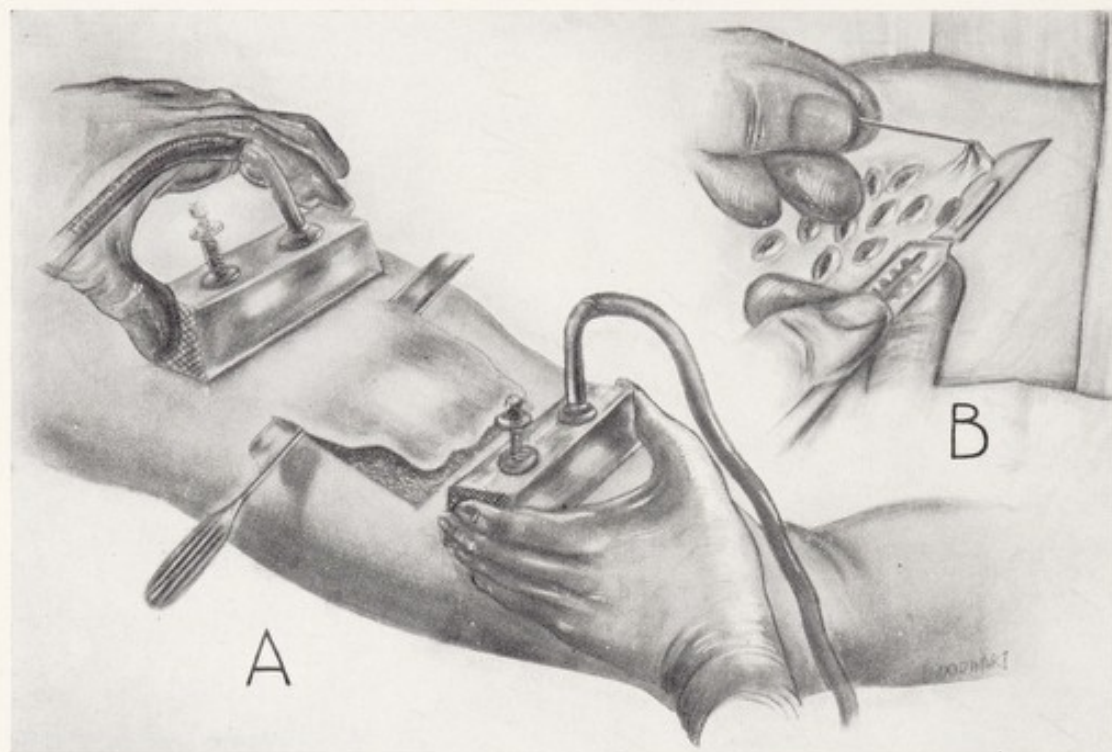


FIG. 6. A. Method of cutting a "split" graft from the inner thigh. The knife and suction boxes shown are those originated by Blair. One can also cut a Thiersch graft in this manner very well. B. (Fig. 10) Method of Davis for cutting small deep grafts.

to be connected to a non-collapsible rubber tube connected to a strong suction machine. There is a strong valve on the top of the box with a screw for the adjustment of the strength suction. The suction usually used is a half of an atmosphere of negative pressure.

With such a suction retractor one is able to cut much more quickly, to make grafts larger and of more uniform thickness and to cut them within certain limits of varying thicknesses—all of which widens the field of usefulness of these grafts. Although not particularly necessary, a very thin film of vaseline may be applied to the donor area. The suction retractor is drawn slowly along the surface, just ahead of the knife, neither raising nor depressing the skin. The fundamental idea in the cutting of the graft is to get an area which is flat, which is on tension and which is immobilized so that the knife cuts uniformly. If muscles are on

tension beneath the area from which the graft is cut, a raised place is likely to cause one to cut through the derma and into the subcutaneous fat. The leg, therefore, has to be placed in a position so that underlying structures are not on tension.

As a general rule, the skin is taken from some part of the inner thigh or the upper outer thigh. These grafts are cut thick enough so that if a new growth of hair on the graft is not desirable they should be cut from a non-hairy surface. In young babies the abdomen may be the site of choice. Considerable difficulty, however, will be experienced in cutting a graft of fair size from the abdomen of a baby, as it is difficult to cut a good split graft from a baby or a young child because the skin is so thin. This difficulty also may be encountered in women in certain regions. If possible, the graft should be large enough to cover the whole area and even to extend beyond the edges. If this cannot be done, the fewer the grafts that one has to cut to gain this end, the better. They should be of as nearly the same thickness as possible. On a large thigh with a fair amount of subcutaneous fat, good-sized grafts of fairly even thickness can be cut with a long light razor-ground knife.

Properties of a Full Thickness Skin Graft

Among the disadvantageous properties of the full-thickness skin graft one may enumerate the following: On granulating surfaces, the probability of a good "take" is too slight to make its use of much practical value; and even on an aseptic denuded surface, on an average, one runs about a twenty percent chance of losing a varying part of the graft. Some superficial loss from blistering is often a feature. Depending upon the depth, this may endanger the final appearance. Less often, focal areas of necrosis will be present. These may not only compromise the final appearance, but, also, depending upon their number and size, may jeopardize the functional result. It is particularly difficult to get a full-thickness skin graft to "take," in its entirety, on an aseptic denuded surface which is concave, or which has a great deal of unevenness such as the axilla. On a concave surface with a rounded firm base, as a rule, a good "take" will occur. Characteristically, especially if there be considerable blistering and areas of focal necrosis, the postoperative dressing period is prolonged over a period of from three to five weeks. Finally, it is necessary to draw together, and to suture, the skin edges of the defect after the removal of a full-thickness graft. A full-thickness graft tends to develop a considerably more plentiful subcutaneous tissue than the thinner graft.

To offset the disadvantages of a full-thickness skin graft one can enumerate the advantages, following the application of a full-thickness graft, that are quite outstanding. After a perfect "take" of a full-thickness

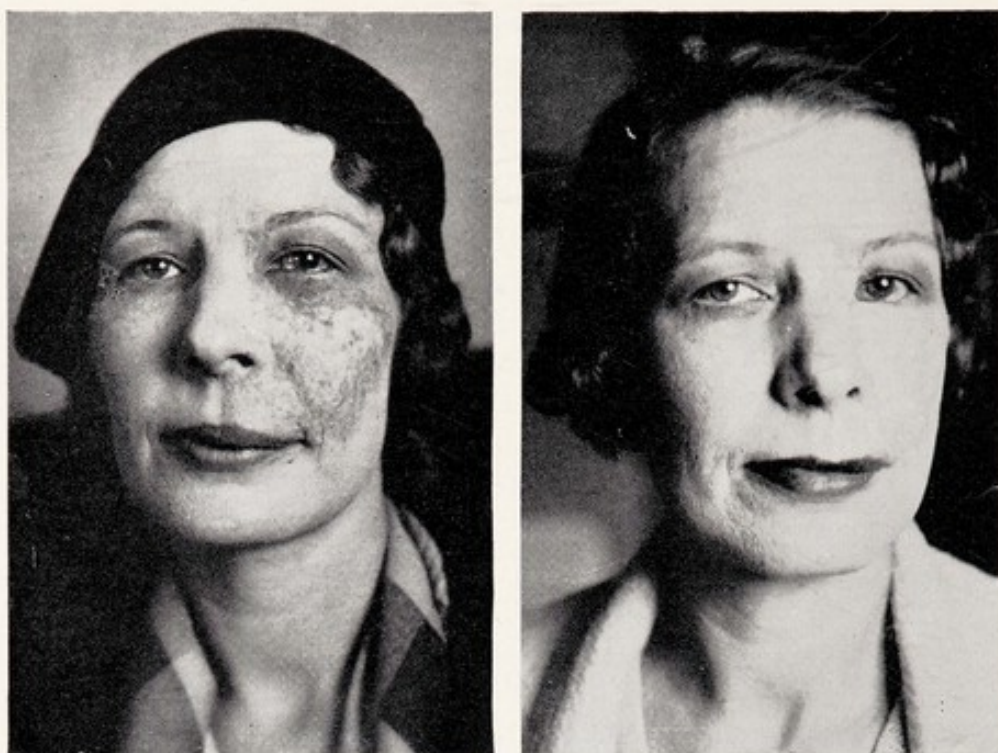

FIG. 7. This girl had a large "port-wine stain" covering one-half of her face which had been overirradiated causing itching, scaliness, and telangiectasis. The whole area was excised and a full-thickness skin graft was applied. At the present time we would correct such a condition by means of a deep intermediate skin graft. A. Before operation. B. One year after operation.

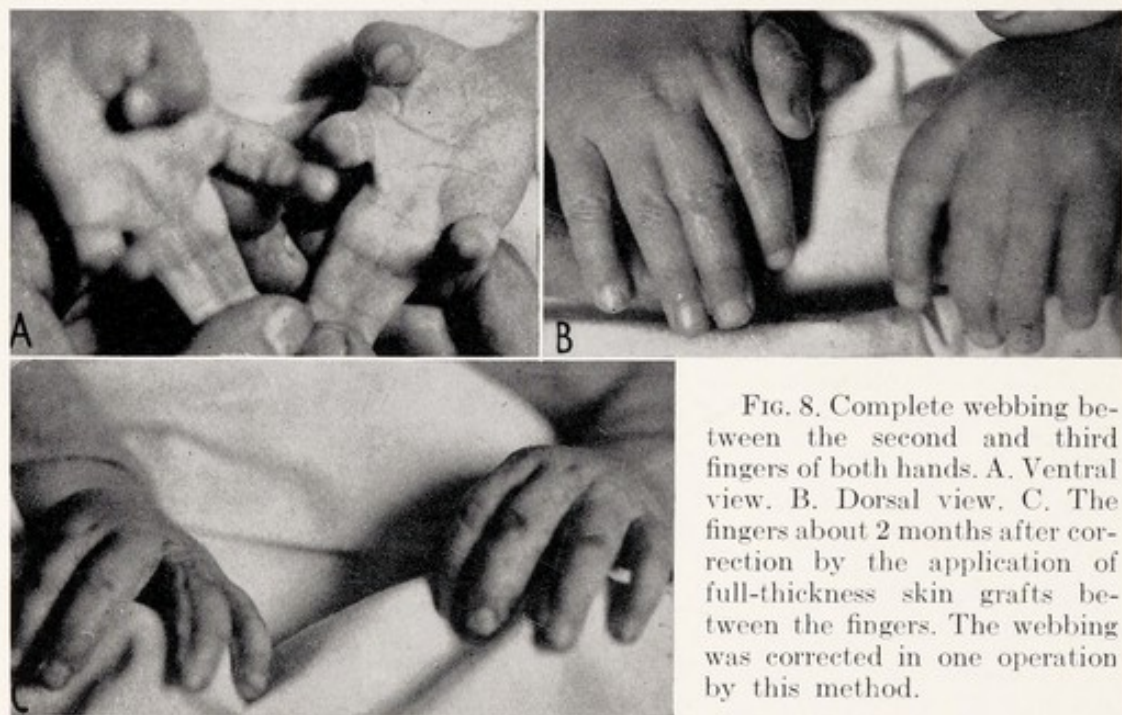


FIG. 8. Complete webbing between the second and third fingers of both hands. A. Ventral view. B. Dorsal view. C. The fingers about 2 months after correction by the application of full-thickness skin grafts between the fingers. The webbing was corrected in one operation by this method.

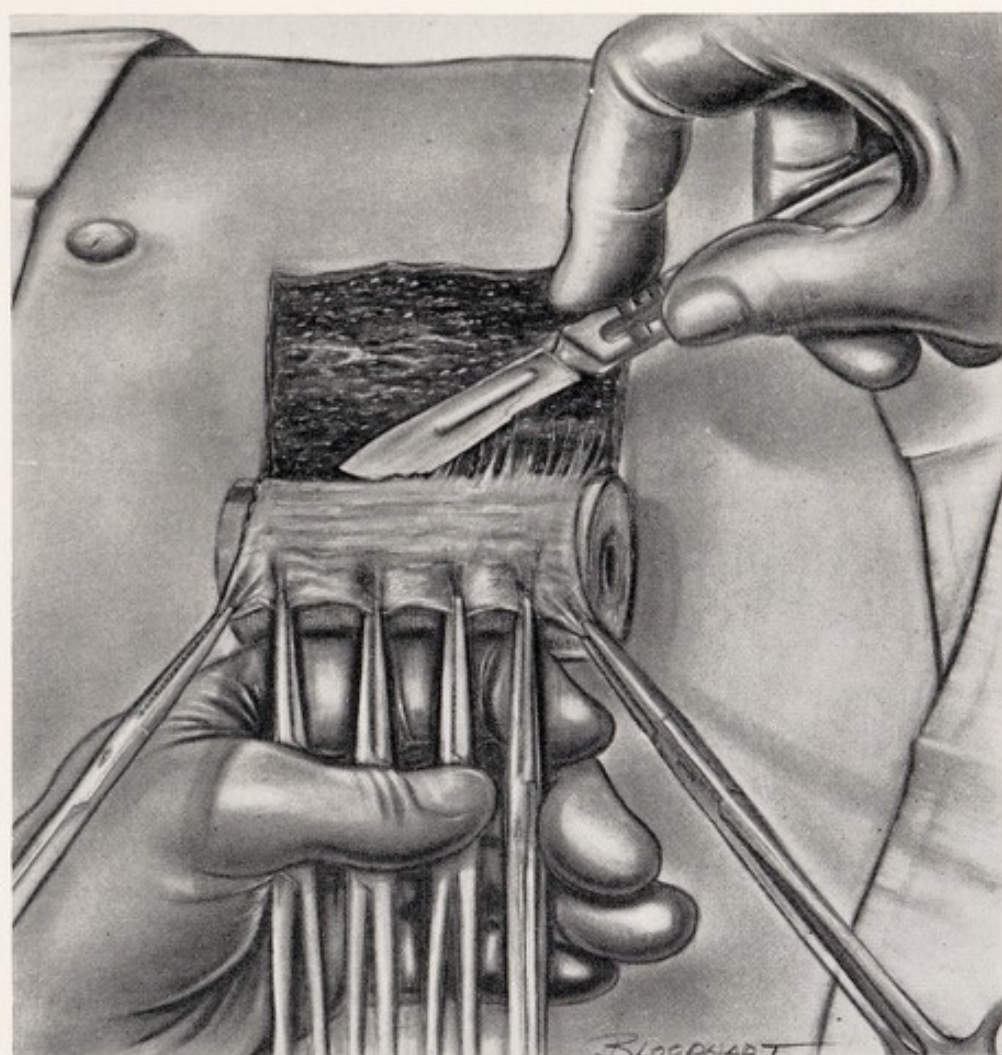


FIG. 9. Technique of removing a full-thickness skin graft from the abdomen. Clamps are placed on the edge and later one may place one on each side for tension. A sharp knife is used for cutting. One cuts in the corium in such a manner that no fat or blood vessels are left on the graft. A roll of gauze may be used or a special roller to hold the skin as flat as possible and to help give the proper tension.

FIG. 10. Refer to Fig. 6 B, for drawing of method of cutting pin point grafts as cut by Davis.

skin graft the appearance will more nearly approach that of normal skin than that following the application of any other skin graft. The amount of subsequent contraction is minimal for the group of skin grafts as a whole. A full-thickness skin graft will give the greatest protection possible to obtain by the application of a free-skin transplant.

On the other hand, on the face (Fig. 7), or on the neck, or on the palm of the hand, or over the dorsum of the hand including the knuckles or between the fingers (Fig. 8), if one can obtain a good "take" of a full-thickness graft, the final result, both as to function and appearance, will be the best that can be obtained.

Technique of Full-Thickness Skin Grafting: In planning the operation one takes into consideration the fact that the graft will contract about one-fourth and opens up the tissue very completely, overcorrecting the deformity as much as possible. In situations like the neck, the axilla and the fingers, the maximum amount of extension is obtained, as the case may require, by cutting across or excising all scar tissue bands that are put on tension by overcorrection.

If the grafting is to be done on account of scar contractures, they are laid wide open without regard to the size of the resulting raw surface, provided that the denuded surface is not of such extent as to jeopardize the life of the patient and that enough skin to cover the area can be obtained.

A raw fairly flat surface having been obtained, the skin is cut by pattern from the abdomen, the back or the thigh in such a manner that no subcutaneous fat remains. The line of incision is on the level of the base of the corium. As one cuts, with the scalpel, the skin must be kept on tension. One will find that if Kelly clamps are placed at the edges, at rather short intervals, proper tension may be kept on the skin by means of traction (Fig. 9). If one rolls the skin graft over a gauze roll held in the fingers of the left hand, this will aid in giving a slightly convex surface at the line of incision. Webster has recommended a special roller for this purpose which is of considerable aid. With practice, one can accomplish the same thing with a wad or roll of gauze as with the special roller. After the graft is removed, the wound, caused by its removal, is closed with superficial and deep sutures, if possible. When this is not possible, the wound is preferably covered with a thin graft to lessen the time of healing that would otherwise follow if the wound has to heal by secondary intention.

CHAPTER V

Special Types of Skin Grafts

Small Deep Skin Grafts

THE SMALL skin graft of Reverdin (1869) was not as deep as the small deep graft introduced by Davis in 1914. The graft of Davis is a conical piece of skin comprising the entire thickness of the corium in the central portion and tapering off toward the periphery to include the upper layers of the epidermis. With a reasonable assurance of a "take" they may be laid directly on intact granulations if some care has been taken in preparing the surface. The graft may be cut from the thigh, the abdomen or from almost any area of the body, and a large number of these grafts can be obtained from a relatively small area, thus making it possible to use these grafts on extensive wounds without any severe tax on a very ill patient. They are fairly easy to remove under local anesthesia. The application of a small deep graft is a simple method of skin grafting, and, because a "take" will usually occur on a granulating area even if it is not scrupulously clean, the small deep skin graft has achieved some popularity with certain surgeons.

The graft has four more or less important disadvantages. First, from the functional standpoint the base on which they are placed shows a rather marked tendency to contracture due to the interspersed scar, and, also, due to this fact, the area on which the graft is placed may not become soft and pliable, but rather thick and keloidal. As a permanent covering they are not of great value on flexor or extensor surfaces. On cosmetic grounds, an objection to their use in certain locations is due to their tendency to pigmentary changes and the interspersed heavy scar formation. Occasionally, at least, the donor area shows a tendency to the formation of a quite heavy scar. This may be quite noticeable if the grafts are taken from the thigh. Finally, sometimes, there is a marked desquamation of the grafted area when it dries out, especially between the grafts, which is evidently due to epithelial overproduction. This scaliness, however, usually can be controlled by the application of an emollient. It has seemed to me that with methods of preparing the surface, and with skin grafting developed to a point that it has been during the past decade and a half, that it is seldom that the small deep graft is the graft of choice. However, previous to the development of the dermatome, which allows one to remove a thin skin graft from almost any area quickly, occasionally

a patient was seen in whom, because of emaciation, long illness, the amount of denuded area, or because of the technical impossibility of removing a sheet of skin from the area where the graft would necessarily have to be taken, small deep grafts were considered to be indicated. Although, in such a case, it may not be possible to get a sufficient amount of the small deep grafts to cover any great percentage of the denuded area, a sufficient area of the granulating surface sometimes may be covered successively so that the patient may gain sufficient ground to allow healing or further skin grafting. There are certain chronic ulcerations which are extremely difficult to get clean enough for a sheet skin graft to "take." The small deep graft has been of value in obtaining reepithelization in such situations. It is a graft which can be used to advantage, sometimes to cover certain wounds, when it is necessary that the patient be ambulatory.

Technique: Agnew first suggested the simplest method of raising a small graft. The technique recommended by Davis is similar. A bit of epidermis is picked up with a straight needle held with an artery clamp (Fig. 10, Fig. 6B). The skin is raised so that a little cone is formed, and the base of the cone is cut through by depressing the blade of the knife. The graft, still on the needle, is transferred to the wound with the raw surface downward. These grafts vary in size from about $\frac{1}{12}$ to $\frac{1}{6}$ of an inch in diameter but usually should not be larger than $\frac{1}{6}$ of an inch. The grafts should be placed on the wound just about as close together as possible. Davis recommends that a dry sterile rubber protector be placed over the graft. This serves to press the graft out somewhat more flatly. The protective rubber tissue is cut into strips so as not to impede any secretion that may drain from the wound. Next, strips of gauze, wet in some antiseptic solution, are placed over the protective strips of rubber. Davis also states that paraffined mosquito netting directly over the graft, followed by a layer of boric acid ointment is useful. The paraffin netting gives immobilization.

Recently Davis (J. S.) has reported some results in resurfacing with small deep grafts which are unusually good. However, as a rule, it has seemed to me that resurfacing with a sheet skin graft is preferable to resurfacing with multiple small grafts. The exception to this rule would be for areas impossible to render surgically clean, or small granulating areas where the ease of the method recommends it.

"Sieve" Graft

In 1930 B. Douglas described a skin graft which he termed the "sieve" graft. The graft, as applied to the recipient site, is essentially a full-thickness skin graft with multiple interspersed holes. The skin which would have been in the graft, if not for the holes, is left in the donor area for the purpose of regeneration. Before the graft is removed the holes are

cut with a special cutting punch. In principle, it is a modification of the small deep graft of Davis.

This sieve graft undoubtedly has certain advantages which lend to it some recommendation. The fact that the donor area heals without suture is an advantage, undoubtedly. The fact that the drainage is good is another point in its favor. But to apply a full-thickness skin graft to a granulating surface, no matter how perfect the drainage, may prove to be a somewhat hazardous procedure. On an aseptic denuded surface one hardly needs as much drainage as this graft, provided that good hemostasis, a proper dressing and good fixation are obtained.

The graft violates what to me, at least, seems to be a fundamental principle in an ideal skin-grafting operation, in that the total area is not covered with epithelium. A certain percentage of the grafted area must be covered by scar, which tends to contract, to interfere with pliability, and, to a certain extent, in certain situations at least, with its ability to withstand wear and tear. I have no doubt that by the use of this graft some excellent results may be obtained, but in the past I have felt that in most instances the selection of either a "split" graft or a full-thickness graft came nearer to fulfilling the requirements of the situation in hand. Now, a deep intermediate graft of proper thickness would seem to be the preferable graft.

The Implantation Method of Skin Grafting

The advantage of the implantation method of skin grafting is that it can be used in certain cases in which commonly practiced methods of skin grafting will fail. The only condition that must be fulfilled is that granulation tissue must be present. Wangensteen, for example, has been successful in obtaining a "take" with this type of skin graft while feces from a colostomy was being discharged over the wound; and also in a large unclean pressure sore over the ischial tuberosities with considerable undermining of skin following thigh amputation for arteriosclerotic gangrene. The method may be useful in ambulatory patients. The indication for the method, in general, is in those cases in which other methods fail.

About eight days after implantation, the grafts make their appearance as whitish areas. These rapidly increase in size, and new skin gradually covers the granulations. The final epithelial layer may be little better than a scar, may break down under trauma and is prone to become somewhat keloidal.

Technique: The technique is simple. The skin is removed, as for a Thiersch graft, and cut into 2 to 4 mm. squares. With the blunt end of a needle each square of skin, after impalement, is pushed obliquely into the granulation tissue until the graft disappears from sight. As the needle

is withdrawn, the graft is held in place with a tissue forceps. The granulating surface is seeded with grafts about 1 cm. apart.

Algave has used the implantation method of skin grafting; but made little excavations in the granulations with a small curette before placing a fragment of skin in each.

Tunnel and Buried Skin Grafts

The buried and tunnel skin grafts do not represent a different type of graft. They represent unique techniques of application. The principle is a modification of the Esser inlay graft.

In tunnel grafting, the skin is introduced beneath the surface. After the buried graft has taken, the overlying tissue is cut through to expose the grafted area. This graft has been used by Keller for both the release of contracture and for insertion beneath a granulating ulcer. The graft has two advantages in that it is not likely to become infected, and that it more or less immobilizes itself. The graft has been stated to be applicable where a full-thickness graft is desirable but cannot be employed because of an infected base. An example would be a chronic ulcer over a weight-bearing surface. The graft can be used to correct contractures over depressions and folds of the body, such as the axilla, where the application of pressure and immobilization may be difficult. A series of grafts are buried at right angles to the contractures.

In our series of cases, preference was given to simply covering a granulating area, after removing an old ulcer or cross-cutting and removing a contracture, after which a sheet skin graft was applied with an indicated dressing to gain pressure and immobilization.

Smith recently has achieved some quite good results by undermining such lesions as flat scars, moles and moderate-sized birth marks after which he inserts a sheet of full-thickness skin over the denuded bed. The wound of insertion is closed. After about ten days the superimposed skin is excised and the edges of the skin graft and the surrounding skin are coapted with sutures. He claims that his percentage of good "takes" is superior to those obtained with a full-thickness skin graft applied directly to a denuded surface. He also states that one can get a "take" even if some fat is left on the graft. If this be true, it is contrary to the ideas most men have had after a large experience with skin grafts of different thicknesses. Another question is also brought to the front, namely: What rôle does heat and the moisture of tissue plasma play in the matter? The place of this method of applying a skin graft is as yet unknown. If the contentions of Smith are true, this technique of applying a full-thickness skin graft holds considerable promise.

Pulpified Epidermis (von Mangoldt—1895)

Von Mangoldt has applied scrapings of epithelium, blood and serum from the donor area to a granulating surface. In Pels-Leusden's Clinic these scrapings were injected into the granulation tissue with a syringe. Also Reschke has injected epithelial scrapings beneath an ulcer.

Although I have never used either of these procedures, by analogy I surmise that the procedures have little to recommend them. It would seem to me that the purposes for which one applies a skin graft could not be fulfilled by the use of these methods. Even though healing by epithelization was obtained, the scar would most likely be excessive. Other methods, used as indicated, should be more effective.

Removal of Skin from Avulsed Skin Flaps to Apply to the Denuded Base

Farmer recently (1939) has removed a full-thickness skin graft from certain avulsed skin flaps. The skin graft was then applied to the denuded area. The results were good. In most cases it will seem advisable to reapply as much of the avulsed skin flap as is viable and then apply a free skin graft to the remaining denuded base.

CHAPTER VI

Calibrated Intermediate Skin Grafts and the New "Three-Quarter Thickness" Skin Graft*

ABOUT a decade ago, Blair and Brown, in an effort to combine the advantageous qualities of the thin razor graft with that of the full-thickness graft, presented a skin graft alleged to transect the uppermost $\frac{1}{3}$ to $\frac{2}{3}$ level of the skin. This graft they designated as the "split" skin graft (Fig. 3, 4 and 5). This graft represented a definite step forward. However, I was never able to cut the graft without considerable variation as to thickness and size.

It occurred to me, after observing the advantages of the "split" graft, that if one could cut a uniform graft at a level below that suggested by Blair and Brown, and yet keep above the lowermost limit of the corium, such a graft would have desirable qualities not yet obtainable. The ideal graft for many purposes should be directed towards getting a graft of such thinness as to assure successful transplantation; as to leave the donor site capable of spontaneous regeneration; and yet of such a thickness as to afford adequate protection, minimum contraction, and, at the same time, match the surrounding skin relatively satisfactorily insofar as texture and color are concerned. Furthermore if one could vary the thickness of the graft at will, depending upon the region to which it was to be applied and the lesion which it aimed to correct, it might prove desirable for varying lesions, in varying locations, to lean towards thinness or thickness as indicated. Again, according to the age of the patient and the particular region from which the skin is to be removed, a variation in thickness may be desirable; as it is well known that the skin of children is thinner than that of adults, and that the skin in certain regions varies, as, for instance, the skin on the inner thigh of a woman is thinner than that of the outer thigh. Moreover, for certain lesions it is evident that if one could remove the skin from any area of the body such as the chest, the back, or over the ribs, certain areas could be resurfaced in a way not now possible by the use of the methods commonly practiced.

But to cut a graft, such as I had in mind, entailed mechanical problems.

* Most of the material under this heading has been published in the article: "Calibrated Intermediate Skin Grafts," *Surgery, Gynecology and Obstetrics*, 1939, 69: 779-793. Additional experience, including the table of cases, has been brought up to date and incorporated up to 1941.

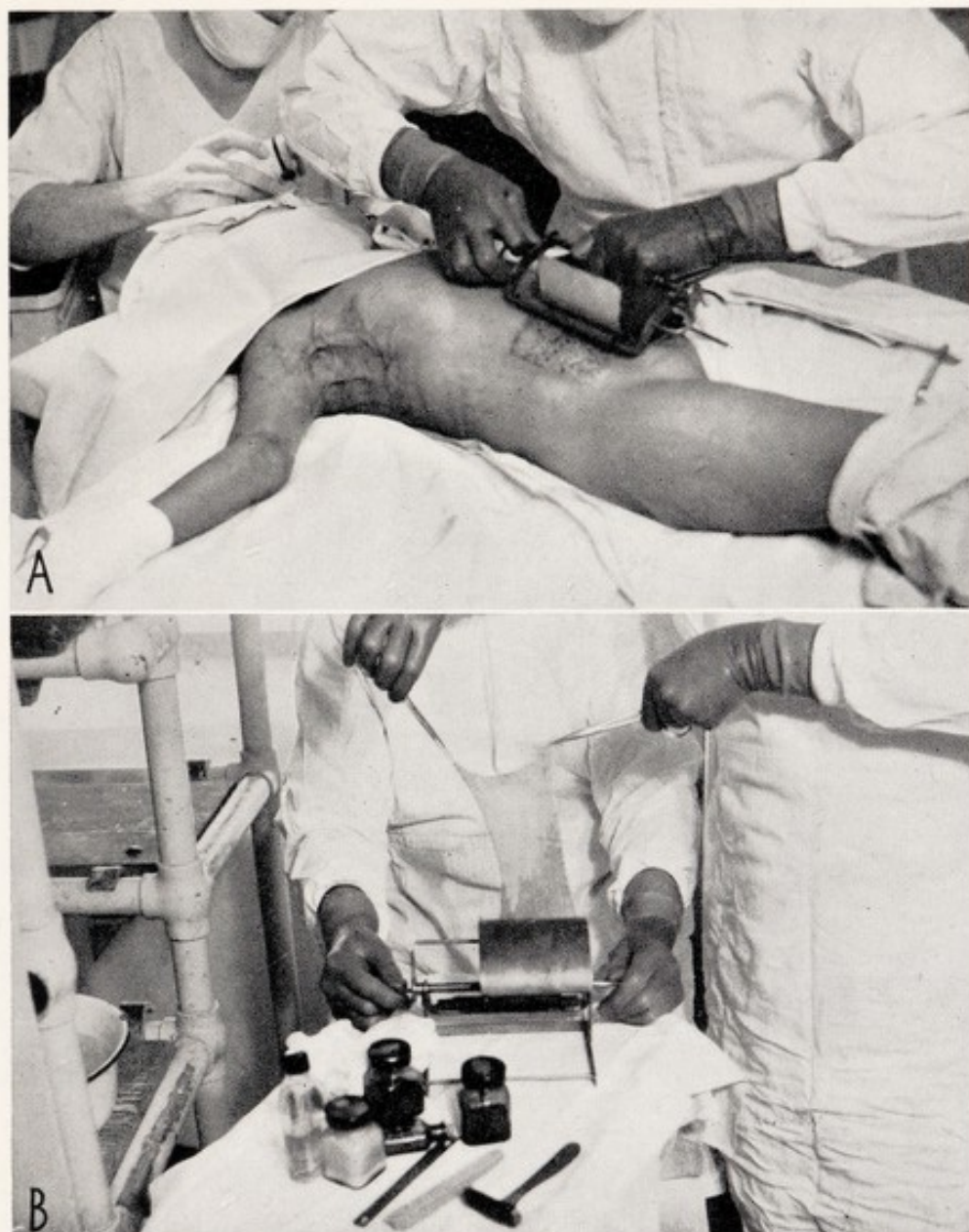


FIG. 11. Adhesive cement is applied to both the drum and the skin. A. The machine is shown working along cutting the skin from the abdomen in a perfect sheet. This skin graft is to be used to correct the axillary contracture shown in the photograph. B. The sheet of skin is being pulled away from the drum with hemostats. It will be noted that the sheet is the same size as the drum and that it is a perfect rectangular shape of uniform thickness.

The ordinary skin-graft knife was found to be inadequate. Aside from the difficulties encountered in its application in relation to anatomical location, age, and sex, the most formidable objection was the inability to cut a uniform sheet of skin at a predetermined level with any mechanical precision.

The Dermatome*

With these ideas in mind, it occurred to me that if one could draw the skin to a smooth surface and hold it in some manner, it could be cut in a sheet of uniform thickness, and of a thickness previously decided upon,

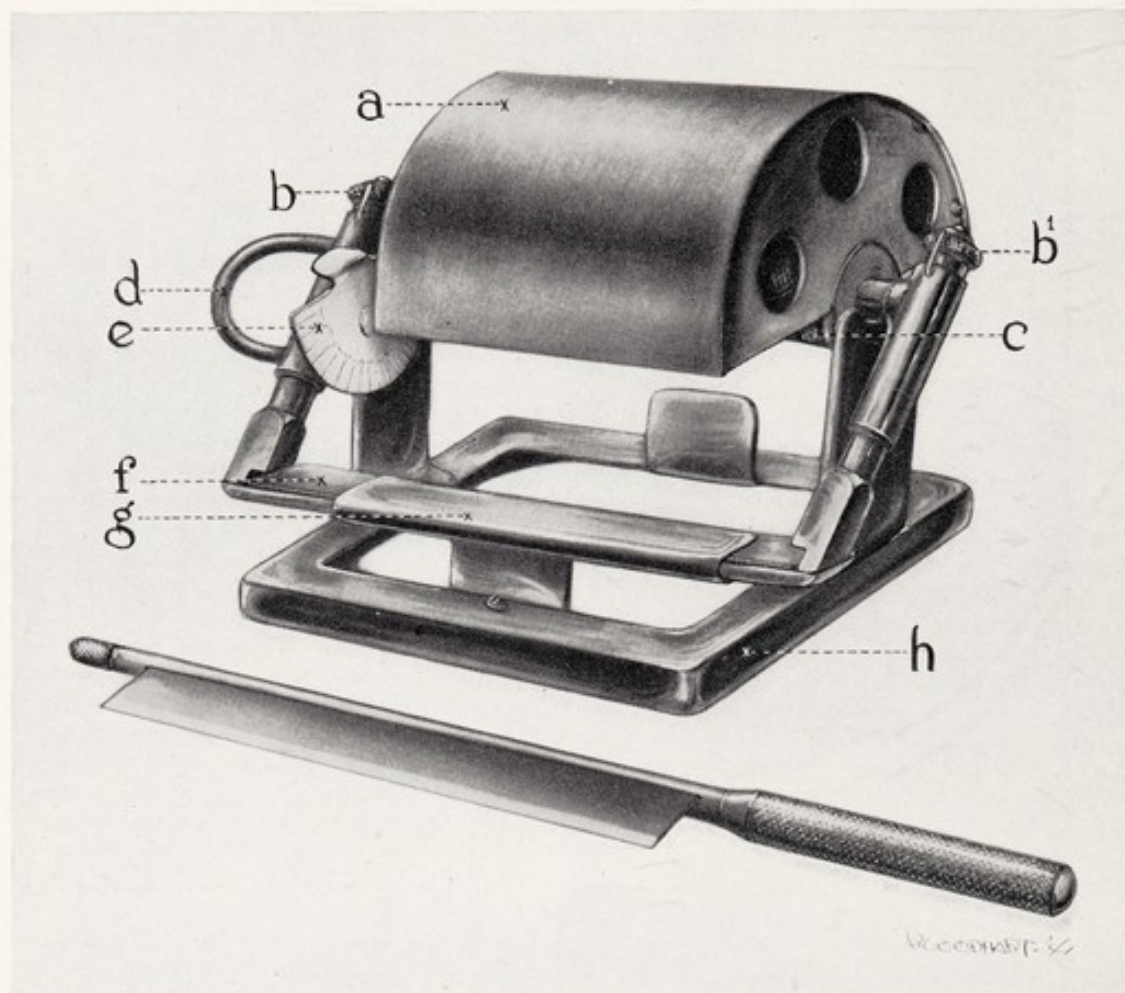


FIG. 12. Drawing of dermatome on stand. a. Semicircular drum. c. Hand holder to rotate the drum (left hand). b and b'. Calibrated screws (.002 inch between lines on screw head) which allow bilateral adjustment of distance of knife from the drum. d. Ring to finger to motivate the knife holder (right finger). f. Knife blade. g. Slide to hold knife blade in position. h. Base of stand to hold drum. e. Calibrated dial (.002 of an inch between lines) attached to eccentrically placed central shaft which passes through the handle of the drum and allows the distance of the knife from the drum to be adjusted unilaterally. By proper setting in conjunction with the screws b and b' the danger of the knife being jammed into the drum is eliminated. Lower drawing shows handle to hold knife when honing or to use when cutting a skin graft by hand.

by passing the knife through the skin at a definite distance from the surface—truly an accurately calibrated dermatome. In 1930 I carried this

* This dermatome is distributed by the Kansas City Assemblage Co., 609-11 East 17th St., Kansas City, Missouri.

conception to Professor Hood, a mechanical engineer at the University of Kansas, and enlisted his aid to see if I could overcome the mechanical difficulties of the problem. From 1930 to 1937, in a more or less desultory fashion, several different mechanisms were discussed, constructed, tried out and discarded as not being workable or practical. Finally, fastening

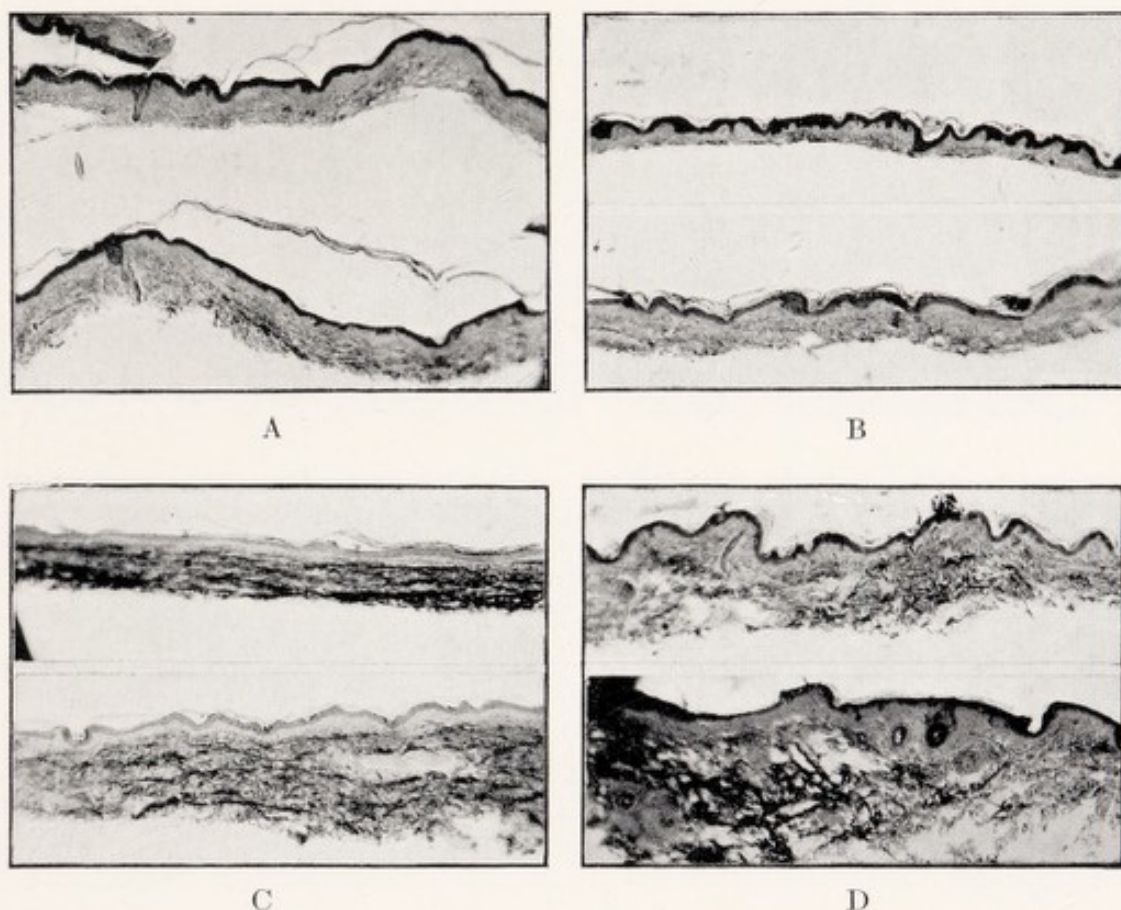


FIG. 13, A and B. Sections of Thiersch skin grafts. C and D. Sections of split skin grafts showing variation in thickness. $\times 16$. A. Thiersch graft cut from outer thigh adult male about .010 of an inch in thickness (.25 millimeter). B. Upper section: Thiersch graft cut from outer thigh of male, age 8 years, about .007 of an inch in thickness (.18 millimeter). Lower section: Thiersch graft cut from outer thigh of male, about .010 of an inch in thickness (.25 millimeter). C. Split graft cut from outer thigh of adult male shows variation from .010 of an inch (upper) (.25 millimeter) to .014 of an inch (lower) (.46 millimeter) in thickness; same graft. D. Split graft cut from outer thigh of adult male shows variation from .010 of an inch (.25 millimeter) to .018 of an inch (.46 millimeter) in thickness; same graft.

the skin to a smooth surface with a cement or adhesive, so that the skin would be held firmly to a longitudinally level surface while being cut, was tried. A mechanism, consisting principally of a drum with a movable knife fixed at a definite distance from the drum, was constructed. It was found that it was possible, with the greatest facility and ease, to remove a sheet of skin as large as the drum, 4 x 8 inches (Fig. 11a, b), or smaller;

to cut it absolutely uniform in thickness and that the thickness could be varied as described by turning a calibrated mechanism which varied at will, in a predetermined fashion, the distance of the knife from the drum. Furthermore, it was found that the graft could be cut to pattern, if one wished, nullifying the adhesive properties of the cement by painting out

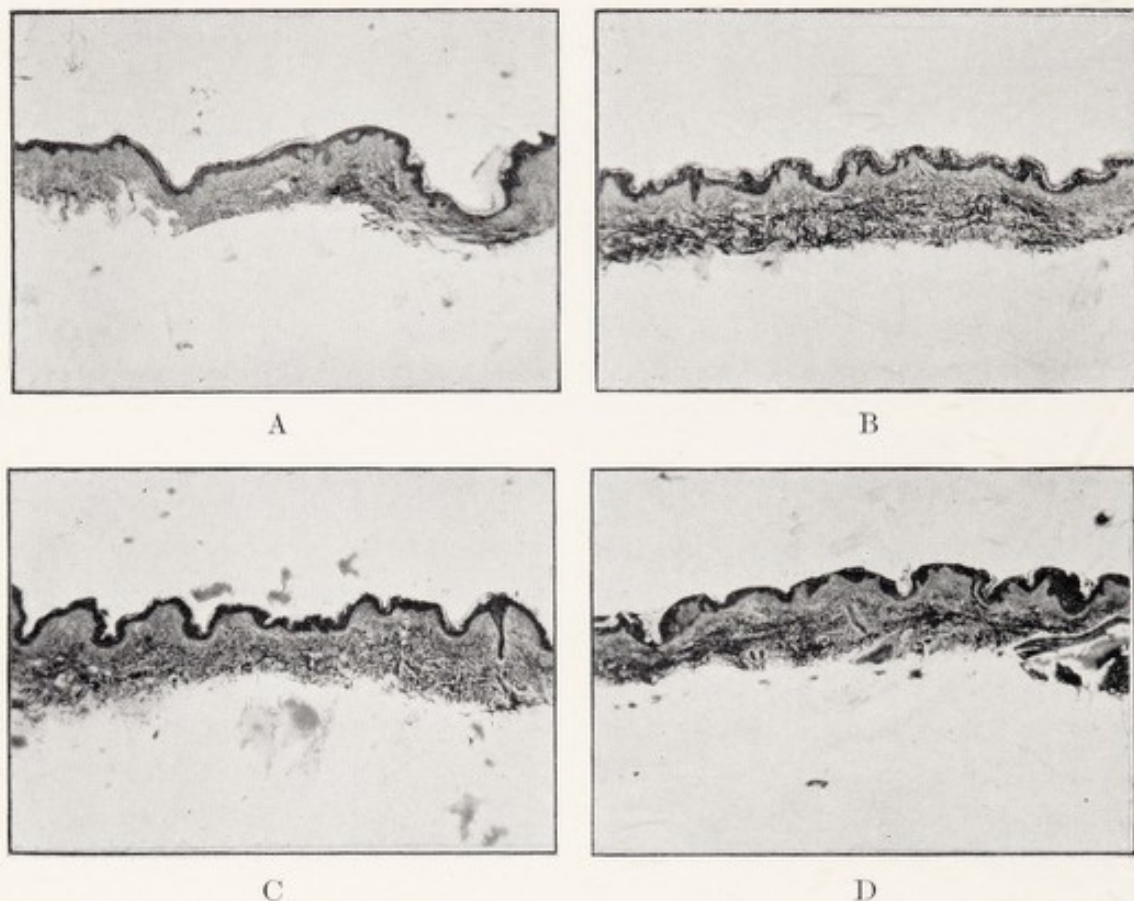


FIG. 14. Sections of thin and moderately thick calibrated skin grafts. $\times 16$. A. Male adult graft cut from abdomen about .010 of an inch (.25 millimeter) in thickness used to cover a granulating area. A good "take." B. Male adult graft cut from abdomen about .012 of an inch (.3 millimeter) in thickness used to cover a granulating area. A good "take." C. Male adult graft cut from abdomen about .018 to .020 of an inch (.46 to .5 millimeter) in thickness. Graft used to cover back of hand on clean raw surface. A perfect "take." No blistering. D. Male adult graft cut from outer thigh used to cover clean raw surface of dorsum and palm of both hands. .014 to .016 of an inch (.36 to .41 millimeter) in thickness. A good "take."

the area not to be removed with a solution of talc and ether. This solution prevents adherence of the skin to the drum. In the summer of 1938 the final model was worked out which, although embodying the fundamental idea of bringing the skin to a smooth surface, contained several very definite improvements which have facilitated the use of the machine (Fig. 12).

During the past three years (1938-1940), since the perfection of the dermatome, I have had occasion to perform 239 operations in which calibrated skin grafts of one thickness or another have been used. These operations were performed upon 207 individuals. I found that I could cut skin at any predetermined uniform depth, and that it was possible to

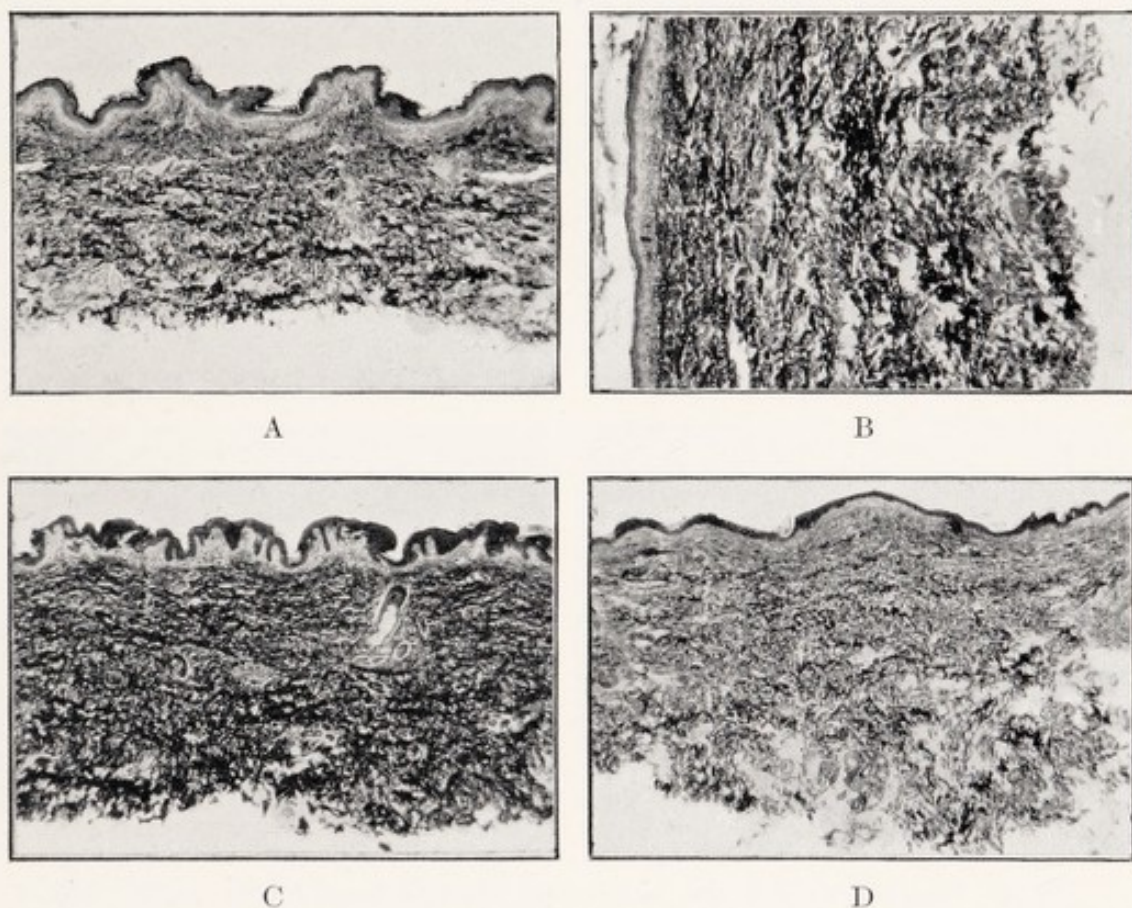


FIG. 15. Sections of full-thickness skin grafts cut with scalpel showing variation in thickness. $\times 16$. A. Full-thickness skin graft cut with scalpel from the abdomen of an adult male; thickness about .032 of an inch (.81 millimeter). B. Full-thickness skin graft cut with scalpel from abdomen of an adult male about .040 of an inch (1.01 millimeter) in thickness. C. Full-thickness skin graft cut with a scalpel from the abdomen of male child age 8 years; about .034 of an inch (.86 millimeter) in thickness. D. Full thickness skin graft cut with scalpel from abdomen of an adult male from .028 of an inch (.71 millimeter) to .034 of an inch (.86 millimeter) in thickness.

consistently cut, at a depth of 75 to 95 percent of the thickness of the skin, a graft I had not previously been able to accurately cut, viz., a deep intermediate graft.* The dermatome was found to be equally useful

* When it is desirable to be absolutely accurate in percentage depth, it is well to incise the skin vertically at its surface in order to judge the thickness of the skin before setting the calibrating mechanism of the dermatome.

in cutting thinner grafts of almost any predetermined thickness—as thin as .008 of an inch in thickness. Particularly was it useful in cutting various thicknesses of superficial intermediate skin grafts.

Varying Thickness: In an adult, when the main indication was one

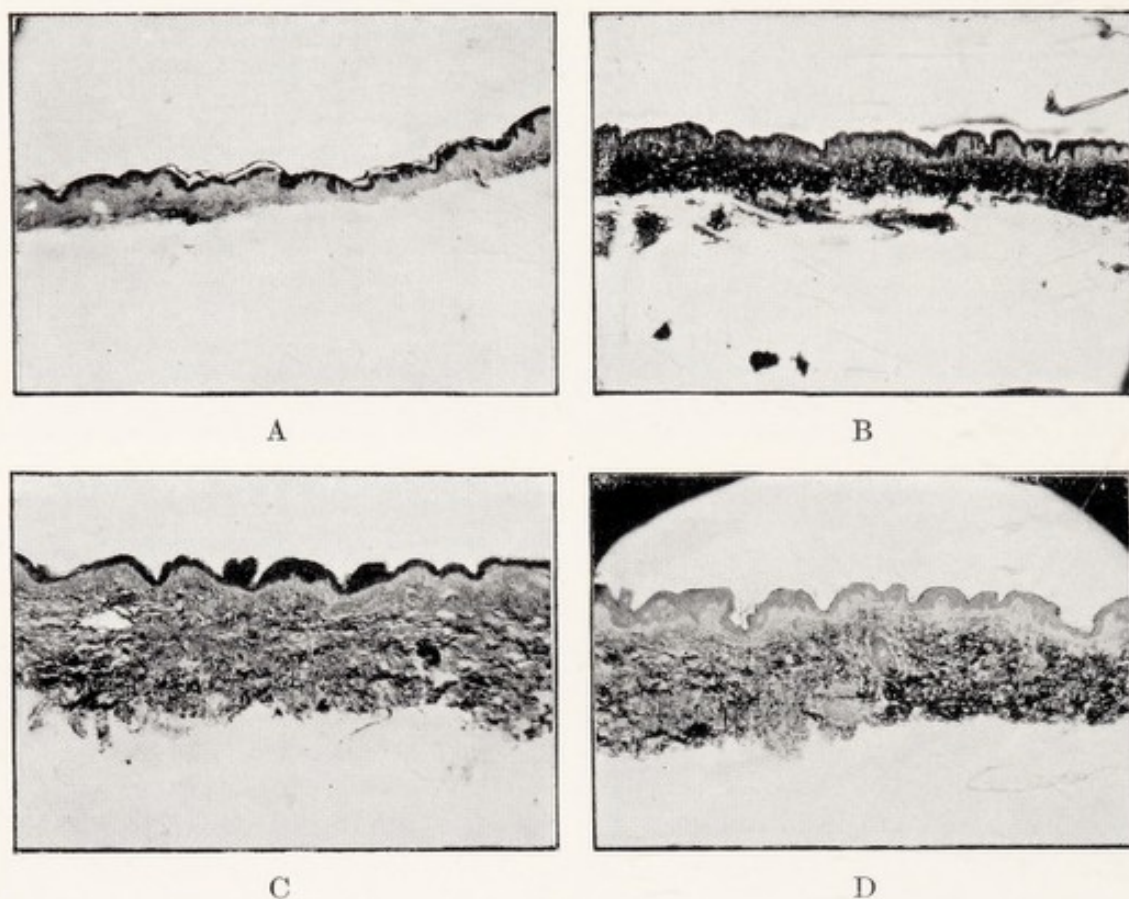


FIG. 16. Sections of thin and moderately thick calibrated skin grafts. $\times 16$. A. Male adult graft cut from abdomen about .010 of an inch (.25 millimeter) in thickness used to cover a granulating area. A good "take." B. Male adult graft cut from abdomen about .012 of an inch (.3 millimeter) in thickness used to cover a granulating area. A good "take." C. Male adult graft cut from abdomen about .018 to .020 of an inch (.46 to .5 millimeter) in thickness. Graft used to cover back of hand on clean raw surface. A perfect "take." No blistering. D. Male adult graft cut from outer thigh used to cover clean raw surface of dorsum and palm of both hands. .014 to .016 of an inch (.36 to .41 millimeter) in thickness. These last two are almost "three-quarter thickness" skin grafts. A good "take."

of resurfacing a granulating area, the graft was usually cut from .008 of an inch (.20 mm.) to .014 of an inch (.36 mm.) in thickness (Fig. 13 to 17). When a clean raw surface is to be covered in the male adult, and if the indication is one where appearance is a prime factor, or if it is essential to have a minimal contracture, the grafts are ordinarily cut from

.020 of an inch (.50 mm.) to .024 of an inch (.60 mm.). It was found that at this thickness sufficient subepithelial elements remained in the base for early regeneration. When maximum appearance of minimum contracture were not such clear-cut indications and the certainty of "take" seemed to rank relatively high in the balancing of the essential factors,

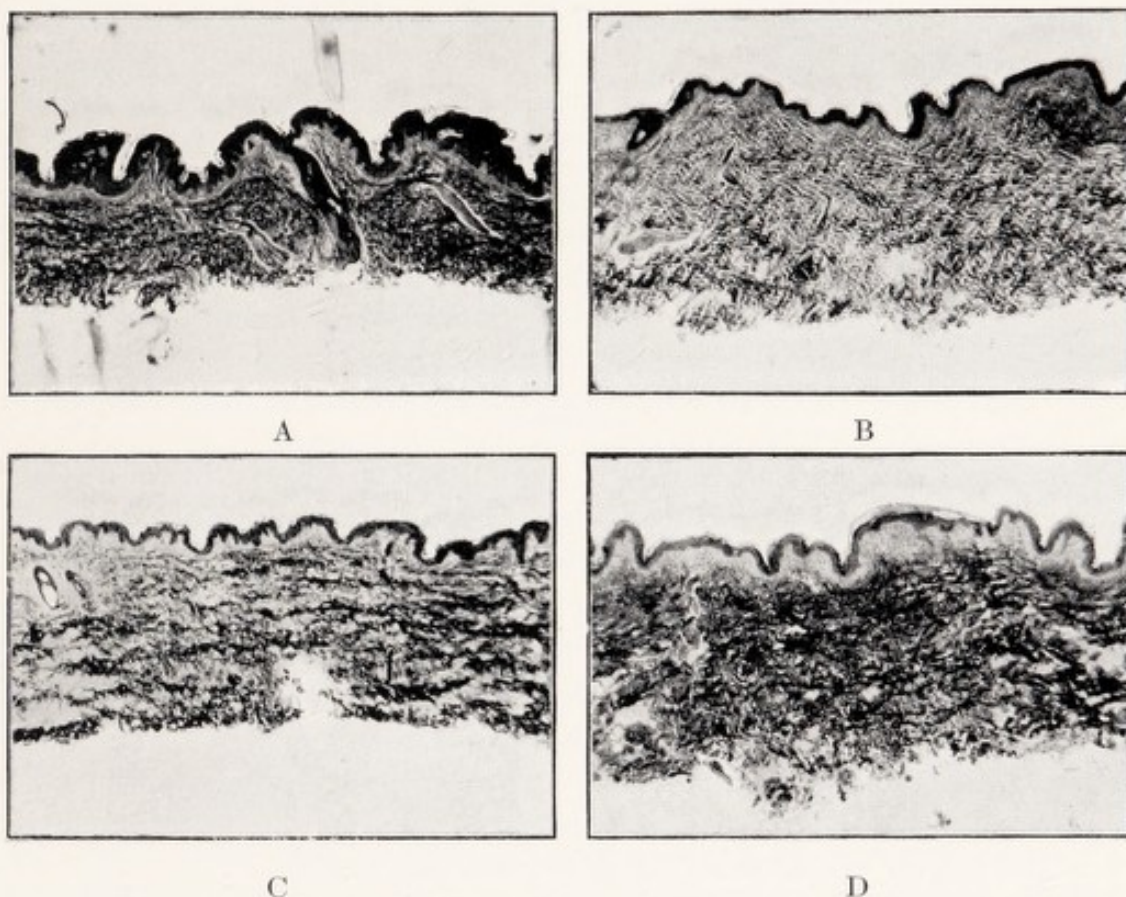


FIG. 17. Sections of new "three-quarter thickness" skin grafts. $\times 16$. A. Graft cut from abdomen of boy 8 years old, about .020 of an inch (.5 millimeter) in thickness. B. Graft cut from abdomen of woman, age 60 years, pregnant previously; about .025 of an inch (.63 millimeter) in thickness. C. Graft of male age 14 years cut from abdomen; about .025 of an inch (.63 millimeter) in thickness. D. Graft of male age 65 years cut from thigh about .030 of an inch (.76 millimeter) in thickness.

the grafts usually were cut between .016 of an inch (.41 mm.) to .020 of an inch (.5 mm.) in thickness. This was also the case when cutting a "three-quarter thickness" skin graft on children or in women where the skin was thinner than in the male adult.

A variation in the thickness of the skin in different locations occurs in both sexes. In children, and in women sometimes after repeated preg-

nancies, if the skin over the abdomen, and normally from the inner thigh or the inner upper arm, is removed at a level of .018 of an inch (.46 mm.) to .020 of an inch (.5 mm.) all of the subepithelial elements will be removed. The variation in the thickness of the skin in different locations varies in the male, but not to as great an extent as in the female. Coincidentally, while making these observations on the thickness of adult skin, children were being operated upon and their skin thickness was checked. In a young child (for instance 6 years of age), if one cuts a graft from the abdomen of as little thickness as .014 of an inch (.36 mm.) to .016 of an inch (.4 mm.), he may remove all of the subepithelial elements of the skin and healing will be by secondary intention. When a calibrated graft is removed from a baby two or three months old to leave sufficient epithelial elements in the bed for regeneration, one can hardly cut the graft more than .010 of an inch (.25 mm.) to .012 of an inch (.3 mm.) in thickness. When the child is about 12 to 14 years of age one cannot cut lower than .016 of an inch (.41 mm.) to possible .018 of an inch (.46 mm.) in thickness if he wishes to leave subepithelial elements.*

Removal of Skin Cut by Various Methods for Comparison with Each Other

Coincidentally with the cutting of a calibrated skin graft, on each patient a Thiersch graft and a split graft cut in the routine manner—usually from the thigh—and a full-thickness graft cut with the scalpel were removed. About one hundred sections were obtained from varying ages. These were carefully cross-sectioned at as nearly right angles to the skin surface as possible after fixation, and their relative thickness compared with the known thickness of the calibrated skin grafts.

Classification

From this microscopic study of skin grafts, cut by all methods, in my own mind at least, a reclassification of sheet skin grafts into four types has been evolved: (1) Thiersch†; (2) Superficial Intermediate

*Skin contracts quite markedly after it is cut, due to the elastic fibers in the corium. These figures are for the skin before it contracts. After it contracts, and is stained and placed on a microscopic slide, it will measure nearly twice as great in thickness. For example, a section cut with the knife set at about .032 of an inch (.81 mm.) away from the drum will measure in width about .060 of an inch (1.5 mm.) on the slide. In the photomicrographs, the skin was crosscut as nearly at right angles as possible. A considerable number of each were taken—about one hundred different sections in all. An average was struck to compensate for error on sectioning. The examples shown are more or less average and considered fairly typical. The photomicrographs were enlarged 22 times above the size of the tissue on the slide.

†Thiersch's original description of his graft as containing only the epithelial layer probably never was or cannot be cut. There is always some corium.

(Blair et al.) $\frac{1}{3}$ to $\frac{2}{3}$ of the skin deep); (3) The so called "three-quarter thickness" skin graft or deep intermediate skin graft (75 to 95 percent of the skin deep); and (4) The Full Thickness.

The following conclusions were reached:

(1) The Thiersch graft is cut at a thickness of about .008 of an inch (.2 mm.) to 0.10 of an inch (.25 mm.) in thickness (Fig. 13).

(2) The "split" graft or superficial intermediate skin graft as cut with the large knife is usually from .012 of an inch (.3 mm.) to .016 of an inch (.4 mm.) (Fig. 13 and 14).

(3) The "three-quarter thickness" skin graft, which is cut with the dermatome and may be predetermined, is from .020 of an inch (.5 mm.) to .024 of an inch (.6 mm.) in thickness (Fig. 17).

(4) A full-thickness skin graft in an adult, according to our sections, varies in thickness from about .032 of an inch (.8 mm.) to .040 of an inch (1. mm.) (Fig. 16).

Material

For the purpose of making a comparison of the properties and results obtained with the following types of skin graft: Thiersch, "split," full thickness, Thiersch and superficial intermediate, as cut with the dermatome, and the "three-quarter thickness" skin graft; two series of cases are available. A series up to May, 1936, of 257 patients on whom thin grafts, cut by hand either with the large knife or full-thickness skin grafts cut with the scalpel, were placed, and, from January 1, 1938, to February 1, 1941, a series of 206 patients on whom Thiersch, superficial intermediate, and the "three-quarter thickness" skin grafts, as cut by the dermatome, were used. After May 1, 1936, a stationary level was reached, as to the percentage of "take," cosmetic and functional results, which was not surpassed during the next two years. Beginning early in 1938, after the invention of the dermatome, six calibrated skin grafts have been used almost exclusively.

In the second series of patients, certain advantageous results were obtained over those in the first series due to a refinement of mechanical technique (Table II). Possibly the most noteworthy advance was caused by the development of a skin graft for the coverage of aseptic denuded surfaces—the "three-quarter thickness" skin graft (cut at a level 75 to 90 percent of the thickness of the skin) (Table III). This graft has shown very superior properties as to the percentage of "take," cosmetic and functional results attained.

TABLE II
EXPERIENCE WITH CALIBRATED SKIN GRAFTS OF SUPERFICIAL AND INTERMEDIATE THICKNESS ON GRANULATING SURFACES

Name	Hospital	Date	Age	Cause	Location Applied	Donor Site	Size of Graft	Thickness	Percentage Take ^a	Functional Result	Cosmetic Result
1. Slinkard	Bell	1-13-38	67 yr.	Removed flap	Forehead	Abdomen	42 sq. cm.	.012 in.	90-100%	Good	Good
2. Dotson	Mercy	5-11-38	3 yr.	Fresh injury	Arm	Abdomen	60 sq. cm.	.012 in.	90-100%	Good	Good
3. Martin	St. Luke's	5-21-38	30 yr.	Injury	Cheek	Abdomen	64 sq. cm.	.014 in.	90%	Fair, 25% contracture	Fair
4. Montgomery	Bell	6- 2-38	15 yr.	X-ray burn	Forearm	Abdomen	63 sq. cm.	.014 in.	90-100%	Good	Good
5. Batson	Mercy	6-14-38	22 mo.	Fresh burn	Scalp	Abdomen	122 sq. cm.	.008 in.	75% Loss due to infection	Little improvement	Little improvement
	Mercy	7-19-38	22 mo.	Fresh burn	Scalp	Abdomen	122 sq. cm.	.008 in.	25% loss	Fair	Fair
6. Egbert	Bell	7- 8-38	17 yr.	Removal flap	Leg	Abdomen	72 sq. cm.	.016 in.	90-100%	Excellent	Excellent
7. Bolan	Bell	7-14-38	31 yr.	Removal flap	Leg	Abdomen	168 sq. cm.	.012 in.	90-100%	Good	Good
8. Stumbaugh	Bell	7-23-38	48 yr.	Removal flap	Leg	Abdomen	96 sq. cm.	.014 in.	90-100%	Good	Good
9. Dunbar	Bell	7-25-38	43 yr.	Fresh burn	Legs, rt. and lt.	Abdomen and chest	1224 sq. cm.	.012 in.	90-100%	Complete coverage of a very large granulating surface in two operations	Good
	Bell	9-13-38	43 yr.	Fresh burn	Legs, rt. and lt.	Abdomen and chest	1224 sq. cm.	.012 in.	90-100%		Good
10. Reichart	General	7-29-38	35 yr.	Fresh burn	Leg	Abdomen	408 sq. cm.	.010 in.	90-100%	Excellent	Excellent
11. Thomson	St. Joseph	9-19-38	40 yr.	Removal flap	Leg, left	Abdomen	221 sq. cm.	.014 in.	90-100%	Good	Good
12. Hughes	St. Joseph	11- 1-38	40 yr.	Old unhealed burn	Legs, rt. and lt.	Abdomen	442 sq. cm.	.025 in.	90-100%	Good	Good
13. Pallascia	St. Luke's	7- 1-38	14 yr.	Removal of flap	Leg	Abdomen	108 sq. cm.	.016 in.	90-100%	Good	Good
14. Price	Bell	10-31-38	6½ yr.	Fresh burn	Legs, rt. and lt.	Abdomen	169 sq. cm.	.012 in.	Lost from Infection	None	None
	Bell	11-29-38	6½ yr.	Fresh burn	Legs, rt. and lt.	Abdomen and thigh	507 sq. cm.	.012 in.	90-100%	Good	Good
15. Truman	Bell	12- 9-38	30 yr.	Removal of flap	Thigh	Thigh	90 sq. cm.	.025 in.	90-100%	Good	Good
16. Tevas	Mercy	11-22-38	11 yr.	Fresh burn	Leg	Abdomen	48 sq. cm.	.014 in.	90-100%	Good	Good
17. Seitz	Bell	12- 5-38	40 yr.	Fresh burn	Hands, rt. and lt., Thighs, rt. and lt.	Abdomen, chest and thigh	605 sq. cm.	.014 in.	50% Partial "take" thigh grafts. Failure arm graft.	Failure	Failure — anemia
	Bell	12-27-38	40 yr.	Fresh burn	Hands, rt. and lt., Thighs, rt. and lt.	Abdomen, chest and thigh	605 sq. cm.	.014 in.	0%	None	None

TABLE II—Continued

Name	Hospital	Date	Age	Cause	Location Applied	Donor Site	Size of Graft	Thickness	Percentage "Take"	Functional Result	Cosmetic Result
18. Davidson	St. Luke's	12-21-38	15 yr.	Fresh burn	Rt. axilla, anterior and lateral chest	Abdomen, thigh and legs	605 sq. cm.	.014 in.	90-100%	Covered whole surface grafted	Good
19. Boss	Bell	6-29-39	15 yr.	Unhealed burn	Neck and back	Abdomen	600 sq. cm.	.012 in.	90%	Good	Good
20. Stogdill	Bell	12-27-38	25 yr.	Raised flap	Leg	Thigh	90 sq. cm.	.012 in.	90-100%	Good	Good
21. Scott	Mercy	1-10-39	13 yr.	Unhealed burn	Hips, rt. and lt. legs	Abdomen	338 sq. cm.	.020 in.	90-100%	Good	Good
22. Disney	General	1-28-39	45 yr.	Fresh burn	Leg	Abdomen	200 sq. cm.	.012 in.	90-100%	Good	Good
23. Collins	General	2-10-39	48 yr.	Varicose ulcer	Hip	Abdomen	200 sq. cm.	.012 in.	90%	Good	Fair
24. Roe	General	2-10-39	52 yr.	Fresh burn	Upper chest, Abdominal wall, Rt. arm.	Abdomen, chest and thigh	1200 sq. cm.	.012 in.	90-100%	Good	Good
25. Schmidt	General	2-10-39	63 yr.	Varicose ulcer	Leg	Abdomen	600 sq. cm.	.012 in.	Died postoperative pneumonia		
26. McDowell	General	2-11-39	3 yr.	Fresh burn	Legs, rt. and lt.	Abdomen	400 sq. cm.	.013 in.	50%	Needs more skin	Fair
27. Curry	General	2-2-40	4 yr.	Unhealed burn	Legs, rt. and lt.	Abdomen	400 sq. cm.	.013 in.	Died postoperative pneumonia		
28. Bradshaw	Bell	2-16-39	35 yr.	Fresh burn	Arm, rt.	Abdomen	100 sq. cm.	.012 in.	90%	Good	Good
29. St. Clair	Bell	3-2-39	25 yr.	Fresh burn	Buttocks	Abdomen	200 sq. cm.	.012 in.	90-100%	Good	Good
30. Trosper	St. Luke's	3-14-39	9 yr.	Osteomyelitis wound	Leg, lt.	Abdomen	200 sq. cm.	.012 in.	90-100%	Good	Good
31. Brown	General	4-8-39	40 yr.	Raised flap	Leg, rt.	Abdomen	200 sq. cm.	.020 in.	90-100%	Good	Good
32. Wiggins	General	4-22-39	22 yr.	Fresh burn	Thighs, knees, rt. and lt. chest	Abdomen	1200 sq. cm.	.012 in.	80%	Fair	Fair
33. Eib	General	4-22-39	26 yr.	Fresh burn	Leg, rt.	Abdomen	800 sq. cm.	.012 in.	60%	Needs more skin	Needs more skin
34. Hudson	St. Joseph	8-25-39	26 yr.	Unhealed burn	Leg, rt.	Abdomen	400 sq. cm.	.020 in.	80%	Needs more skin	Needs more skin
35. Paul	Trinity	4-24-39	40 yr.	Removal of flap	Abdomen	Abdomen	180 sq. cm.	.020 in.	90-100%	Good	Good
36. Taylor	Menorah	4-26-39	45 yr.	Removal of flap	Abdomen	Abdomen	200 sq. cm.	.022 in.	90-100%	Good	Good
	Bell	4-27-39	22 yr.	Fresh burn	Legs and thighs	Abdomen	400 sq. cm.	.012 in.	no "take" 0%	None	None
	Bell	6-29-39	22 yr.	Fresh burn	Legs, rt. and lt.	Abdomen	400 sq. cm.	.012 in.	no "take" 0%	Died	
	St. Joseph	5-1-39	8 yr.	Fresh burn	Rt. leg	Abdomen	400 sq. cm.	.012 in.	90-100%	Good	Good
	St. Luke's	5-8-39	38 yr.	Raised flap	Forehead	Abdomen	80 sq. cm.	.020 in.	90-100%	Good	Good

TABLE II—Continued

Name	Hospital	Date	Age	Cause	Location Applied	Donor Site	Size of Graft	Thickness	Percentage "Take"	Functional Result	Cosmetic Result
37. Hazelgan	Bell	5-12-39	17 yr.	Burn	Legs and toes, rt. and lt.	Abdomen	800 sq. cm.	.025 in.	90-100%	Good	Good
38. Burns	Bell	5-20-39	45 yr.	Varicose ulcer	Leg	Abdomen	200 sq. cm.	.024 in.	80%	Arteriosclerosis, veins, Good.	Good
39. Elliot	St. Mary's	6-7-39	21 yr.	Ulcer	Breast	Abdomen	200 sq. cm.	.012 in.	0%	Poor	Poor
	St. Mary's	6-23-39	21 yr.	Ulcer	Breast	Abdomen	200 sq. cm.	.012 in.	0%	Poor	Poor
40. Crain	St. Luke's	6-26-39	58 yr.	Carcinoma	Forehead	Abdomen	180 sq. cm.	.022 in.	90%	Good	Good
41. Myers	Mersey	8-8-39	9 yr.	Fresh burn	Lower abdomen, rt. and lt.	Thighs	400 sq. cm.	.012 in.	90-100%	Good	Good
42. Tomlin	Bell	8-17-39	61 yr.	Ulcer chest	Chest	Thigh	120 sq. cm.	.010 in.	90-100%	Good	Good
43. Ascher	Bell	8-24-39	38 yr.	Fresh injury	Foot, dorsum	Thigh	65 sq. cm.	.012 in.	90-100%	Good	Good
44. McDonald	General	9-22-39	64 yr.	Malignant tumor, breast removed	Breast	Abdomen	400 sq. cm.	.010 in.	90-100%	Good	Good
45. Wagoner	St. Mary's	11-22-39	35 yr.	Fresh burn	Legs, rt. and lt.	Abdomen	800 sq. cm.	.012 in.	50%—Infection	50% result	Died eventually
46. Hill	Mersey	1-2-40	14 yr.	Fresh burn	Leg, lt.	Abdomen	300 sq. cm.	.012 in.	90-100%	Good	Good
47. Samples	St. Luke's	1-6-40	34 yr.	Removal tumor	Leg	Abdomen	100 sq. cm.	.012 in.	90-100%	Good	Good
48. Killough	General	1-27-40	65 yr.	Burn, fresh	Legs, rt. and lt.	Abdomen	400 sq. cm.	.010 in.	90-100%	Good	Good
49. Curtis	St. Luke's	2-17-40	33 yr.	Fresh burn	Scalp, Fingers, 4	Abdomen	400 sq. cm.	.010 in.	90-100%	Good	Good
50. Duval	St. Luke's	2-26-40	33 yr.	Fresh burn; X-ray	Fingers, 2	Abdomen	40 sq. cm.	.012 in.	None—infection; X-ray burn	None	None
51. Wetzel	Bell	3-13-40	16 yr.	Fresh burn	Leg, lt.	Abdomen	800 sq. cm.	.010 in.	90-100%	Some contracture	Fair
	Bell	5-9-40	16 yr.	Fresh burn	Leg, lt.	Abdomen	600 sq. cm.	.010 in.	90-100%	Good	Good
52. Blanchard	Providence	4-5-40	9 yr.	Fresh burn	Legs, rt. and lt.	Abdomen	600 sq. cm.	.012 in.	90-100%	Good	Excellent
53. Laughlin	Bell	4-6-40	22 yr.	Fresh burn	Legs, rt. and lt.	Abdomen	800 sq. cm.	.012 in.	90-100%	Good	Good
54. Nickel	Bell	5-2-40	18 yr.	Fresh burn	Popliteal space, rt. and lt.	Abdomen and back	400 sq. cm.	.012 in.	90-100%	Good	Good
	Bell	6-7-40	18 yr.	Fresh burn	Popliteal space, rt. and lt.	Abdomen and back	400 sq. cm.	.012 in.	90-100%	Good	Good

TABLE II—Continued

Name	Hospital	Date	Age	Cause	Location Applied	Donor Site	Size of Graft	Thickness	Percentage "Take"	Functional Result	Cosmetic Result
55. Ratcliff	Bell	5-2-40	16 yr.	Fresh burn	Legs, rt. and lt.	Abdomen	400 sq. cm.	.010 in.	90-100%	Good	Good
56. Mehl	General	5-18-40	55 yr.	Fresh burn	Axilla and chest	Buttocks, back and abdomen	800 sq. cm.	.012 in.	90-100%	Fair	Some contracture
57. Green, D.	General	6-22-40	45 yr.	Removal of flap	Forehead	Abdomen	100 sq. cm.	.012 in.	90-100%	Good	Good
58. Green, C.	Bell	7-5-40	50 yr.	Malignant ulcer	Popliteal space	Abdomen	400 sq. cm.	.022 in.	90-100%	Good	Good
59. Atkins	Bell	7-12-40	55 yr.	Flap removal	Forehead	Abdomen	60 sq. cm.	.012 in.	90-100%	Good	Good
60. Piper	Bell	7-18-40	11 yr.	Fresh burn	Arm	Abdomen	200 sq. cm.	.010 in.	25% Infection	Finally healed with some contracture.	Good
	Bell	8-29-40	11 yr.	Fresh burn	Arm	Abdomen	200 sq. cm.	.010 in.	25% Infection	Poor	Poor
61. Van V.	St. Luke's	7-30-40	35 yr.	Fresh burn	Leg	Abdomen	200 sq. cm.	.020 in.	95%	Good	One area size of half dollar uncovered.
62. Voyles	Mercy	8-13-40	10 yr.	Electric burn	Buttocks and back	Abdomen	160 sq. cm.	.010 in.	90-100%	Good	Good
63. Blackburn	Bell	8-29-40	12 yr.	Fresh burn	Legs, rt. and lt.	Abdomen	400 sq. cm.	.010 in.	20% Infection	Poor	Poor
	Bell	11-7-40	12 yr.	Fresh burn	Legs, rt. and lt.	Abdomen	400 sq. cm.	.010 in.	50% Infection	Poor	Poor
64. Snow	Mercy	9-17-40	16 yr.	Osteomyelitis tibia	Leg	Abdomen	200 sq. cm.	.010 in.	95%	Good	Good
65. Stewart	St. Luke's	10-9-40	78 yr.	Carbuncle	Back	Abdomen	200 sq. cm.	.010 in.	0%	No improvement	No improvement
66. Howard	St. Luke's	12-5-40	7 yr.	Fresh burn	Thigh and leg, lt.	Abdomen, chest and thigh	360 sq. cm.	.010 in.	90%	Good	Good
67. Shumaker	General	12-13-40	10 yr.	Fresh burn	Leg, rt. and lt.	Abdomen	400 sq. cm.	.012 in.	90-100%	Good	Good
68. Braton	Mercy	12-10-40	14 yr.	Fresh burn	Leg	Abdomen	200 sq. cm.	.010 in.	95%	Good	Good
69. Cook	St. Luke's	12-31-40	31 yr.	Fresh burn	Axilla	Abdomen and thighs, rt. and lt.	600 sq. cm.	.010 in.	80%	Fair	Fair
Average							357 sq. cm.		78%		

TABLE III
EXPERIENCE WITH "THREE-QUARTER THICKNESS" (75 TO 90 PER CENT THICKNESS) SKIN GRAFTS ON DENUDE AESTHETIC SURFACES

Name	Hospital	Date	Age	Cause	Location Applied	Donor Site	Size of Graft	Thickness	Percentage "Take"	Functional Result	Cosmetic Result
1. Houser	Bell	1-11-38	30 yr.	Burn contracture	Dorsum, lt. hand	Abdomen	120 sq. cm.	.018 in.	100%	Excellent	Excellent
2. Broadman	General	2-22-38	45 yr.	Burn contracture	Left axilla and elbow region	Abdomen and leg	189 sq. cm.	.018 in.	100%	Excellent	Excellent
3. Greer	Bell	2-24-38	25 yr.	Burn contracture	Anterior neck	Abdomen	98 sq. cm.	.018 in.	100%	35% contracture. Contracture relieved	Fair
4. Pugh	Bell	4-3-38	35 yr.	Burn contracture	Left axilla	Abdomen	204 sq. cm.	.018 in.	100%	Excellent	Excellent
5. Ford	Mersey	4-5-38	15 yr.	Removal of nevus, scalp	Scalp	Abdomen	81 sq. cm.	.018 in.	100%	Good	Good
6. Craig	Bell	4-20-38	50 yr.	Removal of flap	Forehead	Abdomen	32 sq. cm.	.018 in.	100%	Good	Good
7. Fuhrken	Bell	4-20-38	34 yr.	Burn contracture	Knuckles and palms, rt. and lt.	Thigh	48 sq. cm.	.018 in.	100%	Good	Good
8. Keirsbliek	Bell	4-26-38	34 yr.	Burn contracture	Hands, rt. and lt.	Abdomen	82 sq. cm.	.018 in.	100%	25% contracture. Good considering amount of contracture	Fair
9. Wildman	St. Luke's	4-30-38	27 yr.	Burn contracture	Popliteal space and leg	Abdomen and thigh	612 sq. cm.	.020 in.	100%	Excellent	Excellent
10. Miner	Mersey	5-11-38	5 yr.	Burn contracture	Cheeks, rt. and lt.	Abdomen	126 sq. cm.	.012 in.	100%	Good	Good
11. Willis	Bell	5-17-38	8 yr.	Burn contracture	Rt. axilla	Abdomen and thigh	390 sq. cm.	.016 in.	100%	35% contracture. Excellent	Excellent
	Bell	6-8-39	9 yr.	Burn contracture	Rt. axilla	Abdomen	400 sq. cm.	.016 in.	100%	10% contracture. Excellent	Excellent
12. Griffin	Providence	5-19-38	10 yr.	Burn contracture	Neck, axilla and elbow	Thigh	204 sq. cm.	.016 in.	100%	Excellent	Excellent
	Providence	8-25-38	10 yr.	Burn contracture	Axilla	Thigh	390 sq. cm.	.016 in.	100%	Excellent	Excellent
	Providence	6-17-39	11 yr.	Burn contracture	Neck	Abdomen	400 sq. cm.	.016 in.	100%	Excellent	Excellent
13. Playford	St. Luke's	6-1-38	27 yr.	Burn contracture	Palm and fingers	Abdomen	76 sq. cm.	.025 in.	90%	Good	Good

TABLE III—Continued

Name	Hospital	Date	Age	Cause	Location Applied	Donor Site	Size of Graft	Thickness	Percentage "Take"	Functional Result	Cosmetic Result
14. Daughenback	Providence	6-3-38	40 yr.	Obliteration of eye socket	Eye socket	Abdomen	64 sq. cm.	.016 in.	100%	Excellent. 40% contracture	Good
15. Mayfield	Providence	6-10-38	5 yr.	Burn contracture	Axilla and back	Abdomen and thigh	612 sq. cm.	.014 in.	100%	Excellent	Good. Some-what pigment-ed. Patient a negro
16. Courtney	St. Luke's	6-11-38	25 yr.	Pigmented skin graft	Forehead	Abdomen	35 sq. cm.	.024 in.	100%	Excellent	Excellent
17. LaFever	Mercy	6-14-38	9 yr.	Contracture of cheeks	Inner mouth	Abdomen	104 sq. cm.	.014 in.	100%	50% correction due to contracture	
		12-28-38	9½ yr.	Lye burn of cheeks	Cheek	Abdomen	104 sq. cm.	.014 in.	100%	Good	Good
18. Bowles	St. Luke's	6-14-38	35 yr.	Atresia of mouth. Cancer paste	Cheek, inner mouth	Abdomen	683 sq. cm.	.025 in.	100%	Good	Good
19. Gaultier	Providence	6-17-38	11 yr.	Burn contracture	Arm and axilla	Abdomen	150 sq. cm.	.016 in.	100%	Good	Good
	Providence	6-23-39	12 yr.	Burn contracture	Breast and axilla	Thigh	200 sq. cm.	.016 in.	100%	Good	Good
20. Roessler	Bell	6-17-38	10 yr.	Burn contracture	Axilla, groin and elbow	Abdomen and thigh	484 sq. cm.	.016 in.	100%	Good	Good
21. Wacow	St. Luke's	6-18-38	18 yr.	Operative scar	Anterior neck	Abdomen	81 sq. cm.	.018 in.	Graft lost. Blood clot beneath graft.	Lost—Blood clot. Improper fixation	
22. Winkle	St. Luke's	6-18-38	11 yr.	Burn contracture	Little finger, lt.	Abdomen	84 sq. cm.	.018 in.	100%	Good	Good
23. Stuart	Mercy	6-21-38	7 yr.	Burn contracture	Neck and axilla, rt.	Abdomen	408 sq. cm.	.014 in.	100%	Some contracture. Needs more skin.	
	Mercy	4-20-39	8 yr.	Burn contracture	Axilla and elbow	Thigh	300 sq. cm.	.014 in.	100%	Good	Good
24. Melton	Mercy	6-21-38	8 yr.	Burn contracture	Cheeks, rt. and lt.	Abdomen	96 sq. cm.	.016 in.	100%	Good	Good
	Mercy	6-6-39	9 yr.	Burn contracture	Hand	Abdomen	60 sq. cm.	.020 in.	100%	Good	Good
25. Richards	Providence	6-25-38	12 yr.	Burn contracture	Cheeks, chin, rt. and lt. Wrist and forearm	Abdomen	223 sq. cm.	.015 in.	100%	Good	Excellent
26. Holly	Bell	6-26-38	25 yr.	Burn contracture	Finger and palm of hand	Abdomen	54 sq. cm.	.020 in.	75%	Fair	Pigmented. Patient a negro.

TABLE III—Continued

Name	Hospital	Date	Age	Cause	Location Applied	Donor Site	Size of Graft	Thickness	Percentage "Take"	Functional Result	Cosmetic Result
27. Redman	St. Mary's	6-27-38	18 yr.	Burn contracture	First finger and palm	Abdomen	24 sq. cm.	.020 in.	100%	Good	Good
28. Johnston	Bell	7-7-38	9 yr.	Burn contracture	Dorsum hand, between fingers	Abdomen	73 sq. cm.	.014 in.	100%	Good as far as graft is concerned	Good as far as graft is concerned
29. Nelson	St. Luke's	7-7-38	40 yr.	Incision to relieve tension	Elbow region	Abdomen	84 sq. cm.	.020 in.	100%	Good	Good
30. Guinn	St. Mary's	7-8-38	40 yr.	Scar, forehead. Snake bite	Forehead	Abdomen	48 sq. cm.	.018 in.	100%	Good	Excellent
31. Boyd	St. Mary's	7-19-38	52 yr.	Carcinoma	Forehead	Abdomen	90 sq. cm.	.018 in.	100%	Excellent	Excellent
32. Nally	Bell	7-30-38	8 yr.	Removal flap, scalp	Scalp	Abdomen	100 sq. cm.	.016 in.	100%	Good	Good
	Bell	9-22-38	8 yr.	Electrical	Scalp	Abdomen	100 sq. cm.	.020 in.	100%	Good	Good
	Bell	9-7-39	9 yr.	Burn. Raised flap	Leg	Abdomen	120 sq. cm.	.016 in.	100%	Good	Good
33. Ferguson	Providence	8-17-38	8 yr.	Burn contracture	Face	Abdomen	125 sq. cm.	.016 in.	100%	Good	Good
34. Van Hoosen	St. Luke's	9-7-38	11 yr.	Burn contracture	Fingers	Abdomen	10 sq. cm.	.016 in.	100%	Good	Good
35. Rohr	Providence	9-14-38	2½ yr.	Removal flap. Burn	Palm of hand	Abdomen	50 sq. cm.	.016 in.	100%	Good	Good
36. Thomson	St. Joseph	9-19-38	40 yr.	Removal flap	Leg, rt.	Abdomen	221 sq. cm.	.014 in.	100%	Good	Good
37. Killen	Bell	9-19-38	55 yr.	Contracture	Beneath chin	Abdomen	48 sq. cm.	.025 in.	100%	Good	Good
38. Carter	Providence	9-22-38	20 yr.	Atresia, nostril	Nostril	Abdomen	9 sq. cm.	.012 in.	100%	50% contracture. Good	Good
39. Blessman	Mercy	9-27-38	5 yr.	Burn contracture	Dorsum of foot	Abdomen	140 sq. cm.	.021 in.	100%	Good	Good
40. Goelport	Mercy	10-11-38	2 yr.	Atresia	Nostril	Abdomen	9 sq. cm.	.012 in.	100%	50% contracture. Good	Good
41. Holtzen	Bell	10-13-38	60 yr.	Burn contracture	Wrist	Abdomen	48 sq. cm.	.025 in.	100%	Good	Good
42. McInerney	Providence	10-14-38	12 yr.	Burn contracture	Popliteal space	Abdomen	221 sq. cm.	.025 in.	100%	Good	Good
43. Allen	St. Luke's	10-14-38	32 yr.	Burn contracture	First and second fingers. Palm	Abdomen	44 sq. cm.	.028 in.	100%	Good	Good
44. Grubb	Bell	10-25-38	19 yr.	Removal osteo-sarcoma	Scalp	Abdomen	72 sq. cm.	.020 in.	100%	Good	Good

TABLE III—Continued

Name	Hospital	Date	Age	Cause	Location Applied	Donor Site	Size of Graft	Thickness	Percentage "Take"	Functional Result	Cosmetic Result
45. Tripp	Bell	10-25-38	31 yr.	Contracture beneath upper lip	Upper lip and nose	Abdomen	96 sq. cm.	.012 in.	100%	Good	Good
46. Bonesteel	Providence	10-27-38	11 yr.	Burn contracture	Fingers and palm	Abdomen	34 sq. cm.	.021 in.	100%	Good	Good
47. Price	Bell	10-31-38	6½ yr.	Burn contracture	Legs, rt. and lt.	Abdomen and thigh	378 sq. cm.	.014 in.	100%	Good	Good
48. Prentice	Providence	11-1-38	20 yr.	Contracture of fingers, injury	Fingers, 1st, 2nd and 3rd	Abdomen	52 sq. cm.	.014 in.	100%	Good	Good
49. Truman	Bell	11-8-38	30 yr.	Removal of flap	Thigh	Abdomen	104 sq. cm.	.025 in.	100%	Good	Good
50. Brosnahan	St. Mary's	11-22-38	50 yr.	Removal of flap	Scalp	Abdomen	72 sq. cm.	.025 in.	100%	Good	Good
51. Condon	Providence	11-28-38	3 yr.	Burn contracture	Side of face and neck	Abdomen	121 sq. cm.	.016 in.	100%	Good	Good
52. Shallenberger	Providence	12-21-38	19 yr.	Burn contracture	Palm and fingers	Abdomen	44 sq. cm.	.025 in.	100%	Good	Good
53. Holmes	Providence	3-10-39	19 yr.	Burn contracture	Palm and fingers	Abdomen	44 sq. cm.	.025 in.	100%	Good	Good
54. Stoghill	St. Luke's	12-29-38	30 yr.	Burn contracture	Neck	Abdomen	90 sq. cm.	.025 in.	100%	Good	Good
55. Allen	Bell	1-10-39	35 yr.	Varicose ulcer	Leg	Abdomen	121 sq. cm.	.020 in.	100%	Good	Good
56. Anderson	Bell	1-26-39	14 yr.	Burn contracture	Forehead	Thigh	378 sq. cm.	.014 in.	100%	Good	Good
57. Haden	Bell	1-26-39	4 yr.	Burn contracture	Fingers and palm	Abdomen	252 sq. cm.	.014 in.	100%	Good	Good
58. Nickel	Providence	2-17-39	2 yr.	Burn contracture	Palm and fingers	Abdomen	325 sq. cm.	.012 in.	100%	½ correction	Good
59. Walter	Bell	2-28-39	22 yr.	Burn contracture	Groin	Abdomen	325 sq. cm.	.012 in.	100%	Good	Good
60. Griese	St. Mary's	3-13-39	4 yr.	Burn contracture	Fingers	Abdomen	210 sq. cm.	.026 in.	100%	Good	Good
61. Beaver	K. C. Gen.	3-18-39	46 yr.	Cancer	Neck	Abdomen	125 sq. cm.	.024 in.	100%	Good	Good
62. Ramariz	Providence	3-21-39	12 yr.	Burn contracture	3rd and 4th fingers, Palm	Abdomen	50 sq. cm.	.022 in.	100%	Good	Good
63. Buryan	Bell	3-30-39	14 yr.	Burn contracture	Lt. hand	Abdomen	35 sq. cm.	.022 in.	100%	Good	Good
64. Tolle	St. Luke's	3-31-39	6 yr.	Burn contracture	Chin and neck	Rt. thigh	200 sq. cm.	.014 in.	100%	Good	Good
	St. Luke's	11-11-39	6 yr.	Burn contracture	Wrists, rt. and lt.	Abdomen	200 sq. cm.	.014 in.	100%	Good	Good
65. Harris	St. Luke's	4-3-39	2 yr.	Burn contracture	Palm and thumb	Abdomen	100 sq. cm.	.016 in.	100%	50% contracture	Good
	St. Luke's	8-4-39	2 yr.	Burn contracture	Palm and thumb	Thigh	100 sq. cm.	.016 in.	100%	Good	Good

TABLE III—Continued

Name	Hospital	Date	Age	Cause	Location Applied	Donor Site	Size of Graft	Thickness	Percentage "Take"	Functional Result	Cosmetic Result
66. Gandy	Providence	4-8-39	3 yr.	Burn contracture	Fingers	Abdomen	120 sq. cm.	.014 in.	100%	Good	Good
67. Baker	Bell	4-8-39	24 yr.	Removal arm flap	Arm	Abdomen	180 sq. cm.	.020 in.	100%	Good	Good
68. Schmidt	Mercy	4-19-39	3½ yr.	Burn contracture	Axilla	Abdomen	300 sq. cm.	.020 in.	100%	Good	Good
69. Miner	Mercy	5-9-39	11 yr.	Burn contracture	Face and ears	Abdomen	220 sq. cm.	.016 in.	100%	Good	Good
70. Redman	Mercy	5-20-39	13 yr.	Burn contracture	Axilla and neck	Abdomen	400 sq. cm.	.014 in.	80%	Considerable contracture	Considerable contracture
71. Spivory	Bell	6-1-39	15 yr.	Burn contracture	Leg and popliteal	Abdomen	400 sq. cm.	.014 in.	100%	Good	Good
72. Raxter	St. Luke's	6-3-49	55 yr.	Burn contracture	Dorsum of hand and wrist	Abdomen	200 sq. cm.	.020 in.	100%	Good	Good
73. Sebrela	Providence	6-5-39	18 yr.	Burn contracture	Axilla	Abdomen	120 sq. cm.	.016 in.	100%	Good	Good
74. George	Mercy	6-13-39	3 yr.	Excision of hemangioma	Face	Abdomen	120 sq. cm.	.013 in.	100%	Good	Fair
75. Kerth	St. Luke's	6-13-39	35 yr.	X-ray burn of face. Old hemangioma	Face and forehead	Abdomen	400 sq. cm.	.024 in.	95%	Good	Good
	St. Luke's	6-18-40	36 yr.	X-ray burn of face. Old hemangioma	Face, mouth, and eyebrows	Abdomen	400 sq. cm.	.022 in.	90%	Fair	Some scar where loss was present. Some contracture
76. Mickey	K. C. Gen.	6-17-39	50 yr.	Syphilitic destruction of nose	Nose	Abdomen	120 sq. cm.	.012 in.	100%	Good	Good, stent nose
77. Goode	K. C. Gen.	6-19-39	7 yr.	Burn contracture	Arm	Abdomen	200 sq. cm.	.016 in.	100%	Good	Good
78. David	Bell	6-22-39	12 yr.	Burn contracture	Popliteal space	Abdomen	200 sq. cm.	.018 in.	100%	Good	Good
79. Saindon	Bell	6-22-39	30 yr.	Burn contractures	Face and neck	Abdomen and legs	800 sq. cm.	.022 in.	90%	Good	Good
	Bell	8-8-40		Burn contractures	Face	Thighs	400 sq. cm.	.022 in.	90%	Good	Good
	Bell	1-25-40		Burn contractures	Face	Abdomen	400 sq. cm.	.020 in.	100%	Good	Good
80. Echoldt	Providence	6-23-39	12 yr.	Burn contracture	Axilla	Abdomen	200 sq. cm.	.018 in.	100%	Good	Good
81. Pappas	General	6-24-39	41 yr.	Burn contracture	Calf and ankle	Abdomen	500 sq. cm.	.010 in.	100%	Good	Good
82. Green, D.	General	6-24-39	44 yr.	Removed flap	Neck	Abdomen	120 sq. cm.	.022 in.	100%	Good	Good

TABLE III—Continued

Name	Hospital	Date	Age	Cause	Location Applied	Donor Site	Size of Graft	Thickness	Percentage "Take"	Functional Result	Cosmetic Result
83. Baird	Providence	7-7-39	17 yr.	Burn contracture	Arm, rt.	Thigh	400 sq. cm.	.018 in.	100%	Good	Good
	Providence	7-8-40	18 yr.	Burn contracture	Arm, elbow and shoulder	Abdomen	600 sq. cm.	.018 in.	100%	Good	Good
84. Kennedy	St. Luke's	8-8-39	20 yr.	Burn contracture	Hand, left	Abdomen	100 sq. cm.	.020 in.	100%	Good	Good
85. Koerner	Providence	8-9-39	5 yr.	Burn contracture	Axilla and neck	Abdomen	400 sq. cm.	.018 in.	100%	Good	Good
86. Palmer	Bethany	8-12-39	16 yr.	Flap removed	Leg	Abdomen	120 sq. cm.	.018 in.	100%	Good	Good
87. Summers	St. Luke's	8-22-39	9 yr.	Burn contracture	Face	Abdomen	120 sq. cm.	.014 in.	100%	Good	Good
88. Nold	Mersey	8-25-39	4 yr.	Burn contracture	Face and arm	Abdomen	300 sq. cm.	.015 in.	100%	Good	Good
89. Walberg	Providence	8-25-39	2 yr.	Nevus	Neck and back	Abdomen	200 sq. cm.	.015 in.	100%	Good	Good
90. Rogers	Mersey	9-26-39	14 yr.	Removed flap for old osteomyelitis	Leg	Abdomen	160 sq. cm.	.017 in.	100%	Good	Good
	Mersey	11-28-39	14 yr.	Osteomyelitis	Leg	Abdomen	80 sq. cm.	.016 in.	0% Infection	No result	No result
91. Gorham	General	10-4-39	50 yr.	Removed flap	Forehead	Abdomen	160 sq. cm.	.022 in.	100%	Good	Good
92. Thomas	Bell	10-3-39	16 yr.	X-ray burn, Hemangioma	Face	Abdomen	120 sq. cm.	.018 in.	100%	Good	Good
	Bell	9-9-40	17 yr.	X-ray burn, Hemangioma	Face	Thigh	120 sq. cm.	.018 in.	100%	Good	Good
93. Hayes	Mersey	11-7-39	16 yr.	Removed flap	Neck	Abdomen	100 sq. cm.	.018 in.	100%	Good	Good
	Mersey	7-16-40	16 yr.	Removed flap	Neck	Abdomen	100 sq. cm.	.018 in.	100%	Good	Good
94. Brown	St. Luke's	11-24-39	10 yr.	Burn contracture	Wrist and hand	Abdomen	120 sq. cm.	.014 in.	100%	Good	Good
	St. Luke's	1-19-40	10 yr.	Burn contracture	Fingers	Abdomen	60 sq. cm.	.016 in.	100%	Good	Good
95. Crawford	St. Luke's	12-7-39	50 yr.	Removed flap	Forehead	Abdomen	80 sq. cm.	.022 in.	100%	Good	Good
96. Davidson	Bell	6-2-40	15 yr.	Burn contracture	Neck and shoulder	Back and abdomen	800 sq. cm.	.018 in.	100%	Good	Good
97. Hunt	General	1-5-39	50 yr.	Powder burns	Eyelid	Thigh	80 sq. cm.	.016 in.	80%	80% improved	Fair
	General	3-15-40	50 yr.	Powder burns	Eyelid	Abdomen	80 sq. cm.	.016 in.	100%	Good	Good
98. Floyd	St. Luke's	2-26-40	9 yr.	Burn contracture	Four fingers, Palm	Abdomen	300 sq. cm.	.014 in.	100%	Good	Good

TABLE III—Continued

Name	Hospital	Date	Age	Cause	Location Applied	Donor Site	Size of Graft	Thickness	Percentage Take	Functional Result	Cosmetic Result
99. Erickson	St. Luke's	2-27-40	25 yr.	Contracture	Eye lid	Thigh	25 sq. cm.	.010 in.	100%	Good	Good
100. Abbott	Bell	1-26-40	45 yr.	X-ray burn	Chin and neck	Abdomen	72 sq. cm.	.022 in.	85%	Fair	Some contracture. One area beneath chin some scarring
101. Park	Bell	2-29-40	18 yr.	Burn contracture	Little finger	Abdomen	25 sq. cm.	.016 in.	100%	Some contracture	Good
102. Smith, E.	Menorah	12-23-40	18 yr.	Burn contracture	Little finger	Abdomen	25 sq. cm.	.014 in.	100%	Good	Good
103. Dye	St. Joseph	3- 9-40	24 yr.	Nevus	Scalp	Abdomen	160 sq. cm.	.014 in.	100%	Good	Good
	Bell	3- 9-40	5 yr.	Hemangioma, Radium telangiectasis	Cheek	Abdomen	48 sq. cm.	.013 in.	75%	Fair	Slight scarring where loss occurred
104. Cummings	St. Luke's	4-18-40	70 yr.	X-ray burn	Face	Abdomen	200 sq. cm.	.018 in.	75%	Fair	Fair
105. Donaldson	Trinity	4-20-40	1 yr.	Burn contracture	Hands, rt. and lt.	Abdomen	100 sq. cm.	.013 in.	100%	Good	Good
106. Campbell	General	4-26-40	40 yr.	X-ray burn	Leg	Abdomen	100 sq. cm.	.022 in.	100%	Good	Good
107. Morgan	St. Luke's	5- 1-40	20 yr.	Hemangioma	Back and shoulders	Abdomen	400 sq. cm.	.020 in.	100%	Good	Excellent
108. Rosenberry	St. Luke's	5- 1-40	50 yr.	Burn contracture	Thigh	Abdomen	400 sq. cm.	.016 in.	100%	Good	Good
109. Gladow	Bell	5- 2-40	18 yr.	Symblepharon	Eye socket	Abdomen	25 sq. cm.	.010 in.	100%	Good	Good
110. Curtis	St. Luke's	5- 8-40	35 yr.	Burn contracture	Hands, rt. and lt.	Abdomen	400 sq. cm.	.021 in.	100%	Good	Good
	St. Luke's	9-30-40	35 yr.	Burn contracture	Hands, rt. and lt.	Abdomen	100 sq. cm.	.022 in.	100%	Good	Good
111. Gay	Bell	5-25-40	13 yr.	Burn contracture	Corner of mouth	Abdomen	40 sq. cm.	.014 in.	20%	Poor	Poor
112. Cleveng	Bell	6- 1-40	18 yr.	Burn contracture	Forehead	Abdomen	200 sq. cm.	.018 in.	100%	Good	Good
113. Green, S.	General	6- 5-40	52 yr.	Burn contracture	Hand	Abdomen	120 sq. cm.	.020 in.	100%	Good	Good
114. Pyle	Bell	6- 7-40	55 yr.	Burn contracture	Neck, arm and axilla	Abdomen	400 sq. cm.	.022 in.	100%	Good	Good
115. Myer	St. Luke's	6-21-40	8 yr.	Nevus	Face	Abdomen	80 sq. cm.	.016 in.	100%	Good	Good
116. Carter	Bell	6-19-40	18 yr.	Burn contracture	Lip, face and thumb	Abdomen	300 sq. cm.	.020 in.	95%	Good	Fair
117. Thompson	Bell	6-19-40	6 yr.	Cicatrix	Nostril	Abdomen	36 sq. cm.	.010 in.	90%	Good	Good

TABLE III—Continued

Name	Hospital	Date	Age	Cause	Location Applied	Donor Site	Size of Graft	Thickness	Percentage "Take"	Functional Result	Cosmetic Result
118. Scott	Providence	6-22-40	11 yr.	Burn contracture	Arm and axilla	Abdomen	220 sq. cm.	.016 in.	100%	Good	Good
119. Ross	Providence	7- 8-40	11 yr.	Burn contracture	Hand and face	Abdomen	300 sq. cm.	.018 in.	100%	Good	Good
120. Caldwell	Providence	7-17-40	28 yr.	X-ray burn. Hemangioma	Corner of mouth	Abdomen	100 sq. cm.	.015 in.	100%	Good	Good
121. Bruns	St. Mary's	7-20-40	5 yr.	Flap removed	Arm	Abdomen	160 sq. cm.	.014 in.	100%	Good	Good
122. Balsukot	St. Luke's	7-22-40	31 yr.	X-ray burns	Legs, rt. and lt.	Abdomen	800 sq. cm.	.020 in.	100%	Good	Good
123. Ferguson	Providence	8-13-40	8 yr.	Burn contracture	Eyelid	Abdomen	25 sq. cm.	.013 in.	100%	Good	Good
124. Breting	St. Luke's	8-14-40	19 yr.	Burn contracture	Finger, little	Abdomen	20 sq. cm.	.018 in.	100%	Tendon frozen	Good
125. Herr	Bell	8-22-40	50 yr.	Flap removal	Forehead	Abdomen	100 sq. cm.	.020 in.	100%	Good	Good
	Bell	9-15-40		Flap removal	Neck	Abdomen	60 sq. cm.	.020 in.	100%	Good	Good
126. Butterworth	Mercy	9-17-40	16 yr.	Flap removal	Arm	Abdomen	84 sq. cm.	.020 in.	100%	Good	Good
127. Kaiser	Bell	9-19-40	55 yr.	Removal of varicose ulcer	Leg	Abdomen	200 sq. cm.	.022 in.	70%	100%	Good
128. Hueber	St. Joseph	10-19-40	21 yr.	Removal flap	Abdomen	Abdomen	200 sq. cm.	.020 in.	100%	Good	Good
129. McKelvy	General	11- 8-40	37 yr.	Burn contracture	Popliteal space	Abdomen	400 sq. cm.	.020 in.	100%	Good	Good
130. Snyder	General	11- 8-40	3 yr.	Burn contracture	Neck	Abdomen	100 sq. cm.	.016 in.	100%	Good	Good
131. Christer	Bell	11- 9-40	50 yr.	Flap removal	Thigh	Abdomen	200 sq. cm.	.022 in.	100%	Good	Good
132. Hammill	St. Luke's	1-22-41	21 yr.	Burn contracture	Hand	Abdomen	80 sq. cm.	.020 in.	100%	Good	Good
133. Hennigh	St. Luke's	8-26-40	40 yr.	Ulcer contracture	Popliteal space	Abdomen	160 sq. cm.	.022 in.	100%	Good	Good
134. Smith	St. Luke's	8-27-40	25 yr.	Burn contracture	Palm and little finger	Abdomen	100 sq. cm.	.020 in.	100%	Good	Good
135. Martinez	General	9- 2-40	9 yr.	Burn contracture	Palm and two fingers	Abdomen	50 sq. cm.	.020 in.	100%	Good	Good
136. Blanck	Bell	9-12-40	25 yr.	Burn contracture	Face, chin, elbow and axilla	Abdomen and buttocks	800 sq. cm.	.022 in.	100%	Good	Good
137. Baker	Bell	9-12-40	45 yr.	Varicose ulcers (ulcers excised and skin graft applied later)	Leg	Abdomen	200 sq. cm.	.022 in.	70% Pyocineous	Good	Good
Average							188 sq. cm.		96%		

Results After Use of the Thiersch, the "Split," the Full-Thickness and the "Three-Quarter Thickness" Skin Grafts on Aseptic Denuded Surfaces

On the first series of patients, up to May 1, 1936, for the coverage of an aseptic denuded surface, 98 patients were skin grafted with thin skin as cut with the large knife. The area covered averaged 29.5 sq. cm. One hundred and eighteen operations were necessary to gain the maximum correction deemed possible. Roughly the amount of contracture was figured to average 40 percent.

For the coverage of an aseptic denuded surface, since January 1, 1938, "three-quarter thickness" skin grafts have been used almost exclusively save when a cavity, such as the eye socket, was being grafted where a relatively thin skin graft was deemed to be more efficient.

Thin Skin Grafts on Aseptic Denuded Surfaces: Provided one uses with efficiency the known prerequisites such as good hemostasis, adequate fixation, and pressure on an aseptic denuded surface, the "take" of the more or less thin skin grafts (Thiersch and the "split") is usually nearly one hundred percent, whether they are cut by hand or by the dermatome. All thin grafts have the disadvantage that on exposed surfaces the cosmetic appearance decreases proportionately to the thinness of the graft; and when the object is to prevent contracture of the underlying bed, the degree of contracture outside of the anatomic factors already enumerated is directly proportionate to the thinness of the graft which is used for coverage. For example, a thin skin graft applied to an aseptic denuded area on the neck may contract from 50 to 70 percent in addition to eventually appearing inadequate from the cosmetic standpoint. Although the contracture may not be as great, a thin skin graft applied to the side of the face as a rule gives an inadequate cosmetic result, either because of the whiteness of the graft or in brunettes because of especially excessive pigmentation. On the other hand, when muscle is directly beneath the graft, as about the eyelids or over the orbicularis oris, the result may be fairly satisfactory, in so far as contracture is concerned, but the graft will appear as a more or less whitish patch. A thin skin graft sometimes will prevent reformation of a cicatricial contracture after its removal from some such area as the axillary or popliteal space, but, as a rule, one or more secondary operations will be necessary if the contracture is excessive because of subsequent contracture of the base underlying the graft. This same defect holds for all other areas, unless the underlying bony framework prevents contracture, and where protection is necessary as on the front of the leg or the palm of the hand, where, as a rule, a thin graft gives an indifferent

result which is very likely to be inadequate. The protection which a thin graft gives, when bone closely underlies the graft or on such surfaces as the palm of the hand or bottom of the foot, is usually inadequate.

Full-Thickness Skin Graft on an Aseptic Denuded Surface

In the first series of patients, up to May 1, 1936, 127 patients with aseptic denuded surfaces averaging 26.4 sq. cm. had been skin grafted with a full-thickness skin graft. One hundred and sixty-three operations were required to obtain the maximum correction deemed possible. Thirty-six second operations were necessary either because of some failure to "take" at the first operation or because of contracture of the heavy scar at the juncture of the graft and the normal skin.

In the second series of patients, since January 1, 1938, no full-thickness skin grafts have been used save where the area to be covered was small because the "three-quarter thickness" skin graft was proving to be more efficient than the full-thickness skin graft, or where the area to be covered had a firm convex base, or in children for some such lesion as syndactylism. The certainty of "take" in children has been considerably increased.

In our series of 155 full-thickness skin grafts, used to correct the damage resulting from a burn after the wound had been resurfaced early or had healed, 130 showed a good "take." A good "take" at that time meant that, although some blistering or even superficial necrosis occurred, a sufficient amount of the graft was saved to cover the defect or to correct the contracture. In 3 instances the whole graft was lost. In 25 instances the loss was partial and ranged from 10 to 90 per cent.

Provided a good "take" occurred, the most important influence on the functional result was the final amount of contracture of the grafted area. The subsequent average contracture of the full-thickness skin graft, when used in the correction of the damage resulting from a burn, averaged 17 per cent.

Anyone who has had a long experience in trying to grow full-thickness skin grafts on uneven concave surfaces, such as the axilla, will admit that one runs at least a 20 or more percent chance of getting an adequate "take" sufficient to correct the contracture. On the face and neck, because of this percentage of chance of not obtaining a complete "take" or even of a total loss, at least two-thirds of the grafts will show superficial blistering and exfoliation, finally resulting in scarred pigmented areas which ultimately interfere with the appearance of the graft. When a good "take" is obtained, in so far as protection is concerned, the full-thickness graft ranks at the top.

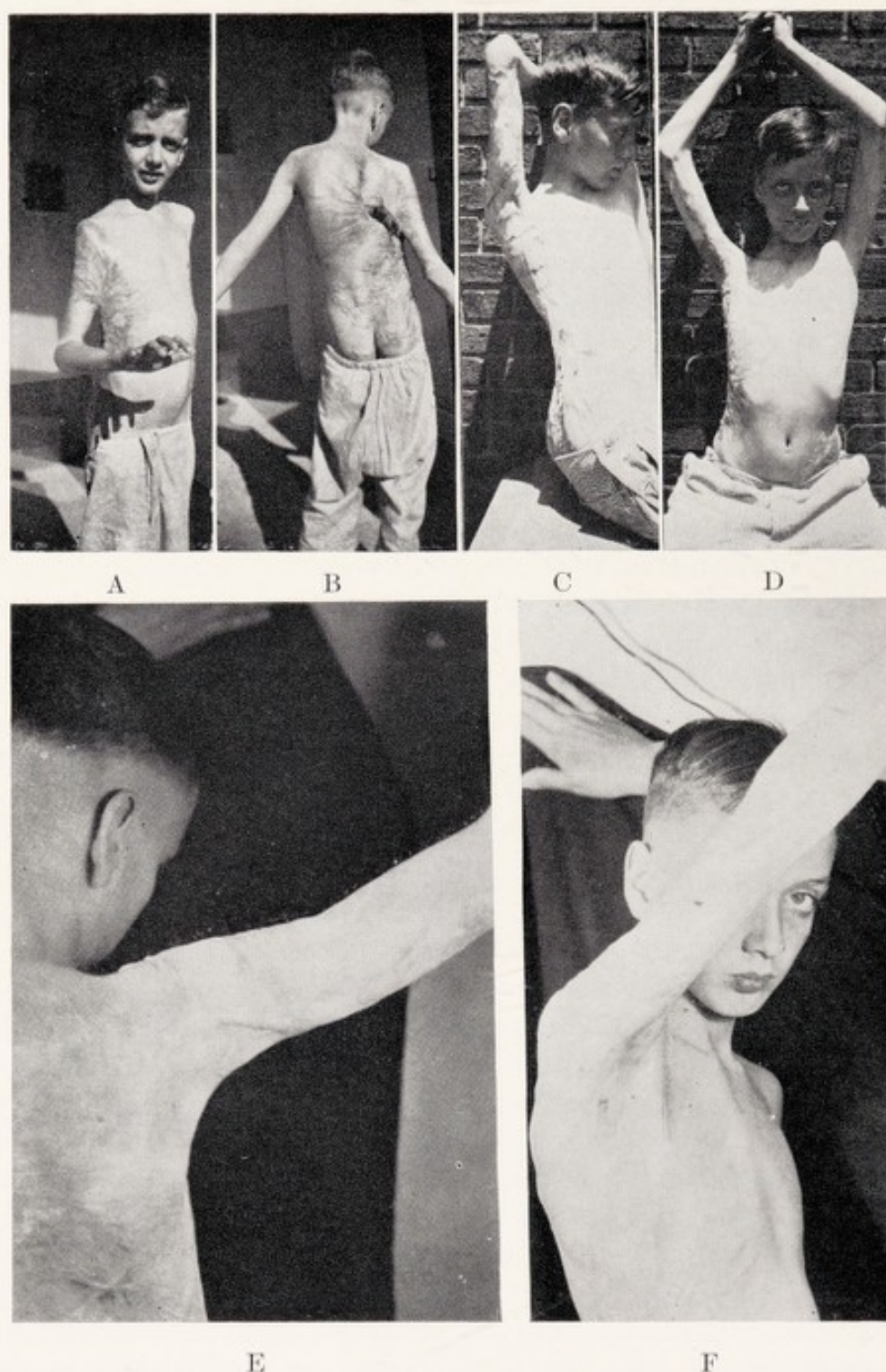


FIG. 18. A boy who had a marked fixation of his arm to his chest wall due to an old heavy scar. A. Anterior view. B. Posterior view. The scar and granulations were excised. The arm was hyperextended leaving a very large denuded area from the elbow to the lower rib region. Calibrated skin grafts of deep intermediate thickness (three-quarter thickness) were taken from both thighs and applied to the raw area. Four drums of skin were used. In this case the grafts were .018 of an inch in thickness. C and D. Show the result about 3 weeks later. E and F. Show the result one year after the grafts were applied.

"Three-Quarter Thickness" Skin Graft

In our series of "three-quarter thickness" skin grafts applied to aseptic denuded surfaces, the results have been as follows, in so far as "takes," contracture, protection and pigmentary changes are concerned: "Three-

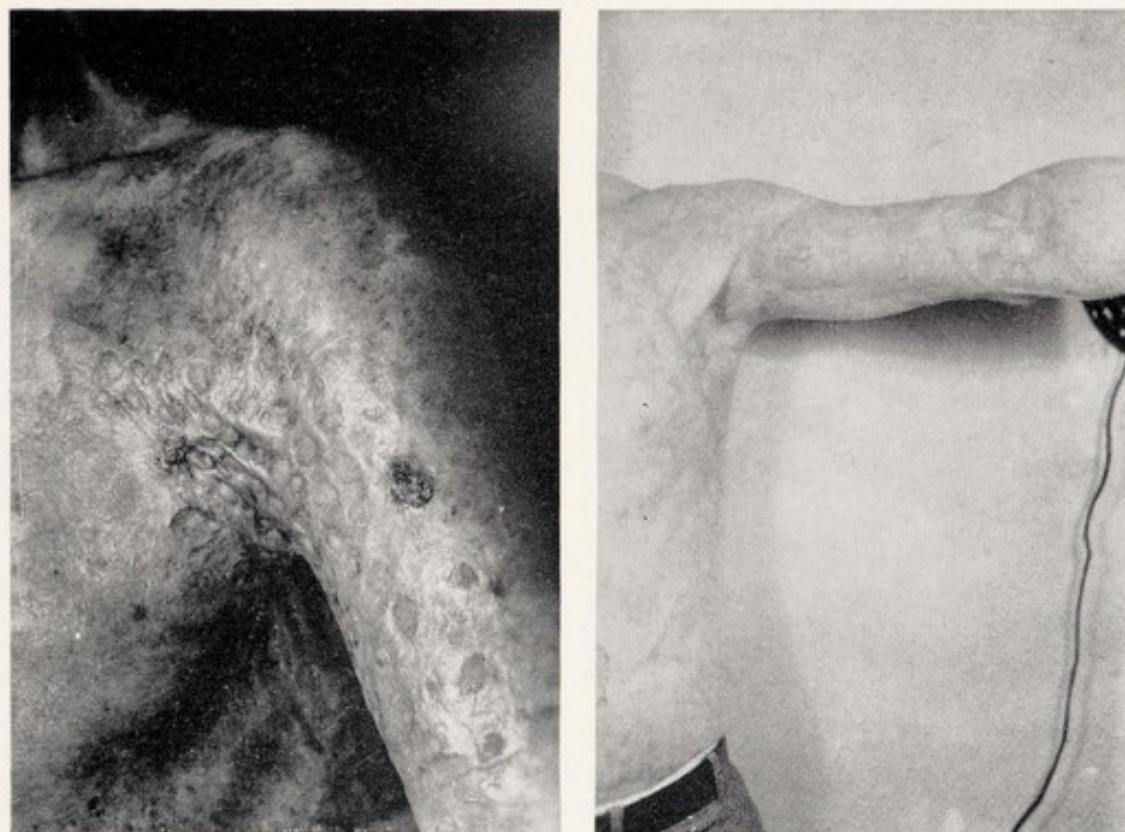

FIG. 19. Example of a patient who had a fixation of his arm to the chest. Pin point grafts had been applied by another surgeon. At the time the photograph was taken healing had occurred but he could not extend his arm. In this case the scar was crosscut and a skin graft of deep intermediate thickness .024 of an inch (over three-quarter thickness) was applied to the axilla. He also had a contracture in the elbow region which does not show in the first photograph but the area which was grafted shows in the final photograph right, which was taken 4 months after the operation.

quarter thickness" skin grafts have been applied to 137 patients to cover aseptic denuded areas averaging 188 sq. cm. The largest areas—four cases—covered were 800 sq. cm.—4 drums (4 x 8 inches) of skin. The percentage of "take" averaged 96 per cent. However, this statement hardly gives the true picture, because, as a rule, if the "take" were not good, it was totally not good due to infection, or partially destroyed due to an underlying blood clot of varying size.

The results of skin grafting with three-quarter thickness skin, in so far as a "take" is concerned, should be compared with the results after

skin grafting with full-thickness skin in order to get a true perspective of the advantages of these grafts.

Our experience with the "three-quarter thickness" skin graft, as cut with the dermatome, indicates that by proper cutting, provided that other factors such as proper fixation, tension, hemostasis, pressure and a clean field are obtained, the chance of failure to "take" is nearly eliminated. Because of the certainty of "take" being increased, one can extend the magnitude of his reconstruction to limits not previously advisable. Diffi-

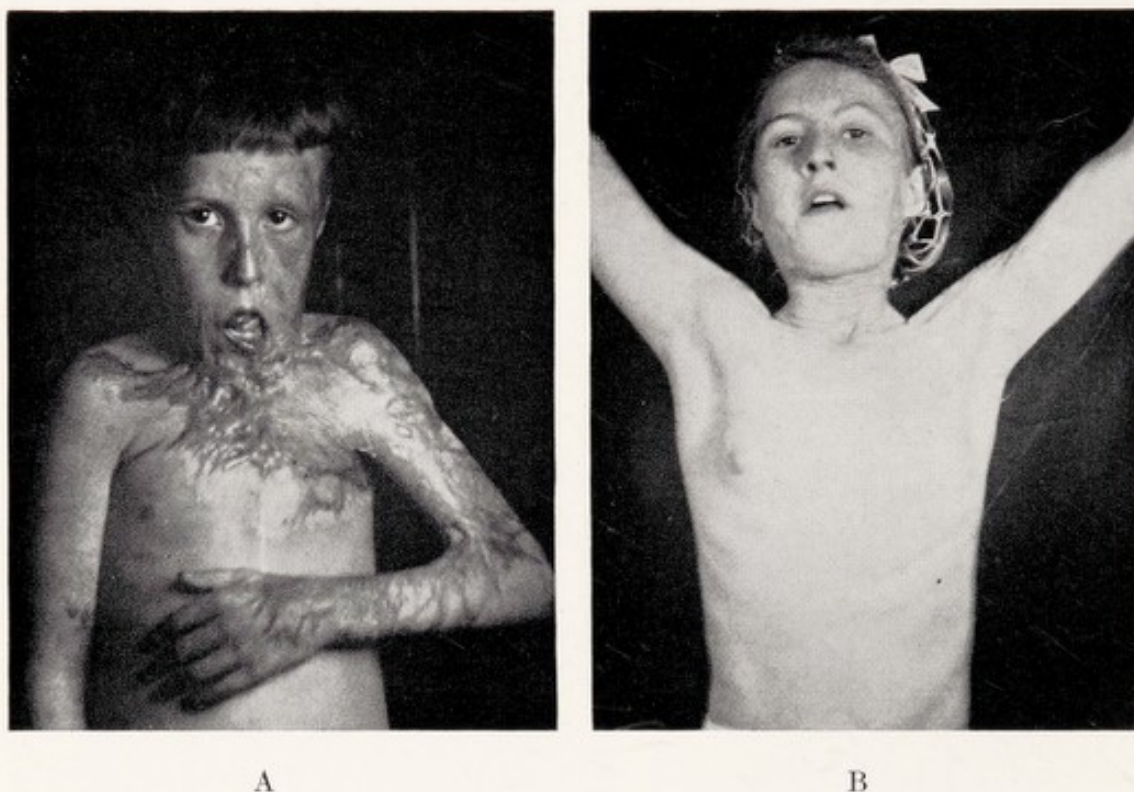


FIG. 20. A. Example of a very severe cicatricial contracture of the neck and arm which was corrected by means of "three-quarter" thickness skin grafts of about .016 of an inch in thickness in three operations. This case was published in *Surgery, Gynecology and Obstetrics*, 69:789, 1939, Fig. 19, but since that time a small operation has been done beneath the chin to eliminate a defect in that region. The first photograph was taken October 18, 1936 when the child was 8 years of age. B. Final result April 20, 1941 (age 13 years). Both the functional and cosmetic results are good. This photograph was published in *Annals of Surgery*, Vol. 113, page 1039, June, 1941.

cult areas to graft with thick grafts, such as the lateral cheek, the neck, and the axilla and dorsum of the hand, become acceptable cases in which successful repair is to be expected and not just hoped for.

The bed on which all skin grafts are placed will contract a little depending upon the anatomy which underlies the graft. The amount of contracture of "three-quarter thickness" skin varies from 10 percent up to 35 percent when the underlying tissues are as loose as those on the neck. This

compares favorably with the amount of contracture which a full-thickness skin graft undergoes when the "take" is good.

The protection given also compares favorably with that given by the full-thickness skin graft after a good "take" has been obtained. For example, adequate protection is given for use over the palm and back of the hand. It will be noted that the number of times two skin grafting operations were required, when the "three-quarter thickness" skin was used, has been reduced, over those required when the full-thickness skin graft was used, by nearly one-half (36 of 127 full-thickness, and 20 or 183 "three-

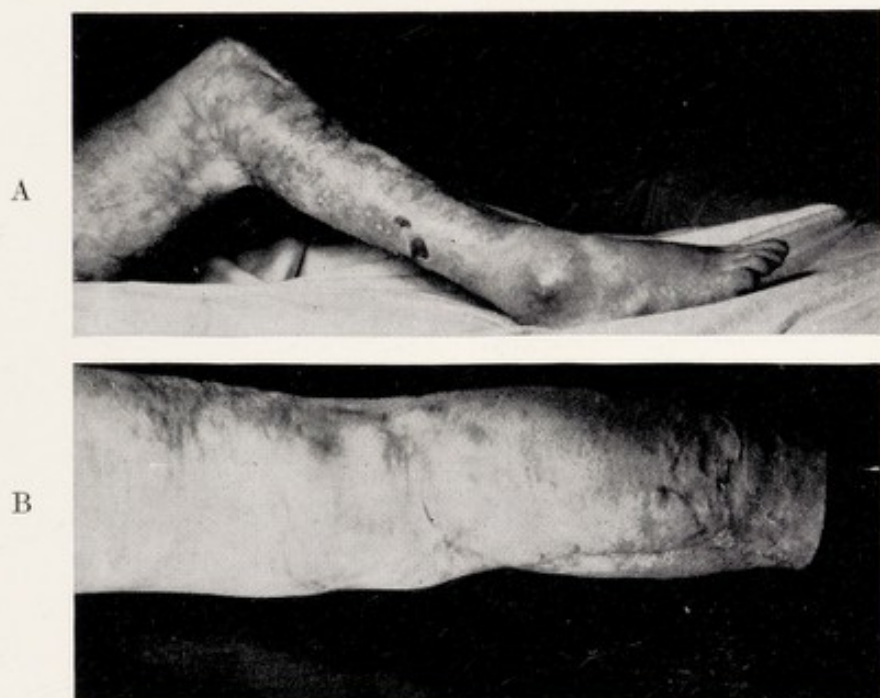

FIG. 21. A patient who had a large marked scar on the leg and a cicatricial contracture of the popliteal space with a scar on the inner side of the malleolus which pulled the foot into a position of varus. After the scar was removed and the area split lengthwise of the leg to release the contracture 3 large skin grafts .024 of an inch in thickness were removed from the abdomen and thigh and were placed from the region of the os calcis to about 3 inches above the knee in the posterior region. The scar on the malleolus also was excised to correct the varus. The idea here was to open up all contractures and to resurface the popliteal space. This was done in one operation. The photographs show the scar and the result 1 year after skin grafts were applied. The burn had occurred 2 years before we saw him.

quarter thickness"). This is due to two reasons: namely, the quantity of skin that can be removed is greater and the percentage of "take" is higher when the "three-quarter thickness" skin graft is used. As the dermatome must be used properly to cut the "three-quarter thickness" skin graft, it has the advantage that the skin can be taken from almost any part of the body (chest, abdomen, thigh, buttocks and back). On babies, small children and the emaciated, it is possible to easily obtain the proper amount and thickness of skin.

The fact that this type of graft shows little blistering, or areas of necrosis, causes the final appearance to approach that of normal skin. Its appearance is as good as that of a full-thickness graft after a perfect "take." The fact that the donor area does not have to be sutured is in its favor. It heals in from 14 to 18 days (Figs. 19 to 23).

Occasionally, after removing a "three-quarter thickness" skin graft, there is a tendency, in about 5 percent of the patients, to heavy scarring

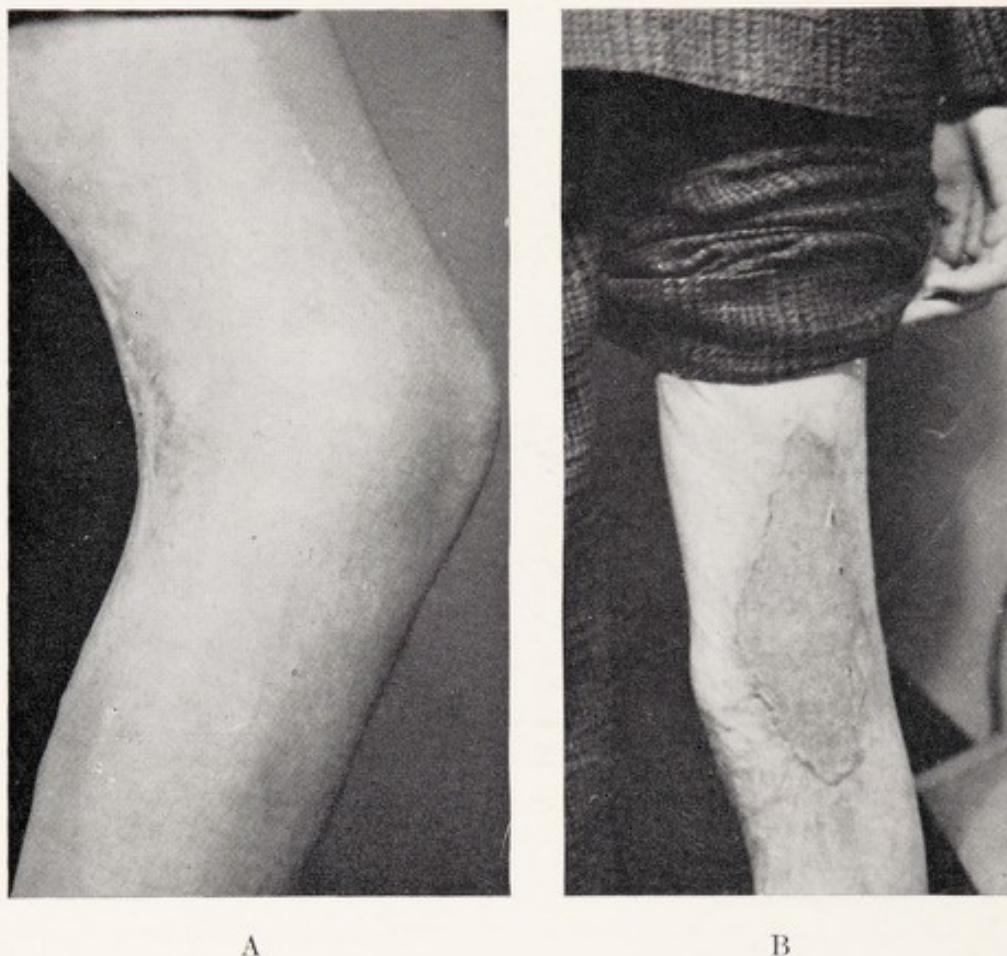


FIG. 22. A. Photograph of boy with cicatrix of the leg. "Three-quarter thickness" (.018 of an inch) skin grafts were applied. Shows patient three weeks after skin grafts were applied.

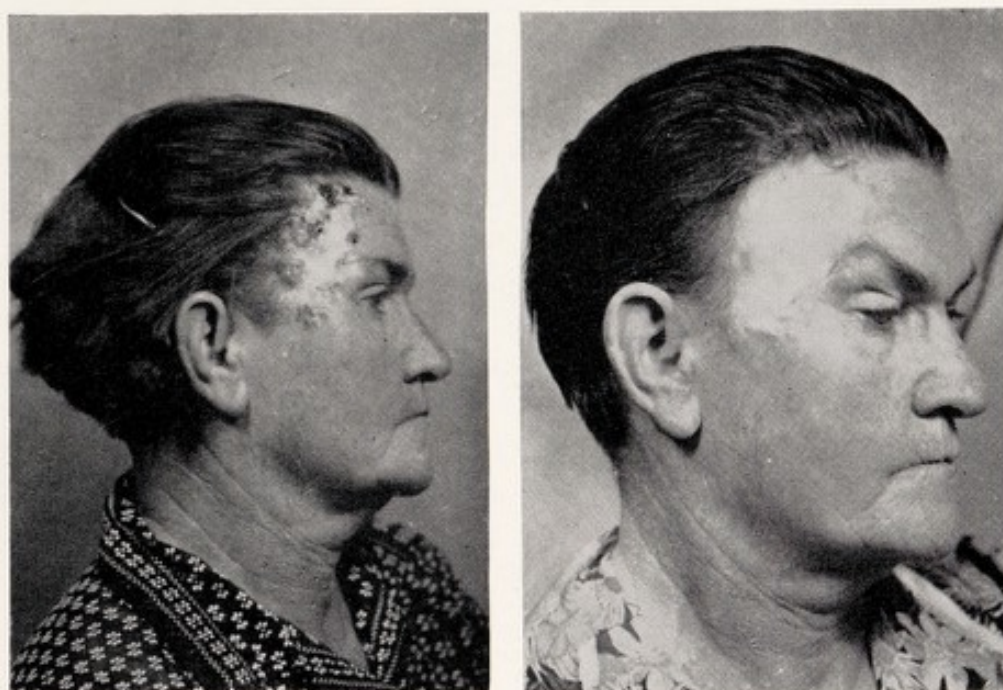of the donor area. In practically all instances, control of this situation has been made by excision of the scar when the heavy scarring is at one side of the donor area, or if distributed diffusely proper roentgen therapy is advantageous.

To recapitulate, the "three-quarter thickness" skin graft as cut with the dermatome is comparatively certain to "take." The new graft shows practically no blisters or local areas of necrosis. The ultimate contracture is reduced to a minimum. Good protection is offered. The appearance as a

rule approaches that of normal skin. The donor area heals quickly. The postoperative period of care is relatively short. Finally, as a rule the usual run of lesions may be corrected in one operation.

Comparison of Properties and Results Obtained After Thin and Superficial Intermediate Skin Grafts as Cut with the Large Knife and the Dermatome When Applied to a Granulating Surface

In the early series of patients, up to May 1, 1936, 59 patients were skin grafted within grafts cut by hand with the large knife. The granulating areas averaged 89.6 sq. cm., and 80 operations were required to gain a



A

B

FIG. 23. A. Basal cell epithelioma of the side of the forehead which had been unsuccessfully irradiated with a recurrence. This area was excised and "three-quarter thickness" skin graft .026 of an inch in thickness removed from the abdomen was applied. B. Appearance 2 months later.

healed surface. As some patients had multiple areas, 93 areas were grafted. Of these, in 42 there occurred a "take" of 90 percent, which may be considered as practically perfect for the purpose in hand; in 13 there occurred a "take" of over 80 percent, which may be considered as good; and in 30 there occurred a "take" of over 70 percent, which was usually sufficient. In 8 the loss ranged from 30 percent to loss of the entire graft. The usual cause of loss was infection.

In the second series of 70 patients, on whom thin grafts cut by the

dermatome were applied, an average area of 357 sq. cm. was covered at one sitting. In 3 operations, six drums of skin were removed—averaging 1200 sq. cm. of skin at an operation.* Eighty-one operations were performed. Four patients died after loss of the skin and after a period of slow “down-hill” progression during which it was not possible to get the patient in condition to do another skin graft. Three of these patients had extremely severe

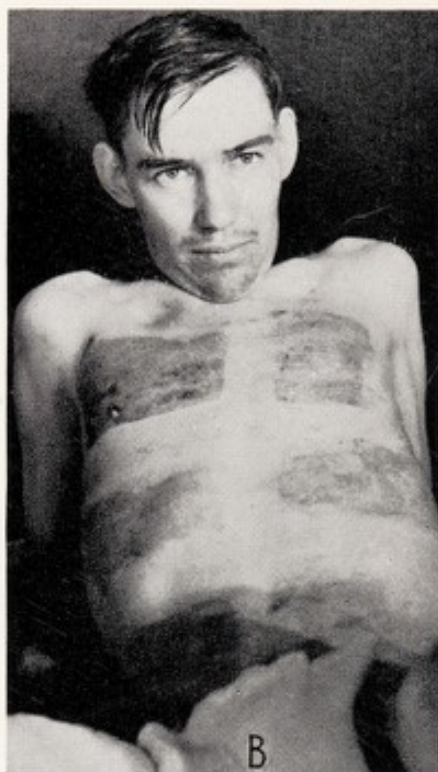
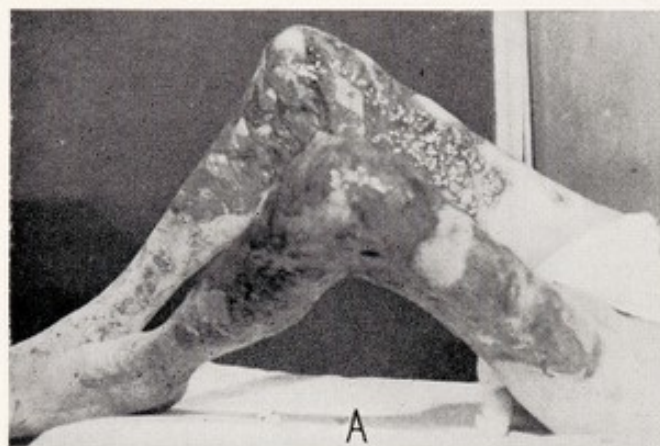

FIG. 24. A. A granulating wound caused by a severe burn of the thighs, the knees, the upper legs, and popliteal spaces. The area involved both the extensor and the medial surfaces of both legs. To correct this area two operations were involved. In the first operation 744 square centimeters of skin were removed from the upper chest and anterior abdominal wall. This amount of skin covered about one half of the denuded area but we considered it about all he could stand at 1 operation. Three weeks later at a second operation 781 square centimeters of skin were removed from the same areas. By that time the subepithelial cells had caused regeneration. This allowed us to resurface his legs in two operations. This is the type of case in which formerly death resulted very often because it was impossible to cut enough skin from the back and abdomen to cover the lower extremities. This was particularly true if the patient was a baby or was emaciated. B. The denuded areas about 10 days after the first operation.

burns. The fourth patient had a very large varicose ulcer which was excised. The base was then skin grafted. Pneumonia developed postoperatively.

An average of 78 percent of skin “took” in the 81 operations. After 4 operations not more than 25 percent of the skin “took.” After 10 opera-

* A warning might be wise here. A blood transfusion may be necessary, because of loss of blood serum, when too much of the body surface is denuded. The same factors are operative as occur when there is too much denudation following a burn.

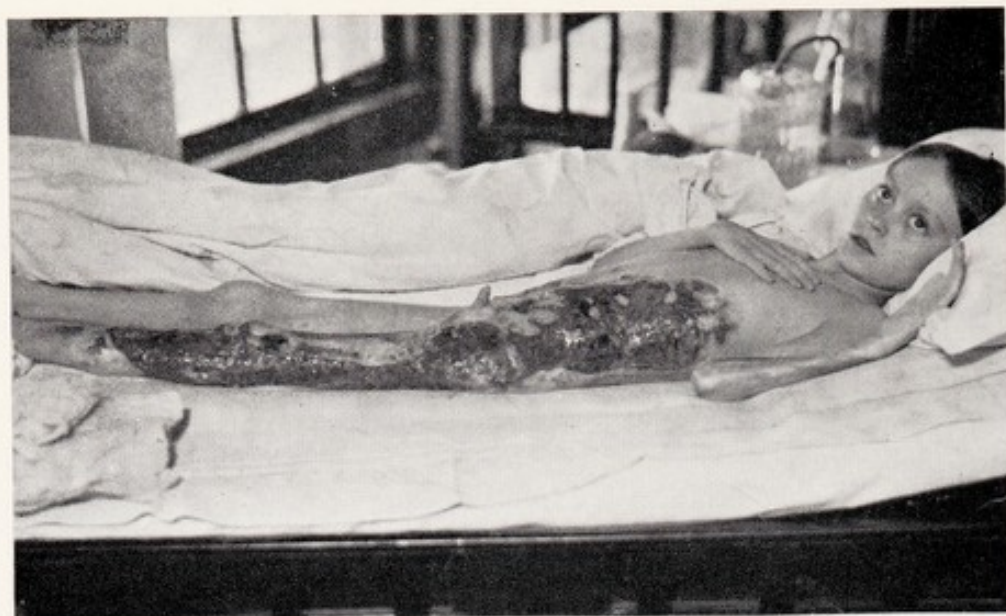tions (the 4 patients who died are included) most of the skin was lost due to infection developing beneath the graft.

The most striking point noted, in comparison of the first and last series of patients on whom thin skin grafts were placed, is that in the latter series an average of 357 sq. cm. of skin (Fig. 24) was applied at one sitting while in the earlier series the average was 89.6 sq. cm. The usual cause of loss was infection developing beneath a part or all of the graft. This usually was due to desultory preparation of the granulating surface, along with an error in judgment as to the time when the surface was in condition to receive a graft. In a few instances, improper fixation was the basic fault. Great care must be given to the proper preparation of the granulating surface. Pyocyanous infection, no matter how small the degree, will guarantee failure. Early in the first series, it was noted that, in patients on whom the skin was grafted when the hemoglobin content was below 65 per cent, the estimated chance of a successful "take," with a thin graft on a granulating surface, was decreased from one-third to one-half because of a greater tendency for the graft to be destroyed by infection. Later in the second series the deleterious effects of an unexplained temperature of over 101 degrees, an improper electrolyte balance and a hypoproteinemia in so far as a good "take" was concerned were noted.

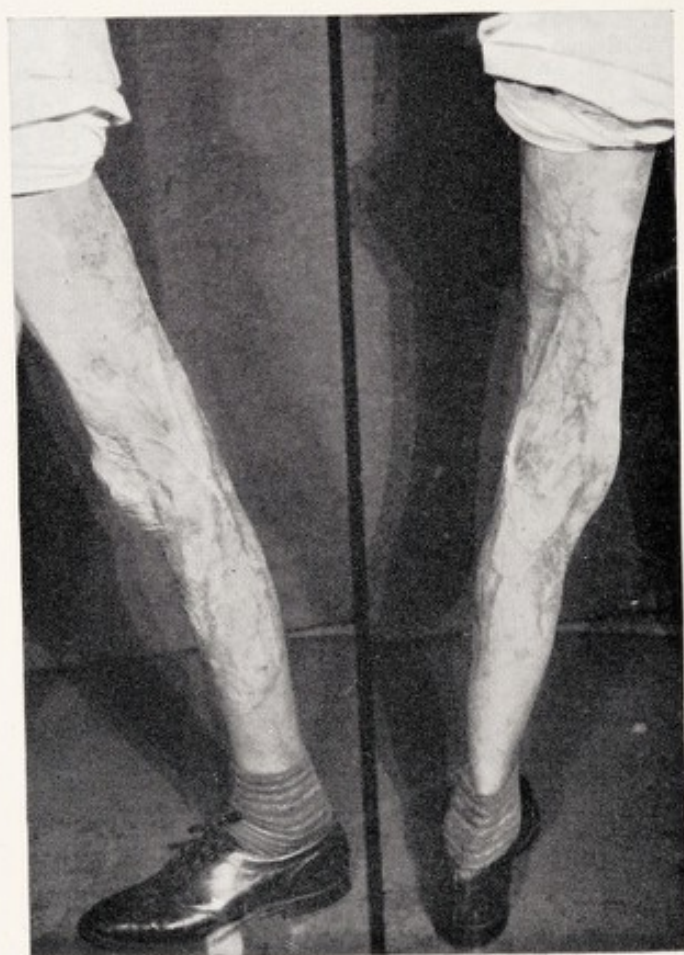As a general rule, thin skin grafts were applied to granulating surfaces with the idea of obtaining early coverage to lessen functional disability about such locations as the hands and fingers or to get earlier healing of the granulating areas so that the period of hospitalization could be cut to a minimum (Fig. 25). In many cases, especially when the denudation had occurred about a joint, a residual contracture remained after healing which was corrected later by the application of a "three-quarter thickness" skin graft when a clean field was obtainable (Fig. 25).

It has been noted that, when the condition of the patient is good and the condition of the granulating surface is above reproach, one may apply a superficial intermediate dermatome-cut skin graft, of about .014 to .016 of an inch in thickness, in the adult with the idea of preventing some of the subsequent contracture which is likely to occur after the application of a thin skin graft. This latter idea should not be carried too far. One of the disadvantages of the dermatome is to cut a thin graft a little too thick. Therefore, the likelihood of a good "take" is decreased. The most important factor, in grafting with thin skin on a granulating surface, is to get a good "take" and early healing.

No new factor is involved, and there is no essential difference between the superficial intermediate calibrated skin grafts as cut with the dermatome and those cut by hand, except that one may select a predetermined thickness and cut the graft with the dermatome at a uniform level, which cannot be done by means of the large knife, and that a graft of very large



A



B

C

FIG. 25. See next page for description.

size may be taken from locations not previously available (Fig. 24). For instance: Satisfactory skin grafts have been obtained from the pectoral and scapular regions in markedly emaciated individuals, the lumbar region, the posterior gluteal region (Fig. 26), relaxed pendulous abdomen and over the ribs if the patient is not too emaciated and in babies; all in regions or under conditions in which the skin graft knife, despite the utmost dexterity, is of no great use.

One cannot but be impressed by the area of skin that is available to one.

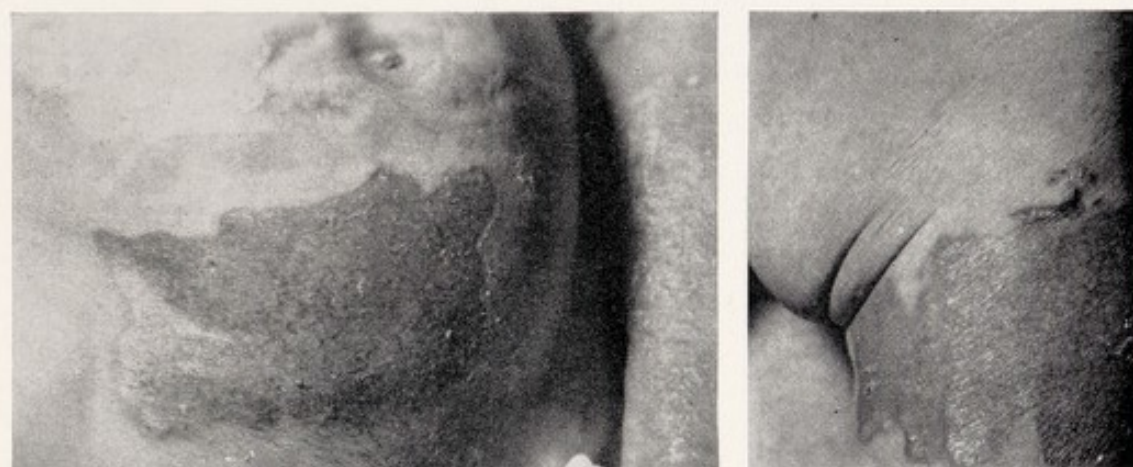

FIG. 26. Abdomen and thigh of the patient shown in Fig. 21. This photograph was taken 3 weeks after the skin grafts had been removed. The grafts were .024 of an inch in thickness.

This factor alone allows the successful grafting of many difficult cases; but possibly the foremost is a type of individual, occasionally seen in the past, who has been hopeless, for example, the type of patient with a large denuded surface involving both thighs and legs with most of the remaining skin on the trunk (Fig. 24).

In addition to the advantages listed above, two particularly outstanding advantages of cutting thin or superficial intermediate skin grafts with the dermatome are: the decrease of the operating time when large denuded areas are to be covered, and, the decrease of the number of operations required to give adequate resurfacing.

FIG. 25. In this boy two operations were necessary. The granulating areas were first covered by thin calibrated skin grafts (.012 of an inch in thickness) and he was allowed to go home. After several months he came back with a certain amount of contracture in the popliteal space. At this time we had a healed field with which to work. After crosscutting the scars, moderately thick calibrated skin grafts (.018 of an inch in thickness) were cut from the abdomen and applied over the denuded areas. B and C show the functional result about three months after the second operation.

CHAPTER VII

The Grafting of Sulci and Cavities

The Forming and the Relining of Cavities with Skin Grafts

MANY defects which involve body cavities, as for instance the mouth, nose, or orbit, can be relieved or reconstructed by a replacement of a lost mucosal or epithelial lining; or a new cavity can be reconstructed (vagina) (Fig. 27) by means of skin grafting on a mold. Up until recent times the problem of resurfacing cavities was an unsolved one. The matter approached solution when Esser demonstrated that free skin grafts could be successfully grafted as a lining membrane in the mouth, and, that in

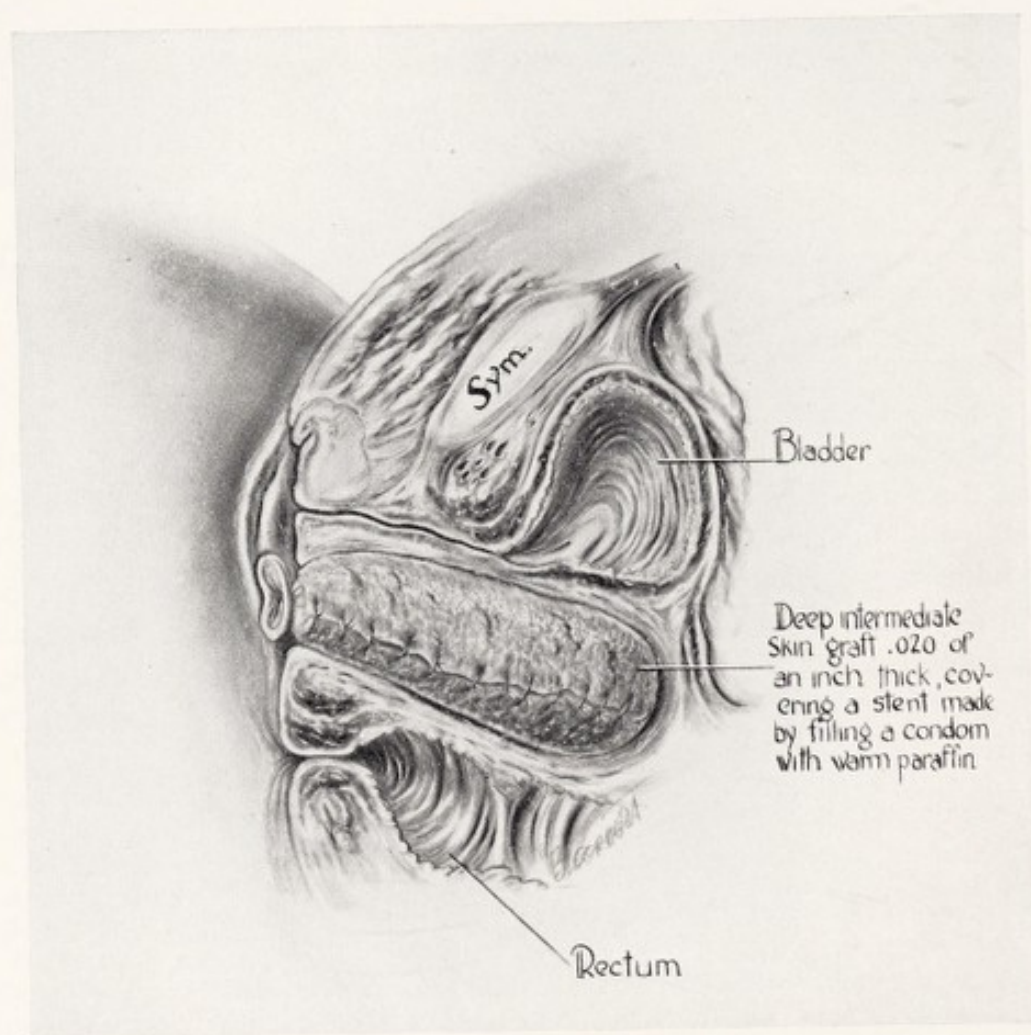


FIG. 27. Method of building an artificial vagina in one operation by placing a stent graft over a condom filled with paraffin into the vagina.

such a case it functioned under conditions originally quite foreign to it. Esser in 1917 introduced through an incision beneath the chin, without opening into the mouth cavity, a mass of modelling composition covered with a Thiersch graft. The incision through which the stent and skin graft had been inserted was closed. Later this skin-lined cavity was opened from

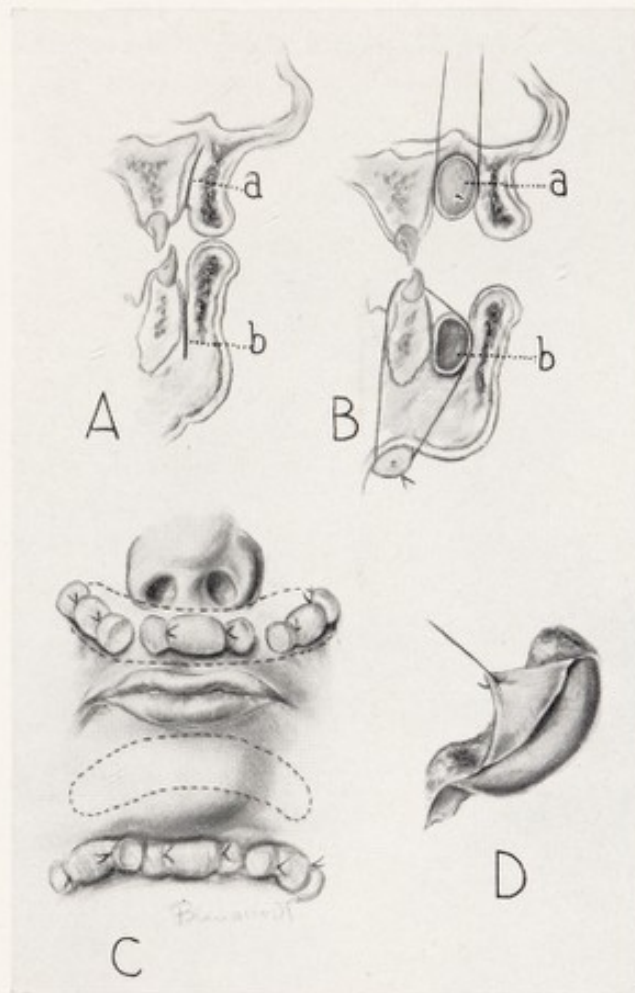


FIG. 28. The application of a stent graft to deepen and rebuild the labial buccal alveolar sulcus. A. *a*, Incision line which encircles the upper jaw; *b*, incision line which encircles the lower jaw. B. *a*, Cross section of stent covered with skin which encircles the upper jaw. A heavy suture is placed around the stent and tied over a dental roll; *b*, cross section of stent covered with skin which encircles the lower jaw. A heavy suture goes around the stent and the jaw and is tied over a dental roll. C. Dotted line shows position of stent held in place by sutures tied over dental rolls. D. Stent over which a split skin graft is being draped.

above. The destroyed buccal sulcus was reproduced quite satisfactorily. Esser termed his method "epithelial inlay grafting."

Waldron, Gillies and Pickerill, in 1918, modified the principle of Esser by introducing the stent covered with the skin graft directly in the mouth, where it was found to "take" on a freshly denuded surface in the presence

of salivary secretion which contained the bacterial flora of the mouth. The method now has a rather wide application in reconstructive surgery. This modification of Esser's method has been termed "epithelial outlay grafting."

Technic: In constructing a new subcutaneous-lined cavity, or in repairing an obliterated one, it is necessary to observe certain rules if the end result is to be satisfactory. Allowance must be made for a considerable amount of subsequent contracture. In other words, one must overcorrect the defect. The amount of contracture will depend somewhat upon two factors: the thickness of the graft, and, the pliability and elasticity of the

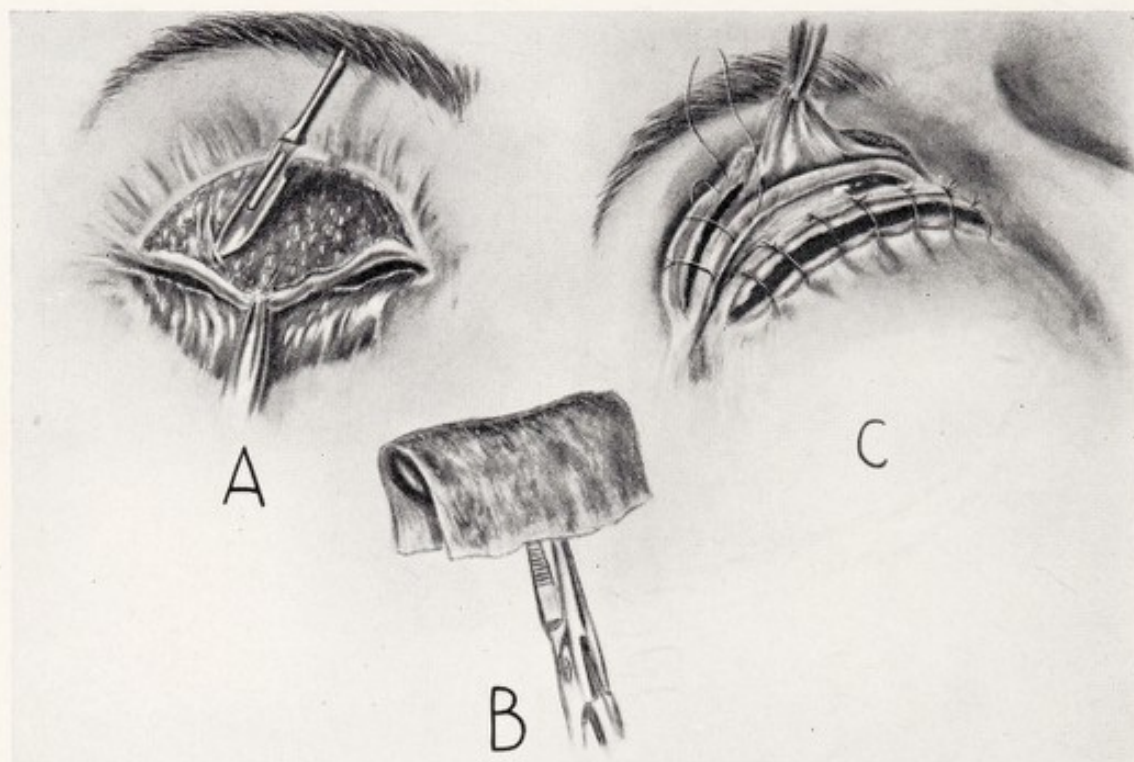


FIG. 29. Method of opening up a contracture of the eyelid and the application of a skin graft about a stent. A. Crosscutting and excising the scar. B. The stent made of modelling composition with the skin graft folded over it. C. Stent and skin graft have been stitched into prepared denuded area of the eyelid about the stent.

underlying bed. The cavity must be overdistended by the mold and the stent must fit the cavity accurately. The skin graft should be in one piece.

For the routine case, when overcorrection is easily obtained so that contracture is allowed for, as, for example, when one is deepening the moderate obliteration of gingivo-labial sulcus or correcting an ectropion of an eyelid or lip, an accurate and easily removable mold of dental compound is made of the cavity. A one-piece skin graft, of the calibrated in-

intermediate type, is cut from an appropriate part of the body; such as the inner arm, inner thigh or posterior of the ear. This graft is then draped, raw surface outward, over the mold (Fig. 28). Mold and graft are then inserted into the cavity or gutter. When the operation has been on the gingivo-labial sulcus, if any circumferential sutures are needed to hold it in place, they are placed about the mold and tied over an external gauze roll, or rolls of dental cotton, to prevent cutting of the skin.

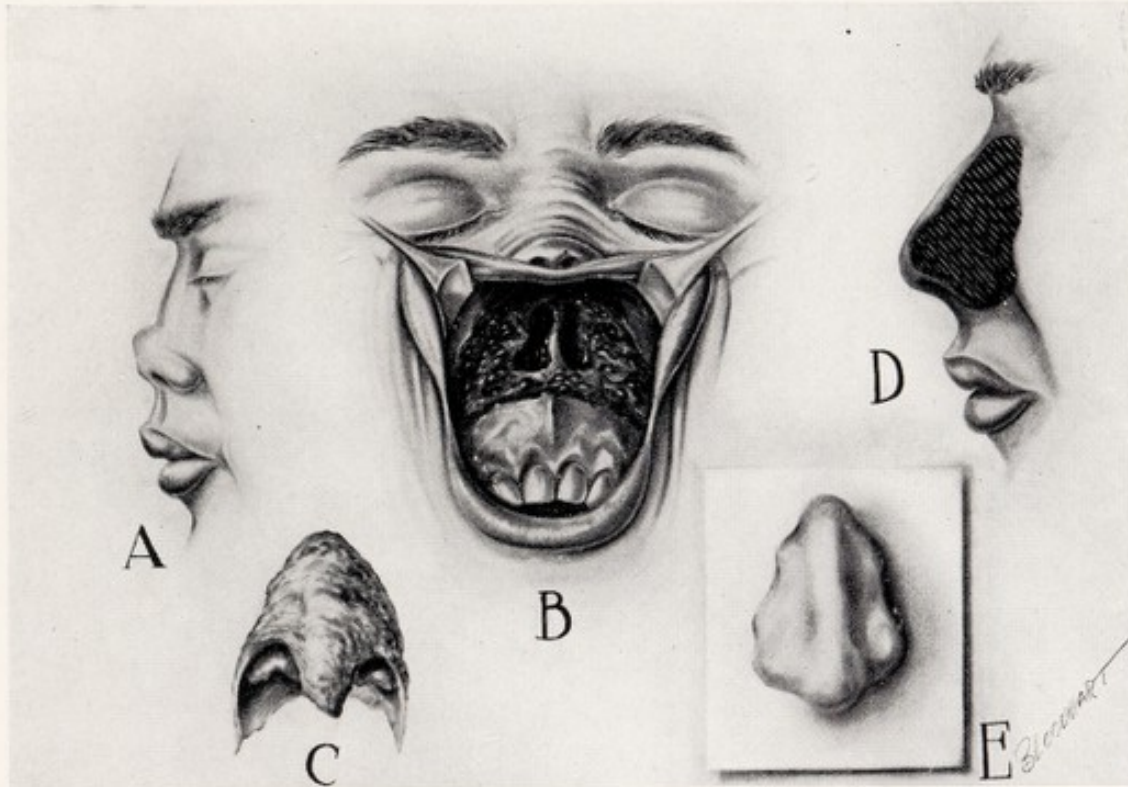


FIG. 30. Method of grafting a nasal cavity. In this case one is attempting to reline the nasal cavity with skin so that a prosthesis can be used for support in order to straighten and improve the contour of the nose. A. Profile view before operative procedure. B. The soft tissues of the upper lip and nose raised to receive the skin graft and stent. C. The skin draped over the stent. D. Diagrammatic drawing of the profile with the stent in place in the nose. E. Shows the stent after some smoothing up so that the contours are not so uneven. This smoothed stent can be used as a pattern for the prosthesis to be worn during the period of contraction. A second smaller prosthesis built with appropriate attachments is the last step in the program.

The after care is simple, and is directed towards keeping the mouth clean with washes. Usually high caloric diet, at first, is advisable. After a week the preliminary mold is removed. The cavity is rinsed and the mold which will be used for the next month or so is placed in position.

When the operation was performed to correct an ectropion of the eyelid or the lip, a rolled stent is formed (Fig. 29) of the proper size. The skin graft is draped over the stent. The stent and the graft are then laid in

the denuded gutter which is present after the scar has been crosscut and removed. Interrupted sutures are now taken both through the skin edges and graft on either side of the stent. These are tied over the stent. No dressing or only a dry dressing is all that is necessary. The stent is removed in about six or seven days.

Thus, if the situation is one where considerable overcorrection can be made, it usually is not necessary to keep the mold in place after the seventh day.

In the relining of luetic noses (Fig. 30) I have had an occasional but satisfactory experience; but in the building of a new urethra (hypospadias) with a skin graft (two successful cases), save when a stricture was present, I have had practically no experience. For the correction of hypospadias I have preferred to use skin flaps. After relining the nose for some such lesion as congenital lues, McIndoe emphasizes that the mold should be kept in place three or four months, and he cautions against ever removing the stent for more than a few hours until the contractile phase is over. In case there is an inflammatory reaction, he says: "Certainly the worst thing to do is to remove the stent entirely and allow the inflammation to subside. Drain an abscess after localization, but keep the stent in place if possible. Leave the mold in place from five to six weeks in the cases of contracted orbit. In the formation of a new urethra, the catheter is left in place three or four months."

The mold may be buried for a considerable period of time provided it is made of some material which does not absorb secretions. A small drain hole should be left for the escape of secretions during the healing phase. When one wishes to line a flap for the purpose of rebuilding some such organ as a part of the nose, it may be advisable to allow the stent to remain *in situ* until the contractile phase of the graft is over. When one is particularly desirous of preventing all the contracture possible, particularly if the field is an aseptic one, it is often advantageous to use a rather thick deep calibrated intermediate skin graft. The thicker the skin graft, the less the tendency to contracture.

When the cavity to be grafted cannot be greatly overcorrected, or if the degree of contracture is likely to be quite marked, it is often advisable to work in cooperation with some one skilled in making splints and prosthetic appliances. Sometimes much ingenuity and patience are required. Sometimes it is advisable to design and attach a part of the retention mechanism before the operation; for example, when the buccal sulcus is obliterated widely and there are sufficient teeth present, a metal cap splint with a detachable "snap-on" device to hold a form may be constructed and placed on the teeth before operation. In edentulous patients,

a combined upper and lower spring retention apparatus may be advisable. Two impressions are taken and two molds are made of the cavity. One mold is given to the dental technician and one is used to hold the graft in place for the first week or ten days. The dental technician then has a week or so to build the appliance which may be inserted into the newly formed cavity when the original form is removed.

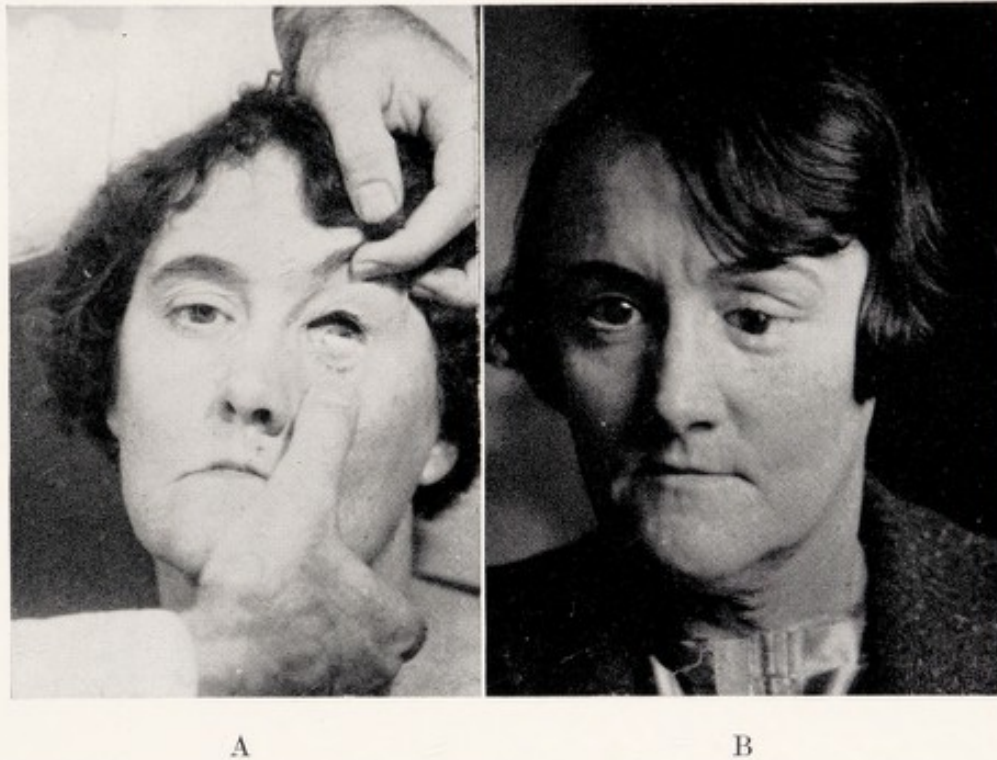


FIG. 31. Obliterated eyesocket which has been relined with a skin graft. A. Socket. B. Eye in position.

After relining a luetic nose (Fig. 30), it is recommended that the mold be made in two pieces—one for the nasal cavity proper extending up over the nasal bones, and a second lying against the first which occupies the lower half of the cavity and the entrance from the mouth to the nose. The double block facilitates removal and reintroduction. A good stent for the building of an artificial vagina is a condom (Fig. 27) filled with paraffin. Later a smaller stent can be made of some non-irritating material. For four or five months this should be worn more or less continually, after which time it need be worn at nights only for a few additional months.

Wheeler, who was most successful in relining an eyesocket, placed stress on the following points (Fig. 31): (1) complete thinning of the eyelids of most of the tarsal cartilage; (2) deepening of the infra-orbital sulcus to the bone; (3) deepening of the external sulcus to the bone; (4) com-

plete freeing of the tissues to the levator palpebral muscle without injuring it; (5) deepening of the sulcus about and freeing of the caruncle; (6) the use of a flattened lozenge-shaped stent as large as could be inserted. Sometimes the outer canthus was widened to allow insertion of the stent, (7) a very thin Thiersch graft without hair to cover the stent. He gained by this means a flattened cavity. The tissues of the orbital cavity were not removed. They were used to push the new prosthesis well forward. By this means he got practically no deepening of the sulcus just below the upper eyebrow. He left his stent in for only a period of two weeks or so. If the graft was thin enough in some cases some of the tear ducts remained patent.

Most men prefer to leave an expanding mold in the eye socket for a period of two months or even more. A glass form is helpful here if one can get union between the upper and lower eyelids after scarification and suture.

CHAPTER VIII

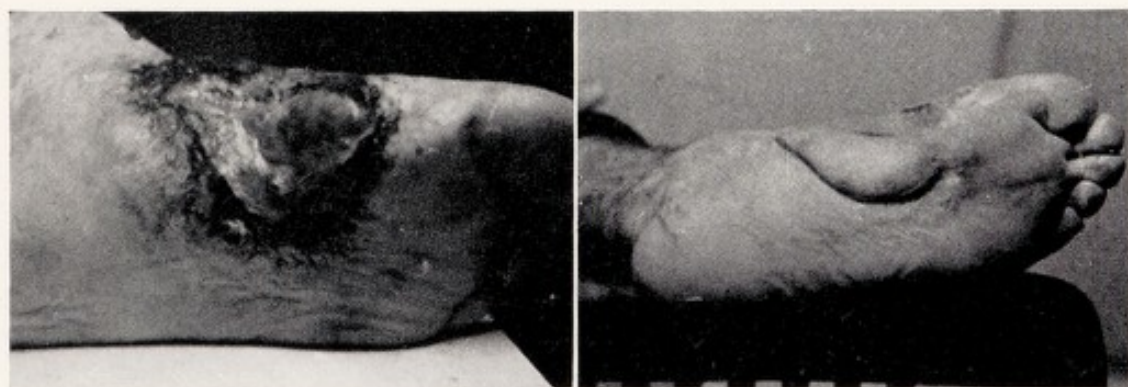
Skin Flaps Versus Skin Grafts

BY A SKIN flap is meant a piece of tissue which has been detached from its underlying support but which still remains partially connected at some portions of its periphery or base through which it receives its blood supply. The flap can be shifted only so far as its pedicle or basal attachment will allow.

In various situations over the body the replacement of skin and subcutaneous tissue requires more than simple skin grafting. The restoration of function in such cases depends upon a reconstruction which can be accomplished only by means of flaps of skin and subcutaneous tissue.

Advantages and Disadvantages of Pedicled Skin Flaps

In making a selection of soft tissue material with which to repair a given deformity often one has to balance the advantages and disadvantages of a flap against the advantages and disadvantages of a free skin transplant. Many factors enter into this decision. Besides the actual advantages or disadvantages of one over the other the decision of the surgeon will be governed somewhat by his familiarity with one method or the



A

B

FIG. 32. A. An electrical burn of the plantar surface of the foot which destroyed the skin and subcutaneous tissue over the internal metatarsal bone, about one-half of the bottom of the foot, most of the inner portion of the foot, and one-half of the external lengthwise half of the metatarsal bone of the foot. In this case a flap from the opposite leg was transplanted over the area to give a subcutaneous pad and so that the foot would stand the trauma to which it would be subjected. B. Photograph of the foot 2 months after correction.

other, and even with equal familiarity a certain amount of personal equation enters the matter. On the whole, in my work I have not used skin flaps as much as have most other reconstructive surgeons. Gillies and Davis and their followers are rather partial to them. Blair and his followers have been rather partial to the advantages of a good skin graft.

In general, a skin flap may have the following advantages (Figs. 32 to 36): A fairly high resistance to infection, some thickness for the purpose of filling a contour defect, little subsequent contracture, trauma is fairly well withstood, the skin is soft and pliable and the color is normal for the

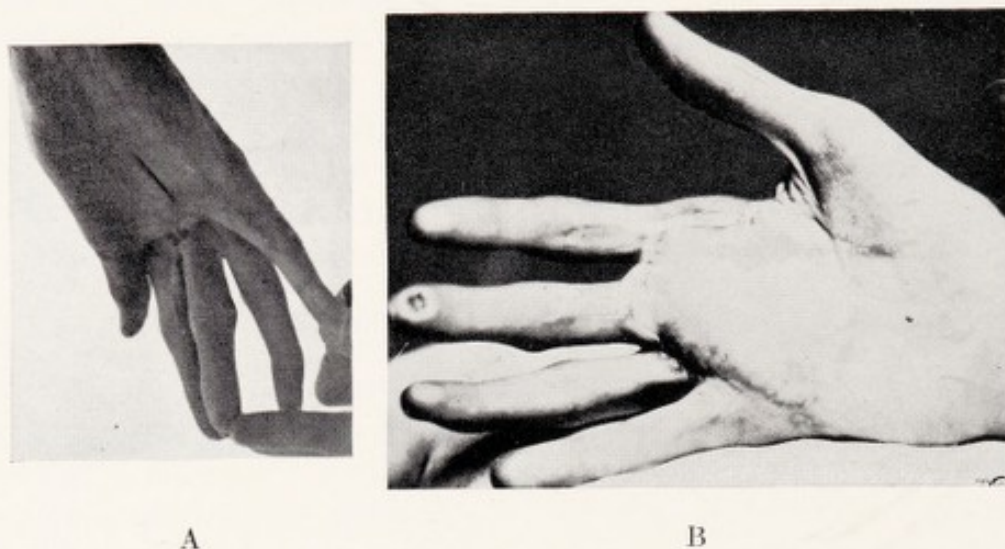


FIG. 33. A. Contracture of the palm of the hand which when opened it was found that the tendons of the hand were laid bare. Therefore instead of a skin graft a skin flap was laid across the palm. B. Result one year later.

area from which the flap is removed. This latter factor may be either an advantage or a disadvantage.

The Length of Time

The main disadvantage besides the one just mentioned, which may or may not apply, is the number of operations entailed in the transfer. To my mind this point of the number of operations entailed is a very important one. One of the greatest criticisms that can be leveled at the reconstructive surgeon is the length of time that he so often takes to complete his job. When so much time is entailed, even if one does not consider the damage to the morale of the patient, the economic difficulties involved are quite tremendous. Within recent years the minds of many reconstructive surgeons have been so dominated by the pedicled skin-flap method of repair—a method which always entails a series of operations, some of them rather trifling but nevertheless time consuming—that they

have neglected the procedures that allow them to accomplish their purpose in one or two operations at the most, in the manner in which other surgeons do their work. These statements apply in particular to the so-called "jump" tubed flap and the tubed pedicled flap but not the sliding or rotated skin flap.

On a flat surface one does not need an increase of thickness to give correct contour. The application of a skin flap is likely to give a rolled or bunched clumsy appearance which detracts quite materially from the cosmetic result even if the functional result is good. Finally, especially



FIG. 34. A. A nose deformity due to congenital lues. B. Shows result six weeks after the final operation. The skin flap was taken from the left arm.

when a large skin flap is removed, the damage to the area from which it is removed may be considerable or even difficult to repair.

For the building of organs requiring thickness, for filling a depression in the soft tissues, for building a part requiring two soft pliable epithelial surfaces and some thickness such as the nose, the cheek, and the lip and as a direct covering for bone or cartilage, the pedicled flap has no competition. But where simple surface epithelial covering is the only indication, a skin graft as a rule gives the most acceptable and efficient result.

For most contractures, wide scars or wide areas that are denuded or need denudation on the face, unless a sliding flap from the immediate region can be utilized, generally a skin graft of one type or another is the preferable material for coverage. The same may be said for the neck in

all areas except over the laryngeal box. Here it is difficult to get a skin graft to "take" and if a sliding flap can be obtained the final result is likely to be better. On the face and on the neck a skin flap tends to appear too thick. However, on the neck this tendency is less pronounced than on the face. For relief of contracture causing ectropion of the eyelids or the lips or for cavity grafting, the proper skin graft is far superior to a pedicled flap. An exception to this is when it is possible to utilize a skin flap from the opposite eyelid—as, for example, from the upper to the lower eye. For practically all contractures about the axilla, elbow, wrist, groin and popliteal space, I believe the application of the proper skin graft to be preferable to a skin flap. On the dorsum of the hand, as a rule, the application of a thick skin graft is preferable to a skin flap and the same may be said for the palm of the hand when a fair amount of subcutaneous tissue remains. When the subcutaneous tissue is largely absent, however, or when the tendons are bare, a skin flap usually is superior. For repair of denuded areas between and about the fingers, as a rule, the application of a skin graft gives a superior result to a skin flap. But to protect the end of an amputated finger or bared bone, a skin flap usually has definite advantages over a skin graft.

As a rule, a skin graft is superior to a skin flap in such ulcerations of the legs as the "varicose ulcer," but, on the other hand, for direct coverage of bone, as following a radical operation for osteomyelitis of the tibia, a skin flap is preferable to a skin graft.

On the bottom of the foot if deep tendons are bared, if the bone is denuded, or if the scar contraction is of a wide or constricting type a skin flap as a general rule will stand trauma to which it will be subjected much better than even a full-thickness skin graft which has taken perfectly.

McIndoe has recommended a stent skin graft for the formation of a new urethra in hypospadias. Personally I have preferred skin flaps because they contract less. Brown has reported the successful coverage of the outside of the penis which was accidentally denuded of skin. When it is possible to obtain I should prefer scrotal flaps because of the elasticity.

The Coverage of Deep Defects by Skin Flaps

The indications for a pedicled flap to an extremity I believe are essentially as follows:

(1) In fingers where it is essential to cover a guillotine amputation to get added length, or where one side of the finger has been denuded leaving bare bone so that padding (Fig. 36) is essential.

Very often it is desirable, in a finger or thumb, to gain as much length as possible, or to protect a projecting bone thinly covered by scar, or

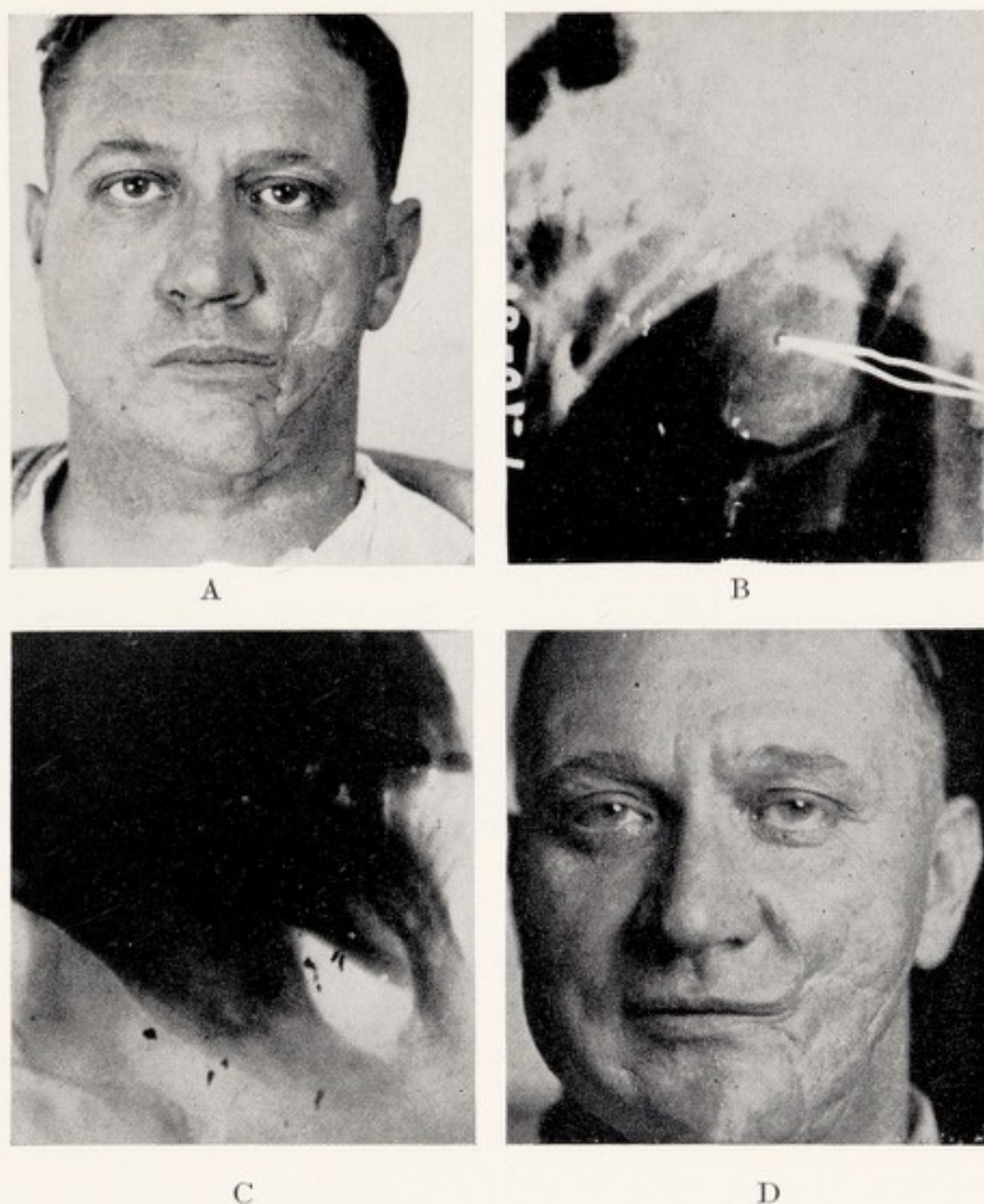


FIG. 35. Case of successful bone graft to the body of the mandible. A. Patient before operation. In this case a skin flap was turned in from the neck to give a lining and the butt end of the flap was used for additional covering for the cheek. The ramus of the jaw had been pulled forward so it was pulled back into position by a wire in a projection in a head cast as shown in B, before the bone graft was placed. C. Piece of seventh rib was inserted into the defect and held by heavy kangaroo tendons and careful suturing about the bone graft. This roentgenogram was taken one year after bone transplant. D. Shows external appearance. This bone graft has been in place now since 1934. The man is seen occasionally and he has perfect function and has had no trouble.

both. About one-fourth of an inch in length and a sufficient padding of skin and subcutaneous tissue can be given by transplanting a pedicled flap over the uncovered or projecting bone (Fig. 36). Some men have used free full-thickness skin grafts for the purpose, but in my experience a skin

flap is the preferable covering. It gives sufficient padding so that trauma is well withstood.

(2) In the fingers, the hand or the foot, a pedicled flap is indicated when tendons are rather widely exposed (Fig. 33).

(3) In certain rather severely burned fingers and hands, better functional results will be obtained if one gets the advantage of a good subcutaneous tissue.

(4) Sometimes one may need the fatty subcutaneous tissue given by

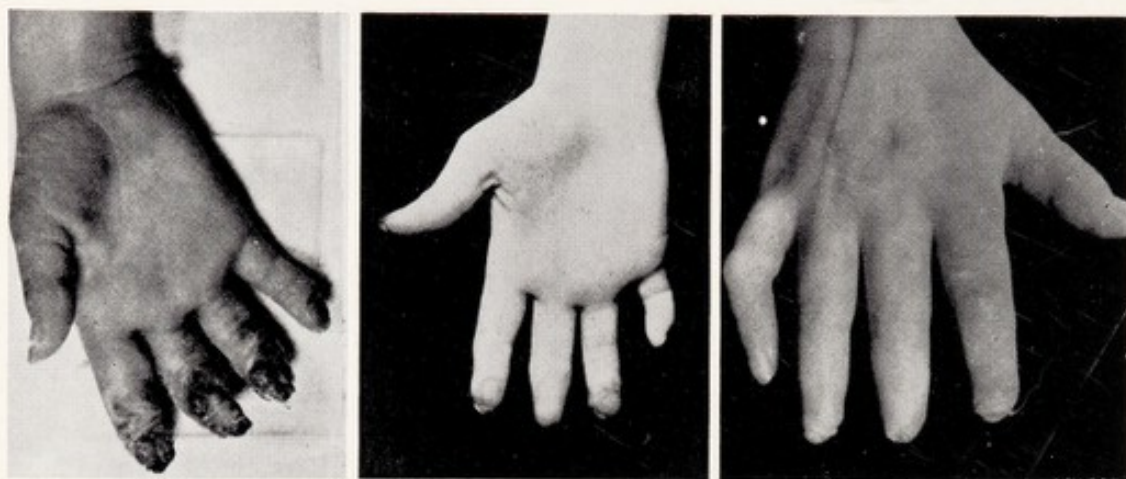


FIG. 36. A hand which had the distal phalanges destroyed by a mangle. To give her padding and to increase the length of the fingers somewhat, flaps from the abdomen were applied to the finger tips. The greater part of the damage was on the ventral surface.

flap transplantation, if, at a subsequent date, one expects to do a tendon transplantation.

(5) If bare bone is exposed on the bottom of the foot, the subcutaneous padding of a pedicled flap is needed (Fig. 32).

(6) When the bare bone is exposed over the tibia, especially, but also elsewhere, the transplantation of a pedicled flap is indicated because of the poor blood supply that may be present and also for the purpose of padding.

(7) Over the Achilles tendon, if an ulcer is present, the transplantation of a pedicled flap is indicated.

(8) When a joint has been opened, the transplantation of a pedicled flap is indicated.

(9) In certain situations where the blood supply is insufficient, or the area will have to stand considerable trauma, to nourish a skin graft proper a pedicled flap is indicated.

(10) Usually a pedicled flap should be chosen instead of a skin graft to cover a scar or unhealed area over the end of an amputated stump.

The ways of transplanting flaps will vary according to the extremity to which the flap is to be transplanted and the available tissue. Usually some method is chosen that allows one to transplant the flap in one operation. The flap, if the base is fairly wide and the surrounding blood supply is good, will establish a sufficient blood supply to be cut. In the meantime definite fixation is necessary. In the leg one usually has a certain disadvantage in that the flap has to be taken along with its base laterally which to a certain extent is against the blood supply. It may be wiser, in certain cases where the blood supply is a little questionable, to delay the transplantation of the flap as advised by Blair.

CHAPTER IX

General Considerations Pertinent to Successful Skin Grafting

BEFORE attempting to transplant a skin graft, cognizance must be taken of the general condition of the patient, the donor area which is to be used, the type and condition of the area on which a skin graft is to be placed, the nature of the tissue lost and the optimum time for skin grafting.

On the Objectives to be Attained

Observation leads one to believe that often resurfacing is attempted with a relatively hazy idea of the real objectives to be attained. The surgeon should have a clear-cut idea of the problem in hand and the shortcomings of the material that is available in producing within a minimum time a relatively good result.

Often the surgeon fails to appreciate adequately the amount of original epithelial destruction that has occurred when he observes or attempts to resurface a granulating wound. If the epithelial destruction has been complete the wound must close by the epithelium coming in from the periphery, by the tension of the resulting fibrous tissue drawing the bed together or by, most commonly, a varying amount of both methods.

The anatomy of the part very largely determines the method of closure. Thus, when the denuded area is located in such areas as over the side of the ribs or in the middle of the thigh, where the bony structures are strong and the soft tissues only moderately yielding, a greater part of the closure of a wound is made by the scarred epithelium, which, according to the natural rapidity of epithelial growth, grows in from the circumference. On the other hand, when the destruction of soft tissues is located in front or back of a joint which can be restricted in its normal radius of movement, the greater part of the wound closes by contractural fibrosis, depending somewhat on whether the limiting scar is within or without the angle of movement. Naturally, the larger the original surface destruction, the greater is the tendency to contracture and limitation of flexion or extension. In some instances an additional factor is added by the density and contractile pull of an innate tendency to the formation of a keloidal scar. Splints and correct position will do little to limit this tendency as scar acts like a rubber band. The contractural tendency is distinctly one of its properties, as a general rule. The only remedy, if one is to prevent

the formation of a healed contracture, is early and complete resurfacing of the wound with a sheet of skin as thick as one dares to use on a granulating surface.

The inexperienced surgeon very often misjudges the amount of original epithelial loss when he attempts to correct a surface scar or a healed cicatricial contracture. The extent of the destruction of epithelium is the amount the wound will gape after all contracting scar has been removed, or crosscut, and the region placed in overcorrection. To give permanent correction one must resurface the denuded area with a skin graft or skin flap of sufficient size to cover the denuded area.

General Condition of the Patient: Skin grafts stand a better chance to "take" if the patient is in good condition. Grafts "take" better in children than in the aged but the difference is not very marked. Individuals debilitated with chronic disease show a greater tendency to infection. An anemic individual is a poor subject for a skin graft. In most instances when one is called upon to graft a healed lesion, or on a recent aseptic denuded area, the patient is in good condition, or else the condition of the lesion and the patient is such that the operation becomes one of election as to time. As a rule, the question arises of whether or not the patient will withstand an operation, which seems imperative, after some such injury as a severe burn which denudes a large area. Often such a patient reaches a point where it is very difficult to decide whether or not to attempt a skin-grafting operation. In some instances it appears that the patient is losing ground, becoming generally more debilitated, more emaciated and more anemic, and still the patient's condition is such that the transference of enough skin to cover a sufficient area to save the patient's life in the long run may risk an immediate operative fatality. Such a decision can only be made by balancing all factors of the patient's condition in conjunction with the chances of supporting the patient with blood transfusions both before and after operation.

Dehydration and Hypoproteinemia

An individual ill from some denuding injury, such as caused by a severe burn, tends to lose blood plasma and become dehydrated. The dehydration is likely to become somewhat more pronounced when wet dressings are used. If the patient is somewhat dehydrated, estimation of the blood proteins may be masked and appear to be within normal limits. When the dehydration is corrected by the addition of a sufficient fluid intake to counteract the increased fluid loss, blood determinations of the protein content are likely to be low. The ill effects of dehydration are fairly well known. Suffice it to say that one should be on guard not

to allow dehydration to occur. The ill effects of hypoproteinemia were not so generally considered until recently. Particularly is a hypoproteinemia deleterious to healing if it is accompanied by edema. Thompson, Ravdin and Frank have reported an increased incidence of disruption of wounds in man and in experimental animals associated with low protein content in the blood. When a high protein diet is given, Harvey and Howes found that there is an increase in fibroblastic growth. To correct hypoproteinemia whole blood or blood plasma, amino acids and predigested food all may have their place.

Vitamin Deficiency

It is probable that an adequate supply of vitamins is important in the prophylaxis of infections, in the healing of wounds and in the "taking" of skin. In operations of election, such as skin grafting, it has been advised that patients be placed on a high-vitamin diet. Holman states: "In addition, during this period the important vitamins are prescribed in the concentrated form: haliver oil, two capsules three times a day for vitamins A and D; brewer's yeast powder, one heaping teaspoon in orange juice (water, milk or coffee) three times a day for the various factors in the vitamin B complex; and the juice of at least four oranges and two lemons daily for vitamin C."

Acid Diet

Hermannsdorfer has found that an acid diet hastens wound healing due to the inhibition of bacterial growth whereas an alkaline diet inhibits wound healing. Reimers and Winkler also have found that experimentally in dogs an acidosis produced by ammonium-chloride administration shortens the period of wound healing.

Age

De Noüy found a faster rate of wound healing in young animals, and Howes and Harvey found in young rats an earlier onset of fibroplasia and an earlier termination of the process than in older rats. Clinical experience has shown that a skin graft "takes" more rapidly in the young than in the old.

Proper Fluid and Electrolyte Requirements

The presence of dehydration should be guarded against. Besides the usual symptoms of thirst and dryness of the mouth, the temperature may be elevated. Signs of acidosis or alkalosis tend to occur, and the laboratory findings may include a high non-protein nitrogen content of the blood, concentrated urine and hemo-concentration. When persistent vomiting occurs, the blood chlorides may be depleted.

Collier and Maddock have suggested the following scheme for calculating the quantity of fluid that should be given to surgical patients:

(1) Water for urine (24 hours)—1,500 cc.

(2) Water for vaporization (24 hours)—2,000 cc.

(3) Approximate replacement of fluid lost in vomiting, blood, feces, drainage from biliary and intestinal fistulae and exudation from inflamed surfaces—variable, and an additional quantity if the patient is already dehydrated.

(4) Water to restore depleted body fluids (6 per cent of body weight, estimated at 60 kg.)—3,600 cc.

Physiologic sodium chloride solution plus 5 per cent glucose solution, as indicated, are the solutions of choice, as a rule.

The Donor Area

Often some attention should be given to the selection of the donor area. In the past this selection sometimes presented quite a problem because with the methods then in use it occasionally was not technically possible to remove sufficient skin from the trunk when the thighs and legs were not available, as in the case of a nearly complete burn of both extremities. Now, however, with the dermatome this difficulty is eliminated. For most routine lesions of the extremities of the body, skin taken from the abdomen, thighs or buttocks is used. When some such an area as the face is to be grafted, often the best result will be obtained if a donor area is selected which is covered with skin of nearly the same thickness, texture and color as that which normally is found in the recipient site. For example, the skin back of the ear or the skin of the upper eyelid is often selected for the repair of the lower eyelid. The skin of the inner side of the arm is quite thin and fine in texture, but it has a tendency to be rather white for the face. When hair is desirable, some such site as the pubic region or the scalp may be selected depending upon the structure to be imitated. A full-thickness scalp graft, for example, should be used to reconstruct an eyebrow. On the contrary, if hair is not a desirable feature, especially if a thick graft is being transferred, one should select a non-hairy donor area. Individuals, of course, vary somewhat as to the color, texture, thickness and hairiness of their skin and they may even vary individually regionally as to these factors.

Recipient Area

The condition and type of base on which a skin graft is to be placed are the most important factors. When the other factors for success are met, for example, proper pressure and fixation, each type of skin graft has

its optimum assurance of "taking" on aseptic bases such as a fresh accidental wound or a freshly denuded surface following a clean operation. And under such conditions the ideal type of skin graft is a thick skin graft. This type of skin graft will more nearly duplicate the surface and the tendency to contracture is less. A thick skin graft ordinarily is not selected to cover a granulating surface, even if the surface is as free from contamination as it is possible to get by antiseptic wet dressings, because of the risk of a failure to "take." A thin graft, or one of superficial intermediate thickness, should be selected to cover a clean granulating area. As a general rule, when the granulating area is unclean, all skin grafting operations should be deferred until the surface has been cleaned up. The argument that such and such a graft is advantageous on an unclean surface should not be a factor. The point is to get the surface clean, as any graft then will stand a better chance of "taking." The only exception to this is in certain granulating areas that cannot be rendered largely aseptic because of continual contamination. An example is the presence of a fecal fistula in the neighborhood of a granulating ulcer. For such conditions the implantation graft is the only graft indicated.

The type of base that is to be grafted has an influence upon the type of graft selected. It is essential for the "taking" of all skin grafts that absolute contact between the graft and the base occurs, and that no movement between the graft and the base is allowed. Therefore, a convex smooth base where the underlying structures are immobile is the ideal base. The forehead is an ideal place to get a good "take" while on the neck, especially over the thyroid cartilage, it may be nearly impossible to get a graft to "take" because of the swallowing movement of the laryngeal box. The amount of blood supply in the base is important. For example, after excision of an old scarred varicose ulcer of the leg, the base may have such a poor blood supply that a considerable degree of uncertainty may be present as to the ability of the graft to develop a blood supply. In one case with a leg ulcer, although the man was only middle-aged, the vessels were so arteriosclerotic that a "take" was not obtained. On a cancellous bone, such as exists after removal of the outer table of the skull, only about fifty per cent of a skin graft will "take," and as much of a thick graft will "take" as a thin graft.

Nature of the Tissue: The nature of the tissue lost brings up the question of skin graft versus skin flap—a question which has just been discussed. Providing that a skin graft is indicated, the relative importance of two factors must be weighed: (a) the cosmetic result and (b) the functional need. When the appearance is of prime importance, the donor area must be carefully selected as to color, texture and the presence of hair, and as thick a graft should be used as will allow assurance of a good "take." Obviously, when the function or mobility is the first con-

sideration, the choice of the donor area selected is not so important. Of more importance is the quantity of skin used and its thickness. Sufficient quantity must be applied to allow for the amount of contracture likely to occur in a particular region, and also likely to occur following a graft of the thickness used. For healed contractures of the extremities and body usually deep intermediate grafts are preferable. But to reline a cavity, such as an eye socket, a thin graft is preferable. When the graft will have to withstand trauma, as in the palm of the hand, it should be as thick as is consistent with an assurance of a good "take."

Optimum Time for Skin Grafting: When one considers the optimum time for skin grafting, it is necessary to take into consideration the cause of the loss. The optimum time to resurface fresh operative defects or to clean accidental destructions is, as a rule, immediately. However, it may be wise after completely excising a lesion, when one has considerable scarring of the base, to place a sterile dressing on the area for a few days. There may be two reasons for this. First, on account of the scar it may be almost impossible to get proper hemostasis, and, second, if the blood supply of the base is deficient some formation of granulations, provided they are kept clean, may enhance the certainty of the "take." An example of such a situation may follow the complete excision of an old large leg ulcer.

In the case of accidental wounds, the nature of the wound, the time it is seen and the extent of the bacterial invasion will all influence the optimum time. If the wound is seen early, although it is somewhat contaminated, and if it is carefully cleaned, irrigated and debrided if need be, the optimum time for placing the skin graft is often immediately. On the other hand, if the wound is infected, covering a denuded area with a skin graft will be a useless gesture. The optimum time to graft contaminated wounds, and wounds with considerable surface destruction such as an acute burn, is after the infection is completely controlled, and after all dead tissue has been separated and a good clean granulating base obtained. In the ordinary mildly contaminated wound this state of affairs is usually present within two or three weeks but following a burn, as a rule, a clean granulating base cannot be obtained much before the fifth week.

Preoperative and Postoperative Care When Grafting with Thin or Superficial Intermediate Skin Grafts

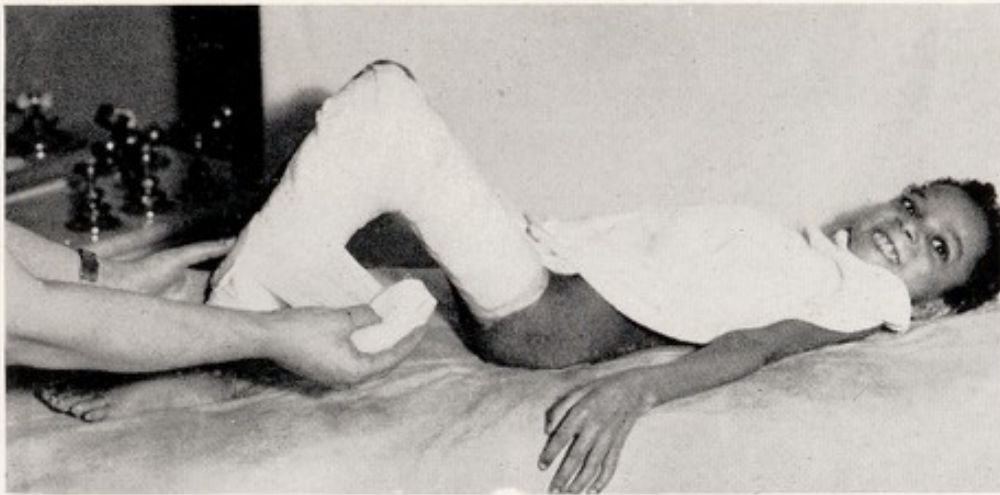In every day practice one encounters two types of patients in whom grafting with thin or superficial intermediate skin grafts is indicated: (A) Those with a granulating surface and (B) those with certain aseptic denuded surfaces.

A. On a Granulating Surface

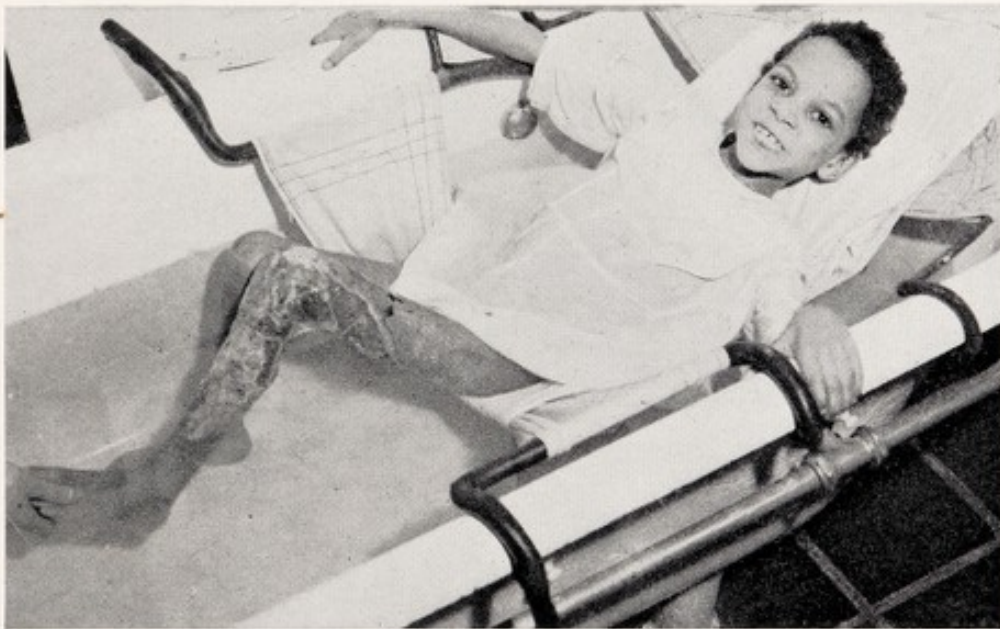When grafts are placed on a granulating surface, success depends to a large extent on the condition of the wound. It is most important that the granulations be clean, firm, red in color and not very exuberant. It is not necessary to have the bacterial count absolutely negative. When the wound is clean, the bacterial count of the secretion on the wound will not be high. One can judge by the appearance of the wound whether or not the chances are good for a "take."

Preparation of the Bed: In my experience the best method to prepare a granulating area for grafting is to apply continuous wet gauze dressings which are changed at least twice daily. We generally use a heavy roller gauze which is wrapped around the granulating area with sufficient cotton on the outside to hold moisture throughout the day. At intervals of about once every hour some antiseptic solution such as Dakin's, azochloramine or even hexylmethylamine, magnesium or saturated boric acid solution is poured upon the cotton and gauze dressing. When the wound is particularly sluggish, as for instance an old varicose ulcer, heat is applied in addition and if stasis is present the part is put in such a position as to eliminate this if possible. The cotton is not allowed to come in contact with the granulating area. The gauze should be rather fine so that no lint can be collected on the granulating surface. If the wound is such that a change of the dressing is particularly painful, if the morale of the patient is low as in children badly burned, if the wound is particularly dirty or if there is a good deal of slough attached, the patient is very often placed in a tub bath and submerged in a solution of hypotonic salt. After removal from the tub the patient is either placed on a clean sheet beneath an electric light canopy and with no gauze or only loose wet gauze laid on the wound, or else a roller gauze is applied according to the type of wound or the morale of the patient. Such a method of treatment removes all crusts, scabs and slough as soon as the line of demarcation is well formed. The preparation of the granulating surface is the most important element in the success with this type of skin grafting (Fig. 37).

There are many other solutions just as valuable as the ones I have mentioned but it just happens that I have not used them to any great extent. Boric acid solution sometimes is toxic when placed on too large a granulating area. Dakin's solution when properly prepared may be difficult to obtain. Some of the other solutions are rather expensive. I believe that the most important factor is the establishment of perfect drainage by a continuous moist pack. Bidaily changing of the dressings is also helpful. It removes bacteria, it aids in removing any loose tissue or slough which is about



A



B

FIG. 37. A. The method of applying a wet roller gauze roll to a wound when the time has arrived for separation of the dead tissues from the live soft tissues. Sufficient cotton pads are placed between the gauze to hold the moisture well. Externally a layer of rubber surrounds the gauze to prevent too rapid evaporation. Periodically the gauze is remoistened. The roll is changed morning and evening. B. If much pain is complained of when the roll is removed, if the condition of the patient permits he may be placed in a tub immersion for a few minutes and the gauze removed under water either by the patient himself or by the interne. The simplest solution to use is hypertonic saline solution. Any antiseptic solution, if nontoxic, will act the same.

the wound and which may be harboring bacteria, and to a certain extent it stimulates the growth of granulation tissue. These factors we believe, along with the condition of the host, are the important ones. The use

of this and that preparation which do not pay attention to these basic fundamentals ordinarily tends to discourage success.

Appearance of Bed before Skin Grafting: When grafting skin on a granulating surface the appearance of the granulating surface should be

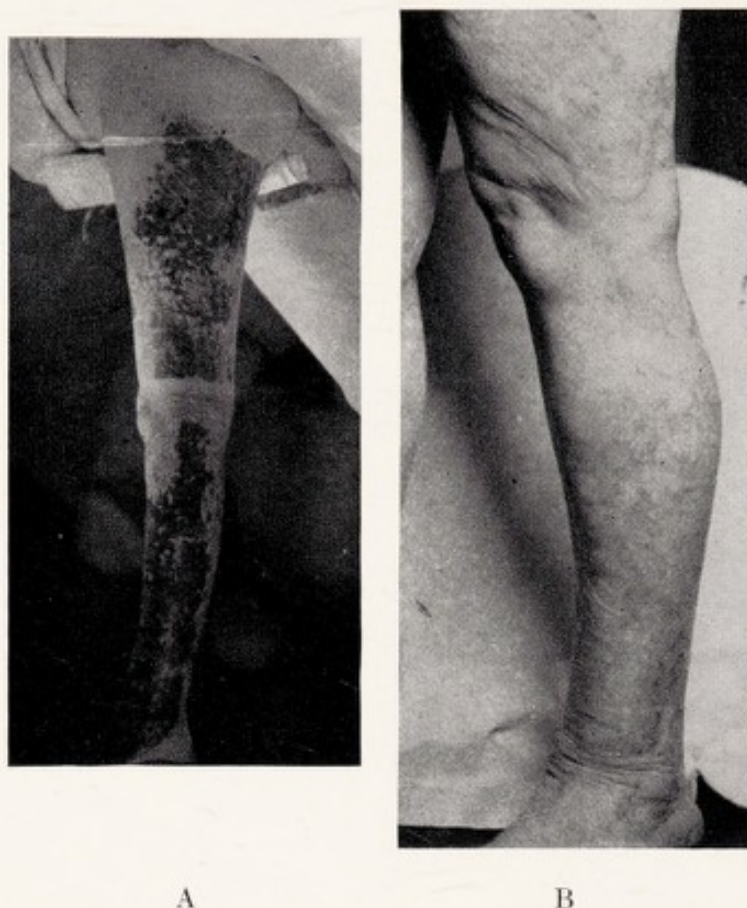


FIG. 38. In a lesion such as this, if at first the skin is tanned with a tanning solution, and, as soon as a line of demarcation between the dead and the live tissue has formed, wet dressings alternated with tub baths are started at the third week, by the middle or end of the fourth week all of the dead tissue will have separated, leaving a clean, granulating base. The indications then are resurfacing of the granulating area with thin skin. The patient should be covered with skin by the end of the sixth week if the burn has not been so severe that constitutional symptoms prevent early resurfacing. In most cases they will not. A. Large granulating wound ten days after beginning the wet dressings and occasional tub immersions. B. One year later. Extension and flexion were normal.

used as the index to the time of grafting. The proper appearance is present when the surface is free from evidence of greyish slough or any gross pus, when the granulating base is firm and not too exuberant or watery, and when the color of the granulations are a "cherry red" (Fig. 38 and 39). If the granulations are exuberant, a rather firm tight meshless bandage will aid in getting a firmer base by squeezing out some of the watery

fluid. Anemic individuals do not present granulation surfaces of the proper texture and color. When evidence of an anemia is present, a blood transfusion should be given. Bacterial counts on smear are not of particular value. Whenever I have attempted skin grafting without these criteria being fulfilled, at least a part and usually most of the graft failed to

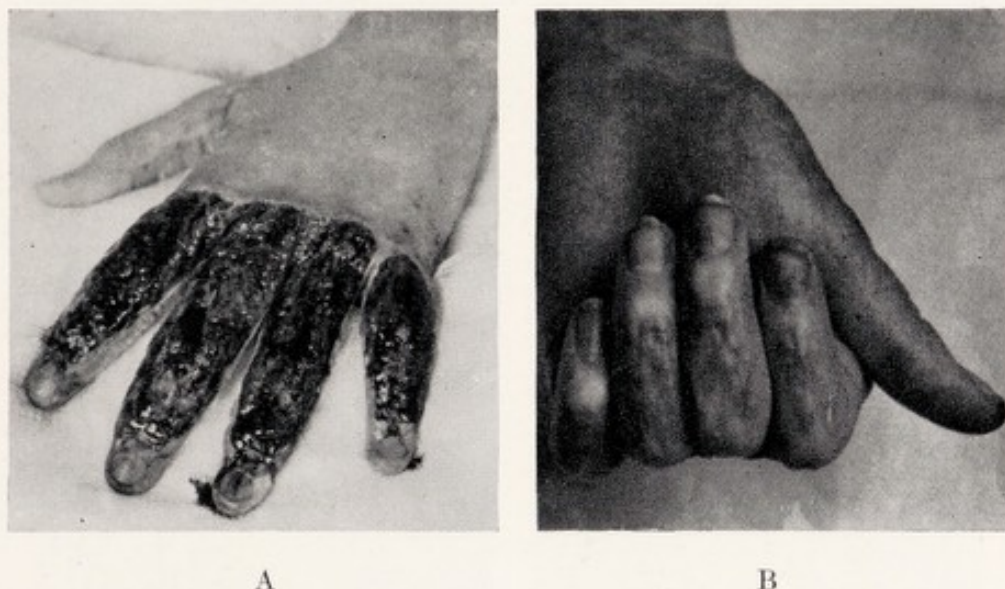

FIG. 39. A. Granulating wound three weeks after infliction of a burn from a clothes mangle. The tendons were not destroyed. A wet dressing was used for one week before the photograph was made. B. Photograph of the hand six months later. The patient obtained perfect flexion after the application of a thin graft to the granulating surface.

“take.” On the other hand, when they were present, in practically all of the cases, 90 percent at least and usually more, of the graft “took.”

Emphasis of Points Necessary to Success: Besides the points already alluded to I wish particularly to stress that cleanliness and repetition of the dressing twice daily are regarded to be of importance in shortening the period of time necessary to give a proper granulating bed. Besides the general condition of the patient, the most important aid to early epidermatization from the circumference of the wound is cleanliness. Reid in an article on wound healing has questioned this concept. He states that the edges of the wound where epithelium is regenerating should not be traumatized by dressing of a nature which sticks, or by repeating the dressing too often, but on the other hand he admits that periodically the wound should be cleaned up. I believe that in practical application cleanliness is seldom too great. Often, the factor that one wishes to promote especially is not so much wound healing as it is the preparation of a base that is to be covered by new skin in such a way that infection can not destroy the graft before it “takes.”

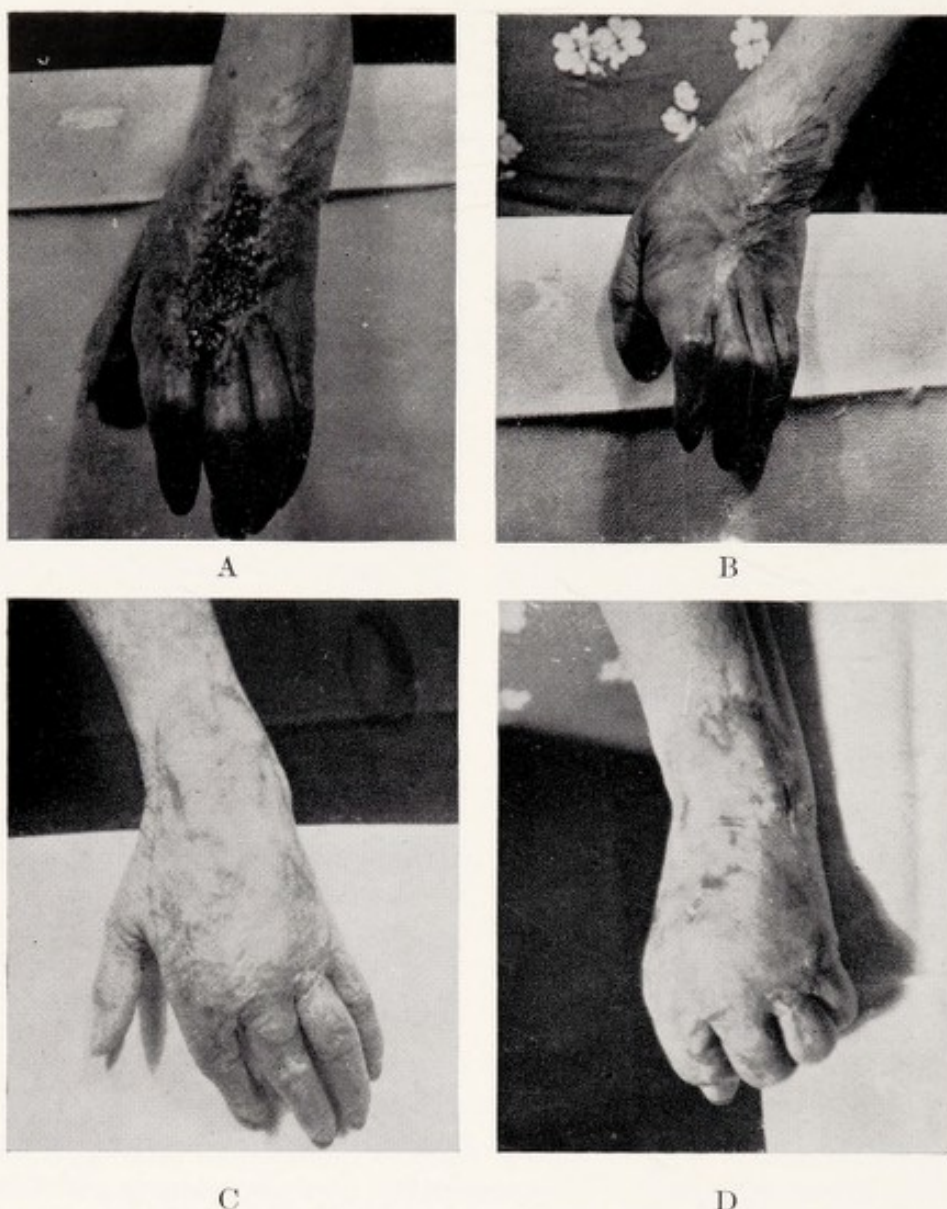


FIG. 40. A. Condition of the hand when first seen. B. Shows the condition at the time of operation. In the mean time another surgeon had thought that he could crosscut the scar and flex her fingers. What happened was that the scar sloughed and the position of her fingers was not improved and the whole situation was made much more difficult by a useless operation which was doomed to failure before it was started. However, after cleaning up the granulating areas the scar and the granulating areas were excised in toto. The tendons had not been destroyed but were bound up in scar. After flexing the fingers as much as possible a skin graft removed from the abdomen cut .020 of an inch thick was applied to the back of the hand. This in our opinion is much better than applying a flap. As much function can be obtained by a graft and the appearance is much better as a flap is always a little thick and clumsy. Extension and flexion were normal after a good "take" of the graft. C and D show final result one month after application of the graft. After a period of time there will be slight additional increase of function and the graft will loosen up and become more pliable.

In the consideration of the general condition of the patient, the factor of a relative secondary anemia will be found to be very important both as to the rapidity of epidermatization and as an influence in obtaining a proper granulation bed on which a graft would "take."

The usual cause of loss of the graft is infection developing beneath a part or all of the graft. This usually is due to desultory preparation of the granulating surface along with an error in judgment as to the time when the surface is in condition to receive a graft. In a few instances, improper fixation will be in the basic fault.

In patients grafted when the hemoglobin was below 65 per cent, I have estimated that the chance of a successful "take" with a thin graft on a granulating surface is decreased from one-third to one-half because of a greater tendency for the graft to be destroyed by infection.

Application of the Graft: After cutting, the graft is laid over as much of the surface to be covered as its size allows. It is then basted or whipped in place all around the edges to the normal skin with a running silk stitch. Practically normal tension is maintained on the graft at all times. Multiple stab wounds are then put through the graft with a pointed knife to allow the escape of blood and serum. Before a dressing is applied, any blood clot underlying the graft is expressed from beneath it with a roll of gauze.

Removal of Ulcerated Area Followed by Grafting of the Base: Sometimes a very successful method of applying grafts, especially on old ulcerated areas, is to totally excise the granulating area and all surrounding scar and get down to a hard firm fibrous tissue base which is relatively sterile. The graft is sewn on a base which has the advantage of having less scar in it, but which has sufficient blood supply to allow the graft to "take" readily (Fig. 40).

It must be remembered that layers of old firm hard scar beneath the graft will decrease its ultimate vitality and cause it to be more vulnerable to any injury that it may sustain. Deeply scarred areas have a lessened central blood supply and tend to stasis. Such tissue is very vulnerable to trauma. After trauma, if infection occurs, the destruction is likely to be considerable.

When the granulating base is relatively new, large thin grafts show a greater tendency to "take" well if the granulation tissue is not interfered with, but, as I have just mentioned, in many cases sufficient fibrosis had occurred to give a firm scar base. The chances of a "take" after slicing off the granulations and all or a part of the yellow scar base, will be

found to be good. Often some of the contracture is relieved and a better functional and cosmetic result is obtained.

In some patients not seen until after an interval of several months after the original injury, healed contractures will have formed but a part of the surface may have remained unhealed. In such patients it may often be possible to remove the granulating area by wide excision through healed tissue after which the contracture may be crosscut so that the contractural deformity can be corrected. The application of a rather thick calibrated deep intermediate graft, along with the placing of the involved member in an over-corrected position, will often correct the condition in one operation.

Postoperative Care: It has been stated that more has been written on the dressings and postoperative care of skin grafts than on any other phase of the subject. In most of these contributions, many of which are a bit lengthy, the factors that will be found most valuable in the promotion of a quick sure "take" either are not mentioned or are not recommended. These factors are: (1) absence of virulent infection, (2) proper fixation, (3) proper pressure and (4) adequate provision for drainage. Although some fixation and pressure can be obtained with almost any good ordinary well-applied dressing as a rule, the best methods according to my experience are not sufficiently stressed.

Good continuous drainage is necessary after the application of a skin graft to a granulating surface. It may be remembered that the wound can be rendered only partly clean. Any secretion drying at the edges of the graft may block drainage. An ointment dressing impedes drainage. The dressing most likely to encourage proper drainage is a continuously wet dressing.

Our usual routine has been as follows: After laying the graft upon the granulating surface, the same type of a thick roller gauze dressing is applied as has been previously described for the preparation of a clean granulating surface for skin grafting.

Often on concave surfaces, a large soft wet marine sponge is laid over the grafted area outside of the gauze. Sometimes a few Dakin's tubes are laid in the dressing. This sponge is bandaged down snugly to maintain a proper pressure. This dressing is not to be changed for four days. During this time the dressing is kept saturated with one of the antiseptic solutions previously mentioned under the preparation of the base. When the graft is located so that joint or muscular movement will probably cause it to slip, a splint of some type should be used so that fixation is definite. When snugly applied, sufficient pressure is given to hold the graft in contact with its base. On the fourth day the dressing is changed and re-

applied. On each successive day until the graft is healed some emollient ointment may be applied.

B. Thin Grafts Applied to Aseptic Denuded Surfaces

The factor of drainage is not so important when the denuded surface is an aseptic one, but the factor of pressure and fixation is equally as important as when grafting upon a granulating surface, and the factor of tension possibly assumes a greater importance. The method of application of a thin graft on an aseptic denuded surface is the same as on a granulating surface. But the prognosis for "take," when the graft has been properly applied, is considerably better—about 100 percent. This prognosis applies even in the mouth when the incision has been made through unclean tissue.

In the type of case that has healed and in which it is necessary to excise a heavy scar, following excision of which there is considerable oozing which cannot be controlled by sutures, it will not always be found possible to prevent a blood clot from forming beneath the graft if it is applied immediately. In such cases it may be better judgment, therefore, to apply a sterile dressing immediately after excision of the scar and to wait until the following or the second day after excision to apply the skin graft. Hemorrhage at this time has ceased, and sufficient time has not elapsed for the surface to become clinically infected.

Technic: The technic outlined in the following pages, with especial reference to the thick skin graft, is also particularly applicable in growing a thin skin graft on a fresh denuded surface.

For the reason just mentioned, namely, that early drainage is not as important a factor when applying a thin graft to an aseptic denuded surface as it is after grafting a granulating surface, the postoperative care may be considerably different. (See the comment on postoperative dressing for a thick skin graft on an aseptic denuded field under the next heading. The same principles are involved and the same method is applicable to a thin skin graft on an aseptic denuded surface.)

Grafting with the "Three-Quarter Thickness" or Full-Thickness Skin Grafts

A full-thickness skin graft is still the graft of choice for lesions in which the area to be grafted is small and the situation is such that the likelihood of a failure to "take" is negligible. In children this is especially true. As, for example, in the correction of "web" fingers, when a skin graft from behind the ear, from the scalp or from an eyelid is used, a full-thickness skin graft must necessarily be cut. The "three-quarter thick-

ness" skin graft, in particular, is applicable for coverage of the following types of surfaces: (1) an aseptic denuded surface caused by the operative removal of some lesion or some tissue; (2) the reconstruction of a cavity if the field is aseptic; (3) for coverage of the resultant denuded area after release of a cicatricial contracture.

Operative Factors Conducive to Success

To obtain the maximum success with the "three-quarter thickness" or full-thickness skin grafts, the following factors are significant: (1) A sterile field increases the chances of success. (2) A dry field with little or no oozing of blood is important. Consequently all the vessels should be tied with the finest suture material. When there is any question of lack of hemostasis, a hole should be made in the skin to prevent the accumulation of blood serum beneath the graft. (3) When the full-thickness skin graft is used, the skin should be cut through the fibrous tissue layer of the corium in such a manner as to separate all of the fat from the graft. (4) The graft should be sutured in place under moderate tension to open the endothelial spaces. (5) The graft must have absolute fixation. (6) Sufficient pressure must be applied to maintain definite contact with the underlying raw surface. A fairly adequate pressure dressing on a concave uneven underlying structure is provided by the damp marine sponge when it is compressed by a snug bandage as suggested by Blair. Later, when the sponge dries, it stiffens and gives a considerable fixation. Convex surfaces with a smooth base do not always need a pressure dressing when the graft is sutured in on a stretch. (7) Later, after the graft has grown to the underlying bed, any superficial infection should have a type of dressing which promotes adequate drainage and tends to inhibit bacterial multiplication. Gauze, saturated in one of the mild antiseptic solutions, is indicated to give drainage.

The Operation for Releasing a Cicatricial Contracture

In correcting the limitation of function which a cicatricial contracture may cause, not only should one crosscut the limiting cicatrix, but all of the hard scar in the base should also be removed if possible. The tissues should be placed in position of overcorrection. Excessive epithelized scar about the periphery of the denuded area should be removed so that the edges are loose and show no tension (Fig. 41).

In old contractures, especially in children, the nerves and the blood vessels may have become somewhat shortened. Care must be taken not to overstretch a shortened nerve. Although one can stretch a nerve it should be gradual. Twice this mistake was made in this series of patients.

Once the nerves to the forearm were overstretched when a limiting axillary scar and a limited scar at the elbow were corrected at the same time. Function largely returned over a period of six months. In another instance a limiting popliteal scar was crosscut and the leg was placed in extension rather forcibly resulting in a temporary paralysis which cleared up after a time.

The main artery to an extremity may be flattened by overstretching.

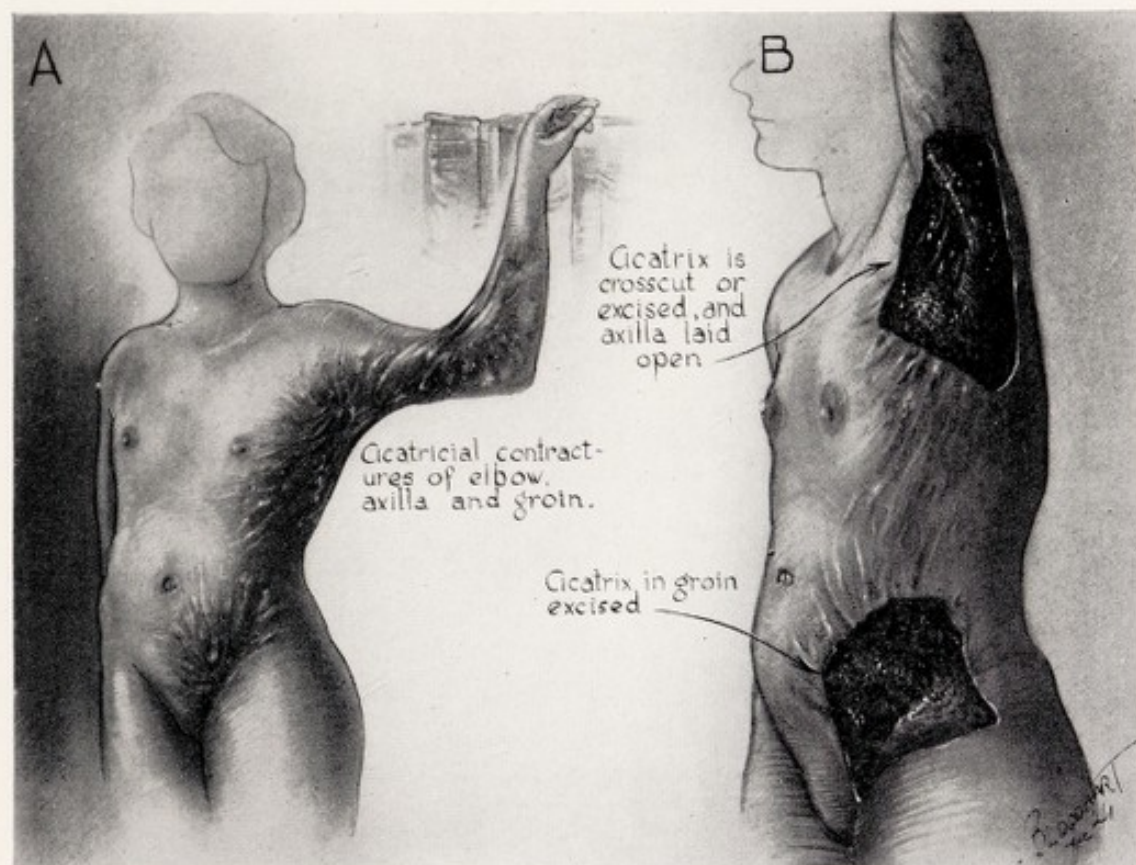


FIG. 41. A. A child with a large limiting cicatrix of the axilla. This child also had a limiting cicatrix of the elbow region and the groin. B. The cicatrix in the axilla has been crosscut and the limiting cicatricial bands removed. The cicatrix in the elbow region also has been cut. A skin graft 4 by 8 inches cut from the abdomen and another from over the thigh were removed with the dermatome to cover the denuded area which resulted after removal and crosscutting of the cicatrix.

Especially should one be aware of this danger when the patient is a growing child and the contracture is an old one. This is most likely to happen when a limiting scar is crosscut and the flexed finger is extended. To avoid interference with the circulation one should not cover the tip of the extremity with a dressing and if in doubt it may be well to nick the skin with a sharp knife. If red blood appears the extremity is not in danger. When correcting a lesion of the finger one should be careful not

to cut both lateral arteries. All effort should be made to get good hemostasis.

Finally, a thick skin graft is removed from some part of the body such as the abdomen or the thigh. The graft is then carefully stitched into the defect on a tension about that of normal skin. When the graft is not on the face it is pierced here and there with a sharp pointed knife.

The Dressing

A dressing is applied consisting of a thin layer of gauze impregnated with a mild antiseptic ointment of usually 50 per cent xeroform ointment in vaseline. Silver foil next to the skin graft is also of value. Several layers of wet gauze follow next (Fig. 42). For pressure a wet marine sponge is next applied. It is fixed by bandage or sutures so as to exert a rather firm even pressure on the graft. Finally, a wet cotton gauze is placed above the sponge and bandaged in place rather firmly. The sponge must not be bandaged so tightly that pressure necrosis is caused. This may happen if the background is a bony one. This original dressing is not removed until eight or ten days have passed. On removal of the dressing the stitches are taken out and a moist saline or boric gauze dressing is applied and changed at least daily.

On a convex surface, such as the forehead which also has a hard uneven surface, it is possible to use only plain wet gauze next to greased gauze. But on uneven surfaces and concave surfaces that lack a firm foundation, such as the front of the neck or the hand, large flat damp marine sponges are recommended as being the best dressing for purposes of fixation and immobilization. (See further discussion of means of gaining pressure and fixation which follows.)

Means of Gaining Pressure and Fixation

The two main factors to which particular attention must be paid, if one is to be successful in obtaining a "take" after the application of a thick skin graft, are uniform pressure and fixation of both the base and the graft. It is pertinent, therefore, to make some further comments on the types of dressings which promote this goal.

Pressure Sponge: Celsus (about 7 B.C.-54 A.D.) in his *De Medicina*, Book VII, states: "after the wound has been filled with lint, a sponge dipped in cold water should be applied over the lint and pressed on the part with the hand." Possibly this is the first mention of the surgical principle of compression for the checking of hemorrhage. The marine sponge by the older operators was often used for sponging blood, or to place in a cavity for purposes of stretching, but owing to the development

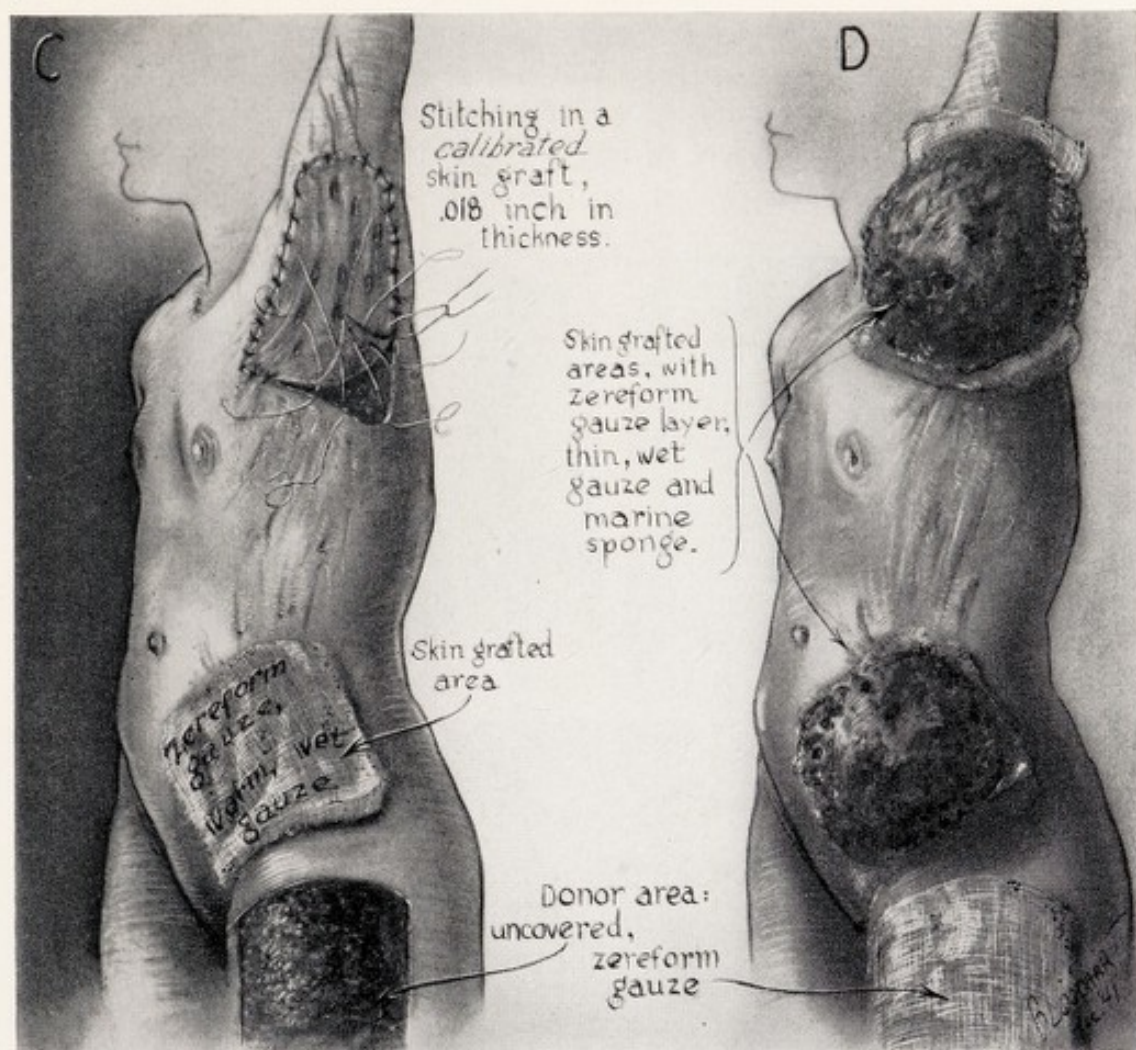
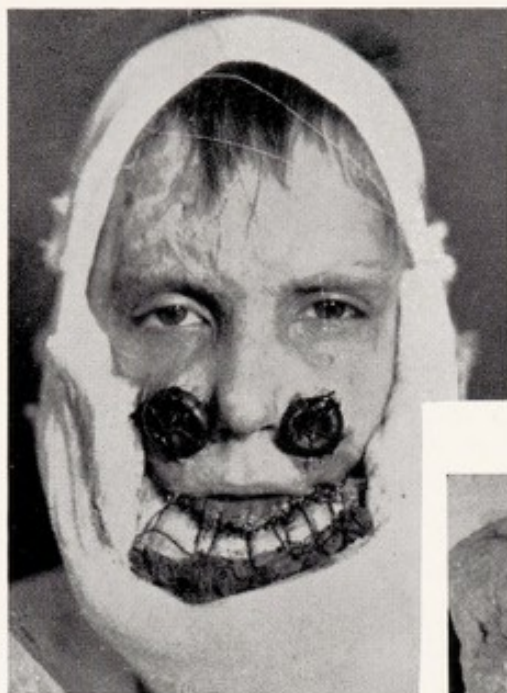

FIG. 42. C. In this case a large calibrated deep intermediate skin graft was taken from the left thigh and one was also taken from the abdomen. The area in the groin which is shown covered with gauze has been skin grafted. In the axillary region the graft is being stitched into the denuded defect. After the graft is in place, small holes for drainage are cut in it. D. The dressings are applied over the skin graft. They consist of one layer of xeroform gauze, and four layers of gauze saturated in normal saline solution, a marine sponge for purposes of pressure, a cotton gauze pad and a tight bandage. This dressing remains in place for 10 days or two weeks. The dressings for the donor area consist of one layer of xeroform gauze, four layers of plain wet gauze and a cotton pad. This is stripped down firmly with adhesive tape.

of other substitutes with certain necessities it had become obsolete until 1921 when Blair reintroduced it. He was striving to find a dressing suitable for pressure over full-thickness skin grafts. For the purpose of obtaining pressure of the type just mentioned, the ordinary "sheep's-wool" marine sponge of the Florida-Keys or Rock-Island variety is very good. Such a sponge when moist is extremely resilient and pliable and will give an almost uniform pressure over an uneven surface if bandaged in place

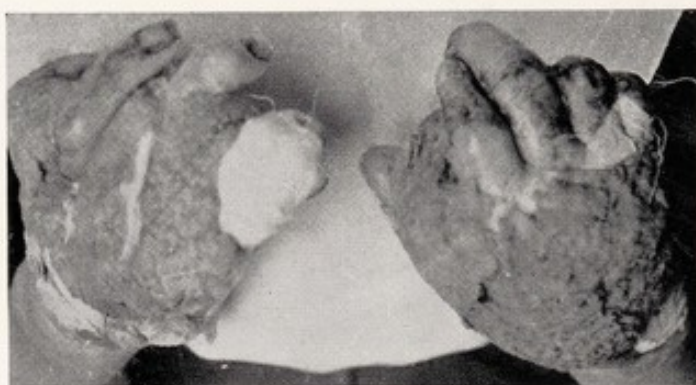under proper tension. Later it has the additional quality in that it becomes hard and forms a splint which, in addition, gives the advantage of immobilization as well as that of fitted pressure. If one desires, a resilient pressure may be continuously maintained for several days or even longer by keeping the sponge wet. Such a sponge may be held in



A



B



C

FIG. 43. A. Method of using a marine sponge and also modelling composition for a stent. A modelling composition stent was used to give pressure on the skin graft applied at the alar bases. Interrupted sutures are taken in the edge of the graft and in the skin edge and then drawn over the stents. B. Sponge stent after removal ten days later. Between the skin graft and the stent one layer of xeroform gauze was laid, then three layers of ordinary gauze. C. Marine sponges used for pressure and fixation of skin graft applied to hands. Ten days after application. The outer gauze has been removed.

place with a bandage or with interrupted stitches as an outlay stent, or be stuffed down into a gutter, tunnel or cavity in the soft tissues.

Lint for Pressure: Recently Brown of St. Louis has been using the lint which one finds about a garage for sponging up grease. The lint is cleaned and dry sterilized before use. He states that it is as good as the marine sponge for the purpose of giving uniform pressure and that it is considerably more economical. As yet I have had no experience with it.

Stents: The principle of the so-called outlay graft, in which the skin graft and the surrounding soft tissues are sutured and stretched over a form previously fitted to the gutter or cavity, is one of pressure primarily along with one of immobilization (Fig. 28, 29 and 43). Necessarily, the two principles act hand in hand. Two types of stents are of especial value—the marine sponge and the wax form modelling composition. Other materials such as celluloid and glass balls also have advantages in special situations.

The Use of the Marine Sponge and Lint as a Stent

The marine sponge used as a stent is a very effective way to get pressure and fixation (Fig. 43). Interrupted sutures are taken and left long all around the graft, catching it and the skin edges at intervals of about 1 cm. distance. A layer of xeroform gauze is laid on the graft. This is followed by three or four layers of wet gauze. A wet marine sponge of the proper size is selected, laid on the gauze, and compressed as each opposite suture is tied over the sponge.

Brown has used his lint as a stent and states that it is not so heavy as a wax stent and is quite as effective.

The Use of Modelling Composition Form as a Stent

(See previous discussion concerning the relining of cavities with skin grafts.)

Within the mouth, about the eyelids and on the lips it is not always practicable to obtain pressure by a marine sponge dressing. In these situations the grafts often are draped about a wax form, raw surfaces out. Lateral tension of the graft is obtained by the suturing of the graft over the wax under tension. In turn, the tissues to be grafted are sutured under tension around the graft covered form which furnishes the desired pressure. Such grafts practically always heal if applied under proper conditions. Ordinarily these wax forms are left in place for five or six days but there are occasions when they have been removed within two days and a "take" obtained. Usually, when sufficient skin has been applied to take into consideration subsequent contraction, after removal of the form the grafts are treated by the simple application of a thick layer of vaseline to prevent the formation of crusts to the newly healed border—another form of drainage.

Considerable care should be exercised in the removal of wax forms. With a sharp knife a series of cuts should be made carefully through all stitches and the excess graft overlying the outer surface of the forms. This process is continued until the form itself can be plainly seen. Then separation to

each side is carefully accomplished. The dead edges of the graft can then be trimmed and the cut sutures removed.

Other Methods of Gaining Pressure

Other substances which give pressure have been tried, such as rubber sponges, inflated toy balloons, lamb's wool, etc. Coelst recently (1936) has described a method of using a celluloid form as a stent. He states that he can follow the growth of the graft by this method as he does it under direct vision. Oval glass forms make very effective stents when an obliterated orbital cavity is to be lined. A large condom filled with paraffin makes an excellent stent when rebuilding a congenital absence of the vagina.

Pressure bags for the purpose of obtaining uniform pressure as one does with a stent of wax in a cavity were described by Ferris Smith in 1926. More recently Taylor (1936) has commented upon their use. An objection to them is the difficulty in getting a perfect fit.

Application of the Dressing

Many primary dressings besides the ones I have described have been from time to time recommended for a dressing after skin grafting. Davis

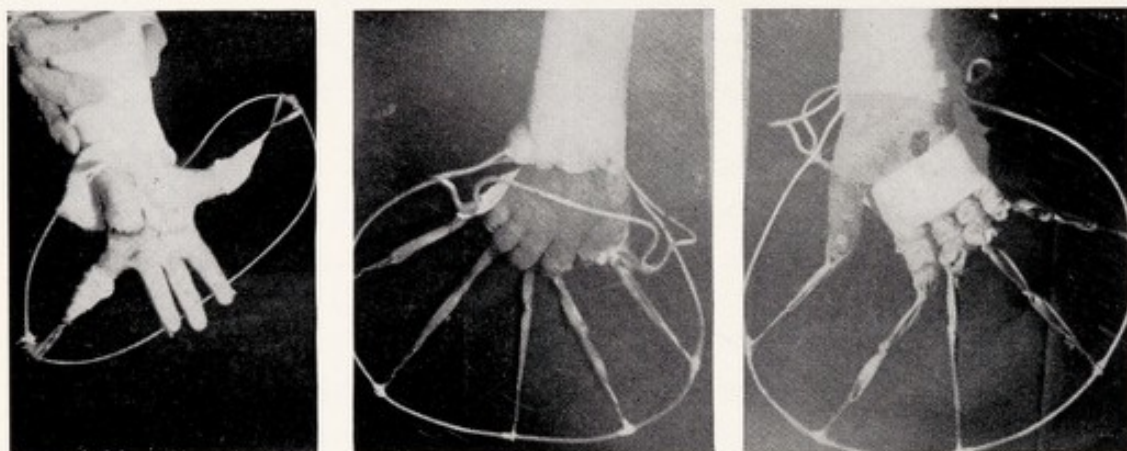


FIG. 44. Photographs of a banjo splint with elastic traction.

in his book described several, and more recently Collier (1925) has spoken of paraffin which was used during the war as a primary dressing. The dressings described come nearer fulfilling the objectives required than do the others. Conway has recently discussed some of the technical details in skin grafting from his viewpoint.

Splints, Casts and Traction: It is almost routine with us to use some type of splint for fixation after the suture of a wound on the extremity or after a skin grafting operation. Usually a simple board splint, well

padded, is sufficient, and, as a rule, adhesive strips are used to hold the respective members in position. When no space is left, as for instance when grafting near the tip of the finger, the digit may be transfixed to the board with a small nail or sometimes may be transfixed with a small wire stirrup to which a rubber traction is attached and which extends and

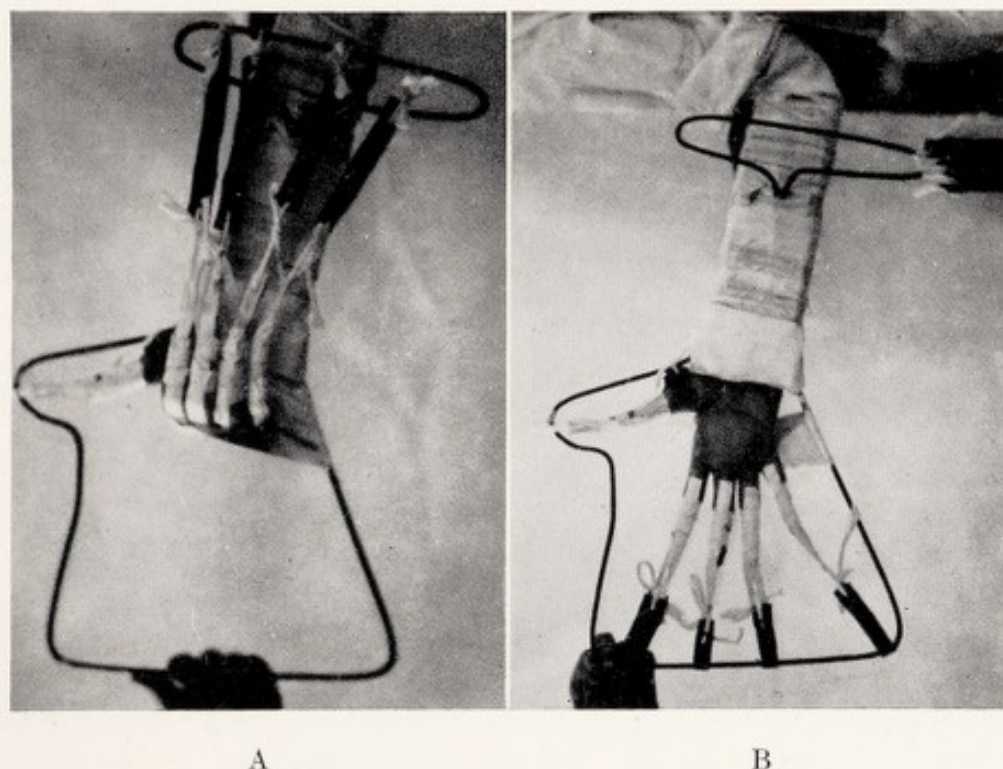


FIG. 45. A. and B. A banjo splint with elastic traction. This splint was arranged so that the fingers could be alternately flexed and extended. This splint is made of wood and wire but the wire may be very easily and inexpensively embedded in plaster.

fixes the finger to a banjo-like hoop for traction. Often, when the fingers are stiff, a double-action splint is used. For two hours the fingers will be extended by traction and for the next two hours flexed. Ace adherent is of value to attach traction to an extremity when the skin is not damaged. A cast is often applied to obtain hyperextension of some member such as the arm or after forcible change of position or an extremity when it is deemed that the new position is likely not to be maintained unless fixation is definite (Fig. 44 and 45).

Various traction mechanisms are often constructed to meet individual demands. When judiciously used, ingenious splints constructed so as to gain elastic traction in many instances are undoubtedly superior to other mechanisms. These traction mechanisms follow no routine. The operator

has to know what he is trying to do and must construct his splint or have it constructed according to the indications.

Dressing of the Donor Area: The manner in which the donor area is dressed after the removal of either a superficial or deep skin graft is of considerable importance. One layer of xeroform gauze is placed next to the denuded area. Directly on top of this is placed a gauze pad. Pieces of dry gauze are allowed to barely overlap the edges of the area. The gauze pad is then strapped very securely in place with adhesive tape, so that the dressing can not move or become displaced. On top of this is placed a bandage. The outer dressing for purposes of cleanliness is changed within a day or two. This inner gauze dressing is not removed before eight to ten days. By this time the epithelium will have largely regenerated beneath the gauze. If one attempts to remove these dressings after two or three days it will be found that the patient is caused a good deal of pain. Daily dressing of such a denuded area is also very uncomfortable. The dressing should be firmly fixed for if the dressing is movable the patient will complain of pain. Of course, if the wound becomes infected it is better to soak the dressing off in a bath tub. A wet dressing is then placed over the area and it is treated as any other infected wound.

Tannic Acid to the Donor Area

A solution of 5 percent tannic acid may be sprayed on the donor area. It makes an effective dressing if the patient is going to be in bed until the area heals. Otherwise the previous dressing is preferable.

What Happens to the Donor Area

Although the donor area will heal from the base when a skin graft is cut in the last quarter thickness of the skin there is a tendency in certain individuals for some scarring. The thinner the graft is cut, the less scar in the donor area. When the graft is cut thin, as a rule, the area ultimately will appear a little whiter than the surrounding skin, but it is as pliable and as thin as normal skin. As a matter of fact, in some individuals when the graft is cut deep the heaviness of the scar may suggest a keloid formation. To prevent this occurrence a practice has been made of watching the donor area carefully. If the scar shows a tendency to become thick, irradiation is applied as a prophylactic measure in the same manner that one would use it to prevent a keloid.

Dressing After Removal of the First Dressing

On removal of the first dressing, after the application of the "three-quarter" thickness skin graft, the "take" will ordinarily be found to be

complete without any blisters or blebs. About an additional week of dressing without pressure is usually advisable. Usually we place one layer of ointment gauze next to the graft followed by several layers of moist gauze. This in turn is covered with a cotton pad. This dressing is sometimes kept moist until the graft is entirely healed. However, if the "take" is perfect it may be allowed to dry. The dressing is changed at least every other day.

When the release of a contracture has been the reason for the grafting operation, an overcorrected position is, if possible, maintained for several weeks, and, if such seems advisable, sometimes longer.

When one removes the first dressing, after applying a full-thickness skin graft, in about 50 percent of the cases some superficial blisters will be seen. These are treated best in about the same manner in which one treats a simple blister due to a burn, i.e., let it rupture when it gets ready provided that the contained fluid is clear. If the fluid in the bleb becomes purulent it should be opened immediately. As long as blebs are present it is, as a rule, wise to maintain pressure with the marine sponge.

The Return of Sensation

The time of the return of sensation has a clinical bearing which may be quite important when a graft is applied to certain situations, as, for example, the fingers or the palm of the hand. It also has a bearing upon the amount and type of trauma that a skin graft can withstand.

Kredel and Evans, Davis and Kitlowski and Davis and McCarroll have studied the matter of the return of sensation. The first three papers reached the conclusion that dissociation of recovery to pain and touch is demonstrated in all types of grafts and that it is more prominent as the thickness increases. They concluded that regeneration of the ability to distinguish differences in temperature lies between pain and touch.

Furthermore, the return of sensation after transplantation of skin is not always complete even after many years but often some return can be noted as early as five weeks. There is considerable difference and variation in the rate and the extent of recovery. The thickness of the graft influences the rate as does also the amount of scar tissue and the state of the adjacent nerves. The return of sensation begins at the proximal and lateral borders and spreads progressively over the graft.

Just recently, however, McCarroll, who made a very careful study of the skin grafting done by Brown at the Shriners' Hospital (St. Louis) in regard to return of sensation, reached conclusions contrary to those just mentioned. He states that, contrary to previous reports, he found that sensation returned over all parts of the graft simultaneously. He also

found that sensation returned in the thinner grafts earlier than in the thicker. In some split grafts the return of the ability to distinguish painful stimulus and to recognize light touch began to appear as early as twenty-two days after placement and within sixty days or less the return was complete. Sensation in the full-thickness graft returned somewhat more slowly.

From my observations I believe that McCarroll is correct. I believe that the reason the previous investigators drew erroneous conclusions was that they had studied grafts in which the sensory nerve to the region involved had been cut, such as in a graft to the forehead similar to the manner in which one cuts the supraorbital nerve when a flap is raised. If one studies such a graft after such a procedure it will naturally be found that the nerve supply will return in a proximal manner, because there is no way by which the nerve supply can return from the granulating bed as the sensory nerve supply of the area has been cut at the original operative procedure.

Regeneration of the sympathetic control of the sudoriferous glands occurs late. According to Kredel and Evans, from one to one and a half years pass before sweating is noted. Kredel and Phemister (1939) found little return of sympathetic function in free skin grafts, but in pedicled flaps sweating function returned in eleven months to several years.

McCarroll did not attempt to reach a conclusion on the return of sensation to distinguish changes of temperature. He concludes that present methods of testing the skin itself were liable to be registered by the subepithelial nerves and not by nerves actually in the skin graft.

CHAPTER X

Skin Grafting for Specific Lesions

PREVIOUSLY the matter of skin grafting has been discussed only in a general way. It is pertinent to the subject to discuss the correction of certain specific lesions as it is necessary to vary the type of graft used and the method of application somewhat in accordance with the lesion to be corrected.

A. Skin Grafting in Severe Burns

My experience to date (February 1, 1941) with skin grafts used for the purpose of alleviating the damage caused by a severe burn is as follows: 209 skin grafting operations have been made on 177 individuals in which grafts of thin or superficial intermediate thickness were used. Ninety-five of these were applied to a granulating surface and 114 to an aseptic denuded surface. Two hundred and thirty-eight operations on 195 individuals were performed in which thick skin grafts were used. The thick skin grafts were all applied to an aseptic denuded surface.*

The type of individuals following a severe burn, which are encountered by the reconstructive surgeon, fall largely into two groups. First, the unhealed lesion which will present or does present a large granulating surface. The destruction may be surface deep or deeper, in which case tendons, bones and joints may be involved. The reconstructive procedure in this group of cases varies according to whether it seems wiser to temporarily alleviate the damage done or whether it seems better to attempt a permanent reconstruction. In the second group of cases, either the base following the preliminary resurfacing has contracted sufficiently to allow a residual contractural deformity, or else the wound has been allowed to heal intentionally by secondary intention with the idea of relieving the contractural deformity at a later date when one has the advantage of an aseptic field which makes it possible to use a thicker skin graft, as such a graft will contract less and will give a better cosmetic result and better protection.

* In Chapter VI on Calibrated Intermediate Skin Grafts and "Three-Quarter Thickness" Skin Grafts, we have gone into the results of skin grafting. Many of these cases are due to granulating burns or to contractures originally caused by a burn. The results of the cases are shown in the table form of all of our cases from January 1, 1938 to February 1, 1941. (See Tables II and III—pages 44-55.)

The Unhealed Lesion: As a general rule, the outstanding demand in the unhealed lesion is to clean up the wound as quickly and as thoroughly as possible so that the granulating area can be resurfaced as early as possible. Although a thin skin graft is not the ideal material, the surgeon has no choice, as the danger of not obtaining a satisfactory "take"

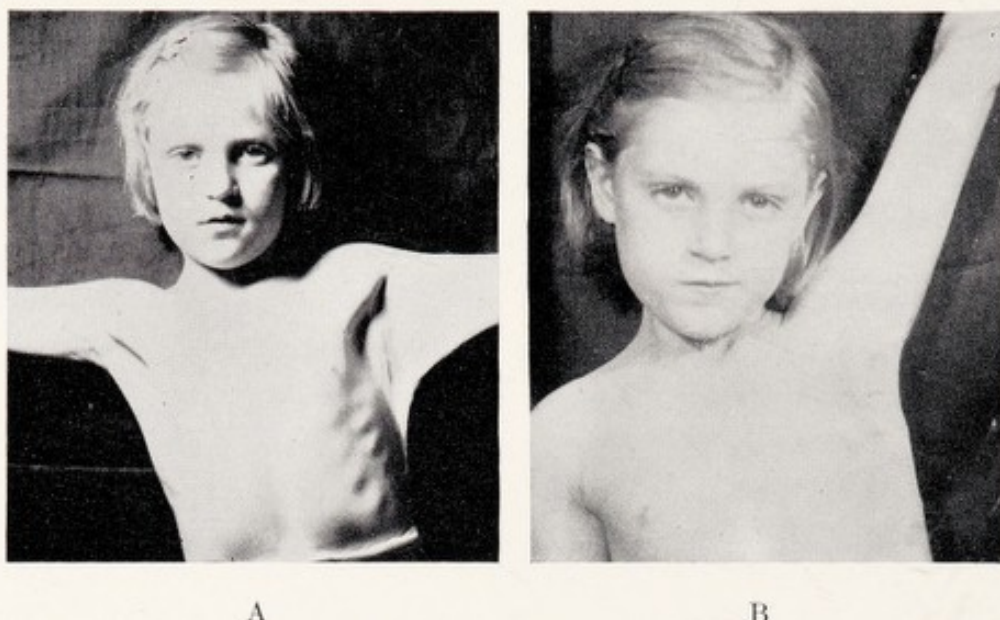


FIG. 46. A. Example of an axillary contracture in which the scar was cross-cut and a "three-quarter" skin graft was applied. B. Final result one year later.

with a thicker skin graft is too great. A large amount of the tendency to contracture, however, may be prevented by the early resurfacing, and the period of disability with its economic potentialities can be very materially lessened (Figs. 38 and 39). The face may be an exception to this general rule. On the face the poor cosmetic appearance will prevent, as a rule, the permanent use of a thin graft even if the contracture were relieved.

When the granulating base is relatively new, a large thin graft will show a greater tendency to "take" well if the granulation tissue is not interfered with, but when sufficient fibrosis has occurred to give a firm scar base, the chances of a complete "take" with a skin graft of a thickness about one half the thickness of the skin, after the granulation area has been rather widely excised, are not decreased. And often some of the contracture is relieved and better functional results thereby obtained because of the scar excised and the greater thickness of the skin graft which has been applied.

The Healed Lesion: Formerly when a full-thickness skin graft was used to correct a healed defect, one unfortunately had to consider the possi-

bility of a partial or even of a complete failure to obtain a good "take" in about 20 percent of the operative attempts—the variation depending principally upon the anatomy of the region.

At the present time a "three-quarter thickness" skin graft is considered the preferable graft. When the "three-quarter thickness" skin graft is used one largely eliminates the chances of failure to get a "take." The amount of contracture is minimal and the cosmetic result is good.

Types of Grafts Preferable for Various Locations and "Take": When one wishes to correct a contracture about such a region as the axilla, the popliteal space or the elbow, full movement of the extremity is the first

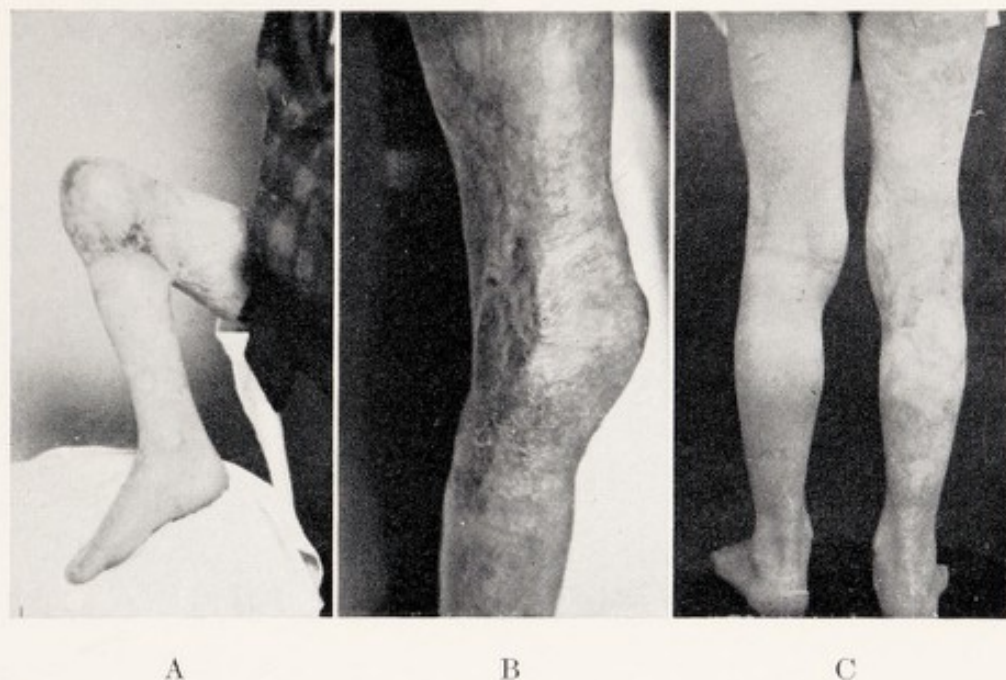


FIG. 47. A. Example of a cicatricial contracture of the popliteal region in a child which had remained uncorrected for two years. B. Result one month after the application of a thick skin graft from the mid thigh region to the mid calf region. C. Result one year after operation.

consideration. In the axilla and on the neck it may be found that a good "take" with a skin graft may be somewhat more difficult to obtain because of the likelihood of not obtaining uniform pressure (Fig. 46). One does not encounter this difficulty about the elbow or the popliteal space (Fig. 47). To correct a neck or axilla after making use of any material available for a switch pedicled flap, the application of a graft of "three-quarter thickness" as a rule is the method of choice. The same applies to perineal contractures. Also about the elbow and about the popliteal space, the groin or the back of the hand, the thicker type of graft is preferable. For cicatricial contractures of the palm of the hand and the flexor surfaces of

the fingers, the thick skin ("three-quarter" or deep intermediate) graft offers the best functional result (Fig. 48, 49, 50, 51 and 52). If one uses a thin graft in these areas it will be found that the final contracture is considerable, that the appearance is not very good, and that in the case

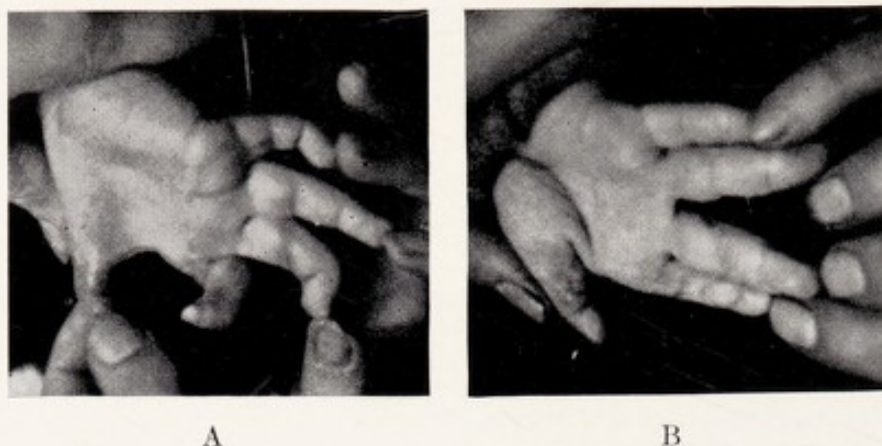

FIG. 48. A. Flexion contracture of the thumb and first and second fingers. The scar was excised and the finger extended. A thick skin graft was placed on the ventral surface. B. Final result.

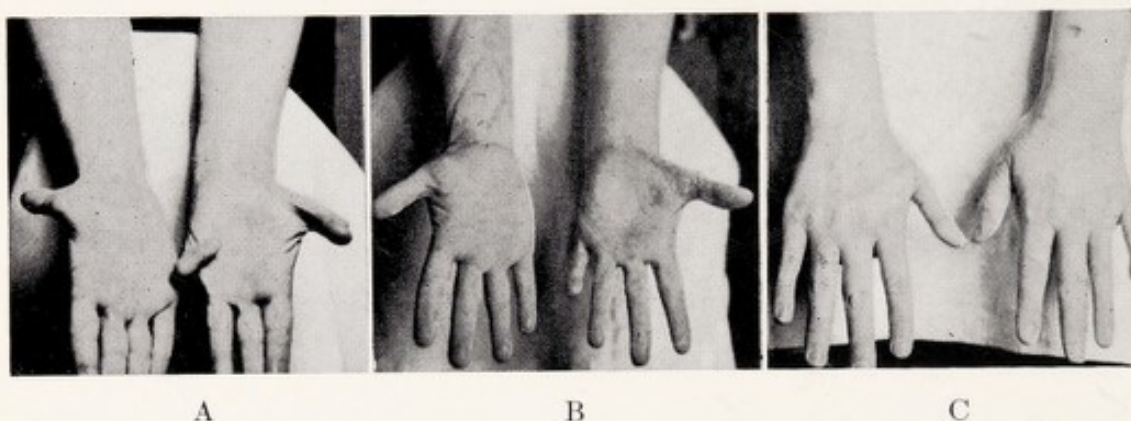
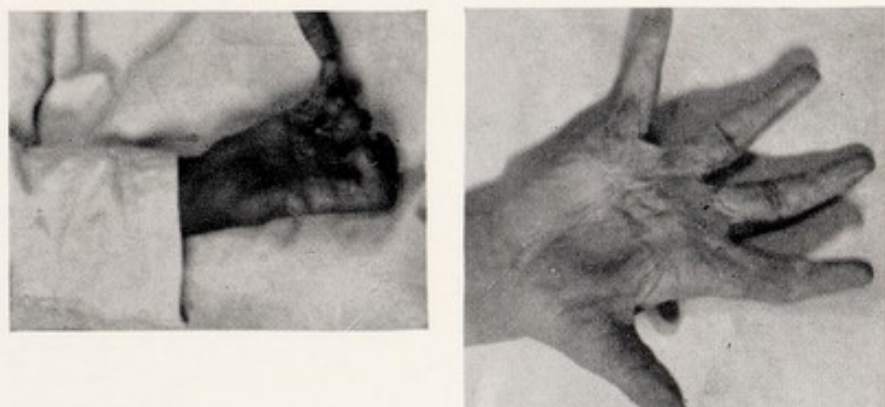


FIG. 49. A. Cicatricial abduction contracture of thumb on right hand and flexion contracture of little finger and thumb on left hand. The right thumb was corrected by excision of the scar, overcorrection in a position of flexion and application of thick skin graft. The little finger was corrected by excision of the scar, overcorrection in a position of flexion and application of a skin graft. The left thumb was corrected by the application of thick skin graft after excision of the scar followed by hyper abduction. B. Ventral surface of hand one year later. C. Dorsal surface.

of the palm of the hand and the ventral surface of the fingers the protection may not be adequate.

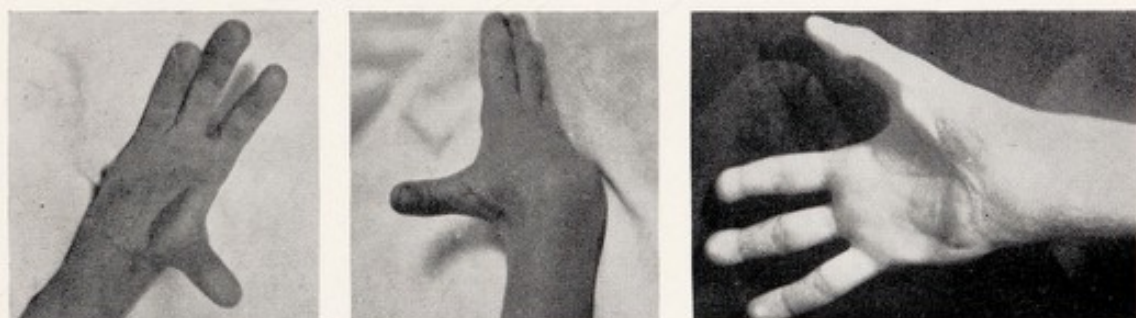On the anterior portion of the neck, a thin skin graft usually contracts from 50 to 70 percent—too greatly to correct the contracture, and the appearance usually is not satisfactory. The swallowing movement is likely to cause some loss of a skin graft over the thyroid cartilage no matter what type of dressing is used with the idea of preventing it. An attempt



A

B

FIG. 50. A. Cicatricial contracture of all fingers, the thumb and the palm of the hand. B. Result after excision of the scar and application of thick skin grafts and extension of the fingers and abduction of thumb one year later.

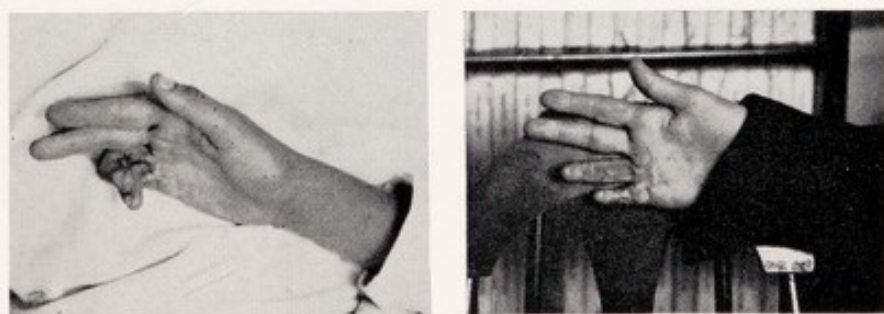


A

B

C

FIG. 51. A. Photograph of a contracture of the palm of the hand, palmar view. B. Dorsal view of the hand. The little finger was removed at some previous operation. The contracture was cross-cut, and a full thickness skin graft was applied. C. Photograph of the preceding hand eight months later.



A

B

FIG. 52. A Cicatricial contracture of the 4th and 5th fingers. B. Patient three weeks after crosscutting the scar and the application of a thick skin graft to the ventral surface of the fingers.

should be made not to leave a raw area over this region if one can prevent it.

On the sides of the cheek and over the mandible (Fig. 53 and 54) the deep intermediate or "three-quarter thickness" skin graft should be given preference because this graft more nearly imitates the normal skin in appearance. Some of our most brilliant results have been obtained with large "three-quarter thickness" skin grafts to the face. Probably a full-thickness skin graft taken from behind the ear or from the opposite eyelid will most nearly imitate the normal skin when applied over the orbicularis palpebrae muscle for an ectropion of the eye. For ectropion of the lips

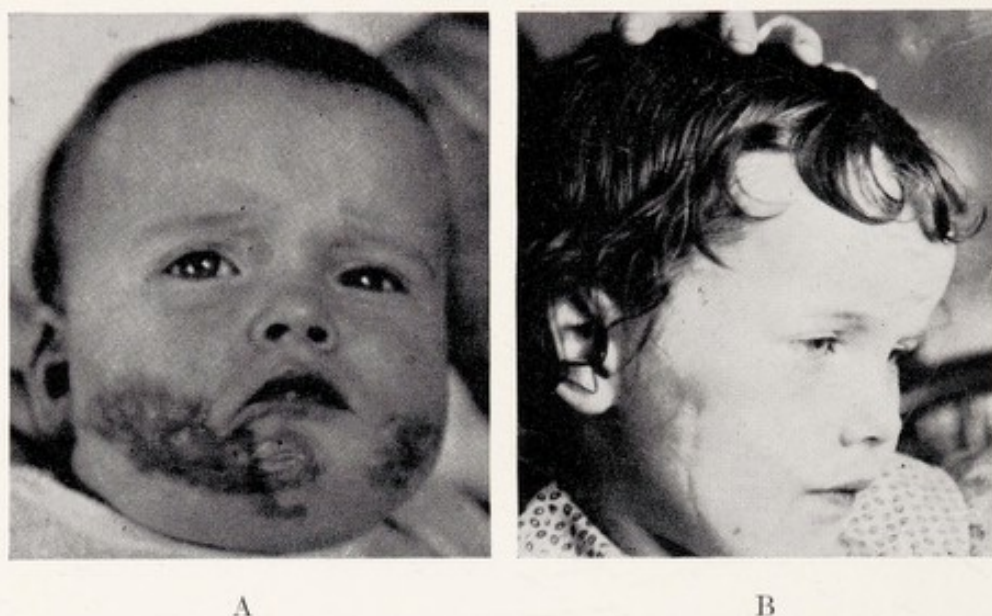
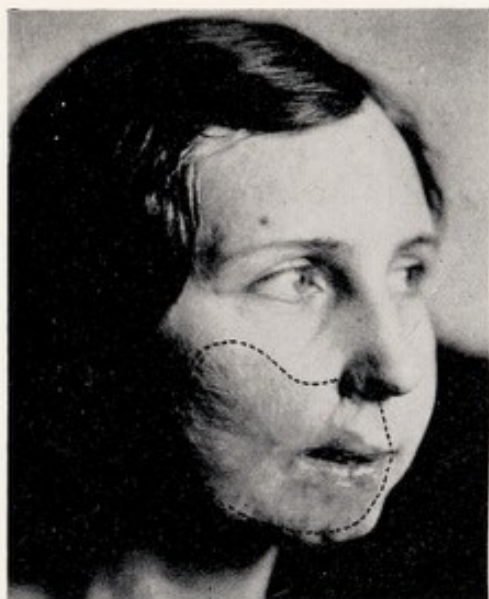

FIG. 53. A. Keloidal scar of both sides of the cheeks due to a burn. This was corrected by excision of the entire scar and the application of a thick skin graft. B. Appearance of patient three years later. The color and texture of the full thickness skin graft very nearly approach that of normal.

a skin graft of "three-quarter thickness" is the graft of choice from the standpoint of appearance and function.

When a "three-quarter thickness" deep intermediate skin graft is used on the neck and chin and about the mouth and over the cheek, in some of the cases a secondary operation is necessary after a period of several months for the purpose of excising the rather heavy scar which tends to form at the juncture of the skin graft with the surrounding normal skin. Moreover, even when the "take" of the "three-quarter thickness" or deep intermediate skin graft is perfect, the possibility has to be considered of having the graft too shiny or in brunettes of presenting a discoloration from pigmentation. Although there is a tendency for the thick

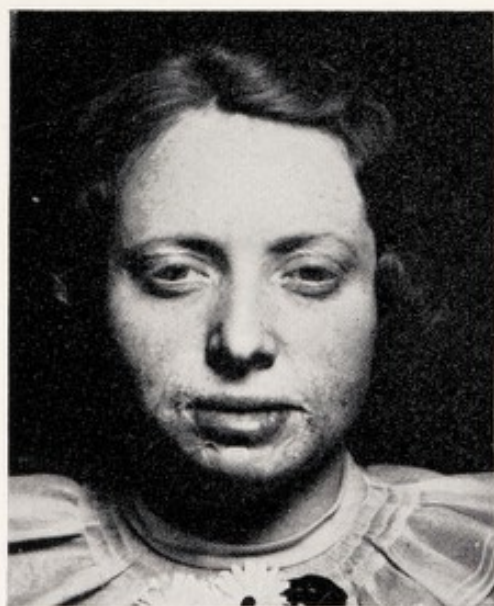

A



B

FIG. 54. A. Scar of two-thirds of the side of the face with ectropion of the upper and lower lip. A thick skin graft was applied to the side of the face. The dotted outline shows extent of the scar. B. Final result two years later after excision of the scar surrounding the skin grafts.



A



B

FIG. 55. Severe burn of chin which pulled lower lip into a position of ectropion. Considerable scarring of upper lip and sides of cheek does not show very clearly in the photograph. B. Scars were completely excised and a full thickness skin graft was applied to the upper lip, the sides of each cheek and beneath the lower lip. A graft 6 by 2 inches was applied beneath the chin. This was necessary for complete relaxation. The face has assumed normal appearance and the lips normal position.

skin graft to have a slightly shiny appearance, the grafts that "take" will, without superficial exfoliation, eventually show almost the normal texture of the skin of the region from which the graft was removed. The grafts in which some superficial exfoliation occurs have more of a tendency to pigmentary changes. In pronounced brunettes pigmentation sometimes occurs after a perfect "take."

On the sides of the neck, over the sternocleidomastoid muscle and the

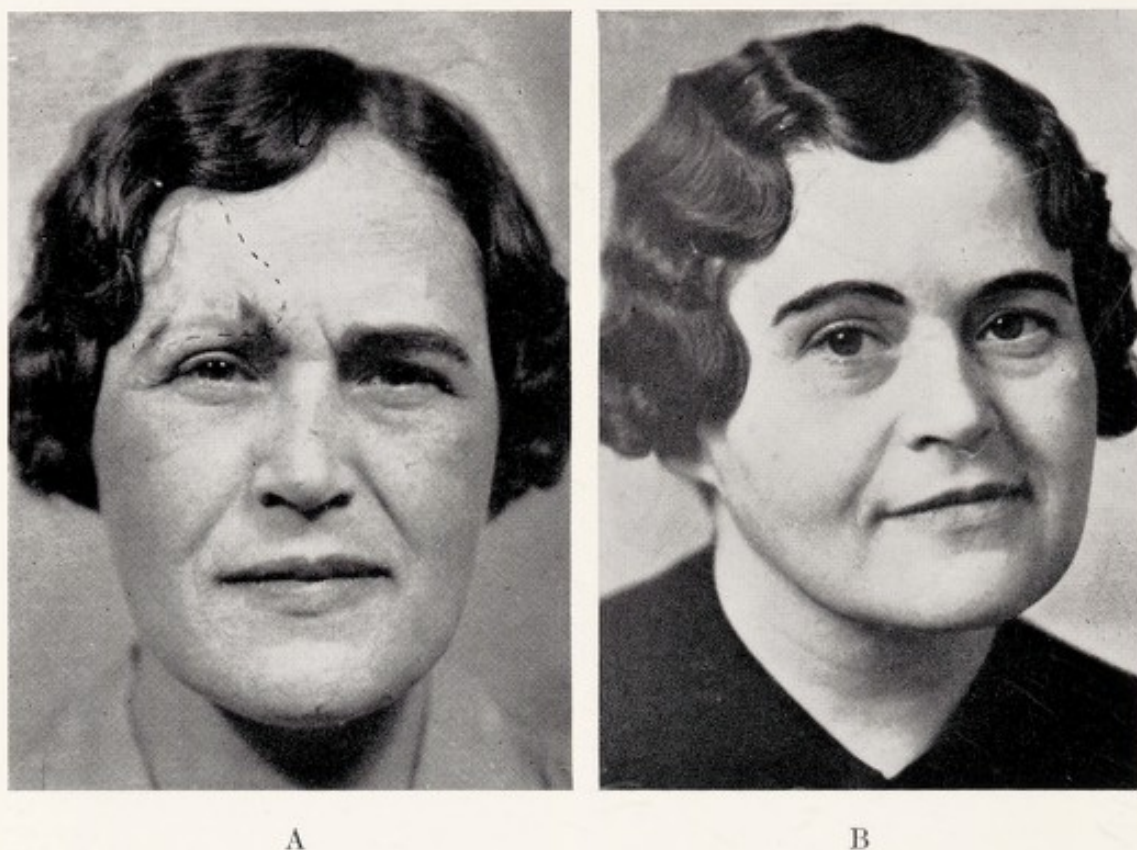


FIG. 56. A. This patient had a scar which had drawn her upper eyelid out of place and had destroyed her eyebrow. In this case a deep intermediate skin graft .026 of an inch in thickness was applied after the scar was excised. A full thickness skin graft was removed from the scalp to make her an eyebrow. B. Appearance of the graft and the eyebrows 1 year later.

posterior portion of the neck a graft of "three-quarter thickness" will be found to give an acceptable result functionally and cosmetically.

When a muscle is near the surface, as about the eyelids, about the lips (Fig. 55) or over the sternocleidomastoid muscles on the side of the neck, the results obtained after the application of a thin graft of "three-quarter thickness" may be as good as those obtained after the application of a deep intermediate skin graft.

Acceptable eyebrows (Fig. 56) may be made with a full-thickness skin graft from the scalp. The hair will be found to be somewhat sparse and less plentiful than in a normal scalp, but with care in clipping the new eyebrow may be fairly successful.

B. Burns Due to Roentgen Rays and Radium

Our records show some 30 patients for whom the application of a large skin graft was the method selected to repair a lesion caused by injudicious

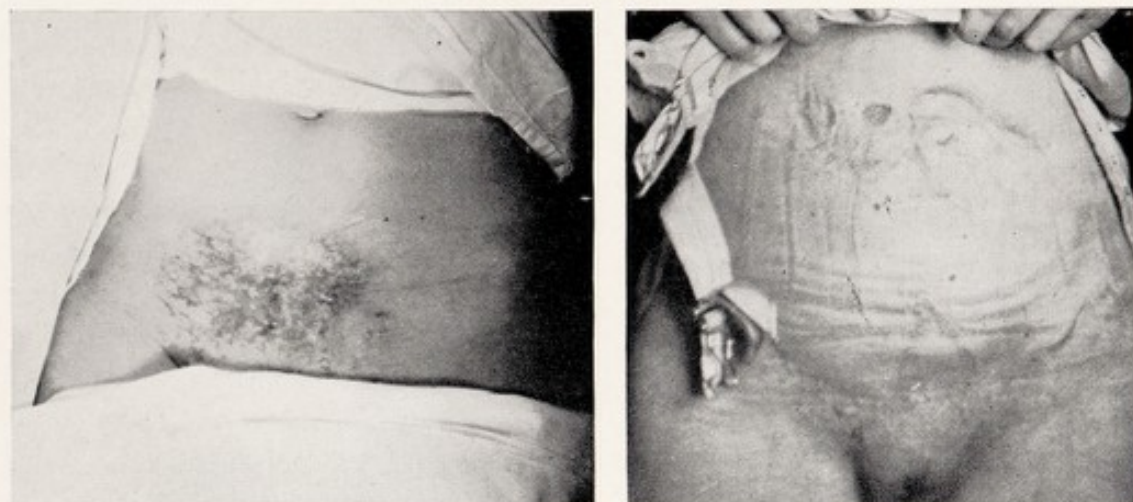


FIG. 57. Before and after operation for the removal of an x-ray burn of the abdominal wall. In this case a double pedicled flap was moved downward after excision of the burnt area and a skin graft was placed on the denuded area which remained above.

irradiation of such lesions as birth marks of the face, exanthematous lesions, psoriasis and certain other skin affections, careless exposure of the hands, over exposure of the neck for hyperthyroidism, the abdominal wall and perineum for menorrhagia and finally to relieve a distressing condition after the successful obliteration of some malignant disease (Fig. 57 and 58).

The patients fall largely into three groups: (1) those who have received a single massive dose for diagnosis or treatment; (2) those who have undergone treatment for a chronic condition and have received small repeated doses, over too long a period of time, and which is the largest grouping owing to the popularity of this type of treatment; (3) those who due to their profession have been too often and too long exposed to irradiation.

Not all roentgen ray burns demand surgical care but, generally speaking, the indications for operation occur because of (1) pain, itching or ulcera-

tion; (2) deformity from contracture; (3) cosmetic appearance or (4) epitheliomatous change. The surgical treatment falls into the two stages of excision and repair, but in most cases both stages of the operation are carried out at one sitting. The exceptions to such a rule are badly infected ulceration or where a healthy base cannot be obtained after excision. Two methods of repair are available: (1) intermediate skin grafts

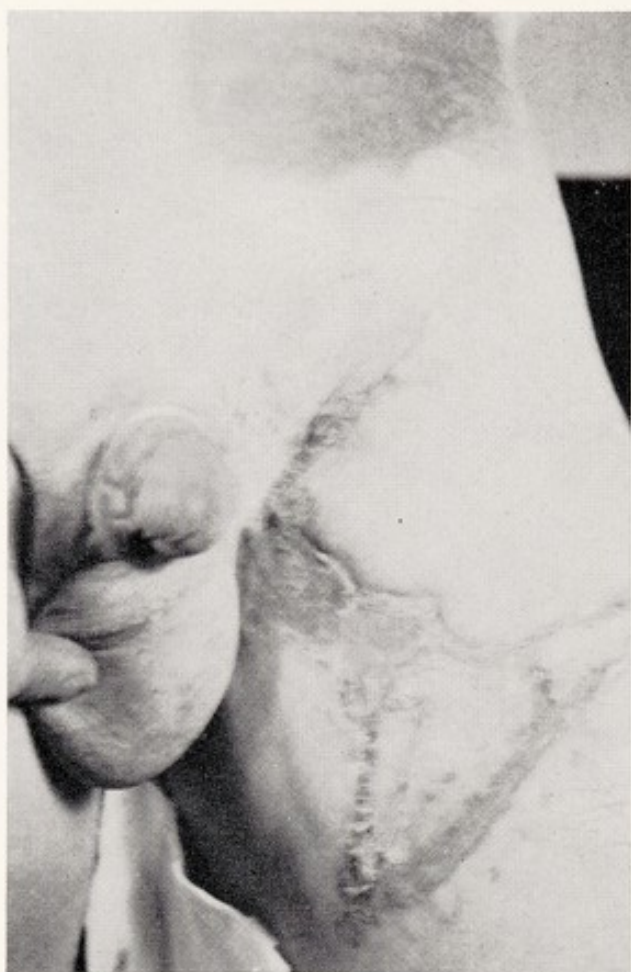

FIG. 58. An area on the thigh which has been over-irradiated. A skin graft was applied after excision of the painful and scaly area.

and (2) skin flaps. The selection of the type of reparative procedure depends upon those general indications for these materials which have been discussed previously with the exception that in comparison with other granulating surfaces, because of the low vitality, skin grafts are less likely to "take" than if the base is normal, and even if they do there may be some subsequent change in the graft itself especially if it is a thin one (Fig. 7 and 62).

Among the more or less radical measures commonly used for destruction of an area are electro desiccation or coagulation, cauterization and sharp excision. After sharp excision, if immediate skin grafting is contemplated or considered advisable, the area should be prepared in a manner similar to the one described under skin grafting for an infected

or granulating surface. Irradiated tissue either has so little resistance to infection that it is actually potentially infected or it has no ability to form a normal granulation tissue wall.

Superficial telangiectatic areas if not cosmetically objectionable may be left untreated if there is no tendency to activity or discomfort. When slight keratosis or ulceration is also present, the involvement is deeper. Such areas are uncomfortable as a rule and are unsightly. One is not

ordinarily warranted in advising conservative treatment. When there is ulceration, heavy keratosis and wide spread telangiectasis accompanied by deeper atrophy and probably discomfort, the treatment should be wide excision followed by replacement of a suitable skin graft. Examples of this are often seen on the so-called "x-ray hands" seen on physicians. Here, areas of the type just mentioned respond best to excision and repair with thick intermediate skin grafts. Thus the damage to both the superficial tissue and the intermediary tissue is gotten rid of.

Carcinomatous changes lend a further complication to a problem already difficult. In dealing with areas which have already shown carcinomatous changes, it is better practice and more time saving to make complete excision of the whole damaged area and by one or a few planned operations either by means of the transference of a flap or a free skin graft, the whole area is resurfaced. Limited operations usually leave skin that is potentially cancerous. Eventually such lesions may be the cause of the patient's death because of glandular metastasis.

Perianal lesions following ill-advised irradiation therapy for pruritis are very difficult to handle. Pain and discomfort are usually marked. The best treatment is excision with switching of a double pedicled flap to cover the area. A skin graft is then applied to the area denuded by shifting the flaps.

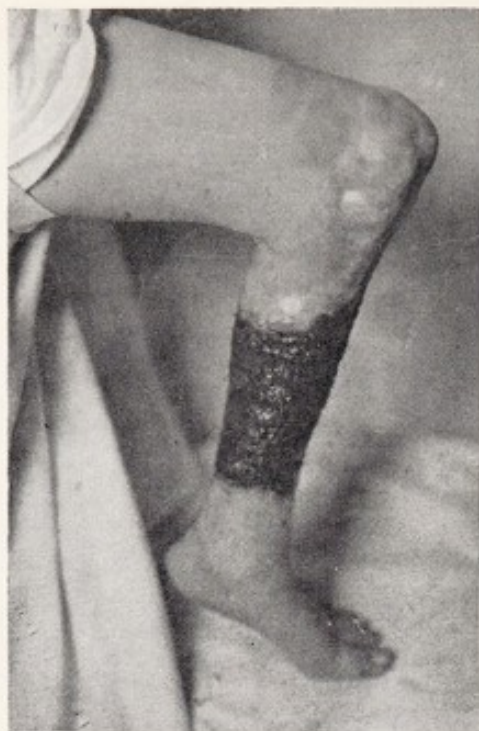Lesions on the sole of the foot sometimes follow the irradiation treatment of plantar warts. When a fairly good pad of subcutaneous tissue is present, repair may be made by means of a free "three-quarter thickness" deep intermediate skin graft but in those in which the scar is attached to deeper tendinous structures or even bone, a pedicled flap from the opposite leg or thigh is advisable.

C. Skin Grafting in Leg Ulcers

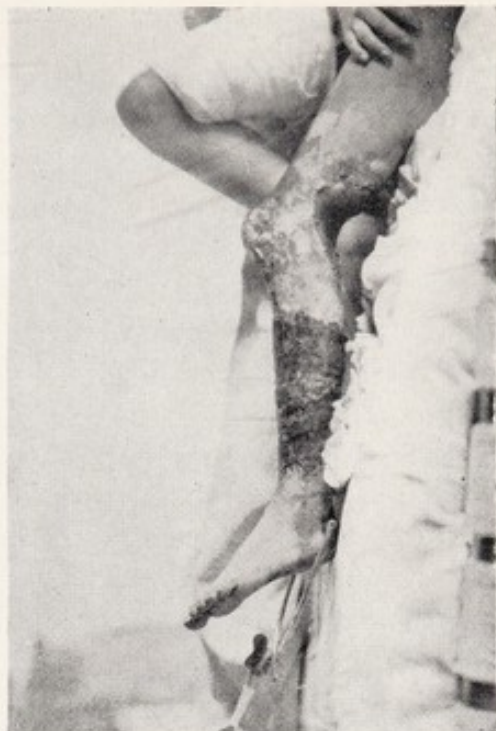A series of 42 patients with old unhealed leg ulcers have been operated. It was judged wise to use skin grafts in 24 patients and in 18 skin flaps were judged to be most likely to give the most permanent result. In most instances when flaps were used, they were obtained from the calf of the opposite leg.

The scarred epithelium that covers varicose ulcerations after spontaneous healing under conservative treatment in some instances will stand the trauma of every day life but there is always a threat of ulceration as normal vitality of such skin is never entirely present. The normal skin appendages are absent and insufficient derma is present.

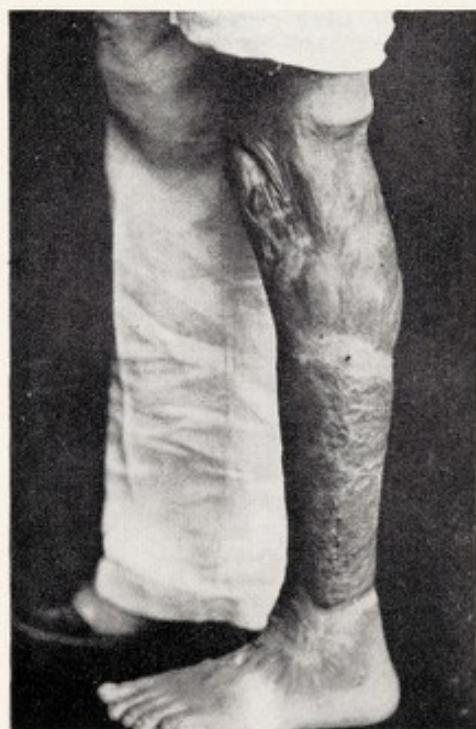Much can be done for most of the stubborn ulcerations of an extremity such as the arm or the leg if one uses the principle of replacing the lost



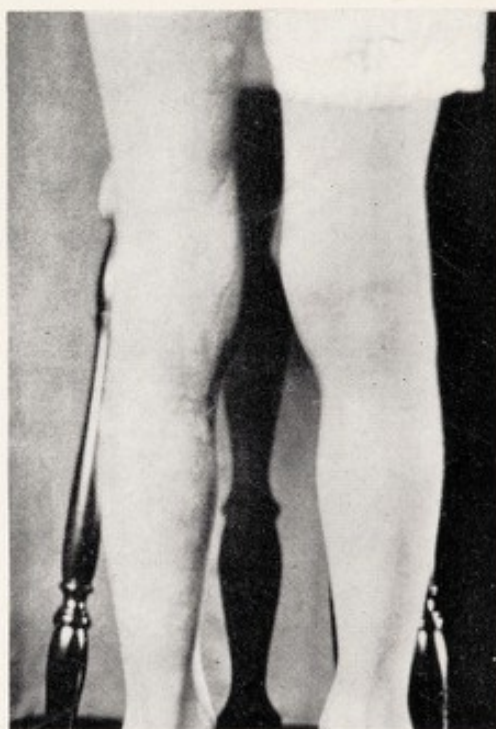
A



B



C



D

FIG. 59. A. Burn of the leg and popliteal region. Leg had been in acute flexion for two years. The hamstring muscles were so shortened that it seemed advisable to lengthen their tendons. B. Skin grafts were applied to the leg and popliteal space after crosscutting the scar. Heavy traction was put on the leg by means of a Steinman pin beneath the os calcis to stretch the nerve and the posterior capsule of the joint. Complete extension was obtained. C. Result two months after the application of the skin grafts. D. Final result one year later.

epithelium or subcutaneous tissue with new similar tissue as completely as possible. This usually means the replacement of the surface over the ulcerated area after excision of the ulcerated base and as much of the surrounding heavy scar as possible. As a matter of fact, this problem is seldom met on the upper extremity. Most commonly it is the leg that is affected.

A leg may become involved with ulcerations and heavy scarring fol-

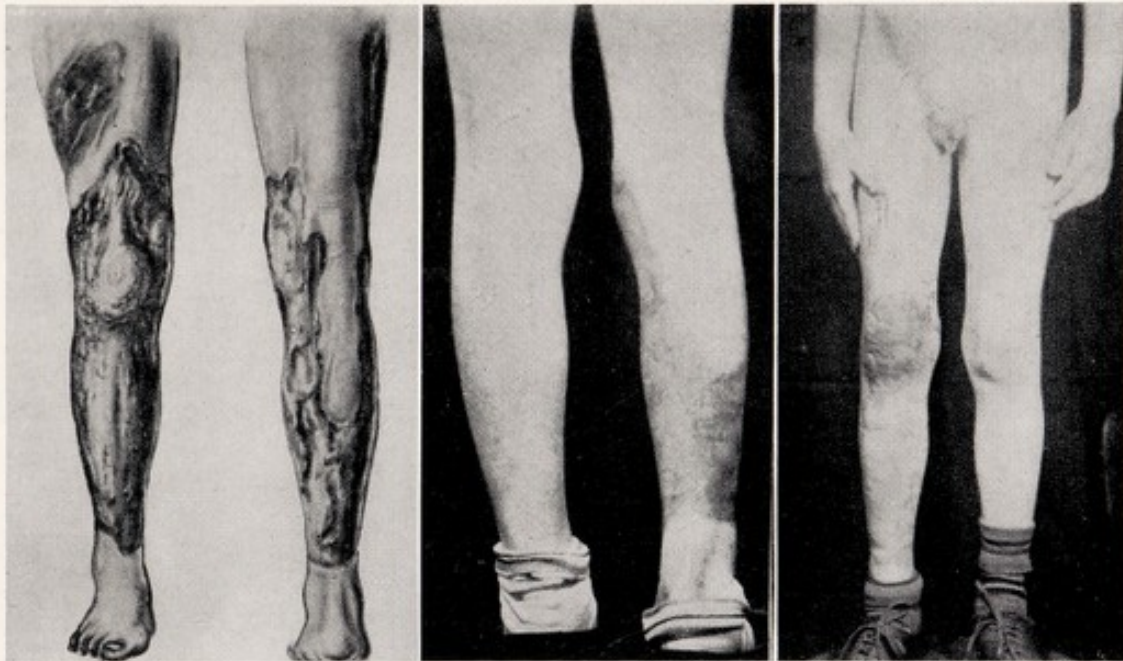

FIG. 60. Drawing of amount of epithelium lost on the anterior and posterior right leg due to a severe burn. Photographs show the result after the application of a skin graft which was cut about .014 of an inch thick from the lower abdomen and chest. The whole area was covered in one operation and a complete "take" was obtained. Function was entirely restored by one operation which resurfaced the large granulating area.

lowing (1) accidental traumatic injury; (2) following a burn; (3) following infection (gumma, etc.) or (4) the ulceration may be primarily due to varicose veins. The latter condition is seen commonly. In many it is difficult to decide upon the cause. I have one case in which the original condition seemed to be an arteriosclerosis of the veins in a comparatively young man. At least on excising the scar tremendously large arteriosclerotic veins were crosscut (Fig. 59 and 60).

A variety of causes may originally account for the skin and subcutaneous tissue lost. The original cause does not have much influence on the type of treatment that is best, provided the deep veins of the leg are present. When the condition is due to varicose veins, all effort should be

made to correct the vein condition before considering surgery to alleviate the scarring or ulceration.

The lower leg presents a particular problem when it is circumferentially scarred or ulcerated. When there is complete circular loss of skin, spontaneous epithelization is very greatly retarded and there may be a complete lack of growth from the lower edge (Brown, Byars and Blair). On the other hand, when a good bridge of epithelium is left throughout the length of the leg, epithelization may occur spontaneously. Deep ulcerations over the tibia and over the malleoli show practically no tendency to heal. Circumferential scarring tends to constrict the leg and interferes with the free up-and-down circulation. If the scarring is fairly deep, especially where the tibia, malleoli or tendon Achilles approach the skin, the proximity of a more or less bloodless structure practically cuts off the blood from the base of the superimposed soft tissues and from the edges the blood supply is lessened by circumferential scarring. Because of its dependent position the additional factor of lymph stasis enters into the picture. All of these factors tend to promote a vicious circle if trauma causes ulceration as repeated ulceration only causes a greater cicatrix and a continued lessened blood supply.

Scarred healing over the tibia or ankle may be quite uncomfortable—a sensation of tightness or even pain often is complained of. When such is the case, many times the patient can be made more comfortable if the scar is split lengthwise to allow relaxation, after which the resultant defect is covered with a thick skin graft. When there are wide areas of scar, frequently it is best to remove the skin and scar covering most of the leg after which the raw area is covered with a "three-quarter thickness" skin graft.

Deep ulcerations involving tendons and exposing bone do not heal spontaneously. Some patients develop firm granulations. The base remains a dirty gray. Others develop an excessively thick, dense scar from surface to bone or tendon. Still others show the deep edema of lymph stasis.

Microscopically there is some marked activity of the skin edge with excessive keratinization while others show practically no epithelial activity. Very rarely will evidence of malignant change be seen.

One can not expect ulceration due to organic arterial disease to be remedied by a local replacement procedure with which we are here concerned.

Radical Treatment: Treatment by excision of the scar and replacement by skin graft is based upon the premise that large surface defects are best repaired with skin as near to normal as possible. Many operators have used the method but in recent years the tendency to wide excision and the use of thicker larger sheets of skin has been emphasized more. Re-

cently Brown, Byars and Blair reported 59 cases of very chronic varicose ulcer which were successfully repaired after excision of the ulcer and scar and the application of large split skin grafts.

The preparation of the area for operation is important. As previously mentioned, any causative factor that can be controlled is taken care of first. After this, one's object is to improve the circulation, to control infection and to get a clean ulcer base. The leg is elevated in bed and continual wet warm dressings are applied. Heavy keratin deposits at the edge of the wound are removed. Very fine meshed gauze or old linen is placed in immediate contact with the wound. All evidence of edema must subside before operation. This may mean rest in bed for as long as three weeks previous to operation. No evidence of pyocyanous infection should exist. Finally, the readiness of the wound for grafting is judged by its appearance. This matter is discussed under the preparation of a granulating surface for grafting.

Our method of handling these cases has been as follows:

Recent Ulceration: When the ulceration is superficial and the granulations are recent the extremity is cleaned up as previously described under the preparation of granulating surfaces for skin grafting.

At operation the ulcer edge and base and the surrounding scar are excised in toto by undercutting. Care is taken not to expose bone or tendon. If granulations have only recently healed over exposed bone or tendon, as a rule one will be wiser if no attempt is made for removal. A "three-quarter thickness" skin graft of about .014 to .018 of an inch in thickness is then applied over the raw area and is basted on tension in place. Multiple stab holes are cut to allow for drainage. Several layers of wet gauze are applied first, then a marine sponge under firm pressure. The original dressing is kept continuously wet. The first dressing is done four days later. If any blebs are present they should be opened. Daily wet dressings are continued for ten days to two weeks.

It has been found that within a year a fairly good pliable subcutaneous tissue will develop and that after this the replaced skin will stand the wear and tear of ordinary life. In several circumferential defects successfully grafted there was some inclination to constriction of the leg with a tendency to ulceration; at a second operation the grafts were split longitudinally, medially and laterally. This released most of the constriction. In the longitudinal defects thick grafts of .024 of an inch in thickness were placed. This procedure relieved the constriction and prevented the tendency to ulceration.

Old Ulceration: In those old cases of ulceration in which the fibrous tissue beneath the old granulation is heavy, practically all of the fibrous base and surrounding scar along with the old granulating ulcer should

be excised with the idea of freeing the constriction and getting a new subcutaneous tissue. After this complete excision sometimes it is wiser not to graft the area for a few days. The main reason for this is that one may have difficulty in preventing a blood clot from forming which might prevent a perfect "take" of the skin graft. After a few days a "three-quarter thickness" skin graft of about .020 to .024 of an inch in thickness is cut and stitched into the defect. In the majority of our cases, however, by carefully ligating the bleeding points the hemostasis was considered good enough to allow immediate application of a deep intermediate skin graft.

The patient is kept in bed for about three weeks to allow the graft to get "set" so to speak and then gradually, under careful observation, the patient is allowed to do some walking. At first an elastic bandage is used.

Unilateral Ulceration Over the Tibia: In several unilateral cases, a flap from the other leg has in a few instances been laid over the part of the surface which had had bone for a base and the remainder skin grafted. Our idea here was to improve the circulation over the bone. It was hoped that if this were corrected the circulation in the area skin grafted would take care of itself due to the soft tissues beneath.

Ulceration Over Tendo Achilles: Not infrequently, after operation on the Achilles tendon, an ulceration develops and will not heal. In our experiences a skin graft will not "take" here or do any good. Therefore, the application of a skin flap is obligatory for permanent healing.

Ulceration Over and About the Malleoli: In ulceration over and about the malleoli, in our experience practically always the application of a skin flap is the indication. After a skin graft is applied, the blood supply is usually insufficient to prevent it from breaking down if it is traumatized or possibly even if it is not.

Prognosis: Brown, Byars and Blair by means of free "split" grafts obtained the following results:

	Cases
1 operation—patients healed in from 1 to 6 years	31
1 operation—patient still under observation	7
1 operation—patients healed but untraceable	4
1 operation—patient dead from malignancy	1
2 operations—patients healed in from 1 to 7 years	12
2 operations—untraced	3
3 operations—patients well in from 1½ to 8 years	3
3 operations—patients still under observation	1
Amputations definitely avoided	3
Malignancy probably avoided	1

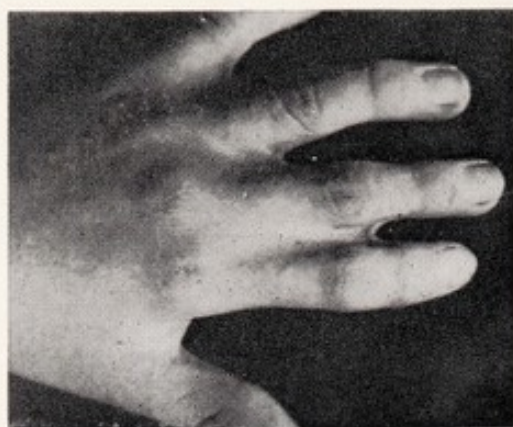More than 1 operation required because of primary loss of graft	3
More than 1 operation necessary because of late ulceration of graft; 1 was an x-ray burn and 1 was an arterial disease plus an x-ray burn	3
Second operation required due to breakdown in adjacent scar. In all others with more than 1 operation, subsequent operations were required because the extent of the lesion prohibited doing complete repair at one time, or because both legs were involved.	
Patient died before repair could be done	2
Repair accomplished with sliding flaps, patients well	2

One bad varicose ulcer was much improved but a small area tended to break down over one tibia. Certain old varicose cases have been turned down as being too greatly damaged for skin grafting to be of any avail. The others that we have grafted, by the methods outlined, as far as we know have remained healed.

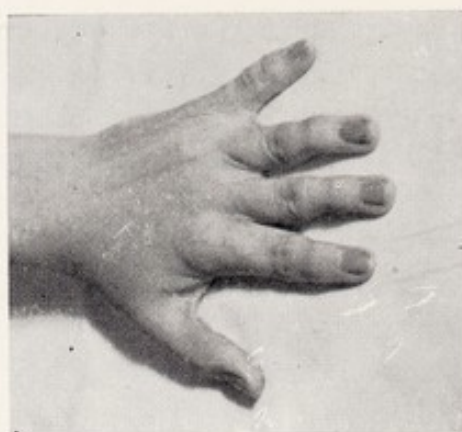D. To Cover Raw Surfaces After the Separation of "Web" Fingers

Our experience with web fingers has been with 30 patients. All degrees of webbing have been included in this group, and also various degrees of congenital deformities of the fingers such as shortening of the fingers and the absence of one or more phalanges. Altogether 12 were bilateral, 12 had three fingers webbed and 6 had four fingers webbed. In all cases thick skin grafts were used for the correction.

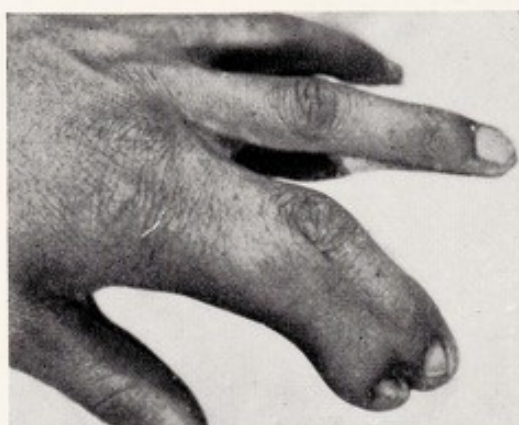In certain congenital anomalies, such as "web" fingers and "web" toes, the application of a full-thickness skin graft offers the best result and it is usually obtainable in one operation. In children, full-thickness grafts take well. As one does not need much skin it is usually advisable to cut the necessary diamond-shaped piece of skin from the abdomen. The plastic operation designed by Agnew or Didot either will not correct syndactylism or will cause limitation of free movement due to lateral scarring. Besides entailing several operations, the application of a pedicled flap on the fingers may result in a thick clumsy appearance. Thin grafts often contract too much and ultimately the webbing between the fingers partially recurs. The fusion should be overcut from one-fourth to one-half of an inch, for the slight contracture which follows will draw the interdigital web somewhat distally. In a few cases the scar will be somewhat heavy at the junction of the graft and the skin of the fingers. It may be necessary, therefore, a year or so later to crosscut the contracture and



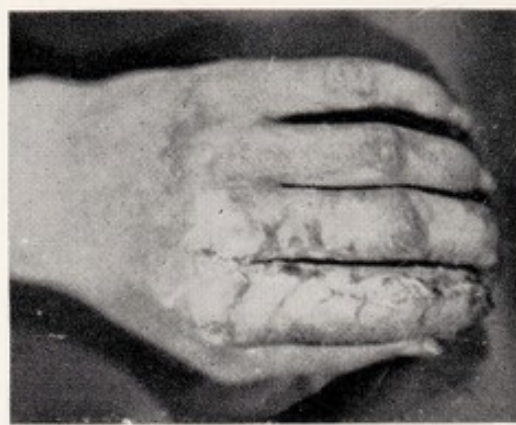A



B



C



D

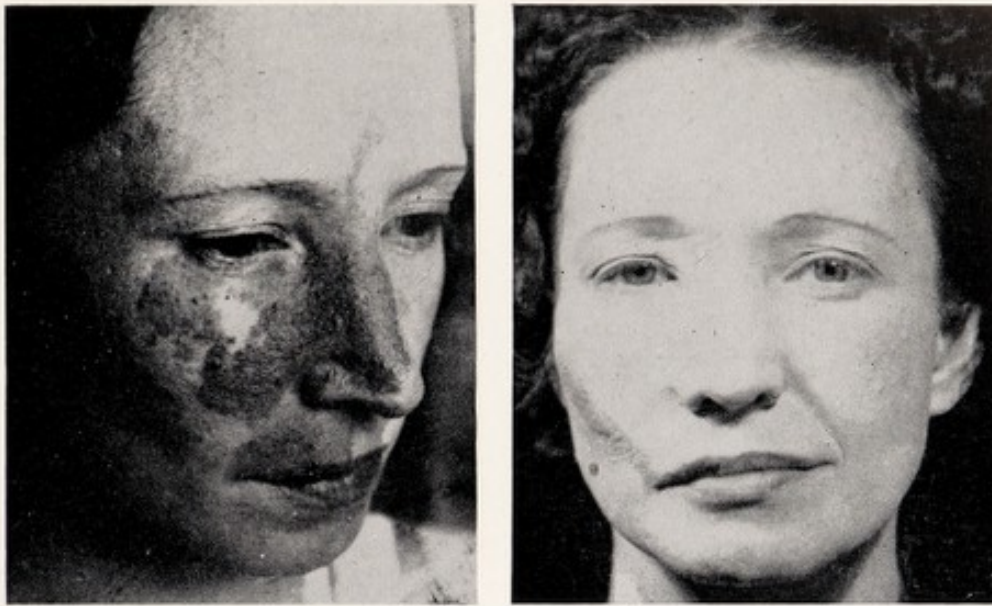FIG. 61. A. Partial syndactyly between the first and second fingers and also between the second and third fingers. B. Result after separating the webbing and placing a thick skin graft between the fingers. C. Complete syndactyly of third and fourth fingers. D. Ten days after separation and application of skin graft.

apply into it a second thick graft to get complete extension as a final end result (Fig. 8 and 61).

E. To Cover Side of Face After Excision of Large "Birthmarks" and Scars

From one-third to the whole of the side of the face has been removed in 10 cases because of involvement with an unsightly "port-wine stain." In 6 of the patients practically all of the correction was made in one operation, but in 4 of them a secondary skin-grafting operation was necessary. In 48 patients large scars of the face have been removed and the resulting defects skin grafted.

"Birthmarks" of the "port-wine" type in adults do not respond well to radium therapy. The color is obliterated only in a splotchy manner, and telangiectasis and scaly areas often form. Often the area, if not actually



A

B

FIG. 62. A. Patient with large hemangioma involving entire right side of face.
B. Five years after application of a thick skin graft.

painful, is at least uncomfortable. It has been our custom to excise such lesions in toto after which a thick skin graft is applied. When the lesion covers the eyelids and the upper lip a stent of modelling composition is used to give pressure for this part of the graft, while on the cheek or forehead a marine sponge is used. In about half of our cases it was neces-

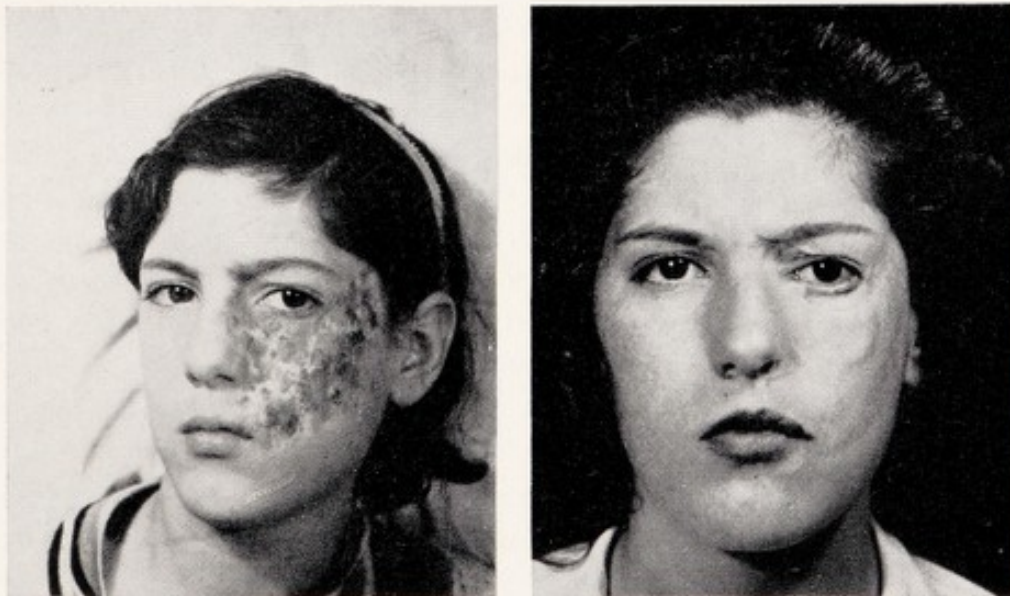

FIG. 63. Photograph of a large port wine birth mark of the face which had been unsuccessfully irradiated. The area was excised and a skin graft applied. Final photograph shows the result one year and a half later.

sary to apply a second graft because of some contracture of either one of the eyelids or of the upper lip. In the other half complete correction was obtained with the first skin graft. As a rule the scar between the normal skin and the graft will be slightly heavy and will need some excision (Fig. 7, 53, 54, 62 and 63).

The majority of these skin grafts are slightly whiter than the surrounding skin but they show good texture. In a dark brunette one runs a chance of getting some permanent pigmentary changes in the graft. However, these may not be very noticeable after a period of years. With the aid of some "cover mark," powder or rouge, the appearance of the skin graft can be made to very closely approach normal skin. On the whole, as a rule, the result is extremely satisfactory to the victim of this extremely noticeable deformity.

F. To Prevent Cicatricial Deformity After the Removal of Large Pedicled Flaps

The number of times that a skin graft of one type or another has been used to resurface a denuded area, or to prevent cicatricial contracture after the removal of large pedicled flaps, is probably not very pertinent even if it were readily available. Suffice it to say that the application of a skin graft is a routine procedure when the surrounding skin cannot be coapted or when the pedicle of the flap will be insufficient to give adequate coverage of the bed from which the skin flap was raised.

Quite commonly when it is necessary to raise a pedicled flap it will not be found possible to coapt the adjacent skin edges. In such cases to get early primary healing the application of a deep intermediate skin graft is in order.

On rounded convex surfaces from which a pedicled flap has been removed to swing elsewhere, such as over the biceps muscle of the arm or forehead, a deep intermediate skin graft is sewed in under tension and a good "take" will usually be obtained whether or not a pressure dressing is used. Tension over the convex surface gives contact with the underlying surface and opens the endothelial spaces of the graft.

G. Full-Thickness Graft for Eyebrow

By means of a full-thickness skin graft from the scalp ten new eyebrows have been made. The most acceptable "homemade" eyebrow is made from a full-thickness graft from the scalp (Fig. 56). The hair will be found to be somewhat sparse and less plentiful than in a normal scalp but with care in clipping the new eyebrow is fairly successful. Contrary

to what one would expect these grafts, as they are rather thick and contain considerable fat, usually take in toto.

H. The Relining of a Cavity, a Sulcus or Some Body Tube

The number of times that a cavity, a sulcus or some body tube has been relined with a certain type of skin graft as a part of another larger operation is not accurately available from our files, but in 20 patients the operation of the relining of the cavity, sulcus or some tube of the body was the outstanding operation and the only procedure carried out (Fig. 28, 29 and 30).

The development of the calibrated skin graft has been a particular boon to the art of relining a cavity such as an eye socket, a sulcus such as the gingivolabial sulcus and for the formation of or for some tube within the body such as the vagina when it is congenitally rudimentary or absent. One can select the required thickness at will and can obtain a sheet of skin which will completely drape a form of almost any size or shape.

A skin graft should be thin for relining an eye socket and to get the best socket the stent should be specially made, flattened and oval. One does not need much depth to the socket but all the diameter possible is necessary. For deepening an obliterated gingivolabial sulcus or to release a scar band in the mouth, nostril or pharynx, one should not fail to remember that about two-thirds more lining should be applied than will be needed to eventually correct the lesion. The tendency to contract is quite marked. As a rule, for these purposes a modelling composition form the shape of the cavity is used over which a sheet of skin of superficial intermediate thickness is draped. The form is removed after a week and often is either replaced or a somewhat smaller one is inserted to counteract the tendency to contracture. When relining a nose, such as a saddle nose as is advocated by McIndoe, a smaller stent is worn for several months.

One of the most striking uses of the "three-quarter thickness" skin graft is the formation of an artificial vagina. There has been some published work which would indicate that an artificial vagina might be formed by inserting a bare stent in the space between the rectum and the bladder, I cannot believe that this is possible unless some remnants of vaginal mucosa are present. In some cases Young found that although the vagina did not open to the perineum it actually was present but that the opening was into the urethra as he demonstrated by cystoscope. If this were the case it might explain the possibility of eventually gaining an epithelial

lined cavity somewhat similar to a vagina. In other words the mucosa was already there and was only opened into.

The formation of an artificial vagina by means of a "three-quarter thickness" skin graft is an easy procedure (Fig. 27). It gives a satisfactory result and is not dangerous. For a stent one may use a condom filled with paraffin. By means of the dermatome a sheet of skin is cut and used to cover the stent. It is held in place by sutures. Counseller in particular has used this method of constructing an artificial vagina with great suc-

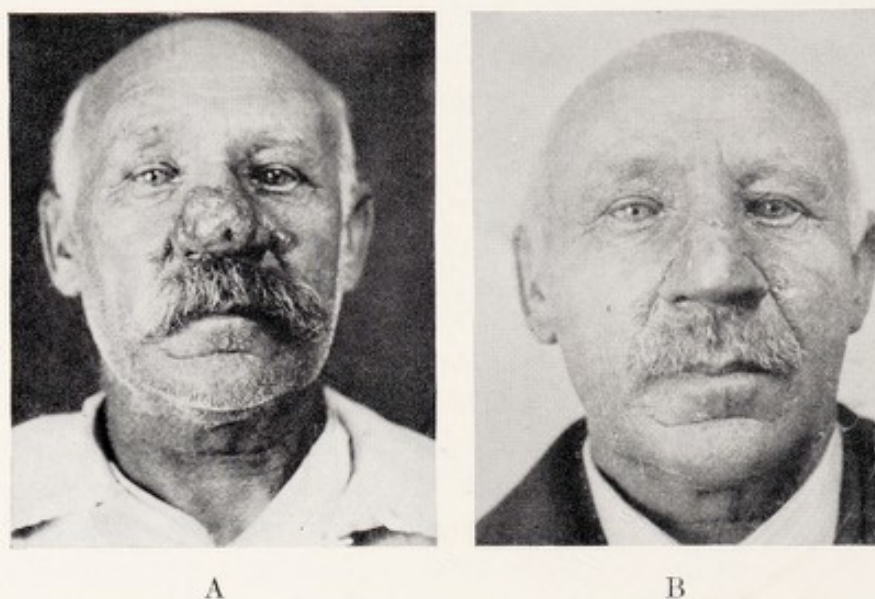


FIG. 64. A. A pronounced rhinophyma of the nose. The rhinophyma was removed and the nose was covered with a skin graft. B. Result after two weeks.

cess. A special smaller stent should be constructed and worn for six months or so after the operation.

McIndoe has successfully reconstructed an acceptable urethra for a hypospadias. The graft is inserted beneath the ventral skin over a specially constructed catheter-like form. After the graft has taken, a catheter is worn for a period of six months.

Miscellaneous Group

Besides the large group of instances after operative excision for one reason or another, the miscellaneous uses for which "three-quarter thickness" skin grafts may be used with success are quite numerous. For example, I believe that the best result which can be obtained in a bad case of rhinophyma of the nose is that obtained by excision of all the excess tissue followed by the immediate application of a skin graft (Fig. 64). Within a week or ten days the condition is alleviated and the skin is

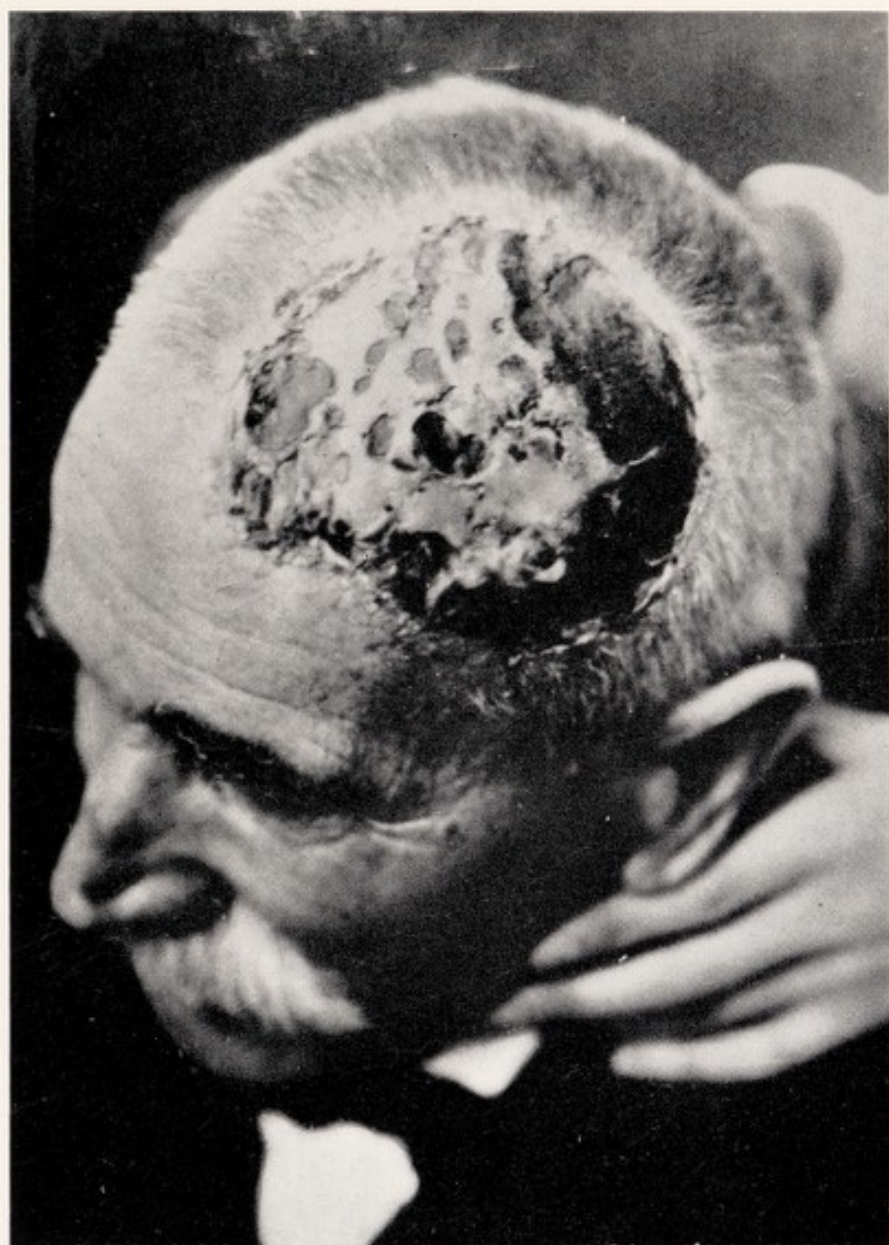


FIG. 65. A skin graft which was applied to the inner table of the skull after chiseling off the outer layer because of an endothelioma. This shows the amount of skin which "took." Photograph was taken three weeks after the skin graft was applied. Within a few weeks the area on which the skin did not "take" will scar over. This was a case of Dr. Ernest Sachs which he allowed me to operate when I was a resident about 1920.

healed. The cosmetic result will be better than if the nose is left to heal by scar as has been recommended.

In several cases a thick graft was applied to cancellous bones (Fig. 65). Two men had a sarcoma of the scalp which was excised along with the outer table of the skull. The skin graft was then laid directly on the cancellous bone and about two-thirds of the graft "took." Spots of

necrosis occurred here and there apparently because of a lack of blood supply. After five weeks the areas were nicely healed and faint brownish spots indicated where the superficial ulceration had been. Not uncommonly one sees large nevi in which a good result can be given by excision followed by skin grafting.

CHAPTER XI

Transplantation of Mucosa and Derma

A. Mucosal Grafts

ONE OF THE earliest attempts to transplant mucous membrane was made by Wolfe in 1872. He employed grafts of the mucous membrane of rabbits for conjunctival defects.

As long ago as 1890 Djatschenko studied experimentally autografts of mucous membrane taken from the lip and oral cavity. He applied them to conjunctival defects and found that the histological changes were analogous to those described by Marchard for skin.

To obtain sufficient buccal mucosa to graft an area of any size, in my hands at least, has so far proven well nigh impossible.

In one situation, at least, it is absolutely essential that mucosa be used. When the eye is in the orbit and conjunctiva has been destroyed, if one uses ordinary epithelium the cornea of the eye will be kept in a state of constant irritation and usually the skin will have to be removed. If a mucosal graft can be gotten of a sufficient size to "take," the difficulty may be alleviated. Several times for a relatively small contracture, under these circumstances, I have successfully grown a mucosal graft of sufficient size to correct the deformity.

There is another type of lesion, not uncommonly seen, in which because of an insufficient conjunctival lining the orbital cavity is too small to hold an artificial eye. The addition of more mucosal lining would be ideal, as the application of a split stent skin graft along with the conjunctiva already present plus the tears results in a certain type of cloudy secretion which often will make the glass eye appear unclean. Several times I have attempted to use a full-thickness mucosal graft from the cheek with the idea of solving the difficulty. So far my results have been only relative and usually eventually I was forced to use skin to line the contracted cavity. We have had the most success with full-thickness mucosal grafts.

Technique: One removes a full-thickness mucosal graft from inside the cheek just as one would remove a full-thickness skin graft. As a general rule this is considerably more difficult than the removal of a full-thickness skin graft, so one will simplify matters if the mucosal graft is removed along with some of the submucosal layer of tissue. After removal, the

graft is placed and stretched upon a flat surface. With a pair of curved scissors the excess subcutaneous tissue is cut from the graft as well as any of the derma that can be removed. Then if one uses modeling composition for a stent and stretches the mucosa over the stent very carefully, one can, as a general rule, obtain a good "take" of the full-thickness mucosa.

Usually in text books of plastic surgery there is described a method of cutting a thin mucosal graft off of the lower lip in the same way that one would cut a Thiersch graft or a thin graft. When there is needed only the smallest amount of mucosa, such as the ophthalmologist uses occasionally at the edges of the eyelids for entropion, this method may have certain advantages. But we have not found this a practicable measure for plastic procedures which require a greater amount of mucosa. Another area from which mucosa has sometimes been obtained is the inner layer of the foreskin. I have never had any success with it.

When trying to build up vermillion border on the lips, a graft will not be sufficient. Some arrangement whereby a pedicled flap of mucosa can be turned across the lip is the only procedure of any great value for this purpose.

Dantrelle in 1932 discussed the uses and the technique of mucosal grafting and gives a rather complete bibliography.

B. The Transplantation of Derma

Von Eitner first introduced the dermal graft. Later Straatsma and Blair used it successfully. The subepithelial layer of the skin is not difficult to transplant. Its principal uses are for the filling of small contoural defects or for the filling of small depressed scars. The layer is principally made up of fibrous tissue. The fibrous tissue undoubtedly undergoes replacement by connective tissue from the host but the amount of atrophy is not as great as after the transplantation of fat. The histologic changes correspond to that about other transplants such as fat. At first there is evidence of degenerative changes, well-marked round cell infiltration with some evidence of replacement changes from resulting fibroblastic tissue.

Peer and Paddock recently have studied the histologic changes of human dermal grafts after they were buried from one week to a year. Usually some remains in spite of attempted removal of the epidermis. This remaining epidermis may form closed cystic cavities of microscopic size which contain horny material or fragments of hair. In later sections Peer and Paddock found horny material in these cavities surrounded by granulation tissue. Sebaceous glands were noted only in implants of one week's duration. Hair follicles were seen only in implants buried up to three

weeks. Sweat glands were found in all sections but in the later sections they were in the process of degeneration and fibrous replacement. The granulation tissue which surrounded the implant was of the chronic type—and contained lymphocytes, microphages, epithelial cells and often giant cells. In some cases a granulomatous nodule was formed. In the granulation tissue which surrounded the implant, and at times within the implant, bodies were observed with the giant cells and nodules which resembled fragments of hair.

For the elevation of small depressed scars, like the scar of a pock mark, it is the only tissue with real chemical merit. The factors which recommend the method are the ease with which the material is obtained and the ease with which it is inserted beneath the scarred depression after it is carefully undermined. For the correction of a slightly larger contour defect, it also as a rule has advantages over cartilage. It is easier to obtain and it does not curl as thin cartilage tends to. But cartilage is superior if the contour defect is of considerable proportion especially where some structural support is desirable. The advantage in derma over fat is that the result is about fifty per cent more permanent.

Technique: One removes the epithelium from over the derma to be used as when removing a very thin full-thickness graft. Later the remaining derma is excised. Some of the underlying fat may be taken. The wound from which the derma is taken is closed. Through an incision, made through the scar of the depression to one side, the epithelium of the depression is undermined with a pointed pair of scissors. Sufficient derma is inserted into the cavity to elevate or slightly overelevate the depression. From one to as many stitches as needed are taken to close the small incision. The smaller the incision, the better. A pressure dressing is placed upon the operative area.

Summary

IN THE foregoing treatise an effort has been made:

(1) To present the subject of skin grafting from the standpoint of a personal clinical experience carried on in conjunction with certain experimental work.

(2) To give a brief chronological review of the subject of skin grafting from its origin to the present time (1941).

(3) To present experimental work which would indicate that homogeneous skin grafting, except in identical twins, is ordinarily not a practicable procedure. The reasons for this are discussed.

(4) To describe the histology of autografts in the human.

(5) To outline the objectives to be gained in performing a good skin-grafting operation.

(6) To present the properties and technique of the removal of the types of skin grafts more commonly used in the past.

(7) To describe the special types of skin grafts and their advantages or disadvantages.

(8) To visualize, in the light of past experience, a concept of the ideal skin graft.

(9) To describe the use of a dermatome which allows one to overcome many of the mechanical difficulties formerly encountered by the surgeon when a difficult skin grafting operation was undertaken.

(10) To tabulate our experience with the new "three-quarter thickness" skin graft which has seemed to fulfill the expectations prophesied for it in that the 20 percent chance of a failure of "take," which previously no one had been able to eliminate when the old full-thickness graft was used, now has been largely eliminated. Moreover, to point out that most of the advantageous properties of the full-thickness skin graft are retained in so far as cosmetic appearance, minimal contracture and maximal protection are concerned.

(11) To point out that coincidentally with the development of the method of removing the "three-quarter thickness" skin graft, it was found that all types of thin and superficial intermediate skin grafts could be cut with the dermatome with greater precision and facility from any part of the body in quantities not previously obtainable.

(12) To discuss the influence that the development of the superficial, intermediate and "three-quarter thickness" skin grafts, as cut with the

dermatome, have had in the realinement of the indications for the use of skin flaps.

(13) To emphasize the advantage in the grafting of cavities or the rebuilding of epithelial tubes or cavities with a uniform sheet of skin to surround the stent.

(14) To describe factors that seem important in growing a successful skin graft. This necessarily includes the preoperative and postoperative care.

(15) To give a more complete discussion of the special lesions for which skin grafting is useful in a general way and the important elements to be considered if success is to follow.

Bibliography

- AGNEW, D. H.: Principles and Practice of Surgery, 1878, XXXI:424.
- ALGLAVE, N.: Réparation des pertes de substance cutanée par des semis dermo-epidermiques suivant in procédé derive de celui de Jacques Reverdin, Bull. et mem. Soc. Anat. de Paris, 1907, LXX XIII:251.
- : De la réparation des substances cutanées par les Semis Dermo-epidermiques, Presse med, 1917, Tr. p. 335.
- BARATOUX, DUBOUSQUET and LABORDERIE: Gaz. d. Hosp., 1886, Nr. 145.
- BARONIO: Degli Innessi Animali, Milan, 1804.
- : Ueber animalische Plastik, translated by Block, Halberstadt, 1819.
- BERT: Quoted by Loeb, Leo: Physiol. Rev., 1930, 10:547-616.
- BLAIR, V. P.: The Delayed Transfer of Long Pedicle Flaps in Plastic Surgery, Surg., Gynec. & Obst., 1921, 33:261.
- : The Full Thickness Skin Graft, Ann. Surg., 1924, 80:298.
- BLAIR, V. P. and BROWN, J. B.: The Use and Uses of Large Split Skin Grafts of Intermediate Thickness, Surg., Gynec. & Obst., 1929, 49:82.
- BRAUN, W.: Quoted by Wangenstein, O. H.: The Implantation Method of Skin Grafting, Surg., Gynec. & Obst., 1930, 50:634.
- BROWN, J. B.: Restoration of the Entire Skin of the Penis, Surg., Gynec. & Obst., 1937, 65:362-365.
- : Plastic Surgery of the Face, Internat. Abstr. of Surg., 1933, LVII:297.
- : Personal communication to author.
- BROWN, J. B., BYARS, L. T. and BLAIR, V. P.: The Repair of Surface Defects from Burns and Other Causes with Thick Split Skin Grafts, South. M. J., 1935, 28:408.
- BROWNING: Communicated through Dr. Richard Bell.
- BUNGER: Graefe and Walther's Journal, 1823.
- CANNADY: J.A.M.A., 1906, p. 1682, Jan. 2.
- CELSUS, AURELIUS CORNELIUS: De ra Medica, etc., Book VII, 1750.
- COELST: Une autre Application de Ma Méthode de "Outlay sur Cadre.", Rev. de chir. structive, March, 1936, page 195.
- COLLIER, F. A.: The Use of Paraffin as a Primary Dressing for Skin Grafts, Surg., Gynec. & Obst., 1925, XLI:221.
- CONWAY, HERBERT: Sweating Function of Transplanted Skin, Surg., Gynec. & Obst., 1939, 69:756-761.
- : Technical Details in Skin Grafting, Surg., Gynec. & Obst., 1936, 63:369.

- CORREUS, C.: Individuen u. Individual stoffe. Naturwissen Schäften, 1910, 4:193-210.
- : Selbst sterilitat u. Individual stoffe. Biol. Censtalblatt, 1913, 33:389.
- COUNSELLER, V. S.: Congenital Absence and Traumatic Obliteration of the Vagina and Its Treatment with Inlaying Thiersch Grafts, Am. J. Obst. & Gynec., 1938, 36:632-638.
- DANTRELLE, D.: Greffes de muqueuse, Rev. de chir. plastique, 1935, 3:15.
- DAVIS, J. S.: The Use of Small Deep Skin Grafts, J.A.M.A., 1914, 63:985.
- : Some Problems in Plastic Surgery, Ann. Surg., 1917, 66:89.
- : Plastic Surgery, Phil., P. Blakiston's Son and Co., 1919.
- : A Case of Cicatricial Contraction Following a Burn With Relief by a Whole Graft, Surg., Gynec. & Obst., 1907, 5:554.
- : The Small Deep Graft: Its Relationship to the True Reverdin Graft, Ann. Surg., 1929, 89:902.
- : The Use of Relaxation Incisions When Dealing with Scars, Pennsylvania M. J., 1938, 41:565.
- : The Use of Small Deep Grafts in the Repair of Surface Defects, Am. J. Surg., 1940, 47:280.
- DAVIS, J. S. and KITLOWSKI, E. A.: A Regeneration of Nerves in Skin Grafts and Skin Flaps, Am. J. Surg., 1934, 24:501.
- DAVIS, J. S. and TRAUT, H. F.: Origin and Development of the Blood Supply of Whole Thickness Skin Grafts, Ann. Surg., 1925, 82:871.
- DAVIS, LOYAL: The Return of Sensation to Transplanted Skin, Surg., Gynec. & Obst., 1934, 59:533.
- DIDOT: Acad. rog. de med. Belg., Brux, 1849, 50, IX:35.
- DJATSCHENKO: Experimentelle Untersuchungen über transplantation der Schleimhaute, Zentralbl. f. d. med. Wissensch, 1890, 641:657.
- DOUGLAS, B.: The Sieve Graft—A Stable Transplant for Covering Larger Skin Defects, Surg., Gynec. & Obst., 1930, 50:1018.
- : Sieve Grafts, Ann. Surg., 1921, 76:673.
- DRAGSTEDT, L. R.: A Modified Sieve Graft, Surg., Gynec. & Obst., 1937, 65:104.
- DUNOÛY, R. L.: Means of Physiologic Activity by Rapidity of Cicatrization in Various Ages, Compt. rend. Soc. de biol., 1932, 109:1227.
- EITER, E. VON: Ueber Unter Polsterung der Gesichtshaut, Med. Klin., 1920, 16:93.
- : Quoted by Brown, J. B.: Plastic Surgery of the Face, Internat. Abstr. Surg., 1933, LVII:297-311.
- ESSER, J. F. S.: Neue Wege für Chirurgische Plastiken durch Heranziehung der Zahnaerztlichen Technik, Beitr. z. klin. Chir., 1916, 103:547.
- : Studies in Plastic Surgery of the Face, Ann. Surg., 1917, 65:297.
- FARMER, H. W.: Treatment of Avulsed Skin Flaps, Ann. Surg., 1939, 110:951.

- FLEGENHEIMER: Virginia M. Monthly, June 26, 1903.
- FREEMAN, LEONARD: Skin Grafting, page 8, St. Louis, C. V. Mosby Co., 1912.
- GARRÉ: Über die histologischen vorgänge bei der Anheilung Thiersch Transplantation, Beitr. z. klin. Chir., 1889, 4:624.
- GILLIES, H. D.: The Design of Direct Pedicle Flaps, Brit. M. J., 1932, 2:1008.
- : Experiences with Tubed Pedicle Flaps, Surg., Gynec. & Obst., 1935, 60:291.
- : Practical Uses of the Tubed Pedicle Flap, Am. J. Surg., 1939, XLIII:201-215.
- GUTTMAN, L.: Re-establishment of Function of the Sweat Glands, etc., Dermat. Ztschr., 1938, 77:73-77.
- HALSTED, W. S.: Surgical Papers of W. S. Halsted, Baltimore, Johns Hopkins Press, 1924, Vol. I and II.
- : Three Cases of Plastic Surgery, Johns Hopkins Hospital Bulletin, 1896, 7:25.
- HARVEY, S. C. and HOWES, E. L.: Effect of High Protein Diet on Velocity of Growth of Fibroblasts in Healing of Wounds, Ann. Surg., 1930, 91:641.
- HERMANNSDORFER, A.: Quoted by Reimers and Winkler.
- HOLMAN, E.: Preoperative Precaution in the Prevention of Postoperative Pulmonary Complications, Surg., Gynec. & Obst., 1939, 68:335.
- : Protein Sensitization in Iso-Skin Grafting, Surg., Gynec. & Obst., 1924, 38:100-106.
- : Quoted by Loeb, Leo: Transplantation and Individuality, Physiol. Rev., 1930, 10:547.
- HOWES, E. L. and HARVEY, S. C.: Age Factor in Velocity of Growth of Fibroblasts in The Healing of Wounds, J. Exper. Med., 1932, 55:577.
- KADANDOFF, D.: Arch. f. Entwicklgsmechn. d. Organ., 1925, CVI:249.
- KELLER, W. L.: Ten Years of the Tunnel Skin Graft, Ann. Surg., 1930, 91:924.
- KRAUSE, F.: Ueber die Transplantation Grosser Ungestelter, Hautlappen, Verhandl. d. deutsch, Gesellsch. f. Chir., 1893, 22:46.
- KREDEL, F. E. and PHEMISTER, D. B.: Recovery of Sympathetic Nerve Functions in Skin Transplants, Arch. Neurol. & Psychiat., 1939, 42:403.
- KREDEL, F. E. and EVANS, J. P.: Recovery of Sensation in Denervated Pedicle and Free Skin Grafts, Arch. Neurol. & Psychiat., 1933, 29:1203.
- LAWSON, G.: On Transplantation of Portions of Skin for Closure of Large Granulating Surfaces, Tr. Clin. Soc., London, 1871, 4:49-53.
- LEFORT: Gaz. d. hop., 1872, Number 7.
- LEXER, E.: Die Freien Transplantation, 2nd Vol., Die Neue Deutsche Chirurgie.

- LOEB, LEO: Transplantations and Individuality, *Physiol. Rev.*, 1930, 10:547.
- : Autotransplantation and Homiotransplantation of Cartilage in the Guinea Pig, *Am. J. Path.*, 1926, 2:111.
- LUSK, Z. J.: Some Additional Facts Relating to Skin Grafting, *J.A.M.A.*, 1879, 29:782.
- MACLENNAN, A.: "Tunnel" Skin Grafting, *Glasgow M. J.*, 1912, 78:86-90.
- MADDOCK, W. G. and COLLIER, F. A.: Body Fluid Changes Due to Upper Intestinal Obstruction, *J.A.M.A.*, 1937, 108:1.
- VON MANGOLDT, F.: Zur Behandlung der Knochenhoehlen in der Tibia, *Arch. f. klin. Chir.*, 1903, 69:82.
- : Die Ueberhautlung von Wundflaechen und Wundhoelen durch Epithelaussaat; eine Neue Methode der Transplantation, *Deutsche med. Wehnschr.*, 1895, 21:798.
- MARCHARD: Der Prozess der Wundheilung mit Einschluss der Transplantationen, *Deutsche Chir.*, 1901.
- MASSON, J. C.: Skin Grafting, *J.A.M.A.*, 1918, 70:1581.
- MCCARROL, H. R.: The Regeneration of Sensation in Transplanted Skin, 1938, *Ann. Surg.*, 108:309.
- MCINDOE, A. H.: The Application of Cavity Grafting, *Surgery*, 1937, 1:535.
- MILES: Edinburgh Hospital Report, 1895, page 647.
- : *Tr. Med.-Chir. Soc. Edinburgh*, 1889-1890, n. s. LX:33
- MOSZKOWICZ: Ueber Verflanzung Thiersch Epidermislappechen in die Munhohle, *Arch. f. Clin. Surg.*, 1916, 108:216.
- NETOLITCHI: Quoted by Davis, J. S.: *Plastic Surgery, Its Principles and Practices*, Phil., P. Blakiston's Son and Co., 1919.
- OLLIER, L.: Greffes Cutanees ou Autoplastiques, *Bull. Acad. de Med.*, 1872, 1:243.
- : *Skin Grafts*, *Lyon med.*, 1872, 9:464.
- PADGETT, E. C.: Free Full Thickness Skin Transplantation, *J. Kansas M. Soc.*, 1927, 27:145-148.
- : Full Thickness Skin Grafts in the Correction of Soft Tissue Deformities, *J.A.M.A.*, 1932, 98:18-22.
- : Is Iso-Grafting Practicable? *J. South. M.A.*, 1932, 25:895-900.
- : Is Skin Grafting with Isografts or Homografts Practicable? *Surg., Gynec. & Obst.*, 1932, 25:786-787.
- : Early and Late Treatment of Burns, *J. Kansas M. Soc.*, 1933, 34:184.
- : Care of the Severely Burned, with Special Reference to Skin Grafting, *Arch. Surg.*, 1937, 36:64-86.
- : Skin Grafting in Severe Burns, *Am. J. Surg.*, 1939, 43:626-636.
- : Calibrated Intermediate Skin Grafts, *Surg., Gynec. & Obst.*, 1939, 69:799-793.
- PARCE, A. D.: An Improved Method of Skin Grafting, *Ann. Surg.*, 1922, 75:658.

- PEER, L.A. and PADDOCK, R.: Histological Studies in the Fate of Deeply Implanted Dermal Grafts, *Arch. Surg.*, 1937, 34:268.
- PERTHES, G.: Is Homoplastic Skin Grafting Between Brother and Sister Comparable to Autografting? *Zentralbl. f. Chir.*, 1917, 44:426.
- PICKERILL, H. P.: The Tube Flap and Tube Graft in Facial Surgery, *Brit. J. Surg.*, Bristol, 1921-1922, 9:321-326.
- POLLOCK, G. D.: Cases of Skin Grafting and Skin Transplantation, *Tr. Clin. Soc. London*, 1871, 4:37.
- REIMERS, C. and WINKLER, H.: Experimentelle untersuchungen zur wundheilung und rhie beinslunssung, durch "Azidose" (saure Kost, *Deutsche-Ztschr. f. Chir.*, 1933, 241:313.
- REVERDIN, J. L.: *Arch. gen. de med.*, 1872, XIX:276, 555, 703.
- : *Bull. gen. de Therap.*, 1872, LXXXII: 71.
- REVIN: *Brit. M. J.*, Nov. 3, 1877, page 623.
- RESCHKE: Epithelizierungsversuche, *Arch. f. klin. Chir.*, 1922, 121:233.
- SABELLA, N.: *Med. Rec. N. Y.*, March 15, 1913, page 1029.
- SAUERBRUCH, F. and HEYDE, M.: Weitere Mitteilungen uber d. Parabiose 1. Warm blutern mit Versuchen uber Ileus u. Uraemie *Zeitschr. f. Exper. Pathol. u Therap.*, 1909, 6:33
- SHAWAN, H. K.: Principle of Blood Grouping Applied to Skin Grafting, *Am. J. M. Sc.*, 1919, 157:503.
- SMITH, FERRIS: Pressure Bags for Skin Grafting, *Surg. Gynec. & Obst.*, 1926, 43:99.
- SMITH, ARTHUR: Personal Communication to author.
- STRAATSMA, C. R.: The Use of the Dermal Graft in the Repair of Small Saddle Defects of the Nose, *Arch. Otolaryngol.*, 1932, XVI:506.
- TAYLOR, F.: Pressure Bags in Grafting, *Am. J. Surg.*, 1936, 33:328-329.
- THIERSCH, KARL: Ueber Hautverpflanzung. *Verhandl. d. deutsch. Gesellschaft. f. chir.*, 1886, 15:17.
- : Ueber die feineren anatomischen veränderungen bei aufheilung von hout auf granulationen, *Verhandl. d. deutsche Gesellschaft, f. chir.*, Berlin, 1874, 3:69-75.
- THOMPSON, W. D., RAVDIN, I. S. and FRANK, I. L.: Effect of Hypoproteinemia on Wound Disruption, *Arch. Surg.*, 1938, 36:500.
- VENABLE, S. S.: *Southwest J. Med. & Surg.*, 1914, XXIX:341.
- WANGENSTEEN, O. H.: The Implantation Method of Skin Grafting, *Surg., Gynec. & Obst.*, 1930, 50:634.
- WEBSTER, J. P.: Quoted by Christopher.
- WESTHUES: Modification der Thiersch Transplantation, *Zentralbl. f. Chir.*, *State J. Med.*, 1926, 36:1372.
- WOLFE, J. R.: New Method of Performing Plastic Operations, *Brit. M. J.*, 1875, 2:360.
- YOUNG, HUGH H.: Genital Abnormalities, Hermaphroditism and Related Adrenal Diseases, Baltimore, Williams and Wilkins Co., 1937.

Index

A

Acid diet	84
Amniotic sac	14
Anatomic factors in skin grafting	19, 82
Anemia	83, 91
Arteriosclerotic gangrene	31
Artificial vagina	68, 127
Technique of building	128
Aseptic denuded surfaces	19, 31, 95, 98
Autogenous grafts	7, 15, 16
Autografts of skin	15
Histology of	16-18
Preservation of	15
Autotransplantation of skin	6, 7
Autotransplantation of thyroid gland	10
Axilla, contracture of	21, 78

B

Birthmarks (See Hemangioma)	
Blair knife for cutting skin grafts	23
Blood grouping	12, 86
Blood plasma	83
Blood, protein count	83
Blood supply	86
Blood transfusion	6, 64, 91
Bone grafts	79
Burns, treatment of	88-93
Burns, roentgen ray and radium	115

C

Calibrated intermediate skin grafts	34-42
Classification	42
Results	44-55
Carcinomatous changes after x-ray burn	117
Casts, application of	102
Cavity grafting	23, 67, 127, 131
Chemical characteristics of tissues	11
Chromosomes	12
Cicatricial contractures (See Contractures)	

Cicatrix	
of axilla	97
of eyebrow region	114
of leg	62
Colostomy, skin graft following	31
Corpuseles of donor area	7
"Cover Mark"	126
Contractures, cicatricial	
of arm, 60; of axilla, 20-23, 58-60, 78, 108; of elbow, 60, 78, 109;	
of face, 113; of fingers, 19, 78, 92, 110; of groin, 78, 101; of neck, 20,	
60, 77, 109; of perineum, 109; of popliteal space, 61, 78, 109, 118; of	
wrist, 78.	
Contractures,	
Healed	94
Prevention of	3, 83
Release of	32
of base after skin grafting	29

D

Dakin's tube	94
Dehydration	83
Denuded surface	10, 19, 31, 95, 98
Dermal grafts	132
Histologic changes in	132
Technic	133
for pock marks and depressed scars	133
Dermatome	19, 29, 35, 60, 85
Advantages of	67
Donor area	29
Corpuseles of	7
Healing of	23, 104
Postoperative dressing	99
Scarring of	62
Selection of	85
Dressings	98, 104
Marine sponge	99-100
Wet roller gauze	88

E

Ectropion	
of eyelids, 21; of lip, 112-113	
Elastic fibers in skin grafts	15

Electrolyte requirements	84
Endothelioma	129
Epithelial inlay grafting	69
Epithelial outlay grafting	70
Epithelioma, basal cell	63
Eyelids, ectropion of	21
Eyebrow, reconstruction of	85, 114, 126
Experimental results with homotransplantation	6

F

Fetal membranes, transplantation of	14
Fibroblastic reaction in skin grafts	13
Flaps, skin	33, 75-81, 122, 126
advantages of 75; disadvantages of, 75	
Fluid requirements	84

G

Gangrene, arteriosclerotic	31
Genetic constitution of host and donor	10
Glands, sweat	17
Grafts	
Autogenous	15, 16
Bone	79
Cutis	16
Dermal grafts	132
histologic changes in	132
technic	133
for pock-marks and depressed scars	133
"Epidermic"	3
Isodermic	6
Homo	6
Mucosal	131
technic	131
Skin (See Skin grafts)	
Granulating areas	19, 23
Postoperative care	94
Preparation of	88-89
Skin grafting on	19, 23, 64-66, 88-94
Granulating wounds	64, 89-91

H

Hemangioma, of face	26, 124-125
Heterografts	13
Heterotransplantation	11, 14
Histology of autografts	15
Homotransplantation	
of skin	7, 12
experimental results	6-9
Hypoproteinemia	83

I

Identical twins	
Skin grafting in	7-13
Results	8-9
Implantation method of skin grafting	31
Technic	32
Infection	93
Pyocyanous	65
Injection experiments	16
Isodermic grafts	6

K

Keloid of face	112
Knife, Blair's, for cutting skin grafts	23

L

Leg ulcers	121
Skin flaps for	122
Skin grafts for	117-122
Prognosis	122
Lymphocytic reaction in skin grafts	13

M

Methods of gaining pressure	102
Mucosa, transplantation of	131
Technic	131
Mucosal grafts	131

N

Nevi	130
Nose, luetic	71
Rebuilding of	71
Nose, rhinophyma of	128

O

- Organismal differentials
 Genetic basis of, 12; theory of, 11
 Osteomyelitis of tibia78

P

- Parabiosis
 Skin grafting after13
 Pedicled flaps75-81, 126
 Advantages of, 75; disadvantages of, 75
 Perianal lesions117
 Pigmentation of grafts29, 112, 126
 Pin point grafts24, 30
 Plantar warts117
 "Pock" marks133
 Preserved autogenous skin grafts15
 Pressure sponge98

R

- Radium burns115
 Recipient area85
 Relationship between host and donor10
 Reconstruction of
 jaw, 79; labial buccal alveolar sulcus, 79, 127; nose, 71, 72, 77, 127;
 orbit, 73, 127; urethra, 72, 128; vagina, 68, 127.
 Relining of cavities with skin grafts68, 127, 131
 Technic70, 131
 Rhinophyma128
 Roentgen ray burns115

S

- Scar, keloidal112
 Scarring of donor area62
 Sensation of skin grafts105
 Skin, autotransplantation of6, 7
 Skin
 Histology15
 Heterotransplantation of11, 15
 Homotransplantation6, 12, 15
 Pigmentary changes in29
 Preservation of7-10
 Syngenesiotransplantation of12

Skin flaps	33
Advantages of	75
Definition of	75
Disadvantages of	75
Indications	78
Versus skin grafts	75
Skin grafts	
After parabiosis	13
Age factor	83-84
Anatomic factors	19, 82
Blood grouping	7, 12
Blood transfusion	6, 91
Classification	42-43
Comparison of methods	42
Donor area	23, 29, 34, 85, 99, 104
Dressings	88, 98, 100-104
Factors conducive to success	86, 91, 96
General considerations	83
Histology	13-15
In identical twins	7-13
Indications	87
Infection	65, 93
Objectives	82
Pigmentary changes	121, 126
Properties of	19, 21, 25
Preoperative care	87-89
Postoperative care	94
Pressure and fixation	65, 98-102
Return of sensation	105
Results	8, 9, 44-56, 122
Type of base	86
Technic	19, 23, 28, 31, 70, 95, 131
Varying thickness	40-42
Versus skin flaps	75
Skin grafts on	
fresh denuded surface	4, 10, 19, 32, 33, 56, 57, 107
granulating surface	15, 19, 31, 63, 86, 88, 107
ulcer surface	4, 32, 64, 78, 86, 107, 120
Skin grafts for	
Arteriosclerotic veins	119
Burns	20, 89-92, 107, 115
Cicatricial contracture	19, 56, 97, 108-115, 118

Hemangioma	26, 124
Nevi	130
Perianal lesions	117
Plantar warts	117
Radium burns	115
Rhinophyma	128
Roentgen ray burns	115
Syndactylism	19, 26, 123
Ulcers of leg	117-123
Varicose veins	119
Skin grafts for rebuilding eyebrow	85, 115, 126
for relining sulci and cavities	23, 56, 68, 73, 127, 131
after removal of endothelioma	129
after removal of pedicled flaps	126
Skin grafts (Types of)	
Autogenous	7, 15, 16
Buried	32
Calibrated	23, 34, 38, 58, 67, 99
Deep intermediate	31, 39
Epidermic	16
Esser inlay	16
Free	33
Full thickness	3, 6, 17, 19, 30, 56, 95
Properties of, 25; removal of, 27, 33; technic, 28	
Homografts	15
Implantation	5
Technic	31-32
Injected	33
"Inlay" stent	4, 69
"Outlay" stent	70
"Pin point"	24
Pulpified epidermic	33
"Sieve"	5, 30
Small deep	4, 24, 29
"Split"	4, 19, 31, 34, 42
Properties of	19, 21
Technic	23
"Stent"	68, 69, 127-128
Technic	70-72, 131
"Sheet"	3, 32
Thiersch	3, 6, 19, 23, 31, 37, 42, 56
Postoperative dressing period	23

Properties of	19, 21
Technic	23
Thin	6, 23, 29, 42, 65, 86, 95
Advantages of	56
Disadvantages of	23, 56
"Three-quarter thickness"	34, 41, 56, 62, 109
Applicable surface	96
Results	59
Tunnel	5
Advantages of	32
Zoografts	13
Splints, application of	102, 103
Stents	
Marine sponge	99
Modeling composition	69, 70, 101
Paraffin	68
Suction retractors	23
Syndactylism	19, 26, 95, 123
Syngenesiotransplantation	12

T

Tannic acid	104
Telangiectasis	116, 117
Thick skin grafts (See Skin grafts)	
Thiersch grafts (See Skin grafts)	
Thin skin grafts (See Skin grafts)	
Three-quarter thickness skin grafts (See Skin grafts)	
Thyroid gland, autotransplantation of	10
Thyroid cartilage, skin grafting over	110
Tissues	
Chemical characteristics of	11
Nature of tissues lost	86
Traction, application of	102
Transplantation of fetal membranes	14
Transplantation of skin (See Skin grafts)	
Tunnel grafts (See Skin grafts)	

U

Ulcers of leg	
Chronic	32, 86, 121
Recent	120-122
Varicose	64, 78, 86
Treatment	93, 107, 120, 122

V

Vagina, reconstruction of	68, 127-128
Varicose ulcer	64, 78
Varicose veins	119
Vitamin deficiency	84

W

Web fingers	19, 26, 95, 123-124
Wounds, healing of	4
Accidental	87

X

X-ray burns	115
"X-ray hands"	117

Y

Y or sex chromosomes	12
----------------------------	----

Z

Zoografts	13
-----------------	----



