

The anatomy of the nervous system : from the standpoint of development and function / by Stephen Walter Ranson.

Contributors

Ranson, Stephen Walter, 1880-1942.

Publication/Creation

Philadelphia : W.B. Saunders, 1920.

Persistent URL


<https://wellcomecollection.org/works/zreqdbsa>

License and attribution

Conditions of use: it is possible this item is protected by copyright and/or related rights. You are free to use this item in any way that is permitted by the copyright and related rights legislation that applies to your use. For other uses you need to obtain permission from the rights-holder(s).



Wellcome Collection
183 Euston Road
London NW1 2BE UK
T +44 (0)20 7611 8722
E library@wellcomecollection.org
<https://wellcomecollection.org>






22102106305


Med
K35188

J Granger Stewart

54 Deane Ave Strat

NY I





Digitized by the Internet Archive
in 2017 with funding from
Wellcome Library

<https://archive.org/details/b29813657>

THE ANATOMY
of the
NERVOUS SYSTEM

FROM THE STANDPOINT OF DEVELOPMENT AND FUNCTION

By
STEPHEN WALTER RANSON, M. D., Ph. D.
Professor of Anatomy in Northwestern University Medical School, Chicago

WITH 260 ILLUSTRATIONS
SOME OF THEM IN COLORS

PHILADELPHIA AND LONDON
W. B. SAUNDERS COMPANY
1920

6525716

Copyright, 1920, by W. B. Saunders Company



| WELLCOME INSTITUTE LIBRARY | |
|----------------------------|----------|
| Coll. | welMOmec |
| Call | |
| No. | WL |
| | |
| | |
| | |

PRINTED IN AMERICA
PRESS OF
W. B. SAUNDERS COMPANY
PHILADELPHIA

P R E F A C E

IN the pages which follow the anatomy of the nervous system has been presented from the dynamic rather than the static point of view; that is to say, emphasis has been laid on the developmental and functional significance of structure. The student is led at the very beginning of his neurologic studies to think of the nervous system in its relation to the rest of the living organism. Structural details, which when considered by themselves are dull and tiresome, become interesting when their functional significance is made obvious. This method of presentation makes more easy the correlation of the various neurologic courses in the medical curriculum. For physiologic and clinical neurology a knowledge of conduction pathways and functional localization is essential, and this information can best be acquired in connection with the course in anatomic neurology. In selecting the material to be included in this book the needs of the medical student have been kept constantly in mind, and emphasis has been placed on those phases of the subject which the student is most likely to find of value to him in his subsequent work.

In many laboratories the head of the shark and the brain of the sheep have been used to supplement human material. The book has been so arranged as to facilitate such comparative studies without making it any the less well adapted to courses where only human material is used.

During the past twenty years very considerable additions have been made to the science of neurology, and the more important of these have been included in the text. While a detailed presentation of the evidence concerning new or disputed points would be out of place in a book of this kind, whenever the statements made here differ from those found in other texts the authority has always been cited, the author's name and the date of his contribution being given in parentheses. A full list of these references to the literature has been included in a Bibliography at the end of the volume.

The terminology adopted is that of the B. N. A., which has been used, for the most part, in its English form. But in the case of the fiber tracts the Basle

terms are often misleading, and wherever this is the case, other names have been substituted.

An outline for a laboratory course in neuro-anatomy has been included, and this has been so arranged as to be easily adapted by the instructor to his particular needs.

Free use has been made of material gathered and arranged by others in the various handbooks, texts, and atlases that deal with the nervous system. The classification of the afferent paths and centers adopted here is based on the work of Sherrington. The terms which he introduced and which are now coming into general use have been employed. In the analysis of the cranial nerves the American conception of nerve components, so ably presented by Herrick, has been utilized.

Illustrations have been borrowed from many sources, in each case duly accredited, and our indebtedness for permission to use them is gladly acknowledged. The majority of the figures have been made from drawings prepared for this purpose by Miss M. E. Bakehouse. The large number of illustrations and the excellent manner in which they have been reproduced is to be credited to the generous policy of the publishers, W. B. Saunders Co. My thanks are due to Dr. Olaf Larsell for reading the manuscript and for many valuable suggestions, and to Mr. Michael Mason for assistance in reading the proof.

S. W. RANSON.

CHICAGO, ILL.,
November, 1920.

CONTENTS

| | PAGE |
|---|------|
| CHAPTER I | |
| ORIGIN AND FUNCTION OF THE NERVOUS SYSTEM..... | 17 |
| The Diffuse Nervous System of Cœlenterates..... | 19 |
| The Central Nervous System..... | 20 |
| CHAPTER II | |
| THE NEURAL TUBE AND ITS DERIVATIVES..... | 24 |
| The Brain of the Dogfish..... | 26 |
| Development of the Neural Tube in the Human Embryo..... | 31 |
| CHAPTER III | |
| HISTOGENESIS OF THE NERVOUS SYSTEM..... | 37 |
| Development of the Neuron..... | 37 |
| Development of the Spinal Nerves..... | 40 |
| Differentiation of the Spinal Cord..... | 42 |
| CHAPTER IV | |
| NEURONS AND NEURON-CHAINS..... | 43 |
| Form and Structure of Neurons..... | 43 |
| Interrelation of Neurons..... | 49 |
| The Neuron as a Trophic Unit..... | 51 |
| The Neuron Concept..... | 52 |
| Neuron Chains..... | 53 |
| CHAPTER V | |
| THE SPINAL NERVES..... | 56 |
| Metamerism..... | 58 |
| Functional Classification of Nerve-fibers..... | 60 |
| The Spinal Ganglia..... | 62 |
| Somatic Sensory Fibers and Nerve Endings..... | 66 |
| CHAPTER VI | |
| THE SPINAL CORD..... | 73 |
| External Form and Topography..... | 73 |
| The Spinal Cord in Section..... | 78 |
| Microscopic Anatomy..... | 85 |
| The Spinal Reflex Mechanism..... | 91 |
| CHAPTER VII | |
| FIBER TRACTS OF THE SPINAL CORD..... | 95 |
| Intramedullary Course of the Dorsal Root Fibers..... | 95 |
| Afferent Paths in the Spinal Cord..... | 98 |
| Ascending and Descending Degeneration in the Spinal Cord..... | 105 |
| Long Descending Tracts of the Spinal Cord..... | 108 |
| CHAPTER VIII | |
| GENERAL TOPOGRAPHY OF THE BRAIN..... | 113 |
| Anatomy of the Medulla Oblongata..... | 118 |
| Anatomy of the Pons..... | 123 |
| The Fourth Ventricle..... | 125 |
| The Mesencephalon..... | 129 |

| CHAPTER IX | | PAGE |
|--|--|------|
| THE STRUCTURE OF THE MEDULLA OBLONGATA..... | | 132 |
| The Rearrangement Within the Medulla Oblongata of the Structures Continued Upward from the Spinal Cord..... | | 133 |
| Decussation of the Pyramids..... | | 136 |
| Nucleus Gracilis, Nucleus Cuneatus, and Medial Lemniscus..... | | 137 |
| Olivary Nuclei..... | | 141 |
| Restiform Body..... | | 143 |
| Formatio Reticularis..... | | 144 |
| CHAPTER X | | |
| INTERNAL STRUCTURE OF THE PONS..... | | 147 |
| Basilar Part of the Pons..... | | 147 |
| Dorsal Part of the Pons..... | | 149 |
| CHAPTER XI | | |
| INTERNAL STRUCTURE OF THE MESENCEPHALON..... | | 158 |
| Tegmentum..... | | 158 |
| Basis Pedunculi..... | | 164 |
| Corpora Quadrigemina..... | | 165 |
| CHAPTER XII | | |
| THE CRANIAL NERVES AND THEIR NUCLEI..... | | 168 |
| Somatic Efferent Column of Nuclei..... | | 170 |
| Special Visceral Efferent Column of Nuclei..... | | 174 |
| General Visceral Efferent Column of Nuclei..... | | 177 |
| Visceral Afferent Column..... | | 180 |
| General Somatic Afferent Nuclei..... | | 182 |
| Special Somatic Afferent Nuclei..... | | 185 |
| Summary of the Origin and Composition of the Cranial Nerves..... | | 190 |
| CHAPTER XIII | | |
| THE CEREBELLUM..... | | 195 |
| Development..... | | 195 |
| Anatomy..... | | 196 |
| Morphology..... | | 199 |
| Nuclei of the Cerebellum..... | | 203 |
| Cerebellar Peduncles..... | | 204 |
| Histology of the Cerebellar Cortex..... | | 206 |
| Efferent Cerebellar Tracts..... | | 211 |
| CHAPTER XIV | | |
| THE DIENCEPHALON AND OPTIC NERVE..... | | 213 |
| Thalamus..... | | 213 |
| Epithalamus and Metathalamus..... | | 220 |
| Hypothalamus..... | | 222 |
| Third Ventricle..... | | 223 |
| Visual Apparatus..... | | 225 |
| CHAPTER XV | | |
| EXTERNAL CONFIGURATION OF THE CEREBRAL HEMISPHERES..... | | 229 |
| Development of the Cerebral Hemispheres..... | | 229 |
| The Dorsolateral Surface..... | | 232 |
| The Medial and Basal Surfaces..... | | 238 |

| CHAPTER XVI | | PAGE |
|---|--|------|
| INTERNAL CONFIGURATION OF THE CEREBRAL HEMISPHERES..... | | 243 |
| Corpus Callosum..... | | 243 |
| Lateral Ventricles..... | | 246 |
| Basal Ganglia of the Telencephalon..... | | 252 |
| Internal Capsule..... | | 257 |
| Connections of the Corpus Striatum and Thalamus..... | | 262 |
| CHAPTER XVII | | |
| THE RHINENCEPHALON..... | | 265 |
| Parts Seen on the Basal Surface of the Brain..... | | 265 |
| Hippocampus..... | | 269 |
| Fornix..... | | 270 |
| Anterior Commissure..... | | 273 |
| Structure and Connections of the Several Parts of the Rhinencephalon..... | | 274 |
| Olfactory Pathways..... | | 280 |
| CHAPTER XVIII | | |
| THE CORTEX AND MEDULLARY CENTER OF THE CEREBRAL HEMISPHERE..... | | 283 |
| Structure of the Cerebral Cortex..... | | 283 |
| Cortical Areas..... | | 287 |
| Localization of Cortical Functions..... | | 290 |
| The Medullary Center of the Cerebral Hemisphere..... | | 296 |
| CHAPTER XIX | | |
| THE GREAT AFFERENT SYSTEMS..... | | 302 |
| Exteroceptive Pathways to the Cerebral Cortex..... | | 302 |
| Spinal Path for Touch and Pressure..... | | 303 |
| Spinal Path for Pain and Temperature Sensations..... | | 306 |
| Secondary Trigeminal Paths..... | | 307 |
| Neural Mechanism for Hearing..... | | 309 |
| Neural Mechanism for Sight..... | | 310 |
| Proprioceptive Pathways..... | | 311 |
| Spinal Proprioceptive Paths (Muscle Sense)..... | | 311 |
| Cerebellar Connections of Vestibular Nerve..... | | 314 |
| CHAPTER XX | | |
| EFFERENT PATHS AND REFLEX ARCS..... | | 316 |
| The Great Motor Path..... | | 317 |
| The Cortico-ponto-cerebellar Path..... | | 325 |
| The Cerebello-rubro-spinal Path..... | | 326 |
| Important Reflex Arcs..... | | 327 |
| CHAPTER XXI | | |
| THE SYMPATHETIC NERVOUS SYSTEM..... | | 334 |
| Fundamental Facts Concerning Visceral Innervation..... | | 335 |
| Structure of the Sympathetic Ganglia..... | | 341 |
| Composition of Sympathetic Nerves and Plexuses..... | | 345 |
| Architecture of the Sympathetic Nervous System..... | | 346 |
| Important Conduction Paths Belonging to the Autonomic Nervous System..... | | 352 |
| A LABORATORY OUTLINE OF NEURO-ANATOMY..... | | 355 |
| BIBLIOGRAPHY..... | | 375 |
| INDEX..... | | 383 |

THE ANATOMY OF THE NERVOUS SYSTEM FROM THE STANDPOINT OF DEVELOP- MENT AND FUNCTION

CHAPTER I

THE ORIGIN AND FUNCTION OF THE NERVOUS SYSTEM

IRRITABILITY and conductivity, which, as every biological student knows, are two of the fundamental properties of protoplasm, reach their maximum development in the highly differentiated tissue of the nervous system. Indeed, it is in response to the need for increased sensitiveness to stimuli and for better transmission of the impulses aroused by them that the nervous system has developed and been perfected in the long process of evolution which has culminated in man.

When an ameba is touched with a pointed glass rod it moves away from the source of stimulation. Changes are initiated in the superficial protoplasm which are transmitted through the unicellular organism, resulting in a flowing out of pseudopodia on the opposite side. Through a continuation of this streaming motion the entire organism moves forward. Thus the relatively undifferentiated living substance of which it is composed receives the stimulus, transmits the resulting disturbance, and carries out the appropriate response.

When in the place of unicellular organisms we study simple metazoa, the sea-anemones for example, we find that considerable differentiation has occurred among the component cells. A cuticle has formed, designed to protect the subjacent parts from the action of the surrounding objects, while other cells have differentiated in the direction of contractile elements or muscle cells. Because the general body surface has been adapted to cope with the environment it becomes necessary to have certain cells at the surface which are sensitive to environmental changes. These sensory elements are able to transmit the waves of activation developed in them directly to the subjacent muscle cells. But in higher animals, because of the large size of the body and the

complicated reactions required, long lines of communication have been established between peripheral sense organs and muscle-fibers in widely separated parts of the body.

The sensory elements and the lines of communication constitute the nervous system and, together with the musculature, the neuromuscular mechanism. It is well to keep in mind the fact that the nervous system was developed for the purpose of enabling the musculature to react to changes in the environment of the organism. But in all higher animals the nervous system responds not only to stimuli from without but also to stimuli from within the body, and helps to

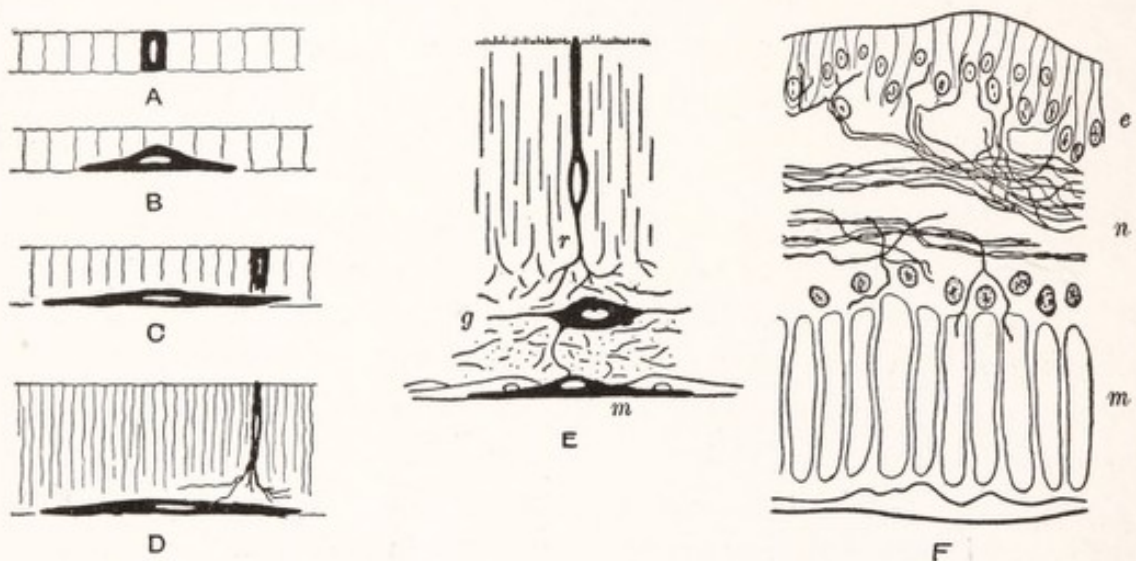


Fig. 1.—Stages in the differentiation of the neuromuscular mechanism: *A* to *C*, Hypothetic early stages: *A*, epithelial stage; *B*, muscle cell at the stage of the sponge; *C*, partially differentiated nerve-cell in proximity to fully differentiated muscle-cell; *D*, nerve- and muscle-cell of coelenterate stage; *E*, a type of receptor-effector system found in many parts of sea-anemones, including not only receptors, *r*, with their nerve-nets, and of muscle cells, *m*, but also of ganglion cells, *g*, in the nerve-net; *F*, section at right angles to the sphincter of the bell of a jellyfish (*Rhizostoma*): *e*, epithelium of the subumbrellar surface; *n*, nervous layer; *m*, muscle layer. (Parker.)

bring about an internal adjustment of part with part. Here again it acts as a sensitive mechanism for receiving stimuli and conducting them to the appropriate organs of response. These organs through which the nervous system produces its effects are known as effectors. While muscles and glands are by far the most important effectors, we must also include certain pigmented cells (or chromatophores) and electric and phosphorescent organs under this heading. Except for the reactions produced through such effectors the nervous system would be meaningless.

We can best understand the significance of the nervous system if we trace its early history. This, as it has been interpreted by Parker (1919), makes an

interesting story. According to this author contractile tissue develops before any trace of the nervous system appears. In sponges, which are devoid of nervous elements, the oscula open and close in response to appropriate stimuli. These movements are brought about by a contractile tissue not unlike smooth muscle. The active element or *effector* is thus the first to make its appearance, and at this stage is brought into action by direct stimulation. Next in the order of development is the sensory cell, derived from the epithelium in the neighborhood of an effector, and specially differentiated to receive stimuli and transmit them to the underlying muscle (Fig. 1, *D*). This stage of development is reached by such cœlenterates as the sea-anemones. The advantage which these forms derive from the specialized sensory cells or *receptors* is seen in the character of their responses, which are more rapid than those of sponges. Such

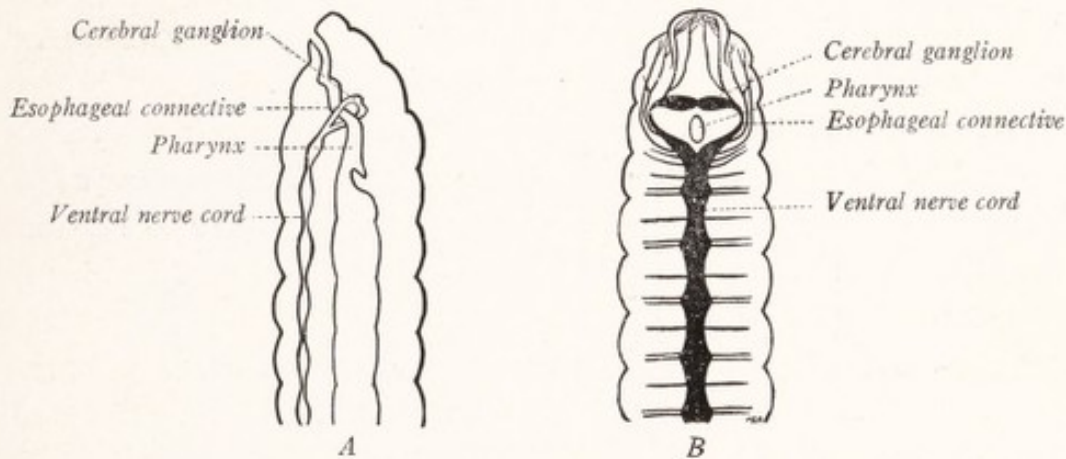


Fig. 2.—Anterior portion of the nervous system of the earthworm: *A*, Lateral view; *B*, dorsal view.

a sensory cell may be compared to a percussion cap through which a charge of powder is ignited.

But cœlenterates usually present a more complex arrangement of receptor and effector elements than that indicated in Fig. 1, *D*. Fine branches from the sensory cells anastomose with each other and form a nervous net within which are scattered nerve-cells. Such a nerve net is seen in many parts of sea-anemones (Fig. 1, *E*) and is well developed in the jellyfish (Fig. 1, *F*). It seems capable of conveying nerve impulses coming from the sensory cells in all directions through the bell-shaped body of the jellyfish and to muscle-fibers far distant from the receptors involved. The conduction of nerve impulses from receptors to effectors seems to occur diffusely through the net—not in stated directions nor along fixed paths. In this respect the *diffuse nervous system* of the cœlenterates is in contrast with the more *centralized system* in the worms.

The sensory cells are not so directly connected with muscle-fibers in the worms as in the sea-anemones, for between receptor and effector there is here interposed a *central nervous system*. This system, as it appears in the earthworm, is illustrated in Fig. 2. It consists of a cerebral ganglion dorsal to the buccal cavity and a row of ventrally placed ganglia bound together by a ventral nerve cord. The most anterior of the ventral series of ganglia is connected to the dorsal one by nerve strands on either side of the esophagus. The ganglia of the ventral cord are placed so that one occurs in each body segment, and from each three pairs of nerves run to the skin and muscles of that segment. The arrangement of the constituent elements can best be studied in transverse sections (Fig. 3). The sensory cells are located in the skin, and from each of them a fiber runs along one of the nerves into the ganglion, within which it branches, helping to form a network known as the neuropil. Within each

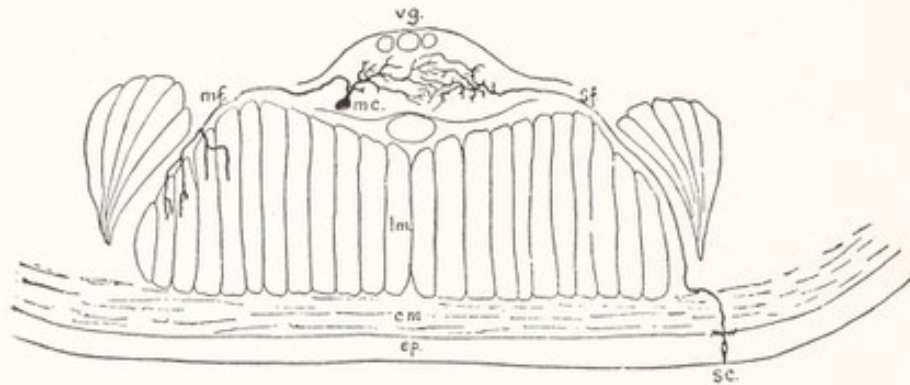


Fig. 3.—Transverse section of the ventral chain and surrounding structures of an earthworm: *cm*, Circular muscles; *ep*, epidermis; *lm*, longitudinal muscles; *mc*, motor cell-body; *mf*, motor nerve-fiber; *sc*, sensory cell-body; *sf*, sensory nerve-fiber; *vg*, ventral ganglion. (Parker.)

ganglion are found large nerve-cells from which fibers run through the nerves to the segmental musculature. Here we have the necessary parts for the simplest reflex arc. Stimulation of the sensory cell causes nerve impulses to travel through its fiber to the neuropil, thence to a motor cell, and finally along a process of the latter to the muscle. In other words, we have a receptor, conductor, center, another conductor, and finally an effector; and all this is for the purpose of bringing the muscle-fiber under the influence of such environmental changes as are able to stimulate the sensitive receptor.

In addition to the primary sensory and motor elements just enumerated the ganglia contain nerve-cells the fibers of which run from one ganglion to another and serve to associate these in co-ordinated activity. These internuncial elements serve to establish functional connections among the different parts of the ganglionated nerve cord that constitutes the central nervous apparatus;

and they lie entirely within this central organ. The slow waves of contraction that pass from head to tail as the worm creeps forward may be advanced from segment to segment by such internuncial or association elements.

The nervous system of the earthworm differs from that of the coelenterate in many ways, but the fundamental difference is one of centralization. In the former the greater part of it has separated from the skin and become concentrated in a series of interconnected ganglia which serve as a *central nervous system*. These ganglia receive nerve-fibers, coming from the sense organs, and give off others, going to the muscles; and the fibers are brought together and grouped into nerves for convenience of passage. The neuropil within a ganglion offers a variety of pathways to each incoming impulse which may accordingly find its way out along one or more of several motor fibers. The spreading of nerve impulses through the chain of ganglia is facilitated by the presence of the association fibers already mentioned. Nevertheless, conduction is not diffuse as in the nerve net of the medusa, but occurs along definite and more or less restricted lines. This is well illustrated by the experiment cited by Parker: "If an earthworm that is creeping forward over a smooth surface is suddenly cut in two near the middle, the anterior portion will move onward without much disturbance, whereas the posterior part will wriggle as though in convulsions. This reaction, which can be repeatedly obtained on even fragments of worms, shows that a single cut involves a stimulation which in a posterior direction gives rise to a wholly different form of response to what it does anteriorly; in other words, transmission in the nerve cord of the worm is specialized as compared with transmission in the nervous net of the coelenterate." In the ganglionated cord of the earthworm, as here described, we find many of the features characteristic of the central nervous system of higher forms.

The vertebrate nervous system has much in common with that of the earthworm. The central nervous system of the annelid is split off from the ectoderm by a process of delamination, as will be seen by comparing the ventral nervous cord of the marine worm, *Sigalion*, with that of the earthworm (Figs. 3, 4). Through a comparable process of infolding of the ectoderm to form a neural tube there is developed the central nervous system of the vertebrate (Fig. 6). The dorsal position of the neural tube in vertebrates as compared with the ventral position of the solid nerve cord of the annelid offers some difficulty and has led to ingenious theories in explanation of their phylogenetic relationship, theories which we need not consider here (Gaskell, 1908). In primitive chordates, such as the amphioxus, we already have a simple, dorsally placed, neural

tube associated with segmental nerves. In true vertebrates the anterior end of the neural tube becomes irregularly enlarged to form the brain, while the posterior end remains less highly but more uniformly developed and forms the spinal cord.

The primary motor nerve-cells of vertebrates resemble very closely those of invertebrates in being located within the central nervous system and in sending motor nerve-fibers to the muscles (Fig. 31). The primary sensory cells lie outside the central system, as in invertebrates. Those for smell are located in the olfactory epithelium. But all others have migrated centrally along the sensory fibers, and now send one process toward the periphery and another into

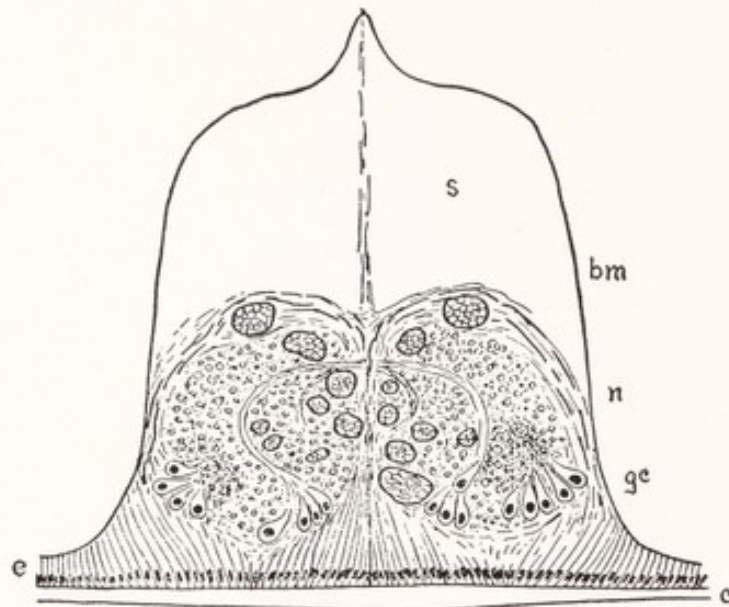


Fig. 4.—Transverse section of the ventral nervous cord of *Sigalion*: *bm*, Basement membrane; *c*, cuticula; *e*, epidermis; *gc*, ganglion-cells; *n*, nerve-fibers and neuropil; *s*, space occupied by vacuolated supporting tissue. (Parker, Hatschek.)

the central system. The relative positions of these cells in the annelid, mollusc, and vertebrate are illustrated in Fig. 5. In the latter the sensory cells are aggregated into masses known as the cerebrospinal ganglia, which are associated with peripheral nerves and are usually placed near the point of origin of these nerves from the brain or spinal cord. A comparison of Figs. 3 and 31 will show a striking similarity between the simple reflex arc in the earthworm and in man. If space permitted we might trace the development of the central nervous system in some detail, but perhaps enough has been given to suggest that the nervous system of man represents the culmination of a long process of evolution which began with a simple sensory mechanism like that of the sea-anemones.

We shall be concerned with a study of the vertebrate nervous system, almost

exclusively with that of the mammal, and more particularly with that of man. In man we are so accustomed to think of the nervous system as the organ and agent of the mind that its true physiologic position is often forgotten. In this introductory chapter we have attempted to show that the primary function of the nervous system is to receive stimuli arising from changes in the environment or within the organism, and to transmit these to effectors which bring about the adjustments necessary for life. Biologically speaking, the nervous system is not to be regarded as an intelligence bureau, which gathers information for

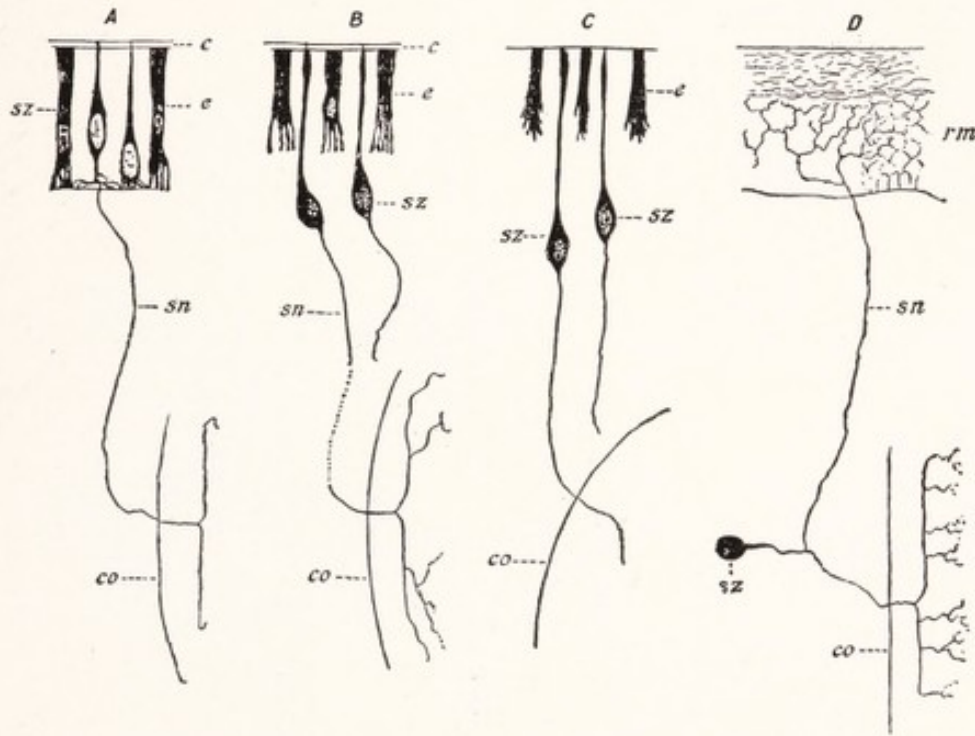


Fig. 5.—Peripheral sensory neurons of various animals: *A*, Oligochaetic worms (*Lumbricus*); *B*, polychaetic worms (*Nereis*); *C*, molluscs (*Limax*); *D*, vertebrates. The figure illustrates the gradual change in the position of the sensory cells in the phylogenetic series: *e*, Epithelial cells of sensory surface; *c*, cuticula; *sz*, cell-body of peripheral sensory neuron; *rm*, rete Malpighii of epidermis; *sn*, axon; *co*, central nervous system. (Barker, Retzius.)

a sovereign mind, enthroned within the brain, nor yet as a chief executive officer to carry out that sovereign's decrees. Sensory impulses from many sources reach the brain, where they pass back and forth through a multitude of association paths, augmenting or inhibiting each other before they finally break through into motor paths. Previous experience of the individual, having left its trace in the organization of the central nervous system, alters the character of the present reactions. It is in connection with the neural activity involved in these complex associational processes that consciousness appears—shall I say as a by-product?—at least as a parallel phenomenon.

CHAPTER II

THE NEURAL TUBE AND ITS DERIVATIVES

Infolding of the Neural Tube.—The vertebrate nervous system develops from a thickened plate of ectoderm along the middorsal line of the embryo. By the infolding of this *neural plate* there is formed the neural groove, which becomes transformed into the *neural tube* (Fig. 6). The neural tube detaches itself from the superficial ectoderm and gives rise through a thickening of its walls to the brain and spinal cord. The latter is formed by a process of uniform

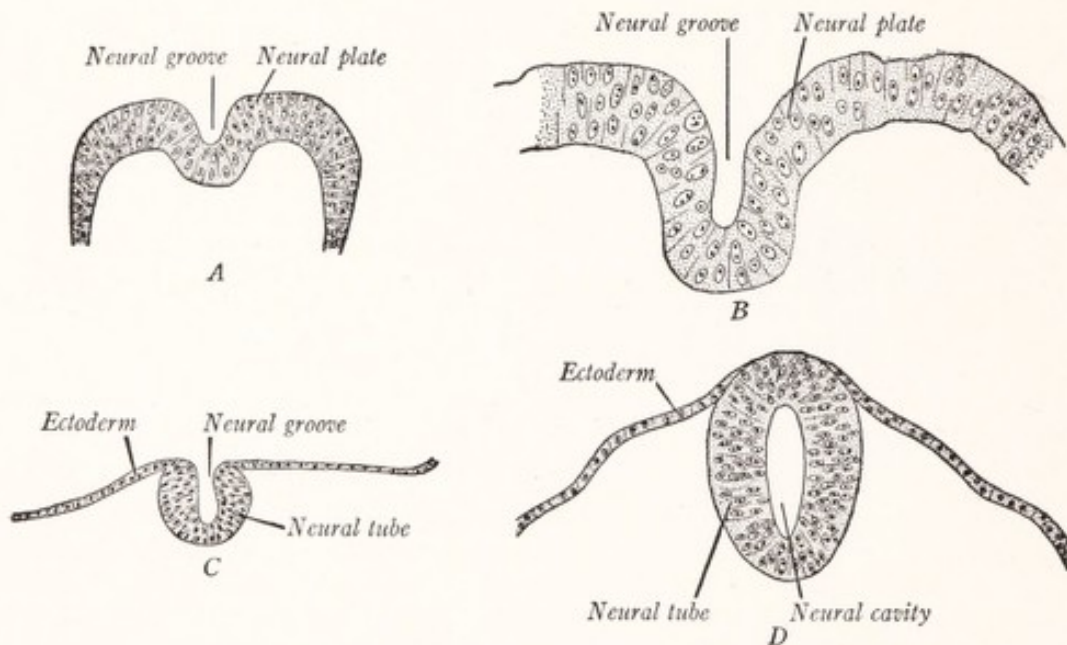


Fig. 6.—Development of the neural tube in human embryos (Prentiss-Arey): *A*, An early embryo (Keibel); *B*, at 2 mm. (Graf Spee); *C*, at 2 mm. (Mall); *D*, at 2.7 mm. (Kollmann).

thickening in the walls of the caudal portion of the tube. The derivatives of the rostral part are well illustrated in the accompanying diagram (Fig. 7).

Brain Vesicles.—At an early stage in the development of any vertebrate embryo the rostral portion of the neural tube is distinguished from the caudal part by the more rapid development of the former, its walls bulging outward to form three bulb-like swellings or vesicles, which together represent the brain, and are named from before backward, the *prosencephalon*, *mesencephalon*, and

rhombencephalon (Fig. 7). The more rostral vesicle becomes subdivided by a constriction into the *telencephalon* and *diencephalon* (Fig. 7, B, C). The rhombencephalon is less sharply subdivided into a rostral part, which includes the cerebellum, and is known as the *metencephalon*, and a more caudal portion, the *myelencephalon*. The optic nerves and retinae, not illustrated in the figure, develop as paired evaginations from the prosencephalon.

The Cerebral Hemispheres.—The *telencephalon* includes a thickened portion of the ventrolateral wall loosely designated as the corpus striatum or, since there

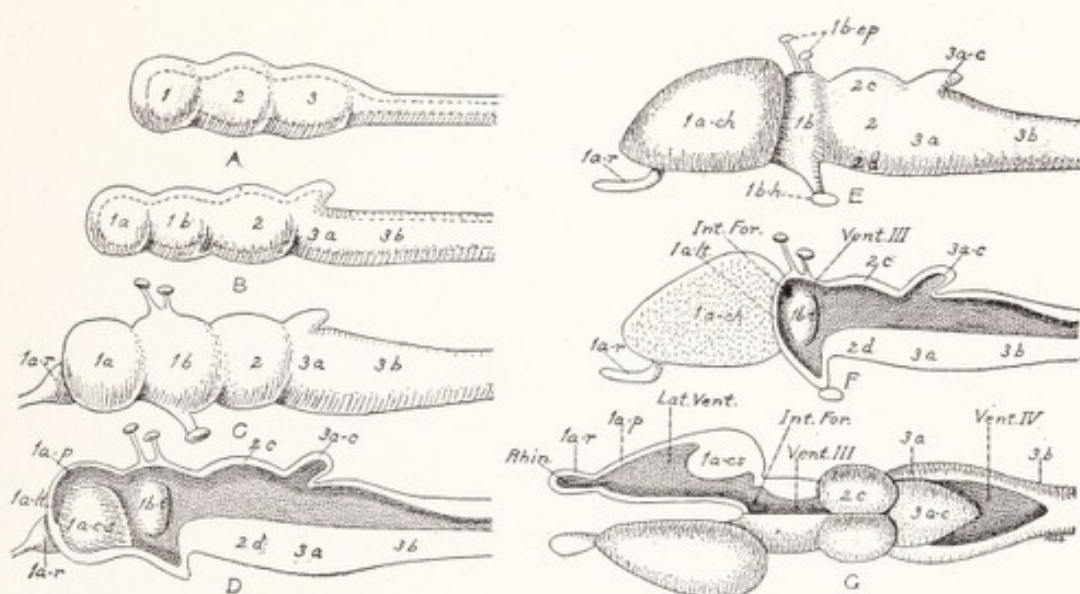


Fig. 7.—Diagrams illustrating the development of the vertebrate brain: A, First stage, side view, the cavity indicated by dotted line; B, second stage; C, third stage, side view of a brain without cerebral hemispheres; D, the same in sagittal section; E, fourth stage, side view of a brain with cerebral hemispheres; F, the same in sagittal section; G, dorsal view of the same with the cavities exposed on the right side. *Rhin.*, rhinocœle; *Lat. Vent.*, lateral ventricle; *Int. For.*, interventricular foramen; *Vent. III*, third ventricle; *Vent. IV*, fourth ventricle. 1, Prosencephalon; 1 a, Telencephalon; 1 a-r, Rhinoencephalon; 1 a-p, Pallium; 1 a-lt, Lamina terminalis; 1 a-ch, Cerebral hemisphere; 1 a-cs, Corpus striatum; 1 b, Diencephalon; 1 b-t, Thalamus. 2, Mesencephalon; 2 c, Optic lobes; 2 d, Crura cerebri. 3, Rhombencephalon; 3 a, Metencephalon; 3 a-c, Cerebellum; 3 b, Myelencephalon.

is one of these on either side, the corpora striata (Fig. 7, D). Another part of the wall is relatively thin and is known as the pallium, while the part directly associated with the olfactory nerve belongs to the rhinoencephalon. The most important factor in the evolution of the vertebrate brain is the progressive evagination of the lateral walls of the telencephalon to form paired masses, the *cerebral hemispheres*. In primitive forms like the cyclostomes only a part of the rhinoencephalon has been evaginated, and in them the hemisphere consists only of an olfactory bulb and olfactory lobe. This stage of development is roughly

indicated in Fig. 7, *C, D*. In the selachians, as illustrated in Figs. 8, 9, 10, and 11, the evagination has progressed further than in cyclostomes. Still further progress in this direction has been made by the amphibians, the cerebral hemispheres of which have reached about the stage of development indicated in Fig. 7, *E, F, G*. Here the entire lateral wall, including the pallium and corpus striatum, has been evaginated in the formation of the cerebral hemisphere.

The Brain Ventricles.—The portions of the original cavity of the neural tube which are contained within the evaginated cerebral hemispheres are known as the *lateral ventricles* (Fig. 7, *G*). These paired ventricles communicate with the median prosencephalic cavity by openings known as the *interventricular foramina*. This median cavity, called the *third ventricle*, represents for the most part the cavity of the diencephalon, but its rostral part, bounded by the lamina terminalis, belongs to the telencephalon. It will be seen by a study of the accompanying diagrams that this lamina also belongs to the telencephalon and represents in a certain sense the rostral end of the brain. Its position should be carefully noted in each of the diagrams. The cavity of the rhombencephalon is known as the *fourth ventricle* and that of the mesencephalon as the *cerebral aqueduct*. The latter connects the third and fourth ventricles. It will help us to understand the morphology of the vertebrate brain if we now consider the shape and arrangement of the various parts of a simple brain like that of the dogfish.

THE BRAIN OF THE DOGFISH—*SQUALUS ACANTHIAS*

The telencephalon of the selachian brain is evaginated to form a pair of laterally placed masses, the cerebral hemispheres, and in this respect is at a stage of development not far removed from that represented in diagrams *E, F, and G* of Fig. 7. The long axis of the brain is almost straight; and this freedom from ventrodorsal curvatures makes it especially easy to recognize the various fundamental divisions already enumerated and to understand their relationship.

The **medulla oblongata**, which together with the cerebellum forms the rhombencephalon, is continuous at the caudal extremity with the cylindrical spinal cord, and within it the central canal of the spinal cord opens out into the fourth ventricle (Fig. 8). The medulla, which has somewhat the shape of a truncated cone, is considerably larger than the cord, but decreases in size as it is traced backward toward their point of junction. In the mammal a conspicuous transverse bundle of fibers, associated with the cerebellum, is found on the ventral and lateral aspects of that part of the medulla which belongs to the metencephalon and is known as the pons. But in the fish it is customary to

consider the medulla oblongata as extending from the spinal cord to the mesencephalon. It forms the ventral and lateral walls of the fourth ventricle; and when the roof of this cavity has been removed these walls are seen to surround a long and rather broad depression—the fossa rhomboidea or floor of the fourth ventricle—which tapers caudally like the point of a pen (Fig. 9).

The **cerebellum** forms an elongated mass the rostral end of which overhangs the optic lobes, while the caudal extremity projects over the medulla oblongata

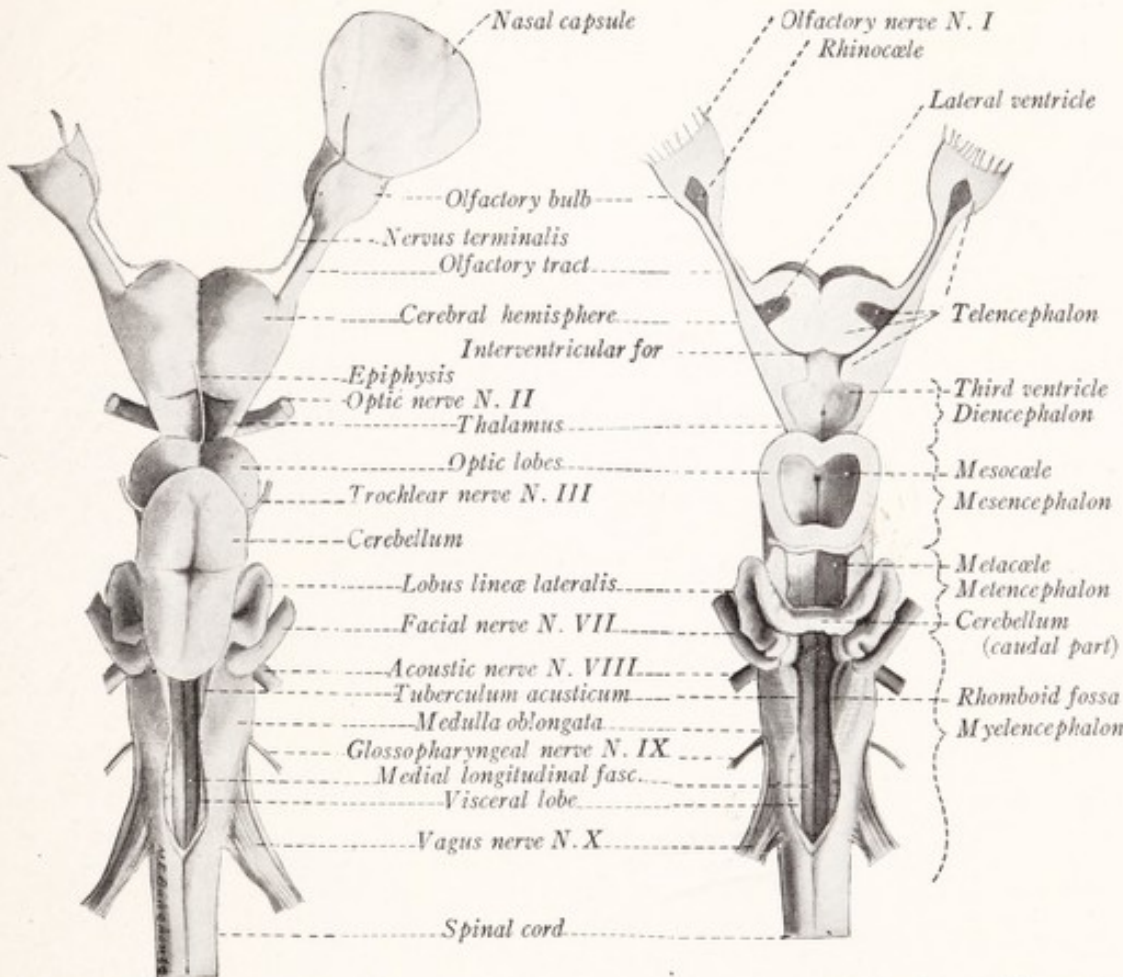


Fig. 8.—The brain of the dogfish, *Squalus acanthias*, dorsal view.

Fig. 9.—The brain of the dogfish, *Squalus acanthias*, with the ventricles opened, dorsal view.

(Fig. 8). Its dorsal surface is grooved by a pair of sulci arranged in the form of a cross. It contains a cavity, a part of the original rhombencephalic vesicle, which communicates with the fourth ventricle proper through a rather wide opening (Fig. 11). Behind the cerebellum the fourth ventricle possesses a thin membranous roof which was torn away in the preparation from which Fig. 8 was drawn.

Mesencephalon.—The *optic lobes* on the dorsal aspect of the mesencephalon are a pair of rounded masses separated by a median sagittal sulcus. They represent the bulging roof of the mesencephalic cavity and are accordingly

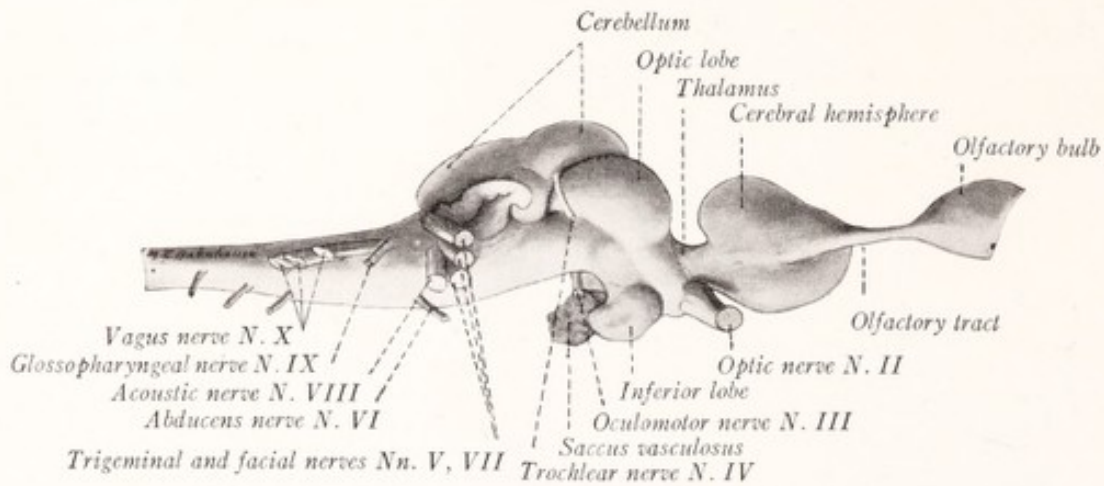


Fig. 10.—The brain of the dogfish, *Squalus acanthias*, lateral view.

spoken of as the tectum mesencephali. Within this roof end the fibers which come from the retinae through the optic nerves. The floor of the cavity is formed by the ventral part of the mesencephalon. This appears like a direct continuation of the medulla oblongata, and in the mammal bears the designation *crura*

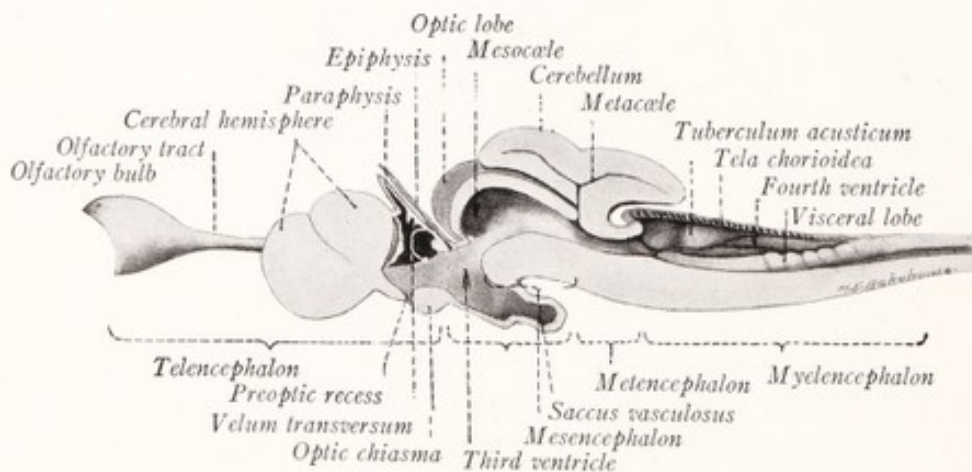


Fig. 11.—The brain of the dogfish, *Squalus acanthias*, medial sagittal section.

cerebri. Emerging from the roof of the mesencephalon between the cerebellum and optic lobe is the fourth or *trochlear nerve*, and from the ventral aspect of this division of the brain arises the third or *oculomotor nerve*.

The Diencephalon.—The thin roof of the diencephalon, which can easily

be torn away so as to expose the third ventricle (Figs. 8, 9), is attached by its caudal margin to a ridge containing a pair of knob-like thickenings, the *habenular nuclei* and a commissure connecting the two (Fig. 11). From a point just caudal to the middle of this commissure there projects forward over the membranous roof of the ventricle a slender tube, the *epiphysis cerebri* or pineal body, which comes in contact with the roof of the skull and ends in a slightly dilated extremity. The epiphysis and habenular nuclei belong to the *epithalamus*. The *thalamus* forms the thick lateral wall of the third ventricle and is traversed by the optic tracts on their way to the optic lobes. The *hypothalamus*

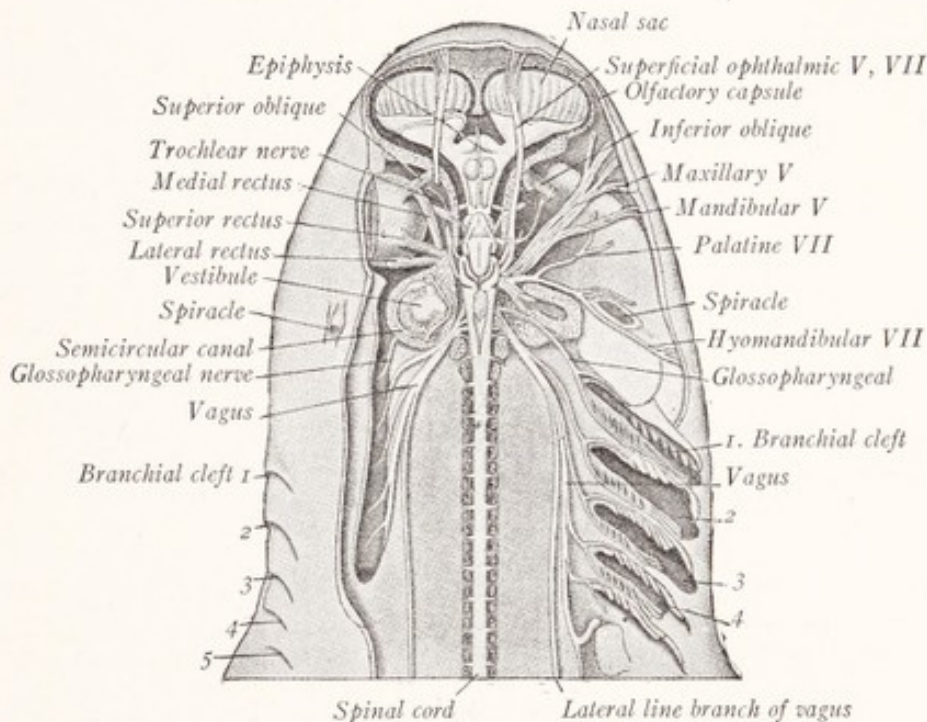


Fig. 12.—Dissection of the brain and cranial nerves of the dogfish, *Scyllium catulus*. The eye is shown on the left side, but has been removed on the right. (Marshall and Hurst, Parker and Haswell.)

is relatively large in the shark and presents, in addition to a pair of laterally placed oval masses, or inferior lobes, a thin walled vascular outgrowth, the *saccus vasculosus*. Closely related to the ventral aspect of the hypothalamus is a glandular mass, derived by a process of evagination from the oral epithelium, and known as the *hypophysis*. For a picture of this structure in the adult dogfish reference should be made to a paper on the subject by Baumgartner (1915). On the ventral surface of the hypothalamus the optic nerves meet and cross in the *optic chiasma*.

The *telencephalon* includes all of the brain in front of the *velum transversum*,

a transverse fold projecting into the third ventricle from the membranous roof (Fig. 11), and consists of a median unpaired portion, and of the two *cerebral hemispheres* with their *olfactory bulbs*. The hemispheres are the evaginated portions of the telencephalon and are partially separated from each other by a

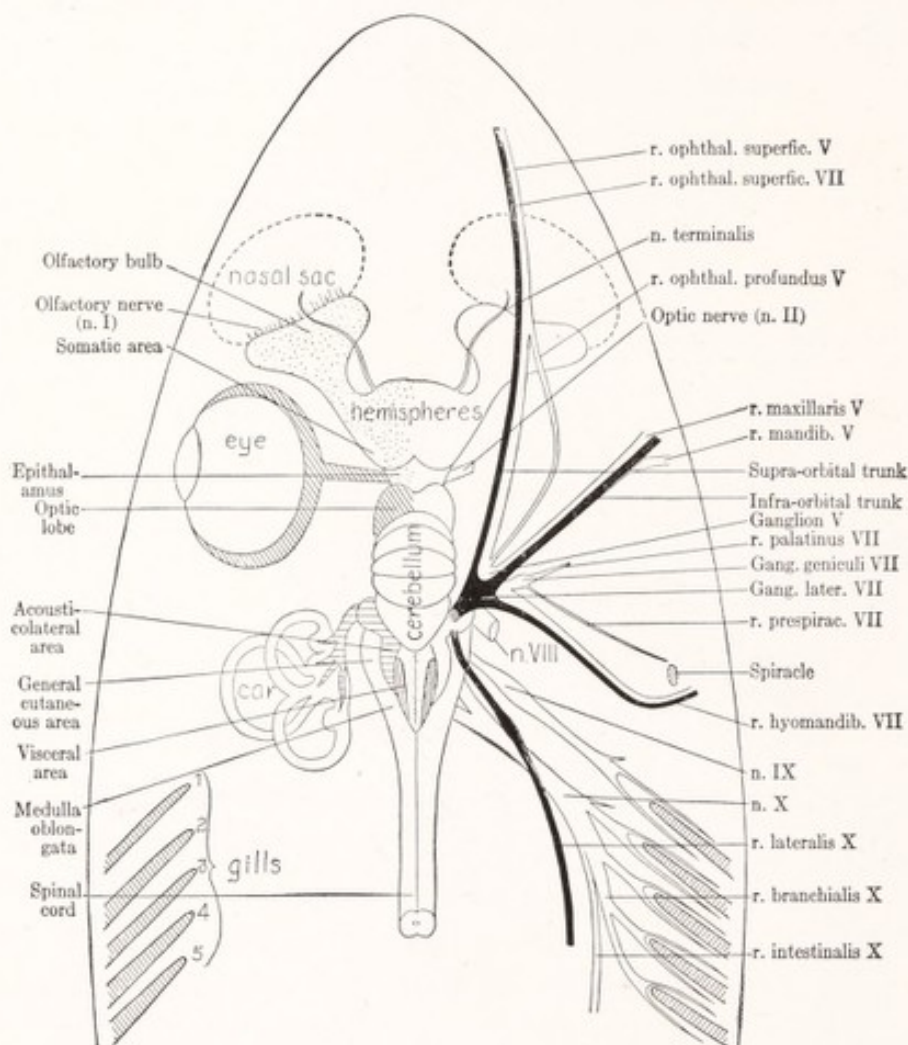


Fig. 13.—Diagram of the brain and sensory nerves of the smooth dogfish, *Mustelus canis*, from above. Natural size. The Roman numerals refer to the cranial nerves. The olfactory part of the brain is dotted, the visual centers are shaded with oblique cross-hatching, the acoustico-lateral centers with horizontal lines, the visceral sensory area with vertical lines, and the general cutaneous area is left unshaded. On the right side the lateral line nerves are drawn in black, the other nerves are unshaded. (From Herrick's Introduction to Neurology.)

median sagittal fissure, which has been to a large extent obliterated by the fusion of their median walls. The shape of the *lateral ventricle* and the position of the *interventricular foramina* are shown in Fig. 9. From the lateral side of the rostral end of the hemisphere there projects forward the long and slender olfactory tract with a terminal enlargement, the *olfactory bulb*. This lies in

contact with the nasal sac to which it gives off a number of fine nerve bundles, which together constitute the *olfactory* or *first cranial nerve*. At the rostral end of the brain an additional nerve makes its exit from the hemisphere. It is known as the *nervus terminalis* and can be followed forward over the olfactory tract and bulb to the nasal sac (Fig. 8).

The roof of the selachian forebrain presents a number of structures of great morphologic interest, two of which have already been mentioned, namely, the epiphysis and velum transversum. The former is an outpocketing of the roof of the diencephalon; the latter is an infolding and marks the line of separation between the two divisions of the prosencephalon. Rostral to the velum the roof of the telencephalon is evaginated to form a thin-walled sac, the *paraphysis*. The velum and paraphysis are readily identified in the mammalian embryo, but become obscured in the course of later development. The morphology of this region has recently been studied in great detail by a number of American investigators: Minot (1901), Johnston (1909), Terry (1910), Warren (1911, 1917), and Bailey (1916).

A good idea of the shape and connections of the various brain ventricles and of the relation of the various parts of the brain to each other can be obtained from a study of Figs. 9 and 11. In Fig. 13 there is indicated the location of the principal sensory areas of the brain of the smooth dogfish, and the relation of these areas to the corresponding peripheral nerves is apparent. The lateral line components of the seventh and tenth cranial nerves are indicated in black.

DEVELOPMENT OF THE NEURAL TUBE IN THE HUMAN EMBRYO

In its embryonic development the nervous system of man presents something like a synopsis of the early chapters of its phyletic history. The neural groove is the most conspicuous part of an *embryo of 2.4 mm.* (Fig. 14). Near the middle of the body it has closed to form the neural tube, and from this region the closure proceeds in both directions. The last points to close are situated at either end and are known as the neuropores. The rostral end of the groove shows enlargements which upon closure will form the brain vesicles. The longer portion, caudal to these enlargements, represents the future spinal cord. Except that it is flexed on itself, the brain of the *human embryo of five weeks* (Fig. 15) shows a marked resemblance to the diagram of a vertebrate brain without cerebral hemispheres (Fig. 7, C, D). The prosencephalic vesicle is divided by a constriction into the telencephalon and diencephalon with freely intercommunicating cavities. The mesencephalon is well defined and presents a sharp bend, the cephalic flexure. The rhombencephalon shows signs of separation into the metencephalon and myelencephalon and is slightly bent dorsally at the pontine flexure. Another curvature which develops at the junction of

the brain and spinal cord is known as the cervical flexure (Fig. 16). From the walls of the prosencephalon there develop outpocketings on either side, which form the optic cups and which are connected to the brain by the optic stalks. From the cup develops the retina and through the stalk grow the fibers of the optic nerve. These structures are, therefore, genetically parts of the brain.

The Telencephalon of the Human Embryo.—By the time the embryo has reached a length of 13 mm. the brain has passed into the stage represented by

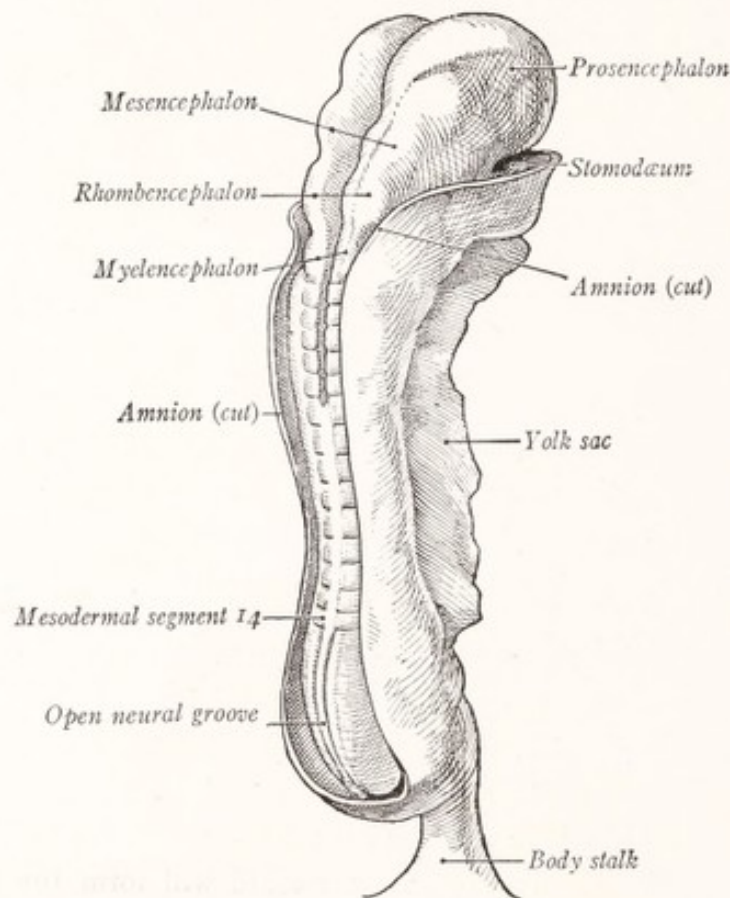


Fig. 14.—Human embryo of 2.4 mm. showing the neural tube partially closed. (Kollmann.)

diagrams *E, F, G* of Fig. 7. The lateral wall of the telencephalon, with the *corpus striatum* and olfactory brain or *rhinencephalon*, has been evaginated on either side to form paired structures, the cerebral hemispheres (Fig. 16). Except for the corpus striatum and rhinencephalon the evaginated wall is relatively thin, develops into the cerebral cortex, and is known as the *pallium*. The *lateral ventricles* within the hemispheres represent portions of the original telencephalic cavity and communicate with the third ventricle through the inter-

ventricular foramina, which at this stage are relatively large. The lamina terminalis, connecting the two hemispheres in front of the third ventricle, repre-

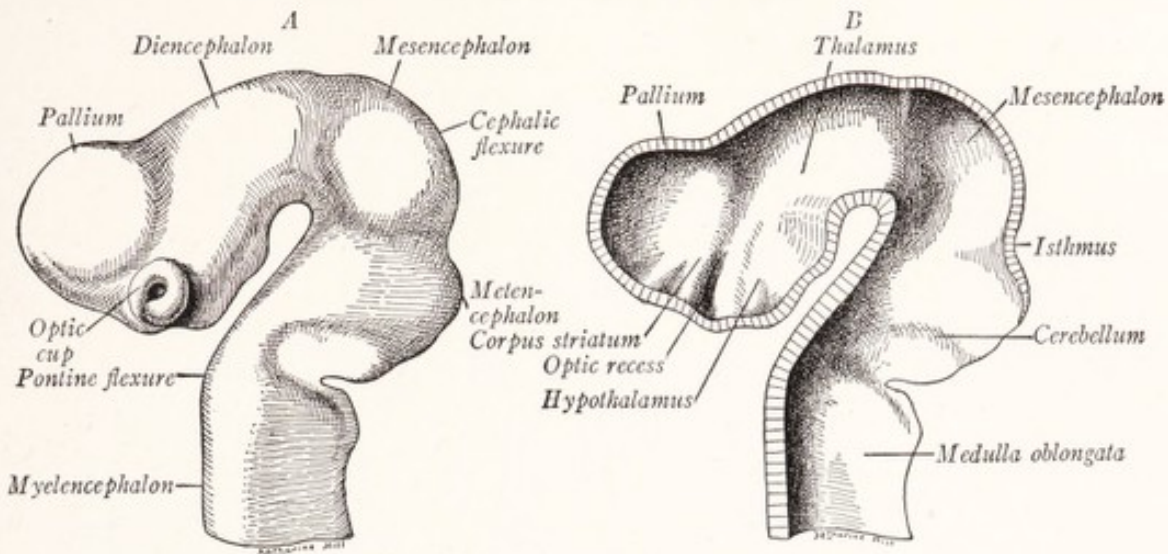


Fig. 15.—Reconstructions of the brain of a 7 mm. embryo: *A*, Lateral view; *B*, in median sagittal section. (His, Prentiss-Arey.)

sents in a certain sense the rostral end of the brain. Immediately behind this lamina is a portion of the telencephalic cavity which forms the anterior part of

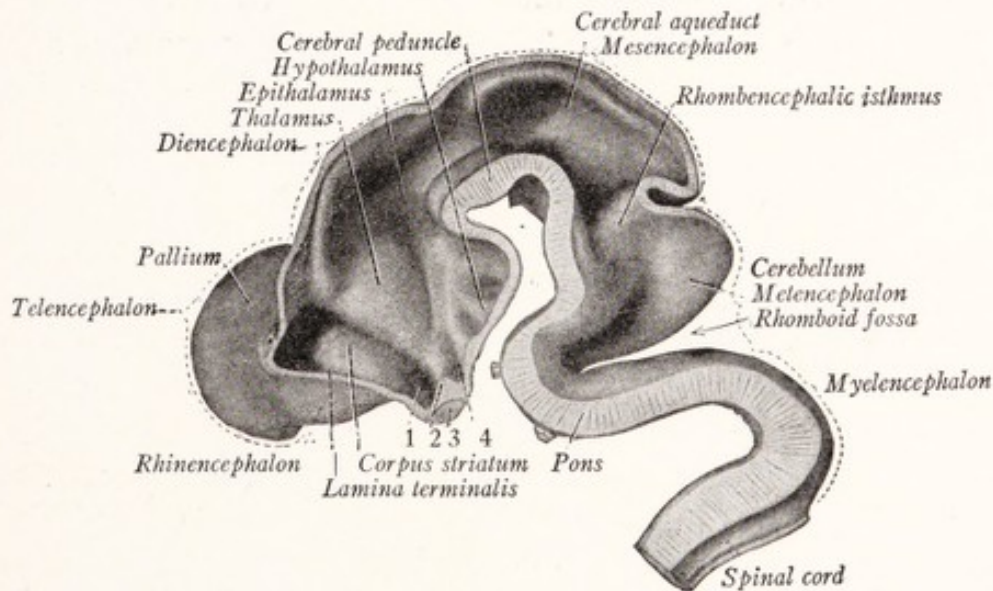


Fig. 16.—A median section of the brain of a 13.6 mm. human embryo: 1, Optic recess; 2, ridge formed by optic chiasma; 3, optic chiasma; 4, infundibular recess. (His, Sobotta.)

the third ventricle. The further development of these structures is readily traced in Fig. 17, which represents the brain of a human fetus of the third

month. The most striking feature of the brain at this stage is the great size attained by the cerebral hemispheres.

The Diencephalon.—The three principal divisions of the diencephalon—the *thalamus*, *epithalamus*, and *hypothalamus*—faintly indicated in an embryo

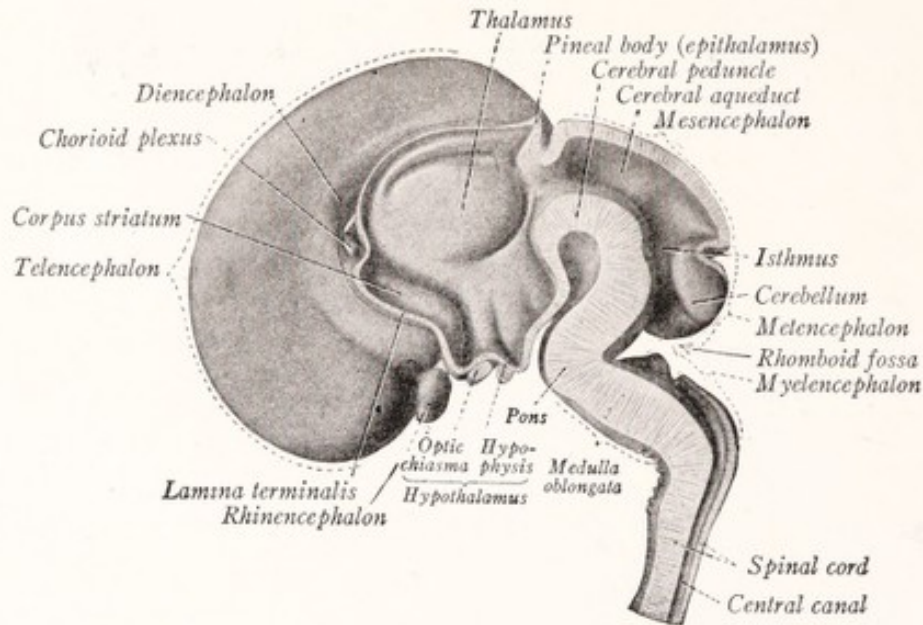


Fig. 17.—The brain of a fetus of the third month in median sagittal section. (His, Sobotta.)

of 13.6 mm., are well defined by the third month (Fig. 17). In transverse sections this division of the embryonic brain is seen to be composed of a pair of plates on either side, which with a roof and floor form the walls of the ventricle

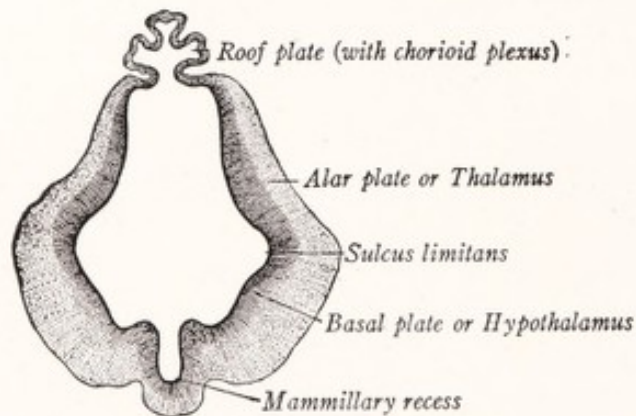


Fig. 18.—Transverse section through the diencephalon of a 13.8 mm. embryo. (His, Prentiss-Arey.)

(Fig. 18). The dorsal lamina is known as the *alar plate*, the ventral as the *basal plate*. On either side these meet at an angle, forming the *sulcus limitans*. These laminae and the sulcus limitans between them can be traced back through the

mesencephalon and rhombencephalon into the spinal cord. The *thalamus* is produced by a thickening in the alar lamina and is separated from the hypothalamus by the sulcus limitans, which can be traced as far as the optic recess rostral to the ridge produced by the optic chiasma.

The *hypothalamus*¹ represents the basal lamina and gives rise to the *tuber cinereum*, *posterior lobe of the hypophysis*, and the *mammillary bodies*. From the dorsal edge of the alar lamina, where this is attached to the thin roof plate, there is developed a thickened ridge, the epithalamus, which is transformed into the habenula and the pineal body. The roof plate of the diencephalon remains thin and forms the epithelial lining of the tela chorioidea or roof of the third ventricle.

The Mesencephalon.—The basal plate of the mesencephalon thickens to form the cerebral peduncles (Fig. 17), the alar plate forms the lamina quadrigemina in which are differentiated the quadrigeminal bodies; the cavity becomes the cerebral aqueduct.

TABLE SHOWING SUBDIVISIONS OF THE NEURAL TUBE AND THEIR DERIVATIVES (Modified from a Table in Keibel and Mall, *Human Embryology*).

| | Primary vesicles. | Subdivisions. | Derivatives. | Lumen. |
|-----------------|---------------------------|---------------------------------|---|---|
| Brain | Prosencephalon | Telencephalon | Cerebral cortex, Corpora striata, Rhinnencephalon, Pars-optica hypo- thalami. | Lateral ventricles. Rostral portion of the third ventricle. |
| | | Diencephalon | Epithalamus, Thalamus, Hypothalamus, Hypophysis, Tuber cinereum, Mammillary bodies, Metathalamus. | The greater part of the third ventricle. |
| | Mesencephalon | Mesencephalon | Corpora quadri- gemina, Crura cerebri. | Cerebral aqueduct. |
| | Rhombencephalon | Metencephalon Myelencephalon | Cerebellum, Pons, Medulla oblongata. | Fourth ventricle. |
| Spinal cord | | | Spinal cord. | Central canal. |

¹ The pars optica hypothalami, including the optic chiasm, is, properly speaking, not a part of the hypothalamus at all, but belongs to the telencephalon (Johnston, 1909, *Jour. Comp. Neur.*, vol. 19, and 1912, *Jour. Comp. Neur.*, vol. 22).

The Rhombencephalon.—The ventral part of the rhombencephalon, including both alar and basal plates, thickens to form the *pons* and *medulla oblongata* (Fig. 17). Most of the roof of this division remains thin and forms the epithelial lining of the tela chorioidea of the fourth ventricle. But in the caudal portion of the myelencephalon the lumen of the neural tube becomes completely surrounded by thickened walls, forming the central canal of the closed portion of the medulla. The posterior edge of the alar plate in the metencephalon becomes greatly thickened and, fusing across the median line with the similar structure of the opposite side, forms the anlage of the *cerebellum* (Figs. 17, 137). Later we shall see that, in general, motor structures develop from the basal, and sensory parts from the alar, plate.

The table on page 35 gives in brief the principal derivatives of the neural tube.

CHAPTER III

HISTOGENESIS OF THE NERVOUS SYSTEM

Early Stages in the Differentiation of the Neural Tube.—Hardesty (1904) has given a good account of the early development of the spinal cord in the pig. At first the neural plate consists of a single layer of ectodermal cells (Fig. 19, *A*). These proliferate and lose their cell boundaries. When the neural tube has closed its wall is formed of several layers of fused cells—a *syncytium*—bounded by an external and an internal limiting membrane (Fig. 19, *B, C*). The syncytium now becomes more open and sponge-like in structure. The nuclei are so arranged that three layers may be differentiated: (1) an *ependymal* layer, (2) a *mantle* layer, with many nuclei, and (3) a *marginal* or non-nuclear layer. The ependymal layer is represented by a row of elongated nuclei, among which are found the large mitotic nuclei of the germinal cells.

These *germinal cells* divide and give rise to *ependymal cells*, and to the *indifferent cells* of the mantle layer. Through division of the latter *spongioblasts* and *neuroblasts* are formed. From the former comes the neuroglia or supporting tissue of the nervous system, while from the latter are derived the nerve-cells and fibers.

The Development of the Neuron.—A neuron may be defined as a nerve-cell with all its processes; and each is derived from a single neuroblast. From the pear-shaped neuroblast a single primary process grows out, and this becomes the *axis-cylinder* of a nerve-fiber (Fig. 20). Other processes which develop later become the *dendrites*. The primary process, or axon, grows into the marginal layer, within which it may turn and run parallel to the long axis of the neural tube as an association fiber; or it may run out of the neural tube in a ventrolateral direction as a motor axon. In this way the motor fibers of the cerebrospinal nerves are laid down. The axis-cylinder of each represents a process which has grown out from a neuroblast in the basal plate of the neural tube.

Development of Afferent Neurons.—The sensory or afferent fibers of the spinal nerves take origin from neuroblasts which are from the beginning outside the neural tube. These neuroblasts are derived from the *neural crest*, a longitudinal ridge of ectodermal cells at the margin of the neural groove, where this becomes continuous with the superficial ectoderm. At first in contact with

the dorsal surface of the neural tube, the neural crest soon separates from it and comes to lie in the angle between it and the myotomes. In this position the neural crest gives rise to a series of *sensory ganglia*. From neuroblasts located in these ganglia arise the sensory fibers of the cerebrospinal nerves.

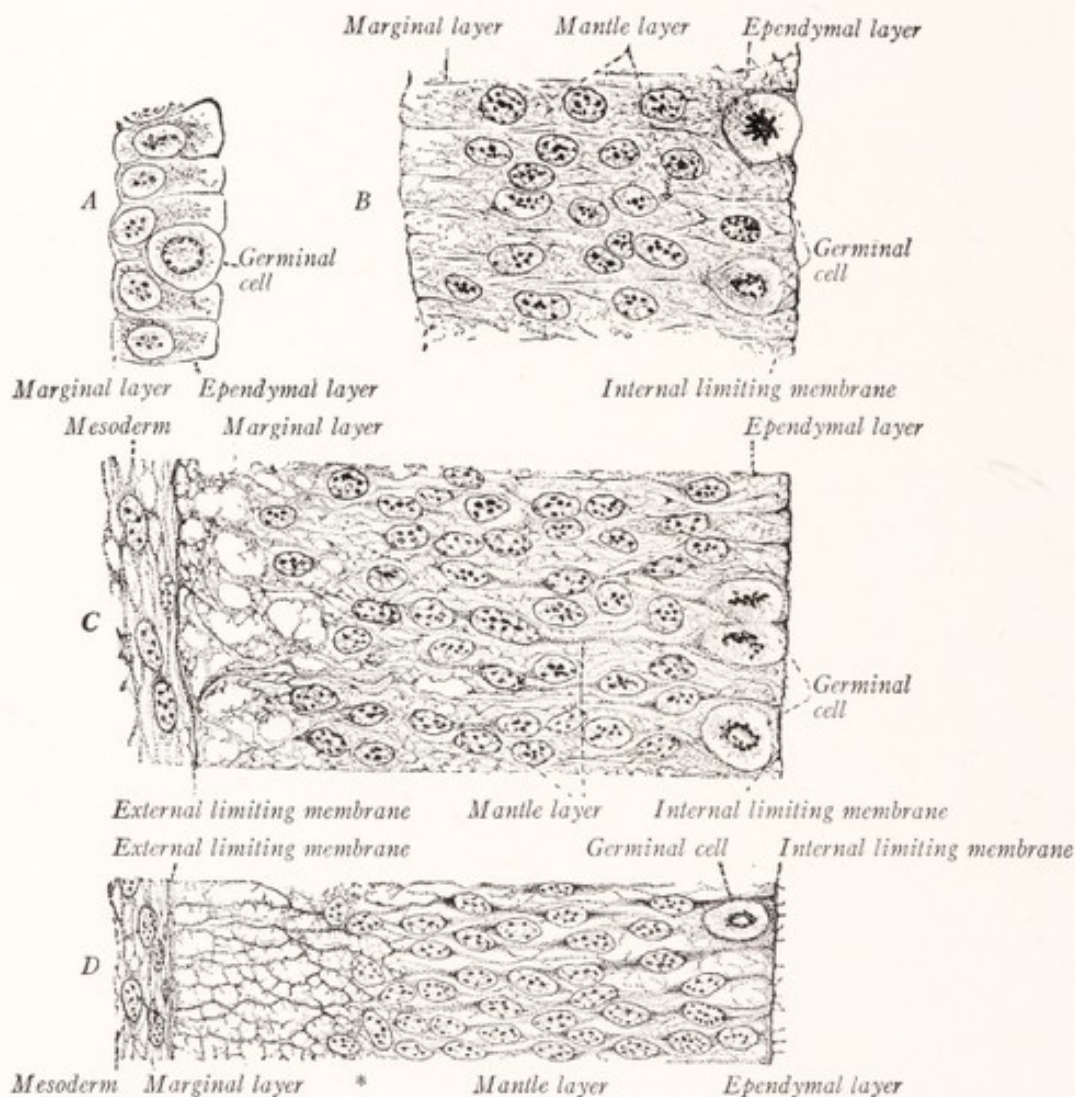


Fig. 19.—Early stages in the differentiation of the neural tube: *A*, From a rabbit embryo before closure of neural tube; *B*, from a 5 mm. pig embryo after closure of tube; *C*, from a 7 mm. pig embryo; *D*, from a 10 mm. pig embryo. *, Boundary between nuclear and marginal layers. (Hardesty, Prentiss-Arey.)

This last statement requires some qualification. The fibers of the olfactory nerve arise from cells in the olfactory mucous membrane. The fibers of the mesencephalic root of the trigeminal nerve, which in all probability are sensory, arise from cells located within the mesencephalon. The optic nerve is also an exception, but this is morphologically a fiber tract of the brain and not a true nerve. An ingenious theory, advanced by Schulte and Tilney (1915), attempts to bring this mesencephalic root and the optic nerve into more ob-

vious relation with the other sensory nerves. They assume that the part of the neural crest, which lies rostral to the anlage of the semilunar ganglion, fails to separate from the neural tube. From this part of the neural crest, retained within the brain, they would derive the mesencephalic nucleus of the trigeminal nerve and the optic vesicles.

On the other hand, there are observations which tend to show that some of the cranial sensory ganglia are derived at least in part from other sources than the neural crest. This is especially true of the acoustic ganglion (Streeter, 1912). According to Landacre (1910) many of the sensory ganglion cells of the seventh, ninth, and tenth nerves are derived from

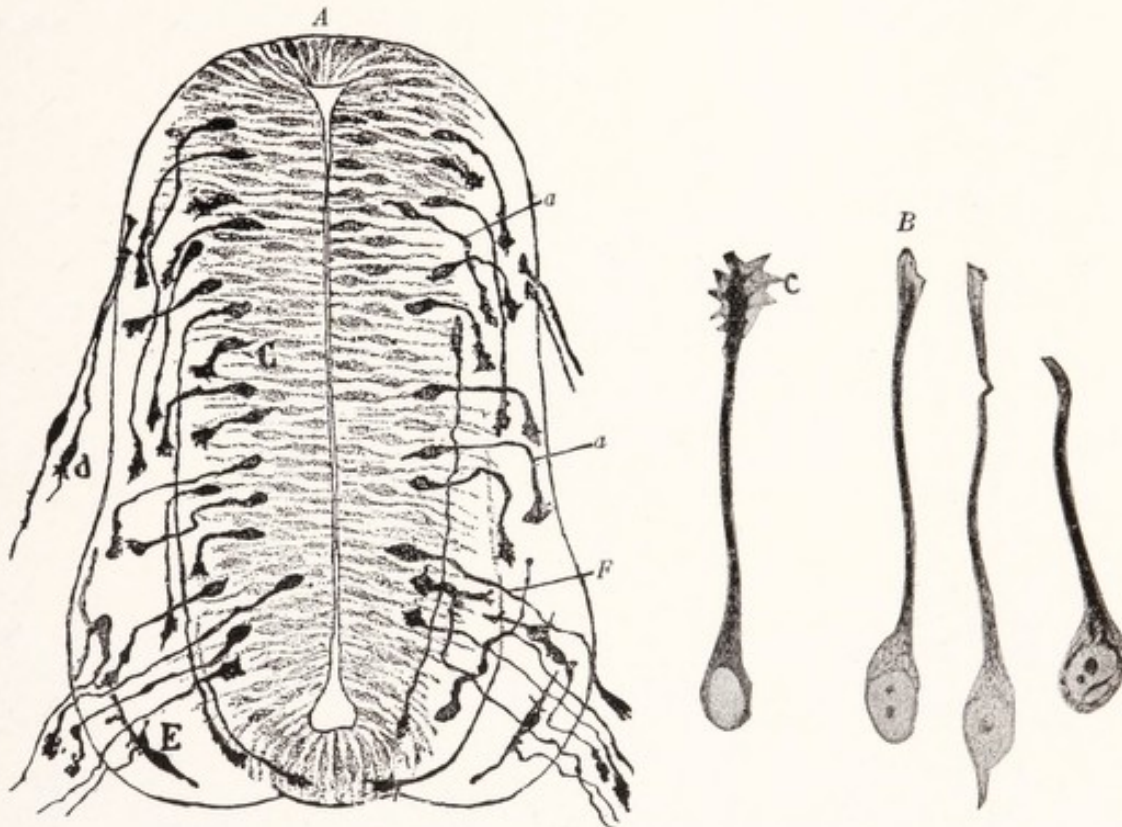


Fig. 20.—A, Transverse section through the spinal cord of a chick embryo of the third day showing neuraxons (*F*) developing from neuroblasts of the neural tube and from the bipolar ganglion cells, *d*. B, Neuroblasts from the spinal cord of a seventy-two-hour chick. The three to the right show neurofibrils; C, incremental cone. (Cajal, Prentiss-Arey.)

thickened patches of the superficial ectoderm, known as placodes, with which the ganglia of these nerves come in contact at an early stage in their embryonic development. The acoustic ganglion of the eighth nerve seems also to have a similar origin, *i. e.*, from the cells of the otic vesicle which is formed by a process of invagination from the superficial ectoderm.

The neuroblasts of these ganglia become *bipolar* through the development of a primary process at either end (Fig. 21). Originally bipolar, a majority of these sensory neurons in the mammal become *unipolar* through the fusion of the two primary processes for some distance into a single main stem. Beyond the point of fusion this divides like a T into two primary branches, one of which

is directed centrally, the other peripherally. The centrally directed branch grows into the neural tube as a sensory root fiber (Fig. 20, *A, d*); the other grows peripherally as an afferent fiber of a cerebrospinal nerve. This general statement requires some qualification. It may be that some bipolar neuroblasts become unipolar by the absorption of one of the primary processes, while the remaining one divides dichotomously into central and peripheral branches (Streeter, 1912). It should also be noted that the cells of the sensory ganglia

of the acoustic nerve remain bipolar throughout life.

Development of the Spinal Nerves.

—We have traced the development of the chief elements entering into the formation of the cerebrospinal nerves, and will now see how these are combined in a typical spinal nerve. The spinal ganglion, derived from the neural crest, contains bipolar neuroblasts, which are transformed into unipolar neurons. The axon of such a nerve-cell divides into a central branch, running through the dorsal root into the spinal cord, and a peripheral branch, running distally through the nerve to reach the skin or other sensitive portion of the body. Mingled with these afferent fibers in

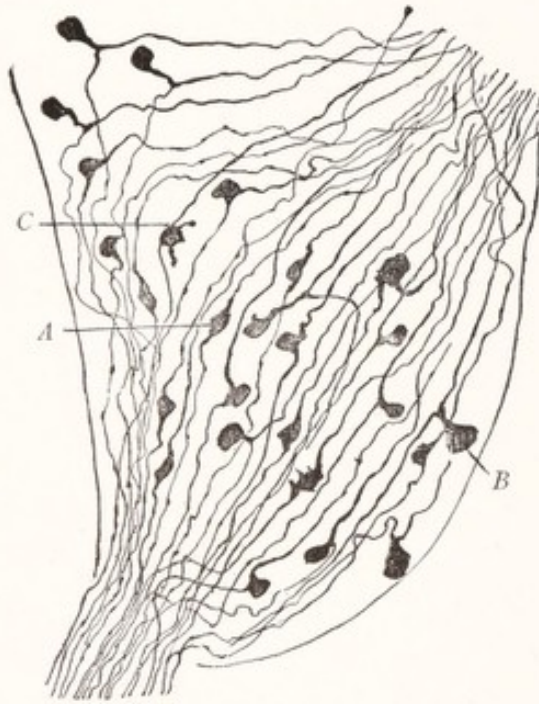


Fig. 21.—A section of a spinal ganglion from a 44 mm. fetus, showing stages in the transformation of bipolar neurons, *A*, into unipolar neurons, *B*. Golgi method. (Cajal.)

the spinal nerves are efferent axons which have grown out from neuroblasts in the basal plate of the spinal cord, through the ventral root, and are distributed by way of the spinal nerve to muscles.

So far we have dealt only with the origin of the axis-cylinders of the nerve-fibers. But these soon become surrounded by protective *sheaths* which are also ectodermal in origin. In the path of the outgrowing axons there are seen numerous spindle-shaped ectodermal cells, which have migrated from the anlage of the spinal ganglia (Harrison, 1906), and perhaps also from the neural tube along the ventral roots (Held, 1909). These cells form such a prominent feature in a developing nerve that some workers have thought the axons differentiate *in situ* from them. This theory, which has been known as the *cell-chain*

hypothesis, and gives to each axon a multicellular origin, has been supported by Schwann, Balfour, Dohrn, and Bethe, and in modified forms by other workers. There are good reasons, however, for believing that each axon arises as an outgrowth from a single cell or neuroblast. This idea, which is in keeping with what is known of the structure and function of the neuron and which forms an integral part of the now generally accepted *neuron theory*, was first developed in the embryologic publications of His. Convincing experimental evidence has been furnished by Harrison (1906). Using amphibian larvæ, this author showed that if the neural crest and tube are removed no peripheral nerves develop. He further showed that isolated nerve-cells cultivated in clotted lymph will

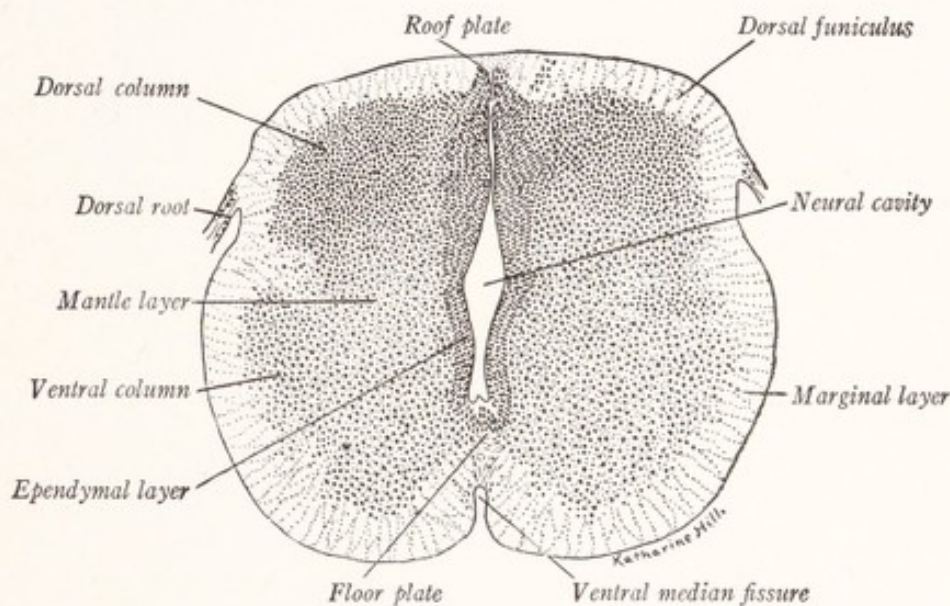


Fig. 22.—Transverse section of the spinal cord of a 20 mm. human embryo. (Prentiss-Arey.)

give rise to long axons in the course of a few hours. But the ectodermal cells, mentioned above, which migrate outward along the course of the developing nerve, take an important part in the differentiation of the fibers. From them is derived the nucleated sheath or neurilemma of the peripheral nerve-fiber. The myelin sheath is composed of a fatty substance of uncertain origin. It may be a product of the axon, of the neurilemma, or of both.

The **sympathetic ganglia** consist of cells derived like those of the spinal ganglia from the neural crest; and, according to Kuntz (1910), also from the neural tube by migration along the course of the cerebrospinal nerves. These cells become aggregated in the ganglia of the sympathetic system and are associated with the innervation of smooth muscle and glands.

The **spinal cord** of a 20 mm. human embryo presents well-defined ependymal, marginal, and mantle layers. Figure 22 should be compared with the appearance presented by a cross-section of the spinal cord in the adult (Fig. 55). The *mantle layer* with its many nuclei differentiates into the *gray matter* of the spinal cord, which contains the nerve-cells and their dendritic processes. The *marginal layer* develops into the white substance as a result of the growth into it of the axons from neuroblasts located within the mantle layer. These form association fibers which ascend or descend through the marginal layer and serve to connect one level of the neural tube with another. It is not until these longitudinally coursing axons develop myelin sheaths that the *white substance* acquires its characteristic coloration.

The cavity of the neural tube is relatively large, and at the point marked "neural cavity" in Fig. 22 a groove is visible. This is the sulcus limitans. It separates the dorsal or *alar plate* from the ventral or *basal plate*. The mantle layer of the alar plate develops into the *dorsal gray column* which, like the other parts developed from this plate, is afferent in function. The afferent fibers, growing into the spinal cord from the spinal ganglia, either terminate in this dorsal column or ascend in the posterior part of the marginal zone to nuclei derived from the alar plate in the myelencephalon. Most of the association fibers which run in the marginal layer have grown out from neuroblasts located in the dorsal column. The mantle layer of the basal plate gives rise to the *ventral gray column*. From the neuroblasts in this region grow out the motor fibers of the ventral roots and spinal nerves.

From what has been said it will be clear that the entire nervous system is ectodermal in origin. The nervous element proper or neurons are derived from the neuroblasts; the supporting tissue of the brain and spinal cord, the neuroglia, is derived from spongioblasts; while the neurilemma of the peripheral nerves is the product of sheath cells which have migrated out from the spinal ganglia and possibly also from the neural tube.

CHAPTER IV

NEURONS AND NEURON-CHAINS

THE nervous system is composed of highly irritable cellular units, or neurons, linked together to form conduction pathways. In the preceding chapter we have seen that each neuron is the product of a single embryonic cell or neuroblast, and that, therefore, the nerve-cell with all its processes constitutes a genetic unit. In the present chapter, as we examine the form and internal structure of the neurons and their relation to each other, we shall learn that they are also the structural and functional units of the nervous system.

Form.—There is the widest possible variation in the shape of nerve-cells, but all present some features in common. About the nucleus there is an accumulation of cytoplasm which together with the nucleus forms what is often called the cell body. A convenient term by which to designate the circumnuclear cytoplasmic mass is *perikaryon*. From the perikaryon cytoplasmic processes are given off, some of which may be of great length. The external form of the neuron depends on the shape of the perikaryon and on the number, shape, and ramification of these processes. Since the variety of forms is almost without limit, we will content ourselves with studying a few typical examples.

The *pyramidal cells* of the cerebral cortex are good examples (Fig. 23). The perikaryon is triangular in form. One angle, that directed toward the surface of the cortex, is prolonged in the form of a long thick branching process, the apical dendrite. From the sides and other angles of the perikaryon arise shorter branching dendrites, while from the base or from one of the basal dendrites arises a long slender process, the axon. The characteristic features of the *dendrites* are as follows: they branch repeatedly, rapidly decrease in size, and terminate not far from the cell body. Their contour is irregular and they are studded with short side branches, or *gemmules*, which give them a spiny appearance. Each neuron usually possesses several dendrites, but in some types of nerve-cells they are absent altogether. The *axon*, on the other hand, is characterized by its uniform smooth contour, relatively small diameter, and in most instances by its great length and relative freedom from side branches. It may give off fine side branches, or collaterals, near its origin; and these arise at right

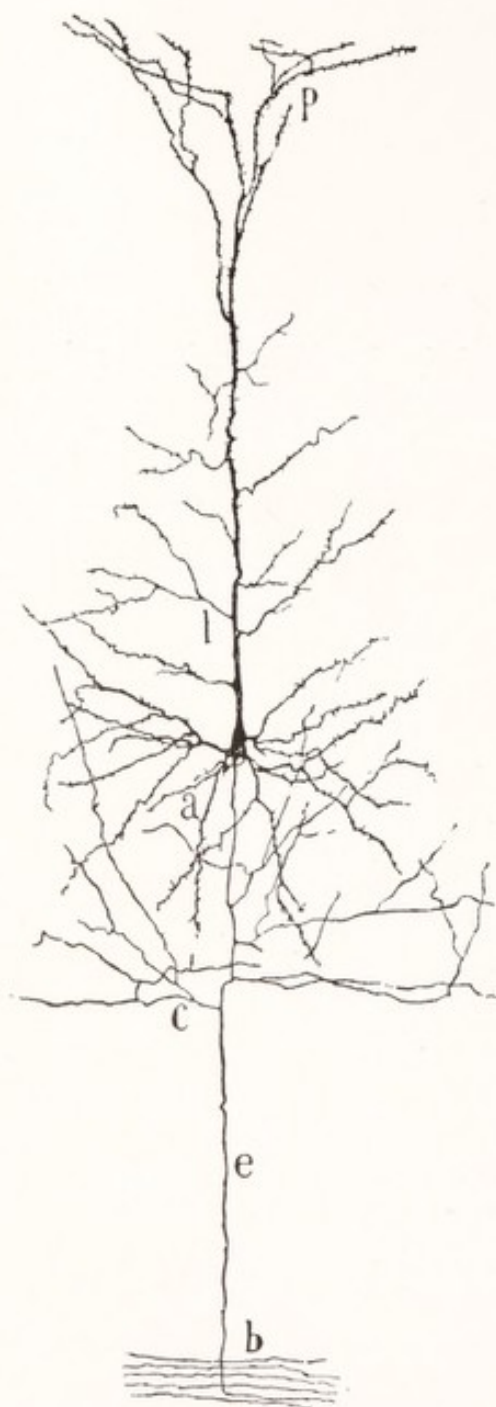

Fig. 23.—A pyramidal cell from the cerebral cortex of a mouse: *a*, Dendrites from the base of the cell; *b*, white substance of the hemisphere into which the axon, *e*, can be traced; *c*, collaterals from the first part of the axon; *l*, apical dendrite; *p*, its terminal branches near the surface of the cortex. Golgi method. (Cajal.)

cerebrospinal ganglia (Fig. 40). These cells, which will be described in more

angles to the parent stem. The axon terminates in a multitude of fine branches usually at a considerable distance and sometimes as much as a meter from its origin. The origin of the axon from the perikaryon is marked by an expansion known as the cone of origin or *implantation cone*. This cone, like the axon, differs somewhat in structure from the perikaryon. Such long axons as have just been described are characteristic of the cells of Golgi's Type I.

That not all axons are long and relatively unbranched is seen from Fig. 24, which illustrates a *cell of Golgi's Type II*. The axons of these cells are short, branch repeatedly, and end in the neighborhood of the cell body.

Another good example is furnished by the *primary motor neurons*. Figure 25 illustrates such a cell from the anterior gray column of the spinal cord. This is a large nerve-cell with many rather long branching dendrites and an axon, which forms the axis-cylinder of a motor nerve-fiber and terminates by forming a motor ending in a muscle. As illustrated in this figure, long axons tend to acquire myelin sheaths, and those which run in the cerebrospinal nerves are also covered by a nucleated membranous sheath—the neurilemma.

Nerve-cells with many processes, such as have just been described, are called *multipolar*. Examples of *unipolar* and *bipolar cells* are furnished by the

detail in another chapter, are devoid of dendrites. The axon of such a unipolar cell divides dichotomously into a central and a peripheral branch, each possessing the characteristics of an axon.

It is not uncommon to regard the peripheral branch of a sensory neuron as a dendrite, because like the dendrites it conducts nerve impulses toward the cell body. But, since it possesses all the morphologic characteristics of an axon, and since any axon is able to conduct nerve impulses throughout its length in either direction, and since these peripheral branches of the sensory neurons actually convey impulses distally in the phenomenon of

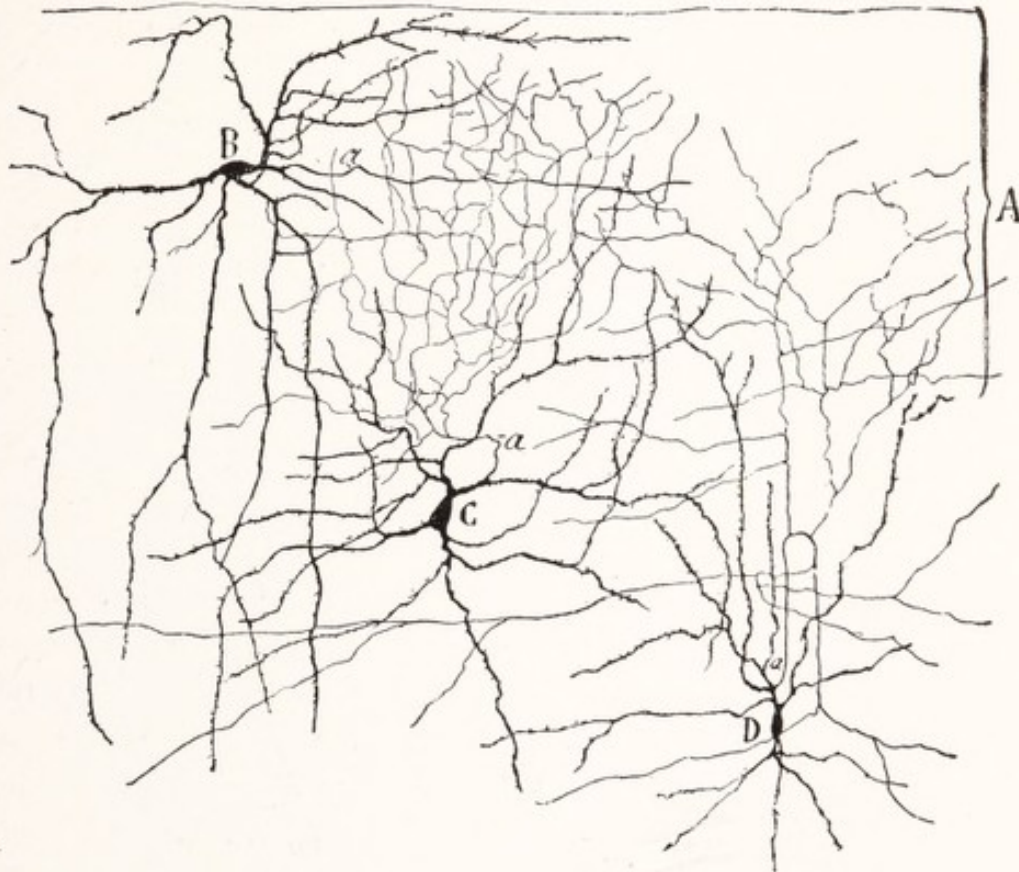


Fig. 24.—Neurons with short axons (Type II of Golgi) from the cerebral cortex of a child: *a*, Axon. Golgi method. (Cajal.)

antidromic conduction (Bayliss, *General Physiology*, p. 474), it seems best to consider both central and peripheral branches as divisions of a common axonic stem. (See Barker, *The Nervous System*, p. 361.)

From what has been said it will be apparent that a neuron usually possesses several dendrites and a single axon, but some have only one process, which is then an axon. It may be added that some neurons have more than one axon.

Nerve-fibers are axons naked or insheathed. Two *myelinated peripheral nerve-fibers* are shown in Fig. 26. The axon or *axis-cylinder* is composed of

delicate neurofibrils embedded in a semifluid neuroplasm. It is surrounded by a relatively thick *myelin sheath* and a nucleated membranous *neurilemma sheath*.

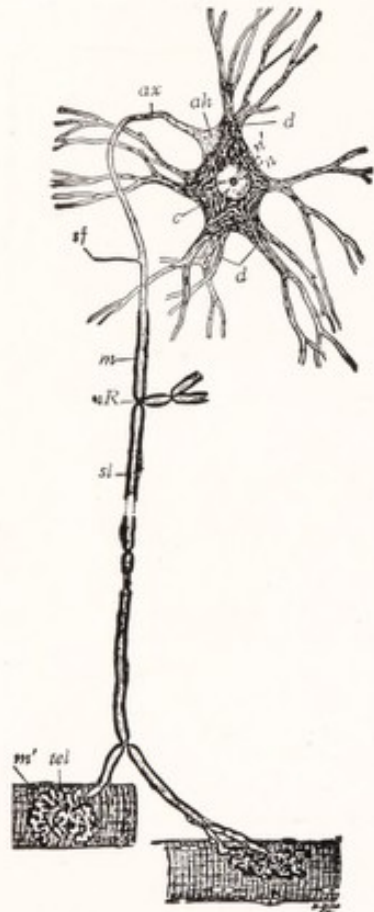


Fig. 25.—Primary motor neuron (diagrammatic): *ah*, Implantation cone of axon; *ax*, axon; *c*, cytoplasm; *d*, dendrites; *m*, myelin sheath; *m'*, striated muscle; *n*, nucleus; *n'*, nucleolus; *nR*, node of Ranvier; *sf*, collateral; *sl*, neurilemma; *tel*, motor end-plate. (Barker, Bailey.)

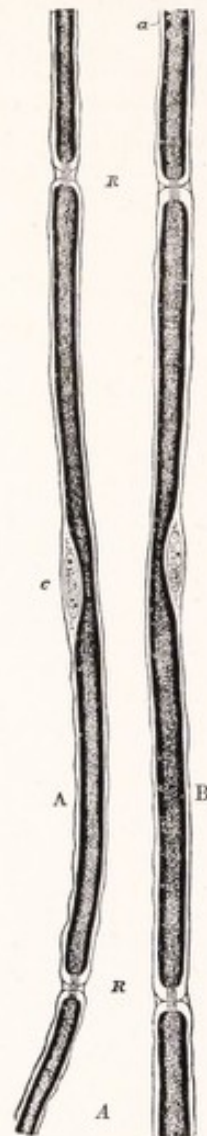

Fig. 26.—Portions of two nerve-fibers stained with osmic acid (from a young rabbit). Diagrammatic. 425 diameters: *RR*, Nodes of Ranvier, with axis-cylinder passing through; *a*, neurilemma; *c*, opposite the middle of the segment, indicates the nucleus and protoplasm lying between the neurilemma and the medullary sheath. In *A* the nodes are wider, and the intersegmental substance more apparent than in *B*. (Schäfer, in Quain's Anatomy.)

The myelin sheath consists of a fatty substance, myelin, supported by a reticulum of neurokeratin. The latter, not seen in the living fiber, may be a coagulation product produced during fixation. The highly refractive myelin gives

to the myelinated fibers a whitish color. This sheath is interrupted at regular intervals by constrictions in the nerve-fiber known as the nodes of Ranvier. The constrictions are produced by a dipping in of the neurilemma sheath toward the axon, which runs without interruption through the node. The part of a fiber between each node is an internodal segment, and each such segment possesses a nucleus which is surrounded by a small amount of cytoplasm and lies just beneath the neurilemma. The latter is a thin membranous outer covering for the fiber. Each segment of the neurilemma sheath, together with the cell which lies beneath, is the product of a single sheath cell of ectodermal origin. Fibers such as have just been described are found in the cerebrospinal nerves, and give these their white glistening appearance.

The *myelinated fibers of the brain and spinal cord* are of somewhat different structure. There is no evidence of segmentation in the myelin sheath and neither the neurilemma nor its cells are present. This fact is of much importance in the phenomena of regeneration, as will be explained later. These are the fibers which give the characteristic color to the white matter of the brain and spinal cord.

Unmyelinated fibers are of two kinds, namely, Remak's fibers and naked axons. The former possess nuclei which may be regarded as belonging to a thin neurilemma. They are found in great numbers in the sympathetic nervous system, and many of the fine afferent fibers of the cerebrospinal nerves also belong to this class (Ranson, 1911). Naked axons are especially numerous in the gray matter of the brain and spinal cord, and it may be added that every axon at its beginning from the nerve-cell, as well as at its terminal arborization, is devoid of covering.

By way of summary we may enumerate *four kinds of nerve-fibers*: (1) myelinated fibers with a neurilemma, found in the peripheral nervous system, especially in the cerebrospinal nerves; (2) myelinated fibers without a neurilemma, found in the central nervous system; (3) unmyelinated fibers with nuclei (Remak's fibers), especially numerous in the sympathetic system, and (4) naked axons, abundant in the gray matter of the brain and spinal cord.

Neuroglia cells and fibers will be considered in connection with the structure of the spinal cord.

Structure of Neurons.—Like other cells, a neuron consists of a nucleus surrounded by cytoplasm, and these possess the fundamental characteristics which belong to nucleus and cytoplasm everywhere, but each presents certain features more or less characteristic of the nerve-cell. The *nucleus* is large and spheric;

and, because it contains little chromatin, it stains lightly with the basic dyes (Fig. 27, *A*). It contains a large spheric nucleolus. The *cytoplasm*, enclosed in a cell membrane, is characterized by the presence of basophil granules and a fibrillar reticulum. The granules, which apparently are a product of the nucleus, are composed of nucleoprotein. They are grouped in dense clumps, known as *Nissl bodies* or *tigroid masses*, and stain deeply with methylene-blue. The size, shape, and arrangement of the Nissl bodies differ with the type of nerve-cell studied. They are much larger in motor than in sensory neurons (Malone, 1913). While they are found in the larger dendrites, the axon and its cone of origin are free from them. They are intimately concerned in the

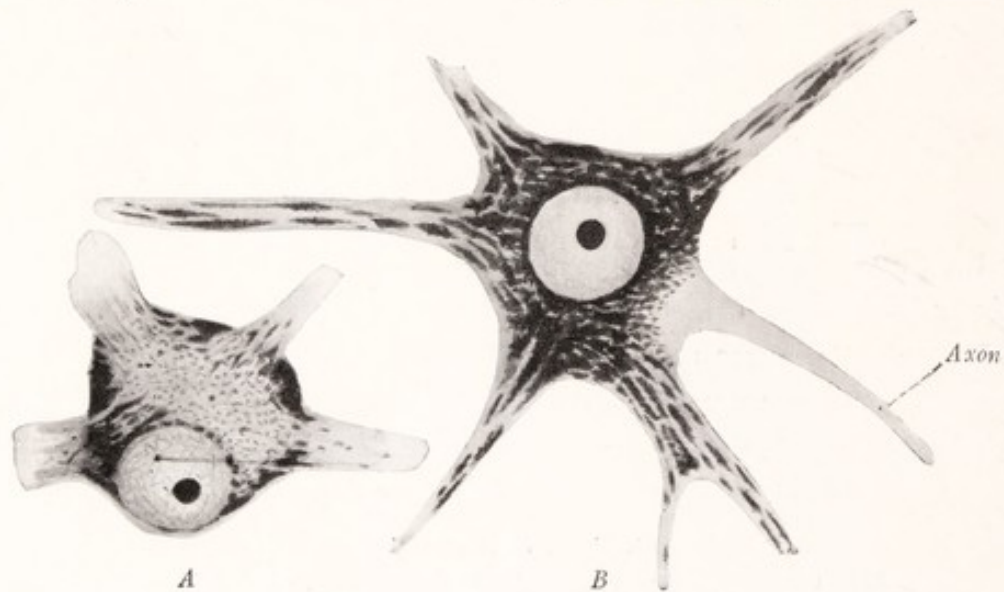


Fig. 27.—Nerve-cells stained with toluidin blue: *A*, From anterior horn of spinal cord of the monkey, shows Nissl bodies in cytoplasm; *B*, from the facial nucleus of a dog, shows a partial disappearance of the Nissl bodies (chromatolysis) resulting from section of the facial nerve. (Schäfer.)

metabolic activity of the cell, increasing during rest and decreasing as a result of fatigue. They also undergo solution as a result of injury to the axon even at a great distance from the cell, the so-called axon-reaction or chromatolysis (Fig. 27, *B*).

The *neurofibrils* were first brought forcefully to the attention of neurologists by Bethe (1903). These are delicate threads which run through the cytoplasm in every direction and extend into the axon and dendrites (Fig. 28). The appearance of the fibrillæ differs according to the technic employed in preparing the tissue for microscopic examination. While in the preparations by Bethe's method the fibrils do not appear to branch or anastomose with each other, those seen in Cajal preparations divide, and by anastomosing with each other form

a true network. The fibrillæ can be traced to the terminations of the dendrites and axons. They have been looked upon by many as the chief elements involved in the conduction of the nerve impulse.

Other elements such as pigment granules may be present. Mitochondria have been described in nerve-cells by Cowdry (1914) and Rasmussen (1919).

Interrelation of Neurons.—In the cœlenterates, as we have learned, a single nerve-cell may receive the stimulus and transmit it to the underlying muscle. But in vertebrates the transmission of a nerve impulse to an effector requires a chain of at least two neurons, the impulse passing from one neuron to the next along the chain. One of the most important problems in neurology, therefore, is this: How are the neurons related to each other so that the impulse may be propagated from one to the other? The place where two such units come into such functional relation is known as a *synapse*. In a synapse the axon of one neuron terminates on the cell body or dendrites of another. Functional connections are never established between the dendrites of one neuron and the cell body or dendrites of another. In Fig. 29 the axon of a basket cell of the cerebellum is seen giving off collaterals which terminate about and form synapses with the Purkinje cells. Another type of synapse is illustrated in Fig. 70.

The processes of one nerve-cell are not directly fused with those of others, but, on the contrary, *each neuron appears to be a distinct anatomic unit*. At least the most detailed study of Golgi and Cajal preparations, in which the finest ramifications of dendrites and axons are stained, has failed to demonstrate a structural continuity between neurons. In especially favorable material

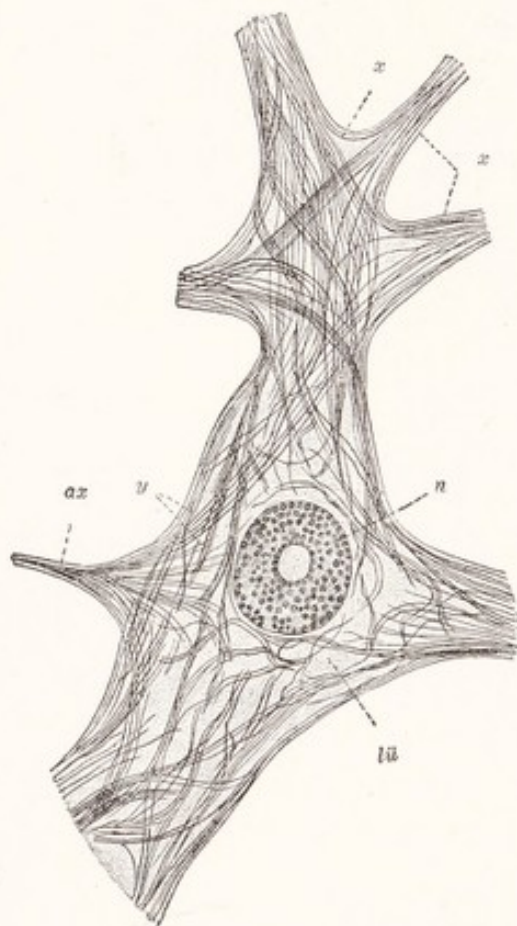


Fig. 28.—Neurofibrils in a cell from the anterior gray column of the human spinal cord: *ax*, Axon; *lü*, interfibrillar spaces; *n*, nucleus; *x*, neurofibrils passing from one dendrite to another; *y*, neurofibrils passing through the body of the cell. (Bethe, Heidenhain.)

Bartelmez (1915) has shown that an axon and dendrite, entering into the formation of a synapse, are each surrounded by a distinct plasma membrane and that there is no direct protoplasmic continuity. It has been maintained by Bethe and others that at such points of contact the neurofibrils pass without interruption from one neuron to another, but this has been denied by Cajal. The relation between two neurons at a synapse appears to be one of contact, but not of continuity of substance.

Nerve impulses pass across the synapse in one direction only, *i. e.*, from the axon to the adjacent cell body or dendrite. As a corollary of this it is obvious that impulses must travel within the neuron from dendrites to perikaryon and then out along the axon, as indicated by the arrow in Fig. 30. This is known

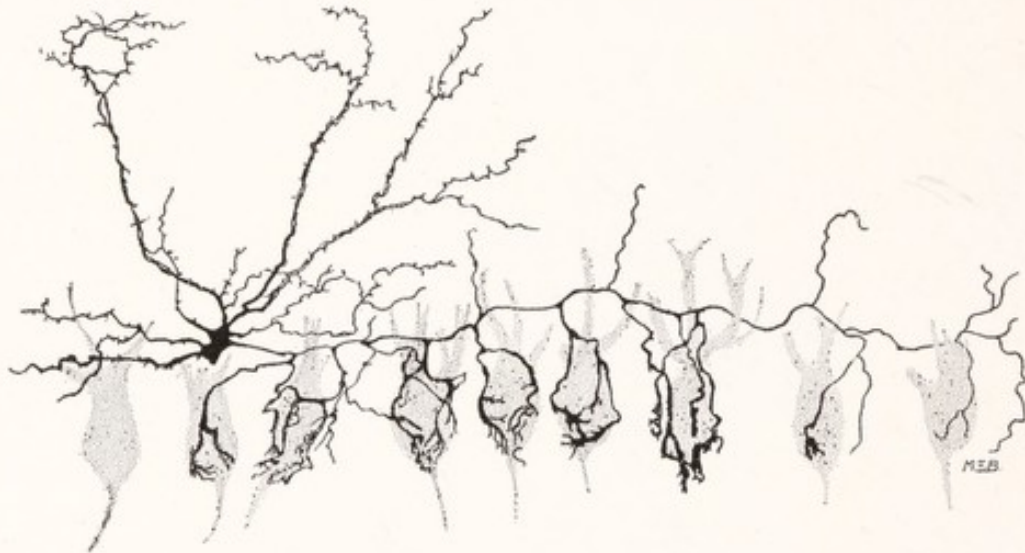

Fig. 29.—Basket cell from the cerebellar cortex of the white rat. The Purkinje cells are indicated in stipple. Golgi method. (Cajal.)

as the *law of dynamic polarity*. The polarity is, however, not dependent upon anything within the neuron itself, but upon something in the nature of the synaptic interval which permits the impulses to travel across it in one direction only. There are many lines of evidence which indicate that when once activated a nerve-fiber conducts equally well in either direction. When a motor fiber bifurcates, sending a branch to each of two separate muscles, stimulation of one branch will cause an impulse to ascend to the point of bifurcation, and then descend along the other branch to its motor ending (Fig. 30). This can often be demonstrated in regenerated nerves (Feiss, 1912). The phenomena of antidromic conduction and the axon reflex (Bayliss, 1915) are also explained by the assumption that impulses are able to travel along a nerve-fiber in either direction.

The Neuron as a Trophic Unit.—All parts of a cell are interdependent, and a continuous interaction between the nucleus and cytoplasm is a necessary condition for life. Any part which is detached from the portion containing the nucleus will disintegrate. In this respect the nerve-cell is no exception. When an axon is divided, that part which is separated from its cell of origin and therefore from its nucleus dies, while the part still connected with the cell usually survives. The degeneration of the distal fragment of the axon extends to its finest ramifications, but does not pass the synapse nor involve the next neuron.

It must not be supposed, however, that the part of the neuron containing the nucleus remains intact, for as a result of the division of an axon important

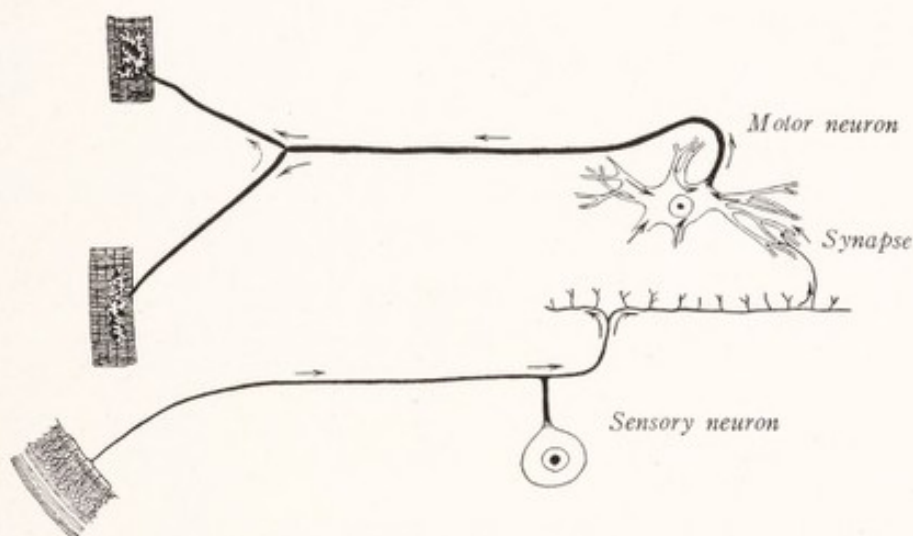


Fig. 30.—Diagram of a reflex arc to illustrate the law of dynamic polarity. The arrows indicate the direction of conduction.

changes occur in the cell body. The Nissl bodies undergo solution, the cell becomes swollen, and the nucleus eccentric. This phenomenon is known as *chromatolysis*, or the axon reaction, and is illustrated in Fig. 27, *B*. If the changes have been very profound the entire neuron may completely disintegrate; but, as a rule, it is restored to normal again by reparative processes. The nucleus becomes more central, the Nissl bodies reform and usually become more abundant than before, while from the cut end of the axon new sprouts grow out to replace the part of the axon which has degenerated. From what has been said it will be apparent that the nucleus presides over the nutrition of the entire neuron, that the latter responds as a whole to an injury of even a distant part of its axon, that the changes produced by such a lesion are limited to the neuron directly involved, and that nerve-fibers are unable to maintain

a separate existence or to regenerate when their continuity with the cell body has been lost. This is what is meant by the statement that the neuron is the trophic unit of the nervous system.

Degeneration and Regeneration of Nerve-fibers.—As has already been stated, that portion of a divided fiber which has been separated from its cell of origin degenerates. The axon breaks up into granular fragments, the myelin undergoes chemical change and forms irregular fatty globules. Later the degenerated axon and myelin are entirely absorbed. The neurilemma cells of a degenerated peripheral nerve-fiber increase in number, their cytoplasm increases in quantity, and they become united end to end to form nucleated protoplasmic bands or band-fibers. These changes in the nerve-fiber are known as *Wallerian degeneration*.

In *regeneration* new axons grow out from the old ones in the central undegenerated portion of the nerve. These grow into the distal degenerated stump and find their way along the nucleated protoplasmic bands, mentioned above, to the terminals of the degenerated nerve. These band-fibers serve as conduits for the growing axons and from them the new neurilemma sheaths are differentiated. Thus, while the neurilemma cells and the band-fibers derived from them appear to be incapable of developing new nerve-fibers by themselves in the peripheral stump, they play an important part in nerve regeneration in co-operation with the new axons from the central stump (Cajal, 1908; Ranson, 1912). It is important to note that the nerve-fibers of the brain and spinal cord, which, as has been stated before, are devoid of neurilemma sheaths, are incapable of regeneration.

The **neuron concept**, which is based on such facts as have been presented in the preceding paragraphs, was first clearly formulated by Waldeyer in 1891, who was also the first to use the name neuron for the elements under consideration. The neuron doctrine may be summarized as follows:

1. The neuron is the genetic unit of the nervous system—each being derived from a single embryonic cell, the neuroblast.
2. The neuron is the structural unit of the nervous system, a nerve-cell with all its processes. These cellular units remain anatomically separate, *i. e.*, while they come into contact with each other at the synapses there is no continuity of their substance.
3. The neurons are the functional units of the nervous system. They are conduction units and the conduction pathways are formed of chains of such units.

4. The neuron is also a trophic unit, as is seen (*a*) in the degeneration of a portion of an axon severed from its cell of origin, (*b*) in the phenomenon of chromatolysis or axon reaction, and (*c*) in the regeneration of the degenerated portion of the axon by an outgrowth from that part of the axon still in contact with its cell of origin.

5. Neurons are the only elements concerned in the conduction of nerve impulses. The nervous system is composed of untold numbers of such units linked together in conduction systems.

While a majority of neurologists now accept the neuron doctrine as presented here, there are dissenters (Marui, 1918). In his very interesting book,

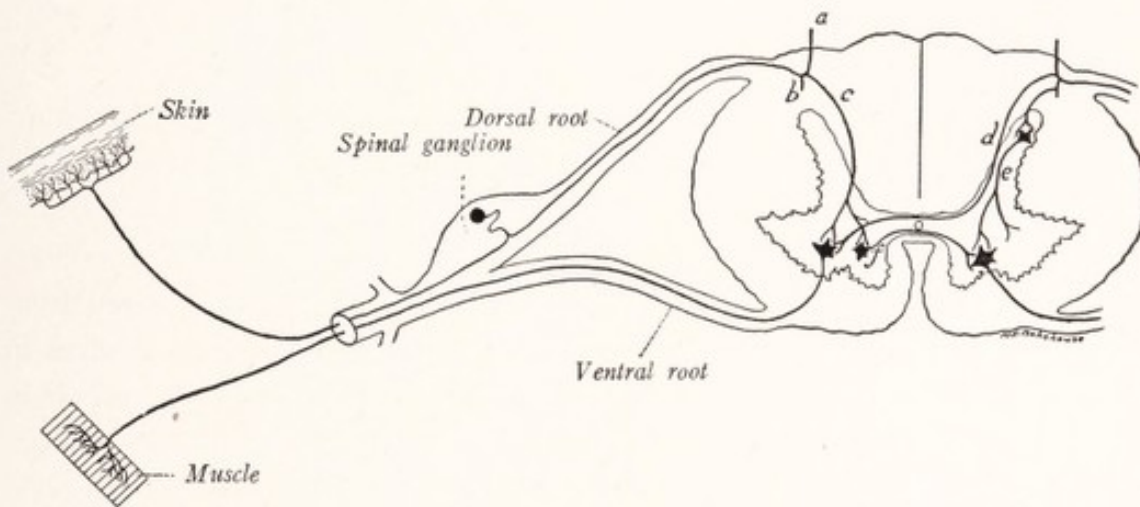


Fig. 31.—Diagrammatic section through the spinal cord and a spinal nerve to illustrate a simple reflex arc: *a*, *b*, *c*, and *d*, Branches of sensory fibers of the dorsal roots; *e*, association neuron; *f*, commissural neuron.

“Allgemeine Anatomie und Physiologie des Nervensystems,” Bethe has vigorously controverted every one of the five cardinal points just presented.

We will next examine some of the simpler chains of neurons to see how they enter into the formation of the conduction pathways.

Neuron-chains.—The simplest functional combination of neurons is seen in the *reflex arc*, and this again in its simplest form is illustrated in Fig. 31. Such an arc may consist of but two neurons, one of which is afferent and conducts toward the spinal cord; the other is efferent and conducts the impulses to the organ of response. The arc consists of the following parts: (1) the receptor, the ramification of the sensory fiber in the skin or other sensory end organ; (2) the first conductor, which includes both branches of the axon of the spinal ganglion cell; (3) a center including the synapse; (4) the second conductor, which

includes the entire motor neuron, with its cell body in the anterior gray column and its motor ending on the muscle, and (5) the effector or organ of response, which in this case is a muscle-fiber. A wave of activation, known as the nerve impulse, is developed in the sensitive receptor, travels over this arc, and on reaching the muscle causes it to contract. So simple a reflex is rare, but probably the knee-jerk is an example (Jolly, 1911). A more common form of reflex arc involves a third, and purely central neuron, as illustrated on the right side of Fig. 31. Such central elements may be spoken of as association and commissural neurons. Many of them serve to connect distant parts of the central

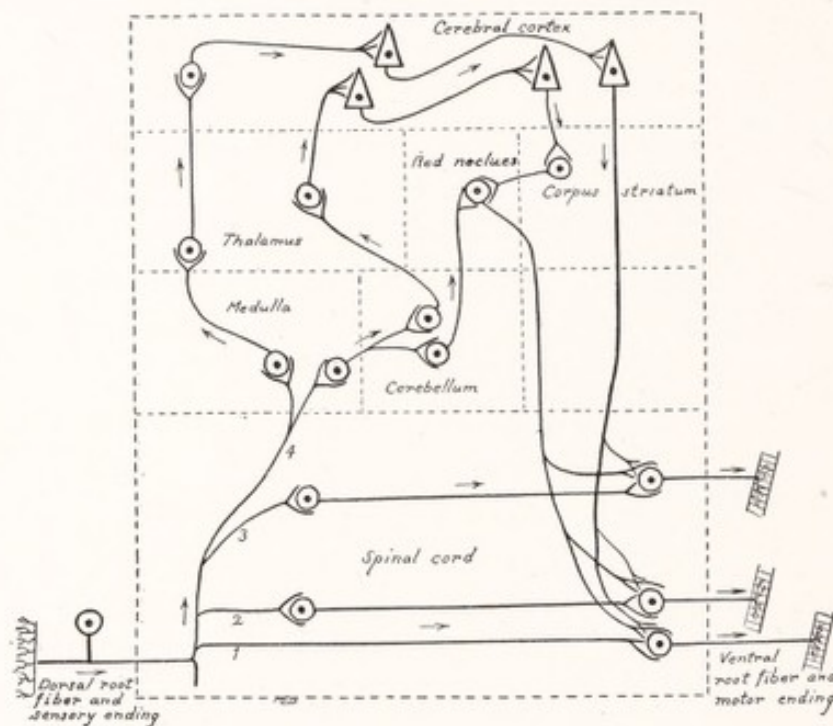


Fig. 32.—Diagram representing some of the conduction paths through the mammalian central nervous system. An elaborate system of central or association neurons furnishes a number of alternative paths between the primary sensory and motor neurons. (Redrawn from Bayliss.)

nervous system with each other (Fig. 68). It is to the multiplication of these central neurons that we owe the complicated pathways within the mammalian brain and spinal cord.

Pathways Through Higher Centers.—A good idea of how the neurons of some of the centers in the brain are related to the primary motor and sensory spinal neurons is given by Fig. 32. It will be seen that many paths are open to an impulse entering the spinal cord by way of a dorsal root fiber: (1) It may pass by way of a collateral to a primary motor neuron in a two-neuron reflex arc. It may travel over an association neuron, belonging (2) to the same level of the

spinal cord, or (3) to other levels, in reflex arcs of three or more neurons each; or (4) it may ascend to the brain along an ascending branch of a dorsal root fiber. Here it may travel over one or more of a number of paths, each consisting of several neurons, and be finally returned to the spinal cord and make its exit by way of a primary motor neuron. The figure illustrates but a few of the possible paths, many of which we shall have occasion to consider in the subsequent chapters.

For an incoming impulse a variety of paths are open, one or more of which may be taken according to the momentary resistance of each. There is reason to believe that the resistance to conduction across a synapse may vary from moment to moment, according to the physiologic state of the neurons involved. It is therefore not necessary that every impulse entering by a given fiber shall travel the same path within the central nervous system nor produce the same result. The pathways themselves are, however, more or less fixed, and depend upon the structural relations established among the neurons. Many of these synaptic connections are formed before birth, follow an hereditary pattern, and are approximately the same for each individual of the species. In the child these are illustrated by the nervous mechanisms involved in breathing and swallowing, which are perfect at birth. The newly hatched chick is able to run about and pick up food, acts which are dependent on nervous connections already established according to hereditary pattern. In man and to a less extent in other mammals the nervous system continues to develop long after birth. This postnatal development is influenced by the experience of the individual and is more or less individual in pattern. It is probable "that in certain parts of the nervous mechanism new connections can always be established through education" (Edinger, 1911).

The neurons which make up the nervous system of an adult man are therefore arranged in a system the larger outlines of which follow an hereditary pattern, but many of the details of which have been shaped by the experiences of the individual.

CHAPTER V

THE SPINAL NERVES

We have had a glance at the earliest beginnings of a nervous system in the animal series and learned something of its biologic significance. We have traced briefly its development in the mammalian embryo, and become familiar with its chief subdivisions. We have studied the microscopic units of which it is composed, learning something of their development, structure, and function. With this information we are prepared to take up a more detailed study of the various subdivisions of the system.

Subdivisions of the Nervous System.—The most convenient and logical classification of the parts of the nervous system is that which emphasizes the distinction between the central organs and those peripheral portions which are concerned chiefly in conducting impulses to and from the central organs, as follows:

The central nervous system:

Brain,
Spinal cord.

The peripheral nervous system:

Cerebrospinal nerves:
Cranial nerves,
Spinal nerves.

The sympathetic nervous system.

The anatomic relationships of these subdivisions in man are illustrated in Figs. 33 and 34. The brain lies within and nearly fills the cranial cavity. It is continuous through the foramen magnum with the spinal cord, which occupies but does not fill the vertebral canal. From the brain arises a series of nerves usually enumerated as twelve pairs and known as cranial or cerebral nerves; while thirty-one pairs of segmentally arranged spinal nerves take origin from the spinal cord.

Branches of the cerebrospinal nerves reach most parts of the body. They are composed of afferent fibers, which receive and carry to the central nervous system sensory impulses produced by external or internal stimuli, and of efferent fibers, which convey outgoing impulses to the organs of response. It is through

the central nervous system that the incoming impulses find their way into the proper outgoing paths. To bring about this shunting of incoming impulses into the appropriate efferent paths requires the presence of untold numbers

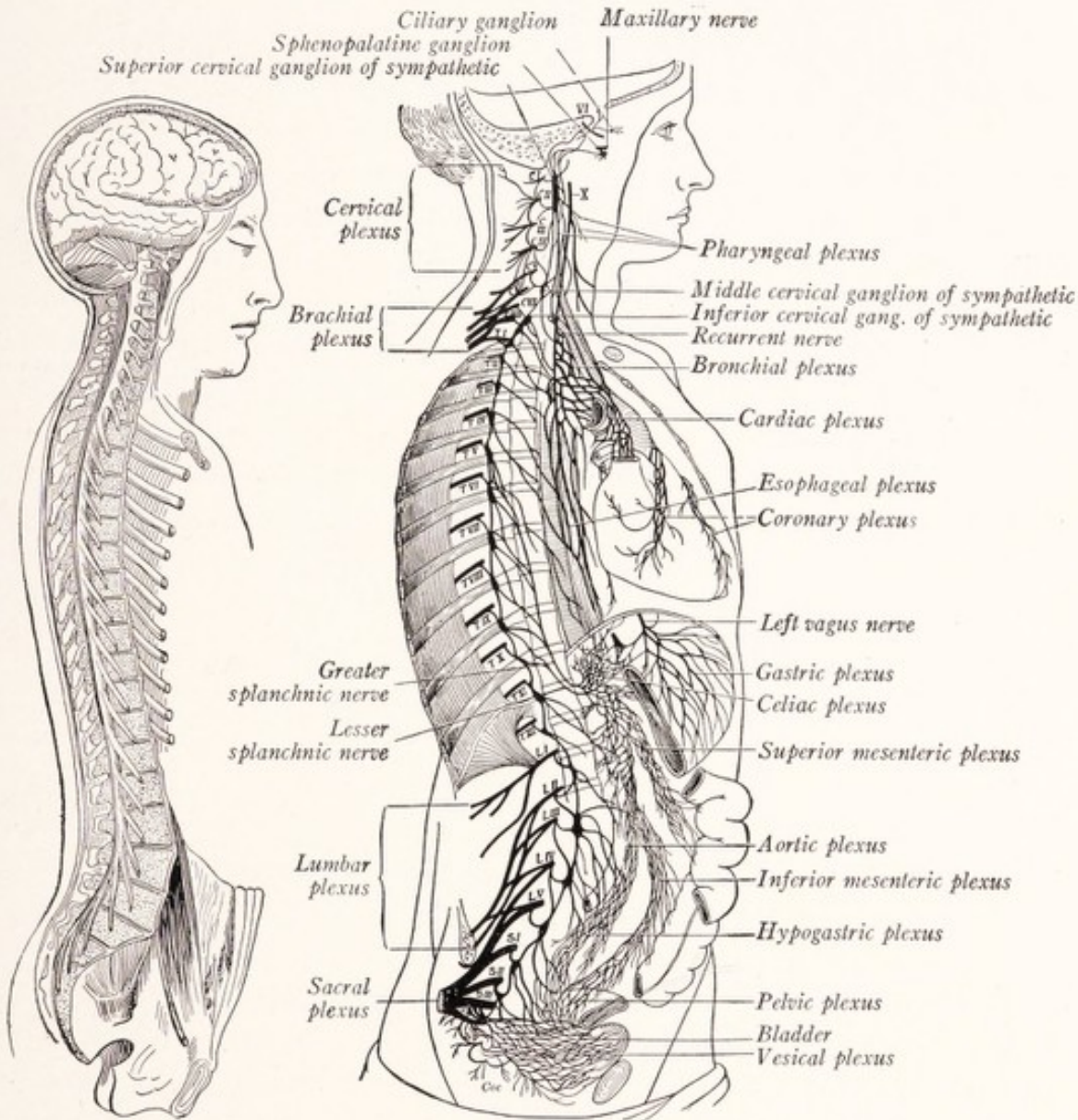


Fig. 33.

Fig. 34.

Fig. 33.—General view of the central nervous system, showing the brain and spinal cord *in situ*. (Bourgery, Schwalbe, van Gehuchten.)

Fig. 34.—Diagram of the sympathetic nervous system and its connections with the cerebrospinal nerves. (Schwalbe, Herrick.)

of central or association neurons, and it is of these that the central organs—brain and spinal cord—are chiefly composed.

Many authors employ a classification which emphasizes the distinction be-

tween the *cerebrospinal nervous system*, composed of the brain and spinal cord with their associated nerves, and the *sympathetic nervous system*. But this usage has the disadvantage that it is likely to engender an entirely false notion of the independence of the sympathetic system.

The **spinal nerves** take origin from the spinal cord within the vertebral canal and make their exit from this canal through the corresponding intervertebral foramina. As component parts of such a nerve there may be recognized a ventral and a dorsal ramus, a ventral and a dorsal root, and associated with the latter a spinal ganglion. The fibers of the ventral root have their cells of origin within the spinal cord and are distributed through both ventral and dorsal rami. Since they conduct impulses from the spinal cord they are known as efferent or motor fibers. The sensory or afferent fibers of the dorsal roots and spinal nerves arise from cells located in the spinal ganglia. These fibers are also distributed through both ventral and dorsal rami (Fig. 37).

Metamerism.—That the spinal nerves are segmentally arranged, a pair for each metamere, is readily appreciated in the case of the typical body segments of the thoracic region. Here it is obvious that a nerve supplies the corresponding dermatome and myotome, or in the adult the skin and musculature of its own segment. While the *thoracic nerves* retain this primitive arrangement in the adult, the distribution of fibers from the other spinal nerves is complicated by the development of the limb buds and by the shifting of myotomes and dermatomes during the development of the embryo.

Opposite the attachment of the limb buds the ventral rami of the corresponding nerves unite to form flattened plates, and from these plates the *brachial* and *lumbosacral plexuses* are developed. Within these plexuses the fibers derived from a number of ventral rami are intermingled in what appears at first to be hopeless confusion. Each nerve which extends from these plexuses into the limbs carries with it fibers from more than one spinal nerve. To determine the exact distribution of the fibers from each segmental nerve has been a very difficult problem, in the elucidation of which the work of clinical neurologists has been of the first importance. A study of the paralyses and areas of anesthesia, resulting from lesions involving one or more nerve roots within the vertebral canal, has contributed much toward its solution.

Sherrington (1894) attacked the problem of the distribution of the *sensory fibers* by experimental methods on cats and monkeys. He found that section of a single dorsal root did not cause complete anesthesia anywhere, and attributed this result to an overlapping of the areas of distribution of adjacent spinal nerves.

Next, selecting a particular dorsal root for study, he cut two or three roots both above and below it. The zone in which sensation still existed and which was surrounded by an area of anesthesia represented the cutaneous field of that particular root. He found that each "*sensory root field*" overlapped those of adjacent roots (Fig. 35). In the thoracic region each such field has the shape of a horizontal band wrapping half-way around the body from the middorsal to the midventral lines (Fig. 36).

Sherrington also found that, although in the plexuses associated with the innervation of the extremities each segmental nerve contributes sensory fibers to two or more peripheral nerves, the cutaneous distribution of these fibers is not composed of disjointed patches, but forms a continuous field running approximately parallel to the long axis of the limb. The general arrangement of these sensory root fields in man is indicated on the right side of Fig. 36. On the

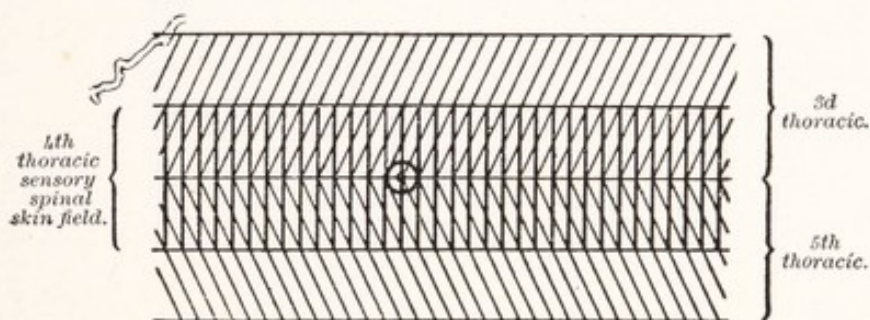


Fig. 35.—Diagram of the position of the nipple in the sensory skin fields of the fourth, third, and fifth thoracic spinal roots. The overlapping of the cutaneous areas is represented. (Sherrington.)

opposite side is indicated the distribution of the cutaneous nerves. It will be seen that in the extremities there is no correspondence between the areas supplied by these peripheral nerves and those supplied by the individual dorsal roots. It will also be evident that the fibers of a given dorsal root reach the corresponding sensory root field by way of more than one cutaneous nerve. A knowledge of the cutaneous distribution of the various nerve roots is of great importance in enabling the clinician to determine the level of a lesion of the spinal cord or nerve roots within the vertebral canal.

In the same way the shifting of muscles during embryonic development has been accompanied by corresponding changes in the spacial distribution of the *motor fibers*. A familiar example is furnished by the diaphragm, the musculature of which is derived from the cervical myotomes and which in its descent carries with it the phrenic nerve. This explains the origin of the phrenic from the third, fourth, and fifth cervical nerves.

If, as seems probable, the musculature of the extremities has not developed along metameric lines, there can be no true metamerism of the motor nerves to the limbs (Streeter, 1912). Yet the fibers from each ventral root are distributed in a very orderly manner. As is indicated in the table on page 77, almost every long muscle receives fibers from two or more ventral roots. It will be apparent that the muscles of the trunk are innervated from the roots belonging to the

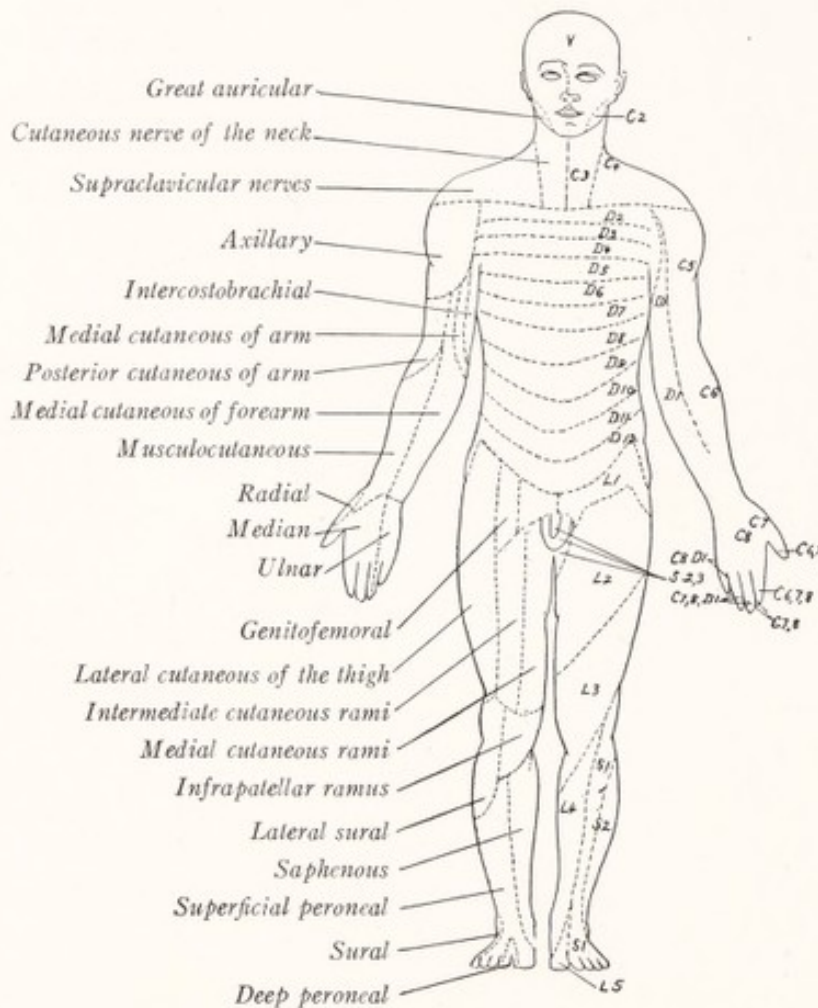


Fig. 36.—Sensory root fields on the right, contrasted with the areas of distribution of cutaneous nerves on the left.

several metameres from the myotomes of which these muscles developed. The table shows in a general way the distribution of the fibers of the several ventral roots.

Functional Classification of Nerve-fibers.—Many years ago Sir Charles Bell (1811, 1844) showed that the dorsal roots are sensory in function and the ventral roots motor; and this has been known since then as Bell's law. He recognized that sensory and motor fibers are distributed to the viscera as well as

to the rest of the body. But Gaskell (1886) was the first to make a detailed study of the nerve-fibers supplying the visceral and vascular systems. We now recognize in the spinal nerves elements belonging to four functionally distinct varieties, namely, *visceral afferent*, *visceral efferent*, *somatic afferent*, and *somatic efferent* fibers (Fig. 37).

Visceral Components.—The fibers which innervate the visceral and vascular systems, including all involuntary muscle and glandular tissue, possess, as Gaskell (1886) pointed out many years ago, certain distinguishing characteristics. They are all fine myelinated fibers and end in sympathetic ganglia

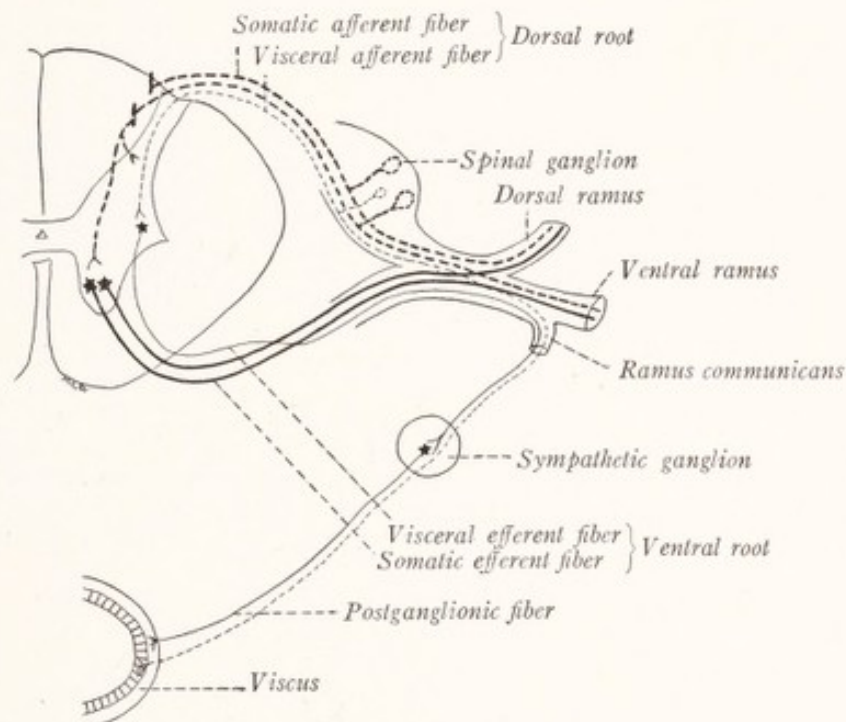


Fig. 37.—Diagrammatic section through a spinal nerve and the spinal cord in the thoracic region to illustrate the chief functional types of peripheral nerve-fibers.

from which the impulses are relayed to involuntary muscles and glands by a second set of neurons (Fig. 37). They are usually designated as *visceral efferent fibers*, and they run by way of the white rami to the sympathetic ganglia. It is usually stated that they are found only in the second thoracic to the second lumbar nerves inclusive, but Langley (1892) has shown that in the cat, dog, and rabbit they are present in all the thoracic and the first four lumbar nerves, and Müller (1909) found white rami associated with the third and fourth lumbar nerves in man.

There are also *visceral afferent fibers* distributed to the thoracic and abdominal viscera by way of the white rami from the thoracic and upper lumbar

nerves. These have their cells of origin in the spinal ganglia and are continued through the dorsal roots into the spinal cord (Fig. 37). We shall have much more to say about the visceral components of the spinal nerves in the chapter on the Sympathetic Nervous System. In the remaining pages of this chapter we will confine our attention to the *somatic components*, *i. e.*, to those fibers which innervate the various parts of the body exclusive of the visceral and vascular systems.

Somatic Efferent Components.—The skeletal muscles are innervated by myelinated fibers, which are, for the most part, of large caliber. The axis-cylinders of these fibers are the axons of cells located in the ventral part of the gray matter of the spinal cord, and they end on the muscle-fibers in special

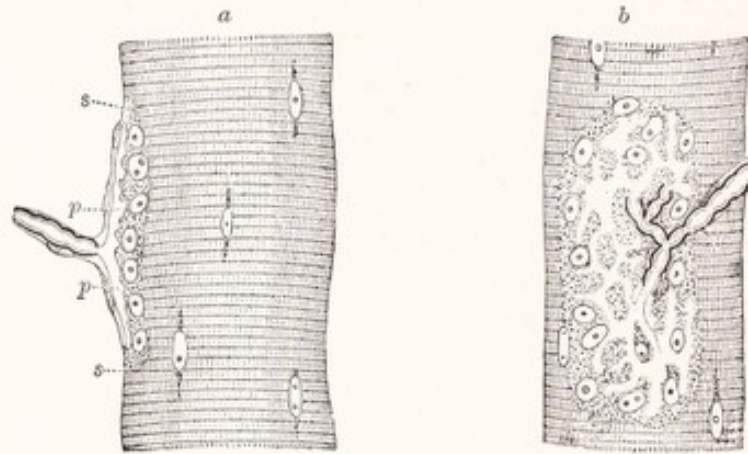


Fig. 38.—Nerve-ending in muscular fiber of a lizard (*Lacerta viridis*). Highly magnified: *a*, End-organ seen in profile; *b*, from the surface; *s*, *s*, sarcolemma; *p*, *p*, expansion of axis-cylinder. Beneath this is granular protoplasm containing a number of large clear nuclei and constituting the "bed" or "sole" of the end-organ. In *b* the expansion of the axis-cylinder appears as a clear network, branching from the divisions of the medullated fiber. (Kühne in Quain's Anatomy.)

motor end-plates. Such a primary motor neuron is illustrated in Fig. 25. A motor fiber undergoes repeated division as it approaches its termination, but each branch retains its myelin sheath until in contact with the muscle-fiber. At this point this sheath terminates abruptly, and the neurilemma becomes continuous with the sarcolemma (Fig. 38). The terminal branches of the axon are short, thick, and irregular. They lie immediately under the sarcolemma in a bed of specialized sarcoplasm containing a number of large clear nuclei. The wave of activation, which travels down an axon as a nerve impulse, is transmitted through these motor nerve endings to the muscle and initiates a contraction.

The Spinal Ganglia.—Since the afferent fibers in the spinal nerves take their

origin from the ganglia on the dorsal roots we will do well to interrupt for a moment our functional analyses of the spinal nerves and consider the structure of these ganglia.

The spinal ganglia are rather simple structures so far as their fundamental plan is concerned, but in recent years, chiefly through the studies of Cajal (1906) and Dogiel (1908), we have learned to recognize in them many complex histologic details, the significance of which is not yet understood. It has long been known that the typical cells of the mammalian spinal ganglion are *unipolar*. The cell body is irregularly spheric. The axon,¹ which is attached to the perikaryon by an implantation cone, is coiled on itself in the neighborhood of the cell, forming what is known as a glomerulus (Fig. 39, *f*). It then runs into one of the central fiber bundles of the ganglion and divides in the form of a T or Y into two branches, of which one is directed toward the spinal cord in the dorsal root. The other and somewhat larger branch is directed distally in the spinal nerve. The cells vary greatly in size and the diameter of the axon varies with that of the cell from which it springs. An axon arising from a *large cell* usually forms a very pronounced glomerulus and soon becomes ensheathed with myelin, and this myelin sheath is continued along both branches into which it divides. The branching occurs at a node of Ranvier.

As was originally pointed out by Cajal (1906) and Dogiel (1908) and recently emphasized by Ranson (1911) the *small cells* of these ganglia give rise to fine unmyelinated fibers. These coil but little near the cell, or the glomerulus may be entirely lacking (Fig. 39, *a*). They divide dichotomously, just as do the myelinated fibers, into finer central and coarser peripheral branches. At the point of bifurcation there is a triangular expansion in place of the constriction so characteristic of a dividing myelinated fiber. It has been shown by Hatai (1902) and Warrington and Griffith (1904) that the small cells are considerably more numerous than the large cells, though because of their small size they constitute a less conspicuous element.

A few cells retain the *bipolar* form characteristic of all the spinal ganglion cells at an early stage of development (Figs. 21, 40, *d*).

The spinal ganglion cells are each surrounded by a *capsule* or membranous sheath with nuclei on its inner surface (Fig. 39, *d, f*) which is continuous with the neurilemma sheath of the associated nerve-fiber. The cells forming the capsule are of ectodermal origin, being derived like the spinal ganglion cells themselves from the neural crest.

¹ See fine print, page 45.

In good methylene-blue preparations and in sections stained by the newer silver methods it is possible to make out many additional details of structure. The axon may split into many branches, which subdivide and anastomose, forming a true network in the neighborhood of the cell (Fig. 39, *b*). From this network the axon is again assembled and passes on to a typical bifurcation. Or the axon may be assembled out of a similar plexus which, however, is con-

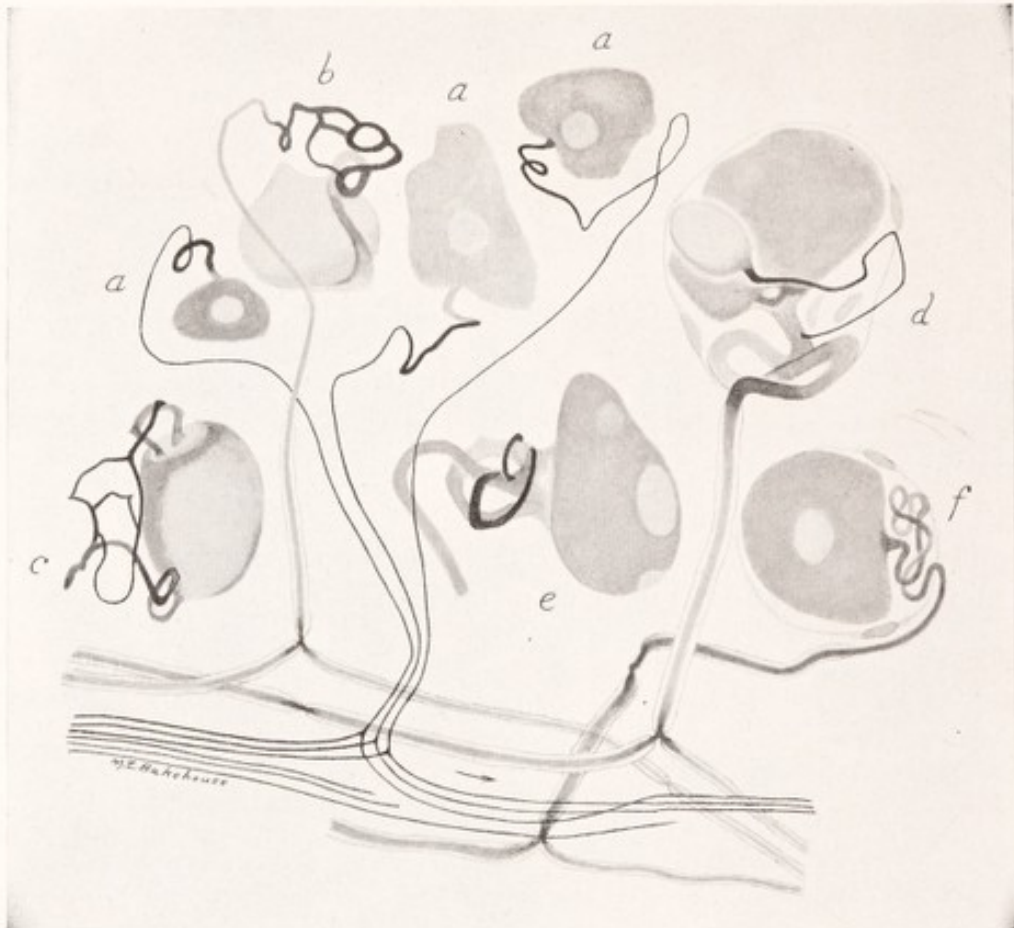


Fig. 39.—Neurons from the spinal ganglion of a dog: *a*, Small cells with unmyelinated axons; *b*, *c*, *d*, *e*, and *f*, large cells with myelinated axons; *f*, typical large spinal ganglion cell showing glomerulus and capsule. The arrow points toward the spinal cord. Pyridin-silver method.

nected with the cell by several roots (Fig. 39, *c*). Some of the fibers give off collaterals terminating in spheric or pear-shaped end-bulbs. Such an end bulb may rest upon the surface of its own perikaryon (Fig. 39, *d*) or elsewhere in the ganglion. From the body of some cells short club-shaped dendrites arise, which, however, terminate beneath the capsules which surround the cells.

Based on such details as these Dogiel (1908) has arranged the spinal ganglion cells in groups and recognizes eleven different types. Two of his eleven types are of special interest. The cells of Type VIII resemble the typical spinal ganglion cell in all respects except that

the peripheral branch of the axon breaks up within the ganglion into numerous myelinated fibers, which after losing their sheaths terminate in what are apparently sensory endings. The central branch runs apparently without division to the spinal cord. The cells of Type XI possess, in addition to an axon, that apparently runs without division through the dorsal root to the spinal cord, several processes that resemble dendrites, in that they divide repeatedly within the ganglion, but resemble axons in their appearance and in possessing myelin sheaths (Fig. 40, *b*). These processes after repeated divisions become unmyelinated and end within the ganglion and dorsal root in what appear to be sensory endings. It would lead us too far afield if we should attempt to summarise Dogiel's work. It should be pointed out, however, that he no longer believes in the existence of the cells which he formerly described under the head of spinal ganglion cells of Type II and which find a conspicuous place in most text-books. He believes that what he formerly described as the branching fibers of these cells are, in reality, the dendrite-like branches of the cells of Type XI.

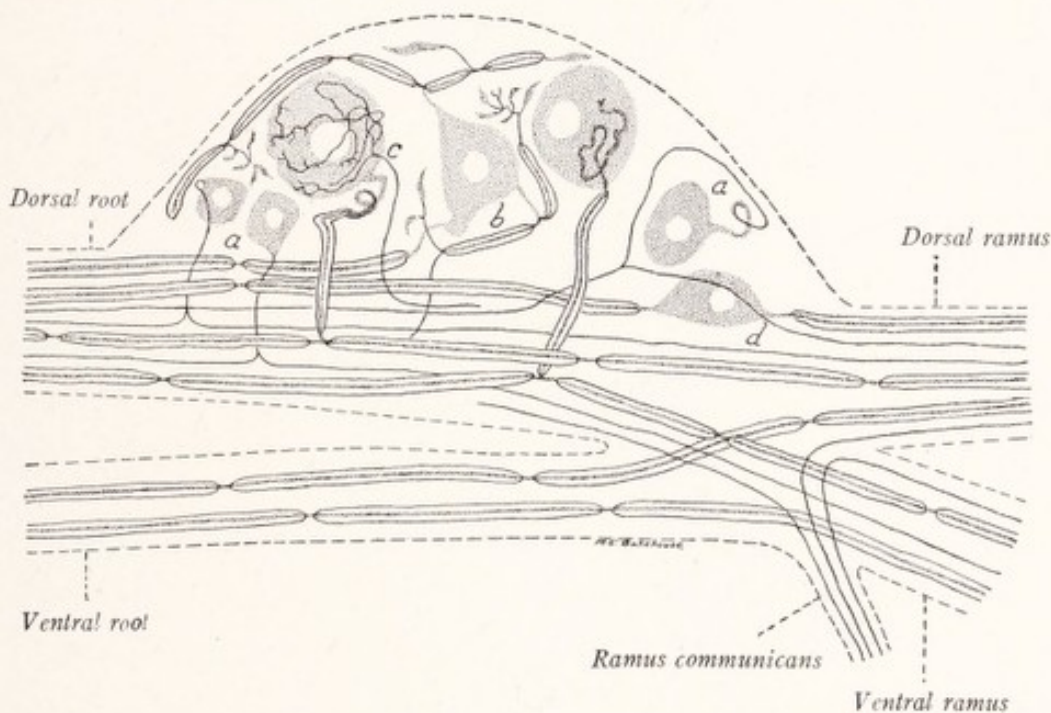


Fig. 40.—Diagrammatic longitudinal section of a spinal ganglion and a spinal nerve (cervical or sacral): *a*, Small cells with unmyelinated axons; *b*, cell of Dogiel's type XI; *c*, large cell possessing a myelinated axon and surrounded by a pericellular plexus; *d*, bipolar cell.

According to Dogiel every spinal ganglion cell is surrounded by a network of fine branching and anastomosing fibers; and he believes that these are formed by the ramifications of fine myelinated and unmyelinated fibers that have entered the spinal ganglion from the sympathetic nervous system through the rami communicantes. While the origin of these fibers is open to question, there can be no doubt that such *pericellular networks* exist on at least a considerable proportion of the cells and constitute an important element in the structure of the ganglion (Fig. 40, *c*).

The *fiber bundles of the ganglia* are composed of both myelinated and un-

myelinated fibers representing the branches of the axons of the spinal ganglion cells. Both types of fibers can be followed through the dorsal roots into the spinal cord, as well as distally into the nerves. In the latter they mingle with the large myelinated fibers coming from the ventral roots (Fig. 40). When traced distally in the peripheral nerve the unmyelinated fibers are found to go in large part to the skin, though a few run in the muscular branches (Ranson, 1911 and 1915).

Classification of the Somatic Afferent Fibers According to Function.—Sherrington (1906) in an instructive book on "The Integrative Action of the Nervous System" has furnished us with a useful classification of the elements belonging to the afferent side of the nervous system. He designates those carrying impulses from the viscera as *interoceptive*, and subdivides the somatic afferent elements into exteroceptive and proprioceptive groups. The *exteroceptive fibers* carry impulses from the surface of the body and from such sense organs, as the eye and ear, that are designed to receive stimuli from without. These fibers, therefore, are activated almost exclusively by external stimuli. The *proprioceptive fibers*, on the other hand, respond to stimuli arising within the body itself and convey impulses from the muscles, joints, tendons, and the semicircular canals of the ear. Each group has receptors or sensory endings designed to respond to its appropriate set of stimuli, and for each there are special connections within the brain and spinal cord.

Exteroceptive fibers and sensory endings are activated by changes in the environment, that is to say, they are stimulated by objects outside the body. The impulses, produced in this way and carried by these fibers to the spinal cord, call forth for the most part reactions of the body to its environment; and, when relayed to the cerebral cortex, they may be accompanied by sensations of touch, heat, cold, or pain. The receptors are, for the most part, located in the skin; yet it is convenient to include in the exteroceptive group the pressure receptors which are closely allied to those for touch, but which lie below the surface of the body. At this point it should be noted that sensibility to those forms of contact which include some slight pressure, such as the placing of a finger on the skin, is not abolished by the section of all of the cutaneous nerves going to the area in question, since the deeper nerves carry fibers capable of responding to such contacts (Head, 1905). This deep contact sensibility, which for lack of a better name we may call "pressure-touch," must not be overlooked in the analysis of cutaneous sensations.

The balance of evidence is in favor of the assumption that each of the vari-

eties of cutaneous sensation is mediated by a separate set of nerve-fibers. But little progress has as yet been made toward identifying these various functional groups. We know that both myelinated and unmyelinated fibers are present in the cutaneous nerves (Ranson, 1915), but are not able to say with certainty which subserve each of the varieties of cutaneous sensation. There are many good reasons, however, for the belief that painful afferent impulses and possibly also those of temperature are carried by the unmyelinated fibers, and that those of the touch and pressure group are mediated by the myelinated fibers. The evidence on which this statement is based has been briefly summarized on pages 102-104.

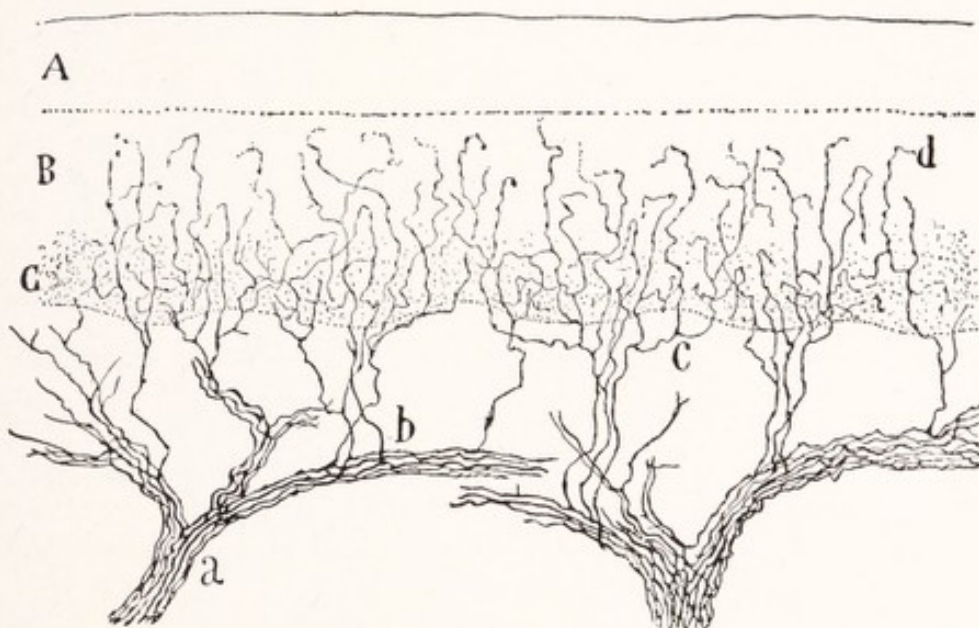


Fig. 41.—Free nerve endings in the epidermis of a cat's paw: *A*, Stratum corneum; *B*, stratum germinativum Malpighii, and *C*, its deepest portion; *a*, large nerve trunk; *b*, collateral fibers; *c*, terminal branches; *d*, terminations among the epithelial cells. Golgi method. (Cajal.)

All sensory nerve endings in the skin belong to the exteroceptive group, but it is not so easy to say which ones are responsible for each of the several varieties of cutaneous sensation, namely, touch, pain, heat, and cold. On structural grounds we may recognize three principal groups: (1) endings in hair-follicles, (2) encapsulated nerve endings, and (3) free terminations in the epidermis.

Free Nerve Endings.—Some of the myelinated fibers as they approach their terminations divide repeatedly. At first the branches retain their sheaths, but after many divisions the myelin sheaths and finally the neurilemma are lost and only the naked axis-cylinders remain. These enter the epidermis, where,

after further divisions, they end among the epithelial cells (Fig. 41). This type of nerve ending is found in the skin, mucous membranes, and cornea. Similar endings are also found in the serous membranes and intermuscular connective tissue.

We do not know what form the endings of the afferent unmyelinated fibers may take, but it is not unlikely that they also ramify in the epidermis like the terminal branches of the myelinated fibers just described. It seems certain that at least a part of the free nerve endings in the epidermis are pain receptors. In the central part of the cornea, the tympanic membrane, and the dentine and pulp of the teeth, such free nerve endings alone are present, and pain is the only sensation that can be appreciated.

Some of the nerve-fibers which enter the epidermis end in disk-like expansions in contact with specialized epithelial cells (Fig. 42). These have been known

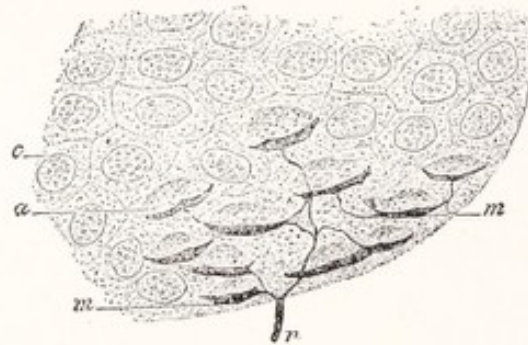

Fig. 42.—Merkel's corpuscles or tactile disks from the skin of the pig's snout. The nerve-fiber, *n*, branches and each division ends in an expanded disk, *m*, which is attached to a modified cell of the epidermis, *a*; *c*, an unmodified epithelial cell. (Ranvier, Herrick.)

as *Merkel's touch-cells* on the supposition that the endings in question are tactile receptors.

Encapsulated Nerve Endings.—Among the encapsulated nerve endings are the *corpuscles of Meissner*. These have quite generally been regarded as tactile end organs and are located in the corium or subepidermal connective tissue of the hands and feet, forearm, lips, and certain other regions. They are of large size, oval, possess a thin connective-tissue capsule, and within each terminate one or more medullated fibers (Fig. 43). Within the capsule the fibers lose their myelin sheaths, make a variable number of spiral turns, and finally break up into many varicose branches, which form a complex network. To another type of encapsulated end organ belong those known as the *end bulbs of Krause*. One of these is illustrated in Fig. 44. They are found in the conjunctiva, edge of the cornea, lips, and some other localities.

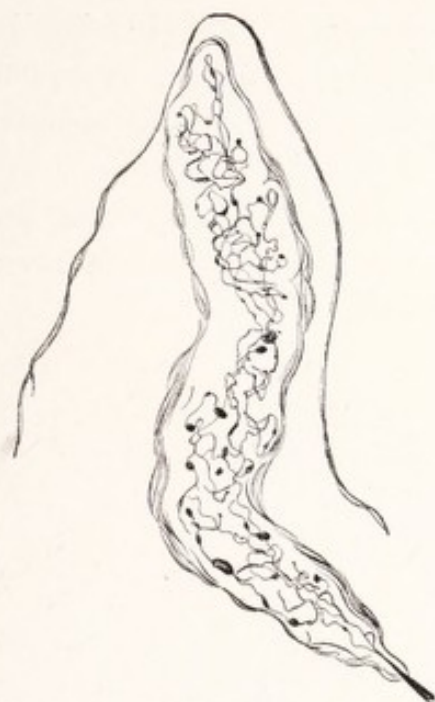

Fig. 43.—Meissner's tactile corpuscle. Methylene-blue stain. (Dogiel, Böhm-Davidoff-Huber.)

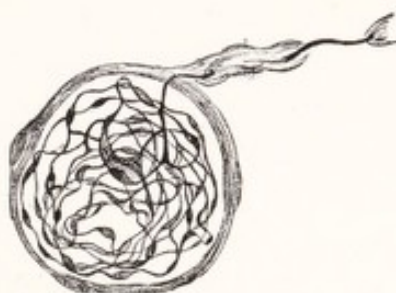

Fig. 44.—End-bulb of Krause from conjunctiva of man. Methylene-blue stain. (Dogiel, Böhm-Davidoff-Huber.)

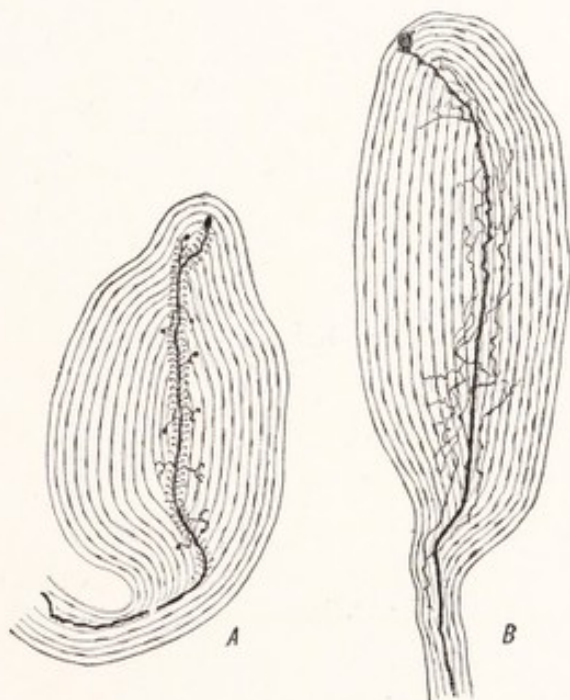


Fig. 45.—Pacini corpuscles from mesorectum of kitten: *A*, Showing the fine branches of the central fiber; *B*, the network of fine nerve-fibers about the central fiber. Methylene-blue stain. (Sala, Böhm-Davidoff-Huber.)

The *Pacini corpuscles*, two of which are illustrated in Fig. 45, have a very wide distribution in the deeper parts of the dermis of the hands and feet, in the

tendons, intermuscular septa, periosteum, peritoneum, pleura, and pericardium. They are also numerous in the neighborhood of the joints. According to Her- rick (1918) it is probable that "by these end organs relatively coarse pressure may be discriminated and localized (exteroceptive function), and movements of muscles and joints can be recognized (proprioceptive function)." They are

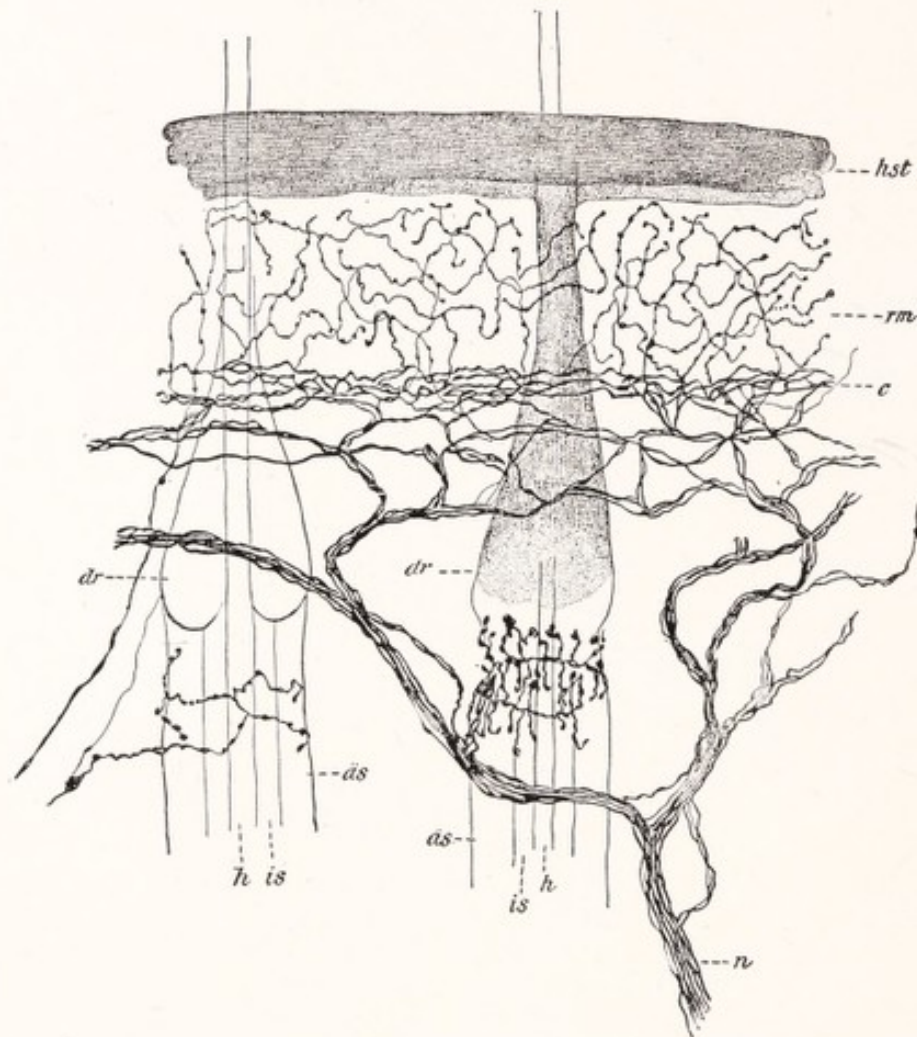


Fig. 46.—Nerves and nerve endings in the skin and hair-follicles: *hst*, Stratum corneum; *rm*, stratum germinativum Malpighii; *c*, most superficial nerve-fiber plexus in the cutis; *n*, cutaneous nerve; *is*, inner root sheath of hair; *as*, outer root sheath; *h*, the hair itself; *dr*, glandulæ sebaceæ. (Retzius, Barker.)

large oval corpuscles, made up in great part of concentric lamellæ of connective tissue. The axis of the corpuscle is occupied by a core of semifluid substance containing the termination of a nerve-fiber. The fiber loses its myelin sheath as it enters the core, through which it passes from end to end. Its terminal branches end in irregular disks. Side branches are also given off within the core.

Nerve Endings in the Hair-follicles.—It has long been known that the *hairs* are delicate *tactile organs*. The hair-clad parts lose much of their responsive-

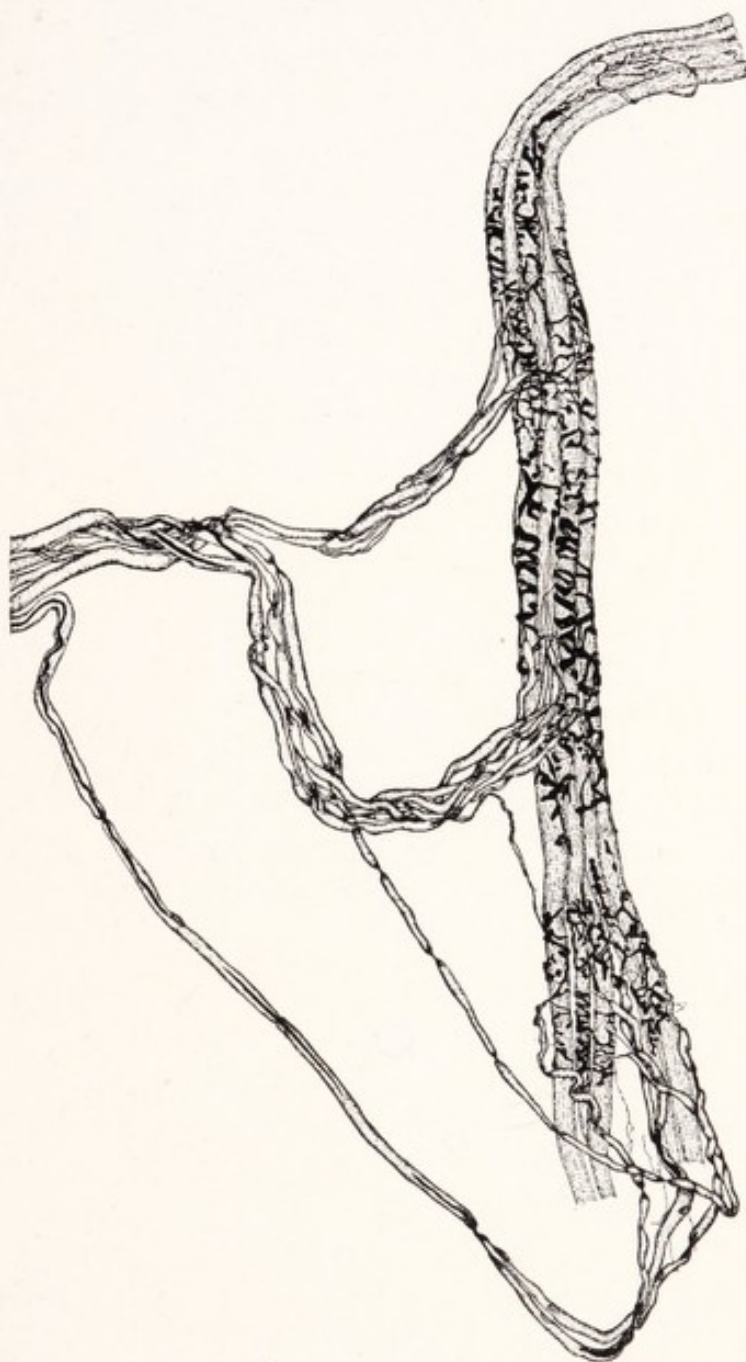

Fig. 47.—Neuromuscular nerve end-organ from a dog. The figure shows the intrafusal muscle-fibers, the nerve-fibers and their terminations, but not the capsule nor the sheath of Henle. Methylene-blue stain. (Huber and De Witt.)

ness to touch when the hair is removed. As would be expected on these grounds, the hair-follicles are richly supplied with nerve endings. Just below the opening of the sebaceous gland into the follicle myelinated nerve-fibers enter it, los-

ing their myelin sheaths as they enter. They give off horizontal branches, which encircle the root of the hair, and from these ascending branches arise (Fig. 46). Some of these are connected with leaf-like expansions, associated with cells resembling Merkel's touch-cells.

Practically nothing is known concerning the receptors for sensations of heat and cold.

Proprioceptive Fibers and Sensory Nerve Endings.—To this group belong the afferent elements which receive and convey the impulses arising in the muscles, joints, and tendons. Changes in tension of muscles and tendons and movements of the joints are adequate stimuli for the receptors of this class and excite nerve impulses which, on reaching the central nervous system, give information concerning tension of the muscles and the relative position of the various parts of the body. For the most part, however, these impulses do not rise into consciousness, but serve for the subconscious control of muscular activity. The unsteady gait of a tabetic patient illustrates the lack of muscular control that results when these impulses are prevented from reaching the central nervous system.

The proprioceptive fibers are myelinated and are associated with motor fibers in the nerves to the muscles. Some follow along the muscles to reach the tendons. Three types of end organs belong to this group, Pacinian corpuscles, muscle spindles, and neurotendinous end organs. Many *Pacinian corpuscles* are found in the neighborhood of the joints. They have been described in a preceding paragraph.

Neuromuscular End Organs.—The afferent fibers to the muscles end on small, spindle-shaped bundles of specialized muscle-fibers (Fig. 47). These *muscle spindles* are invested by connective-tissue capsules; and within each of them one or more large myelinated nerve-fibers terminate. Within the spindle the myelin sheath is lost and the branches of the axis-cylinders wind spirally about the specialized muscle-fibers, or they may end in irregular disks. Somewhat analogous structures are the *neurotendinous end organs* or tendon spindles where myelinated nerve-fibers end in relation to specialized tendon fasciculi.

CHAPTER VI

THE SPINAL CORD

THE spinal cord, or medulla spinalis, is a cylindric mass of nervous tissue occupying the vertebral canal. It is 40 to 45 cm. in length, reaching from the foramen magnum, where it is continuous with the medulla oblongata, to the level of the first or second lumbar vertebra. Even above this level the vertebral canal is by no means fully occupied by the cord (Fig. 48), which, as shown in Fig. 49, is surrounded by protective membranes, while between these and the wall of the canal is a rather thick cushion of adipose tissue containing a plexus

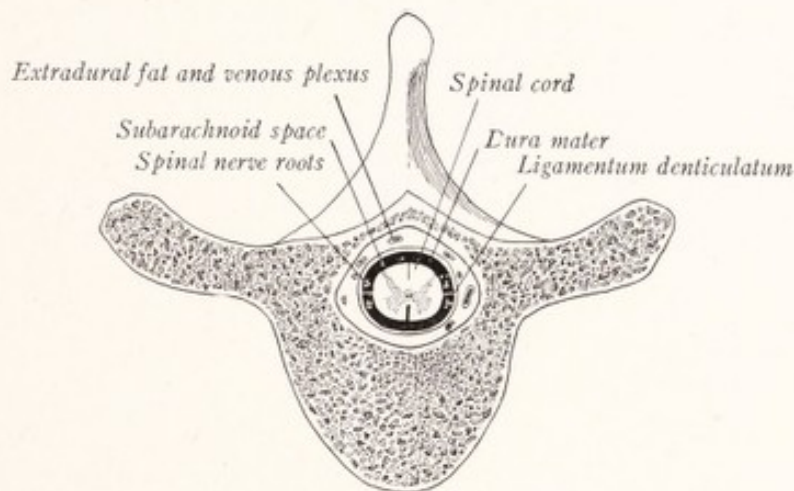


Fig. 48.—Diagram showing the relation of the spinal cord to the vertebral column.

of veins. Immediately surrounding the cord and adherent to it is the delicate, highly vascular *pia mater*. This is separated from the thick, fibrous *dura mater* by a membrane having the tenuity of a spider web, the *arachnoid*, which surrounds the subarachnoid space. This space is broken up by subarachnoid trabeculae and filled with cerebrospinal fluid.

External Form.—The spinal cord is not a perfect cylinder, but is somewhat flattened ventrodorsally, especially in the cervical region. Its diameter is not uniform throughout, being less in the thoracic than in the cervical and lumbar portions. That is to say, the cord presents two swellings (Fig. 51). The *cervical enlargement* (*intumescentia cervicalis*) comprises all that portion of the cord

from which the nerves of the brachial plexus arise, that is, the fourth cervical to the second thoracic segments inclusive. The *lumbar enlargement* (*intumescencia lumbalis*) is not quite so extensive and corresponds less accurately to the origin of the nerves innervating the lower extremity. At an early stage in the embryonic development of the spinal cord these enlargements are not present. In the time of their first appearance and in their subsequent growth they are directly related to the development of the limbs.

Below the lumbar enlargement the spinal cord rapidly decreases in size and has a cone-shaped termination, the *conus medullaris*, from the end of which a slender filament, the *filum terminale*, is prolonged to the posterior surface of the coccyx (Figs. 50, 51). This terminal filament descends in the middle line, surrounded by the roots of the lumbar and sacral nerves, to the caudal end of

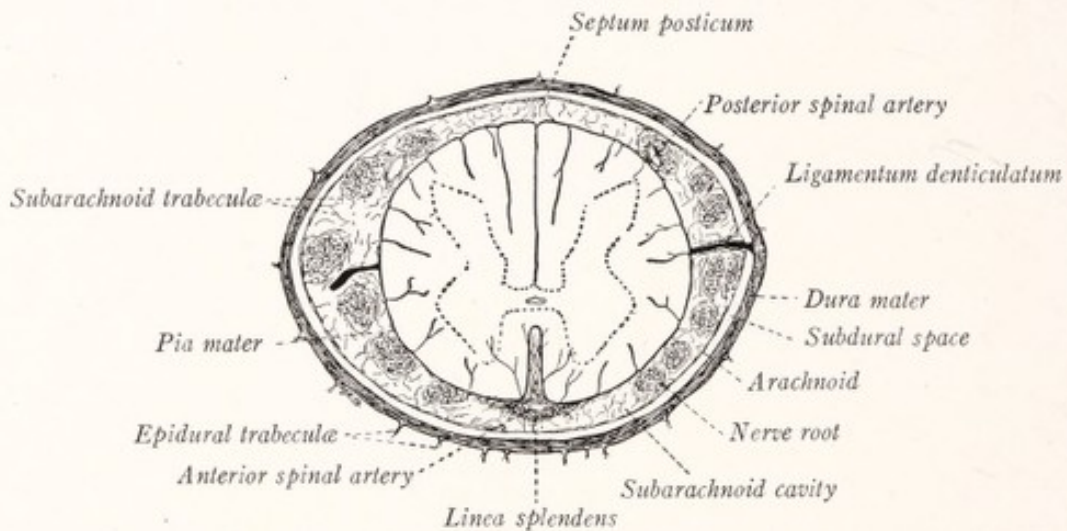


Fig. 49.—Diagram of the spinal cord and meninges.

the dural sac at the level of the second sacral vertebra. Here it perforates the dura mater, from which it receives an investment, and then continues to the posterior surface of the coccyx. The last portion of the filament with its dural investment is often called the *filum of the spinal dura mater* (*filum duræ matris spinalis*). The *filum terminale* is composed chiefly of pia mater; but in its rostral part it contains a prolongation of the central canal of the cord.

The spinal cord shows an obscure *segmentation*, in that it gives origin to thirty-one pairs of metameric nerves. These segments may be somewhat arbitrarily marked off from each other by passing imaginary planes through the highest root filaments of each successive spinal nerve (Donaldson and Davis, 1903). The highest of these planes, being just above the origin of the first cervical nerve, marks the separation of the spinal cord from the medulla oblongata.

This is again an arbitrary line of separation, since both as to external form and internal structure the cord passes over into the medulla oblongata by in-

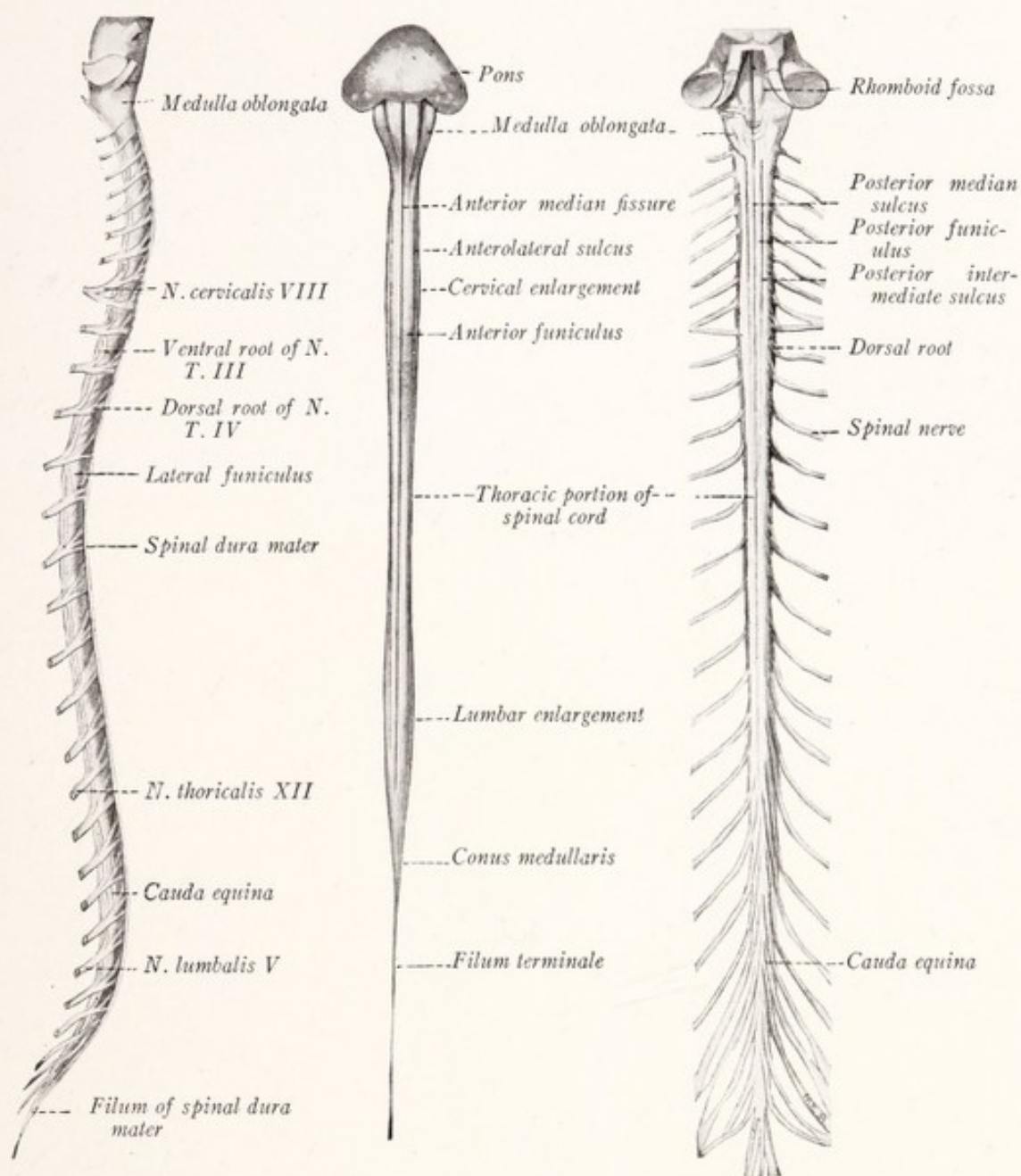


Fig. 50.

Fig. 51.

Fig. 52.

Figs. 50-52.—Three views of the spinal cord and rhombencephalon: Fig. 50, Lateral view with spinal nerves attached; Fig. 51, ventral view with spinal nerves removed; Fig. 52, dorsal view with spinal nerves attached. (Modified from Spalteholz.)

sensible gradations. According to this method of subdivision there are in the cervical portion of the cord eight segments, in the thoracic twelve, in the lumbar five, and in the sacral five, while there is but one coccygeal segment.

Several *longitudinal furrows* are seen upon the surface of the cord (Figs. 51, 52). Along the middle line of the ventral surface is the deep *anterior median fissure* (*fissura mediana anterior*). This extends into the cord to a depth amounting to nearly one-third of its anteroposterior diameter and contains a fold of pia mater. Along the middle line of the dorsal surface there is a shallow groove, the *posterior median sulcus* (*sulcus medianus posterior*). As may be seen in cross-sections of the spinal cord, it is divided into approximately symmetric lateral halves by the two furrows just described and by the posterior median septum (Figs. 55, 56, 57). On either side, corresponding to the line of origin of the ventral roots, is a broad, shallow, almost invisible groove, the *anterolateral sulcus* (*sulcus lateralis anterior*). And again on either side, corresponding to the line of origin of the dorsal roots, is the narrower but deeper *posterolateral sulcus* (*sulcus lateralis posterior*). These six furrows extend the entire length of the spinal cord. In the cervical region an additional longitudinal groove may be seen on the dorsal surface between the posterior median and posterolateral sulci, but somewhat nearer the former. It is known as the *posterior intermediate sulcus* and extends into the thoracic cord, where it gradually disappears.

Funiculi.—By means of these furrows and the subjacent gray matter each lateral half of the cord is subdivided into columns of longitudinally coursing nerve-fibers known as the anterior, lateral, and posterior funiculi (*funiculus anterior*, *funiculus lateralis et funiculus posterior*). In the cervical and upper thoracic regions the posterior intermediate sulcus divides the posterior funiculus into a medial portion, the *fasciculus gracilis*, and a lateral portion, the *fasciculus cuneatus*.

Nerve Roots.—From the lateral funiculus in the upper four to six cervical segments there emerge, a little in front of the dorsal roots of the spinal nerves, a series of root filaments which unite to form the spinal root of the *accessory nerve* (Fig. 125). This small nerve trunk ascends along the side of the cord, enters the cranial cavity through the foramen magnum, and carries to the accessory nerve the fibers for the innervation of the sternocleidomastoid and trapezius muscles.

From the posterolateral sulcus throughout the entire length of the spinal cord emerge an almost uninterrupted series of root filaments (*fila radicularia*). Those from a given segment of the cord unite to form the *dorsal root* of the corresponding spinal nerve. The filaments of the *ventral roots* emerge from the broad, indistinct anterolateral sulcus in groups, several appearing side by side,

rather than in the accurate linear order characteristic of the dorsal roots. Those from a given segment unite with each other to form a ventral root; and that in turn joins with the corresponding dorsal root just beyond the spinal ganglion to form the mixed nerve (Fig. 50).

Relation of the Spinal Cord and Nerve Roots to the Vertebral Column.—

At an early fetal stage the spinal cord occupies the entire length of the vertebral

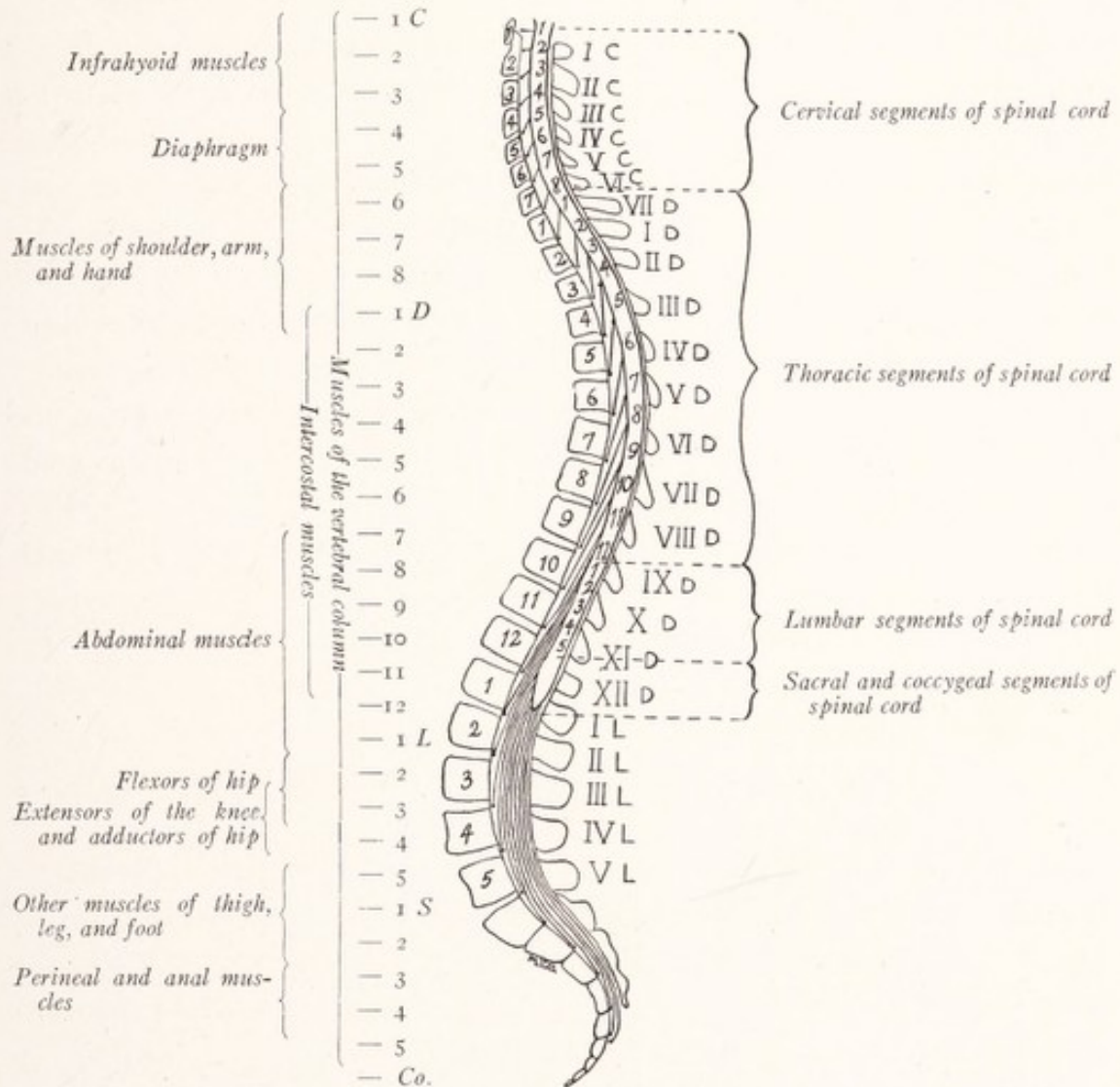


Fig. 53.—Diagram showing the level of the various segments of the spinal cord with reference to the vertebræ, with a table showing the distribution of the fibers of the several ventral roots.

canal and the spinal nerves pass horizontally lateralward to their exit through the intervertebral foramina. As development progresses the vertebral column increases in length more rapidly than the spinal cord, which, being firmly anchored above by its attachment to the brain, is drawn upward along the canal, until in the adult it ends at about the *lower border of the first lumbar vertebra*.

At the same time the roots of the lumbar and sacral nerves become greatly elongated. They run in a caudal direction from their origin to the same intervertebral foramina through which they made their exit before the cord shifted its position. Since the thoracic portion of the cord has changed its relative position but little, and the cervical part even less, the cervical roots run almost directly lateralward, while those of the thoracic nerves incline but little in a caudal direction.

Since the spinal cord ends opposite the first or second lumbar vertebra, the roots of the lumbar, sacral, and coccygeal nerves, in order to reach their proper intervertebral foramina, descend vertically in the canal around the conus medullaris and filum terminale. In this way there is formed a large bundle, which is composed of the roots of all the spinal nerves below the first lumbar and has been given the very descriptive name *cauda equina*.

The amount of relative shortening of the various segments of the cord differs in different individuals. In Fig. 53, where the quadrilateral areas represent the bodies of the vertebræ, we have indicated the average position of each segment of the spinal cord. This figure is based on data published by Reid (1889). It is obvious that the segments are longer in the thoracic than in the cervical and lumbar portions of the cord, while the sacral segments are even shorter (see also Fig. 59).

We have been at some pains to explain the development of the cauda equina and the vertebral level of the various segments of the spinal cord because these are matters of much practical importance. In spinal puncture the needle is made to enter the subdural space caudal to the termination of the cord. In locating lesions of the spinal cord it is necessary to know the position of its various segments with reference to the vertebræ. It is particularly important to be able to distinguish between an injury to the lower part of the spinal cord and one which involves only the nerve roots in the cauda equina, since, although the symptoms in the two cases may be nearly identical, damage to the spinal cord is irreparable, while the nerve roots will regenerate.

The Spinal Cord in Section.—When a section is made through any part of the brain or spinal cord one sees at once that they are composed of two kinds of tissue—the one whitish in color, the other gray, tinged with pink. The white substance consists chiefly of myelinated fibers, the gray is made up of nerve-cells, dendrites, unmyelinated and myelinated fibers, and many blood-vessels. Both have a supporting framework of neuroglia.

The **gray substance** (*substantia grisea*) of the spinal cord is centrally placed

and forms a continuous fluted column, which is everywhere enclosed by the white matter (Fig. 54). In cross-section it has the form of a letter H (Fig. 55). There is a comma-shaped gray field in each lateral half of the cord, and these are united across the middle line by a transverse gray bar. The enlarged anterior end of the comma has been known as the ventral horn, the tapering posterior end as the dorsal horn, and the transverse bar as the *gray commissure*. But, when it is remembered that the gray substance forms a continuous mass throughout the length of the spinal cord, it will be seen that the term "column" is more appropriate than "horn." The long gray mass in either lateral half of the cord is convex medially and concave laterally. It projects in a dorsolateral direction as the *posterior column* (columna posterior).

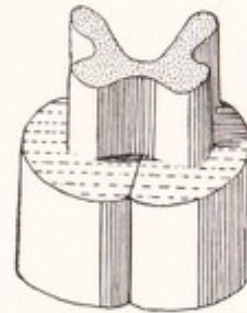


Fig. 54.—Diagram of gray columns of spinal cord.

As seen in a cross-section of the cervical cord, the *posterior column* is relatively long and narrow and nearly reaches the dorsolateral sulcus (Fig. 55).

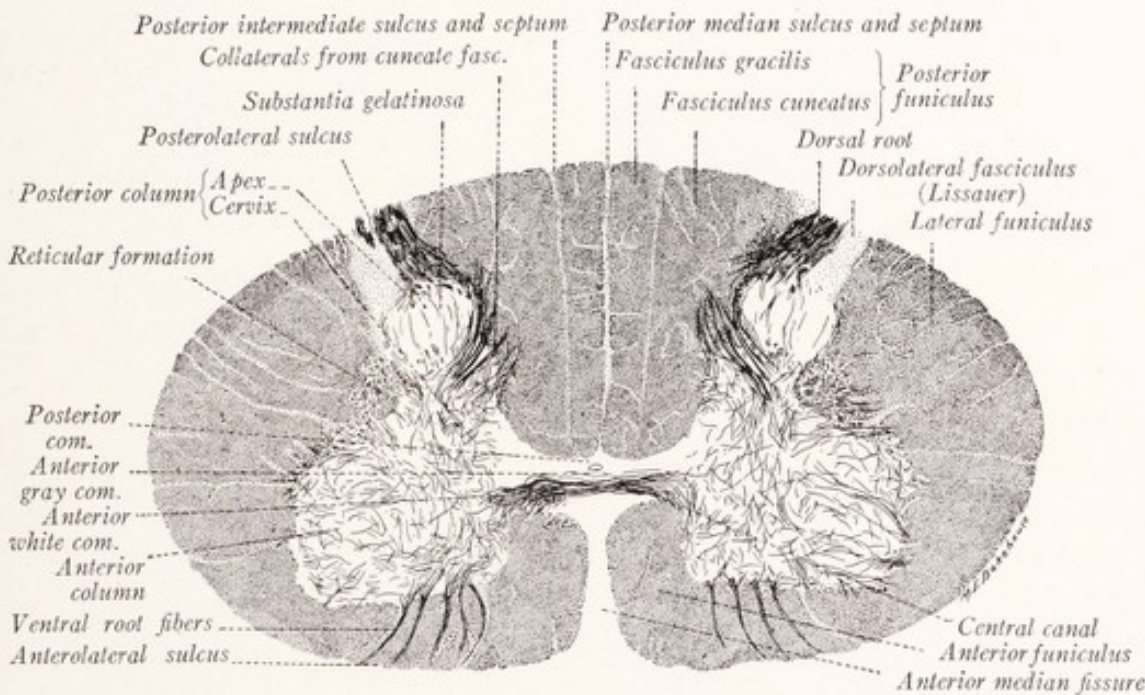


Fig. 55.—Section through seventh cervical segment of the spinal cord of a child. Pal-Weigert method.

It presents a constricted portion known as the *cervix*, a pointed dorsal extremity or *apex*, and between the two an expanded part sometimes called the *caput*. The apex consists largely of a special variety of gray substance, gelatinous in

appearance in the fresh condition and very difficult to stain by neurologic methods, which in sections has a \wedge -shaped outline. It is known as the *substantia gelatinosa Rolandi*. In the thoracic portion the posterior column, which is here very slender, does not come so close to the surface; and in the lumbosacral segments it is much thicker (Figs. 56, 57).

The *anterior column* is relatively short and thick and projects toward the anterolateral sulcus. It contains the cells of origin of the fibers of the ventral root. From its lateral aspect nearly opposite the gray commissure there projects a triangular mass, known as the *lateral column* (*columna lateralis*). This is prominent in the thoracic and upper cervical segments; but it blends with the expanded anterior column in the cervical and lumbar enlargements (Fig. 56).

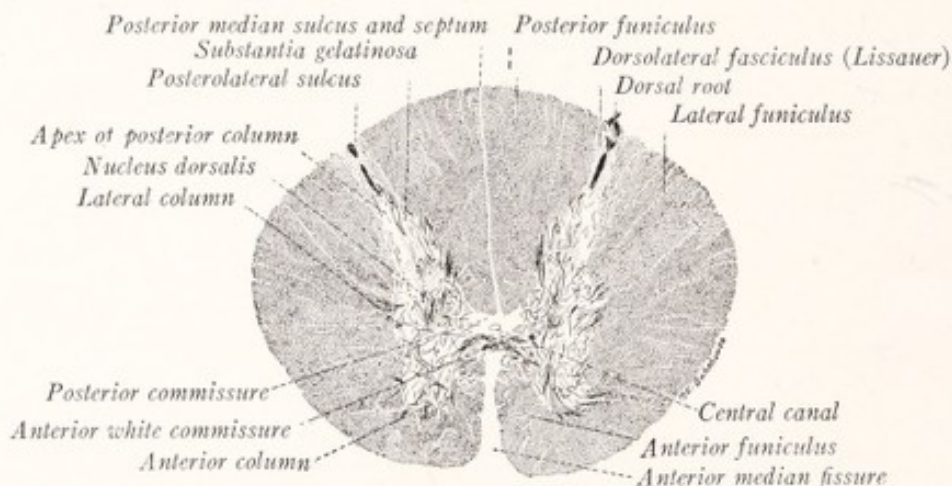


Fig. 56.—Section through the seventh thoracic segment of the spinal cord of a child. Pal-Weigert method.

The *reticular formation* (*formatio reticularis*), situated just lateral to the cervix of the posterior column in the cervical region, is a mixture of gray and white matter (Fig. 55). Here a network of gray matter extends into the white substance, breaking it up into fine bundles of longitudinal fibers. The reticular formation is most evident in the cervical region, but traces of it appear at other levels.

The gray commissure contains the central canal, and by it is divided into the *posterior commissure* (*commissura posterior*) and the *anterior gray commissure* (*commissura anterior grisea*). Ventral to the latter many medullated fibers cross the midline, constituting the *anterior white commissure*.

The cavity of the neural tube persists as the *central canal*, which lies in the gray commissure throughout the entire length of the cord. The canal is so small as to be barely visible to the naked eye. It is lined with ependymal

epithelium and the lumen is often blocked with epithelial débris. The canal, which is narrowest in the thoracic region, expands within the lower part of the conus medullaris to form a fusiform dilatation, the *ventriculus terminalis*.

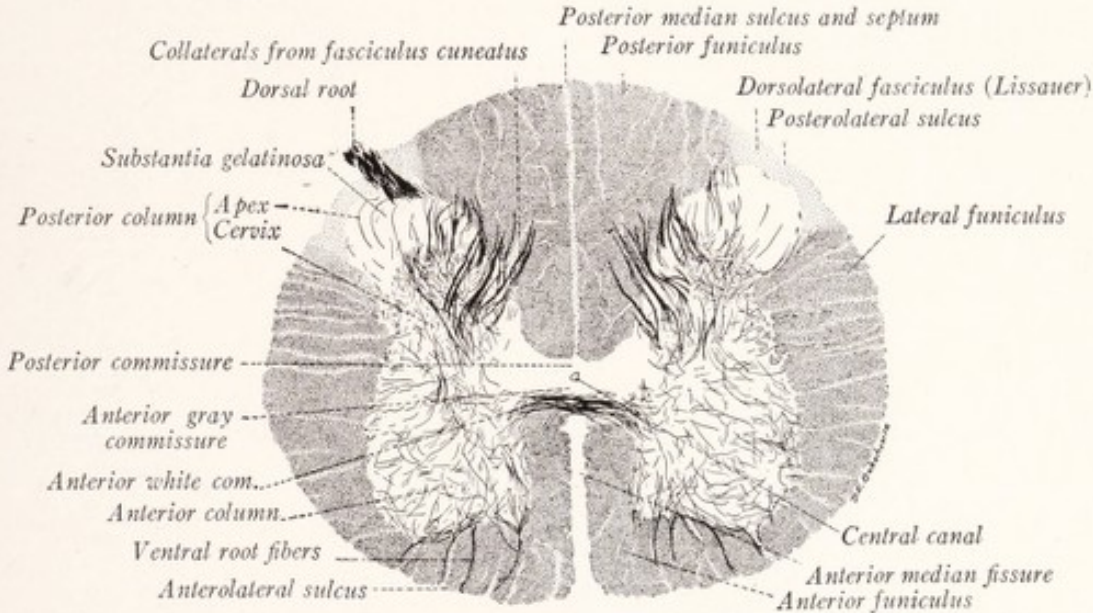


Fig. 57.—Section through the fifth lumbar segment of the spinal cord of a child. Pal-Weigert method.

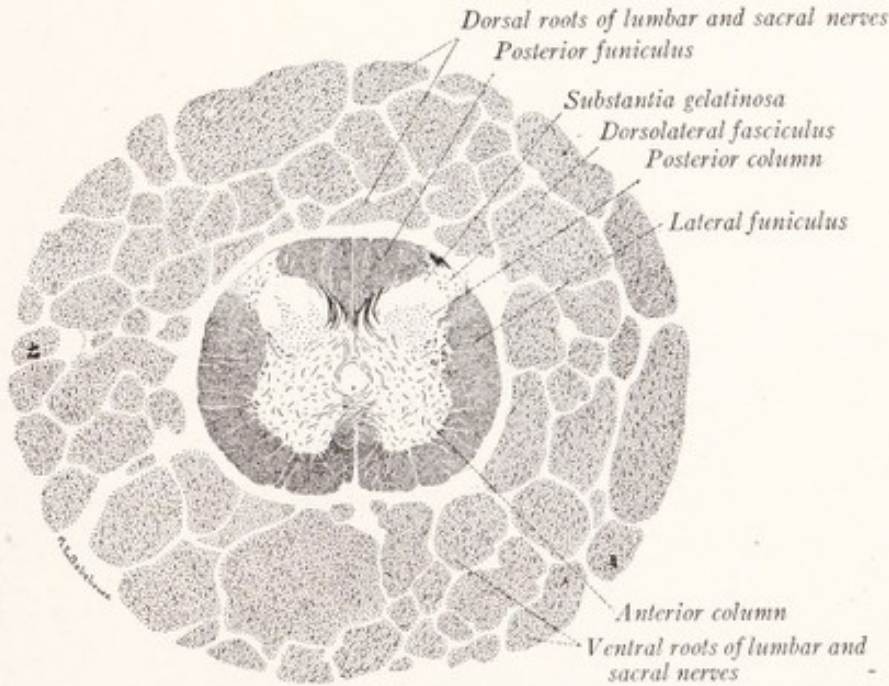


Fig. 58.—Section of the third sacral segment of the human spinal cord and the lumbosacral nerve roots of the cauda equina. Pal-Weigert method.

The White Substance.—The long myelinated fibers of the cord, arranged in parallel longitudinal bundles, constitute the white substance which forms a

CHARACTERISTIC FEATURES OF TRANSVERSE SECTIONS AT VARIOUS LEVELS OF THE SPINAL CORD

| Level. | Cervical. | Thoracic. | Lumbar. | Sacral. |
|------------------------------|--|--|--|---------------------------|
| Outline | Oval, greatest diameter transverse | Oval to circular | Nearly circular | Circular to quadrilateral |
| Volume of gray matter | Large | Small | Large | Relatively large |
| Anterior gray column | Massive | Slender | Massive | Massive |
| Posterior gray column | Relatively slender, but extends far posteriorly | Slender | Massive | Massive |
| Lateral gray column | Absorbed in the anterior except in the upper three cervical segments | Well marked | Absorbed in the anterior column | Present |
| Processus reticularis | Well developed | Poorly developed | Absent | Absent |
| White matter | In large amount | Less than in the cervical region, but relatively a large amount in comparison to the gray matter | Slightly less than in the thoracic region; very little in comparison to the large volume of the gray | Very little |
| Sulcus intermedius posterior | Present throughout | Present in upper seven thoracic segments | Absent | Absent |

umn on the one side, and the posterior median septum on the other. The septum, just mentioned, completely separates the two posterior funiculi from each other. Incomplete septa project into the white substance from the enveloping pia mater. One of these, more regular than the others, enters along the line of the posterior intermediate sulcus. It is restricted to the cervical and upper thoracic segments, is known as the *posterior intermediate septum*, and divides the posterior funiculus into two bundles, the more medial of which is known as the *fasciculus gracilis*, while the other is called the *fasciculus cuneatus*.

Characteristics of the Several Regions of the Spinal Cord.—It will be apparent from Figs. 55–58 that the size and shape of the spinal cord, as seen in transverse section, varies greatly at the different levels and that the relative proportion of gray and white matter is equally variable. Two factors are

primarily responsible for these differences. One of these is the variation in the size of the nerve roots at the different levels; for where great numbers of nerve-fibers enter, they cause an increase in the size of the cord and particularly in the volume of the gray matter. It has already been pointed out that the cervical and lumbar enlargements are directly related to the large nerves supplying the extremities. The second factor is this: Since all levels of the cord are associated with the brain by bundles of long fibers, it is obvious that such long fibers must increase in number and the white matter increase in volume as we follow the cord from its caudal end toward the brain. All this is well illustrated in a diagram by Donaldson and Davis reproduced in Fig. 59.

The outline of a section of the spinal cord at the *fourth sacral segment* is somewhat quadrilateral. The total area is small and the greater part is occupied by the thick gray columns (Fig. 60). The size of the cord is much greater at the level of the *first sacral* and *fifth lumbar segments*, as might be expected from the large size of the associated nerves (Figs. 57, 60). There is both an absolute and a relative increase in the white substance, which here contains the long paths connecting the sacral portions of the spinal cord with the brain. Both the anterior and posterior columns are massive, and the anterior presents a prominent lateral angle. The large nerve-cells in the lateral part of the anterior column give rise to the fibers which run to the muscles of the leg. At the level of the *seventh thoracic segment* (Figs. 56, 60) the cross-sectional area is less than in the lumbar enlargement. Corresponding to the small size of the thoracic nerves the gray matter in this region is much reduced, both anterior and posterior columns being very slender. The apex of the latter is some distance from the surface and its cervix is thickened by a column of cells known as the nucleus dorsalis. The columna lateralis is prominent. The white matter is somewhat more abundant than in the lumbar region, and increases slightly in amount as we follow the cord rostrally through the thoracic region (Fig. 59).

A transverse section at the level of the *seventh cervical segment* is elliptic in outline and has an area greater than that of any other level of the cord (Figs. 55, 60). The white matter is voluminous and contains the long fiber tracts connecting the brain with the more caudal portions of the cord. The gray matter is also abundant, as we might expect from the large size of the seventh cervical nerve. The ventral column is especially thick and presents a prominent lateral angle. The large laterally placed nerve-cells of the anterior column are associated with the innervation of the musculature of the arm. The posterior column is relatively slender, but reaches nearly to the dorsolateral sulcus.

MICROSCOPIC ANATOMY

Neuroglia.—Occupying the interstices among the true nervous elements of the central nervous system is a peculiar supporting tissue, the neuroglia, which is of ectodermal origin. In the chapter on Histogenesis we learned that from the original epithelium of the neural tube there are differentiated spongioblasts and neuroblasts, as well as a special epithelial lining for the tube, the *ependyma*.

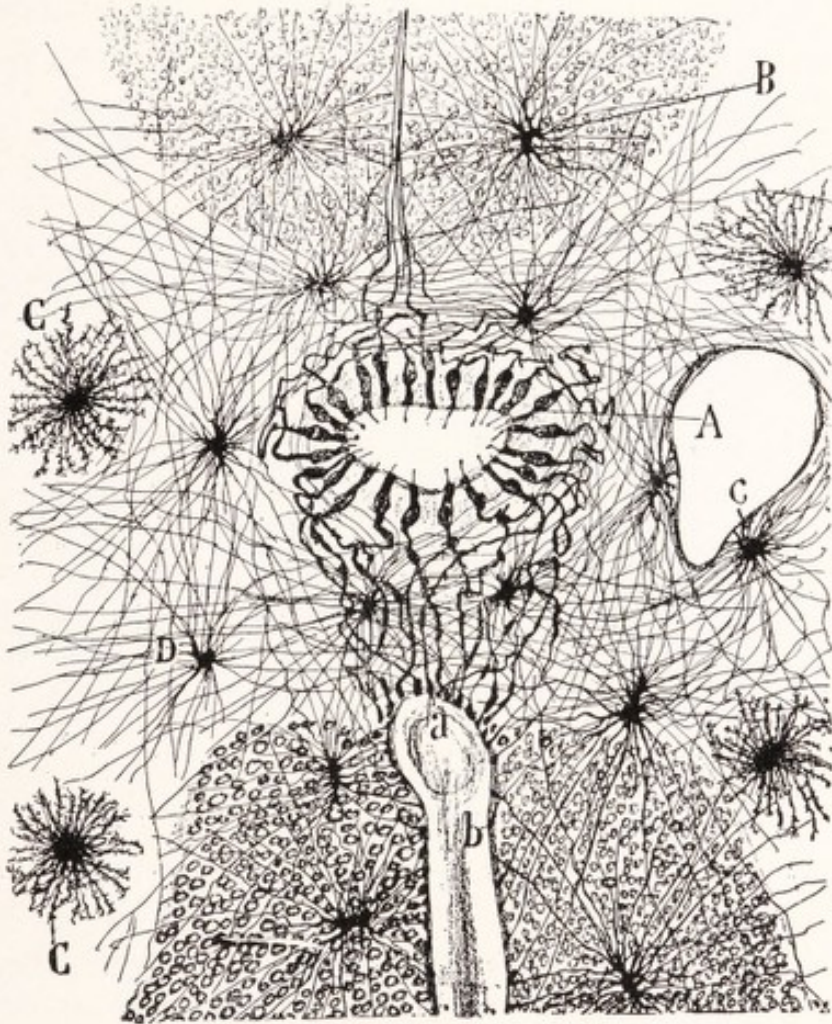


Fig. 61.—Ependyma and neuroglia in the region of the central canal of a child's spinal cord: *A*, Ependymal cells; *B* and *D*, spider cells in the white and gray matter, respectively; *C*, mossy cells. Golgi method. (Cajal.)

The latter consists of long nucleated columnar cells which line the central canal of the spinal cord as well as the ventricles of the brain (Fig. 61). In fetal life their free ends bear cilia, which project into the lumen of the tube, and fine processes from the outer ends extend to the periphery of the cord. In the adult there are no cilia and the peripheral processes reach the surface only along the posterior median septum and in the anterior median fissure.

The *neuroglia cells* are differentiated from the spongioblasts. These, when stained by the Golgi method, appear as small cells with many processes. Some have long slender processes, the *spider cells* or long rayed astrocytes; others have short thick varicose processes, the *mossy cells* or short rayed astrocytes (Fig. 61). Special neuroglia stains, like that of Weigert, show that an astrocyte is composed of a glia cell associated with many *glia fibers*. Some authors maintain that the fibers run through the cytoplasm, while others assert that they merely pass along the surface of the cell. In any case the fibers are to be regarded as products of these cells. Neuroglia cells and fibers are found everywhere throughout the gray and white matter of the spinal cord, forming a supporting framework for the nervous elements. A special condensation of neu-

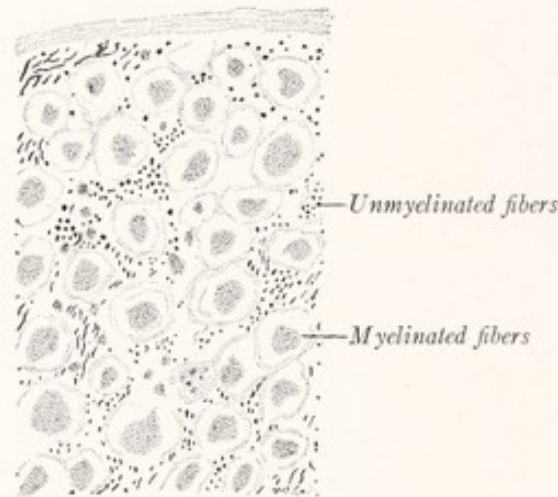


Fig. 62.—From a cross-section through the spinal cord of a rabbit showing the structure of the white matter as revealed by the Cajal method. (Cajal.)

roglia surrounds the central canal and is known as the *substantia gelatinosa centralis*. In addition to the neuroglia this contains some nerve-fibers and cells. Beneath the pia mater and closely investing the spinal cord externally is a thin stratum of neuroglia, the *glial sheath*, which dips into the cord along with the pial septa. The posterior median septum is composed of neuroglia and greatly elongated ependymal elements, and is in no part formed by the pia mater.

White Substance.—The white matter of the spinal cord consists of longitudinally coursing bundles of nerve-fibers, bound together by a feltwork of neuroglia fibers in which are scattered neuroglia cells. A majority of the neuroglia fibers run in a direction transverse to the long axis of the nerve-fibers. Blood-vessels enter the cord from the pia mater and are accompanied by con-

nective tissue from the pia and by the subpial neuroglia. It has been generally supposed that the white fascicles of the cord were composed almost exclusively of myelinated fibers; and it is true that these, partly because of their size, are the most conspicuous elements. In cross-sections stained by the Weigert method the myelin sheaths alone are stained; and since the fibers are cut at right angles to their long axes, they appear as rings. Cajal (1909) has shown that there are also great numbers of unmyelinated fibers in the longitudinal fascicles of the cord (Fig. 62). The different fascicles differ not only in the size of their myelinated fibers but also in the proportion of unmyelinated fibers which they contain. The fasciculus dorsolateralis or tract of Lissauer (Fig. 63) contains fine myelinated fibers with great numbers of unmyelinated axons.

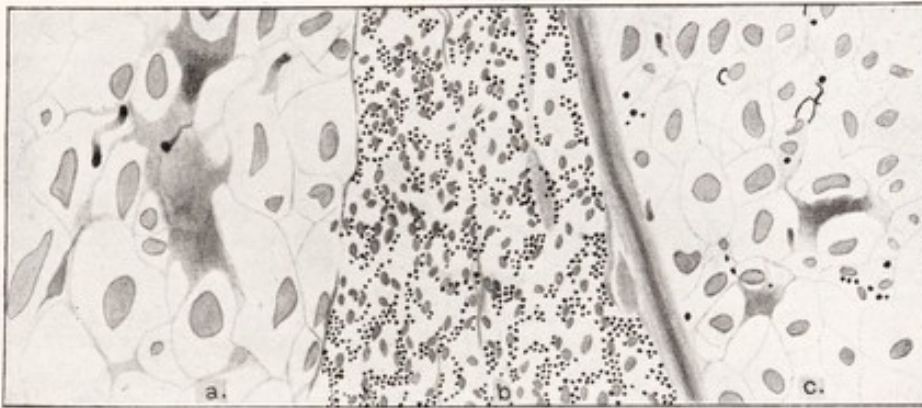


Fig. 63.—From a cross-section of the spinal cord of the cat; a narrow strip extending across the apex of the posterior gray column: *a*, Fasciculus cuneatus; *b*, fasciculus dorsolateralis (Lissauer); *c*, dorsal spinocerebellar tract. The unmyelinated fibers appear as black dots. Pyridin-silver method.

Close to it lies the dorsal spinocerebellar tract which is composed almost exclusively of large myelinated fibers.

Gray Substance.—The gray matter is composed of nerve-cells, including their dendrites, and of unmyelinated axons and smaller numbers of myelinated fibers—all supported by a neuroglia framework and richly supplied with capillary blood-vessels. The axons of the cells of Golgi's Type I are very long and run out into the white substance or into the ventral roots. Those of the cells of his Type II are short and end within the gray matter. In addition, great numbers of collaterals from the dorsal root fibers and from the longitudinal fibers of the cord, as well as terminal branches of these fibers, enter the gray substance and ramify extensively within it, entering into synaptic relations with the neurons which it contains. The branches of the myelinated fibers soon lose their sheaths, and it is this relative scarcity of myelin which gives to

this substance its gray appearance. The ramification of dendrites and unmyelinated fibers forms a very intricate feltwork throughout the gray substance (Fig. 64).

The **nerve-cells** of the spinal cord vary greatly in size. The largest are situated in the anterior column and may measure more than 100 micra. They are all multipolar, possess each a single *axon*, and may be classified in four groups: (1) Some of the cells, found in the posterior horn and particularly in the substantia gelatinosa Rolandi, belong to Golgi's Type II, with short axons confined to the gray substance. These, however, are present in relatively small numbers in the spinal cord. (2) The motor cells, situated in the anterior column and

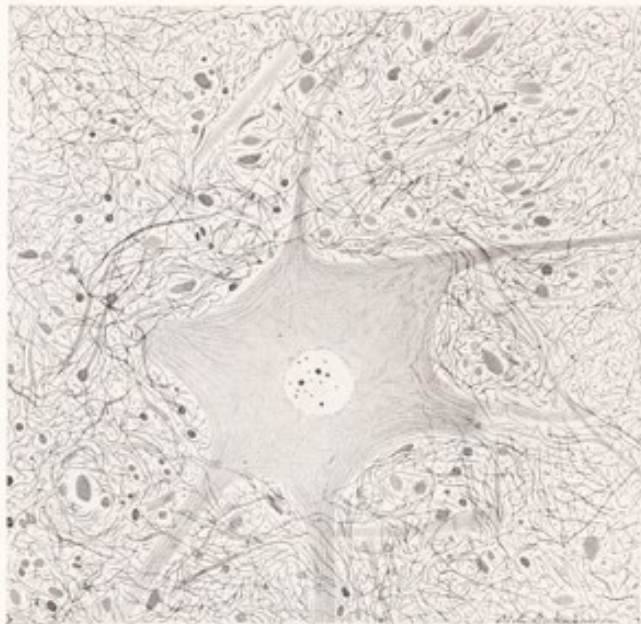


Fig. 64.—From a section through the spinal cord of a monkey; showing part of the anterior gray column including a multipolar nerve-cell and the surrounding neuropil. Pyridin-silver method.

most numerous in the cervical and lumbar enlargements, are of large size and possess axons which leave the cord in the ventral roots. (3) Smaller cells are present in the lateral column in the thoracic region and give rise to the visceral efferent fibers of the ventral roots (Fig. 37). (4) Other cells of small or medium size, found chiefly in the posterior column, possess axons which pass into the white matter, where they bend sharply to become ascending or descending fibers, or divide dichotomously into ascending and descending branches (Fig. 68). Some of the ascending fibers reach the brain; the others merely connect the different levels of the spinal cord. The fibers of the latter group constitute the *fasciculi proprii* and vary greatly in length, some connecting adjacent,

others, more remote, segments. Their collateral and terminal branches re-enter and ramify within the gray substance. Those which remain throughout in the same lateral half of the cord are called *association fibers*; while others, known as *commissural fibers*, cross the median plane chiefly in the white commissure (Fig. 68). Some of the commissural fibers are short and confined to a single level of the cord (Fig. 66).

Cell-columns.—The nerve-cells are not uniformly distributed throughout the gray matter, for many of them are arranged in longitudinal cell-columns. In transverse sections each of these columns appears as a distinct group of cells, somewhat separated from other similar groups within the gray matter (Fig. 65). The large motor cells of the anterior column, which give origin to the ventral root fibers, form several subgroups. One of these, known as the *anteromedian cell-column*, occupies the medial part of the anterior column throughout almost its entire length, being absent only in the fifth lumbar and first sacral segments. Behind it is the *posteromedian cell-column*, which is, however, present only in the thoracic and first lumbar segments and for a short stretch in the cervical region. The axons from these two medial groups of cells probably supply the musculature of the trunk. In the cervical and lumbar enlargements there are laterally placed groups of cells the axons of which supply the muscles of the limbs. These are: (1) the *anterolateral cell-column*, present in the fourth to the eighth cervical and in the second lumbar to the second sacral segments; (2) the *posterolateral cell-column* in the last five cervical, last four lumbar, and first three sacral segments; (3) the *retroposterolateral cell-column* in the eighth cervical, first thoracic, and first three sacral segments, and (4) the *central cell-column* in the second lumbar to the second sacral segments.

The *intermediolateral cell-column* is found in the lateral column in the thoracic region of the cord and is prolonged downward into the upper lumbar segments. It is composed of small cells, the axons of which run through the ventral roots, spinal nerves, and white rami communicantes into the sympathetic nervous system (Fig. 37). They have to do with the innervation of smooth and cardiac muscle and glandular tissue. The longitudinal extent of this column corresponds quite accurately to that of the spinal origin of the white rami. A group of cells, having a similar function, is also found in the third and fourth sacral segments.

The *cells of the posterior gray column* are smaller, as a rule, than those of the ventral column; and except for the nucleus dorsalis they are not arranged in

definite groups. They are concerned with the reception and distribution of the impulses entering along the fibers of the dorsal roots.

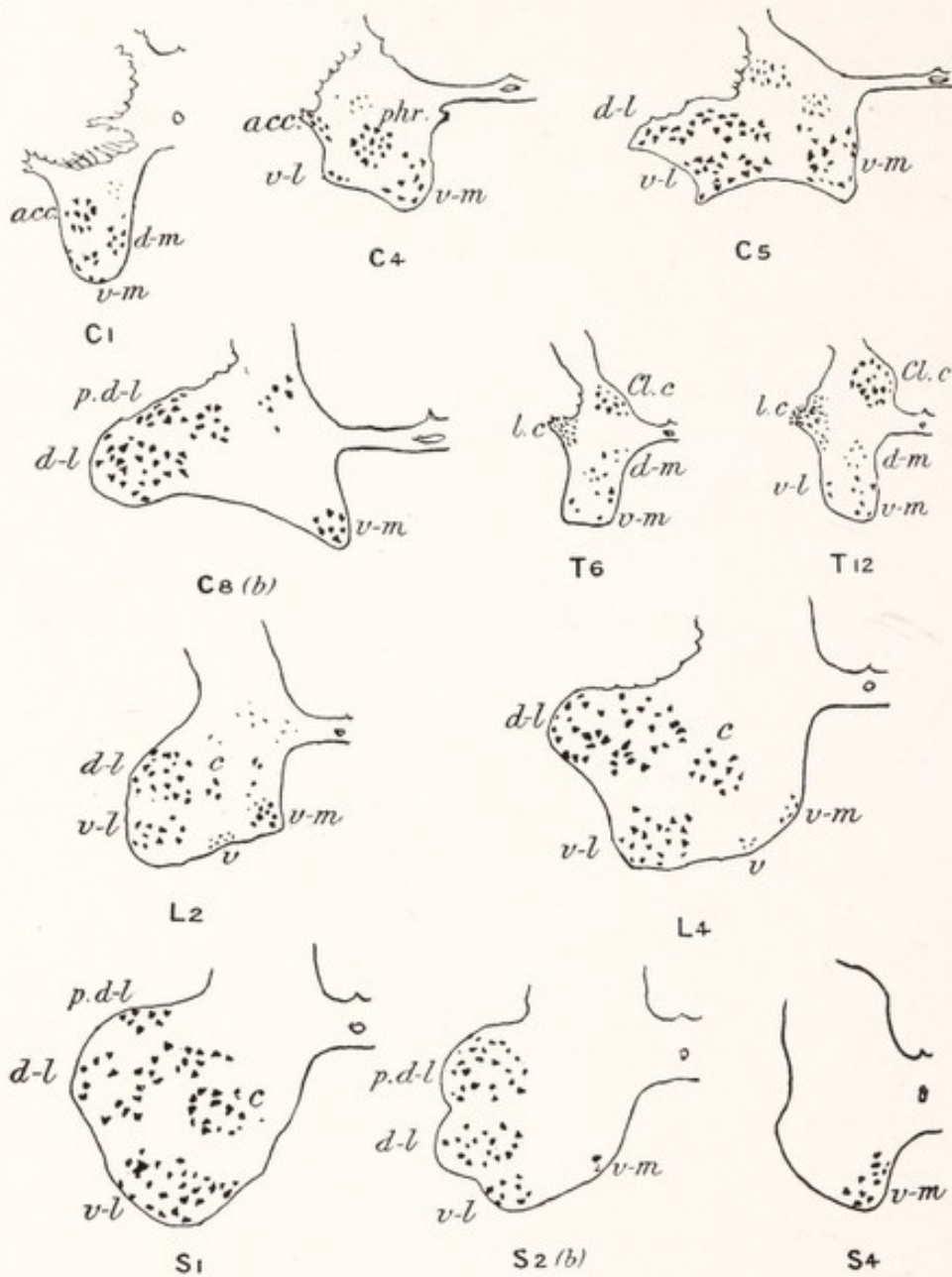


Fig. 65.—Outline sketches of ventral horn of left side of cord at different levels, showing the relative number and position of the chief cell-groups: *C*₁, *C*₄, *T*₆, etc., indicate the segments—*e. g.*, first cervical, fourth cervical, sixth thoracic; *C*₈ (*b*), lower part of eighth cervical. The following letters designate the cell-groups: *v-m*, Anteromedian; *d-m*, posteromedian; *v-l*, anterolateral; *d-l*, posterolateral; *p.d-l*, retroposterolateral; *v* in *L*₂, *L*₄, ventral; *c* in *L*₂, *L*₄, *S*₁, central; *l.c.* in *T*₆, *T*₁₂, intermediolateral; *acc.* in *C*₁, *C*₄, accessorius; *phr.* in *C*₄, phrenic; *Cl.c.* in *T*₆, *T*₁₂, nucleus dorsalis. (Bruce, Quain's Anatomy.)

The *nucleus dorsalis*, or column of Clarke, is a group of large cells in the medial part of the base of the posterior column. It extends from the last cer-

vical or first thoracic to the second or third lumbar segments. It is a prominent feature in cross-sections of the thoracic cord, appearing as a well-defined oval area richly supplied with collaterals from the dorsal roots. The cells have an oval or pyriform shape; each has several dendritic processes and an axon which enters the lateral funiculus, within which it runs toward the cerebellum in the dorsal spinocerebellar tract.

The Spinal Reflex Mechanism.—In the next chapter we will consider at length the long ascending and descending paths in the white substance of the cord by which afferent impulses from the spinal nerves reach the brain, and those through which the motor centers of the brain exert in return a controlling influence over the spinal motor apparatus. But fully as important as these are the purely intraspinal connections—the spinal reflex mechanism.

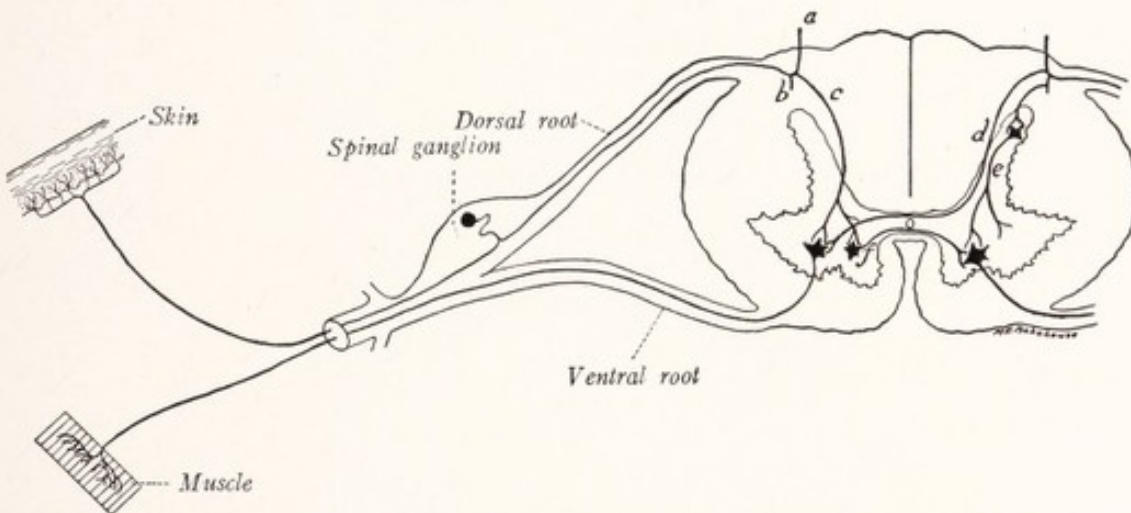


Fig. 66.—Diagrammatic section through the spinal cord and a spinal nerve to illustrate a simple reflex arc: *a*, *b*, *c*, and *d*, Branches of sensory fibers of the dorsal roots; *e*, association neuron; *f*, commissural neuron.

A **reflex arc** in its simplest form may be made up of only two neurons, the primary sensory and motor neurons with a synapse in the gray matter of the anterior column (Fig. 66). It consists of the following parts: (1) a receptor, the peripheral sensory endings; (2) a conductor, the afferent nerve-fiber; (3) a center, including the synapse in the anterior column; (4) a second conductor, the efferent nerve-fiber, and (5) an effector, the muscle-fiber. Usually, however, there are interposed between the primary sensory and motor elements one or more intermediate neurons. These, when restricted to one side of the cord, are known as *association neurons*; when their axons cross the median plane, as many of them do through the anterior white commissure, they are called *commissural neurons*. When the circuit is complete within a single neural

segment it may be said to be intrasegmental (Fig. 66); if it extends through two or more such segments it is an intersegmental reflex arc.

Intersegmental Reflex Arcs.—Impulses entering the spinal cord through a given dorsal root may be transmitted to the primary motor neurons of another segment in one of two ways: (1) by way of the ascending and descending branches of the dorsal root fibers, and (2) along the fibers of the fasciculi proprii (Fig. 67). A full account of these two pathways will be presented in the next chapter, but a word of explanation is required here. The *fibers of the dorsal root* divide,

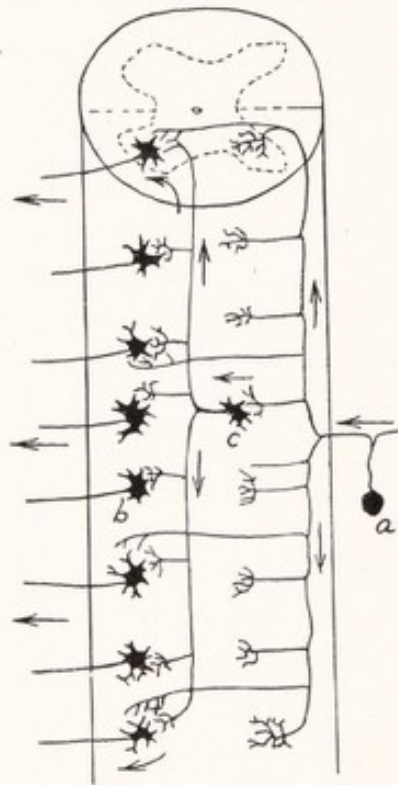


Fig. 67.—Diagram of the spinal cord, showing the elements concerned in a diffuse unilateral reflex: *a*, Spinal ganglion cell; *b*, motor cell in anterior column; *c*, association neuron. (Cajal.)

soon after their entrance into the cord, into long ascending and shorter descending branches, which together form the greater part of the posterior funiculus and give off many collaterals to the gray matter of the successive levels of the cord (Fig. 67). Many of the ascending branches reach the brain; but the others terminate, as do the descending branches and all the collaterals, in the gray matter of the cord (Fig. 68). The *fasciculi proprii* immediately surround the gray columns (Fig. 68) and consist of ascending and descending fibers, which arise and terminate within the gray substance of the cord. Most of these fibers remain on the same side as *association fibers* concerned in unilateral re-

flexes. Others cross in the anterior white commissure and are *commissural fibers* concerned in crossed reflexes. Afferent impulses may be transmitted along the cord in either direction by the branches of the dorsal root fibers; or by means of synapses in the gray matter they may be transferred to the long association and commissural fibers and conveyed to the primary motor neurons of the same or opposite side in more or less distant segments. The course of a nerve impulse in a unilateral intersegmental reflex is indicated on the left side

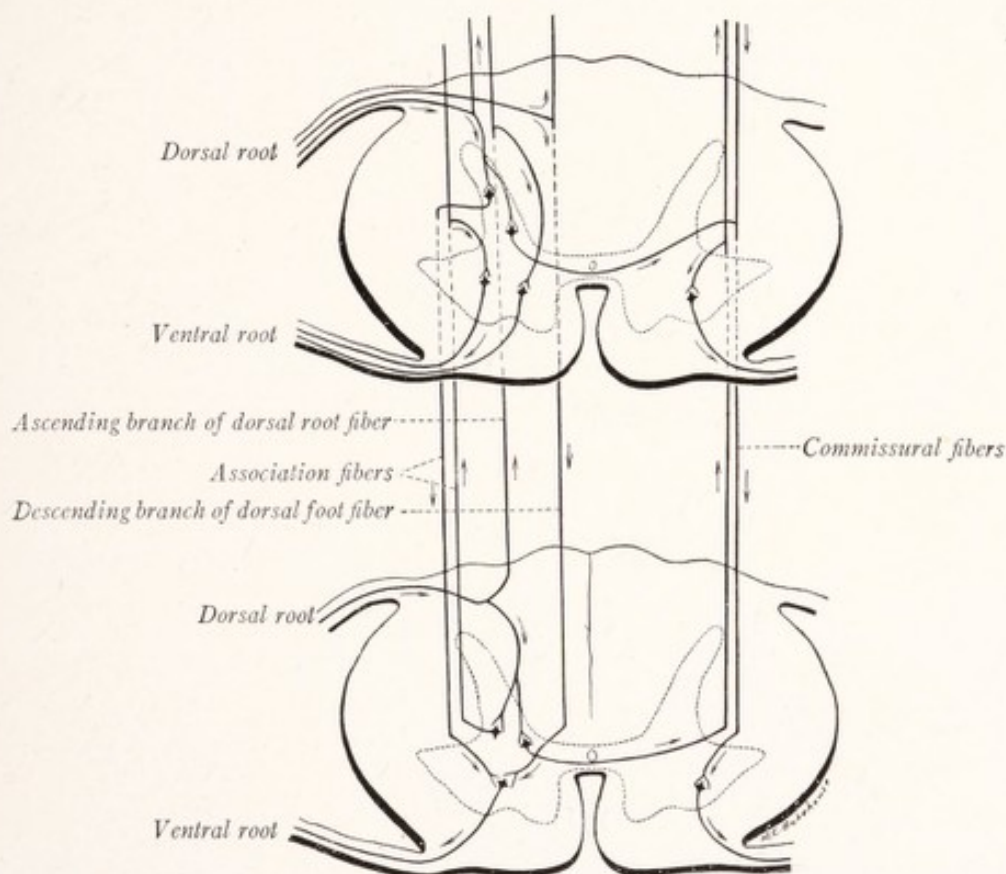


Fig. 68.—Diagram of the spinal cord, showing the elements concerned in intersegmental reflexes.

of Fig. 68, while on the right side of the same figure are shown the elements concerned in crossed reflexes.

The observations of Coghill (1913 and 1914) and of Herrick and Coghill (1915) tend to show that the simple form of reflex arc illustrated in Fig. 66 is not the primitive type. In larval *Amblystoma* the first arcs to become functionally mature are composed of chains of many neurons, so arranged that every cutaneous stimulus elicits the same complex response of the entire somatic musculature, *i. e.*, the swimming movement. It is of particular interest to note that in this primitive reflex mechanism the sensory fibers arise from giant cells located within the spinal cord and that the ventral root fibers are collaterals from the central motor tract. In adult *Amblystoma* these sensory and motor elements are replaced by the usual type of primary sensory and motor neurons.

We may mention as an example of a reflex arc involving many segments of the cord the "scratch-reflex" of the dog, which has been very carefully investigated by Sherrington (1906). If, some time after transection of the spinal cord in the low cervical region, the skin covering the dorsal aspect of the thorax be stimulated by pulling lightly on a hair, the hind limb of the corresponding side begins a series of rhythmic scratching movements. By degeneration experiments it was shown that this reflex arc probably includes the following elements: (1) a primary sensory neuron from the skin to the spinal gray matter of the corresponding neural segment; (2) a long descending association neuron from the

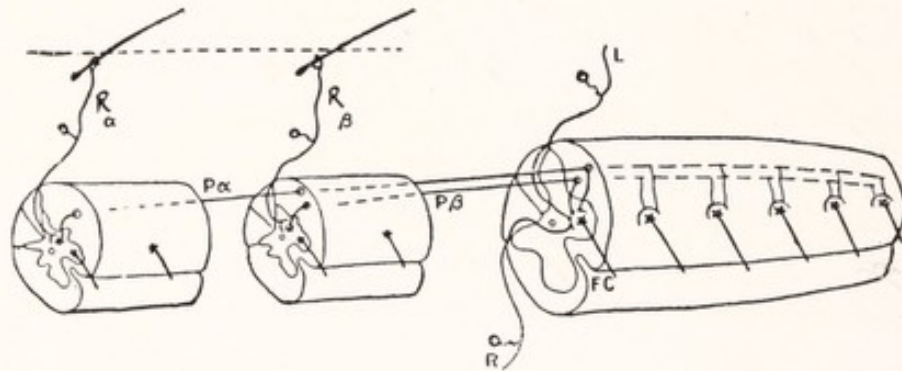


Fig. 69.—Diagram of the spinal arcs involved in the scratch-reflex: R_α and R_β , Receptive paths from hairs in the dorsal skin of left side; P_α and P_β , association neurons; FC , motor fibers of ventral root. (Sherrington.)

shoulder to the leg segments, and (3) a primary motor neuron to a flexor muscle of the leg (Fig. 69).

A **primary motor neuron** seldom, if ever, belongs exclusively to one arc, but serves as the final channel to which many streams converge. Its perikaryon gives off wide-spread dendritic processes, through which it comes into relation with the ramifications of axons from many different sources. In this way impulses reach it from the dorsal roots, and from the fasciculi proprii of the spinal cord, as well as from a number of tracts which descend into the spinal cord from centers in the brain (the corticospinal, rubrospinal, tectospinal, and vestibulospinal tracts). The primary motor neuron is, as Sherrington has said, "*the final common path.*"

CHAPTER VII

FIBER TRACTS OF THE SPINAL CORD

THE fibers composing the white substance of the spinal cord are not scattered and intermingled at random, but, on the contrary, those of a given function are grouped together in more or less definite bundles. A bundle of fibers all of which have the same origin, termination, and function is known as a *fiber tract*. The *funiculi* of the spinal cord are composed of many such tracts of longitudinal fibers, which, while occupying fairly definite areas, blend more or less with each other, in the sense that there is considerable intermingling of the fibers of adjacent tracts. It is convenient to have a name for certain obvious subdivisions of the funiculi which contain fibers belonging to more than one tract. Such a mixed bundle is properly called a *fasciculus*.

THE INTRAMEDULLARY COURSE OF THE DORSAL ROOT FIBERS

The central end of a dorsal root breaks up into many rootlets or filaments (*fila radicularia*), which enter the spinal cord in linear order along the line of the posterior lateral sulcus. As it enters the cord each filament can be seen to separate into a larger medial and a much smaller lateral division. The fibers of the *medial division* are of relatively large caliber and run over the tip of the posterior column into the posterior funiculus (Fig. 72). Those of the *lateral division* are fine and enter a small fascicle which lies along the apex of the posterior column, the *fasciculus dorsolateralis* or tract of Lissauer. Very soon after their entrance into the cord each dorsal root fiber divides in the manner of a Y into a longer ascending and a shorter descending branch (Fig. 70).

The **ascending branches of the fibers of the medial division** of the dorsal root run for considerable but varying distances in the posterior funiculus; some from each root reach the medulla oblongata, others terminate at different levels in the gray matter of the spinal cord. At the level of their entry into the cord these fibers occupy the lateral portion of the *fasciculus cuneatus*; but in their course cephalad, as each successive root adds its quota, those from the more caudal roots are displaced medianward. In this way the longer fibers come to occupy the medial portion of the posterior funiculus (Fig. 71). In the cervical region

the long ascending fibers from the sacral, lumbar, and lower thoracic roots constitute a well-defined medially placed bundle, the *fasciculus gracilis*, separated from the rest of the posterior funiculus by the posterior intermediate septum. Those of the long ascending fibers, which finally reach the brain, terminate in gray masses in the posterior funiculi of the medulla oblongata

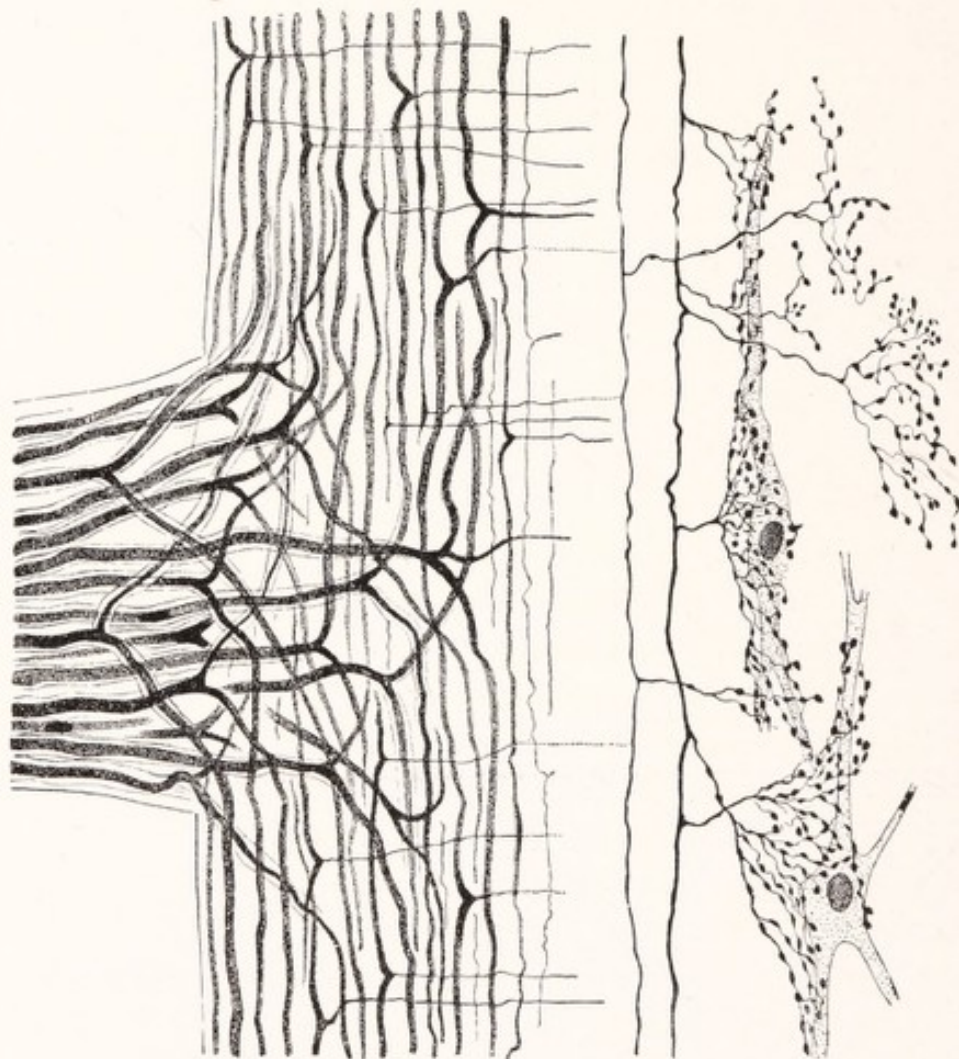


Fig. 70.—Bifurcation of the dorsal root fibers within the spinal cord into ascending and descending branches, which in turn give off collaterals; the termination of some of these collaterals in synaptic relation to cells of the posterior gray column. (Cajal, Edinger.)

(nucleus of the funiculus gracilis and nucleus of the funiculus cuneatus). Since the number of these long ascending branches must increase from below upward it is easy to understand the progressive increase in size of the posterior funiculus from the sacral to the cervical region (Fig. 60).

The *fasciculus gracilis* and *fasciculus cuneatus* are composed for the most

part of these ascending branches of the dorsal root fibers, the former containing those which have the longest intramedullary course.

The **descending branches of the fibers of the medial division** of the dorsal root are all relatively short. The shortest terminate at once in the gray matter of the posterior column. Others descend in the *fasciculus interfascicularis*, or comma tract of Schultze, which is situated near the center of the posterior funiculus; and still others run near the posterior median septum in the *septomarginal fasciculus* (Fig. 76). In both of these fascicles they are intermingled with descending fibers, arising from cells within the gray matter of the spinal cord.

Collaterals.—At intervals along both ascending and descending branches collaterals are given off which run ventrally to end in the gray matter (Fig. 70). They are much finer than the fibers from which they arise, and the total number arising from a given fiber is rather large. Some of them end in the ventral gray column; others, in the posterior gray column, including the substantia gelatinosa and the nucleus dorsalis; still others run through the dorsal commissure to the opposite side of the cord, where they appear to end in the posterior columns (Fig. 72). In Fig. 70 there are illustrated the arborizations formed by some of these collaterals about cells of the posterior column.

The *terminals* of the descending branches and of those ascending branches, which do not reach the brain, end as do the collaterals within the gray matter of the spinal cord.

The **fibers of the lateral division** of the dorsal root are all very fine. The majority are unmyelinated and can be recognized only in preparations in which the axons are stained. A good account of their appearance in Golgi preparations has been given by Barker (1899, pp. 466-468). In Weigert preparations we must look carefully to find the few myelinated fibers contained in this division. But in pyridin-silver preparations great numbers of fine unmyelinated fibers, accompanied by a few which are myelinated, can be seen to turn lateralward as the root filament enters the cord. These constitute the lateral division

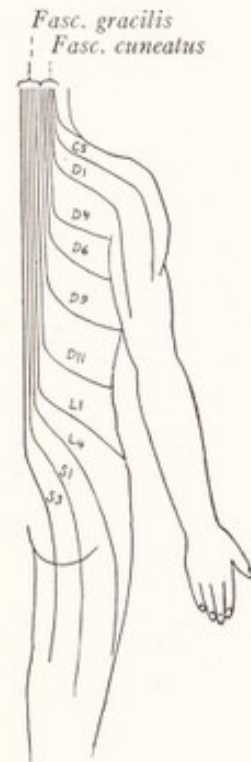


Fig. 71.—Diagram to illustrate the arrangement of the ascending branches of the dorsal root fibers within the posterior funiculus of the spinal cord.

of the root and enter the *dorsolateral fasciculus* or tract of Lissauer (Fig. 72). The medial division, on the other hand, consists exclusively or almost exclusively of myelinated fibers. The fibers of the lateral division of the root divide into ascending and descending branches, both of which, however, are very short. The ascending branch, which is the longer of the two, does not extend at most more than the length of one or two segments in the long axis of the cord (Ranson, 1913, 1914).

The *dorsolateral fasciculus*, or tract of Lissauer, lies between the apex of the posterior column and the periphery of the cord, and varies greatly in shape and size in the different levels of the cord (Figs. 55-58). It is composed of

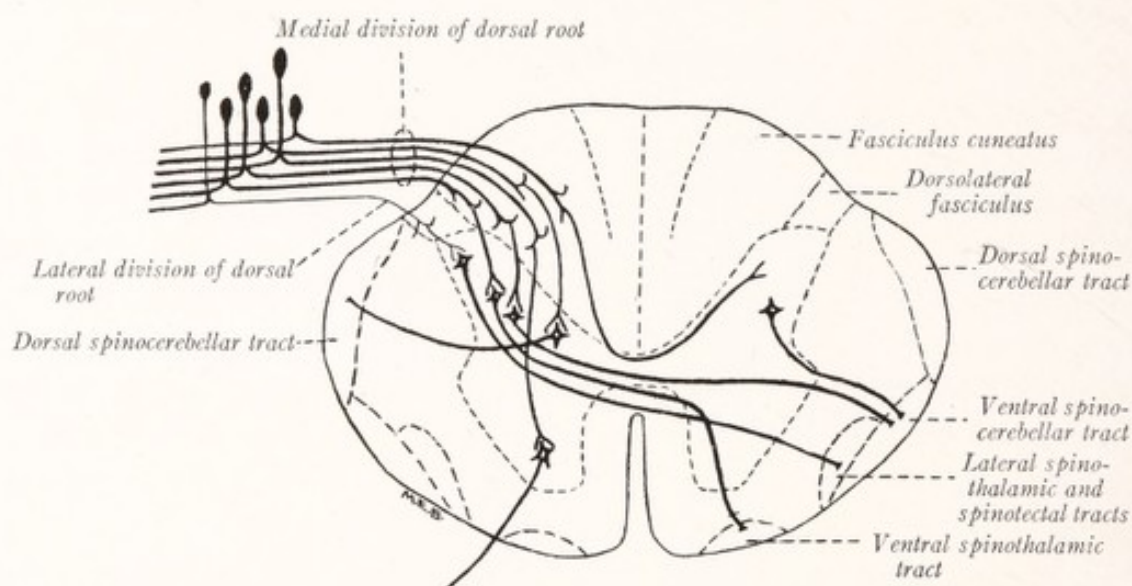


Fig. 72.—Diagram of the spinal cord and dorsal root, showing the divisions of the dorsal root, the collaterals of the dorsal root fibers, and some of the connections which are established by them.

unmyelinated and fine myelinated fibers, which are derived in part from the lateral division of the dorsal root and in part arise from cells in the neighboring gray matter (Fig. 63).

AFFERENT PATHS IN THE SPINAL CORD

We have been at some pains to make clear the course and distribution of the dorsal root fibers within the spinal cord because all afferent impulses which reach the cord are carried by them. Interoceptive fibers from the viscera, proprioceptive fibers from the muscles, tendons, and joints, as well as exteroceptive fibers from the skin are included in these roots; and among the latter group are probably several subvarieties, mediating the afferent impulses out

of which the sensations of touch, heat, cold, and pain are elaborated. An important problem which in great measure awaits solution is this: How are the fibers of the different functional varieties distributed in the spinal cord and along what paths are these various types of afferent impulses carried toward the brain?

The **proprioceptive fibers**, which terminate at the periphery in neuromuscular and neurotendinous spindles and in Pacinian corpuscles, are known to be myelinated. They must, therefore, pass through the well myelinated medial division of the dorsal root into the posterior funiculus. As shown by Brown-Séquard in 1847 by a study of patients with unilateral lesions of the spinal cord, sensations from the muscles, joints, and tendons reach the brain without undergoing a crossing in the spinal cord. This and other evidence points unmistakably to the long ascending branches of the dorsal root fibers, which are continued uncrossed in the posterior funiculus to the medulla oblongata, as the conductors of this type of sensation. When these fibers are destroyed by a tumor or other lesion confined to the posterior funiculus, muscular sensibility and the recognition of posture are abolished, while touch, pain, and temperature sensations remain intact (Déjerine, 1914).

No better exposition of the *proprioceptive functions* could be furnished than by describing the sensory deficiencies found in cases of tabes dorsalis or locomotor ataxia, a disease in which there is degeneration of the posterior funiculi. Lying in bed, with eyes closed, a tabetic may not be able to say in what position his foot has been placed by an attendant because afferent impulses from the muscles, joints, and tendons fail to reach the cerebral cortex and arouse sensations of posture. Not only are the sensations of this variety lacking, but the unconscious reflex motor adjustments initiated by proprioceptive afferent impulses are also impaired. Standing with feet together and eyes closed, the patient loses his balance and sways from side to side. In walking his gait is uncertain and the movements of his limbs poorly coördinated. All of this motor incoördination is explained by a loss of the controlling afferent impulses from the muscles, joints, and tendons.

The long ascending fibers of the posterior funiculus, which reach the brain and end in the nucleus gracilis and cuneatus, are for the most part proprioceptive in function (Fig. 235). The connections which they make there can best be considered in another chapter. Collaterals and many terminal branches end in the gray matter of the cord, entering into *synaptic relations with the neurons of the spinocerebellar paths* and with neurons belonging to spinal reflex arcs.

Proprioceptive Paths to the Cerebellum.—According to the researches of Marburg (1904) and Bing (1906) the spinocerebellar tracts are concerned with the transmission to the cerebellum of afferent impulses from the muscles, joints, and tendons, which remain, however, at a subconscious level (Déjerine, 1914). We may, therefore, appropriately consider these paths at this time.

The **dorsal spinocerebellar tract** (*fasciculus spinocerebellaris dorsalis*, direct cerebellar tract of Flechsig, *fasciculus cerebellospinalis*) is a well-defined bundle at the surface of the lateral funiculus just ventral to the posterior lateral sulcus (Figs. 72, 78). In cross-section it has the form of a flattened band, situated between the periphery of the cord and the lateral corticospinal tract. It begins in the upper lumbar segments and is prominent in the thoracic and cervical portions of the cord. It consists of uniformly large fibers, which take origin from the cells of the *nucleus dorsalis* of the same side. This nucleus forms a prominent feature of the sections through the thoracic portion of the cord, but is not found above the seventh cervical nor below the second lumbar segments. A conspicuous bundle of myelinated collaterals from fibers of the *fasciculus cuneatus* run to this nucleus (Fig. 56) where their arborizations form baskets about the individual cells of the nucleus. *The fibers arising from the cells of the nucleus dorsalis run laterally to the periphery of the lateral funiculus of the same side, where they turn rostrally and form the dorsal spinocerebellar tract.* We will follow this tract into the brain in a later chapter. Here we need only say that it reaches the cerebellum by way of the restiform body (Fig. 235).

The **ventral spinocerebellar tract** constitutes the more superficial portion of a large ascending bundle of fibers, known as the *fasciculus anterolateralis superficialis* or Gower's tract, which also includes the spinotectal and lateral spinothalamic tracts (Fig. 72). It is situated at the periphery of the lateral funiculus ventral to the tract we have just considered. It is said to consist of *fibers which arise from the cells of the posterior gray column and intermediate gray matter of the same and the opposite side* (Page May, 1906; Déjerine, 1914). In a subsequent chapter we will trace these fibers by the way of the medulla, pons, and anterior medullary velum to the cerebellum (Fig. 235).

From what has been presented above it will be apparent that collaterals and terminal branches of dorsal root fibers, doubtless of the proprioceptive group, enter into synaptic relations with certain intraspinal neurons, the axons of which run to the cerebellum by way of the ventral and dorsal spinocerebellar tracts. The entire path from periphery to cerebellum therefore consists of two neurons with a synaptic interruption in the gray matter.

Interoceptive fibers are present in the thoracic and upper lumbar dorsal roots, but are either absent or very few in number in the others. We know practically nothing about their intraspinal course in mammals. They will be considered in the chapter on the Sympathetic Nervous System.

Exteroceptive fibers carry cutaneous afferent impulses, and probably are subdivided into several varieties. Most authors agree that there are separate fibers for the impulses aroused by tactile and thermal stimuli; and Sherrington (1906) has presented evidence for the existence of a separate group of fibers, whose end organs are responsive only to agents capable of inflicting injury, that is, to noxious or painful stimuli.

Conduction of Tactile Impulses in the Spinal Cord.—The phenomena of sensory dissociation, characteristic of syringomyelia, show that the intraspinal path for the sensations of touch is rather widely separated from that for pain and temperature sensation (Fig. 73). In that disease a cavity is developed within the gray matter of the spinal cord; and sensations of pain and temperature may be abolished over a given cutaneous area which is still sensitive to touch. The separation of these two lines of conduction occurs at the place where the dorsal root fibers enter the cord. The fibers, mediating pain and temperature sensations, end almost at once in the gray matter, while those for touch ascend for some distance in the posterior funiculus of the same side (Head and Thompson, 1906; Déjerine, 1914). As these fibers ascend in the posterior funiculus they give off collaterals to the gray matter of the successive levels of the spinal cord through which they pass. The tactile impulses from a given root, therefore, do not enter the gray matter all at once, but filter forward through the collaterals and terminals of these dorsal root fibers to reach the posterior gray column in a considerable number of segments above that at which the root enters the cord. Within the posterior gray column at these successive levels the terminals and collaterals of the tactile fibers establish synaptic connections with neurons of the second order. The axons of these neurons form the ventral spinothalamic tract of the opposite side (Fig. 73).

The **ventral spinothalamic tract** is an ascending bundle of fibers found in the anterior funiculus. It *consists of fibers which take origin from cells in the posterior column of the opposite side, cross the median plane in the anterior white commissure, and ascend in the ventral funiculus to end within the thalamus* (Fig. 73). It is possible that many of the fibers do not reach the thalamus directly, but terminate in the gray matter of the cord and medulla oblongata in relation to other neurons, whose axons continue the course to the thalamus. If

this be so the path consists in part of relays of shorter neurons (Déjerine, 1914).

The uncrossed path in the posterior funiculus for tactile impulses entering the cord through any given dorsal root overlaps by many segments the crossed path in the ventral funiculus (Fig. 230). Some of the uncrossed fibers even reach the nuclei of the funiculus gracilis and funiculus cuneatus in the medulla oblongata. This extensive overlapping of the uncrossed by the crossed paths accounts for the fact that lateral hemisection of the human spinal cord rarely causes marked disturbance of tactile sensibility below the lesion (Petrén, 1902; Head and Thompson, 1906).

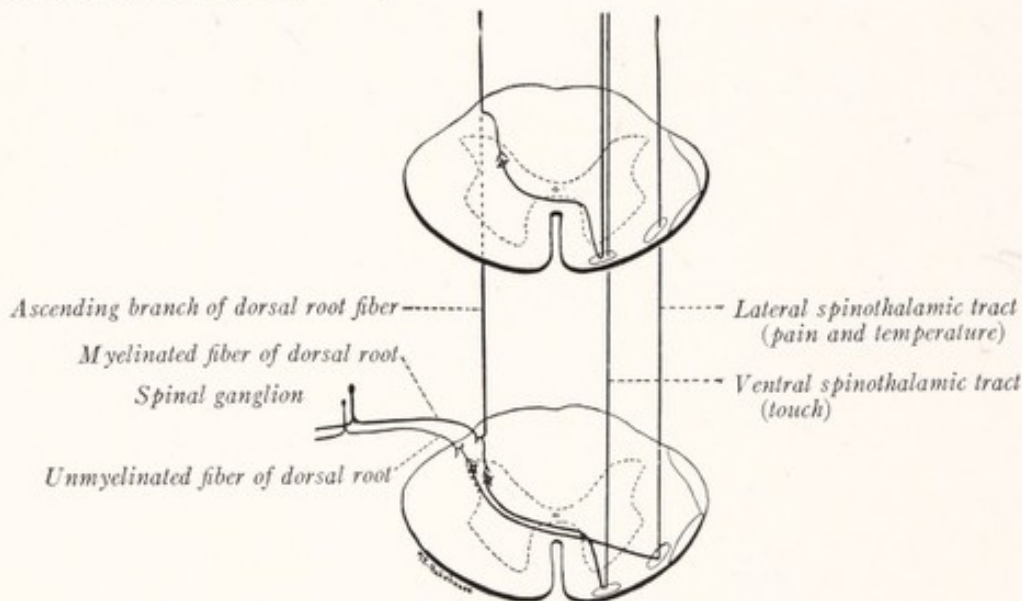


Fig. 73.—Exteroceptive pathways in the spinal cord.

Since it seems clear that the dorsal root fibers subserving tactile sensibility ascend for some distance in the posterior funiculus, they must be included among the myelinated fibers of the medial division of the dorsal root, because only myelinated fibers ascend in that funiculus. This conclusion is in keeping with the facts already mentioned concerning the termination of myelinated fibers in the supposedly tactile end organs, such as Meissner's corpuscles and Pacinian corpuscles. It is also in keeping with facts to be mentioned in a following paragraph concerning the structure of the median nerve.

The Lateral Spinothalamic Tract.—It seems to be well established that the dorsal root fibers, which serve as pain conductors, terminate in the gray matter almost at once after entering the cord, and come into synaptic relations with neurons of the second order, whose axons run in the lateral spinothalamic tract. *From cells in the posterior column fibers arise, which in man cross to the opposite side of the cord in the anterior white commissure and ascend in the lateral spinothalamic tract to end in the thalamus* (Figs. 73, 231). This is a tract of ascending

fibers situated in the lateral funiculus under cover of the ventral spinocerebellar tract. Together with the spinotectal and ventral spinocerebellar tracts it forms the fasciculus anterolateralis superficialis (of Gowers). It mediates pain and temperature sensations.

Conduction of Painful Afferent Impulses in the Spinal Cord.—Not all of the fibers of the lateral spinothalamic tract reach the thalamus. According to May (1906), "Some of these fibers certainly pass directly to the thalamus, while others terminate in the intermediate gray matter, and thus, by means of a series of short chains, afford secondary paths to the same end station, which may supplement the direct path, or be made available after interruption of the direct path." It has been shown in many cases in man and animals that, after a complete hemisection of the spinal cord, the loss of sensibility to pain on the opposite side of the body below the lesion was only temporary. In time there may occur a more or less perfect restoration of pain conduction, showing that the homolateral side of the cord is able to supplement or replace the heterolateral path. According to the researches of Karplus and Kreidl (1914) and Ranson and Billingsley (1916) these short chains, which are of secondary importance in man, are much better developed in the cat. In this animal pain conduction through the spinal cord is bilateral and is effected to a large extent through a series of short relays.

According to Head and Thompson (1906) the path for pain in the spinal cord is the same whether the impulses arise in the skin or in the deeper parts, such as the muscles and joints. But Déjerine (1914) is of the opinion that painful impulses from the muscles may be transmitted in the posterior funiculus and remain uncrossed as far as the medulla oblongata.

Until recently we possessed no information as to which dorsal root fibers served as pain conductors. But in the last few years evidence has been presented which points toward the unmyelinated fibers of the spinal nerves and dorsal roots as the pain fibers (Ranson, 1915). Space does not permit a detailed presentation of the evidence here. It should be noted, however, that the unmyelinated fibers of the lateral division of the dorsal root terminate in the gray matter almost immediately after their entrance into the spinal cord, and in this respect correspond to the known course of the fibers carrying painful impulses. The unmyelinated fibers are chiefly distributed in the cutaneous nerves, although a few run in the muscular branches. This coincides with the much greater sensitiveness to pain of the skin than of the deeper tissues. Furthermore, the median nerve at the wrist, a large nerve supplying a relatively small area of skin richly endowed with the sense of touch, contains relatively few unmyelinated fibers. On the other hand, nerves like the lateral cutaneous of the thigh and the medial cutaneous of the forearm, which supply relatively large cutaneous areas of low tactile sensibility, but not inferior to the fingers in sensitiveness to pain, are composed in large part of unmyelinated fibers. This difference between the composition of the median nerve and the medial cutaneous nerve of the forearm is just what should be expected if the touch fibers are myelinated and the pain fibers unmyelinated. Head and his co-workers (1905, 1906, 1908) have regarded the group of sensations (protopathic), to which according to their classification cutaneous pain belongs, as primitive in character and the first to appear in the phylogenetic series. It is well known that nerve-fibers in their earliest phylogenesis are unmyelinated. If our conception is correct, a great many of the afferent fibers of mammals remain in this primitive undifferentiated state and mediate a relatively primitive form of sensation. In this connection it is interesting to note that Déjerine (1914) believes that pain is conducted by the "sympathetic" fibers contained in the cutaneous and muscular nerves. He does not state the evidence on which this belief is based; but if by "sympathetic" he means to designate the unmyelinated fibers his view agrees perfectly with that presented in the preceding paragraphs.

The problem can be approached from the experimental standpoint. The seventh lumbar dorsal root of the cat is especially adapted for such a test. This root as it approaches the cord breaks up into a number of filaments which spread out in a longitudinal direction and enter the cord along the posterolateral sulcus. Within each root filament, as it approaches this sulcus, the unmyelinated separate out from among the myelinated fibers and take up a position around the circumference of the filament and along septa that divide it into smaller bundles. As the root enters the cord, these unmyelinated fibers turn laterally into the dorsolateral fasciculus, constituting together with a few fine myelinated fibers the lateral division of the root (Fig. 74). Almost all of the myelinated fibers run through the medial division of the root into the cuneate fasciculus. A slight cut in the direction of the

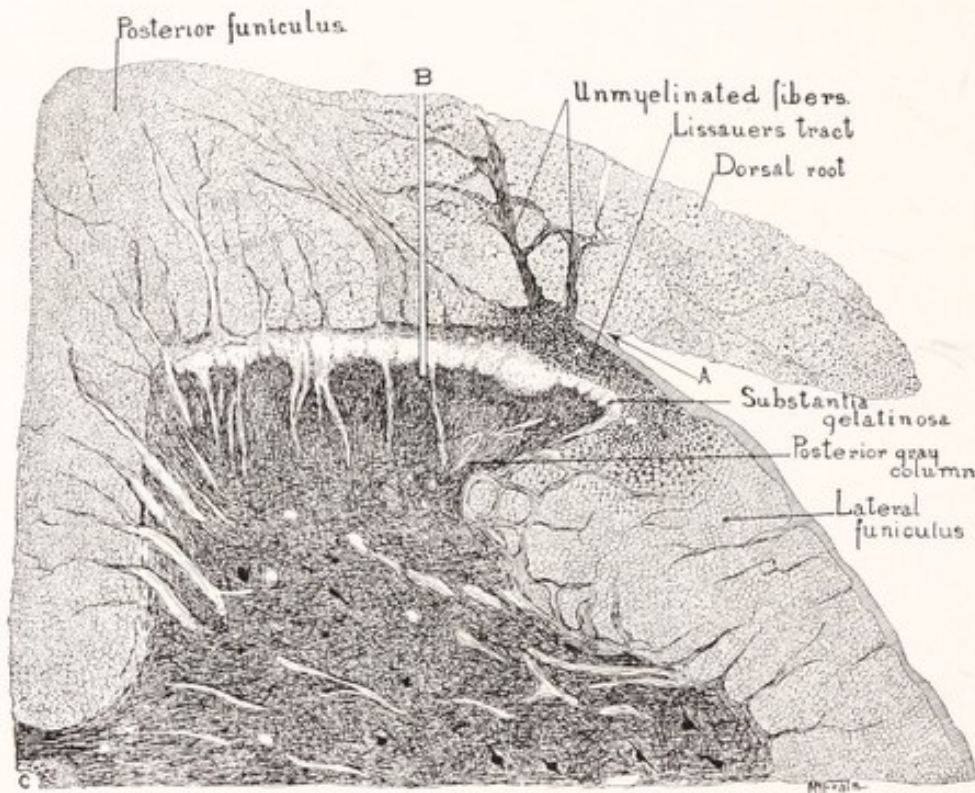


Fig. 74.—From a section of the seventh lumbar segment of the spinal cord of the cat, showing the unmyelinated fibers of the dorsal root entering the tract of Lissauer.

arrow, which as shown by subsequent microscopic examination divided the lateral without injury to the medial division of the root, at once eliminated the pain reflexes obtainable from this root in the anesthetized cat, such as struggling, acceleration of respiration, and rise of blood-pressure. On the other hand, a long deep cut in the plane indicated by *B*, Fig. 74, which severed the medial division of the root as it entered the cord, had little or no effect on the pain reflexes. This series of experiments, the details of which are given elsewhere (Ranson and Billingsley, 1916), furnishes strong evidence that painful afferent impulses are carried by the unmyelinated fibers of the lateral division of the dorsal root.

These fibers probably terminate in the substantia gelatinosa Rolandi, and, if so, it is not unlikely that intermediate neurons are intercalated between them and the neurons whose axons run in the ventral spinothalamic tract.

The Conduction of Sensations of Pain, of Heat, and of Cold.—It is well established on the basis of clinical observations that the paths for sensations of heat and cold follow closely those for pain. They pass through the gray matter immediately after entering the cord, cross to the opposite side, and ascend in the lateral spinothalamic tract.

According to May (1906) "it is clear that there are distinct and separate paths for the impulses of pain, of heat, or of cold in the spinal cord, and that these different and specific qualities of sensation may be dissociated in an affection of the spinal cord." That is, one of these forms of sensibility may be lost, although the other two are retained. "But as these paths are anatomically very closely associated from origin to termination these three forms of sensation are usually affected to a like degree."

From what has been said above it will be apparent that the paths, mediating pain and temperature sensibility, cross promptly to the opposite side of the cord and ascend in the lateral spinothalamic tract. The path for touch crosses more gradually, but finally comes to lie in the ventral spinothalamic tract of the opposite side; while the sensory impulses from the muscles, joints, and tendons, as well as some elements of tactile sensibility, are carried upward on the same side of the cord by the long ascending branches of the dorsal root fibers, which terminate in the nuclei of the funiculus gracilis and the funiculus cuneatus. The connections established within the brain by the fibers of these various paths cannot profitably be discussed at this point, but will be considered in Chapter XIX.

Other afferent paths besides those already mentioned exist in the spinal cord. These include the *spino-olivary and spinotectal tracts* (Fig. 78). The former consists of fibers which arise from cells in the posterior gray column, cross to the opposite side of the cord, and ascend in the ventral funiculus, to end in the inferior olivary nucleus of the medulla oblongata. The spinotectal tract consists of fibers which arise from cells in the posterior gray column and which, after crossing, ascend in the lateral funiculus in company with those of the lateral spinothalamic path to end in the roof (tectum) of the mesencephalon, *i. e.*, in the corpora quadrigemina.

ASCENDING AND DESCENDING DEGENERATION OF THE SPINAL CORD

When as a result of an injury a nerve-fiber is divided, that part which is severed from its cell of origin degenerates, while the part still connected with that cell usually remains intact. This is known as Wallerian degeneration, and, as will be readily understood, gives valuable information concerning the course

of the fiber tracts. In case of a complete transection of the spinal cord all the ascending fibers whose cells are located below the cut will degenerate in the segments above; while those descending fibers whose cells of origin are located above will degenerate below the lesion (Fig. 75). Injury to the dorsal roots proximal to the spinal ganglia causes a degeneration of the dorsal root fibers

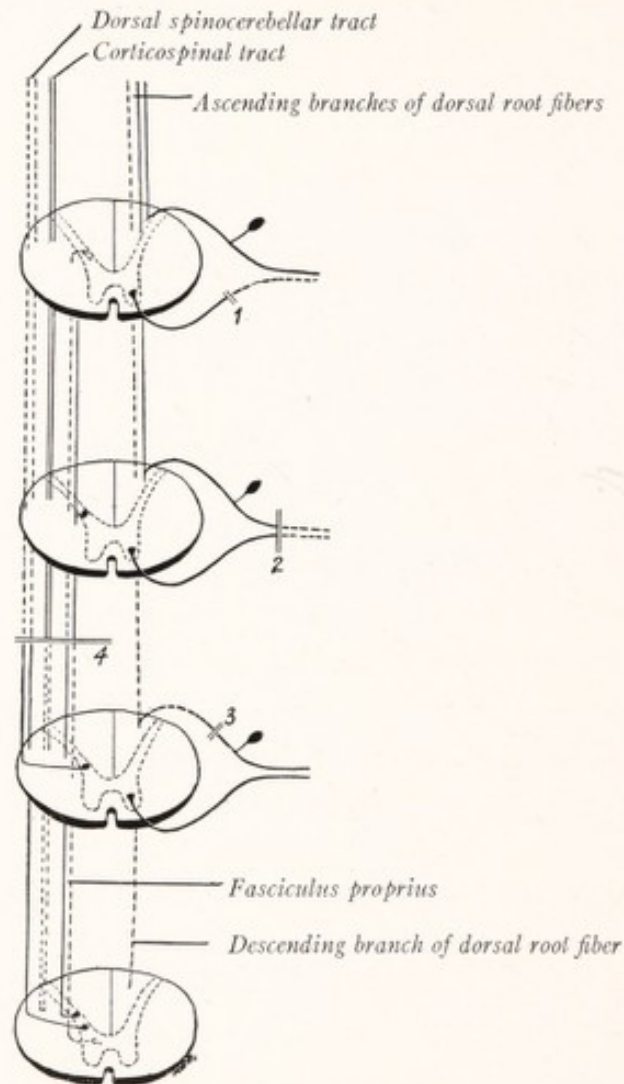


Fig. 75.—Diagram of the spinal cord to illustrate the principle of Wallerian degeneration. The broken lines represent the degeneration resulting from—1, section of the ventral root; 2, section of the spinal nerve distal to the spinal ganglion; 3, section of the dorsal root proximal to the spinal ganglion, and 4, a lesion in the lateral funiculus.

throughout their length in the spinal cord. Brain injuries may, according to their location, result in the degeneration of one or more of the tracts which descend into the spinal cord from above.

By the study of a great many cases of injury to the central nervous system in man and of experimentally produced lesions in animals a very considerable

amount of information has been obtained concerning the fiber tracts of the spinal cord (Collier and Buzzard, 1901, 1903; Stewart, 1901; Thiele and Horsley, 1901; Batten and Holmes, 1913). This is summarized in the accompanying table and in Fig. 78.

TABLE SHOWING THE LOCATION OF THE CHIEF FIBER TRACTS OF THE SPINAL CORD AND THE DIRECTION IN WHICH THEY DEGENERATE

| | Ascending degeneration. | Descending degeneration. |
|---------------------|--|---|
| Anterior funiculus | Ventral spinothalamic tract | Ventral corticospinal tract, Vestibulospinal tract, Tectospinal tract |
| Lateral funiculus | Dorsal spinocerebellar tract, Ventral spinocerebellar tract, Lateral spinothalamic tract, Spinotectal tract | Lateral corticospinal tract, Rubrospinal tract, Bulbospinal tract, Tectospinal tract |
| Posterior funiculus | Ascending branches of the dorsal root fibers | Fasciculus interfascicularis, Septomarginal tract |

The *fasciculi proprii* or ground bundles are composed of short ascending and descending fibers, which arise and terminate within the gray matter of the spinal cord and link together the various segments of the cord. These fascicles, one of which is present in each of the three funiculi, immediately surround the gray columns. After a transection of the spinal cord the *fasciculi proprii* undergo an incomplete degeneration for some distance both above and below the lesion (Figs. 75, 76). In cross-section the ground bundle of the *posterior funiculus* has the form of a narrow band upon the surface of the posterior column and posterior commissure, and was once called the *cornu-commissural bundle* (Fig. 78). In addition to this fascicle there are in the posterior funiculus two other tracts which in part belong to the same system—the *septomarginal tract* and the *fasciculus interfascicularis*, or comma tract of Schultze. These are both composed of descending fibers, in part of intraspinal origin and in part representing the descending branches of the dorsal root fibers. The septomarginal tract is situated along the dorsal periphery of the posterior funiculus in the thoracic region; it takes up a position along the septum in the lumbar segments (oval area of Flechsig); and in the sacral region it forms a triangular field at the dorsomedial angle of the posterior funiculus (triangle of Gombault and Philippe) (Fig. 76). The *fasciculus interfascicularis* is best developed in the thoracic segments, where it occupies a position near the center of the posterior funiculus.

In the *anterior funiculus*, in addition to the *fasciculus proprius* which immediately surrounds the gray matter, there is a thin layer of similar fibers spread out along the border of the anterior fissure and known as the *sulcomarginal fasciculus*. This tract also contains the fibers which descend into the cord from the medial longitudinal bundle of the medulla oblongata.

As a general rule the short fibers of the fasciculus proprius lie nearer the gray substance than the fibers of greater length; and the long tracts, which

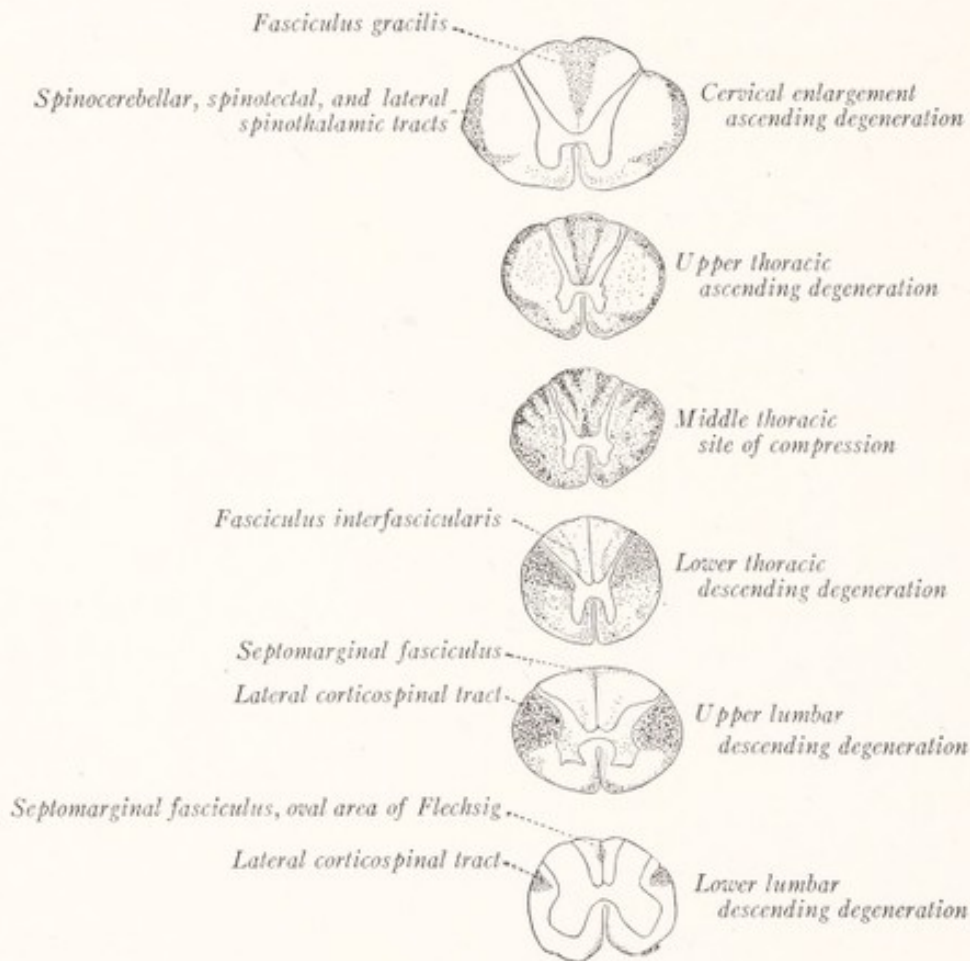


Fig. 76.—Ascending and descending degeneration resulting from a compression of the thoracic spinal cord in man. Marchi method. (Hoche.)

connect the spinal cord with the brain, occupy the most peripheral position. But the fact must not be overlooked that many fibers of the fasciculus proprius are intermingled with those of the long tracts.

LONG DESCENDING TRACTS OF THE SPINAL CORD

Fibers which arise from cells in various parts of the brain descend into the spinal cord, where they form several well-defined tracts. The most important

and most conspicuous of these are the cerebrospinal fasciculi, which are more properly called the *corticospinal tracts*. There are two in each lateral half of the cord, the lateral and the ventral corticospinal tracts. Their constituent fibers take origin from the large pyramidal cells of the precentral gyrus or motor region of the cerebral cortex and pass through the subjacent levels of the brain to reach the spinal cord (Fig. 77). Just before they enter the spinal cord they undergo an incomplete decussation in the medulla oblongata, giving rise to a ventral and a lateral corticospinal tract.

The Lateral Corticospinal Tract (Crossed Pyramidal Tract, Fasciculus Cerebrospinalis Lateralis).—The majority of the pyramidal fibers, after crossing the median plane in the decussation of the pyramids, enter the lateral fu-

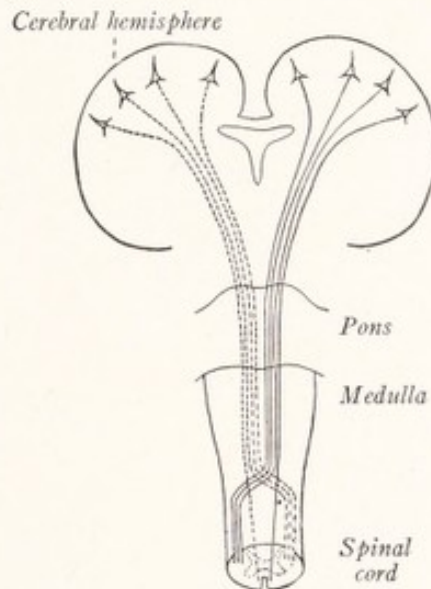


Fig. 77.—Diagram of the corticospinal tracts.

niculus of the spinal cord as the lateral corticospinal tract, which occupies a position between the dorsal spinocerebellar tract and the lateral fasciculus proprius (Fig. 78). In the lumbar and sacral regions, below the origin of the dorsal spinocerebellar tract, the lateral corticospinal tract is more superficial. It can be traced as a distinct strand as far as the fourth sacral segment; and as it descends in the spinal cord it gradually decreases in size. Throughout its course in the spinal cord it gives off collateral and terminal fibers which end in the gray matter.

The **ventral corticospinal tract** (fasciculus cerebrospinalis anterior or direct pyramidal tract) is formed by the smaller part of the corticospinal fibers, which do not cross in the medulla, but pass directly into the ventral funiculus of the

same side of the cord. They form a tract of small size, which lies near the anterior median fissure and which can be traced as a distinct strand as far as the middle of the thoracic region of the spinal cord. Just before terminating these fibers cross in the anterior white commissure. They end like those of the lateral corticospinal tract, either directly or perhaps through an intercalated neuron, in relation to the motor cells in the anterior column. The crossing of these fibers is only delayed, and it will be apparent that all of the corticospinal fibers arising in the right cerebral hemisphere terminate in the anterior column of the left side of the cord, and conversely, those from the left hemisphere end on the right side. It is along these fibers that impulses from the motor portion of the cerebral cortex reach the cord and bring the spinal motor apparatus under voluntary control.

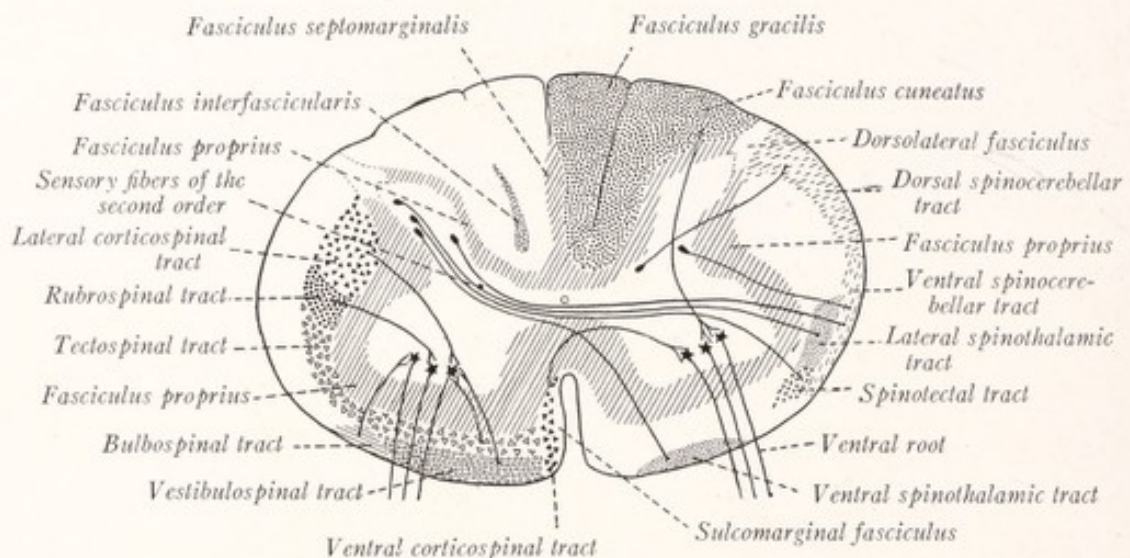


Fig. 78.—Diagram showing the location of the principal fiber tracts in the spinal cord of man. Ascending tracts on the right side, descending tracts on the left.

It is stated by some authors, although on the basis of rather unsatisfactory evidence, that the fibers of the lateral corticospinal tract ramify in the *formatio reticularis* (Monakow, 1895) and the *nucleus dorsalis* (Schäfer, 1899). The corticospinal path is from the standpoint of phylogenesis a relatively new system and varies a great deal in different mammals. It is found in the ventral funiculus in the mole, while in the rat it occupies the posterior funiculus. In the mole it is almost completely unmyelinated, in the rat largely so. It contains many unmyelinated fibers in the cat, fewer in the monkey (Linowiecki, 1914). In man it does not become fully myelinated before the second year. An uncrossed ventral corticospinal tract seems to be present only in man and the anthropoid apes, and this tract varies greatly in size in different individuals.

The **rubrospinal tract** (tract of Monakow) is situated near the center of the lateral funiculus just ventral to the lateral corticospinal tract (Fig. 78). Its fibers come from the red nucleus of the mesencephalon, cross the median plane,

and descend into the spinal cord, within which some of them can be traced to the sacral region. Their collateral and terminal branches end within the anterior column in relation to the primary motor neurons.

Other Descending Tracts.—The *bulbospinal tract* (olivospinal tract, tract of Helweg) is a small bundle of fibers found in the cervical region near the surface of the lateral funiculus opposite the anterior column. The fibers arise from cells in the medulla oblongata, possibly in the inferior olivary nucleus, and end somewhere in the gray matter of the spinal cord. The exact origin and ter-

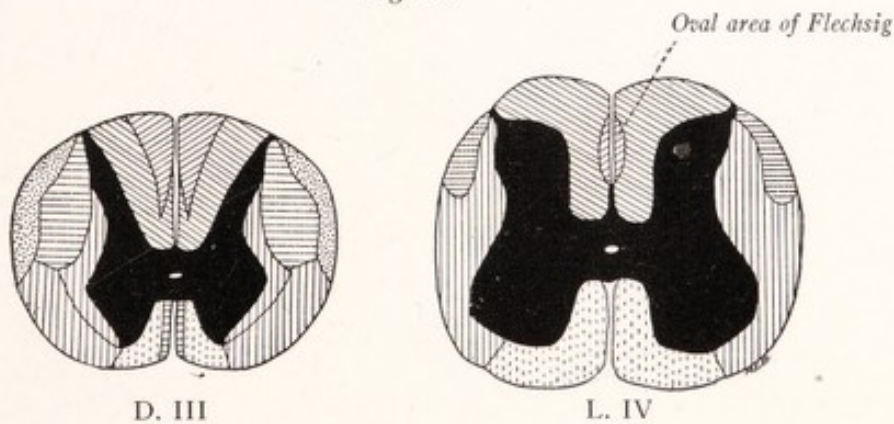
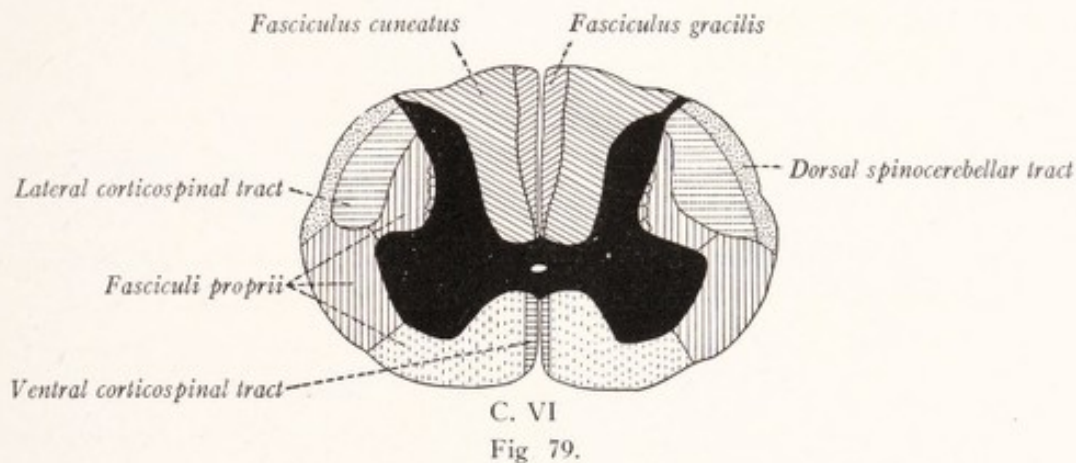


Fig. 80.

Figs. 79 and 80.—Diagrams of the sixth cervical, third thoracic, and fourth lumbar segments of the spinal cord, showing the location of the different tracts as outlined by Flechsig on the basis of differences in time of myelination. (van Gehuchten.)

mination of the tract is unknown. The *tectospinal tract*, located in the ventral funiculus, is composed of fibers which take origin in the roof (tectum) of the mesencephalon, cross the median plane and descend into the anterior funiculus of the spinal cord, and end in the gray matter of the anterior column. The tract is concerned chiefly with optic reflexes. The *vestibulospinal tract*, also located in the anterior funiculus, arises from the lateral nucleus of the vestibular nerve

in the medulla oblongata and conveys impulses concerned in the maintenance of equilibrium. Some of its fibers can be traced as far as the lower lumbar segments. They end in the gray matter of the anterior column.

Hemisection of the spinal cord in man produces a characteristic symptom complex known as the Brown-Séquard's syndrome—which the student is now in position to understand. Below the level of the lesion and on the same side there is found a paralysis of the muscles with a loss of sensation from the muscles, joints, and tendons; while on the opposite side of the body, beginning two or three segments below the level of the lesion, there is loss of sensations of pain and temperature. Tactile sensibility is everywhere retained (Déjerine, 1914).

Order of Myelination.—The fiber tracts of the spinal cord do not all become myelinated at the same time. By a study of the fetal spinal cord at various developmental stages Flechsig was able to identify and trace many of these tracts because of the difference in the time of myelination. His results agree in general with those derived from a study of spinal cords showing ascending and descending degeneration (Figs. 79, 80). Myelination begins during the fifth month of intra-uterine life. The order in which the fibers of the spinal cord acquire their myelin sheaths is as follows: (1) afferent and efferent root fibers, (2) those of the fasciculi proprii, (3) the fasciculus cuneatus, (4) the fasciculus gracilis, (5) the dorsal spinocerebellar tract, (6) the ventral spinocerebellar fasciculus, (7) the corticospinal tracts.

CHAPTER VIII

THE GENERAL TOPOGRAPHY OF THE BRAIN. THE EXTERNAL FORM OF THE MEDULLA OBLONGATA, PONS, AND MESENCEPHALON

The General Topography of the Brain.—The brain rests upon the floor of the cranial cavity, which presents three well-marked fossæ. In the posterior cranial fossa are lodged the medulla oblongata, pons, and cerebellum, which together constitute the rhombencephalon (Fig. 81). This fossa is roofed over by a partition of dura mater, called the *tentorium cerebelli*, that separates the cerebellum from the cerebral hemispheres. Through the notch in the ventral

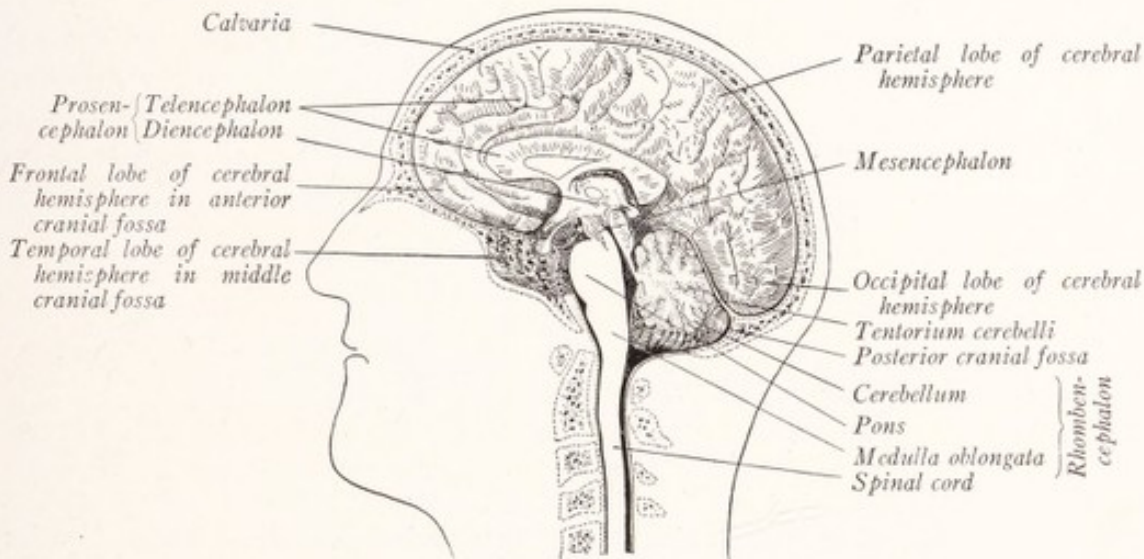

Fig. 81.—Median sagittal section of the head showing the relation of the brain to the cranium. The sphenoid bone is shown in transparency, and through it the temporal lobe may be seen.

border of the tentorium projects the mesencephalon, connecting the rhombencephalon below with the prosencephalon above that partition. The cerebral hemispheres form the largest part of the prosencephalon, occupy the anterior and middle cranial fossæ, and extend to the occiput on the upper surface of the tentorium.

The **dorsal aspect** of the human brain presents an ovoid figure, the large *cerebral hemispheres*, covering the other parts from view. In the sheep's brain the

hemispheres are smaller and fail to hide the cerebellum and medulla oblongata (Fig. 82). The cerebral hemispheres, which are separated by a deep cleft called the *longitudinal fissure of the cerebrum*, together present a broad convex surface which lies in close relation to the internal aspect of the calvaria. From the latter it is separated only by the investing membranes or meninges of the brain. The thin convoluted layer of gray matter upon the surface of the hemispheres is known as the *cerebral cortex*.

The **ventral aspect** or base of the brain presents an irregular surface adapted to the uneven floor of the cranial cavity (Figs. 83, 86). The *medulla oblongata*,

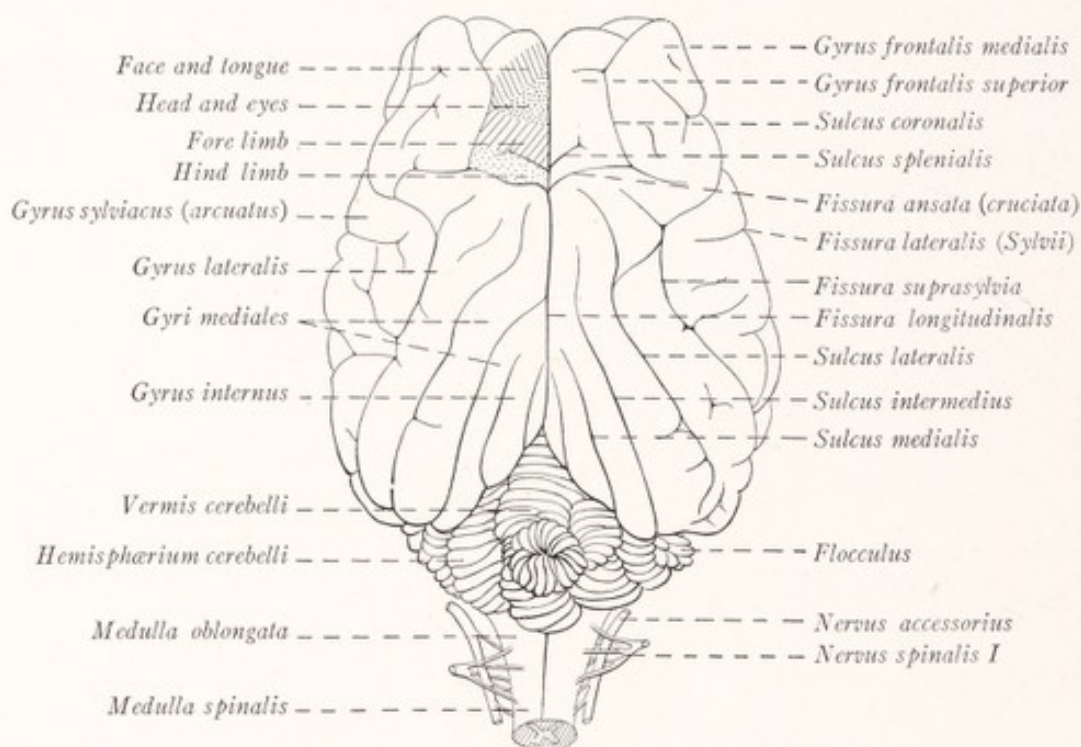


Fig. 82.—Dorsal view of the sheep's brain. The motor cortex is shaded on the left side. (Herrick and Crosby.)

which is continuous through the foramen magnum with the spinal cord, lies on the ventral aspect of the cerebellum in the vallecule between the two cerebellar hemispheres. Rostral to the medulla oblongata and separated from it only by a transverse groove is a broad elevated band of fibers, which plunges into the cerebellum on either side and is known as the *pons*. The *cerebellum* can be seen occupying a position dorsal to the pons and medulla oblongata, and can easily be recognized by its grayish color and many parallel fissures. A pair of large rope-like strands are seen to emerge from the rostral border of the pons and to diverge from each other as they run toward the under surface

of the cerebral hemispheres. These are the *cerebral peduncles* and they form the ventral part of the mesencephalon. At its rostral extremity each peduncle is partially encircled by a flattened band, known as the *optic tract*, which is continuous through the *optic chiasma* with the optic nerves. A lozenge-shaped depression, known as the *interpeduncular fossa*, is outlined by the diverging cerebral peduncles and by the optic chiasma and tracts. Within the area thus outlined and beginning at its caudal angle may be distinguished the following parts: the *interpeduncular nucleus*, which is very large in the sheep and occu-

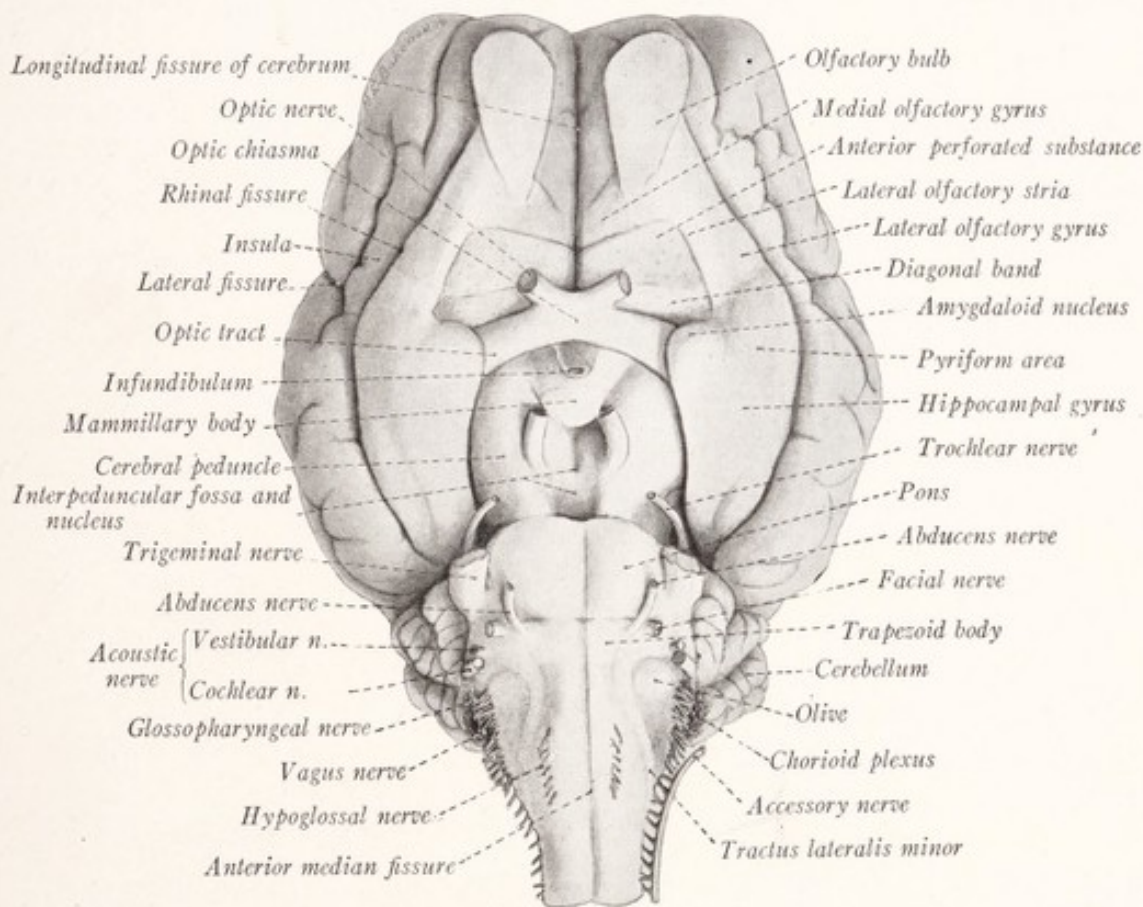


Fig. 83.—Ventral view of the sheep's brain.

pies an area designated in man as the *substantia perforata posterior*; the corpus mammillare, which in man is divided by a longitudinal groove into two *mammillary bodies*; and also the *tuber cinereum*, *infundibulum*, and *hypophysis*. Rostral to the optic tract there is on either side a triangular field of gray matter, studded with minute pit-like depressions and known as the *anterior perforated substance*.

The Rhinencephalon.—The olfactory bulb is situated near the rostral end of the hemisphere, to the ventral surface of which it is attached by the olfactory

peduncle (and in man by the long olfactory tract). In the sheep's brain there diverge from the olfactory peduncle two well-defined gray bands, the *medial* and *lateral olfactory gyri*, which are less evident in man; and furthermore, the lateral olfactory gyrus is obviously continuous with the *hippocampal gyrus*, forming the *pyriform area* (Fig. 83). All of these structures are closely associated in function and belong to the rhinencephalon, or olfactory part of the brain, which, because of the greater importance of the sense of smell in the sheep, is better developed in that animal than in man. A prominent longitudinal fissure separates this part of the brain from the rest of the hemisphere.

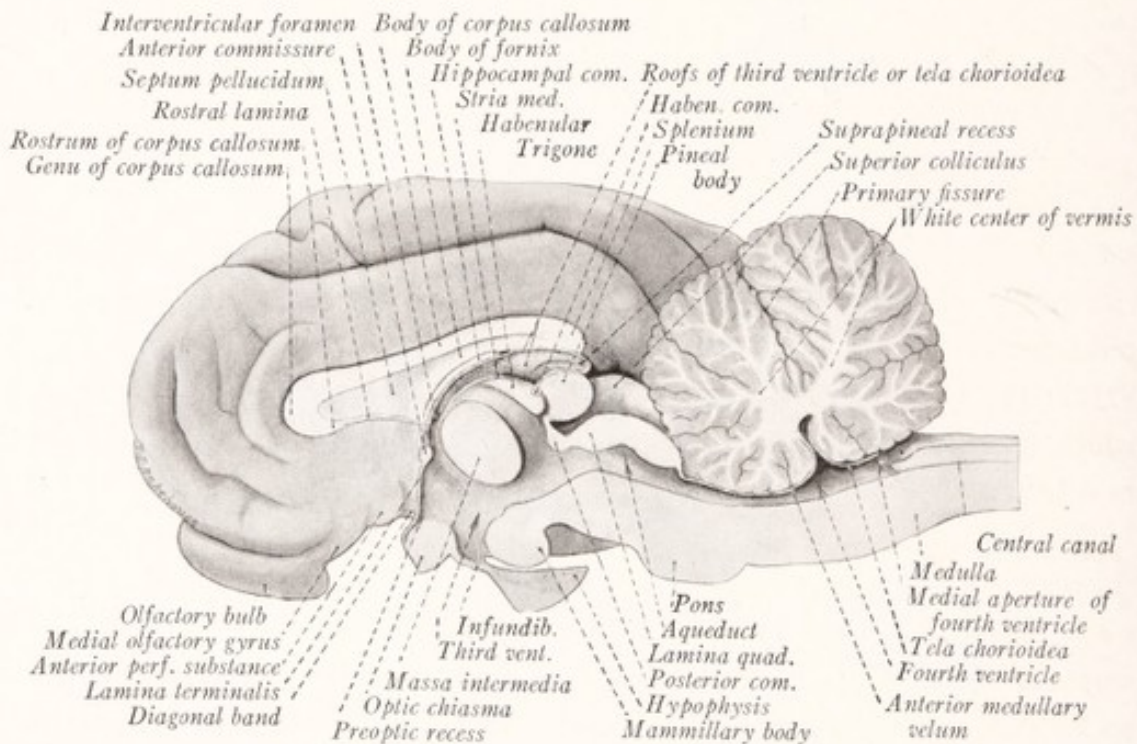


Fig. 84.—Medial sagittal section of the sheep's brain.

This is known as the *rhinal fissure*; and all that portion of the cerebral cortex which lies dorsal to it is the new or non-olfactory cortex, the *neopallium*. In contrast to the older olfactory cortex or *archipallium*, which includes the pyriform area, the neopallium is of recent phyletic development. It first forms a prominent part of the brain in mammals and is by far the most highly developed in man.

Interrelation of the Various Parts of the Brain.—An examination of a medial sagittal section of the brain will make clear the relation which the various parts bear to each other (Fig. 84). The *medulla oblongata*, *pons*, and *cerebellum* are seen surrounding the fourth ventricle, and are intimately connected with one

another. The medulla oblongata is directly continuous with the pons, and on either side a large bundle of fibers from the dorsal aspect of the former runs into the cerebellum. These two strands, which are known as the *restiform bodies* or inferior cerebellar peduncles, constitute the chief avenues of communication between the spinal cord and medulla oblongata on the one hand and the cerebellum on the other. The ventral prominence of the pons is produced in large part by transverse bundles of fibers, which when traced lateralward are seen to form a large strand, the *brachium pontis* or middle cerebellar peduncle, that enters the corresponding cerebellar hemisphere (Figs. 83, 86). The *brachium conjunctivum* or superior cerebellar peduncle can be traced rostrally from the cerebellum to the mesencephalon. The three peduncles are paired structures, symmetrically placed on the two sides of the brain (Figs. 87, 88).

The Cerebrum.—The *mesencephalon* surrounds the cerebral aqueduct and consists of the ventrally placed *cerebral peduncles*, and a dorsal plate with four rounded elevations, the *lamina* and *corpora quadrigemina* (superior and inferior colliculi). The cerebral hemispheres form the most prominent part of the cerebrum and are separated from each other by the longitudinal fissure (Fig. 82), at the bottom of which is a broad commissural band, the *corpus callosum*, which joins the two hemispheres together (Fig. 85). Under cover of the cerebral hemispheres and concealed by them, except on the ventral aspect of the brain, is the *diencephalon*. This includes most of the parts which help to form the walls of the third ventricle. These are from above downward, the *epithalamus*, including the habenular trigone and pineal body near the roof of the ventricle; the *thalamus*, which forms most of the lateral wall of the ventricle, and is united with its fellow across the cavity by a short bar of gray substance, the *massa intermedia*; and the *hypothalamus*, including the mammillary bodies, infundibulum, and part of the hypophysis (Figs. 84, 85).

The Brain Ventricles.—The *central canal* of the spinal cord is prolonged through the caudal portion of the medulla oblongata and finally opens out into the broad rhomboidal *fourth ventricle* of the rhombencephalon. At its pointed rostral extremity this ventricle is continuous with the *cerebral aqueduct*, the elongated slender cavity of the mesencephalon. This, in turn, opens into the *third ventricle*, which is a narrow vertical cleft between the two laterally symmetric halves of the diencephalon. It is bridged by the *massa intermedia*. Near the dorsal part of the rostral border of the ventricle is a small opening in each lateral wall, the *interventricular foramen* or foramen of *Monro*. This leads into the *lateral ventricle*, the cavity of the cerebral hemisphere.

THE ANATOMY OF THE MEDULLA OBLONGATA

At its rostral end the spinal cord increases in size and goes over without sharp line of demarcation into the medulla oblongata, or myelencephalon, which, as we learned in Chapter II, is derived from the posterior part of the third brain vesicle. The medulla oblongata may be said to begin just rostral to the highest rootlet of the first cervical nerve at about the level of the foramen magnum;

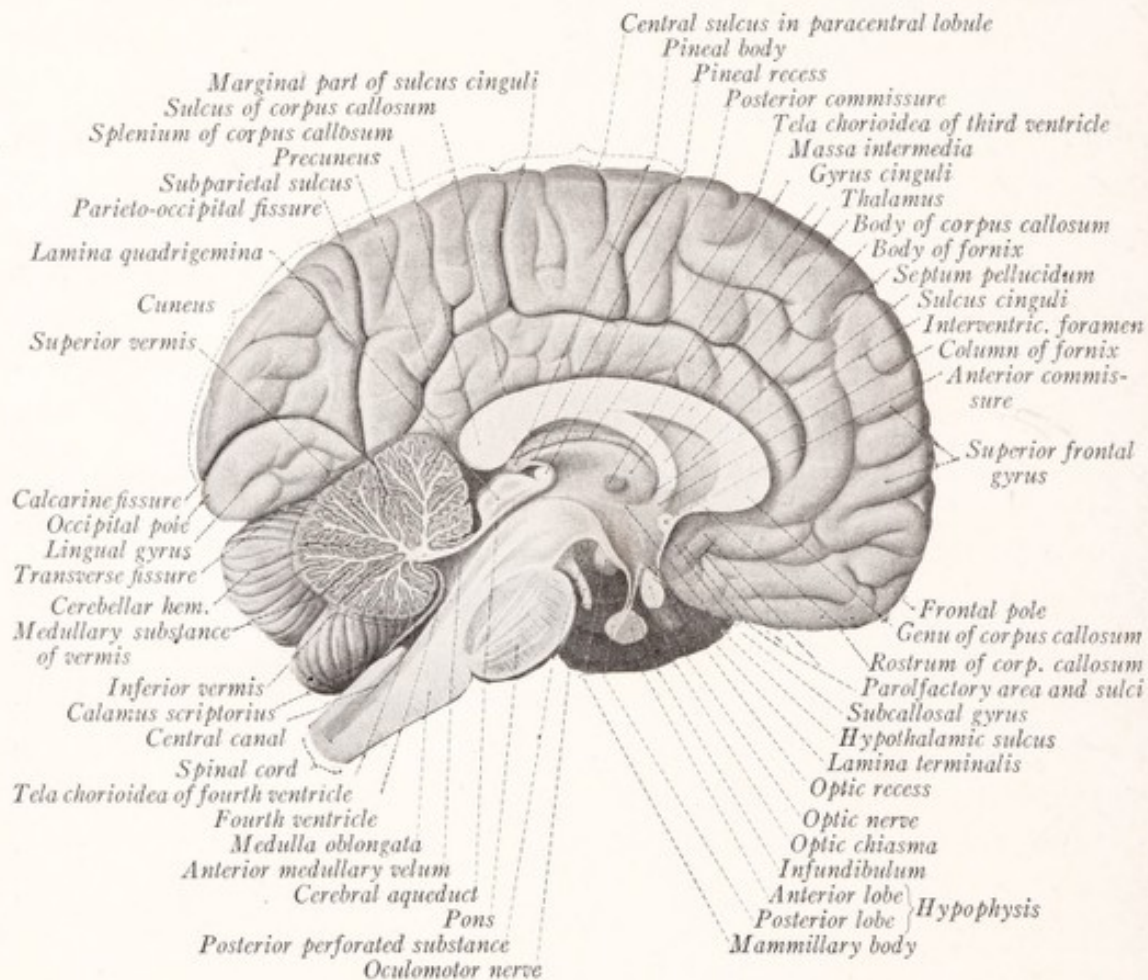


Fig. 85.—Medial sagittal section of the human brain. (Sobotta-McMurrich.)

and at the opposite extremity it is separated from the pons by a horizontal groove (Figs. 81, 85). Its ventral surface rests upon the basilar portion of the occipital bone; while its dorsal surface is in large part covered by the cerebellum. The shape of the medulla oblongata is roughly that of a truncated cone, the smaller end of which is directed caudally and is continuous with the spinal cord. In man it measures about 3 cm., or a little more than 1 inch, in length (Fig. 86).

Like the spinal cord, the medulla oblongata presents a number of more or

less parallel longitudinal grooves. These are the *anterior and posterior median fissures*, and a pair each of *anterior lateral* and *posterior lateral sulci* (Figs. 86, 89). By means of the fissures it is divided symmetrically into right and left halves; while these, in turn, are marked off by the sulci into *ventral, lateral, and dorsal areas*, which as seen from the surface appear to be the direct upward continuation of the anterior, lateral, and posterior funiculi of the spinal cord. But, as we shall see in the following chapter, this continuity is not as perfect as it appears from the surface; because the tracts of the cord undergo a rearrangement as they enter the medulla oblongata. The posterior median fissure does not extend beyond the middle of the oblongata, at which point its lips separate to form the lateral boundaries of the caudal portion of the fourth ventricle. The caudal half of the medulla oblongata contains a canal, the direct continuation of the central canal of the spinal cord, and is known as the *closed portion of the medulla oblongata* (Fig. 85). This canal opens out into the fourth ventricle in the rostral half, which helps to form the ventricular floor, and which is often spoken of as the *open part of the medulla oblongata*.

Fissures and Sulci.—The *posterior median fissure* represents the continuation of the posterior median sulcus of the spinal cord and, as noted above, ends near the middle of the medulla oblongata. The *anterior median fissure* is continued from the spinal cord to the border of the pons, where it ends abruptly in a pit known as the *foramen cæcum*. Near the caudal extremity of the medulla oblongata this fissure is interrupted by interdigitating bundles of fibers which pass obliquely across the median plane. These are the fibers of the lateral corticospinal tract, which undergo a decussation on passing from the medulla oblongata into the spinal cord, known as the *decussation of the pyramids*. The *anterior lateral sulcus* also extends throughout the length of the medulla oblongata and represents the upward continuation of a much more indefinite groove bearing the same name in the spinal cord. From it emerge the root filaments of the hypoglossal nerve. From the *posterior lateral sulcus* emerge the rootlets of the glossopharyngeal, vagus, and accessory nerves (Figs. 86, 88, 89).

The **ventral area of the medulla oblongata** is included between the anterior median fissure and the anterior lateral sulcus, and has the false appearance of being a direct continuation of the anterior funiculus of the spinal cord. On either side of the anterior median fissure there is an elongated eminence, tapering toward the spinal cord, and known as the *pyramid* (pyramis—Fig. 86). It is formed by the fibers of the corticospinal or pyramidal tract. Just before the fibers of this tract enter the spinal cord they undergo a more or less complete

decussation, crossing the median plane in large obliquely interdigitating bundles, which fill up and almost obliterate the anterior median fissure in the caudal part of the medulla oblongata. This is known as the *decussation of the pyramids* (*decussatio pyramidum*). In the sheep these fibers pass into the opposite posterior funiculus of the spinal cord. In man the crossing is incomplete, a

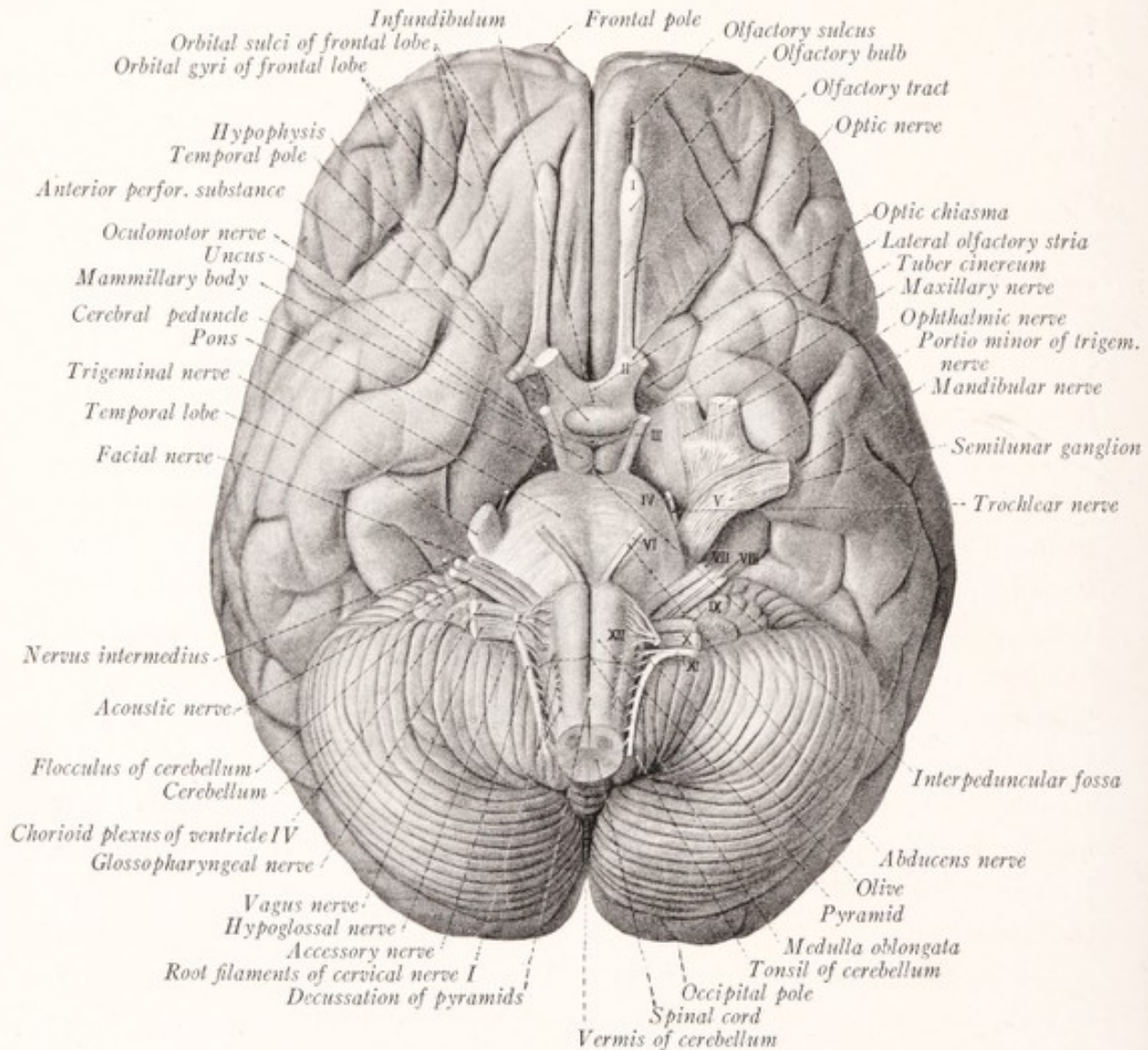


Fig. 86.—Ventral view of the human brain. (Sobotta-McMurrich.)

majority of the fibers descending into the lateral funiculus of the opposite side, a minority into the anterior funiculus of the same side (Fig. 77). We are already acquainted with these bundles in the spinal cord as the *ventral* and *lateral corticospinal tracts* (direct and crossed pyramidal tracts). In addition to the pyramid the ventral area of the medulla also contains a bundle of fibers, the

medial longitudinal fasciculus, which is continuous with the anterior fasciculus proprius of the spinal cord.

The **lateral area of the medulla oblongata**, included between the anterolateral and posterolateral sulci, appears as a direct continuation of the lateral funiculus of the spinal cord; but, as a matter of fact, many of the fibers of that funiculus find their way into the anterior area (as, for example, the lateral corticospinal tract) or into the posterior area (dorsal spinocerebellar tract). In the rostral part of the lateral area, between the root filaments of the glossopharyngeal and vagus nerves, on the one hand, and those of the hypoglossal, on the other, is an oval eminence, the *olive* (*oliva*, olivary body), which is produced by a large irregular mass of gray substance, the inferior olivary nucleus, located just beneath the surface (Figs. 87, 88). By a careful inspection of the surface of the medulla oblongata it is possible to distinguish numerous fine bundles of fibers, which emerge from the anterior median fissure or from the groove between the pyramid and the olive and run dorsally upon the surface of the medulla to enter the restiform bodies. These are the *ventral external arcuate fibers* and are most conspicuous on the surface of the olive (Fig. 88).

In the sheep there are two superficial bands of fibers not seen in the human brain. Placed transversely near the caudal border of the pons is a belt-like elevation, known as the *trapezoid body*, through which emerge the roots of the abducens and facial nerves (Figs. 83, 87). In man the much larger pons covers this band from view and the sixth and seventh nerves emerge from under the caudal border of the pons. Another bundle, beginning on the ventral surface of the trapezoid body near the seventh nerve, describes a graceful curve around the ventral border of the olive and becomes lost in the lateral area of the medulla oblongata. This has been called the *fasciculus lateralis minor*.

The **dorsal area of the medulla oblongata** is bounded ventrally by the posterolateral sulcus and emergent root filaments of the glossopharyngeal, vagus, and accessory nerves. In the closed part of the medulla oblongata it extends to the posterior median fissure, while in the open part its dorsal boundary is formed by the lateral margin of the floor of the fourth ventricle. The caudal portion of this area is, in reality, as it appears, the direct continuation of the posterior funiculus of the spinal cord. On the dorsal aspect of the medulla oblongata the fasciculus cuneatus and fasciculus gracilis of the cord are continued as the *funiculus cuneatus* and *funiculus gracilis*, which soon enlarge into elongated eminences, known respectively as the *cuneate tubercle* and the *clava* (Figs. 89, 91). These enlargements are produced by gray masses, the *nucleus*

gracilis and *nucleus cuneatus*, within which end the fibers of the corresponding fasciculi of the spinal cord. The clava and cuneate tubercle are displaced laterally by the caudal angle of the fourth ventricle. Somewhat rostral to the middle of the medulla oblongata they gradually give place to the *restiform body*.

More laterally, between the cuneate funiculus and tubercle on the one hand and the roots of the glossopharyngeal, vagus, and accessory nerves on the other, is a third longitudinal club-shaped elevation called the *tuberculum cinereum*. It is produced by a tract of descending fibers, derived from the sensory root of the trigeminal nerve, and by an elongated mass of substantia gelatinosa which

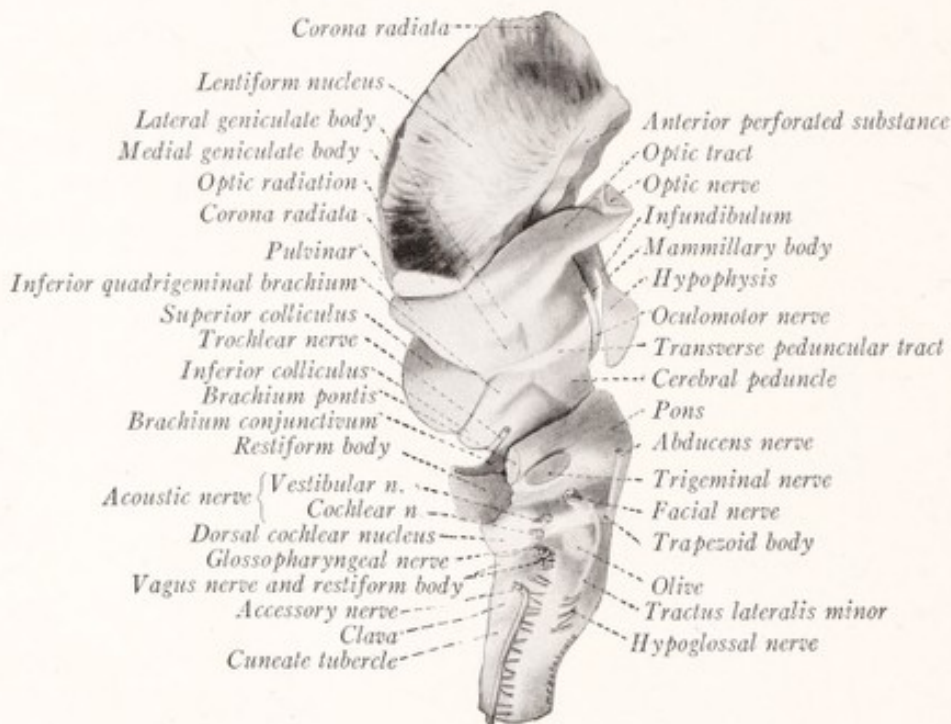


Fig. 87.—Lateral view of brain stem of the sheep.

forms one of the nuclei of this nerve (Fig. 111). This bundle of fibers and the associated mass of gray matter are known as the *spinal tract* and *nucleus of the spinal tract of the trigeminal nerve*.

The **restiform body** (*corpus restiforme* or inferior cerebellar peduncle) lies between the lateral border of the fourth ventricle and the roots of the vagus and glossopharyngeal nerves in the rostral part of the medulla oblongata (Figs. 87-89). There is no sharp line of demarcation between it and the more caudally placed clava and cuneate tubercle. It is produced by a large strand of nerve-fibers, which run along the lateral border of the fourth ventricle and then turn dorsally into the cerebellum. These fibers serve to connect the medulla

oblongata and spinal cord on the one hand with the cerebellum on the other. By a careful inspection of the surface of the medulla it is possible to recognize the source of some of the fibers entering into the composition of the restiform body. The *ventral external arcuate fibers* can be seen entering it after crossing over the surface of the lateral area; and the *dorsal spinocerebellar* tract can also be traced into it from a position dorsal to the caudal extremity of the olive.

At the point where the restiform body begins to turn dorsally toward the cerebellum, it is partly encircled by an elongated transversely placed elevation formed by the *ventral and dorsal cochlear nuclei* (Figs. 87, 88). This ridge is continuous on the one hand with the cochlear nerve, and on the other with several bundles of fibers which run medialward over the floor of the fourth ventricle and are known as the *striæ medullares acusticæ* (Fig. 89). The cochlear nuclei are more prominent in the sheep, while the medullary striæ are best seen in the human brain. Just caudal to this ridge there is sometimes seen another, running more obliquely across the restiform body, which is an outlying portion of the pons and has been described by Essick (1907) under the name *corpus pontobulbare*.

Nerve Roots.—From the surface of the medulla oblongata there emerge in linear order along the posterior lateral sulcus a series of root filaments, which continues the line of the dorsal roots of the spinal nerves. These are the rootlets of the *glossopharyngeal, vagus* and *accessory nerves*. But unlike the dorsal roots, which are made up of afferent fibers, the spinal accessory nerve contains efferent fibers, while the vagus and glossopharyngeal are mixed nerves. The line of the ventral or motor roots of the spinal nerves is continued in the medulla oblongata by the root filaments of the *hypoglossal nerve*, which is also composed of motor fibers. The *abducens, facial, and acoustic nerves* make their exit along the caudal border of the pons in the order named from within outward. The abducens emerges between the pons and the pyramid, the acoustic far lateralward in line with the restiform body, and the facial with its sensory root, the *nervus intermedius*, near the acoustic nerve (Figs. 86–88).

THE ANATOMY OF THE PONS

The pons, which is differentiated from the ventral part of the metencephalon, is interposed between the medulla oblongata and the cerebral peduncles and lies ventral to the cerebellum. As seen from the ventral surface, it is formed by a broad transverse band of nerve-fibers, which on either side become aggregated into a large rounded strand, the *brachium pontis* or middle cerebellar

peduncle, and finally enter the corresponding hemisphere of the cerebellum (Figs. 83, 86). This transverse band of fibers, which gives the bridge-like form from which this part derives its name, belongs to the *basilar portion of the pons* and is superimposed upon a deeper *dorsal portion* that may be regarded as a direct upward continuation of the medulla oblongata. The transverse fibers form a part of the pathway connecting the cerebral hemispheres with the opposite cerebellar hemispheres; and the size of the pons, therefore, varies with

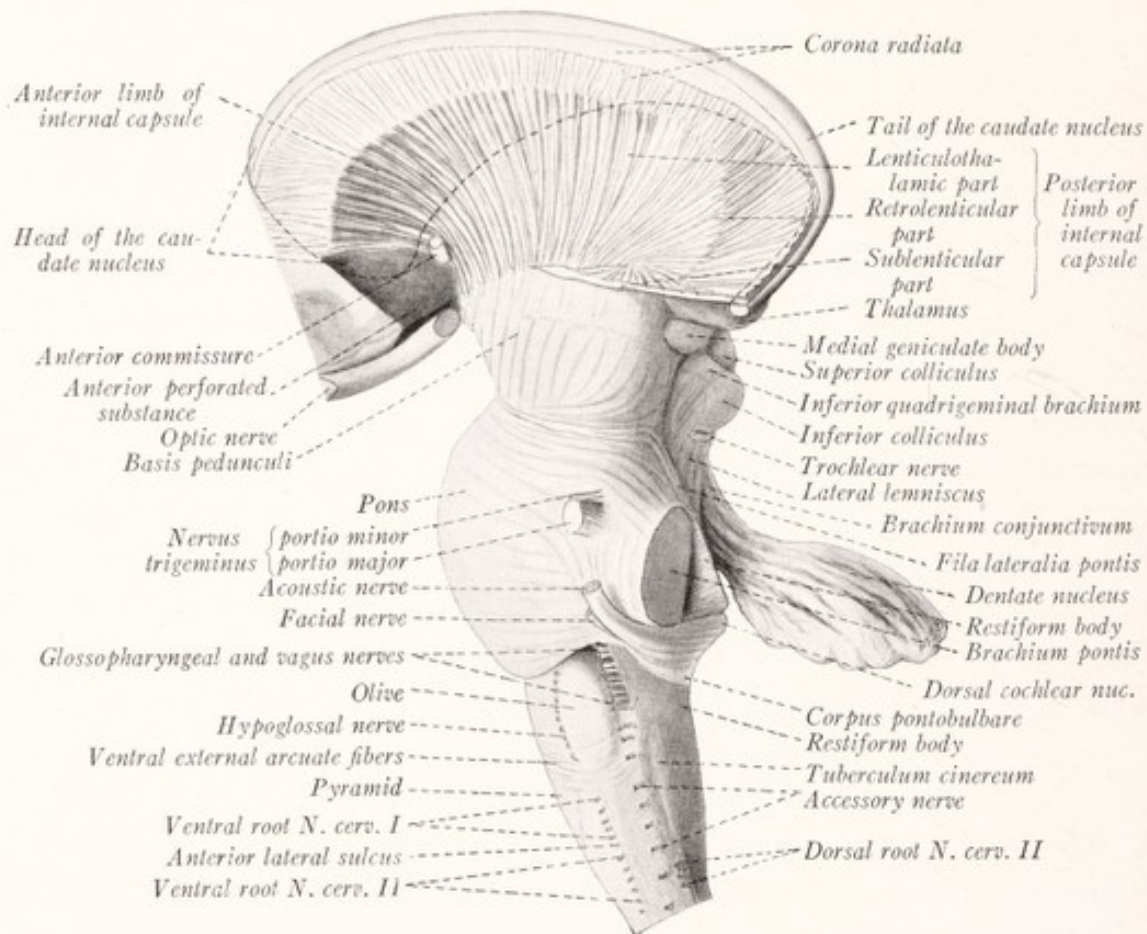


Fig. 88.—Lateral view of human brain stem.

the size of these other structures. It is instructive to compare the brains of the shark, sheep, and man with this point in mind (Figs. 11, 84, 85).

The **ventral surface of the pons** is convex from above downward and from side to side and rests upon the basilar portion of the occipital bone and upon the dorsum sellæ (Fig. 81). A groove along the median line, the *basilar sulcus*, lodges the basilar artery (Fig. 86).

The *trigeminal nerve* emerges from the ventral surface of the pons far lateralward at the point where its constituent transverse fibers are converging to form

the brachium pontis. In fact, it is customary to take the exit of this nerve as marking the point of junction of the pons with its brachium. The nerve has two roots which lie close together: the larger is the *sensory root*, or portio major; the smaller is the *motor root*, or portio minor (Fig. 88).

The **posterior surface of the pons** forms the rostral part of the floor of the fourth ventricle, along the lateral borders of which there are two prominent and rather large strands of nerve-fibers, the *brachia conjunctiva* (Figs. 88, 89).

The **brachia conjunctiva** or superior cerebellar peduncles lie under cover of the cerebellum. As they emerge from the white centers of the cerebellar hemispheres they curve rostrally and take up a position along the lateral border of the fourth ventricle. They converge as they ascend and disappear from view by sinking into the substance of the mesencephalon under cover of the inferior quadrigeminal bodies. Each consists of fibers which connect the cerebellum with the *red nucleus*, a large gray mass situated within the midbrain ventral to the superior colliculus of the corpora quadrigemina. The interval between the two brachia conjunctiva, where these form the lateral boundaries of the fourth ventricle, is occupied by a thin lamina of white matter, the *anterior medullary velum* (Fig. 85). This is stretched between the free dorsomedial borders of the two brachia and forms the roof of the rostral portion of the ventricle. Caudally it is continuous with the white center of the cerebellum. The fibers of the *trochlear nerves* decussate in the anterior medullary velum and emerge from its dorsal surface (Fig. 89). As they run through the velum they produce a raised white line which extends transversely from one brachium to the other.

THE FOURTH VENTRICLE

The lozenge-shaped cavity of the rhombencephalon is known as the fourth ventricle. It lies between the pons and medulla oblongata, ventrally, and the cerebellum dorsally, and is continuous with the central canal of the closed portion of the medulla, on the one hand, and with the cerebral aqueduct on the other (Fig. 84). On each side a narrow curved prolongation of the cavity extends laterally on the dorsal surface of the restiform body. This is known as the *lateral recess* (Figs. 89, 90). It opens into the subarachnoid space near the flocculus of the cerebellum; and through this *lateral aperture* of the fourth ventricle (foramen of Luschka) protrudes a small portion of the chorioid plexus (Fig. 90). There is also a median aperture (foramen of Magendie) through the roof of the ventricle near the caudal extremity. By means of these three openings, one medial and two lateral, the cavity of the ventricle is in communica-

tion with the subarachnoid space, and cerebrospinal fluid may escape from the former into the latter.

The floor of the fourth ventricle is known as the *rhomboid fossa* and is formed by the dorsal surfaces of the pons and open part of the medulla oblongata, which are continuous with each other without any line of demarcation and are irregularly concave from side to side (Figs. 89, 91). The fossa is widest opposite the points where the restiform bodies turn dorsally into the cerebellum; and it gradually narrows toward its rostral and caudal angles. The *lateral boundaries*

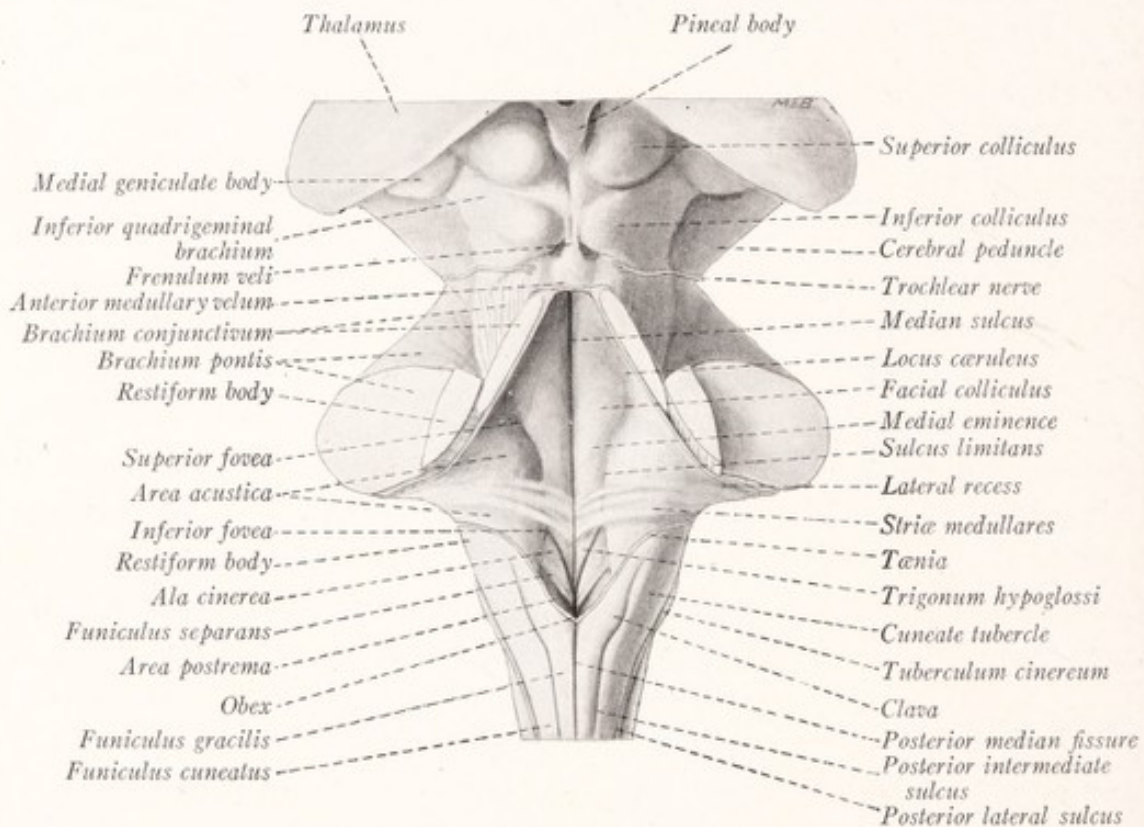


Fig. 89.—Dorsal view of human brain stem.

of the fossa, which are raised some distance above the level of the floor, are formed by the following structures: the *brachia conjunctiva*, *restiform bodies*, *cuneate tubercles*, and *clavæ*. Of the four angles to the rhomboid fossa, two are laterally placed and correspond to the lateral recesses. At its caudal angle the ventricle is continuous with the central canal of the closed part of the medulla oblongata, and at its rostral angle with the cerebral aqueduct. Joining the two last named angles there is a median sulcus which divides the fossa into two symmetric lateral halves.

The rhomboid fossa is arbitrarily divided into three parts. The *superior*

part is triangular, with its apex directed rostrally and its base along an imaginary line through the superior foveæ. The *inferior part* is also triangular, but with its apex directed caudally and its base at the level of the horizontal portions of the tæniæ of the ventricle. Between these two triangular portions is the *intermediate part* of the fossa, which is prolonged outward into the lateral recesses. The floor is covered with a thin lamina of gray matter continuous with that which lines the central canal and cerebral aqueduct. Crossing the fossa transversely in its intermediate portion are several strands of fibers known as the *striæ medullares acusticæ*. These are subject to considerable variation in different specimens. Springing from the dorsal cochlear nuclei they wind around the restiform body in the lateral recess and run transversely across the fossa to disappear in the median sulcus.

The *inferior portion* of the fossa bears some resemblance to the point of a pen and has been called the *calamus scriptorius*. It belongs to the medulla oblongata. In this part of the fossa there is on either side a small depression, the *inferior fovea*, shaped like an arrow-head, the point of which is directed toward the striæ medullares. From the basal angles of this triangle run diverging sulci: a medial groove toward the opening of the central canal and a lateral groove more nearly parallel to the median sulcus. By these sulci the inferior portion of the fossa is divided into three triangular areas. Of these the most medial is called the *trigone of the hypoglossal nerve* or *trigonum nervi hypoglossi*. Beneath the medial part of this slightly elevated area is located the nucleus of the hypoglossal nerve. The area between the two sulci, which diverge from the fovea inferior, is the *ala cinerea* or triangle of the vagus nerve. Both names are appropriate, the one, because of its gray color, and the other, because a nucleus of the vagus nerve lies subjacent to it. The third triangular field, placed more laterally, forms a part of the *area acustica*.

The *area acustica* is, however, not restricted to the inferior portion of the fossa, but extends into the *intermediate part* as well. Here it forms a prominent elevation over which the striæ medullares run. Subjacent to this area lie the nuclei of the vestibular nerve. A part of the acoustic area and all of the ventricular floor rostral to it belong to the pons.

Rostral to the striæ medullares there may be seen a shallow depression, the *fovea superior*, medial to which there is a rounded elevation, the *facial colliculus*. Under cover of this eminence the fibers of the facial nerve bend around the abducens nucleus. Extending from the fovea superior to the cerebral aqueduct is a shallow groove, usually faint blue in color, the *locus*

cæruleus, beneath which lies the *substantia ferruginea*, composed of pigmented nerve-cells.

Beginning at the cerebral aqueduct and extending through both the superior and inferior foveæ is a very important groove, the *sulcus limitans*, which represents the line of separation between the parts derived from the alar plate and those which originate from the basal plate of the embryonic rhombencephalon. Lateral to this sulcus lie the sensory areas of the ventricular floor, including the *area acustica*, all of which are derived from the alar plate. Medial to this sulcus there is a prominent longitudinal elevation, known as the *medial eminence*, which includes two structures already described, namely, the *facial colliculus* and the *trigone of the hypoglossal nerve*. Beneath the medial part of this

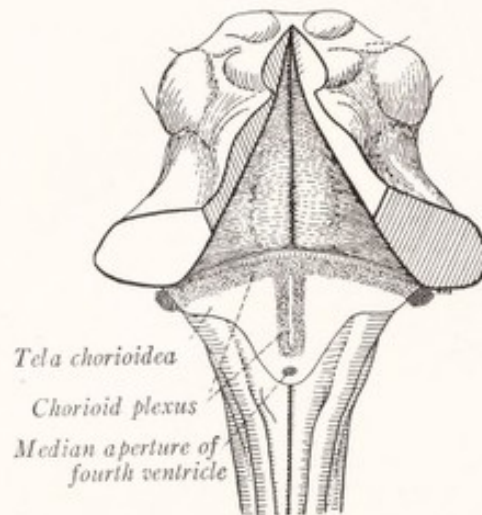


Fig. 90.—Dorsal view of human rhombencephalon showing tela chorioidea and chorioid plexus of the fourth ventricle.

trigone lies the *nucleus of the hypoglossal nerve* and beneath the lateral part is a group of cells designated as the *nucleus intercalatus*.

One or two features remain to be mentioned. At the caudal end of the *ala cinerea* is a narrow translucent obliquely placed ridge of thickened ependyma, known as the *funiculus separans*. Between this ridge and the *clava* is a small strip of the ventricular floor, called the *area postrema*, which on microscopic examination is found to be rich in blood-vessels and neuroglial tissue.

The **roof of the fourth ventricle** is formed by the *anterior medullary velum*, a small part of the *white substance of the cerebellum*, and by the *tela chorioidea* lined internally by *ependymal epithelium* (Fig. 85). Caudal to the cerebellum the true roof of the cavity is very thin and consists only of a layer of ependymal epithelium, which is continuous with that lining the other walls of the ventricle.

This is supported on its outer surface by a layer of pia mater, the *tela chorioidea*, rich in blood-vessels. From this layer vascular tufts, covered by epithelium, are invaginated into the cavity and form the *chorioid plexus* of the fourth ventricle (Fig. 90). The plexus is invaginated along two vertical lines close to the median plane and along two horizontal lines, which diverge at right angles from the vertical ones and run toward the lateral recesses. These right and left halves are joined together at the angles so that the entire plexus has the shape of the letter T, the vertical limb of which, however, is double.

After the *tela chorioidea* with its epithelial lining has been torn away to expose the floor of the ventricle, there remains attached to the lateral boundaries of the caudal part of the cavity the torn edges of this portion of the roof. These appear as lines, the *tæniæ of the fourth ventricle*, which meet over the caudal angle of the cavity in a thin triangular lamina, the *obex* (Fig. 89). Rostrally each *tænia* turns lateralward over the restiform body and forms the caudal boundary of the corresponding lateral recess.

THE MESENCEPHALON

The *midbrain* or mesencephalon occupies the notch in the tentorium and connects the rhombencephalon, on the one side of that shelf-like process of dura, with the prosencephalon on the other (Fig. 81). It consists of a dorsal part, the *corpora quadrigemina*, and a larger ventral portion, the *cerebral peduncles*. It is tunneled by a canal of relatively small caliber, called the cerebral aqueduct, which connects the third and fourth ventricles and is placed nearer the dorsal than the ventral aspect of the midbrain (Fig. 84).

The **cerebral peduncles** (*pedunculi cerebri*, *crura cerebri*), as seen on the ventral aspect of the brain, diverge like a pair of legs from the rostral border of the pons (Fig. 83). Just before they disappear from view by entering the ventral surface of the prosencephalon they enclose between them parts of the hypothalamus, and are encircled by the optic tracts. On section, each peduncle is seen to be composed of a dorsal part, the *tegmentum*, and a ventral part, the *basis pedunculi*. Between the *basis pedunculi* and the *tegmentum* there intervenes a strip of darker color, the *substantia nigra* (Fig. 113). By dissection it is easy to show that the *basis pedunculi* is composed of longitudinally coursing fibers which can be traced rostrally to the internal capsule (Fig. 88). In the other direction some of these fibers can be followed into the corresponding pyramid of the medulla oblongata. On the surface two longitudinal sulci mark the plane of separation between the *tegmentum* and the *basis pedunculi*. The

groove on the medial aspect of the peduncle, through which emerge the fibers of the third nerve, is known as the *sulcus of the oculomotor nerve*, while that on the lateral aspect is called the *lateral sulcus* of the mesencephalon. Dorsal to this latter groove the tegmentum comes to the surface and is faintly marked by fine bundles of fibers which curve dorsally toward the inferior colliculus of the corpora quadrigemina (Fig. 88). These fibers belong to the lateral lemniscus, the central tract associated with the cochlear nerve.

The **corpora quadrigemina** form the dorsal portion of the mesencephalon, and consist of four rounded eminences, the quadrigeminal bodies or *colliculi*,

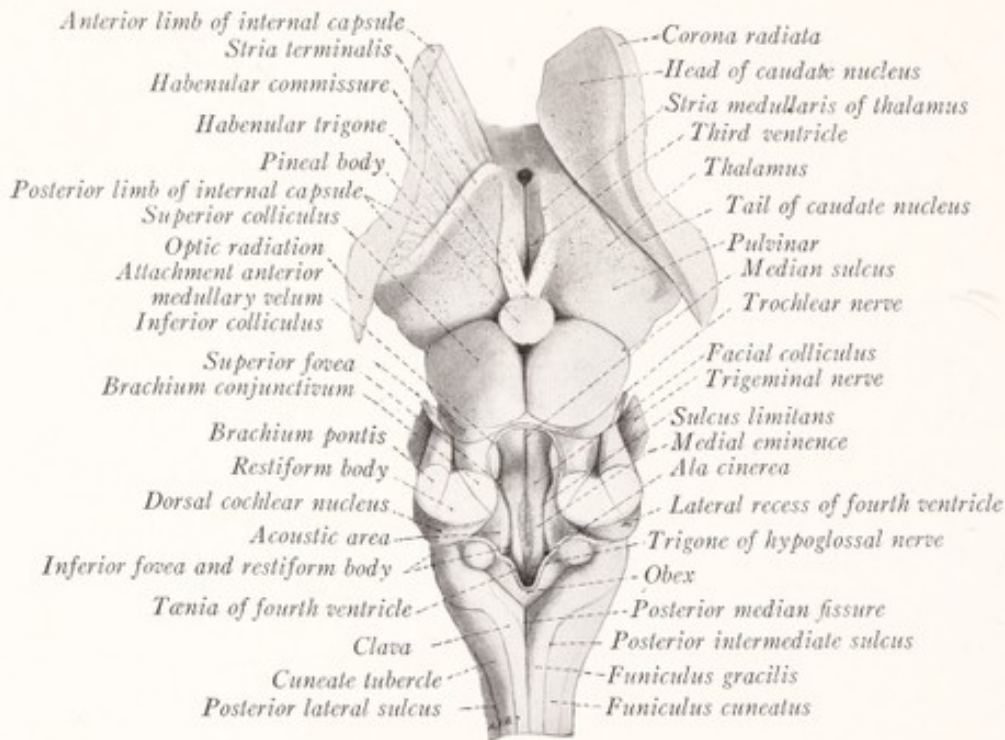


Fig. 91.—Dorsal view of brain stem of sheep.

which arise from the dorsal aspect of a plate of mingled gray and white matter known as the *quadrigeminal lamina* (Figs. 89, 91). The superior colliculi are larger than the inferior, the disproportion being greater in the sheep than in man. A median longitudinal groove separates the colliculi on either side. In the rostral end of this groove rests the *pineal body*, while attached to its caudal end is a band which runs to the anterior medullary velum, and is known as the *frenulum veli*. A transverse groove runs between the superior and inferior colliculi and extends on to the lateral aspect of the mesencephalon, where it intervenes between the superior colliculus and the inferior quadrigeminal brachium (Figs. 87, 89).

The Brachia of the Corpora Quadrigemina.—From each colliculus there runs ventrally and rostrally on the lateral aspect of the mesencephalon an arm or brachium (Figs. 87, 88). The *inferior quadrigeminal brachium* is the more conspicuous and is the only one that can be readily identified in the sheep. It runs from the inferior colliculus to the *medial geniculate body*. This is an oval eminence, belonging to the diencephalon, which has been displaced caudally so as to lie on the lateral aspect of the mesencephalon. The *superior quadrigeminal brachium* runs from the superior colliculus toward the *lateral geniculate body*, passing between the pulvinar of the thalamus and the medial geniculate body. Some of the fibers can be traced beyond the lateral geniculate body into the optic tract.

CHAPTER IX

THE STRUCTURE OF THE MEDULLA OBLONGATA

THE medulla oblongata contains the nerve-cells and fiber tracts associated with certain of the cranial nerves. These include the central mechanisms which control the reflex activities of the tongue, pharynx, and larynx, and in part those of the thoracic and abdominal viscera also. At the same time the ascending and descending fiber tracts, which unite the spinal cord with higher nerve centers, pass through the medulla oblongata.

The **central connections of the cranial nerves**, except those of the first two pairs, are located in the medulla oblongata and in the tegmental portions of the pons and mesencephalon. In many respects they resemble the connections of the spinal nerves within the spinal cord. The following general statements on this topic, most of which are illustrated in Fig. 92, will help to elucidate the structure of the brain stem.

1. The *cells of origin of the sensory fibers* of the cranial nerves (Fig. 92, 1) are found in ganglia which lie outside the cerebrospinal axis and are homologous with the spinal ganglia. These are the semilunar ganglion of the trigeminal, the geniculate ganglion of the facial, the superior and petrous ganglia of the glossopharyngeal, the jugular and nodose ganglia of the vagus, the spiral ganglion of the cochlear, and the vestibular ganglion of the vestibular nerve.

2. All of these sensory ganglia except the last two, the cells of which are bipolar, are formed by unipolar cells, the axons of which divide dichotomously into peripheral and central branches. The latter (or in the case of the acoustic nerve the central processes of the bipolar cells) form the sensory nerve roots, enter the brain stem and divide, each into a *short ascending* and a *long descending* branch. These branches give off numerous collaterals, which with the terminal branches end in gray masses known as *sensory nuclei* or *nuclei of termination*. It is the *descending branches* of the sensory fibers of the *trigeminal nerve* which form the *spinal tract* of that nerve illustrated in Figs. 92, 98, 99, 101.

3. The ascending branch may be entirely wanting, as in the case of the sensory fibers of the *seventh, ninth, and tenth nerves*, all of which bend caudally and form a descending tract in the medulla oblongata, known as the *tractus solitarius* (Figs. 92, 101, 103).

4. The *sensory nuclei* (Fig. 92, 4), within which the afferent fibers terminate, contain the cells of origin of the *sensory fibers of the second order* (Fig. 92, 2). Some of these are short; others are long, and these may be either direct or crossed. Many of them divide into ascending and descending branches. They run in the reticular formation and some of the ascending fibers reach the thalamus.

5. These sensory fibers of the second order give off *collaterals to the motor nuclei*. Direct collaterals from the sensory fibers of the cranial nerves to the motor nuclei are few in number or entirely wanting.

6. The motor nuclei (Fig. 92, 5) are aggregations of multipolar cells which give origin to the motor fibers of the cranial nerves (Fig. 92, 3).

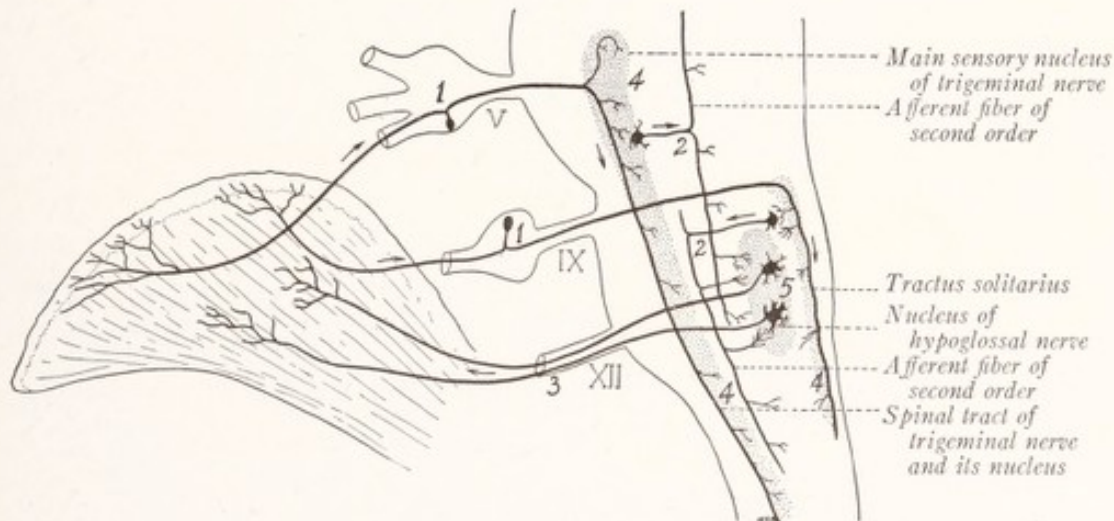


Fig. 92.—Diagram of the tongue and rhombencephalon to illustrate the central connections and functional relationships of certain of the cranial nerves: 1, Sensory neurons of the first order of the trigeminal and glossopharyngeal nerves; 2, sensory neurons of the second order; 3, motor fibers of the hypoglossal nerve; 4, sensory nuclei; 5, motor nucleus of hypoglossal nerve. (Cajal.)

The Rearrangement Within the Medulla Oblongata of the Structures Continued Upward from the Spinal Cord.—At the level of the rostral border of the first cervical nerve the spinal cord goes over without a sharp line of demarcation into the medulla oblongata. The transition is gradual both as to external form and internal structure; but in the caudal part of the medulla there occurs a gradual rearrangement of the fiber tracts and alterations in the shape of the gray matter, until at the level of the olive, a section of the medulla bears no resemblance to one through the spinal cord.

The realignment of the corticospinal tracts and the termination of the fibers of the posterior funiculi of the spinal cord are two of the most important factors

responsible for this gradual transformation. Traced rostrally from the spinal cord, the *ventral corticospinal tracts* are seen to enter the pyramids within the ventral area of the medulla oblongata, that is to say, they enter the medulla without realignment. But the fibers of the *lateral corticospinal tracts* on entering the medulla swing ventromedially in coarse bundles, which run through the anterior gray columns and cut them off from the gray matter surrounding the central canal (Figs. 93, 95). After crossing the median plane in the decussation of the pyramids these fibers join those of the opposite ventral corticospinal tracts and form the pyramids (Fig. 96). Thus fibers from the lateral funiculus come to lie ventral to the central canal and displace this dorsally; and at the same time a start is made toward breaking up the H-shaped gray figure characteristic of the spinal cord.

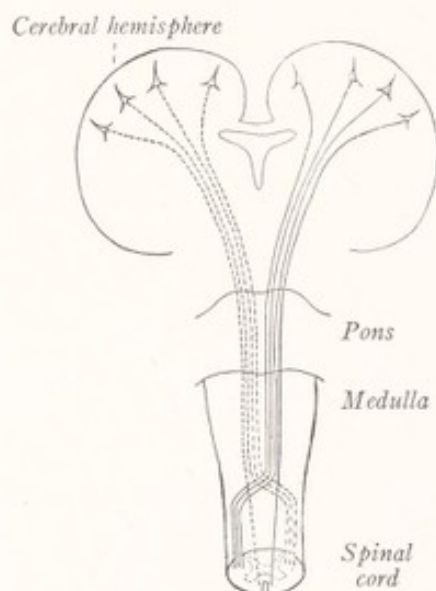


Fig. 93.—Diagram of the corticospinal tracts.

Shortly after entering the medulla oblongata the *fibers of the posterior funiculi* end in nuclear masses which invade the funiculus gracilis and funiculus cuneatus as expansions from the posterior gray columns and central mass of gray substance (Figs. 95, 96). These are known as the *nucleus gracilis* and *nucleus cuneatus*. They cause a considerable increase in the size of the posterior funiculi and a corresponding ventrolateral displacement of the posterior columns of gray matter. The fibers of the posterior funiculi end in these nuclei about cells, the axons of which run ventromedially as the axis-cylinders of *internal arcuate fibers*. These sweep in broad curves through the gray substance, and decussate ventral to the central canal in what is known as the *decussation of the medial lemniscus*. After crossing the median plane they turn rostrally between the

pyramids and the central gray matter to form on either side of the median plane a broad band of fibers known as the *medial lemniscus* (Figs. 96, 97).

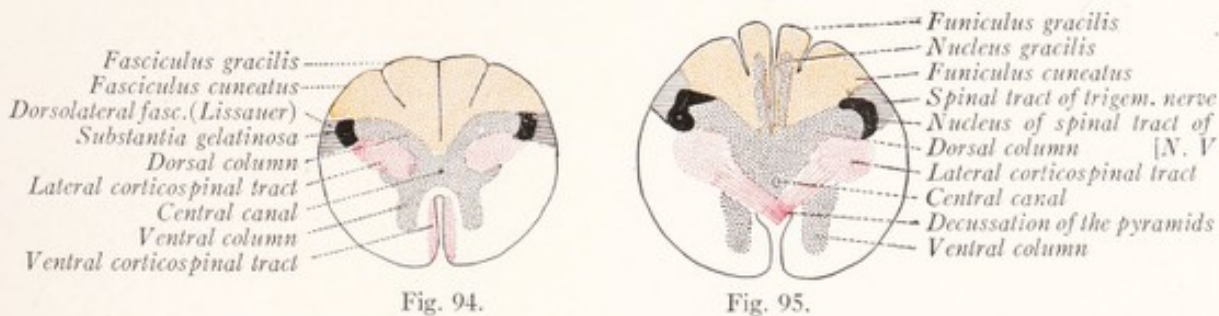


Fig. 94.

Fig. 95.

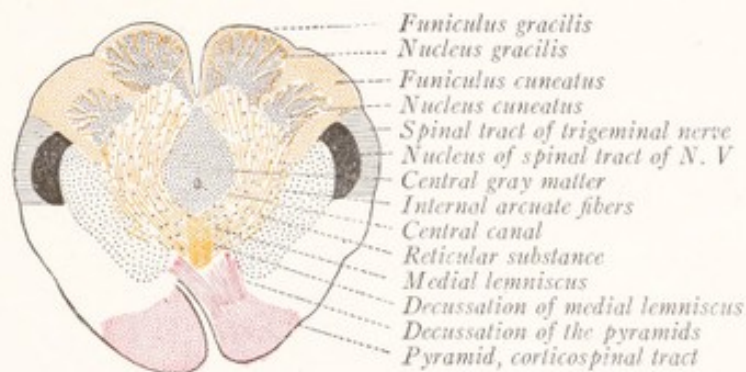


Fig. 96.

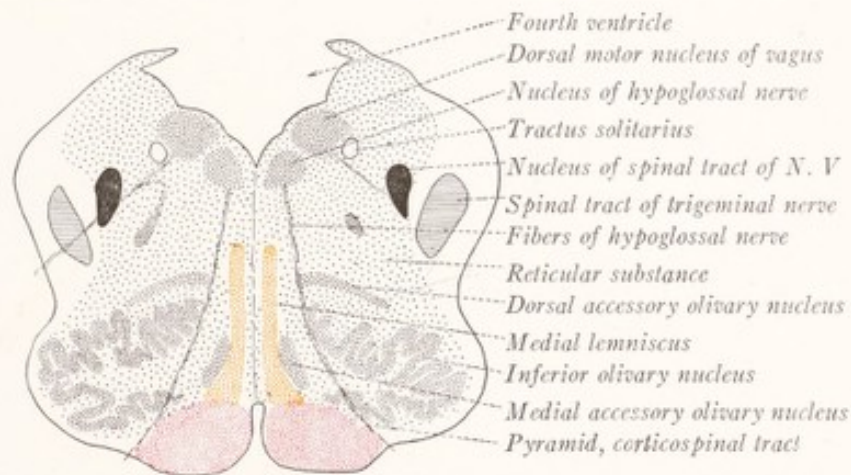


Fig. 97.

Figs. 94-97.—Diagrammatic cross-sections to show the relation of the structures in the medulla oblongata to those in the spinal cord: Fig. 94, First cervical segment of spinal cord; Fig. 95, medulla oblongata, level of decussation of pyramids; Fig. 96, medulla oblongata, level of decussation of medial lemniscus; Fig. 97, medulla oblongata, level of olive.

At the level of the middle of the olive most of the fibers of the funiculus cuneatus and funiculus gracilis have terminated in their respective nuclei; and the nuclei also disappear a short distance farther rostrally (Fig. 97). With the

disappearance of these fibers and nuclei there ceases to be any nervous substance dorsal to the *central canal*, and this, which has been displaced dorsally by the accumulation of the corticospinal fibers and those of the lemniscus ventral to it, opens out as the *floor of the fourth ventricle* (Fig. 97).

The *outline of the gray matter* in the most caudal portions of the medulla oblongata closely resembles that of the spinal cord. The anterior columns are first cut off by the decussation of the pyramids (Fig. 95). Then the posterior columns are displaced ventrolaterally due to the increased size of the posterior funiculi and the disappearance of the lateral corticospinal tracts from their ventral aspects. This rotation of the posterior column causes the apex of that column with its *spinal tract* and *nucleus of the trigeminal nerve*, which are continuous with the fasciculus dorsolateralis and substantia gelatinosa of the spinal cord (Fig. 94), to lie almost directly lateralward from the central canal (Fig. 96). The shape of the gray figure is still further altered by the development of special nuclear masses, many of which are very conspicuous. These include the *nucleus gracilis*, *nucleus cuneatus*, *inferior olivary nucleus*, and the *nuclei of the cranial nerves*. The greater part of the gray substance now becomes broken up by nerve-fibers crossing in every direction, but especially by the internal arcuate fibers. This mixture of gray and white matter is known as the *reticular substance*. The *central gray matter* is pushed dorsad first by the pyramids and later by the medial lemniscus until it finally spreads out to form a thin gray covering for the floor of the fourth ventricle.

The Pyramids and Their Decussation.—We have had occasion repeatedly to refer to the crossing of the lateral corticospinal tracts in this and preceding chapters, but there remain some details to be presented. The pyramids are large, somewhat rounded fascicles of longitudinal fibers, which lie on either side of the anterior median fissure of the medulla oblongata (Fig. 86). The constituent fibers take origin from the large pyramidal cells of the anterior central gyrus or motor cerebral cortex. The *decussation of the pyramids* or motor decussation occurs near the caudal extremity of the medulla oblongata (Fig. 93). Approximately the medial three-fourths of the corticospinal tract passes through the decussation into the lateral funiculus of the opposite side of the spinal cord, as the *lateral corticospinal tract* (fasciculus cerebrospinalis lateralis or lateral pyramidal tract); while the lateral one-fourth is continued without crossing into the ventral funiculus of the same side as the *ventral corticospinal tract* (fasciculus cerebrospinalis anterior or anterior pyramidal tract—Figs. 94, 95, 96, 98). The decussating fibers are grouped into relatively large bundles

as they cross the median plane, the bundles from one side alternating with similar bundles from the other, and largely obliterating the anterior median fissure at this level. There is great individual variation as to the relative size of the ventral and lateral corticospinal tracts; and there may even be marked asymmetry due to a difference in the proportion of the decussating fibers on the two sides.

The **nucleus gracilis** and **nucleus cuneatus** (nucleus funiculi gracilis and nucleus funiculi cuneati) are large masses of gray matter located in the posterior funiculi of the caudal portion of the medulla oblongata. They are surrounded by the fibers of these funiculi except on their ventral aspects, where they are continuous with the remainder of the gray substance (Fig. 99). The fibers

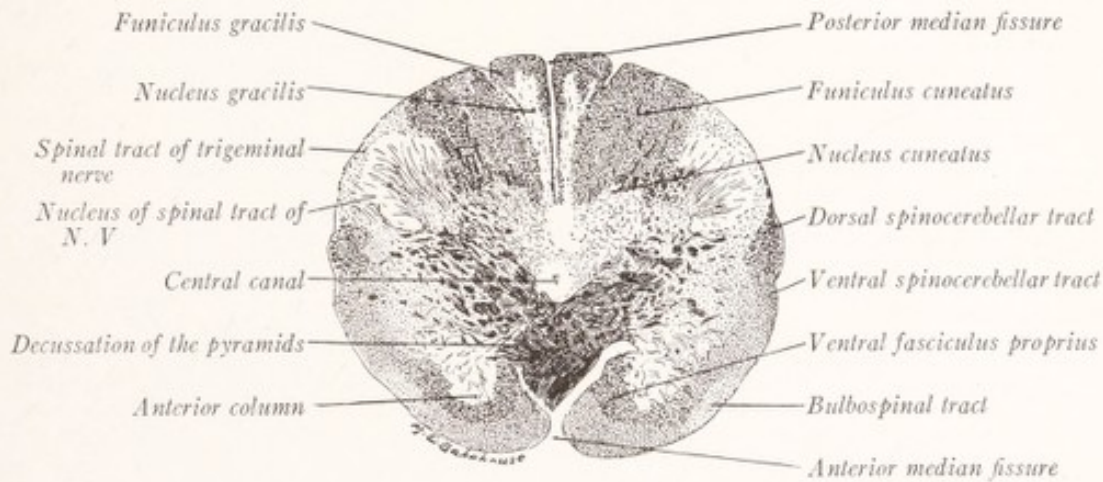


Fig. 98.—Section through the medulla oblongata of a child at the level of the decussation of the pyramids. Pal-Weigert method. ($\times 6$.)

of the gracile and cuneate fasciculi terminate in the corresponding nuclei; and their terminal arborizations are synaptically related to the neurons, whose cell bodies and dendrites are located there (Fig. 100). Accordingly, in sections through successive levels we see the fibers decreasing in number as the nuclei grow larger (Figs. 98, 99, 101). It is due to the presence of these nuclei that the funiculi become swollen to form the club-shaped prominences with which we are already familiar under the names *clava* and *cuneate tubercle*. At the level of the pyramidal decussation the gracile nucleus has the form of a rather thin and ill-defined plate, while the cuneate nucleus is represented by a slight projection from the dorsal surface of the posterior gray column (Fig. 98). At the level of the decussation of the lemniscus both have enlarged and the gracile nucleus has become sharply outlined (Fig. 99). As the central canal opens out into the

fourth ventricle the nuclei are displaced laterally and gradually come to an end as the restiform body becomes clearly defined (Fig. 101).

As one would expect from the fact that there is no sharp line of separation between the spinal cord and medulla oblongata, some of the fibers of the cuneate fasciculus end in the substantia gelatinosa (here known as the nucleus of the spinal tract of the trigeminal nerve) and in the remnant of the head of the posterior gray column (Fig. 100). There are three smaller gray masses within the funiculus cuneatus: (1) the external round nucleus, an isolated portion of the substantia gelatinosa, near which it is situated; (2) the internal round nucleus, more variable in position; and (3) the accessory or lateral cuneate nucleus superficial to the main nuclear mass.

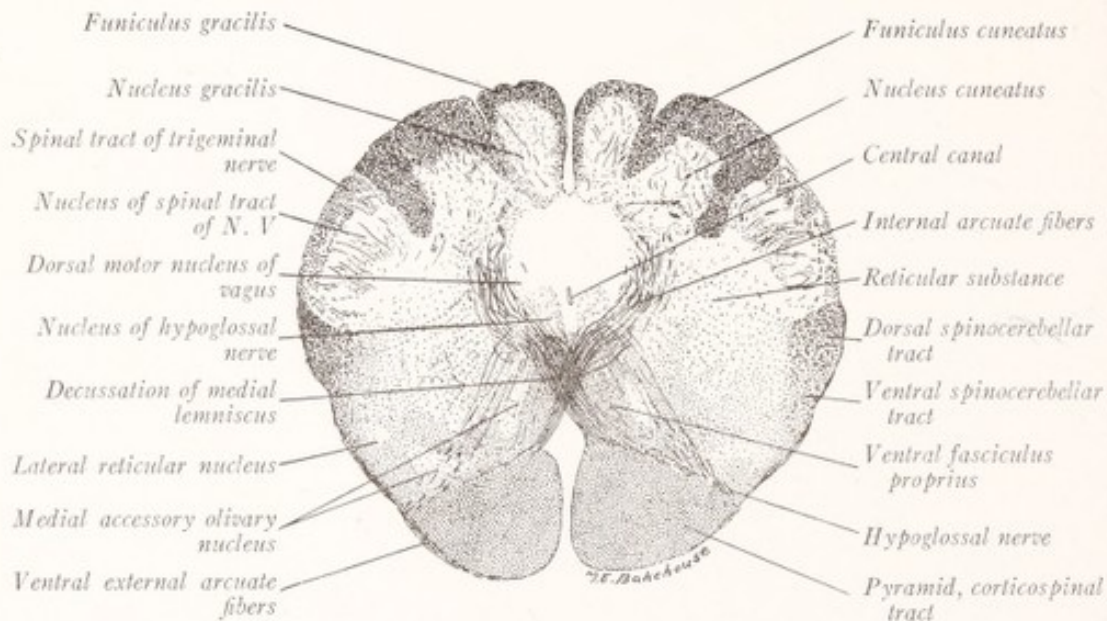


Fig. 99.—Section through the medulla oblongata of a child at the level of the decussation of the medial lemniscus. (Pal-Weigert method.) ($\times 6$.)

The Medial Lemniscus and its Decussation.—The great majority of fibers which arise from the cells in the nucleus gracilis and nucleus cuneatus sweep ventromedially in broad concentric curves around the central gray substance toward the median raphé (Fig. 99). As has been stated on a preceding page, these are known as *internal arcuate fibers*, and as they cross those from the opposite side in the raphé they form the *decussation of the lemniscus* (decussatio lemniscorum, sensory decussation). After crossing the median plane they turn rostrally in the medial lemniscus (fillet), and end in the thalamus (Fig. 235). These longitudinal fibers constitute a broad band which lies close to the median raphé, medial to the inferior olivary nucleus, and dorsal to the pyramids (Figs. 96, 97). By the accession of additional internal arcuate fibers this band increases in size and spreads out dorsally until at the level of the middle of the olive it is separated from the gray matter of the ventricular floor only by the

fibers of the fasciculus longitudinalis medialis and the tectospinal tract (Fig. 101). The decussation of the lemniscus begins at the upper border of the decussation of the pyramids, where the sensory fibers are grouped into coarse bundles arching around the central gray matter (Fig. 99), and extends as far as do the gracile and cuneate nuclei, that is, to about the middle of the olive. In sections through the lower half of the olive the internal arcuate fibers describe broad curves through the reticular formation and their decussation occupies a considerable ventrodorsal extent of the raphé (Fig. 101).

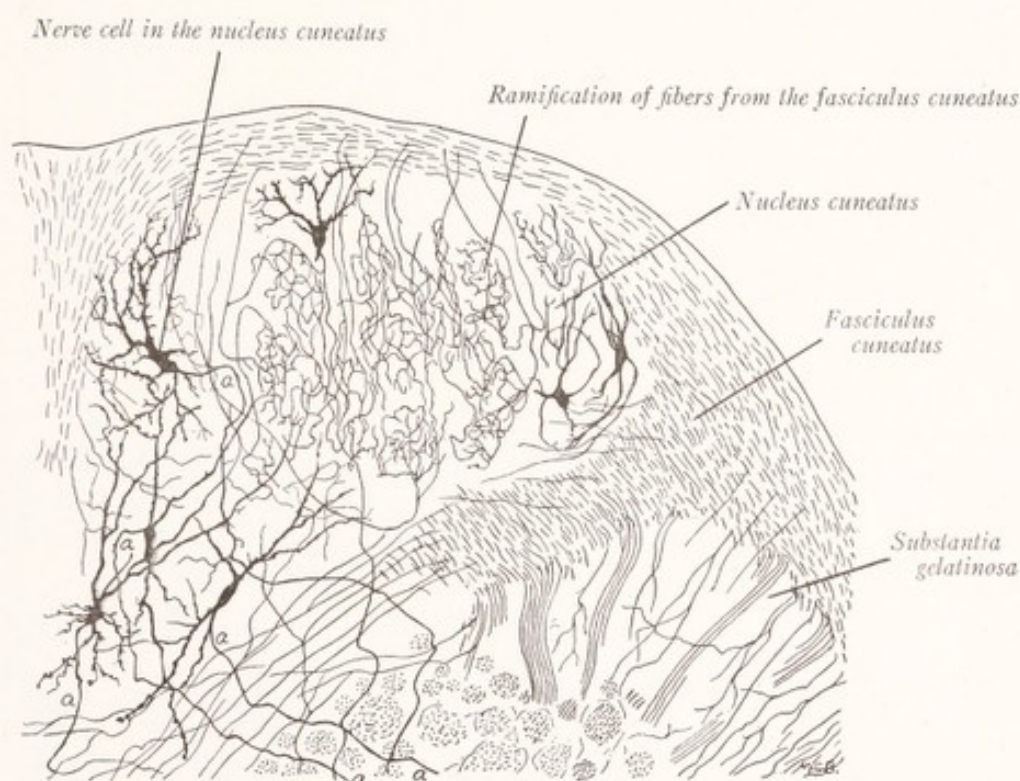


Fig. 100.—From a transverse section through the medulla oblongata of a kitten, to illustrate the termination of the fibers of the fasciculus cuneatus, and at *a* the beginning of the internal arcuate fibers. (Combined from drawings by Cajal.)

The **arcuate fibers** of the medulla oblongata may be separated into two groups: those which run through the reticular formation constitute the internal arcuate fibers; and those which run over the surface of the medulla, the external arcuate fibers. The *internal arcuate fibers* are of at least three kinds: (1) those described in the preceding paragraph, which arise in the gracile and cuneate nuclei and form the medial lemniscus; (2) sensory fibers of the second order, arising in the sensory nuclei of the cranial nerves; and (3) olivocerebellar fibers, which will be considered in another paragraph. Our knowledge of the *external arcuate fibers* is less satisfactory. From the nuclei of the posterior funic-

uli and perhaps also from these funiculi themselves a group of *dorsal external arcuate fibers* make their way to the restiform body along the dorsal surface of the medulla (Fig. 101). According to Cajal these fibers are well developed in man, but absent in the cat and rabbit. The *ventral external arcuate fibers* are said to include a certain number which arise in the lateral reticular and arcuate nuclei and run dorsolaterally over the surface of the medulla to reach the cerebellum by way of the restiform body (Fig. 104). The *arcuate nuclei* are small irregular patches of gray matter situated on the ventromedial aspect of the pyramid and continuous rostrally with the nuclei pontis, with which they

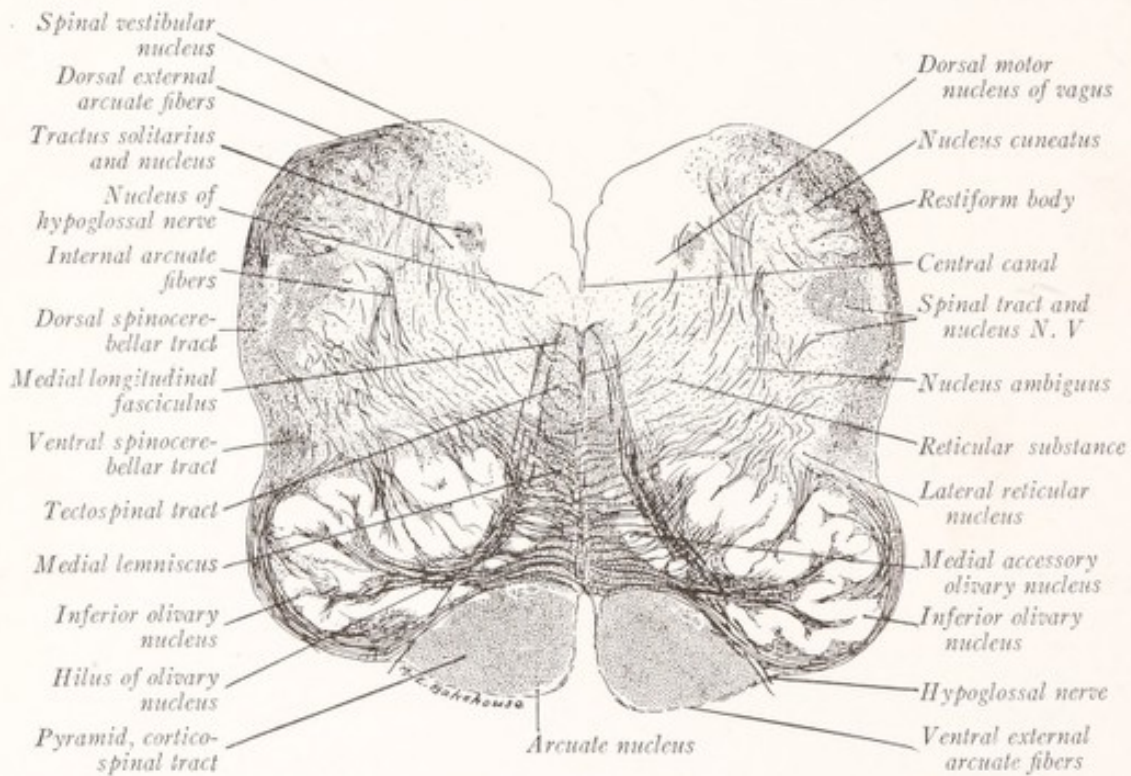


Fig. 101.—Section through the medulla oblongata of a child at the level of the olive. Pal-Weigert method. ($\times 6$.)

seem to be homologous (Figs. 101, 103). They probably receive fibers from the cerebral cortex by way of the pyramidal tracts; and, if so, the external arcuate fibers which arise from them are homologous with the transverse fibers of the pons.

Although the facts stated above are pretty well established, only a small part of the ventral external arcuate fibers are thus accounted for. The origin and course of the majority of these fibers is still obscure. According to Cajal (1909) they arise from the nuclei of the posterior funiculus, curve ventrally and medially over the surface of the medulla oblongata, penetrate the pyramids or the anterior median fissure, cross in the median raphé, and join the medial lemniscus of the opposite side. On the other hand, Edinger (1911) gives to

them the name "tractus cerebello-tegmentalis bulbi," and believes that they descend from the cerebellum by way of the restiform body, then arch ventrally over the surface of the medulla, penetrate the pyramid or the anterior median fissure, and end in the reticular formation of the opposite side (Fig. 153). According to Van Gehuchten (1904) some of the ventral external arcuate fibers arise from cells in the reticular formation of the same and the opposite side, and run through the restiform body to the cerebellum.

Olivary Nuclei.—The oval prominence in the lateral area of the medulla, known as the olive, is produced by the presence just beneath the surface of a large gray mass, the inferior olivary nucleus, with which there are associated

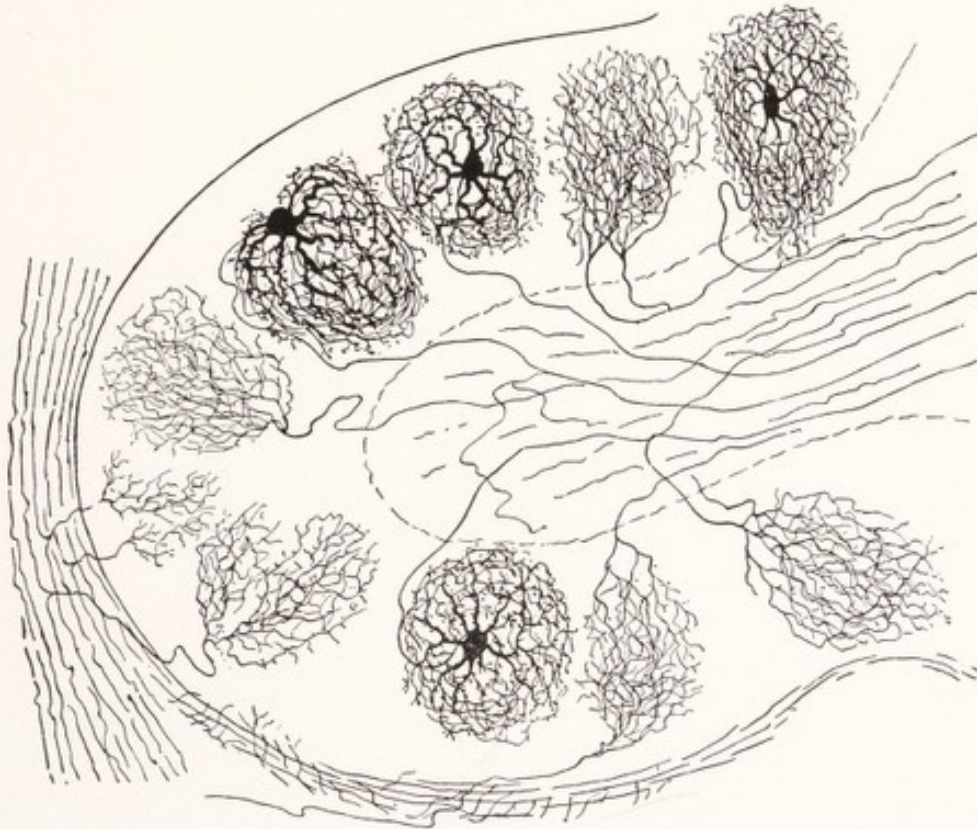


Fig. 102.—Diagram to illustrate the structure of the inferior olivary nucleus. (Cajal, Edinger.)

two accessory olivary nuclei. The *inferior olivary nucleus* is very conspicuous in the sections of this part of the medulla (Fig. 101). It appears as a broad, irregularly folded band of gray matter, curved in such a way as to enclose a white core, which extends into the nucleus from the medial side through an opening, known as the hilus. Considered as a whole this nucleus resembles a crumpled leather purse, with an opening, the hilus, directed medially. Sections at either end of the nucleus do not include this opening, and at these points the central core of white matter is completely surrounded by the gray lamina. The fibers which stream in and out of the hilus constitute the olivary

peduncle. The two accessory olives are plates of gray substance, which in transverse section appear as rods. The *medial accessory olivary nucleus* is placed between the hilus of the inferior olive and the medial lemniscus, while the *dorsal accessory olivary nucleus* is located close to the dorsal aspect of the chief nuclear mass.

Structure and Connections.—The gray lamina of the inferior olivary nucleus consists of neuroglia and many rounded nerve-cells beset with numerous short, frequently branching dendrites, the axons of which run through the white core of the nucleus and out at the hilus as *olivocerebellar fibers* (Fig. 102). About these cells there ramify the end branches of several varieties of afferent fibers, the origin of which is not well understood. Some come from a tract, designated

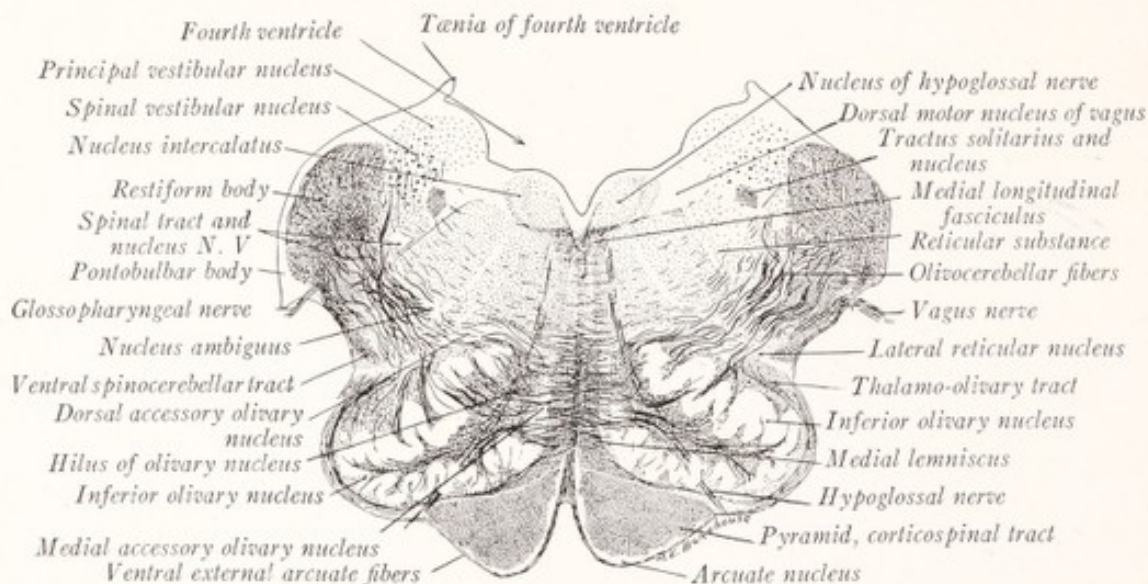


Fig. 103.—Section through the medulla oblongata of a child at the level of the restiform body. Pal-Weigert method. ($\times 4$.)

as the thalamo-olivary fasciculus; but it is not certain that they have their origin in the thalamus; quite possibly they come from some other gray mass in that neighborhood. Another group of fibers, consisting chiefly of collaterals, comes from the ventral funiculus of the spinal cord and may be regarded as ascending sensory fibers (Cajal, 1909). These belong to the so-called spino-olivary fasciculus.

Olivocerebellar Fibers.—The axons from the cells of the inferior olivary nucleus stream out of the hilus, cross the median plane, and either pass through or around the opposite nucleus. Here they are joined by some uncrossed fibers from the olivary nucleus of the same side. Thence they curve dorsally toward the restiform body, passing through the spinal tract of the trigeminal nerve

which becomes split up into several bundles (Fig. 103). They form an important group of internal arcuate fibers, which run through the restiform body to the cerebellum and constitute the olivocerebellar tract (Fig. 104).

The **restiform body** or inferior cerebellar peduncle is a large and prominent strand of fibers which gradually accumulate along the lateral border of the caudal part of the fourth ventricle. It forms the floor of the lateral recess of that cavity and then turns dorsally into the cerebellum (Figs. 88, 89, 103). It is composed for the most part of two large and important fascicles: (1) the

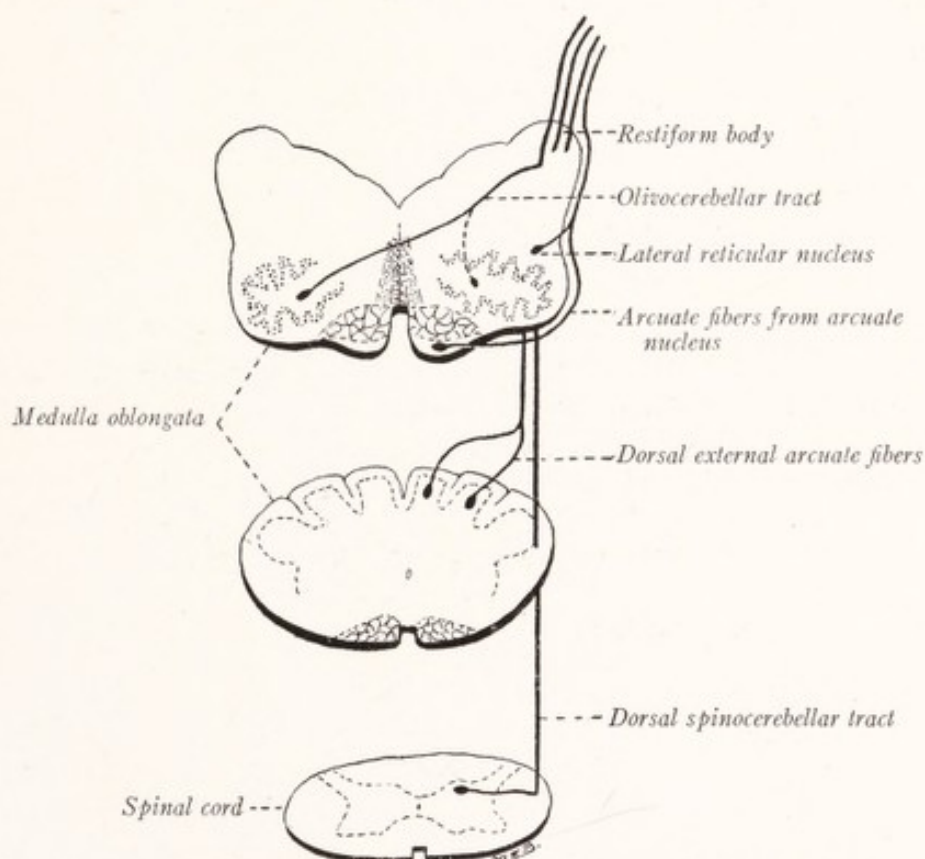


Fig. 104.—Diagram showing the fiber tracts which enter the restiform body from the medulla oblongata.

olivocerebellar fibers, both direct and crossed, but chiefly from the inferior olivary nucleus of the opposite side; and (2) the *dorsal spinocerebellar tract*, from the nucleus dorsalis of the same side of the spinal cord (Fig. 104). In addition, there are fibers in smaller number from other sources: (3) the *dorsal external arcuate fibers* from the gracile and cuneate nuclei of the same side; and *fibers* (4) *from the arcuate nucleus*, (5) *from the lateral reticular nucleus*, and possibly also from other cells scattered through the reticular formation (Van Gehuchten, 1904).

The **dorsal spinocerebellar tract** can readily be traced in serial sections of the medulla because the large, heavily myelinated fibers of which it is composed cause it to be deeply stained by the Weigert technic. It can be followed from the spinal cord along the periphery of the medulla oblongata near the posterior lateral sulcus. At first it lies ventral to the spinal tract of the trigeminal nerve (Figs. 98, 99). But at the level of the lower part of the olive it inclines dorsally, passing over the surface of the spinal tract of this nerve to reach the restiform body (Fig. 101). Between this tract and the olive we find the *ventral spinocerebellar tract* also in a superficial position.

The **spinal tract of the trigeminal nerve** is formed by the descending branches of the sensory fibers of that nerve. They give off collateral and terminal branches to a column of gray matter, resembling the substantia gelatinosa

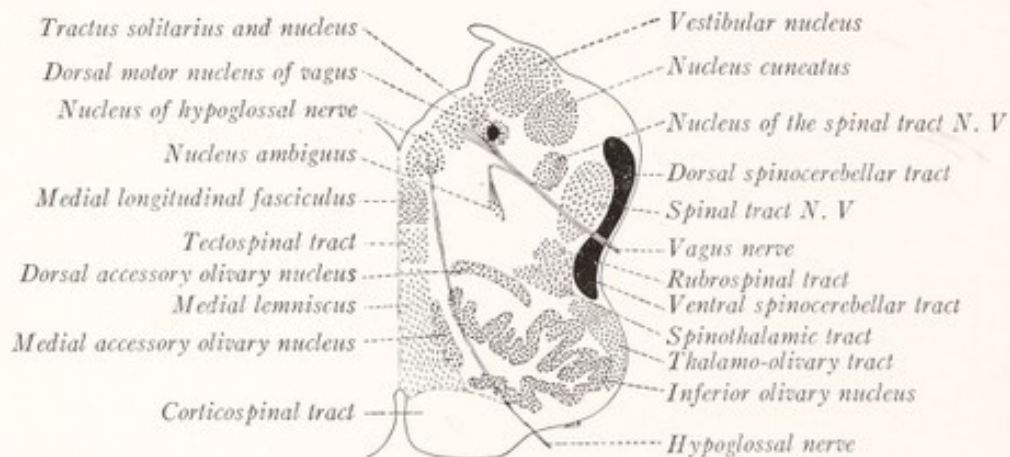


Fig. 105.—Diagram showing the location of the nuclei and fiber tracts of the medulla oblongata at the level of the olive.

Rolandi, with which it is directly continuous, and designated as the *nucleus of the spinal tract of the trigeminal nerve* (Figs. 92, 98, 99, 101, 103). The tract lies along the lateral side of the nucleus and is superficial except in so far as it is covered by the external arcuate fibers, the dorsal spinocerebellar tract, and the restiform body. It forms an elongated elevation, the tuberculum cinereum on the surface of the medulla oblongata (Fig. 88).

The **formatio reticularis** fills the interspaces among the larger fiber tracts and nuclei. It is composed of small islands of gray matter, separated by fine bundles of nerve-fibers which run in every direction, but which are for the most part either longitudinal or transverse. It is subdivided into two parts. The *formatio reticularis alba* is located dorsal to the pyramid and medial to the root filaments of the hypoglossal nerve and is composed in large part of longi-

tudinal nerve-fibers belonging to the *medial lemniscus*, *tectospinal tract*, and the *medial longitudinal fasciculus* (Fig. 105). The latter is closely associated with the vestibular nerve and can best be described with the central connections of that nerve. The *formatio reticularis grisea* is found dorsal to the olive and lateral to the hypoglossal nerve. In it the nerve-cells predominate and the transversely coursing internal arcuate fibers form a conspicuous feature. Its longitudinal fibers, though less prominent, are of great importance. The *descending fibers* include those of the *rubrospinal tract*, which can be followed into the lateral funiculus of the spinal cord, and the *thalamo-olivary fasciculus*, which ends in the olive. Among the *ascending fibers* are those of the *ventral and dorsal spinocerebellar*, the *spinothalamic*, and *spinotectal tracts*.

The *nerve-cells of the reticular formation* are scattered through the mesh of interlacing fibers. In certain localities they are more closely grouped and form fairly well-defined nuclei. Among these we may select two for special attention. The *lateral reticular nucleus* or nucleus of the lateral funiculus is a long column of cells found along the deep surface of the ventral spinocerebellar tract, from which it is said by André Thomas to receive afferent fibers. At any rate, it receives fibers from the lateral funiculus of the spinal cord (Cajal, 1909) and sends its axons to the cerebellum by way of the restiform body (Van Gehuchten, 1904; Yagita, 1906). It seems, therefore, to be a way station on a sensory path from the spinal cord to the cerebellum. Some large cells in the gray part of the reticular formation may be grouped together and called the *motor nucleus of the tegmentum* (nucleus magnocellularis of Cajal). Their axons become ascending or descending fibers or may bifurcate into ascending and descending branches within the reticular formation. Kohnstamm has traced such fibers by means of the degeneration method, and has shown that they run for the most part in a caudal direction and that some of them reach the cervical portion of the spinal cord (tractus reticulospinalis—Fig. 115).

The **nuclei of the cranial nerves** can best be considered in a separate chapter. At this point it will only be necessary to enumerate and locate the nuclei of those nerves which take origin from the medulla oblongata.

The **nucleus of the hypoglossal nerve** contains the cells of origin of the motor fibers which compose that nerve. It forms a long column of nerve-cells on either side of the median plane in the ventral part of the gray matter surrounding the central canal and in the floor of the fourth ventricle (Figs. 99, 101, 103). In the latter region it lies immediately beneath that part of the floor which was described in the preceding chapter under the name of the trigonum

hypoglossi (Fig. 89). In reality, it corresponds only to the medial part of this eminence, for on its lateral side there is found another group of cells known as the nucleus intercalatus (Fig. 103). From their cells of origin the fibers of the hypoglossal nerve stream forward through the reticular formation to emerge at the lateral border of the pyramid.

The **nucleus ambiguus** is a long column of nerve-cells which give origin to the motor fibers that run through the *glossopharyngeal*, *vagus*, and *accessory nerves* to supply the striated musculature of the pharynx and larynx. It is located in the reticular formation of both the open and the closed portions of the medulla, ventromedial to the nucleus of the spinal tract of the trigeminal nerve (Figs. 101, 103).

The **dorsal motor nucleus of the vagus** lies along the lateral side of the nucleus of the hypoglossal. It occupies the ala cinerea of the rhomboid fossa and extends into the closed part of the medulla oblongata along the lateral side of the central canal (Figs. 89, 99, 101, 103). From the cells of this nucleus arise the efferent fibers of the vagus nerve which innervate smooth muscle and glandular tissue. The *afferent fibers of the vagus and glossopharyngeal nerves* bend caudally and run within the *tractus solitarius*.

The **nucleus of the tractus solitarius** is the nucleus of reception of the afferent fibers of the facial, glossopharyngeal, and vagus nerves, *i. e.*, it contains the cells about which these afferent fibers terminate. The tractus solitarius can be traced throughout almost the entire length of the medulla. It decreases in size as the descending fibers terminate in the gray matter which surrounds it (Figs. 92, 101, 103).

CHAPTER X

INTERNAL STRUCTURE OF THE PONS

THE pons consists of two portions which differ greatly in structure and significance. The *dorsal* or *tegmental part* resembles the medulla oblongata, of which it is the direct continuation. The *ventral* or *basilar portion* contains the longitudinal fibers which go to form the pyramids; but except for these it is composed of structures which are peculiar to this level. It is a recent phyletic development and forms a prominent feature of the brain only in those mammals which have relatively large cerebral and cerebellar hemispheres, as might be expected from the fact that it forms part of a conduction path uniting these structures.

THE BASILAR PART OF THE PONS

The basilar portion of the pons is the larger of the two divisions. It is made up of fascicles of longitudinal and transverse fibers and of irregular masses of gray substance, which occupy the spaces left among the bundles of nerve-fibers and which are known as the nuclei pontis.

The **longitudinal fasciculi** of the pons consist of two kinds of fibers: (1) those of the *corticospinal tract*, which are continued through the pons into the pyramids of the medulla oblongata; and (2) those which end in the nuclei of the pons and are known as *corticopontine fibers* (Fig. 106). As they pass through the pons the corticospinal fibers give off collaterals which also end in these nuclei. The longitudinal fibers enter the pons at its rostral border from the basis pedunculi. At first they form on either side a single compact bundle; but this soon becomes broken up into many smaller fascicles, which are separated from each other by the transverse fibers and nuclei of the pons (Fig. 108). At the caudal border these bundles again become assembled into a compact strand, which is continued as the pyramid of the medulla oblongata (Fig. 107). It is evident, however, that the volume of the bundles is much greater at the rostral than at the caudal border. This is to be explained by the fact that the corticopontine fibers have left these bundles during their passage through the pons and have come to an end by arborization within the nuclei pontis.

The **transverse fibers** are designated as *fibræ pontis* and are divisible into a superficial and a deep group (*fibræ pontis superficiales* and *fibræ pontis pro-*

fundæ). Those of the superficial group lie ventral to the longitudinal fasciculi; while the deep transverse bundles interlace with the longitudinal ones or lie dorsal to them. The majority of the fibræ pontis cross the median plane. These are joined by some uncrossed fibers and gathered together on either side of the pons to form a compact and massive strand, known as the *brachium pontis* or middle cerebellar peduncle, which curves dorsally to enter the white center of the cerebellum (Figs. 88, 108).

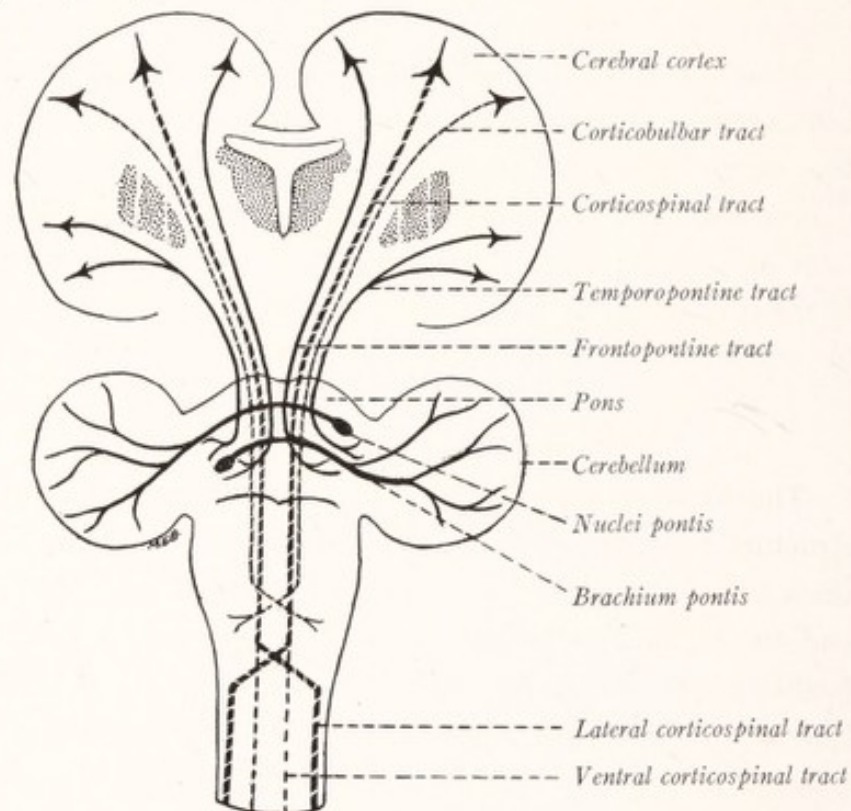


Fig. 106.—Diagram of the cortico-ponto-cerebellar pathway and the corticospinal and corticobulbar tracts.

Along the rostral border of the pons and brachium pontis one or two fiber bundles are sometimes found which run an isolated course to the cerebellum. These are known as the *fila lateralia pontis* or *tania pontis* (Fig. 88). According to Horsley (1906) the constituent fibers arise from a ganglion situated caudal to the interpeduncular ganglion, decussate at once, and end in the cerebellum in the neighborhood of the dentate nucleus. Perhaps they represent slightly displaced fibræ pontis. Some of the transverse fibers on reaching the median plane bend at right angles and run as fibræ rectæ toward the pars dorsalis pontis (Fig. 108). According to Edinger (1911) these belong in part at least to the tractus cerebellotegmentalis pontis, which arises in the nuclei of the cerebellum and runs through the brachium pontis to end in the reticular formation of the opposite side (Fig. 153). Cajal (1909) is doubtful about the existence of such efferent fibers from the cerebellum in the brachium pontis.

The **nuclei pontis**, which are continuous with the arcuate nuclei of the medulla oblongata, contain stellate nerve-cells of varying size, the axons of

which are continuous with the fibræ pontis. There are also some small nerve-cells of Golgi's Type II, the short axons of which end in the adjacent gray matter. Within these nuclei terminate the fibers of the corticopontine tracts and some collaterals from the corticospinal fibers. Collaterals from the medial lemniscus are also found arborizing in those nuclei of the pons which lie immediately ventral to that bundle. This gray matter, therefore, represents an important association apparatus within which there terminate fibers from several different sources.

From what has been said it will be apparent that the pons serves to establish an important and for the most part crossed connection between the cerebral hemispheres and the cerebellum, a *cortico-ponto-cerebellar path*. The corticopontine fibers take origin from pyramidal cells in the frontal and temporal lobes and end in the nuclei pontis. Arising from the cells in these nuclei, most of the transverse fibers cross the median plane and reach the opposite cerebellar hemisphere through the brachium pontis (Fig. 106).

THE DORSAL OR TEGMENTAL PART OF THE PONS

The dorsal or tegmental part of the pons (*pars dorsalis pontis*) resembles in structure the medulla oblongata (Fig. 108). On its dorsal surface there is a thick layer of gray matter which lines the rhomboid fossa. Between this layer and the basilar portion of the pons is the *reticular formation* divided by the median raphé into two symmetric halves. This has essentially the same structure here as in the medulla oblongata, and contains the continuation of many longitudinal tracts with which we are already familiar. The *restiform body* at first occupies a position similar to that which it has in the medulla, along the lateral border of the rhomboid fossa; but it soon bends dorsally into the cerebellum.

The Cochlear Nuclei.—At the point of transition between the medulla and pons the restiform body is partly encircled on its lateral aspect by a mass of gray matter formed by the *terminal nuclei of the cochlear division of the acoustic nerve* (Fig. 107). There may be distinguished a *dorsal* and a *ventral cochlear nucleus* at the dorsal and ventral borders of the restiform body. Within these nuclei the fibers of the cochlear nerve end; while those of the vestibular nerve plunge into the substance of the pons ventromedially to the restiform body to reach the floor of the fourth ventricle (Fig. 134). Fibers from the dorsal cochlear nucleus run medially upon the floor of the fourth ventricle in the *striæ medullares* (Fig. 89), and sinking into the tegmentum join the fibers from the ventral cochlear nucleus in the trapezoid body.

The **trapezoid body** (*corpus trapezoideum*), which in most mammals appears on the surface of the medulla near the border of the pons (Fig. 83), is covered in man by the enlarged *pars basalis pontis*. In sections through the more caudal portions of the pons the trapezoid body forms a conspicuous bundle of transverse fibers in the ventral portion of the reticular formation (Fig. 108). The fibers are associated with the terminal nuclei of the cochlear nerve, especially the ventral one, and with the superior olivary nucleus, around the ventral border of which they swing in such a way as to form a bay for its reception. Farther medialward they pass through the medial lemniscus at right angles to its con-

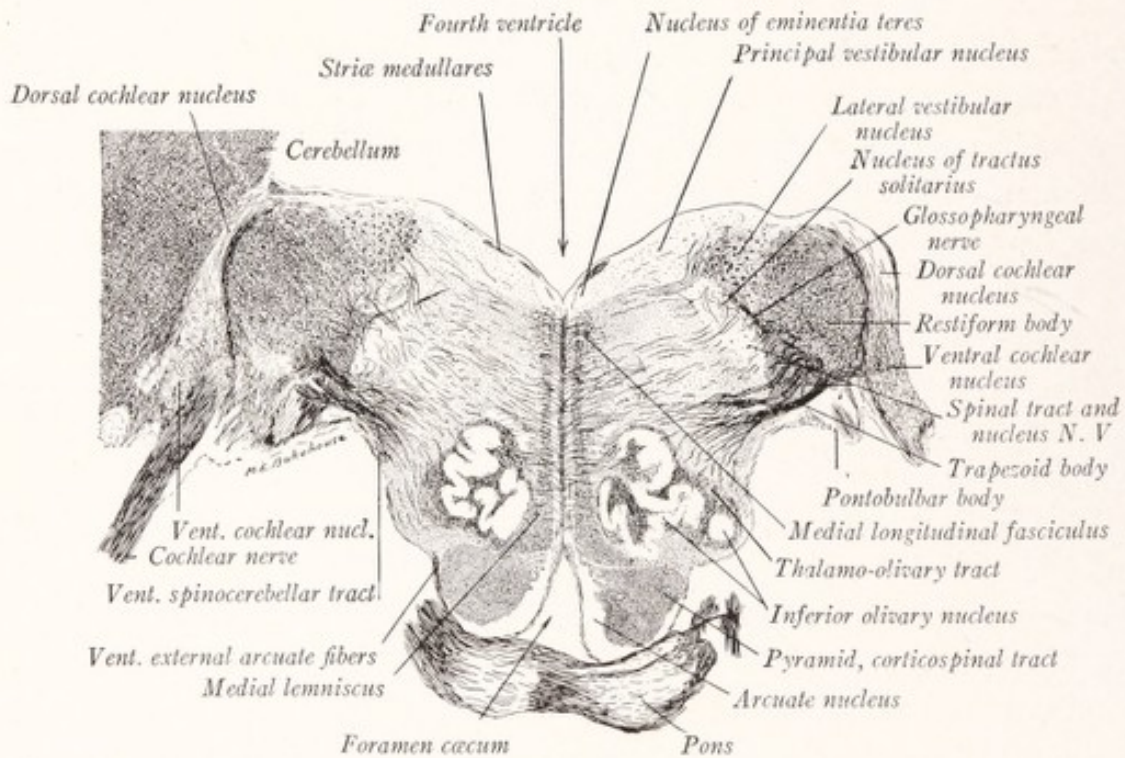


Fig. 107.—Section through caudal border of the pons and the cochlear nuclei of a child. Pal-Weigert method. ($\times 4$.)

stituent fibers and decussate in the median raphé. The trapezoid body describes a curve with convexity directed rostrally as well as ventrally, and as a result its lateral portions are seen best in sections through the lower border of the pons (Fig. 107), while the rest of it is in evidence in sections at a higher level (Fig. 108). Arising from the ventral nucleus of the cochlear nerve (Fig. 107) these fibers pass, with or without interruption in the superior olivary nucleus, across the median plane (Fig. 108); and, on reaching the lateral border of the opposite superior olivary nucleus, they turn rostrally to form a longitudinal band of fibers known as the lateral lemniscus (Fig. 110). This is a

part of the central auditory pathway, the connections of which are represented diagrammatically in Fig. 134.

The **superior olivary nucleus** is a small mass of gray matter located in the ventrolateral portion of the reticular formation of the pons in close relation to the trapezoid body and not far from the rostral pole of the inferior olivary nucleus (Figs. 108, 110). It consists of two or three separate but closely associated nuclear masses composed of small fusiform nerve-cells, among which there ramify collaterals from the fibers of the trapezoid body. From the dorsal aspect

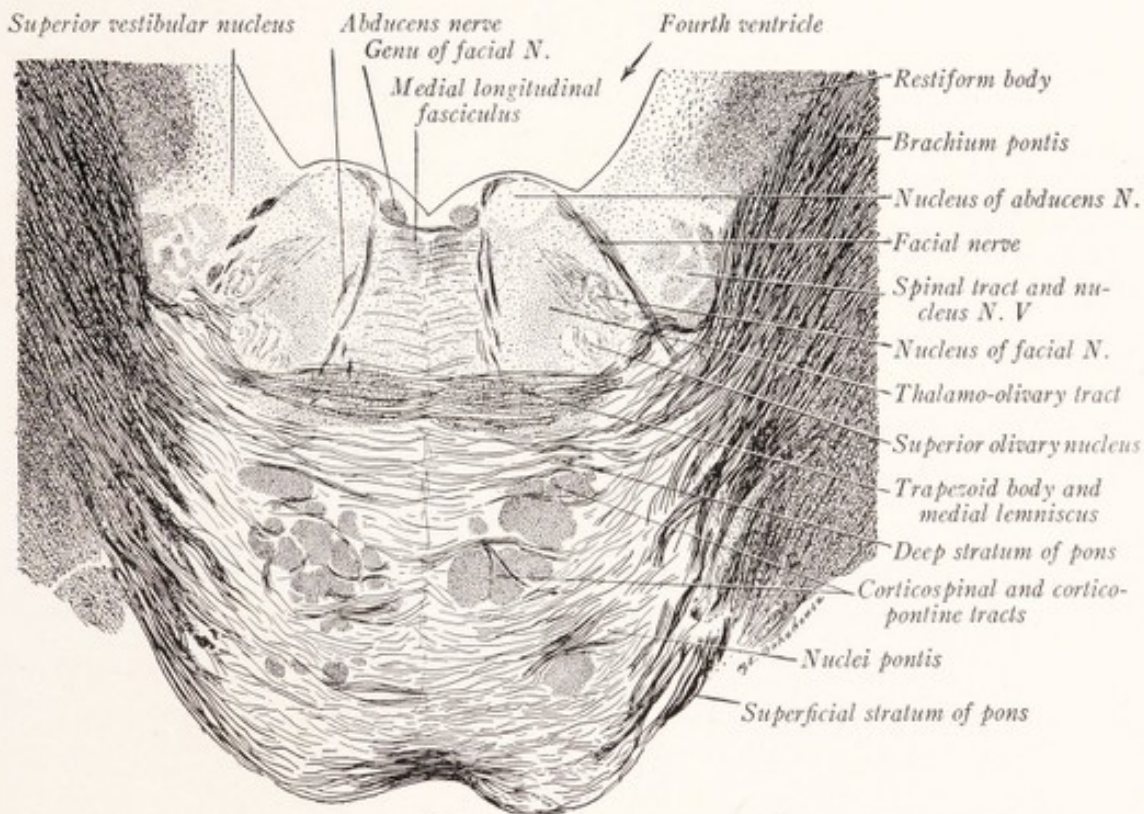


Fig. 108.—Section through the pons of a child at the level of the facial colliculus. Pal-Weigert method. ($\times 4$.)

of this nucleus a bundle of fibers, known as the peduncle of the superior olive, makes its way toward the nucleus of the abducens nerve, and it may be that some of these fibers enter the medial longitudinal bundle (Fig. 124).

The **nuclei of the vestibular nerve** lie in the floor of the fourth ventricle, where they occupy a field with which we are already familiar, namely, the *area acustica* (Fig. 89). The vestibular fibers on approaching the rhomboid fossa divide into ascending and descending branches, and terminate in four nuclear masses: (1) the *medial* (dorsal or principal) *vestibular nucleus* (Figs. 103, 107), (2) the *lateral vestibular nucleus* of Deiters (Fig. 107), (3) the *superior vestibular*

nucleus of Bechterew (Fig. 108), (4) the *spinal* or descending *vestibular nucleus* (Fig. 103). These are represented diagrammatically in Fig. 136.

The **medial longitudinal fasciculus** is an important bundle which extends from near the floor of the third ventricle to the spinal cord, and is especially concerned with the reflex control of the movements of the head and eyes. A large proportion of its fibers are derived from the lateral vestibular nucleus.

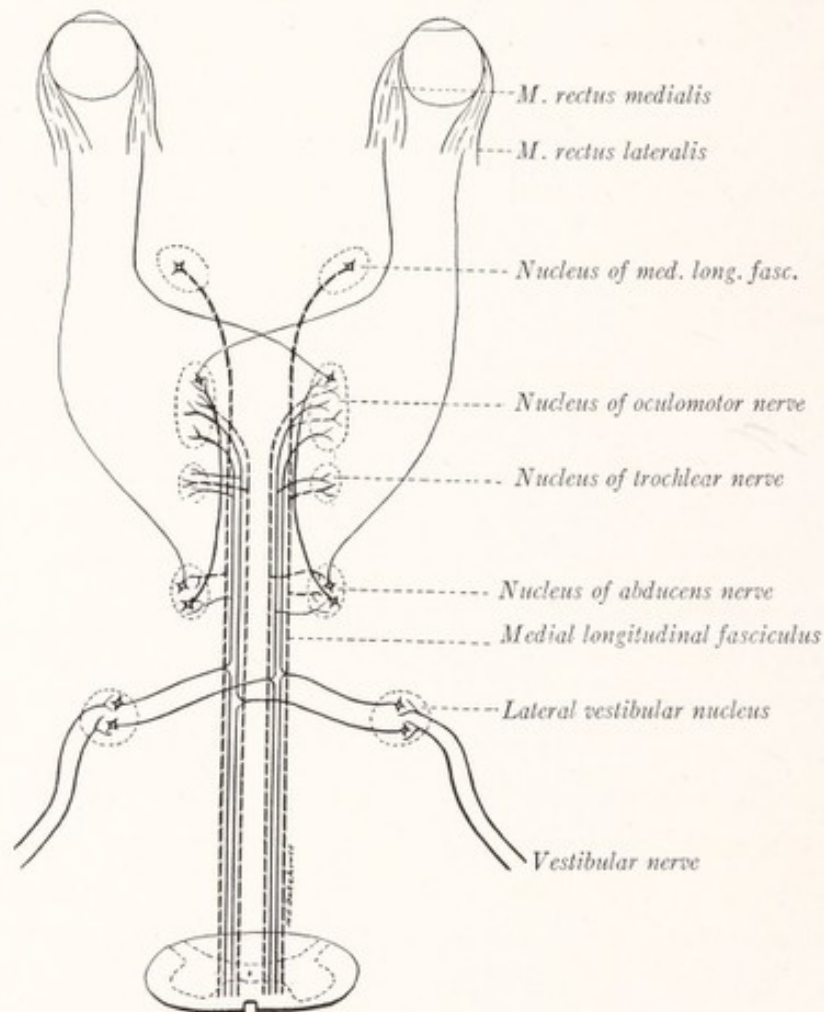


Fig. 109.—Diagram showing the connections of the medial longitudinal fasciculus. (Modified from Villiger.)

From this origin the fibers pass horizontally through the reticular formation to the median longitudinal fasciculus of the same or the opposite side, and there divide into ascending and descending branches (Fig. 109). The former terminate in the nuclei of the oculomotor, trochlear, and abducens nerve, the latter in the nucleus of the spinal accessory nerve and in the column anterior of the cervical portion of the spinal cord. In this way there is established a path for

the reflex control of the movement of the head, neck, and eyes in response to stimulation of the nerve endings in the semicircular canals of the ears. Another important group of fibers within this fasciculus takes origin from a collection of cells situated in the hypothalamus just rostral to the red nucleus, which Cajal (1911) has called the *interstitial nucleus*,¹ but which might properly be designated as the *nucleus of the medial longitudinal fasciculus*. According to Cajal the fascicle also contains ascending fibers from the ventral fasciculus proprius of the spinal cord. Still other fibers serve to connect the nuclei of the oculomotor and abducens nerves.

The *medial longitudinal fasciculus* is continued into the *ventral fasciculus proprius* of the spinal cord. These fibers are displaced dorsolaterally by the decussation of the pyramids (Fig. 98) and then still farther dorsally by the decussation of the lemniscus (Fig. 99) until they come to lie in the most dorsal part of the substantia reticularis alba (Fig. 101), which position they occupy throughout the remainder of their course. The fasciculus is found ventral to the nucleus of the hypoglossal nerve (Fig. 103) and in close apposition to the nuclei of the three motor nerves of the eye (Figs. 108, 114, 116).

The **medial lemniscus** can also be traced within the reticular formation from the medulla into and through the pons. But this broad band of longitudinal fibers, which was spread out along the median raphé in the medulla, shifts ventrally in the pons, assuming first a somewhat triangular outline and a ventromedian position (Fig. 107); then by shifting farther lateralward it takes again the form of a flat band (Figs. 108, 110). But now it is compressed ventrodorsally and occupies the ventral part of the reticular formation, its fibers crossing those of the trapezoid body at right angles. It must not be forgotten that the medial lemniscus is composed of longitudinal fibers, and it is by the gradual shifting of these that the bundle as a whole changes shape and position. As it is displaced ventrally it separates from the medial longitudinal bundle, which retains its dorsal position.

The **motor nucleus of the facial nerve** occupies a position in the reticular formation dorsal to the superior olive (Fig. 108). It is an oval mass of gray matter, which extends from the lower border of the pons to the level of the facial colliculus, and contains the cells of origin of the fibers which innervate

¹ The interstitial nucleus of Cajal must not be confused with the nucleus of the posterior commissure of Darkschewitsch which lies in the mesencephalon just rostral to the oculomotor nucleus and which, according to Cajal, may or may not send fibers into the medial longitudinal bundle.

the platysma and muscles of the face. These fibers emerge from the dorsal surface of the nucleus and run dorsomedially toward the floor of the fourth ventricle. Somewhat widely separated at first, they become united on the medial side of the abducens nerve into a compact strand, which as the *genu of the facial nerve* partly encircles this nucleus, and which then runs ventrolaterally between the spinal tract of the trigeminal nerve and its own nucleus toward its exit from the brain (Figs. 108, 124).

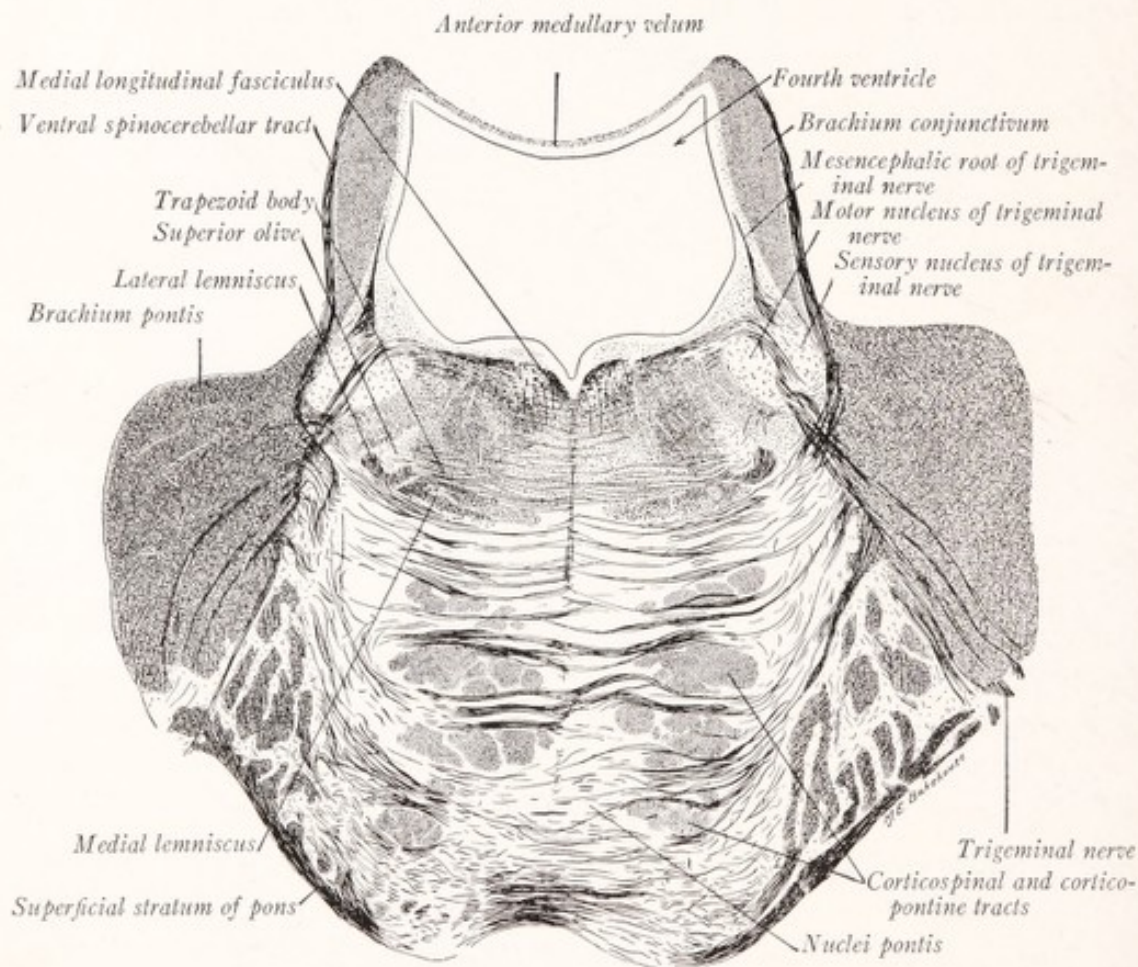


Fig. 110.—Section through the pons of a child at the level of the motor nucleus of the trigeminal nerve. Pal-Weigert method. ($\times 4$.)

The nucleus of the abducens nerve along with the genu of the facial produces a rounded elevation in the rhomboid fossa, known as the *facial colliculus* (Figs. 89, 108). It is a spheric mass of gray matter containing the cells of origin of the fibers which innervate the lateral rectus. These emerge from the dorsal and medial surfaces of the nucleus and run ventrally more or less parallel to the median raphé toward their exit at the lower border of the pons.

The Nuclei of the Trigeminal Nerve.—In transverse section through approxi-

mately the middle of the pons we encounter the fibers of the trigeminal nerve and two associated masses of gray matter, the *motor* and *main sensory nuclei* of that nerve (Fig. 110). These are located close together in the dorsolateral part of the reticular formation near the groove between the middle and superior cerebellar peduncles. Of the two, the *sensory nucleus* is the more superficial. It is, in reality, not a new structure, but rather the enlarged rostral extremity of the column of gray matter which we have followed upward from the substantia gelatinosa Rolandi of the spinal cord and have designated as the *nucleus of the spinal tract* of the trigeminal nerve (Figs. 98, 101). On its medial side is found the *motor nucleus*, a large oval mass of gray matter from the cells of which arise the motor fibers for the muscles of mastication. Some of the fibers of the trigeminal nerve, passing between these two nuclei, are continued as the *mesencephalic root of the trigeminal nerve* (Figs. 110, 111). Reaching the gray matter in the lateral wall of the rostral part of the fourth ventricle, this bundle of fibers turns rostrally along the medial side of the brachium conjunctivum (Fig. 112). It extends into the mesencephalon in the lateral part of the gray matter which surrounds the cerebral aqueduct (Fig. 114). The fibers of this root take origin from unipolar cells scattered along its course and known as the *mesencephalic nucleus* of the trigeminal nerve.

It will be apparent from this description that there are four nuclear masses associated with the trigeminal nerve, namely, the nucleus of the spinal tract, and the main sensory, motor, and mesencephalic nuclei. The relations which each of these groups of cells bear to the fibers of the trigeminal nerve are illustrated in Fig. 111. Note that those fibers which arise from cells in the semilunar ganglion divide into short ascending and long descending branches. The former end in the main sensory nucleus; while the latter run in the spinal tract of the trigeminal nerve and end in the nucleus which accompanies it.

The **brachium conjunctivum** or superior cerebellar peduncle (Fig. 89) is seen in sections through the rostral half of the pons, where it enters into the lateral boundary of the fourth ventricle. It is a large strand of fibers which runs from the dentate nucleus of the cerebellum to the red nucleus of the mesencephalon (Fig. 115). As it emerges from the white center of the cerebellum this brachium is superficially placed, with its ventral border resting on the tegmental portion of the pons (Fig. 110). To its dorsal border is attached a thin plate of white matter, the *anterior medullary velum*, which roofs in the rostral part of the fourth ventricle. As the brachium ascends toward the mesencephalon it sinks deeper and deeper into the dorsal part of the pons until it is entirely submerged

(Fig. 112). Near the rostral border of the pons it assumes a crescentic outline and lies in the lateral part of the reticular formation. From its ventral border

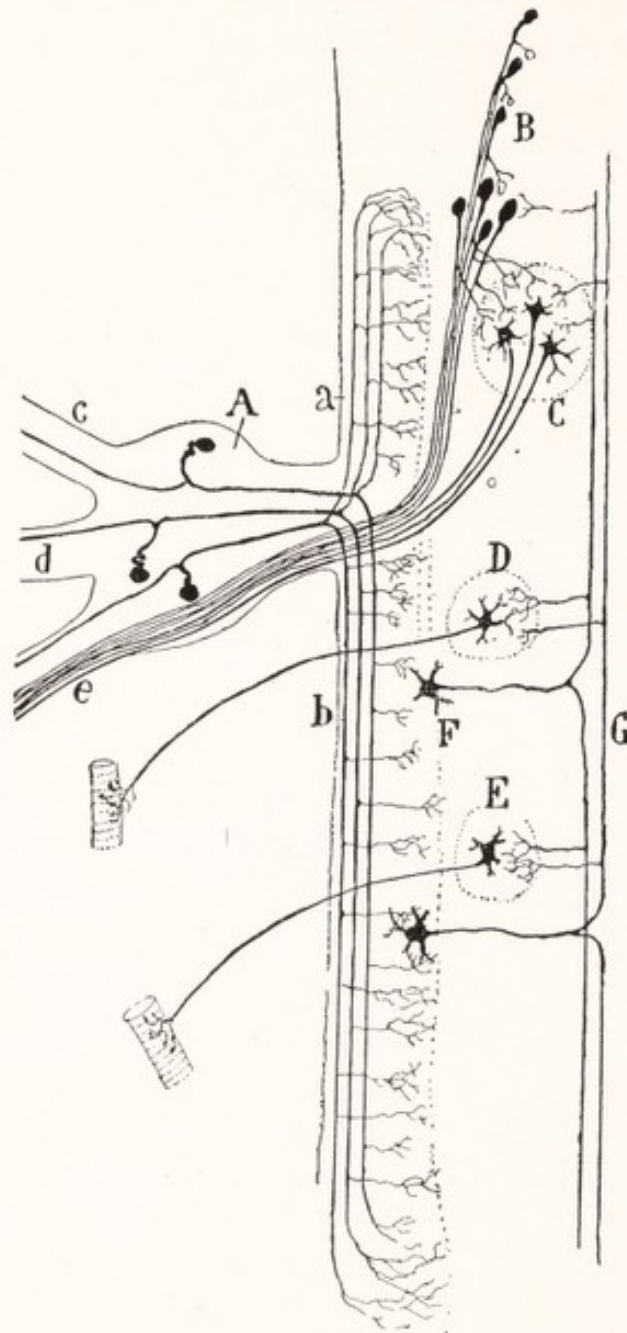


Fig. 111.—Diagram of the nuclei and central connections of the trigeminal nerve: *A*, Semilunar ganglion; *B*, mesencephalic nucleus, N. V.; *C*, motor nucleus, N. V.; *D*, motor nucleus, N. VII; *E*, motor nucleus, N. XII; *F*, nucleus of the spinal tract of N. V.; *G*, sensory fibers of the second order of the trigeminal path; *a*, ascending and *b*, descending branches of the sensory fibers, N. V.; *c*, ophthalmic nerve; *d*, maxillary nerve; *e*, mandibular nerve. (Cajal.)

fibers stream across the median plane, decussating with similar fibers from the opposite side. This is the most caudal portion of the *decussation of the brachium*

conjunctivum, which increases in volume as it is followed rostrally, reaching its maximum in the mesencephalon at the level of the inferior colliculi. In this decussation the fibers of the brachium undergo a complete crossing.

The **ventral spinocerebellar tract**, which has made its way through the reticular formation of the pons, turns dorsolaterally near the rostral end of the pons, winds around the brachium conjunctivum, and enters the anterior medullary velum, in which it descends to the vermis of the cerebellum (Figs. 110, 149).

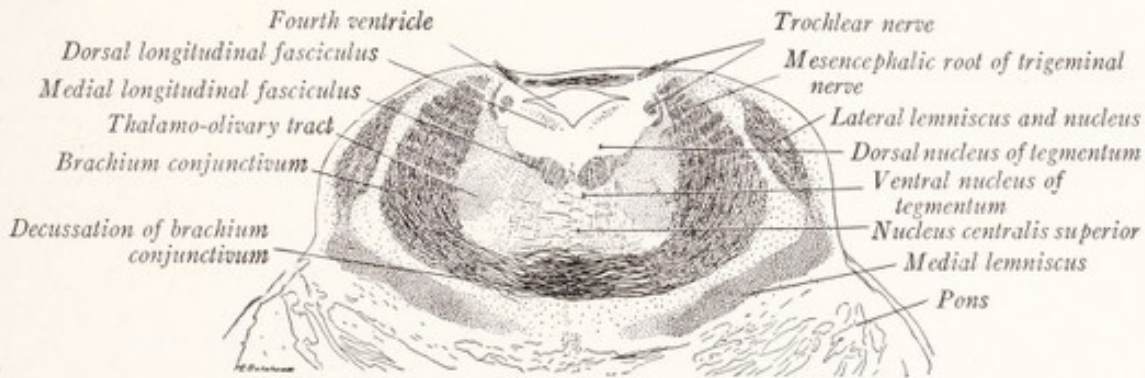


Fig. 112.—Dorsal half of a section through the rostral part of the human pons. The index line to the mesencephalic root of the trigeminal nerve does not quite reach that structure. Pal-Weigert method.

The **lateral lemniscus** is an important tract of fibers which we have already traced from the cochlear nuclei by way of the trapezoid body and striæ medullares acusticæ. It first takes definite shape about the middle of the pons, where it is situated lateral to the medial lemniscus (Fig. 110). As it ascends it becomes displaced dorsolaterally until it occupies a position on the lateral aspect of the brachium conjunctivum (Fig. 112). In this position there is developed in connection with it a collection of nerve-cells, the *nucleus of the lateral lemniscus*, to which its fibers give off collaterals.

CHAPTER XI

THE INTERNAL STRUCTURE OF THE MESENCEPHALON

A DIAGRAM of a transverse section through the rostral part of the mesencephalon will make clear the relation of the various parts of the midbrain to each other (Fig. 113). The *cerebral aqueduct* is surrounded by a thick lamina of gray matter, the *central gray stratum* (*stratum griseum centrale*). Dorsal to this lies the *lamina quadrigemina*, a plate of mingled gray and white matter which bears four rounded elevations, the *corpora quadrigemina*. The ventral

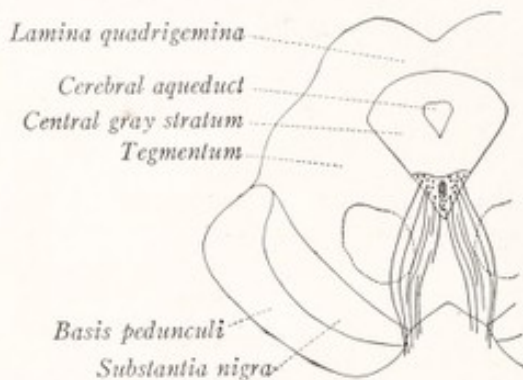

Fig. 113.—Diagrammatic cross-section through the human mesencephalon.

part of the midbrain is formed by the *cerebral peduncles*, each of which is separated into two parts by a lamina of pigmented gray substance, known as the *substantia nigra*. Dorsal to this the peduncle consists of reticular formation continuous with that of the pons and known as the *tegmentum*. Ventral to the *substantia nigra* is a thick plate of longitudinal fibers, called the *basis pedunculi*,

composed of fibers which are continuous with the longitudinal fasciculi of the pons.

The Tegmentum.—The dorsal portion of the pons is directly continuous with the tegmentum of the mesencephalon. Both are composed of reticular formation, consisting of interlacing longitudinal and transverse fibers grouped in fine bundles and separated by minute masses of gray substance, in which are embedded important nuclei and fiber tracts. In the caudal part of the midbrain and the rostral part of the pons are four cellular masses the locations of which are indicated in Fig. 112. They are the dorsal nucleus of the raphé, the superior central nucleus, the *ventral tegmental nucleus*, and the *dorsal tegmental nucleus*. The latter is a collection of small cells in the central gray substance, separated from the ventral tegmental nucleus by the medial longitudinal bundle. Both the ventral and dorsal tegmental nuclei receive fibers from the mammillary body (*tractus mamillotegmentalis*), and within the dorsal one there also ter-

minate fibers from the interpeduncular ganglion (Fig. 211). The tegmentum contains many *longitudinal fiber tracts* which are continued into it from the dorsal part of the pons. The most conspicuous of these is the *brachium conjunctivum*.

The Decussation of the Brachia Conjunctiva.—In the sections of the pons we saw that, as the brachia conjunctiva ascend toward the mesencephalon, they sink deeper and deeper into the pars dorsalis pontis (Fig. 112). When they reach the level of the inferior colliculi of the corpora quadrigemina they are

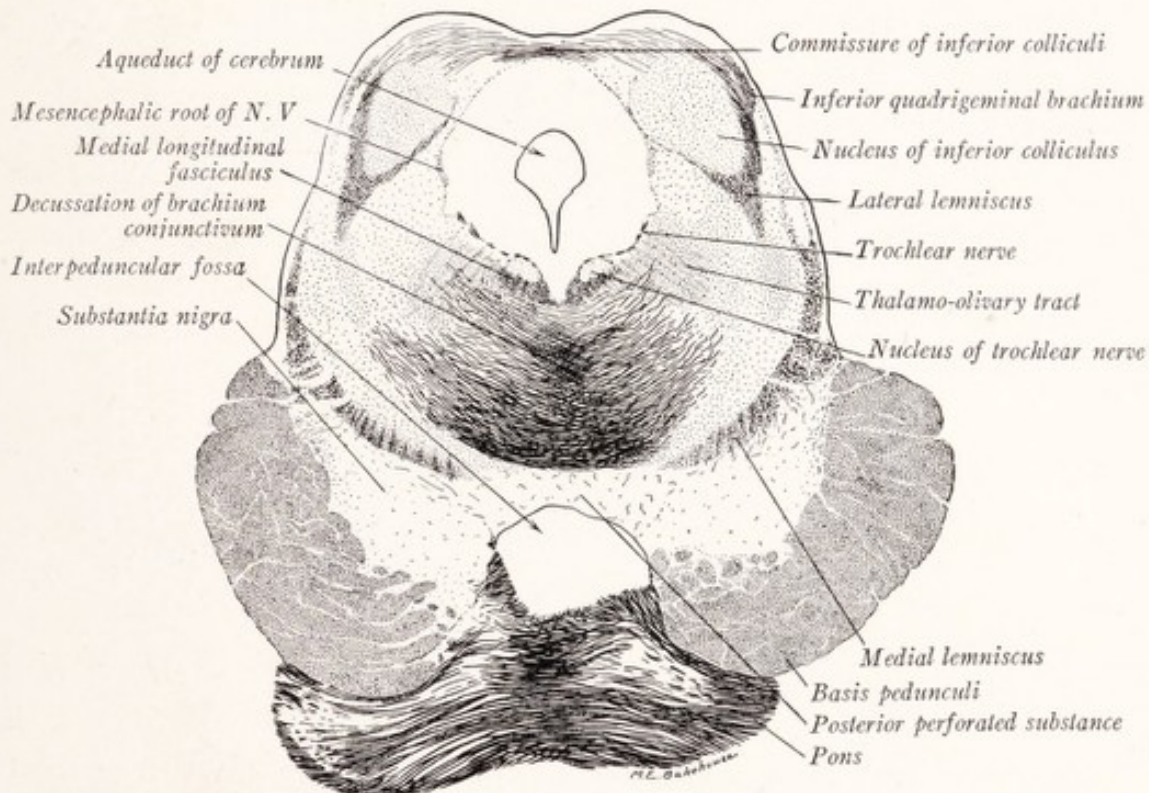


Fig. 114.—Section through the mesencephalon of a child at the level of the inferior colliculus. Pal-Weigert method. ($\times 4$.)

deeply placed in the tegmentum; and here they cross the median plane in the *decussation of the brachium conjunctivum* (Fig. 114). After crossing, each brachium turns rostrally and forms a rounded bundle of ascending fibers, which almost at once comes into relation with the *red nucleus* (Fig. 116). Many of the fibers enter this nucleus directly, while others are prolonged over its surface to form a capsule that is best developed on its medial surface. While the majority of these fibers ultimately end in the red nucleus, some reach and end within the ventral part of the thalamus (Fig. 115). By way of summary we may repeat that the fibers of the brachium conjunctivum, or at least the greater part of them,

arise in the dentate nucleus of the cerebellum; they cross the median plane in the tegmentum at the level of the inferior colliculi and end either in the red nucleus or in the thalamus.

According to Cajal (1911) the fibers of the brachium conjunctivum give off two sets of descending branches, which he has seen in Golgi preparations of the mouse, rabbit, and cat. The first group are collaterals given off as the brachium enters the dorsal part of the pons and before its decussation (Fig. 115). They descend into the pons and medulla oblongata and constitute a direct descending tract from the dentate nucleus of the cerebellum to the reticular formation of the pons and medulla oblongata. The second group of descending

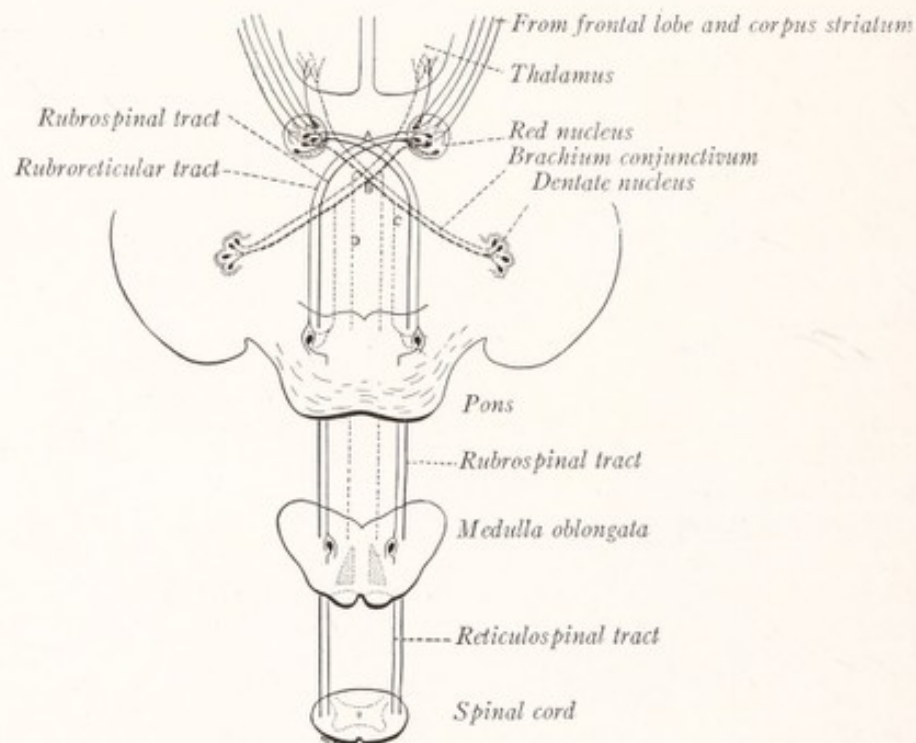


Fig. 115.—Diagram showing the connections of the red nucleus: *A*, Ventral tegmental decussation; *B*, decussation of the brachium conjunctivum; *C* and *D*, descending fibers from brachium conjunctivum, before and after its decussation respectively.

branches is formed by the bifurcation of the fibers of the brachium conjunctivum just beyond the decussation, and constitute a crossed descending tract from the dentate nucleus, which can be followed by degeneration methods through the reticular formation of the brain stem and probably into the anterior and lateral funiculi of the spinal cord (Fig. 115).

The **red nucleus** (nucleus ruber) is a very large oval mass of gray matter, which in the fresh brain has a pink color. It is located on the path of the brachium conjunctivum in the rostral part of the tegmentum (Fig. 116). In transverse sections it presents a circular outline and can be followed from the level of the inferior border of the superior colliculus into the hypothalamus. In its caudal portion it contains great numbers of fibers derived from the brachium

conjunctivum, and stains deeply in Weigert preparations, but farther rostrally these fibers are less numerous and the nucleus takes on more and more the appearance of gray substance.

Afferent fibers reach the red nucleus chiefly through the brachium conjunctivum, but it also receives fibers from the cerebral cortex of the frontal lobe and others from the corpus striatum (Fig. 115). These descending fibers help to form the capsule of the nucleus and are most abundant along its medial surface.

Efferent Fibers.—From the cells of the red nucleus arise the fibers of the *rubrospinal tract*, which after crossing the median plane descend into the spinal cord. Other cells give origin to fibers, which decussate along with those of the rubrospinal tract and terminate in the nuclei of the reticular formation and in the nucleus of the lateral lemniscus. These form the *tractus rubroreticularis* (Fig. 115). Other fibers from the red nucleus reach the thalamus.

The nerve-cells which are found in the red nucleus vary greatly in size. The smaller ones have the character of the cells of the reticular formation and send their axons into the tegmentum of the same and the opposite side. Another group of very large cells furnishes the axons that constitute the rubrospinal tract. This collection of large cells is phylogenetically the older and forms the chief part of the red nucleus in the lower mammals. But in man, where the two parts are rather sharply differentiated, the chief mass is composed of the smaller cells.

The red nucleus may be regarded as an especially highly developed portion of the motor nuclei of the tegmentum. In the lower mammals it serves as a center through which the cerebellum can influence the motor functions of the spinal cord and medulla oblongata. In man it has the same function, but is also more closely linked with the reticular formation of the pons by way of the rubroreticular tract. It is a significant fact that in man where the rubrospinal tract is relatively small the rubroreticular tract is especially well developed. This suggests the possibility that impulses from the red nucleus may be relayed through the reticular nuclei of the pons to the spinal cord (Fig. 115).

The Tegmental Decussations.—At the level of the superior colliculus and between the two red nuclei the median raphé presents an unusual number of crossing fibers (Fig. 116). Among these are included the dorsal tegmental decussation (fountain decussation of Meynert) and the *ventral tegmental decussation* (fountain decussation of Forel). The latter is composed of fibers from the red nucleus, which, after crossing the median plane, descend through the brain stem into the lateral funiculus of the spinal cord as the *rubrospinal tract* (Fig. 115). The *dorsal tegmental decussation* is composed of fibers which arise in the superior colliculi of the corpora quadrigemina, sweep in broad curves around the central gray stratum, and after crossing the median plane in the dorsal part of the raphé, go to form the *tectobulbar* and *tectosplinal tracts*.

The **median longitudinal fasciculus** is more conspicuous in the mesencephalon than in other parts of the brain stem, but it occupies the same relative position, that is, near the median plane close to the central gray matter. At the level of the superior colliculus it forms a rather broad obliquely placed lamina, extending dorsolaterally from the median raphé, which together with the corresponding lamina of the opposite side produces in transverse sections a V-shaped figure (Fig. 116). The apex of this V is directed ventrally; and included between its two limbs are the oculomotor nuclei. At the level of the inferior colliculi the

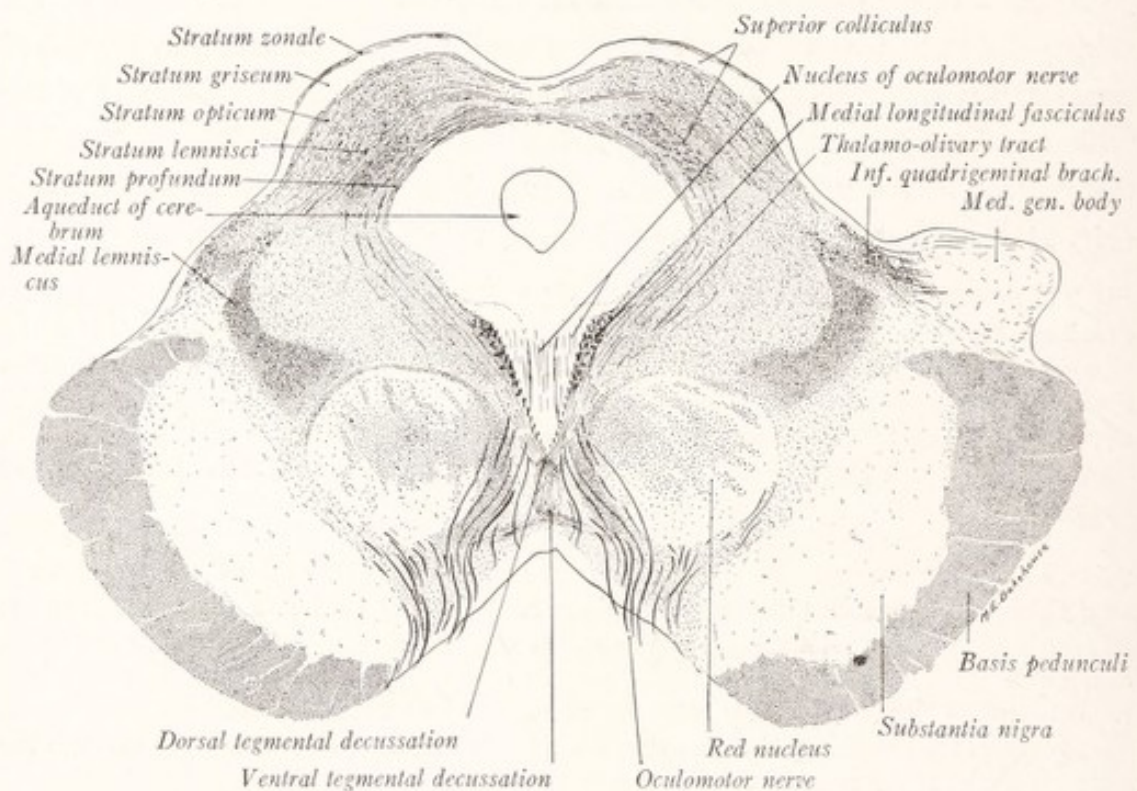


Fig. 116.—Section through the mesencephalon of a child at the level of the superior colliculus. Pal-Weigert method. ($\times 4$.)

medial longitudinal fasciculus lies immediately ventral to the nucleus of the trochlear nerve (Fig. 114). In the pons the nucleus of the abducens nerve is placed on its dorsolateral border. The close relation of this fascicle to the nuclei for the motor nerves of the eye is of considerable significance, since according to the law of neurobiotaxis (p. 179) it is an expression of the fact that the majority of the afferent fibers to these nuclei come from this fascicle. This bundle of fibers, the composition of which is discussed on pages 152 and 329, is a chief factor in the reflex control of the movements of the eyes, and especially in the coordination of these movements with those of the head and neck.

The Lemnisci.—In sections through the rostral border of the pons the two lemnisci form a broad curved band in the ventral and lateral portions of the tegmentum. The fibers of the *lateral lemniscus* are cut obliquely, indicating that they have begun to turn dorsally toward the inferior colliculus (Fig. 112). On entering the midbrain this lateral portion of the fillet separates from the medial lemniscus and runs toward the corpora quadrigemina, where it forms a capsule for the *nucleus of the inferior colliculus* (Fig. 114). Some of these fibers are prolonged beyond the nucleus and decussate with similar fibers from the opposite side. A large proportion of the fibers of the lateral lemniscus end in the inferior colliculus, but others form the *inferior quadrigeminal brachium* (Fig. 114), through which they reach the medial geniculate body (Figs. 116, 134). In the mesencephalon the lateral lemniscus, which, it will be remembered, is the central auditory tract from the cochlear nuclei, is joined by the fibers of the spinotectal tract; and these run with it to the corpora quadrigemina.

The *medial lemniscus*, or bulbothalamic tract from the gracile and cuneate nuclei of the opposite side, is continued through the tegmentum of the mesencephalon to end in the lateral nucleus of the thalamus (Fig. 235). Incorporated with it in this upper part of its course are the fibers of the *spinothalamic tract* and a portion of the *central sensory tract of the trigeminal nerve* (Figs. 132, 234). In the caudal part of the mesencephalon this broad band of longitudinal fibers occupies the ventrolateral portion of the tegmentum (Fig. 114); but at the level of the superior colliculus it has been displaced dorsolaterally by the red nucleus. Here it lies not far from the medial geniculate body and inferior quadrigeminal brachium (Fig. 116).

The Central Gray Stratum.—The *cerebral aqueduct* is lined by ependymal epithelium and surrounded by a thick layer of gray matter, the *central gray stratum*, which, because of its paucity in myelinated fibers, is nearly colorless in Weigert preparations. This layer is continuous with the gray matter surrounding the third ventricle, on the one hand, and with that covering the rhomboid fossa on the other. Numerous nerve-cells of various size and shape are scattered through this central gray substance; and, in addition, there are three compact groups of cells, which are the nuclei of the oculomotor and trochlear nerves and of the mesencephalic root of the trigeminus.

The **nucleus of the trochlear nerve** contains the cells of origin of the motor fibers for the superior oblique muscle of the eye. It is a small oval mass situated in the ventral part of the central gray stratum at the level of the inferior colliculus (Fig. 114). The fibers of the trochlear nerve emerge from the dorsolateral

aspect of this nucleus, curve dorsally around the central gray matter, and decussate in the anterior medullary velum (Fig. 112).

The **nucleus of the oculomotor nerve** is composed of the cells of origin of the motor fibers for all of the ocular muscles except the superior oblique and lateral rectus. It lies in the ventral part of the central gray substance beneath the superior colliculus (Fig. 116). This nucleus, a part of which occupies a median position and supplies fibers to the nerves of both sides, is 6 or 7 mm. long and extends from a little beyond the rostral limit of the mesencephalon to the nucleus of the trochlear nerve, from which it is not sharply separated. From the nucleus the fibers of the oculomotor nerve stream forward through the tegmentum and red nucleus. They emerge through the oculomotor sulcus along the ventromedial surface of the basis pedunculi.

The **interpeduncular ganglion** is a median collection of nerve-cells in the *posterior perforated substance* situated between the two cerebral peduncles near the border of the pons (Fig. 114). It receives fibers from the habenular nucleus of the epithalamus by way of the fasciculus retroflexus of Meynert; and from it spring fibers that run to the dorsal nucleus of the tegmentum (Fig. 211).

The **substantia nigra** is a broad thick plate of pigmented gray matter, which separates the basis pedunculi from the tegmentum and extends from the border of the pons throughout the length of the mesencephalon into the hypothalamus. In transverse section it presents a semilunar outline. Its medial border is superficial in the oculomotor sulcus and is thicker than the lateral border, which reaches the lateral sulcus of the mesencephalon. Its constituent nerve-cells, irregular in shape and deeply pigmented, send their axons into the tegmentum. But we are still ignorant as to the destination these may have; and the function of the substantia nigra is equally obscure. It receives collaterals from the corticifugal fibers of the basis pedunculi. Furthermore, there terminates within it a bundle, consisting of both direct and crossed fibers from the corpus striatum, the *strionigral tract* (Fig. 117).

The **basis pedunculi** is a broad compact strand, crescentic in transverse section, which consists of longitudinal fibers of cortical origin. These are continued from the internal capsule into the longitudinal bundles of the pons through the basis pedunculi. It consists of four tracts. The medial and lateral fifths are occupied by fibers which terminate in the nuclei pontis. Those of the medial one-fifth arise from the cortex of the frontal lobe of the cerebral hemisphere and constitute the *frontopontine tract*. Other fibers, arising from the temporal lobe, form the *temporopontine tract* and occupy the lateral one-

fifth of the basis pedunculi. The intermediate portion, approximately three-fifths, is formed by the *corticospinal tract*, the fibers of which after giving off collaterals to the nuclei pontis are continued into the pyramids of the medulla oblongata and thence into the spinal cord. Many of the fibers of the *corticobulbar tract* are intermingled with the more medially placed corticospinal fibers; but even at this level two large fascicles destined for the nuclei of the cranial nerves have separated from the main strand of motor fibers (D  jerine, 1914). These have been called the medial and lateral corticobulbar tracts (Figs. 106, 117).

The Corpora Quadrigemina.—The rostral portion of the midbrain roof or *tectum mesencephali* is in all vertebrates an end-station for the optic tracts. In the lower vertebrates there are but two elevations in the roof, the *optic lobes* or corpora bigemina, and these, which correspond in a general way to the *superior*

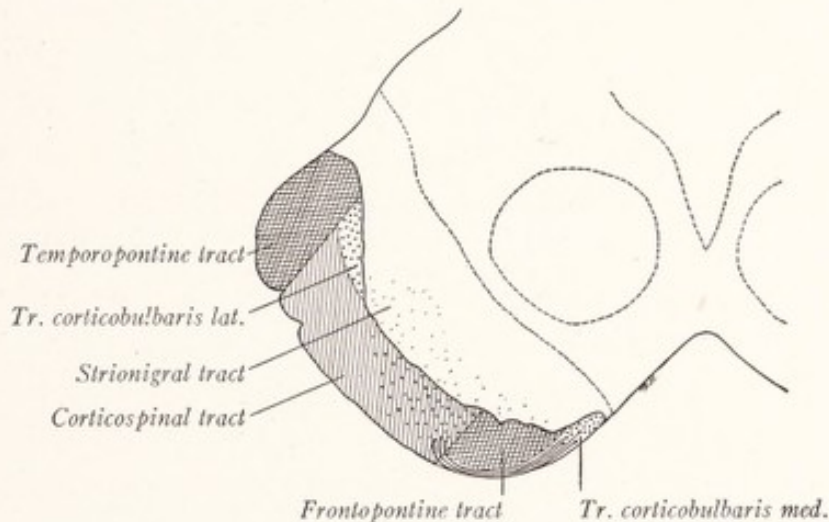


Fig. 117.—Diagram of the basis pedunculi.

colliculi, are visual centers (Fig. 13). In mammals the development of a spirally wound cochlea is associated with the appearance of two additional elevations, the *inferior colliculi*, within which many of the fibers of the central auditory path terminate. The entire tectum receives fibers from the spinal cord and medulla oblongata and sends other fibers back to them; it also receives fibers from the cerebral cortex. It contains important reflex centers, those in the superior colliculus being dominated by visual, those in the inferior colliculus by auditory, impulses.

The **inferior colliculi** or inferior quadrigeminal bodies each contain, in addition to the laminated gray matter of the tectum, a large gray mass, oval in transverse section, and known as the *nucleus of the inferior colliculus* (Fig. 114).

The *lateral lemniscus* has been traced to this nucleus, and while some of the fibers plunge directly into it, others sweep around it to form a capsule, within which it is enclosed. The majority of these fibers ultimately end in this nucleus, but some pass beyond it, reach the median plane, and decussate with similar fibers from the opposite side (Fig. 118). The ramifications of fibers from the lateral lemniscus form an intricate interlacement within the nucleus, and throughout this network are scattered many nerve-cells of various shapes and

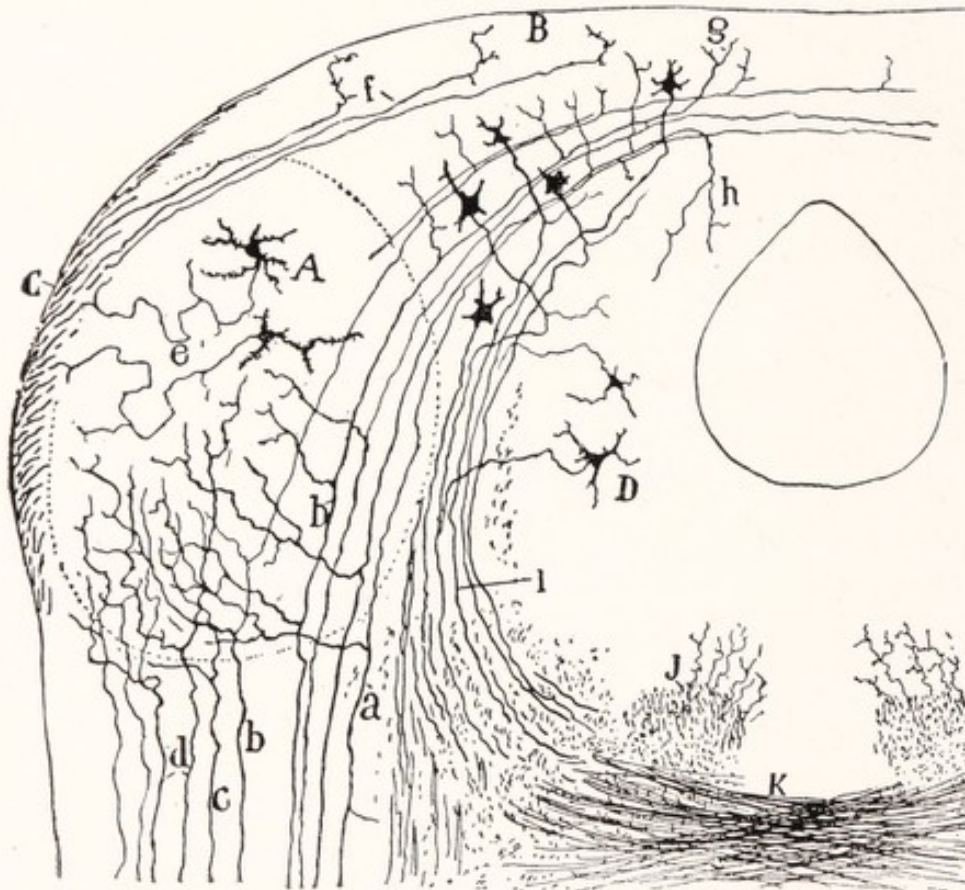


Fig. 118.—Semidiagrammatic section through the inferior colliculus of the mouse: A, Nucleus of inferior colliculus; B, gray matter of the lamina quadrigemina; C, inferior quadrigeminal brachium; D, central gray substance; K, decussation of the brachium conjunctivum; a, b, c, d, fibers of the lateral lemniscus. Golgi method. (Cajal.)

sizes. On the medial side of this circumscribed nuclear mass we find some of the laminated gray matter of the tectum, within which are embedded large multipolar cells with axons directed ventrally in the *stratum profundum*. These partially encircle the central gray matter and after undergoing a partial decussation enter the tectobulbar and tectospinal tracts.

The *inferior quadrigeminal brachium* begins on the lateral side of the nucleus of the inferior colliculus and consists of fibers from the *lateral lemniscus* which

run to and terminate within the *medial geniculate body* (Figs. 114, 116). The fibers of the lateral lemniscus carry auditory impulses from the terminal nuclei of the cochlear nerve. Some of these terminate in the inferior colliculus and are concerned with reflexes in response to sound. Other fibers, some of which are branches of those to the inferior colliculus, run to the medial geniculate body, from which the impulses that they carry are relayed to the cerebral cortex. The inferior quadrigeminal brachium also contains fibers of cortical origin, chiefly from the temporal lobe, which end within the inferior colliculus (Beever and Horsley, 1902).

The **superior colliculi**, or superior quadrigeminal bodies, are composed of laminated gray matter. Each consists of four superimposed, dorsally convex layers (Fig. 116). The most superficial of these is a thin lamina with many transversely coursing nerve-fibers, the *stratum zonale*. The second layer is much thicker, contains few myelinated fibers, and is known as the *stratum griseum*. The third and fourth layers, *stratum opticum* and *stratum lemnisci*, are rich in myelinated fibers. The majority of the afferent fibers of the superior colliculus come from the optic tract by way of the *superior quadrigeminal brachium* and enter the stratum opticum. Many of these end in the superimposed stratum griseum. The superior colliculus also receives fibers from the cerebral cortex and from the spinotectal tract.

It has been generally supposed that the fibers of the stratum zonale come from the optic tract, but according to Cajal (1911) this cannot be the case, since they remain intact in animals which have been operated on in such a way as to produce degeneration of the optic fibers. According to him it is also probable that the fibers from the cerebral cortex, which reach the colliculus by way of the superior quadrigeminal brachium, end in the stratum lemnisci. The fibers of the spinotectal tract run with the lateral lemniscus in the upper part of its course and enter the superior colliculus by way of the stratum profundum.

The **tectobulbar** and **tectospinal tracts** have their origin within the tectum of the mesencephalon, more of the fibers coming from the superior than from the inferior colliculi. These fibers, arising from cells in more superficial layers, are assembled in the *stratum profundum* and sweep ventrally in broad curves around the central gray substance (Figs. 116, 118). The majority of the fibers, after crossing the median plane in the *dorsal tegmental decussation*, run in a caudal direction just ventral to the medial longitudinal bundle in the *tectospinal tract*. They give off collaterals to the reticular formation and the red nucleus. But some of them, instead of taking part in this decussation, leave the mesencephalon by way of the lateral lemniscus of the same side, constituting the *lateral tectobulbar* and *tectospinal tracts* (Cajal, 1911; Edinger, 1911).

CHAPTER XII

THE CRANIAL NERVES AND THEIR NUCLEI

THE cranial nerves contain, in addition to the general somatic and visceral components, which were encountered in the study of the spinal nerves, also other functional groups of fibers of more restricted distribution and specialized function. These *special somatic and visceral components* supply the organs of special sense and the visceral musculature, derived from the branchial arches, which differs from other visceral musculature in that it is striated. The fibers which supply this special musculature are designated as *special visceral efferent fibers*. The eye and ear, being special somatic sense organs, are supplied by *special somatic afferent fibers*. The olfactory mucous membrane and the taste buds are special visceral sense organs and are supplied by *special visceral afferent fibers*.

From what has been said it will be evident that there are seven distinct *functional components* in the cranial nerves, namely: somatic efferent, general somatic afferent, special somatic afferent, general visceral efferent, special visceral efferent, general visceral afferent, and special visceral afferent components (Figs. 119, 120). No single nerve contains all seven types of fibers and the individual cranial nerves vary greatly in their functional composition. On entering the brain a nerve breaks up into its several components, which separate from each other and pass to their respective nuclei, enumerated below. These nuclei may be widely separated in the brain stem. Fibers having the same function tend to be associated together within the brain irrespective of the nerves to which they belong. For example, all the visceral afferent fibers of the facial, glossopharyngeal, and vagus nerves are grouped in the tractus solitarius (Fig. 120, yellow). The nerve-cells, with which the fibers of the several functional varieties are associated within the brain stem, are arranged in *longitudinal nuclear columns*. The analysis of the cranial nerves into their functional components has involved a great amount of labor which has been carried through for the most part by American investigators. Among those who have made important contributions to this subject may be mentioned the following: Gaskell (1886), Strong (1895), Herrick (1899), Johnston (1901), Coghill (1902), Norris (1908), and Willard (1915).

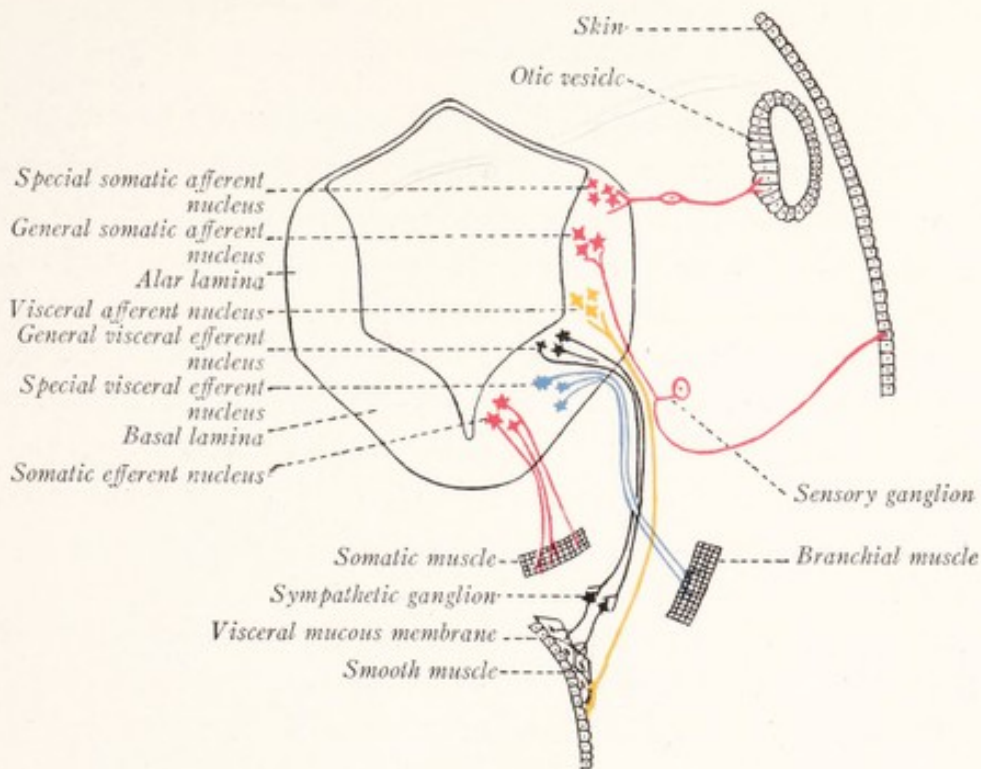


Fig. 119.

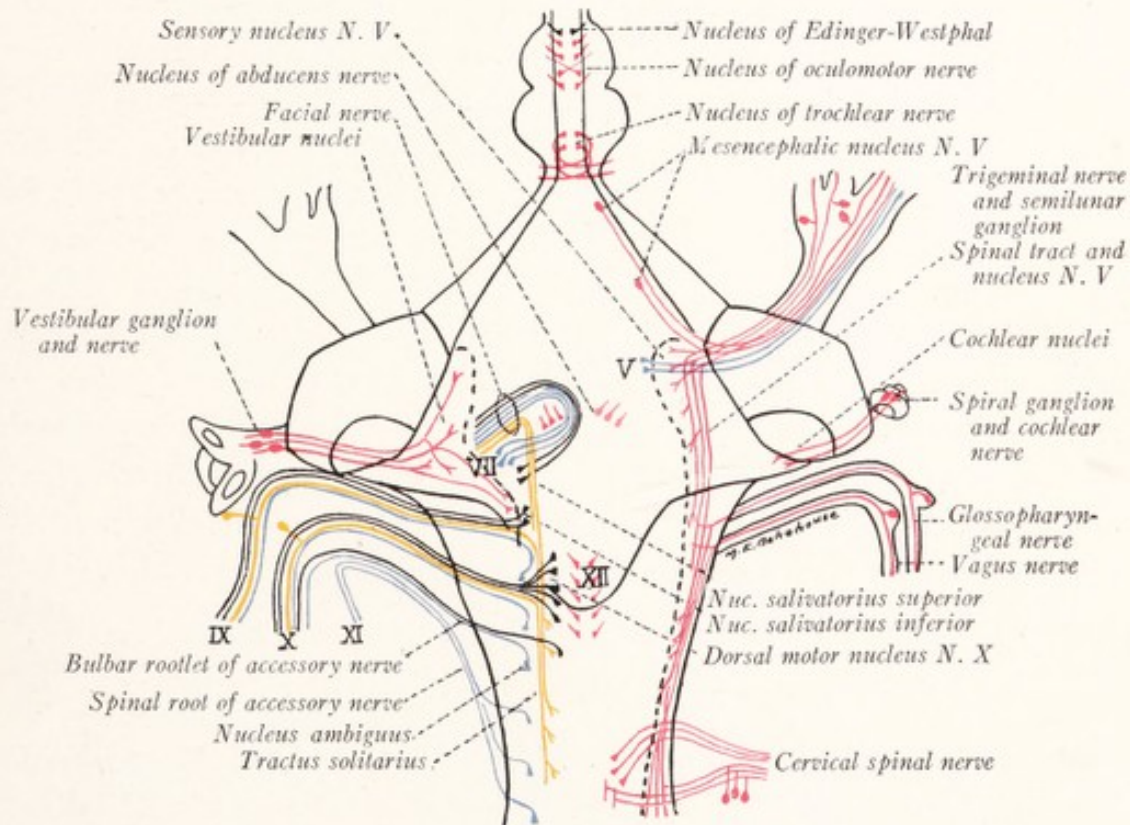


Fig. 120.

Figs. 119 and 120.—Diagrams showing the origin, course, and termination of the functional components of the cranial nerves. Somatic afferent and efferent, red; visceral afferent, yellow; general visceral efferent, black; special visceral efferent, blue. Fig. 119 shows the locations of the several functional cell columns in a section through the medulla oblongata of a human embryo and the peripheral terminations of the several varieties of fibers. Fig. 120, dorsal view of the human brain stem, showing the location of the nuclei and the intramedullary course of the fibers of the cranial nerves.

Longitudinal Nuclear Columns.—In a previous chapter we learned that at an early stage in its development the lateral wall of the neural tube consists of a dorsal or *alar* and a ventral or *basal plate*, separated by a groove, the *sulcus limitans* (Fig. 119). The sensory nuclei of the cranial nerves develop within the alar plate and the motor nuclei within the basal plate. In the rhombencephalon both plates come to lie in the floor of the fourth ventricle, the alar occupying the more lateral position. And, in spite of the changes of position which occur during development, the sensory nuclei retain, on the whole, a lateral, and the motor nuclei a more medial, location. From the basal plate there differentiate a somatic and a visceral column of efferent nuclei, and from the alar plate a visceral and a somatic column of afferent nuclei.

The *somatic efferent column* includes the nuclei of those motor nerves which supply the striated musculature derived from the myotomes, *i. e.*, the extrinsic muscles of the eye and the musculature of the tongue (Figs. 119–121).

The *visceral efferent column* undergoes subdivision into: (1) a ventrolateral column of nuclei, from which arise the special visceral efferent fibers to the striated visceral or branchial musculature, and which includes the nucleus ambiguus and the motor nuclei of the fifth and seventh nerves; and (2) a more dorsally placed group for the innervation of involuntary musculature and glandular tissue, of which the dorsal motor nucleus of the vagus is the chief example. The former may be called the *special visceral efferent* and the latter the *general visceral efferent column*.

The *visceral afferent column* is represented by the nucleus of the tractus solitarius, within which end the afferent fibers from the visceral mucous membrane and the taste buds, *i. e.*, both the general and special visceral afferent fibers. The somatic afferent column splits into two: a *general somatic afferent column*, within which terminate the sensory fibers from the skin; and a *special somatic* group of nuclei for the reception of the fibers of the acoustic nerve and, in aquatic vertebrates, of the lateral line nerves also.

THE SOMATIC EFFERENT COLUMN

As can be seen by reference to Figs. 101, 108, 114, and 116 the nuclei of the hypoglossal, abducens, trochlear, and oculomotor nerves are arranged in linear order in the central gray matter near the median plane. They represent the continuation into the medulla oblongata of the large cells of the anterior column of the spinal cord. The cells of these nuclei are large and multipolar with well-developed Nissl bodies (Fig. 126). From them arise large myelinated

fibers, which innervate the striated musculature derived from the myotomes. This group of nuclei is indicated in red in Fig. 120 and by small circles in Figs. 121 and 122.

The nucleus of the oculomotor nerve is an elongated mass of cells in the central gray matter ventral to the cerebral aqueduct at the level of the superior colliculus (Figs. 121, 122). Even a superficial examination shows that it is divided into a lateral paired and a medial unpaired portion (Fig. 116). The

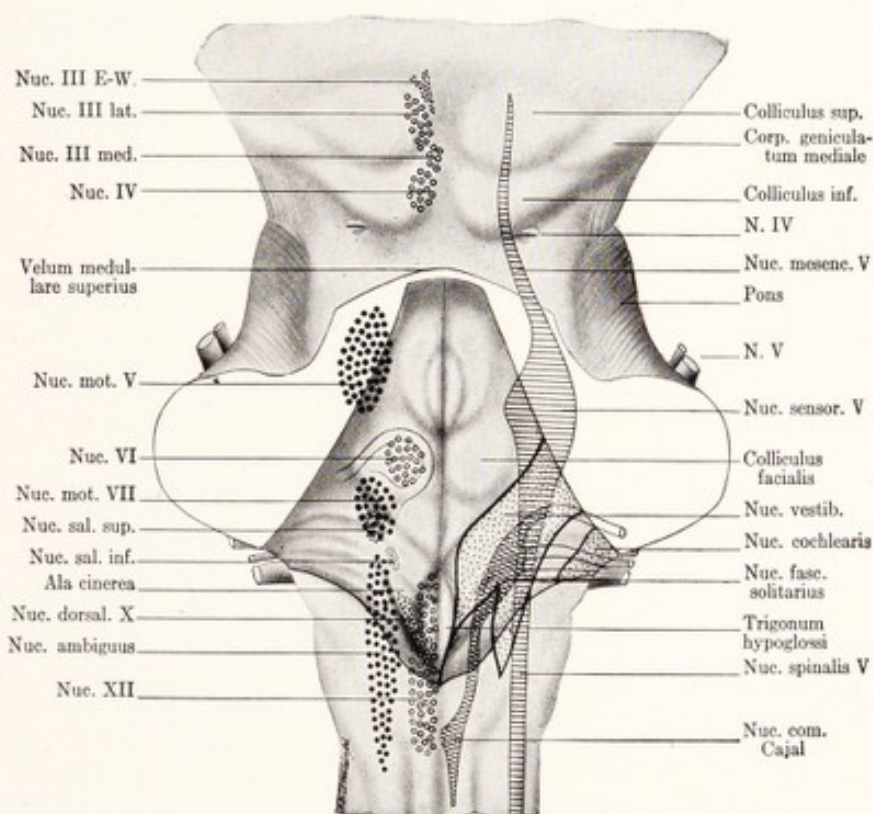


Fig. 121.—Dorsal view of the human brain stem with the positions of the cranial nerve nuclei projected upon the surface. Sensory nuclei on the right side, motor nuclei on the left. Circles indicate somatic efferent nuclei; small dots, general visceral efferent nuclei; large dots, special visceral efferent nuclei; horizontal lines, general somatic sensory nuclei; cross-hatching, visceral sensory nuclei; stipple, special somatic sensory nuclei. (Herrick.)

lateral groups of cells spreads out upon the surface of the medial longitudinal bundle, extends throughout the entire length of the nucleus, and may be divided into ventral and dorsal portions (Fig. 123). The medial group of cells is placed exactly in the median plane and is found only in the rostral half of the nucleus. Dorsolateral from this median group, and restricted to the most rostral part of the nucleus, is a collection of small cells which form the nucleus of Edinger-Westphal. This is a visceromotor nucleus and will be considered elsewhere.

The *fibers* from the medial nucleus enter both right and left nerves. Some from the caudal portion of the dorsal division of the lateral nucleus cross the median plane. The others remain uncrossed. After sweeping in broad curves through the tegmentum and red nucleus the fibers emerge through the oculomotor sulcus. All of the extrinsic muscles of the eye except the lateral rectus and superior oblique are supplied by the medial and lateral groups of cells just described.

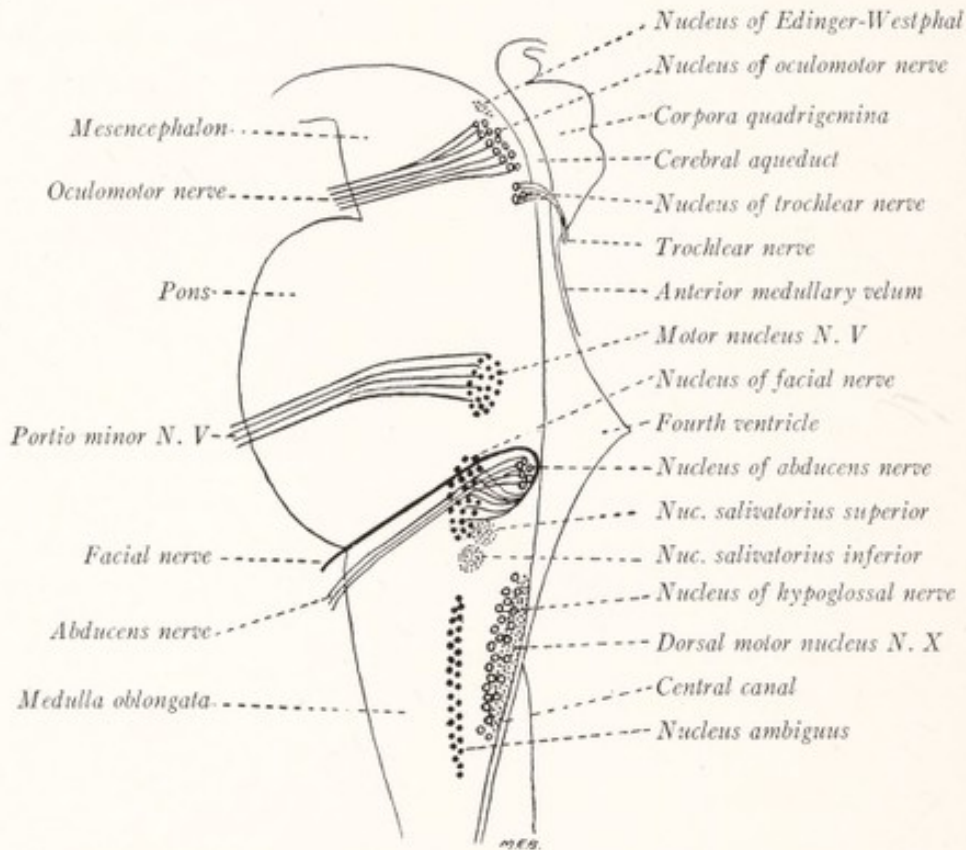


Fig. 122.—Motor nuclei of the cranial nerves projected on a median sagittal section of the human brain stem. Circles indicate somatic efferent nuclei; small dots, general visceral efferent nuclei; large dots, special visceral efferent nuclei.

As one might expect from the fact that the oculomotor nerve supplies several distinct muscles, its nucleus seems to be made up of a number of more or less distinct groups of cells; but the efforts to locate subordinate nuclei have given rise to contradictory results. The most significant work in this field has been done by Bernheimer (1904), who extirpated individual eye muscles in monkeys and studied the resultant changes in the cells of the oculomotor nuclei. According to him, the various muscles are supplied by the lateral nucleus in the following order, beginning at the rostral end: levator palpebræ superioris, rectus superior, rectus medialis, obliquus inferior, and rectus inferior. Bernheimer says that the fibers for the rectus inferior are entirely crossed, those for the obliquus inferior are in greater part crossed, those for the rectus medialis for the most part uncrossed, those for the rectus superior and levator palpebræ superioris entirely uncrossed.

The **nucleus of the trochlear nerve** has already been located in the central gray matter ventral to the cerebral aqueduct at the level of the inferior colliculus, close to the caudal extremity of the oculomotor nucleus (Figs. 114, 121, 122). The fibers of the trochlear nerve emerge from the dorsal and lateral aspects of this nucleus, and, encircling the central gray matter along an angular course which carries them also caudally, enter the anterior medullary velum, decussate within it, and make their exit from its dorsal surface (Fig. 112). They supply the superior oblique muscle.

The **nucleus of the abducens nerve** was encountered in the dorsal portion of the pons as a spheric gray mass, which with the genu of the facial nerve forms the facial colliculus of the rhomboid fossa (Figs. 108, 121, 122). The fibers of the abducens nerve leave the nucleus chiefly on its dorsal and medial surfaces and become assembled into several root bundles, which are directed ventrally toward their exit from the lower border of the pons near the pyramid of the medulla oblongata. It supplies the lateral rectus muscle.

The *axons*, which ramify within the three nuclei for the motor nerves of the eye, are derived from many sources. The most important of these sources are the corticobulbar tract, the medial longitudinal bundle, and the tectospinal tract. The nucleus of the abducens receives fibers also from the central auditory apparatus through the peduncle of the superior olive. These various fibers provide for voluntary movements of the eyes, and for reflex ocular movements in response to vestibular, visual, and auditory impulses. The nuclei probably also receive branches from the central sensory path of the fifth nerve.

The **nucleus of the hypoglossal nerve** is a slender cylindrical mass of gray matter nearly 2 cm. in length, extending from the level of the fovea inferior to that of the decussation of the pyramids. We have already identified it in both the open and the closed portions of the medulla oblongata (Figs. 99, 103). In the floor of the fourth ventricle it lies beneath the trigonum hypoglossi, while more caudally it lies ventral to the central canal (Figs. 121, 122). The root fibers

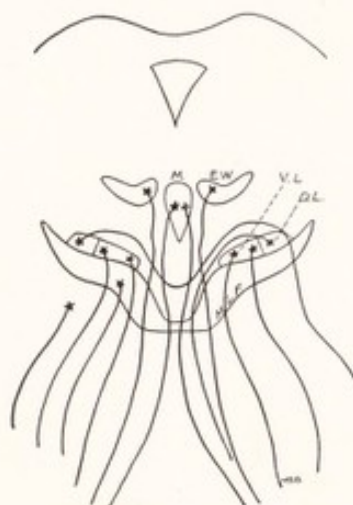


Fig. 123.—Diagram of the nuclei of the oculomotor nerve: *M*, Median nucleus; *E.W.*, nucleus of Edinger-Westphal; *V.L.*, *D.L.*, ventral and dorsal portions of the lateral nucleus. (Obersteiner.)

are assembled into bundles which run ventrally toward their exit along the lateral border of the pyramid.

A conspicuous plexus of myelinated fibers gives the hypoglossal nucleus a characteristic appearance in Weigert preparations. Fibers from many sources reach the nucleus and ramify within it. These include some from the corticobulbar tract and others from the sensory nuclei of the fifth nerve and from the nucleus of the tractus solitarius. The part which such fibers may play in reflex movements of the tongue is illustrated in Fig. 92.

THE SPECIAL VISCERAL EFFERENT COLUMN

The special visceral efferent column of nuclei contains the cells of origin of the motor fibers for the striated musculature derived from the branchial arches, as distinguished from the general skeletal musculature that develops from the myotomes. The branchial musculature includes the following groups of muscles: the *muscles of mastication*, derived from the mesoderm of the first branchial arch and innervated by the trigeminal nerve; the *muscles of expression*, derived from the second or hyoid arch and innervated by the facial nerve; the *musculature of the pharynx and larynx*, derived from the third and fourth arches and innervated by the glossopharyngeal, vagus, and accessory nerves; and probably also the *sternocleidomastoid* and *trapezius muscles*, innervated through the spinal root of the accessory nerve. Some authors prefer to call this column, which includes the *motor nuclei of the fifth and seventh nerves* and the *nucleus ambiguus*, the lateral somatic column, because the cells in these nuclei and the fibers which arise from them possess the characteristics of somatic motor cells and fibers (Malone, 1913). The nuclei are composed of large multipolar cells with well-developed Nissl bodies. These cells give origin to large myelinated fibers which run through the corresponding nerve and terminate in neuromuscular endings in one or another of the muscles indicated above.

The motor nuclei of the fifth and seventh nerves and the nucleus ambiguus of the ninth, tenth, and eleventh nerves form a broken column of gray matter, located in the ventrolateral part of the reticular formation of the pons and medulla oblongata some distance beneath the floor of the fourth ventricle (Figs. 121, 122). The cells of this column and the special visceral efferent fibers which arise from them have been colored blue in Figs. 119 and 120.

The **motor nucleus of the trigeminal nerve** lies on the medial side of the main sensory nucleus of that nerve, and is located at the level of the middle of the pons in the lateral part of the reticular formation some distance from the

ventricular floor (Figs. 110, 121, 122). The fibers, which take their origin here, are collected in the motor root or *portio minor* of the fifth nerve and run with its mandibular division to the muscles of mastication. Within the nucleus there terminate fibers from the corticobulbar tract and many fibers, chiefly collaterals, from the central sensory tract of the trigeminal nerve. It also receives collaterals from the mesencephalic root of the trigeminal and from other sources (Fig. 131).

The **motor nucleus of the facial nerve** is located in the ventrolateral part of the reticular formation of the pons near its caudal border (Figs. 108, 121, 122). Its constituent cells are arranged so as to form a varying number of subgroups which may possibly be concerned with the innervation of individual facial muscles.

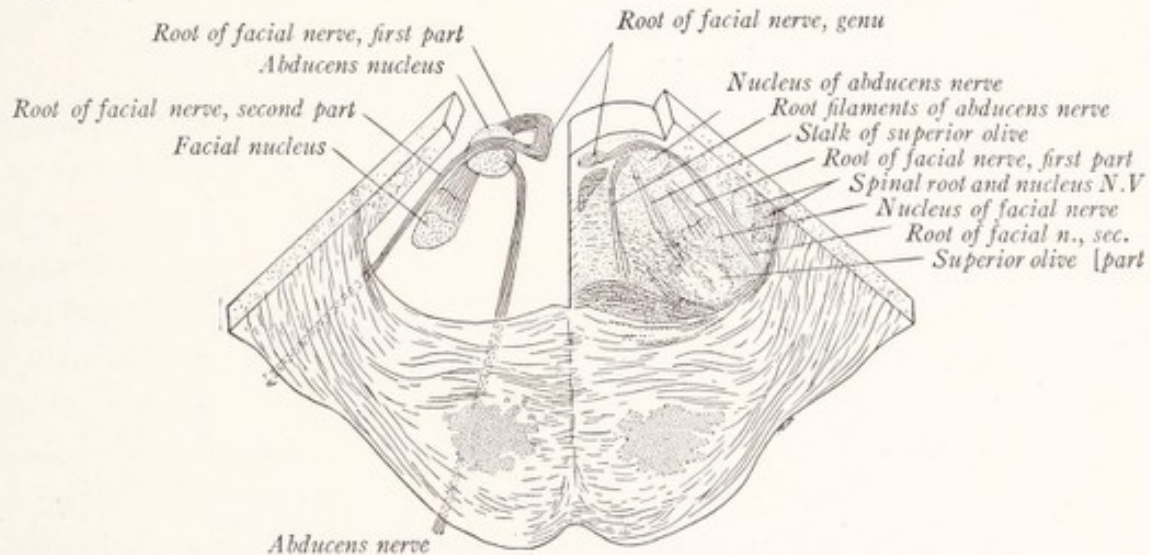


Fig. 124.—Diagram of the root of the facial nerve, shown as if exposed by dissection in a thick section of the pons.

From the dorsal aspect of this nucleus there emerge a large number of fine bundles of fibers, directed dorsomedially through the reticular formation. These rather widely separated bundles constitute the *first part of the root of the facial nerve* (Fig. 124). Beneath the floor of the fourth ventricle the fibers turn sharply rostrad and are assembled into a compact strand of longitudinal fibers, often called the ascending part of the facial nerve. This ascends along the medial side of the abducens nucleus dorsal to the medial longitudinal bundle for a considerable distance (5 mm.). The nerve then turns sharply lateralward over the dorsal surface of the nucleus of the abducens nerve, and helps to form the elevation in the rhomboid fossa, known as the *facial colliculus*. This bend around the abducens nucleus, including the ascending part of the facial nerve, is known

as the *genu*. The *second part of the root of the facial nerve* is directed ventrolaterally and at the same time somewhat caudally, passing close to the lateral side of its own nucleus, to make its exit from the lateral part of the caudal border of the pons (Fig. 108).

Fibers from many sources terminate in the facial nucleus in synaptic relation with its constituent cells. Those from the corticobulbar tract place the facial muscles under voluntary control. Others are collaterals from the secondary sensory paths in the reticular formation and are concerned with bulbar reflexes. Some of these collaterals are given off by fibers arising in the trapezoid body and carry auditory impulses. Others are collaterals of fibers arising in the nucleus of the spinal tract of the fifth nerve; and still others are given off by ascending sensory fibers from the spinal cord (Cajal, 1909).

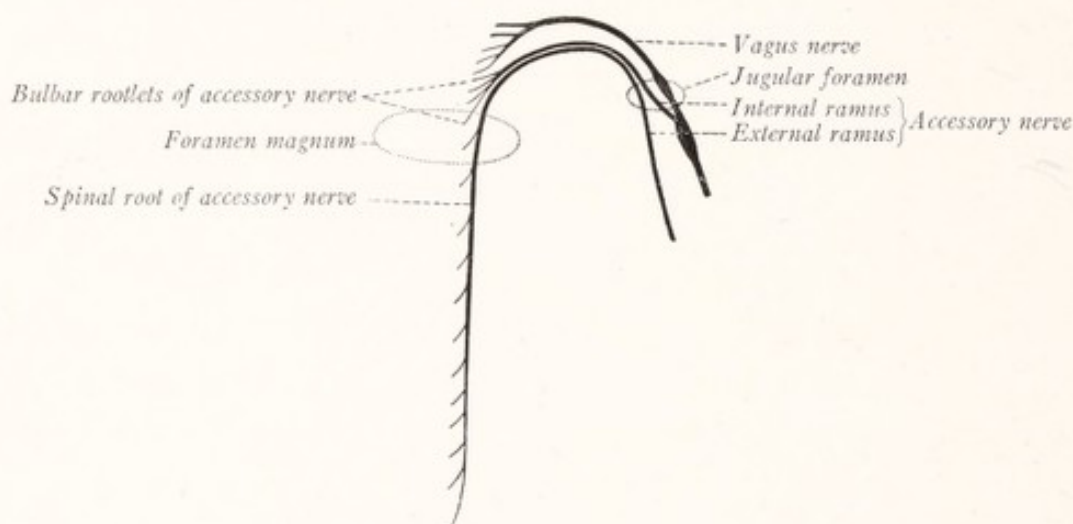


Fig. 125.—Diagram of the roots of the vagus and accessory nerves.

The **nucleus ambiguus** is a long slender column of nerve-cells, extending through the greater part of the length of the medulla oblongata in the ventrolateral part of the reticular formation (Figs. 103, 121, 122). Its constituent cells give rise to the *special visceral efferent fibers* that run through the glossopharyngeal, vagus, and accessory nerves to supply the musculature of the pharynx and larynx. It reaches from the border of the pons to the motor decussation, but is most evident in transverse sections through the caudal part of the rhomboid fossa. Here it can be found in the reticular formation ventral to the nucleus of the spinal root of the trigeminal nerve. The fibers arising from its cells are at first directed dorsally; then curving laterally and ventrally they join the root bundles of the ninth, tenth, and eleventh nerves with which they

emerge from the brain (Fig. 105). A few of the fibers cross the median plane and join the corresponding root bundles of the opposite side.

The accessory nerve consists of a bulbar and a spinal portion. The fibers of the *spinal root* take origin from a linear group of cells in the lateral part of the anterior gray column in the upper cervical segments of the spinal cord. This root ascends along the side of the spinal cord, passes through the foramen magnum, and is joined by the bulbar rootlets of the accessory (Fig. 125). The nerve then divides into an internal and an external branch. In the latter run all the fibers of spinal origin and these are distributed to the trapezius and sternocleidomastoid muscles. If, as seems probable, these muscles are derived from the branchial arches (Lewis, 1910), the fibers which supply them may be regarded as special visceral efferent fibers; and the spinal nucleus of the accessory nerve may be considered as homologous to the nucleus ambiguus. The *bulbar rootlets* of the accessory nerve, which contain both general and special visceral efferent fibers, form a well-defined fascicle, readily distinguished from the spinal portion of the nerve, which, as the internal ramus, *joins the vagus nerve and is distributed through its branches* (Fig. 120—Chase and Ranson, 1914).

The *sensory collaterals* which arborize among the cells of the nucleus ambiguus are derived from the central tracts of the trigeminal, glossopharyngeal, and vagus nerves, from ascending sensory fibers of spinal origin, and from other longitudinal fibers in the reticular formation. Other fibers reach this nucleus from the corticobulbar tract.

THE GENERAL VISCERAL EFFERENT COLUMN

The general visceral efferent column of nuclei is composed of the cells from which arise the efferent fibers innervating cardiac and smooth muscle and glandular tissue.

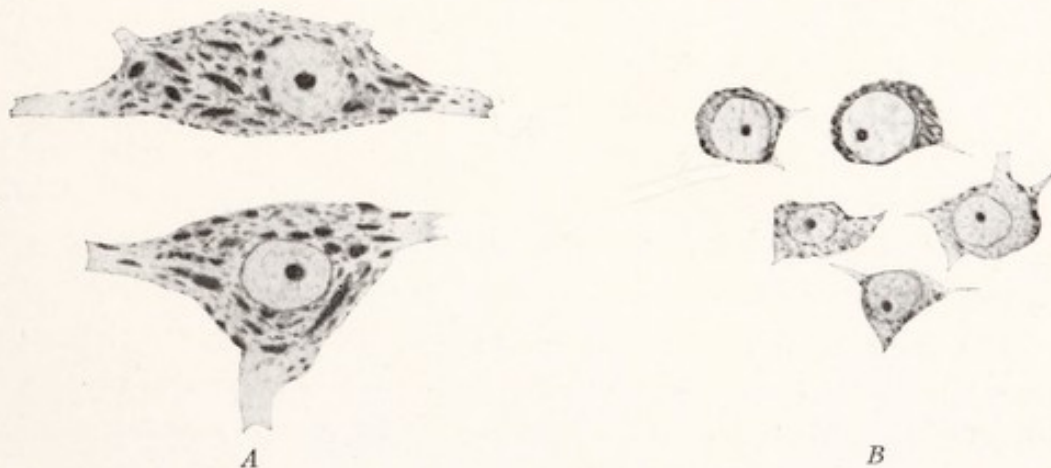


Fig. 126.—Two types of motor nerve-cells from medulla oblongata of lemur: *A*, Cells of the somatic motor type from the hypoglossal nucleus; *B*, cells of the visceral efferent type from the rostral part of the dorsal motor nucleus of the vagus. Toluidin blue stain. (Malone.)

dular tissue. The cells of these nuclei are of small or medium size and their Nissl bodies are not well developed (Fig. 126). They give rise to the *general*

visceral efferent fibers of the cranial nerves. These are small myelinated fibers, which end in sympathetic ganglia, where they arborize about sympathetic cells, the axons of which terminate in smooth or cardiac muscle or in glandular tissue. The neurons of this series are, therefore, characterized by the fact that the impulses which they transmit must be relayed by neurons of a second order before reaching the innervated tissue (Fig. 119). This group of nuclei is indicated by black in Fig. 120 and by fine stipple in Figs. 121 and 122.

The **dorsal motor nucleus of the vagus** (*nucleus vagi dorsalis medialis*) has been noted in the transverse sections through the medulla oblongata (Figs. 99, 103). It lies along the dorsolateral side of the hypoglossal nucleus, subjacent to the ala cinerea of the rhomboid fossa, and along the side of the central canal in the closed part of the medulla oblongata. The *general visceral efferent fibers*, which arise from the cells in this nucleus, leave the medulla oblongata through the roots of the vagus and accessory nerves; but those entering the accessory nerve leave that nerve by its internal ramus and join the vagus (Fig. 120). Hence all of the fibers from this nucleus are distributed through the branches of the vagus to the vagal sympathetic plexuses of the thorax and abdomen for the innervation of the involuntary musculature of the heart, respiratory passages, esophagus, stomach, and small intestines (Van Gehuchten and Molhant, 1912), and for the innervation of the pancreas, liver, and other glands.

There are relatively few sensory collaterals reaching the dorsal motor nucleus, and these come in large part from sensory fibers of the second order, arising in the receptive nuclei of the trigeminal, glossopharyngeal, and vagus nerves.

The **nucleus salivatorius** is located in the reticular formation, some distance from the floor of the fourth ventricle at the junction of the pons and medulla oblongata near the caudal end of the facial nucleus and the rostral end of the nucleus ambiguus (Figs. 121, 122). The more caudal portion, or *nucleus salivatorius inferior*, sends general visceral efferent fibers by way of the *glossopharyngeal nerve* to the otic ganglion for the innervation of the *parotid gland*. The rostral part, or *nucleus salivatorius superior*, lies dorsal to the large motor nucleus of the *facial nerve*, to which nerve it sends general visceral efferent fibers. These run from the facial nerve through the *chorda tympani* to the submaxillary ganglion for the innervation of the *submaxillary* and *sublingual salivary glands* (Kohnstamm, 1902, 1903, 1907; Yagita, 1909; Feiling, 1913).

The **Edinger-Westphal nucleus** is a group of small nerve-cells located in the rostral part of the nucleus of the oculomotor nerve. Here it is placed dorsolateral to the median unpaired portion of that nucleus (Figs. 121-123).

This group of small cells gives origin to the general visceral efferent fibers of the *oculomotor nerve* which run to the ciliary ganglion for the innervation of the *intrinsic muscle of the eye*.

Neurobiotaxis.—The position of the motor nuclei of the brain stem varies greatly in different orders of vertebrates, and is determined by the source of the principal afferent impulses which reach them. The perikarya of the neurons migrate under the influence of an attraction, which has been called neurobiotaxis, in the direction of the chief fiber tracts from which they receive impulses (Ariens Kappers, 1914, 1917; Black, 1917). "When from different places stimuli proceed to a cell, its chief dendrite grows out and its cell body shifts in the direction whence the majority of the stimuli proceed," while the axon grows in the opposite direction (Fig. 127). The nature of the attractive force is not altogether clear. Kap-

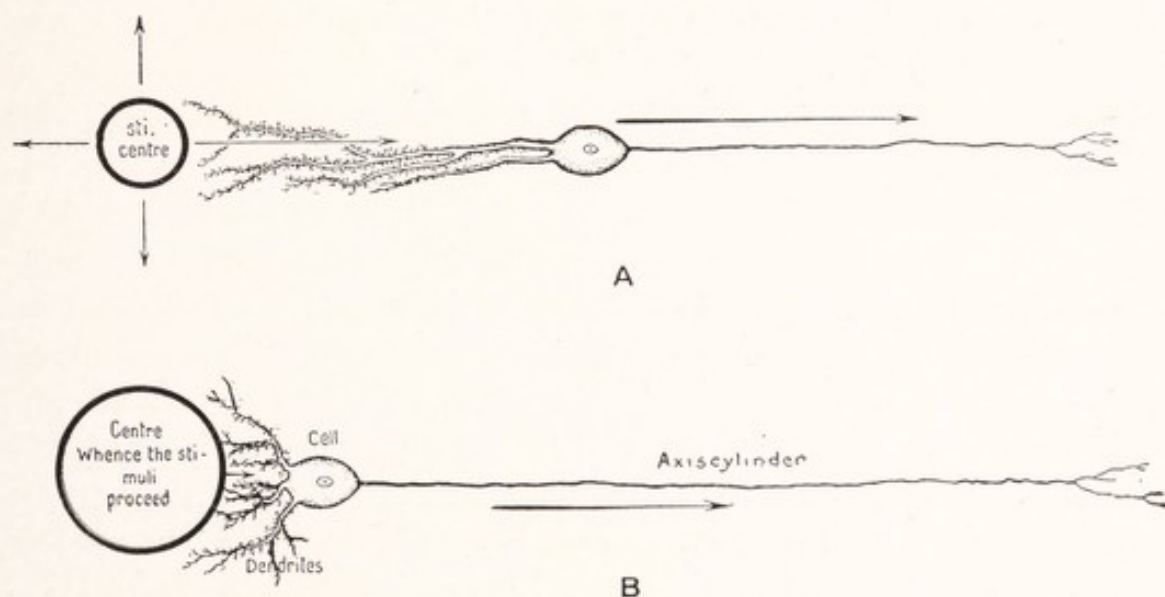


Fig. 127.—Diagram to illustrate the principle of neurobiotaxis. The axis-cylinder grows in the direction of the nervous current, indicated by the arrow, while the dendritic outgrowth and the final shifting of the cell body occur against the nervous current: *A*, Dendrites grown out toward the center of stimulation; *B*, the cell body has shifted toward the center of stimulation; the axis-cylinder is consequently elongated. (Kappers.)

pers believes that it is a galvanotropic phenomenon, on the basis of the fact that the stimulation center is electrically negative, *i. e.*, a cathode with reference to the surrounding tissue.

Numerous instances might be cited of the action of this taxis, but two will suffice. It has already been noted that the *eye-muscle nuclei* receive most of their collaterals from the optic and vestibular reflex tracts; and these appear to be the most important factors in the determination of the positions occupied by those nuclei. The changes in position of the nuclei in the vertebrate series appear to run parallel to the changes in these tracts. The reader will now appreciate the significance of the close relation of these nuclei to the medial longitudinal and tectospinal fasciculi which convey to them impulses from the vestibular and optic centers.

The position of the *nucleus of the facial nerve* and the curved course of its fibers within the pons may be explained in the same way. In a 10 mm. human embryo the nucleus of the facial nerve lies rostral to that of the abducens and the motor fibers pass directly lateralward

to their exit from the brain (Fig. 128). This nucleus, which supplies the muscles that surround the mouth, receives axons from the primary taste center in the medulla oblongata (the nucleus of the tractus solitarius) which is located at a more caudal level. Accordingly, the facial nucleus migrates caudally toward that center. It also receives fibers from the nucleus of the spinal tract of the trigeminal nerve and migrates ventrolaterally toward it. Thus is explained the adult position of the nucleus of the facial nerve, not far from the spinal tract of the trigeminal nerve and near the rostral end of the nucleus of the tractus solitarius. In the same way the curved course of the facial nerve within the pons may be explained. These examples are perhaps sufficient to illustrate the general principle of neurobiotaxis.

Nuclei of Origin and Terminal Nuclei.—The efferent nuclei, which we have examined, all have this in common, that the axons, which take origin from their constituent cells, leave the brain through the efferent roots of the cranial nerves. Hence they may all be included under the term *nuclei of origin*. On the other hand, the afferent fibers of the cerebrospinal nerves have their cells of origin located

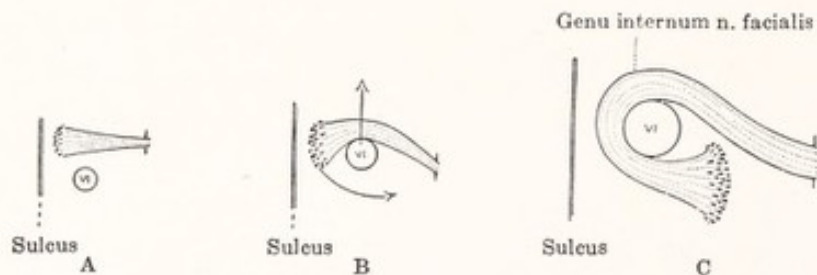


Fig. 128.—Diagram illustrating three stages in the development of the genu of the facial nerve, the youngest, *A*, corresponding to the 10 mm. embryo, and the oldest, *C*, the newborn child. The relative position of the nucleus of the n. abducens is represented in outline. *Sulcus*, Sulcus medianus fossae rhomboideae. (Streeter, in Keibel and Mall's Embryology.)

outside the central nervous system and, with the exception of the first two cranial nerves, in the cerebrospinal ganglia. These fibers enter the central nervous system and end by entering into synaptic relations with sensory neurons of the second order located in *terminal nuclei*. These are classified according to the function of the fibers which end in them as *visceral afferent* and *somatic afferent nuclei*.

THE VISCERAL AFFERENT COLUMN

All of the visceral afferent fibers of the cranial nerves, except those of the first pair, are contained in the facial, glossopharyngeal, and vagus nerves. These include: (1) the fibers from the taste buds, which since they mediate the special sense of taste, may be called *special visceral afferent fibers*; as well as (2) others from the posterior part of the tongue, and from the pharynx, larynx, trachea, esophagus, and thoracic and abdominal viscera, which are known as *general*

visceral afferent fibers. The majority of the taste fibers run through the seventh (via the chorda tympani and lingual) and ninth nerves (Cushing, 1903), but a few reach the epiglottis by way of the tenth (Wilson, 1905—Fig. 129). All of these general and special visceral afferent fibers, whether contained in the seventh, ninth, or tenth nerves, enter the *tractus solitarius*, within which they descend for varying distances (Fig. 120, yellow). They terminate in a column of nerve-cells, which in part surround the tract and in part are scattered among its fibers. This is known as the *nucleus of the tractus solitarius* (Figs. 121, 130). It is a long slender nucleus, which extends throughout the entire length of the medulla oblongata and is best developed at the level of origin of the vagus nerve,

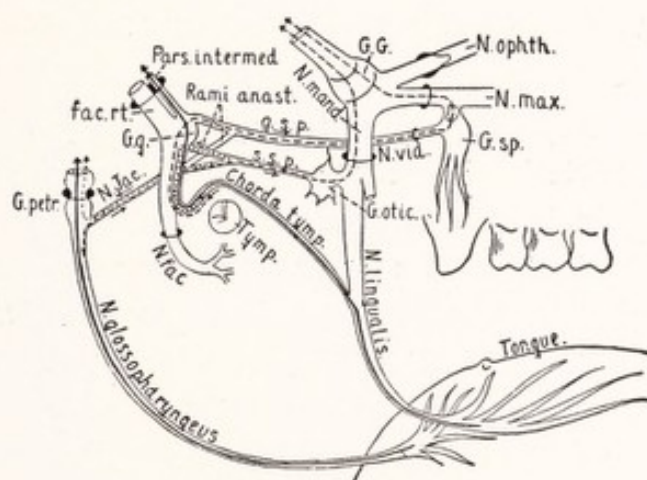


Fig. 129.—Diagram of the trigeminal, facial, and glossopharyngeal nerves showing the course of the taste fibers in solid black lines. The broken and dotted lines indicate the course which according to certain investigators some of the taste fibers are supposed to take: *G. G.*, Gasserian ganglion; *G. g.*, geniculate ganglion; *G. sp.*, sphenopalatine ganglion; *g.s.p.*, great superficial petrosal nerve; *N. Jac.*, the tympanic nerve of Jacobson; *N. vid.*, vidian nerve; *s.s.p.*, small superficial petrosal nerve. (Cushing.)

where it lies ventrolateral to the dorsal motor nucleus of that nerve and some little distance below the floor of the fourth ventricle (Fig. 103). The fibers from the seventh and ninth nerves terminate in the rostral portion of the nucleus, which is therefore the part especially concerned with the sense of taste, while those from the vagus end in the caudal part. Some of these vagus fibers after undergoing a partial decussation terminate in a cell mass, the commissural nucleus, which lies dorsal to the central canal in the closed part of the medulla and unites the nucleus of the tractus solitarius on one side with the corresponding nucleus on the other side (Fig. 121).

The **secondary afferent paths** from the nucleus of the tractus solitarius are not well defined. Since gustatory impulses arouse sensations of taste and the

afferent impulses from the viscera may be vaguely represented in consciousness, there must be a visceral afferent path to the thalamus; but concerning the character and location of this path we are entirely ignorant.¹ The fibers arising from the nucleus of the tractus solitarius enter the reticular formation, and it is probable that a majority of them are distributed to the visceral motor nuclei of the medulla oblongata, including the nucleus ambiguus and the dorsal motor nucleus of the vagus. In this way arcs are established for a large and important group of visceral reflexes. Some of these fibers descend to the spinal cord and may play an important part in the reflex control of respiration and in initiating reflex coughing and vomiting (Figs. 245, 246).

THE GENERAL SOMATIC AFFERENT NUCLEI

The general somatic afferent nuclei receive fibers from the skin and ectodermal mucous membrane of the head by way of the *trigeminal nerve*. These have their cells of origin in the semilunar ganglion, and within the pons they divide into short ascending and long descending branches (Fig. 131). The ascending branches terminate in the *main sensory nucleus*; the descending branches run through the spinal tract and terminate in the *nucleus of the spinal tract of the trigeminal nerve*. Since these nuclei receive sensory fibers from the skin and ectodermal mucous membrane of the head, they are *exteroceptive* in function. The spinal tract and its nucleus also receives a few cutaneous afferent fibers through the glossopharyngeal and vagus nerves from the skin of the external ear (Fig. 120).

The *main sensory nucleus of the trigeminal nerve* is located at the level of the middle of the pons in the lateral part of the reticular formation some distance from the floor of the fourth ventricle (Figs. 110, 121, 130). The *spinal nucleus*, with which it is continuous, at first lies deeply under cover of the restiform body; but when it is traced caudally it approaches the surface and, covered by the spinal tract, forms the tuberculum cinereum (Figs. 99, 103). It finally becomes continuous with the substantia gelatinosa Rolandi of the spinal cord. Thus we have a *continuous column* of gray matter extending from the sacral portion of the spinal cord into the brain stem and ending abruptly in an enlargement, the main sensory nucleus of the trigeminal nerve. This entire column receives afferent fibers from the skin and belongs to the *exteroceptive* portion of the *somatic afferent* division of the nervous system.

¹ Kohnstamm and Hindelang (1910) and von Monakow (1913) have described a secondary visceral afferent path which arises from the gray matter in and around the tractus solitarius and terminates in the thalamus.

Secondary Afferent Paths.—From the cells of the main sensory and spinal nuclei of the trigeminal nerve arise fibers which enter the reticular formation and are there grouped into longitudinal bundles from which collaterals are given off to the motor nuclei of the brain stem (Fig. 131). There are at least two such longitudinal bundles in each lateral half of the brain. The *ventral secondary afferent path of the trigeminal nerve* consists for the most part of crossed fibers and is located in the ventral part of the reticular formation, close to the spinothalamic tract in the medulla, and dorsal to the medial lemniscus in the pons

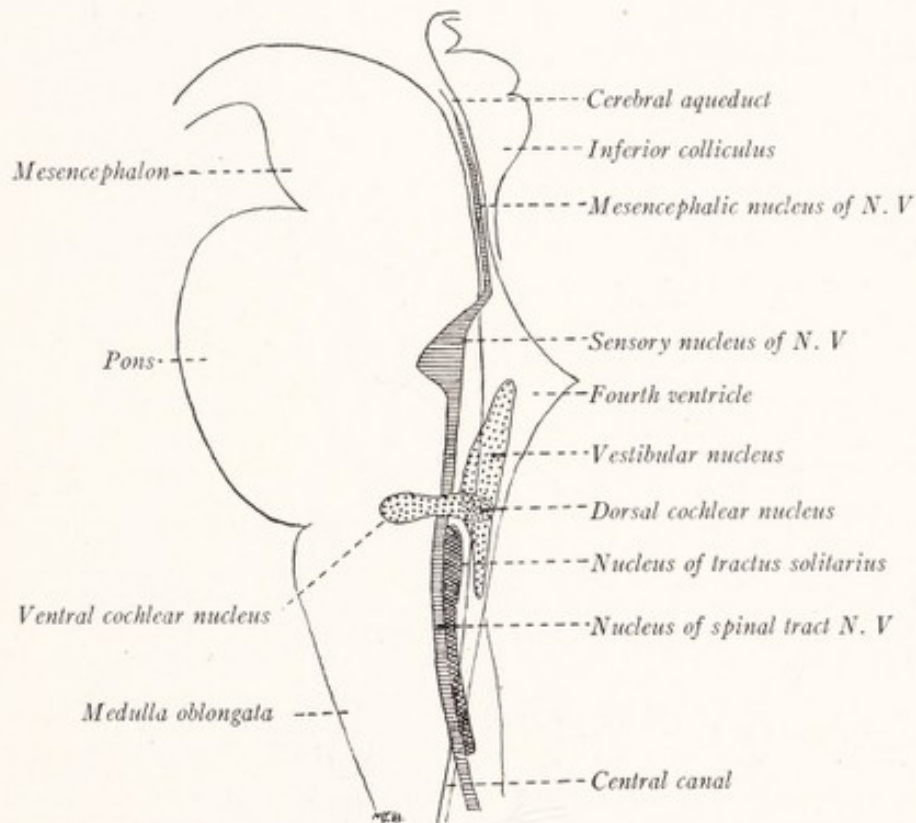


Fig. 130.—Sensory nuclei projected upon a median sagittal section of the human brain stem. Horizontal lines, general somatic sensory nuclei; cross-hatching, visceral sensory nucleus; stipple, special somatic sensory nuclei.

and mesencephalon (Fig. 132). It is composed in large part of long fibers which reach the thalamus. The *dorsal secondary afferent path of the trigeminal nerve* consists chiefly of uncrossed fibers and lies not far from the floor of the fourth ventricle and the central gray matter of the cerebral aqueduct. It consists in considerable part of short fibers (Cajal, 1911; Wallenberg, 1905; Economo, 1911; Déjerine, 1914).

The **proprioceptive nuclei** of the cranial nerves are not well known. They have to do with afferent impulses arising in the muscles of mastication and in

the extrinsic muscles of the eye. Johnston (1909) has shown that the large unipolar cells of the *mesencephalic nucleus of the fifth nerve* which give rise

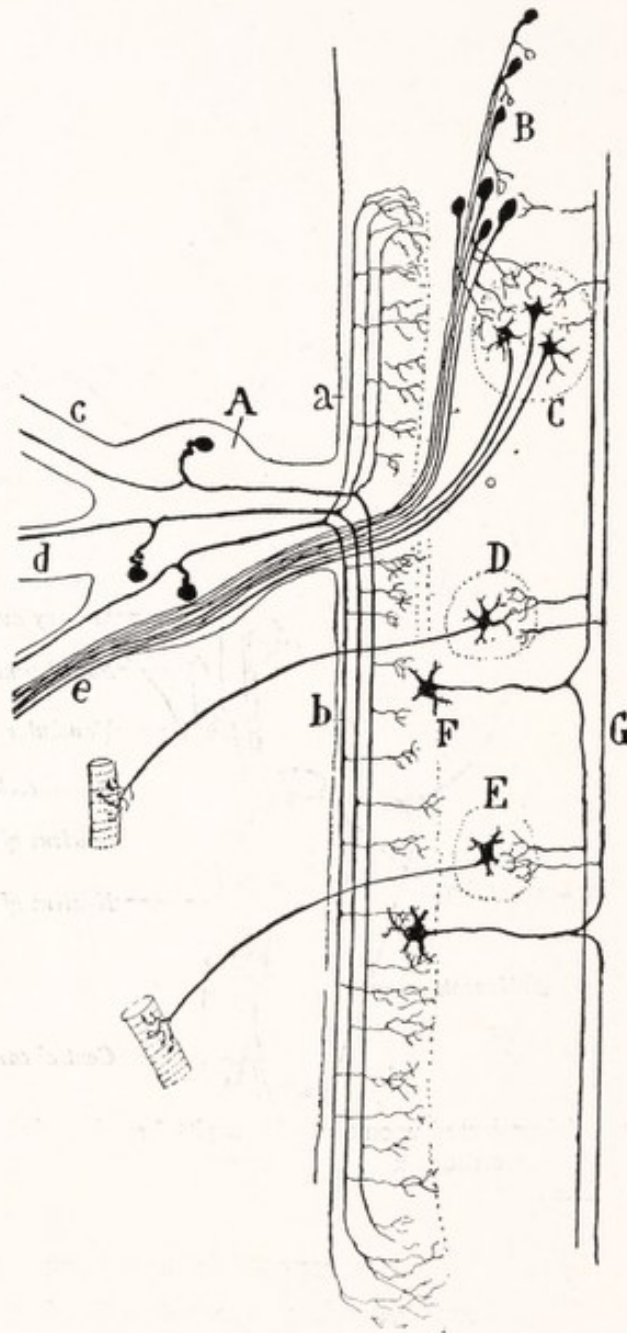


Fig. 131.—Diagram of the nuclei and central connections of the trigeminal nerve: *A*, Semilunar ganglion; *B*, mesencephalic nucleus, N. V.; *C*, motor nucleus, N. V.; *D*, motor nucleus, N. VII; *E*, motor nucleus, N. XII; *F*, nucleus of the spinal tract of N. V.; *G*, sensory fibers of the second order of the trigeminal path: *a*, ascending and *b*, descending branches of the sensory fibers, N. V.; *c*, ophthalmic nerve; *d*, maxillary nerve; *e*, mandibular nerve. (Cajal.)

to the fibers of the mesencephalic root of that nerve, are probably sensory in function. Willems (1911) and Allen (1919) believe that these are sensory fibers

to the muscles of mastication. If this interpretation is correct we are presented with an exception to the rule that the afferent fibers of the cerebrospinal nerves take origin from cells located outside the cerebrospinal axis. This nucleus lies in the lateral wall of the rostral portion of the fourth ventricle and in the lateral part of the gray matter surrounding the cerebral aqueduct (Figs. 114, 121, 130). The origin and termination of the afferent fibers for the extrinsic

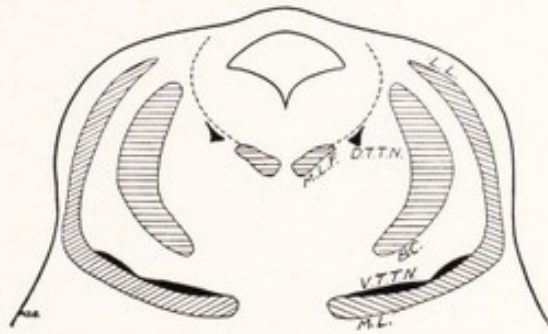


Fig. 132.—Diagram to show the location of the secondary sensory tracts of the trigeminal nerve (solid black) in the tegmental portion of the rostral part of the pons: *B.C.*, Brachium conjunctivum; *D.T.T.N.*, dorsal secondary sensory tract of the trigeminal nerve; *L.L.*, lateral lemniscus; *M.L.*, medial lemniscus; *M.L.F.*, medial longitudinal fasciculus; *V.T.T.N.*, ventral secondary sensory tract of trigeminal nerve.

muscles of the eye are unknown, although we know that such afferent fibers are present in the oculomotor, trochlear, and abducens nerves.

SPECIAL SOMATIC AFFERENT NUCLEI

The special somatic afferent nuclei are associated with the acoustic nerve, which is composed of two divisions. One part, the *cochlear nerve*, conveys impulses aroused by sound waves reaching the cochlea through the outer ear and tympanic cavity. Since it responds to stimuli from without, the cochlear apparatus subserves *exteroceptive* functions. The *vestibular nerve*, on the other hand, conveys impulses from the semicircular canals of the ear. These are important *proprioceptive* sense organs and give information concerning the movements and posture of the head.

The **cochlear nuclei** are the terminal nuclei of the cochlear nerve, the fibers of which take origin in the *spiral ganglion of the cochlea*. This is composed of bipolar cells, each having a short peripheral and a longer central process (Fig. 133). The peripheral process terminates in the *spiral organ of Corti*. The central process is directed toward the brain in the cochlear nerve. These central fibers terminate in two masses of gray matter, located on the restiform body near the point where the latter turns dorsally into the cerebellum (Figs. 107, 121,

130). One of these masses, the *dorsal cochlear nucleus*, is placed on the dorso-lateral aspect of the restiform body and produces a prominent elevation on the surface of the brain (Fig. 91). The other, known as the *ventral cochlear nucleus*, is in contact with the ventrolateral aspect of the restiform body.

Secondary Auditory Path.—From the cells of the ventral cochlear nucleus arise fibers which stream medialward in the ventral part of the pars dorsalis pontis and form the *trapezoid body* (Figs. 108, 134). The fibers cross the median plane and on reaching the lateral border of the opposite superior olivary nucleus turn rostrally as a compact bundle known as the *lateral lemniscus* (Figs. 110,

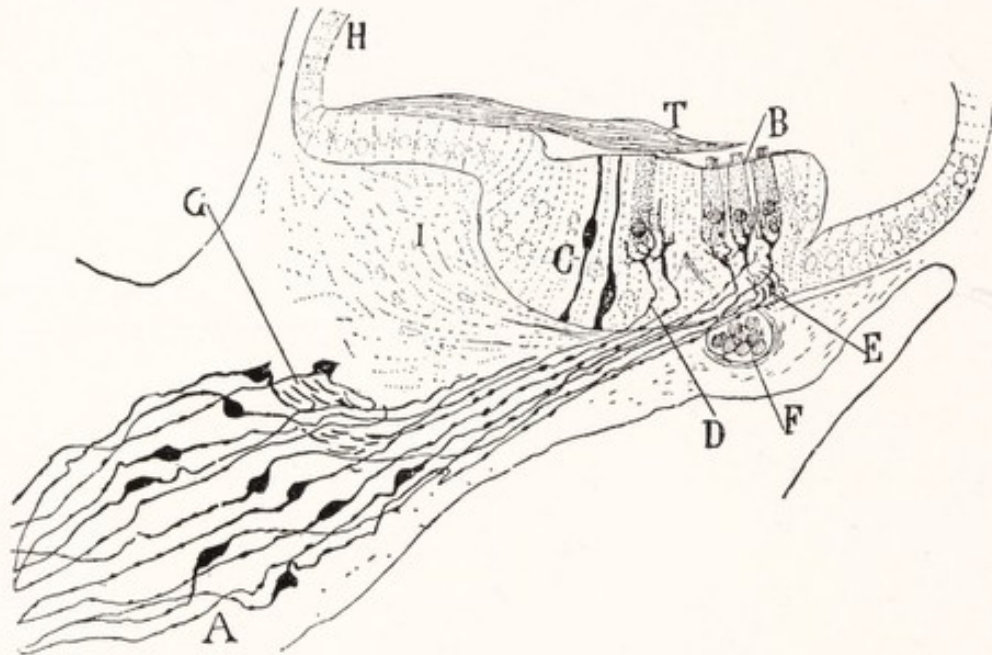


Fig. 133.—Section of the spiral ganglion and organ of Corti of the mouse: *A*, Bipolar cells of the spiral ganglion; *B*, outer hair cells; *C*, sustentacular cells; *D*, terminal arborization of the peripheral branch of a bipolar cell about an inner hair cell; *T*, tectorial membrane. Golgi method. (Cajal.)

112, 114). Some of the fibers of the trapezoid body end in the *superior olivary nuclei* and in the *nuclei of the trapezoid body*, while others give off collaterals to these nuclear masses. Some of the fibers arising in these nuclei, especially in the nuclei of the trapezoid body, join in the formation of the lateral lemniscus; but according to Cajal (1909) a majority of the fibers from the superior olivary nucleus belong to short reflex pathways in the reticular formation connecting the cochlear nerve with the nuclei of the motor nerves of the head and neck. Fibers arising in the dorsal cochlear nucleus, and possibly also some from the ventral cochlear nucleus, sweep over the dorsal surface of the restiform body and the floor of the fourth ventricle as the *striae medullares acusticae*. These may

lie just beneath the ependyma or may be buried in the gray matter of the rhomboid fossa. On reaching the median plane these fibers decussate, sink into the reticular formation, and join the trapezoid body or lateral lemniscus of the opposite side. Some probably fail to cross, since clinical experience and evidence based on animal experiments tend to show that a part of the fibers in the lateral lemniscus represent an uncrossed path from the cochlear nuclei of the same side (Kreidl, 1914).

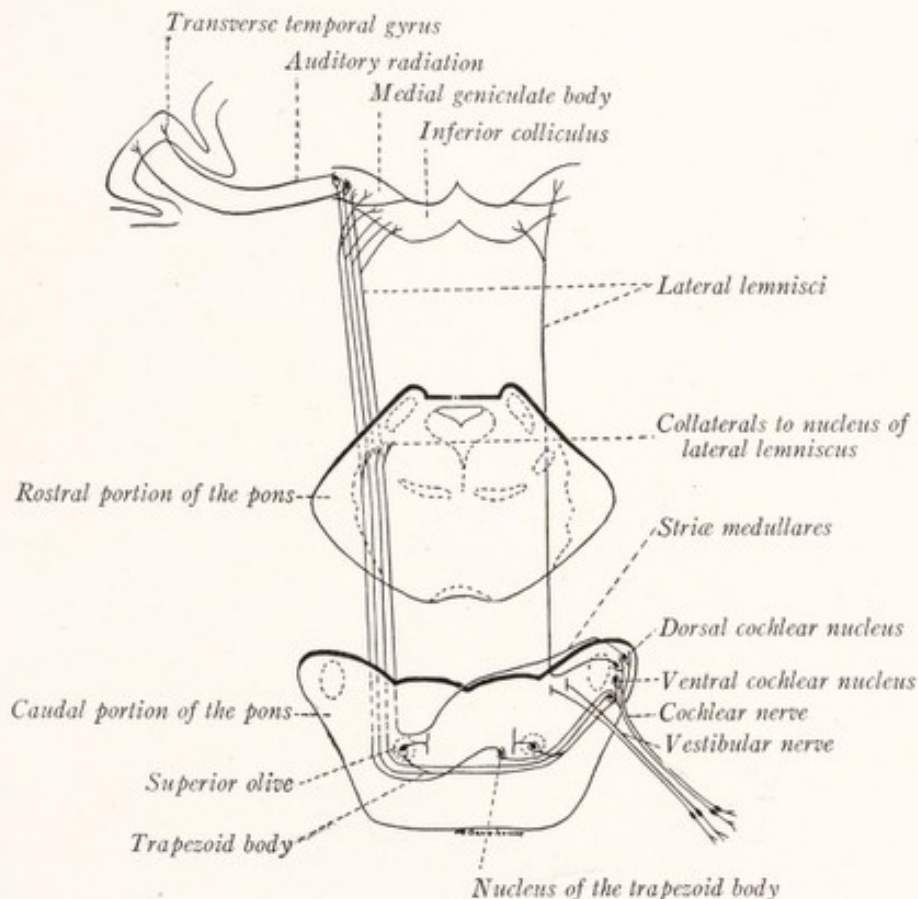


Fig. 134.—Diagram of the auditory pathway. (Based on the researches of Cajal and Kreidl.)

As the *lateral lemniscus* ascends in the reticular formation of the pons, there are scattered among its fibers many nerve-cells which together constitute the *nucleus of the lateral lemniscus*. To these cells it gives off collaterals and possibly also terminal branches, and from them it is said to receive additional fibers. But according to Cajal the axons arising here do not ascend in the lateral lemniscus, but are directed medially into the reticular formation.

On reaching the mesencephalon the *lateral lemniscus* terminates in part in the *inferior colliculus*, but also sends branches and direct fibers by way of the inferior quadrigeminal brachium to the *medial geniculate body*. While the me-

dial geniculate body is a way-station on the auditory path to the cerebral cortex, the inferior colliculus serves as a center for reflexes in response to sound.

The Vestibular Nuclei.—The fibers of the vestibular nerve take origin from the bipolar cells of the *vestibular ganglion* located in the internal auditory meatus (Fig. 135). The cochlear and vestibular divisions of the acoustic nerve separate at the ventral border of the restiform body. Here the vestibular nerve

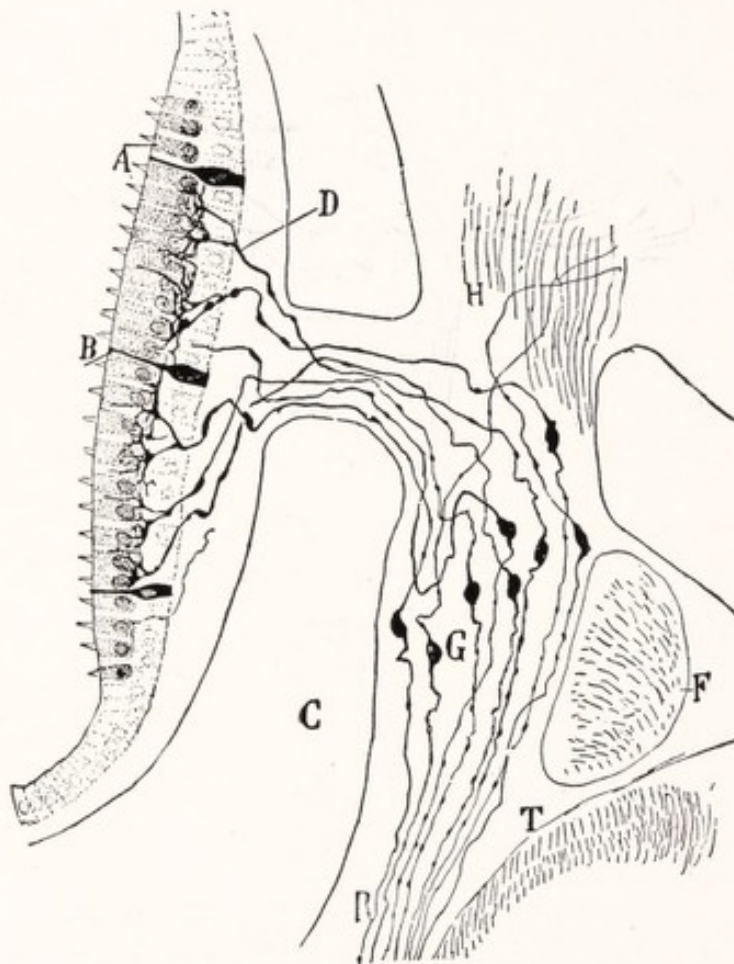


Fig. 135.—The vestibular ganglion and the termination of the peripheral branches of its bipolar cells in a macula acustica: *A*, Hair cells and *B*, sustentacular cells of the macula; *D*, terminal arborization of the peripheral branches of the bipolar cells of the vestibular ganglion (*G*) about the hair cells of the macula; *F*, facial nerve; *R*, central branches of the bipolar cells directed toward the medulla oblongata *T*. Mouse. Golgi method. (Cajal.)

penetrates into the brain, passing between the restiform body and the spinal tract of the trigeminal nerve toward the area acustica of the rhomboid fossa. Under cover of the area acustica the fibers divide into short ascending and longer descending branches (Figs. 134, 136). There may be enumerated five cellular masses within which these fibers terminate, namely: (1) the *principal* or *medial nucleus*, (2) the *descending* or *spinal nucleus*, (3) the *superior nucleus*

of Bechterew, (4) the *lateral nucleus* of Deiters, and (5) the *cerebellum* (Figs. 130, 136).

The *principal*, medial, or dorsal *vestibular nucleus* is very large. It lies subjacent to the major portion of the area acustica and belongs, therefore, to both the pons and the medulla oblongata (Figs. 89, 103, 107). The gray matter, associated with the descending branches from the vestibular nerve and lying on the medial side of the restiform body, constitutes the *spinal* or descending *vestibular nucleus*. Along with the descending fibers it can be followed in serial

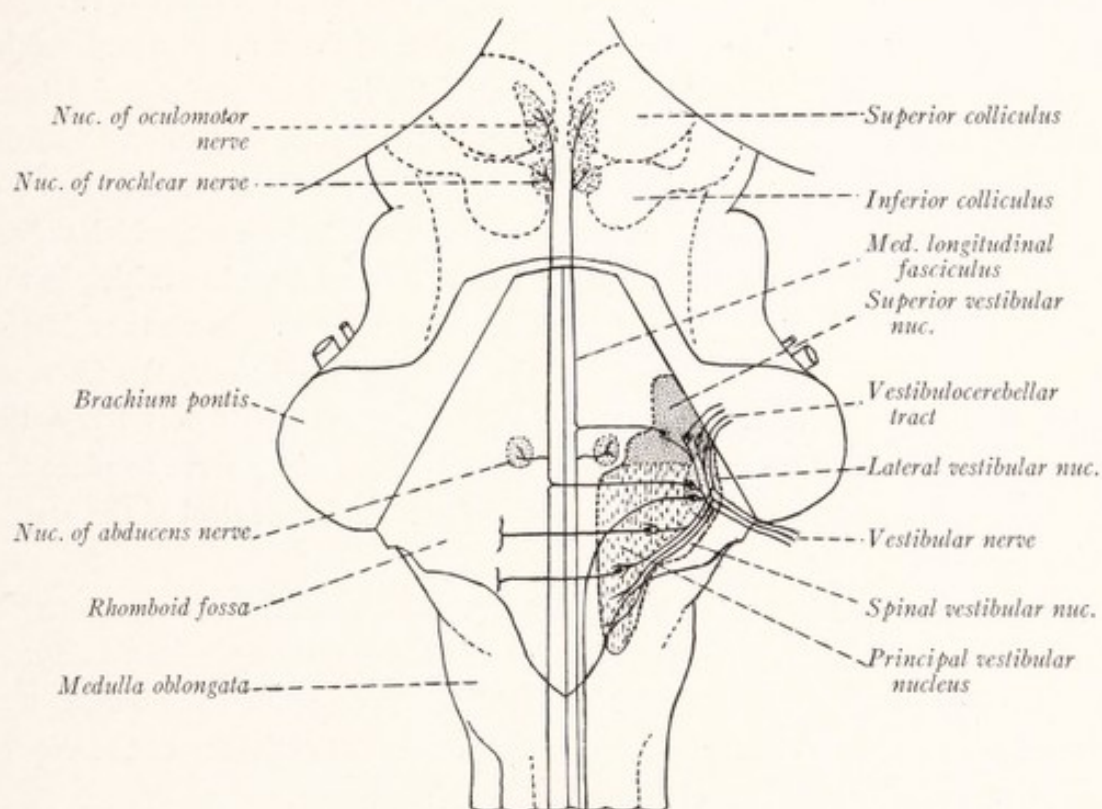


Fig. 136.—Diagram of the nuclei and central connections of the vestibular nerve. (Based on figures by Herrick and Weed.)

sections as far as the rostral extremity of the nucleus gracilis. The *lateral vestibular nucleus* of Deiters is situated close to the restiform body at the point where the fibers of the vestibular nerve begin to diverge (Fig. 107). It is composed of large multipolar cells like those found in motor nuclei. Directly continuous with the medial and lateral nuclei is a mass of medium-sized cells, the *superior vestibular nucleus* of Bechterew, located in the floor and lateral wall of the fourth ventricle lateral to the abducens nucleus, and the emergent fibers of the facial nerve (Fig. 108). It extends as far rostrad as the caudal border of the main sensory nucleus of the trigeminal nerve (Weed, 1914).

Many of the ascending branches of the vestibular nerve, after giving off collaterals to the nuclei of Deiters and Bechterew, are prolonged in the *tractus vestibulocerebellaris*, to end in the cortex of the cerebellum (Cajal, 1909). These are joined by fibers arising in the superior and lateral vestibular nuclei which also run to the cerebellum (Fig. 136). From the standpoint of its embryologic development the cerebellum may properly be regarded as a highly specialized vestibular nucleus (p. 196).

Secondary Vestibular Paths.—In addition to the fibers to the cerebellum mentioned in the preceding paragraph two important tracts of fibers take origin in the superior and lateral vestibular nuclei. One of these was encountered in the study of the *medial longitudinal bundle*. Cells in the superior and lateral vestibular nuclei give rise to fibers which run to the medial longitudinal fascicle of the same and of the opposite side, and through it reach the motor nuclei of the ocular muscles (Fig. 136). In this way there is established an arc, which makes possible the reflex response of the eye muscles to afferent impulses arising in the vestibule and semicircular canals of the ear. The other bundle was considered in connection with the spinal cord as the *vestibulospinal tract*, the fibers of which take origin from the cells of the lateral nucleus and descend into the anterior funiculus of the same side of the cord. These fibers serve to place the primary motor neurons of the spinal cord under the reflex control of the vestibular apparatus.

From the medial border of the principal vestibular nucleus many scattered fibers cross the raphé and enter the reticular formation of the opposite side, where they become longitudinal fibers. No tract to the thalamus is known, a fact which is in keeping with this other, that ordinarily the activities of the vestibular apparatus are not clearly represented in consciousness.

SUMMARY OF THE ORIGIN, COMPOSITION, AND CONNECTIONS OF THE CRANIAL NERVES

The olfactory and optic nerves and the nervus terminalis, which have not yet been considered in detail, have been included in this summary for the sake of completeness.

The **nervus terminalis** is a recently discovered nerve which arises from the cerebral hemisphere in the region of the medial olfactory tract or stria. It is closely associated with the olfactory nerve and its fibers run to the nasal septum. The origin, termination, and function of its component fibers are not yet understood (McKibben, 1911; Huber and Guild, 1913; McCotter, 1913; Johnston,

1914; Brookover, 1914, 1917; Larsell, 1918, 1919). Since it was unknown at the time the cranial nerves were first enumerated, it bears no numerical designation.

I. Olfactory Nerve.—Superficial origin from the olfactory bulb in the form of a number of fine fila which separately pass through the openings in the cribriform plate. It is composed of special visceral afferent fibers with cells of origin in the olfactory mucous membrane. The fibers terminate in the glomeruli of the olfactory bulb.

II. Optic Nerve.—Not a true nerve; but both from the standpoint of its structure and development a fiber tract of the brain. Superficial origin, from the optic chiasma, or after partial decussation, from the lateral geniculate body, pulvinar of the thalamus, and superior colliculus. Component fibers: special somatic afferent—exteroceptive; origin, ganglion cells of the retina; terminations in the lateral geniculate body, pulvinar of the thalamus and superior colliculus. The fibers from the nasal half of each retina cross in the optic chiasma.¹

III. Oculomotor Nerve.—Superficial origin, from the oculomotor sulcus on the medial aspect of the cerebral peduncle. Composition:

1. *Somatic Efferent Fibers.*—Cells of origin, in the oculomotor nucleus of the same and to a less extent of the opposite side (Fig. 120). Termination, in the extrinsic muscles of the eye except the superior oblique and the lateral rectus.

2. *General Visceral Efferent Fibers.*—Cells of origin in the Edinger-Westphal nucleus. Termination in the ciliary ganglion, from the cells of which post-ganglionic fibers run to the intrinsic muscles of the eye.²

IV. Trochlear Nerve.—Superficial origin, from the anterior medullary velum. Composed of *somatic efferent fibers*; cells of origin in the trochlear nucleus; decussation in the anterior medullary velum; termination in the superior oblique muscle of the eye (Fig. 120).

V. Trigeminal Nerve.—Superficial origin, from the lateral aspect of the middle of the pons by two roots: the portio major or sensory root and the portio minor or motor root. Composition (Fig. 120):

1. *General Somatic Afferent Fibers.*—A, Exteroceptive—Cells of origin in the semilunar ganglion (Gasserii), chiefly unipolar with T-shaped axons, peripheral

¹ It has been demonstrated by Arey that there are also efferent fibers in the optic nerves of fishes which control the movement of the retinal elements in response to light, Jour. Comp. Neur., vol. 26, p. 213.

² It is probable that the oculomotor, trochlear, and abducens nerves contain proprioceptive fibers for the extrinsic muscles of the eye, but the cells of origin and the central connections of these sensory components are unknown.

branches to skin and mucous membrane of the head, central branches by way of the portio major to the brain. Termination in the main sensory nucleus and nucleus of the spinal tract of the trigeminal nerve.

2. *General Somatic Afferent Fibers*.—B, Proprioceptive—Cells of origin probably located in the mesencephalic nucleus of the fifth nerve. Fibers by way of the portio major, distributed as sensory fibers to the muscles of mastication.

3. *Special Visceral Efferent Fibers*.—Cells of origin in the motor nucleus of the fifth nerve. Fibers by way of the portio minor and the mandibular nerve to the muscles of mastication.

VI. Abducens Nerve.—Superficial origin, from the lower border of the pons just rostral to the pyramid. Composed of *somatic efferent fibers*; cells of origin in the abducens nucleus; termination in the lateral rectus muscle of the eye.

VII. Facial Nerve and Nervus Intermedius.—Superficial origin from the lateral part of the lower border of the pons separated from the flocculus by the eighth nerve. Composition (Fig. 120):

1. *Special Visceral Afferent Fibers*.—Cells of origin in the ganglion geniculi, chiefly unipolar, with T-shaped axons. The peripheral branches run by way of the chorda tympani and lingual nerves to the taste buds of the anterior two-thirds of the tongue. The central branches run by way of the nervus intermedius to the tractus solitarius and end in the nucleus of that tract. It is probable that the taste fibers terminate in the rostral part of this nucleus.¹

2. *General Visceral Efferent Fibers*.—Cells of origin in the nucleus salivatorius superior. These fibers run by way of the nervus intermedius, facial nerve, chorda tympani, and lingual nerve to the submaxillary ganglion for the innervation of the submaxillary and sublingual salivary glands.

3. *Special Visceral Efferent Fibers*.—Cells of origin in the motor nucleus of the facial nerve. These fibers run by way of the facial nerve to end in the superficial musculature of the face and scalp, and in the platysma, posterior belly of the digastric, and stylohyoid muscles.

VIII. Acoustic Nerve.—Superficial origin from the lateral part of the lower border of the pons near the flocculus. Consists of two separate parts known as the vestibular and cochlear nerves.

¹Herrick (1918) describes general visceral afferent fibers in the facial nerve which he says mediate deep visceral sensibility and are probably found in all the branches of the facial. And Rhinehart (1918) has described a cutaneous branch of the facial in the mouse. This branch contains general somatic afferent fibers, which arise in the geniculate ganglion and terminate in the skin.

The Vestibular Nerve.—The component fibers belong to the *special somatic afferent* group and are proprioceptive. Cells of origin, in the vestibular ganglion, are bipolar. Their peripheral branches run to the semicircular canals, utricle and saccule. Their central branches terminate in the principal, lateral, superior, and spinal vestibular nuclei. Some of them run without interruption to the cerebellum.

The Cochlear Nerve.—The component fibers belong to the *special somatic afferent* group and are exteroceptive. Cells of origin, in the spiral ganglion of the cochlea, are bipolar. Their peripheral branches end in the spiral organ of Corti. Their central branches terminate in the ventral and dorsal cochlear nuclei.

IX. The Glossopharyngeal Nerve.—Superficial origin, from the rostral end of the posterior lateral sulcus of the medulla oblongata in line with the tenth and eleventh nerves. Composition (Fig. 120):

1. *General Visceral Afferent Fibers.*—Cells of origin in the ganglion petrosum, peripheral branches form the general sensory fibers to the pharynx and posterior third of the tongue, central branches run to the tractus solitarius and its nucleus.

2. *Special Visceral Afferent Fibers.*—Cells of origin in the ganglion petrosum, peripheral branches to the taste buds of the posterior third of the tongue, central branches, to the tractus solitarius and its nucleus.

3. *General Visceral Efferent Fibers.*—Cells of origin in the inferior salivatory nucleus; fibers run to the otic ganglion, from the cells of which postganglionic fibers carry the impulses to the parotid gland.

4. *Special Visceral Efferent Fibers.*—Cells of origin in the nucleus ambiguus. Termination in the stylopharyngeus muscle.

X. Vagus Nerve.—Superficial origin from the rostral part of the posterior lateral sulcus of the medulla oblongata in line with the ninth and eleventh and just caudal to the ninth. Composition (Fig. 120):

1. *General Somatic Afferent Fibers.*—Cells of origin in the ganglion jugulare; peripheral branches to the skin of the external ear by way of the ramus auricularis; central branches to the spinal tract of the trigeminal nerve and its nucleus. According to Herrick, some of these fibers from the external ear run by way of the glossopharyngeal nerve also.

2. *General Visceral Afferent Fibers.*—Cells of origin in the ganglion nodosum; peripheral branches run as sensory fibers to the pharynx, larynx, trachea, esophagus, and the thoracic and abdominal viscera; central branches run to the tractus solitarius and terminate in its nucleus.¹

¹ According to Wilson (1905) there are also special visceral afferent fibers in the vagus for the taste buds of the epiglottis. These also terminate in the nucleus of the tractus solitarius.

3. *General Visceral Efferent Fibers*.—Cells of origin in the dorsal motor nucleus of the vagus. Fibers run to the sympathetic ganglia of the vagal plexuses for the innervation of the thoracic and abdominal viscera.

4. *Special Visceral Efferent Fibers*.—Cells of origin in the nucleus ambiguus. Termination in the striated musculature of the pharynx and larynx.

XI. Accessory Nerve.—Superficial origin from the posterior lateral sulcus of the medulla oblongata caudal to the ninth and tenth and from the lateral aspect of the first five or six cervical segments of the spinal cord. Composition (Fig. 120):

1. *General Visceral Efferent Fibers*.—Cells of origin in the dorsal motor nucleus of the vagus. Fibers run in the bulbar rootlets and then by way of the internal ramus of the accessory to join the vagus, and end in the sympathetic plexuses, associated with the vagus nerve, for the innervation of thoracic and abdominal viscera.

2. *Special Visceral Efferent Fibers*.—These fall into two groups: A, fibers, whose cells of origin are located in the nucleus ambiguus, and which run by way of the internal ramus of the accessory to join the vagus and are distributed through it to the striated muscles of the pharynx and larynx; B, fibers, whose cells of origin lie in the lateral part of the anterior gray column of the first five or six cervical segments of the spinal cord, and which ascend in the spinal root of the accessory nerve and then run in its external ramus to end in the trapezius and the sternocleidomastoid muscles.

XII. Hypoglossal Nerve.—Superficial origin from the anterior lateral sulcus of the medulla between the pyramid and the olive. It is composed of somatic efferent fibers, whose cells of origin are located in the hypoglossal nucleus and whose termination is in the musculature of the tongue.

CHAPTER XIII

THE CEREBELLUM

DEVELOPMENT OF THE CEREBELLUM

THE dorsal border of the *alar lamina* occupies a lateral position in the rhombencephalon and, as a result of the development of the pontine flexure, acquires a V-shaped bend at the apex of which is the *lateral recess* of the fourth ventricle (Fig. 137, *A*). This dorsal border becomes everted and forms a prominent

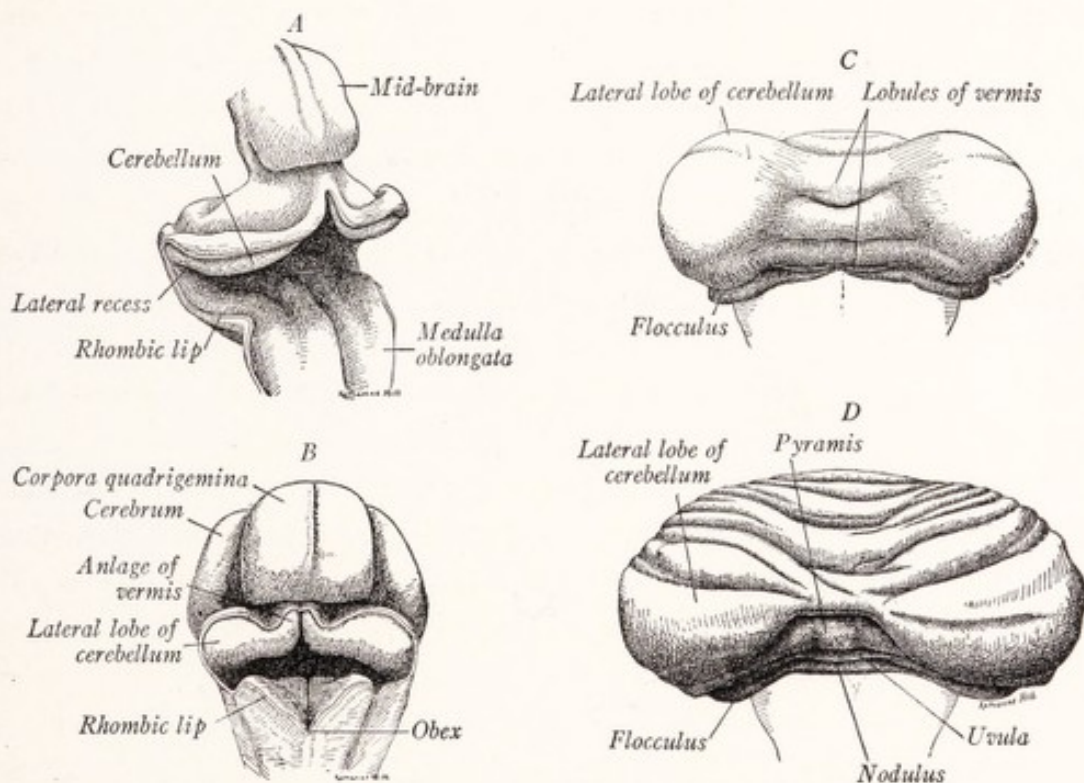


Fig. 137.—Dorsal view of four stages in the development of the cerebellum: *A*, of a 13.6 mm. embryo (His); *B*, of a 24 mm. embryo; *C*, of a 110 mm. fetus; *D*, of a 150 mm. fetus. (Pren-tiss and Arey.)

ridge known as the *rhombic lip*. From the portion of this ridge caudal to the lateral recess develop the tænia of the fourth ventricle and the obex. At the level of the recess the fibers of the acoustic nerve reach the dorsal edge of the alar lamina, which, accordingly, undergoes development at this point into *vestibular* and *cochlear nuclei*. More rostrally it undergoes an excessive devel-

opment, which is stimulated by the growth into it of afferent fibers from the vestibular nerve and of sensory fibers of the second order, bringing afferent impulses from other sources, chiefly from the somatic musculature. This part of the alar lamina, which may be regarded as an overgrown portion of the vestibular nucleus, develops into the *cerebellum*. As the paired *cerebellar plates* increase in thickness during the second month of embryonic development, they bulge inward toward the ventricle and take up a transverse position (Fig. 137, B). As they increase in size they invade the roof plate and unite in the median plane forming a transverse bar above the fourth ventricle. The lateral extremities of this bar expand, and the entire structure assumes a dumb-bell shape, the lateral masses representing the future cerebellar hemispheres and the intermediate part the future vermis.

At the close of the third month transverse sulci begin to appear in the vermis. The first of these, the *fissura prima* or sulcus primarius, extends into the lateral masses on either side and separates an anterior lobe from the remainder of the cerebellum. Other transverse fissures soon appear, due to the rapid expansion and resultant folding of the cortical layers.

The cerebellum differs from the other parts of the nervous system, which we have thus far studied in detail, in that the relative position of the gray and white matter is reversed. The gray substance forms a thin superficial layer, the *cerebellar cortex*, which covers a central white *medullary body* (*corpus medullare*). Originally the cerebellar plate is formed, like other parts of the neural tube, of an ependymal, a nuclear or mantle, and a cell-free marginal zone. The neuroblasts of the *mantle zone* take no part in the formation of the cortex, but become grouped in the internal nuclear masses of the cerebellum. The superficial or *marginal zone* is at first devoid of nuclei; the neuroblasts, from which the cerebellar cortex is differentiated, migrate into this zone from the ependymal and perhaps also from the mantle layers of the rhombic lip. These developing neurons send their axons inward instead of outward as in the case of the spinal cord. These axons accumulate, along with others which enter the cerebellum from without, in the deep part of the marginal layer and form the central medullary body of the cerebellum, separating the developing cortex from the deep nuclear masses that are differentiating from the mantle layer.

THE ANATOMY OF THE CEREBELLUM

It is customary to consider the cerebellum as composed of three parts: a small unpaired median portion, called the *vermis*, because superficially it re-

sembles a worm bent on itself to form almost a complete circle; and two large lateral masses, the *cerebellar hemispheres*, which are connected with each other by the vermis (Figs. 138, 139). Although morphologically incorrect, this subdivision has the advantage of convenience as well as of established usage. On the rostral aspect of the cerebellum the vermis forms a median ridge, not sharply marked off laterally from the hemispheres. This part has been called the *superior vermis*, and in contradistinction the remainder is known as the *inferior vermis*. The latter forms a prominent ridge, marked off from the hemisphere on either side by a well-defined sulcus. It lies in a deep groove between the hemispheres, known as the *vallecula*, within which the medulla oblongata is lodged. The hemispheres are also partially separated from each other by deep notches, the

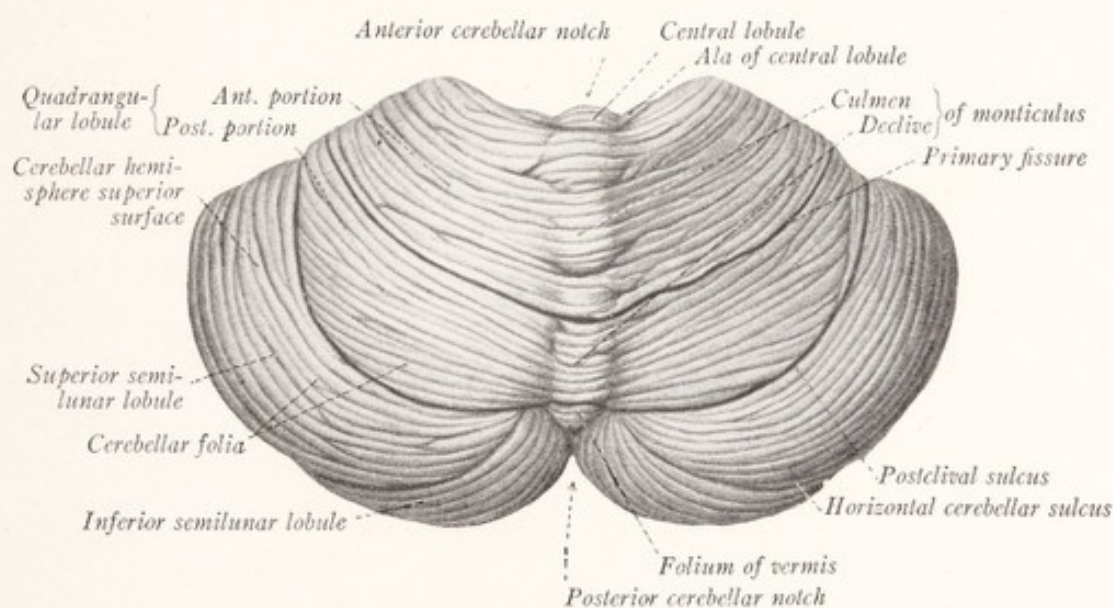


Fig. 138.—Dorsal view of the human cerebellum. (Modified from Sobotta-McMurrich.)

incisuræ cerebelli. The *anterior cerebellar notch* (semilunar notch) is broad and deep; and as seen from above it is occupied by the brachia conjunctiva and the inferior colliculi of the corpora quadrigemina. The *posterior cerebellar notch* (marsupial notch) is smaller, and within it is lodged a fold of the dura mater, the *falx cerebelli*.

The superior vermis is divided by transverse fissures into the following lobules (Fig. 138):

1. *Lingula*, closely applied to the anterior medullary velum between the two brachia conjunctiva.
2. *Central lobule*, associated with the small *alæ lobuli centralis* of the hemisphere.

3. *Monticulus*, which is further subdivided into the *culmen* and *declive*. The former goes over laterally without line of demarcation into the anterior portion of the quadrangular lobule, and the latter into the posterior portion of the same lobule in the hemisphere.

4. *Folium vermis* at the posterior extremity of the superior vermis.

The **rostral or dorsal surface of the hemisphere** is subdivided by curved transverse fissures, which are continued across the vermis, into the following parts:

1. The *anterior part of the quadrangular lobule*, continuous with the culmen monticuli of the vermis.

2. The *posterior part of the quadrangular lobule*, continuous with the declive monticuli.

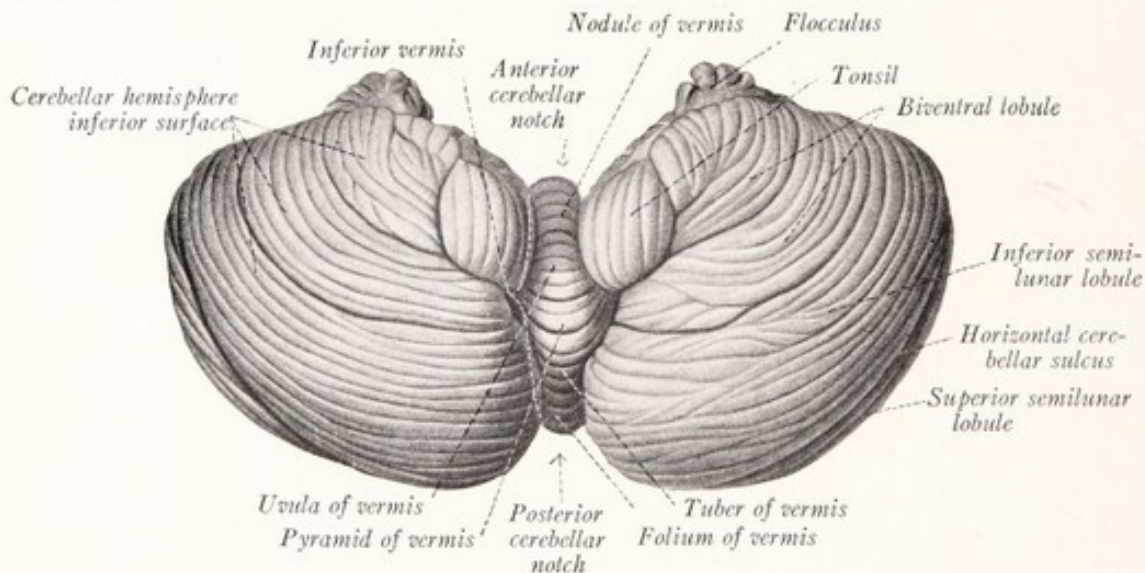


Fig. 139.—Ventral view of the human cerebellum. (Sobotta-McMurrich.)

3. The *superior semilunar lobule*, occupying a large crescentic area along the dorsolateral border of the rostral surface.

The **inferior vermis** (Fig. 139) is divided by transverse sulci into the following lobules:

1. The *tuber vermis*, next to the folium.
2. The *pyramis*.
3. The *uvula*.
4. The *nodulus*.

The **caudal surface of the hemisphere** presents the following subdivisions:

1. The *inferior semilunar lobule*, occupying a large part of this surface along its dorsolateral border.

2. The *biventral lobule*, occupying the ventrolateral part of the inferior surface.
3. The *tonsil*, a small rounded lobule near the inferior vermis.
4. The *flocculus* is the smallest of the lobules; and from it there runs toward the median plane a thin white band, the posterior medullary velum, and the peduncle of the flocculus.

Structure of the Cerebellum.—The cerebellum is composed of a thin superficial lamina of gray matter, spread over an irregular white center that contains several compact nuclear masses. This white medullary body forms a compact mass in the interior and is continuous from hemisphere to hemisphere through the vermis, within which, however, it is smaller than in the hemispheres (Figs. 140, 141). As is most readily seen in sagittal sections through the cerebellum, the medullary body gives off numerous thick laminae, which pro-

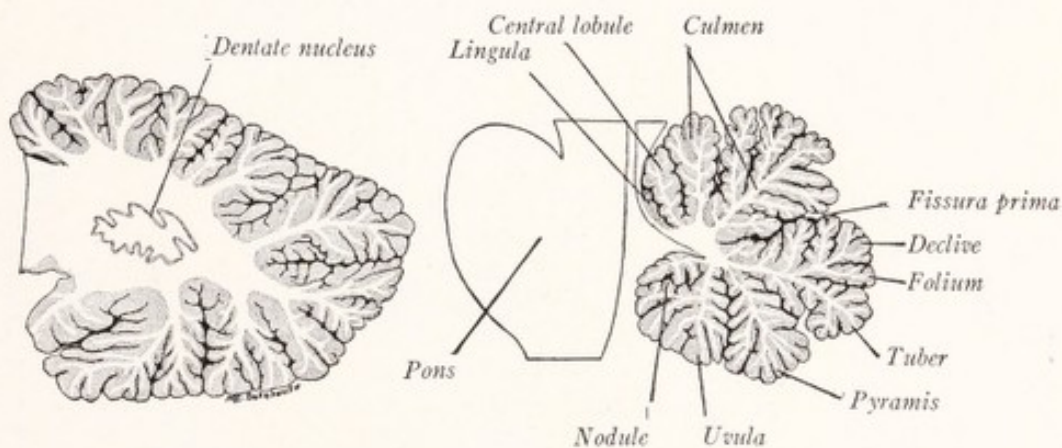


Fig. 140.

Fig. 141.

Figs. 140 and 141.—Sagittal sections of the human cerebellum: Fig. 140 passes through the hemisphere and dentate nucleus; Fig. 141, through the vermis in the median plane.

ject into the lobules of the cerebellum; and from these there are given off secondary and tertiary laminae at various angles. Thus a very irregular white mass is formed, over the surface of which the much folded cortex is spread in a thin but even layer. Supported by the white laminae, the cortex forms long narrow folds, known as *folia*, which are separated by sulci and which are aggregated into lobules that, in turn, are separated by more or less deep fissures. Sections through the cerebellum at right angles to the long axis of the folia thus present an arborescent appearance to which the name *arbor vitae* has been applied. This is particularly evident in sections through the vermis (Fig. 141).

MORPHOLOGY OF THE CEREBELLUM

According to Elliott Smith (1903) and Bolk (1906), who have carried out extensive investigations on the morphology of the mammalian cerebellum, the *fissura prima* is an

important and constant fissure. It extends in a continuous curved line across the rostral aspect of the vermis and both hemispheres. It has been found by Ingvar (1918) in reptiles and birds. All investigators who have given attention to this subject in recent years agree in designating the portion of the cerebellum which lies rostral to the fissura prima as the *anterior lobe*. The portion behind this fissure is composed of several individual lobules; each of which, though subject to considerable variation in form in the different genera, can be identified in every mammalian cerebellum. These lobules have been variously grouped into lobes by different investigators. Here we will follow the grouping employed by Ingvar, which is based on a comparison of the mammalian cerebellum with that of birds and reptiles (Fig. 142). He recognizes three major divisions of the cerebellum, which he designates as the *anterior*, *middle*, and *posterior lobes*. The middle lobe contains those parts of the cerebellum which have been the last to appear during phyletic development, and it is here that the greatest variations are found in the different orders of mammals.

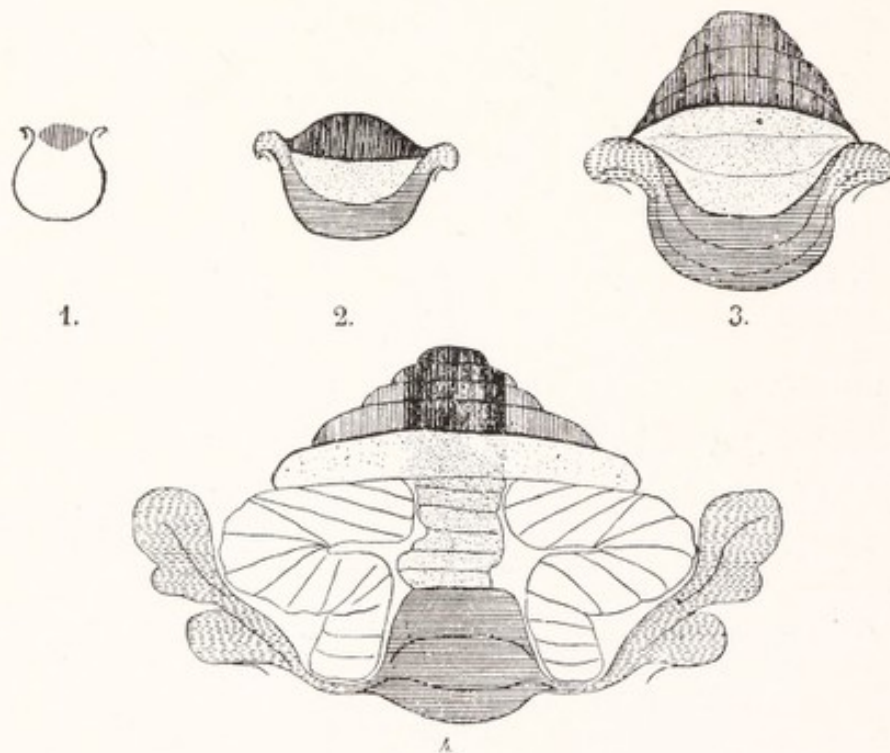


Fig. 142.—Schematic drawing of the cerebellum of 1, lizard; 2, crocodile; 3, bird, and 4, mammal. Vertical lines, anterior lobe; stipple, middle lobe; horizontal lines, posterior lobe; white, lobus ansoparamedianus. (Ingvar.)

The *anterior lobe* includes all that part of the cerebellum that lies on the rostral side of the fissura prima (Figs. 143, 144, 146). In this lobe the folia have a transverse direction and extend without interruption across the vermis into both hemispheres. In the sheep the anterior lobe is bounded laterally by the parafloccular fissure. It includes the three most rostral lobules of the superior vermis, which are designated in order from before backward, the *lingula*, *lobulus centralis*, and *culmen monticuli*. In man it also includes a large wing-shaped portion of each hemisphere (the *pars anterior lobuli quadrangularis*); and the entire lobe has the shape of a butterfly (Fig. 146). Morphologically, it is a median unpaired structure.

The *middle lobe* is subdivided into four parts (Fig. 142). The most rostral of these is the *lobulus simplex*. It is separated from the anterior lobe by the fissura prima, and like that lobe it consists of transverse folia which extend across the superior vermis into both

hemispheres (Figs. 143, 144). In man the lobulus simplex forms a broad crescentic band across the rostral surface of the cerebellum, including what is ordinarily designated as the posterior part of the quadrangular lobule and the declive monticuli (Fig. 146). Like the anterior lobe, it is a median unpaired structure. The remainder of the middle lobe is subdivided into median and lateral portions. The median part, known as the *tuber vermis*

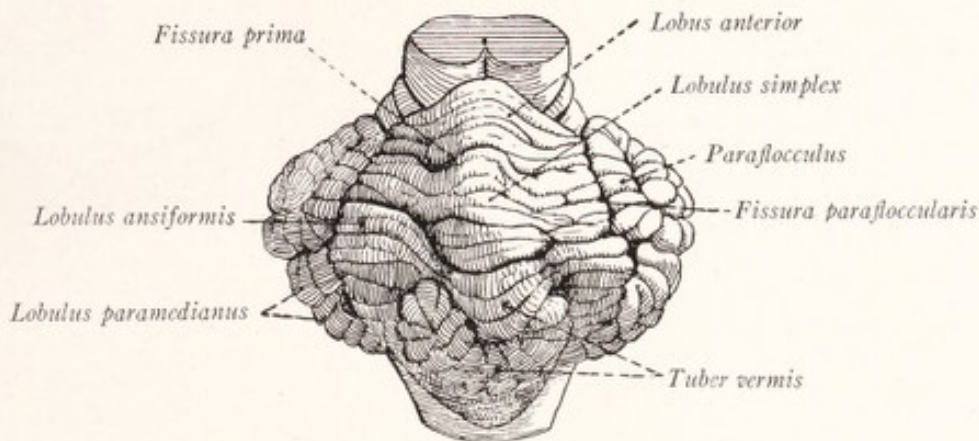


Fig. 143.—Cerebellum of the sheep, dorsorostral view.

(lobulus medius medianus of Ingvar and lobulus C² of Bolk), forms a conspicuous S-shaped lobule in the vermis of the sheep (Fig. 145) and may be readily identified at the occipital extremity of the inferior vermis in man (Figs. 139, 141). The paired lateral portions of the middle lobe each consist of two parts, called the *lobulus ansiformis* and *lobulus paramedianus*. The lobulus ansiformis, relatively small in most mammals (Fig. 144), is very large in man,

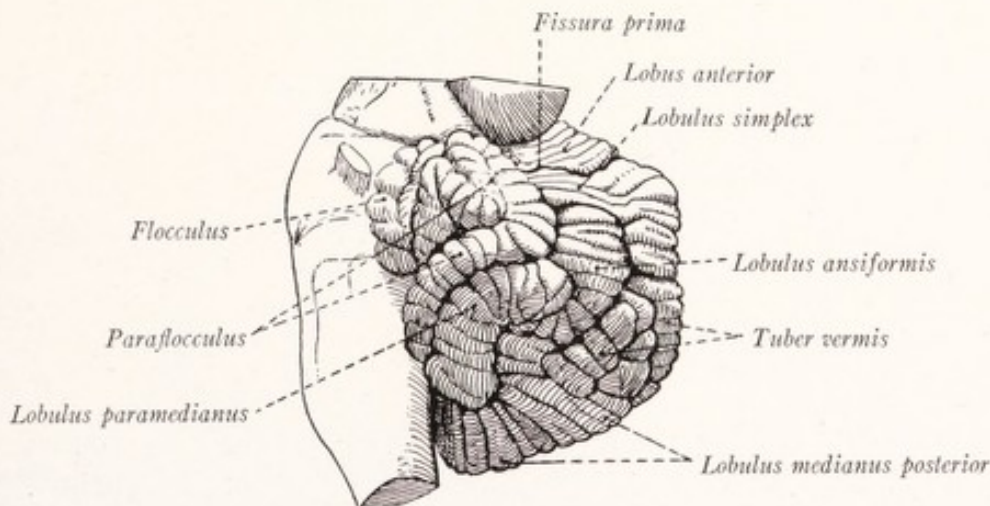


Fig. 144.—Cerebellum of the sheep, lateral view.

and forms approximately the dorsolateral half of the hemisphere, occupying considerable parts of both the rostral and caudal surfaces. It corresponds to what has been known as the superior and inferior semilunar lobules and the biventral lobule (Figs. 146, 147). The lobulus paramedianus, or tonsilla of the B. N. A., is located on the lateral surface of the sheep's cerebellum, but is displaced on to the caudal surface in man by the great expansion of the lobulus ansiformis.

The *posterior lobe*, as outlined by Ingvar, is composed of median and lateral portions. The median part, known as the posterior median lobule, comprises all of the inferior vermis except the tuber, from which it is separated by the prepyramidal sulcus. It is subdivided into three sublobules, known as the *nodule*, *uvula*, and *pyramid* (Figs. 139, 141, 145). The lateral part of the posterior lobe is formed on either side by two lobules, known as the flocculus and paraflocculus. These form the most lateral portion of the hemisphere in most mammals (Figs. 142, 144). In man the paraflocculus is rudimentary and the flocculus lies upon the caudal surface of the hemispheres (Fig. 147). It is connected with the nodule by a thin sheet of white matter, the *posterior medullary velum*.

Functional Localization in the Cerebellum.—We have described the cerebellum in terms of the subdivisions of Bolk and Ingvar, because these have morphologic and physiologic significance, which is not true of the parts into which the cerebellum had previously been divided. By comparison of the size of these subdivisions with the degree of development and functional importance of the various groups of muscles in different animals Bolk endeavored to show that each of these parts was related to a particular group of muscles. On the basis of these comparative studies he concluded that the median unpaired portions of the cerebellum serve as coördination centers for the muscles which function in bilateral

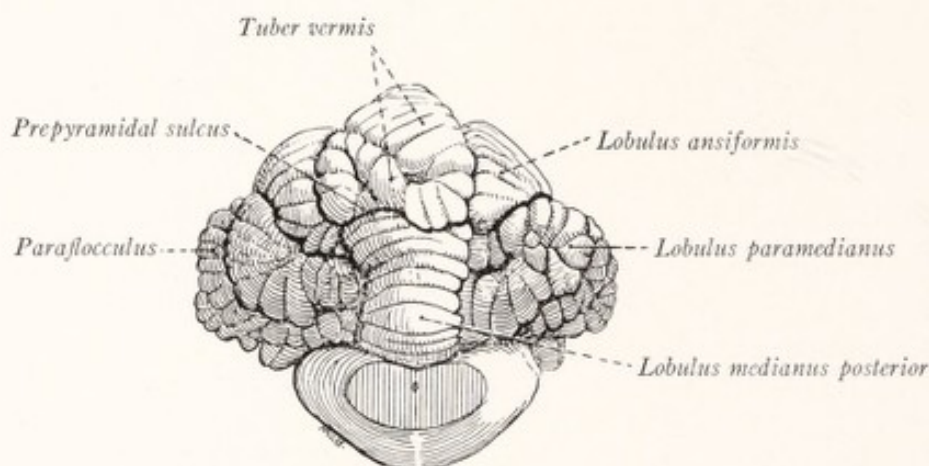


Fig. 145.—Cerebellum of the sheep, caudal view.

synergy. The muscles of expression and mastication, those of the eyes, pharynx, larynx and neck, and many of the trunk muscles are called into action simultaneously on both sides of the body, and should, according to this theory, have a median unpaired representation in the cerebellum. Bolk located the coördination center for the musculature of the head in the anterior lobe, that for the muscles of the neck in the lobulus simplex (Figs. 146, 147). A median center for those movements of the extremities which are strictly bilateral is found in the most dorsal sublobule of the vermis inferior, known as lobulus C² or tuber vermis. The remainder of the inferior vermis forms, according to this theory, a center for the bilateral movements of the trunk. In addition to a median center in the tuber vermis, the limbs are represented in the cerebellum by lateral centers for the coördination of unilateral movements. The lateral center for the arm is located in the rostral part or crus primum of the lobulus ansiformis (superior and inferior semilunar lobules) and that for the legs in the caudal part or crus secundum (biventral lobule), and perhaps also in the lobulus paramedianus (tonsil).

The conclusions concerning the localization of function in the cerebellum, reached by Bolk on the basis of morphologic studies, have been confirmed in so far as the centers for the neck and extremities are concerned by animal experimentation (Van Rynberk, 1908, 1912;

André Thomas and Durupt, 1914) and by clinical observations (Bárány, 1912). There are, however, good reasons for skepticism regarding his localization of centers for the head and trunk. Ingvar (1918) presents evidence which indicates that the anterior and posterior lobes are probably concerned with the maintenance of the equilibrium of the body as a whole. The middle lobe, on the other hand, contains a number of separate centers, which correspond to those outlined by Bolk, for the control of the musculature of the neck and extremities.

It has long been known that the *degree of development of the cerebellar hemispheres* in the different classes of vertebrates is closely correlated with that of the pons and cerebral cortex. This is particularly true of the lobulus ansiformis and lobulus paramedianus, which, like the neopallium, are recent phyletic developments. These belong to what Edinger (1911) calls

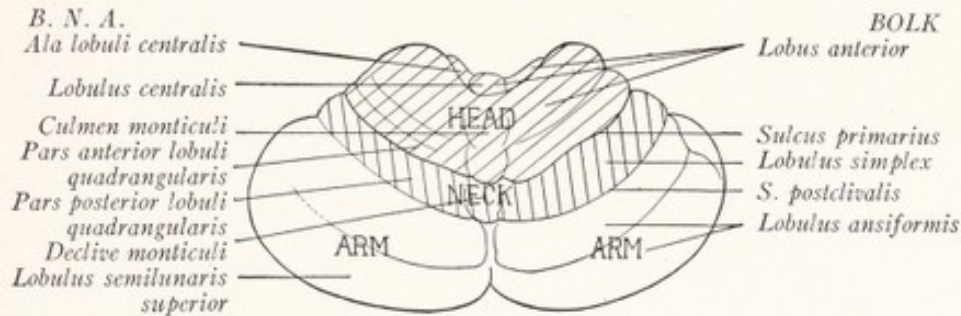


Fig. 146.

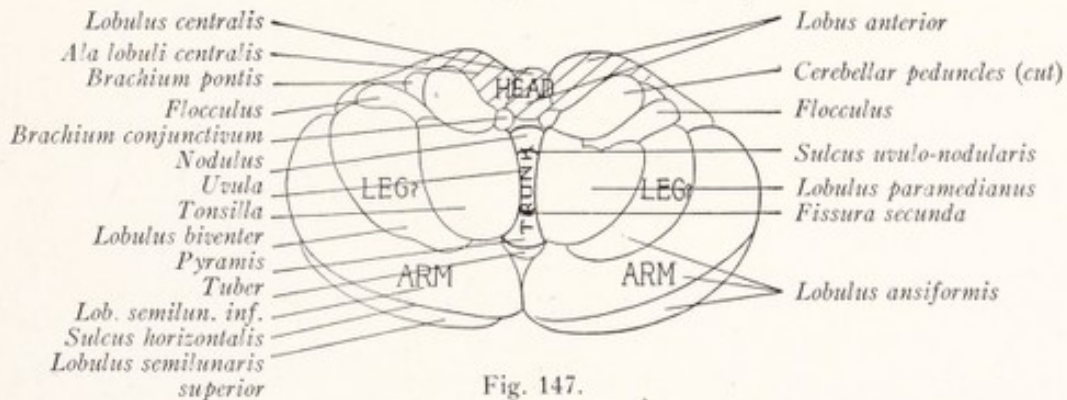


Fig. 147.

Figs. 146 and 147.—Outline drawings of the human cerebellum showing the localization of function according to the theory of Bolk. On the right side the parts are designated according to Bolk's terminology, on the left according to the B. N. A. Fig. 146, dorsal view. Fig. 147, ventral view. (Herrick.)

the neocerebellum, receive the majority of the fibers from the brachium pontis, and may properly be regarded as cortical dependencies. They take an important part in the co-ordination of the voluntary movements of the extremities.

THE NUCLEI OF THE CEREBELLUM

The *dentate nucleus* is a crumpled, purse-like lamina of gray matter within the massive medullary body of each cerebellar hemisphere (Fig. 148). Like the inferior olivary nucleus, which it closely resembles, it has a white center and a medially placed hilus. In close relation to this hilus lies a plate of gray matter, the *emboliform nucleus*, and medial to this is the small *globose nucleus*.

Close to the median plane in the medullary body of the vermis, where this forms the tent-like covering of the fourth ventricle, is the nucleus of the roof or *nucleus fastigii*.

The dentate nucleus is well developed only in those animals which possess large cerebellar hemispheres. It receives fibers from the cortex of the cerebellar hemisphere, while the nuclei fastigii and globosi receive fibers chiefly from the vermis (Clark and Horsley, 1905; Edinger, 1911). It is probable that

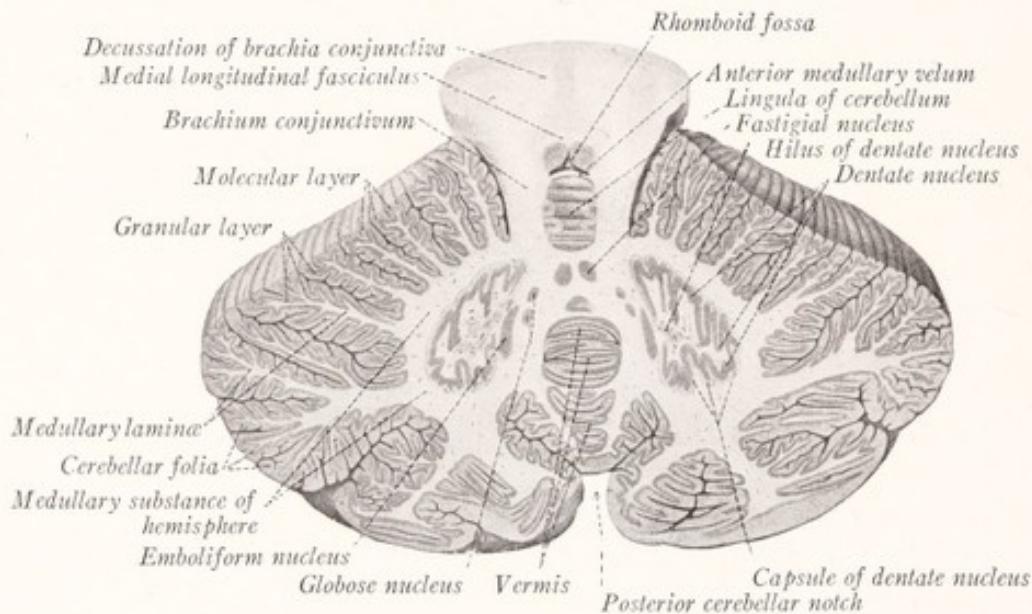


Fig. 148.—Horizontal section through the cerebellum showing the location of the central nuclei. (Sobotta-McMurrich.)

a functional localization similar to that in the cerebellar cortex will be found to exist in the central nuclei. In histologic structure the central nuclei closely resemble the inferior olive.

THE CEREBELLAR PEDUNCLES

The white core of the cerebellum is formed in large part of fibers which enter and leave the cerebellum through its three peduncles.

The **brachium pontis**, or middle cerebellar peduncle, is formed by the transverse fibers of the pons and carries impulses which come from the cerebral cortex of the opposite side. It enters the cerebellum on the lateral side of the other two, and is distributed in two great bundles: one from the rostral part of the pons radiates to the caudal part of the cerebellar hemisphere; the other, from the caudal part of the pons, spreads out to the rostral portion of the hemisphere. In man, as might be expected from the large size of the pons and cerebellar

hemispheres, the brachium pontis is the largest of the three peduncles (Fig. 89). But this is not true in most mammals, where, as in the sheep, the cerebellum receives the majority of its afferent fibers from the spinal cord and medulla oblongata by way of the relatively large restiform bodies (Fig. 91).

The **restiform body** ascends along the lateral border of the fourth ventricle; and at a point just rostral to the lateral recess it makes a sharp turn dorsally to enter the cerebellum between the other two peduncles (Figs. 87, 88). It consists of ascending fibers from the spinal cord and medulla oblongata and probably also of descending fibers from the cerebellum to the reticular formation of the medulla (fastigiobulbar tract, p. 211). Among the ascending fibers are those of the following bundles: (1) *dorsal spinocerebellar tract*, which arises

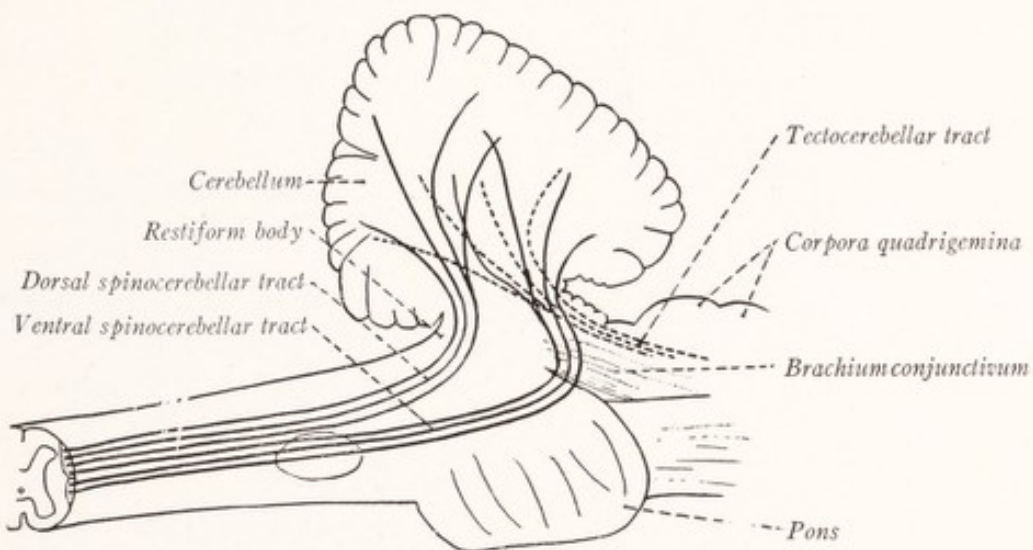


Fig. 149.—Diagram of the spinocerebellar and tectocerebellar tracts.

from the cells of the nucleus dorsalis of the same side of the spinal cord and ends in the cortex of the vermis; (2) the *olivocerebellar tract*, which consists of fibers from the opposite inferior olivary nucleus and to a less extent from that of the same side and which ends in the cortex of the vermis and of the hemisphere and in the central nuclei; (3) the *dorsal external arcuate fibers*, from the nuclei of the posterior funiculi of the same side; (4) *ventral external arcuate fibers* from the arcuate and lateral reticular nuclei (Fig. 104).

The so-called *medial part of the restiform body* consists of bundles of fibers belonging to the *tractus nucleocerebellaris*, which course along the medial side of that peduncle as it turns dorsally into the cerebellum (Fig. 110). These come from the sensory nuclei of the cranial nerves. Most of them arise from the superior and lateral vestibular nuclei or represent the ascending branches of the

fibers of the vestibular nerve and constitute the *tractus vestibulocerebellaris*. According to Cajal (1911) the fibers of this tract are distributed to the cortex of the cerebellum, the majority of them going to the vermis, a smaller proportion to hemisphere. In view of the newer ideas concerning the morphology of the cerebellum, the statements concerning the termination of all these cerebellar afferent fibers require re-examination.

The **brachium conjunctivum** (Fig. 88) consists of efferent fibers from the dentate nucleus to the red nucleus and the thalamus of the opposite side. It is the smallest and most medial of the three peduncles. The *ventral spinocerebellar tract* enters the cerebellum in company with the brachium conjunctivum. It ascends through the medulla oblongata and pons, curves over the brachium conjunctivum (Fig. 110), and enters the anterior medullary velum, within which it runs to the cerebellum (Fig. 149). Its fibers terminate in the rostral part of the vermis and in the nucleus fastigii (Horrax, 1915). According to Edinger, a bundle of fibers, the *tectocerebellar tract*, arises in the tectum of the mesencephalon and descends alongside of the brachium conjunctivum to the cerebellum, probably conveying impulses from visual centers.

According to MacNalty and Horsley (1909) and Ingvar (1918) the fibers of the ventral spinocerebellar tract end in the lobulus centralis, culmen, and most rostral part of the declive. The fibers of the dorsal spinocerebellar tract have the same termination and, in addition, many of them go to the pyramis, and smaller numbers to the uvula and nodule. Practically all of the fibers which end in the cortex, therefore, go to the anterior and posterior lobes (Ingvar). The fact that the anterior lobe receives the majority of these fibers, which convey proprioceptive impulses from the trunk and extremities, is a strong argument against Bolk's conception of the anterior lobe as a co-ordination center for the musculature of the head.

HISTOLOGY OF THE CEREBELLAR CORTEX

The cerebellar cortex differs from that of the cerebral hemispheres in possessing essentially the same structure in all the lobules. This would indicate that it functions in essentially the same way throughout, though as a result of different fiber connections the various lobules act on different muscle groups.

A section through the cerebellum, taken at right angles to the long axis of the folia, shows each folium to be composed of a central white lamina, covered by a layer of gray cortex. Within the white lamina the nerve-fibers are arranged in parallel bundles extending from the medullary center of the cerebellum into the lobules and folia. A few at a time these bundles turn off obliquely into the gray matter, and there is no sharp demarcation between the cortex and the subjacent white lamina. The cortex presents for examination three well-defined

zones: a superficial molecular layer, a layer of Purkinje cells, and a subjacent granular layer.

The cells of Purkinje have large flask-shaped bodies and are arranged in an almost continuous sheet, consisting of a single layer of cells and separating the other two cortical zones (Fig. 150). They are more numerous at the summit than at the base of the folium. Each has a pyriform cell body. The part directed toward the surface of the cortex resembles the neck of a flask and from

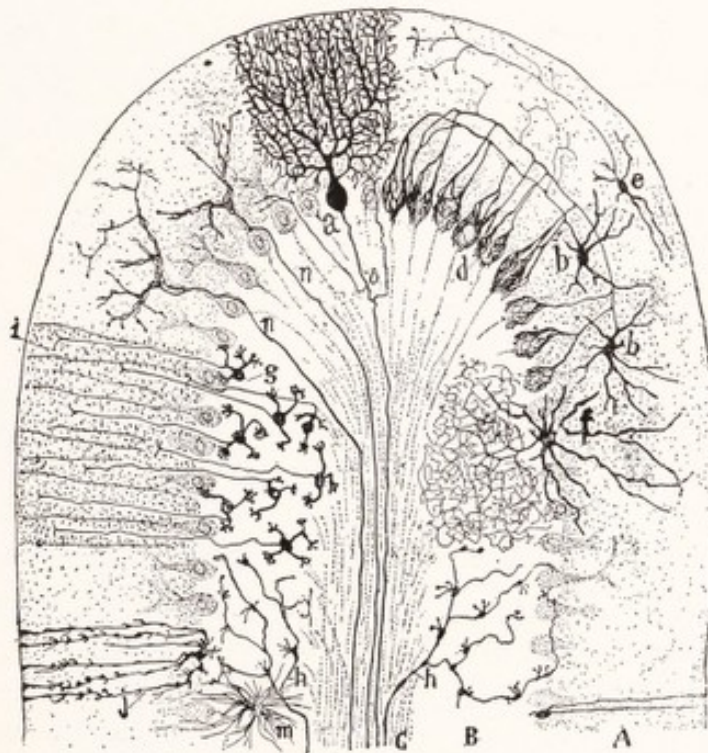


Fig. 150.—Semidiagrammatic transverse section through a folium of the cerebellum. (Golgi method): *A*, Molecular layer; *B*, granular layer; *C*, white matter; *a*, Purkinje cell; *b*, basket cells; *d*, pericellular baskets, surrounding the Purkinje cells and formed by the arborizations of the axons of the basket cells; *e*, superficial stellate cells; *f*, cell of Golgi Type II; *g*, granules, whose axons enter the molecular layer and bifurcate at *i*; *h*, mossy fibers; *j* and *m*, neuroglia; *n*, climbing fibers. (Cajal.)

it spring one or two stout dendrites. These run into the molecular layer and extend throughout its entire thickness, branching repeatedly. This branching occurs in a plane at right angles to the long axis of the folium; and it is only in sections, taken in this plane, that the full extent of the branching can be observed. In a plane corresponding to the long axis of the folium the dendrites occupy a more restricted area (Fig. 151). In this respect the dendritic ramifications resemble the branches of a vine on a trellis. From the larger end of the cell, directed away from the surface of the cortex, there arises an axon which

almost at once becomes myelinated and runs through the granular layer into the white substance of the cerebellum. According to Clarke and Horsley (1905) and Cajal (1911) these axons end in the central cerebellar nuclei. Near their origin they give off collaterals, which run backward through the molecular layer to end in connection with neighboring Purkinje cells—an arrangement designed to bring about the simultaneous discharge of a whole group of such neurons.

The **granular layer**, situated immediately subjacent to that which we have just described, is characterized by the presence of great numbers of small neurons, the *granule cells*. Each of these contains a relatively large nucleus, surrounded by a small amount of cytoplasm; and from each there are given off from three to five short *dendritic branches* with claw-like endings. These are synaptically related with the terminal branches of the moss fibers, soon to be described, and

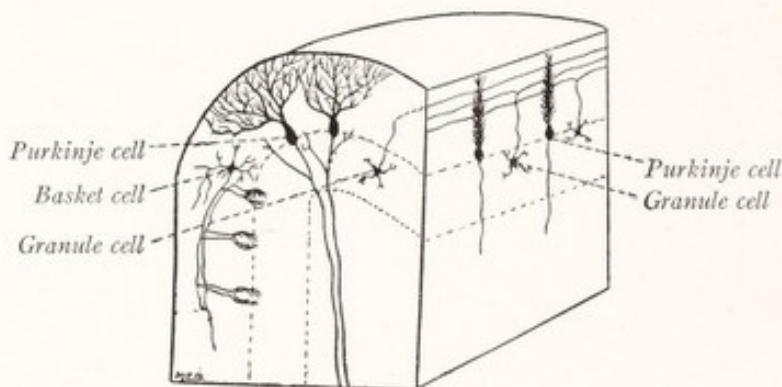


Fig. 151.—Diagrammatic representation of the structure of the cerebellar cortex as seen in a section along the axis of the folium (on the right), and in a section at right angles to the axis of the folium (on the left).

form with them small glomeruli comparable to those of the olfactory bulb (Fig. 208). Each granule cell gives origin to an unmyelinated *axon*, which extends toward the surface of the folium and enters the molecular layer. Here it divides in the manner of a T into two branches. These run parallel to the long axis of the folium through layer after layer of the dendritic expansions of the Purkinje cells, with which they doubtless establish synaptic relations (Fig. 151). Besides the granules just described, this layer contains some large cells of Golgi's Type II (Fig. 150, *f*). Most of these are placed near the line of Purkinje cells and send their dendrites into the molecular layer, while their short axons resolve themselves into plexuses of fine branches in the granular zone.

The **molecular layer** contains few nerve-cells and has in transverse sections a finely punctate appearance. It is composed in large part of the dendritic ramifications of the Purkinje cells and the branches of axons from the granule

cells (Fig. 150). It contains a relatively small number of stellate neurons, the more superficial of which possess short axons and belong to Golgi's Type II. Those more deeply situated have a highly specialized form and are known as *basket cells*. From each of these there arises, in addition to several stout branching dendrites, a single characteristic axon, which runs through the molecular layer in a plane at right angles to the long axis of the folium (Fig. 151). These axons are at first very fine, but soon become coarse and irregular, giving off numerous collaterals which are directed away from the surface of the cortex. These collaterals and the terminal branches of the axons run toward the Purkinje cells, about which their terminal arborizations form basket-like networks (Fig. 29).

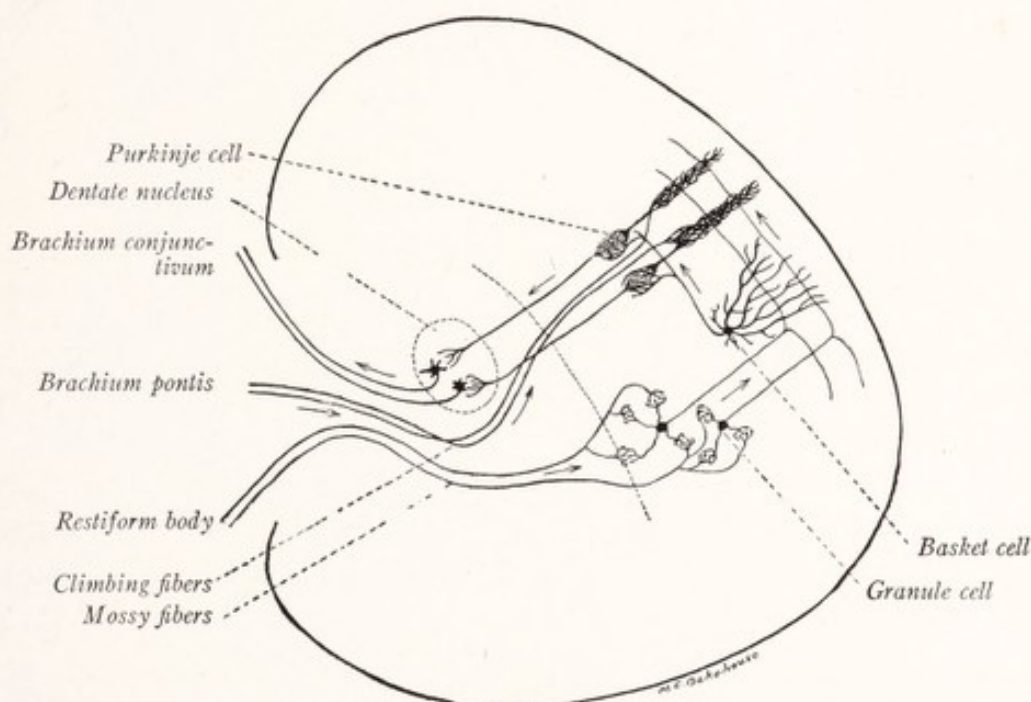


Fig. 152.—Diagram to illustrate the probable lines of conduction through the cerebellum.

Nerve-fibers.—The axons of the Purkinje cells form a considerable volume of fibers directed away from the cortex. There are also two kinds of afferent fibers which enter the cortex from the white center, and are known as *climbing* and *mossy fibers* respectively. The latter are very coarse and give off numerous branches ending within the granular layer. The terminal branches are provided with characteristic moss-like appendages. These mossy tufts are intimately related to the claw-like dendritic ramifications of the granule cells (Fig. 152). The *climbing fibers*, somewhat finer than those of the preceding group, pass through the molecular layer and become associated with the dendrites of the Purkinje cells in the manner of a climbing vine. Branching repeatedly, they

follow closely the dendritic ramifications of these neurons and terminate in free varicose endings.

It would seem reasonable to suppose that the two kinds of *afferent fibers*, just described, have a separate origin and functional significance. According to Cajal (1911) it is probable that those entering the cerebellum through the brachium pontis are distributed as climbing fibers, and those from the restiform body as mossy fibers. The accompanying diagram represents the probable course of impulses through the cerebellum (Fig. 152). The *mossy fibers*, probably derived from the restiform body, transfer their impulses to the granule cells; and these, in turn, relay them, either directly or through the basket neurons, to the Purkinje cells. The *climbing fibers*, which probably come from the brachium pontis, transfer their impulses directly to the dendrites of the Purkinje cells. We do not know to which class the fibers of the vestibulocerebellar tract should be assigned. The *efferent path* may be said to begin with the Purkinje cells, whose axons terminate in the central cerebellar nuclei. From these nuclei, especially the dentate, arise the fibers of the brachium conjunctivum, the great efferent tract from the cerebellum. By means of the axons of the granule cells, basket cells, and neurons of Golgi's Type II, as well as by the collaterals from the axons of the Purkinje cells, an incoming impulse may be diffused through the cortex.

The cerebellum probably receives fibers from all the somatic sensory centers, but especially from those of the proprioceptive group, through which afferent impulses are conveyed to it from the muscles, joints and tendons, and from the semicircular canals of the ear. Its connection with the vestibular apparatus is especially intimate. In fact, as already stated, it may be regarded from the standpoint of development as a very highly specialized portion of the vestibular nucleus. It is the great proprioceptive correlation center. Furthermore, it sends efferent impulses to the various somatic motor centers and plays an important part in the coördination of muscular contraction and in the maintenance of muscular tone. It is the chief center for equilibration, which depends upon the proper adjustment of the muscles in response, very largely, to the impulses from the semicircular canals. In man and mammals it also receives impulses from the cerebral cortex by way of the pons, which probably set the coördinating cerebellar mechanism into activity to bring about the proper adjustment of voluntary movements. For additional details concerning the functions of the cerebellum the reader should consult the recent paper by Holmes (1917).

THE EFFERENT CEREBELLAR TRACTS

The efferent cerebellar tracts arise in the central nuclei. It is probable that no fibers of cortical origin leave the cerebellum except, perhaps, some to Deiter's nucleus (Clarke and Horsley, 1905).

The **brachium conjunctivum**, or tractus cerebellotegmentalis mesencephali, arises for the most part at least in the dentate nucleus and terminates in the red nucleus and thalamus of the opposite side (Fig. 153). It constitutes the chief tract leading from the cerebellum and has been more fully described on page 159. It undergoes a complete decussation beneath the inferior colliculus in the tegmentum of the mesencephalon. Both before and after this crossing its

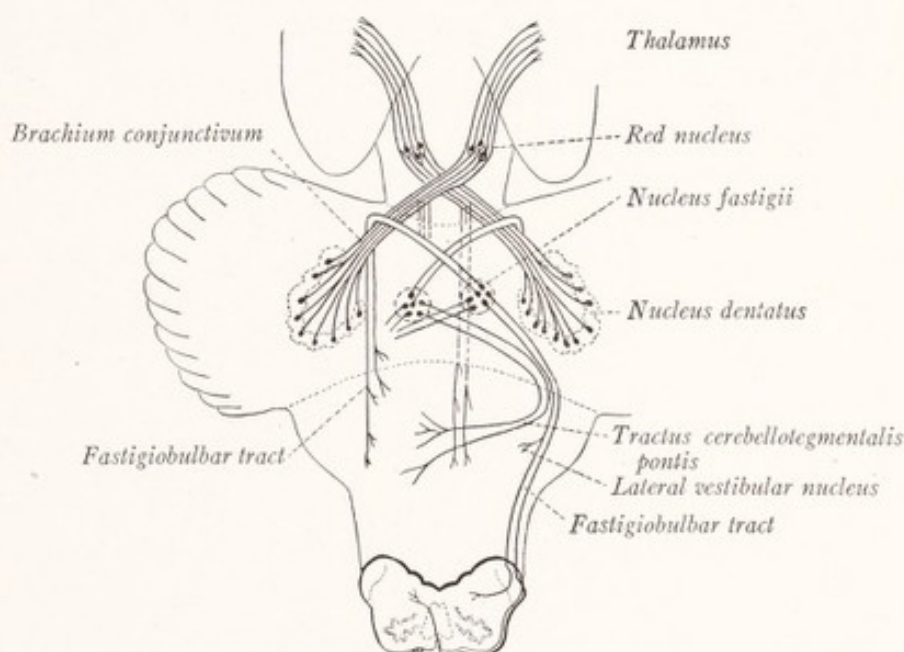


Fig. 153.—Efferent tracts which arise in the central nuclei of the cerebellum. (Modified from Edinger.)

fibers give off branches, which descend in the reticular formation of the pons and medulla. Some of the impulses reach the thalamus, but the others are relayed in the red nucleus along the rubrospinal and rubroreticular tracts to motor neurons in the brain stem and spinal cord (Fig. 115).

Other efferent tracts arise in the *nucleus fastigii* of the same and opposite side, and run, probably by way of all three cerebellar peduncles, to the reticular formation of the pons and medulla oblongata. One bundle of these fibers winds around the brachium conjunctivum before descending through the pons and medulla (Fig. 153). It is probable that other fibers descend by way of the restiform body, and are distributed in the reticular formation of the medulla

oblongata on the same side, or are continued as ventral external arcuate fibers to end on the opposite side. The bundles which run from the nucleus fastigii to the medulla oblongata may be designated as the *fastigiobulbar tracts* (tractus cerebellotegmentales bulbi). These include fibers which terminate in the lateral vestibular nucleus. It is said that some fibers belonging to this system leave the cerebellum by way of the brachium pontis (tractus cerebellotegmentalis pontis).

Since the dentate nucleus receives fibers from the cortex of the corresponding cerebellar hemisphere, and the nucleus fastigii receives similar fibers from the vermis, it may be inferred that the brachium conjunctivum is the chief efferent tract for the hemisphere and that the fastigiobulbar tracts serve the same purpose for the vermis (Strong, 1915).

CHAPTER XIV

THE DIENCEPHALON AND THE OPTIC NERVE

Development.—In an earlier chapter we traced briefly the development of the prosencephalon and showed that the cerebral hemispheres were developed through the evagination of the lateral walls of the telencephalon (Fig. 16). It is, however, only the alar lamina which is involved in this evagination. The basal lamina of the telencephalon retains its primitive position and forms the pars optica hypothalami. This part of the hypothalamus, along with the lamina terminalis and the most rostral part of the third ventricle, constitutes the *telencephalon medium* (Johnston, 1912). Through the excessive growth of the hemisphere the diencephalon becomes covered from view (Fig. 17), and appears to occupy a central position in the adult human brain. It is separated from the hemisphere by the *transverse cerebral fissure*, which is formed by the folding back of the hemisphere over the diencephalon. The differentiation of the alar lamina of the diencephalon into the *thalamus*, *epithalamus*, and *metathalamus*, and of its basal lamina into the *hypothalamus* was briefly traced on page 34. The sulcus limitans, which separates these two plates in the embryo, corresponds to the more caudal portion of the hypothalamic sulcus of the adult; but, since the latter can be followed to the interventricular foramen, while the former ends near the optic chiasma, the rostral ends of these two sulci are not related. The roof plate of the prosencephalon remains thin and constitutes the epithelial roof of the third ventricle, which along the median plane becomes invaginated into the ventricle as the covering of a vascular network to form the chorioid plexus.

THE THALAMUS

The thalamus is a large ovoid mass, consisting chiefly of gray matter, placed obliquely across the rostral end of the cerebral peduncle (Figs. 154, 155). Between the two thalami a deep median cleft is formed by the third ventricle. The *rostral end* is small and lies close to the median plane. It projects slightly above the rest of the dorsal surface, forming the *anterior tubercle* of the thalamus, and helps to bound the interventricular foramen (Fig. 154). The *caudal extremity* is larger and is separated from its fellow by a wide interval, in which the

corpora quadrigemina appear. It forms a marked projection, the pulvinar, which overhangs the medial geniculate body and the brachia of the corpora quadrigemina (Figs. 88, 154). For purposes of description it is convenient to recognize four thalamic surfaces, namely, dorsal, ventral, medial, and lateral.

The **dorsal surface** of the thalamus is free (Figs. 91, 154). It forms the floor of the transverse fissure of the cerebrum and is separated by this fissure from the parts of the cerebral hemisphere which overlie it, that is, from the

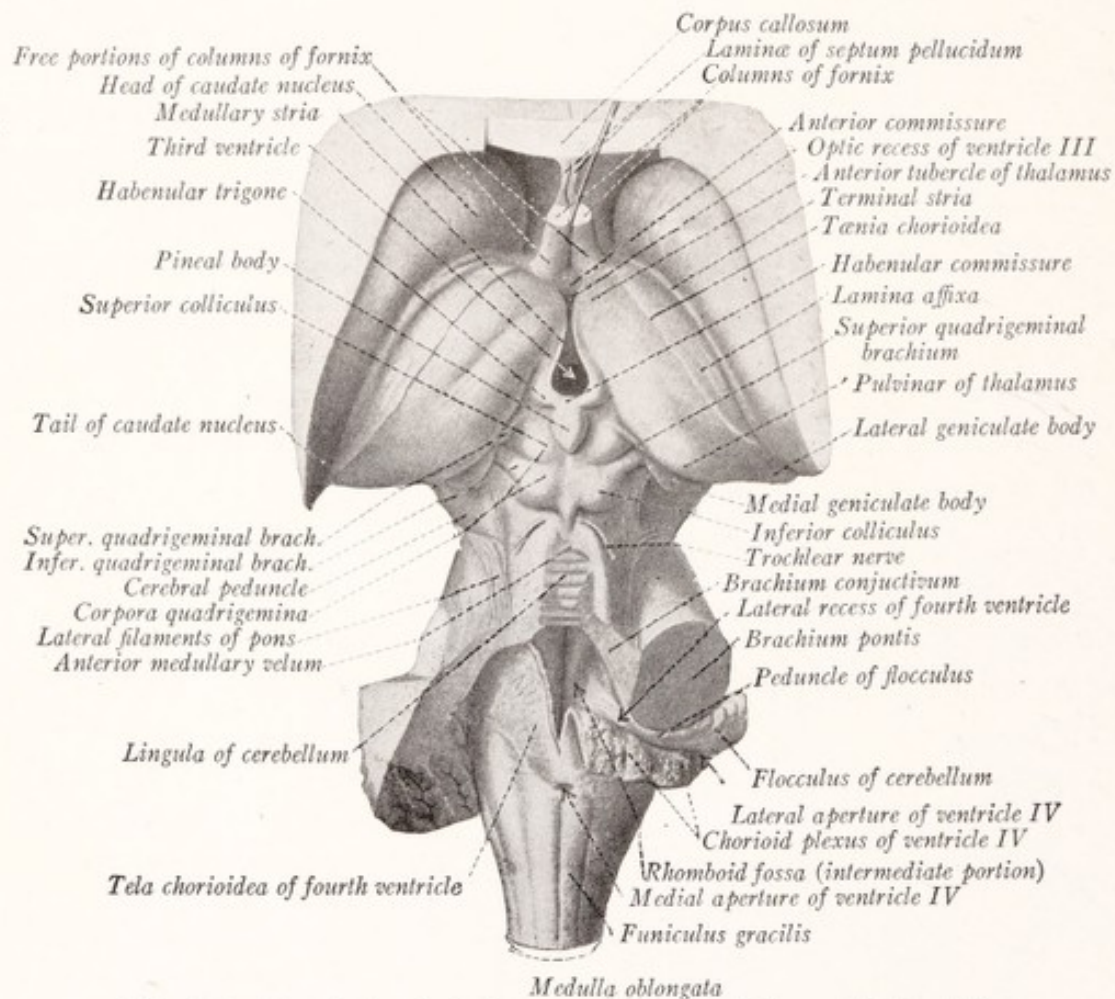


Fig. 154.—Dorsal view of the human brain stem. (Sobotta-McMurrich.)

fornix and corpus callosum. *Laterally* it is bounded by a groove, which separates it from the caudate nucleus and contains a strand of longitudinal fibers, the *stria terminalis* and a vein, the *vena terminalis* (Figs. 154, 155). The dorsal surface is separated from the medial by a sharp ridge, the *tenia thalami*, which represents the torn edge of the ependymal roof of the third ventricle. The *teniae* of the two sides meet in the stalk of the pineal body. The prominence of this torn edge of the roof is increased by a longitudinal bundle of fibers,

the *stria medullaris thalami*. This fascicle, together with the closely related habenular trigone and the pineal body, belong to the epithalamus and will be described later.

The *dorsal surface* of the thalamus is slightly convex and is divided by a faint groove into two parts: a lateral area, covered by the *lamina affixa* and forming a part of the floor of the lateral ventricle; and a larger medial area, which forms the floor of the transverse fissure of the cerebrum. The oblique groove separating these two areas corresponds to the lateral border of the fornix (Figs. 154, 155). The lamina affixa is part of the ependymal lining of the lateral ventricle superim-

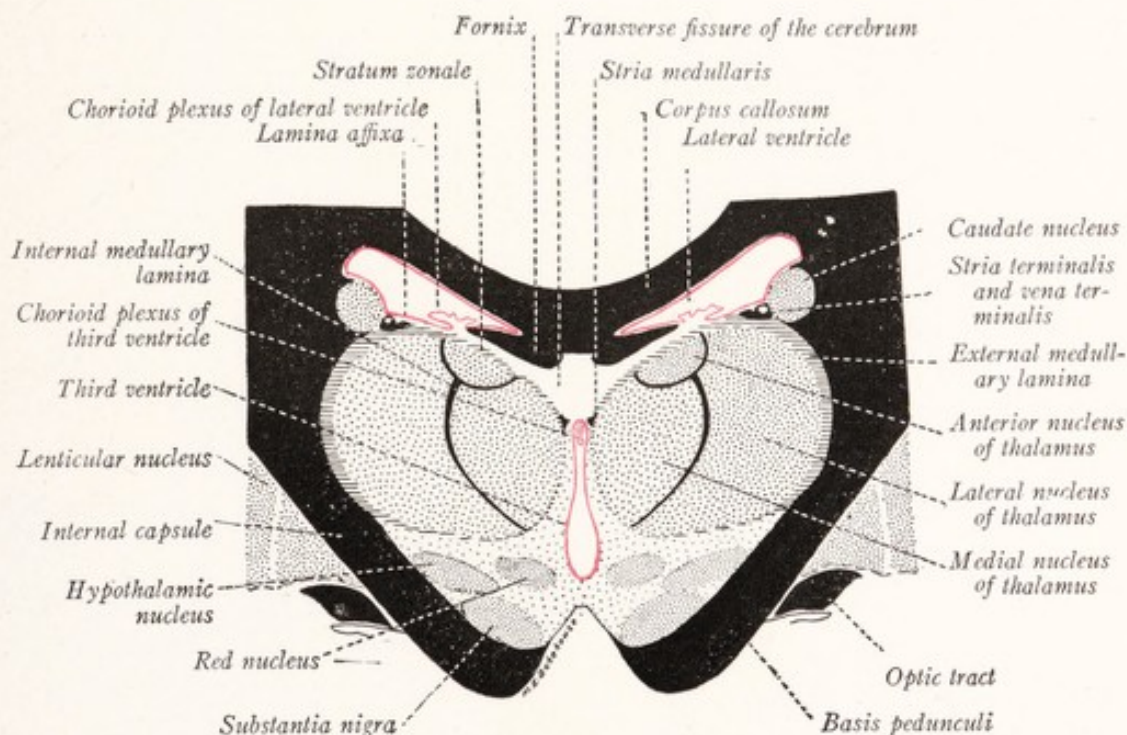


Fig. 155.—Diagrammatic frontal section through the human thalamus and the structures which immediately surround it.

posed upon this part of the thalamus. It is not present in the sheep, where the fornix is larger and the entire dorsal surface of the thalamus belongs to the floor of the transverse fissure. These features are well illustrated in Figs. 179 and 180, as is also the position of the transverse fissure. This fissure intervenes between the thalamus and the cerebral hemisphere, and contains a fold of pia mater, known as the *tela chorioidea*, of the third ventricle.

The **medial surface** of the thalamus forms the lateral wall of the third ventricle (Figs. 158, 159). It is covered by the ependymal lining of that cavity. The medial surfaces of the two thalami are closely approximated, being separated

from each other by the cleft-like space of the third ventricle, and are united across the median plane by a short bar of gray substance, the *massa intermedia*.

The **lateral surface** is hidden from view. It lies against the broad band of fibers, known as the internal capsule, which connects the cerebral hemispheres with the lower levels of the central nervous system. This surface is best examined in sections through the entire cerebrum (Figs. 155-157). Many fibers stream out of the thalamus through its lateral surface and enter the internal capsule, through which they reach the cerebral cortex. To this important stream of fibers the name *thalamic radiation* is applied.

The **ventral surface** of the thalamus is also covered from view and lies on the hypothalamus, by which it is separated from the tegmentum of the mesencephalon (Figs. 155, 157). Many fibers, representing such ascending tegmental paths as the medial lemniscus, spinothalamic tract, and brachium conjunctivum, enter the thalamus through this surface.

Structure of the Thalamus.—The thalamus consists chiefly of gray matter, within which there may be recognized a number of nuclear masses. Its dorsal surface is covered by a thin layer of white matter, called the *stratum zonale*, which in the region of the pulvinar consists in large part of fibers derived from the optic tract. On the lateral surface of the thalamus next the internal capsule there are many myelinated fibers, which constitute the *external medullary lamina* (Figs. 155, 156). The medial surface is covered by a layer of *central gray matter*, continuous with that which lines the cerebral aqueduct and forms the floor of the third ventricle. This central gray matter consists of neuroglia and of scattered nerve-fibers and cells (the nucleus paramedianus of Malone, 1910). Some of these fibers are continued through the gray matter that lines the aqueduct and the floor of the fourth ventricle, as the *dorsal longitudinal bundle* of Schutz (Fig. 112). It is probable that this portion of the thalamus forms a center for vasomotor and visceral reflexes, since lesions in this region are often accompanied by disturbances in the nervous control of the blood-vessels and viscera (Edinger, 1911; Rogers, 1916). If this be true, it is probable that the dorsal longitudinal bundle of Schütz serves to bring this thalamic mechanism for visceral adjustments into connection with the visceral efferent nuclei of the brain.

From the stratum zonale, which clothes its dorsal surface, there penetrates into the thalamus a vertical plate of white matter, called the *internal medullary lamina*. This subdivides the thalamus into three parts: the anterior, medial, and lateral nuclei. At the rostral extremity of its dorsal border the internal

medullary lamina bifurcates and includes between its two limbs the anterior nucleus.

The **anterior nucleus** (or dorsal nucleus) of the thalamus is located in the dorsal part of the rostral extremity of the thalamus and penetrates like a wedge between the medial and lateral nuclei. It protrudes somewhat above the general level of the dorsal surface, forming the anterior tubercle of the thalamus. It receives a large bundle of fibers from the mammillary body, the *mamillothalamic tract* or bundle of Vicq d'Azyr (Figs. 156, 204, 205), and sends fibers to the caudate nucleus of the corpus striatum (Fig. 196).

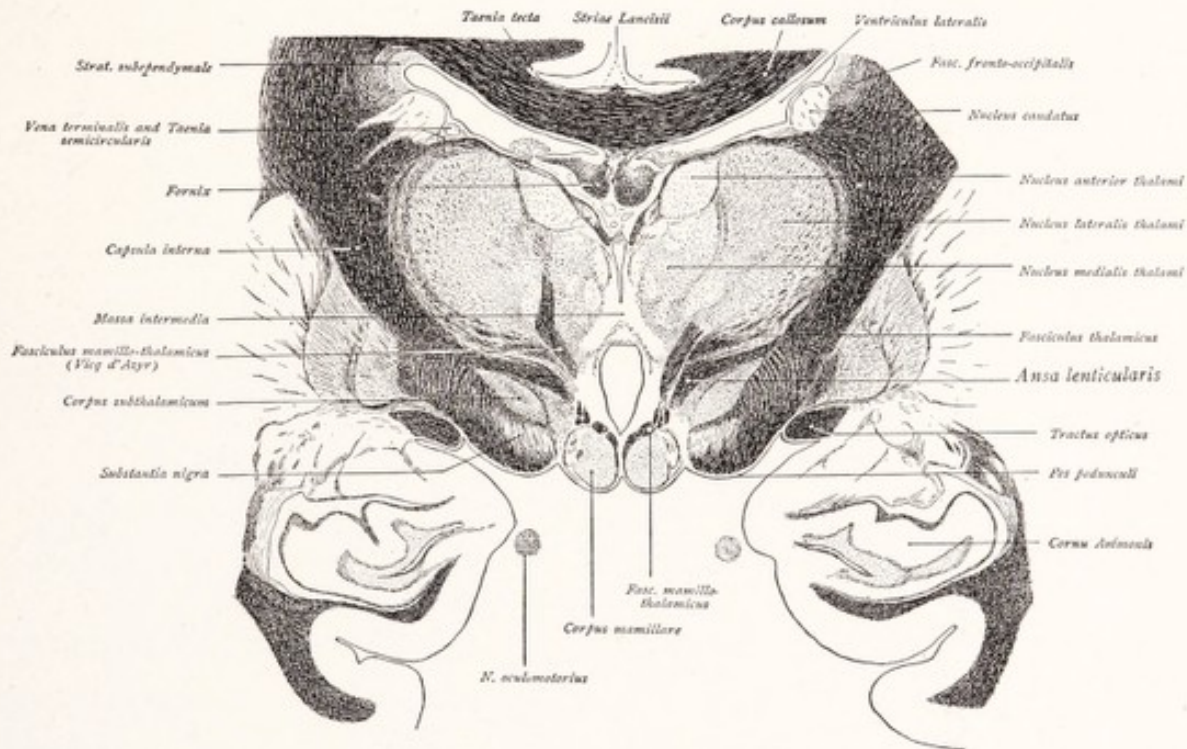


Fig. 156.—Frontal section through the mammillary body, thalamus, and adjacent structures. Weigert method. (Villiger-Piersol.)

The **medial nucleus** of the thalamus is situated between the central gray matter of the third ventricle and the internal medullary lamina, which separates it from the lateral nucleus except in the caudal part, where the line of separation between the two is not distinct. It is said to receive fibers from the olfactory centers and to send fibers to the caudate nucleus and the subthalamus.

The **lateral nucleus** of the thalamus is by far the largest of the three. It extends farther caudad than the medial nucleus and includes all of the pulvinar. Through the external medullary lamina and the internal capsule it sends fibers to the cerebral cortex in the *thalamic radiation* and receives corticothalamic

fibers in return. Especially in its ventral subdivision it receives all of the ascending sensory tracts from the tegmentum of the mesencephalon, as well as fibers from the brachium conjunctivum and red nucleus. It is much more richly supplied throughout with myelinated fibers than are the other nuclei of the thalamus.

The lateral nucleus is subdivided into a dorsal portion, the *lateral nucleus* proper, and a ventral part, better known as the *ventral nucleus* of the thalamus. Within the latter are two well-defined nuclear masses. The more medial of

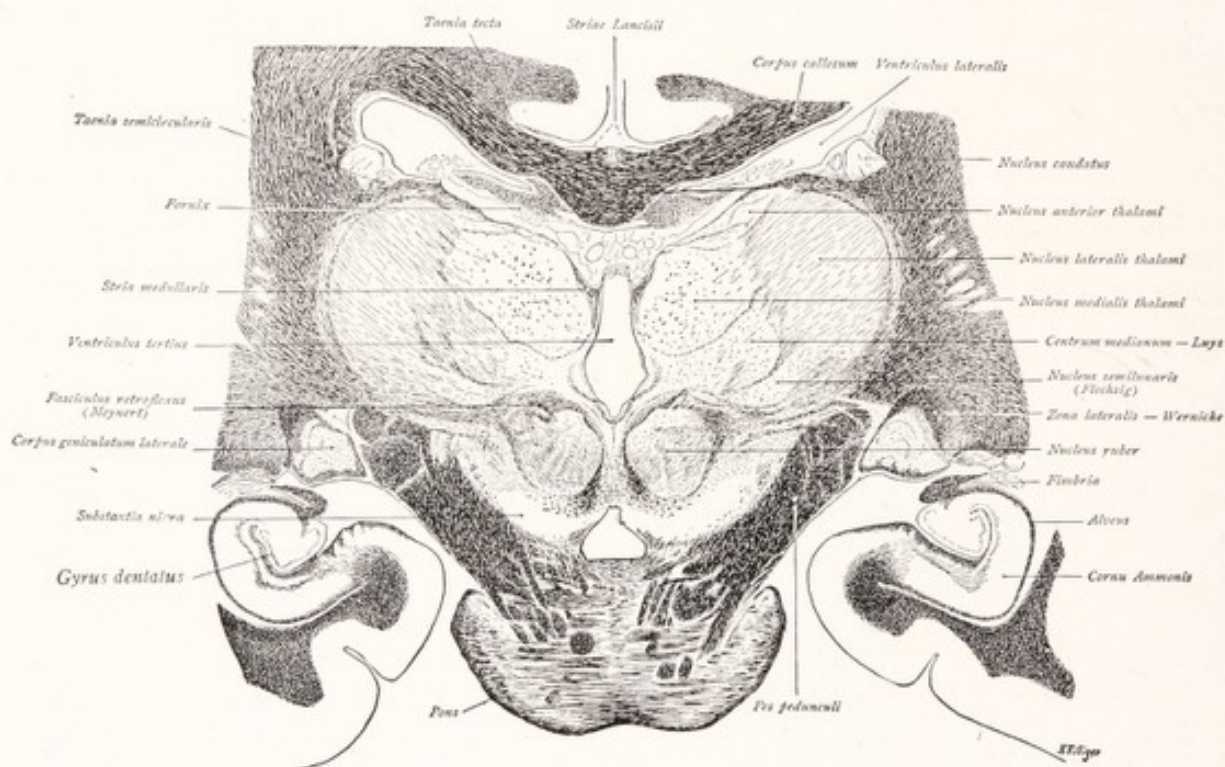


Fig. 157.—Frontal section through the human pons, basis pedunculi, thalamus and adjacent structures. Weigert method. (Villiger-Piersol.)

the two is known as the *nucleus centralis* (nucleus globosus or centrum medianum) and is surrounded by a well-defined capsule of myelinated fibers (Fig. 157). Ventrolateral to this is the well-defined *nucleus arcuatus*, which because of its shape is also called the nucleus semilunaris. The *pulvinar* is a very large mass which forms the most caudal part of the thalamus and is usually considered as a part of the lateral nucleus.

Function.—The *medial* and *anterior thalamic nuclei* are closely associated in function and from a phylogenetic point of view represent the *older part of the thalamus*. They serve as centers for the more primitive thalamic correlations

such as occur in lower vertebrates that lack the cerebral cortex (Herrick, 1917). Both receive fibers from the olfactory centers and both send fibers to the corpus striatum, but none to the cerebral cortex (Sachs, 1909). There is some evidence of a clinical nature to show that the activity of these centers may be accompanied by a crude form of consciousness (Head and Holmes, 1911; Head, 1918). Patients in whom the paths from the thalamus to the cortex have been interrupted are aware of many sensations, but cannot discriminate among them. The thalamus seems to be the chief center for the perception of pain and the affective qualities of other sensations, and in this respect it plays an important rôle in consciousness independently of the cerebral cortex.

The more lateral group of centers, which includes the *lateral nucleus* of the thalamus, the *pulvinar*, and the *geniculate bodies*, is of more recent origin and has been called the *neothalamus*. They serve as relay stations on the somatic sensory paths to the cerebral cortex. The medial lemniscus and spinothalamic tracts terminate in the ventral subdivision of the lateral nucleus. In the pulvinar and lateral geniculate body terminate fibers from the optic tracts, while the lateral lemniscus ends in the medial geniculate body. From these nuclei sensory fibers of the third order run to the cerebral cortex. The lateral nucleus, exclusive of the pulvinar, is therefore a relay station on the paths of cutaneous and deep sensibility, and it is connected with the parietal and frontal cortex through the thalamic radiation. The pulvinar and lateral geniculate body are stations on the optic pathway, and the medial geniculate body on that for hearing.

The thalamic radiation can best be considered in detail after we have acquired some familiarity with the structure of the cerebral hemisphere (p. 263).

The **fiber tract connections**, established by the various nuclear masses composing the thalamus, among themselves and with other parts of the brain, are not as yet well known. This is particularly true of the *descending tracts*. It is known that from the region of the thalamus a large bundle, the *thalamo-olivary tract*, descends to the inferior olivary nucleus. Some authors also describe a *thalamospinal tract* which arises in the thalamus and is closely associated with the rubrospinal tract.

It is fairly well established that each of the ascending sensory tracts of the tegmentum has its own particular field of distribution within the ventral nucleus of the thalamus; and it is, therefore, probable that there are corresponding functional differences in the various subdivisions of this nucleus. Beginning at the lateral side and passing medialward, the terminals of these various tracts are as follows: The *spinothalamic tract* ends in the most lateral part of the ventral nucleus. Next comes the field, within which terminate the fibers of the central tract of the *trigeminal nerve*, and which includes the nucleus arcuatus and nucleus centralis. The *medial lemniscus* ends in the most medial part of the inferior nucleus, including the nucleus centralis. This corresponds to the relative position which these tracts occupy in the tegmentum of the mesencephalon, where the spinothalamic tract is the most lateral of the three.

THE METATHALAMUS

The metathalamus is composed of two small protuberances, the geniculate bodies, which, having been displaced by the excessive development of the thalamus, are situated upon the dorsolateral surface of the rostral end of the mesencephalon (Figs. 87-89, 154, 161). The *lateral geniculate body* is an oval swelling in the course of the optic tract. Its connections will be more fully considered in connection with the discussion of the course of the visual impulses. The *medial geniculate body* is overhung by the pulvinar, from which it is separated by a deep sulcus. It receives fibers by way of the inferior quadrigeminal brachium from the lateral lemniscus, which we have learned to know as the central auditory path from the cochlear nuclei. From it fibers run to the auditory area of the cerebral cortex (the thalamotemporal or acoustic radiation).

THE EPITHALAMUS

The epithalamus includes the pineal body, stria medullaris, and *habenular trigone*. The latter is a small triangular depressed area located on the dorso-medial aspect of the thalamus rostral to the pineal body (Fig. 158). In the sheep, as in most other mammals, it is much larger than in man and bulges both dorsally and medially beyond the surface of the thalamus (Figs. 91, 159). It marks the position of a nuclear mass, called the *habenular ganglion*, which receives fibers from the *stria medullaris*, a fascicle which runs along the border between the dorsal and medial surfaces of the thalamus subjacent to the tania thalami (Figs. 154, 155). The stria medullaris takes origin from the anterior perforated substance and other olfactory centers on the basal surface of the cerebral hemisphere and, partially encircling the thalamus, reaches the habenular ganglion, in which it ends. (See p. 281.) Not all of the fibers terminate on the same side; some cross to the ganglion of the opposite side, forming a transverse bundle of myelinated fibers which joins the caudal end of the two ganglia together and is known as the *habenular commissure*. From the cells in this ganglion arises a bundle of fibers, known as the *fasciculus retroflexus* of Meynert or the tractus habenulopeduncularis. This bundle of fibers is directed ventralward and at the same time caudally along the medial side of the red nucleus toward the base of the brain, where it crosses to the opposite side and ends in the interpeduncular ganglion (Fig. 189). The stria medullaris, habenular ganglion, and fasciculus retroflexus are all parts of an arc for olfactory reflexes, as indicated in Fig. 211. According to Edinger (1911) the cells, from which the stria medullaris arises, are intimately related to a bundle of ascending fibers from

the sensory nuclei of the trigeminal nerve. If this be true, the mechanism in question may receive afferent impulses from the nose, mouth, and tongue and be concerned with feeding reflexes.

The **pineal body** is a small mass, shaped like a fir cone, which rests upon the mesencephalon in the interval between the two thalami. Its base is attached by a short stalk to the habenular and posterior commissures, and into the stalk there extends the small pineal recess of the third ventricle. The pineal body is a rudimentary structure and is not composed of nervous elements. In some

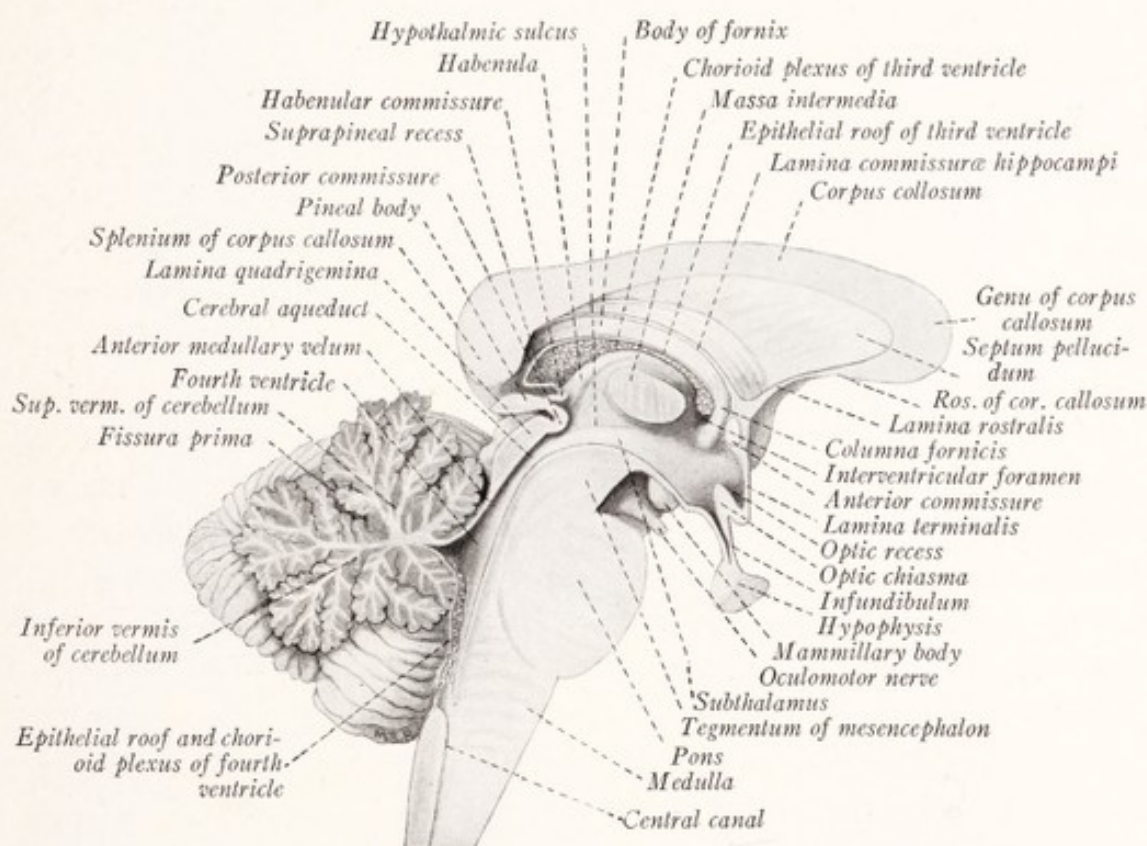


Fig. 158.—Median sagittal section through the human brain stem.

vertebrates, certain lizards for example, it is more highly developed, resembles in structure an invertebrate eye, and lies close to the dorsal surface of the head.

The **posterior commissure** is a large bundle of fibers which crosses the median plane dorsal to the point where the cerebral aqueduct opens into the third ventricle (Figs. 154, 156). The source and termination of the fibers which constitute the bundle are still obscure.

THE HYPOTHALAMUS

The hypothalamus consists of three parts: (1) the *pars optica hypothalami*, which belongs to the telencephalon, (2) the *pars mamillaris hypothalami*, and (3) the *subthalamus*.

The **pars mamillaris hypothalami** includes the corpora mamillaria, tuber cinereum, infundibulum, and hypophysis. The *mammillary bodies* are a pair of small spheric masses of gray matter, situated close together in the interpeduncular space rostral to the posterior perforated substance (Figs. 86, 158, 159). Each is enclosed in a white capsule and projects as a rounded white eminence at the base of the brain (Fig. 156). In the sheep's brain the two are fused together into a single eminence (Fig. 83). Each mammillary body is composed of two nuclear masses: a large medial group of small cells and a smaller lateral collection of large cells. The white capsule is formed by fibers from the hippocampus, which sweep in a broad curve around the thalamus, forming a bundle known as the *fornix* (Figs. 204, 205). This descends in front of the interventricular foramen and reaches the mammillary body, within which a large part of these fibers end. From the dorsal aspect of the medial nucleus springs a stout fascicle, which runs dorsally, to end in the anterior nucleus of the thalamus, and is known as the *mammillothalamic tract* or bundle of Vicq d'Azyr (Figs. 156, 204, 205). A short distance from the mammillary body there branches off from this tract another, the *mammillotegmental tract* of Gudden, which runs caudally in the tegmentum of the mesencephalon and probably ends in the dorsal tegmental ganglion. The lateral nuclear mass is also connected with the tegmentum by way of the *peduncle of the mammillary body* (Fig. 211).

The **tuber cinereum**, as seen from the ventral surface of the brain (Figs. 83, 86), is a slightly elevated gray area rostral to the mammillary bodies. It is one of the olfactory centers. To it there is attached the funnel-shaped stalk of the hypophysis, known as the *infundibulum*. The *hypophysis* is a small gland of internal secretion, which is not composed of nervous tissue and which interests us here only because its posterior portion is developed as an outpocketing of the ventral wall of the diencephalon, to which it remains attached by the infundibulum. A detailed account of this structure may be found in the papers by Tilney (1911 and 1913) listed in the Bibliography at the end of this volume.

The **subthalamus** is situated between the thalamus and the tegmentum of the mesencephalon and forms a zone of transition between these two structures (Figs. 156, 157). The long sensory tracts of the tegmentum run through

it on their way to the thalamus. The red nucleus and the substantia nigra project upward into it from the mesencephalon. An additional mass of gray matter is found in this region lateral to the red nucleus and ventral to the thalamus. It is known as the *hypothalamic nucleus* and has the shape of a biconvex lens. Its function and fiber connections are not well understood; but it is probably a motor coördination center receiving fibers from the thalamus, corpus striatum, and pyramidal tract, and sending fibers downward in the cerebral peduncle.

THE THIRD VENTRICLE

Since the third ventricle is chiefly surrounded by structures belonging to the diencephalon, it will be convenient to consider it at this point and to give at

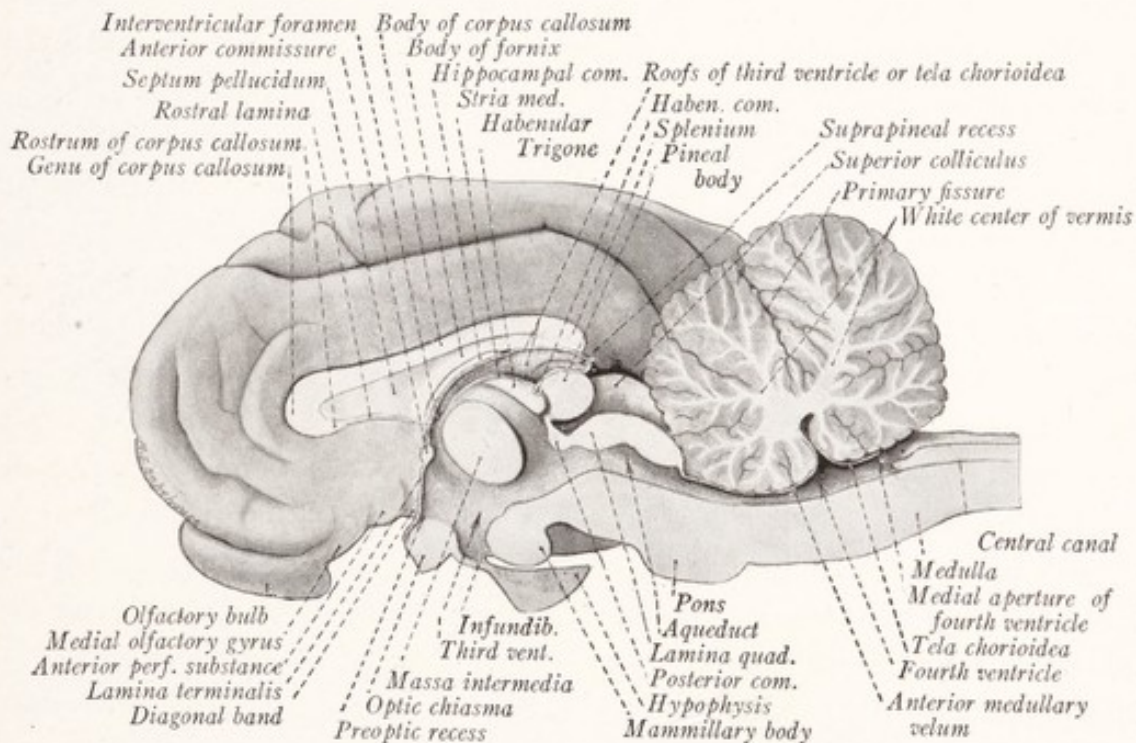


Fig. 159.—Medial sagittal section of the sheep's brain.

the same time an account of the *parts of the telencephalon* which help to form its walls. These include the lamina terminalis, anterior commissure, and the *optic chiasma* (Figs. 158, 159). The latter, formed by the decussation of the fibers of the optic nerve, projects as a transverse ridge in the floor of the ventricle. The *lamina terminalis* is a thin plate joining the two hemispheres, which stretches from the optic chiasma in a dorsal direction to the anterior commissure. Here it becomes continuous with the thin edge of the rostrum of the corpus callosum, known as the *rostral lamina*. As indicated on page 26, the

lamina terminalis is to be regarded as forming the rostral end of the brain; and the part of the third ventricle, which lies behind it and dorsal to the optic chiasma, belongs to the telencephalon. The *anterior commissure* is a bundle of fibers which crosses the median plane in the lamina terminalis and serves to connect certain parts of the two cerebral hemispheres, which are associated with the olfactory nerves. The anterior commissure and the lamina terminalis form the *rostral boundary* of the third ventricle, and between the latter and the optic chiasma is a diverticulum, known as the optic recess.

The *third ventricle* is a narrow vertical cleft, the *lateral walls* of which are formed for the greater part by the medial surfaces of the two thalami. Ventral to the massa intermedia is seen a groove known as the *hypothalamic sulcus*, which if followed rostrally leads to the interventricular foramen, while in the other direction it can be traced to the cerebral aqueduct. Below this groove the lateral wall and floor of the ventricle are formed by the hypothalamus.

In the *floor* of the ventricle there may be enumerated the following structures, beginning at the rostral end: the optic chiasma, infundibulum, tuber cinereum, mammillary bodies, and the subthalamus.

The *roof* of the third ventricle is formed by the thin layer of *ependyma*, which is stretched between the striæ medullares thalami of the two sides, and whose torn edge, in the dissected specimen, is represented by the *tænia thalami* (Figs. 85, 155, 159). Upon the outer surface of this ependymal roof is a fold of pia mater in the transverse fissure. This is known as the *tela chorioidea*; and from it delicate vascular folds are invaginated into the ventricle, carrying a layer of ependyma before them by which they are, in reality, excluded from the cavity. These folds are the *chorioid plexuses*. There are two of them extending side by side from the interventricular foramina to the caudal extremity of the roof. Here they extend into an evagination of the roof above the pineal body, known as the suprapineal recess.

There are three openings into the third ventricle. The aqueduct of the cerebrum opens into it at the caudal end; while at the opposite extremity it communicates with the lateral ventricles through the two interventricular foramina.

THE VISUAL APPARATUS

Development of the Retina and Optic Nerve.—There is but one pair of nerves associated with the diencephalon, and these, the optic nerves, are not true nerves, but fiber tracts joining the retina with the brain. It will be remembered that the retina develops as an evagination of the lateral wall of the prosencephalon in the form of a vesicle whose cavity is continuous with that of

the forebrain. By a folding of its walls in the reverse direction, *i. e.*, by invagination, the *optic vesicle* becomes transformed into the *optic cup* (Fig. 15); and the cavity of the vesicle becomes reduced to a mere slit between the two layers forming the wall of the cup. The inner of these two layers develops into the nervous portion of the retina; and nerve-fibers arising in it grow back to the brain along the course of the *optic stalk*, which still connects the optic cup with the forebrain. This mode of development serves to explain why the structure of the retina resembles that of the brain more than it does that of other sense organs, and why the optic nerve-fibers, like those of the fiber tracts of the central nervous system, are devoid of neurilemma sheaths. These fibers take origin from the ganglion cells of the retina, the structure of which must be briefly considered at this point.

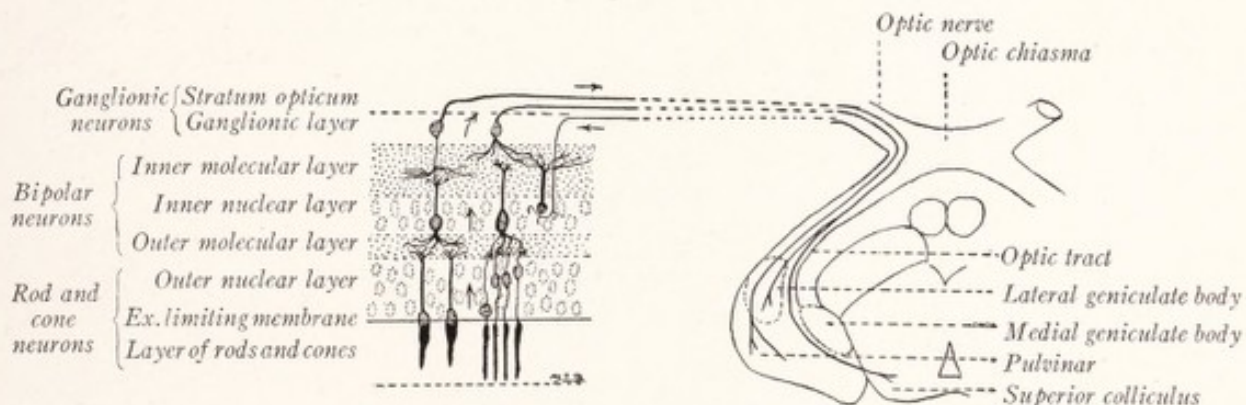


Fig. 160.—Schematic representation of the retina and the connections established by the optic nerve-fibers.

The **retina** presents for consideration three layers of superimposed nervous elements: (1) the visual cells, (2) the bipolar cells, and (3) the ganglion cells (Fig. 160). These, with some horizontally arranged association neurons and supporting elements, form the nervous portion of the retina and are derived from the inner layer of the optic cup. The pigmented stratum of the retina is derived from the outer layer of the cup.

The *visual cells* are bipolar elements, whose perikarya are located in the *outer nuclear layer* (Fig. 160). Each presents an external process in the form of a *rod* or *cone*, so differentiated as to respond to photic stimulation and thus to serve as a visual receptor. The other process terminates in the *outer molecular layer* in relation to processes from the *bipolar cells*. These latter elements have their perikarya in the *inner nuclear layer* and branches in the inner and outer molecular layers. The *ganglion cells* send their dendrites into the *inner molecular layer*, where they are related to the inner branches of the bipolar cells;

while the axons form the innermost stratum of the retina, the *stratum opticum*, through which they enter the optic nerve. It will be apparent from Fig. 160 that the visual cells are the receptors and neurons of the first order in the optic path. The impulses are transmitted through the bipolar cells to the ganglion cells, whose axons, in turn, carry them by way of the optic nerves to the superior colliculus, lateral geniculate body, and pulvinar of the thalamus. In the same figure it may be seen that the nerve also contains some efferent fibers which terminate in the retina (Arey, 1916).

The Optic Chiasma and Optic Tracts.—The optic nerve emerges from the bulbus oculi at the nasal side of the posterior pole and, after entering the cranium through the optic foramen, unites with its fellow of the opposite side to form the

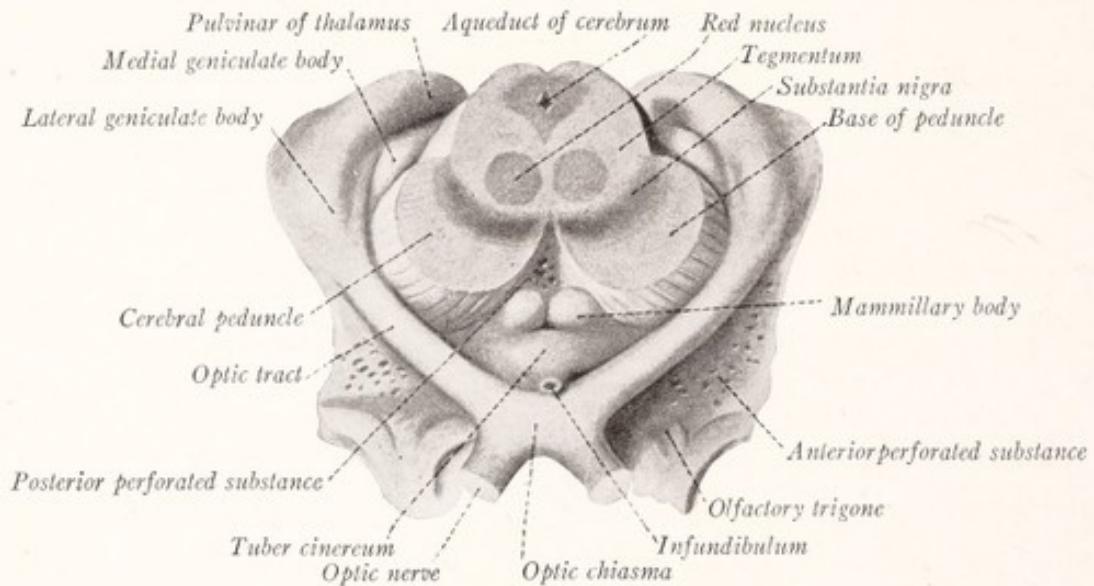


Fig. 161.—The connections and relations of the optic tracts. The mesencephalon has been cut across and the specimen is viewed from below. (Sobotta-McMurrich).

optic chiasma, in which a partial decussation of the fibers takes place (Figs. 161, 162). Beyond the decussation fibers from both retinae are continued in each of the optic tracts. In the chiasma the fibers from the two optic nerves are so distributed that each tract receives the fibers from the lateral half of the retina of its own side and those from the medial half of the opposite retina. The optic tracts partially encircle the ends of the cerebral peduncles. Each tract divides into a medial and a lateral root, of which the former goes to the medial geniculate body and does not consist of optic nerve-fibers. The *lateral root* is much larger and runs to the *lateral geniculate body* and *pulvinar* of the thalamus and to the *superior colliculus* of the corpora quadrigemina. In addition to the optic fibers each tract contains a bundle of fibers, known as the *com-*

missure of Gudden, which crosses the median plane in the posterior part of the optic chiasma and, for the most part at least, connects the medial geniculate bodies of the two sides. These are the fibers which form the *medial root* of the optic tract.

The Optic Radiation.—The superior colliculus is a reflex center, and the fibers of the optic nerve, which terminate in it, subserve optic reflexes. On the other hand, the visual impulses, brought to the *external geniculate body* and the *pul-*

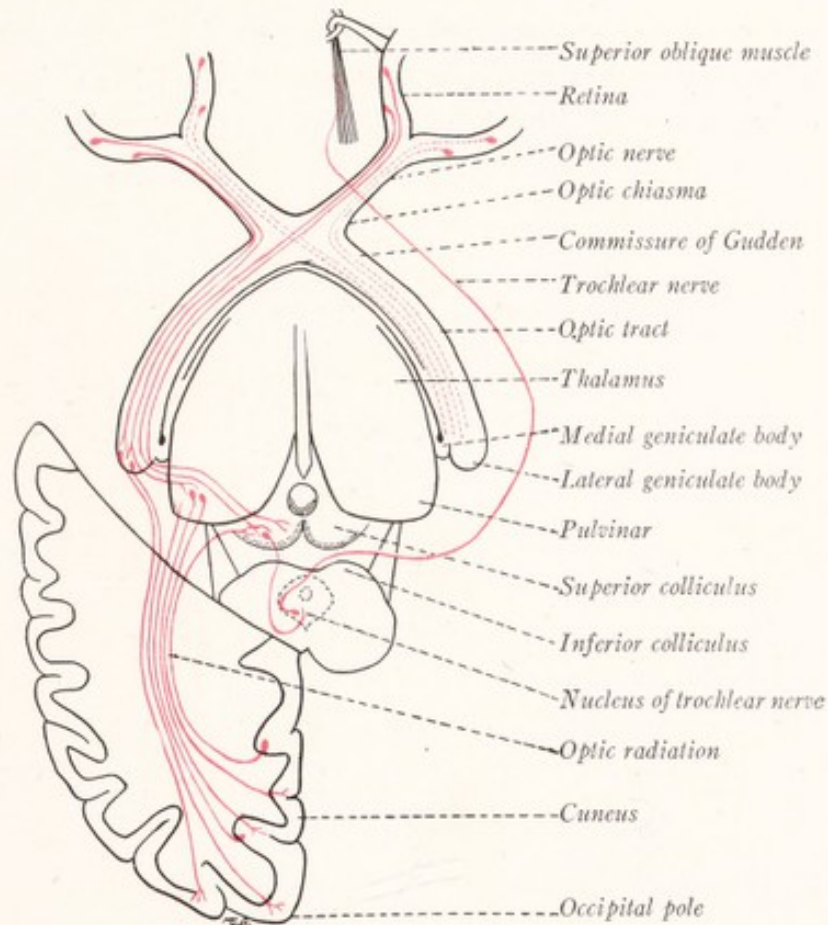


Fig. 162.—Schematic representation of the optic pathways. The index line to the commissure of Gudden does not reach that structure.

vinar of the thalamus, are relayed to the cerebral cortex and give rise to visual sensations. These two parts of the diencephalon are connected with the cerebral cortex on both sides of the calcarine fissure by projection fibers, which form a conspicuous bundle that sweeps backward through the retrolenticular portion of the internal capsule into the occipital lobe. It is known as the optic radiation (Fig. 162). In addition to *corticopetal fibers* arising in the pulvinar and lateral geniculate body, the optic radiation contains *corticifugal fibers*

arising in the cortex and terminating in the pulvinar, lateral geniculate body, and superior colliculus of the corpora quadrigemina.

The significance of the partial decussation of the nerves is made clear by Figs. 162 and 163. The properties of the refracting media of the eyes are such that images of objects to the left of the axis of vision are produced on the nasal side of the left eye and the temporal side of the right eye. And, due to the manner of decussation of the optic nerve-fibers, impulses from both these sources reach the visual area of the right cortex. In the same way the visual cortex of the left side receives impressions from objects to the right of the axis of vision. That is to say, the sensory representation of the outer world in the cerebral cortex is contralateral in the case of sight just as it is in the case of cutaneous

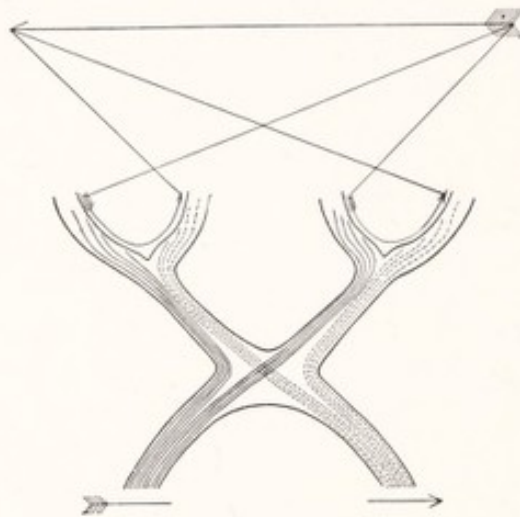


Fig. 163.—Diagram to show why a destruction of one optic tract causes blindness in both eyes for the opposite lateral half of the field of vision.

and auditory sensations. Furthermore, it will be evident that, while destruction of one optic nerve causes total blindness in the corresponding eye, destruction of one optic tract, its thalamic connections, their optic radiations, or the visual cortex in which these radiations terminate, will produce blindness in both eyes for the opposite lateral half of the field of vision. This condition is known as *hemianopsia*, and is produced by a lesion in the optic pathway anywhere behind the chiasma.

CHAPTER XV

THE EXTERNAL CONFIGURATION OF THE CEREBRAL HEMISPHERES

Development.—The *cerebral hemispheres* are formed by the evagination of the alar laminae of the telencephalon, the rest of which remains as the boundary of the rostral part of the third ventricle, and is known as the *telencephalon medium*. The cavities of the evaginated portions are known as the *lateral ventricles* and communicate with the third ventricle by way of the interventricular foramina (Figs. 15–17). Each of the cerebral hemispheres consists of two ventrally placed portions, the *rhinencephalon* or olfactory lobe and *corpus striatum*, and a third part, more extensive than the others, the *pallium* or primitive cerebral cortex. The pallium expands more rapidly than the other parts, both rostrally and caudally, and comes to overlie the diencephalon, from which it is separated by the transverse fissure (Fig. 17). The fold of pia mater which is inclosed within this fissure is known as the *tela chorioidea*; and from it a vascular plexus grows into the lateral ventricle through the thin portion of the medial wall of the hemisphere, where this is attached to the diencephalon. This forms the *chorioid plexus* of the lateral ventricle and carries before it an epithelial covering from the ependymal lining, by which it is, in reality, excluded from the ventricular cavity. This invagination of the medial wall of the hemisphere produces the *chorioid fissure*. Ventrally the thickened part of the hemisphere, known as the *corpus striatum*, remains in uninterrupted continuity with the thalamus.

At first the *cerebral hemisphere* has a relatively large cavity and thin walls. As the pallium and ventricle enlarge they become bent around the thalamus and corpus striatum (Fig. 17). The hemisphere becomes bean shaped and the cavity curved. It expands rostrally to form the *frontal lobe*, caudally to form the *occipital lobe*, and ventrolaterally to form the *temporal lobe* (Fig. 164). Into each of these there is carried a prolongation of the lateral ventricle forming respectively the *anterior*, *posterior*, and *inferior horns*. Between the temporal and frontal lobes a deep fossa appears which is the forerunner of the lateral fissure. At the bottom of this fossa is the *insula*, a portion of the cortex which

overlies the corpus striatum and develops more slowly than the surrounding areas (labelled lateral fissure, Fig. 164). Folds from the surrounding cortex close in over the insula, burying it from sight in the adult brain. These folds are known as the *opercula*, and the deep cleft which separates them as the *lateral fissure*.

Development of the Cerebral Cortex.—At first the pallium, like other parts of the neural tube, consists of three primitive zones: the ependymal, mantle, and marginal layers. But during the third month neuroblasts migrate outward from the ependymal and mantle layers into the marginal zone and there give rise to a superficial layer of gray matter—the cerebral cortex. Nerve-fibers from these neuroblasts and others growing into the hemisphere from the thala-

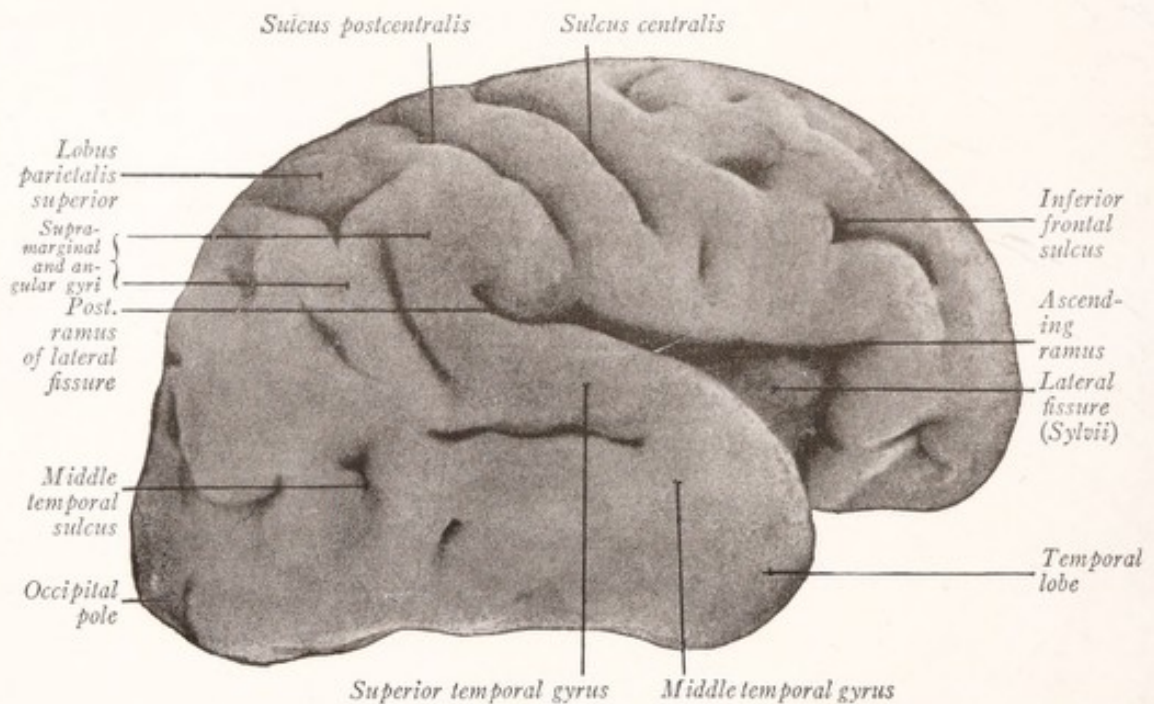


Fig. 164.—Lateral view of the right cerebral hemisphere from a seven months' fetus. (Kollmann.)

mus accumulate on the deep surface of the developing cortex and form the white medullary substance of the hemisphere. As the brain increases in size the area of the cortex expands out of proportion to the increase in volume of the white medullary layer upon which it rests, and is thrown into folds or gyri separated by fissures or sulci. All the larger mammalian brains present well-developed gyri, while the smaller brains are smooth; and it would thus appear that the size of the brain is an important factor in determining the amount of folding that occurs in the cortex.

As we shall learn, the cortex does not differentiate in exactly the same manner throughout, but may be subdivided into structurally and functionally dis-

tinct areas. The sulci develop in more or less definite relation to these areas, the great majority making their appearance along the boundary lines between them. These are known as *terminal sulci*, of which the rhinal fissure and central sulcus are examples. Sometimes the folding occurs entirely within such an area, *i. e.*, along its axis, producing what is known as an *axial sulcus*. But there are still others in which the relation to these functional areas is not so evident. The arrangement of the fissures and sulci in a seven month fetus is shown in Fig. 164.

The Development of the Septum and Commissures.—The two hemispheres are connected by the *lamina terminalis*, which serves as a bridge for fibers which cross from one hemisphere to the other. These form three important bundles:

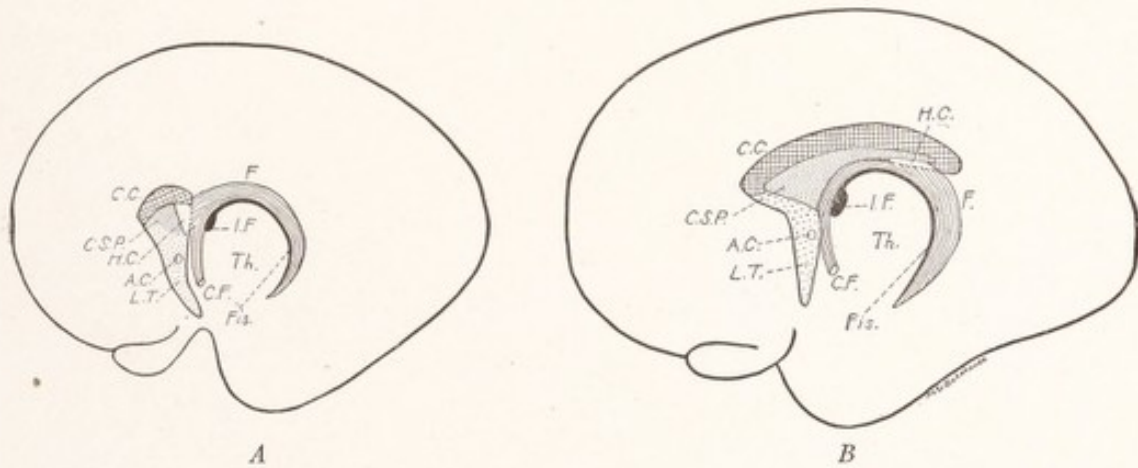


Fig. 165.—Schematic representation of the development of the septum pellucidum and telencephalic commissures: A. C., Anterior commissure; C. C., corpus callosum; C. F., columna fornix; C. S. P., cavum septi pellucidi; F., fornix; H. C., hippocampal commissure; I. F., interventricular foramen; Fis., chorioid fissure; L. T., lamina terminalis. (Based on drawings of models of the telencephalon of a four months' fetus (A) and of a five months' fetus (B) by Streeter.)

the *anterior commissure*, the *hippocampal commissure*, and the *corpus callosum*. The two former connect the olfactory portions of the hemispheres, while the latter is the great commissure of the non-olfactory cortex or neopallium. Everyone admits that the anterior commissure develops in the lamina terminalis (Fig. 165); and the corpus callosum and hippocampal commissures are said to form in its dorsal part (Streeter, 1912). According to this account the lamina terminalis becomes stretched by the great development of the corpus callosum and appropriates part of the paraterminal body. This is the portion of the rhinencephalon that lies immediately rostral to the lamina terminalis in the medial wall of each hemisphere. Eventually the lamina terminalis presents a large cut surface in the median sagittal section and includes the commissures

as well as the septum pellucidum. The portion of the lamina terminalis which enters into the formation of the septum becomes hollow as a result of the stretching to which it is subjected, and the resulting cavity is known as the *cavum septi pellucidi*.

The **cerebral hemispheres** are incompletely separated from each other by the *longitudinal fissure* of the cerebrum, at the bottom of which lies a broad band of commissural fibers, the *corpus callosum*, which forms the chief bond of union between them. Each hemisphere has three surfaces: a convex *dorsolateral surface* (Fig. 166), a *median surface* flattened against the opposite hemisphere (Fig. 170), and a very irregular ventral or *basal surface*. A *dorsal border* separates the dorsolateral from the medial surface; and a *lateral border* marks the transition between the dorsolateral and basal surfaces. One may recognize also *frontal*, *occipital*, and *temporal poles* (Fig. 166). The long axis of the hemisphere extends between the frontal and occipital poles, and in man is placed almost at right angles to the long axis of the body (Fig. 33); while in other mammals it corresponds more nearly to the body axis. On this account it will be convenient in the description of the human cerebral hemisphere to take the occiput as a point of reference and use the term "posterior" in place of "caudal." Otherwise our directive terms remain the same—rostral, dorsal, and ventral—except that for the term "ventral" we shall often use the word "basal."

The **cerebral cortex** is a layer of gray matter spread over the surface of the hemisphere; and its area is greatly increased by the occurrence of folds or gyri separated by deep sulci. That part of the cortex which belongs to the rhinencephalon and is phylogenetically the oldest is designated as the archipallium. It is separated from the newer and in mammals much larger neopallium or non-olfactory cortex by the *rhinal fissure* (Figs. 83, 171).

The Neopallium.—The development of the neopallium is so much greater in man than in the sheep, and the arrangement of the gyri and sulci is so different in the two forms that but little can be learned by a cursory comparison of these structures in the two brains. We shall, accordingly, confine our attention almost exclusively to the arrangement of the neopallium in man.

THE DORSOLATERAL SURFACE OF THE HEMISPHERE

By means of some of the more important sulci the cortex is marked off into well-defined areas, known as the *frontal*, *parietal*, *temporal*, and *occipital lobes* (Fig. 167). To these should be added a lobe buried at the bottom of the lateral fissure and known as the *insula* (Fig. 169). In the delimitation of these lobes

the *lateral fissure* and the *central sulcus* play a prominent part. Some of the more important sulci are designated as fissures. This usage is regulated by custom, but it may be said that a number of the fissures are invaginations of the entire thickness of the wall of the hemisphere and produce corresponding elevations projecting into the lateral ventricle.

The **lateral cerebral fissure**, or fissure of Sylvius, begins on the basal surface of the brain as a deep cleft lateral to the anterior perforated substance (Fig. 172). From this point it extends lateralward between the temporal and frontal lobes to the lateral aspect of the brain, where it divides into three branches (Figs. 166, 167). The *anterior horizontal ramus* of the lateral fissure runs ros-

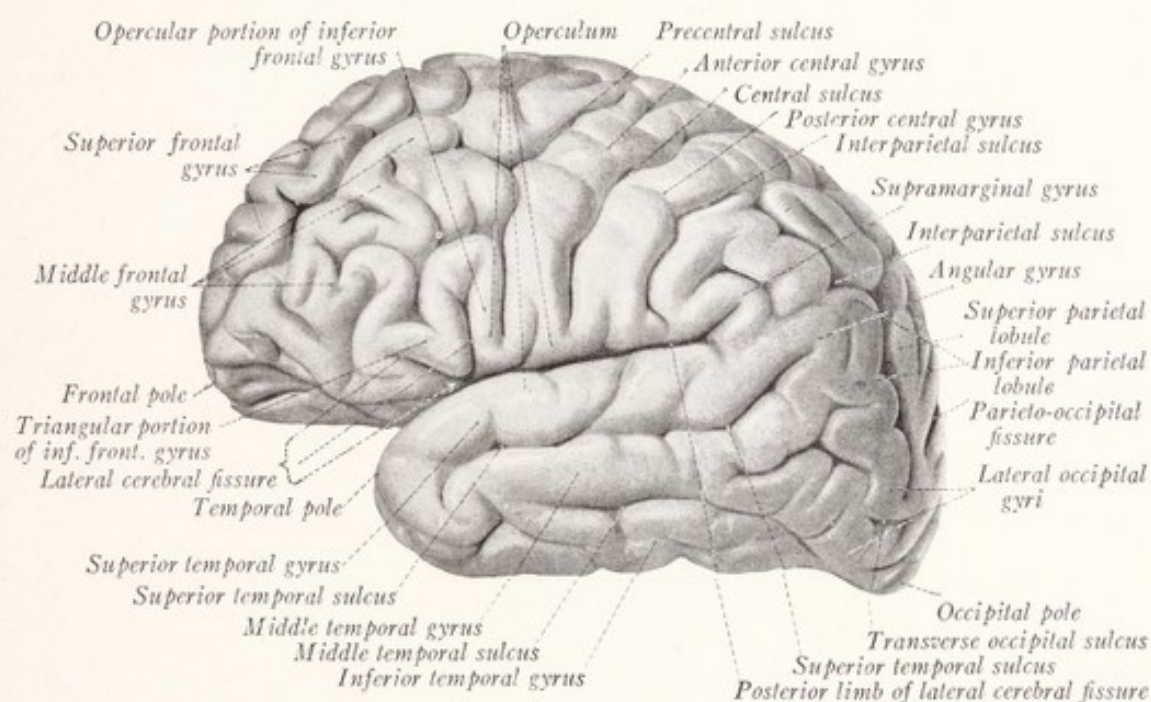


Fig. 166.—Lateral view of the human cerebral hemisphere. (Sobotta-McMurrich.)

trally and the *anterior ascending ramus* dorsally into the frontal lobe. The *posterior ramus* of the lateral fissure is much longer, and runs obliquely toward the occiput and at the same time somewhat dorsally. The terminal part turns dorsally into the parietal lobe. This fissure is, in reality, a deep fossa, at the bottom of which lies the insula. It separates the frontal and parietal lobes which lie dorsal to it from the temporal lobe.

The **central sulcus** or fissure of Rolando runs obliquely across the dorsolateral surface of the hemisphere, separating the frontal from the parietal lobe (Figs. 166, 167). It begins on the medial surface of the hemisphere a little behind the middle of the dorsal border and extends in a sinuous course rostrally and toward

the base, nearly reaching the posterior ramus of the lateral fissure. It makes an angle of about 70 degrees with the dorsal border. It is customary to recognize two knee-like bends in this sulcus; one located at the junction of the dorsal and middle thirds with concavity forward, and the other at the junction of the middle and basal thirds with concavity backward. If the margins of the sulcus are pressed apart a deep annectant gyrus may often be seen extending across it, by which the continuity of the sulcus is to some extent interrupted. This is explained by the fact that the sulcus usually develops in two pieces, which become united as the depth of the sulcus increases.

Lobes.—The *frontal lobe* lies dorsal to the lateral cerebral fissure and rostral to the central sulcus (Fig. 167). The remainder of the dorsolateral surface is subdivided rather arbitrarily into the parietal, occipital, and temporal lobes.

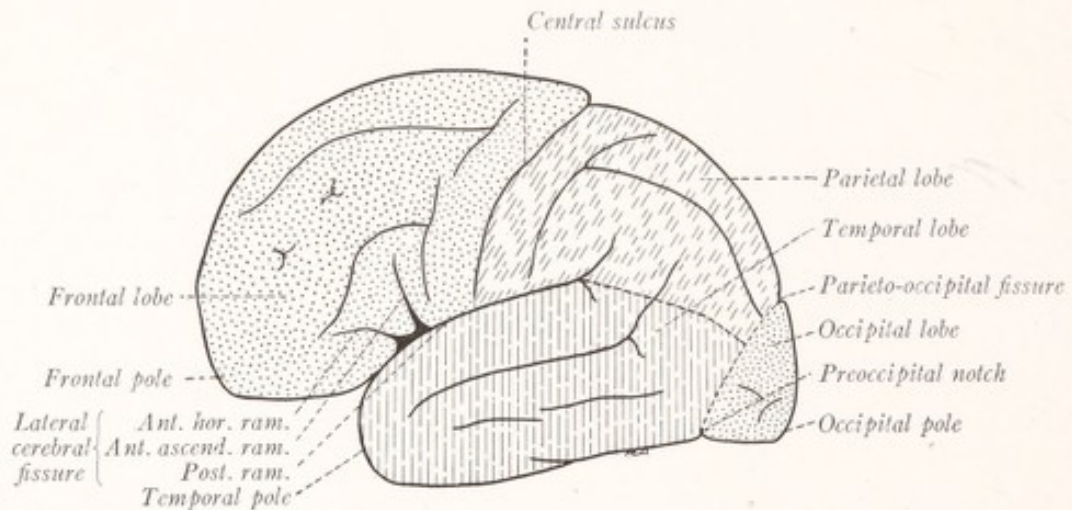


Fig. 167.—Diagram of the lobes on the lateral aspect of the human cerebral hemisphere.

The rostral border of the *occipital lobe* is usually placed at a line joining the end of the parieto-occipital fissure with the preoccipital notch. The latter is a slight indentation on the lateral border of the hemisphere about 4 cm. rostral to the occipital pole; while the parieto-occipital fissure is a deep cleft on the median surface (Fig. 170), which cuts through the dorsal border about midway between the occipital pole and the central sulcus, but a little nearer the former. The *parietal lobe* is situated between the central sulcus and the imaginary line joining the parieto-occipital fissure with the preoccipital notch. It lies dorsal to the lateral fissure and an imaginary line connecting that fissure with the middle of the preceding line. The remainder of the dorsolateral surface belongs to the *temporal lobe*.

The Frontal Lobe.—The rostral part of the hemisphere is formed by the

frontal lobe. Within it one may identify three chief sulci, which are, however, subject to considerable variation. The *precentral sulcus* is more or less parallel with the central sulcus and is often subdivided into two parts, the superior and inferior precentral sulci (Fig. 168). The *superior frontal sulcus* usually begins in the superior precentral sulcus and runs rostrally, following in a general way the curvature of the dorsal border of the hemisphere which it gradually approaches. The *inferior frontal sulcus* usually begins in the inferior precentral sulcus and extends rostrally, arching at the same time toward the base of the hemisphere.

Between the precentral and central sulci lies the *anterior central gyrus* in which is found the motor area of the cerebral cortex. The remainder of this

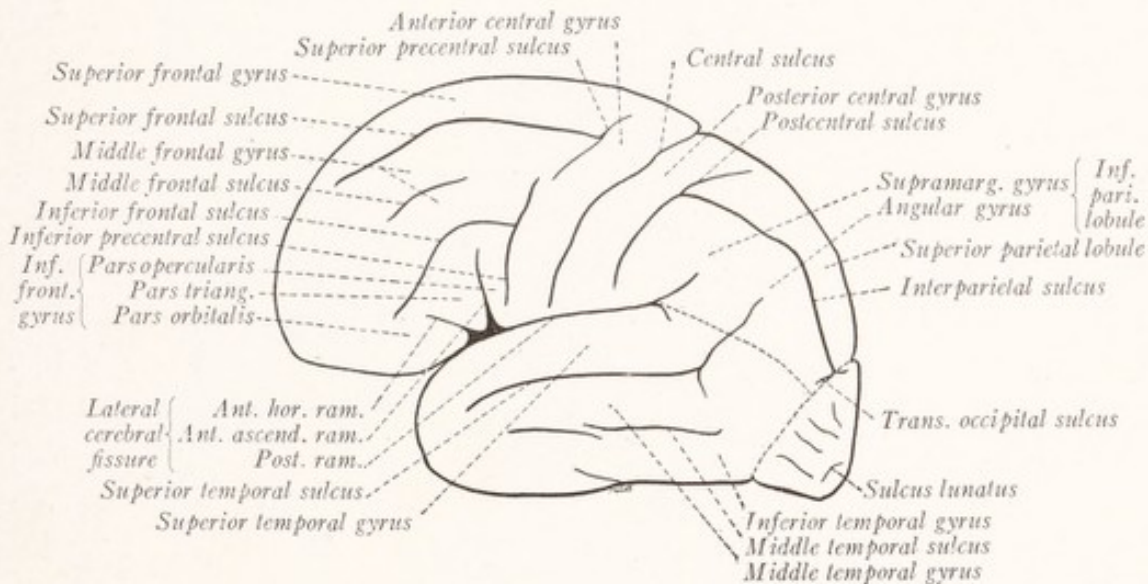


Fig. 168.—Sulci and gyri on the lateral aspect of the human cerebral hemisphere.

surface of the frontal lobe is composed of three convolutions, the *superior*, *middle*, and *inferior frontal gyri*, separated from each other by the *superior* and *inferior frontal sulci*. The inferior frontal gyrus, which in the left hemisphere is also known as Broca's convolution, is subdivided by the two anterior rami of the lateral sulcus into three parts, known as the orbital, triangular, and opercular portions. The *orbital part of the inferior frontal gyrus* lies rostral to the anterior horizontal ramus of the lateral sulcus; the *triangular part* is a wedge-shaped convolution between the two anterior rami of that fissure; while the *opercular portion* lies in the frontal operculum between the precentral sulcus and the anterior ascending ramus of the lateral fissure.

The Temporal Lobe.—Ventral to the lateral fissure is the long tongue-shaped

temporal lobe which terminates rostrally in the temporal pole. The *superior temporal sulcus* is a very constant fissure, which begins near the temporal pole and runs nearly parallel with lateral cerebral fissure. Its terminal part turns dorsally into the parietal lobe. The *middle temporal sulcus*, ventral to the preceding and in general parallel with it, is usually composed of two or more disconnected parts. The *inferior temporal sulcus* is located for the most part on the basal surface of the temporal lobe. Dorsal to each of these fissures is a gyrus which bears a similar name: the *superior temporal gyrus*, between the lateral fissure and the superior temporal sulcus; the *middle temporal gyrus*, between the superior and middle temporal sulci; and the *inferior temporal gyrus*, between the middle and inferior temporal sulci. The lateral fissure is very deep; and the surface of the superior temporal gyrus that bounds it is broad and marked near its posterior extremity by horizontal convolutions, known as the transverse temporal gyri. One of these, more marked than the others, has been called the *anterior transverse temporal gyrus* or Heschl's convolution and represents the cortical center for hearing (Fig. 174).

The Parietal Lobe.—The *postcentral sulcus* runs nearly parallel with the central sulcus and consists of two parts, the *superior* and *inferior postcentral sulci*, which may unite with each other or with the *interparietal sulcus*. Often all three are continuous, forming a complicated fissure, as shown in Fig. 168. The interparietal sulcus extends in an arched course toward the occiput and may end in the *transverse occipital sulcus*. These four sulci are often included under the term "interparietal sulcus." The interparietal sulcus proper is then designated as the horizontal ramus.

The *posterior central gyrus* lies between the central and postcentral sulci. The interparietal sulcus separates the *superior parietal lobule* from the *inferior parietal lobule*. Within the latter we should take note of two convolutions: the *supramarginal gyrus*, which curves around the upturned end of the lateral fissure; and the *angular gyrus*, similarly related to the terminal ascending portion of the superior temporal fissure.

The Occipital Lobe.—Only a small part of the dorsolateral surface of the hemisphere is formed by the occipital lobe. This is a triangular area at the occipital extremity, bounded rostrally by a line joining the parieto-occipital fissure and the preoccipital notch (Fig. 167). The transverse occipital fissure may help to bound this area or may lie within it. Other inconstant sulci help to divide it into irregular convolutions. Sometimes the visual area which lies on the mesial aspect of this lobe is prolonged over the occipital pole to the lateral

aspect. In this case a small semilunar furrow develops around it on the lateral surface and is known as the sulcus lunatus (Fig. 168). This sulcus, called by Rüdinger the "Affenspalte," forms a conspicuous feature of the lateral surface of the cerebral hemisphere in the lower Old World apes (Ingalls, 1914).

The Insula.—The part of the cortex which overlies the corpus striatum lags behind in its development and becomes overlapped by the surrounding pallium. The cortex, which thus becomes hidden from view at the bottom of the lateral fissure, forms in the adult a somewhat conical mass called the insula or island of Reil (Fig. 169). Its base is surrounded by a limiting furrow, the *circular sulcus*, which is, however, more triangular than circular, and in which we may recognize three portions: superior, inferior, and anterior. The apex of this conical lobe

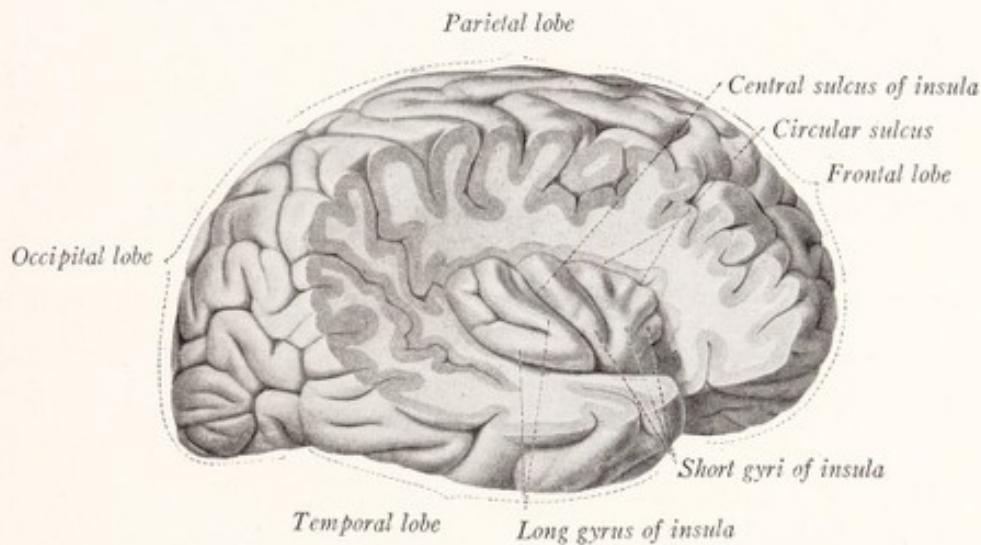


Fig. 169.—Lateral view of the human cerebral hemisphere with the insula exposed by removal of the opercula. (Sobotta-McMurrich.)

is known as the *limen insulæ*; and the remainder is subdivided by an oblique groove (sulcus centralis insulæ) into the long gyrus of the insula and a more rostral portion, which is again subdivided into short gyri.

The Operculum.—As the adjacent portions of the pallium close over the insula (Fig. 164) they form by the approximation of their margins the three rami of the lateral fissure. These folds constitute the opercula of the insula. Each of the three surrounding lobes takes part in this process; and we may accordingly recognize a *frontal*, a *temporal*, and a *parietal operculum* (Fig. 166).

At this point it will be instructive to examine the lateral surface of the cerebral hemisphere of the sheep. It will be seen that the region which corresponds to the insula is on a level with the general surface of the hemisphere; no opercula have developed, and the lateral sulcus is only a shallow groove (Fig. 173).

THE MEDIAN AND BASAL SURFACES

The **occipital lobe** comes more nearly being a structural and functional entity than any of the other lobes. It corresponds in a general way to the "regio occipitalis" as outlined by Brodman (Figs. 216, 217), and it is probably all concerned directly or indirectly with visual processes. We have seen that it forms a small convex area on the lateral surface near the occipital pole; and we now note that it is continued on to the medial surface of the hemisphere, where it forms a somewhat larger triangular field between the parieto-occipital and anterior portion of the calcarine fissure dorsorostrally and the

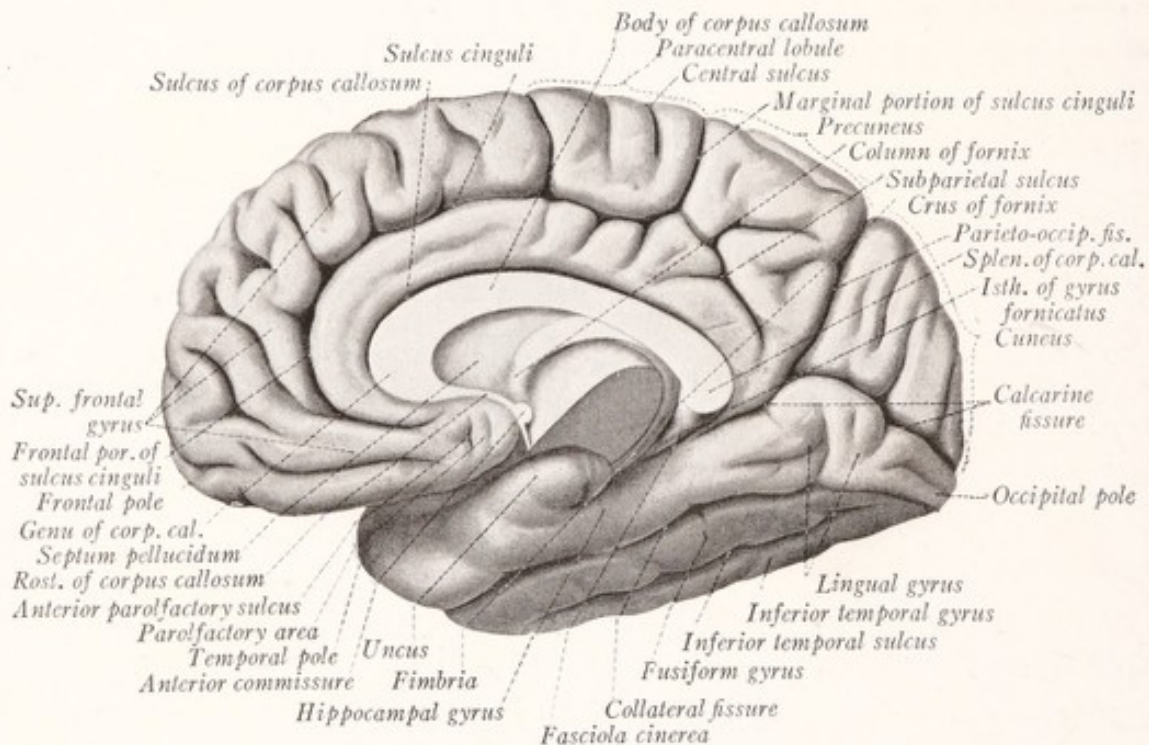


Fig. 170.—Human cerebral hemisphere seen from the medial side. The brain has been divided in the median plane and part of the thalamus has been removed along with the mesencephalon and rhombencephalon. (Sobotta-McMurrich.)

collateral fissure ventrally. On this aspect of the brain it includes two constant and well-defined convolutions: the *cuneus* and the *lingual gyrus* (Figs. 170, 171).

The *calcarine fissure* begins ventrally to the splenium of the corpus callosum and extends toward the occipital pole, arching at the same time somewhat dorsally. It consists of two portions. The rostral part, the calcarine fissure proper, is deeper, more constant in form and position, and phylogenetically much older than the rest, and produces the elevation on the wall of the lateral ventricle known as the *calcar avis* (Fig. 181). This part terminates at the point

where the calcarine is joined by the parieto-occipital fissure. The other portion, sometimes called the "posterior calcarine sulcus," arches downward and backward from this junction toward the occipital pole, and occasionally cuts across the border of the hemisphere to its dorsolateral surface. The *parieto-occipital fissure*, which is really a deep fossa with much buried cortex at its depth, appears to be the direct continuation of the rostral part of the calcarine fissure. It cuts through the dorsal border of the hemisphere somewhat nearer to the occipital pole than to the central sulcus. These fissures form a Y-shaped figure whose stem is the calcarine fissure and whose two limbs are the parieto-occipital fissure and the "posterior calcarine sulcus." If the fissures are opened up the stem is seen to be marked off from the two limbs by buried annectant gyri.

The *cuneus* is a triangular convolution with apex directed rostrally, which lies between the diverging parieto-occipital and calcarine fissures. The rest of the medial surface of the occipital lobe belongs to the *lingual gyrus*, which lies between the calcarine and collateral fissures.

The **remaining sulci and gyri** on the median and basal surfaces may now be briefly described.

The **sulcus of the corpus callosum** (*sulcus corporis callosi*) begins ventrally to the rostrum of the corpus callosum, encircles that great commissure on its convex aspect, and finally bends around the splenium to become continuous with the *hippocampal fissure* (Fig. 171). The latter is a shallow groove, which runs from the region of the splenium of the corpus callosum toward the temporal pole near the dorsomedial border of the temporal lobe. It terminates in the bend between the hippocampal gyrus and the uncus.

The **sulcus cinguli** (*callosomarginal fissure*) begins some distance ventral to the rostrum of the corpus callosum and follows the arched course of the sulcus of the corpus callosum, from which it is separated by the gyrus cinguli. It terminates by dividing into two branches. One of these, the *subparietal sulcus*, continues in the direction of the sulcus cinguli and ends a short distance behind the splenium. The other, known as the *marginal ramus*, turns off at a right angle and is directed toward the dorsal margin of the hemisphere. A side branch, directed dorsally, is usually given off from the main sulcus some distance rostral to its bifurcation, and is known as the *paracentral sulcus*.

The **collateral fissure** begins near the occipital pole and runs rostrally, separated from the calcarine and hippocampal fissures by the lingual and hippocampal gyri. It is sometimes continuous with the *rhinal fissure*. The latter separates the terminal part of the hippocampal gyrus, which belongs to the archi-

pallium, from the rest of the temporal lobe, and is a very conspicuous fissure in most mammalian brains (Fig. 83).

Convolution.—Dorsal to the corpus callosum is the *gyrus cinguli* between the sulcus of the corpus callosum and the sulcus cinguli. The *superior frontal gyrus* is continued over the dorsal border of the hemisphere from the dorso-lateral surface and reaches the sulcus cinguli. Surrounding the end of the central sulcus is a quadrilateral convolution, known as the *paracentral lobule*. It is bounded by the sulcus cinguli, its marginal ramus and the paracentral sulcus. Another quadrilateral area, known as the *precuneus*, is bounded by the parieto-occipital fissure, the subparietal sulcus, and the marginal ramus of the sulcus cinguli. The *hippocampal gyrus* lies between the hippocampal fissure

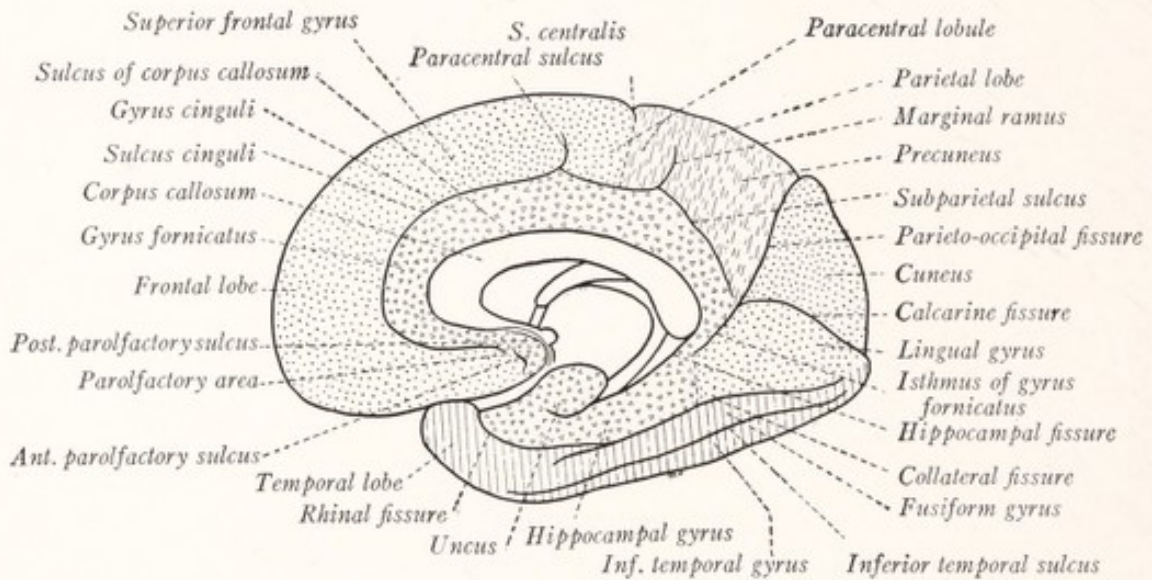


Fig. 171.—Diagram of the lobes, sulci, and gyri on the medial aspect of the human cerebral hemisphere.

dorsally and the collateral and rhinal fissures ventrally. Its rostral extremity bends around the hippocampal fissure to form the uncus. It is connected with the gyrus cinguli by a narrow convolution, the *isthmus of the gyrus fornicatus*. Under the name *gyrus fornicatus* it has been customary to include the gyrus cinguli, isthmus, hippocampal gyrus, and uncus. Between the collateral fissure and the inferior temporal sulcus is the *fusiform gyrus* which lies on the basal surface of the temporal lobe in contact with the tentorium of the cerebellum (Figs. 170, 172).

It has been customary to apportion parts of the medial and basal surfaces of the cerebral hemisphere to the frontal, parietal, occipital, and temporal lobes, as indicated in Fig. 171. According to this scheme the gyrus fornicatus

stands by itself and is sometimes designated as the limbic lobe. This plan of subdivision, which was based on the erroneous belief that all portions of the gyrus fornicatus belonged to the rhinencephalon, should be abandoned. A simpler and more logical arrangement assigns the hippocampal gyrus and uncus to the temporal lobe and divides the gyrus cinguli between the frontal and parietal lobes.

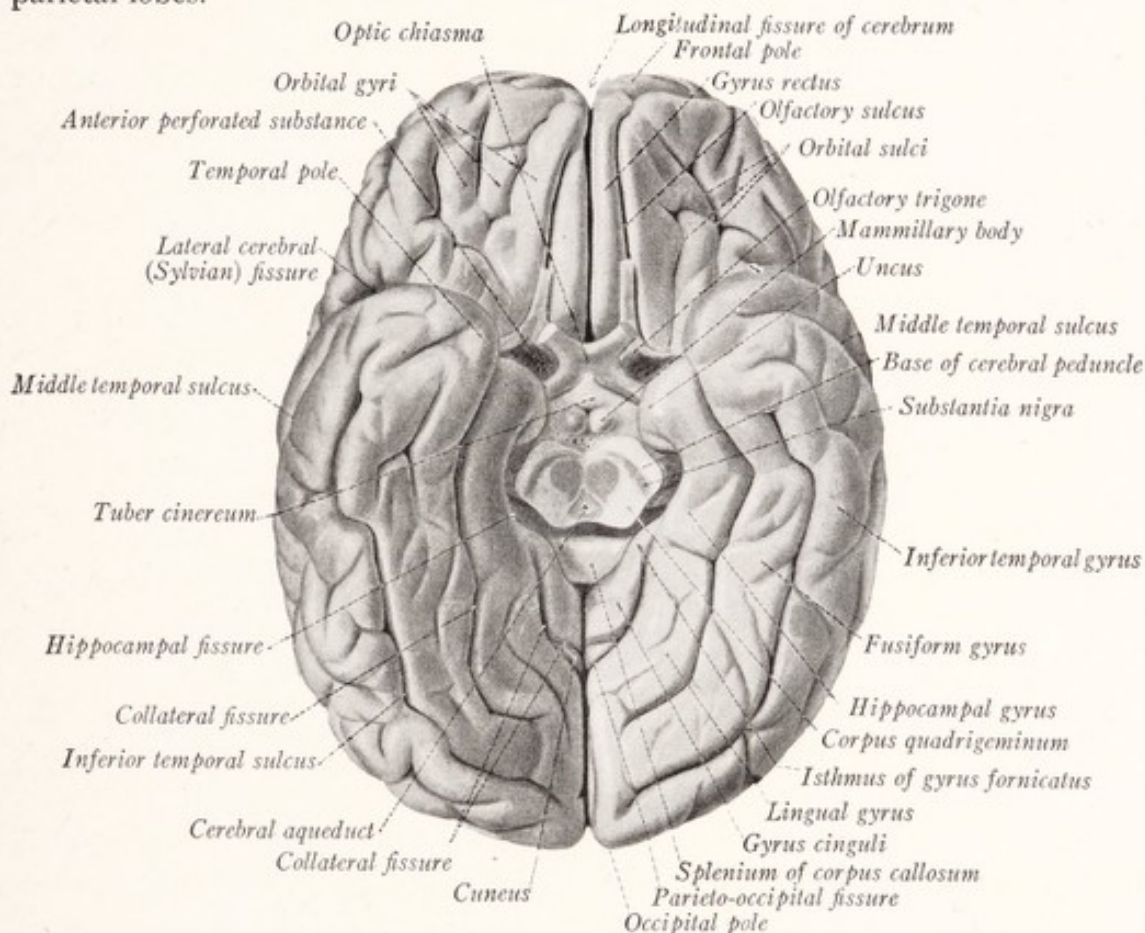


Fig. 172.—Basal aspect of the human cerebral hemisphere. (Sobotta-McMurrich.)

The **basal surface** of the hemisphere (Fig. 172) consists of two parts: (1) the ventral surface of the temporal lobe, whose sulci and gyri have been described in a preceding paragraph, and which rests upon the tentorium cerebelli and the floor of the middle cranial fossa; and (2) the orbital surface of the frontal lobe resting upon the floor of the anterior cranial fossa. The latter surface presents near its medial border the *olfactory sulcus*, a straight, deep furrow, directed rostrally and somewhat medially, that lodges the olfactory tract and bulb. To its medial side is found the *gyrus rectus*. The remainder of the orbital surface of the frontal lobe is subdivided by irregular *orbital sulci* into equally irregular *orbital gyri*.

From the foregoing account it will be apparent that almost the entire surface of the human cerebral hemisphere is formed by *neopallium*. Of the parts already described only the uncus and adjacent part of the hippocampal gyrus belong to the *archipallium*. Other superficial portions of the rhinencephalon, such as the olfactory bulb, tract and trigone, and the anterior perforated substance, will be described in connection with the hidden parts of the rhinencephalon in Chapter XVII.

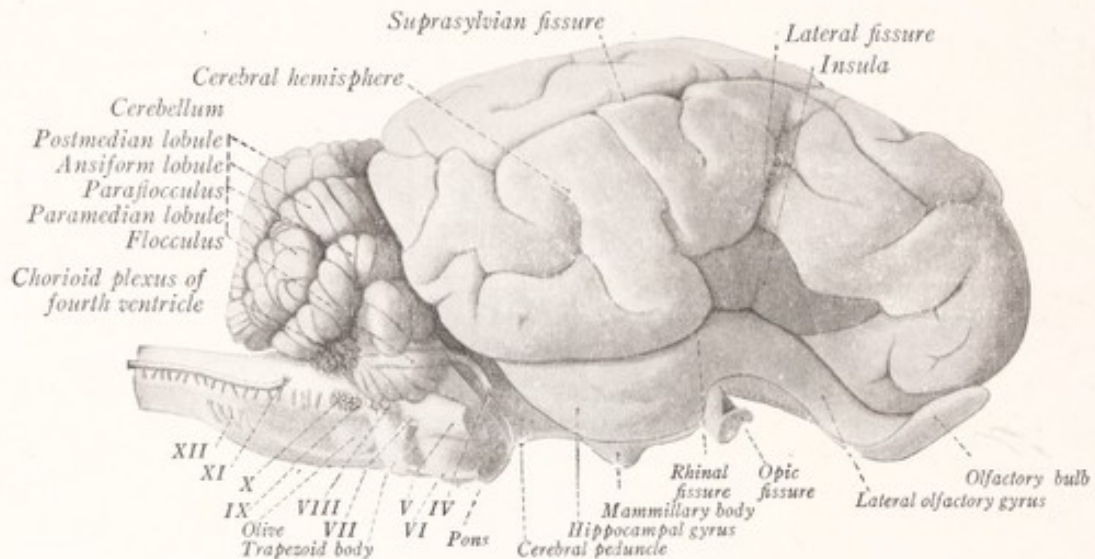


Fig. 173.—Lateral view of the sheep's brain.

The surface form of the cerebral hemisphere of the sheep is illustrated in Figs. 83, 84, and 173. On these figures are indicated the names of the chief sulci and gyri. It will be of interest to note the position of the motor cortex in the sheep as given in Fig. 82. Since this corresponds to the precentral gyrus in man, it will be seen that there is little in the sheep's brain to correspond to the rostral part of the frontal lobe in man.

CHAPTER XVI

THE INTERNAL CONFIGURATION OF THE CEREBRAL HEMISPHERES

WHEN a horizontal section is made through the cerebral hemisphere at the level of the dorsal border of the corpus callosum the central white substance will be displayed in its maximum extent and will appear as a solid, semioval mass, known as the *centrum semiovale* (Figs. 174, 175). It will also be apparent that lamellæ extend from this central white substance to form the medullary centers of the various convolutions, and that over this entire mass the cortex is spread in an uneven layer, thicker over the summit of a convolution than at the bottom of a sulcus. This medullary substance is composed of three kinds of fibers: (1) fibers from the corpus callosum and other commissures joining the cortex of one hemisphere with that of the other; (2) fibers from the internal capsule, uniting the cortex with the thalamus and lower lying centers; and (3) fibers running from one part of the cortex to another within the same hemisphere (p. 296).

The Corpus Callosum.—At the bottom of the longitudinal fissure of the cerebrum is a broad white band of commissural fibers, known as the *corpus callosum*, which connects the neopallium of the two hemispheres. While the medial portion of this commissure is exposed in the floor of the longitudinal fissure, its greater part is concealed in the white center of the hemisphere where its fibers radiate to all parts of the neopallium, forming the *radiation of the corpus callosum*. When examined in a median sagittal section of the brain the corpus callosum is seen to be arched dorsally and to be related on its ventral surface to the fornix and *septum pellucidum* (Figs. 84, 158, 170). The latter consists of two thin membranous plates, stretched between the corpus callosum and the fornix and separated by a narrow cleft-like space, the *cavum septi pellucidi* (Fig. 177). If the septum has been torn away it will be possible to look into the lateral ventricle and see that the corpus callosum forms the roof of a large part of that cavity. At its rostral extremity it curves abruptly toward the base of the brain, forming the *genu*, and then tapers rapidly to form the *rostrum*. The latter is triangular in cross-section, with its edge directed toward the anterior commissure to which it is connected by the *rostral lamina*. The

body of the corpus callosum (*truncus corporis callosi*), arching somewhat dorsally, extends toward the occiput and terminates in the *splenium*, a thickened rounded border situated dorsal to the pineal body and corpora quadrigemina. Related to the concave or ventral side of the corpus callosum are the fornix, septum pellucidum, lateral ventricles, tela chorioidea of the third ventricle, and the pineal body (Fig. 170).

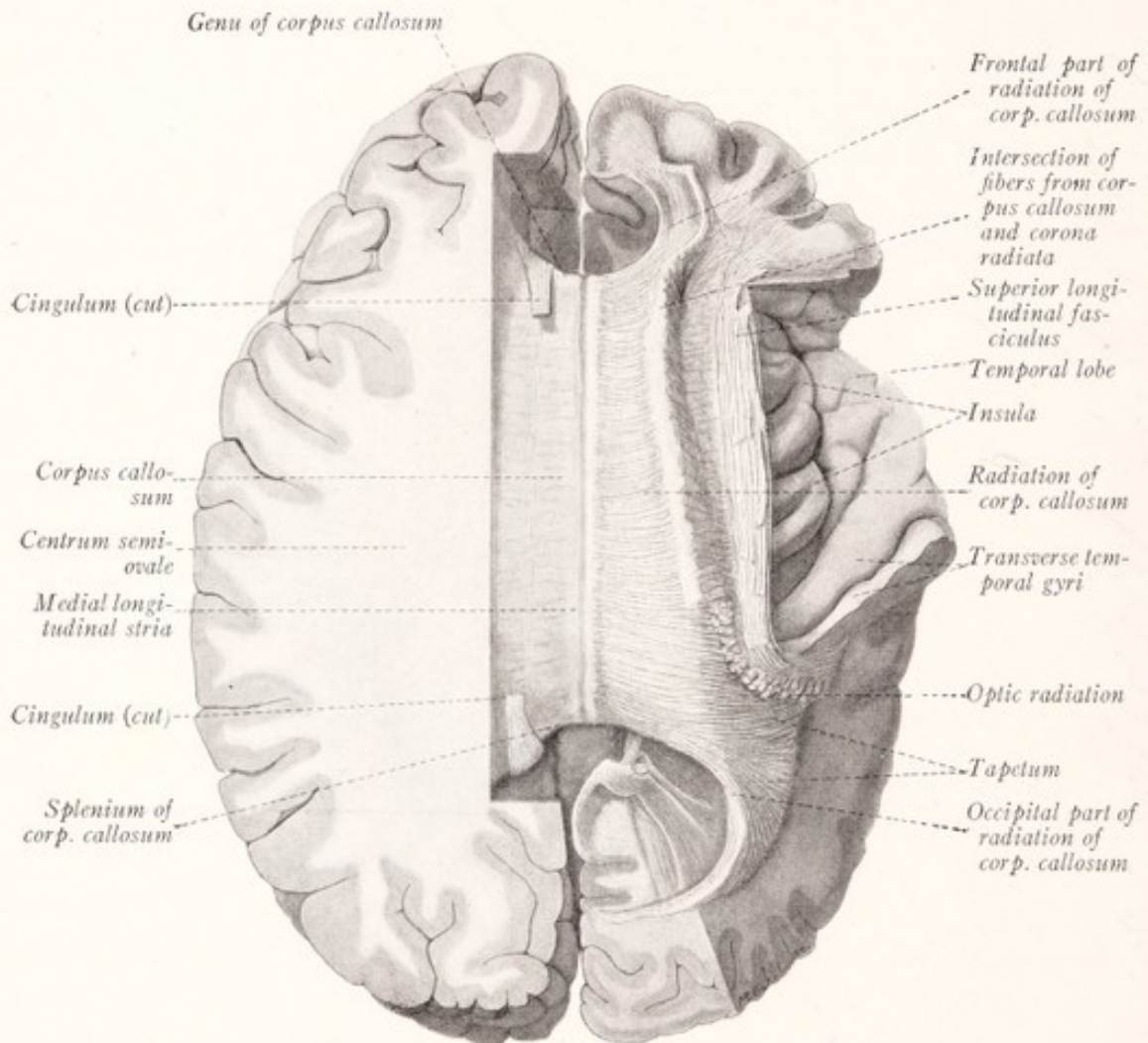


Fig. 174.—Dissection of the human telencephalon to show the radiation of the corpus callosum. Dorsal view.

Turning again to the dorsal aspect of the corpus callosum, a careful inspection will show that at the bottom of the great longitudinal fissure it is covered by a very thin coating of gray matter, continuous with the cerebral cortex in the depths of the sulcus of the corpus callosum (Figs. 174, 175). This is a *rudimentary portion of the hippocampus* and is known as the *supracallosal gyrus* or *indusium griseum*. In this gray band there are embedded delicate longitudinal

strands of nerve-fibers. Two of these, placed close together on either side of the median plane, are known as the *medial longitudinal striæ*. Further lateralward on either side, hidden within the sulcus of the corpus callosum, is a less well-developed band, the *lateral longitudinal stria*.

The corpus callosum is transversely striated and is composed of fibers that pass from one hemisphere to the other. By dissection these may be followed into the centrum semiovale, where they constitute the *radiation of the corpus*

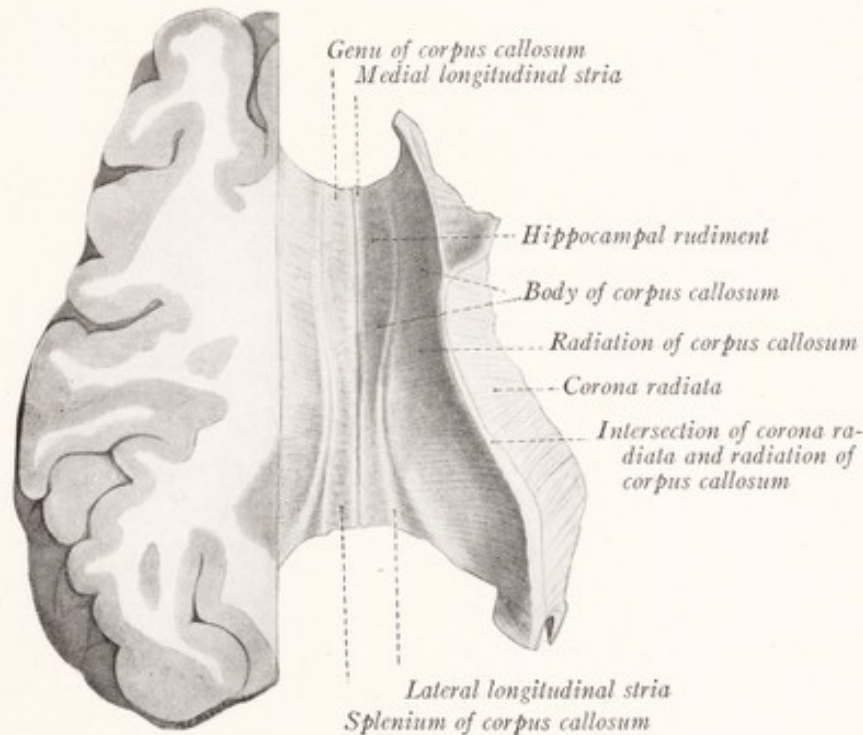


Fig. 175.—Dissection of the telencephalon of the sheep to show the radiation of the corpus callosum. Dorsal view.

callosum and intersect those from the internal capsule in the corona radiata (Figs. 174, 175). The fibers of the genu sweep forward into the frontal lobe, constituting the frontal part of the radiation. Fibers from the splenium bend backward toward the occipital pole, forming the *occipital part of the radiation* or *forceps major*. In the human brain fibers from the body and splenium of the corpus callosum sweep outward over the lateral ventricle, forming the roof and lateral wall of its posterior horn and the lateral wall of its inferior cornu. Here they constitute a very definite stratum called the *tapetum*.

THE LATERAL VENTRICLE

When the corpus callosum and its radiation are cut away a cavity, known as the *lateral ventricle*, is uncovered. It is lined by ependyma, continuous with the ependymal lining of the third ventricle by way of the interventricular foramen. This cavity, which contains cerebrospinal fluid, varies in size in different parts, and in some places is reduced to a mere cleft between closely apposed walls. The shape of the ventricle is highly irregular (Fig. 176). As constituent parts we recognize a *central portion*, *anterior* and *inferior horns*, and in man also a *posterior horn*. The latter part develops rather late in the human fetus as a diverticulum from the main cavity.

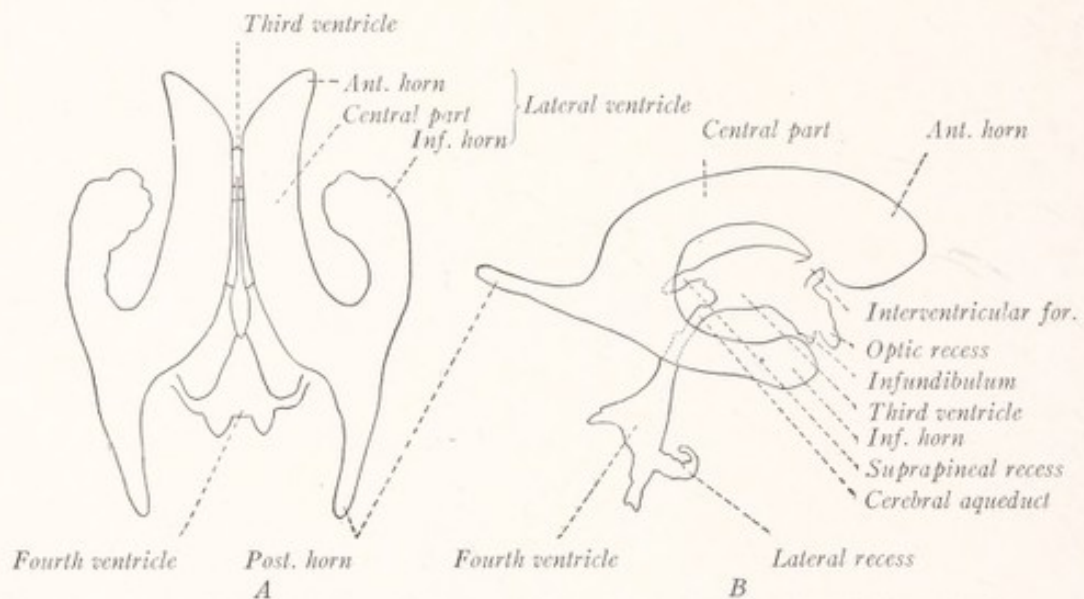


Fig. 176.—Two views of the brain ventricles of man: A, Dorsal view; B, lateral view.

The **anterior horn**, or cornu anterius, is the part which lies rostral to the interventricular foramen. Its *roof* and *rostral boundary* are formed by the corpus callosum. Its *medial wall* is vertical and is formed by the septum pellucidum, which is stretched between the corpus callosum and the fornix (Figs. 177, 178). The sloping *floor* is at the same time the lateral wall, and is formed by the head of the caudate nucleus, which bulges into the ventricle from the ventrolateral side. In frontal section the cavity has a triangular outline; and in such a section its walls and the relation which they bear to the rest of the brain can be studied to advantage (Fig. 186).

The **central part** or **body of the lateral ventricle** extends from the interventricular foramen to the splenium of the corpus callosum, where in man the cavity bifurcates into posterior and inferior horns. The *roof* of the central

part is formed by the corpus callosum, and the *medial* wall by the septum pellucidum. The *floor*, which slants to meet the roof at the lateral angle, is composed from within outward of the following structures: the fornix, chorioid plexus, lateral part of the dorsal surface of the thalamus (in man, but not in the sheep), the stria terminalis, vena terminalis, and the caudate nucleus (Figs. 177-180, 188). The caudate nucleus tapers rapidly as it is followed from the anterior horn into the body of the ventricle (Fig. 177). The cavity

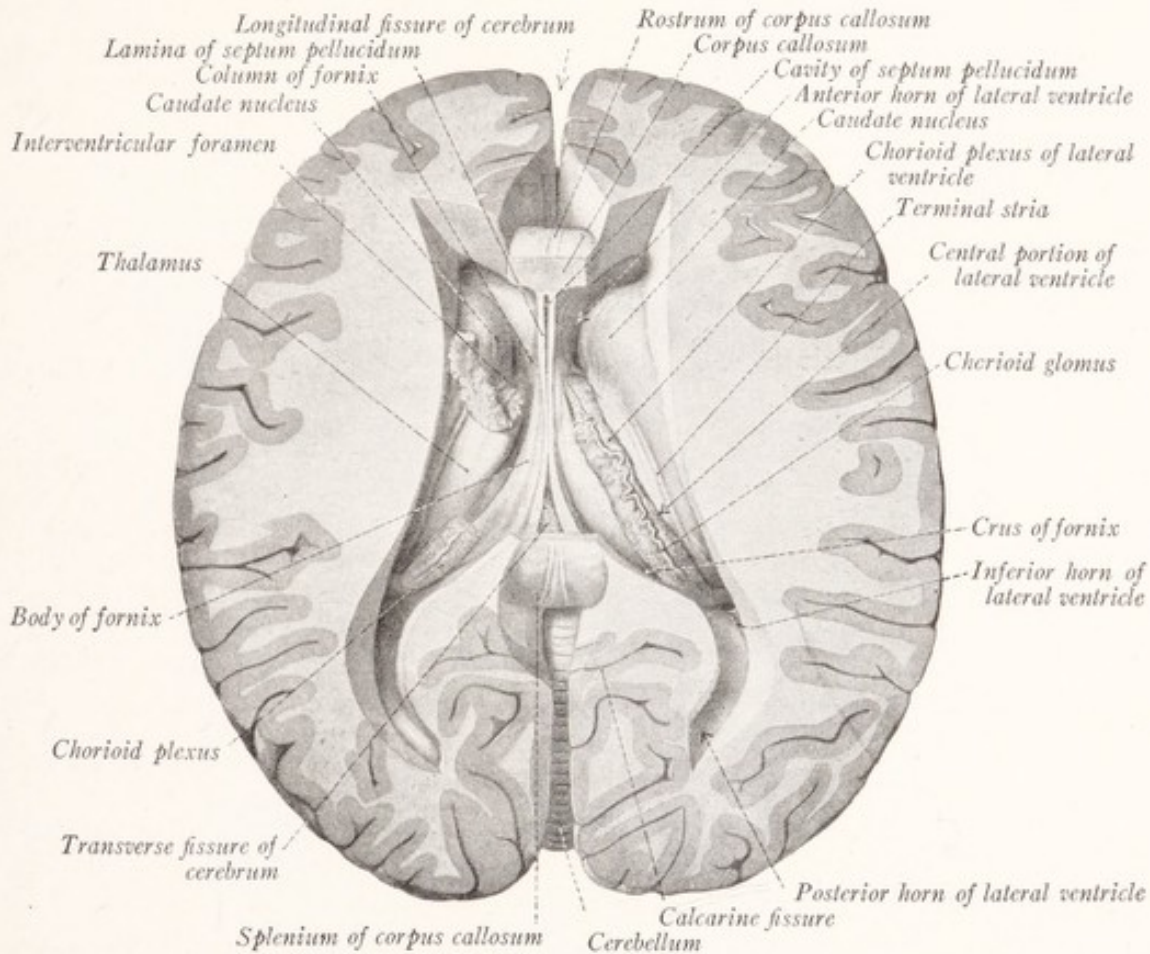


Fig. 177.—Dissection of the human telencephalon. The corpus callosum has been partly removed, and the lateral ventricles have been exposed. Dorsal view. (Sobotta-McMurrich.)

is lined throughout by an ependymal epithelium, indicated in red in Fig. 155. Between the caudate nucleus and the fornix this layer of ependyma constitutes the entire thickness of the wall of the hemisphere. In man, where the fornix and caudate nucleus are more widely separated than in the sheep, this epithelial membrane rests upon the thalamus and becomes adherent to it as the lamina affixa (Figs. 154, 155). At the margin of the fornix a vascular network from the *tela chorioidea*, *i. e.*, from the pia mater in the transverse cerebral fissure, is

invaginated into the ventricle, pushing this epithelial layer before it and constituting the chorioid plexus.

The **posterior horn**, or *cornu posterius*, extends into the occipital lobe of the human brain, tapering to a point, and describing a gentle curve with concavity directed medially (Figs. 177, 181).

The tapetum of the corpus callosum forms a thin but distinct layer in the *roof* and *lateral wall* of the posterior horn, and is covered in turn by a thicker layer of fibers belonging to optic radiation or *radiatio occipitohthalmica* (Fig. 190). In the *medial wall* two longitudinal elevations may be seen. Of these,

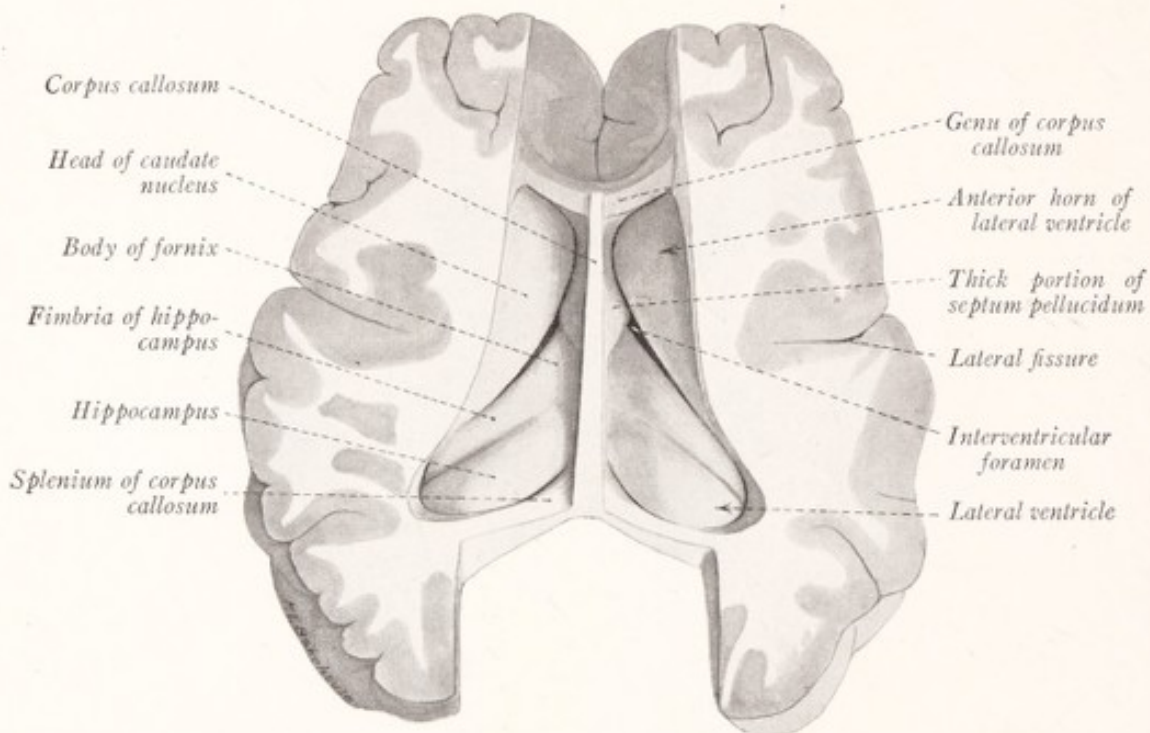


Fig. 178.—Dissection of the telencephalon of the sheep to show the lateral ventricle and the structures which form its floor. Dorsal view.

the more dorsal one is known as the *bulb of the posterior horn* (*bulbus cornu*), and is formed by the occipital portion of the radiation of the corpus callosum or *forceps major*. The other elevation, known as the *calcar avis*, is larger and is produced by the rostral part of the calcarine fissure, which here causes a folding of the entire thickness of the pallium (p. 238).

The **inferior horn**, or *cornu inferius*, curves ventrally and then rostrally into the temporal lobe (Fig. 181). The angle between the diverging inferior and posterior horns is known as the *collateral trigone*. This horn lies in the medial part of the temporal lobe and does not quite reach the temporal pole. The *roof*

is formed by the white substance of the hemisphere, and along its medial border are the *stria terminalis* and *tail of the caudate nucleus*. At the end of the latter

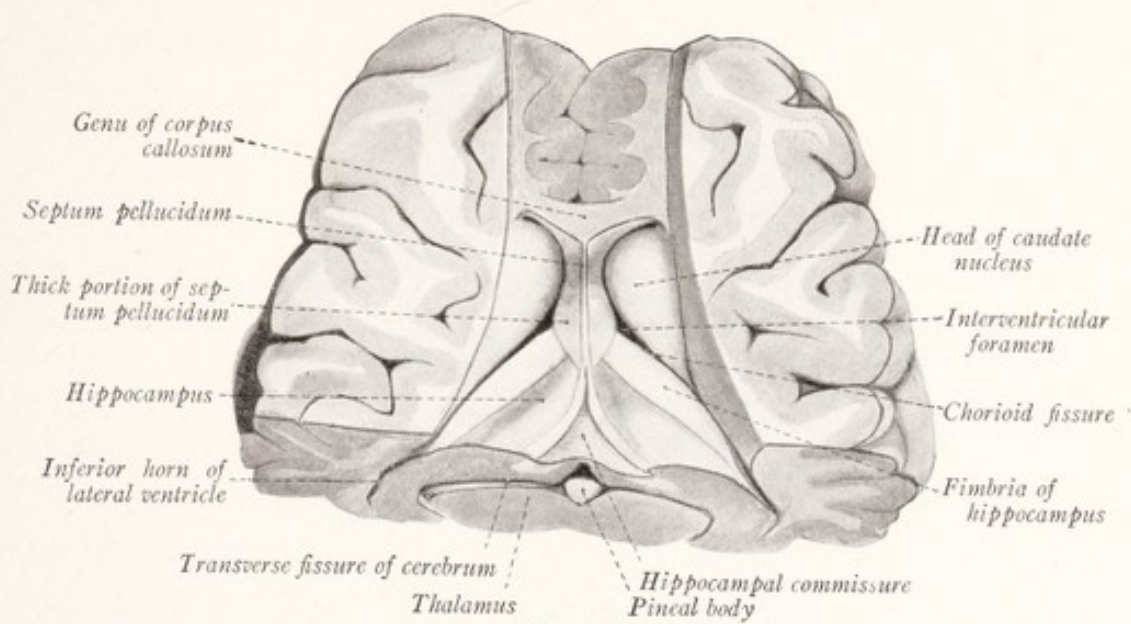


Fig. 179.

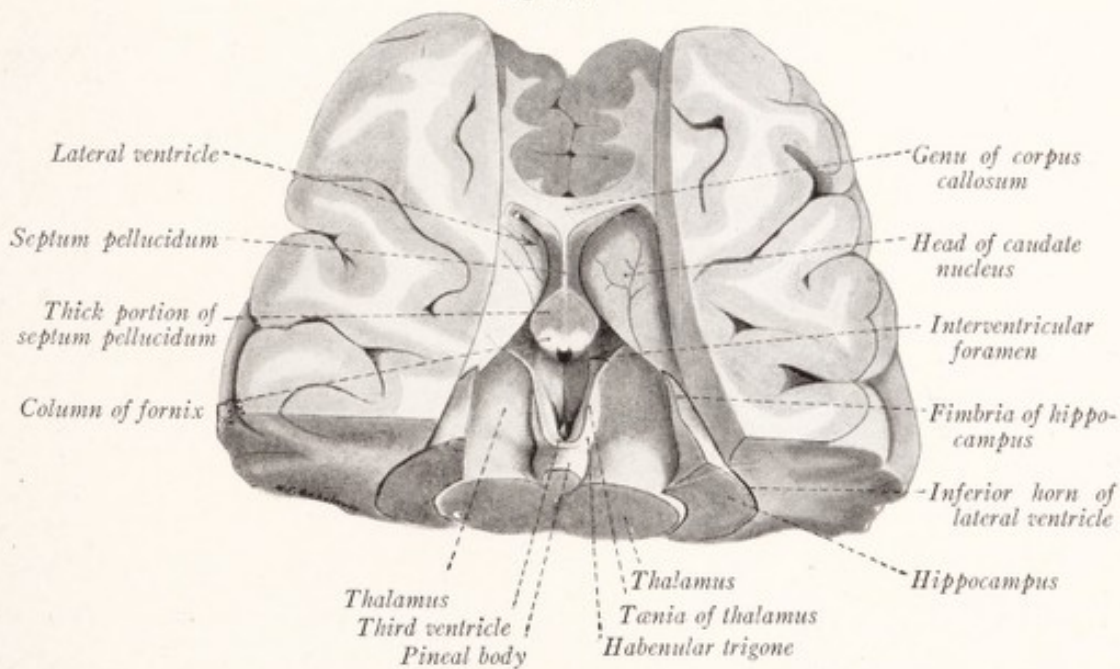


Fig. 180.

Figs. 179 and 180.—Dissections of the rostral part of the sheep's brain to show the relation of the lateral ventricles, fornix, fimbria, and hippocampus to the transverse fissure, thalamus, and third ventricle. Dorsal views. In Fig. 180 a triangular piece, including portions of the fornix, fimbria, and hippocampus, has been removed.

the *amygdaloid nucleus* bulges into the terminal part of the inferior horn (Fig. 185). The *floor* and *medial wall* of the inferior horn are formed in large part

by the following structures, named in their order from within outward: the fimbria, hippocampus, and (in man) the collateral eminence (Figs. 181, 182, 189). Upon the fimbria and hippocampus there is superimposed the chorioid plexus (Fig. 183). The *hippocampus* is a long, prominent, curved elevation, with whose medial border there is associated a band of fibers, representing a continuation of the fornix and known as the *fimbria*. These parts will be de-

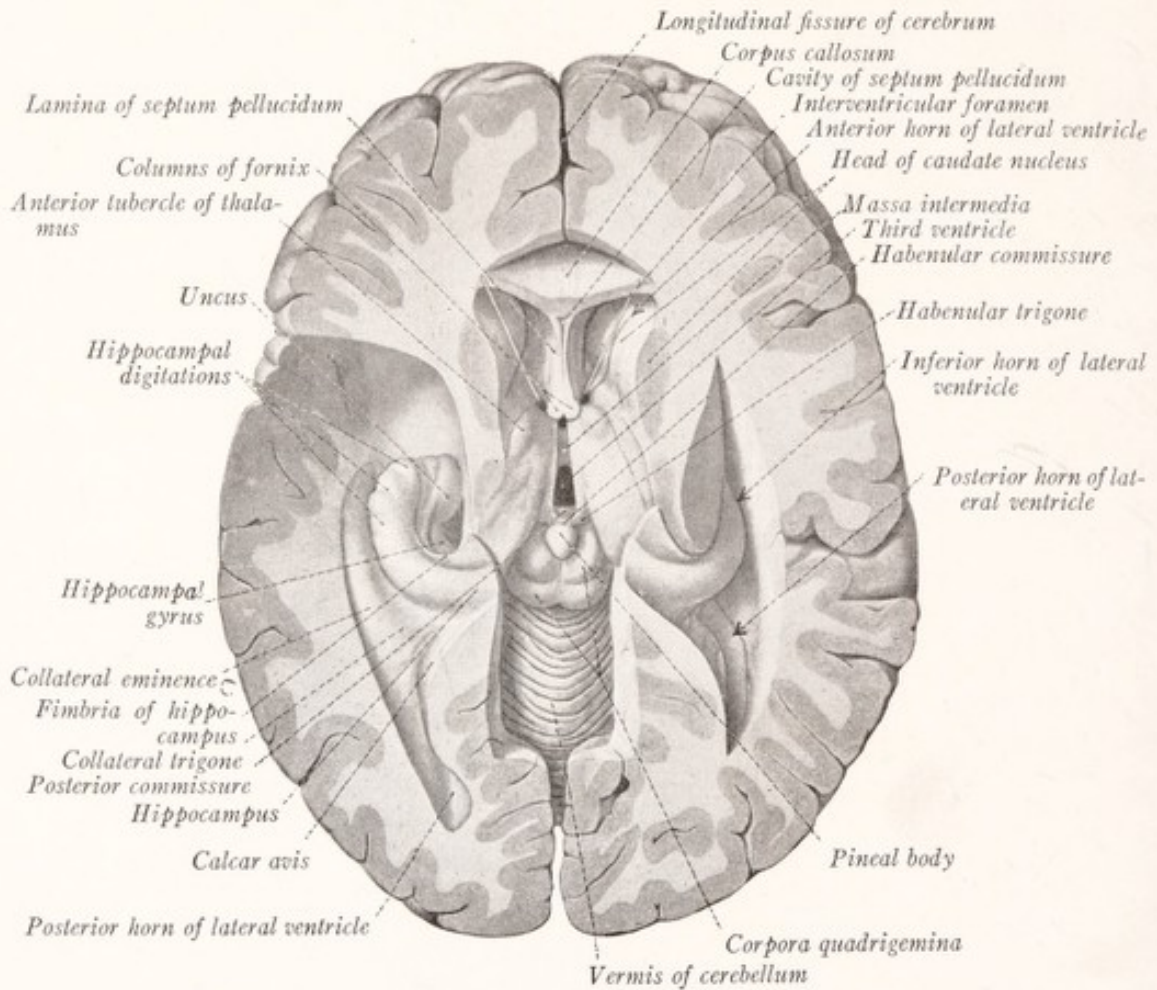


Fig. 181.—Dissection of the human brain to show the posterior and inferior horns of the lateral ventricle. The body and splenium of the corpus callosum have been removed, as have also the body of the fornix and the tela chorioidea of the third ventricle. A sound has been passed through the interventricular foramina. Dorsal view. (Sobotta-McMurrich.)

scribed in connection with the rhinencephalon. The *collateral eminence* is an elevation in the lateral part of the floor produced by the collateral fissure.

The thin epithelial membrane, described above as joining the edge of the fornix with the caudate nucleus (Fig. 155), continues to unite these structures as they both curve downward, the former in the floor, the latter in the roof, of the inferior horn. A vascular plexus from the pia mater is invaginated into the

lateral ventricle along this curved line, carrying before it an epithelial covering from this thin membrane. In this way there is formed the *chorioid plexus of the lateral ventricle* (Figs. 183, 184). The line along which this invagination occurred is the chorioid fissure; and when the plexus is torn away, the position of the

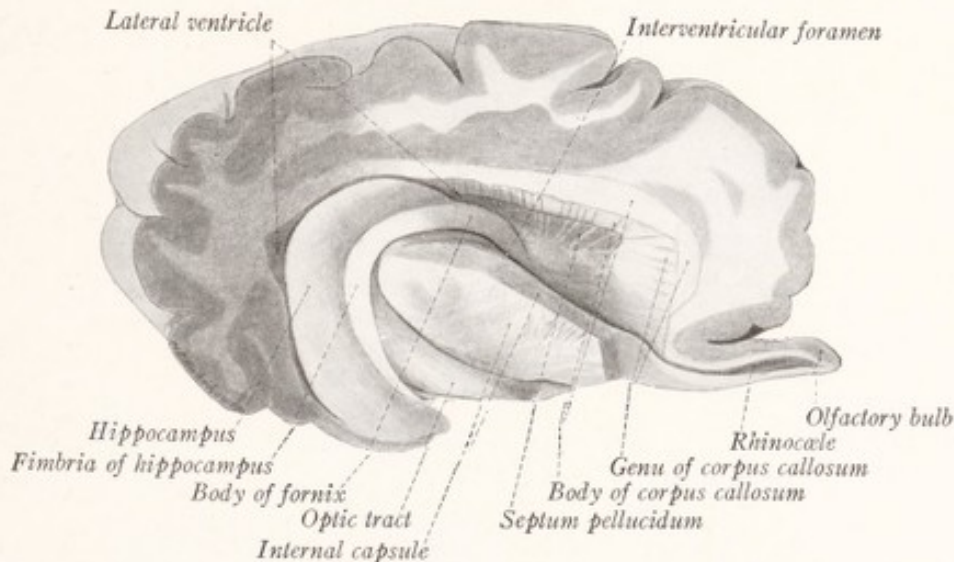


Fig. 182.—Dissection of the cerebral hemisphere of the sheep to show the lateral ventricle. Lateral view.

fissure is indicated by an artificial cleft extending into the ventricle, which begins at the interventricular foramen and follows the fornix and fimbria in an arched course into the temporal lobe (Fig. 205).

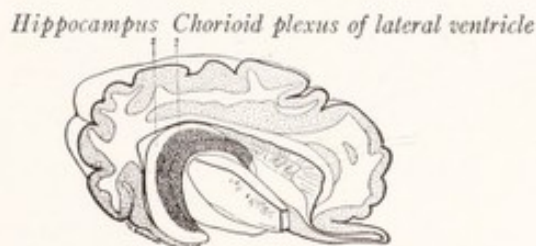


Fig. 183.—Outline drawing from Fig. 182, to show the location of the chorioid plexus of the lateral ventricle.

The **chorioid plexus** of the lateral ventricle (Figs. 183, 184, 188) is continuous with that of the third ventricle at the interventricular foramen, from which point it can be followed backward through the central part into the inferior horn. It is coextensive with the chorioid fissure and is not found in the anterior or posterior horns. It consists of a vascular network derived from the pia

mater, and especially from that part of it enclosed in the transverse fissure and known as the tela chorioidea of the third ventricle. It is covered throughout

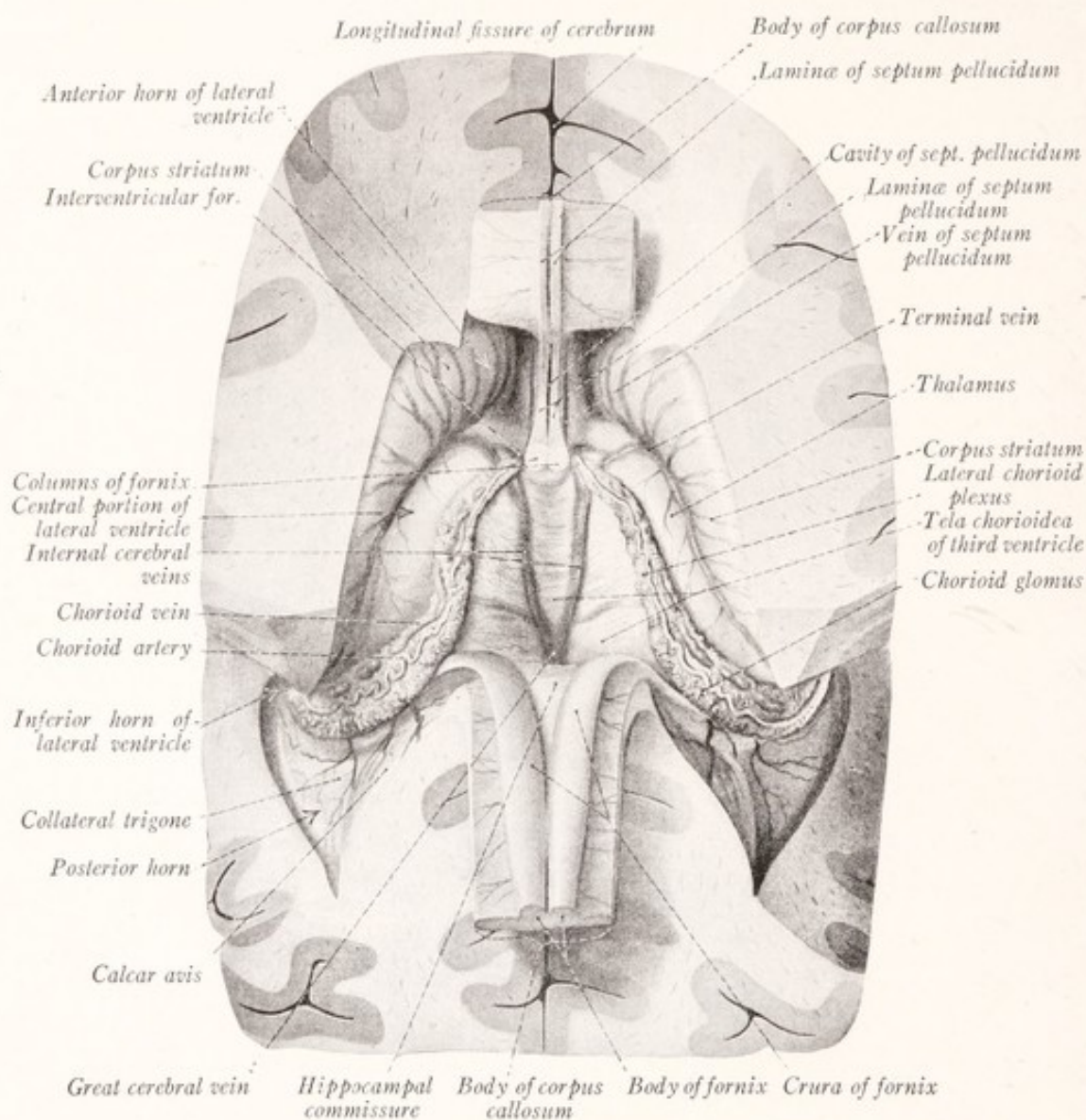


Fig. 184.—Dissection of the human brain to show the tela chorioidea of the third ventricle and the hippocampal commissure. The body of the corpus callosum and the fornix have been divided and reflected. Dorsal view, except that the ventral surfaces of the reflected corpus callosum and hippocampal commissure are seen. (Sobotta-McMurrich.)

by a layer of epithelium of ependymal origin, which is adapted to every unevenness of its surface (Fig. 155).

THE BASAL GANGLIA OF THE TELEENCEPHALON

There are four deeply placed masses of gray matter within the hemisphere, known as the *caudate*, *lentiform* and *amygdaloid nuclei*, and the *claustrum*. The

two former, together with the white fascicles of the internal capsule which separate them, constitute the *corpus striatum* (Fig. 185).

The **caudate nucleus** (*nucleus caudatus*) is an elongated mass of gray matter bent on itself like a horseshoe, and is throughout its entire extent closely re-

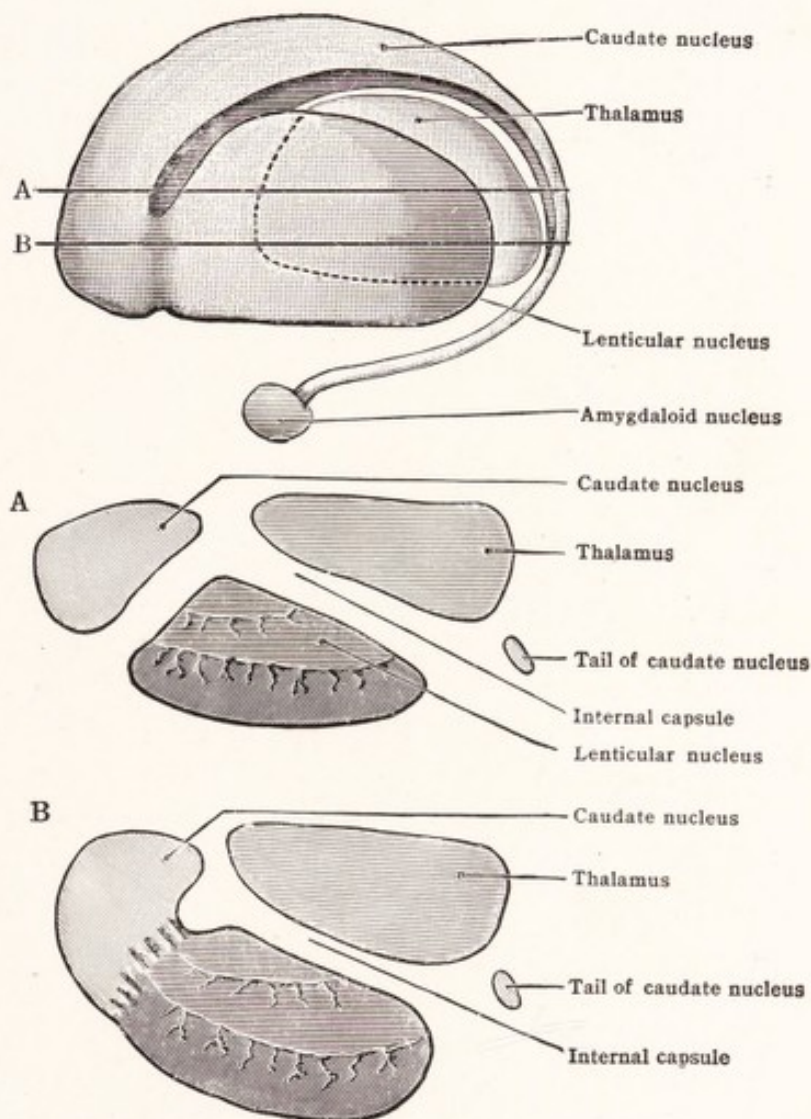


Fig. 185.—Diagrams of lateral view and sections of the nuclei of the corpus striatum with the internal capsule omitted. *A* and *B* below represent horizontal sections along the lines *A* and *B* in the figure above. The figure also shows the relative position of the thalamus and the amygdaloid nucleus. (Jackson-Morris.)

lated to the lateral ventricle (Figs. 91, 177, 178, 186, 187, 188, 191). Its swollen rostral extremity or *head* is pear shaped and bulges into the anterior horn of the lateral ventricle. The remainder of the nucleus is drawn out into a long, slender, highly arched *tail*. In the floor of the central part of the ventricle the head gradually tapers off into the tail, which finally curves around into the roof

of the inferior horn and extends rostrally as far as the amygdaloid nucleus. Because of its arched form it will be cut twice in any horizontal section which passes through the main mass of the corpus striatum, and in any frontal section through that body behind the amygdaloid nucleus (Figs. 185, 189, 191). The head of the caudate nucleus is directly continuous with the anterior perforated substance; and ventral to the anterior limb of the internal capsule it is fused with the lentiform nucleus (Fig. 186).

The **lentiform** or **lenticular nucleus** (*nucleus lentiformis*) is deeply placed in the white center of the hemisphere and intervenes between the insula, on the

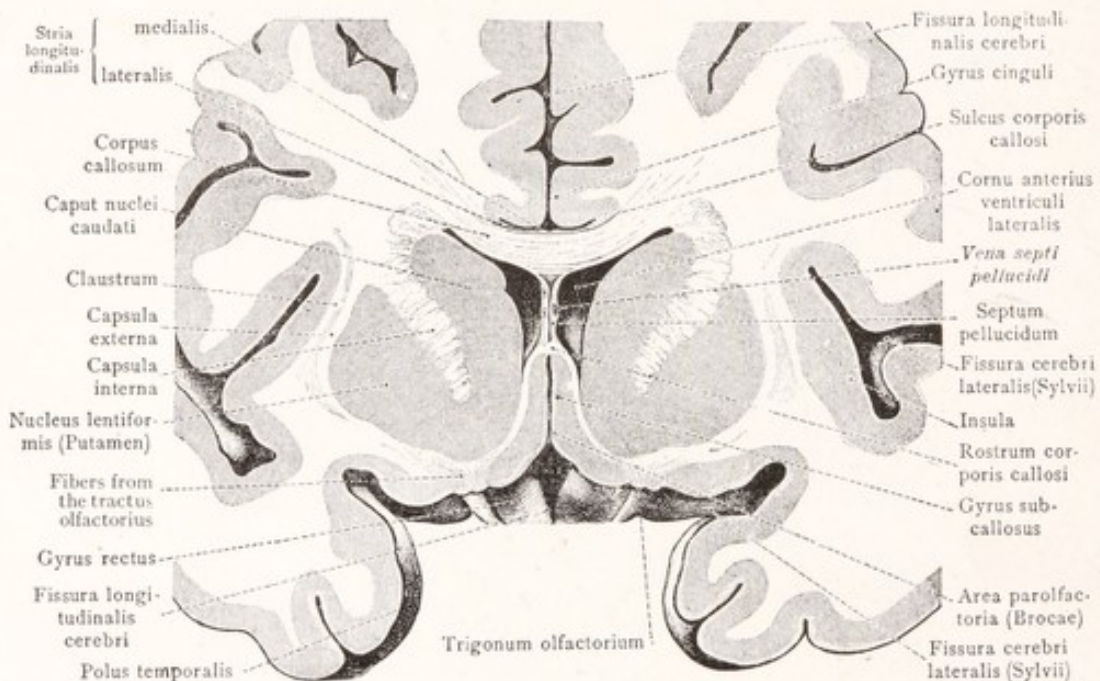


Fig. 186.—Frontal section of the human brain through the rostral end of the corpus striatum and the rostrum of the corpus callosum. (Toldt.)

one hand, and the caudate nucleus and thalamus on the other (Figs. 185, 191, 194). In shape it bears some resemblance to a biconvex lens. Its lateral, moderately convex surface is nearly coextensive with the insula from which it is separated by the claustrum. Its ventral surface rests upon the anterior perforated substance and the white matter forming the roof of the inferior horn of the lateral ventricle (Figs. 187–189). Its sloping medial surface is closely applied to the internal capsule. The lentiform nucleus is not a homogeneous mass, but is divided into three zones by *internal* and *external medullary laminae*. The most lateral zone is the largest and is known as the *putamen*. The two medial zones together form the *globus pallidus*.

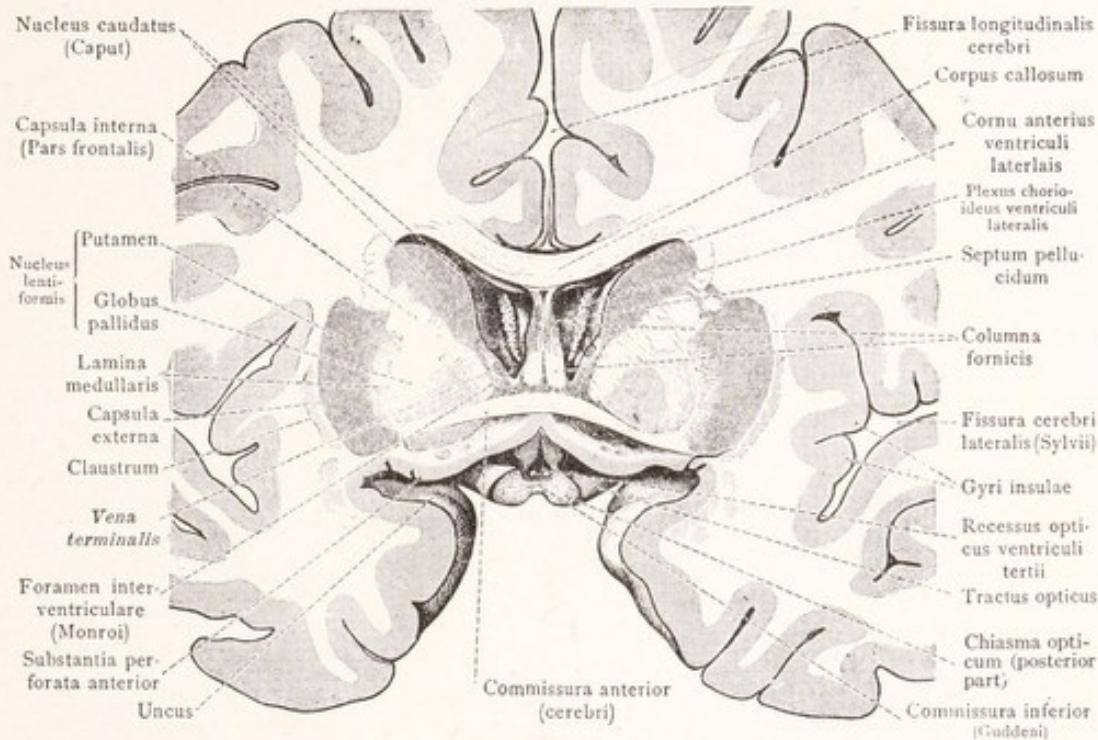


Fig. 187.—Frontal section of the human brain through the anterior commissure. (Toldt.)

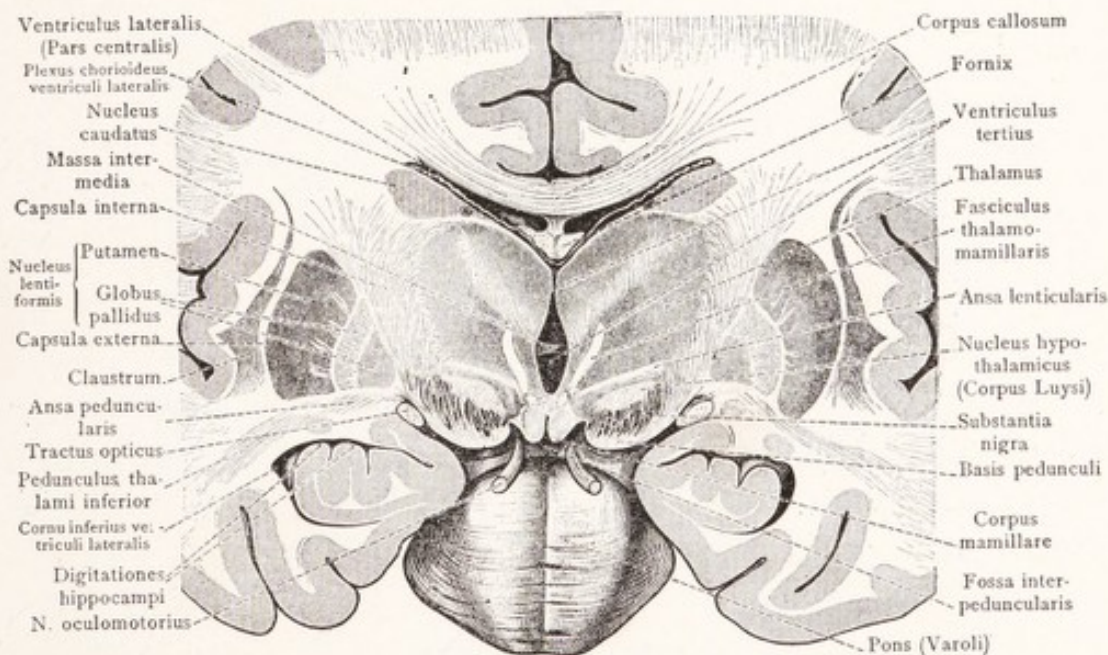


Fig. 188.—Frontal section of the human brain through the mammillary bodies. (Toldt.)

The **putamen** is larger than the globus pallidus and is encountered alone in frontal sections through either the rostral or caudal extremities of the corpus striatum (Fig. 189), and also in horizontal sections above the level of the globus

pallidus (Fig. 191). It is fused rostrally with the caudate nucleus, which it resembles in color and structure.

The **globus pallidus** is lighter in color and is subdivided into two parts, of which the medial is the smaller. Both parts are traversed by many fine white fascicles from the medullary laminae.

Especially in the anterior part of the internal capsule bands of gray substance stretch across from the lentiform to the caudate nucleus, producing a striated appearance (Fig. 187). This appearance, which is accentuated by the medullary laminae and the finer fiber bundles in the lentiform nucleus, makes

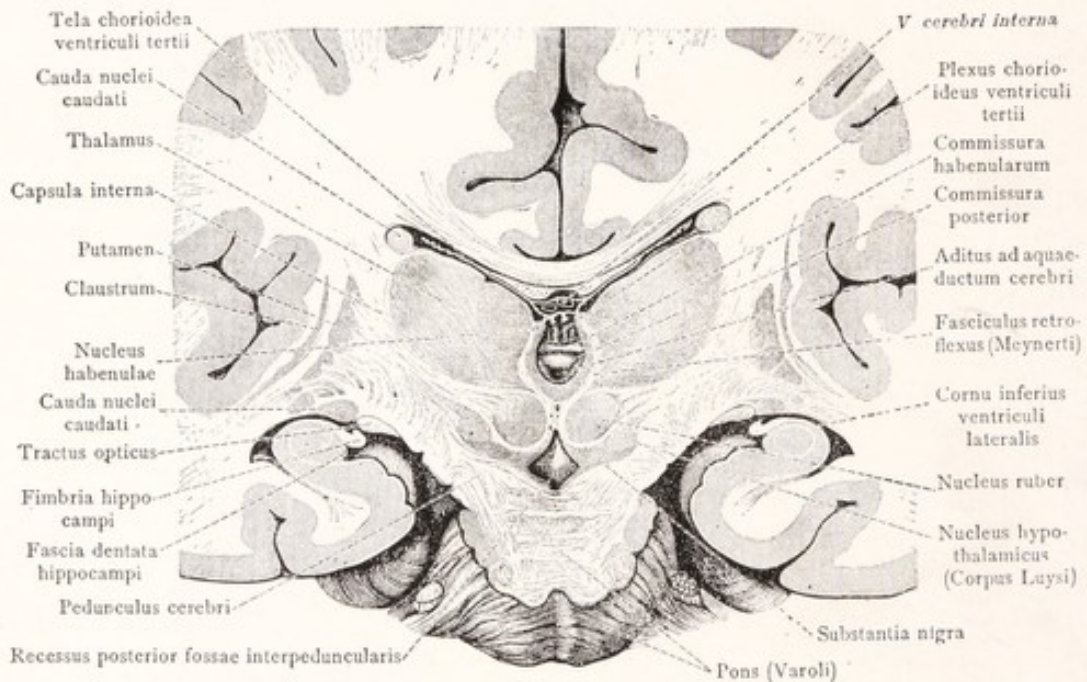


Fig. 189.—Frontal section of the human brain through the rostral part of the pons. (Toldt.)

the term *corpus striatum* an appropriate name to apply to the two nuclei and the internal capsule, which separates them.

The **claustrum** is a thin plate of gray substance, which, along with the white matter in which it is embedded, separates the putamen from the cortex of the insula. Its lateral surface is somewhat irregular, being adapted to the convolutions of the insula, with which it is coextensive (Figs. 188, 191). Its concave medial surface is separated from the putamen by a thin lamina of white matter, known as the external capsule. By some authorities the claustrum is thought to be a detached portion of the lentiform nucleus, while others believe that it has been split off from the insular cortex. It is probable that neither of these views is strictly correct. However, according to the recent work of Elliot

Smith (1919), the claustrum, putamen, amygdaloid nucleus, and the greater part of the caudate nucleus are pallial derivatives and are closely related morphologically to the neopallium; while the globus pallidus is the representative in the mammalian brain of the corpus striatum of lower forms, as seen in the shark (Fig. 9).

The Amygdaloid Nucleus.—In the roof of the terminal part of the inferior ventricular horn, at the point where the tail of the caudate nucleus ends, there is located a small mass of gray matter, known as the amygdaloid nucleus (Fig.

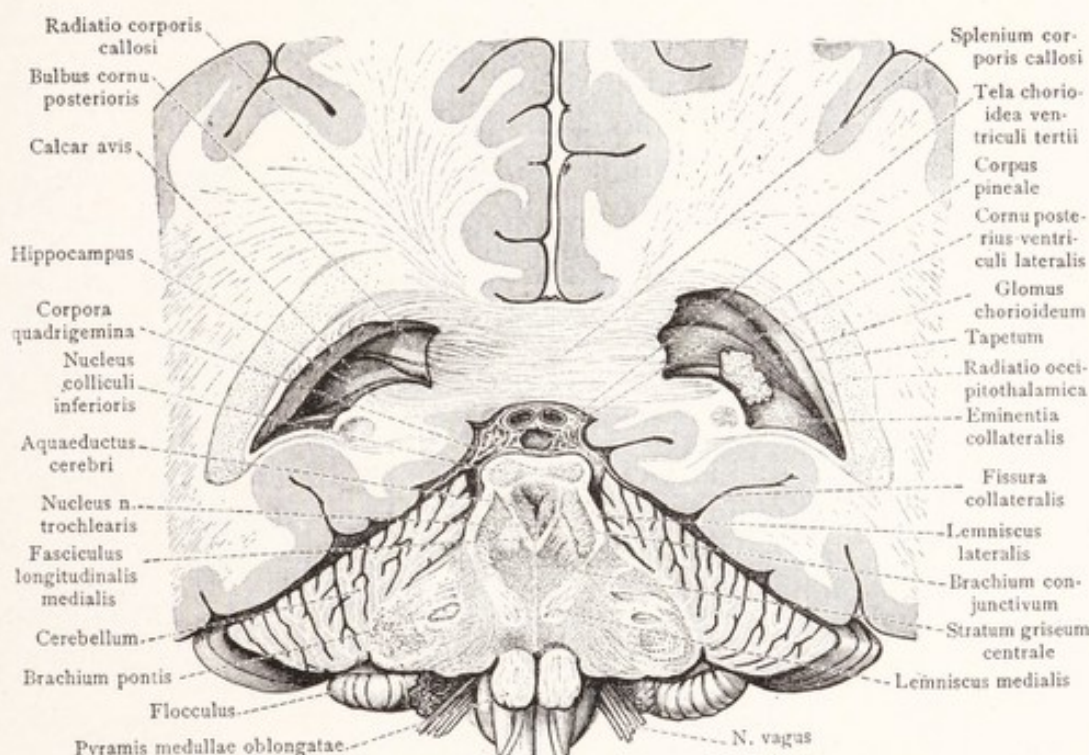


Fig. 190.—Frontal section of the human brain through the splenium of the corpus callosum. View into the posterior horn of the lateral ventricle. (Toldt.)

185). It is continuous with the cerebral cortex of the temporal lobe lateral to the anterior perforated substance (Fig. 198; Landau, 1919).

The **external capsule** is a thin lamina of white matter separating the claustrum from the putamen. Along with the internal capsule it encloses the lentiform nucleus with a coating of white substance.

THE INTERNAL CAPSULE

The internal capsule is a broad band of white substance separating the lentiform nucleus on the lateral side from the caudate nucleus and thalamus on the medial side (Figs. 191, 192). In a horizontal section through the middle

of the corpus striatum it has the shape of a wide open V. The angle, situated in the interval between the caudate nucleus and the thalamus, is known as the

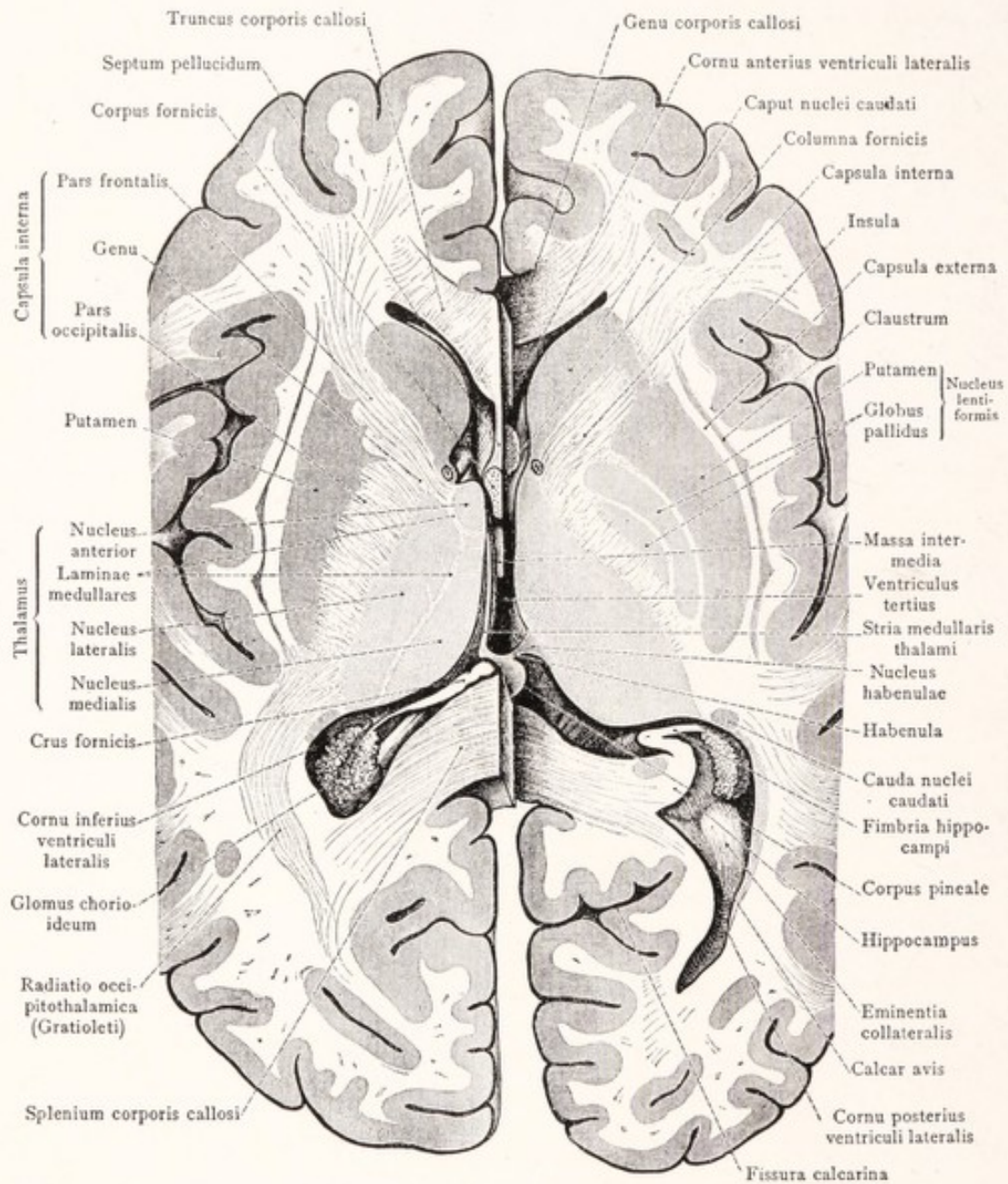


Fig. 191.—Horizontal sections of the human brain through the internal capsule and corpus striatum. The section on the right side was made 1.5 cm. farther ventralward than that on the left. (Toldt.)

genu. From this bend the *frontal part* or *anterior limb* of the *internal capsule* extends laterally and rostrally between the thalamus and the head of the caudate nucleus; while the *occipital part* or *posterior limb* of the *internal capsule* extends

laterally and toward the occiput between the lentiform nucleus and the thalamus.

The **anterior limb of the internal capsule**, intervening between the caudate and lentiform nuclei, is broken up by bands of gray matter connecting these two nuclei. It consists of corticopetal and corticofugal fibers. The former belong to the *frontal stalk of the thalamus* or anterior thalamic radiation from the lateral nucleus of the thalamus to the cortex of the frontal lobe. The corti-

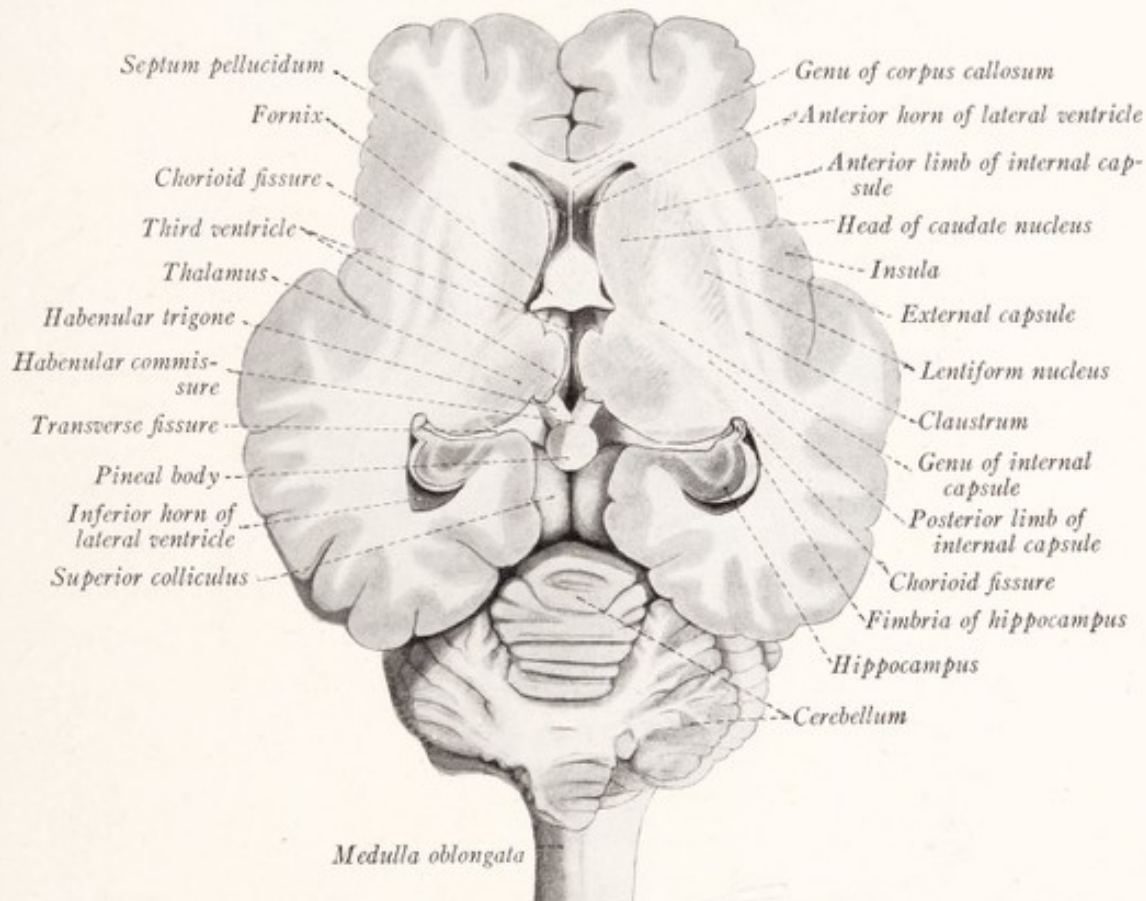


Fig. 192.—Horizontal section through the sheep's brain, passing through the internal capsule and corpus striatum.

fugal fibers form the *frontopontine tract* from the cortex of the frontal lobe to the nuclei pontis (Fig. 193).

The **posterior limb of the internal capsule** intervenes between the thalamus and the lentiform nucleus, and bends around the posterior end of the latter on to its ventral surface (Fig. 194). It accordingly consists of three parts, designated as lenticulothalamic, retrolenticular, and sublenticular. The *lenticulothalamic part* consists of fibers belonging to the *thalamic radiation* intermingled with others representing the great efferent tracts which descend from the cere-

bral cortex (Fig. 193). Of these, the *corticobulbar tract* to the motor nuclei of the cranial nerves occupies the genu, and the *corticospinal tract* the adjacent portion of the posterior limb. The fibers of the corticospinal tract are so ar-

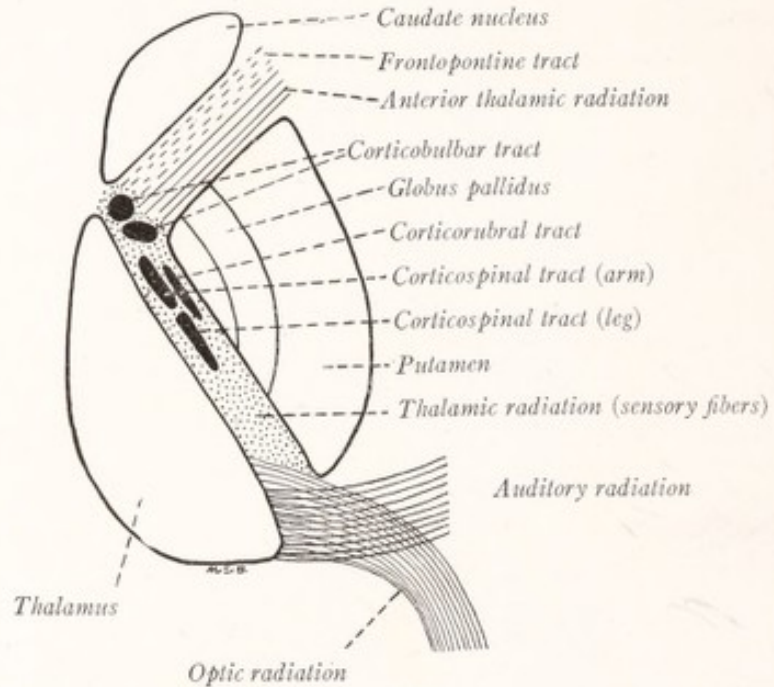


Fig. 193.—Diagram of the internal capsule.

ranged that those for the innervation of the arm are nearer the genu than those for the leg. Accompanying the corticospinal tract are descending fibers from the cortex of the frontal lobe to the red nucleus, the *corticorubral tract*. Those

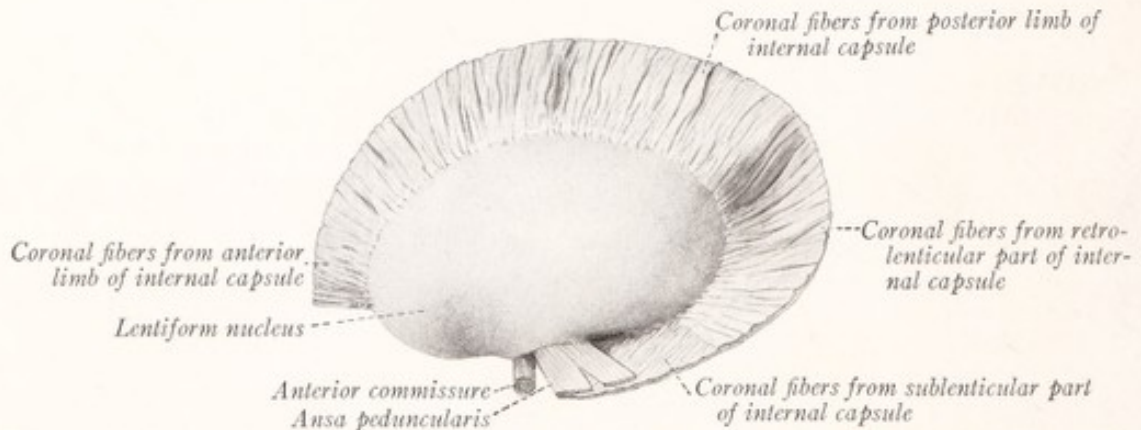


Fig. 194.—The lentiform nucleus and the corona radiata dissected free from the left human cerebral hemisphere. Lateral view.

fibers of the thalamic radiation which run to the posterior central gyrus and convey general sensory impulses from the lateral nucleus of the thalamus are situated behind the corticospinal tract. The *retrolenticular part* of the internal

capsule rests upon the lateral surface of the thalamus behind the lentiform nucleus and contains: (1) the optic radiation from the pulvinar and lateral geniculate body to the cortex in the region of the calcarine fissure, and (2) the acoustic radiation from the medial geniculate body to the transverse temporal gyrus. The *sublenticular part* of the internal capsule lies ventral to the posterior extremity of the lenticular nucleus and contains the temporopontine tract from the cortex of the temporal lobe to the nuclei pontis.

Dissections of the Internal Capsule (Figs. 87, 88, 91, 194, 195).—A large part of the fibers of the internal capsule, including the corticopontine, corticobulbar, and corticospinal tracts, are continued as a broad thick strand on the ventral surface of the cerebral peduncle, with which we are already familiar

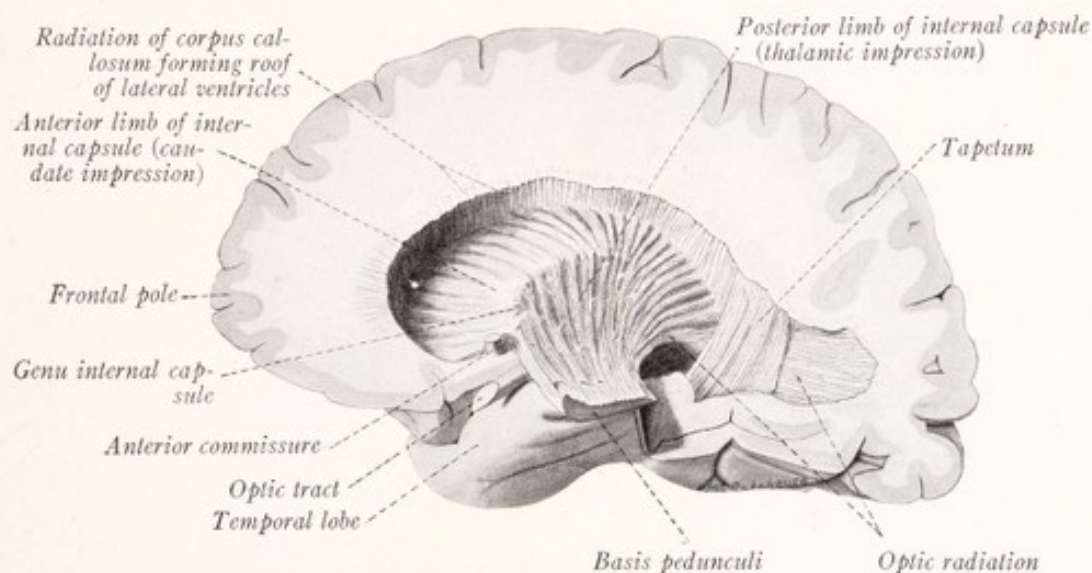


Fig. 195.—Dissection of the human cerebral hemisphere, showing the internal capsule exposed from the medial side. The caudate nucleus and thalamus have been removed.

under the name *basis pedunculi*. By removing the optic tract, temporal lobe, insula, and lentiform nucleus this strand can easily be traced into the internal capsule where it is joined by many fibers radiating from the thalamus and spreads out in a fan-shaped manner (Figs. 87, 88), forming a curved plate which partially encloses the lentiform nucleus. As seen from the lateral side, the line along which the fibers of the internal capsule emerge from behind the lentiform nucleus forms three-fourths of an ellipse (Fig. 194). Beyond the lentiform nucleus the diverging strands from the internal capsule, known as the *corona radiata*, join the central white substance of the hemisphere and intersect with those from the corpus callosum (Figs. 174, 238).

An instructive view of the internal capsule may also be obtained by remov-

ing the thalamus and caudate nucleus from its medial surface. It is then seen to bear the imprint of both of these nuclei, and especially of the thalamus; and between the two impressions it presents a prominent curved ridge (Fig. 195). This ridge is responsible for the sharp bend known as the genu, which is evident in horizontal sections at appropriate levels through the capsule. Many broken bundles of fibers, representing the thalamic radiation, are seen entering the capsule upon its medial surface.

THE CONNECTIONS OF THE CORPUS STRIATUM AND THALAMUS

What is the function of the *corpus striatum*, and what connection does it have with other parts of the nervous system? These questions, to which no

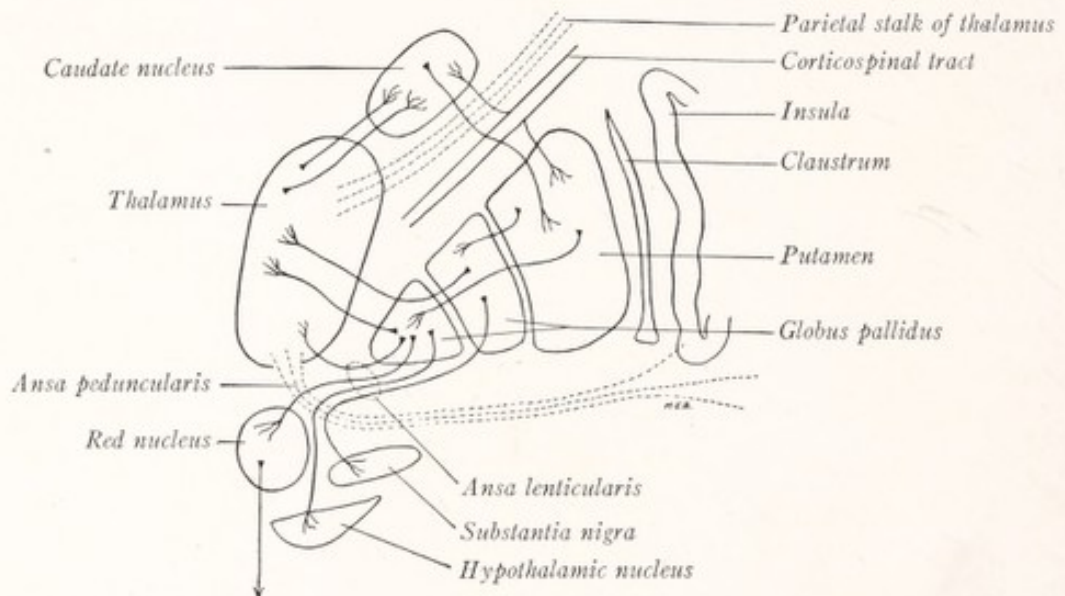


Fig. 196.—Diagram of the connections of the caudate and lenticular nuclei.

final answer can as yet be given, have recently become of great importance, because of the frequency with which degeneration of the lentiform nucleus has been found at autopsy in patients who have shown serious disturbances of the motor mechanism (Wilson, 1912-1914). It seems probable that the corpus striatum exerts a steadying influence upon muscular activity, the abolition of which results in tremor during voluntary movement. The probable connections of the corpus striatum are indicated in Fig. 196. *Striopetal fibers* reach the caudate nucleus from the anterior and medial nuclei of the thalamus (Sachs, 1909). According to Cajal, the corpus striatum also receives collaterals from the corticospinal tract. *Internuncial fibers* join together various parts of the corpus striatum. The majority of these seem to run from the caudate nucleus

to the putamen, on the one hand, and from the putamen to the globus pallidus on the other. The *striofugal fibers* arise, for the most part at least, in the globus pallidus. They are collected into a bundle of transversely directed fibers, known as the *ansa lenticularis* (Fig. 188), which is distributed to the thalamus, red nucleus, hypothalamic nucleus, and substantia nigra. Other fibers belonging to the same general system break through the ventral third of the internal capsule to reach the thalamus (Wilson, 1914). The importance of the connection with the red nucleus is obvious, since by way of the rubrospinal and rubroreticular tracts the corpus striatum is able to exert its influence upon the primary motor neurons of the brain stem and spinal cord. The fibers to the substantia nigra have already been mentioned under the name *strionigral tract* (p. 164). The impulses which travel along them are, in all probability, relayed through the substantia nigra to lower lying motor centers, although the functions and connections of this large nuclear mass are still obscure.

The Thalamic Radiation.—We are now in position to understand the course and distribution of the fascicles, which unite the thalamus with the cerebral cortex and which consist of both *thalamocortical* and *corticothalamic fibers*. This thalamic radiation may be divided into four parts: the frontal, parietal, occipital, and ventral stalks of the thalamus, which will now be traced as fasciculi, without reference to the direction of conduction in the individual fibers.

The **ventral stalk**, or inferior peduncle of the thalamus, streams out of the rostral portion of the ventral thalamic surface and is directed lateralward under cover of the lentiform nucleus. Some of these fibers belong to the *ansa lenticularis* and run from the lentiform nucleus to the thalamus. The others, forming a bundle known as the *ansa peduncularis*, runs lateralward ventral to the lentiform nucleus and are distributed to the cortex of the temporal lobe and insula (Fig. 196).

The **frontal stalk**, or peduncle of the thalamus, consists of fibers which run through the anterior limb of the internal capsule from the lateral thalamic nucleus to the cortex of the frontal lobe (Fig. 193), and in small part to the caudate nucleus also.

The **parietal stalk**, or peduncle, emerges from the lateral surface of the thalamus, and runs through the posterior limb of the internal capsule in close association with the great motor tracts (Figs. 193, 196). It connects the lateral nucleus of the thalamus with the cortex of the parietal and posterior part of the frontal lobe.

Many of these fibers, especially those terminating in the posterior central

gyrus, are afferent fibers of the third order mediating sensations of touch, heat, cold, and perhaps also pain as well as sensations from the muscles, joints, and tendons (Head, 1918). These sensory fibers are located behind the corticospinal tract in the posterior limb of the internal capsule. According to Wilson (1914) the medullary laminae of the lentiform nucleus do not contain any thalamocortical fibers.

The **occipital stalk**, or peduncle, is also known as the *optic radiation* and as the *radiatio occipitohthalmica*. Its fibers stream out of the pulvinar and lateral geniculate body, pass through the retrolenticular part of the internal capsule, and run in a curved course toward the occiput, around the lateral side of the posterior horn of the lateral ventricle to the cortex of the occipital lobe, and especially to the region of the calcarine fissure (Figs. 190, 191). It also contains some fibers arising in the occipital cortex and ending in the superior quadrigeminal body. We have learned that it forms an important part of the visual path (Fig. 162).

Closely associated with the optic radiation in the retrolenticular part of the internal capsule is the acoustic radiation (*radiatio thalamotemporalis*). This connects the medial geniculate body with the anterior transverse temporal gyrus and the adjacent part of the superior temporal gyrus, and mediates auditory sensations. It should be included as a part of the thalamic radiation.

CHAPTER XVII

THE RHINENCEPHALON

THE olfactory portions of the cerebral hemisphere may all be grouped together under the name *rhinencephalon*. Phylogenetically very old, this part of the brain varies greatly in relative importance in the different classes of vertebrates. The central connections of the olfactory nerves form all or almost all of the cerebral hemispheres in the selachian brain (Fig. 13); while in the mammal the non-olfactory cortex or neopallium has become the dominant part. Even among the mammals there is great variation in the importance and relative size of the olfactory apparatus. The rodents, for example, depend to a great extent on the sense of smell in their search for food, and possess a highly developed rhinencephalon. Such mammals are classed as *macrosmatic*. Man, on the other hand, belongs in this respect with the *microsmatic* mammals, because in his activities the sense of smell has ceased to play a very important part, and his olfactory centers have undergone retrogressive changes. The carnivora and ruminants are in an intermediate group. The sheep's brain furnishes a good illustration of this intermediate type, and displays much more clearly than the human brain the various parts of the rhinencephalon and their relation to each other.

Parts Seen on the Basal Surface of the Brain.—A comparison of the basal surface of the sheep's brain with that of the human fetus of the fifth month shows a remarkable similarity in the parts under consideration (Figs. 197, 198). The *olfactory bulb*, which is the olfactory center of the first order, is oval in shape and attached to the hemisphere rostral to the anterior perforated substance. It lies between the orbital surface of the cerebral hemisphere and the cribriform plate of the ethmoid bone. Through the openings in this plate numerous fine filaments, the *olfactory nerves*, reach the bulb from the olfactory mucous membrane. It contains a cavity, the rhinocœle, continuous with the lateral ventricle (Fig. 182). In the adult human brain the cavity is obliterated and the connection between bulb and hemisphere is drawn out into the long *olfactory tract*. This is lodged in the olfactory sulcus on the orbital surface of the frontal lobe and in transverse section presents a triangular outline (Fig. 172). It contains

olfactory fibers of the second order connecting the bulb with the secondary olfactory centers in the hemisphere. At its point of insertion into the hemisphere the olfactory tract forms a triangular enlargement, the *olfactory trigone*.

From the point of insertion of the olfactory bulb or tract a band of gray matter, the *medial olfactory gyrus*, can be seen extending toward the medial surface of the hemisphere (Figs. 159, 197, 198). A similar gray band, the *lateral olfactory gyrus*, runs caudalward on the basal surface of the sheep's brain. Along

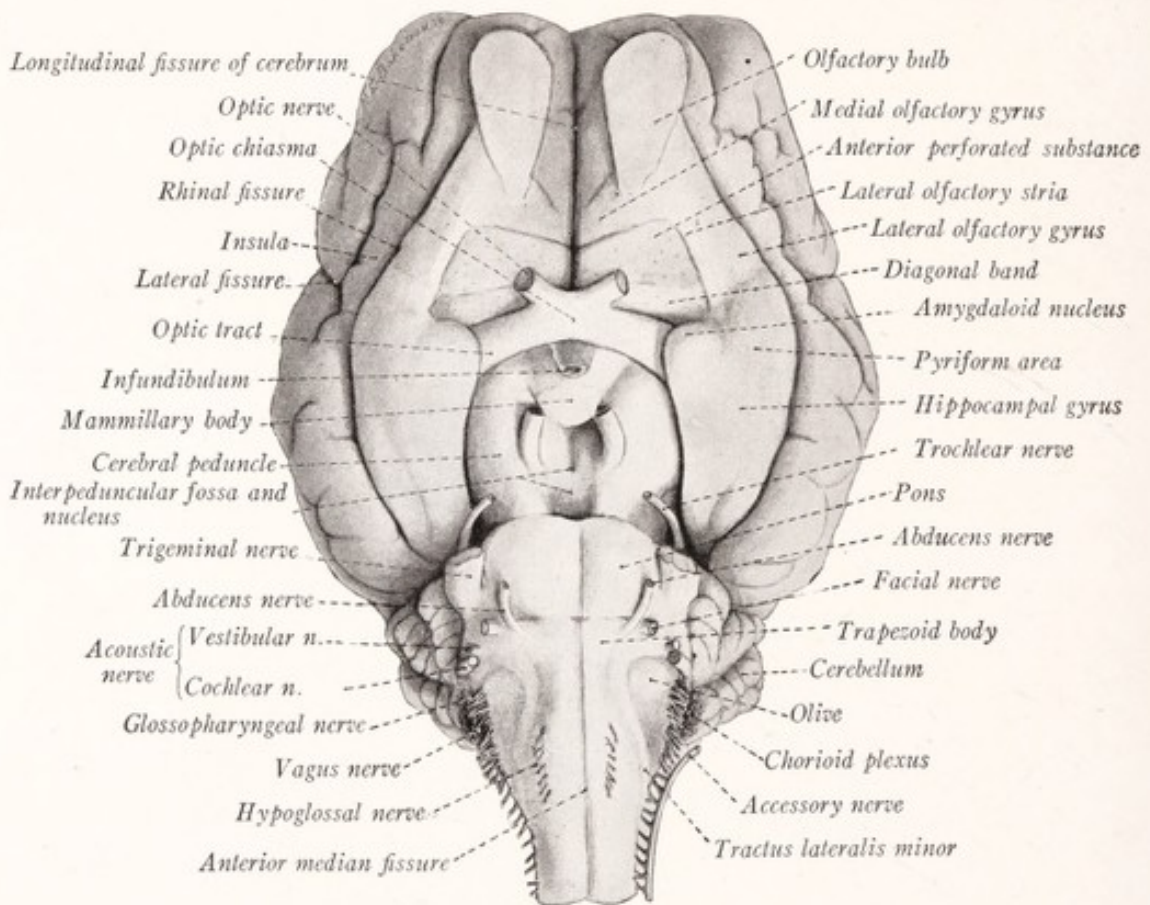


Fig. 197.—Ventral view of the sheep's brain.

its lateral border it is separated from the neopallium by the rhinal fissure; while its medial border contains a band of fibers, the *stria olfactoria lateralis* (Fig. 197). The same gyrus is seen in the brain of the human fetus, but here it is directed outward toward the insula (Fig. 198). In the adult human brain these olfactory convolutions are very inconspicuous, and with the fibers from the olfactory tract which accompany them are usually designated as the *medial* and *lateral olfactory striae*.

The medial olfactory gyrus and stria require further investigation. It has been generally supposed that the stria is formed by olfactory fibers of the second and third order running to the olfactory centers in the rostral part of the medial surface of the hemisphere. These are certainly few in number in the higher mammals, and Cajal (1911), who worked chiefly with rodents, has been unable to identify any such fibers in these animals. The significance of the medial olfactory gyrus is also obscure. According to Elliot Smith (1915), "the rudiment of the hippocampal formation that develops on the medial surface begins in front alongside the place where the stalk of the olfactory peduncle (which becomes the trigonum olfactorium) is inserted; it passes upward to the superior end of the lamina terminalis, from the rest of which it is separated by a triangular mass of gray matter called the corpus paraterminale" (Fig. 200). This description, as well as the figure which accompanies it, suggests a close relation between the rostral end of the hippocampal rudiment and what is ordinarily known as the medial olfactory gyrus. The subdivision of the olfactory lobe into anterior and posterior portions by the morphologically unimportant sulcus parolfactorius posterior, although adopted in the B. N. A., is without justification and leads only to confusion (Elliot Smith, 1907).

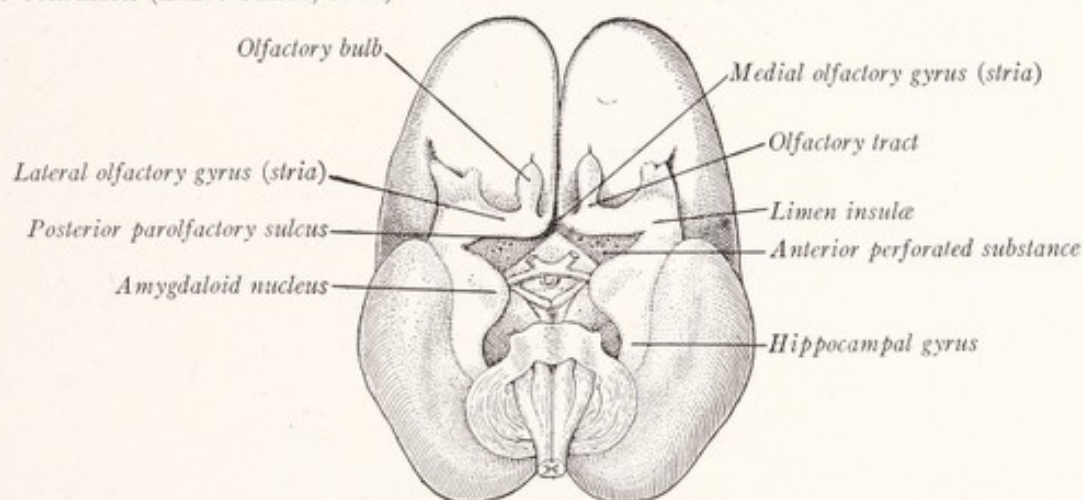


Fig. 198.—Brain of a human fetus of 22.5 cm. Ventral view. (Retzius, Jackson-Morris.)

Between the olfactory trigone and the medial olfactory gyrus, on the one hand, and the optic tract on the other, is a depressed area of gray matter known as the *anterior perforated substance*, through the openings in which numerous small arteries reach the basal ganglia (Figs. 172, 197). The part immediately rostral to the optic tract forms a band of lighter color, known as the diagonal gyrus of the rhinencephalon or the *diagonal band* of Broca (Fig. 197). This can be followed on to the medial surface of the hemisphere, where it is continued as the *paraterminal body* or subcallosal gyrus (Fig. 200). Rostral to this gyrus the *hippocampal rudiment*, which corresponds in part to the parolfactory area of Broca, extends as a narrow band from the rostrum of the corpus callosum toward the medial olfactory gyrus. In those mammals which possess an especially rich innervation of the nose and mouth, the region of the anterior perforated space is marked by a swelling, sometimes of considerable size, called

the *tuberculum olfactorium*. According to Retzius, a small oval mass is present in the anterior perforated substance of man immediately adjacent to the olfactory trigone, which represents this tubercle.

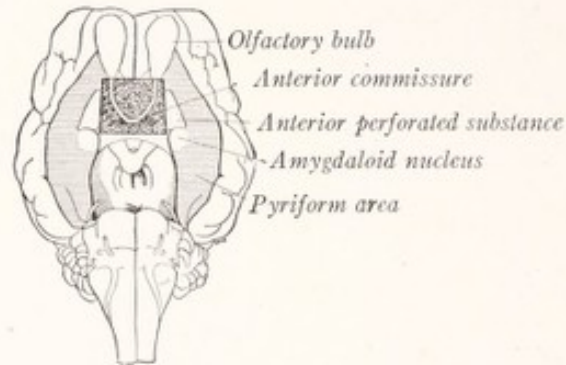


Fig. 199.—Ventral view of a sheep's brain, pyriform area shaded and anterior commissure exposed.

The Pyriform Area.—The lateral olfactory gyrus is continuous at its caudal extremity with the hippocampal gyrus (Figs. 197, 198), and the two together form the pyriform area or lobe (Fig. 199). In the adult human brain it is more difficult to demonstrate the continuity of these parts. As the temporal lobe is

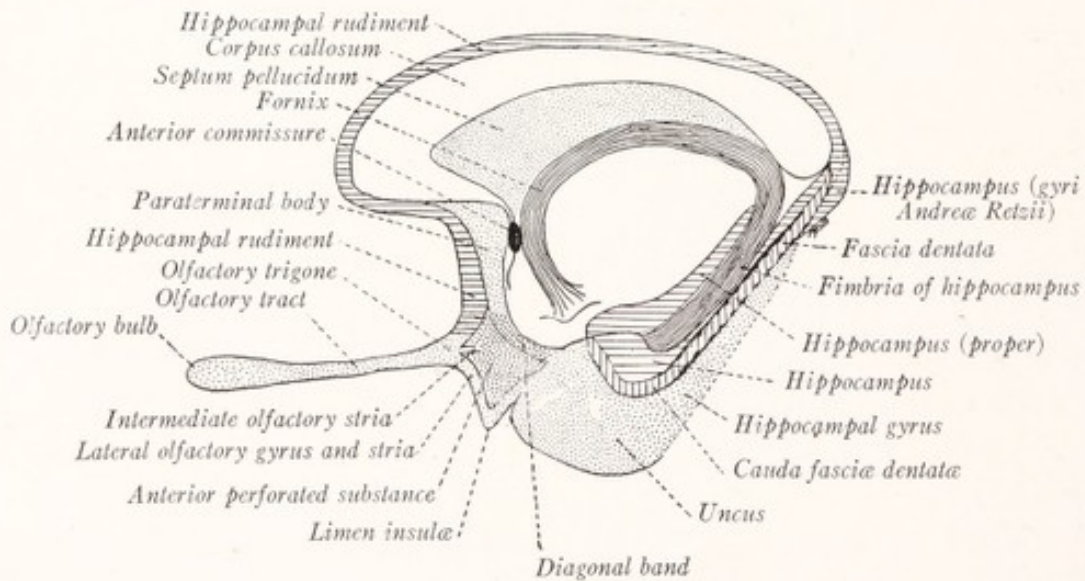


Fig. 200.—Diagram of the rhinencephalon.

thrust rostrally and the insula becomes depressed, the pyriform area is bent on itself like a V (Fig. 198). The knee-like bend forms the *limen insulæ*, and with the rest of the insula becomes buried at the bottom of the lateral fissure. The continuity of the pyriform area is not interrupted in the adult, though part

of it is hidden from view. It includes the *lateral olfactory stria* and the *cortex subjacent* to it (or lateral olfactory gyrus), the *limen insulae*, the *uncus*, and at least a part of the *hippocampal gyrus* (Figs. 169, 172, 200). It is not easy to determine just how much of the human hippocampal gyrus should be included. Cajal (1911) apparently includes the entire gyrus, while Elliot Smith (1915) limits it to the part of the gyrus dorsal to the rhinal fissure. In Fig. 200 we have followed the outlines of the hippocampal region as given by Brodmann (1909).

The Hippocampus.—An olfactory center of still higher order is represented by the hippocampus, which was seen in connection with the study of the lateral

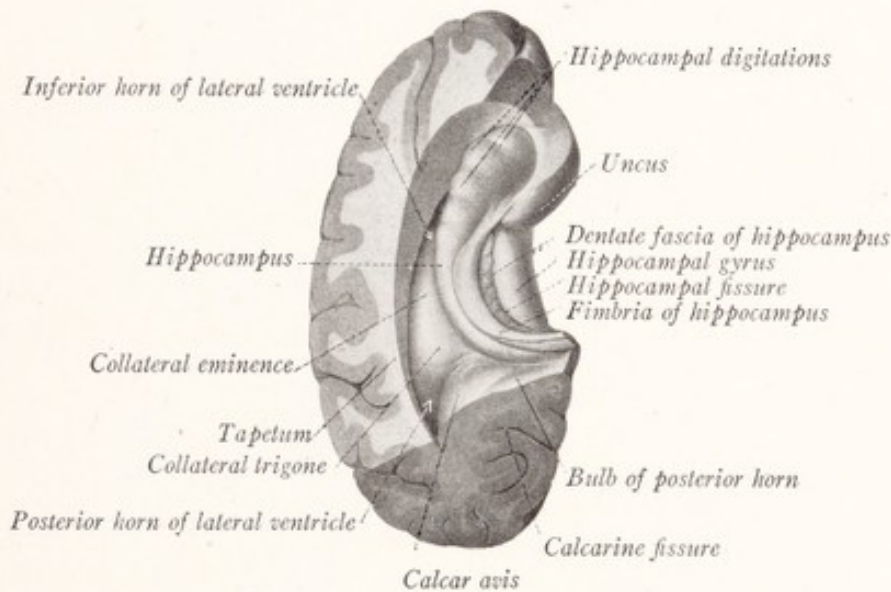


Fig. 201.—Part of temporal lobe of human brain showing inferior horn of lateral ventricle and the hippocampus. Dorsal view. (Sobotta-McMurrich.)

ventricle. If we turn again to the floor of the inferior horn of the lateral ventricle we shall see a long curved elevation projecting into the cavity (Figs. 181, 201). This is the hippocampus and is formed by highly specialized cortex which has been rolled into the ventricle along the line of the hippocampal fissure (Figs. 204, 209). It is covered on its ventricular surface by a thin coating of white matter, called the *alveus*, which is continuous along its medial edge with a band of fibers known as the *fimbria of the hippocampus*. This, in turn, is continuous with the fornix (Fig. 201). In Figs. 201 and 204 there may be seen, along the border of the fimbria, a narrow serrated band of gray matter, the *fascia dentata*, which lies upon the medial side of the hippocampus. It is separated from the hippocampal gyrus by a shallow groove, called the *hippocampal*

fissure, that marks the line along which the hippocampus has been rolled into the ventricle.

The hippocampus and fascia dentata belong to the archipallium. In the marsupials and monotremes this extends dorsally on the medial surface of the hemisphere in a curve, which suggests that of the corpus callosum (Fig. 202). In the higher mammals the presence of a massive corpus callosum seems to inhibit the development of the adjacent part of the hippocampal formation, which remains as the vestigial indusium griseum, or supracallosal gyrus. This *hippocampal rudiment* is a thin layer of gray matter on the dorsal surface of the corpus callosum, within which are found delicate strands of longitudinal fibers. Two of these strands, placed close together on either side of the median plane,

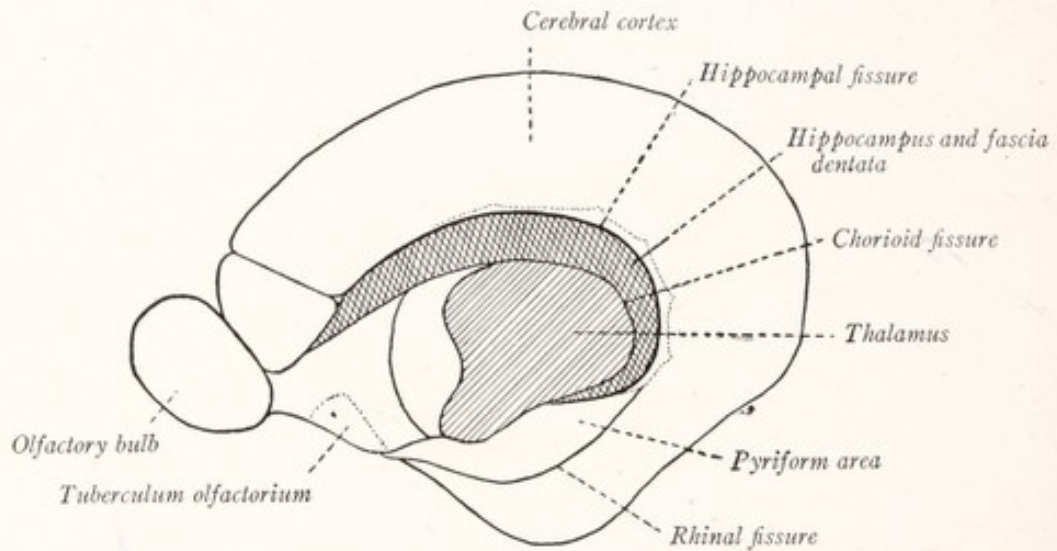


Fig. 202.—Median view of the cerebral hemisphere of a monotreme *Ornithorhynchus*. (Elliot Smith.)

are more conspicuous than the others, and are known as the *medial longitudinal striae*. On either side, where the supracallosal gyrus bounds the sulcus of the corpus callosum, there is a less distinct strand, the lateral longitudinal stria (Figs. 174, 175). The hippocampal rudiment can be traced upon the medial surface of the hemisphere from the region of the medial olfactory gyrus (or stria) toward the rostrum of the corpus callosum, then around the dorsal surface of that great commissure to the splenium, behind which it becomes continuous with the hippocampus proper, where this comes to the surface in the angle between the fascia dentata and the hippocampal gyrus (Fig. 200—Elliot Smith, 1915).

The Fornix.—Within the hippocampus fibers arise which run through the white coat on its ventricular surface, known as the *alveus*, into the *fimbria*. This

is a thin band of fibers, running along the medial surface of the hippocampus and joining with the alveus to form the floor of the inferior horn of the lateral ventricle (Figs. 201, 204, 209). The fimbria increases in volume as it is traced toward the splenium of the corpus callosum, to the under surface of which it becomes applied, where, together with its fellow of the opposite side, it forms the fornix.

The *fornix*, which is represented diagrammatically in Fig. 203, is an arched fiber tract, consisting of two symmetric lateral halves, which are separate at either extremity, but joined together beneath the corpus callosum. This medially placed portion is known as the *body of the fornix*. From its caudal extremity the *fimbriæ* diverge, and one of them runs along the medial aspect of each hippocampus. In man the hippocampus does not reach the under surface

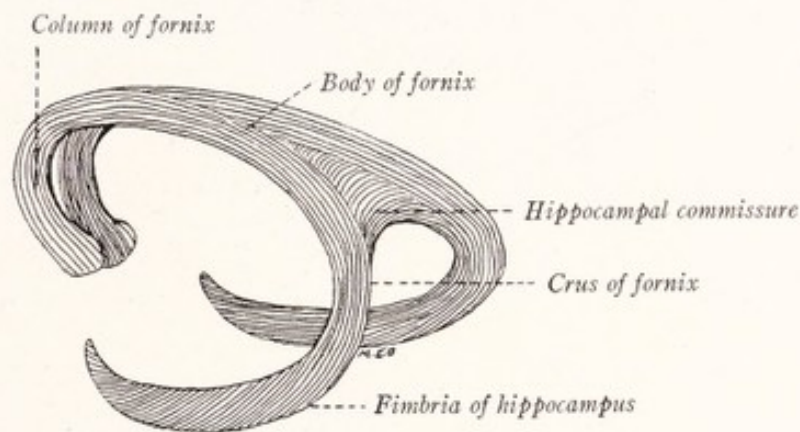


Fig. 203.—Diagram of the fornix.

of the corpus callosum, and the part of the fimbria which joins the body of the fornix, being unaccompanied by hippocampus, is known as the *crus fornicis*. Rostrally the fornix is continued as two arched pillars, the *columnæ fornicis*, to the mammillary bodies.

The *body of the fornix* is triangular, with its apex directed rostrally. It consists in large part of two longitudinal bundles of fibers, representing the continuation of the fimbriæ, widely separated at the base of the triangle, but closely approximated at the apex, whence they are continued as the *columnæ fornicis*. At the point where these longitudinal bundles diverge toward the base of the triangle they are united by transverse fibers which join together the two hippocampi by way of the fimbriæ. These fibers constitute the hippocampal commissure. This part of the fornix, because of its resemblance to a harp, was formerly known as the *psalterium* (Fig. 184). The hippocampal commissure

is not very evident in the human brain, but can be easily dissected out in the sheep (Fig. 204).

The *columnæ fornicis* are round fascicles which can be traced ventrally in an arched course to the mammillary bodies (Figs. 203–205). They are placed on either side of the median plane. Each consists of an initial free portion, which forms the rostral boundary of the interventricular foramen, and a covered part, which runs through the gray matter in the lateral wall of the third ventricle to reach the mammillary body (Figs. 204, 205).

The *relations of the fornix* are well shown in Figs. 155, 200, and 205. The body of the fornix intervenes between the corpus callosum, septum pellucidum,

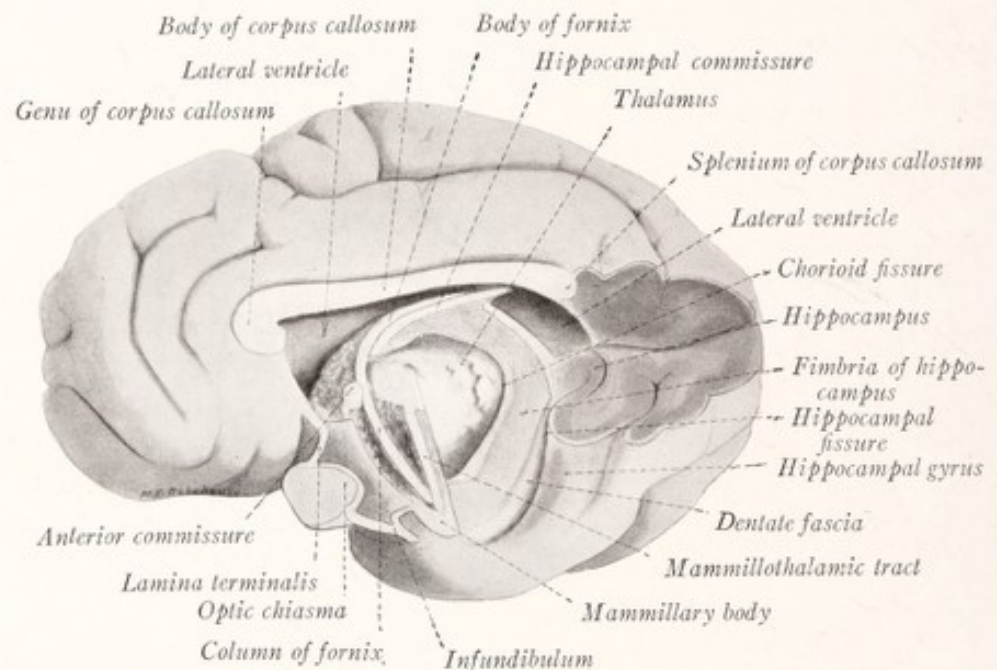


Fig. 204.—Dissection of the cerebral hemisphere of the sheep to show the fornix and hippocampus. Median view.

and cavity of the lateral ventricle on the one hand, and the transverse fissure of the cerebrum and the thalamus on the other. The fimbria and body of the fornix form one boundary of the chorioid fissure. This fissure, which is shown but not labeled in Fig. 205, represents the line along which the chorioid plexus is invaginated into the lateral ventricle. When this plexus has been torn out, the fissure communicates with the interventricular foramen.

The **septum pellucidum** is the thin wall which separates the two lateral ventricles and fills in the triangular interval between the fornix and the corpus callosum (Fig. 205). It consists of two thin vertical laminæ separated by a cleft-like interval, the cavity of the septum pellucidum (Fig. 177). Each lamina

forms part of the medial wall of the corresponding hemisphere (Fig. 182); and the cavity, although sometimes called the fifth ventricle, develops as a cleft within the lamina terminalis and, therefore, bears no relation to the true brain ventricles, which are expansions of the original lumen of the neural tube (Fig. 165).

The **anterior commissure**, like the hippocampal commissure, belongs to the rhinencephalon. It is a rounded fascicle which crosses the median plane in the dorsal part of the lamina terminalis just rostral to the columnæ fornicis (Fig. 205). In a frontal section of the brain, like that represented in Fig. 187, it can

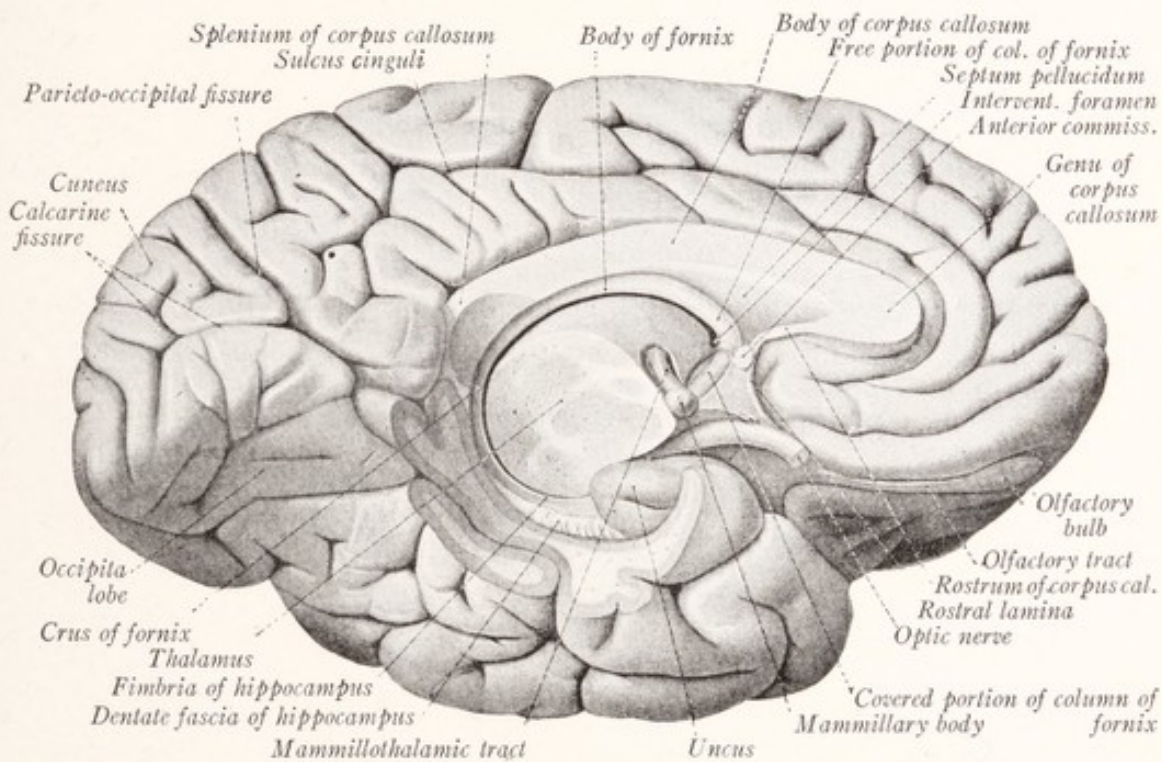


Fig. 205.—Dissection of the human cerebral hemisphere to show the fornix. Median view. (Sobotta-McMurrich.)

be traced lateralward through the most ventral part of the lentiform nucleus. It consists of two parts (Fig. 206). Of these, the more rostral is shaped like a horseshoe and joins together the two olfactory bulbs. This part can be readily dissected out in the sheep's brain (Fig. 199), but is poorly developed in man. The remaining portion, and in man the chief component, joins the pyriform areas of the two hemispheres together (Cajal, 1911).

We are now sufficiently acquainted with the anatomy of the rhinencephalon to undertake a study of the structure and connections of its various parts. Because of the wealth of detail which this subject offers we must confine our at-

tention to the more important facts. Cajal (1911) has carried out extensive investigations concerning the structure and connections of the olfactory parts of the brain both in man and the smaller macrosmatic mammals, especially the mouse. His results, which differ in many respects from the ideas previously current, have been brought together in his "Histologie du Système Nerveux," Vol. II, pp. 646-823. The account which follows is largely based on his work.

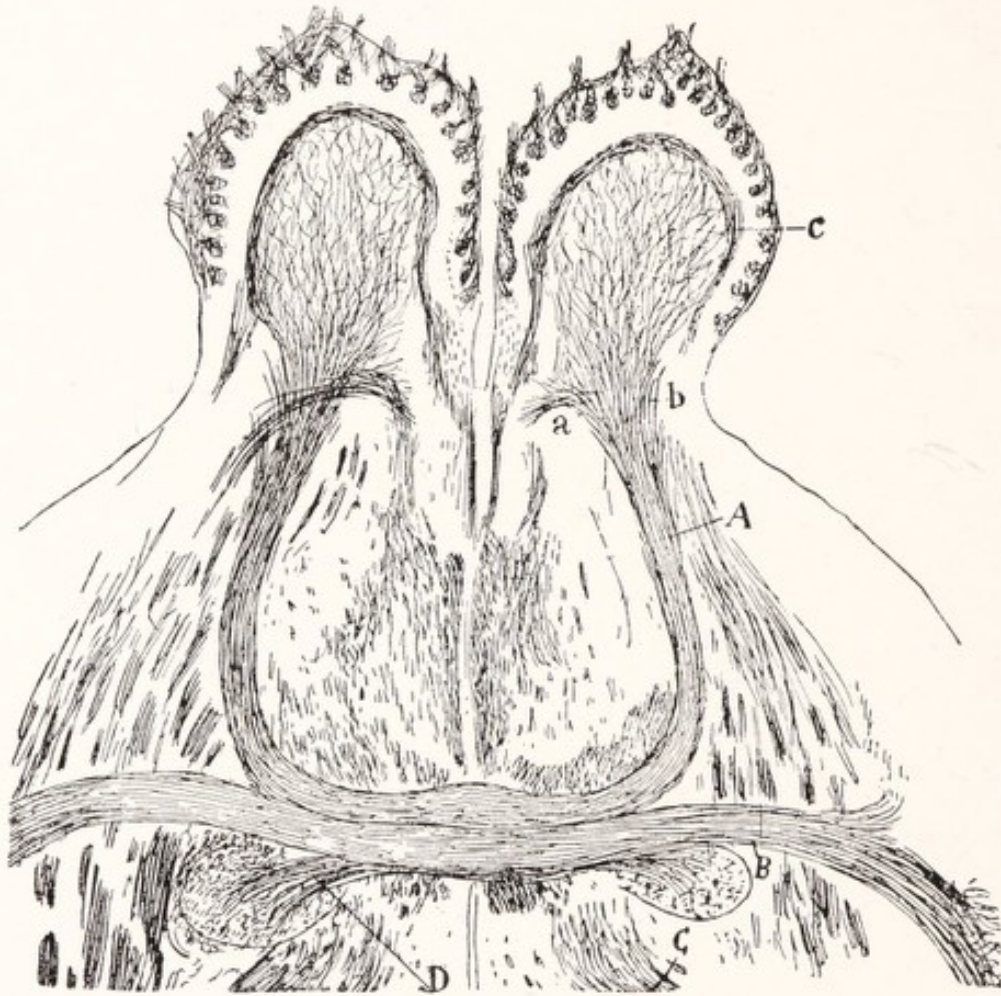

Fig. 206.—Horizontal section of the rostral portion of the cerebral hemispheres of a mouse to show the anterior commissure. Golgi method. *A*, anterior and *B*, posterior portions of anterior commissure; *C*, anterior column of the fornix. (Cajal.)

Structure and Connections of the Olfactory Bulb.—In the olfactory portion of the nasal mucous membrane there are located *bipolar sensory cells*, each with a thick peripheral process, the ciliated extremity of which reaches the surface of the epithelium. These are the olfactory neurons of the first order, and their slender central processes are the unmyelinated axons which constitute the olfactory nerves. These fibers are gathered into numerous small bundles, the fila-

ments of the *olfactory nerve*, which pass through the cribriform plate of the ethmoid bone and immediately enter the olfactory bulb (Fig. 207). Here they form a feltwork of interlacing fibers over that surface of the bulb which is in contact with the cribriform plate.

The *olfactory bulb* of man is solid, and the original cavity is represented by a central gray mass of neuroglia. This is surrounded by a *deep layer of myelinated*

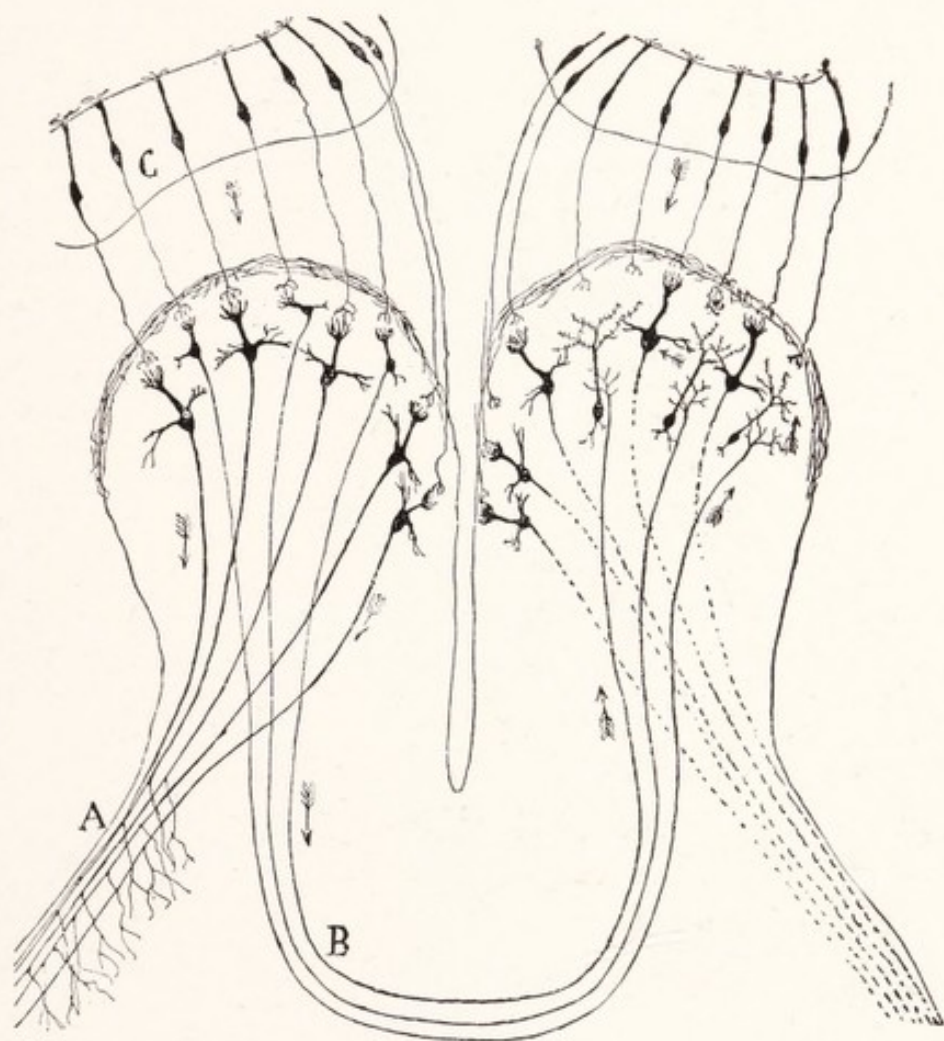


Fig. 207.—Diagram showing the direction of conduction in the olfactory nerve bulb and tract: *A*, lateral olfactory stria; *B*, anterior portion of the anterior commissure; *C*, bipolar cells of the olfactory mucous membrane. (Cajal.)

nerve-fibers passing to and from the olfactory tract. Superficial to this are *several layers of gray matter* of very characteristic structure, and this, in turn, is covered with the *superficial layer of unmyelinated fibers* from the olfactory nerve filaments. Within the gray matter of the bulb are found three types of *neurons*, the mitral, tufted, and granule cells. The large *mitral cells* are the most char-

acteristic element; and their perikarya are closely grouped together, forming a well-defined layer (Fig. 208, C). The *tufted cells* are smaller and more superficially placed (Fig. 208, B). The larger dendrites from both these types of neurons are directed toward the superficial fiber layer. Each of these dendrites

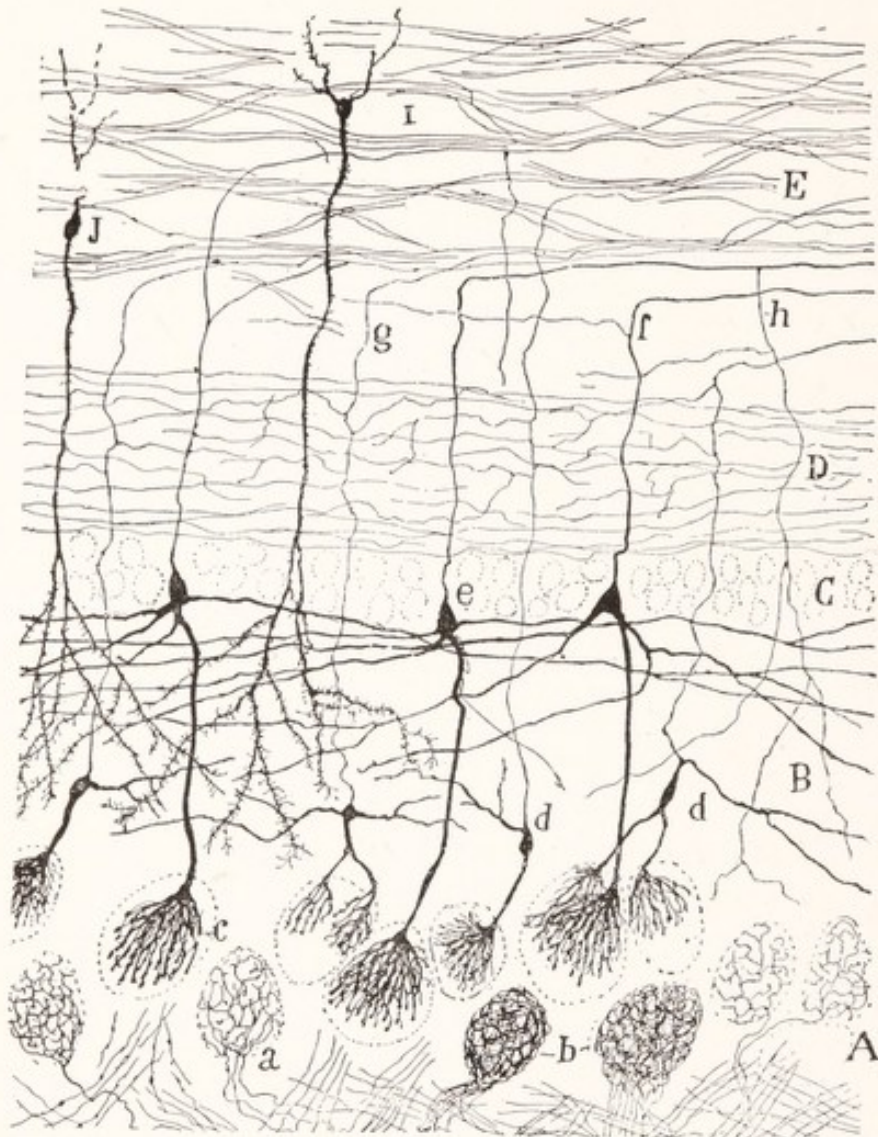


Fig. 208.—Section of the olfactory bulb of a kitten. Golgi method. A, Layer of glomeruli; B, external plexiform layer; C, layer of mitral cells; D, internal plexiform layer; E, layer of granules and white substance; I, J, granule cells; a, b, glomeruli, showing the terminations of the olfactory nerve-fibers; c, glomerulus, showing the terminal arborization of a dendrite of a mitral cell; d, tufted cells; e, mitral cell; h, recurrent collateral from an axon of a mitral cell. (Cajal.)

breaks up into many branches, which form a compact rounded bushy terminal. The terminal ramifications of olfactory nerve-fibers interlace with these dendritic branches, and the two together form a circumscribed, more or less spheric *olfactory glomerulus* (Fig. 208, A). These relations were demonstrated by Cajal

in 1890, and possess considerable theoretic and historic interest. Since in these glomeruli the olfactory nerve-fibers come into contact with only the dendritic ramifications of the mitral and tufted cells, it is evident that these dendrites must take up and transmit the olfactory impulses. That is to say, these glomeruli furnished positive proof that the dendrites are not, as had been thought by many investigators, merely root-like branches which serve for the nutrition of the cell. The mitral cells are larger than the tufted cells and their axons are thicker. These coarse *axons* are directed for the most part into the lateral olfactory stria; while the finer axons of the tufted cells pass through the anterior commissure to the opposite olfactory bulb (Fig. 207). The axons of the deeply placed granule cells are relatively short and are directed toward the surface of the bulb.

The **olfactory tract** consists of fibers passing to and from the olfactory bulb. Through it each bulb receives fibers from the other by way of the anterior commissure as well as from the hippocampal cortex. The fibers leaving the olfactory bulb are the axons of the mitral and tufted cells. By far the greater number of the axons of the mitral cells are continued into the lateral olfactory stria. A much smaller number terminates in the olfactory trigone and in the tuberculum olfactorium within the anterior perforated substance. Other fibers are said to pass by way of the medial olfactory stria to the parolfactory area of Broca, to the subcallosal gyrus, and to the septum pellucidum, but this is open to question. The fibers of the *lateral olfactory stria* run upon the surface of the *lateral olfactory gyrus*, also known as the frontal olfactory cortex, to which they give off collaterals (Fig. 207). The terminal fibers reach the *uncus* and part of the hippocampal gyrus. The chief olfactory centers of the second order are, therefore, found in the *pyriform area*.

According to Cajal (1911), the *hippocampal gyrus* may be subdivided in man, as in the mammals, into five areas: (1) the external region near the rhinal fissure; (2) the principal olfactory region, the most salient part of the convolution; (3) the presubiculum, a transitional area between 2 and 4; (4) the subiculum, near the hippocampal fissure, and (5) the caudal olfactory region, including the caudal part of the hippocampal gyrus. Of these five regions, Cajal finds fibers from the lateral olfactory stria going to the second or principal olfactory region only. The presubiculum and subiculum and the caudal olfactory region represent olfactory association centers. The subiculum is characterized by the presence of a thick layer of myelinated fibers upon its surface.

The **hippocampus**, which constitutes an olfactory center of a still higher order, is directly continuous with the portion of the hippocampal gyrus known as the subiculum (Fig. 209), and is formed by a primitive portion of the cortex

that has been rolled into the ventricle along the line of the hippocampal fissure. Upon its ventricular surface it is covered by a thin layer of white matter, known as the alveus, through which the fibers arising in the hippocampus reach the fimbria and the fornix. Beginning at the line of separation from the fascia dentata, we may enumerate the constituent layers of the hippocampus as follows: the molecular layer, the layer of pyramidal cells, and the layer of polymorphic cells (Figs. 209, 210).

The *molecular layer* contains a superficial stratum of *tangential fibers* derived from the corresponding layer of the subiculum and from bundles of fibers that

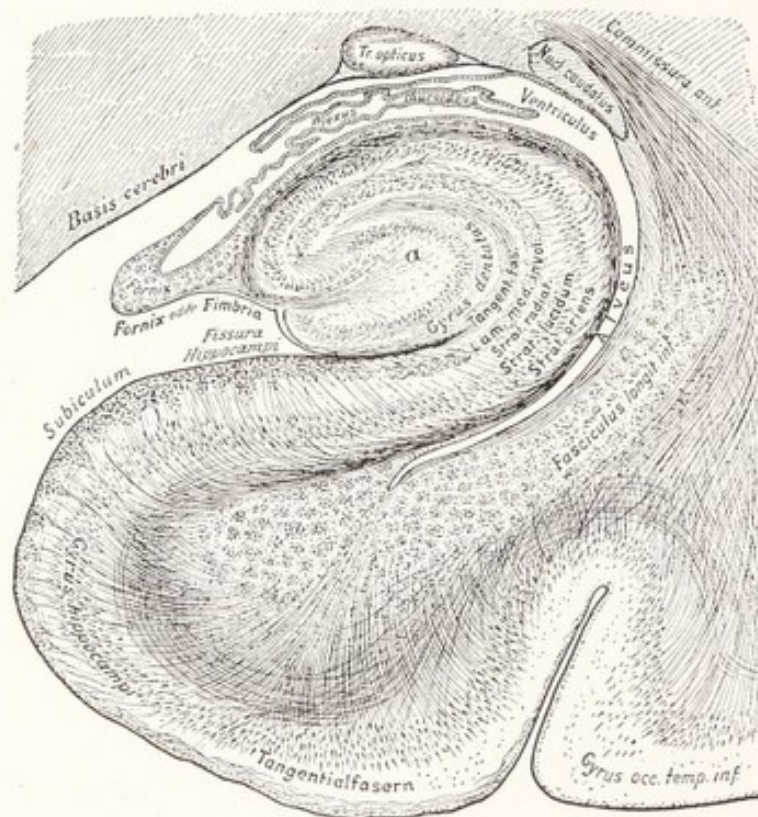

Fig. 209.—Cross-section of the hippocampus and hippocampal gyrus of man. (Edinger.)

perforate the cortex of the subiculum (Fig. 210). More deeply placed is another fiber layer, containing collaterals from the pyramidal cells as well as collateral and terminal fibers from the alveus, and known as the *stratum lacunosum*. The molecular stratum in the hippocampus resembles that in other parts of the cortex in containing the terminal branches of the apical dendrites from the pyramidal cells, and a few nerve-cells which for the most part belong to Golgi's Type II.

The Layer of Pyramidal Cells.—The pyramidal cells are all of medium size and their fusiform bodies are rather closely packed together, forming a well-

defined zone, the *stratum lucidum*. Their apical dendrites are directed toward the molecular layer and form the chief constituent of the *stratum radiatum*. The axons of these cells, after giving off collaterals, enter the alveus.

The *layer of polymorphic cells*, also known as the *stratum oriens*, contains cells of Martinotti, that send their axons into the molecular layer, and still other cells the axons of which enter the alveus.

The *alveus* is a thin white stratum which separates the preceding layer from the ventricle. It is continuous, on the one hand, with the white center of the

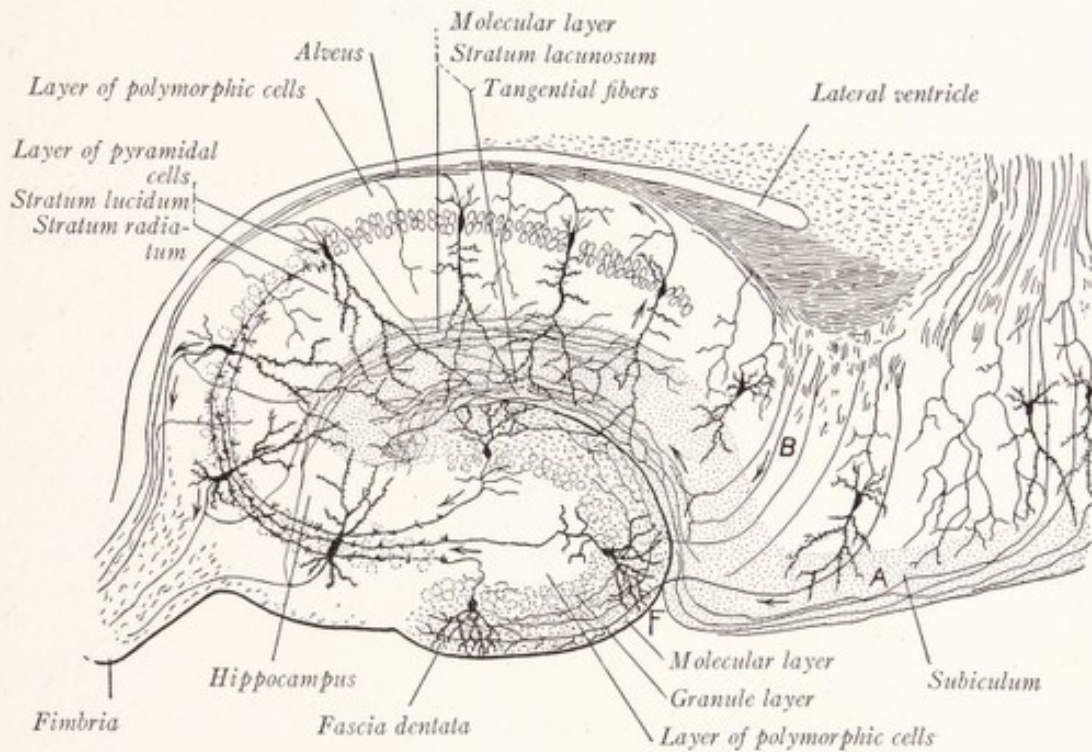


Fig. 210.—Diagram of the structure and connections of the hippocampus. The arrows show the direction of conduction: A, molecular layer, and B, pyramidal cell layer of the subiculum; F, hippocampal fissure. (Cajal.)

hippocampal gyrus, and on the other with the fimbria. Through it the efferent fibers of the hippocampus enter the fimbria and fornix. The fibers of the hippocampal commissure are also carried in the fimbria and enter the hippocampus through the alveus.

The *fascia dentata* also belongs to the archipallium and is closely related to the hippocampus, which it resembles somewhat in the structure of its three strata: the *molecular layer*, *granule layer*, and *layer of polymorphic cells* (Fig. 210). The *granules* may be regarded as modified pyramidal cells of small size, ovoid or fusiform in shape. Each possesses instead of a single apical dendrite two or three branching processes which extend into the molecular layer. The

axons are directed into the layer of pyramidal cells of the hippocampus. Originally this layer of pyramidal cells was continuous with the granule layer of the fascia dentata, but in all the higher mammals a break in this cellular stratum has occurred at the point of transition between the two divisions of the archipallium.

THE OLFACTORY PATHWAYS

Impulses reach the glomeruli of the olfactory bulb along the fibers of the olfactory nerve and are here transferred to the dendrites of the mitral cells. Axons arising from these cells and running in the lateral olfactory stria transmit the impulses to the pyriform area (Fig. 207), whence they are conveyed to the hippocampus and fascia dentata by fibers entering the molecular layer in both of these parts of the hippocampal formation (Fig. 210).

According to Cajal, the fibers of the lateral olfactory stria terminate in the principal olfactory region of the hippocampal gyrus, and there are present within the cortex of the pyriform area sagittal association fibers which unite the principal olfactory region with the caudal olfactory region of the hippocampal gyrus. From this latter region fibers reach the hippocampus and fascia dentata. These are relatively thick fibers which are found at first in the angle of the subiculum and can be traced through all the layers of that center into the molecular layer of the hippocampus and fascia dentata (Fig. 210, *B*). Within the molecular layer the impulses are transferred from these fibers to the dendrites of the pyramidal and granule cells. It was formerly supposed that fibers from the trigonum olfactorium, substantia perforata anterior, and septum pellucidum reached the hippocampus through the striae longitudinales and the fornix, and served as the chief conductors of afferent impulses toward the hippocampus. But according to Cajal, "The hippocampus does not receive olfactory impulses from the frontal region of the brain, nor through the intermediation of the septum pellucidum."

The **efferent fibers from the hippocampus** represent the axons of the pyramidal cells. These penetrate the stratum oriens and enter the alveus (Fig. 210). Thence they are continued into the fimbria and fornix. They include both commissural and projection fibers. The *commissural fibers* serve to unite the two hippocampi and run through the hippocampal commissure as the transverse fibers of the psalterium. The *projection fibers* are continued rostrally; and in their course through the body of the fornix they form on either side of the median plane a longitudinal bundle, which is continued into the columna fornicis (Fig. 203). The latter bends caudally into the hypothalamic region, giving off fibers to the *tuber cinereum* and the *mammillary body*. The remaining fibers of the columna fornicis undergo a decussation just behind the mamillary body and are continued in the reticular formation of the brain stem as far, at least, as the pons. It will be obvious that the fornix is the efferent projection

tract of the archipallium and serves to convey impulses from the hippocampus to the hypothalamus and reticular formation of the brain stem. Through the mammillary bodies olfactory impulses are relayed along the mamillothalamic tract to the anterior nucleus of the thalamus, and along the mamillothalamic bundle to the tegmentum of the pons and medulla oblongata (Fig. 211, *f, g*).

The **frontal olfactory projection tract** takes origin from the gray matter of the olfactory peduncle or trigonum olfactorium and the gyrus olfactorius later-

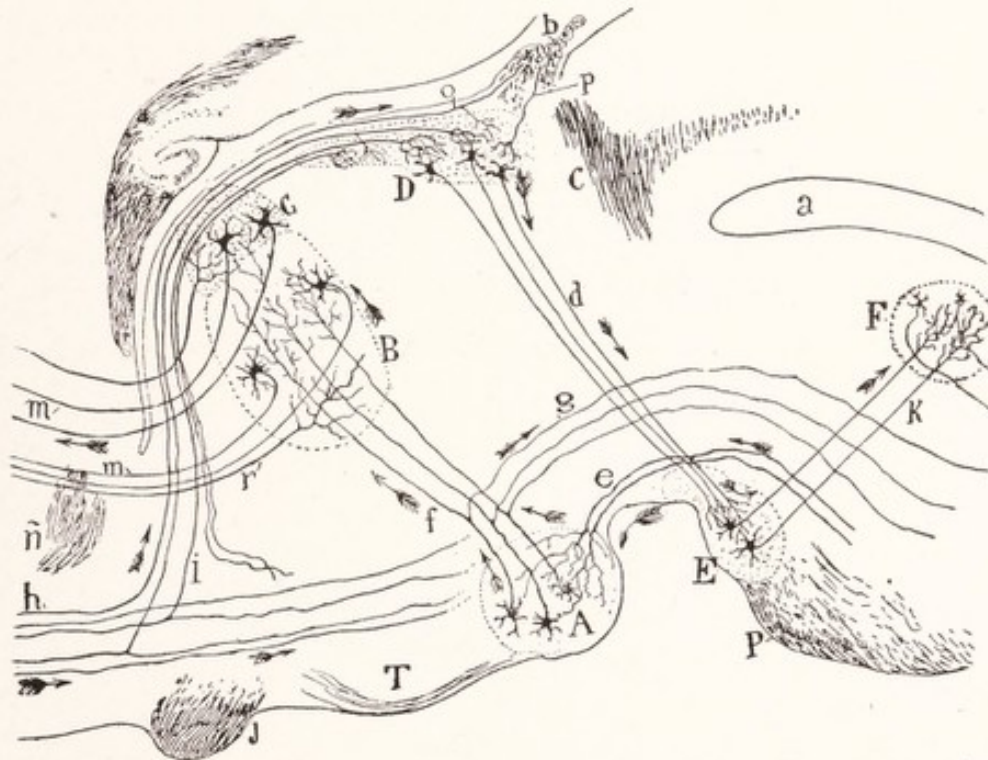


Fig. 211.—Diagram of the afferent and efferent paths of the mammillary body, habenular ganglion, and interpeduncular ganglion: *A*, Medial nucleus of the mammillary body; *B, C*, anterior nucleus of the thalamus; *D*, habenular ganglion; *E*, interpeduncular ganglion; *F*, dorsal tegmental nucleus; *J*, optic chiasma; *T*, tuber cinereum; *P*, pons; *a*, cerebral aqueduct; *b*, habenular commissure; *c*, posterior commissure; *d*, fasciculus retroflexus of Meynert; *e*, peduncle of the mammillary body; *f*, fasciculus mamillothalamicus; *g*, tegmental tract of Gudden; *h*, frontal olfactory projection tract; *i*, stria medullaris thalami. The arrows indicate the direction of conduction. (Cajal.)

alis. It traverses the subthalamie region to reach the pons and medulla oblongata. A bundle of fibers, consisting in part of collaterals, is given off from it, to enter the *stria medullaris thalami*, which we have already traced to the habenular ganglion (Fig. 211, *h, i*).

The *stria terminalis* is a delicate fascicle of nerve-fibers which lies in the sulcus between the thalamus and caudate nucleus (Figs. 155, 177), and accompanies the tail of the latter in

the roof of the inferior horn of the lateral ventricle. According to Cajal (1911), it contains both commissural and projection fibers, the majority of which take origin from the olfactory cortex of the hippocampal gyrus. A smaller number may arise in the amygdaloid nucleus. After following the curved course of the caudate nucleus, it bends ventrad toward the anterior commissure. Some of the fibers cross in the anterior commissure and end in the olfactory cortex of the opposite temporal lobe and in the septum pellucidum. The majority of the fibers, however, enter the mesencephalon and apparently end in the interstitial nucleus.

The striæ longitudinales, fornix longus, and the fiber tracts found in the subcallosal cortex and septum pellucidum have apparently been subject to much misinterpretation; but the subject is too extensive to be considered here. (See Cajal, *Histologie du Système Nerveux*, Vol. II, pp. 783-823.)

The **anterior perforated substance**, or at least its more rostral part, which corresponds to the tuberculum olfactorium of macrosmatic mammals, receives besides fibers from the olfactory tract other afferent fibers which, according to Edinger (1911), come from the pons, perhaps from the sensory nucleus of the trigeminal nerve. It is probably "especially concerned with the feeding reflexes of the snout or muzzle, including smell, touch, taste, and muscular sensibility, a physiologic complex which Edinger has called collectively the 'oral sense'" (Herrick, 1918).

CHAPTER XVIII

THE CORTEX AND MEDULLARY CENTER OF THE CEREBRAL HEMISPHERE

THE **cerebral cortex** forms a convoluted gray lamina, covering the cerebral hemisphere, and varies in thickness from 4 mm. in the anterior central gyrus to 1.25 mm. near the occipital pole. When sections through a fresh brain are examined macroscopically, the cortex is seen to be composed of alternating lighter and darker bands, the light stripes being produced by aggregations of myelinated nerve-fibers (Fig. 212).

Nerve-fibers.—In addition to a very thin superficial white layer of *tangential fibers* there are in most parts of the cerebral cortex two well-defined white bands, the *inner and outer lines of Baillarger* (Figs. 212, 215). These two bands contain large numbers of myelinated nerve-fibers running in planes parallel to the surface of the cortex. In the region of the calcarine fissure only the outer line is visible; but this is very conspicuous and is here known as the *line of Gennari*. Myelinated fibers enter the cortex from the white center in bundles that in general have a direction perpendicular to the surface of the cortex. These bundles radiate into each convolution from its central white core and separate the nerve-cells into columnar groups, thus giving the cortex a radial striation (Fig. 215).

Many of the fibers in these radial bundles are *corticifugal*, representing the axons of the pyramidal and polymorphic cells of the cortex. Within the medullary center they run (1) as association fibers to other parts of the cortex of the same hemisphere, (2) as commissural fibers through the corpus callosum to the opposite hemisphere, or (3) as projection fibers to the thalamus and lower lying centers. The others are *corticipetal* and are derived in part from the thalamic radiation; but an even greater number of them are the terminal portions of as-

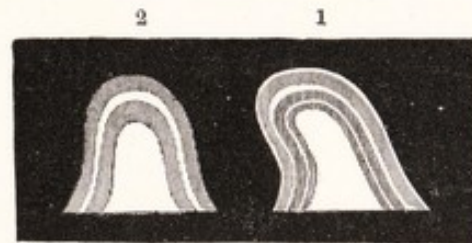


Fig. 212.—Schematic sections of cerebral gyri showing the alternate lighter and darker bands which compose the cerebral cortex: 1 shows the layers as seen in most parts of the cerebral cortex; 2, the layers as seen in the region of the calcarine fissure. (Baillarger, Quain's Anatomy.)

sociation and commissural fibers from other parts of the cortex. Many of these fibers end in the most superficial stratum of the cortex, the plexiform layer, where the terminal branches of the apical dendrites of the pyramidal cells are widely expanded (Fig. 214). Others terminate as indicated in Fig. 213, where they

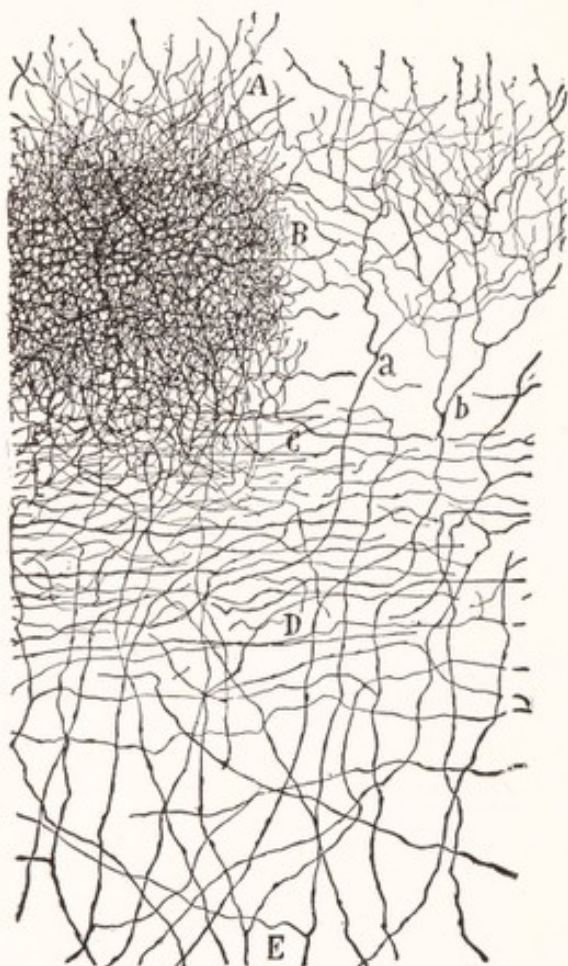


Fig. 213.—From the anterior central gyrus of the human cerebral cortex, showing the terminations of corticopetal fibers: *a, b*, Afferent fibers; *B*, dense network produced by the terminal branches of such fibers. Golgi method. (Cajal.)

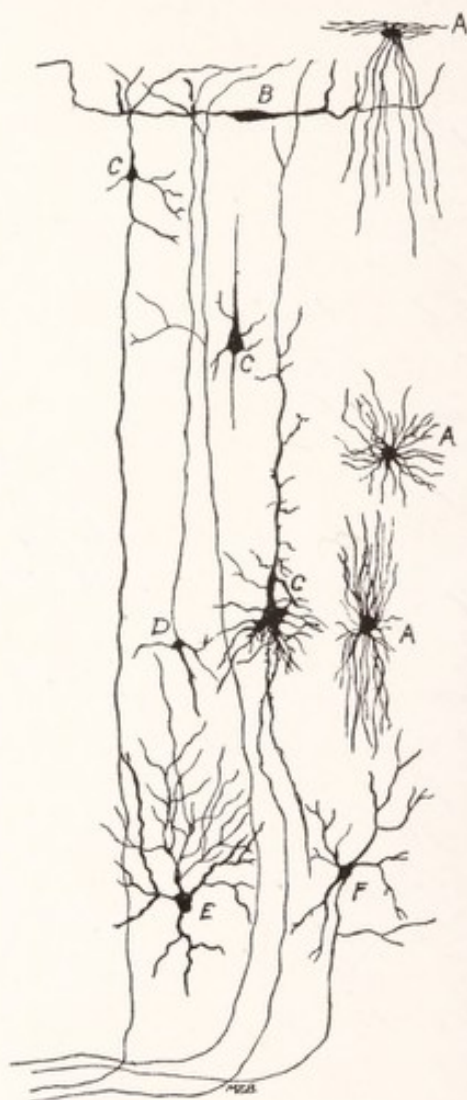


Fig. 214.—Nerve-cells and neuroglia from the cerebral cortex: *A*, Neuroglia; *B*, horizontal cells of Cajal; *C*, pyramidal cells; *D*, cell of Martinotti; *E*, stellate cell.

are seen forming a close network of unmyelinated fibers. Enmeshed in the dense fiber plexus indicated at *B*, Fig. 213, are the pyramidal cells illustrated in Layer III of Fig. 215.

The **nerve-cells** of the cortex are disposed in fairly definite layers as indicated in Fig. 215. We may enumerate five well-recognized varieties: (1) the pyra-

midal, (2) the stellate, and (3) the polymorphous cells, as well as (4) the horizontal cells of Cajal, and (5) the cells of Martinotti.

The **pyramidal cells** are the most numerous and are classified as small, medium, large, and giant pyramidal cells (Fig. 215). From the base of a pyramidal cell body an axon extends toward the subjacent white matter, giving off collaterals which ramify in the adjacent cortex (Figs. 23, 214, *C*). The dendrites are of two kinds: a large apical dendrite and numerous smaller ones attached to the base and sides of the pyramid. The apical dendrite appears as an extension of the cell body and is directed toward the surface of the cortex, near which it ends in spreading branches. Its length varies with the depth of the cell body from the surface. To an even greater extent than other dendrites it is provided with short thorny processes called "spines" or "gemmules." These are supposed by some to effect contact with neighboring axonic ramifications and to be retractile. Upon retraction of these gemmules, conduction across the synapse would be interrupted for the time being; and one might explain the varying sensory thresholds of an individual in sleep or during attention by the varying degree of expansion of the gemmules. But as yet no satisfactory evidence in support of the theory has been presented.

The **stellate cells** are also known as granules. They are, for the most part, of small size, and their short axons branch repeatedly and terminate in the neighborhood of the cell of origin. That is to say, they are cells of Golgi's Type II. Although they occur in most layers of the cortex, they are especially numerous in the fourth stratum, which is accordingly designated as the layer of small stellate cells (Figs. 214, *E*; 215).

The **cells of Martinotti**, which are also found in most of the cortical strata, have this as their distinguishing characteristic, that their axons are directed toward the surface of the cortex and ramify in the superficial layer (Fig. 214, *D*).

The **horizontal cells of Cajal**, which are present only in the superficial layer, are fusiform, with long branching dendrites directed horizontally. Their axons are long and form tangential myelinated fibers in the superficial layer (Fig. 214, *B*).

Polymorphous cells, fusiform or angular in shape, are found in the deepest stratum of the cortex (Figs. 214, 215). Their axons enter the subjacent white matter.

CELL AND FIBER LAMINATION

The size and type of cells found in the cortex vary at different depths from the surface, that is to say, the cells are disposed in fairly definite layers. As already indicated, many of the myelinated fibers are arranged in bands parallel

to the surface. By means of this cell and fiber lamination Brodmann (1909) recognizes six layers in the cerebral cortex (Fig. 215). Other authors, notably Campbell (1905) and Cajal (1906), number these layers somewhat differently. Moreover, the arrangement varies in different parts of the cortex. In certain

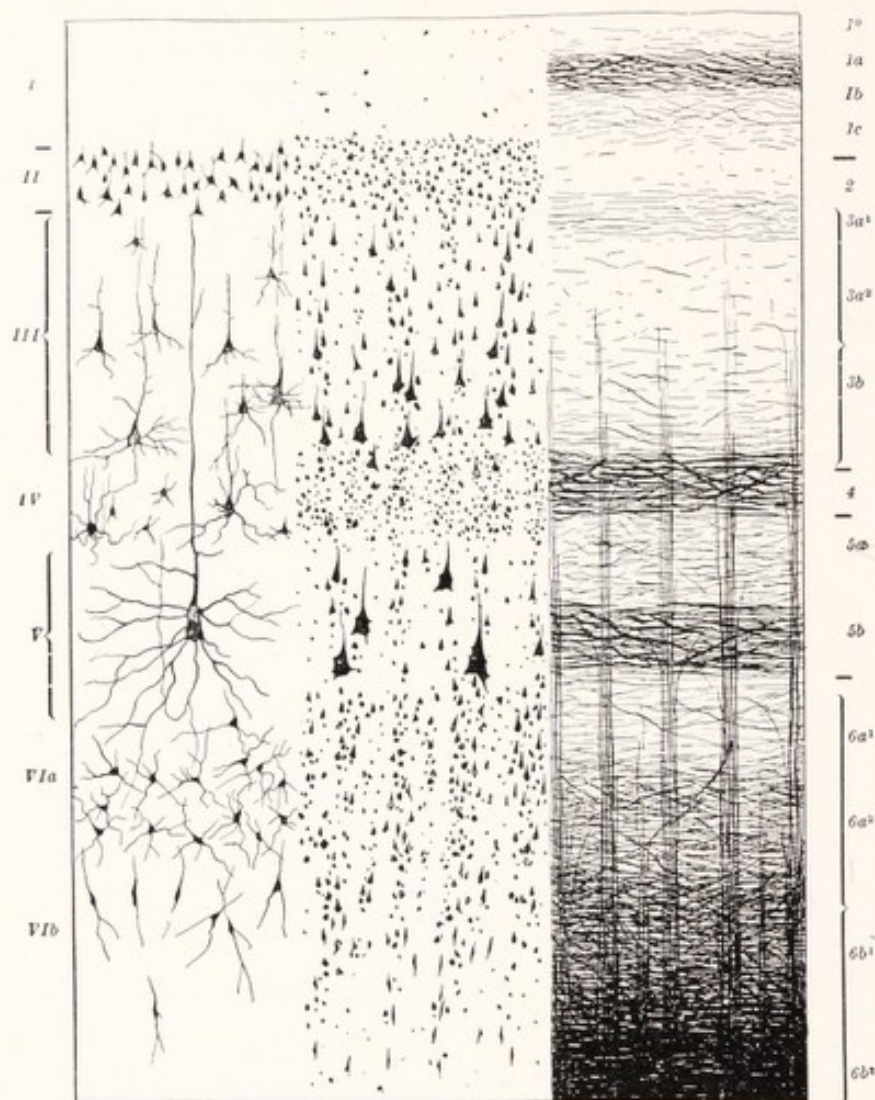


Fig. 215.—Diagram of the structure of the cerebral cortex: *I*, Molecular layer; *II*, layer of small pyramidal cells; *III*, layer of medium-sized and large pyramidal cells; *IV*, layer of small stellate cells; *V*, deep layer of large pyramidal cells; *VI*, layer of polymorphic cells; *3a*¹, band of Bechterew; *4*, outer band of Baillarger; *5b*, inner band of Baillarger. (Brodmann.)

regions one or more of the strata may be reduced, enlarged or subdivided, but the arrangement in most parts is substantially like that illustrated. The six layers are as follows:

1. The **molecular layer** (plexiform layer, lamina zonalis) is the most superficial. It contains the superficial band of tangential myelinated fibers and many

neuroglia cells. The nerve-cells are of two kinds: (1) horizontal cells of Cajal, and (2) cells of Golgi's Type II. Within this layer ramify the terminal branches of the apical dendrites from the pyramidal cells of the deeper layers.

2. The **layer of small pyramidal cells** (*lamina granularis externa*) contains a large number of small nerve-cells. Most of these are small pyramids with axons running to the white center of the hemisphere. Others belong to the short-axoned group (Golgi's Type II).

3. The **layer of medium-sized and large pyramidal cells** (*lamina pyramidalis*) may be subdivided into two substrata, the more superficial stratum containing chiefly medium-sized pyramids and the deeper one chiefly large pyramids. There are also present cells of Golgi's Type II and cells of Martinotti. According to Cajal (1900-1906) and Campbell (1905), it is within this layer that the outer stripe of Baillarger is located, but Brodmann places this line in the next layer.

4. The **layer of small stellate cells** (*lamina granularis interna*) is characterized by the presence of a large number of small multipolar cells with short axons (Golgi's Type II). Scattered among these are small pyramids. Brodmann places the outer line of Baillarger in this stratum.

5. The **deep layer of large pyramidal cells** (*lamina ganglionaris*) contains the largest cells of the cortex. In the motor region these are known as the giant pyramidal cells of Betz and give origin to the fibers of the corticospinal tract. The apical dendrites of these cells are very long and, like those of the more superficial pyramidal cells, reach and ramify within the molecular layer. Smaller cells, both of the pyramidal and short-axoned type, are also present. The horizontal fibers of Baillarger's internal line are found in this layer in most of the cortical areas.

6. The **layer of polymorphic cells** (*lamina multiformis*) contains irregular fusiform and angular cells, the axons of which enter the subjacent white matter.

Cortical Areas.—The six layers of the cortex are arranged in most regions essentially as shown in Fig. 215. But each of more than forty areas presents its own characteristic variation in the structure, thickness, and arrangement of the cellular layers, in the thickness of the cortex as a whole, in the number of afferent and efferent myelinated fibers, and in the number, distinctness, and position of the white striæ. On the basis of such differences the entire cortex has been subdivided into structurally distinct areas. Maps of such cortical areas have been furnished by Brodmann (1909), Campbell (1905), and Elliot Smith (1907); and while these vary in detail, they agree in their larger outlines. The existence and general boundaries of these regions are now well established; and

as a result of experimental and pathologic research it is known that specific differences in function are correlated with these differences in structure.

The maps of the cortical areas furnished by Brodmann are reproduced in Figs. 216 and 217. He recognizes eleven general regions, and each of these may

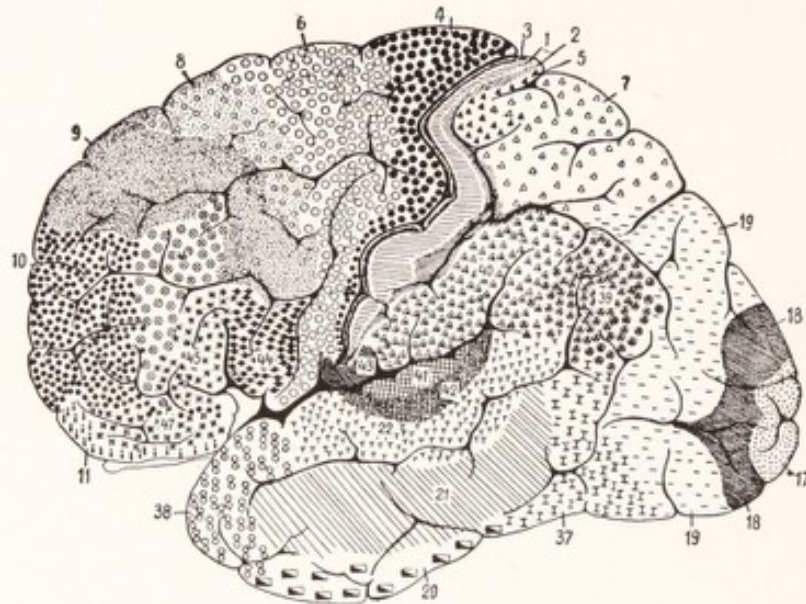


Fig. 216.

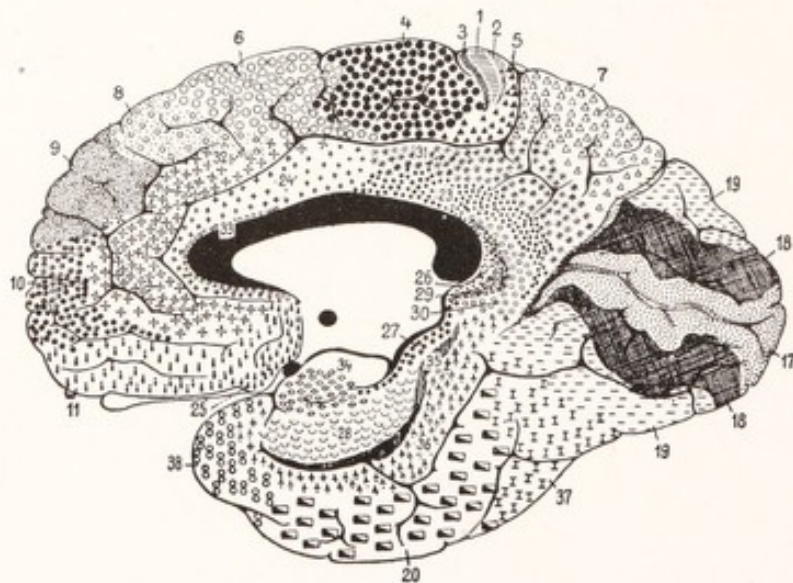


Fig. 217.

Figs. 216 and 217.—Areas of the human cerebral cortex each of which possesses a distinctive structure: Fig. 216, lateral view; Fig. 217, medial view. (Brodmann.)

be subdivided into smaller areas on the basis of characteristic differences in structure. Some of these differences are visible to the naked eye and have been represented in Fig. 218.

Myelination.—The fibers in the various parts of the cortex acquire their myelin sheaths at different times. On this basis Flechsig (1896) identified thirty-six areas, which are numbered in Fig. 219 in the order of myelination. He recognizes three main groups: primary (Nos. 1 to 12), intermediate (Nos. 13

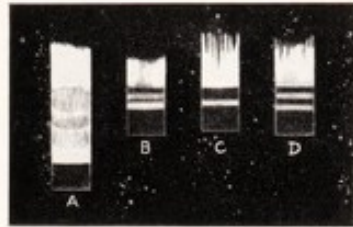


Fig. 218.—Diagram showing the differences in thickness and in the arrangement of the lighter and darker bands in the human cerebral cortex in different regions as seen with the naked eye: A, Motor cortex from anterior central gyrus; B, sensory cortex from the posterior central gyrus; C, visual cortex from the region of the calcarine fissure; D, auditory cortex from the anterior transverse temporal gyrus. (Redrawn after Elliot Smith.)

to 28), and late (Nos. 28 to 36). According to Flechsig, the primary areas, which are myelinated at birth, are *projection centers* and receive the sensory radiation from the thalamus; while the other parts of the cortex, not being provided with projection fibers, serve only as *association centers*. He believed that

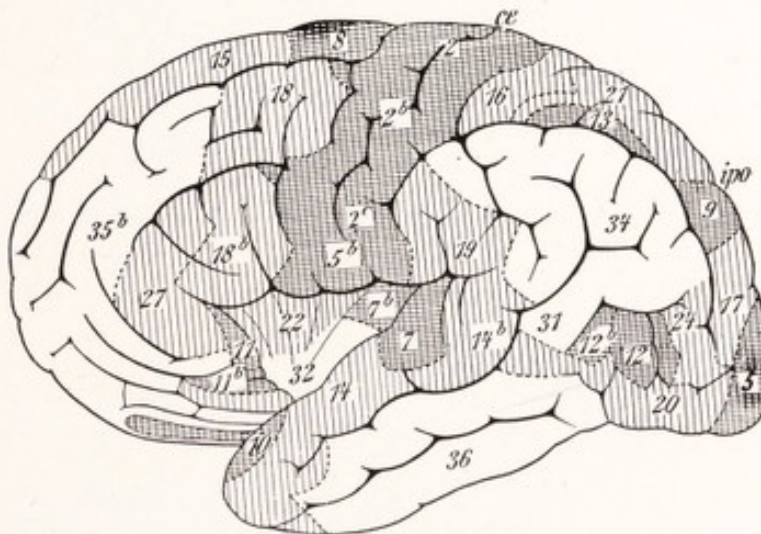


Fig. 219.—Lateral view of the human cerebral hemisphere, showing the cortical areas as outlined by Flechsig on the basis of differences in the time of myelination of their nerve-fibers. The primary areas (first to become well myelinated) are cross-hatched; the intermediate are indicated by vertical lines; the late areas are unshaded. (Lewandowsky.)

myelination of nerve-fibers takes place in the order of conduction, that is, the sheaths are developed first on the afferent fibers, reaching the cortex from the thalamus, and later on the association fibers, linking the various areas together. According to this conception fibers of like function tend to become myelinated

at the same time. Much of Flechsig's work has failed to stand the test of rigid examination. It is now known that practically all regions of the cortex, including those designated by him as association centers, are connected with the thalamus or lower lying centers by afferent or efferent projection fibers. It has been shown that the more mature areas fade off gradually into those whose differentiation is less advanced, and that sharply outlined zones such as are indicated in his figures do not exist. Nevertheless, it is true that the regions designated by him as primary areas, though not sharply outlined by this method from the surrounding cortex, do mature first, and the myelination spreading from these areas reaches its completion last in those areas included in his late group (Brodmann, 1910). The primary areas include the region surrounding the central fissure, the region around the calcarine fissure, a portion of the superior temporal gyrus, and a part of the hippocampal gyrus. These areas are associated with especially important projection tracts and may properly be spoken of as projection centers.

CORTICAL OR CEREBRAL LOCALIZATION

In opposition to the crude conceptions of the localization of cerebral functions introduced by Gall (1825), which formed the basis for phrenology, the French physiologist Florens maintained the doctrine that all parts of the cerebrum are functionally equivalent. In 1861 Broca demonstrated that destruction of the left third frontal convolution may result in a loss of ability to speak; and nine years later Fritsch and Hitzig (1870) discovered that electric excitation of the cortex in the region of the central sulcus will elicit movements from muscles of the opposite side of the body. These observations, confirmed and extended by many observers, definitely proved that certain cortical areas possess specialized functions. Physiologic and pathologic researches have served to outline a number of these with considerable precision, and it is possible to identify them with regions of characteristic cell and fiber lamination. In this way evidence derived from histologic studies reinforces that drawn from physiology and pathology.

The **motor projection center** is located in *the anterior wall of the central sulcus*, in the adjacent part of the *anterior central gyrus*, and in that part of the *para-central lobule* which lies rostral to the continuation of the central sulcus on the medial surface of the hemisphere (Figs. 220, 221). It coincides fairly closely with Area 4 of Brodmann's charts (Figs. 216, 217). This is the center from which the impulses initiating voluntary movements on the opposite side of the body

descend to the motor nuclei of the cerebrospinal nerves. It is subdivided into areas, each of which controls the muscles moving a given part of the opposite half of the body; and these are arranged in inverted order, beginning with the center for movement of the toes near the dorsal border of the hemisphere, and ending with that for the face at the lower end of the anterior central gyrus (Fig. 236).

The structure of the motor cortex is characteristic. Here the gray matter reaches the maximum thickness, the lines of Baillarger are broad and diffused (Fig. 218). The fifth layer contains the giant pyramidal cells of Betz, from which arise the fibers of the corticospinal and corticobulbar tracts. These cells undergo chromatolysis when these motor tracts are cut; and when the motor cortex is destroyed the tracts degenerate (Holmes and May, 1909).

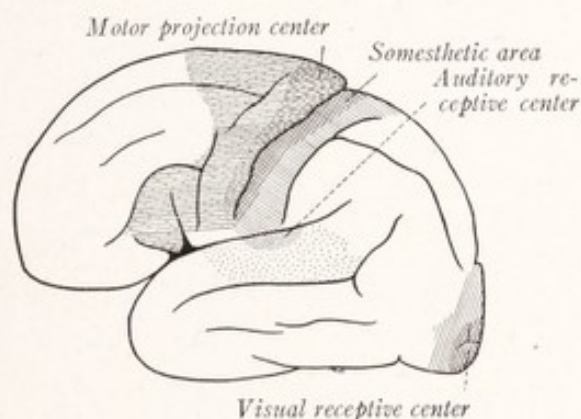


Fig. 220.—Diagram of the cortical projection centers on the lateral aspect of the cerebral hemisphere.

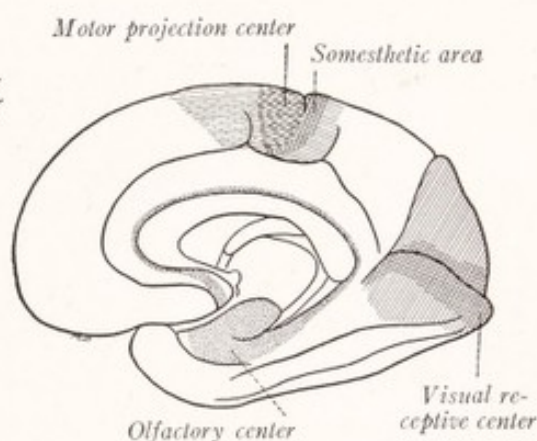


Fig. 221.—Diagram of the cortical projection centers on the medial aspect of the cerebral hemisphere.

The motor cortex of the chimpanzee corresponds in its arrangement with that of man; and by the electric excitation of its different portions muscular contractions can be excited in the corresponding parts of the opposite side of the body (Grünbaum and Sherrington, 1903). In addition, there is an area farther forward in the frontal lobe the stimulation of which produces conjugate movements of the eyes. A similar center for the conjugate deviation of the head and eyes is situated in the posterior part of the middle frontal gyrus in man. It is probable, however, that this motor center is of a different kind from those found in the anterior central gyrus, from which all of the fibers of the pyramidal system are believed to take their origin (Fig. 236).

The **sensory projection centers** are the areas within which terminate the sensory projection fibers. We have learned to locate such centers for vision,

hearing, smell, and the general sensations from the surface of the body and the deeper tissues. The latter region, known as the common sensory or *somesthetic area*, is located in the *posterior central gyrus* (Areas 1, 2, and 3 of Brodmann). It receives fibers belonging to the thalamic radiation from the lateral nucleus of the thalamus and representing neurons of the third order in the afferent paths from the skin, muscles, joints, and tendons.

The most conclusive evidence of the sensory function of the posterior central gyrus is furnished by Cushing's (1909) observations on the electric excitability of the human cerebral cortex. These tests were made on unanesthetized patients in the course of operations for brain tumors. Stimulation of the cortex within the posterior central gyrus caused the patients to experience cutaneous sensations, which seemed to come from the skin of the hand, but did not elicit any motor responses; while in these same cases stimulation of the anterior central

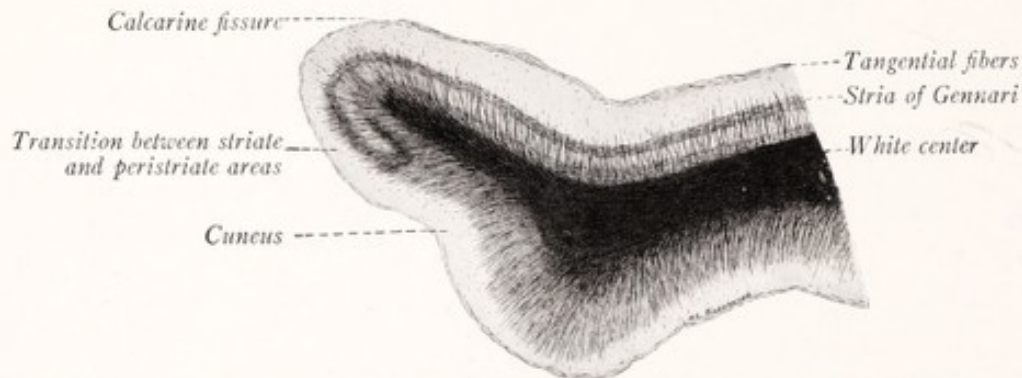


Fig. 222.—Section through the most rostral part of the cuneus. Pai-Weigert method.

gyrus gave rise to no sensations, but did call forth muscular contractions. On the other hand, Head (1918), in a recent study of "Sensation and the Cerebral Cortex," would include in the somesthetic area the anterior as well as the posterior central convolution, and also the anterior part of the superior parietal lobule and the angular gyrus. This study shows, perhaps better than any other work, how intricate and difficult the problem of cortical localization really is and how far we are from an ultimate solution.

The **visual receptive center** is located in the cortex forming the walls of the *calcarine fissure* and in the adjacent portions of the *cuneus* and the *lingual gyrus* (Figs. 217, 221). Rostral to the point where the calcarine is joined by the parieto-occipital fissure the visual cortex is located only along the ventral side of the former. Sometimes the center may extend around the occipital pole on to the lateral surface of the brain (Fig. 216, Area 17). The structural peculiarities of the visual cortex are very evident. It is not more than one-half as thick

as the motor cortex, and the outer line of Baillarger is greatly increased in thickness and known as the line of Gennari (Fig. 218, C). Because of the prominence of this line the region is known as the area striata. It is surrounded by cortex of quite different structure; and nowhere can the differences in adjacent cortical areas be better illustrated than at its border, where the prominent line of Gennari is seen to terminate abruptly (Fig. 222). The fibers of the optic radiation from the pulvinar and lateral geniculate body terminate in the visual projection center. These fibers carry impulses from the temporal side of the corresponding retina and the nasal side of the opposite one. The visual cortex of one hemisphere, therefore, receives impressions from the objects on the opposite side of the line of vision (Figs. 162, 163).

The **auditory receptive center** is located in the *anterior transverse temporal gyrus*, which lies buried in the floor of the lateral sulcus. The area comes to the surface near the middle of the dorsal border of the superior temporal gyrus (Fig. 220). It receives the auditory radiation from the medial geniculate body.

The **olfactory receptive center** is located in the uncus and adjacent portions of the hippocampal gyrus (principal olfactory area of Cajal). Within it terminate the fibers of the lateral olfactory stria. They form a rather thick layer of tangential fibers on its surface, which increases the thickness of the plexiform layer.

Association Centers.—It will be seen that the sensory and motor projection centers occupy only a small part of the entire area of the cortex. The remaining parts are connected with these centers by association fibers and are known as association centers. Each area of sensory projection is surrounded by a zone closely linked up with it by such fibers, and therefore probably under the dominating influence of the particular sensory impulses reaching that projection center. Their positions are indicated by lighter shading in Figs. 220 and 221. Campbell (1905) has applied to them the designations "audito-psychic" and "visuo-psychic fields" (Figs. 223, 224). The same author has designated the portion of the frontal cortex immediately rostral to the motor projection center the "intermediate precentral area," and is of the opinion it is especially concerned with the "execution of complex movements of an associated kind, of skilled movements, and of movements in which consciousness or volition takes an active part." There still remains more than half of the cortical area, indicated in white in Figs. 220 and 221, which is probably less intimately related to any particular projection center. The fact that the increased size of the human cerebral hemisphere over that of the higher apes is due to the much

greater development of the association centers in man, suggests that these are of especial significance for the higher intellectual functions.

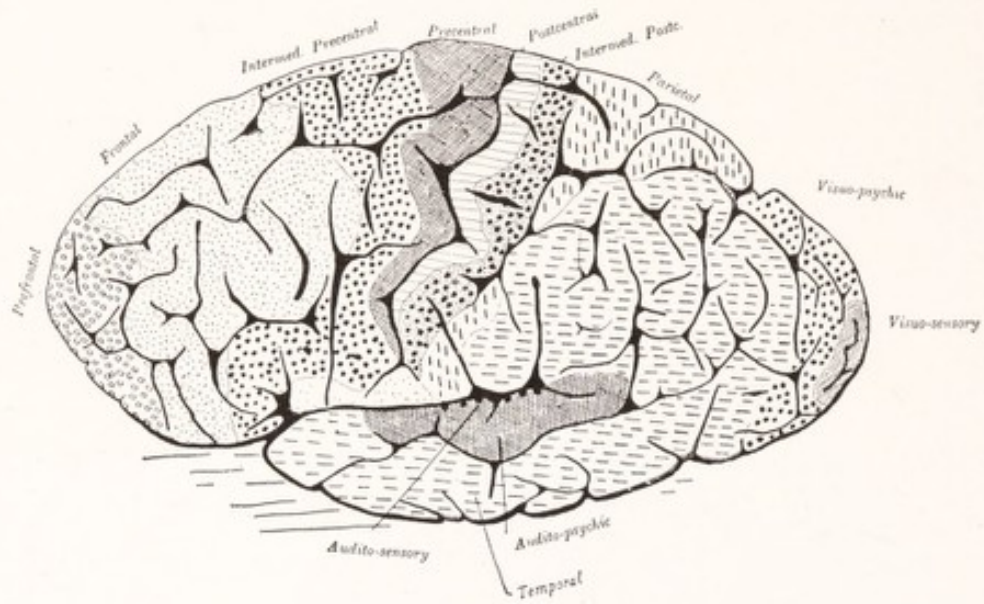


Fig. 223.

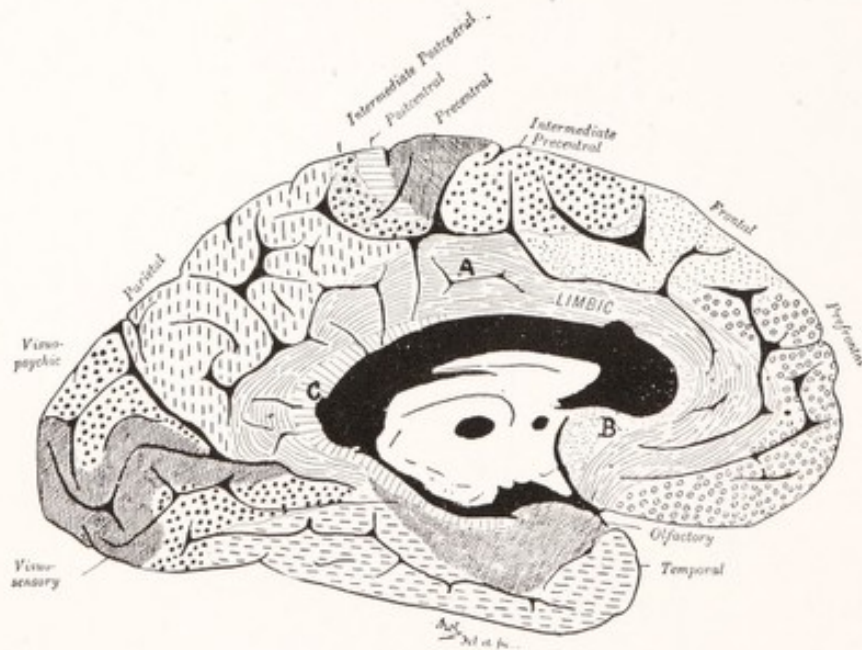


Fig. 224.

Figs. 223 and 224.—Areas of the human cerebral cortex each of which possesses a distinctive structure. (Campbell.)

In the present state of our knowledge of cortical activity and its relation to consciousness it is the part of wisdom to be very conservative in locating any mental faculty or fraction of our conscious experience in any particular part of

the cerebral cortex. We know upon which areas the auditory, visual, and olfactory impulses impinge, and less accurately that in which the thalamic radiation, mediating general bodily sensibility, terminates. Destruction of these areas causes impairment or loss of the corresponding sensations with reference to the opposite side of the body or the opposite half of the field of vision. Total loss of cutaneous sensibility even within circumscribed areas never results from cortical lesions; and it seems probable that the thalamic centers are in themselves sufficient for a certain low grade, non-discriminative consciousness or awareness of cutaneous stimulation. This is particularly true of painful sensations, which seem to be for the most part of thalamic origin (Head, 1918). Furthermore, the various parts of the cerebral cortex are so intimately linked together by association fibers that when afferent impulses reach a given projection center they must not only activate this center, but be propagated to other parts of the cortex

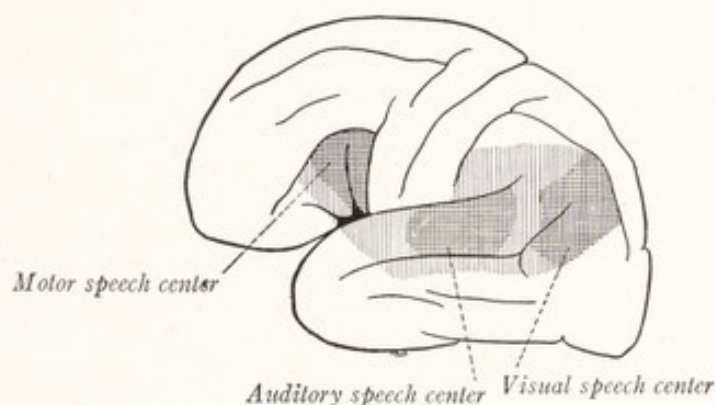


Fig. 225.—The cortical areas especially concerned with language.

as well. In view of these facts it is best to express the known facts of cortical localization in terms of the relation of particular areas to the known projection fiber systems.

Aphasia.—Some idea of the significance of the so-called association centers may be obtained from a study of the group of speech defects included under the term "aphasia." In right-handed individuals these result from lesions in the left hemisphere. Destruction of the triangular and opercular portions of the inferior frontal gyrus usually causes loss of ability to carry out the coordinated movements required in speaking, but does not impair the ability to move the tongue or lips (Fig. 225). This defect is known as *motor aphasia*. Broca's center, as this particular part of the cortex is sometimes called, is located in Campbell's intermediate precentral area; and motor aphasia serves as a good illustration of the importance of the entire intermediate precentral area for the

execution of skilled volitional movements of an associated kind. In the same way, after a lesion in the posterior part of the left superior temporal gyrus, the patient may hear the spoken word, but no longer comprehend its meaning. This is sensory aphasia or *word deafness*. *Word blindness*, the inability to understand the printed or written language, although there is no impairment of vision, may result from lesions in the angular gyrus. These three areas are often spoken of as speech centers and are closely united together by association fibers. In fact, it is not altogether clear to what extent such defects as those mentioned above are dependent upon the destruction of these association tracts which lie subjacent to the speech centers.

THE MEDULLARY CENTER OF THE CEREBRAL HEMISPHERE

The medullary center of the cerebral hemisphere underlies the cortex and separates it from the lateral ventricle and corpus striatum. It varies greatly in thickness, from that of the thin lamina separating the insula and the claustrum (Fig. 191) to that of the massive centrum semiovale (Fig. 174). The myelinated nerve-fibers of which it is composed are of three kinds, namely, association fibers, projection fibers, and commissural fibers.

Commissural Fibers.—As was stated in Chapter XV, there are three commissures joining together the cerebral hemispheres. Of these, the *corpus callosum* is by far the largest and its radiation contributes largely to the bulk of the centrum semiovale (Fig. 174). The fibers which compose it arise in the various parts of the neopallium of each hemisphere; they are assembled into a broad compact plate as they cross the median plane, and then spread out again to terminate in the neopallium of the opposite side. As they spread through the centrum semiovale they form the radiation of the corpus callosum. Some cortical areas are better supplied with these fibers than others, few, if any, being associated with the visual cortex about the calcarine fissure (Van Valkenburg, 1913). The majority of the callosal fibers do not connect together symmetric portions of the cortex; but, after crossing the median plane, the fibers from a given point in one hemisphere spread out to many parts of the opposite side. The *anterior* and *hippocampal commissures* connect portions of the rhinencephalon in one hemisphere, with similar parts on the opposite side. The anterior commissure connects together by its rostral part the two olfactory bulbs and by its caudal part the two pyriform areas (Figs. 187, 194, 195). The hippocampal commissure is composed of fibers which join together the two hippocampi by way of the fimbriae and the psalterium.

Projection Fibers.—Many of the fibers of the medullary white center connect the cerebral cortex with the thalamus and lower lying portions of the nervous system. These are known as projection fibers, and may be divided into two groups according as they convey impulses to or from the cerebral cortex. The corticopetal or *afferent projection fibers* include the following: (1) the *optic radiation*, which arises in the pulvinar of the thalamus and the lateral geniculate body and ends in the visual cortex about the calcarine fissure (Fig. 221); (2) the *auditory radiation*, which arises in the medial geniculate body and terminates in the auditory cortex of the anterior transverse temporal gyrus; (3) the *thalamic radiation* which unites the lateral nucleus of the thalamus with various parts of the cerebral cortex, and which forms the ventral, frontal, and parietal stalks of the thalamus (Fig. 195). The fibers of the parietal stalk include the sensory fibers to the somesthetic cortex in the posterior central gyrus. The lateral olfactory stria, which conveys impulses from the olfactory bulb to the pyriform area, is not a projection system in the strict sense of the word, since it begins and ends within the telencephalon.

Efferent projection fibers convey impulses from the cerebral cortex to the thalamus, brain stem, and spinal cord. They represent the axons of pyramidal cells. The most important groups are those of the *corticospinal* and *corticobulbar tracts*, which together form the great motor or pyramidal system. These fibers begin in the motor cortex of the anterior central gyrus as axons of the giant cells of Betz. Entering the white medullary center of the hemisphere, they are assembled in the corona radiata (Fig. 194) and enter the internal capsule (Fig. 88). Their course beyond this point has been traced in the preceding chapters. They convey impulses to the primary motor neurons of the opposite side of the brain stem and spinal cord. Another important group of corticofugal fibers is contained in the *corticopontine tracts*. Of these there are two main strands. The *frontopontine tract* consists of fibers which begin as axons of cells in the cortex of the frontal lobe, traverse the centrum semiovale, corona radiata, frontal part of the internal capsule and medial one-fifth of the basis pedunculi, and finally terminate in the nuclei pontis. The *temporopontine tract* has a similar origin from the cortical cells of the temporal lobe and possibly of the occipital lobe also, passes through the sublenticular part of the internal capsule and lateral one-fifth of the basis pedunculi, and finally terminates in the nuclei pontis (Figs. 88, 106). The ascending thalamic radiation is paralleled by descending *corticothalamic fibers*, which should be included among the efferent projection systems, although their physiologic significance is not fully understood. Similar

efferent fibers are contained in the optic radiation. They arise in the cortex about the calcarine fissure and terminate in the pulvinar, lateral geniculate body, and superior colliculus of the corpora quadrigemina (Fig. 162). A *corticorubral tract* descends from the frontal lobe through the posterior limb of the internal capsule to end in the red nucleus of the mesencephalon. There do not appear to be any strictly *corticostriate fibers*, but, according to Cajal (1911), collaterals from the corticospinal fibers are given off to the corpus striatum. The efferent projection tracts which we have considered all have their origin in the neopallium.

There are several *projection tracts from the rhinencephalon*, and of these the most important is the fornix. The fibers of this fascicle take origin in the hip-

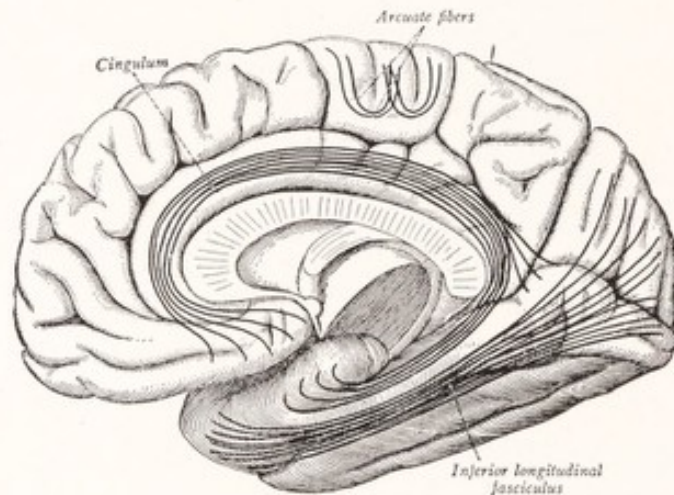


Fig. 226.—Some of the important association bundles projected upon the medial aspect of the cerebral hemisphere. (Sobotta-McMurrich.)

pocampus, follow an arched course already described, and, entering the diencephalon, terminate in part in the mammillary body and in part in the tegmentum of the brain stem (Fig. 205).

The *frontal olfactory projection tract* arises from the gray matter of the olfactory peduncle and the lateral olfactory gyrus. It enters the brain stem and terminates in the pons and the medulla oblongata (Fig. 211).

Association Fibers.—The various parts of the cortex within each hemisphere are bound together by association fibers of varying length. The *short association fibers* are of two kinds: (1) those which run in the deeper part of the cortex and are designated as *intracortical*, and (2) those just beneath the cortex, which are known as the *subcortical fibers*. The greater number of these subcortical association fibers unite adjacent gyri, curving in U-shaped loops beneath the

intervening sulci, and are accordingly often designated as arcuate fibers (Fig. 226). Others unite somewhat more widely separated gyri. The *long association fibers* form bundles of considerable size, deeply situated in the medullary center of the hemisphere, and unite widely separated cortical areas. There are five of these which may be readily displayed by dissection of the human cerebral hemisphere, namely, the uncinata, inferior occipitofrontal, inferior longitudinal, and superior longitudinal fasciculi, and the cingulum. Another, known as the fasciculus occipitofrontalis superior, is less easily displayed.

The *cingulum* is an arched bundle which partly encircles the corpus callosum not far from the median plane (Figs. 174, 226). It begins ventral to the rostrum of the corpus callosum, curves around the genu and over the dorsal surface of

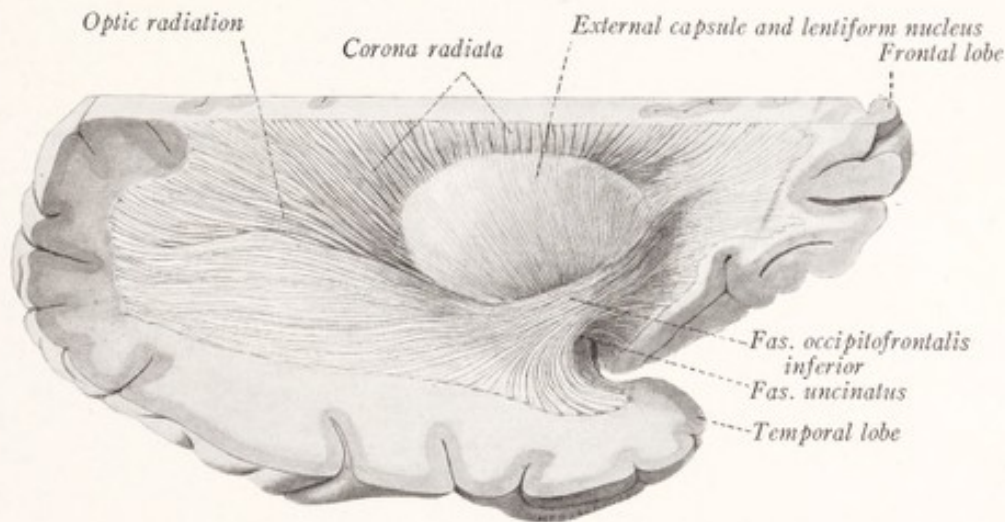


Fig. 227.—Lateral view of a dissection of a human cerebral hemisphere. The dorsal part of the hemisphere has been cut away. On the lateral side the insula, opercula, and adjacent parts have been removed.

that commissure to the splenium, and then bends ventrally to terminate near the temporal pole. It is closely related to the gyrus cinguli and the hippocampal gyrus and is composed for the most part of short fibers, which connect the various parts of these convolutions.

The *uncinate fasciculus* connects the orbital gyri of the frontal lobe with the rostral part of the temporal lobe. It is sharply bent on itself as it passes over the stem of the lateral fissure of the cerebrum (Figs. 227, 228). The *inferior longitudinal fasciculus* is a large bundle which runs through the entire length of the temporal and occipital lobes (Fig. 226). It connects the occipital pole, the cuneus, and other parts of the occipital lobe with the temporal cortex, extending as far forward as the temporal pole. According to Curran (1909) the

uncinate and inferior longitudinal fascicles are formed by the shorter and more superficial fibers of a larger and longer tract, the *inferior occipitofrontal fasciculus*,

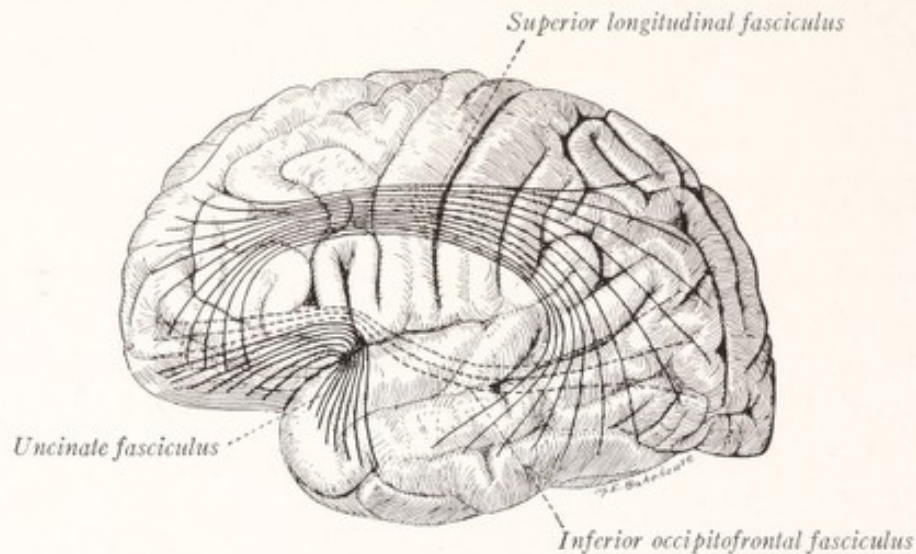


Fig. 228.—Some of the long association bundles projected upon the lateral aspect of the cerebral hemisphere.

which unites the cortex of the frontal and occipital lobes (Figs. 227, 228). Along with the uncinate fasciculus it may easily be exposed by dissection, as it courses along the ventrolateral border of the lentiform nucleus.

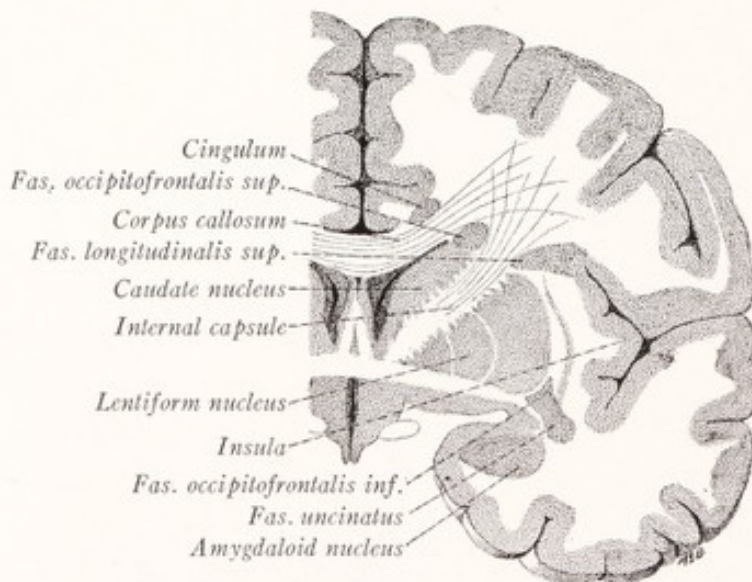


Fig. 229.—Frontal section of the cerebral hemisphere through the anterior commissure showing the location of the long association bundles.

The *superior longitudinal fasciculus* (*fasciculus arcuatus*) is a bundle of association fibers which serves to connect many parts of the cortex on the lateral

surface of the hemisphere (Fig. 228). It sweeps over the insula, occupying the base of the frontal and parietal opercula, and then bends downward into the temporal lobe (Fig. 174). It is composed for the most part of bundles of rather short fibers which radiate from it to the frontal, parietal, occipital, and temporal cortex.

The *superior occipitofrontal fasciculus* runs in an arched course close to the dorsal border of the caudate nucleus and just beneath the corpus callosum. It is separated from the superior longitudinal fasciculus by the corona radiata (Fig. 229).

The **weight of the brain** varies with the sex, age, and size of the individual. The average weight of the brain in young adult men of medium stature is 1360 grams. It is less in women and in persons of small size or advanced age. It is doubtful if there is any close correlation between the brain weight and intelligence or between the latter and the size and arrangement of the cerebral convolutions (Donaldson, 1898).

CHAPTER XIX

THE GREAT AFFERENT SYSTEMS

EXTEROCEPTIVE PATHWAYS TO THE CEREBRAL CORTEX

As has been intimated elsewhere, it is chiefly those nervous impulses, which are aroused by stimuli acting upon the body from without, that rise above the subconscious level and produce clear-cut sensations. The importance of these sensations in our conscious experience is no doubt correlated with the fact that it is through the reactions, called forth by such external stimuli, that the organism is enabled to respond appropriately to the various situations in its constantly changing environment. To meet these complex and variable situations correctly requires the nicest correlation of sensory impulses from the various sources as well as their integration with vestiges of past experience, and it is in connection with these higher correlations and adjustments that consciousness appears. The responses initiated by interoceptive and proprioceptive afferent impulses are more stereotyped and invariable in character; and these reactions are for the most part carried out without the individual being aware either of the stimulus or the response.

It is known that the cerebral cortex is the organ within which occur at least the majority of those complex and highly variable correlations and integrations which have consciousness as their counterpart. A single object may appeal to many sense organs, and our perception of that object involves a synthesis of a corresponding number of sensations and their comparison with past experience. For example, when I meet a friend and grasp his hand in greeting, my perception of him includes not only the image of his face but also the sound of his voice and the warm contact of his hand. Thus thermal, tactile, auditory, and visual sensations may be fused in the perception of a single object, and this involves an integration of the corresponding afferent impulses within the cerebral cortex. Accordingly, it becomes of special interest to trace the course of these afferent impulses from the various exteroceptive sense organs to their cortical receptive centers.

As we shall see, the outer world has for the most part a crossed representation in the cerebral cortex. Cutaneous stimuli, received from objects touching the

right side of the body, and optic stimuli produced by light waves coming from the right half of the field of vision, are propagated to the cortex of the left hemisphere. The crossed representation in the case of hearing is less complete, partly because every sound wave reaches both ears, but also because the crossing of the central auditory pathway seems to be incomplete.

The **grouping of the afferent fibers** in the peripheral nerves differs from that in the spinal cord. In each of the *spinal nerves* several varieties of sensory fibers are freely mingled. In the cutaneous branches are found conductors of thermal, tactile, and painful sensibility; while the deeper nerves contain fibers for pain and sensations of pressure-touch as well as for muscle, joint, and tendon sensibility. Because of the intermingling of the various kinds of fibers a lesion of a spinal nerve results in a loss of all modalities of sensation in the area supplied exclusively by that nerve.

But in the *spinal cord* a regrouping of the afferent impulse occurs, such that all of a given modality travel in a path by themselves. All those of touch and pressure, whether originally conveyed by the superficial or deep nerves, find their way into a common path in the cord. In the same way all painful impulses, whether arising in the skin or deeper parts, follow a special course through the cord. Another intramedullary path conveys impulses from the muscles, joints, and tendons. These various lines of conduction within the cord are so distinct from each other that a localized spinal lesion may interrupt one without affecting the others. A striking illustration of this is the loss of sensibility to pain and temperature over part of the body surface without any impairment of tactile sensibility as a result of a disease of the spinal cord, known as syringomyelia.

While we shall here confine our attention to the afferent channels leading directly toward the cerebral cortex, it should not be forgotten that these are in communication with the reflex apparatus of all levels of the spinal cord and brain stem.

The Spinal Path for Sensations of Touch and Pressure.—Tactile impulses which reach the central nervous system by way of the spinal nerves are relayed to the cerebral cortex by a series of at least three units.

Neuron I.—The first neuron of this conduction system has its cell body, which typically is unipolar, located in the spinal ganglion; and its axon divides in the manner of a T or Y into a central and a peripheral branch. The peripheral branch runs through the corresponding spinal nerve to the skin, or in the case of those fibers subserving the tactile functions of deep sensibility, to the underlying tissues. The central branch from the stem process of the spinal

ganglion cell enters the spinal cord by way of the dorsal roots. The touch fibers are probably myelinated and enter the cuneate fasciculus through the medial division of the dorsal root; and, like all other dorsal root fibers, they divide into ascending and descending branches. The ascending branches run for varying distances in the posterior funiculus, giving off collaterals before they terminate

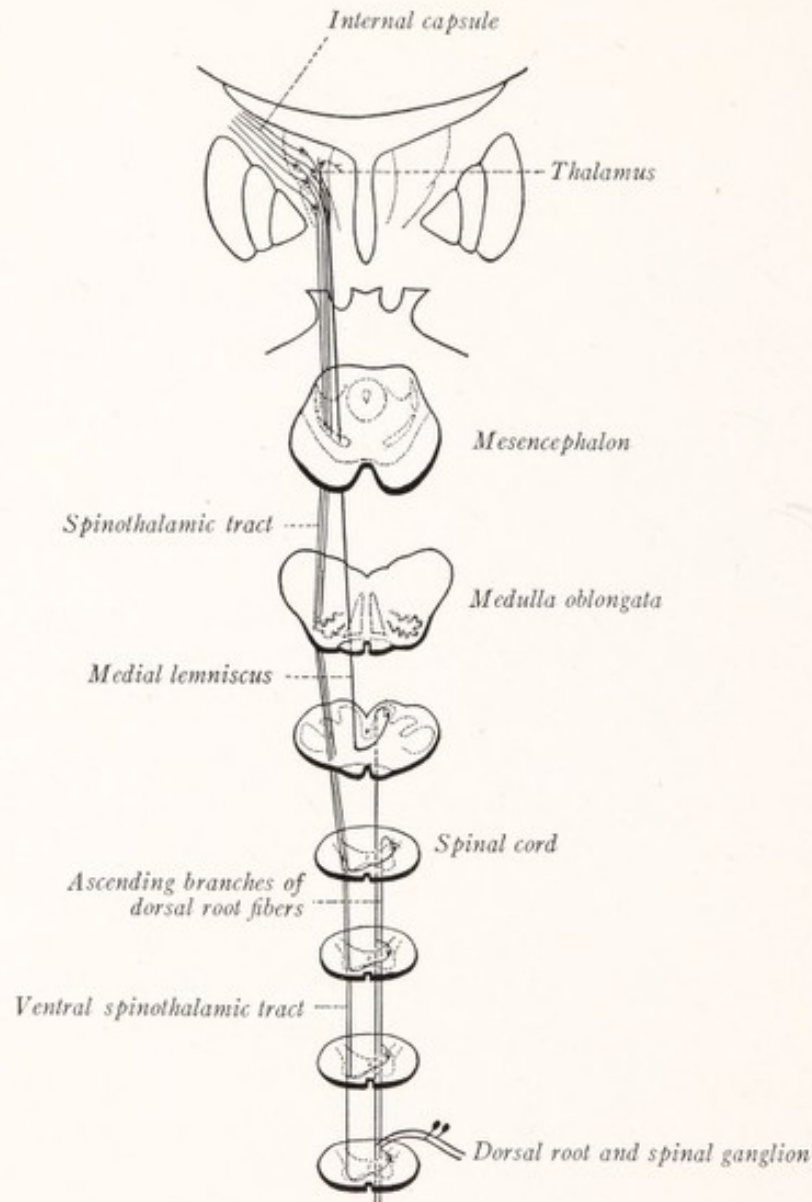


Fig. 230.—Diagram of the tactile path.

in the gray matter of the spinal cord, some few at least even reaching the nucleus gracilis and cuneatus in the medulla oblongata. At varying levels they enter the gray substance of the columna posterior and form synapses with the neurons of the second order (Fig. 230).

Neuron II, with its cell body located in the posterior gray column, sends its axon across the median plane into the ventral spinothalamic tract in the opposite anterior funiculus. In this the fiber ascends through the spinal cord and brain stem to the thalamus. This tract gives off fibers, either collateral or terminal, to the reticular formation of the brain stem. Other neurons of the second order in the tactile path are located in the gracile and cuneate nuclei of the medulla oblongata, and their axons after crossing the median plane ascend in the median lemniscus of the opposite side to end in the thalamus. All of these secondary tactile fibers end within the ventral part of the lateral thalamic nucleus.

The course of the ventral spinothalamic tract through the medulla oblongata and pons is not accurately known. It has generally been figured as joining the lateral spinothalamic tract dorsolateral to the olive (Fig. 230. See also Herrick, Fig. 81). But, since lesions in the lateral area of the medulla oblongata may cause a loss of pain and temperature sensation over the opposite half of the body without affecting tactile sensibility, it is not improbable that Déjerine (1914) is correct in supposing that it follows a median course, its fibers intermingled with those of the tectospinal tract which run, however, in the opposite direction (Fig. 234; Economo, 1911; Spiller, 1915).

There is reason to believe that the ventral as well as the lateral spinothalamic tract consists in part of short relays with synaptic interruptions in the gray matter of the spinal cord and brain stem, and the two tracts are sometimes designated as the spino-reticulo-thalamic path.

In the spinal cord there appear to be two tracts which convey tactile impulses toward the brain, an uncrossed one in the posterior funiculus and another that crosses into the opposite anterior funiculus. Since these overlap each other for many segments, this arrangement would account for the fact that contact sensibility is usually unaffected by a purely unilateral lesion (Head and Thompson, 1906; Rothmann, 1906; Petró, 1902). Among the fibers of contact sensibility, which ascend in the posterior funiculus to the cuneate and gracile nuclei of the same side, are those that subserve the function of tactile discrimination, or, in other words, the ability to recognize the duality of two closely juxtaposed points of contact, as when the two points of the compasses or dividers are applied simultaneously to the skin. Furthermore, those elements of tactile sensibility, which underlie the appreciation of the form of objects or stereognosis, ascend uncrossed in the posterior funiculus to the gracile and cuneate nuclei.

Neuron III.—The neurons located in the ventral portion of the lateral nucleus of the thalamus, with which the tactile fibers of the second order enter into synaptic relations, send their axons by way of the thalamic radiation through the posterior limb of the internal capsule and the corona radiata to the somesthetic area of the cerebral cortex in the posterior central gyrus (Fig. 220).

THE SPINAL PATH FOR PAIN AND TEMPERATURE SENSATIONS

Pain and temperature sensations are mediated by closely associated though not identical paths, and it is convenient to consider them at the same time.

Neuron I.—The first neuron of this system has its cell of origin located in the spinal ganglion. Its axon divides into a peripheral branch, directed through

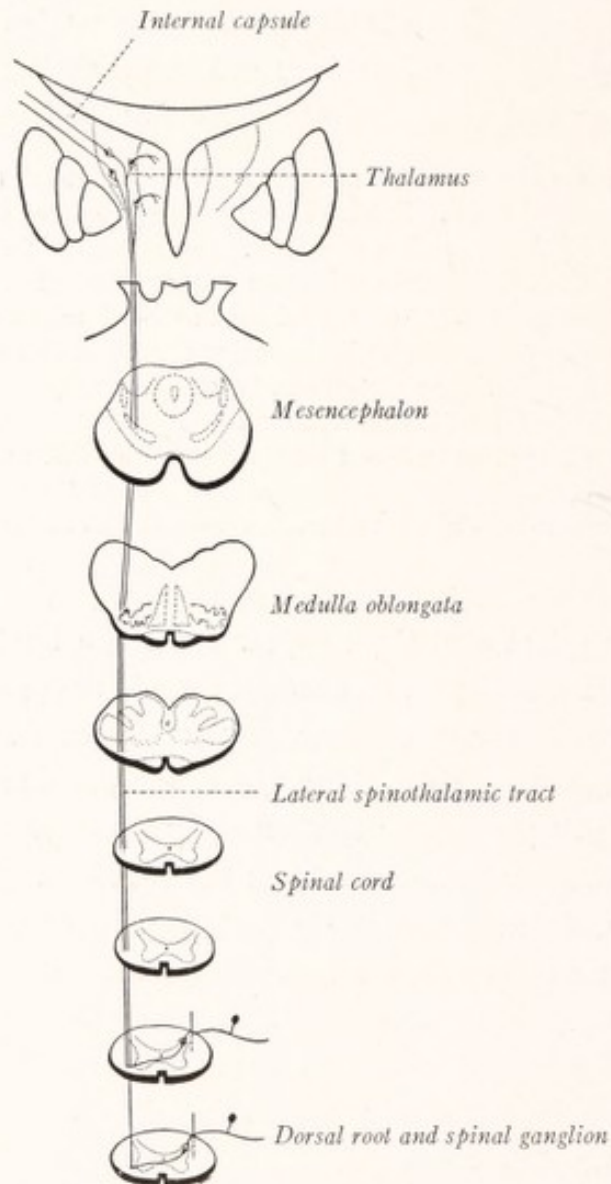


Fig. 231.—Diagram of the path for pain and temperature sensations.

the peripheral nerve to the skin, or in the case of the pain fibers also to the deeper tissues, and a central branch, which enters the spinal cord through the dorsal root and *almost at once* terminates in the gray matter of the posterior gray column (Fig. 231). As was shown in Chapter VII, there is reason to believe that the

fibers of painful sensibility, and possibly those of temperature sensations as well, are unmyelinated and enter the cord through the lateral division of the dorsal root to end in the substantia gelatinosa Rolandi.

Neuron II.—From these dorsal root fibers the impulses are transmitted (perhaps through the intermediation of one or more intercalated neurons) to the neurons of the second order. These have their cell bodies located in the posterior gray column, and their axons cross the median plane and ascend in the lateral spinothalamic tract to end in the ventral part of the lateral nucleus of the thalamus. In addition to this long uninterrupted path, there probably also exists a chain of short neurons with frequent interruptions in the gray matter of the spinal cord, which serves as an accessory path to the same end station. In the medulla oblongata the spinothalamic tract lies dorsolateral to the inferior olivary nucleus. In the pons it joins the medial lemniscus and runs in the lateral part of this fillet through the pons and mesencephalon to the thalamus (Figs. 231, 234).

Neuron III.—Fibers, arising from nerve-cells located in the lateral thalamic nucleus, convey thermal and possibly also painful impulses to the somesthetic area of the cerebral cortex in the posterior central gyrus by way of the thalamic radiation, and the posterior limb of the internal capsule. It is important to note that it is not necessary for painful afferent impulses to reach the cerebral cortex before they make themselves felt in consciousness, the thalamus being in itself sufficient for the perception of pain (Head and Holmes, 1911; Head, 1918).

The Exteroceptive Paths Associated with the Trigeminal Nerve.—The trigeminal nerve mediates tactile, thermal, and painful sensations from a large part of the cutaneous and mucous surfaces of the head. While there is reason to believe that the tactile impulses mediated by this nerve follow a central course distinct from that of thermal and painful sensibility, we cannot as yet assign definite paths to either group, and shall consider the exteroceptive connections of this nerve as a unit.

Neuron I.—The axon of a unipolar cell in the semilunar ganglion divides into a peripheral branch, distributed to the skin or mucous membrane of the head, and a central branch, which runs through the sensory root (pars major) of the trigeminal nerve into the pons. Here it divides into a short ascending and a long descending branch. The former terminates in the main sensory nucleus, and the latter in the spinal nucleus of that nerve (Fig. 232).

Neuron II.—The fibers of the second order in the sensory paths of the trigeminal nerve arise from cells located in the main sensory and the spinal nucleus

of that nerve; and after crossing the raphé they run in two tracts to the ventral part of the lateral nucleus of the thalamus. The *ventral* secondary afferent path is located in the ventral part of the reticular formation, close to the spinothalamic tract in the medulla oblongata and dorsal to the medial lemniscus in the pons and mesencephalon (Figs. 132, 234). The *dorsal* tract lies not far from the floor of the fourth ventricle and the central gray matter of the cerebral

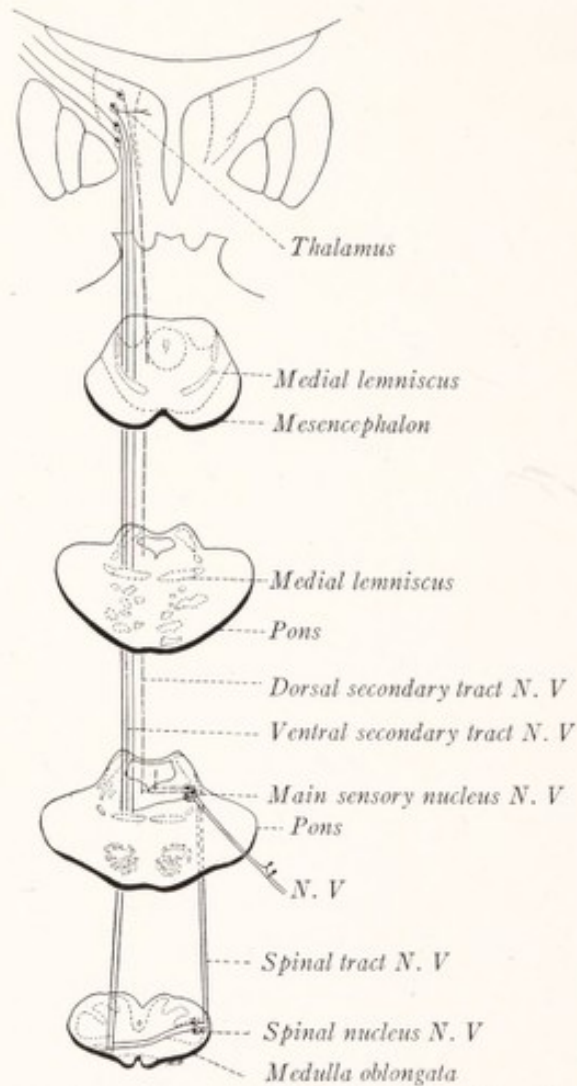


Fig. 232.—Diagram of the exteroceptive pathways associated with the trigeminal nerve.

aqueduct. It consists in considerable part of uncrossed fibers and of fibers having a short course (Wallenberg, 1905; Economo, 1911; Déjerine, 1914).

Neuron III.—The afferent impulses are relayed from the thalamus to the cortex of the posterior central gyrus by fibers of the third order, which run through the posterior limb of the internal capsule. Their cells of origin are located in the lateral nucleus of the thalamus.

The Neural Mechanism for Hearing.—The spiral organ of Corti within the cochlea is connected with the auditory center in the cerebral cortex by a chain of three or more units.

Neuron I.—The bipolar cells of the spiral ganglion within the cochlea send each a peripheral process to end in the spiral organ of Corti. Each sends a central branch to ramify in the cochlear nuclei, where it forms synaptic connections with the auditory neurons of the second order (Fig. 233).

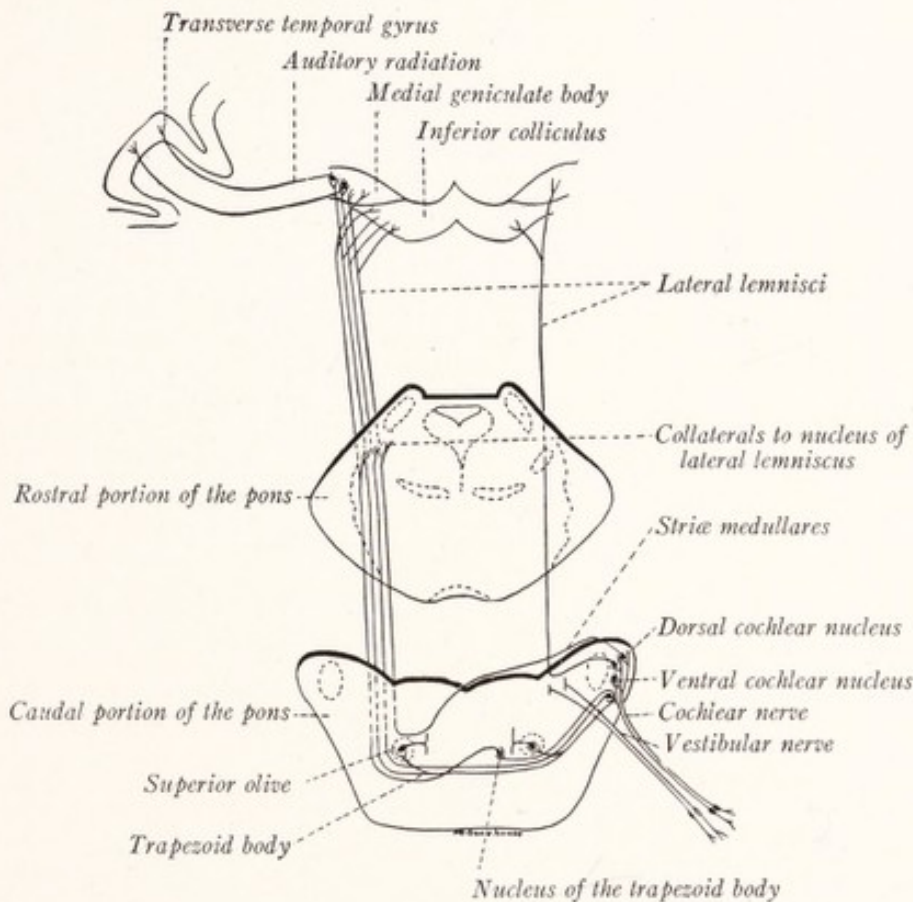


Fig. 233.—Diagram of the auditory pathway. (Based on the researches of Cajal and Kreidl.)

Neuron II.—The cells located in the ventral and dorsal cochlear nuclei give rise to fibers, which after crossing the median plane form the lateral lemniscus of the opposite side. Those from the ventral cochlear nucleus cross the pons in the trapezoid body, giving off collaterals to the superior olivary nuclei and the nuclei of the corpus trapezoideum, and may be joined by fibers taking origin in these nuclei. Lateral to the contralateral superior olivary nucleus they turn abruptly rostrad in the lateral lemniscus. The fibers from the dorsal cochlear nucleus run in the striæ medullares of the fourth ventricle, and then, dipping

into the reticular formation of the pons, cross the median raphé to join the trapezoid body and enter the lateral lemniscus. While this tract is for the most part a crossed one, some fibers probably enter the lateral lemniscus from the cochlear nuclei of the same side. This accounts for the fact that it is very rare to have total deafness in either ear resulting from damage to the auditory pathway within the brain. The fibers of this fillet give off collaterals to the nucleus of the lateral lemniscus, from which some additional fibers may be contributed to the tract, which finally terminates in the medial geniculate body and the inferior colliculus of the corpora quadrigemina. The latter, however, serves only as a reflex center, while the medial geniculate body is the way station on the auditory path to the cerebral cortex.

Neuron III.—Through synapses in the medial geniculate body the auditory impulses are transferred to neurons of the third order, whose cell bodies are located in this nucleus and whose fibers run through the auditory radiation and the retrolenticular part of the internal capsule to the auditory receptive center in the cerebral cortex. It will be remembered that this center is situated in the anterior transverse temporal gyrus, located upon the dorsal surface of the temporal lobe within the lateral cerebral fissure, and in the small portion of the superior temporal convolution with which that gyrus is directly continuous.

The Neural Mechanism for Sight.—The nervous impulses responsible for vision travel over a conduction system composed of at least four units. Since this mechanism has already been considered as a whole on pages 225–228 it is only necessary for us to enumerate here the separate units of which it is composed (Figs. 160, 162).

Neuron I.—Visual cells of the retina including the rods and cones, which are differentiated as receptors for photic stimuli.

Neuron II.—Bipolar cells of the retina, forming synapses with the visual cells, on the one hand, and the ganglion cells on the other.

Neuron III.—Ganglion cells of the retina, whose axons enter the optic nerve, undergo a partial decussation in the optic chiasma, and end in the lateral geniculate body, pulvinar of the thalamus, and superior colliculus of the corpora quadrigemina.

Neuron IV.—From cells in the lateral geniculate body and the pulvinar of the thalamus axons run by way of the optic radiation through the retrolenticular part of the internal capsule to the visual receptive center in the cerebral hemisphere. This is located in the cortex on both sides of the calcarine fissure and occupies portions of the cuneus and the lingual gyrus.

PROPRIOCEPTIVE PATHWAYS

We have traced the course of the afferent impulses from the skin and from the eye and ear to the cerebral cortex, and have learned that they play an especially important part in conscious experience. The stimulation of these exteroceptive sense organs initiates both conscious and reflex adjustments of the body to its environment. But the resulting movements serve to excite the sensory nerve ending in the muscles, joints, and tendons; and any quick movement or change in position of the head will also excite the nerve terminals in the semicircular canals of the ear. From these sources afferent impulses pour back into the nervous system along special paths to centers which to a great extent are separate from those devoted to the exteroceptive functions and serve to regulate the movements already initiated. The necessity for such regulation is well illustrated by the ataxic gait of a tabetic in whom the afferent impulses from the muscles, joints, and tendons are more or less completely lost. In a sense the proprioceptive functions of the nervous system are secondary to the exteroceptive, since the purpose of both is the proper adjustment of the organism to its environment by means of reactions, called forth by external stimuli, but regulated and controlled through afferent impulses arising within the body.

Since in the regulation of movement the proprioceptive subdivision of the nervous system has to deal with constant factors, inherent in the arrangement of the muscles, the resultant responses are more stereotyped and invariable in character and are, for the most part, subconsciously executed. These reactions belong more to the province of the cerebellum than to that of the cerebrum.

Of the long ascending channels mediating afferent impulses from the muscles, joints, and tendons, only one extends to the cerebral cortex by way of the thalamus; all the others end in the cerebellum. In fact, the cerebellum is the great correlation center for afferent impulses of the proprioceptive group, whether they are conveyed by the vestibular nerve or the muscular branches of the spinal nerves.

It will be understood that on the motor side these two subdivisions of the nervous system are not as distinct as on the afferent side. On the contrary, both tend to discharge into common efferent systems. This is particularly true of the primary somatic motor neuron, which serves as "the final common path" for both.

The Spinal Proprioceptive Path to the Cerebral Cortex.—The conduction system, along which those afferent impulses travel which underlie the rather

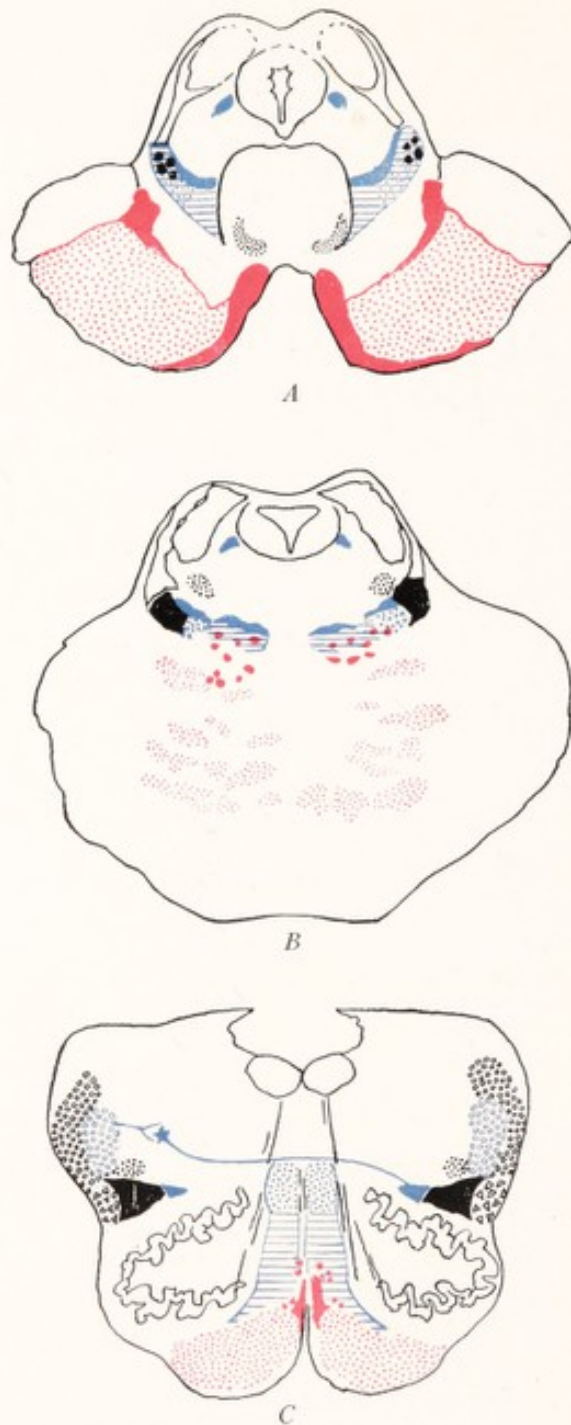


Fig. 234.—Diagrams showing the location of the most important tracts of the brain stem based on figures by Déjerine. Solid red, aberrant bundles of the corticobulbar tract; red stipple, corticospinal tract; solid blue, secondary afferent paths of the trigeminal nerve; horizontal blue lines, the medial lemniscus (proprioceptive); blue stipple, ventral spinothalamic tract (or tactile path); blue circles, spinal root of the trigeminal nerve; solid black, lateral spinothalamic tract (pain and temperature); black triangles, ventral spinocerebellar tract; black circles, dorsal spinocerebellar tract; black stipple, rubrospinal tract. *A*, Through the mesencephalon at the level of the inferior colliculus; *B*, through the rostral part of the pons; *C*, through the medulla at the level of the olive.

vague sensations of position and posture and of active and passive movements, consists of a chain of at least three units.

Neuron I.—The cell bodies of the neurons of the first order belonging to this system are located in the spinal ganglia. Their axons are myelinated and divide into peripheral branches, running to specialized end organs within the muscles, joints and tendons, and central branches directed through the medial division of the dorsal root into the posterior funiculus of the spinal cord. Here they divide; and their ascending branches run through the posterior funiculus to terminate in the gracile and cuneate nuclei of the medulla oblongata, where they enter into synaptic relations with neurons of the second order (Fig. 235).

Neuron II.—From cells located in the gracile and cuneate nuclei the axons run as internal arcuate fibers across the median raphé in the medulla oblongata and ascend by way of the medial lemniscus to end in the ventral part of the lateral nucleus of the thalamus, where they form synapses with neurons of the third order.

Neuron III.—From cells in the lateral nucleus of the thalamus fibers pass by way of the thalamic radiation through the posterior limb of the internal capsule to the posterior central gyrus or somesthetic area of the cerebral cortex.

SPINAL PROPRIOCEPTIVE PATHS TO THE CEREBELLUM

Impulses from the muscles, joints, and tendons may reach the cerebellum by three routes:

A. By Way of the Dorsal External Arcuate Fibers:

Neuron I of this chain is the same as in the path to the cerebral cortex just described, the fibers from the dorsal root reaching the gracile and cuneate nuclei.

Neuron II.—From cells located in these nuclei axons run as posterior external arcuate fibers to the restiform body of the same side, and thence through the white center of the cerebellum, to end in the cerebellar cortex (Fig. 235, red).

B. By Way of the Ventral Spinocerebellar Tract:

Neuron I.—The first neuron in this chain is similar to the primary neuron in the two preceding paths. The impulses, however, travel over collateral and terminal branches of the dorsal root fibers to reach the posterior gray column and intermediate gray matter of the spinal cord.

Neuron II.—From cells located in the posterior gray column and intermediate gray matter fibers run in the ventral spinocerebellar tracts of the same or opposite side through the spinal cord, medulla oblongata and pons, bend around the brachium conjunctivum, and then course back along the anterior medullary velum to the cortex of the rostral part of the vermis (Fig. 235, blue).

C. By Way of the Dorsal Spinocerebellar Tract:

Neuron I.—The first neuron of this chain is similar to the primary neuron in the three preceding paths. The impulses, however, travel over those collateral and terminal branches of the dorsal root fibers which ramify about the cells of the nucleus dorsalis.

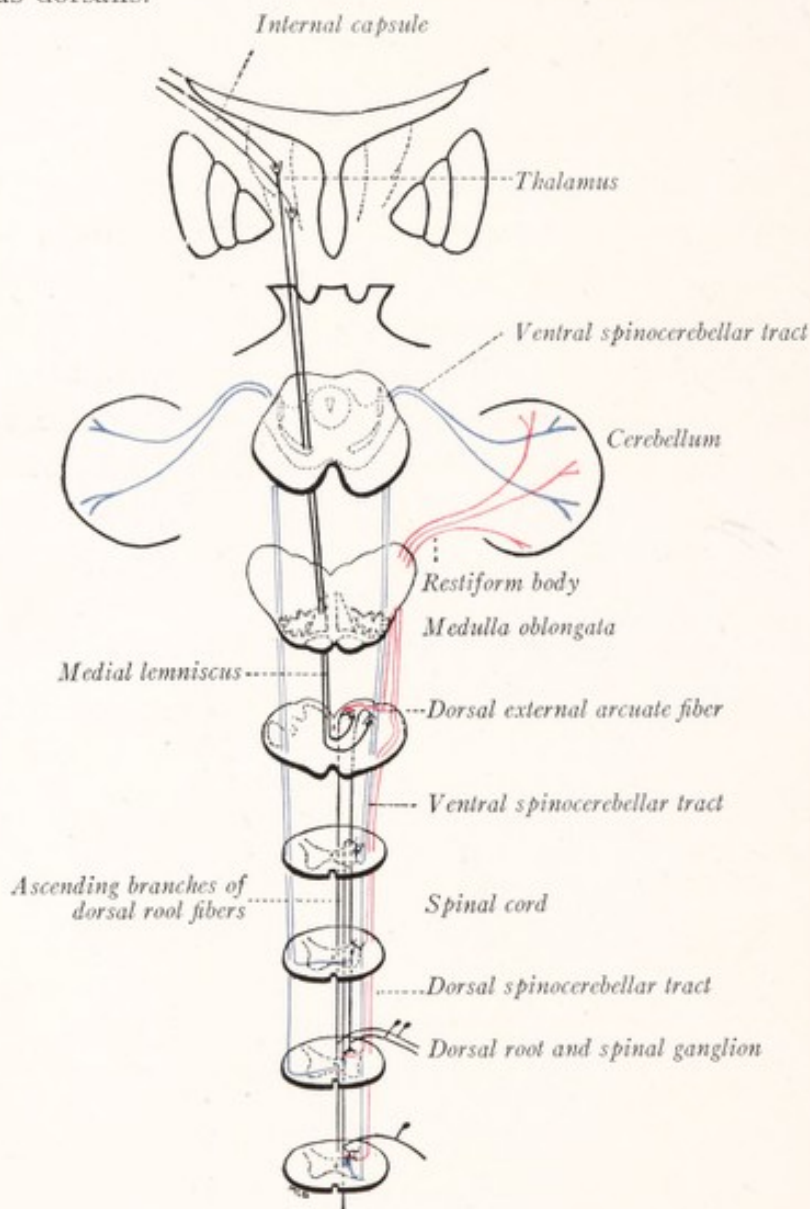


Fig. 235.—The proprioceptive paths.

Neuron II.—From cells in the nucleus dorsalis fibers run to the dorsal spinocerebellar tract of the same side and through the restiform body to the cortex of both the rostral and the caudal portions of the vermis (Fig. 235, red).

Cerebellar Connections of the Vestibular Nerve.—The vestibular nerve

conducts impulses from specialized sense organs in the semicircular canals, saccule and utricle, which are stimulated by movements and changes in posture of the head.

Neuron I.—From the bipolar cells of the vestibular ganglion (of Scarpa), located within the internal auditory meatus, peripheral processes run to the maculae of the utricle and saccule and to the cristae of the semicircular canals. The central processes are directed through the vestibular nerve toward the floor of the fourth ventricle and divide into ascending and descending branches. While the descending and many of the ascending branches terminate in the vestibular nuclei, many other ascending branches pass without interruption to end in the cerebellar cortex and particularly in that of the vermis (Fig. 136).

Neuron II.—Some of the cells situated in the vestibular nuclei send their axons, along with the ascending branches mentioned above in the vestibulo-cerebellar tract, to the cortex of the vermis, and to a less extent to the cortex of the cerebellar hemispheres also.

CHAPTER XX

EFFERENT PATHS AND REFLEX ARCS

THE **motor apparatus** is a complex mechanism into which the pyramidal system enters as a single factor. The primary motor neurons of the brain stem and spinal cord are also under the influence of other motor centers than those found in the cerebral cortex. They receive impulses from the corpora quadrigemina through the tectospinal tract, from the lateral vestibular nucleus by way of the vestibulospinal tract, from the large motor cells of the reticular formation through the reticulospinal path, from the cerebellum, and probably also from the corpus striatum by way of the red nucleus and the rubrospinal fasciculus. Perhaps, also, impulses descend from the thalamus or subthalamus by way of a thalamospinal tract.

We must not think of the individual parts of this complex mechanism as functioning separately, since each of these motor centers contributes its share to the control of the primary motor neuron, upon which as the "final common path" all these efferent pathways converge. Only by keeping this fact constantly in mind can the motor functions be properly understood. The same idea has been well stated by Walshe (1919): "In stimulation experiments on the motor cortex we see a complex motor mechanism at work under the influence of an abnormally induced, crude form of hyperactivity of the predominant partner in this mechanism. Conversely, after destructive lesions, we observe it at work liberated from the control of this predominant partner and deprived of its actual coöperation."

On the other hand, the grave motor disturbances resulting from lesions in the basal ganglia and especially the corpus striatum with little or no involvement of the corticospinal tracts (paralysis agitans, Auer and McCough, 1916; bilateral athetosis, Cecile Vogt, 1911; and progressive lenticular degeneration, Wilson, 1912-14) have recently called attention to the importance of the corpus striatum and the extrapyramidal motor path (see p. 324). In these diseases voluntary movements are impeded by tremor, rigidity, and athetosis; and in all probability these disturbances arise because the pyramidal system is deprived of the cooperation of one of the subordinate "partners" in the motor combine.

Even after cerebral control has been entirely eliminated in the dog by decerebration, many reflex functions remain, which represent the unguided activity of the lower elements in the motor mechanism; and we now know that a similar independent reflex activity may occur in the spinal cord of man after total transverse lesions (Riddoch, 1917).

THE GREAT MOTOR PATH

The great motor path from the cerebral cortex to the skeletal musculature, through which the bodily activities are placed directly under voluntary control, is in man and mammals the dominant factor in the motor mechanism. We have seen that afferent channels from the various exteroceptors reach the cere-

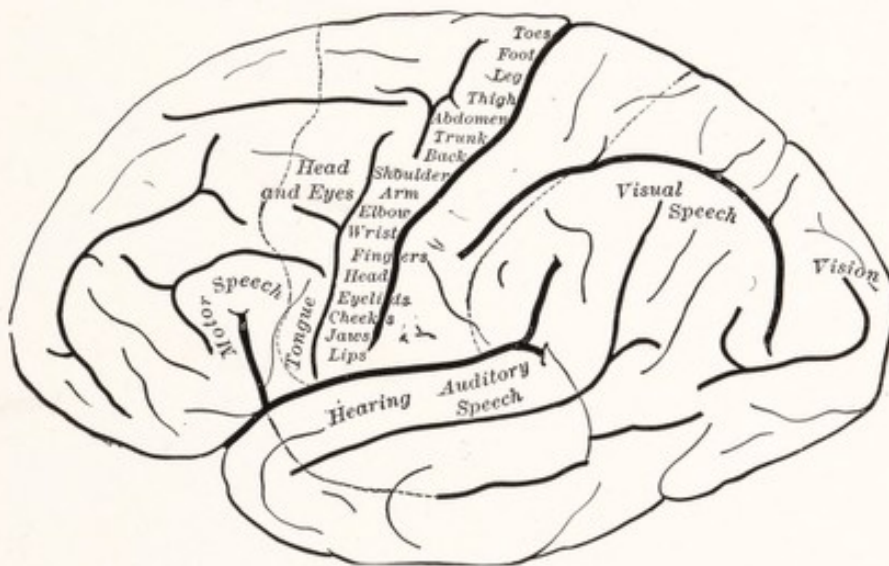


Fig. 236.—Cortical localization upon the lateral aspect of the human cerebral hemisphere. (Starr.)

bral cortex; and that through the correlation of the olfactory, auditory, visual, tactile, thermal, and painful afferent impulses which pour into it, there is built up within the cortex a representation of the outer world and its constantly changing conditions. The responses appropriate to meet the entire situation in which the individual finds himself from moment to moment are in large part at least initiated in the cerebral cortex and are executed through the motor mechanism. In these responses the great motor path is the dominant factor, although other parts of the mechanism are secondarily called into action, especially the proprioceptive reflex arcs, including the coördinating and tonic mechanism of the cerebellum.

This great motor path consists of two-unit chains. The so-called *upper motor neurons* conduct impulses from the motor cortex to the motor nuclei of the

cerebral nerves or to the anterior gray columns of the spinal cord; whence the *lower motor neurons*, also known as *primary motor neurons*, relay the impulses to the muscles. It is possible that another and much shorter element is intercalated between the two chief units of this conduction system.

The motor cortex occupies the rostral lip of the central sulcus and the adjacent portion of the anterior central gyrus, extending over the dorsal border of

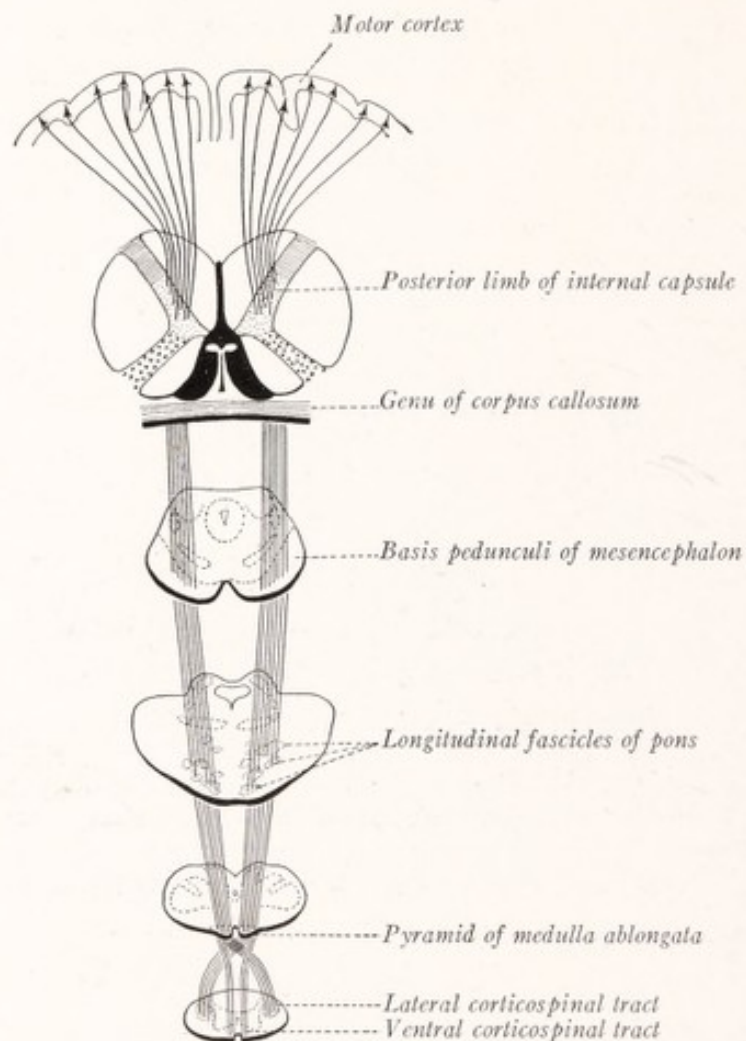


Fig. 237.—The corticospinal path.

the hemisphere into the paracentral lobule. Within this area the skeletal musculature is represented in inverted order, that moving the toes near the dorsal border of the hemisphere. The area from which the corticobulbar tract arises is only a small part of the whole, and is situated near the lateral cerebral fissure (the region marked *Eyelids, Cheeks, Jaws, Lips* in Fig. 236). From all the rest of the motor cortex arise the fibers of the corticospinal tract.

The motor path for the spinal nerves includes the corticospinal tract and the spinal primary motor neurons.

Neuron I, or upper motor neuron. The giant pyramidal cells of the motor cortex give rise to the fibers of the corticospinal tract, which is also known as

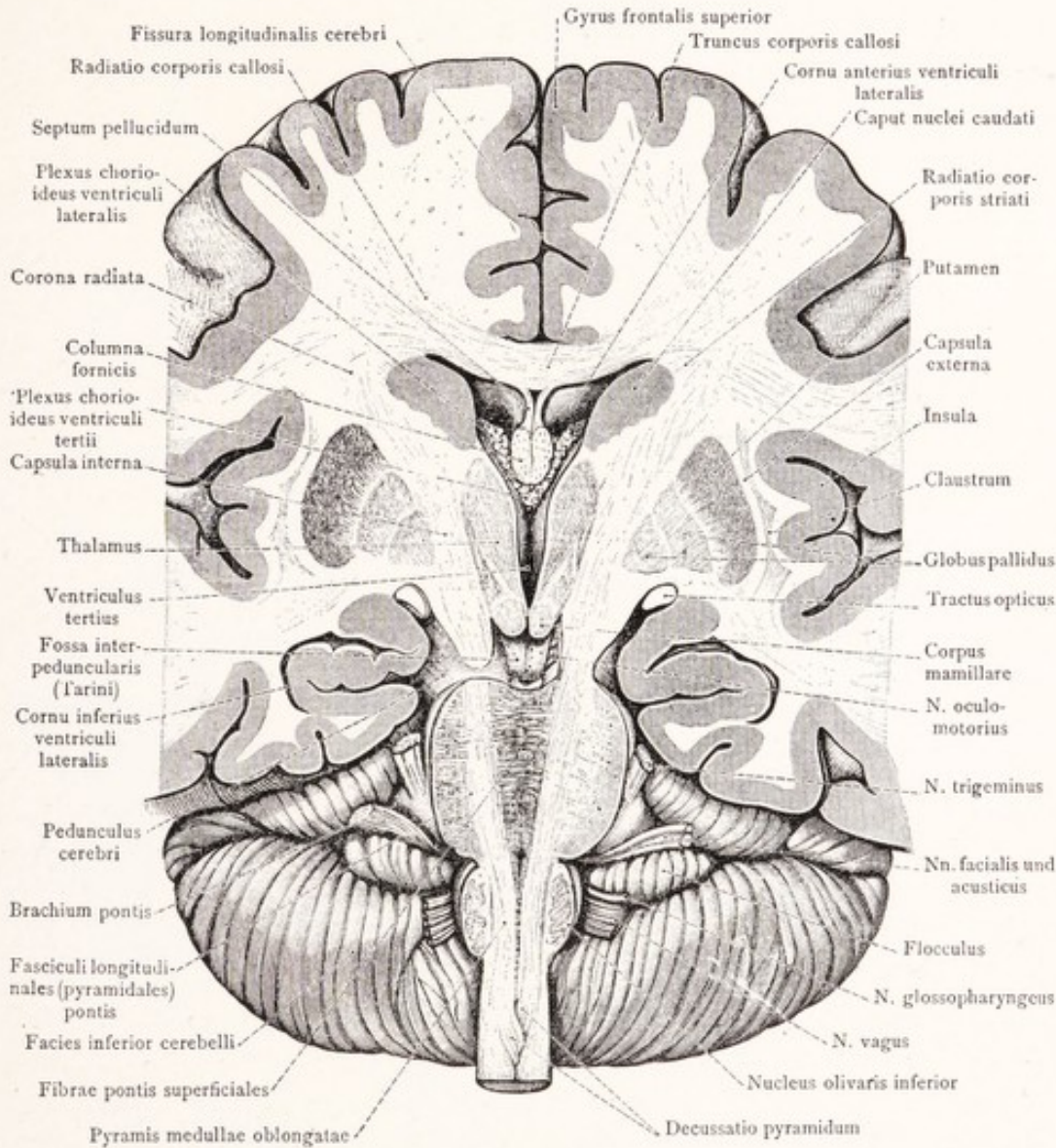


Fig. 238.—Section through the brain in the axis of the brain stem, showing the entire extent of the corticospinal tract. (Toldt.)

the cerebrospinal fasciculus or pyramidal tract. These fibers traverse the rostral half of the posterior limb of the internal capsule, the intermediate three-fifths of the basis pedunculi, the basilar portion of the pons, and the pyramid of the medulla oblongata, and after undergoing a partial decussation are continued into the spinal cord (Figs. 237, 238). At the pyramidal decussation in the caudal

part of the medulla oblongata the greater part of the tract crosses to the opposite side of the spinal cord and is continued as the lateral corticospinal tract in the lateral funiculus. The smaller part is continued directly into the ventral funiculus of the same side, as the ventral corticospinal tract. The fibers of the ventral tract cross the median plane a few at a time and terminate, as do those of the lateral tract, directly or indirectly in synaptic relations with the primary motor neurons within the anterior gray column (Fig. 239). The ventral tract is not evident as a well-marked bundle below the level of the midthoracic region.

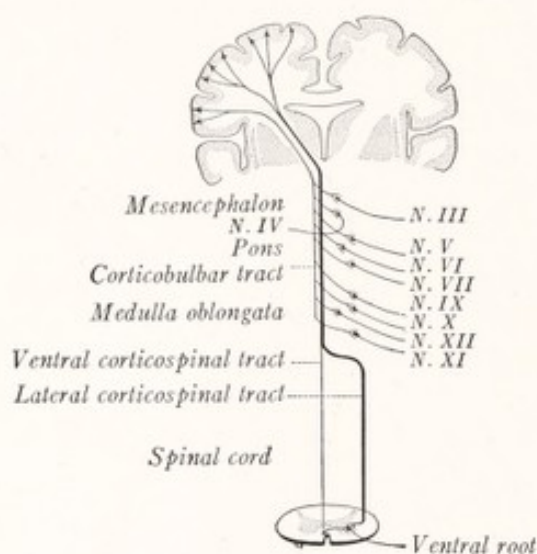


Fig. 239.—The corticobulbar and corticospinal tracts.

It has long been known that in the higher mammals the lateral pyramidal tract, although consisting predominately of crossed fibers, contains a few homolateral fibers also (Simpson, 1902), and according to the observations of Déjerine (1914) and other investigators this holds true for man also. Déjerine speaks of these uncrossed fibers in the lateral corticospinal tract as a third bundle arising out of the motor decussation, and calls it the "homolateral" corticospinal fasciculus. A good account of this tract and of the superficially placed bundle of uncrossed pyramidal fibers that is to be found in the ventral part of the lateral funiculus in the cervical portion of the spinal cord is given by Barnes (1901).

Neuron II.—To the lower or primary motor neurons belong the large multipolar cells of the anterior gray column of the spinal cord. These give rise to the motor fibers that leave the spinal cord through the ventral roots and are distributed through the spinal nerves to the skeletal musculature.

The **motor path for the cranial nerves** is less well known. It includes the corticobulbar tract and those fibers of the cranial nerves which innervate striated musculature.

Neuron I, or upper motor neuron. The corticobulbar fibers arise from the

giant pyramidal cells of the part of the motor cortex near the lateral fissure. These fibers run through the genu of the internal capsule and the basis pedunculi to end, directly or indirectly, in synaptic relation to the primary motor neurons of the somatic motor and special visceral motor nuclei of the brain stem. Before terminating, the majority cross the median plane, but some end in the motor nuclei of the same side (Fig. 239).

Neuron II, lower or primary motor neuron. From the large multipolar cells of the somatic motor and special visceral motor nuclei arise fibers, which run through the cranial nerves to end in striated musculature.

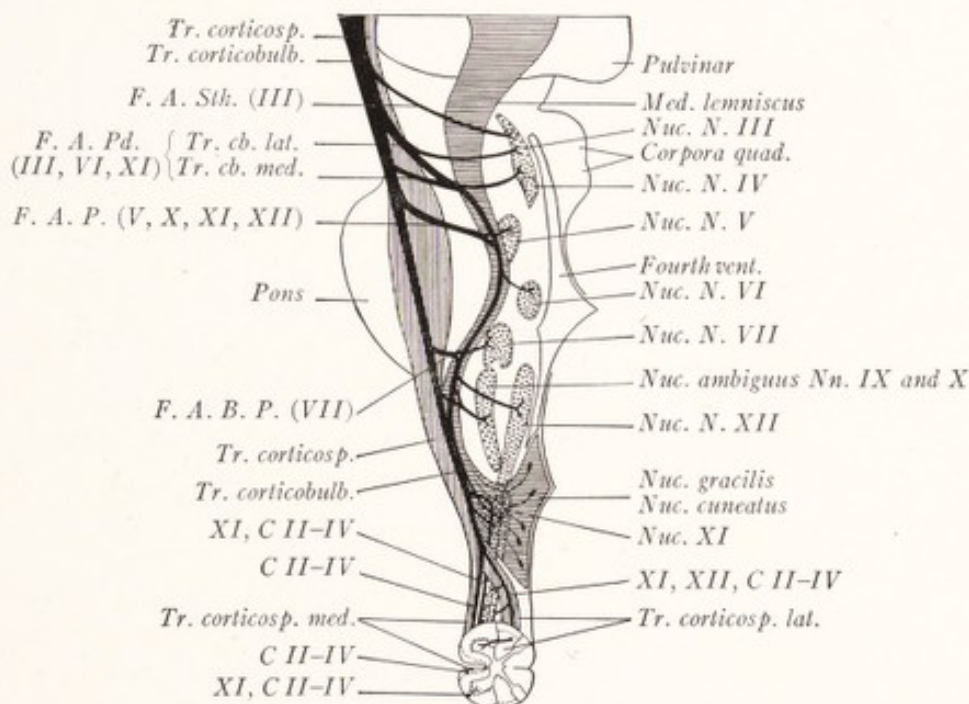


Fig. 240.—The course of the fibers of the corticobulbar tract. Redrawn from Déjerine. Corticobulbar tract, solid black; corticospinal tract, vertical lines; the medial lemniscus, horizontal lines. *F. A. B. P.*, Bulbopontine aberrant fibers; *F. A. P.*, aberrant fibers of the pons; *F. A. Pd.*, aberrant fibers of the peduncle; *F. A. Sth.*, subthalamic aberrant fibers; *Tr. cb. lat.*, tractus corticobulbaris lateralis; *Tr. cb. med.*, tractus corticobulbaris medialis. The Roman numerals indicate the nuclei of the cranial and cervical nerves which are supplied by the various bundles.

The Corticobulbar Tract.—According to Déjerine (1914), who, because of the careful study which he and his associates have made of this efferent system, is most entitled to speak authoritatively on the subject, the corticobulbar fibers occupy chiefly the medial part of the basis pedunculi and its deeper layer. The fibers separate into two major groups. One part follows the course of the corticospinal tract and descends in the basilar portion of the pons and the pyramids of the medulla oblongata. Another part, which he designates as the system of *aberrant pyramidal fibers*, detaches itself from the preceding in small bundles at successive levels of the brain stem. These enter the reticular formation and descend within the region occupied by the medial lemniscus, giving off fibers to the motor nuclei of the cranial nerves (Fig. 240). The fibers undergo an incomplete decussation in the raphé

and go chiefly to the nuclei of the opposite side. The decussating fibers are grouped in very small bundles, those for a given nucleus crossing at the level of that nucleus. There is great variation in the course of the bundles of aberrant pyramidal fibers in different brains.

The *chief aberrant bundles* which can be traced dorsalward into the reticular formation (indicated in solid red in Fig. 234) are as follows:

1. The aberrant fibers of the peduncle (Fig. 240, *F. A. Pd.*) form two bundles, which have been called by some authors the median and lateral corticobulbar tracts. These descend in the territory of the medial lemniscus (Figs. 234, 240) and give off fibers to the nuclei of the third, sixth, and eleventh cranial nerves. With these two bundles run some fibers destined for the upper cervical segments of the spinal cord. This group of aberrant fibers therefore controls the movements of the eyes and the associated movements of the head.

2. The aberrant fibers of the pons (Fig. 240, *F. A. P.*) which join the preceding in the medial lemniscus run to the motor nuclei of the trigeminal and hypoglossal nerves and to the nucleus ambiguus.

3. The bulbopontine aberrant fibers (Fig. 240, *F. A. B. P.*) leave the main trunk of the pyramidal system near the level of the sulcus between the pons and medulla. They reinforce the preceding groups, supply the motor nucleus of the facial nerve, and send fibers to the nucleus ambiguus and to that of the hypoglossal nerve.

These facts are of the greatest importance for the clinical neurologist. Lesions restricted to the basilar portion of the pons are likely to destroy at the same time the corticospinal fibers and those of the corticobulbar tract which end in the facial nucleus. A lesion confined to the reticular formation and involving the medial lemniscus may, according to its level, sever the corticobulbar fibers for the motor nuclei of the eye-muscle nerves or those for the motor nuclei of the trigeminal, accessory, and hypoglossal nerves without involvement of the corticospinal tracts. Conjugate deviation of the head and eyes, not often seen as a result of damage to the basilar portion of the pons, may result from tegmental lesions involving the aberrant fibers of the peduncle.

The *physiologic* and *clinical significance* of the course of the corticospinal and corticobulbar tracts is obvious. It is because of the decussation of these fibers that the muscular contractions produced by cortical stimulation occur chiefly on the opposite side of the body, and that the paralyzes resulting from lesions in the pyramidal system above the decussation are contralateral. If the lower motor neuron is injured, the associated muscle atrophies and a flaccid paralysis results. Injury to the upper motor neuron, on the other hand, leads to a loss of function without atrophy, but rather with an increased tonicity of the affected muscle, *i. e.*, to a spastic paralysis. By means of such differential characteristics as these it is possible to tell which of the two links in the motor chain has been broken.

In order to understand the combination of symptoms, which result from damage to the motor path at different levels, it is necessary to have in mind the topography of its constituent parts. Some of these relations are indicated in Fig. 241. Since the motor cortex is spread out over a rather extensive area, it is usually not entirely destroyed by injury or disease. A restricted cortical

lesion may cause a *monoplegia*, *i. e.*, paralysis of a single part, such as the arm or leg (Fig. 241, *A*). But in the internal capsule the motor fibers are grouped within a small area and are frequently all destroyed together. This causes paralysis of the opposite half of the body or *hemiplegia* (Fig. 241, *B*). Damage to the pyramidal system in the cerebral peduncle, pons, or upper part of the medulla oblongata may also cause hemiplegia; but in such cases those cortico-

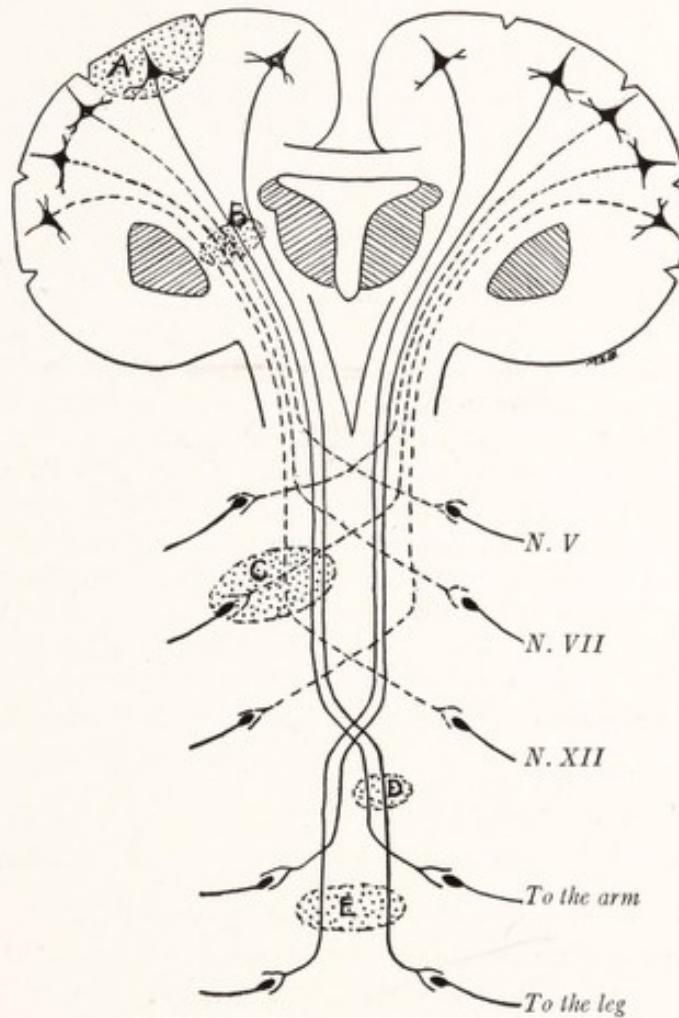


Fig. 241.—Diagram to illustrate the effects of lesions in various parts of the motor path.

bulbar fibers, which leave the main strand of pyramidal fibers above the level of the lesion, may escape injury and the corresponding cranial nerves need not be involved (Fig. 241, *C*). Furthermore, in lesions of the brain stem the motor nucleus or emergent fibers of one of the cranial nerves may be destroyed along with the pyramidal fibers, in which case there would result a paralysis of the muscles supplied by that nerve as well as a paralysis of the opposite half of the body below that level—a *crossed paralysis* (Fig. 241, *C*). While damage to the

spinal cord may affect only one lateral half and cause a homolateral paralysis below the lesion (Fig. 241, *D*), it is common for both lateral halves to be involved and for the resulting paralysis to be bilateral (Fig. 241, *E*).

The Extrapyramidal Motor Paths.—In recent years it has become increasingly evident that the pyramidal system is not the only channel through which volitional impulses are able to reach the primary motor neurons of the brain stem and spinal cord. Rothmann (1907) found that, after section of the lateral corticospinal and the rubrospinal tracts in monkeys at the level of the third cervical nerve, voluntary movements were lost for a time, but soon reappeared; and he concluded that there must be an extrapyramidal volitional path in the ventral funiculus. Three years later Schäfer (1910) showed that in monkeys the paralysis, which results from section of the pyramids of the medulla oblongata, is not complete and persistent; and he agreed with Rothmann that there must be some other path for volitional impulses. He believes that this alternative path is formed by descending fibers in the ventral funiculus and in the ventral part of the lateral funiculus, since section of these fibers produces as complete and persistent paralysis in monkeys as does section of the pyramids themselves.

Sherrington and Graham Brown (1913) excised the arm area of the cerebral cortex in the chimpanzee, and found that function in the corresponding limb was completely restored in a few weeks. They were able to show that this was not attributable to the vicarious activity of the corresponding postcentral or the opposite precentral cortex. Horsley's (1909) patient, who recovered some degree of control over the arm after the removal of its cortical center in the precentral gyrus, shows that the observations of Sherrington and Brown are at least in part applicable to man.

We know that the cerebral cortex is connected through efferent projection tracts with the thalamus and red nucleus and through collaterals from the corticospinal fibers with the corpus striatum (Cajal). But we do not know which, if any, of these systems of projection fibers constitutes a part of the extrapyramidal path for volitional impulses.

A great deal of attention has recently been given by clinical neurologists to the disturbance of voluntary movement by tremor, rigidity, and athetosis, which results from lesions of the corpus striatum. This body seems to contain an important motor center, and according to Wilson (1912 and 1914) it exerts a steadying influence upon voluntary movements. The globus pallidus seems to be connected with the spinal primary motor neurons by way of the striorubral and rubrospinal tracts. It is also possible, especially in view of the important motor functions attributed to the ventrolateral descendign tracts of the spinal cord by Rothmann and Schäfer, that efferent impulses reach the spinal cord from the globus pallidus by way of the substantia nigra over the strionigral, the somewhat hypothetic nigroreticular, and the reticulospinal tracts. It is known that the axons arising in the substantia nigra run into the reticular formation of the mesencephalon, beyond which they cannot be traced (Cajal, 1911). According to Collier and Buzzard (1901) the rubrospinal, vestibulospinal, tectospinal, and reticulospinal tracts probably represent the original paths for impulses from higher to lower parts of the nervous system; and the path from the cerebrum to the spinal cord, at first indirect, has been short-circuited in the mammal through the evolution of the pyramidal system.

When it is remembered that the pyramidal system is a late development, present only in mammals, it does not seem unreasonable to think that some other and older path for volitional impulses may also exist. The globus pallidus, the representative of the primitive corpus striatum of the lower vertebrates, has been called the *paleostriatum* (Elliot Smith, 1919). From this basal nucleus there arises in all vertebrates an important efferent bundle,

“the basal forebrain bundle” of Edinger (1887), which is represented in mammals by the striofugal fibers of the ansa lenticularis. It is clear that this fascicle, which persists throughout the vertebrate series, must subservise important functions; and it is probable that it forms a part of the extrapyramidal motor path.

THE CORTICO-PONTO-CEREBELLAR PATH

The cortico-ponto-cerebellar path is an important descending conduction system which places the cerebellum under the influence of the cerebral cortex. Since a part of the corticopontine fibers are collaterals given off to the nuclei of the pons by the corticospinal fibers, and since in many mammals practically

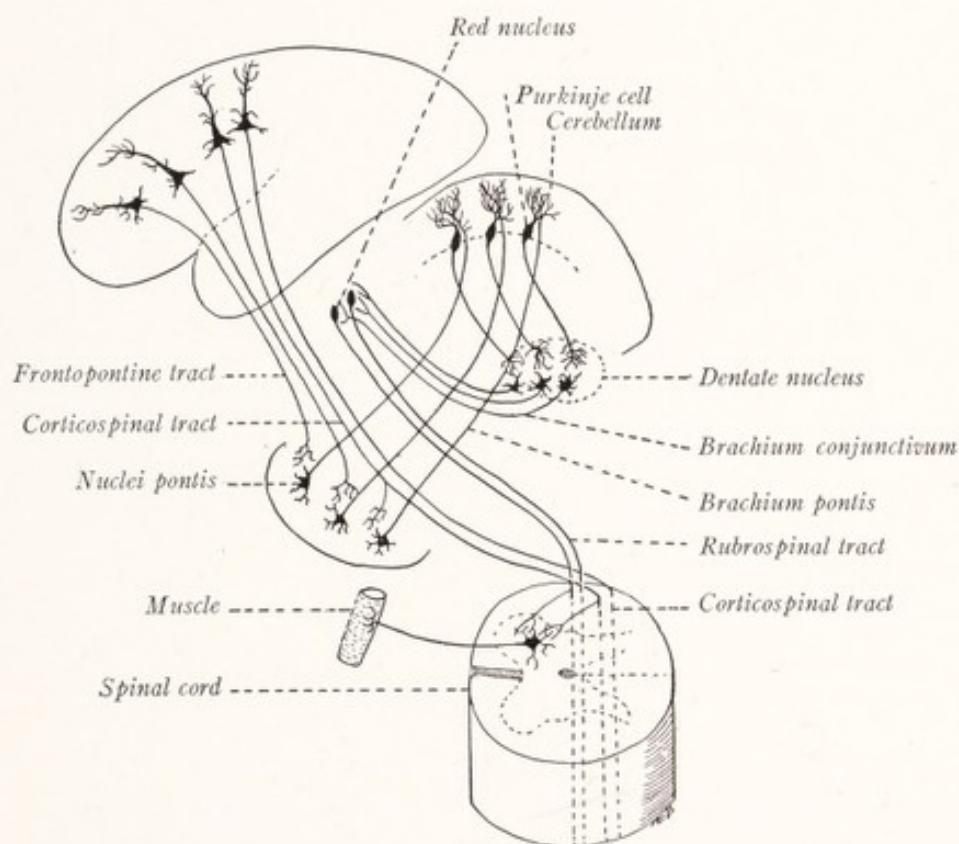


Fig. 242.—The cortico-ponto-cerebellar and cerebello-rubro-spinal paths. (Modified from Cajal.)

all of the corticopontine fibers are represented by such collaterals (Cajal, 1909), one can scarcely avoid the conclusion that through this system the coördinating and tonic mechanism of the cerebellum is brought into play for the regulation of movements initiated from the cerebral cortex. In this sense the idea of Cajal (1911) that there exists an indirect motor path to the spinal cord through the cerebellum is probably correct (Fig. 242).

Neuron I.—From pyramidal cells in the frontal lobe of the cerebral cortex fibers pass through the anterior limb of the internal capsule and the medial one-

fifth of the basis pedunculi; and similar fibers from the temporal lobe descend through the sublenticular part of the internal capsule and the lateral one-fifth of the basis pedunculi. These fibers, together with the corticospinal tract, form the longitudinal fasciculi of the pons; and, along with collaterals from that tract, they end within the nuclei pontis in synaptic relations with the neurons of the second order (Figs. 106, 242).

Neuron II.—Arising from cells in the nuclei pontis, the transverse fibers of the pons cross the median plane and run by way of the brachium pontis and white substance of the cerebellum to the cerebellar cortex of the opposite side.

THE CEREBELLO-RUBRO-SPINAL PATH

The cerebello-rubro-spinal path is the conduction system through which the cerebellum contributes its important share to the control of the primary motor neurons of the spinal cord in the interest of muscular coördination, equilibration, and the maintenance of muscle tone. Other efferent connections of the cerebellum have been discussed on page 211.

Neuron I.—From the Purkinje cells of the cerebellar cortex fibers run to terminate in the central nuclei of the cerebellum, especially the dentate nucleus (Fig. 242).

Neuron II.—Arising chiefly, if not entirely, from the cells of the dentate nucleus, fibers run through the brachium conjunctivum, undergo decussation in the tegmentum of the midbrain ventral to the inferior colliculi, and end in the red nucleus and thalamus (Figs. 242, 243).

Neuron III.—From cells in the red nucleus arise the fibers of the rubrospinal tract, which cross the median plane in the ventral tegmental decussation, and descend through the reticular formation of the brain stem and the lateral funiculus of the spinal cord. Here this tract occupies a position just ventral to the lateral corticospinal tract, and its fibers end in the anterior gray column in relation to the primary motor neurons.

We have learned that the cerebellum is the chief center of the proprioceptive system and is concerned with the maintenance of the proper tonicity of the muscles, the coördination of their contractions, and especially with those reactions necessary to maintain or to re-establish that evenly balanced spacial orientation known as equilibrium. The cerebello-rubro-spinal path is the conduction system primarily concerned in these reactions.

What is perhaps the first direct experimental evidence of the function of this system has been given by Weed (1914). The extensor rigidity, so characteristic

of decerebrated dogs, which Sherrington (1906) clearly showed to be a proprioceptive reflex that under normal conditions serves to keep the limbs from bending under the weight of the body, is apparently dependent upon the integrity of the cerebello-rubro-spinal path. Weed showed that removal of the cerebellum, section of the superior cerebellar peduncles, or transection of the mesencephalon below the level of the red nucleus obliterated or greatly decreased this rigidity.

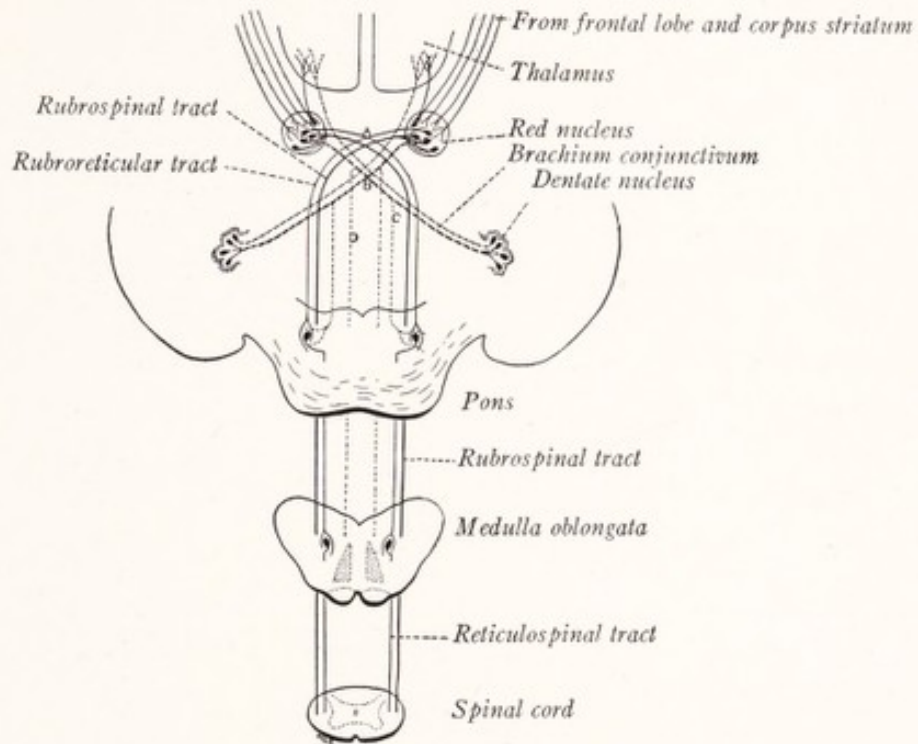


Fig. 243.—Diagram showing the connections of the red nucleus: *A*, Ventral tegmental decussation; *B*, decussation of the brachium conjunctivum; *C* and *D*, descending fibers from brachium conjunctivum, before and after its decussation respectively.

On the other hand, stimulation of the area occupied by the red nucleus on the cut surface of the mesencephalon in decerebrated dogs increased the rigidity.

IMPORTANT REFLEX ARCS

We have considered the afferent paths leading to the cerebral cortex and to the cerebellum as well as the efferent channels which conduct impulses from these centers to the skeletal musculature. But there are many more direct paths by which impulses may travel from receptor to effector, and these are known as reflex arcs. It will be worth while to review briefly a few of the more important of these rather direct receptor to effector circuits.

REFLEX ARCS OF THE SPINAL CORD

Neuron I.—Primary sensory neurons, with cell bodies in the spinal ganglia, convey impulses from the sensory endings to the spinal cord, then along the ascending and descending branches resulting from the bifurcation of the dorsal root fibers within the cord, and along the collaterals of these branches to the primary motor neurons, either directly or through an intercalated central unit (Figs. 66-68).

Neuron II.—The central neurons have their cell bodies in the posterior gray column and may belong to Golgi's Type II, having short axons restricted to the gray matter; or their axons may be long, running through the fasciculi proprii to the ventral horn cells at other levels of the cord. Some of these central axons cross the median plane in the anterior commissure.

Neuron III.—Primary motor neurons, with cell bodies in the anterior gray column, send their axons through the ventral roots and spinal nerves to the skeletal musculature. Or in the case of visceral reflexes, the motor neuron has its cell body located in the intermediolateral cell column, and its axon runs as a preganglionic fiber to a sympathetic ganglion, whence the impulses are relayed by a fourth or postganglionic neuron to involuntary muscle or glandular tissue.

The reflex paths of the cranial nerves are similarly constituted, except that rarely if ever do the sensory fibers form synapses directly with the motor cells. The central neuron, which has its cell located in the sensory nucleus of a given nerve, sends its axon through the reticular formation to the motor nucleus of the same or of some other nerve (Figs. 92, 111). Two of the reflex circuits connected with the vestibular nerve require special attention.

VESTIBULAR REFLEX ARC THROUGH THE MEDIAL LONGITUDINAL BUNDLE

Neuron I.—The bipolar cells of the vestibular ganglion in the external auditory meatus send peripheral processes to the cristæ of the semicircular canals and maculæ of the saccule and utricle. Their central processes run through the vestibular nerve to the vestibular nuclei (Figs. 135, 244).

Neuron II.—Cells in the lateral and superior vestibular nuclei send their axons to the medial longitudinal fasciculus of the same or the opposite side, where they divide into ascending and descending branches, which run in this bundle. From these branches twigs are given off to the nuclei of the oculomotor, trochlear, and abducens nerves and to the motor cells of the cervical portion of the spinal cord (Fig. 244).

Neuron III.—Primary motor neurons of the oculomotor, trochlear, abducens,

accessory, and cervical spinal nerves send their axons to the muscles that move the head and eyes.

This arc is concerned with the reflex regulation of the combined movements of the head and eyes in response to the vestibular stimulation which results from every movement and change of posture of the head. Strong stimulation of the semicircular canals, vestibular nerve, or Deiters' nucleus causes an oscillatory side to side movement of the eyes, known as nystagmus, a reflex response of an abnormal character mediated through this arc (Wilson and Pike, 1915).

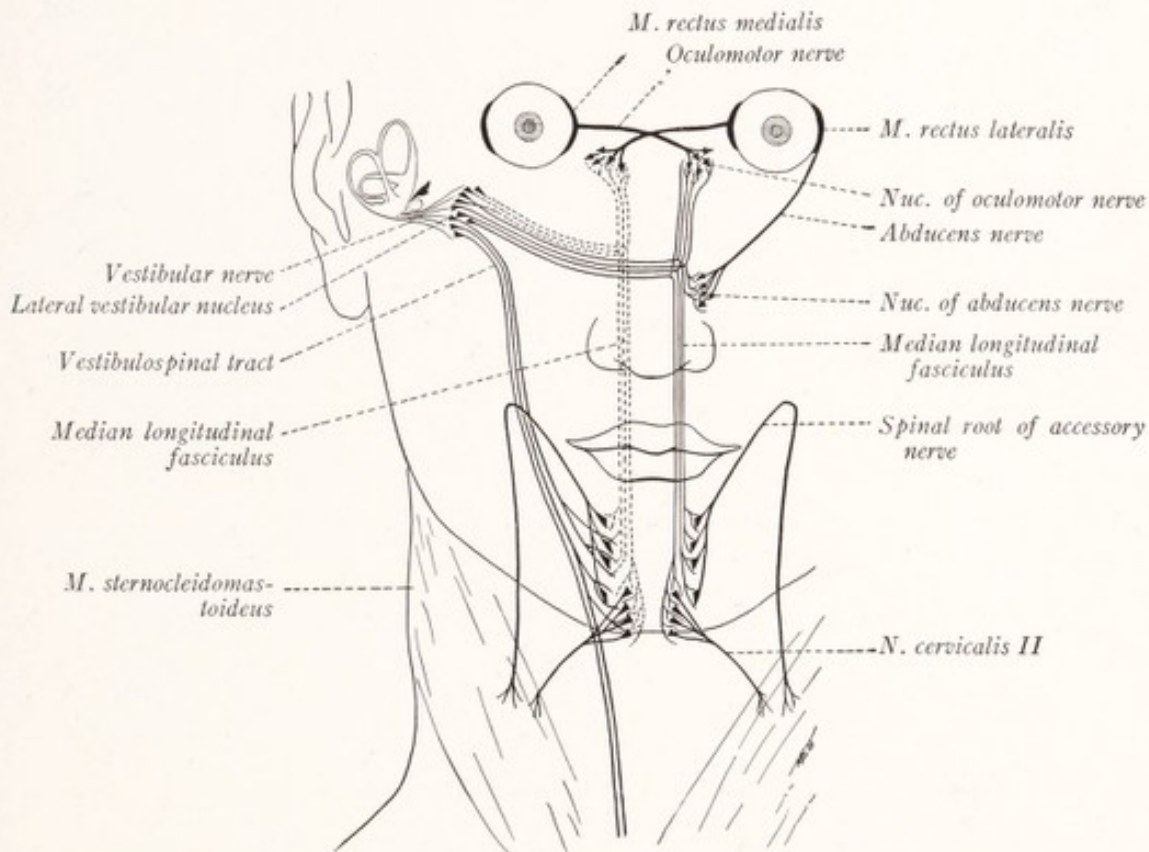


Fig. 244.—Vestibular reflex arcs. (Modified after Edinger.)

A *vestibulospinal reflex arc* is established between the vestibular sense organs and the skeletal musculature and consists of the following parts: the vestibular nerve; the vestibulospinal tract, which has its origin in the lateral vestibular nucleus, and descends in the ventral funiculus of the same side of the spinal cord; and the primary motor neurons of the spinal cord (Fig. 244).

The afferent impulses reaching the medulla oblongata by way of the *vagus* give rise to a great variety of reflexes. While these are for the most part purely visceral, a few are executed by the somatic musculature and should receive attention at this point.

The Respiratory Reflex Mechanism.—The maintenance of the normal respiratory rhythm is dependent upon a respiratory center in the caudal part of the medulla oblongata, which is sensitive to changes in the carbon dioxide content of the blood. But this rhythm is also influenced by afferent impulses coming from the lungs by way of the vagus nerve and the tractus solitarius. It is probable that these impulses are relayed through the nucleus of the tractus solitarius and descending fibers that arise in that nucleus (tractus solitariospinalis) to the primary motor neurons belonging to the phrenic and intercostal nerves (Fig. 245). There must also be a descending tract from the respiratory center to these neurons. Cajal (1909) believes that this center is, in fact, identical with the lower part of the nucleus of the tractus solitarius (the commissural

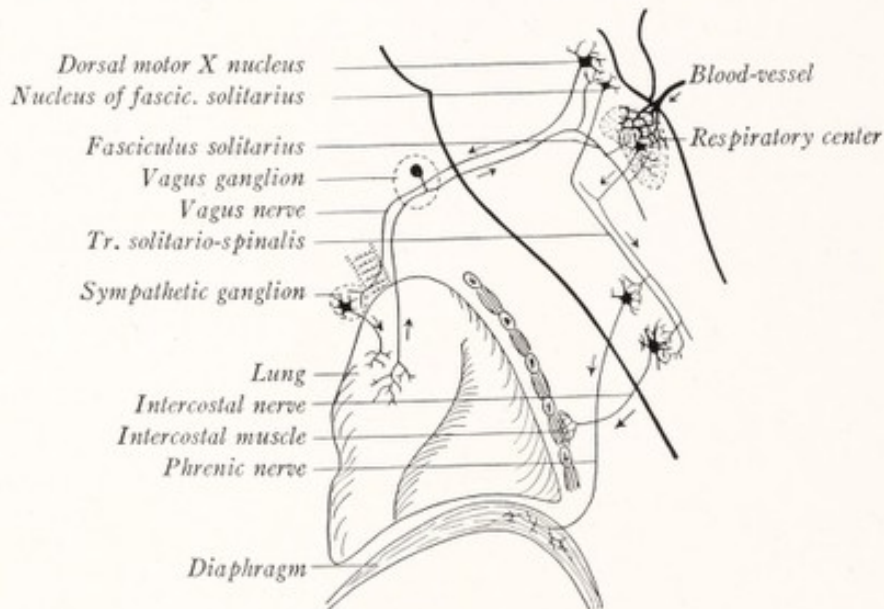


Fig. 245.—Reflex mechanism of respiration. (Herrick, Cajal.)

nucleus), and that this responds both to changes in the chemical composition of the blood and to the afferent impulses coming by way of the vagus nerve. If this be true, the fibers from the nucleus of the tractus solitarius would be the only descending tract needed to carry the respiratory impulses to the spinal cord. Although on its afferent side the respiratory reflex is visceral, it is executed by somatic muscles which are under voluntary control; and hence breathing may be temporarily suspended or the rhythm altered at will.

The **reflex mechanism for vomiting and coughing** is illustrated in Fig. 246. As the result of an irritation of the gastric mucous membrane a wave of excitation travels along the afferent fibers of the vagus nerve and the tractus solitarius. After passing through synapses in the nucleus of that tract, the impulses probably

travel along the descending fibers, which arise in that nucleus, to the primary motor neurons of the spinal cord that give rise to the fibers innervating the diaphragm and abdominal muscles. At the same time the musculature of the stomach is excited to contraction by that part of the wave of excitation which reaches the dorsal motor nucleus of the vagus. These impulses reach the musculature of the stomach over the visceral efferent fibers of the vagus and an intercalated postganglionic neuron.

A similar neural circuit is probably responsible for reflex coughing. From the irritated respiratory mucous membrane, as, for example, of the larynx, the

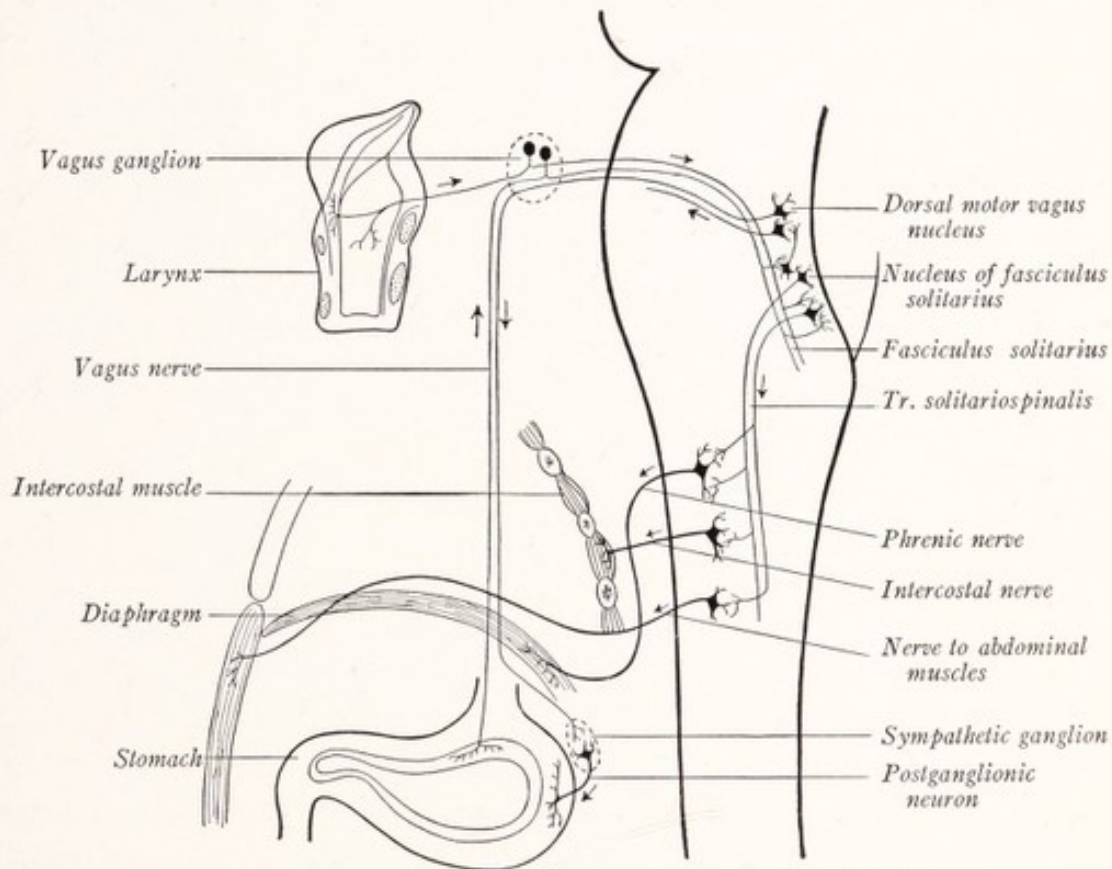


Fig. 246.—Reflex mechanism of coughing and vomiting. (Herrick, Cajal.)

disturbance is propagated along the afferent fibers of the vagus, through the nucleus of the tractus solitarius and the descending fibers arising in it to the spinal primary motor neurons, which innervate the diaphragm and the intercostal and abdominal muscles.

The *corpora quadrigemina* are important reflex centers. The path for *reflexes in response to sound* begins in the spiral organ of Corti and follows the cochlear nerve and its central connections, including the lateral lemniscus, to the inferior colliculus of the opposite side, and to a less extent of the same side also

(see p. 309). Thence the path follows the tectospinal and tectobulbar tracts to the primary motor neurons of the cerebrospinal nerves (see p. 167). The *visual reflex arc* begins in the retina, follows the optic nerve and optic tract with partial decussation in the chiasma, to the superior colliculus of the corpora quadrigemina (p. 226); thence it is continued by way of the tectospinal and tectobulbar paths to the primary motor neurons of the cerebrospinal nerves (Fig. 162).

Pupillary Reactions.—The iris is innervated by two sets of sympathetic nerve-fibers derived from the ciliary and the superior cervical sympathetic ganglia respectively. Impulses reaching the iris through the latter ganglion induce dilatation of the pupil; those through the ciliary ganglion cause constriction. The latter reaction always accompanies accommodation. When vision is fo-

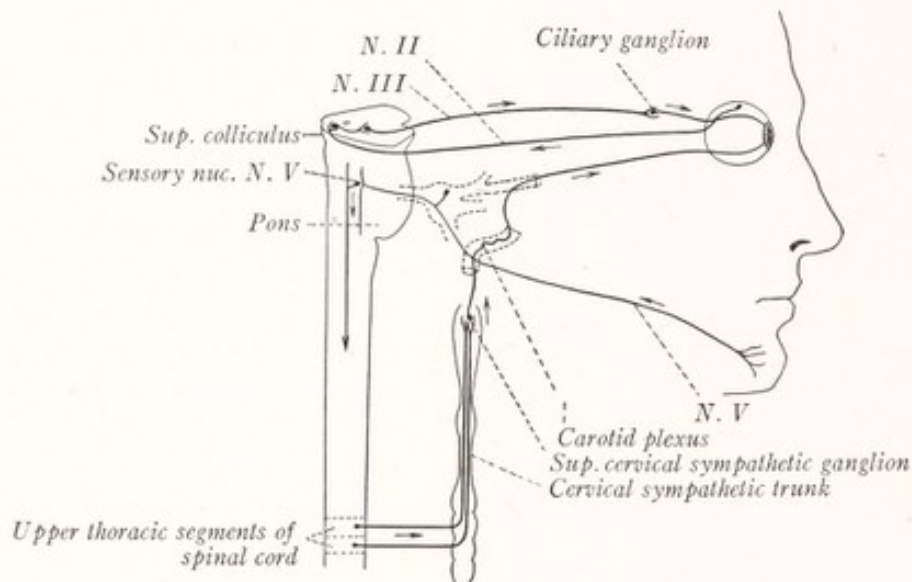


Fig. 247.—Pupillary reflex arcs.

cused on a near object, contraction of the ciliary muscle results in accommodation; and at the same time contraction of the two internal rectus muscles brings about a convergence of the visual axes. These two movements are always associated with a third, the contraction of the sphincter pupillæ. In addition to this constriction of the pupil, which accompanies accommodation, two other pupillary reactions require attention (Fig. 247).

The Pupillary Reflex (Light Reflex).—When light impinges on the retina there results a contraction of the sphincter pupillæ and a corresponding constriction of the pupil. The reflex circuit, which is traversed by the impulses bringing about this reaction, begins in the retina and includes the following elements: the fibers of the optic nerve and tract, with a partial decussation in the optic

chiasma; synapses in the superior colliculus of the corpora quadrigemina; fibers of the tectobulbar tract ending in the nucleus of Edinger-Westphal (visceral efferent portion of the oculomotor nucleus); the visceral efferent fibers of the oculomotor nerve, ending in the ciliary ganglion; and the postganglionic fibers extending from the ciliary ganglion to iris.

The *pupillary-skin reflex* is a dilatation of the pupil following scratching of the skin of the cheek or chin. This is but one example of the fact that dilatation of the pupil can be induced by the stimulation of many sensory nerves and constantly occurs in severe pain. The path includes the following parts: the fibers of these sensory nerves and their central connections in the brain stem and spinal cord; preganglionic visceral efferent fibers, which arise from the cells of the intermediolateral column of the spinal cord and run through the upper white rami and the sympathetic trunk to the superior cervical sympathetic ganglion; and postganglionic fibers, which arise in that ganglion and run through the plexus on the internal carotid artery to end in the iris (Fig. 247).

We have in the case of the pupillary reactions an illustration of the double and antagonistic innervation, which, as we shall see in the next chapter, is a rather characteristic feature of the autonomic nervous system.

CHAPTER XXI

THE SYMPATHETIC NERVOUS SYSTEM

THE *sympathetic nervous system* is an aggregation of ganglia, nerves, and plexuses, through which the viscera, glands, heart, and blood-vessels, as well as

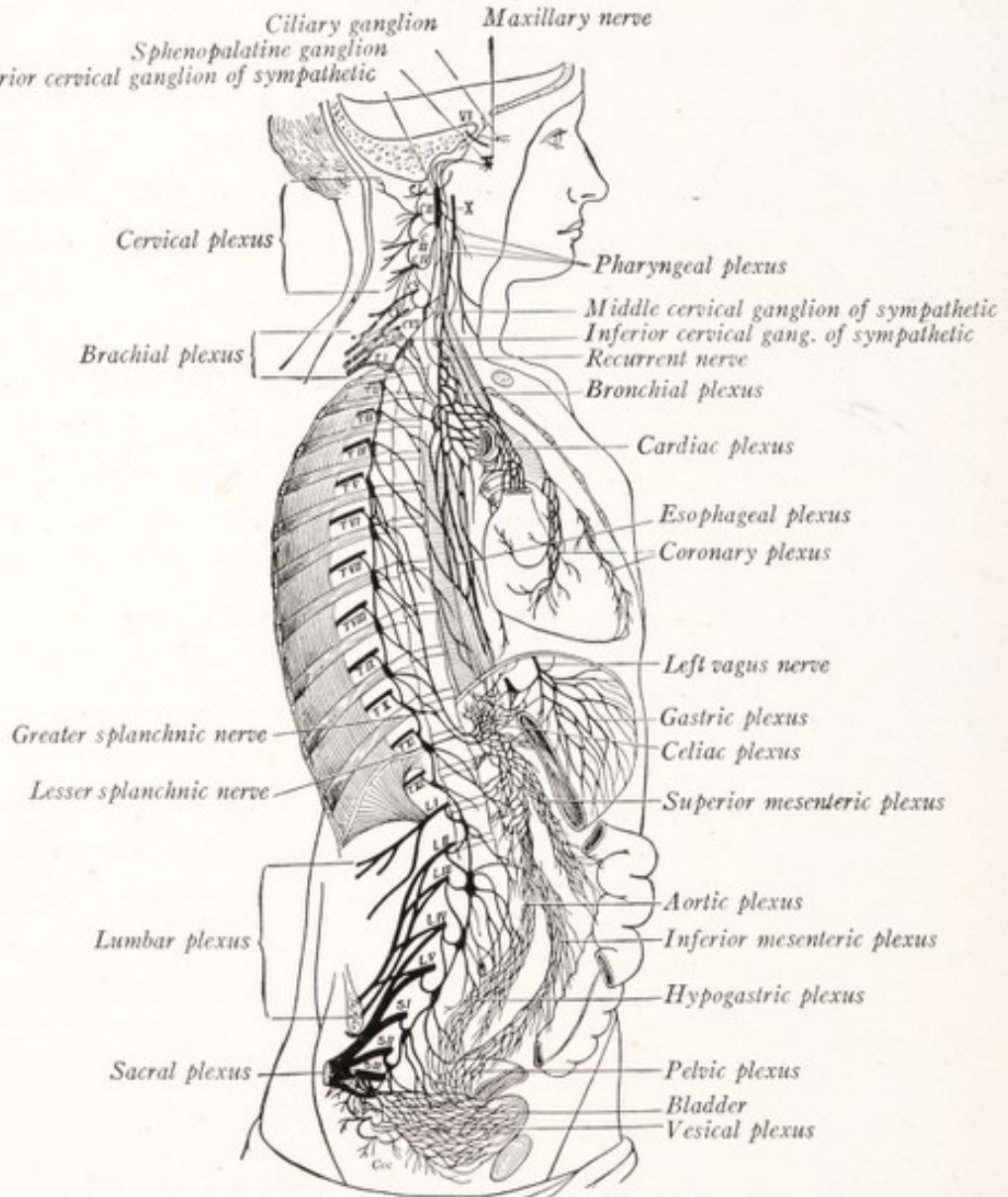


Fig. 248.—The sympathetic nervous system. (Schwalbe, Herrick.)

smooth muscle in other situations, receive their innervation. As illustrated in Fig. 248 it is widely distributed over the body, especially in the head and neck

and in the thoracic and abdominal cavities. It must not be too sharply delimited from the cerebrospinal nervous system, since it contains great numbers of fibers which run to and from the brain and spinal cord. For example, the vagus nerve contains many fibers which are distributed through the thoracic and abdominal sympathetic plexuses for the innervation of the viscera. In the same way the spinal nerves are connected by communicating branches or rami communicantes with the sympathetic trunks.

The *sympathetic trunks* are two nerve cords which extend vertically through the neck, thorax, and abdomen, one on each side of the vertebral column (Fig. 248). Each trunk is composed of a series of ganglia arranged in linear order and bound together by short nerve strands. Every spinal nerve is connected with the sympathetic trunk of its own side by one or more *gray rami communicantes* through which it receives fibers from the sympathetic trunk. Fibers reach this trunk from the thoracic and upper lumbar nerves by way of the *white rami communicantes* (Fig. 257). The sympathetic trunk also gives off branches which enter into the formation of the nerve plexuses which are associated with the larger arteries. The largest of these plexuses is the celiac, which is associated with the upper portion of the abdominal aorta and its branches. In this plexus and located in close relation to the abdominal aorta are the celiac, mesenteric, and aorticorenal ganglia, all of which are in man grouped in a pair of large irregular masses designated as the *celiac ganglia* and placed one on either side of the celiac artery (Fig. 257). The *sympathetic ganglia* may be grouped into three series as follows: (1) the ganglia of the sympathetic trunk, arranged in linear order along each side of the vertebral column and joined together by short nerve strands to form the two sympathetic trunks; (2) collateral ganglia, arranged about the aorta and including the celiac and mesenteric ganglia; and (3) terminal ganglia, located close to or within the structures which they innervate. As examples of the latter group there may be mentioned the ciliary and cardiac ganglia and the small groups of nerve-cells in the myenteric and submucous plexuses (Fig. 257).

FUNDAMENTAL FACTS CONCERNING VISCERAL INNERVATION

General visceral afferent fibers are found in the ninth and tenth cranial nerves and in many of the spinal nerves, especially in those associated with the white rami (thoracic and upper lumbar nerves) and in the second, third, and fourth sacral nerves. These afferent fibers take origin from cells in the cerebrospinal ganglia (Fig. 249). From these ganglia the fibers run through the corres-

ponding cerebrospinal nerves to the sympathetic nervous system, through which they pass without interruption in any of its ganglia to end in the viscera. These fibers are of all sizes, including large and small myelinated fibers and many which are unmyelinated (Chase and Ranson, 1914; Ranson and Billingsley, 1918).

The afferent impulses mediated by these fibers serve to initiate visceral reflexes, and for the most part remain at a subconscious level. Such general visceral sensations as we do experience are vague and poorly localized. Tactile sensibility is entirely lacking in the viscera and thermal sensibility almost so, although sensations of heat and cold may be experienced when very warm or cold substances enter the stomach or colon (Carlson and Braafladt, 1915). Pain cannot be produced by pinching or cutting the thoracic or abdominal viscera. Acute visceral pain may, however, be caused by disease, as in the passage of a stone along the ureter.

From the cerebrospinal ganglia the visceral afferent impulses are carried to the brain and spinal cord by the sensory nerve roots. The relations within the cerebrospinal ganglia are not entirely clear; but it seems probable that the visceral afferent impulses are conducted through the ganglion by way of the two branches of the typical unipolar sensory neuron (Fig. 249). Many authors believe that there are also sensory fibers which arise from cells in the sympathetic ganglia and terminate in the spinal ganglia in the form of pericellular plexuses (Fig. 40, C). Through these plexuses visceral sensory impulses are supposed to be transmitted to somatic sensory neurons and to be relayed by them to the spinal cord. Since it has not been clearly demonstrated that any sensory fibers arise from cells in the sympathetic ganglia, this interpretation of the pericellular plexuses of the spinal ganglia must be regarded as purely hypothetical.

Langley (1903) has presented strong evidence that few if any sensory fibers arise in the sympathetic ganglia. Physiologic experiments show that the visceral afferent fibers run in the white rami, yet all or practically all of the fibers of a white ramus degenerate if the corresponding spinal nerve is severed distal to the spinal ganglion. Huber (1913) states that "it has not been determined that the fine medullated fibers or the unmedullated fibers which appear to enter the spinal ganglia from without and end in pericellular plexuses are, in fact, the neuraxes of sympathetic neurones." The hypothesis that these pericellular plexuses represent the termination of visceral afferent fibers is, therefore, not well supported. This subject is treated in more detail in a series of papers on the sympathetic nervous system by Ranson and Billingsley (1918).

Visceral Efferent Neurons.—The general visceral efferent fibers of the cerebrospinal nerves take origin from cells located within the cerebrospinal axis. They do not run without interruption to the structures which they innervate; instead, they always terminate in sympathetic ganglia, whence the impulses, which they carry, are relayed to their destination by neurons of a second order (Fig. 249). This important information we owe to Langley (1900 and 1903), who showed that the injection of proper doses of nicotin into rabbits prevents

the passage of impulses through the sympathetic ganglia, although an undiminished reaction may be obtained by stimulation of the more peripheral sympathetic nerves. By a long series of experiments Langley has shown that there are always two and probably never more than two neurons concerned in the conduction of an impulse from the central nervous system to smooth muscle or glandular tissue. The neurons of the first order in this series are designated as *preganglionic*, those of the second order as *postganglionic*, with reference to the relation which they bear to the ganglion containing their synapse.

Preganglionic neurons have their cell bodies located in the visceral efferent column of the cerebrospinal axis. The cells of this series are smaller than those

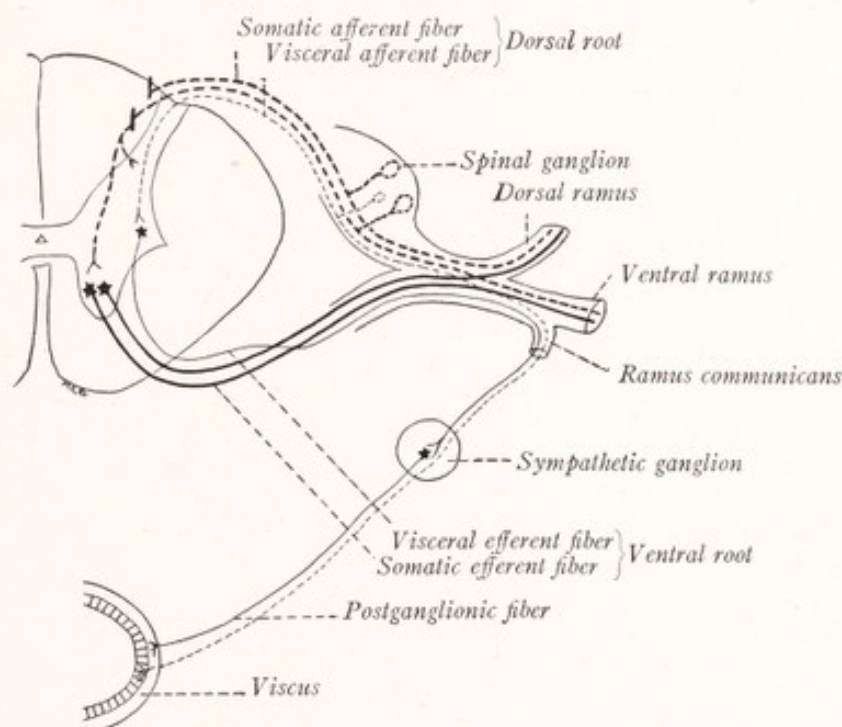


Fig. 249.—Diagrammatic section through a spinal nerve and the spinal cord in the thoracic region to illustrate the chief functional types of peripheral nerve-fibers.

of the somatic motor column and contain less massive Nissl granules. From these cells arise the fine myelinated visceral efferent fibers which run through the cerebrospinal nerves to the sympathetic nervous system and terminate in the sympathetic ganglia (Fig. 249).

Postganglionic neurons have their cell bodies located in the sympathetic ganglia. In fact, these cells with their dendritic ramifications and the terminal branches of the preganglionic fibers synaptically related to them are the essential elements in the sympathetic ganglia. Their axons for the most part remain unmyelinated and run as Remak fibers through the sympathetic nerves

and plexuses, to end in relation with involuntary muscle or glandular tissue. A very few postganglionic fibers acquire delicate myelin sheaths.

Three streams of preganglionic fibers leave the cerebrospinal axis (Fig. 250). The *cranial stream* includes the general visceral efferent fibers of the oculomotor, facial, glossopharyngeal, vagus, and accessory nerves. These fibers end in the terminal ganglia, already mentioned, which are located close to or within the organ which they innervate. In the cervical nerves there are no visceral efferent fibers, the cranial stream being separated from the next by a rather wide gap. The *thoracolumbar stream* includes the fibers which arise from the cells of the intermediolateral column of the spinal cord and make their exit through the thoracic and first four lumbar nerves (Langley, 1892; Müller, 1909). After leaving the spinal nerves by way of the white rami they enter the sympathetic nervous system and terminate in the ganglia of the sympathetic trunk or in the celiac and associated collateral ganglia (Fig. 250). The *sacral stream* includes the visceral efferent fibers of the second, third, and fourth sacral nerves. These arise from cells in the lateral column of gray matter in the sacral portion of the spinal cord and run through the visceral branch of the third sacral and a similar branch from either the second or fourth sacral nerves. These fibers end in the ganglia of the pelvic sympathetic plexuses.

The Autonomic Nervous System.—For many reasons it is convenient to have a name which will designate the sum total of all general visceral efferent neurons, both preganglionic and postganglionic, whether associated with the cerebral or spinal nerves. For this purpose the term "autonomic nervous system" is in general use. It designates that *functional* division of the nervous system which supplies the glands, heart, and smooth musculature with their *efferent* innervation (Fig. 250). It is important to bear in mind that this is a functional and not an anatomic division of the nervous system, that it includes only efferent elements, and that the preganglionic neurons lie in part within the cerebrospinal nervous system. The terminal portions of the preganglionic fibers and the postganglionic neurons are located in the sympathetic system. According to the origin of the preganglionic fibers, we may recognize the following three subdivisions of the autonomic system: (1) the *cranial autonomic system*, whose preganglionic fibers make their exit by way of the third, seventh, ninth, tenth, and eleventh cranial nerves; (2) the *thoracolumbar autonomic system*, whose preganglionic fibers make their exit by way of the thoracic and upper lumbar spinal nerves; and (3) the *sacral autonomic system*, whose preganglionic fibers run in the visceral rami of the second, third, and fourth sacral nerves (Fig. 250).

The fibers of the thoracolumbar stream run by way of the white rami to the sympathetic trunk, while the fibers of the cranial and sacral streams make no connection with that trunk, but run directly to the sympathetic plexuses. And while the thoracolumbar preganglionic fibers terminate in the ganglia of the trunk, those of cranial and sacral origin end in the terminal ganglia. In these two respects the cranial and sacral streams agree with each other and differ from the thoracolumbar outflow. Also in their response to certain drugs, like atropin and adrenalin, the two former agree with each other and differ from the latter. It is, therefore, desirable to group the cranial and sacral systems together as the *craniosacral autonomic system*. This has been called by many physiologists the parasympathetic system. It stands in contrast to the *thoracolumbar autonomic system* to which many physiologists have unfortunately applied the name "sympathetic system." The importance of recognizing these two principal subdivisions is further emphasized by the fact that most of the structures innervated by the autonomic system receive a double nerve supply and are supplied with fibers from both subdivisions. The thoracolumbar fibers are accompanied in most peripheral plexuses by craniosacral fibers of opposite function so that the analysis of these plexuses is greatly facilitated by subdividing the autonomic system in this way.

Visceral Reflexes.—In the gastro-intestinal tract and perhaps within other viscera there may be a mechanism for purely local reactions as indicated in the following paragraph. With this exception the evidence strongly indicates that all visceral reflex arcs pass through the cerebrospinal axis. In such an arc there are at least three neurons, namely, (1) visceral afferent, (2) preganglionic visceral efferent, and (3) postganglionic visceral efferent neurons (Fig. 249).

The purely local reactions which occur in the gut wall after section of all of the nerves leading to the intestine are known as *myenteric reflexes* and must depend upon a mechanism different from that of other visceral reflexes (Langley and Magnus, 1905; Cannon, 1912). Practically nothing is known of this mechanism beyond the fact that it must be located in the enteric plexuses. Some authors have assumed that within these plexuses there is a diffuse nerve net similar to that found in the coelenterates (Parker, 1919). While the evidence is far from satisfactory, it may be that such a net does exist in this situation and that it is responsible for these local reactions.

STRUCTURE OF THE SYMPATHETIC GANGLIA

The nerve-cells of the sympathetic ganglia are almost all multipolar, but there are also a few that are unipolar or bipolar. Each cell is surrounded by a nucleated membranous capsule. Some of the dendrites ramify beneath this capsule and are designated as intracapsular. Others pierce the capsule, run long distances through the ganglia, and are known as extracapsular dendrites.

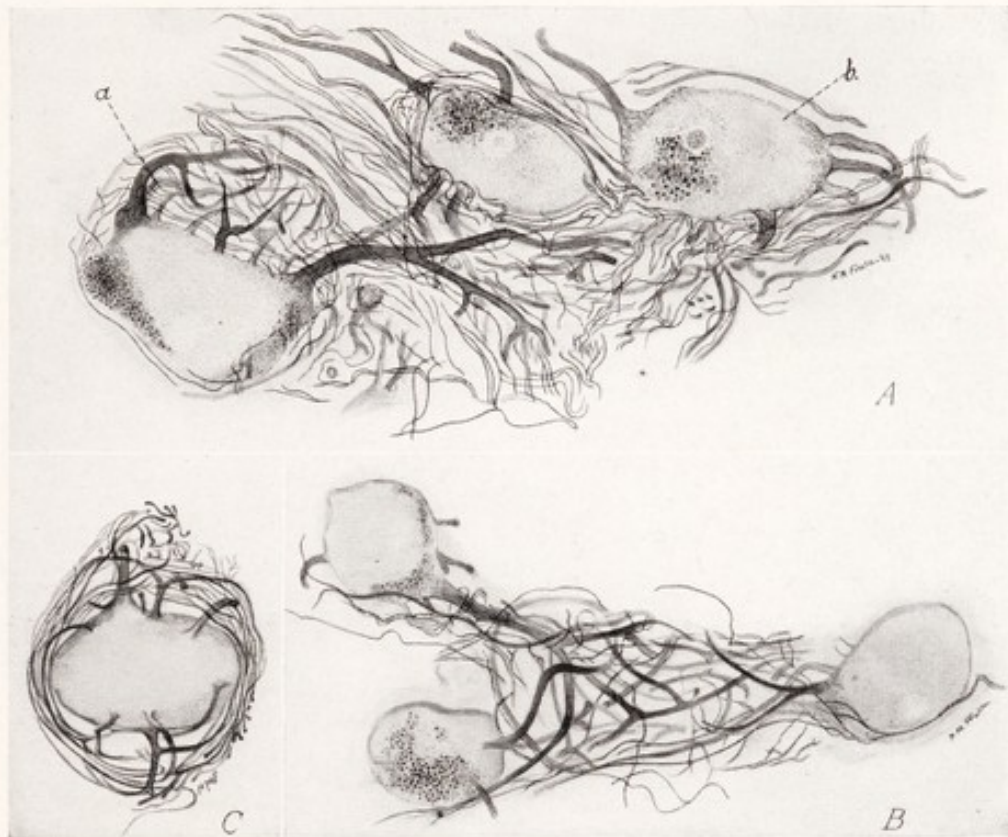


Fig. 251.—Neurons from the human superior cervical sympathetic ganglion (pyridin-silver method): *A*, Three nerve cells and the intercellular plexus: *a*, unicellular glomerulus; *b*, neuron with extracapsular dendrites. *B*, Tricellular glomerulus. *C*, Neuron surrounded by subcapsular dendrites.

Intracapsular dendrites are numerous in the sympathetic ganglia of man, but rare in those of mammals (Marinesco, 1906; Cajal, 1911; Michailow, 1911; Ranson and Billingsley, 1918). Beneath the capsule these dendrites may form an open network more or less uniformly distributed around the cell (Fig. 251, *C*), or they may be grouped on one side of the cell, causing a localized bulging in the capsule (Fig. 251, *A*, *a*). Such a localized mass of subcapsular dendrites with interlacing branches is known as a *glomerulus*. Following Cajal's classification we may distinguish four types of glomeruli according to the number of

neurons whose dendrites enter into their formation, namely, unicellular (Fig. 251, *A, a*), bicellular, tricellular (Fig. 251, *B*), and multicellular glomeruli. Short intracapsular dendrites with swollen ends are sometimes present in the sympathetic ganglia of mammals (Fig. 252, *A*).

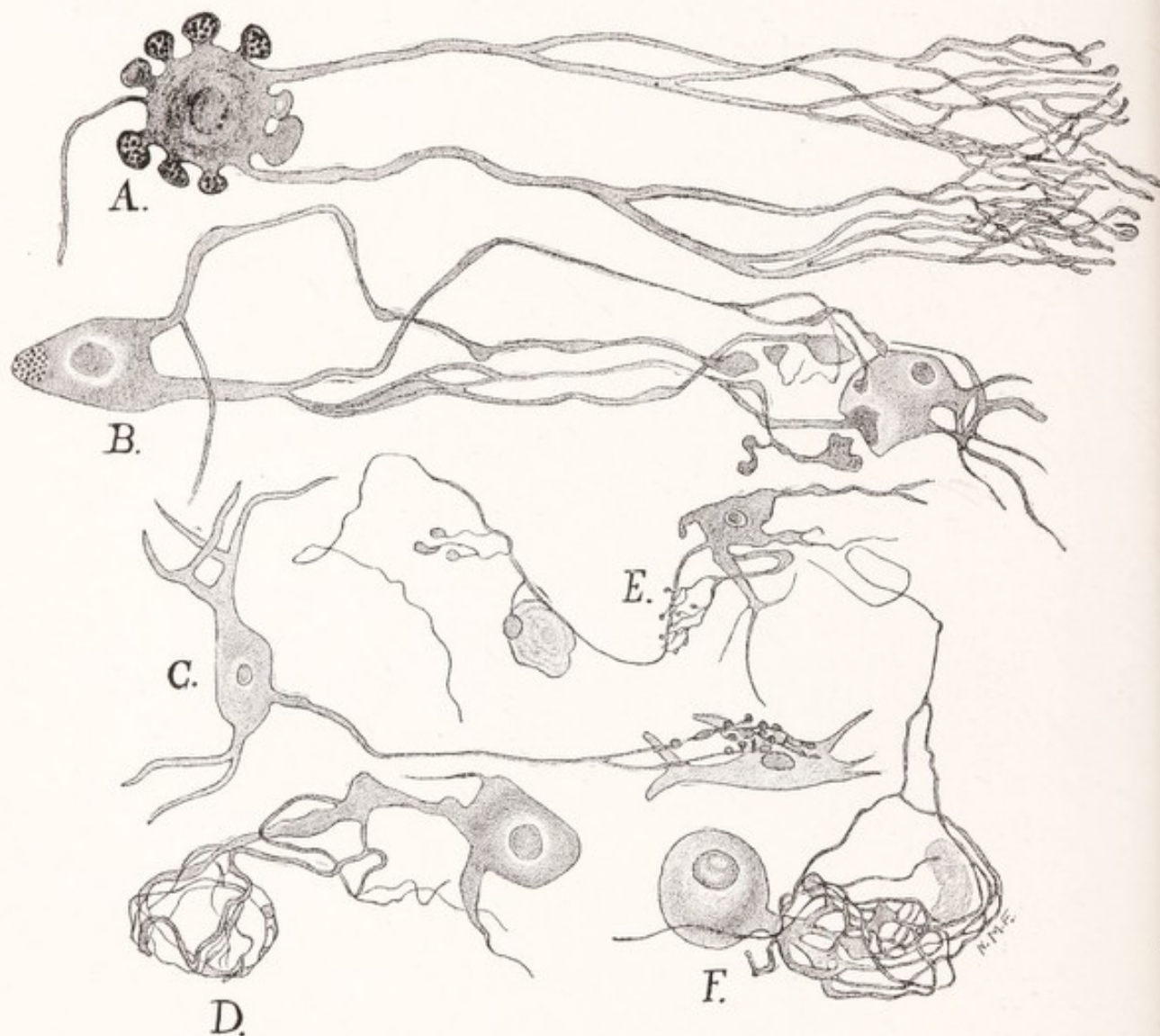


Fig. 252.—Sympathetic ganglion cells showing various types of dendrites. Redrawn from Michailow. Methylene-blue stain. *A*, From superior mesenteric ganglion, horse; *B*, from celiac ganglion, horse; *C*, from stellate ganglion, horse; *D*, from superior cervical ganglion, dog; *E*, celiac ganglion, horse; *F*, superior cervical ganglion, dog.

Extracapsular dendrites pierce the capsule, run for longer or shorter distances among the cells, and help to form an intercellular plexus of dendritic and axonic ramifications (Fig. 251, *A*). These dendrites may end in a variety of ways. Some of these types of endings may be enumerated as follows: (1) brush-like endings (Fig. 252, *A*); (2) plate-like or bulbous terminals applied

against the outer surface of the capsule of another cell (Fig. 252, *B, C*); (3) interlacing branches, which form a plexus upon the outer surface of the capsule of an adjacent cell (Fig. 252, *D*).

Dogiel (1896) thought that the cells possessing the longest dendrites were sensory, but Cajal (1911) could find no evidence for this, and was unable to trace any of them from the ganglia and associated nerves to the viscera. Carpenter and Conel (1914), using the size and arrangement of the Nissl granules as a criterion, were able to find only one cell type in the sympathetic ganglia, and concluded that these ganglia do not contain sensory nerve-cells.

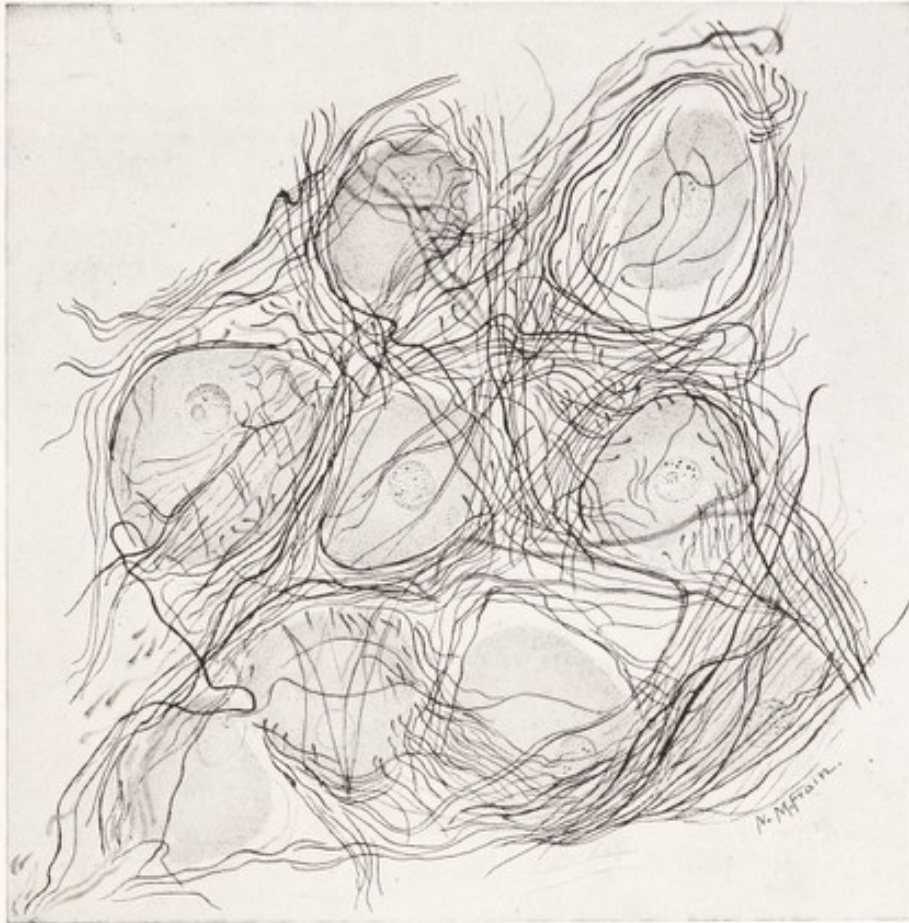

Fig. 253.—Neurons and intercellular plexus from the superior cervical sympathetic ganglion of a dog (pyridin-silver method).

The axons of sympathetic ganglion cells are usually unmyelinated, but a few of them acquire thin myelin sheaths. They are the postganglionic fibers which relay the visceral efferent impulses to the innervated tissue. According to Cajal (1911), who states that his anatomic studies are in accord with the physiologic experiments of Langley, the axons of the cells in the ganglia of the sympathetic trunk dispose themselves in one of the three following ways: (1) Usually they run transversely to the long axis of the ganglion to enter a gray ramus.

(2) The axons may run through a connecting nerve trunk into another ganglion. He is not able to say whether these axons only run through the second ganglion or whether they make connections with its cells. In the chick embryo he at one time described collaterals coming from those longitudinal fibers of the ganglia, which take origin in neighboring ganglia. Now, however, he is inclined to doubt this observation, and thinks it likely that these collaterals all come from fibers that have entered the sympathetic trunk through white rami at other levels.

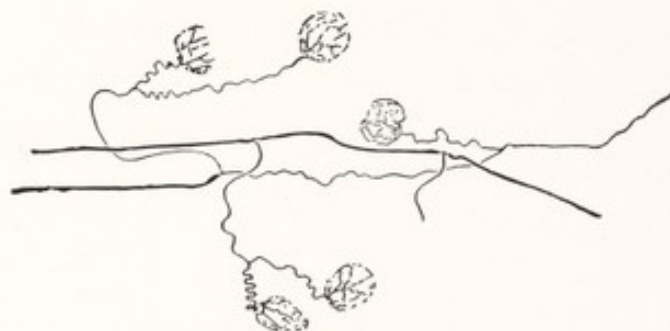


Fig. 254.

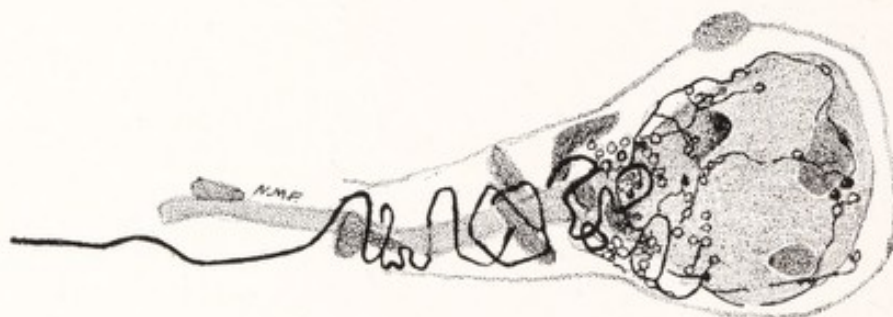

Fig. 255.

Figs. 254 and 255.—Preganglionic fibers and pericellular plexuses of the frog. Fig. 254, Preganglionic fibers, the branches of which form pericellular plexuses; Fig. 255, a unipolar sympathetic ganglion cell in connection with which a preganglionic fiber is terminating. Methylene-blue. (Huber.)

(3) In some cases the axons, arising from cells in the ganglia of the sympathetic trunk, run toward the neighboring arteries in the visceral nerves.

There is no anatomic evidence worth mentioning in favor of the existence of association neurons, uniting one sympathetic ganglion with another or one group of cells with another within such a ganglion. But there is strong physiologic evidence against the existence of such association neurons (Langley, 1900 and 1904); and Johnson (1918) has shown that none are present in the sympathetic trunk of the frog.

Termination of the Preganglionic Fibers.—The spaces among the cells of a sympathetic ganglion are occupied by a rich *intercellular plexus* of dendritic

branches and fine axons (Figs. 251, A; 253). The fine axons represent the ramifications of preganglionic fibers and they degenerate when the connection between the ganglion and the central nervous system is severed (Ranson and Billingsley, 1918). Similar fibers pierce the capsules surrounding the cells and intertwine with the intracapsular dendrites. No doubt synaptic relations are established between the axonic and dendritic ramifications in these plexuses.

Another and very characteristic type of synapse is established in the *pericellular plexuses*, formed by the terminal ramifications of preganglionic fibers upon the surface of the cell bodies of postganglionic neurons. Huber (1899) showed that fibers from the white rami branch repeatedly in the sympathetic ganglia and that the branches terminate in subcapsular pericellular plexuses (Figs. 254, 255).

In the sympathetic ganglia of the frog the pericellular plexus seems to be the only type of synapse and there is no intercellular plexus. In the mammalian sympathetic ganglion these pericellular plexuses are harder to demonstrate and are probably less numerous, while the intercellular plexus is much in evidence. It is well established that one preganglionic fiber may be synaptically related to several postganglionic neurons, probably in some instances to as many as thirty or more (Ranson and Billingsley, 1918).

COMPOSITION OF SYMPATHETIC NERVES AND PLEXUSES

Some of the sympathetic nerves are as well myelinated as the cerebrospinal nerves and present a white glistening appearance. This is true, for example, of the cervical portion of the sympathetic trunk, the white rami, and the splanchnic nerves. Such white sympathetic nerves are composed at least in large part of fibers running to and from the central nervous system. Other nerves like the gray rami and branches to the blood-vessels are gray, because they are composed chiefly of unmyelinated postganglionic fibers. In preceding paragraphs we have shown that there are probably no association or sensory neurons in the sympathetic ganglia; and, if this be true, there are no axons, arising from such cells, in the sympathetic nerve trunks and plexuses. These nerves and plexuses are composed of the following three kinds of fibers (Fig. 256): (1) Preganglionic visceral efferent fibers, which are of small size and myelinated, have their cells of origin in the cerebrospinal axis, and terminate in the sympathetic ganglia. (2) Postganglionic fibers, which are for the most part unmyelinated, have their cells of origin in the sympathetic ganglia and terminate in involuntary muscle or glandular tissue. (3) Visceral afferent fibers, which include myelinated fibers of all sizes as well as many that are unmyelinated, have their cells of origin in

the cerebrospinal ganglia and terminate in the viscera. The statements contained in this paragraph should not be applied without qualification to the ter-

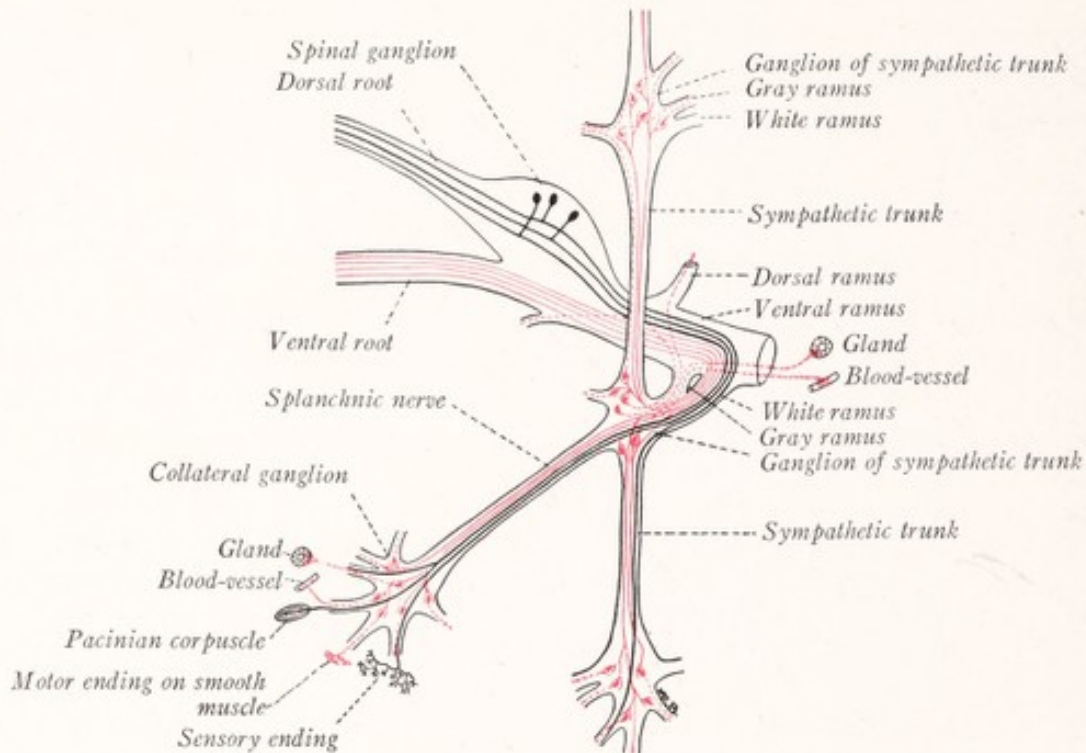


Fig. 256.—Diagram showing the composition of sympathetic nerves. Black lines, visceral afferent fibers; unbroken red lines, preganglionic visceral efferent fibers; dotted red lines, postganglionic visceral efferent fibers.

iminal ganglia and plexuses, since it is probable that these contain additional elements either in the nature of sensory neurons or of a nerve net.

ARCHITECTURE OF THE SYMPATHETIC NERVOUS SYSTEM

The **sympathetic trunks** are two ganglionated cords, each of which consists of a series of more or less segmentally arranged ganglia, bound together by ascending and descending nerve-fibers and extending from the level of the second cervical vertebra to the coccyx (Figs. 248, 257). The two trunks are symmetrically placed along the anterolateral aspects of the bodies of the vertebræ. There are 21 or 22 ganglia in each chain; and of these, 3 are associated with the cervical spinal nerves, 10 or 11 with the thoracic, 4 with the lumbar, and 4 with the sacral spinal nerves. The sympathetic trunks are connected with each of the spinal nerves by one or more delicate nerve strands, called *rami communicantes* (Figs.

248, 257). To each spinal nerve there runs a *gray ramus* from the sympathetic trunk. The *white rami*, on the other hand, are more limited in distribution and unite the thoracic and upper four lumbar nerves with the corresponding portion of the sympathetic trunk.

The **white rami** consist of visceral afferent and preganglionic visceral efferent fibers directed from the central into the sympathetic nervous system. They contribute the great majority of the ascending and descending fibers of the sympathetic trunk (Fig. 257). While some of the fibers may terminate in the ganglion with which the white ramus is associated, and others run directly through the trunk into the splanchnic nerves, the majority of the fibers turn either upward or downward in the trunk and run for considerable distances within it (Fig. 250). The fibers from the upper white rami run upward, those from the lower white rami downward, while those from the intermediate rami may run either upward or downward. The cervical portion of the sympathetic trunk consists almost or quite exclusively of ascending fibers, the lumbar and sacral portions of the trunk largely of descending fibers from the white rami. The *afferent fibers* of the white rami merely pass through the trunk and its branches to the viscera. The *preganglionic fibers*, with the exception of those which run out through the splanchnic nerves, end in the ganglia of the trunk. Here they enter into synaptic relations with the postganglionic neurons. The majority of the postganglionic neurons, located in the ganglia of the sympathetic trunk, send their axons into the *gray rami* (Figs. 250, 256).

The **gray rami** are composed of postganglionic fibers directed from the sympathetic trunk into the spinal nerves. These unmyelinated fibers, after joining the spinal nerves, are distributed with them as vasomotor, secretory, and pilomotor fibers to the blood-vessels, the sweat glands, and the smooth muscle of the hair-follicles.

Especially in the cervical region there are other important branches from the sympathetic trunk, which resemble the gray rami in structure and which convey postganglionic fibers to certain of the cranial nerves and to the heart, pharynx, the internal and external carotid and thyroid arteries, and through the plexuses on these arteries to the thyroid gland, salivary glands, eye, and other structures (Figs. 248, 250, 257).

The **cranial portion of the sympathetic trunk** consists of three ganglia bound together by ascending preganglionic fibers from the white rami. In the cat it has been shown to contain few if any sensory or postganglionic fibers. The *superior cervical ganglion* is the largest of the three ganglia and from it there are given off

numerous gray nerve strands. These are all composed of postganglionic fibers which arise in this ganglion. They run to the neighboring cranial and spinal nerves, to which they carry vasomotor, pilomotor, and secretory fibers, and to the heart, pharynx, and the internal and external carotid arteries (Figs. 248, 250, 257). The most important of these branches of the superior cervical ganglion are the three following: (1) The superior cervical cardiac nerve, which runs from the superior cervical ganglion to the cardiac plexus, carries accelerator fibers to the heart. (2) The internal carotid nerve runs vertically from the ganglion to the internal carotid artery, about which its fibers form a plexus, known as the internal carotid plexus (Fig. 257). It is by way of this nerve and plexus that the pupillary dilator fibers reach the eye (Fig. 247). (3) The branch of the superior cervical ganglion to the external carotid artery breaks up into a plexus on that artery. A continuation of this plexus extends along the external maxillary artery, and carries secretory fibers to the submaxillary salivary gland.

The middle and inferior cervical sympathetic ganglia are smaller. Among the branches from these ganglia we may mention the gray rami to the adjacent spinal nerves and the middle and inferior cardiac nerves to the cardiac plexus (Figs. 248, 257).

The **thoracic portion of the sympathetic trunk** is connected with the thoracic nerves by the gray and white rami. In addition to the rami communicantes and some small branches to the aortic and pulmonary plexuses, there are three important branches of the thoracic portion of the sympathetic trunk known as the splanchnic nerves. These run through the diaphragm for the innervation of abdominal viscera (Figs. 248, 257). The *greater splanchnic nerve* is usually formed by branches from the fifth to the ninth thoracic sympathetic ganglia and after piercing the diaphragm joins the celiac ganglion. The *smaller splanchnic nerve* is usually formed by branches from the ninth and tenth thoracic sympathetic ganglia and terminates in the celiac plexus. The *lowermost splanchnic nerve* arises from the last thoracic sympathetic ganglion and terminates in the renal plexus. These splanchnic nerves, although they appear to be branches of the thoracic sympathetic trunk, are at least in major part composed of fibers from the white rami, which merely pass through the trunk on their way to the ganglia of the celiac plexus (Figs. 250, 257; Langley, 1900; Ranson and Billingsley, 1918).

THE SYMPATHETIC PLEXUSES

The Sympathetic Plexuses of the Thorax.—In close association with the vagus nerve in the thorax are three important sympathetic plexuses. The

cardiac plexus lies in close relation to the arch of the aorta, and from it subordinate plexuses are continued along the coronary arteries. It receives the three cardiac sympathetic nerves from the cervical portion of each sympathetic trunk, as well as branches from both vagus nerves (Figs. 248, 257). The preganglionic fibers of the vagus terminate in synaptic relation with the cells of the cardiac ganglia. They convey inhibitory impulses which are relayed through these ganglia to the cardiac musculature (Fig. 250). The cardiac sympathetic nerves contain postganglionic fibers which take origin in the cervical sympathetic ganglia; and they relay accelerator impulses, coming from the spinal cord by way of the upper white rami and sympathetic trunk to the heart (Fig. 250). The *pulmonary* and *esophageal plexuses* of the vagus are also to be regarded as parts of the sympathetic system (Fig. 257).

The **celiac plexus** (solar plexus) is located in the abdomen in close relation to the celiac artery (Figs. 248, 257). It is continuous with the plexus which surrounds the aorta. Subordinate portions of the celiac plexus accompany the branches of the celiac artery and the branches from the upper part of the abdominal aorta. These are designated as the phrenic, suprarenal, renal, spermatic or ovarian, abdominal aortic, superior gastric, inferior gastric, hepatic, splenic, superior mesenteric, and inferior mesenteric plexuses. The celiac plexus contains a number of ganglia which in man are grouped into two large flat masses, placed one on either side of the celiac artery and known as the celiac ganglia. These ganglia are bound together by strands which cross the median plane above and below this artery. Somewhat detached portions of the celiac ganglion, which lie near the origin of the renal and superior mesenteric arteries, are known respectively as the aorticorenal and superior mesenteric ganglia. In addition, there is a small mass of nerve-cells in the inferior mesenteric plexus close to the beginning of the inferior mesenteric artery. This is known as the *inferior mesenteric ganglion*.

Preganglionic fibers reach the celiac plexus from two sources, namely, from the *white rami* by way of the sympathetic trunk and *splanchnic nerves* and from the *vagus nerve* (Fig. 257). Most if not all of the preganglionic fibers contained in the splanchnic nerves terminate in the ganglia of the celiac plexus. At the lower end of the esophageal plexus the fibers from the right vagus nerve become assembled into a trunk which passes to the posterior surface of the stomach and the celiac plexus. The fibers of the left vagus pass to the anterior surface of the stomach and to the hepatic plexus (Fig. 257). It is probable that the preganglionic fibers of the vagus do not terminate in the ganglia of the celiac plexus,

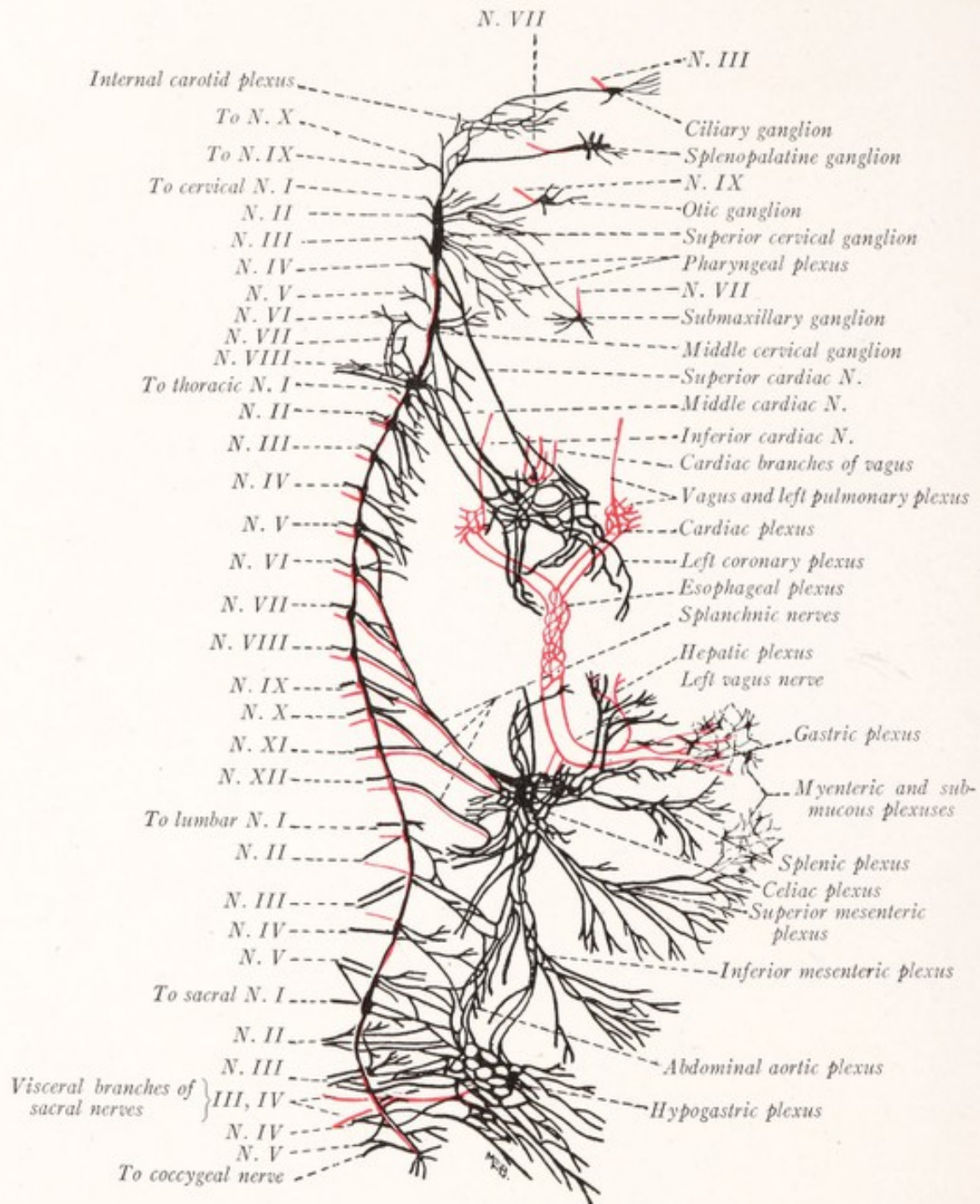


Fig. 257.—Diagram of the sympathetic nervous system. The red lines indicate the branches of the cerebrospinal nerves which join the sympathetic system and those sympathetic nerves which are composed in major part of fibers from the cerebrospinal nerves. (Modified from Jackson-Morris.)

but merely pass through that plexus to end in the terminal ganglia, such as the small groups of nerve-cells in the myenteric and submucous plexuses of the intestine (Fig. 250).

The *myenteric plexus* (of Auerbach) and the *submucous plexus* (of Meissner), located within the walls of the stomach and intestines, receive filaments from the gastric and mesenteric divisions of the celiac plexus. They also receive fibers from the vagus either directly, as in the case of the stomach, or indirectly through the celiac plexus (Fig. 257). Unfortunately, very little is known concerning the synaptic relations established in the ganglia of these plexuses. According to Langley, the postganglionic fibers from the celiac ganglia run through these plexuses without interruption and end in the muscular coats and glands of the gastro-intestinal tract. The preganglionic fibers from the vagus probably end in synaptic relation to cells in these small ganglia; and the axons of these cells serve as postganglionic fibers, relaying the impulses from the vagus to the glands and muscular tissue. As was indicated in a preceding paragraph, the enteric plexuses must also contain a mechanism for purely local reactions, since peristalsis can be set up by distention in an excised portion of the gut. But as yet we are entirely ignorant as to what that mechanism may be.

The **hypogastric plexus** is formed by strands which run into the pelvis from the lower end of the aortic plexus and are joined by the visceral branches of the second, third, and fourth sacral nerves and by branches from the sympathetic trunk (Figs. 248, 257). As the hypogastric plexus enters the pelvis it splits into two parts, which lie on either side of the rectum and are sometimes called the pelvic plexuses. From these plexuses branches are supplied to the pelvic viscera and the external genitalia.

The Cephalic Ganglionated Plexus.—In close topographic relation to the branches of the fifth cranial nerve are four sympathetic ganglia, known as the ciliary, sphenopalatine, otic, and submaxillary ganglia. Each of these is connected with the superior cervical sympathetic ganglion by filaments derived from the plexuses on the internal and external carotid arteries and their branches (Fig. 257). These filaments are designated in descriptive anatomy as the sympathetic roots of the ganglia. Each ganglion receives preganglionic fibers from one of the cranial nerves by way of what is usually designated as its motor root (Fig. 257). Thus the ciliary ganglion receives fibers from the oculomotor nerve; the sphenopalatine ganglion receives fibers from the facial nerve by way of the great superficial petrosal nerve and the nerve of the pterygoid canal; the otic ganglion receives fibers from the glossopharyngeal nerve (Müller and Dahl, 1910); and the submaxillary ganglion receives fibers from the facial nerve by way of the *nervus intermedius* and the lingual nerve. Postganglionic fibers arising in these ganglia are distributed to the structures of the head. From the ciliary

ganglion fibers go to the intrinsic musculature of the eye. Some of the fibers arising in the sphenopalatine ganglion go to the blood-vessels in the mucous membrane of the nose. Fibers from the otic ganglion reach the parotid gland. And those arising in the submaxillary ganglion end in the submaxillary and sublingual salivary glands (Fig. 250).

IMPORTANT CONDUCTION PATHS BELONGING TO THE AUTONOMIC NERVOUS SYSTEM

Thanks to the work of Langley, we know that the conduction pathways in the sympathetic nervous system are at least as sharply defined as those in the brain and spinal cord. A great deal has already been done in the way of tracing these pathways; and some of the more important of these are given in the outline which follows:

1. Paths for the efferent innervation of the eye (Figs. 247, 250):

(a) Ocular craniosacral pathway.

Preganglionic neurons: Cells in the Edinger-Westphal nucleus, fibers by way of the third cranial nerve to end in the ciliary ganglion.

Postganglionic neurons: Cells in the ciliary ganglion, fibers by way of the short ciliary nerves to the ciliary muscle and the circular fibers of the iris.

Function: Accommodation and contraction of the pupil.

(b) Ocular thoracolumbar pathway.

Preganglionic neurons: Cells in the intermediolateral column of the spinal cord, fibers by way of the upper white rami and sympathetic trunk to end in the superior cervical ganglion.

Postganglionic neurons: Cells in the superior cervical ganglion, fibers by way of the internal carotid plexus to the ophthalmic division of the fifth nerve, the nasociliary and long ciliary nerves of the eyeball; other fibers pass from the internal carotid plexus through the ciliary ganglion, without interruption, into the short ciliary nerves and to the eyeball.

Function: Dilatation of the pupil by the radial muscle-fibers of the iris.

2. Paths for the efferent innervation of the submaxillary gland (Fig. 250):

(a) Submaxillary craniosacral pathway.

Preganglionic neurons: Cells in the nucleus salivatorius superior, fibers by way of the seventh cranial nerve, chorda tympani, and

lingual nerve to end in the portion of the submaxillary ganglion located on the submaxillary duct.

Postganglionic neurons: Cells in a number of groups along the chorda tympani fibers as they follow the submaxillary duct, fibers distributed in branches to the submaxillary gland.

Function: Increases secretion.

(b) Submaxillary thoracolumbar pathway.

Preganglionic neurons: Cells in the intermediolateral column of the spinal cord, fibers by way of the upper white rami, and the sympathetic trunk to end in the superior cervical ganglion.

Postganglionic neurons: Cells in the superior cervical ganglion, fibers by way of the plexuses on the external carotid and external maxillary arteries to the submaxillary gland.

Function: Increases secretion.

3. Paths for the efferent innervation of the heart:

(a) Cardiac craniosacral pathway.

Preganglionic neurons: Cells in the dorsal motor nucleus of the vagus, fibers through the vagus nerve to the intrinsic ganglia of the heart, in which they end.

Postganglionic neurons: Cells in the intrinsic cardiac ganglia, fibers to the cardiac muscle.

Function: Cardiac inhibition.

(b) Cardiac thoracolumbar pathway.

Preganglionic neurons: Cells in the intermediolateral column of the spinal cord, fibers by way of the upper white rami and the sympathetic trunk to the superior, middle, and inferior cervical ganglia.

Postganglionic neurons: Cells in the cervical ganglia of the sympathetic trunk, fibers by way of the corresponding cardiac nerves to the musculature of the heart.

Function: Cardiac acceleration.

4. Paths for the efferent innervation of the musculature of the stomach exclusive of the sphincters (Fig. 250):

(a) Gastric craniosacral pathway.

Preganglionic neurons: Cells in the dorsal motor nucleus of the vagus, fibers by way of the vagus nerve, to end in the intrinsic ganglia of the stomach.

Postganglionic neurons: Cells in the intrinsic gastric ganglia. fibers to end in the gastric musculature.

Function: Excites peristalsis.

(b) Gastric thoracolumbar pathway.

Preganglionic neurons: Cells in the intermediolateral column of the spinal cord, fibers by way of the white rami from the fifth or sixth to the twelfth thoracic nerves, through the sympathetic trunk without interruption, and along the splanchnic nerves to the celiac ganglion, where they end.

Postganglionic neurons: Cells in the celiac ganglion, fibers by way of the celiac plexus and its offshoots to the stomach, to end in the musculature of the stomach.

Function: Inhibits peristalsis.

5. Paths for the efferent innervation of the musculature of the urinary bladder.

(a) Vesical craniosacral pathway.

Preganglionic neurons: Cells in the lateral part of the anterior gray column in the sacral portion of the spinal cord, fibers by way of the second and third sacral nerves and their visceral rami through the pelvic plexus to the plexus upon the wall of the bladder.

Postganglionic neurons: Cells in the small ganglia of the vesical plexus, fibers to the vesical musculature.

Function: Excites contraction of the vesical musculature exclusive of the internal sphincter (trigonal area), the contraction of which it inhibits and thus produces urination.

(b) Vesical thoracolumbar pathway.

Preganglionic neurons: Cells in the caudal part of the intermediolateral cell column, fibers by way of the lower white rami to the inferior mesenteric ganglion.

Postganglionic neurons: Cells in the inferior mesenteric ganglion, fibers through the inferior mesenteric plexus to the musculature of the bladder.

Function: Excites contraction of the internal sphincter (trigonal area of the vesical musculature), causing retention of urine.

It will be noted that the viscera receive a double autonomic innervation, and that the impulses transmitted along the craniosacral pathways are usually antagonistic to those transmitted along the thoracolumbar paths.

A LABORATORY OUTLINE OF NEURO-ANATOMY

THE following directions for the study of the gross and microscopic anatomy of the nervous system are intended to aid the student in making the best use of his time and laboratory material. Free use is made of the sheep's brain because in most institutions the number of human brains available is limited, and these are often poorly preserved and entirely unsuited for dissection. Even if an unlimited supply of well-preserved human brains were at hand, there would still be an advantage in the use of the sheep's brain because in it certain structures (such as the olfactory tracts and centers and the really significant subdivisions of the cerebellum) are more easily seen and more readily understood.

The outline has been written in such a way that it can be readily adapted by the instructor to meet his own needs. It is assumed that each instructor will furnish his students with a schedule for the laboratory work, showing the number of laboratory periods available and the topics to be covered each period. This will help the student properly to apportion his time and enable the instructor to arrange the order of the laboratory work to his own liking. The paragraphs have been numbered serially in order that in such a schedule they may be referred to by number. It is not necessary that the topics be taken up in their numeric order. And in a course of one hundred hours some of the topics should be omitted altogether. How much should be omitted will depend largely on the amount of drawing required. It is assumed that the instructor will indicate on the laboratory schedule the drawings which he wishes to have made. For this reason we have, for the most part, omitted specific directions for drawings.

Since it will be necessary for the student in using the outline to make frequent references to figures in the text, it will be convenient to keep in the book several strips of thin paper to serve as bookmarks.

METHODS OF BRAIN DISSECTION

Much information concerning the gray masses and fiber tracts of the brain can be obtained by dissection. This should be carried out, for the most part, with blunt instruments. It is rarely necessary to make a cut with a knife. An orangewood manicure stick makes an excellent instrument. It should be rounded to a point at one end for teasing, while the larger end should be adapted for scraping away nuclear masses. A pair of blunt tissue forceps of medium size with smooth even edges and fine transverse interlocking ridges is also an essential instrument. This is useful in grasping and stripping away small bundles of fibers. In dissecting out a fiber tract it is necessary to have in mind a clear idea of the position and course of the tract, and the dissecting instruments should be carried in the direction of the fibers. Where it is necessary to remove nuclear material in order to display fiber bundles, it will be found very helpful to let a stream of water run over the specimen while the dissection is in progress.

DISSECTION OF THE HEAD OF THE DOGFISH

1. The dogfish is the smallest of the sharks. Either the spiny dogfish (*Squalus acanthias*) or the smooth dogfish (*Mustelus canis*) may be used for dissection.

2. The *special sense organs* include the olfactory organs, the eyes, the ears, and certain sense organs in the skin, known as the lateral line canals, and the ampullæ of Lorenzini.

3. Locate the position of the *lateral line canal* which produces a light colored ridge in the skin extending from head to tail along either side of the body. The line may be recognized by the presence of numerous small pores which open into the canal. It extends on to the head and there forms the supraorbital, infraorbital, and hyomandibular canals. The *ampullæ of Lorenzini* are bulb-shaped bodies connected by long canals with pores in the skin. They are irregularly arranged and are most numerous on the snout.

4. Locate the *olfactory organs* or nasal capsules which have their openings on the ventral surface of the snout in front of the mouth.

5. Note the *gills* and *spiracles* (Fig. 12). Find two minute apertures near the midline between the spiracles. These are the openings of the *endolymphatic ducts*.

6. The *internal ear*, a membranous labyrinth inclosed in a cartilaginous capsule, should be exposed on the left side. Shave off the cartilage in thin slices in the region between the spiracle and the median plane. The membranous labyrinth can be seen through the translucent cartilage, and care should be exercised to avoid injuring it while the cartilage is being removed. It consists of a spheric sac, the *utrículosaccular chamber*, to which there are attached three *semicircular canals* (Fig. 12). The *endolymphatic duct* is a small canal, which extends from this chamber through the roof of the skull to the small opening in the skin, which has previously been identified. Note the enlargement at one end of each *semicircular canal*, known as the *ampulla*, and observe that each of these canals lies in a plane at right angles to the planes of the other two.

7. *The Brain and Cranial Nerves*.—Remove the remainder of the roof of the skull and expose the brain, eyes, and cranial nerves.

8. Examine the brain as seen from the dorsal surface. Note the continuity of the *medulla oblongata* with the spinal cord. Identify the *cerebellum*, the *thalamus*, *epiphysis*, *habenula*, *cerebral hemispheres*, and *olfactory bulbs* (Fig. 8 and pp. 26-31).

9. By dissection display on the left side the *eye-muscles* and the nerves which innervate them, as well as the optic nerve (Fig. 12).

10. Find the *nervus terminalis* (Fig. 8). Now locate each of the *cranial nerves* from the second to the tenth inclusive, and trace them from the brain as far as possible toward their peripheral terminations (Figs. 12, 13). Note particularly that Nn. VII and X each have an extra root, indicated in black in Fig 13, which carries fibers from the lateral line organs to the acusticolateral area of the medulla.

11. Attention should now be paid to the functional types of nerve-fibers which compose each of the cranial nerves (see pp. 168-170 and Figs. 119, 120). The accompanying table shows in which of the cranial nerves of the dogfish each of the four principal functional groups of fibers are to be found (Herrick and Crosby, 1918).

CRANIAL NERVE COMPONENTS OF THE DOGFISH

| Somatic sensory. | Somatic motor. | Visceral sensory. | Visceral motor. |
|---|---|--|---|
| II. Optic III. Muscle sense IV. Muscle sense V. General cutaneous VI. Muscle sense VII. Lateral line fibers VIII. To the ear IX. Lateral line fibers X. Lateral line and general cutaneous fibers | III. To eye-muscles IV. To eye-muscles VI. To eye-muscles | I. Olfactory VII. General visceral and gustatory IX, X. General visceral and gustatory | III. For intrinsic muscles of the eye V. To the jaw muscles VII. To hyoid muscula- ture IX, X. To branchial and general visceral mus- culature |

12. There are six pairs of *cranial nerves associated with the medulla oblongata*. The tenth cranial or *vagus nerve* is one of the largest and arises by two series of roots. One group of rootlets springs from the dorsolateral aspect of the medulla oblongata near its lower end, and contains fibers which are distributed through the branchial and gastrointestinal rami of the vagus, while a large root, carrying fibers for the lateral line sense organs, runs farther cephalad and enters the acusticolateral area. The ninth or *glossopharyngeal nerve*, the nerve of the first branchial arch, arises from the medulla oblongata just ventral to this root of the vagus. Since the gills, as well as the gastrointestinal tract, are visceral organs, both the ninth and tenth nerves carry many visceral fibers. The eighth or *acoustic nerve* arises from the side of the medulla opposite the caudal part of the cerebellum in company with the fifth and seventh nerves, and ends in the membranous labyrinth of the ear. Like the vagus, the *facial* or seventh cranial nerve has, in addition to its main root, another, which runs further dorsally into the acusticolateral area. This root carries sensory fibers for the lateral line organs of the head. The sixth or *abducens* nerve arises more ventrally at the same level as the eighth. The fifth, or *trigeminal* nerve, which sends many branches to the skin of the head, is represented by a large root emerging from the medulla oblongata in company with the seventh. Some idea of the peripheral distribution of these nerves can be gained from a study of Figs. 12 and 13.

13. The *floor of the fourth ventricle* should now be exposed by carefully tearing away the membranous roof of that cavity. The floor presents for examination a series of longitudinal ridges and furrows which are of importance because they mark the position of *longitudinal columns* (Figs. 8, 13), to each of which a special function can be assigned. A ridge on either side of the midline represents the position of the median longitudinal bundle, beneath which lie the nuclei of the third, fourth, and sixth cranial nerves. Since these nerves supply somatic musculature, the longitudinal elevation marks the position of the *somatic motor column*. Separated from this ridge by a broad furrow

is a more prominent ridge with tooth-like secondary elevations. Within this second ridge terminate the fibers of visceral sensation and taste from the seventh, ninth, and tenth nerves. It is known as the *visceral lobe* or *visceral sensory column*. Beneath the groove which separates these two ridges are located the motor nuclei of the fifth, seventh, ninth, and tenth cranial nerves. These nuclei supply visceral musculature and constitute the *visceral motor column*. The dorsal part of the lateral wall of the fossa forms another prominent ridge, which just caudal to the cerebellum is redundant and folded on itself to form an ear-shaped projection. This auricular fold, sometimes called the *lobus lineæ lateralis*, and the prominent margin just caudal to it belong to the acusticolateral area and contain the centers for the reception of impulses coming from the ear (N. VIII) and from the sense organs of the lateral line (Nn. VII and X). Adjacent to the acusticolateral area is a portion of the medulla oblongata which is concerned with the reception of sensory impulses from the skin which reach the medulla oblongata along the fifth and tenth nerves. The nuclei of the acusticolateral and general cutaneous areas together constitute the *somatic afferent column*.

14. Locate these *functional columns* on your specimen. Note the close relation of the olfactory bulb to the nasal sac. By comparison with Fig. 13 locate on your specimen the olfactory portions of the brain. What part of the brain is especially associated with the eyes?

15. Cut the nerve roots at some distance from the brain. Remove the brain, being careful not to injure the olfactory bulbs. Now study the *lateral* and *ventral surfaces of the brain* in order to locate more accurately the points of origin of the various cranial nerves (Fig. 10).

16. Now study the parts of the brain which belong to the *rhombencephalon*. Which parts are they, and what is their relationship to each other? (Figs. 8, 10 and p. 26.)

17. Study the parts of the brain which belong to the *mesencephalon*. Which are they, and what relationship do they bear to each other? (Figs. 8, 10 and p. 28.)

18. In the same way study the parts belonging to the *diencephalon* (Figs. 8, 10 and pp. 28, 29). Make a list of these parts. Tear away the membranous roof of the third ventricle and examine that cavity.

19. Note the external form of the *telencephalon* and the parts which compose it (Figs. 8, 10). Students working at adjacent tables should cooperate in the work which follows in order that two sharks' brains may be available. With a sharp razor blade divide one in the medial sagittal plane; and with a sharp scalpel open up the ventricles in the other as indicated in Fig. 9. Study the ventricles of the brain as they are displayed in these preparations and in Figs. 9 and 11.

20. Find the *velum transversum* and the ridge produced by the *optic chiasma*. All that part of the brain which lies rostral to these structures belongs to the *telencephalon*. Study the *telencephalon* in detail (Figs. 8-11 and p. 30). Of what parts is it composed, and what are their relations to each other? Pay special attention to the several parts of the *telencephalic* cavity.

THE BRAIN OF THE FETAL PIG

21. Using a pig embryo of about 35 mm., slice off the skin and a small amount of the underlying tissue on either side of the head with a sharp razor. Then at one careful

stroke split the specimen lengthwise in the median plane. This provides two preparations for dissection, which should be used by two students.

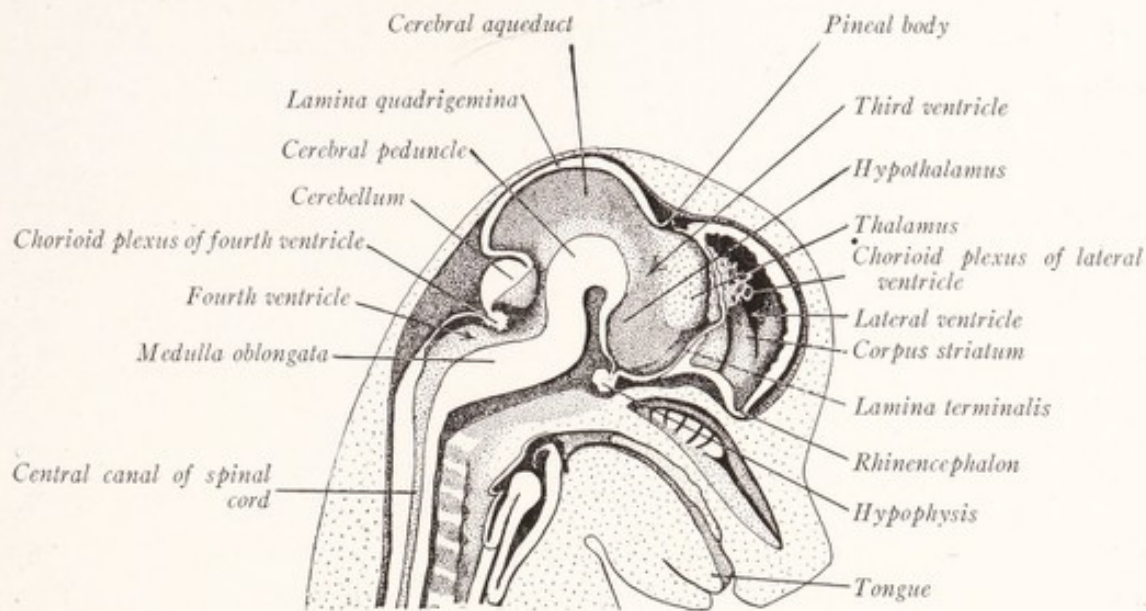


Fig. 258.—Medial sagittal section of the head of a 35 mm. pig embryo. (Redrawn from Prentiss-Arey.)

22. First study the *medial section of the brain*, noting the five divisions of the brain, the ventricles, and the relation of the cerebral hemispheres to other parts of the

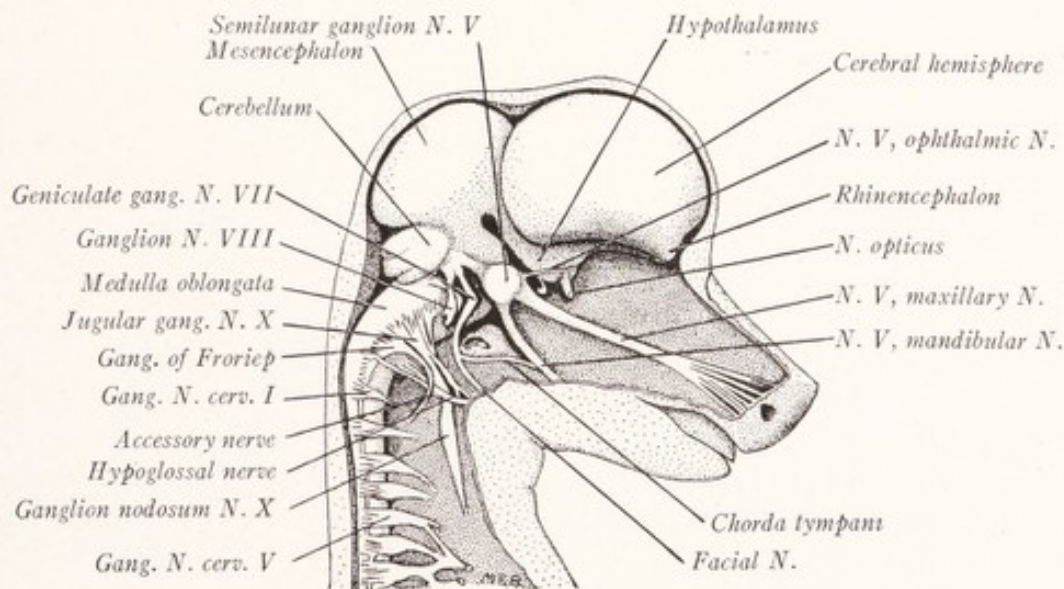


Fig. 259.—Dissection of the head of a 35 mm. pig embryo. Lateral view. (Redrawn from Prentiss-Arey.)

brain (Fig. 258. See also Figs. 16, 17 and pp. 32-36). Of what three parts is the *cerebral hemisphere* composed? Locate each of the subdivisions of the *diencephalon*.

To which part does the pineal body belong? The hypophysis? Locate the *quadrigeminal lamina*, *cerebral peduncle*, *cerebellum*, and *medulla oblongata*.

23. Now turn the specimen over and carefully dissect away what remains of the skin and mesodermal tissues so as to expose the brain and cranial nerves from the lateral side. Identify all the parts labeled in Fig. 259.

GENERAL TOPOGRAPHY OF THE BRAIN

24. The *adult mammalian brain* should now be compared with that of the shark and with that of the fetal pig. If two sheeps' brains are available, one should be divided into lateral halves by a cut made exactly 1 mm. to the left of the median sagittal plane. Use a long, thin brain knife and make the cut with a single sweep. Put away the right half for future study. On the left half and on the intact brain identify all of the chief divisions of the brain, determine their embryologic derivation, and compare them with similar parts in the brains of the shark and fetal pig. (See the table on p. 36, pp. 113-116, and Figs. 82-84.)

25. By a study of the medial aspect of the left half of the brain ascertain what relations the various subdivisions bear to each other. (See Fig. 84 and pp. 116-118.) Note the difference in color between the *cortex* and the *white center of the cerebellum*. By tearing away the cerebellum a little at a time make a dissection of the *cerebellar peduncles* on this half of the brain (Figs. 87, 91). Scrape away the superficial gray matter from the rostral end of the left hemisphere and uncover the white substance beneath. The superficial gray matter is known as the *cerebral cortex* and this covers the *white center of the cerebral hemisphere*.

NEUROLOGIC STAINS

26. Some knowledge of how various stains act on the nervous tissues is essential for an understanding of the special preparations which are to be studied. The technic involved in preparing such material is described in books devoted to technical methods (Hardesty, 1902; Guyer, 1917).

27. *Osmic Acid*.—Small nerves may be fixed in osmic acid. This stains the myelin sheaths black. Why? Axons remain unstained.

28. *The Weigert or Pal-Weigert Method*.—When a portion of the brain or spinal cord has been treated for several weeks with a solution containing potassium bichromate (Müller's fluid) the myelin sheaths acquire a special affinity for hematoxylin, by virtue of which they become deep blue in color when stained by this method. Axons, nerve-cells, and all other tissue elements remain colorless unless the preparation has been counterstained. The method is adapted for the study of the development and extent of myelination and for tracing myelinated fiber tracts. This method may also be used for a study of degenerated fiber tracts, which remain colorless in preparations in which the normal fiber tracts are well stained.

29. The *Marchi method* is a differential stain for degenerating fibers. These contain droplets of chemically altered myelin. The tissue is fixed in a solution containing potassium bichromate (Müller's fluid). This treatment prevents the normal myelinated fibers from staining with osmic acid, but does not prevent the droplets of chemically altered myelin in the degenerated fiber from being stained black by this

reagent. In a section prepared by this method the normal myelinated fibers are light yellow, while the degenerated fibers are represented by rows of black dots.

30. The *newer silver stains*, including the *Cajal method* and the *pyridin-silver technic*, depend upon the special affinity for silver nitrate possessed by nerve-cells and their processes. After treatment with silver nitrate the tissue is transferred to a solution of pyrogallic acid or hydroquinon which reduces the silver in the neurons to a metallic state. Nerve-cells and their processes are stained yellow or brown by these methods. Myelin sheaths remain unstained. The axis-cylinders of the myelinated fibers are light yellow, the unmyelinated axons are dark brown or black. The neurofibrils are stained somewhat more darkly than other parts of the cytoplasm.

31. The *Golgi method* furnishes preparations which demonstrate the external form of the neurons, and make it possible to trace individual axons and dendrites for considerable distances. The method also stains neuroglia. It is selective and rather uncertain in its results, since only a small proportion of the nerve-cells are impregnated in any preparation. The stain is due to the impregnation of the nerve-cells and their processes with silver.

32. The best stains for demonstrating the tigroid masses or Nissl bodies are *toluidin blue* and *Nissl's methylene-blue*. Both are basic dyes; and in properly fixed nervous tissue they color the tigroid masses as well as the nuclear chromatin of nerve-cells blue.

THE PERIPHERAL NERVOUS SYSTEM

33. *The Spinal Ganglia.*—Study a longitudinal section through a spinal nerve and its roots, including the spinal ganglion, stained by the pyridin-silver method. How are myelinated and unmyelinated axons stained by this method? What kinds of cells do you find? Study their axons. (See Figs. 39, 40 and pp. 62-66.) Look for the bifurcation of the myelinated and unmyelinated fibers. Note the differences in composition of the ventral and dorsal roots. What becomes of the various kinds of fibers when traced peripherally? When traced toward the spinal cord? What is the origin of the unmyelinated fibers?

34. Study the *vagus nerve* of the dog in osmic acid and pyridin-silver preparations. How are the various kinds of nerve-fibers stained in each? How does the structure of the vagus differ from that of a spinal nerve?

35. Study the *cervical portion of the sympathetic trunk*, which in the dog lies in a common sheath with the vagus. Of what kind of fibers is it composed? What is the origin and termination of these fibers? (See pp. 345-347.)

36. Study the pyridin-silver preparation from the *superior cervical sympathetic ganglion*. What is the source of the fine black fibers, and where do they end? Study the ganglion cells. What becomes of their axons? (See Figs. 251, 253 and pp. 341-344.)

THE SPINAL CORD

37. Review the development and *gross anatomy of the spinal cord* (p. 42 and pp. 73-78). Examine the demonstration preparations of the vertebral column, showing the spinal cord exposed from the dorsal side. In these preparations study the meninges and ligamentum denticulatum, as well as the shape and size of the spinal cord. Note

the level of the termination of the spinal cord, the level of the origin of the various nerve roots and of their exit from the vertebral canal, and the level of the various segments of the cord with reference to the vertebræ. Note the filum terminale and the cauda equina. From your text-books of anatomy study the meninges and blood-supply of the cord.

38. *The Spinal Cord in Section.*—Examine the Pal-Weigert sections of the cervical, thoracic, lumbar, and sacral regions, and from them reconstruct a mental picture of the topography of the entire cord. How does it vary in shape and size at the different levels? Identify all the fissures, sulci, septa, funiculi, gray columns, commissures and nerve roots, the reticular formation, the substantia gelatinosa and the caput, cervix, and apex of the posterior gray column. (See pp. 78-84.)

39. *The Microscopic Anatomy of the Spinal Cord.*—Study all of the histologic preparations of the spinal cord which have been furnished you. (See pp. 85-90.) Study the neuroglia in Golgi preparations. Study the pia mater, septa, blood-vessels, and ependyma in hematoxylin and eosin preparations. Study the nerve-cells in Nissl, Golgi, and silver preparations. Study the myelinated fibers in Weigert preparations and both the myelinated and unmyelinated fibers in the silver preparations. Note the arrangement of each of these histologic elements and be sure that you understand the relations which they bear to each other.

40. *Draw* in outline, ventral side down, each of four Pal-Weigert sections taken, respectively, through the cervical, thoracic, lumbar, and sacral regions of the human spinal cord. Make the outlines very accurate in shape and size, with an enlargement of 8 times. Put in the outline of the gray columns, the central canal, and the substantia gelatinosa Rolandi. Put each outline on a separate sheet and do not ink the drawings at present.

41. Identify the various *cell columns* in the gray matter and note how they vary in the different levels of the cord (Nissl or counterstained Weigert preparations). (See pp. 89, 90 and Fig. 65.) Indicate these cell groups in their proper places in the four outline sketches of the spinal cord. What becomes of the axons arising from each group of cells? Why are the anterolateral and posterolateral cell groups seen only in the regions associated with the brachial and lumbosacral plexuses? The intermediolateral column only in the thoracic and highest lumbar segments? Why is the gray matter most abundant in the region of the intumescentiæ and the white matter most abundant at the upper end of the spinal cord?

42. What elements are concerned in spinal reflexes? (See pp. 91-94.)

43. What connections do the fibers of the *spinal nerves* establish in the spinal cord? What is the origin and the peripheral termination of the somatic efferent fibers, of the visceral efferent fibers, of the somatic afferent fibers, and of the visceral afferent fibers of the spinal nerves? (See pp. 60-63 and Fig. 37.) What are the proprioceptive and exteroceptive fibers, and in what peripheral structures do they end? (See pp. 66-72.)

44. In a pyridin-silver preparation of the cervical spinal cord of a cat note that as the *dorsal root* enters the cord the unmyelinated fibers run through the lateral division of the root into the dorsolateral fasciculus (Fig. 72). The medial division of the root is formed of myelinated fibers which enter the posterior funiculus. Read about the intramedullary course of these fibers (pp. 95-98).

45. The *fiber tracts*, of which the white substance is composed, cannot be distinguished in the normal adult cord. They can be recognized from differences in the degree of their myelination in fetal cords (p. 112 and Fig. 79) and in preparations showing degeneration resulting from disease or injury in various parts of the nervous system (p. 105; Figs. 75, 76). From such preparations as are available for this purpose and from your reading (pp. 95-112) form a clear conception of the origin, course, and termination of each of the fiber tracts.

46. Indicate the location of each of these tracts in the outline drawing of the cervical portion of the spinal cord, entering the ascending tracts and the ventral cortico-spinal tract on the right side, and all of the descending tracts except the ventral cortico-spinal tract on the left side. Why should the ventral and lateral corticospinal tracts be indicated on opposite sides of the cord? Wax crayons should be used to give the several tracts a differential coloring. Use the following color scheme:

Somatic afferent tracts:

Proprioceptive—yellow.

Exteroceptive—blue.

Somatic motor tracts:

Corticospinal tracts—red.

Rubrospinal tract—brown.

All other tracts—black.

47. The fasciculus cuneatus and fasciculus gracilis should be colored yellow and then dotted over with blue to indicate that while the proprioceptive fibers predominate, there are also some exteroceptive fibers in these tracts.

THE BRAIN STEM

48. Now take the human brain and identify all of its principal divisions. Dissect out the *arterial circle of Willis*, and identify the branches of the internal carotid, vertebral, and basilar arteries. Read about the blood-supply and meninges of the brain in your text-book of anatomy. Identify all of the cranial nerves (Fig. 86).

49. Examine again the *cerebellar peduncles* in the three specimens of the sheep's brain (Figs. 87, 91). Now remove the cerebellum from the previously intact sheep's brain. Cut through the peduncles on both sides of the brain as far as possible from the pons and medulla, sacrificing the cerebellum to some extent in order to leave as much of the peduncles as possible attached to the brain stem. Be careful not to damage the anterior medullary velum and the tela chorioidea which lie under cover of the cerebellum (Fig. 84). In the same way remove the cerebellum from the human brain.

50. Study the *roof of the fourth ventricle* in both the human and the sheep's brain (pp. 128, 129 and Figs. 84, 90, 154). Examine the chorioid plexus of the fourth ventricle. Note the line of attachment of the tela chorioidea. Tear this membrane away. The torn edge which remains attached to the medulla is the *tænia* of the fourth ventricle (Figs. 89, 90). Study the attachments of the anterior medullary velum. The decussation of the trochlear nerve within the velum can easily be seen in the sheep. Remove this membrane. The floor of the fourth ventricle is now fully exposed.

51. Remove the pia mater from the brain stem, carefully cutting around the roots of the cranial nerves with a sharp-pointed knife to prevent these nerves being torn away from the brain when this membrane is removed.

52. Carefully examine the *medulla, pons, floor of the fourth ventricle, and the mesencephalon*, observing all the details mentioned on pp. 118-131 and illustrated in Figs. 84, 86-89, 91.

53. Take selected transverse *sections through the human brain stem* and, by comparison with the gross specimen, determine the level of each section.

54. Draw in outline each of these transverse sections through the brain stem. Put each drawing on a separate page, ventral side down, with the transverse diameter corresponding to the longer dimension of the paper. Study each preparation in detail and identify all of the parts, indicating them lightly in pencil. Do not label the drawings at this time. Make sure that all proportions are correct. The sections through the medulla should be enlarged eight diameters, those through the pons and mesencephalon four diameters.

55. *Section Through the Decussation of the Pyramids.*—Keep in mind the tracts which extend into the brain from the spinal cord and note the changes in their form and position. Identify the decussation of the pyramids, the nucleus gracilis and nucleus cuneatus, the spinal root of the trigeminal nerve and its nucleus, the reticular formation. Note the change in the form of the gray substance (pp. 132-137; Figs. 94, 95, 98).

56. *Section Through the Decussation of the Lemniscus.*—Note the rapid change in the form of the gray matter. Identify the internal and external arcuate fibers, the decussation of the lemniscus and the beginning of the medial lemniscus, as well as the structures continued up from the preceding level (Figs. 96, 99; pp. 137-139).

57. *Section Through the Olive and the Hypoglossal Nucleus.*—At this level the central canal opens out into the fourth ventricle. The posterior funiculi and their nuclei are disappearing or have disappeared. The dorsal spinocerebellar tract lies lateral to the spinal tract of the trigeminal nerve and is directed obliquely backward toward the restiform body. Identify, in addition to those structures which are continued from the preceding level, the inferior olivary nucleus with the olivocerebellar fibers, the dorsal and medial accessory olivary nuclei, the external arcuate fibers, the nucleus and fibers of the hypoglossal nerve, the dorsal motor nucleus of the vagus, the tractus solitarius and its nucleus, the nucleus ambiguus and the lateral reticular nucleus (Figs. 97, 101; pp. 139-142).

58. *Section Through the Restiform Body.*—The restiform body and the spinal tract of the fifth nerve are conspicuous in the dorsolateral part of the section. In the floor of the fourth ventricle locate the nucleus of the hypoglossal nerve, the dorsal motor nucleus of the vagus, the medial and the spinal vestibular nuclei. The spinal tract of the fifth nerve and its nucleus are deeply situated ventral to the restiform body and broken up by the olivocerebellar fibers (Fig. 103; pp. 143-146).

59. *Section Through the Lower Margin of the Pons.*—Identify such portions of the pons, brachium pontis, and cerebellum as are contained in the section. Dorsolateral to the restiform body is the dorsal cochlear nucleus, and ventrolateral to it the ventral cochlear nucleus. Identify the striæ medullares and the beginning of the trapezoid body, also the medial and lateral vestibular nuclei (Fig. 107; pp. 149-152).

60. *Section Through the Facial Colliculus.*—Differentiate between the ventral and the dorsal portions of the pons, and in the ventral portion identify the longitudinal fasciculi, transverse fibers, and the nuclei pontis (pp. 147-149). In the dorsal part identify the nuclei and root fibers of the sixth and seventh nerves including the genu

of the seventh nerve. Locate the spinal tract of the fifth nerve and its nucleus, the trapezoid body, and superior olivary nucleus (Fig. 108; pp. 151-154).

61. *Section Through the Middle of the Pons Showing the Motor and Main Sensory Nuclei of the Fifth Nerve.*—In addition to these nuclei note the beginning of the mesencephalic root of the fifth nerve. The brachium conjunctivum makes its appearance in the dorsal part of the section (Fig. 110; pp. 154-157).

62. *Section Through the Inferior Colliculus.*—Identify the basis pedunculi, substantia nigra, medial and lateral lemnisci, cerebral aqueduct, central gray matter, mesencephalic root of the fifth nerve, fasciculus longitudinalis medialis, nucleus of the trochlear nerve, and the decussation of the brachium conjunctivum (Figs. 113, 114; pp. 158, 165).

63. *Section Through the Superior Colliculus.*—Identify, in addition to the structures continued upward from lower levels, the red nucleus, the nucleus of the third nerve, and the root fibers of that nerve, the ventral and dorsal tegmental decussations, the inferior quadrigeminal brachium, and the medial geniculate body (Fig. 116; pp. 160, 167).

THE CEREBELLUM

64. Compare the human cerebellum with that of the shark and the sheep. How is its size related to the size of the pons and to the extent of the cerebral cortex?

65. On both the human and sheep's cerebellum identify the vermis, hemispheres, and divided peduncles (Figs. 138, 139, 143-145). In the medial sagittal section of the sheep's brain identify the white medullary body of the cerebellum, the arbor vitæ, cerebellar cortex, folia, and sulci (Fig. 84; pp. 196-199).

66. Study the morphology of the cerebellum in the sheep (Figs. 143-145). Locate these same fundamental subdivisions in the human cerebellum (Figs. 146, 147). What functions have recently been assigned to each of these subdivisions? (See pp. 199-203.)

67. Divide the human cerebellum in the median plane. Cut the right half into horizontal sections and the left into sagittal sections and study the medullary center and nuclei of the cerebellum (Figs. 140, 141, 148; pp. 199, 203).

68. Study the histologic sections of the cerebellar cortex and master the details of its structure (Figs. 150, 151; pp. 206-210).

FUNCTIONAL ANALYSIS OF THE BRAIN STEM

69. Review the sections of the brain stem as directed in the following paragraphs, paying special attention to the functional significance of the various nuclei and fiber tracts as far as they can be followed in the series of sections. In general, the afferent tracts and nuclei should be entered in color on the right side of the drawings already made, and the efferent tracts and nuclei on the left side. But this order must be reversed in certain cases to allow for the decussation of the tracts. Label the various tracts and nuclei. Use the following color scheme:

Somatic afferent:

Exteroceptive—blue.

Proprioceptive—yellow.

Visceral afferent—orange.

Visceral efferent—purple.

Somatic efferent—red.

All cerebellar connections not strictly proprioceptive—brown.

Other tracts—black.

PROPRIOCEPTIVE PATHS AND CENTERS (pp. 311-315)

70. The *cerebellum* is the chief proprioceptive correlation center, and the *restiform body* consists for the most part of proprioceptive afferent paths (Fig. 235). Note its shape, position, and connections in all the gross specimens. In the left lateral half of the sheep's brain follow it caudally by dissection, separating it from the other peduncles. Cut and reflect the dorsal cochlear nucleus of the eighth nerve. Trace the restiform body backward and note the accession of external arcuate fibers. At the level of the inferior olive it receives the dorsal spinocerebellar tract. Trace this by dissection from the restiform body obliquely across the upper end of the tuberculum cinereum and then caudally along the ventral border of this elevation to the spinal cord. (See Figs. 87, 88, 104; pp. 143, 205.)

71. Now take the sections of the medulla, locate the *dorsal spinocerebellar tract* in each, and indicate its position in yellow on the right side of your outlines (p. 144). Locate the *external arcuate fibers* (p. 139). From where do they come and where do they go? Draw in yellow those belonging to the right peduncle. Locate in your sections the *olivocerebellar tract*, and with brown indicate in your outline the fibers running into the right peduncle (Fig. 103).

72. From your texts ascertain the course of the *ventral spinocerebellar tract* and indicate its position in yellow on the right side of the outlines (Fig. 149; p. 157).

73. *Proprioceptive Path to the Cerebral Cortex.*—Indicate in yellow the terminal portion of the right *dorsal funiculi*, and with yellow stipple the right *nucleus gracilis* and *nucleus cuneatus* (Figs. 98, 99). Study the internal arcuate fibers and the medial lemniscus, drawing the internal arcuate fibers from right to left and the medial lemniscus on the left side (yellow). Where do the fibers of the medial lemniscus terminate? What is the source and what the destination of the impulses which they carry? (See Figs. 101, 103, 107, 108, 110, 114, 116, 235 and pp. 138, 312.)

74. Locate the *vestibular nuclei* and indicate them with yellow stipple on the right side of the outlines (Figs. 101, 103, 107, 108). Locate the vestibulocerebellar tract (pp. 151, 188; Fig. 136).

EXTEROCEPTIVE PATHS AND CENTERS (pp. 302-310)

75. *The Cochlear Nerve and its Connections.*—On the sheep's brain note the two divisions of the acoustic nerve as well as the ventral and dorsal cochlear nuclei and the trapezoid body (Fig. 87). Examine the cochlear nuclei and the *striae medullares* in the human brain (Fig. 89). Locate the lateral lemniscus where it forms a flat band of fibers directed rostrally and dorsally upon the lateral surface of the mesencephalon. It occupies a triangular space dorsal to the basis pedunculi and rostral to the pons and is superficial to the brachium conjunctivum (Fig. 88).

76. Now take the section through the lower border of the pons and study the *cochlear nuclei*, the *striae medullares*, and the beginning of the *trapezoid body* (Fig. 107). In the section through the facial colliculus study the trapezoid body and the superior

olivary nuclei (Fig. 108). In the section through the middle of the pons identify the *lateral lemniscus*. Trace this tract to the inferior colliculus (Fig. 114) and through the inferior quadrigeminal brachium to the medial geniculate body (Figs. 114, 116). Color these central connections of the cochlear nerve blue, indicating the cochlear nuclei on the right side and the lateral lemniscus on the left (Fig. 134; pp. 149, 185).

77. Dissection of the *spinal tract of the fifth nerve*. On the left half of the sheep's brain locate the fifth nerve and tear away the transverse fibers of the pons caudal to that nerve until the longitudinal fibers of its spinal tract are exposed. By carefully scraping away the structures superficial to this tract follow it to the lower end of the medulla.

78. Locate the *sensory nuclei of the fifth nerve* in your sections and indicate them with colored stipple on the right side of your drawing (pp. 154, 182; Fig. 131): the *mesencephalic nucleus*, yellow (Fig. 114); the *main sensory nucleus*, blue (Fig. 110); the *nucleus of the spinal tract*, blue (Figs. 98, 99, 101, 103, 107, 108). At the same time color the spinal tract of the right side blue. What becomes of the fibers which arise from the cells of the main sensory and the spinal nuclei of the trigeminal nerve? (See pp. 183, 307; Fig. 232.)

79. From the text ascertain the course of the *spinothalamic tract* and trace it up through the brain stem (Figs. 105, 230, 231, 234). Where do these fibers come from, and where do they end? What kind of sensations do they mediate? Enter it in blue on the right side of your drawings. (See pp. 101, 102, 145, 305.)

VISCERAL AFFERENT PATHS AND CENTERS

80. Identify the *tractus solitarius and its nucleus* (Figs. 101, 103, 120). What is the origin, termination, and function of the fibers constituting this tract? (See pp. 180, 181.) Indicate the tract with orange and the nucleus with orange stipple on the right side of your drawing.

VISCERAL MOTOR CENTERS

81. In the sections of the brain stem identify the *dorsal motor nucleus of the vagus* (Figs. 101, 103) and the following special visceral motor nuclei: the *nucleus ambiguus* (Figs. 101, 103), the *motor nucleus of the fifth* (Fig. 110), and the *motor nucleus of the seventh nerve* (Fig. 108). Stipple these nuclei purple on the left side. How are visceral afferent and efferent elements connected to form visceral reflex arcs? (See pp. 174-178.)

SOMATIC MOTOR TRACTS AND CENTERS

82. *The Corticospinal and Corticopontine Tracts*.—From the cerebral cortex the fibers of the pyramidal tract run through the internal capsule and brain stem to the somatic motor and special visceral motor nuclei of the cranial nerves and to the anterior gray column of the spinal cord. Along with these it will be convenient to study the cortico-ponto-cerebellar pathway. Take the left lateral half of the sheep's brain and, being careful not to injure the optic tract and optic radiation, follow the fibers of the basis pedunculi by dissection through the internal capsule to the cerebral cortex (Fig. 260). Now tear away the transverse fibers of the pons a few at a time and follow them by dissection into the brachium pontis. Observe that some of the fibers of the basis pedunculi end in the pons (corticopontine fibers) and that others (corticospinal fibers)

can be traced through the pons into the pyramid of the medulla. Carrying the dissection caudally, observe the decussation in the lower end of the medulla.

83. Examine again the series of sections through the brain stem and color the corticospinal tract red on the right side of your drawings. Draw the fibers from right to left in the decussation (Fig. 237; pp. 136, 317).

84. With red stipple indicate the *somatic motor nuclei* on the left side of your drawings. Which nuclei are they? (See pp. 170-173.)

CEREBELLAR CONNECTIONS

85. The inferior peduncle has already been studied and the *cortico-ponto-cerebellar path* has been dissected. Review this path in your sections. Color the corticopontine tracts of the left side brown (Fig. 117). Indicate the nuclei pontis of the left side by brown stipple. Draw the transverse fibers of the pons from the left nuclei pontis to the right brachium pontis (Fig. 106; pp. 147-149).

86. In the left lateral half of the sheep's brain follow the *brachium conjunctivum* by dissection into the tegmentum of the mesencephalon and note its decussation beneath the inferior colliculus. In your sections trace it rostrally, noting its decussation and termination (Figs. 110, 112, 114-116). Indicate it in brown on your drawings, beginning on the right side and tracing it through the decussation to the left red nucleus. Stipple both red nuclei with brown. (See pp. 159, 326.)

87. *The Rubrospinal Tract.*—Trace the rubrospinal tract from the red nucleus through the ventral tegmental decussation (Fig. 116) and the reticular formation of the brain stem. In the reticular formation it occupies a position ventromedial to the nucleus of the spinal root of the trigeminal nerve (Figs. 115, 234; pp. 161, 326). Color it brown on the left side of your drawings.

THE RETICULAR FORMATION

88. Study the *reticular formation* in the various sections. Of what is it composed? How many kinds of internal arcuate fibers can you find? What is the source of the longitudinal fibers of the reticular formation? Locate the tectospinal tract and indicate it in black on the left side of your drawings. (See pp. 144, 145).

89. *The Fasciculus Longitudinalis Medialis.*—Examine all nine sections, and enter this bundle in black on both sides of your drawings. What is the source of its fibers and what is its function? (See Fig. 109; pp. 152, 162).

PROSENCEPHALON

90. With a sharp brain knife divide the human brain exactly in the median sagittal plane, and then cut the left cerebral hemisphere into a series of frontal sections. The planes of the sections should pass through (1) the rostrum of the corpus callosum, (2) the anterior commissure, (3) the mammillary body, (4) the habenular nucleus, (5) the pineal body and the splenium of the corpus callosum (Figs. 186-190).

91. Take the right half of the sheep's brain and make such dissections as may be necessary to secure a good preparation of the structures indicated in Fig. 84. Begin at the rostral angle of the fourth ventricle and follow the cerebral aqueduct, tearing away with tissue forceps any parts of the left lateral wall which have not been cut away.

Follow the aqueduct into the third ventricle, removing from the latter the remains of its left lateral wall. Care is required in removing the rostral part of this wall in order that the lamina terminalis may be left intact. Now remove such portions of the left cerebral cortex as are still attached to the preparation. By this dissection a much more instructive preparation is obtained than when the original section is made exactly in the median plane.

92. Take the left lateral half of the sheep's brain and tear away what remains of the septum pellucidum and body of the fornix and locate the caudate nucleus. For the identification of these structures see Figs. 84 and 204. † Cut through the internal capsule, which has previously been exposed from the lateral side in this specimen, along a line extending horizontally toward the occipital pole from the highest part of the dorsal border of the caudate nucleus. Remove the portion of the cerebral hemisphere that lies dorsal to the plane of this section and thus expose the dorsal surface of the thalamus (Fig. 91).

93. *Diencephalon*.—Study the *thalamus* as it appears in all of these preparations (pp. 213–216). Examine the dorsal surface of the thalamus on the left half of the sheep's brain (Figs. 89, 91, 180). The lateral surface of the thalamus rests against the internal capsule, as can be readily understood from a study of this dissection. The medial surface forms a part of the wall of the third ventricle (Figs. 158, 159).

94. Study the *epithalamus* in both the human and the sheep's brain. Of what parts is it composed? (See Figs. 91, 158, 159; pp. 220, 221.)

95. Locate all the parts which belong to the *hypothalamus* in both the human and the sheep's brain (Figs. 84, 86, 158, 159; pp. 222, 223).

96. Study the shape and boundaries of the *third ventricle* (Figs. 158, 159; pp. 223, 224).

97. *The Metathalamus*.—On the left half of the sheep's brain identify the *medial geniculate body* (Fig. 87). Immediately rostral to this body is a slight elevation in the optic tract produced by the subjacent *lateral geniculate body*. Identify both of these bodies on the human brain (Figs. 88, 89, 154).

98. In the frontal sections of the left human cerebral hemisphere identify the various parts of the diencephalon (Figs. 188, 189). From these sections something can be learned concerning the *internal structure of the thalamus*, but more information can be obtained on this subject from sections stained by the Weigert method (Figs. 156, 157; p. 216). In these sections trace the basis pedunculi into the internal capsule and the medial lemniscus into the thalamus.

99. *Dissection of the Optic Tract*.—Take the left lateral half of the sheep's brain and, grasping the optic chiasma with the tissue forceps, pull the optic tract lateralward, separating it from the surface of the peduncle. It separates easily until the position of the lateral geniculate body is reached just rostral to the medial geniculate body. Stronger traction will cause it to tear away from the lateral geniculate body, which is now exposed as a prominent curved ridge of gray matter. This nucleus extends rostrally and dorsally from the medial geniculate body and is continuous with the pulvinar of the thalamus. Continued traction will cause the optic fibers to strip off from the surface of the pulvinar. Here they form a rather thick white lamina, the stratum zonale. Continue the dissection, raising the fibers of the optic tract as far as the groove rostral to the superior colliculus. Now cut the transverse peduncular tract, which lies in this

groove, by making a superficial incision across the groove along the lateral border of the optic fibers. Scrape away the superficial gray matter (about 1 mm.) of the superior colliculus and expose the stratum opticum (Fig. 116). Now continue the traction on the optic tract and a striking demonstration will be obtained of the fact that the stratum opticum is composed of fibers from this tract (Figs. 161, 162; pp. 226, 227).

100. *Dissection of the Optic Radiation.*—In the left half of the sheep's brain scrape away part of the gray matter of the pulvinar. Follow fibers from the pulvinar into the posterior limb of the internal capsule. These belong to the optic radiation, which may now be followed by dissection to the cortex near the occipital pole of the cerebral hemisphere (Fig. 260; pp. 227, 228). Now take the right half of the cerebral hemisphere and identify the visual area of the cerebral cortex (Fig. 221).

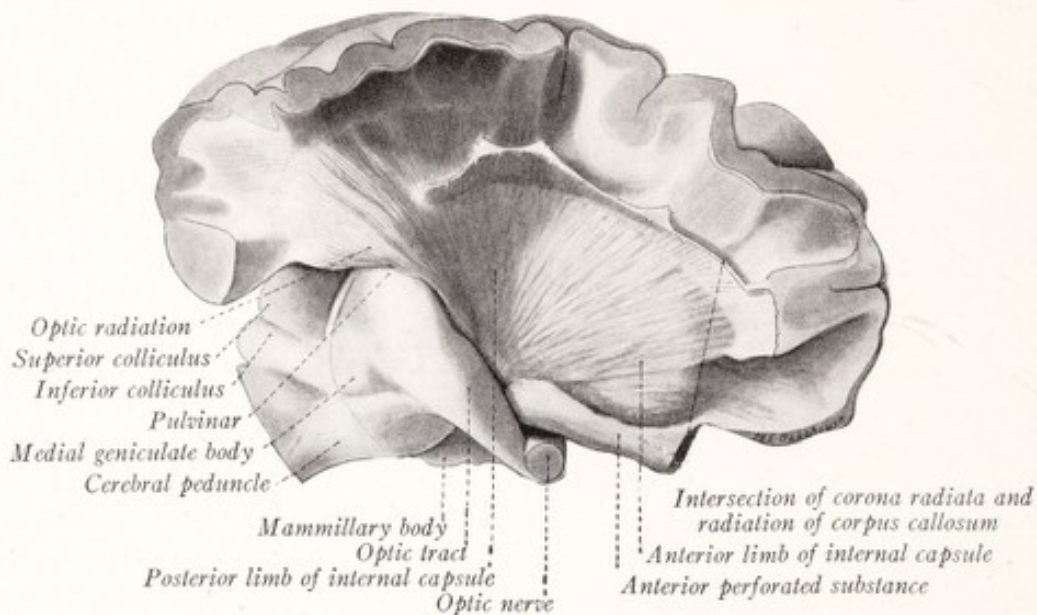


Fig. 260.—Dissection of the cerebrum of a sheep showing the internal capsule and corona radiata. The lentiform nucleus has been removed.

101. *Surface Form of the Cerebral Hemispheres.*—Compare the basal surface of the human brain with that of the sheep. Note in each the parts belonging to the rhinencephalon and locate the rhinal fissure, which separates the neopallium and the archipallium. Nearly all of the surface of the human cerebral hemisphere is formed by the neopallium (Figs. 83, 86; pp. 115, 116).

102. Examine the right cerebral hemisphere of the human brain and identify the poles, fissures, sulci, lobes, and gyri (Figs. 166–168, 170, 171; pp. 232–242). Draw the margins of the lateral fissure apart and locate the insula (Fig. 169). Study the insula in the frontal sections through the left cerebral hemisphere (Figs. 186–189; p. 237).

103. *Internal Configuration of the Cerebral Hemisphere.*—Take the sheep's brain from which the cerebellum has been removed and slice away successive thin layers from the dorsal aspect of both hemispheres. These thin sections should be cut in planes parallel to the dorsal surface of the corpus callosum and the last cut should be $\frac{1}{4}$ inch dorsal to that commissure. The direction and relative depth of the dorsal surface of

the corpus callosum can be determined by examination of the medial aspect of the right half of the sheep's brain. As the sections are removed note the relation of the gray and white matter (Fig. 175). Gently press apart the two hemispheres and note the corpus callosum at the bottom of the longitudinal fissure. Now with a blunt instrument dissect away the gray and white matter from the dorsal surface of the corpus callosum (Fig. 175). Be careful not to injure a thin layer of gray matter, the indusium griseum, which covers this surface. Study the *corpus callosum* in this specimen and in the median sagittal sections of the sheep and human brains (Figs. 158, 159, 175; pp. 243-245). Examine the *septum pellucidum* in the median sagittal sections.

104. *The Lateral Ventricles* (pp. 246-251).—Cut through the corpus callosum of the sheep's brain as indicated in Fig. 178, leaving a median strip in position. Make a careful examination of all the parts thus exposed, including the septum pellucidum. On the right side of the specimen expose the entire extent of the inferior horn of the lateral ventricle by freely cutting away the lateral portion of the hemisphere as indicated in Fig. 182. Remove the caudate nucleus to demonstrate the entire extent of the anterior horn, and finally demonstrate the continuity of the lateral ventricle with the cavity of the olfactory bulb (Fig. 182). Now study the lateral ventricle and the structures which form its walls as these are illustrated on the two sides of this specimen. Note the chorioid plexus (Fig. 183) and chorioid fissure.

105. Study the lateral ventricle as seen in the frontal sections of the left hemisphere of the human brain (Figs. 186-189). It has an additional part, the posterior horn, not seen in the sheep. Endeavor to reconstruct a mental picture of its shape (Fig. 176).

106. *The Corpus Striatum* (pp. 253-257).—Examine again the caudate nucleus as it bulges into the lateral ventricle (Fig. 178). Take the right lateral half of the sheep's brain and make a horizontal section through the cerebral hemisphere, passing through the lower border of the genu of the corpus callosum and the lower border of the habenular trigone. Locate the lentiform and caudate nuclei, the claustrum, and the internal and external capsules (Fig. 192).

107. *Dissection of the Lentiform Nucleus and the Internal Capsule*.—On the left side of the sheep's brain, in which the lateral ventricles have been exposed, remove the cortex and white matter superficial to the lentiform nucleus. Begin by grasping with tissue forceps the olfactory bulb close to its peduncle and tear it away, pulling in a lateral and caudal direction. There should come away with it the superficial part of the anterior perforated substance and part of the lateral olfactory gyrus (Fig. 83). This will expose the ventral part of the lentiform nucleus, and the structures lateral to that nucleus can now be removed. With a blunt dissecting instrument scrape away everything superficial to the lentiform nucleus and continue the dissection until the nucleus and the corona radiata are fully exposed (Fig. 87). Now scrape away the lentiform nucleus and expose the internal capsule (Fig. 260). In removing the nucleus you can obtain a clear idea of its shape and size.

108. *Dissection of the Internal Capsule*.—In the same specimen remove the optic tract and trace the basis pedunculi into the internal capsule and follow the fibers from the internal capsule into the corona radiata. Trace the optic radiation from the posterior extremity of the internal capsule to the cortex near the occipital pole (Fig. 260).

109. *Dissection of the Caudate Nucleus*.—On the left side of the same sheep's

brain note that the tail of the caudate nucleus extends ventrally into the roof of the inferior horn of the lateral ventricle. With a blunt instrument scrape away the head and first part of the tail of the nucleus, exposing the medial surface of the internal capsule (Fig. 91). Note the shape and size of this nucleus as you are removing it.

110. Study a horizontal section stained by the Weigert method through the internal capsule and basal ganglia. From this section and from the dissections endeavor to form a clear mental picture of the internal capsule and its relations (Figs. 191, 193; pp. 257-261).

111. Now take the frontal sections of the left hemisphere of the human brain and identify the various parts of the corpus striatum and internal capsule (Figs. 186-190).

112. *Rhinencephalon*.—Study the olfactory portions of the brain to be seen on the ventral surface of the cerebral hemisphere in the human and sheep's brains (Figs. 172, 197, 199; pp. 265-269). Study the hippocampus, alveus, and fimbria as they lie exposed in the inferior horn of the lateral ventricle of the sheep's brain (Figs. 178, 182). Open up the inferior horn of the lateral ventricle on the left side of this specimen so as to expose the hippocampus and fimbria. Raise the hippocampus and fimbria on both sides at the same time, leaving them still attached to the fornix. This should be done without damaging the underlying tela chorioidea of the third ventricle, which occupies the great transverse fissure. Examine the under surface of the hippocampus, fimbria, and fornix. Note that the two fimbriae unite to form the triangular body of the fornix. The transverse fibers in this triangle constitute the hippocampal commissure (lyra). Note the fascia dentata and hippocampal fissure. Figure 204 will help you to interpret the parts seen in this dissection.

113. The *chorioid plexuses* of the prosencephalon are now fully exposed, and their relations to each other and the brain ventricles can be readily studied (pp. 224, 251).

114. Remove the tela chorioidea of the third ventricle and again identify the parts of the *thalamus* and *epithalamus* which may be seen from above (Figs. 91, 180).

115. Replace the *fornix* and hippocampus in position and divide the fornix and what remains of the cerebral hemispheres by a sagittal section $\frac{1}{2}$ millimeter to the right of the median plane. Take the left half of the preparation and, tearing away any portions of the right columna fornicis that may still be attached to the preparation, follow the left column of the fornix to the mammillary body. This can be accomplished by scraping away some of the medial surface of the thalamus (Fig. 204). At the same time expose the mamillothalamic tract. Remove the posterior part of the thalamus and the remainder of the brain stem by a cut made just caudal to the mamillothalamic tract, as indicated in Fig. 204. This gives a connected view of the entire fornix system. Find the cut surface of the hippocampal commissure and separate it for a few millimeters from the rest of the fornix. Identify again the fimbria, fascia dentata, hippocampal fissure and hippocampal gyrus, and study the fornix as a whole (Figs. 200, 203; pp. 270-272).

116. Study the *septum pellucidum* in the right half of the human brain (Fig. 158; p. 272). Also locate the anterior commissure.

117. Dissect the *anterior commissure* in the right lateral half of the sheep's brain. Locate the commissure on the median surface and by blunt dissection follow it to the olfactory bulb (Fig. 199; p. 273).

118. In the frontal sections of the left cerebral hemisphere of the human brain study the relations of the septum pellucidum, fornix, fimbria, hippocampus, and anterior commissure (Figs. 186-190).

119. *The Cerebral Cortex.*—On the right hemisphere of the human brain identify the motor, somesthetic, auditory, and visual centers (Figs. 220, 221; pp. 290-293). With a scalpel remove a cube of cortex and subjacent white matter from each of these areas. Each block should measure about 1 cm. in each dimension. With a sharp razor make section through each of these blocks at right angles to the surface of the cortex and perpendicular to the long axis of the gyrus from which the block was cut. Note the differences in thickness of the cortex in the various regions. Observe the white striations in the cortex, and note how these differ in the several specimens (Fig. 218). Study the stained and mounted sections of the cerebral cortex which are furnished you. What details of cell and fiber lamination do these preparations show, and how does this lamination differ in the several regions of the cortex? (See Fig. 215; pp. 284-287.)

120. *Association Fibers* (Figs. 226, 228; pp. 298-301).—If the human brain is reasonably well preserved the larger bundles of association fibers may be easily exposed by dissection. This can be done on the right hemisphere. But if the material is very soft this half of the brain can more profitably be laid into a series of horizontal sections and these used for a review of the form and relations of the component parts of the cerebral hemisphere. If the material is fairly well preserved, make the following review dissection and at the same time expose and study the various bundles of association fibers.

121. *Review Dissection of the Human Brain.*—Take the right half of the human brain and scrape away the cerebral cortex from a portion of the dorsal surface of the frontal lobe. This will expose the short association or arcuate fibers (Fig. 226).

122. Now make a horizontal section through the hemisphere parallel to the dorsal surface of the corpus callosum and $\frac{3}{8}$ inch dorsal to it. Note the *centrum semiovale*. Scrape away the cortex of the gyrus cinguli and the white matter immediately subjacent to it. In making this dissection carry the orangewood stick in an anteroposterior direction, removing the white matter a little at a time until a longitudinal bundle of fibers, the *cingulum*, is exposed (Fig. 174). The indusium griseum and striæ longitudinales should now be uncovered.

123. Remove the cingulum, scrape away the indusium griseum, and expose the radiation of the corpus callosum as indicated on the right side of Fig. 174, but do not cut the optic radiation or expose the tapetum at this time.

124. Remove the parietal operculum a little at a time. This can be done with tissue forceps. Grasp small portions and tear them away by upward traction. Note the bundles of transverse fibers which enter this operculum from the corpus callosum and internal capsule. These intersect at right angles with the fibers of the *superior longitudinal fasciculus* which should come into view as the dissection progresses (Fig. 174). The transverse bundles should be made to break off at the point where they pass through the superior longitudinal fasciculus. Complete the dissection of this fasciculus, carrying the dissecting instrument in the direction of its fibers. Now demonstrate the intersection of the corona radiata with the radiation of the corpus callosum (Fig. 174).

By this dissection the insula and the dorsal surface of the temporal lobe have been exposed. Note in particular the transverse temporal gyri.

125. Now dissect away the dorsal part of the temporal lobe and remove the insula. This will expose the *uncinate and inferior occipitofrontal fasciculi* as well as the *external capsule* (Fig. 227). These fiber bundles can best be displayed by carrying the dissecting instrument in the direction of the fibers. Complete the dissection of the corona radiata and the optic radiation (Fig. 227).

126. Now turn the specimen over and make a dissection of the *column of the fornix and the mamillothalamic tract* as in Fig. 205, but do not cut away the brain stem as indicated in that figure.

127. *Dissection of the Internal Capsule from the Medial Side* (Fig. 195).—Tear away the fornix and septum pellucidum, opening up the lateral ventricle. With the brain knife cut away a slice from the medial surface of the hemisphere, varying in thickness from $\frac{1}{4}$ inch at the frontal end to $\frac{1}{2}$ inch at the occipital end, cutting through the corpus callosum and into the ventricle, but not into the basal ganglia. With a scalpel and tissue forceps remove what remains of the medial wall of the lateral ventricle, except in the inferior horn. Grasp with tissue forceps the stria terminalis in the rostral end of the sulcus terminalis and tear it away, carrying the forceps toward the occipital pole (p. 214). By blunt dissection remove the thalamus and subthalamus as well as the tegmentum and corpora quadrigemina of the mesencephalon. In scraping away these parts carry the dissecting instrument from the sulcus terminalis in a ventral direction. This will uncover the basis pedunculi and its continuation into the internal capsule. The fibers of the thalamic radiation will be broken off at the point where they enter the internal capsule (Fig. 195). Remove the ependymal lining of the posterior horn of the ventricle and uncover the tapetum. Scrape away the caudate nucleus, carrying the dissecting instrument in the direction of the fibers of the internal capsule (Fig. 195). Trace the anterior commissure to the point where it disappears under the anterior limb of the internal capsule. Study the internal capsule as seen from the medial surface, and note particularly the direction of the fibers, the anterior limb, the posterior limb, the optic radiation, and the curved ridge which represents the genu.

128. Now turn again to the lateral side of the specimen (Fig. 227), and grasping with tissue forceps individual strands of the uncinata fasciculus in temporal lobe strip them forward into the frontal lobe. Remove the entire fasciculus in this manner. In the same way strip away the fibers of the inferior occipitofrontal fasciculus, beginning in the frontal lobe and tracing them toward the occiput. Strip off the fibers of the external capsule and expose the lentiform nucleus and the corona radiata (Fig. 194). Pay special attention to the fibers of the corona radiata which come from the sublenticular part of the internal capsule and enter the temporal lobe. Follow the anterior commissure to the point where it disappears under the lentiform nucleus.

129. Remove what remains of the temporal lobe and examine the hippocampus, fimbria, and inferior horn of the lateral ventricle from the dorsal surface (Fig. 201).

130. Next scrape away the lentiform nucleus and trace the basis pedunculi into the internal capsule (Fig. 88). Study the corona radiata, internal capsule, and basis pedunculi from both sides of this preparation. The thalamus and the caudate and lentiform nuclei produce well-marked impressions on the internal capsule (Figs. 88, 195).

BIBLIOGRAPHY

- Allen, W. F., 1919: Application of the Marchi Method to the Study of the Radix Mesencephalica Trigemini in the Guinea-pig, *Jour. Comp. Neurol.*, vol. xxx, p. 169.
- André-Thomas and Durupt, 1914: *Localisations cérébelleuses*, Paris.
- Arey, L. B., 1916: The Function of the Efferent Fibers of the Optic Nerve of Fishes, *Jour. Comp. Neurol.*, vol. xxvi, p. 213.
- Bailey, P., 1916: The Morphology and Morphogenesis of the Chorioid Plexuses with Especial Reference to the Development of the Lateral Telencephalic Plexus in *Chrysemys Marginata*, *Jour. Comp. Neurol.*, vol. xxvi, pp. 507-531.
- , 1916: Morphology of the Roof Plate of the Forebrain and the Lateral Chorioid Plexuses in the Human Embryo, *Jour. Comp. Neurol.*, vol. xxvi, p. 79.
- Bárány, R., 1912: Lokalisation in der Rinde der Kleinhirnhemisphären des Menschen, *Wiener klinische Wochenschrift*, Bd. xxv, p. 2033.
- Barnes, S., 1901: Degenerations in Hemiplegia with Special Reference to a Ventrolateral Pyramidal Tract, the Accessory Fillet, and Pick's Bundle, *Brain*, vol. xxiv, p. 463.
- Bartelmez, G. W., 1915: Mauthner's Cell and the Nucleus Motorius Tegmenti, *Jour. Comp. Neurol.*, vol. xxv, p. 87.
- Batten, F. E., and G. Holmes, 1913: The Endogenous Fibers of the Human Spinal Cord (from the Examination of Acute Poliomyelitis), *Brain*, vol. xxxv, p. 259.
- Baumgartner, E. A., 1915: The Development of the Hypophysis in *Squalus Acanthias*, *Jour. Morph.*, vol. xxvi, p. 391.
- Bayliss, W. B., 1918: *Principles of General Physiology*, New York.
- Beevor, C. E., and Victor Horsley, 1902: On the Pallio-tectal or Cortico-mesencephalic System of Fibers, *Brain*, vol. xxv, p. 436.
- Bell, C., 1811: *Idea of a New Anatomy of the Brain*, London.
- , 1844: *The Nervous System of the Human Body*, London.
- Bernheimer, S., 1904: Ueber Ursprung und Verlauf des Nervus oculomotorius im Mittelhirn, *Monatschrift f. Psych. u. Neurol.*, Bd. xv, p. 151.
- Bethe, A., 1903: *Allgemeine Anatomie und Physiologie des Nervensystems*, G. Thieme, Leipzig.
- Bing, R., 1906: Experimentelles zur Physiologie der Tractus Spinocerebellares, *Arch. f. Anat. u. Physiol., Physiol. Abt.*, 1906, s. 251.
- Black, D., 1916: Cerebellar Localization in the Light of Recent Research, *Jour. Lab. and Clin. Med.*, vol. i, p. 467.
- , 1917: The Motor Nuclei of the Cerebral Nerves in Phylogeny, *Jour. Comp. Neurol.*, vol. xxvii, p. 467, and vol. xxviii, p. 379.
- Bolk, L., 1906: *Das Cerebellum der Säugetiere*, Gustav Fischer, Jena, 1906.
- Bolton, J. S., 1910: A Contribution to the Localization of Cerebral Function, Based on the Clinico-pathologic Study of Mental Disease, *Brain*, vol. xxxiii, pp. 26-147.
- Brodmann, K., 1907: Die Kortexgliederung des Menschen, *Jour. f. Psychol. u. Neurol.*, Bd. x, p. 231.
- , 1909: Vergleichende Lokalisationslehre der Grosshirnrinde, Barth., Leipzig, 1909.
- , 1910: Feinere Anatomie des Grosshirns, Lewandowsky's Handbuch der Neurologie, Bd. v, pp. 206-307, Berlin, 1910.
- Brookover, Chas., 1914: The Nervus Terminalis in Adult Man, *Jour. Comp. Neurol.*, vol. xxiv, pp. 131-135.
- , 1917: The Peripheral Distribution of the Nervus Terminalis in an Infant, *Jour. Comp. Neurol.*, vol. xxviii, pp. 349-360.
- Bruce, A., and R. Muir, 1896: On a Descending Degeneration in the Posterior Columns in the Lumbo-sacral Region of the Spinal Cord, *Brain*, vol. xix, p. 333.
- Bruce, A. N., 1910: The Tract of Gowers, *Quart. Jour. Exper. Phys.*, vol. iii, p. 391.
- , 1914: Arcuate Nucleus in Man, the Anthropoid Apes, and the Microcephalic Idiot, *Rev. Neurol. and Psychiat.*, vol. xii, pp. 51-53.

- Cajal, S. R., 1890: Origen y terminación de las fibras nerviosas olfatorias, *Gac. sanitaria de Barcelona*, 1890.
- , 1900-06: *Studien über die Hirnrinde des Menschen*, Leipzig.
- , 1907: Die Structur der sensiblen Ganglien des Menschen und der Tiere, *Anat. Hefte*, Zweite Abt., Bd. xvi, p. 177.
- , 1908: *Studien über Nervenregeneration*, Übersetzt von J. Bresler, Leipzig, 1908.
- , 1909: *Histologie du système nerveux de l'homme et des vertébrés*, vol. i, A. Maloine, Paris.
- , 1911: *Histologie du système nerveux de l'homme et des vertébrés*, vol. ii, A. Maloine, Paris.
- Campbell, A. W., 1905: *Histological Studies on the Localization of Cerebral Function*, Cambridge.
- Cannon, W. B., 1912: Peristalsis, Segmentation, and the Myenteric Reflex, *Amer. Jour. Physiol.*, vol. xxx, pp. 114-128.
- Carlson, A. J., and L. H. Braafladt, 1915: On the Sensibility of the Gastric Mucosa, *Amer. Jour. Physiol.*, vol. xxxvi, p. 153.
- Carpenter, F. W., and J. L. Conel, 1914: A Study of Ganglion Cells in the Sympathetic Nervous System with Special Reference to Intrinsic Sensory Neurons, *Jour. Comp. Neurol.*, vol. xxiv, pp. 269-281.
- Chase, M. R., and S. W. Ranson, 1914: The Structure of the Roots, Trunk, and Branches of the Vagus Nerve, *Jour. Comp. Neurol.*, vol. xxiv, p. 31.
- Clarke, R. H., and Victor Horsley, 1905: On the Intrinsic Fibers of the Cerebellum, its Nuclei, and its Efferent Tracts, *Brain*, vol. xxviii, p. 13.
- Coghill, G. E., 1902: The Cranial Nerves of *Amblystoma Trigrinum*, *Jour. Comp. Neurol.*, vol. xii, pp. 205-289.
- , 1913: The Primary Ventral Roots and Somatic Motor Column of *Amblystoma*, *Jour. Comp. Neurol.*, vol. xxiii, pp. 121-143.
- , 1914: Correlated Anatomical and Physiological Studies of the Growth of the Nervous System of Amphibia, I, *Jour. Comp. Neurol.*, vol. xxiv, pp. 161-223.
- Collier, J., and F. Buzzard, 1901: Descending Mesencephalic Tracts in Cat, Monkey, and Man, *Brain*, vol. xxiv, p. 177.
- , 1903: The Degenerations Resulting from Lesions of Posterior Nerve Roots and from Transverse Lesions of the Spinal Cord in Man, *Brain*, vol. xxvi, p. 559.
- Cowdry, E. V., 1914: The Comparative Distribution of Mitochondria in Spinal Ganglion Cells of Vertebrates, *Amer. Jour. Anat.*, vol. xvii, p. 1.
- Curran, E. J., 1909: A New Association Tract in the Cerebrum with Remarks on the Fiber Tract Dissection Method of Studying the Brain, *Jour. Comp. Neurol.*, vol. xix, p. 645.
- Cushing, H., 1903: The Taste Fibers and Their Independence of the N. Trigemini, *Johns Hopkins Hospital Bulletin*, vol. xiv, p. 71.
- , 1909: A Note Upon the Faradic Stimulation of the Postcentral Gyrus in Conscious Patients, *Brain*, vol. xxxii, pp. 44-54.
- Déjerine, J., 1914: *Sémiologie des affections du système nerveux*, Paris, 1914.
- Dogiel, A. S., 1896: Zwei Arten sympathischer Nervenzellen, *Anat. Anz.*, Bd. xi, pp. 679-687.
- , 1908, *Der Bau der Spinalganglien des Menschen und der Säugetiere*, Gustav Fischer, Jena.
- Donaldson, H. H., 1898: *The Growth of the Brain*, Chas. Scribner's Sons, New York.
- Donaldson, H. H., and D. J. Davis, 1903: A Description of Charts Showing the Areas of the Cross-sections of the Human Spinal Cord at the Level of Each Spinal Nerve, *Jour. Comp. Neurol.*, vol. xiii, p. 19.
- Economo, C., 1911: Über dissoziierte Empfindungslähmung bei Pontumoren und über die zentralen Bahnen des sensiblen Trigemini, *Jahrbücher f. Psychiatrie*, vol. xxxii, p. 107.
- Edinger, L., 1887: On the Importance of the Corpus Striatum and the Basal Forebrain Bundle, *Jour. Nerv. and Ment. Diseases*, vol. xiv, p. 674.
- , 1911: *Vorlesungen über den Bau der Nervösen Zentralorgane des Menschen und der Tiere*, F. C. W. Vogel, Leipzig.
- Edinger, L., and A. Wallenberg, 1903: Bericht über die Leistungen auf dem Gebiete der Anatomie des Centralnervensystems, 1901-02, p. 152.
- Essick, C. R., 1907: The Corpus Ponto-bulbare—A Hitherto Undescribed Nuclear Mass in the Human Hind Brain, *Amer. Jour. Anat.*, vol. vii, p. 119.
- Feilberg, A., 1913: On the Bulbar Nuclei, with Special Reference to the Existence of a Salivary Center in Man, *Brain*, vol. xxxvi, p. 255.

- Feiss, H. O., 1912: On the Fusion of Nerves, *Quart. Jour. Exp. Physiol.*, vol. v, p. 1.
- Flechsig, P., 1896: *Gehirn und Seele*, Leipzig.
- , 1896: Die Lokalisation der geistigen Vorgänge, Leipzig.
- Fritsch, G., and E. Hitzig, 1870: Über die elektrische Erregbarkeit des Grosshirns, *Arch. f. Anat., Physiol., u. Wissen. Med.*, 1870, p. 300.
- Gall, F. J., 1825: *Sur les fonctions du cerveau*, Paris.
- Gaskell, W. H., 1886: On the Structure, Distribution, and Function of the Nerves which Innervate the Visceral and Vascular Systems, *Jour. Physiol.*, vol. vii, p. 1.
- , 1908: *The Origin of Vertebrates*, London, Longmans.
- Goldstein, K., 1910: Ueber die aufsteigende Degeneration und Querschnittsunterbrechung des Rückenmarks (Tractus spinocerebellaris posterior, Tractus spino-olivaris, Tractus spino-thalamicus), *Neurol. Centralblatt*, vol. xxix, p. 897.
- Grünbaum, A. S. F., and C. S. Sherrington, 1903: Observations on the Physiology of the Cerebral Cortex of the Anthropoid Apes, *Proc. Roy. Soc.*, vol. lxxii, p. 152.
- Guyer, M. F., 1917: *Animal Micrology*, Chicago.
- Hardesty, I., 1902: *Neurological Technique*, Chicago.
- , 1904: On the Development and Nature of the Neuroglia, *Amer. Jour. Anat.*, vol. iii, p. 229.
- Harrison, R. G., 1906: Further Experiments on the Development of Peripheral Nerves, *Amer. Jour. of Anat.*, vol. v, p. 121.
- , 1910: The Outgrowth of the Nerve-fiber as a Mode of Protoplasmic Movement, *Jour. Exp. Zool.*, vol. ix, p. 788.
- , 1910: The Development of Peripheral Nerve-fibers in Altered Surroundings, *Archiv f. Entw. d. Org.*, vol. xxx, zweiter Teil, p. 15.
- Hatai, S., 1902: Number and Size of the Spinal Ganglion Cells and Dorsal Root Fibers of the White Rat at Different Ages, *Jour. Comp. Neurol.*, vol. xii, p. 107.
- Head, H., 1905: The Afferent Nervous System from a New Aspect, *Brain*, vol. xxviii, p. 99.
- , 1918: Sensation and the Cerebral Cortex, *Brain*, vol. xli, p. 57.
- Head, H., and T. Thompson, 1906: The Grouping of Afferent Impulses Within the Spinal Cord, *Brain*, vol. xxix, p. 537.
- Head, H., and G. Holmes, 1911: Sensory Disturbances from Cerebral Lesions, *Brain*, vol. xxxiv, p. 102.
- , 1911: A Case of Lesion of the Optic Thalamus with Autopsy, *Brain*, vol. xxxiv, p. 254.
- Held, H., 1909: Die Entwicklung des Nervengewebes bei den Wirbeltieren, Barth, Leipzig.
- Herrick, C. J., 1899: The Cranial and First Spinal Nerves of *Menidia*, *Jour. Comp. Neurol.*, vol. ix, pp. 153-455.
- , 1917: The Internal Structure of the Midbrain and Thalamus of *Necturus*, *Jour. Comp. Neurol.*, vol. xxviii, p. 215.
- , 1918: *An Introduction to Neurology*, W. B. Saunders Co., Philadelphia.
- Herrick, C. J., and G. E. Coghill, 1915: The Development of Reflex Mechanisms in *Amblystoma*, *Jour. Comp. Neurol.*, vol. xxv, pp. 65-85.
- Herrick, C. J., and E. C. Crosby, 1918: *A Laboratory Outline of Neurology*, Philadelphia.
- Holmes, Gordon, 1917: The Symptoms of Acute Cerebellar Injuries Due to Gunshot Injuries, *Brain*, vol. xl, p. 461.
- Holmes, G., and W. P. May, 1909: On the Exact Origin of the Pyramidal Tracts in Man and Other Mammals, *Brain*, vol. xxxii, p. 1.
- Holmes, G., and W. T. Lister, 1916: Disturbances of Vision from Cerebral Lesions with Special Reference to the Cortical Representation of the Macula, *Brain*, vol. xxxix, p. 34.
- Horrax, G., 1915: A Study of the Afferent Fibers of the Body Wall and of the Hind Legs to the Cerebellum of the Dog by the Method of Degeneration, *Jour. Comp. Neurol.*, vol. ix, p. 307.
- Horsley, Victor, 1906: Note on the *Tænia Pontis*, *Brain*, vol. xxix, p. 28.
- , 1909: The Function of the So-called Motor Area of the Brain, *Brit. Med. Jour.*, 1909, ii, p. 125.
- Horsley, Victor, and R. H. Clarke, 1908: The Structure and Functions of the Cerebellum Examined by a New Method, *Brain*, vol. xxxi, pp. 45-124.
- Huber, G. C., 1899: A Contribution on the Minute Anatomy of the Sympathetic Ganglia of the Different Classes of Vertebrates, *Jour. Morph.*, vol. 16, pp. 27-90.
- , 1913: The Morphology of the Sympathetic Nervous System, XVIIth International Congress of Medicine, London, 1913, Sec. 1, p. 211.
- Huber, G. C., and S. R. Guild, 1913: Observations on the Peripheral Distribution of the *Nervus Terminalis* in Mammalia, *Anat. Rec.*, vol. vii, p. 253.

- Ingalls, N. W., 1914: The Parietal Region in the Primate Brain, *Jour. Comp. Neurol.*, vol. xxiv, pp. 291-341.
- Ingvar, Sven, 1918: Zur Phylo- und Ontogenese des Kleinhirns, *Folia Neuro-biologica*, Bd. xi, p. 205.
- Johnson, S. E., 1918: On the Question of Commissural Neurones in the Sympathetic Ganglia, *Jour. Comp. Neurol.*, vol. xxix, p. 385.
- Johnston, J. B., 1901: The Brain of Acipenser, *Zoöl. Jahrb.*, Bd. xxv, pp. 1-204.
- , 1909: The Morphology of the Forebrain Vesicle in Vertebrates, *Jour. Comp. Neurol.*, vol. xix, p. 457.
- , 1909: The Radix Mesencephalica Trigemini, *Jour. Comp. Neurol.*, vol. xix, pp. 593-644.
- , 1912: The Telencephalon in Cyclostomes, *Jour. Comp. Neurol.*, vol. xxii, p. 341.
- , 1913: The Morphology of the Septum, Hippocampus, and Pallial Commissures in Reptiles and Mammals, *Jour. Comp. Neurol.*, vol. xxiii, p. 371.
- , 1914: The Nervus Terminalis in Man and Mammals, *Anat. Rec.*, vol. viii, p. 185.
- Jolly, W. A., 1911: On the Time Relations of the Knee-jerk and Simple Reflexes, *Quart. Jour. Exp. Physiol.*, vol. iv, p. 67.
- Kappers, C. U. Ariëns, 1914: The Phenomena of Neurobiotaxis in the Central Nervous System, XVIIth International Cong. Med., Sec. I, Part II, p. 109.
- , 1917: Further Contributions on Neurobiotaxis, *IX Jour. Comp. Neurol.*, vol. xxvii, pp. 261-298.
- Karplus, J. P., and A. Kreidl, 1914: Ein Beitrag zur Kenntnis der Schmerzleitung im Rückenmark, *Pflüger's Archiv*, Bd. clviii, p. 275.
- Kohnstamm, O., 1902: Der Nucleus salivatorius chordae tympani (nervi intermedi), *Anat. Anz.*, vol. xxi, pp. 362, 363.
- , 1903: Der Nucleus Salivatorius inferior und cranio-visceral System, *Neurol. Centralblatt*, Bd. xxii, p. 699.
- , 1907: Versuch einer physiologischen Anatomie der Vagusursprünge und des Kopfsympathicus, *Jour. f. Psych. u. Neurol.* VIII.
- Kohnstamm and Hindelang, 1910: Der nucleus intermedius sensibilis als Ursprung einer gekreuzt aufsteigenden Bahn (Visceralbahn), *Referat in Neurol. Centralbl.*, Bd. xxix, p. 663.
- Kölliker, H., 1891: Zur feineren Anatomie des central Nervensystems, *Zeit. f. wiss. Zoöl.*, Bd. li, p. 1.
- Kreidl, A., 1914: Zur Frage der sekundären Hörbahnen, *Monatschrift f. Ohrenheilkunde und Laryngo-Rhinologie*, 1914, H. 1.
- Kuntz, A., 1910: The Development of the Sympathetic Nervous System in Mammals, *Jour. Comp. Neurol.*, vol. xx, p. 211.
- Landacre, F. L., 1910: The Origin of the Cranial Ganglia in Ameiurus, *Jour. Comp. Neurol.*, vol. xx, pp. 309-411.
- , 1910: The Origin of the Sensory Components of the Cranial Ganglia, *Anat. Rec.*, vol. iv, pp. 71-79.
- Landau, E., 1919: Nucleus Amygdalæ, Claustrum and Insular Cortex, *Jour. of Anat.*, vol. liii, p. 351.
- Langley, J. N., 1892: The Origin from the Spinal Cord of the Cervical and Upper Thoracic Sympathetic Fibers, with Some Observations on White and Gray Rami Communicantes, *Phil. Trans. Roy. Soc., London*, vol. clxxxiii, p. 114.
- , 1900: The Sympathetic and Other Related Systems of Nerves, Schäfer's Text-book of Physiology, vol. ii.
- , 1900: Remarks on the Results of Degeneration of the Upper Thoracic White Rami Communicantes, Chiefly in Relation to Commissural Fibers in the Sympathetic System, *Jour. of Phys.*, vol. xxv, p. 468.
- , 1903: The Autonomic Nervous System, *Brain*, vol. xxvi, p. 1.
- , 1904: On the Question of Commissural Fibers Between Nerve-cells Having the Same Function, *Jour. of Physiol.*, vol. xxxi, p. 244.
- Langley and Magnus, 1905: Some Observations on the Movements of the Intestines Before and After Degenerative Section of the Mesenteric Nerves, *Jour. of Physiol.*, vol. xxxiii, p. 34.
- Larsell, O., 1918: Studies on the Nervus Terminalis: Mammals, *Jour. Comp. Neurol.*, vol. xxx, p. 1.
- , 1919: Studies on the Nervus Terminalis: Turtle, *Jour. Comp. Neurol.*, vol. xxx, pp. 423-443.

- Lewandowsky, M., 1907: Die Funktionen des Zentralen nervensystems, Jena.
- Lewis, W. H., 1910: The Development of the Muscular System, Keibel and Mall's Manual of Human Embryology, vol. i, p. 454.
- Linowiecki, A. J., 1914: The Comparative Anatomy of the Pyramidal Tract, Jour. Comp. Neurol., vol. xxiv, p. 509.
- MacNalty, A. S., and Victor Horsley, 1909: On the Cervical Spino-bulbar and Spino-Cerebellar Tracts and on the Question of Topographical Representation in the Cerebellum, Brain, vol. xxxii, p. 237.
- McCotter, R. E., 1913: The Nervus Terminalis in the Adult Dog and Cat, Jour. Comp. Neurol., vol. xxiii, p. 145-152.
- McKibben, P. S., 1911: The Nervus Terminalis in Urodele Amphibia, Jour. Comp. Neurol., vol. xxi, p. 261.
- Malone, E. F., 1910: Über die Kerne des menschlichen Diencephalon, Neur. Centralbl., 1910.
- , 1913: Recognition of Members of the Somatic Motor Chain of Nerve-cells by Means of a Fundamental Type of Cell Structure, Anat. Rec., vol. vii, p. 67.
- , 1913: The Nucleus Cardiacus Nervi Vagi and the Three Distinct Types of Nerve-cells which Innervate the Three Different Types of Muscle, Amer. Jour. Anat., vol. xv, p. 121.
- Marburg, O., 1904: Die Physiologische Funktion der Kleinhirnseitenstrangbahn, Arch. f. Anat. u. Physiol., Physiol. Abt., Suppl. 1904, S. 457.
- Marinesco, M. G., 1906: Quelques recherches sur la morphologie normale et pathologique des cellules des ganglions spinaux et sympathiques de l'homme, Le Névrose, t. viii, p. 9.
- Mauri, K., 1918: On the Finer Structure of the Synapse of the Mauthner Cell, Jour. Comp. Neurol., vol. xxx, p. 127.
- May, W. P., 1906: The Afferent Path, Brain, vol. xxix, p. 742.
- Michailow, S., 1911: Der Bau der zentralen sympathischen Ganglien, Internat. Monatschrift f. Anat. u. Physiol., vol. xxviii, pp. 26-115.
- Minot, C. S., 1901: On the Morphology of the Pineal Region Based Upon its Development in Acanthias, Amer. Jour. Anat., vol. i.
- Monakow, C. v., 1895: Experimentelle und pathologisch-anatomische Untersuchungen über die Haubenregion, den sehnhügel und die Regio subthalamica nebst Beiträgen zur Kenntnis früh erworbene Gross und Kleinhirndefecte, Archiv. f. Psych., vol. xxvii.
- , 1913: Zur Kenntnis der Grosshirnanteile (Vago-glossopharyngeusschleife), Neurol. Centr., 1913, p. 331.
- Müller, L. R., 1909: Studien über die Anatomie und Histologie des sympathischen Grenzstranges, XXVI Kongr. innere Med., Wiesbaden, p. 658.
- Müller, L. R., and W. Dahl, 1910: Die Beteiligung des sympathischen Nervensystems an der Kopfinnervation, Deutsches Arch. f. klin. Med., Bd. xcix, pp. 48-107.
- Muskens, L. J. J., 1914: An Anatomico-physiological Study of the Posterior Longitudinal Bundle in its Relation to Forced Movements, Brain, vol. xxxvi, pp. 352-426.
- Norris, H. W., 1908: The Cranial Nerves of Amphiuma Means, Jour. Comp. Neurol., vol. xviii, pp. 527-568.
- Parker, G. H., 1919: The Elementary Nervous System, Lippincott, Philadelphia.
- Petrén, K., 1902: Ein Beitrag zur Frage vom Verlaufe der Bahnen der Hautsinne im Rückenmarke, Skandinav. Archiv f. Physiol., Bd. xiii, s. 9.
- Ranson, S. W., 1911: Non-medullated Nerve-fibers in the Spinal Nerves, Amer. Jour. Anat., vol. xii, p. 67.
- , 1912: The Structure of the Spinal Ganglia and of the Spinal Nerves, Jour. Comp. Neurol., vol. xxii, p. 159.
- , 1912: Degeneration and Regeneration of Nerve-fibers, Jour. Comp. Neurol., vol. xxii, p. 487.
- , 1913: The Fasciculus Cerebrospinalis in the Albino Rat, Amer. Jour. Anat., vol. xiv, p. 411.
- , 1913: The Course Within the Spinal Cord of the Non-medullated Fibers of the Dorsal Roots. A Study of Lissauer's Tract in the Cat, Jour. Comp. Neurol., vol. xxiii, p. 259.
- , 1914: The Tract of Lissauer and the Substantia Gelatinosa Rolandi, Amer. Jour. Anat., vol. xvi, p. 97.
- , 1915: Unmyelinated Nerve-fibers as Conductors of Protopathic Sensation, Brain, vol. xxxviii, p. 381.
- Ranson, S. W., and P. R. Billingsley, 1916: Afferent Spinal Paths and the Vasomotor Reflexes, Amer. Jour. Physiol., vol. xlii, p. 16.

- Ranson, S. W., and P. R. Billingsley, 1916: The Conduction of Painful Afferent Impulses in the Spinal Nerves, *Amer. Jour. Physiol.*, vol. xl, p. 571.
- , 1918: Studies on the Sympathetic Nervous System, *Jour. Comp. Neurol.*, vol. xxix, p. 305.
- Rasmussen, A. T., 1919: The Mitochondria in Nerve-cells During Hibernation and Inanition in the Woodchuck, *Jour. Comp. Neurol.*, vol. xxxi, pp. 37-49.
- Reid, R. W., 1889: The Relations Between the Superficial Origins of the Spinal Nerves from the Spinal Cord and the Spinous Processes of the Vertebrae, *Jour. of Anat. and Physiol.*, vol. xxiii, p. 343.
- Retzius, J., 1880: Untersuchungen über die Nervenzellen der cerebrosinialen Ganglien und der übrigen peripherischen Kopfganglien, *Arch. f. Anat. u. Physiol., Anat. Abteil.*, 1880.
- Rhinehart, D. A., 1918: The Nervus Fascialis of the Albino Mouse, *Jour. Comp. Neurol.*, vol. xxx, pp. 81-125.
- Riddoch, George, 1917: The Reflex Functions of the Completely Divided Spinal Cord in Man, Compared with Those Associated with Less Severe Lesions, *Brain*, vol. xl, p. 264.
- Rogers, F. T., 1916: The Hunger Mechanism of the Pigeon and its Relation to the Central Nervous System, *Amer. Jour. Physiol.*, vol. xli, pp. 555-570.
- Rothmann, M., 1903: Zur Anatomie und Physiologie des Vorderstranges, *Neurol. Centralb.*, Bd. xxii, p. 744.
- , 1906: Über die Leitung der Sensibilität im Rückenmark, *Berlin, Klin. Wochensch.*, Bd. xliii, pp. 47, 76.
- , 1907: Über die physiologische Wertung der corticospinalen (Pyramiden-) Bahn, *Arch. f. (Anat. u.) Physiol.*, p. 217.
- Sabin, Florence, 1901: *An Atlas of the Medulla and Midbrain*, Baltimore.
- Sachs, E., 1909: On the Structure and Functional Relations of the Optic Thalamus, *Brain*, vol. xxxii, p. 95.
- Schäffer, E. A., 1899: Some Results of Partial Transverse Section of the Spinal Cord, *Proc. Physiol. Soc., Jour. Physiol.*, vol. xxiv, p. xxii.
- , 1910: Experiments on the Paths Taken by Volitional Impulses Passing from the Cortex to the Cord; the Pyramids and the Ventrolateral Descending Tracts, *Quart. Jour. Exp. Physiol.*, vol. iii, p. 355.
- Schulte, H. von W., and F. Tilney, 1915: Development of the Neuraxis in the Domestic Cat to the Stage of Twenty-one Somites, *Annals of the New York Acad. of Sciences*, vol. xxiv, pp. 319-346.
- Sherrington, C. S., 1894: Experiments in Examination of the Peripheral Distribution of the Fibers of the Posterior Roots of Some Spinal Nerves, *Phil. Tr. London (B)*, vol. clxxxiv, pp. 641-763.
- , 1894: On the Anatomical Constitution of Nerves of Skeletal Muscles; with Remarks on Recurrent Fibers in the Ventral Spinal Nerve Root, *Jour. of Physiol.*, vol. xvii, p. 211.
- , 1906: *The Integrative Action of the Nervous System*, Yale University Press, New Haven.
- Sherrington, C. S., and Graham Brown, 1913: Note on the Functions of the Cortex Cerebri, *Jour. Physiol.*, vol. xlvi, p. 22.
- Simpson, S., 1902: Secondary Degeneration Following Unilateral Lesions of the Cerebral Motor Cortex, *Internat. Monatsschrift f. Anat. u. Physiol.*, Bd. xix.
- Smith, G. Elliot, 1895: Morphology of the True Limbic Lobe, Corpus Callosum, Septum Pellucidum and Fornix, *Jour. of Anat. and Physiol.*, vol. xxx, pp. 157-167 and 185-205.
- , 1903: Further Observations on the Natural Mode of Subdivision of the Mammalian Cerebellum, *Anat. Anz.*, Bd. xxiii, p. 368.
- , 1907: A New Topographical Survey of the Human Cerebral Cortex, *Jour. Anat. and Physiol.*, vol. xli, p. 237.
- , 1915: *The Central Nervous System*, Cunningham's Anatomy, William Wood & Co., New York.
- , 1919: The Significance of the Cerebral Cortex, *Brit. Med. Jour.*, 1919, ii, p. 11.
- , 1919: Morphology of the Corpus Striatum and Origin of the Neopallium, *Jour. of Anat.*, vol. liii, p. 271.
- Solomowicz, von J., 1908: Vom Centrum der Submaxillardrüse, *Neurol. Centralb.*, Bd. xxvii, No. 15.
- Spiller, W. G., 1915: Remarks on the Central Representation of Sensation, *Jour. Nerv. and Ment. Diseases*, vol. xlii, p. 399.
- Starling, E. H., 1912: *Principles of Human Physiology*, Lea & Febiger, New York and Philadelphia.

- Stewart, P., 1901: Degenerations Following a Traumatic Lesion of the Spinal Cord, Brain, vol. xxiv, p. 222.
- Streeter, G. L., 1912: The Development of the Nervous System, Keibel and Mall, Human Embryology, vol. ii, Lippincott, Philadelphia.
- Strong, O. S., 1895: The Cranial Nerves of Amphibia, Jour. Morph., vol. x, pp. 101-230.
- , 1915: A Case of Unilateral Cerebellar Agenesis, Jour. Comp. Neurol., vol. xxv, p. 361.
- Terry, R. J., 1910: The Morphology of the Pineal Region in Teleosts, Jour. Morph., vol. xxi.
- Thiele, F. H., and Victor Horsley, 1901: A Study of the Degenerations Observed in the Central Nervous System in a Case of Fracture-dislocation of the Spine, Brain, vol. xxiv, p. 519.
- Thompson, T., 1912: A Case of Subacute Combined Degeneration of the Spinal Cord Demonstrating the Nature of the Afferent Impulses in the Posterior Columns, Brain, vol. xxxiv, p. 510.
- Tilney, F., 1911: Contribution to the Study of the Hypophysis Cerebri with Especial Reference to its Comparative Histology, Memoirs of the Wistar Institute of Anatomy and Biology, No. 2.
- , 1913: An Analysis of the Juxtaneural Epithelial Portion of the Hypophysis Cerebri, Internat. Monatsschrift f. Anat. u. Physiol., Bd. xxx, p. 258.
- Van Gehuchten, A., 1901: Recherches sur les voies sensitives centrales, La voie centrale du trigémeau, Le Névraxe, vol. iii, p. 235.
- , 1903: Recherches sur la voie acoustique centrale, Le Névraxe, vol. iv, pp. 253-300.
- , 1904: Le corps restiforme et les connexions bulbo-cérébelleuses, Le Névraxe, vol. vi, p. 125.
- Van Gehuchten, A., and M. Molhant, 1912: Contribution a l'étude anatomique du nerf pneumogastrique, Le Névraxe, vol. xiii, p. 55.
- Van Rynberk, G., 1908: Die neueren Beiträge zur Anatomie und Physiologie des Kleinhirns der Säuger. Folia Neuro-biologica, vol. i, p. 535.
- , 1908, 1912: Das Lokalisationsproblem im Kleinhirn, Ergebnisse der Physiol., Bd. vii, p. 653, and Bd. xii, p. 533.
- Van Valkenburg, C. T., 1913: Experimental and Pathologico-anatomical Researches on the Corpus Callosum, Brain, vol. xxxvi, p. 119.
- Vészi, J., 1918: Untersuchungen über die Erregungsleitung in Rückenmark. Ztschr. f. allg. Physiol., vol. xviii, pp. 58-92.
- Wallenberg, A., 1905: Sekundären Bahnen aus dem frontalen sensibeln Trigemuskern des Kaninchens., Anat. Anz., Bd. xxvi, p. 145.
- Walshe, F. M. R., 1919: On the Genesis and Physiological Significance of Spasticity and Other Disorders of Motor Innervation, Brain, vol. xlii, p. 1.
- Warren, J., 1911: The Development of the Paraphysis and Pineal Region in Reptilia, Amer. Jour. Anat., vol. xi, pp. 313-392.
- , 1917: The Development of the Paraphysis and Pineal Region in Mammalia, Jour. Comp. Neurol., vol. xxviii, pp. 75-103.
- Warrington, W. B., and F. Griffith, 1904: On the Cells of the Spinal Ganglia and on the Relationship of their Histological Structure to the Axonal Distribution, Brain, vol. xxvii, p. 297.
- Weed, L. H., 1914: A Reconstruction of the Nuclear Masses in the Lower Portion of the Human Brain-stem, Publications of the Carnegie Institution of Washington, 1914.
- , 1914: Observations Upon Decerebrate Rigidity, Jour. Physiol., vol. xlvi, p. 205.
- Willard, W. A., 1915: The Cranial Nerves of Anolis Carolinensis, Bul. Museum of Comp. Zoöl., Harvard, vol. lix, p. 17.
- Willems, E., 1911: Les noyaux masticateurs et mésencéphaliques du trigémeau, Le Névraxe, vol. xii, p. 7.
- Wilson, J. G., 1905: The Structure and Function of the Taste-buds of the Larynx, Brain, vol. xxviii, p. 339.
- Wilson, J. G., and F. H. Pike, 1915: The Mechanism of Labyrinthine Nystagmus, Arch. of Int. Med., vol. xv, p. 31.
- Wilson, S. A. K., 1912: Progressive Lenticular Degeneration, Brain, vol. xxxiv, p. 295.
- , 1914: An Experimental Research into the Anatomy and Physiology of the Corpus Striatum, Brain, vol. xxxvi, p. 427.
- Yagita, K. von, 1909: Weitere Untersuchungen über das Speichelzentrum, Anat. Anzeiger, Bd. xxxv, p. 70.
- Yagita, K., and S. Hayama, 1909: Über das Speichelsekretionszentrum, Neur. Centralb., Bd. xxviii, p. 738.

INDEX

NOTE.—In cross references the key words are *italicized*. The numbers in *Italics* refer to the pages on which the structures are illustrated.

- ACCOMMODATION of vision, 332
 Acoustic area of cortex. See *Center*, auditory.
 Acousticolateral area, 358
 Affenspalte, 237
 Ala cinerea, 127
 lobuli centralis, 197
 Alveus, 270, 278, 279
 Ameba, 17
 Ammon's horn. See *Hippocampus*.
 Ampulla of semicircular canal, 358
 Amygdala. See *Nucleus*, amygdaloid.
 Ansa lenticularis, 263
 peduncularis, 263
 Aperture, lateral, of fourth ventricle, 125
 medial, of fourth ventricle, 125
 Apex columnæ posterioris, 79
 Aphasia, 295
 Aqueductus cerebri (aqueduct of Sylvius), 26, 158
 Arachnoid, 73
 Arbor vitæ, 199
 Archipallium, 116, 242, 270, 277, 278, 279
 Area, acousticolateral, 358
 acustica, 127
 cortical, 287. (See also *Center*.)
 oval, of Flechsig, 107
 parolfactoria of Broca, 267
 postrema, 129
 pyriform, 116, 268, 277
 striata, 293
 Association bundles of cerebrum, 298
 arcuate, 298, 300
 cingulum, 299
 inferior longitudinal, 299
 occipitofrontal, 300
 superior longitudinal, 300
 occipitofrontal, 301
 uncinate, 299
 Ataxia, 99
 Auditory apparatus, 186, 309
 Auerbach's plexus, 351
 Autonomic system, 339
 cranial, 339
 craniosacral, 340, 354
 sacral, 339
 thoracolumbar, 339, 354
 Axon (axis-cylinder), 37, 43, 45
 hillock. See *Cone*, implantation.
 Axonal reaction. See *Chromatolysis*.
 BAILLARGER, lines of, 283
 Band, diagonal, 267
 Basis cerebri, 115, 120
 pedunculi, 129, 158, 164
 Basket-cells, 209
 Bell's law, 60
 Betz, cells of, 290
 Bladder, innervation of, 354
 Body of cell, 43
 of fornix, 271
 geniculate, lateral, 131, 220
 medial, 131, 167, 220
 mammillary, 222, 280
 of Nissl, 48, 51
 paraterminal, 267
 pineal, 221
 pituitary. See *Hypophysis*.
 quadrigeminal, 130, 165
 restiform, 122, 143, 205
 striate. See *Corpus striatum*.
 tigroid. See *Nissl* body.
 trapezoid, 121, 150, 186
 Brachium (or brachia), conjunctivum, 125, 155, 159, 160, 206, 211
 of corpora quadrigemina, 131
 pontis, 123, 204
 quadrigeminum inferius, 131, 163, 166
 superius, 131, 167
 Brain, 56, 113
 development, 25
 divisions of, 25
 end-. See *Telencephalon*.
 fore-. See *Prosencephalon*.
 hind-. See *Metencephalon* and *Rhombencephalon*.
 inter-. See *Diencephalon*.
 stem. See *Medulla oblongata*, *Pons*, *Mesencephalon*, and *Ganglia*, basal.
 vesicles, 24, 25
 weight, 301
 Broca's convolution, 235
 Brown-Séquard syndrome, 112
 Bulb, olfactory, 265, 274
 of posterior horn, 248
 Bundle. (See also *Fasciculus* and *Tract*.)
 association, of cerebrum, 298, 299, 300
 cornucommissural, 107
 ground. See *Fasciculus proprius*.
 of Gudden, tegmental. See *Tract*, mammillo-tegmental.
 marginal. See *Fasciculus dorsolateralis*.
 oval. See *Area*, oval.
 posterior longitudinal. See *Fasciculus*, medial longitudinal.
 of Türck. See *Tract*, ventral corticospinal.
 ventral longitudinal. See *Tract*, tectospinal.
 Burdach, column of. See *Fasciculus cuneatus*.
 nucleus of. See *Nucleus cuneatus*.
 CAJAL, commissural nucleus of, 330
 horizontal cells of, 285
 Calamus scriptorius, 127

- Calcar avis, 238, 248
 Canal, central (canalis centralis), 80, 136
 lateral line, 356
 semicircular, 315, 356
 spinal, 73
 Capsule, external, 257
 internal, 257, 259, 261
 nasal, 356
 of spinal ganglion cell, 63
 Cauda equina, 78
 Cavum septi pellucidi, 272
 Cell. (See also *Neuron*.)
 basket, 209
 of Betz, 290
 body, 43
 ependymal, 37, 85
 germinal, 37
 granule, of cerebellum, 208
 of cerebral cortex. See *Neurons*, stellate.
 of olfactory bulb, 276
 mitral, 275
 neuroglia, 85, 86
 of Purkinje, 207
 pyramidal, 285
 Cell-columns of Clarke. See *Nucleus dorsalis*.
 intermediolateral, 89
 of spinal cord, 89, 90
 Center, cortical, 290
 association, 293
 auditory, 293
 motor, 290, 317, 318
 olfactory, 293
 optic, 292
 projection, 290
 somesthetic, 292
 of speech, 295
 visual, 292
 for pain, 219
 projection, 290
 respiratory, 330
 Central nervous system, 20, 21, 56, 57
 Centrum medianum thalami, 218
 semiovale, 243
 Cerebellum, 195
 in birds and reptiles, 200
 central white matter, 199
 cortex, 199, 206, 207, 208, 209
 development of, 195
 in the dogfish, 27, 28
 fiber tracts of, 204, 205, 206, 209, 210, 211
 folia, 199
 hemispheres of, 197, 198
 histogenesis, 196
 laminae, 199
 lobes or lobules, 197, 198, 200, 201, 202
 in mammals, 200
 microscopic structure, 206
 morphology of, 199
 notches, 197
 nucleus dentatus, 203, 211
 emboliformis, 203
 fastigii or tecti, 204, 211
 globosus, 203
 peduncles, 204
 inferior, 122, 143, 205
 middle, 123, 204
 superior, 125, 155, 159, 160, 206, 211
 section, median, 199
 through hemisphere, 199
 Cerebellum in the sheep, 200, 201, 202
 vermis of, 196
 white matter, 199
 Cerebral aqueduct. See *Aqueductus cerebri*.
 cortex, 114, 232, 283
 area of, acoustic, 293
 association, 293
 audito-psychic, 293, 294
 audito-sensory, 294
 of Broca, 295
 motor, 290, 317, 318
 striata, 293
 visuo-psychic, 293, 294
 visuo-sensory, 294
 centers of, 290, 292, 295
 development, 230
 electric excitability of, 291
 frontal olfactory, 277
 hippocampal, 278, 279
 histogenesis, 230
 layers of, 286, 287
 localization of function in, 290
 myelination of fibers, 289
 nerve-cells, 284, 285
 nerve-fibers, 283, 284
 neuroglia-cells, 284
 structure, 283, 284, 285, 286
 hemispheres, 113, 229, 232
 borders, 232
 commissural fibers, 296
 convolutions. See *Gyri*.
 corticifugal or efferent fibers, 283
 corticipetal or afferent fibers, 283
 development, 25, 32, 229
 in the dogfish, 27, 28, 30
 external conformation, 229
 fissures. See *Fissure*.
 gyri. See *Gyrus*.
 lobes. See *Lobe*.
 lobules. See *Lobule*.
 medullary center, 243, 296
 pallium, 25, 32, 33, 229
 poles, 232
 sulci. See *Sulcus*.
 surfaces, 232
 ventricles, lateral, 246
 peduncles. See *Peduncles*.
 vesicles, 24, 25
 Cerebrospinal fluid, 73, 126
 system, 58
 Cerebrum, 117
 Cervix, columnae posterioris, 79
 Chiasma, optic, 223, 226
 Chorda tympani, 192, 352
 Chorioid fissure, 229, 251
 plexuses. See *Plexus*.
 Chromatolysis, 51
 Chromophilic bodies. See *Nissl* bodies.
 Cingulum, 299
 Clarke, column of. See *Nucleus dorsalis*.
 Claustrum, 256
 Clava, 121, 137
 Climbing fibers, 209, 210
 Clivus monticuli. See *Declive* monticuli.
 Cochlea, 185
 Cœlenterates, 19
 Cold, sensations of, 105, 306
 Collateral fibers, 43, 97
 Colliculus facialis, 127

- Colliculus, inferior, 130, 165
 superior, 130, 165, 167
- Column, anterior, 80
 of Burdach. See *Fasciculus cuneatus*.
 of Clarke. See *Nucleus dorsalis*.
 dorsal (columna dorsalis grisea), 42
 of fornix, 272
 of Goll. See *Fasciculus gracilis*.
 gray, 79
 intermediolateral, 89
 lateral, 80
 nuclear, of brain stem, 168, 170, 171, 174
 posterior, 79
 somatic afferent, 170, 182, 185
 efferent, 170
 ventral, 42, 80
 vesicular. See *Nucleus dorsalis*.
 visceral afferent, 170, 180
 efferent, 170, 174, 177
- Comma tract of Schultze. See *Fasciculus inter-fascicularis*.
- Commissura anterior alba, 80
 grisea, 80
 habenularum, 220
- Commissure or commissures, anterior cerebri, 223, 231, 273, 296
 gray, 80
 white, 80
 great transverse. See *Corpus callosum*.
 of Gudden, 227
 habenular, 220
 hippocampal, 231, 271, 280, 296
 of inferior colliculi, 159
 middle. See *Massa intermedia*.
 optic. See *Chiasma*, optic.
 posterior, of cerebrum, 221
 of spinal cord, 80
 superior. See *Commissure*, habenular.
- Components of nerves, 61, 168. (See also *Nerve-fibers*.)
- Conduction of nerve impulses, 50
- Cone, implantation, 44
 of origin. See *Cone*, implantation.
- Cones of retina, 226
- Consciousness, 23, 302
- Conus medullaris, 74
- Convolution. See *Gyrus*.
- Coördination, 99, 210, 311
- Cornu ammonis. See *Hippocampus*.
- Cornucommissural bundle, 107
- Corona radiata, 261
- Corpus (or corpora) callosum, 243, 296
 development, 231
 fornix, 271
 geniculatum laterale, 220
 mediale, 131, 167, 220
 mamillaria, 222, 230
 pineale, 221
 ponto-bulbare, 123
 quadrigemina, 130, 165
 restiforme, 122, 143, 205
 striatum, 25, 32, 33, 256, 262, 324
 subthalamicum (Luysi), 223
 trapezoideum, 121, 150, 186
- Cortex, cerebellar, 199, 206, 207, 208, 209
 localization of function in, 202
 neurons of, 207, 208, 209
 cerebral. See *Cerebral cortex*.
- Corti, ganglion of. See *Ganglion*, spiral.
- Corti, organ of, 185, 186
- Cough, mechanism of, 331
- Crus (or crura) cerebri. See *Peduncle*, cerebral.
 fornix, 271
- Crusta. See *Basis pedunculi*.
- Culmen monticuli, 198
- Cuneate tubercle, 121, 137
- Cuneus, 239, 292
- Cup, optic, 32, 33, 225
- Cytoplasm of nerve-cells, 42, 47, 48
- DECLIVE monticuli, 198
- Decussation (decussatio) of brachium conjunctivum, 156, 159
 dorsal tegmental, 161, 167
 of fillet. See *Decussation* of lemniscus.
 of Forel. See *Decussation*, ventral tegmental.
 fountain. See *Decussation*, dorsal tegmental.
 of lemniscus (lemniscorum), 134, 138
 of Meynert. See *Decussation*, dorsal tegmental.
 optic. See *Chiasma*, optic.
 of pyramids, 119, 120, 134, 136
 tegmental. See *Decussations*, ventral and dorsal tegmental.
 ventral tegmental, 161
- Degeneration of fiber tracts, 105, 106, 107
 of nerve-fibers, 51, 52
 Wallerian, 105, 106, 107
- Deiters, nucleus of, 151, 189
- Dendrites or dendrons, 43
- Dermatome, 58
- Development of the nervous system, 24, 31
- Diencephalon, 24, 25, 26, 28, 31, 33, 213
- Digitationes hippocampi, 269
- Dogfish, brain of, 26, 27, 28
- Dogiel's Type II cells, 65
- Dura mater, 73
- Dynamic polarity, law of, 50
- EARTHWORM, nervous system of, 19
- Edinger-Westphal nucleus, 178
- Effector, 18, 19, 54, 91
- Embryology of nervous system, 31, 37, 195, 213, 229
- Eminentia cinerea. See *Ala cinerea*.
 collateralis, 250
 facialis. See *Colliculus facialis*.
 hypoglossi. See *Trigonum hypoglossi*.
 medialis, 129
 teres. See *Eminentia medialis*.
- Encephalon. See *Brain*.
- End-brain. See *Telencephalon*.
- End-plates, motor, 62
- Ependyma, 85
- Epiphysis, 29, 31
- Epithalamus, 29, 35, 220
- Exteroceptor, exteroceptive, 66, 182, 185, 304
- Eye, development, 225
 innervation, 225
 retina, 225
- FASCIA dentata, 269, 279
- Fasciculus, 95. (See also *Tract and Bundle*.)
 anterior proprius, 107
 anterolateralis superficialis, 100
 arcuatus, 300
 cerebellospinalis. See *Tract*, dorsal spinocerebellar.
 cerebrospinalis. See *Tract*, corticospinal.

- Fasciculus cerebrosppinalis, anterior.** See *Tract*, ventral corticospinal.
 lateralis. See *Tract*, lateral corticospinal.
 cuneatus, 76, 83, 95, 96, 121, 137
 dorsal longitudinal (Schütz), 216
 dorsolateralis (Lissauer), 79, 87, 98, 104
 gracilis, 76, 83, 96, 121, 137
 interfascicularis, 97, 107
 lateralis, minor, 121
 proprius, 107
 longitudinalis inferior, 299
 medialis, 145, 152, 162, 190, 328
 superior, 300
 medial longitudinal, 145, 152, 162, 190, 328
 of Meynert, 220
 occipitofrontalis, inferior, 300
 superior, 301
 peduncularis transversus, 369
 posterior longitudinal. See *Fasciculus*, medial longitudinal.
 proprius of spinal cord, 107
 pyramidal. See *Tract*, corticospinal.
 retroflexus, 220
 septomarginal, 97, 107
 solitarius, 132, 181, 330
 sulcomarginalis, 108
 superior longitudinal, 300
 thalamomammillar. See *Tract*, mammillo-thalamic.
 uncinatus, 299
- Fibers, fibræ.** (See also *Nerve-fibers*.)
 arcuate, of cerebrum, 299
 of medulla oblongata, 139
 external, 121, 123, 139, 140, 143
 internal, 134, 138, 139
 association, 92, 298
 cerebello-olivary. See *Fibers*, olivocerebellar.
 climbing, 209, 210
 commissural, 296
 mossy, 209, 210
 olivocerebellar, 139, 142, 143, 205
 pontis, 147
 postganglionic, 337, 343
 preganglionic, 337, 344
 projection, 297
 propriae. See *Fibers*, arcuate, of cerebrum.
 rectæ, 148
- Fila lateralia pontis**, 148
- Fillet.** See *Lemniscus*.
- Filum duræ matris spinalis**, 74
 terminale, 74
 externum, 74
 internum, 74
- Fimbria hippocampi**, 250, 269
- Final common path**, 94, 311
- Fissure (or fissura), calcarine**, 238, 292
 callosal. See *Sulcus* of corpus callosum.
 callosomarginal, 240
 central, of Rolando, 233
 cerebri lateralis, 233
 chorioid, 229, 251
 collateral, 239
 dentate. See *Fissure*, hippocampal.
 development, 230, 231
 great longitudinal, 232
 transverse. See *Fissure*, transverse cerebral.
 hippocampal, 239, 269, 270
 lateral cerebral, 233
- Fissure, longitudinal cerebral**, 114, 232
 mediana, anterior, of medulla oblongata, 119
 of spinal cord, 76, 82
 posterior, of medulla oblongata, 119
 parieto-occipital, 239
 prima, 196, 199
 rhinal, 116, 240
 of Rolando. See *Sulcus*, central.
 secunda, 203
 Sylvian. See *Fissure*, lateral cerebral.
 transverse cerebral, 213
- Flechsig, direct cerebellar tract of.** See *Tract*, dorsal spinocerebellar.
- Flexure, cephalic**, 31, 33
 cervical, 32, 33
 pontine, 31, 33
- Flocculus**, 199
- Fluid, cerebrospinal**, 73, 126
- Folium vermis**, 198
- Foramen cæcum**, 119
 interventricular, 26, 118
 of Luschka. See *Aperture*, lateral, of fourth ventricle.
 of Majendie. See *Aperture*, medial, of fourth ventricle.
 of Monro. See *Foramen*, interventricular.
- Forceps, major**, 245
 minor (frontal part of radiation of corpus callosum).
- Fore-brain.** See *Prosencephalon*.
- Forel, fountain decussation of.** See *Decussation*, ventral tegmental.
- Formatio reticularis**, 80, 136, 144
- Fornix**, 270, 280
 body, 271
 columns, 271, 272
 commissure, 271, 280
 crura, 271
 fimbria, 270, 271
 longus, 282
- Fossa interpeduncularis**, 115
 rhomboid, 126, 127
- Fountain decussations of Forel and of Meynert**, 161, 167
- Fovea, inferior**, 127
 superior, 127
- Frenulum veli medullaris anterior**, 130
- Frog, sympathetic ganglia of**, 344, 345
- Funiculus**, 95
 anterior, 76, 82
 cuneatus, 121, 137
 dorsal. See *Funiculus*, posterior.
 gracilis, 121, 137
 lateralis, 76, 82
 posterior, 76, 82
 separans, 129
 teres. See *Eminentia medialis*.
 ventral. See *Funiculus*, anterior.
- GANGLIATED cord.** See *Trunk*, sympathetic.
- Ganglion or ganglia, autonomic.** See *Ganglia*, sympathetic.
 basal, 252
 celiac, 349
 cerebrospinal (sensory ganglia on the cerebrospinal nerves), 38
 cervical, inferior, 348
 middle, 348
 superior, 347

- Ganglion, ciliary, 351
 of Corti. See *Ganglion*, spiral.
 enteric, small ganglia of myenteric and submucous plexuses, 351
 of facial nerve. See *Ganglion*, geniculate.
 Gasserian. See *Ganglion*, semilunar.
 geniculate, 192
 habenulæ, 29, 220
 interpeduncular, 115, 164
 jugular, 193
 mesenteric, 349
 nodosum, 193
 otic, 351
 petrosal, 193
 of Scarpa. See *Ganglion*, vestibular.
 semilunar, 191
 sensory, 38
 sphenopalatine, 351
 spiral, 62
 development of, 38, 40
 structure of, 63, 64, 65
 spiral, 185, 186
 submaxillary, 351
 sympathetic, collateral, 335
 development of, 41, 335
 prevertebral. See *Ganglia*, collateral sympathetic.
 structure of, 341
 of sympathetic trunk, 335
 terminal, 335
 vertebral. See *Ganglia* of sympathetic trunk.
 of trigeminus. See *Ganglion*, semilunar.
 vestibular, 188
 Gemmules, 43
 Geniculate body. See *Body*.
 ganglion. See *Ganglion*.
 Gennari, line of, 283
 Genu of corpus callosum, 243
 of internal capsule, 258, 262
 internum of facial nerve, 175, 176, 180
 Glia-cells. See *Cells*, neuroglia.
 Glial sheath, 86
 Globus pallidus, 254, 256, 324
 Glomeruli, cerebellar, 208
 olfactory, 276
 of sensory axons, 63
 of sympathetic ganglia, 341
 Golgi cells of Type II, 44, 87
 method of, 361
 Goll, column or tract of. See *Fasciculus gracilis*.
 Gowers, bundle of. See *Fasciculus anterolateralis superficialis*.
 Granular layer of cerebellum, 208
 Gudden, commissure of, 227
 Gustatory apparatus, 181
 Gyrus (or gyri), angular, 236
 annectent, 234
 anterior central, 235, 290
 ascending parietal. See *Gyrus*, posterior central.
 breves or short gyri of insula, 237
 callosal. See *Gyrus* cinguli.
 centralis, anterior, 235, 290
 posterior, 236, 292
 cinguli, 240
 dentatus. See *Fascia dentata*.
 diagonal, of rhinencephalon, 267
 Gyrus fornicatus, 240
 frontal, ascending. See *Gyrus*, anterior central.
 inferior, 235
 middle, 235
 superior, 235, 240
 fusiform, 240
 hippocampal, 116, 240, 277
 insulæ, 237
 limbic. See *Lobe*, limbic.
 lingual, 239, 292
 longus insulæ, 237
 marginalis. See *Gyrus*, superior frontal.
 olfactory, lateral, 116, 266, 277
 medial, 116, 266
 orbital, 241
 postcentral. See *Gyrus*, posterior central.
 posterior central, 236, 292
 precentral. See *Gyrus*, anterior central.
 rectus, 241
 subcallosus (pedunculus corporis callosi), 267
 supracallosal, 244, 270
 supramarginal, 236
 temporal, inferior, 236
 middle, 236
 superior, 236
 transverse, 236, 293
 uncinatus. See *Gyrus*, hippocampal.
 HABENULA. See *Nucleus habenulæ*.
 Hearing, organs of, 185, 186, 187, 309
 Heart, innervation of, 353
 Heat, sensations of, 105, 306
 Hemianopsia, 228
 Hemiplegia, 323
 Hemispheres, cerebellar, 197, 198
 cerebral. See *Cerebral* hemispheres.
 Hilus nuclei olivaris, 141
 Hind-brain. See *Metencephalon* and *Rhombencephalon*.
 Hippocampal gyrus, 116, 240, 277
 commissure, 231, 271, 280, 296
 Hippocampus, 250, 269, 277
 Histogenesis of cerebellar cortex, 196
 of cerebral cortex, 230
 of nervous system, 37
 of peripheral nervous system, 40
 of spinal cord, 38, 39, 42
 ganglia, 38, 40
 Horizontal cells of Cajal, 285
 Horn of lateral ventricle, 246. (See also *Column*.)
 Hypophysis, 222
 in the dogfish, 29
 Hypothalamus, 35, 222
 in the dogfish, 29
 pars mamillaris, 222
 optica, 35
 INCISURA. See *Notch*.
 Indusium griseum, 244, 270
 Infundibulum, 222
 Insula, 229, 237
 Inter-brain. See *Diencephalon*.
 Interoceptor, interoceptive, 66, 101
 Interpeduncular fossa (or space), 115
 Interventricular foramen, 26, 118
 Intumescencia cervicalis, 73, 84
 lumbalis, 74, 84

- Island of Reil. See *Insula*.
 Iter a tertio ad quartum ventriculum. See *Aqueductus cerebri*.
- JELLY-FISHES, 19
 Joints, sensory fibers of, 72
- KRAUSE, end-bulb of, 68
- LAMINA affixa, 215
 alar. See *Plate*, alar.
 basal. See *Plate*, basal.
 medullaris involuta. See *Stratum lacunosum*.
 quadrigemina, 130, 158
 rostralis, 223, 243
 septi pellucidi, 272
 terminalis, 25, 33, 223, 231
- Laminae medullares of lentiform nucleus, 254
 thalami, 216
- Lancisi, nerve of. See *Stria longitudinalis medialis*.
- Lateral line organs, 356
- Layers of cerebellar cortex, 208
 of cerebral cortex, 286, 287
 ependymal, 37
 mantle, 37, 42, 196
 marginal, 37, 42, 196
 of retina, 225
- Lemniscus, lateral, 130, 157, 163, 165, 166, 186, 187, 309
 medial, 135, 138, 145, 153, 163, 219, 313
 spinal. See *Tract*, spinothalamic.
 trigeminal. See *Path*, secondary afferent, of trigeminal nerve.
- Ligamentum denticulatum, 74
- Limen insulae, 237, 268
- Line (or lines) of Baillarger, 283
 of Gennari, 283
- Linea splendens, 74
- Lingula of cerebellum, 197
- Lissauer, tract of. See *Fasciculus dorsolateralis*.
- Lobe (lobus or lobes) of cerebellum, 197, 198, 200, 201, 202
 of cerebrum, 234
 frontal, 234
 inferior, 28
 insular. See *Insula*.
 limbic. See *Gyrus fornicatus*.
 lineae lateralis, 27
 occipital, 236, 238
 olfactory, 267
 optic, 27, 28, 165
 parietal, 236
 pyriform. See *Area*, pyriform.
 temporal, 235
 visceral, 27
- Lobule (or lobulus) ansiformis, 201
 biventer, 199
 centralis, 197
 paracentral, 240, 290
 paramedianus, 201
 parietal, inferior, 236
 superior, 236
 postcentral. See *Gyrus longus insulae*.
 precentral. See *Gyri breves insulae*.
 quadrangularis, 198
 quadrate. See *Precuneus*.
 semilunaris, inferior, 198
- Lobule semilunaris, superior, 198
 simplex, 200
- Localization of function in cerebellum, 202
 in cerebral cortex, 290
 in thalamus, 219
- Locus caeruleus, 128
- Luschka, foramen of. See *Aperture*, lateral, of fourth ventricle.
- Luys, nucleus of. See *Nucleus hypothalamicus*.
- Lyra. See *Commissure*, hippocampal.
- MACROSMATIC mammals, 265
- Magendie, foramen of. See *Aperture*, medial, of fourth ventricle.
- Mammillary body, 222, 280
- Mantle. See *Cerebral cortex*.
 layer. See *Layer*.
- Marchi stain for degenerated nerves, 360
- Martinotti, cells of, 285
- Massa intermedia, 216
- Matter, central gray, 136, 158
 gray, 42, 79, 87
 white, 42, 79, 86
- Medulla oblongata, 114, 118
 closed portion of, 119
 development, 35. (See also *Myelencephalon*.)
 in the dogfish, 26, 27, 28
 fissure, anterior median, 119
 posterior median, 119
 form, 118, 119, 120, 121, 122
 gray matter, 136
 internal structure, 132
 length, 118
 motor nuclei, 170, 174
 open portion of, 119
 sensory nuclei, 180, 182
 sulci, 119
 spinalis. See *Spinal cord*.
- Meissner, corpuscles of, 68
 plexus of, 351
- Meninges, 73, 74
- Merkel, corpuscle of, 68
- Mesencephalon, 129, 158
 development, 24, 31, 35, 36
 in the dogfish, 27, 28
 form, 129
 internal structure, 158
- Metamerism, 58. (See also *Segmentation*.)
- Metathalamus, 220
- Metencephalon, 31, 33, 36
- Meynert, fasciculus retroflexus of, 220
 fountain decussation of. See *Decussation*, dorsal tegmental.
- Microsmatic mammals, 265
- Mid-brain. See *Mesencephalon*.
- Mitochondria, 49
- Molecular layer of cerebellum, 208
 of cerebral cortex, 286
- Monakow, bundle of. See *Tract*, rubrospinal.
- Monro, foramen of. See *Foramen*, interventricular.
- Monticulus, 198
- Moss-fibers of cerebellum, 209, 210
- Motor apparatus, 316
 area of cerebral cortex, 290, 317, 318
 end-plate, 62
- Muscle, branchial, 174
 cardiac, innervation of, 353

- Muscle of eyeball, innervation of, 352
of facial expression, innervation of, 192
of larynx, innervation of, 194
of mastication, innervation of, 192
nerve endings in, 62, 72
sense (proprioceptive), 72, 99, 100, 311
skeletal. See *Muscle*, branchial and somatic.
smooth or unstriated. See *Muscle*, visceral.
somatic, innervation of, 62, 170
striated. See *Muscle*, branchial and somatic.
of tongue, innervation of, 194
visceral, innervation of, 61, 174, 177
- Muscle-spindles, 72
- Myelencephalon, 31, 32, 33, 36
- Myelin, 46
sheath. See *Sheath*.
- Myelination in cerebral cortex, 289
in spinal cord, 112
- Myotome, 58, 170
- NEOPALLIUM, 116, 232, 242
- Neothalamus, 219
- Nerve (Nervus), abducens, 123, 154, 173, 192
accessory, 123, 176, 177, 194
acoustic, 123, 185, 192
auditory. See *Nerve*, acoustic.
cardiac, 348, 349
cerebrospinal, 56
chorda tympani, 192, 352
ciliary, 352
cochlear, 149, 185, 193
components, 61. (See also *Nerve-fibers*.)
cranial, 56, 132, 133, 168
facial, 123, 153, 175, 192
glossopharyngeal, 123, 193
hypoglossal, 123, 173, 194
intermedius, 123, 192
of Lancisi. See *Stria longitudinalis medialis*.
lingual, 192
oculomotor, 130, 164, 171, 172, 191
olfactory, 191, 265
optic, 191, 225
phrenic, 59
pneumogastric. See *Nerve*, vagus.
spinal, 56, 58, 65
development of, 40
splanchnic, 348
sympathetic, 345
terminalis, 27, 190
thoracic, 58
trigeminal, 124, 154, 174, 182, 191
trochlear, 125, 163, 173, 191
vagus, 123, 178, 193
vestibular, 149, 185, 193, 314
of Wrisberg. See *Nervus intermedius*.
- Nerve-cells, 43. (See also *Neurons* and *Cells*.)
autonomic. See *Neurons*, sympathetic.
motor, for involuntary muscles, 177
for voluntary muscles, 177
processes, 43
shape, 43
structure, 47
types of, 43, 44
- Nerve-endings, encapsulated, 68
free in epidermis, 67
in free arborizations, 67
in hair-follicles, 70, 71
in Meissner's corpuscles, 68
on Merkel's touch-cells, 68
- Nerve-endings in muscle-spindles, 71, 72
in Pacinian corpuscles, 69
peripheral, 66-72
plexuses of sensory nerve-fibers, 67
in synapses. See *Synapse*.
in tactile corpuscles, 68
in tendons, 72
in voluntary muscles, 62
- Nerve-fibers, 45. (See also *Fibers*.)
afferent, 58, 63. (See also *Nerve-fibers*, somatic and visceral afferent.)
autonomic. See *Nerve-fibers*, preganglionic and postganglionic.
of cerebellar cortex, 209
of cerebral cortex, 283
classification of, 60
collateral, 43, 97
degeneration of, 52, 105, 106, 107
development, 40, 41
of dorsal root, 95
efferent, 58
exteroceptive, 66
gray. See *Nerve-fibers*, postganglionic.
interoceptive, 66
to involuntary muscles, 61
medullated. See *Nerve-fibers*, myelinated.
motor, 59, 62, 94
myelinated, 45, 46, 47, 63, 66, 67, 87
non-medullated. See *Nerve-fibers*, unmyelinated.
postganglionic, 337, 343
preganglionic, 337, 344
primary motor, 62, 90
proprioceptive, 66, 72
regeneration, 52
of Remak. See *Nerve-fibers*, unmyelinated.
somatic afferent, 61, 66
general, 168, 182, 192, 193
special, 168, 191, 193
efferent, 61, 62, 168, 191, 192, 194
sympathetic. See *Nerve-fibers*, postganglionic.
unmyelinated, 47, 63, 66, 67, 87, 98, 104
visceral afferent, 61
general, 168, 181, 193, 337
special, 168, 180, 192, 193
efferent, 61
general, 168, 178, 192, 193, 194, 336
special, 168, 174, 192, 193, 194
to voluntary muscles. See *Nerve-fibers*, somatic efferent and special visceral efferent.
of white rami, 61, 347
substance of brain and cord, 47
- Nerve-root. See *Root*.
- Nervous system, autonomic, 339
cranial, 339
craniosacral, 340
sacral, 339
thoracolumbar, 339, 340
central, 20, 21, 56, 57
cerebrospinal, 58
development of, 24, 32, 36, 37
diffuse, 18, 19, 340
invertebrate, 19, 20, 21, 22
peripheral, 56
subdivisions of, 56
sympathetic, 56, 57, 334
vertebrate, 21, 22
- Net, nervous, 19, 340. (See also *Plexus*.)

- Neural crest, 37
 groove, 24, 31
 tube, 24, 31, 36
- Neurilemma, 41, 46, 47
- Neurobiotaxis, 179
- Neuroblasts, 37, 39
- Neurofibrils, 48, 49, 50
- Neuroglia, 85, 86
- Neuromuscular end-organ, 72
 mechanism, 17
- Neuron or neurons, 43. (See also *Nerve-cells*.)
 basket cell, 50
 bipolar, 39, 44, 63
 chains, 43, 49, 53, 54
 concept, 52
 of cerebellar cortex, 207, 208, 209
 of cerebral cortex, 285
 development of, 37
 form of, 42
 horizontal, of Cajal, 285
 interrelation of, 49
 lower motor, 318
 of Martinotti, 285
 motor, 22, 44, 46, 177
 multipolar, 44
 of olfactory bulb, 275
 polarization of, 50
 postganglionic, 337
 preganglionic, 337, 339, 341
 of Purkinje, 207
 pyramidal, 43, 44, 285
 of retina, 225, 226
 sensory, 22, 23, 37, 63
 stellate, 285
 structure of, 47
 sympathetic, 341
 theory of. See *Neuron* concept.
 type I, 44, 87
 type II, 44, 45, 87, 88
 unipolar, 39, 44, 63
 upper motor, 317
- Neuropil, 20, 21
- Neuropore, 31
- Nissl bodies or granules, 48, 51
- Nodes of Ranvier, 47
- Nodule of vermis, 198
- Non-medullated fibers. See *Nerve-fibers*, unmyelinated.
- Notch, anterior cerebellar, 197
 posterior cerebellar, 197
 preoccipital, 234
- Nucleated sheath. See *Neurilemma*.
- Nucleus (or nuclei) of abducens N., 154, 173
 accessory cuneate, 138
 of accessory N., 194
 of acoustic N. See *Nuclei*, cochlear and vestibular.
 ambiguus, 146, 176
 amygdaloid, 249, 257
 anterior thalami, 217, 218
 arcuate, 140, 143
 arcuatus thalami, 218
 of Bechterew, 152, 189
 caudatus, 253
 centralis, superior, 157
 of thalamus, 218
 of cerebellum, 203, 204
 cochlear, 123, 149, 185
 commissural, 330
- Nucleus of corpus mamillare, 222
 cuneatus, 122, 134, 137, 139
 of Darkschewitsch, 153
 of Deiters, 151, 189
 dentatus, 203, 206, 211
 dorsalis, 90, 100
 of dorsal funiculus. See *Nucleus gracilis* and *Nucleus cuneatus*.
 dorsal motor, of vagus, 146, 178
 thalamic. See *Nucleus*, anterior thalami.
 of Edinger and Westphal, 178
 emboliformis, 203
 external round, 138
 of facial N., motor, 153, 175, 179
 of fasciculus cuneatus. See *Nucleus cuneatus*.
 gracilis. See *Nucleus gracilis*.
 solitarius. See *Nucleus of tractus solitarius*.
 fastigii, 204, 211
 of fifth nerve. See *Nuclei* of trigeminal nerve.
 of fourth nerve. See *Nucleus* of trochlear nerve.
 funiculi cuneati. See *Nucleus cuneatus*.
 gracilis. See *Nucleus gracilis*.
 globosus of cerebellum, 203
 of thalamus, 218
 of glossopharyngeal nerve. See *Nucleus ambiguus* and *Nucleus of tractus solitarius*.
 of Goll. See *Nucleus gracilis*.
 gracilis, 122, 134, 137
 habenulae, 29, 220
 of hypoglossal nerve, 145, 173
 hypothalamicus (Corpus Luysi), 223
 of inferior colliculus, 165
 internal round nucleus, 138
 interpeduncular, 115, 164
 interstitial, 153
 of lateral lemniscus, 157, 187
 lateral reticular, of medulla oblongata, 143, 145
 lateral thalamic, 217, 219
 lemnisci lateralis, 157, 187
 lenticular, 254
 lentiform, 254
 of Luys. See *Nucleus hypothalamicus*.
 of medial longitudinal fasciculus, 153
 medial thalamic, 217, 218
 mesencephalic. See *Nucleus* of trigeminal N.
 motor, of tegmentum (motorius tegmenti), 145, 161
 of nerve-cell, 47
 of oculomotor N., 164, 171
 olivary, 141, 142
 accessory, 142
 dorsal, 142
 medial, 142
 inferior, 141
 superior, 151, 186
 of origin, 180
 pontis, 148, 149
 radialis descendens N. trigemini. See *Nucleus* of tractus spinalis of N. V.
 red, 159, 160
 roof, of cerebellum. See *Nucleus fastigii*.
 ruber. See *Nucleus*, red.
 salivatory, 178
 of Schwalbe. See *Nucleus*, medial vestibular.
 semilunar, of thalamus, 218
 of sixth nerve, 154, 173
 somatic afferent, 182, 185

- Nucleus, somatic efferent, 170
 of spinal tract N. V, 136, 144, 155, 182
 tecti. See *Nucleus fastigii*.
 tegmental, dorsal, 158
 ventral, 158
 terminal, 180
 thalamic, 217, 218
 of tractus solitarius, 146, 181, 330
 spinalis N. trigemini, 136, 144, 145, 182
 of trapezoid body, 186
 of trigeminal N., 154, 156
 main sensory, 155, 182
 mesencephalic, 155, 184
 motor, 155, 174
 spinal, 136, 144, 155, 182
 of trochlear N., 163, 173
 of vagus, motor. See *Nucleus*, dorsal motor,
 of vagus and *Nucleus ambiguus*.
 sensory. See *Nucleus* of tractus solitarius.
 ventral thalamic, 218
 vestibular, 151, 188
 visceral afferent, 180
 efferent, 174, 177
- OBEX, 129
- Olfactory apparatus, 274-282
 bulb, 265, 274
 cells of nasal mucous membrane, 274
 cortex, 277, 278, 279. (See also *Archipallium*.)
 glomeruli, 276
 gyri, 116, 266, 277
 lobe, 267
 nerve, 265, 275
 roots. See *Gyri*, olfactory.
 striæ, 266, 277
 tract, 265, 277
 trigone, 266
 tubercle, 268, 282
- Olive (oliva, olivary body), 121
 accessory, 142
 inferior, 141
 superior, 151, 186
- Opercula, 230, 237
- Optic apparatus, 225
 chiasma, 223, 226
 cup, 32, 33, 225
 lobes, 27, 28, 165
 nerve, 225, 226
 radiation, 227
 tectum. See *Colliculus*, superior.
 tract, 226
 vesicle, 225
- Organ of Corti, 185, 186
 lateral line, 356
 spiral, 185, 186
- PACINIAN corpuscles, 69
- Pain, apparatus of, 68, 103, 105, 306
- Palæothalamus. See *Thalamus*, old.
- Pallium, 25, 32, 33, 229
- Paraflocculus, 202
- Paralysis, 322, 323
- Paraphysis, 31
- Parasympathetic system. See *Nervous system*,
 craniosacral autonomic.
- Pars anterior lobuli quadrangularis, 198
 basilaris pontis, 124, 147
 dorsalis pontis, 124, 149
 frontalis capsulæ internæ, 258, 259
- Pars intermedia of Wrisberg. See *Nervus in-*
termedius.
 mamillaris hypothalami, 222
 occipitalis capsulæ internæ, 258, 259
 optica hypothalami, 35
 posterior lobuli quadrangularis, 198
- Path (or pathway), afferent cerebellar, 313, 314
 spinal, 98, 303
 auditory, 186, 309
 cerebello-rubro-spinal, 326
 cortico-ponto-cerebellar, 149, 325
 craniosacral, 352, 353, 354
 efferent, 216
 for eye, 352
 for heart, 353
 for stomach, 353
 for submaxillary gland, 352
 for urinary bladder, 354
 exteroceptive, 66, 101, 102, 302
 extrapyramidal motor, 324
 final common, 94, 311
 motor, 109, 216
 for cranial nerves, 320
 for spinal nerves, 319
 for muscular sense. See *Path*, proprioceptive.
 olfactory, 280
 for pain, 103, 104, 105, 306
 proprioceptive, 72, 99, 100, 311
 secondary afferent, from tractus solitarius,
 181
 of trigeminal N., 163, 183, 185, 307
 vestibular, 190
 for thermal sensibility, 105, 306
 thoracolumbar, 352, 353, 354
 for touch, 101, 102, 303
 vestibular, 190
 visual, 226, 227, 228, 310
- Peduncle (or peduncles), cerebellar, 204, 205,
 206, 211
 cerebral, 129, 158
 of corpus callosum. See *Gyrus subcallosus*.
 of mammillary body, 222
 olivary. See *Stalk* of superior olive.
 of pineal body. See *Stalk* of pineal body.
- Perforated space, anterior. See *Substantia per-*
forata anterior.
- Perikaryon, 43
- Pes pedunculi. See *Basis pedunculi*.
- Pia mater, 73
- Pineal body, 130
- Pituitary body. See *Hypophysis*.
- Plate, alar, 34, 42, 194
 basal, 34, 42
 neural, 24
 roof, of prosencephalon, 213
- Plexus of Auerbach, 351
 brachial, 58
 cardiac, 349
 celiac, 349
 chorioid, lateral, 251
 of fourth ventricle, 128
 of third ventricle, 223
 esophageal, 349
 gastric, 349
 hypogastric, 351
 intercellular, of sympathetic ganglion, 344
 lumbosacral, 58
 Meissner's, 351
 mesenteric, 349

- Plexus, myenteric, 351
 pelvic, 351
 pericellular, of spinal ganglion, 65
 of sympathetic ganglion, 345
 pulmonary, 349
 solar, 349
 submucous, 351
 sympathetic, 345, 348
 vesical, 354
- Polarity of the neuron, 50
- Poles of cerebral hemisphere, 232
- Pons (Varoli), 114, 123
 basilar or ventral part of, 124, 147
 dorsal or tegmental part of, 124, 149
 form, 123
 internal structure, 147
 longitudinal fasciculi, 147
 nuclei of, 148
 tænia of, 148
 transverse fibers of, 147
- Ponticulus. See *Tænia* of fourth ventricle.
- Portio major N. trigemini, 125
 minor N. trigemini, 125
- Postganglionic fibers, 337, 343
- Precuneus, 240
- Preganglionic fibers, 337, 344
- Pressure, apparatus of sensibility to, 66
- Presubiculum, 277
- Processus reticularis. See *Reticular* formation of spinal cord.
- Projection centers, 290
 fibers, 297
- Proprioceptor, proprioceptive, 72, 99, 100, 183, 185, 311
- Prosencephalon, 24, 25, 31, 36, 113
- Protoplasm, 17
- Psalterium. See *Commissure*, hippocampal.
- Pulvinar, 214, 217, 227
- Purkinje, cells of, 207
- Putamen, 254, 255
- Pyramid (or pyramis) of cerebellum, 198
 of medulla oblongata, 119, 136
 of vermis, 198
- Pyriform lobe, 116, 268, 277
- RADIATION (or radiatio), auditory or acoustic, 261
 of corpus callosum, 243, 245
 occipitohalamic. See *Radiation*, optic.
 optic, 227, 261, 264
 sensory, 264
 thalamic, 216, 217, 260, 263
 thalamotemporal, 264
- Radix descendens (mesencephalica) N. trigemini. See *Root*, mesencephalic N. V.
 N. facialis, 175
- Ramus communicans, 335, 346
 gray, 335, 347
 white, 335, 347
 dorsal, 58
 ventral, 58
- Ranvier, constrictions or nodes of, 47
- Receptor, 19, 53, 91
- Recess, lateral, of fourth ventricle, 125
 lateralis fossæ rhomboideæ, 125
 optic, 223
 pineal, 221
 suprapineal, 221
- Reflex act, 91
- Reflex arc, 20, 53, 91, 92, 93, 327
 auditory, 331
 of brain stem, 328, 329, 330, 331, 332
 for coughing and vomiting, 330
 of medulla oblongata, 328, 329, 330
 myenteric, 340
 optic, 332
 pupillary, 332, 333
 respiratory, 330
 scratch, 94
 of spinal cord, 91, 92, 93, 94, 328
 vestibular, 328, 329
 visceral, 340
- Regeneration of nerve-fibers, 52
- Reil, island of. See *Insula*.
- Respiratory apparatus, 330
- Restiform body, 122, 143, 205
 medial part of, 205
- Reticular formation (or substance), 80, 136, 144
- Retina, 225
- Rhinencephalon, 25, 32, 115, 265
- Rhombencephalon, 25, 31, 32, 35, 36, 113
- Rhombic lip, 195
- Rod and cone cells, 226
- Rolando, fissure of. See *Sulcus centralis*.
 substantia gelatinosa of, 80
 tubercle of. See *Tuberculum cinereum*.
- Root of abducens nerve, 123
 of accessory nerve, 76, 123
 of acoustic nerve, 123
 anterior spinal. See *Root*, ventral.
 dorsal, 58, 76, 95, 96, 97
 of facial nerve, 123
 field. See *Sensory* root field.
 of glossopharyngeal nerve, 123
 of hypoglossal nerve, 123
 mesencephalic, N. V. 155, 156
 of oculomotor nerve, 130
 posterior spinal. See *Root*, dorsal.
 spinal, 78
 of trigeminal nerve, 124, 125
 of trochlear nerve, 191
 of vagus nerve, 123
 ventral, 58, 76
- Rostrum of corpus callosum, 243
- Rudiment of hippocampus, 244, 267, 270
- SACCULE, 193
- Saccus vasculosus, 28, 29
- Scarpa, ganglion of. See *Ganglion*, vestibular.
- Schultze, comma-tract of, 97, 107
- Schwalbe, vestibular nucleus of. See *Nucleus*, medial vestibular.
- Schwann, sheath of. See *Neurilemma*.
- Sea-anemones, 17, 19
- Segmentation of spinal cord, 74
- Semicircular canals, 193
- Septomarginal bundle or fasciculus, 97, 107
- Sensation (or sensibility) of cold, 105, 306
 of hearing, 185, 186, 187, 309
 of heat, 105, 306
 muscular, 72, 99, 100, 311
 of pain, 68, 103, 105, 306
 of pressure, 303
 of sight, 225, 228
 of smell, 265
 of taste, 181
 of touch, 66, 77, 101, 303
 visceral, 336

- Sensory root field, 59, 60
 Septum pellucidum, 243, 272
 posterior intermediate, 83
 median, 83
 posticum, 74
 Shark. See *Dogfish*.
 Sheath, glial, 86
 medullary. See *Sheath, myelin*.
 myelin, 41, 46, 47
 of Schwann. See *Neurilemma*.
 Sight, organs of, 225-228
 Smell, organs of, 265-282
 Solitary bundle. See *Tractus solitarius*.
 Somesthetic area, 292
 Speech, apparatus of, 295, 296
 Spider-cells, 86
 Spinal cord, 56, 72, 75
 cervical enlargement, 73, 79, 84
 characters of different regions, 83
 columns of gray matter, 79
 of white matter. See *Funiculus*.
 of cells. See *Cell-columns*.
 commissures, 80
 coverings, 73
 cornua. See *Columnns*.
 degenerations from brain lesions, 105, 106
 from cord lesions, 105, 106
 from section of dorsal roots, 106
 development, 41, 42
 in fetus and infant, 77
 fissure, anterior median, 76
 funiculi, 82
 glial sheath, 86
 gray matter or substance, 78, 79, 80, 81, 87
 cell-columns, 89, 90
 columns, 79
 horns. See *Columnns*.
 microscopic structure, 87
 nuclei. See *Cell-columns*.
 relation to size of nerves, 84
 horn. See *Columnns*.
 internal structure, 85
 lumbar enlargement, 74, 81, 84
 microscopic structure, 85
 relation to vertebral canal, 77
 reflex mechanism of, 91, 92, 93
 sacral region, 74, 81, 84
 segmentation, 74
 sulcus, anterolateral, 76
 posterior, 76
 intermediate, 76
 posterolateral, 76
 thoracic region, 80, 84
 tracts, 95-112, 110
 white matter (or substance), 81, 86
 area in different regions, 82
 microscopic structure, 86, 87
 ganglion. See *Ganglion*.
 nerve. See *Nerve*.
 Spiraclae, 356
 Splanchnic nerves, 348
 Splenium corporis callosi, 244
 Spongioblasts, 37
 Stalk, optic, 32, 225
 of pineal body, 221
 of superior olive, 151, 175
 Stomach, innervation of, 353
 Stratum griseum centrale, 163
 of superior colliculus, 167
 Stratum lacunosum, 278
 lemnisci, 167
 lucidum, 279
 opticum, 167
 oriens, 279
 profundum, 166, 167
 radiatum, 279
 zonale of superior colliculus, 167
 of thalamus, 216
 Stria (or striæ) acustica. See *Stria medullares acustica*.
 of Baillarger, 283
 of Gennari, 283
 longitudinalis lateralis, 245, 270
 medialis, 245, 270
 medullaris acustica, 123, 127, 186
 thalami, 215, 220, 281
 olfactoria lateralis, 266, 277
 medialis, 266
 semicircularis. See *Stria terminalis*.
 terminalis, 214, 281
 Stripe of Baillarger, 283
 of Gennari, 283
 Subarachnoid space, 73
 Subiculum, 277, 280
 Substantia alba, 42, 79, 86
 ferruginea, 128
 grisea, 42, 79, 87
 centralis, 136, 158, 163
 gelatinosa, Rolandi, 80
 centralis, 86
 externa. See *Sheath, glial*.
 nigra, 129, 158, 164
 perforata, anterior, 267, 282
 posterior, 115
 reticularis. See *Reticular formation*.
 alba, 144
 grisea, 145
 Subthalamic tegmental region. See *Subthalamus*.
 Subthalamus, 222
 Sulcus (or sulci), anterior lateral, 76, 119
 parolfactory, 239
 basilar, 124
 callosal. See *Sulcus of corpus callosum*.
 central, of Rolandi, 233
 cerebellar, 199
 cerebral, 233, 235, 236, 239
 cinguli, 239
 circularis insulae, 237
 of corpus callosum, 239
 cruciate, 114
 frontal, inferior, 235
 middle, 235
 superior, 235
 horizontalis cerebelli, 197
 hypothalamicus, 223
 insulae, 237
 intermedius, posterior, 76, 127
 intraparietal, 236
 lateral, of mesencephalon, 130
 lateralis, anterior. See *Sulcus, anterior lateral*.
 posterior. See *Sulcus, posterior lateral*.
 limitans, 34, 42, 129
 insulae. See *Sulcus circularis insulae*.
 lunatus, 237
 medianus posterior of spinal cord, 76
 of medulla oblongata, 119
 occipitalis transversus, 236

- Sulcus of oculomotor nerve, 130
 olfactory, 241
 orbital, 241
 paracentral, 239
 parolfactorius, anterior, 239
 posterior, 267, 239
 postcentral, inferior, 236
 superior, 236
 postclivalis, 197
 posterior lateral, 76, 119
 parolfactory, 239, 267
 precentral, 235
 inferior, 235
 superior, 235
 prepyramidal, 202
 primarius. See *Fissura prima*.
 rhinalis. See *Fissure*, rhinal.
 of spinal cord, 76
 subparietal, 239
 temporal, inferior, 236
 middle, 236
 superior, 236
 uvulo-nodularis, 203
- Sylvius, aqueduct of, 26, 158
 fissure of, 233
- Sympathetic ganglia. See *Ganglion*.
 system, 50, 57, 334
- Synapse, 49, 50, 51, 55
- Synectium, 38
- System. See *Nervous system*.
- TACTILE corpuscles, 68
- Tænia chorioidea, 214
 of fourth ventricle, 126
 pontis. See *Fila lateralia pontis*.
 tecti. See *Stria longitudinalis lateralis*.
 thalami, 214, 224
 ventriculi quarti, 126
- Tapetum, 245
- Taste, apparatus of, 181
- Tectum mesencephali, 28, 165
- Tegmentum, 129, 158
- Tela chorioidea of fourth ventricle, 128
 of third ventricle, 215, 224
- Telencephalon, 36
 development, 25, 31, 32, 33
 in the dogfish, 27, 28
 medium, 212, 229
- Temperature, apparatus of, 105, 306
- Tendon, nerve endings in, 72
- Tentorium cerebelli, 113
- Thalamencephalon. See *Diencephalon*.
- Thalamus, 213
 development, 35, 213
 in the dogfish, 29
 ending of sensory tracts in, 219
 lamina, external medullary, 216
 internal medullary, 216
 new, 219
 nuclei, 217
 old, 218
 pulvinar, 218
 radiation of, 216, 217, 260, 263
 stalks, 263
 stratum zonale, 216
 thalamocortical fibers, 263
 tubercle, anterior, 213
- Tigroid bodies. See *Nissl bodies*.
- Tonsil (tonsilla cerebelli), 199
- Touch, apparatus of, 66, 71, 101, 303
- Tract or tracts, 95. (See also *Bundle* and *Fasciculus*.)
 bulbospinal, 111
 of Burdach. See *Fasciculus cuneatus*.
 central sensory. See *Path*.
 cerebellobulbar. See *Tract*, fastigiobulbar.
 cerebellotegmental, 211, 212
 comma, 97, 107
 corticobulbar, 165, 260, 321
 corticopontine, 147, 164. (See also *Tracts*,
 frontopontine and temporopontine.)
 corticorubral, 161, 260
 corticospinal, 109, 133, 136, 147, 165, 260, 320
 lateral, 109, 134, 136
 ventral, 134, 136
 corticothalamic, 263
 direct cerebellar. See *Tract*, dorsal spinocerebellar.
 dorsal spinocerebellar, 110, 143, 144, 145, 205
 efferent, from cerebellum, 211
 from cerebral hemisphere, 297
 from mesencephalon. See *Tracts*, tecto-
 spinal, tectobulbar, and rubrospinal.
 fastigiobulbar, 212
 of Flechsig. See *Tract*, dorsal spinocerebellar.
 frontal olfactory projection, 281
 frontopontine, 164, 259
 of Goll. See *Fasciculus gracilis*.
 of Gowers. See *Tract*, ventral spinocerebellar.
 habenulo-peduncular. See *Fasciculus retroflexus*.
 of Helweg. See *Tract*, bulbospinal.
 lateralis minor. See *Fasciculus lateralis minor*.
 of Lissauer. See *Fasciculus dorsolateralis*.
 mamillotegmental, 222, 281
 mamillothalamic, 217, 222
 mesencephalic, of N. V. See *Root*, mesen-
 cephalic, N. V.
 of Meynert. See *Fasciculus retroflexus*.
 of Monakow. See *Tract*, rubrospinal.
 nucleocerebellar, 205
 olfactory, 265, 277
 olivocerebellar. See *Fibers*, olivocerebellar.
 olivospinal. See *Tract*, bulbospinal.
 optic, 226
 pontocerebellar. See *Brachium pontis*.
 pontospinal. See *Tract*, reticulospinal.
 predorsal. See *Tract*, tectospinal.
 prepyramidal. See *Tract*, rubrospinal.
 projection, 297
 pyramidal, 109
 aberrant, 321
 direct, 109
 crossed, 109
 uncrossed lateral, 320
 reticulospinal, 160
 rubroreticular, 160, 161
 rubrospinal, of Monakow, 110, 145, 161
 of Schultze, 107
 septomarginal, 97, 107
 solitariospinalis, 330
 solitary (solitarius), 132, 181, 330
 spinal, of N. V., 132, 136, 144
 of spinal cord, 94-112, 110
 spinocerebellar, dorsal, 100, 314
 ventral, 100, 313
 spino-olivary, 105
 spinotectal, 105, 145

- Tract, spinothalamic, 145, 163, 219, 307
 lateral, 102
 ventral, 101, 305
 strionigral, 164, 263
 sulcomarginal, 108
 tectobulbar, 161, 167
 tectocerebellar, 206
 tectospinal, 111, 145, 161, 167
 tegmentospinal. See *Tract*, reticulospinal.
 temporopontine, 164, 261
 thalamocortical, 263
 thalamo-olivary, 145, 219
 thalamospinal, 219
 transverse peduncular, 369
 trigeminothalamic, 183, 185
 ventral spinocerebellar, 100, 144, 145, 157, 206
 vestibulocerebellar, 190, 206
 vestibulospinal, 111, 190, 329
 of Vicq d'Azyr. See *Tract*, mamillothalamic.
 Trapezium. See *Trapezoid* body.
 Trapezoid body, 121, 150, 186
 Triangle of Gombault and Philippe, 107
 Trigone (or trigonum) acustici. See *Area*
 acustica.
 collateral, 248
 habenulae, 220
 hypoglossi, 127
 interpeduncular. See *Fossa* interpeduncularis.
 olfactory, 266
 vagi. See *Ala* cinerea.
 Trophic unity of neuron, 51
 Truncus corporis callosi, 244
 Trunk, sympathetic, 335, 346, 347, 348
 Tuber vermis, 198, 201
 Tubercle (or tuberculum) acusticum. See *Nucleus*, dorsal cochlear.
 anterior, of thalamus, 213
 cinereum, 122, 280
 cuneate, 121, 137
 olfactorium, 268, 282
 of Rolando. See *Tuberculum* cinereum.
 Tufted cells, 276
 Türck's bundle. See *Tract*, ventral cortico-spinal.

 UNCUS, 240, 269, 277
 Utricle, 193
 Uvula vermis, 198

 VALLECULA of cerebellum, 197
 Valve of Vieussens. See *Velum*, anterior medullary.
 Velum, anterior medullary, 125, 128, 155
 anticum. See *Velum*, anterior medullary.
 interpositum. See *Tela* chorioidea of third ventricle.
 medullare, anterius, 125
 inferius. See *Velum* medullare, posterius.
 posterius, 202
 superius. See *Velum*, anterior medullary.
 transversum, 29, 31
 Vena terminalis, 214
 Ventricle (or ventricles) of the brain, 25, 26, 27, 117
 development, 26, 33, 34
 in the dogfish, 27, 28, 30, 31
 fourth, 26, 118, 125, 126, 127, 128
 lateral, 26, 118, 246
 third, 26, 118, 223
 Ventriculus lateralis, 26, 246
 terminalis, 81
 tertius. See *Ventricle*, third.
 Vermis, inferior, 197, 198
 superior, 197
 Vesicles, cerebral, primary, 24, 25
 optic, 225
 Vestibular apparatus, 188, 189, 190
 Vicq d'Azyr, bundle of. See *Tract*, mamillothalamic.
 Vieussens, valve of. See *Velum*, anterior medullary.
 Visceral innervation, 335
 Visual apparatus, 225
 receptive center, 292
 Visuo-psychic area, 293, 294
 Vomiting, mechanism of, 331

 WALLERIAN degeneration, 105, 106, 107
 Weight of brain, 301
 Worms, nervous system of, 19, 20, 21, 22
 Wrisberg, nerve of. See *Nervus* intermedius.

 ZONE, cortical. See *Center*, cortical.
 ependymal, 37
 mantle, 37, 42, 196
 marginal, 37, 42, 196



