

## **The field defects produced by temporal lobe lesions / by Harvey Cushing.**

### **Contributors**

Cushing, Harvey, 1869-1939.

### **Publication/Creation**

London : John Bale, Sons & Danielsson, 1921.

### **Persistent URL**

<https://wellcomecollection.org/works/cj8xx8yd>

### **License and attribution**

Conditions of use: it is possible this item is protected by copyright and/or related rights. You are free to use this item in any way that is permitted by the copyright and related rights legislation that applies to your use. For other uses you need to obtain permission from the rights-holder(s).

**wellcome  
collection**

Wellcome Collection  
183 Euston Road  
London NW1 2BE UK  
T +44 (0)20 7611 8722  
E [library@wellcomecollection.org](mailto:library@wellcomecollection.org)  
<https://wellcomecollection.org>

H. CUSHING,

The field defects produced by temporal  
lobe lesions.

170 962

WELLCOME INSTITUTE LIBRARY	
Coll.	weIMOmec
Call	
No.	WL



DISTORTIONS OF THE VISUAL FIELDS IN CASES OF BRAIN  
TUMOUR.

(Sixth Paper.)

THE FIELD DEFECTS PRODUCED BY TEMPORAL  
LOBE LESIONS.<sup>1</sup>

BY HARVEY CUSHING, M.D.

*Professor of Surgery, Harvard Medical School ;  
Surgeon-in-Chief, the Peter Bent Brigham Hospital ;  
Boston.*

INTRODUCTION.

TEN years ago when this series of papers<sup>2</sup> was projected, accurate perimetry as we understand it to-day was rarely employed ; and, indeed, as an instrument of precision the perimeter was rather an ornament and object of curiosity than an instrument of daily use in ophthalmological and neurological clinics.

To be sure, for the sake of record, the fields were occasionally plotted when the presence of a hemianopsia was more or less obvious,

<sup>1</sup> Presented before the American Neurological Association, Atlantic City, June 14, 1921.

<sup>2</sup> The preceding numbers have been as follows:—

First Paper (with George J. Heuer): "Statistical Studies." *Johns Hopkins Hosp. Bull.*, 1911, **22**, 190-5.

Second Paper (with George J. Heuer): "Dyschromatopsia in Relation to Stages of Choked Disc." *Journ. Amer. Med. Assoc.*, 1911, **57**, 200-8.

Third Paper (with Clifford B. Walker): "Binasal Hemianopsia." *Arch. Ophthalm.*, 1912, **41**, 559-98.

Fourth Paper (with Clifford B. Walker): "Chiasmal Lesions with especial Reference to Bitemporal Hemianopsia." *Brain*, 1915, **37**, 524-42.

Unnumbered Paper (with Clifford B. Walker): "Studies of Optic Nerve Atrophy in Association with Chiasmal Lesions." *Arch. Ophthalm.*, 1916, **45**, 407-37.

Fifth Paper (with Clifford B. Walker): "Chiasmal Lesions with especial Reference to Homonymous Hemianopsia with Hypophyseal Tumour." *Arch. Ophthalm.*, 1918, **47**, 119-45.



or when vision was impaired by a large scotoma. But the cases were infrequent and few clinicians cared to perfect themselves in the use of the instrument which was time-consuming and at best gave information of only secondary diagnostic importance.

There were, perhaps, other reasons to account for its neglect. Lesions affecting the visual pathway, whether from tumour, trauma or vascular disease, were more or less hopeless from a therapeutic standpoint, and, what is more, in the presence of tumour such field defects as might be of localizing value were usually obscured by the contractions due to the secondary optic atrophy usually present before the diagnosis of tumour was ventured upon. Then, too, pituitary tumours in which successive perimetric records are especially important were regarded as rare, and usually passed unrecognized.

All this has greatly changed, more so, I fear, than is generally appreciated, if one may judge by the imperfect readings, taken with a single test object and recorded on small charts, such as are commonly sent to us when patients are referred to the clinic. Our own early records were of this sort, but when compared with readings such as those taken by Dr. Walker while attached to the clinic, the difference is as great as that between a child's sketch and an architect's drawing to scale. One gives an impression often misleading; the other the exact details. And many of the early errors into which we were trapped, such as our mistaken views on colour-interlacing, have thereby come to be explained and avoided [6]. Dr. Walker's chief contributions to the subject, as set down in his independent papers [7, 8], lie in the direction of accuracy as well as of simplification, and of late we have come to rely for clinical purposes on quantitative perimetry with test objects graded down to the smallest visible size. By so doing we may safely disregard the recording of the colour fields, provided those for form are sufficiently exact, for, as he has stated, "Colour defects are practically always represented by form defects when the visual angle is made small enough." Though few can hope to have the experience and acquire the facility in perimetry possessed by Dr. Walker, nevertheless the time necessary for the examination may be kept within reasonable bounds and trustworthy fields of vision secured after some practice by any intelligent observer copying his methods.<sup>1</sup>

<sup>1</sup> It may be said that the perimetric charts introduced by Dr. Walker are large sheets the same size as the hospital history sheets. They have necessarily been reduced to such an extent for purposes of this publication that many of the figures indicating the size of the discs, which have been employed in plotting the fields, are illegible in the reproductions accompanying the text.—ED.



## THE TEMPORAL LOOP OF THE OPTIC RADIATION.

Before describing the disposition of the geniculo-calcarine fibres in the lobe, which is the matter of primary importance, the story given in the first paper in this series, as an illustration of the value of accuracy in perimetry, may deserve re-telling.

There entered the Johns Hopkins Hospital in 1910 a man subject to convulsive seizures, with a gustatory aura typical of fits of uncinate gyrus origin. Some years before he had been shot in the left eye, and, as a radiogram showed, the ball had lodged in the petrous portion of the left temporal

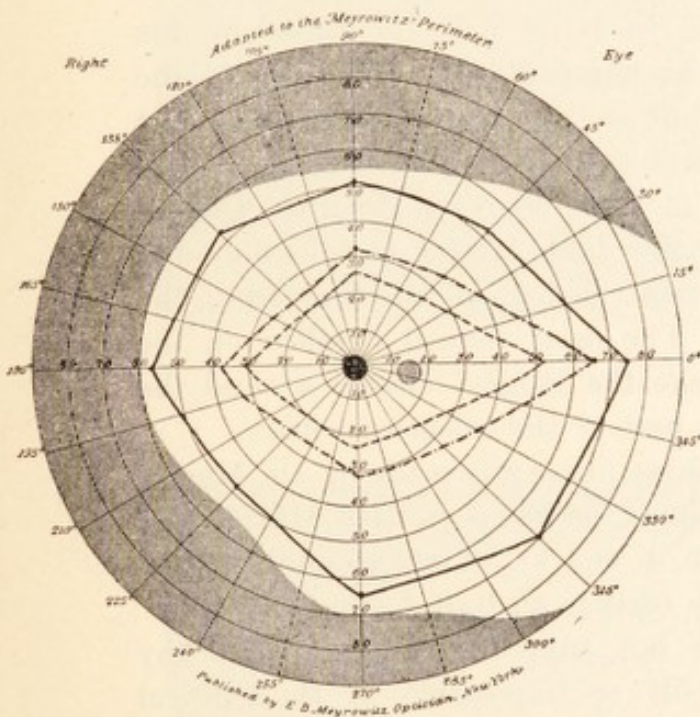


FIG. 1.—Chart of October 18, 1910, showing what were regarded as practically normal field relations. Note that eight points were relied upon for the form field and only four for the blue and red fields.

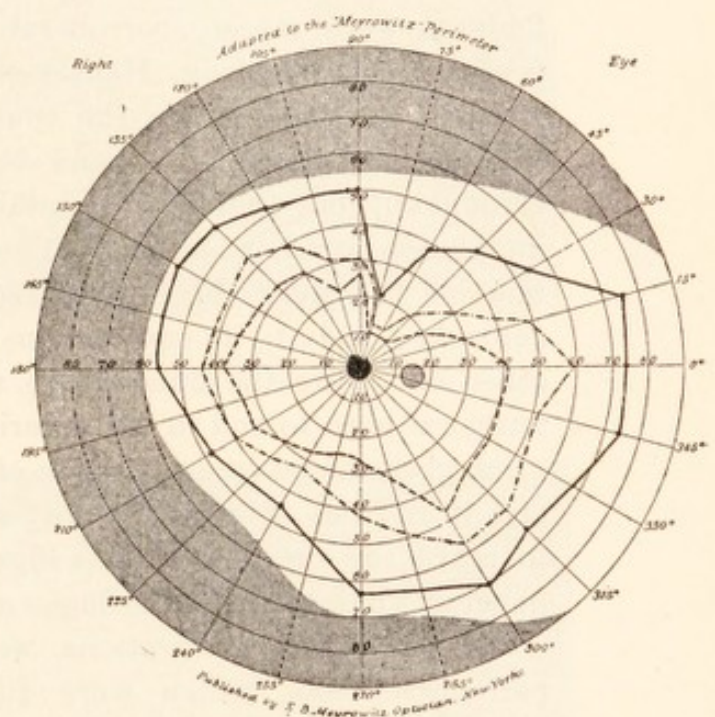


FIG. 2.—Corrected chart of October 19, 1910, for comparison with fig. 1, disclosing upper right temporal defect.

bone. Obviously the lower part of the left temporal lobe had been traversed. The field of vision of the remaining eye (fig. 1) had been plotted by Dr. S. J. Crowe, my then assistant, and it was regarded as normal. Indeed, no defect was anticipated, and the observation was made merely as the routine procedure of a painstaking house officer. The patient was shown one day on a ward visit which Dr. Adolf Meyer happened to attend, and he pointed out that the field periphery which had been plotted from tests at every thirty degrees might show a sector-shaped defect if taken with closer angulation, as only a few fibres of the pathway might have been damaged. This was done, with the result shown in fig. 2. Had the left eye not been destroyed, the defective sector would presumably have appeared as a homonymous one.



Three years before, in a paper which has received an undeserved lack of attention, Meyer [5] had described "the peculiar detour of the ventral portion of the geniculo-calcarine path which simulates the existence of an inferior longitudinal fasciculus." By the study of secondary degenerations following old vascular or traumatic lesions which had shown a fortunate limitation, either by exclusion or inclusion, to the visual pathway, he had observed that a portion of the optic radiation, on leaving the geniculate body, plunges far forward into the temporal lobe to sweep around the horn of the ventricle before it turns backward to end in the calcarine cortex. Though Meyer's findings were merely corroborative, in large part, of those by his predecessors—Flechsig, Henschen, Archambault [1], and others—he was able to demonstrate the course of isolated paths which show not only that the dorso-lateral and ventral bundles remain the same size throughout, but that they maintain in their course a definite position in relation to other bundles. Thus, the dorso-lateral bundle not only remains the most dorsal, but the most direct, all the way from the geniculate body to its end stations. The most ventral bundles, on the other hand, are the ones which make the longest detour around the temporal horn to end in the anterior part of the calcarine cortex.

A glass-model reconstruction of these fibres was made by Dr. Meyer, and it is from this that, at my request, he has permitted Max Brödel to make the superb diagrams (figs. 3, 4, and 5), which accompany this paper. They render superfluous any further written description.

Meyer's own observations were not supported or confirmed by perimetric tests, which were difficult or impossible in the clinical material of the type he had at his command. Nevertheless, he shrewdly surmised in connection with the few reported cases of quadrant hemianopsia in which small defects had been found post mortem that the dorsal bundles have an upper retinal distribution and hence correspond with field defects in the lower quadrants, whereas *per contra* involvement of the ventral bundles is responsible for defects of the upper field quadrants such as was shown in fig. 2. In other words, the disposition of the fibres in the geniculo-calcarine radiation is practically the same as that in the optic nerve itself. Whether or not this means, as I believe it does, separate representation on the cortex for different areas of the retina, need not now detain us, for our present concern lies with the course of the fibres through the temporal lobe and not with their calcarine end-stations.

From the series of cases to be reported, we shall see that tumours



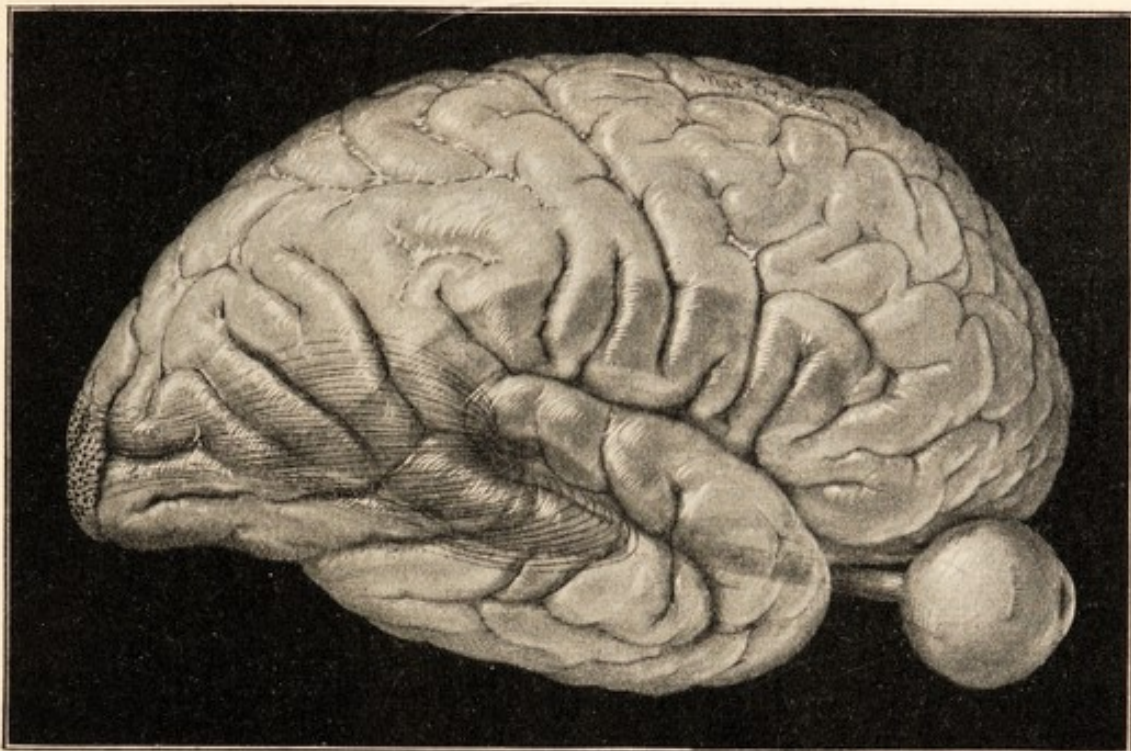


FIG. 3.—Showing the brain, as transparent, to indicate the lateral ventricle and the disposition of the fibres of the optic radiation.

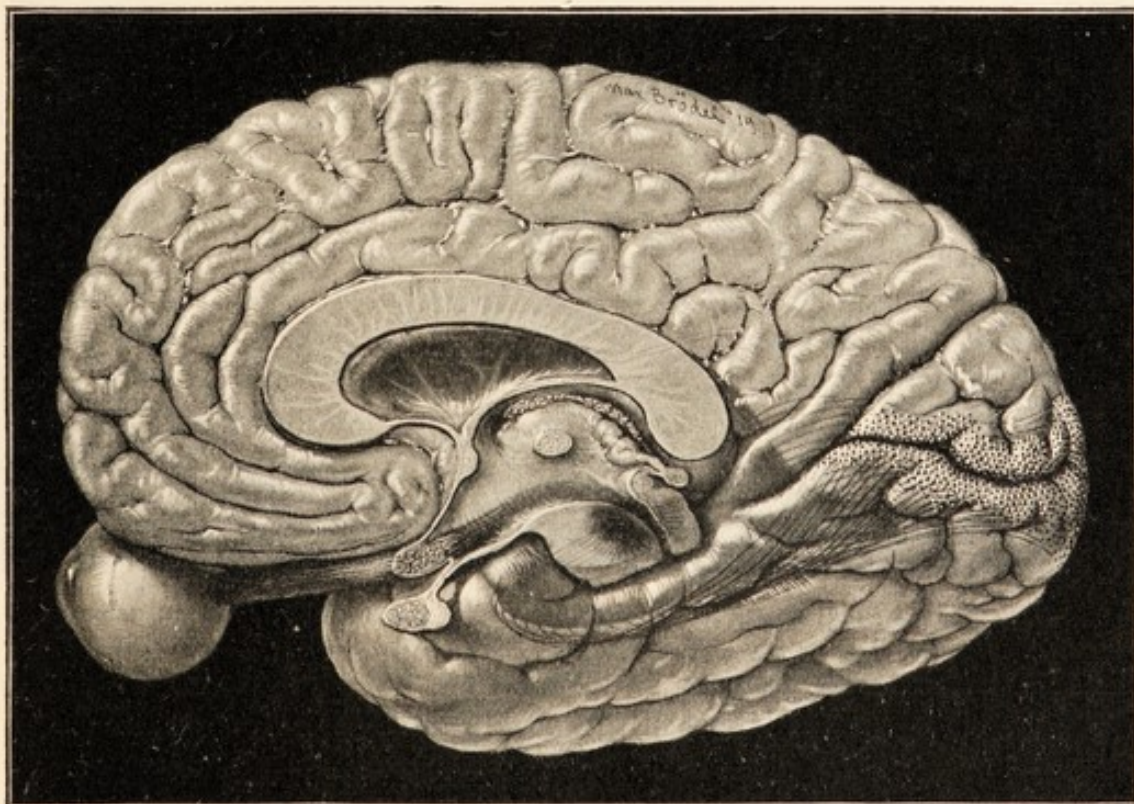


FIG. 4.—Mesial aspect of the brain with disposition of the geniculo-calcarine pathway.



in the temporal lobe may produce homonymous field defects in the upper or lower quadrants which are of extreme value in localization. Lesions more posteriorly situated are in my experience less likely to

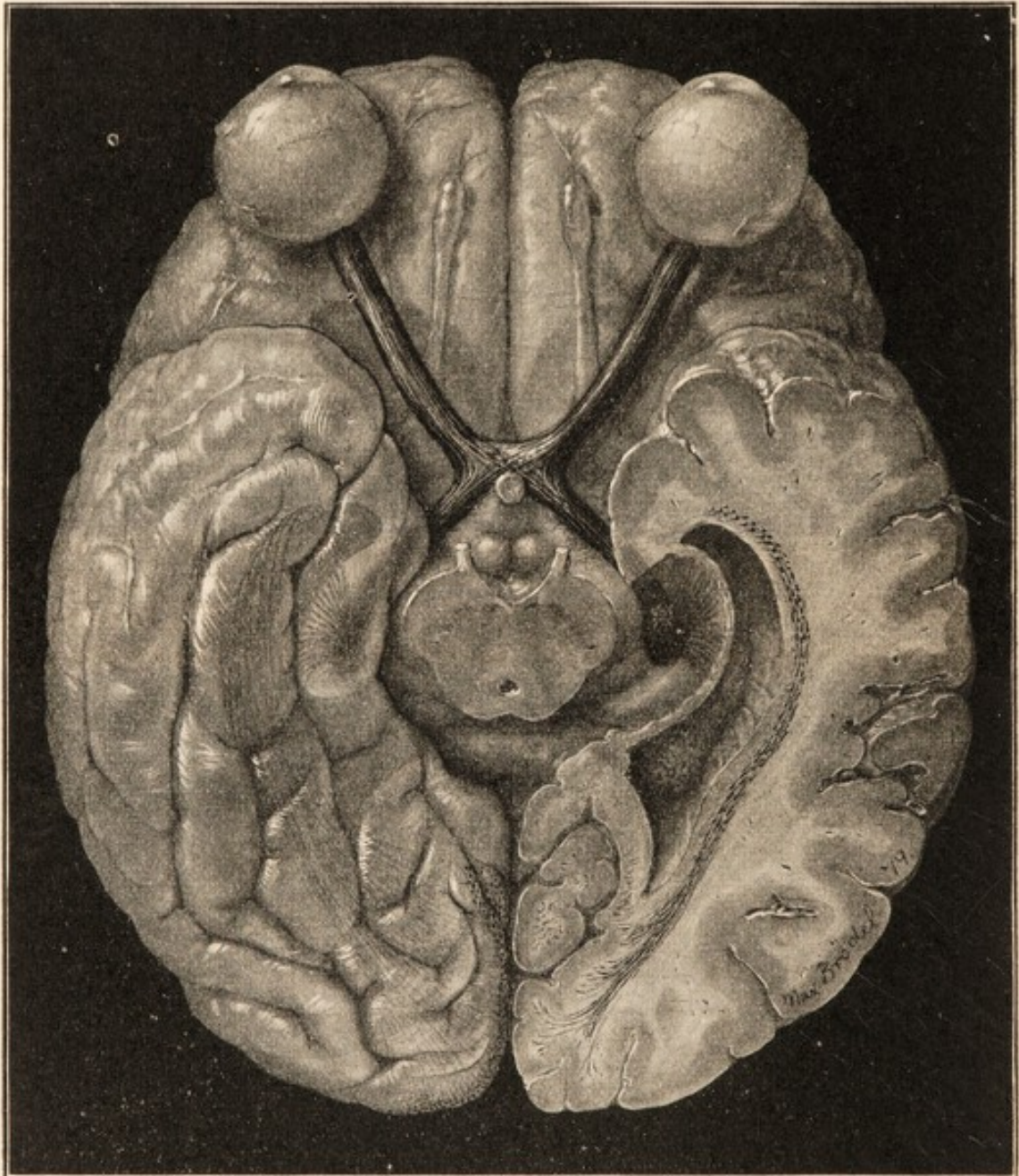


FIG. 5. —The radiation shown on the right in section and on the left in transparency.

produce these partial defects, or at least are less likely to be caught by the observer in a stage short of the usual midline hemianopsia.

#### SOURCE OF MATERIAL.

In the writer's series of 663 verified intracranial tumours, to April 1, 1921, there have been 197 tumours involving the hind-brain



(subtentorial), 190 pituitary tumours (including suprasellar lesions) and 276 tumours involving the cerebrum proper. Of this group of 276 cerebral tumours, in 59 the lesion has been situated largely within or has chiefly deformed the temporo-sphenoidal lobe. This by no means represents all the temporal lesions, but the doubtful cases have been excluded, since for our present purposes it is best to limit the discussion to those tumours which appear to have originated in the lobe itself.

Even so, that 59 out of 276, or over one-fifth of all verified cerebral tumours, should have primarily involved the temporal lobe may appear an unduly large number. For this, two explanations may be offered. One lies in the fact that, owing to the common practice of performing a right subtemporal decompression in tumours of doubtful situation, an unexpected temporo-sphenoidal lesion has not infrequently been disclosed.<sup>1</sup>

Another explanation is that tumour localization in this relatively silent area has of late years become more and more exact owing to the interpretation of field defects, which this communication, it is hoped, will serve to point out.

In 39 of these 59 temporal lobe cases perimetric charts sufficiently trustworthy for our present purposes were obtained and in many instances repeated observations over long periods have been made. In the remaining 20 cases the tests were untrustworthy or impossible for a variety of reasons, owing to practical blindness from secondary optic atrophy (six cases); owing to such a degree of stupor or mental confusion as to preclude dependable responses (eight cases); owing to other causes as aphasia, childhood, &c. (six cases). The fields of vision in the 39 dependable cases may be subdivided as follows into those showing:—

<sup>1</sup> It may need emphasizing that the cranial defect in a subtemporal decompression is made below the attachment of the muscle to the temporal ridge and consequently it is unusual to have more than temporal convolutions exposed. Occasionally one may barely expose the Sylvian vessels, but when there is a tumour of the lobe the Sylvian fissure is apt to be dislocated upward.

It is significant (1) that in the fifty-nine cases the lesion was found on the right side in thirty-two and on the left in twenty-seven instances; (2) that in only sixteen of the thirty-two right-sided cases was the lateralization helped out by perimetry. Some of the remaining sixteen had uncinat attacks and contralateral facial weakness assuring the localization, but the others were stumbled upon in the course of a routine decompression.

In a correspondingly large series of unverified tumours there is a long list of undoubted temporal lobe cases which have been excluded from this discussion. Many of these cases had uncinat seizures and field defects comparable to those in the verified cases, to the discussion of which this paper will be limited.



(1) *No defect (six cases)*.—In these the fields were at all times normal. Three of them were slow-growing endotheliomata and one an angioma deforming the lobe from without, and therefore less likely to affect the pathway. That field defects may occur under corresponding conditions, however, some of the cases to be reported later on will make clear. A fifth case was a rare one of dermoid cyst in the tip of the lobe accompanied by uncinata seizures. From the situation of the lesion one would have expected a partial hemianopsia which repeated examinations failed to reveal. The sixth case was a glioma disclosed by a right decompression in which only a single preoperative test had been made.

(2) *Homonymous hemianopsia (eight cases)*.—In these the condition had advanced to a median vertical separation of blind and seeing fields, indicating an interruption of the entire pathway, though the macular fibres were oftentimes spared. In none of these cases had fields been plotted sufficiently early to detect quadrantic defects, nor in any of them was a post-operative recession from the hemianopsia observed. The findings indicated that the cerebral lesion was on the right in five and on the left in three of these cases, but it did not otherwise indicate the position of the tumour in the hemisphere. It is presumable that in many or all of them the growth may have come to involve the geniculate body or even to have affected the optic tract itself by pressure. If reliance is to be placed on the sparing or otherwise of the macular bundle as an indication of the involvement of optic radiation *versus* optic tract it would appear that tract involvement may be expected as a late feature of all temporal lobe tumours. In four of these eight cases the macula was included in the field bisection at the time of the examination and in all likelihood in the course of time the macula came to be involved in all. Several examples of hemianopsia, both with macula spared as well as included, which occurred in the series, have been classified under the following heading for the reason that the patients showed at one time or another the partial defects (e.g., Case 7) with which we are chiefly concerned.

(3) *Partial hemianopsia (twenty-five cases)*.—It is upon these defects, more or less quadrantic in character, that chief emphasis will be laid. At one time or another while under observation the patients all showed an homonymous defect, which fell short of a complete hemianopsia. As will be indicated by the case histories which have been selected for purposes of illustration, these partial defects have been observed either as : (1) a stationary condition ; (2) a con-



dition advancing toward a hemianopsia; or (3) a condition in process of recession after a successful operation.<sup>1</sup>

#### CASE REPORTS.

At the outset one or two examples of some of the earlier cases in the series may be given. The fields were then taken with standard 5-mm. test objects, and many of the details of the more recent examinations are therefore wanting. These early observations, nevertheless, served to give us our first hints of the localizing value of these partial defects. This was particularly true of defects in the colour fields which were seen to precede those for form, a matter which is of less importance to-day, since practically the same information is secured by utilizing white discs of minute size. It was from some of these early cases, furthermore, that we first came to appreciate the fact that the field defect in the eye on the side of the lesion is apt to be in advance of the other.

*Case 1.—Gliomatous cyst of right temporal lobe producing a lower homonymous defect short of hemianopsia. Post-operative widening of fields to normal. (J. H. H., Surg. No. 23551.)*

January 30, 1909: Admission of S. G. W., a clerk, aged 26, with the complaint of headaches, fainting attacks and failing vision.

Chronology of symptoms: Always well until July, 1905, when he had a sudden loss of consciousness without warning or convulsive movements. One year later another similar attack, preceded by dizziness. Since then he has been "nervous" and somewhat less alert intellectually.

<sup>1</sup>On two earlier occasions, in 1912 with Dr. Heuer, and again in 1916 with Dr. Walker, preliminary steps were taken to assemble material for this paper, and to review the literature pertaining thereto. The first interruption came from my transfer to Boston, and the second was due to our entry into the war. To have been deprived of their collaboration is by no means made up for by the fact that the number of cases which can be drawn upon has greatly increased. My acknowledgments are due not only to them for a great deal of the preliminary work, but also to a succession of neuro-surgical assistants who will recognize many of their own charts and case reports in the text.

Our studies in 1912 were chiefly directed toward a determination of the value of Wernicke's hemiopic pupillary reaction, and also of Wilbrand's prism test in differentiating, in cases of pure hemianopsia, between an interruption of the pathway central or peripheral to the geniculate body. The tests, though sharply positive in some cases, were so obscure in others, that we subsequently have abandoned them, for at best the information they give is but confirmatory of what one may gain in other ways. Moreover, it is highly desirable to recognize and interpret field defects before a total hemianopsia has supervened and at that time these tests are not applicable. A homonymous hemianopsia, whether or not the macula is spared, which is accompanied by a primary optic atrophy, one may safely ascribe to a chiasmal lesion usually pituitary in origin: one which is accompanied by a choked disc probably involves the radiation somewhere in its course. This is not an invariable rule, but it is less likely to mislead than a dependence on the Wernicke and Wilbrand tests.



In August, 1908, onset of persistent headaches, chiefly nocturnal, increasing in severity. At about this time some disturbance of vision was first noticed, with occasional diplopia. Also, from time to time, flashes of light described as "luminous things" have been seen, but they are not lateralized. Also vague "dizzy spells" without loss of consciousness, but with no features suggesting an uncinate origin.

Physical examination: This was quite negative except for: (1) a choked disc of 3 D. right, with beginning atrophy and  $\frac{2}{80}$  vision: 4 D. left, with  $\frac{2}{80}$  vision; (2) an incomplete left homonymous hemianopsia (fig. 6). No hemiopic pupillary reaction (Wernicke).

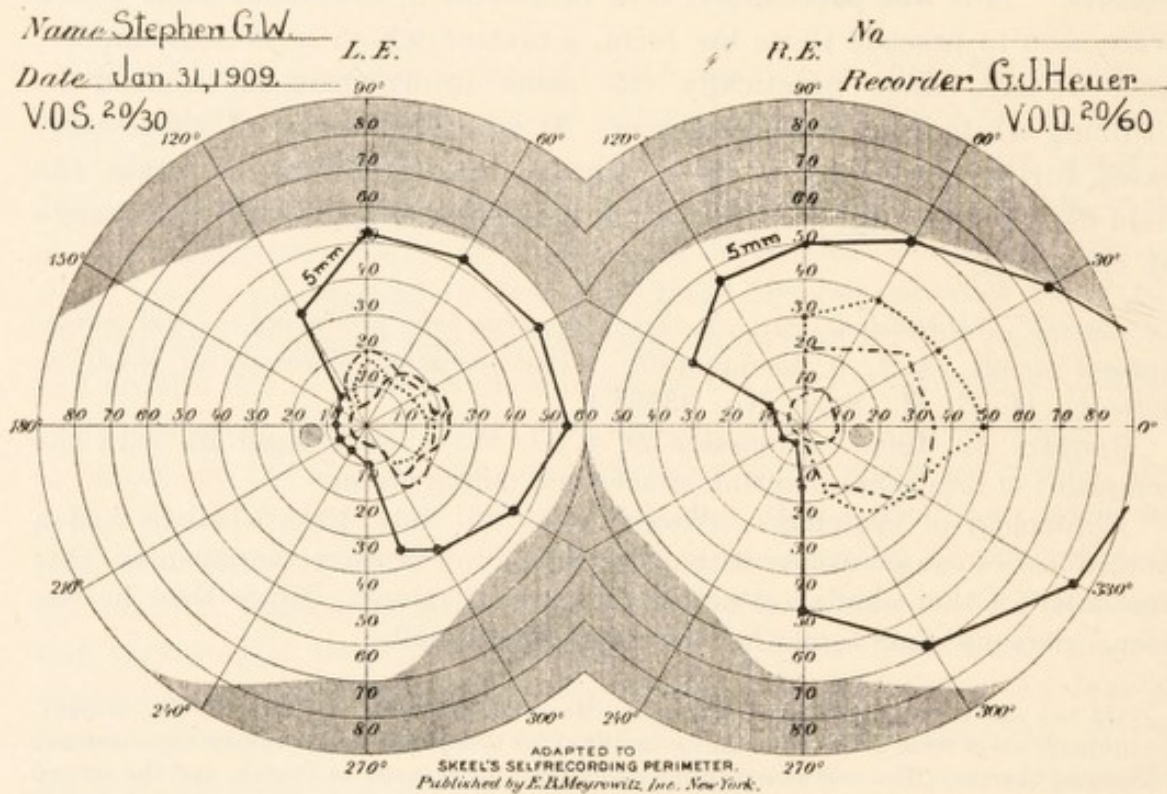


FIG. 6.—Case 1. Fields before operation which disclosed a gliomatous cyst of the right temporal lobe.

February 2, 1909: Operation.—Right subtemporal decompression. This disclosed a dry bulging temporal lobe which from surface appearances contained a subjacent lesion. A large gliomatous cyst pointing in the upper temporal convolution was widely opened and was drained for a week.

Post-operative: An immediate cessation of pressure symptoms. The choked discs subsided with gradual restoration of visual acuity to normal. Fields were taken every few days after February 10, on which date they showed normal outlines for form, though the colour fields were still slightly contracted (e.g., fig. 7). He was discharged March 4 with normal fields and vision of  $\frac{2}{15}$  in each eye.



Subsequent note: Three years later (February 19, 1912) he returned for observation. He had been free from symptoms during the interval. The fields remained normal. After this the patient passed out of my hands. Two years later—nine years from the time of his primary loss of consciousness—he died with a recurrence of tumour symptoms.

Comment: When this patient was first seen, without the perimeter even a lateralizing diagnosis would have been impossible. It may be observed in the first charts (fig. 6) that there was a hemiachromatopsia on the right, the side of the lesion, the macula being spared. Doubtless the primary field defect began in the lower left quadrants, but it is improbable that the significance of this was sufficiently appreciated twelve years ago to justify us in anticipating the temporal lesion which was stumbled upon.

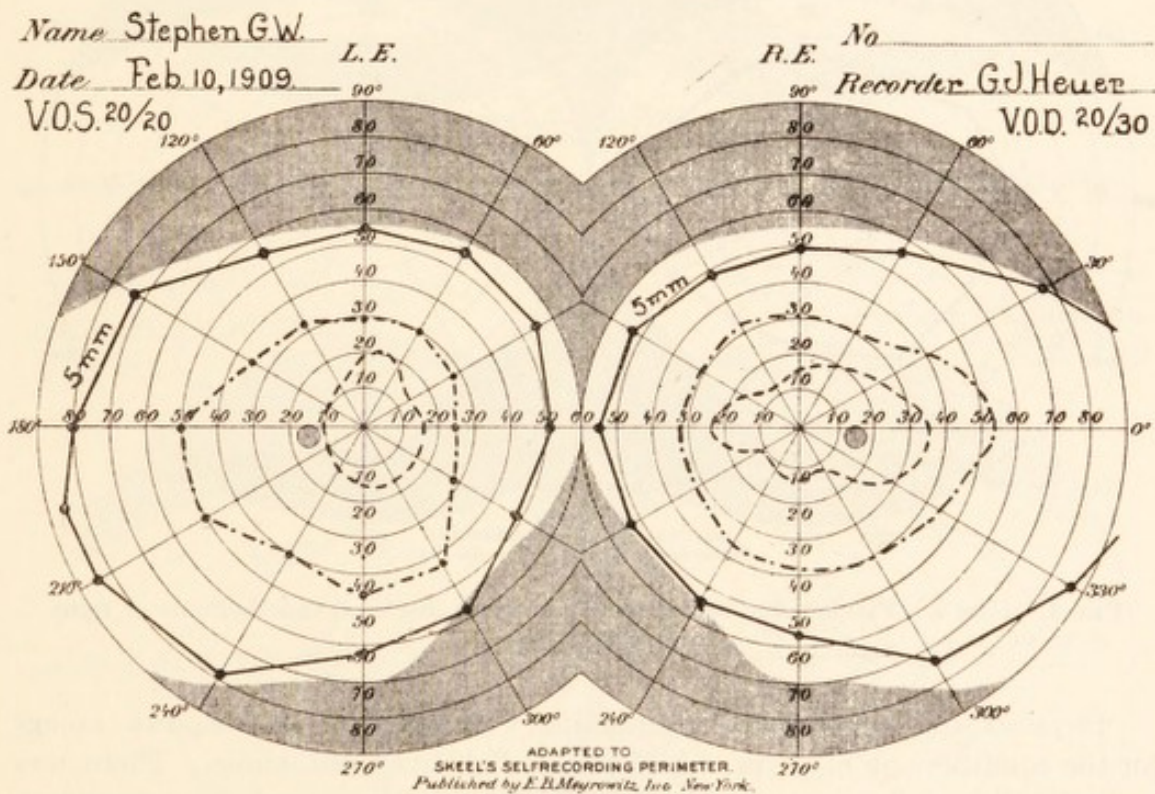


FIG. 7.—Case 1 (contd.). Fields eight days after operation, for comparison with fig. 6.

In the following case the conditions so far as the diagnosis was concerned were much the same as the above, though produced by a tumour of different type—a meningeal endothelioma. The case is one which interested us greatly at the time and was studied in detail, though the bare outline of the history must suffice for this report.



Case 2.—Large endothelioma involving right temporo-sphenoidal lobe producing a homonymous field defect unequal in the two eyes. Operation: Partial recession of field defect. (J. H. H., Surg. No. 30210.)

July 9, 1912: Admission of Louis C., a tailor, aged 33, complaining of headaches and failing vision.

Tumour history: For three years mild but more or less continuous headache referred to the right parietal region. For three months progressive failure of vision in the right eye. No other subjective disturbances. He had worked until the day of admission.

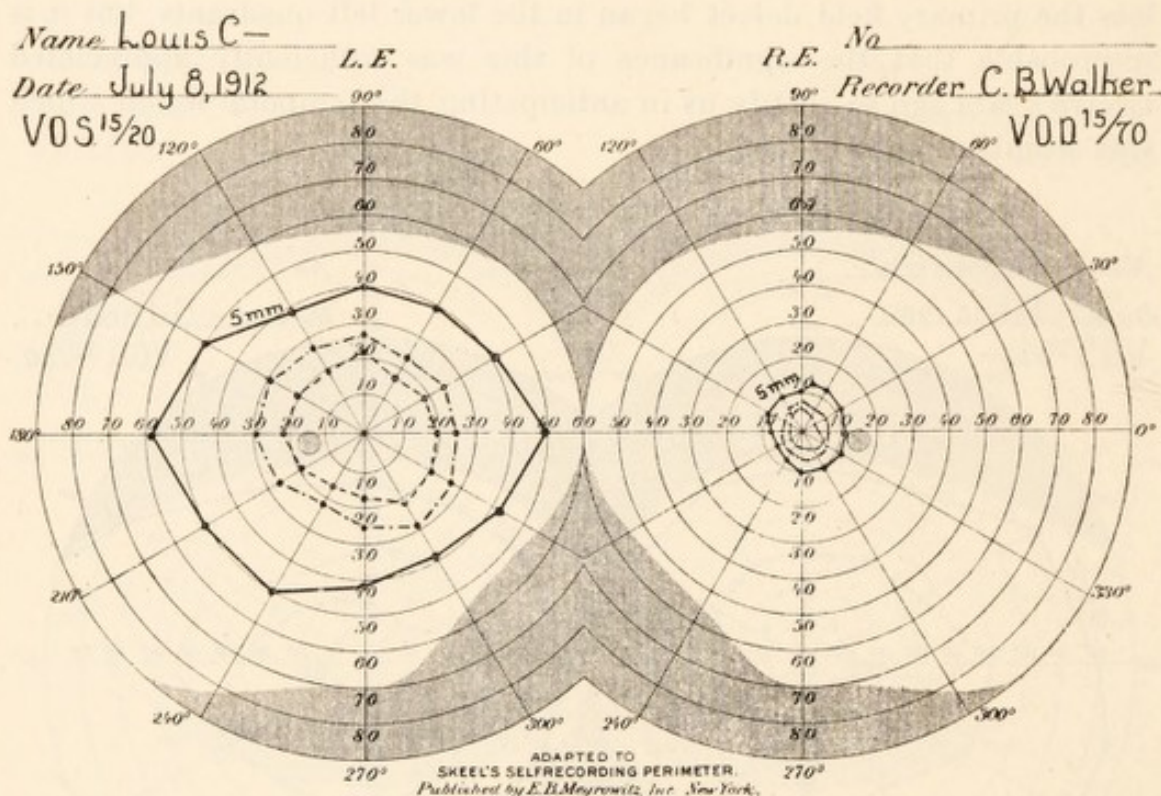


FIG. 8.—Case 2. Fields taken before operation which disclosed endothelioma of right temporal lobe.

Physical and neurological examination: Negative in all respects except for the condition of his eyes, which were slightly exophthalmic. There was a choked disc of 3 D. right and 2 D. left, with new tissue and some secondary atrophy, more marked right than left. The fields showed (fig. 8) concentric constriction, slight on the left but extreme on the right, where vision was practically tubular. V.O.S.  $\frac{15}{20}$ ; V.O.D.  $\frac{15}{70}$ . The X-ray showed signs of general pressure but nothing of localizing value.

July 11, 1912: Operation 1: A right subtemporal decompression performed by my then assistant, W. E. Dandy, unexpectedly disclosed the edge of a tumour occupying the lower anterior part of the temporal lobe.

Post-operative: He made a good recovery with partial subsidence of his



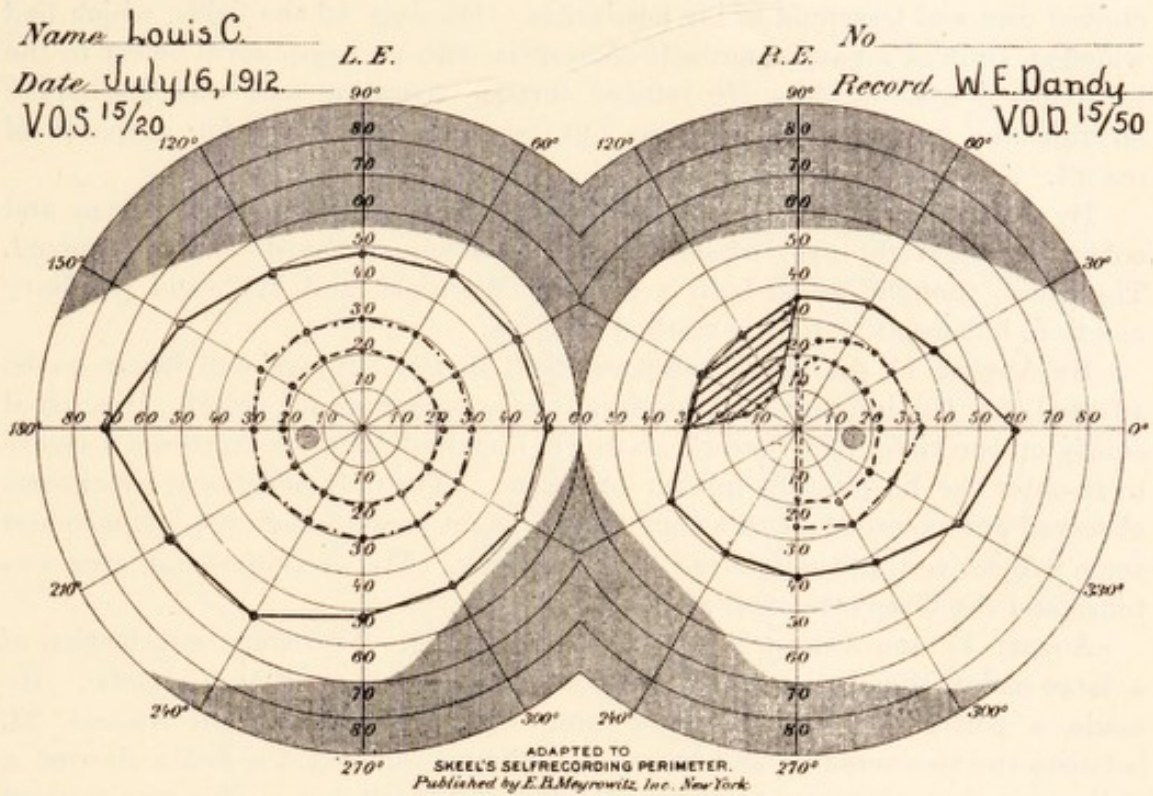


FIG. 9.—Case 2 (contd.). Fields five days after decompression which disclosed tumour. (Cf. fig. 8.)

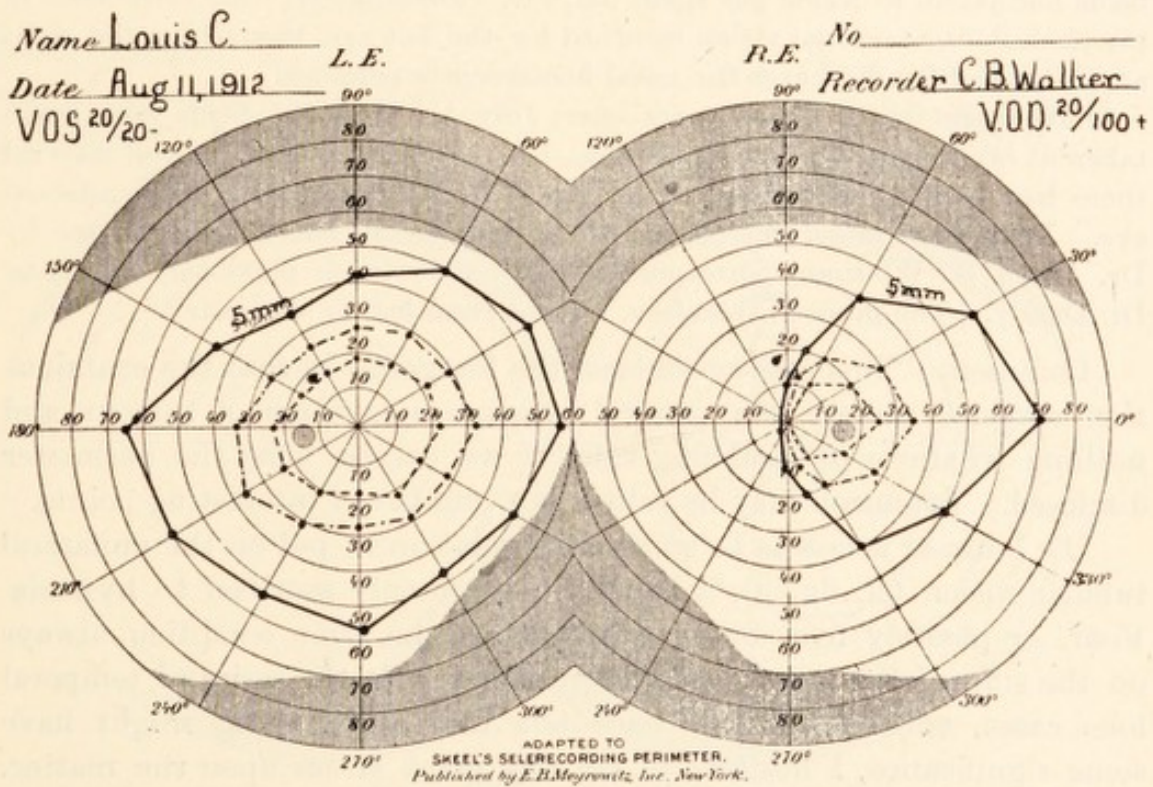


FIG. 10.—Case 2 (contd.). Fields one month after those shown in fig. 9. Tumour as yet not removed. Note beginning upper temporal defect on the left with complete right hemianopsia.



choked disc and lessening of his headaches. On July 16 the fields, which had widened, showed a nasal hemiachromatopsia with an upper form defect in the homolateral eye (fig. 9). He refused further operation and was discharged on this day to his home near by, but returned frequently for purposes of record.

By July 29 there was a fully established hemianopsia for both form and colour in the right eye, where further elevation of the disc had occurred. There was thought to be both a positive Wernicke and Wilbrand pupillary reaction, but negative by the method of Hess.

By August 11 the upper temporal field in the left eye had begun to be affected (fig. 10), indicating the beginning of a homonymous defect. His visual acuity on the right had become so much impaired that he expressed a desire to re-enter the hospital for further operation. The only additional symptoms observed and recorded at this time were a slight weakness of the left face and some subjective tinnitus referred to the left ear. The decompression area was tense and the discs measured about 2 D.

August 17 and August 26, 1912: Operation 2. Two-stage enucleation of a large endothelioma deforming the lower and anterior portion of lobe. He made a perfect surgical recovery from both procedures. On August 23, between the two sessions and before the tumour removal, the fields showed a still more marked upper temporal defect for the left eye. This was present also on August 29, three days after the extirpation, though by this time the fields had begun to widen out again (fig. 11). Fortunately, with subsidence of the choked discs normal vision returned for the left eye, though on the right at the time of his discharge the nasal hemianopsia persisted.

Subsequent note: Three years later, July 15, 1915, the fields were again taken at my request by Dr. Dandy (fig. 12). They show that in the interval there had been a slight filling out of the lower nasal quadrant in the affected eye. Four years later, October 27, 1919, visual fields kindly taken for me by Dr. Lloyd B. Whitham correspond exactly with those previously taken by Dr. Dandy. The process, therefore, may be regarded as stationary.

Comment: This case resembled the foregoing in that the examination revealed merely the general pressure symptoms of tumour and nothing whatever of localizing value if we except what the perimeter disclosed. Attention may be called to a number of interesting points.

(1) I am at a loss as to what interpretation to put on the unilateral tubular vision (cf. fig. 8), a condition commonly ascribed to hysteria. Four, or possibly five, other examples of the same condition, always on the side of the lesion, have been observed in the series of temporal lobe cases, and though we once felt that the finding might have some significance, I hesitate to lay any great stress upon the matter. (2) Of greater importance, though not observed till the tumour diagnosis had been made, was the gradual onset of the field defect in the homo-



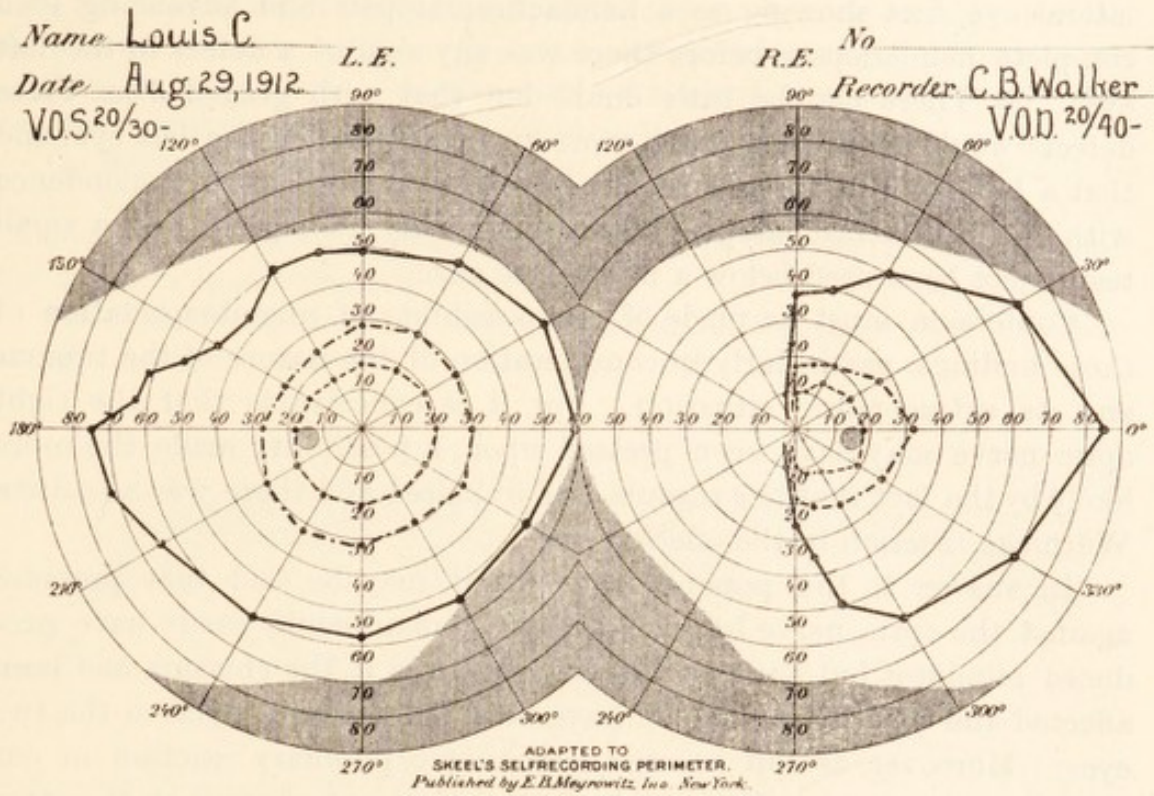


FIG. 11.—Case 2 (contd.). Three days after tumour extirpation. Note widening of fields compared with fig. 10.

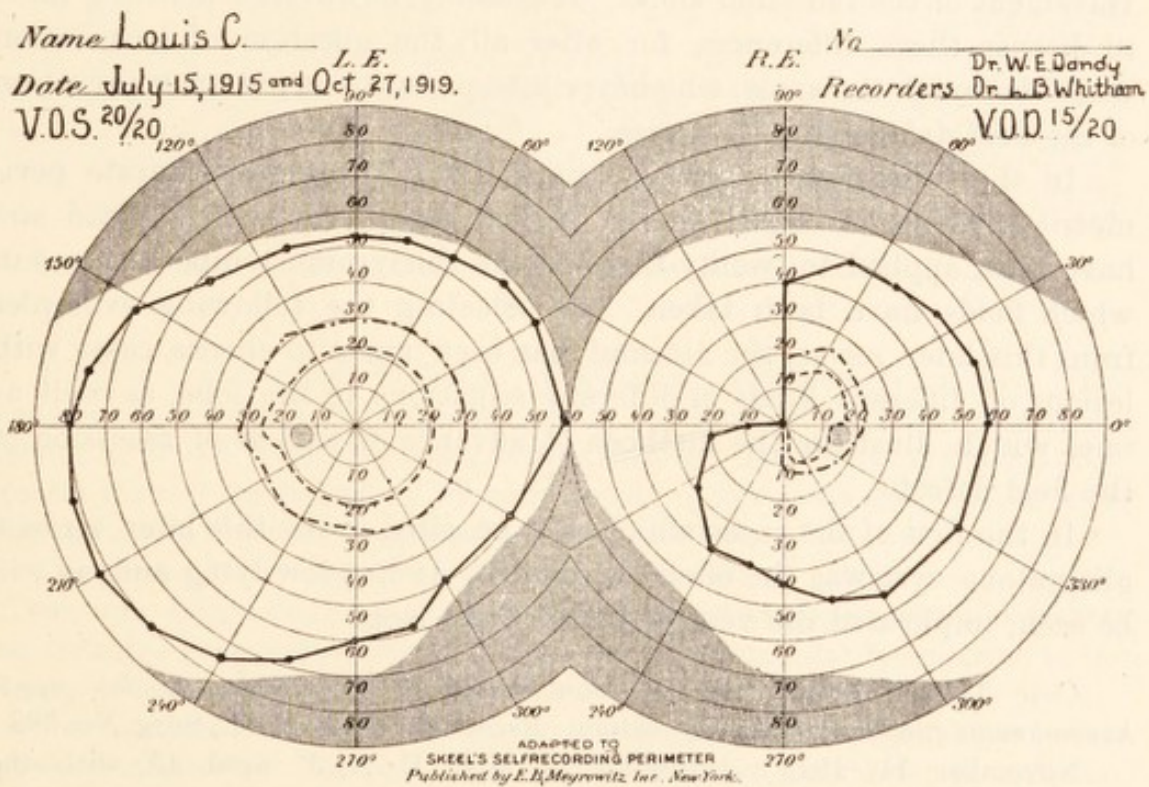


FIG. 12.—Case 2 (contd.). Present and stationary condition seven years after the tumour extirpation.



lateral eye, first showing as a hemiachromatopsia and advancing to a complete hemianopsia before there was any sign of a defect in the left eye. (3) There can be little doubt but that with graded discs these defects would have been much more apparent even in the left eye, and that a hemianopsia to form would have shown itself in correspondence with the hemiachromatopsia observed on July 16 (fig. 9), had a small test object been used below a millimetre size.

Confession must be made of one possibility of misinterpretation of these findings, particularly in consideration of the nature of the tumour and its extracerebral situation. For it is conceivable that the right optic nerve may have been pressed upon, a possibility made the more likely by the fact that the macula was impaired and there was a positive Wernicke reaction in the affected eye.

In answer to this possible criticism it may be said that pressure against the optic nerve by such a large tumour could easily have produced blindness but hardly a hemianopsia, and if the chiasma had been affected the field defects would have been more nearly equal in the two eyes. Moreover, as will be seen, a hemiopic pupillary reaction in our experience is not very dependable and the patient showed at the same time a positive reaction to the prism test which would indicate an involvement of the radiation alone. It possibly, however, is splitting hairs to discuss these differences, for, after all, the question of localization would be much the same, whichever interpretation is put upon causation of the field defects in such a case.

In the tumour cases subsequent to 1912, the more accurate perimetric methods developed by Dr. Walker have come to be utilized and have been applied to twenty-three of the thirty-nine temporal cases in which fields have been taken. In selecting the following examples from this later series, the attempt has been made to choose cases with lesions of different kinds in different situations in the lobe, as well as ones which illustrate the methods of advance as well as of recession of the field defects.

In the first of the cases which will be cited from this later series a gliomatous cyst was the offending agent. It was low-lying and, as will be seen, implicated the ventral fibres of the loop.

*Case 3.—Gliomatous cyst of right temporal lobe producing left upper homonymous quadrantopsia. Operation. Recovery. (P. B. B. H., Surg. No. 582.)*

November 14, 1913: Admission of Miss E. A. J., aged 43, with the complaint of headache and diplopia.

History: Subject to frontal headaches all her life. For six months there



have been severe attacks of pain referred to the suboccipital region. For four months considerable vertigo. Of late, some unsteadiness of gait which she ascribes to her diplopia. Also of late, paræsthesia of extremities and great despondency through a morbid fear of insanity.

On September 18, two months before her entrance, fields of vision taken by C. B. Walker disclosed a left upper quadrantal hemianopsia for form and colours (fig. 13). A month later, October 17, 1913, Dr. George S. Derby found the defect to remain practically unaltered.

Physical examination: Considerable exophthalmos, more right than left; a slightly enlarged thyroid.

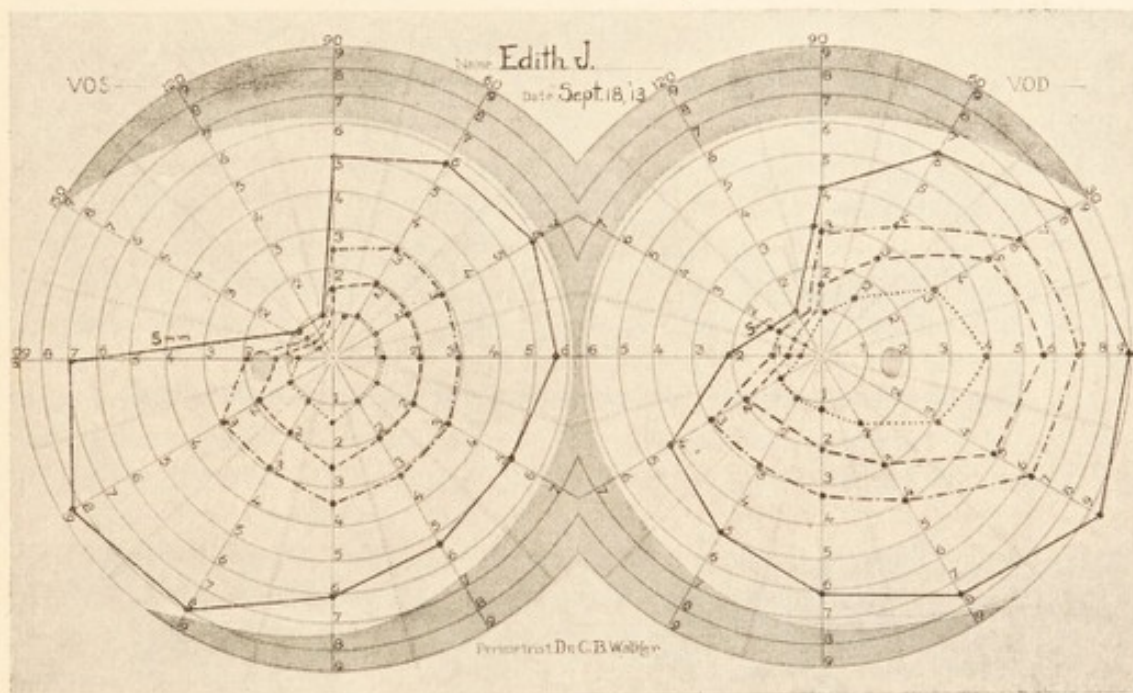


FIG. 13.—Case 3. Fields as found practically stationary during the two months before operation.

Positive neurological findings: A complete abducens paralysis. The eye-grounds showed slight hyperæmia with haziness of the nasal margins and overfilling of the veins; no measurable swelling. The fields taken by Gilbert Horrax showed approximately the same defect observed on the previous tests. The condition, therefore, had been stationary for two months.

The examination otherwise was absolutely negative. There was no history of anything suggesting uncinæ attacks. Nothing in the examination except her abducens palsy supported the suggestion of a cerebellar lesion given in the history of her complaints.

She remained under observation for a week, during which time she had no special discomforts. The perimetric findings favoured a right temporal lesion, but the diagnosis was uncertain and a choked disc questionable. She was discharged as a "brain tumour suspect" to report for observation.



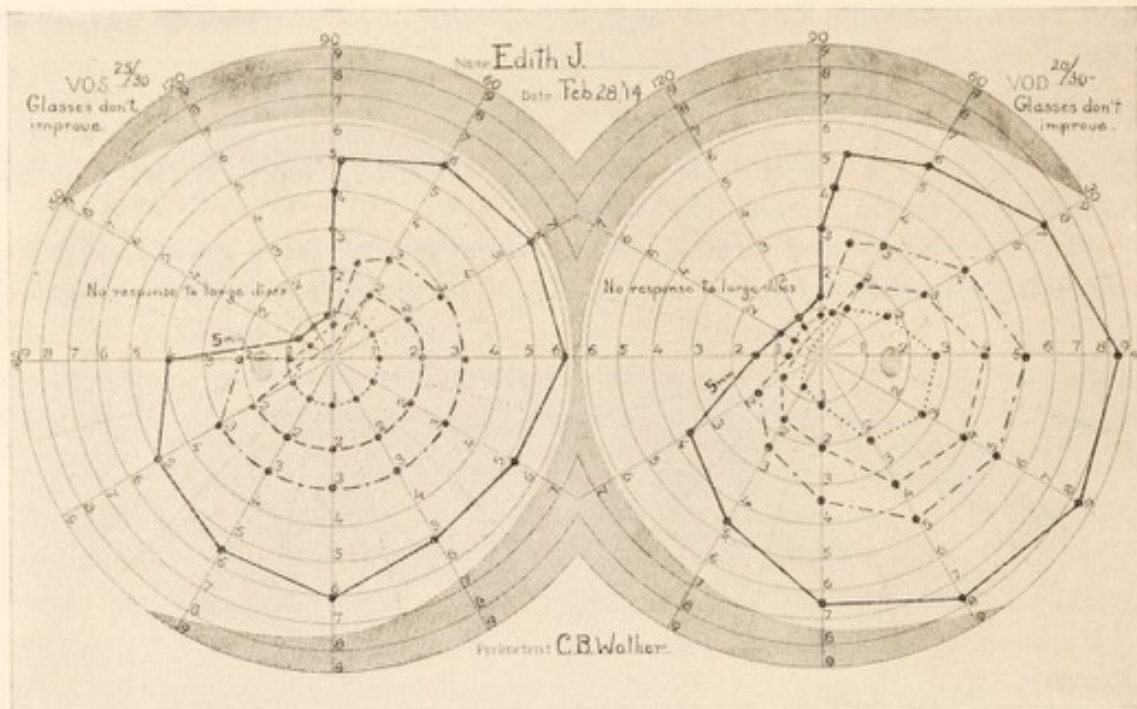


FIG. 14.—Case 3 (contd.). For comparison with fig. 13 five months later.

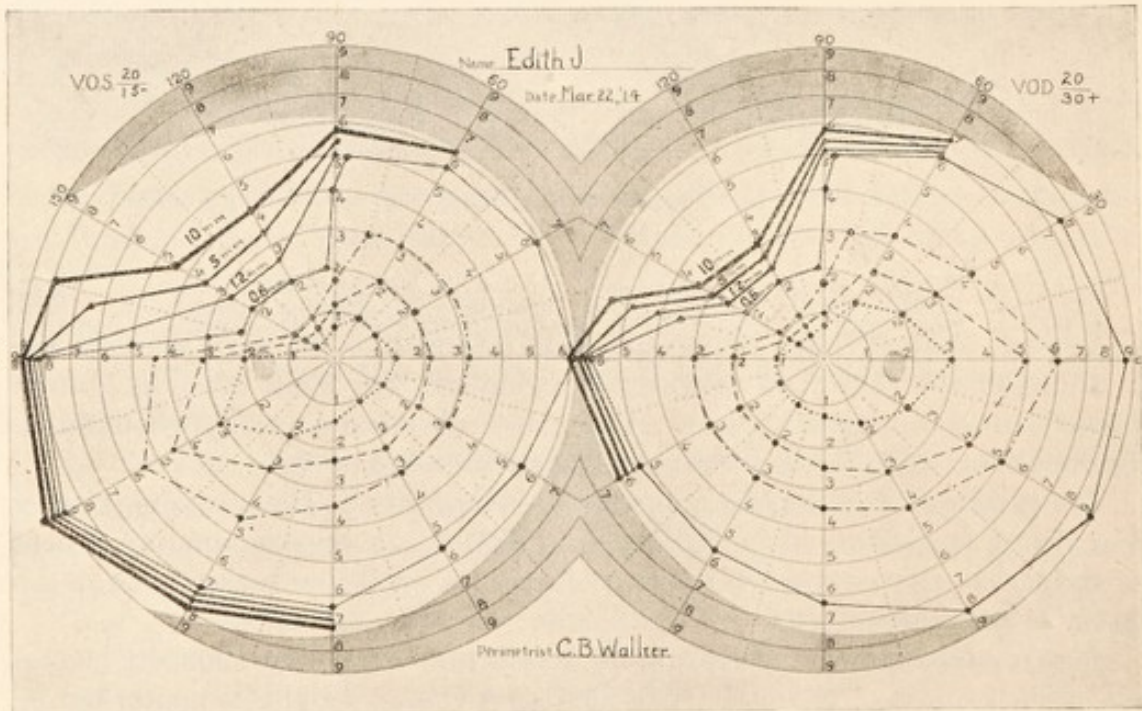


FIG. 15.—Case 3 (contd.). Fields sixteen days after operation disclosing gliomatous cyst in right temporal lobe.



During the next three months the condition remained unchanged except that her diplopia practically disappeared.

In February of 1914, she had several attacks of severe suboccipital pain with recurrence of the diplopia. This led to her re-entry. The fields were much as before, though the contraction was somewhat more marked (fig. 14). Haziness of the nerve head, however, was definitely more pronounced.

March 6, 1914: Operation. A right subtemporal decompression was performed. The temporal lobe was full, its convolutions flattened and an exploratory puncture through the second temporal convolution disclosed a gliomatous cyst containing about 30 c.c. of straw-coloured fluid.

She was discharged March 24, 1914, her mental condition having greatly improved on the subsidence of her headaches. The fields, as shown by Dr. Walker's charts (fig. 15), had begun to fill out to their normal outlines.

Following her discharge she remained free from symptoms for five years. The abducens palsy disappeared. Though from time to time the decompression area would become prominent and tight, this would soon pass off and there was no real headache. She had been active at social functions, and was engaged in the Y.M.C.A. corps during the war.

On the afternoon of April 16, 1919, while at the dressmaker's, she suddenly became nauseated and vomited. She was readmitted to the hospital three hours later. The decompression area was tense and her vomiting persisted. She began to have auditory hallucinations of people knocking at her door and of telephone conversations. There were visual hallucinations also—of seeing coloured lights and processions of queer figures marching on the ceiling. Her old diplopia again became marked.

Examination showed, as before, nothing but a low grade of papilloedema and a right abducens palsy. The fields of vision, though from inattention they were plotted with some difficulty, showed the same defects as on her first admission (fig. 13).

April 25, 1919: Operation 2. The temporal lobe was again exposed and the cyst was easily entered. It contained about 30 c.c. of straw-coloured fluid which set on standing. The walls were thoroughly fixed with Zenker's fluid until of a leathery consistency and the wound was closed. She made a perfect recovery, and the history records a recession of the field defects (the charts unfortunately have been lost). She was discharged May 22, 1919.

She reported in September, 1919, having been free from symptoms since her discharge. At this time the fields (fig. 16) still showed a slight notching. At the present time, two years from her last operation, and eight years since the onset of symptoms, she remains perfectly well, and her last perimetric examination, April 21, 1921, shows normal field peripheries (fig. 17).

Comment: This experience might be multiplied many times. The defect had never advanced to a hemianopsia but remained quadrantal, and on the side of the lesion, as is often the case, was a little in advance of the other. It involved chiefly the upper field quadrants, and hence indicated pressure on the ventral fibres of the pathway.



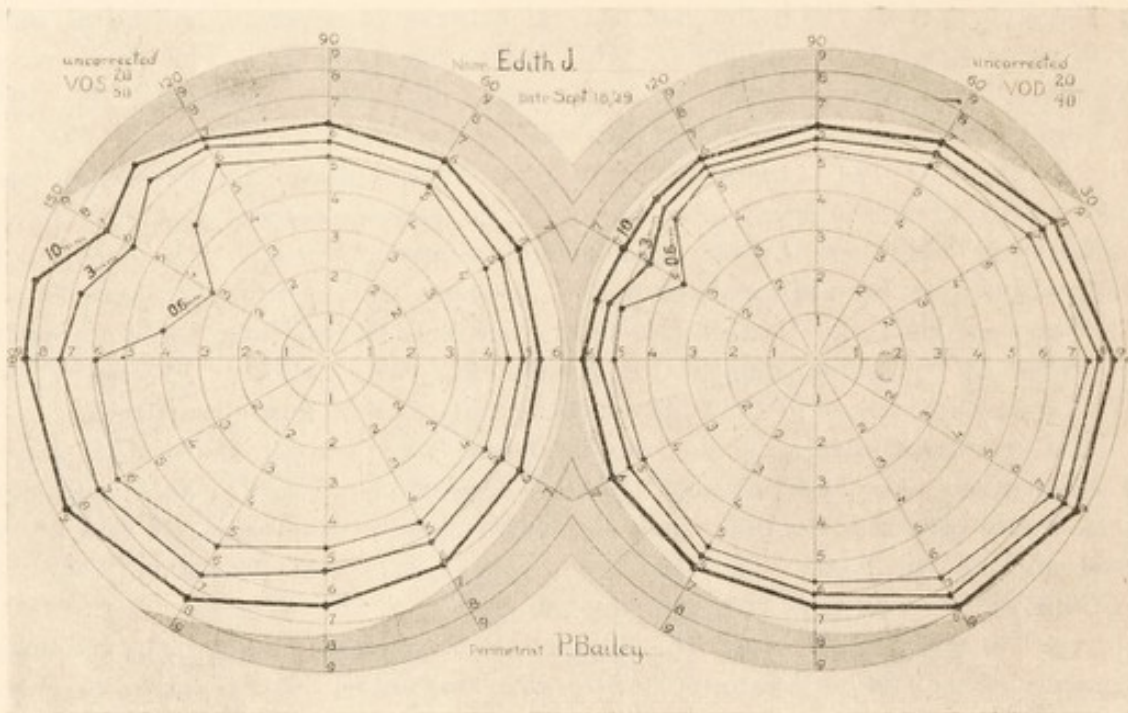


FIG. 16.—Case 3 (contd.). Showing persistence of slight homonymous defect five months after second operation.

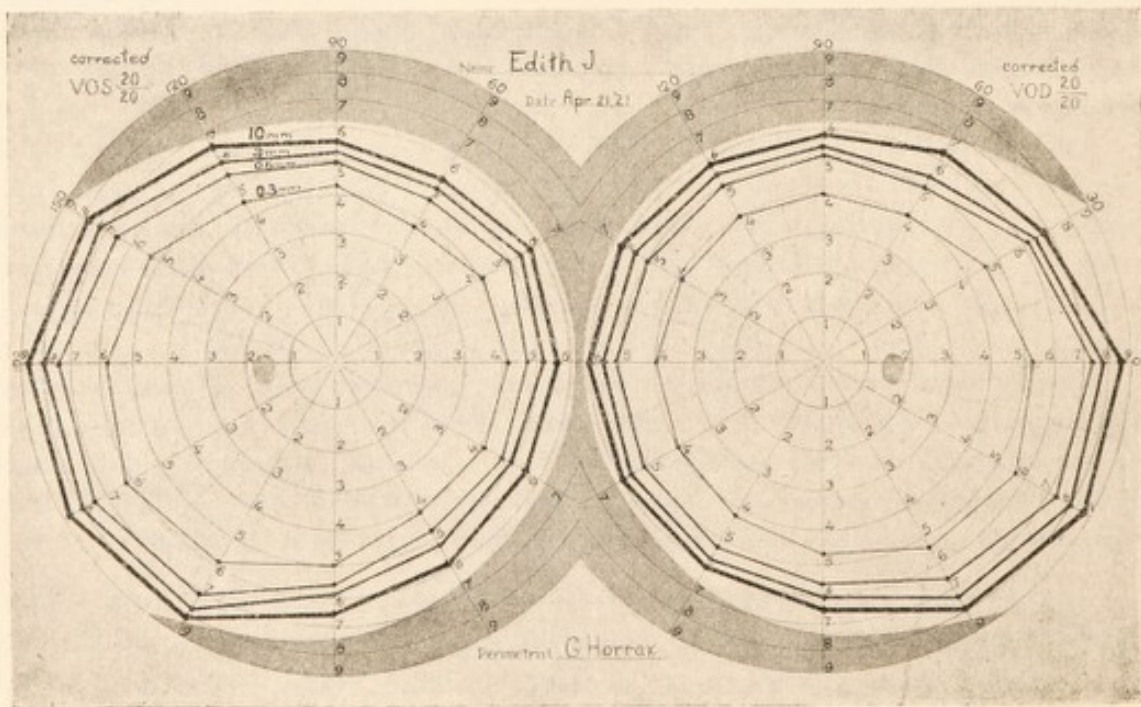


FIG. 17.—Case 3 (contd.). Normal fields two years after second operation.



Another example of this same type may be given, also a glioma, though one with a less favourable ultimate outcome. The patient was admitted at a time when Dr. Walker was making very detailed studies, as shown by the elaborateness of the first chart (fig. 18), which gives not only the form peripheries, but those for colours as well. It will be seen that there was a homonymous hemianopsia for colour as well as for form when the minute test objects were used. The condition, therefore, was somewhat more advanced than in Case 3, though the lesion was of the same type and in the same situation. A localizing diagnosis would not have been possible without the fields. They show still better than those of the foregoing case that the quadrantal defect on the side of the lesion, as shown by the larger discs, is somewhat in advance of that on the opposite side.

*Case 4.—Homonymous hemianopsia produced by a gliomatous cyst of right temporal lobe. Operation followed by improvement. (P. B. B. H., Surg. No. 4550.)*

April 8, 1916: Admission of Robert S., aged 36, a machinist, referred from the Boston Psychopathic Hospital, with the complaint of headaches and failing vision.

Clinical story: Four years before, he had been struck by a heavy piece of metal on the right forehead and rendered unconscious. There were no subsequent symptoms. For the past year he has not felt well, and has been drinking heavily. Six months before entrance (October, 1915) he had a general convulsion without warning. Since then there have been two similar attacks (November, 1915, and January, 1916). Since December he has had spells of suboccipital headache accompanied by nausea and vomiting. These have increased in intensity and there is now continued discomfort. For two months past there has been progressive blurring of vision. He has had numbness of arms and legs, some unsteadiness of gait, and also tinnitus in the left ear for the past year. He has had a few attacks suggesting *petit mal* in which he feels dazed and experiences a sensation of numbness and pricking in the right arm. Otherwise there has been nothing suggestive of unciniate attacks. He has been treated all this time for stomach trouble.

Physical examination. This disclosed nothing except the following few positive neurological findings. Bilateral choked disc of 5 D. with abundant hæmorrhages. Definite nystagmoid jerks on looking to the left. Slight impairment of hearing, i.e., conduction to watch less good on left than right (6 in. to 24 in.). Positive Romberg with falling to the right.

Aside from the evidences of a marked increase in intracranial tension the findings therefore were few. There was nothing to justify a localizing diagnosis, though it is evident from the history that the first examiner wavered between the suggestive cerebellar signs and the history of possible involvement of the right arm in the *petit mal* attacks. These possibilities were promptly set aside when the fields of vision came to be taken. They showed



a left homonymous defect which therefore lateralized the lesion in the right hemisphere beyond any diagnostic doubt (fig. 18).

April 19, 1916: Operation. Right subtemporal decompression. This disclosed an exceedingly tense temporal lobe. An exploratory trocar was inserted in the second temporal convolution toward the ventricle and at a depth of 3 cm. tapped a large gliomatous cyst containing over 30 c.c. of fluid. The tension was completely relieved. The cyst was widely opened by an incision through the second temporal convolution but its walls were not treated. A fragment of the wall removed for histological study showed a diffuse glioma.

He made a perfect recovery (figs. 19-20), and was discharged May 5, practically without symptoms, though the choked disc had not as yet com-

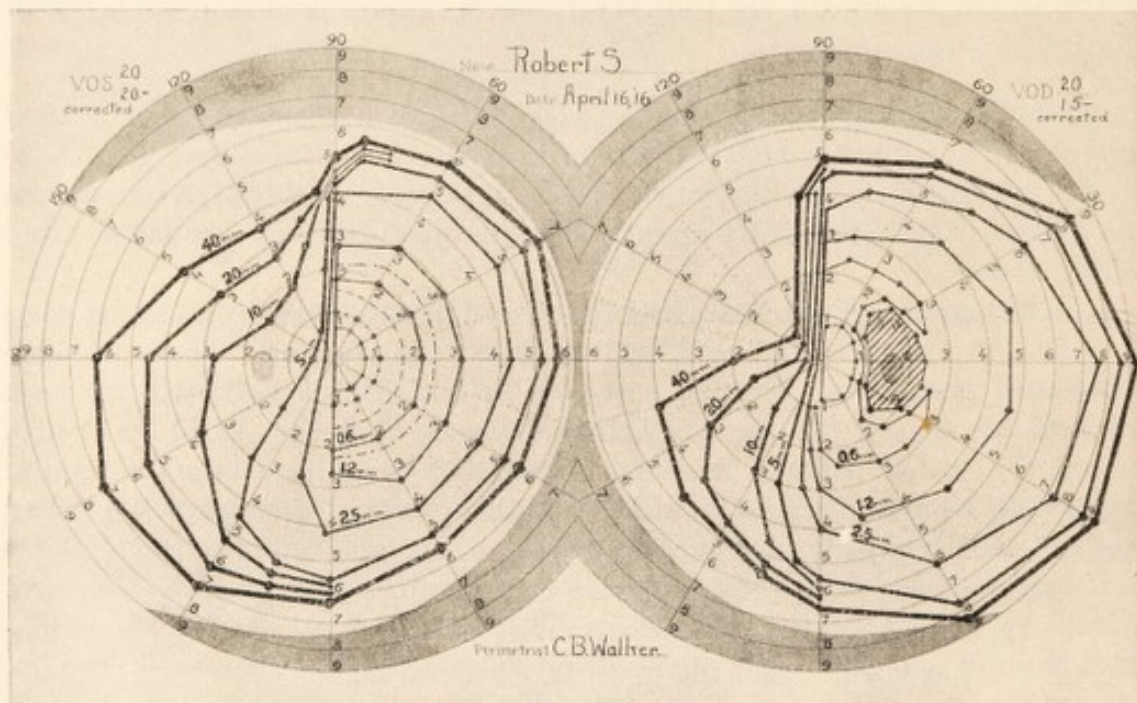


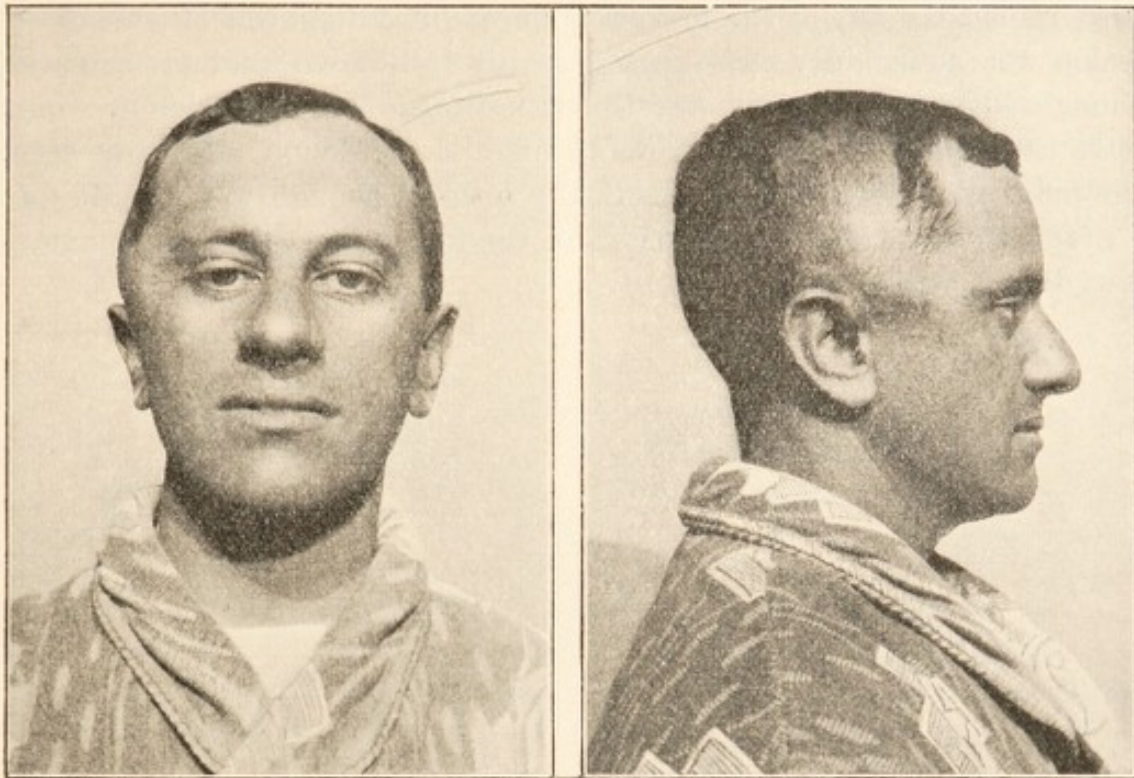FIG. 18.—Case 4. Field taken before operation disclosing a right temporal gliomatous cyst. Note complete hemianopsia to discs below 1.2 mm. size. Also greater advance in defect to larger discs for right than left eye.

pletely subsided. The fields, except those for colour, had by this time partly regained their normal outlines (fig. 21).

December 22, 1916: Reported in person, having been working at his trade since shortly after his discharge. Condition excellent. No symptoms. Decompression soft. Fundi normal. Fields are normal except for a slight defect in the left temporal region to the smallest visible disc (fig. 22).<sup>1</sup>

<sup>1</sup>This patient re-entered the hospital October 22, 1918. Unfortunately no fields were taken at the time as the staff was mostly in army service. He had been quite well until the month previous and had worked regularly until a few days before. His decompression had become tense. The cyst was tapped on several occasions, but immediately refilled. An exploratory operation was performed which revealed an extensive gliomatous growth. He was discharged and his death was reported a few months later.





FIGS. 19 and 20.—Case 4 (contd.). Condition on discharge sixteen days after subtemporal decompression, showing slight protrusion at seat of defect.

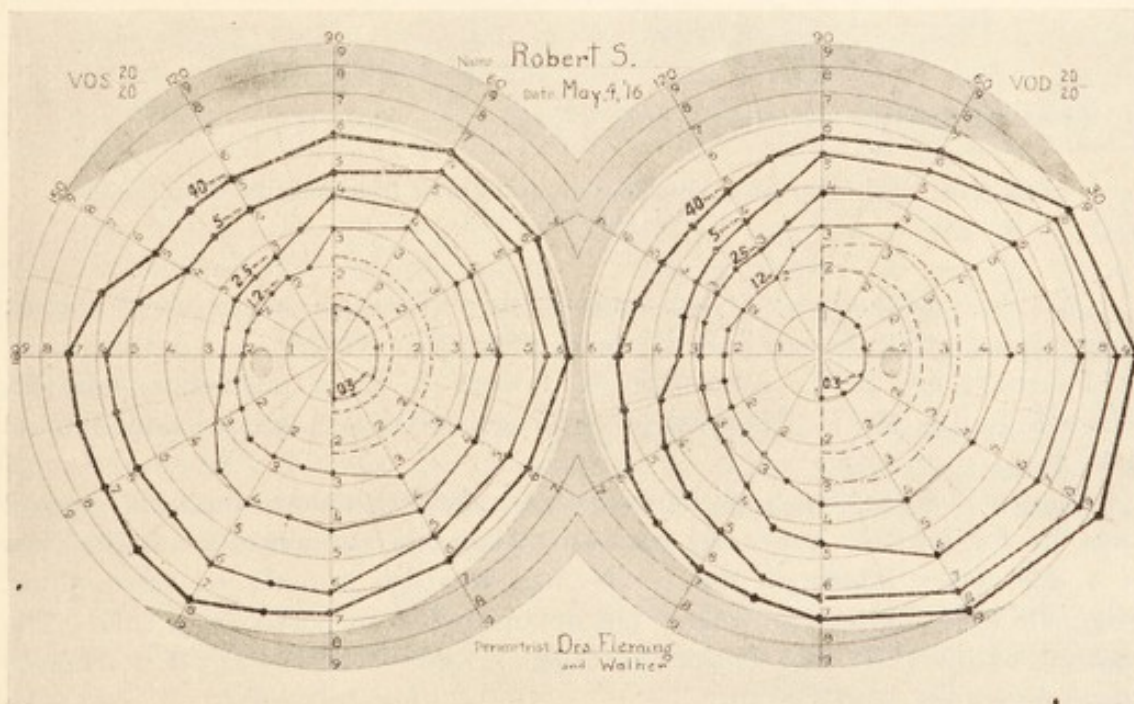


FIG. 21.—Case 4 (contd.). Fields on patient's discharge sixteen days after operation. Note persistence of homonymous hemianopsia to 0.3 mm. disc.



The following case, owing to the nature of the growth, was far less favourable than any of the preceding ones. The diagnosis of a temporal lesion was sufficiently clear owing to his full-blown unciniate seizures, though without the perimeter the lateralization of the tumour would have been difficult. At the time of his first admission, as will be seen, the fields were regarded as practically normal, though to a minute disc a notch in the right upper quadrant, the forerunner of a more extensive defect, was already apparent.

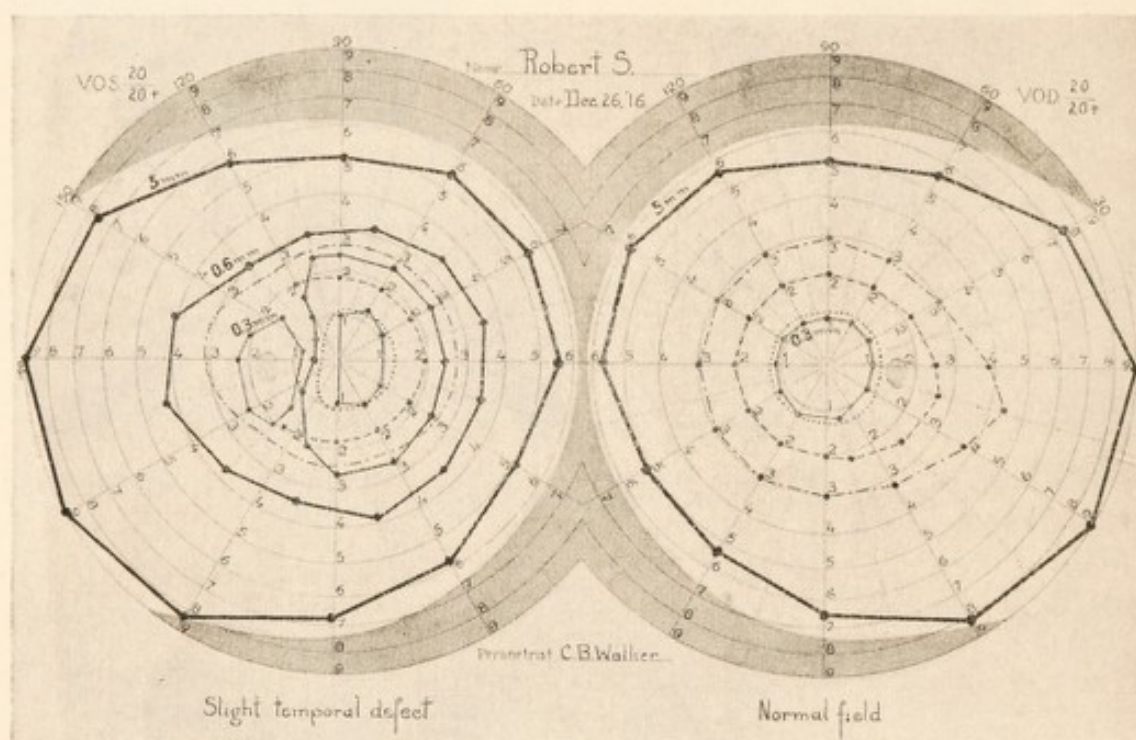


FIG. 22.—Case 4 (contd.). Fields six months after operation, for comparison with figs. 18 and 21.

*Case 5.*—Solid glioma of left temporal lobe with unciniate seizures and an upper right quadrantopsia. (P. B. B. H., Surg. No. 6273.)

February 16, 1917: Admission of Robert A. C., a physician, aged 36, referred by Dr. A. B. Kanavel, of Chicago, with the major complaint of *petit mal*.

History: Somewhat apprehensive about his health ever since his student days, he for fourteen years has regularly taken his temperature and in view of a customary afternoon rise to  $99^{\circ}$  has regarded himself as tuberculous. Frequent examinations by many physicians failed to corroborate this. The account of his *petit mal* attacks as taken in the records by Dr. S. J. Harvey is as follows:—

Uncinate attacks: "Eight and a half years ago began to have attacks of *petit mal*. The first one came on suddenly while taking a needle from a



patient's hand. He became dizzy, felt faint, had 'air hunger,' went to a window, opened it and soon revived. One month later there was a similar attack and soon they came with increasing frequency, often ten or twenty a day. The attacks are usually accompanied by what he describes as an exaggeration of his special sense impressions, i.e., flowers become extraordinarily beautiful, odours are intensified, his vision appears to be remarkably keen, so that objects seem to be increased in size. The olfactory hallucinations were never of an unpleasant nature.

"There has never been any loss of consciousness and the attacks have always been so fleeting that a bystander would hardly know he was having one. There is usually an aura 'as if something were to happen,' and during the attack he feigns to be meditating or cogitating over what may have just been said. He states that no two of the attacks are exactly alike but that they vary according to the time of day, his surroundings or the season of the year. For the past two or three years the attacks have been a little more severe; they would leave him momentarily dazed and disorientated; for instance, while talking to a friend he might be seized with an attack which would cause him to stop his conversation, and when he 'came to' would have to ask what he had been saying, or at other times would plead an important engagement to cover his confusion. He has occasionally had a sense of seeing objects to his right which were not there. For some years he has taken bromides in large doses, 70 to 80 gr. per diem."

Headaches: For fourteen months he has had occasional severe suboccipital headaches but without vomiting. During these periods there has been some retraction and rigidity of the neck.

Vision: Has never noticed any diminution of vision, but he had glasses fitted when his headaches came on and found he had been seeing double without being aware of it. For a month he has had considerable bilateral tinnitus.

Physical examination: A robust individual over six feet in height and weighing 230 lb. The findings were absolutely negative except for a low grade of choked disc with swelling of 1 D., a fairly well marked lateral nystagmus, a slight weakness of the right face on expressional movements (discounted by the patient as a personal characteristic) and a slight weakness of the left abducens.

The fields of vision taken at this time with only two test objects (fig. 23) showed to a small 0.3 mm. disc a notch in the right upper quadrant of the left eye, whereas the peripheries to a 5 mm. disc were normal. No special significance was attached to these fields.

It is evident from this early history that the case despite the uncinata seizures was regarded, on the basis of the suboccipital headache and the nystagmus, as a cerebellar tumour suspect. He returned to his home and re-entered the hospital a month later. At this time his choked disc had become more pronounced with elevation of 3 D.



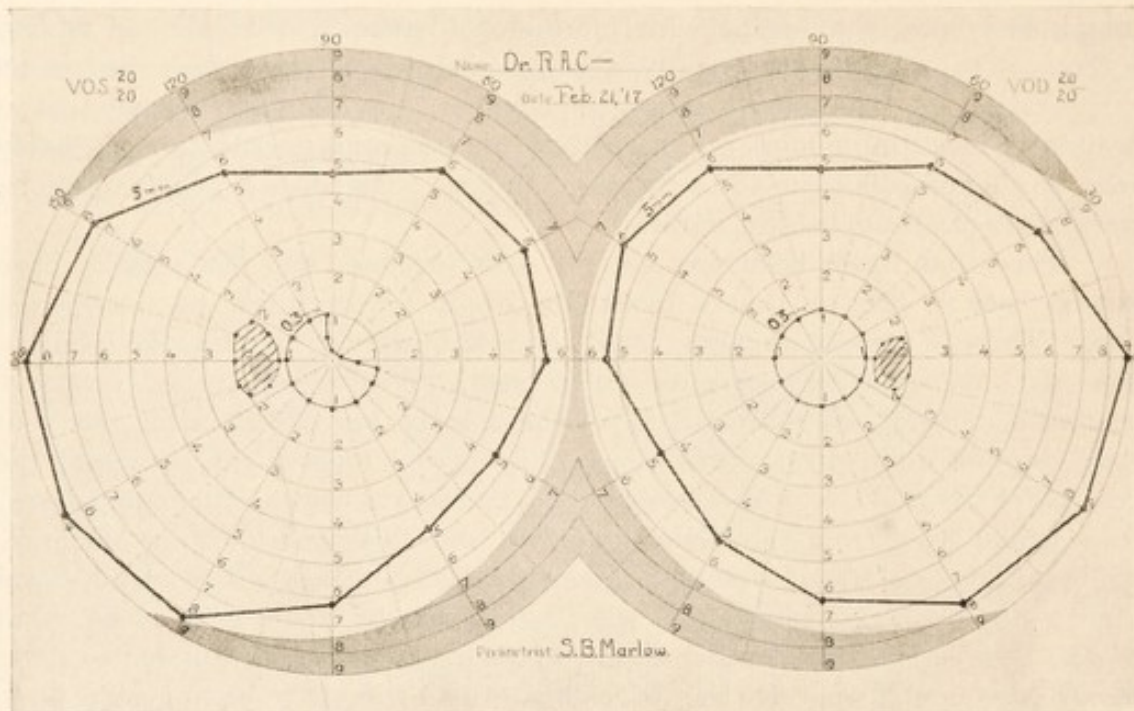


FIG. 23.—Case 5. Fields three weeks before operation. Note upper nasal notch in left to 0.3 mm. disc. Not regarded at time as of particular significance.

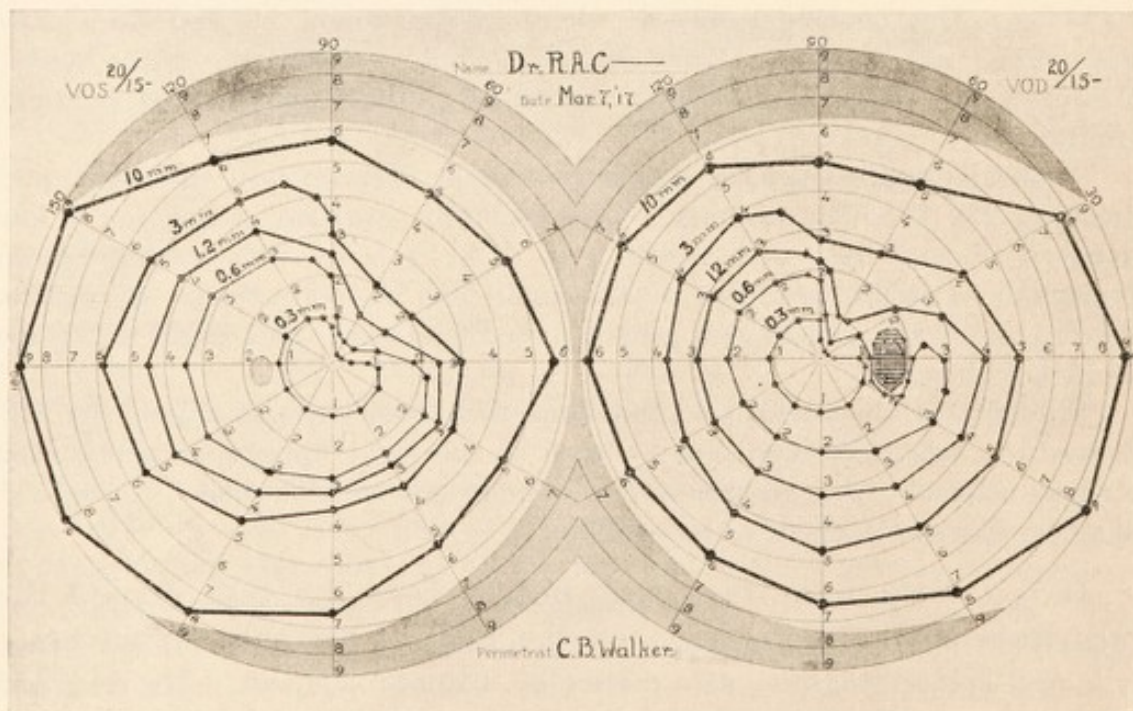


FIG. 24.—Case 5 (contd.). Fields showing homonymous involvement of which those in fig. 23 gave promise. Note notch at this session to the 0.3 mm. disc in each eye.



and the fields taken by Dr. Walker (fig. 24) showed an advancing defect, the right field now being involved. There remained no doubt as to the situation of the lesion in the left temporal lobe.

March 10, 1917: Operation. Left subtemporal decompression disclosing a tense bulging temporal lobe with flattened convolutions. Exploratory puncture secured about 2 c.c. of yellowish fluid. Diagnosis: glioma.

Subsequent notes: He made a good recovery. The choked disc subsided. He was discharged March 24. During my absence in the Army he reported by letter on October 10 as being in good health despite his continued *petit mal* attacks. He is reported to have died January 8, 1918. It may be assumed that before the end he had a complete homonymous hemianopsia.

The following case illustrates the terminal condition of complete hemianopsia which in the preceding would probably have been observed had a perimetric test been made toward the end. The patient had visual hallucinations referred to the defective fields (left) and a few gustatory impressions suggesting uncinata stimulation, though there were no "dreamy states." The lesion, therefore, even without the field defects, might possibly have been localized in one or the other temporal lobe, but the characteristic fields made its lateralization possible.

*Case 6.—A rapidly growing cystic glioma of lower right temporal lobe producing upper quadrantopsia unrelieved by operation and advancing to hemianopsia. (P. B. B. H., Surg. No. 4002.)*

December 14, 1915: Admission of Jacob B., aged 11, a right-handed boy, with the complaint of headaches and vomiting.

Clinical history (notes by Dr. Horrax): "Onset a year before admission, with frontal headaches and pain in the eyes, chiefly the right. The headaches were usually associated with nausea, vomiting, and often with dizziness. These symptoms have increased until of late headache has been constant. For a month he has had buzzing in the right ear, and he recently was operated upon in a local hospital for adenoids. Some occasional blurring of vision has also been observed during the past month, but his acuity remains unimpaired. For the past week there has been some double vision, and on three occasions he had had definite visual hallucinations, always to the left. Once he had the impression of seeing a boy on the wall. Another time a man dressed in white was seen sitting by the fire bending over to tie his shoe, and this impression remained a long time. One night, after his admission, he thought he saw some children sitting around a desk on the wall, but they were gone when the nurse turned on the light.

"On one occasion, just before entrance, he thought that he had smelled and tasted peaches when none were around, and after his hospital admission he insisted that he smelled and tasted roasted peanuts. These two occasions



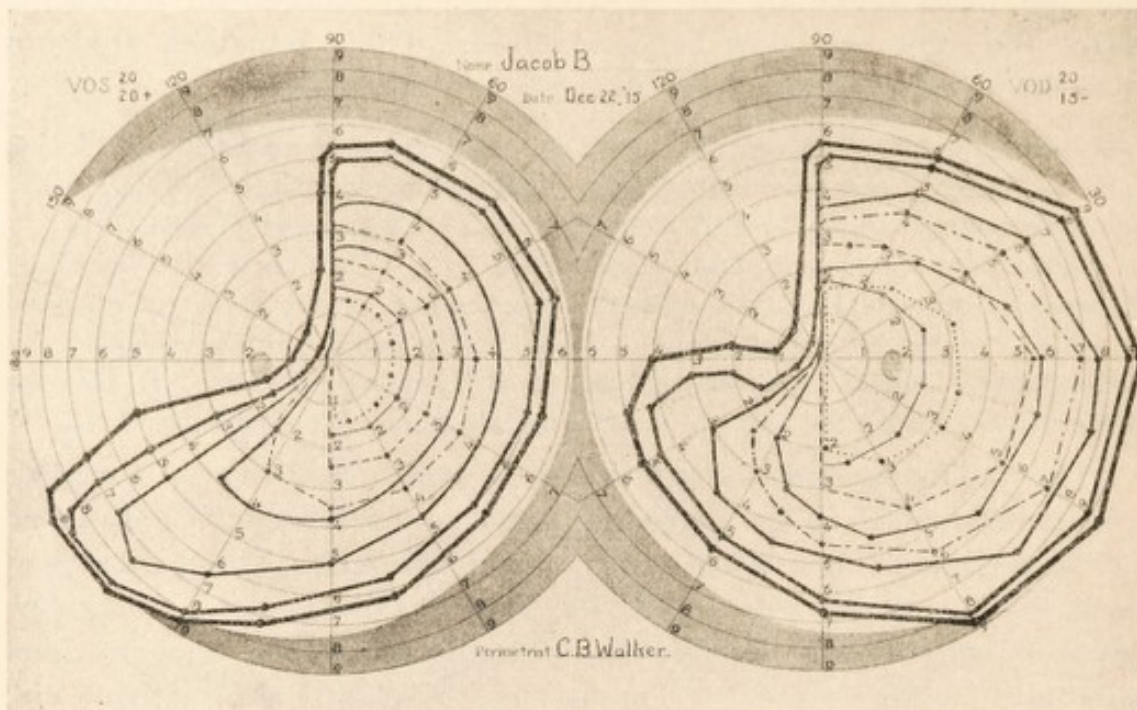
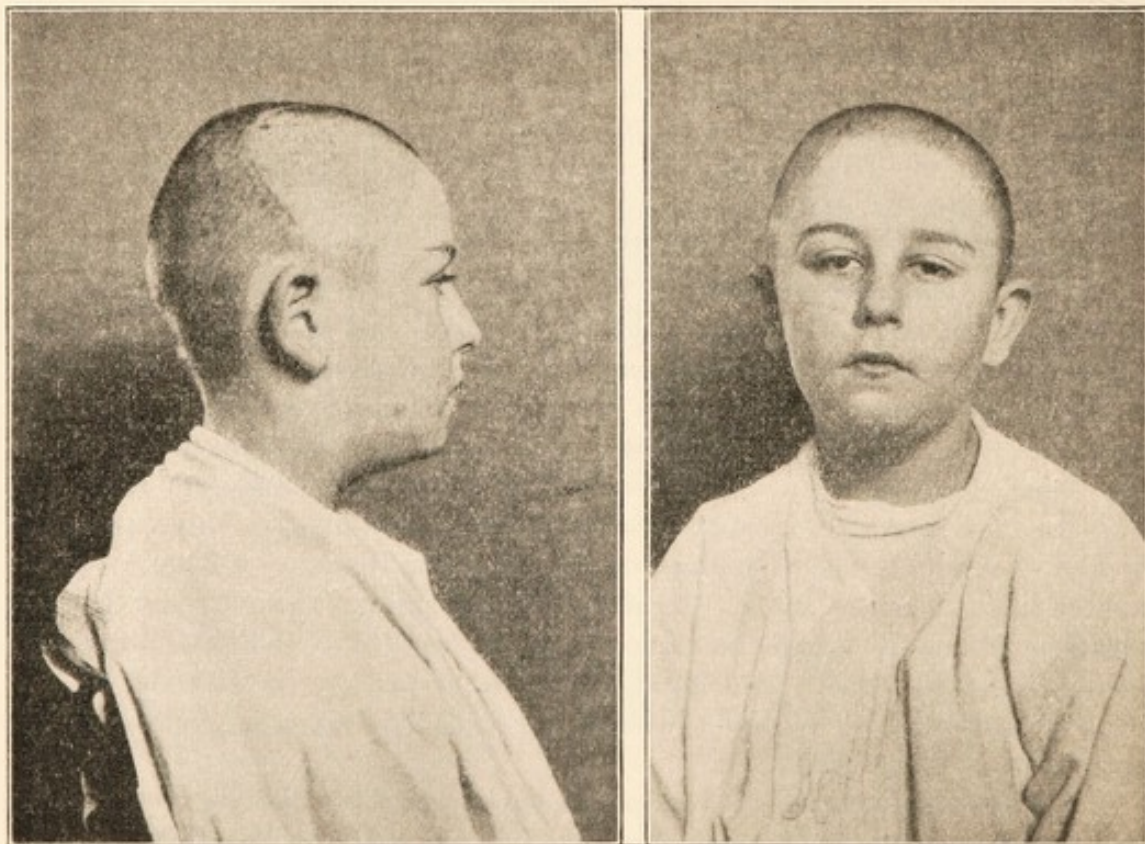


FIG. 25.—Case 6. Fields shortly before operation disclosing a right temporal glioma.



FIGS. 26 and 27.—Case 6 (contd.). Two weeks after operation showing situation of bone flap and slight temporal protrusion through the subtemporal defect.



were not associated with anything resembling a 'dreamy state.' He had never had any known losses of consciousness."

Physical examination: A healthy, intelligent, and co-operative boy, with no positive neurological findings except for a choked disc of 3 D., signs of intracranial pressure shown by the X-ray, and a left upper homonymous quadrantanopsia (fig. 25).

December 31, 1915: Operation. The right hemisphere was exposed by an osteoplastic flap carried well down in the temporal region. Here the bone was found greatly thinned. The dura was opened over the temporal lobe and reflected upward. The convolutions were not greatly flattened, nor was the Sylvian fissure pushed upward. Palpation of the lower part of the temporal lobe gave the impression of a subjacent cyst. An exploratory puncture in the second temporal gyrus at a depth of 4 cm. reached a small cyst, giving a few cubic centimetres of typical yellow fluid. A subtemporal bone defect was made and the flap replaced.

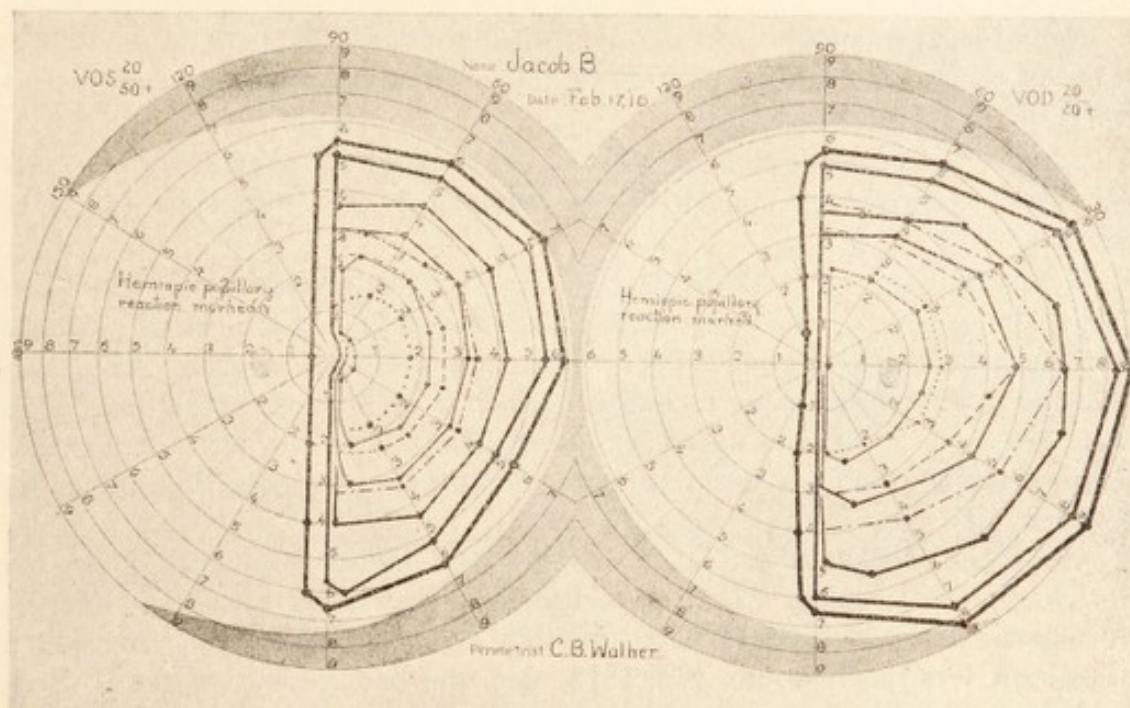


FIG. 28.—Case 6 (contd.). Fields two months after operation, for comparison with fig. 25, showing ultimate complete homonymous hemianopsia with macular inclusion.

The boy made a perfect recovery (figs. 26, 27), with relief of all subjective symptoms, except that once during his convalescence he had another vivid hallucination—of seeing "a lady wearing a hat." His choked discs subsided, but the fields of vision remained unaltered.

He was discharged January 22, 1916, much improved, but his period of relief was short. The decompression gradually became tense, and he began to have some left-sided numbness and weakness.



He re-entered the hospital February 16, 1916, owing to the increase of symptoms. His fields at this time (fig. 28) showed a complete hemianopsia. An operation was performed, and a large mass of gliomatous tissue containing small cysts was removed from the temporal lobe. There was again a temporary period of improvement, and he was discharged. The prognosis was hopeless, and he died a few months later at his home.

Doubtless, in a case of this kind, the geniculate body itself comes to be involved in course of time, and in all probability could a series of fields have been taken, there would have been a stage in which the macula was not completely bisected.

The patient whose history follows was first seen at such a stage, and there was considerable subsequent improvement, though in the end a fatal issue. In this case, too, visual hallucinations were a pronounced feature, as the story will relate.

*Case 7.—Cystic glioma of right temporo-sphenoidal lobe, with hallucinations of vision and a lower left quadrantopsia. Operation. Temporary improvement. (P. B. B. H., Surg. No. 3043.)*

June 9, 1915: Admission of Mrs. Helen L., aged 33, referred by Dr. D. B. Steuer, of Cleveland, Ohio, with the complaint of "headache and optic neuritis."

Clinical history: *Petit mal* attacks. In 1911, four years before admission, during the course of her first pregnancy, she began having attacks of *petit mal*. In these attacks her left hand was involved and would feel swollen. They were followed by twitching of the fingers and drawing up of the arm and face. She was invariably conscious during these attacks. After the birth of her baby these seizures, which had occurred many times a day, decreased in number and gradually disappeared completely.

Headache and diplopia: In 1912 she began having headaches referred to the right frontal region. They have become increasingly severe, culminating in a particularly bad attack three months ago, since when they are said to have been less troublesome. In 1912, also, she had for two weeks a period of diplopia. The eye-grounds were examined, and a choked disc of 4 D. was found. This condition continued throughout 1913, during which time she was under the care of a succession of "specialists."

*Grand mal* attacks: On four occasions she has had a general convulsion with loss of consciousness. The first occurred in June, 1913, the others eighteen, twelve and ten months ago respectively.

Anosmia and hallucinations of smell: Immediately after the birth of her child in 1912, she found that she had lost the sense of smell, and during the past year she has frequently had olfactory hallucinations, occasionally disagreeable ones. She describes them as "like something from another world; nothing that is in the environment—I can't describe it."



Left hemiparesis: First noted two years ago, as dragging of the leg and tendency to drop things from the hand. The symptoms became more definite three months ago in association with the series of severe headaches. The face then became weak and the arm and leg still more so. Some loss of sensation on the left has also been noted.

Failing vision: Choked disc first noted three years ago, but vision not greatly impaired until two months ago. She is conscious of loss of vision to the left.

Hallucinations of vision: Present for the past two or three weeks. For example, the following quotation is taken from the history: "She repeatedly told the nurse on awakening that a woman friend of hers, whom she named,

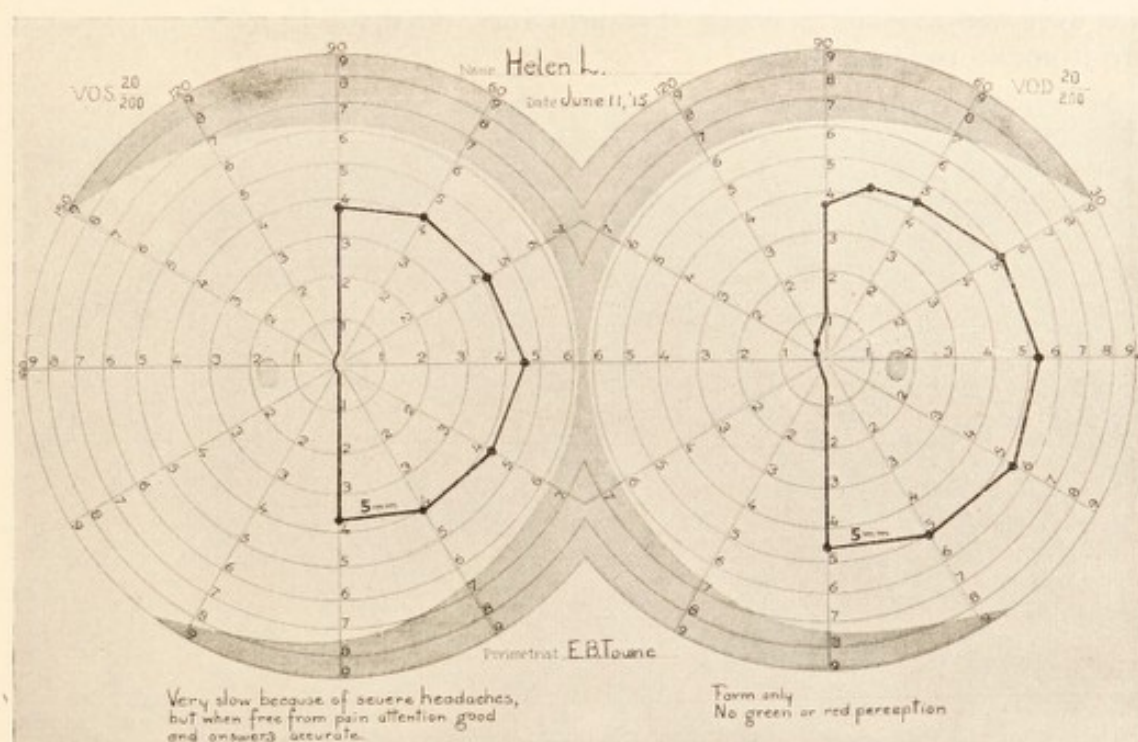


FIG. 29.—Case 7. Fields on admission shortly before operation.

was in the room, and she wanted her husband called to talk to this woman. The imaginary person stayed in the room all night, moving about, but did not talk. She was always to the patient's left. When the patient turned her head to follow her, the hallucination would also go to the left and disappear from the field of vision. To-day during the taking of the history she asked several times if the doctor had come back. Finally, she said, 'Well, who is it in the room?' On questioning it appeared that a man with a gold helmet on his head came into the room with the examiner and sat in a chair beside him. During the history-taking he also had a paper and took notes. He did not leave the room until the examiner left. His face was not recognized and she could not describe it clearly. Both examiner and this hallucination were to patient's left side."



Physical examination: A well-developed and nourished woman, showing the following positive neurological signs: a choked disc of 4 D., a total anosmia, a sharply-cut left homonymous hemianopsia (fig. 29). Hemihypæsthesia over entire left side of body with slight weakness of musculature. Deep reflexes increased to exaggeration on the left, with clonus and a positive Babinski.

June 14, 1915: Operation. Right osteoplastic flap, disclosing a tense dura. On exposing the hemisphere the temporal lobe protruded markedly and the Sylvian fissure was much dislocated upward. The convolutions were greatly flattened. A needle introduced into the posterior portion of the first temporal convolution struck a large gliomatous cyst containing nearly 100 c.c. of yellow fluid which clotted on standing. The tension completely subsided. This cyst was at such a depth that no effort was made to make an incision into it nor to treat its walls.

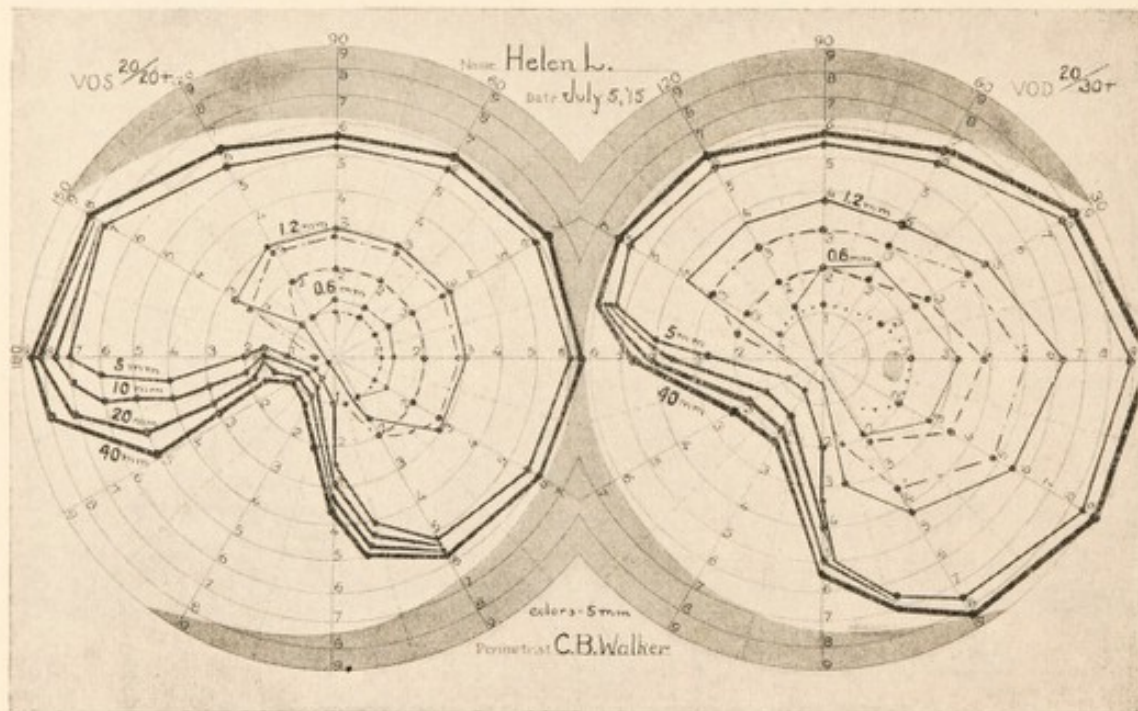


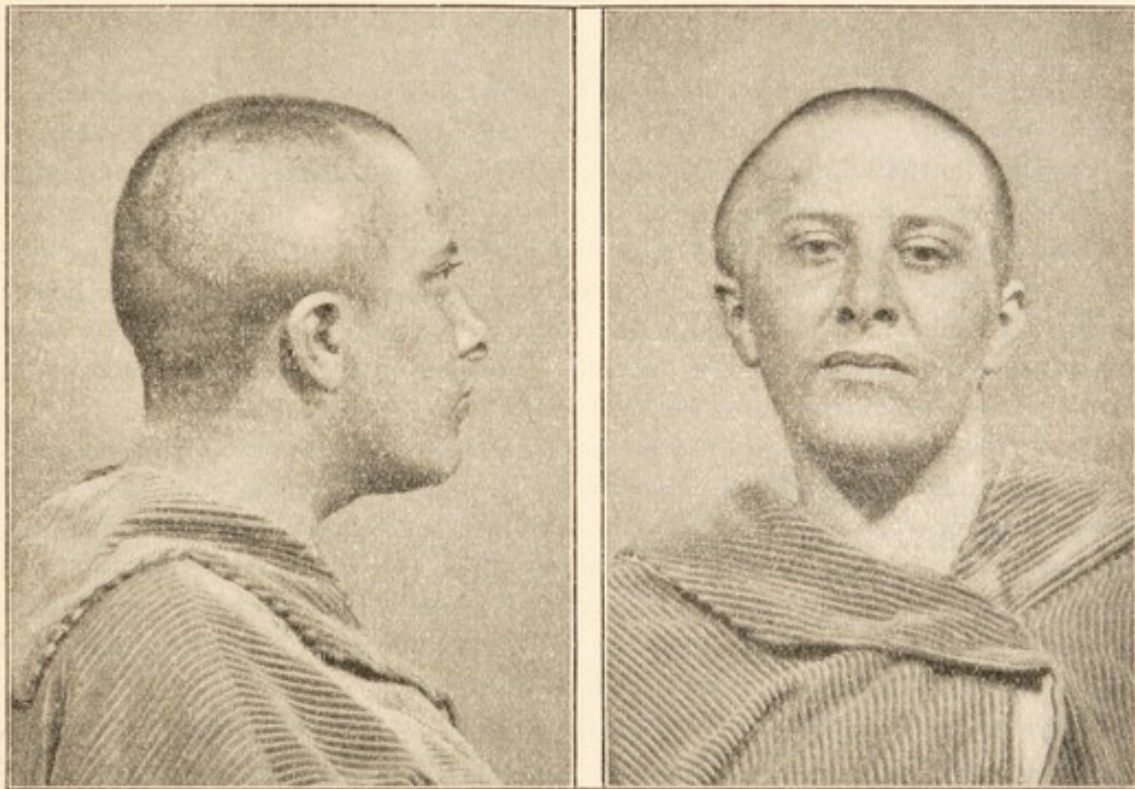FIG. 30.—Case 7 (contd.). Fields three weeks after operation which disclosed a high temporal defect (for comparison with fig. 29).

Post-operative: For a few days she continued to have many bizarre visual hallucinations, always seen to the left. They were usually of people doing queer things, for example: "A woman riding horseback with a sheet of music propped in front of her and she used her hands as though playing the piano on the horse's neck." On one or two occasions also complained of disagreeable odours. These attacks subsided, however, and she made an excellent recovery with practical disappearance for the time being of all her previous symptoms. Normal reflexes, sensation and sense of smell were all regained. The choked



discs subsided with unexpectedly good vision in view of their original appearance. The fields taken on July 5, by Dr. Walker (fig. 30), showed a widening of the peripheries to the left with a persisting lower quadrantal defect which the high temporal situation of the lesion would have led one to expect.

She was discharged to her home July 9. Dr. Towne's final note is as follows: "Of late no convulsions, headache, hallucinations of smell, taste or vision. Left side now almost as strong as right, face still a trifle weak; dynamometer right 24, left 18. Vision very much improved—cf. fields. Choked discs almost flat. No Babinski; no ankle clonus. Deep reflex, still +, but less than before. Mental condition markedly improved; still rather jocular but perfectly sane; knows what serious condition she was in at entrance." (Figs. 31, 32.)



FIGS. 31 and 32.—Case 7 (contd.). Shortly before discharge, showing situation of osteoplastic flap and considerable protrusion through subtemporal defect.

Subsequent note: She passed into other hands and apparently no further fields of vision were taken. The cyst had to be tapped on several occasions. Her death was reported to have occurred a year after her discharge.

Even without the fields there should have been no real difficulty in making a diagnosis in this case, though the early attacks of *petit mal*, said to have begun in the hand, might have led one to anticipate a lesion which originated in the paracentral convolutions. Her homony-



mous hemianopsia, however, was enough to place it below the Sylvian fissure; and that the lower part of the pathway at least was not destroyed is apparent from the fields of July 5, which showed a return of vision in the upper areas.

The combination of visual, gustatory and olfactory hallucinations in a temporal lobe lesion is deserving of comment. The growth was of such a size that it must have occupied a large part of the lobe and, as was noted at the time of the operation, the Sylvian fissure was markedly dislocated, a condition not infrequently observed in large temporal lobe tumours.

The following case, one with a more favourable outcome, is another example of a cyst in practically the same situation as the foregoing, though at the time of admission the defect had not advanced to the stage of hemianopsia.

*Case 8.—Gliomatous cyst of right temporal lobe producing a lower homonymous quadrantal defect. Operation. Recovery. (P. B. B. H., Surg. No. 11283.)*

October 8, 1919: Admission of Dorothy D., aged 19, with the complaint of fainting spells and headaches.

Four years previously (1915) she had a severe fall on the ice, striking her head. To this she attributes her present illness, for soon after she began having headaches. These headaches grew worse, and one day, a year after the injury, while at school she fainted. Subsequently, fainting attacks with slight convulsive movements occurred every two to three weeks.

In 1916, at the Boston City Hospital, a right subtemporal decompression was performed by Dr. E. H. Nichols. Though her discomforts were completely relieved thereby until a few months ago, the fainting attacks continued. They are preceded by a feeling of numbness over the whole body, but there is no gustatory sense impression. The convulsive features of the attacks, hardly apparent at first, have of late become more pronounced. A large subtemporal protrusion has gradually formed (cf. figs. 36, 37).

Physical examination: An intelligent, alert, co-operative young woman, free from discomforts, and in excellent physical condition. While under observation she had a convulsion, beginning with a vague stare. For two or three minutes she could respond to questions and denied the presence of any olfactory or gustatory impressions. The left face, then the arm and leg, began to twitch, and a general convulsion followed.

Positive neurological findings: A bilateral choked disc with beginning secondary atrophy. Nerve head on the right elevated 1.5 D. On the left 3 D. Slight hypæsthesia over the left side of body without appreciable motor involvement, though the deep reflexes were possibly more brisk on the left than right. The fields of vision revealed a lower left homonymous defect (fig. 33).

October 10, 1919: Operation. An osteoplastic exploration was made to expose fully the right hemisphere. The temporal lobe was bulging, and its



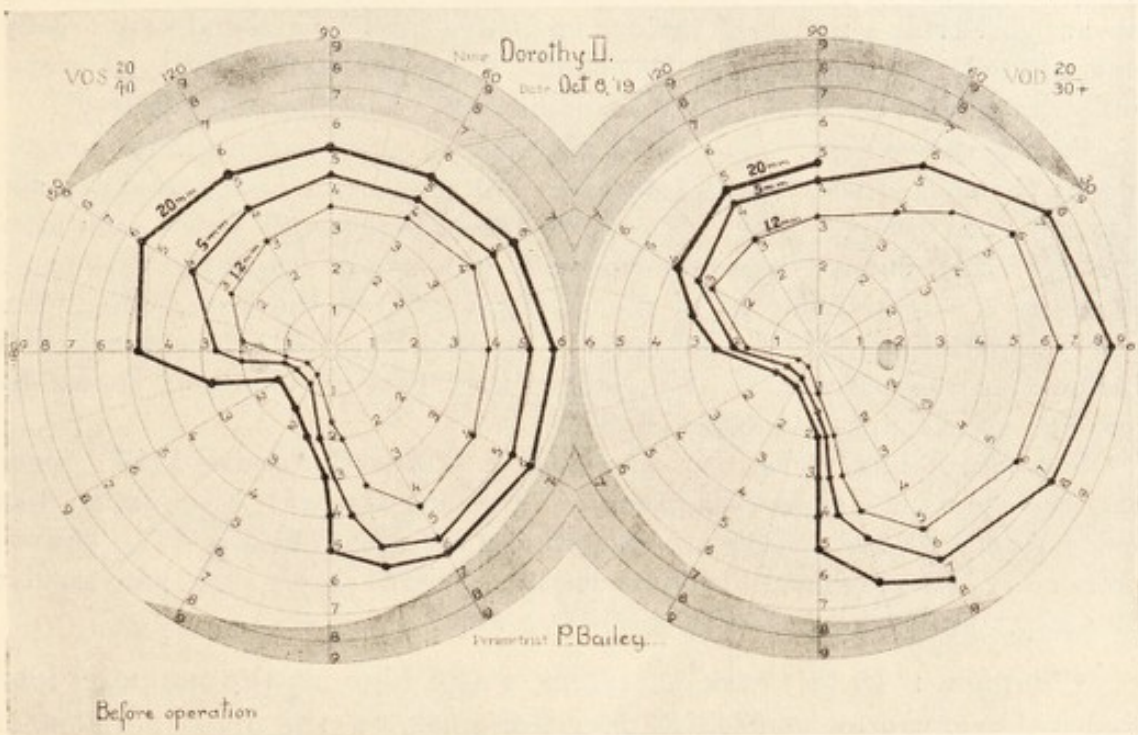


FIG. 33.—Case 8. Fields before operation which disclosed a high temporal lobe cyst.

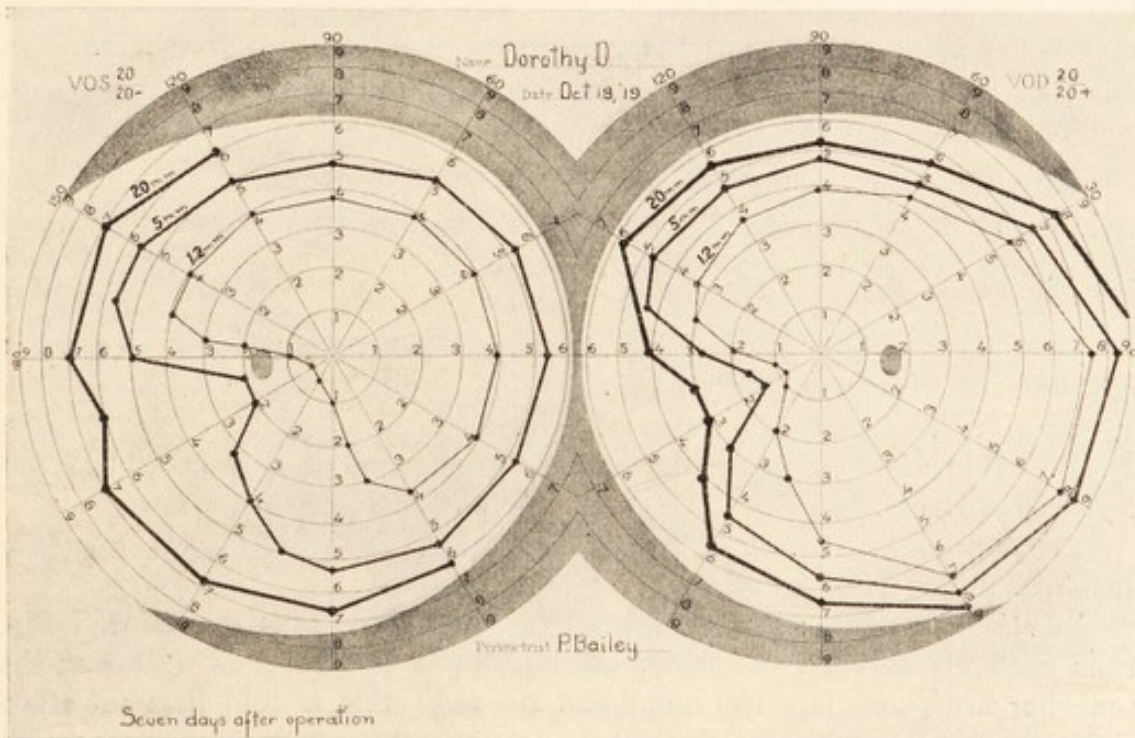


FIG. 34.—Case 8 (contd.). Fields nine days after operation, showing recession of defect.



convolutions flattened. Puncture of the first temporal convolution revealed a large cyst containing characteristic yellow clotting fluid. The cyst was widely opened disclosing a nodule of tumour projecting from its external wall directly under the old decompression. This nodule was completely excised. The cyst wall was treated as usual with a tissue fixative. The flap was replaced.

Post-operative note: She made a good recovery; had no more convulsions; the choked disc rapidly subsided, the hypæsthesia disappeared and she has remained perfectly well. The fields taken October 19, seven days after the operation, showed improvement, with widening of the peripheries to all discs and a definite filling in of the defect (fig. 34) to the larger ones. Ten days later (October 29), the day before her discharge, the field outlines were restored to the normal (fig. 35), where they have remained as shown by subsequent examinations (figs. 36, 37).

Subsequent note: She had one fainting attack Christmas, 1919. Since then no symptoms of her old trouble. Her most recent examination was made March 16, 1921, six years from the onset of symptoms. The decompression is now quite flat. Fields are normal. Fundus shows slight perivascular streaking: no swelling. She is steadily at work.

Comment: In this case, therefore, a cyst high in the temporal lobe and rather posterior exerted its pressure effect on the upper portions of the pathway, leaving the lower fibres unimpaired. The rapid restoration of the field peripheries show that it was a pressure effect only. There was nothing in her neurological examination to suggest a temporal lesion, except the perimetric findings, and in their absence as likely as not the temporal lobe might not have been exposed in the exploration. A puncture of the lobe at the first operation probably would have revealed the lesion.

The following history is one of an incurable glioma in which the field defects were seen to pass from a mild involvement through advancing stages to complete blindness.

*Case 9.—Right temporal diffuse glioma with uncinatę seizures. Successive operations. Advancing process. (P. B. B. H., Surg. No. 3774.)*

October 28, 1915: Admission of Mrs. Sadie G., aged 28, referred by Dr. H. B. Eaton of the Boston Dispensary, complaining of *petit mal*, headaches and loss of vision.

Present illness: Dr. E. B. Towne's recital of her story may be quoted in full from the hospital record.

"*Petit mal* attacks: Began about a year ago. She says a peculiar feeling runs suddenly through the body, lasting only a few seconds. During this time her arms and legs feel numb and relaxed. She is told that she stares and that her face becomes flushed, and later pale. This happens possibly once a week. They are liable to come on while she is at the table. There is



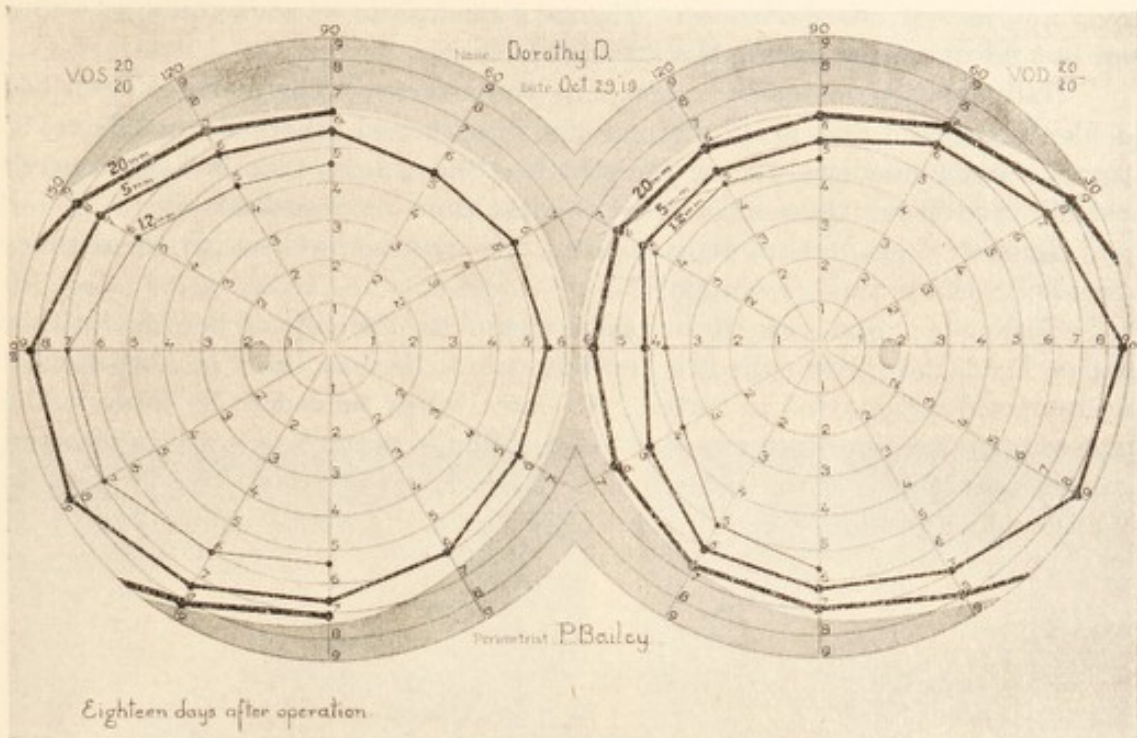
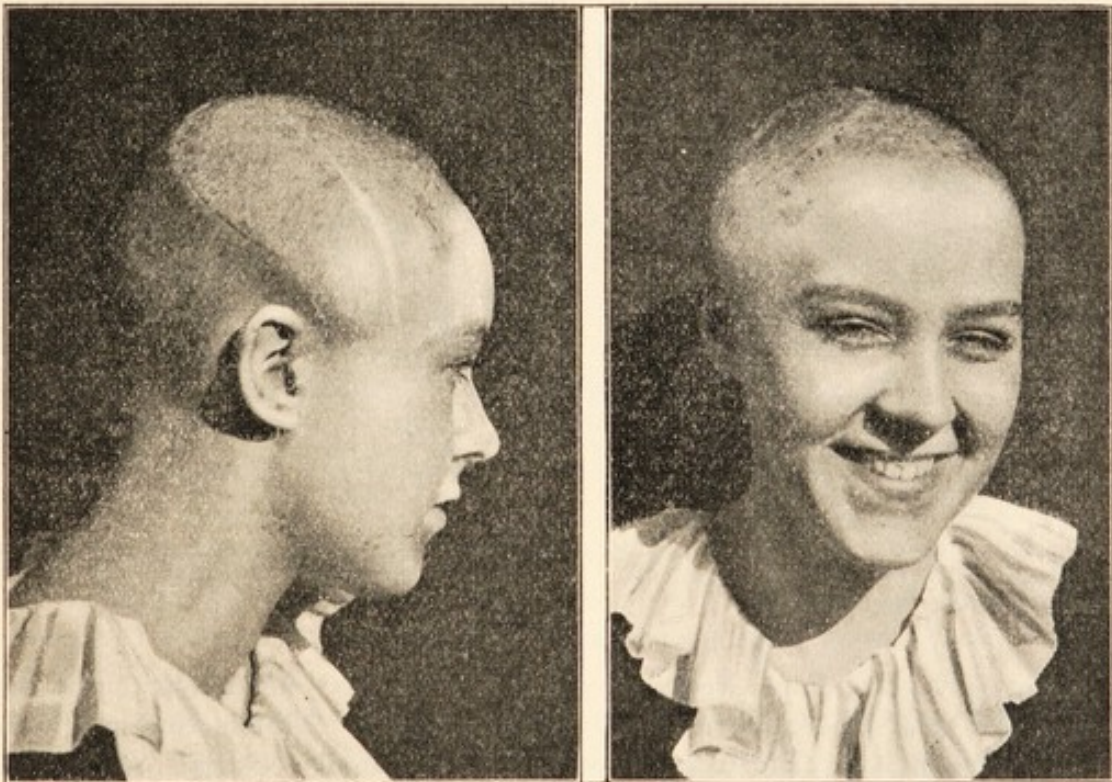

FIG. 35.—Case 8 (contd.). Showing normal peripheries on discharge nineteen days after operation, for comparison with figs. 33 and 34.



FIGS. 36 and 37.—Case 8 (contd.). Circa two weeks after operation, showing the position of the bone flap with soft protrusion at the seat of the old subtemporal defect, the scar of which is apparent and which directly overlays the tumour nodule.



never any loss of consciousness. She says she knows what is going on about her, but never speaks during the attacks.

"Hallucinations of smell accompany the attacks. The odour is described as like fresh paint and is so distinct she is surprised others do not detect it. It goes away immediately after the attack. She thinks that it has occurred possibly nine to ten times altogether, the last time about a week ago.

"Nausea: Began about eight months ago and comes two to three times a week. She has rarely vomited.

"Headache: She says it is really a pain on the top of her head rather than a headache. She calls it a 'pulling pain.' It has been in both frontal and temporal regions and in vertex. Of late it has tended to be more in the right temporal region than anywhere else. She is some days entirely free and again is miserable for two to three days. Headache is liable to be brought on by any sudden motion, as getting out of bed or sitting down suddenly?"

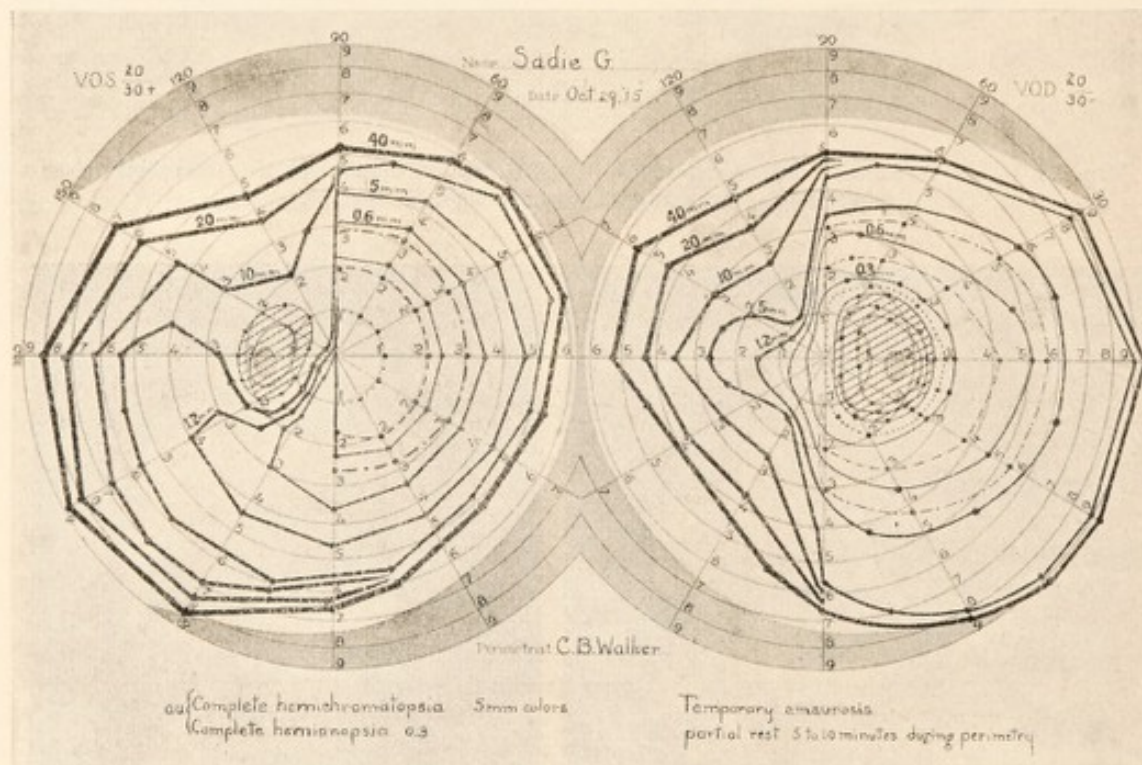


FIG. 38.—Case 9. Fields shortly before operation showing left homonymous hemianopsia complete in both eyes to a 0.3-mm. disc. Charts show unusually well gradations of discernible defect to larger discs.

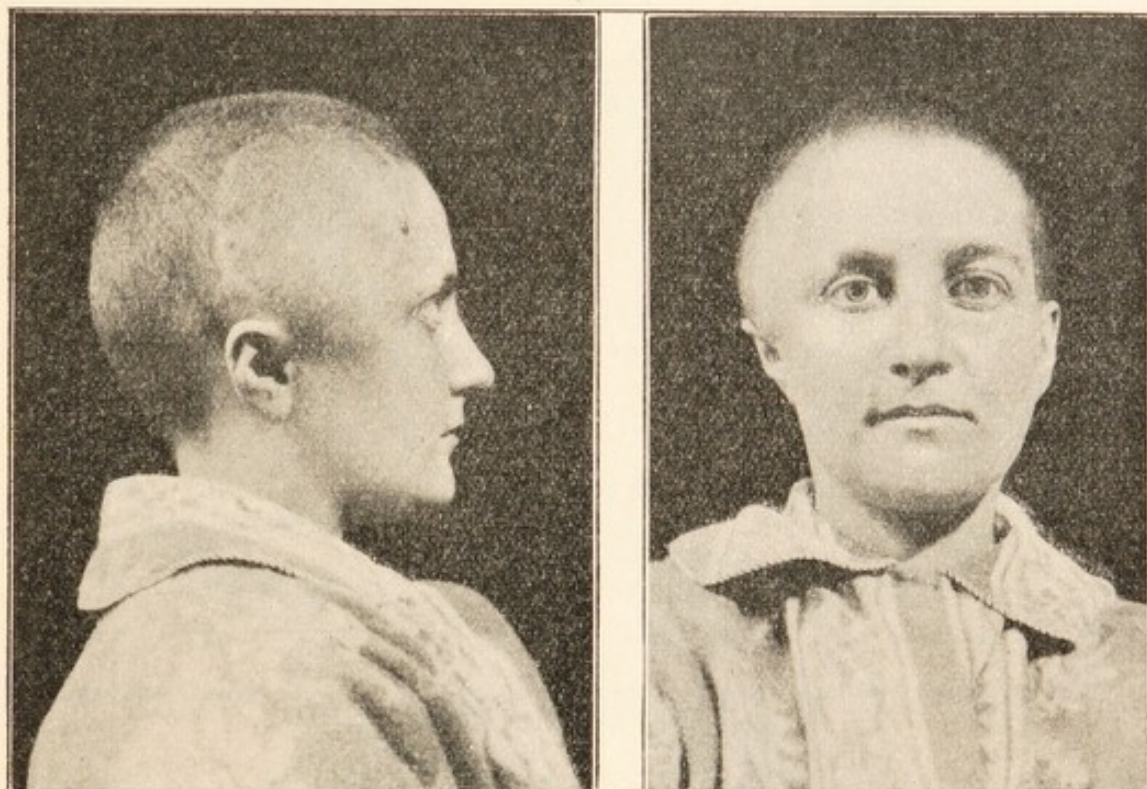
Loss of vision: Four weeks ago she noticed that newspaper print was blurred and that she could read only with difficulty. Thinks that eyes were equally affected and that they have become gradually worse. At present cannot read print in telephone book. There have been attacks of temporary amblyopia quite frequently during the last two weeks.

Twitching of left face: During the past four weeks it has happened three



to four times. Corner of mouth draws up and eye closes. It is difficult to open eye again. It lasts a few moments. There is no twitching of arm and leg. No association with *petit mal*.

Hallucinations of vision: One week ago was walking across the room and thought that she saw a cat to her left. Says cat was very black and was hunched up as if angry. She turned around and looked about the room before she was convinced that the cat was not there. Two days later she again saw the same black cat on the left side. On two to three other occasions she has seen what she describes as black specks to her left, and she turns her head to look at them. There have been no other visual hallucinations.



FIGS. 39 and 40.—Case 9 (contd.). Patient on discharge, to show situation of osteoplastic exploration with subsequent protrusion through subtemporal defect.

Physical condition: A healthy, vigorous, intelligent, co-operative patient, sound in every respect. She was right-handed.

Neurological examination: This revealed absolutely no abnormalities except an advanced choked disc with hæmorrhage and exudates, and an elevation of 5 D. right and 6 D. left.

Her history was sufficient to suggest a temporal lobe lesion, but the side could not have been determined without the perimeter. An abnormality in the fields was first detected by Dr. Woodward, the interne, and they were subsequently plotted in great detail by C. B. Walker (fig 38). They showed an oncoming left homonymous hemianopsia with the process more advanced



in the right eye. To the 5-mm. discs there was a hemiachromatopsia which showed for form likewise when the 0.3-mm. test objects were used.

November 5, 1915: Operation. A low osteoplastic resection was made over the right hemisphere. The bone in the temporal region was thinned by pressure. A subtemporal defect was made to allow for subsequent decompression. The temporal lobe was full and bulging. Aspiration revealed no cyst. An incision was made through the first temporal convolution and carried down to a depth of about 3 cm., when it came upon a soft reddish tumour. A fragment removed for verification showed glioma.

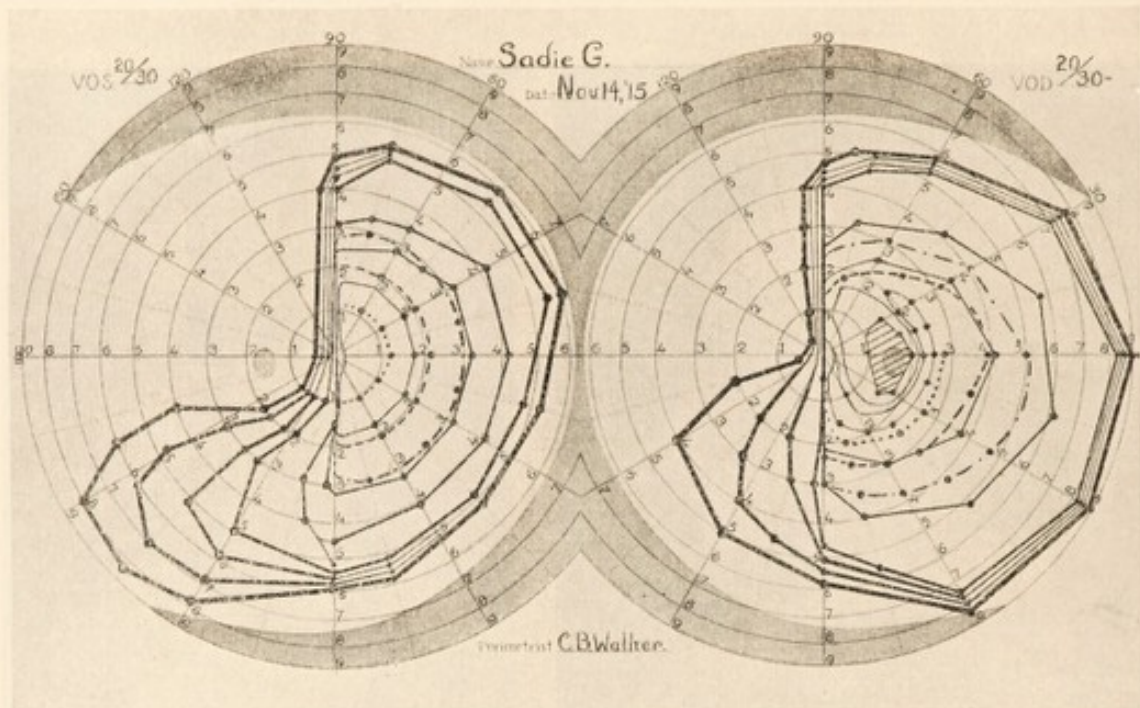


FIG. 41.—Case 9 (contd.). Fields three weeks after operation, for comparison with fig. 38, to show increasing field defects.

Post-operative: She did exceedingly well (figs. 39, 40). Headache and *petit mal* attacks ceased. The choked disc had subsided to 1 D. by November 26, the day of her discharge. The fields, however, showed a slight advance in the process (fig. 41).

In January, 1916, she reported subjectively free from symptoms. Dr. Walker's fields at this time (fig. 42) show a further slight advance in the process.

She remained perfectly well for nearly four years despite an increasing subtemporal protrusion. A note on January 24, 1917, states: "Patient reports in excellent condition. No symptoms. Says she never felt better in her life. There is a fairly large, rather soft subtemporal protrusion which she conceals perfectly with the arrangement of her hair (fig. 43). No further hallucinations or *petit mal* attacks. No fields taken."

March 10, 1919: She reported on my return from abroad in excellent general condition. No headache, hallucinations or *petit mal* attacks. The



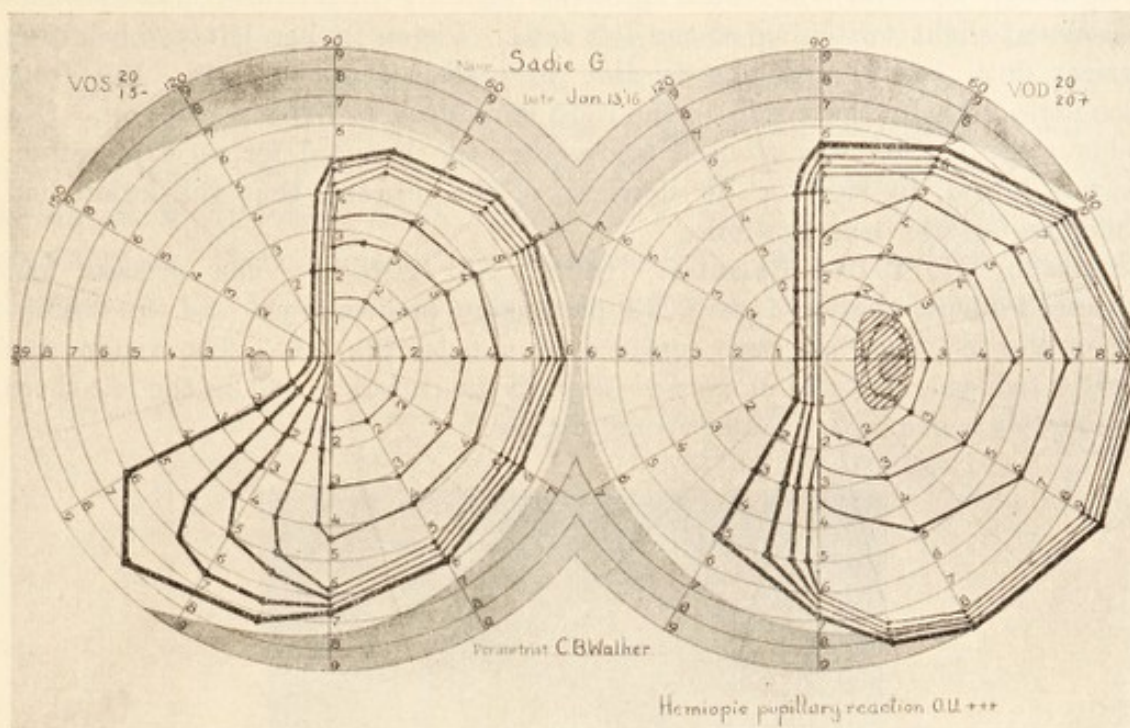


FIG. 42.—Case 9 (contd.). Field two months after operation to show further advance. (Cf. figs. 38 and 41.)



FIG. 43.—Case 9 (contd.). Patient fifteen months after operation, when she was subjectively free from symptoms.



protrusion, however, has been growing steadily larger and she has had occasional slight twitching of the left face. Vision in her left eye has been perfect until lately, and she is able to read without glasses. But from secondary atrophy the vision in the right is reduced to light perception. (No fields taken.) She was advised to re-enter the hospital for an exploration. It was hoped, in view of the slowness of the process, that the lesion had undergone cystic degeneration.

March 21, 1919: Re-entry. (Surg. No. 10165.) The process had advanced during the ten days. The protrusion had enlarged and the twitching of the left face had been replaced by a palsy (fig. 44). The vision was greatly reduced, shadows alone were seen in the right eye and in the left there was merely a hemiopic tubular vision (fig. 45).



FIG. 44.—Case 9 (contd.). Patient before last operation, showing huge protrusion with left facial palsy.

April 11, 1919: Secondary operation. A soft tumour mass the size of a fist practically extruded itself through the subtemporal defect on exposing the brain. As could be seen, this represented only the external part of the growth. Closure.

This procedure gave but little subjective relief and led to no improvement in vision. She died February 18, 1920, six years from the onset of her symptoms.

The patient's history on admission suggested a temporal lobe lesion in view of her visual and olfactory hallucinations. There was nothing



in the examination, however, to show whether the process was right or left, unless the slightly more advanced choking of the left disc could have been taken to favour this side. The visual fields on rough finger tests showed no hemianopsia, so that without the perimeter it would not have been possible to lateralize the process. The perimetric defects which were disclosed were typical of a low right temporal lesion affecting the ventral bundle of the radiation. As is usual the eye on the side of the lesion showed, throughout, the more advanced defect.

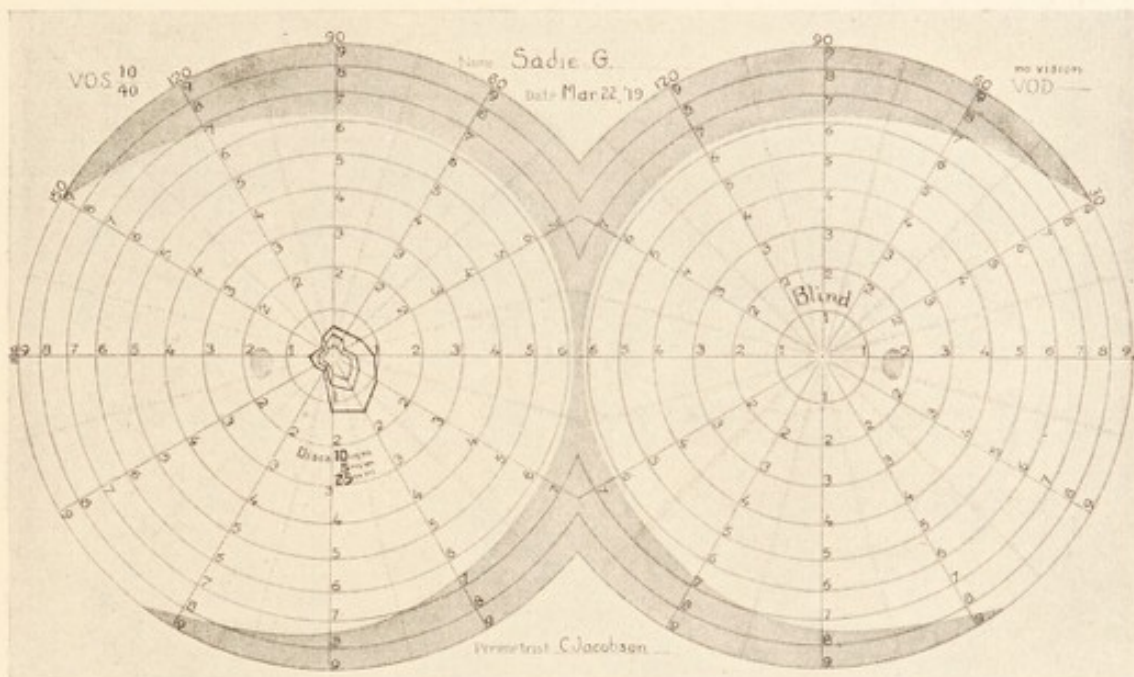


FIG 45.—Case 9 (contd.). Residual of vision on last admission four years following her first operation. For comparison with figs. 38, 41 and 42.

This peculiarity of an unequal progress in the defect on the two sides is still better shown in the next and last of the ten cases which have been selected for this report. The diagnosis was most obscure until the field defects began to appear.

*Case 10.—Brain tumour suspect. Decompression. Tumour localization made probable by early field distortions. Partial enucleation of meningeal endothelioma of left temporal fossa. (P. B. B. H., Surg. No. 10671.)*

June 19, 1919. Admission of Mrs. Ruth K., referred by Dr. E. O. Morrow, of Canton, Ohio, with the complaint of headache, vomiting and defective vision.

History: One year before entrance received a blow on the head and was temporarily stunned. Five months later began having suboccipital headaches, also pain over the left eye. Soon the eye began to protrude and turn inward.



Other complaints were transient numbness of left forehead, and pains referred to the left teeth. Morning nausea and vomiting frequent of late. Considerable dizziness and general weakness. Occasional subjective numbness in fingers of right hand.

Neurological examination: The only positive findings were a bilateral choked disc; slight exophthalmos of the left eye; left abducens palsy; left pupil larger than right; slight expressional weakness of right face. A presumptive diagnosis of tumour involving the temporal lobe was made, possibly an endothelioma of the Gasserian envelopes. This was further supported by the disclosure, on taking her fields, of a notch in the upper nasal quadrant in the left eye (fig. 46).

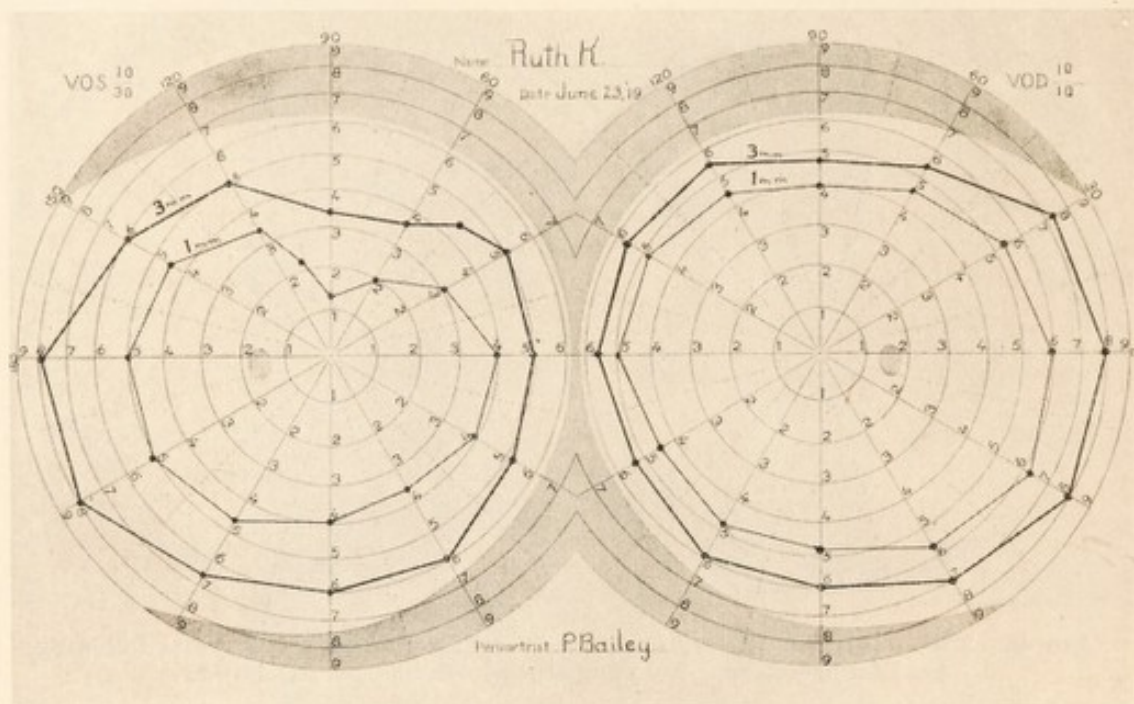


FIG. 46.—Case 10. Fields on admission of patient who was a left temporal lobe tumour suspect.

June 25, 1919: Operation. Left osteoplastic flap. Combined exploration and decompression. The brain was found under practically normal tension. The ventricle was tapped to permit of a good view under the temporal lobe in the direction of the fifth nerve. Negative findings. The lobe seemed a little full but an exploratory needle introduced in two places revealed no lesion. Closure.

The symptoms remained unaltered. Occasional periods of numbness in the fingers of the right hand continued, accompanied sometimes by slight paraphasia. On July 7 she complained for the first time of sudden gustatory sensations—like peppermint. On this date the fields of vision showed a marked advance in the defect in the left eye and a homonymous notch in the right similar to that first seen in the left (fig. 47).



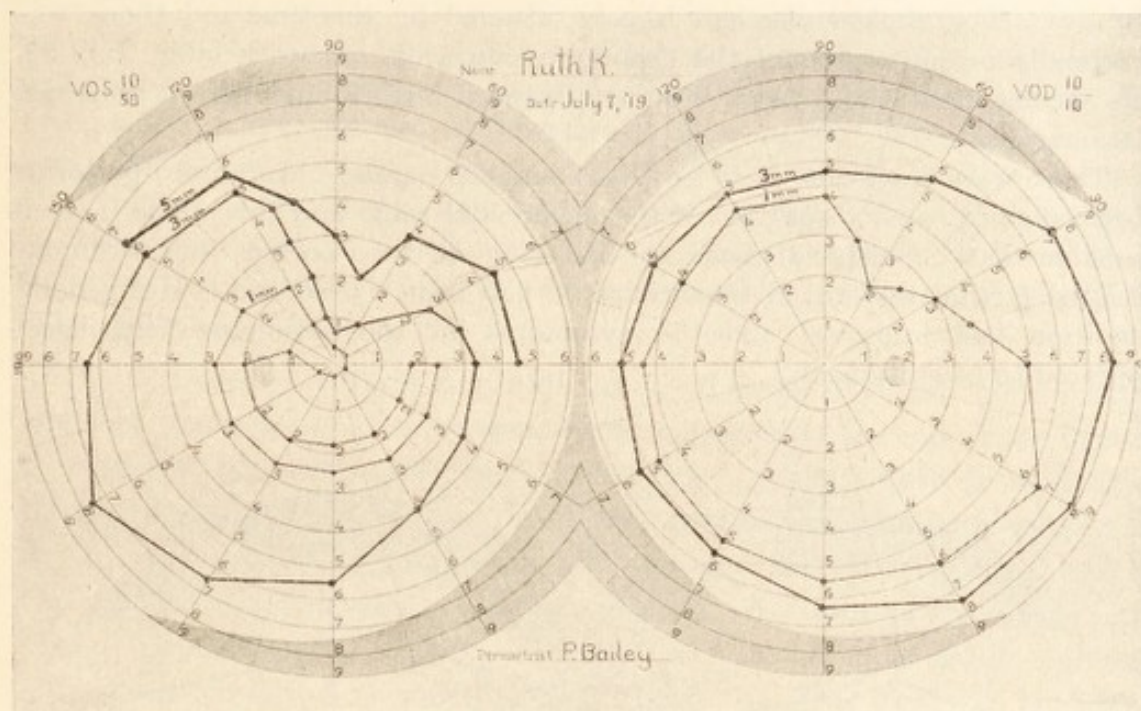


FIG. 47.—Case 10 (contd.). Field two weeks after negative exploration showing advance in process. (Cf. fig. 46.) On July 16 there was found a slightly more marked defect in the fields.

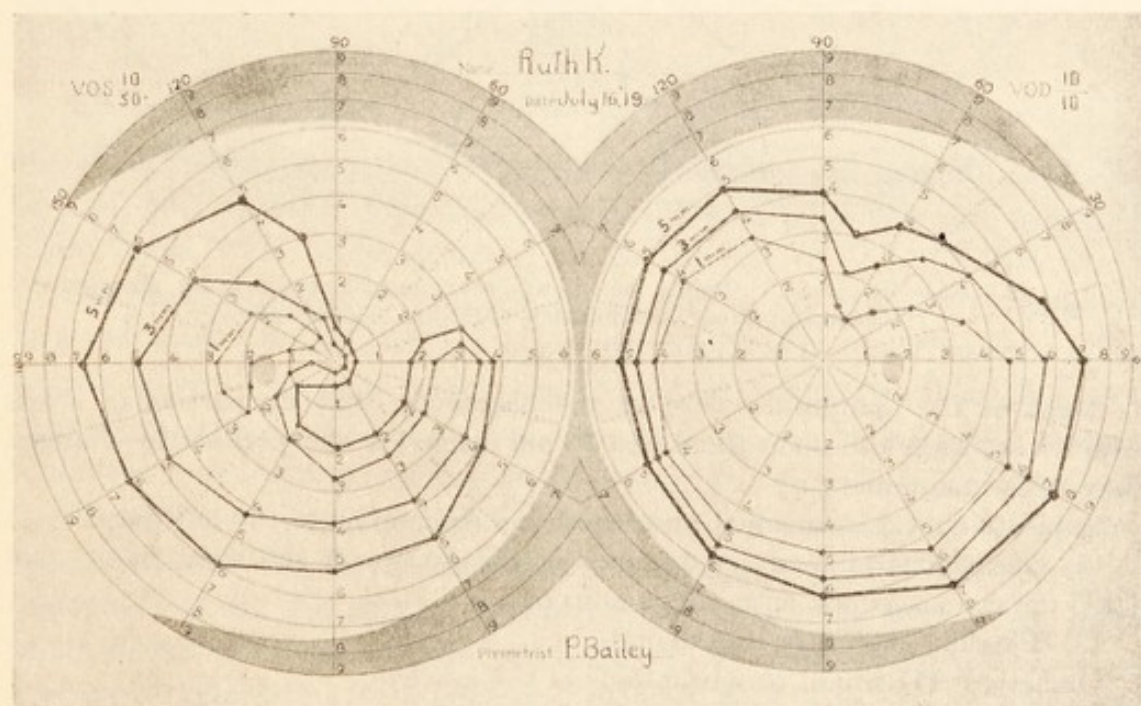


FIG. 48.—Case 10 (contd.). Fields three weeks after operation, showing further advance in defect.



On July 16 there was found a still more marked defect in the fields (fig. 48). The choked disc had largely subsided by this time and there was practically no protrusion of the decompression area. A week later, July 23, this peculiar field defect was still more advanced (fig. 49) and here it remained stationary.

There were grave doubts as to what course to pursue. An antero-posterior X-ray showed some absorption of the sphenoidal ridge and this made it seem probable that our original diagnosis had after all been correct and a tumour situated farther forward than anticipated had been overlooked. Her general condition had improved and the symptoms for the advancing field defect appeared to be stationary.

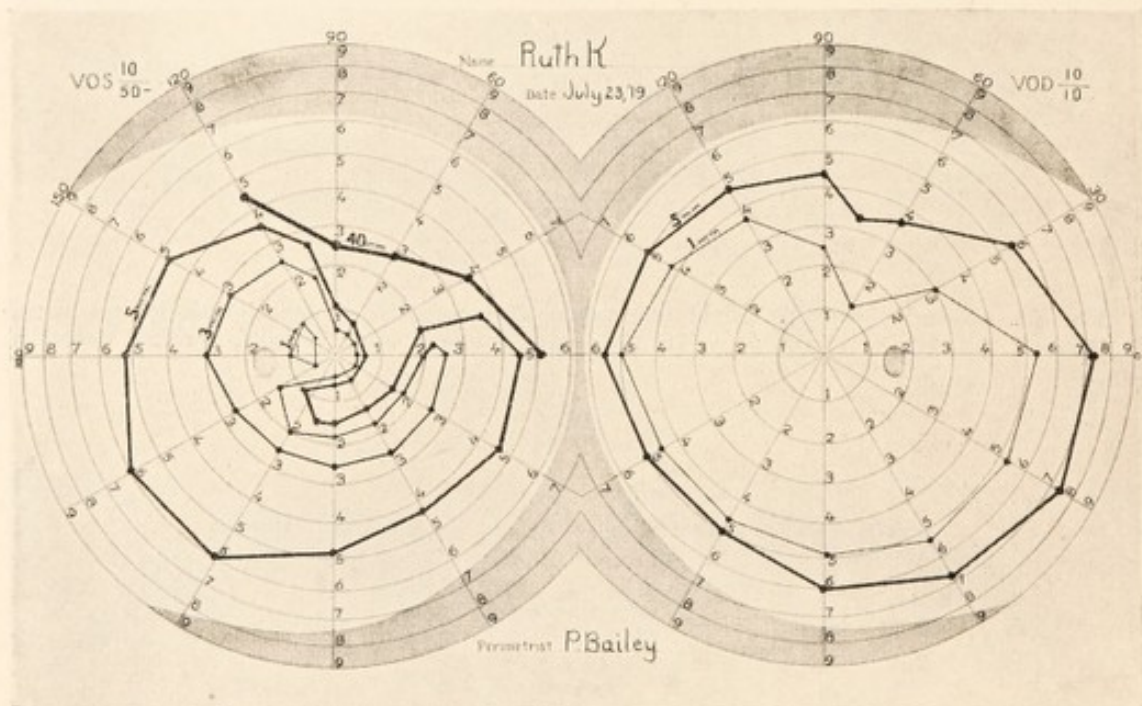


FIG. 49.—Case 10 (contd.). Fields one month after negative exploration, showing continued progress in the defect, chiefly of the left eye.

Most of the symptoms were so inconspicuous that no particular stress would have been laid upon them had it not been for the perimetric changes. They were in summary:—

- Subjective: (1) Occasional numbness and discomfort of the left teeth.  
 (2) Occasional momentary tingling of the fingers of the right hand associated on two occasions with slight aphasia.

(3) Fleeting gustatory impressions.

Objective: (1) Slight exophthalmos of the left eye.

(2) Slight choking of left disc more than right.

(3) Upper right homonymous field defects.

August 11, 1919: Operation 2. Partial enucleation of a large endothe-



lioma. A more thorough and more anterior exploration was carried out at this time. The margin of the tumour was brought into view. It had been covered and concealed by a thin shell of the temporal lobe. Its base of attachment was obviously at the sphenoidal ridge. The large growth was fragmented in removal and in the attempt to complete the enucleation there was bleeding and the remaining fragment had to be left in position. Even so, a cavernous sinus thrombosis was provoked which led to such a degree of proptosis that the eye, owing to keratitis, was finally enucleated on September 4. Normal field outlines were regained in the right eye by the time of her discharge.

One cannot be sure in a case of this kind (with a tumour compressing the lobe and a tumour, moreover, which arises from the meninges in such a situation that the optic tract itself may possibly have been pressed upon) whether the field distortion was actually due to involvement of the temporal loop. It, however, is more than likely, but in either case the diagnosis of a temporal lobe lesion was chiefly based on the advancing quadrantal defect. For the purposes of this paper, the case is important for the reason that the original fields of June 23 represent the earliest stage of such a defect that has been recorded in the series. To make a diagnosis of temporal lobe tumour largely on the basis of a notch in the upper nasal field in one eye would seem absurd were it not for the accumulated evidence regarding the localizing significance of these partial defects which this paper is intended to emphasize.

#### TEMPORAL LESIONS OTHER THAN TUMOUR.

Though this communication deals primarily with tumour cases, it is not to be forgotten that the same principles hold true for lesions of other sorts. The illustration given at the outset, of a gunshot wound of the temporal lobe, is a case in point, and in all probability when the war material has been fully worked up, important contributions to our knowledge of temporal lobe symptomatology will be forthcoming, even though the urgency of military service in most hospitals for the recently wounded may have precluded such details as the use of the perimeter.

That the position of the radiation is poorly understood even when the perimeter has been used and a hemianopsia disclosed is evident enough, and in the minds of many physicians a homonymous hemianopsia indicates an occipital lobe lesion. I have even known of an occipital exploration for a shrapnel ball on this basis, conducted under the direction of a neurologist, when, as subsequent events showed, the missile actually was in the temporal lobe. Probably all of us have made



similar mistakes in tumour cases when the distractions of war could not be offered as an excuse.

But in civil life there are other sources of injury to the temporal lobe far more common than gunshot or stab wounds which may produce these field defects. Fractures of the base of the skull are possibly the most frequent source, for, as is well known, they are prone severely to contuse the tips of the temporal lobes. There are a number of cases of this sort in our records in which the perimeter has been employed with the disclosure of sharply cut sector-shaped defects (fig. 50). And I am

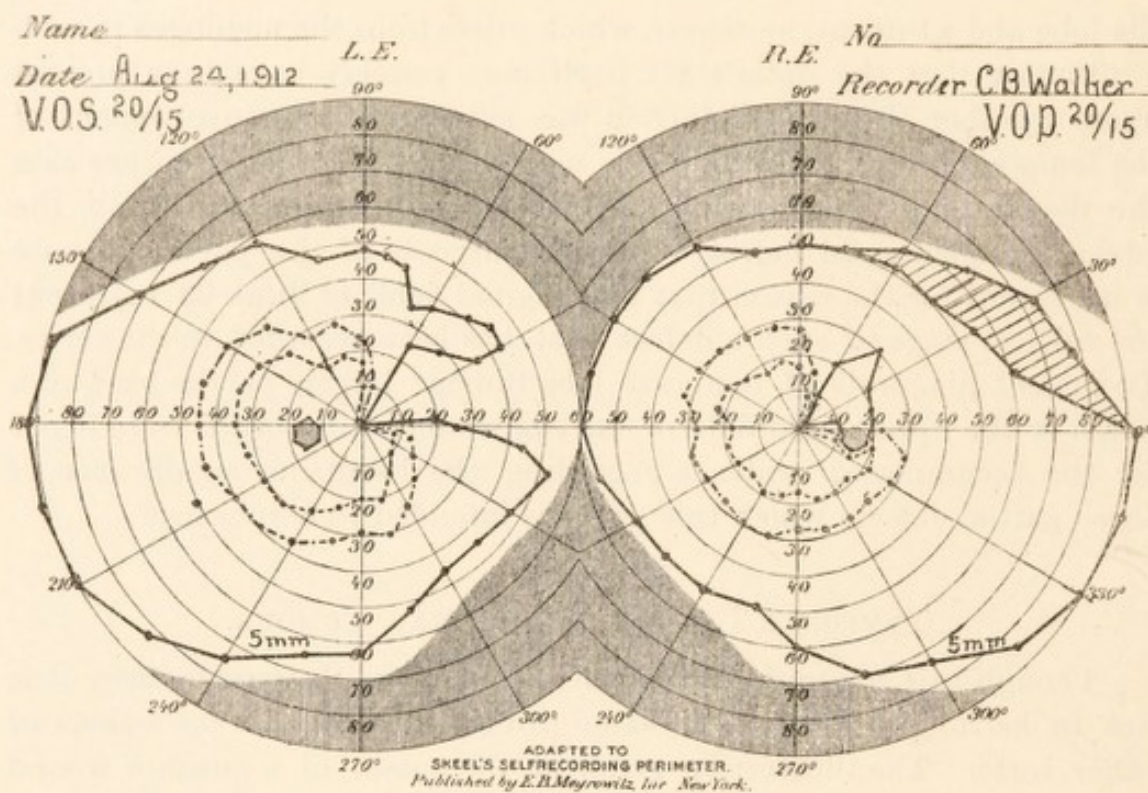


FIG. 50.—Sharply angulated homonymous field defects reaching to the central point following fracture of base of skull, with contusion by contrecoup of left temporal lobe.

under the impression that these traumatic lesions are more apt to produce defects in the fields characterized by sharp angulations than are tumours in whose presence the defects are ordinarily, if not always, rounded off. I have twice seen such defects as the result of the so-called prize-fighter's fracture of the base following a blow on the jaw transmitted through the condyle (fig. 51).

Another and still more important condition producing these defects is a temporal lobe abscess. Difficulty is often experienced in differentiating between a possible cerebellar or temporal lobe lesion when patients



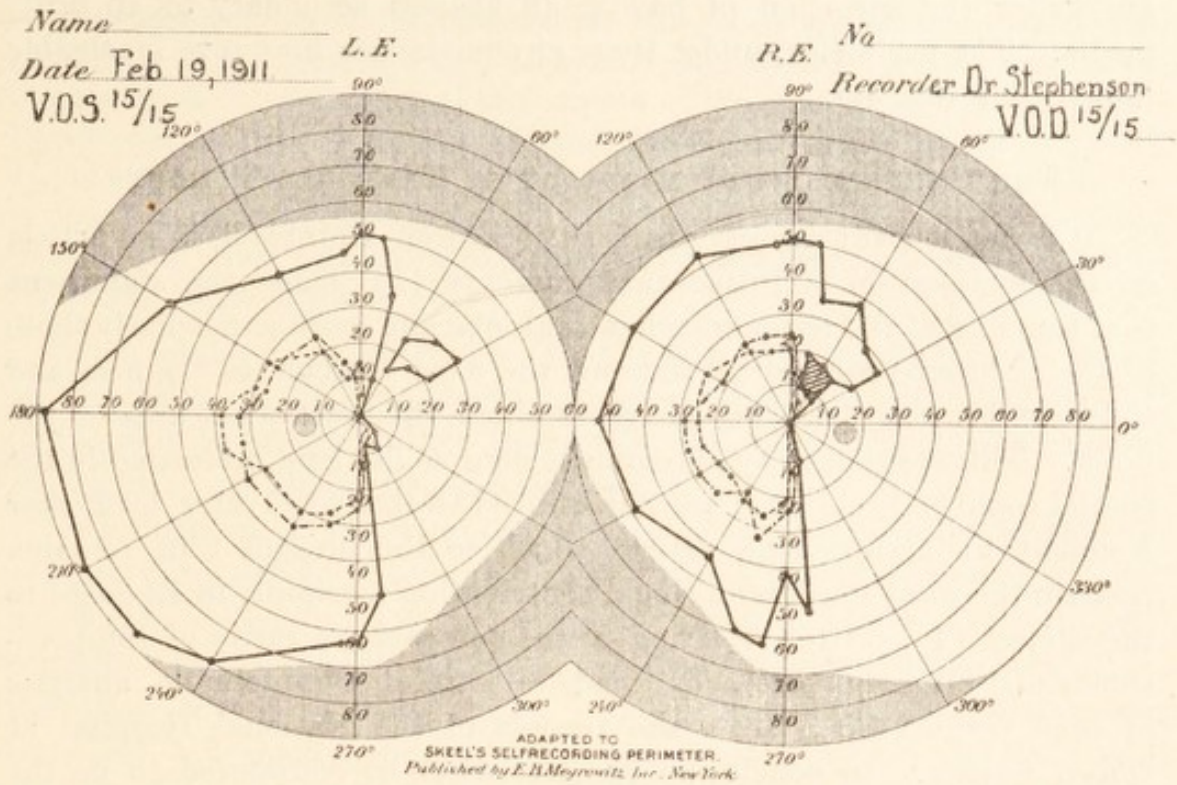


FIG. 51.—Incomplete homonymous hemianopsia following left temporal lobe lesion following a blow received in a boxing contest.

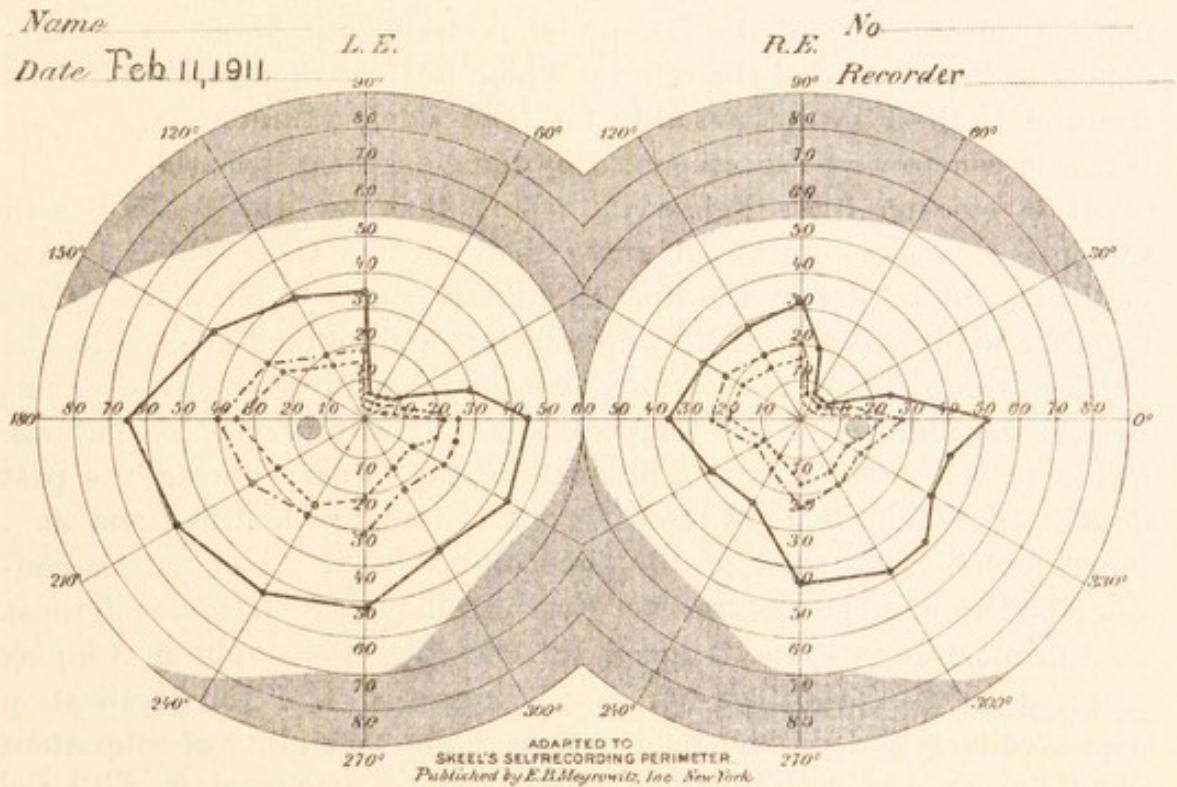


FIG. 52.—Right upper quadrantsopia in patient with left temporal lobe abscess.



are under the suspicion of having an abscess secondary to an otitis media. The perimeter, under these circumstances, may give invaluable information (fig. 52).

#### THE GENERAL SYMPTOMATOLOGY OF TEMPORAL TUMOURS.

It is but a scant twenty years since Byrom Bramwell, in an article on the localization of intracranial tumours [2], made the statement that tumours of the temporo-sphenoidal lobe and more particularly those of the right side were of all tumours the most difficult to diagnose and to locate, because these regions represented the most silent area of the brain. This statement by an eminent neurologist long interested in the special topic of brain tumours was utilized twelve years later by Foster Kennedy to introduce his article, which to the present time remains perhaps the most important single contribution (certainly in English) to the subject [4]. After referring to the comparative rarity of temporo-sphenoidal tumours Kennedy made a careful symptomatic analysis of nine verified cases from the records of the National Hospital at Queen Square. In conclusion he gave what he considered to be the essential symptom complex of these tumours for both right and left lobes. Common to a tumour of either lobe were: (1) convulsions of major and minor (uncinate) type, (2) bilateral choked disc, usually more marked on the side of the lesion, (3) post-epileptic transitory disturbances of motion and of the reflexes which later become persistent. In addition to these symptoms alike for both sides, a tumour on the left was said usually to be accompanied by some degree of aphasia.

It is evident from Kennedy's report that he was dealing with tumours of a more advanced grade than most of those which I have used as examples, for by the time an aphasia occurs in left-sided lesions together with weakness in the opposite face and marked change in the reflexes there is, in my opinion, considerable involvement of areas beyond the confines of the temporal lobe. It is, however, but natural, owing to the great advances in neurological surgery during the past decade, that many more of these lesions are to-day identified and at a much earlier stage than at the time of his paper. Hence in a considerable number of our verified cases, as indicated in some of those used in illustration (Cases 2 and 3 for example), the symptom complex pictured by Kennedy had not as yet appeared and the localization depended largely upon the field defects. The possibility of co-existent field defects was in Kennedy's mind, but he dismissed it with the following statement:—



"An examination of the pathological findings in my patients suggests the probability of hemianopia or hemiachromatopsia having been present during life owing to the proximity of the growth to the optic tract and radiations. In all cases the existence of hemianopic defect was considered and negatived as the result of examination. Five patients were examined perimetrically for various colours; the sole abnormality discovered was the concentric contraction of the visual field so often associated with severe, and especially with protracted papilloedema."

This quotation is given for the purpose of laying further emphasis on the value of the field defects in question, in the early diagnosis of temporal lobe lesions, rather than with any intent of pointing out an oversight of my distinguished predecessor.<sup>1</sup>

A tabulation of the symptoms recorded in the histories of the 59 verified temporal lobe tumours in my series has been prepared. As heretofore stated, in 6 only of the 39 cases in which the patient's condition made reliable perimetry possible were the fields normal at the time the tests were made. These were with two exceptions temporal endotheliomata which did not greatly deform the lobe and which in the absence of a choked disc probably would not have been detected at all had it not been for the unilateral exophthalmos and the overlying cranial hyperostosis, the usual tell-tale of these not uncommon tumours. The exceptions were: (1) a meningeal angioma; and (2) a glioma in which the recorded normality of the fields is perhaps subject to question. The fact, however, that field defects were present in 33 of 39 cases tested indicates that the perimeter, as a diagnostic aid in these lesions, is possibly the most important agent of all.

Though it was not my intent, in outlining this paper, to enter into a general discussion of temporal lobe symptomatology, the table which has been prepared to aid in this study brings out certain things in relation to the diagnosis which deserve to be briefly commented upon.

*Generalized convulsions.*—These were recorded in 20 of the 59 cases. They usually were few in number. A single convulsion without aura or sudden loss of consciousness, possibly unattended by convulsion, had been the inaugural symptom in three or four instances. A few of the patients had had only two or three convulsions and twelve was the largest recorded number.

<sup>1</sup> While this paper was going through the press my attention was called to an important article, "Die Tumoren des Schläfenlappens," by Albert Knapp, in the *Deutsche Zeitschr. f. d. g. Neurol. u. Psychiat.*, 1918, **43**, 226-89. In this elaborate study based on two cases Knapp mentions the fact that hemianopsia has been described. He does not lay any great stress upon this condition however.



*The so-called uncinatc seizures.*—For the forty-five years since Hughlings Jackson's original description of these peculiar disturbances they have held the ground as the most distinctive and characteristic of all symptoms relating to the environment of the temporal lobe. This notable contribution to cerebral symptomatology, entirely consistent with the characteristics of its discoverer, was based on knowledge gained through animal experimentation subsequently transferred to the clinic and ultimately confirmed at the post-mortem table.

In the 59 cases of this series attacks often described as *petit mal*, or as more or less characteristic "dreamy states," were present in 24 cases. In 14 only of these cases, however, were there any olfactory or gustatory impressions and in some of these the possible uncinatc character of the attacks was not particularly definite and appears to have been read into the patient's history after the lesion had been verified as a temporal one by operation. Nevertheless, when these Jacksonian seizures do occur in outspoken fashion they are unmistakable and of great diagnostic value, but, even so, speaking for the temporal lobe as a whole, they are far less common than are the field defects. Indeed, as might be expected of a lesion involving the uncinatc gyrus, field defects were present with but one exception in every case having presumed uncinatc seizures in which the use of the perimeter was not precluded by blindness or some other cause. On the other hand, field defects were present in eighteen cases in which no history suggestive of *petit mal* or dreamy states could be secured.<sup>1</sup>

*Visual hallucinations.*—Examples of these states have been given in the case histories (e.g., Case 6). Considerably to my surprise these visual pictures, often as vivid impressions, are recorded in thirteen out of the fifty-nine cases in the series. They, presumably, are part and parcel of the uncinatc seizure, for in only three of the thirteen cases did they occur unrelated to what were regarded as attacks of this type. Hughlings Jackson, with Beevor, was among the first to describe this symptom [3] in a patient who had the impression of seeing "a little black woman engaged in cooking." A good example of the same thing is given by Kennedy in the history of his first case. These projection

<sup>1</sup> It is a matter of surprise to me that Hughlings Jackson did not emphasize the importance of the perimeter as well as of the ophthalmoscope, on which he laid such great stress in his writings (*Brain*, 1915, **38**, p. 391). The latter is unquestionably the more important instrument of the two, and as the profession was loath to adopt it, and still is for that matter, he may have felt that it was enough to urge its employment without forcing the perimeter on a reluctant profession at the same time.



pictures cannot be at all uncommon, and whether they are related in any way to the olfactory and gustatory discharges of the typical uncinate fit or are merely associated with some pressure implication of the visual pathway or the geniculate body, I am at a loss to say. Certainly they bear some relation to the damaged geniculo-calcarine radiation, for in this series, whenever its situation has been mentioned, the hallucination has always been referred by the patient to the side opposite that occupied by the lesion, in other words, in the defective fields.

One of the most remarkable examples of these hallucinations of which I have record occurred in one of the patients in my Baltimore series. It was a young man under observation for a long period who had repeated uncinate attacks, many of which were observed and described in detail. They invariably had the same character and left a vivid and disagreeable recollection. As in a dream he saw, always to his left side, his father and some other men in an unfamiliar room engaged in a game of cards which ultimately led to an altercation. The scene would fade and leave him with a bad taste and smell of something indescribably horrid. Objectively, during the course of ordinary conversation, possibly while standing, a vague look would come over his face, he would turn his head and stare to the left and shortly after would begin to make smacking and tasting movements with his lips. This was followed by an expression of disgust and the attack would be over. He had an homonymous upper quadrantal defect produced by a temporal lobe glioma.

One would naturally expect visual hallucinations to be a feature of occipital rather than of temporal lobe tumours, but the former are far less common in my series and, though they have not been thoroughly studied with this point in view, it is my impression that they are less prone to have *petit mal* attacks and that the subjective visual phenomena, if any, are more likely to be of colours and lights than of pictured scenes.<sup>1</sup>

<sup>1</sup> Though I have not fully looked up the general subject of visual hallucinations in this connection, it appears to me that those who have observed these states in association with a homonymous hemianopsia have taken it for granted, without any real justification, that the lesion necessarily was in the occipital lobe. This certainly is true of the case reported by Paul Camus (*L'Encéphale*, 1911, 6, Part I, 521-531) and also of some of the other cases in the literature to which he refers. In an earlier paper by Pick (*Amer. J. M. Sc.*, 1904, 127, 82-92) there is a good example of what I would take to be a left temporal tumour which he localizes, however, in the angular gyrus. All that can be said of such case reports is that without a post-mortem examination or verification of the situation of the lesion at operation, judging from the cases in this series, one at least is not justified in ascribing too much to the occipital lobe.



*Auditory symptoms.*—In view of the supposed relation of the temporal lobe and particularly of the transverse temporal gyrus to audition and the speech mechanism, it is extraordinary how slight and inconspicuous are the clinical evidences of any disturbance in this sphere. Certainly in none of the cases in this series has there been anything suggestive of auditory hallucinations of musical sounds or imagined speech, as might have been expected.

Without wishing to provoke a discussion regarding the location of the centres for the perception of speech, it has always been a matter difficult for me to understand why after a left subtemporal decompression for an unlocalizable tumour no disturbance of hearing occurs even though the lobe may bulge markedly through the defect. On the analogy of the paralyses which are known to result from the protrusion of cortex through a defect made over other parts of the brain, one would certainly expect some disturbance of hearing from a protrusion of the first temporal gyrus if this is as important an area as we have been led to believe.

In this series of 59 cases hearing was absolutely unimpaired in 38 of the patients. In eleven cases there was tinnitus heard in one or both ears but it was never a particularly constant or annoying symptom as in acoustic tumours. Slight contralateral deafness was recorded in five cases, slight relative deafness on the side of the lesion in two cases. In the remaining cases the tests were obscured by an old otitis media. To be sure, these tests were made merely by the voice, the watch and the fork and without any such accuracy of measurement as the perimeter gives for the fields of vision, but certainly, were contralateral deafness a common sequence of temporal tumours, occasional cases with pronounced loss of hearing would be encountered, and of these the records contain no example.

So far as aphasia is concerned there can be little question but that, when in left-sided cases a disturbance of speech is evident, one almost invariably can detect some evidence at the same time of a right facial weakness which indicates that the pressure effects of the tumour are exerting themselves on areas above the Sylvian fissure. I am a little in doubt, after re-reading Kennedy's paper, whether he regards the aphasia sometimes seen with left-sided temporal tumours as really temporal in origin. To my thinking, however valuable it may be in tumour lateralization, aphasia is a neighbourhood symptom and not a true temporal lobe phenomenon.

*The temporal versus a cerebellar syndrome.*—It would seem improbable that one could ever be misled by the symptoms of a temporal



lobe tumour into making the diagnosis of a subtentorial lesion. This nevertheless may occur, particularly in the absence of uncinatc seizures and when field defects either are wanting or the perimeter cannot be used.

In fifteen of the fifty-nine cases there was definite nystagmus and in some of the patients it was a marked feature. Dizziness and vertigo are not unusual, and curiously enough primary suboccipital headaches have been fairly common. Then, too, in a few cases there has been definite ataxia and marked static instability. A few years ago one of my assistants, who had been devoting himself particularly to the cerebellar symptomatology and was an expert in the interpretation of Bárány tests, was led to make a suboccipital exploration in a patient who did not survive, and autopsy disclosed a temporal lobe tumour. By a sad oversight the fields of vision in this case had not been taken, for the cerebellar symptoms were supposed to be sufficiently definite to make this unnecessary.

It is not at all infrequent for my assistants or myself to make a tentative rating of a patient on the first superficial study as a cerebellar suspect and to have this presumptive diagnosis ruled out beyond question as soon as the fields have been taken. The chief difficulties arise when the patient is blind or uncooperative. It is of course one of the traditions of neuro-surgery that one may easily mistake a frontal for a cerebellar case or vice versa. This is well brought out by the tables of operations given in Tooth's studies of the National Hospital series, and I have twice been led to make a cerebral exploration for tumours as definitely localizable in the long run as are those of the acoustic nerve. Undoubtedly one must also bear in mind the possibility of confusing a temporal and cerebellar lesion, and it is safe to say that in every case of any obscurity whatsoever the perimeter should be employed.<sup>1</sup>

<sup>1</sup> In his article, "Die Tumoren des Schläfenlappens," by Albert Knapp (*op. cit.*), emphasis is also laid upon the difficulty of diagnosis between a temporal lobe and a cerebellar lesion. In his summary he says: "In the third place, of especial importance are the disturbances of equilibrium which are likely to be chiefly confused with cerebellar symptoms, and can be described as a pseudo-cerebellar temporal lobe ataxia. Less often there are other symptoms which are characteristic of affections of the posterior fossa, such as pain and stiffness in the neck, grinding of the teeth, corneal areflexa, nystagmus, and abducens palsy." He further adds that if these three things—oculomotor palsy, pressure against the cerebral peduncle, and inco-ordination—are present, the diagnosis of a temporal lobe tumour is assured. He evidently regards these three things as the essential feature of temporal tumours and the other symptoms of secondary importance, even disturbances of taste and smell.



## SUMMARY AND CONCLUSION.

(1) The temporal lobe is a common seat of cerebral tumour (fifty-nine cases in a series of 276 verified supratentorial tumours).

(2) In the fifty-nine verified temporal lobe tumours, perimetry, owing to the advanced stage of the process, was precluded in twenty cases, but of the remaining thirty-nine homonymous field defects indicating involvement of the temporal loop of the optic radiation were present in thirty-three instances.

(3) Heretofore the most important symptom for temporal lobe localization has been the occurrence of the so-called uncinata fits, but in this series, even including as such all attacks of *petit mal* without gustatory impression, they have been recorded in twenty-four cases only.

(4) Visual hallucinations have been a frequent symptom of the temporal tumours in this series (thirteen out of the fifty-nine cases).

(5) Auditory phenomena in this series are conspicuous by their absence. In a few cases only has there been tinnitus and rarely some lowering of sound perception.

(6) The chief errors of diagnosis arise (i) when, with a total median hemianopsia, the occipital lobe is considered to be the tumour seat; (ii) in the absence of demonstrable field defects, when symptoms supposedly of cerebellar origin are to the fore.

Hence it is fair to conclude that perimetry gives us information of paramount diagnostic value, particularly in the early recognition of temporal lobe tumours, the partial field defects short of a hemianopsia being especially characteristic of involvement of the optic radiation in this region.

## REFERENCES.

- [1] ARCHAMBAULT, LA SALLE. "Inferior Longitudinal Bundle and the Geniculo-calcarine Fasciculus," *Albany Med. Ann.*, January, 1909.
- [2] BRAMWELL, BYROM. *Brain*, 1899, **22**, 37.
- [3] JACKSON, HUGHLINGS. *Ibid.*, 1889-90, **12**, p. 358.
- [4] KENNEDY, FOSTER. "The Symptomatology of Temporosphenoidal Tumours," *Arch. Int. Med.*, 1911, **8**, 317-50.
- [5] MEYER, ADOLF. "The Connections of the Occipital Lobes and the Present Status of the Cerebral Visual Affections," *Trans. Assoc. Amer. Physicians*, 1907.
- [6] WALKER, C. B. "Colour Interlacing and Perimetry," *Trans. Amer. Ophthalm. Soc.*, 1916, **14**, 684.
- [7] *Idem.* "Quantitative Perimetry: Practical Devices and Errors," *Arch. Ophthalm.*, 1917, **46**, 537-61.
- [8] *Idem.* "Neurological Perimetry," *Trans. Ophthalm. Sect., Journ. Amer. Med. Assoc.*, June, 1917, 189-202.









