

## **Notes on some points in military orthopaedics / by Robert Jones.**

### **Contributors**

Jones, Robert, 1857-1933.

### **Publication/Creation**

London : Printed at the Office of the British Medical Association, 1916.

### **Persistent URL**

<https://wellcomecollection.org/works/ps98as6j>

### **License and attribution**

Conditions of use: it is possible this item is protected by copyright and/or related rights. You are free to use this item in any way that is permitted by the copyright and related rights legislation that applies to your use. For other uses you need to obtain permission from the rights-holder(s).



Wellcome Collection  
183 Euston Road  
London NW1 2BE UK  
T +44 (0)20 7611 8722  
E [library@wellcomecollection.org](mailto:library@wellcomecollection.org)  
<https://wellcomecollection.org>

89/8

Notes on

# Some Points in Military Orthopaedics

BY

LIEUTENANT-COLONEL ROBERT JONES,

CH.M., F.R.C.S.I.(HON.),

INSPECTOR OF MILITARY ORTHOPAEDICS, ARMY MEDICAL SERVICE.

---

*Reprinted from the BRITISH MEDICAL JOURNAL, April—August, 1916.*

---

LONDON:

PRINTED AT THE OFFICE OF THE BRITISH MEDICAL ASSOCIATION,  
429, STRAND, W.C.

1916.

110 A



22102122314


Med  
K29864





# Index

Albee's operation	87
"    "    sliding inlay method	89
Ankle joint	7-71
Body weight deflexion	13
Bone graft, for recent fractures	89
"    "    lateral	91
"    "    substitute for plates & screws	85
"    "    Technique of	85
"    "    Transplantation	80
"    "    Use in military Surgery	83
Boots - 30 marching	43
"    "    quality of	44
Claw foot	37
"    "    five degrees of.	37-43
Drop foot - due to injury of popliteal Nerve	23
Elbow joint	2-69
Femur fracture of	74
Fibula ununited	62
Flail joints	8



Digitized by the Internet Archive  
in 2017 with funding from  
Wellcome Library

<https://archive.org/details/b29812264>

Flat foot		27. 28
"	" acute	29
"	" osseus	33
"	" from periarthritis	31
"	" Rigid	32
"	" due to spasm of Peronei	33
"	" Sub acute (ordinary)	36
"	" Traumatic	31
Foot	Deformities & Disabilities	28
"	Soldiers' common deformities	27
Fore arm		3
Fractures	Compound comminuted	64
"	fixation after setting	65
"	functional impairment	68
"	inefficient reduction of.	64
"	malunited	59. 64
"	of Spine of Tibia	104
"	ununited	59. 91
"	weak union	64
Gunshot Injuries of Nerves -		15
Hallux Rigidus		43 45.
Hallux Valgus		43-46
"	" operative treatment technique	48. 50





Hammer toe	52
Heel - painful	56
Hibbs' operation	88
Hip joint	5
Humerus	68
Injuries	see nerves
Inlay (sliding)	93
Internal semilunar cartilage - operations on.	100
Intra medullary plug	92
Joint mobility	10
Knee joint	6
" " disabilities	95
" " External semilunar cartilage	103
" " initial injury, treatment	99
" " internal derangement	96
" " mechanism of certain injuries	96
" " operations on	100
" " rupture of crucial ligaments	103
" " " " internal ligaments	96
" " " semilunar cartilage	96
" " Semilunar cartilage - displaced	98
" " " " external, dislocation	103
" " Sprains of internal lateral ligament	95
" " Thickened cicatrice about semilunar cartilage	98



Lateral Graft	91
Massage	11
Metatarsalgia	43 54
Metatarsus	7
Morton's Disease <u>see</u> Hallux Valgus	
Muscles - freeing of	10
" relaxation of	10
" late recovery of power of	14
" supplied by exterior popliteal Nerve	
" paralysis of	21
" voluntary use & massage	11
Musculo spiral nerve	18
Nerves	
Gunshot injuries - tendon	
transplantation	15
" median - injury to	18
" musculo spiral nerve	18
" suture of	9
" ulnar injury	18
Os calcis - spurs of bone under	57
Osteitis	58
Paralysis of muscles	21
" musculo spiral	18
" of ulnar - transplantation	19



Periostitis	58
Optical nerve - injury	23
Pronator Radii Teres - Transpl.	18
Radial Flexor	18
Radius & Ulnar	69
Sciatic Trunk injury	25
Shoulder joint	1
Sliding Inlay	93
Spinal fixation	87
Spurs of bone under os calcis	57
Tarsus joints of	7
Tendon fixation	22
" operation for	23
" see Transplantation of.	
Tibia Fracture of	74
" Ununited	62
" fracture of Spine of	104
Toe - little displacement	54
Transplantation in complete paral of Ulnar	19
" of Tendons in Median Paralysis	19
" in Gunshot injuries of Nerves	15



Ulnar	Complete paralysis	
	transplantation	19
Upper limb -	Irreparable injuries of	
	Musculo spiral nerve	18
Wrist joint	injuries	3



27 838 179

WELLCOME INSTITUTE LIBRARY	
Coll.	welMOmec
Call	
No.	WE

## I. REMARKS ON POSITIONS OF ELECTION FOR ANKYLOSIS FOLLOWING GUNSHOT INJURIES OF JOINTS.

THERE are certain injuries to joints occurring after gunshot wounds which must inevitably end in bony ankylosis. From their very nature some of these will not admit of excision.

When a joint has been shattered, and the muscles governing it have been in part or wholly destroyed, excision is not merely difficult from the point of view of surgical technique, but often results in a flail articulation which renders the limb quite useless. This is especially the case when such joints as the shoulder, elbow, and wrist are concerned. Excisions of the upper part of the humerus are frequently practised as a conservative procedure in the presence of acute or persistent sepsis, especially at the French front. This may be very necessary, but the resulting condition will at a later date require further surgical intervention. The question has often been put to me, "What should be done with these flail joints, and, if ankylosis is to be expected, in what position should the joint be placed in order to be of the greatest use to the patient?" The question as to flail joints will be considered at the end of this article, but in the first place it may be of service to indicate briefly the conclusions as to the positions for ankylosis to which experience has led me.

### SHOULDER-JOINT.

#### *Position.*

The arm should be abducted to about 50 degrees (Figs. 1 and 2). The elbow should be slightly in front of the coronal plane of the body (Fig. 2), so that when it is at right angles and the forearm supinated, the palm of the hand is towards the face. The arm is placed in this position while the scapula retains its normal position of rest.

#### *Reasons.*

If the arm be correctly placed the hand (Fig. 3) can be brought easily to the mouth by bending the elbow. Further, the humerus, being fixed to the scapula at the angle indicated, the arm can be lifted to a considerable height by

scapular action (Fig. 4); moreover, pockets can be reached, the hair brushed, and the patient can pick up a plate or cup without spilling the contents.

The arm should never be kept to the patient's side if ankylosis is feared, for in such a case the functional result must be most unsatisfactory; not only will it be difficult to reach many parts of the body, but difficult also to reach across a table or to perform many simple movements constantly recurring in everyday life. Flail shoulder-joints also should be ankylosed in the position described, and joints which have been allowed to ankylose in an adducted position (Figs. 5A, 5B) may require osteotomy of the humerus high up to correct this faulty position. The shoulder-joint should never be allowed to become fixed

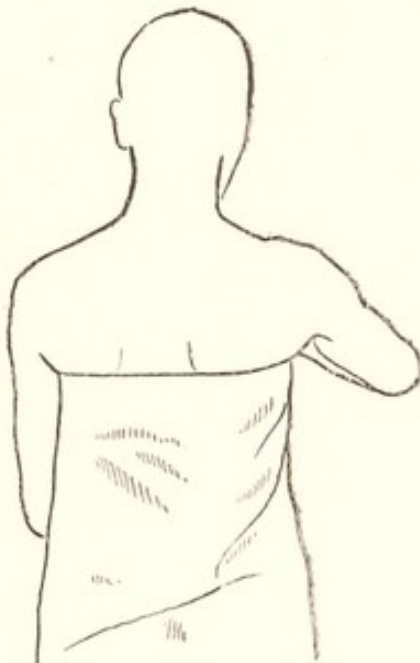


FIG. 1.

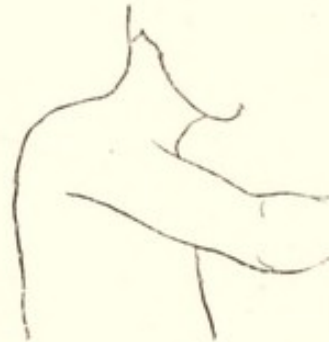


FIG. 2.

FIGS. 1 and 2.—To illustrate the position for ankylosis of the shoulder in abduction.

at right angles to the side in adults, as in that case the patient will be unable to bring his arm down to his side.

It is to be clearly understood that I am dealing with injuries to soldiers and sailors, and not with children in whom other means can be adopted owing to anatomical considerations.

#### ELBOW-JOINT.

##### *Position.*

The proper course to adopt will depend upon the patient and his calling, but by far the greater number of men would prefer the fixation to be at just below a right angle—that is, about 100 degrees (Fig. 6). It is important to bear in mind that in cases in which *both* elbows will become ankylosed it is necessary to fix the one at an angle of 80 degrees and the other at 100 degrees as recommended

for one-sided trouble (Fig. 7). The ankylosis commonly met with at 130 degrees is not useful.

*Reasons.*

This position enables the patient to move his hand to his mouth, button his clothes, brush his hair and to reach over a table. At an angle less than a right angle it is certainly more easy to get the hand to the mouth and to various parts of the head, but limitations in other directions more than counterbalance these advantages.

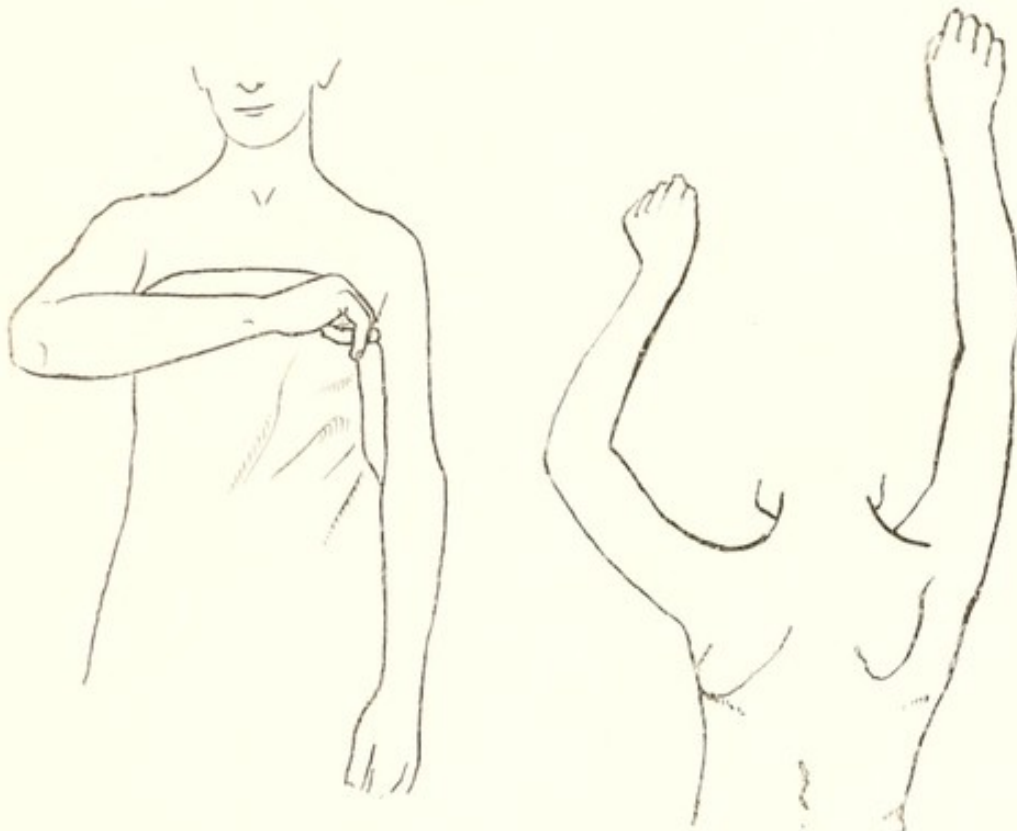


FIG. 3.

FIG. 4.

Figs. 3 and 4.—Ankylosis of the shoulder in abduction to show, (Fig. 3) degree of abduction, (Fig. 4) the degree of power of lifting the arm.

**FOREARM.**

*Position.*

If the movements of pronation and supination are lost, the radius should be fixed midway between pronation and supination.

*Reasons.*

The hand is more useful for dressing and eating and for manual labour in this position. A minor advantage is that of appearance.

**WRIST-JOINT.**

*Position.*

All injuries of the wrist-joint should be treated with the wrist dorsiflexed (Fig. 8).

*This is a priceless surgical axiom, the neglect of which is grave.*

It is an urgent necessity where ankylosis is expected, or where even limitation in movement is likely to occur.

The common deformity of palmar flexion occurs when no splint is applied, or from the use of a straight splint; in all cases in which the arm and fingers are kept on such a splint palmar flexion of the wrist occurs, and this condition is a lifelong handicap to the usefulness of the hand.

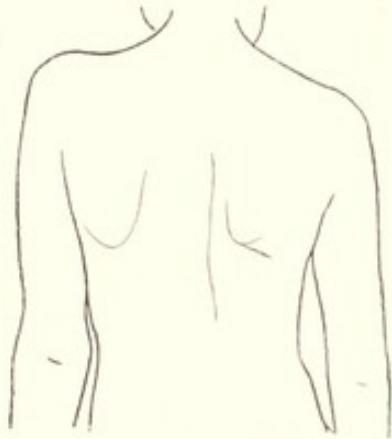


FIG. 5 A.

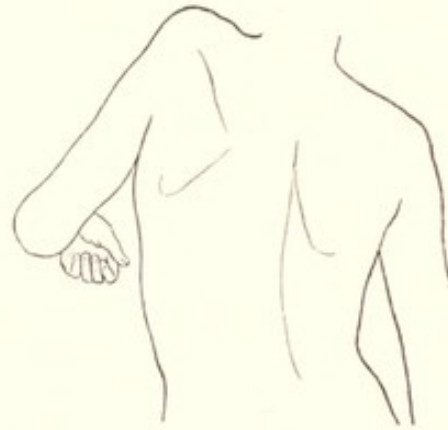

FIG. 5 B.

FIG. 5 A shows faulty adducted position of arm, and Fig. 5 B the consequent extremely limited power of abduction.

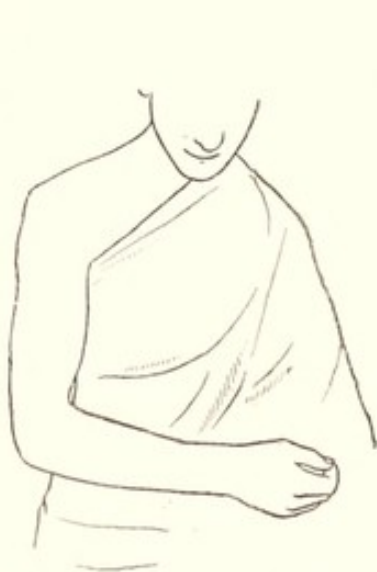

FIG. 6.—Ankylosis of elbow-joint at 100 degrees.

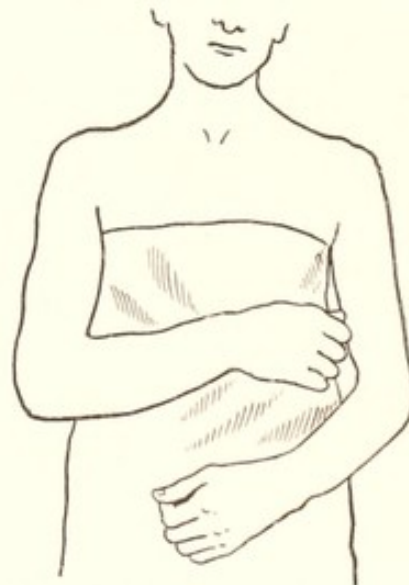

FIG. 7.—Right elbow at 80 degrees, left elbow at 100 degrees.

#### *Reasons.*

The grip of the fingers is diminished if the wrist is palmar-flexed. The strong flexors overpower the extensors of the fingers, and in consequence proper co-ordination of the finger movements is impaired. The grasp of the hand is strongest when the wrist is in the dorsiflexed position, the balance between the flexors and extensors is better preserved, and the co-ordinated movement of the fingers is secured.

The splints required are simple.

In proof of the importance I attach to the dorsiflexed ankylosed wrist, I may state that I always restore hyper-extension of the ankylosed joint from the position of flexion by manipulation or incision. This invariably improves the grip of the fingers.

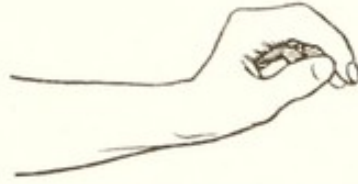

FIG. 8.—Dorsiflexion of the wrist.

Apart from the impairment of function, a flexed wrist is unsightly.

#### HIP-JOINT.

##### *Position.*

Ankylosis should be encouraged in a position of very slight abduction, with thigh extended and very slight outward rotation (Fig. 9).

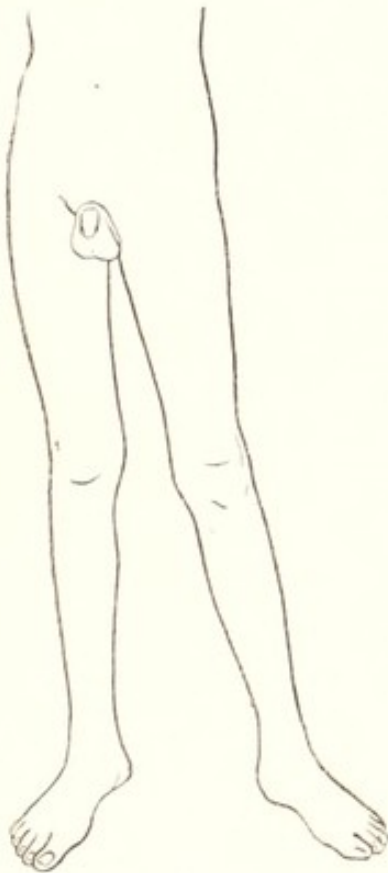


FIG. 9.

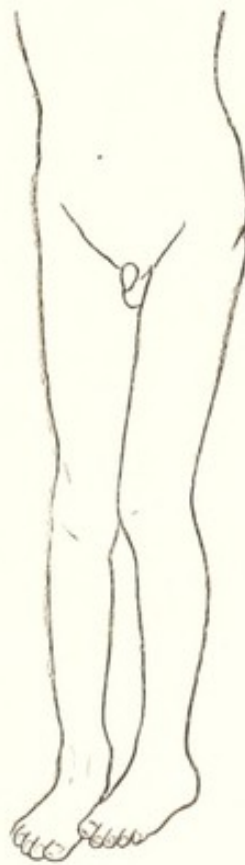

FIG. 10.

FIGS. 9 and 10.—Ankylosis of hip. (9) Correct position, in slight abduction with extended thigh and slight outward rotation. (10) Faulty position of ankylosis in flexion with adduction and internal rotation.

*Reasons.*

The common deformity in ankylosis of the hip is flexion, adduction and internal rotation (Fig. 10), which is the characteristic position we find in an untreated or imperfectly treated tuberculous hip-joint; it leads to lumbar lordosis and an ugly limp. Adduction deformity brings the limb too near the middle line, interferes with the normal position of the sound limb in walking, and by involving abduction of the sound limb, interferes also with a free gait.

If the hip-joint is ankylosed in the fully extended position lordosis and the consequent trouble from back-ache is avoided, and there is freer pelvic movement in walking if the thigh is slightly abducted.

The limb should be very slightly rotated outwards, to avoid the unsightly lift of the pelvis as the patient rises on

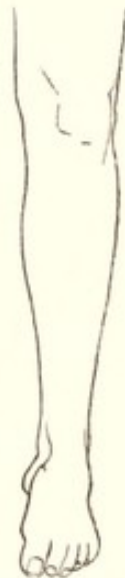

FIG. 11.—Ankylosis of ankle with foot at right angle and sole inslightly varus position.

his toes when walking, due to the immobile condition of the hip-joint. This gives an easier walk than if the toes are pointed straight forward.

**KNEE.***Position.*

This joint should be fixed in an extended position.

*Reasons.*

Very good reasons may be given in favour of slight flexion from the point of view of elegance in repose and that of ease in mounting stairs. Due weight should be given to these arguments, but in the case of war injuries the straight position obviates many risks. Ankylosis, as we know, is not necessarily bony; when it is fibrous the tendency is for the flexion angle to increase by exercise. The incidence of the body weight on a slightly bent knee, unless

the ankylosis is sound and bony, will increase the flexion. The position, therefore, is mechanically a weak one for carrying body weight. Even when new bone is forming its complete consolidation is sometimes a slow process, and if the surgeon places such a knee in a slightly flexed position the degree of ultimate flexion is often much greater than he would wish. The advantage of increased strength and stability ensured by an extended joint will generally outweigh all other considerations.

#### ANKLE.

##### *Position.*

The foot should be kept at a right angle with the leg, so that the sole impinges on the ground in a slightly varus rather than a valgus position (Fig. 11).

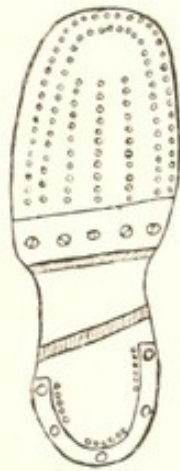


FIG. 12.—Boot with bar behind head to relieve injured metatarsal joints and phalanges from pressure.

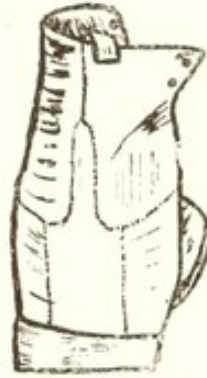
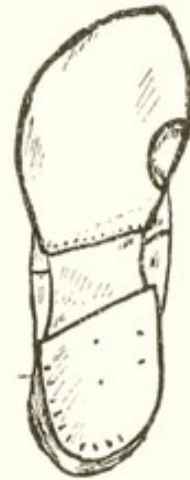


FIG. 13.—Heel elongated and raised  $\frac{1}{2}$  in. on inner border, with small piece on inner side of sole.



##### *Reasons.*

If the reader will recall the ankylosed ankles he has seen, he will remember that most of them were in a varoid position. A varoid position conduces to a strong type of foot; a valgoid (flat-foot) to a weak foot, and all the disability associated with erroneous deflection of body weight.

#### JOINTS OF THE TARSUS AND METATARSUS.

In gunshot wounds and other injuries of the tarsus and metatarsus, the deformities to be feared correspond to the common static deformity of flat or pronated foot—a subject with which I propose to deal more at length in a subsequent article—that is to say, to pronation at the mid-tarsal joint, flattening of the longitudinal arch, and sometimes flattening of the transverse arch associated with pain in the metatarso-phalangeal joints. Callus exudation added to plantar malposition results in a very crippled foot. In all gunshot injuries of tarsus and metatarsus the surgeon should take care during the later stages of healing not



to bandage the sole rigidly against a flat foot-piece, for if that be done every irregularity of bone will conduce to callosity when walking is resumed. It is necessary, therefore, at this stage to adjust a splint having an inside arch padded to conform to the natural shape of the foot. Eversion of the foot should be guarded against, and the hollow of the arch should, when possible, be emphasized. Later, the heel of the boot should be raised on the inner side to obviate eversion, and, if the metatarsals are involved, in order to allow of early walking, a bar should be placed across the sole of the boot behind the tread (Figs. 12, 13). Light duty can then be undertaken at a much earlier date.

#### FLAIL JOINTS.

In answer to the question "What should be done with flail joints?" I would say, "Secure by operation an ankylosis in the most useful position." The only exception is in the case of the hip-joint where by means of simple mechanism a very useful limb may be obtained in spite of the joint being flail.

## II. ON SUTURE OF NERVES, AND ALTERNATIVE METHODS OF TREATMENT BY TRANSPLANTATION OF TENDON.

THERE are few problems more urgently needing solution at the present moment than those involved in the treatment of limbs disabled by injuries involving nerves. The conditions vary and are often very complex. The nerve may be irretrievably injured beyond all hope of suture; it may be entangled in cicatricial tissue; one or more of the muscles it supplies may have suffered grave lesions, varying from partial to complete destruction; the tendons or muscles themselves may be bound down by adhesions, or the joint or joints the muscles govern may be stiff or ankylosed, or held in a deformed position by a skin cicatrix, or more than one of these hampering conditions may be present. The simple condition, where the nerve or some of its fibres receive a clean severance, is exceptional.

If once these facts are realized it will require no argument to establish the proposition that certain orthopaedic problems must be mastered in connexion with the suture of nerves if proper restoration of motor function and of the normal efferent and afferent connexion between muscle and the central nervous system are to be secured. In certain fortunate cases the conductivity of the nerve is restored and good muscular function may result. In other instances, although the conductivity is restored, the function of the muscles and joint may not be regained because certain fundamental principles have been neglected. There are other cases in which the conducting power of the nerve is not properly restored, and yet others in which, owing to extensive destruction of the nerve, any attempt at suture would be futile. We must therefore be prepared with alternative methods in order to secure for the patient a satisfactory limb.

### LATE SUTURE OF NERVE.

With regard, however, in the first place, to late suture of the nerve, certain general principles must be borne in mind. These are:

1. The correction of contractures of skin or muscle and all the anatomical constituents, from skin to bone,

on the concave aspect—that is to say, on the side of the abnormal direction the contracture takes.

2. When possible, the freeing of joints from all adhesions and the restoration of the mobility of the joint in all cases where ankylosis is threatened.

3. The maintenance of the paralysed muscles in a position of relaxation throughout the period of recovery.

4. The practice of massage during the recovery, but without once allowing the relaxed muscles to be stretched.

In short, the principles and their application coincide with those I have so often emphasized in the treatment of poliomyelitis.<sup>1</sup>

### 1. *Freeing the Muscles.*

In the first place, it is necessary to free the muscles from all mechanical obstructions to their action. If this be not done they cannot respond to stimuli sent to them through the nerve, and therefore cannot in their turn send the answering afferent impulse which is necessary to bring the apparatus into proper working order. It is essential to dwell on this point, inasmuch as many operations are being performed while the muscles and joints are stiff. This stiffness is not due to the nerve injury, but to the consequences of trauma and sepsis affecting the muscles, tendons, blood vessels, nerves and ligaments about the joint. When we realize how anaemic an unused muscle becomes, we shall not delay in giving help to prepare it for the reception of nerve impulses.

### 2. *Mobility of Joint.*

In the second place, where the joint is threatened with ankylosis, every effort should be made to restore its function.

Operation on the nerves is doomed to failure if these fundamental principles be disregarded.

### 3. *Relaxation of Muscles.*

Thirdly, the importance of keeping the partially paralysed and overstretched muscles in relaxation during treatment has been so forcibly brought home in ordinary civil practice in the treatment of residual paralyses after poliomyelitis, lead palsy, injuries of the brachial plexus and of isolated nerves, that it should be scarcely necessary for me again to call attention to it. Nevertheless, visits to wards prove that this elementary orthopaedic measure is too frequently entirely omitted by surgeons who have performed suture of injured nerves. Thus we find men who have had the musculo-spiral sutured allowed to walk about with the hand dangling in palmar flexion instead of its being kept continuously in dorsiflexion! By letting the hand hang in palmar flexion the muscles supplied by the sutured musculo-spiral, which can only recover if kept relaxed, are allowed to become stretched. The result is that the fingers and hand do not regain, can

hardly be expected to regain, full normal function. A similar grave error is perpetrated often in the case of the external popliteal nerve also, with the same disappointing result in the foot. Frequently I have noticed that the foot of a patient whose popliteal nerve has been sutured is allowed to remain in an equinus position! Sometimes, indeed, the operation is even performed while the tendo Achillis is contracted. Were it not so frequently happening I should feel ashamed to refer to this matter, but as it is happening I again urge surgeons who suture nerves to insist that the affected muscles be kept in complete relaxation until power returns. The most skilful operation performed on the most suitable case will prove a fiasco unless the affected muscles are continuously kept relaxed until recovery takes place.

In some cases it will be found not only that no provision is made for the muscle to be in the most favourable condition to respond to the earliest motor impulses which come through the block in the nerve, but, further, the mechanical condition of the muscle as to function seems to be entirely neglected, and suture of the nerve is performed when the paralysed muscle or the joint on which it acts is immobilized by cicatricial adhesions. If restoration of function is to follow nerve suture, the new axis cylinders growing through a cicatrix must of course be enabled to establish some sort of normal relation as to function with the end organs in muscle. If the muscle is mechanically disabled from making any response, it is absurd to hope for good functional result, even though the physiological processes of repair of the nerve be perfect. I desire to emphasize again the fundamental principle of procedure—namely, that the restoration of the mobility of joint and muscle must precede the operation of nerve suture. It is useless to attempt it otherwise.

#### 4. *Voluntary Use and Massage.*

Fourthly, for precisely similar reasons, it is important that the patient should as soon as possible exercise the limb in normal movements. In the case of the lower limb this usually means the application of some apparatus designed to prevent strain on the recovering muscles while the patient is permitted a moderately free physiological use of his limb. In order to make the foregoing observations more lucid to those who have not followed my writings, which are based on the late Mr. H. O. Thomas's theory of "muscle lengthening," I will briefly indicate their tenor.

It is well, in view of the enormous number of injuries to nerves occurring in this war, to emphasize the fact that principles applicable in poliomyelitis are applicable here. When speaking, some years ago, of the results of acute poliomyelitis, I pointed out<sup>2</sup> that, though the disease might permanently destroy motor cells in the anterior horns of the grey matter, so rendering the muscles dependent upon them for ever useless, unless nerve transplantation might at some later date come to their

rescue, yet *complete* destruction was fortunately the rarer condition. The clinical evidence afforded by rapid and complete recoveries from complete paralysis and the very many partial recoveries proved that the motor cells concerned had suffered from temporary injury and had not been destroyed. Something had happened to make the muscle incapable of responding to motor stimulus. Whether this was to be attributed to the absence of afferent muscle-sense stimulus, as seemed probable, or whether it was due to some other cause, it

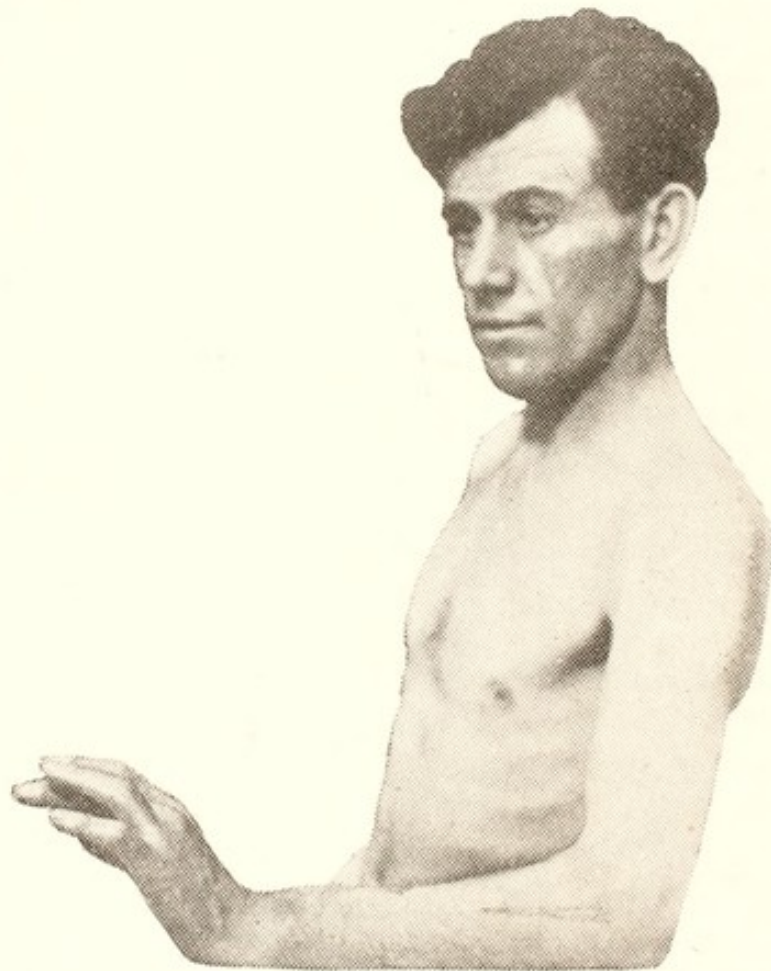


FIG. 1.—Showing action of dorsiflexing after transplantation of tendons. Captain McMurray's case.

was clinically certain that the nerve cells became partially inactive, not extinct, and that with appropriate treatment of the muscle or group of muscles functional activity could be reinstated. When a muscle governed by a live cell, or rather a group of live cells, fails to act, the disability may be spoken of as functional. Of this disability the great outstanding cause is overstretching of muscle fibres. A surgeon must recognize the difference between a truly paralysed muscle and a muscle which is over-stretched, and must know how to distinguish the one condition from the other.

The first essential of treatment is that the muscle or muscular groups must be prevented from being overstretched. If the wrist is, for instance, allowed to remain flexed the flexor muscles undergo adaptive shortening, and the extensors become overstretched and consequently placed at a mechanical disadvantage. This point is well illustrated by dropped wrist from lead poisoning. The lesion here may be either in the cord or in the nerve trunks; in either case the muscles cease to be controlled by their nerve centres, and the patient goes about with his wrist flexed by gravity, and the extensor muscles become disabled by continuous overstretching. As the condition is usually bilateral, an interesting experiment to test my contention may be made, if the case be of some weeks' standing, by placing one of the paralysed arms on a splint to keep the hand dorsiflexed. It will be found that recovery will be much more rapid on the side on which the extensors are relieved from overstretching than on the other neglected side. When a

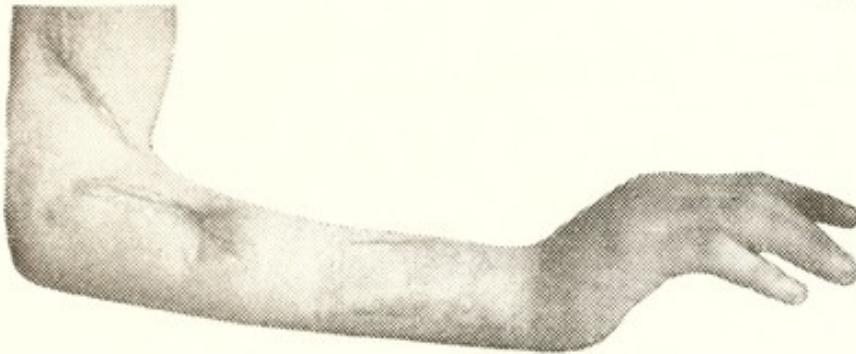


FIG. 2 illustrates a similar result in another of Captain McMurray's cases.

muscle is deprived of the natural motor stimuli, its condition from the point of view of function and nutrition is the same, whether the absence of stimuli be due to inactivity of the central nerve cells or to interruption of the conducting paths along the peripheral nerves. Its motor function is suspended, its nutrition suffers, it becomes anaemic, and it may easily be overstretched by gravity, by the unrestrained action of the opposing muscle, or by these two forces acting in combination. If the wrist and fingers are kept in extreme dorsiflexion, the extensor muscles, thus relieved of strain, undergo adaptive shortening, and soon begin to respond to the constant stream of tonic stimuli sent to them by efferent impulses; later they come under the higher control of the voluntary centres.

Another cause of persistence of functional disability is an unequal degree of recovery in opposing muscular groups.

#### *Deflection of Body Weight.*

A most potent factor for evil is what I have called the erroneous deflection of body weight, which, for physical reasons, operates chiefly in the lower limbs. If, for example, there be weakness in the tibial group and the

patient be allowed to walk, the valgoid deformity will constantly increase, the tibial muscles will be more and more stretched, adaptive contraction will affect the peronei, and structural alteration will ensue in the tarsal bone, terminating in a troublesome flat-foot. All these untoward results may be avoided by simple treatment on sound scientific principles; a little alteration of the boot which, by raising the inside of the heel of the boot, will deviate pressure from the inner to the outer side of the foot, may suffice. When we have to deal with a group of muscles in which the power is only slightly impaired, the muscular balance may be restored by over-developing the weaker group. If, for instance, the peronei are weak, but the foot can quite easily be placed in the everted position, then massage and exercises may reasonably be expected to succeed. But if the foot cannot be everted because of adaptive shortening of the tibial tendons, then massage and exercise of the peronei will be perfectly useless until such time as the deformity has been corrected and the overstretched muscles kept relaxed for a sufficient period to permit them to recover by interstitial shortening.

#### LATE RECOVERY OF MUSCLE POWER.

But before any operations are performed affecting the mobility of a joint, every use should be made of available muscle power. No surgeon should operate on these cases until he has fully satisfied himself whether or no it be possible to restore the apparently paralysed muscle. Neglect of this precaution produces such a distressing occurrence as the unexpected recovery of muscles which were ignored because assumed to be paralysed. For example, a patient was brought to me once with a partially ankylosed knee. The operation of arthrodesis had been performed with a view of bringing about bony ankylosis. As an arthrodesis the operation had failed, for the knee had a short range of movement. As an experiment, illustrating the principle we are discussing, it was very successful, because the quadriceps was acting with considerable strength. Prolonged fixation had relieved the quadriceps from all strain, and restoration of function resulted. This case exemplifies the mistake of taking for granted that a muscle is paralysed without first making quite certain that it is *really* paralysed. It is only possible to make quite certain by relaxing the muscle and thus putting it into the position most favourable to recovery for a sufficient length of time. Electrical tests cannot be relied upon to give this information.

#### *Treatment to Promote This.*

The first stage of treatment is the correction of existing deformity. When deformity has been corrected the limb should be kept immovable until the ligaments, muscles, and even bone have become of normal length and shape. The continuity of treatment must be maintained or a relapse will result. This point is fundamental, and neglect to observe

it spells failure, as the slightest stretching of a muscle on the point of recovery disables it again. All the good work may be thwarted by a single indiscretion. I cannot emphasize this point too strongly. For instance, let us take the case of a drop-wrist which has been placed in a splint designed to dorsiflex the hand and wrist. The position must be constantly maintained. The hand must not be allowed to flex for a single moment until recovery has occurred. Even while the patient washes, the hand must be held dorsiflexed.

The clinical test of the recoverability of a muscle, therefore, depends on an experiment. Let it be kept for a prolonged period—for at least six months—in a position of relaxation. This test should always be made before condemning any muscle, no matter how long the period for which it may apparently have been paralysed. When, therefore, one reads in textbooks statements to the effect that we are to despair of the return of power after a certain length of time, we can quite well afford to ignore the advice unless in addition to this time test there has been an uninterrupted muscular relaxation during that time.

These are views which I have without ceasing urged upon my professional brethren as applicable to infantile paralysis. They are equally applicable, with certain modifications, in the case of gunshot injuries. It is obvious that in infantile paralysis long mechanical treatment can do no harm. This is not so in the case of a soldier in whom a nerve has been injured. If suture is to give any promise of success there must be a limit to conservative methods. In any case, an exploration of the nerve is a harmless procedure.

#### TENDON TRANSPLANTATION IN GUNSHOT INJURIES OF NERVES.

In recommending tendon transplantation in gunshot injuries I have profited by the experience gained in anterior poliomyelitis. I have frequently performed tendon transplantation with success in the adult in cases in which isolated nerves have been destroyed. Similarly unrecorded cases have been operated upon by my friends Mr. Thelwall Thomas and Mr. Bickersteth. At the Military Orthopaedic Hospital, Liverpool, my colleague, Captain McMurray, has at this moment three successful cases in which transplantation has been done for musculo-spiral paralysis. As I have previously indicated, the object of a transplantation is to improve or restore muscular balance. It is not justified unless it improves function. There is little satisfaction to a patient if the transplanted muscle merely responds to faradism, or even makes a feeble movement by the effort of the will. It must be, or give the promise of becoming, a substitute for the muscle it supplants. It can only be judged by its ultimate usefulness.

A tendon may be transplanted in order to restore the balance between opposing groups of muscles by helping a redistribution of power, or its attachment may be slightly altered to prevent deformity.



Recognizing that the principles involved in tendon transplantation are the same in both conditions, I will briefly describe in the second part of this communication certain transplantation operations I recommend for various injuries.

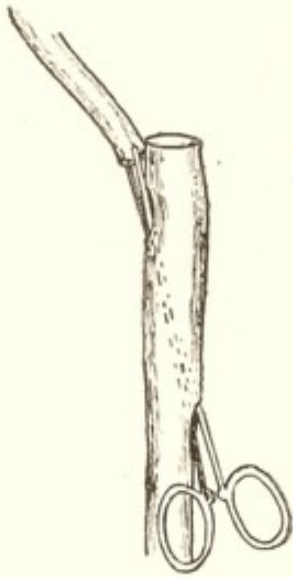


FIG. 3 A.—Showing the tendon which is to be transplanted about to be passed through a tunnel in the other tendon. The tunnel is being dilated to receive the transplanted tendon.

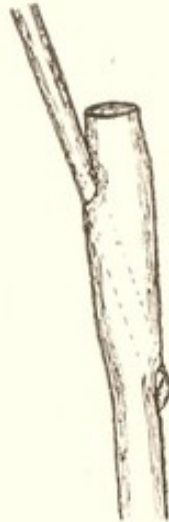

FIG. 3 B.—Transplant in position. The angulation is dealt with as shown in Fig. 3 c.

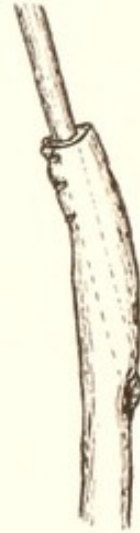

FIG. 3 c.—In order to overcome angulation a slit is made in the upper part of the receiving tendon, which is then wrapped round the transplanted tendon.

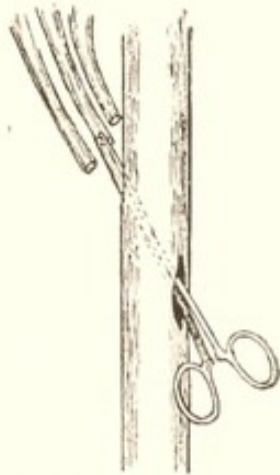


FIG. 4 A.—Tendons about to be pulled through another before suturing.

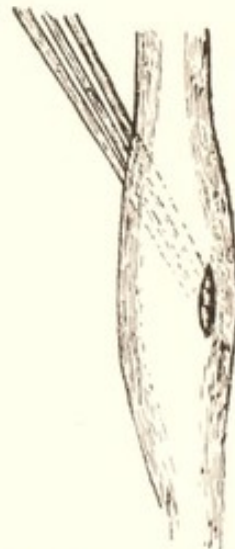


FIG. 4 B.—The divided ends of three tendons passed through another tendon in its course.

As a preliminary I give here a series of diagrams Figs. 3, 4, 5, 6, and 7, illustrating methods of transplantation of tendon applicable under various anatomical conditions.

In the first part of this paper I considered some general principles which should guide the surgeon in the treatment of limbs disabled by injuries involving nerves. I pointed out the importance of giving the muscles ample time

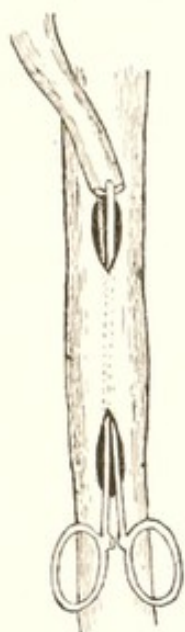


FIG. 5 A.—Showing transplanted tendon about to be passed along a tunnel in the receiving (active) tendon.

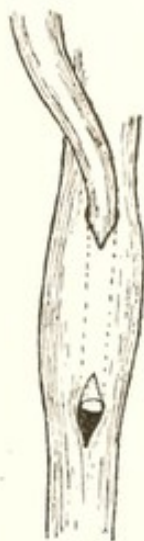

FIG. 5 B.—Tendon passed along course of active tendon.

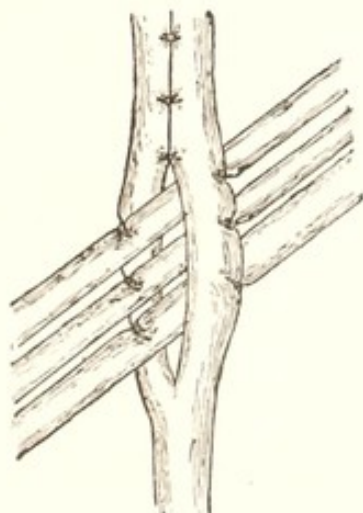


FIG. 6.—Three tendons passed through another tendon, which has been split to receive them.

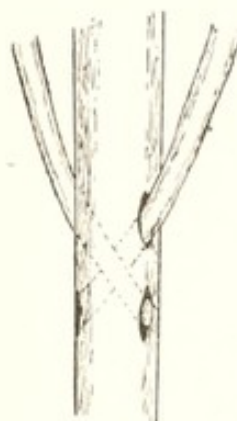


FIG. 7.—Tendons inserted into either side of active tendon.

and opportunity to recover by keeping them in a relaxed position for a sufficiently long period, and I began the discussion of tendon transplantation as an alternative method of treatment where nerve suture was not possible. I now propose to consider the transplantation operations my experience leads me to recommend in various injuries.

## UPPER LIMB.

*Irreparable Injury of Musculo-spiral Nerve.*

1. In cases of musculo-spiral injury the deformity is a dropped wrist, with loss of the power of extending the fingers. The uncontrolled action of the flexor group causes the fingers to curl into the palm, and the hand to become useless.

In such a case :

- (a) The flexor carpi radialis and the flexor carpi ulnaris can be transplanted into the paralysed extensor of thumb and fingers ; and
- (b) in addition the pronator radii teres may be affixed to the two radial extensors.

*Transplantation of Pronator Radii Teres and the Radial and Ulnar Flexors in Musculo-spiral Paralysis.*

I would recommend for this condition of musculo-spiral paralysis the double operation (a) and (b), and I will briefly indicate the method of its performance.

With the forearm midway between pronation and supination an incision is made along the radial border of the forearm in its middle third. Under cover of the tendon of the supinator longus the pronator radii teres will be found where it becomes inserted into the outer border of the radius. From this it is detached, and is then inserted into the tendons of the extensor carpi radialis longus and brevis, which lie closely applied to it on the dorsal surface.

A horseshoe incision, with the convexity resting on the back of the carpus, with the two straight sides extending along the radial and ulnar borders, is now made. Through the lateral aspects of this incision the tendons of the carpi ulnaris and radialis are identified, and are detached from their insertion as near the carpus as possible.

The tendons are brought round the ulna and radius respectively in very slanting fashion, and are then attached to the extensors of the fingers and thumb, the carpi ulnaris being attached to the tendons of the three inner fingers and the flexor carpi radialis to those of the thumb and index finger. The method of fixation should be neat and workmanlike.

*Injury to Median and Ulnar Nerves.*

In the case of great damage to the median and ulnar nerves, operations on tendons alternative to those on the nerves will be very rarely required as compared with those on the external popliteal and the musculo-spiral, for the reason that by means of flexion of the elbow a gap of two or three inches in the median may be closed up; by flexing the elbow and displacing the ulnar to the front a similar space in this nerve can be obliterated. End-to-end

suture, therefore, is much more easily secured in these two nerves than in the case of the musculo-spiral and external popliteal.

In cases of complete and irreparable paralysis of the muscles supplied by the median nerve the only active muscles on the flexor aspect of the forearm are the flexor carpi ulnaris and the inner half of the flexor profundus digitorum.

*Operation of Transplantation of Tendons in Median Paralysis.*

(a) The outer tendons of the flexor profundis are inserted into the inner tendons of the same muscle.

(b) The tendons of the flexor sublimis are inserted into the tendon of the flexor carpi ulnaris. The extensor carpi radialis longior is attached to the flexor longus pollicis.

*Method.*—A curved incision is made convex downwards with the apex just above the anterior annular ligament of

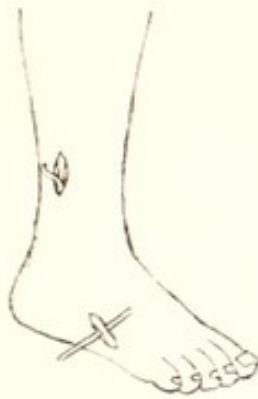

FIG. 8.—Tendon of peroneus longus divided in its course, and identified at the outer border of the foot.

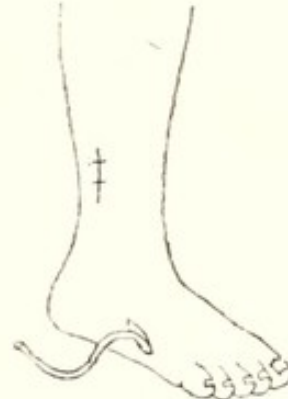


FIG. 9.—Tendon of peroneus longus drawn out through the lower incision.

the wrist. After retracting the flexor sublimis tendons, the outer two tendons of the flexor profundus are inserted into the two active inner tendons of the same muscle. The flexor ulnaris is then divided close to its insertion, and between the two portions of its split end the tendons of the flexor sublimis to the four fingers are inserted. The tendon of the extensor carpi radialis longior is now found at the outer border of the incision, and after division is inserted into the tendon of the flexor longus pollicis round the outer border of the radius.

*Operation of Transplantation in Complete Paralysis of the Ulnar.*

The two inner tendons of the flexor profundus are attached to the two outer.

The palmaris longus is inserted into the tendon of the flexor carpi ulnaris.

*After-Treatment.*

After operations for musculo-spiral paralysis the hand should be kept dorsiflexed until recovery of the muscle is complete. When the grafted muscles are acting sufficiently

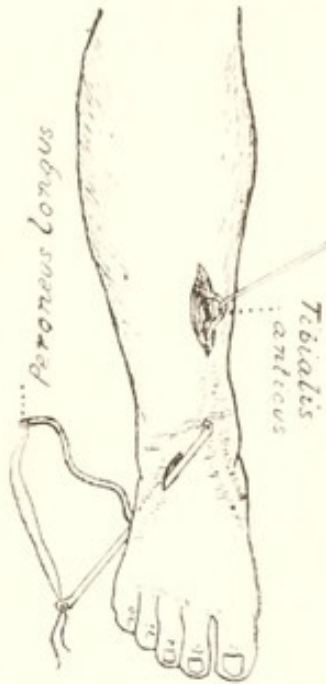

FIG. 10.—Tendon of peroneus longus about to be drawn through the incision opposite the annular ligament under which it has to pass.

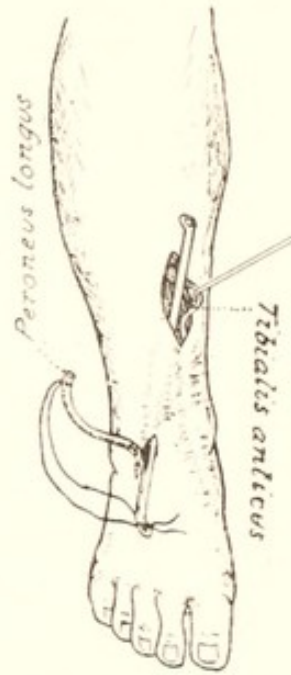


FIG. 11.—Tendon of peroneus longus about to be drawn under the annular ligament to be inserted in the tibia.

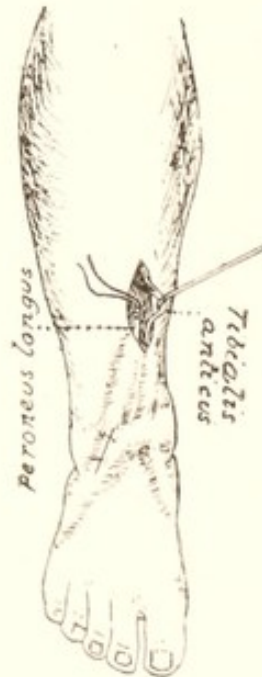


FIG. 12.—Tendon of tibialis anticus being drawn taut, the foot being kept at right angles; tendon is then cut and passed through a tunnel in the tibia. The tendon of the peroneus longus is shown drawn up through the same opening.

well and strongly to lift the hand and fingers, the time will have come for gradual training in co-ordination and balanced movement. Even after the patient has learnt to use his hand it is still necessary that he should continue to wear a dorsiflexion splint at night to prevent contractures of the flexors during sleep.

#### LOWER LIMB.

##### *Paralysis of the Anterior Crural Nerve.*

Transplant the sartorius and biceps into the patella.

An alternative measure would be the application of a knee cage with an extension spring to take the place of the paralysed quadriceps. This should be worn permanently.

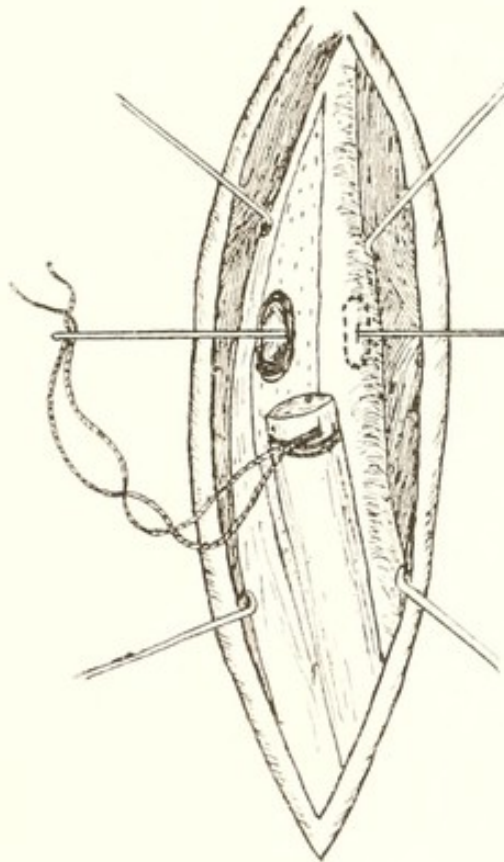


FIG. 13.—Tendon of peroneus longus about to be drawn through the hole drilled in the tibia.

#### PARALYSIS OF MUSCLES SUPPLIED BY EXTERNAL POPLITEAL NERVE.

The anterior group of muscles and the peronei are paralysed. The deformity is a dropped foot with varus due to gravity and the uncontrolled action of the muscles attached to the tendo Achillis and of the tibialis posticus.

##### *Tendon Transplantation.*

There is not much scope for effective tendon transplantation in this injury, except in cases in which only

particular branches of the nerve have been picked out. For instance, an injury paralysing the two peronei muscles, but leaving the anterior tibial nerve intact, would result in a deformity consisting chiefly of inversion of the foot at the midtarsal joint—that is, pes varus. In such cases, transplantation of the insertion of the tibialis anticus into the dorsum of the cuboid or into the base of the fifth metatarsal, replaces the loss of the evertors, and restores the balance of the foot.

#### *Tendon Fixation.*

In cases of more extensive paralysis there is not sufficient muscle power remaining for it to be effectually

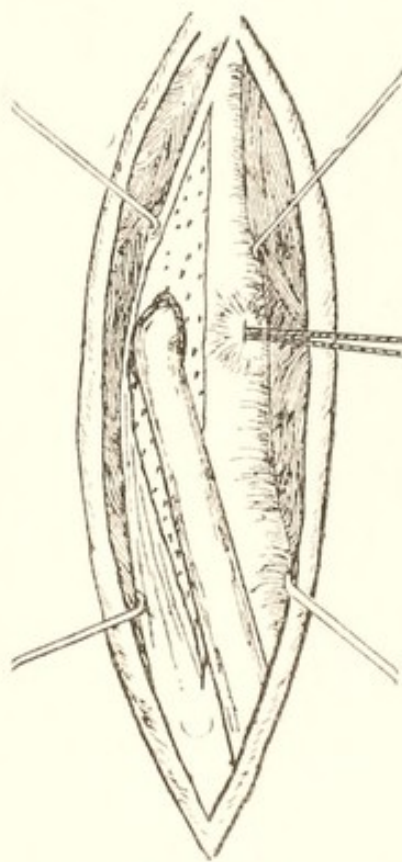


FIG. 14.—Tendon of peroneus longus drawn through the tibia.

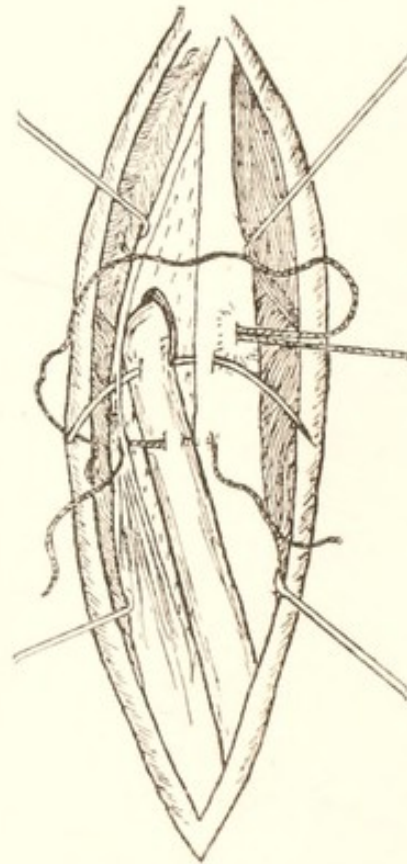


FIG. 15.—Tendon of peroneus longus about to be stitched to the periosteum of the tibia.

distributed; there is, so to say, not enough power to go round. Tendon fixation is then the best operative procedure, for it establishes a firm barrier against drop-foot, and yet allows useful mobility. Tilanus, of Holland, suggested tendon fixation for certain types of flail-foot many years ago, and I am hoping that it will prove increasingly useful in military surgery.

The object of tendon fixation is to utilize the tendons of completely paralysed muscles as accessory ligaments to hold a paralysed foot in a correct position. This can be brought about in an endless variety of ways, and will supply the ingenious surgeon with many interesting and

useful problems for reflection. Personally, after many successful operations, I would recommend this method of treatment to meet the disabilities of paralysis due to injury of the external popliteal.

*An Operation for Tendon Fixation in Drop-foot due to Injury of the External Popliteal Nerve.*

Two small incisions are made along the course of the peroneus longus tendon. The first is placed over the tendon, just before it turns round the outer border of the foot (Fig. 8) on to the sole, and the other about three to four inches above the tip of the external malleolus (Fig. 8).

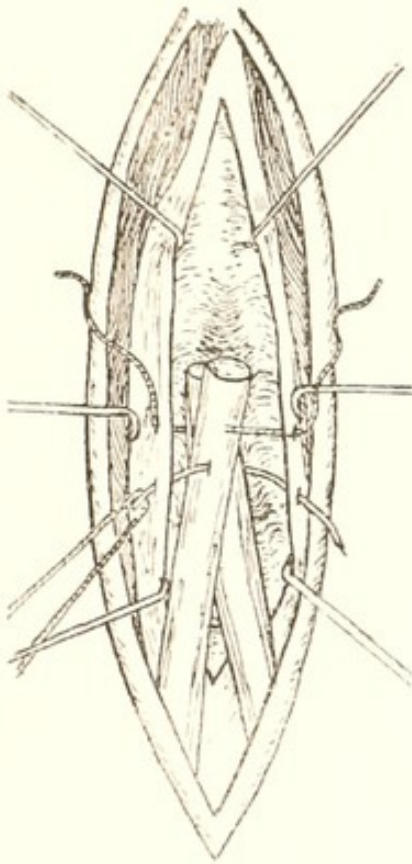


FIG. 16.—Tendons of peroneus longus and tibialis anticus inserted into a groove made on the surface of the tibia, showing the periosteum raised and drawn aside before being sewn in place.

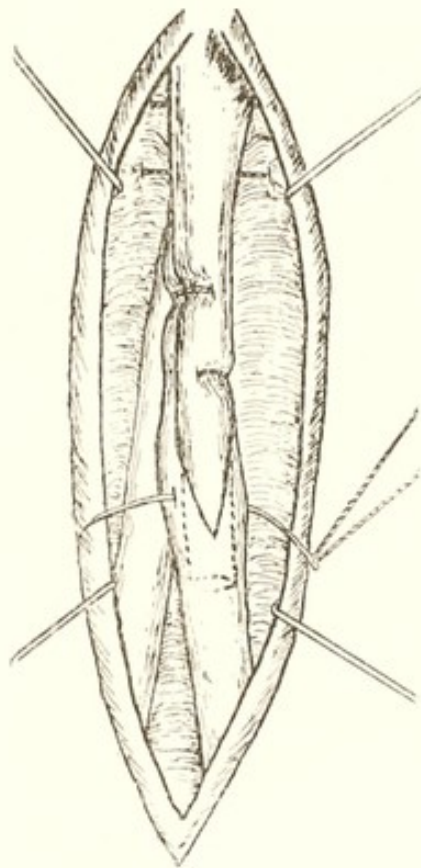


FIG. 17.—Lower divided portions of the tendons of the peroneus longus and tibialis anticus inserted into the tibia. The upper end of the tendon of the tibialis anticus sutured to the lower end below its insertion in the bone.

The tendon is now divided through this upper incision, and the lower freed portion is then pulled out of its sheath through the lower opening while its normal attachment to the sole remains undisturbed (Figs. 8 and 9).

An incision 2 to 3 in. above the tip of the external malleolus is made just external to the anterior border of the tibia, and the divided lower portion of the peroneus longus tendon is passed up from the lower incision to this



new one. In its new course the tendon should pass under the anterior annular ligament (Figs. 10 and 11), but if this cannot be done it may be passed in the deep fascial layer (Fig. 19).

The periosteum is now raised from the anterior aspect of the tibia and a deep groove is made in the bone; the tightly pulled tendon, whose outer surface has previously been roughened, is then laid in the groove and is retained in it by a small nail or it is fixed by strong catgut into fascia. The periosteum is then replaced over it (Figs. 16 and 17).

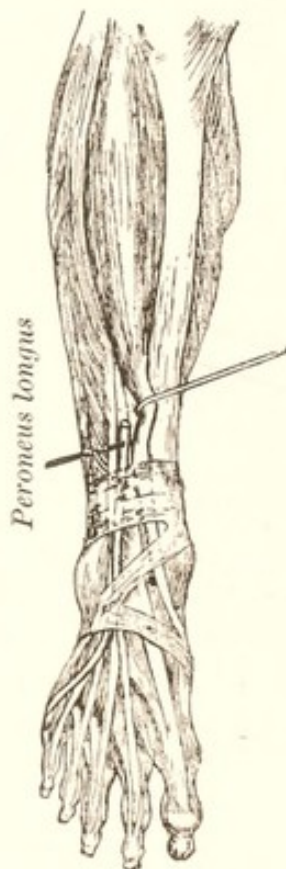


FIG. 18.—Diagram to show the anatomy of the area concerned; the three parts of the annular ligament are shown, the tendon of the tibialis anticus is hooked inwards, the tendon of the peroneus longus has been passed under the annular ligament and brought into contact with the tibia

Another effective method of fixing the tendon is to bore a hole through the anterior border of the tibia and pull the tendon through (Figs. 13, 14, and 15). The free end can then be stitched to periosteum, on the inner side of the tibia, or in some cases it may be more convenient to turn the tendon over the crest of the tibia and stitch it to the tendon before it enters the tunnel. Through this same incision the tendon of the tibialis anticus (Fig. 12) is divided and the upper end of the lower portion inserted beneath the periosteum in front of the tibia, in a manner similar to that first described, by nailing, or through a hole bored in the substance of the bone after the second method.

When this has been done the cut end of the upper part of the tibialis anticus tendon is inserted into the lower part of the tendon distal to its insertion into the tibia (Fig. 17).

The peroneus brevis tendon may then be shortened and inserted into a gutter along the anterior surface of the external malleolus, by another short nail.

If the patient refuses operation he may wear a leather band above the ankle and one round the instep. These leather bands are connected by indiarubber bands sufficiently strong to keep the foot at right angles. The boot can be worn over this.

#### *Injury to Sciatic Trunk.*

If the whole sciatic nerve has been divided high up in the thigh there is total loss of power below the knee and

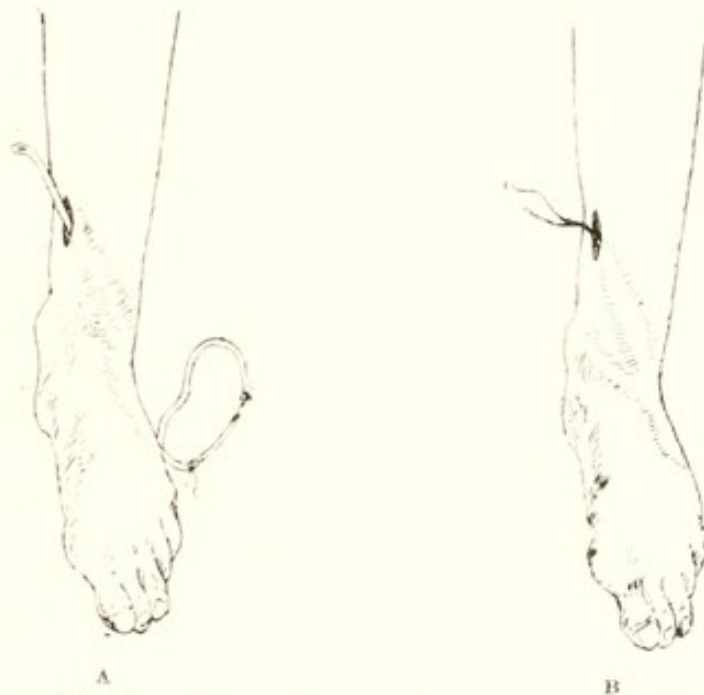

FIG. 19.—Alternative operation in which the tendon of the peroneus longus is pulled through the subcutaneous tissue without regard to the annular ligament. A, First stage. B, Tendon of peroneus longus drawn upwards and inwards.

in certain muscles governing the knee-joint. In such cases the patient can walk quite well in a jointed caliper splint with a filling inside the boot to keep the foot at right angles. Another useful plan is to fit a jointed knee cage with a spring and a right-angled support for the ankle. This really means that we make the paralysed distal part of the leg into a species of artificial limb, and this, in actual practice, has proved much better than any artificial limb that I have ever met with.

The idea of rushing to amputation of a limb merely because the sciatic nerve is destroyed and therefore theoretically the nutrition of the foot must go wrong, is too horrible to be contemplated. Actual experience has proved that, in many cases, the errors of nutrition which ought in theory to occur do not occur, or, at worst, are not nearly so serious as might be expected.

## CONCLUSION.

Surgeons will glean from what has been written that there are many ways in which the disabilities following nerve destruction can be met, and that hardly any case is bad enough to justify a counsel of despair. Our knowledge of what can be done in poliomyelitis will invite us to take a cheerful outlook in traumatic paralyses.

This article is intended not merely to indicate ways in which the ground can be prepared for the operations of nerve suturing, or to point out the value of keeping a paralysed muscle relaxed by opposing the force of gravitation, but to indicate the great and ever-increasing field of usefulness that is opened up by utilizing tendon, whether that of an active or a hopelessly paralysed muscle, for the restoration of movement or the correction of deformity, thereby restoring to a greater or less extent the economic efficiency of an individual who will otherwise sink into the position of a non-productive and dependent member of the community.

## REFERENCES.

- <sup>1</sup> The Annual Oration, Medical Society, May 18th, 1914, on Infantile Paralysis: its Early Treatment and the Surgical Means for the Alleviation of Deformities. <sup>2</sup> BRITISH MEDICAL JOURNAL, December 9th, 1911.

### III. THE SOLDIER'S FOOT AND THE TREATMENT OF COMMON DEFORMITIES OF THE FOOT.

#### PART I.—FLAT-FOOT.

THE foot must be regarded for our present purpose as consisting of two parts : The hinder part, behind the mid-tarsal joint formed by the os calcis and astragalus ; and the fore part, in front of that joint, consisting of the rest of the tarsus, the metatarsus and the toes.

#### *The Three Arches of the Foot.*

The hinder part of the foot is designed to carry the body weight when standing. The os calcis and astragalus are strongly bound together by ligaments, and the astragalus is securely set between the two malleoli at the ankle-joint.

The fore part of the foot is much more mobile, and is designed to give spring to the foot when walking. This spring depends on the efficiency of the small muscles of the foot, on the integrity of the longitudinal and transverse arches, and on the freedom of movement of the toes themselves.

Regarded as a base of support, the foot is a tripod resting on the heel, the head of the first metatarsal bone, and the heads of the fourth and fifth metatarsal bones. Each side of the triangle formed by these three points is arched. The outer side formed by the os calcis, cuboid, and the fourth and fifth metatarsal bones is so slightly arched that practically the whole length of it rests on the ground when standing. This element of the foot is therefore not very susceptible of strain, and need concern us no more.

The inner side is strongly arched ; the arch runs from the heel upwards and forwards to the neck of the astragalus, then downwards, forwards, and *inwards* through the scaphoid, internal cuneiform, and first metatarsal bones to the ball of the great toe. This arch, which varies in height in different individuals, is composed of a number of bones, is very susceptible to strain, and is in consequence

the seat of a number of disabilities which we shall group together as "flat-foot."

The third side of the triangle runs from the head of the first metatarsal bone to the heads of the fourth and fifth metatarsal bones, and forms the front part of the transverse arch of the foot. It must be remembered that this transverse arch extends backward throughout the whole of the forepart of the foot. The cuneiform bones and cuboid bones are arranged in a transverse arch as well as the metatarsal bones.

#### *Deformities and Disabilities of the Foot.*

In considering deformities and disabilities of the foot due value must be given to its various mechanical elements—that is to say, not only to its bony structure but also to the muscles and ligaments which help to maintain its shape.

Looked at in this way we find among the deformities and disabilities of the toes such conditions as hallux rigidus, hallux valgus, and hammer-toe, and we note that the two former in particular are frequently associated with some degree of flat-foot.

Impairment of the transverse arch is specially apt to be associated with the painful condition known as metatarsalgia.

Impairments of the longitudinal arch are associated with a train of symptoms which are found in the various degrees of weak foot, everted foot, and flat-foot.

All these types of derangement of the mechanical elements of the foot and the resulting disabilities depend on strains about the complicated series of joints in the fore part of the foot.

In the hind part of the foot the disabilities are fewer. They are mainly connected with painful conditions of the heel, due to such conditions as strain of the insertion of the tendo Achillis, or periostitis of the os calcis, due to trauma or sepsis.

When a clear idea of these several disabilities and of the measures suitable for the prevention or treatment of each has been obtained, it will be more easy to grasp and understand the various disabilities of the foot to which the soldier is liable, always remembering that two or more types often occur simultaneously, and that all must be appropriately treated.

#### *Flat-foot.*

The term "flat-foot" may be taken as a generic term to include all degrees of strain of the longitudinal arch of the foot. To these various conditions different names have been given, which need not detain us here. The point to be understood is that all degrees occur, from slight strain of the ligaments and tendons by which the arch is maintained to complete descent of the arch with osseous deformity, obvious to the most casual observer.

The essential fact in the deformity is abduction and eversion of the fore part of the foot (Fig. 1). If it commences as a sudden acute condition, it is associated with strain of the inferior calcaneo-scaphoid ligament; to this is due the tenderness elicited on pressure on this ligament just below the tubercle of the scaphoid. This tenderness is characteristic. Pain in this situation is often most acute in patients who have naturally a very high arch. When such an arch begins to give way the strain on the "spring" ligament is great and the pain correspondingly severe, but the foot is not physically flat, for the arch may still be higher than is normal in most people.

As the foot becomes more strained under continued exercise, the bones of the tarsus begin to descend and pain is complained of across the dorsum of the foot.

Finally, when the deformity becomes still greater, there may be pain on the outer side of the os calcis below the tip of the external malleolus. This is probably to be

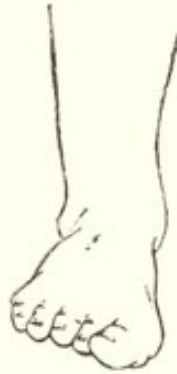

FIG. 1. — Flat everted foot.

attributed to bruising of the periosteum due to the os calcis impinging on the malleolus; in some cases an adventitious bursa is ultimately produced in this situation.

#### *Acute Flat-foot.*

All the above symptoms, and also actual descent of the arch with pronounced abduction and eversion of the foot at the mid-tarsal joint, may come on with great rapidity and then be associated with very severe pain, so that the patient cannot walk and can hardly bear to have the foot touched. Such a condition may fairly be described as acute flat-foot. It occurs in its typical form in people who are in poor physical condition, as, for instance, after an attack of influenza, and return too soon to work which involves much standing and lifting of weights—for example, hospital nurses. It occurs in exactly the same way in the recruit. Take, for example, the clerk who has taken little exercise and who has been in the habit of wearing boots in which there is no room for movement of the toes and bones of the fore part of the foot; all the muscles and ligaments controlling and supporting the

arches of the foot are weak and out of condition from want of use; under the strain of hard drill they give way.

#### *Treatment of Acute Flat-foot.*

The treatment of such a case falls into three stages.

*First Stage.*—If the foot is acutely painful the patient should be put to bed and the feet gently massaged for two or three days till the acute tenderness passes off. During this time he must never be allowed to set foot to the ground, for the weight of the body would again strain the ligaments.

*Second Stage.*—As soon as the acute tenderness has passed off, the foot should be adducted and inverted so as completely to restore the arch, and the foot kept continuously in this position to allow stretched ligaments to shorten and become adapted to the correct position. Mere rest in bed is not enough, for then nothing is done to restore the proper shape of the arches, adaptation takes place in the flat-foot position, and the patient is left with a real flat-foot. It is often best to mould the foot into correct position and fix it in plaster-of-Paris for about ten days to allow the strained ligaments to recover completely.

*Third Stage.*—When the plaster is removed, after, say, ten days, the patient's foot is exercised—first of all by massage and exercise, particularly movements of the toes and inversion movements, never eversion movements. These inversion movements are intended to strengthen the muscles controlling the arch.

#### *Boots.*

The patient is allowed up in specially altered boots. The boots should grip comfortably round the ankle and heel, but the whole fore part of the boot should be roomy to allow free play of the small muscles inside the boot.

Pointed toes are very harmful, as they abduct the fore part of the foot and help to produce the condition of flat-foot. The inner side of the boot should be straight, so that when the two boots are placed side by side the inner sides are parallel right forward to the great toe. This is not the conventional boot of the shoemaker, but it is the correct boot for a strong foot.

The present army boot is not perfect, but it is much better than it was some years ago.

Having seen that the boots are of suitable shape, they should be sent to the shoemaker to have the heels "crooked" on the inner side. By this is meant that the heel of the boot is made a third of an inch higher on the inner side, and tapering gradually to its outer side, so that the inner side of the heel is a third of an inch higher than the outer side. In addition, the length of the heel should be extended forwards by three-quarters of an inch on the inner side, and the sole should be raised one-

third of an inch by a patch on the inner side of the sole just below the toe-joint (Fig. 2).

The patient must never put foot to the ground without an altered boot or shoe on, otherwise he will unwittingly let his arch descend and so inflict a fresh strain on the ligaments.

The man should then be instructed to walk with feet parallel, not with the toes turned out. The altered heel helps the patient to keep his toe turned in. Exercises should be graduated till the man is fit for full duty.

A bad case of *acute flat-foot* should be fit for light duty in three weeks, and for full duty with the *heels of his boots raised on the inner side* in six weeks to two months.

It is really a question whether the army authorities ought not to issue all boots with heels raised on the inner side, as this is a great relief to the foot on a long march and increases the man's weight-carrying and lasting power.

Certainly all recruits with weak feet should be started off with crooked heels on the boots until the muscles of

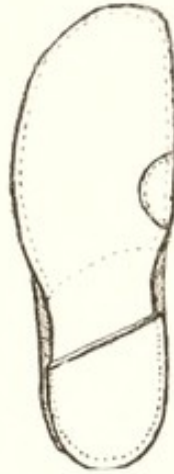

FIG. 2.—Boot with straight inner border, crooked and lengthened heel, patch to thicken sole.

their feet get into training. They should also be taught to walk with their feet parallel. If this were done the feet would grow stronger rather than weaker, and considerably fewer men would require to be taken off duty.

#### *Traumatic Flat-foot.*

Flat-foot in every respect similar to that just described as *acute flat-foot* may arise from injury. For example, when the wheel of a trap runs over a man's foot and strains all the ligaments.

#### *Flat-foot from Periarthritis.*

Similar mechanical conditions arise in gonorrhoeal periarthritis when all the ligaments are sodden with exudate, become soft, and stretch. The same is true when the infection is of an ordinary septic character, for if the man puts weight on his foot before the arch is restored to its strength he will get a flat-foot. He can,



however, walk with safety in a boot with the heel well crooked almost as soon as the disappearance of pain allows him to put his foot to the ground.

#### *Rigid Flat-foot.*

These cases lead us naturally to the rigid form of flat-foot which results from neglect in the acuter stages, whether the cause of the sudden yielding of the ligaments be overstrain due to unaccustomed exertion in walking, to injury, or to weakening of the ligaments by the products of infective agents.

The foot, therefore, should be maintained in the inverted and adducted position during recovery from the acuter conditions, and when the patient begins to

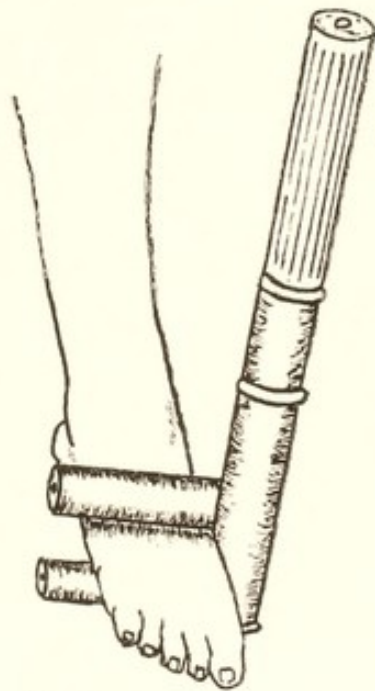


FIG. 3 A.—Thomas's wrench applied to invert everted foot.

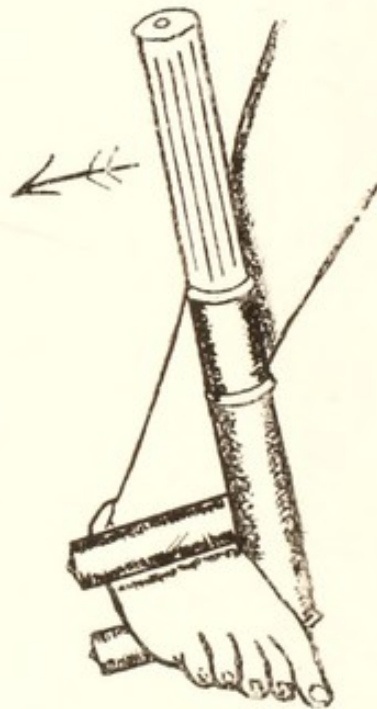


FIG. 3 B.—Showing the position of the foot and direction of force at end of correction to inversion.

walk the body weight should be deviated from the inner to the outer side (Fig. 2). If this important routine should be neglected the recovery of ligaments will occur in a flat-footed position with stiffness in all the joints. The patient in that case cannot stand on the outer edge of the foot or turn it into an arched shape.

*Treatment* is very simple, but must be thorough. The foot should be wrenched so as to break down all adhesions and make it thoroughly pliable (Fig. 3). The foot is by this means converted into an acute traumatic flat-foot, and it must undergo the course of treatment already described for that condition. It should be moulded into the correct position, and plaster-of-Paris applied. After two or three weeks of such rest, to allow recovery from the trauma, graduated exercise may be taken in boots so altered as to

deviate body weight from the inner to outer side of tarsus. An outside iron is often found a great assistance in maintaining the correct position of the foot during walking (Fig. 4).

*Osseous Flat-foot.*

A real stiff flat-foot which has been neglected for years becomes an "osseous flat-foot"—that is to say, changes occur in the shapes of the bones to adapt them to the erroneous position. Though something can be done to improve such cases, they cannot always be made fit to be soldiers; the surgeon must, however, be sure that he is

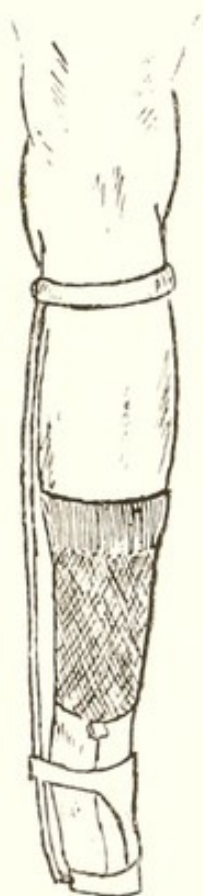


FIG. 4.—Outside iron in addition to crooked long heel and piece to sole.

dealing with real osseous change and not merely with a flat-foot which is rigid owing to ligamentous contractures and adhesions.

*Flat-foot due to Spasm of the Peronei.*

I described this condition many years ago (Fig. 5), and stated that it was by no means uncommon. It may be found in any out-patient department if looked for, and I have operated upon as many as 150 cases in one year. It occurs usually after puberty and in early adolescence; it is common among the robust, not only among the weakly, and is not associated with the temperament known as neurotic. I will describe a typical case. A young man

of 18 limbs with a springless gait into the out-patient room. He walks with feet practically rigid and with toes pointing out. They are both everted, and the inner border over the region of the scaphoid appears thickened and even angular. Both the character of the walk and the appearance of the feet might lead to the diagnosis that osseous changes were advanced. On being questioned the patient may give a history of injury such as a fall on the feet;

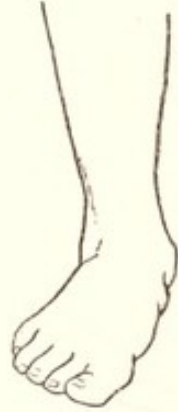

FIG. 5.—Peroneal spasm producing a flat everted foot.

usually he cannot account for the origin of his trouble. The pain is often acute, the feet may perspire abnormally, and the patient may not be able to walk more than a short distance. Relief is experienced on removal of his boots; if he is asked to invert his foot he cannot do it, and when he attempts to do so the peronei become rigid. The surgeon when he examines the foot manually finds there is pain on pressure over the deltoid ligament, over the

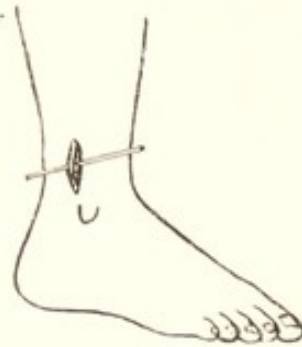


FIG. 6.—Exposure of tendons of peronei preparatory to exsection of about  $\frac{3}{4}$  in.

scaphoid, and over the tip of the external malleolus, where it impinges upon the os calcis, and tenderness over the peronei along the outer border of the foot. If the surgeon gently attempts to invert the ankle much pain is experienced and the peronei, so to speak, immediately place themselves on guard and strongly resist the surgeon's efforts. Now while the surgeon has firm hold of the foot, let him engage the patient in conversation, at the same

time gently press in the direction of inversion. Then at the psychological moment, while the peronei are quiescent, very suddenly and very forcibly let the foot be inverted and held there. It is a very painful movement, but the character and contour of the foot is completely changed. It is no longer rigid, osseous changes are obviously absent, and the general appearance of the foot is almost normal. The moment the surgeon releases his hold, the old rigidity and deformity return.

For this condition mechanical measures are of no avail. The patient must be anaesthetized to relax all spasm, and about three-quarters of an inch of each peroneus should be removed about an inch and a half above the malleolus (Fig. 6). The foot must then be fixed for about three weeks, well inverted and adducted at the mid-tarsal joint, and later the ordinary treatment for flat-foot. My old house-surgeon, Mr. Naughten Dunn, secured equally good results by pinching with a pair of forceps the nerve as it enters to supply the peronei. Simple tenotomy of the peronei is not sufficiently drastic to prevent recurrence of deformity.

#### *Diagnosis.*

It is not an easy matter to lay down rules for a hard and fast differential diagnosis between these types of rigid feet, but the following considerations will help.

An osseous flat-foot which has become adapted to its new position is usually strong and painless.

A flat-foot rigid from adhesions and shortened ligaments is still susceptible to strain, and is liable to become painful after unusual exercise.

The type due to a spasmodic contraction of the peronei is characterized by pain, and the spasm may be overcome in the manner I have just indicated.

In the two last varieties, after the deformity has been over-corrected for a time, energetic massage and a correct deviation of body weight are essential elements in bringing about a cure. The osseous type, once the bones have completely dropped, may not only be painless, but may be strong enough to bear the strain of long marches. Wounded soldiers may constantly be met with whose feet are very flat, whose mid-tarsal joints are fixed, but who have undergone several months of hard training without a complaint. If in addition to these osseous changes the power of inversion of the foot is lost or the peronei are in spasm surgical attention is urgently called for.

The flat-foot for clinical purposes may be divided into two classes.

- (a) The foot which the patient can invert.
- (b) The foot which he cannot invert.

The second class will not respond to any mechanical treatment, such as a plate or alteration of the boot. It will not even suffer correction by means of a bandage to an outside iron from knee to heel. An operation, or

forcible manipulation and fixation under an anaesthetic, are essential preliminaries to the simpler mechanical methods.

The first class will never require an operation.

This simple clinical division should be helpful to the military surgeon.

*Subacute Flat-foot (Ordinary Flat-foot).*

The stage of flat-foot most commonly seen is neither an acutely painful foot too tender to be handled, nor a rigid flat-foot, but an intermediate stage, which may be called subacute.

The patient's feet give him little trouble in ordinary life, but a long walk makes them ache round the instep. When he goes to bed after a hard day's exercise his feet are apt to get stiff. Next morning they are stiff and painful when he gets up, but as he moves about this passes off; but later in the day, especially if he has to do a lot of standing and walking, the feet again become very painful.

*Diagnosis.*—This is made by considering the patient's history and by finding distinct tenderness on pressure below the tuberosity of the scaphoid; there may or may not be pain in other localities. Finally, the patient can voluntarily stand on the outer edge of his foot and can crook his foot into the arched position. This last point is very important, for it means that the patient will recover if the heels of his boots are crooked so as to deviate body weight on to the outer side of the foot.

The case should therefore at once be put through the last stage of treatment described under acute flat-foot—namely, graduated exercises—and he need not be taken off duty for more than a day or two while his boots are being altered. "Contrast baths" of hot and cold water alternately, to stimulate the circulation of the foot, are a great relief to the patient, especially at night, when his feet may be a little sore and swollen after having been walking about all day.

*Conclusion.*

I have purposely avoided all mention of tiptoe exercise. These exercises are excellent, but they will not cure a flat-foot if the patient is allowed to come down in the flat-footed position between the period of exercises.

If the principle of deviation of body weight on to the outer edge be loyally adhered to every ordinary case will recover, even without special tiptoe exercise. Loyal adherence to the principle stated means that the patient never sets foot to the ground except in a properly crooked boot, shoe, or slipper. Even in his bath he must be careful to stand on the outer edge of the foot. The whole idea of treatment is to ensure that uninterrupted adaptive shortening of stretched structures shall take place.

Massage, tiptoe exercises, electric stimulation of muscles all help to hasten the recovery, but a few

minutes' careless walking in stocking soles will undo all benefit from other treatment by again stretching recovering structures.

Frequently the high arched foot is the most troublesome type when the tendons are strained and the ligaments begin to give. The strain upon the astragaloscaphoid joint in this type is, for obvious mechanical reasons, great, and the progress of the affection is often marked by a prominence about the scaphoid due to pressure osteitis.

---

## PART II.—CLAW-FOOT.

One of the surprises the military surgeon meets is the number of men with claw-feet who have been passed into the army; but still more surprising is the fact that many such cases have found their way to the front after the vigorous initial training which the recruit undergoes. Sooner or later, however, these men gravitate to hospital, and very few of them return to the ranks as efficient. A patient with this condition of the foot is quite unfit for military service, and should never be accepted as a recruit. The affection usually begins in early life, and is often not recognized until it has reached what I have termed its second stage; until then serious trouble hardly ever arises.

The etiology of "claw" or "hollow" foot is still uncertain. It is very often associated with a slight contraction of the Achilles tendon in childhood, and in some cases is due to a transitory paralysis of the extensor group of muscles. The short boot also stands in some causal relation to it. The whole question is, however, too vexed to be discussed here.

Clinically the condition presents five degrees or stages. The progress of the development of the deformity from one degree to another, though often continuous, is frequently arrested in one of the early stages; or perhaps the facts may be better stated by saying that progress from the first two stages to the later more severe stages is very slow, and sometimes does not take place.

### 1. *The First Degree of Claw-foot.*

The first degree occurs in childhood, and is easily overlooked. There is no visible increase in the height of the arch—in fact, the foot looks normal. The complaint made is that the child is clumsy, especially when running, and frequently stumbles or trips without obvious cause.

It will be found in such a case that the foot cannot be dorsiflexed beyond a right angle with the leg, and that there is commencing contraction of the Achilles tendon and the structures in the sole. The child's tendency to stumble is thus explained, for the fore part of his foot gets in his way as he tries to run.

The treatment in this stage is obviously to stretch the Achilles tendon and the plantar structures and so restore the power of dorsiflexion of the foot at the ankle. This can usually be effected by manipulation, after which the boot in which the patient walks should have no heel to it, but a bar half an inch thick placed transversely under the tread. In some cases it may be necessary to lengthen the Achilles tendon. This is best done subcutaneously by the following procedure (Fig. 1). The tenotome is entered on one side near the heel, and one-half only of the tendon is divided. The tenotome is next entered one and a half to two inches further up on the other side, and the other half of the tendon is divided. Now, by forcible dorsiflexion of the foot, the two halves of the tendon are made to slide on one another until the required lengthening is obtained. A

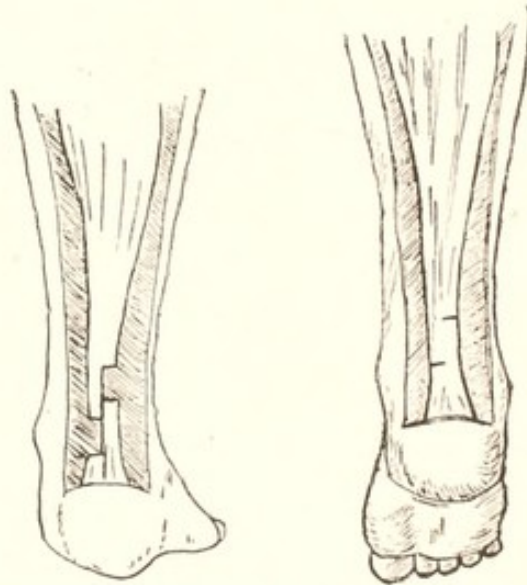


FIG. 1.—Anatomical diagram to illustrate the two stages of the operation for the lengthening of the Achilles tendon by subcutaneous tenotomy.

rectangular splint is then applied so as to keep the Achilles tendon at rest in the corrected position and to maintain tension on the sole of the foot. This method is always preferable to the other method of complete division of the tendon at one level as the period of convalescence is shortened, and functional power in the calf muscles is more speedily restored.

## 2. Degree of Claw-foot.

In the second degree there is definite contraction of the plantar fascia, and the characteristic deformity of the foot is easily observed (Fig. 2). The fore part of the foot is dropped—that is to say, there is flexion at the mid-tarsal joint or exaggeration of the arch of the foot. At the same time the great toe is dorsiflexed at the metatarsophalangeal joint, and the tendon of the extensor proprius

hallucis stands out prominently. Further, if the surgeon places his finger under the ball of the great toe he easily lifts it, and the toe automatically straightens out (Fig. 3). The other toes do not present a similar deformity at this stage, but the Achilles tendon is shortened. Even in this condition the patient may not complain of pain or disability; especially is this the case in the very young. In older folk, such as the recruit, complaints may begin whenever long marches are repeated. The men have to fall out because of pain and fatigue. They have frequently been suspected unjustly, for even at this stage there are no very obvious objective signs. The arch of the foot is not collapsed, but, on the contrary, slightly exaggerated. But if the surgeon makes a careful examination he will note tenderness beneath the metatarso-phalangeal range, and when the patient is asked to extend his toes the big toe responds to a disproportionate extent.

Treatment at this stage must be drastic. If the patient is to be rendered able to get about with ease and comfort, nothing less than operation will suffice. A radical attack

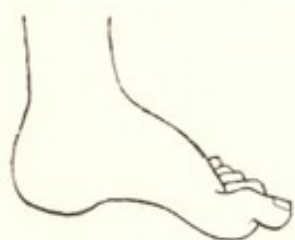

FIG. 2. — Claw-foot, second degree.

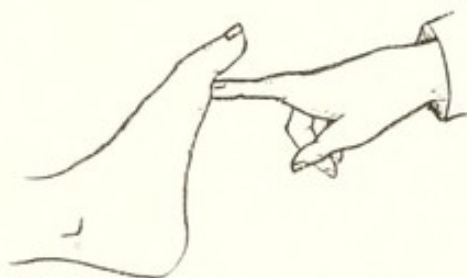

FIG. 3. — Claw-foot, second degree. The surgeon's finger easily replaces the dropped head of the metatarsal bone of the great toe; a case in this stage is suitable for tendon transplantation.

may save the situation, and in a few weeks the soldier may return to duty. The operation consists in dividing and stretching the plantar fascia and then in making an incision over the tendon of the extensor of the great toe (*extensor proprius hallucis*), and the tendon is severed from its attachment. Two holes are drilled close to each other behind the metatarsal head, forming a tunnel through which the tendon is drawn by means of a catgut ligature (Fig. 4). The tendon is then pulled so as to raise the dropped metatarsal head into position (Fig. 5), and its lower end is stitched to its upper part just above its entrance into the bone (Fig. 6). This completes the operation, but the foot must be firmly bandaged down to a metal sole plate with a thick roll of wool placed transversely just behind the heads of the metatarsals so as to flatten the arch as much as possible. The whole foot is then fixed in a shoe splint, which is bent to rather less than a right angle. After the stitches are taken out, the foot is put up in plaster-of-Paris in the fully corrected position, and the patient is allowed to walk in this for from three to six



weeks. He should then for a few weeks wear boots with no heels, and a bar across the sole beneath the heads of the metatarsal bones so as to keep the foot dorsiflexed when walking.

### 3. Degree of Claw-foot.

In the third degree the characteristic deformity is more pronounced (Fig. 7); it is no longer possible with the finger to lift the head of the first metatarsal into normal line owing to the increased contraction of plantar structures; the operation just described for the second degree would therefore be useless. Further, the other toes also

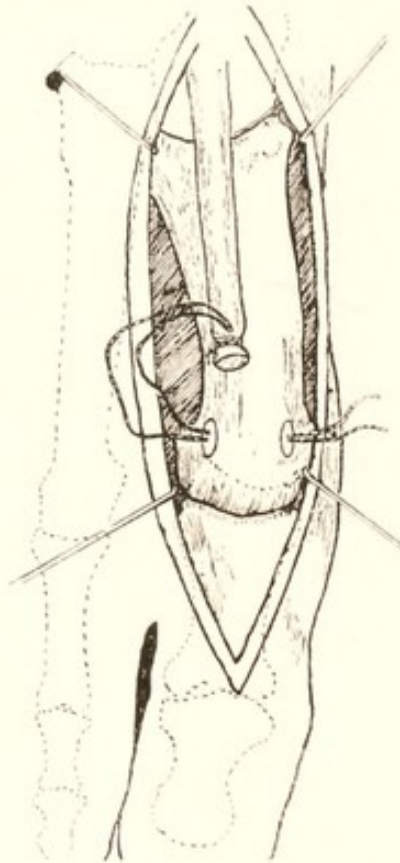


FIG 4.—Claw-foot, second degree. Operation by transplantation of tendon of the extensor of the great toe. The diagram shows how the tendon of the extensor proprius hallucis is introduced through the tunnel above the head of the metatarsal bone.

are now dorsiflexed, and the characteristic deformity which at first was visible only in the great toe is now shared by all the toes. The movements of the toes are limited, and they are beginning to become rigid in the position of deformity. Corns and callosities are formed across the ball of the foot owing to the increased pressure of body weight, for in this stage the patient can hardly get his heel to the ground at all. The Achilles tendon and plantar fascia are still more contracted than in the first two stages.

*Operative treatment* has now to be carried out in two stages.

A. The first stage includes division of the plantar fascia and severe wrenching to flatten the foot as far as possible, but as at this stage all the metatarsal bones are very obliquely placed it is necessary also to remove bone. The

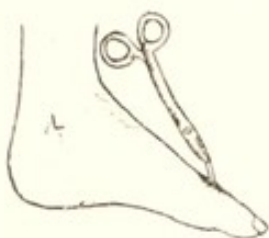


FIG. 5.—Claw-foot, second degree. Operation showing the tendon of the extensor proprius hallucis passed through the head of the metatarsal bone of the great toe and pulled before fixing.

operation consists in removing through separate incisions on the dorsum of the foot a half to one inch from the shafts of the first, second, third, and fourth metatarsal bones toward the bases without opening the joints. The

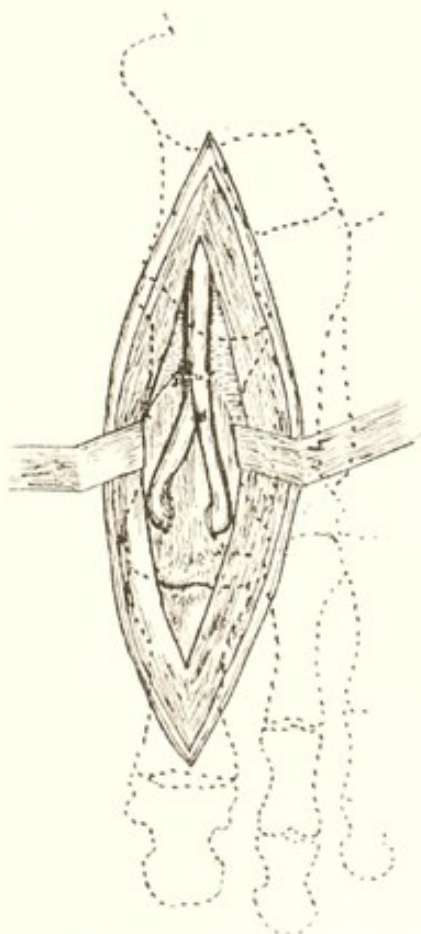


FIG. 6.—Claw-foot. Operation for second degree, showing how the tendon of the extensor proprius hallucis, after traversing the tunnel in the bone, is attached to itself and secured.

fifth metatarsal is retained intact, as it forms a useful splint for the rest of the bones. Removal of the head of the metatarsal should be avoided. The extensor and flexor tendons should be divided.

B. As it is impossible to correct all the cavus deformity in this way, at a later stage the Achilles tendon is divided by the sliding operation, and the foot wrenched into dorsiflexion. The after-treatment and alteration in boots follow the same lines as those already prescribed.

#### 4. Fourth Degree of Claw-foot.

In the fourth stage, in addition to all the deformities already described the foot acquires a well-marked varus deformity (Fig. 8). Callosities are even more tender, and walking is painful and difficult.

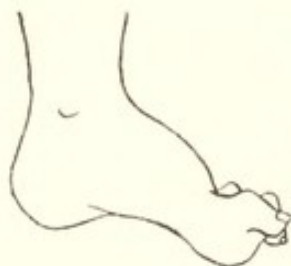

FIG. 7.—Claw-foot, third degree.

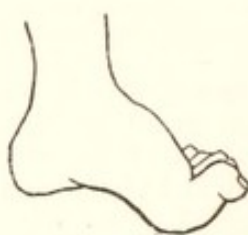

FIG. 8.—Claw-foot, fourth degree.

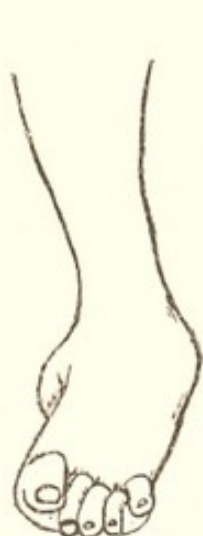

FIG. 9.—Claw-foot, fifth degree.

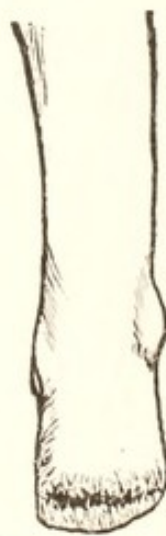

FIG. 10.—Claw-foot, fifth degree. Front view after operation recommended in the text. The toes and the heads of the metatarsal bones, as well as the astragalus, have been removed.

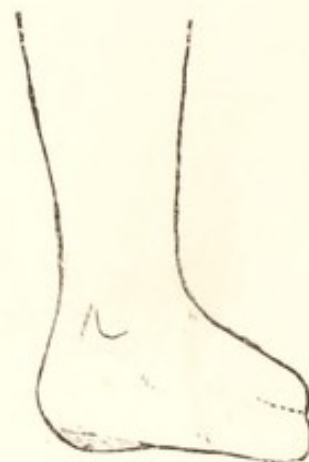

FIG. 11.—Claw-foot, fifth degree. Side view after same operation.

*Treatment* has to be still more drastic. After dividing and wrenching all tense structures so as to mould the foot towards the correct position, it will be necessary to divide also the flexor and extensor tendons, and then remove the astragalus. This releases the remaining tension on the sole, and the foot can be moulded into shape, so as eventually to carry body weight with comfort to the patient.

### 5. *Fifth Degree of Claw-foot.*

The last stage of claw-foot leaves the patient in a pitiable condition. The toes are blue and contracted, the callosities exquisitely tender. The deformity is that of equinovarus (Fig. 9). The patient longs for amputation. This should never be done, and I would recommend as a substitute an operation I have designed and practised with success on many occasions.

In such a case the astragalus should first be removed, and then a flap incision made along the base of the toes on the sole of the foot. A flap should also be raised from the dorsum of the foot, and the heads of the metatarsal bones exposed. The toes and the heads of the metatarsal bones are removed. The result of this operation is excellent (Figs. 10 and 11).

Although the various operative procedures I have described as necessary in the treatment of the later stages of "claw-foot" do not result in producing an efficient soldier, there is every reason that they should be known. The military surgeon has to consider the usefulness of citizens when the war is ended, and operations such as I have described, with appropriate variation, will be needed for many types of contracted feet following injuries received from the enemy.

### HALLUX RIGIDUS, HALLUX VALGUS, AND METATARSALGIA.

The conditions known as hallux rigidus, hallux valgus, and metatarsalgia, or Morton's disease, are all frequently associated with flat-foot; they all have some features in common both as regards the nature of the pain experienced and the alterations required in the boot to relieve mild cases and to complete the after-treatment in cases which have required operation.

### THE MARCHING BOOT.

#### *Mobility of the Toe.*

This is a convenient point at which to make a digression to discuss the importance of correct position and free mobility of the great toe in marching.

In young children of all races the great toe is directed slightly inwards towards the middle line of the body, in line with the anterior part of the inner longitudinal arch of the foot, to the structure of which attention was directed in the article on flat-foot. (See pages 27-37.) In races who habitually go barefoot this position of the great toe is preserved in adult life. In civilized races—those, at least, who wear boots—the toes are often cramped into boots of unsuitable shape, so that the small muscles of the foot suffer atrophy from disuse, and the power to spread the great toe inwards in walking is much impaired. In a strong foot which has not been deformed by wearing pointed boots the great toe is spread inwards

by the action of the abductor hallucis when balancing on one foot, when the weight of the body is on the fore part of the foot in walking, and still more so when carrying a pack on the shoulders.

*Qualities of a Good Marching Boot.*

A good marching boot should therefore leave the foot free to adapt itself to altering conditions of balance and strain.

*First.* The boot should fit comfortably and closely round the heel and ankle so as to avoid lifting of the heel in the boot, which results in chafing, ending in a blister of the heel.

*Second.* To save the arch from giving way and to avoid flat-foot the heel of the boot should be slightly higher on the inner side than on the outer. (See page 33.)

*Third.* The inner side of the boot should be straight right up to the tip of the big toe—that is to say, the inner sides of the two boots should be parallel to each other all the way along to the great toe. There should be no trace of pointedness, for pointedness tends to produce hallux valgus, and helps to cause flat-foot.

*Fourth.* The sole of the boot inside should be as broad as the foot with the weight of the body on it. In the case of a soldier it should be as broad as the foot is when carrying the weight of the soldier in full marching order—that is to say, the weight of the soldier himself, his pack, and all his accoutrements.

*Fifth.* The upper of the boot should not compress the fore part of the foot in any way. The toecap should be stiff and deep enough to clear the toes and allow free movement inside the boot. This stiffening should run back on the inner side of the boot to a point behind the metatarso-phalangeal joint of the great toe.

*Sixth.* The boot should be long enough to allow the foot to extend to its full length when the soldier is carrying his pack and all his accoutrements.

These last points, dealing with freedom of movement of the fore part of the foot, are essential to the full development of the small muscles of the foot on which the soldier's endurance and marching powers depend to so large an extent.

Corns do not develop in a foot encased in a boot which allows free play to the fore part of the foot. The regimental chiropodist is a most valuable asset, but his existence is, *ipso facto*, a confession that the fit of the men's boots is not all it might and ought to be. The man should not be allowed to judge of the tightness of his boot when his foot is cool. On the contrary, boots should be served out when men have come in from a long route march, and their feet are engorged with blood, and therefore at their largest. If this were done, interference with the circulation of the foot by the boot would less often occur. When a foot swells after a march, the swelling is practically all in the fore part, not round the

heel. To serve out boots, therefore, after a route march would not prevent a man from choosing a pair which fitted properly round the heel and ankle.

The present army boot is a great improvement on the boot served out at the time of the South African war, but it is still lacking in two points—namely, the straight inner side and the clear free stiffened arch in the upper of the fore part.

#### HALLUX RIGIDUS.

Hallux rigidus (Fig. 12) is a condition characterized by limitation of the power to dorsiflex the great toe at the metatarso-phalangeal joint.

If we remember that in straining on tip-toe or in stepping off with the foot in marching this joint must be dorsiflexed, it is evident that any limitation of the movement of dorsiflexion must, in the course of a long or hard march, result in straining the joint so that it becomes painful and inflamed.

As hallux rigidus and hallux valgus are both disorders of the same joint and are often intimately connected, the



FIG. 12.—Hallux rigidus.

rigid toe may lead on to valgus deformity and a hallux valgus may become rigid. There is no essential difference in the pathological condition of the joint, but only in the direction of the deformity associated with it.

#### *Treatment.*

The treatment of hallux rigidus must be to restore the power of dorsiflexion of the great toe at the metatarso-phalangeal joint.

In the early stages, when the tenderness and inflammation either about the joint or in the joint has not resulted in osseous changes, palliative measures may still lead to recovery.

First the joint must be relieved of strain, so that the inflammation may be allayed. This can be brought about by arranging a bar like a football bar fully one-third of an inch thick and about an inch broad placed on the boot *behind* the head of the metatarsal bone. This causes the body weight to be borne on the neck of the metatarsal rather than on the tender joint, so assuring rest to the joint. As soon as the inflammatory tenderness becomes less the patient finds that the power to dorsiflex the toe

begins to return. This is the moment to begin massage, movement, and hot and cold contrast bathing in order to hurry up the processes of repair.

In more advanced cases, and in cases resulting directly from trauma—as, for instance, dropping a weight on the joint or violently “stubbing” the toe, osseous changes due to formative periostitis occur round the joint. There may be lipping of the base of the phalanx, and usually some nodular thickening of the head of the metatarsal, especially in its upper aspect. This osseous outgrowth forms a mechanical block, preventing hyperextension. The impact of the bones on each other maintains the periostitis, and the condition gets progressively worse. Palliative measures may enable a civilian to go about his business with some degree of comfort, but he cannot do a day's shooting, and palliative measures are of no use for a man who must march.

Operation alone will remove the obstruction to movement and give permanent relief.

The operation follows exactly the lines to be described below for hallux valgus, and need not be described here.

#### HALLUX VALGUS.

Hallux valgus (Fig. 13) is a deformity of the first metatarso-phalangeal joint, the essential feature of which is that the great toe is deflected outwards, and in extreme cases may lie over or under the second toe.

One consequence of this position of deformity is that the head of the metatarsal and the base of the proximal phalanx form an undue angular prominence on the inner border of the foot. As a result of chafing and pressure by the boot a bursa, or bunion, forms over the thinned inner part of the capsule of the joint. It may communicate with the synovial cavity.

The continued pressure and friction causes the skin over the bursa to become indurated and horny, and this greatly adds to the pain and discomfort suffered by the patient.

Frequently suppurative inflammation occurs in the bursa (septic bursitis); this may be followed by septic cellulitis with inflammatory thickening of the tissues round the joint, or, in cases in which the bursa communicates with the joint cavity, it may lead directly to septic arthritis.

It has been a surprise to many surgeons that soldiers have been able to go through their training and even to serve in France with pronounced hallux valgus deformity. The reason is that the disability is not due merely to the visible deformity but to the addition of the following three conditions:

1. Inflammation of the bursa (bunion).
2. Traumatic arthritis, of the same type as the arthritis in cases of hallux rigidus.
3. Tenderness due to pressure on digital nerves in every respect similar to the tenderness in a classical case of metatarsalgia or Morton's disease.

Of these three causes of disability bursitis is the most common; the dangers of septic bursitis communicating with the joint have already been noted.

Arthritis is much more rare, and is usually of the sub-acute type common in cases of hallux rigidus without the valgoid deformity. It is diagnosed by tenderness and pain on any movement of the joint, even gentle attempts at passive rotation of the toe.

The third variety, comparable to Morton's disease, is marked by acute pain on oblique pressure on the joint between the finger and thumb, and is due to excessive sensitiveness of the digital nerves and adjacent tissues outside the joint. It is not, as a rule, marked by any

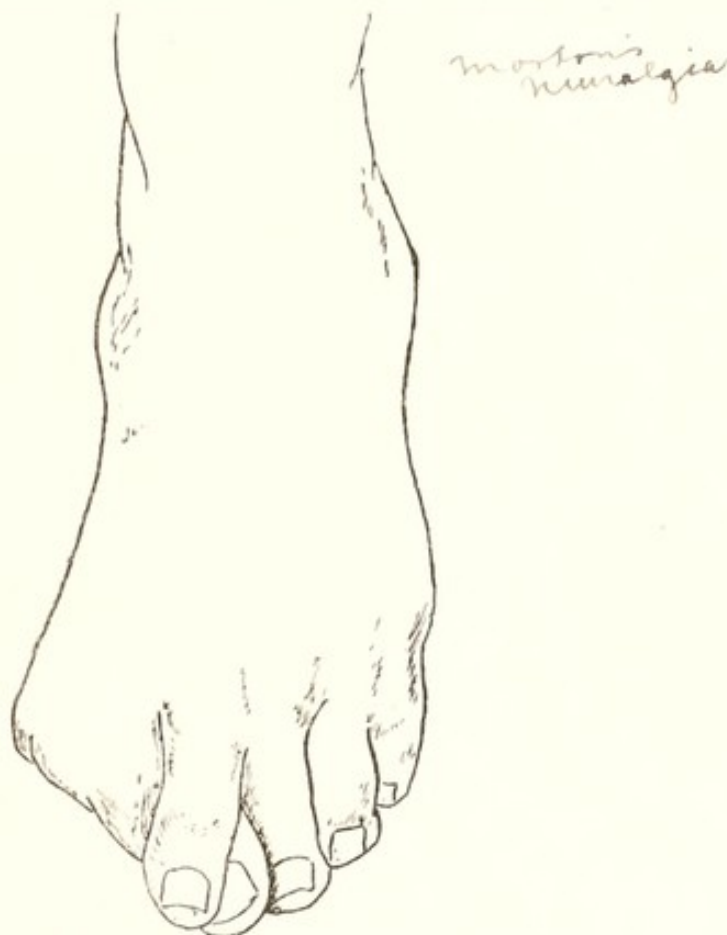


FIG. 13.—Hallux valgus.

objective signs other than the valgoid deformity, and in cases of hallux rigidus of this variety there is no visible deformity—only tenderness on pressure on the joint.

It is difficult to make a sharp division between hallux rigidus and hallux valgus. The same types of pain and disability occur in both. It may, however, be said that with a distinct valgoid deformity it is comparatively rare to find rigidity, but that in cases of painful great toe without valgoid deformity—that is, in cases classed as hallux rigidus—arthritis and the resulting rigidity are much more common. Hence the difference in descriptive terminology—but to understand the conditions properly they should be taken together.



### Treatment

In mild cases palliative measures may suffice. First, the weight of the body should be taken off the joint by putting a bar—like a football bar—across the sole of the boot behind the head of the metatarsal. If the boots are specially made, this is worked into the thickness of the sole with a hollow in the sole for the great toe joint. The bar on the sole will, however, keep a man on his feet who would otherwise be disabled by pain in the great toe joint. The boot should, of course, be straight on the inner side, and the upper should spring clear up, leaving room for the large head of the first metatarsal—a feature unfortunately absent from the regulation boot. If the boots are roomy

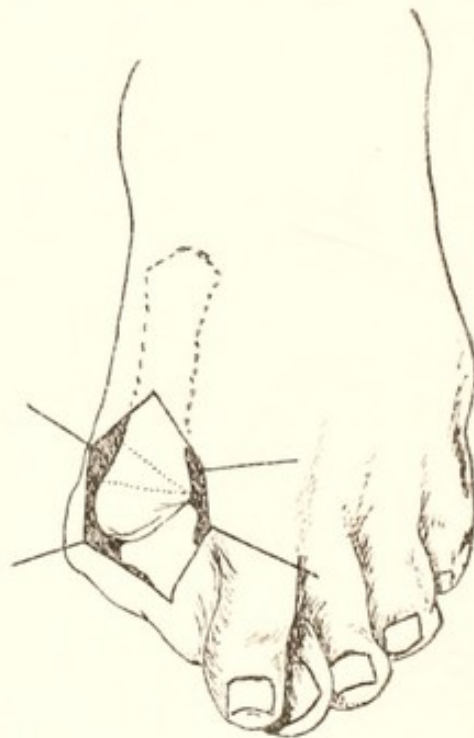


FIG. 14.—Hallux valgus. To illustrate osteotomy of the neck of the metatarsal bone, showing the wedge to be removed.

enough, a piece of felt with a hole in it to accommodate the bunion will afford relief.

Such measures, however, are only curative in the milder cases, and are not applicable to the man on service.

### Operative Treatment.

Operative treatment of hallux valgus must not merely aim at correcting the deviation, but must also be directed to securing free dorsiflexion of the great toe, otherwise the patient will be left with all the disability of a hallux rigidus.

It follows, therefore, that, apart from the correction of the valgoid deformity, the operative procedure is practically the same in principle in both conditions, and one description suffices for both.

First let it be stated that there are two operations sometimes performed, which need only be mentioned to be condemned. The first is transplantation of the extensor proprius hallucis tendon to the inner side of the metatarsal head in the hope that it will correct the outward deviation. Experience has proved that this operation is generally useless; it is therefore a waste of time to perform it. The second operation—excision of the joint—cannot be too emphatically condemned, as it is liable to end in a stiff joint, bringing with it all the crippling disability of hallux rigidus in its worst form.

Finally, no operation should be performed while there is any inflammation of the bursa or surrounding tissues.

A. In early cases in which there is valgoid deformity but not much enlargement of the head of the metatarsal by bony outgrowths, osteotomy of the neck of the first metatarsal bone, either linear or cuneiform (Fig. 14), associated with tenotomy of the extensor proprius hallucis tendon will suffice.

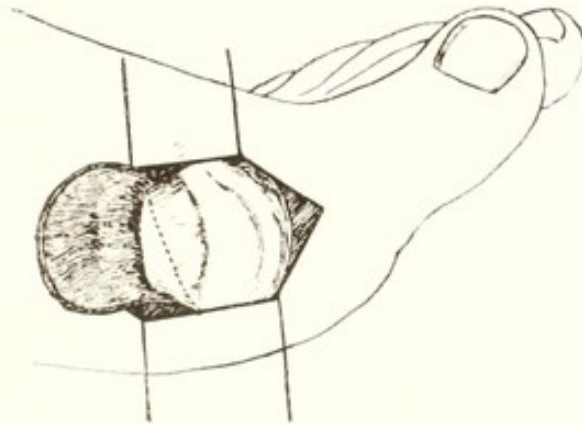


FIG. 15.—Hallux valgus. To illustrate resection of head of the metatarsal bone by oblique incision through the bone.

B. In later stages, with bony excrescences round the joint, more free removal of bone and some form of pseudarthrosis must be performed to secure the free movement of the toe, which is essential to comfort.

1. Free excision of the head of the first metatarsal bone, with interposition of a flap of tissue, or of part of the bursa, is not satisfactory in a soldier, though it has proved satisfactory in civilians who do not have hard walking or marching to do. The reason is that the lower part of the head of the bone is an important part of the weight-bearing apparatus, and must be preserved.

2. The operation to be preferred is resection of the head of the metatarsal bone (Fig. 15), leaving as much as possible of the lower part, taking care to clear away all bony excrescences which obstruct dorsiflexion or full correction of the valgus deformity. The bursal flap is then interposed as a covering for the raw surface of bone. At one time I used to interpose the whole bursal sac, but nearly twenty years ago several patients developed bursitis in the transposed bursa. The procedure I now adopt,

therefore, is to open the bursa and interpose only one wall as a covering for the bone (Fig. 16), or obliterate the bursal cavity.

3. In some cases (more often in cases of hallux rigidus than in those of hallux valgus) it is possible to preserve the articular cartilage of the head of the metatarsal bone. This may be done in two ways: The one method is to remove a wedge or slice from the posterior part of the head and then apply the cartilage to the raw surface of bone. The other is to cut a wedge of bone with the cartilage and mortice it into a cleft made in the bone further back, removing the intermediate bone.

In every case division of the extensor proprius hallucis is an essential part of the operation for hallux valgus, otherwise the traction of this muscle will tend to reproduce the deformity.

*Technique of the Operation and After-Treatment.*

The skin incision should be a linear incision along the inner side of the joint. The flap incision round the bursa

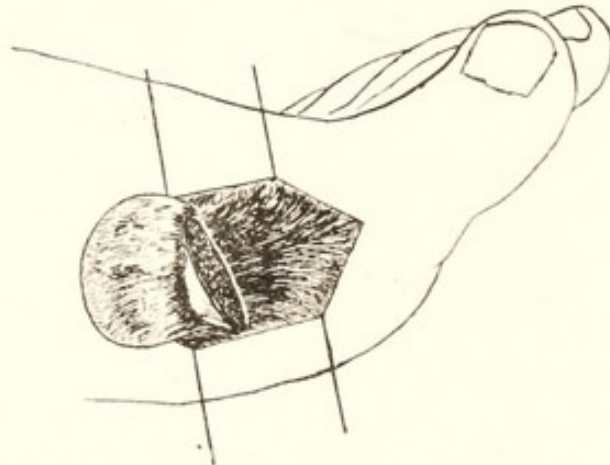


FIG. 16. — Hallux valgus. Showing flap to cover the end of the metatarsal bone in the operation illustrated in Fig. 15

described by Mayo has not proved entirely satisfactory in my experience.

The skin having been freed and retracted, a flap incision is made in the underlying tissues with a second knife. The knife used for the skin may be infected with *Staphylococcus albus* from the skin; it is therefore a wise precaution never to use the skin knife for any deeper dissection, especially in plastic operations where the least infection may destroy the value of the operation.

The joint is thus opened, and the head of the metatarsal freely exposed. The surgeon can then decide how much bone he is to remove and exactly how the wedge is to be made so that the toe will be correctly in line after the operation. He can also decide whether he can usefully retain the articular cartilage or is to dissect out a flap of the wall of the bursa to cover the raw bone.

It should be noted that the sesamoid bones should rarely be removed, as they seem to form an essential part of the tread of the ball of the great toe. The pad of fat

between the sesamoid bones is, however, sometimes thickened, red, and tender; if so it may be clipped away.

The whole operation must be carefully carried out with the most scrupulous attention to three points:

1. Preservation of part of the lower or weight-bearing portion of the head.
2. Restoration of free dorsiflexion, or the soldier will not march freely.
3. Correction of the valgoid deformity in cases of hallux valgus.

The valgoid deformity is purposely placed last, for in a sense it is the least important from the point of view of restoring the man's marching power.

A hallux valgus splint should be applied at the end of the operation. The splint I use is made of thin metal, as shown in Fig. 17. The hole in the splint fits over the inner side of the head of the metatarsal bone and prevents pressure from occurring at this prominent point. The base of the splint is strapped or bandaged to the inner side

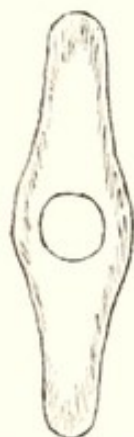

FIG. 17.—Splint for hallux valgus after operation.

of the foot. The toe is then drawn inwards and secured to the narrow end of the splint, care being taken that the alignment is correct.

After-treatment in cases of hallux rigidus and hallux valgus is quite as important as the operation if we are to succeed in restoring function. Three weeks after the operation the patient may walk, provided he has a proper boot. Gradual exercise and the correct bearing of the body weight in a properly designed boot is an essential part of the treatment.

The boot, in the first instance, should be made of soft material with a stiff leather sole. On the sole is put a leather bar  $\frac{1}{2}$  in. thick and  $\frac{3}{4}$  in. to 1 in. wide behind the heads of the metatarsal bones. The body weight thus falls for the time on the necks of the metatarsals rather than on the heads. Further, the heel should be made  $\frac{1}{2}$  in. higher on the inner side than on the outer side, in order to deviate body weight to the outer side of the foot and relieve strain on the inner side and great toe. This is, of course, also the appropriate treatment for the

flat-foot so commonly associated both with hallux valgus and rigidus. The inner border of the boot must be straight, so as to allow the toe to be drawn inwards freely, so that no pressure of the boot will tend to reproduce the valgus deformity.

As a rule, patients shod in this way can walk at once with comfort. Later, an ordinary boot may be altered in the same way. The operation area is too tender to bear the pressure of leather for two or three weeks after operation.

It is while walking in these boots, with the body weight carried on the outer edge of the foot, that the real cure takes place. Under the normal physiological stimulus of walking repair is hastened, and the small muscles of the foot recover strength.

To let the patient get up in a slipper is absurd, for the weight falls then on the head of the metatarsal, and by irritating the new bone formed at the site of operation it sets up a fresh process of osteo-arthritis, which may leave him worse than he was before. The patient must therefore be strictly kept reclining, and *never* allowed to set foot to the ground till the time has come when he may be allowed to walk in a properly altered boot.

### PART III.—HAMMER-TOE.

Hammer-toe is a deformity which usually affects the second toe, though it is common to find slighter degrees of the condition in other toes. It consists of flexion of the proximal interphalangeal joint and dorsiflexion of the metatarso-phalangeal joint (Fig. 1). The prominent

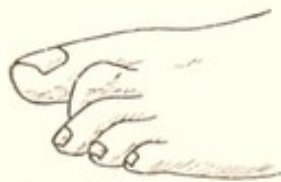

FIG. 1.—Hammer-toe.

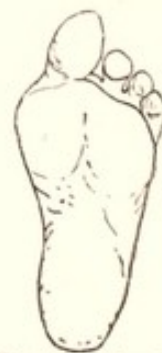

FIG. 2.—The disability produced by amputation of second toe.

knuckle of the proximal interphalangeal joint chafes on the upper of the boot, while the tip of the toe is pressed on the sole. Painful corns naturally develop at these points of pressure, making the man unfit to march.

The causes are numerous: sometimes the deformity runs in families, but the commonest cause is the crowding of

the toes in ill-fitting, badly designed boots. Hence it is common to find hammer-toe associated with hallux valgus.

#### *Treatment.*

In the adult operative procedure is indicated if we are to produce a quick and lasting recovery. Neither amputation of the toe nor an attempt at pseudo-arthritis of the proximal interphalangeal should ever be undertaken. Amputation should not be done, because the absence of the second toe increases the tendency to the production of hallux valgus, and often leads to a second disability more serious than the original hammer-toe (Fig. 2).

Some surgeons, when operating to correct the deformity, leave the articular cartilage on one side of the joint in order to obtain a new joint. My experience is that this

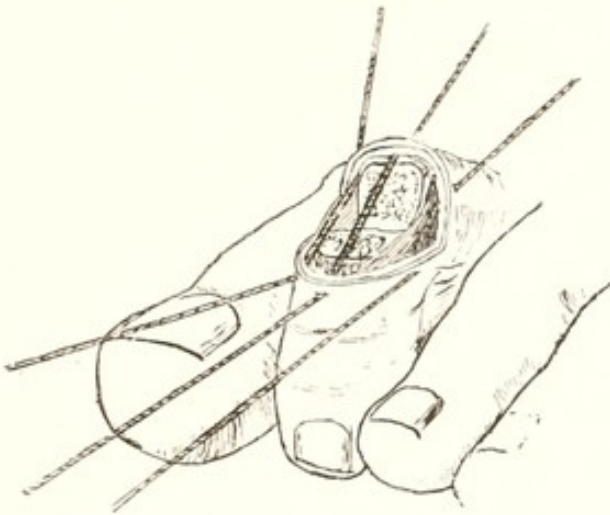


FIG. 3. - Wedge resection of joint for hammer-toe.

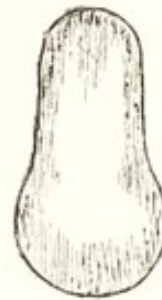

FIG. 4. - Splint for hammer-toe.

is followed by recurrence so frequently that the operation should be condemned as uncertain.

#### *Operation.*

The operation found most uniformly satisfactory is a wedge shaped excision removing the articular cartilage on both sides of the joint, so as definitely to ankylose the joint in extension. An oval piece of skin, including the corn, is excised over the prominent knuckle. A wedge, base upwards, including the joint, is then excised, of sufficient size to allow the toe to be straightened (Fig. 3). The flexor tendon is divided by tenotomy. The skin incision is then stitched so as to leave a transverse linear scar. The toe is fixed down to the toe-splint shown in Fig. 4, and the patient walks about, still wearing the splint inside his boots, for some weeks, to make sure that solid ankylosis occurs without any return of the deformity.

### DISPLACEMENT OF THE LITTLE TOE.

A displacement of the little toe, similar in nature to hallux valgus, frequently occurs, usually as the result of wearing boots which are too tight and too pointed. Occasionally the condition is congenital. The toe is displaced inwards either over the dorsal or under the palmar aspect of the fourth toe. In either position it is subjected to undue pressure in any ordinary boot, and therefore becomes painful.

#### *Treatment.*

This condition is very troublesome, and when it occurs in a soldier an operation is essential. The treatment which may be applied successfully in children has no place here, as the structures have become so contracted, especially the skin, that tenotomies, excisions, or simple splintings are wholly inefficient. Amputation of the toe is simple and effective in most cases, especially if no callosities have formed under the metatarsal head. In amputating it is advisable to make an ample flap to obviate the result of subsequent contractures and to secure a lax fleshy covering for the bone. If a callosity has formed, no pressure should be allowed upon that area until by rest and treatment it has become soft and normal. If the head of the bone is arthritic and the condition is complicated by exostoses or irregularities, these should be pared away. Only in very exceptional circumstances should the head of the metatarsal be removed, for, as pointed out in a previous article, this forms one of the points of support in the foot on which a soldier's marching powers depend.

### METATARSALGIA.

Metatarsalgia is a peculiarly painful disability of the foot associated with flattening of the transverse arch. The characteristic pain is usually felt in the fourth metatarso-phalangeal joint, frequently in the third, and less often in the second. The pain is variously described as a sharp stab, a burning pain, or as if the patient was "stepping on a red-hot pea." The pain may come on suddenly as the patient is walking in the street, and cripple him, so that he has to hobble into a shop and get his boot off. The device adopted by most patients to obtain relief is to grasp the metatarsals in the hands and squeeze them so as to restore the transverse arch. In more chronic cases the affected toe becomes glazed and shows signs of trophic disturbance, while in some cases there is complaint of severe pain shooting up the leg.

Morton in his original description attributed the pain to pinching of the digital nerves between the metatarsal heads. The fact that relief is obtained by squeezing the metatarsal heads casts doubt on the truth of this. I described the condition fully in 1897, and stated that, as the result of the study of dissections and frozen sections, I had come to the conclusion that descent of the

transverse arch and consequent pressure on the nerves in the sole was the real cause of the pain.

Diagnosis is easily made by the characteristic tenderness elicited by pressing the offending joint between the finger and the thumb. In addition, obvious flattening of the transverse arch is usually present, and the fatty pad under the heads of the metatarsals is absorbed by the pressure of the descended arch, so that the "ball of the foot" feels unnaturally thin, and there are corns in the sole under the unusual points of pressure. The condition is therefore to be regarded as directly connected with overstrain of the foot, and is consequently associated with flat-foot.

#### *Treatment.*

Immediate relief can nearly always be given by removing the pressure of the body weight off the heads of the metatarsal bones by a bar behind them (Fig. 5).

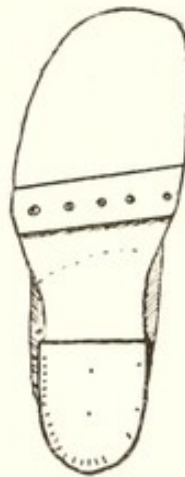


FIG. 5.—Treatment of metatarsalgia. Bar on sole of boot behind the heads of the metatarsal bones.

The effect of this is to carry the body weight on the necks of the metatarsals. The heel of the boot should also be raised one-third of an inch on the inner side, as for ordinary flat-foot. A band of strapping round the bases of the metatarsals to prevent spreading also helps. These measures, combined with exercise of all the small muscles of the foot to restore the arch, and massage to relieve the pain and improve nutrition, will suffice to cure all early cases in the space of a few weeks.

The patient should then be warned against wearing narrow boots, which impede the free play of the fore part of the foot, and conduce to atrophy of the muscles of the foot from disuse.

In cases which have lasted for some time these measures do not suffice for a cure, though they give some relief.

#### *Operation.*

More drastic measures are required for the soldier's foot. Removal of the head of the offending metatarsal through



a small dorsal incision completely relieves the condition in ninety per cent. of cases, even when the crippling effects have lasted a long time, and the patient is suffering so much that he asks for amputation of the foot. In the remaining cases it gives enough relief for the patient to be made comfortable with a bar across the sole of the boot.

#### *After-Treatment.*

The bar on the sole of the boot and crooked heel, already described, should be employed as an essential part of the after-treatment. The patient may then walk during the whole period of convalescence without injuring the site of operation, and so exciting new inflammatory changes.

#### PAINFUL CONDITIONS ABOUT THE HEEL.

The painful conditions about the heel most commonly met with may generally be traced to one of three causes :

1. Injuries or strain about the insertion of the tendo Achillis.
2. Spurs of bone and adventitious bursae under the os calcis.
3. Osteitis and periostitis from direct injury of the os calcis.

Injuries and strains about the insertion of the tendo Achillis are marked by pain about the back of the heel which is aggravated by walking and relieved by rest, but the pain recurs again if the patient is tempted to take exercise. The condition may be divided into three types :

1. *Tenosynovitis*, in which there is swelling due to effusion within the tendon sheath. This swelling extends some distance up the tendon, and is both palpable and visible.

*The treatment* is counter irritation, firm bandaging and rest. When the acute stage is passed the patient may be allowed to walk limited distances with the heel of the boot raised  $\frac{3}{4}$  in., so as to relax the tendon and diminish the strain. If the condition tends to become chronic, the actual cautery may be used with great benefit, especially in the form of the heated needle.

2. *Bursitis* of the bursa under the insertion of the tendon into the os calcis. This is diagnosed by localizing the tenderness at the site of the bursa and by detecting a small area of fluctuation.

*Treatment.*—Relax the tendon by raising the heel  $\frac{3}{4}$  in. Apply a band of strapping round the leg above the malleoli to act like the wristlet worn by workmen who have strained a tendon at the wrist. The patient should be instructed to walk a little every day, but should not be allowed to do an indefinite amount of walking; this is one of the difficulties connected with letting soldiers out from hospital on pass.

3. *Periostitis* at the site of insertion of the tendon, due to strain of the insertion.

The diagnosis is made by localizing the tenderness on pressure a little lower down than in the case of bursitis, and by the absence of deep fluctuation in the bursa beneath the tendon. *The treatment* by rest is the same as for the preceding condition.

Both these last-mentioned conditions may be present simultaneously and become chronic. The best treatment then is first to puncture the bursa or the inflamed area of periosteum several times with a hot needle. The process is exactly that known to the farrier as "pin-firing." The effect of this is to excite an active vascularization of the part, after which repair takes place more rapidly if the rest treatment is carried out.

Further, cauterizing a patient's heel deters him from wearing a boot and going out for too long walks, and gives the deep lesion an opportunity to recover while the surface blister is healing.

*Irregular fibrous masses* are sometimes noted in the Achilles tendon. These are usually the result of partial ruptures, and if large and persistently painful they should be removed.

#### SPURS OF BONE UNDER THE OS CALCIS.

Spurs of bone running forward into the plantar fascia or short muscles of the sole are frequently seen in skiagraphs (Fig. 6). They often cause no symptoms. On the other hand, if the patient accidentally jumps on to a stone

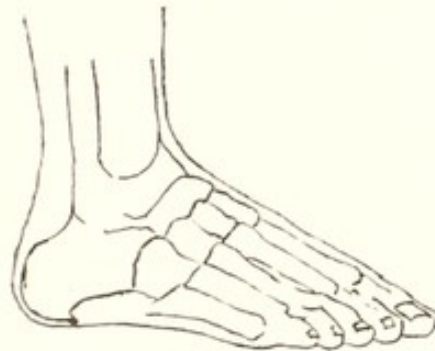

FIG. 6.—Spur of bone under os calcis.

and bruises the periosteum over one of these spurs, it may become enlarged, or an adventitious bursa may develop under it. After this, the patient feels pain every time he puts his heel on the ground, and in the course of a long march.

#### *Treatment.*

Make an incision along the side of the foot and gouge away the spur and tissue round it to make sure of clearing out the bursa and any chronically inflamed periosteum. The incision should, of course, not be made in the sole, as a scar in these regions is often itself the cause of trouble.

*Osteitis and Periostitis.*

Osteitis and periostitis of the os calcis often arise from bruising of the bone by a jump or fall from a height, or by injury due to gunshot. There may be no gross fracture, only some crumpling of the lamellae, which may be seen in a good skiagram. When a fracture occurs, the disability is often due to bony irregularities on the under surface of the bone.

*Treatment* is often unsatisfactory, and if the bony masses are felt in the sole under the heel they should be freely removed. Palliative measures are of no use in the case of a soldier; and one may state as a general proposition that a soldier with a badly-fractured astragalus or os calcis will not again be fit for service.

#### IV. ON MALUNITED AND UNUNITED FRACTURES.

THE conditions to which the terms "delayed union" and "non-union" are applied may be difficult to distinguish, because often we find that, even after months, osteogenetic changes leading to consolidation will take place in a fracture considered to be permanently united. If we are to avoid disagreeable experiences, we must recognize that for various reasons, some of which we know and some of

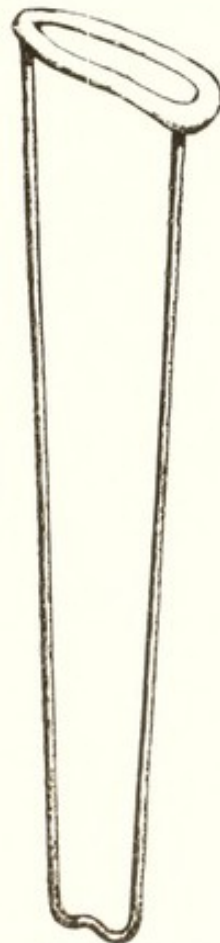


FIG. 1.—Thomas's bed splint.

which are still unknown, a certain proportion of fractures take longer to unite than others. Some years ago I was called to a distance to operate upon a fractured femur. The accident had occurred three months previously. The length and alignment were good, but the patient had some sugar in the urine, and we decided, instead of operating, to place the limb, free from circular constriction, in a Thomas's bed splint (Fig. 1). Certain other procedures which I

advise were not carried out, but in four weeks very firm consolidation had occurred. This case affords an example of a clinical type. There may be several weeks of apparent inactivity in callus formation, and then consolidation occurs quite rapidly. If a practitioner takes care to maintain a good length and accurate alignment, he should look forward cheerfully to a happy issue even if union is delayed. As a rule, this is exactly what he does not do. At the end of the fifth week he begins to feel nervous, he disturbs the bone ends, modifies his methods, and by degree transforms into a permanent disability a condition which merely demanded patience.

*Delayed union* is most common in the middle of the femur, in the humerus at the junction of the middle and upper third, and in the tibia and fibula at their lower third.

#### CAUSES OF DELAYED UNION.

In many cases there is an obvious reason for the delayed union. Very often it is not due to malposition; it is, indeed, quite remarkable how often in delayed and ununited fractures the bones are almost automatically opposed. I will not waste time by doing more than mention some of the academic causes assigned—such as tabes, syphilis, and acute diseases. I would prefer to focus attention on the more real and practical conditions which have a direct relation to the method of treatment.

#### *Circular Compression.*

An obvious and frequent cause is inefficient reduction, and later on, in dealing with malunion, I will refer to this in greater detail. I will, however, deal first with another cause of delayed union—circular compression of the limb by splint and bandage.

A fundamental principle in the treatment of fractures is to *secure and maintain good length and good alignment*, and in attaining these ends care should be taken that the circulation of the limb shall be in no way hampered. The splint used should be so constructed that after the bandage is applied the fingers can be readily introduced between it and the lateral aspects of the limb. In looking back upon the ununited fractures I have seen, I generally recall an attenuated limb and a thick plaster case. When the casing is removed the blanched limb becomes red, and the blanched bone begins to take its fill of blood. It is because plaster generally fails to secure length and adequate blood supply that it is a prolific source of delayed union and ununited fracture. I would not condemn the use of plaster altogether, much as I dislike it, but it should be used with discrimination. It should be fixed in such a way that the limb remains in extension and in good alignment, and that the circulation of the limb is in no way hampered.

#### *Duration of Period of Consolidation.*

Textbooks have led us astray in regard to the period required for the consolidation of bone. Fractured adult bones are never firm after four or five weeks, as the books would lead us to infer.

For practical purposes, ignorance of this fact may make no difference in the case of the upper limb, but in the case of the lower limb, where the effect of body weight has to be considered, to underestimate the period of consolidation is to invite disaster.

#### TREATMENT.

If a case of delayed union is first seen in the seventh or eighth week we need do no more than make quite sure of good alignment, length, and circulation. Nature will do the rest.

#### *Percussion and Damming.*

If a long time has elapsed the need for action is more pressing, and we must endeavour to transform the indolent callus into an osteogenetic factory, so that bone may be generated. I know of no better means than that suggested by H. O. Thomas, and named by him "percussion and damming."

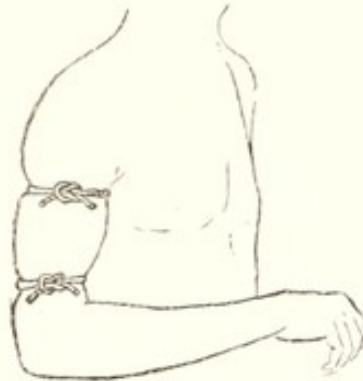

FIG. 2.—"Damming" or congestive treatment of ununited fracture of the humerus by Thomas's method.

#### *Femur.*

As an example, I will take non-union of the femur with shortening probably of two or three inches. Under an anaesthetic the soft fibrous callus is broken down and the fractured ends are turned towards the skin and beaten with a mallet; a pulley is then applied to the limb, and as much length as possible gained. A Thomas knee splint is then adjusted and the extension maintained. Two pieces of indiarubber tubing are tied around the limb, one three or four inches above the fracture, and the other at an equal distance below. They are kept on, to begin with, for about twenty minutes each day until they can be borne for several hours at a time. They should be kept tied sufficiently tightly to produce considerable swelling and stasis. Usually in two or three weeks callus is thrown out, and the osteoblasts begin actively to produce bone. Local congestion between two indiarubber tubes is much more effective than congestion by one proximal tube. I can recall many cases in which bones that had remained ununited for several months became firmly consolidated after use of this simple device (invented by Thomas and ascribed twenty years later to Bier) for stimulating osteogenesis. The method of applying the indiarubber tubes to produce congestion is shown, applied to the humerus, in Fig. 2.

*Tibia and Fibula.*

In old ununited fractures of the tibia and fibula complete extension is not so easily attained, and it may be necessary to remove bone. If this be done, the operation should be performed under pulley extension (Fig. 3), or by turning the ends of the bone out of the wound and engaging the fragments in shoe-horn fashion after the method of Lane. If the case be suitable and the surgeon possess the mechanical skill subsequently to keep a good alignment, it is best to avoid the introduction of plates or screws. The bones should be kept in absolutely good apposition, and where it can be easily accomplished they should be wrapped in transplanted fascia which will act as a binding membrane in the same way as periosteum.

In another type of case in which the bone is eburnated with feeble callus production, it is well after sawing the ends to crenate the edges with bone nibblers, and to transplant bone from some other part of the body. The

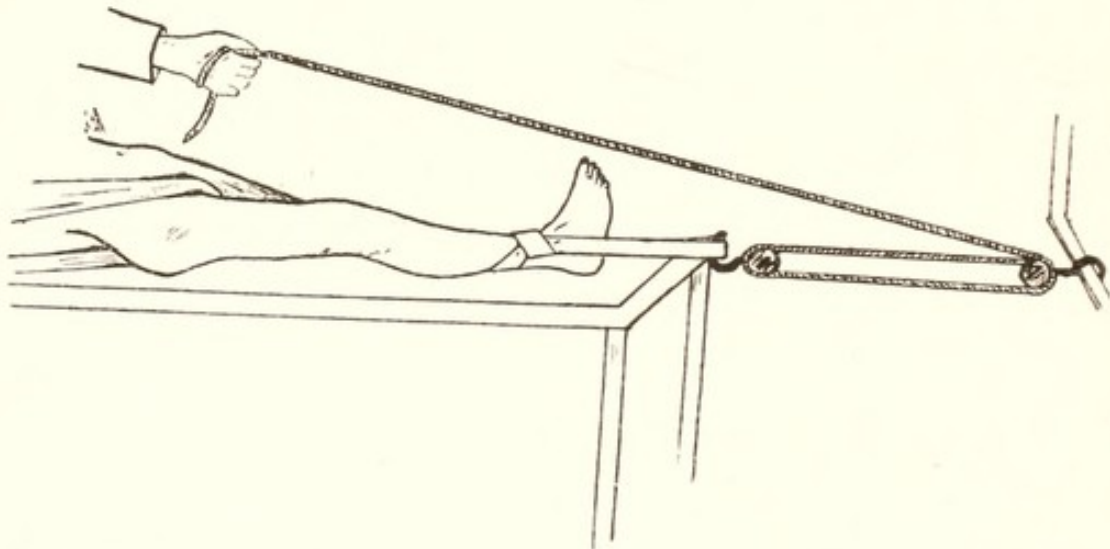


FIG. 3.—Pulley used in setting and operating upon fracture of tibia and fibula; counter-extension shown.

sides of the fractured ends should be prepared to receive the transplanted portion, which can be affixed laterally (Fig. 4 A), or driven into each end of the medulla. The transplanted bones and the fractured ends are held in position with transplanted fascia wrapped around them.

Figures 5 A and 5 B illustrate a method of sliding a transplant to bridge over the fracture. Albee's twin saw is used to enable the operator to detach with mathematical correctness a strip of bone partly above and partly below the line of fracture. A chisel is used at either end to complete the detachment. The shorter detached piece (in the figure the lower) is removed and the larger piece is slid down (Fig. 5 B).

Autogenous transplantation of bone is far more effective than transplantation from another patient or from an animal. A bone graft without periosteum is sometimes as effective as one taken with its periosteum. This fact is

important, for if bone is removed from some other part of the body subperiosteally, the removed bone is very rapidly replaced by new bone. Where convenient, however, the periosteum should be retained.

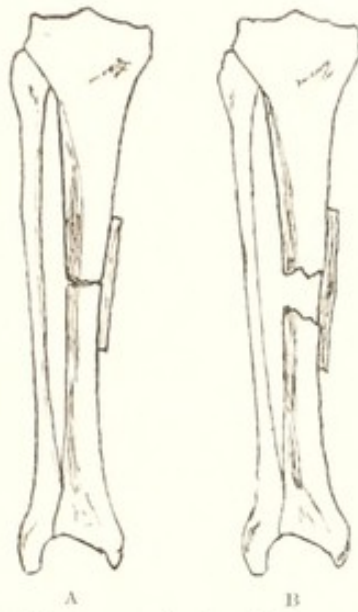


FIG. 4.—Bone grafting. A, Lateral bone graft for fracture. B, Lateral bone graft for a case in which bone has been removed.

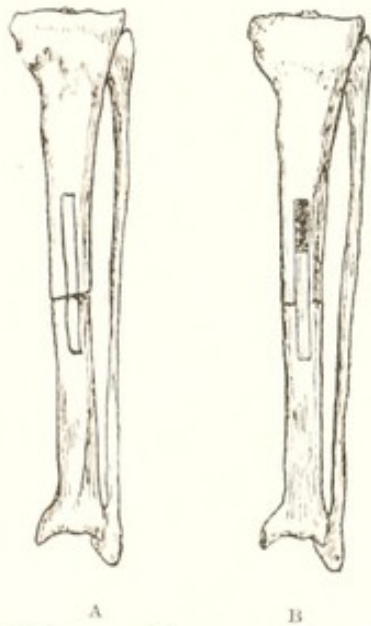


FIG. 5.—Bone grafting. A, Diagram showing incisions through tibia by twin saw and chisel, detaching a strip above and below the fracture. B, Second stage of operation. The lower fragment has been removed, and the upper has been pushed down so as to bridge the fracture (Albee).

Non-union is very apt to occur where a wide gap exists between the bones. In the case of fracture of the tibia of long standing, where the growth of the fibula has progressed, I have operated with success by removing a large lateral slice from the upper end of the fractured tibia, and using it as a bridge to span the gap (Fig. 4 B).



*Compound Comminuted Fractures : Retention of  
Fragments.*

This leads me to speak of compound comminuted fractures associated with loose pieces of bone. The removal of these pieces is very frequently the cause of non-union. If loose pieces are felt, provided the wound is not suppurating, they should be scrupulously saved; the pieces, if quite loose, should be taken out of the wound and laid in alcohol, and then carefully replaced in position or round the site of fracture. In such cases I refrain from introducing any foreign bodies, such as nails, plates, or wires. If a drain be used at all, it should be for forty-eight hours only.

*Weak Union : Exuberant Callus.*

Malunion of the femur of six or seven weeks' duration can almost always be corrected by powerful manipulation. The same is true of all the long bones. At my clinic every week I am accustomed, by wrench or hand, to correct malunited fractures of several weeks' standing. The method is especially applicable to a Colles's or a Pott's fracture.

Weak union can be diagnosed almost with certainty even when ordinary manipulation fails to detect it. It is suggested by tenderness on pressure over the site of the old fracture, and confirmed by the additional sign of exuberant callus exudation. A malunited fracture of some months' duration, if accompanied by these two signs, can usually be corrected by forcible manipulation. This is a very important clinical fact to remember from the point of view of immediate or gradual correction.

Exuberant callus is sometimes so abundant as to be mistaken for malignant disease, and I have met with many instances in which the patient has narrowly escaped amputation. This error is more likely to occur in the femur than in any other of the long bones, especially when the force applied to produce it has been so slight as to suggest that the fracture was spontaneous.

MALUNION.

Malunion of a fracture can always be prevented, and should raise a strong presumption of inefficient treatment. Our duty, therefore, is to examine the cause of malunion, and to arm ourselves with a knowledge of the weak points in our method of treatment.

The causes of malunion may be found (1) in errors in the initial treatment or setting of the fracture, (2) in errors in the method of maintaining the fracture in position, or (3) in errors of after-treatment.

I. INEFFICIENT REDUCTION OF THE FRACTURE.

Malunion of a fractured bone is due to this cause more often than is commonly supposed. Sometimes it is

due to want of knowledge, but more often to want of experience and confidence.

It is necessary, of course, to have a clear knowledge of the anatomical proportions of the limb and of the mechanics of its action; but it is still more important to know the nature of the impairment of function likely to occur after any particular fracture, so as to be ready to take means to anticipate and to prevent it.

Common causes of inefficient reduction are—

(a) Insufficient extension of the limb in fractures of long bones—such as the femur or humerus—so that the overriding of the fragments is not completely corrected.

(b) In Pott's fracture there is always an associated dislocation of the ankle outwards and backwards. If the backward dislocation is not fully corrected there is pain over the front of the ankle when the patient walks, and, in addition, inability to dorsiflex the ankle, which causes a serious impairment of function.

(c) In Colles's fracture the backward displacement of the lower fragment is very serious, and is not always corrected by the orthodox traditional "hand-shaking" method of reduction. The lower fragment carries with it the articular surface for the head of the ulna, and if this is out of line, the upper and lower articulations between the radius and ulna are thrown "out of truth" and the radius will not rotate properly. This leads to impairment of pronation and supination, and consequent very serious interference with function.

These are merely instances of how a want of sufficient determination in reducing the initial deformity may play an important part in causing subsequent loss of function. I have referred to them because they occur in common fractures, with the treatment of which everybody ought to be familiar, yet I see a large number of cases of serious impairment of function really due to these causes.

## II. FIXATION AFTER SETTING OF FRACTURE.

If the fixation of the limb after the fracture has been reduced is inefficient so that material amount of movement can take place between the fragments, then every such movement causes pain, and produces a reflex contraction of the muscles. This reflex spasm may very readily cause overriding of the fragments, and in the case of the shafts of long bones lead to shortening. In fracture of the neck of the femur it modifies the angle between the neck and the shaft and so causes the flexion of the joint, with the result that body weight is not transmitted in the normal line. In consequence of this, crippling changes of an osteo-arthritic character subsequently occur in the joint. Faulty alignment of the bones may arise from inefficient fixation, even in a case in which the fracture

was originally fully reduced and the bones brought into correct alignment (Fig. 6). The result is that the true line of the shaft of the bone is not maintained, and the joint at one end of the bone is thrown out of its proper relation to the joint at the other; in consequence, muscles do not act in their correct line, and the usefulness of the limb is impaired. Further, in the lower limb the line of transmission of body weight is altered, and this throws an

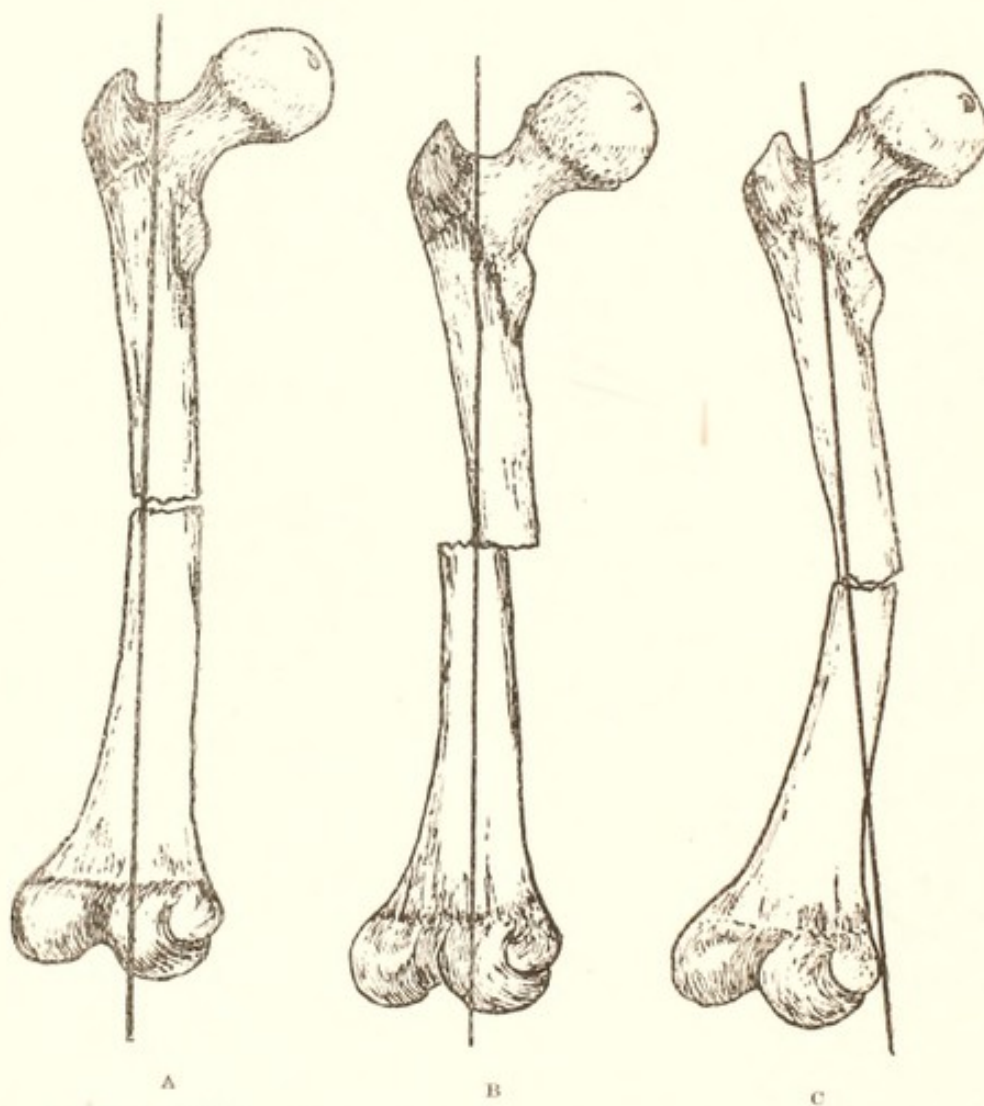


FIG. 6.—End-to-end apposition of fractured femur. A, End-to-end apposition and perfect alignment; B, imperfect apposition but with good alignment; C, end-to-end apposition with faulty alignment.

improper strain on joints and ligaments, resulting in changes in the joints, in flat-foot, and in other disabling deformities. For instance, in fracture of the tibia and fibula a little shortening of the limb does not seriously impair its strength if the alignment is good. A slight bow-leg even is not serious (Fig. 7 A), for slight bow-leg is a harmless type. Many muscular and powerful men are, indeed, slightly bow-legged, but in a valgoid deformity the weight of the body is carried too far to the inner side

of the foot, and this throws too much weight on the arch, and the result is a flat and everted foot (Fig. 7 B).

Any valgus deformity at the knee, in the leg, or at the ankle is a weakening deformity, and greatly reduces the usefulness of the limb. It is a good fault, therefore, to err on the side of producing a slight bow-leg, with its varoid accompaniment, if there is to be any error at all. In cases of malunion, when the callus is still tender, it is generally not difficult to readjust the limb by manipulation without having to perform an open operation. In the case of the

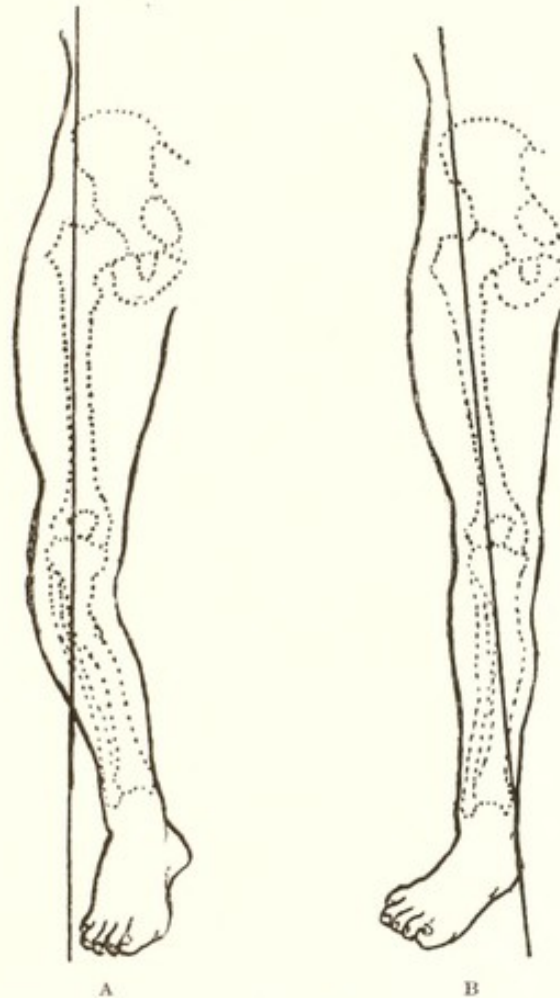


FIG. 7.—Diagrams to illustrate effects of malunion of tibia. A. Malunited fracture of tibia producing bow-leg and throwing body weight on to outer side of foot. B. Malunited fracture of tibia in such a position that the weight of the body is carried to the inner side of the foot, producing flat-foot.

femur, this can usually be done two, or even three, months after the original fracture. As a rule, the worse the position of the bones the longer will the callus take to consolidate.

The next point to which I would draw attention is that callus may yield in such a way as to throw the bone out of proper alignment. A good example of this is frequently afforded by cases of Pott's fracture which have been correctly reduced, and six weeks later are in good position and united. A month after this, however, the patient may

complain of some pain at the site of the fracture, and also of symptoms of flat-foot.

Here the counter pressure of the ground on the foot forces the astragalus against the external malleolus, and so produces a lever action, straining the callus. To avoid this, every case of Pott's fracture should be set to walk with the inner side of the heel raised to keep the foot inverted, and if the patient is a heavy subject an outside brace also should be worn (Fig. 8 A and 8 B). It is disconcerting and puzzling to see a perfectly good functional result replaced by a bad one; to avoid disappointment of

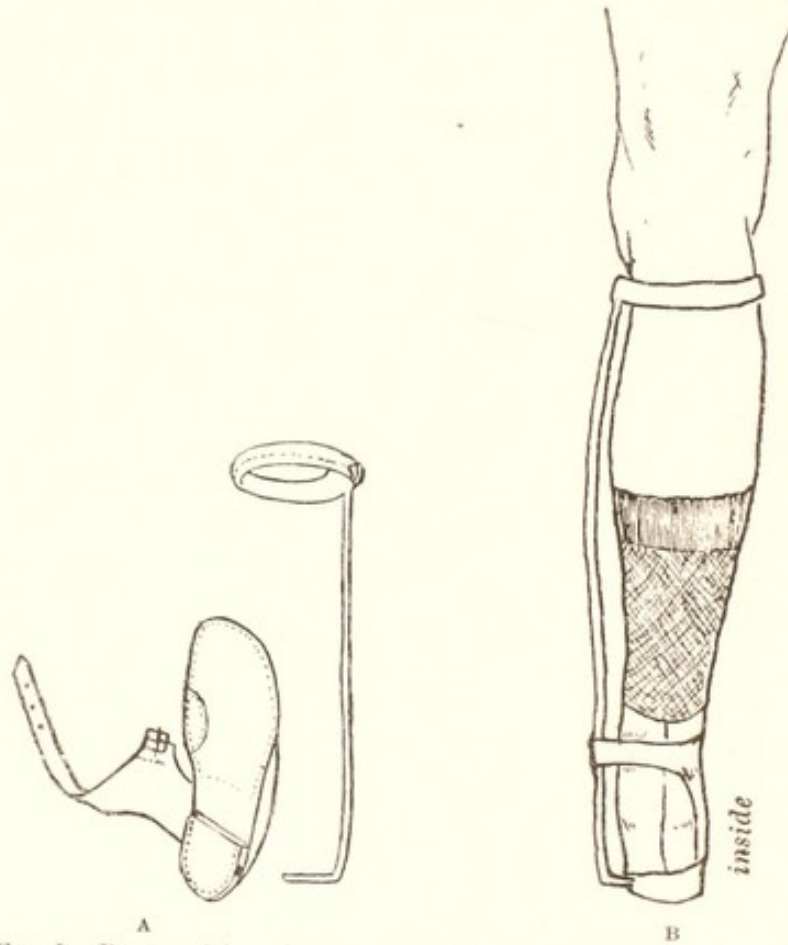


FIG. 8.—Boot and iron for use after Pott's fracture. A, Showing the boot with crooked and elongated heel and the outside iron; B, the same applied.

this kind it is advisable, particularly in fractures of the lower limb, to apply some sort of guard to prevent straining of the callus.

#### THE FUNCTIONAL IMPAIRMENT ASSOCIATED WITH VARIOUS FRACTURES.

Before discussing the treatment to be adopted in particular cases, it is well to recognize the forms of impairment of functions commonly associated with each fracture.

##### *Humerus.*

Fractures of the humerus near the shoulder-joint (that is, those of the surgical neck and above the insertion of

the deltoid) are commonly associated with inability to abduct the limb fully. The reason is that the upper fragment is often tilted outwards, and end-to-end union does not take place. In order to avoid this, the surgeon's object when setting the fracture should be to bring the fragments end to end if possible. He should pull the arm at right angles to the trunk, or even straight upwards until all over-riding is completely overcome, and should then endeavour to engage the end of the lower fragment on the broken end of the upper fragment. By pressing the two together he can at once tell if they are engaged or are sliding past each other. If they are engaged, the arm can be gently brought down to the side and secured to the trunk by bandages. Once the fragments are engaged they are not likely to become disengaged again.

#### *Elbow-joint.*

In fractures about the elbow-joint, with the single exception of fracture of the olecranon process, the usual disability is limitation of flexion.

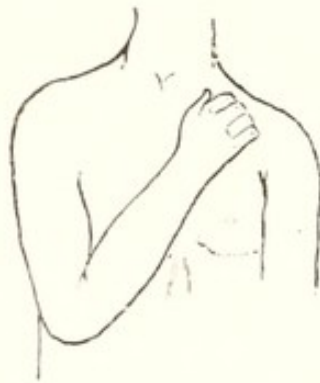

FIG. 9.—Position for fractures about elbow in the adult.  
The elbow is even more flexed in children.

The limb should therefore be extended to push away any fragment likely to obstruct extension afterwards. The forearm should be supinated to make sure of clearing a right of way in that direction, and then the elbow should be fully flexed and bandaged (Fig. 9), care being taken not to produce tight circular constriction of the limb in any part. In this way we may make sure that there shall be no callus exudate in the bend of the elbow, and at the same time the tendon of the triceps acts as a posterior splint.

When a stiff elbow, after an injury, has to be dealt with, the same manœuvres are gone through so as to force the recently formed callus out of the way until full flexion is secured. Usually this can be done on one occasion, but in some cases it may be necessary to flex the joint in two or three stages.

#### *Radius and Ulna.*

In fractures of the bones of the forearm the disability most to be feared is obstruction to supination; pronation is usually good. Therefore, in setting the fracture, or

when breaking down callus and resetting the fracture, the surgeon should extend the forearm and supinate fully in order to make sure of a clear right of way for supination, and then set the fracture, taking great care that the ulna is perfectly straight, and that there is no lateral pressure anywhere on the shaft of the radius (Fig. 10). It must, however, be remembered that the radius is a curved bone which rotates on the ulna like the handle of a bucket; if the arched shape of the radius is destroyed the joints at its ends will be out of their true line, and impairment of function will be the result.

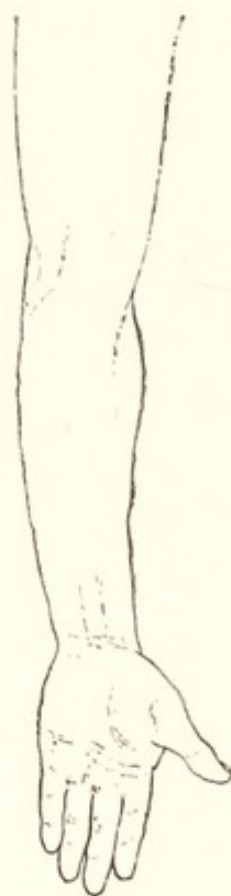

FIG. 10.—To show the complete supination and extension of the arm necessary in fractures of radius and ulna.

#### *Carpus.*

Fractures of the carpus often result in a stiff wrist in a flexed position. Every schoolboy knows that the grasp of the hand is weakest when the wrist is flexed. Therefore, in every case of fracture or injury of the carpus, the wrist should be put up in a hyper-extended position (Fig. 11).

If the wrist has been allowed to get stiff in a flexed position, it should be dorsiflexed under an anaesthetic and fixed in that position. In rare instances a fragment of the scaphoid is displaced on to the dorsum and blocks extension; if this has occurred, it may be necessary to remove the fragment before the wrist can be hyper-extended.

*Ankle-joint.*

When we turn to fractures near the ankle-joint we find that many patients complain of both pain and stiffness which lasts for months or years. A study of the causes brings to light two principal factors responsible for loss of function here. Eversion of the foot, for instance, is

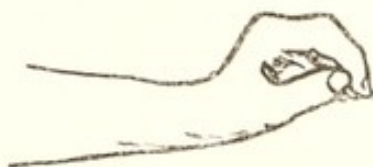

FIG. 11.—Dorsiflexion of wrist for fracture of carpus.

fairly well recognized as one of them (Fig. 12). If the patient is allowed to recover with the ankle in a valgus position, the body weight when he stands will fall too far to the inner side of the foot, and at once all the factors which make for the production of flat-foot are produced. It is, however, not sufficiently well recognized that these conditions may be at work in an ankle which has every appearance of being in good position when the patient is discharged from hospital. Straining of young callus by body weight is very common in fractures around the ankle-joint, owing to the patient being allowed to walk

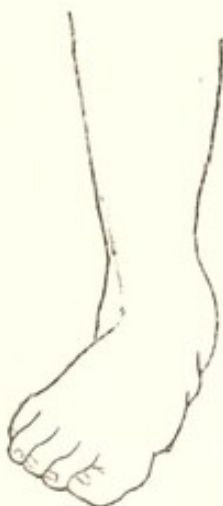

FIG. 12.—Malunited Pott's fracture, showing eversion of foot.

on the unprotected joint too early. I therefore always turn these patients out with a "crooked" heel and often with an outside brace as well, to ensure that the body weight shall fall on the outer side of the foot (Fig. 8 A, 8 B). The natural corollary of this is that if body weight will produce a valgus deformity by straining the callus, it will also correct it if we "crook" the boot well, and therefore when the callus is already strained in the valgus direction, and the patient comes with a stiff painful ankle and foot, all we need do in many of the milder cases is to crook the boot well on the inner side, and let the patient "walk out" his



deformity. In older and more severe cases it is from the first necessary or advisable to wrench the foot into an inverted position under an anaesthetic, and then let him walk with his heel well crooked; this is made easier by the application of an outside brace (Fig. 8). If this after-treatment is not persisted in for some weeks the condition will most likely recur.

The second great disability, after injuries about the ankle-joint, is inability to dorsiflex the ankle. The patient, when walking, cannot get forward on to the toes and fore part of the toes without pain across the front of the ankle.

This is a very difficult condition to correct once the deformity has been allowed to become established. The proper thing is to prevent it when the injury is recent; to make sure of this the surgeon should dorsiflex the foot and so satisfy himself that he has commanded a complete and clear right of way for this movement in the future.

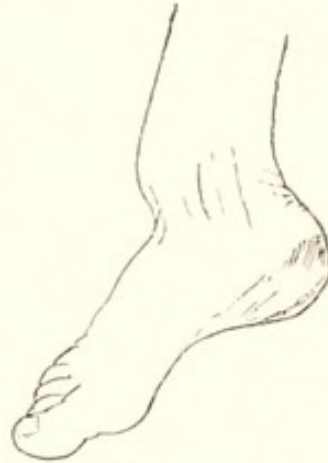

FIG. 13.—Malunited Pott's fracture, showing dislocation backwards of the foot.

Both these disabilities are well illustrated by cases of Pott's fracture; this injury essentially consists of a fracture of the fibula about three or four inches above the external malleolus with a dislocation of the ankle outwards and backwards (Fig. 13). There may be minor complications, such as fracture of the tip of the internal malleolus or the less well recognized fracture of the edge of the articular surface of the tibia. These, however, do not alter the general nature of the disability.

The method of reduction I adopt is the following: The knee is flexed to relax the calf muscles. If these muscles give trouble, tenotomy of the Achilles tendon will put them out of action, but this is only necessary in exceptional cases, and strength returns but slowly after this apparently harmless operation. Grasping the foot by the heel in one hand and the dorsum in the other, the foot is pulled and everted to make sure of thoroughly disentangling the fractured ends. While still pulling, the foot is fully inverted and the ankle dorsiflexed. If the ankle cannot be dorsiflexed fully, it means that there is a definite posterior dislocation or that the anterior edge of the tibia is fractured.

It is necessary then to push the tibia back and bring the foot well forward until the ankle can be well dorsiflexed. The foot is then fixed in splints in the fully inverted position and dorsiflexed a little beyond the right angle. If the surgeon maintains it in this position, he may wait with confidence for a good result. If he is content with a less thorough reposition, he is in great danger of getting a result with some stiffness, pain, or limitation of movement, which will seriously interfere with comfort in walking. Since the days of Percival Pott many splints have been devised. The shape and style of the splint does not matter a jot. The important element is the surgeon. If he knows his work, he will fix the foot in the position described and will be rewarded by a good result.

As we have seen, malunion and consequent functional disability depend on two factors: (*a*) eversion, (*b*) diminished dorsiflexion.

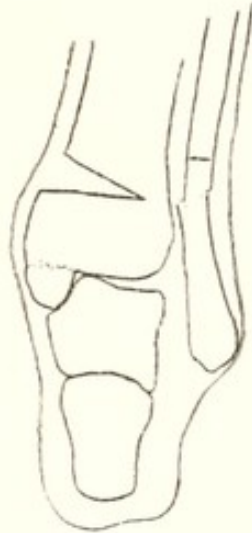


FIG. 14.—Operation for malunited Pott's fracture; wedge from tibia and osteotomy of fibula.

(*a*) Eversion often calls for operation. In comparatively simple cases all that is needed is to pass a chisel through the internal malleolus, and also through the site of the old fibular fracture. The foot should then be forcibly inverted, and treatment continued to maintain the inversion. In the more severe type of case an open operation is advisable. A wedge of bone is removed from the lower end and inner side of the tibia (Fig. 14). The wedge should only go a distance of four-fifths through the bone. An osteotomy of the fibula is next performed. The wounds are closed, and not dressed for twelve or fourteen days. The stitches are then removed, and, under gas, the limb is fractured by forcible inversion. This two-stage operation eliminates the anxiety which must attend the treatment of a compound fracture, and this is an important matter when powerful manipulation is necessary. For many reasons, however, it may be advisable to complete the reduction at the time of operation.

(b) Dorsiflexion of the ankle may be blocked by callus exudate the result of fracture of the anterior articular edge of the tibia. Complete dorsiflexion of the ankle at the time of accident would save the patient from this deformity, for the fragment of bone would in this way be pushed to one side, but if this has not been done, and at a later date we find that dorsiflexion is prevented, an incision should be made and the offending prominence chiselled away. The space left by the removal of bone should be packed with fat removed from any convenient part. This prevents the new callus exudate from giving rise to trouble. In all operations where bone is removed

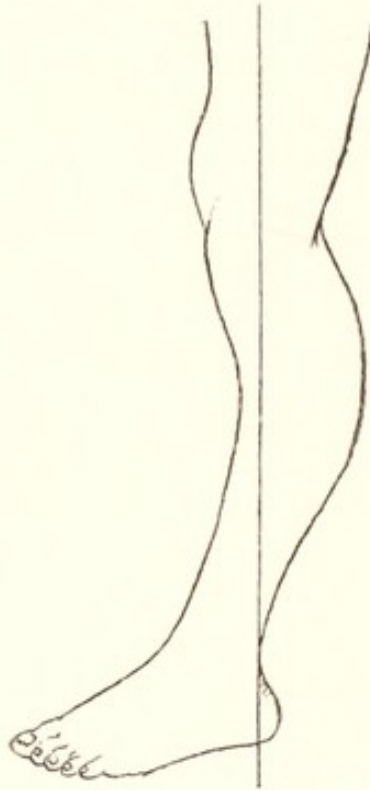


FIG. 15.—Diagram to illustrate position of leg and foot in posterior bowing of fractured tibia.

and pseudarthrosis is desired I find the generous employment of fat most helpful, and in order to reduce the callus exudation the exposed cancellous bone should be lightly hammered.

#### *Tibia.*

In fracture of the tibia faulty alignment may be brought about by posterior bowing; the weight of the body may be thrown so far back that it passes at some distance behind the ankle, as shown in Fig. 15.

#### *Fractures of the Femur.*

Fractures of the neck of the femur, and all fractures about the small trochanter, should be treated in the abducted position to prevent deformity of the coxa vara

type (Fig. 16 A and B). Stiffness of the hip associated with limitation of abduction, often accompanied by "osteoarthritic" changes in the hip-joint, is the sequel of malunion in this region. To prevent this it is necessary

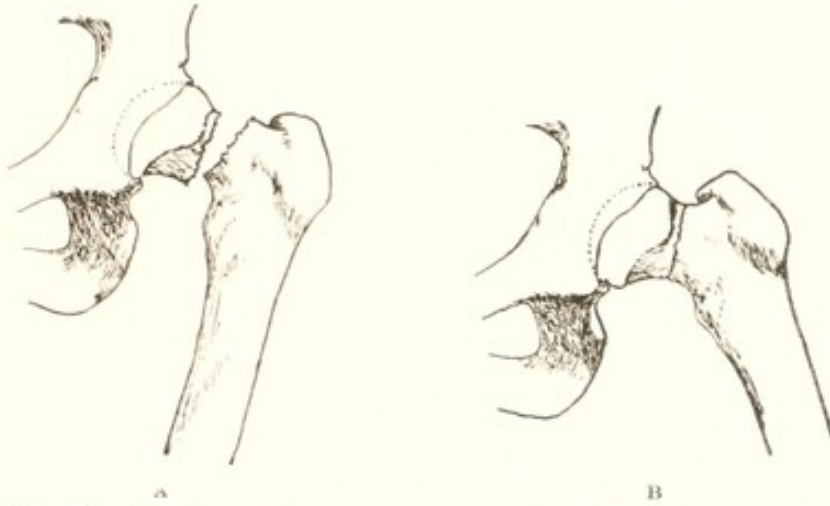


FIG. 16.—Fracture of neck of femur. A, Fractured neck, showing position in adduction. B, Fractured neck of femur correctly reduced in abduction.

to secure abduction and to maintain extension in the abducted position. If the fracture is of some weeks' standing and the area is still tender, the callus is certainly not consolidated; forcible abduction and extension in an abduction frame and rigid fixation in this position will

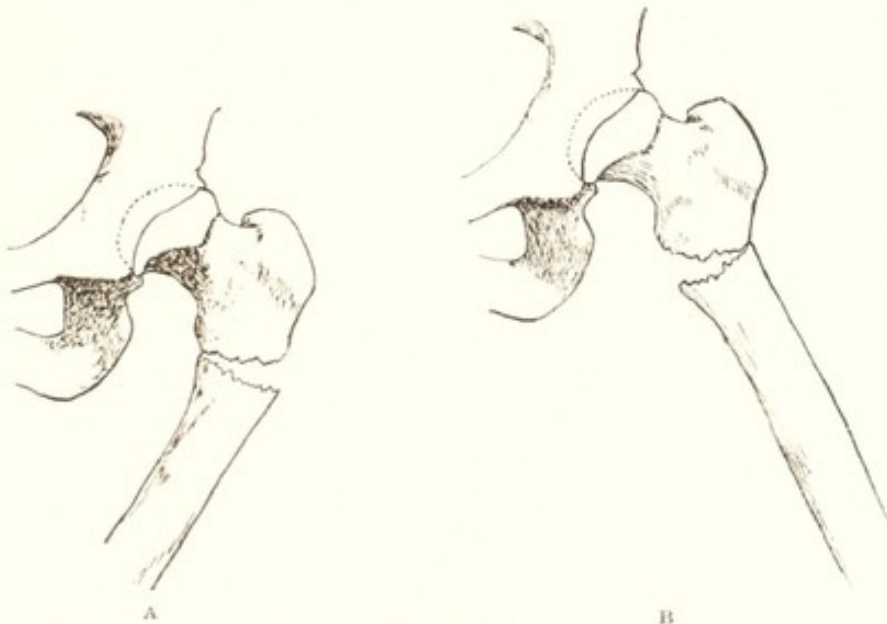


FIG. 17.—Fracture of upper third of femur. A, Adduction deformity. B, Abduction faulty, as the upper fragment does not participate.

then be followed by adaptation of the callus to the corrected position.

Fractures of the shaft of the femur, especially in the middle third, are frequently followed by gross forms of

malunion, which will excellently serve to illustrate malunion in long bones.

The faults commonly found are:

1. *Shortening or overriding*, due to the fact that (a) reduction has been incomplete, the surgeon not having pulled until the fractured limb was at least as long as its fellow; (b) the method of fixation and extension used has been inefficient, and the muscles have caused overriding after the fracture was set; (c) the body weight

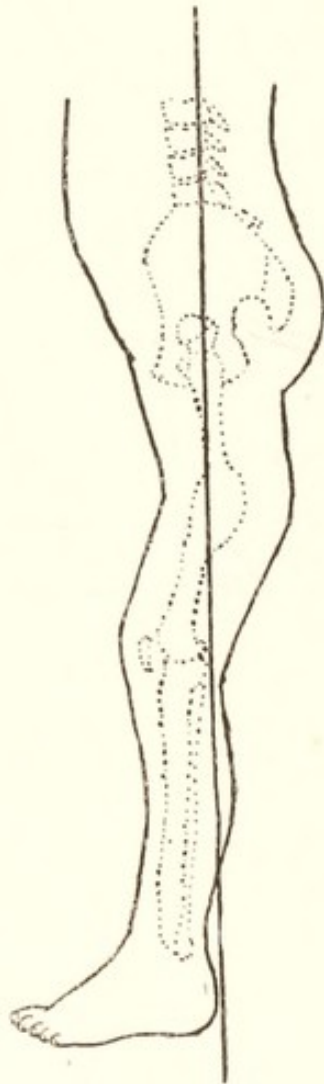


FIG. 18.—Diagram to illustrate posterior sagging in malunited fracture of femur in the middle third.

has caused yielding of the callus after the patient has begun to walk.

2. *Angular deformity or erroneous alignment* is the result of inefficient methods of fixation, and more particularly of inefficient extension in the line of the limb. Erroneous alignment throws all the muscles of the part out of line, and, what is more important, puts the joints above and below out of their correct relations. A common fault in fractures at the junction of the lower and middle third is a posterior sagging (Fig. 18), which is best seen

when the patient begins to walk. The body weight is thus thrown on the posterior part of the capsule. The deformity resembles a genu recurvatum.

3. *Rotation deformity* is far too common, and can only be the result of careless and inefficient treatment.

#### *Diagnosis.*

In a case of malunion of the shaft of the femur in which one or more of these elements are present the whole region of the fracture is tender, and is also the seat of pain for weeks and months after consolidation ought to be complete. This means that consolidation is far from complete, and that the callus is the seat of active change. Nature, in fact, is struggling with the problem of buttressing up the malunited fragments so that they can meet the forces which are acting in them: hence the exuberant production of callus, which is attended by pain and tenderness.

#### *Treatment.*

In such cases it is not difficult to break down the callus by manipulation. Extension with block pulley and suitable tackle will then stretch the muscles and reduce the over-riding by  $2\frac{1}{2}$  inches on a single occasion (Fig. 3, p. 62). Rotation deformity is, of course, corrected at the same time.

If open operation is employed, the simplest form of osteotomy is an oblique one through the callus between the original fragments of the shaft. Once these are cut through the greatest part of the remaining difficulty is in fully restoring the length of the limb by extension. The big muscles of the thigh can only be fully overpowered by the use of block pulley and tackle (Fig. 3). When this has been accomplished the leg is fixed in a Thomas's knee splint, the tuber ischii rests on the padded ring, the extension straps are secured to the bottom of the splint. We are then sure that, whatever happens, the muscles cannot contract and cause further overriding. The only thing the muscles can do is to give up the struggle, and, as a matter of experience, this is what always happens. The surgeon finds on his next visit that he can get perhaps another half inch of lengthening by further extension on the straps. Further, in a Thomas's knee splint good general alignment of the limb can easily be secured—in fact, is obtained almost automatically. The only points to which the surgeon has really to attend are the position of the foot—to see that there is no outward rotation—and to keep up firm extension.

Locally, splints are applied to control lateral movement. In the first instance this is not difficult. When resetting a malunited fracture it is not so easy, for the callus already formed gets in the way.

In these malunited fractures of the femur of some weeks' standing with considerable overlapping, after refracturing the bone by force the pulleys should always be applied and a great effort made to secure both length

and alignment. To render this less difficult, it may be wise to move the fractured ends freely in all directions to disturb and disengage the fibrous and bony exudate. The extension by pulley should be maintained for several minutes to lessen the resiliency of structure and to reduce the chance of telescoping. The limb is then maintained in extension by a Thomas's splint, and on two or three subsequent occasions the pulleys are applied. By these

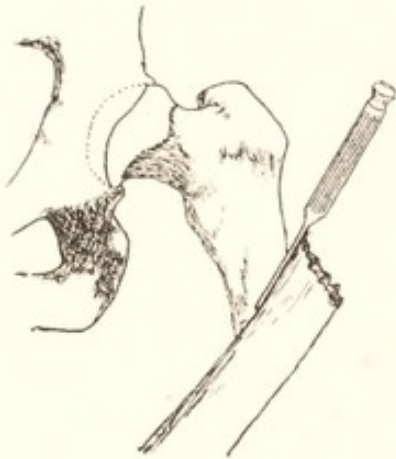

FIG. 19.—Fracture of upper third of femur. Diagram to illustrate osteotomy to correct common deformity.

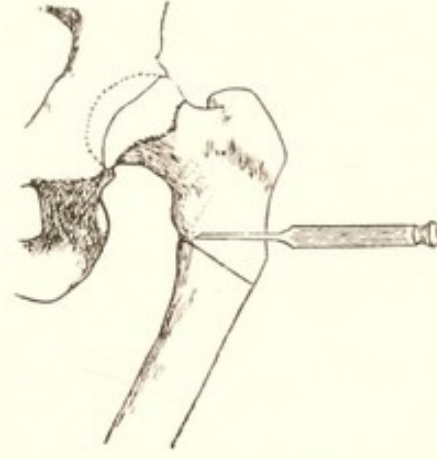


FIG. 20.—Fracture of upper third of femur. Diagram showing removal of wedge of bone to correct adduction.

simple means overlapping of three or four inches can be overcome, and an open operation is avoided. The "damming" method already described is applied to assist osteogenesis, aided when necessary by percussion.

Whatever operation may subsequently be needed, I cannot too strongly urge the necessity of preliminary pulley traction in order to secure a better length, and in this way prevent the sacrifice of bone.

In cases in which union in the vicious position is so complete and firm as to render operative procedures necessary, the procedure to be followed is influenced by the

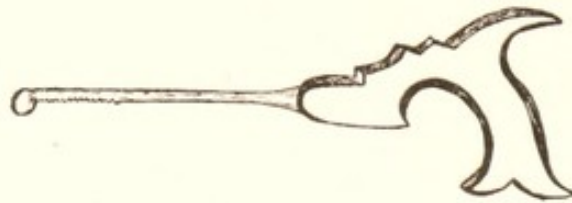

FIG. 21.—Author's osteotomy saw with protected end.

special type of union present. If it is a mere case of faulty alignment, with fair apposition, a small puncture and an osteotomy saw will do what is desired (Fig. 19). An *x-ray* photograph should be taken, and the section made through the angle. The case is then treated as one of simple fracture. If there is overlapping of the fragments, with no excessive callus, the saw is introduced between the fragments and the lateral fixation undone. Pulley extension will

then diminish or obliterate the shortening, and the subsequent treatment will maintain both length and alignment. In other fractures higher up, with great thickening and lateral deflexion, a wedge is removed from the convex side of the bent bone, and a fracture at the point preferred may be produced some days later (Fig. 20). Extension and abduction of the limb should then be secured. In rarer instances, when unusual deformity and overlapping have occurred, it may be necessary to explore the fracture by a free exposure, to separate the fragments, to remove bone, and to plate.

#### CONCLUSION.

It may appear that in this paper I have dealt more with the treatment of fractures than with the treatment of malunited fractures, but a moment's reflection will satisfy us that there is only one problem before us—the restoration of function. Operation or manipulation to free the ends of the bones when union has occurred in a faulty position is only a preliminary step. In short, a malunited fracture cannot be cured by operation—all the operation can do is to reconstitute the fracture or make another fracture similar to the first.

If after this the subsequent treatment is not better than the treatment adopted in the first instance, an improvement in the result is not to be expected. This is probably why the statistics of late operations to correct malunion are often disappointing. The surgeon must not merely reduce the fracture, but must maintain the corrected alignment until consolidation of the bone is secured.

The fundamental principles applicable to simple fractures hold good in the case of compound fractures. The difficulties in carrying them out are obviously materially increased. Once, however, serious complications are past there will be ample time and opportunity to correct faulty alignment and to restore the best possible function to the fractured limb.

The fractures met with as a result of gunshot wounds are usually very serious, and I have witnessed with pride the splendid efforts made by the young surgeons in France to save these mangled limbs. Sometimes we hear criticisms at home, not always kindly, sometimes very unjust, because amputations are performed without flaps, and limbs still suppurating are not in the best position. If the whole truth were known, these mangled limbs and flapless amputations often represent surgical triumphs where every art and device has been concentrated upon the salvation of life and limb.



## V. TRANSPLANTATION OF BONE, AND SOME USES OF THE BONE GRAFT.

INJURIES inflicted by modern instruments of warfare are so often associated with loss of considerable portions of bone that it is necessary to bring together various known means of replacing these defects. The present paper aims at giving a brief account of my experience of the grafting of bone.

Clinical experience in recent years justifies the expectation that a bone graft will grow and fulfil the purpose desired by the surgeon if the operative technique is appropriate and scrupulous attention is paid to asepsis. Before dealing with the practical difficulties to be encountered, brief reference must be made to various theories which have been advanced concerning the growth of transplanted bone.

Three of the theories may be mentioned :

One which has been widely held in Europe is that, when a bone graft is transplanted, the grafted bone always dies and is absorbed, and that any new bone formed in its place is laid down by the periosteum, which is the only part of the graft which really survives.

The second is the well-known view of Macewen that the new bone is formed by the proliferation of osteoblasts within the bone itself, and is quite independent of the periosteum, which is only a limiting membrane.

The third theory is that the graft is not osteogenetic, but merely acts as a suitable and appropriate scaffolding along and through which new capillaries and granulation tissue can grow, taking with them osteogenetic cells from the living bone ends, between which the graft is placed.

Recent investigations definitely prove that bone transplanted even into the abdominal wall may grow, and that this may happen whether periosteum alone or bone alone is transplanted.

McWilliams, of New York, whose investigations are thorough, concludes that the survival of the graft depends on the establishment of an efficient blood supply, and that the blood supply is more quickly and efficiently established when periosteum is transplanted with the grafted bone.

I advise that, whenever possible, it is best to transplant periosteum with the bone, and further, to be sure that the graft should also contain part of the endosteum.

Every surgeon knows that in simple comminuted fractures portions of bone must often be entirely, or almost entirely, cut off from their usual blood supply, but that necrosis of these fragments is extremely rare, while in the presence of toxins of bacteria, as in septic compound fractures, more or less necrosis is very prone

to occur even in portions of bone still connected with their blood supply.

It is therefore safe to conclude that whether the osteogenic cells are derived from periosteum or from bone, scrupulous asepsis is essential to their welfare; that if they are not poisoned by septic toxins they can survive on exuded lymph or plasma for a reasonable period while a new blood supply is being established; and further, that the open cancellous medullary aspect of the bone and the periosteum both furnish convenient means of access for the new blood supply, and should be retained in the graft whenever it is possible.

It is important to remember certain further facts, which are established beyond doubt. First, that bone taken from one of the lower animals and grafted into man very rarely lives, even with the most careful technique. Secondly, that bone transplanted from one individual to another only lives in exceptional cases. These, therefore, are methods which cannot be recommended. Finally, it is established that autogenous transplantation of a portion of the patient's own bone from one portion of the body to another is fairly constantly successful if the conditions are suitable and the technique correct. The nature of the technique and the conditions found suitable will appear in the subsequent parts of this paper.

Professor Tuffier's experiences in relation to the transplantation of ovaries are interesting and instructive. He found that when ovaries were removed, it was possible to retain the internal secretory influence of the ovary by implanting a healthy portion of one ovary in the abdominal wall. If the patient's own ovary was employed it almost invariably survived and became tender at each subsequent monthly period. In cases in which no part of the patient's ovaries could be used, he tried borrowing an ovary from another woman on whom ovariectomy had to be performed. In every case this transplantation from one individual to another failed.

There are other facts which should be kept in mind when repairing bony defects. For example, if a bridge of periosteum can be preserved, osteogenesis, or new bone formation, is much more likely to occur, and the gap will be filled with greater rapidity than when no bridge is possible. Stiles's cases of subperiosteal resection for tubercle are evidence of this.

Since the survival of implanted bone is dependent on the establishment of circulation within it, it follows that necrosis is less likely to occur in small fragments than in large pieces, when the periosteum cannot be preserved. It is therefore a good practice to scatter small fragments of bone along the site of the defect, for the cells in them can live for some time on exuded plasma; the new blood supply will reach them in a few days.

#### GENERAL CONSIDERATIONS AS TO TRANSPLANTATION OF BONE.

In performing transplantation of bone to replace a defect in the continuity of a long bone the surgeon has to

keep certain points in view, and in all must follow Nature's rules.

### 1. *Nutrition of the Graft.*

In order to ensure the nutrition of the graft it is essential to observe the following points :

(a) *Perfect haemostasis* in the bed in which the graft is to be laid. A mass of blood clot round the graft endangers its life, for this blood clot must first be "organized" before the new capillaries or granulations can reach or grow into the bone graft to supply it with blood.

(b) *Perfect asepsis*, for toxins, if virulent, will almost certainly cause the death of the bone cells in the graft before a protective vascularization can occur.

(c) *Preparation of the bed* in which the graft is to lie. It should be freshened, so that rapid adhesion and organization may take place between the graft and surrounding tissue. Moreover, the soft tissues should be brought round the implanted bone.

### 2. *Union of the Graft.*

The union of the graft with the ends of the bones between which it is placed can be helped in a number of ways. The ends of the bone should be opened up and prepared for the reception of the ends of the graft. It is desirable that some part of the graft should be in contact with the vascular medullary cavity. Sometimes it is possible to push the graft straight into the open medullary cavity (Fig. 1). As a rule I avoid the use of plates and screws, as they tend to delay union. Various methods of fixing grafts will be mentioned later.

Perfect immobilization is an important factor in securing early vascularization and union. It is quite true that a certain amount of mobility at the seat of a fracture increases the output of callus, but this is of a vicious and really useless type. It is produced merely by osteogenesis occurring in the increased exudate caused by tearing and injuring the granulation tissue which is being produced to unite the fragments of bone. It is much more reasonable to keep the part immobile until union is firm and has begun to ossify; then the next stage mentioned below comes into play to strengthen the union.

### 3. *The Growth of the Graft.*

The growth and development of the graft so that it can perform the function of the bone it replaces is best promoted by a modified or guarded exercise of the function of the bone, for then the bone cells respond to the stresses to which the part is subjected, and build according. This is known as Wolff's law, which is an essential foundation of all surgery of bones and joints. This law is familiar to all surgeons, but it will not be out of place to quote it here : "Every change in the formation and function of the bones, or of their function alone, is followed by certain definite

changes in their internal architecture, and equally definite secondary alterations of their external conformation in accordance with mathematical laws." It follows from this that when the graft and the bone have begun to unite firmly the union will become stronger if a certain amount of functional use is allowed, provided it is not violent enough to tear up or break the union. Thus in a graft in the leg or in the forearm the patient is encouraged to move the toes or fingers while the part is still in splints, so that the slight traction of the muscles on their origins round the site of the graft may produce a physiological stimulus to increased growth.

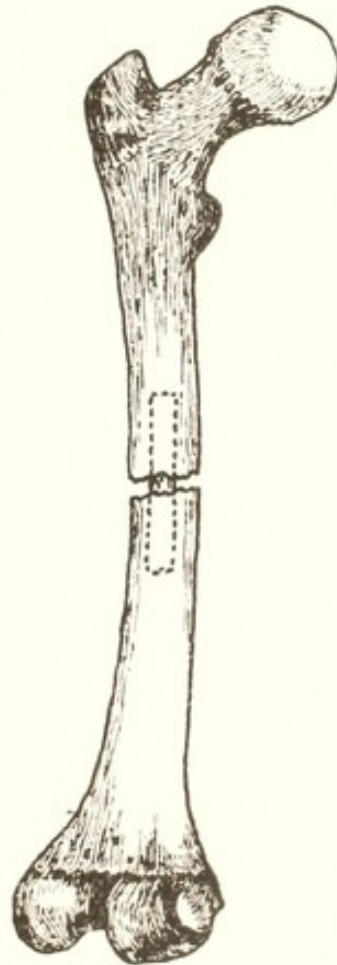


FIG. 1.—Graft pushed into open medullary cavity.

In the next stage the splints adapted must allow more active use, while at the same time guarding against strain which might cause a "fracture" at the seat of the graft. Thus in the case of the lower limb an ambulatory splint is allowed while the part is still firmly controlled by local splints.

#### THE USES OF BONE GRAFTS IN MILITARY SURGERY.

1. *To Replace Bone Destroyed by Infective Processes, such as Acute Osteomyelitis.*

As an instance of bone grafting after osteomyelitis and of the extraordinary vitality of the transplant, I would relate the following facts: Several years ago I was

consulted in the case of a youth (A. B.) with advanced osteomyelitis of the tibia. I cut down along the whole length of the site of the tibia, and found that the shaft had completely disappeared, and the periosteum also. When I had scraped away all putrid material, there remained little except the epiphyses and exposed muscles. A long sinus probe was fixed lengthwise between the epiphyses in order to maintain the distance between them, and the wound was allowed to granulate. Several months after the wound had healed and the probe had been



FIG. 2 A.—Case of A. B. Osteomyelitis of tibia: condition after removal of necrosed bone. (Sketch from skiagram.)



FIG. 2 B.—Case of A. B. Probe to hold end of tibia apart during healing of wound. (Sketch from skiagram.)

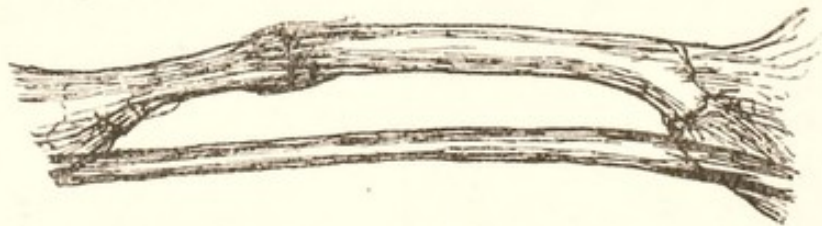

FIG. 2 C.—Case of A. B. Fracture of graft; marked callus exudation. (Sketch from skiagram.)

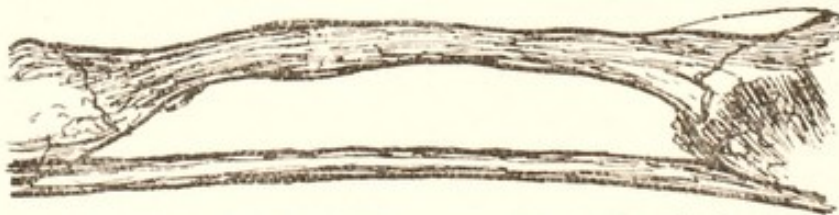

FIG. 2 D.—Case of A. B. The fracture of the graft united. (Sketch from skiagram.)

removed I transplanted a long strip of tibia from the sound limb. This rapidly grew in thickness. The patient was discharged from hospital, and gradually discarded all supports. Seven months later he was knocked down one day, receiving a blow on the leg which broke the transplant, and I possess interesting radiographs of the callus exudation and firm union at the site of fracture. This case was a great encouragement to me, for the transplant was laid in an environment of firm cicatricial tissue. The illustrations are drawn from the *x*-ray photographs (Figs. 2 A, 2 B, 2 C, 2 D).

2. *To Replace Defects of Bone where Portions of Bone have been blown away by Gunshot Wounds.*

Treatment here follows the same lines as in the case cited.

3. *To Immobilize Injuries of the Spine in Cases of Tuberculous Arthritis, or Injuries which lead to the Development of Kyphosis.*

In the present war there have been many injuries of the spine which have been followed by the rapid development of a kyphos, sometimes due to traumatic osteo-arthritis, sometimes to tuberculous changes following the original injury. In either case the treatment requires prolonged rest, during which the patient is fixed in recumbency. The period of recumbency can be very materially reduced by a judicious operation.

4. *As a Substitute for Plates and Screws.*

Bone grafting can be used as a substitute for plates and screws in the treatment of certain types of fractures, and to assist in securing union in cases of ununited fractures.

#### TECHNIQUE OF BONE GRAFTING.

Pieces of bone for grafts may be taken from almost any bone in the body, but for most purposes the tibia is the most convenient quarry in which to delve, for from it pieces of bone can easily be cut of any length or thickness likely to be needed. When a curved piece of bone is required, as in surgery of the jaw, a portion of suitable shape may be found in one of the ribs. I have employed the shaft of the first metatarsal to replace a defect in the ulna. The periosteum is left behind, the required length of the shaft with the whole of the endosteum being transplanted. The shaft of the metatarsal bone is rapidly regenerated. The tibia, however, is the bone of choice, as periosteum can be transplanted with the bone.

#### *Operation.*

The first stage of the operation is to prepare the bed for the graft, freshening the bone ends. A pliable probe is then laid in the defect and bent to the exact length of the graft required. The wound is packed with gauze to stop bleeding and covered with a sterile towel while the surgeon removes the graft from the selected area.

If the tibia is chosen, an incision of suitable length is made along the outer side of the anterior border of the tibia and the tibialis anticus is partially separated from its insertion. The bent probe is then laid on the bone, and the exact length of the graft required is marked off. The periosteum is then incised on the outer and inner surfaces of the bone, completely mapping out the portion to be removed.

The removal of the graft is greatly expedited by the use of a double circular saw (Fig. 3) electrically driven. Great care must be taken to ensure that any part of the apparatus with which the surgeon or his assistant may come in contact is scrupulously sterilized.

If an electric motor is not available a good hand motor may be used. Failing both, the graft may be cut out with drill and chisel, but this is a slower process, and requires

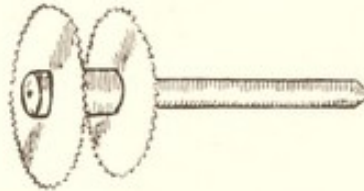


FIG. 3.—Double circular saw for cutting bone grafts.

some care to avoid splintering the graft or splitting the tibia. The method of procedure is to drill a series of holes along the line of the incision in the periosteum, and then connect these with the chisel. The drill holes should be made into the medullary canal, so as to ensure having some of the medullary aspects of the bone in the graft (Fig. 4.)

The transplantation should be made immediately; the graft should be picked up with forceps and not touched even with the gloved fingers. It is laid directly into the

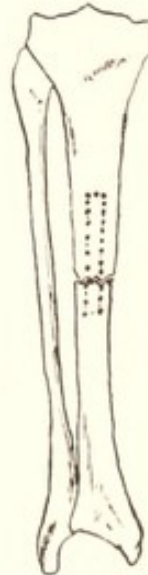


FIG. 4.—Sliding graft marked out by drill holes preparatory to cutting out with chisel.

prepared bed, in which all bleeding has stopped by this time. I am convinced that it is a mistake to wash the graft in saline lotion or leave it in saline while something else is being done. The best results follow immediate closure of the deep tissues round it and suture of the surface wound. The limb must then be securely controlled in correct position either by splints or by a plaster-of-Paris case.

## SPINAL FIXATION.

Two operations are generally described for spinal fixation—*Albee's* and *Hibb's*. The details of the operations ought to be pretty well known, as they have been before the profession for several years.

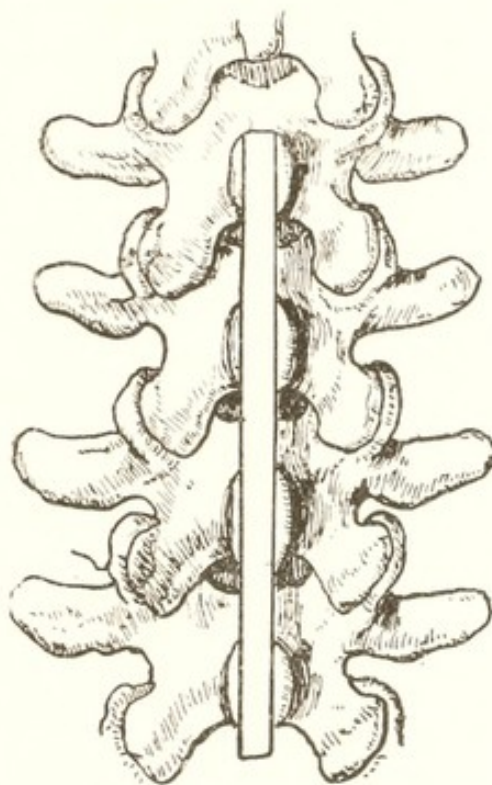


FIG. 5.—Bone transplanted into cleft made in spinous processes (Albee's method).

*Albee's Operation.*

This operation consists in transplanting a slip of the tibia into a series of spines of vertebrae, bridging the weak spot in the vertebral column (Fig. 5).

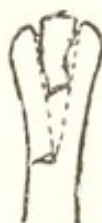

FIG. 6.—Diagram of split spinous process with graft inserted in cleft.

The surgeon should begin by preparing the site for the graft. Each spine, including two above and two below the weak or diseased vertebra or vertebrae, is split and broken outwards (Fig. 6), the junction of spine and lamella being also roughened. The bed is packed with gauze to stop bleeding.



The graft from the tibia is then cut with the circular saw, or chisel and drill. The front of the tibia is reached by securing the heel against the buttock with the knee in acute flexion. This enables the surgeon to cut the graft without turning the patient over. The whole operation can thus be performed quietly and expeditiously.

The graft is then transferred and implanted while an assistant stitches the wound in the leg.

No difficulty has been experienced in nursing these cases on their backs in a Thomas's frame. This is applied most easily after these operations by laying the frame face downwards over the patient and turning the patient and splint together with the aid of a sheet, thus avoiding any strain upon the implant.

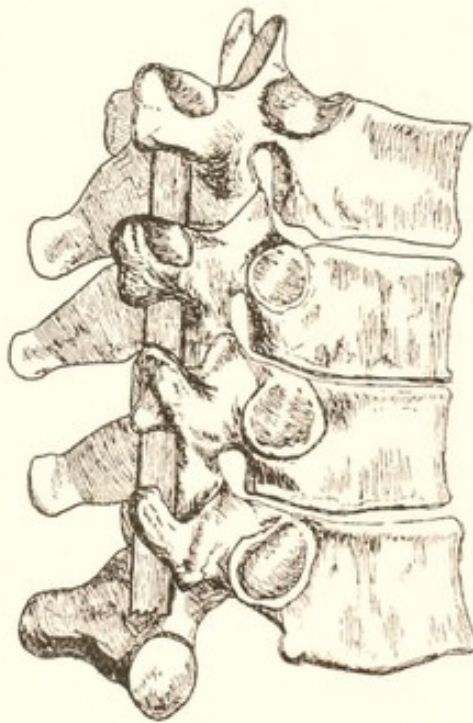


FIG. 7.—Bone graft laid upon the laminae.

#### *Hibb's Operation.*

In this operation bony fixation of the spines is obtained without transplanting bone from the tibia. The spines are split, the upper and lower margins are broken away towards the adjacent spine, so that the fragments split away from one spine interlock with those split from the next. The laminae can also be ankylosed. Superfluous chips of bone are sprinkled along the site of the operation, so that a line of callus is formed locking all the spines together. I often prefer to lay the graft upon the laminae rather than between the spinous processes. A very suitable bed can be prepared there upon which the transplanted bone easily lies (Fig. 7).

These operations are particularly useful in cases in which the vertebrae affected are in the lower dorsal or lumbar

regions, for it is difficult to control these areas completely in a support or jacket in which the patient can go about. The alternative is prolonged recumbency fixed in a splint or Thomas's frame. The result of one or other of these operations is that a patient who in former days would have been kept fixed in recumbency for a year or more can be allowed up in a light spinal support in three months, and can go about his ordinary business as soon as he can walk comfortably, for with this osseous bond between the vertebrae there is practically no fear of kyphotic deformity occurring.

#### TECHNIQUE OF BONE GRAFTING FOR FRACTURES AND DEFECTS IN CONTINUITY.

The technique of bone grafting for fractures and for the replacing of defects in continuity of long bones, either from loss of bone or from non-union, follows very similar lines.

My views on the use of plates and screws in the immediate treatment of fractures have been stated before, and need not be repeated at length. In most parts of the limbs good alignment and good functional results can be obtained by simple reduction and setting in appropriate splints, and therefore the routine use of plates seems superfluous. The art of setting fractures is deserving of more study than has been given to it by many members of our profession in recent years. In the long bones correct alignment of the limbs, and therefore of the lines of action of muscles and joints, is more important than faultless apposition of the ends of the fractured bone.

Excellent as plates and screws are in certain emergencies, experienced surgeons know that they produce actual delay in true and efficient osseous union of the fracture.

In any case a metallic plate is a foreign body, and the inevitable tendency of the tissues is to encapsule or encyst the foreign body, while transplanted bone can be built into the structure of the part, and therefore assists osteogenesis.

#### *Bone Grafting for Recent Fracture.*

In my experience, spiral fracture of both bones of the leg, especially in the lower third, is the only fracture in the limbs which regularly presents almost insuperable difficulties to satisfactory reduction and setting by non-operative means. The difficulty is not in reducing the fracture, but in persuading the fragments to stay in correct alignment. The cause lies in the great tendency of the foot and lower fragment to rotate, and then the fragments override.

#### *The Sliding Inlay Method (Albee).*

In this fracture the sliding inlay of bone, described in a previous article (see page 63), is a very fascinating and

simple way of locking the two fragments so that they do not easily disengage when they undergo slight rotatory movements. All that is required is the parallel circular saw shown in Fig. 3.

The fracture is reduced and held or clamped in position while the cuts are made as in the diagram (Fig. 8, A and B). The shorter piece is lifted out and then the longer piece with the medulla is slipped down to lock the two fragments of the broken bone. The smaller fragment is then laid into the gap above the longer fragment which has been slid down. Muscles, periosteum, or any other of the deep tissue belonging to the part are stitched over the graft, the wound is closed and the fracture put up in sheet-iron splints or plaster, taking care that no displacement occurs. In a few days organization has occurred sufficient to prevent any further danger of displacement

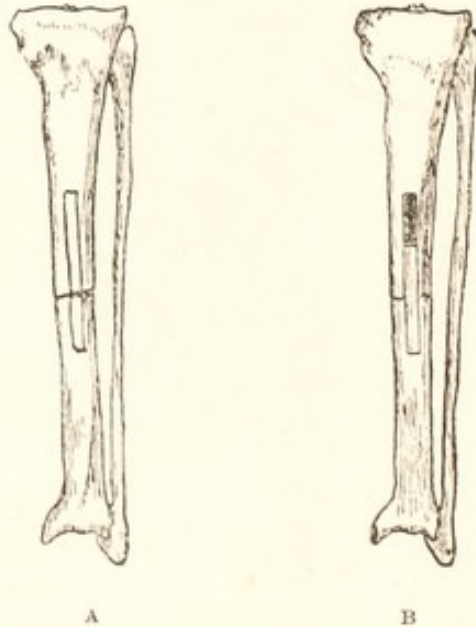


FIG. 8.—A, Inlay slide before being placed in position. B, Inlay graft placed in position.

unless there is carelessness or some unusual disturbance of the part. It is seldom necessary to peg or screw the fragments, and the introduction of a foreign body is to be avoided.

This spiral fracture of the tibia in the lower third of the leg is practically the only ordinary fracture for which, in my opinion, operation should be considered at once as an immediate procedure, and then fixation by bone to prevent rotation is preferable to plating if it can be done. Failing facilities for a proper fixation by bone, plating comes next.

Neither plating nor bony fixation seems necessary in any other ordinary fracture of the limbs. In the case of unusual fractures exceptions occur. Further, each surgeon must, of course, use his own judgement in every case that comes under his notice, and employ those methods which he best understands and in which he feels most confidence. These

will differ according to the surgeon's training. My contention is, however, that a surgeon skilled in the use of splints can get good results so generally that operation is rarely needed.

### *Ununited Fractures.*

It may be admitted that in dealing with ununited fractures when firm fixation is required, plates and screws afford a most secure and rapid means of fixing the fragments. This method requires less surgical skill than when bone grafts are used, both in the operative procedure and the after-treatment. There is, however, always the point to be considered that in these cases the patient has already shown defective osteogenetic power at the seat of fracture, and the plate is, after all, a foreign body, which will be likely to impede osteogenesis, while a bone graft is a direct assistance to osteogenesis.

#### *Method of Dealing with Ununited Fracture.*

For many years I used to cut down on the ununited fracture, crush and drill the ends of the bones to open

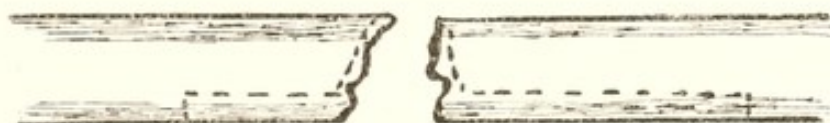

FIG. 9 A.—Fashioning of bed and freshening of ends for a slide graft in an ununited fracture.

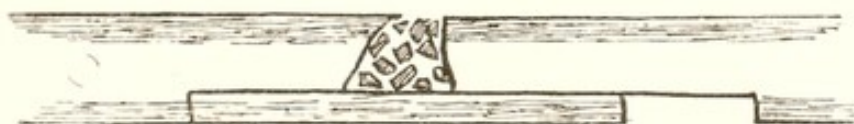

FIG. 9 B.—The slide in position; portion removed from bed distributed between ends of bone.

up new routes for fresh blood vessels, and turn a strip of periosteum off one fragment down to the other.

At a later period I employed in addition animal bone as a graft, with results which were not very encouraging. The use of a strip of the fractured bone as a bridge between the two fragments was followed by much better results. (Figs. 9 A and 9 B.)

It is assumed in the methods now to be described that autogenous grafts are always used. The three methods of employing a graft have been referred to in a previous article.

#### *1. The Lateral Graft.*

This consists of laying a strip of bone along the side of the bone to be repaired, taking care to make a fresh bed for

the graft along its whole length, so that raw bone is in contact with raw bone (Fig. 10).

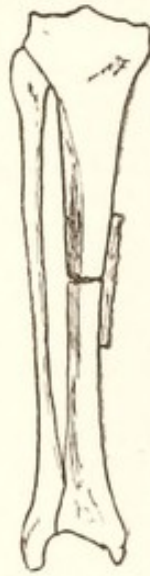

FIG. 10.—Lateral graft.

It is the simplest method, and often the only one which can be used—for example, when the ends of the broken bone are tapering and wasted (Fig. 11, A, B, C).

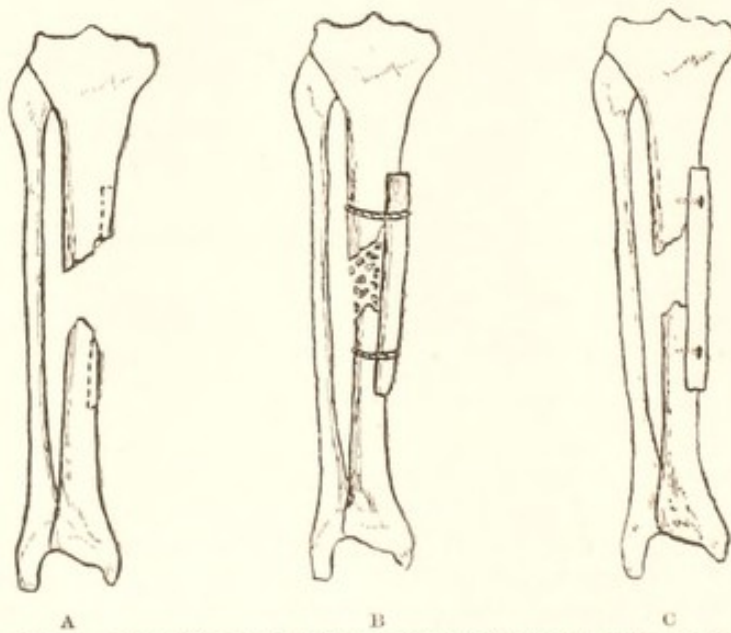


FIG. 11.—A, Preparing bed for transplanted lateral graft. B, Transplanted lateral graft held in position by catgut. C, Transplanted lateral graft held in position by nails.

## 2. *The Intramedullary Plug* (Fig. 1).

This can only be employed when a good open medullary canal is available and the transplanted bone can be inserted into the medulla above and below the fracture. This is often difficult. It is advisable, when possible, to use it in combination with the sliding or the lateral grafts.

### 3. *The Sliding Inlay.*

The inlay method described above can be employed when bridging a gap; the bits of bone cut from the end of the slide must not be wasted, but should be broken up and sown along the site of the defect to form additional foci of osteogenesis.

A combination of the sliding inlay (Figs. 9 A and 9 B) and medullary plug is a strong and satisfactory method when available (Fig. 12).

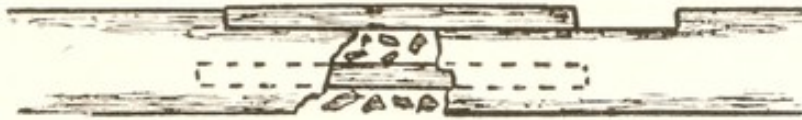


FIG. 12.—The intramedullary plug used in combination with the sliding or lateral graft

### CONCLUSION.

Recapitulating in brief, it may be said that, whatever particular theory of osteogenesis may be the true one, the following points have proved valuable in practice :

The area of the graft must be kept scrupulously aseptic, and free from unnecessary blood clot. Adequate blood supply is necessary to the growth of the graft.

The graft must be placed in close apposition to raw surfaces of the bone with which it is to unite.

The whole region must be kept fixed for a long period for undisturbed organization to take place.

The bone graft should be autogenous, and it is better that it should include both periosteum and medulla wherever this is possible, for both these aspects of the bone afford facilities for the growth of new blood vessels.

Surgeons should have patience, for union is often delayed, and hasty conclusions that union is not going to take place, and consequent relaxation of strict fixation of the part, may convert a case of delayed union into one of non-union.

After any of these procedures it is essential to fix the limb absolutely to let new vessels grow undisturbed by chance movements, for the idea of the operation is that all the transplanted bits of bone shall become vascularized.

As a general rule, the limb should be kept fixed and undisturbed for at least twice the time necessary for union of the same bone in an ordinary simple fracture.

I often see cases which have been operated on, often plated, by some other surgeon, in which splints have been removed at the end of a few weeks, and the case has been regarded as a failure because union has not taken place.

There is no definite time within which a fracture will unite. The times given in textbooks are understated as applied to the majority of cases. For example, I may quote the case of a patient, seen in 1908, with an ununited fracture of the humerus of twelve months' duration, which was treated by the "hammer and dam" method, but

had to be kept still for nearly six months before the bones united. The ultimate union was absolutely satisfactory. Operative procedures had previously failed. This question of the consolidation of fractures has been discussed in a previous paper. The wounds received in this war have brought the surgery of septic bones very much into the foreground, and bone grafting will have to be very extensively practised. We must be careful to allow a sufficient time to elapse before proceeding to this operation. It is difficult to formulate an exact rule as to when the operation should be performed, for we seem never to be quite free from the danger of recrudescence of sepsis. My habit is to wait for at least six months after a sinus is closed, during which time and for a variable period afterwards efforts can be made to improve the general nutrition of the limb. It frequently happens that during this delay union of the fragments takes place, and no transplantation is needed. Early operation is to be discouraged from every point of view, and failure to observe this fact has resulted in many a tragedy. It is very exceptional, unless there has been a great loss of bone, for non-union to persist in fractures which are the seat of the type of suppuration met with at this time.

## VI. DISABILITIES OF THE KNEE-JOINT.

---

EVERY kind of disability of the knee-joint may occur in military practice, from a simple sprain to the results of a severe wound.

An attempt will be made in this article to give a broad classification of these derangements and disabilities, with their diagnostic signs, and to indicate appropriate lines of treatment.

There are three common conditions which are not always as clearly distinguished by practitioners as they might be. They are, (1) simple sprain of the lateral ligament, usually the internal, (2) slipping of the semilunar cartilage, and (3) nipping of the infrapatellar pad of fat. All these injuries may be produced by a twist or fall, which at first does not seem serious; all are associated with effusion of fluid in the joint, and in all the patient complains of more or less recurring disability after the lesion, unless it has been recognized and treated in the first instance.

### SPRAIN OF INTERNAL LATERAL LIGAMENT.

Sprain of the internal lateral ligament is distinguished by definite pain and tenderness on pressure over the attachments of the internal lateral ligament; the patient himself localizes the pain of which he complains to the inner side of the knee; definite pain and tenderness is not found anywhere else about the knee, and the movement of eversion and external rotation of the leg stretches the injured ligament and retards recovery.

The treatment indicated, therefore, is firm strapping round the knee in order to steady it, and a raising of the inner side of the heel to divert body weight to the outer side of the foot, and thus relieve the ligament from tension. It is hardly necessary to say this treatment is preceded by rest in bed, usually with the aid of a straight posterior splint. This is the initial treatment, but neglect of the after-treatment just mentioned renders the patient liable to recurring injuries of the ligament.



## INTERNAL DERANGEMENTS OF THE KNEE.

A regular gradation of injuries is met with, from a slight strain of the attachments of the internal semilunar cartilage of varying degrees of gravity to fractures of the spines of the tibia with rupture of the crucial ligaments. The former is a condition scarcely distinguishable at first sight from a simple sprain; the latter is at once obvious as a grave disability. It has become very important in military surgery to be able to distinguish these conditions clearly from signs which can be determined by the surgeon rather than by symptoms described by the patient; as, in my experience, a considerable number of men who wish to avoid service have found that they can puzzle the medical officer by complaining of obscure pain and disability in the knee.

There are very many cases in which military surgeons have been led to operate upon a normal joint, expecting to find some abnormality of the semilunar cartilage. The cartilage is very frequently torn in its posterior portion, and before deciding at operation that it is not damaged it is necessary to dislodge it outwards. Hence the necessity for careful consideration of symptoms before deciding to operate; it must be realized that exploration, in the case of a cartilage, really involves its removal, otherwise a damage at the posterior part of the cartilage may be overlooked.

*Mechanism of Certain Injuries.*

Probably the best way in which to get a clear idea of the injuries which lead to error is to consider the mechanism of the various injuries, beginning with simple sprain and going on to real rupture or tear of the semilunar cartilage, and to compare them with bruising of the infrapatellar pad of fat, which is a lesion not always recognized or understood.

All these conditions may lead to a recurring chronic synovitis. Every case of recurring synovitis has a cause, and practically each is curable if the cause is recognized and receives appropriate treatment.

It has already been stated that simple sprain of the internal lateral ligament is marked by a specially tender spot over the attachments of the ligament and nowhere else.

*Rupture of Internal Ligament and Damage of the Semilunar Cartilage.*

If we remember the anatomical fact that the internal semilunar cartilage is closely connected round its convex margin with the deepest layers of the internal ligament and with the capsule of the knee-joint, we will understand why a severe twist of the knee, with the leg abducted, may rupture the ligament and drag the semilunar cartilage with it, straining or tearing the attachments of the anterior horn. At this stage the inner side of the knee-joint is, so to speak, opened out, and everything depends upon what

happens when it closes again as soon as the distorting force ceases to act.

If the cartilage is caught in displacement between the bones the knee "locks" in the manner familiar to us all. The cartilage may be split, fractured transversely, rolled up, or completely torn from its attachments. A perusal of the literature of the subject, indeed, shows that every conceivable injury to the semilunar cartilage may take place, and such cases have often been fully described. Sometimes the cartilage slips back into position without being crushed or caught between the bones; there is then no locking of the joint, but, in every respect, the etiology of the lesion is the same with the exception of the actual injury to the cartilage, and the patient generally states that he felt something "slip" or "click" in the knee, but could quite easily straighten it immediately after the accident.

The history suggests the usual cartilage injury of textbooks but without locking; the knee becomes distended with fluid, and the patient refers his pain to the inner side. The physical signs are tenderness on pressure over the internal lateral ligament, and a specially tender spot to the inner side of the ligamentum patellæ just over the border of the tibia, a symptom always strongly suggestive of an injury about the attachment of the anterior end of the internal semilunar cartilage.

The treatment of the condition when the knee cannot be fully extended without causing pain will be discussed later. If the knee can be fully extended without causing pain, the aim should be to ensure complete rest until the torn attachments have united. The knee should be kept absolutely straight on a back splint for at least ten days, the bandage being firmly applied over cotton-wool. After this the patient may begin to walk, and when he does so he should have a firm bandage over the knee to prevent effusion into it. Movements of the joint should be very limited the first day, and should gradually increase in range.

A common fault in treatment is to allow the patient up without a proper protective bandage on the knee, the result of which is effusion into the joint, and, what is more harmful, into the newly formed cicatrix about the anterior horn of the semilunar cartilage, thus stretching the newly formed scar and letting the end of the cartilage shift about. When this happens the patient is often put to bed for a week until the effusion has disappeared, but when he gets up again the effusion recurs, and so he goes on week after week, until finally the attachments of the anterior end of the cartilage become elongated and slack. The patient then complains that occasionally he feels a "give" in the knee, but it does not "lock." Some day a slight unusual twist may result in a real locking of the joint.

A joint such as this which has been the seat of a definite injury will generally fill up with synovial fluid when first used. Therefore the application of a pressure bandage

should never be omitted. If the knee is carefully brought into use by graduated exercise, there should never be much effusion, and each day it should be less in amount; that is to say, there is no effusion in the morning, although by the end of the day it may have appeared, and each evening the amount is less than on the preceding one.

*Thickened Cicatrix about the Semilunar Cartilage.*

If the effusion does not become progressively less, either the patient is using the knee too much and moving it too roughly, or some injudicious masseur is moving it too roughly for him, or the surgeon has made a mistake in his diagnosis and there is some condition in the joint which requires further attention, and he should make a careful examination and reconsider his opinion of the case. When these cases have been the victims of defective after-treatment, repeated stretching and effusion about the anterior end of the semilunar cartilage gives rise to a thickened cicatrix, which is tender, and can sometimes even be felt by the surgeon moving under his finger as the knee is flexed and extended. This painful spot is situated at the diagnostic point, already described, on the front of the knee, well to the inner side of the ligamentum patellae. Sometimes this cicatricial thickening is so great that it is pinched between the bones when the knee is fully extended, and this causes sharp, well localized pain and tenderness.

*Treatment* in such cases depends upon the exact condition, and two types must be distinguished:

1. In cases in which the cicatrix is not pinched, but merely gives rise to a sense of insecurity as if something is moving or "clicking" inside the joint, a rigorous course of strict rest, followed by massage and carefully graduated exercises, may cure the condition in a month.

2. In cases in which the cicatricial mass gets definitely nipped, the condition has become similar to the type of displaced semilunar cartilage usually described, and if rest and careful exercise fail, an operation to remove the whole mass is indicated—the opportunity being taken to inspect the cartilage at the same time.

DISPLACED CARTILAGE WITH LOCKING.

It has long been recognized that definite "locking" of the knee-joint is a characteristic sign of displacement of the internal semilunar cartilage, as described in textbooks. This condition is a more severe variety of the injury just described; it differs from it in the fact that some portion of the cartilage is, for a time at least, caught between the bones and prevents full extension.

The treatment of this condition aims at the restoration of the power of extending the knee fully without pain.

If the displaced cartilage is fully reduced the knee can be fully extended, both actively and passively, without

pain. If this cannot be done, the cartilage is not reduced. When the cartilage becomes disengaged the patient is aware of it—in fact, he is the most competent judge of the success or failure of the manipulation.

#### *Treatment of the Initial Injury.*

First complete reduction is necessary. This can usually be effected by manipulation without the use of force, and the routine I prefer involves the active assistance of the patient. The patient should lie on his back with the thigh flexed on the body and the leg on the thigh. When in this position the surgeon can manipulate the leg, and can sometimes feel a fullness over the site of the displaced cartilage.

The patient is then told that he will be given the word "One, two, three, *kick!*" On the word "kick" the patient extends the limb as suddenly as he can. At the same time the surgeon rotates the foot inwards and pulls, while pressure is placed upon the thigh. If the dislocated cartilage is reduced, the patient is almost certain to announce the fact, and the objective sign is that the knee can be completely extended without impediment. The knee, surrounded by wool, should be bandaged firmly, and fixed on a posterior knee splint. If the patient is not of a temperament likely to be helpful, an anaesthetic is advisable.

Our next effort is to secure the healing of the lesions in and about the cartilage, so that it may have a chance of adhering in its proper position. The patient should, therefore, wear the splint for about ten days, but can usually be allowed up in his room at the end of five days. After ten days he may walk with the knee bandaged, taking care not to bend the knee suddenly. Active flexion of the joint should be practised very gradually, and the quadriceps muscle should be massaged and exercised gently. If the progression is carefully made from gentle to stronger movements, the full range should be recovered without the recurrence of any effusion in the joint in about three weeks. The majority of these cases, carefully and efficiently treated in the first instance, do not give any further trouble.

Where a successful reduction is not accomplished, and, in consequence, the patient is not able to extend the knee fully, an operation will probably be required.

#### *Cases of Imperfect Reduction.*

I see many cases two or three weeks or more after the accident, in which it is obvious that attempts at reduction have either not been made or have failed. The surgeon in charge of the case may have thought that he had got the knee fully extended, but passive extension still caused pain, localized over the anterior end of the cartilage; the knee filled with fluid when the patient walked, and, though comparatively free from pain after rest, it became tender after exercise. It is often possible, even

after weeks of displacement, to reduce the cartilage in these cases by manipulation similar in kind but more forcible than that necessary in dealing with the original injury. This manipulation forces the displaced cartilage from its abnormal to its normal position, where it may become firmly and accurately fixed. This late reduction so often succeeds that it is always worth trying. If, after an attempt at reduction under anaesthesia, the cartilage still remains in a position in which it gives trouble, or if it remains loose and frequently gets nipped, operation is the only sure treatment; for the case now has become one of recurring dislocation of the semilunar cartilage with "locking" of the joint.

A word of warning may here be given about cases in which reduction is apparently complete, and the patient can get about with tolerable comfort, but complains that the knee-joint does not feel quite secure, although there is no evidence of the intrusion of any structure between the bones. These symptoms are often due to some minute adhesion within the joint which does not produce sufficient limitation of movement to be detected by the surgeon, but leaves the patient with the sense that he cannot use the joint without a feeling of restraint. Full movement of the joint, particularly in rotation, under gas anaesthesia, will often remove these symptoms, although the surgeon cannot always feel any definite adhesion give way during the manipulation.

#### OPERATION ON THE INTERNAL SEMILUNAR CARTILAGE.

It is needless to say that the knee should never be opened except under the most scrupulously aseptic conditions, and never in a hospital in which there are a large number of septic cases. Operations on cartilages, even at base hospitals at the front, should be discouraged. It is not a practice which can be recommended, as the environment is a source of danger, no matter how experienced the surgeon.

The procedure which I prefer is the following: The leg is placed to hang over the end of a table at right angles to the thigh; the knee is wrapped in sterile gauze, soaked in biniodide solution; the incision is made through the gauze, and the edges of the gauze clipped over the skin edges to the superficial fascia. As the knife with which the skin is cut may become infected by *Staphylococcus albus*, a second clean knife should be used for all the deeper dissections. The incision need not be more than an inch or an inch and a half in length; it is made over the anterior end of the cartilage, sloping very slightly downwards and inwards—that is, nearly, but not quite, parallel to the upper edge of the tibia (Fig. 1). Great care should be taken never to allow the incision to extend far enough to the inner side to cut any fibres of the internal lateral ligament; this is a fault which leads to weakness of the knee lasting for months or years, and is, unfortunately, still frequently to be met with in cases which have been operated on by the old large J-shaped incision described in textbooks.

The joint being opened, a blunt hook can be slipped under the free margin of the cartilage, and by picking it up it can easily be seen whether the front part is intact, or torn, or has tags or projections producing disability. In removing the whole cartilage great care should be taken that no tags of cartilage are left projecting from the attachment to the coronary ligament, as these frequently give rise to continued symptoms, due to nipping or adhesions, and may necessitate a second operation. The condition of the fringes should be examined before closing the knee, and by retracting the patella the opposite front part of the cartilage can be inspected, if this be deemed necessary.

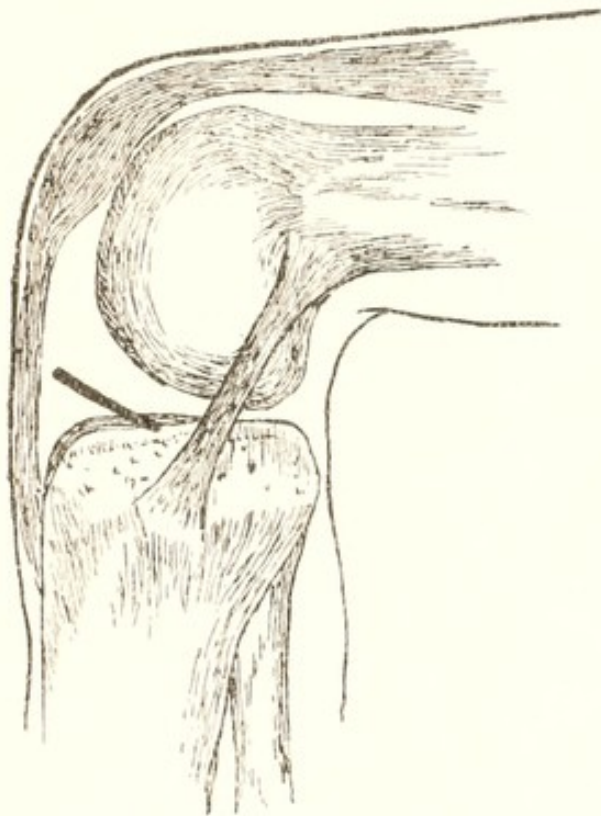


FIG. 1.—Showing position of incision.

No movement of the knee must be allowed after the incision has been made, as this may favour the entrance of air—a minute risk, but an avoidable one, and therefore one which the surgeon has no right to take. It is not until the stitching is complete and pads placed over the wound that the knee is straightened. Dressings are then applied, elastic pressure put on by bandaging over large pads of wool, and a simple posterior knee splint affixed to keep the knee straight. If the operation is performed with a tourniquet around the thigh—and this is advisable—no vessels need be tied; and if the elastic pressure is applied before the tourniquet is removed there need be no fear of bleeding into the joint. My experience of these operations now extends to over 2,000 cases, and I feel that I can speak with some authority.

*After-Treatment.*

In a straightforward case there is no reason why the patient should not get out of bed on to a couch on the third or fourth day. He should not, however, put his foot to the ground for the first week. The stitches are removed as usual about the tenth day and massage may be commenced, the patient being allowed gradually to bend his knee. Each day he exercises, bending and extending the knee more and more, until in about three weeks he should reach the full range of movement and walk with freedom. In my practice several professional footballers have resumed their game in six or eight weeks after the operation. There is no reason why in suitable cases men should not return to light duty about five weeks after the operation and, if properly exercised, be fit for full duty three weeks from that date. This, however, depends upon the patient being put through a course of carefully graduated movements and exercises through the whole period of his convalescence.

Surgeons who have been operating upon soldiers complain of the weakness in the knee which so often follows operation. This experience is common, but if the operation has been properly performed and the after-treatment by massage and exercise has been thorough, these disappointments will not occur. The surgeon should be assured that the thigh muscles are restored to their normal condition, and a patient should not be discharged from hospital until the thigh has attained its normal girth. We must also retain a critical attitude of mind, for some soldiers are keen to remain off duty, and the knee is often only an excuse.

## RECURRENT EFFUSION INTO THE KNEE-JOINT.

Recurrent effusions into the knee-joint are often very puzzling. It is possible, however, to lay down a few rules for guidance.

I. After injury of the knee, effusion of fluid into the joint is very liable to occur, and if the patient is kept resting and not using the limb, the effusion will probably recur the first time he uses it. The patient is again put to bed, but when he gets up effusion reappears. The rational treatment in such cases is to bandage the knee firmly and let him walk, and in the evening there will be some effusion, which will disappear by morning. The knee should again be bandaged and the patient allowed to walk. In the evening there will be still effusion, but not so much as before. By following this routine the joint will gradually become accustomed to the increasing exercise, with a diminishing amount of effusion on each day. This is the real test that a joint which has been injured is really recovering and is fit for gradually increasing exercise.

II. The second point is that recurring effusion which increases instead of diminishes under the above careful

treatment is a sure indication that the joint is not fit for use, and localizing symptoms and signs should be searched for to find what the precise cause of disability is.

III. Recurring effusion, which is associated on each occasion with some slight mishap—a trifling strain, such as a twist of the knee, a feeling that something has slipped in the joint, or definitely localized pain—is rather an indication that there is some definite body loose in the joint which is occasionally getting nipped, though not retained long enough in one position to produce “locking.” The surgeon should then decide whether it is an enlarged pad of fat, a loosened cartilage, or a loose “body,” or a portion of the cartilage left after operation.

#### DISLOCATIONS OF THE EXTERNAL SEMILUNAR CARTILAGE.

The symptoms associated with accidents to the external semilunar cartilage are much less clearly defined than those associated with injury of the internal cartilage. One reason for this is that the external cartilage is not attached to the external lateral ligament of the joint, and there is no definite mechanism by which it is pulled out of place. “Locking” may occur, the pain being referred to the front or back portion of the outer part of the knee according as the anterior or posterior end of the cartilage is torn from its attachment or crumpled up. Cases occur in which both cartilages are displaced by one injury, suggesting that it is only a rather more severe accident than that usually associated with the displacement of the internal cartilage which damages the external one also, probably the mechanism being a lateral sliding of the condyle on the top of the tibia, squeezing the cartilage out of place and tearing its attachment.

#### RUPTURE OF CRUCIAL LIGAMENTS AND FRACTURE OF THE SPINE OF THE TIBIA.

In more severe accidents to the knee the displacement of the tibia on the femur may be sufficiently great to cause rupture, not only of lateral ligaments, but of the intrinsic ligaments of the joint. This may or may not amount to what may be described as complete dislocation. Experience of cases of dislocation of the knee-joint, in which of necessity all the ligaments have been torn, proves that with appropriate rest in a correct position an astonishingly good result can be obtained. When called on to treat a serious accident such as this, the practitioner's instinct is to get the limb straight and to keep it fixed for a long time. It is when the accident has been less than a complete dislocation that one is liable to think that less strict treatment may suffice. Consequently, cases are met with in which the patient suffers from abnormal mobility of the knee-joint, clearly indicating that one or both of the crucial ligaments have been ruptured or stretched. Bearing in mind the mechanism of the crucial ligaments, it is not difficult to make a diagnosis.



1. The anterior crucial ligament is tense when the knee is fully extended, and prevents the tibia from being displaced forwards on the femur.

2. The posterior crucial ligament is tense in complete flexion, and prevents the tibia from being displaced backwards on the femur.

3. Both ligaments check inward rotation of the tibia. Hence, if the tibia cannot be displaced forwards in the extended position, it may be assumed that the anterior crucial ligament is not completely torn; and if the tibia cannot be displaced backwards in full flexion, the posterior crucial ligament is presumably not ruptured. Abnormal mobility indicates elongation or rupture of the corresponding ligament. The history of an injury helps the surgeon to exclude cases in which prolonged distension of the joint with fluid has caused elongation of all the ligaments, as well as the conditions associated with diseases, such as Charcot's disease or locomotor ataxia. The treatment, when any such condition is diagnosed, is prolonged rest with the knee in extension, or fixed in plaster, or a Thomas caliper splint, in which the patient can walk, the object being to keep the joint immobilized for a time long enough to allow union of the torn ligaments or adaptive shortening of stretched tissue. The operation of stitching the ligaments is absolutely futile as a mechanical procedure. Natural cicatricial tissue, allowed to mature without being stretched, is the only reliable means of repair.

#### *Fracture of the Spine of the Tibia.*

The mechanism of this accident appears to be the following. The knee is subjected to violent torsion, such as might produce a dislocation or rupture of the crucial ligaments; at the time when the force is applied the condyle of the femur grinds across the surface of the tibia, and the sharp intercondylar margin shears off the spine. In some cases avulsion of the spine occurs instead of rupture of the crucial ligaments. The displaced fragment of bone may be lodged in the front part of the knee-joint, and so prevent its full extension. Diagnosis is verified by *x*-ray examination.

*Symptoms.*—The most constant symptom is a somewhat rigid block to full extension, usually accompanied by pain behind the patella.

*Treatment.*—If the knee can be fully extended the displaced fragment of bone being presumably pushed back somewhere between the condyles, the knee should be fixed in this position for a long period to allow the torn structures to reunite. On the other hand, if the displaced fragment blocks extension, and the surgeon cannot manipulate it back into a harmless position, or extend the knee even by moderate force, it is best to remove the obstructing fragment of bone, fixing the knee afterwards in a straight position, and leaving Nature to effect her own repair. The surgeon must use his own judgement as to the route he

adopts : the freest access is obtained by splitting the patella longitudinally (Fig. 2), but if the *x* rays show that the offending fragment of bone could be reached by an incision at the side of the patella, this is a less severe method of procedure. As I am largely responsible for the split patellar route in dealing with unusual derangements, I am anxious to emphasize that it is only needed in exceptional cases.

#### THICKENED RETRO-PATELLAR PADS OF FAT.

Almost any injury of the knee which is associated with increased vascularity or bruising may give rise to swelling of the pad of fat situated behind the patellar ligament. Consequently this fat is liable to be nipped

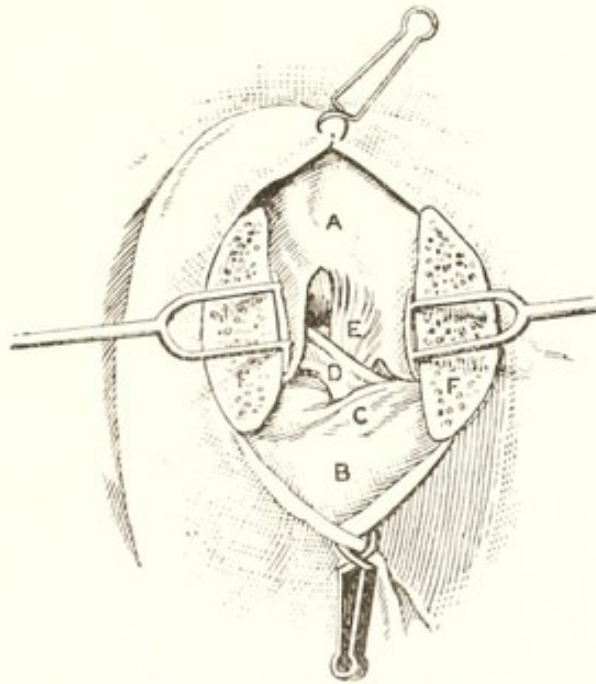


FIG. 2.—Showing patella split. A, Femur; B, tibia; C, transverse ligament; D, anterior cruciate ligament; E, posterior cruciate ligament; F, cut halves of patella.

in full extension of the knee. In ordinary civil life, this forms one of the varieties of the initial stage of a local monarticular rheumatoid arthritis. The condition, however, is in no sense rheumatic. The patient complains of pain and tenderness in the knee after walking, and especially when going up and down stairs, or when getting up suddenly from a chair after sitting for any length of time. The condition is maintained by the repeated small injuries which occur every time the knee is fully extended. The treatment, therefore, is obviously to prevent the patient from inflicting small bruises on the tender fat and its covering of synovial membrane. This can easily be done by putting a cork pad, half an inch thick, inside the boot under the heel, to prevent the complete extension of the knee during walking, and by fitting the knee with

a cage support (Fig. 3), which allows full flexion but limits extension by about 30 degrees. Wearing this boot and cage splint the patient cannot fully extend the joint and in this way bruise the post-patellar fat. The swelling gradually disappears, and after a few weeks full extension can be performed without pain. The diagnosis of this condition is easy. The patient complains of pain in the knee, or, more often, in the front of the knee, not at the inner side. Passive extension of the knee by the surgeon produces the pain, which is definitely localized just below and behind the patella. On palpation the thickening of the pad of fat may be felt; it is enlarged and tender, but there is no sensitiveness over the internal cartilage or the

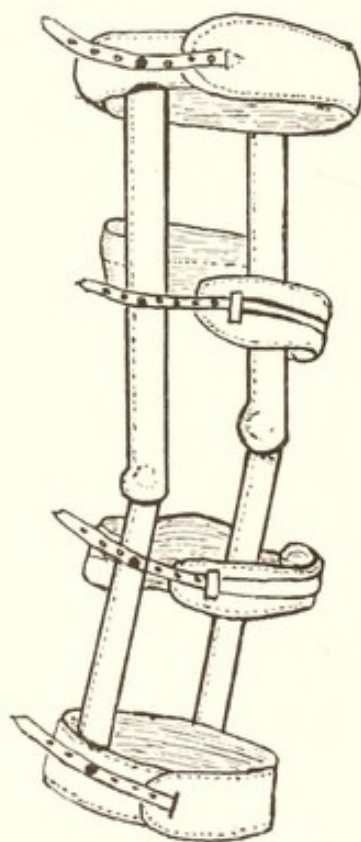


FIG. 3.—Cage support for knee.

internal lateral ligament. In some instances the retro-patellar pad of fat may be bruised in common with injury to the semilunar cartilage. The full tender point of the internal lateral ligament, cartilage, and fatty pad will be found in such a case.

In all the injuries of the knee which I have been discussing wasting and weakening of the quadriceps muscle is a characteristic feature, and no treatment can be regarded as sufficient which does not provide for the restoration of the efficiency of this muscle during the stage of convalescence. This is particularly to be noted in the condition which is now under discussion, for some of the deep short fibres of the subcrureus muscle are inserted into

the synovial membrane of the joint, and when they contract they draw up the synovial membrane and help to pull the pad of fat out of danger when the knee is extended. Neglect, therefore, of the quadriceps muscle will leave the patient peculiarly liable to a recurrence of the injury.

If the reader has appreciated the regular gradation of disorders of the knee already described, he should have little difficulty in applying and adapting the method of diagnosis and treatment to unusual types which occur as a result of injuries in military service. Even bullet wounds through the joint, which sometimes chip off fragments of bone, can be dealt with on lines similar to those indicated for fractures of the spine of the tibia. The whole question of septic arthritis in and about the joints, with resulting ankylosis, is a larger subject, which cannot be dealt with in the present article.













