

Bone-graft surgery / by Fred H. Albee.

Contributors

Albee, Fred H. 1876-1945.

Publication/Creation

Philadelphia ; London : W.B. Saunders company, 1915.

Persistent URL


<https://wellcomecollection.org/works/hkfefaaj>

License and attribution

Conditions of use: it is possible this item is protected by copyright and/or related rights. You are free to use this item in any way that is permitted by the copyright and related rights legislation that applies to your use. For other uses you need to obtain permission from the rights-holder(s).



Wellcome Collection
183 Euston Road
London NW1 2BE UK
T +44 (0)20 7611 8722
E library@wellcomecollection.org
<https://wellcomecollection.org>



H xxiv v.

~~VNM.C (2)~~

GM 5757



22102121547

Med

K29278



Digitized by the Internet Archive
in 2017 with funding from
Wellcome Library

BONE - GRAFT SURGERY

BY

FRED H. ALBEE, A. B., M. D., F. A. C. S.

Professor of Orthopedic Surgery at the New York Post-Graduate Medical School and the University of Vermont; Visiting Orthopedic Surgeon to the New York Post-Graduate Hospital and Blythedale Hospital; Consulting Orthopedic Surgeon to the Mary Fletcher Hospital, Burlington, Vermont, Sea View Hospital, New York, Muhlenburg Hospital, Plainfield, New Jersey, German Hospital, Newark, New Jersey, and Waterbury Hospital, Waterbury, Conn.; Member of the American Orthopedic Association; Corresponding Member of the German Orthopedic Association, Etc.

*WITH 332 ILLUSTRATIONS
THREE OF THEM IN COLORS*

PHILADELPHIA AND LONDON

W. B. SAUNDERS COMPANY

1915

S, Transplantation, Texts 20 cent

94984 (3)

~~VNPT. C~~)

GM 5757

Copyright, 1915, by W. B. Saunders Company



WELLCOME INSTITUTE	
LIBRARY	
Call	W. B. Saunders
No.	

Printed in America

THIS BOOK IS DEDICATED
TO THE
PROGRESS OF SURGERY
OF THE
BONES AND JOINTS

PREFACE

THE author has been induced to write this book in order to answer as far as possible the many inquiries in regard to bone grafting and to present the technique of the application of the bone graft in the widening field for its use, which is covered in no other work yet published. The greater portion of this book presents the author's original applied technique with ample illustrations.

Bone, being one of the simple connective tissues, lends itself favorably to transplantation and to the repair of skeletal deficiencies and is the most reliable means of internal bone fixation. Instead of antagonizing Nature by attempting to introduce a foreign substance, the surgeon, by using autogenous material is following Nature's own method, being thereby able to overcome mechanical surgical defects which he has hitherto been unable to cope with. The use of uncertain extemporizing methods and the application of external fixation braces cannot compare with the accurate, direct internal implantation of an autogenous bone graft contacting corresponding structures of graft and host bone, *i.e.*, periosteum to periosteum, compact bone to compact bone, endosteum to endosteum and marrow to marrow.

As improved machinery and tools have made the skilled artisan more efficient, so likewise has the introduction of röntgenography and electrically driven tools augmented the skill and accuracy of the surgeon in arresting bone diseases and restoring bone defects and has opened ways of dealing with bone and joint conditions such as have never been attempted with the cruder hand tools. Though the author considers the use of the motor-driven tools as more nearly approaching the ideal conditions yet there are instances where their use is not absolutely essential.

Bone and joint work is a difficult surgical specialty, involving not only the surgical management of soft tissues but bone tissue as well. The successful outcome of any procedure to restore the skeletal architecture depends not only upon a proper operative technique but in many cases in a greater degree upon the skill with which the post-operative external fixation dressing is applied and in the convalescent management of the case.

The author wishes to express his deep obligation to his associate Dr. Robert E. Soule for his cordial collaboration. He is also indebted to Dr. Penn-Gaskell Skillern, Jr., for his most valuable criticisms, corrections and suggestions.

FRED H. ALBEE.

40 EAST 41ST STREET,
NEW YORK CITY.
October, 1915.

CONTENTS

CHAPTER I

	PAGE
THE FUNDAMENTAL PRINCIPLES UNDERLYING THE USE OF THE BONE GRAFT IN SURGERY	17

CHAPTER II

AUTHOR'S ELECTRIC MOTOR OPERATING OUTFIT AND TECHNIQUE OF USAGE	52
---	----

CHAPTER III

THE BONE GRAFT IN THE TREATMENT OF POTT'S DISEASE AND OTHER LESIONS OF THE SPINE	64
--	----

CHAPTER IV

THE INLAY BONE GRAFT IN THE OPERATIVE TREATMENT OF FRACTURES	149
--	-----

CHAPTER V

OPERATIVE METHODS FOR REMODELLING OR ANKYLOSING THE HIP-JOINT.	242
--	-----

CHAPTER VI

THE INLAY BONE GRAFT FOR FIXATION OF TUBERCULOUS KNEE-JOINTS; INFANTILE PARALYSIS; OSTEOARTHROPATHY (CHARCOT'S DISEASE); THE WEDGE GRAFT FOR HABITUAL DISLOCATION OF THE PATELLA	276
--	-----

CHAPTER VII

THE BONE GRAFT IN THE TREATMENT OF DISEASES AND DEFORMITIES OF THE FOOT AND LEG	308
---	-----

CHAPTER VIII

MISCELLANEOUS SURGICAL USES OF THE BONE GRAFT	357
---	-----

INDEX OF NAMES	407
INDEX	409

BONE-GRAFT SURGERY

CHAPTER I

THE FUNDAMENTAL PRINCIPLES UNDERLYING THE USE OF THE BONE GRAFT IN SURGERY

Cellular life may be quite independent of organic or somatic life and, under favorable conditions, tissue cells may retain their viability long after being detached from the living organism. "The remarkable viability of transplanted periosteum has been demonstrated by Grohe and Morfurgo, the former showing that it is capable of preservation for 100 hours and yet able to be implanted and exert its osteogenetic powers. The latter (Morfurgo) has shown the periosteum of a corpse kept at 15° can produce new bone when implanted after 168 hours."—Janeway. The duration of this cellular life depends largely upon the means of preservation of the detached parts or, in the case of organic death, the preservation of the whole cadaver, and also upon the amount of disintegration from the cause of death. It is on account of this phenomenon that detached portions of living tissues can be successfully transplanted from a corpse to a living organism. The higher the specialization of the cell the less marked are its resisting and proliferating powers. This is especially well illustrated in the case of tissue grafts. The lower order of tissues, which need less nutrition, continue to live for days on their own substance which is contained in the serum that permeates them, but the more highly specialized ones are liable to necrosis in a short time unless nourished by a blood circulation. This viability varies with the individual tissue, as the higher the development of the cell—such as the ganglion or parenchymatous cells—and the richer the tissue is in blood-vessels, the less likely it is to survive.

The most favorable tissues for grafting purposes are the simpler connective tissues, such as bone, fat, fascia, etc., which are endowed with the capacity of extracting nutrition from the soil into which they are planted and at the same time are able to regenerate so that the portion of the graft which disintegrates is replaced. Muscles and nerves are most unfavorable.

Bone has been successfully transplanted since 1809, when Merrem obtained successful healing of bone plates in the skulls of animals after trephining. Subsequently, Walther, in applying this technique to the human subject, secured partial healing of the graft, in spite of the co-incident suppuration. In 1858, Ollier, after extensive investigations in the use of the bone graft in both animals and man, concluded that fresh bony tissue, covered with periosteum, remains viable. Autogenous grafts, or those derived from the same individual into which they are engrafted, are by far the most trustworthy. The fluids, albumins, and tissues of every individual vary in degree from those of every other, and while this incompatibility may be slight, it is sufficient cause for using, whenever feasible, the individual's own tissue for the repair of his defects.

With primary union and in the absence of infection, autogenous bone grafts, properly contacted, are always successful, and even infection does not necessarily indicate failure. "The vegetative capacity of the bone cell is as great as that of the epithelial cell, and if one grants not only the viability of the transplanted epithelium but also its power of extensive proliferation, then, judging by analogy, the bone cell ought to show, as it has bone in this instance, equal capability of living and growing when transplanted. In proportion to the size of the graft, the smaller the graft the greater the proliferation."—Macewen.

The knowledge of the exact histological rôle which the bone graft plays is, fortunately, immaterial to its clinical usefulness, whether it serves as an osteoconductive scaffold or as an active osteogenetic force. The extensive experiments and histological studies of Ollier, Macewen, Frangenheim, Cotton and Loder, McWilliams, Mayer, Phemister, and the author (see Chap. III),

have proved the viability and osteogenesis of the grafts when inserted by the proper technique.

Cotton states: "Our specimens show a practically uniform survival of the transplant when the technique is adequate. The articular transplant of the cartilage usually shows no gross change in color or texture from that of the surrounding undisturbed joint surface. *The fragment very rapidly becomes firmly fixed in place.* Histological preparations obtained at varying intervals show a series of changes in the bony portions of the grafts, the more important of which are constant and very definite. The essential picture shown is briefly: (1) the early disappearance of the bone corpuscles in the transplanted trabeculae and in the trabeculae of the host bone for a short distance from the wound surface; (2) without any loss of substance in (or any marked foreign body reaction around) the bone from which the corpuscles have disappeared, this bone was rapidly and completely covered by a layer of new endosteal bone, which unites with endosteal bone of the host; (3) the new bone is laid down by the activity of end-osteoblasts in all portions of the grafts, centre as well as periphery. It has not yet been proved that some of the end-osteoblasts which are active in the graft may not have originated from the endosteum of the host and extended, or even emigrated, from it to the graft; but no one, after study of our sections, can doubt that in part, at least, these osteoblasts represent the actively proliferating covering membrane of the transplanted trabeculae; (4) practically no changes, either of degeneration or proliferation in transplanted articular cartilage, at least up to 4 weeks."

McWilliams concludes in a recent publication: "Living bone grafts have life inherent in themselves, and the theory that contact with living bone is necessary for subsequent life of the graft must be given up."

"As important as the properties of the transplant are the qualities of the "wound soil" which serves the function of supplying as quickly as possible nutrition to the graft. The first step in the establishment of the lymph flow and the cir-

culation is the early adhesion between wound edges and the transplant. The more quickly and surely this takes place, the more promptly is nourishment assured. Should the cells of the wound be injured because of antiseptic applications, or should they be abnormal because of the presence of scars or hæmatomata, or the seat of previous disease, as tuberculosis, necessary nutrition will be delayed. Very important contributing factors to failure are errors in operative technique, causing infection with a very slight transudate, which is instrumental in destroying the first intimate contact, thus preventing nutrition, partially or absolutely, and predisposing to partial or total necrosis due to suppuration. By means of strict asepsis, this element of failure can be eradicated. Most important, however, is a second factor, which prevents the early intimate adhesion of the wound edge, namely, imperfect hæmostasis. The presence of the slightest amount of blood is dangerous, as it interferes with the nutrition. That this factor has been heretofore disregarded is apparent from the literature. It is the general belief that a smooth, uninfected wound is a sign of perfect technique. This is not true in connection with transplantation. In this instance, perfect technique is recognized by a complete gumming and coaptation of the wound edges. For this reason, every experimenter in recording the results of his transplantations should convince himself that the transplant is really grafted as it should be, in order that his operation be perfect."—Lexer.

Homoplastic grafts are those which are derived from another individual of the same species, and when composed of the lower order of tissues, such as bone or fascia, they may be employed successfully, though not with the same certainty as autogenous grafts; when they consist of the more highly specialized tissues, they result in failures. Homoplastic grafts are often difficult to obtain, and there always exists the danger of transmitting disease from the donor to the host, even when the greatest care has been exercised. Fibrous encapsulation occurs more frequently in homoplasty than in autoplasty. This, as Lexer has pointed out, is probably due to the irritation of a foreign proteid, which

varies most with difference in race, next with distant relatives, near relatives, and least with the individuals of one family. This variation prevents proper nourishment of many tissues and, as a result, substitution in the regenerative process occurs very slowly while degeneration takes place rapidly.

Heteroplastic grafts are those which are obtained from an individual of another species. Living grafts from different species may die when implanted into man or the higher animals. The graft in these cases acts as a foreign body, and if there is even mild infection it is liable to ulcerate out. In the event of no infection, it either becomes encapsulated or disappears, and is slowly substituted by the proliferation and migration of the tissues in which it is embedded. This process may require months in the case of the bone graft, and thus it follows that the graft may be a success clinically, though histologically it undergoes partial or even complete absorption, or, in other words, it acts as an osteoconductive scaffold.

after the insertion of the grafts, on account of the recurrence of the sarcoma, and in this short time the grafts had become firmly united (at *C*) by solid bone, although the diameters of the grafts both above and below the union remained the same as when implanted. These proliferating callus bone cells could have originated from no other source than the two graft ends, thus proving conclusively the active osteogenesis of these free grafts. The efficiency of the bone graft could not be better demonstrated than by this specimen. *A*, indicates where firm union has occurred between the upper graft and the upper remaining end of the tibia; *B*, where the lower graft has become united to the lower fragment of the tibia; *C*, indicates firm bony union between the two graft ends which were contacted in the centre of the leg far away from any other possible source of new bone.



FIG. 1.—Röntgenogram of two grafts, each 3 in. long, inserted by the author for a tibial defect from the removal of two-thirds of its shaft for sarcoma. It was necessary to amputate the leg just 4 weeks



Just what happens to the autogenous bone graft from a microscopical standpoint, is still a matter of discussion. Whether the bone graft lives as such, or whether the cells wander into it from the bone with which it is connected, is still *sub judica*.

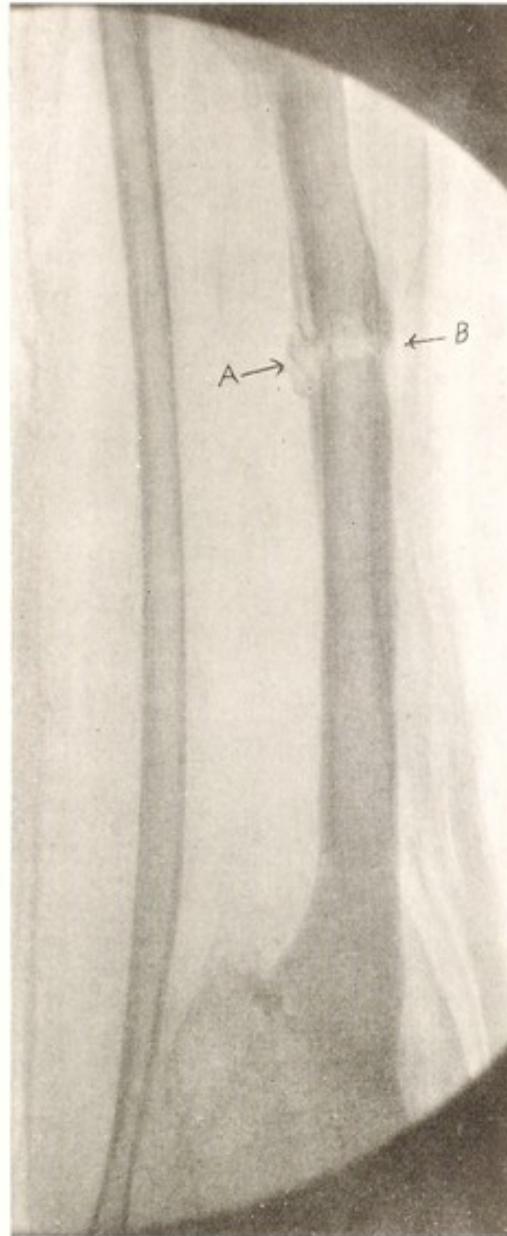


FIG. 3.—By the kindness of Mr. Robert Jones. *AB* indicates firm union and callus thrown out by the graft fragments.

In the author's experience both with human beings and with animals, perfect union of the autogenous aseptic bone graft with the bone into which it was placed has been secured in 100 per cent. of cases, and, after all is said, this is the important consideration.

The subject of the bone graft is being widely discussed, and the men who are studying this problem may be divided into two schools: those who claim that a certain portion of the cells in the graft live and that the graft is a distinct and separate osteogenetic force; and those who claim that the cells of the graft do not *per se* have any osteogenetic power and that the graft merely serves an osteoconductive purpose. There are at present, however, very few who continue to uphold the latter view, especially since Barth, its originator, has been convinced that his former position was wrong and that the cells of a portion of an autogenous periosteum-covered bone graft live and play an important osteogenetic rôle (see Figs. 1 and 3).

One should not be too dogmatic concerning the exact rôle that every graft must play. Individual conditions or individual environment determine the exact rôle of each particular graft. There may be a considerable blood-clot, or tissue shreds, which interfere with the nourishment of the graft, preventing an immediate and perfect union; or there may be a slight or severe infection, or other disturbances to deal with, and these conditions determine the exact histology in each individual case or, in other words, how many of the graft cells have received sufficiently early nutrition and remain viable, and how much of the graft dies and serves in an osteoconductive rôle. It fortunately does not matter, from a surgical standpoint, what happens histologically, so far as the exact rôle of the graft is concerned. It is known that an autogenous bone graft always "takes" and becomes permanent, if it is put in under aseptic conditions; and, if it has function to perform, it stays there and adapts itself in structure, size, contour, and in strength to the new environment.

Boiled bone has been used by Kausch and others for years as a substitute for the bone graft. From a recent discussion of this matter, one would gather that this material had never been used before. Boiled bone is far inferior to an autogenous bone graft, and Kausch, in 1910, from an extensive experience prepared a table illustrating the scale of value of different material

for bone substitution and made the following statement: Boiled bone and bone from the cadaver are not adapted for implantation in a bed free from periosteum, and foreign substances are still less suitable for this purpose.

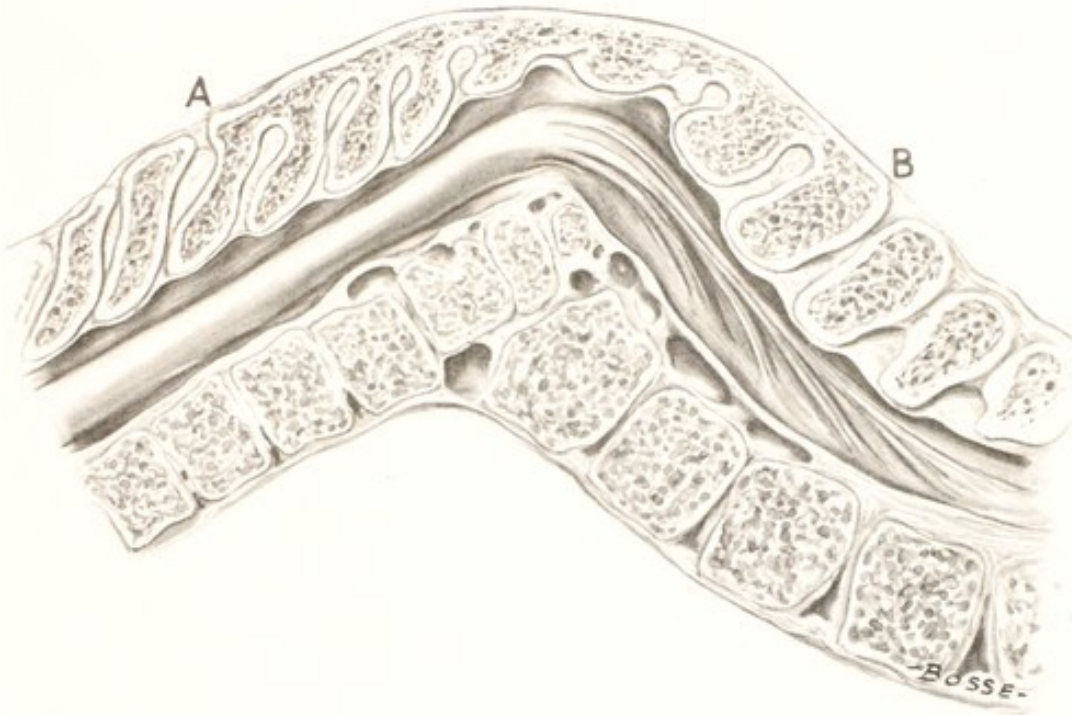


FIG. 4.—An antero-posterior longitudinal section of a spine 2 years after the tibia bone graft had been implanted into its split spinous processes to ankylose the tuberculous infected vertebrae present between *A* and *B*.

The drawing was made from an actual specimen and represents the alteration which has taken place in the character of the graft and its bed.

The area *A* to *B* has been so changed that it presents the characteristics of a single bone with a distinct cortex enclosing cancellous bone structure throughout or in other words it has become identical in its anatomical structure to the spinous processes to which it has become amalgamated.

This is a fortunate characteristic of the bone graft, *i.e.*, it adapts itself to its environment.

KAUSCH'S TABLE OF VALUE OF DIFFERENT MATERIALS FOR BONE TRANSPLANTATION

1. Pedunculated soft parts with periosteum-covered bone flap.
2. Free transplanted periosteum-covered autoplasmic bone.
3. Free transplanted periosteum-covered homoplasmic bone.
4. Fresh boiled bone.
5. Fresh preserved bone.
6. Cadaver or fetal bone, obtained under sterile conditions.

7. The same bone, boiled.
8. Ivory.
9. Foreign bodies, such as metal.
10. Fresh animal bone, living or boiled.

Lexer states: "Boiled bone, obtained from a cadaver, or fresh bone which has been sterilized, acts as does a foreign body which slowly undergoes substitution; it is rapidly destroyed by vigorous granulations. Foreign body suppuration with extrusion of the dead graft, long after primary union, occasionally occurs."

Barth (*Verhandlung der Deutsch. Gesell. für Chir.*, xxxviii, 1909) makes this statement in reference to boiled bone for transplantation purposes: "Personally, I (Barth) have had nothing but failures. Absorption follows in these cases, or secondary suppuration if the patients are allowed to use their limbs, and the bone must be removed. I therefore believe that it would be going backward to make use of dead bone as a routine measure in osteoplastic work. Accordingly it can no longer be doubted that in the substitution of very large defects, only the living bone covered with periosteum furnishes trustworthy results."

Baum reported five cases of intramedullary graft for ununited fractures. Four were homoplasty grafts (taken from amputated limbs and fetal bones). The fifth graft was an autogenous graft and was the only one which resulted in solid union, thereby proving the value of live autogenous bone grafts and possibly the disadvantage of the intramedullary technique.

In this connection, Bier claims that most bone regeneration comes from the endosteum and bone-marrow and that no regeneration occurs in a scraped (or reamed-out) medullary cavity. This undoubtedly explains in part, at least, failures from the intramedullary technique of inserting the graft in ununited fractures.

Implanted ivory is merely absorbed, without any substitution formation of new bone.

Autogenous live bone is the only material which can be implanted with safety in a bed free of periosteum.

Laewen made histological studies of bone grafts which had been transplanted 11 weeks, and by injecting the blood-vessels of the amputated arm found that there had been a complete vascularization of the transplant which had been obtained from the tibia of the same patient. The graft was being gradually absorbed and replaced by new bone which proliferated from the osteogenetic bone-cells in the periphery of the Haversian canals of the graft itself; and also the periosteum lived and was active in proliferating new bone from its deep osteogenetic layer. The new bone always took on the contour of the part which it replaced.

After extensive experimental investigations and a large amount of human work, the author is convinced that the best transplant is a live piece of autogenous bone including all its elements, namely, periosteum, compact bone, endosteum, and marrow substance; that the periosteum which is separated from attached muscles should be incised in numerous places to provoke a greater stimulation and also a freer blood supply; it lets out osteogenetic cells and lets in nourishment, that the bone is best taken from the same individual or, if this is impracticable, from another individual of the nearest kin, preferably a brother or sister; that the bone should never be obtained from an animal, because its viability or replacement is uncertain or,

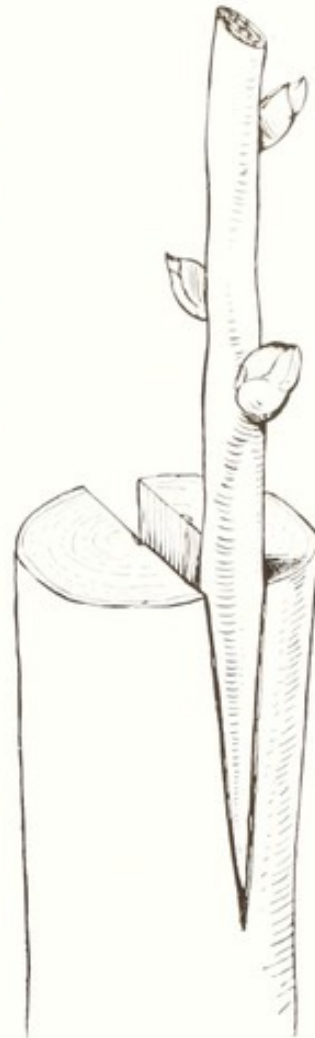

FIG. 5.—A diagram illustrating the method used most frequently in grafting fruit trees. It will be noted that it is an inlay graft and that the three elements of the graft or scion (namely, the bark, alburnum (sap) and wood) are closely coapted with their corresponding elements of the stock or recipient branch. This contact of individual tissue layers is most essential in tree grafting, and it is believed to be analogous to bone or other animal-tissue grafting.

at best, delayed, and according to Axhausen its periosteum does not proliferate.

There are certain fundamental rules which should always be observed in the transplantation of all tissues. These rules must be adhered to as closely in the animal as in the vegetable kingdom. The science of grafting in the plant kingdom is centuries old. The most important rule of the process of grafting in the vegetable kingdom is the contacting of the alburnum of the scion or graft

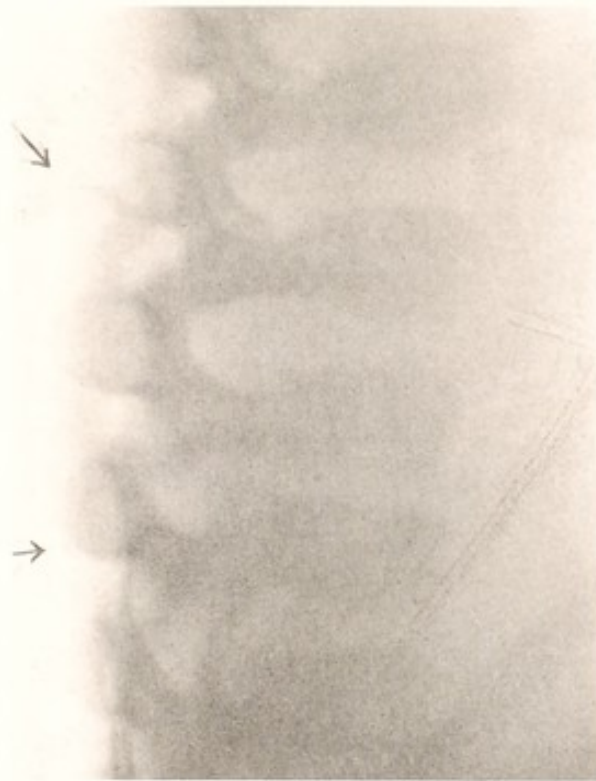


FIG. 6.—Note increased density of the graft in (Fig. 7). This röntgenogram was taken 5 weeks after the implantation.

(which, in a way, corresponds to the periosteum) to the alburnum of the stock, or the part grafted. (See Fig. 5.) The contacting of the corresponding histological layers is not of such paramount importance in the grafting of bone as it is in vegetable life, but the importance of its observance is unquestionable.

The more closely these rules are adhered to, the greater will be the percentage of clinical successes. In the case of the bone transplant, nature is confronted with the following problems: (1) the rapid establishment of cellular nutrition and blood supply,

which is brought about by the extension of blood-vessels, and by the cellular assimilation of the serum in which the graft is immersed; (2) the union of the graft to the contacted bones or fragments of bones by osteogenesis on the part of the graft or recipient bone, or both; (3) through Wolff's law, which is the adaptation in form and increased strength of the graft to its mechanical requirements. If nature is to succeed in accomplish-

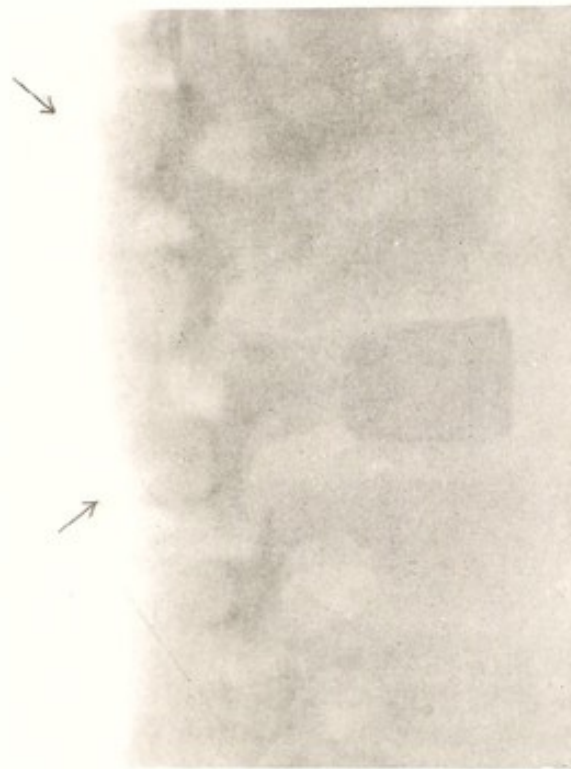


FIG. 7.—Röntgenogram of a case of Pott's disease showing a tibial graft spanning three vertebral spinous processes and although this graft is considered to be too short, yet it has held the diseased vertebrae hyperextended and arrested the progress of the disease. The principal interest of this röntgenogram is that it shows a marked increase of density of the graft (6 months after implantation) from functional stimulation. (Wolff's law.)

ing this, it is quite essential that both the graft and the recipient bone should be favorable to cellular life and proliferation.

The surgeon can do much in aiding nature by strict asepsis, by minimizing the trauma to all the tissues involved, by avoiding cellular death through either bruising or comminuting with hand tools, or by frictional heat from motor-driven instruments; by the avoidance of traumatism, thus guarding against necrosis of portions of the graft and lessening the danger of wound infec-

tion; by the proper protection and preservation of the graft bed and the graft itself from drying and possible infection; by so arranging his skin incision that it will not come directly over a superficially placed transplant, as this lessens the danger of skin necrosis and infection; by excising, if possible, extensive scars from the field of operation, as their poor blood supply is likely to interfere with the establishment of nutrition to the graft; by closely fitting and contacting bone surfaces which should, whenever possible, include the accurate coaptation of periosteum of graft to periosteum of recipient bone, of cortex to cortex, of endosteum to endosteum, and of marrow to marrow; by properly suturing muscle origins and insertions to the suitable mechanical locations on grafts which replace skeletal bones or portions of them (this is important if muscle control is to be reestablished); by securing sufficient hæmostasis in the graft bed by means of repeated applications of hot saline solutions, and by careful tying of blood-vessels. (A hæmatoma not only favors the development of infection, but also interferes with the early nutrition of the transplant by the permeating serum; a small amount of blood-clot, however, may be desirable); by including in the graft the periosteum, endosteum, and marrow, which not only contain active osteogenetic elements but, on account of their loose structure, are more favorable than compact bone to a rapid reestablishment of the blood supply with the recipient tissues of the graft bed, from whence nourishment rapidly reaches the compact part of the graft through the numerous blood-vessels passing from these enveloping membranes into the compact bone. In other words, a bone graft consisting of all its elements approaches more closely a complete physiological unit—especially in reference to nutritional distribution—which is obviously an advantage.

Stöhr, in his text-book on *Histology*, states: "The blood-vessels of the bone, the marrow, and the periosteum are in the closest connection with one another and also with the surrounding structures. Small branches (not capillaries) of the numerous arteries and veins of the periosteum enter the Haversian and

PLATE I

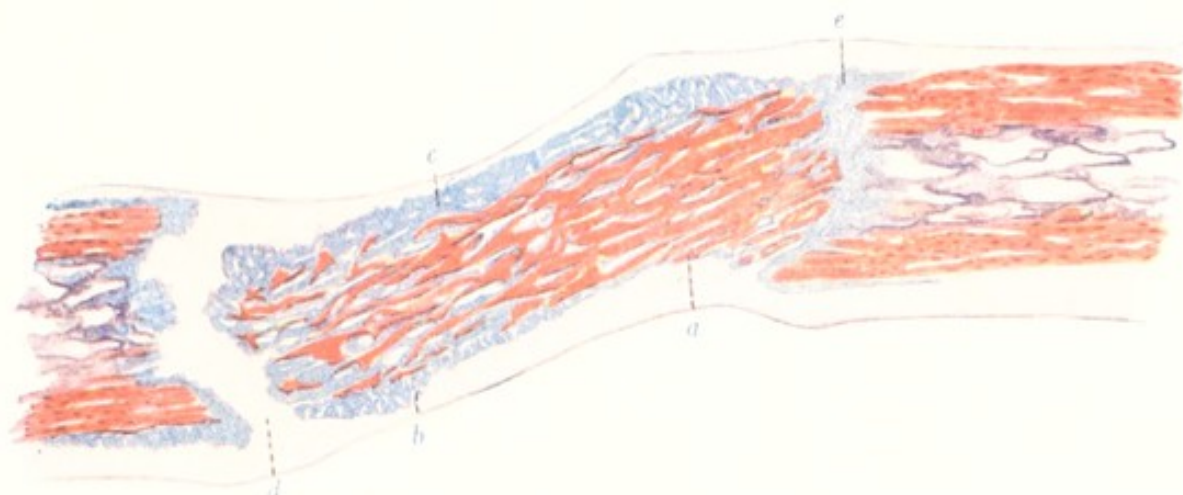


FIG. 1.—Sixty-four day Exp. No. 153. One-half of the shaft split longitudinally; periosteum and endosteum on; *a*, Old dead cortex; *b*, new bone from periosteum; *c*, extensive new bone from endosteum; *d*, fibrous intermediary callus above; *e*, bony union lower end. This specimen emphasizes the importance of the endosteum in the production of new bone.

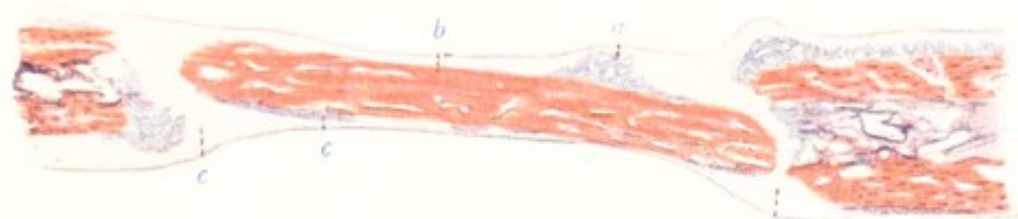

FIG. 2.—Forty-six day Exp. No. 176. Periosteum and endosteum both removed; *a*, Callus formed on transplant from surviving cells; *b*, dead cortex; *c*, fibrous intermediary calluses. This specimen proves that a cortical bone transplant will produce new bone from its "marrow canals," although all its periosteum and endosteum has been removed.

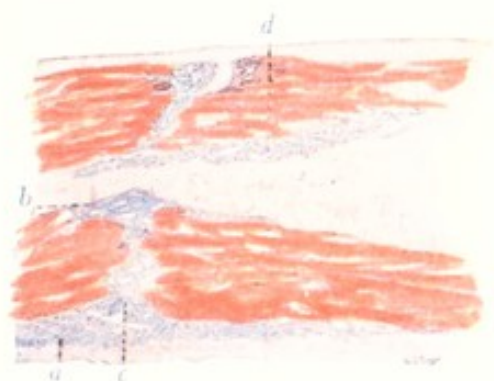


FIG. 3.—Forty-six day Exp. 161 R. Showing rapid bony union—a fracture through a transplant with periosteum and endosteum on; *a*, Bony periosteal callus; *b*, bony endosteal callus; *c*, bony intermediary callus; *d*, cortex with cells dead. The rapid bone formation and union in this specimen emphasizes the importance of coaptating like layers of bony parts, whether they are fracture fragments or bone-grafts. There is an important correlation between these layers (viz., periosteum, compact bone, endosteum, and marrow) in the formation of bony callus, and a bone-graft should always, when possible, be inserted by the inlay method, which brings all its layers in coaptation with the corresponding ones of the host bone. According to Ely the periosteum furnishes connective tissue from which the osteoblasts of the marrow tissue build new bone.

Volkman's canals, which on the inner surface of the bone are in communication with the blood-vessels of the marrow. The latter is supplied by the nutrient artery, which on its way through the compact substance gives off branches to the same, and in the marrow breaks up into a rich vascular network."

The bone contact should be of generous extent and always with healthy vascular osteogenetic bone—the more unfavorable the bone, the greater should be the area of contact. Careful suturing as well as accurate coaptation should be secured when early use is to be made of the part, in order to obtain the benefits of functional irritation. In many instances where close contact and exact coaptation cannot be secured, early bony union may be accelerated by the interposition of numerous small grafts or fragments of bone. In early ununited fractures, it is the practice of the author to remove most of the fibrous union and substitute for it (after the inlay has been fixed in position) numerous bone chips between the ends of the fragments. These coalesce with each other and also with the graft and recipient fragments.

The proper contact of these bone elements can be secured only by the employment of the author's inlay principle of procedure, which should always be carried out as carefully as circumstances permit. Examples of the various modifications of this principle are the inlay spinal graft for Pott's disease, the bone-graft wedge for the correction of deformities, and the inlay bone graft for fresh and ununited fractures. In many of the latter type of cases, the callus formation is so meagre that it may well be compared to the cabinet-maker's glue, which will not hold unless the wood is exactly fitted and coaptated. It will not bridge space. The same holds true in a long-existing ununited fracture. The surgeon must execute cabinet bone work in order to approximate 100 per cent. of successful results, and this can be accomplished only by employing the inlay method with the author's bone mill.

Bone grafts have been successfully applied by other means, but the following are some of the obvious advantages of the author's inlay method, besides the approximation of correspond-

ing bone elements of graft to recipient bone which this procedure makes possible. In the repair process, especially in fractures, new bone appears from both the periosteum and the endosteum on both sides of the cortex, possibly more markedly on the concave side of the fracture. The space between an inlay bone graft and its host bone becomes filled by cells arising from both the endosteum and the periosteum. Cotton and Loder consider the endosteum as the more important factor in the formation of bone about the transplant. In view of these facts, the inlay method of inserting a bone graft is apparent, in that it affords the coaptation of both these structures of the graft to the corresponding ones of the host bone.

The modifications of the inlay technique meet practically all mechanical requirements; it is as applicable to fracture of the small bones of the forearm as of the tibia or femur; it controls the deformity of the foot, as well as of spinal caries; its inherent mechanics favor the fixation of the graft as well as the immobilization of the fragments into which it is inserted; its technique is not difficult, because it has to do with plane surfaces. The inlay method allows the highest efficiency of Roux's post-operative functional irritation. To increase the potency of this factor, Roux advises frictional dressings during the after treatment, which consist of pressing or weighting of the bones and stretching the tendons.

That it is not absolutely necessary for the success of the graft to be contacted with a host bone, has been proved by Carter, who states (*Med. Record*, Feb. 7, 1914): "Bone grafts either covered by periosteum or bare, but accidentally separated from the living periosteum covered bone (host bone) appear to be osteoinductive and very likely osteogenetic." He reports 20 cases where the bone graft was used to elevate the bridge of the nose. In many of these cases the graft was not contacted to the bone of the face but was usually embedded in soft tissue, nevertheless the transplants are still in place and some are larger than they were when they were implanted 2 or 3 years before.

Chiari has succeeded experimentally in grafting portions of

bone-marrow into the spleen of the same animal. The grafts survived and increased in size from that of a hempseed at the time of transplantation to the size of a pea 5 months later. Histological examinations of the grafts in the spleen showed that

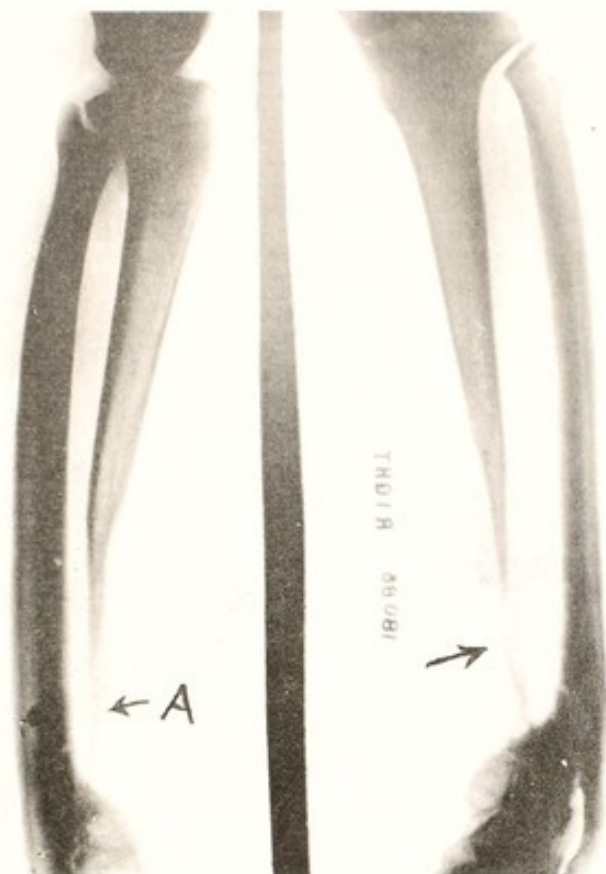


FIG. 8.—This is a röntgenogram of a case of loss of the lower one-third of the tibia one year before from osteomyelitis. The remaining periosteum attempted to reform the shaft and a small interrupted thread of bone can be seen. It, however, either became broken in two places or a complete bridge of bone was never produced; therefore, the influence of Wolff's law did not operate to stimulate bone proliferation for the tibia at A, as it would have if there had not been a solution of continuity. The potency of this same Wolff's law, however, could not be better demonstrated than it is in this same röntgenogram, as shown by the enormous hypertrophy of the fibula, which has become the size and strength of a normal tibia. This is a physiological property of bone, and shows itself as strikingly in bone grafts under functional stress as it does in complete skeletal bones. Therefore, as stated elsewhere, at the same time the graft is proliferating, in order to be of sufficient strength for its new environment, the tibia from which it was removed proliferates under the stimulus of function until it has returned to its normal strength and size.

the growth was actually due to an increase in bulk of the specific bone-marrow tissue.

A thorough understanding of the *modus operandi* and theory of Wolff's law is imperative. The influence of this law upon the success of bone-grafting procedures of all kinds cannot be

too strongly emphasized. It not only influences the graft to proliferate and strengthen to an almost unlimited degree, if the new mechanical environment of the graft requires it, but

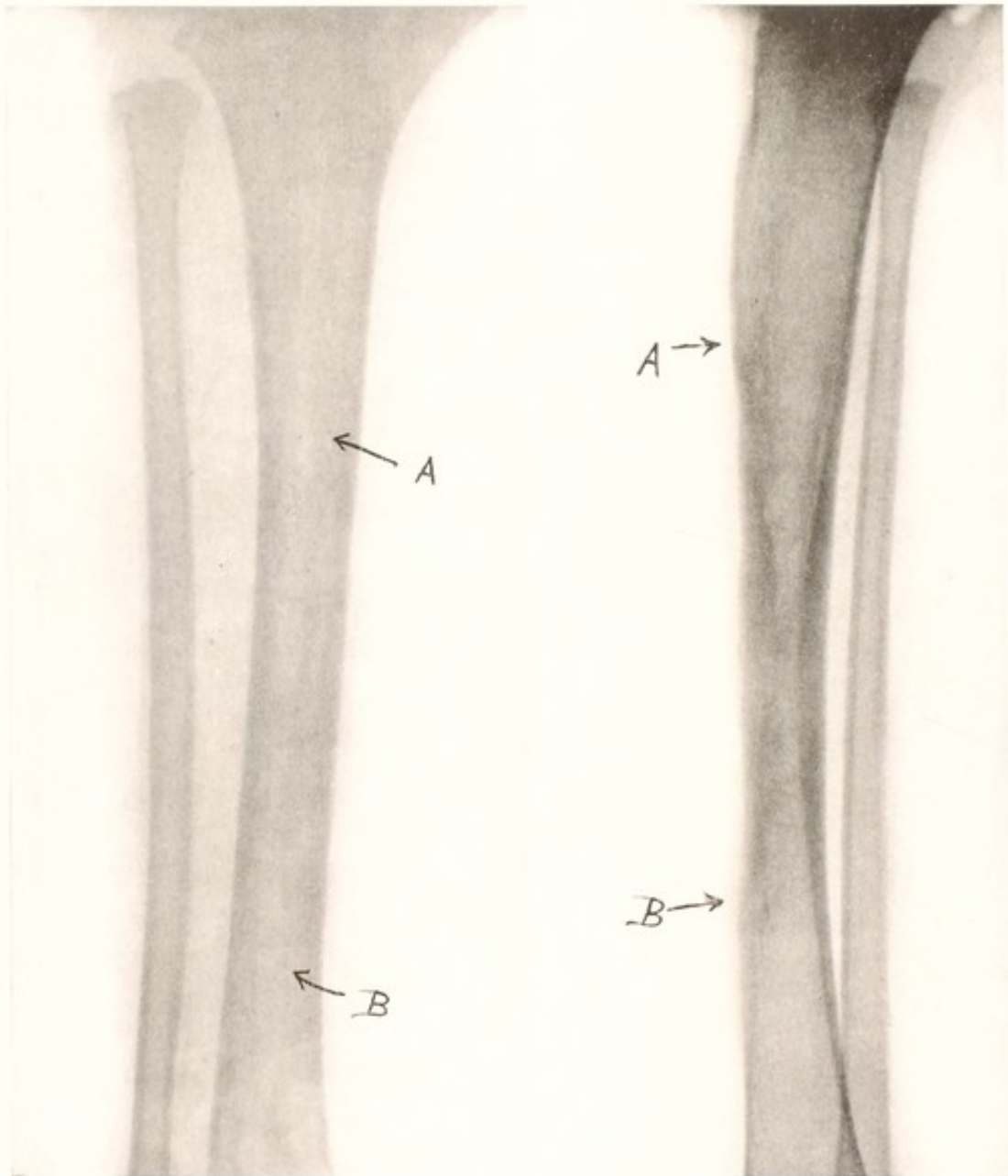


FIG. 9.—Anterior posterior and lateral röntgenograms of a tibia from which a graft had been removed for Pott's disease 12 weeks before. *AB* indicates location from which graft was removed. The cavity has filled in and under influence of Wolff's law the tibia has become nearly if not as strong as it was before the graft was removed.

the action of this law also causes the bone from which the graft was removed to be restored to its original strength. (See Fig 9.) This same influence also causes internal reconstruction of not

only the trabeculae, as the mechanical forces demand, but also of the general histological character of the bone, *i.e.*, cortical bone ultimately becomes spongy bone if implanted in or contacted with bone of that character, and *vice versa*. (See Fig. 4.)

A brief statement of Wolff's law is as follows: "Every change in the form and position of the bones or of their function is followed by certain definite changes in their internal architecture, and by equally definite secondary alterations of their external conformation, in accordance with mechanical laws."

The question as to what factors control the growth and development of a transplanted bone, or fragment of bone, and cause it to take, later on, the size and shape of the bone which it replaces, is a most interesting one. It is undoubtedly intimately connected with the corresponding problem of the factors concerned in the development of normal bones. Museum specimens and Nichols' cases (reported in *Jour. A. M. A.*, Feb. 3, 1914) demonstrate that when a new bone casing or involucrum is thrown out around the necrotic shaft of a long bone, it is thicker opposite the middle of the shaft than at the ends.

The physiological repair of fractures badly reduced, with a wide separation of fragments, and the restoration of the original contour of the shaft of that bone from the two over-lapping broken ends, demonstrates clearly what can be done by diaphyseal osteoblasts, apart from the aid of the epiphyseal cartilage, in not only restoring the external contour but also the medullary canal of the original bone. The osteoblasts will not only restore the outlines of a fractured fibula or form a new fibula shaft but, as has been demonstrated by Huntington, Stone, Bond, and others, they will transform a transplanted fibula into a new tibia. Skiagrams show that not only does bone deposit on the outside of the shaft, but the medullary canal is enlarged and the fibula thus approximates the structure, size and contour of the normal tibia. Bond believes that: "This must be the outcome of original hereditary capacity on the part of the osteoblast concerned, as well as the result of new pressures and strains ex-

perienced by these bone-cells during their growth under altered conditions. This must mean that, although a considerable amount of young bony material may have been supplied by osteoblasts from the shaft and ends of the fibula—when used to replace the tibia—yet the real task of modelling the new bone thus thrown out and of depositing it in the right situations must fall upon the osteoblasts of tibial ancestry, upon bone-cells which are thrown out by the tibial extremities after these have been rejoined by the interposition of a new shaft.”

The way in which osteoblasts derived from separate bones may work in coördination to build up bony trabeculæ in situations of stress is well illustrated in Fig. 212, showing excision of a knee, with ankylosis of the femur and tibia at a right angle to each other. Under the mechanical disadvantage of the two longest bones in the body being united into one at a right angle, the bony trabeculæ have arranged themselves to carry the weight of the body and this result has been arrived at by osteoblasts of femoral and tibial origin, each having taken part in the formation of the new bone. “The key-note of all bone development seems to be a coördinated arrangement of bone-cells in lateral and end-on relations to each other under the stimulus of pressure and strain within certain limits of innate capacity.”—(Bond.)

This, in brief, is Wolff's law, which always requires a bony connecting medium if its influence is to be potent. In the same way, a shaft seems to be essential to the proper growth of all epiphyses—all of which is in confirmation of Murphy's statement that “the amount of growth in a bone depends on the need for it.” The bone-cell colony has its investing and limiting membrane, the periosteum, just as the liver has its capsule and, as Macewen has shown, this periosteum or bone-capsule serves to keep the bone-cells within circumscribed limits and prevents them from invading neighboring tissue. The fact that the transplanted fibula shaft develops into a bone of the size and shape of the tibia, shows that the failure to do so in some cases is not due primarily to the fact that the transplanted bone is naturally a smaller bone, but to the fact that it is not mechan-

ically sufficiently taken over or that its growth is not sufficiently stimulated by osteoblasts of tibial origin.

Bond has suggested the following theory: "It may not be entirely useless to regard for the moment an individual bone as an organ, to think of it as a mass of bone cells of definite ancestry whose activities are exercised in becoming adapted to a physical environment of definite stress and strain." If this supposition be true, the selection of the bone from which the graft is to be used becomes of the greatest importance, as the degree of possible cellular proliferation of grafts or fragments of bone would be determined by the size and strength of the bone from which they were removed. This would argue in favor of obtaining grafts from a large and active bone, such as the tibia, when they are to be placed in an environment where it is necessary for them actively to proliferate and withstand a large amount of functional stress. Under this supposition, a graft obtained from a rib would not have the mechanical possibilities of a tibial graft, but would be suitable for the correction of facial bony defects, as was so well demonstrated by Carter, or for any purpose where excessive mechanical stress is not required.

The external shape of the bone is the result of functional adaptation. The bone is strengthened and thickened at those points where most stress and pressure come upon it, and is weakened at the opposite points. Such transformations have the object of enabling the bones or grafts in their altered positions and relationships to meet the new and abnormally directed stress upon them.

A good illustration of the influence of Wolff's law is where a portion of the tibia has been destroyed by osteomyelitis and removed. Without the support of the tibia, the use of the leg causes an abnormal amount of stress from both weight-bearing and muscular pull to be borne by the fibula, which hypertrophies up to a strength commensurate with this added strain. (See Fig. 8.) The same thing happens to a graft which is not of sufficient diameter to withstand the stress that comes upon it—it proliferates to an adequate size. Again, the tibia or bone from which the

graft has been removed proliferates until it becomes of the same size and strength that it was before the graft was removed; and this occurs in about two to four months, if the skiagrams can be trusted. Thus it is seen that Wolff's law has to do with function and is operable in fragments of bone as well as complete skeletal bones, and that it has an important bearing upon the plan of treatment and the progress of convalescence in a very large portion of bone and joint work.

Local or general hypertrophy of a bone may occur. Local hypertrophy may occur in consequence of increased strain upon certain parts of a graft, either directly or through the muscle pull. Schulze-Berge (*Central. für Chir.*, No. 48, 1913, p. 1854) reports the removal of the knee joint, including 8 cm. of head of tibia, for spindle-cell sarcoma, and the substitution of a segment of the fibula from the opposite leg. Radiographs taken 1 year later showed that the transplant had attained the strength and size of the diaphysis of the tibia.

The recognition and full appreciation of these important conclusions of Wolff constitute the foundation of the treatment of deformities and the application of grafts of all kinds. It is obvious that it is always advisable to allow the graft to functionate as early as possible by bearing mechanical stress within the limits of safety. This is highly favorable to osteogenesis, establishment of blood supply, and bony union. This functioning period should be preceded by the most efficient fixation of the parts grafted for an interval of not less than 8 weeks.

THE ROLE OF THE PERIOSTEUM

It is largely a question of the definition of what the periosteum is and what it includes as to whether it is to be considered actively osteogenetic or not. If by chance the cleavage is deep, as when the periosteum is removed with a sharp elevator and the underlying cortical bone scraped, the periosteum is sure to be actively osteogenetic, and it is only by this technique that the whole anatomical or histological periosteum is secured. On

the other hand, if the normal periosteum is stripped off or removed with a blunt instrument, the cleavage is not likely to be deep enough to include the osteogenetic layer of cells on the periphery of the compact bone. In that instance the periosteum constitutes a connective-tissue limiting membrane (Macewen) only and slight or no osteogenesis occurs.

Every graft should have as large a covering of periosteum as possible, because it not only favors the establishment of blood supply to the graft but is also an important factor in influencing the permanency of the graft, as was so well demonstrated by McWilliams.

In the study of bone injuries and bone growth, the three burning questions of the origin of bone callus, the rôle of the periosteum and of the bone graft have largely dominated the recent literature.

In 1692, Havers, whose name has been perpetuated by association with the vascular canals of the bone, described the periosteum as a simple connective-tissue "limiting and vascularizing membrane," but his work was based, apart from mere speculation, upon purely anatomical data.

Antoine de Heyde, in 1684, published the first experimental observations upon the repair of fractures, based upon work on frogs, and came to the conclusion that callus was formed by calcification of the blood which had extravasated around the broken ends.

Duhamel (1739 to 1743) brought forth the first systematic work on this subject and was the originator of the generally accepted modern theory of the reparative rôle of the periosteum. It was his belief that the periosteum proliferated and became thickened about a fracture and formed the callus by throwing out the new tissue. He was also the first to define and use the term "cambium layer" of the periosteum which, since the writings of Macewen, has become recognized as the all-important bone-governing element of that membrane.

Over 100 years later, after the less important investigations of Troja and others, appeared the great and important work of

Ollier (1858 to 1867), which has stood the test of time and remains to-day the principal foundation of all our exact knowledge of bone growth, although for a time it was thought that Barth and others had definitely refuted Ollier's views. These very men, however, have largely come back to Ollier's position. His work was so thorough and careful that his conclusions have attained an almost unassailable position. He proved the regeneration of bone from periosteum in every possible way, and ever since his day the periosteum has been regarded as the most important vital tissue of the bone. Nearly 50 years have elapsed since Ollier's treatise, and during this period practically the whole of modern surgery has arisen. Very many works have been written, dealing with fractures experimentally produced, but these have chiefly concerned themselves with the structure and origin of callus. More recently, the practical question of filling bone defects by grafts of dead or living bone obtained from various sources has absorbed the attention of workers who have sought to examine experimentally this method of bone reconstruction (Groves). Most important contributions on the subject have been made by Axhausen (1898), who showed that certain portions of transplanted living bone retain their viability and act as the centres of new bone proliferation. Groves states that: "Every practical worker on the subject has, moreover, endorsed the opinion that a living bone of the same species gives much quicker, stronger, and more certain results than dead bone or than that taken from another species."

Living bone is the chief source and origin of callus, which grows mainly from its outer or periosteal surface and to a less extent from its deep or medullary surface and its cut or broken ends.

Ollier, in 1858, described his technique for subperiosteal resection, but, so far as I am aware, he did not emphasize the importance of vigorous scraping with a sharp instrument in order to separate with the periosteum the embryonic layer of active osteogenetic cells which is situated on the periphery of the compact bone, although it is evident from the description of his work

that he frequently practised this technique. It seems certain that osteogenesis on the part of the healthy periosteum removed from a healthy bone is largely dependent on the presence of these active embryonic cells from the outer surface of the cortical bone. Therefore, the wisdom of the use of the sharp periosteum elevator in bone resection is apparent if a regeneration of bone from the periosteum is desired.

This statement, however, refers to normal periosteum removed from an uninfected bone. Infection of a bone, especially of the marrow cavity in osteomyelitis, causes an immediate migration of osteogenetic cells from the Haversian canals of the underlying bone into the loose areolar tissues of the periosteum. The meshes of this layer become filled with osteoblasts, from which layers of bone later form. If the pyogenic infection be progressive, the diaphysis may be involved and die; but the osteoblasts in the periosteum, which have escaped before the necrosis occurred, avoid destruction. Occasionally the whole shaft necroses without a reproduction of bone from the periosteum. This arises from one of at least two causes. The first occurs when the pyogenic invasion is more virulent, rapid, and extensive, causing blockage of the vessels not only of the medulla but also of the shaft, producing necrosis without a preliminary period of hyperæmia and consequently before regenerative changes have had time to occur in the shaft. The second, where the main nutrient vessels of the shaft at a very early stage become thrombosed by pyogenic invasion, the blood supply of a large portion of bone is cut off, and necrosis occurs before proliferation within the bone can take place. In some of these cases, the periosteum participates in the destructive process, but it does not do so in all. Owing to its separate blood supply, it is possible for the periosteum to live, and it sometimes does so apart from the bone. In such a case, however, there is no regeneration of osseous tissue, there having been no osteoblasts regenerated from the bone and thrown from the shaft into the subperiosteal areolar tissue before necrosis set in. It is in these cases in which an involucrum fails to regenerate that the bone

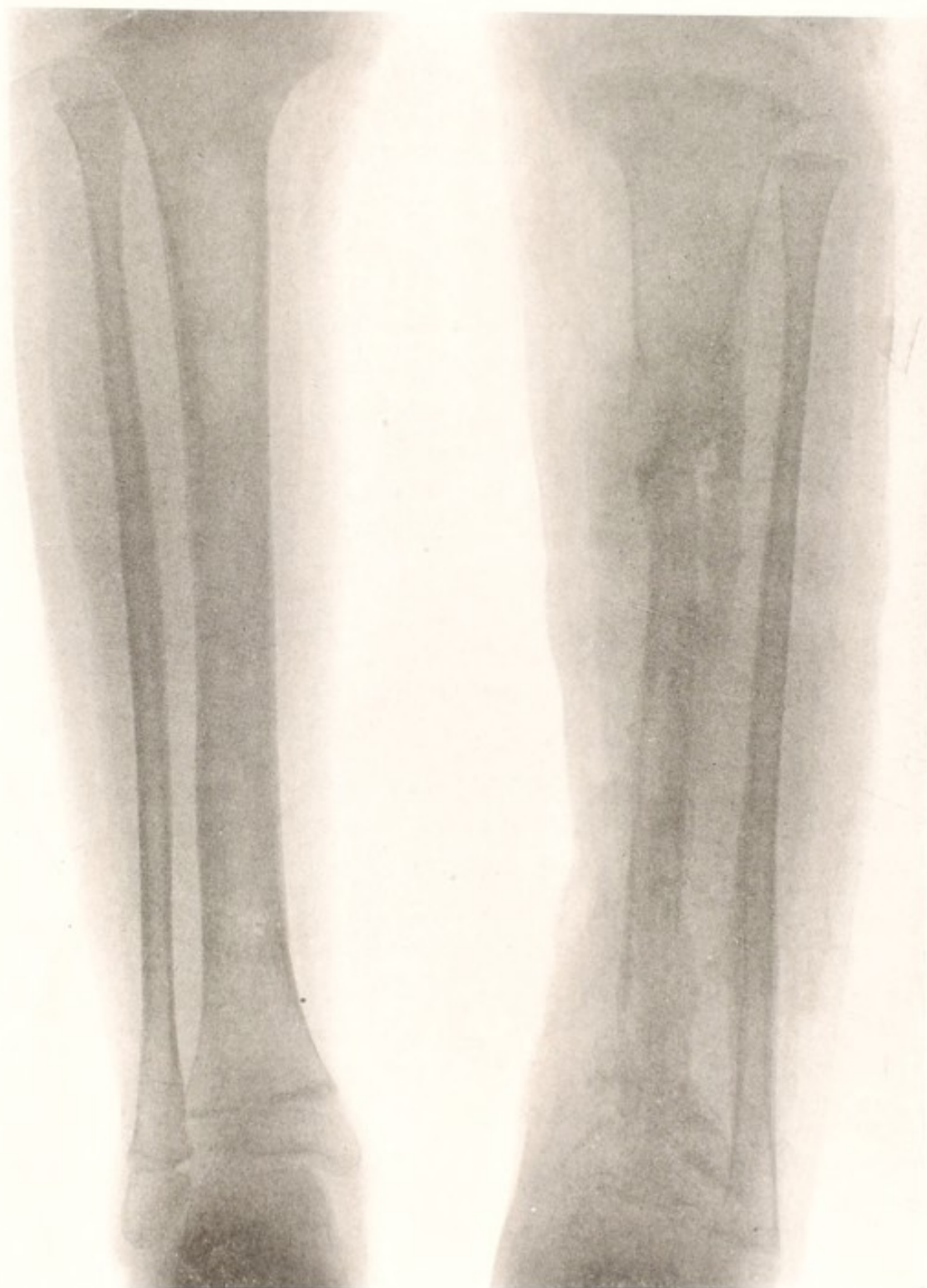

FIG. 10.—The author is indebted to Dr. Ellis W. Jones of Los Angeles, Cal., for the privilege of reporting this case, which was an absence of one-half the tibia from an old osteomyelitis. A graft from the other tibia was inserted by the author's inlay method. The wound became septic (*staphylococcus aureus*) and the whole graft was laid bare; nevertheless the graft lived, and the result was excellent. (See Fig. 12.)

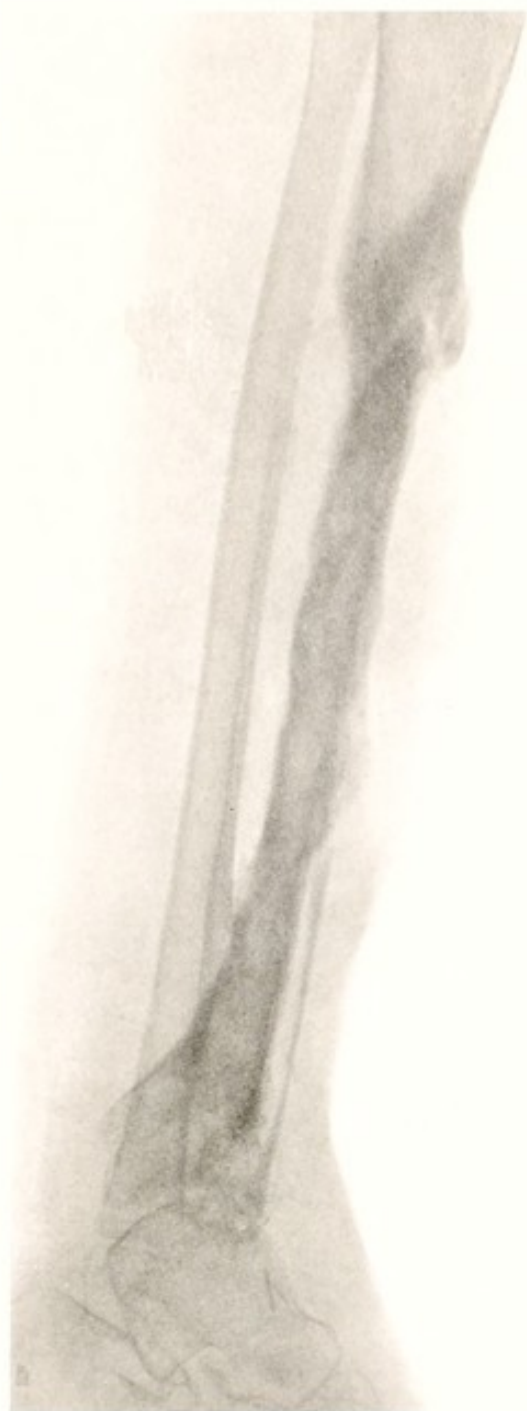

FIG. 11.—By the kindness of Dr. E. W. Jones, Los Angeles, Cal. Same case as (Fig. 10) 1 month later.

This case illustrates splendidly the inherent bacteria-resisting properties of the bone graft when properly inserted.

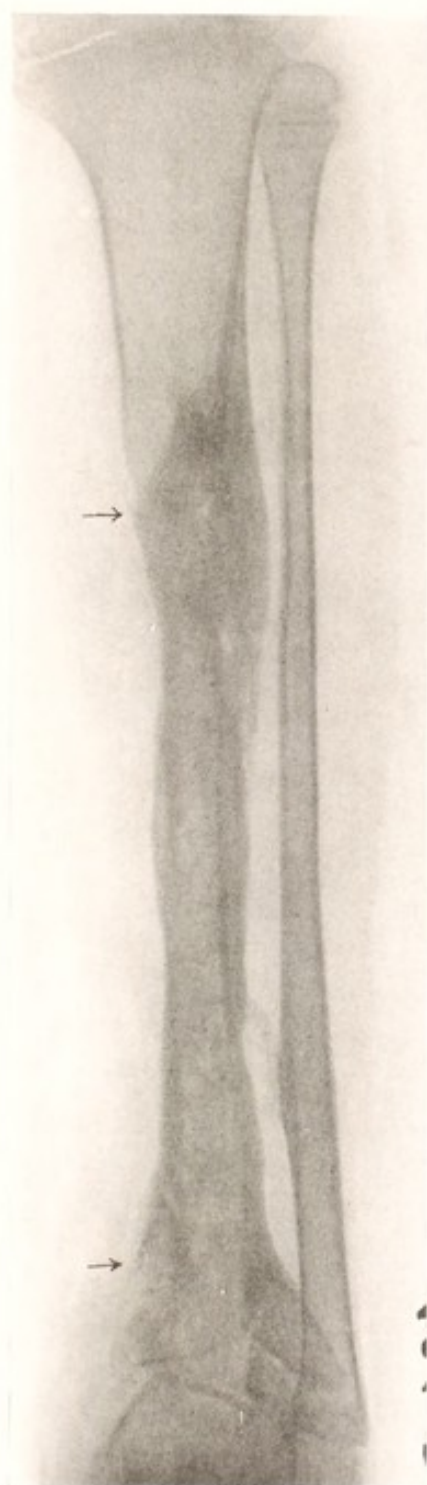


FIG. 12.—(Same case as Figs. 10 and 11.) A röntgenogram taken about 3 months later, after the wound had entirely healed, showing the increase in size of the graft and its firm union to the tibial fragments, indicated by the arrows. Also the development of a medullary canal.

graft is of the greatest service. In fact, it is in many cases the only possible means of avoiding an amputation. (For technique, see Chapter on Miscellaneous Uses of the Bone Graft.)

Davis and Hunnicutt, in *Bulletin of Johns Hopkins Hospital*, record the following findings: Free periosteal transplants did not produce bone in a large majority of experiments, even though osteoblasts were adherent to the transplants. Pedunculated flaps of periosteum did not produce bone. Free and pedunculated periosteal flaps with bone shavings attached produced bone in each experiment. Autogenous bone, both with and without periosteum, lived and was successfully transplanted to fill defects in bone.

Although not advisable, many liberties can be taken with the bone graft without interfering with its success. It has certain bacteria-resisting properties.

The author's experimental grafts were kept in normal salt solution for varying periods up to 1 week, with successful results following their implantation. In other cases, sepsis occurred immediately after insertion of the graft (experimental); nevertheless parts of the graft became united to recipient bone, while the rest of the implant sequestered.

Human autogenous grafts have been repeatedly so placed that, at their middle portion, they extend through tubercular foci, and in no instance has primary union or taking care of the graft failed. Likewise, grafts have been so placed as to span attenuated pyogenic infected areas, and here the grafts have been equally successful.

To substantiate the author's previous statement, based upon animal experimentation and many similar surgical experiences, that many liberties may be taken with the bone graft without interfering with its success" (Albee: *Experimental Study of the Bone Growth and the Spinal Bone Transplant, Jour. A. M. A.*, April 5, 1914), Galloway (*Western Canada Med. Jour.*, April, 1914) cites the following personal experiences: "I have operated on four patients (bone graft for Pott's disease) in whom a discharging lumbar sinus was present. Of course, extra precautions were taken, the mouths of the sinuses and the surrounding skin being thoroughly disinfected with iodine and then sealed with collodion on the day preceding the operation and before the regular pre-operative disinfection of the patient's skin was commenced. In all four cases primary healing took place.

"In several instances where there was a prominent kyphosis, small pressure sores occurred, causing exposure of the edge of the graft, but in only two or three of these did any sequestration occur, and in these not enough to interfere with the success of the operation.

"In one patient, pseudo-arthritis of the tibia, I (Galloway) put in one graft which greatly improved the condition of the limb and became firmly healed in. The tibia could still be easily bent, however, and a second operation was attempted. The first graft was firmly united throughout and was firm, but the recipient bone, which was noted to be very soft at the time of the first operation, had not improved, but was almost like dense fibrous tissue. A second graft was then cut. In shaping it after removal, it unfortunately slipped out of my hands and fell upon the floor. It was immediately picked up, washed in

watery solution of hydrarg. biniodide, 1 in 1,000, followed by rinsing with normal saline solution, and was placed in position. Mild suppuration followed but healing finally occurred. Unfortunately, however, the *recipient* bone remained fibrous and the limb failed to become firm, and I was finally forced to amputate."

The author has found that experimental grafts taken from long bones, such as the tibia or ulna, showed evidence of greater osteogenesis than those taken from vertebral spinous processes. Bone from which the periosteum had been removed proved as satisfactory as bone grafts on which the periosteum had not been removed.

It is deemed advisable, as stated elsewhere, to always include the periosteum and marrow substance, when possible, on the graft.

The bone graft acts always as a stimulus to osteogenesis to the bone into which it is engrafted or to which it is contacted. This is a constant and important factor, and may be depended upon toward securing results. If the graft is placed in a location where there is no mechanical function for it to perform its cells retain their vitality, but nearly always there will be few or no proliferative changes in the transplant. On the other hand, if it is transplanted into a defect where there is a demand for it to perform a mechanical function, proliferative changes are usually marked, and it rapidly becomes united and similar in structure to the part into which it is grafted. This is the law of functional irritation as laid down by Roux. The more perfect the technique of transplantation, the greater will be the effect of this law of irritation.

The bone graft, when well contacted, becomes immediately adherent to the recipient bone by newly formed tissue, which changes to solid bone within 4 weeks. In the author's opinion, this, together with the graft's bacteria-resisting property, strongly favors, when feasible, the employment of the bone graft in place of any metal internal splints, especially when it is appreciated that metal has an effect opposite to that of a graft in that it

inhibits callus formation, produces bone absorption, and favors infection.

The dowel, the inlay, and the wedge bone graft fulfil all mechanical requirements and afford a means of repairing and remodelling the skeleton which the surgeon has not hitherto possessed.

PRESERVATION OF THE BONE GRAFT

Various methods have been suggested for the preservation of bone-graft material, but in the experience of the author the following have proved most convenient and reliable.

The temporary immersion in normal salt solution is most satisfactory, and even this is usually not necessary, since, when possible, the graft bed should always be prepared prior to the removal of the graft, and the graft is immediately implanted in the prepared bed. This sequence of the operation is important, because (1) it assures an interval of time for the more perfect hæmostasis in the graft bed; (2) it enables the surgeon by means of calipers, bone wax model and flexible sterile pattern rod or flexible probe to obtain the exact size and contour of the graft required, thus avoiding unnecessary traumatization from holding forceps in reshaping a graft after its removal. Even in grafts where drill holes are necessary, it is far preferable to drill the graft before loosening it from the bone from which it is obtained. A graft should always be used as soon after its removal as possible, but if it is necessary for any amount of time to elapse before it can be used, normal saline is not satisfactory as a preserving medium because of its evaporation and the consequent toxic effect. In the experiments of the author, sterile vaseline has proved a most satisfactory medium in which to keep the graft. It is not only perfectly non-toxic, but it is an efficient preventive of drying. The graft should either be immersed in a jar of vaseline or wrapped in gauze smeared with the same and placed in cold storage at a temperature of 4° to 5° C. Freezing is not desirable, as the resultant contraction and expansion damage the cellular content of the graft. Human grafts removed from

the living as well as from a cadaver have been successfully kept by the author for 48 hours on different occasions. Emphasis should again, however, be laid upon the importance of using autogenous bone grafts whenever possible, as they are the most reliable; and as they are always used immediately, no preserving medium is necessary.

The surgical status of the value of the bone graft has now become so thoroughly established that the surgeon should be ready and equipped to make the best use of it in every individual case requiring osteoplasty. An unabridged enumeration of the indications for the employment of the bone graft would be most difficult, and the following tabulation serves only as a suggestion of its broad field of usefulness.

GENERAL INDICATIONS

1. To immobilize and stimulate osteogenesis in certain tuberculous joints.
2. To repair traumatic bone injuries.
3. To replace bone destroyed by infection.
4. To supply bone congenitally absent.
5. To strengthen or replace bone weakened or destroyed by benign or malignant growths.
6. To correct congenital or acquired deformities of the face.
7. To establish joints congenitally absent and restore those destroyed by disease.
8. To fix in place certain dislocated joints (acquired or congenital).
9. To close bone foramina in neuralgias.
10. To correct congenital or acquired deformities of extremities or trunk.

More specific indications for bone grafting are:

1. To immobilize, support, and stimulate repair in spinal vertebrae whose bodies are infected with tuberculous or other chronic infections where mechanical treatment is indicated. It is also applicable in cases of persistent non-union following

fracture of the spine, presenting pain, disability, and increasing deformity, and should be inserted as for Pott's disease. Further indications are for certain fresh fractures of the spine: spondylitis traumatica (Kümmell's disease) and neuropathic spine (Charcot) where, on account of a rarefying osteitis, crushing of the vertebral bodies and increasing deformity is likely to produce cord compression.

2. In the support and immobilization of cases of tuberculosis of the sacro-iliac joint, in certain desperate cases of tuberculosis of the tarsus, and in the form of inlays to hasten or insure bony union in erasure or excision operations for adult tuberculosis of the knee or hip.

3. In certain cases of paralytic scoliosis to support the weakened spine and prevent lateral deviation, due to superincumbent weight and unbalanced muscle pull.

4. To immobilize and support or replace bones of the tarsus destroyed, or partly destroyed, by tuberculosis.

5. To correct deformity or restore balance in congenital clubfoot and acquired deformity from local disease or paralysis.

6. As a substitute for all metal plates, screws, nails, spikes, and wires, as used in the internal fixation of fractures and other conditions. The graft, in the form of inlays and various sizes of nails or pegs, is employed by the author in all types of fractures, such as fresh and ununited fracture of the long bones and of the neck of the femur.

7. To produce a permanent closure of nerve foramina after nerve resection for neuralgia (Kanavel).

8. As a prevention of luxating or slipping patellæ by raising the low femoral condyle by inserting a graft in the form of a wedge.

9. To aid, in the form of numerous small grafts, rapid bone union where joint resection has been done or where a large graft has been used.

10. To strengthen and prevent lordosis or other deformity of the spine, in cases of spina bifida, where a large amount of bone is congenitally absent.

11. To replace the head and neck of the femur, when previously destroyed by disease, the head and neck of the astragalus being used as a graft (Roberts).

12. In congenital and paralytic dislocations of the hip where the acetabulum is shallow and the femoral head will not remain in place. The upper half of the meagre rim of the acetabulum is separated with a chisel and forced out and down, forming a pronounced rim. The cuneiform cavity thus produced is filled with wedge grafts.

13. To produce an ankylosis of the ankle joint in severe paralytic cases, or tuberculosis in the adult, by placing a bone-graft peg through the os calcis and astragalus into the lower end of the tibia (Lexer).

14. To replace bone removed for osteomyelitis, tuberculosis, and spina ventosa.

15. For deformities of the nose, by contacting graft with nasal bones. If the skin incision is made in the tip of the nose, the scar is not noticeable.

16. To replace or repair defects of the lower jaw; to fill in sunken spaces in the face, in the forehead following operation, in bony defects due to tuberculous osteitis of the facial bones, in recession of the superior maxilla due to harelip. To replace a mastoid process removed by operation.

17. In intraarticular fracture-dislocations, the head of the humerus or femur, etc., should be replaced, at an open operation, as a graft.

18. To repair cavities in the cranial bones by transferring from the immediate neighborhood one or two segments of the external table covered with periosteum. The cortex of the tibia or a portion of the scapula may likewise be used; the latter source is preferable, as both surfaces of the graft are covered with periosteum.

SUMMARY

The bone graft is a trustworthy surgical agent, as proved by the author's uniform success in its use in over 400 surgical cases;

also by a careful study of its results, microscopically, macroscopically, and by the X-ray, when used experimentally in the presence of both primary union and sepsis. The field of usefulness of the cortical graft is distinctly enhanced because of its resistance to tubercular and attenuated pyogenic infection. Its field is also enlarged by the employment of motor-driven instruments, circular saws of different sizes, the adjustable twin saws, and the lathe or dowel instrument with different adjustments for making, as conditions demand, various sizes of bone-graft inlays, nails, or spikes. By the use of this motor outfit and its products, in conjunction with kangaroo-tendon, the author has been able during the past two years to avoid entirely the use of metal in the form of screws, nails, Lane's plates, wire, etc., for internal bone-fixation purposes. This has been made possible, largely, by utilizing the best of well-known mechanical devices hitherto rarely, if at all, used in surgery—such as bone inlays, wedges, dowels, tongue and groove joints, mortised and dove-tailed joints.

CONTRAINDICATIONS

The only contraindications to the surgical use of the bone graft are a markedly septic field of operation and excessive scar tissue as an environment. Syphilis should be cured before operation, although one case of syphilitic osteitis of the spine has been unintentionally operated. The graft healed in immediately and controlled entirely the spinal symptoms.

CHAPTER II

AUTHOR'S ELECTRIC MOTOR OPERATING OUTFIT AND TECHNIQUE OF USAGE

Until 1911, when the author first began to do his bone-grafting operation for Pott's disease, the bone transplant had been so infrequently used as a surgical agent that no special technique had been developed for its removal. The electric motor circular saw (Doyen) had been used for skull work—driven by either a flexible shaft from a motor on a near-by stand, or by the Hartley-Kenyon apparatus, where the cutting tool is attached directly to the motor shaft—and, so far as the author is aware, it had not been used in any systematic way for the removal or the modelling of bone transplants.

The author began his spinal work by removing the graft from the tibia with chisel and mallet, and later others made use of the Gigli saw. It was soon found that these methods were not only slow and inaccurate, but that they presented the dangers of bruising, cracking, or fracturing the graft or tibia, or both. This is especially true in adult patients, on account of the brittleness and thickness of the cortex. In the child, on account of the small diameter of the bone, the danger of fracture is evident, although the graft is obtained by means of hand tools with much less difficulty and much less likelihood of fracturing it.

Also, in obtaining grafts 8 in. or more in length, it was found that the hand-tool methods were crude, requiring too much time, tiring the surgeon, and unnecessarily shocking the patient. In removing the graft with the chisel and mallet, the graft must many times be handled and shaped after its removal, whereas with the circular motor-driven saw a pattern marked in the periosteum with a scalpel can be followed accurately and the graft shaped *in situ* during its removal. The graft pattern is usually

obtained by bending a flexible probe or leaden bar into the prepared graft-bed, whose shape is transferred to the tibial surface from which the transplant is to be removed.

In modelling the graft into dowels, wedges, inlays, and in making use of the different well-known mechanical devices, such as tongue and groove joint, dove-tail joints, mortises, etc., the motor outfit is still more indispensable. An accurate cabinet-maker fit may mean success in many instances where an ordinary crude coaptation would mean failure. Especially is this true in ununited fractures.

The scepticism as to the value of the graft, plus the difficulty in obtaining and moulding it, has undoubtedly delayed the earlier development of the use of this most valuable surgical agent. It is difficult to give an adequate reason why in the rapid advance of surgery the work of osteoplasty has, until very recently, stood for so long a time practically at a standstill, especially in view of the fact that Ollier, in 1858, from extensive animal experiments and surgical work—although working in the pre-antiseptic era—furnished abundant evidence that the autoplasmic bone graft survived and lived when consisting of cortex, periosteum, and endosteum, and implanted into a bony defect where it had function to perform.

As in many other fields of endeavor, electric power has been the chief means of placing this valuable agent at the disposal of the surgeon. In recent years the generalization of the use of electricity for lighting, heating, and power purposes in most hospitals, private dwellings, etc., has also been a potent influence, and has enabled the surgeon always to be in reach of the necessary power for operating his motor outfit—whether he is operating in the city, suburban hospital, or private dwelling. The electric automobile or storage battery can also be made to furnish a movable source of supply which can be utilized at any time or place.

The ideal surgical electro-motor outfit should measure up to the following requirements:

1. It should permit of the thorough and rapid sterilization

of every part which comes in contact with the surgeon or the field of operation, including the electric cable for transmitting the power.

2. It should permit of ready application to all types of osteoplasty, whether situated superficially or in a deep wound; whether the work to be done is the procuring of the graft, the preparation of its bed, the drilling of holes, the removal of bone for the correction of deformity or disease, or to allow the proper approximation and alignment of bone fragments in cases of fracture.

3. It should permit accurate control and guidance of the motor cutting tool in all wounds and at all angles.

4. It should permit easy and convenient control of the electric current.

5. It should be light in weight, small in bulk, and permit of easy transportation.

6. The motor should be universal and adapted to all types of electric current.

7. The motor instruments—saws of different types, drills, dowel shapers, etc.—should be held in place in the motor by an automatic catch favoring their speedy interchange.

8. The motor-cutting tools should be constructed similarly to those long-used by the artisan for working hard materials, and should be of sufficient variety to meet every requirement of bone carpentry. The twin saw for inlay work should be so constructed that it can be readily adjusted—to the fraction of a millimetre—by the gloved hands of the surgeon at the operating table. The dowel cutters with drills of corresponding diameters should vary in size sufficiently to meet all requirements.

9. The motor should furnish enough power to drive rapidly a saw or large drill through the thickest human cortex without tendency to stall.

The author's outfit, described in this chapter, has been carefully devised and perfected to fulfil all of the above-mentioned requirements. The motor tool is attached directly to the motor

shaft; the motor is covered by an adjustable sterilizable shell, enabling the surgeon to hold the motor in his hands while the tool is cutting; the weight of the outfit has been found to be an advantage rather than a detriment in its application, and it is believed that it completely fulfils every demand.

DESCRIPTION OF OUTFIT

The author's electric operating bone set consists of a small universal motor, *i.e.*, one which will operate without readjustment on all types of electric currents, such as direct, alternating, and of varying cycles. If it is to be used on a 220-volt direct current, a 100-c.p. 220-volt lamp should be placed in series with motor. Electrical engineers have found it impossible to construct a light motor which will resist deterioration from repeated boiling of the motor itself, or any other safe type of sterilization. Both the insulating material and the carbon brushes are liable to disintegration from repeated subjection to heat. Therefore, the Hartley-Kenyon method of removable, sterilizable shells has been adopted, as it seemed by all means the most desirable.

The apparatus consists of a small portable motor with a sterilizable shell which is divided into two parts, so that it can be removed for boiling. A guide handle, which also can be boiled, is adjusted at right angles to the small end of the motor over the shell.

A foot switch is supplied to make and break the electric circuit. A long electro-conducting cord is provided to transmit the current from the source of supply. In one end of the cable is a fitting, to be inserted into the electric supply, and on the other end is a connection for the foot switch. Midway between the two terminals, a connecting block is mounted into which is inserted the connecting cord leading to the operating motor. This connecting cord has fitted on to one end of it a metal tube and connection for the motor, and is the only portion of the electric cable necessary to be boiled.

The foot switch can be used with either side upward. If the

corrugated rubber side is upward, the connection is made by pushing down with the foot. If the other side is used upward, the foot should be placed over the entire switch, and by depressing, or allowing the aluminum lever to rise by moving the heel




FIG. 13.—Author's armamentarium for bone work. 1. Calipers. 2. Doyen washers or guards for motor saw. 3. Spray and guard for saw. 4. Twin saw. 5. Dowelling instrument or lathe. 6. Right angle twin saw. 7. Wrenches for twin saw and drill chuck. 8. Drill with guard to prevent it penetrating too deeply. 9. Drill chuck and small drill in place. 10. Burr for drilling fractured neck of femur for peg graft. 11. Small circular saw. 12. Large saw. 13. Carver's gouge. 14. Lowman fracture clamp. 15. Berg fracture clamp. 16. Wide osteotome for splitting spinous processes for the insertion of bone graft for Pott's disease. 17. Surgical electric motor. 18. Compasses. 19. Lambotte fracture clamp, large and small.

up and down, the current is turned on or off in varying degrees and acts as a speed regulator to the cutting tool.

Cutting Instruments.—The *single* (circular) *saw*, about $1\frac{1}{4}$ in. in diam., with Doyen graduated washers or guards, is used

more than any other of the cutting tools. These saws are of the best steel and are very thin, and are held on the shaft by means of nuts which allow the saw blades to be changed when they become dulled.

The *twin saw* is so constructed that it can be adjusted to any desired width, even to the fraction of a millimetre. It consists of two single saws, which can be used singly or together. Each saw is mounted on a separate shaft, one of which is hollow so that the other shaft can be inserted into it and so bring the saws at any distance apart that may be desired, according to the size of the bone being operated upon and the width of the graft or gutter to be formed.

In determining the size of the inlay or the gutter, the saw teeth are placed on the exposed bone in the manner of a compass or calipers in order to determine the width of the inlay or gutter, and, with the saws undisturbed, the shaft of the proximal saw is prevented from turning by placing the accompanying wrench or a heavy clamp on the flat-sided end of the shaft, while the operator locks the saws together by turning the saw (proximal) on this shaft away from him protecting his gloved right hand with a piece of gauze over the saw teeth.

The *dowel instrument or lathe* is fastened into the motor by the automatic catch, precisely as are the other cutting tools. Its speed of rotation is reduced about 10 times by steel gears.

The size of the bone graft dowel or nail is regulated by the size of the cutter, which is adjusted in the lathe. The largest cutter is for turning out a bone graft spike for a fracture of the neck of the femur. The smallest one is for making pegs to hold inlay grafts in place. The medium-sized cutter is for making graft nails for pinning the scaphoid to the head of the astragalus in an arthrodesis for advanced flat-foot, or other condition.

The dowel-shaper is used by first inserting it into the motor, and then placing the apparatus, parallel with and on the edge of the instrument table. While the assistant steadies the motor and lathe by gently pressing the same on the table, the operator, holding with a strong clamp the strip of bone to be shaped,

pushes it into the dowel-cutter. When withdrawn, it is a perfectly round dowel, and is ready to be driven into the drill hole made by a drill of a size corresponding to the dowel-cutter used. The strip of bone is obtained by means of the single or the twin saw.

The *small saw* is used for cutting the ends of the inlay graft or the strip of bone which is being removed to produce a gutter. On account of its small diameter ($\frac{3}{4}$ in.) the saw does not encroach into the gutter walls while it is cutting across the inlay.

The *guard with spray* is an important attachment. It is connected by a sterile rubber tube with a douche bag suspended over the operating table, and maintains a constant spray of saline solution on the saw, preventing friction, heat, and flying of the solution.

The *twist drills* are of the type used by the machinist for drilling metal.

STERILIZATION (Hartley-Kenyon Method)

The parts to be sterilized are first removed from the motor by releasing the plunger on the end of the electric cable so as to allow it to come out. This part of the electric cable, from the motor to the black rubber union on the contacting cord, is boiled. The handle and shells are removed and, together with the cutting tools, sterilized by boiling. The part into which the cutting instruments are inserted is removed from the motor, with the long part of the sterilized shell. This is the part which contains the automatic catch. A little vaseline is placed in the motor shaft opening, and the motor is laid aside until the sterilizable parts are ready to be readjusted.

After sterilization, the operator picks up the long part of the shell with his gloved hand and places it on the corresponding end of the motor, which the nurse holds with the small end up. (See Fig. 14.) The nurse holds the large end of the motor in the palm of her hand while the surgeon fastens the shell to the other end by turning the shell toward the right as far as it will go, or

until the dart on the shell comes opposite the dart on the motor (Fig. 15). The operator can then manage the motor alone by grasping the sterile half shell which is firmly secured to the motor.

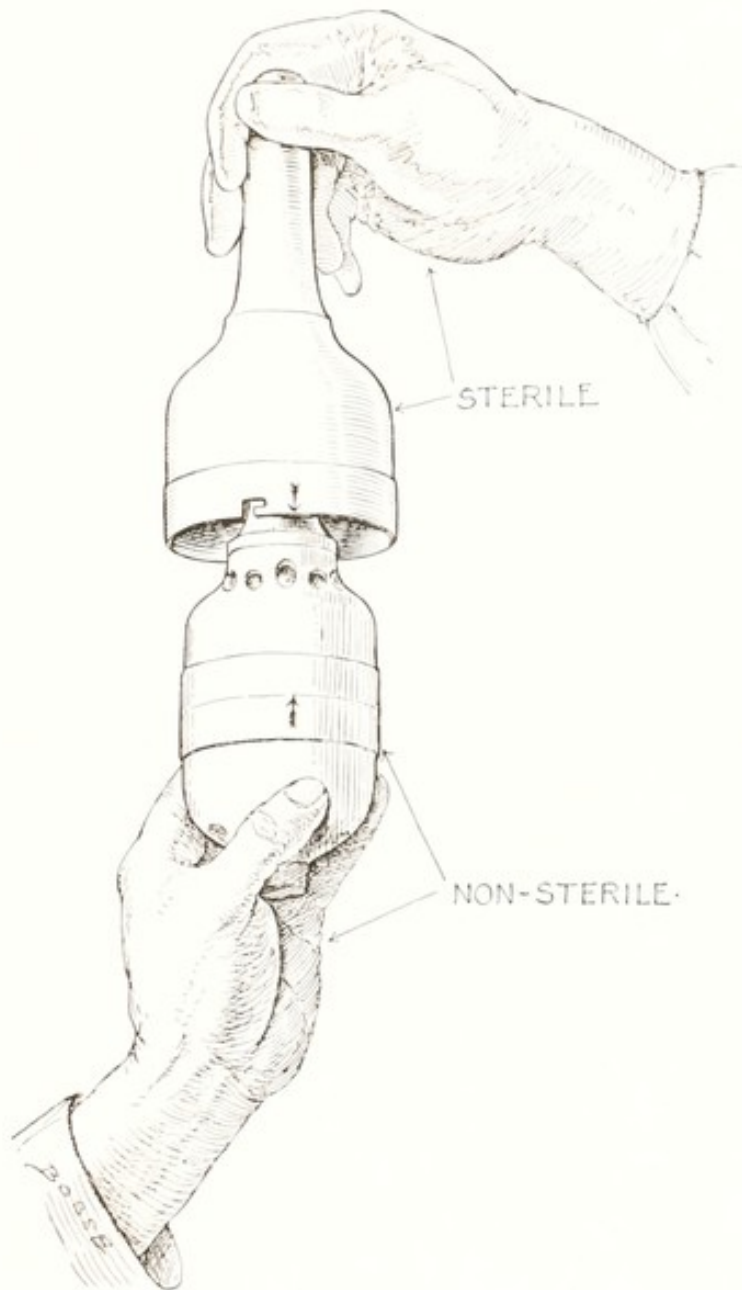


FIG. 14.—Method of putting author's motor outfit together. The sterile shell is turned to the left until it can be turned no further and the arrow on the shell comes in line with the arrow on the motor. The surgeon then has control of the motor and turns it over. (See Fig. 15.)

The second half of the shell is placed over the other end of the motor and is locked in place to the first half shell by a bayonet fitting (Fig. 15). The guide handle is placed over the neck

of the motor and securely fastened by the set screw. The connecting plunger on the side of the electric cable is then inserted through the sleeve on the shell into the motor. This portion of the electric cable, with its metal tube and block connectors,

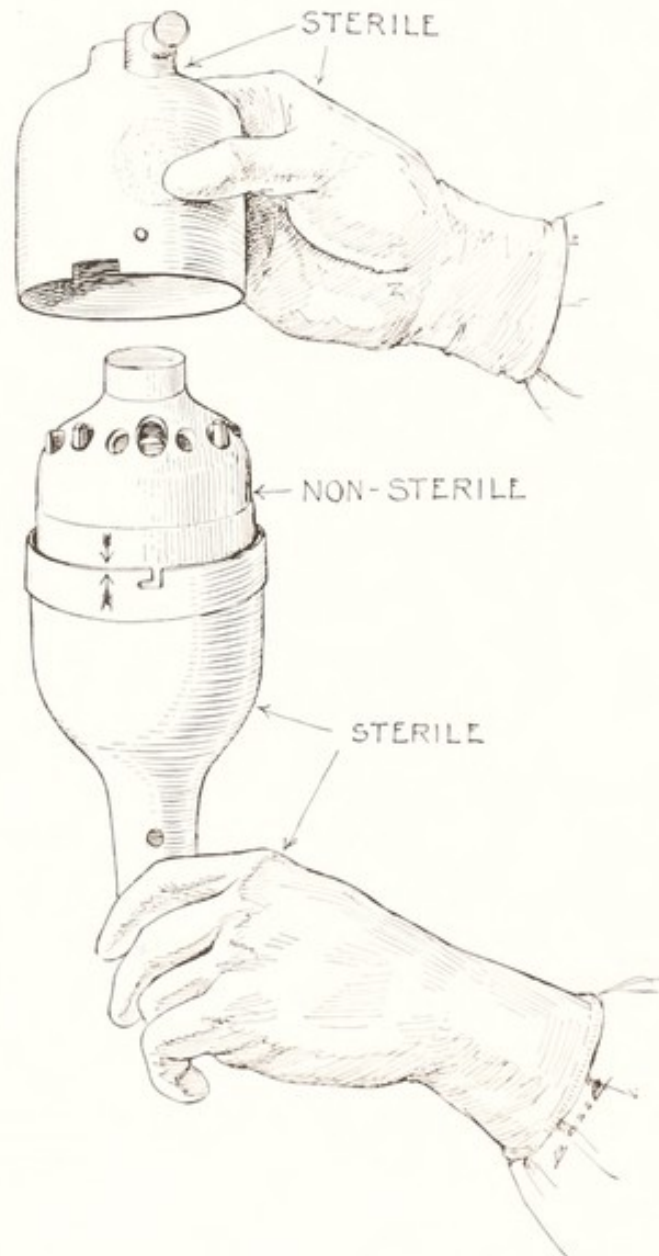


FIG. 15.—While the surgeon holds the motor by the sterile shell already attached, he locks the other half shell in place.

is especially constructed to withstand sterilization by boiling. The corresponding connector is next inserted into the black connecting block in the central portion of the cable leading from the socket of electric supply to the foot switch which the nurse has

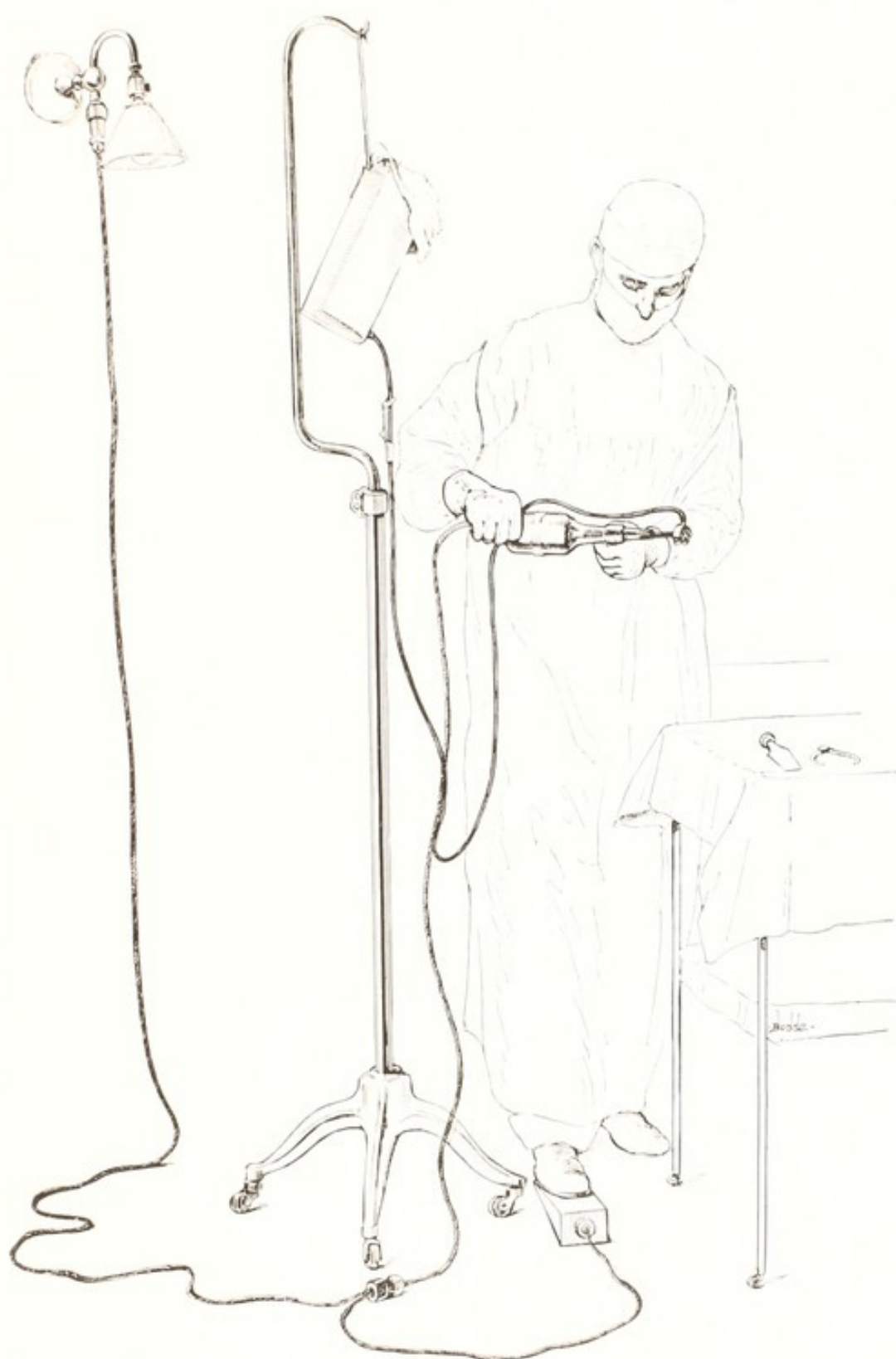

FIG. 16.—The manner of holding the motor saw. The connecting wire to the electric wall fixture. The foot switch control. The sterilizable connecting wire to the motor. The sterilized rubber tube connecting the tank of normal saline solution and the spray attachment above the saw are shown. The author's broad thin osteotome for splitting the spinous processes and the calipers for determining the length of the graft are on the instrument table.

previously connected and arranged with the foot switch in a convenient position for the surgeon's controlling foot while he is operating. The motor is then ready for use. The saws or the cutting tools are inserted by turning them over a little to the right or the left while the knurled ring on end of the shaft




FIG. 17.—Martel's attachment to author's electrical surgical outfit for laminectomy and skull work.

is pressed in by the operator's thumb, or until the spring engages the slot on the side of the shaft of the instrument. The cutting tool is unlocked by pressing the knurled ring on the end of the shaft at the same time that the instrument is withdrawn.




FIG. 18.—Martel's attachment to author's electrical surgical outfit for skull work.

The action of the motor is controlled by the foot switch which makes and breaks the electric circuit, and the surgeon thus has the uninterrupted use of both hands and the most precise speed control of the cutting instruments.

This automatic control is a great improvement over the

screw and screw-driver arrangement for holding the cutting instruments as used on the Hartley-Kenyon motor. In certain plastic work, especially fracture work, it may be necessary at one operation to employ several different cutting tools, such as two sizes of single saws, twin saw, different sized drills, and surgical lathe, and also to interchange these several times. The automatic catch permits of almost as speedy a change of motor tool as of hand instruments, and is a most important feature of the outfit. As far as the author is aware, this is the first automatic catch to be incorporated into an electric-motor surgical outfit, and it is almost indispensable to rapid work. Then, again, the screw-driver is a source of danger to the operator's gloved hand, because while loosening or tightening the screw, the motor shaft may turn, allowing the screw-driver to push by and puncture the surgeon's glove.

TECHNIQUE OF USING MOTOR

When the motor tool is cutting, the handle, which is placed at a right angle to the long axis of the motor, is held in the operator's right hand; the base of the motor is grasped in the left hand, and the right foot manipulates the foot switch, which is placed on the floor beside the operating table, at a place convenient for the operator's foot. If found necessary, the position of the motor and the hands may be reversed. The various technical applications of the outfit will be illustrated in detail in the various special chapters.

CHAPTER III

THE BONE GRAFT IN THE TREATMENT OF POTT'S DISEASE AND OTHER LESIONS OF THE SPINE

Pott's disease was so called from the fact that Percival Pott, in 1779, was the first to describe accurately this slowly developing deformity, accompanied by pain and at times by paralysis.

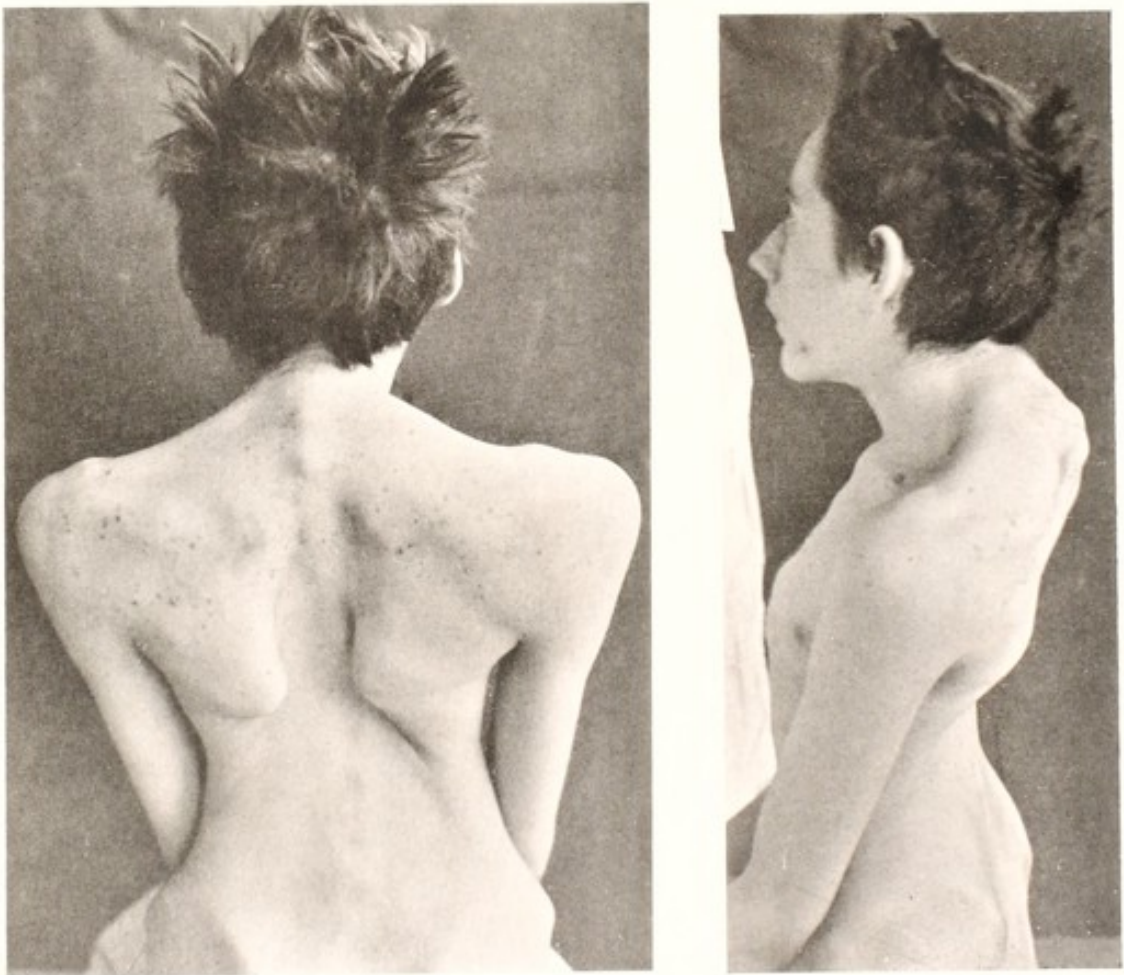


FIG. 19.—A case of Pott's disease in a young man of 17 years, after 10 years of plaster-of-Paris jacket treatment. The marked compression of the thorax is very striking.

He did not, however, ascertain its cause, and it was not until 1882 when Robert Koch made his discovery of the tubercle organism that its etiology was definitely determined.

At the present time the term, instead of including the various causes of angular deformity, such as may be the result of fracture, malignant disease, erosion of an aneurism, syphilis, or other pathological process, is confined to those cases of kyphosis where the deformity is due to a tuberculous infection of the bodies of

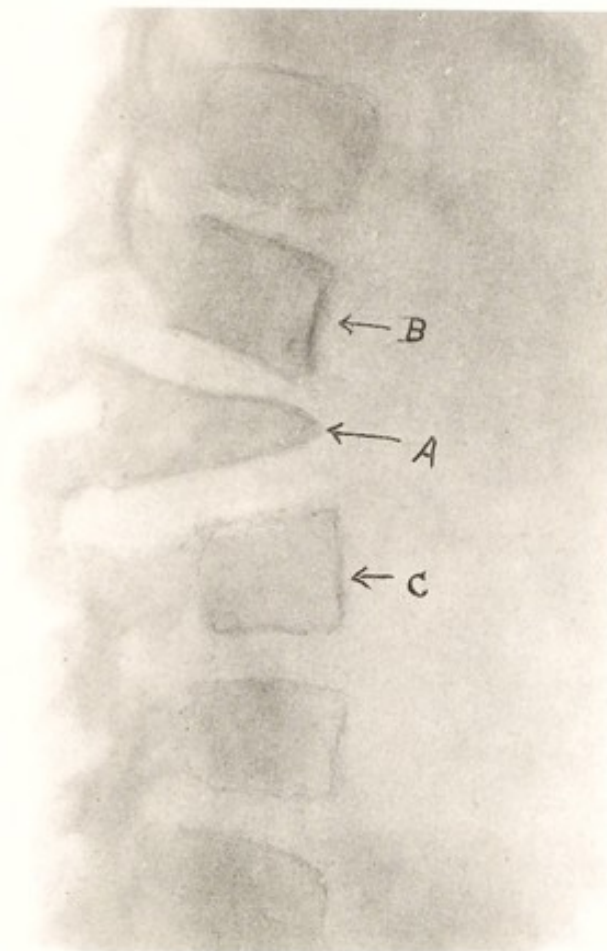


FIG. 20.—Röntgenogram of a case of Pott's disease of the spine showing extreme rarefaction of the wedge-shaped mass of bone detritus at *A*, which has resulted from the disintegration and crushing of two vertebral bodies, during plaster-jacket treatment, although there has been a large destruction of bone there has been no coincident proliferation of osseous tissue.

This factor is largely responsible for the striking tendency to progression of disease and deformity in spite of conservative treatment, and is at the same time a strong argument in favor of the bone-graft instrument.

the vertebræ. The compression and disintegration of these vertebral bodies produces the characteristic angular deformity of Pott's disease.

As the structure of the bodies of the vertebræ is made up almost entirely of spongy bone, and as tuberculous disease in

bone is confined almost entirely to this cancellous bone structure, it follows that this portion of the vertebra is involved to the exclusion of the denser or cortical portion, *i.e.*, the lateral masses and spinous processes.

As the action of each vertebra in the spinal column is for the most part a leverage action, and as the superincumbent body

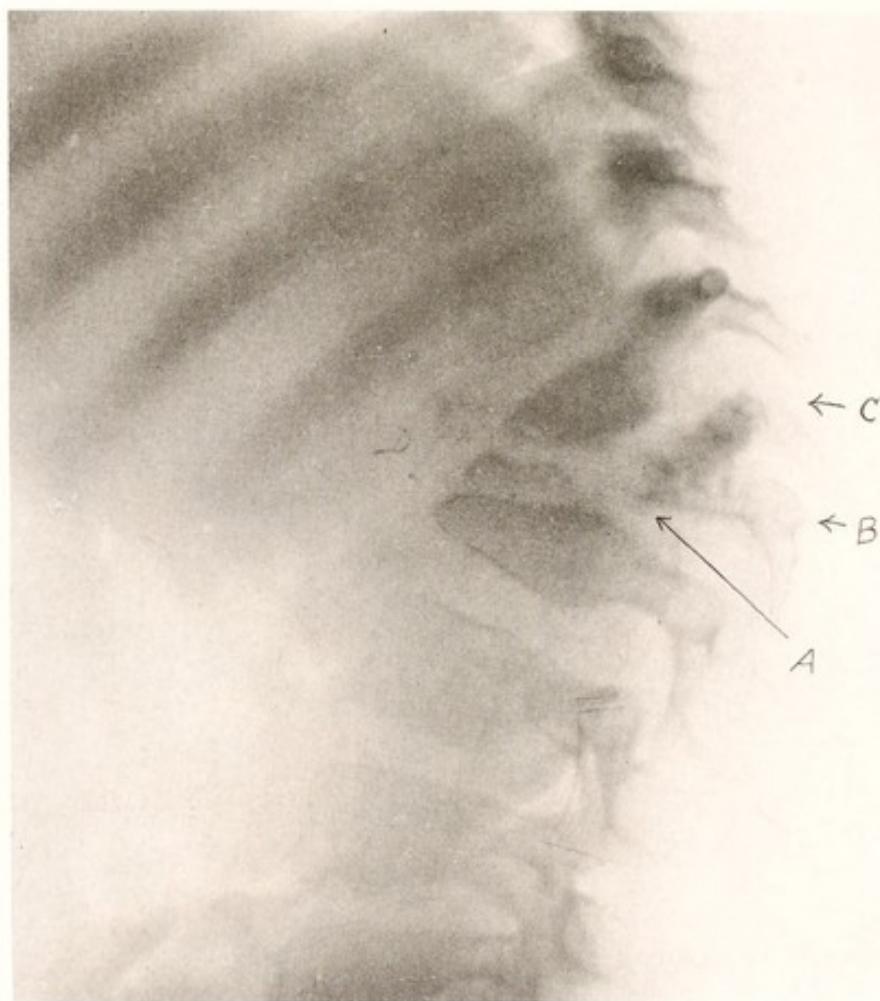


FIG. 21.—Röntgenogram of the dorso-lumbar spine showing the bodies of the vertebrae *B* and *C* completely obliterated and one directly above and below thinned and wedge shaped due to the tuberculous process.

The resulting kyphotic angle of the spine thus produced should be noted.

The principal feature, however, of this röntgenogram as in Fig. 20 is that no repair by bone proliferation is shown, although the destructive lesion in this case had existed for not less than 3 years. The need of the implantation of bone is apparent.

weight is borne in very large measure by the individual bodies of the vertebral column with their interposed intervertebral cartilaginous discs, it follows that as respiratory action and involuntary contraction of the abdominal muscles, together with

the activity of the tuberculous focus, weakens the resistance of the bodies to weight-bearing, these bodies are crushed, and unless measures are taken to prevent this crushing and transfer the weight-bearing more upon the articular processes and lateral

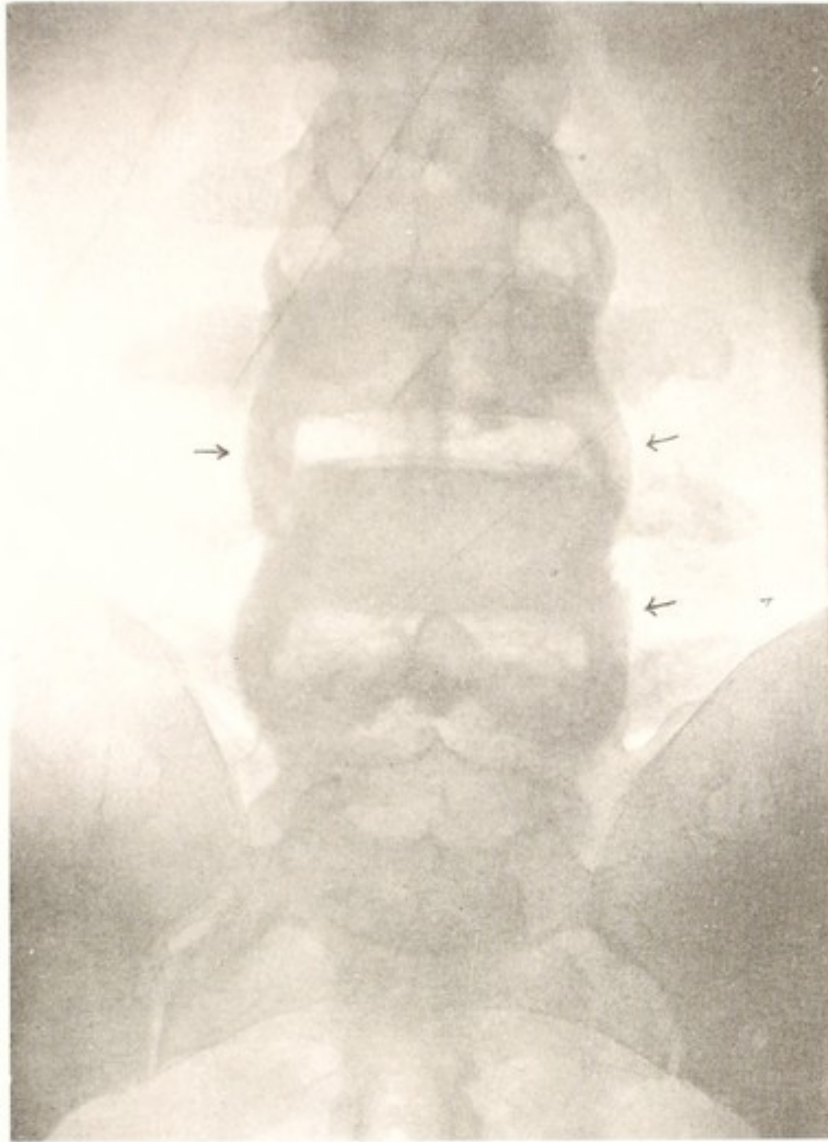

FIG. 22.—A case of infectious spondylitis of the lumbar spine. The arrows indicate the large amount of new bone formation which is in such marked contrast to the absence of bone proliferation in tuberculosis of the spine. Ultimate telescoping of the vertebral bodies can be prevented in such cases by conservative splint treatment because of the active bone proliferation.

masses, this crushing effect continues and the vertebral column collapses forward at the expense of the anterior arms of the levers (the vertebral bodies), causing a separation of the posterior arms of the levers (the spinous processes), thus producing the

increasing angular deformity, or kyphosis, so noticeable in these cases.

Various procedures have been adopted on the basis of this principle of the leverage action of the vertebræ in order to prevent the increase of this posterior angular deformity. The arrest of the tuberculous process depends upon the ability to check this increasing kyphosis and prevent further collapse of the vertebral bodies. As can be readily seen, any external fixation applied to the series of levers of the spine as a whole



FIG. 23.—Acute Pott's disease, with an angular kyphosis and much respiratory motion between the vertebræ of the gibbus. This was partially straightened and a graft inserted. (See Fig. 24.)

cannot be so exact in its control of any segment thereof as a fixation applied directly to the leverage action of the particular vertebræ involved. Thus, we can compare the inexactness of the plaster jacket with the direct fixation of the bone graft.

The means adopted to bring about this arrest of increasing deformity also relieve the other symptoms accompanying the disease—pain, involuntary muscle-spasm, general weakness

and the characteristic awkwardness of attitude. The methods heretofore employed to accomplish this have been: (1) *Recumbency*, which removes one of the chief exciting factors, namely, the superincumbent weight of the body. This must be maintained during the activity of the destructive process. (2) *The application of plaster-of-Paris jackets or braces*, either as a further means of fixation following the months of compulsory

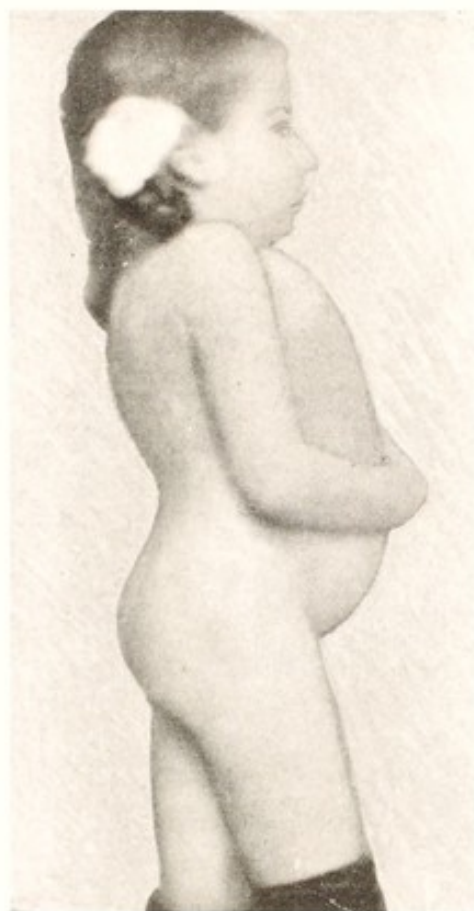

FIG. 24.—Same case as Fig. 23. Two years after correction and insertion of graft.

recumbent treatment on a gas-pipe frame or, as it is employed by many, in conjunction with a certain amount of rest in the recumbent posture from the time the lesion is discovered—the so-called ambulatory treatment.

Nature, in her endeavor to protect the spine when attacked by tuberculosis, resorts to immobilization of the diseased area by the means at her command, and, by fixing the attached spinal and abdominal muscles in involuntary spasm, accomplishes this

immobilization to a certain degree, but in so doing increases the crushing effect of the diseased vertebral bodies with increasing collapse of the spine, which together with the added influence of respiratory motion usually results in extensive kyphosis and disability.

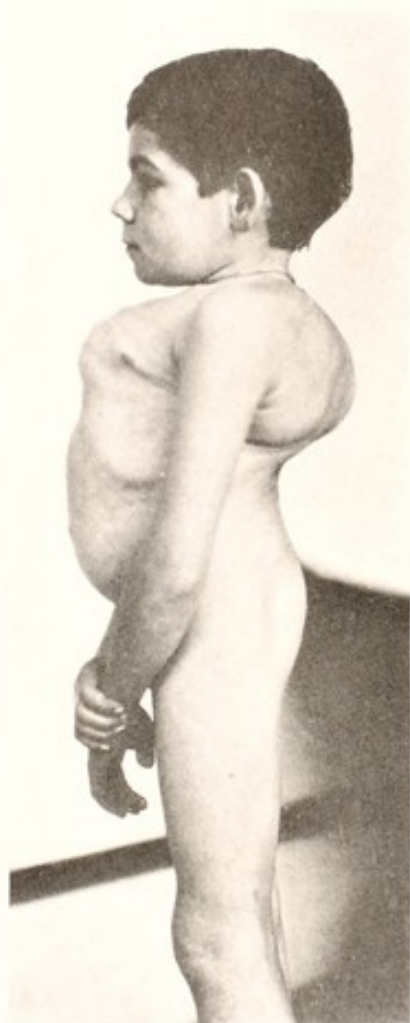

FIG. 25.—A result of 10 years of conservative treatment, including $1\frac{1}{2}$ years on gas-pipe frame and $8\frac{1}{2}$ years of plaster-of-Paris jackets. A spinal support was still necessary.

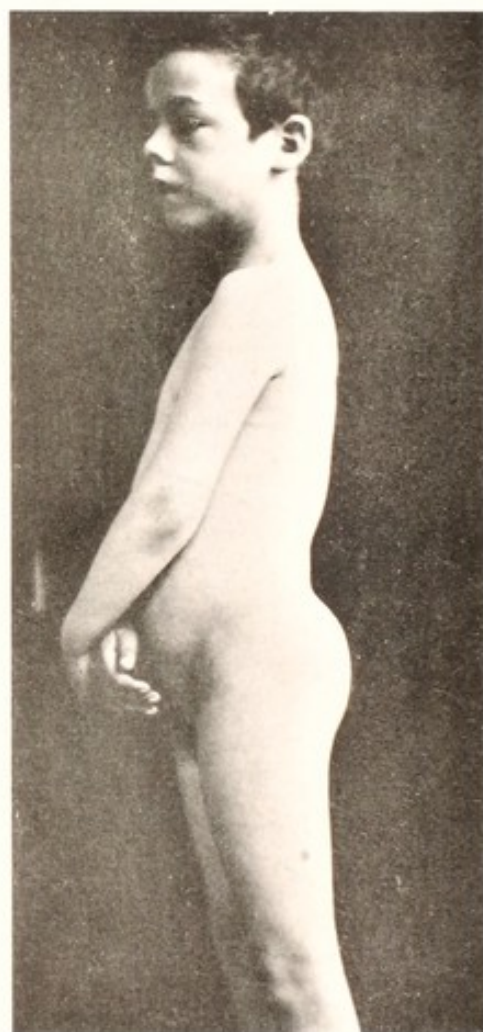

FIG. 26.—Case of acute Pott's disease operated during the first year of the disease when there was a very small kyphosis.

As nature has taught us that immobilization is the prime factor in arresting tuberculous osteitis, we have endeavored to substitute for nature's method our artificial fixation in an attempt to prevent the disfiguring and crippling angular deformity and progress of the disease; but as in conservative brace methods we had the means *only* approximately to accomplish this end,

many cases continued to develop increasing deformity and complete invalidism and succumbed to this debilitated state.

It is the exception and not the rule for cases of Pott's disease treated by the conventional methods of externally applied fixation to produce a solid bony union, and when actual firm bony fixation is not accomplished the case cannot be considered cured.

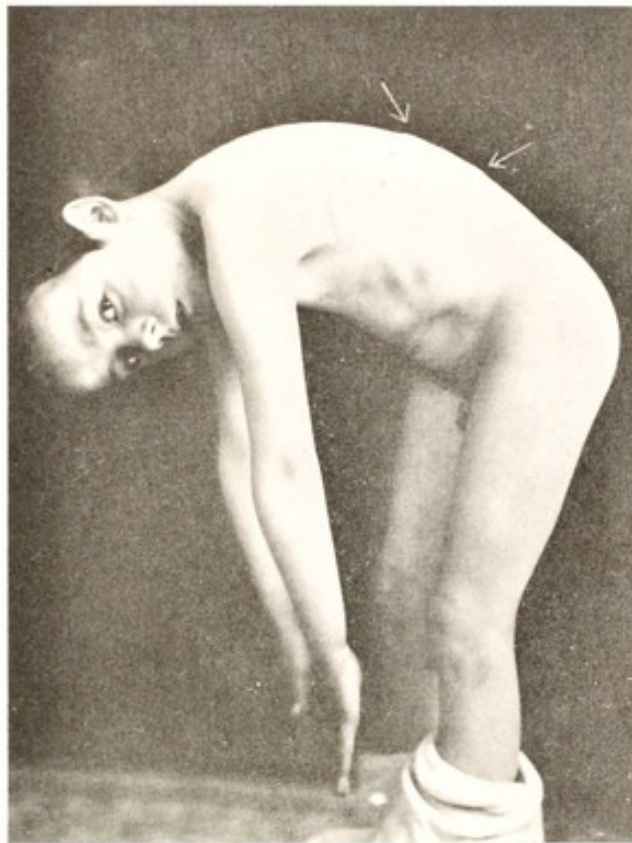


FIG. 27.—Same case as Fig. 26. Shows function of spine 2 years after operation. The arrow indicates location of graft.

These joints, like other joints of the body attacked by tuberculosis where only fibrous union has taken place, are always liable to a relapse. As has been pointed out by many men dealing with tuberculous osteitis, it is always essential to secure a strong bony ankylosis in order to arrest and cure tuberculous lesions where actual bone destruction has taken place. This rule applies even more strongly to the vertebral joints of the spine.

With such examples of ineffectual control of this progressive

tuberculous disease constantly in evidence, further efforts were made to provide more accurate fixation of the tuberculous spine. Appreciating the leverage action of these vertebræ and failures to arrest the disease by external appliances, actual surgical intervention by wiring together the spinous processes of the diseased vertebræ with silver was tried; but as silver wire stands very

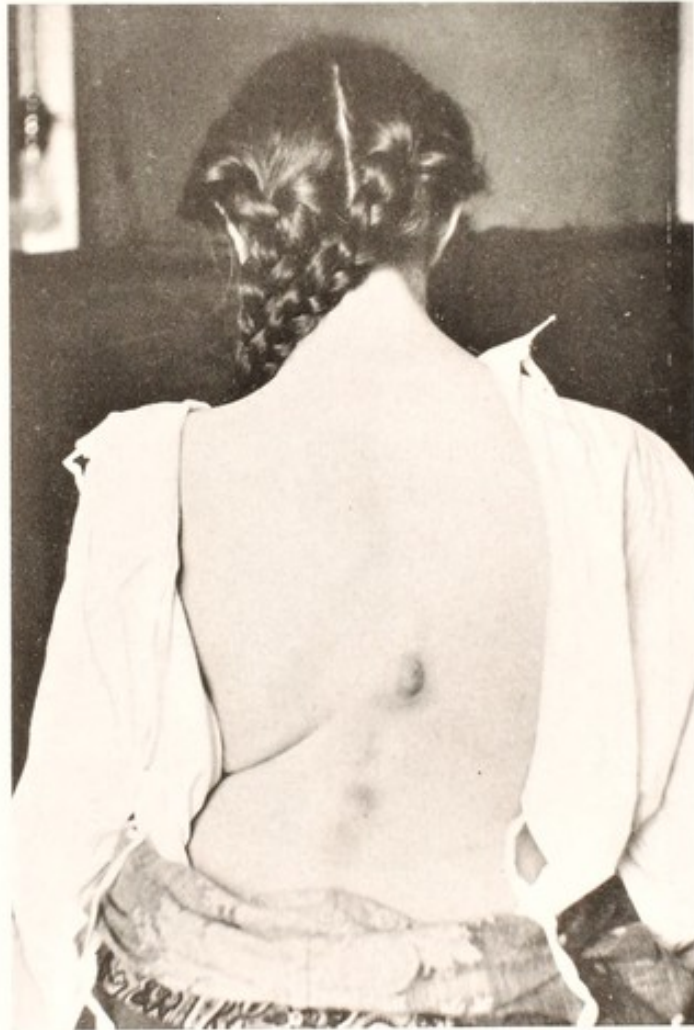

FIG. 28.—Photograph of acute case of Pott's disease before insertion of bone graft.

little strain, this wiring breaks, or, being a foreign material, it causes absorption of the bony structure in which it is placed and pulls through and drops out by its own weight, and so loses its value; or infection takes place and the resultant necrosis neutralizes any possible benefit.

Lange, in 1910, presented before the American Orthopædic Association a method which he had tried, which consisted in

placing a metal bar on either side of the spinous processes, secured by metal or silk sutures. This method has not been adopted, undoubtedly because of reasons similar to those given for the failure of the silver wire fixation of the vertebra. Nevertheless, the suggestion was offered that if some means could be provided for rendering the posterior arms of the vertebral levers more accurately fixed, a consequent arrest of the increasing deformity and disability could be rendered more certain.

In the folder of the American Orthopaedic Association published May 15, 1911, and distributed to its members, the author described a method of ankylosing together the spinous processes of tuberculous infected vertebrae by autogenous osteoplasty, which seemed to offer advantages over the methods previously employed, conservative or operative.

The technique employed upon *four* cases consisted in splitting the spinous processes longitudinally in halves, fracturing these halves at their bases, freeing them of ligamentous and muscular attachments, turning one-half down to contact with the fractured base at the fractured half of the spinous process below, and turning up the other half to contact with the base of the fractured half of the spinous process above, and so on until a sufficient number of spinous processes had been so dealt with as to include the entire area of the diseased vertebrae and ex-



FIG. 29.—Same case as Fig. 28. Eight months after bone-graft operation. Function excellent.

tend above and below to include a healthy vertebra. Practically the whole spinous process is covered with ligamentous and muscular attachments, consequently there is very little actual periosteum obtainable.

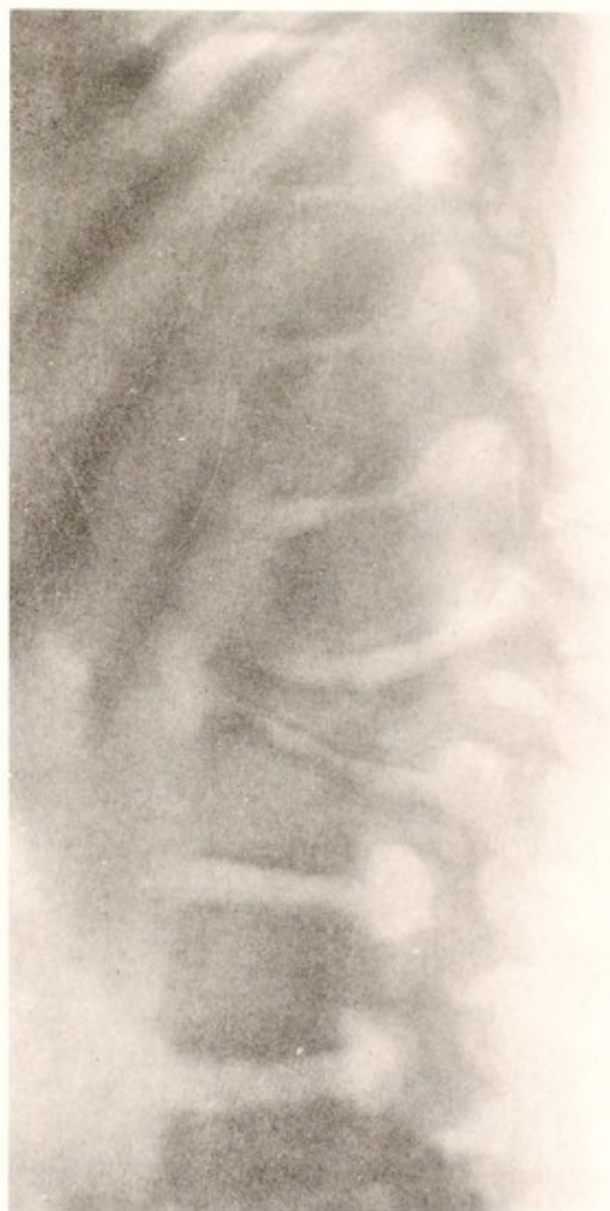

FIG. 30.—Röntgenogram of a case of Pott's disease showing two vertebral bodies crushed into a thin wedge shape mass less in thickness than one normal vertebral body. The resulting kyphosis is clearly demonstrated. (See Fig. 31, after implantation of the graft.)

In these cases, which were all children, this ligamentous covering, together with what periosteum was found, was separated off these spines and sutured over and about the arranged split fragments of the spinous processes. In this

way, an attempt was made to ankylose together the posterior segments of these vertebrae and thus actually to inhibit all intervertebral motion from respiration or muscle action, and finally to stop the further crushing together of the diseased bodies of these vertebrae.

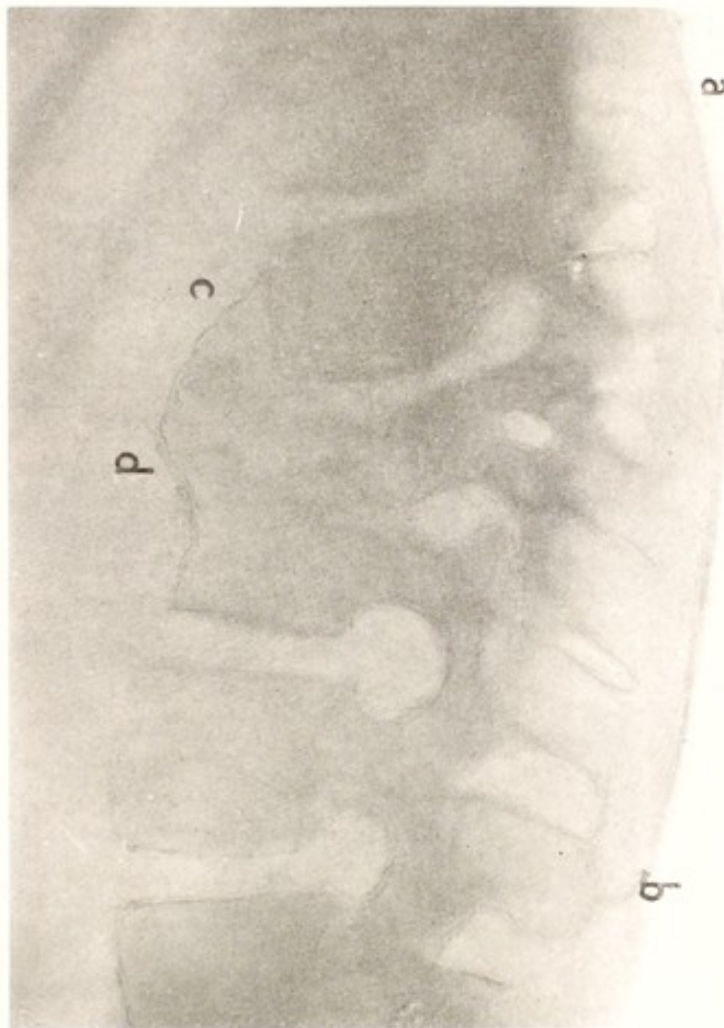


FIG. 31.—Lateral röntgenogram of a bone graft (*ab*) in place 1 year for tuberculosis of the second, third and fourth lumbar vertebrae; *cd* indicates the bone repair and fusion of the formerly diseased vertebral bodies, induced by the bone-graft fixation. (See Fig. 30.)

Since this method consumed much operative time and involved dealing with a number of small pieces of bone which had to be secured in a position favorable to final bony ankylosis, and as there was an element of uncertainty (on account of constant uncontrollable respiratory motion) in bringing about this desired ankylosed condition of all these segments of

bone—a failure to produce this ankylosis between any two given vertebræ necessarily producing a failure in the ultimate result—the author was further influenced to change the method on account of the meagre amount of osteogenetic bone present in the spinous processes (especially in children, where it is largely in a cartilagi-

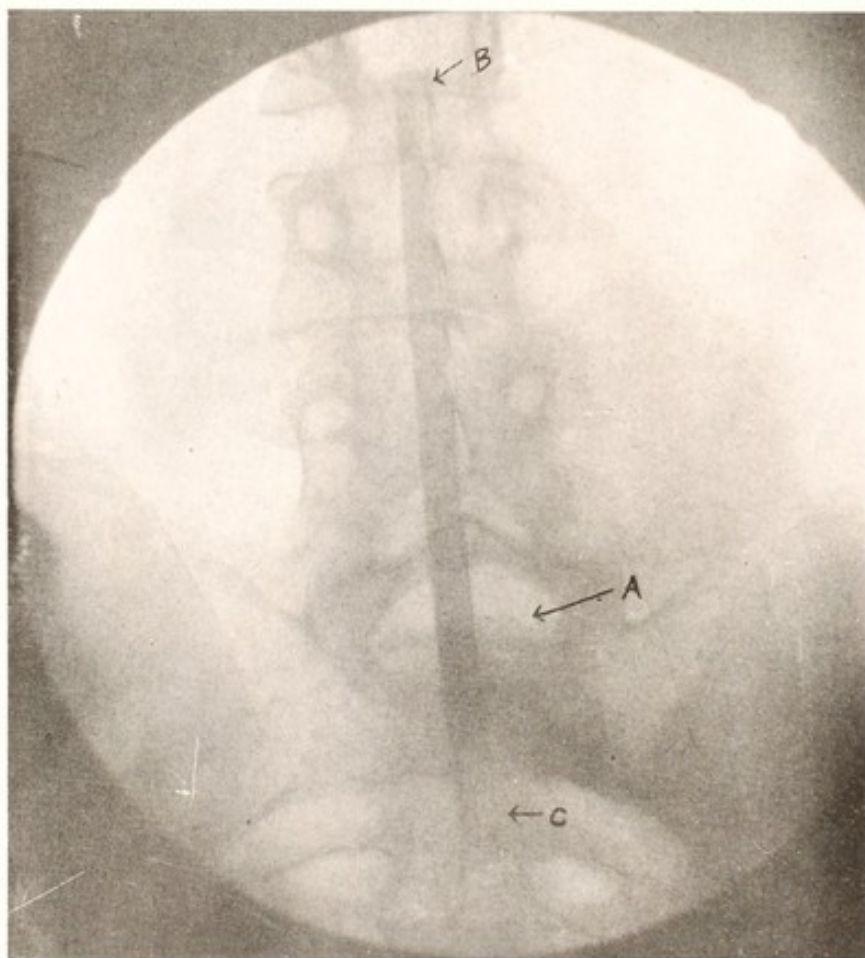


FIG. 32.—Pott's disease of last lumbar vertebræ and first segment of sacrum in a young woman of 28 years. A mistaken diagnosis led to previous removal of most of the pelvic viscera for pelvic pain. Patient was then placed on a plaster-of-Paris bed for 1 year for Pott's disease. At the end of this time patient was allowed up with a long spinal brace. A relapse of her old symptoms with a threatening paraplegia occurred in a few weeks. A well-known orthopaedic surgeon advised another year on a plaster bed, was refused and the graft *AB* was inserted 2 years ago with continued relief of all symptoms to date.

nous state) and to adopt the much simpler bone-graft method now employed, which has given extremely satisfactory results.

This consists in the implantation of *one* continuous strip of bone (removed preferably from the tibia) sufficiently long to span the diseased vertebræ and include one or two healthy

vertebræ above and below those involved in the tuberculous infection. This tibial bone graft is implanted in a gutter previously made by splitting the spinous processes to receive this long graft of bone between their split halves.

As broken or incised cartilage tends to heal by the formation

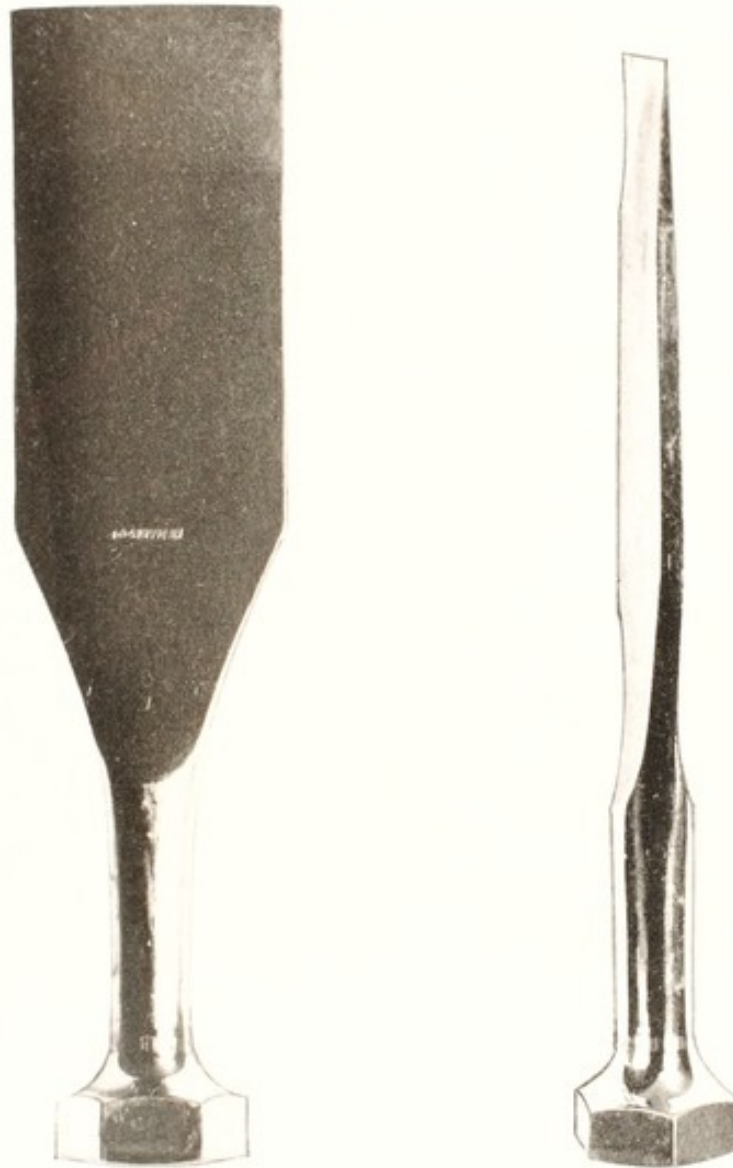


FIG. 33.—Author's broad thin osteotome for splitting the spinous processes of the spine in preparing the graft bed.

of bony callus, and as the implantation of a bone graft into cartilage also influences the surrounding cartilage to immediately change to bone, the increased trustworthiness of the bone graft (especially in small children), as compared with the previous osteoplasty, is apparent.

The detailed steps of the technique of preparing the graft bed, together with the removal of a suitable graft and its implantation, as carried out by the author, is as follows (and this applies in a general way to its use in the different segments of the spine):

The patient, having been prepared for operation in the usual way, is placed prone upon the operating table, and a general anæsthetic is administered. The region of the spine included in the field of operation is sterilized, as well as the leg from which the graft is to be obtained. The author uses the iodine method.

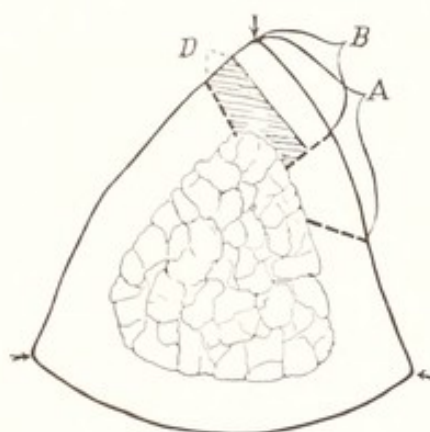


FIG. 34.

FIG. 34.—Drawing of cross-section of tibia. *A* is spinal graft for an early case that has not become kyphotic. *B* is cross-section of graft which on account of the large size of the kyphosis is bent over it. *D* represents the multiple saw cuts on the marrow side.

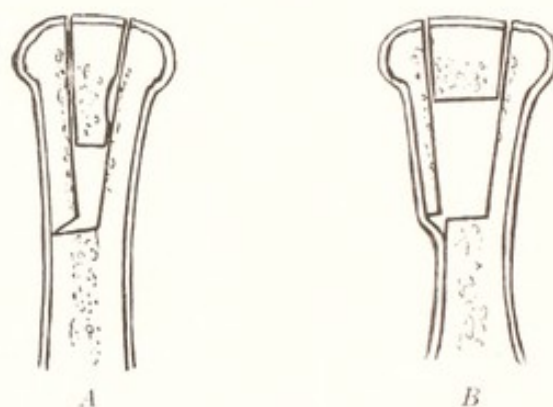


FIG. 35.

FIG. 35.—*A* illustrates a cross-section of a spinous process split in half and fractured at its base. The deep, thin graft in cross-section has been removed from the crest of the tibia having its periosteum attached to two sides. The side in contact with the unbroken half of the spinous process is the saw cut or the medullary surface of the graft.

B illustrates a cross-section of a spinous process which has been split and one-half has been set over to produce a gap sufficient to receive a broad graft removed from the antero-internal surface of the tibia having periosteum on one surface only; the medullary surface of the graft lies nearest the base of the spinous process in the gap.

Author's Operative Technique.—A sufficiently long skin incision is made, starting well above the diseased area and swerving to one side of the midline, and carried back to the midline well below the affected area, thus forming a semilunar skin flap with its border well away from this midline to avoid having the skin wound directly over the bone incisions and graft, thus fortifying the grafted area should any skin or suture infection take place.

Having dissected up this skin flap with its subcutaneous structure, the tips of the spinous processes, with the supraspinous ligaments, are exposed. As no important vessels are encountered in this region, hemorrhage is of slight consequence. If need be, the bleeding points may be clipped and tied off, but a hot saline compress is usually sufficient to control any undue oozing and prevent large blood-clots from forming. A certain amount of serous exudate and blood is considered advantageous to early fixation of the grafted area.

With a scalpel, the supraspinous ligament is split over the tips of the spinous processes, dividing them into equal halves; the interspinous ligaments are also split, care being exercised further not to sever any of the muscle or ligamentous attachments to these spinous processes. Then, with the author's broad thin sharp osteotome, $1\frac{1}{2}$ in. wide (made by Tiemann & Co. of New York), the spinous processes are split to a depth, usually, of from one-third to two-thirds of an inch. One-half of each spinous process, always on the same side, is fractured completely at its base and set over a distance varying according to the thickness of the graft which is to be implanted. All bleeding points are ligated or checked by hot saline compresses.

It necessarily rests with the operator to determine the size and thickness of the graft required, taking into consideration the segment of the spine to be grafted and the amount of strain

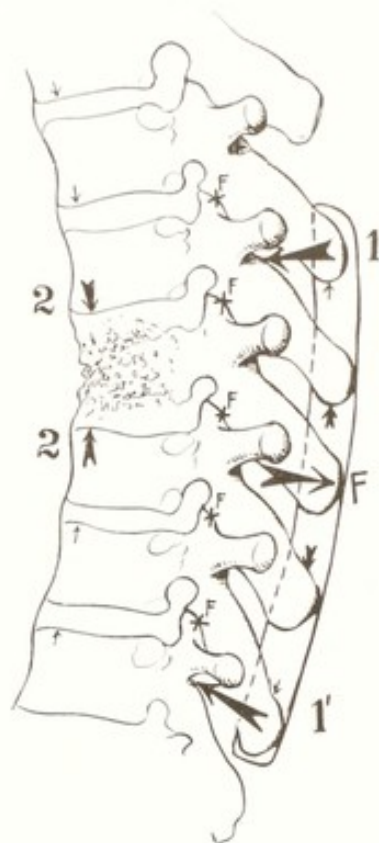


FIG. 36.—Each vertebra is a lever with its fulcrum point at small *F*. The arrow on the vertebral bodies at 2, 2, indicates lines of force from weight bearing, involuntary muscle spasm, etc., influencing crushing of vertebral bodies and progress of deformity by the approximation of the anterior lever arms. Which is associated with an equal separation of the spinous processes or the posterior lever arms. This is prevented by a pull lengthwise on the graft as indicated by the small arrows situated at each spinous process. The graft in respect to this direction of force is under a great mechanical advantage.

the graft must endure. In general, the thickness of the graft should include the total thickness of the tibial cortex, including periosteum, endosteum, and marrow substance.

The graft bed now prepared presents on one side of the gutter the incised surfaces of the unbroken halves of the spinous processes, and in the intervals between these processes are the cut surfaces of the halves of the supraspinous and interspinous ligaments with their osseous attachments undisturbed. The opposite wall of this gutter is formed by the incised surfaces of the fractured halves of the spinous processes, with their portions

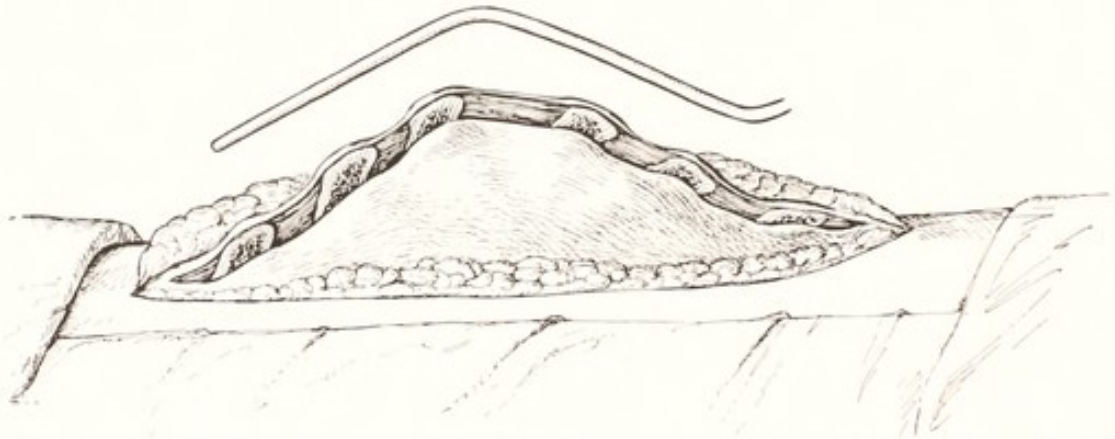


FIG. 37.—The flexible probe bent to conform to the spinal kyphosis and used as a pattern in removing the curved graft from the antero-internal surface of the tibia if the spine is not suitable to be straightened.

of supra- and interspinous ligaments undisturbed, as in the opposite side of the gutter. This leaves the muscle and ligamentous attachments intact, save for the splitting, fracturing, and spreading on one side of the spinous process halves with their attached ligaments. In other words, the antero-posterior diameter of the spinal column has not been diminished or weakened to any degree by the preparation of the graft bed. The full leverage of the spinous processes, as posterior arms of vertebral levers, has been preserved.

In this connection, it should be appreciated that the spine is made up of a series of levers, and that each vertebra is an individual lever with its fulcrum at the lateral facets, and that its anterior arm is the vertebral body, the posterior arm being the spinous process.

The length and shape of the required graft is determined by calipers and a flexible probe applied to the gutter-bed. The whole denuded field is packed with a hot saline compress until the next

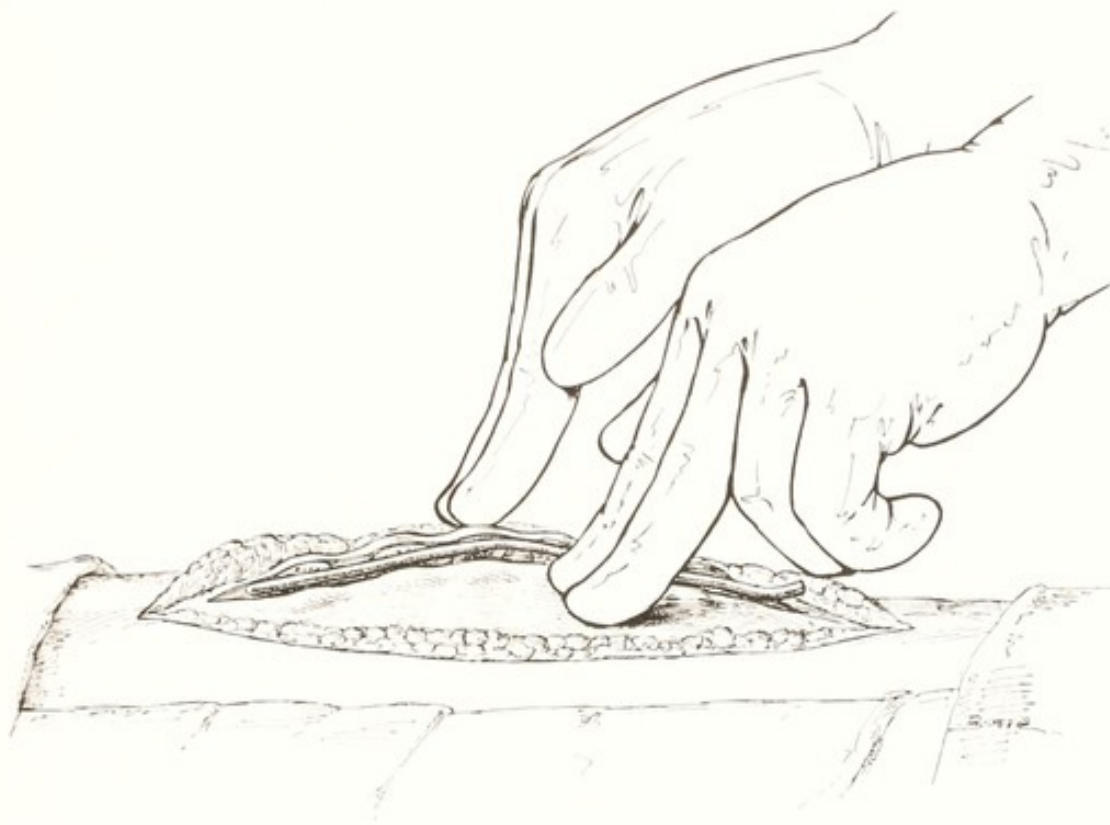

FIG. 38.—To illustrate method of applying force to straighten spine, at the same time that the contour of the corrected kyphosis is obtained with flexible probe for purpose of pattern for removal of graft from tibia. (See Fig. 37.)

step is completed, namely, the removal of the graft from the tibia.

Removal of Graft.—With the patient still in the prone position on the operating table, the leg from which the graft is to

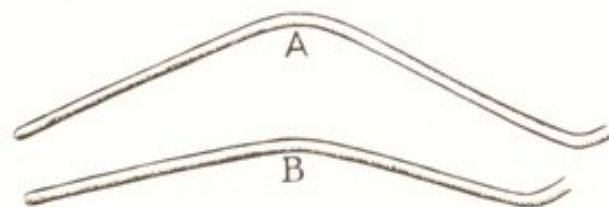


FIG. 39.—Actual contour of flexible probes, bent into tips of spinous processes before and after forcible correction. *A* is before correction. *B* after correction. (See Figs. 37 and 38.)

be removed is raised from the table and flexed to an acute angle on the thigh. A skin incision is made along the antero-internal

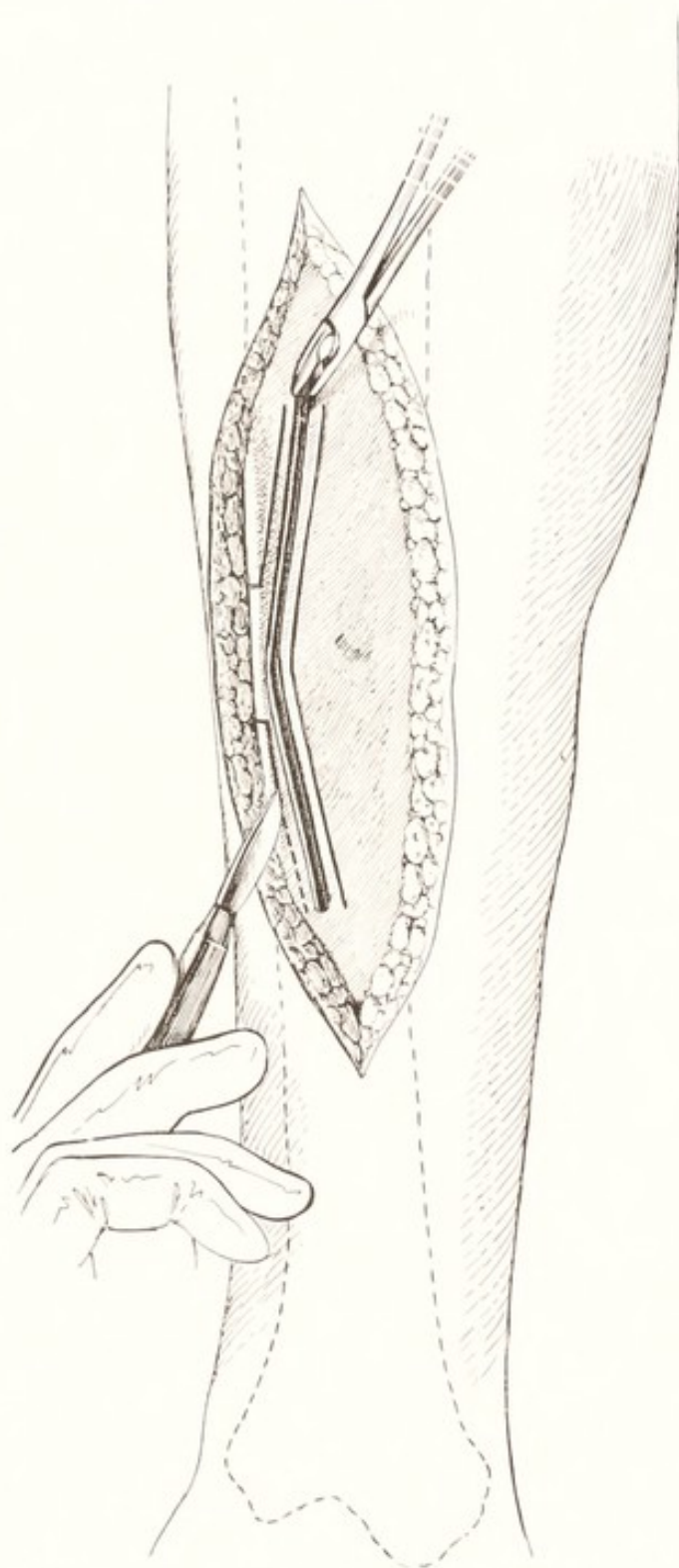


FIG. 40.—The flexible probe bent to conform to the spinal kyphosis and applied to the antero-internal surface of the tibia, held by a forcep while the shaped graft is being outlined in the periosteum by the scalpel prior to the removal by the motor single saw of the graft thus outlined.

The centre of the graft angle includes the crest of the tibia thus strengthening its centre.

The ends of the graft include the cortical surface, the full thickness to the marrow cavity on the antero-internal surface.

surface of the tibia, sufficiently long to allow a generous exposure of the tibia for the removal of the graft, and so placed that its closure will not bring the skin sutures over the bone cavity produced by the removal of the graft. The skin is dissected up from the periosteum, which is left undisturbed, and the muscles attached to the crest of the tibia are freed. The pattern of the required graft is outlined by incising the periosteum with a scalpel, using the moulded probe as a pattern rod. The graft is best taken from the lower three-fourths of the antero-internal surface, as this portion of the tibia is usually sufficiently broad and furnishes a cortex denser and stronger than the upper portion of the bone.

If the graft is to be straight, it is best removed from the crest, wide enough to encroach upon the antero-internal surface,




FIG. 41.—The outline in the periosteum on the antero-internal surface of the tibia of the curved bone graft for the operative treatment of Pott's disease.

so as to furnish the width required. If the graft is to be moulded for a moderate kyphosis, the pattern probe is so applied to the antero-internal surface of the tibia that the central or fulcrum portion of the curved graft includes the crest of the tibia and each end is cut obliquely across the antero-internal surface (see drawing, Fig. 40). The advantage of the graft thus obtained is that it includes at its fulcrum portion the dense and thick cortical bone of the crest. This is important, because the strength of any lever is dependent upon the strength of its fulcrum portion (*a, b*, Fig. 41).

It has been found that kyphoses sharply angular and of short duration, especially in children, are amenable to varying degrees of correction, which fact can be taken advantage of in moulding the graft to conform to this amount of correction.

After preparing the gutter bed, the spine is corrected by manual pressure on either side over the lateral masses, while the contour of the spine thus corrected is obtained by bending the probe into the clefts of the split spinous processes. The technique is carried out precisely as described above, except for the addition of the correction pressure while the kangaroo sutures are being placed to secure the graft in position.

The straight graft is obtained by cutting the tibial cortex through to the marrow cavity with the motor circular saw, following the periosteal outlines already made; this includes a saw-cut just to the outer side of the tibial crest and at a right

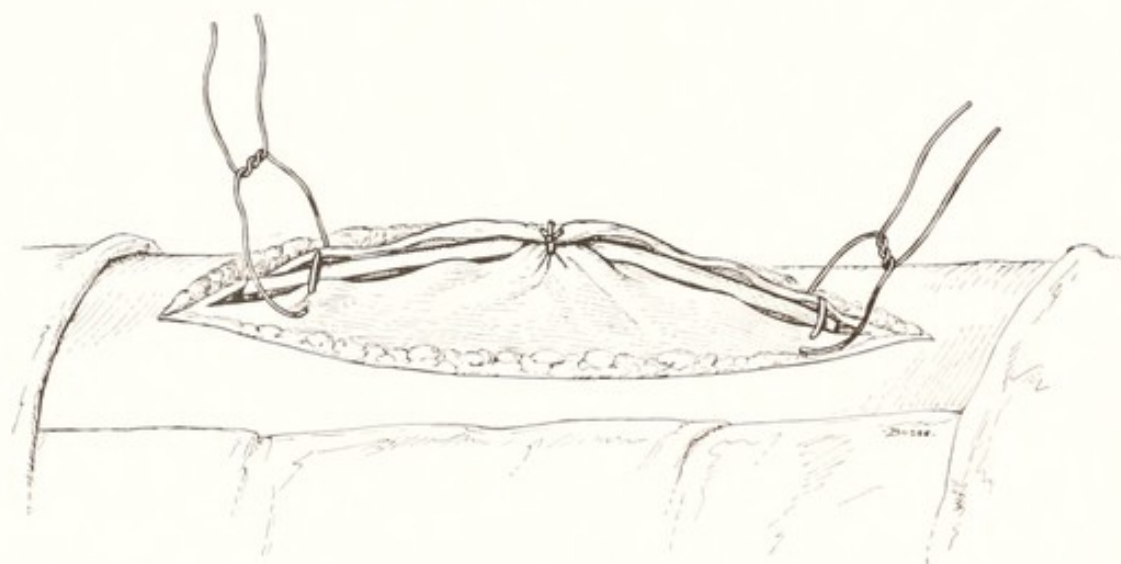


FIG. 42.—Moulded graft for Pott's disease in place with the kangaroo-tendon sutures in process of being inserted.

angle to the one previously made on the antero-internal surface. This cut must be made the whole length of the graft, if a straight one; and, if a moulded one, only to include the middle or fulcral portion. At either end beyond this central or crest portion the graft overlies the marrow cavity and the saw-cuts, therefore, need only to come on the antero-internal surface of the tibia.

At the ends of the graft, saw-cuts are made with a very small motor saw, to finish freeing the graft from the tibia. It is then loosened by a thin osteotome introduced into the longitudinal saw-cuts and pried free. The motor saw is not absolutely necessary for the removal of the graft, since thin chisel or osteo-

tome and a mallet serve the purpose and certain operators have continued to remove the graft in this way. In adults, the motor saw has a distinct advantage, as the bone is very dense and brittle and if the chisel and mallet are used it requires the greatest care on the part of the operator to avoid cracking the graft or the remaining portion of the tibia. The method is not only slow, but the constant blows of the mallet on the chisel traumatize the graft and does not allow its accurate moulding. Pain in the leg has also been observed to be less since the motor outfit has been perfected for this use.

After the graft is freed it is seized by clamps, and placed in the bed previously prepared for its reception, thus avoiding handling even with sterile gloved hands.

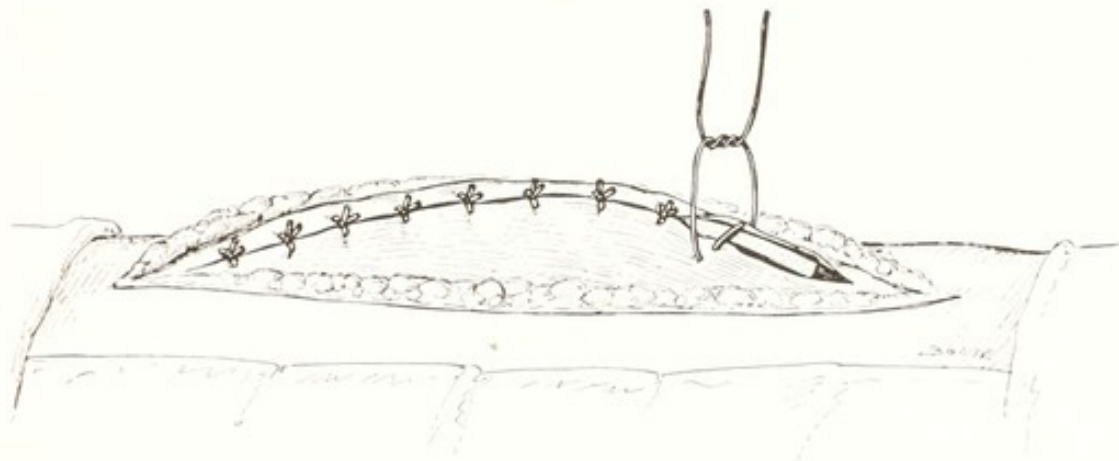


FIG. 43.—Spinal graft for Pott's disease in place and kangaroo-tendon sutures being inserted.

Fixation of the graft in position.—If the graft is a straight one, it is held in place by first passing a strong kangaroo-tendon suture through one-half of the split supraspinous ligament at one side of the gutter; then the suture is passed up over the graft at its middle portion and through the other split half of the supraspinous ligament opposite. This suture is drawn taut and tied, thus approximating the two halves of the split supraspinous ligament over the graft at its central portion. The ends are next secured in like manner, always aiming to pass the suture deeply so as to get a firm hold upon the ligament and close to the spinous processes, either above or just below

them. This insures a firmer contact of the graft to the separated halves of the split processes.

In certain instances it is advisable to place the suture either in the supraspinous ligament midway between the spinous processes or at a varying distance to the side of these processes, in order that the ligament may yield and the graft be completely covered. In the lumbar region, especially in adults, the supra-

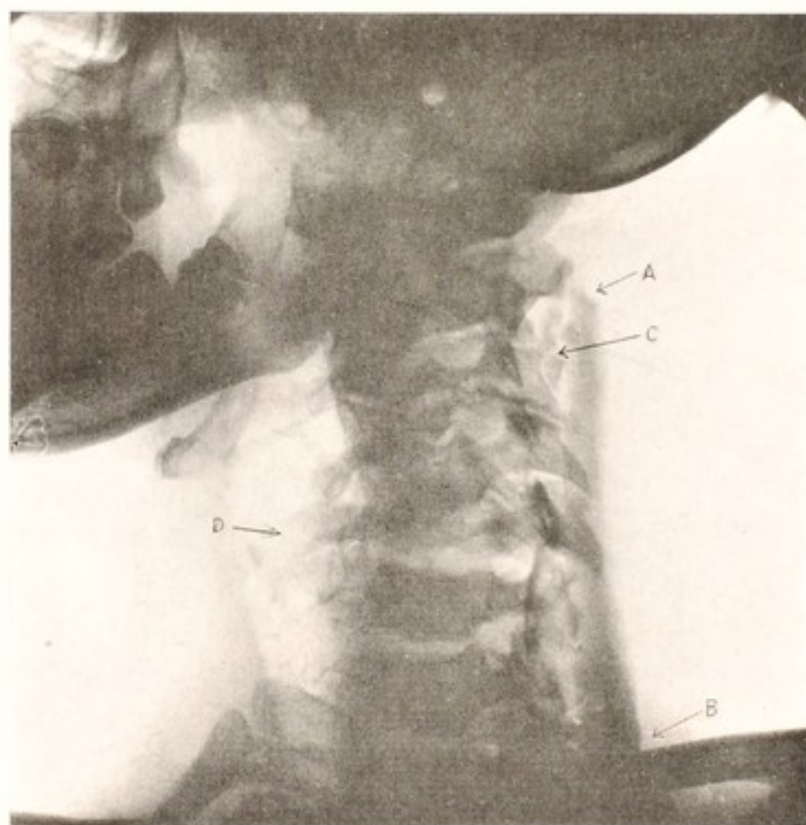


FIG. 44.—Pott's disease of third and fourth cervical vertebrae (at *D*) with almost complete paralysis of the right arm. The graft *AB* was inserted with immediate relief of all symptoms, including the paralysis of the arm, in 10 days time. *C* indicates small grafts. For anterior-posterior view, see Fig. 45.

spinous ligament may be so dense and tense that it is difficult on account of the required thickness of the graft to cover it satisfactorily unless the vertebral aponeurosis is incised on either side just external to the line of sutures. This allows a separation of the ligament sufficient to cover the graft.

Before the two ends of the graft are secured in position, it should be made certain that the graft reaches far enough below the diseased vertebrae to include two healthy spines; also

the same should be made certain above the diseased area. Emphasis is laid upon having the graft reach low enough because on account of the natural obliquity of the spinous processes in certain segments of the vertebral column, as in the thoracic region, the fact that the tips are well below their corresponding bodies may be somewhat misleading and the applied graft may be insufficient in not including the healthy vertebral

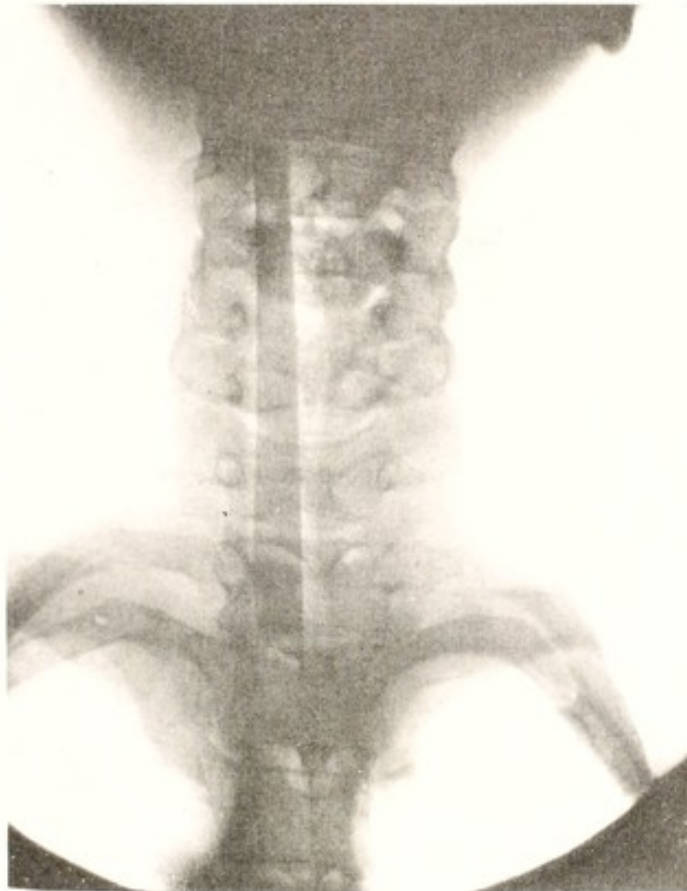


FIG. 45.—Antero-posterior view of same case as Fig. 44.

spines below. Also, at this point in the fixation of the ends of the graft into position, the sharp posterior corners are removed by Rongeur forceps, and these bone chips are placed about and under the graft ends before tying the graft end sutures. The graft ends should be sure to contact with spinous processes. The small fragments of bone so placed furnish added foci for bone proliferation, so as still more securely to amalgamate the graft ends to the contacted spinous processes, it being borne in

mind, as Macewen has pointed out, that the bone graft varies in its osteogenesis in inverse ratio to its volume. In other words, the smaller the graft the greater its comparative surface and the more active its bone-growing ability. It has been further demonstrated that small grafts, because of their size, obtain their

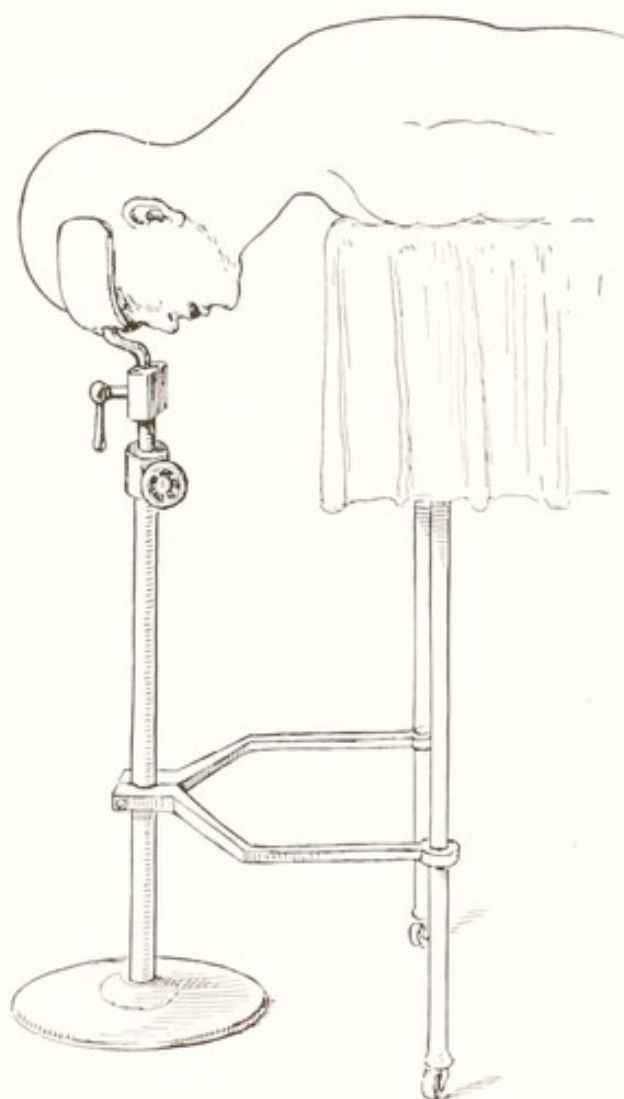


FIG. 46.—Position of patient and adjustment of head-rest for insertion of spinal graft for Pott's disease of cervical region.

nourishment more readily from their surrounding serum or blood, and a periosteal covering is not essential.

Kangaroo-tendon sutures at intervals of half an inch are now passed in similar manner as the sutures mentioned above, until the entire length of the graft is closed in and firmly secured in position.

If the graft is a curved one, cut from the surface of the tibia according to the pattern previously determined, the graft when placed in its bed must necessarily, from its curved shape, in order to fit the deformity, be placed edgewise, so that its periosteal surface lies to one side and its marrow surface to the other.

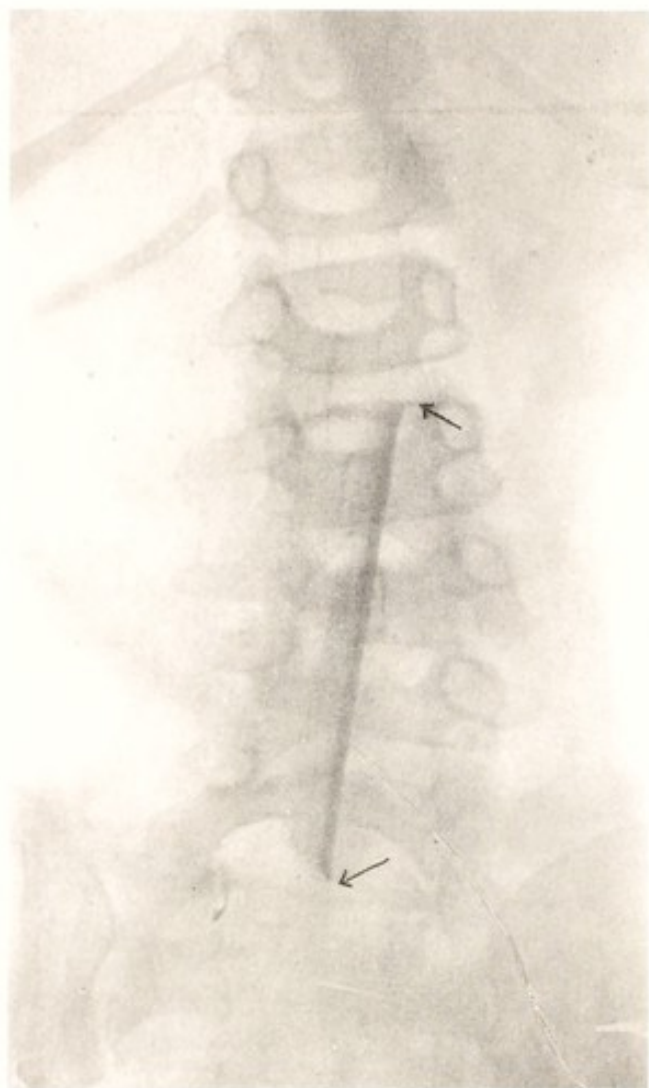


FIG. 47.—To demonstrate a bone graft inserted for Pott's disease with a lateral deviation of the spine. The spinous processes are split in as straight line as possible and then the graft is moulded to meet the condition.

The graft is so placed that the marrow or saw-cut surface shall contact with the side of the gutter formed by the unfractured halves of the spinous processes, and this periosteal surface, consequently, contact with the opposite side of the gutter containing the fractured halves of the spines. The endosteal surface

of the graft with its attached marrow substance seems to be more active in its bone proliferative power than the periosteal surface. The curved graft is secured in position in the same manner as the straight graft.

If the graft to be used is a straight graft with transverse saw-cuts made two-thirds to three-quarters through its thickness, cutting on its marrow-surface, the graft had best be taken from the lower two-thirds to three-quarters of the antero-internal surface of the tibia, where the cortex is thick, and to include the crest or not as the operator chooses. If the graft is removed from the antero-internal surface, not including the crest, the twin saw hastens its removal and insures its uniform width throughout. If the crest is to be included, cuts at right angles to each other on each side of the crest are necessary. The graft in this case includes two periosteal surfaces, and therefore is more active osteogenetically and is mechanically stronger. Again, it is emphasized that every graft should include all bone elements, namely, periosteum, compact bone, endosteum, and marrow substance. This is the author's bent-in graft, and as the transverse saw-cuts naturally weaken the graft, when possible the moulded graft, as previously described, should always be used.

In making the transverse saw-cuts to allow the graft to bend, as a carpenter cuts a board to cause it to bend about a curved surface, the graft is held securely by the operator with two strong clamps, one at either end. With the motor held by an assistant firmly against the instrument table and the saw overhanging the edge (Fig. 48), the current under control of the foot-switch is turned on by the operator, who is in a position to regulate the spacing and depth of the cuts along the marrow surface of the graft as he presses the graft against the rapidly revolving saw from below. By holding the graft in this way, he is able to test its flexibility (Fig. 48C) as he proceeds with its cutting, and can judge very accurately when he has produced the desired flexibility in the graft to enable it to conform to the bed and span the deformity, without actually having repeatedly to place the graft

in the bed to determine its adaptation to the kyphosis. The uniform depth of the saw-cuts is regulated by adjusting the proper guard to the saw, in accordance with the thickness of each graft. This expedites matters, as the surgeon has no fear

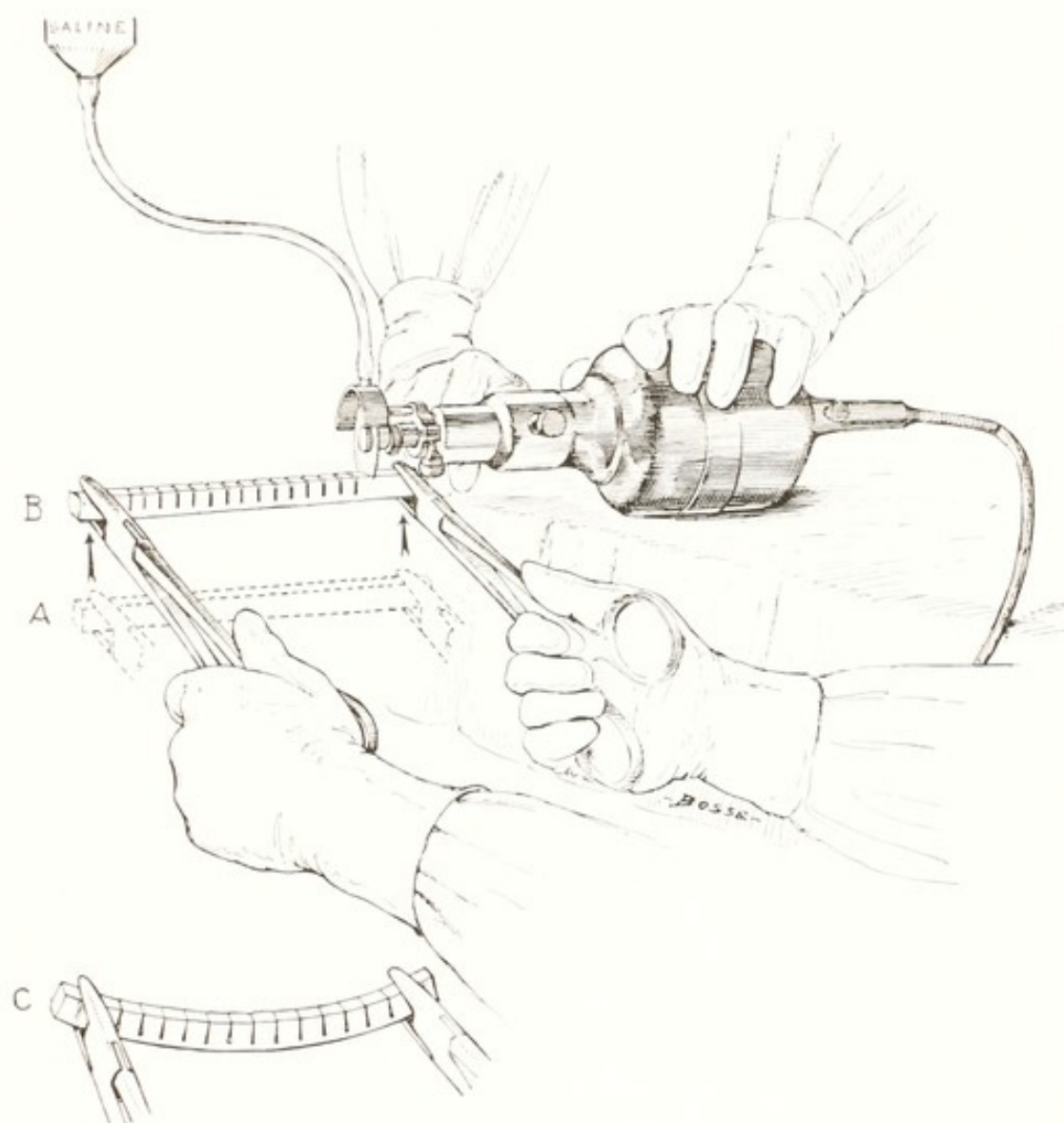


FIG. 48.—*A*, the manner of holding the graft while making the transverse saw-cuts to increase its flexibility.

B, transverse saw-cuts at equal intervals and three-quarters through the diameter of the graft on its marrow surface.

C, testing for the desired amount of curve in the graft obtained by making the transverse saw-cuts before applying it to the kyphosis of the spine.

of entirely severing the graft and the saw cuts to the same depth at each point. The author's automatic spray attachment provides a constant spray of saline solution upon the saw,

preventing any possibility of over-heating. This is an important point, as otherwise osteogenetic cells may be destroyed.

In the application of the bent-in graft, the medullary surface (bearing the transverse saw-cuts) naturally lies next to the gutter bed, with the periosteal surface posteriorly. The edges of this graft contact with the cut surfaces of the gutter sides and the split spines. The same method is adopted in the application of the sutures as is used in securing the other shaped grafts, with

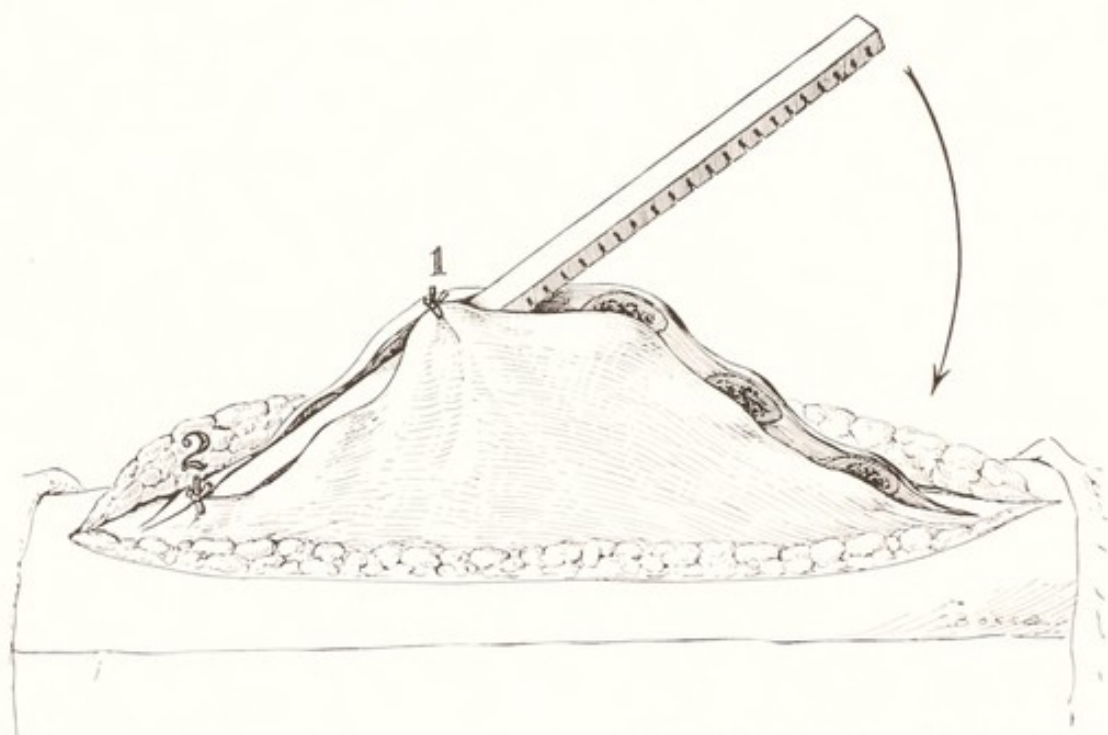


FIG. 49.—Method of securing the bent in bone graft to adapt it to the curve of the kyphosis. (1) First fixation suture. (2) Second fixation suture. The arrow indicates the direction which the graft is to be bent to fit over the kyphosis.

the exception that the bent-in graft is completely sutured into position at one end while the other end projects ready to be bent in, and the interrupted sutures are then inserted consecutively (see Fig. 49) until the projecting end of the graft is reached and the placing of the imbedding sutures is completed.

If the bent-in graft is held by one imbedding suture applied at each end, holding it bent into position while the other sutures are added, the graft is in danger of fracturing through one of its transverse saw-cuts. In any case, whether this fracture of the graft occurs or not, it is well to reinforce this graft by placing

along each of its sides, at the maximum point of curvature, thin strips of cortical bone cut with the motor saw from the tibia where the graft was obtained.

The skin wound is closed in the usual way and sterile dressings are applied. Thick pads of gauze and cotton, varying in thickness according to the degree of the kyphosis, are placed on each side of the implanted graft. This is important in order to prevent pressure sores on the apex of the grafted kyphosis. The dressings and pads are then secured in place by broad strips

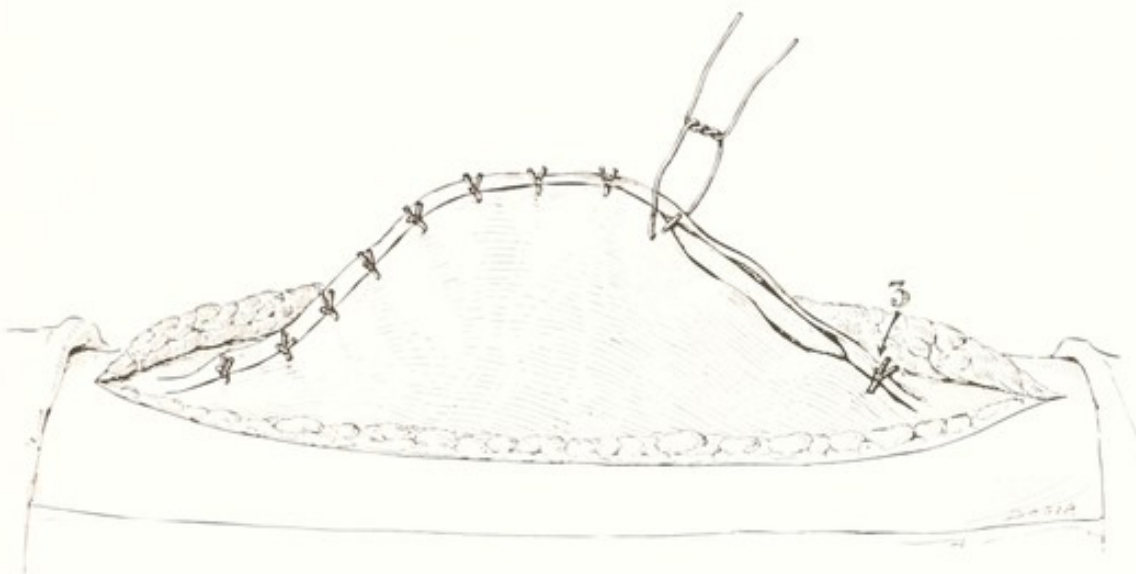


FIG. 50.—The bent-in graft in position, with the interrupted kangaroo-tendon sutures being placed to secure it and enclose it beneath the supraspinous ligament.

of zinc oxide adhesive plaster. It is not safe, even with this dressing, to allow patients with prominent kyphosis to lie upon the back, but they must be restrained upon the side or obliquely on the back during the post-operative recumbent period.

The technique just described is applied to the bone-graft implantation into all segments of the spine. The anatomical variations of the spinous processes of the different segments must be borne in mind, as well as the increased strain and leverage action of the different segments. For instance, in the cervical or upper thoracic region, being at the upper end or portion of the spine, the strain placed upon the graft is much less than lower down, from the mid-thoracic region to the sacrum. The strain and leverage action of the column, as a whole, increase materially

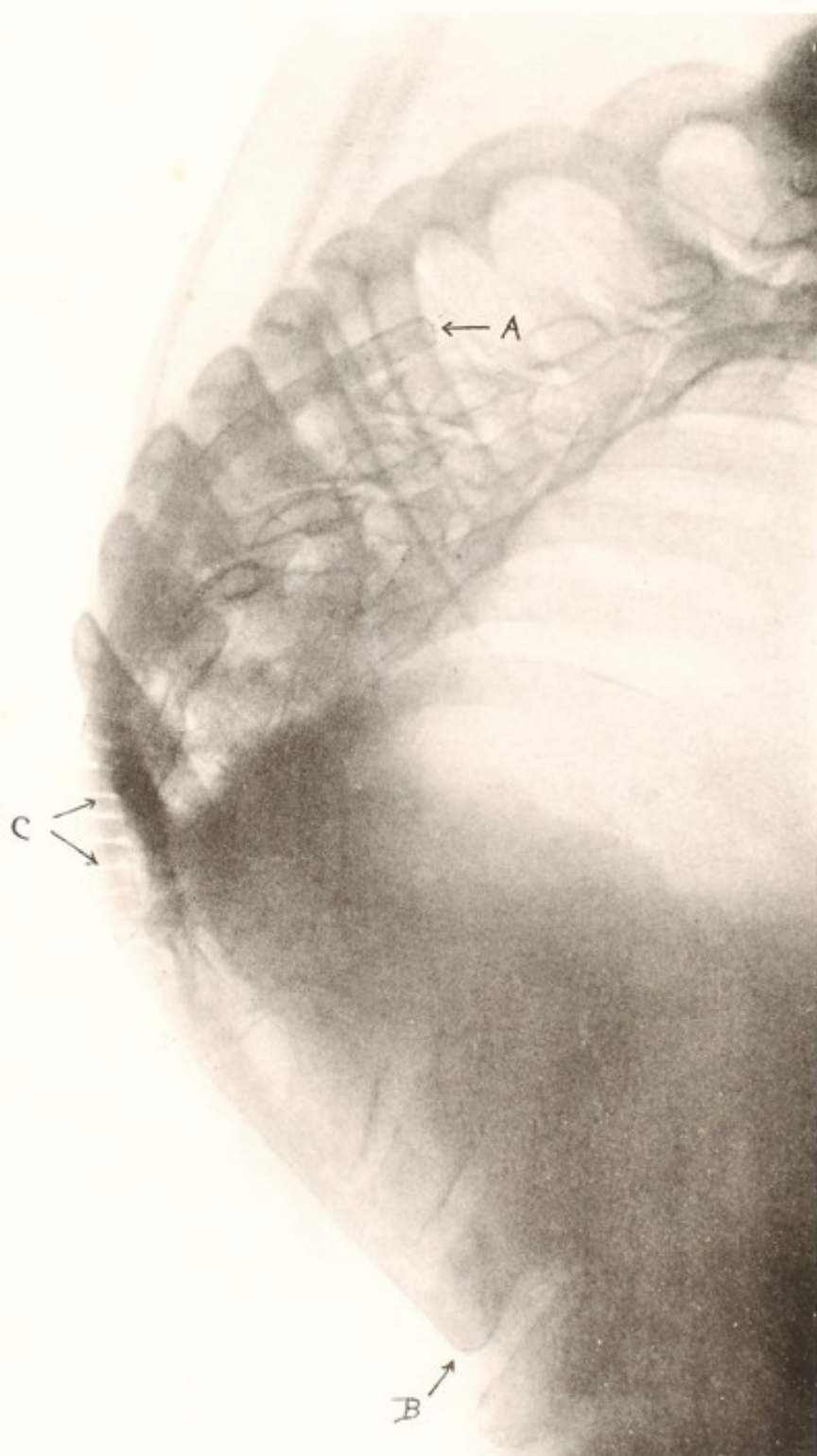


FIG. 51.—Lateral röntgenogram of a spine of a man 22 years old, which is illustrative of the extreme degree to which an adult tibial bone graft can be bent. *C* indicates the saw cuts in the marrow side of the graft. This case had been under conservative treatment 17 years as a private case by two very competent orthopaedic surgeons; nevertheless, a relapse with paraplegia occurred after that period of treatment. The result after the insertion of the bone graft was immediate and excellent.

toward the sacrum. In the act of flexion, side-bending, or rotation, the farther away from the general centre of the long axis of the total lever a graft is implanted, the less is the strain placed upon it; so that a graft implanted into the lumbar re-

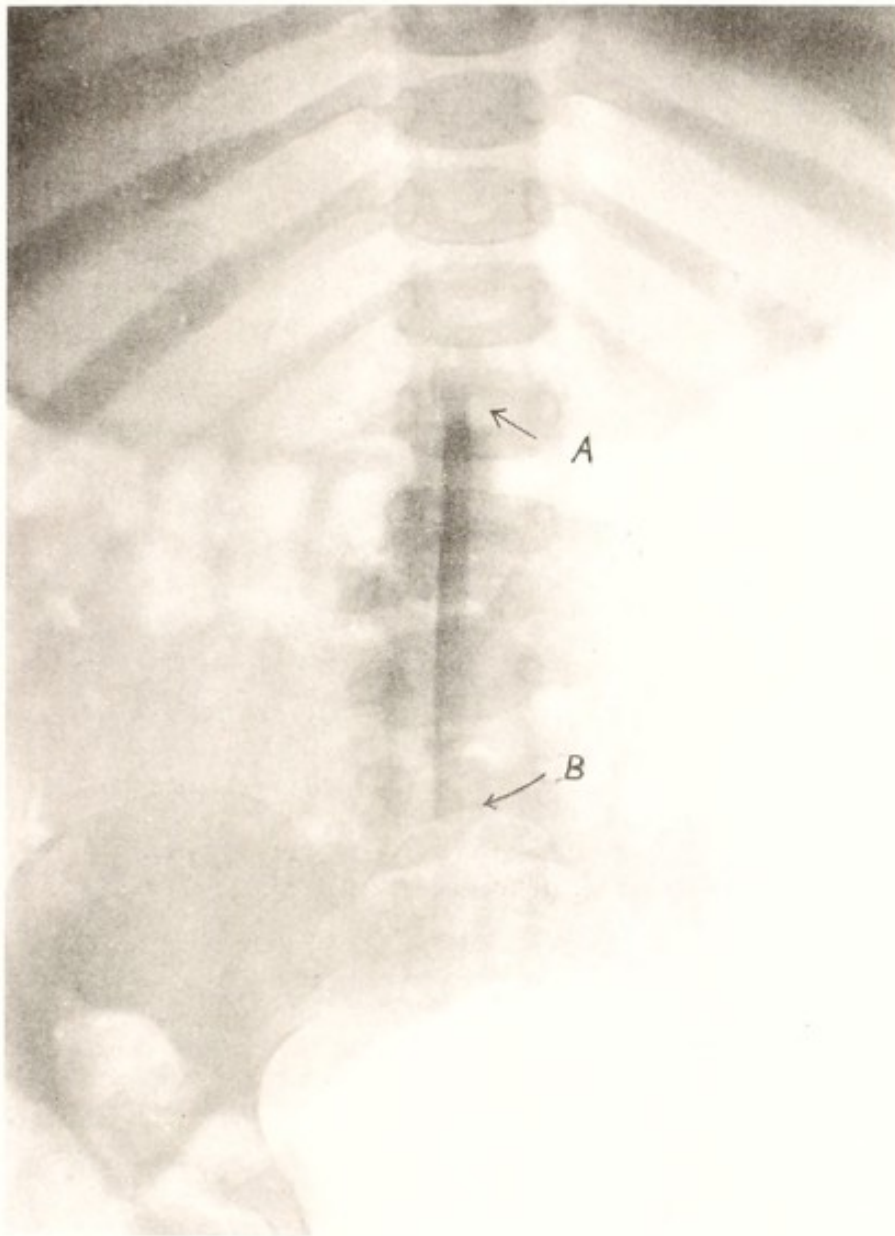


FIG. 52.—Graft *AB* inserted for acute Pott's disease with discharging sinuses in both iliac fossæ. Symptoms were relieved and sinuses healed in 10 weeks time.

gion will have a greater amount of strain to resist than one at any segment above. In this region, the general leverage that will have direct bearing upon the graft includes not only the weight and force applied through the entire length of the

spinal column above the implanted graft, but also includes the force of the leverage action of that portion of the trunk and lower limbs which extends below the graft. The grafted area is here considered the fulcrum, consequently the graft should be relatively stronger. This added strength is supplied by inserting a broader graft, and as in the lumbar region we

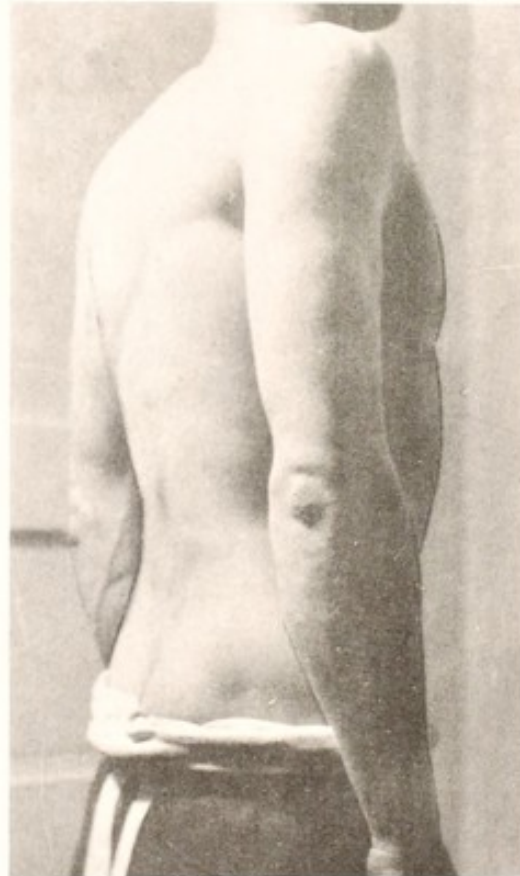

FIG. 53.—Acute Pott's disease of the lower thoracic region with large psoas abscess, 4 years after the insertion of a tibial graft. The abscess immediately disappeared and the patient has not lost a day's work on account of his back since 7 weeks after the operation.

seldom find a kyphosis of very great angulation, a straight graft with no transverse saw-cuts can usually be employed.

The graft is applied readily between the bifid portions of cervical spines, as well as to the corresponding projections on the posterior surface of the sacrum in low lumbar Pott's disease.

The Immediate Post-operative Treatment.—The immediate post-operative care of these cases consists in recumbency upon the back on a fracture bed for 5 weeks in adult cases and 6

weeks for children, with no more restraint than that afforded by pinning a towel about the thorax to which are attached four strips of a broad muslin bandage. Two strips are pinned to the upper side of the encircling towel in front, to be secured to each side of the mattress of the bed above the shoulders. The

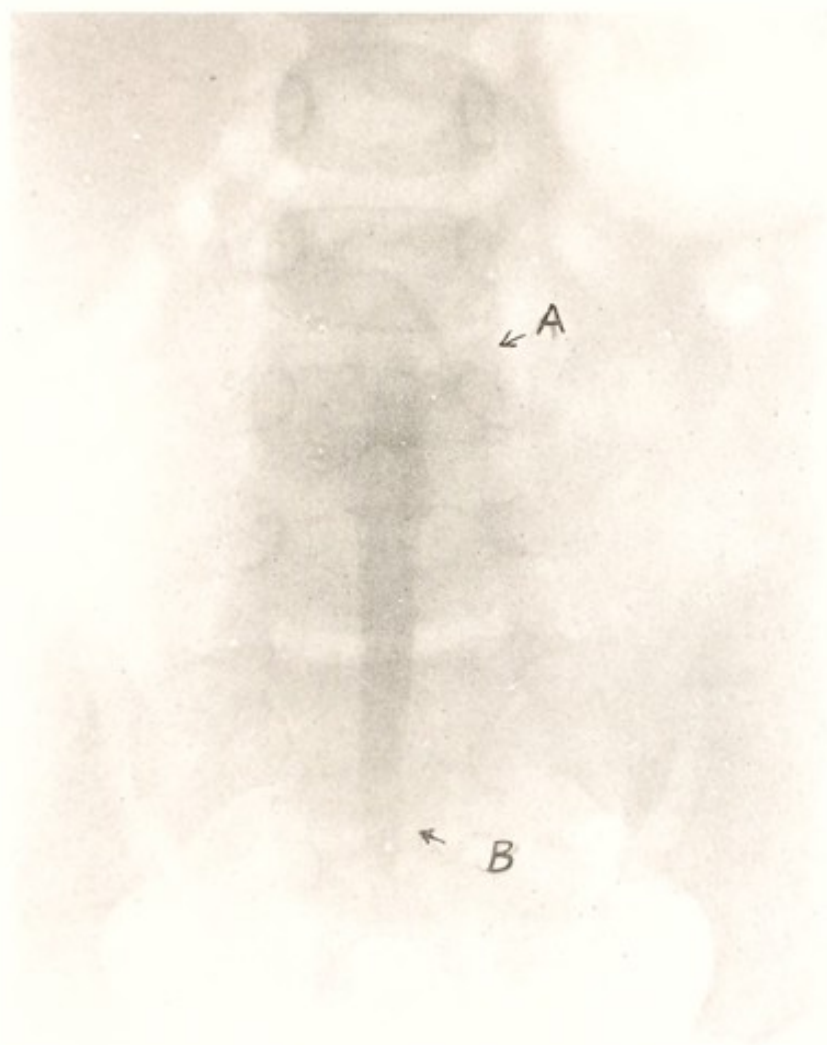


FIG. 54.—This röntgenogram demonstrates the large amount of proliferation a spina graft (*AB*) will undergo when the mechanics of its environment demand it.

remaining two strips of bandage are fastened to the encircling towel near its lower edge and to the two sides of the mattress at the foot end of the bed (Fig. 56). These restraining bandage strips are so placed to prevent the patient from attempting to sit up or roll from side to side, and are usually necessary only with

children. Adult patients, as a rule, lie recumbent without restraint.

Where the spine presents a marked kyphosis, it is necessary to apply thick pads of soft material on each side of the

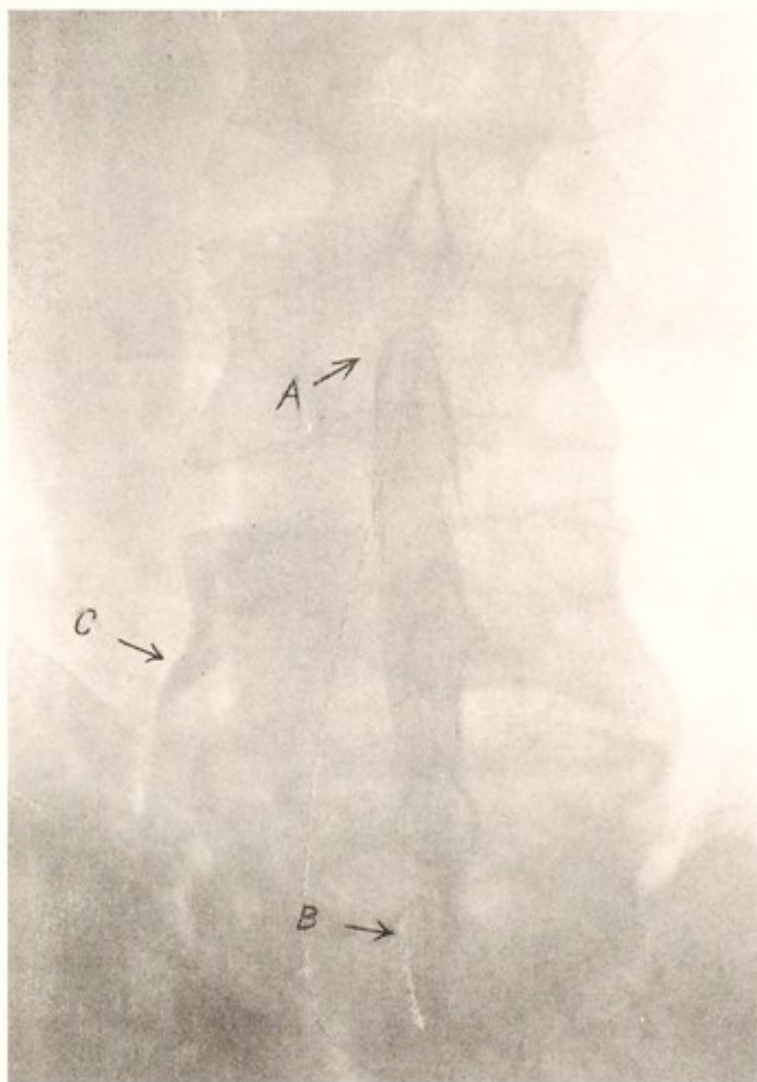


FIG. 55.—Acute Pott's disease of fourth and fifth lumbar vertebrae in a laborer of 22 years. Two abscesses size of cocoanuts in iliac fossae. At Roosevelt Hospital (Dr. Chas. H. Peck's Service), Feb. 12, 1913, a tibial graft was inserted into the spinous processes of the third, fourth and fifth lumbar vertebrae and sacrum. The patient went to work as a laborer in a brickyard 2½ months after operation. In September, 6½ months after the operation, he obtained a position as fireman and has continued to shovel coal ever since. In Feb., 1914, just 1 year after the operation, he reported at the O. P. D. for examination, although he had no complaints to make. No evidence of his former psoas abscesses could be palpated, although they had never been aspirated and no spinal support had been worn.

spine before placing the patient on his back, or when there is an excessive deformity it is best to secure the patient in bed lying upon his side, to obviate undue pressure on the grafted area,

in this way preventing necrosis of the skin flap. For a similar reason, it is unwise to employ the gas-pipe frame with its rigid canvas covering, or a plaster-of-Paris jacket, immediately following the operation. The slight amount of motion produced by respiration is not detrimental to the adhesion of the graft, but rather is considered to stimulate proliferation of callus between the contacting cut surfaces of bone and thus hasten the fixation of the graft.

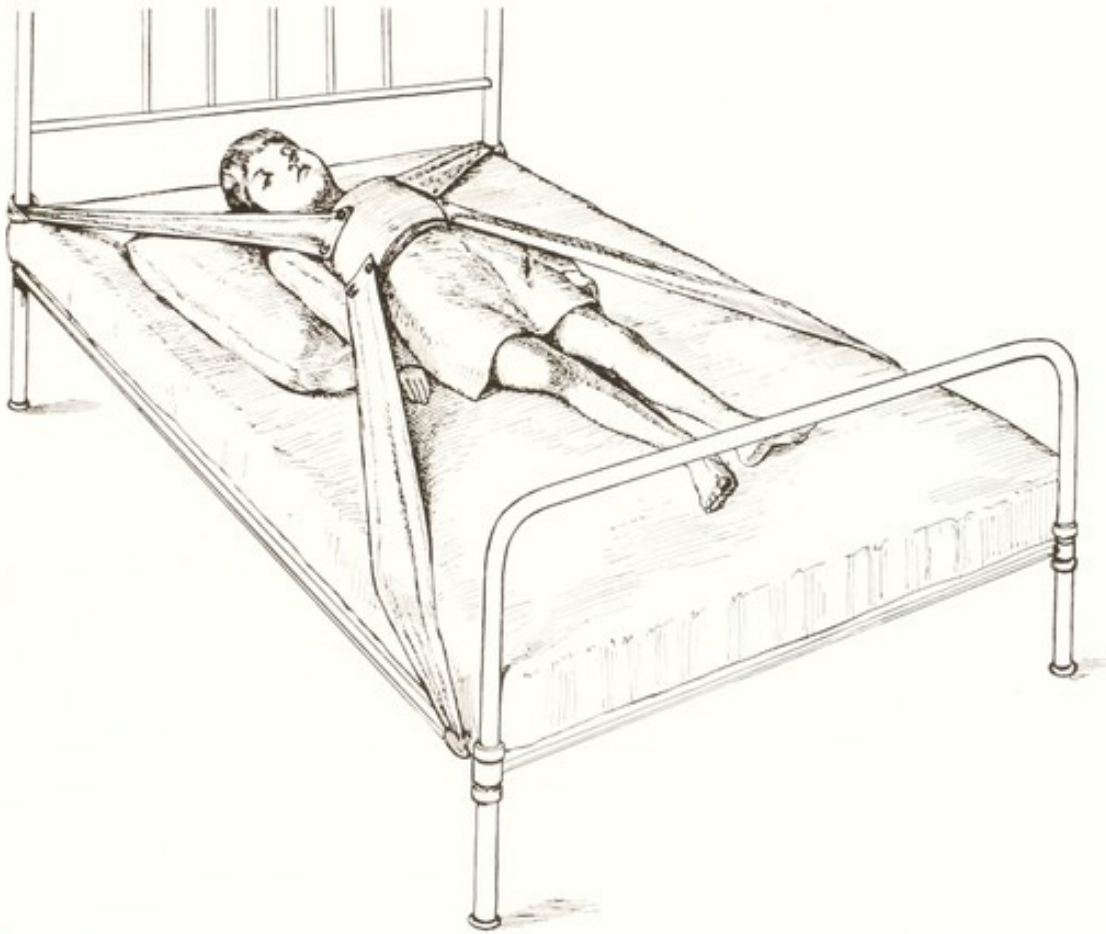

FIG. 56.—Method of fixation in bed after the bone-graft implant for Pott's disease has been applied.

The General Post-operative Treatment and Convalescence.

—It should be observed that while the implantation of this bone graft for the purpose of ankylosing the affected vertebræ accomplishes the long-sought-for immobilization of these diseased joints, it does not directly remove the disease itself, which is an impossibility. However, as ankylosis of other tuberculous joints has proved so satisfactory in arresting the disease with-

out requiring the removal of all the infected bone (as evidenced in cases of knee- and hip-joint disease, see Chapters V and VI), so, in the case of tuberculous infection of the vertebral joints, ankylosis acts with even greater advantage in that by the bone

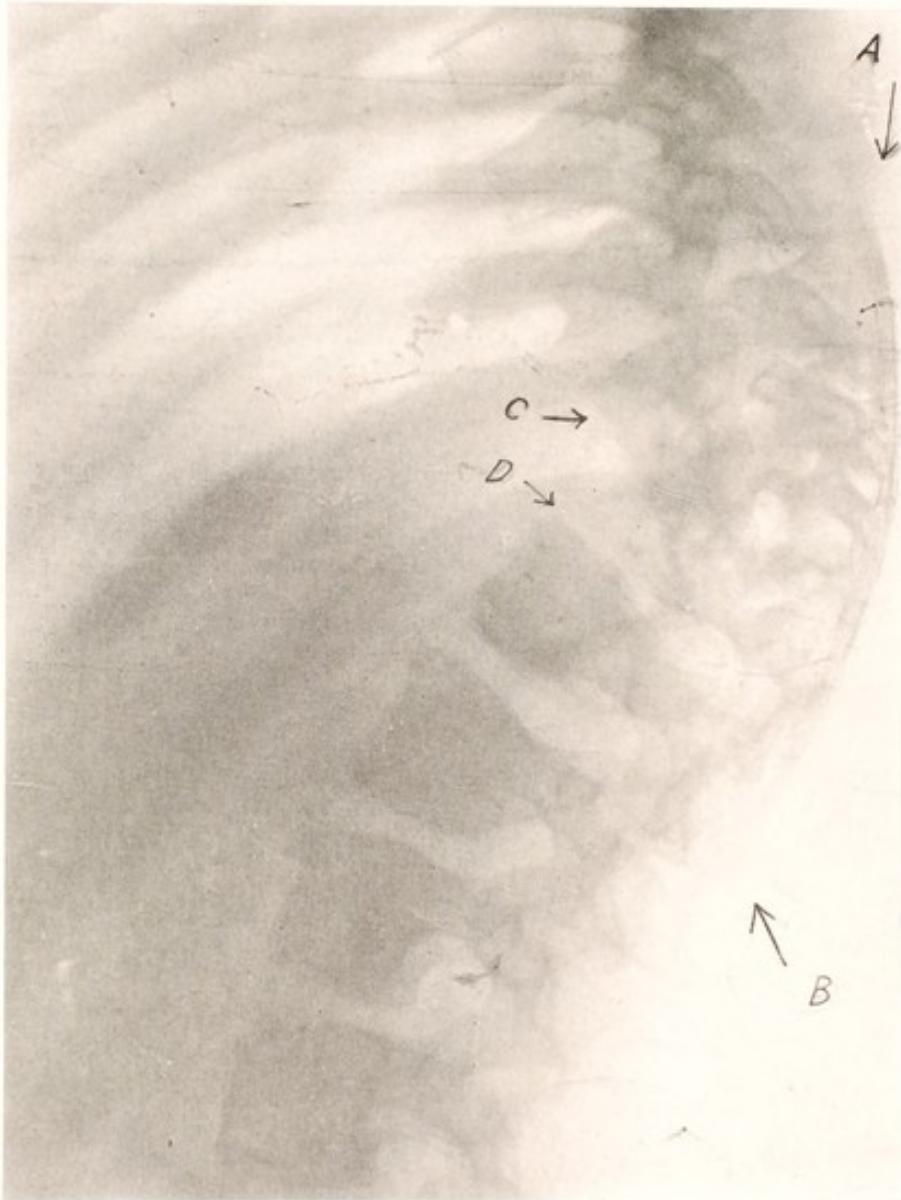


FIG. 57.—Lateral röntgenogram to illustrate the bone graft in place after 18 months and the efficacy with which it is holding the spine, although the vertebral bodies at *CD* are entirely disintegrated and absorbed. This destruction occurred before the graft was inserted.

graft implanted in the spinous processes the vertebræ are not only ankylosed, but their diseased bodies can be separated, thus removing active causative elements in the extension of the disease. Although, as a rule, the patient is immediately relieved

from symptoms and evidence of active disease, he should have the general careful régime of bodily rest, wholesome feeding, sunlight and fresh air that has been found of so great importance in these cases heretofore.

It is always advisable that in these cases 6 months or more of post-operative convalescence shall have passed before the patients resume active or heavy work. However, in a number of instances where the author has applied the bone graft for



FIG. 58.—A group of 17 children at the Blythedale Home, Hawthorne, N. Y., all of whom have had the bone graft inserted for Pott's disease. The convalescence of all has been most satisfactory and without plaster jackets.

One of this number had been operated at another clinic and came to the Home wearing a plaster jacket about 10 weeks after the bone graft had been implanted. It was noticed that in spite of the jacket the child refused to play, rested his chin in his hand and had night cries. A röntgenogram was taken and it showed that the graft only included one-half of the vertebrae involved. A second operation was done and the graft lengthened to include sufficient vertebrae, and from that time his spinal symptoms have entirely disappeared.

Pott's disease in adults, they have returned to work in 6 to 8 weeks after the operation, and without external support. These were patients who had been compelled to cease work on account of the disease but who, because of necessity, as soon as pain and weakness were relieved felt obliged to return to work against advice.

Children should have at least a year of more or less restraint from general activity, with daily rest periods and outdoor life.

It proves particularly beneficial to these cases, following the 5 to 6 weeks' post-operative confinement in bed, if they can be removed from the city to more healthy surroundings in the country. In other words, they should be managed in a similar way to cases suffering from lung or glandular tuberculosis. This can be carried out in every detail, because the mechanical spinal requirements have been met by the implanted bone graft. In the Blythedale Home for Tuberculous Crippled Children the author has a very valuable example of these advantages, as evidenced in such of these cases as could take the opportunity this Home offered, compared with those who were not so fortunate and remained in the city.

External Support to the Spine during Convalescence.—As a general rule, the author has followed the practice of applying no external fixation to the spine after his operation. There are certain cases and exceptions, however, where for definite reasons it has been deemed advisable to have the patient wear a spinal brace or a plaster-of-Paris jacket for varying lengths of time after the 5 or 6 weeks of immediate post-operative fixation in bed.

For instance, when it is necessary for the patient to leave the hospital before the prescribed period of 5 to 6 weeks in bed has elapsed; or in cases where a marked kyphosis in the thoracic region has developed before the operation, necessitating a temporary weakening of the graft by transverse saw-cuts in order to bend it into place. In addition, such a graft is subject to strain varying according to the severity of the kyphosis. In these cases a plaster-of-Paris jacket is advisable for a few months, or a longer period of recumbency in bed.

SUMMARY

Remarks on the Employment of Bone-graft Fixation of the Vertebrae in Pott's Disease, and Its Advantages

Following the bone graft, the full natural leverage action of each vertebra is not lost but is changed from a crushing together of the bodies anteriorly (due to respiratory motion, contraction

of abdominal muscles, and general attempt on the part of nature to immobilize the diseased vertebræ) to a pulling of the ankylosed spinous processes on the ankylosing graft posteriorly. The change from the crushing effect taking place in the bodies by the approximation of the anterior arms of the levers to a

traction effect through the long axis of the graft implanted in the ends of the posterior arms of the levers, preventing separation of the spinous processes, is obvious. The fulcra of these levers remain constant. In comparatively early cases of sharply angular antero-posterior deformity of the spine, further progress of the kyphosis can be prevented and actual

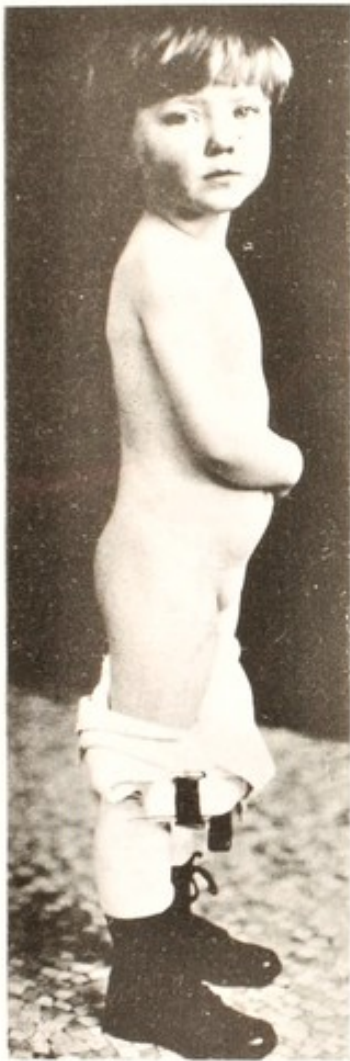


FIG. 59.



FIG. 60.

FIGS. 59 AND 60.—A very acute case of tuberculosis of lumbar spine, 3 months after bone graft was inserted. Child has remained well 2 years after operation. The excellent spinal function is shown.

correction maintained by this bone-graft implantation. Besides accomplishing this, the accurate immobilization of the involved segment of the spinal column is secured without interference with body activity or respiratory function, or resorting to protracted recumbency, fixation on a gas-pipe frame, plaster-of-Paris jacket or brace.

Indications for Operative Treatment.—Fixation by the bone graft is indicated in all cases and at all ages where pain or muscle-spasm demands it, and the earlier the operation the more favorable the prognosis. It is indicated for the prevention and correction of increasing deformity, and is even more urgently demanded in the presence of complicating conditions, such as psoas spasm, cold abscesses, or paraplegia.

The only special **contra-indication** is the inability to secure a clean field of operation. This, however, is rare, as cold abscesses seldom point in or invade the region of the spinous processes. Uninfected cold abscesses between the spinous processes have not interfered with primary union of the graft, when encountered unexpectedly in implanting the graft, and cases can be cited where bone grafts have spanned through these cold abscesses with no detriment to the graft or delay in its bony union.

Prognosis Following the Bone-graft Operation.—The prognosis in all operated cases is most favorable, as to relief of all symptoms and decrease of the deformity. Correction of deformity is most favorable in cases of children operated on early; and in cases of longer duration where the kyphosis is sharply angular, or presents a considerable amount of motion, a certain amount of correction is possible.

In 250 cases operated upon by the author, a surprising amount of respiratory mobility was noted in the centre of the kyphosis in all early cases, as well as in a considerable percentage of cases of even 4 to 6 years' duration. These observations were made after the spinous processes were exposed and while the patient was lying prone on a firm operating table, breathing quietly under an anæsthetic. Under these conditions, slight motion only could be detected between the healthy vertebræ above or below the kyphosis. Undoubtedly the reason for this increased motion is the loss of support due to the destruction and absorption of the diseased vertebral bodies, leaving only the lateral masses with their articular facets and the spinous processes to support the column.

The prognosis is much influenced by the patient's post-operative environment and daily régime of life. This is of as great importance as in the case of tubercular involvement of other organs. Rest, forced feeding, fresh air, and exposure to sunlight are important elements of treatment.

With the object of ascertaining the results obtained by other surgeons with the bone-graft treatment for Pott's disease, a large number of printed question blanks were sent out to every surgeon who, it was known, had done this operation, in this country and foreign countries.

From these blanks and the author's personal cases the following statistics of 532 cases were tabulated:

The ages of the patients vary from 20 months to 65 years. The **duration** of the **disease** (and this in many cases was synonymous with duration of previous conservative treatment) was: under 1 year 58 cases; over 1 year 71 cases; over 2 years 62; over 3 years 71 cases; over 4 years 56 cases; over 5 years 36 cases; over 6 years 33 cases; over 7 years 21 cases; over 8 years 16 cases; over 9 years 13 cases; over 10 years 10 cases; over 11 years 8 cases; over 12 years 8 cases; over 15 years 5 cases; over 19 years 3 cases; over 21 years 5 cases; over 26 years 2 cases.

Location of Disease.—Cervical spine 6 cases; Cervico-dorsal region 42 cases; dorsal region, 168 cases; Dorso-lumbar 78 cases; lumbar 122 cases; lumbo-sacral 34 cases.

Thirty-one surgeons reported a total of 292 results, in 222 of which the disease was pronounced arrested. In 59 the condition was improved. Twelve cases died, 4 of which were reported as from shock. The remaining 8 cases died 4 months or longer after operation from either complications or intercurrent diseases. In 5 of these cases the spinal condition was entirely controlled. In 3 of 4 cases dying from shock, the chisel and mallet were used to obtain the graft.

Fourteen of the 31 surgeons reported 100 per cent. of cases of good results (disease arrested). There were 8 surgeons who

reported that they did not use plaster jackets or spinal supports beyond the period of immediate post-operative recumbency. Seven of these men obtained 100 per cent. of good results and one secured 88 per cent. of good results.

Of the author's personal cases only those that have been operated 1 year or longer are included in this report. Of these there are 198. In 184 the disease was arrested. In two there was improvement.

Up to the present time 12 have died; 6 of these cases were entirely relieved of their Pott's disease and died from some inter-current disease. One, a child of 6 years, in poor general condition, after 5 years of conservative treatment died the next day after the operation, cause unknown; the graft in this case was removed with chisel and mallet; one case in 4 days from acetoneuria; one from status lymphaticus; one from middle-ear disease complicated by a suppurative meningitis, two years after the spinal operation. The autopsy showed a complete cure of the tuberculous spine. One died about 1 week after operation from pneumonia. The causes of the death of others have been amyloid degeneration of the viscera, tuberculosis of the lung, and acute abdominal condition.

There have been only 3 cases, of the 532, die of tuberculous meningitis, and there has been no serious trouble with the tibia from which the graft was removed in any case.

Of the total number (532) in 449 the disease was arrested, in 59 the condition was improved, in 9 the condition was unimproved. There were 9 deaths soon after the operation, and 6 deaths occurred long after the operation and were relieved of their spinal symptoms. The percentage of results of this large number of cases is most gratifying, especially, when it is realized that most of these cases were operated and treated during a period when the technique of procedure was being developed.

With the present motor tools and the perfected technique it is believed that a fatality from shock should practically never happen.

EXPERIMENTAL APPLICATION OF THE METHOD TO THE SPINES OF
13 DOGS, VERIFYING THE WORK DONE ON THE
HUMAN SUBJECT

The special object of the animal experimentation about to be described was to afford means for studying both, macroscopically and microscopically, a bone graft when implanted in a dog by the same technique as that employed by the author in the human subject for the treatment of Pott's disease of the spine.

REPORT OF EXPERIMENTS

Experiment 1.—December 10, 1911. Dog, mongrel, male; approximate weight, 30 lb. Ether anæsthesia. Anæsthetist, Mr. Cassellius. Fields of operation: thoracic region of back and left foreleg, prepared by shaving and scrubbing with tincture of green soap and water, followed by corrosive sublimate, 1:1,000, and 70 per cent. alcohol. The spinous processes of three of the mid-dorsal vertebræ were approached by an incision through the skin and areolar tissue directly over their tips. The supraspinous and interspinous ligaments were split with a scalpel to a depth of two-thirds of an inch between the spinous processes, without disturbing the attachments of the ligaments to the spinous processes. Each of the three spinous processes was split longitudinally with a chisel and mallet into halves, for a depth of about two-thirds of an inch, care being taken that the right halves of the spinous processes were not broken. A separation of the tips of the halves of these spinous processes produced a wedge-shaped cavity, into which the ulnar transplant was later inserted. A hot saline compress was placed in the wound until the bone insert was obtained. This was for the purpose of securing as perfect hæmostasis as possible for the bone-graft bed. Half the diameter of the shaft of the dog's right ulna was then removed with chisel and bone forceps. The graft consisted of periosteum, compact bone, endosteum, and marrow substance. It was inserted between the halves of the interspinous ligaments and spinous processes, and held in place with interrupted sutures of

linen, which were passed through the supraspinous ligaments and the posterior edge of the halves of the interspinous ligaments near the tip of each spinous process. These ligaments were thus drawn over the graft posteriorly. The procedure was precisely that which has been applied to human subjects.

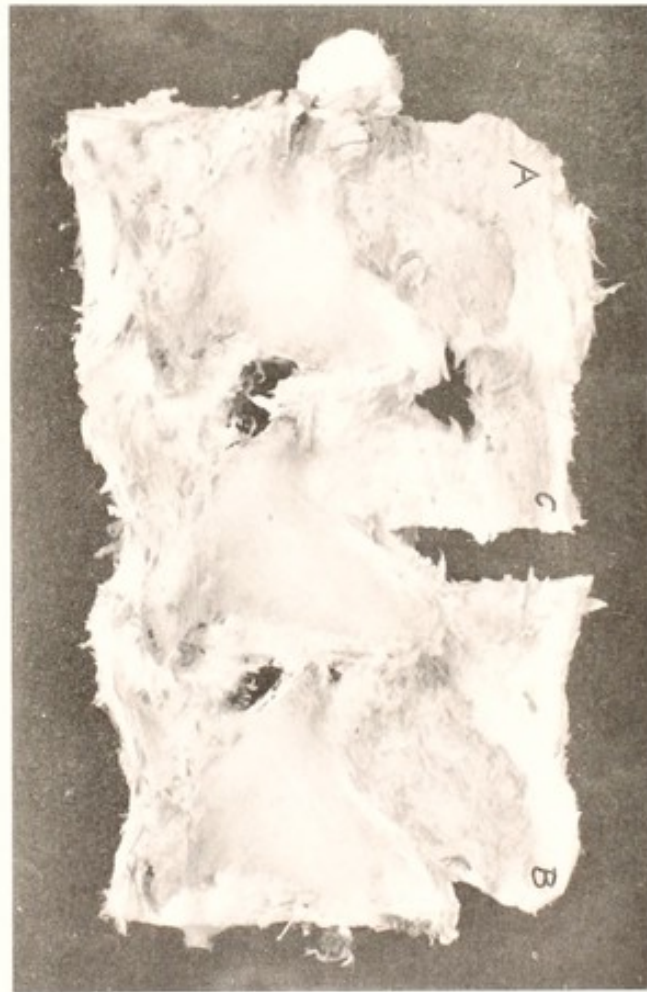

FIG. 61.—Photograph of three vertebrae of a dog bridged together by a strong bone graft *AB*. This specimen was obtained at necropsy 6 months after the graft was inserted.

December 13, the wound was septic. December 20, much pus was discharging from the wound. The sinus slowly decreased in size during the next few weeks.

Necropsy.—May 28, 1912. The wound had healed, with the exception of a small sinus. A sliver of nearly one-third the diameter of the graft anteriorly and tapering to a pointed end

posteriorly had sequestered from the rest of the graft, which had become firmly united to the spinous processes. The whole posterior diameter had lived and become firmly grown into the spinous processes. Although sepsis had occurred and no at-

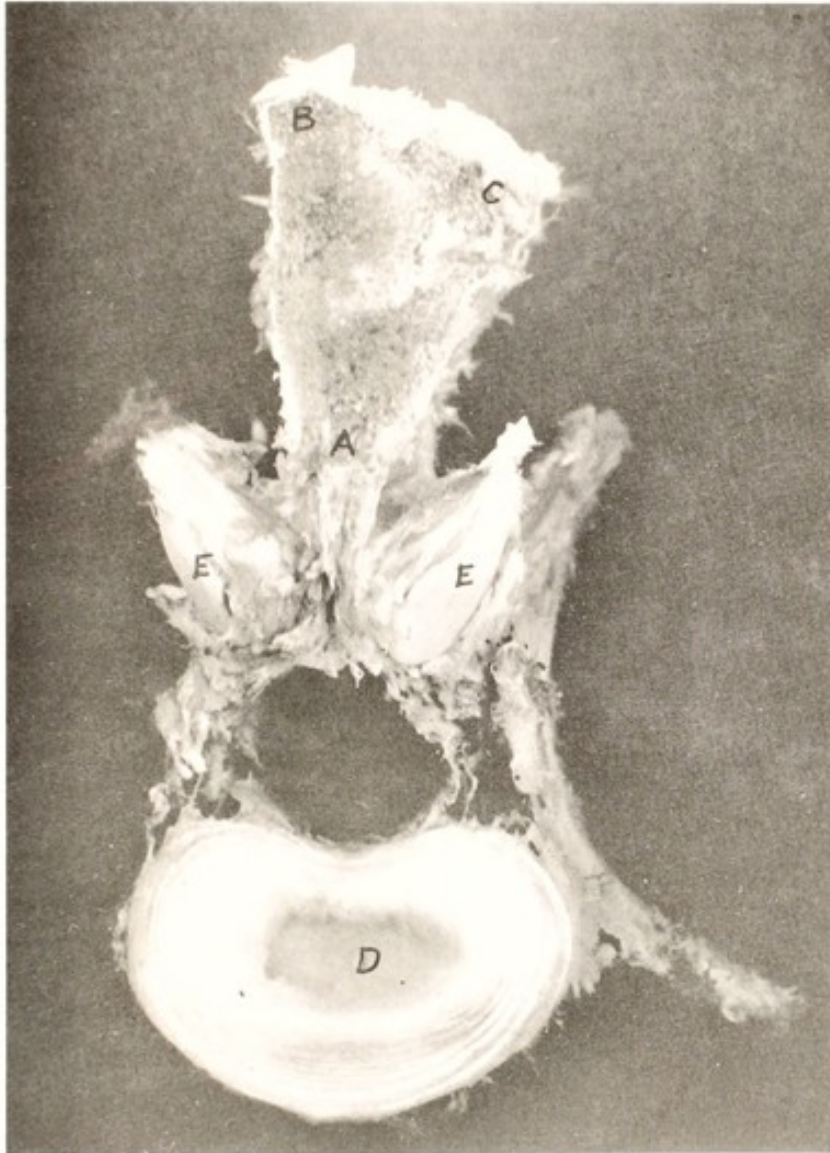


FIG. 62.—View of a dog's vertebra (Experiment 1), into the spinous process of which a portion of his ulna had been ingrafted 6 months before; *A*, *B* and *C* indicate the outlines of the graft, which has become firmly grown into the split spinous process. Fig. 66 is from a photomicrograph of a section of graft at this point. *E* is articular facet.

tempt had been made to immobilize the dog's spine, the result was a bridge of bone uniting three vertebrae. X-ray examinations of the gross specimen and a microscopic study of decalcified and non-decalcified sections failed to show degeneration of

that part of the graft which had become united. No cartilage cells could be found; the union of graft to spinous process was by new bone formation.

Experiment 2.—January 18, 1912. Dog, terrier, male, mongrel; weight, 20½ lb. Ether anæsthesia. Assistant, Dr. Keller. Precisely the same technique was carried out in this case as in Experiment No. 1, except that the whole diameter of the shaft of the ulna was removed subperiosteally. A sharp periosteal elevator was used, and the periosteum was removed from the bone with force for the purpose of being certain of separating the deep osteogenetic layers from the bone cortex and obtaining it as a part of the periosteum. The periosteum was left *in situ* in the leg. The transplant was inserted by the same technique as in Experiment No. 1, except that the periosteum had been removed as just described. The leg and back wounds were closed by continuous sutures of linen. The periosteal tube was allowed to collapse.

January 22, back wound septic. January 28, leg wound healed by primary union.

Necropsy.—February 29, 1912. Back wound was septic; graft had sequestered. It is believed that the difficulty in preparing the dog's skin for operation, in addition to large hæmatomata which invariably collect in the loose areolar tissue of the dog's back, in spite of all precautions, was largely responsible for the sepsis in the back wound, since at the same time the leg wounds were clean. The conditions about the back wound were precisely the same as those in Experiment 1, namely, a deposit of osteoid tissue in the wall of the sequestrum pocket; the graft, however, had sequestered.

In the foreleg, a bridge of bone had appeared where the shaft of the ulna had been removed. In the centre, it tapered to a diameter about half that of the original bone. This bone growth had been very rapid, and connected the ends of the ulna.

Experiment 3.—January 23, 1912. Dog, terrier, female; weight, 22 lb. Ether anæsthesia. Anæsthetist, Mr. Cassellius. Assistant, Dr. Keller. The spinous processes of the

last two thoracic and first, second, and third lumbar vertebrae were prepared as usual for the graft. With chisel and mallet and saw, about $1\frac{3}{4}$ in. of the left ulna were removed, leaving the periosteum from half its diameter *in situ* in the leg. In

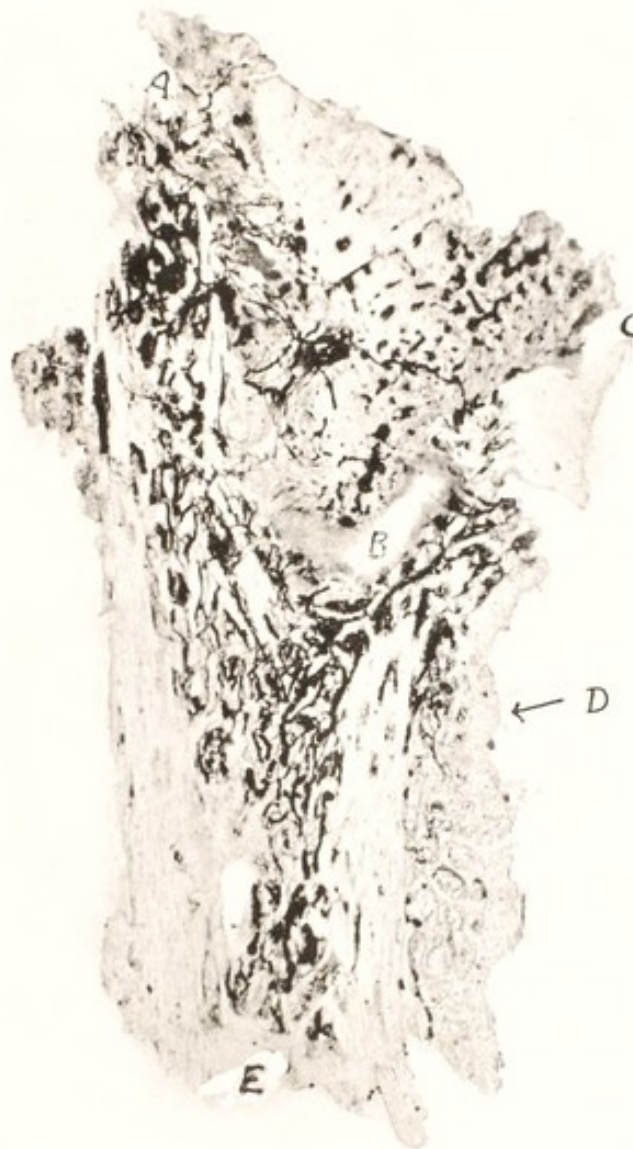

FIG. 63.—Longitudinal section through spinous process with cross-section of graft (ABC) which had been inserted 6 months; from a low-power photomicrograph of a non-decalcified ground specimen. Numerous blood-vessels can be seen, under high magnification, extending from spinous process into graft. D is new bone. E is base of spinous process.

this instance, the periosteum which was removed was separated with the blunt end of a pair of scissors so that no force was employed in scraping it from the bone; it peeled off easily. The portion of the ulna which had been removed was then split

longitudinally with a chisel into equal parts, one-half being covered with periosteum. This fragment was inserted into the last two thoracic vertebræ. The fragment from which the periosteum had been removed was inserted into the second and third lumbar vertebræ.

Necropsy.—February 29, 1912. The posterior end of the wound was filled with pus; the anterior end had healed by granulation. The graft from which the periosteum had been removed, and which had been placed in the lumbar vertebræ, had sequestered and was surrounded with pus. The graft insert which was placed in the thoracic vertebræ was firmly united into those vertebræ. A microscopic examination showed the union to be bony. No evidence of degeneration or cellular death could be found. No bone or evidence of osteogenesis appeared between the ends of the ulna where the graft had been obtained except about the bone ends. The periosteum, in this case, as stated, was removed from the bone by means of a blunt instrument and with no effort to get into a deep cleavage.

Experiment 4.—January 25, 1912. Dog, mongrel, female. Ether anæsthesia. Anæsthetist, Mr. Cassellius. Assistant, Dr. Soule. On the evening before the operation, the dog received a bath in 2 per cent. aqueous solution of liquor cresolis compositum. In the following experiments this bath was given. Two inches of the shaft of the left ulna were removed subperiosteally. A sharp periosteal elevator was used for the purpose of getting into deep cleavage. The portion of the ulna shaft removed was then split longitudinally with a chisel and mallet into halves. One of the bone fragments was inserted by the usual technique into the last thoracic and first and second lumbar vertebræ. The remaining bone fragment was placed in sterile normal salt solution in an ordinary ice-box for the purpose of transplanting it into the next dog operated on. Wounds healed by primary union.

Necropsy.—May 9, 1912. The transplant was found to be firmly united with the spinous processes. The graft had lost

its identity. From the appearance of the bridge of bone between the tips of the three spinous processes one could not say

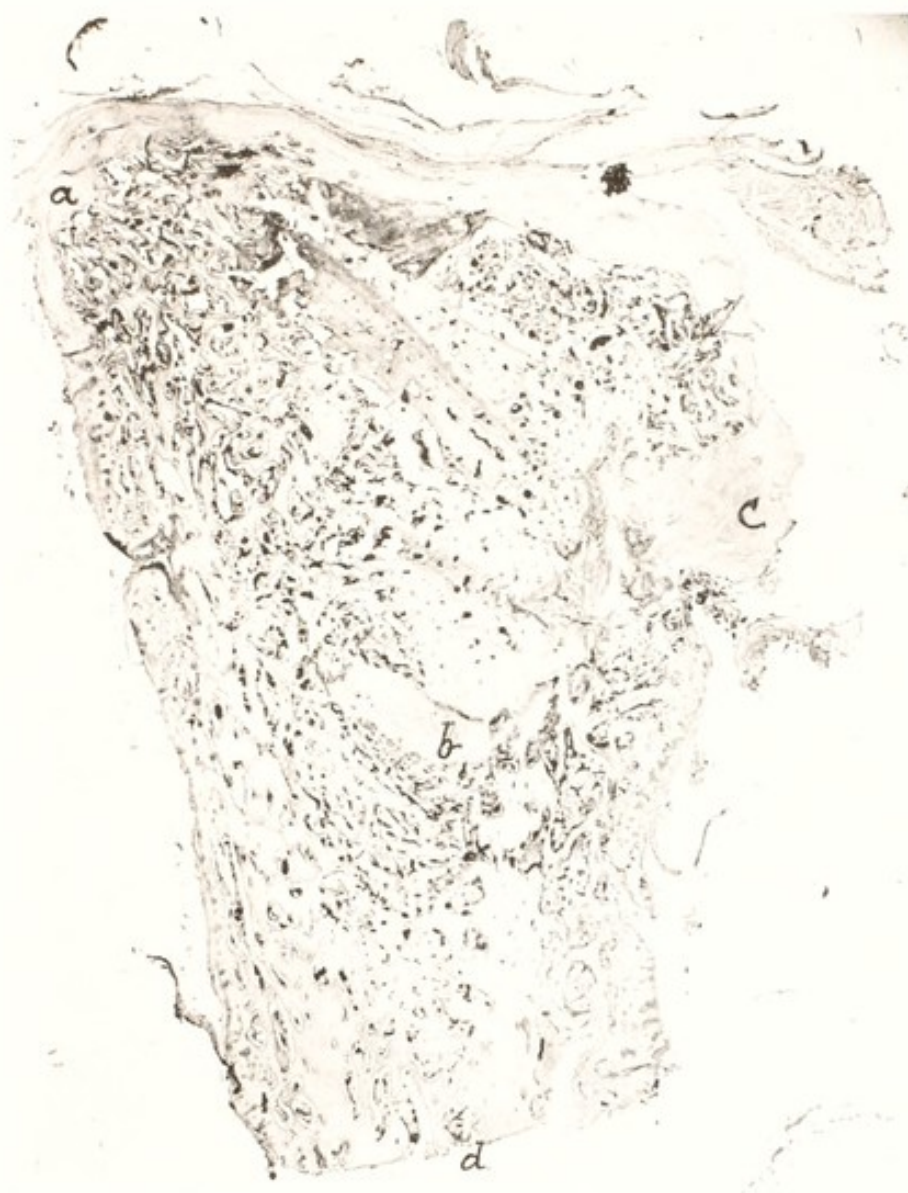

FIG. 64.—Photomicrograph of section through the long axis of spinous process of a dog with a cross-section of an autogenous ulnar graft (*abc*) thoroughly united by new bone 2 months after the graft was inlaid into the split tips of three spinous processes. The analogy to the technique of the tree graft (Fig. 5) is apparent. A careful microscopic study of this section has failed to disclose dead bone-cells. The corners of the graft are indicated by *a*, *b*, and *c*. *d* indicates base of spinous process. The author's surgical experience in over 250 cases, as well as a large amount of animal experimental work, has convinced him that the inlay method of insertion affords by all means the most favorable graft environment, as this and many other microscopic sections have proved.

from what it had originated. Microscopic examination showed bony union of graft to spinous process and no evidence of cellular degeneration. A strong bridge of bone was present between the

ulnar ends, filling in the space where the transplant had been removed. This bridge of bone was not quite so large in diameter as the normal ulnar shaft. It was, however, sufficiently strong for functional purposes. It is believed that the satisfactory osteogenesis obtained in this case as, for instance, compared with practically no bone growth in Experiment 3, was

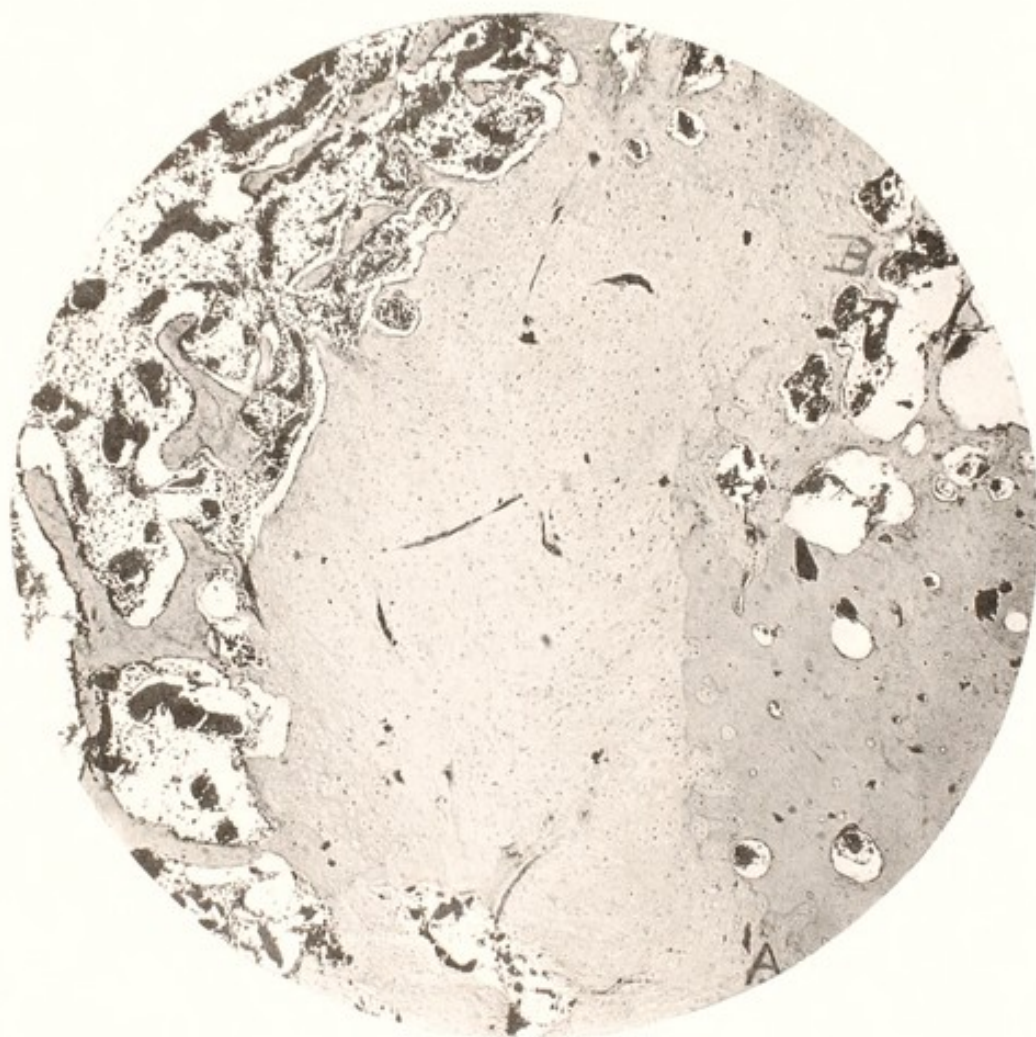


FIG. 65.—Junction of graft and spinous process (AB). The transplant had been inserted 4 months (Experiment 5). From a high-power photomicrograph.

due to the method of removing the periosteum by a sharp instrument for the purpose of getting into deep cleavage. In this way the chances are large that the very active osteogenetic layer of cells, which is situated on the surface of and considerably adherent to the compact bone, will be loosened either entirely or partly, and will separate off as a part of the periosteum.

Experiment 5.—January 30, 1912. Dog, black hound, male. Ether anæsthesia. Anæsthetist, Mr. Cassellius. Assistant, Dr. Soule. Incision was made over the last three thoracic and first three lumbar vertebræ. The spinous processes of the three lumbar vertebræ were split into right and left halves with a chisel, and the bone fragment 2 in. long, which had been removed from the dog's ulna in Experiment 4, January 25, 1912, and kept in normal salt solution in an ice-box, was inserted into the prepared lumbar vertebræ. The spinous processes of the tenth and eleventh thoracic vertebræ were denuded of periosteum with a blunt instrument from the neural arches anteriorly to the tips of the spinous processes. The separated ends of the periosteum were then held in approximation by linen sutures. The skin was sutured by the subcutaneous method. In all previous cases the skin was closed with the ordinary through-and-through stitch; all succeeding wounds were closed with the subcutaneous suture, resulting in much less skin infection.

Necropsy.—May 8, 1912. The transplant was amalgamated into the spinous processes and had nearly lost its identity. It showed the contour of the graft on one end. From the appearance of the bridge of bone, one would not have thought that it was due to a bone transplant. There were only a few small disconnected plaques of proliferated bone from the periosteum which had been stretched across between the thoracic spinous processes.

It is thought that the fact that there was not a satisfactory bone growth from the periosteum may be accounted for in two ways: first, the periosteum on the spinous processes is meagre and unsatisfactory on account of so many muscular and ligamentous attachments; second, the periosteum was removed with a blunt instrument without a special effort being made to get into deep cleavage.

Experiment 6.—January 30, 1912. Dog, bull, male; weight, 28 lb. Ether anæsthesia. Anæsthetist, Mr. Cassellius. Assistant, Dr. Soule. Incision was made over and down to the spinous processes of the last two thoracic and first three lumbar

vertebræ. Two and one-fourth inches of the left ulna with its periosteum were removed with saw and split with chisel longitudinally into halves. These fragments of bone were then inserted into the spinous processes by the usual technique, one into the lumbar vertebræ, the other into the lower thoracic. The wounds healed by primary union.

The dog was found dead on May 6, 1912. In my absence, Mr. Cassellius removed the operated portion of the spine and placed it in fixing solution for future examination. These transplants, like all the others in the presence of asepsis, had become firmly united to the spinous processes into which they had been inserted.

Experiment 7.—February 1, 1912. Young dog, mongrel terrier; weight, 18 lb. Ether anæsthesia. Anæsthetist, Mr. Cassellius. Fields of operation prepared by iodine method. An incision over the last three thoracic and first three lumbar vertebræ was made. The lumbar spinous processes were split longitudinally on the left side of their centre down to the neural arches. Wound, as usual, packed with hot saline compress. One and three-fourths inches of diaphysis of left ulna were removed subperiosteally. A blunt instrument was used to separate the periosteum which was left *in situ* in leg. One-half of the ulnar shaft was placed by the usual technique into the posterior lumbar vertebræ. Pieces of periosteum stripped, without aid of a sharp instrument, from the ulna, varying in size from one-fourth by one-fourth of an inch to small bits, were sutured into the belly of the muscle, which had been turned aside when the ulnar shaft was removed. The muscle was then sutured into its normal position. The periosteum on the left side of the two anterior spinous processes was stripped and retained in two pieces with some difficulty. These periosteal flaps were then drawn together and sutured, thus producing a periosteal bridge between these processes. The remaining half of the ulna was placed in salt solution for the purpose of transplanting it into the next dog operated on.

Necropsy.—At necropsy, 3 months later, the transplant was

firmly united into the spinous processes. No osseous tissue could be found as a development from the periosteal bridge between the spinous processes. Only a small plaque of new bone

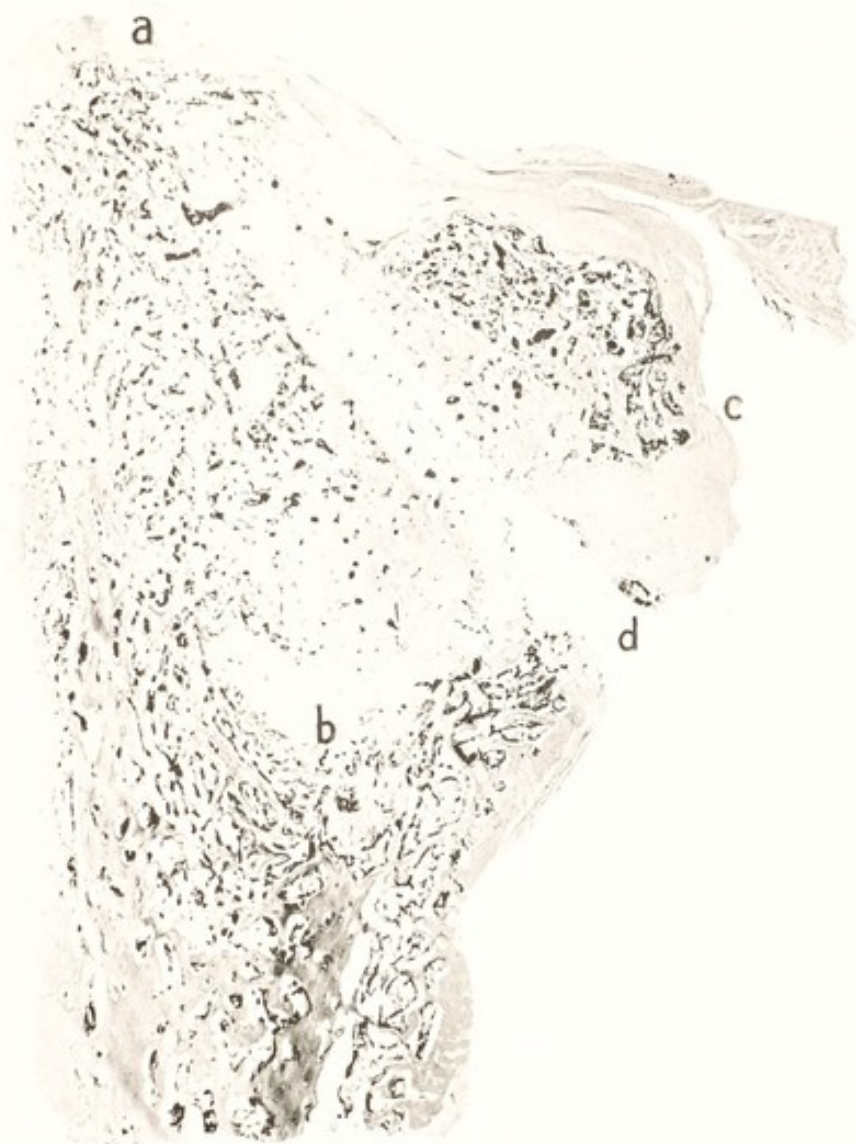

FIG. 66.—Decalcified section through long axis of spinous process with cross-section of the grown-in graft, 6 months after a portion of same animal's ulna had been grafted into spinous processes. A careful microscopic study of these sections and all others has failed to disclose dead bone-cells. The corners of the graft are indicated by *a*, *b* and *c* (*d* is a microtome artefact); *e* is base of spinous process.

could be found where the ulna had been resected. There was new growth of bone about the cut ends of the ulna.

Experiment 8.—Dog. Ether anaesthesia. Anaesthetist, Mr. Cassellius. Assistant, Dr. Soule. The last three thoracic and

first three lumbar processes were split as usual. Numerous slivers of the previous dog's ulna, devoid of periosteum, were placed between the split portions of the two upper thoracic vertebræ. The supraspinous and interspinous ligaments were drawn over in the same way as when a large graft was used. All the ligaments and muscles were separated from the second and third lumbar spinous processes for about two-thirds of an inch from their tips. These two spinous processes were then split longitudinally into equal anterior and posterior portions. Green-stick fractures were produced in the anterior half of the posterior process and the posterior half of the anterior process. The tips of these fragments, well denuded of periosteum and soft tissues, were then contacted and held with a linen ligature. The ligaments and fascia were drawn over all with a continuous linen suture. The skin was closed as usual with a subcutaneous continuous suture.

Necropsy.—At necropsy, $2\frac{1}{2}$ months later, there was evidence of some skin infection which had nearly subsided. The slivers of bone had united and produced a bridge of bone between the spinous processes, but not so firm as one resulting from one large graft. There was no bony union between the approximated fragments of the second and third lumbar spinous processes.

Experiment 9.—Dog, terrier, male; weight, $18\frac{1}{4}$ lb. Preparation: bath in compound solution of cresol, and shaving, the night before operation. The field of operation was allowed to dry over night and treated with American tincture of iodine just before operation. This preparation was used in all of the succeeding cases and was found very satisfactory. Ether anæsthesia. Assistant, Dr. Soule. Site in back for graft was prepared as in previous cases and packed with saline compress. Two inches of middle of left ulna were removed subperiosteally with blunt dissector. This portion of the ulna was then split longitudinally into quarters, two of which were placed in the tips of three lumbar vertebræ. A strip of periosteum $1\frac{1}{4}$ in. by $\frac{1}{3}$ in., taken from the ulna by a blunt dissector, was placed into the

tips of two split spinous processes anterior to those that contained the graft previously inserted. The periosteum was placed in a similar manner to that of the bone graft. The back wound was closed. Two pieces of bone $\frac{1}{4}$ in. by $\frac{1}{4}$ in. by $\frac{1}{8}$ in. in diam., which had been taken from the tip of a spinous process of the same dog, were placed in the belly of a muscle in the left foreleg. Two pieces of bone of the same size were taken from the ulna and placed in the belly of another muscle in the left foreleg, the object being to determine which was the more osteogenetic.

The dog was found dead February 27, 1912.

Necropsy.—February 28, 1912. Assistant, Dr. Soule. The bone transplant was found firmly united by callus to those spinous processes into which it had been inserted. The graft presented every appearance of being live bone. The small pieces of bone from the tip of a spinous process, which had been implanted into a muscle belly at operation, had changed very little; there was a very small proliferation on the side of the periosteum. The pieces of bone taken from the ulna and inserted into a muscle belly had also changed very little. There was, however, considerable proliferation on the side of the periosteum. The piece of periosteum ($1\frac{1}{4}$ in. by $\frac{1}{3}$ in.), which had been placed between the tips of two split spinous processes, presented no evidence of proliferation and was difficult to find.

Experiment 10.—February 13, 1912. Puppy, terrier. Ether anæsthesia. Assistant, Dr. Soule. An incision 5 in. long was made over and down to the tips of the last thoracic and first three lumbar vertebræ. Interspinous ligaments split with scalpel, spinous process with chisel. A piece of the ulna of the dog previously operated on ($1\frac{3}{4}$ in. long and one-half the diameter of the bone) was inserted, by the technique already described, into the spinous processes of the second and third lumbar vertebræ. A piece of the same dog's left ulna of about the same size was then removed subperiosteally with chisel and saw and inserted into the last thoracic and first lumbar vertebræ. A piece of periosteum ($1\frac{1}{4}$ in. by $\frac{1}{3}$ in.), removed by blunt dissection from the ulna, was placed into the fascia $1\frac{1}{2}$

in. to the left of the first lumbar vertebra and fixed with linen sutures. On the opposite side (right), and in the same relation to the first lumbar vertebra, a piece of the left ulna ($1\frac{1}{2}$ in. by $\frac{1}{8}$ in.) was placed in the same manner as the periosteum. The right foreleg was broken over the side of a table and a splint

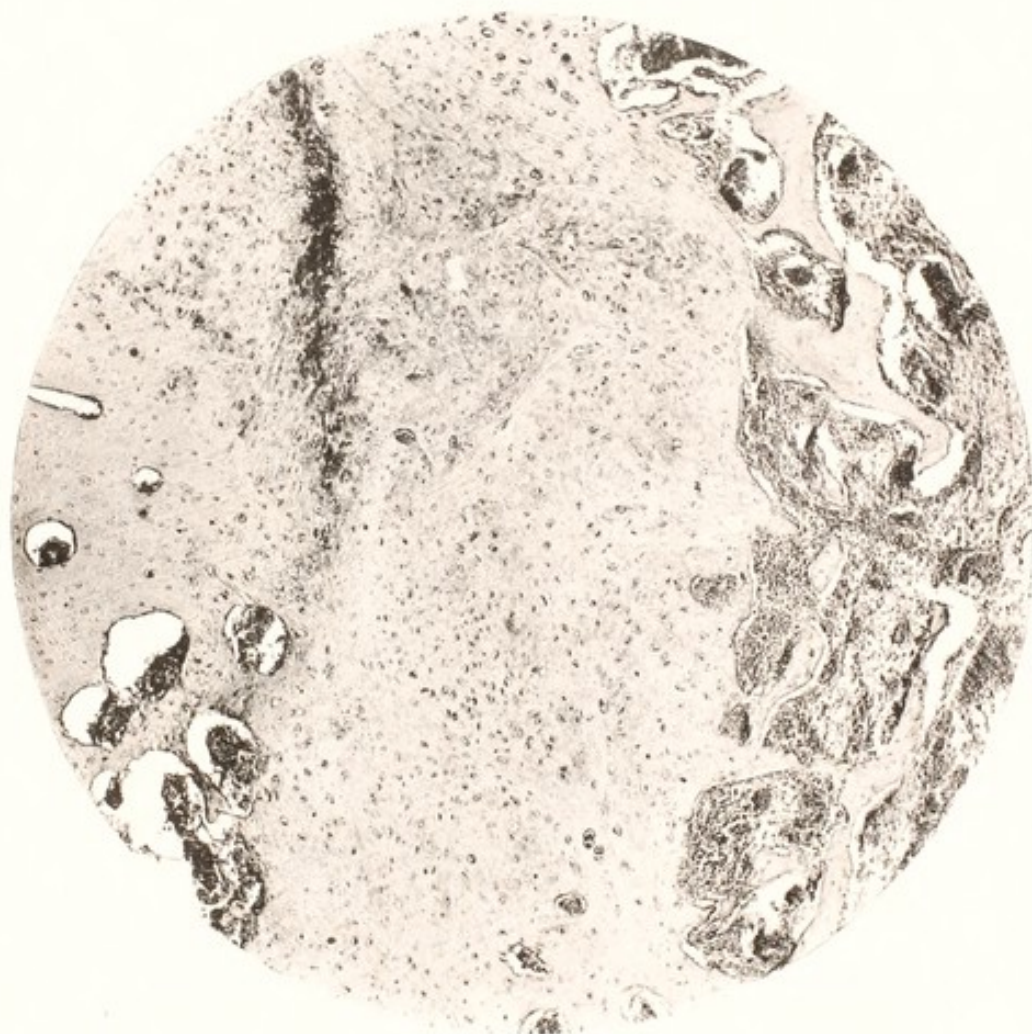


FIG. 67.—Junction of graft and spinous process in a case of 6 months (Experiment 1). No dead bone-cells could be found in these specimens. From a high-power photomicrograph.

was applied, in order to obtain thickened proliferating periosteum for grafting purposes in 10 days' time.

Necropsy.—February 27, 1912. Both pieces of bone, the one from another dog and the one from the same dog, were equally firmly united into the spinous processes. A careful microscopic examination of sections made through graft at various places, and through junction of union of graft to spinous process, failed

to show any evidence of degenerated bone-cells. The periosteum inserted into the fascia to the left of the spine presented no evidence of proliferation, either periosteal or bone. The bone placed under similar conditions to the right of the spine showed considerable proliferation, especially on the periosteal side.

Experiment 11.—February 15, 1912. Puppy, male mongrel; weight, $17\frac{3}{4}$ lb. Ether anaesthesia. Assistant, Dr. Soule. The shaft of the left ulna was removed with its periosteum intact and placed in normal salt solution, to be kept in the ice-box for a following case. The spinous processes of the last thoracic and first lumbar vertebrae were prepared as usual and a piece of a puppy's ulna (one-half its diameter and $1\frac{3}{4}$ in. long), which had been removed 2 days previously and kept in Ringer's solution in an ice-box, was inserted by the usual technique into the second and third lumbar vertebrae. A fragment of ulna with periosteum of approximately the same size, which had been removed from an old dog 2 days previously and kept in salt solution in an ice-box, was inserted into the last two thoracic vertebrae.

Necropsy.—Six weeks from time of operation. Both bone grafts were found firmly united into the spinous processes. X-rays taken in different planes of specimens (see Fig. 68) failed to show any areas of degeneration in the graft. Both decalcified and non-decalcified (ground) microscopic specimens were prepared and examined carefully. No dead bone-cells could be found. The graft, although only 6 weeks after insertion, was very completely united into the spinous processes by newly formed bone. No cartilage cells could be found.

Experiment 12.—February 20, 1912. Dog. Ether anaesthesia. Anaesthetist, Mr. Cassellius. An incision 3 in. long was made over the lower three thoracic spinous processes. The muscles and ligaments with periosteum were separated from them down to the neural arches, and retracted. The processes were divided at their base with bone forceps and chisel close to the neural arches. The processes were then placed longitudinally so that the tip of one process came into approximation

with the severed base of the next superior process. The soft tissues with periosteum were brought back with interrupted sutures of linen. The skin was closed with subcutaneous linen suture. The second and third lumbar processes were then exposed. Their tips were split in the usual manner for two-thirds of an inch *in situ*, with supraspinous and interspinous ligaments undetached. A fragment of an ulna removed from a dog 1 week previously, and kept meantime in normal salt solution in an ice box, was inserted as a graft by the usual technique. This transplant was $1\frac{3}{4}$ in. long and one-half the diameter of the ulnar shaft. The skin was closed by subcutaneous sutures of linen.

Necropsy.—Two and one-half months after operation. Bony union had not occurred between the thoracic vertebræ whose spinous processes had been broken down. It should be stated, however, that, as in all other cases, no attempt to fix or immobilize the dog's spine was made. The graft which had been inserted into the second and third lumbar processes was well united.

Experiment 13.—April 24, 1912. Dog, mongrel, male; weight, $21\frac{1}{2}$ lb. This experiment was possible only through the kindness of Drs. Beebe and Berkeley, who allowed me to remove a part of a sheep's ulna while Dr. Berkeley was operating on it. A fragment of ulna $3\frac{1}{2}$ in. by $\frac{1}{3}$ in., including periosteum as well as marrow substance, was removed from a large sheep and placed in normal salt solution until the dog's spinous processes, three in number (first thoracic and first and second lumbar), could be split and prepared in the usual way. The transplant was then inserted and covered with the ligaments as already described.

Necropsy.—Five weeks after operation. Although the wound had healed kindly by primary union, the transplant was found in a pocket filled with serum. No evidence of osteogenesis on the part of the graft or union to spinous processes was present.

The following deductions and conclusions are based on the experimental work just described, in conjunction with a clinical experience gained from 500 bone-grafting operations on the human subject: In ten of the cases of Pott's disease the bone

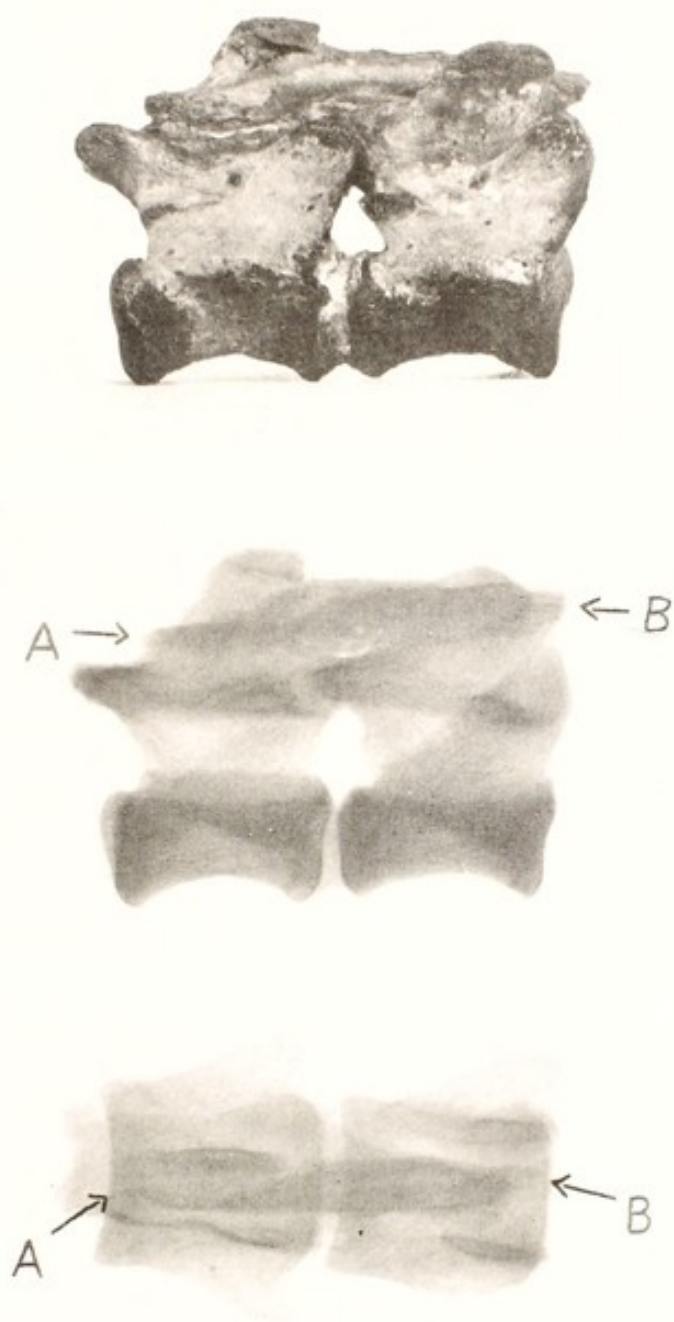


FIG. 68.—Photograph and röntgenograms of an ulna autogenous graft *AB*, 6 weeks after being inserted into the spinous processes of a dog's vertebrae. The röntgenograms show firm union and no osteoporosis or degeneration of the graft.

transplant has been cut down on for minor reasons, inspected, and parts removed for examination. The time after operation has been 3, 5 and 7 weeks, 6 months, and 1 year. In all of these cases the grafts have been well united into the spinous processes wherever contacted. In two cases the end of the graft had sprung posteriorly into the soft tissues. In every instance the portion of the graft which was contained in the spinous processes bled wherever cut with bone forceps; its periosteum had proliferated and the transplanted portion presented every appearance of viability. On the other hand, in two cases the portion of the graft projecting into the soft tissues was pale, and the periosteum had not proliferated; the bone did not bleed in its central portion when cut and was thought to be acting as an "osteogenetic scaffold," whereas there seemed every reason to believe, especially in the light of our microscopic results, that the portion in and between the spinous processes was viable, on account of the contacted points of Haversian blood supply being so numerous and near together.

SUMMARY

1. Many liberties may be taken with the bone graft without interfering with its success. It has certain bacteria-resisting properties. In one case the transplant was kept in normal salt solution in an ice-box for 1 week, and in others for shorter periods, and successful results followed. In two cases sepsis occurred in the same wound; nevertheless, parts of the graft in each case became united to the recipient bone and remained, while the rest of the transplant sequestered. From these experiences and the fact that in the author's series of 500 bone-grafting procedures on human subjects only parts of eight grafts and two whole grafts sequestered, it is believed that one is safe in deducing that the bone graft has considerable germ-resisting properties.

2. It seems very probable that the amount of Haversian blood supply is in a very large degree, if not wholly, responsible in determining whether the bone graft lives as such or acts as an osteoconductive scaffold. This was especially emphasized in

the three human cases cut down upon. If the graft is to live as such, the blood-supply contacts must be of favorable character and numerous distributed along its whole extent, such as is the case with the spine graft or the transplant used for ununited fractures, described elsewhere.

3. The bone transplant apparently acts always as a stimulant to osteogenesis on the part of the bone into which it has been implanted.

4. The spinal graft in the dog loses its identity at about the fourth month. After that time, one would not know from its appearance that the bone bridge had originated in this way.

5. Bone taken from another species, such as the sheep, did not unite to the recipient bone of the dog, although in the presence of asepsis. This one experiment does not prove that sheep's bone will not unite to dog's bone as a graft, but it does prove the unreliability of the procedure.

6. A bone bridge between different vertebræ was accomplished in this small series of experiments only by the bone graft. Breaking down the spinous processes, splitting the spinous processes with approximation to the contiguous halves, and the insertion of periosteal bridges failed to produce the desired continuous bone bridge.

7. Bone transplants taken from a long bone, such as the ulna, showed evidence of greater osteogenesis than when taken from the spinous processes.

8. Bone from which the periosteum had been removed proved equally satisfactory to bone grafts on which the periosteum had been retained, but their persistency was not tested because the animals were not allowed to live long enough. It seems certain that the fate of a bone graft depends largely on its exact environment, especially as to the numerous bone contacts closely situated.

9. The above-mentioned germ-resisting property of the bone graft, in addition to its early adhesion by bone growth to the bones with which it is contacted, in the author's opinion, favors its substitution, when feasible, in place of all-metal internal

splints, especially when it is considered that the metal splint has absolutely the opposite influence, namely, the production of bone absorption, and that it favors infection.

11. It also seems that it is largely a question of definition of what the periosteum is and what it includes as to whether it is to be actively osteogenetic or not. If by chance the cleavage is deep, as when the periosteum is removed with a sharp elevator and the bone scraped, the periosteum is sure to be actively osteogenetic. On the other hand, if the periosteum is stripped off or removed with a blunt instrument, the cleavage is not likely to be deep enough to include the osteogenetic layer of cells on the periphery of the compact bone. In that case the periosteum would be incomplete and would constitute a connective-tissue-limiting membrane (Macewen) only, and slight or no osteogenesis would occur.

12. It is believed that periosteum and marrow substance, on the bone graft, serve an important rôle in aiding to establish an early and more abundant blood supply from recipient bone to the transplant.

PARALYTIC SCOLIOSIS

Paralytic scoliosis usually results from the unbalancing of the spinal column through asymmetrical involvement of the spinal and abdominal groups of muscles from anterior poliomyelitis. The selection of the motor nerve cells of the anterior horns of the spinal cord which supply these spinal muscles is comparatively rare, excepting where there is a very general cord involvement. The conduct of this affection is the same when the groups of spinal muscles are attacked as when the disease has resulted in the paralysis of extremity muscle groups.

This deformity is a variable one, the severity of the lateral deviation depending largely upon the posture of the patient when in the erect or reclining position. The lateral deviation always diminishes in recumbency and increases in a varying degree in the erect posture, according to the severity of the paralysis. A certain degree of rotation of the vertebræ is always

present, varying in amount also with the severity of the paralysis, but rarely reaching the same degree of rotation met with in static scoliosis.

The general rules of treatment applying to all types of in-

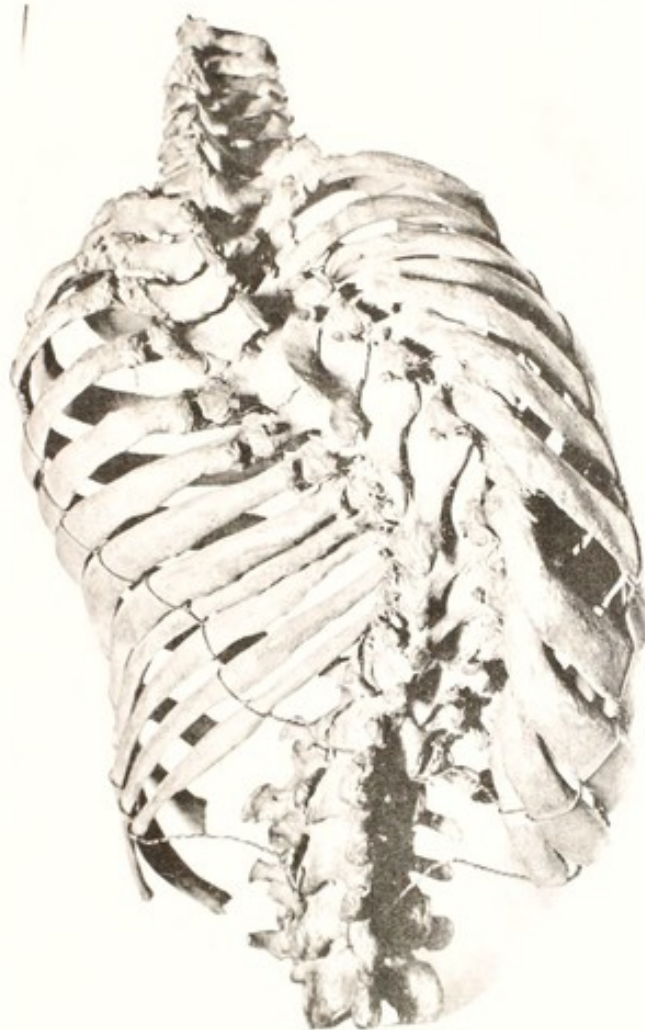

FIG. 69.—Specimen of a pronounced scoliosis of the spine which shows the atrophy and approximation of the lateral processes of the concave side, with an equal separation of the lateral processes of the convex side of the curvatures. If this curve is straightened it causes the lateral processes of the convex side to approximate at the same time that those on the concave side separate. Therefore, if a graft is placed on the convex side in the tips of the lateral processes of a straightened paralytic or static scoliotic spine, it is under the same mechanical advantage as the graft inserted into the spinous processes for Pott's disease. (See Fig. 70 for drawing.)

fantile paralysis should be carried out during the initial febrile stage—namely, restraint in bed or on a gas-pipe frame, to restrict motion of the vertebræ of the involved area of the spine. Following the febrile stage, external supports, such as plaster-of-Paris corsets and metal frame braces, should be applied,

together with corrective gymnastic exercises, until no further improvement can be attained, thus indicating that the paralysis still persists and the spinal deviation therefrom is a result of permanently destroyed motor nerve-cells.

It is difficult to maintain a correction of this spinal deviation in the severer cases by any external appliance, because the spine slumps into an S-curve inside of the brace, due to the lack of muscle support, whenever the patient assumes the erect posture. After a lapse of 2 years it devolves upon the surgeon to decide whether the muscle weakness and the resulting curvature warrant the implantation of the more corrective and trustworthy bone-graft support.

Mechanics of Correction by the Bone Graft.—The bone graft can be applied in two ways, either by the same technique as the author's operation for Pott's disease, or by the placing of the graft into the tips of the transverse processes of the vertebræ on the convex side at the apex of the sharpest curve, preference being given to the thoracic region for the implant and six to eight transverse or spinous processes included by this graft.

From a mechanical standpoint, the transverse processes afford a much better leverage action to the correction of the lateral curvature than the spinous processes. A lateral deviation in the spine causes a separation of the transverse processes of the convex side, coincident with the approximation of the transverse processes of the concave side. Much of this lateral deformity can be readily corrected by manual force under an anæsthetic. This correction causes the transverse processes of the convex side to approach each other at the same time that the transverse processes of the concave side separate. The implantation of the graft with the spine so corrected acts in a like manner in preventing the relapse to lateral curvature, by controlling the separation of the transverse processes of the convex side, as does the graft implanted into the spinous processes for the control of the antero-posterior deformity of Pott's disease. The graft thus embedded acts at a great mechanical advantage, in that it is pulled upon lengthwise, in preventing the separation

of the transverse processes, which are arms of levers, at the same time acting as an internal fixation splint.

Author's Technique of Operation.—A plaster-of-Paris bed with firm lateral walls should be moulded before the operation to

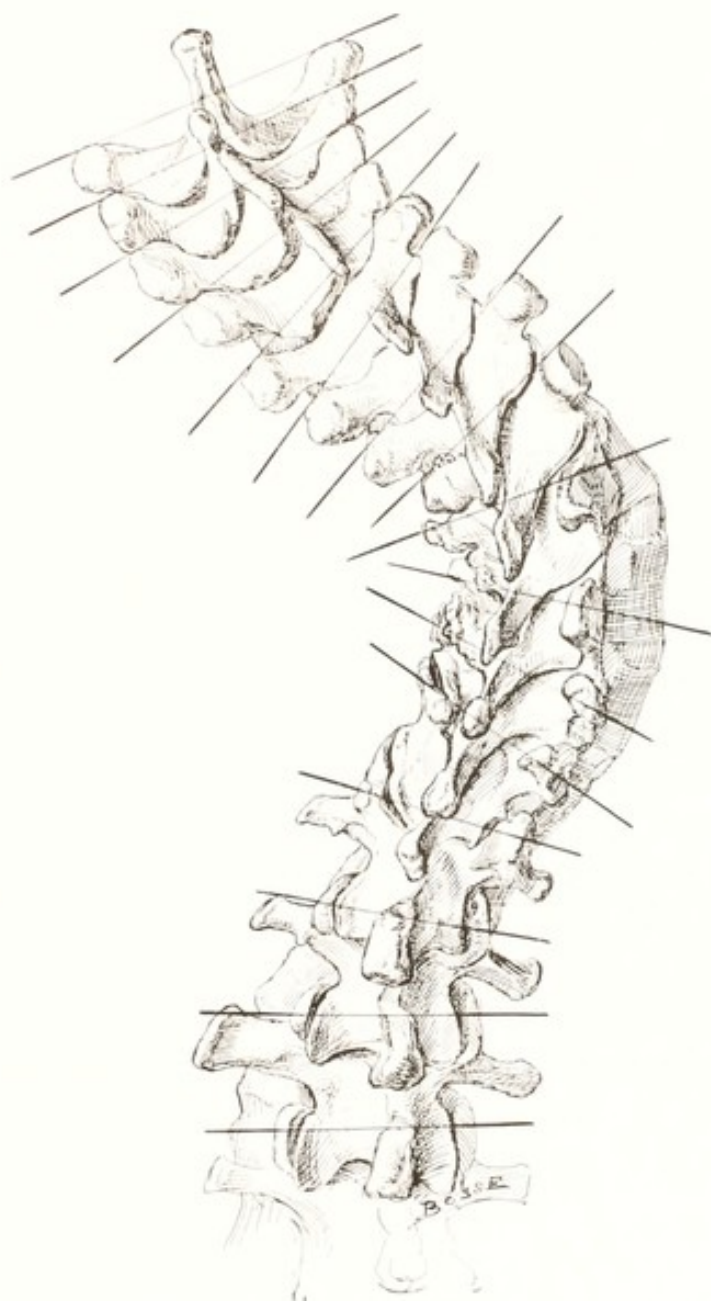

FIG. 70.—Drawing from a scoliotic spine. The lines indicate the axis of the lateral process and show how near together they are on the concave side of the curve and how much separated they are on the convex side. (See Fig. 71.)

the back and sides of the patient's trunk, and allowed to harden while the patient is held in the corrected position. The field of operation on the back, as well as the leg, is prepared by the iodine

method. Six to eight transverse processes at the apex of the most acute curve are laid bare on the convex side by a curved skin

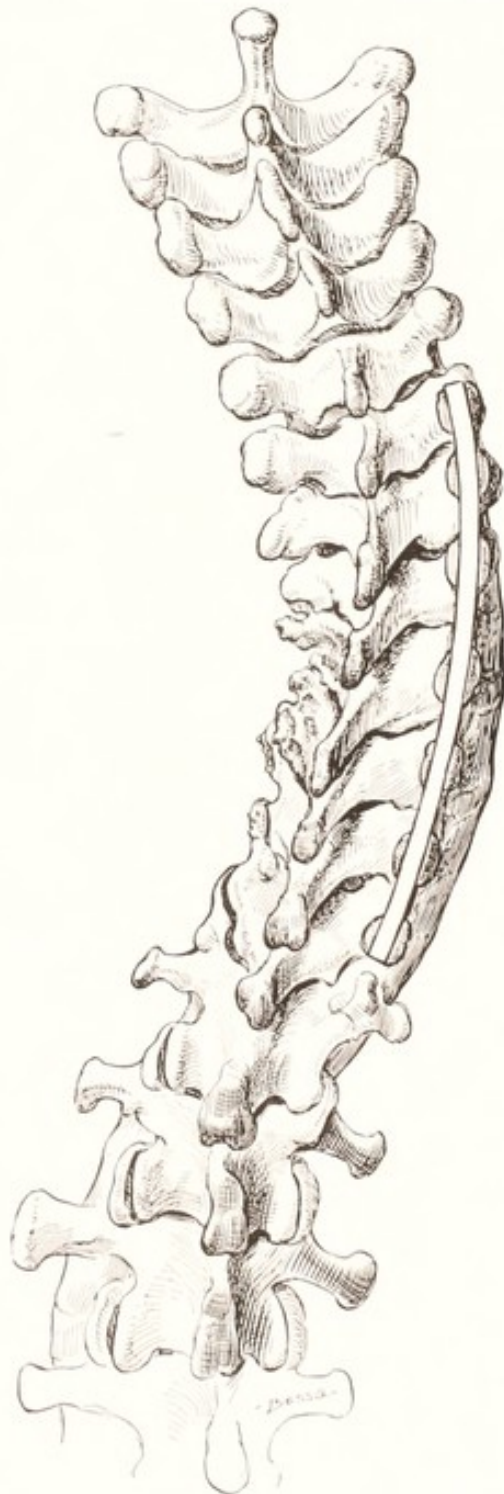

FIG. 71.—Drawing to illustrate straightening of paralytic scoliotic spine and the tibial graft in place. (See Fig. 70, illustrating spine before correction.)

incision, similar to the skin incision in the bone-graft operation for Pott's disease. The muscles and ligaments over the tips and

between the transverse processes are split into approximately equal halves with a scalpel. The transverse processes are split longitudinally into halves and at the same time the posterior half is set over to give room for the graft. With flexible probe and calipers the contour and length of the desired graft are determined. The tibia is flexed on the thigh and its antero-internal surface laid bare. The flexible probe pattern is applied to this exposed tibial surface, and the desired graft is outlined in the periosteum with a scalpel, its length being determined by the previous measurement with the calipers. The motor saw is then made to cut along this periosteal outline and the graft is re-

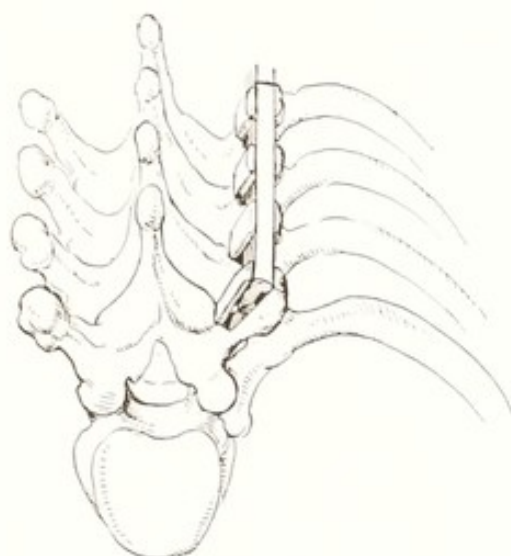


FIG. 72.—To illustrate tibial bone graft in place in tips of lateral processes of convex side of a corrected paralytic scoliosis.

moved, including the full thickness of the cortex, and placed into its bed already prepared between the halves of the split transverse processes. While the patient is held in the corrected position, the ligaments and muscles are drawn over the graft with interrupted sutures of medium kangaroo tendon.

The wound is closed by a continuous suture of No. 1 chromic gut, and a generous dressing applied. The patient is bandaged into the plaster-of-Paris bed, previously prepared (or see Fig. 77).

After 6 weeks of recumbency in this plaster bed, a well-moulded plaster case is applied to the spine to remain on for 10 to 12 weeks. Following the immediate post-operative fixa-

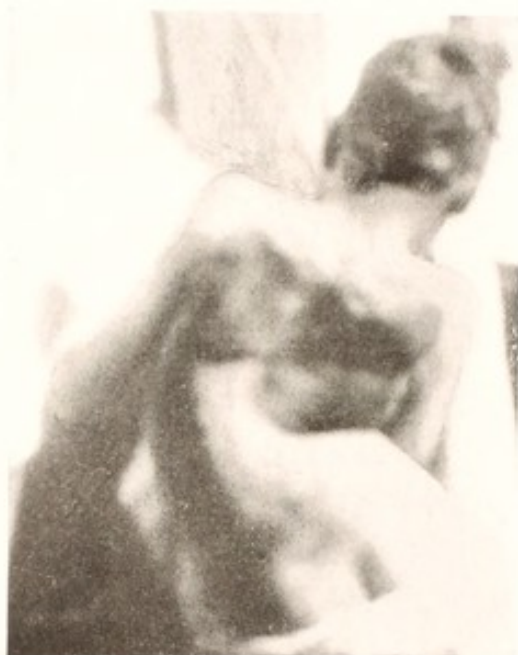

FIG. 73.—A case of paralytic scoliosis before correction and insertion of graft.
(See Fig. 74.)



FIG. 74.—Paralytic scoliosis; same case as Fig. 73, 1 year after the insertion of a graft into the tips of the transverse processes of the apex of the convex side of the worse curve. The graft included the thoracic vertebrae from the fifth to the twelfth inclusive. The marked straightened condition and increased stability of the back is most gratifying.

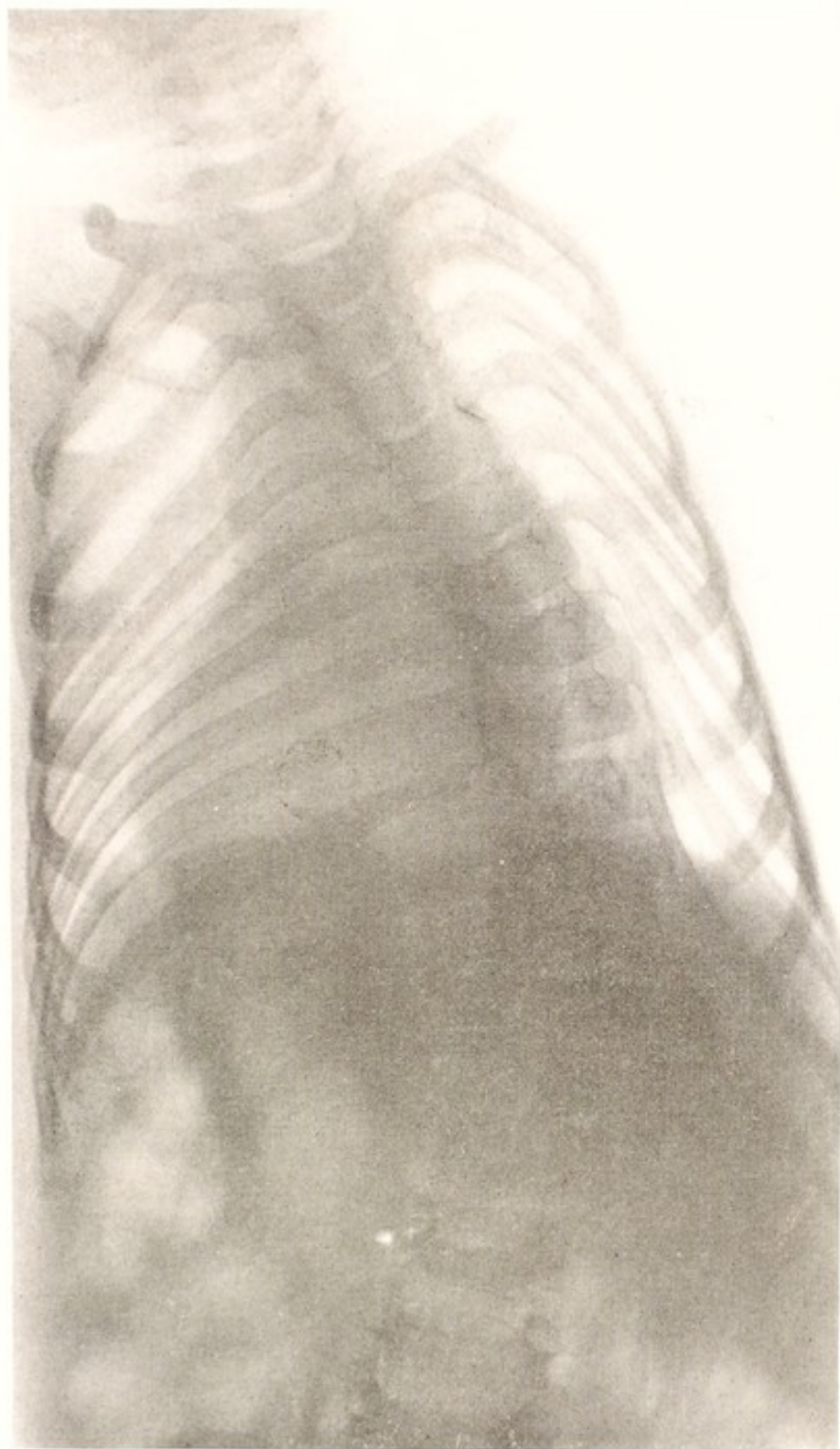


FIG. 75.—Paralytic scoliosis before correction by the insertion of a bone graft.
(See Fig. 76.)

tion, a corset brace is applied to those cases which need further support supplemental to the graft.

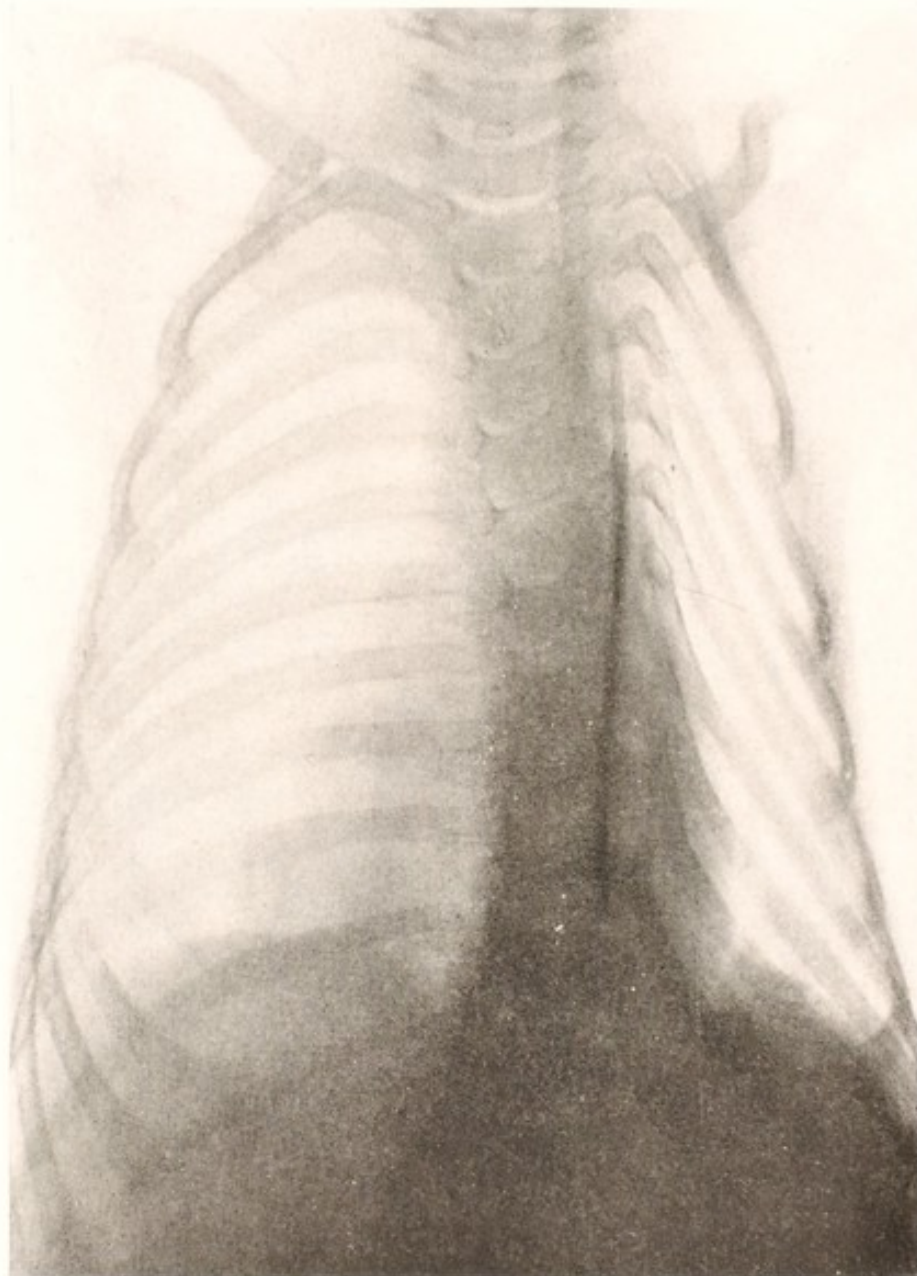


FIG. 76.—Same case as Fig. 75, 1 year after correction and insertion of bone graft for paralytic scoliosis.

SPONDYLOLISTHESIS

Spondylolisthesis is a term applied to the luxation of the body of one of the lower vertebræ. The extent of this luxation varies from a slight displacement to a complete dislocation, and

in some cases the displaced vertebral body has slid down and become anterior to the vertebral body next below.

The condition was first described by Killian in 1854, and was thoroughly studied by Neugebauer in 1890. The causes are: congenital malformation, injury, and disease of the lumbo-




FIG. 77.—Dr. Silver's attachment to the Hawley table. Illustrating the method for the application of plaster jackets by the hammock method, thus enabling the operator to apply a jacket after the operation on the spine or back without turning or moving the patient. The hammock is laid upon the narrow portion of the table with one end slipped through the special two-piece pelvic support and the patient is then placed in the reversed position, the head and body resting on the narrow portion of the table. The other end of the hammock is slipped over the U-shaped frame, which fits into the foot extension pieces, but this need not be put in until the operator is ready to apply the cast. The hammock may be readily tightened or loosened by moving the foot pieces on the sliding bars. If desired, one or both thighs may be included in the cast by moving the sliding platform far enough away from the patient's body. This table is of especial advantage in the application of a plaster jacket after the insertion of bone graft for paralytic scoliosis.

sacral articulations. The effect of the luxation is to cause an exaggeration of the lumbar lordosis and to increase the prominence of the sacrum. The condition exists more often in women than in men.

It occurs almost always at puberty or in early adult life, and a large percentage of all cases give a history of a severe trau-

matism. The displacement may follow immediately after the accident, or may not appear until a later period.

The appearance of the patient is very suggestive of a double congenital dislocation of the hips, although on closer inspection

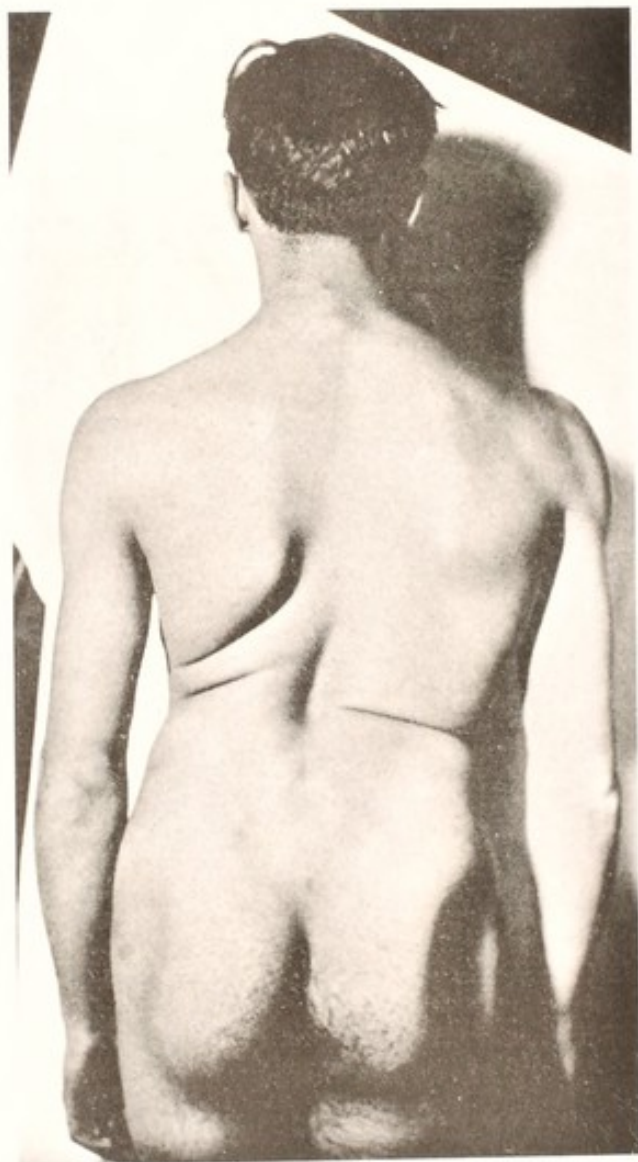


FIG. 78.—A case of spondylolisthesis in a young man of 18 following an injury in a prize fight. Deformity reduced and reduction maintained with bone graft. (See Figs. 79, 82.)

it is seen that the back is shortened and not the limbs. The flexibility of this portion of the spine is not impaired, but may even be greater than normal.

The former treatment of this condition has proven most unsatisfactory. It consisted of prolonged rest in bed with ex-

tension applied to the legs, followed by a long plaster-of-Paris or steel spinal support, reaching well down over the buttocks. In some instances, laminectomies have been performed in an effort to relieve paralytic symptoms. One such case has been reported by Arbuthnot Lane, of London. In cases of great deformity, permanent support has been necessary.

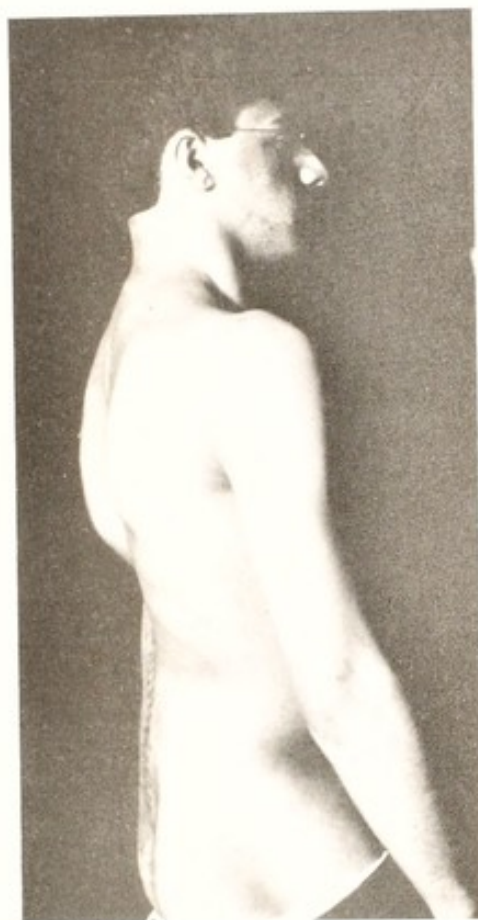

FIG. 79.—Illustrating a case of the application of the bone graft for marked spondylolistheses of the lumbar vertebra on the sacrum. A strong graft removed from the tibia has fixed this segment of the spine to the sacrum correcting the lordosis and relieving all symptoms.

The bone graft, applied as for the treatment of Pott's disease, has solved this hitherto most difficult problem. The graft is inserted by precisely the same technique as that employed by the author for lumbar Pott's disease (see Chapter II). The lordosis, as a rule, is readily corrected under an anæsthetic, by placing the patient in the prone position on the operating table. If this should not produce sufficient correction, further flexion

of the spine can be accomplished by placing a firm pillow under the lower portion of the abdomen. The bone graft offers the only means to effect a permanent cure.

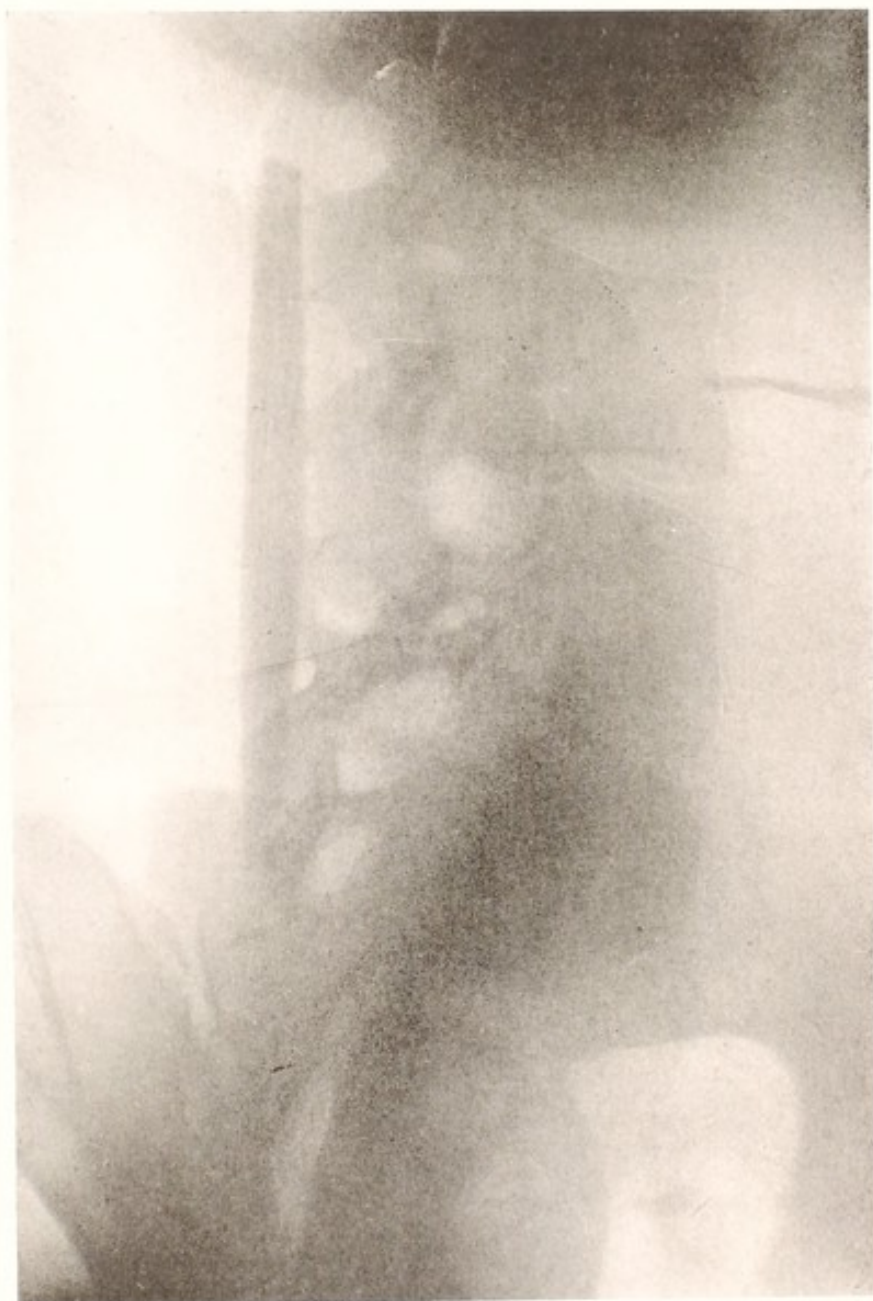

FIG. 80.—Lateral röntgenogram of spondylolisthesis between the third and fourth lumbar vertebræ after reduction and fixation by author's spinal bone graft in spinous processes. The dislocation forward of the third lumbar vertebra on the fourth, in this male patient of 18 years of age, occurred in the boxing ring from being knocked through the ropes. Pressure on the spinal cord resulted which has been entirely relieved by the operation.

An illustrative case is that of a young man, 18 years of age, who while boxing, 1½ years previously, sustained a severe

injury to the lumbar spine by being knocked against the ropes—a trauma which could produce such a displacement. Soon after, the patient noticed muscular weakness, numbness, and prickly sensations in the legs when standing or walking for any length of time. These symptoms increased until he was obliged to give up his occupation. He also noticed the increasing deformity of his lumbar spine. The recumbent position relieved his symptoms.

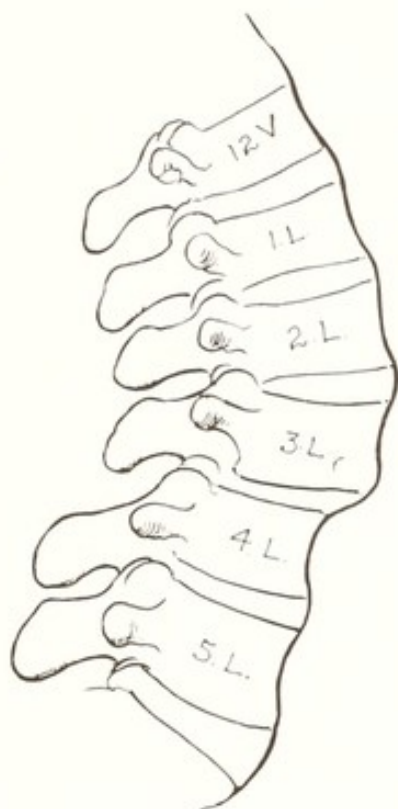

FIG. 81.—Drawing of same case as Fig. 80. The lateral röntgenogram of this case before reduction and insertion of graft; although it showed the luxation, it was so poor that it was unintentionally destroyed before a print was obtained. This drawing is an attempt to represent the luxation which existed.

Under full anæsthesia, prone upon the operating table, the displacement easily corrected itself, and an unusually strong graft, spanning the third, fourth and fifth lumbar spines, and the first and second segments of the sacrum, held this portion rigidly fixed in its corrected position.

The patient was kept on a fracture bed for 5 weeks, after which a long plaster-of-Paris jacket, moulded over the buttocks, was applied to remain on for 2 months (see Figs. 79, 82).

Ryerson has, also, reported a very successful case treated by this method.

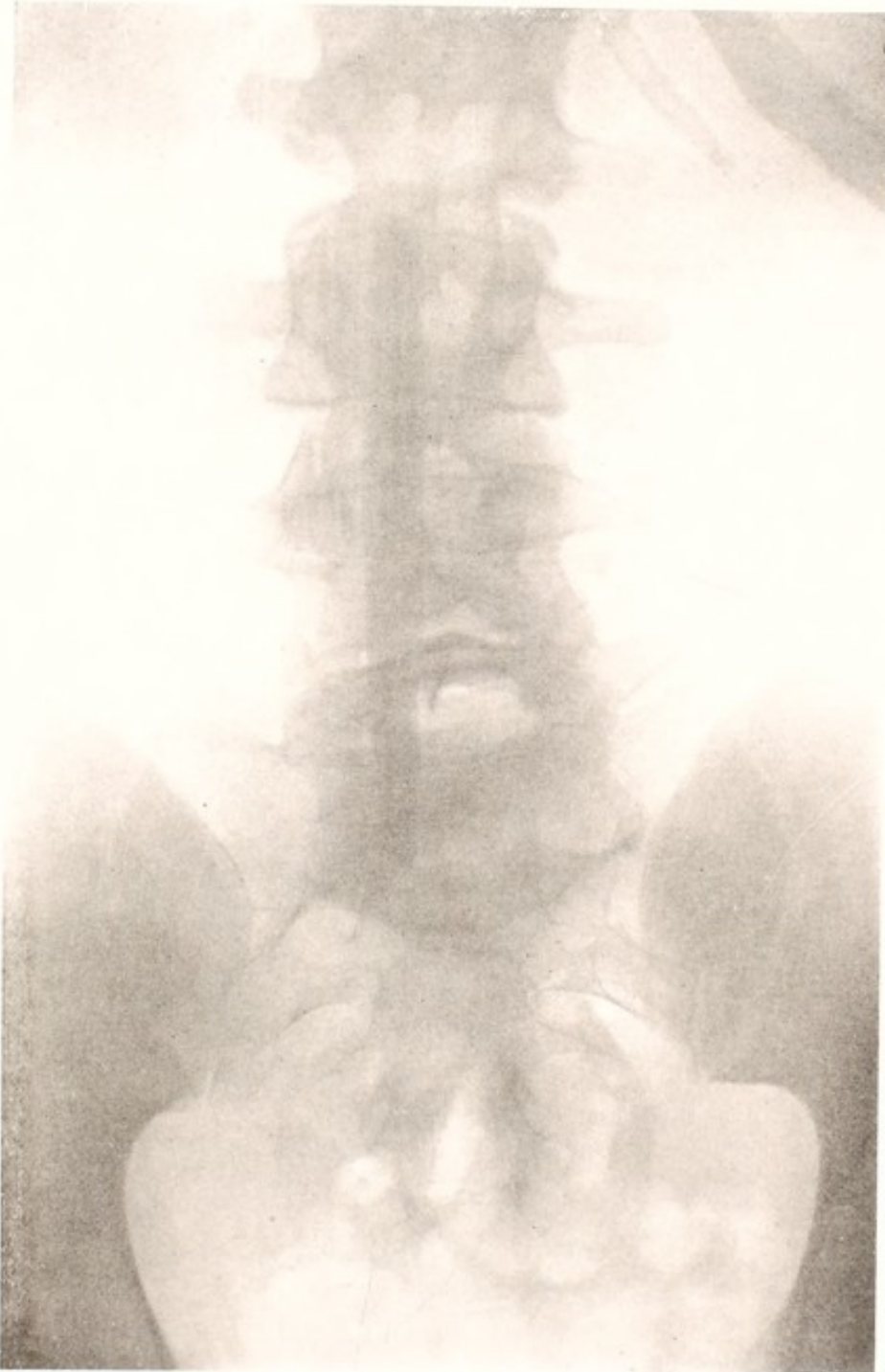


FIG. 82.—Anterior posterior view of same case as Fig. 80.

SPINA BIFIDA

In cases of spina bifida, where the meningocele has been controlled, and a large deficiency of vertebral bone exists, to-

gether with weakness, as evidenced by lordosis or other deformity, the bone graft offers an excellent means for strengthening the spine weakened from the congenital bone deficiency.

Author's Technique.—The technique is somewhat similar to that adopted in Pott's disease. Modification is necessary on account of the absence of spinous processes and parts of neural arches. The spinous processes above the cleft and the lateral masses of the last lumbar vertebrae and the first part of the sacrum are reached from each side by two curved skin incisions, as

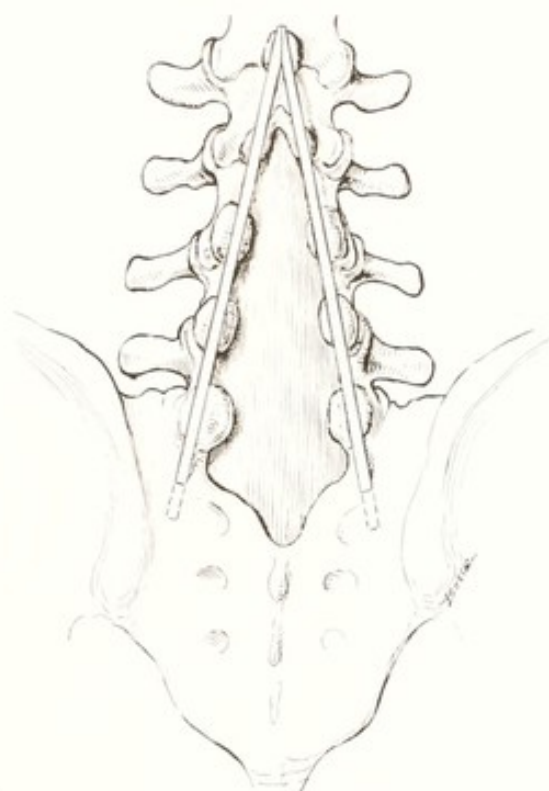


FIG. 83.—Drawing illustrating author's technique of inserting a tibia graft to straighten and support a lordotic bifid spine (spina bifida).

it is undesirable to interfere with the nerve tissue which is usually involved in the cicatrix following the operative reduction of the meningocele. The second spinous process above the cleft is split longitudinally, and a greenstick fracture produced in each half. The first spinous process above the cleft is denuded of its muscular and ligamentous attachments, and both sides are freshened. Below the cleft, the lateral masses of the fifth lumbar vertebra (or the congenitally deformed stumps of the neural arches, if sufficiently prominent) and the first segment of the

sacrum which is usually congenitally hypertrophied, are split with the osteotome, and the halves are separated to receive the lower ends of the two grafts.

The wounds are packed with saline compresses, and the two grafts are removed and prepared from the crest of the tibia, being long enough to reach from the split spines above to the

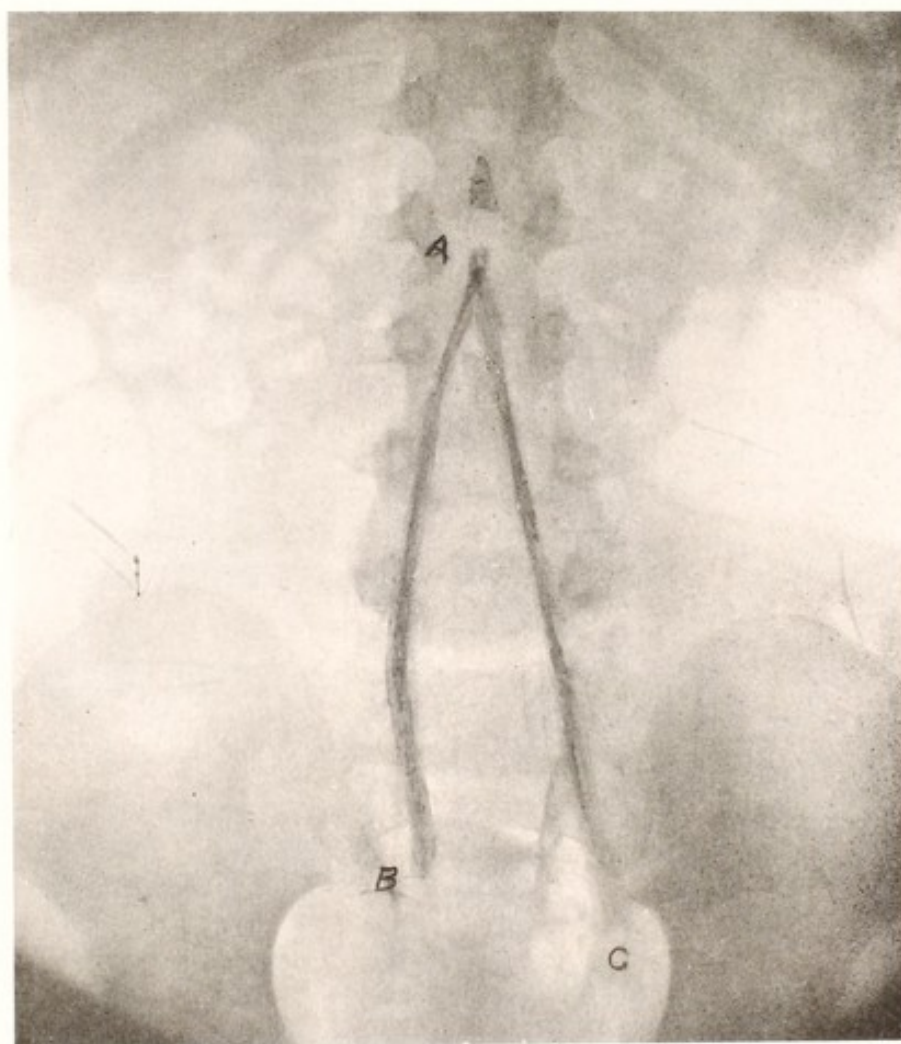


FIG. 84.—A retouched roentgenogram of a case of spina bifida in which tibia grafts (*AB* and *AC*) had been inserted 6 months previously for marked lordosis and weakness. The grafts in this case were obtained from the tibia of a colored child of 5 years.

sacrum below. The upper ends are bevelled, so that when these bevelled surfaces come together the grafts form an acute angle, like an inverted V. The grafts are placed at this angle in the beds prepared for them, and are held firmly in place in their bony contacts by drawing the split ligaments over them with interrupted sutures of medium kangaroo tendon (see Fig. 83).

Skin wounds are closed and the patient placed on a fracture bed for 6 weeks.

FRACTURE OF THE SPINE

In cases of fracture of the spine with persistent non-union, presenting the symptoms of pain, disability and increasing de-

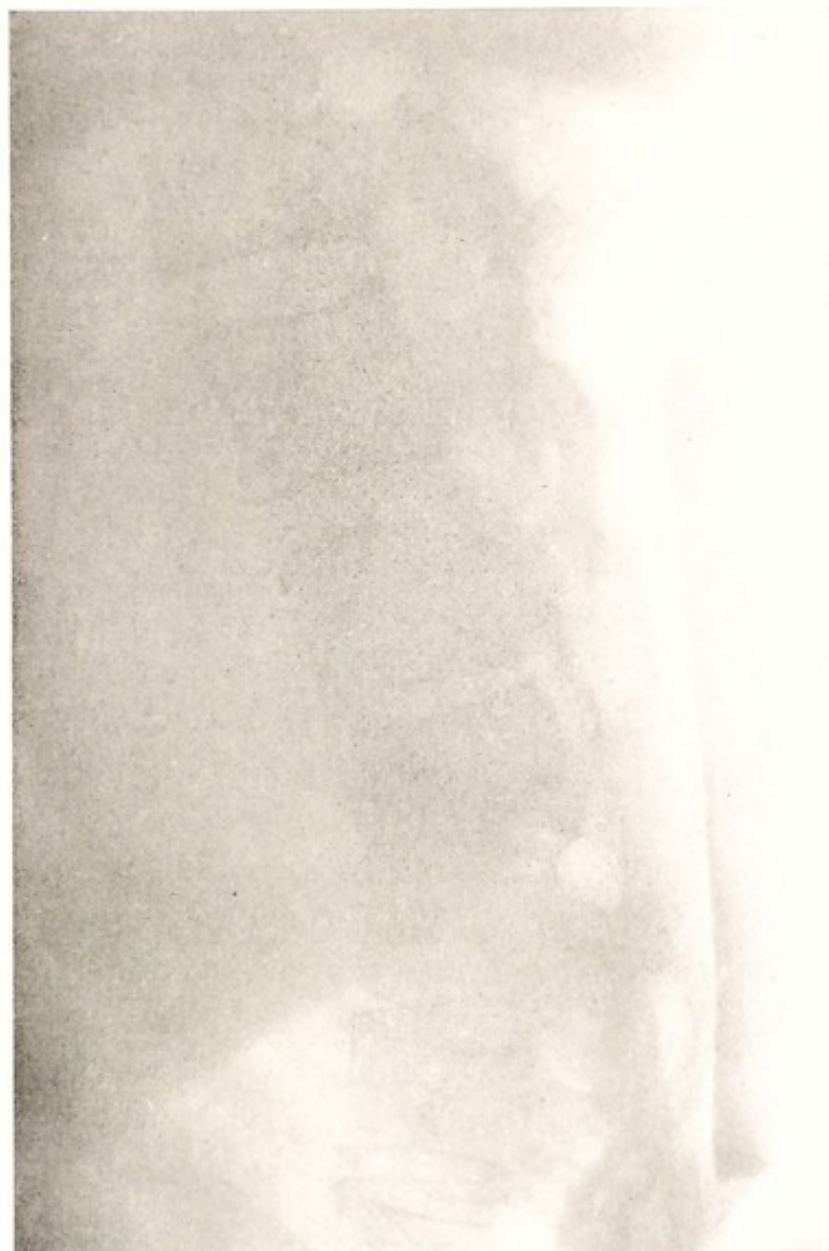


FIG. 85.—Bone graft inserted into spinous processes (as for Pott's disease) for a fracture of the spine with complete relief of symptoms. (*Palmer.*)

formity, the treatment indicated is mechanical support. This has hitherto been attempted, with varying success, by plaster-of-Paris jackets and spinal braces. If there has not been vertebral

displacement with decided pressure on the cord, the bone graft, as inserted for Pott's disease, furnishes a most reliable and permanent relief. Slight vertebral displacement may be overcome when placing the graft. Pressure of any amount should be relieved by laminectomy. If subsequently a kyphosis appears as a result of the laminectomy, a bone graft may be inserted to include the laminectomized vertebræ, as well as one spinous process above and another below.

The bone graft is especially needed in fracture of the cervical spine when a displacement has been reduced and there is danger of a relapse of the displacement. The method of treatment is indicated in spondylitis traumatica (Kümmell's disease) and neuro-pathic spine (Charcot) where, on account of rarefying osteitis, crushing of the vertebral bodies produces increasing deformities, with possible cord compression; also in certain fresh fractures.

TUBERCULOSIS OF THE SACROILIAC JOINT

The prognosis of tuberculosis of the sacroiliac joint, when treated by conservative methods, is most unfavorable. Tubby states that 7.9 per cent. only recovered in the moist type when treated by conservative means, in a series of thirty-eight cases. As in the case of bone and joint tuberculosis elsewhere, the prognosis is more favorable in children than in adults. The joint is most unfavorable for external splint fixation, largely on account of its anatomical architecture. Its joint surfaces are oblique, inclining from above downward, forward, and outward. Its strength is wholly dependent upon its ligaments. It furnishes no chance for leverage control by external appliances.

The sacrum, on account of its extreme inclination, is at the disadvantage of being an inverted key to an arch.

Conservative treatment is best carried out by the double Thomas hip splint or the double plaster-of-Paris spica, in conjunction with recumbency during the acute stage.

Internal bone fixation offers the only satisfactory means of immobilization, on account of the above-mentioned anatomical

conformation, together with the very powerful muscular action which affects this joint.

Author's Operative Technique.—The following technique has been devised by the author for using the bone graft in this condition, and has furnished most satisfactory results. The posterior-superior spine, the wing of the ilium and first spinous

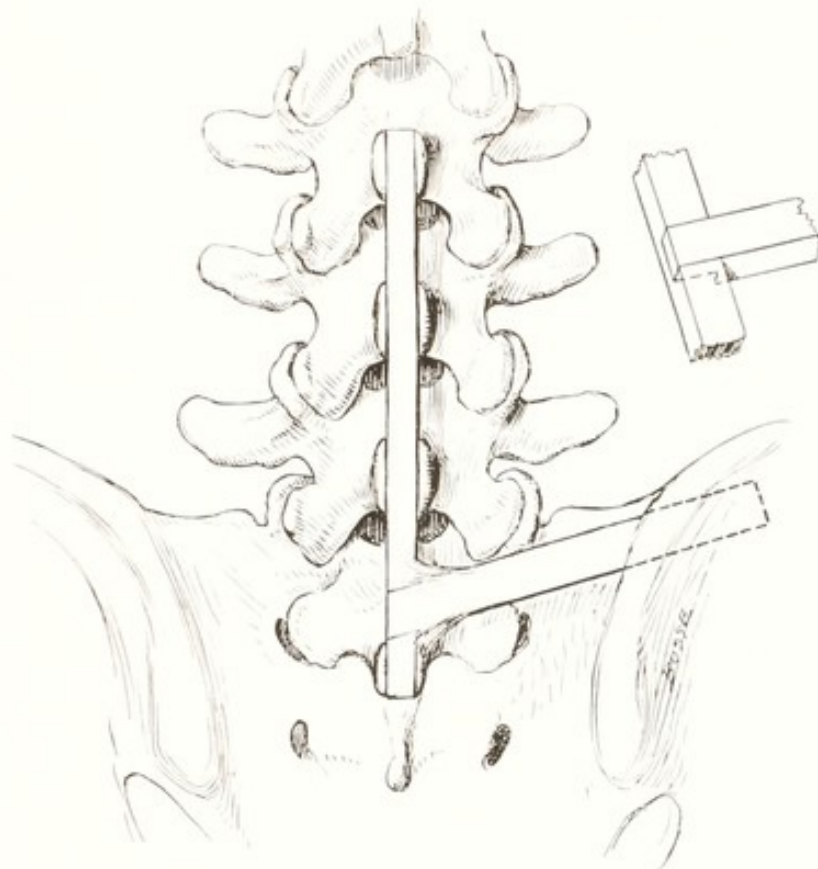


FIG. 86.—Diagram from the röntgenogram of an actual case of tuberculosis of the last lumbar vertebrae and the right sacro-iliac joint. The spinal graft was inserted by the author's regular technique for Pott's disease. The graft controlling the sacroiliac joint was joined by a carpenter's half mortise to the spinal graft (see small upper right-hand drawing.) The callus uniting the two grafts is indicated. The graft was joined to the posterior wing of the ilium by shaping it into a wedge end which was forced into a split in the ilium made by an osteotome.

process of the sacrum are reached by a curved incision. The posterior border of the wing of the ilium and the spinous process are split, with their attached ligaments, by a thin osteotome, forming a gutter to receive the ends of the graft. A cleft is made in the posterior wing of the ilium by driving a broad and thin osteotome into it just anterior to its superior edge (see illustration) and in a direction laterally from within outward. The

graft, which is later secured, is formed with a wedge end to be driven into this cleft.

If practicable, a surface of the sacrum is denuded to furnish additional contact with the graft. The wound is packed with a saline compress and, with the patient still in the prone position,

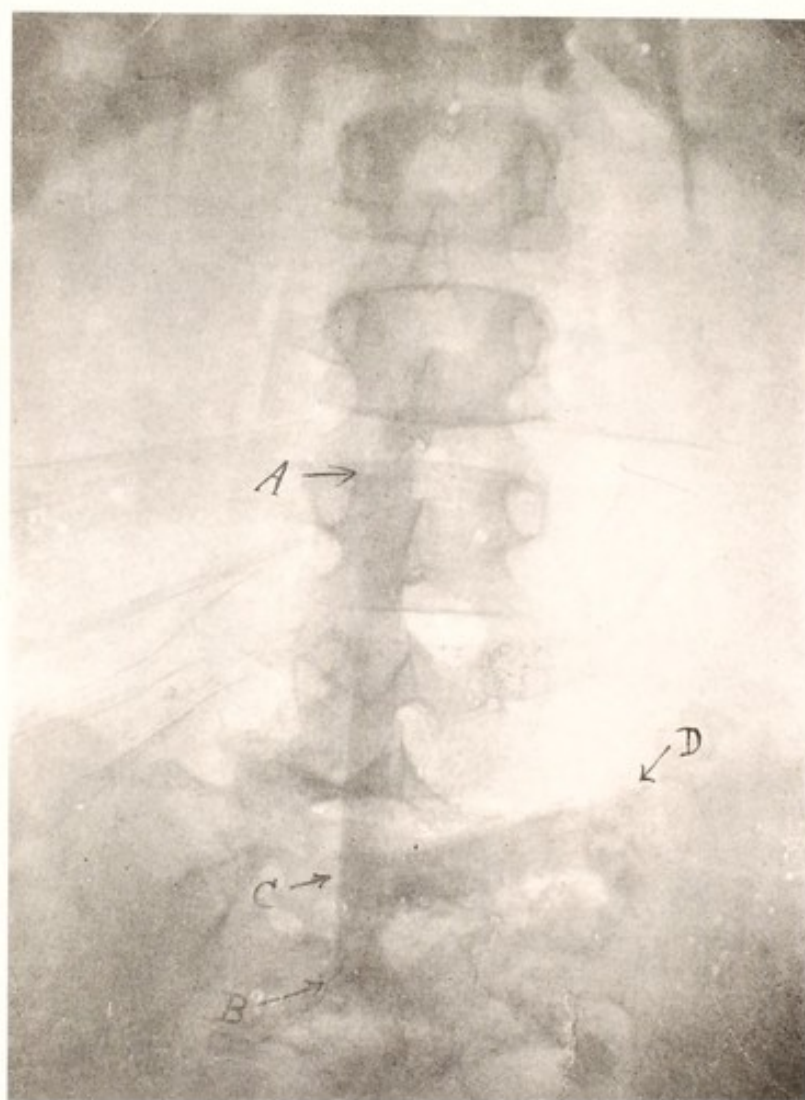


FIG. 87.—Röntgenogram of case of tuberculosis of last lumbar vertebra and sacroiliac joint of which Fig. 86 is a drawing.

AB is spinal graft; *CD* is graft for fixation of sacroiliac joint.

the leg is flexed and a graft of sufficient length removed from the crest of the tibia by the motor saw, as described in the use of the bone graft in Pott's disease, except for the just-mentioned wedge end. The width of the graft should be three times the thickness of the cortex. The thickness should include the whole cortex,

periosteum, endosteum, and a small amount of the adhering marrow. The graft is placed in its prepared bed, and the ligaments are drawn over it by interrupted sutures of medium kangaroo tendon (see Fig. 86). The skin wound is closed, and the patient placed on the back on a fracture bed for a period of not less than 5 weeks. There should be no necessity for further mechanical treatment.

DISLOCATION OR RELAXATION OF THE SACROILIAC JOINT

Dislocation of this joint is a most rare condition, but if met with, reduction under general anaesthesia should be resorted to. This is best accomplished by hyperextending the spine, making traction upon the leg of the affected side, and by manipulation of the ilium into a proper relation with the rest of the pelvis. Post-operative dressings should consist of a well-moulded plaster-of-Paris spica extending from the axilla to the knee, with the lumbar spine in hyperextension. The spica should be worn for 10 to 12 weeks. In relapsing cases, the bone graft as applied for the treatment of tuberculous sacroiliac-joint disease is a permanent and reliable means for relieving this condition.

The joint may suffer a relaxation from a sudden trauma, difficult labor, or a long-continued strain in an awkward or stooping posture. The symptoms are pain over the involved joint and total lateral deviation of the spine to the side opposite the involved joint. Pain is elicited upon assuming any attitude which brings strain upon the articulation, such as going up or down stairs, sitting with the normal lumbar curve obliterated, lying in bed flat upon the back and turning in bed which is a most constant symptom.

Upon palpation physical examination reveals pain at the affected joint and muscular rigidity of the lumbar spine. With the patient upon his back, motion at the hip is normal and free with the leg flexed upon the thigh. Flexion of the thigh with the leg extended produces pain in the involved sacroiliac joint of that side (Goldthwait symptom). In severe cases pain is even produced on the opposite side by flexing the thigh

in this way. Pain is elicited by pressing the wings of the ilia together.

The usual conservative treatment, consisting of belts or corsets with sacral pads is, as a rule, satisfactory. Occasionally, however, in severe long-standing cases, conservative treatment is insufficient, and it becomes necessary to resort to bone-graft fixation. The technique in such cases is precisely the same as described elsewhere in this volume for the treatment of tuberculous osteitis of this joint.

CHAPTER IV

THE INLAY BONE GRAFT IN THE OPERATIVE TREATMENT OF FRACTURES

Author's Technique.—In no other field of surgical practice is there a greater difference of opinion than that existing in reference to the open or operative treatment of fractures, as contrasted with the conservative or non-operative treatment. The important question arises: In which case is operative treatment demanded, and in which will non-operative treatment give a perfectly satisfactory result?

It is exceedingly difficult to answer this question with any approach to accuracy from clinical evidence alone. The circumstances of clinical observation have such a wide range that comparison of the results of different methods of treatment is almost impossible. Some of the more important of these varying factors are: The age and health of the patient; the site and anatomical condition of the fracture; the length of time that has elapsed before treatment was undertaken; the period between the termination of the treatment and the recording of the result; the skill and attitude of mind of the surgeon; and the method employed. "It is only by experiment that these variables can be replaced by constants and a true estimate made of the factors which underlie success or failure of operative methods" (Groves).

Lane operates on all cases of simple fracture of the long bones in which he is unable to obtain accurate apposition of fragments, when the restoration of the bone to its normal form is of mechanical importance to the patient. With the development and perfection of aseptic surgical technique, there has been a natural coincident increase in the number of simple fresh fractures submitted to operation. Many surgeons are feeling at present that the numerous badly set fractures which

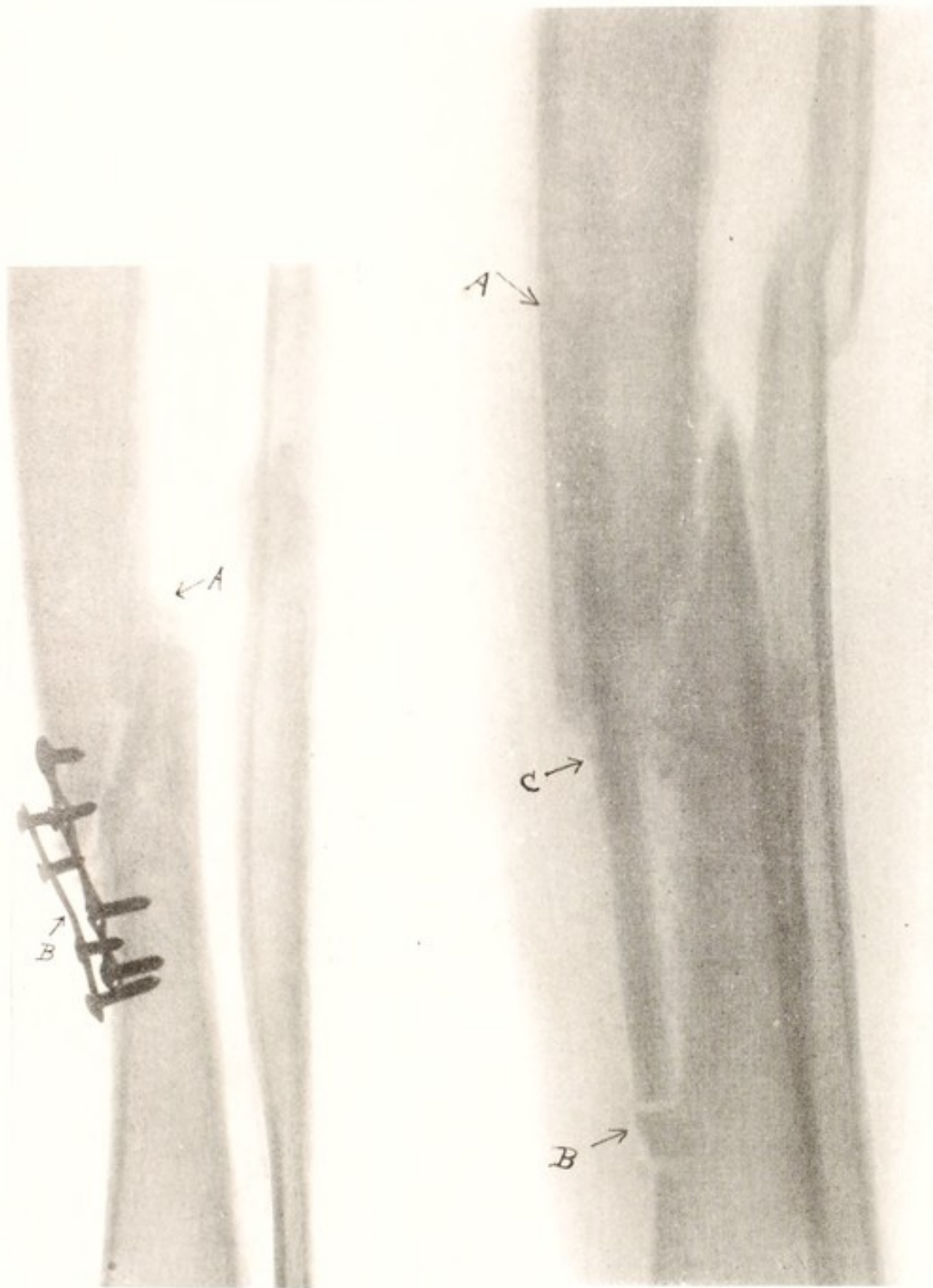
become useful only after 1 year to 18 months might have better functional results in a much shorter period.

Whatever methods are adopted should be efficient from the start. "If a surgeon is doubtful whether he can treat a fracture efficiently by non-operative means, he ought to consider whether he cannot do better by operating at once. He ought not to say: 'Well, we can see what becomes of it, and if it is not satisfactory we can operate later,' for by so doing the only opportunity of getting a good functional result may be irretrievably lost" (Jones).

Fortunately the day is fast disappearing when fracture cases in our large hospitals are passed over for treatment to internes or to some disinterested junior attending. The advent of the X-ray has helped to awaken the profession to a recognition of the fact that in fractures we have some of the most difficult and interesting problems to be met with in the whole realm of surgery, and that there is nothing that taxes the experience, anatomical knowledge, and good judgment of a surgeon to a greater degree than a difficult fracture.

During the last few years, as the profession has been more carefully investigating the end results after fractures, a strong feeling has developed that the results must be improved. Both the profession and the public, since the advent of the X-ray, have become educated to higher ideals and are demanding shorter and more efficient treatment, a shorter period of disability and better functional results.

A plea, however, should be made for caution against the too enthusiastic adoption of the open method of treatment as a routine means of dealing with simple fractures. Hitzrot has well stated that: "The most striking contra-indications to an open operation upon a broken bone are inexperience on the part of the surgeon, unsuitable surroundings, and *insufficient equipment*. Furthermore, the operator should have a thorough knowledge of the anatomy of the region to be operated upon and should understand the physical function, *i.e.*, the physics of the muscles, ligaments, etc., involved in the injury. Such knowl-



FIGS. 88 AND 89.—A is a röntgenogram of an ununited fracture of the tibia of 8 months' duration. Two Lane's plates were put on immediately after the fracture occurred and primary union of soft tissues and excellent apposition of the fragments were obtained as X-ray shows. Nevertheless, union did not occur, as has been observed in many other similarly plated cases. The metal plates were removed and an inlay graft (AB) 5½ in. long slid down from the upper fragment as shown in röntgenogram Fig. 89. The arrow (c) indicates region between the fragment ends where a large number of small grafts were inserted. The screws were found disengaged from the bone and laying in large cavities in the bones. There was a large amount of bone destruction about the plates and screws. There was no callus formation whatsoever in the region of the metal. Bony union occurred almost immediately after the inlay graft. In 5 weeks' time the union was very firm and the limb is functioning normally, now 9 months after the graft operation. It is believed that in this case as well as many others that the metal plates contributed to non-union.

edge may prevent some of the glaring faults already existent in the treatment of broken bones."

It should be emphasized that while operative treatment is necessary in many cases, there are plenty of instances of closed fracture in which it is not needed. Excellent results can often

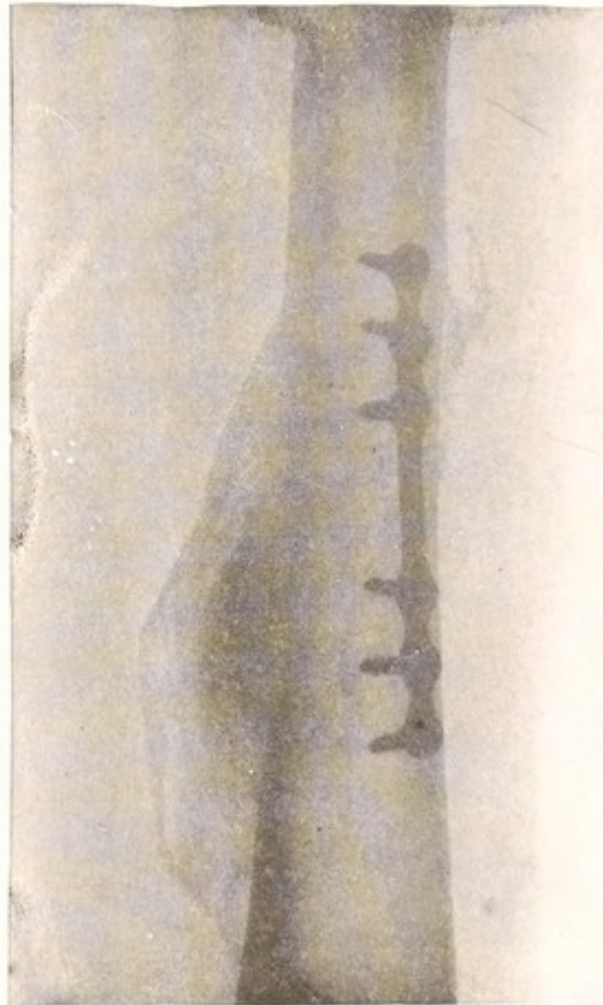


FIG. 90.—Fracture of syphilitic femur, 4 months after operation; plate behind left femur. The swelling on the opposite side of femur from the metal plate is callus. Note that there is no callus in region of the plate. (Rutherford Morison in *British Journal of Surgery*.)

be secured, both as to anatomical restoration and function, by non-operative treatment by a careful, experienced surgeon who has a mechanical mind, anatomical knowledge, and experience in the management of plaster of Paris and the various fixation splints.

The strong objections to the operative treatment by using

internal metal plate (Lane) are the danger of infection and delayed or non-union. Both of these objections, especially the latter—and to a very large degree the former—can be overcome by the use of the inlay bone graft instead of the metal

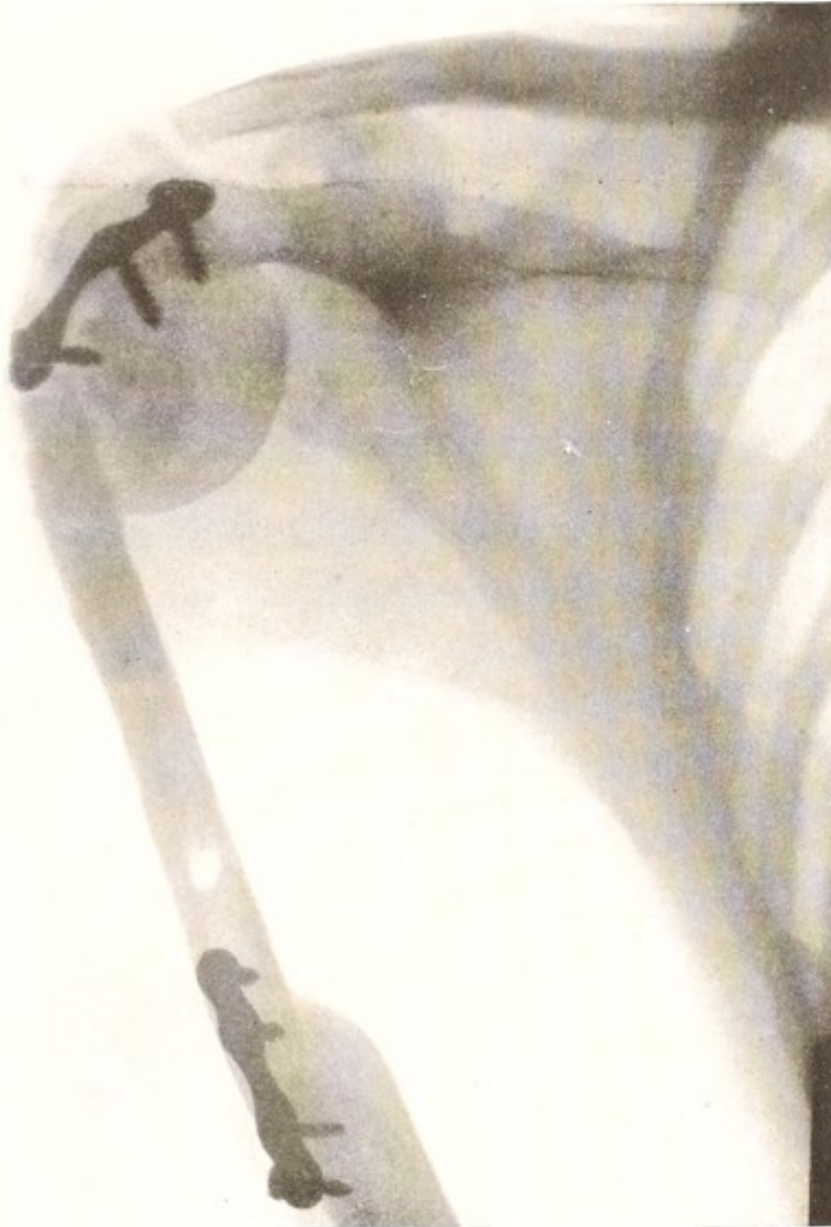


FIG. 91.—Six months after insertion of graft. Note destruction of upper end of graft from contact with metal plate and screws, with resulting non-union. (Morison, *British Journal of Surgery*.)

plate. Dr. J. B. Roberts, in the *Annals of Surgery*, of April, 1913, emphasized the inhibitory influence of the Lane plate upon union by quoting Martin, who states: "It is noteworthy that union is usually delayed, that the time of treatment is not

materially shortened, that the results are not uniformly good; but taken as a whole, they are infinitely better than could possibly have been secured by other than operative means. There has seemed to be a relation between the size of the internal (metal) splint and the promptness of final union. In other words, we have felt that the less foreign matter we have put into the wound the quicker it got well."

In a recent paper, W. P. Carr states: "I have never put on a Lane plate, but I have had to remove many. Of 54 that were applied by half a dozen of our best surgeons at the Emergency Hospital, 30 had to be removed for non-union, suppuration, irritation, breaking or bending of the plate. The other 24 may have trouble later."

Blake has well said: "I have always believed that the less non-absorbable foreign material used the better, and my next preference to nothing is chromicized gut; and I prefer a single screw to a plate and eight screws. Even as the indications for operation vary, so do those for the method of internal fixation. The amount of internal fixation depends upon whether it is only necessary to steady the fragments until the external fixation is applied, or whether it is to be subjected to violent strains as may happen, for instance, in some fractures of the femur. It has been amply proven by experimental and clinical evidence that a constant strain will loosen the strongest form of internal fixation. Just as a suture drawn too tight will produce absorption and cut the soft parts, so will a constant strain draw the screws of a plate, no matter how well introduced. The point I wish to make is that we have to rely chiefly upon external dressings; the function of the internal fixation being to obviate motions or displacements which may be caused by muscular action, or by sudden strain, such as may happen during the application or change of external splints or dressings. One of the chief advantages of internal fixation is the possibility of early and frequent passive motion of neighboring joints without endangering union."

Martin states (*Surgery, Gynecology and Obstetrics*, August,

1906): "Metal plates, screws, or wires are open to the objection that, even though the wound heals primarily over them, they remain always a potential cause of localizing infection. There are probably few surgeons, who because of discharging sinuses, have not been compelled to remove such foreign bodies from patients who had been reported by their colleagues as permanently healed. The liability of both early and late suppuration is in direct proportion to the size of the foreign body employed."

Groves reports that in all his experiments (2 cats' tibiae; 2 rabbits' tibiae; 5 rabbits' femora) where metal plates were used to hold fractures, "the bone ends became disunited within the first week, with more or less angulation and deformity. This was due in every case to the screws coming out. Usually both screws came out from one fragment and the plate remained fixed to the other; but sometimes all the screws were out and the plate was loose among the muscles. Examination of the bone from these cases showed that the screw holes became enlarged, so that whereas the screws held tightly at the time they were inserted, later the same sized screw would drop loosely out of the hole." The screws quickly gave way from bone absorption around them. "A second undesirable feature of these series of experiments was the tendency to sepsis, with occasional extrusion of the plate. "That it was not due to faulty technique is shown by the fact that in other methods (no metal used) where the same procedure was observed, there was very little sepsis. This marked tendency to sepsis as compared with other methods, is due to the combination of a great irritation, caused by free movement of the displaced fragments on account of loosened screws, with the presence of a foreign body. Groves believes that "many times the sepsis is the result and not the cause of the loosening of the screws," and it is evident from his series of experiments that the screws do rapidly become loose in all cases.

The presence of a metal plate, instead of stimulating osteogenesis, retards it. This is in strong contrast to the bone graft, which not only produces bone itself but also stimulates the bone

ends to more active osteogenesis. There is an immediate adhesion of the inlay graft to the gutter walls of the fragments, and as times elapses this becomes a firmer and firmer bone union. Furthermore, the graft has certain bacteria-resisting and bactericidal properties.




FIG. 92.—Röntgenogram of comminuted oblique fracture of femur in a woman 68 years of age, 3 months after operation, in which a screw, two wires and a plate were used. (Blake.)

Hitzrot enumerates the following indications for operative treatment:

- “Fracture of the patella, with separation of the fragments.
- “Fracture of the olecranon, with separation of the fragments.
- “Fracture of the head of the radius, with displacement

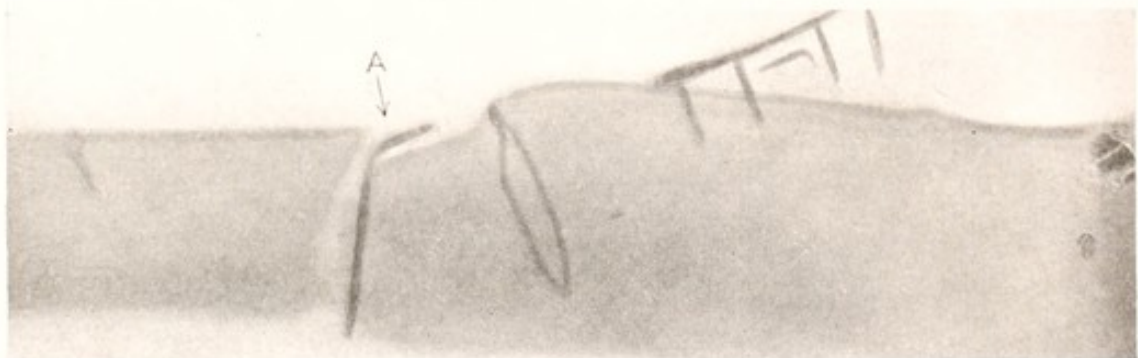


FIG. 93.—Röntgenogram of same fracture as shown in Fig. 92. The screws have come out and plate has become partly displaced into the soft tissues. One of the wires has produced absorption and a spontaneous refracture at A. (Blake.)

of the fragments, or where the fracture line involves the radio-ulnar joint.

“Fracture of the shaft of a long bone in which the soft parts become interposed between the fractured ends of the bone.

- “Fracture of the carpal and tarsal bones, with wide separa-

tion of the fragments or displacement of the fragments (carpal scaphoid and the astragalus).

“Fracture dislocation, viz., fracture of the surgical neck of the humerus with dislocation of the head.

“Fractures of the tuberosities and condyles of the various bones, with rotation of the fractured process, for example, fracture of the external condyle of the humerus with rotation of

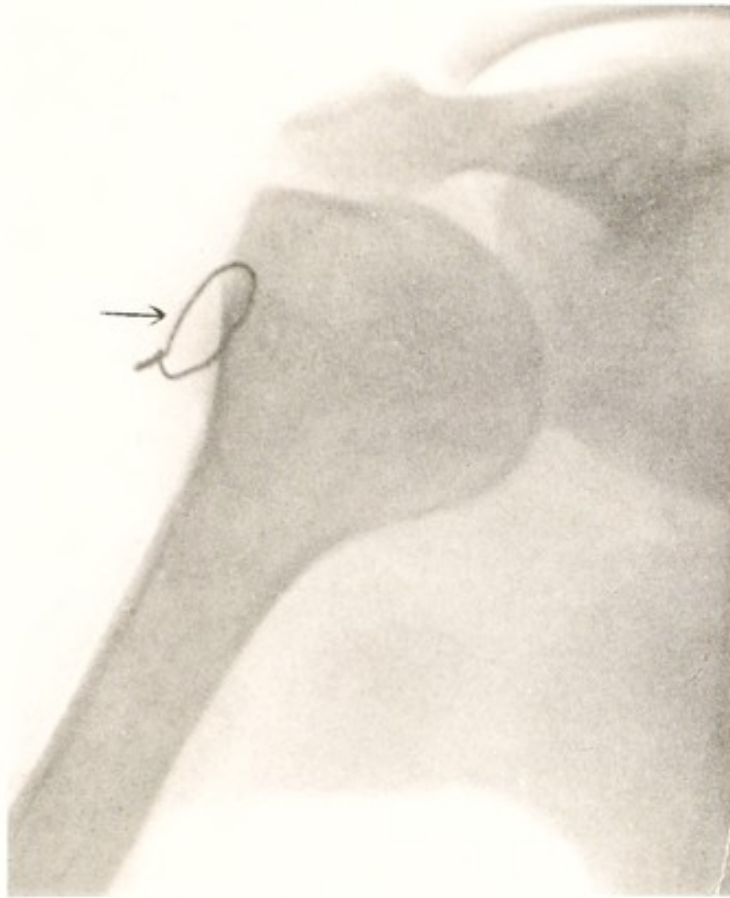


FIG. 94.—This case illustrates how treacherous foreign substances are when left imbedded in the tissues. The loop of silver wire shown in this röntgenogram was employed to fix an epiphyseal fracture. The wound healed by primary union and the convalescence was uneventful. Four years later a large abscess appeared about the wire, necessitating removal of wire and drainage of abscess.

the condyle, so that the fractured surface points outward or away from the line of fracture in the shaft.

“Furthermore, operation is indicated when there is hemorrhage due to the injury of a large vessel; when there are signs of compression of a nerve; when the sharp point of a fragment is caught in the skin; and when infection has occurred in the region of the fracture.”

Practically every type of fracture may need operation if reduction is otherwise unfeasible. Necessity for open operation should be recognized within the first 2 weeks after the injury. The X-ray obviates any difficulty in determining this fact.

Those fractures which need operation the most frequently are fractures of all long bones—especially the femur; lower third of tibia; fractures involving joints, as fractures of the neck of the femur, lower end of humerus, and femur; and fractures of the forearm.

In February, 1911, the council of the British Medical Association appointed a committee "to report on the ultimate



FIG. 95.—Skiagram of rabbit's tibia, 21 days after plating. Screws have come out of the lower fragment, and the plate protruded from the wound. (Groves, in *British Journal of Surgery*.)

results obtained in the treatment of simple fractures, with and without operation," and the following conclusions were arrived at by the committee:

"1. It is possible by either non-operative or operative treatment to obtain a high percentage of good results in children. The results of non-operative treatment in children, with the exception of both bones of the forearm, are unlikely to be improved upon by any other method. Operative results expressed in percentage are approximately the same as the non-operative: 1,017 non-operative cases, 90.5 per cent. good functional results; 64 operative cases, 93.6 per cent. good functional results.

"2. In comparison with the results in children, the non-operative results in those past 15 are not satisfactory, and from

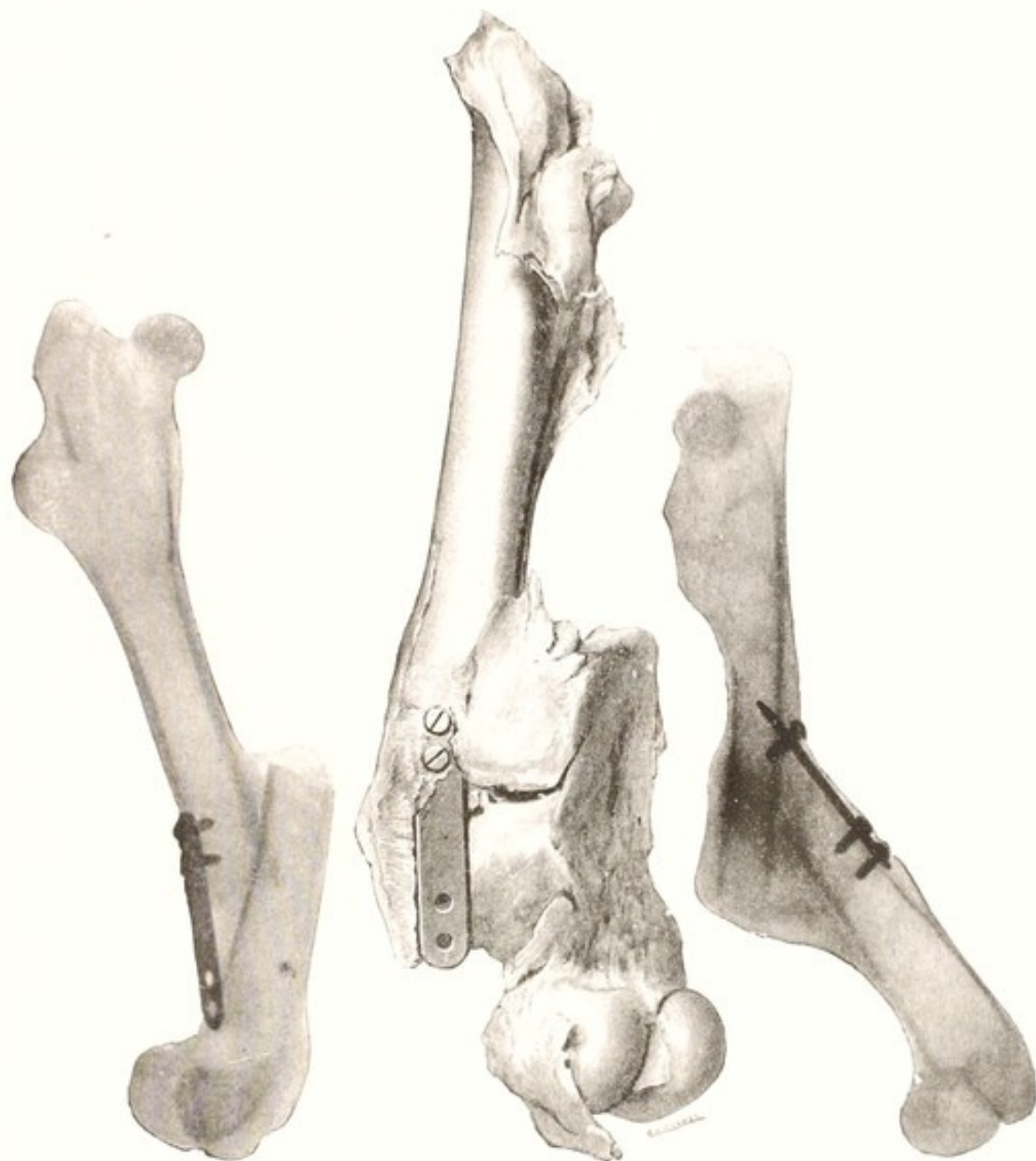

FIG. 96.

FIG. 97.

FIG. 98.

FIG. 96.—Skiagram of rabbit's femur (No. 26), 21 days after plating. Screws have come out from lower end. Mal-union. (Groves, in *British Journal of Surgery*.)

FIG. 97.—Rabbit's femur (No. 26), 21 days after plating. Screws have come out from the lower fragment. Mal-union with lateral displacement. (Groves, in *British Journal of Surgery*.)

FIG. 98.—Rabbit's femur (No. 28), 31 days after plating. The screws have come out from the upper fragment. Note the quantity and density of the callus. (Groves, in *British Journal of Surgery*.)

the analysis of the age groups it is clear that there is a progressive depreciation in the functional result as the age advances

in those cases submitted to non-operative treatment—*i.e.*, the older the patient, the worse the result.

“3. Although the functional result may be good with an in-

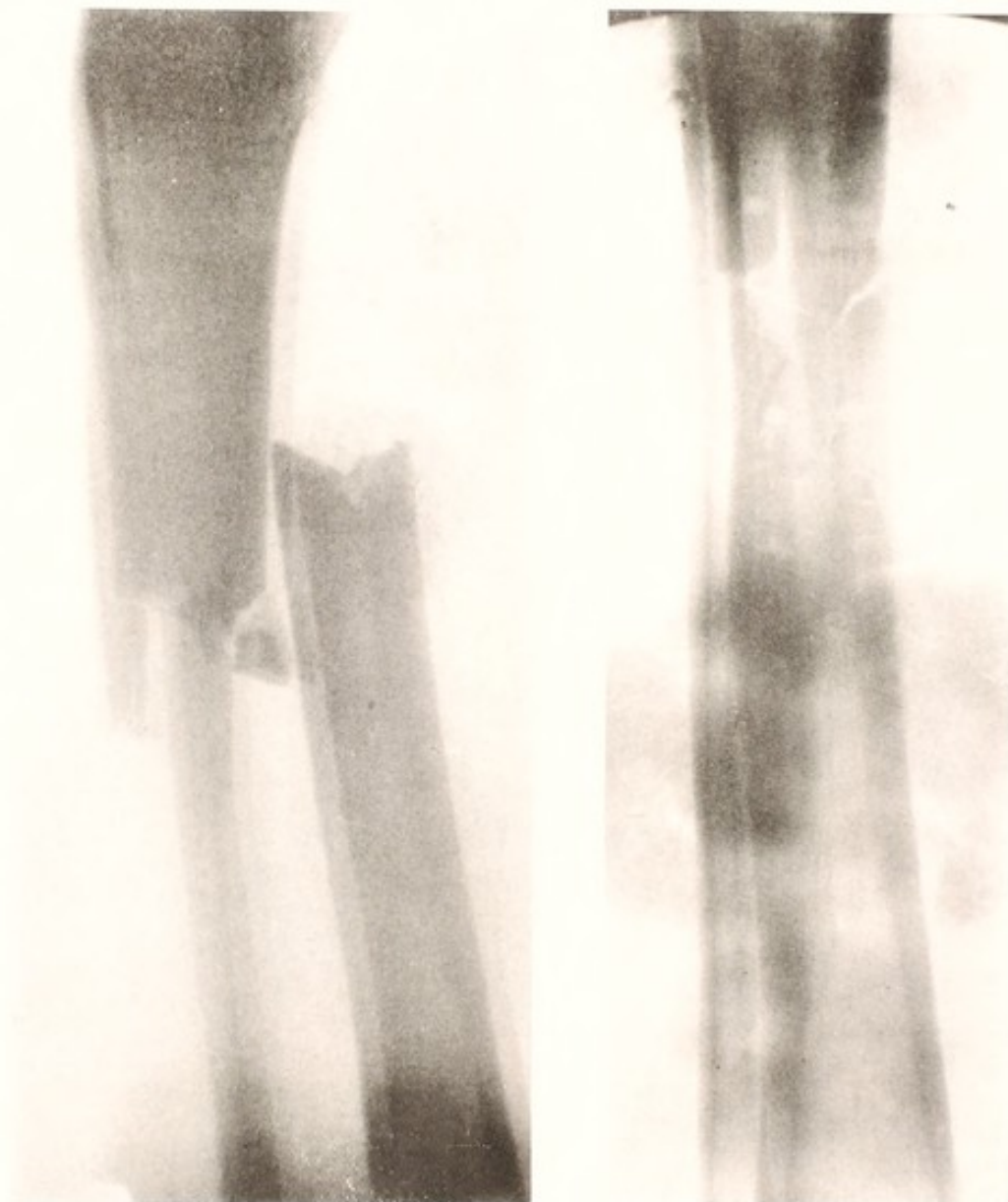

FIG. 99.—The author is indebted to Dr. Lathrop of Hazleton, Penna., for the privilege of reporting this case, which was a fresh comminuted fracture of the tibia and fibula. A sliding inlay graft from upper fragment held the fragments perfectly (author's technique). The röntgenograms show position of fragments before and after operation. The result was excellent.

different anatomic one, the most certain way to obtain a good functional result is to secure a good anatomic one. Of the operative methods, those which secure perfect reposition and absolute fixation of the fragments yield better results than meth-

ods which fall short of this, and imperfect fixation of the fragments by wire or other suture has been found unsatisfactory in fractures of the long bones (the olecranon excepted).

“4. In order to secure the most satisfactory results from

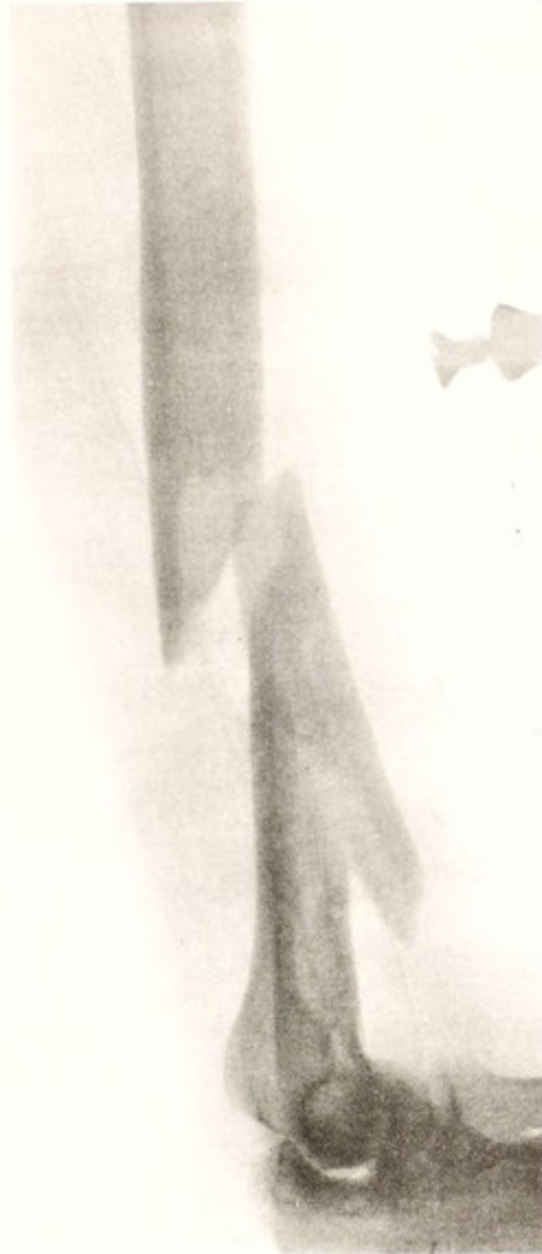

FIG. 100.—A fresh three-fragment fracture of the humerus inserted to illustrate a new point of view in operative management of this case and others of similar nature. The small third fragment in this case, which had been pulled downward by the brachialis muscle, was in the way of fixing the long fragments, therefore it was removed and placed in saline. This facilitated the operation and gave free access to the long fragment, the tips of which were fixed together with heavy kangaroo tendon. The third fragment was then taken from the saline solution and placed in position. It was fixed firmly with kangaroo tendon and furnished a very efficient bone-graft internal splint.

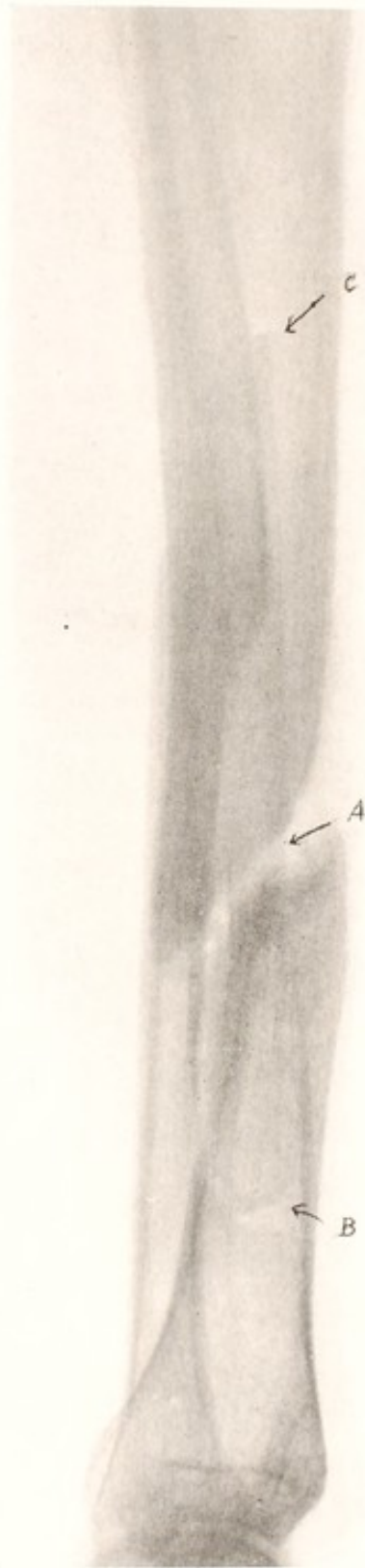

FIG. 101.—Pseudarthrosis of the tibia united by the inlay bone graft *CB*. Firm union 3 months after the operation, notwithstanding that there has been no callus between the fragments at *A*.

operative treatment, it should be resorted to as soon as practicable. Operative treatment should not be regarded as a method to be employed when non-operative measures have failed, as the results of secondary operations compare very unfavorably with those of immediate operations.

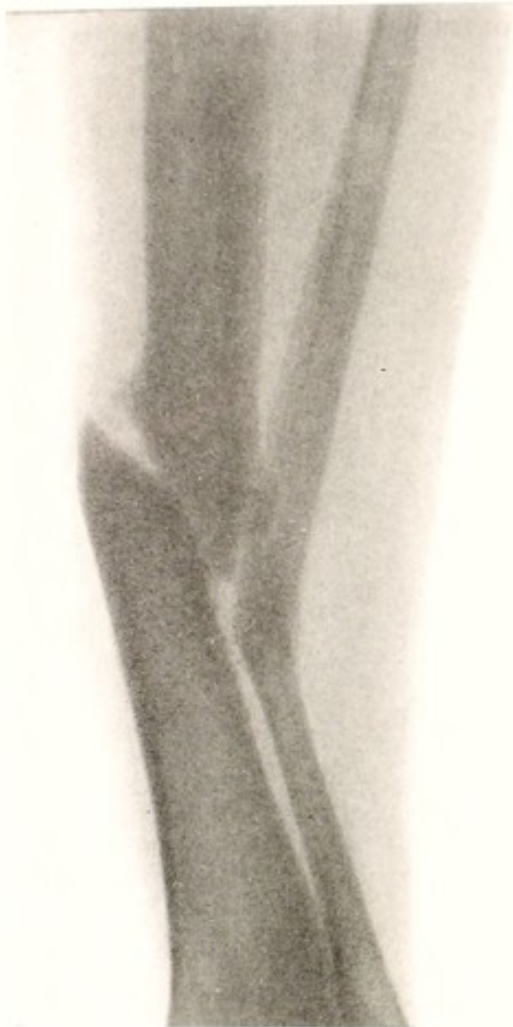

FIG. 102.

FIG. 102.—Ununited fracture of tibia of 1 year's duration after 3 months of Bier hyperæmia and repeated blood injections between fragments. An inlay graft was inserted from the other tibia with immediate union. This was one of the author's first cases and was operated in Dec., 1911.

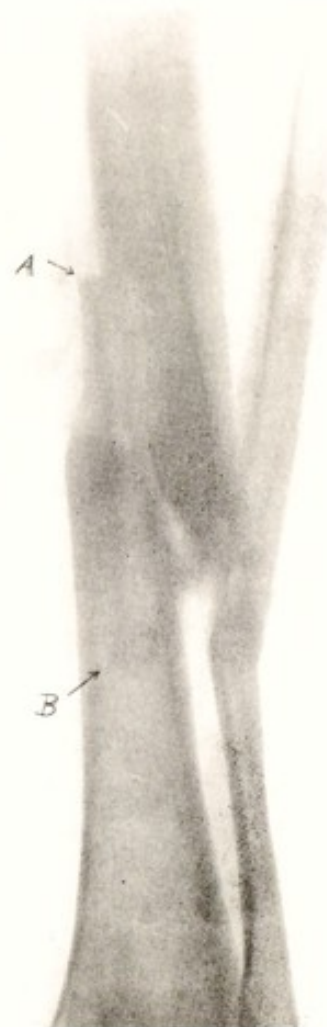

FIG. 103.

FIG. 103.—Same case as Fig. 102. The inlay graft *AB* is too short, but on account of its accurate fit the union was immediate.

“5. Operative treatment of fractures requires special skill and experience.

“6. A considerable portion of the failures is due to infection.

“7. The mortality due to operative treatment is so small

that it cannot be urged as a sufficient reason against this method of treatment" (Hitzrot).

8. In nearly all age groups, operative cases show a higher percentage of good results than non-operative cases.

The author has used the inlay graft in the treatment of

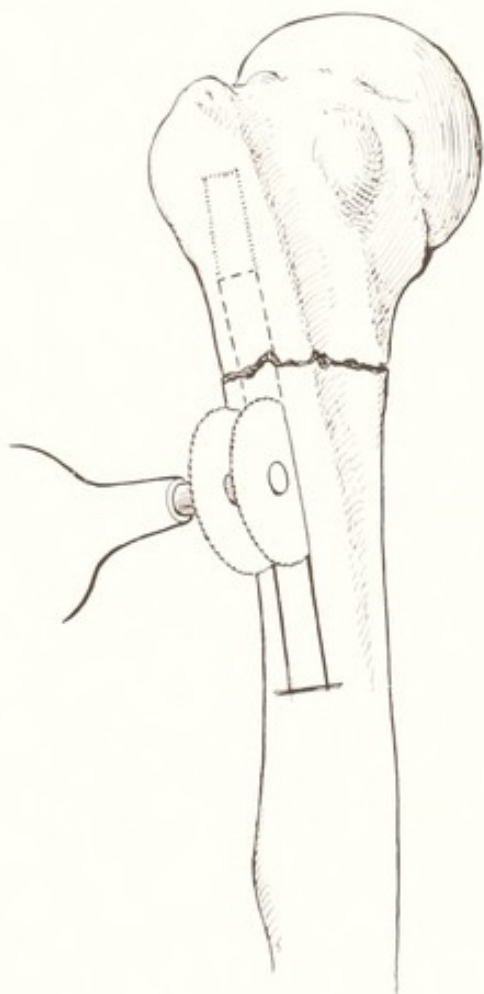


FIG. 104.

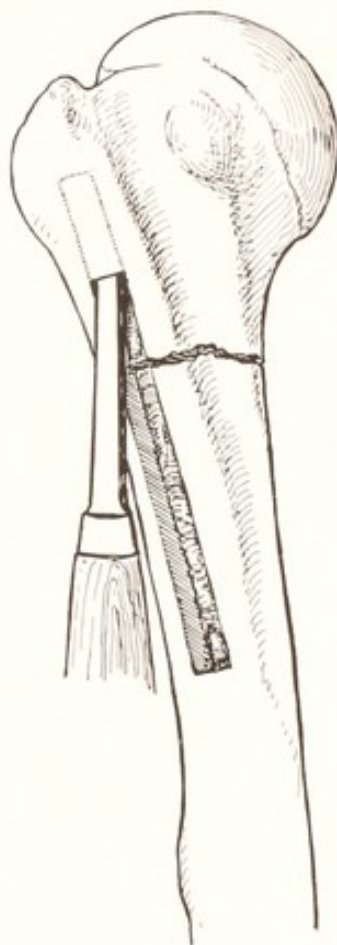


FIG. 105.

FIG. 104.—Preparing gutter for inlay tibial graft in a fracture at the surgical neck of the humerus.

FIG. 105.—Strips of bone are removed, forming a cortical gutter in lower fragment and lower part of upper fragment. A tunnel under the projecting humeral head is being prepared so as to lengthen gutter and get a longer contact of graft to upper fragment.

fractures since 1911, and has secured union in every instance in a series of 50 cases of fresh and ununited fractures. Many of the ununited fractures were of the most desperate character. One of the series had been operated upon seven times, including intramedullary grafting. In three of the series, the intramedullary graft had been unsuccessfully employed; two had been

operated upon unsuccessfully three times; and three of the cases, twice. Twenty-seven of these cases were previously plated with Lane's plates.

In reference to these statistics the author wishes to advance a further statement. A metal plate placed on a fracture inhibits seriously, as a rule, the formation of callus on that area of the fragments at the same time that osteogenesis may be

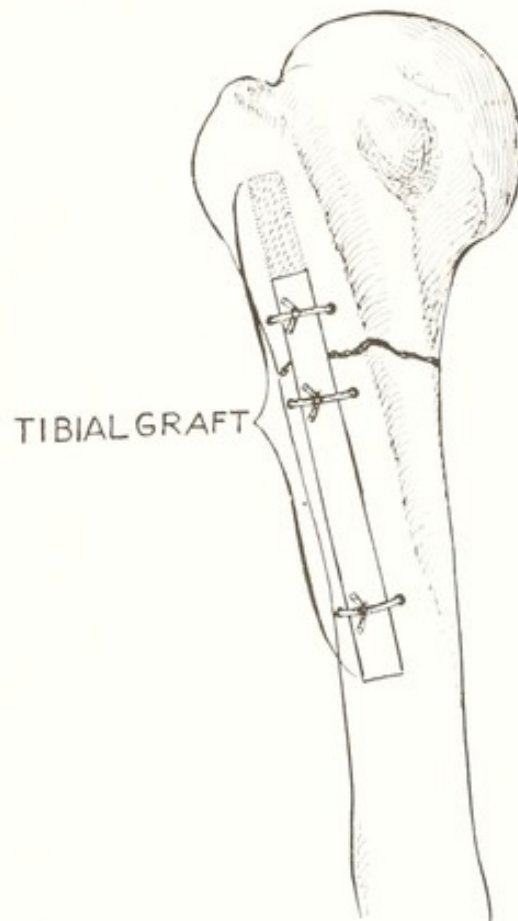


FIG. 106.—Inlay graft fixed in place with kangaroo tendon.

active on the other areas of the fragments, and in a certain percentage of cases the inhibition to callus formation is sufficient to result in non-union, even though there may have been no infection. There are few surgeons who execute Lane's technique, therefore infection occurs in a varying percentage of cases, which is a frequent cause of non-union. Apropos of this, Thomas has emphasized the unreliability of the Lane plate as used by a number of operators, and cites statistics of 450 fracture

cases gathered by him at the Cook County Hospital. It was found that it had been necessary to remove the Lane plates, on account of suppuration or other causes, in 48 per cent. of the cases which had been plated.

When the author first began (1911) to employ the inlay bone graft in the treatment of fractures and other bone conditions, hand tools were used. After doing about 50 of these operations and thoroughly realizing the inadequacy of all hand tools,

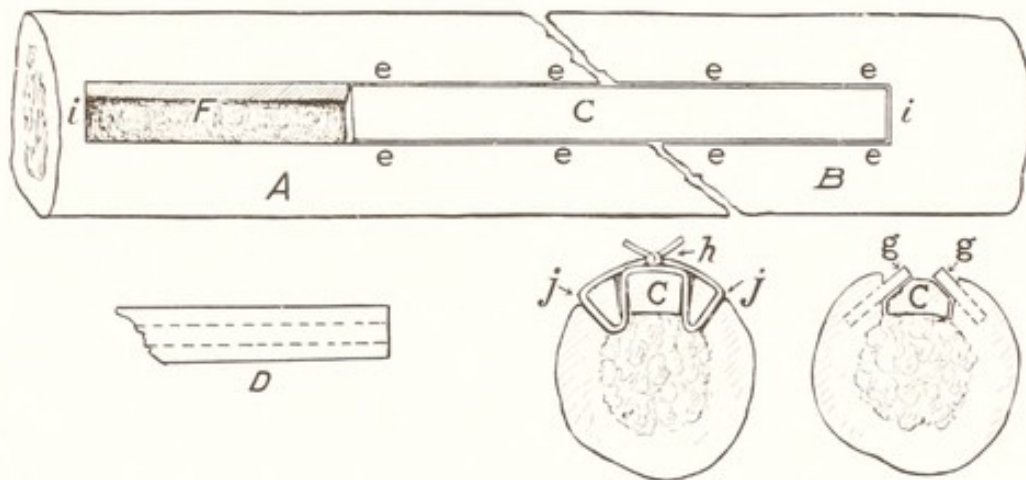


FIG. 107.—Bone-graft inlay method for treating fresh and ununited fractures. (A) Proximal fragment. (B) Distal fragment. (C) Graft sawed from proximal fragment and slid half across point of fracture. The inlay should always be inserted when possible on the side of an oblique fracture as indicated in this drawing. Over-riding of fragments and shortening of the limb are then prevented by virtue of the mechanical property of the inlay. (D) Portion of bone removed from distal fragment by motor twin saw in forming gutter for graft C. Dotted lines represent division of this fragment for making dowel pegs to be inserted at *gg*, at the point *e*. (*e*) Indicates location of drill holes for reception of dowel pegs to hold graft in position. These holes are made with a motor drill which is the counterpart in size to the dowel cutter used in making the pegs. Therefore the fit must be accurate. (*F*) Gap remaining in shaft following the sliding distally of graft C. (*i*) Cuts at end of gutter made by small motor saw in freeing the bone from the gutter. (*j*) The converging drill holes at the side of the gutter showing kangaroo tendon passed through and tied in position securing graft C, that is, if tendon is chosen as the fixation agent.

he turned to the development of motor-driven tools, and about 2½ years ago he began to perfect the motor mill which he is now using with so much satisfaction. It is almost like a cabinet-maker's or carpenter's mill. With it the surgeon can saw bone, drill it, turn it into nails (with attached lathe), or mould it into any shape or form required with accuracy and speed, so that he can devote himself to the fixation-ligature work and delicate tissue work that is necessary with the least

amount of time and trauma. All the heavy and laborious bone work is done by electrical power. The surgeon can also do many things with motor-driven tools which it would be impossible to do with hand tools.

The twin saws cut bone into inlays or make grooves for the same of exactly uniform width throughout, thus assuring a "cabinet-maker's fit," which in ununited fracture work is absolutely essential to success in many instances. In this respect the callus may be compared to the glue of the cabinet-maker, and the graft to the accurately fitted wood of the glued furniture. It is essential that the wood be accurately fitted, otherwise the glue would not hold. This is a fair comparison in many respects, especially in the case of pseudarthrosis where the callus is meagre in amount on account of the sclerosis of the fragment ends. An accurate fit may mean success and an inaccurate fit, failure.

In cases of fresh fracture, the bone being normal, the material can be taken from the fragments themselves and used as bone grafts. This, as well as other similar inlay technique, would be difficult without the use of the circular saw. The motor saw has opened up a field of osteoplasty and of application of the bone graft in various forms that it has been impossible to develop heretofore.

In place of wire, the author always uses kangaroo tendon. During the last 2 years, he has not used metal for any internal-fixation purpose. Metal has a destructive influence upon bone, and frequently adds an inhibiting effect which may be sufficient to prevent the fractured bone from uniting. An osteoporosis or necrosis usually develops around the metal screws or nails, causing them to loosen and drop out in a very short time. Then, too, metal favors infection, absorption, and disintegration of tissues. Instead of Lane's plates or other metal plates, the

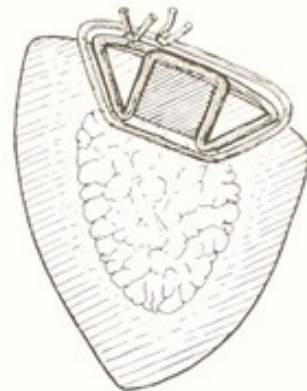

FIG. 108.—Illustrates using two strands of kangaroo tendon, one to prevent graft from coming out and the other to prevent the graft displacing into the marrow cavity in fresh fractures of large bones when it (medullary cavity) is not filled with new-formed bone.

author uses the inlay graft for all cases of fracture of the long bones. For balancing up deformities of the limbs, especially of the feet, the author has used bone-graft wedges, taken mostly

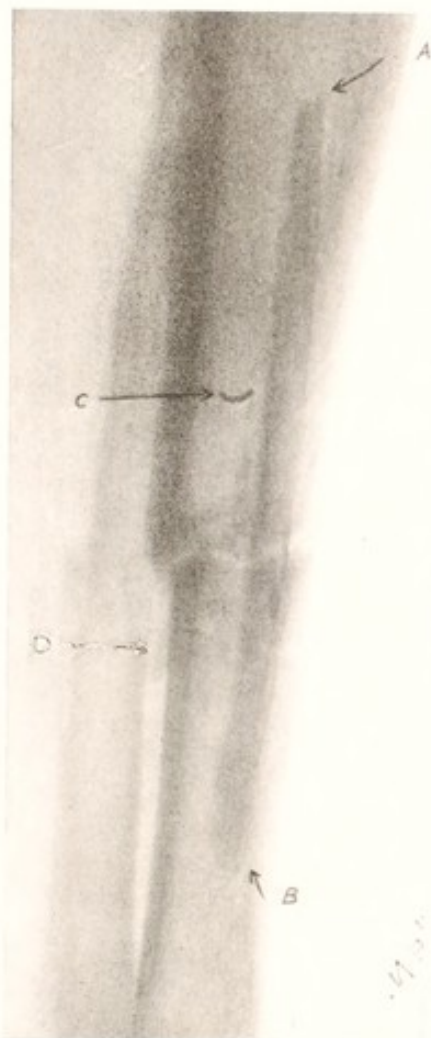


Fig. 109.—Ununited fracture of a tibia 4 months after the insertion of inlay graft *AB*. *C* is piece of broken silver wire inserted at a previous unsuccessful operation. *D* is screw hole of a previous Lane's plate. The union from the inlay is firm at the time this X-ray was made the patient is walking on the limb. Nevertheless, there is no callus at the ends of the fragments.

from the tibia or opposite side of the foot. In ununited fractures, it is very important that the graft be long enough to have ample contact with active bone beyond the sclerosed or infected area. Through the influence of Wolff's law, a tibia whose diameter has been lessened by obtaining a bone graft from it will return to its normal size and strength in about 2 or 3 months; at the same time, the graft will likewise proliferate and become of a size and strength commensurate with the mechanical requirements of its new environment. In other words, it is a physiological hypertrophy.

In every case of non-union which has existed for any length of time, from any cause whatsoever—whether from soft tissue between the fragments, local infection, systemic disease, idiosyncrasy in lack of osteogenesis, or from any inhibitory influence to bone growth from a Lane's plate or other metal appliance—there is always a distinct pathological change in the fragment ends, consisting in diminution and degeneration of bone-cells and a coincident increase of calcium salts, or, in other words, a sclerosis. (See Fig. 110.) This eburnated area may extend as much as $1\frac{1}{2}$ in. into each fragment, and osteogenesis is greatly impaired, so much so that bone fragments ideally contacted

and perfectly immobilized by external splints or internal metal devices do not unite. (See Fig. 88.) In other words, it is clear that the surgical problem which presents itself is not the securing of better fixation and a more close approximation of the fragment ends by bone removal and freshening, but the furnishing of an



FIG. 110.—Microphotograph of a section taken from the end of a fragment of an ununited fracture. To demonstrate the microscopical appearance of bone which has undergone sclerotic changes. The bone is partially necrotic as manifested by the few and poorly stained nuclei. The attempt at regeneration is slight and abortive, there being few active osteoblasts.

efficient internal splint and at the same time supplying a bone-growing and osteoconductive element which spans these sclerosed areas and is closely and favorably contacted with the healthy vascular osteogenetic bone in each fragment beyond the eburnated area and distal to the point of fracture. The inlay bone

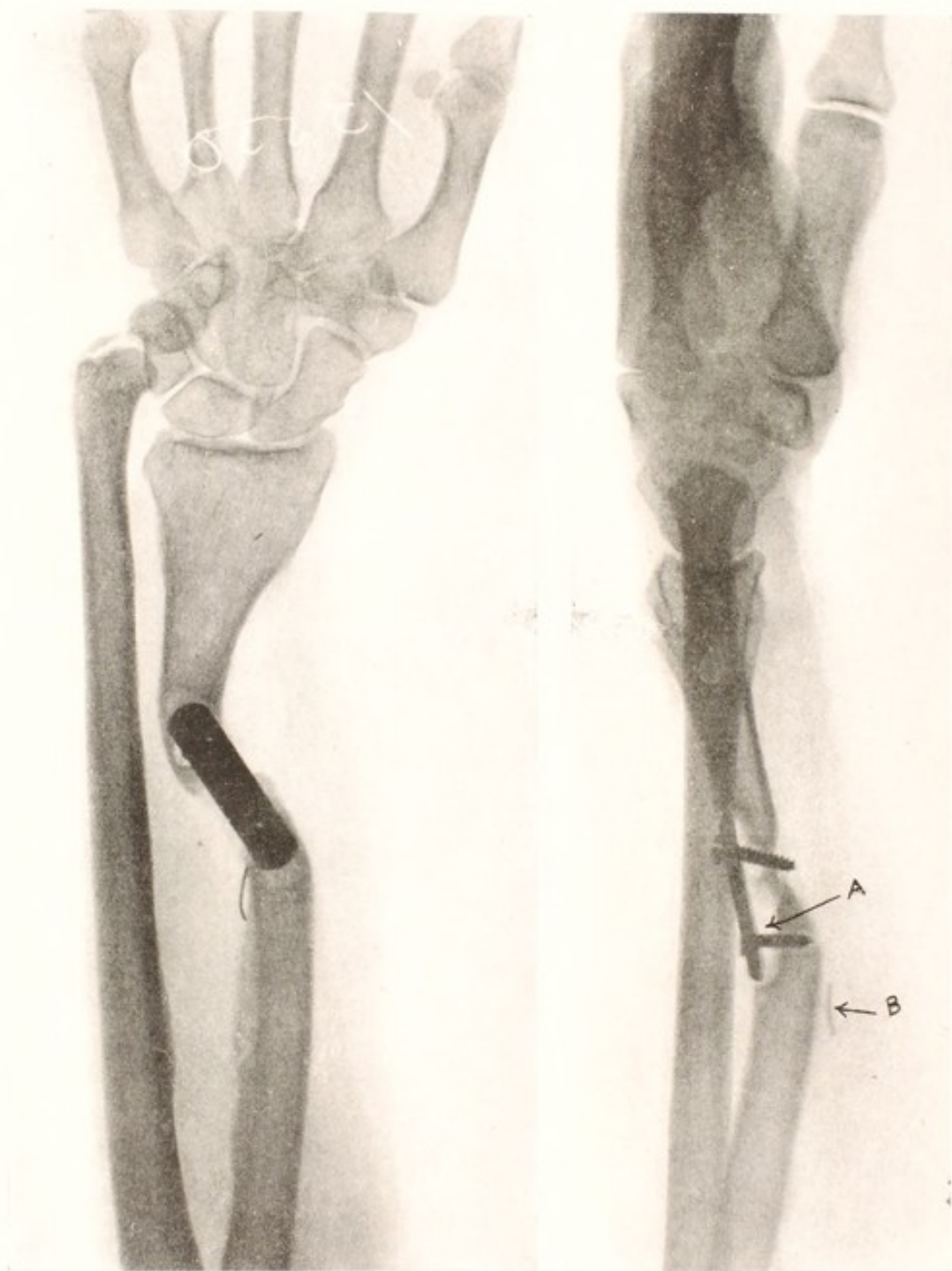


FIG. 111.

FIG. 112.

FIGS. 111 AND 112.—Ununited fracture of the radius after four operations, and the last Lane's plate in position. The large amount of bone destruction from the contact with metal is shown at *A*. *B* is a fragment of silver wire put in at a former operation.

graft fulfils all these requirements and even more, in that it acts as a strong stimulus to osteogenesis on the part of the host fragments themselves.

In three cases where there had been non-union and even loss of bone, following severe comminution or osteomyelitis with death of the complete diameter of ends of the fragments after Lane plating, amputation or marked shortening was avoided by spanning these areas with long inlays. In one case, where $2\frac{1}{2}$ in. of the tibia had been destroyed by osteomyelitis, the graft was placed so as to span the infected cavity, and although it was impossible to cover the graft at this point on account of a large sinus in the skin, nevertheless granulations slowly covered up the graft, none of which sequesterated, and a perfect result was obtained. (See Figs. 153, 154 and 155.)

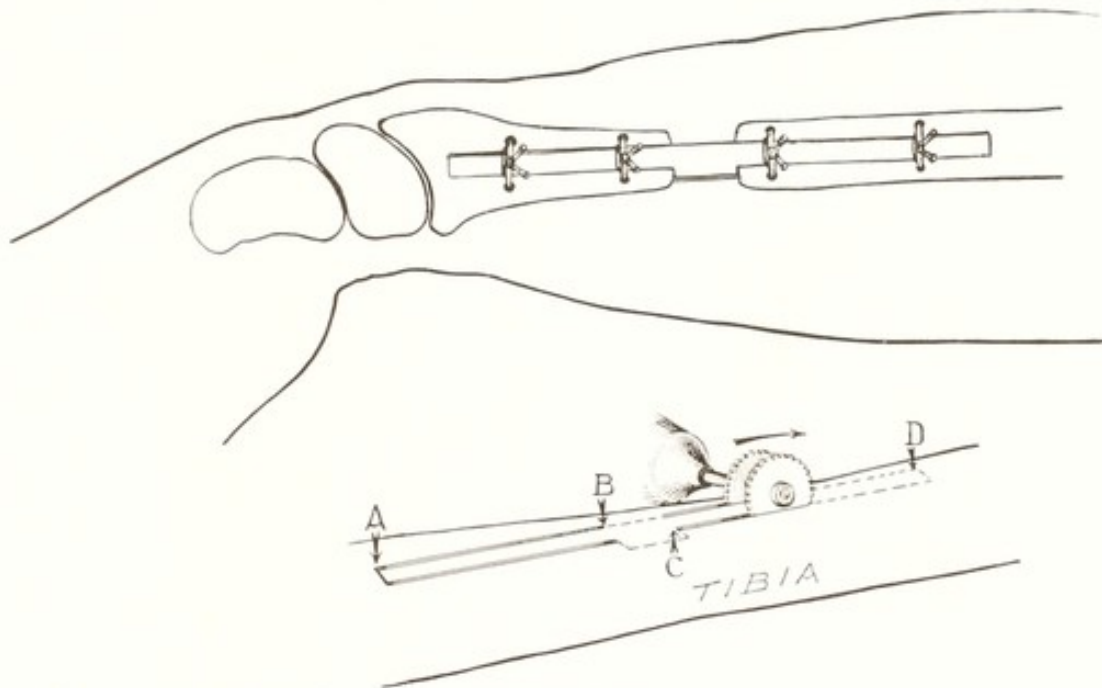


FIG. 113.—Drawing illustrating technique employed in the application of the graft in Figs. 111 and 112. The twin saw has cut from *A* to *B* and is in process of cutting from *C* to *D*. The graft was made larger from *B* to *C* so as to fit into the hiatus and furnish shoulders to prevent muscle pull shortening the radius.

FRESH FRACTURES

Time for Operation.—In fresh fractures, the most desirable time for operation is from the fifth to the fifteenth day after the injury. This allows time for the absorption of the exudates in the region of the fracture, and for improvement in the drainage

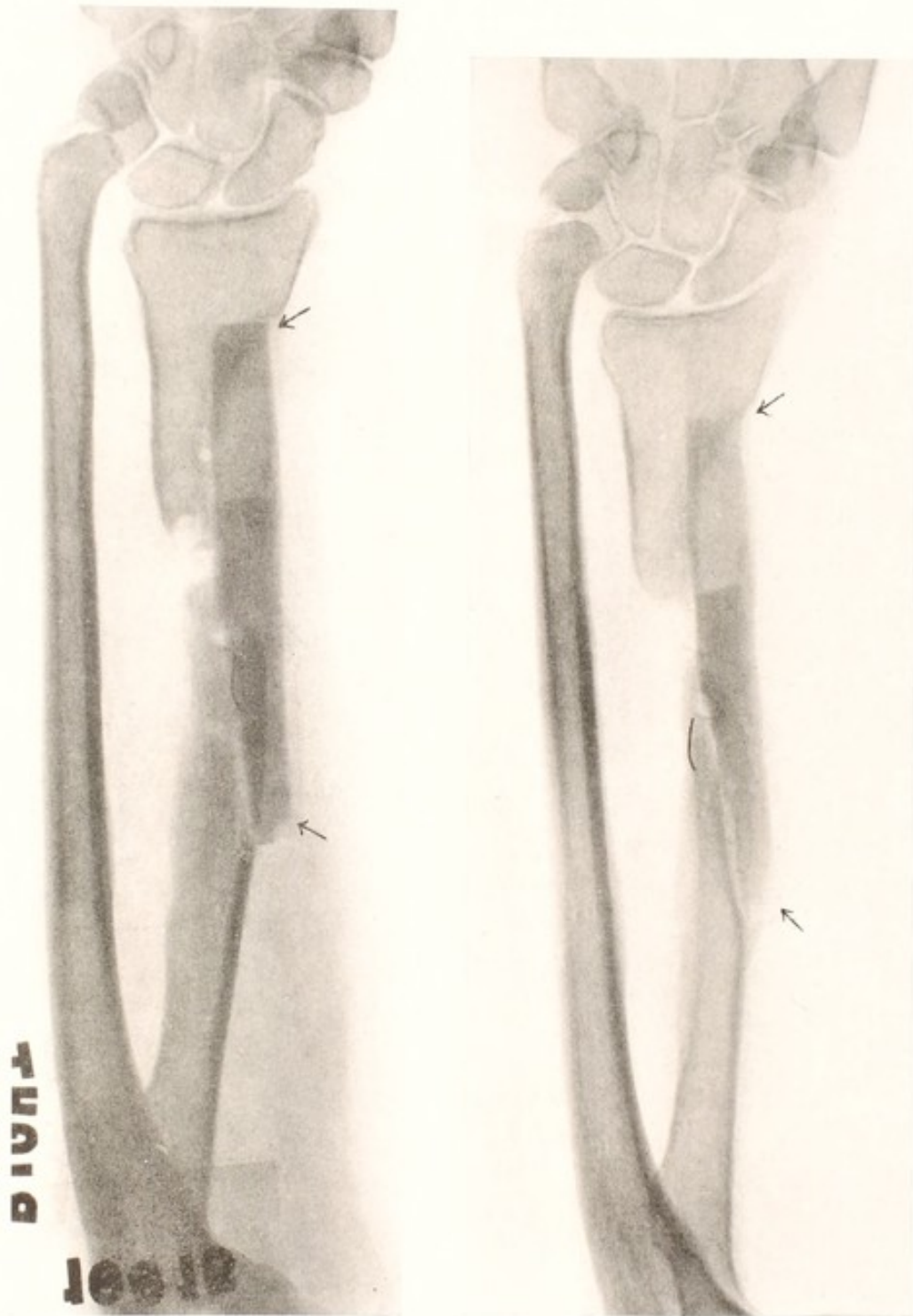


FIG. 114.

FIG. 115.

FIGS. 114 AND 115.—Röntgenogram of same case as Figs. 111 and 112 after union had been obtained by a tibial inlay graft. The fragment ends had been so much disintegrated by contact with the screws and plate that a considerable shortening had occurred. The graft was inserted so as to span a hiatus of over $\frac{1}{2}$ in., and the radius was restored to nearly its normal length. For technique see diagram, Fig. 113. *A* is röntgenogram taken 6 weeks after insertion of graft. *B* is 6 months later and shows progress of the adaptation of the graft to the bones into which it is inserted.

of the lymphatic system; also the ends of the bones have become covered with fibrin and have gone through the processes preparatory to repair. All the conditions are favorable for

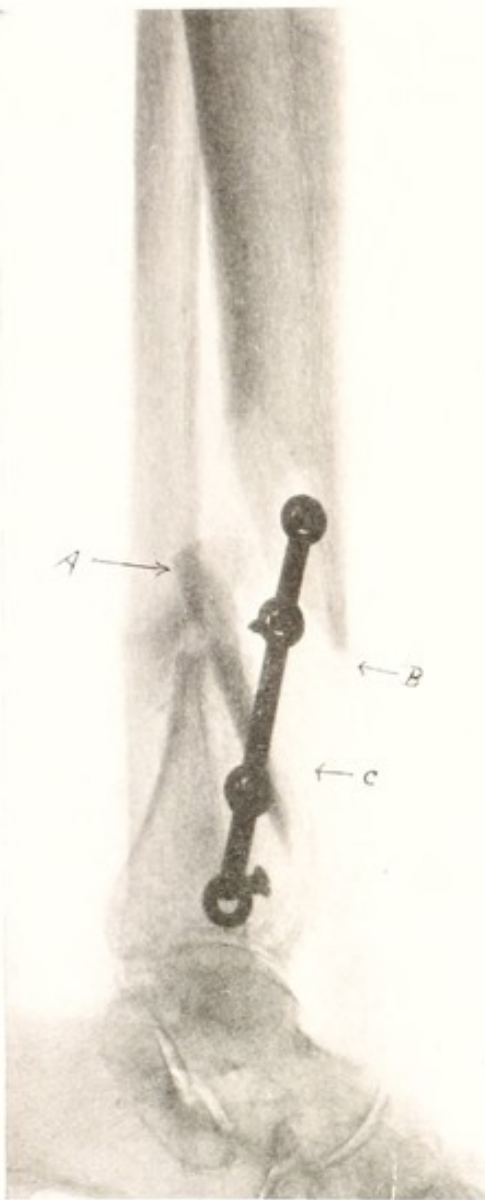


FIG. 116.

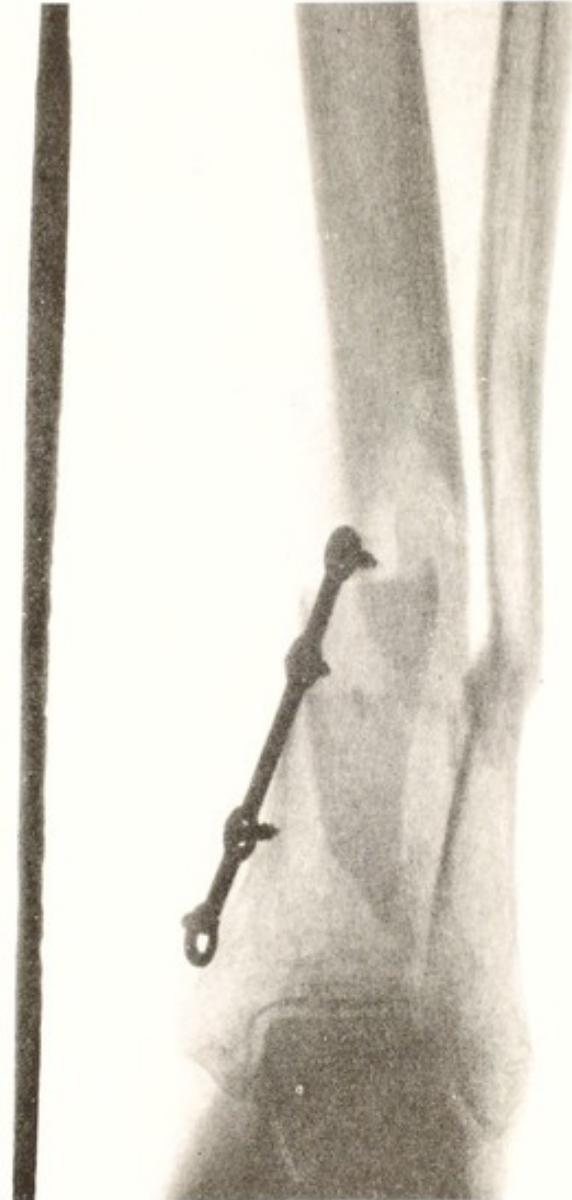

FIG. 117.

FIGS. 116 AND 117.—Röntgenogram of an ununited fracture of the tibia of 4 months' duration. This patient sustained two fractures of the fibula, one about 3 in. from its lower end and the other about 3 in. from the upper end. The fracture of the tibia was a three-fragment oblique fracture and was immediately Lane plated; A indicates the third fragment. Both of the two fractures of the fibula united and the plated tibia fracture did not unite. This röntgenogram shows considerable bone destruction both from the plate and the screws which have loosened and come out of the bone.

operating, and by this time the usual means of reducing and fixing the fracture have been tried and their failure to accom-

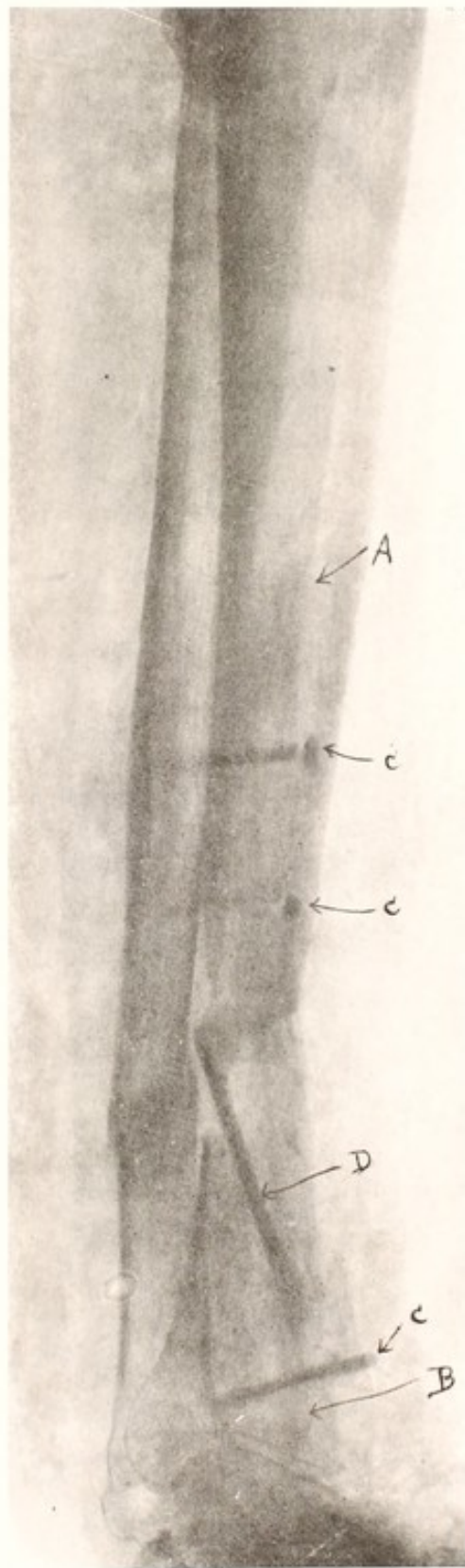


FIG. 118.—Röntgenogram of the same case as Figs. 116 and 117, 6 weeks after the removal of the Lane's plate and a sliding inlay graft had been brought down from the upper fragment and firm union had resulted. *C, C, C* indicates the bone-graft pegs which were used to fix in place the inlay *AB*. The pegs were made from the strip of bone removed from the lower fragment for the purpose of forming a gutter bed for the sliding inlay.

plish the desired result demonstrates the necessity for operation. A longer delay is not desirable, as nature's efforts at repair and the appearance of contractures increase the difficulties of operative reduction.

Arbuthnot Lane favors early operation, to which there are several disadvantages. Much tissue is so injured that its resisting power is lowered, and hence there is increased danger of




FIG. 119.—Hawley table. This table is specially designed for the treatment of fractures by the closed or open method. It provides almost perfect control of the extremities, and makes reduction and immobilization more accurate and certain. The extremities can be placed in various positions, so that flexion, extension, abduction and rotation can be regulated, reliable traction obtained, and lateral pressure applied directly to the fracture ends. After reduction the limb can be immobilized without changing its position or releasing the traction.

This photograph shows the table in position for the treatment of fractures of the lower extremity. All the work of manipulation or operation is done with the patient on a flat surface and the limbs held, not by assistants, but by fixed supports. The table top is made with a section which can be lowered, leaving the patient suspended for the application of plaster, and then raised while the cast is hardening.

This table is well adapted to röntgenographic examination of fractures.

accidental infection. The patient may be—and is likely to be—in a state of shock. There is an increased danger of operative complications, such as pneumonia, delirium tremens, etc. The skin may be œdematous, infiltrated, and excoriated, and primary union of the tissues difficult to obtain.

The following lesser advantages of early operation may be enumerated: The tissues are freshly lacerated, there is no effu-




FIG. 120.—Hawley table. Table with section of top depressed, leaving post with sacral support and head rest projecting. The latter is mounted on runners, so that its position can be adjusted to different subjects. With the sliding foot-pieces it becomes equally suited to the treatment of adults and children. This lowering section can be raised or depressed at will and is automatically locked when raised.

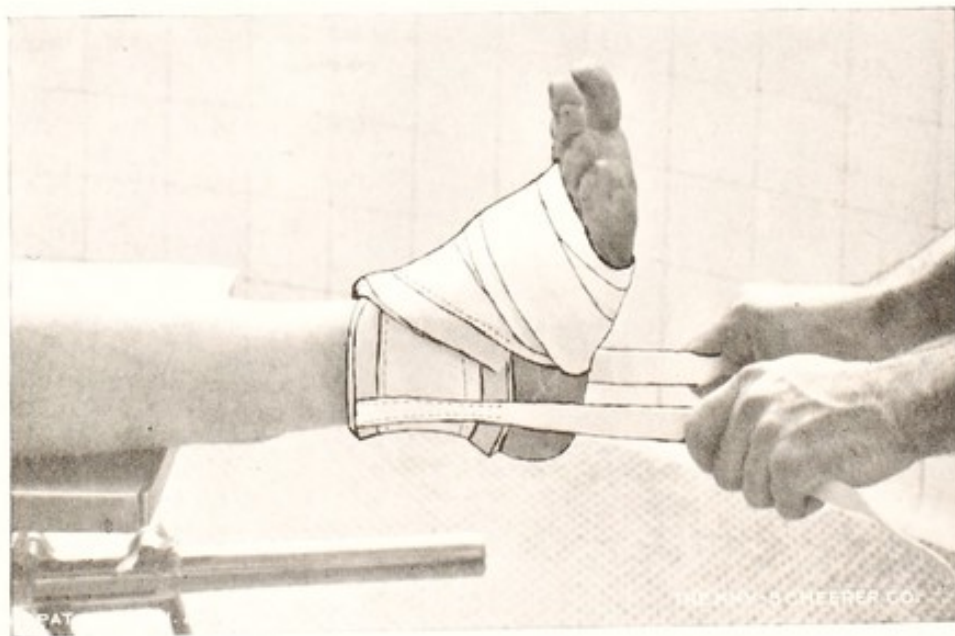


FIG. 121.—Hawley table. An ordinary 3-in. muslin bandage, in the centre of which has been sewn a piece of Mexican felt 4 in. wide by 15 in. long, is used to secure the foot to the traction foot-piece. This acts as a protective cuff for the ankle. To this cuff are stitched two heavy woven straps, so placed that the pull will be in a line just forward of the heel. After this bandage is snugly applied, the foot is placed against the foot-plate and the straps fastened to the buckles.

sion into the periosteous structures, and the lymphatics are freely open.

Preparation of Patient.—The general preparation is not different from that required for any major surgical procedure. The local preparation should be generous in its extent and by the iodine method, which should be carried out both on the night

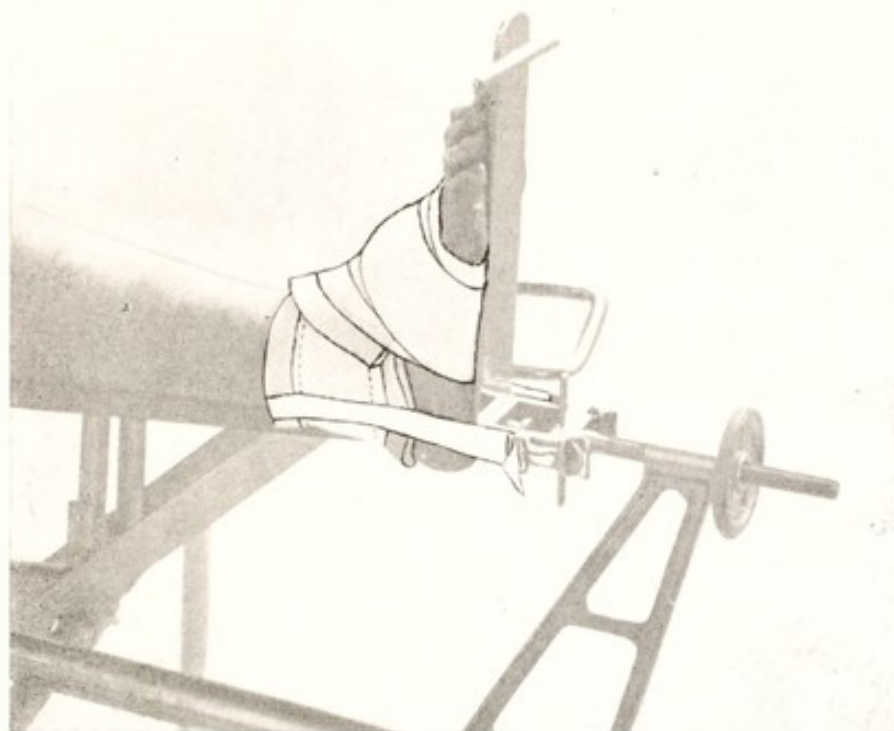


FIG. 122.—Hawley table. The foot is held in firm right-angled flexion and the force of the traction applied so as to draw the heel downward and maintain this position. A plaster cast includes the foot to the base of the toes and encloses the foot plate. To release the foot and cast, the straps are cut and the foot plate lifted out. When powerful traction has been employed, slits in the plaster at the back and front of the ankle are cut, to relieve the constriction and prevent pressure sores.

before and on the day of the operation in the most thorough manner.

In all fractures of the lower extremities an efficient traction apparatus of some type should always be available at the time of operation. In the author's opinion, the Hawley table is the most ideal traction apparatus for handling these cases. The traction can be applied with a limb in any degree of abduction or flexion, which is frequently a great advantage, especially in fractures of




FIG. 123.—Hawley table. Flexion and abduction of the thigh in the treatment of subtrochanteric fractures of the femur with or without counter-pressure on the upper fragment. There is a material advantage in having the knee flexed, over the customary thigh flexion with the knee extended, in that the relaxation of the powerful hamstrings greatly aids reduction, the quadriceps also being relaxed by the hip flexion. The traction obtained with the knee flexed is quite as effective as with the knee in extension. It is often advantageous in many tibial and femoral fractures to immobilize with some flexion of the hip and knee, because flexion naturally aids relaxation, and the angles in the cast make the immobilization more secure.




FIG. 124. Hawley table. Subject with the legs in extreme abduction, the Whitman position for the treatment of fracture of the neck of the femur. The rotation of the femur is controlled by the foot-plate. This picture shows the heavy felt pad used to protect the perineum, and the U-shaped perineal post, similar to the double posts, is designed to avoid pressure on the urethra.

Attachment used for support of the trunk and upper extremities. The position of the patient is reversed with the spine and head resting on this narrow board. Traction on the arms is applied laterally. The patient lies on the table with the top raised, except during the process of immobilization.

the upper third of the femur (see illustration, Fig. 123). The neutral position should be made the most of in any fracture where certain muscles are exerting a strong displacing force. In other words, the reduction should be accomplished and the plaster-of-Paris fixation dressing should be applied without the position of the limb being changed or the traction released at all.

This dictum applies in any case, whether operative or non-operative methods have been employed, also irrespective of the



FIG. 125.—Hawley table. Support and traction of the left arm with counter-traction by a wide sling around the body. This position is used for operations on the humerus and for reduction of fractures of both bones of the forearm (also for the reduction of shoulder dislocation).

type of the internal-fixation agent, if one has been used. No internal-fixation appliance will for any length of time withstand the pull of strong muscles at cross angles to the fractured part, as screws will pull out and wire will cut completely through the bone if union has not taken place.

TECHNIQUE OF INLAY

Armamentarium Necessary for Inlay-graft Operation.—(1) Hawley fracture table. (2) Two Lambotte clamps. (3) Low-

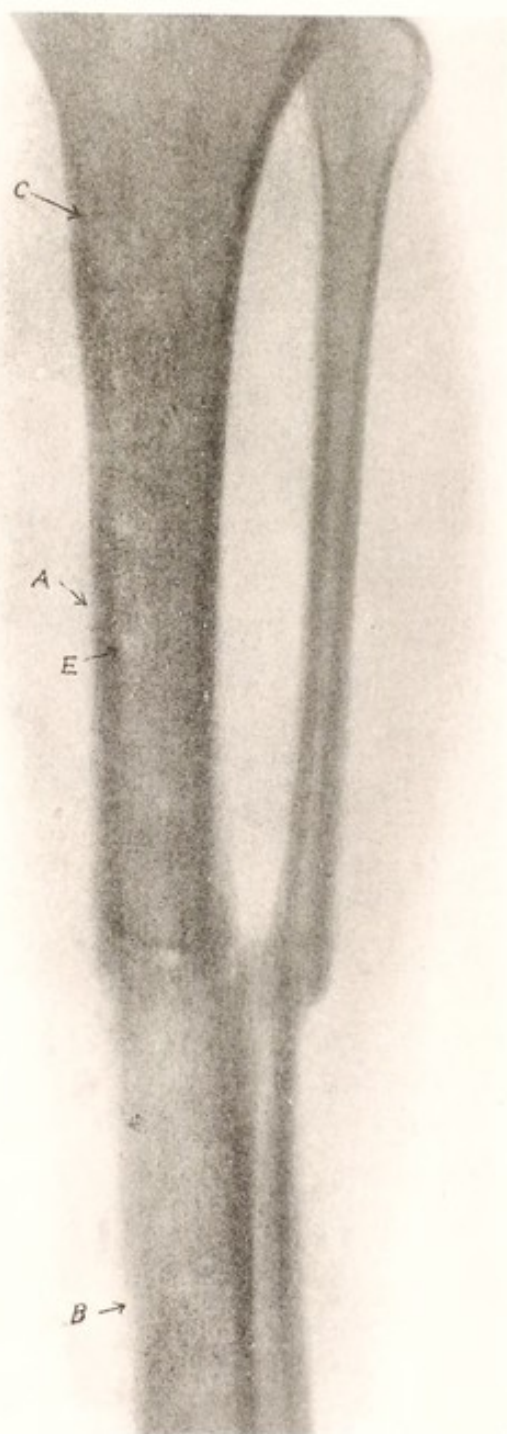


FIG. 126.—A case of ununited fracture of the tibia after the application of Lane's plate. The fragment ends of the tibia were in perfect apposition and an inlay (*AB*) was slid down from *C*, the upper fragment. This case is illustrative of how simple the inlay operation can be when the fragments are already in position. This case was done in 18 minutes, including the closure of the skin. *E* indicates screw hole of former Lane's plate.

man or Berg clamp. (4) Albee electric-operating bone set, with twin rotary saws, burrs, drills, dowelling attachment, etc. (5) Periosteum elevator. (6) Lane bone spatula. (7) Chisels, osteotomes, and mallets. (8) Lion jaw forceps.

Author's Technique of Inlay-graft Operation for Fractures (Fresh and Ununited).—If traction is required, the patient is placed on a traction table, preferably the Hawley table. The perineal counter-traction post and patient are properly adjusted. The foot or hand is bandaged to the extremity traction plate. (See Fig. 122.) A generous skin incision is made overlying the point of fracture, and when possible should be made to the side of the intended site of the transplant. The fascia and muscles overlying the point of fracture and the fragment ends are opened by scalpel and blunt dissection, and the region of the fracture well exposed.

If the fracture is an ununited one and the fragments are in good apposition, merely a part of the fibrous union is removed with a thin sharp osteotome. In executing the inlay technique, the periosteous structures are disturbed as little as possible and the relationship of the fragment ends left undisturbed if possible. This is important in minimizing the amount of local trauma. In this connection it is desirable to emphasize the pronounced inhibitory influence of severe trauma to cellular proliferation, and especially to osteogenesis. In no line of work is there greater danger of devitalizing trauma than in bone work, and this applies not only to the bone itself but to the surrounding soft tissues. A resulting infection of any of the involved tissue may interfere with a successful result.

Traumata may arise from the retraction of powerful muscles and their soft tissues—especially where too short an incision has been employed in the operative treatment of a fracture—from bone elevators or levers, bone clamps, the macerating and jarring effects of dull and blunt chisels, etc. Too great emphasis cannot be placed upon the importance of making the skin incision of sufficient length in all operative fracture work.

The periosteum is incised longitudinally and peeled back to

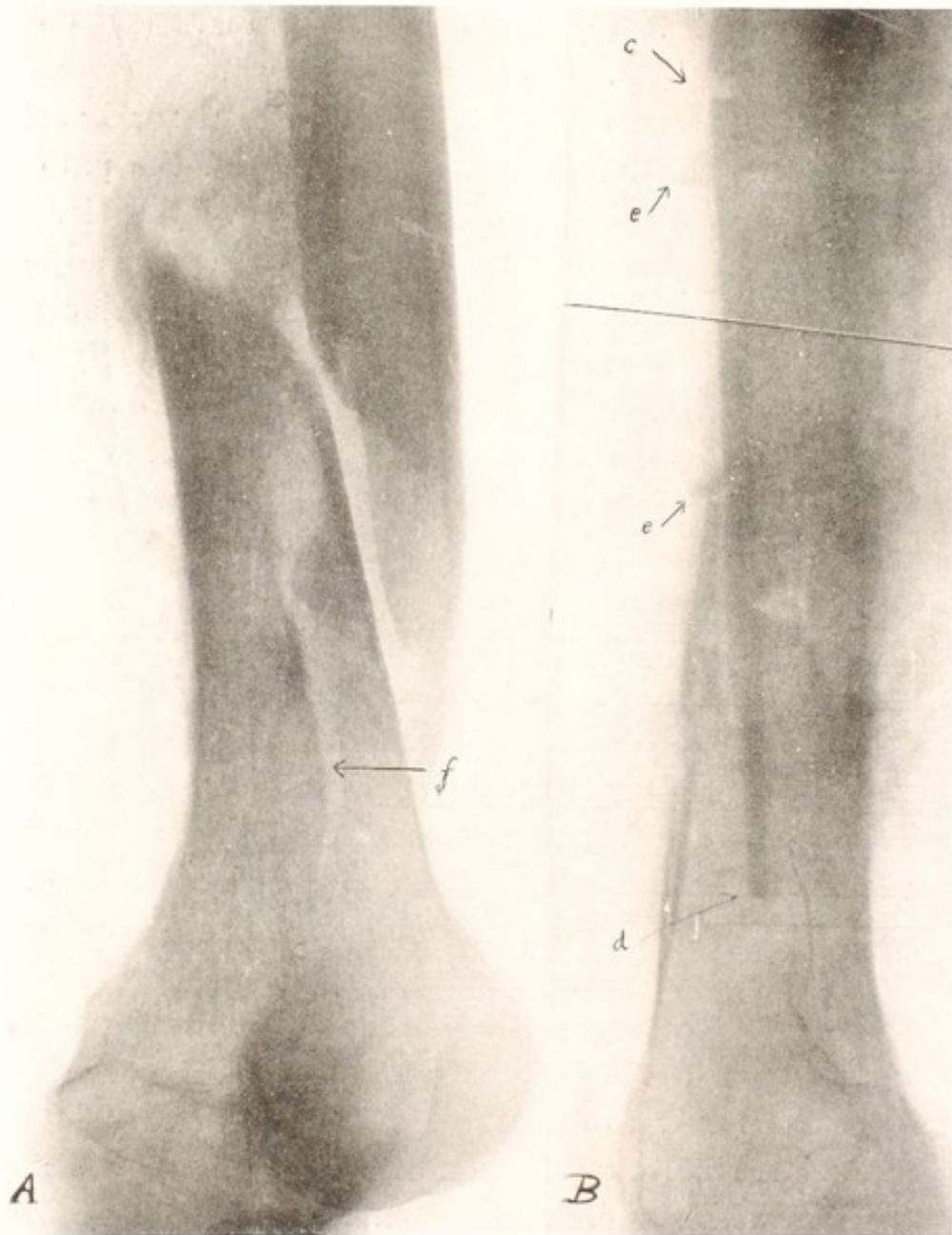


FIG. 127.

FIG. 128.

FIGS. 127 AND 128.—A is a röntgenogram taken 5 weeks after an oblique fracture of the lower third of the femur with a considerable shortening, in a muscular individual. Two unsuccessful attempts had been made, before the author saw this case, to hold these fragments with Lane's plates. *f* is a long fracture in the lower fragment, which resulted from one of these previous operations; *cd*, in B is graft obtained from the well tibia on account of the rarefaction of the bone in upper fragment; *e, e* are bone-graft pegs which were made from the strip of bone removed to produce the gutter in the upper fragment and were used to fix the inlay in its gutter. This case illustrates the peculiar efficacy of the inlay graft in holding difficult oblique fractures.

either side in the form of flaps, exposing the bone which is to be removed for the purpose of forming a gutter in the fragment or

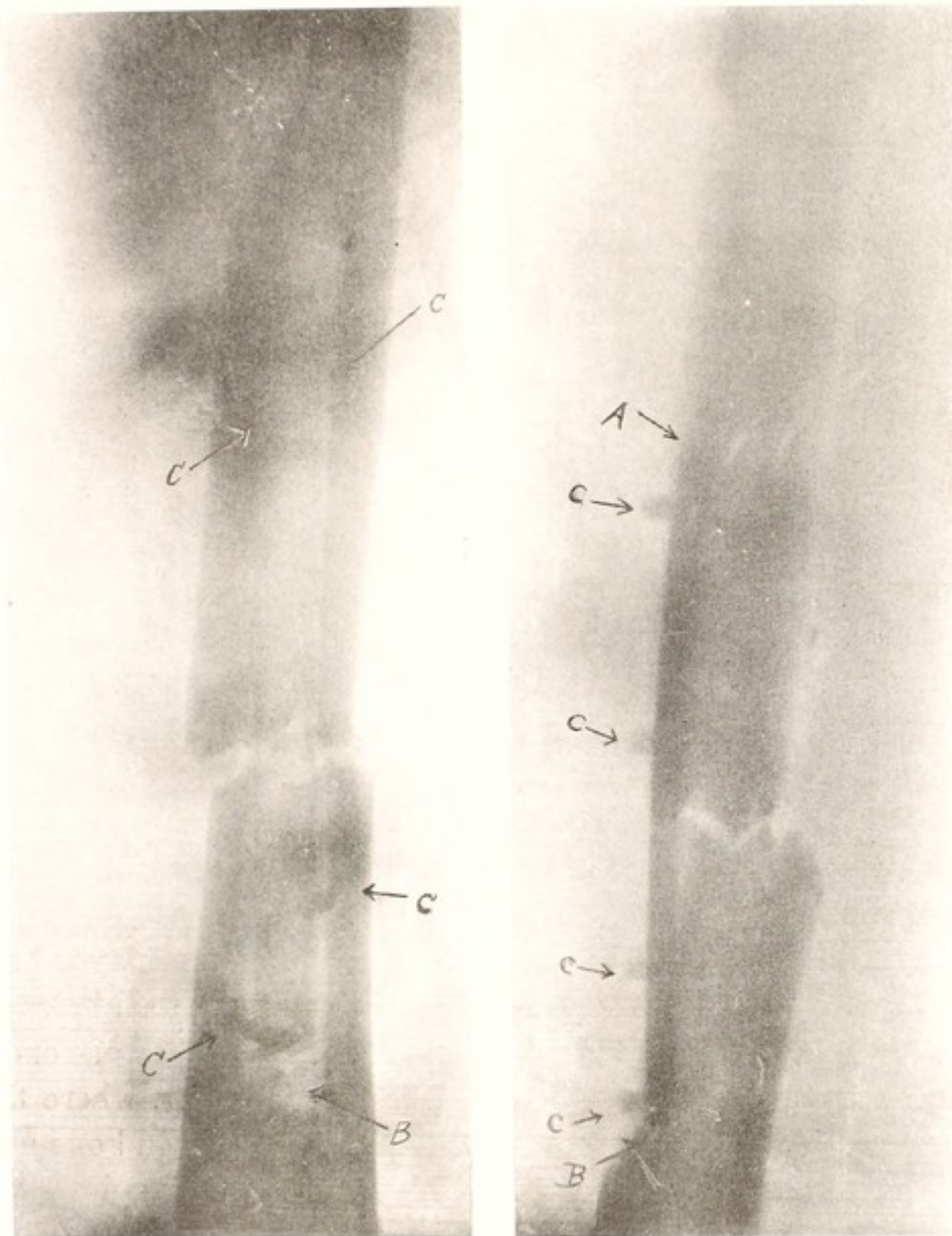


FIG. 129.—Anterior-posterior and lateral view of a fresh fracture of the femur after fixation of the fragments by a sliding inlay graft from the upper fragment. *AB* is inlay graft; *C, C* are the pegs holding it in place. This case had been treated by conservative means for 3½ weeks before operation with 2 in. of over-riding.

fragments, as the case may be. If the inlay graft is to be obtained from the proximal fragment, the periosteum on this fragment is not disturbed, because it is always desirable that the

graft include periosteum as well as endosteum and marrow substance. In fresh fractures, the graft material can practically always be taken from the fragments themselves, as the osteogenetic function of this bone has not become impaired. In most of our later cases of non-union the graft material has also been taken from the fragments, with uniform success. In such cases, however, the inlay fragment should always, when possible, be obtained from the upper fragment and slid downward into the distal fragment. This is important on account of the large amount of rarefaction which always appears in the distal fragment of a pseudo-arthritis of long standing, and the relatively smaller amount of osteoporosis in the proximal fragment.

The author's inlay technique varies somewhat according to individual cases and requirements. The strength of the graft can be made to vary over wide limits. Its thickness will vary according to whether it is obtained from the upper or the lower portion of the antero-internal aspect of the tibia. Unless there is some reason to the contrary, it is better, as a rule, to obtain the graft from the lower part, where the bone cortex is thicker, stronger, and osteogenetically more active. The crest of the tibia at its lower third furnishes the strongest graft on account of its increased thickness of cortex and the fact that two cortical tables meet here.

In small bones, such as those of the forearm, the inlay is best held in place by kangaroo tendon, either placed in drill holes to the side of the groove or wrapped completely about the bone ends. In fresh fractures of large bones, such as the femur, where the marrow cavity has not become filled with new-formed bone and there is nothing to prevent the inlay from slipping into the marrow cavity, the graft and gutter beds are made wider at their periphery than at the marrow side.

The fragment ends are freed and strong traction applied by means of the traction screw on Hawley table. Lambotte clamps are placed on each fragment, and the bone is manipulated into apposition and adjusted so that the ends fit together perfectly. Loose fragments are replaced in their proper positions or are re-

moved as seems wise. When the ends are in apposition they are held so either by strong traction or by the use of a Lowman or Berg clamp placed on the fragments. If the fragment ends cannot be brought into apposition, it is not of serious moment when the inlay graft is used. It is not necessary to shorten the limb in order to get satisfactory apposition, as it would be if metal fixation plates were being used. The graft can safely be allowed to span a hiatus of any length.

The graft to be employed is usually removed from the fractured bone—generally the proximal fragment—and then slid into a groove one-half its length which has been prepared for it in the distal fragment. In a femur, the sliding inlay should be about 5 to 6 in. long.

TECHNIQUE FOR INLAY GRAFT WITH WEDGE CROSS-SECTION

The removal of both long and short grafts is started by making parallel cuts $\frac{1}{32}$ to $\frac{1}{16}$ in. deep, with the twin saws adjusted at a suitable distance apart, depending upon the size of graft and gutter to be formed. The purpose is to outline a graft of uniform width throughout its whole extent. These parallel saw-cuts are then continued through the cortex to the medullary cavity with the single motor saw held at such an angle as to cause the cuts to converge in approaching the medullary cavity, in order to prevent the graft when pressed tightly into position from slipping into the medullary cavity. The ends of the grafts are freed with transverse cuts made with either a very small motor saw or a narrow chisel. The thickness of the saw blade makes sufficient difference in the size of the graft and gutter to allow the inlay, when slid into position, to sink slightly below the borders of the gutter, thus furnishing a margin of the gutter sides above the graft into which holes are drilled obliquely to receive the autogenous dowel pegs.

The inlay, which has a wedge-shaped cross section, is pressed tightly into position and held there firmly by either a Lowman or a Berg clamp while the holes are drilled and the dowel pegs inserted. It may be necessary or wise to allow the drill to sink

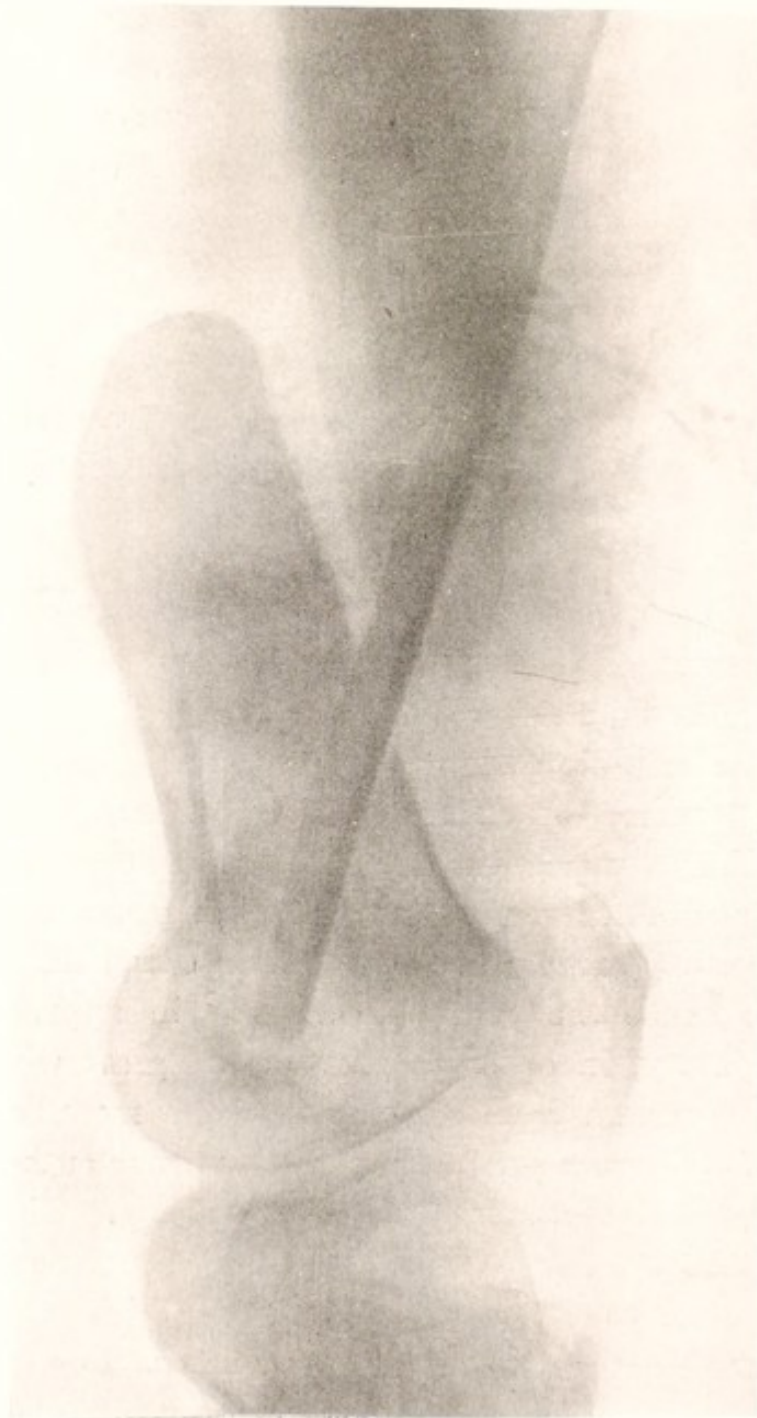

FIG. 130.—Röntgenogram of an old ununited fracture at the lower third of the femur with a marked over-lapping. A bone graft has been removed from the crest of the tibia and inlaid into the lower end of the upper fragment and inserted into the lower fragment by tunnelling this fragment. A proper reduction was impossible on account of adherent popliteal vessels to the lower fragment.

a fraction of or its whole diameter into the edge of the graft. The pegs are obtained by splitting the short segment (removed from the distal fragment for the purpose of making the groove

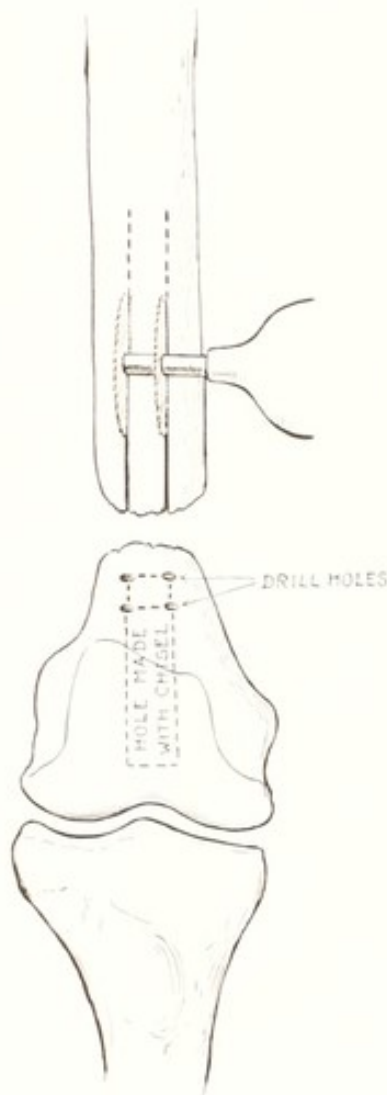


FIG. 131.

FIG. 131.—Diagram showing the method of preparing the ununited fragments of the lower end of the femur, which cannot be got into alignment or apposition (see X-ray, Fig. 130), for the reception of the autogenous bone graft procured from the tibia. The drill holes are made in the four corners of the square tunnel as a guide in cutting out the bone with the narrow chisel. The graft is forced into this tunnel at this end and the other end is then placed in the gutter of the upper fragment and secured.

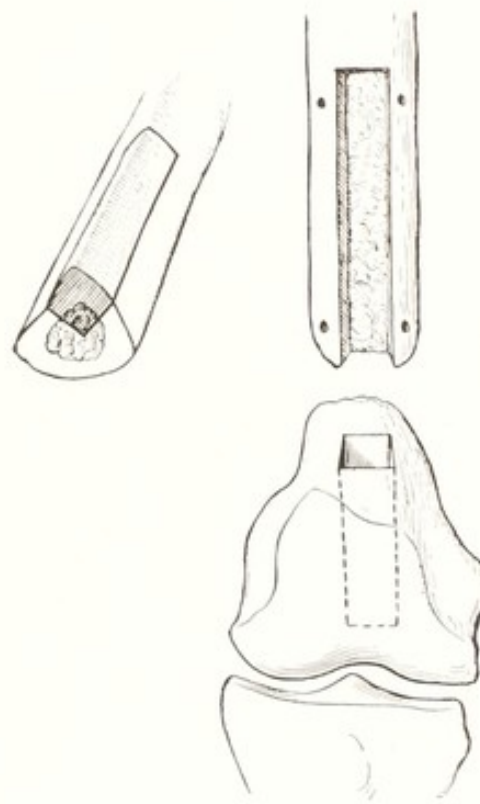


FIG. 132.

FIG. 132.—Diagram showing the gutter in the lower end of the upper fragment completed, also the square tunnel prepared in the lower fragment of this ununited fracture of the femur; also the drawing to the left shows the outline of the graft to be removed from the crest of the tibia. Note that it includes two surfaces and the crest and is cut to the marrow cavity.

for the inlay) into two or three fragments, and pushing them through the author's motor lathe or dowelling instrument. Each

of these dowels, which is long enough to make two or three fixation pegs, is driven lightly into the holes over the inlay, and while an assistant holds its distal end with a forceps the surgeon cuts the peg off with the small motor saw at the desired place. The remaining portion of the dowel is then used in like manner for additional pegs.

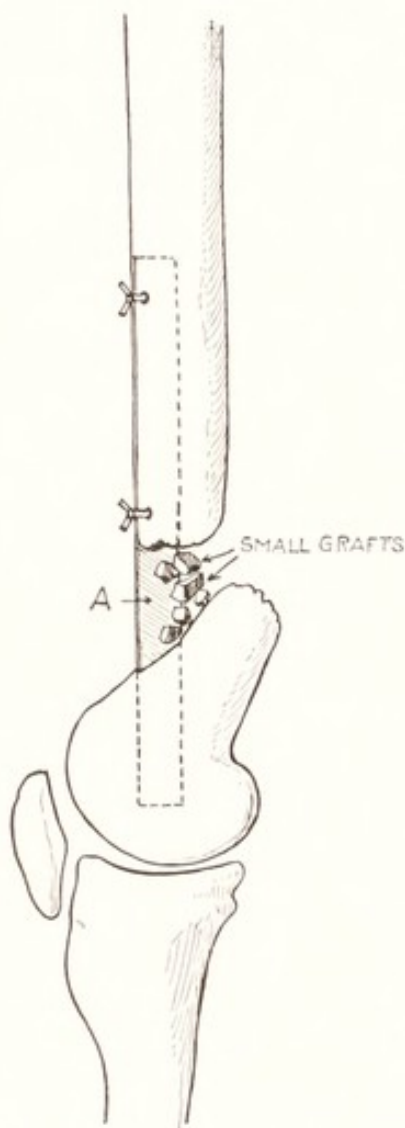


FIG. 133.—Diagram is a lateral view of an ununited fracture of the lower end of the femur with the autogenous bone graft in position uniting the fragments; also note that the space at A has small grafts placed about this free portion of the long graft to aid in the rapid production of new bone. This is illustrative of a case where the fragments cannot be brought into alignment.

In ununited fractures of large bones, where the marrow cavity is filled with a bone plug which prevents the inlay from slipping into the medullary canal, and in all the smaller bones and in all individual cases where the mechanics are favorable, the twin motor saw alone is used in removing the inlay graft and preparing its gutter bed. In fractures of long bones where the difficulty of fixation is great, the inlay is held in place by the bone-graft pegs or heavy kangaroo tendon, or both, as seems best. The fragments are motor drilled on each side of the gutter, and the tendon is placed as indicated by the diagram. When the graft and its gutter bed are formed wholly by the twin saws, the graft is just twice the thickness of a saw-cut narrower than its bed, which allows space for heavy kangaroo tendon to be placed between the graft and gutter wall on each side.

In the case of small bones, such as the radius or ulna, the encircling of the fragments with the tendon is very efficacious in holding the insert firmly in its place. In severe comminuted fractures from gunshots or other causes, where there is a space to be

spanned and the length of the limb is to be maintained by the inlay, it is best to tongue and groove the ends of the graft and bone cortex of gutter ends. The groove should be in the end of the graft, and the tongue in the gutter ends. Any tendency to shortening of the limb by muscular pull, etc., causes the tongue and groove joints to become all the more firmly locked and is thus a sure preventive of shortening. The graft, however

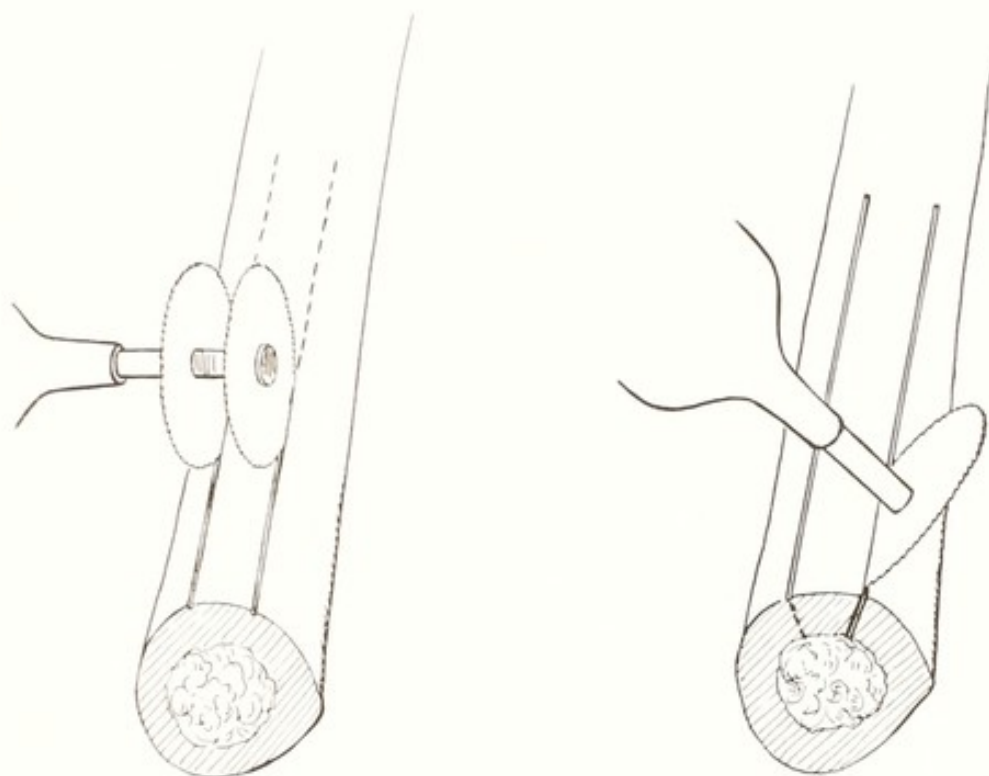


FIG. 134.—Demonstrates author's technique of obtaining the sliding or tibial graft with sawcuts converging to the marrow cavity. This technique is used in fresh fractures of large bones. (See Fig. 135.)

small, will in time hypertrophy, under the action of Wolff's law, and will become the size and strength of the bone whose substance it is supplying. The value of the graft in this type of cases cannot be over-estimated.

An important point in the technique of bone grafting in its application to all types of fractures is that the transplant should be of *sufficient length*. In the case of the intramedullary graft this might afford a great deal of difficulty, but with the inlay graft it is accomplished with ease. A graft 6 in. long can be inlaid as easily as one 2 in. in length. Several unsuccessful

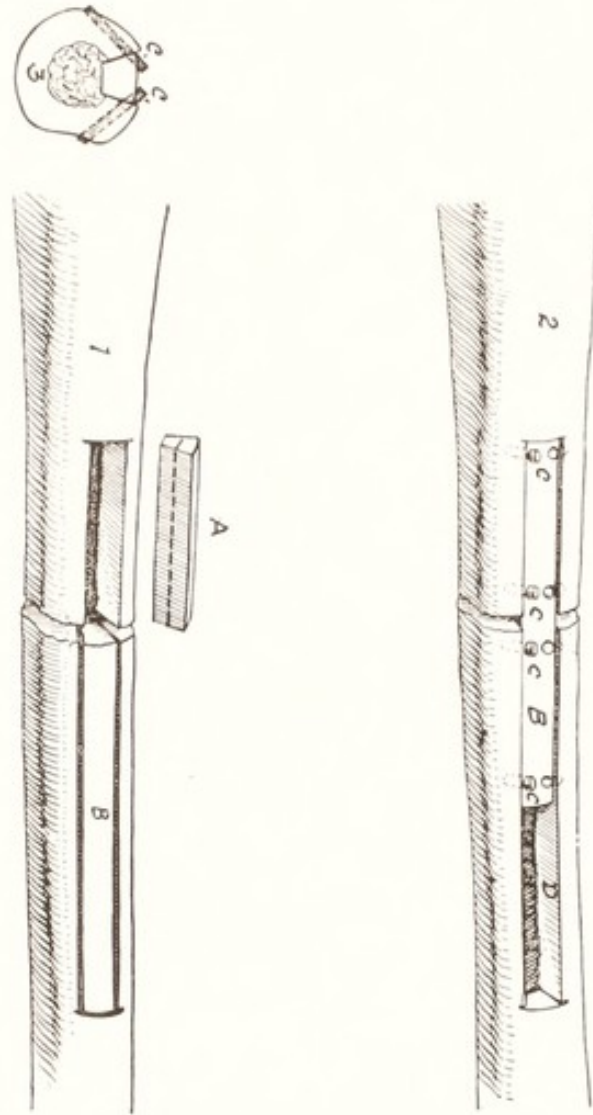


FIG. 135.—Illustrates the author's method of making use of the bone graft with wedge cross-section removed from the fractured fragments or from some other bone, as the tibia, in the treatment of fresh as well as ununited fractures of long bones. The smaller drawing 3, top of page, illustrates the graft dowel pegs in position holding the graft in place, and also shows the shape of the graft and gutter bed on cross-section. *c*, Dowel grafts in place.




FIG. 136.—Diagram of the cross-section of a graft inlaid in a long bone, illustrating the manner of its fixation by kangaroo-tendon sutures passed through drill holes at either side of the gutter. Note that one suture passes through the drill holes and loops up over the graft and is tied; also note that a second suture passes under the graft and through the same drill holes, thus preventing the graft from falling into the medullary cavity. The gutter and graft in this instance are formed entirely by the twin saws.

results have come to the author in which he is sure the contributing causes of failure were the shortness of the graft, the intramedullary method, and the fact that the graft did not extend sufficiently beyond the sclerosed fragment ends to offer adequate and exact contact with vascular osteogenetic bone. In one of these cases the inlay graft had been used, but the

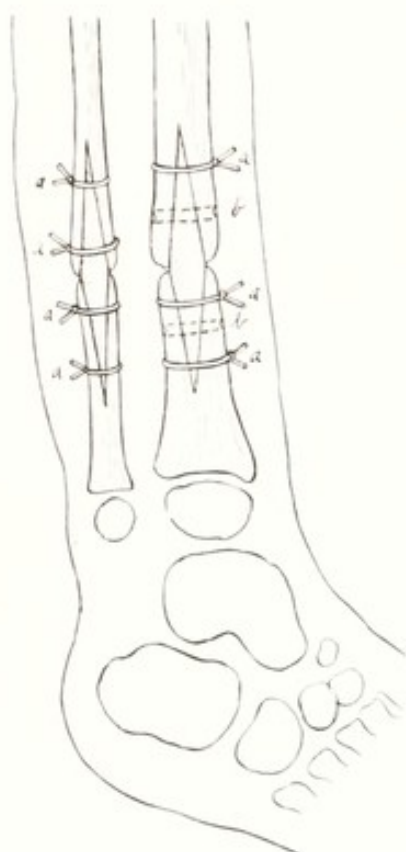


FIG. 137.—Is a drawing of author's modification of his inlay graft adapted to extremely atrophied fragments with marked conical ends (see Fig. 138) and bones of forearm, clavicle, etc., which are small. The ends are split with motor saw and the resulting halves are wedged apart with the wedge ends of the grafts which are moulded into this form during their removal from the well tibia. *aa* Indicates the fixing kangaroo tendon which can be wrapped completely about the fragment end, or it may be placed in drill holes through both graft and fragment ends; *b, b* are bone-graft pegs, which may or may not be used in large bones to supplement the tendon in fixing the graft in place. This drawing is from the skiagram of an actual case.

technique had been most defective and the unsuccessful result was not surprising. The case was a long-standing ununited fracture, with marked sclerosis of bone extending into each fragment for about $1\frac{1}{2}$ in., as was shown by the X-ray. The graft insert was only about 2 in. long and did not even extend through the eburnated bone. The graft should have been not less than

5 in. long, thus extending well into the vascular osteogenetic bone of both fragments, beyond the sclerosed area. This is an important technical point and cannot be too strongly emphasized.

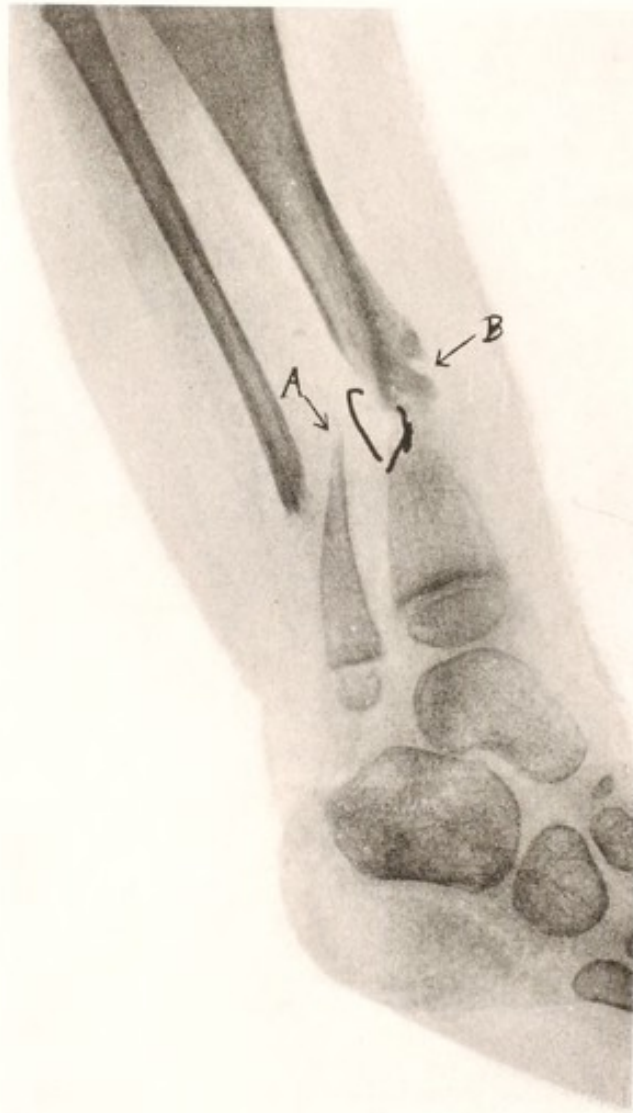


FIG. 138.—Ununited fracture of both tibia and fibula after the insertion of silver wire, which has broken. *B* indicates bone destruction from contact with the metal. The fragments were soft and had spindle-shaped ends, especially at *A*. The preferable technique in this type of pseudarthrosis is to split the fragment ends and insert wedge-end grafts.

In pseudarthrosis the inlay graft may vary from 4 to 6 in. in length—never less than 4—according to the size of the bone fractured, the extent of osteogenetic impairment, or the amount of comminution. If the comminution is extensive, or if the fracture is of long standing, resulting in an unusual amount of

osteoporosis in the fragment ends, it is preferable to obtain a transplant from the sound tibia, in which case the graft bed should be prepared first and packed with a saline compress in order to secure a sufficient hæmostasis. Two parallel saw-cuts

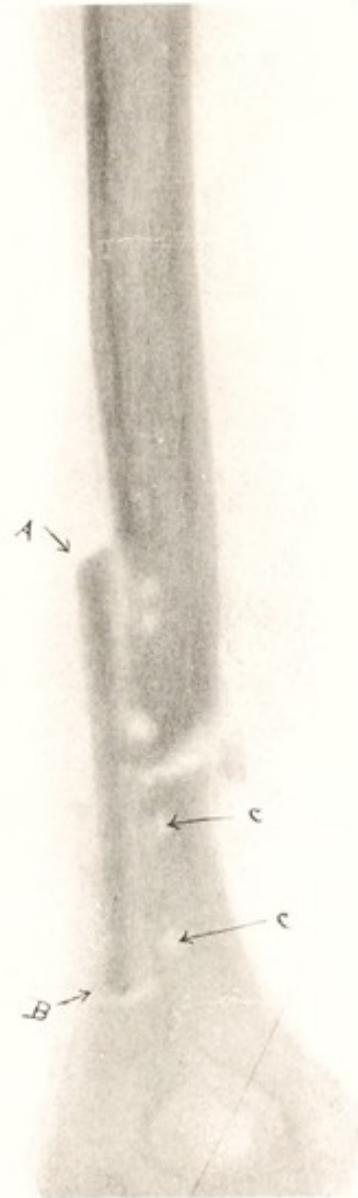

FIG. 139.—Ununited fracture of the lower end of the humerus. *cc* indicates screw holes of former Lane's plate, *AB* is an inlay graft inserted by faulty technique, in that the upper end of the graft was not placed completely into the cortex of the proximal fragment.

are made lengthwise in the fragment ends, extending through the complete thickness of the cortex and into the marrow cavity. The distance between the motor twin saws is readily adjusted, according to the diameter of the bone and the point of fracture.

The graft is then removed from the tibia, either from the crest or from the antero-internal surface, according to the strength required, with the twin saws adjusted as they were in making the gutter. In this way an accurate fit is assured.

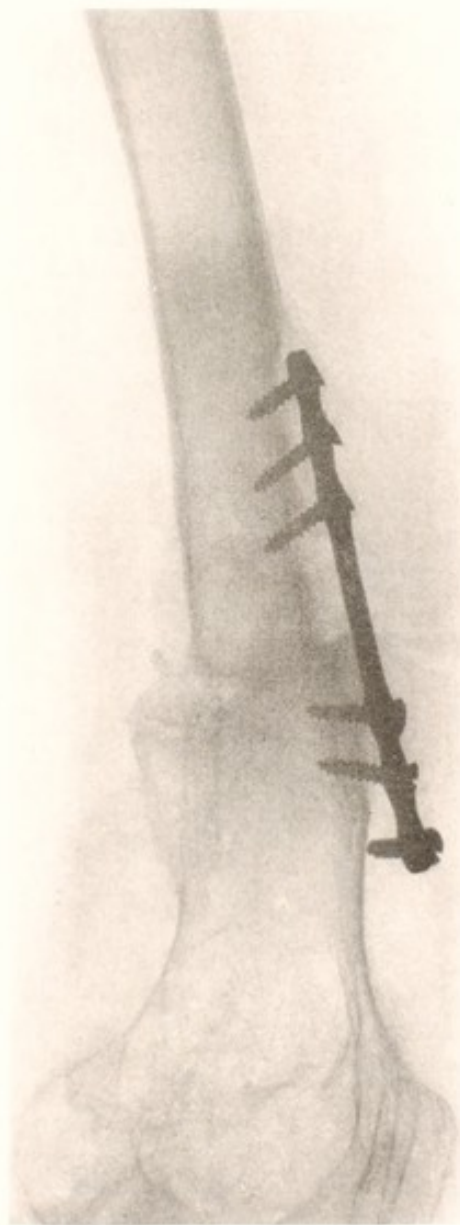


FIG. 140.—Ununited fracture following the application of the Lane plate. The screws have loosened and fallen out. Much bone destruction from contact with the metal is shown. The Lane plate was removed and an inlay graft from the tibia inserted with excellent result. (See Figs. 141, 142.)

The cuts should extend 2 or 3 in. into the end of each fragment, if the transplant is to be obtained elsewhere, as for instance from the tibia, and they should always extend far enough to

reach well into active osteogenetic bone of each fragment. While the saws are cutting, they are constantly sprayed with

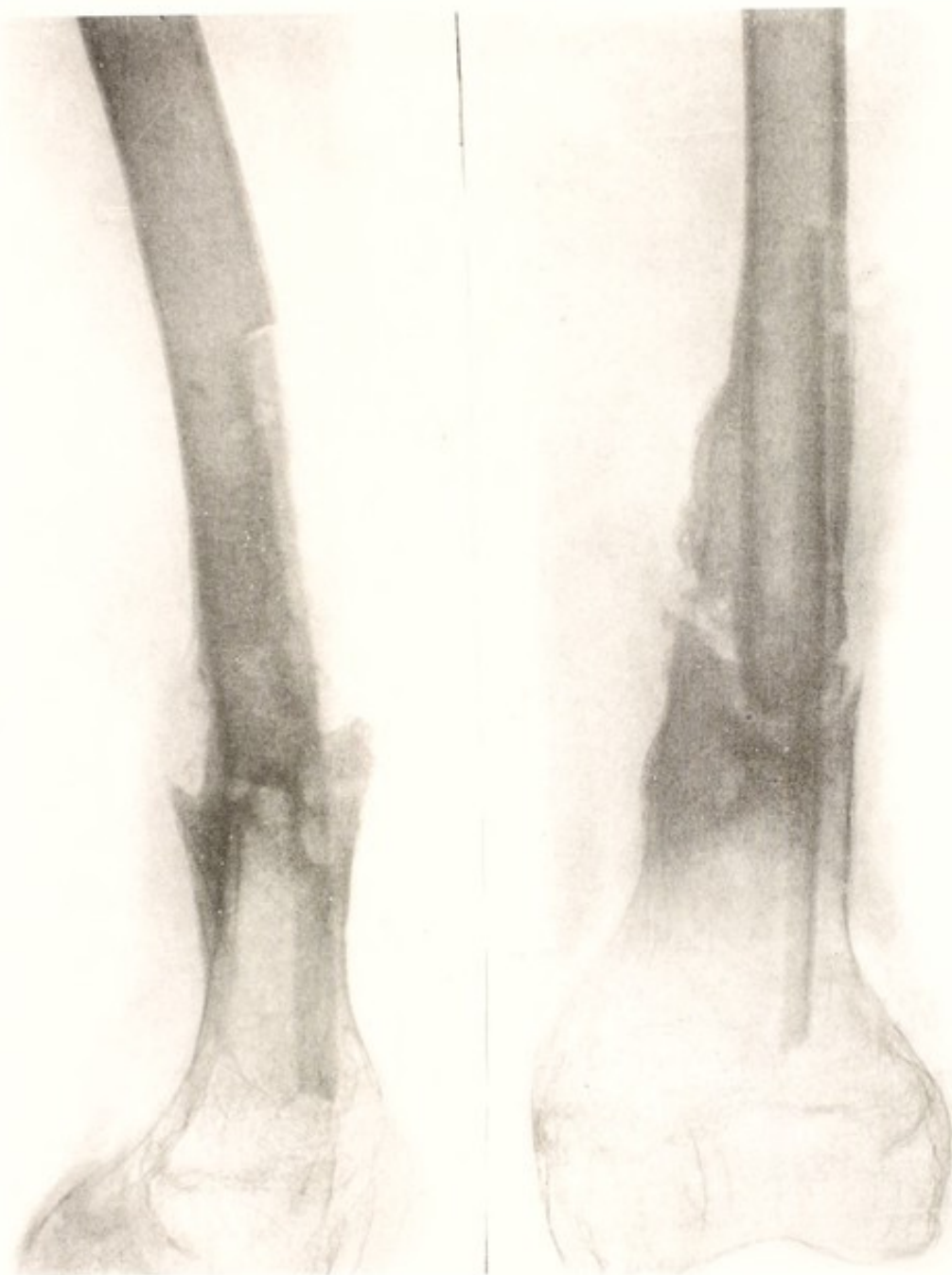

FIG. 141.

FIG. 142.

FIGS. 141 AND 142.—Same case as Fig. 140, after removal of Lane's plates. The röntgenogram shows the bone inlay in place with small grafts placed about fragment ends. Firm union had occurred in 4 weeks.

saline solution, supplied either by squeezing a saline compress held over the saw or by an automatic spray attachment furnished by a sterile tube from a douche bag suspended over the table.

This prevents excessive heating of the bone from the friction of the revolving saws.

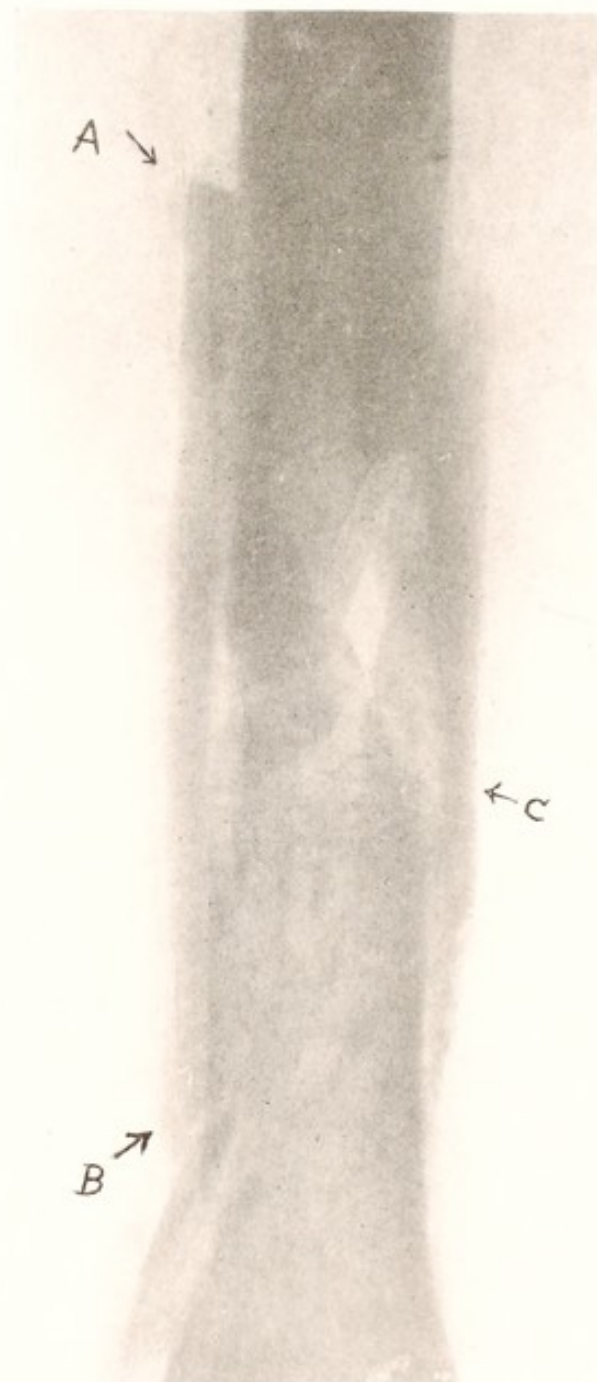


FIG. 143.—A severely comminuted fracture of the femur which had not united or showed any callus formation after 10 weeks of Buck's extension and coaptation splints. A strong graft, *AB*, obtained from tibia inserted in fragments *C* drawn to it with kangaroo tendon. The union was immediate and has remained firm over 2 years. This case was referred by the kindness of Dr. J. B. Bissell.

The ends of the graft, as well as the strips of bone which, when removed, produce the gutter graft beds, are cut for pur-

pose of removal with a circular saw so small that it does not encroach into the walls of the gutter at the sides.

If the graft is to be obtained from one of the fragments, the twin-saw cuts are made twice the distance into that fragment. The strip of bone thus obtained is slid endwise into the gutter

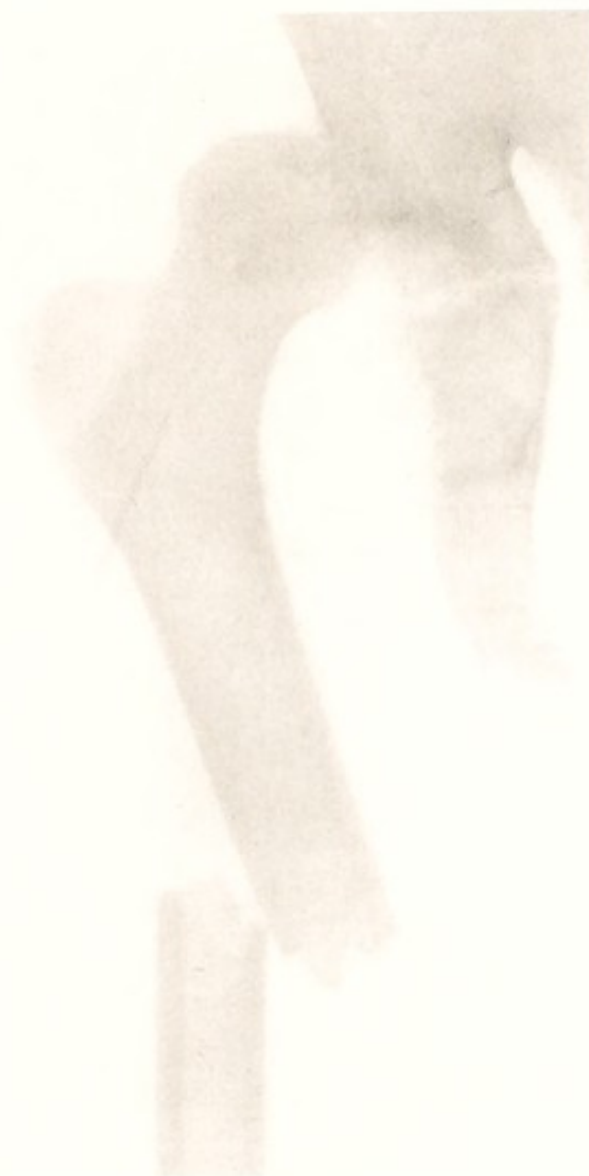

FIG. 144.—By the kindness of Dr. Emil Geist. Fractured dislocation of the femur. Author's inlay graft was used for fixation. (See Fig. 145.)

in the other fragment. The fragments are fixed by holding the inlay firmly in place by heavy kangaroo tendon or by bone-graft pegs, as the case indicates. The kangaroo tendon is passed through holes drilled by the motor in the cortex on either side

of the gutter. The tendon—two strands in each fragment—is threaded through from one side of the gutter to the other and is then pulled up from the gutter in the form of loops, under which the inlay graft is forced into place, and then the kangaroo

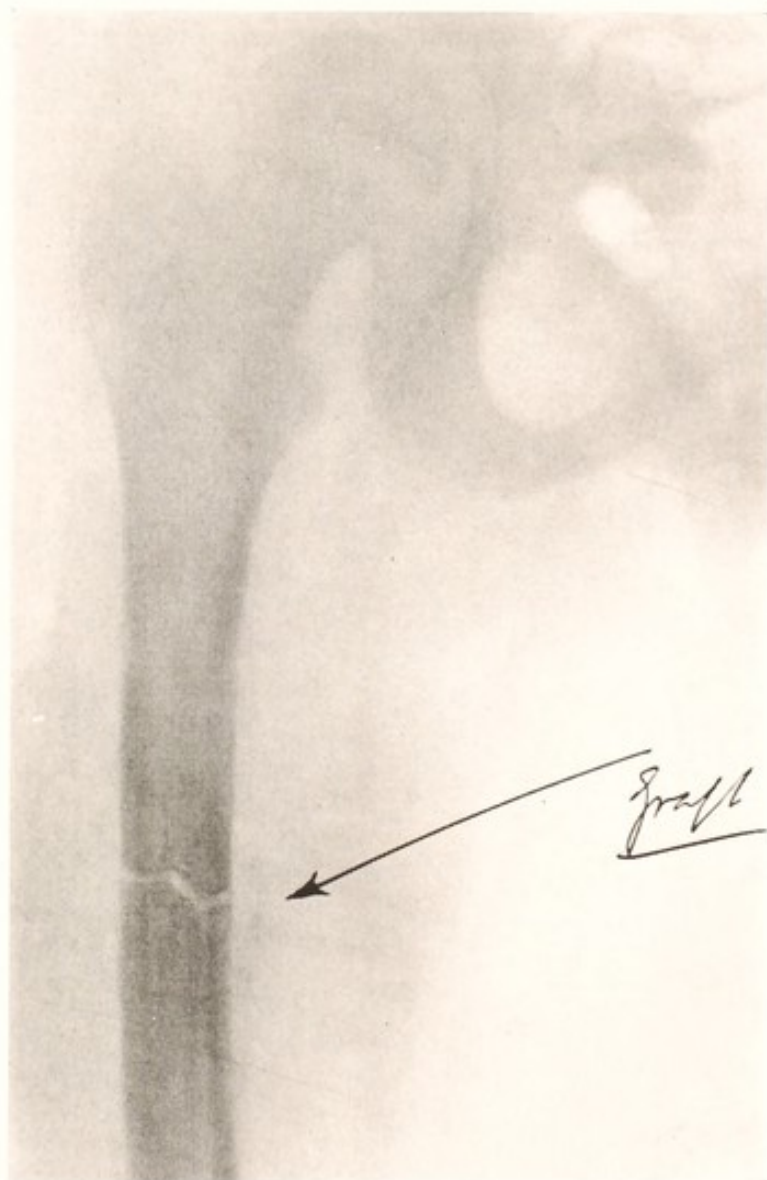


FIG. 145.—Röntgenogram of a transverse fracture of the femur showing perfect alignment. The inlay bone graft fixing these fragments can be faintly demonstrated near the centre in the long axis of the bone. A perfect result was produced.

tendon is tied over it. The bone removed in the form of sawdust by the twin saws causes the graft to be just enough smaller than the gutter to allow room for the kangaroo tendon.

If the bone is large and the problem of mechanical fixation is more difficult, bone-graft pegs may be used exclusively or

may be supplemented by kangaroo tendon. The bone-graft pegs are made by sawing longitudinally the piece of bone removed for the purpose of producing the gutter into two or three strips, which are turned into dowel pegs by pushing them through the motor lathe. The inlay graft is held in place by clamps while, with the electric drill, holes are drilled into the cortical bone of the sides of the gutter bed. The pegs, which always fit accurately, on account of the drill being of the same diameter as the aperture of the dowel cutter, are forced into place by a few gentle blows with a mallet, and are cut off with a motor saw close down so that just enough projects to hold the inlay securely in place. The original dowel pegs are from 2 to 3 in. long, and will make from two to four fixation pegs. Numerous small fragments of bone are placed in between the ends of the fragments and about the graft at that point, just before closing the wound. These fragments should be of active osteogenetic bone, and are best made by a Rongeur forceps. Macewen was the first to point out that the smaller the bone graft, the greater its *relative* osteogenesis. This has been repeatedly confirmed by the author from both surgical and experimental experience.

By this technique foreign bodies are entirely avoided. The material used is either autogenous bone or absorbable material. The fit of the inlay and the pegs must be accurate by virtue of the motor-cutting tools employed.

This technique also allows the most ideal coaptation of the graft to its bed; that is, every graft should comprise four different tissues—namely, periosteum, compact bone, endosteum, and marrow substance; and this is the only technique which permits of the coaptation of each of these individual elements to those of the recipient bone. In three cases where there had been non-union and loss of bone following severe comminution, or osteomyelitis with death of the complete diameter of the ends of the fragments after Lane plating, amputation or marked shortening was avoided by spanning the areas with long inlays. In one case, where $2\frac{1}{2}$ in. of the tibia had been destroyed by osteomyelitis, the graft was placed so as to span the granulating

cavity, and although it was impossible to cover the graft at the affected point on account of a large sinus in the skin, neverthe-

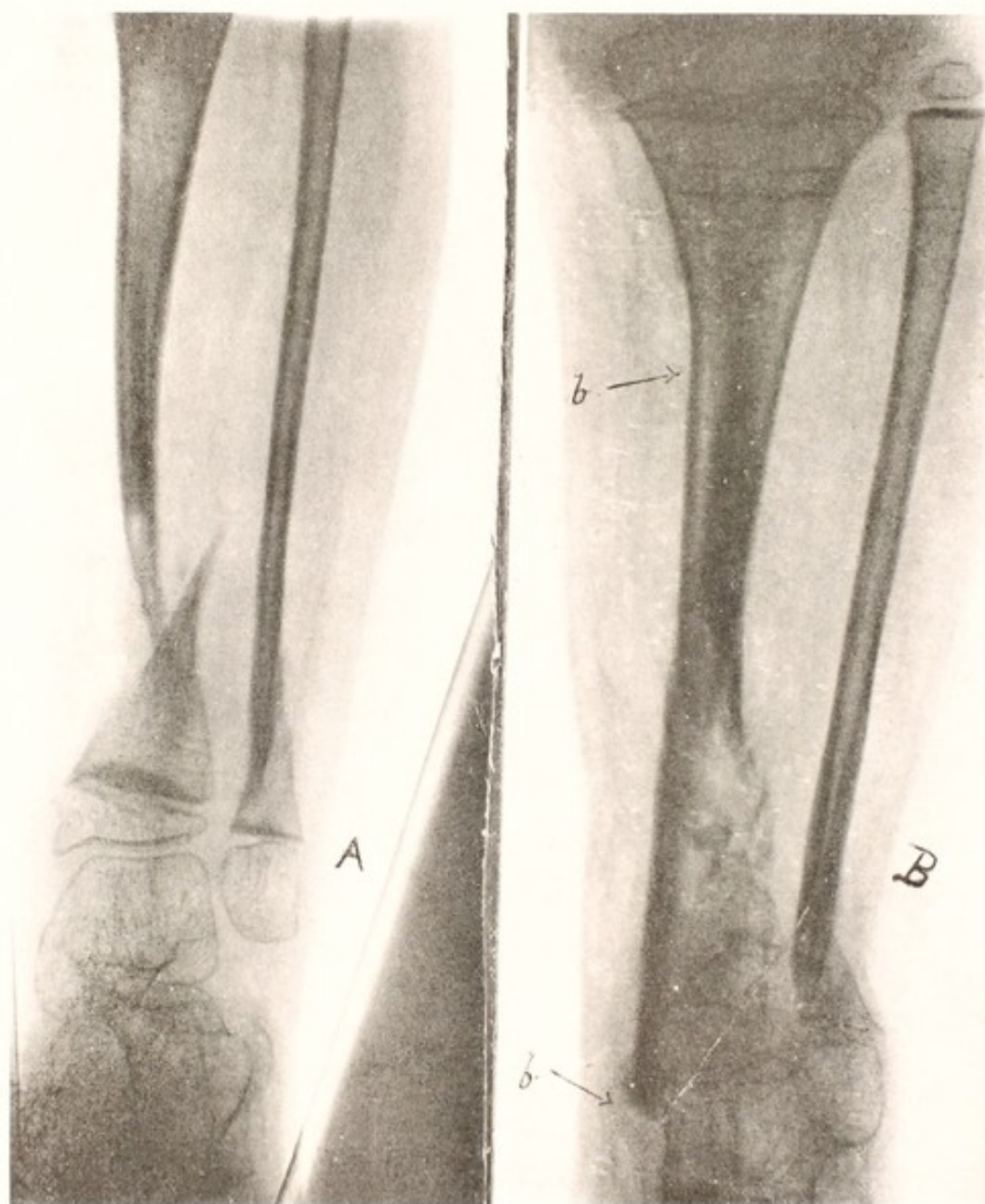


FIG. 146.—Before and after insertion of bone graft, *bb*, for ununited fracture of the tibia of 10 years' duration in a child of 11 years. Several unsuccessful operations to secure union, including an intermedullary graft, had been done. The graft was inlaid into the lower fragment by the author's usual technique. There had been so much atrophy in the upper fragment, and its lower end had become so conical shaped, that it was split upward for about 1½ in. and the upper wedge end of the graft was inserted into the saw-cut cleft. The resulting tongue and groove joint was held by two strands of kangaroo tendon wrapped about it. (See Fig. 137.) Firm union between the graft and the fragments occurred immediately.

less granulations slowly covered up the graft—none of which sequestered—and a perfect result was obtained (see Figs.

153, 154 and 155). One could not wish better proof of the germ resisting property of the bone graft.

Another instance which illustrates the marked efficacy of the inlay graft is that of a case referred to the author by Dr. W. W. Plummer at a clinic held at Buffalo in March, 1914. The patient was a boy, 11 years of age. In 1904, when he was a year old, both bones of the right leg were fractured, followed by complete non-union due to neglect. In 1906 an operation was done for non-union. An intramedullary graft obtained from the well leg was used. On account of bone atrophy, the cortex of the tibial fragments had to be split longitudinally with a chisel. In 9 weeks there was a very fair degree of rigidity. A few weeks later the boy fell and refractured the tibia, and this fracture failed to unite. In 1909 another operation for non-union was performed. This time, on account of bone atrophy, the region of the bone ends was opened and several small pieces of bone, taken from the well tibia and including periosteum and medulla, were introduced. This operation also failed. In March, 1914, the author operated, using the motor bone outfit, and an inlay graft taken from the well tibia was inserted. The graft was fixed into the lower fragment by the usual inlay technique, but the lower end of the upper fragment proved to be so atrophied and conical in shape (see Fig. 146A) that it was decided to split it upward with the motor saw for about 2 in. The upper end of the graft was shaped into a wedge at the time it was removed. This wedge end was forced into the saw-cut in the lower end of the upper fragment (see Fig. 137, diagram of author's technique), and the lower end of the graft was fixed into the lower fragment by the usual inlay technique. A plaster-of-Paris splint was applied, which was removed early in June, 1914. Union was certain. At present the patient is walking on the leg, which is short from the old deformity. The union of the tibia is secure, and the blood supply of the extremity is much improved. This case of relief after 10 years of non-union is a striking illustration of the efficacy of the inlay autogenous graft.

Four of the author's series of ununited fractures had previously been unsuccessfully operated upon by the intramedullary technique. These failures are largely explained by the fact that this technique affords a faulty histological contact of graft to host fragments, even when well executed.

Two important advantages of the inlay technique as applied to ununited fractures are: first, the ease with which sufficient contact with osteogenetic bone beyond the sclerosed area can be secured; and second, the readiness with which this contact can be varied in accordance with the difficulties encountered. The more desperate the case and the more frequently it has been unsuccessfully operated upon, the longer must be the inlay transplant. One of the author's series, an ununited fracture of the radius and ulna, had been operated upon unsuccessfully seven times—including the use of Lane's plates, silver wire, nails, and intramedullary grafts—and it was then pronounced impossible to secure union. (Fig. 147.) The inlay grafts employed were very long, extending to the tips of the styloid processes and well beyond the eburnated area in the upper fragments. In 5 weeks there was firm union. The X-ray showed that all through there was firm union of graft to that portion of the distal fragment beyond the eburnated area. There was, however, no union between the fragments themselves or between the eburnated area in the ends of the fragments and the graft. The result would undoubtedly have been a failure had the graft inlays been short and had not extended well beyond the areas of the fragment ends. Again, it would have been most difficult to have inserted medullary grafts without breaking the ulna graft while inserting the radial transplant, or *vice versa*. To the author's knowledge, a united fibula has been broken in attempting to insert the intramedullary graft into the tibia. It would have been most difficult to have reached and secured satisfactory contact with osteogenetic bone beyond the eburnated zone. This difficulty, however, is inherent in the intramedullary technique, and no doubt was largely responsible for the previous failure from this operation in this particular case.

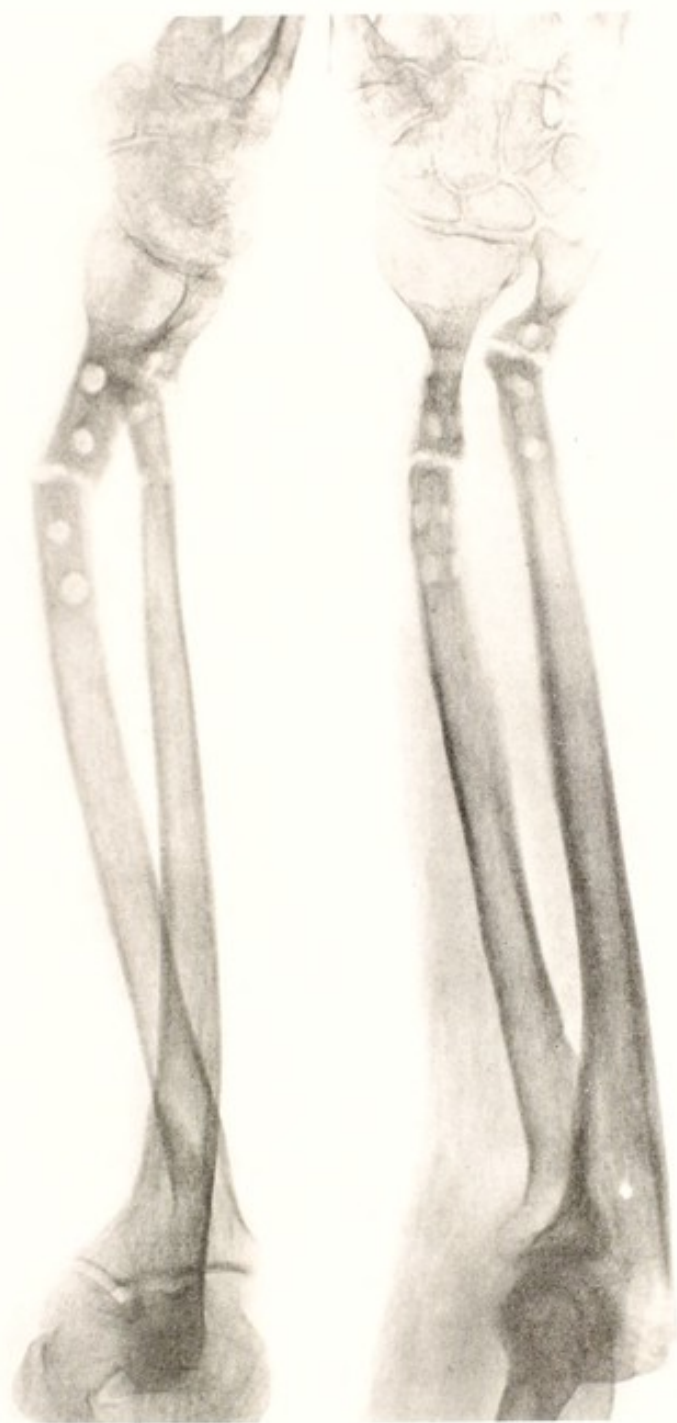


FIG. 147.—Röntgenograms of ununited fractures of the radius and ulna of 4 years' duration after seven unsuccessful open operations to secure union, including Lane's plating, wiring and intramedullary bone grafting. The röntgenograms show the large holes and bone destruction in both radius and ulna, which originated from the screws of the former Lane's plates and the metal contact of the plate itself.

A strong argument for the inlay technique, as compared with the intramedullary, is its universal applicability to all types of fractures of the long bones, however near the joints they may

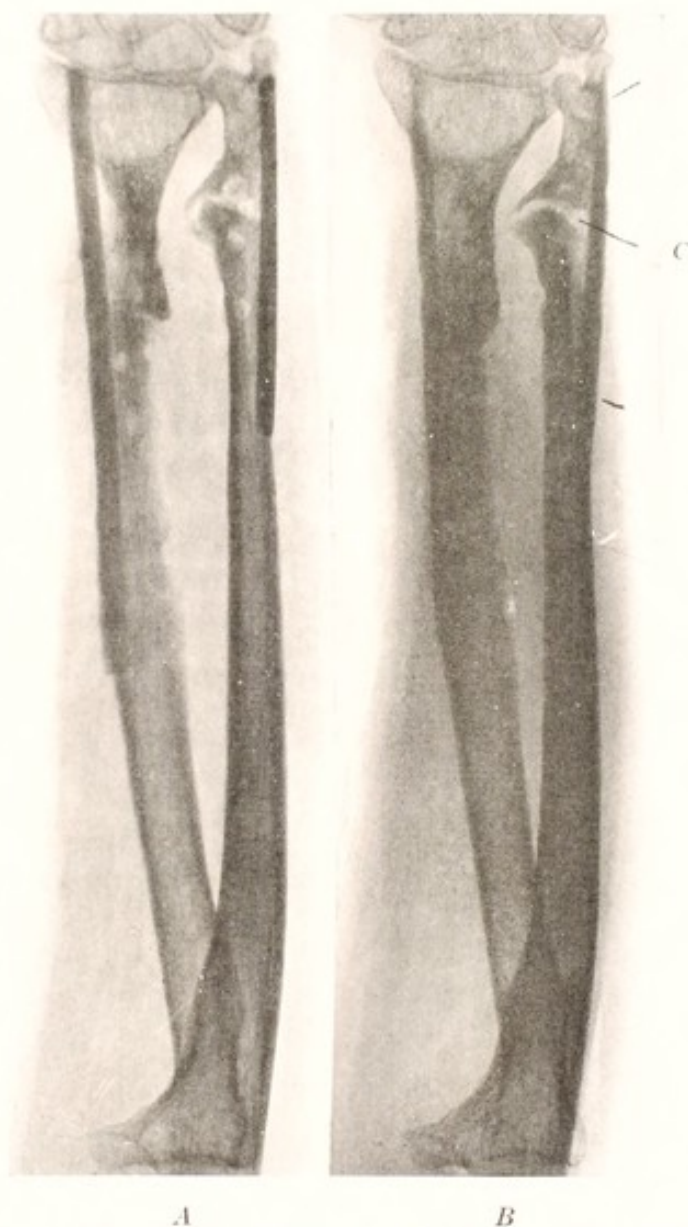


FIG. 148.—*A* is a röntgenogram taken 5 weeks after the successful implantation of tibial inlay grafts; *B* was taken 6 months after the operation and shows that the grafts have lost their sharpness of outline and are taking on the density and characteristics of the bone in which they are inserted. On account of the desperate nature of the case, very long implants were used and the wisdom of this is shown at *C*, where there is no union between the fragments or between the proximal fragment and the graft for a space of two-thirds of an inch from the end of the fragment, although there has been firm union for 5 months, because of the long graft coming in contact with the vascular-osteogenetic bone back of the sclerosed bone at the ends of the fragments.

be. A good illustration is an ununited fracture of the tibia in good apposition near the ankle-joint, where the fibula has be-

come united. The accessible portion of the fibrous union is removed. There is no occasion to disturb the relationship of the fragments. The thickened periosteum is split and peeled sidewise on the lower fragment only, and with the motor twin saws and a narrow chisel a groove is made in the lower fragment

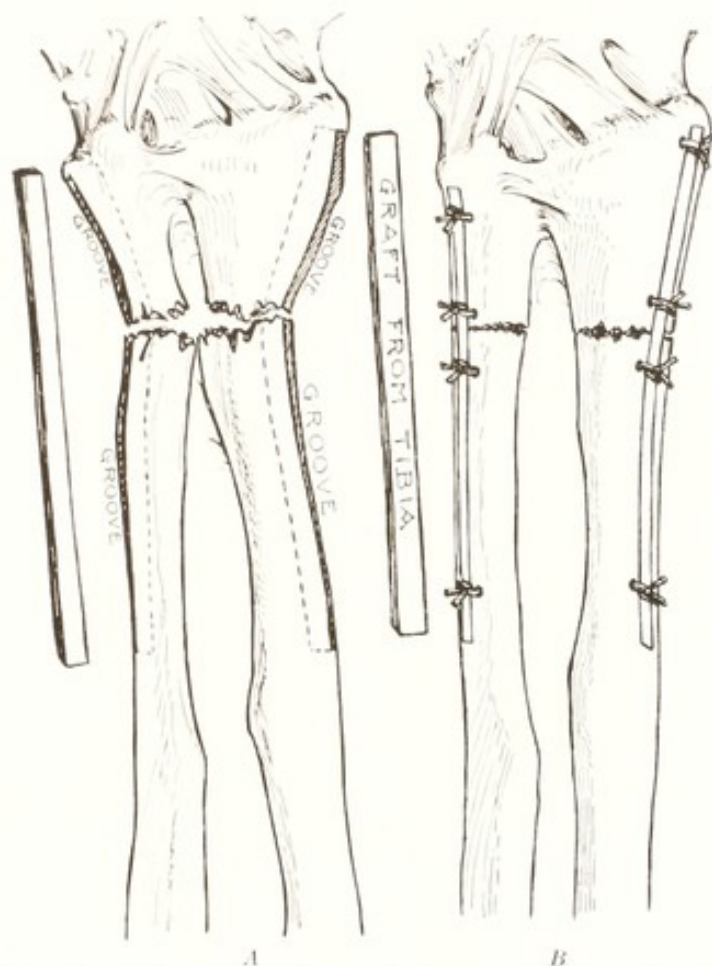


FIG. 149.—Drawings illustrating the technique carried out in the case of which Figs. 147 and 148 are röntgenograms. *A* indicates grooves and grafts before insertion and *B*, after the insertion of graft and kangaroo-tendon fixation sutures. The grafts were long and were placed into the radial side of the radius and the ulnar side of the ulnar. The radial and ulnar fragments were very satisfactorily separated by drawing them to the grafts with kangaroo sutures as indicated in *B*. This is a special important feature of the inlay graft as compared with that of the intramedullary type in its application to fractures of both bones of the leg or forearm. (See also Fig. 137.)

completely to the tip of the malleolus, if the fragment is very short. Then, by means of the same twin saw, a cortical graft 4 or 5 in. long is removed from the upper fragment and slid down into the groove in the lower fragment.

When the fracture is very near a joint, as the ankle, and the lower fragment affords a very short contact, the graft can be

extended to the tip of the malleolus so that joint support will be largely supplied by the end of the graft which is in the malleolus as in a shell, even if by chance bony union should not occur between the graft and lower fragment, provided, of course, that union has taken place between the upper fragment and the graft,

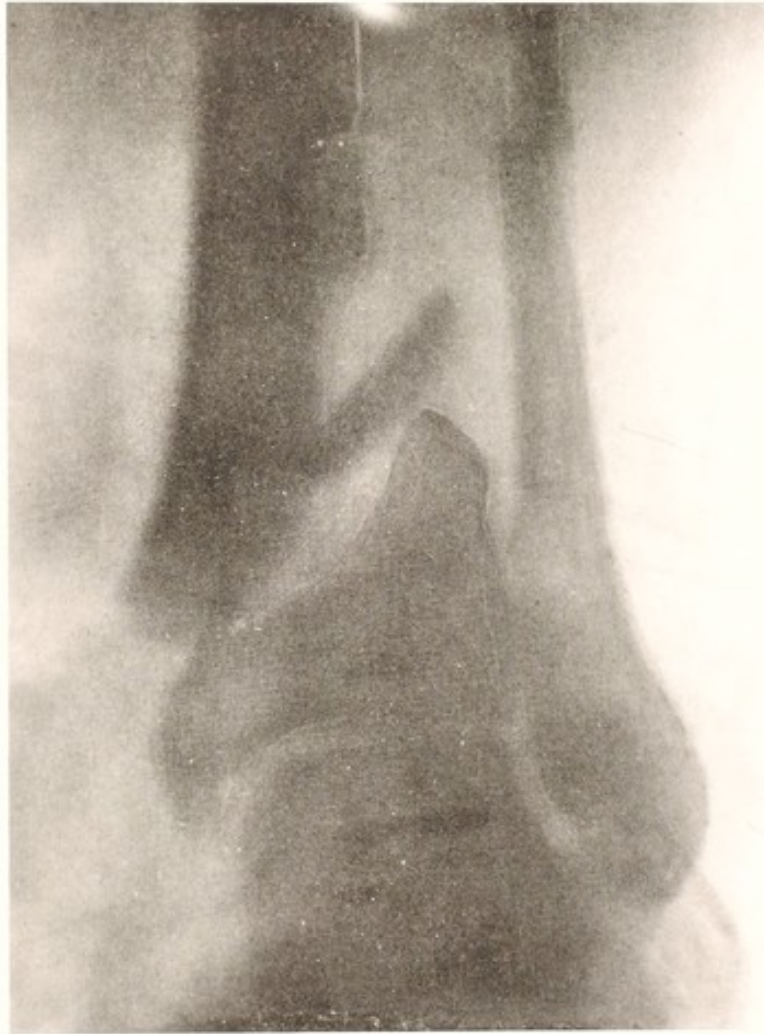

FIG. 150.—Röntgenogram of a comminuted fracture at the lower end of the tibia with displacement of the fragments. This is the same case as Fig. 151, 2 months after the fracture.

which should be made certain by a long inlay and consequent extensive contact. (Fig. 151.)

In exceptional instances, there is no necessity for using any means to hold the graft in place.

To fix the inlay in place, the question arises of the choice for the purpose between bone pegs and heavy kangaroo tendon

placed in drill holes or wrapped entirely around the bone when it is small, as the bones of the forearm.

An important mechanical feature of the inlay, which should not be overlooked, is that if it is inserted in proper relationship to the forces which are causing displacement it becomes by its own inherent mechanics a most effective fixation agent, irrespective of the means used to keep it in place. An illustrative case is that of a very stout woman with a 1-year ununited fracture of the tibia (about 1 in. from the ankle-joint). (Fig. 151.) There was a marked displacement of the lower fragment and foot posteriorly. The bone ends were freshened and the lower fragment was forced forward into place. Although there was a strong tendency for this fragment to spring back into its old position, a long inlay placed into the inner side of the fragments held them securely by virtue of the mechanics of the inlay, without depending upon the kangaroo tendon and the graft pegs which held it in place. On the other hand, if this inlay had been placed into the anterior or posterior surface of the tibial fragments, its fixation force would have been wholly dependent upon the pegs or tendon which held it in place. (See also Fig. 107.)

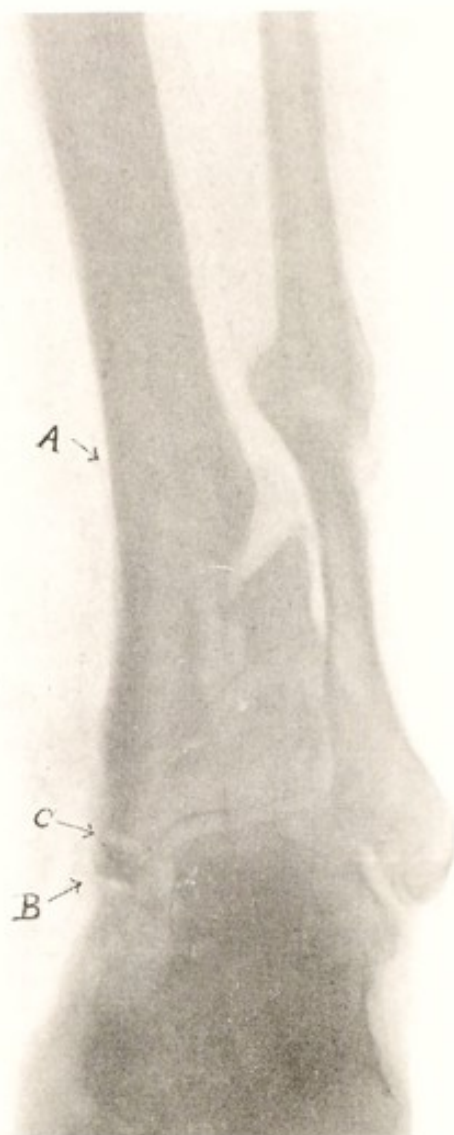


FIG. 151.—Ununited fracture of lower end of tibia of 1 year's duration in a woman of 250 lb. The lower fragment was markedly displaced posteriorly. *AB* indicates graft in which was inserted into the malleolus completely to its tip on account of the shortness of the lower fragment. The inherent mechanics of this inlay into the inner surface of the tibia prevented the relapse of the position of the lower fragment. (See Fig. 152.)

The author has repeatedly and successfully used the bone graft for spanning through tuberculous foci in Pott's disease of the spine and tuberculosis of the ankle- and knee-joints. The cortical bone graft has always withstood pure tuberculous infection, provided it had satisfactory contact with healthy bone on each side of the infected focus. It will also resist attenuated pyogenic infection under similar conditions, as has been proven

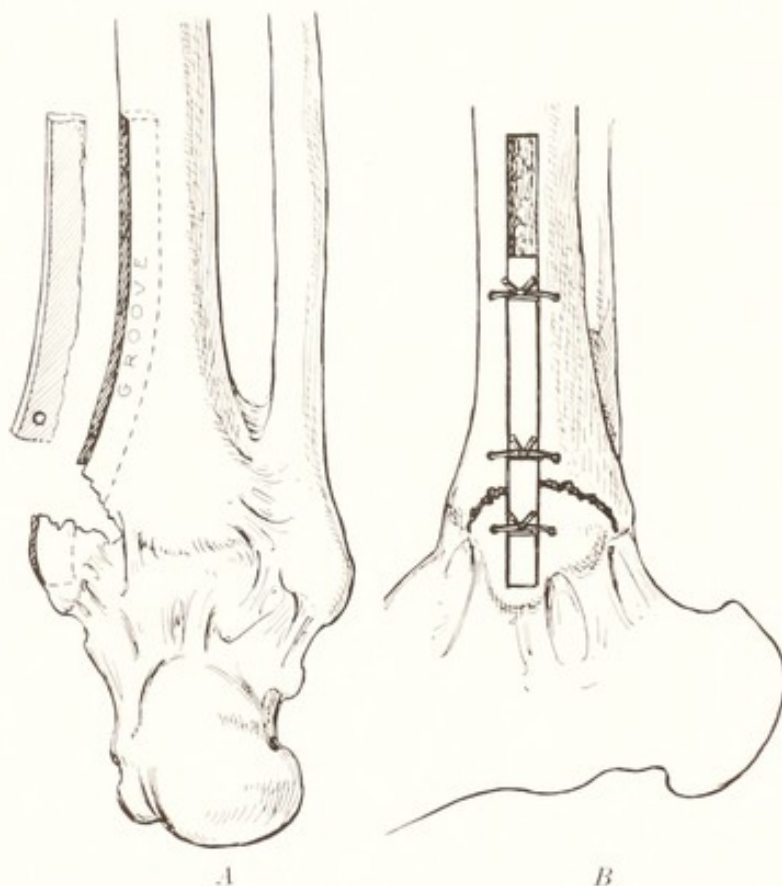


FIG. 152.—Bone-graft inlay for fracture of the internal malleolus. *A* shows inlay graft removed from its bed by the twin motor saw, dotted lines in shaft and fractured malleolus indicating the gutter. *B* shows the external malleolus restored to its position and the inlay fixed by kangaroo-tendon suture. The kangaroo tendon in the malleolus is placed through drill hole in lower end of graft.

by experiments conducted by Phemister and the author in both surgical (Fig. 154) and laboratory work. (See Albee: "Experimental Study of Bone Growth and the Spinal Bone Transplant," *Jour. A. M. A.*, April 5, 1913, lx, pp. 1044-49, also Chapter III.) The importance of this inherent germ-resisting property of the bone graft is readily apparent, in that it doubly assures its trustworthiness as a general surgical agent (when compared with

metal). Especially is this true in its application to compound fractures in which infection is feared or where a mild infection has already occurred. The following is an illustrative case:

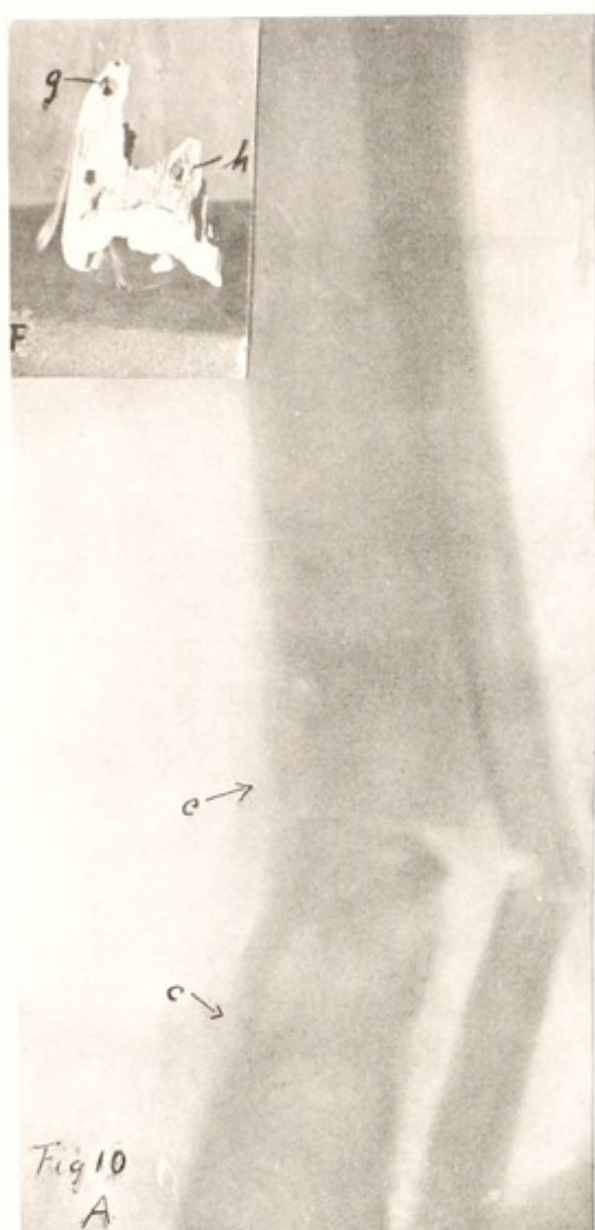


FIG. 153.

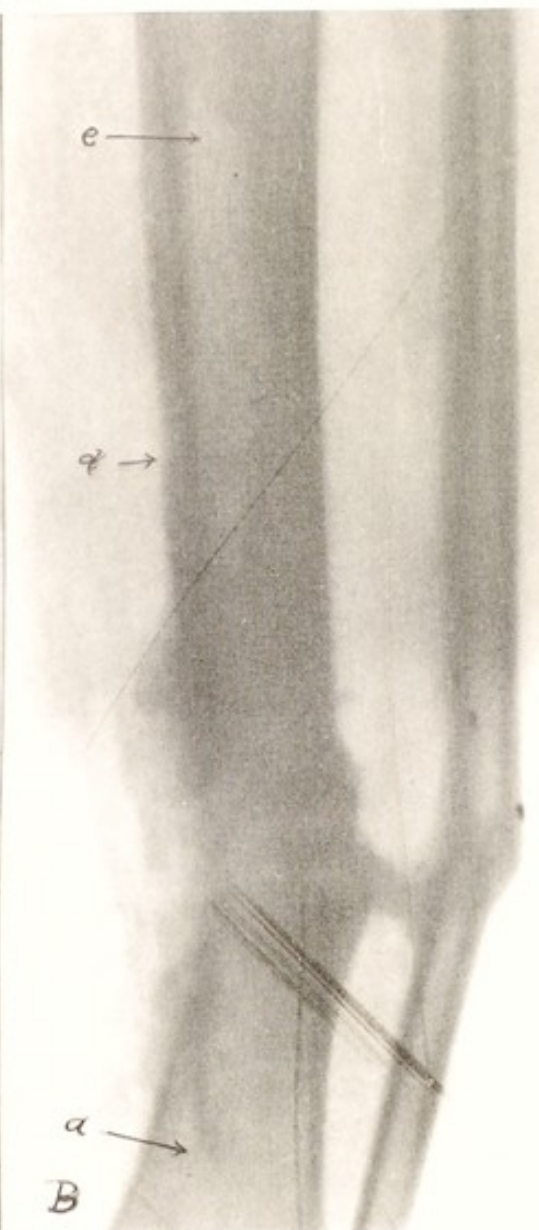


FIG. 154.

FIGS. 153 AND 154.—*A* is a röntgenogram of an infected, ununited fracture 6 months after the insertion of two Lane's plates. The plates were removed a few weeks after their insertion. *ec* Indicates a sequestrum of the complete diameter of the tibia from the upper screw holes of the Lane plate to lower end of upper fragment of which *F* is the photograph, and *g* and *h* are the screw holes. *B* is röntgenogram 4 months after the insertion of the graft. Bone union between fragments and graft was immediate, although there was a discharging sinus and a hiatus of 2 in. at the time of operation. (See text.)

A man, 45 years of age, came to the author with an infected ununited fracture of the tibia of 6 months' duration, and gave the

following history: Six months previously he had sustained a fracture of the lower third of the tibia and fibula. The tibia was immediately plated with two long Lane's plates. Infection occurred, and the plates were removed in 3 weeks' time. The wound continued to discharge profusely, and an X-ray examination revealed a sequestration of the complete diameter of the upper fragment of the tibia, from the upper screw holes of the Lane plates down to the end of the fragment. The discharging sinus was increased in size and the sequestrum, about $2\frac{1}{2}$ in. long, comprising the entire diameter of the tibia, was removed. The cavity thus produced was packed and the leg was put up in a plaster case, making use of the united fibula to prevent approximation of the remaining tibial fragments and consequent shortening of the leg. At the end of 8 weeks the sinus was still discharging a considerable amount of sero-purulent material and, on account of the large cavity between the fragment ends, the prognosis as to when the sinus would heal was most uncertain.

As the patient was very anxious to have something done immediately to get a union of his tibia, it was decided to make the attempt, and with the use of the motor twin saw a strong cortical graft was dragged down from the upper fragment into a groove made with the same instrument in the lower fragment. (The cavity was first curetted out carefully and filled with tincture of iodine—3.5 per cent.—and the whole operating outfit was then changed.) The inlay was slid into place from the upper fragment, spanning an hiatus of $2\frac{1}{2}$ in., and held with peg grafts which were made on the operating table by splitting into three portions with the motor saw the fragment of bone removed from the lower fragment in making the groove for the inlay, and then shaping these portions into three long pegs by means of the motor lathe. On account of the large size of the sinus, it was impossible to cover about an inch of the centre of the graft, where it spanned across the sinus opening. However, much to our gratification, the convalescence was most satisfactory; granulations covered the exposed portion of the graft very rap-

idly, and there was firm union between transplant and fragments in 6 weeks' time. In 4 months' time, Wolff's law had caused the graft to hypertrophy, and the hiatus between the tibial fragments had completely filled in and the long bone had apparently become as strong as it had ever been. (Fig. 155.)

This case has a very important bearing in demonstrating the striking superiority of the bone graft as compared with internally inserted metal. The graft was inserted into a wound

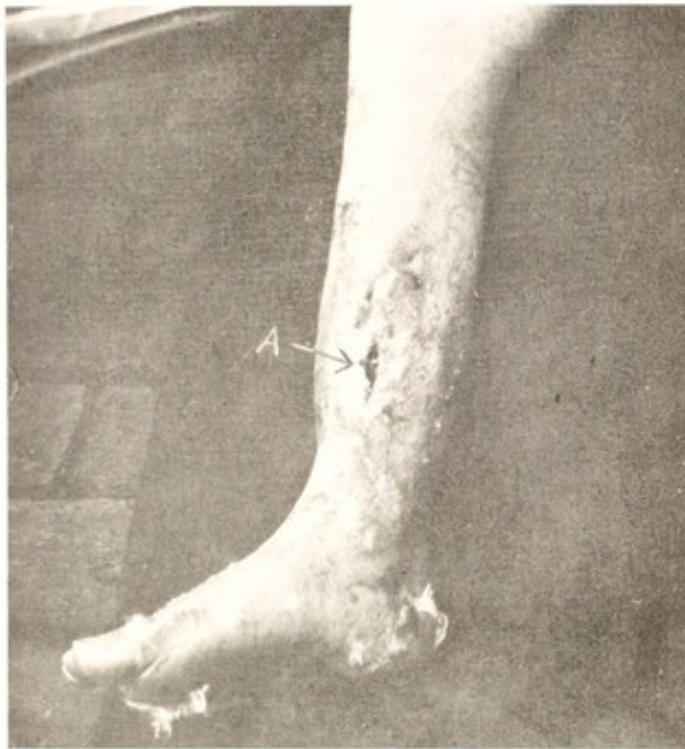

FIG. 155.—Photograph of same case as Figs. 153 and 154. A indicates large sinus at the bottom of which is the uncovered graft, which it was impossible to entirely cover at the operation. This sinus was discharging sero-purulent material at the time the graft was inserted. Nevertheless, the graft healed in immediately and covered over with granulations.

which even showed macroscopic evidence of infection; nevertheless it healed in rapidly and has given no trouble since, although it is over a year since the operation. The surgical technique of inserting a metal plate must be of the most rigid and special type in order to avoid infection in clean cases, as pointed out by Lane; and if the slightest infection occurs, it is very likely to extend the whole length of the plate and to its screws, and the plate must come out. In this case, as well as in

several others, the inlay graft was successful and resisted infection that was already present.

In view of these experiences, the value of this method in compound comminuted fracture from gunshot or other causes, mildly infected or not, is apparent.

Experimental graft work on the dog demonstrated still more conclusively the bacteria-resisting properties of the bone-graft. Wounds have become virulently septic on the second and third days after operation, laying bare the graft which was bathed in pus at the bottom of the wound. Nevertheless, either a portion or the whole of the grafts took and lived.

Whatever be the modes of internal fixation—whether the Lane plate or the inlay graft—the limb should be firmly immobilized in a plaster-of-Paris splint in as nearly a neutral position as possible, *i.e.*, a posture of the limb which causes the relaxation of those muscles which have a displacing influence in that particular fracture. If this be done, inlay or peg grafts, Lane plates or neck of femur spikes will not bend nor break during the period of the post-operative fixation. Weight-bearing function, in the presence of non-union or soft callus, and bone absorption are the causes for the yielding of internal metal-fixation splints.

In all cases of persistent non-union where syphilis and other systemic conditions are contributing causes of meagre callus formation, these conditions should be treated before operation is undertaken.

FIXATION BY BONE-GRAFT DOWEL PEGS

Epiphyses, condyles, tubercles, trochanters, tuberosities, bone fragments, etc., may be very satisfactorily secured to the bone from which they have been fractured by the employment of bone-graft dowel pegs, which are aseptically and speedily made by the author's dowel instrument (see chapter on motor outfit). Their accurate fit is secured by employing the proper drill to make the hole into which they are driven.

The material from which they are made can always be ob-

tained from the crest of the tibia if it cannot be more readily obtained in the original field. Enough has already been said to emphasize the superiority of the bone-graft pegs over metal nails or screws. Screws of dead bone or ivory have a certain theoretical value in that they become absorbed, as a rule, after a very long time. From a practical standpoint, however, they act precisely as foreign bodies in the bone and soft tissues, and may at any time have to be removed.

OTHER METHODS OF FIXATION

The Parkhill clamp has most of the disadvantages of the Lane plate, and in addition leaves an open wound down to the region of fracture. Either this type of clamp or that of Lambotte has an argument for its employment in the treatment of compound fractures in that no foreign material is placed in the wound across the line of fracture. Since the advent of the inlay graft, however, even this narrow field of usefulness for these clamps has still further been circumscribed.

FIXATION BY ABSORBABLE OR NON-ABSORBABLE LIGATURE MATERIAL

It is only on the rarest occasions that a wiring operation should be done. In the practice of the author, no metal appliances of any kind are ever employed for the internal fixation of broken bones. Metal wire is not only a foreign body with all its disadvantages, but it (silver wire especially) is a most untrustworthy fixation agent, as it so frequently breaks. Many röntgenograms, both those observed in X-ray laboratories and those in the author's own practice, have been studied by him and show that the wire has either broken or become so loose as to be of no service, with the fragments nevertheless in good position, which means that the fragments would have remained in position anyway, whether the wire had been used or not.

If wire is to be used at all, it is certainly to be desired that stronger material than silver wire be used. The varieties most

commonly employed are copper, phosphor bronze, galvanized iron wire, and twisted steel wire. Personally, the author is in thorough agreement with Hitzrot, who states that he "can see no use for any of these types of non-absorbable material," both because of their non-disappearance in the tissues by absorption and because they afford so little real fixation—certainly no more than is furnished by an absorbable ligature, such as kangaroo tendon, in the cases in which this type of fixation is suitable.

Kangaroo tendon of large size (especially prepared for the author by Van Horn and Sawtelle) is preferable in every particular to silver wire. It is stronger; it does not cause bone absorption; it becomes adherent to the tissues and does not lie in a cavity filled with a serous exudate, as wire is sure to do. It is a much more trustworthy fixation agent, as wire is liable to crack in the process of insertion and then give way from muscle pull as the patient comes out of his anæsthesia, or at some later time. Kangaroo tendon remains for not less than 40 days, and then becomes absorbed. Infection may start about wire years after its insertion. (Fig. 94.)

CONTRA-INDICATIONS TO OPERATION

These do not differ from those applying to operations in general. Infected abrasion of the skin or ulcers near the field of operation are to be carefully avoided; also patients with actively suppurating wounds or abscesses in any part of the body should not be operated upon because of the danger of metastatic infection at the field of operation, predisposed by the lowering of local resistance from trauma and the general depression arising from the operation.

The most scrupulous aseptic technique should always be observed.

FIXATION DRESSING

The plaster-of-Paris splint applied over a thin padding of Shaker flannel or cotton wadding to protect the bony prominences has, in the hands of the author, proved to be by all means

the most satisfactory. It can be readily split into a bivalvular splint by means of the author's motor saw (a special saw being used for the purpose) or by the Stillé cutter. The splint can then be easily removed for necessary treatment, etc.

Other satisfactory splints are Stimson's moulded plaster-of-Paris splints. Splints of tin or wood-plastic splints of felt, papier maché, celluloid, etc., have been used, but are greatly excelled by plaster-of-Paris ones for the usual fixation dressing.

As stated elsewhere, the limb should always be placed in such a position that displacing muscles are relaxed by approximating their insertion to as near their origin as is practicable. An illustration would be the flexion-abduction posture used in fractures at the lesser trochanter, for the purpose of relaxing the psoas magnus and short trochanter muscles which pull the upper fragment into that position.

AFTER-TREATMENT OF FRESH FRACTURES

After the insertion of the inlay, union is so rapid in fresh fractures that massage and passive motion can be instituted somewhat earlier than after any other treatment. This should be apparent because of the extensive and accurate approximation of the bone elements involved in the union (namely, the graft and the fragments) and the small amount of callus formation required to produce bony union. Massage and passive motion should be instituted as soon as the wound of entrance has healed, or at about the end of the second week after the operation, and should be performed by a trained masseur, the splint being replaced after each treatment until bony union is complete.

Baking.—Baking by hot air is especially efficacious in fractures about joints, and should be begun at the same time with the massage and passive motion and should immediately precede those exercises.

Hot compresses, consisting of towels or pads of cotton covered with gauze wrung out of very hot water may, in certain cases, be of service.

Liniments.—Liniments have no special therapeutic effect except that they encourage massage or rubbing. Strong lotions which are liable to blister the skin should not be employed.

AFTER-TREATMENT OF UNUNITED FRACTURES OR PSEUDARTHROSIS

On account of the sluggish osteogenesis of the bony elements making up a pseudarthrosis, a support should be continued much longer than in case of fresh fractures. In the more desperate cases some support should be continued for 3 to 4 months, because the callus formation from the bone ends is slow at best and all the stress may be borne by the graft, which will hypertrophy sufficiently if in the meantime it is protected from breaking.

FRACTURE OF THE CLAVICLE

Recent simple fracture of the clavicle can, as a rule, be satisfactorily reduced and maintained in position by the usual external methods. In rare instances, either on account of the obliquity of the fracture or for some other cause, the displacement cannot be controlled. An open reduction is then justifiable. The open reduction of the fragments may be all that is necessary, without resort to internal-fixation appliances. In this instance local infiltration anæsthesia may be adequate. If bone work is to be done, general anæsthesia is desirable. It is the conviction of the author that metal plates (Lane) should never be employed in fracture of this bone, and that the choice should lie between kangaroo tendon and the inlay bone graft for fresh fractures. The inlay graft for ununited fractures is the operation of choice. The so-called intramedullary graft is impossible of application.

In *Annals of Surgery* for September, 1914, Dr. H. H. M. Lyle reports a case of ununited fracture of the clavicle in which he implanted a bone graft, 6 by 11.5 cm., from the tibia. The graft was fastened as a splint on the outside of the bone, spanning the point of non-union, by means of kangaroo tendon

passed through the graft and clavicle. Twenty-seven days after the operation the graft, having become displaced upward and producing a pressure necrosis on the skin, was removed. "The graft was smooth and clean and apparently viable, indicating that bone regeneration had already begun." The wound healed in a few days, and a week later blood injections, according to the Bier method, were begun. Bony union and a satisfactory result was obtained. Dr. Lyle remarks that in this situation, when the soft parts are thin and it is difficult to secure immobilization, a bone graft should not be used as a splint but

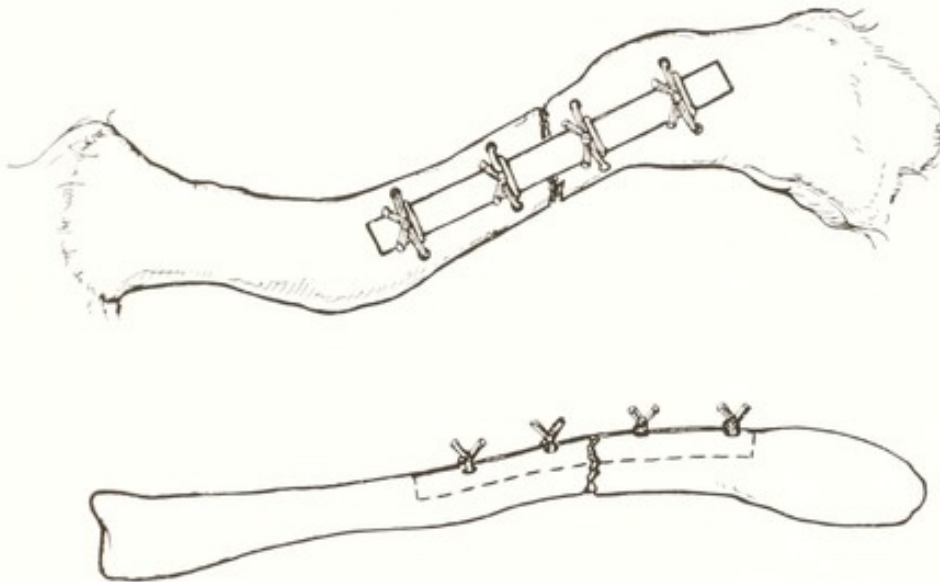


FIG. 156.—Drawing of inlay graft inserted for an ununited fracture of the clavicle. (For technique, see also Fig. 137.)

rather as a means of stimulating bone growth, and that this is the chief therapeutic value of the graft; and that he obtained better results from the use of this bone graft than from thick ones. This case is a strong argument in favor of the inlay technique, which would have brought the surface of the graft level or flush with that of the clavicle itself, and there would have been no danger whatever of pressure necrosis of the overlying skin. The graft should consist of the full thickness of the tibial cortex with periosteum, endosteum, and some marrow substance, and should be obtained from the upper portion of the tibia where the cortex is not so thick. Such a graft, held in place by kangaroo tendon, furnishes perfect fixation.

FRACTURE OF THE OLECRANON

In fresh fracture of the olecranon process, opening, drilling, and the insertion of kangaroo tendon is believed to be the best treatment. In ununited fractures of this process, the inlay graft held in place by kangaroo tendon is very easy of application and promises better results than any other treatment. The graft is inlaid completely to the tip of the olecranon and as far into the shaft as the amount of bone sclerosis indicates. A sliding graft or a tibial one may be used, as conditions indicate.

FRACTURE OF BOTH BONES OF THE FOREARM

Fracture of both bones of the forearm requires operative treatment when there is soft tissue between the fragments, when it is compound, or when proper alignment cannot be obtained by the usual traction methods, with the patient under an anæsthetic. Many factors unite in the indications for and against open treatment in these fractures.

The function of the forearm is so apt to be interfered with by faulty alignment that individuals whose livelihood depends upon a strong and useful arm will get a far better and more rapid result from an open operation than from any other treatment. The inlay graft affords an ideal fixation for either the fresh or the ununited fracture of the bones.

The grafts should always be inserted into the radial side of the radius and into the ulnar side of the ulna, unless otherwise indicated. Any tendency of the ulnar and radial fragments to approximate each other is mechanically prevented by long inlays thus placed.

The grafts are best taken with twin saws from the central portion of the antero-internal surface of the tibia and are fixed in place with kangaroo tendon (or technique, Fig. 137).

The arm should be put up in a position midway between pronation and supination, in a plaster-of-Paris splint extending from the base of the fingers over the elbow, thus leaving the fingers free.

In the after-treatment, active motion of the fingers should be encouraged from the beginning. In fresh fracture cases, massage and passive motion of the wrist and elbows should be begun in the third week. The bone healing should be studied by the X-ray, and the time for removing the splints determined by the amount of callus formation.

When Lane plates or other metal fixation appliances are used it is, as a rule, necessary to leave the external fixation splints on for 8 to 14 weeks, and "complete use of the arm for strenuous

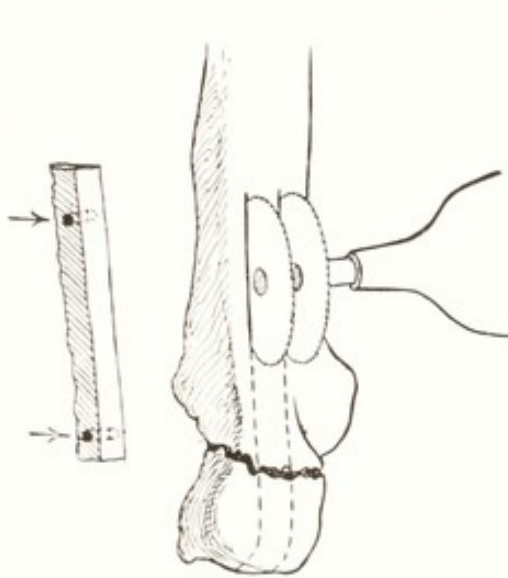


FIG. 157.—Technique of sliding inlay graft for fracture of the olecranon process. Arrows indicate drill hole in graft.

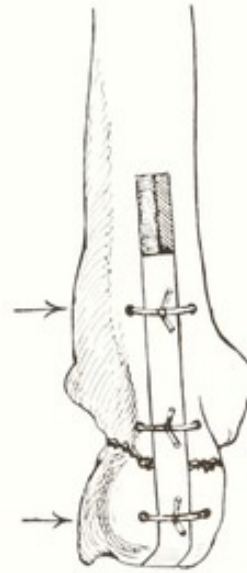


FIG. 158.—The inlay graft is held firmly in place with kangaroo tendon.

labor should not be allowed for four months" (Hitzrot). These periods are distinctly shortened by the employment of the inlay graft, because of its own osteogenesis and the stimulus it affords to the fragments themselves. This shortening of the convalescence should be expected when it is realized that the influence of the metal fixation appliances is quite the opposite, in that its contact destroys bone and inhibits callus formation.

In cases of pseudarthrosis, supporting splints should be continued for a much longer period, according to the nature of the case and the amount of callus formation.

FRACTURE OF THE NECK OF THE FEMUR

Fracture of the neck of the femur is by all means the most disabling of all types of fractures. These fractures were formerly regarded as occurring mainly in old age. Recent personal statistics, as well as those of other surgeons who have large fracture clinics, show a large number of fractures of the femoral neck occurring in individuals below the age of 45 or 50. Senile osteoporosis, associated with thinning of the cortex and absorption of many of the lamellæ of the spongiosa of the neck, is the chief cause of the increased frequency of this fracture in the aged; and, as would be expected, traumata need be much less severe to cause fracture in the aged than in younger individuals. There seems to be no object, as far as treatment or prognosis is concerned, in classifying these fractures further than the single term "fracture of the neck." The terms intracapsular and extracapsular are inaccurate and misleading. The capsular insertion to the neck of the femur is oblique, thus causing the joint to include more of the neck on its anterior and inferior surfaces than on the posterior and superior.

Then, again, most fractures are oblique and diagonal, and are only infrequently strictly transverse. If any classification is used, that of Stimson is by all means the preferable one, *i.e.*, subcapital, or fracture through the neck, and fracture at the base of the neck. A fracture is apt to occur in one of these two places, either at the junction of neck with head or with the trochanter. The associated outward rotation in epiphyseal separation or fracture occurs as frequently and is often more pronounced than in fractures of the neck, which fact cannot be explained by a more fragile posterior portion of the neck. The predominance of the external rotators, especially the short trochanteric muscles, is believed to be the more tenable explanation.

Shortening depends upon the lessening of the angle between the femoral neck and the shaft or a sliding by of the fragments.

TREATMENT OF FRACTURE OF THE NECK OF THE FEMUR

In speaking of the poor results obtained in treatment of fractures of the femoral neck by the conventional methods, an authority states: "At first one can hardly appreciate how startling these results are unless he has carefully studied various series of statistics, and wherever the usually accepted principles of practice are employed—the long side splints with Buck's extension—there the average results are uniformly unsatisfactory."

Of value in this connection are the conditions existing in 16 cases of fracture of the limb observed by Scudder many years after the accidents. "In only two cases, or 12 per cent., could it be said that the leg was functionally useful."

Walker studied the records of 112 cases of fracture of the neck of the femur treated in Bellevue Hospital between 1906 and 1907. Only 15 cases, or 13 per cent., recovered good function.

The British fracture committee tabulated 91 cases, in which 87 of the patients were over 15 years of age. Only 20 of the adults, or 23 per cent., recovered good function.

Unquestionably Whitman's abduction method offers better results than the foregoing. Certain men, however, have not obtained the favorable results secured by Whitman.

Cotton offers the following objections to this treatment: "First, many men are inclined to doubt the locking of the upper fragment at the limit of abduction, believing rather that tension on the abductor muscles gives the limit of abduction; second, there is real danger that in less expert hands the fragments may be forced by one another—not jammed together; third, plaster spicas in stout patients do not hold abduction firmly."

At best, fracture of the neck of the femur is one of the most difficult problems in all surgery. The anatomico-mechanical conditions, the poor blood supply, the sluggish osteogenesis, and the difficulty of fixation are all potent adverse influences to securing satisfactory union and good functional results, and it is believed that if ever radical measures are justifiable they are indicated in the treatment of this desperate condition. Realizing

this, certain surgeons have employed the metal spikes to assure better approximation and fixation than could be obtained by non-operative measures. This method has not given uniformly good results because of the failure of sufficient callus formation.

An illustrative personal case was that of a woman 30 years of age suffering from a fracture of the neck of the femur ununited after 8 weeks. There was no destruction of the fragments from friction, nor was there any systemic disease to inhibit callus formation. It was a favorable case, and a tin-plated square steel spike, $3\frac{1}{2}$ in. long, was driven into good position longitudinally through the centre of both fragments of the neck, which were in excellent apposition. The convalescence was uneventful. The wound healed by primary union, and at no time was there a temperature above half a degree after the day following the operation. The operation, however, resulted in failure, and non-union occurred. Fig. 159 is a skiagram taken 4 months after the operation, showing that the spike, owing to its own weight and bone-destroying influence, had dropped through the lower portion of the capital fragment and no longer engaged it. The metal spike had not only destroyed bone, but it had inhibited callus formation, in a region where osteogenesis is at a low grade, to such a degree that it prevented union or, at any rate, was a contributing cause to non-union.

To avoid the disadvantages of metal the author began, in 1912, to use a bone-graft peg as a substitute for the metal spike (for report, see author's report in Murphy's "Clinics," June, 1913). If this bone peg is placed in the cervical fragments by the technique described elsewhere, an equally satisfactory amount of internal fixation is furnished at the same time that the disadvantages of a metallic foreign body are avoided, and the advantages of a living bone graft gained.

A strong autogenous bone peg, accurately fitted into a hole drilled longitudinally through the neck of the femur, with the fragments in good position, offers unquestionably the most ideal condition for the rapid and satisfactory union, in good position, of this difficult fracture. In other words, the influences adverse

to union, enumerated elsewhere, are better overcome by this procedure than by any other treatment; also every argument for the autogenous inlay graft in ununited and selected fresh fractures of shafts of long bones holds equally in fractures of the neck of the femur.

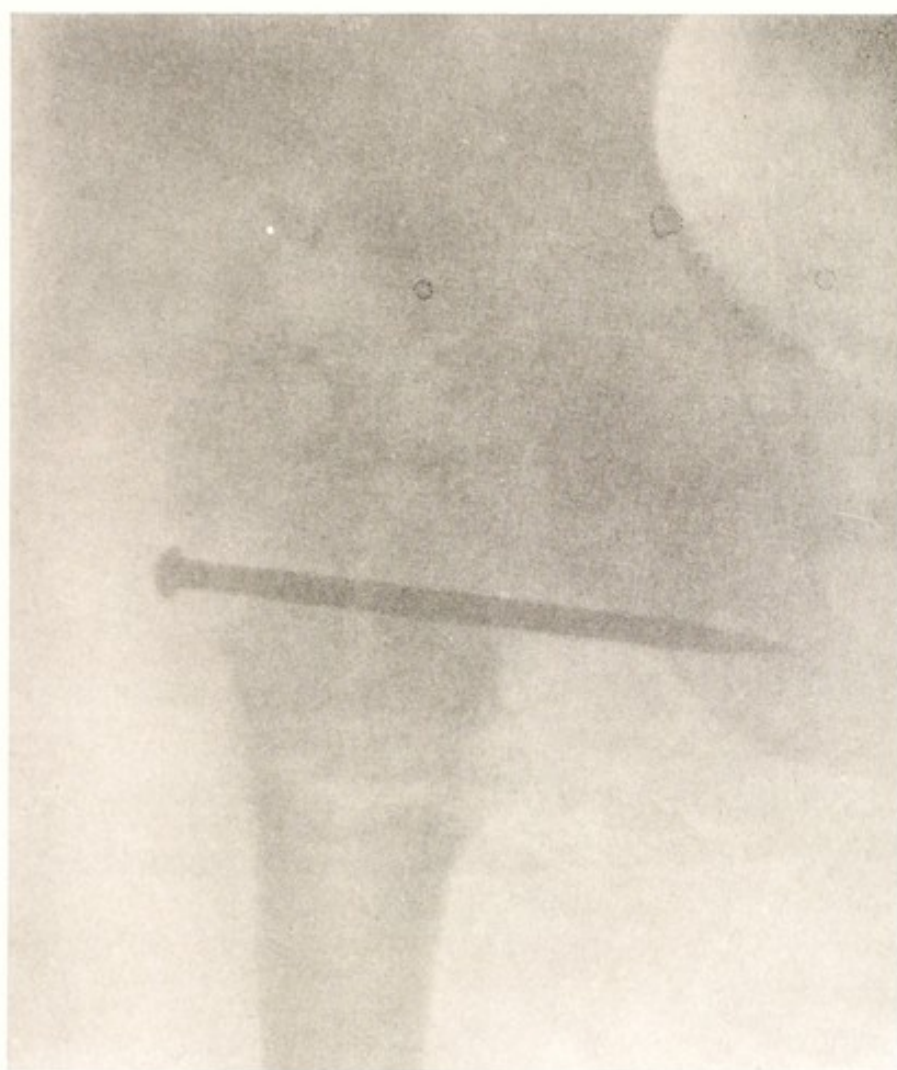

FIG. 159.—This spike was placed in the centre of head at operation. It has destroyed bone and dropped out of the capital fragment entirely, non-union resulting. (See text.)

Soft tissues are removed, if present, from between the ends of fragments; the fragment ends are secured in good apposition; callus formation is stimulated by the presence of the graft at the same time that the graft produces bone growth itself; and an osteogenetic bridge, capable of conducting both blood-vessels and bone cells from one fragment to the other is furnished.

Indications for Bone-graft Peg in Fracture of Neck of Femur.—This operation is believed to be indicated in all ununited fractures of the neck of the femur; in most unimpacted fresh fractures, in operable subjects under 50 years of age; in all

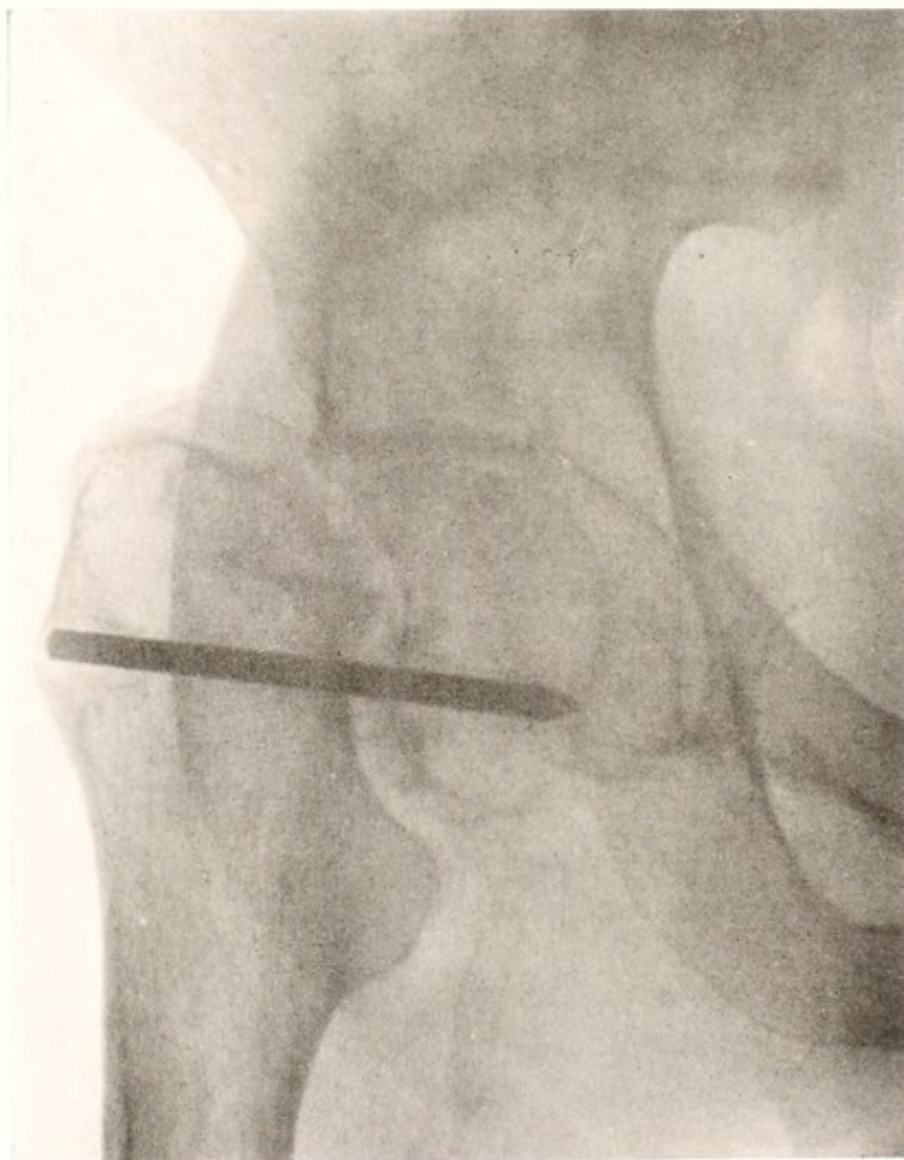


FIG. 160.—A röntgenogram (kindly supplied by Dr. B. C. Darling) which shows a metal spike inserted for a fracture of the neck of the femur in a young person. The result was a failure and the large amount of bone destruction about the metal is clearly shown.

old fractures of the neck or at the epiphyseal cartilage where malunion has resulted, with the neck depressed in a *coxa vara* relationship with the shaft. The bony deformity is corrected by either a cuneiform or linear osteotomy, and placing the limb in full physiological abduction (Whitman).

After the operative correction of these latter two conditions by the usual cuneiform osteotomy Hitzrot states that weight bearing should be prohibited for at least a year. The employment of the bone-graft peg reduces this time by at least 6 months.

Technique of the Author's Bone-graft Peg Operation for Fracture of the Neck of Femur.—A most careful iodine prepara-

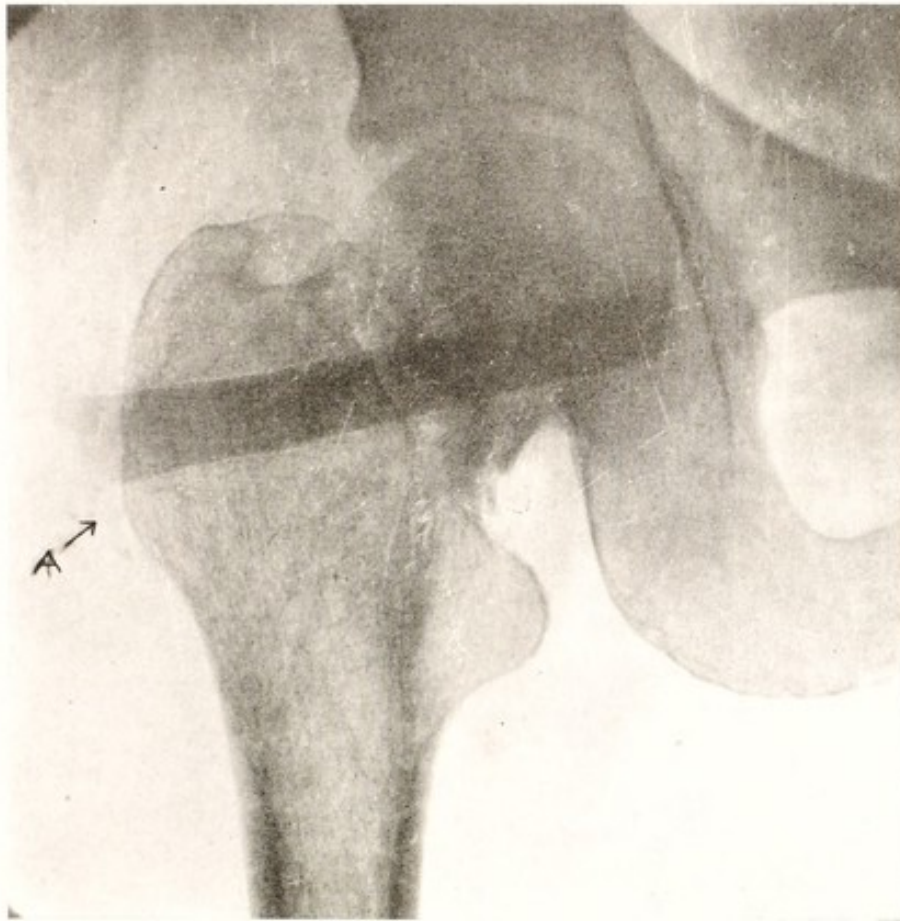


FIG. 161.—Röntgenogram of an ununited fracture of the neck of the femur of 5 months' duration which has been united by an autogenous tibial bone-graft peg. The union in this case was immediate (*i.e.*, 5 weeks) and the union has remained solid 2 years after operation. A indicates graft peg, from the end of which projects a mass of new bone.

tion of a wide field of operation should always be carried out. The pubes should be shaved on the day before the operation and the preparation started.

The patient should be placed upon some traction table (Hawley) which will allow, simultaneously, abduction and traction. The point of fracture is reached by an incision starting from a point a finger's breadth inside of the anterior-superior

spine and curved downward 3 to 5 in. along the inner border of the sartorius. The inner border of the muscle is exposed and retracted outward. The tendon of the rectus femoris is also exposed and retracted outward. The ilio-psoas muscle is next exposed and retracted inward. The point of fracture is exposed and all soft tissue is cleared from between the fractured ends, which are curetted and freshened.

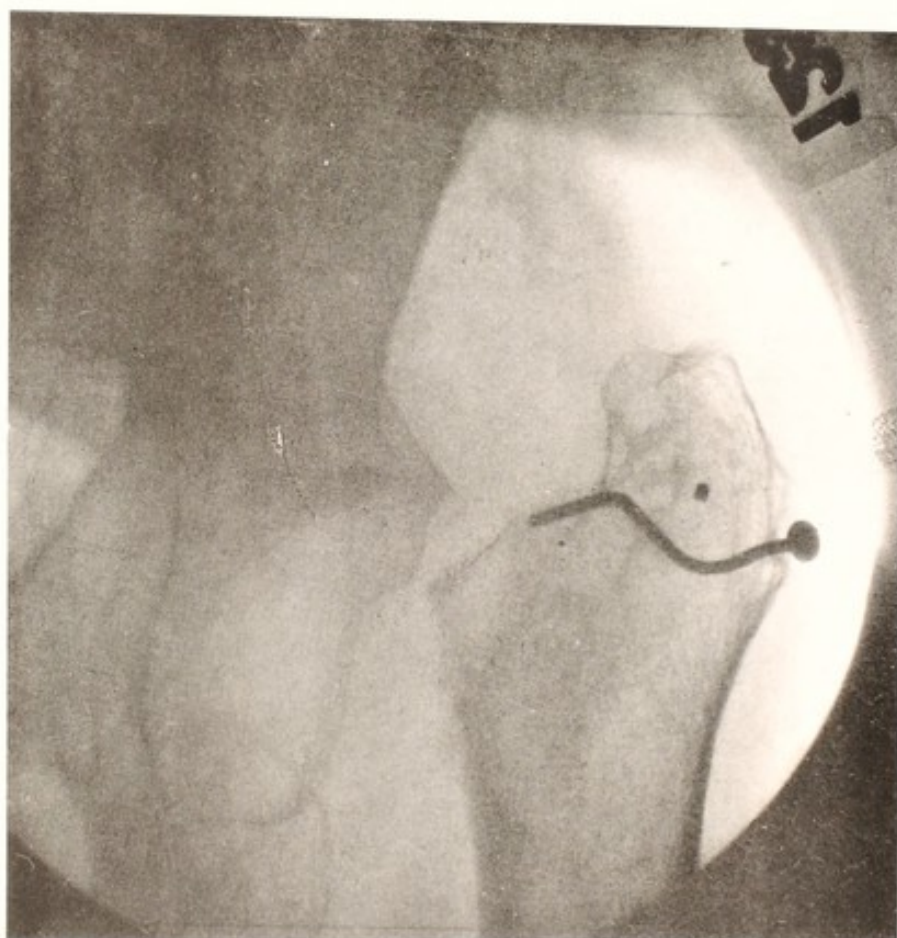


FIG. 162.—A small wire nail which was by mistake previously placed too high and did not engage the capital fragment. This case emphasizes the danger of misplacing a nail or bone graft and the wisdom of a small hand drill for orientation as pointed out by the author.

The limb is now placed in abduction and sufficient traction applied to bring the fragments into good apposition as determined by both sight and palpation through the anterior wound. An incision 2 to 3 in. long is then made over and just below the great trochanter, which is exposed. With a small hand drill, the proper direction for the motor drill is determined by trial, as

shown by observation through both wounds. The drill hole should be situated in the centre of the neck of both distal and proximal fragments, and parallel to the neck. The small hand drill may have to be reinserted in order to locate the proper tract for the motor drill. The motor drill should be held ready by the operator for insertion into the tract of the hand drill as it is withdrawn by the assistant. The motor drill, which forms a hole

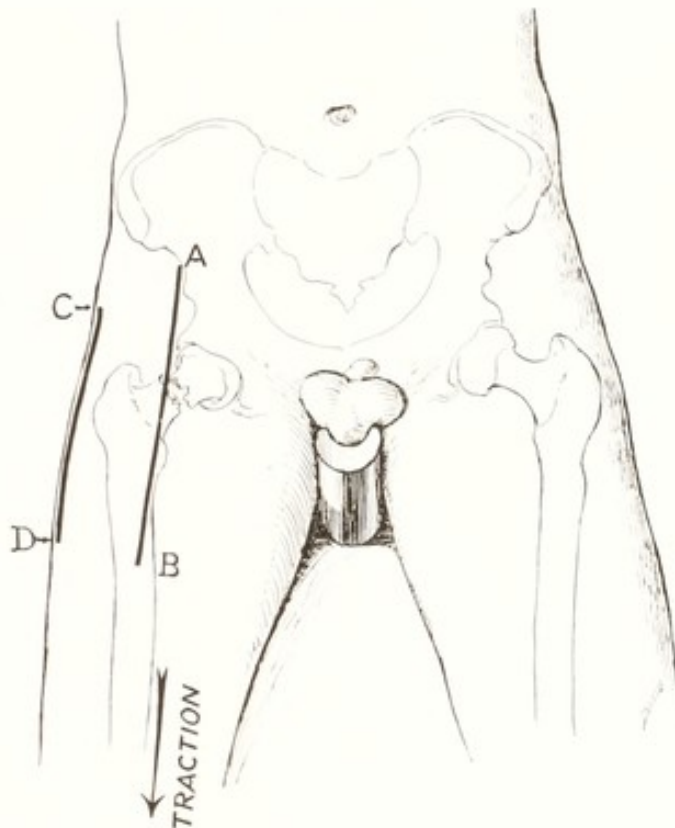


FIG. 163.—Drawing representing patient on Hawley traction table. *AB* and *CD* are skin incisions.

three-eighths of an inch in diameter, is pushed through the distal fragment until the burr end of the drill appears between the fragments, as seen through the anterior wound. Just as the end of the drill is engaging the broken end of the proximal surface, a reading on the graduated drill shaft is taken at its entrance aperture in the great trochanter, so that by making additional readings it can be determined just how deep the capital fragment is being penetrated. By studying the röntgenogram, the length of this fragment can be very accurately determined, and hence

the desired depth of the drill hole obtained. When the fracture has occurred near the head and is consequently short, the drill hole should extend close to the articular cartilage of the head.

The drill is disengaged from the motor and left in place, to avoid any possible displacement of the fragments while the tibial graft is being procured.

The crest of the lower portion of the tibia is laid bare, and an area of the desired size and shape is mapped out in the periosteum

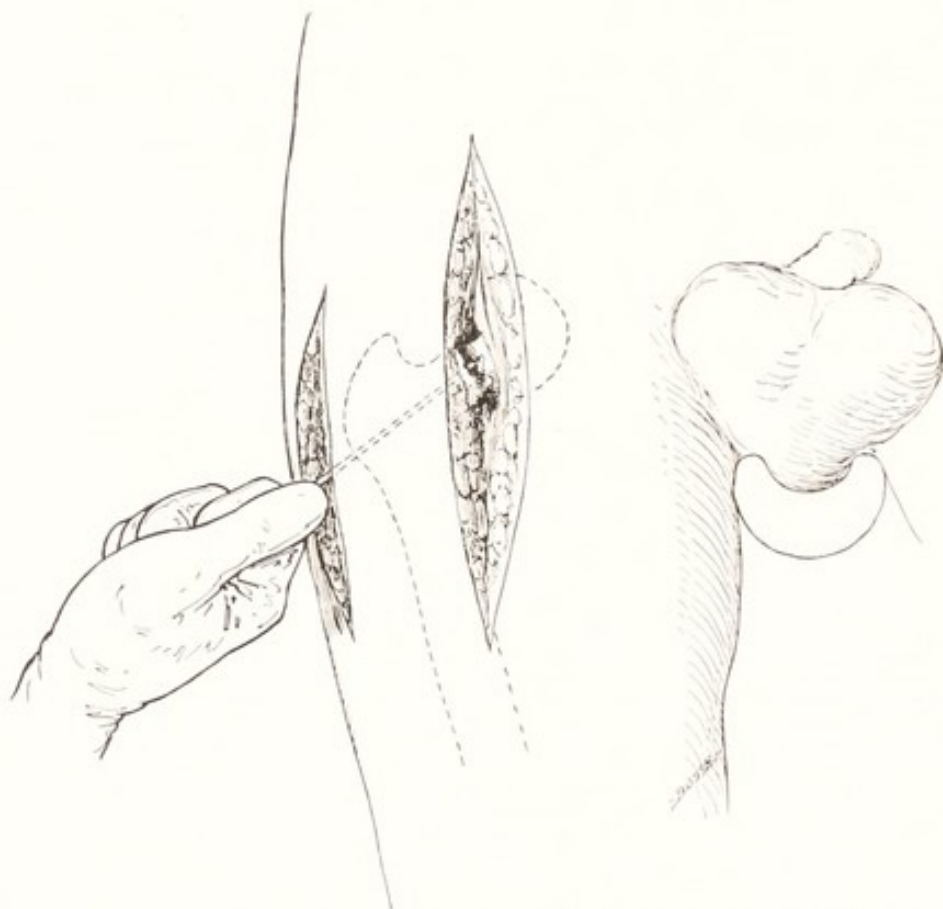


FIG. 164.—Drawing to illustrate author's method of determining with small hand drill the proper situation and direction for the motor drill. This hand drill is withdrawn as the motor drill is inserted. (See Fig. 165.)

with a scalpel. The desired length of graft can be determined by the graduated scale on the motor drill. The cross-section of the graft should be just large enough to be shaped into the peg when the dowel shaper is used.

When the graft peg is ready, the drill is withdrawn from the femur and the peg inserted. The fit must be accurate because the dowel cutter is the counterpart of the drill used. This accu-

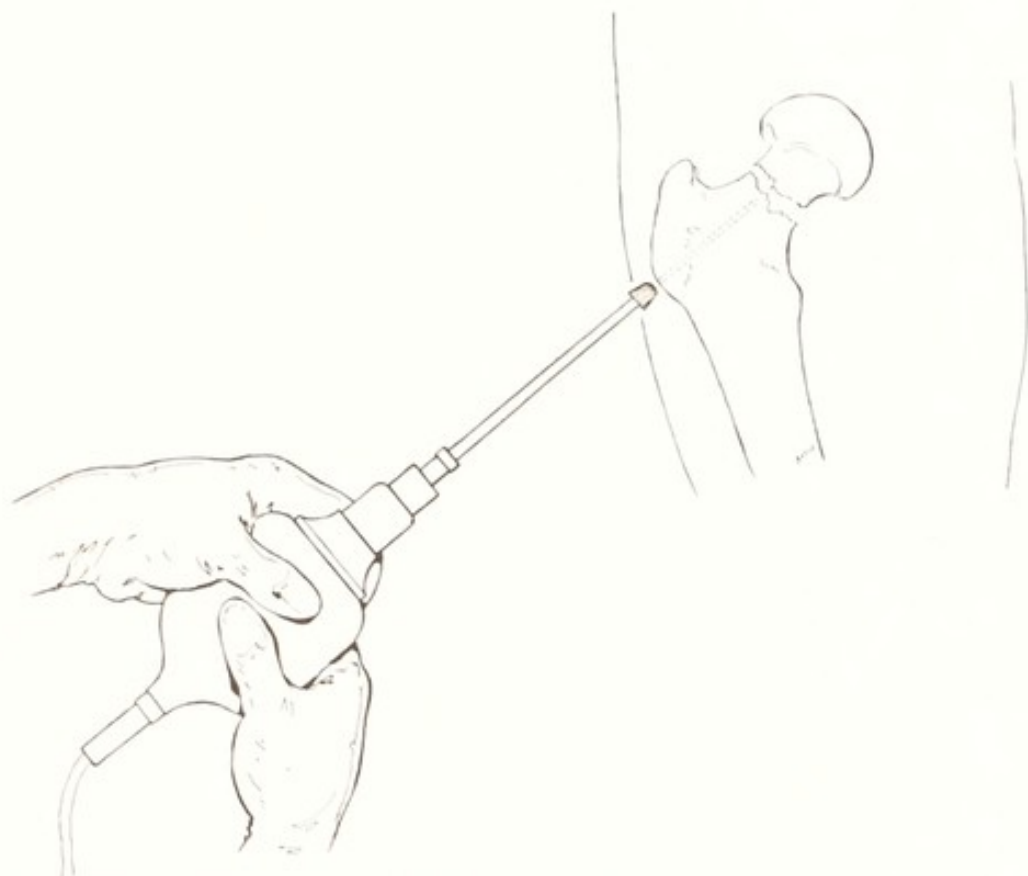


FIG. 165.—Insertion of motor drill into outer side of great trochanter at point determined by hand drill.

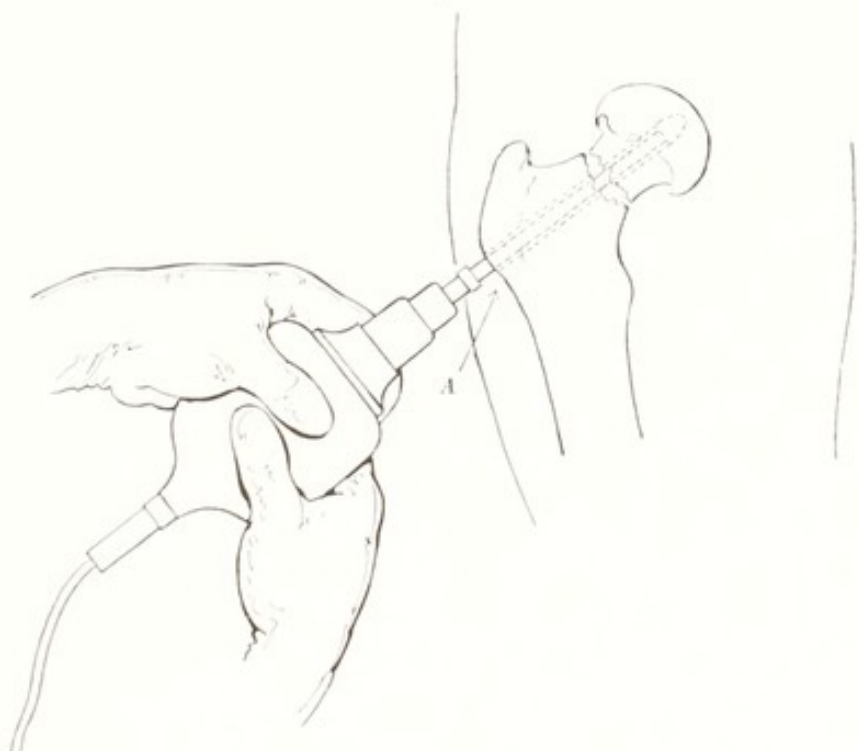


FIG. 166.—When the end of the burr has reached the space between the fragments and is ready to enter the capital fragment, a reading on the graduated shaft of the burr is taken at *A*, one is then able to tell by a study of the röntgenogram just how far the burr should penetrate this fragment.

racy of fit is very important. Too tight a fit is undesirable because a pressure anæmia of the surrounding cancellous bone would be produced. Too loose a fit, or an irregular inaccurate fit would not produce good fixation or favor an immediate bony union of graft to the host fragments.

The deep fasciæ are approximated with interrupted sutures of No. 2 chromic catgut; the skin wound is closed with continuous suture of No. 1 chromic catgut.

The limb is put up in abduction (Whitman's position) in a plaster-of-Paris spica extending from the toes to the axilla. Three weeks after the operation, windows are cut in the plaster, and the wounds dressed. The dressing should be replaced with cotton for the purpose of restoring the tension of the plaster splint and retaining the fixation. The long spica should be continued for 6 weeks, and followed by a short one for 6 weeks longer.

THE AUTOGENOUS BONE GRAFT FOR FRACTURE OF THE PATELLA

The usual treatment for fracture of the patella consists in exposing the line of fracture and uniting the fragments with either absorbable or non-absorbable sutures. Formerly metal wire, such as silver or phosphor-bronze wire, was used; but recently the surgical pendulum has been swinging away from non-absorbable foreign materials, and kangaroo tendon or chromicized catgut has been more frequently chosen. The metal wire, as a rule, has either been placed in a drill hole in each fragment, or in such a way as to encircle the patella. The degree of separation of the fragments depends largely upon the amount of laceration of the capsule and connective tissue on either side of the patella. Muscle pull may interfere with the union of the patellar fragments, however carefully the clots and fibrous fragments are cleaned from between the fragments, or whatever may be the material used to hold the fragments in close apposition. Not infrequently a refracture occurs, either immediately or remotely after operation, in spite of every precaution. Fi-

brous union, with a varying degree of separation of the fragments and a proportional amount of disability in the extremity, is a more frequent unfortunate result. To remedy either of these conditions, Rogers has suggested that an autogenous bone graft be taken from the crest of the patient's tibia and implanted on

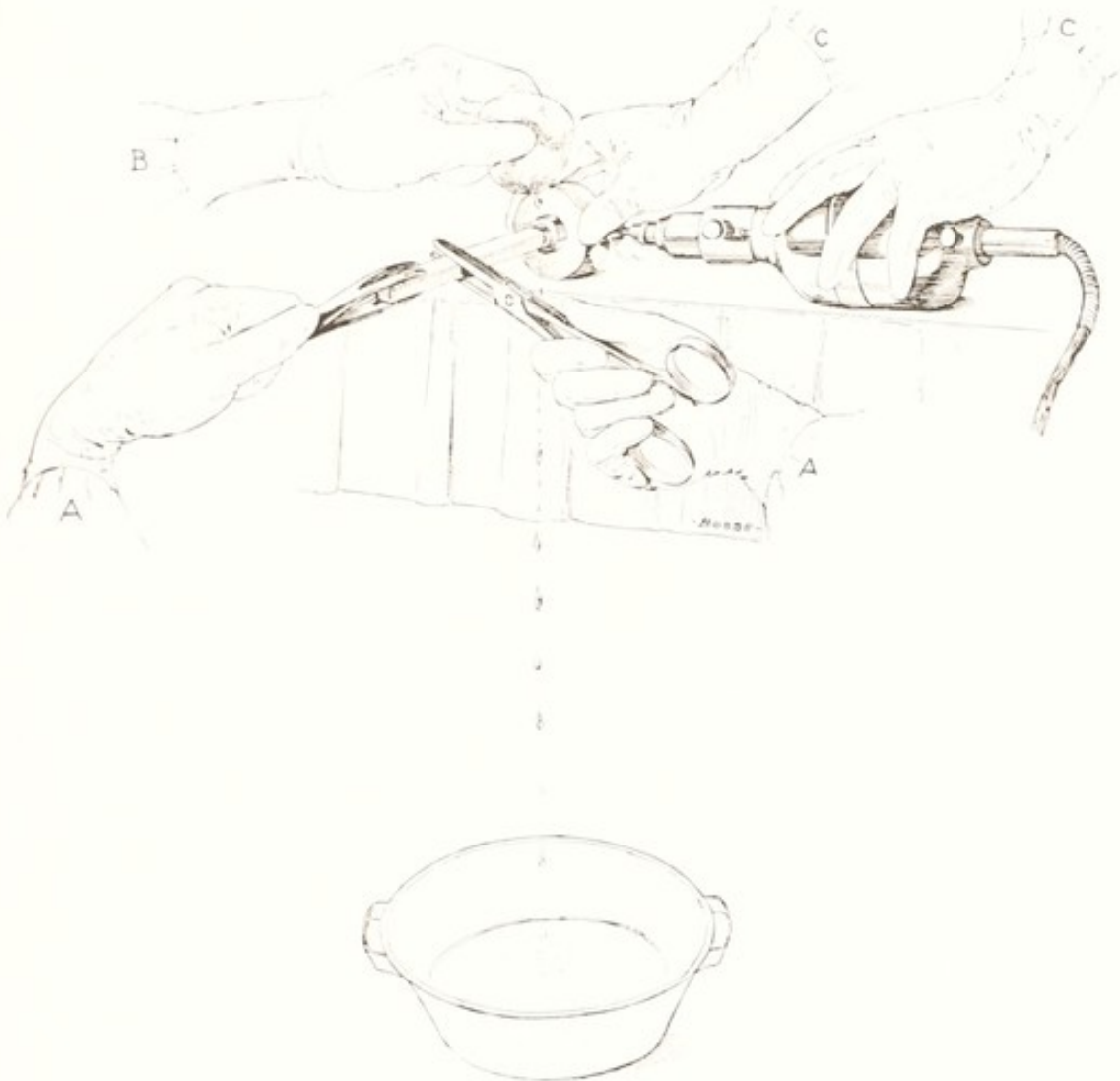

FIG. 167.—*A* is surgeon grasping and feeding the bone cuts. Author's motor-driven lathe. *B* is nurse supplying normal saline drip to avoid over-heating the graft as fed. *C* illustrates assistant's manner of holding the motor and the lathe securely upon the edge of instrument table while the dowel is being shaped.

the front of the patella, to bridge the line of fracture. It is believed that this is an important step and that it offers a very trustworthy means of relieving these conditions. It is believed, however, that Rogers' technique can be much improved by using the author's inlay method, which he has not only applied to

relieve fibrous union and refracture, but which he offers as a means of securing immediate and solid bony union in certain fresh fractures of the patella (see Figs. 171 and 172). In other words, the inlay graft is a reliable prophylaxis to fibrous union and refracture, as well as a remedy for those conditions



FIG. 168.—The upper drawing represents crest of tibia of the proper cross-section for a hip-fracture peg. The lower drawing illustrates the peg and the author's lathe cutter which was used to shape it.

when already existing, without resorting to a foreign body. Besides affording slight and imperfect contact, the graft placed on the anterior surface of the patella fragments is liable to

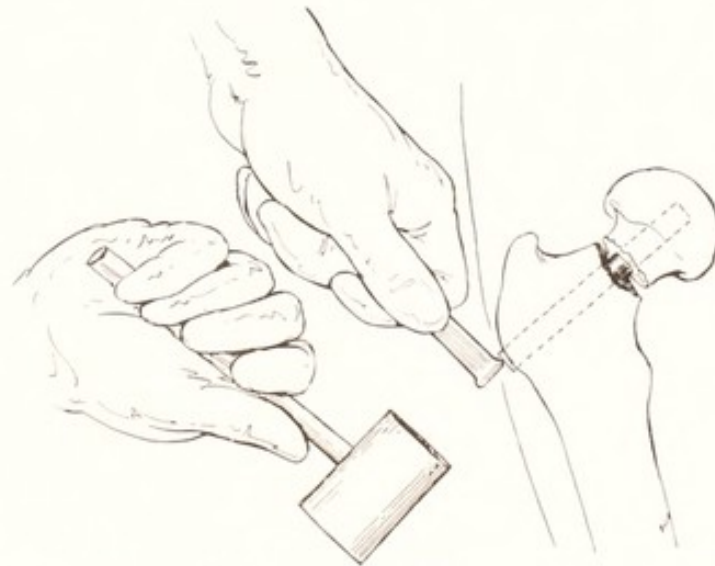


FIG. 169.—Drawing representing graft peg being driven home.

cause a pressure sore in the overlying skin because of its superficial location (see p. 217).

Technique of Inlay Bone Graft for Fractures of the Patella.—Place tight tourniquet on the upper portion of the thigh. The fracture fragments are reached by a U-shaped flap with the

apex of its convexity over the ligamentum patella and its base over the condyles of the femur. Clear away carefully all blood clots or fragments of fibrous tissue from between the fragments,

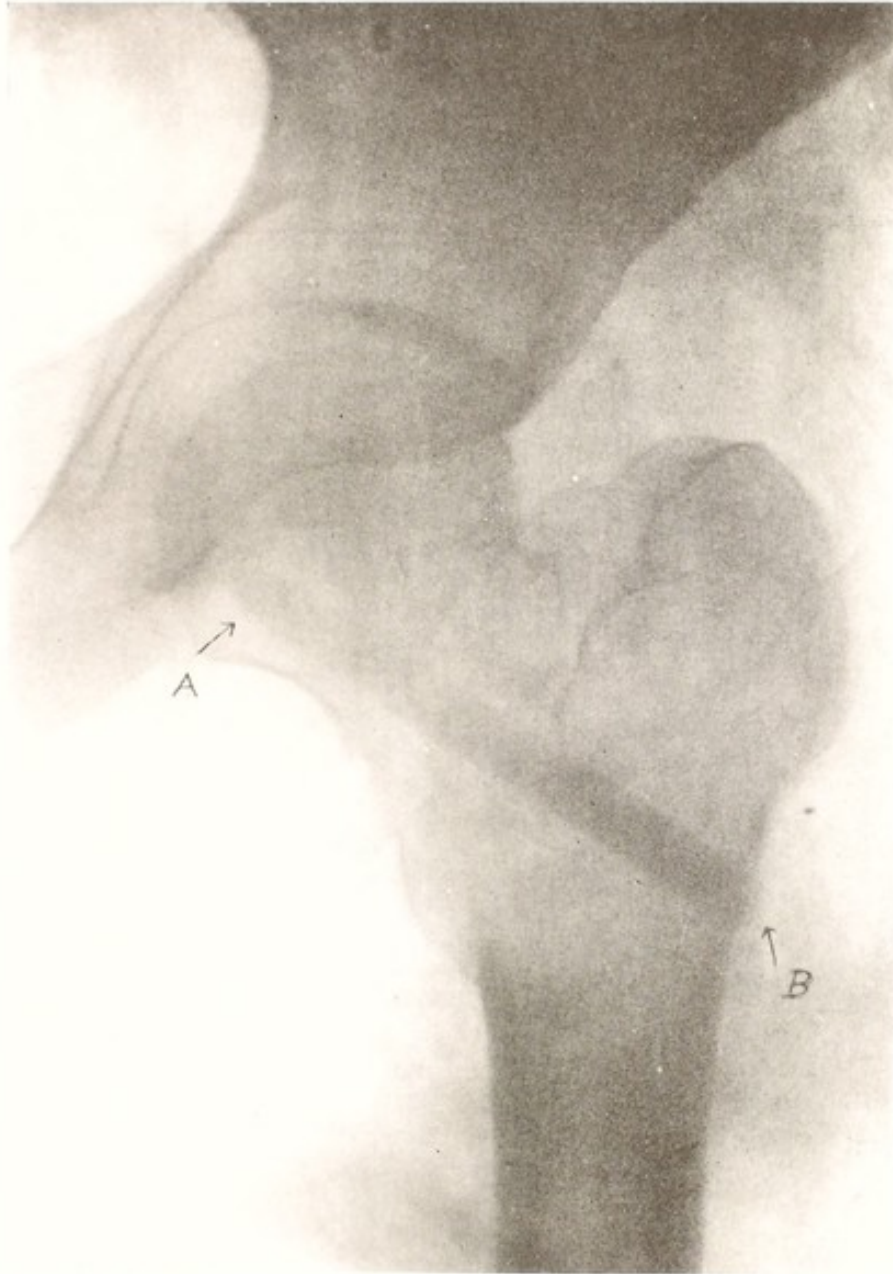


FIG. 170.—*AB* is tibial bone-graft peg inserted 6 months before for an ununited fracture of 5 months' duration in a man of 28 years. There was firm union at the end of 5 weeks after operation. The graft was placed lower than it was intended but did not interfere with the result.

if it is a fresh fracture; or, in the case of refracture or fibrous union, freshen the fragment ends. The fragments are approximated, and the lateral rents in the fibrous capsule are partially

sutured at the sides with interrupted sutures of small kangaroo tendon. The central portion of the anterior surface of the patella is then denuded of its periosteum and periosseous tissues by turning back to each side flaps on each fragment.

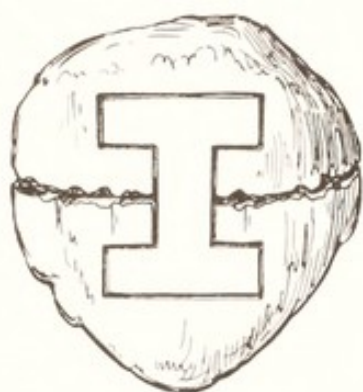


FIG. 171.

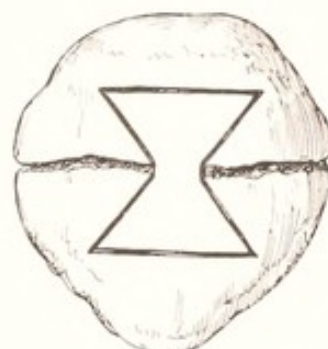

FIG. 172.

FIGS. 171 AND 172.—Different types of the inlay graft applied to fractures of the patella.

An outline of the bone to be removed—about $1\frac{1}{4}$ by $\frac{3}{4}$ in.—is made on the anterior surface of the patella with the point of a scalpel. With the author's small motor saw, cuts are made to a

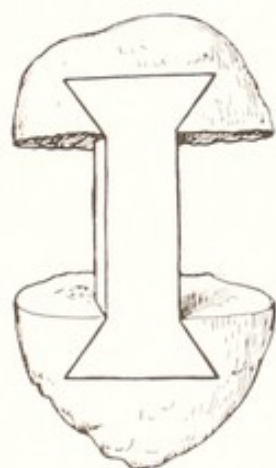


FIG. 173.—Dove-tailed inlay graft for ununited fracture of the patella with unavoidable separation of the fragments.

depth of one-third of an inch along the outlines already made. The fracture surfaces of the fragments are tilted forward, and with small motor saw and narrow, thin, sharp osteotome the bone within the previously made saw-cuts is removed to a depth of one-third of an inch from the anterior patellar surface.

With the patellar fragments in good apposition, make careful measurements of the inlay gutter with calipers. Expose the antero-internal surface of the upper portion of the tibia, where the surface is broad and the cortex thin, and by means of the caliper measurements or wax model of gutter in patella, outline in its periosteum the inlay graft required. The cortex in this portion of the tibia is of the proper thickness for the graft. The inlay is inserted with its periosteal surface anterior, and the periosteal flaps of the patella are pulled over it with interrupted chromic

catgut sutures. The capsule rents are then sutured with kangaroo tendon up to the sides of the patella. The fragments are still more securely held together by a figure-of-eight suture of medium kangaroo tendon, which is passed laterally through the anterior portion of the ligamentum patellæ and quadriceps tendon, directly below and above the fractured bone, and crosses in front of the transplant. The skin incision is closed by a continuous suture of No. 1 chromic catgut.

The limb is put up in a plaster-of-Paris splint for 4 weeks.

This operation is of the greatest advantage where there has been a fibrous union in an old case, and a separation of the fragments coincident with a shortening of the quadriceps tendon and muscle; and when the fragments cannot be brought into close apposition. This space can be spanned by a long graft, which will hypertrophy and fill in to a large degree (or entirely) the hiatus between the fragments. (See Fig. 173.)

THE BONE-GRAFT PEG AS A TREATMENT OF FRACTURE OF THE OS CALCIS

A fall in an elevator or from a height, striking on the plantar surface of the foot, is very likely to produce a fracture of one of the tarsal bones, especially the os calcis, which is by far the most common fracture. These fractures of the os calcis may be classified into three groups: first, the one in which the fracture is transversely through the central portion of the bone, with a displacement upward of the posterior fragment by the pull of the tendo Achillis; second, when a portion of the bone is torn away by muscle pull; third, where there is a fracture of the sustentaculum tali; and, fourth, where there is comminution, especially in the region where this bone articulates with the posterior portion of the astragalus.

The type of case in group one only will be considered in this connection.

The chief consideration in the treatment of all fractures of the os calcis, and especially this one, is to preserve or restore the arch of the foot. From the functional as well as from the cosmetic standpoint, this is most important.

Method of Reduction of Posterior Fragment.—The patient is anæsthetized to full muscular relaxation; the foot is brought into full plantar flexion for the purpose of relaxing the tendo Achillis; and the heel is grasped firmly and an attempt is made to pull it downward into its proper position. In order to loosen the fragment, and break up the impaction it may be necessary to force the heel laterally (both right and left). It may then be possible to bring down the fragment. If this fails, as it is apt to do on account of the difficulty of securing a sufficient grip on the heel, Cotton has advised thrusting a steel spindle (or, more conveniently, a small urethral sound) through, just in front of the tendo Achillis. With this hold, there is no difficulty in bringing the fragment down, if it has not been more than a week or two since the fracture. In old, malunited fractures, an open cuneiform osteotomy on the inferior aspect of the bone at the point of the fracture will be necessary, before attempting to bring the fragment down. The incision is made directly over the inferior aspect through the plantar surface of the foot. It is usually safer to tenotomize the tendo Achillis.

In some instances internal fixation is advisable, and in these cases the bone-graft peg is by all means the most ideal agent.

Author's Technique of Bone-graft Peg for Fracture of the Os Calcis.—The most satisfactory incision is one which passes along the outer side of the tendo Achillis down to the edge of the plantar skin, and then internally around the posterior part of the heel. The skin flap thus outlined is freed from the posterior end of the os calcis and retracted inward. Care should be exercised to keep close to the bone in freeing up this flap, so as not to interfere with the circulation of the flap.

With the posterior calcaneal fragment in good position, a hole about the size of a slate pencil is made longitudinally in the fragments with the author's motor drill. The drill should be started in the centre of the posterior end of the os calcis, driven through, and then disengaged from the motor and left in place while the peg is prepared. A strip of bone of sufficient size to shape into a dowel peg is then removed from the crest of the

tibia with a motor saw. With the author's surgical lathe, held by an assistant on the edge of the instrument table, this strip of bone is pushed into the dowelling instrument, which shapes it into a round peg that will just fit into the drill hole in the os calcis (see illustration, chapter on Hip Fracture). The drill

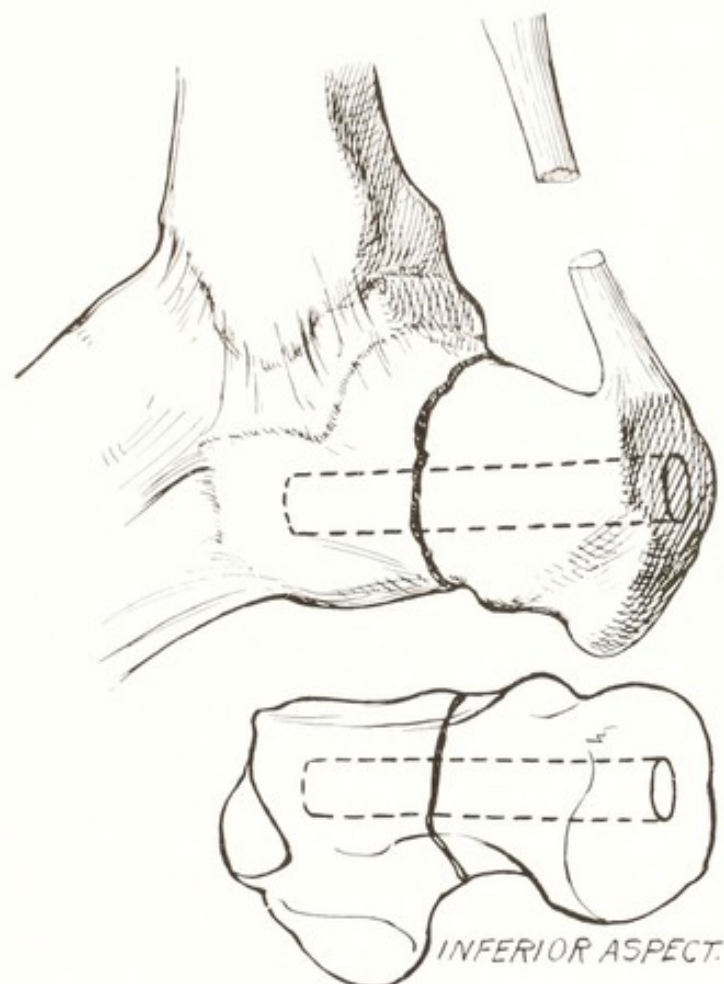


FIG. 174.—Illustrates peg bone graft inserted for fracture of the os calcis. The tendo Achillis has been tenotomized to prevent posterior fragment being displaced upward.

is then withdrawn from the os calcis, the peg inserted and driven home with blows of the mallet. The end of the peg should be well counter-sunk into the end of the os calcis, so as not to cause pressure on the overlying skin, with danger of pressure ulceration.

Fractures of the avulsion type from muscular pull may be treated in a similar way. In this instance, the avulsed fragment is replaced and pegged securely in position by one or two small bone-graft pegs, a very similar technique being used.

Fixation Dressing.—The foot is put up in a plaster-of-Paris dressing, in moderate plantar flexion. A pad of gauze is placed

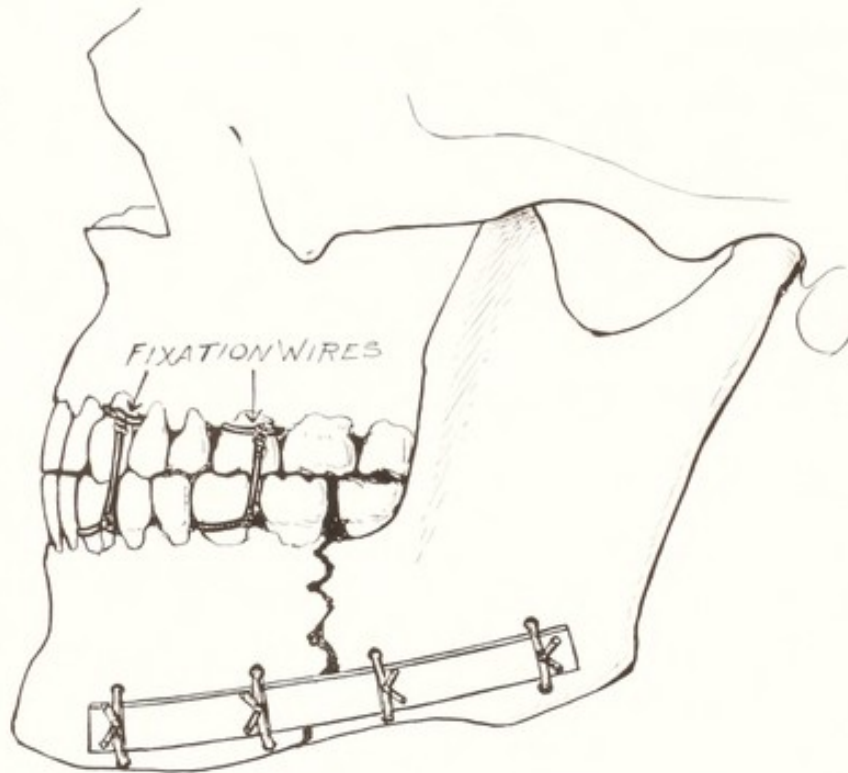


FIG. 175.—Diagram of a fractured lower jaw illustrating the inlay bone graft in place imbedded in the gutter cut in both fragments by the twin motor saws. The graft has been procured from the antero-internal surface of the tibia cut by the twin motor saws adjusted at the same distance apart as when cutting the gutter in the jaw fragments. Note the drill holes and that the graft is fixed in place by kangaroo sutures.

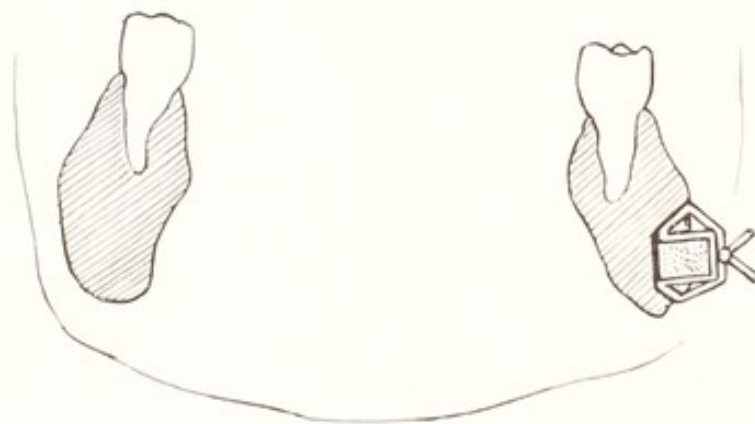


FIG. 176.—Diagram showing a cross-section of the inlay bone graft implanted for a fracture of the lower jaw, and showing the method of securing the graft in position by the kangaroo-tendon suture passed through the drill holes and over the graft holding it securely in position.

smoothly over the superior and posterior part of the heel, and as the plaster sets it is moulded over the heel, with traction

downward. The full arch of the foot is maintained by moulding the plaster well over the dorsal and plantar aspects of the foot. Union in these cases, after this treatment, is very prompt. The plaster should be cut and transformed into a bivalvular splint at the end of 2 weeks, when active motion of the foot is allowed, with gentle massage. If the case is a fresh fracture, weight bearing may be allowed in 4 weeks' time. If it is a case of malunion, this period of time should be somewhat lengthened, in accordance with the individual requirements.

SIMPLE COMMINUTED AND UNUNITED FRACTURE OF JAW

Application of the Inlay Graft.—Fracture of the lower jaw occurs as a rule in the body of the bone and is usually associated with displacement which persistently recurs if proper fixation is not provided. The biting surface of the teeth is a very trustworthy guide to the proper reduction of the fracture.

Fractures of this bone do not as a rule require operative treatment. Maintenance of satisfactory alignment can usually be accomplished either by the interdental splint or by wiring the teeth.

Fractures of the ramus are the most difficult to treat by conservative means especially as the interdental splint is inapplicable in these cases.

If the fragments cannot be maintained in satisfactory alignment after a reasonable perseverance by conservative means, or if non-union has resulted, operative measures should be advised.

The inlay tibial graft offers a very satisfactory agent for the internal fixation of this group of cases. Also for comminuted fractures with loss of bone substance where it should be chosen as immediate treatment. The bone graft's

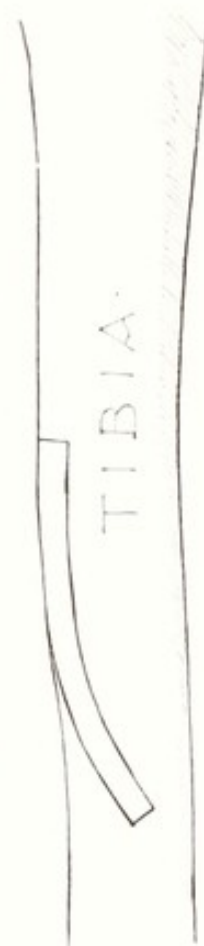


FIG. 177.—Diagram illustrating the curved graft as it is outlined on the antero-internal surface of the tibia preparatory to cutting the bone with the motor saw. This pattern has been previously determined by bending a flexible probe into the gutter on the side of the broken jaw.

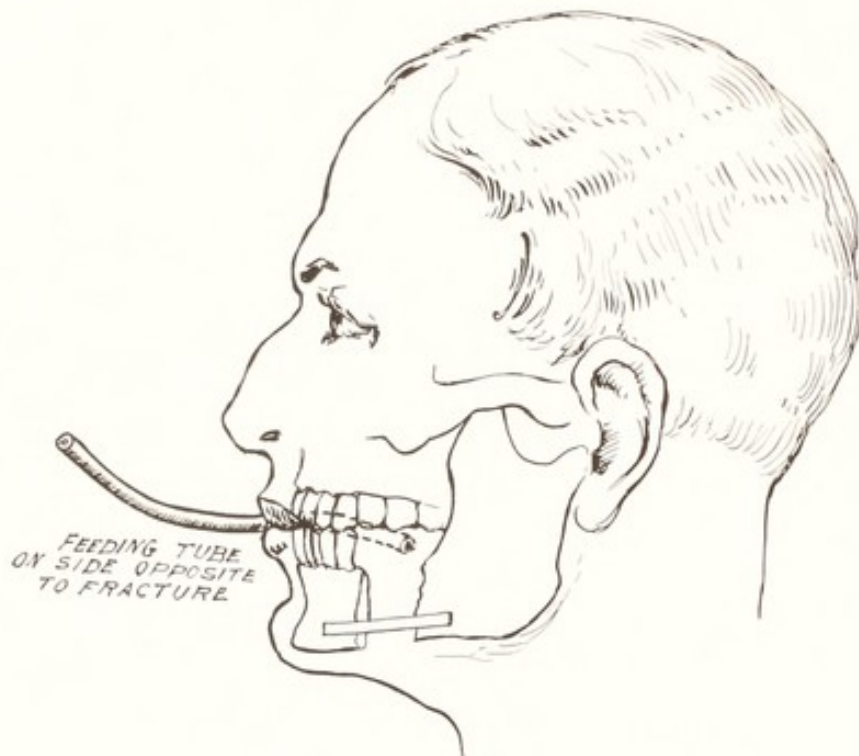


FIG. 178.—Diagram illustrating a fractured jaw with the gap spanned and the fragments held by the inlay bone graft; also illustrates the manner of feeding such a patient through a tube introduced into the mouth from the side opposite the fracture.

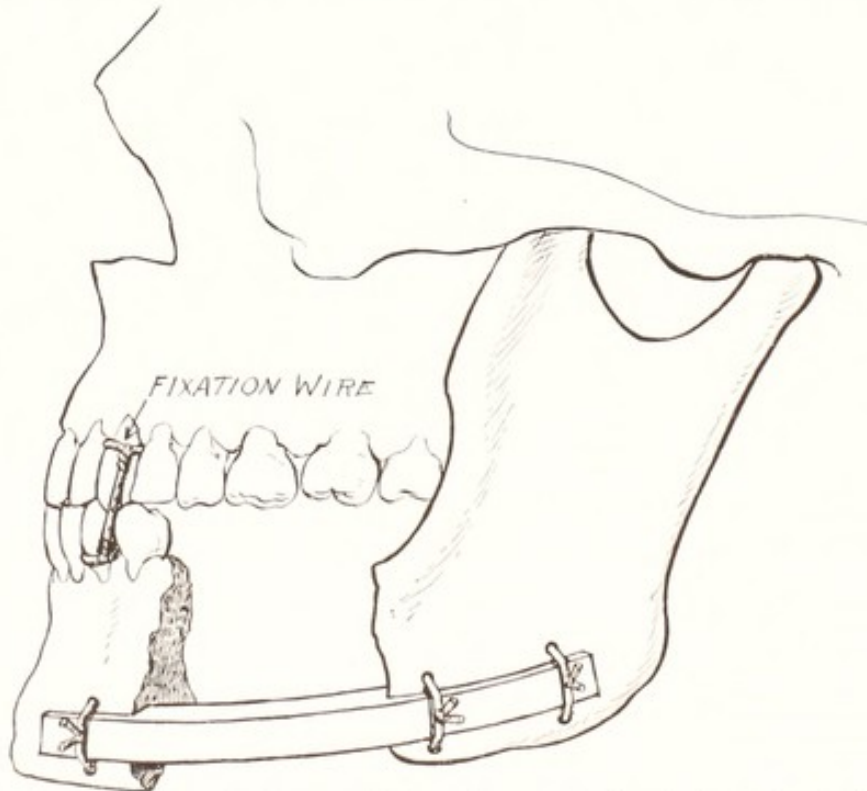


FIG. 179.—Diagram of a fractured lower jaw so badly shattered as to leave a gap where a proper position of the remaining fragments is maintained. This gap can be satisfactorily spanned and the fragments securely united through the inlay method with a graft and gutter produced by the twin motor saws adjusted at the same distance apart, producing an accurate fit of the graft which is held in position by kangaroo-tendon sutures passed through drill holes in jaw fragments. This is a frequent condition in the present war, resulting from the trench warfare.

most important asset in this type of case is its germ-resisting property.

The inlay bone graft is placed into the lower portion of the outer surface of the fragments. The graft is curved and shaped to the contour of the jaw (see illustrations 175, 177 and 179). Kangaroo tendon affords the best fixation of the graft.

The support and fixation of the fragments may be sufficient but it is safer to wire the teeth of the lower jaw to corresponding ones of the upper jaw. The teeth adjoining the site of fracture should never be selected for wiring as they are likely to become loosened.

The post-operative dressing should consist of leather chin piece or a four-tail bandage.

Especial directions should be given that the patient take liquid diet and keep the mouth clean as possible with mouth washes.

Comminuted compound fracture of the jaw, due to modern rifle-bullet and trench warfare, is one of the most frequent injuries in the present European war. It has been reported that 500 soldiers with comminuted gunshot fractures of the lower jaw have been segregated in one hospital in Germany.

CHAPTER V

OPERATIVE METHODS FOR REMODELLING OR ANKYLOSING THE HIP-JOINT

THE BONE-GRAFT WEDGE APPLIED IN TREATMENT OF ACQUIRED DISLOCATION AND RELAPSING CONGENITAL DISLOCATION OF THE HIP

Acquired Dislocation of the Hip, such as paralytic luxation, was described as early as 1877 by Reclus, since which time a number of writers have set forth the nature, ætiology and treatment of the deformity; but up to the present time no unanimity of opinion has been reached in regard to these points.

There are two kinds of paralytic luxation of the hip: The *iliac luxation*, from paralysis of the abductors and external rotators; and the *pubic luxation* from the paralysis of the adductors and internal rotators. Dislocations of this nature are not infrequent, but are usually diagnosed by associated contractures, adduction in the case of posterior luxation, and abduction of the thigh with flexion in the pubic luxations. The iliac dislocation is believed to be the one more frequently met with. The pubic displacement is difficult to confirm by röntgenogram, because of the obscurity rendered by the neighboring bony parts, where-as the iliac luxation is readily revealed by the röntgenogram. Clinical examination is rendered somewhat difficult by the atrophy of the muscles and altered direction and shape of the femoral neck, as well as by the presence of contractures.

These luxations may be due to muscle contraction, or extreme paralysis of hip muscles and a stretching of the unsupported capsule in cases unable to walk, but they also occur from static causes, even where paralysis is slight and there is an otherwise perfectly useful limb. Among the important physical signs indicating luxation are adduction and abduction contractures, with or without flexion of the thigh. An iliac luxation lordosis is

to be looked for, and if the luxation is unilateral a tilting of the pelvis out of proportion to the atrophy and shortening of the leg, due directly to the paralysis, is appreciable.

The use of external appliances in treating these cases beyond the immediate correction of deformity is unsatisfactory, and in order to control these redislocating paralytic hips the author has applied the autogenous bone wedge to deepen the overhanging rim of the acetabulum which, in conjunction with reefing the ballooned portion of the joint capsule, furnishes a stable and satisfactory hip-joint.

The indications for an open operation in paralytic dislocations of the hip are the inability to replace the head of the femur, owing to contractures of the soft parts; faulty displacement of joint structures; or such relaxation as to permit of redislocation after repeated reductions.

Contractured structures are thoroughly stretched and the dislocation reduced, if possible, by the closed method. Failing in this, or succeeding only to have a redisplacement occur subsequently, the open method devised by the author can be resorted to when it is found that the redisplacement is due to a relaxed capsule and a shallow acetabulum. The difficulty in paralytic dislocations of the hip, as a rule, is not the reducing of the dislocation but the retaining of the hip in position after the reduction. The wearing away or flattening of the rim of the acetabulum results from the head slipping in and out repeatedly. In some cases this occurs with every step the child takes.

This open method for retention of the femoral head applies both to paralytic and congenital dislocations. In congenital dislocations, it has been applied only in those cases where the acetabulum is shallow and the hip will not stay in place after a reasonable trial by the bloodless method. An open operation for the reduction of hip dislocation must be considered a major operation and should be undertaken under strictest aseptic precautions. The result to be expected is a stable joint with the widest range of motion, without pain, and with the least shortening possible.

In many cases of hip dislocation the acetabulum is found to be too shallow and with a superior rim insufficient to retain the femoral head. To obviate this defect, Hoffa, in 1890, did his first successful operation, which consisted chiefly in deepening the acetabulum by scooping out the contained fat, articular cartilage and bone, to furnish an adequate concavity to receive and hold the head of the femur. By this method he was enabled to produce a stable joint, but in many instances with little or no motion without pain, and in many others producing a stiff hip with a varying amount of shortening of the leg, depending upon the amount of excavation made in the superior portion of the acetabulum to receive the head of the femur. In cases where motion seemed free shortly after the operation, a later examination showed it to be slight, if any at all, and at a still later period there was evidence of a proliferative arthritis.

The author's method, which has been performed successfully in a number of instances, obviates the above-mentioned disadvantages and produces a stable joint with full and free motion and without pain or shortening. The most important feature is that it preserves the entire acetabulum and joint cartilage, thus guarding against any later joint change. It may be described as the *bone-wedge graft remodelling operation* for paralytic and congenital dislocation of the hip.

The important points of advantage which it possesses over the Hoffa open operation are:

1. It is an operation of less magnitude, producing less shock and mutilation of the anatomical joint structures.
2. There is a preservation of the synovial membrane and hyaline cartilage of the joint as well as the ligamentum teres, which remains undisturbed if it is present.
3. The operation is performed without the disarticulation or extensive traumatization of the head of the femur, a most important factor in avoiding shock and subsequent traumatic degenerative change in the joint.
4. There is no shortening of the limb produced by the opera-

tion, as no portion of the existing articular structures is removed or scooped out, as in the Hoffa operation.

5. There is a restoration of joint stability and a reinforcing of the joint structures present, and an actual addition to the joint anatomy by the insertion of these bone grafts, to be described.

6. The author's method minimizes any possibility of limited motion of the remodelled joint, or subsequent production of osteoarthritis to limit motion or produce painful motion.

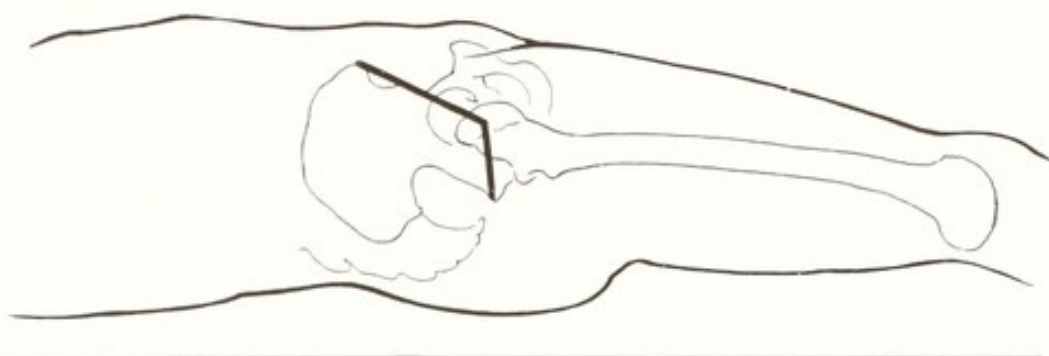


FIG. 180.—Heavy line indicates lateral skin incision when tip of trochanter is turned up for an approach to the hip-joint.

THE BONE-GRAFT WEDGE IN THE TREATMENT OF CONGENITAL AND ACQUIRED DISLOCATION OF THE HIP

Author's Technique.—The technique of the operation is as follows: All existing contractures having been overcome by forcible manipulation or open division, and the dislocation made easily reducible by weight and pulley traction or manipulation under ether, an incision is made from the anterior-superior spine of the ilium to the great trochanter, then backward 1 to 2 in. in the direction of the ischial tuberosity; the skin and subcutaneous structures are dissected back and the trochanter exposed; the tip of the trochanter is developed, with its muscle attachments, and sawed off with the motor saw. This trochanter tip, with its attached muscles, is turned upward, giving a free exposure of the superior and posterior portions of the capsule of the joint, together with its attached portion of the superior and posterior acetabular rim; this portion of the capsule

is seen and felt to be lax if the head is in the acetabulum, and if the head of the femur is disarticulated it distends the capsule by pressure from beneath and further displacement of the head is resisted. Upon manipulation of the femur, the head is readily felt as a rounded hard surface slipping about beneath the capsule.

The amount of deficiency of the acetabular rim can be very easily determined at this stage by direct palpation, and manipulation of the thigh, and also the amount of laxity of this portion of the capsule. Above the capsule attachment to the acetabular rim the bone surface is cleared of soft tissue, and with a narrow thin osteotome the bone is incised just above the insertion of the capsule in a semicircular line in this posterior-superior-anterior surface, to conform to the natural curvature of the superior rim of the acetabulum. This semicircular bone incision produces a strip of the superior curved bone margin of the acetabulum with its attached and undisturbed capsule segment. This curved acetabular bone segment is pried outward and downward with the osteotome to deepen the acetabulum sufficiently to offer an obstruction to displacement of the femoral head, *i.e.*, this superior curved rim of the acetabulum is made to overhang and more securely grasp the head of the femur when placed in its socket (see illustration 187). The prying downward and outward of this curved superior bony rim segment produces still more laxity and wrinkling of the attached portion of the capsular ligament. The slack is taken up by reefing this portion of the capsule by a row of mattress sutures of kangaroo tendon placed at right angles to the long axis of the neck of the femur. The stitches are so placed as to make the reef of the capsule lie equidistant from the two ends of the capsular bone insertions. This reefing avoids entering the joint, takes up the slack of the capsule, and at the same time holds the new-formed or placed acetabular rim in position.

To fill in the bone gap produced by the prying downward and outward of this curved bone rim segment, and to further secure the permanent fixation of this new-formed acetabular

rim, a segment of bone having a triangular cross-section is removed from the crest of the tibia, long enough when cut into three or more portions to fill in this gutter. Before disengaging this graft from the tibia, six drill holes are made in this bone segment, so placed that when this long graft is cut into three portions prior to being placed in position there are two holes in each portion. The illustration shows the direction in which the saw-cut is made in the crest of the tibia to produce the wedge graft.

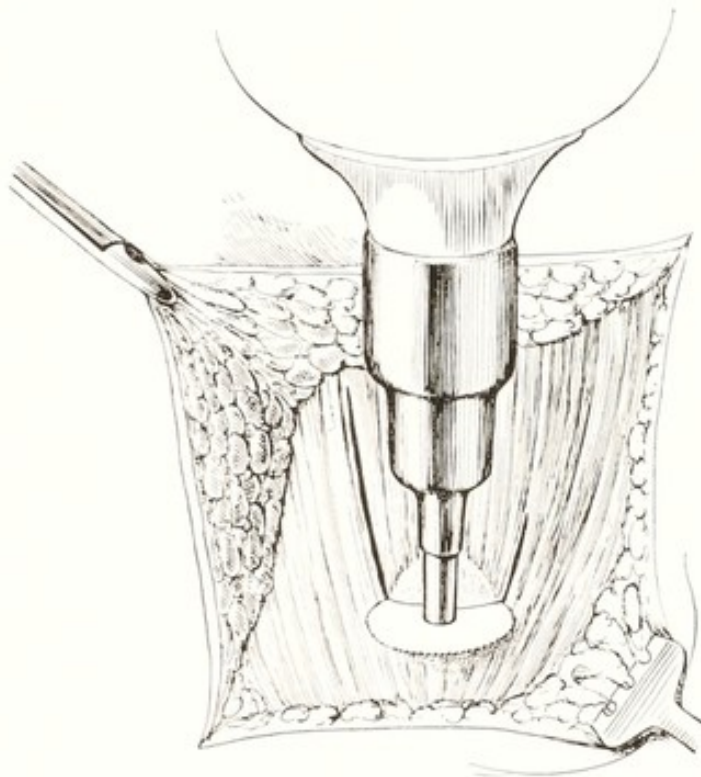


FIG. 181.—Method of using motor to incise tip of great trochanter for the purpose of exposing the hip-joint by turning of trochanter with the muscles, attached, upward. A chisel or gigli saw can be used for this purpose.

Bone pegs, if used, are made from additional strips of bone obtained from the tibia just above where the bone graft is obtained, and these are turned to fit the previously formed drill holes in the graft segments. This is quickly accomplished in the motor-driven surgical lathe. The long wedge graft is removed from the tibia and cut into the three mentioned portions, which are placed in position and pegged to the pelvis. As a rule, the cancellous bone structure of this portion of the pelvis is satisfactorily penetrated by the cortical bone pegs without

further drilling. These pegs should extend through the graft and into the pelvic bone for one-half to three-quarters of an inch. In certain cases it has been found that these bone pegs to hold the graft in position are unnecessary, and that sufficient fixation is produced by drawing the soft tissues over the graft with kangaroo sutures.

The tip of the trochanter with its attached muscle insertions is returned to its normal position and sutured with kangaroo

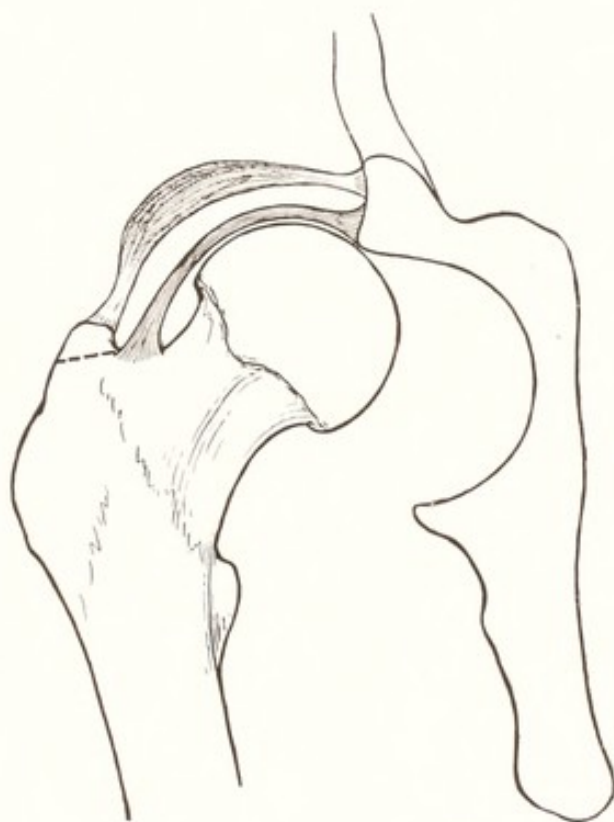


FIG. 182.—Congenital or paralytic dislocation of the hip with the head of the femur stretching the capsule.

tendon through the periosteous structures. The skin is closed with continuous sutures of No. 1 chromic catgut, without drainage. The limb is placed in an abducted position and fixed by a long plaster-of-Paris spica reaching from the thorax to the toes, which remains on for 6 weeks, and is then replaced by a short spica for an additional 6 weeks, when the cast is removed and passive and active exercises are instituted, together with massage and guarded functional use of the limb.

OPERATIVE TREATMENT IN SELECTED CASES OF OSTEOARTHRITIS,
ADULT TUBERCULOUS HIP-JOINT DISEASE, AND CERTAIN
TRAUMATIC AND DANGLE (PARALYTIC) HIPS

It has long been a well-known fact that a large number of progressive and advanced cases of arthritis deformans (osteoarthritis) of the hip, with the accompanying deformity and disability, fail to respond to the conventional methods of systemic, hygienic, rest, or brace treatment, and progress toward

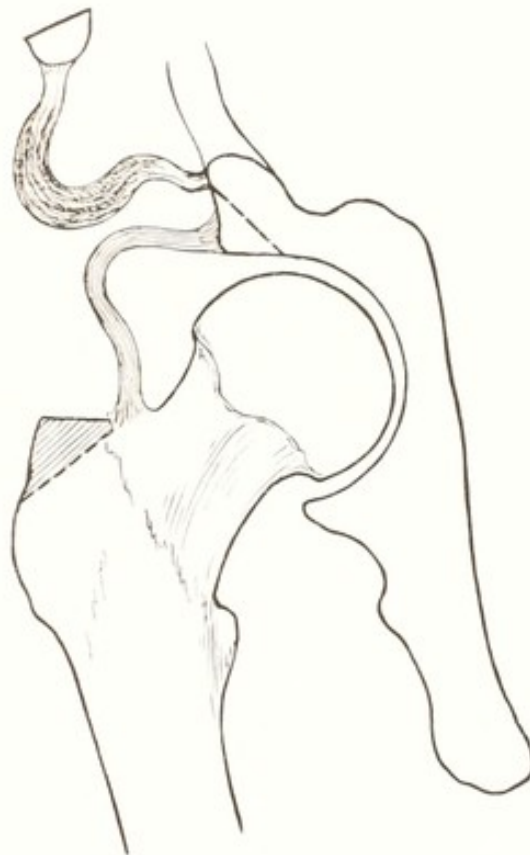


FIG. 183.—Represents the head of the femur reduced and in the acetabulum. The tip of the great trochanter is turned upward with its attached muscles. The superior and posterior portions of the capsule are much ballooned. The dotted line indicates the bone section which is carried one-half the way around the rim of the acetabulum on its anterior-superior and posterior aspects. (See Fig. 184 and 186.)

complete invalidism. This class of cases is met with in adult life, and the length of time required by the treatment heretofore employed cannot be satisfactorily undertaken by the working man with a family dependent upon him, even though the chances are good for an ultimate recovery.

With marked anatomical and pathological changes present,

such as the wearing away of the femoral head and acetabulum, eburnation, osteophytes, and the associated flexion and adduction deformity, satisfactory results can rarely be expected from expectant treatment. (See Fig. 188.) A resection of the upper extremity of the femur has been practised by Hoffa and others, with very unsatisfactory results. Hoffa was one of the last to discard complete excision. Forcible manipulation under ether has produced disastrous results in both the hypertrophic and the atrophic types. In the hypertrophic type, forcible manipula-

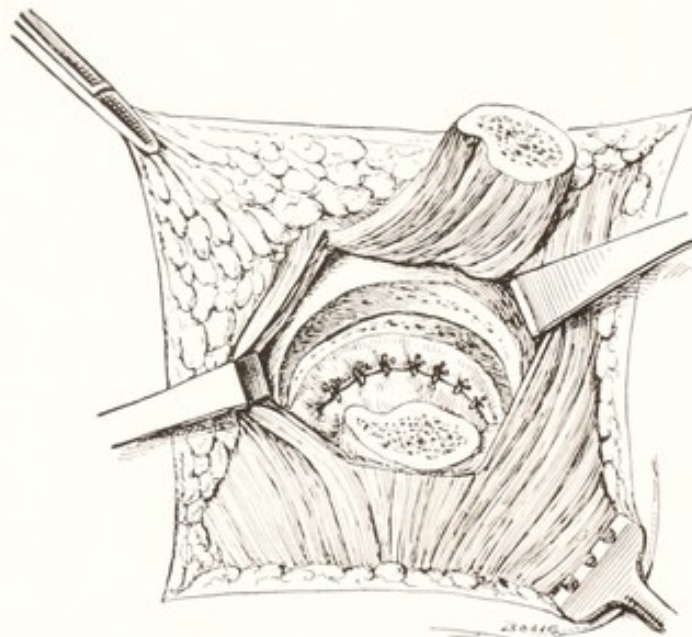


FIG. 184.—Author's technique of operation for paralytic and congenital dislocation of the hip, illustrating the division of the tip of the great trochanter with its attached muscles lifted upward to expose the joint capsule. The supra-acetabular curved bone incision and reef sutures in the capsule are shown after depressing the curved bony superior rim of the acetabulum.

tions of the parts produces further hypertrophy in many instances, more pain, and ultimate deformity by the traumatization of the joint structures; and in the atrophic condition, on account of osseous rarefaction, further damage is likely to occur from the crushing of this rarefied bone. When this disorganizing condition of the hip-joint exists, with its accompanying adduction and flexion, with firm muscular contractures and a progressive bony obstructive ankylosis with the thigh in this faulty position, it has seemed best to aim for an immediate firm ankylosis by means of an operation (see Albee: *The Journal of the American*

Medical Association, June, 1908), at which time the limb is placed in a position of slight over-correction to compensate for the existing practical shortening, there being but little further actual bone shortening produced by the operation.

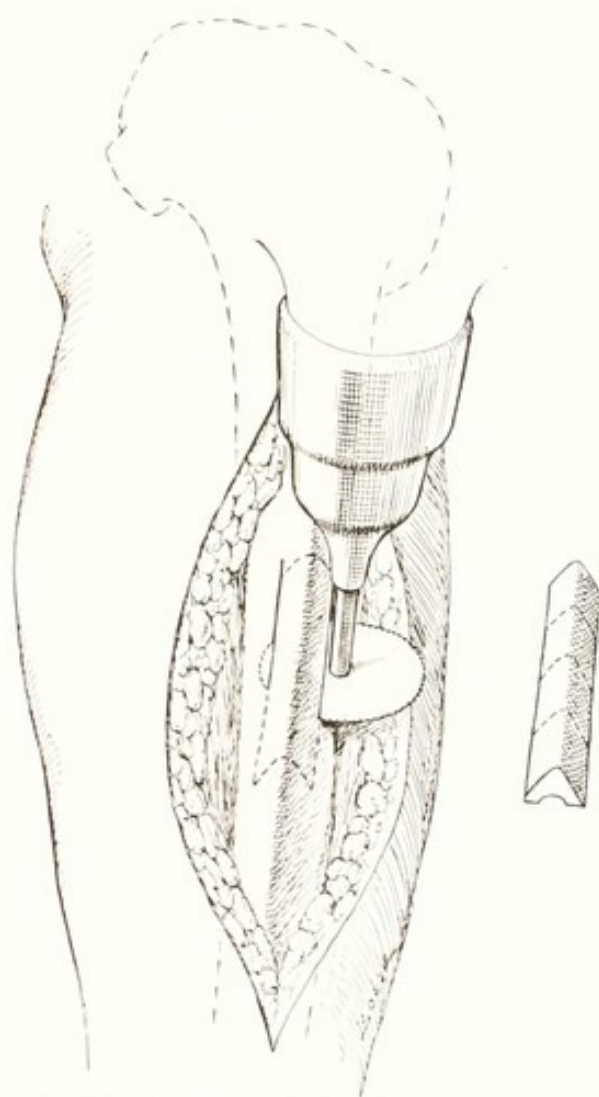


FIG. 185.—The method of the removal of the bone from the crest of the tibia, to be divided into segments with the motor saw and used as bone-graft wedges in paralytic and congenital dislocation of the hip.

The author has operated by the following method in 50 cases, the patients ranging from 22 to 67 years of age, and the time since the first cases were so treated has been over 7 years. Furthermore, to the author's knowledge, the operation has been performed by a number of other surgeons, all of whom have reported satisfactory results.

Technique of the Author's Arthrodesis Operation of the Hip.—The hip-joint is reached in thin subjects by an anterior incision, 5 in. long, through the skin and subcutaneous tissues, starting from just below and inside of the anterior-superior spine of the ilium and extending downward. The sartorius muscle is retracted outward; the deeper muscles and structures are separated by blunt dissection and the iliacus and the rectus femoris muscles are retracted inward. A part of any group of osteophytes about the acetabulum is turned upward with the soft tissues adherent to them, since it is con-

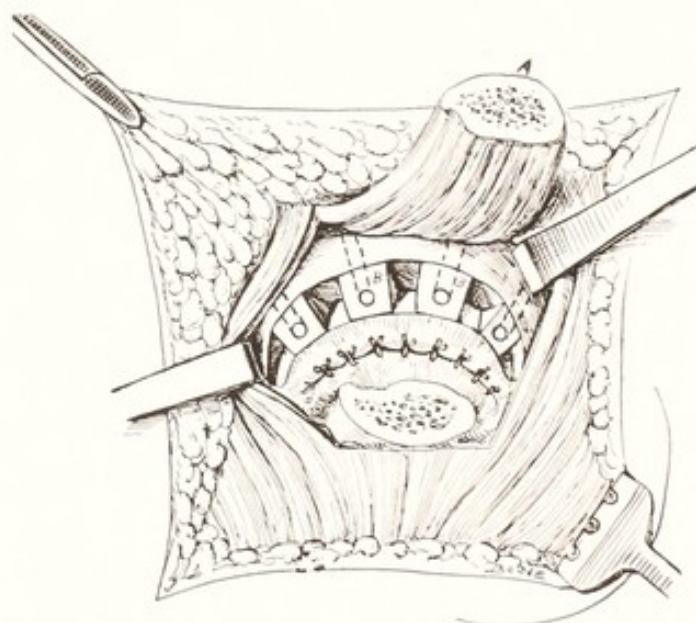


FIG. 186.—Technique of operation for paralytic and congenital dislocation of the hip, illustrating four autogenous bone-graft wedges. *B* held in position in the supra-acetabula curved bone gutter by autogenous bone dowel pegs inserted through drill holes extending through each graft wedge into the adjacent bony wall of the pelvis. *A* is tip of trochanter turned up with its attached muscles. Four wedge grafts are shown in this drawing. Two or three are often sufficient.

sidered advisable to preserve as many as feasible on account of their bone-producing possibilities. In a thick muscular thigh where there is much bony outgrowth overhanging the joint, it requires some care to locate the joint accurately. The capsule is opened. With the head of the femur *in situ*, approximately one-third of its upper hemisphere is removed with a long osteotome or chisel—five-eighths of an inch in width—in a plane nearly parallel with the long axis of the neck of the femur. With the same instrument and a strong

curette with a cross handle, the acetabulum is transformed into a flat-surfaced roof against which the flat surface of the head is finally brought into firm contact by abduction of the thigh. If the adductor muscles prevent the required amount of abduction, an open division of these muscles and tendons is made to permit the leg to be brought into the desired position. The acetabular and femoral head surfaces are brought into contact by simply abducting the thigh. The capsule and soft tissues are sutured.

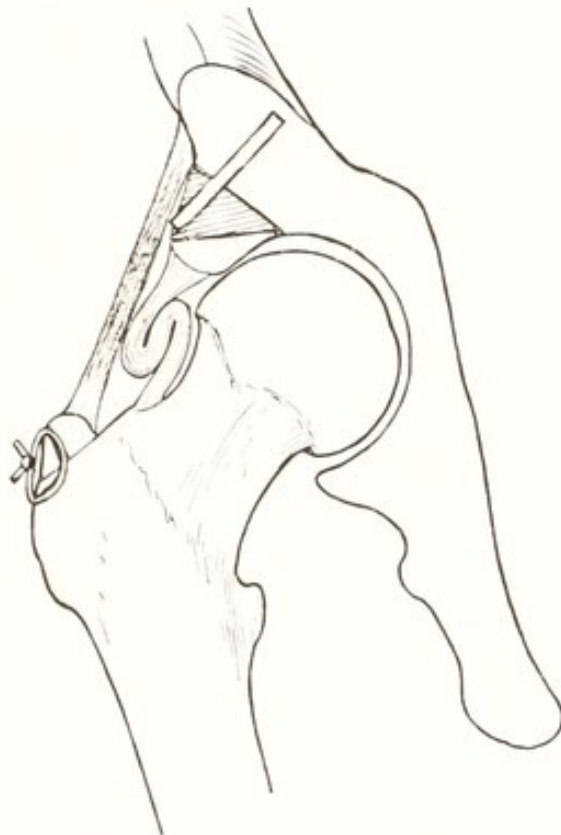


FIG. 187.—Antero-posterior view of remodelled hip-joint with wedge bone graft pinned in position depressing the superior rim of the acetabulum, the superior portion of the capsule reefed, and the tip of trochanter with its attached muscles restored to its position and fastened with kangaroo tendon.

Access to the joint is much facilitated by a position of extreme *adduction* of the limb. For the purpose of orientation, an assistant is kept in constant readiness to rotate the femur while the operation is in progress. The bone is removed in such a way that the flat pelvic surface is tilted up mesially somewhat, in order to produce a locking of the parts and to prevent any possibility of dislocation from weight-bearing.

In very stout patients, with thick thigh muscles, the technique of lateral approach to the hip-joint described by Brackett may be used to advantage as follows:

The hip-joint is reached by an incision from the anterior-superior spine, obliquely downward and outward to the middle of the outer side of the trochanter, and then downward 2 in. in the line of the femur. At the point where the oblique por-

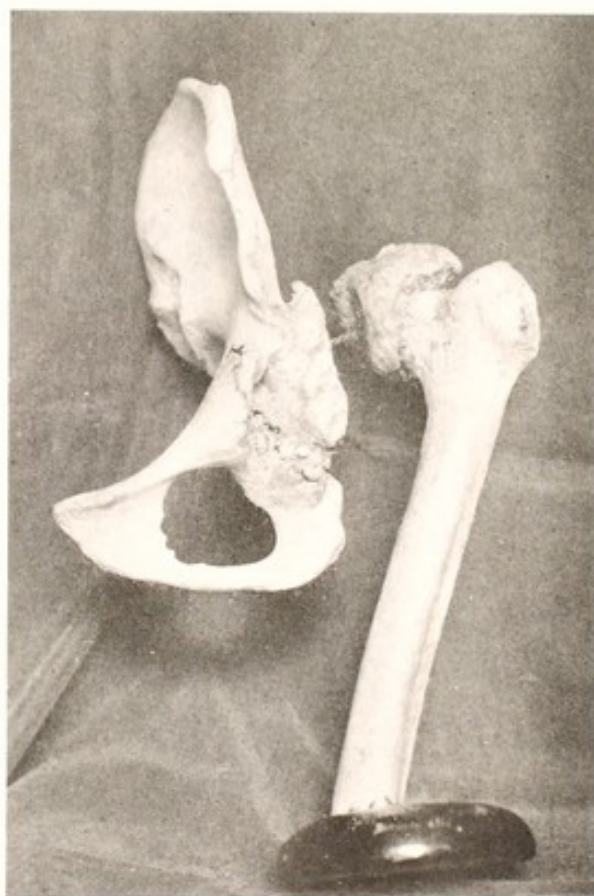

FIG. 188.—Advanced arthritis deformans (osteoarthritis) of the hip in which the acetabulum has become filled with new bone and the head of the femur dislocated. (From specimen in the College of Physicians and Surgeons.)

tion joins the vertical, just over the trochanter, an incision is made directly backward, 2 to 3 in. in length, down to the fascial portion of the gluteus maximus. After separating the tensor fascia femoris and the gluteus medius, the line of separation is extended downward along the line of the original incision, through the fascia lata to the femur, freeing the attachment of the muscles (vastus externus) from the outer and upper surfaces

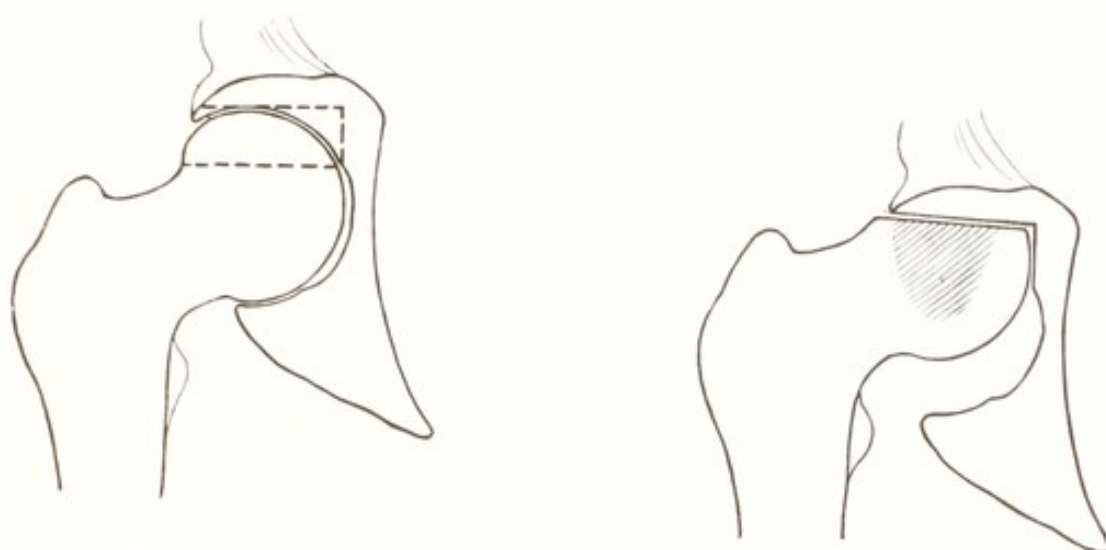


FIG. 189.—The broken lines indicate the amount of bone to be removed. It is removed from the head and the acetabulum in different planes in order to secure the desired abduction of the thigh, when the freshened bone surfaces are brought together.

Apposition of the freshened bone surfaces after the removal of the bone from the head and the acetabulum, and the femur placed in slight abduction. The blackened area indicates where the cartilage is removed when the femur is strongly rotated outward for that purpose.

All the small fragments of bone are not removed with as much care as formerly. They are left in or selected ones replaced on account of their osteogenetic activity.

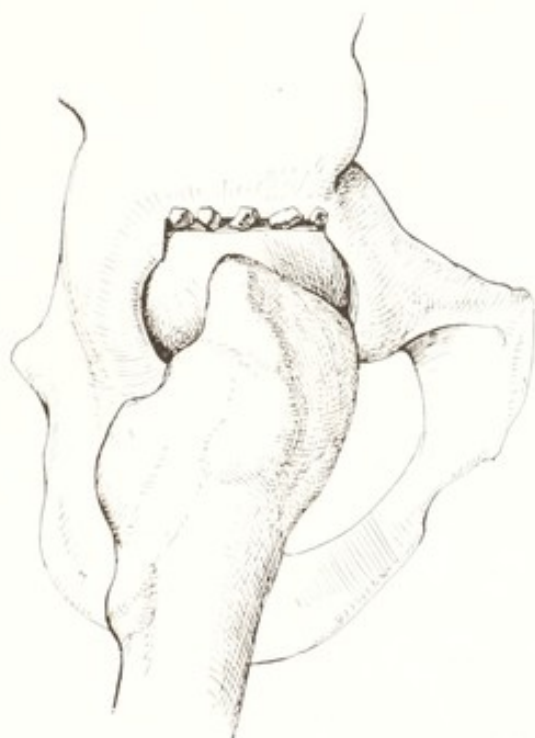

FIG. 190.—Author's arthrodesis of the hip-joint showing the incised flattened superior surface of the head of the femur in apposition with the incised flattened superior surface of the acetabulum, with the parts of osteophytes and small bone grafts placed along the contacted bone area. Lateral view.

of the femur. The fascial expansion of the gluteus maximus is then cut through along the line of the posterior part of the original incision, and the outer part of the trochanter exposed.

This gluteal flap is turned backward, and the outer and upper surfaces of the trochanter are fully exposed. The upper portion of the trochanter is then chiselled off by cutting directly backward with a narrow osteotome, on a curved line beginning on the outer surface of the trochanter, $1\frac{1}{2}$ in. below the tip, and cutting inward for $\frac{1}{4}$ in., then curving upward to the fossa at the junction of the upper part of the neck and the trochanter. This removes the outer portion and tip of the trochanter, and with it the attachments of the gluteus medius, gluteus minimus, and piriformis. The motor or Gigli saw can be used. Care should be taken in the removal of this piece not to encroach on the neck, or the bone will be weakened at this angle. The portion of bone removed, with the muscles attached, is deflected backward and upward enough to uncover the upper part of the femoral neck, and the muscular covering of the anterior fibres of the gluteus medius and minimus are easily separated from the region above the acetabular rim. The incision through the trochanter just borders on or opens the outer edge of the capsule on the upper surface of the neck, and the incision of the capsule opens directly into the cavity of the joint. The capsule may be split along its upper surface, parallel to the neck, and near to its acetabular insertion and cut transversely on each side, which opens the view of the edge of the head and rim of the upper half of the acetabulum.

The leg is finally put in a long spica extending from the axilla to the toes, in strong abduction and 10 degrees of flexion. If the convalescence is uneventful, the patient is usually walking in 5 weeks, with the aid of crutches. A short spica is then substituted for the long one for a period of 7 weeks longer.

It has been found in the later cases that to remove the overhanging edge of the acetabulum first renders the removal of the upper surface of the head of the femur easier. If the upper third of the femoral head to be removed is cut into segments

by a thin osteotome, and by cutting at right angles to the first bone incision, the removal of this portion of the head is facilitated. After this segment of the head is removed, all the accessible articular cartilage is sliced from the anterior portion of the head, brought into view by strongly rotating the femur outward. The cartilage is also removed from the contiguous

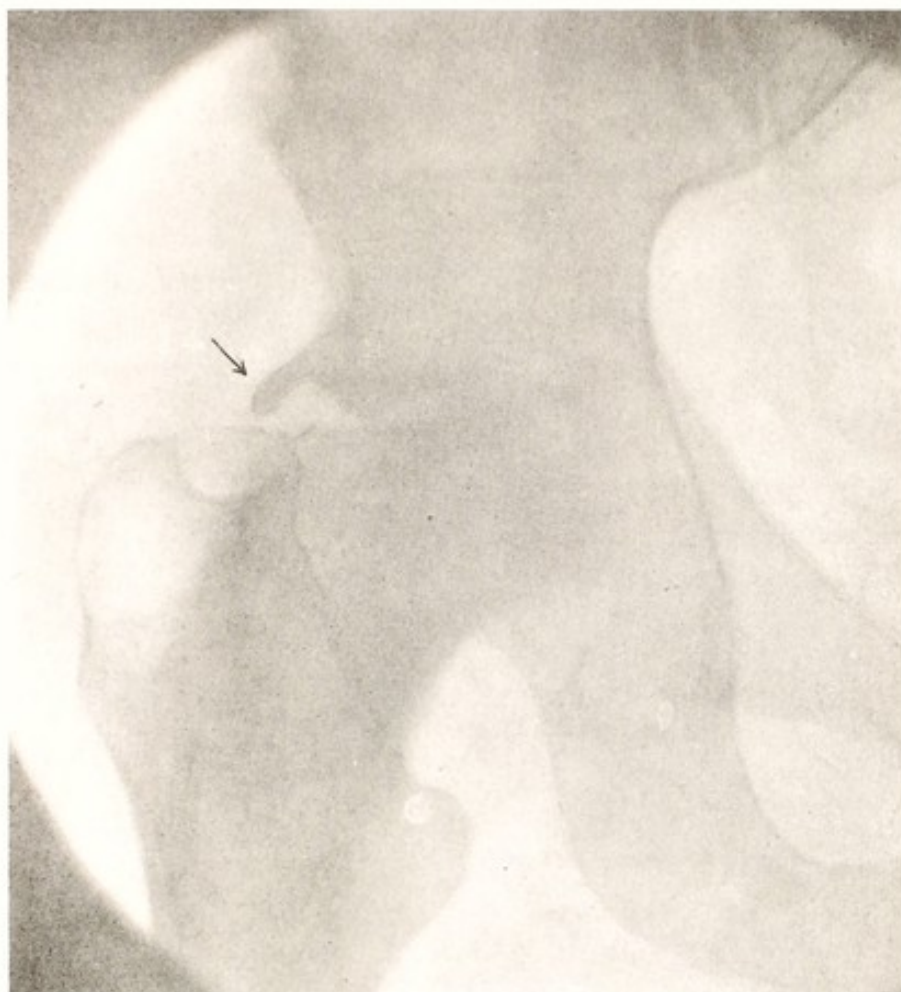


FIG. 191.—Bony union after author's arthrodesis for osteoarthritis of the hip with relief of all symptoms. The arrow indicates small bone grafts placed about rim of joint.

portion of the acetabulum with a thin osteotome. In operating upon stout persons, one is forced to depend very largely upon the sense of touch in this removal of bone and cartilage.

One precaution should be emphasized, and that is the removal of the overhanging shell of osteophytes before incising the femoral head. The reason for this is to avoid being misled

and making the capital incision too low, and thus removing a larger segment than is desirable. The removal of one-third of the head furnishes as extensive a fresh bone surface as can be obtained for ankylosis, and at the same time the hip is not loosened nor the limb shortened to any material degree. The tendency always is to regard the hip-joint as being situated lower than it actually is.

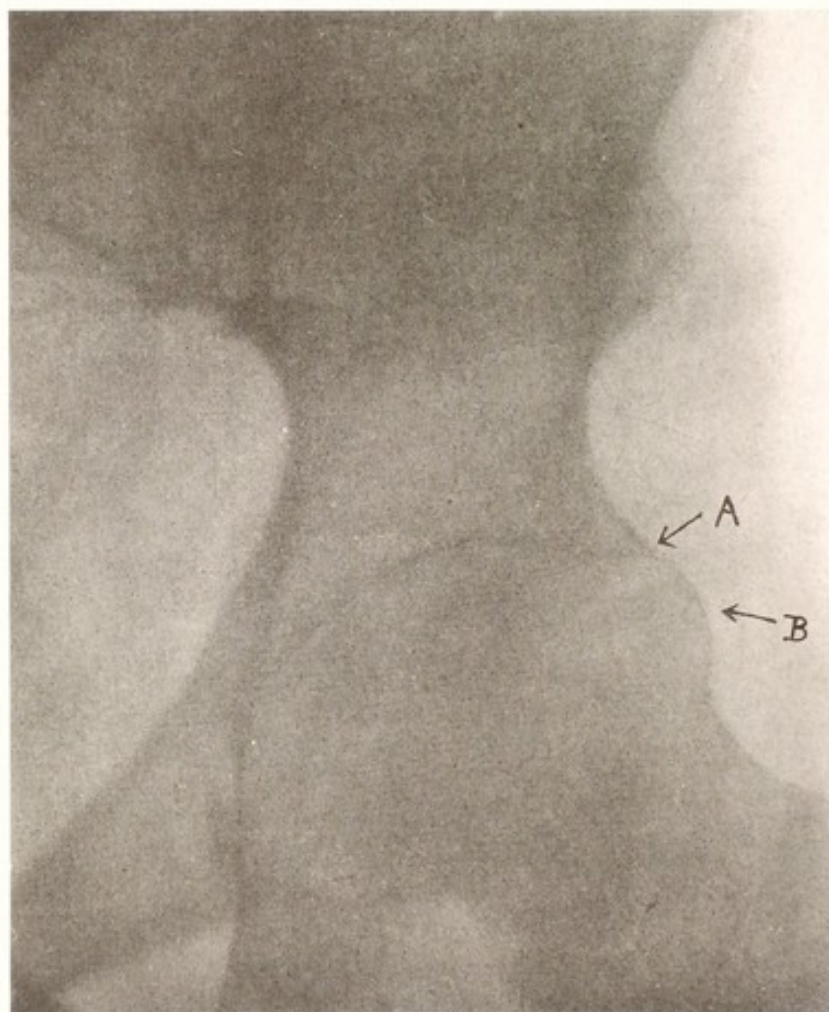


FIG. 192.—A case of osteoarthritis with flattening of the head and osteophytes at *A* and *B*. A bony ankylosis was produced by author's technique of arthrodesis and all symptoms were immediately relieved.

Illustrative cases of osteoarthritis of the hip operated by this method:

Case I.—In October, 1906, M. N., a policeman 59 years of age, was referred to the author by Dr. J. L. Moriarty of Waterbury, Conn. An examination revealed arthritis deformans of

the right hip. Hygienic and brace treatment were recommended and explained. It was declined on the ground that the time required was so long and that the possible results were too uncertain for a working man with a dependent family. The following May (1907) this patient returned to the writer and begged that something be done for him. He was admitted to the New York Post-Graduate Hospital May 14, 1907, with the following history: Policeman for the past 25 years. Three years before, he first began to notice pain and stiffness in the right thigh and hip. Soon after this he went to Mount Clemens, where he took a considerable number of baths. His general health was improved, but the pain and disability continued as before. Two years ago he was examined by a physician and was told that his right hip was dislocated and that the right leg was 2 in. shorter than the left. The symptoms became so severe that, 3 months after consulting the writer in December, 1907, patient went to New Haven and submitted to an operation, the nature of which could not be ascertained. Lameness, stiffness, and pain continued unabated.

The physical examination revealed a muscular man with a pale and careworn countenance and a markedly shortened right limb. His right shoe was built up with a cork extension $2\frac{1}{2}$ in. thick. The limb was much atrophied and was markedly adducted and flexed. A long linear scar was noted over the right trochanter. The actual bony shortening of the right limb was $\frac{1}{4}$ in.; the practical shortening was $2\frac{3}{4}$ in. The motion was very slight, except for the presence of about one-half the normal amount of flexion. Attempts at passive motion were painful. There was some muscular spasm. A röntgenogram showed the head of the femur much worn away and flattened, with many bony outgrowths about the rim of the acetabulum.

In view of the disorganization of the joint, the marked adduction and flexion, with firm muscular contractures, and the progression toward bony obstructive ankylosis with the leg in the above-mentioned faulty position, in a person so large and

muscular, it seemed best to aim for an immediate firm ankylosis by means of an operation, and in order to compensate for the existing practical shortening, to place the limb in a position of slight over-correction of the deformity. Therefore, the operative indications were to devise a procedure which would fulfil the above requirements and at the same time produce as little bony shortening as possible.

Access to the joint was much facilitated by a position of extreme adduction of the limb. For purposes of orientation an assistant was kept in constant readiness to rotate the femur while the operation was going on. The bone was removed in such a way that the flat pelvic surface was tilted up mesially somewhat, in order to produce a locking of the parts and to prevent any possible dislocation from weight-bearing. The leg was finally put up in a spica extending from the axilla to the toes, in strong abduction and 10 degrees of flexion. The convalescence was uneventful, and at the end of 4 weeks the patient was walking with the aid of crutches. A short spica was substituted for the long one at the end of 5 weeks. At the end of 9 weeks the patient walked without the aid of crutches or cane. He went back to work as a patrolman in 4 months. The patient stated, 2 years and 3 months after the operation, that he had not suffered any pain whatever since he left the hospital, although he was at work continuously. The leg remained extremely well in the corrected position, and only $\frac{1}{4}$ in. of extra leather was worn on the heel. His occupation since the operation vouches for his locomotive abilities. He has continued as a patrolman, working 9 hours a day, and has not lost any time on account of his hip since he went back to work in September, 1907. (Note of March, 1910.)

Case II.—A. N., consulted the author on September 14, 1906. Before a question could be asked, the patient volunteered the diagnosis. He said that his right hip had been fractured 15 years before. The following history was obtained: Age, 30; always well. No trouble with joints before injury. Was struck on right hip with a stone the size of a goose egg, thrown

by his brother, 15 years before. Careful questioning brought out the fact that he walked home after the injury and did not have any trouble with the hip for over a year. The first symptom was stiffness, slowly increasing until pain appeared about a year and a half ago. Since then, notwithstanding much treatment by many physicians, the symptoms have increased in severity until 2 months ago, when he was compelled to dis-

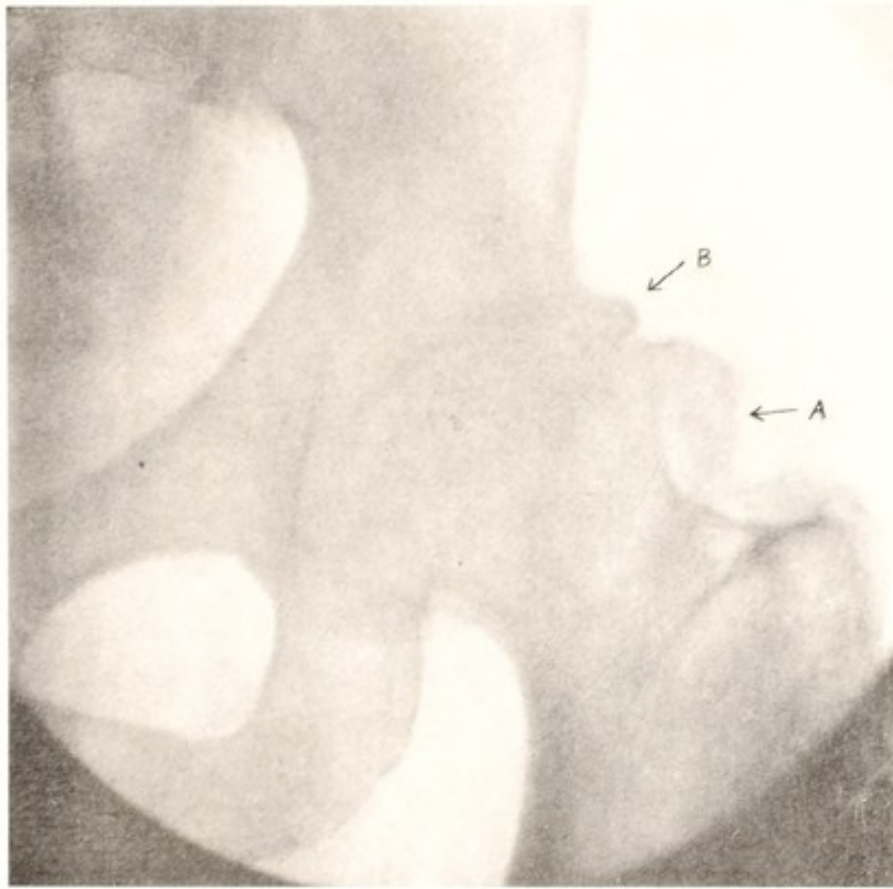


FIG. 193.—Case of advanced osteoarthritis with flattening of the femoral head and osteophytes at *AB*.

continue work. Sleep has been much interfered with on account of pain.

Physical examination: Pale and careworn. Walks with a marked right limp. No other joints involved. Actual shortening of right leg, $\frac{1}{2}$ in.; practical shortening, $1\frac{1}{2}$ in. Rotation and abduction of thigh much limited by obstruction. Flexion to 100 degrees. Hyperextension much limited. Some spasm of muscle. Atrophy of limb was marked. The buttock

was flaccid and flattened. A röntgenogram showed the head much worn away and flattened, with many osteophytes about the rim of the acetabulum.

The patient was put to bed with traction of 5 lb., and the hip was immobilized. The pain promptly disappeared, and at the end of 2 weeks a short spica was applied and the patient was allowed to go about with the aid of crutches. This was very annoying to him, and he refused to wear the spica. A brace was advised, but was refused. Patient was not seen again for over a year. When he reported, he had been taking some injection treatment in hip and was much worse in respect to both pain and disability. He was admitted to the New York Post-Graduate Hospital November 25, 1907, and was immediately operated upon.

This patient has been back at work since 10 weeks after the operation, and he has been entirely relieved of pain.

Case III.—J. K., referred to the author by Dr. A. W. Hollis, of New York. He was previously an active business man, 63 years of age. Past history negative. Twelve years ago a sidewalk over which patient was walking broke, letting his right leg through. The right hip received a "severe jar." Soon after this he began to have pain in the knee and thigh, especially while walking. Ten years ago he began also to have pain in the region of the right sciatic nerve. This has gradually increased in severity. Three years ago a severe pain began just posterior to the hip-joint. This continued to increase until, for the past 3 months, the patient was practically confined to his chair or bed. He lost interest in things and refused to go about, and retired from business.

Physical examination: Patient very large: height, 5 ft. 11 in.; weight, 220 lb. Right thigh much atrophied. Patient walked with difficulty, hopping along as if it were very painful. Flexion limited to about two-thirds its normal arc. Abduction and rotation nearly absent. Limb adducted: actual shortening, $\frac{3}{8}$ in.; practical shortening, $1\frac{1}{2}$ in. Joint sensitive to

the extremes of motion. Patient locates most severe pain just posterior and internal to the hip-joint.

He was admitted to St. Luke's Hospital, private pavilion, by the kindness of Dr. Lyle. The operation was done February 20, 1908. The head had slipped up on the rim of the acetabulum and was apparently progressing toward a complete dislocation.

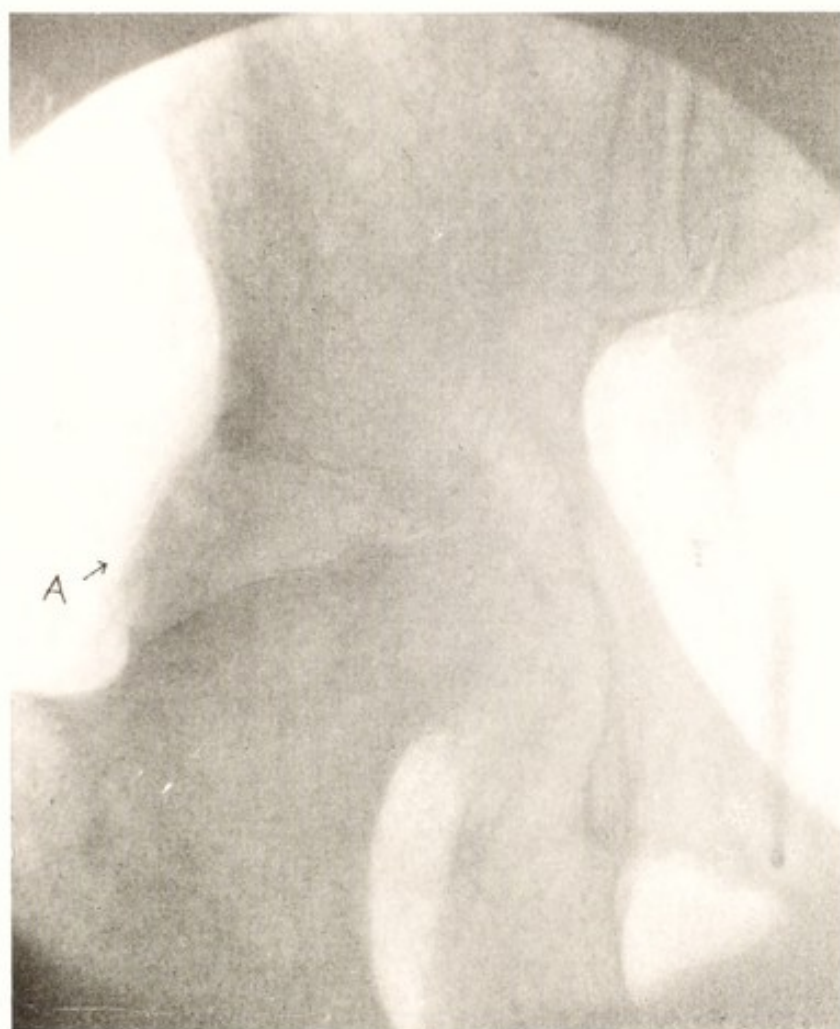

FIG. 194.—Good union secured in a case of advanced osteoarthritis of the hip by author's arthrodesis. A indicates small bone grafts.

There were many osteophytes and much disorganization of the joint.

The convalescence was uneventful. This wound also healed by primary union. The patient was walking with the aid of crutches at the end of 4 weeks, and could place his whole weight upon the operated leg without pain. The spica was

changed to a short one at the end of 5 weeks. This was removed at the end of 11 weeks.

This patient was seen June 1, 1908, when he stated that he had not experienced a twinge of pain in his hip since the operation. His family stated that he had undergone a great change mentally since relieved of his constant pain, and that he was much more cheerful than formerly. In a letter dated January 12, 1909, the patient states: "I am very much pleased to be able to report that the operation has been a wonderful success. All pain has left me, and you may remember that I was very anxious about my right knee-joint, which had pained me for so many years and which I feared might have become chronic, but now this knee is as strong as the other and is entirely free from pain. I can walk all day, if necessary. The resulting freedom from pain allows me to attend to my business and I feel at least 20 years younger."

Case IV.—Miss B., 18 years of age, was admitted to the New York Post-Graduate Hospital August, 1907, and a diagnosis of ankylosis with flexion adduction deformity following tuberculosis of hip was made, and a Gant's osteotomy, with correction of the deformity, was done. The immediate convalescence was uneventful, but when the patient began to walk, weight-bearing produced pain and a short spica with crutches was instituted again, but to no avail. A röntgenogram taken 1 year after the operation showed the bones well united at the point of operation, but there was slight motion at the hip-joint, indicating that the ankylosis was fibrous and not bony, as was supposed—which, by the way, is very likely to be the case in tubercular infection, and accounts for the frequent relapse of the deformity after a trochanteric osteotomy. In this case, then, we had an analogous problem to that of a knee-joint in a similar condition with its contingent joint strain, the universal treatment for which is an excision for ankylosis. After palliative treatment for 1 year and 10 months, without relief, a partial arthrectomy was done June 1, 1908. The hip was found to be much disintegrated, but the ankylosis was fibrous. The convalescence, in

a neurotic girl, has been uneventful, and a firm bony ankylosis has been secured.

GRAFTING OF THE ASTRAGALUS TO SECURE AN ABSENT HEAD AND NECK OF THE FEMUR

In cases of loss of bone substance of the upper end of the femur, as in instances of destruction of the head and neck following septic arthritis, or of deformity of the head following injury, it has been found that the astragalus furnishes an excellent substitute for such deficiency or deformity. This operation was first suggested by Roberts, who reported five cases that underwent such treatment.

In one instance where the author grafted the astragalus to the upper end of the femur of a child 4½ years old, the head and neck of the femur had been destroyed by septic arthritis, 8 months before the operation. The astragalus used in this instance was removed from the foot of a young woman 18 years of age, of Polish nationality, and had been kept for 24 hours in cold storage in sterile vaseline at 4 to 5° C. Instead of employing a metal spike or screw to fix the adapted portion of the astragalus to the femur, as advised by Roberts, a live-bone dowel spike was employed, which had been obtained from the tibia of a colored patient 26 years old. The operation was done November 14, 1912. When last seen, 8 months after the operation, the child was walking with good motion of the joint and with no shortening.

Technique of Astragalus Graft for Loss of Femoral Head.—*Author's Modification of Roberts' Technique.*—The hip-joint is exposed through an antero-lateral incision extending from just internal to and below the anterior-superior spine of the ilium to just below the great trochanter, and then curved backward toward the tuber ischii for 1 to 2 in. The skin and subcutaneous structures are dissected up, exposing the great trochanter, the tip of which with its muscle attachments is cut through with the motor saw or a sharp osteotome and mallet and lifted up, exposing the joint capsule. The latter is split longitudinally,

and the interior of the joint examined to determine the condition of the acetabular cavity and of the remaining portion of the neck of the femur. The remnant of the femoral neck is trimmed up with a sharp osteotome, preparatory to fitting the adapted portion of the astragalus which has been obtained for the

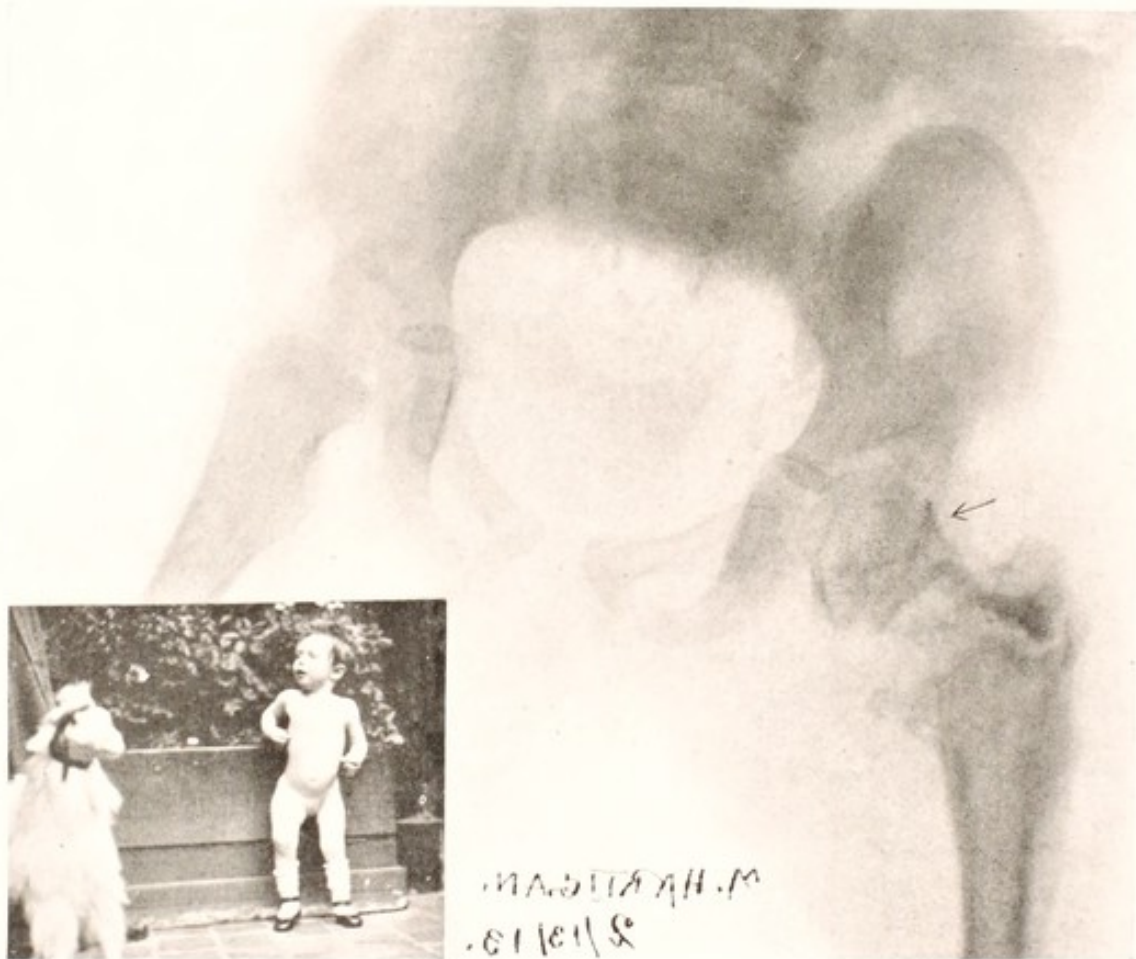


FIG. 195.—Child of $4\frac{1}{2}$ years whose head and neck of femur had been previously destroyed by a suppurative arthritis of the hip. This portion of the femur had been restored 6 months before by the implantation of the head and neck of an astragalus from a young woman and kept 24 hours in cold storage at 4 to 5° C. The astragalus graft was held in place by a peg graft made from a strip of cortical bone removed from the tibia of a young man on the same afternoon. This röntgenogram and photograph were taken 6 months after the insertion of the graft. The functional result is excellent.

graft and shaped to fill the space resulting from the absent femoral head.

The astragalus is secured in position, having been fitted accurately so that its head rests in the acetabulum tightly, its body end cut with the motor saw to contact well with the

freshened stump of the neck of the femur and at a proper angle in its relation to the shaft.

The large motor drill is now driven from without inward through the great trochanter—remnant of the femoral neck—and well into the new astragalus-graft head, and the drill, being disengaged from the motor, is left in position while the live-bone dowel is being prepared from a segment of cortical bone removed from the crest of the tibia along its middle and lower third. This segment of the tibia is passed through the author's motor lathe, which turns out a dowel to fit exactly the hole drilled through the trochanter into the grafted astragalus. When the dowel is prepared, the drill is withdrawn from its position in the trochanter and astragalus graft and the dowel pin is driven into position, thus securely fixing the astragalus graft to the upper end of the femur.

The author believes that the substitution of the live-bone spike in place of the metal screw is very essential to the uniform success of this procedure. A large portion of the astragalus graft being in the acetabular cavity, it is at best in a poor environment for the establishment of a nourishing blood supply which must largely come through its contacted end. The metal screw not only diminishes the diameter of this contacting surface, but, as is well known, produces bone absorption and destruction, while in the case of the bone graft not only is efficacious mechanical fixation furnished, but also a stimulative influence to the callus formation of the contacting bone surfaces supplied, as well as an osteogenetic force provided, at the same time that it serves as an osteoconductive scaffold well into the astragalus graft. This feature is well illustrated also in the treatment by the author's method of fracture of the neck of the femur by bone-graft spike, either in old ununited fractures or in fresh unimpacted fractures with malposition of the fragments, requiring an operation for reduction and fixation.

The capsule, if distinguishable, is closed with small kangaroo-tendon suture; the tip of the great trochanter is replaced and held by strong kangaroo sutures; the soft parts are closed in,

and the skin wound is closed by a continuous catgut suture, without drainage.

The leg being held in a position of slight abduction and flexion and dressings applied, a long plaster-of-Paris spica is made, reaching from the toes to the axilla, which remains on for

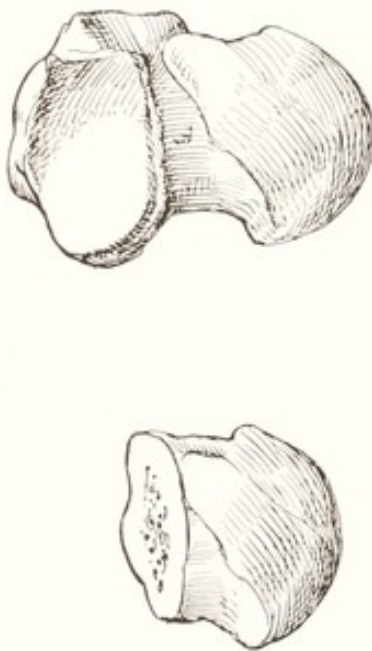


FIG. 196

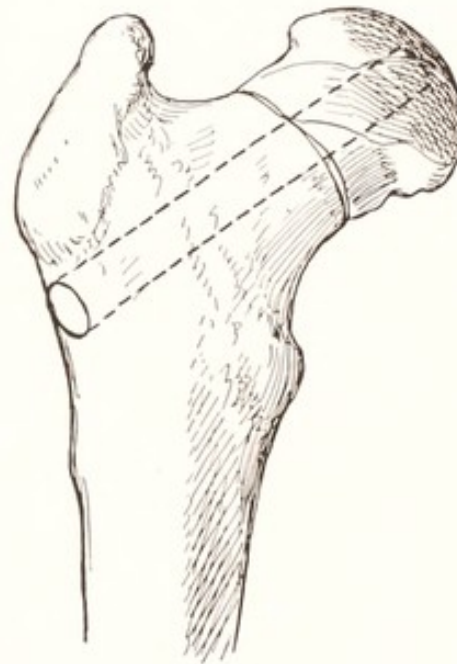


FIG. 197

FIG. 196.—Drawing of the astragalus and the portion used to restore the head of the femur.

FIG. 197.—Drawing to demonstrate the author's modification of Roberts' technique of inserting a portion of an astragalus for the absence of the head and neck of the femur. The dotted lines indicate the author's tibial bone-graft peg, which not only holds the astragalus fragment in position, but also serves in an equally important rôle of furnishing both an osteogenetic and osteoconductive bridge between the femur and the astragalus graft.

6 to 8 weeks, after which time a short spica is substituted and worn for 4 to 6 weeks longer.

THE USE OF THE BONE GRAFT TAKEN FROM EITHER THE TIBIA OR FIBULA TO REPLACE A PORTION OF THE UPPER END OF THE FEMUR REMOVED ON ACCOUNT OF BENIGN NEW GROWTHS

The Application of the Autogenous Bone Graft in the Operative Treatment of Osteitis Fibrosa Cystica of the Upper End of the Femur.—In cases of osteitis fibrosa cystica with a gradual extension of bone involvement, with or without pain, accompanied

by weakening of the bony structure with varying degrees of deformity and at times fracture, either the segment of bone affected should be removed and a graft of bone—preferably removed from the tibia—substituted or, if there is but, a small portion of the diameter of the bone involved, that portion can be chiselled and curetted away and a graft of bone implanted

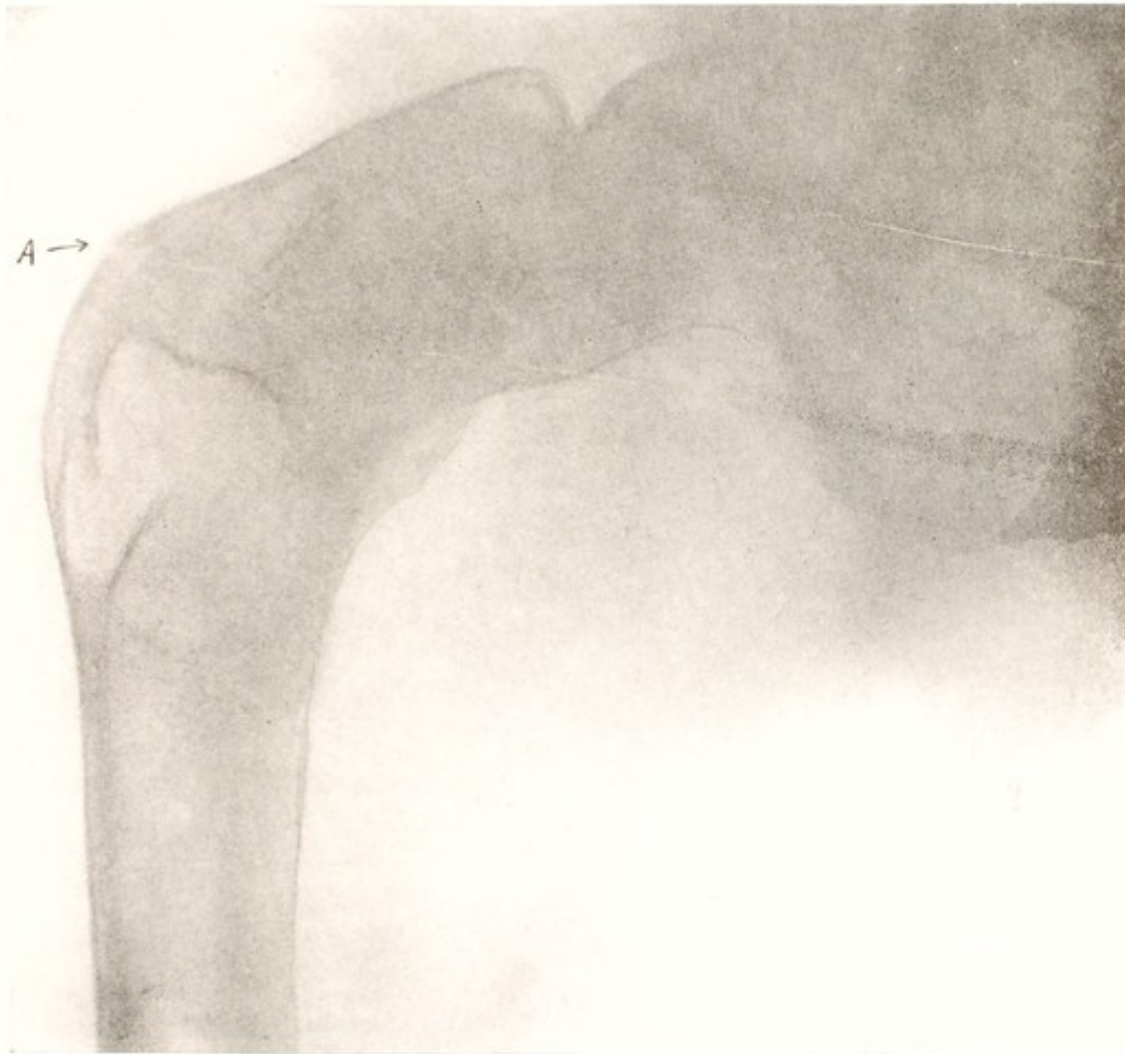


FIG. 198.—Large cyst of upper end of femur of syphilitic origin, with fracture at *A*. The cyst was removed and a strong tibial graft inlaid. (See Fig. 199.)

to reinforce the weakened area. Numerous cases of this character have been reported where, if substitution had not been made by some means, as by grafting bone, great bowing, shortening and crippling deformity would have resulted, or even amputation would have been deemed advisable.

In cases where a thorough cleaning out of this cystic fibrous

portion has been effected, fracture of the weakened wall has taken place, either at the time of operation or at some subsequent period. An autogenous graft of bone, properly adapted and accurately contacted throughout the weakened area, fulfils all

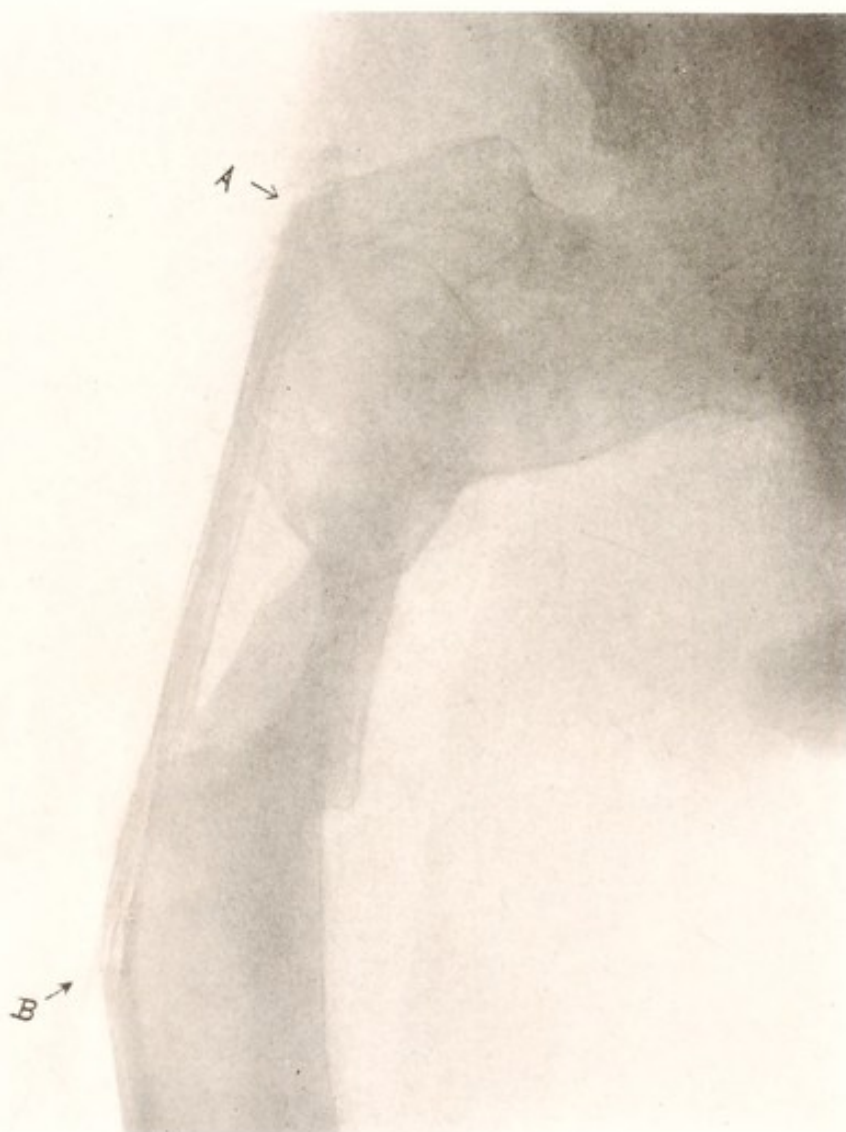


FIG. 199.—Same case as Fig. 198. The cyst has been removed, femur somewhat straightened and the graft *AB* inserted. About 3 months after the operation the patient fell and completely fractured the graft and the femur. The limb was put in a spica and the graft immediately united.

requirements in strengthening and preventing further distortion or loss of function by excessive shortening.

Murphy ("Surgical Clinics," vol. ii, No. 5) reports three instances where such a procedure was adopted by him in osteitis fibrosa cystica of the upper end of the femur, tibia, and humerus.

The first case was that of a male, 27 years of age, who applied for treatment on account of deformity of the right thigh. The history states that when the patient was 9 years old (1895) he fell, while running, and landed on both knees, striking harder on the right than on the left. He could not get up on account

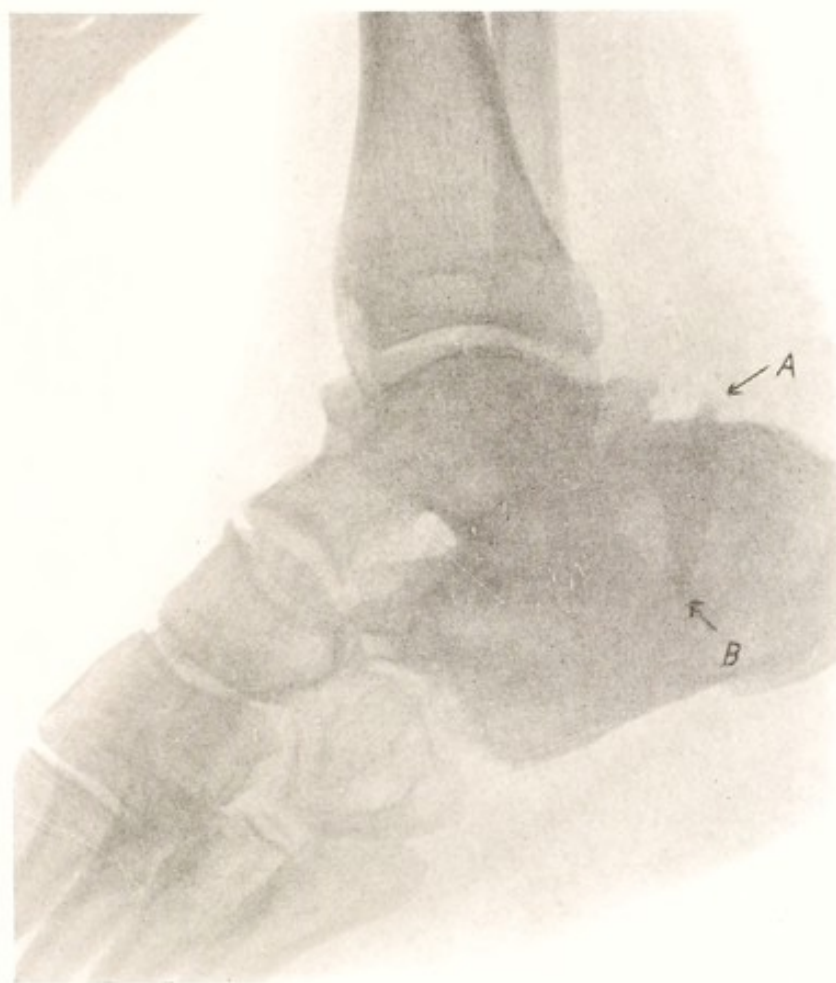

FIG. 200.—*AB* is bone graft inserted into an old osteomyelitic cavity for the purpose of supplying bone growth to fill the cavity.

of severe pain extending from the right hip to the knee. He was confined to bed for 2 weeks after the injury and had pain in the right thigh for the next 2 months. No chills or fever. When 14 years old (1900) he tried to jump, slipped and fell, one leg extending forward the other backward. He immediately had severe pain in the right thigh just below the hip, was unable to rise, and was carried home. Acute pain continued for the next 2 weeks, shooting in character, extending down the right thigh

to the knee. The slightest movement of the leg increased the severity of the pain. It gradually subsided, but continued as a dull pain for the following 3 months. At the end of 3 months he was able to walk, and after 6 months he was free from pain. When the pain ceased, he noticed a change in his gait. The right leg seemed to be shorter than the left, and slight bowing appeared in the upper third of the thigh. Röntgenograms were

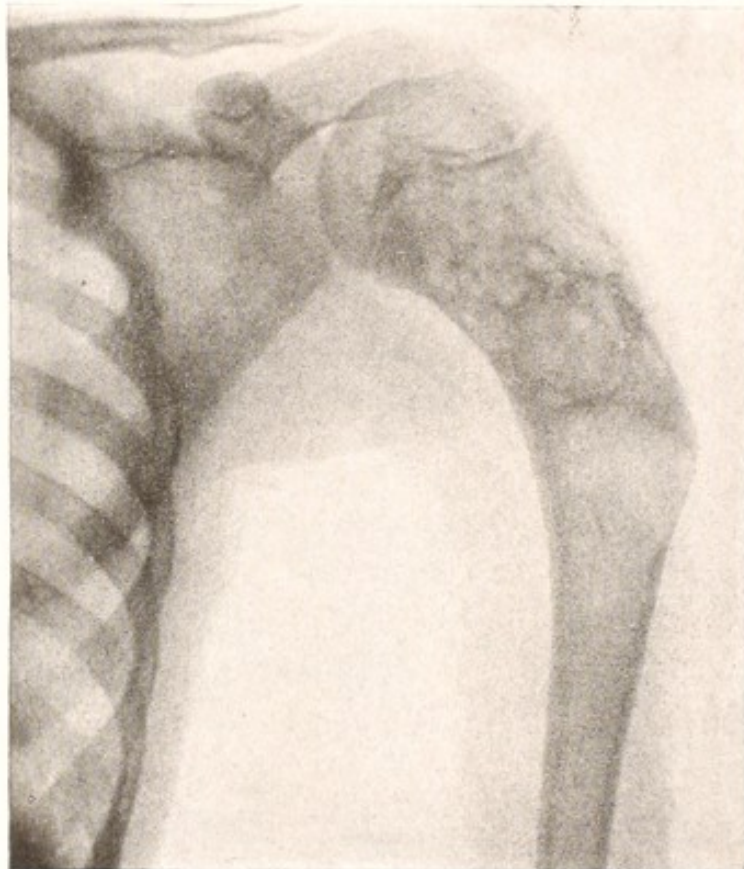

FIG. 201.—Skiagram made two months before operation. By comparing these five skiagrams the progress of the disease is well shown. The articular surface of the head of the humerus does not appear to be involved at any time. The epiphyseal line is well shown, and the change in its direction occurring with the growth of the tumor is marked. (Clinics of John B. Murphy, M. D.)

taken, and it was judged that a green-stick fracture had occurred with a possible focalization of a low type of infection, which is considered a cause of osteitis fibrosa cystica. Bowing gradually increased, and after walking a little distance pain was experienced; shortening was compensated for by the addition of a high shoe. There was a history of a Neisserian infection, also he has had measles, scarlet fever, whooping-cough, and

pneumonia. No history of lues. Family history negative. The röntgenogram illustrates a typical case of osteitis fibrosa cystica (Figs. 201 to 205).

The technique of operation was as follows: An incision was made on the outer aspect of the thigh, between the flexor

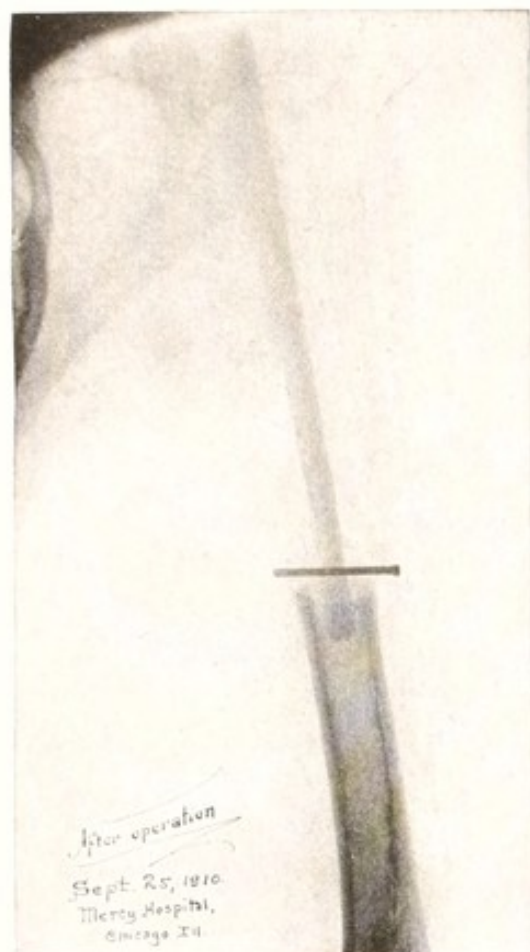


FIG. 202.

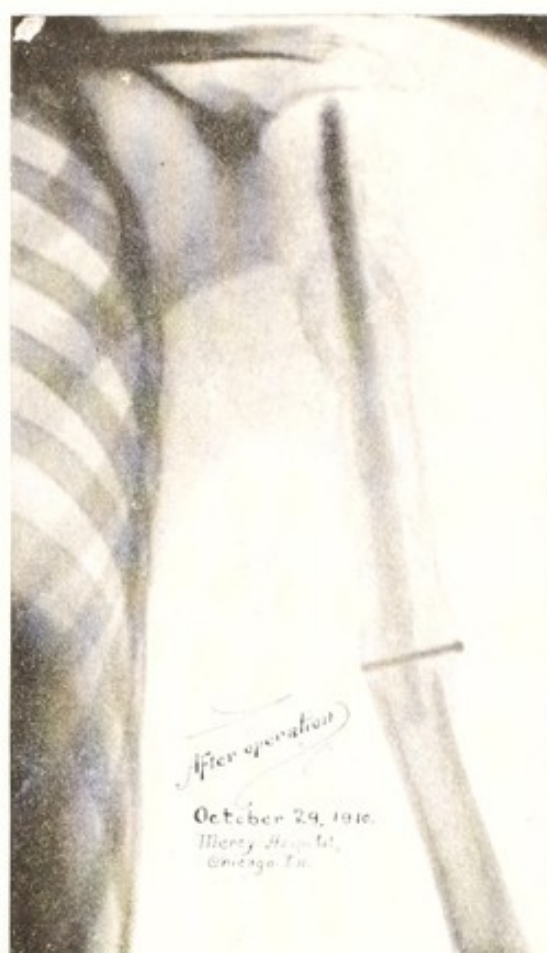

FIG. 203.

FIG. 202.—Skiagram made immediately after the operation. The lower end of the transplant is impacted in the medullary canal, and the remaining portion of the shaft of the humerus is fixed with a small wire nail. The upper end of the transplant is in the glenoid cavity, the capsule of the joint having been sutured around it. (Clinics of John B. Murphy, M. D.)

FIG. 203.—Skiagram made about 5 weeks after operation. The arm is a little straighter than in the preceding skiagram. Bone regeneration is progressing well, and the periosteum is still plainly to be seen. (Clinics of John B. Murphy, M. D.)

and extensor groups of muscles and directly over the lesion, and by resecting the soft parts the tumor was exposed. The overlying periosteum was incised and easily lifted free by a periosteal elevator, as it was deemed advisable to save it. The canopy or roof of the tumor was broken down with a chisel so

as to expose the cyst pockets underlying, which were cleaned out thoroughly preparatory to inserting the transplant, which was applied on the slant through the affected area. The lining granulation tissue was removed with a curette. The walls between the pockets were broken down sufficiently to admit the graft. Care was taken not to fracture the femur during this

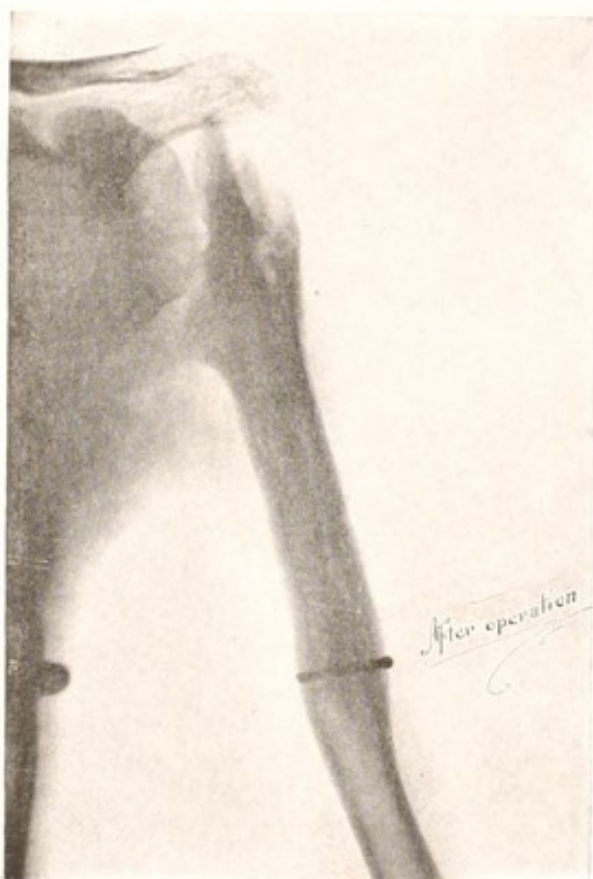

FIG. 204.

FIG. 204.—Skiagram taken 16 weeks after operation. Bone regeneration is progressing rapidly. (Clinics of John B. Murphy, M. D.)

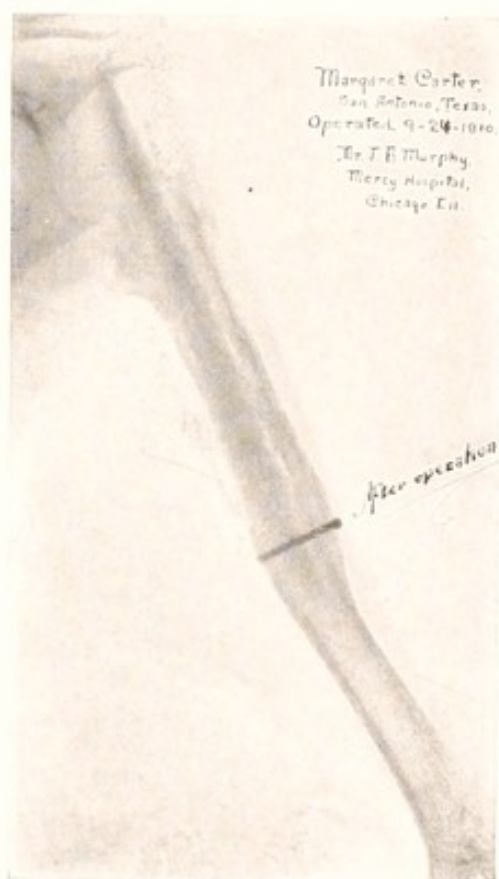

FIG. 205.

FIG. 205.—Skiagram taken about 7½ months after operation. The upper end of the humerus has been regenerated to a considerable extent, including the tuberosity and the articular surface. The white line a little to the right of the central axis of new part of the shaft represents the periosteum which was left on the transplant. The new bone is slightly thicker than the old bone. (Clinics of John B. Murphy, M. D.)

process, as the result of this cleansing out of the cyst pockets left but a thin cortex to the shaft. From the crest of the tibia of the other leg, a graft with its periosteal covering attached was removed in the usual way, the transplant measuring 7 in. in length by $\frac{1}{2} \times \frac{1}{4} \times \frac{3}{8}$. The graft was placed in its bed and the wound closed by approximating the cut edges of the

aponeurosis with plain catgut, and the skin edges with horse-hair. By placing the aponeurosis sutures well back from the edges, the muscle was caused to roll into the bone cavity and fill it when the suture was drawn taut. As both ends of the graft were securely bound by a shelf of bone, no nailing was necessary. The periosteal surface of the graft was turned outward. The usual dressing was applied and a Buck's extension with a 25-lb. weight attached. The patient remained in bed for 7 weeks with extension. The wound healed *per primam*. The stitches were removed on the seventeenth day, when the first dressing was made. After 7 weeks the patient was allowed up and about on crutches. He was without pain or discomfort in the leg.

The author believes that in all instances, when possible, the inlay method of fixing the graft into the fragments on either side of the hiatus left by the removal of the tumor should be employed.

CHAPTER VI

THE INLAY BONE GRAFT FOR FIXATION OF TUBERCULOUS KNEE-JOINTS; INFANTILE PARALYSIS; OSTEOARTHROPATHY (CHARCOT'S DISEASE); THE WEDGE GRAFT FOR HABITUAL DISLOCATION OF THE PATELLA

The knee-joint, unlike the hip-joint, is situated superficially and is not deeply covered by musculature. Early recognition of disease is possible, and because of the size and character of the joint architecture, together with the long leverage control, made possible by its position at the ends of long bones, the control of joint motion is easily maintained.

Tuberculous Osteitis in Childhood.—Tuberculous osteitis of the knee is not so frequently met with in childhood as is tuberculous infection of the spine or hip. Compared with other lesions of the knee-joint, it is the most common. Primary tuberculous involvement of the joint synovia in children is rare. The joint invasion is from a primary bone focus in either the upper end of the tibia or the lower end of the femur, which gradually extends and involves the joint structures. Occasionally the patella is found to be the seat of the infection.

The characteristic symptoms of tuberculous osteitis manifest themselves at a very early stage in the disease, and readily suggest themselves to the experienced clinician. Occasionally other causes of the local symptoms are present which must be borne in mind—as acute infections and gonorrhœal arthritis, acute articular rheumatism, hæmophilia, syphilis, sarcoma, Charcot's disease, arthritis deformans, hysterical joint—from which the tuberculous infection should be differentiated, by the special means of investigation at hand, to eliminate error. The röntgenogram should always be resorted to, and both the well knee and the involved knee should be taken for comparison in the two planes, lateral and antero-posterior.

As in other joints infected with tuberculosis in childhood, the essential treatment is conservative when a distinct focus cannot be localized and removed, and a well-ordered régime of life, plenty of fresh air, sunlight, and a full diet, varied and of an easily assimilated character, are important factors in the treatment.

Local treatment consists of uninterrupted immobilization of the joint as the prime factor in arresting the activity of the disease and the prevention or correction of deformity. The drainage of a tuberculous abscess should be avoided, as it is impossible to guard against mixed infection after drainage is established. Infection will occur, although dressings may be made ever so carefully, especially as the sinus is liable to persist for a long period of time, and repeated dressings are necessary. This rule does not apply to the aseptic incising of an uninfected cold abscess and the immediate closure of the abscess incision by carefully placed subcutaneous and skin sutures after the contents have been evacuated. Excision of the joint should be abstained from in all cases where the patient is under 16 to 18 years of age, on account of the damage to the epiphyseal cartilages and the extreme shortening of the limb resulting therefrom.

Tuberculous Osteitis in the Adult.—In late adolescent and adult life where the prognosis is much more unfavorable and time is such an important factor to the individual with a tuberculous knee, more radical treatment has been resorted to in the effort to arrest the disease, relieve pain, prevent relapse, and provide a useful limb at an earlier period than could be expected by conservative treatment.

Rogers, in a statistical paper in the *American Journal of Orthopaedic Surgery*, April, 1915, states that of 100 consecutive cases of adult tuberculous osteitis of the knee treated by conservative methods at the Massachusetts General Hospital from 1900 to 1907, the general trend was progressively bad and always came to excision or an amputation as an end result within 4 years' time. There was no record of any cured case by the conservative method. He also states, from the study

of 47 operated cases, that "the effect of an excision, no matter how stormy a convalescence there was nor the length of time required to obtain ankylosis, caused the active tuberculosis to become quiescent."

Operative procedure has proved advantageous in properly selected adult cases, while in childhood it has been very bad practice. In the adult there exists a full development of bone and joint structure, and therefore excessive shortening from interference with the epiphyses is eliminated. In long-standing cases angular deformity, resisting correction by the usual conservative measures, is readily remedied, and firm bony union between femur and tibia is the result. Formerly, excision of the knee was undertaken with the primary object of the removal of all the tuberculous tissues, and the production of an ankylosis was considered of secondary importance. This led to excessive removal of bone, with shortening; to the lessening of the diameters of the opposed ends of the femur and tibia on account of the bone incisions being made above the expansions of the femoral condyles and below the tibial head; to prevention of the approximation of the incised bone end surfaces resulting often in non-union; and to the constant liability of not removing all tuberculous tissues.

In a large percentage of cases subjected to this measure the results are not ultimately satisfactory, and not a few come later to an amputation of the limb, either as a life-saving measure or in order to allow the application of a serviceable artificial limb on account of the failure of bony union or the occurrence of excessive deformity.

It has been found by experienced operators that the essential factor in the arrest of a tuberculous process of the joint is the production of a bony ankylosis. This point has been strongly emphasized by Ely in his writings, and has been followed by such satisfactory results that, in the author's opinion, it cannot be too emphatically advised. As the chief consideration rests upon the production of bony ankylosis in these adult tuberculous knees, it is the author's purpose to outline his

methods of technique which experience has proved to be the most certain and reliable.

First, to emphasize more forcibly the accuracy, ease, and certainty of these methods, some statistics of methods and results as applied by other authors will be reviewed for contrast, as for example 28 consecutive excisions of the knee for tuberculosis, done in the period from 1907 to 1913 in the orthopædic service of the Massachusetts General Hospital by different orthopædic surgeons, reported by Osgood, and this report is herewith abstracted by the author.

The cases, following at least a month's fixation in plaster so as to render the disease somewhat quiescent, receive a 2- to 4-day preparation of the knee. On the table benzine-iodine skin preparation is given, and an Esmarch or tourniquet is applied. The usual U-shaped incision is made from above one femoral condyle to the other, crossing the patellar tendon about an inch above its insertion. The proximal cut end of the patellar tendon is seized and turned back, with all the structures overlying the joint included, dissected up, and the knee gently flexed as the dissection takes place. Much of the exposed tuberculous tissue is removed, and the articular ends of femur and tibia developed. Only sufficient bone is sawed off the articulating ends of the femur and tibia to reach beyond the disease, and the patella is either removed or its under surface sawed off. Only evident masses of diseased soft parts are removed. Bone and soft-tissue surfaces are swabbed with tincture of iodine. The tourniquet is removed and bleeding controlled.

For the past 4 years the custom in the orthopædic service, in the absence of a sinus or a mixed infection, has been to fix the bone ends by malleable iron plates or aluminum wire clamps screwed in place by steel-wood screws, with the thread cut to the head. A test of the fixation is demonstrated by lifting the leg by the foot. The patellar ligament is reunited, as well as the deep structures overlying the joint, followed by the skin-flap suture, and the limb is placed in a plaster splint which is changed in 4 weeks when, if favorable, the patient is discharged in a plaster

splint, with crutches. The immediate post-operative freedom from pain, together with the earlier firm union, by these methods of fixation was noted.

End Results Obtained by this Plating Fixation, above Described.—Comparison is made in the reported 28 cases between the results when metal plating was used and when simple excision was performed. Of the 14 simple excisions, including 2 cases wired by silver wire, 4 had a second operation for re-excision, and 2 of these and 1 other were subsequently amputated to save life. Four had sinuses before the operation, and 9 after. Pain persisted several months after operation in 5 cases. Eventual union occurred in 6. The time of union was 2 months or less in 2; 3 months or more in 11; and there is no record of eventual union in 5. In both cases in which wire was used it had to be subsequently removed.

Comparing the cases where metal clamps or plates (8 clamps and 6 plates) were used: None required a re-excision. One case was amputated later, because of secondary infection. Two had sinuses before operation; 5 had sinuses after operation. All healed except 1. Pain persisted several months after the operation only in the amputated case, and to a slight degree in 1 other case for 4 months after operation. Eventual union occurred in 13. Time of apparent firm union was 1 month or less in 6 cases; 2 months or less in 4; and 3 months or more in 3. In 5 cases the metal clamps or plates gave subsequent trouble and were removed.

From the foregoing report, it is obvious that the actual fixing together of the denuded bone ends has a decided advantage, not only in relief of pain but in hastening bony union, but it is also apparent here, as has been the universal experience of other users of foreign material in securing bone fixation, that the removal of the metal at a subsequent operation was necessitated on account of the trouble it was causing.

From the author's experience, it is reasonable to believe that had autogenous bone grafts been used for fixation purposes, a subsequent operation (for the removal of the metal clamp)

with the accompanying disturbance and inconvenience could have been avoided. For a fuller amplification of this point, the reader is referred to the chapters (IV and I) on the treatment of fractures and the fundamental principles involved in the use of the bone graft.

As compared with the foregoing report of 28 cases done by various men at the Massachusetts General Hospital in the 5 years mentioned, the author outlines his technique of application of the inlay bone graft in his fixation operation for tuberculous knee-joint disease in late adolescence and in the adult. During the past 2 years 10 cases have been done, the youngest patient being 18 years of age, and bony union was obtained in every instance in 6 weeks' time, as shown clinically and by the röntgenogram. In every case the graft has taken, and in no instance has it come out or had to be removed. These cases, as well as various other applications of the bone graft in tuberculous joints where they span through tuberculous areas, have conclusively proved the resistance of the bone graft to that infection as well as to attenuated pyogenic infections elsewhere described (Chapters I and IV). In view of these facts and the excellent mechanical fixation afforded by the inlays, as well as the stimulation to osteogenesis on the part of the host bone and the osteogenetic force which the bone graft exhibits, its striking advantage over metal for the purpose not only of securing bony union, but of securing it early, is apparent. No pain was experienced after the inlay-graft method, and the patients were up and walking in their plaster splints in 6 weeks' time, with the aid of crutches. Where formerly a long plaster-of-Paris spica was relied upon for the fixation and relief from pain, following the ordinary excisions, it is found that a simple plaster splint extending from the toes to the groin is sufficient.

The Author's Technique as Applied to the Knee.—Following the usual preparation of the patient, including the application of a tourniquet, access to the knee-joint is through a U-shaped incision reaching from one femoral condyle to the other and crossing the patellar ligament about 1 in. above its insertion.

The patellar ligament is divided, and the deep structures overlying the joint are dissected up and turned back, freely exposing the articular surfaces. The crucial ligaments, if present, are divided, as well as the lateral ligaments of the joint, and the upper end of the tibia is drawn forward and fixed.

With a narrow-bladed bow-saw, the upper articular surface of the head of the tibia is removed, cutting transversely and

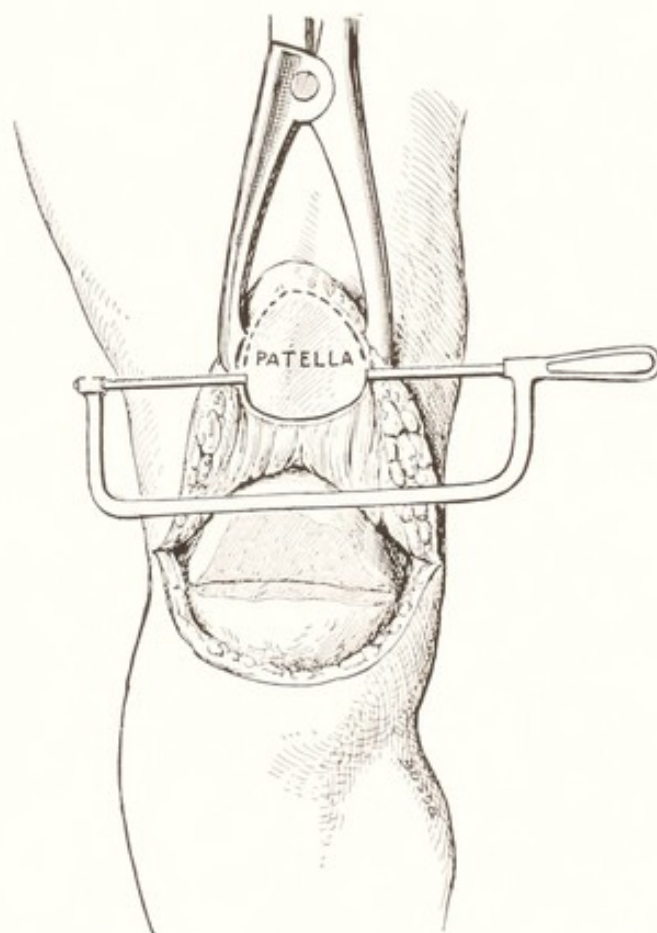


FIG. 206.—Illustrates method of removing posterior infected or cartilaginous surface of patella before enucleation and forming into inlay grafts. (See Fig. 207.)

forming a flat concave surface from before backward. With the same saw, the articular surfaces of the condyles of the femur are removed, forming a flat ovoid surface from before backward, to fit the concavity of the upper cut end of the tibia. These surfaces are apposed.

With the twin motor saw, two gutters are formed across this line of apposed femur and tibia. One gutter, about $\frac{1}{2}$ in.

wide and 2 in. long, depending upon the size of the patella, is made from the external condyle into the outer and anterior portion of the head of the tibia, and another gutter of the same dimensions is formed across from the internal condyle to the inner anterior surface of the head. The segments of bone filling these gutters are cut across at the ends of the gutters with

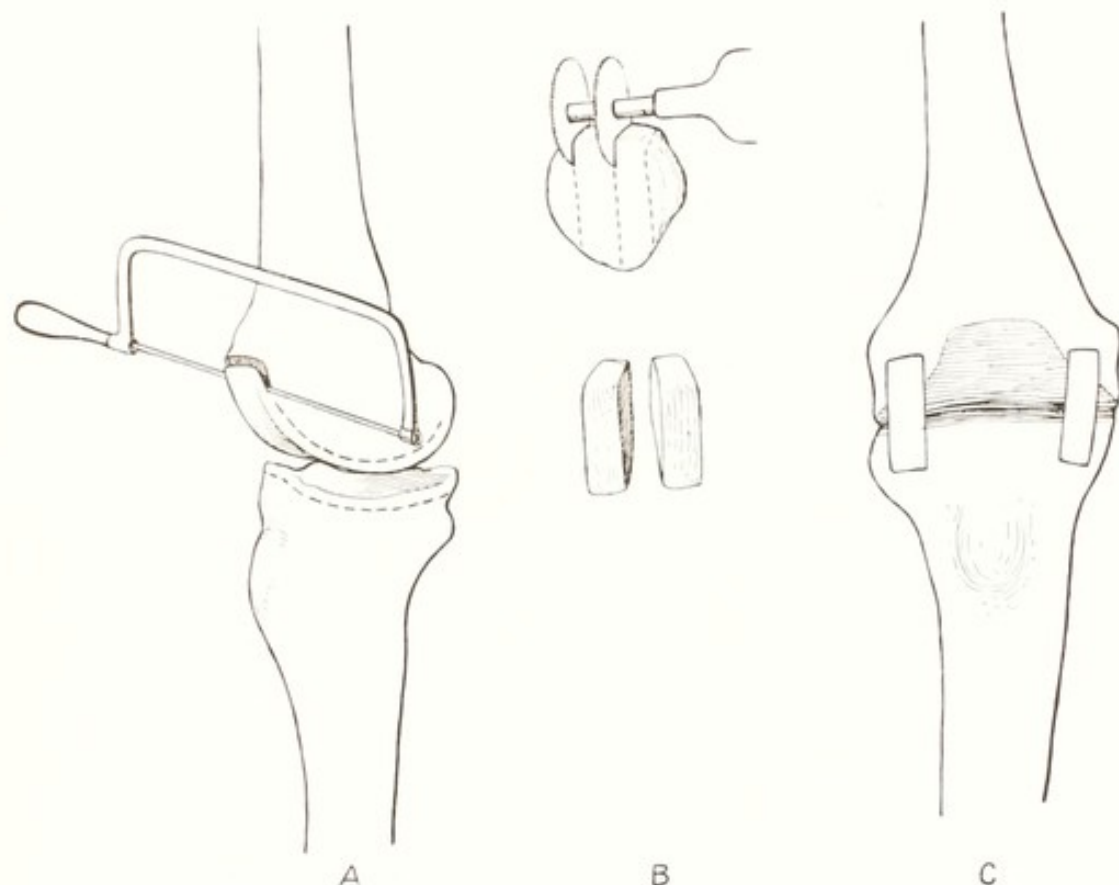


FIG. 207.—*A* shows the line of removal of the articulating surface of femur and tibia by the narrow bow-saw in producing the arthrodesis of the knee-joint. *B*, the splitting of the patella into segments by the twin motor saw, to produce two bone grafts to be placed in gutters *C* sawed from the two condyles of the femur into the head of the tibia by the twin motor saw adjusted at the same distance apart as when cutting the two inlay grafts from the patella.

the small motor saw and are removed with the aid of a thin, narrow, sharp osteotome.

The twin motor saw, adjusted to the same width as when forming the gutters, is used in cutting from the patella two strips which are used to span between the femur and tibia and fit tightly into the previously prepared gutters. Holes are drilled on either side of the gutters with the small motor drill,

in both the femoral condyles and head of the tibia, and strong kangaroo-tendon sutures are passed and tied over both ends of the two patellar grafts, holding them securely in position.

It is to be noted that only sufficient bone is removed from the articulating surfaces of the tibial tuberosities and femoral con-

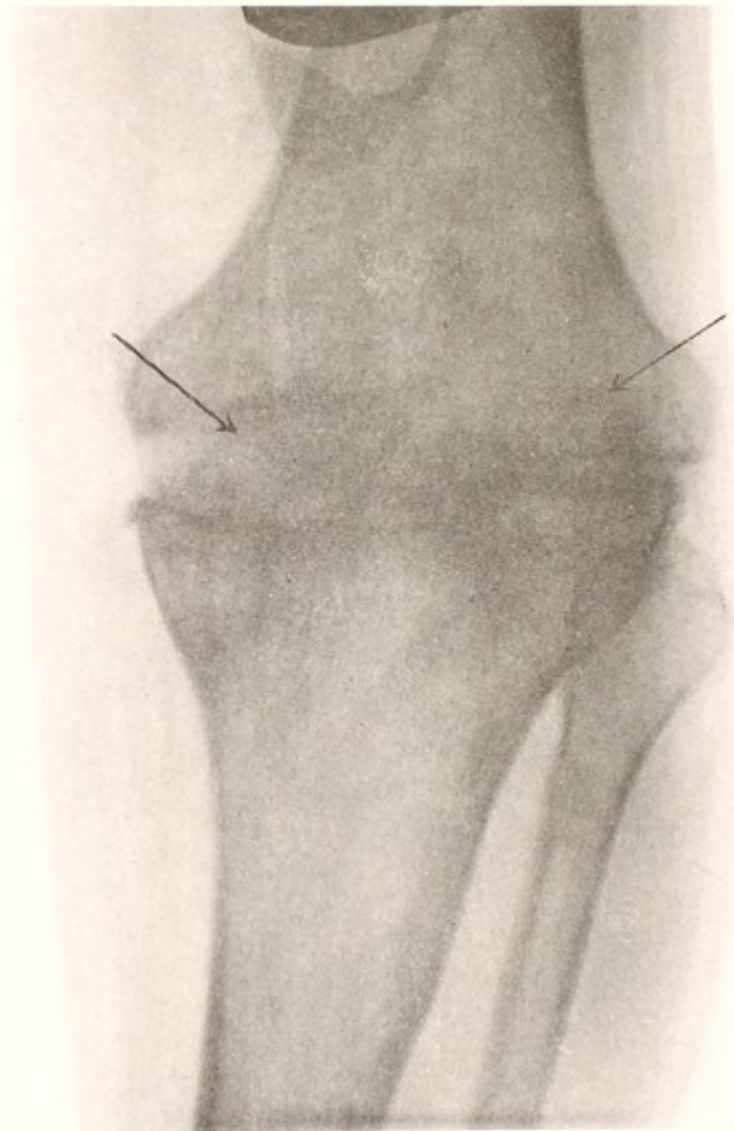


FIG. 208.—Cured tuberculous knee. Röntgenogram taken 6 months after arthrodesis and the insertion at arrow points of inlay graft formed from the patella. There was firm union in 6 weeks.

dyles to furnish closely apposed raw-bone surfaces; and only apparent and easily accessible tuberculous infected soft tissues are cut away, together with whatever synovia that can be easily reached with curved scissors. No undue effort is made to remove all tuberculous bone, so that very little additional short-

ening results from the operation. If the patella is found to be tuberculous—which is rare—it is discarded and a bone graft about 3 in. in length is removed from the antero-internal surface of the tibia to supply the two bone inlay grafts. The grafts can

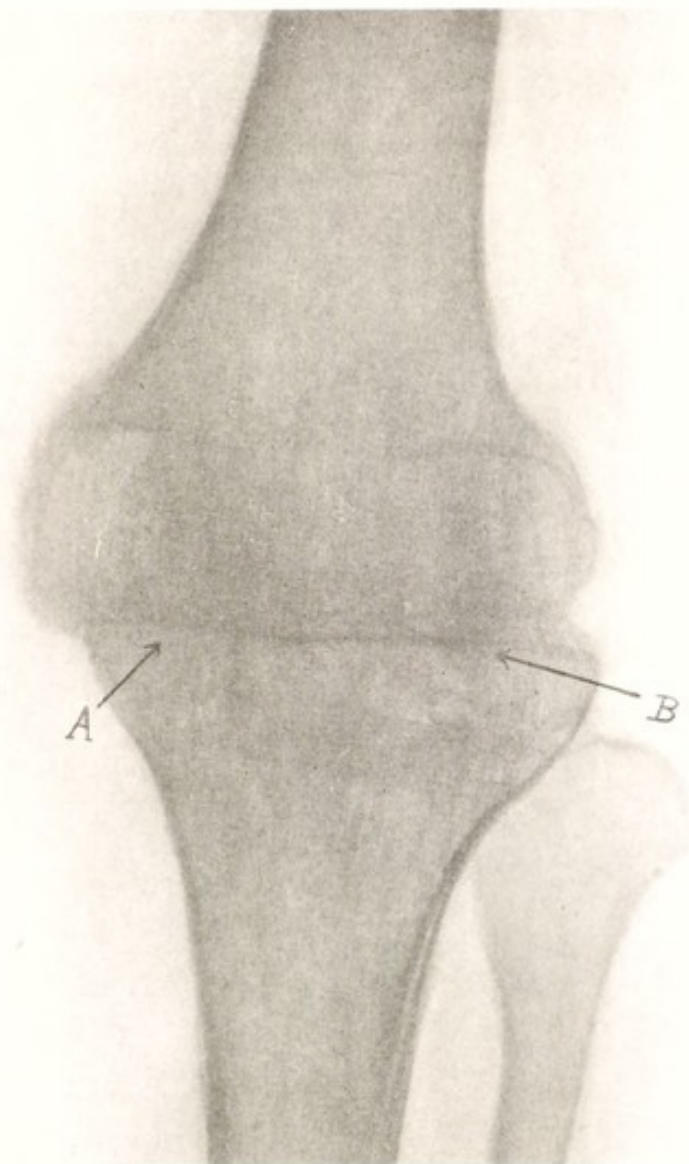


FIG. 209.—A cured tuberculous knee. Tibial inlay grafts, each 2 in. long, were placed at *A* and *B* equally into condyles of femur and head of tibia 18 months before. Firm union occurred in 5 weeks. The grafts have become altered to the bone structure in which they are imbedded and do not show prominently in the röntgenogram.

easily be made of this length, as they are not limited by the size of the patella. The other dimensions of these grafts should comprise a width of $\frac{1}{2}$ in. and the entire thickness of the cortex to the marrow cavity, according to the size of the patient.

In applying the inlay bone graft for ununited fracture of a long bone, the inlay graft can be easily fixed in position, preferably by kangaroo tendon or by bone pegs formed of additional bone strips removed from the crest of the tibia at the time the inlay segment is removed. This additional strip of inlay bone is split lengthwise into suitable pieces to form the bone pegs, which is done by passing them through the small cutter of the motor lathe to fit the drill holes made by the corresponding

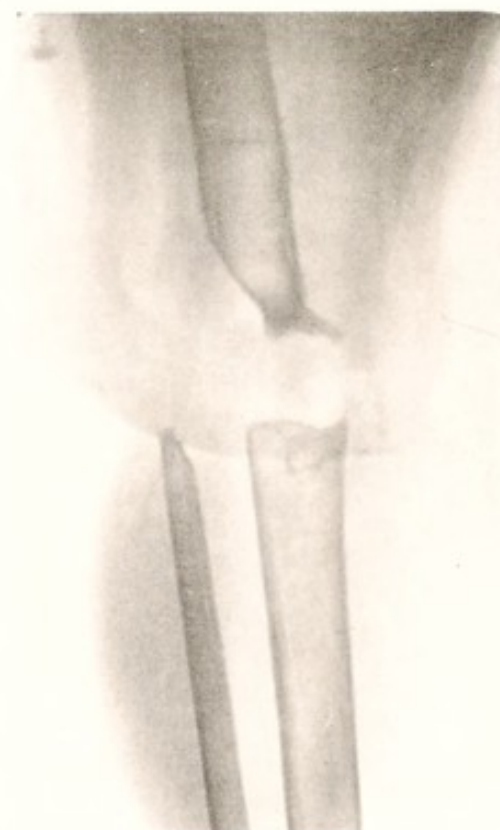

FIG. 210.—Röntgenogram of a flail knee following an excision of the joint. The liberal removal of bone has resulted in non-union and a limb perfectly useless. This condition could have readily been avoided by simply producing an arthrodesis after a more conservative removal of bone and the implantation of inlay grafts. Sinuses still persist and the result is a failure.

motor drill. As these drill holes are made to diverge from the graft into the receiving bone and are placed at or through the edges of the graft, it is readily seen that when the bone graft pins are inserted they bind the graft securely in position and no retaining sutures are required. If space permits, four pins can be inserted at either end of each graft, into the femur and into

the tibia—two on each side at each end into the respective bones—but one on each side at each end is usually sufficient.

The soft structures are replaced over the operated field and sutured; the sound patellar ligament is reunited with chromic catgut sutures, and the skin is closed by a continuous catgut mattress suture, without drainage.

The limb, being now made secure by the inlays, is placed in

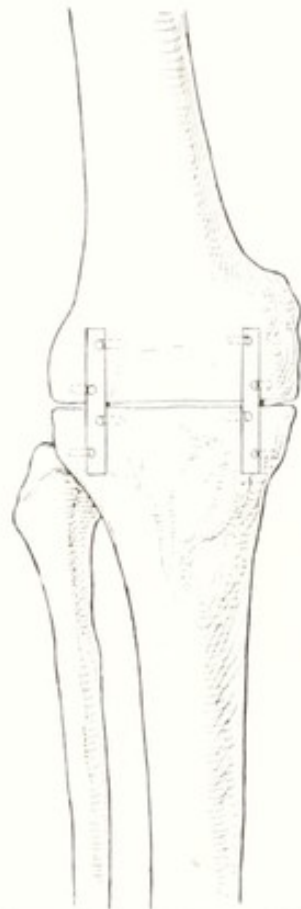

FIG. 211.—Arthrodesis of the knee-joint with two tibial inlay grafts implanted spanning the apposed ends of femur and tibia. These grafts are imbedded and pinned in with autogenous bone dowel pins, or held in place with kangaroo tendon.

a plaster-of-Paris splint reaching from the toes to the groin. The tourniquet is not removed until the plaster dressing, with firm even compression about the knee, has been applied to the limb from the foot to the tourniquet. This is important, and should never be overlooked. The removal of the tourniquet before the compressive dressing is applied allows uncontrolled bone ooze, and leads to a tourniquet paralytic dilatation of the

arterioles; also the rubbing of the bone surfaces on each other during the application of the dressing, dislodges the adherent blood-clots and prevents hæmostasis (*i.e.*, if the tourniquet is removed before the application of the fixation dressing).

It has been found unnecessary to continue the plaster splint

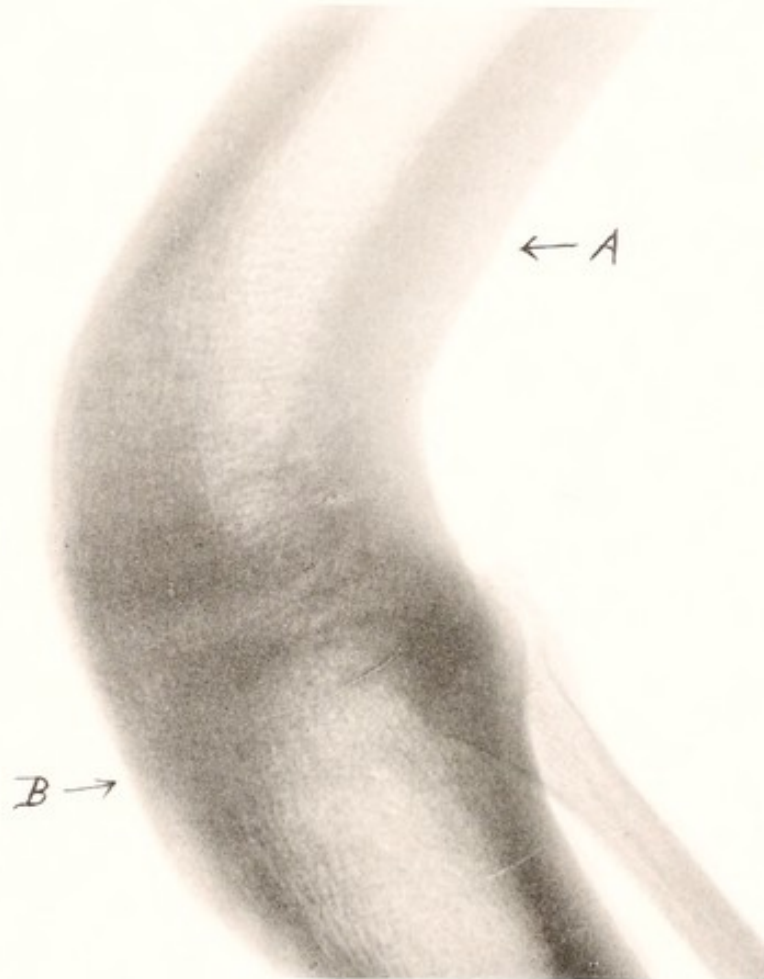

FIG. 212.—To illustrate the potency of Wolff's law. This is a lateral view of an ankylosed knee which is the result of a stiffening operation for tuberculous osteitis. Delayed union and insufficient post-operative support resulted in a flexion deformity to nearly a right angle. Weight-bearing under these disadvantageous conditions caused the hypertrophy of the shafts of the tibia and femur at and near the angulation. The cortex at *A* and *B* is two to three times its normal thickness.

above the groin, as was formerly required to insure against displacement and pain. The splint is left on for 4 weeks, at which time it is changed and the patient is allowed up on crutches. The second plaster splint can usually be discarded in from 4 to 6 weeks.

There is no doubt that the accurate mortising together of

the femur and tibia by the graft hastens firm ankylosis and renders it more certain; also that the post-operative relief from pain experienced by these patients following the inlay fixation offers a great advantage over the former simple excision of the knee. As compared with the fixation methods referred to

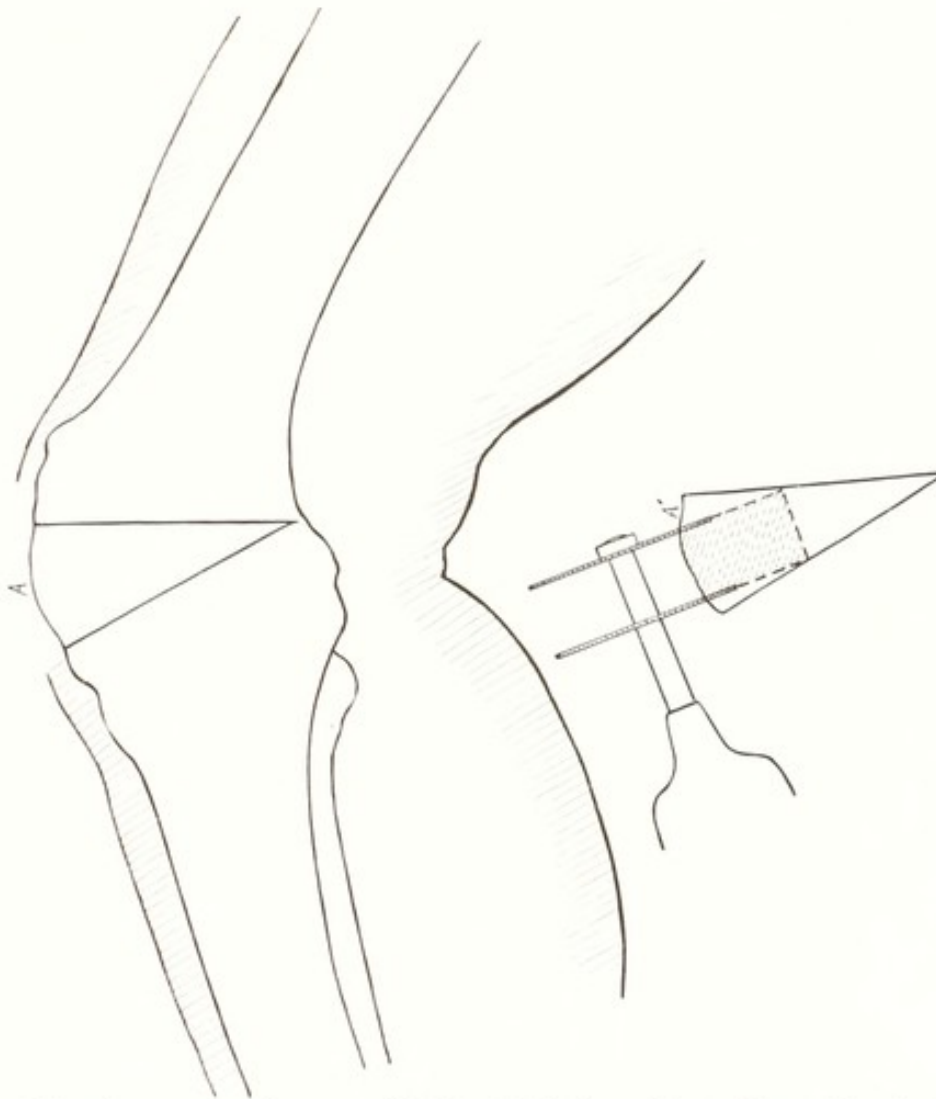


FIG. 213.—An angular bony ankylosis of the knee-joint, the wedge *A* removed from the convex side of the deformity and *A'* the cutting of this wedge with the twin saw to form one large bone-graft inlay, to be implanted in the anterior surface of the knee to span from femur to tibia when the leg is straightened.

when metal plates or clamps were used, there can be no question but that the autogenous bone graft applied in these cases for fixation has a decided advantage. The same rôle is played by the bone graft in this instance as in its application elsewhere in bringing about firm union between bones or fragments of bone.

It stimulates osteogenesis; whereas the metal, when used, furnishes only temporary fixation and inhibits osteogenesis in its immediate vicinity, exposes the parts to infection, and in certain instances contributes to the necessity of a subsequent operation for amputation or the removal of the offending metal.

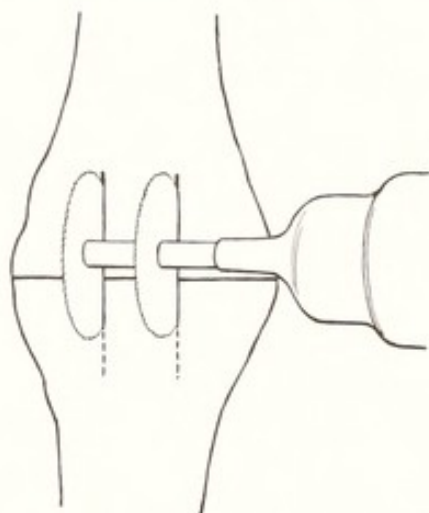


FIG. 214.—Twin saw-cuts to form gutter for inlay graft after wedge has been removed as shown in Fig. 213.

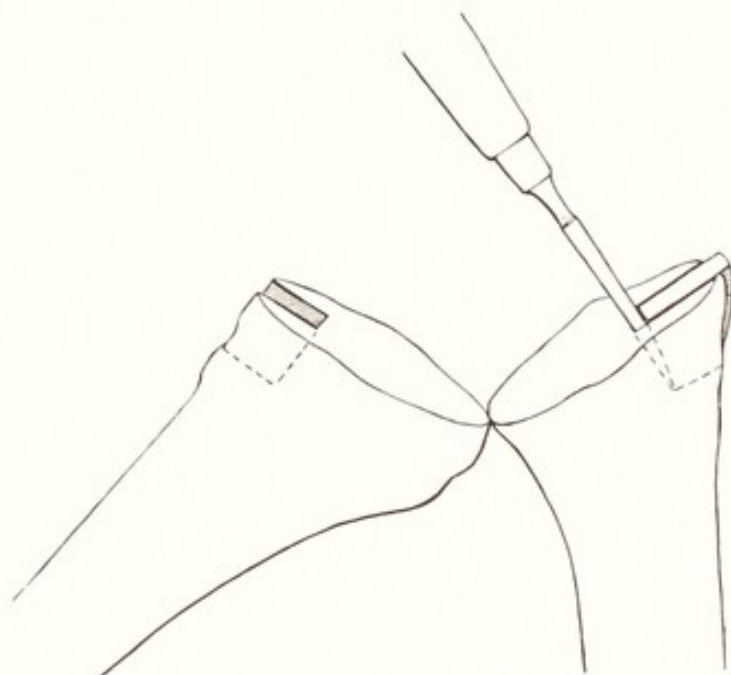


FIG. 215.—Method of removing strips of bone between twin saw-cuts to form gutter for inlay graft.

THE USE OF THE BONE GRAFT FOR STIFFENING THE KNEE-JOINT IN INFANTILE PARALYSIS

Extensive or partial paralysis of the muscles controlling the knee-joint often causes instability to such a degree that the

patient cannot bear weight upon the affected limb, in walking or standing, without its giving way beneath him. Such patients should be informed of the advantages and disadvantages to be expected from stiffening the knee-joint, whether by the employment of a brace with a mechanical joint at the knee or by producing a permanently stiff knee by a bone operation.

In some instances where the paralysis is not too extensive, the transference of one or two of the flexor muscles of the knee, taking the place of extensors, is of advantage, as in the instances where the insertion of the semitendinosus is changed to an

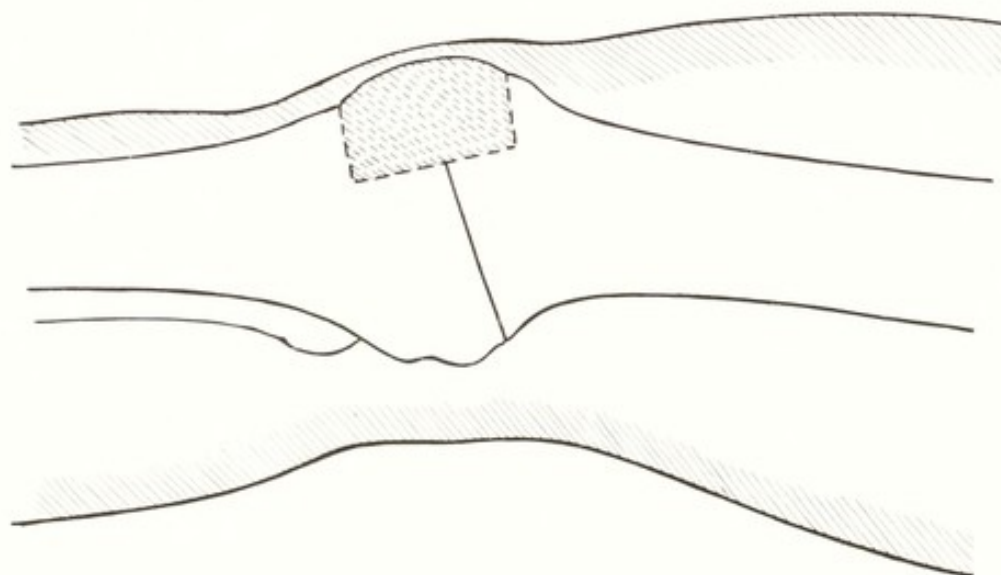


FIG. 216.—Lateral view of inlay graft in place, which was formed from the bone wedge removed for straightening the ankylosed leg. (See Figs. 213–215.)

anterior insertion, in order to bring about more stability to the limb; but as this treatise does not deal with operative procedures other than bone surgery, the reader is referred elsewhere for information on muscle transference.

The comparative advantages and disadvantages of brace and operative treatment should be impartially presented to the patient or his parents. The only advantage in the use of braces for such a disability is in allowing motion of the knee. The advantages of a stiffening operation of the knee-joint are the avoidance of constant dependence on braces, the prevention of deformities, and the production of a stable limb.

As there is always an undue laxity of the knee-joint in these infantile cases, it is not advisable to do a simple arthrodesis or excision of the joint, as bony ankylosis by these methods is very uncertain. A method adopted by Hibbs, which has

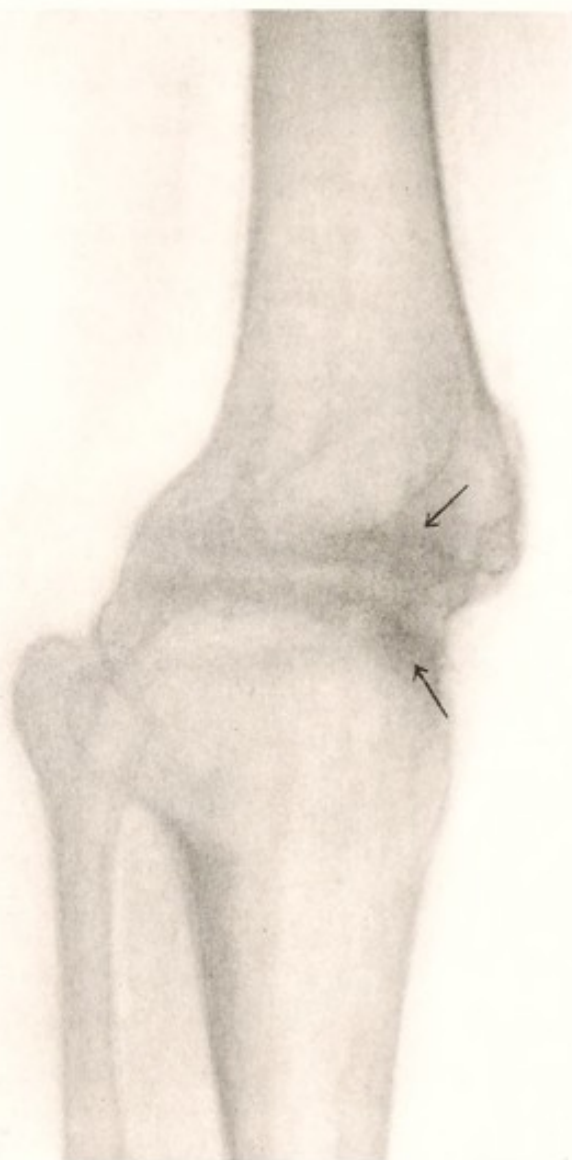

FIG. 217.—Röntgenogram of an arthrodesis of the knee-joint with the patella enucleated and inlaid as the arrows indicate to aid in the union of the femur to the tibia. Note the good alignment of tibia and femur.

proved satisfactory, is to use the patella *in toto* as a bone graft, inserted between the apposed femoral and tibial ends after denuding the patella and the surfaces of the femur and tibia with which it is to be contacted. By using the patella fitted into suitable concavities fashioned in the denuded articular surfaces

of the head of the tibia and the condyles of the femur, the slack of the lateral ligaments of the joint is taken up and the joint is stiffened by its ankylosis through the patella. In performing this technique, it is always advisable to remove all accessible articular cartilage and synovial membrane. The joint must be rigid after the patellar graft is inserted, and the limb brought to 10 to 15 degrees of flexion.

The approach to the joint is usually made best by the customary U-shaped skin incision, and the parts are closed in the usual way. A long fixation plaster-of-Paris spica dressing is necessary, reaching from the toes to and including the pelvis, to insure perfect fixation of the joint and prevent dislodgment of the patellar graft, which may be held in place between the ends of the femur and tibia by the cup-shaped concavities formed in these bones to receive it, or it may be held against these bone ends by suture material.

Technique of the Author's Bone-graft Inlays for Ankylosing the Paralytic Knee.—This method of stiffening the knee-joint is that previously described in the fixation of this joint in adult tuberculosis, and has been found to be extremely satisfactory from every point of view. It is rendered very simple and accurate and is rapidly done when the author's motor-driven outfit is employed.

In this connection a striking example is herewith cited, emphasizing the importance of accuracy of technique and the advantage of using the inlay-graft method. A child 14 years of age was brought to the author, having suffered an attack of infantile paralysis in early childhood, which left the lower limbs markedly paralyzed. The patient had had both knees operated upon in Russia when he was 10 years of age. At the time the author saw the case, both knees were stiff and flexed at an angle of 90 degrees. Röntgenograms showed bony union at this angle and also the embedded broken wire with which the excised joints had presumably been fastened. The accompanying illustrations of this case add another to the many failures to produce a satisfactory result by using wire to se-

cure fixation for bony union. The patella was disregarded and left as seen in the Röntgenogram. It was valuable fixation and osteogenetic material which, if used as inlays, would have

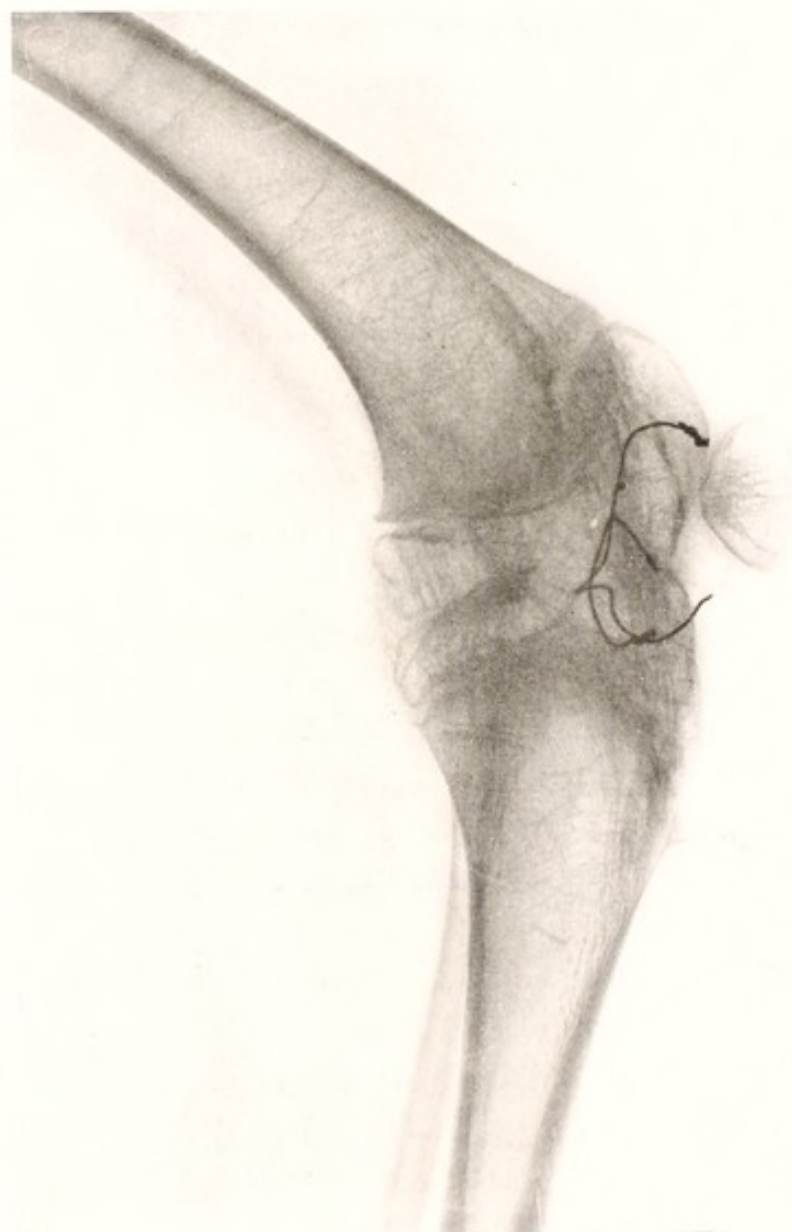

FIG. 218.—This is a case of arthrodesis of the knee for paralysis, done in Warsaw, Russia. Two strands of silver wire were inserted both of which broke, allowing the knee to flex to nearly a right angle before bony union occurred. If the patella had been used as an inlay to hasten union, it is very probable that this deformity would not have occurred.

undoubtedly contributed to immediate bony union and avoided the angulation.

The case was operated upon by the author. The joint areas

were exposed through the usual U-shaped incision; the overlying soft parts were dissected up; the patella was dissected out and placed in sterile normal saline solution until the deformity was corrected and the gutter bed prepared. A wedge-shaped sec-

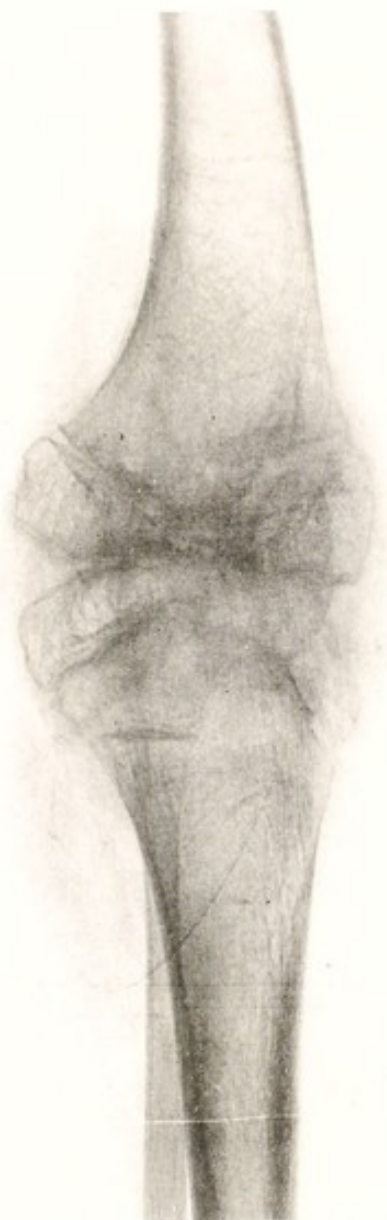

FIG. 219.—Same case as Fig. 218 after removal of the silver wire and the insertion of the patella as an inlay. Firm union occurred in 5 weeks after this operation.

tion of bone, with the base forward, was removed from the region of the angular bony ankylosis. This wedge was made of such a size that when it was removed and the cut surfaces of the femur and tibia brought together, these bones were in a position

of 10 to 15 degrees flexion to each other. A guide to determining the plane of these saw-cuts is that they should be approximately at right angles with the femur and tibia, respectively. The twin saw was adjusted so as to fashion as wide an inlay as possible from the patella and at the same time utilize its full length. With this adjustment of the twin saw undisturbed, and with the limb held so that the cut surfaces of the femur and tibia were properly approximated, a broad gutter of the length of the patellar inlay was made in the midline on the anterior surfaces of the tibia and femur, one-half of the gutter in each. The strip of bone between these saw-cuts was cut across in both the femur and the tibia, with a small motor saw. These strips of bone were removed, while the leg was flexed, by a narrow osteotome cutting lengthwise in the bones. With the tibia and femur again brought into their proper position, holes were drilled on either side of the gutter. Kangaroo tendon was threaded into them and the patella inlay was placed in position, and the sutures tied over it. The subcutaneous structures were drawn over the bone and sutured with chromic catgut. The skin wound was closed by a continuous mattress suture of plain catgut, without drainage. A plaster-of-Paris case was applied from the toes to the groin, and the patient was placed in bed with the limb elevated on an incline, to relieve pain and lessen the tendency of œdema of the foot and leg. The first plaster splint was left on for 5 weeks, at the end of which time there was firm union. The patient was allowed up and about with the aid of crutches at the end of 4 weeks. The second plaster splint was kept on for 6 weeks.

This method is also applicable to Charcot's knee, if the tibial grafts are made to reach well beyond the affected bone area.

HABITUAL DISLOCATION OF THE PATELLA

The usual direction of congenital or habitual dislocation of the patella is outward, and the external condyle is often found to be on a horizontal plane relatively much below that of the internal condyle, thus giving the appearance of rotation of the

lower end of the femur, so that the external condyle is farther back and the internal condyle farther forward than is normal. When the leg is extended, the patella usually takes its normal position between the condyles, but upon flexion is found to be displaced outward and even to lie over the external condyle or somewhat external to it.

Various methods have been devised to correct this displacement, but of the procedures which have been practised those where correction was attempted by using the soft tissues have been far less successful in securing permanent control than those where the control was attempted by furnishing bony obstruction to redislocation.

Krogius (*Zentralbl. f. Chir.*, March 5, 1904) reports two cases (one double) in which it was evident that the patella was drawn outward by the tense outer portion of the capsule against which the relaxed and stretched inner portion offered but weak resistance. He devised the following operation for controlling the displacement:

The first step is the approach to the knee by Kocher's incision. Second, an incision is made extending from slightly above the patella down a few inches in front of its outer edge to the insertion of the ligamentum patellæ through the ilio-tibial band, tendinous expansion of the vastus externus, and fibrous capsular wall. Third, the formation of a bridge-shaped flap on the inner side of the patella, connecting below with the tendinous expansion of the vastus internus, and fibrous capsule, and above with muscle and fascia. Fourth, the transplantation of the flap, left attached at both sides, across the patella into the gap at its outer edge.

In the first case, after 6 months, the patella again began to slip outward, although complete dislocation did not occur. In the second case, the result was perfect after 3 months.

Whitlock, in the *British Surgical Journal*, July, 1914, states: "Outward luxation of the patella may be the result of direct violence applied to the inner edge of the patella, but quite as often follows sudden muscular action."

Knock-knee, undue laxity of the ligaments, especially of the capsular, and more particularly a deficiency of the external lateral ridge of the external condyle, all predispose not only to the occurrence but to the recurrence of the disability. A sudden muscular contraction with the leg extended or in mid-flexion, especially if the knee is inverted and the foot and leg are everted, is sufficient cause to produce displacement. Eversion of the leg brings the insertion of the ligament further out and affords a straighter pull for the extensor muscles. Reduction is generally easy.

The advice of the text-books is to extend the knee, fully flex the thigh to relax the rectus, manipulate the knee-cap by pushing it medialward, at the same time correcting any rotation. The quadriceps with the knee extended may be pulled down to aid relaxation. If these manipulations fail, they may often be successful with the joint in slight flexion instead of extension.

Recurrence may happen only occasionally—usually unexpectedly in the course of flexion—or it may occur very frequently, the patient learning to replace it himself. It means, in time, a relaxed, weakened, and uncertain joint. The recurrence may be relieved by a knee-cap or by a bandage. As a rule, the annoyance is so great that something more radical must be done.

One operative procedure consists in reefing the medial side of the capsule, with or without opening the joint. Another consists in transplanting the insertion of the patellar ligament medialward. These operations have sometimes been performed with good results, according to Whitlock, but he offers as a third method that of reenforcing the patellar ligament by grafting the tendon of the gracilis into it (Tenney, *American Surgery*, 1908, xlviii, 7313).

Dumferline, in *Surgery, Gynecology, and Obstetrics*, April, 1912, describes a technique which he has used successfully. He takes a semilunar flap of skin and fascia from the medial and posterior surfaces of the knee, far enough back to enable him to reach the tendons of the semitendinosus muscle; the base of

the flap crosses the line of the patella and the patellar ligament. The semitendinosus muscle is dissected as low as possible. The patellar ligament is split, a portion being turned up to be sutured to the cut end of the tendon of the semitendinosus. The medial portion of the capsule and the fascia are then plicated with several sutures, chromic catgut being used for both tendon and capsule.

Whitlock's method consists of turning forward a long horse-shoe-shaped flap of skin and fascia, with its base in front and its apex reaching backward to the line of the medial ham-strings, the base corresponding with the line of the medial margins of the patella and the patellar ligament. The ligamentum patellæ is exposed in its course for about three-fourths of an inch by dividing the thin capsular fascia overlapping its anterior surface, and a thin Kocher fenestrated blunt dissector is thrust through the ligament from behind forward so as to separate the fibres as near its middle as possible, making a space of half an inch vertically. This is done without entering the general synovial cavity of the joint. The ligament is then split for a space of half an inch or more and prepared to receive the end of the gracilis tendon. This tendon is found by taking the sartorius muscle as a guide; the fascial attachment of the sartorius is divided above and posteriorly so that its edge may be thrown forward. The slim tendon of the gracilis is then seen lying proximal to that of the semitendinosus, and parallel with it are some vessels and a nerve which should be avoided. The gracilis tendon is isolated and divided as near its tibial attachment as possible. It is brought forward and threaded through the fenestrated director and passed through the patellar ligament, and is sutured with chromic catgut. Whitlock states that the gracilis was chosen partly because of its superficial position and its very long and supple tendon, but mainly because it is primarily an adductor in its action and innervation, being supplied by the obturator nerve. It is a less important flexor of the knee than the semitendinosus. The altered position of the transplanted tendon acts as a tie, fixing the ligamentum patellæ and preventing the passage of the patella outward during full extension of the knee, while it

tends also to rotate the joint medialward. In cases in which there is a large amount of flaccidity of the capsule of the tendon, transplantation is fortified by reefing the capsule.

Goldthwait in the *American Journal of Orthopaedic Surgery*, vol. i, No. 3, reports 11 cases operated upon for dislocation of the patella. Through a 5-in. incision, beginning at the tubercle of the tibia, the patellar tendon was exposed and split into halves. The outer half was freed from its attachment to the tubercle and drawn inward under the remaining half, and sutured securely to the periosteum together with the expansion of the tendon of the sartorius muscle at the inner side of the anterior surface of the tibia. A number of these cases have recurred after this operation.

Murphy ("The Clinics," vol. iii, No. 4, August, 1914) reports his method of dealing with congenital luxation of the patella, which consists of exposing the joint freely through two longitudinal incisions, one on each side of the patella, and turning the patella with its attached ligamentum patellæ to one side. With a broad gauge to correspond to the under surface of the patella, a segment of bone lying between the condyles is removed to deepen this intercondylar groove. A flap of fascia and fat is then turned in from above and sutured over this denuded bone area to prevent ankylosis of the patella to the femur. The patella is placed in position resting on this fascia flap, and the inner portion of the fibrous capsule is drawn over the patella and sutured to its fibrous covering.

The extent of trauma to the joint surfaces would indicate great possibility of adhesions and limitation of joint motion, and the absorption of the fascia fat flap covering in the incised bone area would also tend to cause adhesions and limitation of joint function.

Graser (*Deutsche Gesellschaft f. Chirurgie, and Zentralbl. f. Chir.*, July 9, 1904) presents his method, and reports several cases in which the outer condyle of the femur stood considerably further backward than the inner condyle when the leg was rotated outward. He effected a cure of the dislocation by per-

forming a supracondyloid osteotomy of the femur and twisting the condyles so as to bring the outer portion forward and the inner condyle farther backward. This procedure carries forward the insertion of the ligamentum patellæ or upper end of tibia with the outer condyle of the femur, and thus loses much of its potency. He recommends the procedure only when the posterior position of the outer condyle is marked.

The Author's Operation for Habitual or Congenital Dislocation of the Patella.—From the multiplicity of methods devised for the correction of this deformity, particularly those procedures having to do with the soft parts as a means for correction of dislocated patellæ, also from the case reports following such operations, it can be safely concluded that no method has proved universally satisfactory. Many of the patellæ have become redisplaced after varying periods of time following soft-tissue operations for fixation, as might reasonably be expected. Grafted soft tissue, whether it be ligament, or fascia, will withstand but little strain and will gradually pull out if any great amount of traction is placed upon it. The most secure anchorage for tendons, fascia, or ligaments is through bone structure, and even then unless great care is exercised and the ligament itself be made to unite with the bone to which it is secured, independently of the suturing material, one cannot be assured that the new anchorage will remain secure. Any foreign material sutured into bone, where sufficient strain is placed upon it, will gradually pull through by its own destructive action.

On account of the failures reported by the various operators using different methods, the author has devised a method which, from his experience with its use, appeals very strongly as a most rational and trustworthy means of restoring the displaced patella without interfering with joint function, or offering any appreciable chance for failure. Instead of attempting to rectify the deformity by a complicated procedure or subjecting the joint to damage, a simple change of the architecture of the outer condyle of the femur suffices.

A semilunar skin incision is made to the outer side of the patella, sufficiently long to reach below the tibial tubercle and to above the external condyle. Without unduly disturbing the underlying joint structures, the external condyle is incised with a broad thin osteotome on its external surface, making a bone incision of from $1\frac{1}{2}$ to 2 in. in length, and about $\frac{1}{2}$ in. below its anterior articulating surface, and nearly in line with the long axis of the femur. This bone incision allows the anterior surface of the external condyle to be raised to a plane above the internal condyle, by producing a greenstick fracture near the intercondylar groove, the object being to place a permanent and

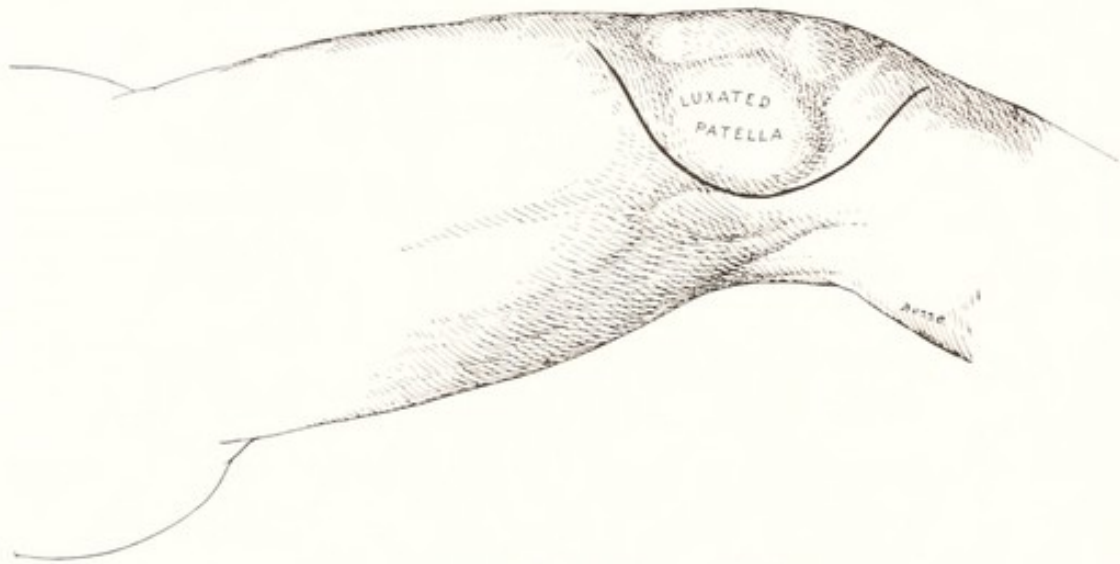


FIG. 220.—Luxated patella outward.

rigid obstacle in the way of the outward displacement of the patella.

When the anterior segment of the external condyle has been pried forward sufficiently to demonstrate its obstructing effect, the width of the bone gap thus formed is measured and a section of bone sufficiently large to fill this cuneiform gap is removed from the crest of the tibia through the lower portion of the same skin wound extended below the tubercle. This bone-graft wedge can be very easily and quickly procured by the use of the motor saw. Before the graft is removed, it is drilled obliquely in one or two places by the motor drill, so that it may be pinned to the under portion of the external condyle when put into its

place. Dowel pins, made from an additional portion of the bone removed from the crest of the tibia at the time the graft is

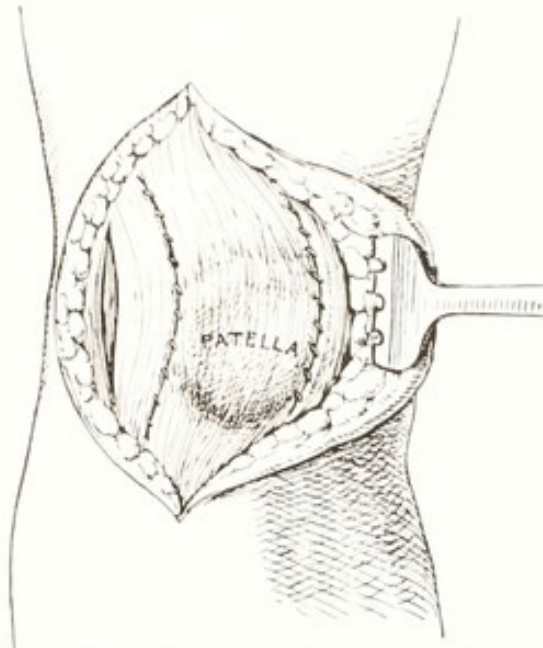


FIG. 221.—Patella fixed in position by wedge graft under external condyle and plicating sutures.

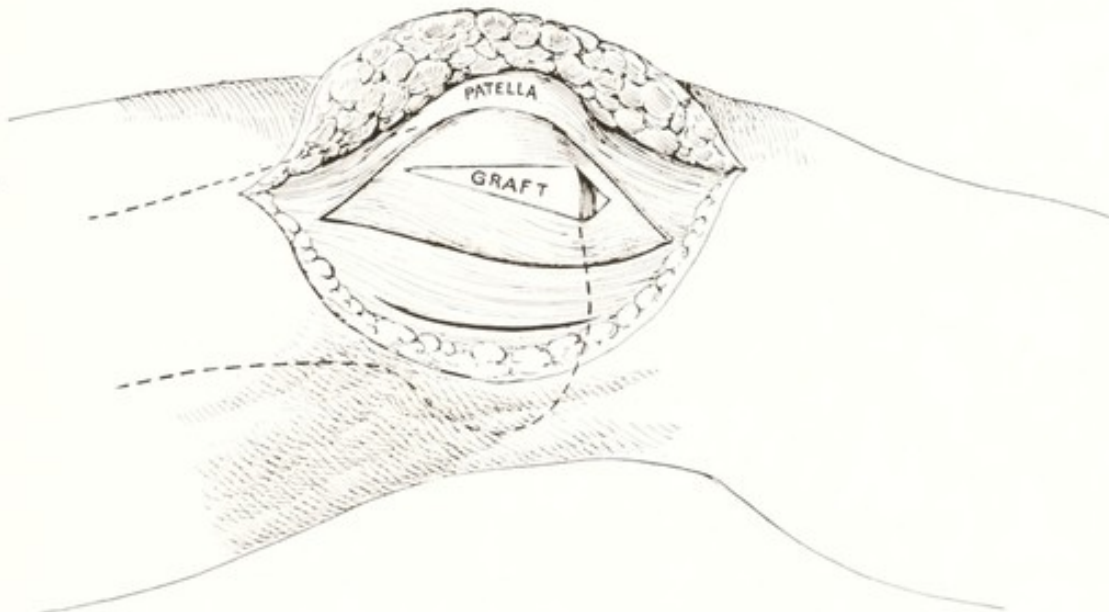


FIG. 222.—Author's operation for outward dislocation of the patella, showing shape of graft in position, lifting anterior portion of external condyle to block the recurrence of the dislocation.

obtained, and rounded by the motor lathe to fit the drill holes in the graft.

The cancellous structure of the condyle receives the bone-graft pins easily when they are driven into place; or the motor drill

can again be inserted into the holes already made in the graft and continue them into the external condyle. The ligaments and tendinous expansions are sutured over the graft, thus holding the lifted portion of the condyle securely by kangaroo tendon. The skin wound is closed by a continuous mattress suture of catgut, without drainage, and the leg up to the groin is placed in a plaster-of-Paris splint for three weeks. Passive motion and massage are begun.

The advantages of this procedure are that, with no sacrifice of joint cartilage, a minimum of joint injury is produced at the time of operation, thereby greatly lessening the chances of limitation of motion or the formation of adhesions, and that the permanent blocking of any further tendency to displacement

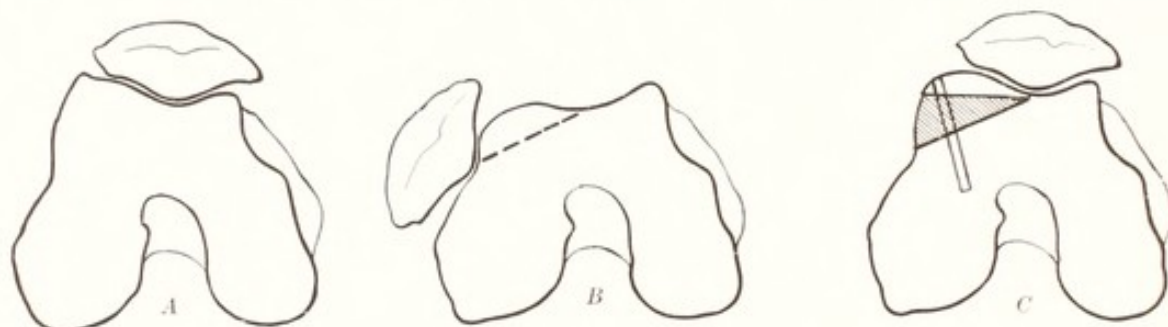

FIG. 223.—*A* indicates the normal size and anterior prominence of the external femoral condyle. *B* indicates the flattened external condyle with a consequent luxation of the patella outward. *C* indicates anterior lifting of the condyle to block the recurrence of the luxation of the patella with the wedge graft (dark area) in position.

of the patella is effected by the actual elevation of the external condyle, or an actual restoration of the normal mechanico-anatomical conditions. The soft parts are not interfered with, and the only further suggestion in the case of extremely lax and stretched internal capsular ligaments is their plication with kangaroo tendon; but usually this is unnecessary, for if the external condyle is propped well forward it, in itself, fulfils all requirements.

GRAFTING OF AN EPIPHYSIS TO STIMULATE CONTINUOUS BONE GROWTH IN AN EPIPHYSIS DAMAGED BY DISEASE

Bond, in the *British Journal of Surgery*, vol. i, p. 610, reports an interesting case of a child 4 years of age who had had a tuberculous infection of the inner portion of the upper

epiphysis of the left tibia, resulting in a sharp angular bow-leg deformity of the tibia, following the cessation of the tuberculous infection. This deformity was reported to be due to the uninterrupted growth of the fibula. "The fibula was divided just below its head and this, with the epiphysis, was removed. A V-shaped portion of bone was then removed from the inner side of the head of the deformed tibia in the situation normally of its epiphyseal junction. The deformity was corrected by forcibly straightening the shaft of the bone. The removed head of the fibula was cut down to a V shape and inserted into the wedge-shaped gap in the head of the tibia. In this way a piece of new and growing epiphyseal cartilage was introduced into the inner side of the head of the tibia in the situation of the damaged epiphyseal line."

TRANSPLANTATION OF ENTIRE JOINTS

Deutschländer, in *Deutsche Zeitschrift f. Chirurgie*, vol. cxxviii, 1914, p. 183, reports a case of transplantation of an entire knee-joint of a 4-year-old boy into a boy 13 years of age, grafted practically in its entire extent, including the joint capsule and the interligamentous apparatus as well as the patella. Although the result fell short of the expectations, the healing in of this manifold tissue complex was associated with a series of very interesting processes, well worthy of

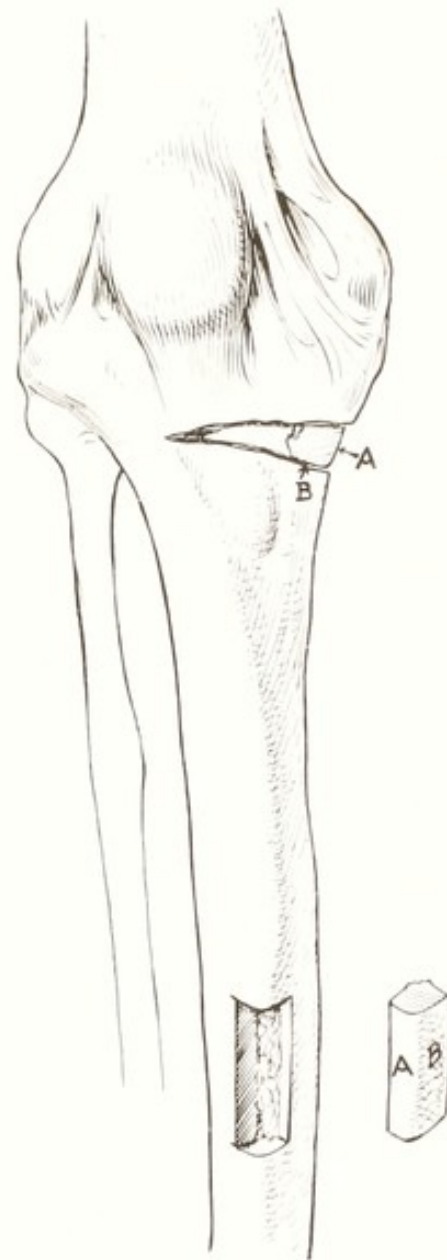


FIG. 224.—This is a drawing illustrating method of correction of a very pronounced bow leg from an old intra-articular fracture of the upper end of the tibia. An osteotomy was done and a graft, which was obtained from the crest of the tibia lower down was inserted. No fixation sutures were necessary. The operation of which this is a drawing was done in March, 1912.

publication. The patient was improved in that the resulting slightly movable pseudarthrosis was preferable to the bilateral bony ankylosis of the knees which had existed before the operation. Transplantation of the patella was made, but proved unsuccessful. Röntgenograms taken 20 days after operation showed that even at this stage no trace of the transplanted patella could be demonstrated.

“The probability of viable transplantation of the patella would seem to be extremely slight. The articular cartilage was found to be the only viable element in the transplantation of entire articular segments. It apparently possesses a great power of resistance and can be successfully transplanted, even under unfavorable conditions.

“Taking into consideration the total result of the healing processes in this case of an entire transplanted knee-joint, we find that the larger portion of the transplanted tissue was destroyed and only an extremely small fraction actually healed in. It was really only the articular cartilage which was shown to remain viable for a long time, although not without a very considerable loss of cellular material. In view of these findings, it is advisable to abandon the transplantation of tissue complexes, which are doomed to destruction, as a rule. The organism will thus be saved an amount of work which it can more profitably employ for the functional development of the joint.”

Bone Transplantation in a Case of Sarcoma of the Bone.—Schulze-Berge, in *Centralblatt für Chirurgie*, No. 48, 1913, records the case of a patient, a woman, 26 years of age, with a spindle-cell sarcoma of the head of the tibia. As no fresh joint was available for transplantation, the writer endeavored to preserve a useful leg, though abandoning motility in the knee-joint. After resection of the diseased articular end of the tibia to an extent of about 8 cm., the femoral condyle as well as the head of the fibula was freshened and, for the substitution of the tibia, a piece of the fibula of the healthy side, of suitable length, was transplanted into the tibia as well as into the femoral

condyle. The transplanted bone segment healed solidly in place, although the covering of the soft parts could not be firmly applied around the transplanted bone, which led to suppuration.

Röntgenograms taken 1 year later showed that the transplanted bone had attained the strength of the tibial diaphysis by periosteal proliferation. In the lower half, the transplanted bone had disappeared through absorption; while in the upper half it still remained visible. The leg was solid, except possibly slight motion from before backward.

CHAPTER VII

THE BONE GRAFT IN THE TREATMENT OF DISEASES AND DEFORMITIES OF THE FOOT AND LEG

CLUBFOOT. AUTHOR'S TECHNIQUE

The treatment of clubfoot must necessarily take into consideration not alone the age of the patient and the degree of the deformity but the type or class of the deformity into which it can be subdivided for convenience, so far as treatment is concerned, *i.e.*, (1) those cases where the treatment is begun in early infancy and carried to complete correction by manipulation and external fixation; (2) those cases where early treatment has been indifferently carried out, or has been interrupted, resulting in partial or complete relapse of deformity; and (3) those cases which have received no corrective treatment whatever.

In the first group proper manipulation and fixation treatment is all sufficient and will not be dealt with in this treatise. In the second and third groups—the relapsed or untreated cases—bone plastic operations are recommended only beyond infancy, where the tarsal bones have partially or completely ossified and resist remoulding by long-continued manipulations and fixation in over-correction. Such cases have been made to yield to the varied technique herein described (Fig. 228).

Group II, may be again subdivided into two types of relapsed congenital clubfoot, *viz.*, that of the long, comparatively slender, foot where the osseous development has gone so far as to resist correction in spite of the tenotomy of the tendo Achillis to overcome equinus and forcible stretching followed by fixation in plaster of Paris or braces, and with still gradually relapsing forefoot, particularly toward varus; and another group which will include those cases of relapsed clubfoot consisting of a short chunky foot in extreme varus. In many of these latter cases we

find that the patient has by the impact of walking produced an hypertrophy of the cuboid, the foot being so markedly inverted and supinated that the weight of the body rests directly upon the cuboid; the peroneal muscles from long disuse are undeveloped and elongated, and the dorsal flexors of the foot on the leg are shortened and act as direct agents to increased varus and supination of the foot.

The technique of the operative treatment devised and applied by the author for dealing with the first subdivision of this group

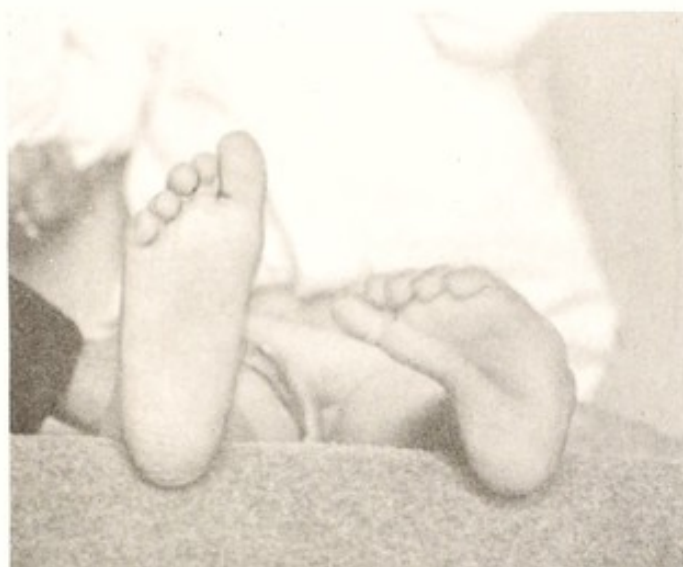

FIG. 225.—Plantar view of a clubfoot showing the marked adduction of forefoot, which produces the concave contour or short inner side and long or convex outer surface of the foot.

The author's technique for this type of foot, in older children, is to restore permanently the shape of the foot by placing a bone graft into the skeleton of the inner side of the foot. If the deformity is of congenital origin the graft is placed into the split scaphoid bone. If it is of paralytic origin, with consequent instability, the graft is placed into the astragalo-scaphoid joint. (See text.)

of relapsed clubfoot, namely, the long slender type with marked varus and moderate adduction of the forefoot, but without marked hypertrophy of the cuboid, is as follows:

The deformed foot, and the leg also, having been prepared for operation, and a tourniquet securely applied above the knee, the equinus is first corrected by tenotomizing the tendo Achillis, to enable the operator to force the foot into dorsal flexion on the leg. A narrow sharp tenotome is thrust through the skin with its blade parallel with and just anterior to the

tendon, and about three-quarters of an inch above its insertion into the os calcis. The cutting edge of the tenotome is turned posteriorly and the tendon is divided from before backward, care being taken to divide the plantaris tendon as well. The division is easily perceptible in the sudden giving way of the resistance to dorsal flexion of the foot. The heel is brought down thoroughly by forcible dorso-flexing of the forefoot.

The next step, when no true bone operation is done, is the thorough stretching out of the varus by manipulation—either

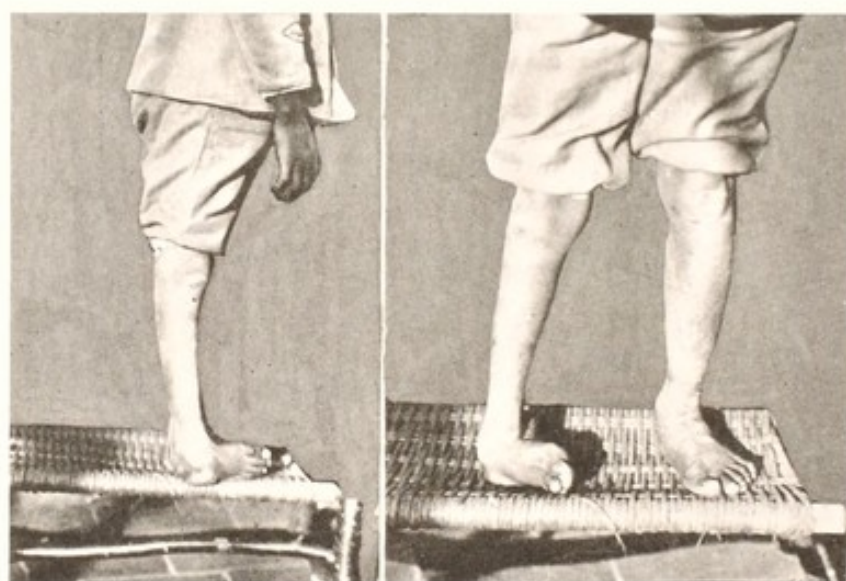


Fig. 226.

Fig. 227.

FIGS. 226 AND 227.—Marked untreated clubfoot of a boy 7 years old. Before operative correction. A wedge-shaped graft was removed from the cuboid bone on outer side of the foot and placed into the split scaphoid after the tendo Achillis and inner portion of the plantar fascia had been severed and foot forcibly corrected. (See Figs. 228 and 229 for result.)

manual or with the Thomas wrench—with or without the wedge block as a fulcrum. The foot is then so lax as to be easily placed in an over-corrected position, but it is obvious that if reliance is placed upon external correction alone relapse would take place. This is very prone to occur following the Phelps operation where a free division of all soft structures is made down to the bone and the foot forced into valgus, leaving the wide gaping wound to heal by granulation—resulting in a contracting scar—and the articular surfaces of the tarsal bones

widely separated with no provision made to prevent these articulations from closing up again.

Having had exceptional clinical opportunity for observing a large number of relapses in clubfeet following these soft-tissue operations, it became evident to the author that if relapse was to be prevented a remodelling of the tissues or bony framework of the foot was essential. All previous clubfoot bone operations

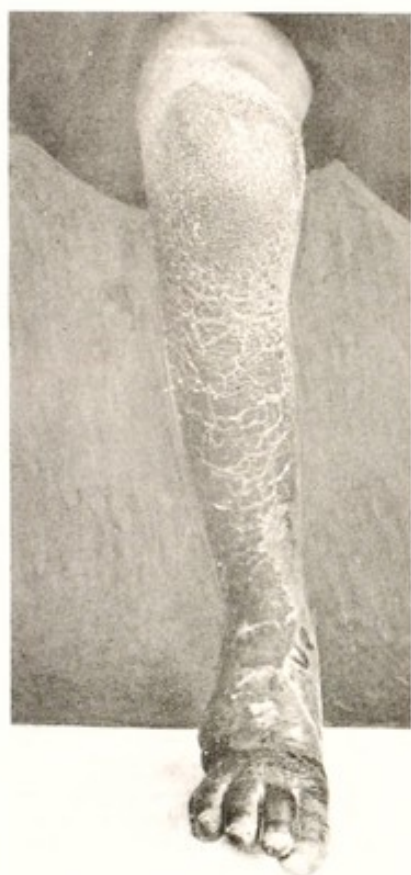

Fig. 228.



Fig. 229.

FIGS. 228 AND 229.—Same case as Figs. 226 and 227 after correction of clubfoot deformity by insertion of bone graft.

have entailed removal of wedges of bone from the outer or long side of the tarsus, and have thus still further shortened an already short and undeveloped foot. Since the trustworthiness of the bone graft had been so thoroughly proven, it occurred to the author in 1911 that the surgeon could well follow carpentry methods and remodel the tarsus by elongating the concave or short inner side of the foot by placing a bone-wedge graft be-

between the split halves of the scaphoid bone. At the same time, that this permanently corrects the bony deformity of the foot it may lengthen it sufficiently to avoid mismated shoes. Any degree of lengthening of the foot is far preferable to any further shortening of the same.

The technique of the operation is as follows: A U-shaped skin incision is made on the inner aspect of the foot and the flap with its subcutaneous tissue is dissected back, exposing

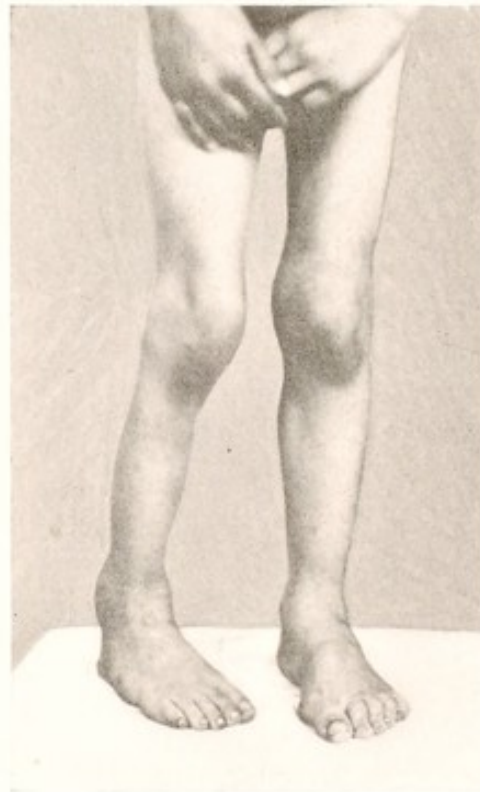

FIG. 230.—A congenital clubfoot of less severe type of deformity. The varus is not extreme and there it is not necessary to remove bone from the outer side of the foot. A tibial graft is placed into the split scaphoid bone. (See Fig. 231.)

the scaphoid bone. The apex of this incision should extend well forward in the region of the great toe; or a straight incision may be made over and parallel with the long axis of the dorsum of the foot so that the superior surface of the scaphoid is approached. Whatever incision is employed, however, it should always be so situated that when the wound is closed the skin sutures do not come over the graft. The development of the field of the bone operation should be carefully done, as the changed bone formation and landmarks may be extremely distorted.

With a half-inch, thin and sharp osteotome, the scaphoid is split into anterior and posterior halves, either by a linear osteotomy through the long axis or by a curved bone incision from above following the general curved contour of the bone. The foot is then forced into the required degree of over-correction, and the gap between the halves is widened. All resistance by plantar fascia or other tissues is relieved by severing the structures with a scalpel through the wound already made, or by means of subcutaneous fasciotomy through an additional tenotome wound. The width of the gap is taken with calipers, as

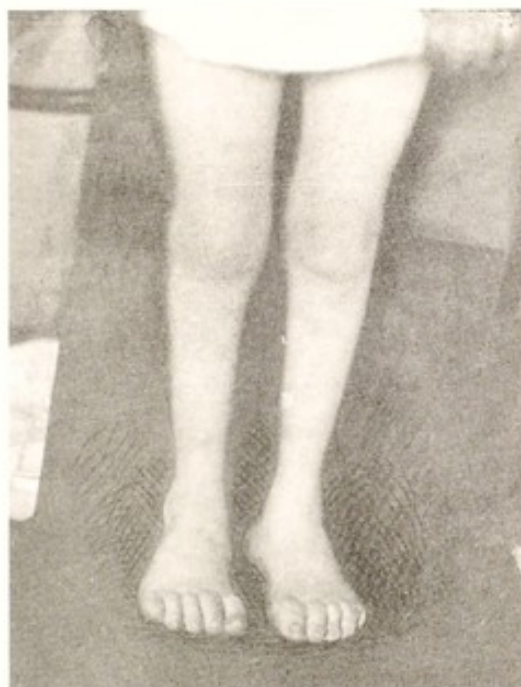

FIG. 231.—Same as Fig. 230 after operative correction and insertion of graft.

a measurement for the size of the bone wedge to be obtained preferably from the tibia of the same limb. The skin and subcutaneous structures overlying the anterior internal aspect of the tibia are incised at about the junction of the middle and lower thirds of the shaft, which region is selected as it yields a denser and thicker bone cortex than higher up. The skin incision should be situated so that it does not overlie the cavity from which the graft is removed.

Having freed the crest from muscle attachment, and with the skin and soft parts well retracted by sharp retractors, the

width and thickness of the required wedge is marked off by a scalpel, cutting into the periosteum.

The motor saw is then employed to cut the wedge graft from the tibia. The two cuts are made transversely through the cortex of the crest at the measured distance apart, and are caused to converge to each other as the medullary cavity is approached.

Before its dislodgment from the tibia, the graft is drilled

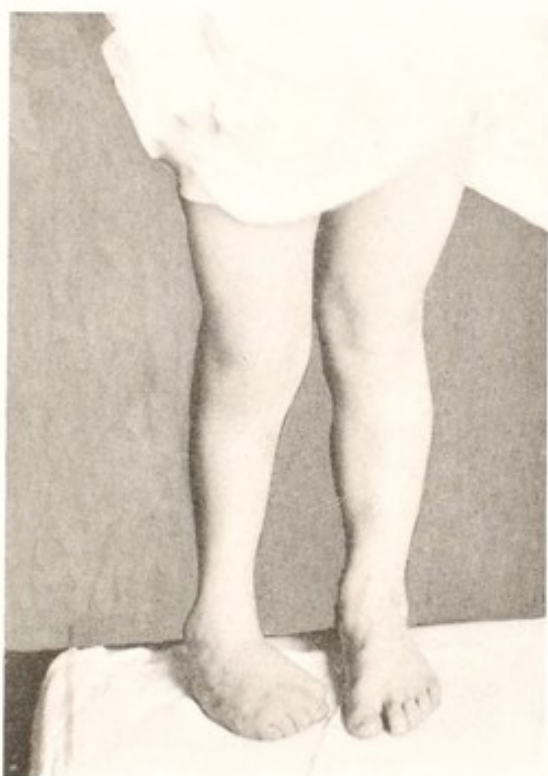

Fig. 232.

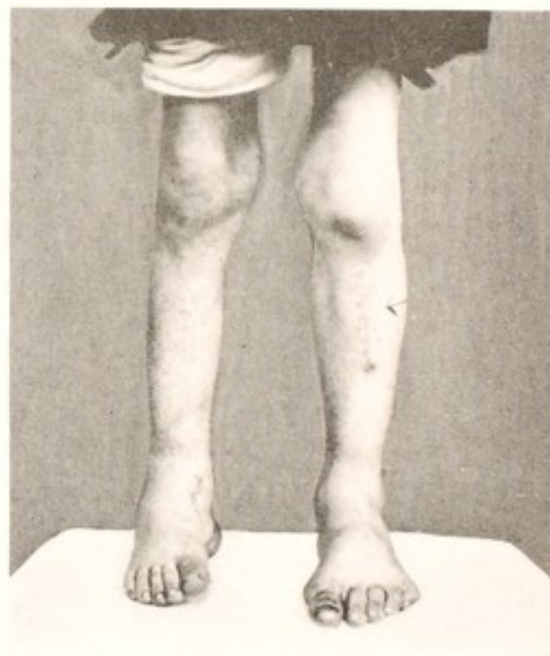

Fig. 233.

FIGS. 232 AND 233.—Before and after operation. Congenital clubfoot of same type and treated by same method as (Figs. 226 to 229).

with the small motor drill through the centre of its cortex for retaining sutures, and is then removed from its bed with the aid of a sharp osteotome, and either placed in normal saline solution until used, or transferred directly to its position between the halves of the split scaphoid. It should fit so tightly as to prevent any return to varus and adduction deformity when the forefoot is released by the assistant.

If the cortex of the scaphoid is too dense to permit the passage of a short strong curved cervix needle, the edges of the

scaphoid halves are drilled with the motor drill. Ordinarily, in children, the scaphoid edges readily permit puncture by the cervix needle. The technique is carried out as follows, in either case: The kangaroo tendon is threaded through the drill holes of the graft wedge, which is readily done on account of the stiffness of the tendon. With the graft in the centre of the tendon strand, a cervix needle is threaded to each end. These needles are thrust through the scaphoid edges from the cut-surface side,

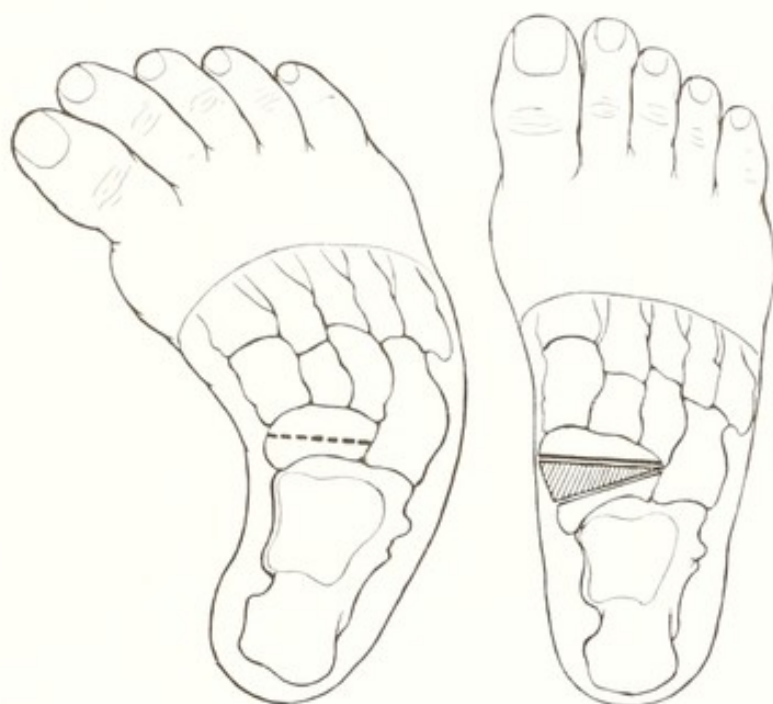


FIG. 234.—Diagram illustrating an inlay-wedge bone graft removed from the crest of the tibia or the cuboid of the other side of the foot and placed into the split scaphoid for the purpose of permanently remodelling the tarsus of a congenital clubfoot. In this deformity the inner side of the tarsus is shorter than its outer side, and the graft is inserted to overcome this distortion in older children and adults. The advantage of guarding against relapse by remodelling the bony tarsus is also augmented by lengthening the foot, which is always short.

either through the drill holes in the edges or through holes made by the needles themselves. The bone-graft wedge is then forced into place between these scaphoid halves, the tendon is drawn taut, and tied over the graft. The subcutaneous structures are then drawn together over the grafted area and the skin flap is closed over all by plain catgut without drainage. If the deformity is a severe one and the skin wound cannot be closed without too great tension and danger of slough, it is best

not to attempt to approximate the flaps by too great tension, but if a skin gap is necessitated it should be as far from the graft as possible, and will readily granulate over.

The dressings are then applied. Cotton is placed between the toes to take up secretion; the foot and leg, to above the knee, are covered with a Shaker-flannel bandage or sheet

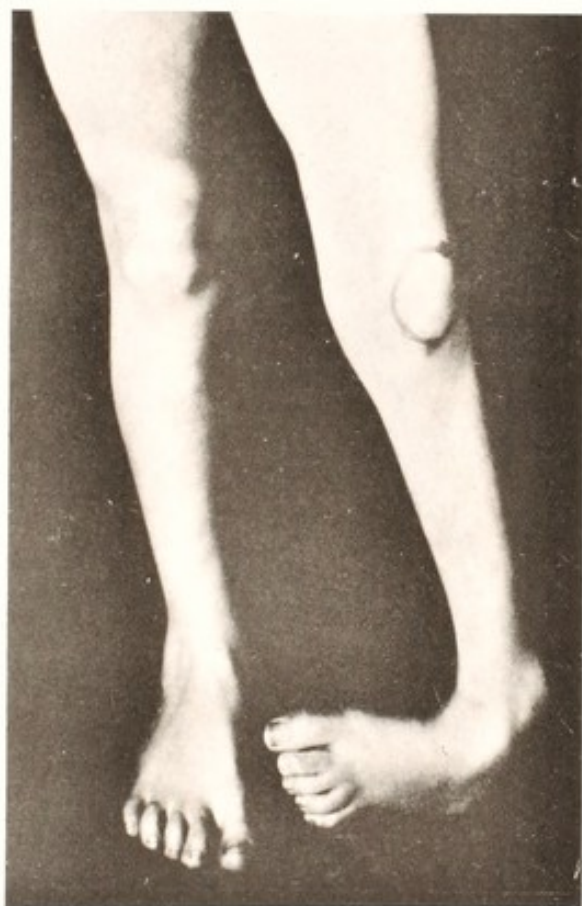

FIG. 235.

FIG. 235.—A marked case of paralytic equino varus. The lateral deformity was corrected and maintained by placing a tibia graft into the astragalo-scaphoid joint, after the bones forming that joint has been separated by the correction of the deformity.

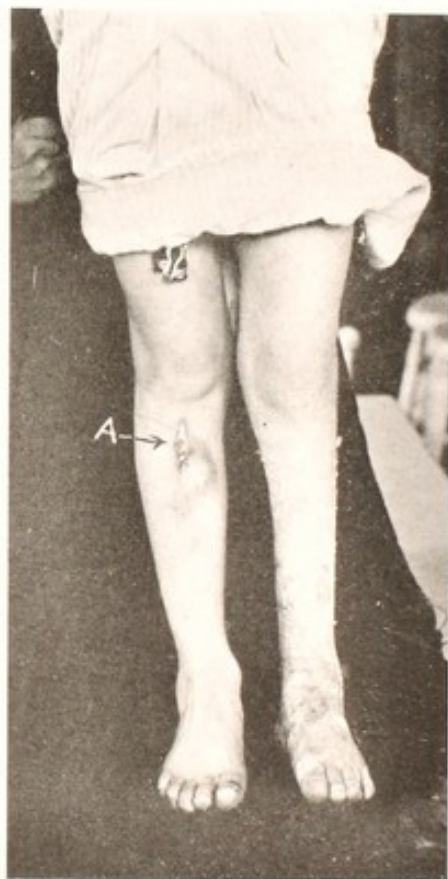

FIG. 236.

FIG. 236.—Photograph of case (Fig. 235) after correction of deformity. A, indicates location in tibia from where the graft was obtained.

wadding, as a lining to the plaster-of-Paris fixation dressing which is next applied with the foot held in slight over-correction and the knee flexed nearly to a right angle. The knee is flexed to this angle in order to afford a leverage action against the tendency of relapse of the forefoot. This plaster dressing should remain in place for 4 to 6 weeks, when that portion

above the flexed knee is cut off, the remainder of the dressing being left in place for 4 to 6 weeks longer, when the entire protective dressing is removed and massage and exercise of the foot and leg is instituted.

Should it be deemed advisable for the comfort of the patient or as a means of maintaining the protective fixation for a longer



FIG. 237.

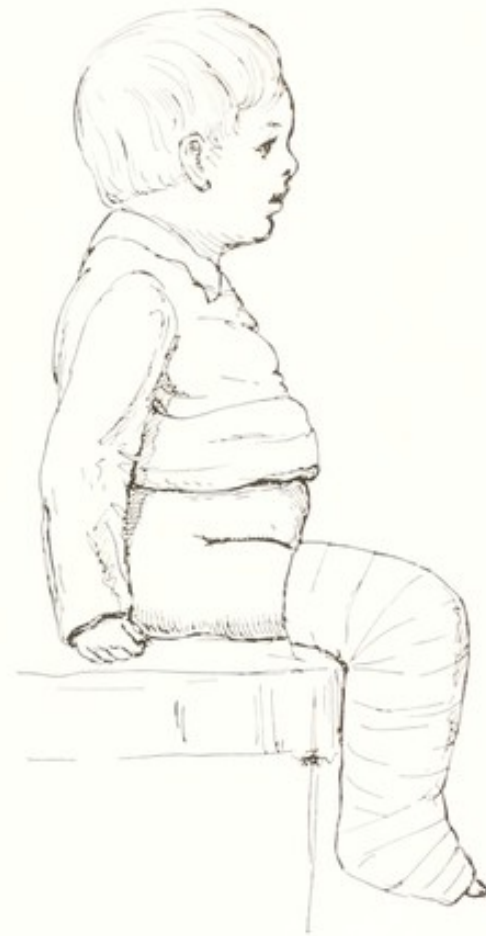

FIG. 238.

FIGS. 237 AND 238.—Illustrate method of applying plaster-of-Paris dressing for club-foot. The knee is flexed to a right angle and the thigh is used as lever to prevent the relapse of the adduction deformity of the forefoot.

period, the simple clubfoot sling support is the most serviceable form of brace to be applied. It consists of a strip of canton flannel folded upon itself four to six times, making a flannel strip three-quarters of an inch to an inch wide, and long enough to encircle the ankle and pass down under the foot and up to the external malleolus; to the ends of the strip a strong webbing strap is sewed, which extends up the outside of the leg to below

the head of the fibula, where it buckles to the upper end of a steel upright which is fastened about the upper part of the calf by a strap and to the shoe below, between the heel and the sole. This steel upright has a simple joint at the ankle, or, if there is still a need for preventing the tendency to equinus of the foot, a catch can be arranged at the joint to stop extension beyond a right angle. The pull of this sling with each step is sufficient to hold the foot in abduction and prevent varus. A less efficient brace is that with an inner single bar and straps about the ankle.

The technique of the operative treatment devised by the author for dealing with the second subdivision of this group of relapsed clubfoot, namely, those cases with a short chunky foot in extreme varus with the cuboid so hypertrophied and malformed as to resist any reasonable attempt at forcible correction of the foot, even after the scaphoid is split, is somewhat different. To these cases, the author applies the bone-graft wedge between the halves of the scaphoid split transversely across the foot, precisely as in the technique just described, with the exception that the bone wedge is removed from the body of the hypertrophied cuboid, instead of from the crest of the tibia, and inserted between the halves of the split scaphoid.

The technique of the removal of the cuboid wedge is as follows: A skin incision is made through the calloused skin and subcutaneous tissue, down to the cuboid along the outer border of the foot, sufficiently long to give a good exposure of this bone. Having previously determined with the calipers the approximate thickness of the wedge desired—this wedge is outlined with the scalpel—cutting through the periosteum transversely to the long axis of the foot, being careful to remove a wedge of sufficient width to allow full over-correction of the foot. With the motor saw the bone is then cut following the periosteal incisions; the planes are made to converge slightly, and as the entire division of the bone cannot be safely made with the motor saw, the bone incision is completed by a thin sharp osteotome driven into the saw-cuts. Before dislodging

the wedge from the cuboid, it is drilled at its centre for the passage of the kangaroo fixation suture. Then with curved scissors the soft tissues still holding the graft are freed and the wedge is removed, to be placed immediately in normal saline solution or directly into its position between the split halves of the scaphoid.

The foot is thus divided transversely through its entire tarsal structure, which allows the forefoot not only to be swung outward at this point but to be rotated about the cubo-scaphoid ligament; thus, at the same time, both adduction and varus are corrected. As this ligament lies approximately equidistant from the inner border of the scaphoid and the outer border of the cuboid, it is the centre of a circle of which a wedge taken from the cuboid is a sector, and when used to fill the gap formed by splitting the scaphoid and correcting the foot, it exactly fits and at the same time the gap formed by its removal from the cuboid is necessarily closed.

The foot and limb are included in a plaster-of-Paris dressing, from the toes to above the knee, with the foot well over-corrected and the knee flexed. This dressing should remain on the limb for 8 weeks, followed by a second plaster-of-Paris dressing up to the knee which should remain on for 4 weeks.

Advantages of the bone graft in clubfoot: (1) It lengthens an already much shortened foot. (2) It permanently lengthens the short side of the skeleton of the foot and insures in a most trustworthy way against a relapse of the deformity. (3) No joint is involved by the operation, therefore there is no interference with joint function or mobility. (4) It furnishes a means for permanently correcting the severest types of club-foot, even in the adult.

ACQUIRED CLUBFOOT

Paralytic Equino Varus.—This type of clubfoot is usually due to an attack of anterior polyomyelitis (infantile paralysis), and is caused by either partial or complete paralysis of the peroneal muscles, producing an unbalanced condition of muscle

control of the foot. This results in a deformity similar to that of congenital clubfoot. The outer border of the foot drops, the forefoot adducts and the patient walks on the outer aspect of the foot, causing it to further adduct by weight bearing. An undue laxity of the astragalo-scaphoid articulation results, and the unopposed muscle action of the anterior and posterior tibial muscles pulls the foot further into varus and adduction.

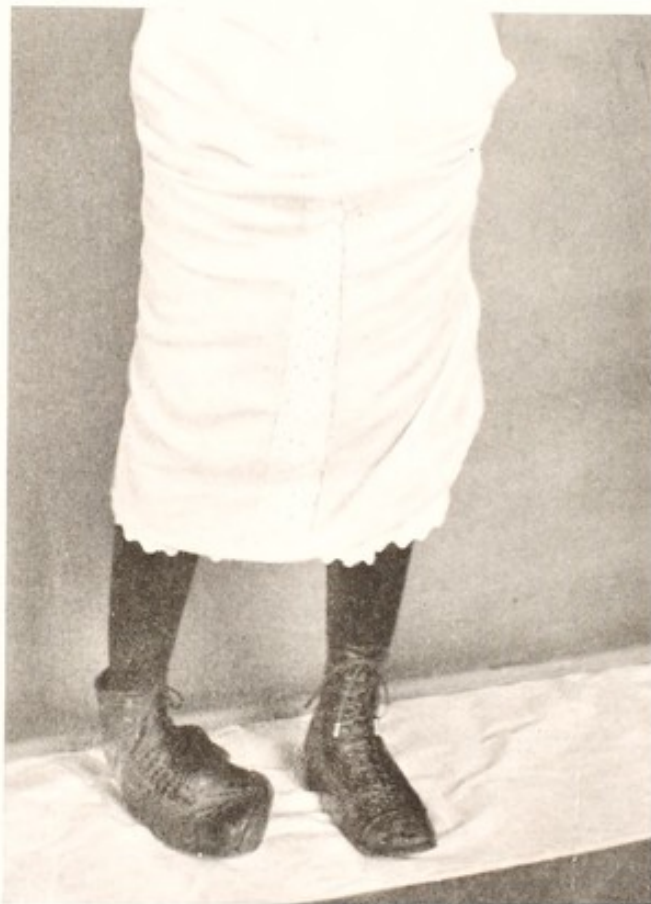

FIG. 239.—To illustrate weight-bearing of a paralytic clubfoot. The peroneal muscles were entirely paralyzed in this case.

The pull of the anterior tibial muscle, when the foot is in full adduction, forces the foot into further varus and adduction on the leg, and cases have been seen where the forefoot is so markedly adducted and inverted upon the leg that the patient walks wholly upon the outer side of the *os calcis* and cuboid bones. The forefoot in the more severe cases is limp and hardly touches the ground, and there is sharp angulation at the medio-tarsal joint.

This type of clubfoot presents four principal defects, namely: (1) equinus resulting from the shortened calf muscles; (2) lack of support of the outer border of the foot; (3) abnormal laxity of the astragalo-scaphoid articulation; and (4) misplaced centre

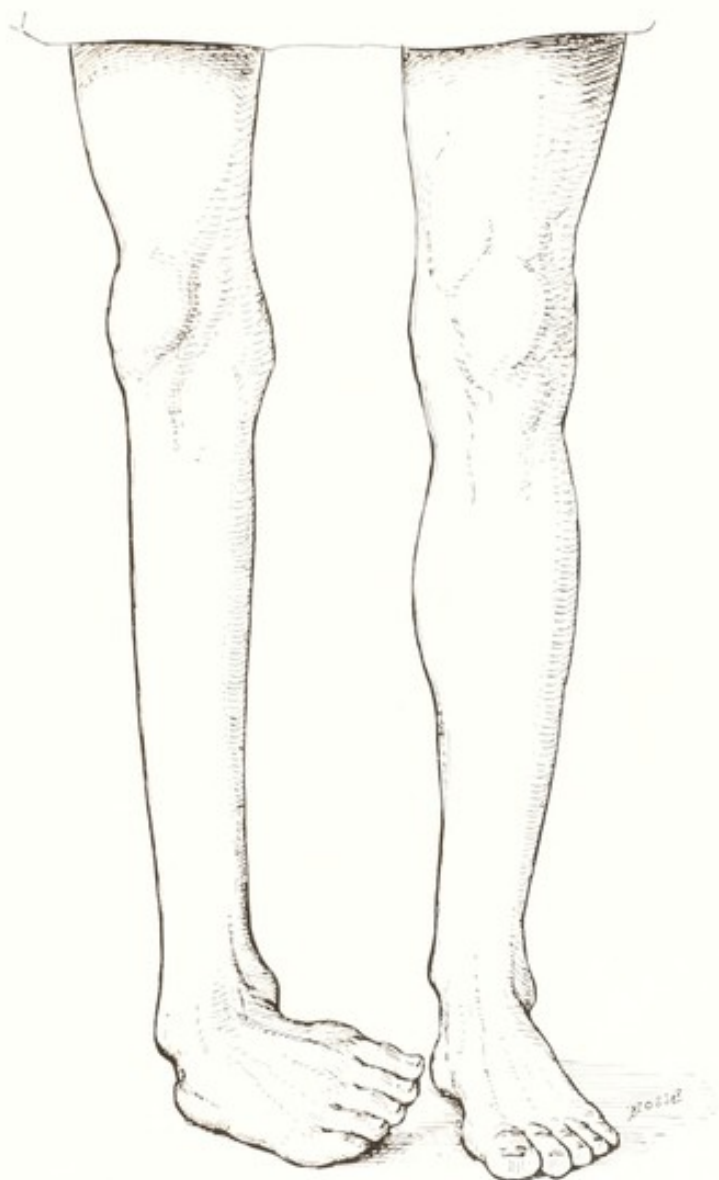


FIG. 240.—Drawing of paralytic clubfoot showing turning out of the patella, adduction and varus deformity of the foot, largely from paralysis of the peroneal muscles.

of weight bearing in the foot, due to its faulty adducted varus position.

These faulty mechanical conditions are best met by the following measures. The leg and foot having been prepared for operation, and a tourniquet applied above the knee, the equinus is overcome by the subcutaneous tenotomy of the

tendo Achillis, and the heel is brought well down by forcible manipulation.

The astragalo-scaphoid joint is reached by a U-shaped in-

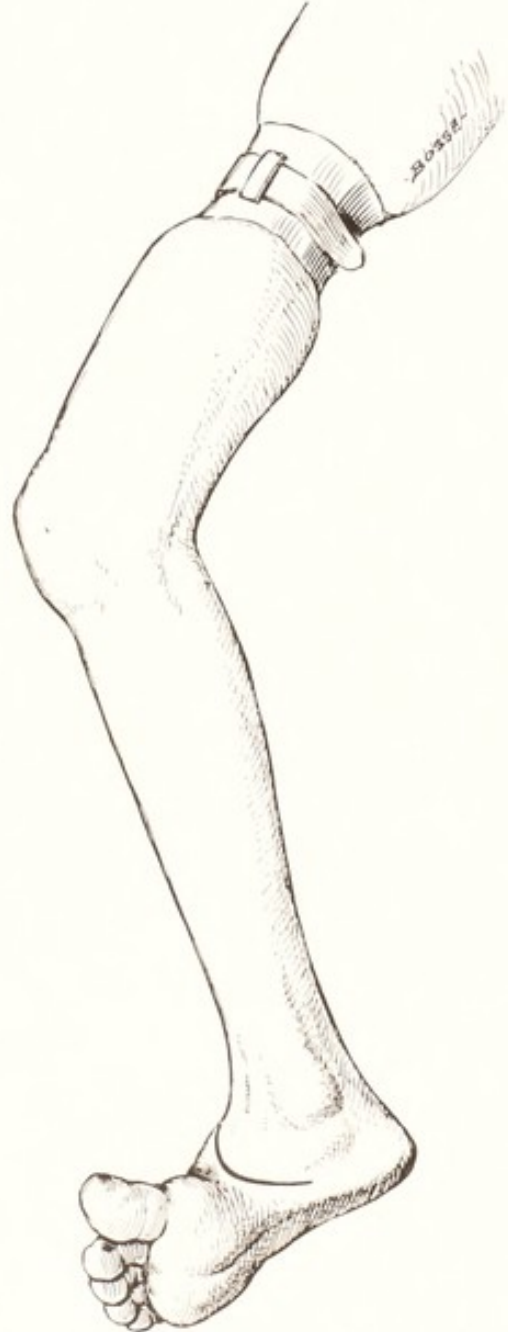

FIG. 241.—Curved skin incision for the purpose of furnishing a skin flap so skin sutures will not come over the graft.

cision, precisely as described for congenital clubfoot. The curved part of this skin incision should be well forward so as to afford an ample flap to cover in the grafted field. If preferred,

the joint may be exposed by a straight incision, parallel with the anterior tibial tendon on the dorsum of the foot.

The articulating surfaces of the head of the astragalus and scaphoid are removed with a narrow osteotome and mallet, following the contour of the joint or forming plane surfaces, as may appear better adapted to the individual case at the time



FIG. 242.—Method of applying manual force in correcting clubfoot.

of operation, the idea being to secure the maximum amount of bone surface for contact with the graft.

If over-correction of the foot is resisted by the soft structures, they are subcutaneously severed.

The over-correction of the foot produces a wedge-shaped cavity between the separated cut surfaces of the head of the astragalus and scaphoid. This wound is packed with a hot saline compress.

To overcome the dropping of the outer border of the foot,

due to the paralysis of the peroneal muscles, the tendons of these muscles are made to serve as ligaments (Codivilla, Gallie),

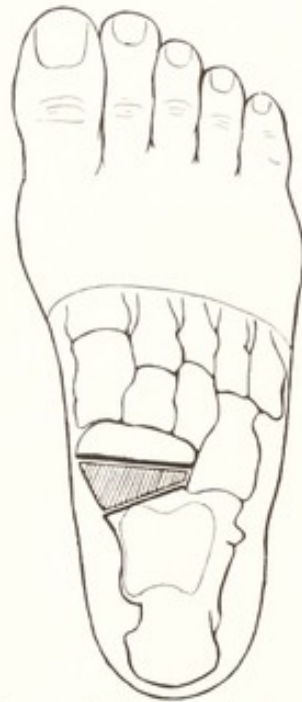

FIG. 243.—Wedge graft in place for paralytic clubfoot.

the external malleolus and tendons are exposed by a curved skin incision encircling the lower end of the malleolus.

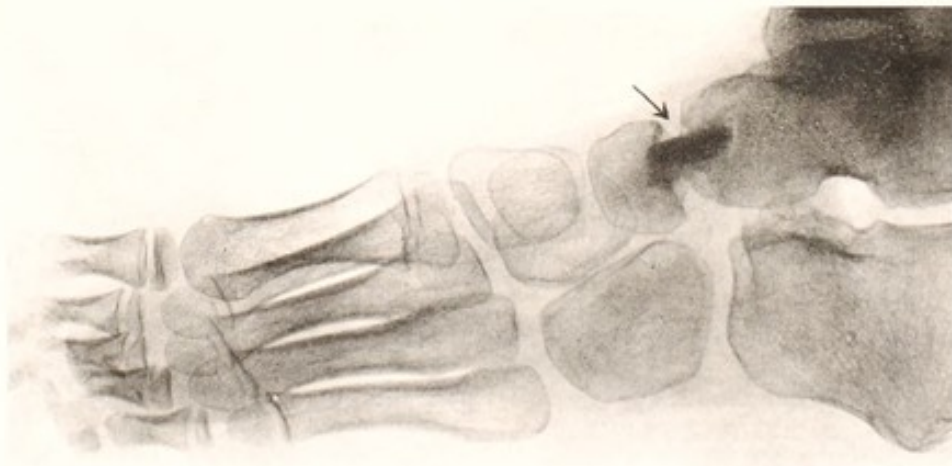

FIG. 244.—Röntgenogram of graft in place 6 months after operation for paralytic clubfoot.

An osteoperiosteal flap with its overlying periosteal tissues is lifted from the external malleolus and turned posteriorly on the periosteal tissues as a hinge. The osseous incisions for

forming this trap-door are easily and quickly made with the author's small motor saw, and further freeing of this flap is accomplished by a sharp osteotome. The peroneal tendon sheaths are split and the tendons are freed and placed under this osteoperiosteal trap-door.

The foot is then forced into pronation and the peroneal

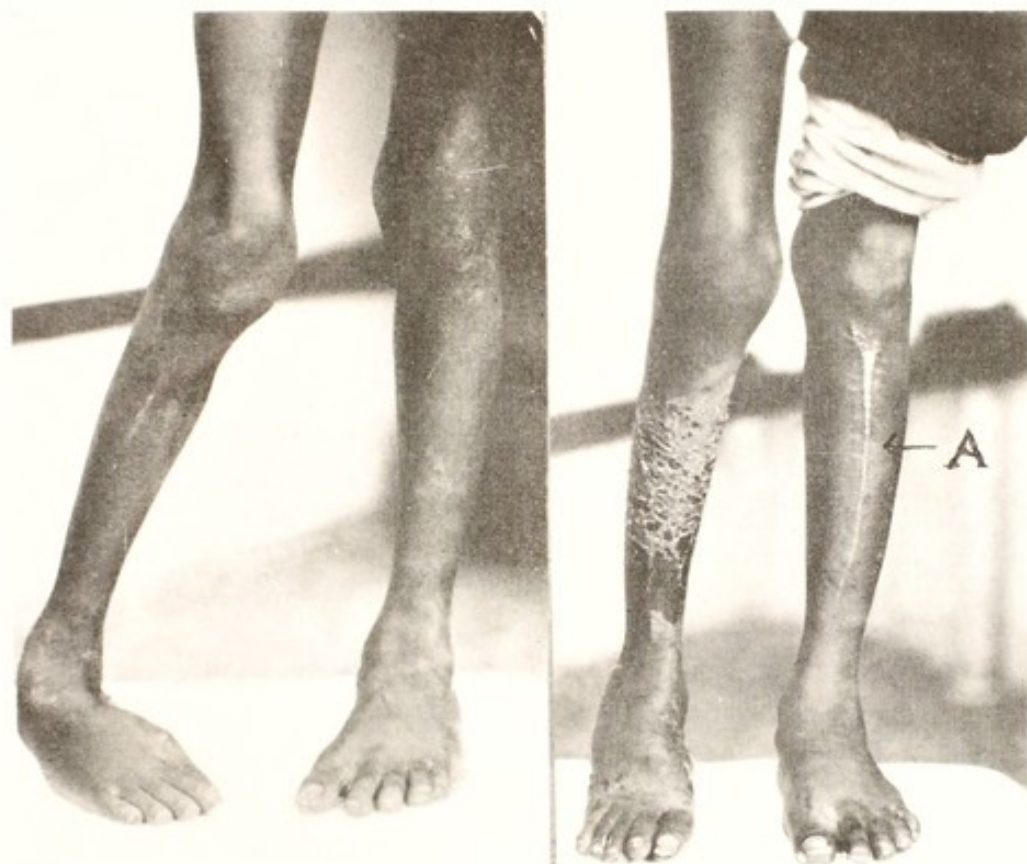

FIG. 245.

FIG. 246.

FIGS. 245 AND 246.—Before and after operative correction, paralytic clubfoot (Talipes equino varus) from infantile paralysis and loss of power in the peroneal muscle. A bone graft obtained from opposite tibia at A was mortised into the head of the astragalus and the scaphoid after correction of the deformity of the foot. The peroneus, longus and brevis tendons were anchored into the external malleolus as ligaments. For röntgenogram see Fig. 247.

tendons are drawn taut by reefing or suturing them securely to the periosteous tissues above this bone flap.

The edges of this osseous flap, as well as the adjacent cortex, are drilled, the tendons fitted into the grooves, and the trap-door is closed over and held firmly in place by kangaroo-tendon sutures passed through the drill holes and tied.

The skin wound is closed by a continuous catgut suture without drainage.

The outer border of the foot is thus held firmly elevated in an over-corrected position.

The saline compress is removed from the wound on the inner border of the foot, and while the foot is held by an assistant in a well-abducted position, an accurate measure is obtained of the resulting cavity between the head of the astragalus and the scaphoid. A saline compress is again placed in this

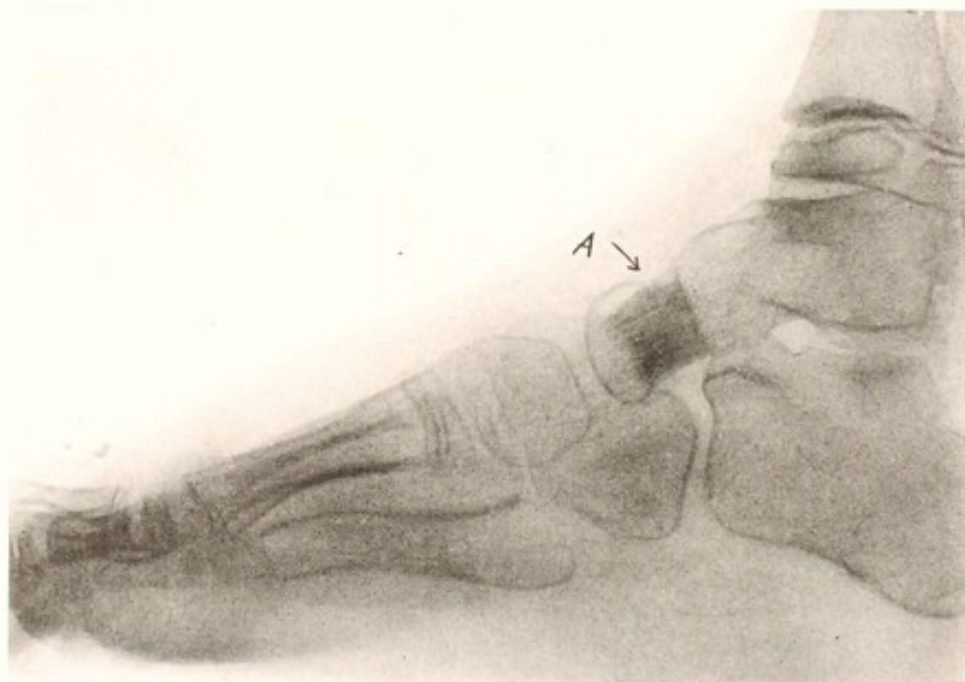


FIG. 247.—A indicates tibial graft mortised into head of astragalus and scaphoid 6 months before.

wound, and a graft corresponding to the measurements obtained is removed from the central portion of the tibia where the cortex is of sufficient thickness. As in the case of the graft obtained for the correction of congenital clubfoot. It is drilled for fixation sutures before it is dislodged from the tibia. If the bone of the head of the astragalus and scaphoid is too dense to permit the passage of a strong curved needle, the necessary holes are drilled with the motor drill. Ordinarily in children, the softness of the bones permits puncture by the strong cervix needle, and the technique is carried out as follows in either case:

The kangaroo tendon is threaded through the drill holes of the graft wedge, by virtue of its own stiffness. A cervix needle is then threaded to each end of this tendon. These needles are thrust through the head of the astragalus and the scaphoid at their inner borders from their cut surfaces.

The bone-graft wedge is then forced into place and the tendon suture is drawn taut and tied over the graft.

Soule's modification of author's technique which is simple in that it does not require drilling of bone or fixation

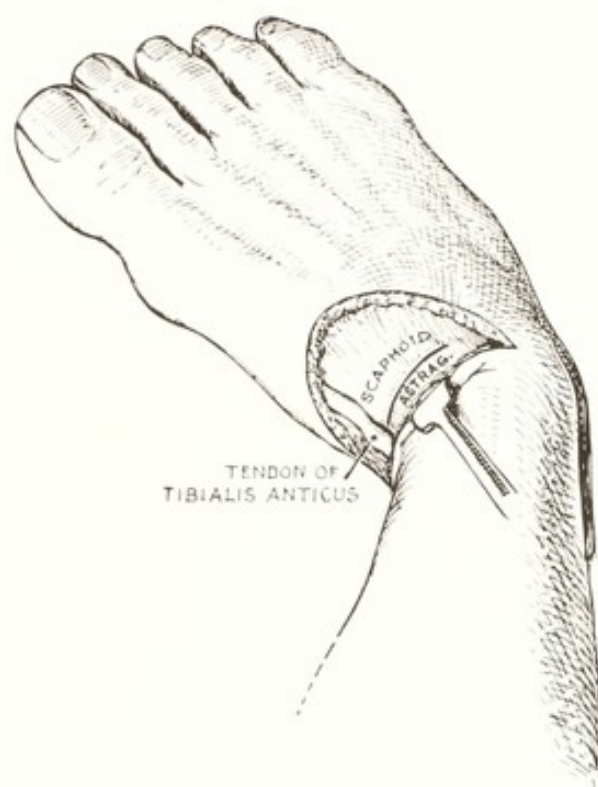


FIG. 248.—Demonstrates exposure of astragalo-scaphoid joint for insertion mortise graft for paralytic clubfoot (foot represented as on operating table).

suture, is recommended whenever it is found feasible. The astragalo-scaphoid joint is approached from its superior aspect and all the articular cartilage is removed from both bones, preserving the original contour of the joint. A mortise is formed in the inner portion of the cut surface of each bone, as shown by the diagrams. The graft is so shaped in its removal from the tibia that it fits accurately into these mortises when the foot is over-corrected. These mortises lock the graft in position and the foot is wedged securely into full correction.

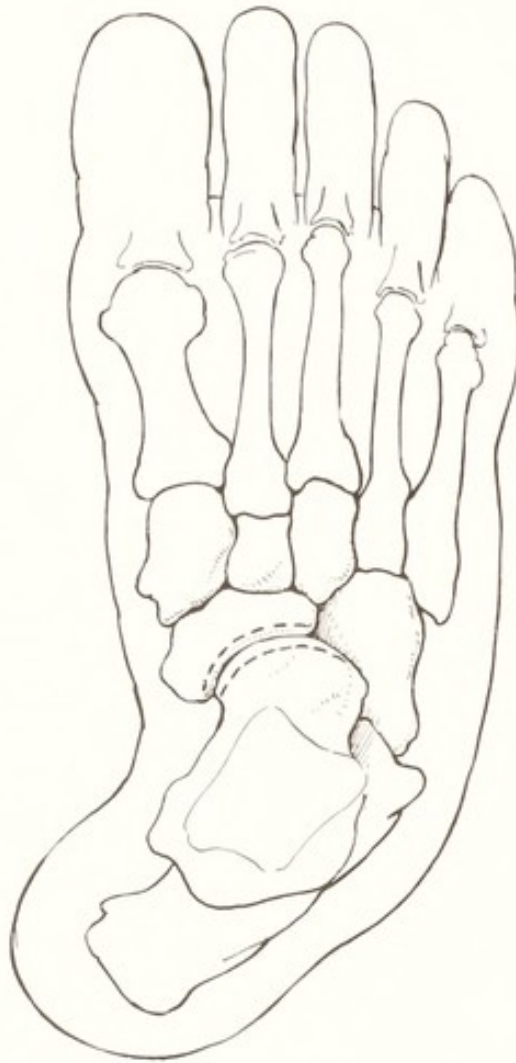


FIG. 249.—Dotted lines indicate removal of cartilage in arthrodesing the astragalo-scaphoid joint or as a preliminary measure before mortising in graft for paralytic club-foot (*talipes equino varus*).

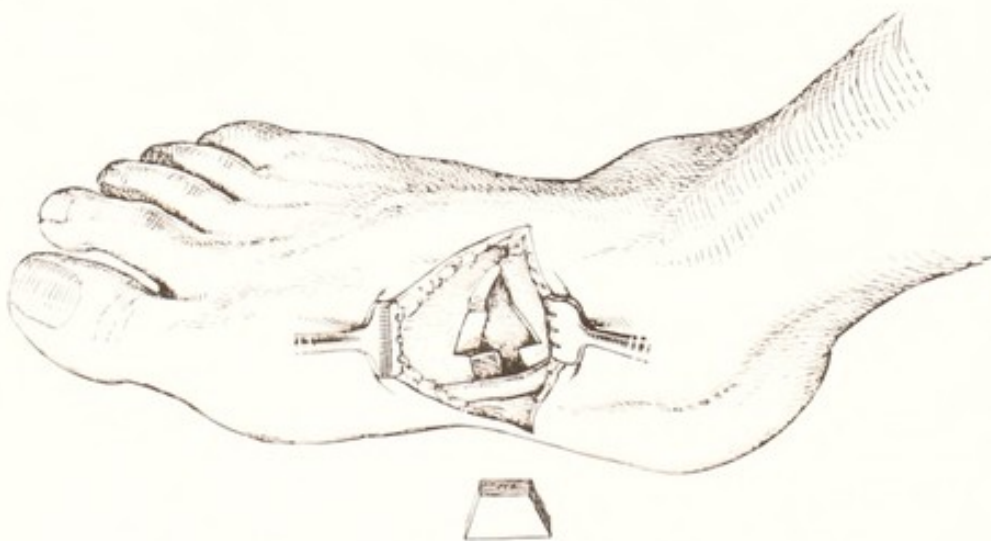


FIG. 250.—To illustrate method of mortising tibial graft for paralytic *talipes equino varus* (clubfoot).




FIG. 251.—Carvers gouge, with three different cutting edges. These tools are used by the author in various osteoplastic operations and are very useful.

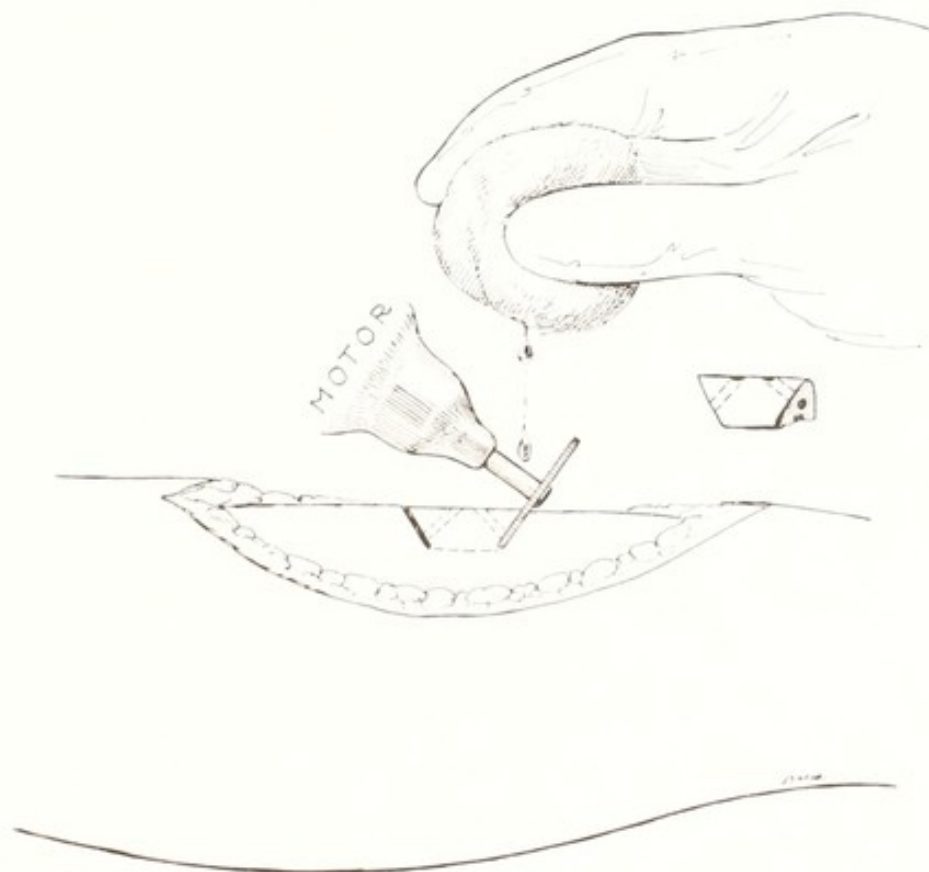


FIG. 252.—Method of removal and type of graft used to mortise into the head of the astragalus and the scaphoid in the correction of paralytic clubfoot.

By this method, the foot is insured against relapse, and at the same time the abnormal laxity of the medio-tarsal joint is permanently overcome by the ankylosis of this joint. Weight bearing is placed further toward the inner border of the foot, and the anterior tibial muscle, which was barely able to func-

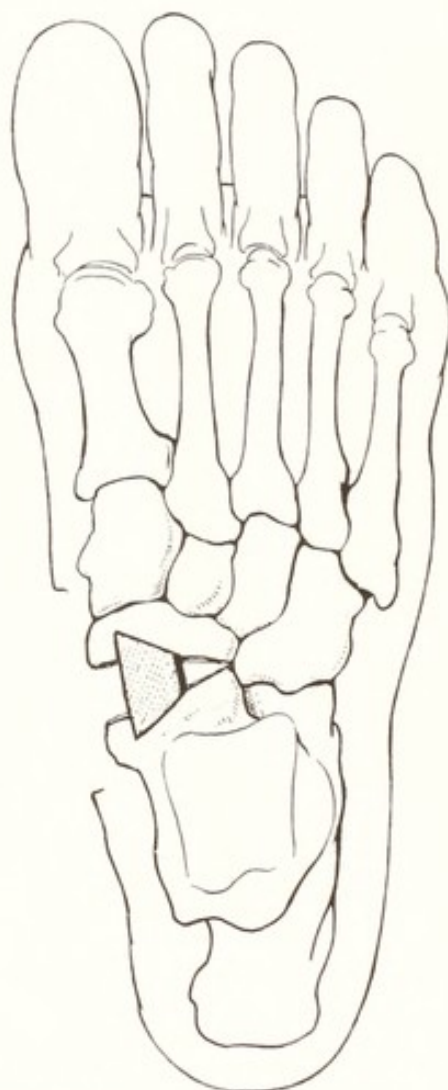


FIG. 253.—Paralytic clubfoot (talipes equino varus) with mortise graft in place. No fixation suture is necessary.

tionate before the operation, is now made to do more than its normal amount of work. A stable foot is furnished, capable of weight bearing, usually without the additional support from a brace.

Arthrodesis of Astragalo-scaploid Joint for Flat-foot.—Persistently relapsing, painful, and relaxed pronated flat-foot

after thorough treatment by conservative means has failed, can be restored by arthrodesing the astragalo-scaphoid joint, and where the scaphoid presents prominently the fixation and corrected position of the foot is fortified by drilling through this prominent scaphoid into the head of the astragalus, as advocated by Soule.

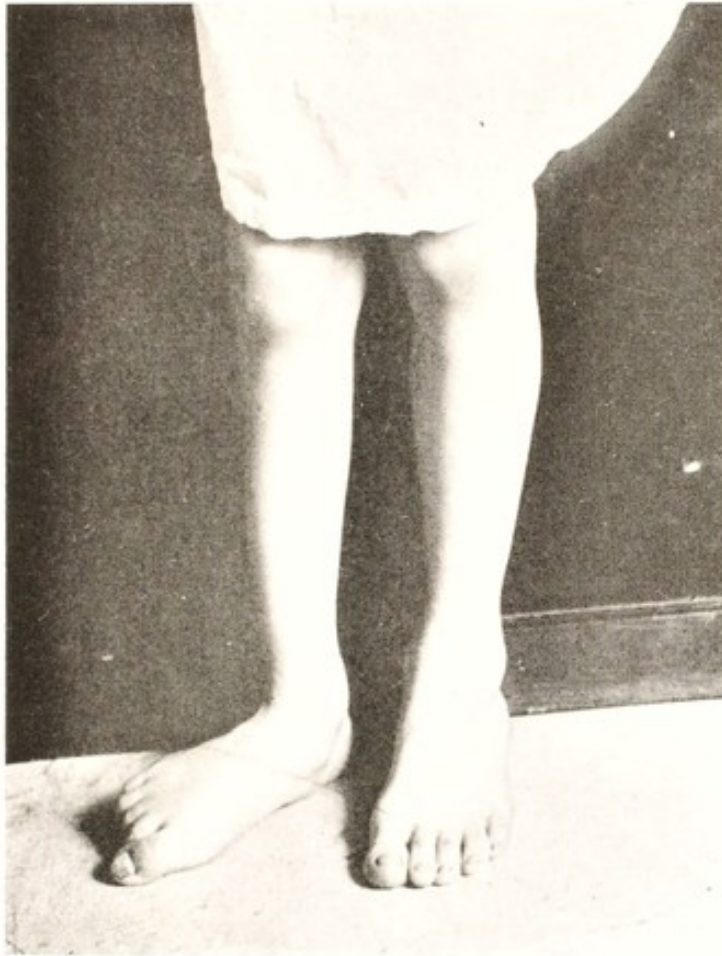

FIG. 254.—Paralytic flat-foot from paralysis of the anterior tibial muscle. This type of deformity can be best corrected and controlled by an arthrodesis of the astragalo-scaphoid joint with or without a bone-graft peg and a transplantation of the peronei into the anterior tibial tendon and scaphoid bone.

The foot and leg having been prepared, and a tourniquet tightly applied above the knee, the foot, if rigid, is thoroughly loosened up, after the manner of correcting rigid flat-foot—first, by forcing the foot into equinus, and then by strongly adducting and dorso-flexing the forefoot. This causes the scaphoid to rotate about the head of the astragalus into a more normal position. The foot is thoroughly loosened up by

wrenching. The arthrodesis of the astragalo-scaphoid joint is done with a curved gouge through a skin incision, about 2 in. long, beginning just in front of the internal malleolus and extending along the course of the anterior tibial tendon, which is then retracted and the joint exposed along its dorsal aspect by freeing the overlying joint ligaments and making strong flexion of the foot. The joint surfaces are thoroughly freed of articular cartilage, but care is taken to preserve the ovoid shape of the head of the astragalus and the convexity of the scaphoid, so that

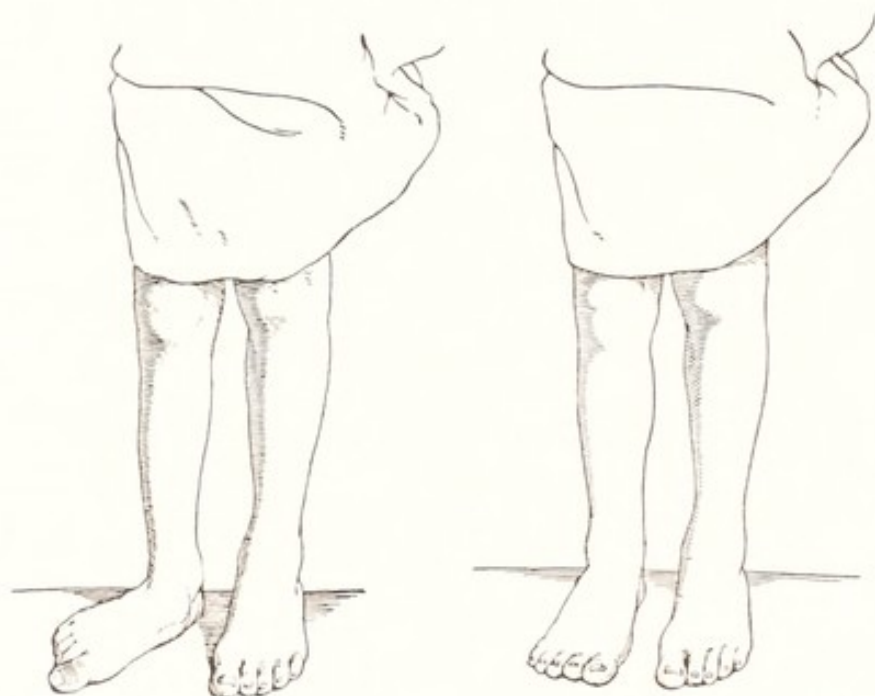


FIG. 255.—Drawing of a case of paralytic talipes valgus before and after arthrodesis of the astragalo-scaphoid joint and transplantation of peroneus longus and brevis into the scaphoid bone to functionate for the lost anterior tibial muscle.

when the forefoot is adducted to its proper corrected position the convexity of the scaphoid rotates about and remains in contact with the denuded head of the astragalus.

With the foot held in its corrected position by an assistant, a hole is drilled through the prominent inner portion of the scaphoid obliquely into the head of the astragalus, large enough to admit a sufficiently strong autogenous bone dowel. The drill is left in position while the bone graft is being removed from the crest of the tibia at about its middle third where the cortex is thick, either with mallet and chisel or, preferably, by the motor saw.

This bone is next passed through the author's motor dowel shaper, forming a bone nail to fit the drilled hole in the scaphoid. This bone nail can be shaped with cutting forceps and a rasp or file, if the dowel-shaper and motor outfit is not available.

The foot being held securely by the assistant, the drill is withdrawn and the bone dowel is driven into its place. The superfluous end of the dowel protruding from the scaphoid is cut off with the small motor saw, and the skin is closed over with plain catgut sutures, without drainage. The foot is put up in a plaster-of-Paris case extending above the flexed knee. This case remains on for the same length of time as advocated for the bone-wedge cases of clubfoot, and is removed in the same sequence, namely, that portion enclosing the knee is removed after 6 weeks, followed 4 weeks later by the removal of the remainder.

As in the case of other bone-grafting procedures, it is well in some instances to protect the part from undue strain by having the patient wear a metal flat-foot plate for a few months, until the proliferation changes and adjustment of the grafted parts are complete. This plate should be accurately made over a plaster-of-Paris model of the corrected foot, as in the case of all flat-foot plates, the Whitman plate being preferred.

ARTHRODESIS OF ANKLE

In cases of marked laxity of the foot on the leg, Lexer has applied the autogenous bone-graft dowel by passing it through the anterior end of the os calcis and body of the astragalus into the lower end of the tibia. According to Lexer: "This canal should not be made too wide, as the bolt must be inserted forcibly so that blood and detached marrow cannot collect between it and the bone, since bone will unite with the surrounding bony tissue only when it lies in intimate contact with it, otherwise granulations appear in the walls of the canal, interfere with nutrition and predispose to rapid absorption. Some of the failures reported are due to this technical error. It is a strange fact that this bolt stimulates thickening of the spongy portion of

the bone, while it is absorbed in the upper ankle. Therefore ossification rarely takes place in this joint, as a rule, only the necessary immobilization. This procedure is simpler than the usual arthroplasty, and with proper care yields satisfactory and permanent results" (Lexer). The author, however, believes that this is not an operation to be depended upon, as the articular cartilages are not disturbed and cellular

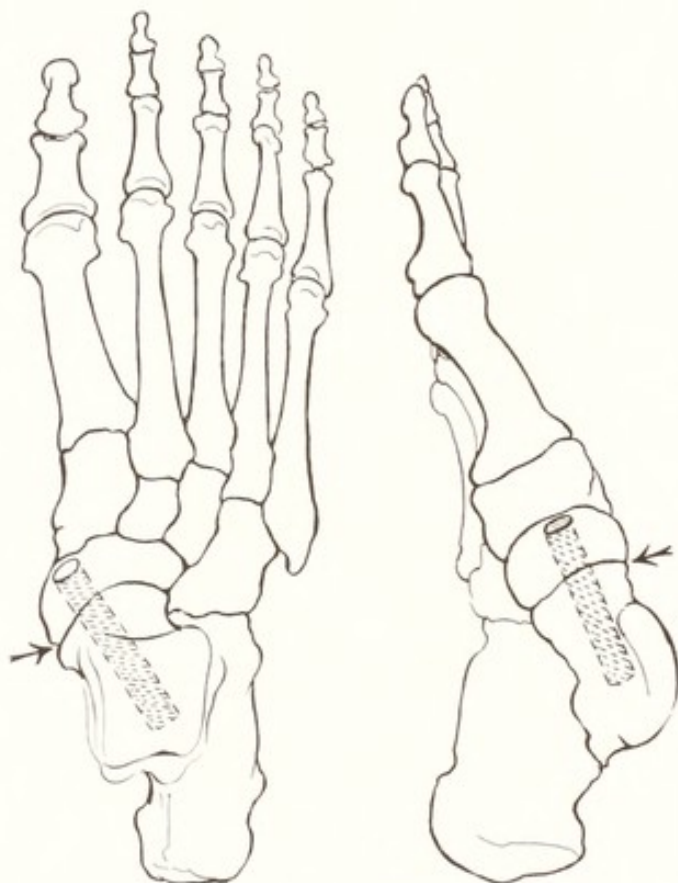


FIG. 256.—Illustrating Soule's technique for severe flat-foot and the pronated foot resulting from infantile paralysis. The cartilage from head of astragalus and posterior surface of the scaphoid bone is removed at arrow point. A tibial graft peg is then inserted as indicated.

osteoclasia is likely to interfere with the integrity of the transplant. This opinion is supported by Schewandin who reports in *Archiv. f. klin. Chir.*, vol. ci, p. 1009, a few failures due to the giving way of the graft at the joint surfaces. It is believed that had the articular cartilages been removed from the ankle-joint at the time the transplant was inserted the results would have been permanent.

ASTRAGALUS USED AS TRANSPLANT TO ARTHRODESE ANKLE

Wrede's arthrodesis of the ankle-joint promises to be a trustworthy operation, since it establishes a somewhat elastic joint instead of a complete ankylosis. At the same time the ankle-

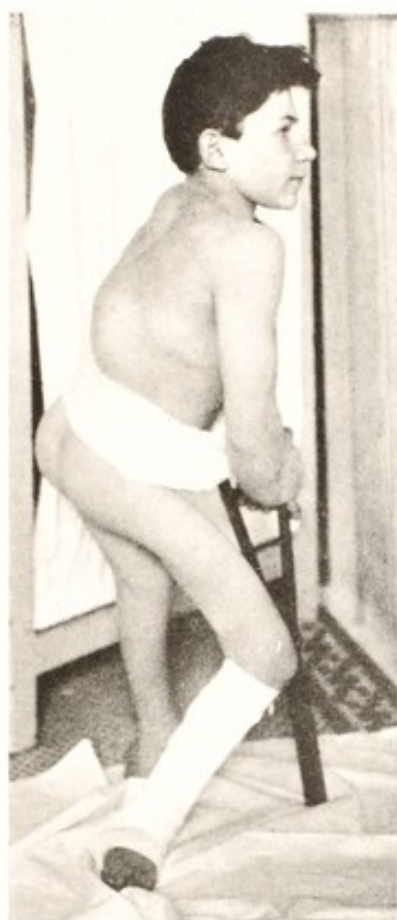

FIG. 257.—A case of anterior poliomyelitis with complete paralysis of all the muscles controlling the right knee. An arthrodesis operation for stiffening the right knee was done in Warsaw, 3 years before. The knee was fixed with two strands of silver wire, both of which broke (see Fig. 218) allowing the limb to become ankylosed at nearly a right angle. A cuneiform osteotomy was done by the author and the patella used as an inlay. Bony union occurred immediately. (See Fig. 219.) To produce a stable foot, right astragalus was removed and all its articular cartilage was peeled off, as well as the cartilage on the contiguous surfaces of the os calcis, scaphoid, tibia and fibula. The astragalus was then replaced in its normal position and the skin wound was closed. The foot was thereby changed from a flaccid to a stable weight-bearing foot.

joint does not become flail-like. It is indicated in cases where the transplantation of tendons is either contra-indicated or has not given satisfactory results. The ankle-joint having been exposed by a Kocher incision, the astragalus is removed without being fractured. The cartilaginous surfaces of the astragalus as

well as those surfaces articulating with the astragalus are removed. The author uses the electric rotary saw and burrs to do

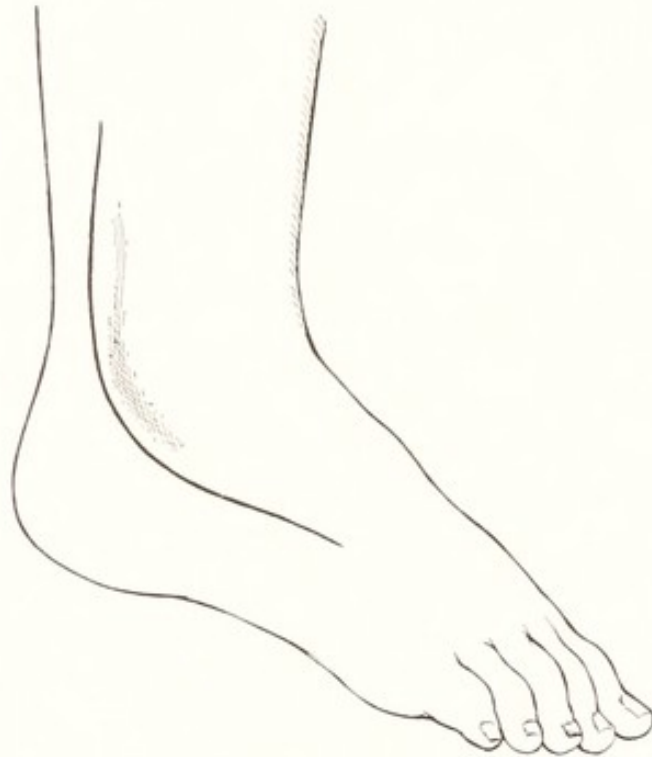

FIG. 258.—The heavy line indicates incision for removal of the astragalus.

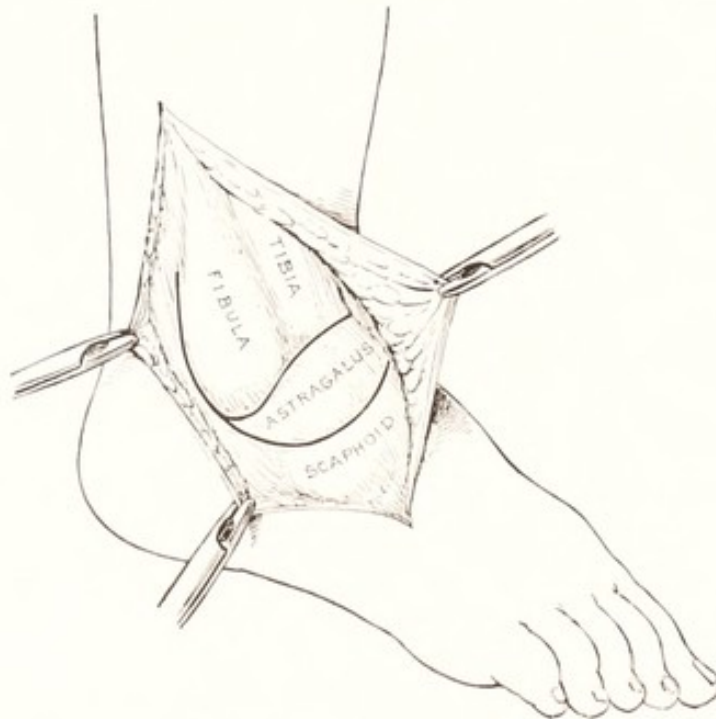


FIG. 259.—Exposure of astragalus for removal.

this with. The astragalus denuded of its periosteum is then replaced into its normal site. The wound is closed and a plaster-

of-Paris dressing applied for 12 weeks. The astragalus is thus used as an autogenous free graft. Bone ankylosis is not the

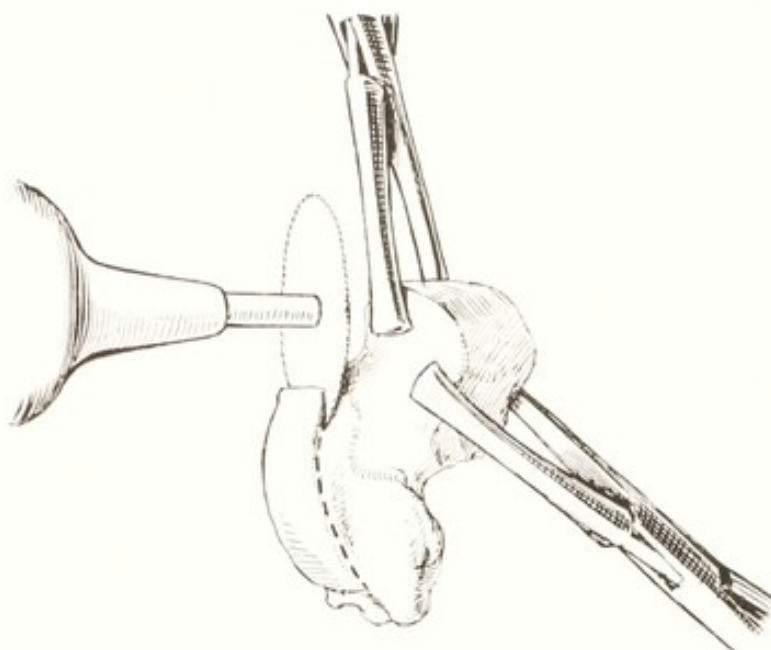


FIG. 260.—Removing cartilage from the astragalus before placing it back in the foot as a graft.

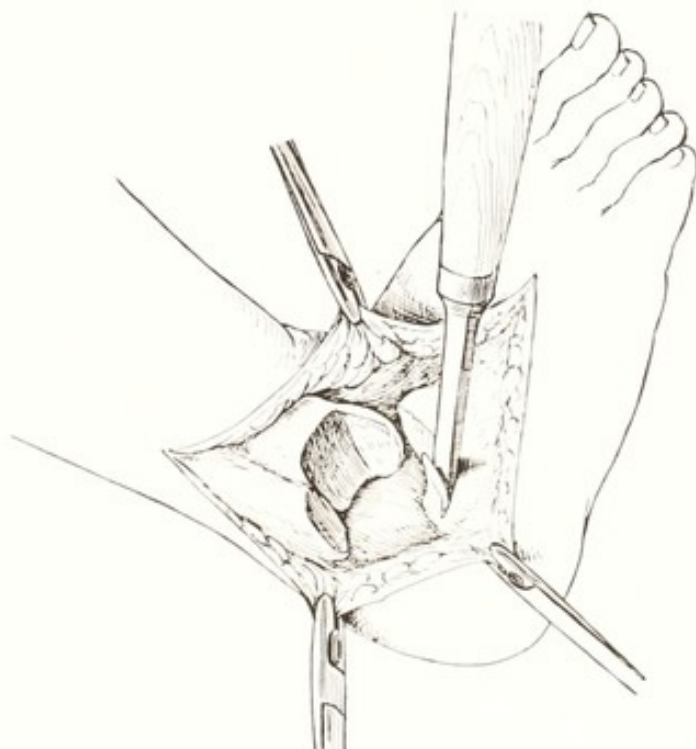


FIG. 261.—Removing cartilage from surface of scaphoid, os calcis, tibia and fibula which articulate with the astragalus.

usual result unless the cartilage is removed too deeply. Fibrous union is the usual result.

FIXATION OF TUBERCULOUS OSTITIS OF THE ANKLE BY BONE GRAFT

For the treatment of tubercular ankle-joint and tarsal disease, the author has applied the bone graft as an internal fixation splint, supporting and immobilizing the diseased parts to a

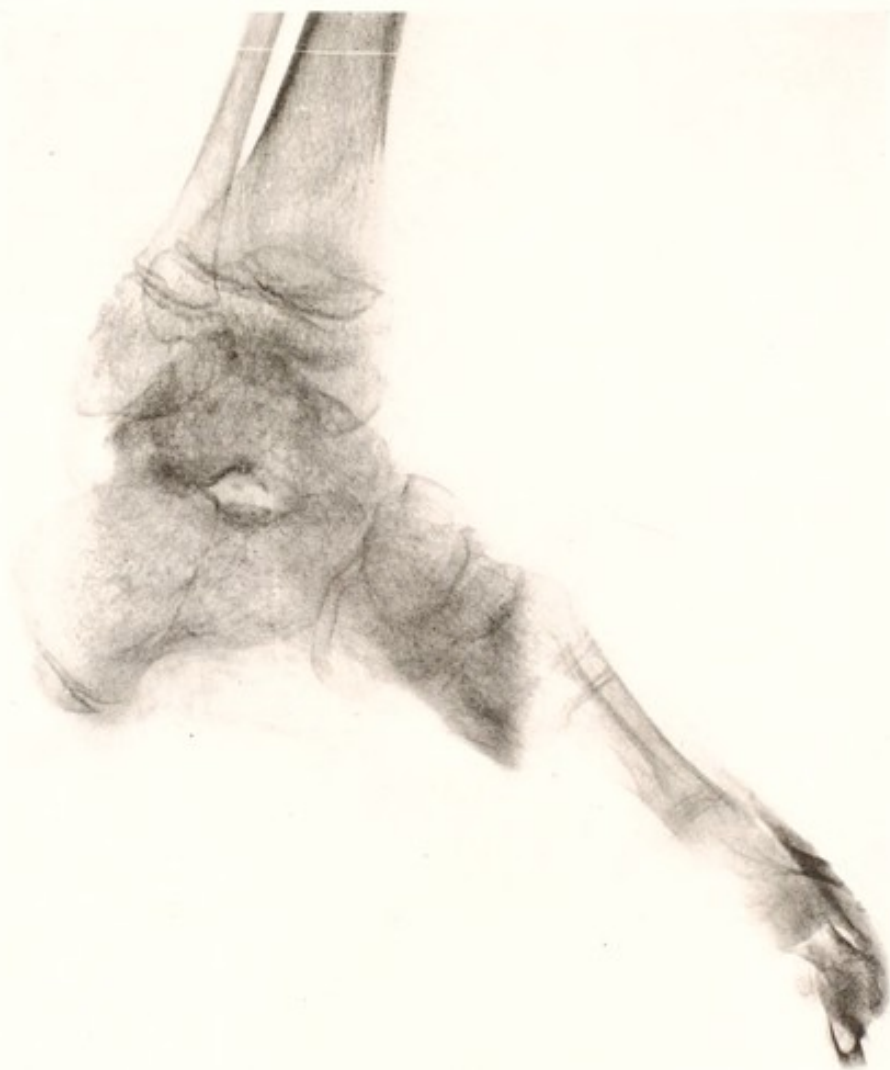

FIG. 262.—Complete paralysis of all the muscles controlling the foot from infantile paralysis. The astragalus was removed and all its articular cartilage peeled off with motor saw. Also the cartilage from the bones articulating with it was removed. The denuded astragalus was then put back for the purpose of making a stable ankle and foot. (For anterior-posterior view see Fig. 263.)

degree impossible to attain by external splints, and thereby hastening the arrest of the tuberculous process.

In the instance of an adult, when the question of amputation was strongly considered to relieve the patient of an extensive tuberculous infection of the tarsus, three bone grafts were

inserted, one from the internal malleolus to the os calcis; a second, from the internal malleolus to the internal cuneiform bone; and a third, from the external malleolus to the cuboid bone.

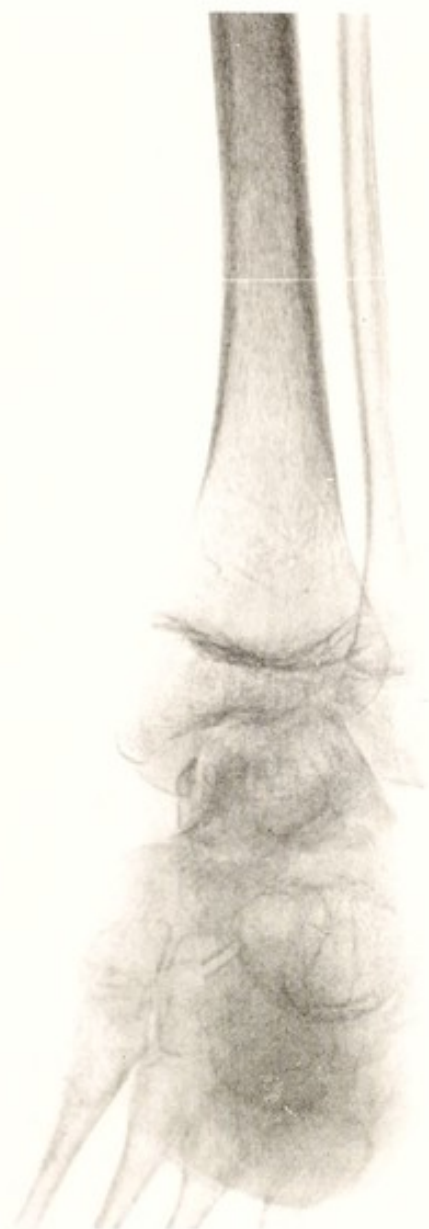

FIG. 263.

The leg and foot were prepared for operation, and a tourniquet tightly applied above the knee. A U-shaped skin flap was turned up, exposing the internal malleolus. A bed for the fixation of joined ends of the grafts coming from the internal cuneiform bone and the os calcis was prepared. As these two grafts

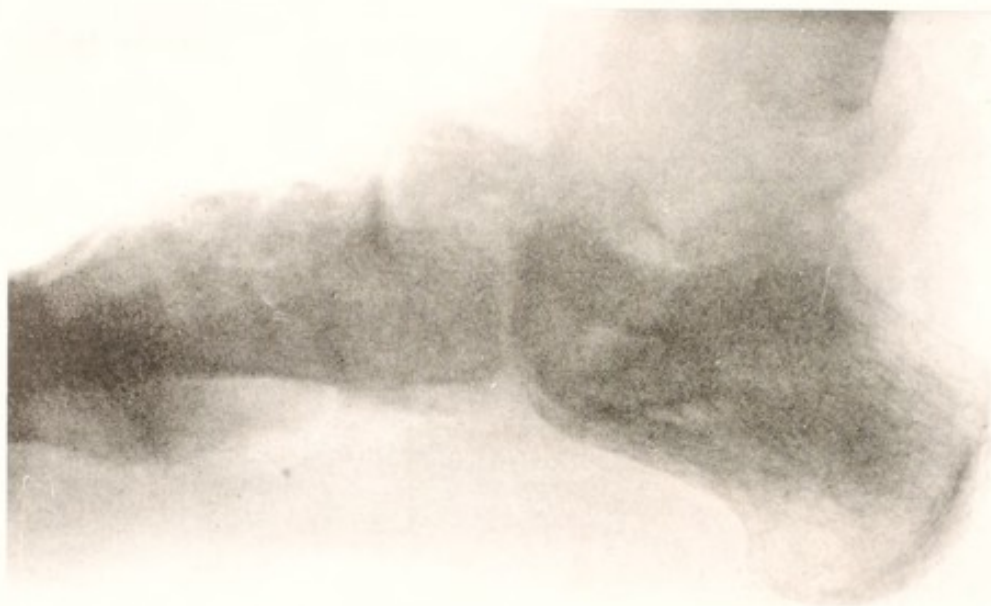


FIG. 264.—Röntgenogram of an acute tubercular ankle in a young man 20 years of age. The symptoms were not relieved by a carefully fitted plaster-of-Paris dressing and month of recumbency in bed. Pain was entirely relieved by the insertion of bone grafts from the external and internal malleoli to the posterior end of the os calcis, the cuboid bone and the internal cuneiform.

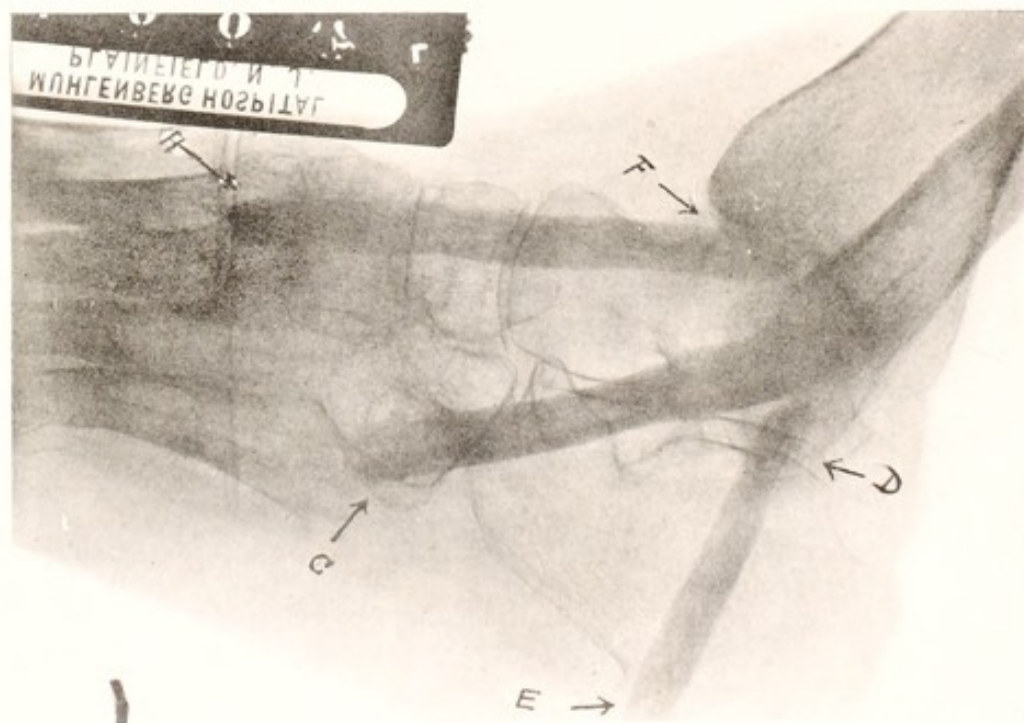


FIG. 265.—Röntgenogram taken 2 months after the insertion of the graft. *AF* is graft from internal malleolus to internal cuneiform. *CD* is graft from external malleolus to the cuboid. *DE* is graft from external malleolus to the os calcis.

were to be joined at an obtuse angle, in the manner of an inverted "V," the bed was prepared by turning one osteoperiosteal flap down and two upward, with a sharp osteotome. Short skin incisions were likewise made over the inner surface of the posterior portion of the os calcis and internal cuneiform bone, and beds were prepared for the ends of the grafts by turn-

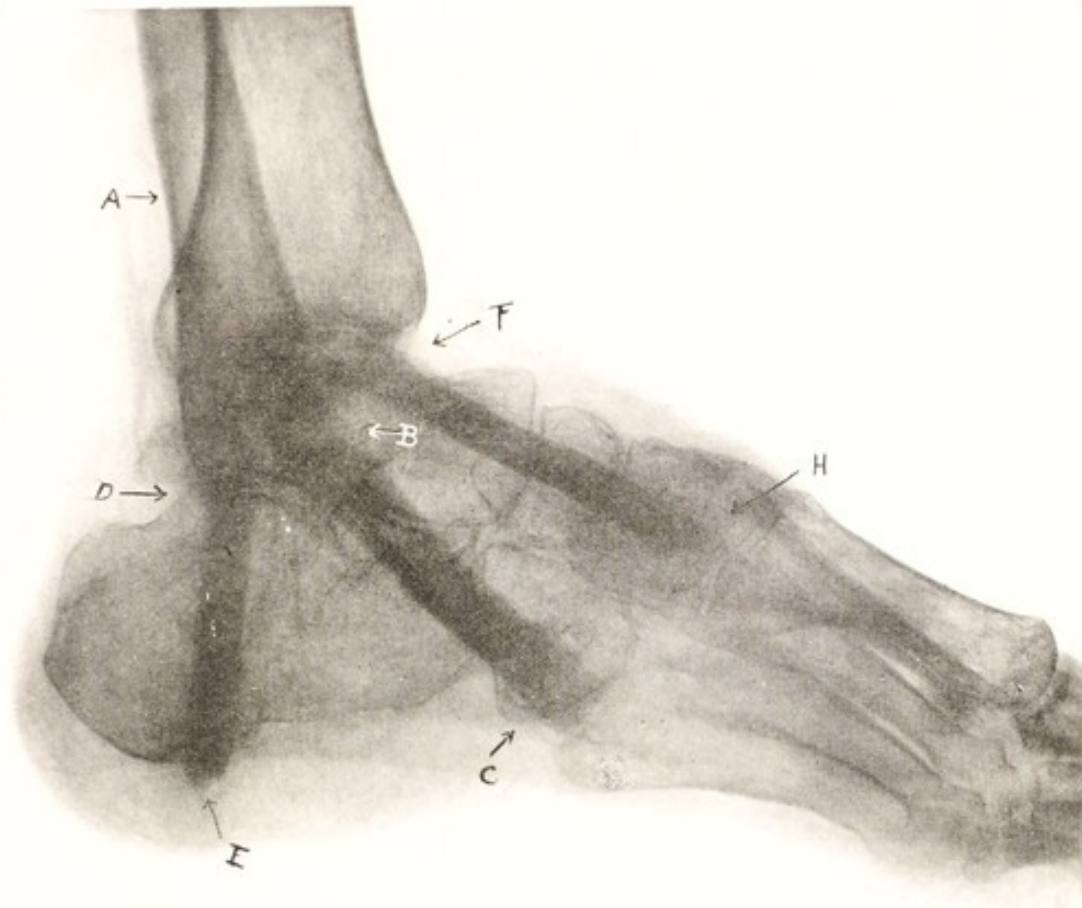

FIG. 266.—Röntgenogram of same case as Fig. 267 taken 2 years and 4 months after the insertion of the bone grafts. The symptoms remain entirely relieved and the disease apparently cured. The hypertrophy and increase in density of the graft are very striking, especially at *B* and *D*. The fibula in which they are inserted is even hypertrophied from increased stress at *A*.

ing up osteoperiosteal flaps. Subcutaneous tunnels were made with a broad ligament clamp, joining these incisions with the one over the internal malleolus.

The same procedure was carried out in forming a bed for a graft reaching from the external malleolus forward to the cuboid bone. The lengths of these grafts were determined with calipers.

The antero-internal surface of the tibia of the same leg was then exposed, and with the twin motor saw, the required grafts, each three-eighths of an inch wide and the full thickness of the cortex, were removed from the central portion of this tibial surface. The ends of the two grafts which were to be joined at the internal malleolus were mortised. This was very quickly done with the motor saw. These two grafts were pushed through the subcutaneous tunnels already prepared for them, the mortised ends joined, and they were covered in by the osteoperiosteal flaps

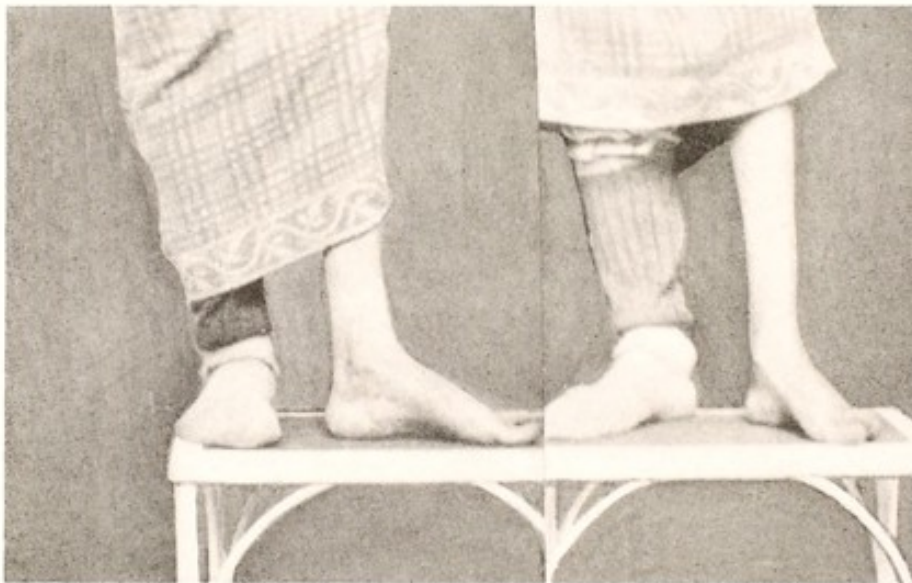

FIG. 267.—Same case as Figs. 265 and 266 showing excellent weight-bearing function and outline of graft extending from internal malleolus to internal cuneiform bone.

which were drawn over them with interrupted sutures of medium kangaroo tendon.

The other ends of these grafts, as well as the graft implanted on the outside of the foot, were secured in place in a similar manner. The skin wounds were closed by continuous catgut sutures, and a plaster-of-Paris dressing was applied with the foot at a right angle.

Figure 266 is a röntgenogram of this patient's foot, taken over 2 years after operation, showing the grafts present and securely grown in. At the time of operation, in preparing the bed for the graft of the external side of the foot, tuberculous tissue was accidentally opened into and, although the graft spanned

through this area of infected tissue, it healed in promptly. This is one of many instances where the author has placed grafts through tuberculous areas without interference with the union of the graft to its bed. The result in this case was especially gratifying because the tarsal osteitis was advanced and very acute at the time of operation, and a well-moulded plaster cast with recumbency in bed had failed to relieve the pain. With the implantation of the bone grafts, pain immediately subsided and the disease was completely arrested. One year later walking and weight-bearing produced no pain or other evidence of active disease, and this relief of symptoms has persisted to the present time, over 2 years after the operation, in spite of the fact that during the past 6 months the patient has developed a tuberculous infection of the kidney and a relapse of the lung condition from which he suffered prior to the operation.

BONE GRAFT TO RESTORE BONES DESTROYED BY TUBERCULOSIS

In case the tuberculous process is limited to an individual tarsal bone or group of bones, shorter grafts can be used to fix these localized diseased areas with equal success. In this event, the graft is implanted into the healthy bones on each side of the focus of disease, and spans it. The diseased tissues may or may not be removed, according to judgment.

In the case of a single tuberculous bone of the tarsus being involved, this bone can in selected cases be removed and a bone graft modelled to take its place and fill in the deficiency, thus preventing malformation of the foot resulting from loss of support by the removal of the infected bone.

THE BONE GRAFT IN THE TREATMENT OF CONGENITAL ABSENCE OF FIBULA

Author's Technique.—The congenital absence of one or both bones of the leg is a deformity which owes a great deal of its interest to its rarity.

The absence of this bone is practically always associated with other malformations in the leg, such as talipes valgus, syndac-

tylism, the suppression of one or more toes, deformity of the femur, malformations of the tarsus or knee.

According to Corner, 200 cases of absence of the fibula have been collected. He also states that all operative treatment of congenital absence of the fibula is generally unsatisfactory, and "amputation in consequence is only too often necessary."

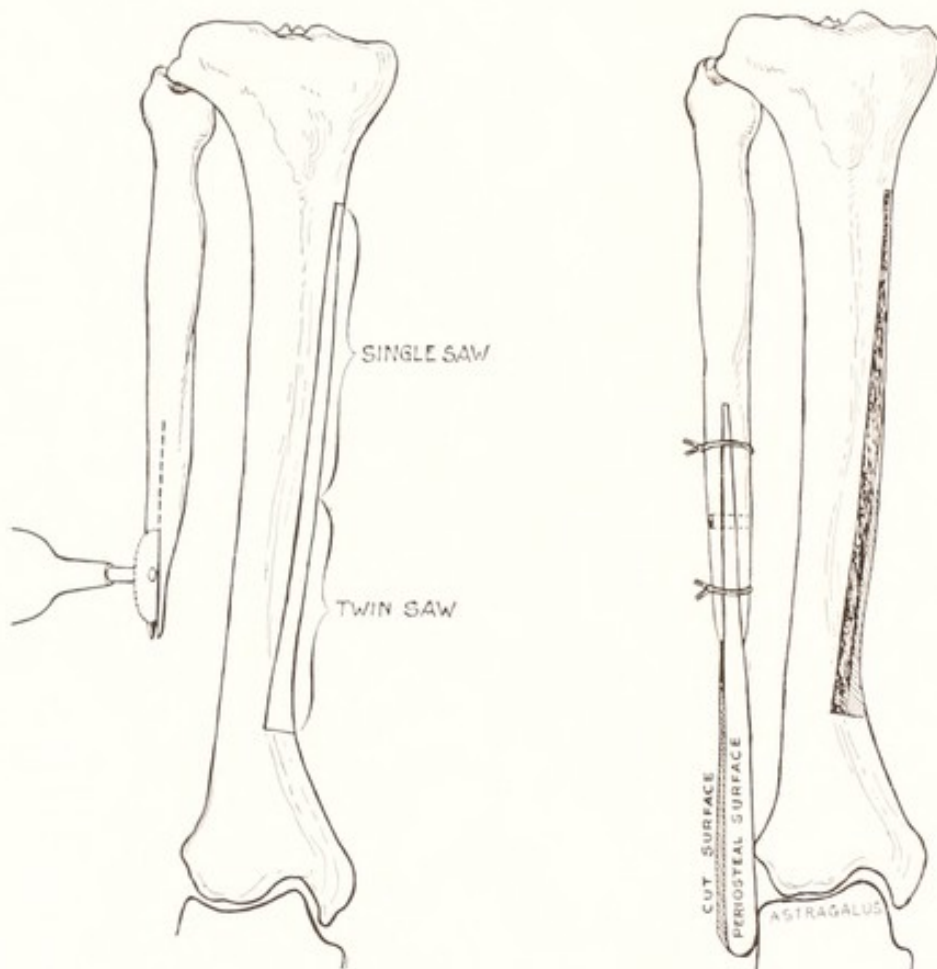


FIG. 268.

FIG. 268.—Absent lower end of fibula. Indicates method of splitting lower end of upper fragment of a fibula and of obtaining the graft from the tibia. That portion of the graft marked as cut with single saw is wedge shaped. (See Fig. 269.)

FIG. 269.

FIG. 269.—Graft used for absence (congenitally or otherwise) of lower end of fibula, joined to the upper end of fibula by the tongue and groove joint and ligatures of kangaroo tendon. The cavity in a tibia indicates the source of the graft material.

Wille in 1909 did an arthrodesis by driving a portion of a fibula (obtained from an amputated leg) up from the sole of the foot through the os calcis, astragalus and tibia, and obtained a fair result but without motion.

Where there is found to be a congenital deficiency, the

implantation of bone shaped and adapted to correct the resulting deformity can be resorted to. The following case illustrates the treatment of such a condition:

A child was born with the foot and lower third of the left

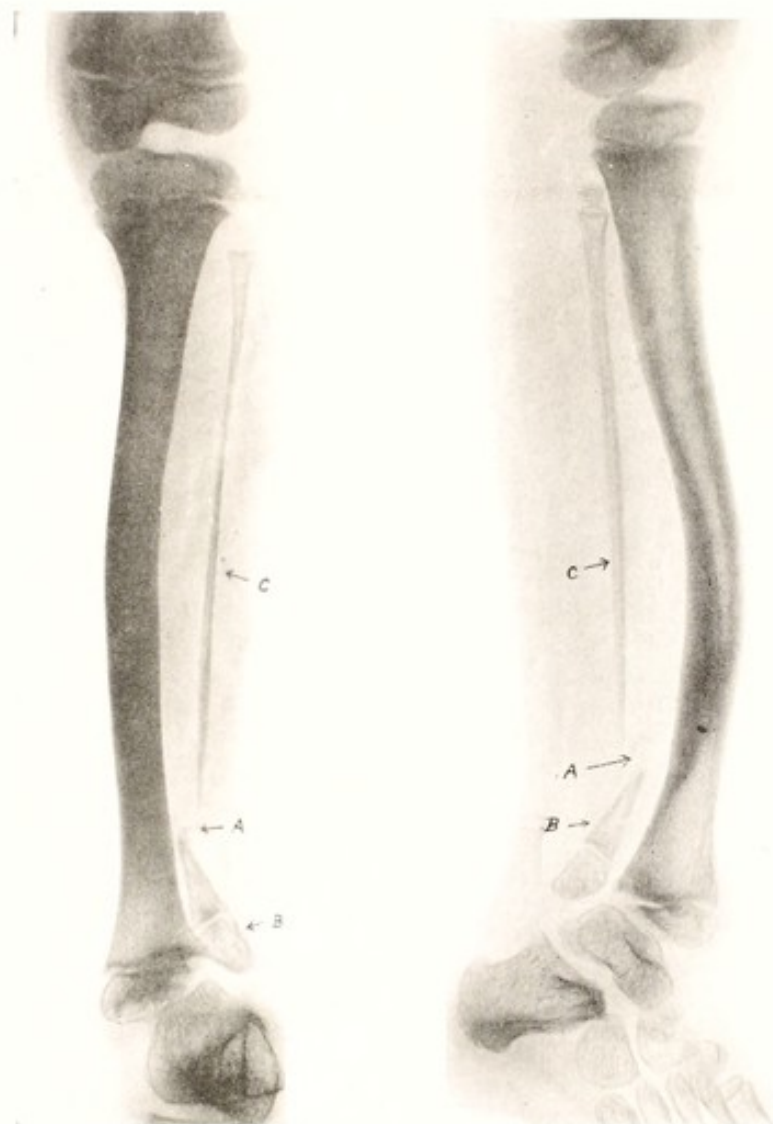


FIG. 270.—Röntgenograms of case of partial congenital absence or interuterine fracture of the lower end of the fibula with a marked valgus deformity on account of the absent support of the external malleolus. It will be noted that the lower end of fibula, *B*, has become displaced and is posterior to body of the astragalus rather than lateral to it. This fragment was removed. The deformity corrected by severing soft structures and forcible stretching. The lower end of the fibula with its support was then supplied by a graft from the opposite tibia.

leg absent. A conical stump containing an undeveloped tibia projected backward from the posterior aspect of the thigh. The right fibula was entirely absent, and on this account the foot on this limb had become displaced from weight-bearing and muscle-

pull to a pronated position, with its plantar surface facing directly outward and firmly contracted. The lower end of the internal malleolus had become the chief weight-bearing portion of the foot.

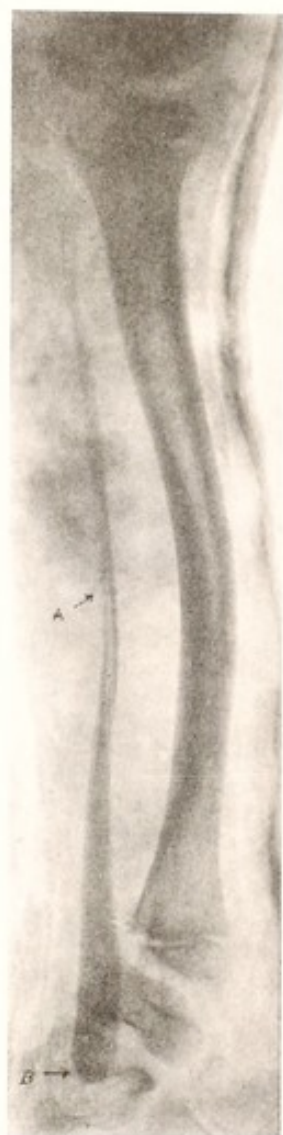

FIG. 271.

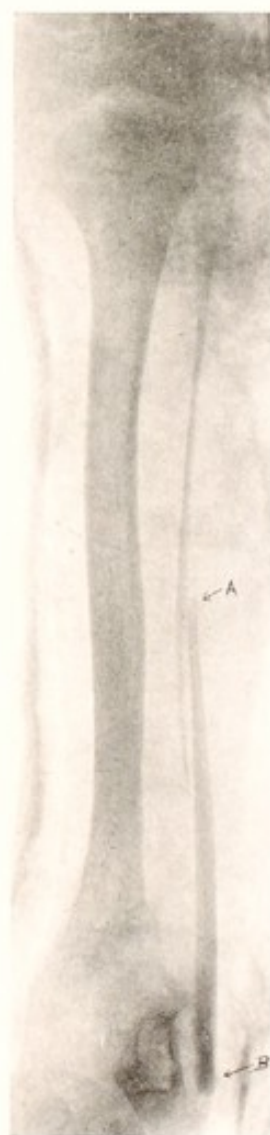

FIG. 272.

FIGS. 271 AND 272.—Partial congenital absence of the lower end of the fibula with a consequent marked valgus deformity of the foot from lack of support of the external malleolus. *AB* is a tibial graft to restore fibula after correction of deformity.

The problem which presented in this case (a child 5 years of age) was, if possible, to correct the distorted foot and provide a means of maintaining the correction without at the same time interfering seriously with its function by the loss of ankle motion. The most feasible method in these cases is to supply the missing

support of the lower end of the fibula. This is best done by restoring the bony anatomy of the part, which can be accomplished in no other way than by resorting to the use of the bone graft.

In this instance, excellent material for this purpose was easily obtained from the conical stump of the left leg. (Figs. 274-276.) The technique of the procedure was as follows: A curved incision, so placed that its closure would not bring the skin sutures over the contemplated site of the graft, was made over the outer and

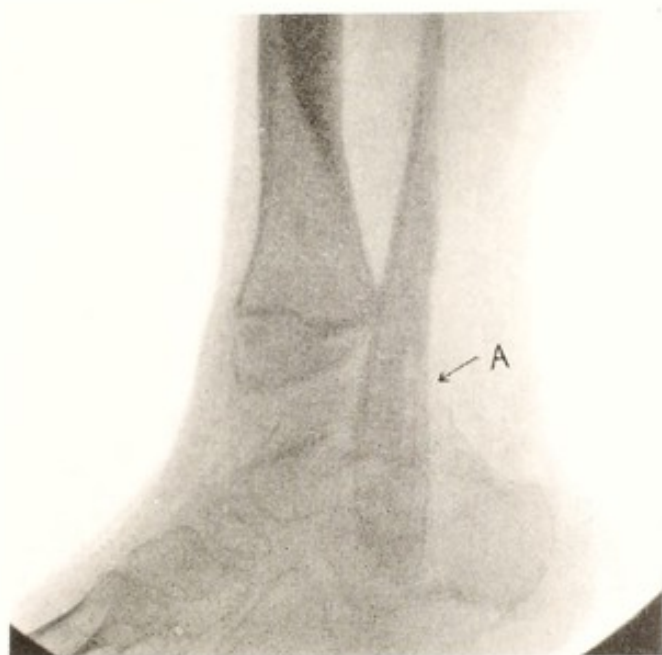

FIG. 273.—Röntgenogram of same case as Figs. 270 to 272. A is tibial graft 6 months after insertion for absent lower end of fibula. It supplies very firm support and allows very free ankle motion. The upper end of graft was made with a wedge end and was inserted into the split end of the upper fragment of the fibula.

lower end of the tibia and the outer surface of the os calcis. The position of the foot was corrected after extensive division of fascia, ligaments, and contracted tissue. The outer aspect of the lower end of the tibia was exposed, and the periosteum was split longitudinally from a point about $\frac{1}{2}$ in. above the epiphyseal line extending upward for about $1\frac{1}{2}$ in. These periosteal flaps were retracted laterally and, with the twin saw adjusted about $\frac{1}{4}$ to $\frac{3}{8}$ in. apart, cuts were made in the long axis of this bone from $\frac{1}{2}$ in. above the epiphyseal cartilage upward for about 1 in. The strip of bone between these saw-cuts was then

removed with the help of the author's small circular motor saw and a sharp narrow osteotome. Caliper measurements were taken and the size and shape of the desired graft planned. The lower end of the tibia near its outer portion was drilled for a

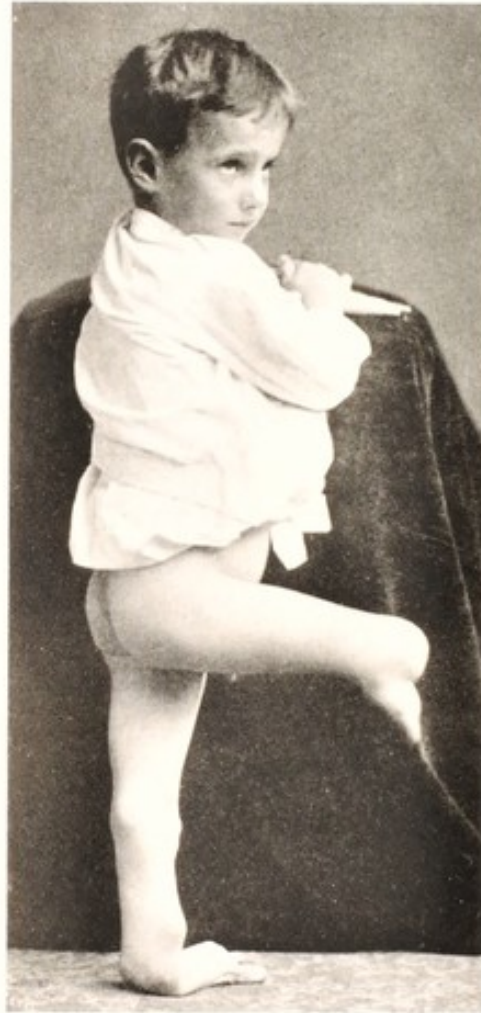

FIG. 274.—Congenital absence of the right leg. The conical stump contains an under-developed tibia, shown in Fig. 276 A, as well as small under-developed foot bones. It was necessary in any event to remove this conical projection in order to furnish a suitable stump for an artificial limb.

The fibula is entirely absent from the left leg and the foot and on account of lack of support of the external malleolus the foot is so distorted that the internal malleolus rests on the floor. The deformity of the foot was corrected by lengthening the tendons and severing the soft tissues on the outer side of the ankle, and the under-developed tibia of the amputated stump of the right leg served as an ideal graft according to the technique illustrated in Fig. 277. This case was kindly referred by Dr. C. B. Lufburrow, Plainfield, N. J.

kangaroo fixation suture, antero-posteriorly about $\frac{1}{4}$ in. above its epiphyseal cartilage.

The wound was packed with a hot saline compress, and the conical stump of the left leg containing the undeveloped tibia was

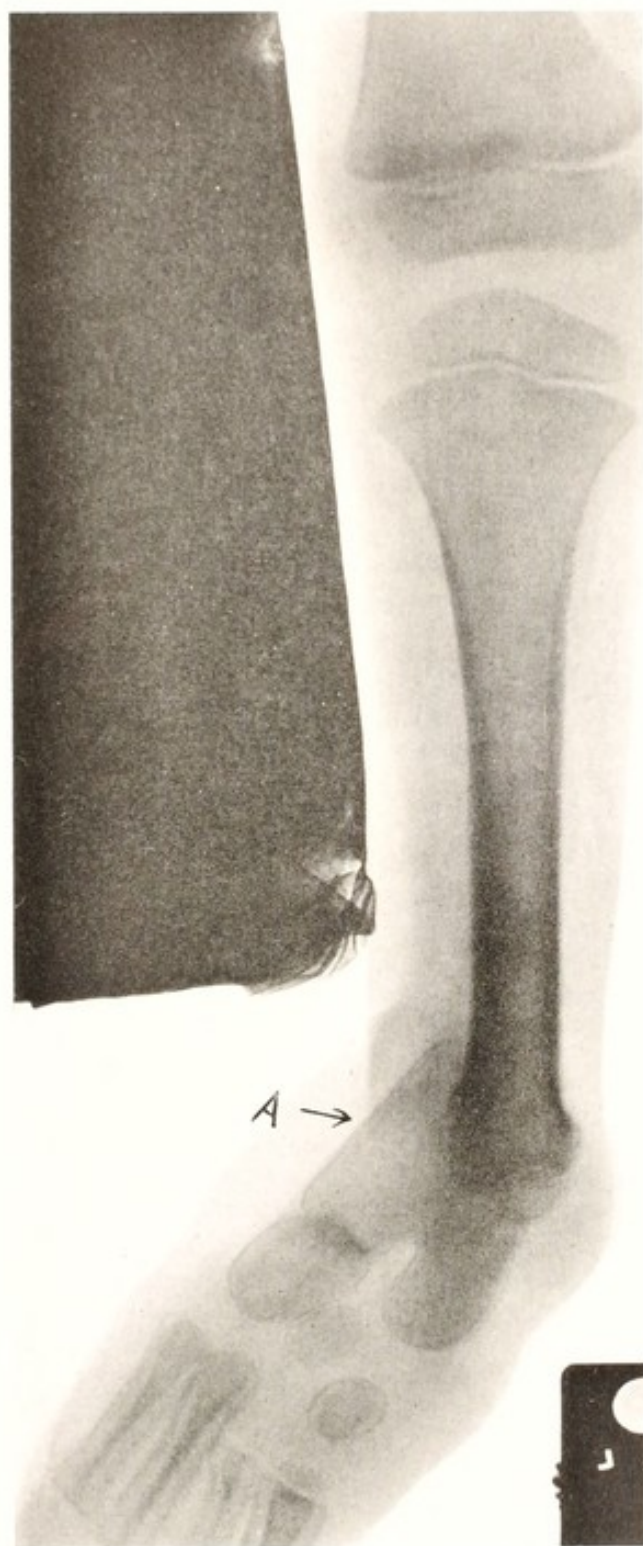


FIG. 275.—Anterior-posterior röntgenogram of same case as Fig. 274. The absence of the fibula and the displacement of the os calcis, *A*, and astragalus is shown.

removed through an elliptical incision, so planned that a satisfactory artificial limb-bearing stump would be produced. This wound in the left leg was closed by a continuous catgut suture and sterile dressings were applied. The conical stump of this left leg which had been removed was then freed of its undeveloped tibial segment, which was moulded with motor tools to simulate the contour of the lower end of the fibula. With the twin motor

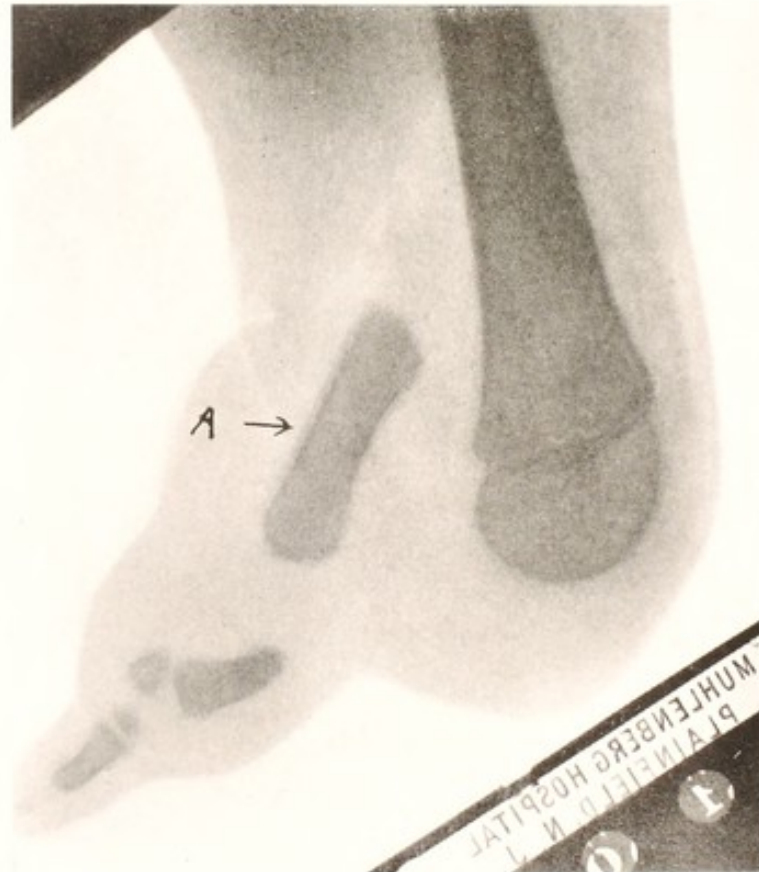


FIG. 276.—Is a röntgenogram of stump of same case as Fig. 274. It shows the under-developed tibia which was used as a graft to restore the external malleolus of the child's left leg.

saw adjusted for making the gutter in the tibia, cuts were made into the upper end of this graft for the purpose of framing a tongue which would mortise into the groove already prepared in the tibia, as shown by drawings (Fig. 277), which prevented the graft from riding up on the tibia. The upper end of this mortised tongue was shaped into an extended hook for the purpose of hooking under and internally (medullary side) to the cortex of the upper end of the tibial groove. When the graft was

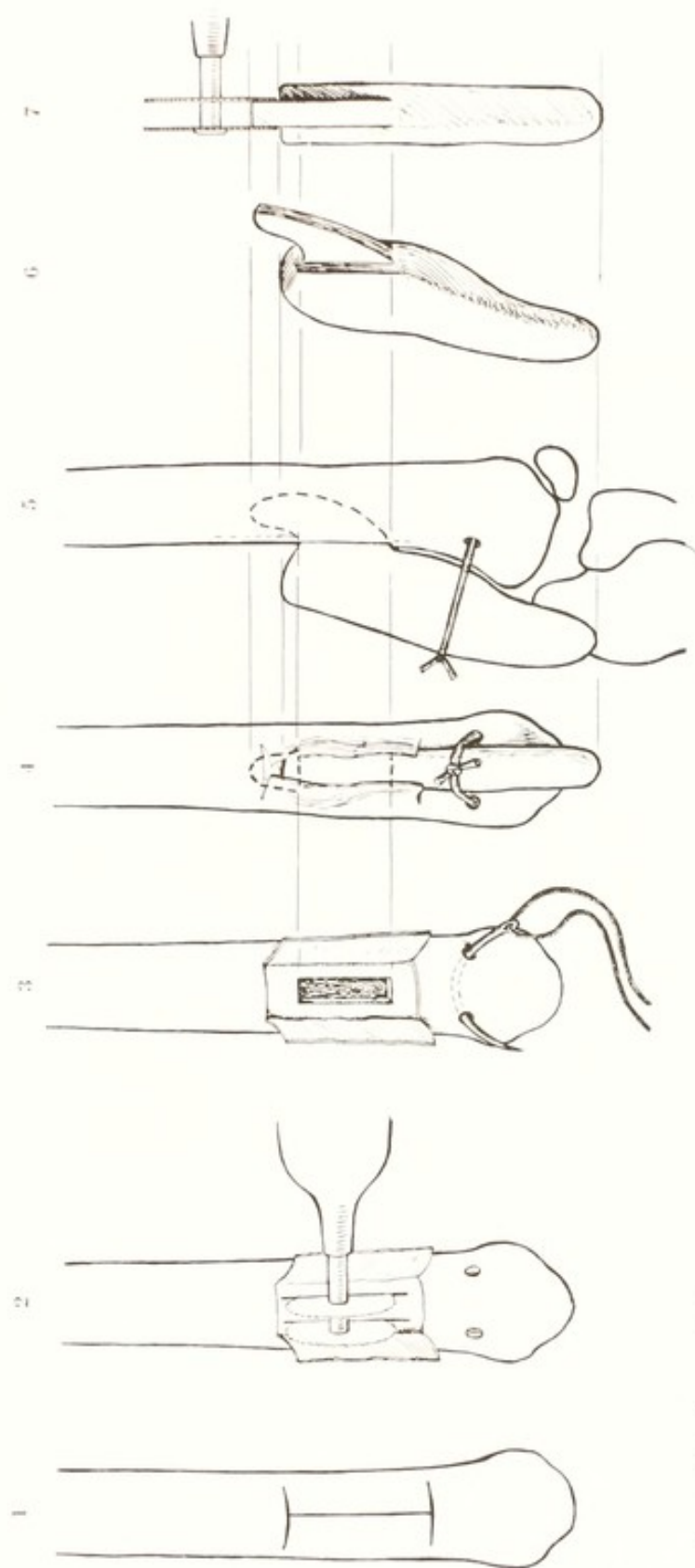


FIG. 277.—Improving an external malleolus. 1. Periosteal incisions. 2. Formation of gutter to the medullary cavity in the outer aspect of the lower end of the tibia with the motor twin saws, after turning back the periosteal flaps. The drill holes for fixation sutures. 3. The gutter formed and a curved cervix needle threaded with strong kangaroo tendon inserted in the drilled holes. 4. The graft (see Fig. 276) secured in position, lateral view. 5. The graft secured in position, antero-posterior view. 6 and 7. With the motor twin saws adjusted the same distance apart as when forming the gutter in Fig. 2, the hook is accurately shaped on the graft. This hook is important in that it prevents the upward displacement of the graft by muscle-pull and weight-bearing.

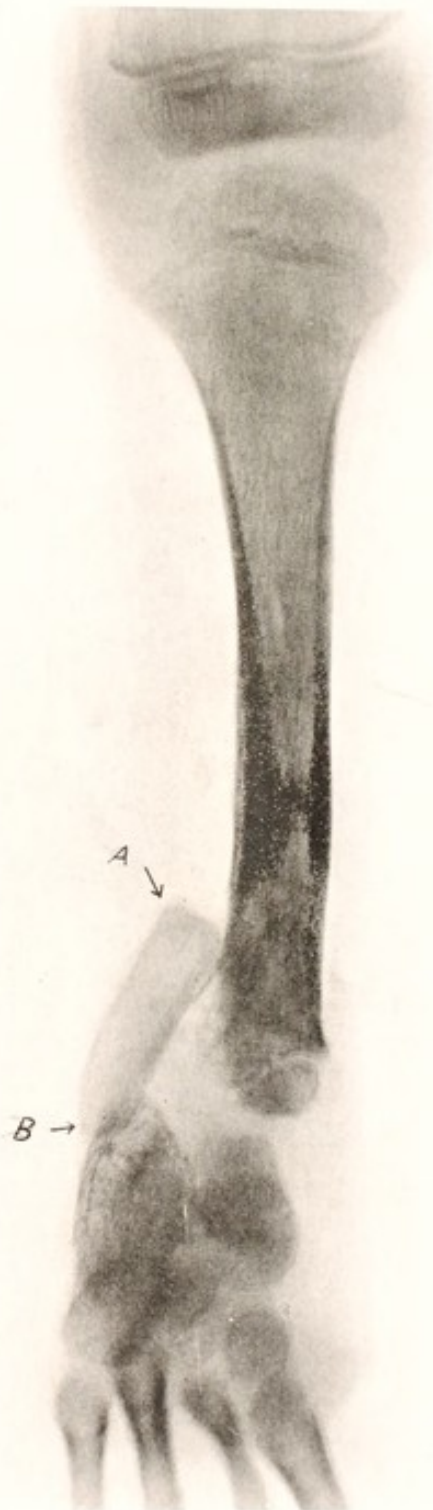

FIG. 278.—Is a röntgenogram of the same case as Fig. 274. Shows the correction of the marked valgus deformity and the bone graft, *AB*, united in position 4 months after its transplantation.

in position, this mortised joint fitted accurately because both groove in tibia and mortised tongue of graft were fashioned with the twin saws at the same distance apart.

The graft was further secured in its position by passing the heavy kangaroo tendon through drill holes in the lower end of the tibia and tying it securely about the graft (Fig. 277). The freshened surfaces of the graft on either side and below the



FIG. 279.—Photograph of the same case as Fig. 274, 4 months after operation. Shows correction of the distortion of the left foot, also the well-formed stump of the right leg. The arrow indicates a Wolff's skin graft (about $2\frac{1}{4}$ in. by $1\frac{1}{2}$ in.), which had been obtained from the trimming of the stump of the right leg.

It was found after the correction of the valgus deformity of the foot and the insertion of the bone graft that there was not enough skin to close in the external side of the leg, and a skin graft was used to fill in the uncovered area. Both skin and bone grafts healed in by primary union.

mortised joint were held in close apposition to the periosteal-denuded surface of the lower end of the tibia. An attempt to close the skin over the graft disclosed the fact that the correction of this extreme deformity had so elongated the outer side of the leg and foot that the contracted skin was not sufficient to cover it, and therefore the skin wound could not be closed. To meet this difficulty we again returned to the trimmings of the left leg, and dissected therefrom an oval segment of skin

(a Wolff graft) about $2\frac{1}{4}$ in. long by about $1\frac{1}{2}$ in. wide. This was sufficient to complete the skin closure, and was so placed as not to overlie the bone graft or bring the skin sutures over the graft. Sterile dressings were applied and a plaster-of-Paris dressing was put over all.

The convalescence was uninterrupted. All the wounds healed by primary union, and both skin graft and bone graft healed in kindly. The result, after 6 months, is most gratifying, the foot being corrected and held in excellent position by this improvised malleolus.



FIG. 280.—A result after the correction of congenital deformities of both feet and the insertion of bone grafts obtained from two cadavera. The deformities in this case were very unusual and due to the absence of the internal cuneiform and partial absence of the scaphoid bones. The forefeet were consequently markedly adducted because of the lack of bony support. (For röntgenogram, see Fig. 281.)

Another case of a similar nature, but with only a portion of the lower half of the fibula absent, was corrected by taking a sufficiently long graft from the tibia and bevelling one end on both sides into the shape of a wedge, so as to slip it in between the two halves of the split lower end of the remaining portion of the fibula. The lower end of the graft was made to take the place of the absent external malleolus and prop the foot into a corrected position (Figs. 268–273).

RESTORATION OF BONES OF FOOT

Another instance of the use of the bone graft is that of the disintegration of an individual tarsal bone of the foot, such as is

occasionally found in the destruction and breaking down of the scaphoid, causing the foot to sharply contract at this point, forming by the resultant cicatrix a sharply inverted forefoot. In such a case, to overcome the deformity, the remnants of the

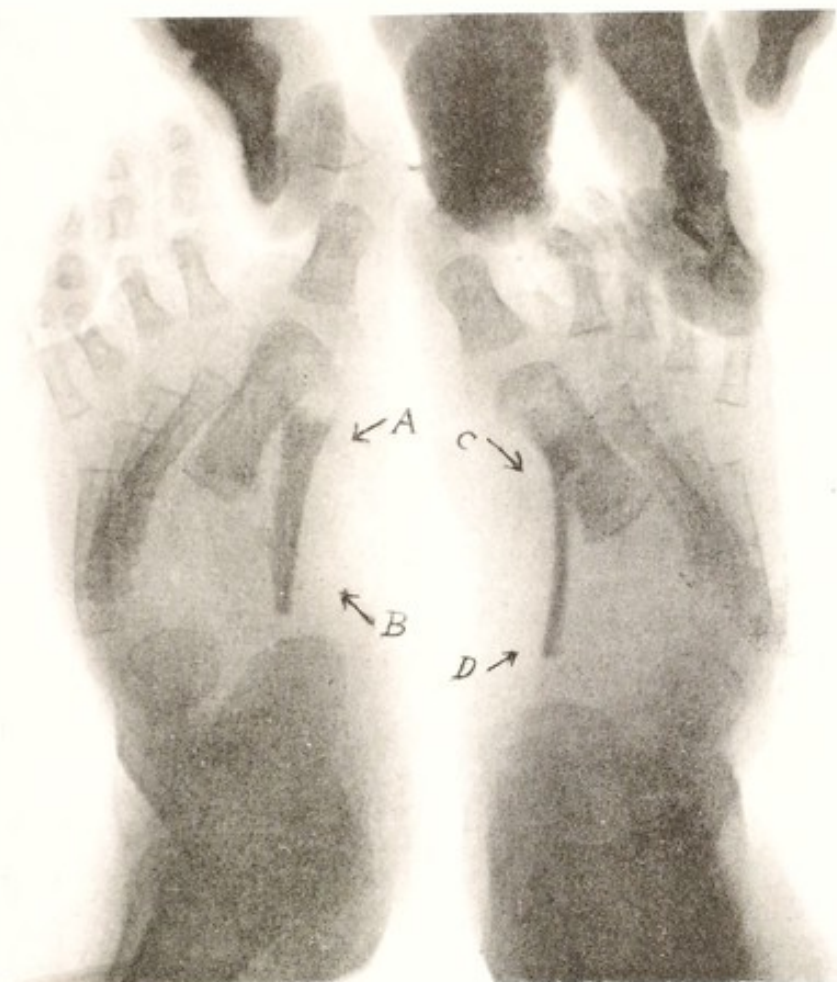

FIG. 281.—*AB* is a graft consisting of about one-third of a humerus obtained from the body of an infant strangulated at birth, and used as a prop support to the inner side of the foot. One end is inserted into a notch made in the side of the first metacarpal bone and the other end into a cup-shaped cavity made in the anterior surface of the under-developed scaphoid. *CD* is a portion of a femur obtained from the body of another infant strangulated at birth, and inserted by the same technique. Both bone grafts were immersed in sterile vaseline and left 48 hours in a cold storage plant at 4 to 5° C. This case has been under observation 3 years since the insertion of the graft. The result is excellent.

broken-down or infected bone are removed, and the head of the astragalus and internal cuneiform bone are exposed through the usual curved skin incision, and either by the inlay method or by boring one of these bones and slotting the other, a graft previously removed from the crest of the tibia is inserted. The

shape of such a graft is formed by the motor saw, and is illustrated in a general way by the accompanying diagrams (Figs. 296 and 297).

The implant fits into gutters made in the superior aspects of the bones which are to hold the graft. Fixation sutures may or may not be necessary. The centrally placed end of the implant is held by the natural tension of the tissues, tending to draw the separated bones together, and the dowel ends fit into a drill hole at one end while the inlaid other end is held by a bone suture, if it is found necessary. The thicker central portion of the graft gives strength and furnishes shoulders to the inlay or dowel, which prevents further approximation of the astragalus and cuneiform bones.

This same technique is applicable also in the case of the destruction or partial disintegration of any bone by tuberculosis or attenuated pyogenic infection, such as a tarsal or carpal bone or a phalanx in spina ventosa, etc.

CHAPTER VIII

MISCELLANEOUS SURGICAL USES OF THE BONE GRAFT

In this chapter an attempt will be made to cover the technique of a considerable number of additional surgical uses for the bone graft. Conditions which make it necessary to replace bony

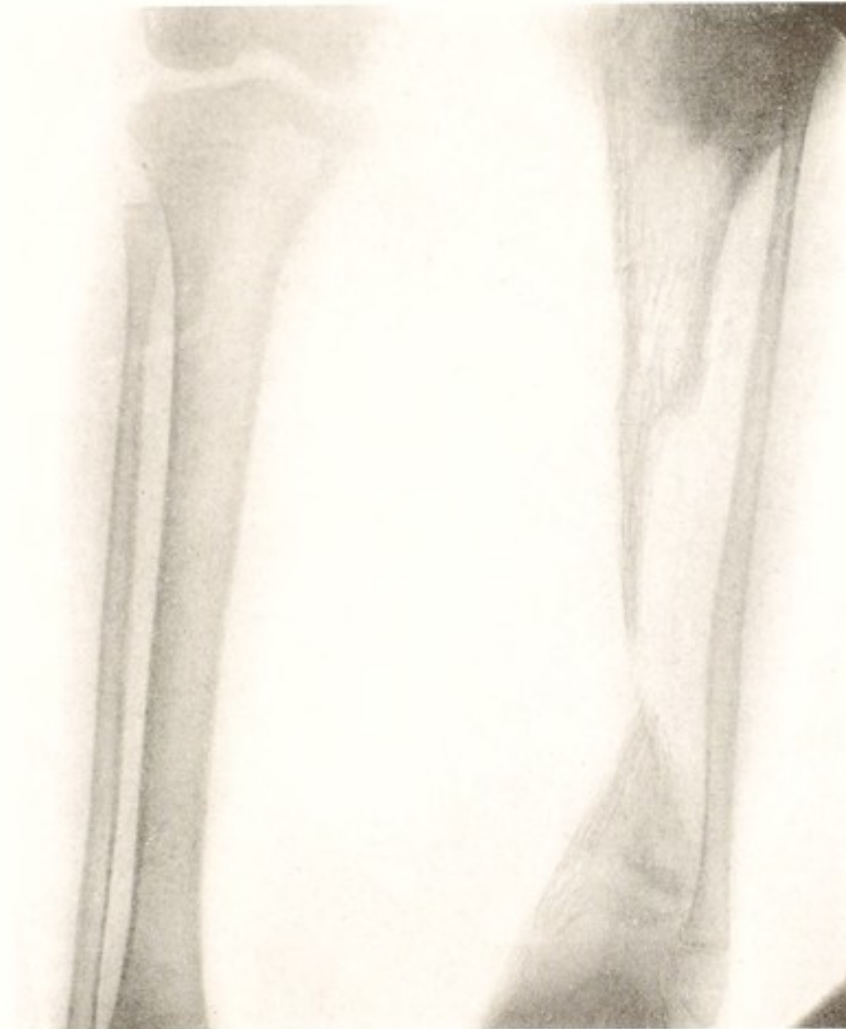

FIG. 282.—Absence of central portion of tibia from old osteomyelitis.

defects are by no means of rare occurrence. The most frequent and important of these are deficiencies of the cranial bones, of the inferior maxilla, and of the long bones of the extremities,

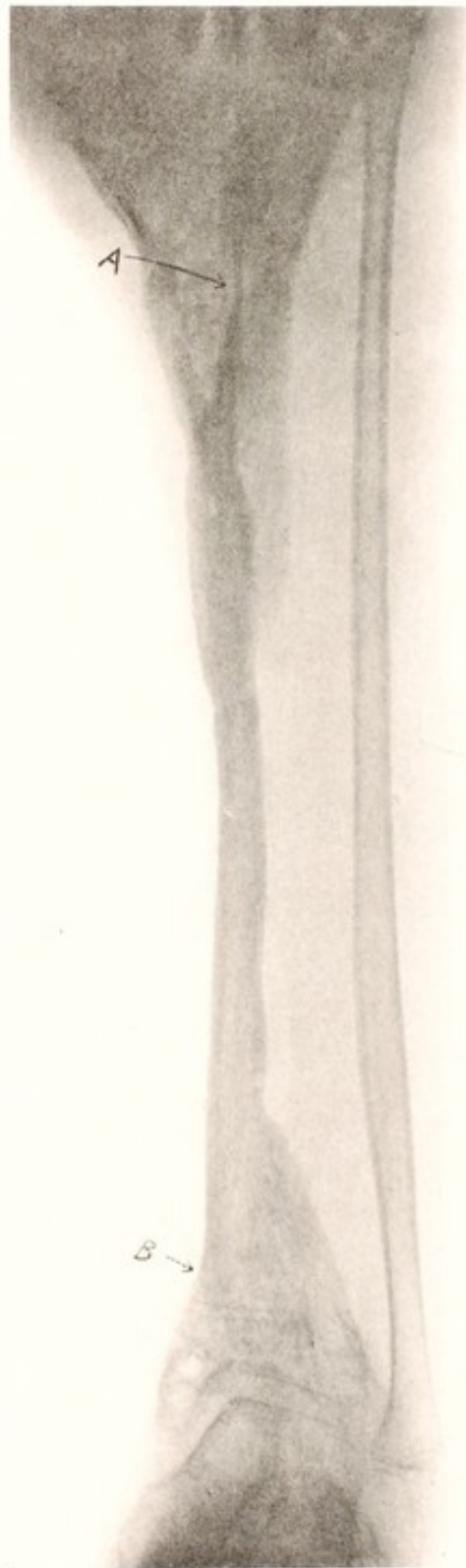

FIG. 283.—Same case as Fig. 282, one year after insertion of graft. The upper tibial fragment was split with motor saw and the upper end of the graft, being made with wedge end, was inserted into saw-cut cleft at *A*. The lower end was inlaid by author's usual technique at *B*.

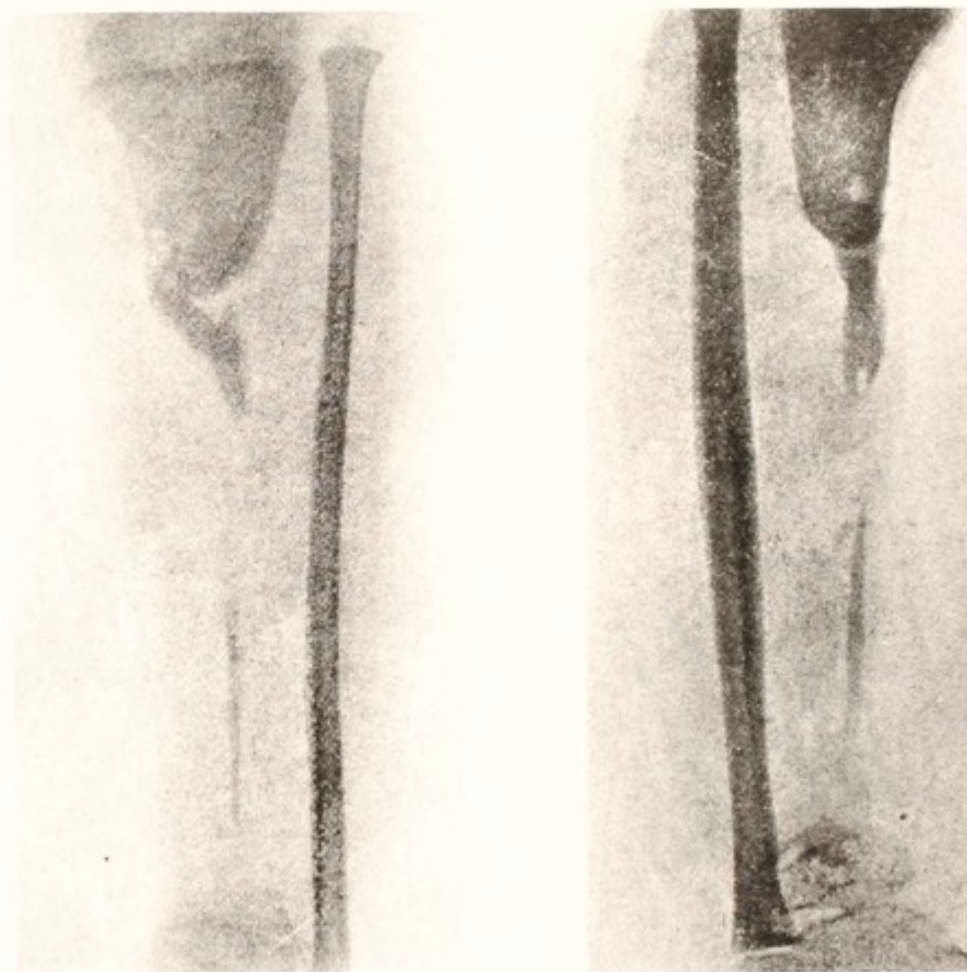
caused by removal of tumors, by osteomyelitis, and by injuries. Many modifications of the pedunculated method of restoring bony defects have been described by Bittner, Ollier, Müller, Vulpius, Codivilla, and Huntington. These methods were devised and practised largely before the trustworthiness of the free autogenous bone graft had become established. On account of the added complexity of operative technique and the small chances of blood supply reaching the graft through its twisted pedicle, the disadvantages of this technique far outweigh its advantages.

For absence of the tibia from destruction by osteomyelitis or new growths, or failure of regeneration, or from congenital absence, etc., the upper part of the fibula may be moved over to a socket cut in the upper epiphysis of the tibia. As reported by Hahn (1884), Nichols (1904), Huntington (1905) and others, the fibula underwent hypertrophy and supported the weight of the body very well. Huntington, in the *Annals of Surgery*, 1905, vol. xli, p. 249, first described his operation for substituting for the whole diaphysis of the tibia that of the fibula of the same leg. The fibula is divided with a saw at a point opposite the lower end of the upper tibial fragment, the distal portion of the fibula is firmly planted in a cup-shaped depression in the upper fragment of the tibia. In Huntington's first case the union was very slow and solidification did not finally occur until 6 months later. In this case he did not transfer the lower end of the fibula to the lower fragment of the tibia until 8 months later. The consequent faulty weight bearing over this long period of time caused a permanent change in the conformation of the tarsus and an outward alignment of the axis of the lower end of the tibia.

Stone (*Annals of Surgery*, xlvi, p. 628) transfers the upper end of the fibula into the tibia by precisely the same technique as Huntington. The lower end of the diaphysis, however, he splits longitudinally with a chisel for a distance of 4 in., care being taken to avoid separating the periosteum from either half of the bone. At the lower end of the split portion, the inner half is cut transversely at the level of the upper part

of the remaining lower epiphysis of the tibia. A small pocket is then cut in the epiphyseal cartilage covering the end of the tibial epiphysis, just large enough to receive the inner half of the fibula fragment which is then sprung into its new position in the tibia.

The second step at the lower end of the fibula was planned to maintain connection between the shaft of the fibula and the



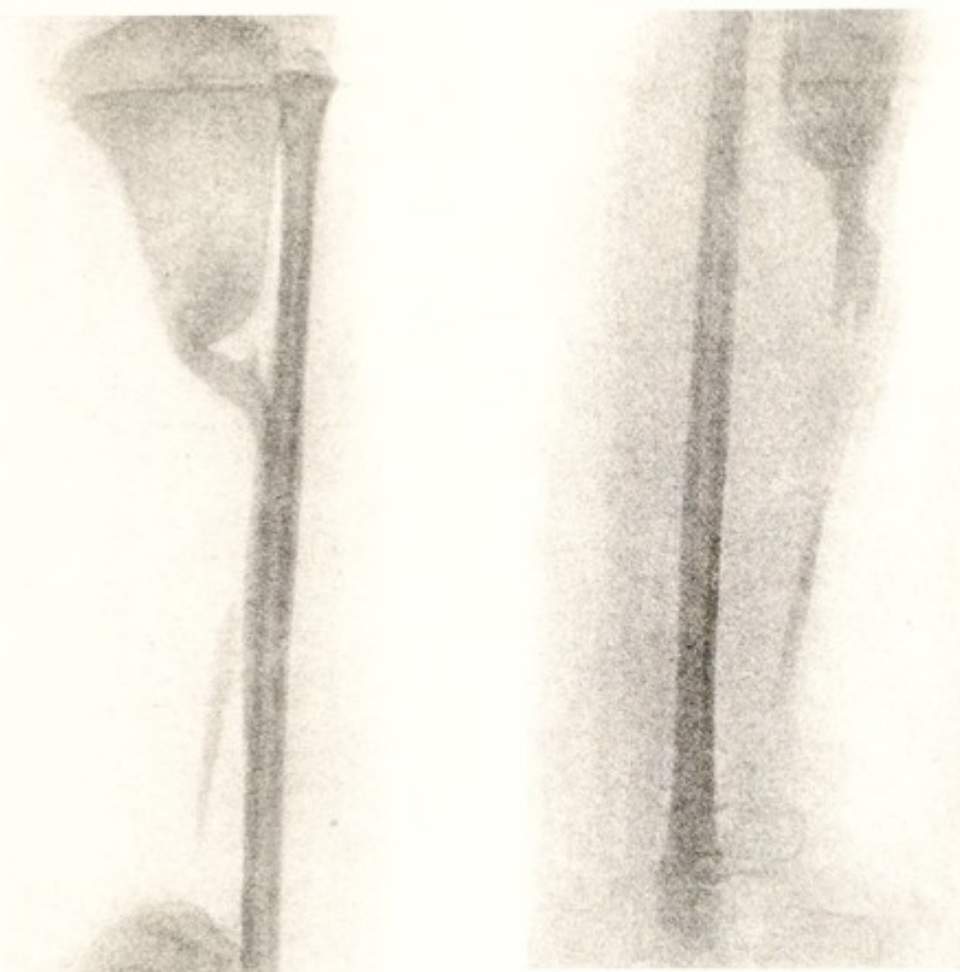
Antero-posterior view.

Lateral view.

FIG. 284.—Radiographs taken 9 months after the removal of the shaft of the tibia. The amount of regeneration is well shown. (James S. Stone, in *Annals of Surgery*.)

external malleolus, because if this is lost the outer side of the ankle-joint would be seriously weakened. At the same time it is necessary to bring a portion of the fibula above and contact it with the lower epiphysis of the tibia. The promptness and the extent of new bone formation from each of the fibula halves was very satisfactory (see Figs. 287, 288).

Bond (*British Jour. Surgery*, April, 1914) described two cases in which he did the Huntington operation of replacing the whole shaft of the tibia by transplanting the shaft of the fibula into its place. "The fibula was cut across just below the head of the bone, and this portion was left in its normal position. The divided end of the shaft of the fibula was then pushed over to



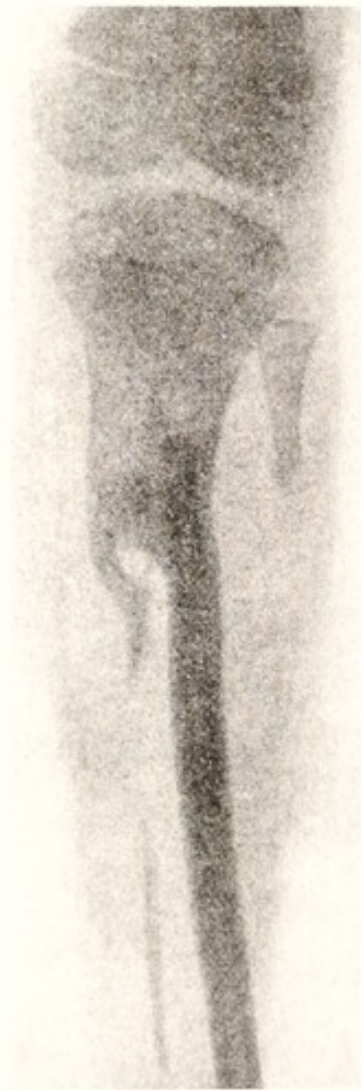Antero-posterior view.

Lateral view.

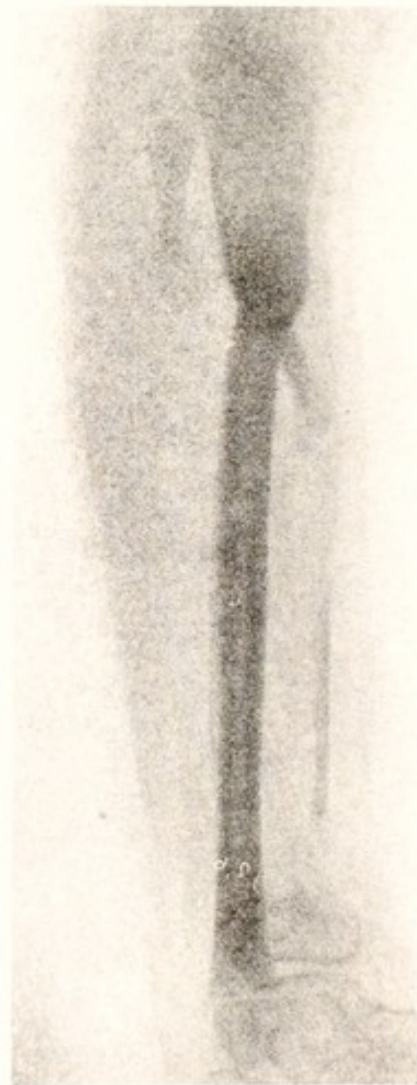
FIG. 285.—Radiographs taken a year after the removal of the shaft of the tibia. They show that no further regeneration of bone had occurred since the preceding X-rays were taken. They show, however, the beginning hypertrophy of the shaft of the fibula, most pronounced about the middle. (James S. Stone, in *Annals of Surgery*.)

the inner side and inserted into the freshened lower surface of the tibial epiphyses, to which it was wired in position. Some difficulty was experienced in keeping the sutured bones in good position, owing to the friability of the softened bony tissues and to the drag of the muscles, which tended to displace the fibula outward to its old position. This necessitated a second opera-

tion and the introduction of a second silver wire." In 1 year and 10 months, the transference of the lower end of the fibula was done at a third operation. The fibula was divided just above the external malleolus and the lower end of the shaft was displaced inward and inserted into the soft cancellous tissue of the lower tibial extremity. The fibula shaft in its new



Antero-posterior view.



Lateral view.

FIG. 286.—Radiographs taken five months after the first operation. Solid union but slight impaction of fibula into medullary cavity of the tibia. (James S. Stone, in *Annals of Surgery*.)

location gradually hypertrophied, resulting in a firm limb. Röntgenograms taken at intervals showed that the upper end of the shaft of the fibula gradually assumed the flattened inverted-cone-shaped outlines characteristic of the normal tibia,

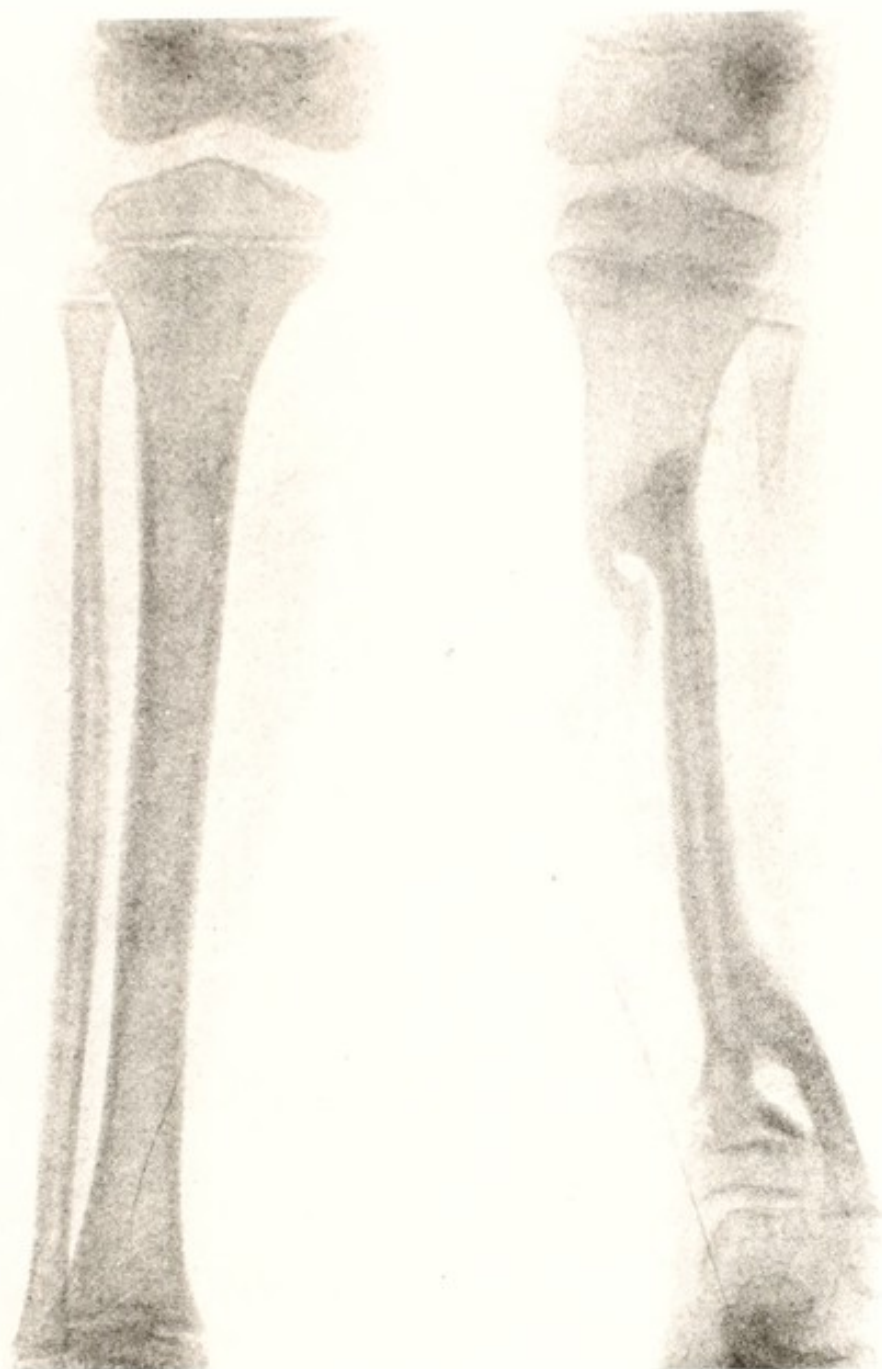


FIG. 287.—Radiograph taken of both legs nearly two years after the removal of the shaft of the tibia, about four months after the fibula was split and the inner half was inserted in the tibia. There is a shortening of exactly 4 c.m. (1½ in). About one half of this is due to retarded growth, while the other half is due to a crowding up of fibula into the medullary cavity of the tibia.

Note the hypertrophy of the transferred portion of the fibula and compare it with the atrophy of the upper useless end of the fibula. Note the thickening and firm union of the lower divided halves of the fibula.

The normal relations of the malleoli and lower end of the tibia are retained. The spot from which the small sequestrum was discharged is shown at the inner side of the bone just above the lower epiphysis of the tibia. (James S. Stone, in *Annals of Surgery*.)

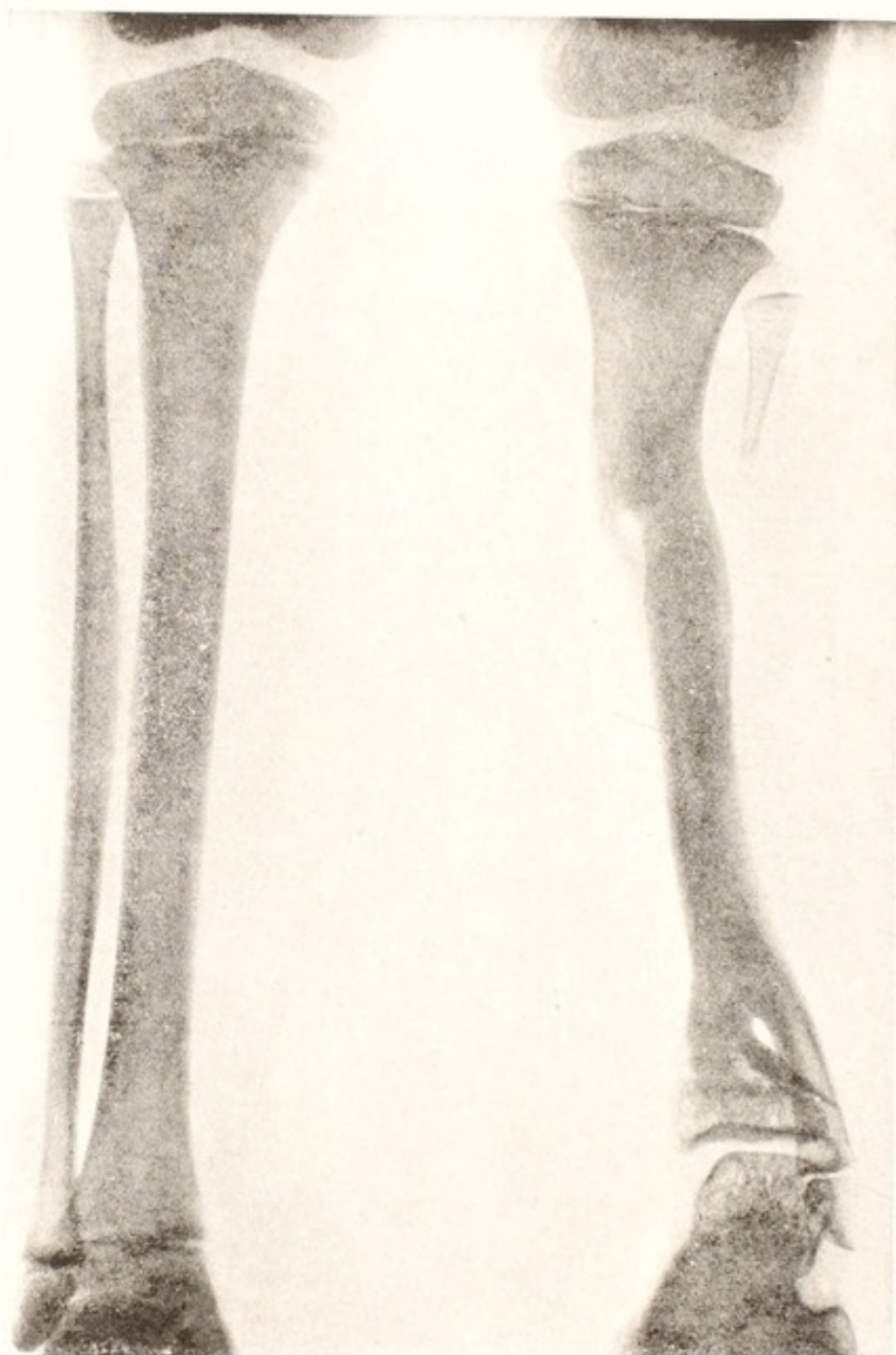

FIG. 288.—Radiograph taken in February, 1907, 2 years and 8 months after the removal of the tibia, 9 months after the preceding radiograph. The tremendous increase in the diameter of the transferred fibula occurring under the stimulus of functional use is strikingly shown. Accurate measurements of the radiographs show that the tibia of the normal side has grown 1.1 cm. in length in 9 months while the bone on the other side has grown .8 cm. in the same period. In other words, the interference with growth at the lower epiphyseal line of the tibia has been only .3 cm. in 9 months.

There has been no change in the relations between the lower epiphyseal lines of the tibia and fibula. There is no tendency toward the development of a talipes varus or talipes valgus. (James S. Stone, in *Annals of Surgery*.)

again demonstrating the efficacy of the action of Wolff's law in causing both detached and undetached bone grafts to take on, in their new environment, both the size and shape which function demands. The actual shortening, however, was $3\frac{1}{2}$ in.

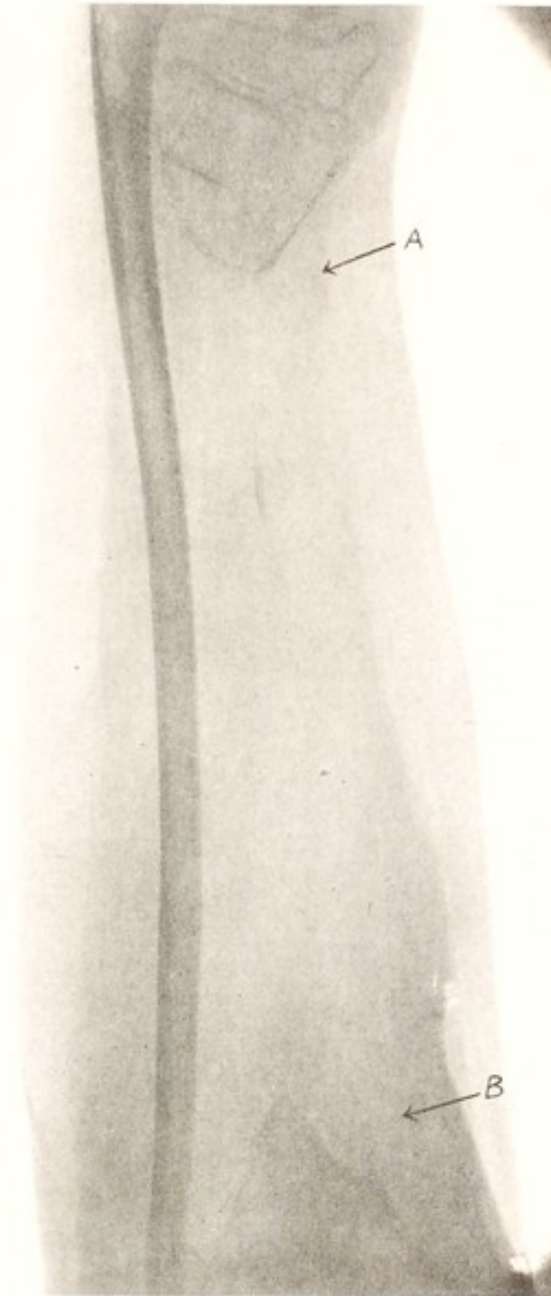


FIG. 289.—By the kindness of Mr. Robert Jones. Absence of the tibia from osteomyelitis.

M. Bond's case illustrates some of the difficulties and disadvantages inherent in this technique.

A more ideal procedure has for its aim complete anatomical

and mechanical restoration, leaving the fibula to functionate and supplying the absent portion of the tibia by a free transplant from the other tibia. A portion or the whole of the tibia may be

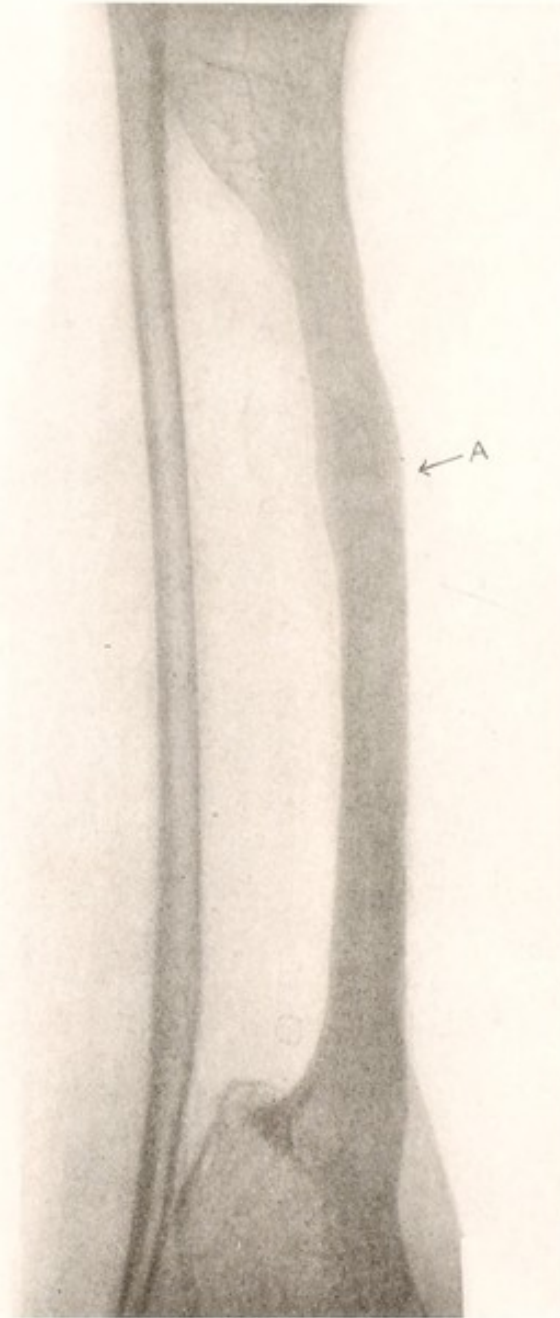


FIG. 290.—By the kindness of Mr. Robert Jones. (Same case as Fig. 289.) The tibia has been restored by a tibial graft which became broken at *A*, and immediately united.

absent congenitally or from removal on account of osteomyelitis or tumor involvement. During the past few years the pendulum has swung away from amputation and more toward bone re-

section in the treatment of malignant involvement of bone, and the bone graft has had an important influence in making this possible.

Author's Technique for the Insertion of a Graft for an Absent Long Bone.—The fragment ends on either side of the hiatus are laid bare and the bed for the graft is prepared, care being exercised not to place the graft in dense cicatricial tissue. The graft is inserted into the fragment ends by precisely the same tech-

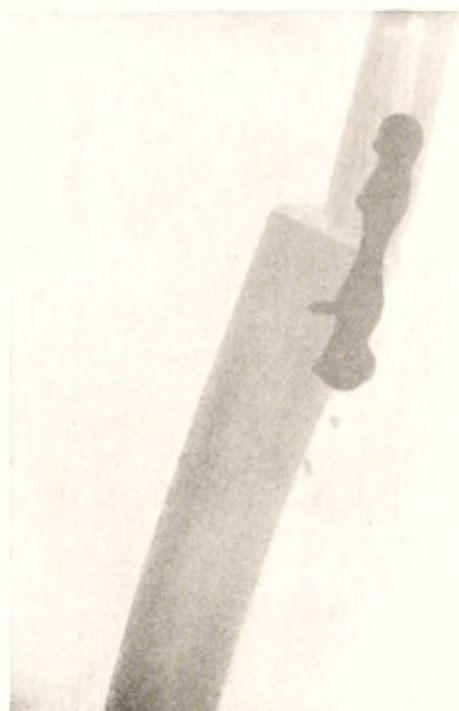

FIG. 291.—(Morison in *British Journal of Surgery*.) Three months after Morison inserted portion of fibula to restore portion of shaft of humerus removed for chondro-sarcoma. Note that there is no callous formation. Morison states that soon after this röntgenogram the graft became entirely detached at this point and non-union still persisted at his writing. In the light of an extensive experience, it is believed that if this graft had been fixed to the humerus fragment by the inlay method, instead of by a metal plate, union would have occurred.

nique as that employed in applying the inlay to fractures (see Chapter IV), except that a shouldered, or tongued and grooved, joint is used at the ends of the graft, to prevent muscle-pull from shortening the limb by forcing the fragments together before union occurs (see illustrations, Figs. 292 and 293).

The graft should always include the complete thickness of the tibial cortex, periosteum, endosteum, and some marrow substance. The other dimensions depend upon the bone whose

place it takes or the mechanical strain to which it will be subjected. The muscle-ends, which have been detached from the removed bone, are attached to the graft in their normal anatom-

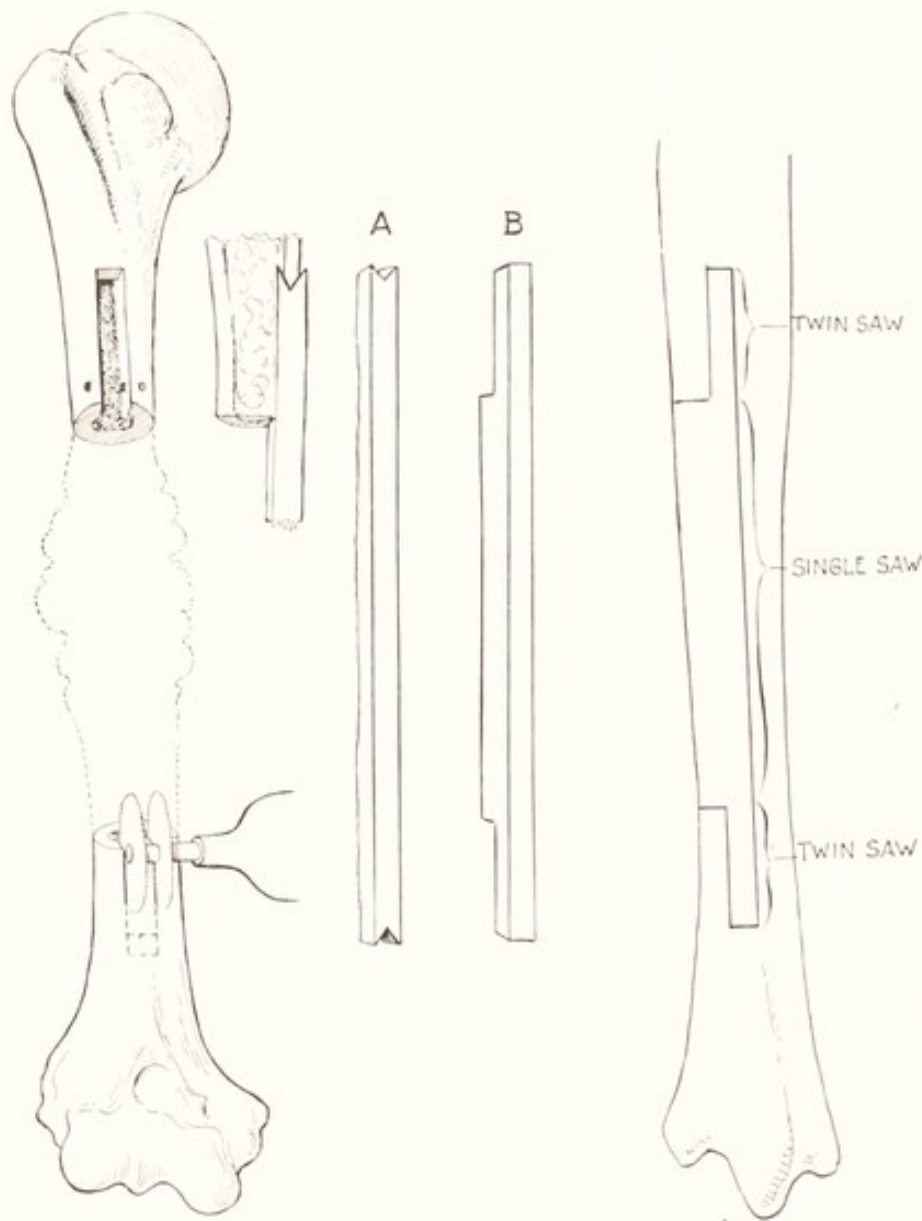


FIG. 292.—Inlay technique for the insertion of a tibial graft after the resection of a portion of the shaft of a long bone. The prevention of the limb shortening may be accomplished in two ways, either by a tongue and grooved joint as indicated at *A* or by shaping the graft so that it is larger in diameter where it spans the bone hiatus and has mechanical shoulders at either end, as indicated by *B*, which is mapped out in the periosteum of the anterior internal surface of the tibia. (See drawing to the right, also Fig. 113.) The tibia is the source of the graft.

ical position by means of encircling sutures of kangaroo tendon. If the graft is inserted to take the place of the end of a bone, such as the upper end of the humerus or the femur, the upper end

should be placed in the glenoid or acetabular cavity and the capsule sutured around it. Extension is necessary at the shoulder to prevent the end of the graft from pushing through the capsule. If the ends of the fragments are small in diameter and spindle- or conical-shaped, it is best to split them with the motor saw into equal portions for a distance of 1 or 2 in. The corresponding end of the graft is made wedge-shaped (when it is removed) and is jammed into the cleft made in the end of its recipient fragment. The graft ends are secured to the host fragments by means of kangaroo tendon either placed in drill holes or wrapped about the ends of the recipient bones and graft (see illustrative diagrams 137 and 297). The soft structures are drawn about the graft, and the wound is closed with a continuous suture of No. 1 chromic catgut.

A carefully fitted plaster-of-Paris dressing, including the joints on either side of the grafted bone, should be applied. If there is no cause for its earlier removal, it should remain upon the limb for 4 or 5 weeks, at the end of which time it should be replaced by a second plaster splint for 2 or 3 months, or until the röntgenograms and physical examination show that there has been a sufficient hypertrophy of the graft to be trusted without support.

A RIB GRAFT FOR THE CLAVICLE

Tschirch reports a case of bone graft of the clavicle in a girl 18 years of age, in which it proved necessary to replace not only the clavicle (after this bone had been removed) but also to form a new clavicular joint. This was accomplished by means of the right eleventh rib, which was resected to an extent of 13 cm., together with



FIG. 293.—Inlay graft with tongue and grooved ends held in place with kangaroo tendon. (See Fig. 292.)

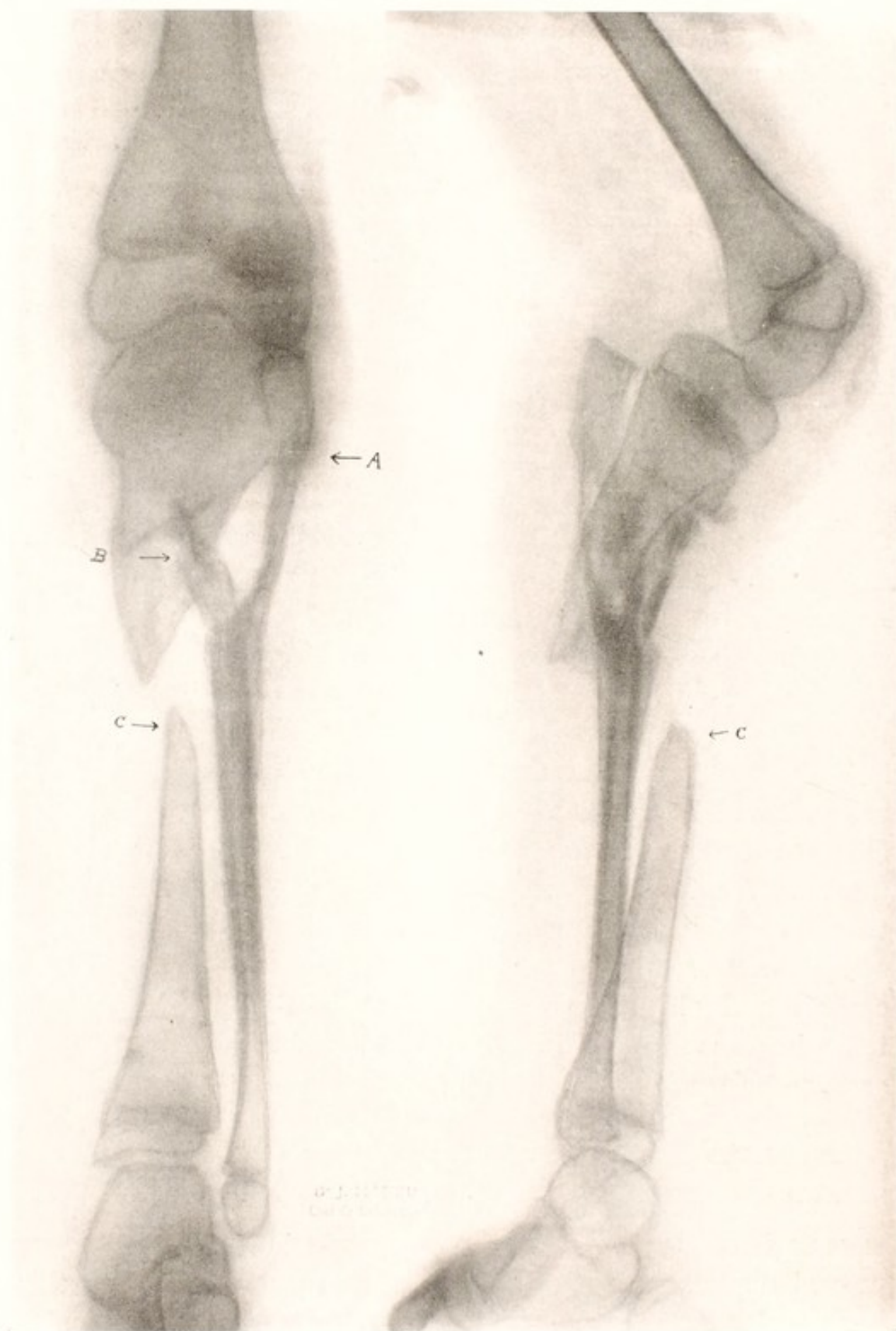


FIG. 294.—Prof. Kirmisson split the upper portion of fibula and contacted one-half with the upper fragment of tibia at *B*. A second operation of similar nature is necessary to connect fibula with lower tibial fragment in order to get ankle support. A short, free tibial graft connecting fragments *BC* would have been much simpler and would have offered a more ideal result. (By the kindness of Prof. Kirmisson.)

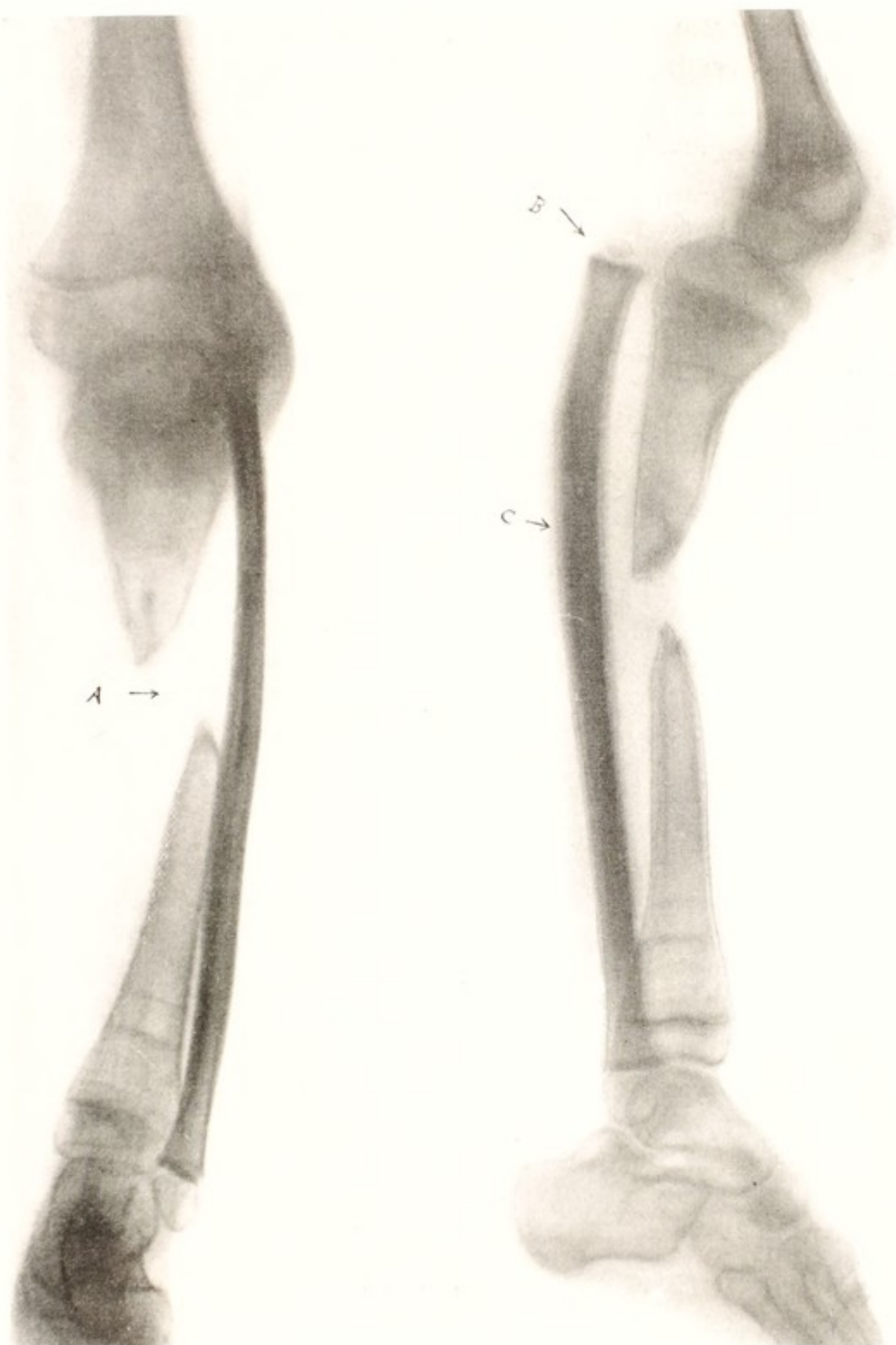


FIG. 295.—By the kindness of Prof. Kirmisson. Loss of portion of tibia at *A*; from osteomyelitis. Luxation of head of fibula and hypertrophy at *C* of fibula opposite hiatus in tibia.

the entire costal cartilage of about 2.5 cm. in length. The periosteal covering of the anterior surface of the rib was removed, together with the bone, whereas the periosteum of the posterior costal surface, which is applied to the pleura, was left in position. The young girl's rib proved to be good plastic material which readily assumed and retained the desired shape.

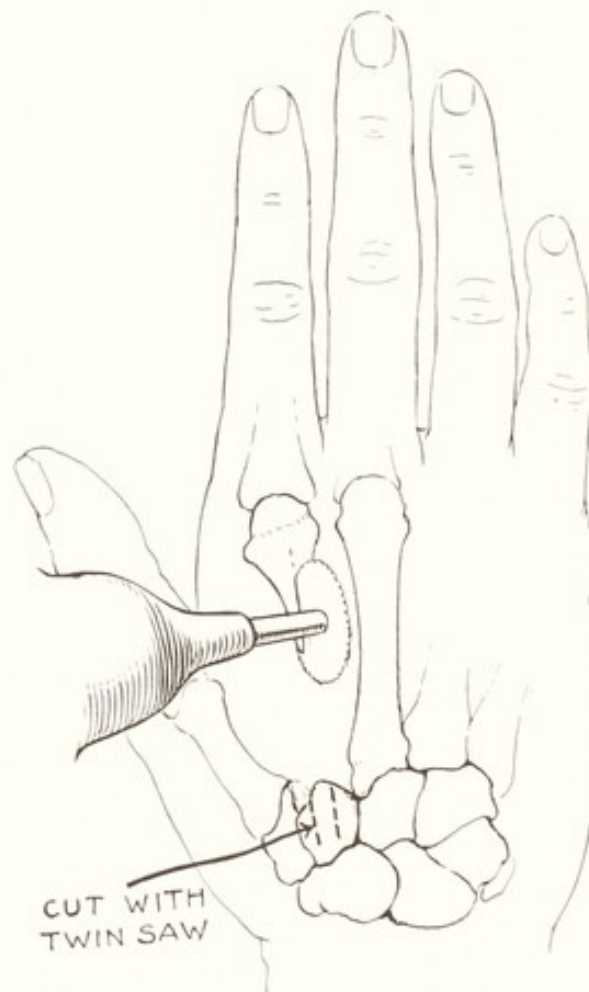


FIG. 296.—Illustrates technique in case of which Figs. 298 and 299 are röntgenograms.

Holes were drilled near the end of the rib and in the acromial process of the scapula. This end of the rib was then united by means of a silver wire to the acromial process. Finally, the whole rib graft was surrounded by muscle-tissue, except the costal cartilage. The post-operative course was very favorable. A good cosmetic result was obtained, and from the functional point of view the outcome was ideal.

BONE GRAFT FOR THE RADIUS

In the case of a young woman suffering from sarcoma of the distal fragment of the radius, Walther performed a resection, followed by substitution for the defect by a bone fragment from the proximal end of the fibula. The patient made a good recovery and was enabled to make use of her hand, about 2

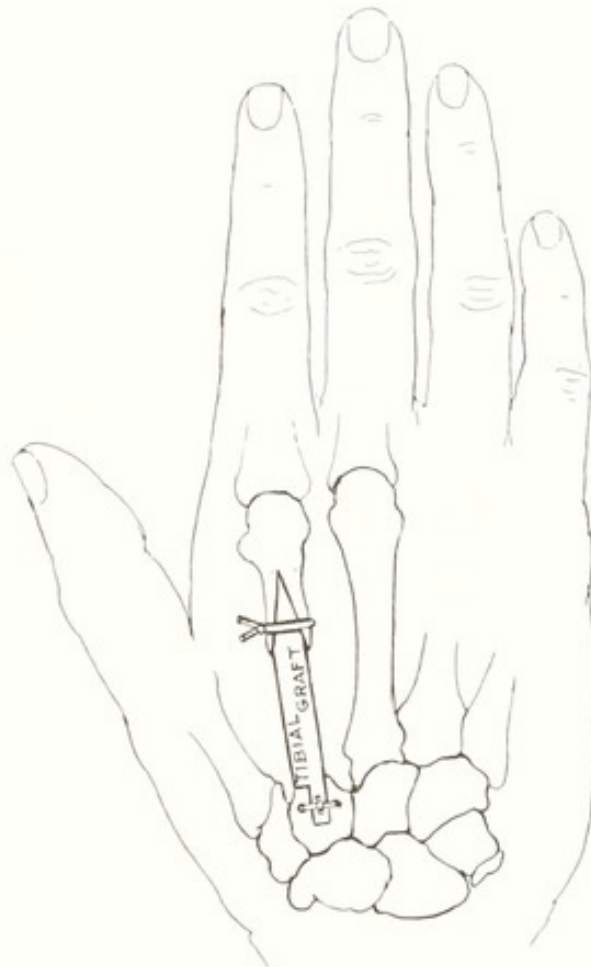

FIG. 297.—Illustrates completion of technique with tibial graft held in place with kangaroo tendon.

months later, with almost normal motility of the wrist and fingers.

Rovsing reported a case of sarcoma of the internal condyle in which a resection of the lower end of the femur was performed and a temporary insertion of a piece of humerus was applied, articulating with the tibia, in order to preserve the length and form of the leg while the patient was under observation for a

recurrence. No recurrence having taken place at the end of 2½ months the dead humerus was replaced by a femur newly amputated from another individual, after freshening the upper end of the tibia. The patient made a good recovery, was free from

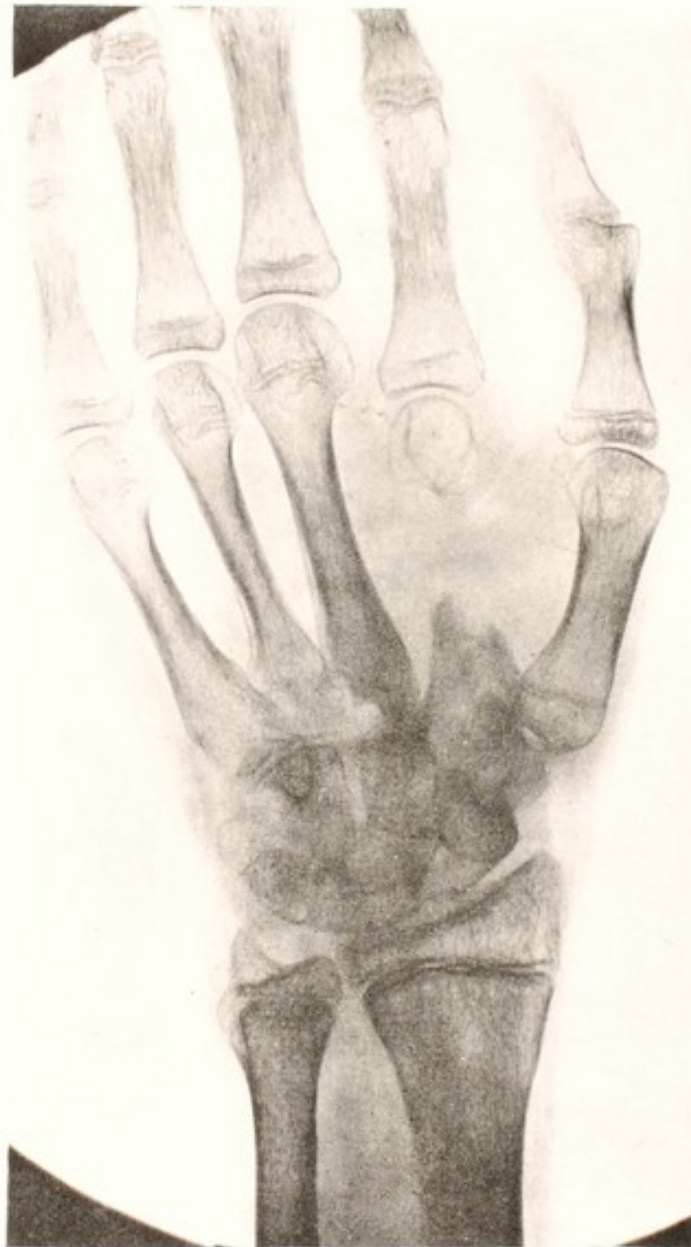

FIG. 298.—Loss of the central portion of the metacarpal of the index-finger from osteomyelitis, no periosteal regeneration after 1 year. Absent bone shaft restored by bone graft. (See Fig. 299.)

recurrence 1 year after the first operation, able to walk with a cane, and in a condition to work.

This case is illustrative of an important principle, *i.e.*, the support and the prevention from shortening of a limb from which

a malignant bone growth has been removed, the hiatus being supplied by a temporary graft until sufficient time for observa-

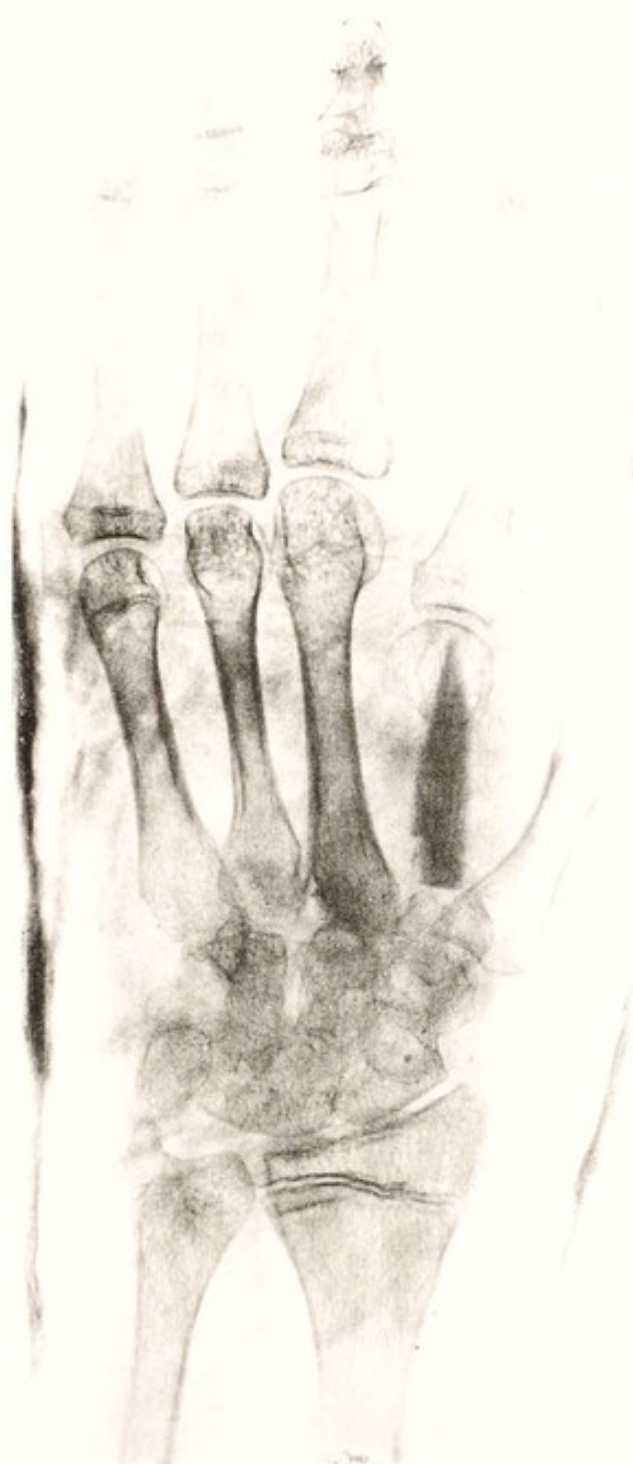

FIG. 299.—Same case as Fig. 298, after missing portion of metacarpal bone has been restored by author with a tibial graft. See Fig. 297 for diagram of technique.

tion as to a recurrence has elapsed, or until suitable material for a permanent joint graft can be obtained.

SPINA VENTOSA

Advanced cases of spina ventosa are best treated by removal of the diseased diaphyseal bone and periosteum and the substitution of a bone transplant with its periosteum. Damage to the



FIG. 300.—Complete congenital absence of the radius. Contraction of either the extension or flexion of the forearm caused even more marked adduction of the hand on the forearm than shown in this photograph, on account of lack of skeletal support of the radius.

The author has met this condition in two ways, either by restoring the complete radius (see Figs. 301 and 302) or, preferably, by mortising a graft into the radial side of ulna (at the junction of its middle and lower third) and the scaphoid bone. The latter graft functionates better and benefits by the distal growth of the epiphyseal cartilage of the upper end of ulna. (See Figs. 303 and 304.)

epiphyseal cartilages, which in the metacarpal bones are situated at their distal and in the phalangeal bones at their proximal end, should be carefully avoided. The bone defect is replaced by a graft taken from the crest of the tibia of the same

patient. If phalangeal or metacarpal stumps are not too short, the graft is mortised or inlaid into them. Strong traction should be applied to the distal end of the finger while the graft

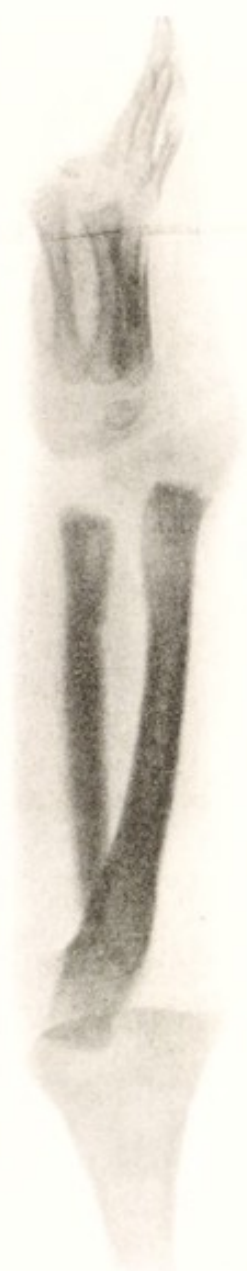

FIG. 301.—Same as Fig. 302.

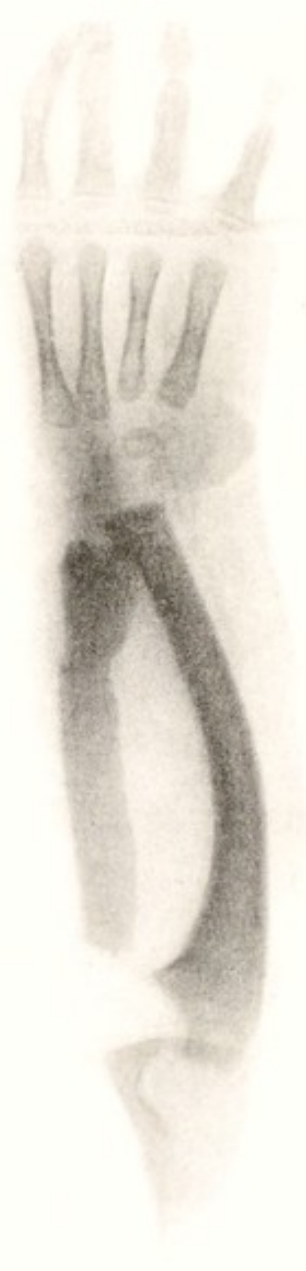

FIG. 302.—Complete absence of radius restored by a tibial graft.

is being inserted tightly into place. A snugly fitting plaster splint should be applied to the finger and the hand and allowed to remain in place for 8 to 12 weeks. The resistance of cortical bone graft to tubercular infections and to attenuated infections

of other varieties has been repeatedly proved by the author. As a rule, the functional and cosmetic results are excellent. The motion in the joints of children gradually returns by use.

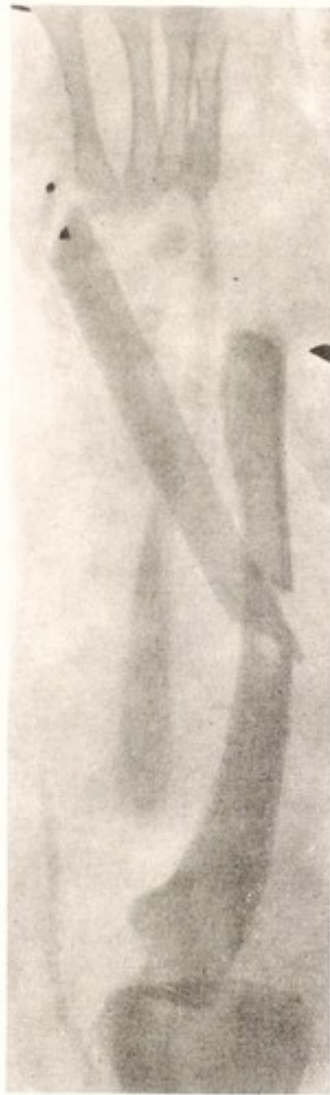

FIG. 303.—Complete congenital absence of the radius. A tibial bone graft was mortised into ulna and scaphoid bones 2 weeks before.

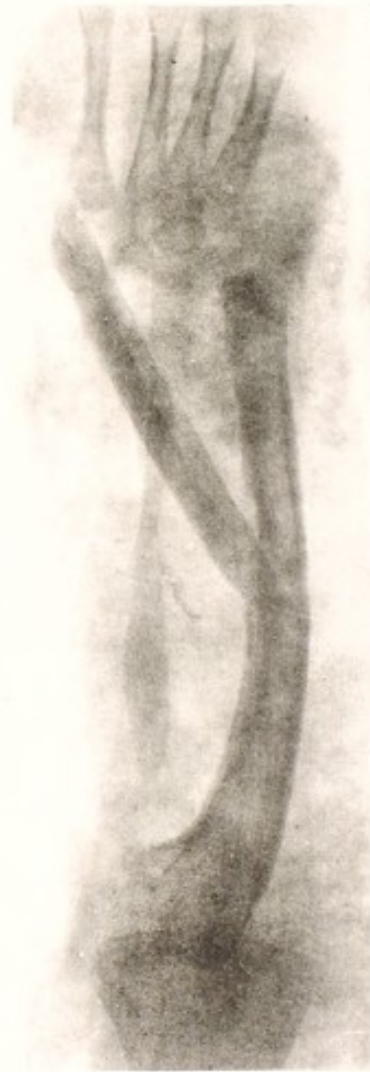

FIG. 304.—Röntgenogram taken 4 months later. The hand is supported perfectly and the result has been most satisfactory.

This treatment is also applicable to the bones of the foot, as well as to the carpal bones.

OSTEITIS FIBROSA CYSTICA

The case of osteitis fibrosa cystica of the humerus described in Murphy's Clinics, vol. ii., No. 5, where a bone graft was used

to supply a deficiency caused by the removal of the cystic portion, is well illustrated by the röntgenograms taken from that publication (Figs. 201-205).

The patient was a girl, 10 years of age, presenting a typical condition of osteitis fibrosa cystica of the humerus. She had undergone mercurial treatment, with negative result.

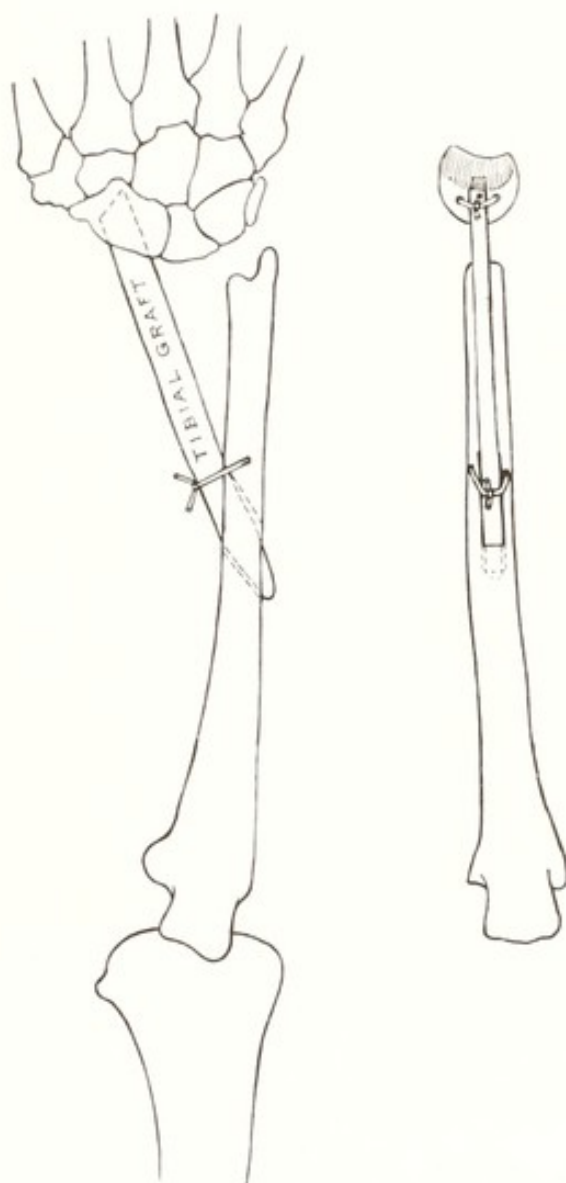


FIG. 305.—Drawing illustrating author's technique for congenital absence of the radius. The tibial graft is mortised into the ulna and scaphoid bones.

Technique of Operation.—“An incision was made along the anterior border of the bicipital groove, extending down below the attachment of the deltoid. The muscular attachments were separated and retained in position for recognition. The

bone was then freed from all its surrounding tissue, leaving the periosteum attached to the excised bone. Six and a half inches were excised, including the head and epiphyseal line. A $7\frac{1}{2}$ -in. transplant was prepared from the crest of the tibia; the periosteum was retained. This transplant measured $\frac{7}{8} \times \frac{1}{2}$ in. The medulla of the remaining portion of the shaft of the humerus was reamed out and the transplant was inserted for $\frac{3}{4}$ in. A nail was then passed through a drill hole

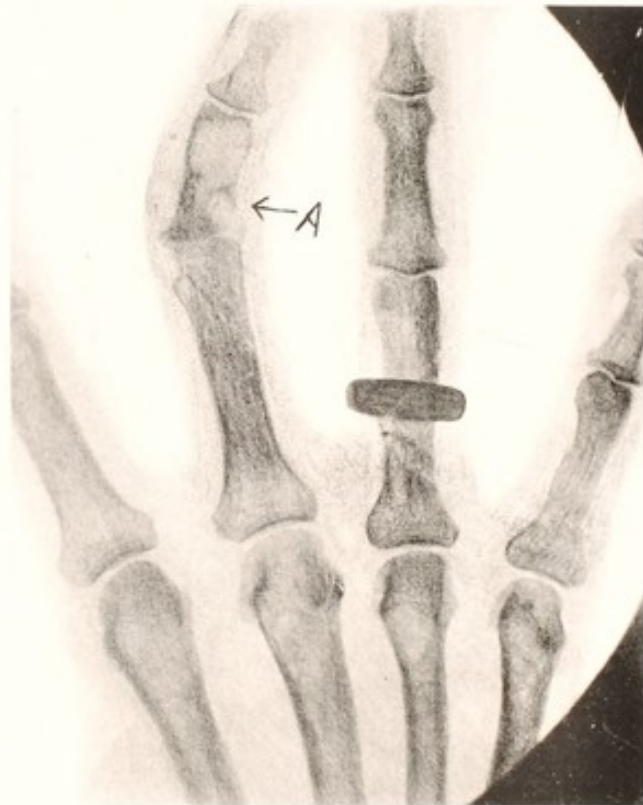

FIG. 306.—A indicates cystic involvement of phalanx with marked lateral deviation of the finger. This type of case can be most satisfactorily treated by the implantation of a bone to replace the cystic bone, and cannot be managed by any other method.

transversely, to prevent it from imbedding itself more deeply. The upper end of the implant was inserted into the glenoid cavity, and the capsule was accurately sutured around it. The muscle ends were then attached by an encircling suture around the implant in about their normal anatomical position. The wound was closed by a deep row of catgut sutures and superficial horsehair sutures. The arm was dressed in abduction at about a right angle to the body. A Buck's extension was

applied to the forearm and a 10-lb. weight attached with a line running from a pulley. This was to prevent muscular contractions during the period of regeneration, which would probably have driven the upper end of the bone through the capsule. It was kept on for 5 weeks."

Result.—"There was complete primary union, and at the end of 5 weeks the humerus appeared on palpation to be as large as the normal humerus. The patient had good voluntary

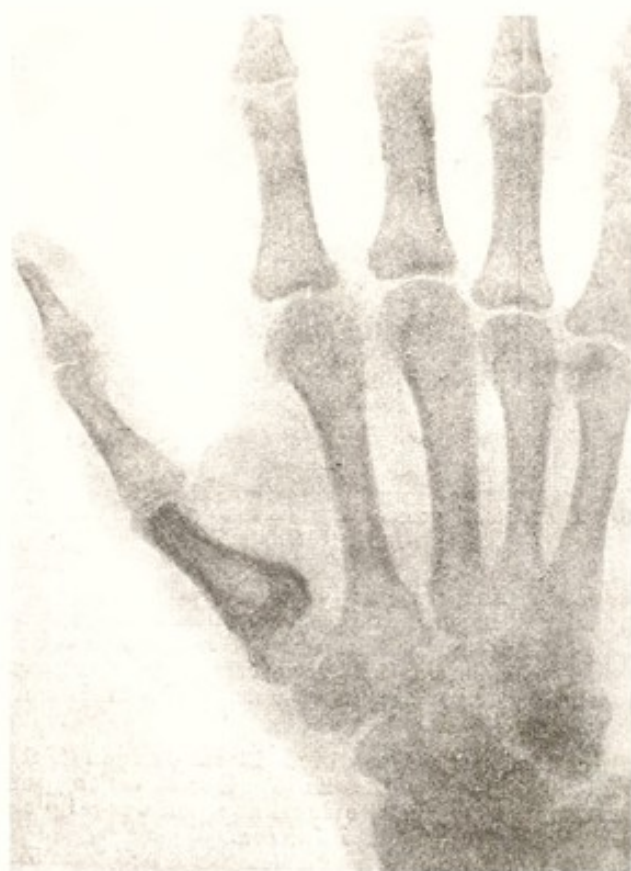

FIG. 307.—Restoration of the first metacarpal bone with a tibial graft. The metacarpal bone was destroyed by tuberculosis. (Katzenstein.)

motion. The position to which she could extend the arm when she left the hospital, 5 weeks after operation, showed how much abduction was produced by the deltoid and supinator muscles. A subsequent röntgenogram shows how completely this bone regenerated, not only in the part outside the capsule, but also how it has filled in within the capsule. It also shows the periosteum remaining intact and not becoming ossified even after this date, so that it would appear in this case that the

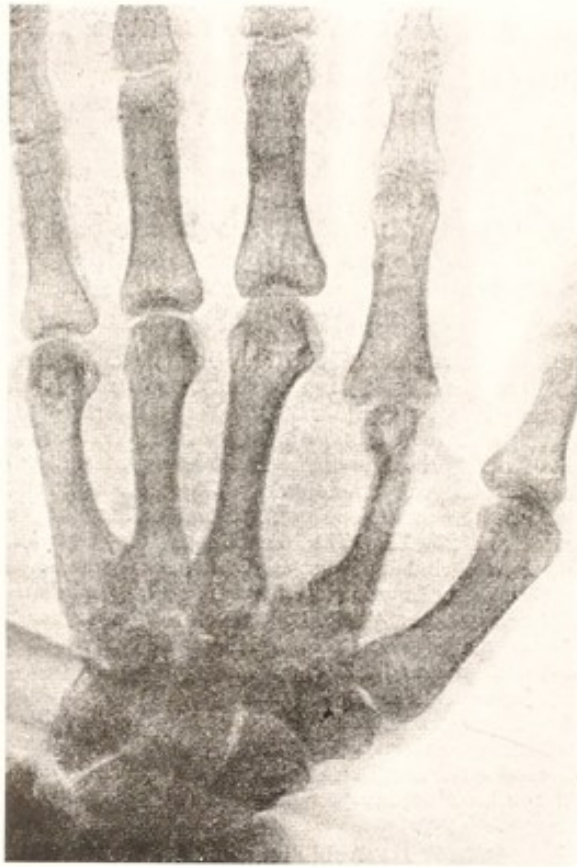

FIG. 308.—A tuberculous second metacarpal bone removed and restored with a tibial graft. (Katzenstein.)

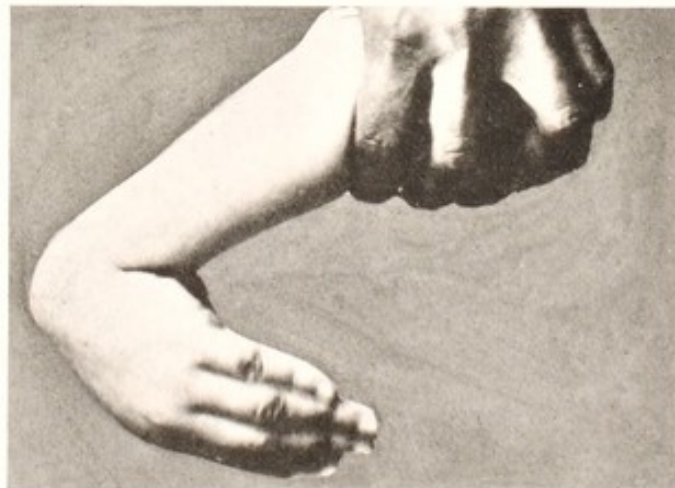

FIG. 309.—A case of drop wrist from anterior poliomyelitis and complete paralysis of the extensor muscles of the forearm. Any attempt to use the hand caused the unopposed muscles of the anterior forearm to acutely flex the hand, and therefore a complete loss of power to flex the fingers. (See Figs. 310 and 311.)

periosteum on the transplant is a detriment rather than an advantage. The series of röntgenograms shows the progress of bone development. Extension from the living periosteum below was the most important; next, from the medulla. This rapidly shot upward around the transplant to the capsule of the joint, and later into the capsule. She can now abduct her arm to a right angle in extension, and flexion is likewise complete, so that she does not know any serious operation has been done on her arm so far as its usefulness is concerned."

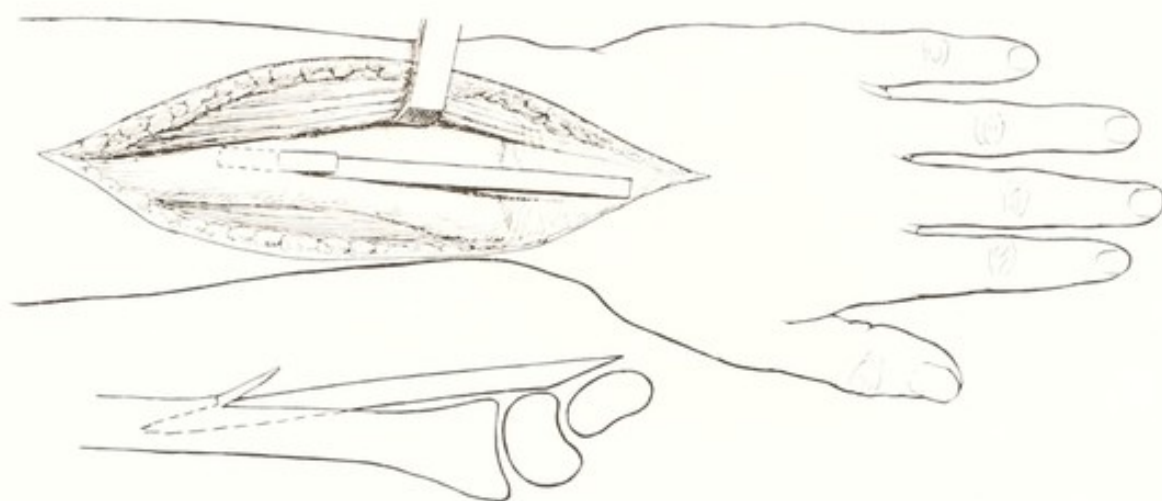


FIG. 310.—The illustration indicates the shape and position of the bone graft in its application to support a paralytic drop wrist in extension to restore the grasp of the flexors of the fingers. (Author's technique.)

TRANSPLANTATION OF COMPLETE SMALL BONES

The smaller long bones can be grafted in their entirety, with both articular surfaces, as demonstrated by Lexer; and in the event of a destructive lesion (from trauma or other cause) of a phalanx with loss of function, one is able to obtain a phalanx from an amputated limb, or autoplasty can be done by removing a toe or a segment of a rib cartilage. Formerly, fingers thus affected were amputated.

A HETEROPLASTIC GRAFT FOR TOTAL ABSENCE OF FIBULA

Küttner has reported a case of complete absence of the fibula, for which the fibula of a Java monkey was implanted. The bone

healed in without reaction of any kind and showed not the slightest trace of absorption, and the epiphyseal line of the implanted segment is well preserved. He also observes that in

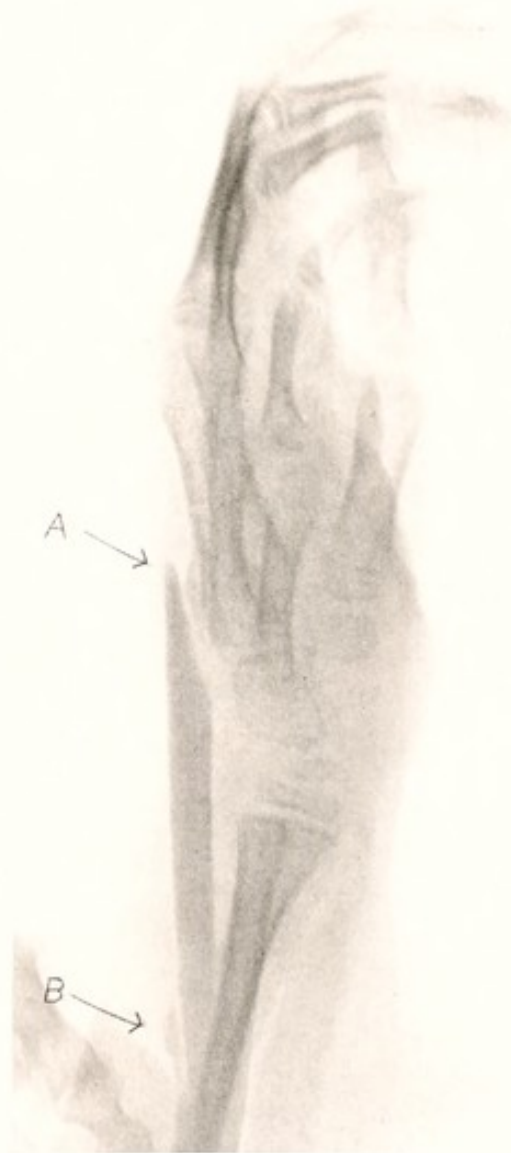

FIG. 311.—Röntgenogram of case (Fig. 309) after tibial bone graft had been inserted into radius and onto posterior surface of the os magnum. For diagrammatic drawing of author's technique, see Fig. 310. The grasp of the hand was almost completely restored by the mechanical support of hand in extension.

children transplantation from young monkeys is especially well adapted to replace entire bones.

TRANSPLANTATION OF JOINTS

To Lexer is due the credit of the first joint transplantation, which was an outgrowth from his cartilage and bone trans-

plantations. It necessarily follows that if one can perform homoplasty with large segments of long bones, it is possible to transplant the bone with its articular surfaces. Lexer's earliest experiment in this field was attempted in November, 1907. It occurred in a case of a defect in the tibia involving the entire upper third, including the articular surface, from a central sarcoma. The earlier procedure in similar cases was to engage the lower end of the femur into the tibia by boring, thus permitting union between the bones with considerable shortening of

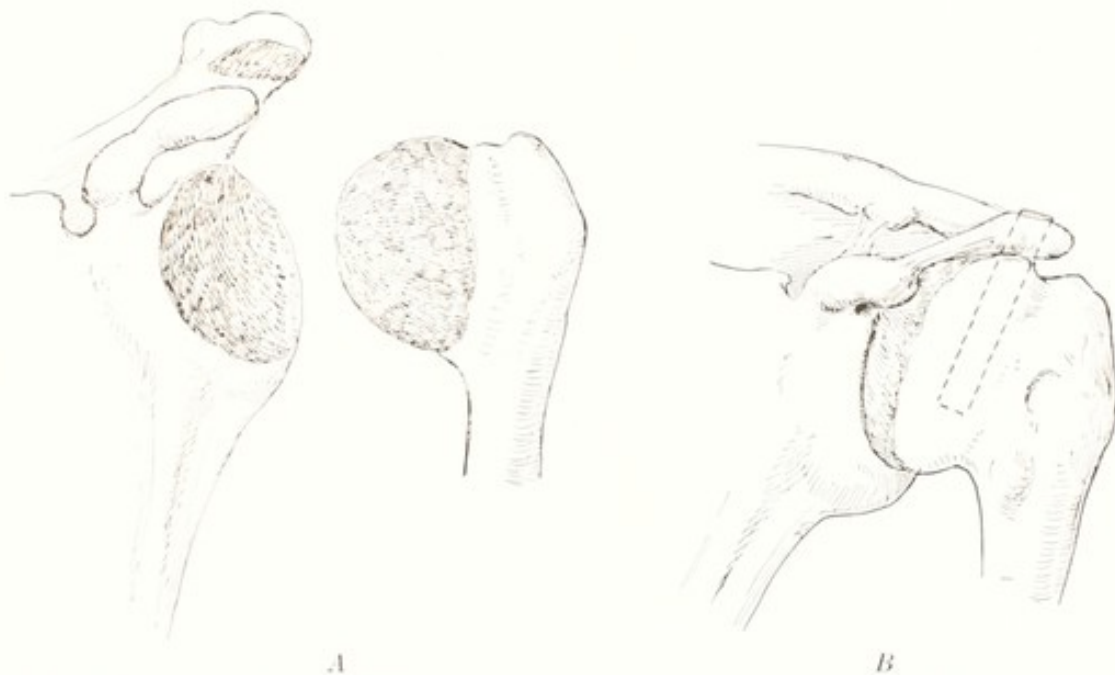


FIG. 312.—To illustrate technique for ankylosing the shoulder. *A*. The cartilage from the glenoid fossa and acromion process, and contiguous surface of the head of the humerus, is removed. *B*. The humeral head is placed in the glenoid fossa and a bone-graft peg inserted into it through the acromion process.

the limb. In order to obviate the latter result, and if possible to restore the mobile functions of the joint, a similar portion of the tibia was removed from a freshly amputated limb and implanted with its articular cartilage and periosteum. Then the thought arose to advance a step farther. If it were possible to achieve healing of this large segment of bone with its articular extremity, like success might be attained by transplanting the articular surfaces for the repair of joints. This idea was immediately carried into action, as there was at hand a freshly

amputated limb, and on numerous occasions attempts had been made to use other tissues and, lately, fat to mobilize joints.

After resection of the synovial sac and the articular surfaces of the tibia and femur, with their attachments, the crucial ligaments of considerable thickness were dissected and implanted in their entirety over the previously prepared defect. The first method has been called "half-joint transplantation" and the second, "whole-joint transplantation." By half-joint transplantation is implied transplantation of bony extremities, utilizing their articular membrane as much as possible, while in whole-joint transplantation is meant the imbedding of long bones with both articular surfaces. This work was successfully carried out by others (Küttner, Rovsing, Wolff, Enderlen, etc.), as well as by Lexer. The source of the material has been freshly amputated limbs. The use of material from the fresh cadaver has been discontinued: first, because of the difficulty in obtaining sterile tissues from the morgue; and second, because fibrous encapsulation took place in one case of knee transplantation.

Of six cases, in two the knee-joints from amputated extremities were transplanted with the internal ligaments intact, to replace knee-joints resected for bony ankylosis. The functional result in these cases has not yet been determined. In one of them, however, it was demonstrated by chiselling off a piece of the graft on the occasion of a secondary operation to relieve ankylosis of the patella to the femur that there was firm union of the transplanted surface, through which new blood-vessels were growing. In another case, the entire upper end of a tibia from an amputated extremity was grafted to replace a corresponding piece of bone removed for sarcoma; the patellar fragment was sewed to the new tibial tuberosity. There was complete healing and excellent functional result. A good result is promising in the fifth case, in which the lower end of a femur, with one condyle shaped to articulate in the glenoid fossa, was substituted for the upper two-thirds of a humerus removed for sarcoma; a piece of the fibula was used as an intramedullary splint to unite the graft with the shaft of the humerus. In the

sixth case, the first phalanx of the second toe of an amputated foot was used to replace the first phalanx of a finger. Healing was perfect and the joints are movable.

In two cases of bony ankylosis of the elbow-joint, Buchmann implanted an entire closed joint into the wound of the resected bones, the graft being the first metatarso-phalangeal joint, which permits a fairly wide range of extension and flexion. By means of this transplantation, the mobility of the elbow-joint may be restored. Bone suture is not necessary in this operation. The joint between the eminentia capitata humeri and the radial head should be widely resected. Dressings are first applied in extension, followed 2 weeks later (not before) by dressings in the flexed position. Active and passive movements are possible, without pain, in the transplanted joint, in the range of motion permitted by the contracted muscles. Buchmann states that this new method of treating bony ankylosis of the elbow-joint may also be found useful in the treatment of flail joints, and that the resection of the patient's first metatarso-phalangeal joint exerts no injurious effect upon the function of the foot. The wound in the foot is closed by sutures and allowed to heal. Buchmann's patients were young girls 14 and 19 years of age.

Küttner has further worked out the utilization of the fresh cadaver, and reports successes in half-joint transplantation. He employed homoplastic material under great difficulties, and in fact performed heteroplasty with tissues in which the albumen is closely related to that of man, *i.e.*, from the ape.

Autoplasty is applicable only to the finger joints, as the toe joints can be substituted for them.

That massive bone sections and entire joint surfaces may be thus substituted and made to unite is, in itself, a very important advance. "It affords the hope that only the development of the technique will be needed to establish such substitutions as regular surgical procedures."

In certain cases of luxation fracture it is necessary to remove the broken and luxated joint segments or entire articular ends, because the fragments are considerably displaced and entirely

detached from their surroundings. In case of joint fragments with well-preserved cartilage, when the bone is not crushed or splintered, reimplantation may be given a trial. The prospects of healing are especially favorable in such autoplastic grafts, in that very good and permanent results are obtained. Lexer has succeeded even by homoplastic implantation of articular bone ends. The so-called half-joint transplantations, where the segments can be surrounded by the preserved capsule, are the most favorable. All grafts require in the first place a rapid healing with the surrounding tissues and prompt nourishment from the same. In those defects due to operative removal of sarcomatous bone segments, the wound cavities are surrounded by fresh tissue which are very favorable to the early nourishment of the graft. After injuries, the nutritional conditions are not so favorable, especially in old cases where the cicatricial tissue is very poor for the nutrition of the graft; while in recent cases (after the end of the second week, at the earliest) the wound surfaces are improperly nourished, infiltrated with blood and contaminated with necrotic tissue constituents. Nevertheless, Lexer regards an attempt as justified because he argues that, at the worst, the result after the onset of necrosis is the same as after the immediate removal of the articular segment at the first operation.

The first of his two cases reported occurred in a young laborer who came under treatment with an untreated oblique fracture of 2 months' standing at the lower end of the left humerus, with ankylosis of the elbow in rectangular flexion and pronounced valgus position. The fragment, including the external condyle, together with the trochlea and the capitellar eminence, was much displaced in the anterior and mesial direction, and was imbedded throughout in scar tissue. After exposure, it was seen to be disconnected with the muscle and the capsule, so that it could be taken out. After freshening the fractured surface of the humerus, it was replaced in the proper position and fixed with a horn peg. After the wound had healed, the patient left the clinic, because he would not consent to

exercise of the joint. It is noteworthy that a good result was obtained without any after-treatment. Six months after his discharge, extension was possible up to 150 degrees; flexion at 105 degrees. Pronation and supination were not inhibited. The patient was well able to work as a carrier of heavy sacks.

Röntgenograms showed a properly placed well-preserved joint surface, with slight bone proliferation in the region of the brachial muscles.

The second patient was a woman who had suffered a severe luxation fracture of the humeral head, in a fall from a carriage, with extensive longitudinal splitting in the region of the greater tuberosity. The fracture line passed obliquely behind the surgical neck. Reduction being impossible, exposure of the broken head was made at the beginning of the third week, by way of the axilla. The articular segment (4 cm. in its largest diameter) was found to be far displaced to the inside, and rotated downward at a right angle. There was no connection with the muscle insertions and the joint capsule; only a few ragged muscular insertions were left on the splinters of the greater tuberosity; these splinters were so badly crushed that they were removed. The wound cavity was well trimmed, with removal of all tissue shreds, remnants of tendons, muscles, etc. The articular head, the cartilage of which appeared intact throughout, was then united so tightly with the oblique fragment of the diaphysis, by means of a few wire sutures, that reduction could be accomplished according to the usual method. The joint capsule was then sutured to the periosteum near the head. Everything healed well, and the detached muscle insertions became reunited to the bone through scar tissue, so that the loss of active function was not great. At any rate, the outcome was better than after resection, as is usually performed in these cases.

Perthes adopted a similar procedure in a case of long-standing fracture of the humeral head with simultaneous posterior luxation of the head. The luxated head segment was removed in a general way, but the cartilaginous joint segment was sawed off

and was grafted on the end on the diaphyseal stump, where it healed in good position. Active mobility in the shoulder-joint was still slight, but not lost.

Lasse, in two cases of articular fracture of the elbow-joint in children (in which the trochlea was completely broken off and had become rotated so that the fractured surface of the humerus was confronted by the cartilaginous articular surface) opened the joint, replaced the detached trochlea (which was separated from all connections with the articular capsule and synovial membrane), and fixed it to the humerus by means of small tacks. Uninterrupted healing with ideal function of the elbow-joint resulted.

According to Lasse's experience, the outcome of these operations is primarily governed by two factors: (1) careful and complete detachment of the unfavorably displaced distal fragment. This detachment can hardly be carried too far. Lexer, as well as Lasse, in certain cases entirely detached this distal fragment. Care should be taken to preserve the periosteum of this bone fragment, as far as possible. (2) On the other hand, it is necessary to remove very carefully with the scissors and scalpel any callus, capsular remnants, etc., which interfere with the proper position of the fragment. It is in this way only that it is possible to avoid a displacement of the fragment, and to provide for its sufficient nutrition by imbedding it in fresh normal muscle- or tendon-tissue, instead of the poorly nourished cicatricial tissue. This probably accounts for the absence of even a partial necrosis of the detached bone segments. It is not always necessary to detach all connections with the surrounding structures. The detaching and the removal of tissue should only be continued until the proper position can be reestablished and maintained without difficulty. As a rule, this fixation can be accomplished by simply wedging the fragment in place in such a way that the distal fragment is moulded and placed into a groove of the proximal fragment (rarely the other way around). Circumstances alter cases, and the available material should be utilized as well as possible.

BONE GRAFT FOR BONE DEFECT OF SKULL

Various methods have been devised for employing the bone graft to restore the protecting skull, when a portion of it has been lost. Homoplastic and autoplastic grafts have been used. The latter type of graft should always be employed when possible. The outer table of the bone near the aperture has been split from the inner table and swung over to cover the opening, the overlying soft structures being undetached. As pointed out elsewhere, the pedunculated graft has doubtful advantages over the free graft, and if the bony outer table is not too thin, the simpler technique of the free transplant should be chosen. In children, where the skull is so thin that even pedunculated skin-covered flaps cannot be removed, periosteal bone flaps should be transferred from the tibia.

Röpke has suggested the resection of a portion of the wing of the scapula so that the graft be covered with periosteum on both surfaces.

Technique of Inserting Bone Graft for Skull Defect.—A scalp flap about $\frac{1}{4}$ to $\frac{3}{4}$ in. larger on every side than the skull opening, is turned back. The separation of the scalp and the dura is carefully done. If the dura is thickened and adherent to the brain cortex, it should be dissected away, providing cortical symptoms have appeared. The bony edge of the aperture is freshened by drilling several holes about $\frac{1}{4}$ to $\frac{1}{3}$ in. from the edge of the opening, with the Martel attachment to the author's motor. The thickness of the skull is then measured and a thin strip of bone is removed all around the edge of the opening with the motor saw protected by a proper sized washer. These saw-cuts should be made markedly bevelled. Additional protection to the dura from the saw can be furnished by slipping a thin piece of ivory under the bony edge which the saw is cutting.

All the dimensions of the operation are then carefully taken with calipers or compasses, and are transferred to the upper portion of the anterior internal surface of the tibia selected as the source of the graft material. The exact size and contour of the graft is outlined in the periosteum with the point of a scalpel,

from the caliper measurements. The graft is removed with the author's small saw, the cuts being bevelled the same as those at the edge of the skull opening, so that the transplant will rest firmly on the skull and cannot be driven down upon the brain beneath. The graft is held in place by two or three ligatures of medium kangaroo tendon placed in corresponding drill holes in the edges of the graft and skull opening. The upper end of the tibia is selected rather than the lower portion because its cortex is thinner and its surface flatter and broader. A graft covered

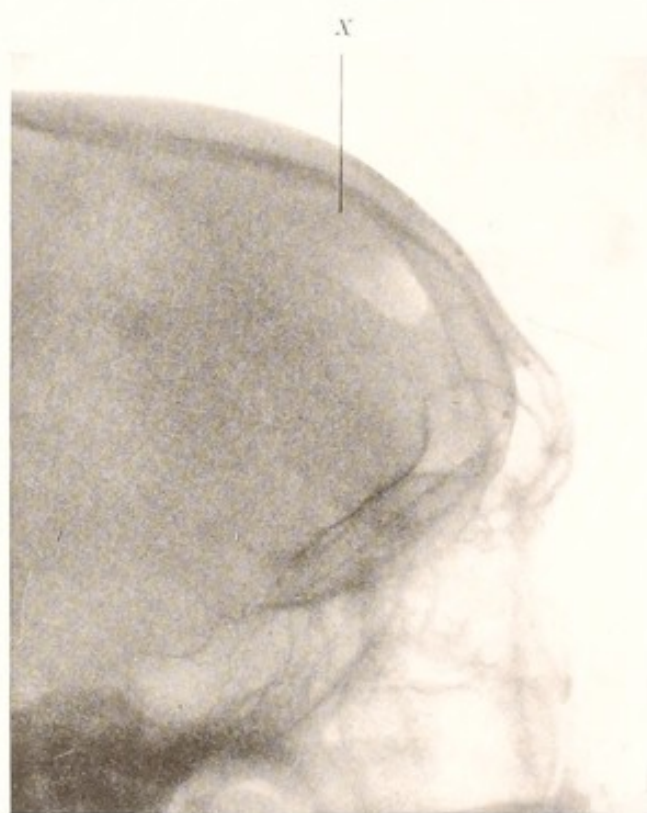


FIG. 313.—The upper dark area (X) was filled by a disc of bone, the lower light area by chips. (Rutherford Morison in *British Jour. of Surgery*.)

on both sides with periosteum may be obtained by the same technique from the scapula. A rib also has been utilized for the purpose.

If the dura is lacking, the brain should be covered by a thin sheet of collodion (Prime) or Cargile membrane just before the transplant is fixed in place. The scalp is closed in the usual way. This technique is applicable to all bone defects of the head such as mastoid depression following drainage operations, etc.

DEFECTS OF THE NOSE

Rhinoplasty by Means of a Finger as a Transplant.—Defects of the nose were previously restored, as a rule, by a reflection of periosteal and bony flaps from the forehead or cheeks and have the great disadvantage of leading to extensive scars and possible necrosis. Gold, silver wire, and other materials have been used in forming a framework for the new nose, but they should be discarded for this purpose because of the fact that as foreign substances they give rise to irritation and sooner or later have to be removed. The injection of paraffine is not liable to be permanent, and does not give a satisfactory framework. In a recent case of the author's when a tibial bone graft was inserted, paraffine which had been injected 5 years previously had entirely disappeared, leaving a deformity worse than the original.

Animal bone has been suggested by Sir Watson Cheyne for this purpose, but should not be employed on account of its unreliability.

Finney (*Surg. Gyn. and Obstet.*, June, 1907) used successfully a finger for material to reconstruct a nose that had been lost as a result of congenital lues. The bony support of the nose, including the septum, had been entirely destroyed. The integument remained, but was retracted and distorted. In place of the nose, there was a depression.

“The ring-finger of the left hand was selected as being the one best adapted for this purpose and the one perhaps least missed from the hand. The nail and matrix were completely removed, and the dorsum of the finger, up to the distal end of the first phalanx, was denuded of skin. The tip of the finger, throughout its entire circumference, was also denuded of skin for about the distance of 1 cm. from the end, leaving the distal phalanx exposed, although not completely so. All bleeding was stopped. The skin covering the nose, which was retracted and deformed, owing to cicatricial contraction, was then carefully freed from its attachments below, without making any external scar. The skin of the nose was then stretched carefully

and thoroughly by inserting the rounded end of a blunt instrument into the nasal opening, in order to give as much covering as possible for the new nose. The soft parts were next freed from the nasal process of the frontal bone, from within the nose, by a knife or instrument passed up through the nasal opening. The inner surface of the skin forming the nasal covering was denuded on the inner side in the middle line, in order that a raw surface might be opposed to the denuded surface of the dorsum of the finger, described above, which was then inserted into the nasal opening until the tip of the distal phalanx rested upon the nasal process of the frontal bone. The finger was held in place by sutures through the free border of the tip of the nose and the edge of the skin, over the dorsum of the first phalanx. Thus raw surfaces were opposed when it was desired to secure new blood supply for the finger, namely, on the tip and dorsum, while skin covered the palmar surface of the finger, which formed the inner lining of the nose. The hand was held in this position by adhesive strips and plaster-of-Paris bandages for 2 weeks, whereupon the finger was disarticulated at the metacarpophalangeal joint, and left for another week, at the end of which time the tissues in the middle line over the nasal spine of the superior maxilla were split, the finger flexed to a right angle at its proximal phalangeal joint, and the free end of the first phalanx then inserted into this opening and held there by stitches through the soft parts. The first phalanx then formed the column of the nose, while the second and third phalanges formed a very satisfactory support for the dorsum. Later, smaller operations, under cocaine, were performed to improve the appearance of the column, which of course was too large."

Since bone was not apposed to bone, the nose was freely movable from side to side, which was of advantage in case of injury. The results were very satisfactory.

Finney recommends that a piece of rubber tubing be kept in each nostril for a time after the operation, as this furnishes a support for the alæ and prevents undue contraction. Previous to the successful results reported by Finney, attempts to use the

finger by similar technique for this purpose had been made by Hardie (1875), Sabine (1879), Bloxam (1895), Tums (1897), and Vredena (1902).

The Free Bone Graft in Correction of Deformities of the Nose.—Carter, in considering deformities of the nose, divides them into two classes: (1) "Those without loss of tissue; (2) those in which there has been more or less destruction of the bony

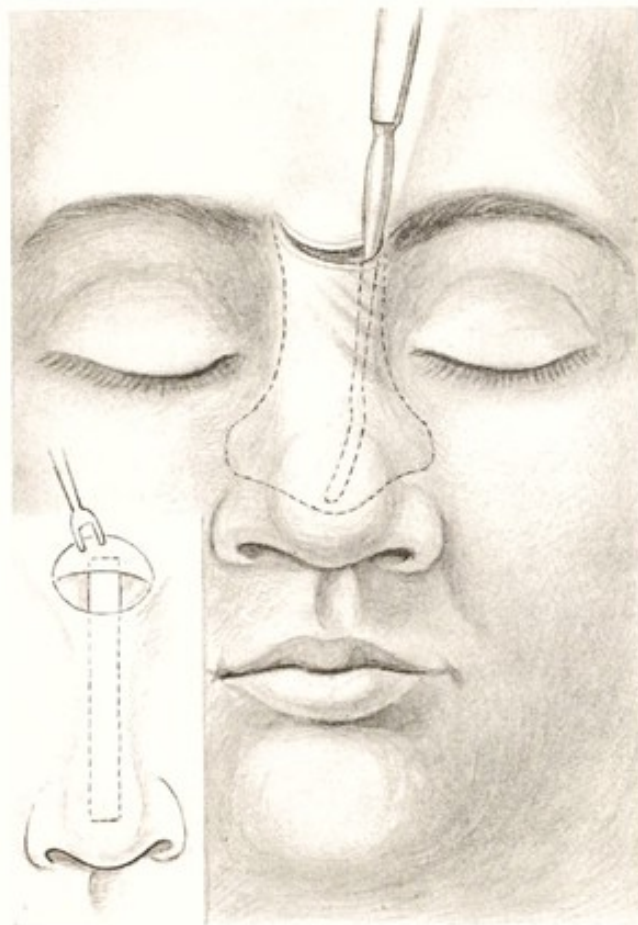


FIG. 314.—Bone transplantation for nasal deformity. The central figure shows method of elevating skin and sub-cutaneous tissues; the insert figure shows the bone in place. (William Wesley Carter, *Medical Record*.)

and cartilaginous framework of the organ. In the first class, the deformity is congenital, acquired, or due to traumatism," and is amenable to procedures other than bone transplantation. In the second class, where there is a deficiency in the bony framework, bone grafting is indicated. Cases of this class may be syphilitic, congenital, traumatic, or due to atrophic rhinitis.



FIG. 315.



FIG. 316.

FIGS. 315 AND 316.—Specific destruction of entire nose. In this case bone from rib was first transplanted into the arm, and later flap containing bone was transplanted to face. Patient breathes through nose. Condition excellent 2 years after operation. (William Wesley Carter, in *Medical Record*.)

Technique of Carter's Bone-graft Operation for Deformity of the Nose.—*Preparation of the Patient:* Several hours before the operation, the skin over the nose, face, and right side of the chest is scrubbed with green soap, followed by alcohol. A wet dressing of bichloride, 1-1,000, is then applied. Just before the operation, both operative fields are painted with tincture of iodine, and the eyebrows are covered with collodion. After the operation begins, no solution is used except sterilized physiological saline solution (salt, 9 gm.; sterile water, 1,000 cc.).

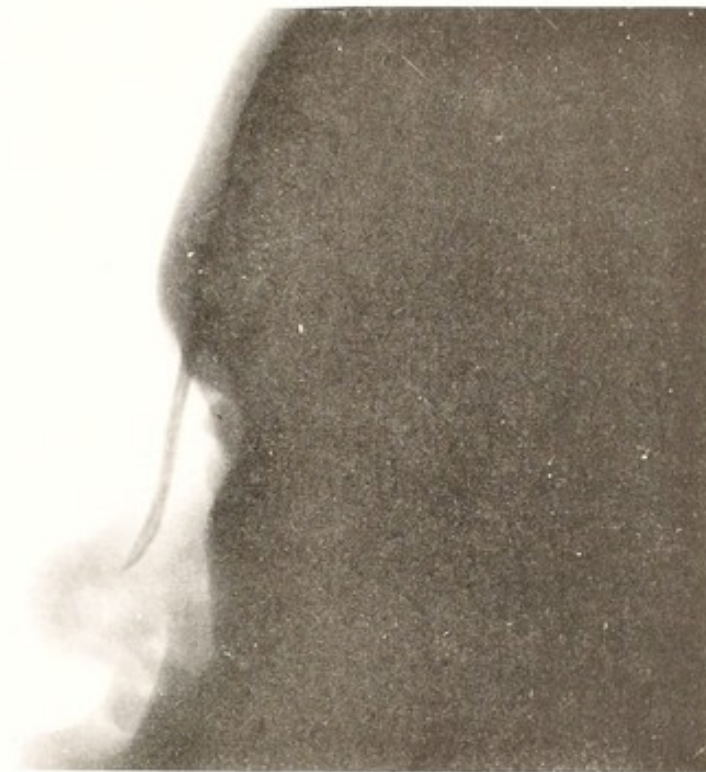

FIG. 317.—Bone with periosteum 7 months after transplantation. (William Wesley Carter, in *Medical Record*.)

Technique of Operation.—A curvilinear incision, convexity downward, is made between the eyebrows; this incision extends down to the periosteum over the frontal bone. Lifting the flap up, a transverse incision is made through the periosteum and into the bone in order to favor osteogenesis at this point. This incision corresponds to a line connecting the two cornua of the semilunar incision, and is at a point just below the glabella. Above this incision, the periosteum is elevated for about $\frac{3}{8}$ in.

With the sharp elevator devised especially for this purpose, the skin and subcutaneous tissue is then elevated over the dorsum of the nose, and, to an extent corresponding to the degree of deformity, over the sides of the nose and in some instances over the cheeks. If any of the nasal bone is left, its periosteum should be elevated so that the bone graft, when it is introduced, will lie in close contact with the bone and its torn periosteum.

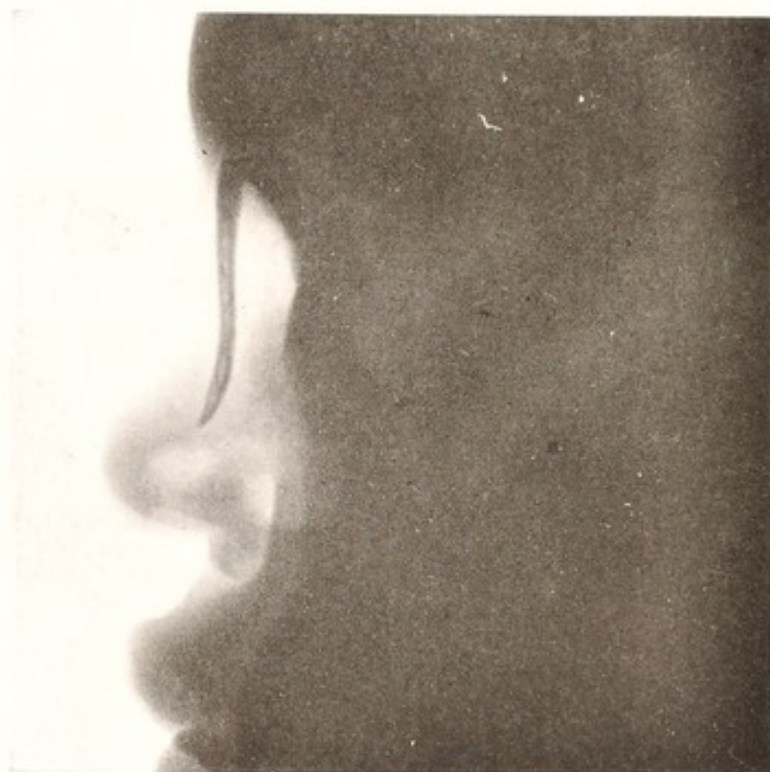

FIG. 318.—Bone transplanted with periosteum, 20 months after operation. (Same case as Fig. 317.) Note growth of bone and development of canal in center. (William Wesley Carter, in *Medical Record*.)

“The nose having been prepared for the reception of the graft, the next step is to remove about 2 in. of the ninth rib, preserving the periosteum on the outer surface. This piece of rib is then split in its transverse diameter; the outer half is shaped to suit the deformity, and the cancellous tissue is scraped away, leaving only a thin layer of compact bone. Without removing the blood which by this time has accumulated in the wound in the nose the bone graft is inserted nearly to the tip of the nose, and the upper end is carefully placed beneath

the periosteum over the frontal bone. The semilunar flap is then brought down into its place, and the wound closed with horsehair sutures. A collodion and gauze dressing is applied. The sutures may be removed on the fifth day, but great care must be exercised not to disturb in any way by manipulation the blood-clot which has formed about the graft.

"Bone grafts, either covered by periosteum or bare, but accidentally separated from the living periosteum-covered bone, appear to be osteo-conductive and very likely osteogenetic.

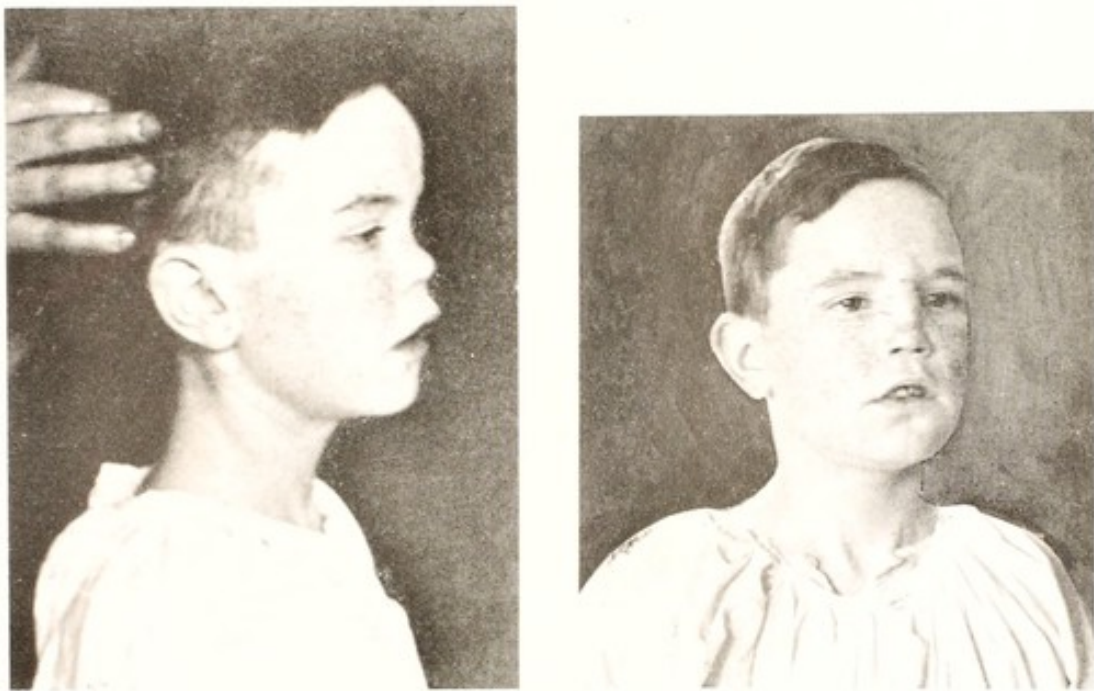


FIG. 319.—Before and after operation. Marked depression of the bridge of the nose coming on since disease of the nose and curettage 4 years before. A tibial bone graft was inserted by the author with an excellent cosmetic result.

In one case now under observation, the transplant is considerably larger than when it was introduced, the operation having been done 2 years and 5 months ago."

The author has obtained equally good results in this class of cases by placing the graft through an incision in the tip of the nose. The bed for the graft is prepared by thrusting a small scalpel longitudinally through the subcutaneous tissue of the nose, half way between the skin of the bridge and the mucous membrane beneath it, until the glabella of the frontal bone is reached. The periosteum of this bone is incised in the median

line, and with a small curette under the guidance of external palpation the periosteum is peeled side-ways and the bone beneath scarified for a fresh contact with the upper end of the graft. This incision leaves a scar so situated that it is hardly noticeable.

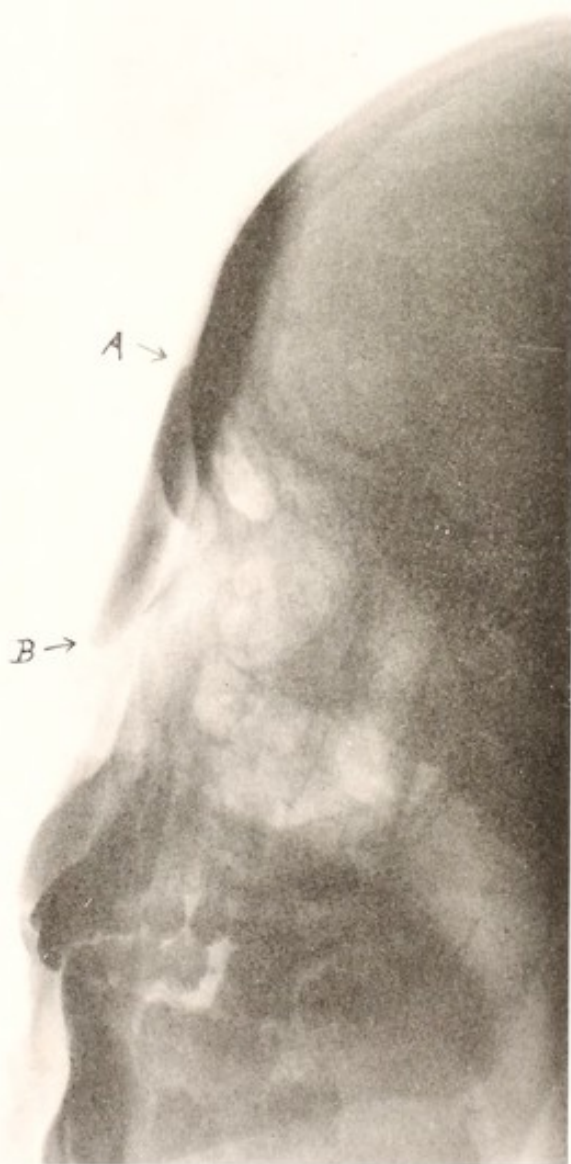


FIG. 320.—Röntgenogram of same case as Fig. 319. *AB* is bone graft in place and contacted with the anterior surface of nasal bones and glabella.

KANAHEL'S OSTEOPLASTIC CLOSURE OF THE FACIAL FORAMINA

Kanavel recommends his osteoplastic operation on those cases of tic douloureux in greatly debilitated patients who are not good surgical risks and who are not relieved by alcohol injections,

or in those patients who refuse intracranial procedures; in other words, where it has been customary to avulse the nerve or fill the foramina with foreign bodies. As a rule, the procedure can be done under local anesthesia, especially by trunk injection.

"In the operation on the infraorbital nerve, the incision is made in the line of the skin crease, and the nerve is slowly twisted from its trunk." A pedicle trap-door flap of periosteum about the foramen is turned up. The canal is carefully curetted, paying special attention to the foramen. A small bone plug

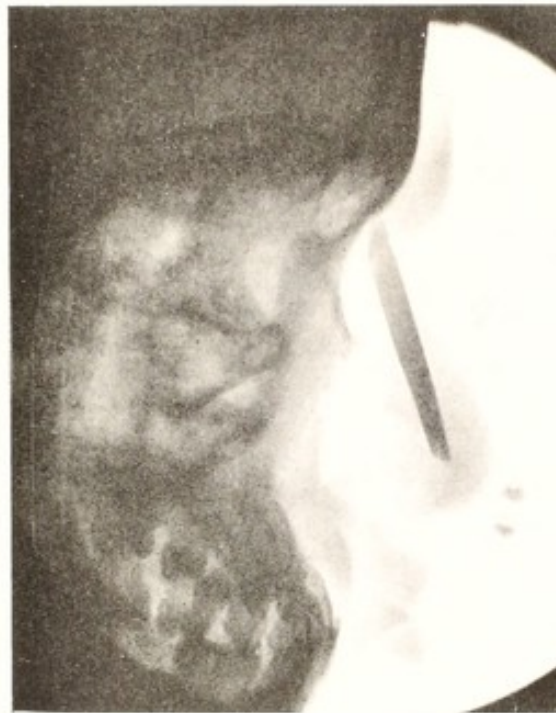

FIG. 321.—Graft inserted for depressed bridge of nose. (Author's case.)

$\frac{3}{4}$ in. in length and as near the size of the canal as possible is removed from the tibia, a piece of periosteum the size of a penny being left attached to its outer end. This is then wedged into the canal down to the attached periosteum. The adjacent periosteum is pushed over it, and the skin closed by a subcutaneous stitch. (See Fig. 325.) A word of warning should be given against extending the infraorbital incision too far toward the nose, thus endangering the lachrymal sac."

"In the inferior dental branch, an incision is made under the

angle of the jaw so that the scar is out of sight. The skin and muscles are next detached from the angle upward. A crucial

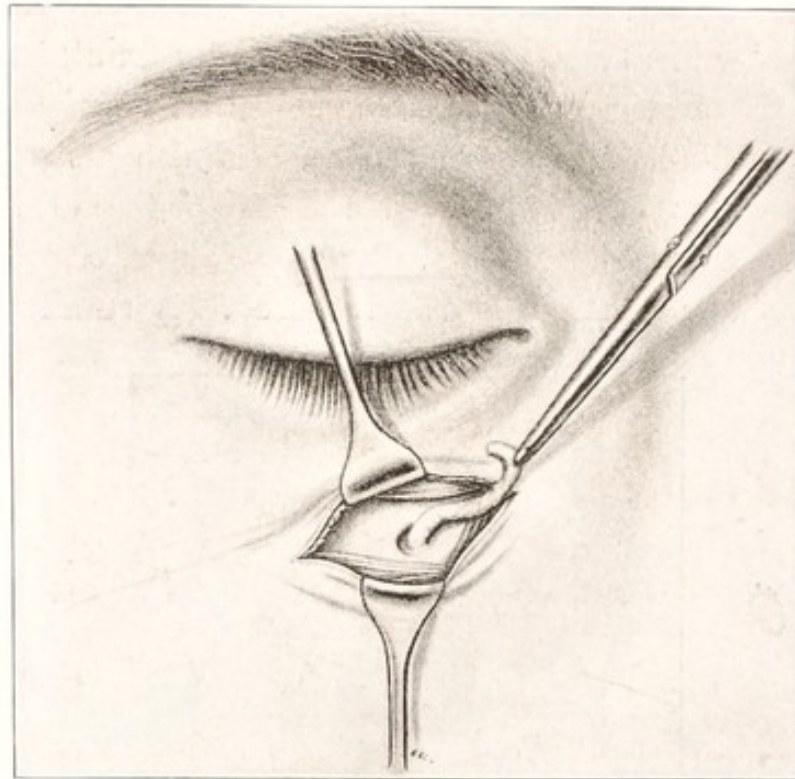


FIG. 322.—Method of exposing and removing the infraorbital nerve by torsion. (Kanavel, in *Journal of the American Medical Association*.)

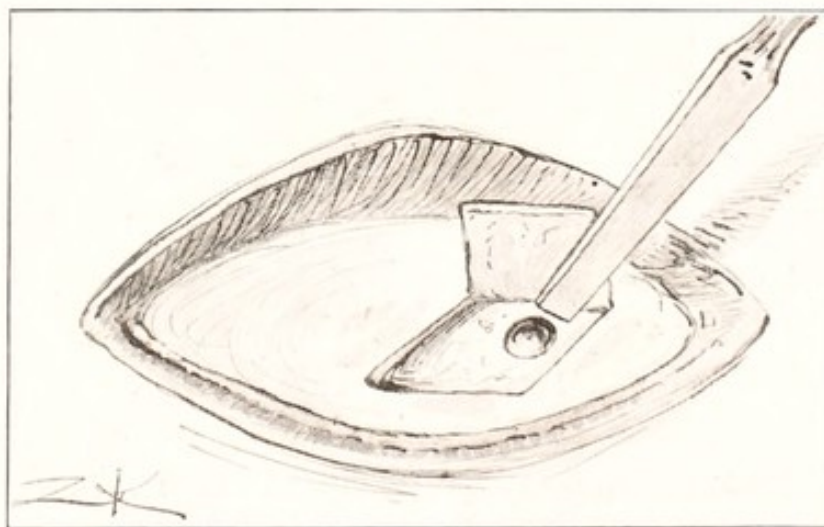


FIG. 323.—Breaking down the rim of the infraorbital canal. (Kanavel, in *Journal of the American Medical Association*.)

incision (Fig. 326) is made in the periosteum at the angle over the area of the nerve; then with a small trephine a button of the

outer plate of bone down to the medulla is removed (Fig. 327). The nerve is found and twisted out of its canal. The canal is

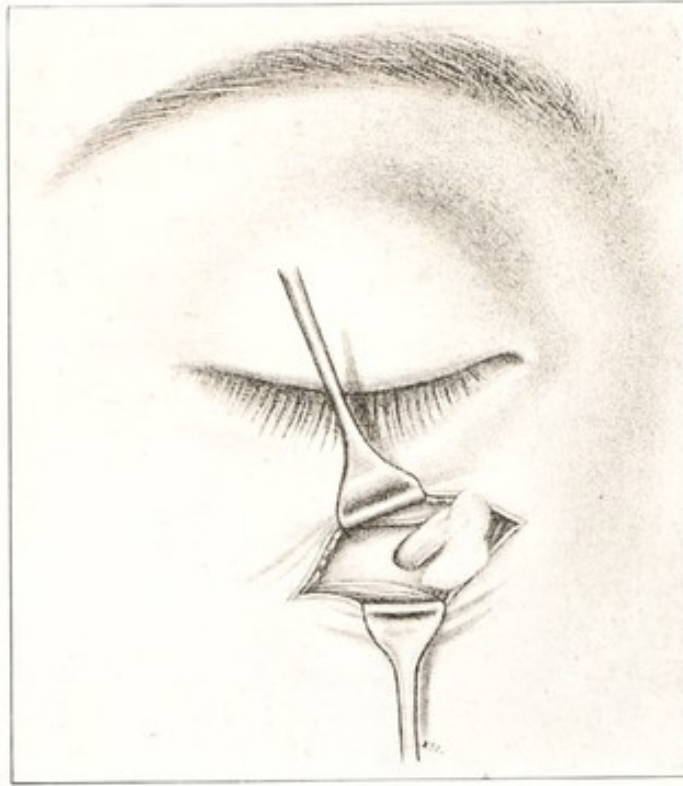


FIG. 324.—Transplanted bone plug in position with periosteum attached. (Kanavel, in *Journal of the American Medical Association*.)

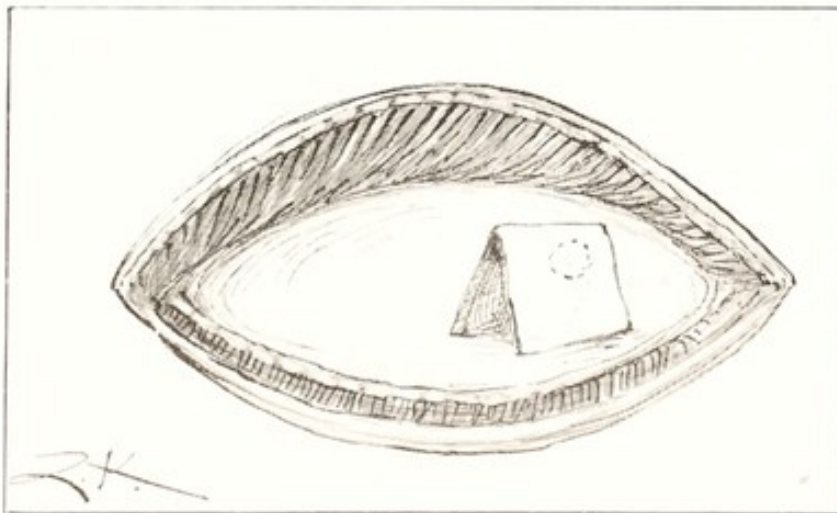


FIG. 325.—Detached periosteum thrown over site of operation. In the operation this could not be as satisfactorily done as would appear from the picture. (Kanavel, in *Journal of the American Medical Association*.)

then curetted thoroughly and broken down. The button of the outer plate is now reinserted, being rotated 90 degrees so

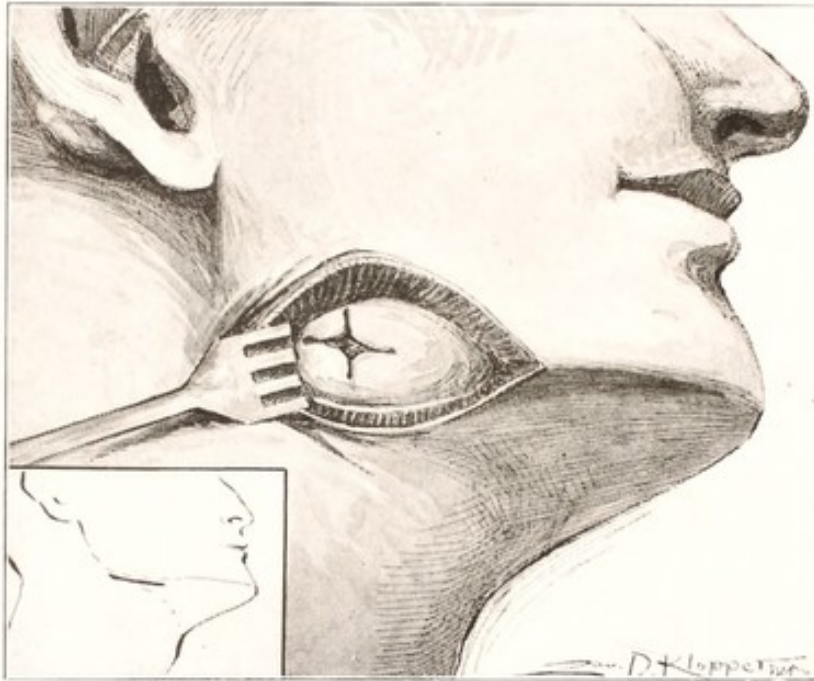


FIG. 326.—Crucial incision over site for bone plug over infradental canal. (Kanavel, in *Journal of the American Medical Association*.)




FIG. 327.—Torsion and removal of infradental nerve. (Kanavel, in *Journal of the American Medical Association*.)

that the destroyed canal of the button is at right angles to the canal in the bone, and it is driven into the medulla between the two tables at the proximal side for a fraction of a centimeter. The periosteum and muscle-flaps being now restored, the skin is

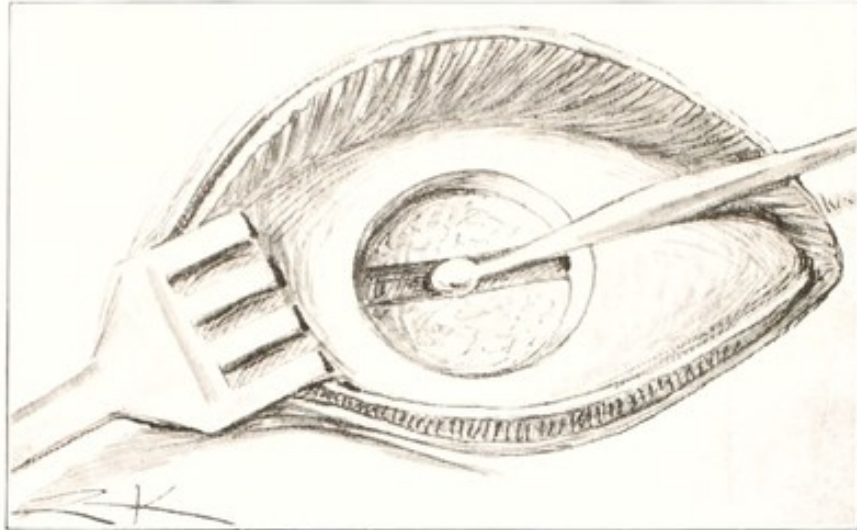


FIG. 328.—Curetting infradental canal. (Kanavel, in *Journal of the American Medical Association*.)

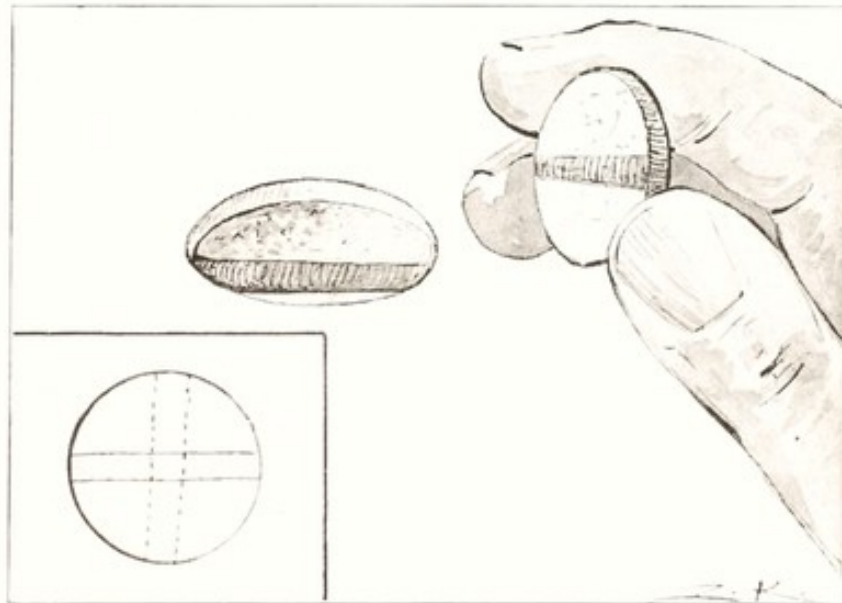


FIG. 329.—Replacing bone plug at right angle to the canal. (Kanavel, in *Journal of the American Medical Association*.)

closed by a subcutaneous stitch. The patient is warned not to use the jaw too violently for some weeks.

Care must be taken not to injure the facial nerve when retracting the muscle at the angle of the jaw."

INDEX OF NAMES

- ANHAUSEN, 28, 40
- BARTH, 24, 26, 40
Baum, 26
Beebe, 122
Berg, 56, 181, 185
Berkeley, 122
Bier, 26, 217
Bissell, 196
Bittner, 359
Blake, 154, 156
Bloxam, 395
Bond, 35, 36, 37, 304, 361, 365
Brackett, 254
Buchmann, 387
Buck, 196, 221, 275, 380
- CARR, 154
Carter, 32, 37, 395, 396, 397, 398
Charcot, 49, 144, 276, 296
Cheyne, 393
Chiari, 32
Codivilla, 324, 359
Corner, 344
Cotton, 19, 221, 236
Cotton and Loder, 18, 32
- DARLING, 224
Davis and Hunnicutt, 44
de Heyde, 39
Deutschländer, 305
Doyen, 52, 56
Duhamel, 39
Dunferline, 298
- ELY, 278
Enderlen, 386
Esmarch, 279
- FINNEY, 393, 394
Fragenheim, 18
- GALLIE, 324
Galloway, 45
- Gant, 264
Geist, 197
Gigli, 52
Goldthwait, 147, 300
Graser, 300
Grohe and Morfurgo, 17
Groves, 40, 149, 155, 158, 159
- Hahn, 359
Hardie, 395
Hartley and Kenyon, 52, 55, 58, 63
Havers, 39
Hawley, 135, 175, 176, 177, 178, 179
181, 184, 225, 227
Hitzrot, 150, 156, 164, 214, 219, 225
Hoffa, 244, 245, 250
Hollis, 262
Hunnicutt and Davis, 44
Huntington, 35, 359
- JANEWAY, 17
Jones (Ellis W.), 42, 43
Jones (Robert), 22, 23, 150, 365, 366
- KANAVEL, 49, 400, 402, 403, 404, 405
Katzenstein, 381, 382
Kausch, 24, 25
Keller, 110
Kenyon and Hartley, 52, 55, 58, 63
Killian, 135
Kirmisson, 370, 371
Koch, 64, 297, 299, 335
Krogius, 297
Kümmell, 144
Küttner, 22, 383, 386, 387
- LAEWEN, 27
Lambotte, 56, 179, 184, 213
Lane, 137, 149, 151, 153, 154, 165,
167, 168, 170, 171, 175, 180, 181,
182, 193, 194, 195, 199, 202, 203,
209, 210, 211, 212, 213, 216, 219
Lange, 72
Lasse, 390

- Lathrop, 160
 Lexer, 20, 22, 26, 50, 333, 334, 383,
 384, 385, 386, 388, 390
 Loder and Cotton, 18, 32
 Lowman, 56, 180, 185
 Lufborrow, 348
 Lyle, 216, 217, 263
- MACEWEN, 18, 36, 39, 88, 126, 199
 Martel, 62, 391
 Martin, 153, 154
 Mayer, 18
 Müller, 359
 McWilliams, 18, 19, 39
 Merrem, 18
 Morfurgo and Grohe, 17
- NEUGEBAUER, 135
 Nichols, 35, 359
- OLLIER, 18, 40, 53, 359
 Osgood, 279
- PALMER, 143
 Parkhill, 213
 Peck, 98
 Perthes, 389
 Phems, 310
 Phelpister, 18, 208
 Plummer, 201
 Pott, 64
- RECLUS, 242
 Roberts, 50, 153, 265, 268
 Rogers, 231, 277
 Röpke, 391
- Roux, 32, 46
 Rovsing, 373, 386
 Ryerson, 140
- SABINE, 395
 Sawtelle, 214
 Schewandin, 334
 Schulze-Berge, 38, 306
 Seudder, 221
 Silver, 135
 Soule, 112, 115, 117, 118, 119, 121,
 327, 331, 334
 Stillé, 215
 Stimson, 215, 220
 Stöhr, 30
 Stone, 35, 359, 360, 361, 362, 363,
 364
- TENNEY, 298
 Thomas, 144, 165, 310
 Troja, 39
 Tschireh, 369
 Tums, 395
- VAN HORN, 214
 Vredena, 395
 Vulpius, 359
- WALKER, 221
 Walther, 18, 373
 Whitlock, 297, 298, 299
 Whitman, 178, 221, 224, 230, 333
 Wille, 344
 Wolff, 29, 33, 34, 35, 36, 37, 38, 168,
 189, 211, 288, 353, 365, 386
 Wrede, 335

INDEX

- ABSENCE of fibula, 383
 congenital, Albee's technique in, 343
 of tibia, 359
 Albee's technique in, 367
 Huntington's technique in, 359
 Stone's technique in, 359
- Albee's arthrodesis operation of hip, 252
 bone-wedge graft operation for
 acquired dislocation of
 hip, 245
 for congenital dislocation
 of hip, 245
- electric motor operating outfit, 52
 cutting instruments, 56
 description, 55
 dowel instrument or
 lathe, 57
 guard with spray, 58
 Hartley-Kenyon method
 of sterilization, 58
 manner of holding saw, 61
 Martel's attachment, 62
 method of putting to-
 gether, 59
 single saw, 56
 small saw, 58
 technique of using, 63
 twin saw, 57
 twist drills, 58
- inlay method, 31
osteotome, 77
technique in absence of tibia, 367
 in acquired clubfoot, 321
 Soule's modification, 327
 in ankylosis of hip, 252
 in Charcot's knee, 296
 in clubfoot, 308
 in congenital absence of fibula,
 343
 dislocation of patella, 301
 in flat-foot, 331
 in habitual dislocation of pa-
 tella, 301
- Albee's technique in paralytic scoli-
 osis, 129
 in Pott's disease, 73, 76, 78
 advantages, 102
 contra-indication to, 104
 convalescence after, 99
 dressings after, 93
 experimental application of
 method to spine of dog, 107
 external support to spine
 after, 102
 fixation of graft in position,
 85
 indications for, 104
 method of fixation in bed
 after, 99
 post-operative treatment,
 general, 99
 immediate, 96
 prognosis after, 104
 removal of graft, 81
 summary, 102, 124
 in spina bifida, 141
 in spondylolisthesis, 137
 in stiffening knee in infantile
 paralysis, 293
 in tuberculosis of sacroiliac
 joint, 145
 of bone-graft peg in fracture of
 os calcis, 236
 of inlay bone graft in fracture of
 patella, 232
 in fractures, 149, 181
 with wedge cross-sec-
 tion, 185
 in tuberculosis of knee-
 joint, 281
- Ankle-joint, arthrodesis of, 333
 astragalus used as transplant
 for, 335
 Lexer's technique, 333
 Wrede's, 335
 tuberculosis of, bone graft in, 338
 tuberculous osteitis of, bone graft
 in, 338

- Ankylosing hip-joint, operative methods, 242
 knee-joint in infantile paralysis, 290
 Albee's technique, 293
 Hibbs' technique, 293
- Ankylosis of hip, Albee's operation for, 252
- Arthritis deformans of hip, Albee's operation, 252
 operative treatment, 249
- Arthrodesis of ankle-joint, 333
 astragalus used as transplant for, 335
 Lexer's technique, 333
 Wrede's, 335
 of astragalo-scaphoid joint for flat-foot, 330
 of knee-joint in infantile paralysis, 290
 Albee's technique, 293
 Hibbs' technique, 293
 operation of hip, Albee's technique, 252
- Asepsis, 29
- Astragalo-scaphoid joint, arthrodesis of, for flat-foot, 330
- Astragalus graft for loss of femoral head and neck, Albee's modification of Roberts' technique, 265
 used as transplant to arthrodesis ankle, 335
- Autogenous bone graft, 23, 27
 in fracture of patella, 230
 in osteitis fibrosa cystica of upper end of femur, 268
- BACTERIA-RESISTING properties of bone graft, 44
- Baking in fractures, 215
- Blood, danger of, 20
- Blood-vessels of bone, 30
- Boiled bone as substitute for bone graft, 24, 26
- Bond's theory, 37
- Bone, blood-vessels of, 30
 boiled as substitute for bone graft, 24, 26
 contact, 31
 defect of skull, bone graft for, 391
- Bone graft, autogenous, 23, 27
 in fracture of patella, 230
 in osteitis fibrosa cystica of upper end of femur, 268
 bacteria-resisting properties of, 44
 contra-indications, 51
 factors controlling growth and development, 35
 failures in use of, 20
 fixation in position, in Pott's disease, 85
 for radius, 373
 from fibula to replace upper end of femur, 268
 from tibia to replace upper end of femur, 268
 fundamental principles underlying use of, 17
 rules for, 28
 general indications, 48-50
 heteroplastic, 21
 difficulty with, 22
 histological rôle of, 18
 homoplastic, 20
 fibrous encapsulation in, 20
 in absence of fibula, 383
 of tibia, 359
 in acquired clubfoot, 319
 in angular curvature of spine, 64
 in caries of spine, 64
 in Charcot's disease, 144
 in clubfoot, 308
 advantages of, 319
 in congenital absence of fibula, Albee's technique, 343
 in defects of nose, 395
 Carter's technique, 397
 of skull, 391
 in diseases and deformities of foot and leg, 308
 in disintegration of tarsal bone, 354
 in dislocation fractures, 387
 of sacroiliac joint, 147
 in fracture of cervical spine, 144
 of spine, 143
 in hump-back, 64
 in hydrorrhachis, 140
 in Kümmell's disease, 144
 in kyphosis, 64

- Bone graft in lateral curvature of spine, 126
 in lesions of spine, 64
 in neuropathic spine, 144
 in osteitis fibrosa cystica of humerus, 378
 in paralytic equino varus, 319
 scoliosis, 126
 mechanics of correction by, 128
 in Pott's disease, 64
 in relaxation of sacroiliac joint, 147
 in restoration of bones of foot, 354
 in sarcoma of bone, 306
 of radius, 373
 in spina bifida, 140
 ventosa, 376
 in spondylitis, 64
 in spondylolisthesis, 134
 in tarsal disease, 338
 in traumatic spondylitis, 144
 in tuberculosis of bone, 343
 of sacroiliac joint, 144
 of vertebrae, 64
 in tuberculous osteitis of ankle, 338
 inlay, in fracture of both bones
 of forearm, 218
 of clavicle, 216
 of jaw, 239
 of olecranon, 218
 of patella, 232
 of ulna and radius, 218
 in fractures, 149
 after-treatment, 216
 Albee's technique, 149, 181
 with wedge cross-section, 185
 armamentarium for, 179
 technique, 179
 in pseudarthrosis, 192
 after-treatment, 216
 in stiffening knee-joint in infantile paralysis, 290
 in tuberculous knee-joints, 276
 Albee's technique, 281
 osteitis of knee in adult, 277
- Bone graft inlay, in tuberculous osteitis of knee in childhood, 276
 intramedullary, 26
 Kausch's table of value of different materials for, 25
 miscellaneous surgical uses, 357
 of small bones, 383
 preservation of, 47
 removal of, for use in Pott's disease, 81
 growth, continuous, grafting of epiphysis to stimulate, 304
 hypertrophy of, 38
 infection of, 41
 sarcoma of, bone graft in, 306
 tarsal, disintegration of, bone graft in, 354
 tuberculosis of, bone graft in, 343
- Bone-graft peg in fracture of neck of femur, 222
 Albee's technique, 225
 indications for, 224
 of os calcis, 235
 Albee's technique, 236
 fixation dressing after, 238
 in fractures, 212
 wedge in acquired dislocation of hip, 242
 Albee's technique, 245
 in congenital dislocation of hip, Albee's technique, 245
 in paralytic dislocation of hip, 242
 in relapsing congenital dislocation of hip, 242
- Bone-marrow, grafting of, into spleen, 33
- Bones of foot, restoration of bone graft in, 354
 small, transplantation of, 383
- Braces in Pott's disease, 69
- Brackett's method of lateral approach to hip-joint, 254
- British Medical Association, council of, report of, on treatment of fractures, 158
- Buchmann's technique in bony ankylosis of elbow-joint, 387
- CAMBium layer of periosteum, 39
- Caries of spine, 64

- Carter's technique of bone graft operation for deformity of nose, 397
- Cellular life, 17
duration of, 17
- Cervical spine, fracture of, 144
- Charcot's disease, 144
Albee's technique for, 296
- Clamp, Parkhill, in fractures, 213
- Clavicle, fracture of, inlay bone graft in, 216
rib graft for, 369
- Clubfoot, 308
acquired, 319
Albee's technique, 321
Soule's modification, 327
advantages of bone graft in, 319
Albee's technique, 308
paralytic, 319
sling, 317
- Contra-indications to bone grafts, 51
- Convalescence after Albee's technique in Pott's disease, 99
- Council of British Medical Association, report of, on treatment of fractures, 158
- Curvature, angular, of spine, 64
lateral, of spine, 126
- DANGLE hip, operative treatment, 249
- Deformities of foot and leg, 308
of nose, 393, 395
Carter's technique, 397
- Dislocation, congenital, of patella,
Albee's technique, 301
fracture, bone graft in, 387
habitual, of patella, 296
Albee's technique, 301
Dumferline's technique, 298
Goldthwait's technique, 300
Graser's technique, 300
Krogius' technique, 297
Murphy's technique, 300
Whitlock's technique, 299
of hip, acquired, Albee's bone-wedge graft operation for, 245
bone-graft wedge in, 242
congenital, Albee's bone-wedge graft operation for, 245
relapsing, bone-graft wedge in, 242
- Dislocation of hip, paralytic, bone-graft wedge in, 242
of sacroiliac joint, 147
Goldthwait's symptom, 147
- Dowel instrument, 57
- Dressing after Albee's technique in paralytic scoliosis, 131
in Pott's disease, 93
fixation, after bone-graft peg in fracture of os calcis, 238
for fractures, 214
- Drills, twist, 58
- Dumferline's technique for habitual dislocation of patella, 298
- ELECTRIC motor operating outfit, 52. See also *Albee's electric motor operating outfit*.
- Epiphysis, grafting of, to stimulate continuous bone growth, 304
- Equino varus, paralytic, 319
- FACIAL foramina, Kanavel's osteoplastic closure of, 400
neuralgia, Kanavel's operation for, 400
- Femur, head and neck, astragalus graft for loss of, Albee's modification of Roberts' technique, 265
neck of, fracture, 220
bone-graft peg in, 222
Albee's technique, 225
indications for, 224
treatment of, 221
upper end, osteitis fibrosa cystica of, autogenous bone graft in, 268
- Fibrous encapsulation in homoplasty, 20
- Fibula, absence of, bone graft in, 383
bone graft from, to replace upper end of femur, 268
congenital absence of, Albee's technique in, 343
- Finger as transplant, rhinoplasty by means of, 393
- Finney's rhinoplasty by means of finger, 393
- Fixation dressing after bone-graft peg in fracture of os calcis, 238

- Fixation dressing for fractures, 214
 of fractures by absorbable or non-absorbable ligature material, 213
 by bone-graft dowel pegs, 212
- Flat-foot, Albee's technique, 331
 arthrodesis of astragalo-scaploid joint for, 319
- Flexible probe, 80
- Foot and leg, diseases and deformities, bone graft in, 308
 bones of, restoration of, bone graft in, 354
- Foramina, facial, Kanavel's osteoplastic closure of, 400
- Forearm, both bones, fracture of, inlay bone graft in, 218
- Fracture of both bones of forearm, inlay bone graft in, 218
 of cervical spine, 144
 of clavicle, inlay bone graft in, 216
 of jaw, inlay bone graft in, 239
 of neck of femur, 220
 bone-graft peg in, 222
 Albee's technique, 225
 indications for, 224
 treatment, 221
 of olecranon, inlay bone graft in, 218
 of os calcis, bone-graft peg in, 235
 Albee's technique, 236
 fixation dressing after, 238
 of patella, Albee's technique, 232
 autogenous bone graft for, 230
 of radius and ulna, inlay bone graft in, 218
 of spine, 143
 of ulna and radius, inlay bone graft in, 218
- Fractures, Albee's technique of inlay bone graft in, 149, 181
 with wedge cross-section, 185
 baking in, 215
 dislocation, bone graft in, 387
 fixation of, by absorbable or non-absorbable ligature material, 213
 by bone-graft dowel pegs in, 212
 dressing for, 214
- Fractures, fresh, after-treatment of, 215
 operative treatment, 171
 preparation of patient, 177
 time for, 171
- inlay bone graft in, 149
 after-treatment, 216
 Albee's technique, 149, 181
 with wedge cross-section, 185
 armamentarium for, 179
 technique of, 179
- kangaroo tendon for, 214
- Lane's plates in, 153, 165
- liniments in, 216
- operative treatment, 149
 contra-indications to, 214
 indications for, 156
 osteoblasts in repair of, 35
- Parkhill clamp in, 213
- physiological repair of, 35
- plaster-of-Paris splint in, 214
- pseudarthrosis after, inlay bone graft for, 192
 after-treatment, 216
- report of council of British Medical Association on treatment of, 158
- wiring of, 213
- Freezing for preservation of bone-graft material, 47
- Functional irritation, Roux's post-operative, 32
- Fundamental rules for bone grafts, 28
- GOLDTHWAIT'S symptom in dislocation of sacroiliac joint, 147
 technique for habitual dislocation of patella, 300
- Graft, astragalus, for loss of femoral head and neck, Albee's modification of Roberts' technique, 265
 bone. *See Bone graft.*
 of epiphysis to stimulate continuous bone growth, 304
 rib, for clavicle, 369
- Graser's technique for habitual dislocation of patella, 300
- Guard with spray, 58

- HABITUAL dislocation of patella, 296
 Albee's technique, 301
 Dumferline's technique, 298
 Goldthwait's technique, 300
 Graser's technique, 300
 Krogius' technique, 297
 Murphy's technique, 300
 Whitlock's technique, 299
- Hæmatoma, 30
- Half-joint transplantation, 386
- Hartley-Kenyon method of sterilization of electric motor operating outfit, 58
- Hawley table, 175, 176, 177, 178
 Silver's attachment to, 135
- Hematoma, 30
- Heteroplastic grafts, 21
 difficulty with, 22
- Hibbs' operation for stiffening knee-joint in infantile paralysis, 292
- Hip-joint, Albee's arthrodesis operation of, 252
 ankylosing, operative methods, 242
 arthritis deformans of, Albee's operation for, 252
 operative treatment, 249
 dangle, operative treatment, 249
 disease, tuberculous, adult, operative treatment, 249
 dislocation of, acquired, Albee's bone-wedge graft operation for, 245
 bone-graft wedge in, 242
 congenital, Albee's bone-wedge graft operation for, 245
 relapsing, bone-graft wedge in, 242
 paralytic, bone-graft wedge in, 242
 osteoarthritis of, Albee's operation for, 252
 operative treatment, 249
 paralytic, operative treatment, 249
 remodelling of, operative methods for, 242
 traumatic, operative treatment, 249
 tuberculosis of, adult, operative treatment, 249
- Homoplastic grafts, 20
- Humerus, osteitis fibrosa cystica of, 378
- Hump-back, 64
- Huntington's technique in absence of tibia, 359
- Hydrorrhachis, 140
- Hypertrophy of bone, 38
- INDICATIONS, general, for bone grafts, 48-50
- Infantile paralysis, Hibbs' operation for stiffening knee-joint in, 292
 inlay bone graft for stiffening knee in, 290
 stiffening knee in, Albee's technique, 293
- Infection of bone, 41
- Inlay bone graft, 31
 in fracture of clavicle, 216
 of jaw, 239
 of olecranon, 218
 in fractures, 149
 after-treatment, 216
 Albee's technique, 149, 181
 with wedge cross-section, 185
 armamentarium for, 179
 of both bones of forearm, 218
 of patella, 232
 of ulna and radius, 218
 technique, 179
 in pseudarthrosis, 192
 after-treatment, 216
 in stiffening knee-joint in infantile paralysis, 290
 in tuberculous knee-joints, 276
 Albee's technique, 281
 osteitis of knee in adults, 277
 in childhood, 276
- Intramedullary graft, 26
- Irritation, functional, Roux's post-operative, 32
- Ivory as substitute for bone grafts, 26
- JAW, fracture of, inlay bone graft in, 239
- Joints, transplantation of, 305, 384
- KANAVEL'S osteoplastic closure of facial foramina, 400

- Kangaroo tendon for fractures, 214
- Kausch's table of value of different materials for bone transplantation, 25
- Knee-joint, Chareot's, Albee's technique, 296
 stiffening of, in infantile paralysis, 290
 Albee's technique, 293
 Hibbs' technique, 292
 transplantation of, 305
 tuberculosis of, inlay bone graft for, 276
 Albee's technique, 281
 tuberculous osteitis of, in adult, inlay bone graft for, 277
 in childhood, inlay bone graft for, 276
- Krogius' technique for habitual dislocation of patella, 297
- Kümmell's disease, 144
- Kyphosis, 64
- LANE'S plates in fractures, 153, 165
- Lange's treatment of Pott's disease, 72
- Lathe, 57
- Law, Wolff's, 29, 33, 35
- Layer, cambium, of periosteum, 39
- Leg and foot, diseases and deformities, 308
- Lexer's technique for arthrodesis of ankle, 333
- Ligature material, absorbable or non-absorbable, fixation of fractures by, 213
- Liniments in fractures, 216
- MARTEL'S attachment to Albee's electrical surgical outfit, 62
- Murphy's technique for habitual dislocation of patella, 300
- NEURALGIA, facial, Kanavel's operation for, 400
- Neuropathic spine, 144
- Nose, defects of, 393, 395
 Carter's technique, 397
- OLECRANON, fracture of, inlay bone graft in, 218
- Operative treatment of fractures, 149
 contra-indications, 214
 indications, 156
 inlay bone graft in, 149
 of fresh fractures, 171
 preparation of patient, 177
 time for, 171
- Os calcis, fracture of, bone-graft peg in, 235
 Albee's technique, 236
 fixation dressing after, 238
- Osteitis fibrosa cystica of humerus, 378
 of upper end of femur, 268
 tuberculous, of ankle, bone graft in, 338
 of knee, in adult, inlay bone graft for, 277
 in childhood, inlay bone graft for, 276
- Osteoarthritis of hip, Albee's operation for, 252
 operative treatment, 249
- Osteoblasts in repair of fractures, 35
- Osteogenesis, relative, 199
- Osteoplastic closure, Kanavel's, of facial foramina, 400
- Osteotome, Albee's, 77
- PARALYSIS, infantile, Hibbs' operation for stiffening knee-joint in, 292
 inlay bone graft for stiffening knee in, 290
 stiffening knee in, Albee's technique, 293
- Paralytic clubfoot, 319
 dislocation of hip, bone-graft wedge in, 242
 equino varus, 319
 hip, operative treatment, 249
 scoliosis, 126
 Albee's technique, 129
 post-operative treatment, 131
 mechanics of correction by bone graft, 128
- Parkhill clamp in fractures, 213

- Patella, congenital dislocation of,
 Albee's technique, 301
 fracture of, Albee's technique in,
 232
 autogenous bone graft for, 230
 habitual dislocation of, 296
 Albee's technique, 301
 Dumferline's technique, 298
 Goldthwait's technique, 300
 Graser's technique, 300
 Krogius' technique, 297
 Murphy's technique, 300
 Whitlock's technique, 299
- Peg, bone-graft. See *Bone-graft
 peg.*
- Periosteum, cambium layer of, 39
 rôle of, 38
 transplanted, viability of, 17
- Plaster-of-Paris jackets in Pott's dis-
 ease, 69
 splint in fractures, 214
- Post-operative treatment after
 Albee's technique in para-
 lytic scoliosis, 131
 general, after Albee's technique
 in Pott's disease, 99
 immediate, after Albee's tech-
 nique in Pott's disease, 96
- Pott's disease, 64
 Albee's technique, 73, 76, 78
 advantages, 102
 contra-indication to, 104
 convalescence after, 99
 dressings after, 93
 experimental application of
 method to spines of dogs,
 107
 external support to spine
 after, 102
 fixation of grafts in posi-
 tion, 85
 indications for, 104
 method of fixation in bed
 after, 99
 post-operative treatment,
 general, 99
 immediate, 96
 prognosis after, 104
 removal of graft, 81
 summary, 102, 124
 braces in, 69
- Pott's disease, duration, 105
 Lange's treatment, 72
 location, 105
 plaster-of-Paris jackets in, 69
 recumbency in, 69
- Preparation of patient for operative
 treatment of fresh fractures, 177
- Preservation of bone graft, 47
- Probe, flexible, 80
- Pseudarthrosis, inlay bone graft in,
 192
 after-treatment, 216
- RADIUS and ulna, fracture of, inlay
 bone graft in, 218
 bone graft for, 373
 sarcoma of, bone graft in, 373
- Recumbency in Pott's disease, 69
- Relaxation of sacroiliac joint, 147
- Remodelling hip-joint, operative
 methods, 242
- Report of Council of British Medical
 Association on results of treatment
 of fractures, 158
- Rhinoplasty by means of finger as
 transplant, 393
- Rib graft for clavicle, 369
- Roberts' technique of astragalus
 graft for loss of femoral head and
 neck, Albee's modification, 265
- Roux's post-operative functional ir-
 ritation, 32
- SACROILIAC joint, dislocation of, 147
 Goldthwait's symptom, 147
 relaxation of, 147
 tuberculosis of, 144
 Albee's technique, 145
- Salt solution for preservation of
 bone-graft material, 47
- Sarcoma of bone, 306
 of radius, 373
- Saw, single, 56
 small, 58
 twin, 57
- Scoliosis, paralytic, 126
 Albee's technique, 129
 post-operative treatment,
 131
 mechanics of correction by bone
 graft, 128

- Silver's attachment to Hawley table, 135
- Skull, defect of, 391
- Sling, clubfoot, 317
- Soil, wound, 19
- Soule's modification of Albee's technique for acquired clubfoot, 327
- Spina bifida, 140
Albee's technique, 141
ventosa, 376
- Spine, angular curvature of, 64
caries of, 64
cervical, fracture of, 144
curvature of, lateral, 126
external support to, after Albee's technique in Pott's disease, 102
fracture of, 143
lesions of, 64
neuropathic, 144
tuberculosis of, 64
- Spleen, grafting of bone-marrow into, 33
- Splint, plaster-of-Paris, in fractures, 214
- Spondylitis, 64
traumatic, 144
- Spondylolisthesis, 134
Albee's technique, 137
- Sterilization of electric motor operating outfit, Hartley-Kenyon method, 58
- Stiffening of knee-joint in infantile paralysis, 290
Albee's technique, 293
Hibbs' technique, 293
- Stone's technique in absence of tibia, 359
- Syphilis, 51
- TABLE, Hawley, 175, 176, 177, 178
Silver's attachment to, 135
- Talipes equino varus, 319
- Tarsal bone, disintegration of, 354
disease, 338
- Tibia, absence of, 359
Albee's technique in, 367
Huntington's technique in, 359
- Tibia, absence of, Stone's technique in, 359
bone graft from, to replace upper end of femur, 268
- Tic douloureux, Kanavel's operation for, 400
- Transplantation, half-joint, 386
of joints, 305, 384
of knee-joint, 305
of periosteum, viability of, 17
of small bones, 383
whole-joint, 386
- Trauma, 29
- Traumatic hip, operative treatment, 249
spondylitis, 144
- Tuberculosis of ankle-joint, 338
of bone, 343
of hip, adult, operative treatment, 249
of knee-joint, inlay bone graft for, 276
Albee's technique, 281
of sacroiliac joint, 144
Albee's technique, 145
of vertebrae, 64
- Tuberculous osteitis of ankle, 338
of knee in adult, inlay bone graft for, 277
in childhood, inlay bone graft for, 276
- Twin saw, 57
- Twist drills, 58
- ULNA and radius, fracture of, inlay bone graft in, 218
- VASELINE for preservation of bone-graft material, 47
- Vertebrae, tuberculosis of, 64
- WHITLOCK'S technique for habitual dislocation of patella, 299
- Whole-joint transplantation, 386
- Wiring of fractures, 213
- Wolff's law, 29, 33, 35
- Wound soil, 19
- Wrede's arthrodesis of ankle-joint, 335



SAUNDERS' BOOKS

on

**Practice, Pharmacy,
Materia Medica, Thera-
peutics, Pharmacology,
and the Allied Sciences**

W. B. SAUNDERS COMPANY

WEST WASHINGTON SQUARE

PHILADELPHIA

9, HENRIETTA STREET, COVENT GARDEN, LONDON

**Garrison's
History of Medicine**

History of Medicine. With Medical Chronology, Bibliographic Data, and Test Questions. By FIELDING H. GARRISON, M. D., Principal Assistant Librarian, Surgeon-General's Office, Washington, D. C. Cloth, \$6.00 net; Half Morocco, \$7.50 net.

REPRINTED IN THREE MONTHS—THE BAEDEKER OF MEDICAL HISTORY

The work begins with ancient and primitive medicine, and carries you in a most interesting and instructive way on through Egyptian medicine, Sumerian and Oriental medicine, Greek medicine, the Byzantine period; the Mohammedan and Jewish periods, the Medieval period, the period of the Renaissance, the Revival of learning and the Reformation; the Seventeenth Century (the age of individual scientific endeavor), the Eighteenth Century (the age of theories and systems), the Nineteenth Century (the beginning of organized advancement of science), the Twentieth Century (the beginning of organized preventive medicine). You get all the important facts in medical history; a *biographic dictionary* of the makers of medical history, arranged alphabetically; an album of *medical portraits*; a complete *medical chronology* (data on diseases, drugs, operations, etc.); a brief survey of the *social and cultural phases* of each period.

A NEW CLINICAL PUBLICATION

Medical Clinics of Chicago

Issued serially, one octavo of 200 pages, illustrated, every other month. Per Clinic Year of six numbers, \$8.00 net; in Cloth, \$12.00 net.

EXCLUSIVELY INTERNAL MEDICINE

These bi-monthly publications are devoted exclusively to *Clinical Internal Medicine* in all its departments—Diseases of Children, Contagious Diseases, Neurology, Dermatology, General Constitutional and Functional Disorders, X-Ray Therapy, etc., etc. They give you the bedside and amphitheater teachings of such leading Chicago internists as Mix, Tivnen, Tice, Hamburger, Pusey, Williamson, Abt, Preble, Goodkind, Hamill, representing such large hospitals as Mercy, Cook County, St. Luke's, Michael Reese, and Sarah Morris Memorial for Children, with their wealth and diversity of clinical material. These clinics are stenographically reported by a corps of competent medical stenographers, and thoroughly edited by the clinical teachers themselves.

The widest variety of cases is included, bringing out forcibly every feature of history-taking, diagnosis, treatment, and general management. The cases are illustrated with x-ray pictures, photographs, pulse-tracings, and temperature charts; the technic of all laboratory tests is given in detail, and every aid that can serve to make the diagnosis and treatment of the cases thoroughly clear to the general practitioner is emphasized. These publications are *clinical in the strictest sense*—they are an exposition of diagnosis and treatment as *actually practiced* at the bedside and in the amphitheater.

Goepp's State Board Questions

Third Edition

STATE BOARD QUESTIONS AND ANSWERS. By R. MAX GOEPP, M. D., Professor of Clinical Medicine, Philadelphia Polyclinic. Octavo of 715 pages. Cloth, \$4.00 net; Half Morocco, \$5.50 net.

"Nothing has been printed which is so admirably adapted as a guide and self-quiz for those intending to take State Board Examinations."—*Pennsylvania Medical Journal*.

Cabot's Works on Diagnosis

Differential Diagnosis. Presented through an Analysis of Cases. By RICHARD C. CABOT, M. D., Assistant Professor of Clinical Medicine, Harvard Medical School, Boston. Each volume an octavo of about 750 pages, illustrated. Per volume: Cloth, \$5.50 net.

Dr. Cabot's work takes up diagnosis from the point of view of the *presenting symptom*—the symptom in any disease which holds the foreground in the clinical picture: the principal complaint. It groups diseases under these symptoms, and points the way to proper reasoning in coming to a correct diagnosis. It works backward from each leading symptom to the actual organic cause of the symptom. This the author does by means of *case-teaching*.

The *symptom-groups* considered in Volume I [New (3d) Edition] are: Headache, general abdominal pain, epigastric pain, right hypochondriac pain, left hypochondriac pain, right iliac pain, left iliac pain, axillary pain, pain in arms, pain in legs and feet, fevers, chills, coma, convulsions, weakness, cough, vomiting, hematuria, dyspnea, jaundice, and nervousness—21 symptoms and 385 cases.

Volume II (Just Out): Abdominal and other tumors, vertigo, diarrhea, dyspepsia, hematemesis, enlarged glands, blood in stools, swelling of face, hemoptysis, edema of legs, frequent micturition and polyuria, fainting, hoarseness, pallor, swelling of arm, delirium, palpitation and arrhythmia, tremor, ascites and abdominal enlargement—a total of 19 symptoms and 317 instructive cases.

Morrow's Diagnostic and Therapeutic Technic

Diagnostic and Therapeutic Technic. By ALBERT S. MORROW, M. D., Clinical Professor of Surgery, New York Polyclinic. Octavo of 834 pages, with 860 original line drawings. Cloth, \$5.00 net.

NEW (2d) EDITION

Dr. Morrow's new work is decidedly a work for you—the physician engaged in general practice. It is a work you need because it tells you just how to perform those procedures required of you every day, and it tells you and *shows* you by clear, *new* line-drawings, in a way never before approached. It is not a book on drug therapy; it deals alone with physical or mechanical diagnostic and therapeutic measures. The information it gives is such as you need to know every day—transfusion and infusion, hypodermic medication, Bier's hyperemia, exploratory punctures, aspirations, anesthesia, etc. Then follow descriptions of those measures employed in the diagnosis and treatment of diseases of special regions or organs: proctoclysis, cystoscopy, etc.

Journal American Medical Association

"The procedures described are those which practitioners may at some time be called on to perform."

Musser and Kelly on Treatment

A Handbook of Practical Treatment. By 82 eminent specialists. Edited by JOHN H. MUSSER, M. D., and A. O. J. KELLY, M. D., University of Pennsylvania. Three octavos of 950 pages each, illustrated. Per volume: Cloth, \$6.00 net; Half Morocco, \$7.50 net. *Subscription.*

IN THREE VOLUMES

A PRACTICE FOR QUICK REFERENCE AND DAILY USE

Every chapter in this work was written by a specialist of unquestioned authority. Not only is drug therapy given but also dietotherapy, serumtherapy, organotherapy, rest-cure, exercise and massage, hydrotherapy, climatology, electrotherapy, x-ray, and radial activity are fully, clearly, and definitely discussed. Those measures partaking of a *surgical nature* have been presented by *surgeons*.

The Medical Record

"The most modern and advanced views are presented. It is difficult to pick out any one topic that deserves special commendation, all parts fully covering their particular field, and written with that fulness of detail demanded by the every-day needs of the practitioner."

Thomson's Clinical Medicine

Clinical Medicine. By WILLIAM HANNA THOMSON, M. D., LL. D., formerly Professor of the Practice of Medicine and of Diseases of the Nervous System, New York University Medical College. Octavo of 675 pages. Cloth, \$5.00 net; Half Morocco, \$6.50 net.

TWO PRINTINGS IN FOUR MONTHS

This new work represents over a *half century of active practice and teaching*. It deals with *bedside medicine*—the *application* of medical knowledge for the relief of the sick. First the meaning of common and important symptoms is stated *definitely*; then follows a chapter on the use of remedies and a classification of them; next the section on infections, and last a section on diseases of particular organs and tissues. It is medical knowledge *applied*—from cover to cover. An important chapter is that on the mechanism of surface chill and "catching cold," going very clearly into the etiologic factors, and outlining the treatment. The chapter on remedies takes up non-medicinal and medicinal remedies and *vaccine and serum therapy*. In the chapter on the ductless glands the subject of *internal secretions* is very clearly presented, giving you the latest advances. The infectious diseases are taken up in Part II, while Part III deals with diseases of special organs or tissues, every disease being fully presented from the *clinical side*. Treatment, naturally, is very full.

Ward's Bedside Hematology

Bedside Hematology. By GORDON R. WARD, M.D., Fellow of the Royal Society of Medicine, London, England. Octavo of 394 pages, illustrated. Cloth, \$3.50 net.

INCLUDING VACCINES AND SERUMS

Dr. Ward's work gives you the exact technic for obtaining the blood for examination, the making of smears, the blood-count, finding coagulation time, etc. Then it takes up each disease, giving you the synonyms, definition, nature, general pathology, etiology, bearings of age and sex, the onset, symptomatology (discussing each symptom *in detail*), course of the disease, clinical varieties, complications, diagnosis, and treatment (drug, diet, rest, *vaccines and serums*, etc.).

Faught's Blood-Pressure

Blood-Pressure from the Clinical Standpoint. By FRANCIS A. FAUGHT, M. D., Instructor in Medicine, Medico-Chirurgical College of Philadelphia. Octavo of 281 pages, illustrated. Cloth, \$3.00 net.

THREE PRINTINGS IN SIX MONTHS

Dr. Faught's book is designed for practical help *at the bedside*. Besides the actual technic of using the sphygmomanometer in diagnosing disease, Dr. Faught has included a brief general discussion of the process of circulation. The practical application of sphygmomanometric findings within recent years make it imperative for every medical man to have close at hand an up-to-date work on this subject.

Smith's What to Eat and Why

What to Eat and Why. By G. CARROLL SMITH, M.D., Boston. 12mo of 377 pages. Cloth, \$2.50 net.

JUST OUT—NEW (2d) EDITION

With this book you no longer need send your patients to a specialist to be dieted—you will be able to prescribe the suitable diet yourself just as you do other forms of therapy. Dr. Smith gives the "why" of each statement he makes. It is this knowing why which gives you confidence in the book, which makes you feel that Dr. Smith *knows*.

Pennsylvania Medical Journal

"All through this book Dr. Smith has added to his dietetic hints a great many valuable ones of a general nature, which will appeal to the general practitioner."

Kolmer's Specific Therapy

Infection, Immunity, and Specific Therapy. By JOHN A. KOLMER, M. D., DR. P. H., Instructor in Experimental Pathology, University of Pennsylvania. Octavo of 900 pages, with 143 original illustrations, 43 in colors, drawn by Erwin F. Faber. Cloth, \$6.00 net; Half Morocco, \$7.50 net.

ORIGINAL ILLUSTRATIONS

Dr. Kolmer's book gives you a full account of infection and immunity, and *the application of this knowledge* in the specific diagnosis, prevention, and treatment of disease. The section devoted to *immunologic technic* gives you every detail, from the care of the centrifuge and making a simple pipet to the actual production of serums and vaccines. Under *specific therapy* you get methods of making *autogenous vaccines* and their *actual use* in diagnosis and treatment. The directions for injecting vaccines, serums, salvarsan, etc.—with the *exact dosage*—are here given so clearly that you will be able to use these means of treatment in your daily practice. You also get full directions for making the *clinical diagnostic reactions*—the various tuberculin tests, luetin, mallein, and similar reactions, all illustrated with *colored plates*. The final section is devoted to *laboratory experiments*.

Anders & Boston's Medical Diagnosis

A Text-Book of Medical Diagnosis. By JAMES M. ANDERS, M. D., PH. D., LL.D., Professor of the Theory and Practice of Medicine and of Clinical Medicine, and L. NAPOLEON BOSTON, M. D., Professor of Physical Diagnosis, Medico-Chirurgical College, Philadelphia. Octavo of 1248 pages, with 466 illustrations, a number in colors. Cloth, \$6.00 net; Half Morocco, \$7.50 net.

NEW (2d) EDITION

This new edition is designed expressly for the general practitioner. The methods given are practical and especially adapted for quick reference. The diagnostic methods are presented in a forceful, definite way by men who have had wide experience at the bedside and in the clinical laboratory.

The Medical Record

"The association in its authorship of a celebrated clinician and a well-known laboratory worker is most fortunate. It must long occupy a pre-eminent position."

Anders' Practice of Medicine

A Text-Book of the Practice of Medicine. By JAMES M. ANDERS, M. D., PH. D., LL. D., Professor of the Practice of Medicine and of Clinical Medicine, Medico-Chirurgical College, Philadelphia. Handsome octavo, 1335 pages, fully illustrated. Cloth, \$5.50 net; Half Morocco, \$7.00 net.

THE NEW (11th) EDITION

The success of this work is no doubt due to the extensive consideration given to Diagnosis and Treatment, under Differential Diagnosis the points of distinction of simulating diseases being presented in tabular form. In this new edition Dr. Anders has included all the most important advances in medicine, keeping the book within bounds by a judicious elimination of obsolete matter. A great many articles have also been rewritten.

Wm. E. Quine, M. D.,

Professor of Medicine and Clinical Medicine, College of Physicians and Surgeons, Chicago.

"I consider Anders' Practice one of the best single-volume works before the profession at this time, and one of the best text-books for medical students."

DaCosta's Physical Diagnosis

Physical Diagnosis. By JOHN C. DACOSTA, JR., M. D., Associate Professor of Medicine, Jefferson Medical College, Philadelphia. Octavo of 557 pages, with 225 original illustrations. Cloth, \$3.50 net.

NEW (2d) EDITION

Dr. DaCosta's work is a thoroughly new and original one. Every method given has been carefully tested and proved of value by the author himself. Normal physical signs are explained in detail in order to aid the diagnostician in determining the abnormal. Both direct and differential diagnosis are emphasized. The cardinal methods of examination are supplemented by full descriptions of technic and the clinical utility of certain instrumental means of research.

Dr. Henry L. Elsner, *Professor of Medicine at Syracuse University.*

"I have reviewed this book, and am thoroughly convinced that it is one of the best ever written on this subject. In every way I find it a superior production."

Sahli's Diagnostic Methods

A Treatise on Diagnostic Methods of Examination. By PROF. DR. H. SAHLI, of Bern. Edited, with additions, by NATH'L BOWDITCH POTTER, M. D., Assistant Professor of Clinical Medicine, Columbia University (College of Physicians and Surgeons), New York. Octavo of 1229 pages, illustrated. Cloth, \$6.50 net; Half Morocco, \$8.00 net.

THE NEW (2d) EDITION, ENLARGED AND RESET

Dr. Sahli's great work is a practical diagnosis, written and edited by practical clinicians. So thorough has been the revision for this edition that it was found necessary practically to reset the entire work. Every line has received careful scrutiny, adding new matter, eliminating the old.

Lewellys F. Barker, M. D.

Professor of the Principles and Practice of Medicine, Johns Hopkins University

"I am delighted with it, and it will be a pleasure to recommend it to our students in the Johns Hopkins Medical School."

Friedenwald and Ruhrah on Diet

Diet in Health and Disease. By JULIUS FRIEDENWALD, M. D., Professor of Diseases of the Stomach, and JOHN RUHRÄH, M. D., Professor of Diseases of Children, College of Physicians and Surgeons, Baltimore. Octavo of 857 pages. Cloth, \$4.00 net.

THE NEW (4th) EDITION

This new edition has been carefully revised, making it still more useful than the two editions previously exhausted. The articles on milk and alcohol have been rewritten, additions made to those on tuberculosis, the salt-free diet, and rectal feeding, and several tables added, including Winton's, showing the composition of diabetic foods.

George Dock, M. D.

Professor of Theory and Practice and of Clinical Medicine, Tulane University.

"It seems to me that you have prepared the most valuable work of the kind now available. I am especially glad to see the long list of analyses of different kinds of foods."

Carter's Diet Lists

DIET LISTS OF THE PRESBYTERIAN HOSPITAL OF NEW YORK CITY. Compiled, with notes, by HERBERT S. CARTER, M. D. 12mo of 129 pages. Cloth, \$1.00 net.

Here Dr. Carter has compiled all the diet lists for the various diseases and for convalescence as prescribed at the Presbyterian Hospital. Recipes are also included.

Kemp on Stomach, Intestines, and Pancreas

Diseases of the Stomach, Intestines, and Pancreas. By ROBERT COLEMAN KEMP, M. D., Professor of Gastro-intestinal Diseases at the New York School of Clinical Medicine. Octavo of 1021 pages, with 388 illustrations. Cloth, \$6.50 net; Half Morocco, \$8.00 net.

NEW (2d) EDITION

The new edition of Dr. Kemp's successful work appears after a most searching revision. Several new subjects have been introduced, notably chapters on *Colon Bacillus Infection* and on *Diseases of the Pancreas*, the latter article being really an exhaustive monograph, covering over one hundred pages. The section on *Duodenal Ulcer* has been entirely rewritten. *Visceral Displacements* are given special consideration, in every case giving definite indications for surgical intervention when deemed advisable. There are also important chapters on the *Intestinal Complications of Typhoid Fever* and on *Diverticulitis*.

The Therapeutic Gazette

"The therapeutic advice which is given is excellent. Methods of physical and clinical examination are adequately and correctly described."

Gant on Diarrheas

Diarrheal, Inflammatory, Obstructive, and Parasitic Diseases of the Gastro-intestinal Tract. By SAMUEL G. GANT, M. D., LL.D., Professor of Diseases of Sigmoid Flexure, Colon, Rectum, and Anus, New York Post-graduate Medical School and Hospital. Octavo of 604 pages, 181 illustrations. Cloth, \$6.00 net; Half Morocco, \$7.50 net.

JUST OUT

This new work is particularly full on the two practical phases of the subject—*diagnosis* and *treatment*. For instance: While the essential diagnostic points are given under each disease, a fuller description of diagnostic methods is given in a special chapter. The *differential diagnosis* of diarrheas of local and those of systemic disturbances is strongly brought out. There is a special chapter on *nervous diarrheas* and those originating from *gastrogenic* and *enterogenic dyspepsias*. You get methods of simultaneously controlling associated constipation and diarrhea. You get a complete *formulary*. The limitations of drugs are pointed out, and the indications and *technic* of all surgical procedures given.

Gant on Constipation and Obstruction

This work is medical, non-medical (mechanical), and surgical, the latter really being a complete work on rectocolonic surgery.

Octavo of 575 pages, with 250 illustrations. By SAMUEL G. GANT, M. D. Cloth, \$6.00 net.

NOTHNAGEL'S PRACTICE

Edited by **ALFRED STENGEL, M. D.**

Typhoid and Typhus Fevers

By DR. H. CURSCHMANN. Edited, with additions, by WILLIAM OSLER, M. D., F. R. C. P., Oxford, England. Octavo of 646 pages, illustrated.

Smallpox, Varicella, Cholera, Erysipelas, Pertussis, Hay Fever

By DR. H. IMMERMANN, DR. TH. VON JURGENSEN, DR. C. LIEBERMEISTER, DR. H. LENHARTZ, and DR. G. STICKER. Edited, with additions, by SIR J. W. MOORE, M. D., F. R. C. P. I., Ireland. Octavo of 682 pages, illustrated.

Diphtheria, Measles, Scarlet Fever, and Rotheln

By WILLIAM P. NORTHRUP, M. D., and DR. TH. VON JURGENSEN. Edited, with additions, by WILLIAM P. NORTHRUP, M. D., New York. Octavo of 672 pages, illustrated.

Bronchi, Pleura, and Inflammations of the Lungs

By DR. F. A. HOFFMANN, DR. O. ROSENBACH, and DR. F. AUFRECHT. Edited, with additions, by JOHN H. MUSSER, M. D. Octavo of 1029 pages.

Pancreas, Suprarenals, and Liver

By DR. L. OSER, DR. E. NEUSSER, and DRs. H. QUINCKE and G. HOPPE-SEYLER. Edited, with additions, by REGINALD H. FITZ, M. D., Boston; and FRED. A. PACKARD, M. D., Phila. Octavo of 918 pages, illustrated.

Diseases of the Stomach

By DR. F. RIEGEL, of Giessen. Edited, with additions, by CHARLES G. STOCKTON, M. D., Buffalo. Octavo of 835 pages.

Diseases of the Intestines and Peritoneum **Second Edition**

By DR. HERMANN NOTHNAGEL. Edited, with additions, by H. D. ROLLESTON, M. D., F. R. C. P., London. Octavo of 1100 pages, illustrated.

Tuberculosis and Acute General Miliary Tuberculosis

By DR. G. CORNET. Edited, with additions, by WALTER B. JAMES, M. D., New York. Octavo of 806 pages.

Diseases of the Blood

By DR. P. EHRLICH, DR. A. LAZARUS, DR. K. VON NOORDEN, and DR. FELIX PINKUS. Edited, with additions, by ALFRED STENGEL, M. D., Philadelphia. Octavo of 714 pages, illustrated.

Malarial Diseases, Influenza, and Dengue

By DR. J. MANNABERG and DR. O. LEICHTENSTERN. Edited, with additions, by RONALD ROSS, F. R. C. S.; J. W. W. STEPHENS, M. D.; and ALBERT S. GRUNBAUM, F. R. C. P., Liverpool. Octavo of 769 pages, illustrated.

Kidneys, Spleen, and Hemorrhagic Diatheses

By DR. H. SENATOR and DR. M. LITTEN. Edited, with additions, by JAMES B. HERRICK, M. D., Chicago. Octavo of 815 pages, illustrated.

Diseases of the Heart

By PROF. DR. TH. VON JURGENSEN, PROF. DR. L. KREHL, and PROF. DR. L. VON SCHRÖTTER. Edited by GEORGE DOCK, M. D., New Orleans. Octavo of 848 pages, illustrated.

SOLD SEPARATELY—PER VOLUME: CLOTH, \$5.00 NET; HALF MOROCCO, \$6.00 NET

Bastedo's Materia Medica **Pharmacology, Therapeutics, Prescription Writing**

Materia Medica, Pharmacology, Therapeutics, and Prescription Writing. By W. A. BASTEDO, PH. D., M. D., Associate in Pharmacology and Therapeutics at Columbia University, New York. Octavo of 602 pages, illustrated. Cloth, \$3.50 net.

THREE PRINTINGS IN SIX MONTHS

Dr. Bastedo's discussion of his subject is very complete. As an illustration, take the pharmacologic action of the drug. It gives you the antiseptic action, the local action on the skin, mucous membranes, and the alimentary tract; where the drug is absorbed, if at all—and how rapidly. It gives you the systemic action on the circulatory organs, respiratory organs, nervous system, and sense organs. It tells you how the drug is changed in the body. It gives you the route of elimination and in what form. It gives you the action on the kidneys, bladder, urethra, skin, bowels, lungs, and mammary glands during elimination. It gives you the after-effects. It gives you the unexpected—the unusual—effects. It gives you the tolerance—habit formation. Could any discussion be more complete, more thorough?

Boston Medical and Surgical Journal

"Its aim throughout is therapeutic and practical, rather than theoretic and pharmacologic. The text is illustrated with sixty well-chosen plates and cuts. It should prove a useful contribution to the text-book literature on these subjects."

McKenzie on Exercise in Education and Medicine

Exercise in Education and Medicine. By R. TAIT MCKENZIE, B. A., M. D., Professor of Physical Education and Director of the Department, University of Pennsylvania. Octavo of 585 pages, with 478 original illustrations. Cloth, \$4.00 net.

D. A. Sargeant, M. D., Director of Hemenway Gymnasium, Harvard University.

"It cannot fail to be helpful to practitioners in medicine. The classification of athletic games and exercises in tabular form for different ages, sexes, and occupations is the work of an expert. It should be in the hands of every physical educator and medical practitioner."

Bonney's Tuberculosis

Second Edition

TUBERCULOSIS. By SHERMAN G. BONNEY, M. D., Professor of Medicine, Denver and Gross College of Medicine. Octavo of 955 pages, with 243 illustrations. Cloth, \$7.00 net; Half Morocco, \$8.50 net.

Maryland Medical Journal

"Dr. Bonney's book is one of the best and most exact works on tuberculosis, in all its aspects, that has yet been published."

Stevens' Therapeutics

New (5th) Edition

A TEXT-BOOK OF MODERN MATERIA MEDICA AND THERAPEUTICS. By A. A. STEVENS, A. M., M. D., Lecturer on Physical Diagnosis in the University of Pennsylvania. Octavo of 675 pages. Cloth, \$3.50 net.

Dr. Stevens' Therapeutics is one of the most successful works on the subject ever published. In this new edition the work has undergone a very thorough revision, and now represents the very latest advances.

The Medical Record, New York

"Among the numerous treatises on this most important branch of medical practice, this by Dr. Stevens has ranked with the best."

Butler's Materia Medica

New (6th) Edition

A TEXT-BOOK OF MATERIA MEDICA, THERAPEUTICS, AND PHARMACOLOGY. By GEORGE F. BUTLER, PH. G., M. D., Professor and Head of the Department of Therapeutics and Professor of Preventive and Clinical Medicine, Chicago College of Medicine and Surgery, Medical Department Valpariso University. Octavo of 702 pages, illustrated. Cloth, \$4.00 net; Half Morocco, \$5.50 net.

For this sixth edition Dr. Butler has entirely remodeled his work, a great part having been rewritten. All obsolete matter has been eliminated, and special attention has been given to the toxicologic and therapeutic effects of the newer compounds.

Medical Record, New York

"Nothing has been omitted by the author which, in his judgment, would add to the completeness of the text."

Sollmann's Pharmacology

New (2d) Edition

A TEXT-BOOK OF PHARMACOLOGY. By TORALD SOLLMANN, M. D., Professor of Pharmacology and Materia Medica, Western Reserve University. Octavo of 1070 pages, illustrated. Cloth, \$4.00 net.

The author bases the study of therapeutics on systematic knowledge of the nature and properties of drugs, and thus brings out forcibly the intimate relation between pharmacology and practical medicine.

Slade's Physical Examination and Diagnostic Anatomy

PHYSICAL EXAMINATION AND DIAGNOSTIC ANATOMY. By CHARLES B. SLADE, M. D., Chief of Clinic in General Medicine, University and Bellevue Hospital Medical College. Cloth, \$1.25 net.

"The fundamental methods and principles of physical examination, well illustrated, largely by line drawings. The book is to be strongly recommended."—*Boston Medical and Surgical Journal*.

Arny's Pharmacy

PRINCIPLES OF PHARMACY. By HENRY V. ARNY, PH. G., PH. D., Professor of Chemistry, New York College of Pharmacy. Octavo of 1175 pages, with 246 illustrations. Cloth, \$5.00 net.

Tousey's Medical Electricity Röntgen Rays, and Radium

Medical Electricity, Röntgen Rays, and Radium. By SINCLAIR TOUSEY, M. D., Consulting Surgeon to St. Bartholomew's Hospital, New York. Octavo of 1219 pages, with 801 illustrations, 19 in colors. Cloth, \$7.50 net; Half Morocco, \$9.00 net.

NEW (2d) EDITION, RESET

The revision for this edition was extremely heavy; new matter has increased the size of the book by some 100 pages. About 50 new illustrations have been added. The new matter added includes: Diathermy, sinusoidal currents, radiography with intensifying screens, röntgenotherapy, the Coolidge and similar Röntgen tubes and the author's method of dosage, and radium therapy are noted. The book has been enriched by including several of Machado's tabular classifications of electric methods, effects, and uses.

Throughout the entire work everything concerning electricity, x-rays, and radium in medicine, as well as phototherapy, is explained in detail—nothing is omitted. It tells you how to equip your office, and, more than that, how to use your apparatus, explaining away all difficulties. It tells you just how to apply these measures in the treatment of disease. The chapters on *dental radiography* are particularly valuable to those interested in dental work.

Abbott's Medical Electricity for Nurses

MEDICAL ELECTRICITY FOR NURSES. By GEORGE KNAPP ABBOTT, M. D., Dean and Professor of Physiologic Therapy and Practice, College of Medical Evangelists, Loma Linda, California. 12mo of 132 pages, illustrated. Cloth, \$1.25 net.

This new work gives the nurse the essentials of this subject. Dr. Abbott's style has made the difficult simple. The text is illustrated.

Kelly's American Medical Biography

CYCLOPEDIA OF AMERICAN MEDICAL BIOGRAPHY. By HOWARD A. KELLY, M. D., Johns Hopkins University. Two octavos, averaging 525 pages each, with portraits. Per set: Cloth, \$10.00 net; Half Morocco, \$13.00 net.

Dr. Kelly, in these two handsome volumes, presents concise, yet complete, biographies of those men and women who have contributed noteworthy to the advancement of medicine in America. Dr. Kelly's reputation for painstaking care assures accuracy of statement. There are about one thousand biographies included.

GET
THE BEST

American Illustrated Dictionary

THE NEW
STANDARD

Just Out—New (8th) Edition—1500 New Words

The American Illustrated Medical Dictionary.—By W. A. NEWMAN DORLAND, M. D., Editor of "The American Pocket Medical Dictionary." Large octavo of 1137 pages, bound in full flexible leather. Price, \$4.50 net; with thumb index, \$5.00 net.

KEY TO CAPITALIZATION AND PRONUNCIATION—ALL THE NEW WORDS

Howard A. Kelly, M.D., *Professor of Gynecologic Surgery, Johns Hopkins University.*

"Dr. Dorland's dictionary is admirable. It is so well gotten up and of such convenient size. No errors have been found in my use of it."

Thornton's Dose-Book.

New (4th) Edition

DOSE-BOOK AND MANUAL OF PRESCRIPTION-WRITING. By E. Q. THORNTON, M.D., Assistant Professor of Materia Medica, Jefferson Medical College, Philadelphia. Post-octavo, 410 pages, illustrated. Flexible leather, \$2.00 net.

"I will be able to make considerable use of that part of its contents relating to the correct terminology as used in prescription-writing, and it will afford me much pleasure to recommend the book to my classes, who often fail to find this information in their other textbooks."—C. H. MILLER, M. D., *Professor of Pharmacology, Northwestern University Medical School.*

Lusk on Nutrition

New (2d) Edition

ELEMENTS OF THE SCIENCE OF NUTRITION. By GRAHAM LUSK, PH. D., Professor of Physiology in Cornell University Medical School. Octavo of 402 pages. Cloth, \$3.00 net.

"I shall recommend it highly. It is a comfort to have such a discussion of the subject."—LEWELLYS F. BARKER, M. D., *Johns Hopkins University.*

Camac's "Epoch-making Contributions"

EPOCH-MAKING CONTRIBUTIONS IN MEDICINE AND SURGERY. Collected and arranged by C. N. B. CAMAC, M. D., of New York City. Octavo of 450 pages, illustrated. Artistically bound, \$4.00 net.

"Dr. Camac has provided us with a most interesting aggregation of classical essays. We hope that members of the profession will show their appreciation of his endeavors."—THERAPEUTIC GAZETTE.

The American Pocket Medical Dictionary **New (9th) Edition**

THE AMERICAN POCKET MEDICAL DICTIONARY. Edited by W. A. NEWMAN DORLAND, M. D., Editor "American Illustrated Medical Dictionary." 693 pages. Flexible leather, with gold edges, \$1.00 net; with thumb index, \$1.25 net.

Pusey and Caldwell on X-Rays **Second Edition**

THE PRACTICAL APPLICATION OF THE RÖNTGEN RAYS IN THERAPEUTICS AND DIAGNOSIS. By WILLIAM ALLEN PUSEY, A. M., M. D., Professor of Dermatology in the University of Illinois; and EUGENE W. CALDWELL, B. S., Director of the Edward N. Gibbs X-Ray Memorial Laboratory of the University and Bellevue Hospital Medical College, New York. Octavo of 625 pages, with 200 illustrations. Cloth, \$5.00 net; Half Morocco, \$6.50 net.

Cohen and Eshner's Diagnosis. **Second Revised Edition**

ESSENTIALS OF DIAGNOSIS. By S. SOLIS-COHEN, M. D., Senior Assistant Professor in Clinical Medicine, Jefferson Medical College, Phila.; and A. A. ESHNER, M. D., Professor of Clinical Medicine, Philadelphia Polyclinic. Post-octavo, 382 pages; 55 illustrations. Cloth, \$1.00 net. *In Saunders' Question-Compend Series.*

Morris' Materia Medica and Therapeutics. **New (7th) Edition**

ESSENTIALS OF MATERIA MEDICA, THERAPEUTICS, AND PRESCRIPTION-WRITING. By HENRY MORRIS, M. D., late Demonstrator of Therapeutics, Jefferson Medical College, Phila. Revised by W. A. BASTEDO, M. D., Instructor in Materia Medica and Pharmacology at Columbia University. 12mo, 300 pages. Cloth, \$1.00 net. *In Saunders' Question-Compend Series.*

Williams' Practice of Medicine

ESSENTIALS OF THE PRACTICE OF MEDICINE. By W. R. WILLIAMS, M.D., formerly Instructor in Medicine and Lecturer on Hygiene, Cornell University; and Tutor in Therapeutics, Columbia University, N. Y. 12mo of 456 pages, illustrated. *In Saunders' Question-Compend Series.* Double number, \$1.75 net.

Todd's Clinical Diagnosis **The New (3d) Edition**

A MANUAL OF CLINICAL DIAGNOSIS. By JAMES CAMPBELL TODD, M.D., Professor of Pathology, University of Colorado. 12mo of 585 pages, with 164 text-illustrations and 10 colored plates. Cloth, \$2.50 net.

Bridge on Tuberculosis

TUBERCULOSIS. By NORMAN BRIDGE, A. M., M. D., Emeritus Professor of Medicine in Rush Medical College. 12mo of 302 pages, illustrated. Cloth, \$1.50 net.

Oertel on Bright's Disease **Illustrated**

THE ANATOMIC HISTOLOGICAL PROCESSES OF BRIGHT'S DISEASE. By HORST OERTEL, M. D., Director of the Russell Sage Institute of Pathology, New York. Octavo of 227 pages, with 44 text-cuts and 6 colored plates. Cloth, \$5.00 net.

Arnold's Medical Diet Charts

MEDICAL DIET CHARTS. Prepared by H. D. ARNOLD, M. D., Dean of Harvard Graduate Medical School, Boston. Single charts, 5 cents; 50 charts, \$2.00 net; 500 charts, \$18.00 net; 1000 charts, \$30.00 net.

Eggleston's Prescription Writing

ESSENTIALS OF PRESCRIPTION WRITING. By CARY EGGLESTON, M. D., Instructor in Pharmacology, Cornell University Medical School. 16mo of 125 pages. Cloth, \$1.00 net.

Jakob and Eshner's Internal Medicine and Diagnosis

ATLAS AND EPITOME OF INTERNAL MEDICINE AND CLINICAL DIAGNOSIS. By DR. CHR. JAKOB, of Erlangen. Edited, with additions, by A. A. ESHNER, M. D., Professor of Clinical Medicine, Philadelphia Polyclinic. With 182 colored figures on 68 plates, 64 text-illustrations, 259 pages of text. Cloth, \$3.00 net. *In Saunders' Hand-Atlas Series.*

Lockwood's Practice of Medicine.

Second Edition,
Revised and Enlarged

A MANUAL OF THE PRACTICE OF MEDICINE. By GEO. ROE LOCKWOOD, M. D., Attending Physician to the Bellevue Hospital, New York City. Octavo, 847 pages, with 79 illustrations in the text and 22 full-page plates. Cloth, \$4.00 net.

Stevens' Practice of Medicine

Just Out—New (10th) Edition

A MANUAL OF THE PRACTICE OF MEDICINE. By A. A. STEVENS, A. M., M. D., Professor of Pathology, Woman's Medical College, Phila. Specially intended for students preparing for graduation and hospital examinations. Post-octavo, 629 pages, illustrated. Flexible leather, \$2.50 net.

Saunders' Pocket Formulary

New (9th) Edition

SAUNDERS' POCKET MEDICAL FORMULARY. By WILLIAM M. POWELL, M. D. Containing 1831 formulas from the best-known authorities. With an Appendix containing Posologic Table, Formulas and Doses for Hypodermic Medication, Poisons and their Antidotes, Diameters of the Female Pelvis and Fetal Head, Obstetrical Table, Diet-list, Materials and Drugs used in Antiseptic Surgery, Treatment of Asphyxia from Drowning, Surgical Remembrancer, Tables of Incompatibles, Eruptive Fevers, etc., etc. In flexible leather, with side index, wallet, and flap, \$1.75 net.

Deaderick on Malaria

PRACTICAL STUDY OF MALARIA. By WILLIAM H. DEADERICK, M. D., Member American Society of Tropical Medicine; Fellow London Society of Tropical Medicine and Hygiene. Octavo of 402 pages, illustrated. Cloth, \$4.50 net; Half Morocco, \$6.00 net.

Niles on Pellagra

PELLAGRA. By GEORGE M. NILES, M. D., Professor of Gastro-enterology and Therapeutics, Atlanta School of Medicine. Octavo of 253 pages, illustrated. Cloth, \$3.00 net.

Hinsdale's Hydrotherapy

HYDROTHERAPY. By GUY HINSDALE, M. D., Fellow Royal Society of Medicine of Great Britain. Octavo of 466 pages, illustrated. Cloth, \$3.50 net.

Swan's Prescription-writing and Formulary

PRESCRIPTION-WRITING AND FORMULARY. By JOHN M. SWAN, M. D., formerly Director Glen Springs Sanitarium, Watkins, N. Y. 16mo of 185 pages. Flexible leather, \$1.25 net.

Stewart's Pocket Therapeutics and Dose-book

Fourth
Edition

POCKET THERAPEUTICS AND DOSE-BOOK. By MORSE STEWART, JR., M. D. 32mo of 263 pages. Cloth, \$1.00 net.

