

Ligations of the left subclavian artery in its first portion / by William S. Halsted.

Contributors

Halsted, William, 1852-1922.

Publication/Creation

[Place of publication not identified] : [publisher not identified], [between 1900 and 1999]

Persistent URL

<https://wellcomecollection.org/works/h2jz5an3>

License and attribution

Conditions of use: it is possible this item is protected by copyright and/or related rights. You are free to use this item in any way that is permitted by the copyright and related rights legislation that applies to your use. For other uses you need to obtain permission from the rights-holder(s).



Wellcome Collection
183 Euston Road
London NW1 2BE UK
T +44 (0)20 7611 8722
E library@wellcomecollection.org
<https://wellcomecollection.org>

To Mr. Stanton
with the author's
compliments

LIGATIONS OF THE LEFT SUBCLAVIAN ARTERY
IN ITS FIRST PORTION

By WILLIAM S. HALSTED, Baltimore, Md.

Reprinted from
THE JOHNS HOPKINS HOSPITAL REPORTS
Volume XXI



22102248028

LIGATIONS OF THE LEFT SUBCLAVIAN ARTERY IN ITS
FIRST PORTION *

By WILLIAM S. HALSTED, M. D.

In a delightful discourse " on arterio-venous aneurism Osler takes a swift flight into a vibrant domain of surgery, tracing into and out of the dark ages steps of the few surgeons who blazed the way. Well he knew and loved the crystal springs and sources bearing their tiny freights of knowledge to the flood. Readers of *The Johns Hopkins Hospital Reports* will welcome the quotation from Sir William's paper:

" Better than any other disease aneurysm illustrates how borderless are the boundaries of medicine and surgery. Here am I talking on the most surgical of all its aspects, while very likely not far away a surgeon is practising the best possible prevention against internal aneurysm in giving a syphilitic patient an injection of salvarsan! Aneurysm has been a medico-chirurgical affection ever since some bungling young 'minutor' first nicked the brachial artery in performing venesection. One of the earliest and most interesting references in literature is to an instance of this kind. Galen was called in consultation by a young and inexperienced surgeon who had opened the artery at the bend of the elbow instead of the vein, and the blood spurted out 'clarus, rubens, lucidus et calidus.'

'I took in the situation at once; there happened to be an elderly physician with me, so we prepared a medicine, viscid, conglutinable, and obstructive, and placing it strongly against the lips of the wound bound over it a soft sponge. The surgeon who had opened the artery wondered, but said nothing. When we went out [note the professional touch!] I said to the surgeon that he had opened the pulsating vessel, and charged him not to dress the wound before the fourth day, and not without me.'

" The cure was complete, and Galen remarks that this was his only successful case of the kind, as in all others aneurysm had followed. This account, taken from Symphorien Campegius *Claudii Galeni Pergameni Historiales Campi, Basilae, 1532, p. 43*, is doubtless of the case referred to in the *Methodus Medendi*.† The only other references to aneurysm in Galen are in the *De Tumoribus præter Naturam* ‡ and in the *De Curandi Ratione per Sanguinis Missionem*,§ in which he refers to the possibility of gangrene.

* Received for publication June 26, 1920.

† "Linacre's edition, 1517, f. lxii, v."

‡ "Junta, fifth edition, 1576, iii, p. 84."

§ "Ibid., vi, p. 21."

HISTORICAL SURVEY

"Rational surgery was one of the gifts of the Greeks, but in the 800 years between Hippocrates and Oribasius few names have survived specially associated with this branch of medicine. Who among us off-hand could recall more than two or three in addition to Hippocrates and Galen? Yet in this period scores of important schools flourished with great teachers of surgery, men honoured in their generation and the glory of their times. As one reads the partial list in Haller's *Bibliotheca Chirurgica* and scans the few golden remains of their writings fortunately preserved by encyclopædists such as Oribasius and Paul of Ægina, the truth of Sir Thomas Browne's remarks comes home: 'Who knows whether the best of men be known, whether there be not more remarkable persons forgot than any that stand remembered in the known account of time?' Two of these comparatively unknown men created the surgery of arteries, Rufus of Ephesus and Antyllus, the Cosmas and Damien of Greek surgery.*

RUFUS OF EPHESUS

"To generations of practitioners unworthy to hand him ligatures Rufus of Ephesus (Reign of Trajan, early part of second century A. D.) was known by the 'pilulae Ruffi,' 'the pills I would not be without'—'pilulae sine quibus esse nolo'—still in the British Pharmacopœia as the pill of aloes and myrrh. In the brilliant Ionian profession of the early days of our era Rufus doubtless had predecessors and teachers, but he stands out a strong, clear figure, a great 'magister chirurgiae,' a title justly earned by his remarkable contribution to the surgery of hæmorrhage. We know it only through a section in Aetius, a sixth-century physician.† Nothing is lacking in a description, which might be transferred to any modern textbook—digital compression, styptics, the cautery, torsion, and the ligature—only I am sorry not to find, as is sometimes said, a description suggestive of arterio-venous aneurysm, though he speaks of the possibility of traumatic aneurysm.

"Through the Arabians the name of Rufus was on the lips of every mediæval physician, and we find him among the favorites of Chaucer's well-read Doctor. In one of the earliest and most beautiful of medical manuscripts, the famous *Juliana Anicia Dioscorides* (A. D. 525), of the Vienna Library, he is figured with Galen, Hippocrates, and others.

* "These practitioners, who became the Christian saints of surgery, suffered martyrdom in Cilicia in the third century. In their Western Mother Church, on the Roman Forum, I have seen the little parcel said to contain the instruments with which they performed the most famous operation in hagiological surgery, substitution of the healthy thigh of a just-dead man for one that was gangrenous."

† "Tetrabiblos, lib. xiv, cap. 51."

WELLCOME INSTITUTE LIBRARY	
Coll.	welMomec
Call	
No.	WG

8657150

ANTYLLUS

"Upon the other great surgical figure of antiquity, Antyllus, so blindly has oblivion scattered her poppies, to quote Sir Thomas Browne again, that not a fact of his life is known; yet through the mists of 18 centuries he looms large as one of the most daring and accomplished surgeons of all time. A resector of bones and joints, one of the first to perform tracheotomy, the founder of the surgery of fistula, a successful operator upon cataract, and we may say the creator of the surgery of the arteries—these are among his known achievements. His remains are chiefly in the works of Oribasius, the physician and friend of the Emperor Julian.

"Nowhere are we impressed with the note of directness so characteristic of the Greek (see R. W. Livingstone's *Meaning of the Greek Genius, second edition, 1915*) as in the brilliant account given by this author of aneurysm, of which he was the first to recognise two forms—one by dilatation, the other following wound of the artery. So far as I can gather, he was also the first to describe the thrill or bruit so characteristic of the latter form. No ancient writer has anything like the same accuracy of pathological description, and you may search the surgical literature for centuries before there is found such a gem as the account of his method of operation still in use, and by which his name has been permanently enshrined. Not finding one in English, I asked Mr. Livingstone, of Corpus Christi College, to give us a complete translation of the fragment.

ABOUT ANEURYSMS (FROM THE WORKS OF ANTYLLUS*)

'There are two different kinds of aneurysms. The one kind occurs when there is a local dilatation of an artery (this was the origin of the name aneurysm or dilatation). The other kind arises from the rupture of an artery and the discharge of the blood into the flesh beneath it. Aneurysms due to the dilatation of an artery are longer than others; those due to a rupture are rounder. In the former there is a thicker layer of tissue; in the latter you can hear a certain crepitation if you press them with your finger; while in aneurysms due to dilatation there is no sound.

'It is foolish to follow the practice of the ancient surgeons and decline to treat any aneurysm, but it is dangerous to apply surgical treatment to all types. So we will excuse ourselves from treating aneurysms in the armpit, groin, and neck on the ground that the vessels are large and that it is impossible or dangerous to isolate and tie them. We also decline exceptionally big aneurysms, even if they occur elsewhere. But we will operate as follows on aneurysms in the extremities, the limbs and the head.

'If the aneurysm results from dilatation, we will make a straight incision in the skin the whole length of the vessel; then, after separating the edges of the incision with hooks, we will carefully sever all the membranes between the skin and the artery. Then pushing aside with blunt hooks the vein adjacent to the artery, we will expose the dilated portion of the artery on all sides. Next, we will introduce the head of a probe underneath, and, lifting the aneurysm, insert along the probe a needle with a double

* "Oribasius, iv., p. 52 (ed. Daremberg)."

thread, so that it passes beneath the artery. We will cut the thread at the eye of the needle, making two threads and four ends of thread; then, taking the two ends of one of the threads, we will pass them gently to one end of the aneurysm and tie them with precision. Similarly, we will pass the other thread to the opposite end of the aneurysm, and then tie up the artery, so that the entire aneurysm lies between the two ligatures. Then we will lance the aneurysm with a small incision at its centre; in this way its contents will all be evacuated without any danger of hæmorrhage. Those who tie the artery, as I advise, at each extremity, but amputate the intervening dilated part, perform a dangerous operation. The violent tension of the arterial pneuma often displaces the ligatures.

'If the aneurysm originates in the rupture of an artery, isolate with your fingers as much of the aneurysm as you can, including the skin. Then below the isolated part introduce a needle with a double thread of flax or of gut; after passing it through, cut it at the needle's eye, forming two threads. Take hold of the two ends of one of these and pass it to the right, there tie it tightly, so as not to slip. Pass the other end similarly in the opposite direction—to the left. If there is any fear of the threads slipping, pass a second needle with a similar double thread through the same spot, intersecting the first thread and crossing it in the form of the letter X (chi). Cut the threads as before, and tie them like the first ones, so that four threads form the ligature. Then open the tumour at its top, and, after evacuating the contents, remove the superfluous skin, leaving the part tied by the threads. In this way the operation is effected without hæmorrhage.'

"And I must read Mr. Livingstone's comment:

'It certainly is a beautiful piece of lucid writing. I felt that if I was alone on a desert island with someone suffering from aneurysm, and the tide had washed ashore sufficient ἀγκίστρα, etc., that I shouldn't have minded trying the operation. And Antyllus had real literary power. What an admirable phrase is ἐκπνέεται, the "spitting out" of the ligature by the throbbing artery: I don't think you can get it in English, and I fell back on a lame substitute, "displaces."'

"Not unjustly does Paul Broca in his great monograph, *Des Anévrismes*, claim that not only did Antyllus create operative medicine but the pathology of aneurysm: 'A chaque ligne on reconnaît l'écrivain qui parle de ce qu'il a fait.'

DECAY AND REVIVAL OF VASCULAR SURGERY

"Aetius in the middle of the sixth century describes the method for cure of aneurysm at the elbow, known later as that of Anel (1710), ligation of the brachial artery three or four fingers' breadth below the axilla, followed by opening the sac, which was allowed to heal by supuration. A curious error of Sprengel has led to the connexion of the name of Philagrius,† a fourth century surgeon, with this operation.

* "Blows off" might serve—the expression fits the conception of air (πνεῦμα) in the arteries. But it is difficult, as Mr. Livingstone remarks, to improve upon "spits off," for to spit one inflates the lungs. (W. S. H.)

† The method ordinarily attributed to Philagrius is the one practised by Purmann* (1680)—an aneurismectomy. For the seemingly final word on the subject of the operations for aneurism of Philagrius and Antyllus

In the fragments of this writer given by Aetius aneurysm is not mentioned, but Sprengel never noticed that the extract on aneurysm which follows directly after one upon ganglion by Philagrius did not belong to this author but to Aetius himself.

"A casual perusal of the fragments of the Greek surgeons of the first three or four centuries of our era as given in Gurlt's *Geschichte der Chirurgie* gives the impression of a great and fruitful period with scores of men whose qualifications were those demanded by Thomas Fuller for the good operator—the eagle's eye, the lion's heart, and the lady's hand. Then came the tragedy, the death in the West of the science of the Greeks. The Church took over their philosophy, the Arabs absorbed much of the best of their medicine and added to it, but surgery as a progressive science and a successful art died with its founders, the great Greeks of the Græco-Roman Empire. So far as the surgery of arteries is concerned we might take a jump of a thousand years or more were it not for an Arabian, Albucasis of Cordova (tenth century), who wrote a famous surgical treatise, of which we have in the Bodleian the two earliest manuscripts. A young scholar of Wadham and Student of Christ Church, John Channing, in 1778 issued from the Clarendon Press a beautiful edition. The description which he gives of aneurysm with its treatment is practically that of Antyllus. He notes the stridor to be felt, which indicates that he was probably dealing with the arterio-venous form.

"In vascular surgery the men of the Middle Ages and of the Renaissance, Henri de Mondeville, Guy de Chauliac, and even Ambroise Paré, were blind followers, who never even approached the position of their masters. Not much more than a century has passed since men of the John Hunter type took up vascular surgery where Rufus and Antyllus had left it. You may think perhaps, that I am scarcely just to the great mediæval surgeons, particularly to such a master as Ambroise Paré, who reintroduced the ligature, but in vascular surgery, the touchstone of the position of the art, they never wholly regained what the profession had lost." *

What surgeon called upon to treat a huge aneurism of the neck or groin has not experienced the disturbing sensations which only such tumors can arouse? When confronted with an inoperable, malignant neoplasm one feels the great pity of it but not, as in the case of an

the reader is referred to the illuminating paper of Köhler.²⁸ It would lead us too far afield to follow him through the mazes of the discussion or even to indicate the ramifications of the contradictions found in the most authentic documents. We must for the present accept the conclusions reached by this painstaking scholar. (W. S. H.)

* True also it is, as I have so often said, that the surgeon's method of dealing with the bloodvessels is a criterion of his proficiency in his art. (W. S. H.)

aneurism, a peremptory challenge to face the exigency and cope promptly with a situation demanding skilful, resourceful, and possibly even temerous intervention. Few of the surgeons to come will have occasion to be stirred as Valentine Mott must have been by his dramatic experience in ligating the common iliac artery. The surgeon of today looks rather to science than to his art for stimulating rewards of his endeavor. In ligating the first portion of the left subclavian within the chest the operator may not, as formerly, be more greatly impressed by the magnitude and cleverness of his performance than by the miraculous effect of the ligation of the artery upon the great, pulsating tumor which with each beat of the heart jarred the whole frame of the sufferer. The moment of tying the ligature is indeed a dramatic one. The monstrous, booming tumor is stilled by a tiny thread, the tempest silenced by the magic wand.

We have reports of several aneurisms of the subclavian artery which may have been quite as large as the one which I am about to record, but no one of these was operated upon.

HUGE SUBCLAVIAN ANEURISM. LIGATION OF THE FIRST PORTION OF
THE LEFT SUBCLAVIAN ARTERY, AND, TWO YEARS LATER,
EXCISION OF THE CONTRACTED TUMOR

Sur. No. 46179. Alexander Miller. Negro, *æt.* 29. Admitted to The Johns Hopkins Hospital, April 22, 1918; discharged August 12, 1918.

The patient states that he has always been perfectly well. In April, 1917, he noticed a swelling about the size of an egg above the left clavicle. Almost simultaneously with the recognition of the swelling, pain and numbness in the upper extremity were observed. The growth of the tumor was gradual until about March, 1918; since then it has been very rapid. For the past two weeks the limb has been totally paralyzed. The patient recalls that until Christmas, 1917, he could still raise his arm a little.

About four years before admission the patient was shot just above the left clavicle. The wound healed promptly. The bullet was not removed and has given him no indication of its presence.

Examination.—The patient is evidently suffering severe pain, and constantly supports his left wrist with his right hand. The pain, he says, is most intense from the elbow joint to the hand and in the left shoulder.

A huge aneurism occupies the left neck from the clavicle to the ear (Plate I, Figs. 1 and 2). The head is deflected and rotated to the right. The vertex of the pulsating mass is about on a plumb-line dropped to the junction of the middle and inner thirds of the clavicle. The swelling and pulsation extend on to the chest, and the whole body is jarred with each heartbeat. Posteriorly the diffuse pulsating tumefaction spreads out to a point below the spine of the scapula. The aneurism extends upward in dome-shape; a hand can be inserted between it and the face down to the angle of the lower jaw. The whole shoulder-girdle appears to be raised away from the chest wall, the acromio-clavicular articulation being apparently disrupted. The skin over the tumor is extremely tense and glistening. From the clavicle to about the level of the nipple the brawny tissues are probably infiltrated with blood as well as inflammatory products. The trachea is displaced to the right. A systolic bruit, most distinct above the inner third of the clavicle, can be heard over the greater part of the pulsating mass. No thrill can be felt. The left radial pulse is absent. There is slight ptosis of the left eyelid, but the pupils seem to respond equally. Only the inner third and the acromial tip of the clavicle can be defined with the fingers; the remainder of the bone is buried in the tumefaction. A bullet is palpable just beneath the skin to the left and below the spine of the seventh cervical vertebra. The muscles of the left shoulder, arm, and forearm are paralyzed; there remains a trace of power to flex the fingers and wrist. The deep reflexes are absent and the muscular atrophy is marked. The entire extremity up to and over the aneurism is insensitive to touch, pin-prick, and temperature.

Fluoroscopic Examination.—The shadow of the aneurism extends to the lower border of the clavicle but not to the first rib. The heart seems not to be enlarged. The right subclavian and carotid arteries, distinctly seen, are normal in size.

Skiagraphic Report.—Large mass in left neck. Clavicle deeply eroded, perhaps fragmented. Bullet in upper dorsal region.

The thought of excising or incising the aneurism was hardly entertained. The patient's condition contraindicated such a prolongation of the intervention, and an operation on so large a scale and through so great an expanse of infiltrated and inflamed tissues might have menaced from infection the life of the patient and have imperiled the artery at the site of the ligature, deep within the thorax.

Operation.—April 26, 1918. Dr. Halsted. *Ligation of the left common carotid and the left subclavian arteries near their origin from the aorta.*

Ether. Wide protection of the operative field with celloidin silk.²⁰

Transverse bow-incision just below the cervico-thoracic junction, supplemented by a vertical one along the left border of the sternum (bow and plummet incision). Free exposure of manubrium and left sterno-clavicular joint. The incised tissues were œdematous, particularly so below the clavicle. The superficial vessels were abnormally large. Careful hemostasis by the fine silk transfixion method. The left two-thirds of the manubrium and the left sterno-clavicular joint were resected with the giant rongeur forceps of Esmarch, care being taken to avoid disturbing the fragments of the eroded clavicle. The thymus gland and the left innominate vein were drawn upward and to the right with a retractor.

The trachea in the thorax, as well as in the neck, was displaced to the right by the pressure of the aneurism. The left carotid, deeply situated and occupying the midline in the chest, was gently occluded with a broad tape ligature. This artery was thought at first to be the left subclavian inasmuch as, according to the erroneous testimony of an onlooker, its occlusion did not affect the pulse in the left temporal artery, and lessened the force of the pulsation in the aneurism. To obtain access to the left subclavian artery the cartilage of the left first rib and the adjoining margin of the sternum were cut away. The arch, the aortic isthmus and descending aorta, and the left auricle of the heart were palpated with the finger of the operator before the left subclavian, lying close to the vertebral column, was identified. With the aid of four long, narrow dissectors, two of which were manipulated by the operator and two by Dr. Mont Reid, the vessel was clearly exposed at its origin from the aorta and for several centimeters distal to this point. As it was evident that none of the various aneurism needles was suitable for the passage of a ligature at this depth, a narrow blunt dissector, slightly curved and pierced at its tip, was armed with fine silk and passed under the artery. By means of this thread and then another, narrow linen tapes were drawn under the subclavian; both of these were tied, the second distal and close to the first, with force only sufficient to close completely the artery's lumen. The aneurism became very tense and hard immediately after the ligation, but was pulseless.

The patient's condition, bad on admission and particularly so just before operation, caused us some anxiety. Traction within the thorax

on the branches of the aortic arch or on the pulmonary artery affects unfavorably and eventually disastrously the action of the heart. The pulse, about 120 at the beginning, was 140+ and quite weak at the termination of the operation. The wound was completely and accurately closed with interrupted sutures of fine silk. A great dead space in the mediastinum was, naturally, unavoidable.

Healing per primam.

November 9, 1918. The patient has been examined frequently since his discharge from the hospital. He can make slight movements with the left fingers, otherwise there has been no appreciable return of power or sensation in the paralyzed arm. There has been no pulsation in the aneurism since the operation. The mass has steadily but slowly been absorbed.

Throughout the year following the operation the pulseless tumor slowly but steadily diminished in size. Then for a year the patient, living out of town, was lost sight of. Exactly two years after the first operation he returned, at our solicitation, to the hospital. Now for the first time since the operation a very faint pulsation was discernible. The tumor (Plate IV, Fig. 7) measured in its transverse (frontal) diameter precisely the same as when last seen a year before; the antero-posterior measurement (sagittal), however, gave an increase of about 4 cm. Sensation of the left shoulder, arm, forearm, and hand was quite normal except for slight impairment to touch and pin-pricks at the finger-tips and over the palm of the hand. Power had returned to the deltoid, supraspinatus, pectoralis major, and rhomboid muscles, and in slight degree to the biceps and triceps. From the atrophied infraspinatus there was no response. The patient was unable to pronate or supinate the forearm but he could slightly flex and faintly extend the wrist. For the interossei and lumbricales no improvement was observable.

I decided that the aneurism should be excised, and on April 20, 1920, operated as follows:

The skin over the tumor and a wide area about it were protected with Chinese silk dipped in celloidin. The incision, made through the tightly adherent silk, ran with the clavicle in its central part, curving up into the neck at its inner end, and down along the cephalic vein at its outer. Superimposed on and not attached to the greatly broadened and thickened clavicle was a sharply convex bow of bone about 9 cm. long and 6 mm. thick. This bow, recognizable in the

photograph (Plate III, Fig. 6), was cut away and the clavicle bitten through with a heavy rongeur forceps at two points as close to the aneurism as possible. The cephalic vein was divided, and the axillary artery—pulseless, tape-like,* reduced in size, apparently not quite empty—was ligated about at the junction of its first and second portions, through a split made in the pectoralis minor muscle; the aneurismal sac and the resected rib were excised in one piece. The aneurism was matted to the surrounding parts by dense connective tissue, and hence had to be carved out rather than enucleated. The identification and freeing of the roots of the brachial plexus, which were in places embedded in the wall of the sac, consumed much time. The operation was conducted in a bloodless manner until nothing remained to be done except to divide the narrow neck of the sac. The tissues of this neck proved to be thin and friable, and the patient lost a few cubic centimeters of blood through a little tear, which was readily repaired with three stitches of fine silk. The wound was closed without drainage. I am greatly indebted to Dr. Heuer and Dr. Reid for their skilful and highly competent assistance which enabled me without fatigue to conduct the operation to a satisfactory conclusion. The excised aneurism was carefully examined by Dr. MacCallum, Dr. Reid, Dr. Heuer and myself and the decision reached that no portion of the artery had been excised.

At the first dressing, made on the 10th day after operation, it was noted that a little fluid had accumulated in the outer part of the wound. This was evacuated by puncture with a wooden toothpick wrapped with a few fibres of cotton dipped in pure carbolic acid. Closure of the puncture was prevented by the reapplication of the acid in the same manner on two alternate days. The introduction of a drain of any kind we scrupulously avoid. The word "drainage-tube" is in disfavor in our clinic. Should a wound become infected, tubes would be properly introduced for the purpose of disinfection, but not for drainage.

* I have several times made the observation, both on the human subject and animals, that a stretch of artery destined to become obliterated may be partially or totally collapsed beyond the point of occlusion and nearly to the first distal branches although the bloodpressure in the vessel peripheral to these branches may be approximately normal (*vid.* Jour. Exp. Med., 1916, xxiv, 276). Hence I have questioned the validity of the universally accepted view that the conversion of the artery into a fibrous cord is due primarily to the thickening of the intima. May not the lowering of the bloodpressure in the discarded, pocketed segment be the primary factor?

Noteworthy is the fact that the patient's hand, which prior to and ever since the first operation had been markedly cold, became strikingly warm about six hours after the second operation. It is improbable that the ligation of the cephalic vein was in any part responsible for this indubitable improvement in the circulation. The elevation of the temperature of the hand and forearm must, I believe, be attributable solely to vasodilatation incident to the ligations and severings of the subclavian and axillary arteries (Leriche).²²

Today (June 16, 1920), the 57th since the operation, the left hand and forearm are still warm—quite as warm as the right. There are a few well-defined, cooler areas, one of them to the outer side of and below the olecranon process of the ulna.

ANALYSIS OF THE RESULTS OF LIGATION OF THE FIRST PORTION OF THE LEFT SUBCLAVIAN ARTERY

Six of the 21 cases (28.5 per cent) died; only two of these (Rodgers and Marchesano) were operated upon in the days before Listerism; in three (Bardenheuer, Kammerer, Duval), antiseptic precautions were observed; the remaining fatality (Lane) occurred in 1883. The wound of the first operation in Lane's case was closed and is believed to have healed *per primam*; the hemorrhage, noted two weeks after the first operation, may have been due either to the fineness of the silk ligature or to infection or to both; infection must have been the chief cause of the hemorrhage after the second operation. Bardenheuer's patient died 18 hours after a difficult, very extensive, and presumably bloody operation for carcinoma; Kammerer's lived one month, and died of secondary hemorrhage due to faulty ligature-material (catgut); in Duval's case the cause assigned for the sudden death a few hours after the operation was speculative. Thus, infection was responsible for three of the six fatalities, and a catgut ligature for a fourth. All of the 10 cases operated upon in the last decade recovered. The 21 ligations of the first portion of the left subclavian were all except one (Bardenheuer) for aneurism. Of the recovered cases the aneurism was spontaneous in six, and of traumatic origin in nine. Of the spontaneous aneurisms Stonham's (IX) is the only one not pronounced cured by the simple ligation of the subclavian.* As the artery in this case coursed high in the

* The case of Schumpert (VI), however, was observed only for nine weeks, and of Newbolt for three months.

neck and the aneurism was apparently at the highest point of the subclavian's arch, and as, furthermore, the radial pulse reappeared 24 hours after the ligation of the subclavian, it would seem that there must have been a well established collateral circulation before the first operation. May not a cervical rib have been the primary cause of this aneurism? The effect of merely tying the subclavian artery was tested in five (Browne, Rubritius, White, Ballance, Halsted) of the nine traumatic cases. If my case (XXI) had been observed for a period less than the two years we should have believed that the ligation alone had effected a cure in every instance. In Browne's case, to be sure, the axillary hematoma was evacuated, but as no bleeding ensued it may be classed in this group of cures by simple ligation. In three (Jüngst, Delbet, Wieting) of the remaining four cases of this traumatic group the blood sac was opened, evacuated, and stuffed with gauze. The hemorrhage was profuse on opening the sac in all the three cases, and in two of them (Delbet, Wieting) the tight stuffing was for the purpose of controlling it. In Jüngst's case a ligature was placed on each side of the slit in the artery made by the bullet, and in Delbet's the subclavian was ligated in its third portion also, in order to control the "formidable hemorrhage" which occurred on opening the sac. In the remaining one of the nine traumatic cases (Neff) the ligation of the subclavian was made for the control of hemorrhage resulting from a tear inflicted by the operator in the course of a dissection of the neck for the removal of enlarged lymphatic glands. For the remarkable operative and post-operative complications in this case the reader is referred to the abstract (XIII).

Thus the aneurism was cured by the simple ligation of the subclavian, whether proximal or distal to the branches of the first portion, in all the spontaneous aneurisms but one (Stonham), and in all but one (Halsted) of the traumatic variety. By reference to the diagrams (Plates VII, VIII, IX, X) we note at a glance that the ligature of the first portion was distal to the branches of this portion of the artery in eight instances (Rodgers, Marchesano, Schumpert, Browne, Newbolt, Wieting, Hamann, White) and proximal to them in six (Bardenheuer, Kammerer, Jüngst, Rubritius, Gaudiani, Ballance *). In seven of the

* We have placed the ligature of Ballance proximal to all the branches except the vertebral, although its precise location is doubtful. Ballance states that he tied the artery behind the vertebral vein. This vein, irregular in origin, is usually internal and anterior (Henle) to the artery in this part of its course.

cases (Lane, Halsted, Stonham, Delbet, Duval, Neff,* Halsted) the subclavian was ligated on both sides of the origins of its branches, and in two of these (Halsted, Halsted) the aneurism was excised.

In no case, Stonham's excepted, was there restoration of the radial pulse after operation. In Stonham's patient it was equal on the two sides before operation and reappeared 24 hours after the ligation of the subclavian. The anastomotic circulation was presumably well established before the operation, for the reason, as stated above, that the presence of a cervical rib may be assumed.

Perusal of the original accounts of the cases of gangrene following ligation of the subclavian artery reveals the fact that in each instance there was a serious complication—thrombosis, arterio-venous fistula, ligation of the axillary artery, etc. I have failed to obtain any evidence that gangrene has been caused by the uncomplicated ligation or ligations of either subclavian artery.

In a paper by Bean⁹ based upon 129 dissections by students of the subclavian and its branches recorded upon Bardeen's charts we find summarized the views of Quain, Testut, Gray, Henle, Tiedemann, Spalteholtz and Toldt, Sappey, and himself as to the normal origin of the branches of this artery on both sides of the body (*vid.* Plate VI). The conclusions arrived at by Bean from his study of Bardeen's charts are as follows:

"I. The branches of the subclavian artery differ in their origin on the two sides of the body. . . .

"(a) There is a tendency in the branches of the subclavian artery to bunch themselves in their origin on the left side, whereas on the right side there is a tendency in each branch to arise directly from the subclavian artery.

"(b) The thyroid axis, dividing into the suprascapular, transverse cervical, and inferior thyroid arteries, is not normal, except on the left side.

"(c) The transverse cervical artery and the costo-cervical trunk arise from the second part of the subclavian artery more frequently on the right side than on the left side.

"(d) The superficial cervical artery is of infrequent occurrence, and is found more often on the right side.

* In Neff's patient the thyroid axis and the vertebral and internal mammary arteries were also tied. The exact position of the hole torn in the subclavian in this case was not determined and consequently may be erroneously indicated in our diagram.

"(e) The transverse cervical artery terminates by dividing into ascending and descending rami, the latter being commonly called the posterior scapular artery. The former divides underneath the trapezius muscle and supplies the upper and middle part of the back.

"II. There are five important, and not infrequent, anomalies to which the attention is directed:

"(a) The origin of the right subclavian artery from the descending part of the aorta. This occurs 4-6-8 times in 1000 cases (0.5% to 1% of all persons).

"(b) Variableness in the origin of the transverse cervical artery, especially on the right side.

"(c) The presence of a middle thyroid artery (Thyroidea Ima).

"(d) The suprascapular artery arising from the internal mammary artery.

"(e) The lateral thoracic artery arising from the internal mammary artery.

"III. Eighty per cent of the dissections were made in negro subjects, a large number of whom may have been mulattoes or mixed bloods. That hybrids tend toward variation is a recognized biological law. This may explain the unusually large number of abnormalities encountered.

"IV. Twenty-three infants were dissected and many of these show irregularities, particularly in the distribution of the suprascapular artery, which is frequently deficient, its place being taken by the dorsal scapular artery.

"V. The branches of the subclavian artery may be more numerous in adults than in infants. The branches rise from all parts of the artery in adults, whereas in infants the branches frequently rise in a bunch from Part I."

In choosing a diagram to represent the norm for the left side I have accepted the representations of Quain, Gray, Testut, and Bean. According to Bean, our diagram depicts correctly the norm for the left side—the side which at present concerns us—but not for the right side. Bean states that the arrangement shown in the diagram which I have adopted as typical was found by him in 55 per cent of the students' dissections of the left subclavian. For the right side the majority of anatomists give the origin of the *arteria transversa colli* to the third or second portion of the vessel (*vid.* Plate VI).

THE TREATMENT OF ANEURISMS OF THE SUBCLAVIAN ARTERY

The six patients upon whom I have operated for aneurism of the subclavian artery recovered ideally without gangrene or added loss of function; the wounds, all closed without drain, healed *per primam*, and in all the aneurism was cured, but I am sure that in several

instances the operative measures were not quite those I should under like circumstances practise today. For example, I should not again, as in my first case (V), excise the aneurism in an old man unless a proximal ligature had failed to cure it; and I believe that the excision of the aneurism in case No. XXI should have been undertaken much earlier in order to liberate more promptly the matted nerves.

We can forecast with greater confidence than for the subclavian certain generalizations in regard to the treatment of aneurisms of the extremities situated so low that an elastic band or tourniquet may be satisfactorily applied above them. In such cases the sac should be opened and excised and a suture—lateral or end-to-end—be made, when feasible. The openings in the sac of the afferent and efferent ends of the artery may be only a few lines apart. Within the past 18 months Dr. Mont Reid (resident surgeon) of our staff at The Johns Hopkins Hospital has once made a lateral and twice an end-to-end suture in cases of aneurism of the popliteal artery. In each instance the pulse in the tibial arteries was immediately and permanently restored. If the artery has been ligated the operator must carefully observe the state of the circulation in the foot, making use of one or more of the several tests at his disposal. If there is reason to fear gangrene, he should note the effect of occlusion (temporary or permanent) of the corresponding vein. If gangrene still threatens, the interpolation of a piece of vein between the arterial ends is indicated and should be undertaken provided the surgeon has made himself proficient in the art of suturing bloodvessels. It is clearly the duty of every surgeon to practise on animals the end-to-end suture of arteries until he has become master of the technique. To consider the proper procedures for surgeons of diverse degrees of qualification would involve us in a discussion too prolonged.

Agreed as to what the treatment should be of aneurisms of the extremities whose blood supply can usually be controlled, we may advance to the consideration of the extent to which these ideal procedures may be applicable to aneurisms in or above the groin and axilla—above, in other words, the domain of the tourniquet. It is clear, I think, that aneurisms of the neck and groin should not be incised until their arterial supply on all sides has been temporarily shut off. When a ligature can be applied between the proximal pole of the aneurism and the branches of the first and second portions of the subclavian artery and another beyond and close to the distal pole,

the sac may, if there are indications for doing so, be safely opened, for in only a small percentage of the cases would a branch (the *arteria transversalis colli*) be a possible source of annoyance. If the aneurism is of one of the first two portions of the subclavian and the ligature has been applied proximal to the grouped branches it would always be troublesome and sometimes impossible to shut off its blood supply completely. It is fortunate, therefore, that such a large percentage of the aneurisms of the left subclavian have been cured merely by ligation of its first portion. An indication for immediate opening of the sac might be the paralysis due to pressure. In the majority of cases I should be inclined to test the effect of proximal, or proximal and distal, ligation. Should pulsation persist after the double (proximal and distal) ligation of the subclavian I should, when the wounds from the first operation were firmly healed, or sometime thereafter, excise the aneurism. Certainly one should not cut into a pulsating aneurism, and to search for and ligate all the branches of the first portion might be an undertaking more formidable than the excision of the sac; it might indeed be quite impossible to secure these tributaries without first dislodging the tumor. I should even hesitate to open a non-pulsating aneurism which had shown no tendency to decrease in size. If for any reason a surgeon has decided to slice into an aneurism of the subclavian, my advice to him would be to free first by dissection as much of the tumor as possible and then split it widely to the deepest parts. An operator searching for a bleeding point in a pool of blood, and particularly so when embarrassed in his movements by the adherent walls of an aneurism within which he is working so disadvantageously, presents a distressing spectacle. I would rather devote an additional hour or more to an operation than be caught for a few moments in such a predicament.

Common errors in the treatment of aneurisms are the following: (1) opening the sac or pulsating hematoma without first making a temporary occlusion of all the possible sources of hemorrhage; (2) permanent ligation of a great arterial trunk as a precautionary measure in the search for a distal bleeding point; (3) ligation of a trunk too far from the aneurism; (4) stuffing the wound with gauze to arrest hemorrhage; (5) drainage; (6) the employment of catgut for the ligature, or of silk that is too fine; (7) ligation of the artery proximal to an arterio-venous aneurism or fistula.

MAY GANGRENE BE PREVENTED BY LIGATION OF THE VEIN
CORRESPONDING TO THE OCCLUDED ARTERY?

In 1906 von Oppel⁴³ and Korotkow made observations in the course of three operations in one day for the cure of arterio-venous fistula which are of fundamental importance in their bearing on the question of ligating the vein corresponding to the artery with the idea of preventing gangrene. Von Oppel's account of this experiment on the human subject, well worth preserving in the English language, is as follows:

"Male, æt. 32. Wounded in the left shoulder by a rifle ball. Entered hospital in St. Petersburg, April 26, 1905.

"*Diagnosis*.—Aneurysma arterio-venosum axillare; collateral arterial routes fairly developed.

"May 5, 1905. The first operation began at 11 o'clock in the morning, and ended at 11.30. The incision was begun a finger-breadth above the border of the pectoralis major muscle and carried 7 cm. downwards. The N. cutaneus medius was drawn outwards, the vein exposed. Exactly in the neighborhood of the pulsating tumor two brachial veins emptied into the axillary vein. The latter was varicose immediately above the site of the junction. A rather thick collateral branch was given off from the inner of the two brachial veins. Wishing to abbreviate the intervention as much as possible I decided (1) to ligate the axillary artery above the aneurism; (2) to ligate the external brachial vein in order to retard the flow of the venous blood. I believed that the communication with the aneurismal sac was located in the varicose portion of the dilated vein. Without laying bare the aneurismal sac, I pushed the N. medianus and the axillary vein outwards and divided the axillary artery between ligatures.

"The operation was carried on without the application of an elastic bandage above the aneurism, hence Korotkow was able, immediately after the division of the artery, to measure the blood pressure in the fingers. To our surprise this was 0, and the extremity became pale. As I was sure from previous examinations that the collateral routes were sufficient and attributed the result of the measurement of the blood pressure to some accidental cause, I completely closed the wound and applied a dressing.

"However, although the extremity became warmer, the blood pressure did not rise. At 1.30 in the afternoon the arm was deathly pale, the blood pressure 0. On the volar surface of the thenar eminence there developed a bluish dark red oval spot. Immediately on regaining consciousness the patient began to complain of extraordinarily severe pains in the arm. The forearm and hand were insensitive and completely paralyzed (ischemic paralysis), the cutaneous veins entirely collapsed—in a word, gangrene of the extremity was developing beneath our eyes.

"This state of affairs needed clarifying and the explanation which Korotkow gave was so convincing that I declared myself in full agreement with him. Korotkow reasoned as follows: Since the axillary vein above the aneurism and the axillary artery below the aneurism were not ligated, the arterial blood of the collateral routes was being carried off by the veins through the aneurismal sac. In order to remove this influence of the veins one should ligate the axillary ~~artery~~ *vein* above the aneurism.

"The second operation, likewise under chloroform narcosis, was begun, without elastic bandage, at 3.30 in the afternoon, and finished at 4.30 o'clock. The wound was opened, the axillary vein exposed above the aneurism and divided between ligatures. In spite of this the blood pressure remained 0. As the explanation given above in regard to the cause of the gangrene appeared to be irrefutable, one had, in seeking a reason for the lack of effect of the ligation of the axillary vein, to find it in the existence of some accessory veins which might carry away the blood from the aneurismal sac. Consequently, I began to search for accessory veins, whereupon quickly the evolution was as follows: Scarcely had I compressed with the finger the space between the stumps of the divided artery, when the forearm and hand immediately became red, and Korotkow, who uninterruptedly was measuring the blood pressure in the fingers, observed a rise in the blood pressure to 40 mm. I had hardly removed the finger when the blood pressure went back to 0, and the extremity again became pale.

"Considering these facts, I began to dissect the deeper parts of the axilla behind the artery and, in fact, found there an abnormally thick venous trunk. The size of this vein was not less than that of the axillary vein, which lay in front of the artery. This venous trunk—the V. axillaris profunda—was isolated, and divided between ligatures. The blood pressure in the fingers rose to 40 mm.; the extremity became red. Wound completely closed; aseptic dressing.

"When the dressing was about completed I noticed that the arm was again becoming pale. In putting on the dressings the arm had been held in the vertical position. When lowered, the arm reddened somewhat. The patient was put to bed, and to the arm, dependent, hot water bottles were applied.

"As the patient came to himself he again began to complain of severe pains; the blood pressure was falling fast. Although complete paralysis was not present, there were suggestions of beginning gangrene in the hand and forearm. The second operation had undoubtedly brought about an improvement in the circulation in the hand and forearm; but the improvement was not yet sufficient, and the danger of gangrene developing had not passed. At 7.30 in the evening the blood pressure in the fingers again sank to 0. When the arm was held up a high degree of bloodlessness ensued immediately; when lowered, it recolored barely if at all. Pains as before; the ischemic paralysis increased.

"On account of the threatening symptoms I decided to operate again, to excise the aneurismal sac. We attributed the increase in the symptoms of beginning gangrene to the dilatation of the collateral venous routes, which again, through the efferent arterial trunk, took up the collateral blood by way of the aneurismal sac.

"Third operation under chloroform narcosis, without elastic bandage. Begun at 8.30 P. M., ended at 9.30 P. M. The lower half of the wound was opened, the incision lengthened downwards. Starting at the point above the sac where the artery and the veins were divided, I began gradually to dissect out the sac. The radial nerve, which was somewhat adherent to the sac, was freed. The sac itself had invaded the M. brachialis internus. During the dissection the sac was wounded and a feeble stream of arterial blood issued from it. This circumstance was the best evidence that the blood, actually streaming back out of the efferent arterial trunk, coursed into the aneurismal sac, to be carried out of it back to the heart by the veins. After the sac was excised it was found that several veins led out from it.

"Scarcely were the distal veins * ligated and the sac excised when the hand and the lower third of the forearm became very hyperæmic; the blood pressure in the fingers rose to 30 mm. Hg. The hyperæmia reminded one exactly of that which usually follows the removal of the elastic bandage; it was sharply circumscribed, on the dorsal surface of the forearm reaching to 13 cm. above the radio-carpal joint, and on the volar surface to 7 cm. above this joint. In addition, I would say that this hyperæmia lasted for 24 hours.†

"It was also clear that if the third operation had not been performed, it was exactly this hyperæmic region which would have broken down.

"Closure of the wound. Introduction of a strip of gauze into the lower angle of the wound. Aseptic dressing.

"At 11.30 P. M. the patient became conscious. No trace of the pains and paralysis remained. The pareses which were present before the operation and which were caused by the adhesion of the radial nerve to the aneurismal sac had likewise disappeared.

"Uneventful post-operative course. Temperature normal. Stitches removed on the 5th day. Healing throughout *per primam*. From out of the region of the tampon a moderate quantity of clear lymph issued for the first few days. On the day after operation the arterial pressure

* In the course of the excision of the sac the axillary artery must have been ligated both above and below the fistulous communication with it or, what amounts to the same thing so far as the circulation is concerned, the arterial neck of the sac must have been tied. Thus the result of the three operations was excision of the aneurism with ligation of axillary artery and vein both above and below the sac and of other vessels encountered in the course of the dissection. (W. S. H.)

† May not the persistence of the hyperæmia be ascribed to the arterial sympathectomy? (W. S. H.)

in the fingers rose to 40 mm. Over the gangrenous spot on the thenar eminence the necrotic, superficial skin came away. The patient was discharged entirely cured and in good health."

If the sac had been excised at the primary operation of von Oppel the result would have taught us nothing—an opportunity would have been lost. I wish to emphasize this fact in the hope that surgeons may bear always in mind the opportunities which they have daily at the operating table to strive for results which may be contributory to the advancement of their science.

The operating room is a laboratory for the surgeon.

Learning by the ordinary routine experiences of practice what might have been ascertained from experimentation on animals cost in the last war an appalling loss of life and limb.

The lesson taught by von Oppel and Korotkow seems to have been forgotten or overlooked even by the Germans, for no mention is made of it by either Sehrt⁵⁵ or Propping,⁵⁶ the first of the surgeons of Germany—one must conclude from their communications—to discuss in general terms the vascular balance and to advocate as a routine procedure the simultaneous ligation of the vein and artery:

SEHRT. "The outflow or better the sucking up of the venous blood may best be prevented by ligation of the veins. Everything which accelerates the sucking away of venous blood (activity of the heart, etc.) from an extremity robbed of its arterial supply must contribute to the death of the part deprived. Thus may be explained cases in which definite gangrene of a segment of an extremity has appeared some little time after the receipt of the injury and after the general condition and especially the heart's force had improved. Every one may well have seen such cases. Under certain circumstances a severely injured member may be carried over the most dangerous period by venous blockage."

PROPPING. "One sees, therefore, that my explanation of the possible cause of gangrene of a limb after ligation of an artery goes farther than Sehrt's. In place of the 'sucking away of the venous blood' I advance the idea of a disproportion between in- and out-flow—to a certain extent a disturbance of balance of these two factors*—in order to explain the insufficient filling of the capillary bed and the thereby conditioned derangement of the nutrition of the tissues."

At the Séance of July 4, 1917, of the Société de Chirurgie Professor Tuffier⁶⁰ gave his views on the subject of the ligation of the vein:

"We all know that the three arterial ligations which most often expose patients to grave dangers of disturbance are (1) those of the

* Stromeyer in his *Handbuch der Chirurgie*, 1844, p. 371, proposes: "In Fällen wo varicöse Beingeschwüre für die Erhaltung des Gliedes Gefahr drohen und die Operation der Varices nicht rathsam erscheint, glaube ich, dass man durch Unterbindung der *arteria cruralis* das Gleichgewicht in der Zuleitung und dem erschwerten Abflusse des Blutes wieder herstellen könne."

femoral trunk, (2) those of the carotid at its bifurcation, and (3) those of the popliteal artery in the lower half of the popliteal space. If I believe everything that I have seen of ligations since the beginning of this war, it is that the occlusion of the popliteal in its lower half causes most disasters; gangrene of the limb is very often a consequence of it.

"To lessen the chances of ischemia or of the gangrene following ligatures in these regions, it has been advised to have recourse more often to lateral sutures in all cases where the nature of the lesions permitted it, and I fully share this opinion. There is a great advantage in having recourse to arterial sutures; they are less difficult to place than one believes.

"There is a practice to which I desire again to direct your attention in this connection; it is ligation of the corresponding healthy vein in all cases of ligation of the great vessels of the root of the limbs. This question, raised long ago, can find in actual occurrences some particularly suggestive statistics. There is first a fact which appears well demonstrated; it is that ligation of the vein and of the artery in the case of wounds of the two vessels does not increase the danger of ischemia. Moreover, the statistics of the English army, which Sir George Makins has communicated to us, give in this connection the following ratios: Ligation of the artery alone is followed in a general way by gangrene in 40.2 per cent, whereas simultaneous ligation of the artery and of the vein under the same conditions gives 24.5 per cent; and I speak only of gangrene from ischemia.

"The most marked difference is in connection with the popliteal; ligation of the artery alone in 24 cases gave favorable results in 58.33 per cent, and gangrene in 41.66 per cent. Simultaneous ligation of the artery and of the vein has given in 28 cases 22 favorable results and only six cases of gangrene."

The firm position taken by such an authority as Sir George Makins has greatly influenced the surgeons of England and France, and his advocacy of the procedure made it almost mandatory in these countries in the last years of the war to occlude the vein accompanying the ligated artery. The arguments, summarized in his most admirable book, "*On Gunshot Injuries to the Blood-Vessels*"²³ (1919) are as follows:

"In preparing a former contribution to the surgery of wounded arteries,* I was much struck by the observation that proximal ligation of the femoral artery in cases of arterio-venous aneurysm was followed in a large proportion of instances by gangrene of the limb, while excision of the implicated segments of both artery and vein gave consistently good results. An explanation of this apparent inconsistency will be found below, as also further considerations which led me to conclude that when an artery needs to be tied, the satellite vein should be occluded also.

* "*Bradshaw Lecture, 1913.*"

"It is to be regretted that John Hunter himself did not write the paper describing his operation of proximal ligature and the grounds upon which he was led to undertake it. In at least one of the cases described in the paper by Sir Everard Home,* possibly in the first three, both the femoral artery and vein were included in the ligature; in the fourth we are definitely told that the artery only was included. From that period onwards surgical opinion has been definitely to the effect that the greatest care should be taken, when occluding a main artery, to avoid all injury to the vein. In fact, every operation for the ligature of an artery has been so devised that the aneurysm needle is passed in a direction away from the vein in order to minimize the risk of injury to that vessel, not alone to avoid the technical inconvenience of immediate hæmorrhage, but also with the definite object of preserving the venous circulation intact.

"Observation of a large number of coincident wounds of large arteries and veins has in no way endorsed the view that simultaneous occlusion of both artery and vein exercises any deleterious influence on the subsequent collateral arterial circulation and the vitality of the limb. In support of this statement a few examples illustrating the innocuous nature of operations for the occlusion of veins in general may be first given. Operations for the cure of varicose veins have demonstrated the ease with which a compensatory balance is attained when the blood is diverted from the larger channels. Occlusion of the internal jugular and other large venous trunks effected in order to prevent the diffusion of septic emboli has not given rise to obvious permanent trouble. As is well known also, occlusion even of the vena cava by surgical methods has been survived, and the capacity of the venous circulation to maintain itself by compensatory changes, which is seen when this vessel undergoes obstruction by thrombosis, is a familiar experience.

"In a very considerable proportion of gunshot injuries to large arterial trunks the neighboring vein is contused and becomes thrombosed, and this has not been shown to give rise to increased risk of gangrene of the limbs. Ligature of the common carotid artery together with the internal jugular vein *en masse* has been performed in cases of emergency without increased risk of the development of the cerebral anæmia and softening so often a consequence of ligature of the artery alone. Further, where simultaneous ligature of both artery and vein in other parts of the body has been obligatory on account of wounds of both vessels, untoward events have not been observed.

"Evidence exists, moreover, that under certain conditions simultaneous occlusion of both artery and vein is a preferable procedure. The first example, not an unmixed or simple one, may be sought in the results observed to follow the application of a single proximal ligature to the artery in cases of arterio-venous aneurysm or aneurysmal varices

* "John Hunter's Works. Palmer's edition, vol. iii, p. 604."

of the femoral vessels. In patients so treated during the South African War,* gangrene of the limb followed in more than 50 per cent of the cases. The frequency of this accident finds a simple explanation if we consider what actually results from the operation. The main vessel being occluded and the direct arterial pressure from behind being abolished, blood which has been carried by the arterial collaterals to the distal portion of the injured trunk, instead of passing to the peripheral circulation, takes the course of least resistance backwards into the vein through the arterio-venous communication, and thus the limb practically bleeds to death much in the same way as if the distal end of the wounded artery opened on the surface of the limb. Hence the comparative safety of removal of the communication *en masse* and occlusion of all four openings by ligature which has been confirmed by numerous operations during the present war.

"A more striking example is offered by the result of ligaturing the popliteal vein alone for the treatment of senile gangrene of the foot. W. A. Oppel,† ascribing the good results occasionally observed to follow arterio-venous anastomosis for the cure of this condition to control of the venous circulation and consequent rise in the blood-pressure of the limb, was led to substitute simple occlusion of the popliteal vein to produce the same effects. In six cases thus treated the extremities were seen to recover not only their warmth and color without the development of œdema, but also a certain degree of hyperæmia of the feet and toes.

"On these and other grounds it must be admitted that the balance of the collateral circulation is likely to be more efficiently maintained if the vessels which carry it on more nearly correspond in size and consequent equality in the bloodpressure and rate of flow. The elimination, in fact, of the capacious main vein is a real advantage, since this for the time affords a too ready channel of exit for the diminished arterial supply, as well as an undesirable reservoir for stagnation.

"These considerations have led me not only to regard obligatory simultaneous occlusion of a main artery and vein as a negligible factor in the risk of gangrene of a limb; but to hold further, that the procedure is preferable whether the vein be wounded or not; the result of the combined procedure being to maintain within the limb for a longer period the smaller amount of blood supplied by the collateral arterial circulation, and hence to improve the conditions necessary for the preservation of the vitality of the limb.‡

"M. van Kend tested the accuracy of the above conclusions as to the rise of bloodpressure at the laboratory of the Ocean Ambulance at La Panne by some experiments on animals, and made the following

* "Surgeon-General W. F. Stevenson, Report on the Surgical Cases noted in the South African War, 1899-1902."

† "Zentralblatt für Chirurgie, 1913, No. 31, p. 1241."

‡ "Hunterian Oration, Lancet, Vol. i, 1917, Feb. 17, p. 249."

remarks in his observations at the Inter-allied Conference of Surgeons held in Paris in May, 1917:

'In carrying out a series of experiments made with the object of determining the indications and the physiological basis for transfusion of blood, I have had the opportunity of measuring the blood-pressure in limbs of which the main artery had been ligatured. The blood-pressure was taken successively after the artery alone had been tied, and again when ligature of the vein had been superadded. My observations confirm the view that has been expressed by Sir George Makins; in fact, plethysmographic tracings demonstrate clearly that a slight rise in the blood-pressure in the limb follows the application of a ligature to a main vein, after previous ligature of the artery.

'It appears, then, from the standpoint of the physiologist, that to leave the main vein viable after occlusion of the main artery of a limb, diminishes what may be called the *residuary blood-pressure* maintained by the collateral circulation. If the contribution of the collateral circulation is allowed to remain with the main vein intact, it is natural that the *residuary blood-pressure* should fall. If this view be adopted, ligature of the vein as well as the artery should be recommended in order to retain the blood supplied in longer contact with the tissues. Thus the most satisfactory conditions for the maintenance of the nutrition of the organs are provided, because the obstacle to the return circulation provided by ligature of the vein retains the blood for a longer period in the member.'

"After discussion of the question at the meeting, the following conclusion was adopted:

'Contrary to what has until now been believed, simultaneous ligature of both artery and vein when both vessels have been wounded does not give rise to increased risks of gangrene; in fact it diminishes them. Facts tend to prove, even when the wound is limited to the artery, that simultaneous occlusion of the unwounded vein is to be recommended.'*

"Major Hamilton Drummond has kindly furnished me with a note regarding some investigations which he made on this subject in the case of the visceral vessels. Loops of the small intestine of the cat, and of the colon of the Belgian hare, were made use of. After a careful study made by means of barium injections and X-ray photographs to determine the number of vessels which should be ligatured in order to avoid error from leaving too free an anastomotic supply, the following experiment was made six times on cats' intestine.

'A loop of ileum towards the caecal end was drawn out of the abdomen, and the arteries and veins supplying about five inches of the gut were ligatured, cutting off the total macroscopical blood-supply to that portion. The loop was returned into the abdomen, and a second loop about six inches higher was delivered and devascularized by ligature of the artery alone.

'Of six experiments performed upon the cat, in three a definite ring of gangrene developed in the middle of the segment of bowel which had been deprived of its arterial supply alone, while the segment treated by simultaneous ligature of artery and vein showed little or no change. In one case where the animal was killed while still looking in good health, twenty-four hours after ligature of the vessels, the segment treated by ligature of the arteries only showed more serious changes than the segment treated by simultaneous ligature of artery and vein. Of the remaining two cases,

* "Comptes Rendus, Conf. Chir. Interall., Paris, 1917, p. 348."

one showed no change at all, consequent upon the fact that too short a segment of the bowel had been deprived of its blood-supply, while the result in the sixth case was complicated by the development of an acute volvulus.'"

Dr. D. R. Hooker has very kindly tested for me in the dog the effect on the arterial blood pressure in the vessels of the leg of temporary occlusion of the external iliac vein after ligation of the corresponding artery, and sends me the following report: "The saphenous artery (a small branch of the femoral) was cannulated and the arterial pressure (femoral) recorded. When the external iliac artery was ligated the pressure promptly fell from 114 to 26 mm. Hg. In the course of an hour the pressure rose to about 50 mm. Hg., but the point of interest lay in the response of this pressure to temporary occlusion of the external iliac vein, the chief arterial supply to the part remaining shut off. In six observations in the period of an hour in which the vein was occluded from one to eight minutes the arterial pressure rose 20, 12, 8, 3, 10, and 14 mm. Hg. Deocclusion of the vein was followed by a sudden fall in pressure and a subsequent slow rise. This rise, however, never reached the level established when the vein was occluded."

The necessity for maintaining a proper balance between the arterial and venous systems is suggested by the prompt diminution of the swelling of the limb on ligation of the artery feeding the pulsating tumor. In the case of a very large ilio-femoral aneurism the swelling of the thigh and leg rapidly subsided after a partially occluding band had been applied by me to the external iliac artery. Three or four weeks after the application of the band the aneurism and the deep and superficial femoral veins were excised. These veins were found to be completely occluded by the tumor; hence the reduction in swelling which promptly followed the ligation of the artery could not have been due to relief of pressure on these veins. The operation was performed about five years ago. The patient, a stevedore, writes that the function of the limb is perfect. In striking contrast to this is the result obtained in another patient whose common iliac artery I ligated, many years ago, but not the corresponding vein. In this instance the patient was prevented by claudication from ever walking more than one or two hundred yards.

We are compelled, I believe, to subscribe to the view that some degree of equilibrium of the arterial and venous systems must be maintained. Granting this, there vanishes any difficulty that there may have been in accounting for the very high percentage of gangrene observed to follow ligation of the artery in cases of arterio-venous fistula. There is

in these cases not only a great enlargement of the venous bed but also a curtailment of the arterial tubage—a shrinkage or hypoplasia of the arteries distal to the fistula. Thus even before the artery is ligated the limb is handicapped by this lack of balance. When, now, the artery above a fistula is tied, irrigation with arterial blood is suppressed on one side of the capillary bed and on the other side of it the mixed blood is deprived of a share of the pressure by virtue of which the life of the limb was partly sustained. It seems permissible to conjecture that in some instances the limb distal to the fistula may have been hardly less dependent on the pressure from the venous than from the arterial side, and if so we can more readily comprehend the ensuing gangrene than the frequent absence of it after ligation of the fistuled artery. The gangrene, almost unprecedented in extent, which followed the remarkably brilliant operation of Matas²⁵ for the cure of a fistula of the subclavian vessels was undoubtedly intensified by the fact that this skilful surgeon succeeded, by careful suturing, in preserving the lumen of the vein.

The reversed picture of disbalance—the obturated vein with the patulous artery—is a more familiar one.

Ultimately we may be less disinclined to ligate arteries for the relief of swelling due to occluded veins—veins plugged by carcinoma or thrombus. Our thoughts revert to the important contribution of Carnochan⁹ who cured a case of elephantiasis Arabum by ligation of the femoral artery, and to the unpublished experimental work of Welch and Mall^{*} on intestinal infarction.

Since ligation of the vein raises the blood pressure in the ischemic area, is it not possible that the response of the arterial side for anastomotic development may be delayed or lessened for a period and to a degree conformable to the time and amount that the obstruction of the vein contributes to the maintenance of the circulation of the extremity? If this is so, might not the ligation of the like-named vein be postponed, when this can be done without danger, in order not to relieve the arterial side of its responsibility? Then if after a time there should be evidence of disability from ischemia, such as claudication on exercise, the surgeon would have the ideal opportunity to demonstrate the value of the venous ligation.

^{*} This paper will be included in "Papers and Addresses by William Henry Welch," 1920, being published by The Johns Hopkins Press.

Another possible expedient is to be borne in mind. A metal band (aluminum) might be applied temporarily to the vein. The pressure within veins is so slight that a band might perhaps, without producing necrosis as of an artery, be tolerated for weeks or months or indefinitely.* I suggest this as an experiment which might help to solve the problem; but first we must determine how long a totally and how long a partially occluding band may remain on the wall of a vein without bringing about its permanent obturation.

Gangrene has so rarely followed ligation of the subclavian and common iliac † arteries that in the case of these vessels I should for the present be disinclined to tie off simultaneously the corresponding vein.

ABSTRACTS OF THE CASES OF LIGATION OF THE FIRST PORTION OF THE LEFT SUBCLAVIAN ARTERY. COMMENTS

J. KEARNY RODGERS. (1.) *Case of ligature of the left subclavian artery within the scalenus muscle, for aneurism.* New York Journal of Medicine and the Collateral Sciences, 1846, vii, 219.

"Michael Larman, born in Germany, aged 42 years, was admitted under my care, into the New York Hospital, Sept. 13th, 1845, with

* A few years ago Dr. Reid and I, at his suggestion, applied an aluminum band to the pulmonary artery of a dog, reducing the lumen of this vessel by about one-half. Eighteen months later the dog, in good health, was sacrificed. The wall of the pulmonary artery was found to be nearly intact; only at one point on its proximal edge had the band perforated the wall of the vessel. The lungs were apparently unaffected by the diminished supply of blood.

About ten years ago, with Dr. James F. Mitchell of Washington, I partially occluded with an aluminum band an enormously dilated ilio-femoral vein, above an arterio-venous fistula, after a prolonged attempt on the part of both of us to dissect free the involved vessels. Only slight relief was afforded by the constriction of the vein; and the desperate condition of the patient precluded further intervention.

† It is still believed (Wolfe,³³ Matas,³⁶ and others) that ligation of the common iliac artery is followed by gangrene in from 33 to 50 per cent of the cases. That this belief is erroneous is proved by my careful study of each reported case. On page 215 of my paper²² is the following statement: "Granted that in the cases of Lange and Cranwell the ligation of the artery was solely responsible for the gangrene, we have only two such cases in the thirty of my collection, a percentage of six and six-tenths. If it should appear later that Cranwell's case might, for unascertained reasons, be excluded, the percentage would be three and three-tenths, and the sum total of gangrene the cutaneous necrosis of one toe."

aneurism of the left subclavian artery. The account he gives of it is as follows:

'About four weeks ago, when carrying a basket of peaches (containing about a bushel) on his left shoulder, he was suddenly seized with a severe pain in the shoulder and arm, and was obliged to lay down the basket. On examining the part, he then, for the first time, observed a swelling above the clavicle, about the size of a pullet's egg. Since last winter, about February, he had suffered pain in the arm, and observed that it was occasionally swollen; but was not obliged to give up work.'

"On examination, a pulsating tumor can be seen above the left clavicle, about the size of a small hen's egg, rising beyond the bone about two inches; extending externally to the outer third of the clavicle, and internally, covered by the outer edge of the sterno-mastoid muscle. Pulsation was very distinct over the entire surface of the tumor. The cutaneous veins below the sternal end of the clavicle very much enlarged and their coats thickened. There were marks of cupping over the shoulder.

"The patient complains of severe pains in the axilla, extending down the arm to the finger ends. He cannot sleep, and his general health has suffered from the want of rest, being obliged to walk his room at night on account of the severe pain; the left arm and hand are swollen, so as to interfere with the flexion of the fingers.

"There was no perceptible difference in the pulse at the wrists. Its beat was 92, soft and full. . . .

"September 28th, 1845. A consultation of the surgeons being called, they, after a full discussion of the case, very kindly left it with me to decide whether the operation should be performed.

"The tumor continued slowly and gradually to increase, and passed more under the mastoid muscle than on his admission, so as to give me some apprehension of trouble from it in the operation.

"He was apprised of the fatal nature of the disease, and the dangers of an operation, but his sufferings were so great that he expressed his willingness to undergo whatever operation afforded the least prospect of relief from pain and of restoration to health.

"Having decided on tying the subclavian artery, I summoned my colleagues on the 14th of October, and the operation was performed in the theatre of the hospital at 1 P. M. of that day, in the presence of Drs. Mott and Stevens, consulting surgeons, of Drs. Cheesman, Post, Hoffman, Buck, and Watson, surgeons, and an assemblage of about three hundred physicians and students.

"The patient was laid on a low bed, with his head and shoulders raised, and his face turned to the right side. The light from the dome shone directly on the part to be operated on.

"An incision was made three inches and a half in length on the inner edge of the mastoid, terminating at the sternum, and dividing the integuments and platysma myoides. This was met by another extending along the sternal extremity of the clavicle, about two and a

half inches. This last incision divided a plexus of varicose veins passing in the integuments, covering the clavicle to the subclavian. Free bleeding taking place from their cut and patulous extremities, it became necessary to check it by ligature.

"The flap of integuments and platysma myoides was now dissected up, and the lower end of the mastoid laid bare; a director was passed under this muscle, and the sternal portion and half of the clavicular divided by the bistoury. This muscle was now turned up, and the sterno-hyoideus muscle, the omo-hyoideus, and the deep-seated jugular vein were seen covered by the fascia.

"On turning up the mastoid, a portion of the aneurismal sac strongly pulsating was brought into view, overlapping about half the width of the scalenus, forming now the outer part of the track through which I was to pass, showing fearfully one of the dangers of the operation, which, from my previous examination of the part, I had of course anticipated.

"The fascia being divided by the handle of the scalpel and the fingers, I passed in contact with the deep jugular on its outer side to the inner edge of the scalenus anticus, intending, for the purpose of avoiding as much as possible all danger to the thoracic duct, to reach this muscle fully half an inch above the rib, rather than at its insertion. I now felt distinctly the phrenic nerve running down on the anterior surface of the scalenus, and was confident that I should be able to avoid any injury to it. Having attained the inner edge of the scalenus, by pressing downwards with the finger, I soon discovered the rib, and after some little search easily found the subclavian artery. By pressing it against the rib, all pulsation ceased in the tumor, and by removing the finger, pulsation returned.

"I now felt that great care was necessary to detach the artery, and avoid danger to the pleura and thoracic duct. In accomplishing this part of the operation, I at first tried Sir Philip Crampton's instrument, but ascertaining that I could better carry the ligature around the artery and bring up its end, by the invention of Drs. Parrish, Hewson, and Hartshorne, of Philadelphia (long since given to the profession by them, and lately claimed by Mr. l'Estrange of Dublin), I accordingly adopted that instrument.

"This part of the operation it will be imagined was not very readily accomplished. The great depth of the vessel (nearly the length of my forefinger), and narrowness of the wound, prevented a very easy management of instruments. The point was introduced under the artery, and soon directed upwards so as to avoid injury to the pleura. The needle carrying the ligature was now detached from the shaft of the instrument, and drawn upwards so as to include the artery. I readily tied the ligature, and tightened it with the forefingers in the bottom of the wound. All pulsation immediately ceased in the aneurism and the arteries of the extremity.

"The patient complained of no pain or unusual feeling in the head, as might have been expected from so suddenly changing the current of so large a quantity of blood. . . .

"6th day, Oct. 19th. . . . wound suppurating; its sutures were removed; . . . poultice to the wound. . . .

"9th day. Oct. 22d. . . . wound doing well, and suppurating freely. . . .

"13th day. Oct. 26th.—2 a. m. The patient, on changing his position from the right side to his back, felt a trickling down his chest of what he supposed was matter, but which the nurse ascertained to be blood. The house surgeon was immediately called, and controlled the hemorrhage by filling the wound with layers of dry hard sponge, placing a compress over this, and securing the whole by a bandage. About 20 ounces of blood were lost. . . .

"14th day. Oct. 27th.—6 a. m. There has been no bleeding during the night; pressure has been firmly made over the wound; the blood has passed under the integuments of the neck in so great quantity that there is a decided bulging of the skin on the left side, extending to the back of the shoulder. . . .

"15th day. Oct. 28th.—6 a. m. . . . On removing the outer sponge there is a firm clot seen which for a time controls the bleeding, but the least effort causes a free gush of blood; gentle pressure to be continued. 1 p. m. The clot beneath the integuments causes so much pressure on the oesophagus as nearly to prevent deglutition; the tendency to external hemorrhage is less, and the external clot firm; there is danger that the blood effused may press on the larynx sufficiently to prevent respiration, and the pressure was accordingly discontinued; oozing continues. 5 p. m. Patient dying; no external hemorrhage. 5½. Died.

"*Post-mortem Examination, Eighteen Hours After Death.*—The wound was filled with coagula and sponge, which had been introduced for the purpose of making pressure. The blood was already in a state of partial decomposition. The dissection was carefully performed, exposing the different layers of muscles. The lower incisions made at the operation were found to include three-fourths of the mastoid, leaving a small portion of the clavicular portion undivided. Below this the aneurismal sac and the scalenus anticus formed the outer and posterior wall of the wound. The inner wall was formed of condensed cellular tissue covering the carotid artery, jugular vein, thoracic duct, and the edges of the thyroid muscle. At the bottom was the subclavian artery, completely divided by the ligature, which was found free in the coagula. The cellular tissue of all the parts around the wound was condensed by adhesive inflammation, rendering the dissection exceedingly tedious and difficult. The jugular vein, which skirted the inner wall of the wound, was obliterated and filled with fibrinous coagula. Opposite the track of the ligature the vein was contracted to a cord, and impervious as far as its junction with the subclavian. The vena

innominata and subclavian were normal. The pleura at the bottom of the wound presented a large irregular lacerated opening, communicating from the wound with the left pleural cavity, which was filled with coagulated blood. This formed one large uniform coagulum, and had every appearance of being of rapid and recent formation; the membrane around these was thickened. On exposing and tracing the subclavian artery, it was found that the ligature had been applied about one and a quarter inches from its origin at the aorta, and immediately at the root of the vertebral, on its cardiac side. The artery had been completely divided by the ligature, which as mentioned above was found loose in the wound. The stump of the subclavian, between the aorta and ligature, presented the appearance of a round solid cord, about an inch and a quarter long, and impervious to liquids or air. The external coat of the stump was thickened and adherent near the ligature to the surrounding tissues, by adhesive inflammation. On laying open the vessel longitudinally it was found that a firm fibrinous coagulum occupied the vessel, and was adherent firmly to its inner coat for three quarters of an inch; near the aorta, the coagulum was softer. The coats of the vessel were moderately thickened, and presenting a small patch of atheromatous deposit about a third of an inch from the tied end. Around this deposit the adhesion seemed as perfect as at any other part. Beyond the ligature the vessel presented a different appearance. No plug other than a soft coagulum of blood occupied its cavity, and it presented much less evidence of adhesive inflammatory process in its coats. The vertebral was given off immediately at the point of ligature, and was open, containing a thin blood coagulum like the one in the subclavian. These were drawn out with ease, and evidently had formed during the last moments of life. About one third of an inch from the vertebral came off the thyroid axis, and nearly opposite the vertebral was the internal mammary. These vessels were all patulous and healthy. About half an inch from the thyroid axis commenced the dilatation of the artery to form the aneurismal sac. This tumor was about the size of a small orange, and had involved in its growth part of the scalenus anticus, the cervical nerves going to form the cervical plexus, the surrounding cellular tissue, and the glands. The aneurism was completely blocked up with coagula, and the axillary artery which emerged from its distal side was plugged with a fibrinous clot exactly similar to the one in the stump of the subclavian, though perhaps not so perfect. It appeared sufficiently so, however, to obliterate entirely the calibre of the vessel. The plug extended some distance down the axillary artery. The thoracic duct, which had been injected with wax from the abdomen, was found uninjured. The aorta was thickened, and its coats irregular from a considerable deposit of atheromatous matter in its tissues. The heart was somewhat larger than natural, but apparently sound. The other

organs were not examined, as the friends insisted on an early removal of the body for burial.

"Although a decided majority of the consultation agreed as to the propriety of the operation of securing the artery for aneurism, still, as my colleagues kindly left it with me to decide whether it should be undertaken, I felt it incumbent on me to investigate the subject with great care, and accordingly gave it my most sedulous attention. I was the more anxious, because, in the only case in which the attempt had been made by Sir Astley Cooper, in 1809, that eminent surgeon failed of securing the vessel, and is said to have entertained apprehensions that he had wounded the thoracic duct.

"I had always considered it as a perfectly justifiable operation, and one that a careful surgeon conversant with anatomy could accomplish, if the tumor were of a moderate size.

"The want of success in the four or five operations on the right subclavian in its first stage did not discourage me, nor did they alter my opinion. The difference in the anatomy of the right and left arteries was so very great, that I did not consider it fair to argue that a similar result was to follow on the left side. The greater depth of the left, indeed, rendered the operation more formidable, but if accomplished, not less likely to succeed.

"The point where the ligature must necessarily be applied on the right side is but a quarter or at most half an inch from the innominate and the coming off of the carotid; so that it could scarcely be expected that a coagulum would form sufficiently firm to adhere to the vessel, and resist the force of the heart's action. Besides, too, the greater force of the circulation on the right side was additionally unfavorable to success on that vessel, and, therefore, is an additional reason for distrusting an argument drawn from a parallel between the two.

"In examining anatomical and surgical authorities I found the opinion prevalent among almost all British authors that the operation on the left side was 'impracticable.'

"Colles, the eminent Irish surgeon who first tied the right subclavian in its first stage, says:

'This operation, difficult on the right, must be deemed impracticable on the left subclavian. For the great depth from the surface at which this vessel is placed—the direct course which it runs in ascending to the top of the pleura—the sudden descent which it makes from this to sink under the protection of the clavicle, and the danger of including in the same ligature the eighth pair of nerves, the internal jugular vein or the carotid, which all run close to, and nearly parallel with, this artery; these all constitute such a combination of difficulties as must deter the most enterprising surgeon from undertaking this operation on the left side.'—*Edinburgh Med. and Surg. Journal*, Jan. 7, 1815, p. 23.

"Harrison,* Flood,† Guthrie,‡ and Quain,§ all coincide in this opinion.

"The opinions of those eminent anatomists and surgeons being so decidedly against the *possibility* of the operation, it was only left for me to examine with great care the surgical anatomy of this vessel.

"Having had the thoracic duct injected with wax, I repeatedly dissected the parts concerned, and operated in every way that suggested itself to me as likely to present any advantages. My opinion of its feasibility was thus confirmed, and having never entertained any doubts of its propriety, I accordingly undertook it.

"I regret, indeed, deeply, the death of my patient, but the appearances presented on examination after death, have only strengthened the opinion I had previously formed, and have encouraged me to undertake it with some slight variations, should another case ever present itself.

"It has often happened with important operations that many of the first cases have been unsuccessful, while the carefully noted observations made on dissection have led to different modes of operating, and more uniform success.

"Previously to the performance of this operation many entertained doubts whether the force of the circulation so near the heart in so large a vessel would not prevent the formation of a coagulum, and of course interfere with the obliteration of the vessel.

"These doubts have now been removed, and I consider that all reasonable objections fall with them, except those arising from the anatomy.

"Danger to the thoracic duct and pleura are in my opinion the most serious of these, for, with ordinary coolness and care, there will be little danger of including the pneumogastric and phrenic nerves, or carotid artery, in the ligature. The veins may be lacerated by great roughness, but can scarcely be included.

"The thoracic duct, I think, can almost always be avoided by reaching the inner edge of the scalenus half or three quarters of an inch above its insertion, and then pressing the finger down towards the rib. The duct is thus kept out of the way of laceration by the finger, and afterwards by the aneurismal needle. I am aware that this duct varies in its course, but this direction I am confident will usually secure its safety. By adopting it in the many times I operated and dissected the parts in the dead body, it was uninjured.

* "Harrison on the Anatomy of the Arteries. Dublin: 1833. Vol. i, p. 125."

† "Flood. The Surgical Anatomy of the Arteries. London: 1839, p. 84."

‡ "C. J. Guthrie on the Diseases and Injuries of the Arteries, etc. London: 1830, p. 396."

§ "Quain's Anatomy, 3d edition. London: p. 492."

"The artery lies in contact with the pleura, the laceration of which might be attended with very distressing and dangerous consequences. A careful introduction of the aneurismal needle, and soon turning up its point, will usually secure the safety of this membrane. In none of my operations on the dead body, where it was performed in this way, was it injured.

"The hemorrhage in this case came from the distal end of the artery, and the very free and direct anastomosis of the internal carotid at the base of the brain with the vertebral induce me to think that it was the latter vessel which transmitted the blood. Some indeed may have come through the thyroid axis, but I consider the former mode more direct.

"Should this operation be repeated, I would suggest the securing of the vertebral, and if possible the thyroid axis, by ligature. The difficulties are indeed thus increased, but not insurmountable.

"I present this case to the Profession with the confident hope that they will give it their approval. I do not covet the empty honor of performing for the first time, be it ever so skilfully, any operation, however bold and difficult, but of doing that, which, though once unsuccessful, will, from the knowledge thence derived, enable us to enlarge our sphere of usefulness, and be the means of preserving human life."

V. MARCHESANO. (II.) *Legatura della succlavia sinistra fra la trachea e gli scaleni.* *L'Osservatore Medico, Palermo, 1875, vol. v, p. 327.*

"On the evening of July 17, 1875, a carpenter, *æt.* 34, presented himself at the Ospedale di S. Francesco.

"He was covered with bloody old clothes, and with his right hand pressed a wound which he had received a few moments before in the left side of the neck. The wound, he said, had been made by a blow from a chisel; it was immediately followed by abundant hemorrhage which was partly or entirely controlled by the hand of the wounded man himself so that he could be carried to the hospital. Having arrived there, the ward surgeon found a freely bleeding wound in the left supraclavicular triangle.

"This wound was about 4 or 5 cm. from the superior border of the clavicle, and 2 cm. from the posterior border of the sternomastoid.

"The surgeon of the ward dilated the wound with the intention of practising direct ligature, but not having succeeded, he made compression, and in view of the gravity of the case sent for the head surgeons of the hospital.

"I was the first to arrive, and from the quantity of blood which accompanied the discontinuance of the compression concluded that we had to contend with a hemorrhage proceeding from one of the

superior branches of the subclavian, and probably of the posterior scapular.

"The wound was very deep; the finger of the observer did not fall on the bony plane formed by the anterior part of the cervical portion of the vertebral column, but ran along the transverse processes of the vertebræ. By pressing on the posterior face of these apophyses I could so hook the finger as to arrest the hemorrhage because in this attitude compression was exerted from without inwards upon the muscles which are inserted in the transverse processes. The blood came out through the fibres of these muscles, not in a direct jet as when a wounded artery is laid bare, but 'a nappo,' as if the jet, before coming into view, had encountered an obstacle.

"Considering the serious predicament in which one would surely find oneself in case it were not possible by the direct means to arrest this hemorrhage, I decided that it was justifiable to have recourse to any method which might be of service; I therefore practised anew the dilatation of the wound, with the object of discovering definitely the vessel from which the blood came and in order to be able to manœuvre with greater ease; but in spite of this dilatation it was impossible for me to discover and seize the wounded vessel or even to grasp it by the inclusion of tissues.

"I had manœuvred for about 20 minutes, when Prof. Errico Albanese happened in, who for about the same period of time repeated the same manœuvre with the same lack of success. As the patient had already lost much blood we agreed to make use of a tampon of cotton saturated with perchloride of iron, combining by this procedure the effects of compression and of a styptic. But although applied with the greatest care, the tampon did not check the hemorrhage even for a moment, hence it was necessary, in order that we should not see the patient die beneath our eyes, to decide to ligate the subclavian between the trachea and the scaleni. I adopted the process used by Mott for ligating the innominate, which consists, as you know, in making two incisions which join at an angle in the neck, one of which runs along the internal border of the sternomastoid muscle for a distance of 5 cm., and the other over the clavicle as far as the clavicular insertion of this muscle, and in incising finally the sternal portion of the sternomastoid, the middle cervical aponeuroses, and the tracheal muscles, thus reaching the artery. Therefore, since it is my principle to avail myself of all possible means in carrying out an operation, and since it was a case of ligating the left subclavian in the first portion, at night and by artificial light, and since we had to manœuvre in the vicinity of vital organs such as the internal jugular vein, the subclavian vein, the pneumogastric nerve, and the common carotid, I made the transverse incision longer than is prescribed by Mott, dividing a good part of the clavicular portion of the sternomastoid, the tracheal muscles, and more than the internal half of the scalenus anticus.

"At the moment when I cut the fibres of the scalenus anticus, I had Dr. Perni draw aside the phrenic nerve with a blunt hook. Opening the sheath of the artery I pushed as far inwards as I could the Cooper needle armed with a ligature.

"Assured that the tightening of the ligature controlled the hemorrhage, the direct compression which had been practised during the operation was released and the ligature tied. The operation was accomplished without serious accident.

"July 18, 1875. The temperature of the left arm was the same as that of the rest of the body. July 24, 1875: In the middle of the night there was a hemorrhage, which was controlled by tampon and compression. Two hours later another hemorrhage occurred, which was controlled by the same means. July 25, 1875: Another hemorrhage, this time very serious. Compression and perchloride controlled this also. The patient was menaced with syncope. On July 30 there was noticed a small collection of purulent matter in the superior third of the internal region of the arm. A small incision was made, also lavage with disinfectants. On August 6, 1875, the patient's condition seemed to be fair and the wound of good aspect, but during the night at 2.30 A. M. there suddenly occurred a tremendous hemorrhage from the site of the ligature, and in a few moments the patient died.

"*Autopsy.*—The ligature had been applied 40 mm. from the arch of the aorta, exactly at the point where the subclavian artery departs from the vertical direction to turn outwards. The vertebral artery arose 7 mm. inside of the point of ligature, and immediately behind this arose the ascending cervical with an independent origin; 5 mm. inside of the ligature the inferior thyroid arose. All the other arteries springing from the subclavian arose distal to the ligature. The two scapulars, the superior and the posterior, arose from a common trunk, which, situated 3 mm. outside of the ligature, after a course of 23 mm. running from in front towards the back and crossing the nerves of the brachial plexus, bifurcated and gave rise to them. This trunk was intact, but the posterior scapular was cut 6 mm. from its origin. The origins of the left subclavian and the left common carotid were 1 cm. apart. The ligature at the site of the ligation was not found; perhaps it had been removed with the débris in the dressings in the hurried examination which I made of the cadaver. At the point of ligation the artery was completely cut through in jagged fashion."

L. C. LANE. (III.) *Ligations done for the cure of aneurism.* Pacific Medical and Surgical Journal, San Francisco, 1883-84, vol. xxvi, p. 145.

Page 149. "*Subclavian Artery.*—1. An engineer from a Sandwich Island plantation was brought from the Islands in an ambulance litter, afflicted with aneurism involving the termination of the left subclavian and the entirety of the axillary artery. The tumor, large as a fetal

head, had apparently only the cutis for external wall. Through a quadrangular cut, the flap being attached above, the subclavian was reached in its trans-scalene site, and tied close to the muscle. Ligature was of small silk, carbolized, ends cut short and wound closed. The wound healed in two weeks and recovery was complete in two months. To-day, eighteen months after the ligation, the man writes that the tumor has disappeared, his arm is restored, and he is doing his work as an engineer."

Although the ligation in this instance quite surely was not of the first portion of the artery, the quotation from Dr. Lane's brief report is given because it supplies the missing details of the first operation performed in the second case. Reciprocally, the description of the second operation in the second case makes it quite clear that Lane did not ligate the first portion of the subclavian in the first of his two cases.

"2. A miner from Alaska, with similar aneurism, though one-third less in volume, had the left subclavian ligated similarly,* except that the vessel was reached through a vertical cut. In one week, primary union of the wound. The man, of obstinate temper, near the end of the second week, though cautioned to maintain quiet, rose from his bed and used the close stool. A slight bleeding ensued through the re-opened wound; later, another violent bleeding occurred. On the fourteenth day the wound was opened, and, while the blood that gushed from the distal end was controlled by sponge used as a tampon, the artery was exposed by severing the sternal leg of the sterno-cleido-mastoid muscle, and a thread thrown around the subclavian just as it emerges from the thorax. This so arrested bleeding that a ligature was passed around the vessel close to the aneurism on the proximal side. Though there was no more hemorrhage, and the vitality of the arm was well maintained, yet the man died from exhaustion on the 19th day after the first ligation. It should have been remarked that before this man came under my care, there had been made an unsuccessful attempt to cure him by indirect compression digitally applied, at the point where ligation was afterwards done."

If the left subclavian was ligated by this "thread thrown around" it "just as it emerges from the thorax," Lane was the first to ligate the first part of this artery for the arrest of hemorrhage. If the thread was merely a provisional loop and not tied, then we should not credit him with a ligation of the left subclavian in its first portion.

Undoubtedly the hemorrhage took place from the subclavian at the site of the original ligature and, if so, two ligatures must have been applied at the second operation, the one, as Lane says, proximal and

* Between the scaleni muscle (*vid.* Case 1).

close to the aneurism, the other probably being the "thread thrown around the subclavian just as it emerges from the thorax."

Inasmuch as the two ligatures applied at the second operation (one proximal to the branches of the first portion, the other to the third portion, proximal and close to the axillary aneurism) controlled the hemorrhage, we must conclude that the bleeding occurred only from the distal end of the artery divided or at least cut into by the original ligature; for had the proximal end been open, the hemorrhage would not have been checked by the ligature "thrown around" the subclavian just at its point of emergence from the thorax, nor would the two ligatures applied at the second operation have sufficed; it would have been necessary to close the central stump of the artery cut through by the primary ligature.

It would not have been surprising if the result in Lane's first case had been disastrous, as it was in the second, for he tied the artery with "small" silk. Many times have I warned against the use of a fine thread of any kind for the ligation of large arteries, particularly for ligation in continuity. The danger from this we have had opportunities to observe in the course of our experiments on dogs. The fatal result in Lane's second case may have been due primarily to the fineness of the silk. This was quite surely the cause of the hemorrhage if infection can be excluded. But infection may well have played a part from the outset notwithstanding the fact that the wound is believed to have healed *per primam*. The act of getting out of bed, to which the surgeon attributes the hemorrhage, could hardly have been the only or even the chief factor in bringing about the fatal result.

BERNARD BARDENHEUER. (IV.) *Die Verletzungen der oberen Extremitäten*. Deutsche Chirurgie, Stuttgart, 1886, Lieferung 63a, Theil I, p. 445.

"Heinrich Grenberg, 47 years old, had a very large hard tumor in the left supraclavicular fossa. I pronounced it to be a carcinoma having origin in the internal jugular vein. The tumor extended inwards to the central plane, the larynx was pushed far to the right; above, the tumor was one inch removed from the mastoid process, outside, it came in contact with the outer border of the trapezius, and below, it disappeared behind the clavicle, or rather, the manubrium sterni; it was *in toto* rather freely movable on the underlying parts. Above the tumor one felt the pulsating common carotid, likewise the radial artery pulsating synchronously and in equal strength with the corresponding vessel of the other side. There was no œdema of the

arm. Behind the clavicle one heard vesicular breathing. The mobility of the tumor, the presence of pulsation in the common carotid above the tumor, the presence of pulsation in the radial artery, the absence of disturbance on the part of the brachial plexus, led me to the opinion that a cure of the tumor might be effected without wounding one of the vital organs; tentatively, I proposed to ligate the arteries centrally. I did not fear to wound the pleura—which I knew was possible—after my own experience and after the contributions of König. . . .

“To sum up, it evolved that the tumor was much more extensive than I had supposed. The carotid artery, the subclavian artery, the internal jugular vein, and the subclavian vein entered the tumor. I decided to ligate the common carotid and the subclavian in its first portion, a ligation which ranks with the ligation of the innominate artery.

“I accordingly resected half the clavicle, a piece of the first rib 2 inches long, a piece of the manubrium sterni 2 inches broad and $1\frac{1}{2}$ inches high, and hereupon, after having cut through the sternomastoid, sternothyroid, and sternohyoid muscles, likewise the posterior layer of the fascia profunda diagonally, and the periosteum vertically in the whole exposed space, I had the subclavian vein, the jugular vein, the junction of these two, and the left innominate vein lying freely before me. Since the veins ran into the tumor, I ligated first the left innominate vein in order to guard against the aspiration of air. After double ligation of the left innominate vein the common carotid was doubly ligated directly behind the sternoclavicular articulation and cut through. The subclavian artery at this point lay unusually deep and was pushed still further back by the tumor.

“The pleura inflated greatly with each inspiration. At last I freed the subclavian artery from the surrounding tissues below inwards and behind and doubly ligated it, at the most 1.5 cm. from the arch of the aorta.

“The operation was performed with the greatest ease and comfort as soon as I had oriented myself as to the location of the subclavian; however, it is incomprehensible to me how one is able to complete the ligation with any surgical satisfaction and certainty without this extensive exposure. After the ligation of the innominate vein, of the common carotid, and of the subclavian (central), and after ligation of the subclavian vein, the internal jugular, the common carotid, and the subclavian (peripheral), the operation was easily completed. The whole procedure consumed $1\frac{1}{2}$ hours. Unfortunately, the vagus nerve, which emerged from the tumor, had to be cut through; likewise the jugular trunk of the lymphatic system in the neighborhood of the transverse process of the third or fourth cervical vertebra was opened, so that a stream of lymph poured into the wound.

“In the thorax it was very easy to avoid wounding the thoracic duct, likewise the transparent pleura fluttering back and forth: altogether the operation was accomplished with the same ease and calm as at the dissecting table.*

"The patient recovered somewhat after the operation and felt relatively well and had no dyspnoea; nevertheless he collapsed suddenly 18 hours thereafter, having said a short time before death that he felt quite well."

There is no pathological report.

W. S. HALSTED. (V.) *Ligation of the first portion of the left subclavian artery and excision of a subclavio-axillary aneurysm.* Johns Hopkins Hospital Bulletin, Baltimore, 1892, vol. iii, p. 93.

"Surg. No. 1589. Levin Waters, colored, *æt.* '52' (?) years, was admitted to the Johns Hopkins Hospital April 30th, 1892. Patient is a vigorous man, gives a good family history and denies having had syphilis. Was perfectly well until eight months ago; he then noticed a small swelling about the size of a madeira nut under the left clavicle. He is sure that there was at this time a distinct pulsation in the tumor. He 'could feel it beat like my heart' when he put his finger upon it. The tumor has grown rapidly since it was first observed. Until one month before the operation the patient worked regularly, did heavy lifting, etc., and had experienced little or no discomfort from the aneurysm. His only symptoms were a slight numbness in the left hand and forearm, and, subsequently, a shortness of breath and a hoarseness—both of which he attributed to a cold.

"Patient says that he has never had a pain which could be referred to the tumor.

"On admission the patient had an almost spherical, perfectly smooth tumor under the left clavicle. It was somewhat flattened on the side which pressed against the chest-wall, and measured 42 cm. in circumference at its base. The middle third of the clavicle was overlapped and almost concealed by the tumor.

"Internally the tumor extended to within 5 cm. of the left sternoclavicular articulation, and externally to within 4 cm. of the coracoid process. It was only after careful inspection that pulsation could be seen. To the touch the tumor was quite solid but elastic, and it was not easy to appreciate the feeble expansile pulsation. No pulse could be felt at the wrist nor anywhere below the aneurysm. The left arm was neither swollen nor perceptibly cooler than the right.

"*The Operation*—May 10, 1892. The skin incisions: 1. Horizontal, about 33 cm. long, from the sternal notch to the acromio-clavicular articulation, and thence down the arm to the lower border of the major pectoral muscle over the greatest convexity of the tumor. 2. Ascending, vertical, about 5 cm. long, from the inner end of the horizontal incision. 3. Descending, vertical, about 10 cm. long, from the middle of the horizontal incision. 4. Ascending, vertical, about 4 cm. long, from the horizontal incision at the acromio-clavicular articulation.

"The flaps so outlined were reflected: The first, upwards and outwards; the second, downwards and inwards; the third, downwards and

outwards. The inner third of the clavicle was then excised. Its middle third was somewhat eroded by the aneurysm which slightly overlapped it.

"The wall of the aneurysm was inflamed, soft, and so very thin where it pressed upon the bone that it would have been imprudent to attempt to dissect this part of the clavicle from the tumor.

"The next step in the operation was the deligation of the first portion of the left subclavian artery. This portion of the artery had been drawn down by the tumor, so as to occupy a horizontal position rather than a vertical one. It was entirely concealed by the subclavian vein, and lay below and behind the vein instead of above and behind it. I thought for a moment that it might be necessary to excise a portion of the first rib in order to expose the artery. Two strong silk ligatures were applied to the artery as it emerged from the chest, and the vessel was divided between them. The deltoid muscle was cut through a little below the clavicle, and the clavicle sawed through at about 2.5 cm. from its outer end. The aneurysm, the greater part of the clavicle, a piece of the deltoid muscle and about 6 cm. of the subclavio-axillary vein were then removed in one piece. The vein was intimately adherent to the aneurysm. The axillary artery was ligated at the beginning of its second part. The operation as a whole was a tedious one and consumed 3½ hours. The wound was closed with interrupted buried skin sutures of fine black silk. The large dead space incompletely covered by the skin was bridged over with guttapercha tissue.

"May 23, 1892. At this, the second dressing, 13 days after the operation, it may be observed that the dead space is almost completely filled with a blood clot. This clot has not broken down and is quite throughout replaced by granulation tissue. The patient has not had a disturbing symptom since the operation.

"The left arm has never swelled and has at no time been cold. For a few days only there was a slight numbness of the tips of the fingers and particularly of the thumb. The case was altogether a most fortunate one for operation in that, thanks to the clot which occupied the sac, the collateral circulation had already been well established."

In a recent number (January, 1920, vol. vii, p. 390) of the *British Journal of Surgery* Mr. L. R. Braithwaite,⁷ of Leeds, recounts interestingly his quite stirring experiences in excising an aneurism, about the size of a hen's egg, of the right subclavian artery. This is the fifth case of which I happen to know of excision of a subclavian aneurism, Moynihan's³⁸ (1897) being the second, Dunow's³⁴ the third, and Duval's³⁵ the fourth. With these the case of Schopf³² might be perhaps enumerated, although Schopf's aneurism was essentially of the axillary artery, his proximal ligature being applied from below the clavicle.

In exposing his aneurism Braithwaite adopted the method of Moynihan, turning down in a flap of pectoral muscle a central piece of the clavicle.

The operation in all of the five cases was successful, but Moynihan's patient, who survived the operation of this brilliant surgeon 58 days, died on the 59th from rupture of another aneurism proximal to the one excised.

T. E. SCHUMPERT. (VI.) *Ligature of the left subclavian in its first portion for aneurism of third (Recovery)*. Medical Record, New York, 1898, vol. liv, p. 338.

"Ligature of the innominate has been undertaken in all 21 times, with one recovery.* The right subclavian has been ligated in its first part 15 times, with a similar result; the left subclavian has been ligated in its first part only twice, once by Dr. J. Kearny Rodgers, of New York, whose patient died of secondary hemorrhage on the thirteenth day. The second case is my own, which I am about to report.†

". . . . Wyeth considers the operation of ligation of the first part of the left subclavian as the most formidable in the domain of operative surgery. Sir Astley Cooper ‡ failed in an attempt to secure the vessel,

* The innominate artery has been ligated once by my associate Dr. Finney, and four times by myself at The Johns Hopkins Hospital. All of the patients recovered promptly. (W. S. H.)

† "It is true, however, that Dr. Halsted recently successfully ligated this vessel for the extirpation of a tumor. It was not ligated in continuity and the operation was altogether a different procedure with a different aim in view."

‡ The aneurism in this case of Sir Astley Cooper was below the clavicle and forced this bone upwards. He attempted to tie the subclavian artery external to the scaleni muscles—not in its first portion.

The London Medical Review, 1809, i, p. 300. "Medical and Surgical Intelligence, Art. 2. In a case of subclavian aneurism which lately occurred in Guy's Hospital, Mr. A. Cooper attempted to tie the subclavian artery above the clavicle. The aneurism was very large, and the clavicle was thrust upward by the tumour, so as to make it impossible to pass a ligature under the artery without incurring the risk of including some of the nerves of the axillary plexus. The attempt was therefore abandoned. This artery has been successfully tied *below* the clavicle by Mr. Keate, but never yet as far as we know, *above* that bone."

"Case of Subclavian aneurism, which occurred in Guy's Hospital, London; communicated to Dr. Miller, by Valentine Mott, M.D., Corresponding Member of the Medical Society of London, etc."

The Medical Repository, N. Y., 1810, third Hexade, vol. i, p. 331. (W. S. H.)

and is said to have wounded the thoracic duct. Jacobson, in his 'Surgery,' writes: 'It seems most doubtful whether the improvement in modern surgery will ever render this a successful operation; however, as it affords good practice on the dead subject, it will be given.' Erichsen considers the operation as bad in principle and most unfortunate in practice, and that it should be banished from surgical practice. Bryant says ligature of the subclavian in its first part on the left is scarcely practicable, and Mulley says the operation is quite out of the question. Treves believes that no artery could be less favorably placed for the application of a ligature, and in like unencouraging manner treat all authorities writing on this subject. Yet in the face of these words of warning emanating from the brightest stars of the surgical world, when confronted with a malady so universally fatal, we are prompted to summon courage and skill and attempt what has heretofore seemed an impossibility.

"A negro . . . J. H., aged 56 years, was admitted to the Shreveport Charity Hospital with an aneurism, about the size of an orange, involving the third part of the left subclavian. The corresponding shoulder and arm were very œdematous and supported by the right hand. He complained of a constant great weight and aching of the parts; that he never had one moment of relief. He stated that about April 1st, while chopping a piece of timber overhead with a heavy axe, suddenly his arm gave way and the axe dropped by his side. After he had rubbed his arm for a moment its usefulness was restored and he proceeded with his work. Shortly after this a small pulsating tumor was noticed in the supraclavicular fossa, which obtained the size of an orange a month later (March 7th), when I operated. . . . My incision was begun on the sternum, two inches below its crest, and carried across the sterno-clavicular articulation parallel to but one-half an inch external to the inner border of the sterno-mastoid muscle, the entire incision measuring seven and one-fourth inches. I then divided the sternal attachment of the sterno-cleido-mastoid muscle, and penetrated the deep fascia by blunt dissecting with flat curved scissors. I was now brought in contact with the internal jugular vein and actually denuded the carotid artery of its sheath two inches in an attempt to go between it and the vein, but at last was compelled to abandon this route and proceed by the tracheal side to the inner edge of the scalenus anticus muscle, half an inch above the first rib. My finger placed at the bottom of the wound first recognized the dorsal vertebra, then the artery, which was dissected clean, and an aneurism needle, carrying No. 8 braided silk, passed beneath it from the inner side. The pulse in the left arm was now taken note of and found to be of the same character as when the operation was begun, but when the

ligature was tightened it ceased entirely. I was careful to see that no twist was in my ligature, that the side and not the edge lay in contact with the vessel, and that it was drawn only sufficiently to control entirely its circulation. A second ligature in like manner was placed about one-sixteenth of an inch above. The broad base of my first incision rapidly formed itself into a cone with a very narrow apex, which made ligature of this deep-seated artery extremely difficult. During the operation I found it necessary to use a long-bladed smooth retractor in order that it might be applied deeply in the wound and press away the jugular vein and aneurismal tumor, which was almost in contact with the trachea.

"The divided segment of the sterno-mastoid muscle was brought together with catgut and the wound closed with catgut and dressed with iodoform collodion. Primary union subsequently followed under one dressing. It was not necessary to ligate a single bleeding point. My patient made an uneventful recovery, and is making himself generally useful about the hospital in this, the ninth week after operation. The oedema of his arm, shoulder, and hand has entirely disappeared, normal function being about restored, but no radial pulse is yet perceptible in the left arm.*"

F. KAMMERER. (VII.) *Ligature of the first portion of the left subclavian artery for aneurism; death after four weeks.* Medical Record, New York, 1899, vol. lvi, p. 924.

"L. W., aged 47 years, was admitted to the German Hospital, in New York, on September 27, 1899. Twenty years ago he had contracted syphilis, but had had no secondary or tertiary lesions, according to his statement. In July of this year, he for the first time noticed a small swelling in the left supraclavicular region. He distinctly stated that he had received a blow at this point, some weeks previous. The growth gradually increased in size until he came to the hospital. For three weeks he had noticed a numbness in the third and fourth fingers of the left hand. When I first saw him, a tumor about as large as a man's fist, was present in the region above stated. The tumor was in part covered by the sternal end of both the left sterno-mastoid muscle and the clavicle. It entirely filled the angle formed by them, and overlapped the clavicle to a slight extent. Immediately above the clavicle, it was in close relation and adherent to the skin covering it. The pulse at the radial artery was scarcely retarded on the left side. Expansile pulsation of the tumor was very marked. There was no dulness on percussion of the anterior upper part of the thorax.

"The case seemed a very urgent one indeed, more especially as the aneurism was already adherent to the skin above the clavicle and

* Was the aneurism cured? (W. S. H.)

evidently preparing to rupture. I therefore concluded that palliative treatment would be of little value, and that the patient's only chance lay in ligature of the subclavian on the cardiac side, the distal ligature being unavailable owing to the many collateral branches of the sac. I was encouraged in this view by the belief that the aneurism did not extend for a great distance into the thorax, and, secondly, by a perusal of Wyeth's able article on 'Special Aneurisms,' in his 'Text-Book of Surgery,' where the author gives a more favorable prognosis of ligature of the left than of the right subclavian artery. He bases this opinion mainly on the unfortunate position of the innominate artery, which is in a direct line with the impact of the blood current forced out by the left ventricle.

Operation.—October 18, 1899. Under chloroform a transverse incision passing over the ends of both clavicles and the manubrium of the sternum, fully six inches in length, was made. A vertical incision in the median line of the body, beginning at the cricoid cartilage and meeting the transverse incision on the sternum, was now added. The flaps thus outlined were dissected from the underlying parts. With the help of Gigli's saw, about one and a half inches of the right and two inches of the left clavicle, bordering on the sternum, were resected. The aneurism was in such close relation to the left clavicle that great care had to be taken at this stage of the operation. The upper end of the sternum was now removed for about a half an inch. The two innominate veins were thus exposed, whereupon it became apparent that access could not be had to the left subclavian artery, owing to adhesions of the left subclavian vein with the aneurism, as a result of which the space between the first left rib and the left innominate vein was entirely too small for any manipulations at such depth as is made necessary by the course of the subclavian artery after its origin from the aortic arch. I, therefore, resected two inches of the sternal end of the first rib, and removed the corresponding part of the manubrium. Even now, the arch formed by the superior vena cava and mainly by the left innominate vein, below which, of course, I had to search for the subclavian artery, proved a great hindrance, as I did not venture to dissect the innominate vein from the aneurismal sac. Two blunt curved retractors were inserted below the venous arch, and the latter was, with great care, pulled somewhat in an upward direction, out of harm's way. However, during the entire operation, I was in continual fear of a lesion to these vessels, as at times strong traction had to be exerted upon them. I now separated the tissues to the left of the three arteries springing from the arch of the aorta, with my fingers, and as I was doing this I could very distinctly, in turn, recognize by the touch first the innominate, then the left carotid, and finally the left subclavian artery, the latter at about a distance of two and a half inches from the posterior surface of the sternum. When pressure was exerted upon the subclavian with the tip of my finger, forcing it toward the vertebral column, pulsation immediately ceased in the aneurism and in the left

radial artery. Under such circumstances, it was impossible to expose the subclavian artery to view, and then to separate it from its sheath. To accomplish the latter, I had to rely upon the sense of touch, and separation of the artery from the surrounding tissues was done entirely by the aid of my left index and a pair of long curved scissors, which were not used as a cutting instrument. Contrary to my expectations, I succeeded in this very well, and I soon had the vessel sufficiently isolated to think of passing a ligature around it. This proved a very difficult task, however, and it was only after many and prolonged attempts that I succeeded in passing an aneurism needle and a thread. With the assistance of the latter, I also passed the ligature beneath the artery. It consisted of several pieces of chromicized catgut, wound together. I now tightened the first hitch of a surgical knot until I felt a resistance, and until pulsation in the aneurism and the arteries of the left upper extremity entirely ceased, my object being to stop the circulation, but not to injure the coats of the vessel. The knot was now completed. No drainage was established from the seat of the ligature, but the soft parts were allowed to come together, closing the deep wound cavity. The vertical incision was entirely closed by sutures, as were also the ends of the horizontal incision, thus covering what remained of the clavicles. The remainder of the wound was covered with loose gauze. The operation had lasted over three hours.

"The course of the case for the first three weeks was entirely uneventful. After the first few days, the patient's temperature and pulse became practically normal, and the wound cavity was soon lined with healthy granulations and filled up rapidly. On the day after operation, there was no pulse in the left radial nor in the aneurism. The latter had decreased considerably in size. The left arm was not swollen, nor was its temperature appreciably lowered, and sensation and muscular power were intact. On the following day, October 20th, there was faint pulsation at the left radial, but none could be detected in the aneurism, and sensation in the arm was slightly retarded. . . .

"October 25th: The patient complained of shooting pains in the left arm. October 30th: There was slight oedema of the left hand. . . . November 6th: On that day the patient complained of a feeling of weakness. Temperature, 101° F.; pulse, 120. On removing the dressings, it was seen that they were saturated with a considerable quantity of fresh blood. Several clots were found on the wound surfaces, which otherwise had the appearance of healthy granulations. On the left side, near the aneurismal sac, a blood-clot lay, which was firmly attached to the surrounding tissues.

"From this time until November 15th, the dressings, which were changed at least once a day, were always filled with blood, although when they were removed no bleeding point could be found on the granulating surface. . . .

"November 15th: The patient showed the effect of the continuous loss of blood during the last ten days. At 1 P. M. there was a sudden

and very severe hemorrhage, saturating the dressings and the bed linen. . . . There was slight collapse, but he rallied well.

"November 16th: At 4 A. M. another hemorrhage occurred. . . . At 2.15 P. M., death from exhaustion took place, on the thirtieth day after operation.

"*Autopsy*:—At the autopsy, it was found that hemorrhages had been caused by rupture of the artery at the site of the ligature. The wound was in an aseptic condition. The loop of chromicized catgut had been to a great extent absorbed, especially at the point immediately opposite the knot, but a few strands were still present here, to hold the loop together. The latter had cut through the coats of the artery and almost completely severed the vessel; but it was still lying within the lumen. The knot, however, rested on the outside of the vessel. The distance from the aorta to the ligature was one inch. There was not the slightest trace of a clot on the proximal side of the ligature. The aneurismal sac was lined on its inner surface with a layer of fibrin, varying from one-half an inch to an inch in thickness.

"The left subclavian artery has to my knowledge been tied twice before in its first portion as it emerges from the thorax, once by Kearney Rodgers in 1845 with a fatal result, and once by Halsted during extirpation of an aneurism as a preliminary step. His patient recovered. In my own case the situation of the aneurism made such a procedure impossible and necessitated the application of a ligature nearer the aortic arch. The unfortunate final result after an undisturbed course for several weeks was rather discouraging. I had used an absorbable ligature, and the wound surfaces had closed around the same without suppuration—two requisites for a favorable result after deligation of large arteries. Whether or not I avoided rupturing the inner coats of the artery while tightening the first hitch of the surgical knot, I cannot say—a very important point, according to the experiments of Ballance and Edmunds, Senn, and others. 'The living and uninjured wall is the only true safeguard against hemorrhage,'* to quote Ballance and Edmunds,³ and this must be especially true of the first portion of the subclavian in man, as the walls of this artery are exceptionally thin in proportion to its size. The clot on either side of the ligature has really little to do with the tissue transformation that occurs within the uninjured vessel and about the aseptic ligature, leading to permanent occlusion of the artery. Some authors (Bruns) even believe that when the coats are not ruptured clotting does not occur. In my case there was no trace of a clot on the proximal side of the ligature, but I cannot accept this as a proof of my not having injured the coats during the application of the ligature. Senn's plan of applying two ligatures, at some distance from each other, thus

* I cannot endorse this statement of Ballance and Edmunds, Senn, and others, for, in my opinion, the force required to occlude the artery necessarily causes necrosis of its wall at the site of the ligature. (W. S. H.)

leaving a bloodless space between them, was not applicable to my case. Nor did I feel that I could have applied a stayknot, as Ballance and Edmunds recommend, with any amount of exactness, owing to the depth of the wound. Still it seems to me now that an attempt should always be made, in ligating large arteries, to pass several ligatures. We will thus most readily avoid injury to the coats of large vessels and succeed in arresting the circulation."

To Kammerer belongs the credit of having been the second to ligate the left subclavian artery within the thorax, Bardenheuer (1886) being the first. The operation, courageously and cautiously performed, was, for its time, a surgical feat of the first magnitude. The leak in the artery at the site of the ligature probably began not later than the seventh day after operation, when the patient first complained of shooting pains in the left arm, although there was no external indication of hemorrhage until on the eighteenth day the dressings were removed. This is the story of a ligature in an aseptic wound cutting its way through an artery. At the autopsy it was found that all but a few of the strands of the catgut had been absorbed; thus, the ligature had been reduced to a size dangerously small. The cause of the fatal result was probably either the fineness of the remaining strands of the ligature or an incomplete occlusion of the artery due to absorption of the catgut or to the slipping of the knot.

Dr. Kammerer felt that "the unfortunate result after an undisturbed course for several weeks was rather discouraging." It would indeed be discouraging were we not in a position to profit by the lesson which it and similar cases have taught. Let the surgeon who is about to ligate a large artery bear in mind the following facts:

1. Fine ligatures cut through the arterial wall more rapidly than coarse ones.
2. Partially occluding ligatures and crushing ligatures are dangerous.
3. Absorbable ligatures may disintegrate unevenly, and thus a coarse ligature be reduced to a fine one; or the knot may slip and thus convert a total into a partial occlusion.
4. Intimal surfaces brought in contact cannot unite because the wall of the artery becomes necrotic under the constricting ligature.
5. The necrosed wall under ideal conditions becomes converted into fibrous tissue, into a solid cord by the in-growth of blood vessels from the ends.
6. Under certain conditions, for example when the lumen has not been totally occluded, or the wall of the artery has been too severely

crushed, hemorrhage may be prevented by the formation of a fibrous tissue capsule enveloping the ligature and the arterial defect. Moderately coarse ligatures may, without causing leakage of blood, cut their way through an artery ligated in continuity. In the wake of such a slowly cutting ligature a partially obturating diaphragm is likely to form. There may be several crescentic-like diaphragms, their free concave edges bounding the lumen which remains.

7. A coarser ligature should be used in tying an artery in continuity than for occluding the ends of a divided one.

8. It is probably safer, when feasible, to divide an artery, tying off the ends, than to ligate it in continuity.

9. Catgut ligatures should not be employed, lest some strands be absorbed or loosened before the others, and it is probably inadvisable to tie with a bundle of threads of any kind. It is decidedly risky to apply—as has been recommended and practised—a partially coarcting ligature central to the totally occluding one, for the arterial wall eventually giving way as it must under the former, it is only by the formation of an enveloping fibrous tissue capsule or by repair in the wake of the cutting thread that fatal hemorrhage is prevented. For the ligation in continuity of large arteries I have been using narrow tape.

10. The wound should be closed without drainage, and completely.

11. If infected, the wound should be promptly and freely opened and treated by the Carrel method with an antiseptic solution which will not endanger the devitalized wall of the artery under the ligature.

DR. JÜNGST (Saarbrücken). (VIII.) *Ein geheilter Fall von Unterbindung der Arteria subclavia sinistra am Aortenbogen.* Beiträge z. klin. Chirurgie, Tübingen, 1902, Bd. xxxiv, p. 307.

“Although the following case has already been published as a dissertation by my one-time assistant, Dr. Philipp,” yet I may be permitted to communicate it again as a statistical contribution, since it would appear that up to this time it is the first case of ligation of the subclavian artery at the arch of the aorta which has resulted in cure, and since it may be difficult to obtain access to Dr. Philipp’s dissertation.

“The patient, female, *æt.* 35, was shot in the left side of the neck on the night of June 12-13, 1899, the shot entering in front, and passing outwards and upwards. The injury was followed by severe bleeding, which ceased of itself, and the next morning the patient was sent to the Bürgerhospital of Saarbrücken.

"We find a poorly nourished, moderately anemic woman. The skin in the left supraclavicular region is sprinkled with a large number of black grains of gunpowder, is red, inflamed and swollen, and the skin of the whole left side of the neck, shoulder and upper thorax almost to the other side of the chest is purple. About 2 cm. from the sternal end of the left clavicle, close to its upper edge, there is a pea-sized entrance wound with ragged burnt edges from which only very little watery blood can be pressed out. There is no exit wound. The whole supraclavicular region is filled with a hard-soft swelling, in which there is neither pulsation nor bruit. The radial and ulnar pulses are unchanged and on both sides are equal in strength; there is no perceptible difference in the height of the pulse wave. There are sharp shooting pains in the left shoulder, radiating towards the arm. The left upper arm is quite a little swollen; there is complete motor paralysis of the whole arm, passive movements are very painful. The sensation of the skin to touch, temperature and pain is much diminished—in places entirely absent. There are no pulmonary symptoms.

"The presence of a large hematoma in the left supraclavicular fossa, considered in its relation to the serious hemorrhage which followed the gunshot wound, made it probable that a large vessel had been injured, although at the outset the subclavian artery seemed not to be involved, for the pulse in the left arm was normal, and no abnormal sounds were to be heard at the site of the wound. The complete motor paralysis had to be regarded, in part at least, as due to compression of the plexus by the outpoured blood, for it was unbelievable that a single bullet could have injured all the roots of the plexus, which at this point lie so far apart. The treatment for the moment had to abide the issue, for hemorrhage had ceased and closure of the involved artery seemed probable. Under bandages of acetated white clay the signs of inflammation subsided and movement of the first three fingers and sensation in the radial area improved; only in the ulnar region did paralysis and anesthesia persist. The general condition was good.

"Suddenly, in the night of June 20-21, after the woman had complained the whole previous day of not feeling well, a hemorrhage occurred which was slight and of short duration, and which was controlled by a compressive bandage and ice. But the next day the condition was quite changed; the swelling in the left supraclavicular region had become much larger and showed distinct pulsation, the radial and ulnar pulses were barely palpable, motility and sensation were becoming less; but still no bruit was heard and no thrill felt.

"There can be no doubt now that in spite of the absence of symptoms at the beginning we are confronted with a wound of the subclavian artery, since hemorrhage from one of the smaller arteries of this region would not cause pulsation of this sort in the hematoma or an almost complete suppression of the peripheral arterial pulse. Taking into consideration the topographical situation, this wound of the artery must in all probability lie in the neighborhood of the cleft between the

scaleni muscles, and therefore the ligation would be unusually difficult and fraught with danger. For this reason an attempt was first made to produce thrombosis of the hematoma with injections of thinned chloride of iron (*Liquor Piazza*)—without result, it is true, because the injections were very painful and had to be discontinued as they excited the already nervous and over-sensitive woman. Since, in spite of ice and compressive bandages, smaller secondary hemorrhages frequently occurred (June 30, July 6, 12, 14, 19), and on July 19 the radial pulse, which up to this time had been weakly palpable, entirely disappeared, the resolution to ligate had to be made and carried out. But meanwhile the topographical conditions had been made much more difficult by the oft recurring hemorrhages: there was a hematoma almost the size of a man's fist, which could be followed deep into the soft parts of the neck and had thinned the skin almost to perforation.

"On July 24, 1899, under chloroform narcosis, an incision, 10 cm. long, was made outwards from the insertion of the sternomastoid along the upper border of the clavicle, and one of the same length upwards along the lateral border of the muscle. The acute-angled skin flap was dissected up, whereupon the muscle, lying like a smooth band on the tumor, was cut through below. On the clavicle, corresponding to the entrance wound, was found a shallow groove and in it a small detached bit of lead, which had evidently glanced off from the shot. Now beneath the fascia lay a thick black coagulum; this was being carefully removed towards the depths of the neck, when suddenly a great thick stream of blood gushed out of the wound. Happily we succeeded, by digital compression towards the depths, in suppressing further hemorrhage, although it was not possible to reach the bleeding point; first because it lay too deep, and further because the approach was covered by the compressing hand. Both angle incisions were so lengthened over the summit that the horizontal portion reached to the right sternoclavicular articulation, the oblique one as far as the second left rib; and now the sternal third of the left clavicle and the whole manubrium sterni were resected. Although the cervical aperture to the thorax was now opened, we did not succeed in identifying with certainty the subclavian artery at the inner side of the scaleni, because orientation was made very difficult on account of the indurated mass which had formed around the large hematoma. Therefore, one had first of all to locate the left carotid; by tracing this downwards, we were enabled to reach the arch of the aorta and there to expose the subclavian artery and ligate it with a silk ligature about 1.5 to 2 cm. from its origin. Now, after removal of the compressing finger the bleeding ceased, and we were proceeding with the evacuation of the coagula from the large cavity, when suddenly again a rather severe hemorrhage occurred, which was again controlled at the same spot by digital compression. By careful evacuation of the peripheral part of the cavity the subclavian artery was now discovered and followed centrally as far as the finger compressing it on the first rib, and here

was found a longitudinal slit 3 mm. long, with sharp edges, on the upper part of the artery precisely at the point where it emerges from between the scaleni muscles. As it appeared quite certain that this subsequent hemorrhage must have been a retrograde one from the left vertebral artery, the subclavian was once more ligated peripheral and central to its wound. Bleeding now finally ceased and the entire large wound cavity was stuffed with strips of iodoform gauze, which were also carried as far as the arch of the aorta, without, however, coming directly into contact with the point of ligature. The cavity was reduced in size by some stitches from the clavicle to the sternomastoid.

"The course for the first few days was rather stormy, and quite marked collapse made repeated infusions of salt and injections of ether necessary. July 26 the temperature rose to 39.1° and quite a large quantity of milky fluid came from the dressing, necessitating frequent renewals of the superficial bandages, and the removal on July 28 of part of the iodoform gauze, whereupon the temperature gradually sank. The constant moistening with the milky secretion produced a maceration of the neck and back, which required special attention in order to prevent decubitus and eczema. This flow gradually diminished and ceased entirely August 6. While the flow of chyle continued there was very marked thirst, which gradually disappeared as the leakage diminished. At each change of dressing all the loosened iodoform gauze was cut away, the last piece being removed August 6. During the final days the wound and the dressings had a decidedly fetid odor, evidently due to the putrefaction of the remains of the chyle in the tampons, but the temperature was normal, and the wound was granulating satisfactorily.

"On the first day after the operation the weakness was so great that the patient could not speak aloud. As the condition improved the peculiar rough sound of her voice was striking and made one suspicious of one-sided paralysis of the vocal cord. It was later found by laryngoscopic examination that there was a complete paralysis of the left recurrent nerve; this was still present when the patient was discharged. . . . The radial and ulnar pulses did not reappear. Motility in the upper arm was regained very soon, in the forearm and hand only gradually. The wound healed slowly *per secundam* and was closed by the middle of October.

"The patient remained in the hospital until her recovery, and the left arm was treated with massage and electricity until December 2, 1899, when she was discharged with the following findings: Wound healed with a broad scar, left side of the neck sunken in on account of the absence of the cord of the sternomastoid. At the place of resection of the bones of the clavicle and manubrium sterni there are firm periosteal bone formations. Left arm can be moved in the shoulder-joint, but cannot be raised. The left hand can be lifted to the mouth, but cannot make a fist; fingers only very slightly movable, actively or passively. In the ulnar region sensibility of all qualities extinct;

no striking atrophic changes. Complete left-sided paralysis of the recurrent nerve, voice loud and rough.

"In the foregoing case the cure was effected by ligation of the subclavian artery in its first portion. At the time of the publication of the dissertation, Dr. Philipp could not discover a case which had been cured by this ligation; all of the 18 * cases collected by him died very soon after the operation, which, as far as could be ascertained, had been undertaken only three times on the left side. I have searched the literature since that time and have not been able to find another cured case. My case may first of all prove that, under favorable conditions, a cure following this ligation is possible, and that the prognosis is not so absolutely bad that in a similar case one should not at least undertake the operation. Further, my case confirms what has been emphasized by all observers, the difficulty of diagnosis, which in this case was greatly increased because there was no real division of the artery, but only a lateral wound, which caused the symptoms of a severe wound to make their appearance gradually.

"The technical difficulties are naturally much greater on the left side than on the right and necessitate free exposure of the field of operation by the resection of a portion of the clavicle and of the manubrium sterni, whereby alone it is possible to orient oneself and to secure freedom of action. The wounding of the thoracic duct and of the recurrent nerve (or the vagus trunk?), which occurred in my case, are technical faults, which are certainly to be avoided and may be excused by the haste with which I was obliged to operate since the compressing finger of the assistant was becoming tired and had to be supported by the finger of still another assistant. That the wounding of the thoracic duct does not always have serious consequences is also proved."

The first step in the operation of Dr. Jüngst should, in my opinion, have been the exposure and provisional occlusion of the thoracic portion of the subclavian. Had this been done the patient would have been spared the major part of the loss of blood. The evidence is insufficient to sustain the contention that the ultimate hemorrhage was altogether a retrograde one from the *vertebral* artery. I shudder to fancy what the result might have been in our second case (No. XXI) had I proceeded after the manner of Jüngst. To stuff the wound with gauze was also an error; the wound should, I think, have been closed without drainage, absolute hemostasis having, of course, been attained.

CHARLES STONHAM. (IX.) "*Westminster Hospital. A case of aneurysm of the second and third parts of the left subclavian artery;*

* Philipp's collection includes the ligations of the first portion of the right as well as of the left subclavian. (W. S. H.)

ligature of the first part; recurrent pulsation; simultaneous ligature of the inferior thyroid, vertebral, and third part of the axillary arteries; recovery." Lancet, London, 1902, vol. ii, p. 291.

"A man, aged 43 years, was admitted into Westminster Hospital on April 13th, 1899, in consequence of a swelling 'in the root of the neck on the left side.' The patient had contracted syphilis 14 years previously and 10 months before admission he had a gumma on the left calf, one on the inner side of the left thigh, and a third on the left forearm. In November 1895, he was admitted into St. Peter's Hospital, Bristol, in consequence of 'bronchitis and considerable hæmoptysis'; he was an in-patient 10 months, when he was discharged as suffering from phthisis and being incurable. He was then admitted into the St. George's Infirmary, Fulham-road, and improved considerably. On his discharge he resumed his work as a carpenter and worked regularly until he came to the hospital, although he was 'troubled with his chest and a cough.' He had also suffered from piles and right-sided sciatica. As regards his present illness, five months before admission the patient experienced an aching pain in the upper part of the left chest and noticed a swelling of about the size of a walnut at the root of the neck above the left clavicle. This swelling was at first very tender, but the pain soon passed off and the patient put pressure on the swelling for two or three days, after which, according to him, it disappeared, but suddenly reappeared two or three days later. This swelling gradually increased in size, but although at first he occasionally suffered acute stabbing pain in the left chest and down the left arm this did not trouble him latterly and he continued his work until April 12th, 1899, the day before his admission.

"On April 17th the patient was thin and had a worn expression. The chest was badly formed and its mobility was markedly deficient. The percussion note was somewhat impaired at the apex on both sides; there were no moist sounds or other abnormality; there was no expectoration. The heart was normal. The arteries were not rigid or particularly tortuous. . . . The ends of the fingers were clubbed, especially on the left hand. There was a swelling in the left supra-clavicular region of about the size of a duck's egg rising well above the clavicle and situated over the third and part of the second part of the sub-clavian artery, extending forwards beneath the clavicular head of the sterno-mastoid to near the middle of the sternal head. The swelling occupied the whole of the supraclavicular fossa, but there was no dulness below the clavicle indicative of its extension in that direction, although it is true that there was deficient resonance at the apex of both lungs; this deficiency was equal on both sides. The swelling was expansile and there was a very distinct systolic bruit and thrill. The diagnosis was aneurysm affecting the convexity of the second and third parts of the left subclavian artery. . . . After carefully considering this case in all its bearings and being convinced that rupture of the

sac would occur in a short time, Mr. Stonham determined to attempt cure by proximal ligation in spite of the general opinion that such an operation should not be undertaken.

Operation.—April 26, 1899. An operation was performed on April 26th. The patient was placed under chloroform and Mr. Stonham proceeded to tie the vessel in the thorax, being most ably assisted by Mr. E. P. Paton. The shoulders being somewhat raised by pillows, the head thrown slightly backwards, and the face turned to the opposite side, a vertical incision about six inches long was made parallel to, and just outside, the sternal head of the sterno-mastoid, the centre of the incision being placed over the sterno-clavicular articulation. The upper part of this incision exposed the muscular fibres while the lower half was made right down to the sternum. A second incision was then made along the inner half of the clavicle, the knife being made to cut down to the bone. The clavicular head of the sterno-mastoid was separated from its attachment, the clavicle being closely ‘hugged’ all the time; this part of the muscle with the upper triangular flap of skin was very carefully turned upwards and outwards. A small portion of the pectoralis major was now separated from the sternum and clavicle and was turned with the second triangular portion of skin downwards and outwards. The parts were very vascular but no vessel of any importance was encountered; all bleeding points were at once clamped and tied, the most troublesome one being a small perforating branch in the first intercostal space. The clavicle was now very carefully sawn about one inch, or rather more, from its sternal end, the division being completed with bone forceps; the sternal portion of the bone was isolated by means of a raspatory and by the knife, both instruments being kept as close as possible to the bone so that in point of fact the resection was practically sub-periosteal. During the division of the bone the deeper parts were protected by a retractor. The floor of the wound was now seen to consist of a portion of the clavicular periosteum, a layer of the deep cervical fascia and muscular tissue. By means of two pairs of dissecting forceps the outer edge of the muscular layer was clearly defined, the muscles being the sterno-hyoid and the sterno-thyroid; these were drawn inwards. Further blunt dissection revealed the carotid artery running vertically upwards along the inner border of the wound which was now becoming very deep. On the outer side and below was the dome of the pleura covered by the junction of the subclavian and internal jugular veins and a short piece of the left innominate. These veins were carefully drawn downwards and outwards, when deeply behind them about two thirds of an inch of the subclavian artery were revealed, surrounded by a little loose fat. The thoracic duct was not seen nor were any nerves or veins other than those mentioned. Little difficulty was experienced in passing an ordinary aneurysm needle armed with salicylic floss silk round the vessel from within outwards; the finger was then placed upon the vessel (which was apparently quite healthy and highly elastic) and the loop of the

ligature drawn tight beneath it, the radial pulse and all pulsation in the aneurysmal sac were arrested, and the ligature was then tied with a surgeon's knot, the ends being cut quite short. The ligature was only tied with sufficient force to occlude the artery, not to rupture the inner coats; it was situated behind the sterno-clavicular joint about half an inch from the aneurysmal sac. The deep wound was carefully dried and the displaced structures were allowed to resume their normal position, the sterno-hyoid and sterno-thyroid muscles completely hiding the artery from view. The skin wound was closed with silkworm gut and horsehair interrupted sutures, a short gauze drain being placed in the middle of the incision as deep as the sterno-hyoid and thyroid muscles. The wound was dressed with double cyanide gauze and salicylic wool, the left arm, covered in Gamgee tissue, was bandaged to the side, and one-third of a grain of morphia was administered hypodermically. . . .

"On April 27th . . . he had slept for six hours and had been comfortable. The pulse was 84, regular, and of rather low tension. The temperature was normal. One of the fingers when examined was quite warm and the circulation was good. There was no pain. The pulse was 76. The circulation in the left hand was good and the radial pulse distinct. He complained a good deal of thirst. . . . On May 2nd the wound was dressed and the gauze drain was removed. Slight pulsation, not expansile, was felt in the sac, which was much smaller and harder. On the 9th the stitches were removed; the wound was soundly healed; it was now covered with a collodion dressing. The sac was smaller, denser, and more localised; slight pulsation could be felt in it, but could not be seen. The radial pulse was more distinct. From May 9th to June 2nd the patient was kept quiet in bed. . . . On the latter date the pulsation in the sac was distinctly excentric and the sac had somewhat increased in size in the outward direction. Until a week before June 21st this increased size of the sac slightly diminished, but now the pulsation was more evident, especially at the upper and outer part. The patient also complained of pain in the shoulder and down the upper arm. *The radial pulse was very good but delayed in time.** On the 22nd equable and continuous pressure was applied to the sac by means of marine sponges and bandages. On the 24th there was no result from the pressure and it was consequently discontinued; indeed, the sac was clearly increasing outwards and upwards and the pulsation was becoming more evident. Dr. Allechin kindly saw the case with Mr. Stonham and it was decided that something further must be done. On the 27th the left hand was slightly swollen and congested and the patient complained that he could not move the fingers properly.

"On June 28th the vertebral, inferior thyroid, and the third part of the axillary artery were ligatured. A vertical incision was made just external to that employed for the previous operation and was

* Italics mine. W. S. H.

carried further upwards along the outer border of the sternal head of the sterno-mastoid. A second incision was made from the lower end of this outwards along the line of the clavicle and this triangular flap of skin was then turned upwards and outwards; the remains of the clavicular head of the sterno-mastoid were drawn outwards and the internal jugular vein exposed. Blunt dissection external to the vein exposed the anterior scalene muscle and phrenic nerve. The jugular vein was drawn inwards and the muscle outwards. The transverse process of the sixth cervical vertebra was exposed. A vessel of no great size was now defined in the position of the vertebral artery and was ligatured with silk; the ligature unfortunately broke, dividing the vessel, which was secured with difficulty and tied at both ends. No other vessel could be found in this situation, though the foramen through the transverse process could be clearly defined. A second vessel—the inferior thyroid artery—was also tied. A piece of gauze was carried to the bottom of the wound as a drain and the incision was sutured with horsehair. Ligature of these vessels materially diminished but did not arrest the pulsation in the sac and it was therefore determined to apply a distal ligature to the third part of the axillary artery, and this was accordingly done just above the subscapular branch and was followed by complete arrest of the pulsation.

“On June 29th the patient was comfortable. . . . The circulation in the fingers was good. The wound in the neck had oozed a little and the dressing was stained; this had been packed. On the 30th the wound was dressed and a smaller plug of gauze was put in the cervical wound. The wounds were healthy. On July 3rd the patient was progressing satisfactorily and was kept on fluid diet. The dressings had not been touched. The circulation in the arm was good but no pulse was present either at the wrist or the elbow. . . . On the 5th there had been uninterrupted progress. The wound was dressed and the sutures and gauze plug were removed. No pulse was to be felt. The aneurysm was decidedly smaller, harder and denser; there was no trace of pulsation in the sac. On the 11th the wounds were soundly healed. The aneurysm was still smaller and harder; over it slight pulsation could be felt along a transverse line (? the transverse cervical artery). The radial pulse was just perceptible. The further progress of the case was uninterrupted. The sac gradually diminished in size and the pulse became stronger in the radial. The patient complained for a few days of stiffness in the fingers. . . .

Remarks by Mr. Stonham: “In November [year not stated] I saw the patient and could find absolutely no trace of the sac. . . . The movements of the arm were necessarily weak. . . . I have seen this man as lately as March 1902, and he continues quite well. He is doing light work as a carpenter.”

In Mr. Stonham's description of the primary operation no mention is made of the branches given off from the first portion of the artery;

I presume, therefore, that he saw none and consequently did not know the position of his ligature in its relation to any one of them. Since, however, he ligated the vertebral and inferior thyroid arteries at the second operation we may infer that he believed his ligation to have been made proximal to these branches.

Stonham's is the only aneurism of the spontaneous variety on our list not cured by the simple ligation of the subclavian artery. Since the artery coursed high in the neck and the aneurism was apparently at its highest point, and as, furthermore, the ligation of the vertebral and inferior thyroid arteries at the second operation had less effect on the aneurism than the ligation of the third part of the axillary, and as the radial pulse reappeared 24 hours after the first operation and 13 days after the second, I wonder if this may not have been a case of aneurism due primarily to a cervical rib—secondarily perhaps to the syphilis. It would seem that there must have been a well established anastomotic circulation before the first operation.

Surgeons have rarely noted the location of the ligature in its relation to the origin of the branches of the first division of the subclavian artery. Only from the cases in which this relationship is known could we find justification for inference as to the effect which secondary ligation of the branches in question might exert upon the aneurism. There can be little doubt, I think, that we should make for ourselves the rule always to ligate as close to the aneurism as possible, whether on its afferent or efferent side. I have never failed to cure the aneurism when both the afferent and efferent arteries have been ligated in accord with this precept. In one instance of this kind, however, the pulsation, which had ceased for a moment after the ligation of the artery on both sides of the aneurism, returned before the toilet of the wound was completed, but we noted that the sac became larger and tenser—a sign which I have learned to regard as favorable. At the first dressing of this case of mine,* which was not made until the 9th day after operation, the tumor no longer pulsated nor did it ever pulsate again. I have read of at least two similar observations, but unfortunately neglected to make a memorandum of either.

I do not understand why Mr. Stonham should have ligated the axillary artery at so low a point. A ligation as near the aneurism as

* Johns Hopkins Hospital, Sur. No. 18357.

possible would have been more likely to cure it and have less imperilled the circulation of the arm.

PIERRE DELBET. (X.) *Anévrisme de la sous-clavière gauche.* Bull. et mém. Soc. de Chir., Paris, 1910, t. xxxvi, p. 1114. (Séance du 16 novembre, 1910.)

"I have the honor to present to you a patient upon whom I have operated for a traumatic aneurism of the left subclavian. I operated with the assistance of our colleague Pierre Duval, whose counsels have been extremely valuable.

"I first exposed the sac, because it was not absolutely certain that the aneurism had its origin in the subclavian: it might have developed at the expense of one of its branches.

"Then, I resected the internal third of the clavicle and a part of the manubrium in order to proceed with the search for the subclavian at its origin from the aorta. This was very deep. I passed a ligature beneath the artery and, pulling on this ligature so as to bend the artery and stop the circulation in it, I opened the sac. Formidable hemorrhage. Having tamponed and made compression, I proceeded with the search for the peripheral end of the subclavian, and I passed a thread underneath it as had been done for the central end. The two ligatures being tied, I removed the tampon. Hemostasis was not perfect, but the hemorrhage was not menacing.

"We could see the orifice through which the blood came and we closed it with two forceps. In spite of its deep location, it would perhaps have been possible to suture it, but I judged that this would not have been of any advantage. I ligated with a single ligature passed around the two forceps.

"As the patient had terrible neuralgic pains, *je réséquai les deux dernières paires cervicales*,* which were imbedded in the fibrous tissue forming the sac. The pains completely disappeared.

"But the patient had irregular phenomena of paralysis, which made one think that the first 'fronto-dorsal' was wounded. I did not think it necessary to search for this root, the operation being already traumatic enough.

"The paralytic phenomena persist, and I do not know whether they will ameliorate, because it is impossible for me to determine whether the root has been divided by the stroke of the knife and secondarily compressed.

"The radial pulse, which was not perceptible before the operation, has not yet become so, but at no time has the nutrition of the member given the least anxiety.

* Presumably *dissected free* is meant. It is interesting to note that the freeing of the nerves entirely relieved the pains. (W. S. H.)

"I shall not discourse further on this case, because I have to make a report on an analogous one of Dr. Pierre Duval." *

This would seem to have been a case for extirpation of the sac rather than for tamponage.

ED. SCHWARTZ. (XI.) *Enorme anévrisme diffus du cou et de la région sous-claviculaire. Paralysie du membre supérieur gauche. Compression du récurrent gauche.* Bull. et mém. Soc. de Chir., Paris, 1910, t. xxxvi, pp. 874 and 1138.

Séance du 20 juillet 1910. M. Ed. Schwartz: "I have the honor to present to you this wounded man, for whose treatment I ask your advice. . . .

"M. X., *æt.* 33, was thrown from his bicycle against the shaft of a cart which struck him in the left supraclavicular region. The accident occurred June 6, 1910, about 6 weeks ago. The patient did not lose consciousness, but got up, and noticed at the point where he had been struck the formation of a swelling which increased as he watched it, while the skin became tense and purple. He consulted a physician who ordered leeches.

"He returned to his home in the evening and felt greatly oppressed. The leeches were applied and gave relief.

"At the end of five or six days the tumor appeared to have diminished, the ecchymosis disappeared, the voice, which had been a little hoarse, regained its normal timbre; the patient remained in bed on a strict diet.

"Then there occurred attacks of pain in the left arm, especially at night. These attacks lasted about half an hour and were accompanied by contraction of the muscles of the arm. Pyramidon was ordered for him and on June 13, 1910, the actual cautery was applied.

"From June 14 the tumor again began to increase in size and hardness during three or four days, and at the same time there appeared difficulty in breathing, roughness of the voice, and a complete flaccid paralysis of the left arm. The attacks of pain persisted. June 24, 1910, the patient entered the Hospital of Langres, where iodide of sodium was administered and electric treatment of the paralyzed muscles periodically given. As his condition remained stationary he was sent to the Hôpital Cochin, July 18, 1910.

* The case of Duval is probably the one announced by title at the séance of April 20, 1910, p. 420: "*Anévrisme de l'artère sous-clavière droite. Extirpation du sac après résection temporaire de la clavicule. Ligature latérale de la veine sous-clavière. Guérison.* Présentation de la pièce anatomique et du malade, par M. Pierre Duval, chirurgien des hôpitaux.

"Le travail de M. Duval est renvoyé à une commission, dont M. Delbet est nommé rapporteur."

Examination.—"One finds an enormous, tense, fluctuant tumor occupying the whole left carotid and supraclavicular regions, reaching from the jaw to the clavicle, and pressing the larynx and trachea to the right.

"One perceives neither pulsation, bruit, nor expansion of the tumor. The skin is movable over it.

"The left temporal pulse is hardly perceptible; the left radial pulse is feebler than the right but not appreciably retarded.

"The left arm is completely paralyzed; there is atrophy of the muscles, especially of the great pectoral; the patient can raise the shoulder by means of the clavicular fasciculus of the trapezius; sensation is preserved.

"There is raucity of the voice, which is a little muffled; there is dysphagia when solid food, especially bread, is taken; there are signs of compression of the left great sympathetic, manifest in the narrowing of the left palpebral cleft, in myosis and enophthalmus.

"Aspiration with a Pravaz syringe drew out a little black sanguineous liquid.

"In our opinion, we can only be confronted in this instance with the rupture of a large vessel of the neck. In spite of the absence of pulsation we believe that there is a rupture of an artery like the carotid or subclavian; there have been two affluxes of blood, the first at the time of the accident, the second 6 days later when the severe symptoms of paralysis appeared.

"What treatment would you advise? Were it not for the paralysis and the atrocious suffering I would await developments in the hope of seeing the tumor diminish in size. Do these symptoms demand intervention, opening the sac, searching for and tying off the torn ends of the vessel?

"M. Lucas-Championniere: Is there definite amelioration, or is there aggravation?

"M. Schwartz: After a period of augmentation we observe undoubtedly a slight abatement.

"Several speakers took part in the discussion, some advising intervention, others abstention. It was demonstrated that the tumor was pulsating."

Séance du 23 novembre 1910. "*Anévrisme diffus de la sous-clavière gauche.* Communication par M. Schwartz." Bull. et mém. Soc. de Chir., Paris, 1910, t. xxxvi, p. 1138.

"I presented to you on the 20th of last July a patient with an enormous aneurismal tumor of the neck following a wound in the left supraclavicular triangle, and asked what course you would counsel me to take in such case.

"As the tumor was increasing and the patient was suffering continuously, my colleague Nélaton, who had the goodness to give me his

valuable and illuminating advice, was with me inclined towards an intervention—to search for the two ends of the wounded artery, having first made as far as possible preventive occlusion of the wounded vessel, which, as will be remembered, might be the common carotid, but more likely the left subclavian or one of its large branches.

“After experiments on the cadaver, for which we are indebted to the kindness of our colleague Prof. Hartmann, we thought of proceeding in the following manner: make a resection of the internal extremity of the clavicle and of the left half of the manubrium, search for the common carotid at its origin from the aorta, apply a temporary ligature to this artery, search for the very deeply situated subclavian, and against the vertebral column make digital compression of this vessel at its origin. Of course, the ligature was not to be permanently tied until, after splitting the aneurismal sac, the arterial wound had been located.

“In the meantime, I had the patient injected subcutaneously with 10 to 15 cubes of *sérum gelatiné*, one each day. Under the influence of this it appeared to us that the tumor diminished; at all events, the pains became much less intense and the general condition improved.

“My colleague Nélaton and I met to decide and to perform the projected operation. The tumor began to grow anew, and it seemed to us impossible to proceed with the claviculo-sternal resection without entering the aneurismal field and being immediately inundated with blood. In view of this conclusion we believed that we should refrain from operation, and continue to make the injections of *sérum gelatiné* and the application of bladders of ice. Meanwhile my wards were closed for repairs and the wounded man passed into the service of my colleague Quénu, under the care of our colleague Pierre Duval, who believed that he ought to operate and sent me the following note:

‘*Operation.*—August 8, 1910. Doubtful as to whether the aneurism had its origin in the common carotid or the subclavian, it appeared to me prudent to make a search for these two vessels at their origin from the aorta, to place on each of them a temporary ligature, then, to split freely the aneurism and to find my way to the wounded artery as circumstances might permit.

‘Incision parallel to the clavicle curving over the manubrium; resection of the clavicle (inner half), of the left half of the manubrium, and of the first costal cartilage.

‘The pleura and the pleural dome were pressed aside. The arch of the aorta was exposed. A ligature was placed about the left common carotid and also on the subclavian. Free vertical incision of the aneurism.

‘At the moment the jet of blood spurted my assistant pulled quickly on the precautionary ligatures. After evacuation of the clots, I easily found the subclavian, cut across at the internal border of the first rib. Ligature of the two ends. Suture and drainage. The patient’s pulse after operation was 84. The operation had lasted 50 minutes. At 3 o’clock in the afternoon, sudden death.

‘I am persuaded that he died from an embolus. The ligature, placed as a precaution which I now recognize as useless and dangerous, on the common carotid, had been sharply drawn, must have wounded the internal coats of the artery, from which there was a clot and mortal embolus.’

"I cannot, in spite of the unsuccessful outcome, help felicitating our colleague Pierre Duval on the course which he adopted. I allowed myself to be halted through fear that I should not be able to control the hemorrhage; the operation which he performed has shown that that fear was unfounded. He added to the operation planned by Nélaton and me resection of the cartilage of the first rib, which gives still better access and permitted the application of a ligature to the subclavian. . . ."

Whether the precautionary loop about the subclavian within the thorax was tied is not stated. In any event, the proximal ligation must have been of the first portion.

I am unable to share with M. Duval his confident belief that an embolus from the carotid artery was the cause of the patient's death. Have we any proof that embolism of a cerebral artery has ever caused sudden death, or have we evidence that, infection being excluded, emboli may become dislodged or a thrombosis form as the result and at the site of a temporary ligature? Many times have I occluded temporarily large arteries in the human subject and never have I had occasion to regret it. The aorta of dogs, which on the average is not larger than the carotid of man, we have repeatedly ligated as a temporary measure and have never observed thrombosis at the line made by the crushing ligature. In any event, the temporary occlusion of arteries should, when possible, be made in a manner not likely to rupture their coats.

I commonly employ a narrow tape in making temporary occlusion. Close to the artery the two arms of the tape are twisted and the twist maintained by clamping it with an artery forceps. Dr. Mack Rogers of Birmingham, Alabama, discussing the paper of Dr. Sherrill, advocates the following method:

"In connection with this subject of aneurysm, I desire to call attention to a method of controlling hemorrhage that has been of great utility in these cases. It is the use of an ordinary white tape that is used for binding purposes. It should be about 12 inches long and half an inch wide. An aperture is provided about one inch from the centre, through which the other end of the tape is carried after it has been passed around the vessel; then by pulling on the two ends of the tape, pressure is exerted over a broad area of the vessel, controlling the hemorrhage perfectly, yet it does not injure the vessel. By the use of this tape an assistant is in absolute control of the situation. He can increase or diminish the pressure on the vessel at will, while the operator is dealing with the aneurysmal sac, and this will greatly assist the operator in locating the vessels that enter the sac.

"This method of controlling hemorrhage is, of course, not an entirely new one, but I wish to call the attention of this Association particularly to its application in these desperate cases of aneurysm."

CAPT. C. G. BROWNE. (XII.) *A case of diffuse traumatic aneurysm and ligature of the first part of the subclavian.* British Medical Journal, London, 1911, vol. ii, p. 1534. (Reports on medical and surgical practice in the hospitals and asylums of the British Empire. Station Hospital, Barrackpore, Bengal.)

"Ligature of the first part of the left subclavian artery is an operation attended by many difficulties and dangers. I have only been able to find two successful cases recorded of ligature on the right side and none on the left. My references are, however, limited. Erichsen condemns the operation as 'bad in principle,' and 'most unfortunate in practice,' and considers that it should be 'banished from surgical practice.' Hence a few notes on a recent successful case may be of interest.

"Private C. was brought to the hospital on the evening of August 25th, 1911. He was faint and his clothes were blood-stained. He had been on guard, had fainted, and fallen forwards on his bayonet, the point of which had entered through the left anterior axillary fold for an uncertain distance. There was no bleeding from the wound, but there was evidence of a collection of blood in the subclavicular region and inner part of the axilla. He complained of an aching distended feeling in the arm. The wound was dressed and pressure applied. The temperature in the evening was 100.6°.

"The patient had a restless night, but no external hæmorrhage; there was marked pulsation and a bruit over the subclavian swelling, which had not increased in size. The left radial pulse, which was at first feeble, was now equal to the right. The venous return from the arm was apparently slightly obstructed. The temperature was 99.8° in the morning and 100.4° in the evening. He had another restless night, and on the morning of August 27th he complained of severe pain down the arm, which was slightly swollen; the pulsation, bruit, and size of the swelling were unaltered. The temperature was 99.6° in the morning and 100.4° in the evening. He had a very restless night, being almost delirious with pain, and had attempted to tear off his bandage. On August 28th the arm was more swollen, and the obstruction to the venous return was more obvious. I saw him for the first time on this day in consultation with Lieutenant-Colonel F. J. Morgan, R. A. M. C., and decided to operate at once. The temperature was 99.4°.

"*Operation.*—August 28, 1911. The usual incision for ligature of the third part of the subclavian was made, the omo-hyoid was pulled up, and the outer border of the scalenus anticus exposed. Owing to

the clavicle being very much pushed upwards and forwards, the wound was of considerable depth. No trace of either subclavian artery or vein could be found external to the scalenus anticus muscle. The wound was extended inwards and the sterno-mastoid partially divided; the depth of the wound increased, and presently a large artery, partially overlapped on its inner side by a vein, was exposed, descending vertically along the inner border of the scalenus anticus. The wound was now very deep, and the greatest care had to be exercised. Unfortunately at this point a small vein was torn close to its junction with the large vein and the wound was flooded with blood. A ligature was placed on this after much trouble and waste of valuable time. The artery was now compressed by the finger and the radial pulse was at once obliterated; pulsation below the clavicle also ceased. The vessel was taken to be the first part of the subclavian and was ligatured. The passing of the ligature took some time, as I had to proceed with the utmost caution, and the depth of the wound and condition of the patient did not warrant me in tracing the artery any further. The wound was sewn up, leaving a gauze drain. The axilla was then opened, clot and serum evacuated, and a large drainage tube inserted. The temperature in the evening was 102.8°.

"On August 29th the part was dressed, a light plug inserted in the upper wound, and a tube left in the lower. The temperature was 99.4°. He stated that he was absolutely free from pain in the arm but there was a slight tingling of the fingers. There was no pulsation below the clavicle and no radial pulse. The arm was kept swathed in cotton wool.

"On September 4th he was doing very well; there was a little serous exudation from the upper wound.

"On September 18th both wounds were completely healed; there was some stiffness about the muscles of the shoulder, which was being massaged. No pulse could be felt in the radial artery.

"On September 27th he was discharged from hospital, complaining of some numbness of the first and second fingers.

"On October 11th he was marked 'light duty' for one week (before resuming his full military duty on October 18th). No pulsation was felt in the radial artery.

"The chief point of interest about the case was the abnormal course of the artery. When first exposed I thought it must be the common carotid from its vertical course. The result of the ligature, however, leaves no doubt that it was the subclavian. The vessel must have either (1) made a very high arch in the neck on the inner side of the scalenus anticus, or (2) taken origin from the common carotid in the neck instead of from the arch of the aorta, though this is an abnormality I have never read of. The almost immediate relief of the pain, presumably due to nerve pressure, was a gratifying feature. I am indebted to Lieutenant-Colonel F. J. Morgan, R. A. M. C., for his in-

valuable assistance during the operation and permission to publish this case."

As there was no pulsation in the axillary hematoma and no hemorrhage after evacuation of the clots it is improbable that the axillary artery had been pierced by the bayonet. Possibly only a vein was injured. I should not be inclined in a case like this to make a permanent ligation of the subclavian. Compression of the artery above the clavicle would have been especially easy as the artery coursed high in the neck.

The "high arch in the neck" of the subclavian artery must have simplified the operation greatly. The former of Captain Browne's two conjectures in regard to the "abnormal course of the artery" is quite surely the correct one. My studies, clinical and experimental, on the dilatation of arteries distal to the point of coarctation have led me to observe with greater interest and care the course of the subclavian artery in patients with cervical ribs and also in those without them, and I have been surprised at the frequency with which the subclavian occupies an abnormally high position in the otherwise apparently normal neck, sometimes quite as high as in people with cervical ribs.

My colleague, Professor Howland, recently called my attention to a child's neck, the configuration and great length of which convinced him that the boy had a cervical rib or ribs. The subclavian artery coursed so high above the clavicle that from this sign alone I was quite sure that Dr. Howland's interpretation was correct. The skiagraph showed abnormally large transverse processes of the seventh cervical vertebræ, but no trace of cervical ribs. We shall follow skiagraphically the development of the neck of this boy in the expectation that the unossified primordium (*Anlage*) for a cervical rib may be present.

Is it not probable that the occurrence of very high subclavian arteries in people without cervical ribs may be traceable to an *Anlage* for the undeveloped ribs? We have several times found in these cases stumps of bone articulating with the transverse processes of the seventh cervical vertebræ, and in one such case there were definite symptoms of pressure on the roots of the brachial plexus, symptoms which were relieved by the removal of the abnormal stump of bone, although at the operation in this case we found nothing to explain the relief afforded by it.

I hope that some younger men who read the above paragraphs may be interested to note skiagraphically for a period of years the cervical development of children with abnormally long necks and high subclavian arteries.

JAMES M. NEFF. (XIII.) *Ligation of the first portion of the left subclavian artery. With report of a recent successful case.* Annals of Surgery, Phila., 1911, vol. liv, p. 503.

"Mr. H. W., age twenty-three years, single. In December, 1909, patient first noticed an enlargement of the glands in the left side of the neck.

"Patient entered the Deaconess Hospital, Spokane, on February 11, 1910. In left side of neck there was a chain of enlarged lymphatic glands extending from the mastoid process to the clavicle. The centre of the mass was more prominent, tender to pressure, and presented deep fluctuation. There was considerable periadenitis, the glands being adherent to each other and quite immovable. Examination of heart, lungs, and abdomen negative.

"*Operation.*—February 12, 1910. An incision was made, extending from the mastoid process downward along the anterior border of the sternomastoid muscle to the middle of the neck, then backward, severing the muscle, and continuing downward to the clavicle along its posterior border. The chain of enlarged glands was reached through this incision, and their removal begun from below by clearing the space between the internal jugular vein and the clavicle. The glands and infiltrated gland bearing tissue in this situation were dissected free with some difficulty, but without apparent injury to any of the important structures in the neighborhood. The lower angle of the wound was then tamponed to produce distension of the internal jugular vein, and the dissection of the glands was continued in an upward direction. This was accomplished with a good deal of difficulty, owing to the extensive periadenitis and suppuration in the centre of the mass. It was finally completed, however, and we were about ready to close the wound, when there was a sudden gush of blood from the lower part of the wound behind the clavicle. The hemorrhage was very profuse and came on without the slightest warning, as we had been working in the upper part of the neck and had not touched the lower portion since the beginning of the operation. The flow of blood was stopped by pressure with the fingers behind the clavicle, and the field cleared by sponging. An examination was then made and it was found that the hemorrhage had come from the subclavian artery just internal to the scalenus anticus muscle. By cautiously moving the fingers inward, the outer border of the small opening in the artery was revealed. A hæmostat was then placed on the vessel in this situation and two more to the inner side of the first, thus closing the opening. The wound in the neck was now closed in the usual manner, after uniting the cut ends of the sternomastoid muscle with catgut sutures. A drainage tube was placed in the upper part of the wound on account of the secondary infection, and the hæmostats were allowed to protrude through the lower angle of the incision.

"Patient was returned to bed in fair condition, with pulse 110 and temperature 100.8° F.

"On February 14, 48 hours after operation, the hæmostats were carefully removed and two moderately firm gauze packings were inserted, one upon the other behind the clavicle and down to the artery. No bleeding occurred immediately after the removal of the forceps, but three hours later the patient had a very severe hemorrhage which stopped spontaneously. The outer packing was then removed and replaced by a firmer one, which was held in position by a tight adhesive plaster drawn across the wound and over the shoulder. After the hemorrhage the patient was anæmic and pulse went up to 118. On February 18, four days later, there having been no hemorrhage in the interval, the outer packing was removed, but the one next to the artery left undisturbed. The wound looked well, though there was slight purulent discharge from the upper part through the drainage tube. Pulse 112, temperature 101.6° F. Early the next morning, 11 hours after the last dressing, patient had another very severe hemorrhage. On the 19th he became delirious and on the 20th had two more hemorrhages. From this date until the 25th there were no hemorrhages, his pulse went down to 98, temperature nearly to normal, and we were greatly encouraged about his condition. On February 25th another severe hemorrhage occurred, and between this date and March 4, a period of seven days, he had 14 hemorrhages of greater or less severity. During this time the temperature ranged from 99.6° to 101° F. On February 27 cultures were taken by Dr. Frank Hinman from the pus in the drainage tube for the purpose of making autogenous vaccines. On this date, slight œdema of the arm and weakening of the radial pulse were noted, the result of long-continued pressure on the subclavian artery [*Sic*]. On March 3 Dr. Hinman injected 150,000,000 bacteria in right arm. On March 4, condition of patient became so grave that we decided that his only hope lay in the ligation of the first division of the subclavian. This procedure had been considered several times before, but as we had been unable to find in the literature the report of a single successful case of ligation of the first portion in the presence of sepsis, we had looked upon the operation as a last resort. At the time we decided to ligate the artery our patient had a temperature of 103.6° F., pulse 160, and he was delirious from anæmia and sepsis. For five hours before the operation we kept up continuous digital compression of the artery, as the hemorrhage would recur whenever the pressure was released.

"Operation, March 4, 1910, 7.30 p. m.

"Before beginning the operation an intravenous saline transfusion was given in the median basilic vein of the right arm.

"An incision was made along the upper border of the clavicle, from the outer third to the sternoclavicular articulation and then upward for 2½ inches through the old incision along the posterior border of the sternomastoid. An abscess cavity containing several drachms of foul-smelling pus was found beneath the latter muscle. The clavicle was divided with bone-cutting forceps 1½ inches from the sternum, and

the ends retracted in a downward direction, thus giving good access to the subclavian space. Up to this time pressure on the subclavian had been maintained, but when all was in readiness the pressure was released and the packing removed. A gush of blood immediately followed but was at once controlled by direct pressure with the fingers, followed by the application of hæmostats to the opening in the artery. The scalenus anticus was next divided, the thyroid axis and vertebral artery recognized, and the subclavian dissected free in a downward direction from the surrounding structures. The dissection was particularly difficult because of the previous operation and the infection of the field, which had caused a matting together of all the tissues. By careful work, however, the subclavian and innominate veins were isolated and drawn forward and the thoracic duct recognized and separated from the artery. After the vessel was completely isolated, two attempts were made to ligate it in the upper portion of the first division, but both ligatures cut through the outer coats and had to be removed. Finally three-quarters of an inch * above the aorta the wall was strong enough to tolerate a ligature, and a double strand of medium sized silk on an aneurism needle was passed from below upward, behind, and around the vessel. This double ligature was tied in a simple square knot (not the Ballance and Edmunds stay knot) just tight enough to occlude the artery and stop pulsation. A hæmostat was then clamped on the vessel about one-quarter inch distal to the ligature. Another double-silk ligature was tied around the artery distal to the opening in its wall and a second hæmostat applied proximal to it. The thyroid axis, vertebral and internal mammary arteries were then ligated with silk and the forceps removed from the wound in the subclavian. A loose packing of iodoform gauze was placed in the deep cavity behind the clavicle, the ends of the clavicle united with aluminum bronze wire, and the external wound closed with interrupted silkworm gut sutures.

"When the patient was returned from the operating room, his pulse was 140 and temperature 103° F. For ten days after operation the blood-pressure was kept below 112 mm. of mercury by diminishing the amount of ingested liquids and giving spirits of nitroglycerin whenever it reached that point.

"Restlessness was controlled by hypodermics of morphine. Five days after operation the autogenous vaccines were again given and repeated every three or four days thereafter. The temperature ranged from 102.2° F. to 104.2° F. and pulse 120 to 150, until March 19, 15 days from time of operation, after which both gradually went down to normal. Patient continued delirious at intervals until March 15. The hæmostats were removed from the ligated vessels on March 13, nine days after operation. On March 13, he developed a

* I am surprised to learn that division of the clavicle 1¼ inches from the sternum should have permitted an exposure sufficient to enable the operator to apply a ligature so close to the aorta. (W. S. H.)

right-sided pleurisy and cough, with yellowish expectoration. His temperature was 103° F. to 104° F. and pulse 130 to 140 for a few days, but the trouble entirely subsided within a week. On March 19 the ends of the clavicle, which had become separated, were reunited. He was allowed out of bed for the first time on March 20, 16 days after operation. The wound, which was infected at the time of operation, continued to suppurate until the patient left the hospital on April 2, although it filled rapidly with granulations and was about flush with the clavicle at the time of his discharge.

"The radial pulse disappeared when the artery was ligated and has not returned to date, 16 months after operation.

"The peripheral circulation remained good after the ligation and the hand and arm were warm at all times.

"Marked atrophy of the arm, forearm, and hand took place during the two or three months following operation, and there was great weakness of all the muscles of the left upper extremity from shoulder to fingers.

"Tactile and pain sense were abolished over the lower third of the forearm, hand, wrist, and fingers for four months, and muscular sense in the hand was greatly impaired for the same time.

"As a result of almost constant exercise, frequent massage, and faradic electricity to the weakened and atrophied muscles, the muscular power is now about normal and the muscles have regained their normal volume and tone. There still remains, however, slight impairment of tactile sense in the tips of the fingers. The general health of the patient at the present time is perfect, weight up to normal, and he is able to attend to his regular business affairs."

Dr. Neff is to be congratulated on his rare good fortune in not losing the patient, and thanked for courageously narrating unhappy experiences which so clearly convey messages of warning.

The major errors in Neff's case were: (1) the leaving of hemostats hanging in the wound; (2) the attempt to control the infection of the wound by vaccination rather than by antiseptics; (3) the postponement of operation for the arrest of bleeding until, after about a score of secondary hemorrhages, the patient had become exsanguinated; (4) the ligation of the branches of the first portion of the subclavian (thyroid axis, vertebral, internal mammary) unless, as the author probably believed, the condition of the subclavian precluded ligation. The operator should consider how the closure of an artery permanently clamped in continuity may be accomplished. Surely the intimal surfaces which cannot adhere under ligature or band even when brought together in the gentlest manner cannot do so when compressed under a crushing hemostat. Nor can organization of the remaining shreds of the arterial

wall take place under the spring of the clamp. In the absence of infection the artery may be sealed by endothelial proliferation and by adhesion, perhaps, of the intimal surfaces held in contact for a short distance on both sides of the clamp. In the presence of infection the closure may, of course, be effected by the organization of a thrombus.

HANS RUBRITIUS. (XIV.) *Die chirurgische Behandlung der Aneurysmen der Arteria subclavia.* Beiträge z. klin. Chirurgie, Tübingen, 1911, Bd. lxxvi, p. 144.

"P. L., æt. 21, laborer. Entered the Prague Clinic Oct. 2, 1909. On Sept. 13, 1909, he was stabbed in a brawl in the left side of the neck. Violent bleeding followed, which was controlled by a firm bandage. Later he was brought to the dispensary, where Primärarzt Dr. Rösler observed that there was virtually no bleeding, but there was a high grade of anæmia. As no hemorrhage occurred in the days following, the wound was simply dressed aseptically. Sept. 20, 1909, on changing the dressing, a considerable swelling was noticed in the left supraclavicular region, in which in the following days a pulsation developed. On the assumption that it was a case of false aneurism of the carotid, Dr. Rösler sent the patient to the Clinic.

"*Examination.*—Middle-sized man, well nourished. Lungs and heart sound. In the left supraclavicular region there is a pulsating tumor the size of a fist, at the summit of which, close to the outer edge of the left sternomastoid, there is a scar about 1 cm. long. On auscultation there is heard over the tumor a systolic bruit, which is also audible over the axillary artery. The left radial pulse is weaker than the right. Blood pressure measured with the Gärtner tonometer is, right, 70-75 mm. Hg., left, 60-65. The left arm is slightly cyanotic, but there is no swelling or dilation of the veins. Movements in the left shoulder-joint are somewhat impeded.

"*Diagnosis.*—False aneurism of the left subclavian artery.

"*Operation I.*—October 5, 1909. Anesthetic, Billroth mixture. Length of operation 1½ hours. Skin incision over the tumor downwards to the middle of the clavicle, which was cut through in its centre with a Gigli saw. It now developed that the aneurism was situated very far central on the subclavian, indeed in its middle portion. In order to approach the artery so that it could be ligated central to the aneurism, the sternal half of the clavicle was completely removed, and a piece of the first rib about 4 cm. long was resected; also the left half of the manubrium had to be taken away. Now for the first time it was possible to reach the central pole of the tumor and to expose the artery at its origin. In dissecting the artery the pleura was wounded, and with a hissing sound pneumothorax developed. Carefully protecting the very full subclavian and jugular veins, between these two vessels with the aid of a curved foreign-body forceps a thin rubber tube was

drawn around the artery. The ends of the tube were now made fast to a probe about 20 cm. long in order that by twisting the probe the tube might be gradually tightened, and thus by degrees compression of the artery be brought about. Tampon of the large wound; dressing.

"In the course of the next 24 hours the probe was twice rotated through 180 degrees.

"*Operation II.*—October 27, 1909. Examination shows that the pleural cavity is distended with air and the heart completely pushed to the right. The tumor in the left supraclavicular region now pulsates no longer. At the point where the rubber tube had been two strong silk threads were placed around the subclavian artery, thus doubly ligating it.

"Some days thereafter there appeared an exudate in the pleural cavity; at first only blood was obtained by aspiration; as this soon became fetid an operation was undertaken on Nov. 15th. An incision 10 cm. long was made between the 7th and 8th ribs, a piece of the 8th rib resected, the pleura opened and drained with a rubber tube.

"Nov. 16th, 1909, drain removed from the pleura. The wound resulting from the first operation decreased gradually; at the site of the aneurismal tumor one feels a firm mass. The left radial pulse is not palpable; the left arm shows muscular atrophy, but except for this there is no disturbance of motion. . . . The patient was discharged Dec. 1, 1909.

"On Dec. 10, 1909, Herr Primärarzt Dr. Rösler stated that the patient, a few days after his discharge from the clinic, again made application to be admitted to the Aussiger Spital. On admission it was found that he had fever and that the entire left half of the thorax was dull. Soon thereafter a great quantity of foul smelling pus emptied itself spontaneously out of the wound from which the rib had been resected. A drainage tube was again inserted. According to a further communication on April 18th, 1910, from Dr. Rösler the secretion still persisted, hence he was again admitted to our clinic.

"April 19, 1910. The patient is found to be greatly emaciated and anemic. The left lung is markedly retracted, pulmonary resonance is present only to the middle of the scapula. In the posterior axillary line at the level of the 8th rib there is a fistulous opening which leads far into the pleural cavity and from this a purulent secretion runs continuously. Accordingly, on the 25th of April a thoracoplastic operation was done. After reflecting a great flap, 8 or 10 cm. of the 7th, 8th, 9th, and 10th ribs were resected, and the skin-flap turned into the great hole. Not until the middle of June did the secretion begin to decrease. On the 30th of June the wound was completely healed and the patient was discharged."

No statement is made in regard to the fate of the hematoma. Presumably it became infected and was thus dissipated.

The case of Rubritius is another to emphasize the importance of closing wounds, and not only those made for the ligation of large arteries. It was clearly an error in the first instance to have undertaken to occlude gradually the subclavian artery of a youth and, particularly so, by a method which prevented closure of the wound. I have found no evidence, after a careful survey of all the recorded cases, to sustain the fear that gangrene may follow the uncomplicated ligation of any portion of either subclavian artery; there was therefore no indication for the attempt to occlude the artery gradually, and particularly none by a method which superimposed the danger from infection—to the wound, to the artery, and to the opened pleural cavity. The gangrene which followed the difficult and brilliantly executed operation of Matas³³ for arterio-venous fistula of the right subclavian vessels seems quite unquestionably to have been chiefly due to the derangement of the arterial and venous flow incident to the fistula. The ligation of the branches of the first and second portions of the artery may also possibly have been a determining factor.

Although sternly disapproving of the method pursued by Rubritius in the management of his case, I can endorse in greater part his generalizations in respect to the treatment of subclavian aneurisms:

"We believe that one should always first test the central ligation; if this intervention has been simple and accomplished in a short time one may proceed to make a peripheral ligation and perhaps an incision into and a clearing out of the aneurismal sac. If the operation has been difficult and the condition of the patient such that one dare not venture to do more, the surgeon should rest content with the central ligation.

"Usually this operation alone will accomplish the desired result. When not, then must one at a second operation make the peripheral ligation and incise the aneurism. This is the operation which Hofmann^{*} proposed at the initiative of von Mikulicz. We believe that this latter procedure deserves serious heeding under the pictured circumstances; and contrary to the views of v. Frisch[†] and Saigo,[‡] who advise extirpation in every case, we would pronounce the central

* "H. Hofmann. Zur operativen Behandlung d. Aneurysmen. Beitr. z. Klin. Chir., Tüb., 1899, xxiv, p. 418."

† "Otto v. Frisch. Beitrag zur Behandlung peripherer Aneurysmen. Arch. f. klin. Chir., Berlin, 1906, lxxix, p. 515."

‡ "K. Saigo. Traumatische Aneurysmen im Japanisch-Russischen Kriege. D. Zeitschr. f. Chir., Leipz., 1906, lxxxv, p. 577."

ligation as the operation of choice in the treatment of subclavian aneurisms, as already Oberst* and Rotter† have done."

G. P. NEWBOLT. (XV.) *A case of aneurysm of the second and third parts of the left subclavian artery in a woman.* British Medical Journal, London, 1912, vol. ii, p. 867.

"Miss E. aged 50, consulted me on February 3, 1912, concerning a pulsating swelling at the root of her neck on the left side which filled up the hollow above her collar-bone. This swelling had existed for three years in spite of treatment. It pulsated and the pulsation was distensible. The swelling involved the second and third parts of the left subclavian artery and the tumour extended into the axilla, where it could easily be felt. At one place above the collar-bone the swelling seemed to be just under the skin and threatened to come through. The inner margin extended well under the outer border of the sterno-mastoid muscle. . . . Her doctor (W. H. Carse, of Rochdale) informed me that she had had marked endarteritis three years ago, when the vessels of her right arm were affected and her right radial pulse disappeared."

The patient was admitted to the Royal Southern Hospital March 2, 1912.

"On March 14 I tied the first part of her left subclavian artery.

"An incision 6 or 7 in. long was made down the line of the sterno-mastoid on to the sternum, taking the sterno-clavicular joint as the centre of the incision. A second incision was made at right angles to the first extending along the collar-bone. Flaps were turned up and the collar-bone was exposed at its inner end. This structure was cleared by dividing the clavicular portion of the sterno-mastoid, and a rib elevator was passed under it, followed by a Gigli's saw, with which the bone was divided, the sternal end being turned inwards and dissected out. A small vein connecting the internal and external jugulars was tied, but there was practically no bleeding. The sterno-hyoid muscle was defined with dissecting forceps and partially divided. The internal jugular was very large and there was a high innominate junction, so that these veins practically filled the floor of the wound. By working down on the inner side of the internal jugular, the common carotid was exposed with the pneumogastric nerve lying on its outer side and behind. The big veins were now retracted downwards and outwards, and by drawing the carotid to the inner side the subclavian was felt pulsating deep down between the two. A vein crossing this space was tied, but the inferior thyroid vein was left untouched, and

* "Oberst. Das Aneurysma der Subclavia. Beitr. z. klin. Chir., Tüb., 1904, xli, p. 459."

† "Rotter. Zwei Fälle von traumatischen Aneurysma. Zentralbl. f. Chir., Leipz., 1906, xxxiii, p. 783."

by scraping down with a blunt dissector the artery was exposed for a space of about three quarters of an inch. The sheath was opened and the vessel found to be quite healthy. An aneurysm needle was passed from the inner side armed with a catgut ligature, and by means of the latter a loop of thick silk was drawn under the vessel. The latter was secured by tying the silk in two places with just enough force to occlude the vessel without damaging its coats. These ligatures were placed one-half inch apart, but one end of each was left uncut, and these were tied together. A reef knot was used. Pulsation at once stopped in the aneurysm. The wound was closed without drainage, but the cavity was obliterated as much as possible by bringing divided structures together. The arm, which was quite warm, was wrapped in cotton-wool.

"The operation took 40 minutes, but was not hurried over, and it was not as difficult as might have been expected. . . . There was no hæmorrhage. The vessel lay very deep at a distance of from two and a half to three inches from the surface. . . . The subsequent history was uneventful as far as recovery went.

"On the 15th she was very well, and her right carotid pulse was 84; no pulsation could be felt in the left radial, but her fingers were warm, and she moved them easily. There was no tingling of the fingers. . . . On the 16th she complained of a little pain down the left arm. On the 21st . . . she had only a little tingling in her fingers. March 23d . . . the stitches were removed; the wound had healed, and the sac was hard and did not pulsate; she felt quite well and wanted to sit up. On April 5th . . . the aneurysmal swelling was smaller and decidedly softer, but there was no pulsation, and the swelling in the axilla was much smaller; there was no pulsation in the radial at the wrist. On April 15th there was a small ulcer over the lower part of the scar on the chest, and this was dressed. The swelling in the neck now felt like a soft cyst, and the axillary sac was smaller and harder. . . .

"On May 10th she returned home, exactly eight weeks after ligation of the vessel, there being no sign of pulsation in the sac, which was rapidly disappearing. She was able to raise her arm fairly well, and could place her hand to the back of her head. The small ulcer on the scar had practically healed. On June 8th I saw her; she was very well, and her only trouble was the limitation in the power of abduction. The aneurysm had practically disappeared, but her left hand was decidedly colder than her right. . . .

". . . This successful case is, of course, well known as the first, if not the only one, in this country. The vessel has, I believe, been tied by Halsted, J. K. Rodgers, and by Schumpert, but I am not familiar with the results of these cases. . . ."

Mr. Newbolt erred in believing that he was the first, in his country, to ligate the left subclavian artery in its first portion. Stonham reported a successful case in 1902 (*l. c.*, no. IX), and Browne another in 1911 (*l. c.*, no. XII). Sir Wm. Banks attempted the ligation in 1903 (*l. c.*).

PROF. WIETING. (XVI.) *Die Unterbindung der Arteria subclavia sin. in ihrem I. Abschnitt.* Zentralblatt f. Chirurgie, Leipzig, 1912, Bd. xxxix, p. 1156.

P. 1157. "Aneurysma spurium traumaticum A. subclaviæ durch S-Geschoss."

"December 26, 1911. The patient, male, *æt.* 35, . . . was shot in the left shoulder, the projectile entering the back at the upper inner angle of the shoulderblade. He immediately coughed up blood and was referred to the first aid military dressing station, whence two days later he was sent on foot to Gülhane, arriving in a weakened condition.

"*Examination.*—The entrance wound, about 1 cm. in diameter, is inflamed at the edges, and is situated behind at the upper inner angle of the left shoulderblade. There is no exit wound. The X-rays show the projectile behind about the middle of the clavicle. Above and on the clavicle, beginning about 3 cm. from the left sterno-clavicular articulation and reaching to the shoulder joint is a strongly pulsating tumor, about half the size of a goose egg. Ecchymosis extends over the whole left side of the neck to the nape, and downwards on the thorax to the pelvis. The pulsating swelling extends far into the depths towards the back, and can be felt to within a few centimeters of the entrance wound. The external jugular vein is visibly dilated. The radial pulse is absent, otherwise the nutrition of the arm, with the exception of slight venous hyperæmia, is not disturbed. But there is complete paralysis of the left arm up to and including the shoulder, while sensation is intact. The patient complains of shooting pains in the left arm.

"A few times there was expectoration of bloody sputum, but this has ceased. The left side of the thorax is completely filled with blood. General condition is tolerably good.

"*Diagnosis.*—Gunshot wound of the left subclavian artery above the clavicle with traumatic spurious aneurism; whether the subclavian vein is also wounded cannot be determined. Compression and perhaps partial laceration of the brachial plexus; wound of the left pleural apex and lung and a left-sided hemothorax.

"A compressive bandage was applied in order to promote the formation of collateral circulation. The pressure had no favorable influence on the aneurism itself; on the contrary it was extending towards the skin and towards the back, and also somewhat medially. Rupture through the skin, which is very thin over the tumor, appears imminent. Indication is vital.

"The plan of operation is to reach the left subclavian artery central to the aneurismal sac, to clamp it temporarily, and then to remove the hematoma, in order, if feasible, to close the wound in the vessel.

"First of all it was intended to search for the left subclavian artery near its origin from the arch of the aorta, using the common carotid artery as a guide. The internal jugular vein must be sacrificed, the

vagus nerve and the thoracic duct must be spared. The space central to the aneurism is small, hardly 3 cm. broad, therefore it is best to resect the clavicle centrally, in order to make room.

"In order to establish blood-depots the veins of both legs and of the left arm were occluded by a constricting bandage. The right arm was left free for pulse control and a possible infusion.

"*Operation.*—January 4, 1912. Incision over the left sterno-clavicular joint, beginning on the right at the inner end of the right clavicle; on the left, ending temporarily before the aneurism. Dissection of the left sternomastoid, and of the sterno-laryngo-hyoid-bone muscles with ligation of the neighboring veins. In the depths one can feel the pulsating dome-like sac projecting outwards and backwards. The external jugular vein, greatly compressed and thrust forward, was doubly ligated. Now the median end of the left clavicle was snapped off in pieces for 2 cm. with the cutting forceps, since, from behind, the aneurism left no space. In the same way, starting at the sterno-clavicular joint, a piece of the sternum was removed. Thus, the common carotid, the vagus nerve and the innominate vein were well exposed. The V. jug. comm.—huge at this point—was doubly ligated with celluloid thread 1 cm. above its junction with the subclavian vein and divided; the left vertebral vein was treated in the same manner. Now the subclavian artery, ascending in an arch, was well exposed. The thoracic duct was left outside and above, lying close to the aneurism. The common carotid artery with the vagus nerve was drawn strongly inwards with a blunt retractor, the innominate vein downwards. Compression of the ascending portion of the subclavian artery caused all pulsation in the aneurism to cease; for this reason a thick celluloid thread in a Deschamps needle was temporarily placed around the artery and a half knot made so that in case of need it could be drawn taut. The temporary clamping was done with the rubber-covered artery clamp of Höpfner-Stich.

"The skin incision was now lengthened superficially outwards to the shoulder, and the aneurism, which lay close under the skin, was opened wide. The projectile lay, dull end foremost, not far behind the clavicle near the inner edge of the sac. About 300 c.cm. of spongy black coagulum and fluid blood were evacuated with the finger from a cavity which was deep, extending almost to the nape, and behind the clavicle and first rib. . . . From the walls of the aneurismal sac there is moderately abundant arterial and venous bleeding, so that exploration of its great cavity is difficult. As the condition of the patient would not admit of prolonging the narcosis in order to search for the site of the wound, and since sewing it up at the great depth, although certainly possible, would be very uncertain and time-consuming, it was abandoned. The ligature around the subclavian artery was tied and this wound entirely sewed up. The aneurismal sac was firmly stuffed with gauze and the overlying skin temporarily closed. Pressure bandage over the wound.

"After the operation the patient was soon in good spirits. There was no cerebral disturbance. The left arm remained nourished as formerly. As the ligation was done central to the vertebral artery and the thyroid axis and likewise the internal mammary, the collateral circulation was assured.* The pains in the left arm diminished. Unfortunately on the following day marked paresis of the right arm was noticed, which was referable to the compression of the pressure-bandage on the right plexus. This paralysis, of which that of the radial nerve continued the longest, soon subsided.

"On the 8th day the outer stitches over the tampon were removed without hemorrhage. The great cavity is clean. New light tampon with iodoform gauze. Jan. 13, 1912. Very light tampon with new compress bandage. The left arm is somewhat swollen from too tightly drawn bandage. Jan. 16, 1912. The cavity is fast getting smaller, principally through expansion of the lung. In front pulmonary resonance, behind, dullness to the spine of the scapula.

"Two months after operation the patient left the hospital with the wound healed. Pulse in the radial artery is still absent. Motility in the left arm is slowly returning; fingers and elbow can be moved. Further news of the patient not obtainable."

The day is, I trust, near when to pack a wound in order to arrest hemorrhage except under compelling circumstances will be considered reprehensible.

V. GAUDIANI. (XVII.) *Ligation of the first part of the left subclavian for aneurysm.* Medical Record, New York, 1915, vol. lxxxvii, p. 331. New York Academy of Medicine, Stated meeting, held January 8, 1915.

"Dr. V. Gaudiani presented a man, 46 years old, who came under his care in May, 1913. He had had luetic infection 20 years before, but had never taken any treatment. A few months before he had noticed a pulsating tumor of the size of an egg rising from the sternal notch and extending behind the sternocleidomastoid muscle. He did not show any other trouble with the exception of an area of anæsthesia on the inner side of the forearm, and a dilatation of the left pupil. A murmur could be heard over the tumor; this was also audible along the axillary vessels. Although the case had been considered an in-

* An incorrect assumption, it seems to me, for the enumerated branches of the first portion had then been blocked on both sides, centrally by the ligature and distally by the stuffing in the aneurismal sac. A ligature applied distal to the origin of these branches would less have imperiled the circulation of the arm. The circulation would nevertheless be carried on by the anastomoses of these branches of the first portion of the subclavian. The closer the ligature, central or peripheral, to the sac the better. (W. S. H.)

operable one, Dr. Gaudiani advised a central ligation of the subclavian. The operation was performed under intra-tracheal insufflation to prevent possible pneumothorax. An incision was made from the manubrium of the sternum, curving upward over the sternocleidomastoid muscle, and reaching down the outer extremity of the clavicle. Such an incision was decided on because it would permit eventually the resection of the sternum or clavicle and allow also a peripheral ligature in case the central was not feasible. After the muscle had been cut through, the tumor appeared covered by the internal jugular and by the upper part of the vena anonyma. The former was ligated and severed and the latter was gently pulled down. By means of blunt dissection it was possible to penetrate behind the sternum, along the carotid, until central compression of the aneurism was possible. Such compression stopped the pulsation in the sac and the radial pulse. A silk ligature was passed and a stop knot was made. The patient made a good recovery and he could now attend to his duties in iron foundry work. No radial pulse could be felt. The stretching and isolation of the subclavian loop of the sympathetic nerve, known as the *ansa Vieussensi*, which surrounded the sac, could explain the mydriasis of the left pupil."

The aneurism seems to have been of the first portion of the subclavian; presumably no branches were given off between the ligature and the proximal pole. The patient made a good recovery and resumed work in a foundry. Nothing is said about the fate of the aneurism. He was observed seven months or less.

CARL A. HAMANN. (XVIII.) *Ligation of the first part of the left subclavian artery*. *Annals of Surgery*, Philadelphia, 1918, vol. lxviii, p. 219.

"E. R., aged 50 years, had an aneurism about 1 inch in diameter, involving the third portion of the left subclavian artery, which had been noticed for about one year; there were no marked evidences of pressure on the vein or nerves, though he had some pain. Wassermann reaction negative. There was a moderate degree of arteriosclerosis and the arch of the aorta was somewhat dilated.

"He was operated upon at Charity Hospital May 10, 1917.

"The third portion of the artery was exposed by the usual incision, and it was found that the dilatation extended beneath the scalenus anticus; this muscle was therefore divided after displacing the phrenic nerve. The subclavian and internal jugular veins and thoracic duct and vagus nerve were held aside and the first portion of the artery well exposed; it was somewhat dilated. A double ligature of braided silk was passed around the vessel and firmly tied. Pulsation in the sac ceased at once and did not return.

"The wound healed *per primam* and no disturbances in the circulation of the upper extremity, except for the absence of the pulse beyond the ligature, ever appeared. The sac contracted into a small firm mass and when last seen, four or five months afterwards, the patient was quite well.

"In this case the branches of the subclavian were not tied, as has been suggested and practised by a number of surgeons, in order to lessen the dangers of secondary hemorrhage."

Dr. Hamann did well to refrain from tying the branches of the subclavian. The danger of secondary hemorrhage is practically nil in the absence of infection and if the ligation is properly performed.

The first portion of the subclavian was so easily and so well exposed that it would seem to have coursed high in the neck. It is interesting to note that the artery was somewhat dilated at the site of the ligature. We have, I think, good reason to believe that the danger of ligating dilated or diseased arteries is overestimated. I have twice successfully ligated a dilated innominate artery, and Col. J. S. White has ligated the base of an aneurism without mishap (*vid.* Case No. XIX of our table).

J. SINCLAIR WHITE. (XIX.) *Traumatic aneurysm of the left subclavian artery: successful ligation at the junction of the first and second portions.* British Medical Journal, London, 1918, vol. ii, p. 131.

"The treatment of aneurysm of the left subclavian artery by ligature of the vessel always presents considerable difficulties, which are the greater the nearer the ligature is applied to the origin of the artery. From the experience of the following case I have been led to draw certain conclusions, which are set out at the end of the report.

"Pte. M., aged 35 years, sustained a gunshot wound of the chest on August 16th, 1917, at Ypres. The bullet entered behind to the left of the third dorsal vertebra and escaped just above the clavicle at a point corresponding to the junction of the middle and inner thirds of the bone. He spat blood for a day or two afterwards, but the wound progressed favourably, and on August 30th he was transferred to England. By September 3rd his wound was soundly healed. There was partial paralysis of the left deltoid muscle, for which daily massage and galvanism were prescribed. He continued to pick up until November 16th, when a pulsating swelling appeared at the root of the neck. It had all the characters of an aneurysm, and as it steadily increased in size, Colonel A. M. Connell, assisted by Major E. F. Finch, operated on December 8th. The swelling proved to be a saccular aneurysm arising from the second part of the subclavian artery. Owing to the dense matting of the tissues around the aneurysm the placing of a proximal ligature was not attempted. Instead a stout catgut

strand was tied around the base of the aneurysm where it sprang from the upper convex margin of the artery.

"This procedure was for a time followed by marked improvement, and both swelling and pulsation almost entirely disappeared. Then the aneurysm began to enlarge again, and by the end of December it had become obvious that, unless something further could be done, it was merely a question of how long he would live. In view of its position and the knowledge that one would have to conduct a deep dissection through tissues distorted by inflammatory exudate and containing vessels and nerves of the first importance, further operative measures could not be lightly entertained, but, as the alternative seemed wholly black, the facts of his case were placed clearly before him, and he elected to be operated on a second time. The operation took place on January 2nd, 1918, under chloroform anæsthesia given by Captain N. Milner. I had the valuable assistance of Major G. Wilkinson and Major E. F. Finch.

"*Operation.*—Jan. 2d, 1918. The steps of the operation were: (1) Removal of the scar of the first operation, together with some unhealthy granulation tissue. (2) Subperiosteal resection of the inner half of the clavicle. The sternal attachments of the bone were not divided, and the decorticated bone was made to pivot over to the right after being surrounded by gauze. (3) A long and tedious dissection involving the ligation and division of several veins, injury to the thoracic duct or one of its branches, from which much milky fluid escaped, and identification of the subclavian and internal jugular veins and the lower part of the scalenus anticus muscle. (4) Careful division of the scalene muscle with a small scalpel from without inwards. The fibres were divided close to the rib and very cautiously, taking especial care not to encroach on the anterior or internal portions of the muscle sheath. (5) The subclavian artery at the junction of its first and second portions was ligatured with a double strand of No. 1 Van Horn's catgut after it had been ascertained that occlusion of the artery at this point controlled the circulation in the aneurysm. (6) The displaced portion of the clavicle was fixed in position by strands of catgut passed through holes drilled in the bone, and the extensive wound closed by a series of superimposed catgut sutures, a small rubber tube being left in for 72 hours.

"Aseptic healing followed, and beyond a small mass of cicatricial tissue no local evidence of the aneurysm can be discerned.

"I am indebted to Captain J. E. Stacey for the notes of the case.

"The lessons which I have learnt from a study of this case are:

"1. To be prepared to meet with extraordinary difficulty in exposing the artery on account of inflammatory exudate caused by the bullet or shell fragment.

"2. The value—indeed I might say the necessity—of resecting the clavicle in order to secure adequate room.

"3. The advantage to be derived from dividing the scalenus anticus muscle in the way I have described. By the judicious use of small

retractors after its division it is possible to draw inwards the phrenic nerve and to displace the pneumogastric and sympathetic nerves, together with the other important structures lying to the inner side of the muscle, and so reach the distal part of the first portion of the artery."

Should this case be regarded as a ligation of the first portion of the artery? To question it is perhaps to quibble. Inasmuch as the clavicle and the scalenus anticus muscles were divided, it would have been quite as easy to ligate the artery definitely in its first portion unless the superior intercostal branch were just proximal to the site of ligation. In any event the operator did well to ligate, as I presume he did, distal to the superior intercostal artery and as close to the aneurism as feasible.

SIR CHARLES BALLANCE. (XX.) *A case of ligation of the first part of the left subclavian artery.* Journal of the Royal Army Medical Corps, London, 1918, vol. xxxi, p. 417.

"Private K., Dublin Fusiliers, aged 31, was admitted to Cottonara Hospital, Malta, under the care of Lieutenant-Colonel Dundon, R. A. M. C., on January 13, 1918, from Saloniki.

"*History.*—Before joining the Army he had been in the Navy, from which he was discharged; reason unknown. No history of syphilis. In July, 1916, he was wounded by a shrapnel bullet in the left supra-clavicular region. The wound was just above the middle of the clavicle and had healed. He had recently had an attack of tertian malaria.

"*On Admission.*—Patient complains of numbness and shooting pains in the left arm and hand with muscular weakness. A well pulsating tumour can be seen and felt above the left clavicle; an area of dullness continuous with this swelling extends for two inches below the inner half of the clavicle. The radial pulse can only just be felt at the wrist but the arm is quite warm. X-ray examination shows the presence of a tumour, part of which is in the chest cavity, and the rest, curving over the first rib, extends into the root of the neck. It seems more dense in the lower part, probably on account of organized bloodclot in the aneurysmal sac. A shrapnel bullet is lodged in the right side of the chest at the level of the seventh rib. It has not been definitely localized as there is no likelihood of its being removed. A diagnosis of aneurysm of the second and third portions of the left subclavian artery was made and it was decided to ligate the subclavian on the proximal side of the aneurysm. Antisyphilitic remedies had no effect.

"*Operation.*—February 4, 1918.—A general anæsthetic was given by Lieutenant-Colonel Shirley with the Vernon-Harcourt apparatus. An incision was made along the anterior border of the lower half of the sterno-mastoid down to the manubrium and another horizontally along the inner half of the clavicle. The common carotid artery, internal jugular vein, and vagus nerve were exposed in the middle of

the neck and the dissection was continued downwards, keeping well towards the middle line of the neck, as the wall of the aneurysm extended in this direction and was very thin. The fingers of the left hand protected the wall of the aneurysm from injury. More room was required, so the inner third of the clavicle was resected, by division with a Gigli saw and disarticulation at the sterno-clavicular joint. The dissection became increasingly difficult, the aneurysm and internal jugular vein had to be gently pressed outwards with the fingers while the common carotid artery and vagus nerve were retracted inwards with a copper retractor. The deeper part of the tumour was nearer the middle line than the superficial part; the vessel had probably been injured at the junction of the first with the second part, and the aneurysm had developed in front of the artery and displaced it and the dome of the pleura backwards as it increased in size. It had extended below the first rib through the upper opening of the thorax. At last the vertebral vein was recognized and behind it the artery was both seen and felt. It was cleared and ligated with three medium-sized strands of kangaroo tendon tied in a stay knot. Pulsation in the aneurysm immediately ceased. The patient left the table in good condition. I was admirably assisted in the operation by Captain James Anderson, R. A. M. C.

"*Progress.*—No untoward symptoms followed the operation and the wound healed throughout by first intention. Five weeks after operation the patient had an attack of malaria; tertian parasites were found in the blood. Tartar emetic (0.04 to 0.12 gramme) and quinine bihydrochloride (15 grains) were injected intravenously on alternate days. The fever did not recur.

"Radiograms taken after the operation show progressive consolidation of the aneurysm. This is most marked in the upper part. Before operation the part above the clavicle showed no defined border but only a fluffy edge from the constant pulsating movement during the exposure of the plate. In the later photograph taken some time after the operation this upper part shows a well-defined outline.

"With the contraction of the aneurysm the pain and weakness of the upper extremity exhibited week by week progressive improvement.

"No evident inconvenience resulted from the loss of the inner third of the clavicle; the arm, when he left the hospital, was in excellent condition and could be moved in any direction. The clavicle became fixed to the first rib.

"The rarity of ligation of the first part of the left subclavian gives an interest to this case."

W. S. HALSTED. (XXI.) (Pp. 6 to 11.)

SIR WILLIAM H. BANKS. *Unsuccessful attempt to ligate the first portion of the left subclavian artery.* Liverpool Medical Institute. Meeting of Dec. 18, 1902. *Lancet*, London, 1903, vol. i, p. 103.

"In the second case degeneration of the artery was unlikely, as the patient was a young, healthy man, the condition being due to a railway

crush. The aneurysm had spread into the neck and was as much subclavian as axillary. With the aid of his colleague, Mr. Paul, Sir William Banks made a strenuous attempt to ligature the first part of the left subclavian artery in the thorax; the pleura was a good deal injured and the patient died from pleurisy."

The above is the entire memorandum.

J. GARLAND SHERRILL. *Report of a case of aneurysm, with a new method of ligature of the left subclavian.* Transactions of the Southern Surgical and Gynecological Association, 1911, vol. xxiii, p. 190.

"In January 1910, a colored man, aged 30 years, was admitted to the hospital; family history negative; . . . chills and fever at the age of 19. . . . he had had occasional pain in the chest since August 1908. . . .

"In August, 1909, he was injured in the subclavian region of the left side by a wagon crank; followed within one month by a swelling in the same region, which remained a few weeks and became smaller; to be followed in a short time by another enlargement in the same region, which also remained about a month and became smaller. The present tumor began to enlarge about December 15, 1909, and had gradually increased in size. . . . At present he complains of pain and tenderness in the left shoulder, also suffers tenderness just above the spine of the left scapula and in the left axilla.

"When I first saw him about January 1, 1910, he had a pulsating tumor about the size of a small melon situated at the upper part of the thorax, extending from near the median line and just above the level of the clavicle downward and outward almost to the margin of the pectoralis major muscle. This tumor pulsated synchronously with the heart and was distinctly expansile in character. No distinct bruit could be heard over the tumor, but an accentuated second sound of the heart was easily detected. The patient had an almost imperceptible pulse in the left radial, and it was delayed somewhat compared to that of the right radial. The pulse of the left carotid was synchronous with that of the right radial. Patient had no tracheal tug; had no marked dyspnea, although he was more comfortable sitting up in bed. He had no cough and no interference with deglutition or respiration. A diagnosis of subclavian aneurysm was made, and the various methods of treatment were discussed with the patient and with several physicians in attendance.

"Distal ligation of the subclavian was considered inadvisable owing to the distance the tumor extended out upon the chest, and also because we believed that this measure would not prove curative. Ligature in the first portion anteriorly was not to be considered owing to the position of the tumor, which would have interfered greatly with the accomplishment of that step. After discussing the merits of wiring

the sac and the possibility of complete cure if we could successfully ligate the subclavian in the first portion of its course by attacking it from the posterior surface of the thorax, the patient decided to accept the latter method.

Operation.—On January 27, 1910, the subclavian was tied a short distance from its origin at the aorta. The operation was performed in the following manner: An incision was made along the posterior margin of the scapula about four inches long, dividing the skin and the muscles attached to the posterior portion of this bone. It was joined by an incision running inward from its inferior extremity to the spinous process. A similar incision was carried from its upper end in toward the spine. The soft tissues were dissected from the ribs with the skin and all hemorrhage controlled. The second, third and fourth ribs were removed for a distance of about three inches. The intercostal muscles were lifted off the pleura; the latter was gently pushed downward and outward with the finger, and the subclavian artery readily came into view as it left the aorta at the level of the fourth dorsal vertebra. A small opening was made in its sheath and the needle was readily carried around it and a No. 3 catgut ligature placed in position. At this point of the operation it was discovered by the assistants that the pulsation in the aneurysm did not cease. We then discovered, much to our disappointment, that the diagnosis as to the location of the aneurysm had not been correctly made. Further search revealed below the origin of the subclavian a rounded mass seemingly not larger than a small orange, which was pulsating. On discovering this, we decided that the ligature upon the subclavian, being useless, should be removed. This having been accomplished, the wound was closed and the patient left the table in good condition, and within an hour he was conversing freely with the attendants in the ward.

"Patient died February 7, 1910, on raising up suddenly in bed to eat his meal, although positively ordered not to make any sudden exertion. The postmortem demonstrated an aneurysm of the arch of the aorta in its lower portion, which had ruptured into the esophagus."

Interested in the unique and clever operative procedure and the puzzling and misleading physical signs, I wrote to Dr. Sherrill, who kindly replied as follows: "My case of ligature of the left subclavian was based on an incorrect reading of the skiagram and also on the fact that the pulsating mass was situated in the upper portion of the left chest over the site of the subclavian artery. There was present in this case a sacculated aneurism of the thoracic aorta which had a secondary sac extending upward and forward, and this simulated aneurism of the subclavian. To produce this secondary sac there must have been a small rupture and the wall of the secondary sac was found to be made up of connective tissue."

LIGATION OF THE FIRST PORTION OF THE LEFT SUBCLAVIAN ARTERY

No.	Operator and Publication	Sex and Age	Description of Tumor	Symptoms	Operation	Result	Comments
I	Rodgers, J. Kearny. Case of ligation of the left subclavian artery within the scalenus muscle, for aneurism. N. Y. Jour. of Med. & the Collateral Sciences, 1846, vii, p. 219.	M. at. 42.	Pulsating tumor, above the clavicle about the size of a hen's egg; it extended externally to the outer third of the clavicle and internally was covered by the outer edge of the sternomastoid. Cutaneous veins below sternal end of clavicle much enlarged.	Pains from axilla to finger-tips, so severe that patient cannot rest. Whole upper extremity swollen. Radial pulse unaffected.	Oct. 14, 1845. Tumor overlapped outer half of scalenus anticus. Subclavian artery ligated just internal to the scalenus muscle.	† Died on 15th day. Suppuration; secondary hemorrhages on 13th, 14th and 15th days.	May not the fact that the radial pulse was unaffected account in part for the great swelling of the arm in this case in which the aneurism was so small?
II	Marchesano, V. Legatura della succlavia sinistra fra la trachea e gli scaleni. L'Osservatore med., Palermo, 1875, s. 3, v, p. 327.	M. at. 34.	Profuse bleeding from wound made with a sharp instrument (chisel) a few hours before the operation.	Hemorrhage.	July 17, 1875. Division of the sternal and part of the clavicular portions of sternomastoid and of the inner half of scalenus anticus. Ligation of left subclavian artery about at junction of the first and second portions. Size and material of the ligature not stated.	† Died July 24 from "tremendous" hemorrhage.	Autopsy: The final hemorrhage had come from the subclavian at the site of the ligature which had cut completely through the vessel and had been applied distal to all the branches of the first portion. The posterior and suprascapular arteries sprang from a common trunk distal to the ligature. The original hemorrhage had come from the posterior scapular which had been cut with the chisel. No mention is made of the superior intercostal artery.
III	Lane, L. C. Ligations done for the cure of aneurism. Pacific Med. & Surg. Jour., San Fran., 1883-1884, xxvi, p. 145. Case II, p. 149.	M. age not stated.	Tumor two-thirds the size of a fetal head.	None given.	No dates given. Op. I.—Ligation between the scaleni muscles, closed wound. Op. II.—Two weeks later, for control of secondary hemorrhage, subclavian artery ligated proximal and close to the aneurism and also in its first part.	† Died from "exhaustion" 19 days after the first operation—5 days after the second operation. Patient had severe secondary hemorrhages. Infected wound.	The case is so briefly and indefinitely reported that one is not quite sure that the artery was ligated in its first part. The author states that he "threw a thread around" this portion. Fine silk used for the ligation of the subclavian was probably responsible for the first hemorrhage if the operator is correct in assuming that there was no infection.
IV	Bardenheuer, B. Die Verletzungen d. oberen Extremitäten. Deutsche Chirurgie, Stuttgart, 1886, Lief. 63a, Th. I, p. 445.	M. at. 47.	A very large, hard, quite freely movable tumor, believed to be carcinoma, in the left supraclavicular fossa. It extended to the midline and pushed the larynx far to the right; externally it touched the outer edge of the sternomastoid; below it disappeared behind the clavicle and manubrium. The carotid and subclavian arteries and the internal jugular and subclavian veins entered the tumor.	Radial pulse unaffected. No edema of arm, nor pressure upon nerves.	Date not given. Resection of inner half of clavicle, 5 cm. of first rib, and a piece of manubrium 5 x 4 cm. Subclavian vein doubly ligated and divided peripheral to tumor. Ligation also of internal jugular and innominate veins, of the carotid and subclavian (central and peripheral) arteries. The proximal ligature of the subclavian was placed 1½ cm. from the aortic arch. Excision of the tumor. The vagus nerve and the thoracic duct in the neck had to be divided in the neck.	† Died suddenly 18 hours after operation.	No pathological report.

LIGATION OF THE FIRST PORTION OF THE LEFT SUBCLAVIAN ARTERY.—CONTINUED

No.	Operator and Publication	Sex and Age	Description of Tumor	Symptoms	Operation	Result	Comments
V	Halsted, W. S. Ligation of the first portion of the left subclavian artery and excision of a subclavio-axillary aneurism. Johns Hopkins Hosp. Bull., Balt., 1892, iii, p. 93.	M. et. 52.	Spherical tumor above, behind, and below the clavicle, overlapping in front and almost concealing its middle third. The tumor's circumference at base measured 42 cm. Internally it extended to within 5 cm. of the left sterno-clavicular joint; externally, to within 4 cm. of the coracoid process. Pulsation in the tumor was feeble.	No pulse palpable at any point distal to the tumor. Left arm not swollen nor cooler than the right; shortness of breath; hoarseness; slight numbness in forearm and hand. Entire absence of pain.	May 10, 1892. Excision of inner third of clavicle; double ligation and division of subclavian artery in its first portion; excision of aneurism, the greater part of the remaining clavicle, a piece of the deltoid muscle and about 6 cm. of the subclavio-axillary vein and the first part of the axillary artery in one piece. A large dead space which could not be completely covered by skin was sealed with gutta percha tissue.	Cure.	The blood clot filling the dead space, only partly covered by skin, organized throughout. There was no swelling nor coldness of the extremity after the operation.
VI	Schumpert, T. E. Ligature of the left subclavian in its first part for aneurism of third. (Recovery.) Med. Rec., N. Y., 1898, liv, p. 338.	M. et. 56.	"An aneurism about the size of an orange involving the third part of the left subclavian artery."	Edema of shoulder and arm. Constant pain. No mention made of examination for loss of nerve-function. Radial pulse present—whether affected is not stated.	March 7 (year not given). Double ligation with No. 8 braided silk of the first portion of subclavian artery; the ligatures placed 1/16 inch apart. Clavicle not resected or divided. Wound completely closed. Collodion dressing.	Recovery. No statement in regard to the ultimate effect on the aneurism.	Patient observed for only 9 weeks. The edema of the arm, shoulder and hand had entirely vanished; the radial pulse had not reappeared. Interesting to note that when the radial pulse is present and the subclavian vein obstructed the edema may be greater than in the cases of obliterated radial pulse (cf. preceding case).
VII	Kammerer, F. Ligature of the first portion of the left subclavian artery for aneurism; death after 4 weeks. Med. Rec., N. Y., 1899, lvi, p. 924.	M. et. 47.	Pulsating tumor as large as a man's fist in left supra-clavicular fossa external to and under the sternomastoid muscle.	Radial pulse "scarcely retarded." Numbness of third and fourth fingers. No preoperative statement in regard to swelling of the arm.	Oct. 18, 1899. Resection of 2 inches of left clavicle, 1 1/2 inches of right clavicle, 2 in. of 1st left rib and a part of the manubrium. Ligation of the left subclavian artery 1 inch from its origin.	Died 1 month after operation from secondary hemorrhages. No statement in regard to effect of the operation upon the aneurism.	Death was probably due to unequal absorption of the several strands of the catgut ligature—to a cutting through of the final strand which may or may not have totally occluded the artery. There was no swelling of the arm in consequence of the ligation—whether swollen before operation is not stated.
VIII	Jüngst. Ein geheilter Fall von Unterbindung d. Arteria subclavia sin. am Aortenbogen. Beitr. z. klin. Chir., Tub., 1902, xxiv, p. 307. Philipp, J. A. Unterbindung d. Arteria subclavia in ihrem ersten Abschnitt nach Schussverletzung. Inaug. Diss., Leipz., 1900, p. 17.	F. et. 35.	"The whole supraclavicular region is filled with a hard soft swelling." Neither bruit nor pulsation perceptible. Pea-sized bullet wound about 2 cm. from sternal end of left clavicle. No exit wound.	Radial and ulnar pulses unaffected; upper arm quite swollen. Pains in shoulder radiating to arm. "Sensation of skin to touch, temperature and pain much diminished—in places absent." "Complete motor paralysis."	July 24, 1899. Resection of sternal third of clavicle and of the whole manubrium. Ligation with silk of subclavian 1 1/2 to 2 cm. from its origin, also on each side of slit, made by a bullet, "precisely at the point where the artery emerges from between the scaleni." The entire large wound was stuffed with gauze. Severe hemorrhages occurred during the operation.	Recovery and cure. Convalescence stormy. Thoracic duct wounded. Maceration of skin of neck and back. Marked thirst while flow of chyle continued. Complete paralysis of left recurrent nerve. Mobility of upper arm regained quickly; of forearm and hand slowly.	Wound cavity stuffed with gauze down to aortic arch.

LIGATION OF THE FIRST PORTION OF THE LEFT SUBCLAVIAN ARTERY.—CONTINUED

No.	Operator and Publication	Sex and Age	Description of Tumor	Symptoms	Operation	Result	Comments
IX	Stonham, C. A case of aneurism of the second and third parts of the left subclavian artery; ligation of the first part, etc. Lancet, Lond., 1902, ii, p. 291.	M. et. 43.	Swelling size of a duck's egg in left supraclavicular fossa extending inwards to middle of sternal part of sternomastoid. Expansile pulsation and bruit.	Radial pulse unaffected. No mention is made of pain or swelling or impairment of function.	Op. I. Apr. 26, 1899. Resection of 1 inch of sternal end of clavicle. Ligation with floss silk of the first portion of a presumably rather high subclavian artery. The ligature "was situated behind the sternoclavicular joint about $\frac{1}{2}$ in. from the aneurismal sac. Gauze drain." Pulse in the sac and radial artery "arrested." Op. II. June 28, 1899. Ligation of the vertebral, inferior thyroid and third part of axillary arteries; wound packed with gauze.	Cure.	Pulse in radial distinct in 24 hours, and in sac in 4 days post op. I. Gradual increase in size of aneurism. Hand became swollen; pain; impairment of finger motions. The ligation of the vertebral and inferior thyroid arteries at the second operation did not arrest the pulsation of the sac. The axillary artery was therefore ligated "just above" the subscapular branch and thereupon pulsation in the sac and brachial and radial arteries ceased. This is the only aneurism of the spontaneous variety on our list not cured by the ligation of the subclavian. May not this aneurism have been due primarily to a cervical rib (vid. discussion in text)?
X	Banks, Sir Wm. [Attempted ligation of the first portion of the left subclavian artery.] Lancet, Lond., 1903, i, p. 103.	"Young healthy man."	"The aneurism, due to a railway crash, had spread into neck and was as much subclavian as axillary."	Date not given. "Made a strenuous attempt to ligature the first part of the left subclavian artery in the thorax; the pleura was a good deal injured and the patient died from pleurisy." The attempt was unsuccessful.	Pleurisy.	The operator probably merely freed the last two cervical pairs, it being hardly conceivable that he would have resected them. It is interesting to note that the freeing of the nerves entirely relieved the pains. It would seem that the sac should have been excised rather than tamponed.
X	Delbet, P. Aneurisme de la sous-clavière gauche. Bull. et mêm. soc. de chir., Paris, 1910, xxxvi, p. 1114.	M. age not given.	Traumatic aneurism in supra-clavicular fossa. Size and precise situation of tumor not specified.	Terrible neuralgic pains relieved by "resection of the last two cervical pairs." Radial pulse absent. No mention of swelling.	Date not given. Exposure of sac; resection of inner third of clavicle and a part of the manubrium; ligation of subclavian within the thorax and also distal to the sac; "formidable hemorrhage" on opening sac before the distal subclavian was tied. Permanent tamponage of sac to control bleeding.	Recovery. Paralysis persists. Nutrition of limb unimpaired.	
XI	Pierre Duval, Reported by Schwartz, Ed. Enorme anévrisme diffus du cou et de la région sous-claviculaire. Paralyse du membre sup. gauche. Compression du récurrent gauche. Bull. et mêm. soc. de chir., Par., 1910, xxxvi, pp. 874, 1138.	M. et. 31.	Enormous, tense, fluctuant tumor reaching from clavicle to jaw and displacing larynx and trachea. There was neither pulsation nor bruit. Diagnosis: traumatic aneurism.	Temporal pulse hardly perceptible; radial pulse enfeebled; complete paralysis of limb (edema not mentioned); raucous, inaudible voice; dysphagia; ptosis, myosis and enophthalmus.	Aug. 8, 1910. Resection of inner half of the clavicle, of left half of manubrium and of the first costal cartilage; arch of aorta exposed; precautionary loops within thorax about carotid and subclavian; incision of aneurism; subclavian found to be cut across at the inter-nal border of 1st rib; ligation of the two ends. Time, 50 minutes.	† Died suddenly a few hours post op.	Duval believed that death was due to embolus originating from clot at site of temporary ligation of carotid. I am unable to share this belief. Duval very briefly describes the operation in a letter to Schwartz. Whether the precautionary loop about subclavian was tied is not stated. In any event the proximal ligature must have been on the first portion.

LIGATION OF THE FIRST PORTION OF THE LEFT SUBCLAVIAN ARTERY.—CONTINUED

No.	Operator and Publication	Sex and Age	Description of Tumor	Symptoms	Operation	Result	Comments
XII	Browne, Capt. C. G. A case of diffuse traumatic aneurysm and ligation of the first part of the subclavian. Brit. Med. Jour., Lond., 1911, ii, p. 1534.	M. age not given.	Bayonet wound of left axilla. "Collection of blood in the subclavicular region and inner part of the axilla."	Left radial pulse equal to right. Arm swollen.	Aug. 28, 1911. Subclavian artery "descending vertically along the inner border of scalenus anticus" was ligated. Cervical wound drained. Axilla opened, clots removed, drainage tube inserted.	Cure.	The better the pulse and the greater the obstruction to the veins the greater, naturally, should be the swelling of the limb. The high course of the artery suggests cervical rib or its Anlage. As there was no pulsation in the axillary hematoma and no hemorrhage after eversion of the clots it is improbable that the axillary artery had been pierced by the bayonet. Possibly only a vein was injured. Ligation of the subclavian was perhaps not indicated.
XIII	Neff, J. M. Ligation of the first portion of the left subclavian artery. Ann. of Surg., Phila., 1911, liv, p. 503.	M. at. 23.	The operation was for hemorrhage from a hole in the subclavian artery discovered in the course of a dissection for the removal of cervical glands.	Op. I. Feb. 12, 1910. Two clamps placed on either side of a "hole" in the subclavian artery discovered at end of operation for excision of cervical glands. Drainage tube. Op. II. March 4, 1910. Clavicle divided about 1 1/4 inches from sternum and ends retracted downwards. Ligation of subclavian 3/4 inch above aortic origin; permanent clamp placed on the artery 1/4 inch distal to the ligature; double-silk ligature distal to defect in subclavian, and proximal to this another permanent hemostat; ligation of thyroid axis, vertebral and internal mammary arteries.	Recovery. Marked atrophy and weakness of limb; sensation abolished for 4 months post op. Ultimate restoration of function.	How remarkable that the operator should have left the clamps hanging in the wound when he might have ligated the subclavian on either side of the "hole" in the artery! (vid. text for further comments). The thyroid axis, vertebral and internal mammary arteries were ligated because the first portion of the subclavian was too soft to admit of ligation. The softness may well have been due in part to the infection and the permanent hemostat.
XIV	Rubritius, H. Die chir. Aneurysmen d. Arteria subclavia. Beitr. z. klin. Chir., Tüb., 1911, lxxvi, p. 144.	M. at. 21.	Stab wound. "In the left supraclavicular region there is a pulsating tumor the size of a fist at the summit of which, close to the outer edge of the sternomastoid, there is a scar about 1 cm. long." Systolic bruit, audible also over axillary artery. At operation it developed that the aneurysm was of the second part of the subclavian.	Left pulse slightly weaker than right. Left arm somewhat cyanotic.	Op. I. Oct. 5, 1909. Clavicle sawed through at middle, and sternal half removed; resection of the left half of manubrium and 4 cm. of first rib. Pleura wounded. Rubber tube carried around first portion of the artery and twisted at intervals during next 24 hours in order to make the occlusion gradual. Drainage. Op. II. Oct. 27. Rubber tube replaced by 2 silk ligatures. Some days later drainage of left empyema. Op. III. Apr. 25, 1910. Resection of seventh, eighth, ninth and tenth ribs (thoracoplasty) for empyema.	Recovery. Nov. 16, 1909: "At site of aneurismal tumor one feels a firm mass." No subsequent note in regard to tumor.	I have found no evidence to sustain the fear that gangrene may follow the ligation of any portion of either subclavian artery. There was therefore no indication for the attempt to occlude the artery gradually, and particularly none by a method which superimposed the danger from infection of the wound. The gangrene which followed the difficult and brilliantly executed operation of Matas for arterio-venous fistula of the right subclavian vessels seems quite unquestionably to have been due to the fact that a fistula had existed for some days prior to the operation. The ligation of the branches of the first and second portions of the subclavian artery may have been a contributing factor. The existence of a fistula may retard the development of the anastomotic circulation.

LIGATION OF THE FIRST PORTION OF THE LEFT SUBCLAVIAN ARTERY.—CONTINUED

No.	Operator and Publication	Sex and Age	Description of Tumor	Symptoms	Operation	Result	Comments
	Sherrill, J. G. Report of a case of aneurysm, with a new method of ligation of the left subclavian. Trans. Southern Surg. & Gyn. Assn., 1911, xxiii, p. 190.	M. et. 30.	The operation was undertaken for "a pulsating tumor about the size of a small melon situated at the upper part of the thorax, extending from near the median line and just above the level of the clavicle downward and outward almost to the margin of the pectoralis major muscle." No bruit.	Pain and tenderness in the left shoulder; tenderness above spine of scapula and in the left axilla. Left radial pulse almost imperceptible.	Jan. 27, 1910. Resection in the back of about 3 inches of the second, third and fourth ribs. Left subclavian artery ligated extra-pleurally near its origin with No. 3 catgut. As pulsation in the aneurism was unaffected by this ligation and it was discovered that a diagnostic error had been made the ligature was removed. "Further search revealed below the origin of the subclavian a rounded mass, seemingly not larger than a small orange, which was pulsating." Wound closed.	"Patient died Feb. 7, 1910, on raising up suddenly in bed." "The postmortem demonstrated an aneurism of the arch of the aorta in its lower portion, which had ruptured into the esophagus."	As Dr. Sherrill removed the ligature on discovering that the aneurism was not of the subclavian artery, his case, well worth recording, is entitled only to be classed with the cases of temporary ligation. The novel method of operative approach (from the back) is notable. It was adopted because the location of the supposed aneurism seemed to block the usual route.
XV	Newbolt, G. P. A case of aneurysm of the second and third parts of the left subclavian artery in a woman. Brit. Med. Jour., Lond., 1912, ii, p. 867.	F. et. 50.	Pulsating swelling involving the second and third parts of the subclavian artery and extending into the axilla.	March 14, 1912. Resection of sternal end of clavicle. Subclavian tied in its first portion by two silk ligatures placed $\frac{1}{2}$ inch apart. Effort made not to damage the arterial wall in tying. One end of each ligature was left uncut and the two threads were then tied together. Pulsation in aneurism stopped. Wound closed without drain.	Recovery. March 15: No pulse in radial; fingers warm. Apr. 15: "Swelling in neck felt like a soft cyst, and the axillary sac was smaller and harder." June 8, 1912: "The aneurism had practically disappeared, but her left hand was decidedly colder than the right." There is no further note.	Have we reason to believe that two ligatures $\frac{1}{2}$ inch apart are safer than one? Possibly the second (distal) ligature might safeguard the first by taking off the back-pressure but this pressure would probably be slight unless there were a branch distal to and near the proximal ligature.
XVI	Wieting, Prof. Die Unterbindung d. Arteria subclavia sin. in ihrem I. Abschnitt. Zentralb. f. Chir., Leipz., 1912, xxxix, p. 1156.	M. et. 35.	Dec. 24, 1911. Shot in back at upper angle of left scapula. "Above and on the clavicle, beginning about 3 cm. from left sternoclavicular articulation and reaching to the shoulder-joint is a strongly pulsating tumor about half the size of a goose egg. Ectymosis extends over the whole left side of the neck to the nape, and downwards on the thorax to the pelvis. The pulsating swelling extends far into the depths towards the back and can be felt to within a few cm. of the entrance wound."	Radial pulse absent; arm not swollen. Complete paralysis of the limb including shoulder; sensation intact; shooting pains. Left side of thorax filled with blood. Bloody sputum.	Jan. 4, 1912. Blood deposits established in both legs and left arm. Resection of sternal end of clavicle and a piece of sternum. Double ligation and division of internal jugular and vertebral veins. Thick celluloid thread provisionally passed around the first portion of the subclavian artery. Temporary occlusion with rubber-covered Höpfer-Stich clamp. Aneurism opened wide, clots removed. Quite abundant hemorrhage, hence exploration of the great cavity difficult. The precautionary ligature was tied, the sac stuffed firmly with gauze, and the wound closed.	Recovery. Radial pulse still absent. Two months post op., "Mobility slowly returning; fingers and elbow can be moved. Further news of patient not obtainable."	To pack a wound to arrest hemorrhage, particularly one in which a large artery has been tied, is inadvisable; it is also a confession of defeat.
XVII	Gaudiani, V. Ligation of the first part of the left subclavian for aneurysm. Med. Rec., N. Y., 1915, lxxvii, p. 331.	M. et. 46.	"Pulsating tumor the size of an egg" behind the sternal notch and under the left sternomastoid. Murmur over tumor; audible also over axillary artery.	Anesthesia of inner side of forearm and dilation of the left pupil. Radial pulse present.	May, 1913. Intratracheal insufflation. Ligation and division of internal jugular. Ligation of the first portion of subclavian artery with a silk ligature.	Recovery.	

LIGATION OF THE FIRST PORTION OF THE LEFT SUBCLAVIAN ARTERY.—CONTINUED

No.	Operator and Publication	Sex and Age	Description of Tumor	Symptoms	Operation	Result	Comments
XVIII	Hamann, C. A. Ligation of the first part of the left subclavian artery. Ann. of Surg., Phila., 1918, lxviii, p. 219.	M. at. 50.	Aneurism about 1 inch in diameter of the second and third portions of the left subclavian artery; this tumor had been noticed for about one year.	Some pain; "no marked evidences of pressure on the vein or nerves."	May 10, 1917. Scalenus anticus muscle divided. "A double ligature of braided silk was passed around the vessel and firmly tied. Pulsation in the sac ceased and did not return."	Recovery. Four or 5 months post operation the sac had contracted into a small firm mass; the patient was quite well.	The subclavian artery seems to have coursed high in the neck, and the ligation of its first portion to have been simplified in consequence. We have in mind the possibility of cervical rib or its Anlage.
XIX	White, J. S. Traumatic aneurysm of the left subclavian artery; successful ligation at the junction of the first and second portions. Brit. Med. Jour., Lond., 1918, ii, p. 131.	M. at. 35.	Gunshot wound Aug. 16, 1917. Pulsating swelling appeared Nov. 16. Small sacular aneurism of second portion of subclavian.	No mention of symptoms from pressure upon nerves or vessels. As the neck of the sac was between the scaleni the cords of the brachial plexus would presumably have been compressed.	Op. I. Dec. 8, 1917. Col. A. M. Connell. Proximal ligature not attempted owing to dense matting of tissues. Strand of stout catgut tied around base of aneurism where it sprang from the upper convex margin of the artery. Op. II. Jan. 2, 1918. J. S. White. Clavicle divided, inner half pivoted to right; scalenus anticus severed. Subclavian ligated at junction of first and second portions with double strand of No. 1 Van Horn's catgut. Ends of clavicle sutured with catgut. Rubber drainage tube for 72 hours.	Recovery.	The improvement following ligation of neck of sac was of very brief duration. The second operation should not, perhaps, be classed as a frank ligation of the first portion. As no mention is made of the superior intercostal I assume that the ligation was external to this branch.
XX	Ballance, Sir C. A case of ligation of the first part of the left subclavian artery. Jour. Roy. Army Med. Corps, Lond., 1918, xxxi, p. 417.	M. at. 31.	July, 1916. Wound by shrapnel bullet. Jan., 1918. Small pulsating tumor in supraclavicular fossa; dullness for 2 inches below clavicle. <i>Vid.</i> original paper for radiograms and sketches. Diagnosis: aneurism of second and third portions.	Numbness, shooting pains, weakness; faint radial pulse; arm warm; no mention of swelling.	Feb. 4, 1918. Resection of inner third of clavicle. Discovery made that the artery had probably been wounded at junction of first and second portions. Ligation of subclavian artery behind the vertebral vein, with three medium-sized strands of kangaroo tendon; stay-knot. Pulsion in aneurism ceased. No mention made of drainage. Healing throughout <i>per primam</i> .	Recovery. Progressive improvement in function. Aneurism solidifying. "The clavicle became fixed to the first rib."	This is the only case, Gaudiani's excepted, in which the point of origin of the aneurism was so far inwards as the junction of the first and second portions.
XXI	Halsted, W. S. Intrathoracic ligation of the left common carotid artery and of the first portion of the left subclavian artery for huge subclavian aneurism. Johns Hopkins Hosp. Surg. Hist. No. 46179.	M. at. 29.	Patient was shot in neck about 4 years before admission; 3 years later first noticed a swelling above the clavicle. A huge aneurism of the left neck extending from clavicle to ear; the pulsating tumefaction extends on to the chest and posteriorly spreads out to a point below the spine of the scapula; the clavicle is eroded completely through at about its middle; the head is deflected and rotated to the right; the larynx and trachea displaced. <i>Vid.</i> photographs. The soft parts all about the aneurism are infiltrated.	Paralysis, almost total, of motion and sensation. Very severe pain from shoulder to fingers. Radial pulse absent; arm swollen. The whole body is jarred with each pulsation.	Op. I. Apr. 26, 1918. Ligation of left common carotid and left subclavian arteries near their origins. Wound sealed. Op. II. Apr. 10, 1920. Excision of the sac which had become reduced to about the size of a small fist, but was beginning to enlarge. Wound sealed.	Recovery. Apr. 20, 1920; Paralysis slowly but steadily diminishing; sensation improving. Patient can flex and extend elbow, abduct shoulder, and move, slightly, the flexed fingers.	Primary healing of the wounds. This is probably the largest subclavian aneurism ever operated upon.

BIBLIOGRAPHY

1. Babinski, J., and Heitz, J.: Hyperthermie locale du membre supérieur, après résection d'un anévrisme axillaire, chez un blessé présentant une paralysie complète du plexus brachial du même côté. *Bull. et mém. Soc. méd. d. hôp. de Paris*, 1916, 3me. s., xl, 2324.
2. Ballance, Sir Charles: A case of ligation of the first part of the left subclavian artery. *Jour. Roy. Army Med. Corps, Lond.*, 1918, xxxi, 417.
3. Ballance, C. A., and Edmunds, W.: A treatise on the ligation of the great arteries in continuity, with observations on the nature, progress and treatment of aneurism. London, 1891.
4. Banks, Sir William H.: [Unsuccessful attempt to ligate the first portion of the left subclavian artery.] *Lancet, Lond.*, 1903, i, 103.
5. Bardenheuer, B.: Die Verletzungen der oberen Extremitäten. *Deut. Chir., Stuttgart*, 1886, Lieferung 63a, Theil I, p. 445.
6. Bean, R. B.: A composite study of the subclavian artery in man. *Amer. Jour. of Anat., Balto.*, 1905, iv, 303.
7. Braithwaite, L. R.: Excision of a subclavian aneurysm. *Brit. Jour. of Surg.*, 1920, vii, 390.
8. Browne, C. G.: A case of diffuse traumatic aneurysm and ligature of the first part of the subclavian. *Brit. Med. Jour., Lond.*, 1911, ii, 1534.
9. Carnochan, J. M.: Elephantiasis Arabum of the right inferior extremity, successfully treated by ligature of the femoral artery. *New York Jour. Med. and the Collateral Sciences*, 1852, ix, 161.
10. Cooper, Sir Astley: Reported in *The London Medical Review*, 1809, ii, 300: *Medical and Surgical Intelligence*, Art. 2.
Reported by Dr. Mott: Case of subclavian aneurism, which occurred in Guy's Hospital, London; communicated to Dr. Miller, by Valentine Mott, M. D., Corresponding Member of the Medical Society of London, etc. *The Medical Repository, N. Y.*, 1810, third Hexade, vol. i, p. 331.
11. Delbet, P.: Anévrisme de la sous-clavière gauche. *Bull. et mém. Soc. de Chir., Paris*, 1910, xxxvi, 1114.
12. Delbet, P., and Mocquot, P.: Affections chirurgicales des artères. Being Vol. xi of *Nouveau traité de chirurgie*, published under the direction of A. le Dentu and P. Delbet. Paris, 1911.

13. Dreist, K.: Ueber Ligatur und Kompression der Arteria iliaca communis. *D. Zeit. f. Chir.*, Leipzig, 1904, lxii, 5.
14. Dünow, K. F. E.: Durch Exstirpation geheilter Fall eines traumatischen Aneurysma der Arteria subclavia mit Bemerkungen über die operative Behandlung dieser Aneurysmen. *Inaug.-Diss.*, Heidelberg, 1904.
15. Duval, P.: Anévrisme de l'artère sous-clavière droite. Extirpation du sac après résection temporaire de la clavicule. Ligature latérale de la veine sous-clavière. Guérison. *Bull. et mém. Soc. de Chir.*, Paris, 1910, xxxvi, 420.
16. *Idem*: Schwartz, *Bull. et mém. Soc. de Chir.*, Paris, 1910, xxxvi, 874, 1138.
17. Gaudiani, V.: Ligation of the first part of the left subclavian for aneurysm. *Med. Rec.*, N. Y., 1915, lxxxvii, 331.
18. Gurlt, E.: *Geschichte der Chirurgie und ihrer Ausübung*. Berlin, 1898.
19. Halsted, W. S.: Ligation of the first portion of the left subclavian artery and excision of a subclavio-axillary aneurism. *Bull. of The Johns Hopkins Hospital*, Balto., 1892, iii, 93.
20. *Idem*: Clinical and experimental contributions to the surgery of the thorax. *Trans. Amer. Surg. Assn.*, Phila., 1909, xxvii, 111.
21. *Idem*: The effect of ligation of the common iliac artery on the circulation and function of the lower extremity. Report of a cure of ilio-femoral aneurism by the application of an aluminum band to that vessel. *Bull. of The Johns Hopkins Hospital*, Balto., 1912, xxiii, 191.
22. *Idem*: A striking elevation of the temperature of the hand and forearm following the excision of a subclavian aneurism and a part of the third portion of the left subclavian artery. *Bull. of The Johns Hopkins Hospital*, Balto., July, 1920, xxxi, 219.
23. Hamann, C. A.: Ligation of the abdominal aorta: ligation of the first portion of the left subclavian. *Annals of Surgery*, Phila., 1918, lxviii, 217.
24. Jacobsthal, H.: Beiträge zur Statistik der operativ behandelten Aneurysmen. II. Das Aneurysma der Arteria subclavia. *D. Zeit. f. Chir.*, Leipzig, 1903, lxviii, 239.
25. Jüngst, of Saarbrücken: Ein geheilter Fall von Unterbindung der Arteria subclavia sinistra am Aortenbogen. *Beitr. z. klin.*

- Chir., Tübingen, 1902, xxxiv, 307. (Also reported by Philipp, J. A.: Unterbindung der Arteria subclavia in ihrem ersten Abschnitt nach Schussverletzung. Inaug.-Diss., Leipzig, 1900, p. 17.)
26. Kammerer, F.: Ligature of the first portion of the left subclavian artery for aneurism; death after four weeks. *Med. Rec.*, N. Y., 1899, lvi, 924.
 27. Koch, W.: Ueber Unterbindungen und Aneurysmen der Arteria subclavia. *Arch. f. klin. Chir.*, Berlin, 1869, x, 195.
 28. Köhler, A.: Beiträge zur Geschichte der Exstirpatio aneurysmatis. *Arch. f. klin. Chir.*, Berlin, 1906, lxxxi, Theil I, p. 333.
 29. Lane, L. C.: Ligations done for the cure of aneurism. *Pacific Med. and Surg. Jour.*, San Fran., 1883-84, xxvi, 145.
 30. Leriche, R.: Du syndrome sympathique consécutif à certaines oblitérations artérielles traumatiques et de son traitement par la sympathectomie périphérique. *Bull. et mém. Soc. de Chir.*, Paris, 1917, xliii, 310.
 31. Leriche, R., and Heitz, J.: Résultats de la sympathectomie péri-artérielle dans le traitement des troubles nerveux post-traumatiques d'ordre réflexe (type Babinski-Froment). *Lyon Chir.*, Paris, 1917, xiv, 754.
 32. Makins, Sir George Henry: Gunshot injuries of the arteries. The Bradshaw Lecture. London, 1914.
 33. *Idem*: On gunshot injuries to the blood-vessels. Founded on experience gained in France during the Great War, 1914-1918. New York, 1919.
 34. Marchesano, V.: Legatura della succlavia sinistra fra la trachea e gli scaleni. *L'Osservatore medico*, Palermo, 1875 (anno 18), s. 3, vol. v, p. 327.
 35. Matas, R.: Traumatic arterio-venous aneurysms of the subclavian vessels, with an analytical study of fifteen reported cases, including one operated upon. *Jour. Amer. Med. Assn.*, Chicago, 1902, xxxviii, 103, 173, 242, 318.
 36. *Idem*: Surgery of the vascular system. Being Chapter lxx in Keen's Surgery, Phila., 1909, vol. v.
 37. Monod, Ch., and Vanverts, J.: Du traitement des anévrismes artériels. Documents et remarques. *Rev. de Chir.*, Paris, 1910, xli, 784, 1098; *ibid.*, 1910, xlii, 163, 407.
- Mott, Valentine: Reports Sir Astley Cooper's case, *Medical Repository*, N. Y., 1810, third Hexade, vol. i, p. 331.

38. Moynihan, B. G. A.: A case of subclavian aneurism treated by excision of the sac, with remarks on the ligation of the innominate artery and on the treatment of aneurism. *Annals of Surg.*, Phila., 1898, xxviii, 1.
39. Neff, J. M.: Ligation of the first portion of the left subclavian artery. With report of a recent successful case. *Annals of Surg.*, Phila., 1911, liv, 503.
40. Newbolt, G. P.: A case of aneurysm of the second and third parts of the left subclavian artery in a woman. *Brit. Med. Jour.*, Lond., 1912, ii, 867.
41. Norris, G. W.: Table showing the mortality following the operation of tying the subclavian artery. *Amer. Jour. Med. Sci.*, 1845, n. s. x, 13.
42. Oberst, ———: Das Aneurysma der Subclavia. *Beitr. z. klin. Chir.*, Tüb., 1904, xli, 459.
43. v. Oppel, W. A.: Zur operativen Behandlung der arterio-venösen Aneurysmen. *Arch. f. klin. Chir.*, Berl., 1908, lxxxvi, 31.
44. Osler, Sir William: Remarks on arterio-venous aneurysm. *Lancet*, Lond., 1915, i, 949.
45. Philipp, J. A.: Unterbindung der Arteria subclavia in ihrem ersten Abschnitt nach Schussverletzung. *Inaug.-Diss.*, Leipzig, 1900, p. 17. (Reports Jüngst's case.)
46. Poland, A.: Statistics of subclavian aneurism. *Guy's Hosp. Rep.*, Lond., 1870, 3d s., xv, 47. Statistical report on the treatment of subclavian aneurism. *Guy's Hosp. Rep.*, 1871, 3d s., xvi, 1; 1872, 3d s., xvii, 1.
47. Propping, K.: Ueber die Ursache der Gangrän nach Unterbindung grosser Arterien. *Münch. med. Wochenschr.*, 1917, lxiv, 598.
48. Purmann, Matthäus Gottfried. *Chirurgia curiosa*, ed. 1716.
49. Rodgers, J. K.: Case of ligature of the left subclavian artery within the scalenus muscle, for aneurism. *New York Jour. of Med. and the Collateral Sciences*, 1846, vii, 219.
50. Rubritius, H.: Die chirurgische Behandlung der Aneurysmen der Arteria subclavia. *Beitr. z. klin. Chir.*, Tüb., 1911, Bd. 76, p. 144.
51. Savariaud, M.: Le traitement chirurgical des anévrysmes de l'artère sous-clavière. *Rev. de Chir.*, Paris, 1906, xxxiv, 1.
52. Schopf, F.: Zur Aneurysma Behandlung. *Wiener klin. Wochenschr.*, 1891, iv, 840.

53. Schumpert, T. E.: Ligature of the left subclavian in third part for axillary aneurism—recovery—ligature of the innominate for innominate aneurism—also left subclavian in its first part for aneurism of third part—recovery. *Med. Rec., N. Y.*, 1898, liv, 338.
54. Schwartz, E.: Enorme anévrisme diffus du cou et de la région sous-claviculaire. Paralysie du membre supérieur gauche. Compression du récurrent gauche. *Bull. et mém. Soc. de Chir., Paris*, 1910, xxxvi, 874; Anévrisme diffus traumatique de la sous-clavière gauche. *Ibid.*, p. 1138. (Reports Duval's case.)
55. Sehart, E.: Ueber die künstliche Blutleere von Gliedmassen und unterer Körperhälfte, sowie über die Ursache der Gangrän des Gliedes nach Unterbindung der Arterie allein. *Med. klin., Berlin*, 1916, xii, 1338.
56. Sencert, L.: Le traitement des plaies vasculaires à l'avant. *Lyon Chir., Paris*, 1917, xiv, 640.
57. Sherrill, J. G.: Report of a case of aneurysm, with a new method of ligature of the left subclavian. *Trans. South. Surg. and Gyn. Assn., Nashville*, 1911, xxiii, 190.
58. Souchon, E.: Operative treatment of aneurisms of the third portion of the subclavian artery. *Annals of Surgery, Phila.*, 1895, xxii, 545, 743.
59. Stonham, C.: A case of aneurysm of the second and third parts of the left subclavian artery; ligature of the first part; recurrent pulsation; simultaneous ligature of the inferior thyroid, vertebral, and third part of the axillary arteries; recovery. *Lancet, Lond.*, 1902, ii, 291.
60. Tuffier, Th.: A propos des plaies des artères. *Bull. et mém. Soc. de Chir., Paris*, 1917, xliii, 1469.
61. White, J. S.: Traumatic aneurysm of the left subclavian artery: successful ligation at the junction of the first and second portions. *Brit. Med. Jour., Lond.*, 1918, ii, 131.
62. Wieting, Prof.: Die Unterbindung der A. subclavia sin. in ihrem I. Abschnitt. *Zentralbl. f. Chir., Leipzig*, 1912, xxxix, 1156.
63. Wolff, E.: Die Häufigkeit der Extremitätennekrose nach Unterbindung grosser Gefässstämme. *Beitr. z. klin. Chir., Tüb.*, 1908, lviii, 762.



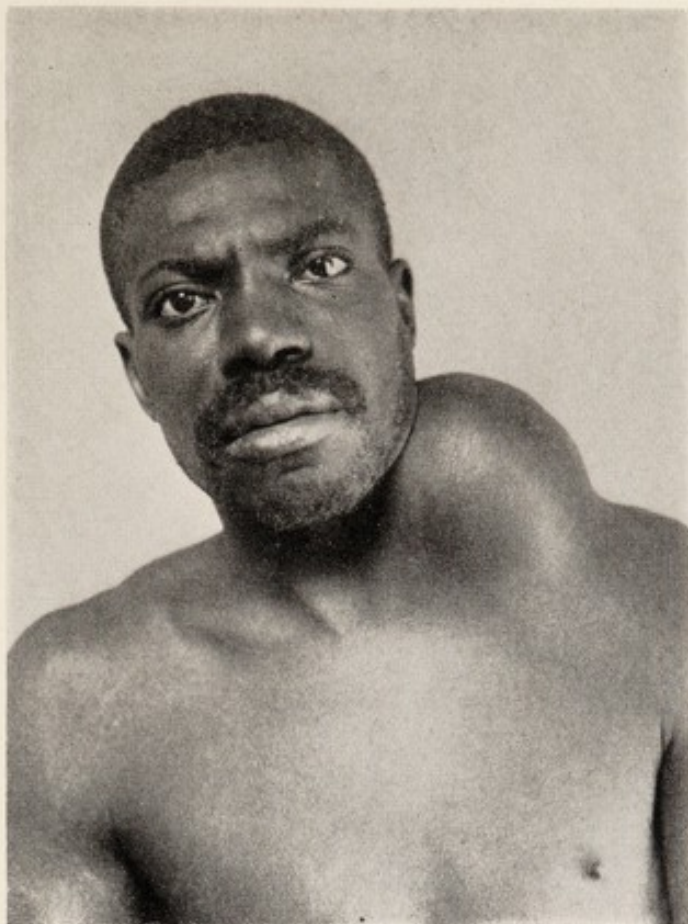


FIG. 1.—Aneurism of the left subclavian artery,
Alexander Miller, April 22, 1918.

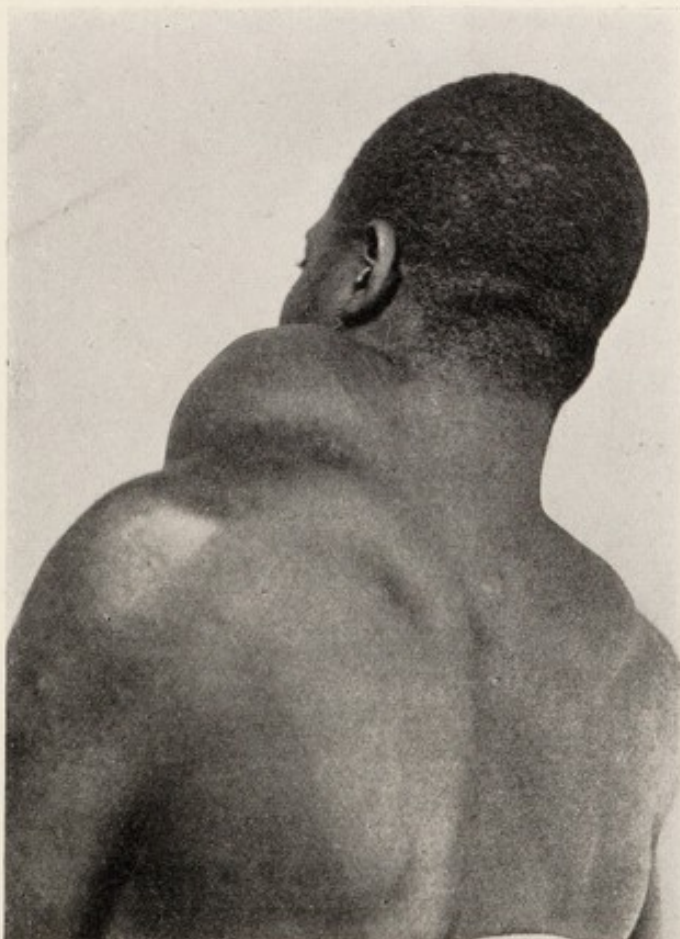


FIG. 2.—Alexander Miller, April 22, 1918.

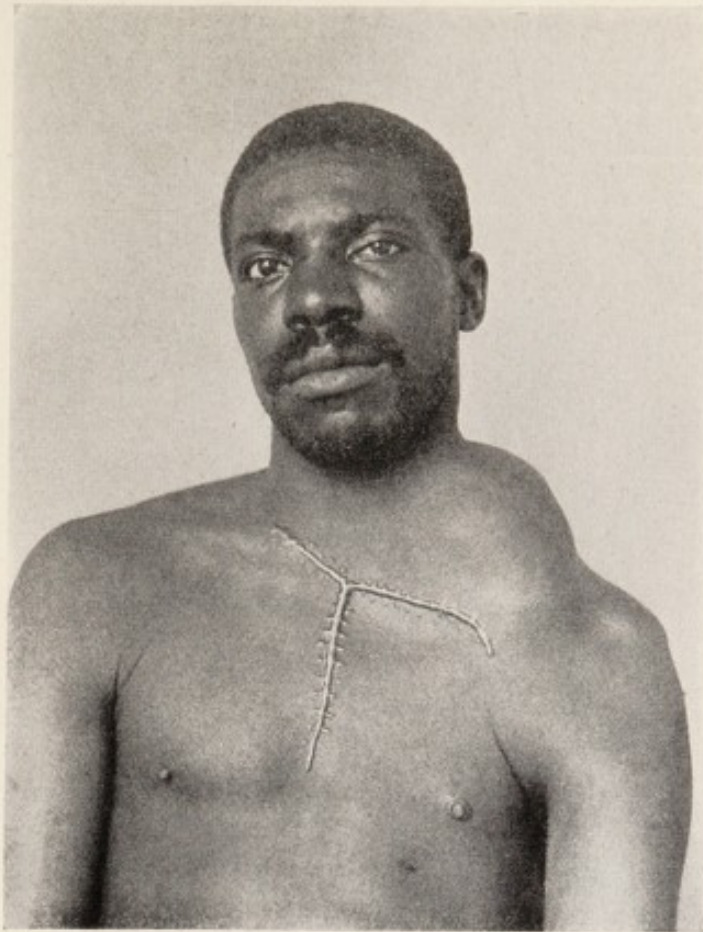


FIG. 3.—Alexander Miller, 109 days after ligation of the subclavian artery near its origin.

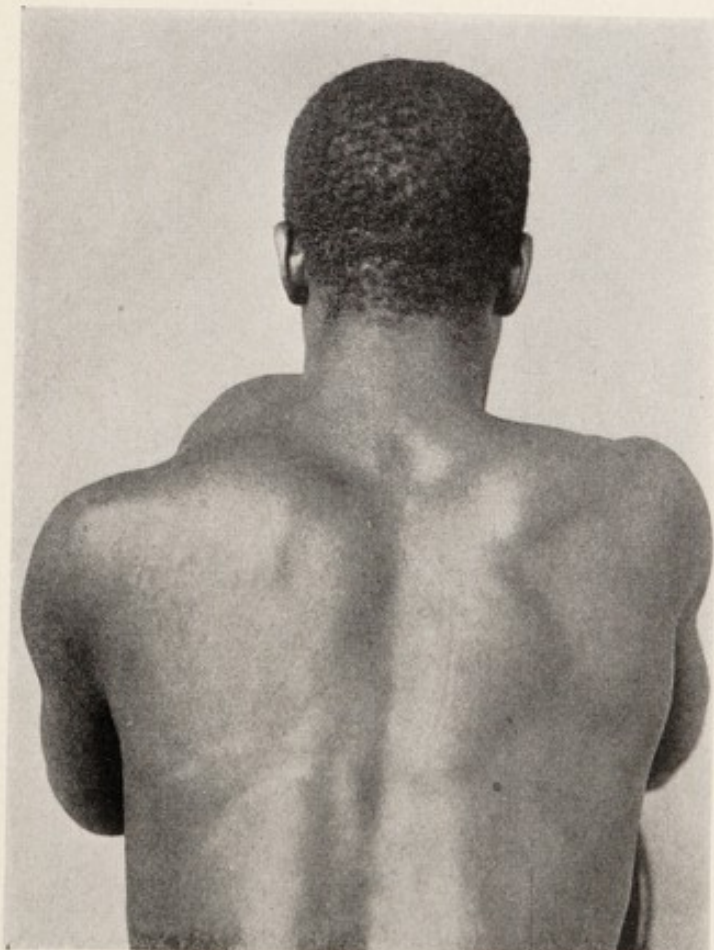


FIG. 4.—Alexander Miller, 109 days after the ligation.

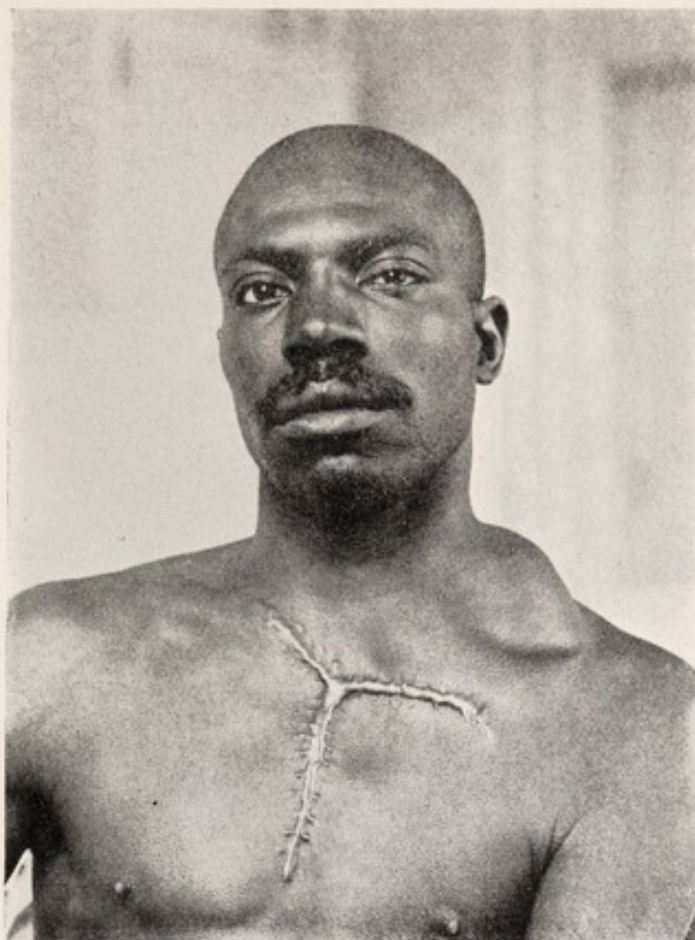


FIG. 5.—Alexander Miller, 10 months after the ligation.

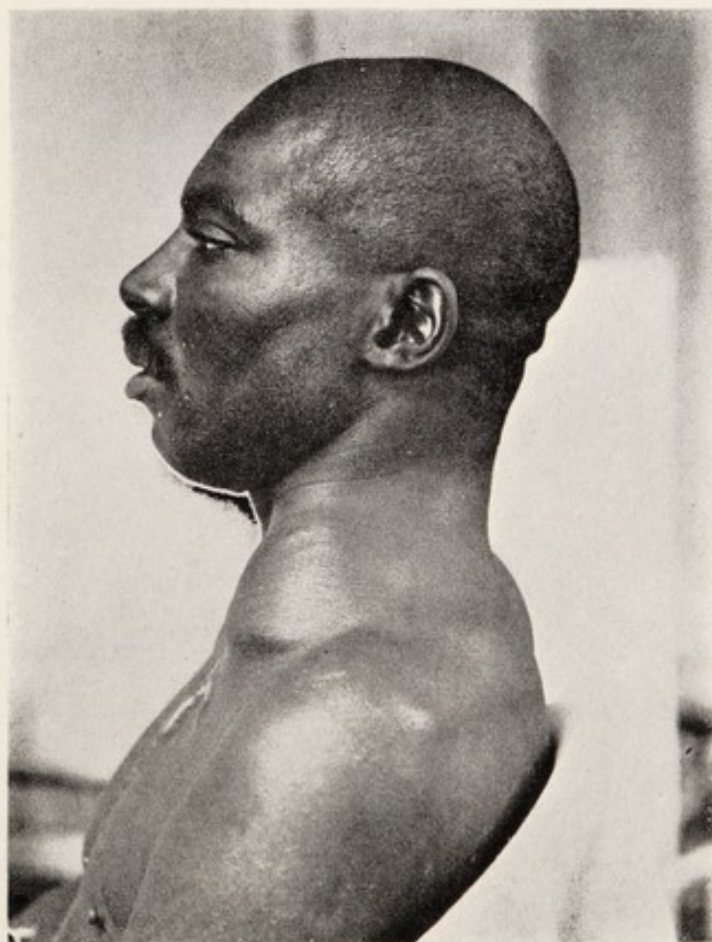


FIG. 6.—Alexander Miller, 10 months after the ligation.

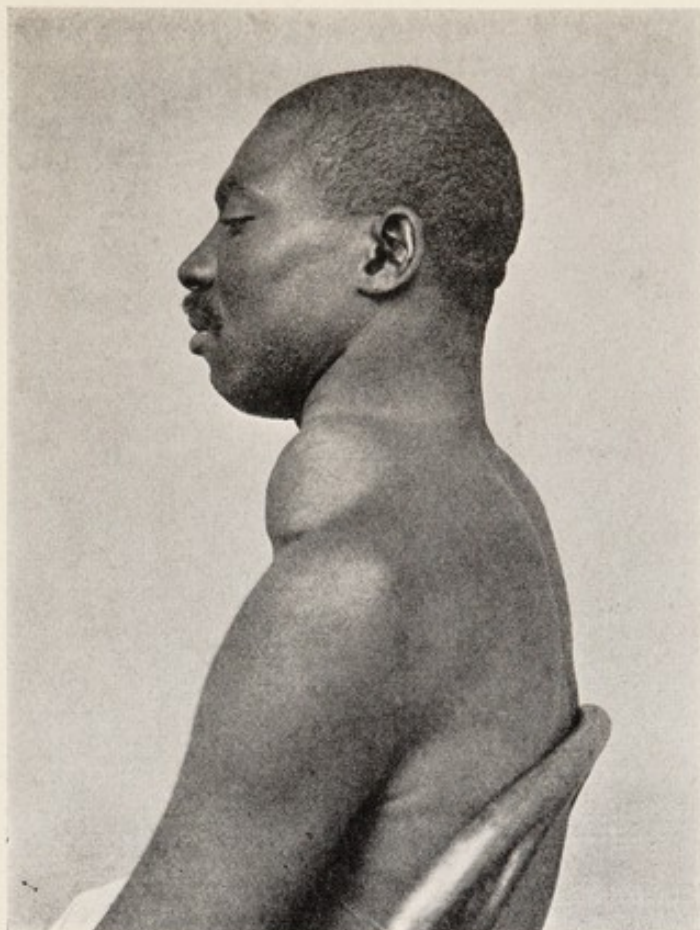


FIG. 7.—Alexander Miller, 2 years after the ligation of the subclavian, and 2 weeks before the excision of the aneurism.

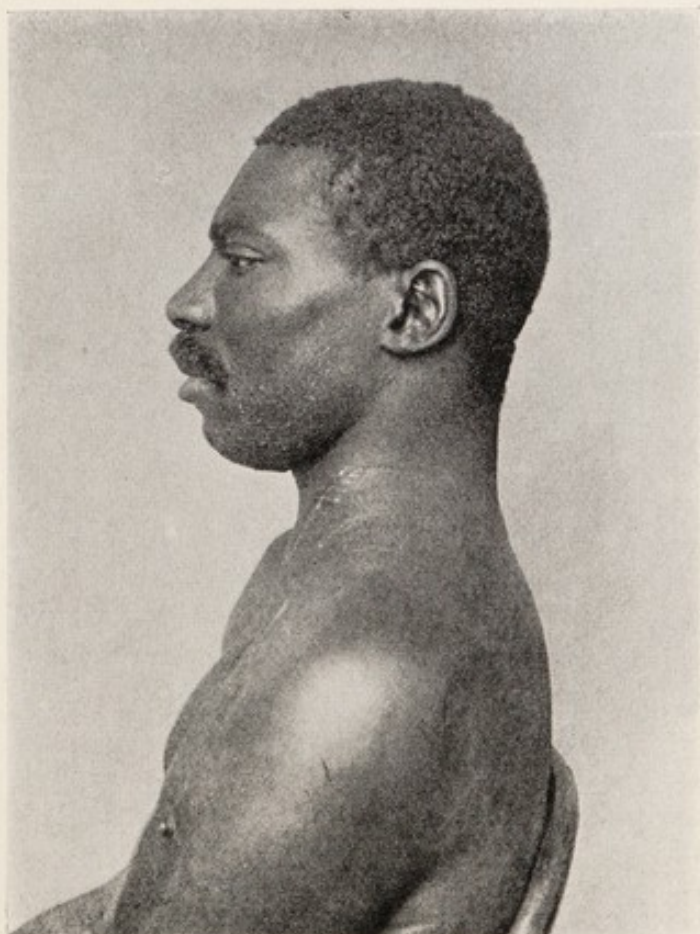
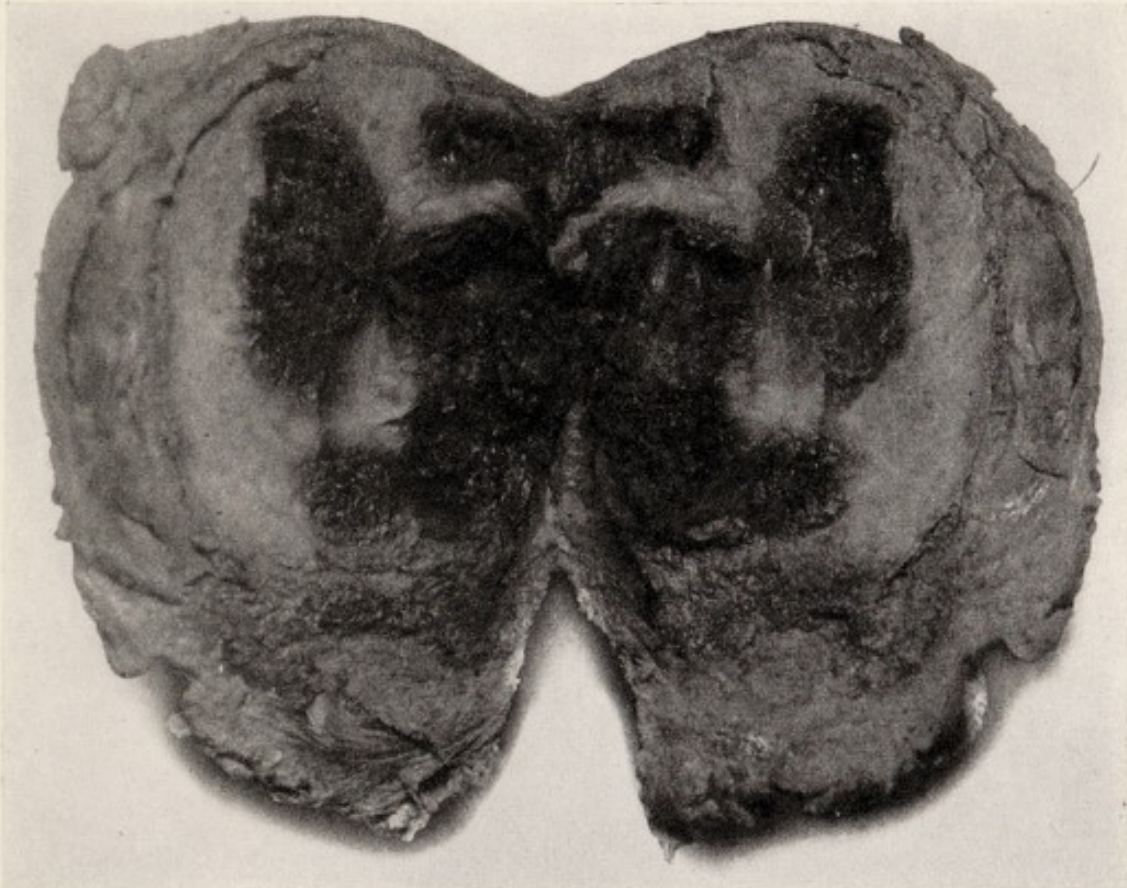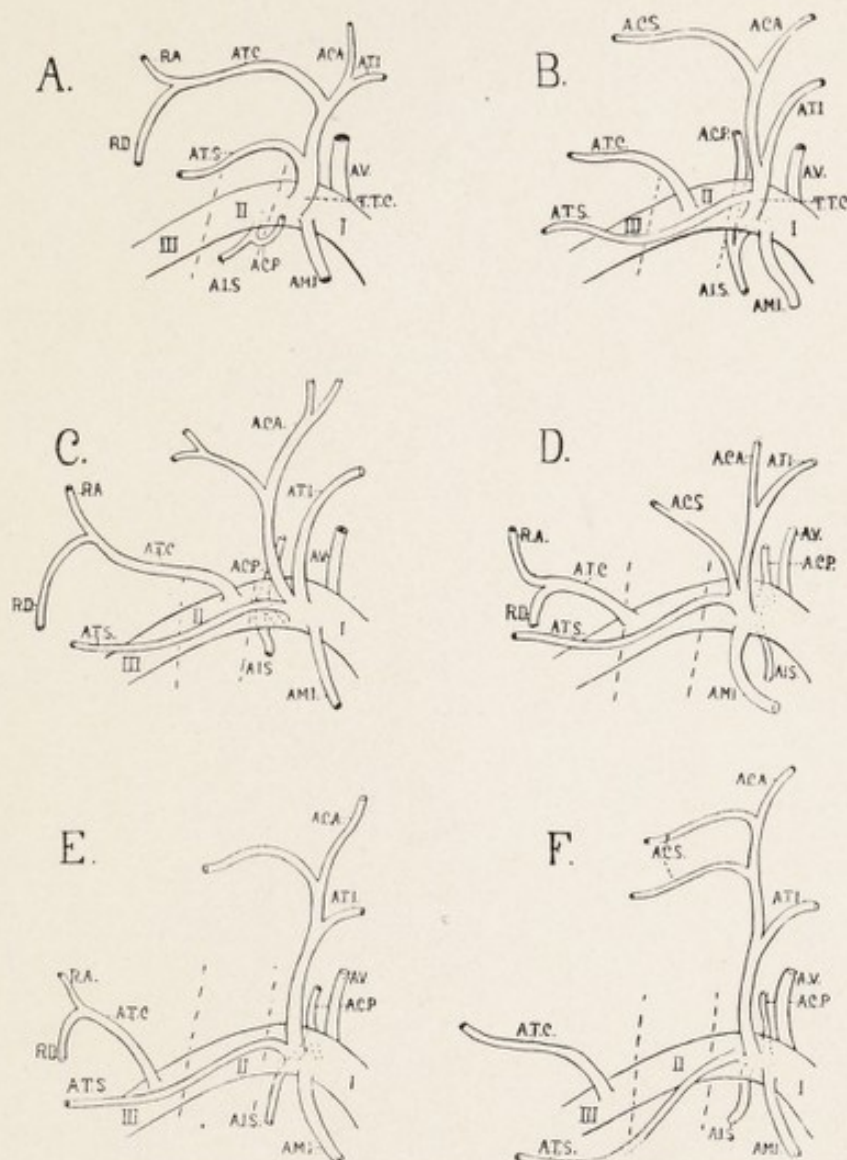


FIG. 8.—Alexander Miller, 1 month after excision of the aneurism.



The excised aneurism, bisected (Case No. XXI). The sac is filled with hyalin and compressed, laminated old clot, canalized at the periphery by the bloodstream.

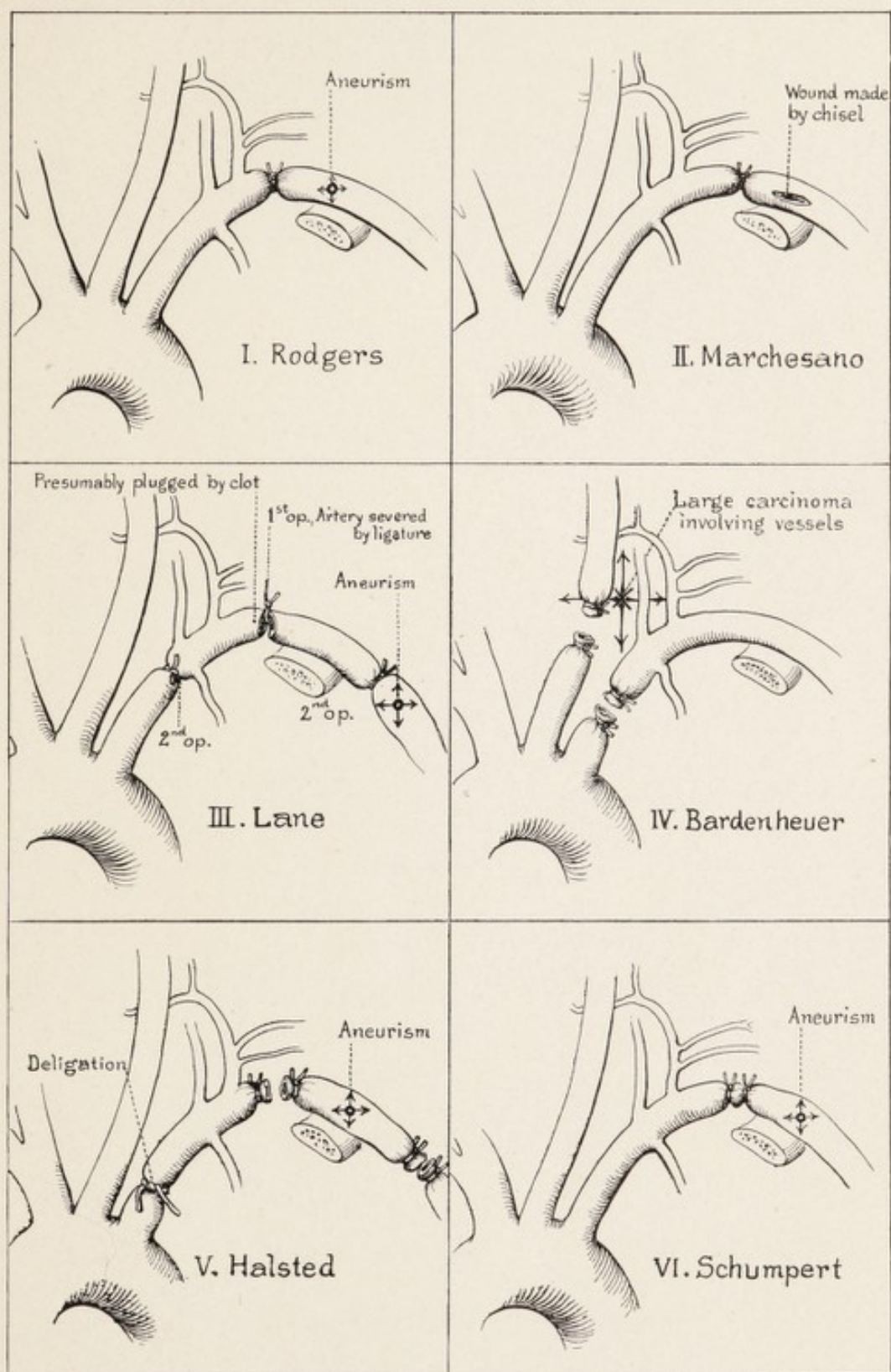
In the dark, central areas the imbedded clots are younger and studded with cavities containing fluid blood. The specimen (actual size) is probably unique.

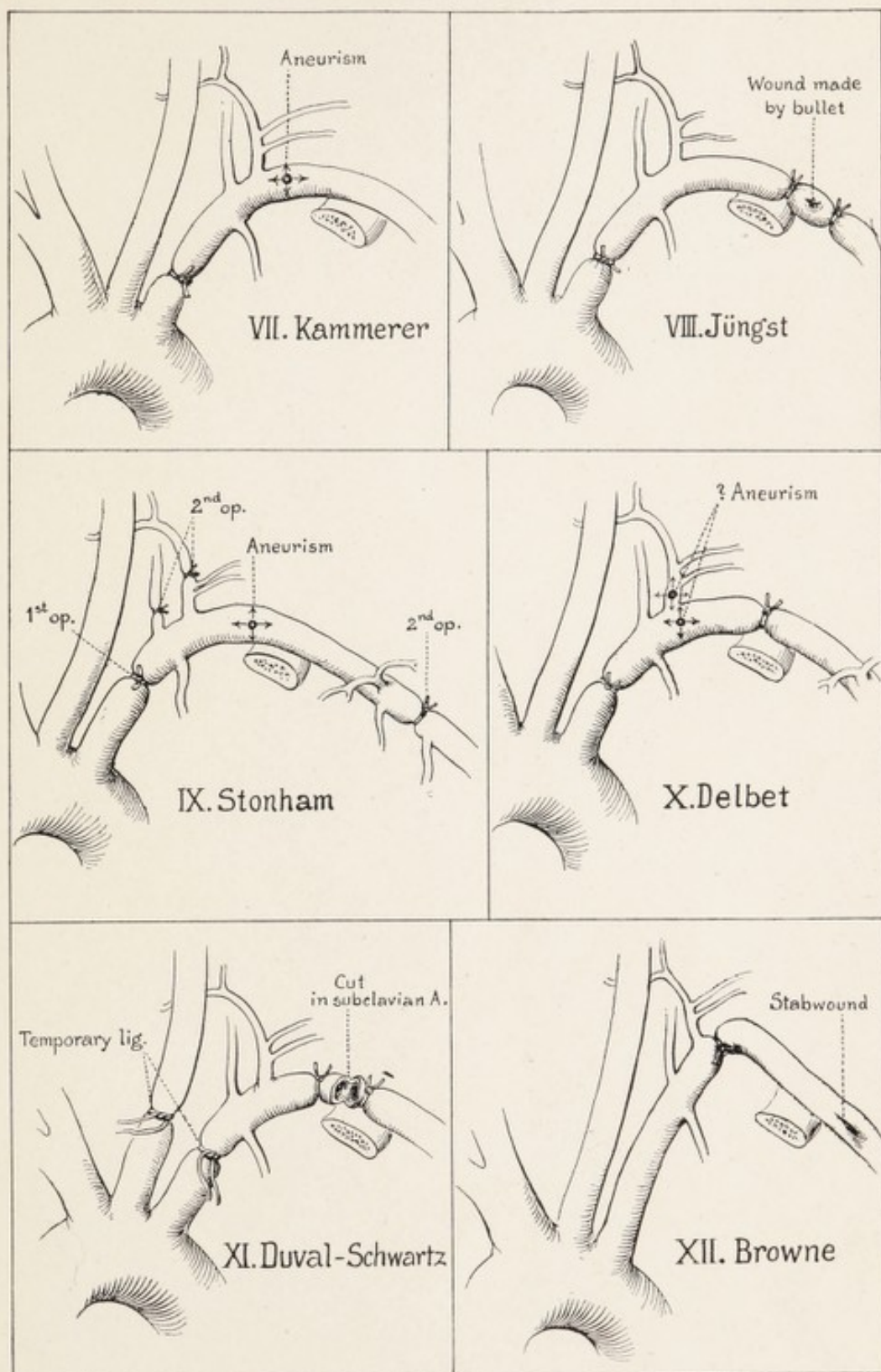


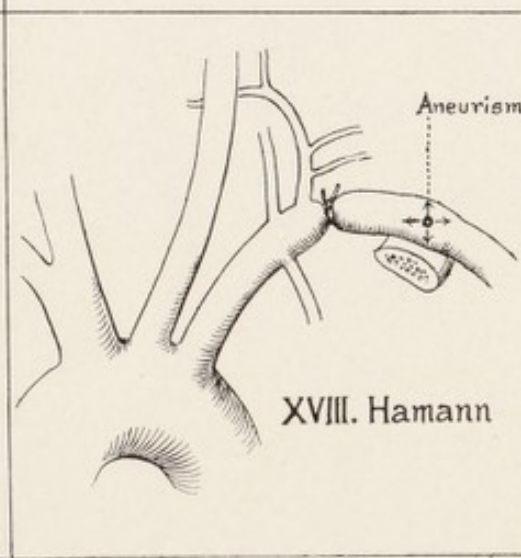
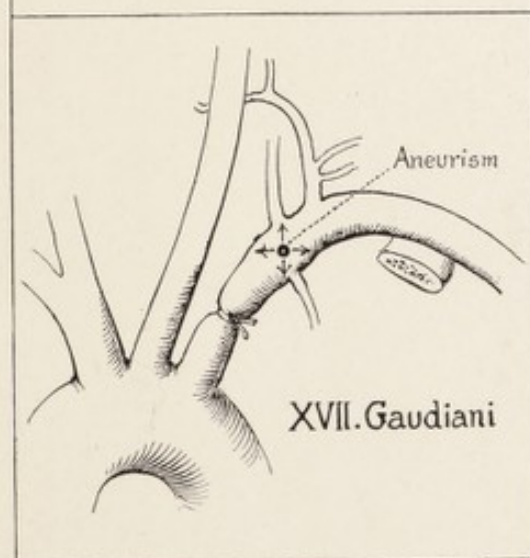
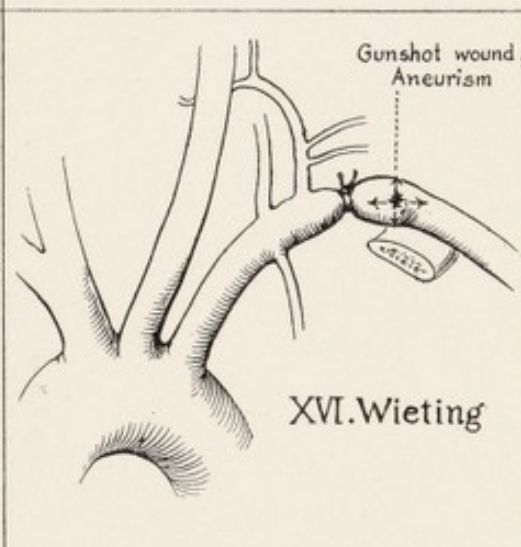
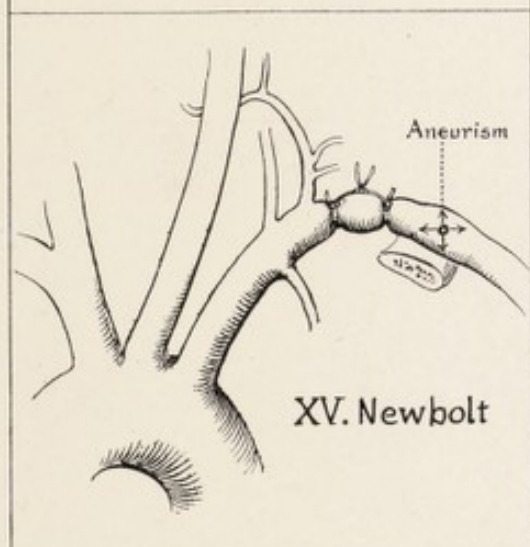
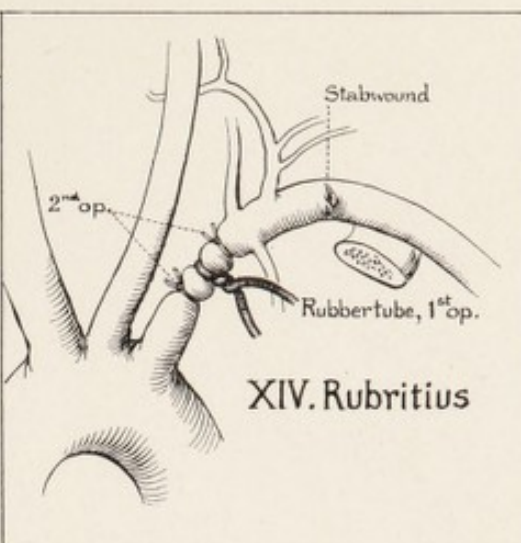
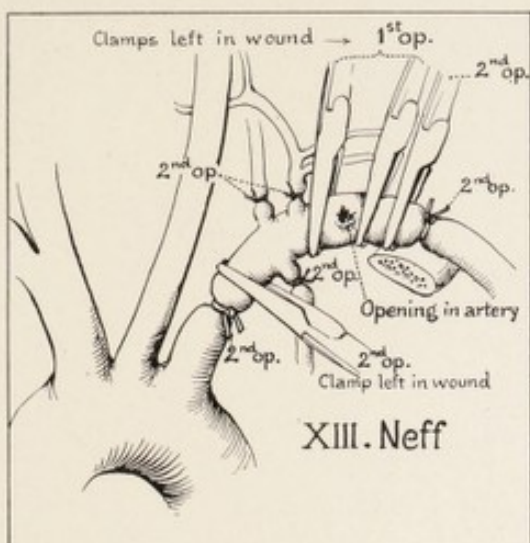
(Reproduced by the courtesy of Dr. R. B. Bean and the editors of the American Journal of Anatomy.)

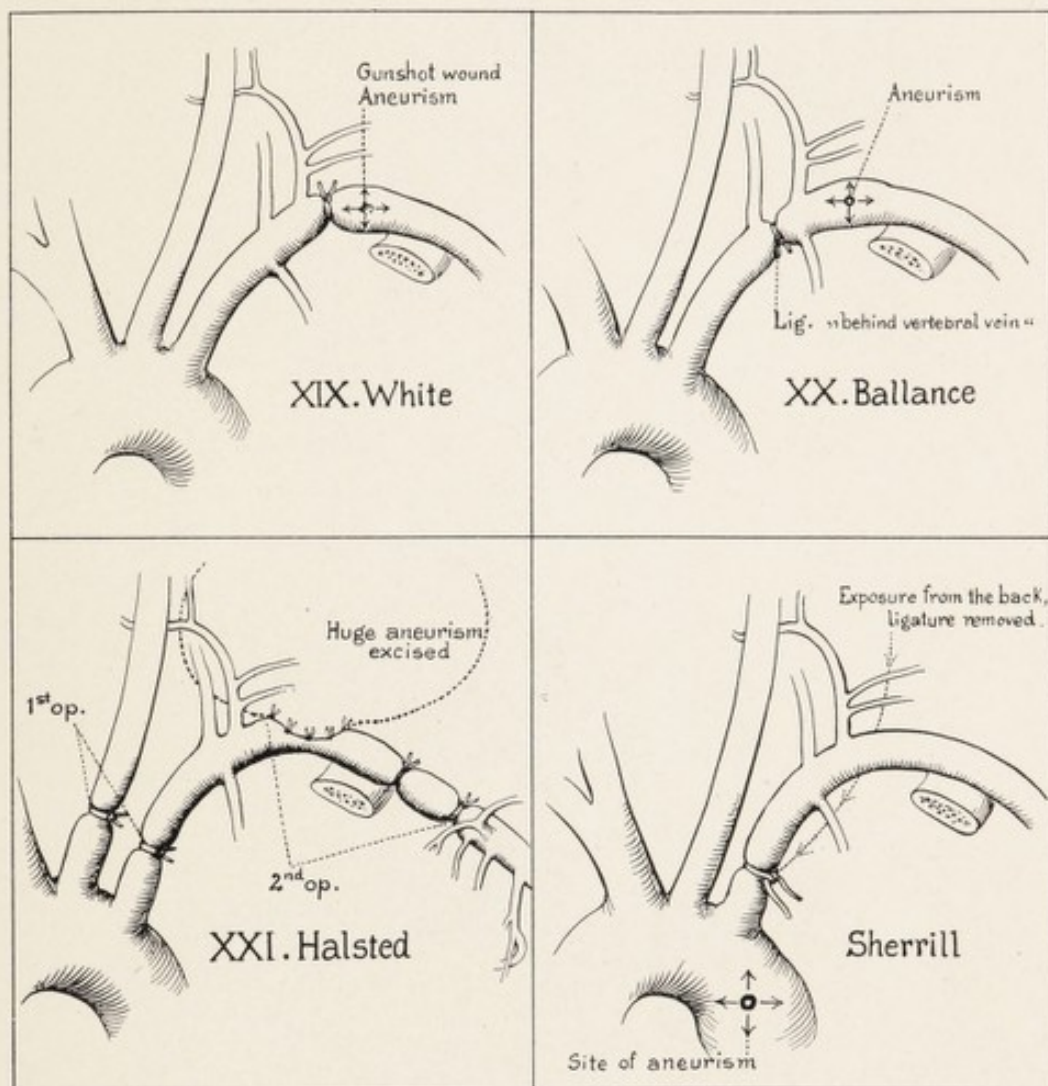
FIG. 1.—Branches of the subclavian artery according to different authors. *A*, according to Quain, Testut and Gray; *B*, according to Henle; *C*, according to Tiedemann; *D*, according to Spalteholz and Toldt (B. N. A.); *E*, according to Gegenbauer; *F*, according to Sappey.

The lettering on all the figures is alike and as follows: *I*, *II* and *III*, the three parts of the subclavian artery; *A. V.*, arteria vertebralis; *A. M. I.*, arteria mammaria interna; *T. T. C.*, truncus thyreo-cervicalis; *A. T. I.*, arteria thyroidea inferior; *A. T. S.*, arteria transversa scapula; *A. T. C.*, arteria transversa colli; *R. A. T. C.*, ramus ascendens transversa colli; *R. D. T. C.*, ramus descendens transversa colli; *A. C. S.*, arteria cervicalis superficialis; *A. C. A.*, arteria cervicalis ascendens; *T. C. C.*, truncus costocervicalis; *A. I. S.*, arteria intercostalis suprema; *A. C. P.*, arteria cervicalis profunda; *C. T.*, common trunk.











Purmann's operation (1680). "Anno 1680. habe ich zu Halberstadt eine Frau, Anna Peterin, gewesene Kretschmerin zu Langenstein, 38. Jahr alt, mit einem sehr grossen Anevristmate des lincken Armes in die Cur bekommen, damit sie sich schon über 3. Jahr geplaget; Die Grösse und Form zeigt beykommende Figur." Purmann, *Chirurgia curiosa*, ed. 1716, p. 612.



