

On the nature and structural characteristics of cancer, and those morbid growths which may be confounded with it ... / by J. Müller ; Translated from the German, with notes, by Charles West.

Contributors

Müller, Johannes, 1801-1858.

West, Charles, 1816-1898.

Publication/Creation

London : Printed for Sherwood, Gilbert, and Piper ..., 1840.

Persistent URL

<https://wellcomecollection.org/works/zuzjnj6d>

License and attribution

This work has been identified as being free of known restrictions under copyright law, including all related and neighbouring rights and is being made available under the Creative Commons, Public Domain Mark.

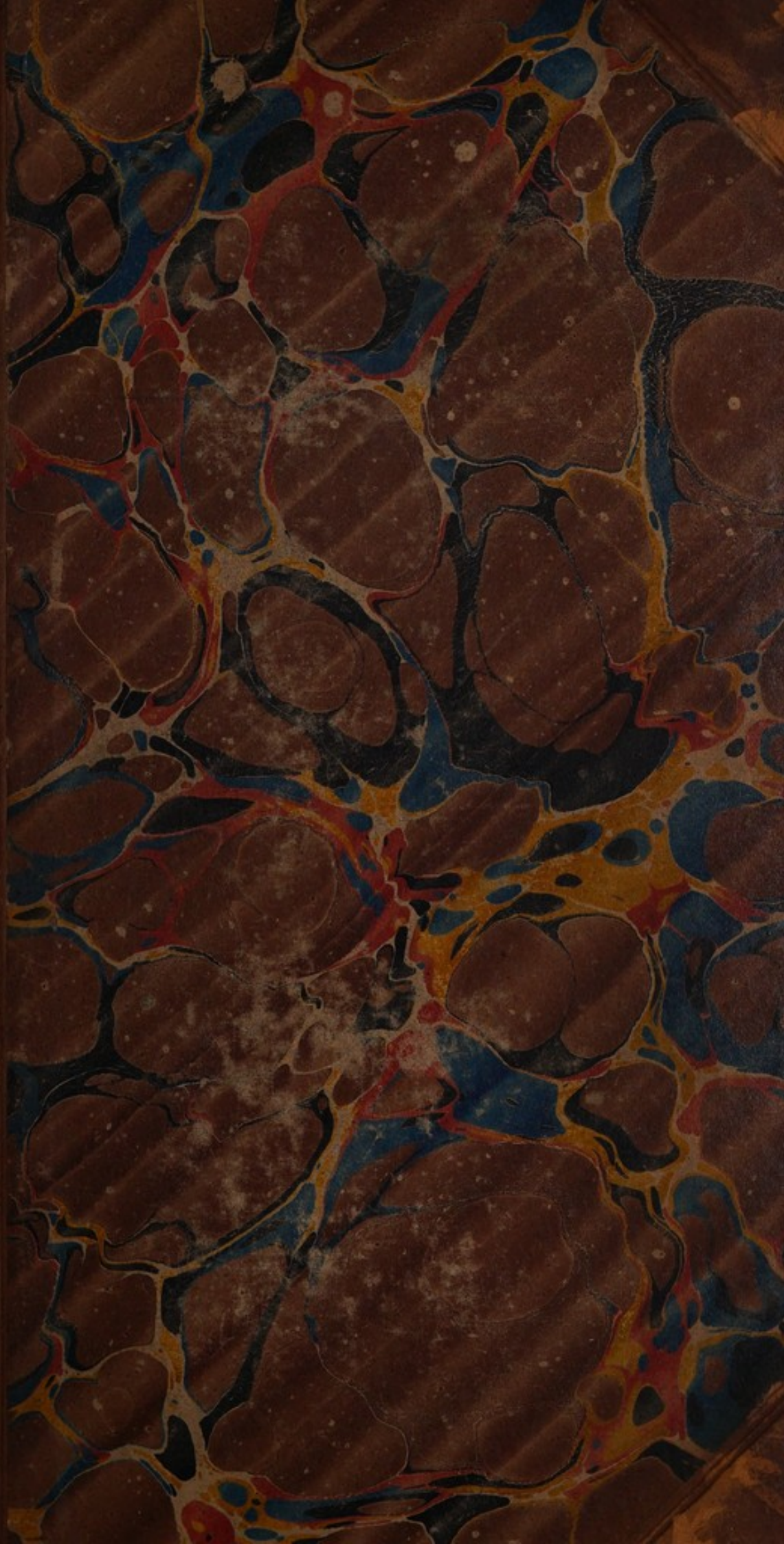
You can copy, modify, distribute and perform the work, even for commercial purposes, without asking permission.

**wellcome
collection**

Wellcome Collection
183 Euston Road
London NW1 2BE UK
T +44 (0)20 7611 8722
E library@wellcomecollection.org
<https://wellcomecollection.org>

D

g/14



62908/B

$\frac{\pi}{8.14}$


The Library of the
Wellcome Institute for
the History of Medicine

MEDICAL SOCIETY
OF LONDON

Accession Number

Press Mark

- 1) MUELLER, J.
- 2) SÉDILLOT, C.



Theriac



TURE

CHARACTERISTICS

ICER,

GROWTHS

CONTAINED WITH IN

J. L. B. M.D.

OF THE UNIVERSITY OF LONDON

OF THE GENERAL

PHYSICIAN

IN WEST. M.D.


A FELLOW OF THE SOCIETY OF PHYSICIANS

JOHN STEEL PLATE AND ENGRAVING

LONDON:

PRINTED BY SHERWOOD, GILBERT & SONS

1890



ON THE
NATURE
AND
STRUCTURAL CHARACTERISTICS
OF
CANCER,
AND OF THOSE
MORBID GROWTHS
WHICH MAY BE CONFOUNDED WITH IT.

BY J. MÜLLER, M.D.

PROFESSOR OF ANATOMY AND PHYSIOLOGY IN THE UNIVERSITY OF BERLIN,
&c. &c. &c.

TRANSLATED FROM THE GERMAN,
WITH NOTES,

BY CHARLES WEST, M.D.


GRADUATE IN MEDICINE OF THE UNIVERSITY OF BERLIN.

ILLUSTRATED WITH NUMEROUS STEEL PLATES AND WOOD
ENGRAVINGS.

LONDON:

PRINTED FOR SHERWOOD, GILBERT, AND PIPER,
PATERNOSTER ROW.

—
1840.





BY THE
AUTHOR

STUDY OF THE CHARACTERISTICS

OF THE

MORPHOLOGICAL

CHARACTERISTICS OF THE

PLANT

COMPTON AND RITCHIE, PRINTERS, MIDDLE STREET, CLOTH FAIR.

TRANSLATED FROM THE GERMAN

BY THE AUTHOR

BY CHARLES J. J. J.

OF THE UNIVERSITY OF

THE UNIVERSITY OF

LONDON

PRINTED FOR THE AUTHOR, BY

COMPTON AND RITCHIE,

1891

D2

CONTENTS.*

GENERAL OBSERVATIONS ON THE MINUTE STRUCTURE OF MORBID GROWTHS.....	1
--	---

FIRST PART.

ON THE MINUTE STRUCTURE OF CARCINOMATOUS GROWTHS.

On carcinomatous growths in general.....	28
I.— <i>Of scirrhus, or carcinoma simplex</i>	33
II.— <i>Of carcinoma reticulare</i>	44
III.— <i>Of carcinoma alveolare</i>	50
IV.— <i>Of carcinoma melanodes</i>	55
V.— <i>Of carcinoma medullare</i>	58
VI.— <i>Of carcinoma fasciculatum</i>	66
Development and softening of carcinoma.....	69
Chemical properties of carcinoma.....	73
Nature of carcinoma.....	78

SECOND PART.

OF THOSE MORBID GROWTHS WHICH MAY BE CONFOUNDED WITH CARCINOMA.

I.— <i>Of enchondroma</i>	96
General description of enchondroma.....	97
Different forms of enchondroma	102
Its microscopic structure	107
Its chemical composition	110
Development of enchondroma	124
Its duration and termination	127
Its nature	130
Local causes	130
General causes	131

* The additions by the Translator are distinguished by being included within brackets.

	Page
Differences between enchondroma and other tumors of the bones.....	135
Cases of enchondroma on record.....	139
Preparations of enchondroma in museums.....	148
II.— <i>Of adipose tumors</i>	152
Lipoma	153
Adipose cysts.....	154
Cholesteatoma	155
Its structure	157
Its chemical relations	160
Its seat and varieties	161
Its development	163
Its nature	164
Preparations of cholesteatoma in museums.....	165
III.— <i>Of compound cystoid and cystosarcomatous growths</i>	166
Compound cystoid growths.....	166
Cystosarcomatous growths.....	170
Observations relating to cystosarcoma.....	174
Curability of cystosarcoma by operation.....	179

ADVERTISEMENT BY THE TRANSLATOR.

THE well-known reputation of Professor Müller renders it unnecessary that I should insist on the merits of this work, or apologize for presenting an English version of it to my countrymen.

In the absence of the ordinary topics of a preface, there remains for me only the pleasing duty of thanking those gentlemen whose assistance has forwarded my present undertaking, or to whose friendship on other occasions I am indebted. My best acknowledgements are due to Dr. R. WILLIS for very many and various favours. The courtesy of Mr. PAGET, Demonstrator of Morbid Anatomy at St. Bartholomew's Hospital, gave me an opportunity of examining many morbid structures; and the help of my good friend, Dr. BALY, I have throughout found most serviceable.

Lastly, I rejoice in having this opportunity of owning my obligations to Dr. G. BURROWS for that unvarying kindness which he has shewn me for some years, and for which I beg him to receive my most grateful thanks.

CHARLES WEST

40, Craven Street,
March 1840.

ADVERTISEMENT BY THE TRANSLATOR

The well-known reputation of Professor Müller renders it unnecessary that I should insist on the merits of this work, or apologize for presenting an English version of it to my countrymen.

In the absence of the ordinary topics of a preface, there remains for me only the pleasing duty of thanking those gentlemen whose assistance has forwarded my present undertaking, or to whose friendship on other occasions I am indebted. My best acknowledgments are due to Dr. H. W. Müller for very many and various favours. The courtesy of Mr. P. B. Anatomist of Medical Anatomy at St. Bartholomew's Hospital, gave me an opportunity of examining many models, structures; and the help of my good friend, Dr. Bay, I have throughout found most serviceable. Lastly, I rejoice in having this opportunity of expressing my obligations to Dr. O. Barrow for that many of his kindness which he has shown me for some years, and for which I beg him to receive my most grateful

thanks

Charles Ware

to Charles Ware
New York



FIG. 4.



FIG. 1.

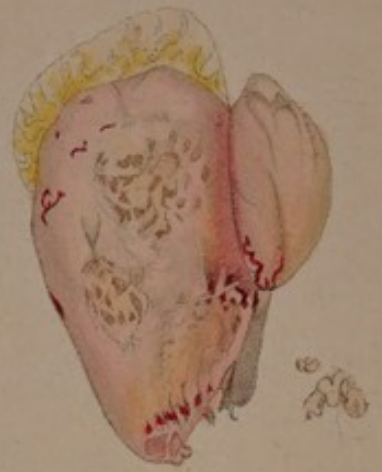

FIG. 5.



FIG. 6.



FIG. 7.

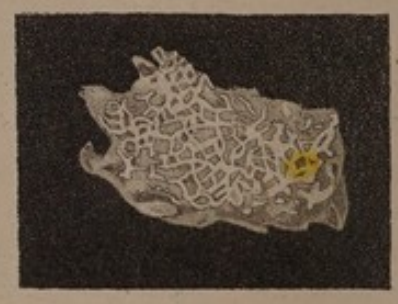

FIG. 8.

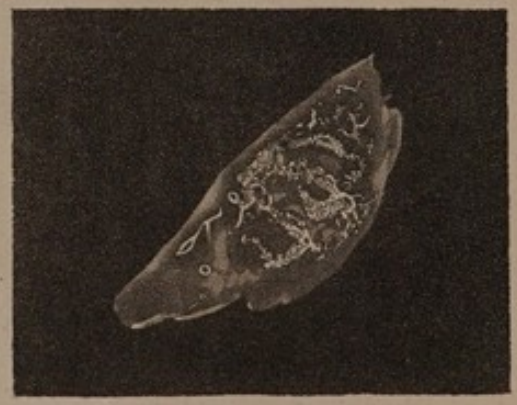

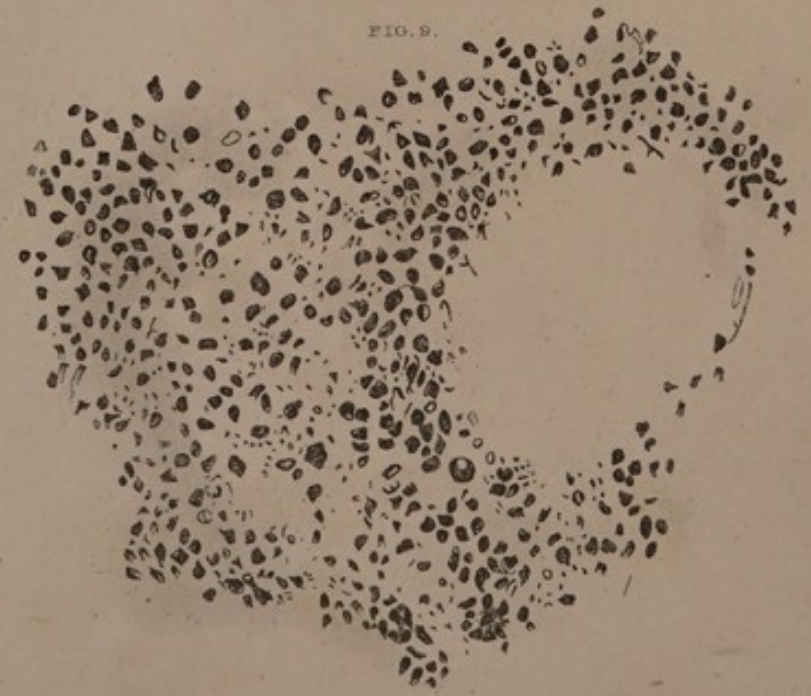
FIG. 3.

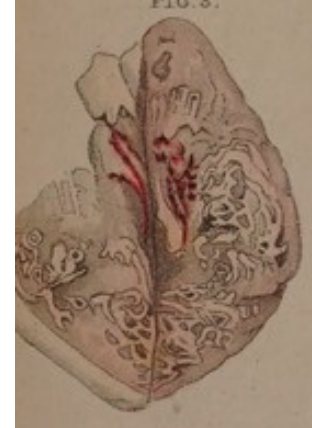

FIG. 2.

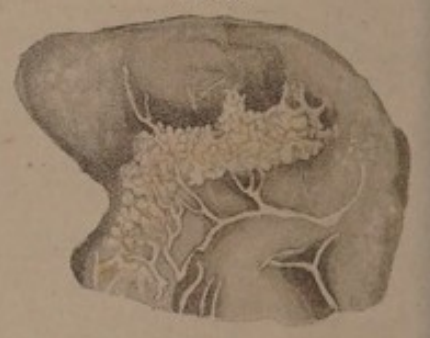

FIG. 9.






FIG. 10.



FIG. 16.



FIG. 14.

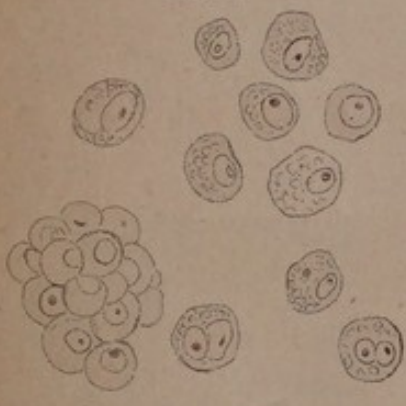


FIG. 15.



FIG. 17.

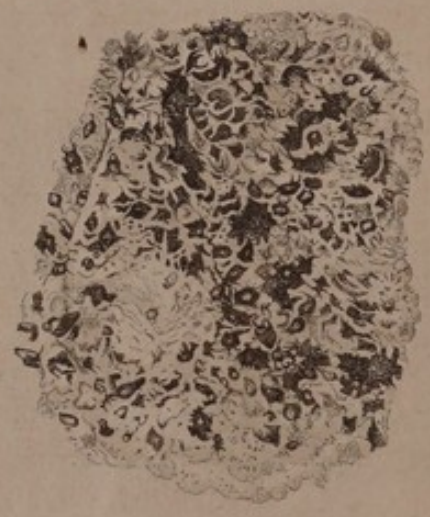

FIG. 10.

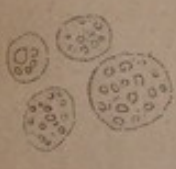

FIG. 12.




FIG. 13.

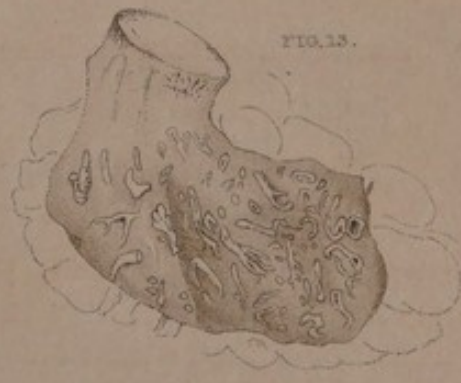

FIG. 18.

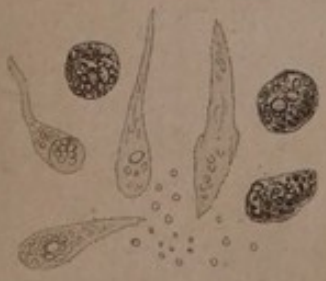



FIG. 11.



EXPLANATION OF THE PLATES*.

PLATES I AND II.

Fig. 1. Section of a carcinoma reticulare of the female breast; seen with a common lens.

Fig. 2. Section of a carcinoma reticulare of the female breast. The network is not so regular as in the preceding case. The aborescent figures are vessels.

Fig. 3. Section of a carcinoma reticulare of the female breast; seen with a common lens.

Fig. 4. Carcinoma reticulare from the orbit of a child, complicated with melanosis; seen with a common lens.

Fig. 5. Another portion of the same tumor.

Fig. 6 and 7. Lamina from a carcinoma reticulare of the female breast; seen with a common lens.

Fig. 8. The reticulum of another lamina, viewed with the higher magnifying power of a triple lens. The granules are visible which compose the reticulated figures.

Fig. 9. A portion of a delicate lamina of the same breast, magnified 100 diameters, and seen by transmitted light, owing to which the white corpuscles which compose the network appear dark.

Fig. 10. Cells from a carcinoma mammæ, containing small corpuscles; magnified 450 diameters.

Fig. 11. The same, from another cancer of the breast. Some of the cells contain several granules, others one large granule resembling a nucleus.

Fig. 12. White granular corpuscles from the network of a carcinoma mammæ reticulare; magnified 450 diameters.

* All the plates are copied from those in the original work; the drawings for which were made by Pr. Müller and Dr. Schwann: *unam.*

EXPLANATION OF THE PLATES.

Fig. 13. Section of a common cancer of the breast, shewing vessels with thickened walls, and not collapsing when divided.

Fig. 14. Cells with germinal cells and nuclei, from an extremely hard carcinoma mammæ simplex which had passed into the ulcerated stage. Diameter of the cells 0,00048 to 0,00128 of an English inch.


Fig. 15. Layer of fibres from a cancer of the breast, which had been subjected to maceration.

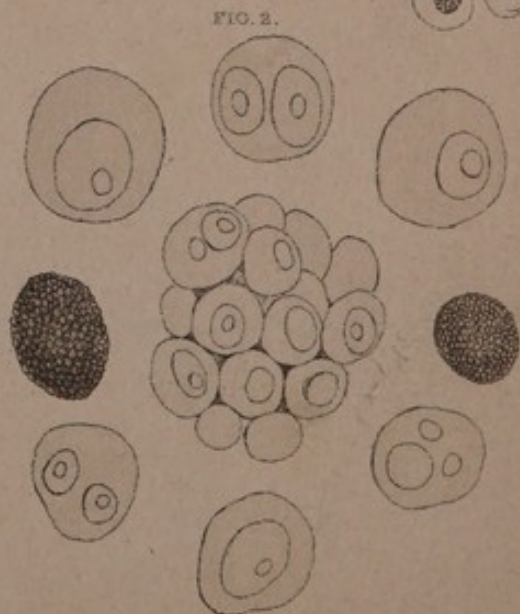
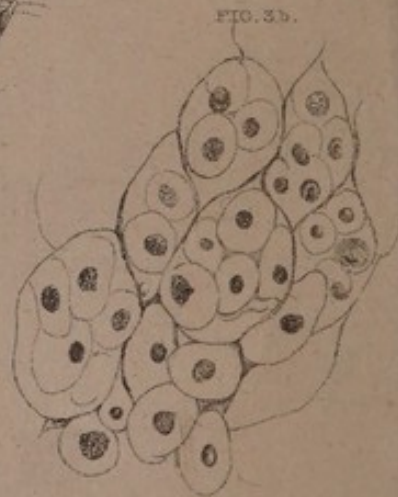
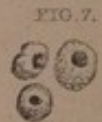

Fig. 16. Caudate corpuscles from a medullary fungus of the thigh of a child; magnified 450 diameters.

Fig. 17. Lamina of carcinoma melanodes of the eye and orbit of a young woman; slightly magnified.

Fig. 18. Pigment cells, caudate bodies, and some pigment granules from a carcinoma melanodes of the lower jaw.

Fig. 19. Indistinctly fibrous structure of cystosarcoma phyllodes.






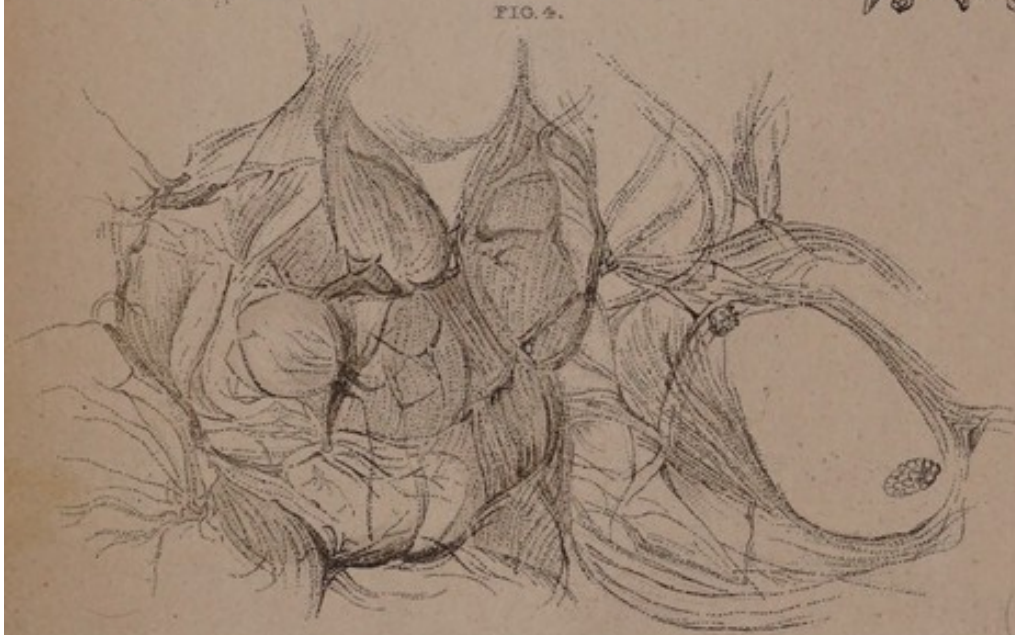
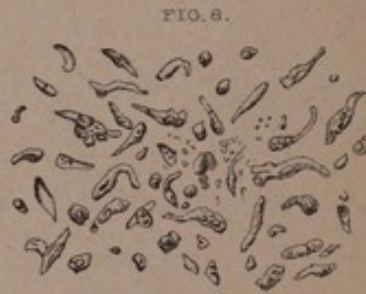
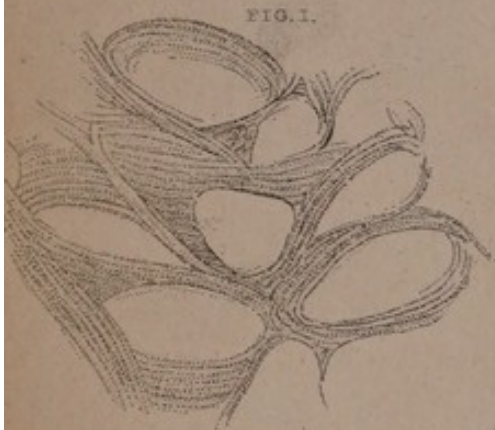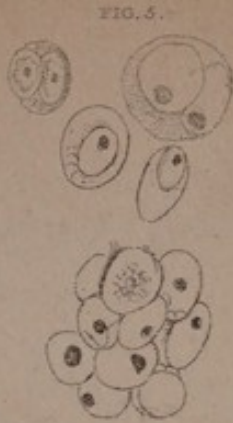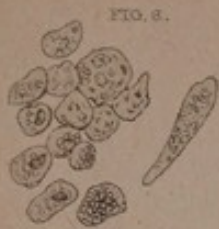FIG. 16

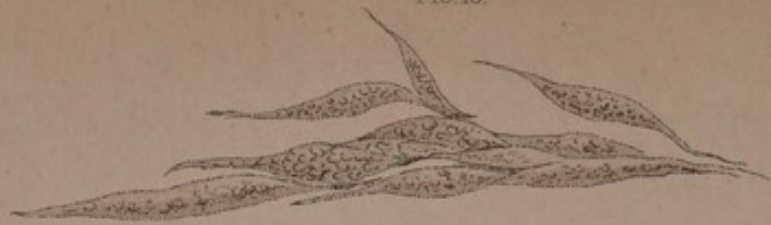

FIG. 15.

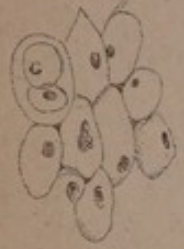

FIG. 9.

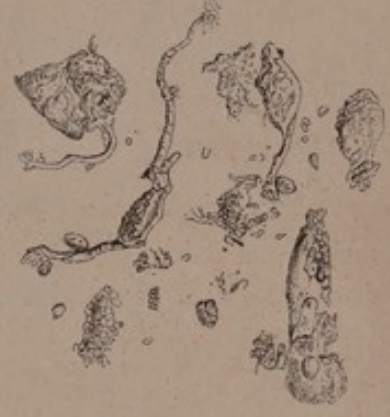

FIG. 14.

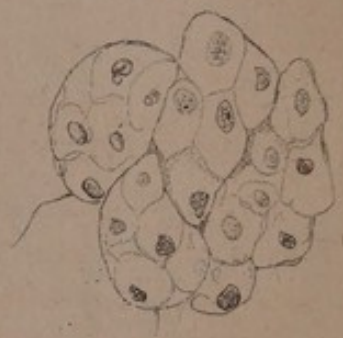

FIG. 13.

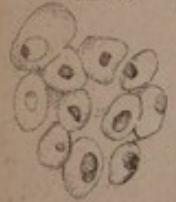

FIG. 18.




FIG. 12.



FIG. 11.



FIG. 17.



EXPLANATION OF THE PLATES.

PLATES III AND IV.

Fig. 1. Meshes formed by the bundles of fibres of carcinoma reticulare of the breast as they appear after the globules are removed.

Fig. 2. Globules from the reticulum of carcinoma reticulare. Within the globules are germinal cells with their nuclei, and on either side of the figure is a granular and opaque corpuscle.

Fig. 3. a. Cells of carcinoma alveolare of the stomach, magnified 100 diameters.

Fig. 3, b. Smaller cells, within which others still smaller are contained, from the same carcinoma alveolare. Magnified 450 diameters.

Fig. 4. Large cells from a carcinoma alveolare, containing a jelly-like substance, and furnished with fibrous walls. At page 54, a suspicion was stated that these large cells are produced by the cohesion of smaller cells; but it must be borne in mind, that this process has not been the subject of direct observation, and that the fibrous structure might be owing to the existence of such a tissue between the layers of the cells, where it might serve as a nidus for their development.

Fig. 5. Cells, some of which contain germinal cells and nuclei from a soft tremulous gelatiniform sarcoma of the brain, in the museum of Professor Pockels. Magnified 450 diameters.

Fig. 6. Nucleated cells and caudate corpuscles, from an enormous carcinoma medullare, removed from the abdomen of a woman. The smallest cells measured 0,00020, the largest 0,00102 of an English inch in diameter.

Fig. 7. Nucleated cells from a medullary fungus of the thigh of a woman. The same growth contained caudate corpuscles.

Fig. 8. Caudate corpuscles and cells containing nuclei and granules, from a medullary fungus of the liver. Magnified 100 diameters.

Fig. 9. Very irregular caudate bodies from a soft fungus of the female breast, the nature of which was never very accurately ascertained.

Fig. 10. Elliptical corpuscles; from a fungus medullaris of the foot and tarsal bones of a man.

Fig. 11. Caudate corpuscles united into fasciculi; from a very large medullary fungus in the thigh of a child.

EXPLANATION OF THE PLATES.

Fig. 12. Exceedingly delicate fibres, from a specimen of hyaloid carcinoma fasciculatum of the female breast, described at p. 68.

Fig. 13. Nucleated cells from an osteosarcoma of the jaw bone. Diameter of the cells 0,00073 ; of the nuclei 0,00015 of an English inch.

Fig. 14. Cellular osteosarcoma, which affected the tibia of a man during many years. The nuclei varied in diameter from 0,00026 to 0,00037 of an English inch.

Fig. 15. Nucleated cells from a cellular sarcoma. Magnified 450 diameters.

Fig. 16. (Numbered by mistake fig. 10 in plate iv). Caudate corpuscles from an albuminous sarcoma of the conjunctiva, as large as the fist. The disease returned after several operations, and was at length successfully removed, together with the globe of the eye, by Dr. Helling. The eye was found to be quite healthy.

Fig. 17. Caudate cells, some of them with a nucleus and nucleolus, from a soft osteosarcoma of the lower jaw. Smallest diameter of the cells, 0,00022 or 0,00054 of an English inch. The tumor was principally albuminous, but yielded, when boiled, a small quantity of gelatine.

Fig. 18. Bundle of fibres from a fibrous tumor of the mamma, in Professor Pockels' museum.




FIG. 16.



FIG. 9.

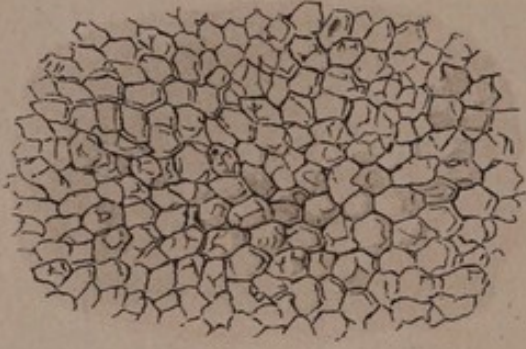


FIG. 18.

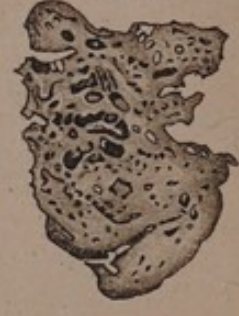

FIG. 13.



FIG. 11.

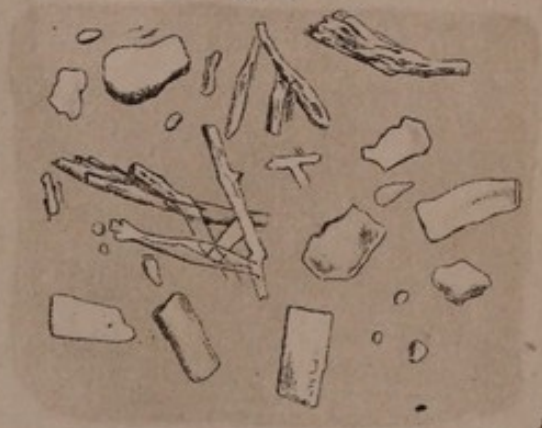

FIG. 3.

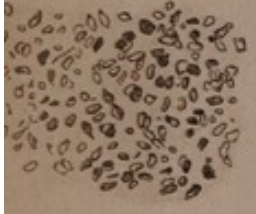


FIG. 2.

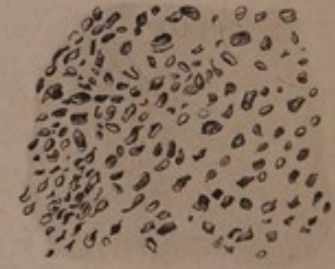

FIG. 6.

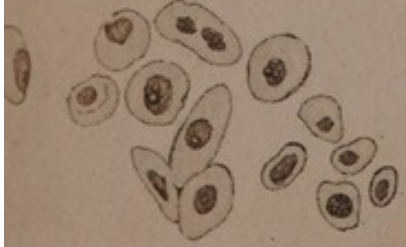

FIG. 5.



FIG. 7.

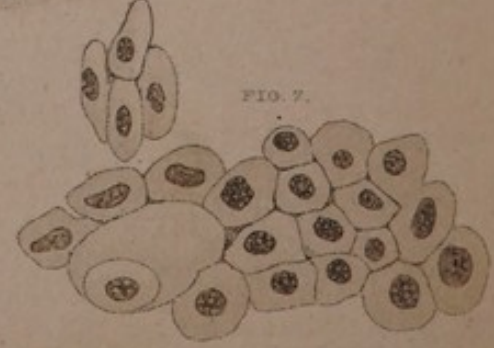



FIG. 12.

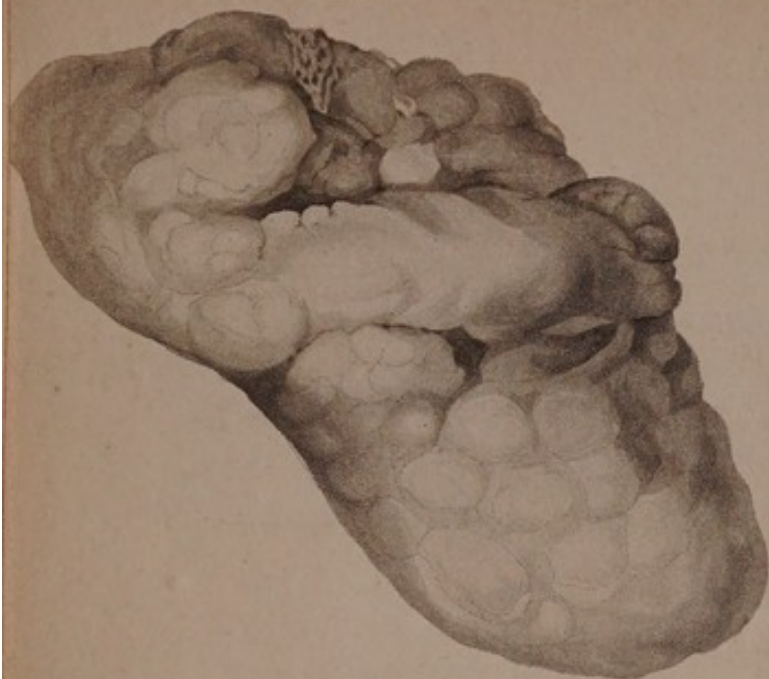


FIG. 17.

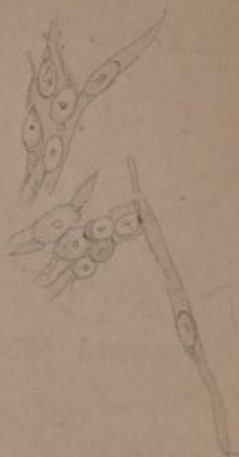

FIG. 1.

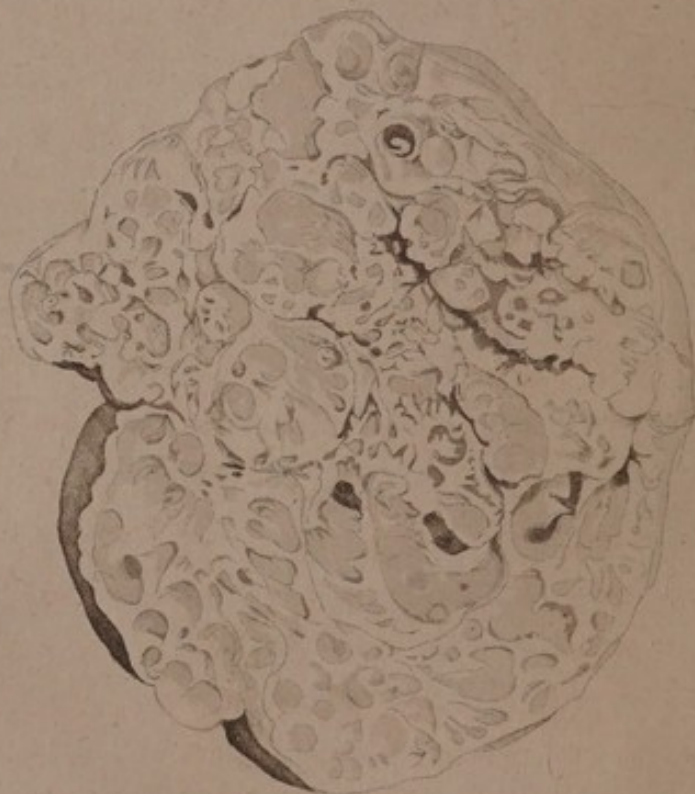


FIG. 10.



FIG. 14.



EXPLANATION OF THE PLATES.

PLATES V AND VI.

- Fig. 1.* Section of enchondroma of the parotid gland. See page 101.
- Fig. 2 and 3.* Very delicate sections of enchondroma of the hand, slightly magnified.
- Fig. 4.* Separate cells, with germinal cells and nuclei (magnified 450 diameters), from an enchondroma of the parotid gland.
- Fig. 5.* A single cell, with its granular nucleus.
- Fig. 6 and 7.* Nucleated cells, from an enchondroma of the hand.
- Fig. 8.* Spiked corpuscles, from an enchondroma of the hand.
- Fig. 9.* Polyedrous cells of cholesteatoma. Magnified 290 diameters.
- Fig. 10.* Granular and crystalline lamellæ of fat, deposited from the ethereal extract of cholesteatoma.
- Fig. 11.* Crystalline fat from cholesteatoma; magnified 100 diameters. This figure represents the fat which has not been subjected to chemical reagents.
- Fig. 12.* External form of an exceedingly soft tremulous gelatiniform sarcoma, which had become developed in the brain. From Pr. Pockels' museum.
- Fig. 13.* Globules and needle-shaped crystals, from the same tumor.
- Fig. 14.* Fasciculi of fibres, from a very firm fibrous tumor of the hand which sprang from the metacarpal bones.
- Fig. 15.* A portion of skin and subcutaneous cellular tissue affected with aneurism by anastomosis, from a person whose face was deformed by a number of growths of that nature. The enlarged capillaries have been injected, and are represented as they appear when viewed with a common lens.
- Fig. 16.* Enlarged vessels from an aneurism by anastomosis, which affected the remnant of the cranial integuments in a hemicephalous fœtus.
- Fig. 17.* Caudate cells with nuclei (magnified 450 diameters), from an aneurism by anastomosis, which was seated under the skin of the face, to which it imparted a blue colour.

EXPLANATION OF THE PLATES.

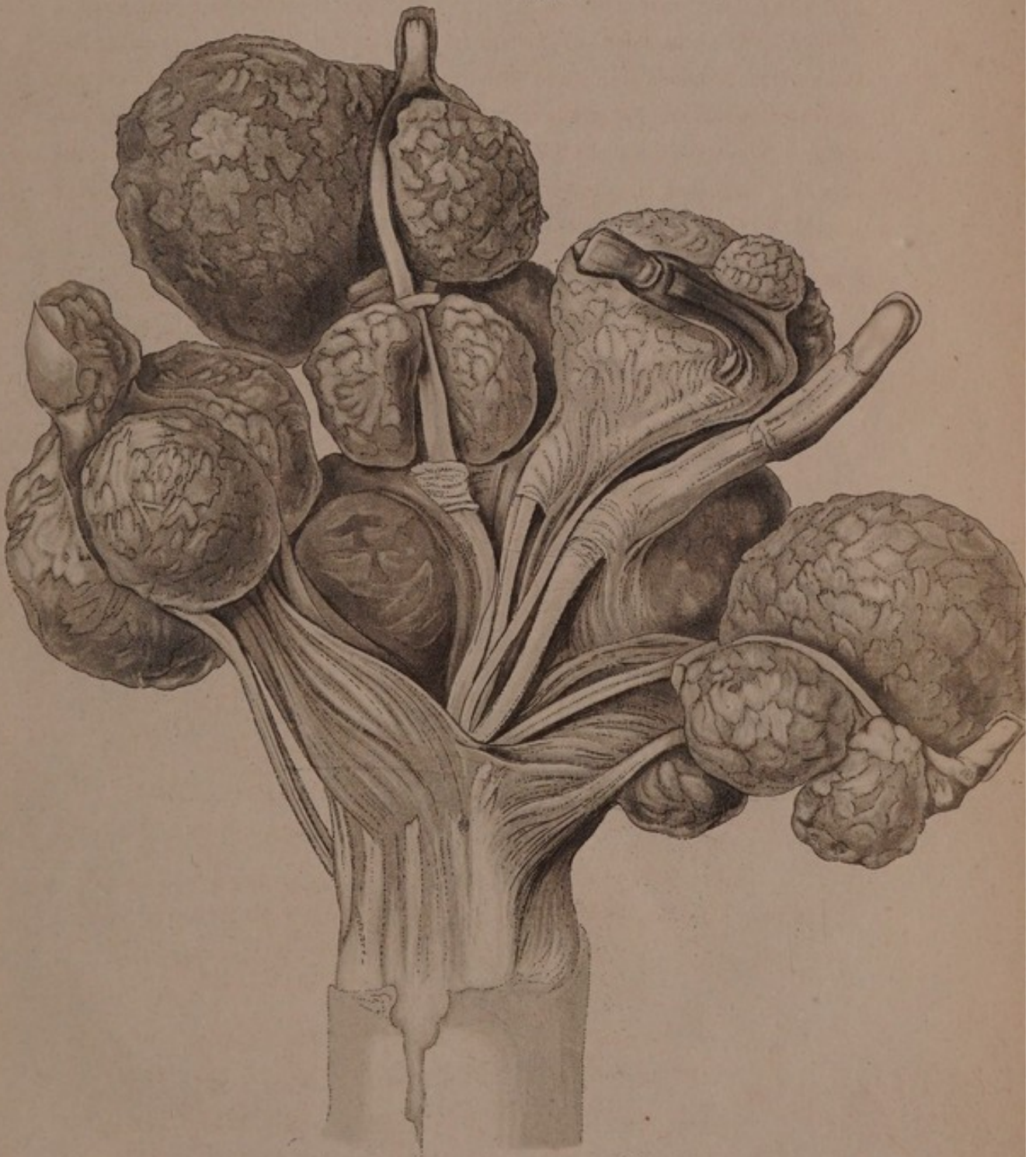
PLATES VII AND VIII.

Fig. 1. Enchondroma of the metacarpal bones, and of most of the phalanges of the fingers. The phalanges not affected are those of the fourth finger, and the last phalanx of the second, third, and fifth finger. Externally the tumors were covered with isolated lamellæ of bone; internally, they were entirely made up of soft cartilage. The small muscles of the thumb and little finger, and the tendons of the flexors and extensors, are perfectly healthy. The hand was amputated from a girl by M. v. Graefe, and is now numbered 8817 in the museum at Berlin.

Fig. 2. Section of one of these tumors.

Fig. 3. Enchondroma of the metacarpal bones and phalanges of the two outer fingers of a man 28 years old. No. 8846 in the museum at Berlin. For an account of it see page I43, No. 10.

FIG. 1.




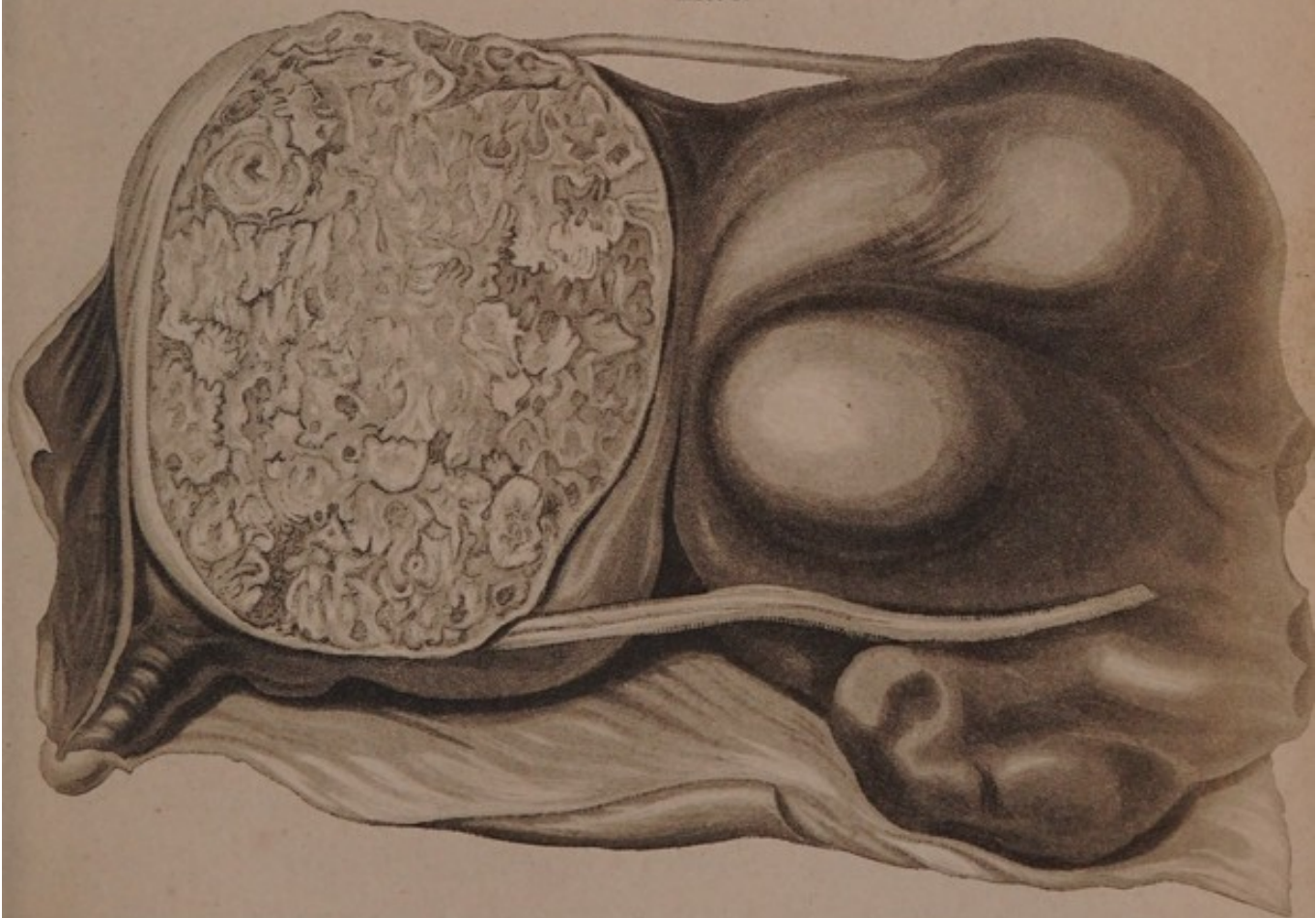
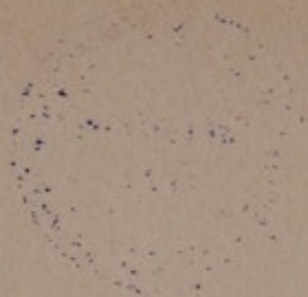


FIG. 2.

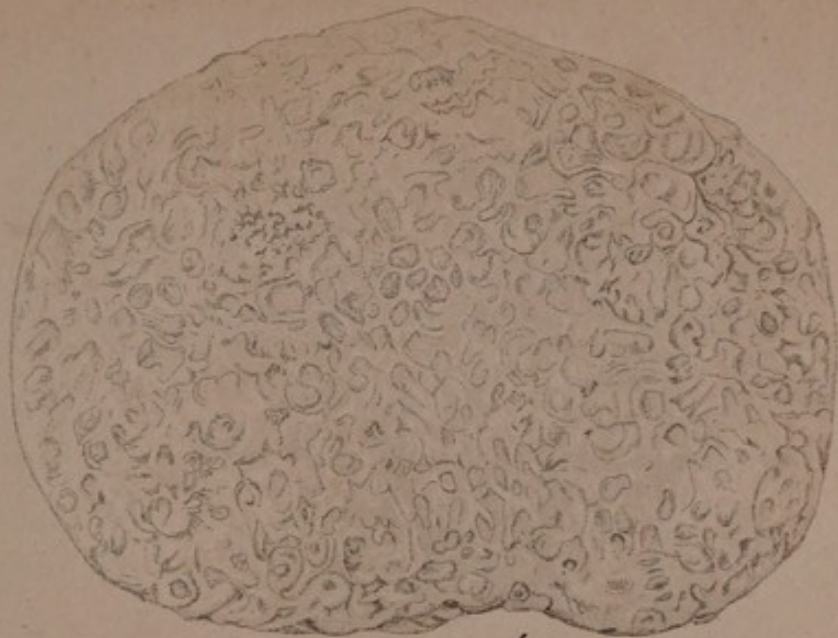

FIG. 3.







GENERAL OBSERVATIONS

ON THE

MINUTE STRUCTURE OF MORBID GROWTHS.

THE pathology of morbid tumors and fungoid growths is at present in its infancy; peculiarities in the contour and consistence of tumors, or differences which their sections may present to the naked eye, have formed, hitherto, the only basis of classifications, while no one has had recourse to microscopic examination of their structure, or to chemical analysis of their constituents. So numerous, however, are the transitions into each other of those general mechanical differences which the exterior or interior of morbid growths presents, that the observation of the abovementioned characteristics is alone insufficient for the purposes of accurate diagnosis. Growths, indeed, which are peculiar to certain tissues may often be distinguished with certainty without minute examination, as is the case with neuroma in nerves, and with polypi in mucous membranes. If, however, any organic tissue is subject to many and various changes, some of which are peculiar to it, while others occur also in different tissues, then does accurate diagnosis often become exceedingly difficult, or, in the present state of our knowledge, even impossible. These difficulties are greatest in the case of tumors which do not owe their existence to the peculiarities of any par-

ticular structure, but which may occur at the same time in many and very different tissues. A tumor of a non-malignant nature may readily assume the appearance of one that is carcinomatous, and be easily mistaken for it. The different stages of development of tumors are a further cause of the great confusion which prevails throughout this subject.

tumor Many innocent growths have the peculiarity of progressing in their development with greater or less rapidity. If inflammation should be set up in their substance, solution of continuity may take place in the parts covering them, and a fungoid growth with an ulcerated surface may be formed. The more independent, however, that a growth has become, the further is it removed from the healing, restorative influence of the organism. Moreover, a tumor originally not malignant may, owing to the decomposition which goes on in its inflamed and diseased interior, as well as on its ulcerated surface, exert an injurious influence on the whole constitution; it may give rise to repeated hæmorrhages from its surface, and may induce a state of general cachexy. Should, however, the nidus of these morbid changes be extirpated, their cause is removed; the health will, under favourable circumstances, be restored; and the tumor will not return, unless there exist in the constitution a tendency to the local deposition and organization of the substance which formed the growth. The tumor of aneurism by anastomosis affords an instance of this, as do albuminous sarcoma, and the tumor fibrosus, s. desmoides, both of which will be hereafter described. All these circumstances, while they render it extremely easy to confound tumors naturally innocent, and dangerous only under certain circumstances, with such as are by nature malignant, afford many additional reasons for seeking some surer means of distinguishing between the two than we at present possess.

The difficulty of distinguishing between tumors naturally in-

nocent and such as are of a carcinomatous character, is greatly increased by the analogous appearance which they often assume when once they have passed into the open state, and continue to grow with an ulcerated and decomposed surface. Thus, aneurism by anastomosis becomes, when in the open state, very similar to fungus hæmatodes in the same condition; and cases will be hereafter adduced in which other innocent growths presented at their surface a malignant appearance.

Usually it is regarded as an infallible sign of malignity if a tumor, after having been extirpated once or twice, returns at the same spot, as is so often observed in the case of carcinomatous tumors; but even on this point it is possible to be deceived. Several cases will be detailed in which tumors returned at the same spot after having been extirpated once or oftener, and which, nevertheless, were not carcinomatous; but at last disappeared after their final extirpation, and were followed by the perfect recovery of the patient. In these cases the reappearance of the tumor depended on its not having been thoroughly extirpated: the life of these growths is too independent, and their vegetation too little under the healing influence of the whole organism, for any part of them which may be left to be susceptible of a return to a healthy condition. The organism does not exert on growths such as these, which form no necessary part of the whole, that regulating power to which all essential parts of the body are subjected.

The foregoing observations explain the discordant opinions of practitioners with regard to the curability or incurability of carcinoma by extirpation. Carcinoma would be much less frequently confounded with innocent, curable growths, if the points ordinarily insisted on as pathognomonic were really trustworthy.

The diagnosis of morbid growths is rendered still more difficult, by the circumstance that, though carcinoma is generally a

constitutional disease, yet, under certain circumstances, non-carcinomatous growths may be so too, without necessarily assuming the nature of carcinoma. Tumors formed of tubercular matter, imply the previous existence of the tubercular diathesis. If such a growth is extirpated, it may not return either in its old seat, or in any other part; but, under certain conditions, it may reappear. This would depend entirely, upon whether the tubercular diathesis still existed at the time when the operation was performed, or whether, though previously present, it had already ceased. Other non-carcinomatous tumors afford instances of similar occurrences; thus, enchondroma of the osseous system may exist in many different parts, in consequence of a diathesis to its formation. The tumors once formed, continue to exist; but if the hand of a patient is removed in after-life, in consequence of the large size which the tumor there may have acquired, the disease will not return in that situation, though it remains unaltered in other parts of the osseous system previously affected during youth.

This condition of one of the most important parts of pathology and pathological anatomy rendered an accurate microscopical and chemical examination of these growths very desirable. Miescher first trod the path in his excellent pathological observations with regard to the alterations which bones undergo from inflammation, and, with the same object, the author instituted his investigations into the chemical changes in the bones during healthy and morbid development. The object of a microscopico-chemical analysis of tumors would be to ascertain whether there are any important internal differences in their organization and chemical composition, and, if they do exist, exactly to determine their nature: it is evident, however, that in practice no such subtle differences can serve as a foundation for the diagnosis of morbid growths. Some pathognomonic

characters must, therefore, be found out, such as are easily recognizable, and which do not imply the possession of any peculiar talent, nor of physiological skill. Microscopical and chemical analyses can never become a means of surgical diagnosis: it were ridiculous to desire it, or to suppose it practicable. These analyses, however, make us acquainted with the most important internal differences of pathological products; and when these have been ascertained, we may next seek to discover easily distinguishable characteristics for the purposes of practical diagnosis.

The means of which we have hitherto been possessed have sufficed, indeed, to distinguish fatty tumors, polypi of mucous membranes, neuroma, aneurism by anastomosis, tumor fibrosus, and some forms of carcinomatous disease, as cancer alveolaris, melanodes, and medullaris. The diagnosis of carcinoma of the mammary gland is still exceedingly difficult, if not impossible; cancer medullaris, too, cannot always be certainly distinguished. Tumors not of a carcinomatous nature have often been confounded with it, because they returned after having been completely extirpated; and, the operation being at length successful, persons have fancied that they had thus cured medullary carcinoma. Scarcely any definite meaning can be attached to the terms sarcoma, steatoma, osteo-sarcoma, osteo-steatoma, although they are words in current use in medicine, and even in pathological anatomy. A glance at the literature of spina ventosa shews that this obscure appellation has been given to a variety of different diseases of bone; and, lastly, many important forms of morbid structure have been totally undescribed. It must, indeed, be owned, that the greater attention which has of late been paid to the external and internal characters of morbid structure has much advanced the progress of pathological anatomy. Thus, though Mr. Abernethy's attempt at a systematic

arrangement of tumors was not very successful, yet his observations, together with those of Burns and Hey, have made us acquainted with the peculiar nature of medullary sarcoma. Equally valuable is the knowledge of cancer alveolaris, for which we are indebted to Laennec, Otto, and Cruveilhier. Fibrous tumors, which certainly are most easily recognized, owing to the peculiarity of their texture, which is usually firm and fibrous, often tendinous and glistening like satin, have been separated from the debatable classes of steatoma and sarcoma, while Bayle has examined their nature with great success. Sir A. Cooper has taught us to distinguish many morbid growths of the breast and testicle; and, further, to him we owe a valuable work on osseous tumors. The various forms of encysted tumor have been well and carefully examined by Dr. Hodgkin. Lastly, we thankfully acknowledge our obligations to the labors of Wardrop, Langstaff, Travers, v. Walther, &c. on carcinomatous growths, as well as to the systematic treatises of Laennec, Cruveilhier, Heusinger, and others, whose share in promoting the advances of pathological anatomy will be exhibited in the historical part of this work. Nevertheless, it is not possible to determine the fundamental points of difference between various morbid structures, except by means of chemical and microscopical examination. The structure of a part, when examined by the naked eye, and without the aid of chemistry, is often but obscurely comprehended by the observer, and its nature confusedly described to others. Though Mr. Abernethy labored hard to form a systematic arrangement of tumors, yet the author is unable to identify many of the forms he has described, and is consequently obliged to abandon all attempts at explaining their synonyms. Notwithstanding the meritorious attempts at classification which have been made, and the greatly increased number of morbid growths which have been distin-

guished from each other, still the system followed by most writers is scarcely superior to that adopted by Marcus Aurelius Severinus, whose observations, for the time in which he lived, are excellent.

Such were the considerations with which the author some years since began the arrangement of the large collection of tumors in the Royal Museum at Berlin. On a close inspection of the preparations, many were met with presenting such peculiarities, that it was not possible to assign them any certain place, in accordance with the state of knowledge at that time. Soon it became evident that, if the classification of so many important objects were to have any real value, it would be necessary to devote many years to the examination of them, and of other fresh pathological specimens; and to this task the author accordingly betook himself. In an oration* on a public occasion the author set forth the principles in accordance with which such investigations must be conducted, and adduced one example in illustration of his opinions. The materials afforded by the Royal Museum, by that at the Charité Hospital, and in the Veterinary School, though numerous, yet left room for doubt on many points. Subsequent visits to Halle, Brunswick, and London, and the inspection of the rich collections in those places, cleared up many difficulties; while the author's investigations were still further facilitated by the kind assistance of professors v. Graefe, Jüngken, Dieffenbach, Froriep, and Gurlt. Subsequently, having learnt the importance of seeing much, in order not to lay too great stress on accidental varieties, the author had the satisfaction of finding certain peculiarities continually recurring; and at length he arrived at the conviction, that in all these structures there are constant differences which may be

* Rede zur Feier des 42sten. Stiftungstages des Königl. med. chir. Friedrich-Wilhelms-Instituts, am 2 August 1836. *Berlin.*

recognized with certainty. The author found that he had formed the most correct notions with regard to those forms which present analogies to healthy structure, as the tumor fibrosus s. desmoides, the albumino-fibrous tumor, enchondroma,—the parallel to cartilaginous structure,—and cellular sarcoma a parallel structure to the tissues of the chorda dorsalis, and of the decidua, which are composed of cells analogous to those of plants.

As early as the year 1836, the author had recognized with the microscope the cellular structure of various morbid growths*; namely, of laminated cholesteatoma, of cellular polypit, and of osteo-sarcoma†. At the same time the author pointed out the analogy between cholesteatoma with its polyedrous cells, resembling those of vegetable parenchyma, and that cellular structure of the chorda dorsalis which he had been the first to demonstrate. Enchondroma also was described as a structure parallel to cartilage, both in anatomical and chemical characters, and sufficiently distinguished, by the presence of chondrine, from other morbid growths. Fibrous structure was shewn to predominate in the tendino-fibrous and albumino-fibrous tumors, as well as in carcinoma hyalinum. Very regular crystals were observed in many growths, and several new and peculiar forms of carcinomatous degeneration were described. The presence of caudate bodies, as a primary element of morbid structure, was soon afterwards ascertained by the author, who gave a description of them as they exist in fungus medullaris, and in melanosis‡.

* Bericht über die zur Bekanntmachung geeigneten Verhandlungen der K. Academie der Wissenschaften, December 1836. Müller's Archiv. 1836, CCXIX.

† Bericht, &c.: Müller's Archiv. 1836, CCXXIV.

‡ Rede zur Feier, &c., page 15.

§ Müller's Archiv. 1837, v. Hft. p. 466.

Nuclei, cells, caudate bodies, fibres, and crystals, are the only elementary bodies which have hitherto been discovered. The part which cells sustain in the composition of all morbid growths has, however, recently acquired additional importance from the investigations of Schleiden and Schwann*. The researches of the former relate to the development of the young cellules of plants from nuclei formed in the interior of the parent cells; those of the latter refer to the analogy between animal and vegetable structure. According to Schwann, all the tissues in the embryo are formed from cells, which are themselves developed from nuclei; growth being the result of fresh formations of cells, which afterwards undergo transformation into other tissues. These observations led the author to examine morbid growths very carefully; both those in which no cells had hitherto been discovered, and also such as were known to present a cellular structure. The former were scrutinized in order to ascertain whether or no cells did exist in them; the latter with a view to determine the presence of nuclei in the walls, or within the interior of the cells; while the author further hoped to verify the truth of that principle which Schwann has laid down as regulating the increase and growth of animal tissues. By employing a high magnifying power, cells were observed in many morbid growths in which they were not previously known to exist, as in collonema, in many varieties of carcinoma, and in enchondroma. In most growths presenting a cellular structure, with the exception of cholesteatoma and cellular polypi, the nuclei of the cells were discovered, situated either in their walls or in their interior: in many instances, too, young cells were formed within older ones, as was the case in sarcoma,

* Froriep's Not. January 1838, No. 3 [and Mikroskopische Untersuchungen über die Uebereinstimmung in der Structur und dem Wachstume der Thiere und Pflanzen. Berlin, 1839.]

enchondroma, carcinoma, and collonema. Thus, then, as might have been anticipated, did the examination of morbid structures confirm Schwann's observations touching the development and growth of healthy tissues.

In proportion, however, as a greater uniformity has been observed in the structure of all morbid growths, does it become an increasingly difficult task to light upon such anatomical and chemical characters as may be relied on for distinguishing between those most dissimilar in physiological properties. We now, therefore, pass to a more minute examination of the chemical composition and microscopic structure of morbid growths.

Chemical composition

The chemical composition of morbid growths, independently of those products of disorganization found on their surface when ulcerated, is found to differ less than might have been imagined from the ordinary constituents of the animal body. Possibly this is the result of the imperfection of animal chemistry, and of our inability to detect important differences between substances, on account of the similarity of the results they yield when treated by chemical reagents. Slight, however, as these differences are, they acquire great interest when viewed in combination with the slight microscopic differences presented by sound and morbid tissues, and with the wonderful correspondence in the manner of their development.

Chemistry points out three grand differences between morbid growths. The proximate animal principles which exist in them are composed either of some kind of fat or gelatine, or of albumen. This, of course, is not asserted strictly, but only with reference to the mass, since other materials, as osmazome, salivary matter, caseine, &c. are present in small quantities. The division of morbid structures into the three classes distinguished by the presence of fatty matter, of gelatine, and of albumen, is moreover only relative, for those materials occur combined

in pathological products. Free fat, indeed, is met with in the form of oil-globules, or of fat granules in almost all structures. Thus, too, even from structures composed principally of albumen a little gelatine may sometimes be obtained by long boiling, in proportion as cellular tissue entered into their composition. Nevertheless, this division is useful, for there is always a predominance of one of the three abovementioned constituents, and often one only is detected in a morbid growth. For the present, therefore, a division may be made of all tumors into the fatty, those which contain gelatine, and the albuminous; though the advantages of this classification are not sufficient to warrant its being extended to minutiae.

Fatty tumors present many varieties, partly in their structure, partly in the nature of the fat they contain. They always consist of an animal, organized base, composed, not of fat, but of cells or cysts secreting it, and of the fat itself. Their nature may be, in part, determined by the physical appearance of the fat: in part it is discovered by the action of certain reagents; some fat being capable of conversion into soap, while another kind of fat is incapable of undergoing that process. The fatty constituent of these growths is fusible at a certain temperature, greases blotting paper, is extracted by hot alcohol or ether, and is again deposited in forms either crystalline, or irregular, on cooling or evaporation. To this class, lipoma, or the common fatty tumor, may be referred, and cholesteatoma, or the laminated fatty tumor. In these growths the fat is usually almost entirely contained within its secreting organs, but, in those other structures of which fat is not the chief element, it generally exists either in the form of oil-globules, or of granules, or as minute crystals.

Morbid growths of the second class are recognized by long boiling reducing them almost entirely to gelatine. The length

3 kinds
of tumors
1. Fatty
2. Containing
3. Albuminous

1. Fatty

Lipoma
Cholesteoma

2. By long
boiling
reduced almost
entirely to gelatine

of time requisite for obtaining much gelatine from these structures differs greatly in different cases. In many instances from ten to twelve hours suffice; eighteen or more hours are often requisite; and to effect a complete solution of all parts containing gelatine, a longer period is frequently necessary. Growths yielding gelatine, when once known, may easily be recognized. Especially striking is the difference between their appearance and that of structures the main constituent of which is some albuminous substance. The gelatine obtained by boiling, whether chondrine or ordinary gelatine,—*colla*,—is naturally mixed with osmazome, which must be removed. Gelatine rendered impure by osmazome is affected by the same chemical reagents as osmazome. When impure, it is precipitated by acetate of lead. Among the class of growths yielding gelatine may be ranged the cellulo-fibrous tumor, the tumor fibrosus s. desmoides, enchondroma, and the osteoid tumor.

Albuminous structures either yield no gelatine, even when boiled from eighteen to twenty-four hours; or if, after long boiling, some gelatine should appear, still by far the greatest portion of the growth remains undissolved, thus shewing, that some substance of an albuminous nature is its main constituent. The water in which these structures have been boiled may contain, even after having been filtered, a substance soluble both in hot and cold water. Some of these growths yield a trace of caseine, which may be detected, in addition to the ordinary not very decisive tests, by a little acetic or hydrochloric acid, which renders the filtered fluid turbid, but restores its pellucidity when added in excess. The fluid is also rendered turbid by alum, but does not recover its transparency on the addition of an excess of that substance. Caseine exists in a very minute quantity in most albuminous structures, as in albuminous sarcoma, in carcinoma simplex, or reticulare. Sometimes, also, these growths contain

cellulo fibrous
fibrosus s. desmoides
enchondroma
osteoid tumor.

Albuminous

(Original)
p. 5.

a substance closely allied to salivary matter, and precipitated neither by acids, alkalies, metals, nor earthy salts, and even not by alcohol nor tannin. The presence of this matter can be discovered only negatively, by evaporation to dryness and carbonization. The author found it in collonema, and in carcinoma alveolare; in the gelatiniform mass of which latter growth no caseine could be detected.

When these growths had not been kept for a long time in spirit, they contained osmazome, which, however, was easily extracted from them by water or alcohol, if they were previously pounded.

The external appearance of albuminous structures, and of all those which do not yield gelatine, is so striking, that, when once seen, they are easily identified. They never have a compact, tendinous texture: sometimes they are tender and gelatiniform, like the chorda dorsalis; at other times fibrinous, like decidua; sometimes they are cellular, granular, or fibrous; generally they are friable and easily torn. To this class belong collonema, scrofulous tumors, albuminous sarcoma, albuminous osteo-sarcoma, and all varieties of real carcinoma. In repeated examinations of cancer of the mammary gland the author never detected gelatine, even after boiling for eighteen or twenty-four hours. Once, a small quantity of gelatine was obtained by boiling fungus medullaris for eighteen hours, but the great mass of the tumor shewed no inclination to become dissolved, or in any way altered. The existence of cellular tissue in the growth was probably the cause of the accidental presence of gelatine.

The minute microscopic elements of morbid growths are, in addition to capillary vessels; fibres, granules, cells both with and without nuclei, caudate or spindle-shaped bodies, and vessels. Hitherto the author has not succeeded in detecting other elements. Bloodvessels exist in almost all morbid structures;

*Collonema
Sarcoma
Alb: Sarco
alb: osteo
all real can*

Bl: Vessels

*Bl: vessels
all morb: struct
except*

indeed, the author has detected them in all with the exception of cholesteatoma, a growth often developed within cysts, with which it maintains no organic connexion. The notion that scirrhus is an unorganized and extra-vascular structure, is perfectly ridiculous: vessels may almost always be seen on making a section of a scirrhous growth, but fine injections exhibit them still more clearly. Fine injections are, however, by no means well suited to display the minute texture of morbid growths. Indeed, with the exception of aneurism by anastomosis, these growths present no remarkable arrangement of vessels, and, consequently, no peculiarity which injections could render more distinct; while they have the disadvantage of concealing important forms of structure, such as may be satisfactorily studied by means of the microscope, in fresh specimens, or even in such as have been kept for some time in alcohol.

Fibres form a grand constituent both of albuminous growths and of those which yield gelatine. Thus, for instance, the cellulo-fibrous tumor is composed entirely of fibres exactly resembling those of cellular tissue, and presenting the same wavy arrangement of their bundles. Another of the gelatine-yielding structures, the tendino-fibrous tumor, or tumor-fibrosus s. desmoides, is likewise formed of fibres. Among the albuminous structures, or those the chief element of which is a substance insoluble by boiling, there are some which have a completely fibrous texture. Instances of this are afforded by the albumino-fibrous tumor, and by carcinoma fasciculatum s. hyalinum, the latter of which is made up entirely of bundles of soft fibres, with granules in their intervals. These fibres are very transparent, and therefore not easily distinguishable under the microscope. In these growths the fibrous structure forms their most striking characteristic: but there are other albuminous tumors, as, for instance, the cellular, in which it is quite a secondary ele-

cholesteatoma

fine injections

use.

fibres

constituent of

223

ment. In carcinoma alveolare, the walls of the old cells, in which the generation of new cells takes place, become at last split into isolated fibres, having scarcely any connexion with each other. Occasionally, too, the caudate cells, when arranged in a certain manner, produce in albuminous growths an approximation to fibrous structure.

The name of granule is applied to such spheroidal or elliptical bodies as do not present any internal cavity when viewed under the microscope. They are present in vast numbers in some albuminous tumors. Often, too, in different specimens of carcinoma, the germinal cells were found to contain, in addition to the formative globules and young cellules, a number of small granules perfectly distinct from both. In carcinoma fasciculatum, of which fibres form a chief element, many round granules are situated between the fibres, the bundles of which they so beset, as to render it very difficult accurately to observe their structure.

The cell is by far the most frequent element of morbid growths. Thus, it exists in sarcoma cellulare, in enchondroma, in carcinoma simplex, reticulare, and alveolare. A low magnifying power does not suffice to shew this fact, since the cells, unless magnified from 400 to 500 times, generally look like granules; but on the employment of a high power (as, for instance, of the object glass 4, 5, or 6, and of the ocular 2 of one of Schiek's microscopes) the cellular structure of most morbid growths becomes apparent. In many growths this cellular texture is so coarse as to be evident by a very low magnifying power, or even to be distinguishable by the naked eye.

Cells sometimes form the only tissue of morbid growths, as in the case of cholesteatoma, of carcinoma alveolare, of cellular sarcoma, and of osteo-sarcoma. In these instances, cells cohering by their walls form the important parts of the structure, while

fibres of cellular tissue serve only to form membranes uniting together its several lobuli.

In other cases, where microscopic cells still form the basis of the growth, these cells do not cohere, though in close apposition; but, on the contrary, are free, may be separated from each other, and, when looked at under the microscope, present the appearance of globules. It is only by employing high magnifying powers that their real structure becomes evident: then they are seen to be spheroidal cells, the presence of a small cellule, or of several corpuscles in their interior, serving to mark their cavity. These minute globular cells, which form the real *seminium morbi* in several forms of carcinoma, as in carcinoma simplex, reticulare, and alveolare, are deposited in extraordinary number in the meshes of a fibrous texture.

Nuclei The presence or absence of a nucleus in the walls of the cell constitutes a structural difference between morbid growths. The nucleus, when present, is situated in the substance of the wall of the cell, and from it the cell has been developed. Sometimes also a cell contains within its cavity nuclei, which serve as the germs of new cellules. This is the case in enchondroma, and in carcinoma alveolare. In most cases, as in enchondroma, in several forms of carcinoma, in cellular sarcoma, and in osteosarcoma, the parietal nucleus, at least, of each cell is evident, and may be recognized by its flat or roundish form, and generally by its darker tint. In other instances, however, the cells have no nuclei; of this, cholesteatoma affords an example.

The substance of some cellular structures yields gelatine, while from that of others it cannot be obtained. Among healthy structures, cartilage is the type of the former; the parallel pathological structure to which is enchondroma. Instances of cellular structures not yielding gelatine, and more or less albu-

minous in their composition are the chorda dorsalis, the nature of which was described some years ago by the author, and the decidua; both of which display the most perfect correspondence with the primitive structure of cartilage, while, chemically, they differ from it so widely. As parallel pathological products may be mentioned, gelatiniform tumors and cellular sarcoma.

Some cells do not contain young cellules, while within others a series of younger ones are encased one within another, and this furnishes us with a new means for distinguishing between different morbid growths. Laminated cholesteatoma affords an example of the former kind, for it consists of a polyedrous cellular tissue, resembling vegetable parenchyma, in which the author has never detected smaller cellules. In other cases the cells are encased, one within the other. A cell, when viewed under the microscope, appears to contain corpuscles in its interior; but careful examination shews, in accordance with Schwann's discoveries as to the primitive formation of healthy tissues, that these corpuscles are either young cells, one contained within the other; or nuclei, from which young cellules are developed. This holds good of many of the cells in sarcoma cellulare, in carcinoma alveolare, and in enchondroma, as also of some formative globules in carcinoma simplex and reticulare. The finest cells can be recognised only by the most powerful magnifying-glasses, and often are not larger than 0.00015 to 0.00021 of an English inch: the average size of the cells in growths with a cellular base is 0.00054 of an English inch.

The caudate bodies are another frequent element of morbid growths. The author has described them in another place, as they occur in fungus medullaris, and sometimes also in melanosis; Valentin*, too, described them under the name of spindle-

* Valentin Repertorium für Anatomie und Physiologie, 1837, 2 Abtheilung, p. 277.

shaped bodies, as constituting the structure of encephaloid growths.

Character
Caudate
bodies

These corpuscles are elliptical pouches, or cells, terminating at one or both extremities in a fine caudiform fibril of uncertain length. Sometimes the interior of these bodies is granulated, and filled with a greater or less number of granules. The interior of their cavities is, however, seldom distinctly visible, though occasionally a nucleus, of a somewhat darker tint than the surrounding substance, may be observed, together with one or more nucleoli. (See the figures in Plates i, ii, iii, iv.) This structure is exactly the same as that which Schwann observed in primitive cellular tissue, and in other tissues which undergo the transformation from cellular to fibrous structure. Elongated cells become fibres, and thus do most fibres in the animal body seem to be formed: but in ~~those structures~~ ^{tumours} which consist of caudate corpuscles, it would appear as though the development of the fibres had been arrested while they were in the half cellular state in which they exist in the embryo. (2) Frequently, one end only of the corpuscles is prolonged into a fibril, while the other remains obtuse. There is great difference, too, in the length of the fibril: sometimes it is no longer than the corpuscle, or even does not equal it in length, while at other times it greatly exceeds it. The diameter of each fibril is generally from $\frac{1}{4}$ to $\frac{1}{5}$ only of that of the corpuscle. In no case has the author observed several corpuscles connected with one fibril. In some instances, however, not only does each end of the corpuscle give origin to a fibril, but a third springs from its side, and sometimes the fibril which proceeds from the end of the corpuscle becomes bifurcated at its extremity. (Plate iv, fig. 17, shews the various forms of the caudate corpuscles from the same morbid growth.) The arrangement of the caudate corpuscles often presents great varieties. Sometimes a few only

original
p. 7

(1) Die Faser entsteht nämlich aus der Verlängerung der kernhaltigen Zelle in einem Faden.

(2) schreitet die Faserbildung nicht über die embryonale Form Lattenfaser fort.

are met with among the round, cellular, formative globules of fungus medullaris, which may constitute the chief mass of the morbid structure; an occurrence which was observed in two specimens of fungus medullaris of the liver, and in an enormous medullary fungus of the abdominal cavity. Just in the same way a few may be scattered through the tissue of melanotic carcinoma, as the author has seen in many instances. Sometimes they are present in great number, and then form the main substance of a tumor; this was the case in a fungus medullaris of the thigh, and in another specimen of the same disease, affecting the abdominal cavity. In these cases, however, there was no distinctly linear arrangement of the corpuscles, nor was the structure more easily rent in one than in another direction. Instances do, nevertheless, occur in which these corpuscles are arranged regularly in lines, forming fasciculi, which run in one direction, and which present to the naked eye the appearance of a fibrous structure. Such apparently fibrous tissues are always soft, and may be easily torn or broken. Valentin has described and delineated the fibrous arrangement of the caudate corpuscles, as constituting the structure of encephaloid growths. (See Plate iv, fig. 11—16.)

The caudate corpuscles are by no means peculiar to fungus medullaris; they may, indeed, often be observed in its substance, but often they do not exist in it, while they are as frequently met with in non-carcinomatous as in medullary growths. They occur in the substance of aneurism by anastomosis, and in one instance the author saw them in an albuminous osteo-sarcoma of the lower jaw, which was extirpated with success. The mass of the tumour was formed of these bodies, which were distributed irregularly through its tissue. (Plate iv, fig. 17.) On another occasion, a large, benignant fungus of the conjunctiva palpebrarum was made up almost entirely of these corpuscles,

arranged in the fibrous manner which Valentin has described. (Plate iv, fig. 16.) This growth was lobulated: it could be broken, and presented a fibrous fracture, fasciculi appearing to radiate towards the periphery from one common centre.

Like those already mentioned, it belonged to the category of benignant albuminous sarcoma. It was extirpated thrice, but returned after each operation, having been cut into rather than excised. After having been extirpated for the last time, on which occasion the eye was also removed, it ceased to return, and the patient recovered completely. It had attained the size of the fist, but proceeded entirely from the conjunctiva, the globe of the eye being perfectly sound*.

The caudate corpuscles are elements of carcinomatous growths, as well as of perfectly innocent albuminous sarcoma; but in no instance has the author met with them in large number, in those tumors which become converted into gelatine by boiling. Nevertheless, it is possible that, even in these latter growths, they may be found at certain periods in considerable number, for they probably depend only on the transformation of cells into fibres, and consequently are merely fibres in an early stage of development.

Differences in the structure of the microscopic forms of morbid growths depend on the way in which their development proceeds. Cellular growths are those in which the process of development can be most easily traced, now that Schwann has laid the foundation for such investigations by his discoveries with regard to the development of healthy tissues. According to Schwann's observations, nearly all animal tissues are, in their primitive form, composed of cells, which have precisely the

* The history of the above case is detailed by Helling, in Rust's Magazin, Band ii.

same structure as those of vegetables, and their formation and growth are regulated by laws exactly resembling those to which Schleiden discovered the cells of plants to be subject. In the wall of each young cellule is a nucleus from which it is developed. New cells are formed either within the interior or on the surface of old cells: in the former case they are developed from a nucleus loose within the cavity of the parent cell, and unconnected with its parietes. Schwann has demonstrated the former process as it occurs in cartilage, and in the *chorda dorsalis*: the latter appears to take place in the case of many other textures, for Schwann has shewn that all tissues in the embryo consist of cells with parietal nuclei, though it is not possible in all to prove the formation of new cells in the interior of old ones. An instance of the constant formation of new cells with parietal nuclei, external to the old cells, is afforded in the adult by the cells of the epithelium, which do not display any approach to an endogenous mode of growth. The formation of young cells can, however, be best observed in those cases in which they are developed internal to the old ones, or, in other words, in which the nuclei of new cells are situated within the cavity of old cells. In these cases the process of development as observed by Schleiden in vegetable tissues, and by Schwann in those of animals, is as follows:—

The nuclei protrude young cellules, which project from their surface as the watch-glass from the watch. As growth proceeds, the young cell increases in size, while the nucleus remains imbedded in its wall. If several young cells should be formed from several nuclei seated within the parent cell, they progress in growth so as to fill up its cavity, and then their walls usually become confounded with those of the parent cell. Fresh nuclei form within the cavity of these young cells, and from a repetition of this process result successive generations of cells. The

walls of the young cells are perfectly transparent, but those of the older cells become thickened, and, in animal tissues, often converted more or less into a fibrous structure. In this way the cells of cartilage and of the chorda dorsalis, probably also those of the decidua, become developed.

It would be natural to expect a repetition of this process in the formation of many pathological structures. In fact, the young cells in enchondroma and in cancer alveolaris are formed in a precisely similar way; and the author's observations render it probable that the same process also obtains in the development of many forms of carcinoma, and of cellular sarcoma.

In enchondroma, the bodies hitherto looked upon as the cartilaginous corpuscles are now seen to be cells with parietal nuclei. The author has often observed young cells with parietal nuclei encased within the parent cells. (Plate v, fig. 4, 6.) This structure was sufficiently evident in osseous enchondroma, but still more distinct in enchondroma of the parotid gland. Enchondroma is formed entirely, or nearly so, of round or oval cells, the walls of which are transparent, and, for the most part, closely in apposition with each other.

Albumino-cellular sarcoma and osteo-sarcoma, and gelatiniform sarcoma, appear to be developed in this way, as is also collonema. In many of the parent cells the young cellules with their parietal nuclei, were very distinctly seen. The external appearance of these growths, however, as viewed by the naked eye, is very different. Enchondroma is cartilaginous, diaphanous, and grey: cellular sarcoma is white and granular; but when viewed by strong magnifying powers, their structure is seen to be identical. Successive series of cells, encased the one within the other, are seen to make up the structure of carcinoma alveolare. The large cells, which are visible to the naked eye, contain in their cavities a second generation, and so forth, till we

arrive at the smallest cells of all, in which are nuclei of a darkish yellow tint, generally somewhat elongated, and presenting a minutely granular structure. Here and there these nuclei may be seen lying free in the cavity of the cells: in other parts they have already evolved a germinal cell, and may be seen imbedded in the substance of its parietes. The walls of the large cells, when greatly developed, appear to assume a fibrous structure, and at last to burst.

The formative globules of simple and of reticular cancer of the breast are not merely cells containing granules, but sometimes in the interior of each are one or more roundish or elongated germinal cells, with a darkish nucleus in their parietes, from which they have probably been developed.

How similar soever the most different morbid growths may be at their first origin, still they present great diversities in their subsequent development. This is most strikingly exemplified in carcinoma alveolare, and in carcinoma simplex and reticulare. In carcinoma alveolare the parent cells continue to grow for a long time, and attain a size even of two, three, or more lines. The young cellules by degrees fill the parent cell, and then their walls grow together, and become confounded with each other and with those of the parent cell. In carcinoma simplex and reticulare, on the contrary, this cohesion of the cells does not take place, neither do the cells continue to increase in size; but their development is arrested when at the point of microscopic formative globules, which are strewn through the meshes of a fibrous structure, and may be separated from each other with the greatest ease. The old cells appear to become destroyed.

The process of development of the caudate corpuscles seems also to be thoroughly understood. It results from Schwann's observations on the tissues of the embryo, that these bodies are

*Morbid
similar
origin
frequent
the
develop
process*

cells which have undergone a metamorphosis. In proof of this may be adduced the fact, that not only has the author seen caudate corpuscles in carcinoma medullare scattered among cells; but likewise in a specimen of sarcoma with caudate corpuscles in the midst of the fasciculi of these bodies were cells, some elongated, and others round, containing a germinal cellule with its parietal nucleus. In this instance the greater part of the morbid growth presented a fibrous appearance, owing to its being formed of caudate corpuscles arranged in fasciculi; but towards the surface the fibrous part seemed to assume a granular structure, and examination with the microscope shewed that there cellular globules existed in place of the caudate corpuscles. In melanosis some of the cells containing pigment were seen by the author to be round or oval, while others had a caudate form. Lastly, caudate corpuscles are sometimes seen in which there is a distinct cavity. The external skin of the fœtus is, according to Schwann's observations, entirely formed of caudate corpuscles which terminate in long fibres, and constitute the fibres of the skin. In many other situations, too, Schwann saw caudate corpuscles in cellular tissue. These facts satisfactorily account for the presence of caudate corpuscles in innocent as well as in malignant growths. They are, like the germinal cells, an embryonic formation; and embryonic formations are found to be repeated in a remarkable manner in morbid growths.

From the preceding remarks it is evident that no division of pathological structures into homologous and heterologous can be established. Such a classification is formed without any knowledge of the structure of morbid growths, and is founded on blind, gratuitous hypothesis. The most innocent growths do not differ in their minute elements, nor in their origin, from carcinoma. If, then, it is of such great importance for practical me-

At least so far as is at present known

dicine to find out some pathognomonic marks of carcinomatous growths, they must evidently not be sought for in any supposed heterologous tissues, which, notwithstanding all that has been said about homology and heterology, no anatomist or pathologist has hitherto been able to define. The distinction between the carcinomatous and the innocent forms of albuminous growths presents the greatest difficulties. Here, neither the minute structure nor the chemical characters of the growth can be our guide, for carcinomatous tumors belong to that class the main constituent of which is a substance yielding albumen; consequently there are malignant albuminous growths. On the other hand, the diagnosis between carcinomatous structures and such as yield gelatine is very simple.

Whether the carcinomatous diathesis be peculiar and distinct from all others, or whether, under certain circumstances, any other structure may pass into the state of carcinoma, still the same question presents itself;—is there any other characteristic of carcinomatous growths than such as are derived from their minute structure, or from the process of their development? The solution of this question must always be the grand problem in the anatomy of morbid growths. The examination of numerous specimens of carcinoma has taught the author that they are, indeed, possessed of certain peculiar anatomical characters, which may serve to identify them; and, further, that these characters are distinguishable, on making a section of the growth, either by the naked eye, or at any rate by the aid of a common magnifying glass.

Although the structures which belong to this class are extremely various, still one may take the place of another. After the extirpation of carcinoma simplex, for example, carcinoma alveolare or fasciculatum may succeed, and often the several forms are coexistent. But, although transitions of the different

What
is the
of the
ant

forms into each other may occur, yet their extremes are very dissimilar, and no sort of resemblance can be traced between carcinoma simplex, or scirrhus, and carcinoma fasciculatum. In order, therefore, to be able to recognize carcinoma, a person must make himself acquainted with the individual peculiarities of every form of morbid structure, both innocent and malignant: in short, he must proceed as the botanist does who busies himself with the study of poisonous plants. The botanist acquires his knowledge, not by the discovery of any characteristics distinguishing poisonous plants from all others, for such are not presented by them, any more than by carcinomatous diseases, but rather by the patient examination of each individual plant. The author is firmly convinced that, by these means, such a knowledge may be obtained of the different forms of carcinoma; for he has succeeded in arriving at a tolerable degree of certainty in their diagnosis, by applying certain characteristics with which careful observation has made him acquainted. Still, however, there are some forms of disease, which, being destitute of any well-marked external peculiarities, may easily be confounded with others.

The principles in accordance with which morbid structures must be classified cannot be exclusively derived either from their minute structure, or from their chemical composition. For growths widely differing in their physiological characters and in their susceptibility of cure may present a perfect identity in their minute structure: similarity of structure may coexist with differences in their chemical constituents, or the same chemical characters may be found in growths, between which the greatest diversity exists with regard to their structure, physiological characters, or curableness. In determining the different genera, therefore, the subject must be regarded in all these points of view. Such a method of proceeding is the best to adopt in the

classification of all bodies in nature, for even in zoology no systematic arrangement of animals can be formed in subservience to only one principle. The practical aim of our investigations makes it incumbent on us, at any rate, to separate from each other growths of different physiological diatheses, of innocent or of malignant character.

FIRST PART.

INVESTIGATIONS INTO THE MINUTE STRUCTURE
OF CARCINOMATOUS GROWTHS.

function
necessary
with
 THOSE growths may be termed cancerous which destroy the natural structure of all tissues, which are constitutional from their very commencement, or become so in the natural process of their development, and which, when once they have infected the constitution, if extirpated, invariably return, and conduct the persons who are affected by them to inevitable destruction. The forms of disease which may be classed under this head are extremely various, though in some cases they pass into each other by imperceptible gradations. This fact, and the circumstance that, after extirpation of the disease, one form may take the place of another, serve to exhibit the physiological connexion between growths, the extremes of which often do not shew even the most remote similarity of structure. After extirpation of common cancer of the mammary gland, fungus medullaris may form either in the breast, or in some internal organ. Carcinoma simplex and alveolare are sometimes met with together in the mammary gland, and carcinoma reticulare and melanodes in the orbit. Carcinoma fasciculatum, altogether fibrous in structure, and destitute of even the most remote resemblance either to fungus medullaris or to common cancer, resembles them exactly in physiological characters.

bif
in the part
not
affected
 The most invariable anatomical character of the carcinomatous degeneration is loss of the proper tissue of the affected part, which always disappears during the progress of cancer. Vessels,

muscles, nerves, glands, bones, and all other tissues, how different soever from each other, become alike involved in the same cancerous degeneration. The first appearance of cancerous degeneration, however, does not consist in the mere transformation of the previously healthy tissues; but, between their interstices the elementary forms of carcinoma become developed, and thus displace the natural structure. That this is the case is shewn by the way in which the elementary forms of carcinoma are produced. It can be easily proved that the germinal cells of carcinoma are formed not from any previously existing fibres, but from a real *seminium morbi*, which develops itself between the tissues of the affected organ. This is best displayed in the alterations which the muscular coat of the stomach undergoes from carcinoma alveolare. The germinal cells of carcinoma are deposited between the bundles of muscular fibre, which in the early stages of the disease are easily distinguishable: at even a later period the muscular layer of the stomach, though enormously swollen, may still be recognized, until at length the production of the germinal cells equally in all the coats of the stomach obliterates every trace of their different layers, and of the natural structure of the organ.

The parts in the neighbourhood of a cancer usually become firmly connected with it at an early period, hence carcinoma is less moveable than other growths. Carcinoma of the stomach adheres to the pancreas, or the liver; that of the female breast to the skin, or the pectoral muscles. In the female breast the condition of the nipple and its early retraction are characteristic, though neither that nor the connexion of the scirrhus growth to the pectoral muscles is invariably met with; indeed, the author has often observed carcinomatous growths in which neither of these occurrences had taken place. The retraction of the nipple in cancer of the mammary gland depends on its proxi-

*Case of carcinoma in stomach, 1843-

mity to the disease. The swelling of the axillary glands in carcinoma of the breast, and the existence of similar swellings in other neighbouring parts, are both important; the dilatation of the veins, however, cannot be depended on as a sign of malignancy.

In cancer of the stomach, the condition of the muscular coat affords a sure anatomical sign of carcinoma, whatever may be its form. In most cases of carcinomatous disease of the walls of the stomach, the muscular coat not merely becomes exceedingly swollen, but its section presents a partitioned appearance, which is partly the result of the bundles of muscular fibre having been divided, but in part also is caused by the division of membranous and fibrous septa and capsules. In the intervals of the bundles of muscular fibre there become developed, in some parts, the cellular globules of carcinoma simplex, and the cells of carcinoma alveolare: in other situations fibrous septa run in different directions. Often, on closely inspecting the surfaces of these sections, membrano-fibrous septa are seen running between the interstices of the muscular bundles, and crossing each other irregularly. These compartments are filled with gelatiniform cells, which enclose smaller cellules, so that the interior of the capsules themselves seems to be subdivided. On a few occasions, the author saw similar capsules apparently filled with fibrous masses. The septate appearance of the muscular coat shews itself at the very commencement of cancerous degeneration: in carcinoma alveolare it may subsequently disappear, when all distinction of tissues in the different layers of the stomach has been completely confounded, having given place to the cells filled with a gelatiniform substance. Engravings of this appearance of the muscular coat of the stomach are to be met with in most illustrated works on pathological anatomy, in which the structure of cancer of the stomach, as far as it is

visible with the naked eye, is represented*. Dr. A. Monro seems to have been the first who noticed that sections of the carcinomatous muscular coat of the stomach appear traversed by septa. He says†, "The muscular fibres of the muscular coat are seldom to be seen, and, when visible, are generally of a paler colour than natural, and are separated from each other by cartilaginous (?) septa of different thickness in different cases."

This septate character is not peculiar to the muscular coat of the cancerous stomach, but it is also observed in other muscular parts, when affected by carcinoma. In Pockel's museum, at Brunswick, the author noticed this appearance in a specimen of scirrhus of the rectum, and in another of scirrhus esophagi, complicated with scirrhus of the stomach. It occurs also in the urinary bladder‡.

This appearance is not characteristic of any peculiar form of cancer, but occurs in most of its varieties. The author has often seen it in cancer alveolaris of the stomach, as well as in carcinoma simplex of that organ. It was equally well marked in a medullary sarcoma of the stomach in Pockel's collection.

There are no other general characters of carcinoma. Eccentric development is not peculiar to it, neither does softening always begin at the centre of the growth; nor is it always characterized in its early stages either by lack of vessels, or by any

* See Cruveilhier, Anatomie Pathologique, livr. 12, pl. 6; Carswell, Pathological Anatomy, Carcinoma, pl. i, fig. 1, 2, pl. iii, fig. 1; Seymour, Medico-chirurgical Transactions, vol. xiv, pl. 1; Baillie, a Series of Engravings, &c., Fasc. 3, pl. vii, fig. 1.

† The morbid Anatomy of the Human Gullet, Stomach, and Intestines, Edinb. 1811, p. 322.

‡ In Baillie's Morbid Anatomy, Fasc. 3, pl. iv, fig. 2, is an engraving of the septate structure of carcinoma of the esophagus; and another of carcinoma of the rectum in Fasc. 4, pl. iv, fig. 1.

peculiar distribution of them. The vessels in it bear the same relations as in other parts: sometimes they are scanty, at other times exceedingly numerous.

The positive characters of carcinoma do not display any thing heterologous or foreign to healthy organization: some of the elements of cancer occur in the healthy organism of the adult, while others are such as exist in the primitive foetal state of tissues, as cells, varicose fibres, and cylindrical fibres. Varicose fibres are produced by the elongation of cells and their linear arrangement, and perfect fibres are, in their turn, formed from such as are in the varicose state; whence it follows that the differences of the extremes depend merely on the point at which the development of the tissues is arrested. A structure, the development of which is arrested while the cells are in their primary state, will be very unlike one in which the cells are elongated, and in progress of transformation into fibres; while those growths which tend rapidly to assume a fibrous texture will also present a different appearance.

An albuminous substance forms the basis of all carcinomatous growths; for, if freed from skin and cellular tissue, they may be boiled for eighteen or twenty-four hours, without yielding more than a very small quantity of gelatine; often, indeed, without the slightest trace of it being discovered. The author has often repeated this experiment with carcinomatous growths, and always has arrived at the same result, namely, that the mass of carcinoma is perfectly insoluble in water. What little of it is dissolved occasionally contains caseine and salivary matter.

Four varieties only of the carcinomatous degeneration have been hitherto distinguished, namely, scirrhus, medullary sarcoma, carcinoma alveolare, and carcinoma melanodes. To these the author has ventured to add two very well-marked forms, carcinoma reticulare, and fasciculatum.

I. OF SCIRRHUS, OR CARCINOMA SIMPLEX (*Syn. Carcinoma fibrosum*).

BEFORE the discovery of medullary sarcoma by Mr. Burns, and of cancer alveolaris by M. Laennec, this, the most simple species of carcinoma of the female breast, was regarded as the only form of cancerous degeneration. Indeed, most descriptions of cancer by the earlier writers refer to this variety of morbid growth, characterized by its almost cartilaginous hardness, by its being irregular in outline, seldom lobulated, presenting a grey appearance when divided, and generally giving rise to connexions between it and the skin, and to retraction of the nipple.

Adams, Baillie, Abernethy, Bayle and Cayol, Laennec, Breschet and Ferrus, Cruveilhier, Wardrop, Travers, Home, Scarpa, and many others, have devoted their attention to the anatomical investigation of common cancer of the breast.

Dr. Adams proposed*, though with little proof, the hypothesis that carcinoma is produced by animated hydatid vesicles. Probably, he was led to form this notion merely by observing the cells of carcinoma alveolare with the naked eye; for it does not appear that he employed the compound microscope in his investigations. The development of carcinoma from microscopic germinal cells, endowed with organic life, certainly reminds us of Dr. Adams' notion, to which, however, we can scarcely attribute any great importance, since all tissues are developed from cells, and cells compose a great portion of non-carcinomatous growths. Somewhat similar to the ideas of Adams is the notion, recently put forth by Dr. Hodgkin†, that

* J. Adams, Observations on the Cancerous Breast. London, 1801, 8vo.

† Medico-Chirurgical Transactions, vol. xv, Pt. ii, and Morbid Anatomy of the Serous and Mucous Membranes. London, 1836.

scirrhus and medullary sarcoma are formed, like the compound cystoids, of cysts, from the inner wall of which young cysts, attached by pedicles, shoot forth; and that from the inner wall of these young cysts, new, secondary, pedunculated cysts are again formed, till the whole mass becomes firm and solid.

Baillie Dr. Baillie* defines scirrhus to be a firm, sometimes cartilaginous substance, of a lightish brown colour, and intersected by membranous septa.

Abernethy According to Mr. Abernethy†, the indurated part shews firm white bands, which either run in all directions from the centre to the circumference of the morbid growth, with but little tissue in their interstices, or they intersect the growth irregularly, while a firm brownish substance, which may be scraped off with the finger, is deposited between them, or else they form cells which contain a pultaceous matter, varying in colour and consistence; or, lastly, they display a ramified arrangement.

Breschet
Ferrus Breschet and Ferrus‡ describe scirrhus as a hard, white structure, resisting the knife, and composed of two different parts. The one is fibrous, firm, creaking when cut; is distinctly organized, and composed of laminae irregularly arranged, and forming cells, in which is contained an apparently unorganized matter, of a whitish, bluish, greenish, or reddish tint. This latter substance they both look upon as the product of secretion. They remark, very justly, that the softening of scirrhus begins sometimes in its interior, at other times at its surface.

Cruveilhier Cruveilhier§ says that scirrhus has the appearance of lard, and that it is composed of a fibro-cellular tissue thoroughly impregnated with an albuminous matter.

* Quoted by Adams, *Lib. cit.* p. 32.

† *Surgical Observations on Tumours*, fourth edition. *London*, 1827.

‡ *Dict. de Médecine*, t. iv, p. 138.

§ *Essai sur l'Anatomie Pathologique*. *Paris*, 1816.

The description given by Beclard* is more definite. He says that scirrhus is hard, like cartilage; not so soft as the intervertebral fibro-cartilage. It is white with a bluish tinge, and pellucid when cut into thin laminæ. Its tissue forms more irregular meshes than tubercle, like which it undergoes softening, and then becomes transparent, of a grey or red colour, and assumes the appearance of jelly or syrup.

Laennec† describes scirrhus as of a whitish, bluish, or greyish colour, differing in consistence, when in the crude state, from that of bacon rind to nearly that of cartilage. Its texture is homogeneous, traversed by very firm ligamentous bands, of an ashy grey colour; which are distributed irregularly, and intersect each other in different directions.

Bayle and Cayol‡, whose treatise on cancer has great practical worth, express themselves too indefinitely with regard to its anatomical structure. They characterize scirrhus as “Une substance d'un blanc grisâtre ou bleuâtre, luisante, légèrement demitransparente, dont la consistance varie depuis celle de la couenne de lard jusqu'à une dureté voisine de celle des cartilages.”

Wardrop§ speaks more at length of the anatomical structure of scirrhus:—“It consists of two distinct and very different substances; the one hard and fibrous, the other more soft, and, apparently, inorganic. The fibrous substance composes the chief part of the scirrhous mass, and consists of septa, which are opaque,

* Uebersicht der neuern Entdeckungen in der Anatomie und Physiologie. Uebers, v. Cerutti. *Leips.* 1823, p. 341.

† Dict. des Sciences Medicales, art. Anat. Pathol.

‡ Dict. des Sciences Médicales, t. iii.

§ Observations on Fungus Hæmatodes or soft Cancer. *Edinb.* 1809. 8vo. [Baillie's Morbid Anatomy, by Wardrop.—Preliminary Observations, pp. 13, 14].

and of a paler colour than the soft part. These septa or bands are very unequal in their length, breadth, and thickness, and are disposed in various directions, so as sometimes to form an almost solid mass; and in other instances, a number of cells or irregular cavities, containing the soft part. The soft, or inorganic part, is sometimes semi-transparent, of a bluish colour, and resembles, in consistence, softened glue or horn. In other cases it is more opaque, softer, somewhat oleaginous, and like cream in colour and consistence. In some scirrhus tumors the fibrous part is most conspicuous, and is condensed into a very solid mass, having the appearance of a nucleus, from which septa come off in various directions, and giving a section of the tumor a radiated appearance. This is, perhaps, the most usual appearance of the disease. In some, the tumor is very irregularly shaped, and is nearly a uniform, hard mass, in which scarcely any defined structure can be traced." He states that it begins to soften at the centre.

Travers Travers* describes the structure of scirrhus as it appears after washing in water and maceration. Concentric areolæ are then seen, the interstices of which are filled with a white granular matter, which may be scraped out from between the meshes of the tissue. These areolæ are divided into irregular compartments by lines which have a radiated arrangement and a dullish white colour. This structure, which may be distinguished by the naked eye, and still more clearly with the aid of a magnifying glass, gives to sections of a scirrhus growth much the same appearance as is presented by a divided lemon.

Bell Sir C. Bell† says, that carcinoma consists of ligamentous bands proceeding from a common centre, while between them a matter

* Med. Chi. Transactions, vol. xv, Pt. i, p. 208.

† Ibid, vol. xii, Pt. i, p. 213.

of a whiter colour is usually deposited, though in some cases the space is occupied by cells containing a darkish fluid. He speaks, likewise, of a carcinoma mammæ hydatides, to which reference will again be made when we come to treat of cysto-sarcoma.

Sir A. Cooper* defines scirrhus in a few words, as “an excessively hard swelling, intersected by a network of strong fibrous bands.”

The comparison of scirrhus with cartilaginous or fibro-cartilaginous substances, though very frequently made use of, is inapt; for the great mass of cancer cannot be reduced to gelatine. Rouzet†, indeed, has asserted, that accidental cartilaginous tissues sometimes occur in cancerous growths, and seems to place too much reliance on the article “Cartilage,” by M. Laennec, in the “Dict. des Sciences Médicales.” The author, however, is disposed to refer any such occurrence to an accidental complication; for it is possible that, in some rare cases, cartilage may become developed in a scirrhus growth, although not the cause of that disease. M. Rouzet quotes a case, related by M. Lecomte‡, in which cartilage was found in the substance of a carcinoma of the mammary gland, which had returned after being extirpated. “Ces portions cartilagineuses étaient inégalement dispersées dans la tumeur tantôt en petites masses, tantôt en grenailles, ailleurs en aiguilles.” In one case which came under the author’s notice, but of the result of which he is ignorant, carcinoma reticulare was found in the testicle, while the epididymis had become converted into cartilage. The presence of bone in carcinomatous growths is also very rare, when any other than osseous structures are affected by the disease. Even

* Observations on the Structure and Diseases of the Testis. *London*, 1830.

† Recherches et Observations sur le Cancer. *Paris*, 1818.

‡ Journ. de Méd. a 1787, tom. 73.

Walter
Cooper

Rouzet

the case related by Morgagni* is not referred by him to the class of carcinoma. The affection of the mamma had already existed thirty years, when the concretion was extracted: the part healed, but ulceration once more broke out; the patient, however, died of a different disease. A case quoted by Rouzett, from M. Bridault, is likewise not very clear. In the midst of the carcinomatous breast was an ossification. The patient died of the consequences of the operation.

Langstaff
The existence of the firm white bands in scirrhus has also been far too generally assumed. Mr. Langstaff† states that he has never seen in cancer of the breast those fine white ligamentous bands described by different authors. He speaks of a dense white substance, interspersed with spots of a pultaceous matter, as characteristic of scirrhus. The ligamentous bands are, on the other hand, pathognomonic of the fibrous non-suppurating tumors of the uterus. The erroneous statements of authors are doubtless, in a great measure, owing to their having confounded scirrhus with the innocent fibrous tumor: still the bands of fibres between which the grey matter is deposited, sometimes diffusely, at other times in a more circumscribed manner, may frequently be seen in a scirrhus growth, even with the naked eye.

Scarpa
Scarpa's‡ investigations have not thrown much new light on the structure of scirrhus, but relate principally to the differences between scirrhus and the structure which he calls struma. He compares scirrhus to softened cartilage, and says that it bears a close resemblance to the softened substance of the ligaments and cartilages of the joints in cases of white swelling. Sections

* De Sedibus et Causis Morborum, Epist. I., Obs. 41.

† Lib. cit. p. 194.

‡ Med. Chir. Transactions, vol. ix, p. 333.

§ Sullo Scirro e sul Cancro. *Pavia*, 1825.

of scirrhus present an uniform whitish surface, intersected by striæ of a still whiter colour, and presenting a radiated or ramified arrangement; "lardaceo tessuto dello scirro ghiandolare, intersecato da piccole linee biancastre," as he describes it at page 5 of his work. He quotes Baillie's Morbid Anatomy, and refers to Abernethy's investigations in support of his statements. Scirrhus and cancer do not occur in the lymphatic glands, but the conglomerate glands and the skin are their favourite seat. Struma, on the other hand, is not confined to the thyroid gland, but occurs in every secreting conglomerate gland, and is very common in the lymphatic glands. Some persons seem to entertain a very confused notion with regard to the struma of Scarpa; it appears, however, to the author very evident that he included under that term tubercle, and also some scrofulous swellings. Ordinary bronchocele, indeed, is of a different nature from tubercle, and presents a coarse, cellular structure, such as is not usual in absorbent glands. There is, however, both a scrofulous and a tubercular bronchocele. Scarpa employs the terms struma and scrofula in many places as synonyms: ("Strumà o scrofula.") Struma, he says, when divided, presents a compact vascular texture, filled with a thick, milky, albuminous fluid containing granules. He regards cancer of the uterus and of the stomach as coming under the same class with cancer of the skin. He represents cancer of the stomach as beginning in the mucous membrane, but the author greatly doubts the accuracy of this statement; and, were he to meet in a post-mortem examination with a tumor of the mucous membrane of the stomach without any affection of the muscular coat, he would think its carcinomatous nature to be, at the least, extremely questionable.

It is surprising how some anatomists should, like M. Lobstein,

Lobstein

has always found them, on searching for them narrowly, even in the crude state of scirrhus. It likewise seems difficult to demonstrate any difference in its arteries and veins from those of other parts. Bérard* succeeded in injecting the arteries of a carcinomatous growth of the thyroïd gland, but none of the injection entered the veins. From this, however, no conclusion can be drawn, for veins must certainly have existed, in order to carry back the blood. Cruveilhier† saw the veins of a carcinomatous uterus filled with yellow cancerous matter, whence he concludes that the seat of cancer is in the system of venous capillaries; the author would, however, be inclined to look upon this merely as an evidence of inflammation of the veins. Even the areolæ of cancer alveolaris, the meshes of which are filled with a jelly-like substance, are regarded by Cruveilhier as the venous tissue of the affected part. Thus is this very meritorious investigator led to adopt the theory, that, in cancer, the venous tissue alone is the seat of disease, and that the other organic elements of the affected part are atrophied in proportion as the venous structure becomes enormously developed; and this he illustrates by reference to carcinoma uteri. But the author is firmly convinced, in opposition to Cruveilhier, that, in examining the structure of carcinoma, our attention should be directed principally to the arrangement of the fibres which form the framework of all cancerous growths, and to the matter which is deposited between the fibres, in some instances diffusely, in other instances in cells, and which is, in both cases, perfectly unconnected with the vessels.

Persons formerly did not occupy themselves with these minute investigations into the structure of scirrhus. Sir E.

* Cruveilhier, *Anat. Pathol.*, livr. 18, p. 2.

† *Op. cit.*, livr. 24.

Home*, indeed, examined the globules of scirrhus under the microscope, and has given delineations of them, as regular in form and equal in size; neither of which representations can the author confirm. He likewise considers these globules to be lymph globules, to which they do not bear even the most distant resemblance.

The opportunity of examining a great number of recently extirpated carcinomatous breasts, in all stages of the disease, for which the author is indebted to the kindness of MM. v. Graefe and Dieffenbach, has enabled him to form a very accurate notion of the appearance of common cancer of the mammary gland. The diseased masses are generally irregular in form, not lobulated, hard, and resisting the knife, and presenting, when divided, a greyish appearance, which has but very little similarity to cartilage. Whitish bands are not invariably present. Scirrhus of the mammary gland occasionally shews, here and there, whitish filaments, some of which are hollow, and contain a colourless, whitish, or yellowish matter. Probably this appearance of white filaments is the result of thickening of the walls of the lactiferous tubes and lymphatics (Plate ii, fig. 13), and this idea is confirmed by the absence of these filaments from scirrhus of non-glandular parts. The mass of scirrhus is composed of two substances, the one fibrous, the other grey and granular. The fibrous substance is rarely apparent immediately on making a section of these growths, but is seen on scraping away the grey matter, for which it serves as a sort of basis. On removing the grey matter, either by scraping it away or by maceration, the fibrous substratum is seen to be composed of a very irregular network of firm bundles of fibres. (Plate ii, fig. 15.)

* A short Tract on the Formation of Tumors, and the peculiarities that are met with in the structure of those that have become cancerous. *London*, 1830.—Lectures on Comp. Anat. vol. iv, pl. 9. *London*, 1823.

Home

Character
Present
Common
Cancer
Mammary

The grey matter is found to consist of microscopic, formative globules, but slightly adherent to each other. These globules may be seen on examining fine sections of scirrhus with the compound microscope, or, still better, by scraping out the grey matter, and examining it alone. The formative globules are then seen to be transparent, hollow cellules, from 0.00048 to 0.00108 or 0.00130 of an English inch in diameter. They are insoluble in acetic acid, and also in water, at any temperature. In many of these cells, only a few points, which look like small granules, can be seen (Plate ii, fig. 10, 11); while in others a larger body may be distinguished, which looks like a nucleus, or like a smaller vesicle, contained within a formative globule (Plate ii, fig. 14). In many scirrhous breasts which the author examined, he was unable to convince himself of the presence of smaller cellules within the formative globules, while in other instances their existence was distinctly recognized. The appearance of these smaller vesicles within the larger seems to depend on the formative globules being in the stage of development. In one case of exceedingly hard scirrhus of the breast, which had passed into the open state, many formative globules were seen in the condition represented at Plate ii, fig. 14*. In several of these cells no vesicular content was observed, but in many others, under a high magnifying power (from 400 to 500 times), one or two smaller cellules were seen, each of which was furnished with a small, darkish corpuscle—a nucleus. Though crowded closely together, the formative globules lie between the meshes of a fibrous structure, with which they have no connexion, and from which they can be easily removed, while, notwithstanding the thinness of their walls, they

* The author gave a short notice of this structure in a postscript to an article by Schwann, in *Froriep's Notizen*, 1838. Januar. No. 3.

can be isolated from each other with the greatest facility. It is difficult to make out whether the single or double vesicular corpuscle, which is often distinctly seen within the formative globule, corresponds to the nucleus of a cell, or whether it is a young cell encased within the old one. If it be a nucleus, then the small spot upon it would be analogous to the nucleolus which Schwann usually found on the nucleus of the cells in the fœtus. If, on the other hand, the pale, apparently vesicular, corpuscles be in reality young cellules, then the corpuscles on their surface would correspond to the parietal nucleus from which other cells are developed. The paleness and transparency of the vesicular corpuscle which may be contained within the formative globule, does not by any means prove it not to be a nucleus; for, in the fœtal tissues the nuclei are sometimes remarkably pale, and even present a vesicular appearance. Probably, however, the vesicular bodies do correspond to young cells, and the analogy of this structure to that of cancer alveolaris is greatly in favour of this supposition. In a case of carcinoma mammæ which occurred in a woman aged fifty, the same structure which was observed in the breast, and there appeared to contain young cellules, shewed itself also in small tumors of the ribs. Since many structures in the embryo are originally developed from cells, there exists a general resemblance between the cellular texture of carcinoma and the primitive state of those tissues. But this is merely a general analogy, for the structure of carcinoma does not resemble one tissue more than another. Professor Valentin*, indeed, has observed bodies with central nuclei, which he considered to be cartilage corpuscles somewhat altered, in the sanies from a carcinomatous sore of the face, as well as in the substance of the

* Repertorium für Anatomie und Physiologie, 1837. 2 Abth. p. 263, 292.

diseased mass itself. It is, however, uncertain whether these bodies were real cartilage corpuscles, or whether they might not have been cells of the kind just mentioned*.

In addition to the formative globules of carcinoma, oil globules are always seen in considerable number diffused through scirrhus growths.

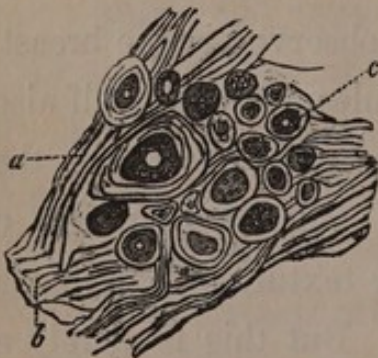
The above described form of carcinoma occurs frequently in the female breast, though it is not the only variety of the disease to which the term scirrhus is commonly applied.

*canine
dog*
The author likewise examined the structure of cancer of the mammary gland of dogs, but is unable to give a satisfactory description of it, owing to the long time that the specimens in the museum of the Veterinary College had been kept in spirit.

II.—OF CARCINOMA RETICULARE.

THE form of carcinoma to which the author applied the name of carcinoma reticulare, and which he was, to the best of his

Fig. 1.



* [The nature of these bodies will be best seen in the accompanying woodcuts, which are copied from the engravings in Valentin's Repertorium. Fig. 1 represents the surface of the cancerous sore above alluded to; *a*, the fibrous tissue; *b*, the membranous structure; *c*, the cartilage corpuscles.

Fig. 2.

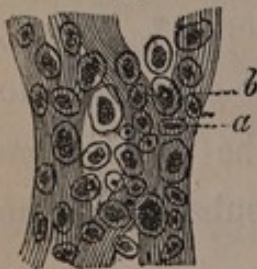


Fig. 2 shews a section of ordinary cancer of the lip: *a*, the fibrous texture, forming the basis of the mass; *b*, the cells, with granular nuclei, which Professor Valentin formerly regarded as cartilage corpuscles. This opinion, however, he has abandoned, and now regards the bodies as morbid cells. See his Repertorium, 1838, 2 Abth. p. 311.]

knowledge, the first to describe*, occurs in the female breast even more frequently than carcinoma simplex. On making a section of it, it may be immediately distinguished from the latter by the white reticulated figures intersecting the grey mass, which are perfectly evident to the naked eye. It acquires a large size more readily than carcinoma simplex, and is further distinguished from it by its tendency to assume a lobulated form. It sometimes approaches the consistence of scirrhus; at other times it is softer, and more nearly resembles fungus medullaris. A great number of observations have convinced the author that the consistence of this form of carcinoma is very variable, while its structure always remains the same, and is so peculiar that it may in all cases be recognized by the naked eye on making a section of the growth. Indeed, with the exception of cancer alveolaris, no form of carcinoma can be so readily distinguished. By far the greater number of cancerous degenerations of the female breast belong to this class, and more than thirty recent specimens of it have come under the author's notice within the last four years, for all of which the author is indebted to the generous kindness of MM. v. Graefe and Dieffenbach.

The occurrence of carcinoma reticulare in other organs also is far from infrequent. The author saw it in the swollen axillary glands in a case of cancer reticularis of the mamma: once he observed it in the stomach, and he has seen it both in adults and in children in tumors of the orbit and of the ball of the eye, attended with complete degeneration of the muscles of the eye, of its coats, and of the optic nerve. In these cases the tumors were extirpated by M. Jüngken. Among many instances of cancer of the lip, the disease was once only found

* Bericht über die zur Bekanntmachung geeigneten Verhandlungen der Königl. Akademie der Wissenschaften, December 1836.

to be carcinoma reticulare. In one instance it had developed itself in enormous masses in the anterior mediastinum, while similar though smaller growths had formed on the surface of the heart.

Carcinoma reticulare is composed of a grey mass made up of globules, and imbedded in a reticulated fibrous tissue, which is not seen until after the removal of the grey granular mass. The grey mass consists of transparent formative globules or cells similar to those of carcinoma simplex. These globules likewise often contain two or more smaller vesicles with nuclei of a pale colour (Plate iii, fig. 2). In other cases, however, the smaller germinal cellules could not be distinguished within the interior of the larger formative globules, which were then found to contain a number of small granules. Occasionally these granules were present in great number in the interspaces between the cells, and in some of them a molecular motion was distinctly evident. The cells themselves had a diameter of 0.00022 to 0.00039 or 0.00043 of an English inch, while the diameter of the granules contained within them did not amount to one-fourth or one-fifth of that size.

*white or
yellowish
white reticulated
red granules*

The white, or yellowish white, reticulated figures which are always more or less distinctly evident in this form of cancer, present a very peculiar appearance (Plate i, fig. 1, 8). These figures are irregularly reticulated: sometimes they present a branched arrangement, at other times they appear in spots. They are peculiar formations, not dilated vessels with thickened parietes, such as are sometimes seen in carcinoma simplex, but they are produced by the deposition of grains of white matter in the grey mass. These grains do not appear to be cells, but generally seem to be made up of opaque granules agglomerated together, so as to form roundish or elongated corpuscles (Plate ii, fig. 12). These corpuscles are usually of a round

or oval shape; sometimes, however, they are elongated, and it is not uncommon for them to be much longer than they are broad. They are two or three times as large as the red particles of the blood, their greatest diameter being 0.00076 of an English inch. This structure of the white substance of carcinoma reticulare is not, however, in general evident to the naked eye, nor even with the aid of a lens; but the corpuscles of which it is composed are usually so distributed through the grey matter, as to present the appearance of a white net-work (Plate i, fig. 9).

If these white figures are examined under the simple microscope with a magnifying power of eight or sixteen diameters, the corpuscles of which they are composed may be distinguished (Plate i, fig. 8).

A higher magnifying power exhibits the granular appearance of these corpuscles, which, when seen by transmitted light, of course appear dark. (Plate ii, fig. 12.) Lastly, we may isolate these bodies under the compound microscope, and convince ourselves that they are formed by the agglomeration of small granules, either perfectly opaque, or but slightly pellucid. These white granules are not rendered transparent either by acetic acid or by alcohol.

The white corpuscles which form the reticulated figures of carcinoma reticulare accumulate more and more as the development of the disease proceeds; and by the time that disorganization commences in the structure, they form a great part of its texture. Often they lie in large masses, imbedded in the surrounding tissue, or invest with a cream-like lining the interior of cavities which may have formed in the diseased growth. They also, as might be expected, make up a portion of the softened matter, and purulent secretion yielded by the ulcerated surface.

Occasionally, in carcinoma reticulare of the female breast, cavities form in the interior of the structure. Once, the author observed a large cavity, the walls of which were completely occupied by white corpuscles. Masses of this sort extend, still preserving their reticulated figure, and may be separated in large portions of a soft consistence, for the purposes of chemical analysis. The matter composing them is found to be very similar to coagulated albumen; but the author will treat more fully of its composition when he comes to the consideration of the chemical characters of carcinoma.

As the development of the disease proceeds, the reticular figures readily become confluent, and then appear like irregular white spots. When this occurs, the mass presents some resemblance to the first appearance of white tubercle in a grey tissue.

In one specimen of cancer reticularis mammæ, the author observed throughout its tissue many little cavities varying in size from that of a millet-seed to that of a pea, filled with a yellow, puriform, or cheesy matter. These cells were furnished with distinct walls, but their cavities communicated here and there with each other, so that the contents of several cells could be squeezed out through an opening in one. The larger ramifications of these cells gave off smaller branches. The interior of even the smallest cells, the diameter of which did not exceed half a line, was found to be furnished with a distinct lining membrane, to which bloodvessels were distributed. The matter which these cells contain must not be confounded with the white globules strewn through the reticulated figures, although it is possible that both may have a common origin. In the instance just spoken of, the white reticulated figures formed here and there large masses, which were merely imbedded firmly in the surrounding tissue, and did not exhibit the slightest approach

to a cellular structure. In another part of the same morbid growth was a carcinoma alveolare of the size of a hazel nut, the cells of which were filled with a jelly-like matter. The author has frequently seen patches of carcinoma alveolare, forming part of the morbid growth, in cases of carcinoma simplex mammæ.

It is scarcely necessary to remark, that the reticulated figures of this form of cancer have no relation to the structure of the mammary gland, since the author has observed the same texture in carcinoma of many other organs.

Carcinoma reticulare is sometimes developed slowly, at other times with great rapidity. In by far the greater number of cases it returns after having been extirpated. Professor Pockels, however, informed the author, that, in one instance, he extirpated a cancer which actually belonged to this class with perfect success. Two cases may also be mentioned, in which the disease, having once been extirpated, did not reappear for a very long time. In the one instance, indeed, the disease, though extirpated two years ago by M. Jüngken, has not yet returned. This case was one of carcinoma reticulare, complicated with carcinoma melanodes, and affected the ball of the eye and the orbit. The patient in whom it occurred was a young woman. The other case was one of carcinoma mammæ, in a woman whose breast M. v. Graefe removed, the same disease having been extirpated five years previously from the other breast. Here the disease did not return to its original seat, although it shewed itself in the other breast after some time had elapsed. The author has examined many cases of cancer reticularis which had a fatal termination.

*Sometimes
slow
times
never
return
reappear*

III.—OF CARCINOMA ALVEOLARE.

THIS form of carcinoma was described in Germany, by Otto, as a peculiar species of scirrhus of the stomach, and in France, by Laennec and Cruveilhier, under the names of "cancer gelatiniforme," and "areolaire."

The description which Otto has given* represents the main features of this degeneration (which always appears under one form) so exactly, that it may be detailed as affording a good illustration of the general anatomical characters of the disease.

notes
The scirrhus occupied more than two-thirds of the whole stomach, and extended from the pylorus over a width of more than seven inches of its anterior and posterior wall. The walls of the stomach were so thickened at the diseased parts, that they did not collapse. In several places they were two inches and a half in thickness. The surface of the scirrhus part was uneven and tuberculated. Otto says that its substance differed so much from that of ordinary scirrhus, that, perhaps, it ought not to be referred at all to that class of diseases. The basis of its structure was composed of innumerable white fibres and laminae crossing each other in all directions, and having their interspaces occupied by cells which varied in size from that of a grain of sand to that of a very large pea. Some of the cells were closed, but many of them communicated with each other: they all contained a very viscous, clear, perfectly transparent jelly. Externally, the diseased growth was covered by peritoneum, through which the half-projecting sacculi and cells were seen. The inner surface of the stomach was almost entirely deprived of its lining wherever the disease extended, and most

* Seltene Beobachtungen zur Anatomie, Physiologie, und Pathologie. Breslau, 1816, tab. 1, fig. 4.

of the cells, both large and small, opened into the cavity of the stomach, into which, when firmly pressed, they poured their contents. The inner coats of the stomach were entirely destroyed by the disease, the muscular coat extended for a short distance into the morbid structure, but small cells filled with jelly-like matter were everywhere deposited between the muscular fibres.

The cases of carcinoma alveolare of the stomach, which the author has examined, correspond so exactly to this description, that he can but confirm it in all points. At the commencement of the degeneration, the mucous and the muscular coats of the stomach swell, and sections of the latter present that striated appearance observed in all forms of carcinoma of the stomach. The cellular structure containing the jelly-like matter develops itself between the bundles of muscular fibre, but the like process takes place at the same time in the mucous membrane. In the early stages of the disease the cells can be distinguished only by means of the microscope.

Occasionally, this cellular structure not only becomes developed in the stomach, but also forms isolated nodules in different parts of the surface of the peritoneum. In M. Pockels' museum at Brunswick, the author observed such masses of cells which had formed on the abdominal peritoneum, in a case of carcinoma alveolare of the stomach. The smallest clusters of cells were scarcely larger than the head of a pin*.

The symptoms of this form of cancer, which occurs most frequently in the stomach, are, according to Cruveilhier, more obscure than those of any other variety of carcinomatous disease. It, certainly, is less prone than other forms of cancer to

* Engravings of carcinoma alveolare of the stomach may be found in Otto, lib. cit. tab. 1, fig. 4; Cruveilhier, Anatomie Pathologique, livr. 10, tab. 4; Carswell, Pathological Anatomy, fasc. 3, plate 1, fig. 8.

give rise to symptoms of general reaction, and is more slow in producing the cachexia cancerosa. Pöckels observed neither pain nor vomiting; but the peculiar colour of the face which characterizes organic diseases of the stomach was not absent. Though most often met with in the stomach, cancer alveolaris is not by any means confined to this organ; for Cruveilhier has seen it in the small intestines, in the rectum, cæcum, uterus, ovary, and in the bones; and the author has also met with it in the intestines, in the female breast, in the great omentum, and especially in the peritoneum.

The jelly-like matter contained in the cells preserves its transparency even if kept in alcohol; and if expressed from the cells, and boiled, it does not yield a trace of gelatine. After boiling for eighteen hours a portion of cancer alveolaris which had been macerated in alcohol, nothing was dissolved but a small portion of a substance somewhat allied to salivary matter, not precipitated by any re-agent, not even by tannin, and of the existence of which evaporation afforded the only evidence.

Cruveilhier distinguished between "cancer areolaire gelatini-forme," and "cancer areolaire pultacé:" the cells of the former contain a transparent jelly, those of the latter a turbid pultaceous matter. He has observed the latter form in the uterus and in the bones*. The case which he relates of "cancer alveolaire pultacé" of the skull is very remarkable, and the representation he gives of it is very interesting†. The diseased bones were the frontal, the ethmoid, the inferior turbinated bones, and the vomer. The morbid growth extended both outwards and inwards, and had attacked the mucous membrane of the nose, and the dura mater. A somewhat similar structure was once observed by the author in a breast which M. Dieffenbach had re-

* Anat. Pathologique, livr. 24, tab. 2, fig. 1, and livr. 27, tab. 2.

† Ibid. livr. 21, tab. 1.

moved. In this instance the very firm puriform matter was contained within cells which had numerous communications with each other, and were lined by a membrane evidently vascular. Some lobules of this tumor were completely permeated by these cells, while other parts of the same growth presented no trace of this structure, but only the ordinary network of carcinoma reticulare.

In the remarkable case of "cancer pultacé" of the skull, abovementioned, M. Boutin Limousineau, assistant to M. Gay-Lussac, analysed the yellow matter from the cells, and found that it contained caseine. The matter had in this case the colour of tallow.

The author obtained the following results* from microscopic examination of carcinoma alveolare of the stomach. If the smaller cells are looked at under the microscope, they are found to contain encased within them many still smaller cellules, which in their turn include others of yet more diminutive size. In the smaller cells the darkish yellow parietal nucleus is distinctly evident. Many cells, likewise, contain mere nuclei, free within their cavity, as cytoblasts from which new cells are to be afterwards developed (Plate iii, fig. 3). The walls of the largest cells are distinctly fibrous, and their fibres run from one cell to another (Plate iii, fig. 4). Twice the author observed rod-shaped crystals in the jelly-like matter of preparations which had been kept in spirit; and on another occasion he saw spindle-shaped corpuscles in the jelly from a cancer alveolaris of the breast.

The history of the development of carcinoma alveolare corresponds exactly to that of the primitive formation of cartilage and of the chorda dorsalis, as described by Schwann. The young cells are produced from cystoblasts, or nuclei developed in the

* A short notice of them appeared in an article by Schwann, in Froriep's Not. 1838, Januar. No. 3.

*Microscopical
Character*

*Its mode
of developm.*

interior of the parent cell; and although the parent cell continues to increase in size, these young cellules by degrees fill up its cavity. At length the walls of the young cells come in contact with each other, and they form together with the parent cell, within which they are encased, one compound cell. Thus, the process of development goes on, till the larger cells on the internal wall of the stomach burst, and pour their jelly-like contents into its cavity.

The fibres forming the walls of the largest cells constitute a nidus within which younger generations of cells are developed. In order, however, to observe the manner in which the cells are encased one within the other, and the relation they bear to their nuclei, it is necessary to examine them in an earlier stage, and before their walls have begun to be split up into fibres.

Structure
non Alveolar
ventriculi
can
The main point distinguishing carcinoma alveolare from carcinoma reticulare and carcinoma simplex seems to be, that, in the former the cells continue to grow, and their walls become adherent to each other, while this progressive development and mutual cohesion do not take place in the delicate cellular globules of the two latter forms of cancer*.

* The author has seen preparations of carcinoma alveolare,

I. In the anatomical museum at Berlin,

No. 10,333. Carcinoma alveolare of the stomach and omentum.

No. 10,334. Carcinoma alveolare of the stomach.

No. 5970. Carcinoma alveolare of the stomach.

No. 10,459. Carcinoma alveolare of the stomach.

II. In the anatomical museum at Halle (in Meckel's collection),

Carcinoma alveolare of the stomach; under the name of "Steatoma ventriculi ingens."

A second preparation of cancer alveolaris of the stomach.

III. In Professor Pockels' museum at Brunswick,

Carcinoma alveolare of the stomach, omentum, and peritoneum lining the abdomen.

A second preparation of carcinoma alveolare of the stomach.

IV.—OF CARCINOMA MELANODES.

ALTHOUGH melanosis appears as a peculiar morbid growth, yet it is merely a variety of cancerous degeneration, and terminates in the same way as other forms of carcinoma. This similarity is shown in the, by no means unusual, combination of melanosis with other species of cancer. Thus, the author has often observed carcinoma reticulare of the globe of the eye and of the orbit combined with melanosis; some lobules of the morbid growth being more or less completely occupied by melanosis, while other parts displayed the ordinary network made up of white corpuscles, characteristic of carcinoma reticulare. In several truly cancerous degenerations of the eye and of the neighbouring textures, which M. Jüngken extirpated, and which were afterwards placed as preparations in the anatomical museum at Berlin, this complication was by no means infrequent. Carcinoma melanodes is generally lobulated, whether it forms the whole of a morbid growth, or is merely interspersed through the substance of some other form of cancer. When it appears in the substance of an organ, it forms masses more or less completely isolated.

Microscopic examination detects two forms of melanotic structure. In both instances the basis of the structure is formed of a fibrous network, the stroma of melanosis, within the meshes of

IV. In the museum of the London Hospital, in London,
Carcinoma alveolare of the breast.

V. In the museum of St. Thomas's Hospital, in London,
No. 1918. Carcinoma alveolare of the breast.

VI. In the museum of King's College, in London,
No. 121 and 122. Carcinoma alveolare of the mesentery, and intestine.
No. *e.* 91. Another case of the same kind.

*Janety
Cancer*

*Accum
Carc: u*

*Melan
Examination*

which the melanoid matter is deposited. This matter is generally composed of cells, filled with yellowish or blackish granules. (Plate ii, fig. 17). These cells are, and always continue to be free, never becoming coherent. Their forms are very various. Many, indeed most, are round, oval, or irregular; some are elongated; a few actually caudate, terminating at one or both extremities in a point, or in a fibril. Still more rarely the cells present several points. They are real pigment cells*; some of them are of a palish yellow colour, others darker, while the interior of others is stained of a dark brown by the granular pigment they contain. It was but seldom, and then only with difficulty, that the author succeeded in detecting, in one of the larger cells, a nucleus with its nucleolus, independently of the pigment granules. The diameter of the cells varies greatly; the largest are more than 0.00108 of an English inch in diameter; while smaller ones had a diameter of 0.00105, 0.00095, 0.00073, 0.00045, 0.00039, or even less, of an English inch. Different forms of the pigment cells are represented at Plate ii, fig. 18. They were all taken from a large lobulated melanosis of the lower jaw, which was removed, together with a large portion of the bone, by M. v. Graefe. The structure of the pigment cells and caudate corpuscles was precisely the same, in a specimen of melanosis of the eye, complicated with other forms of carcinomatous structure, which M. Jüngken extirpated; and also in some melanoid growths, which had formed simultaneously in different parts of the body, for which I am indebted to Dr. Baum, of Dantzic. It has not been determined with cer-

* A short notice, by the author, of the caudate corpuscles in melanosis appeared in Müller's Archiv, 1837, Heft. v, p. 466, Anmerkung. The author likewise made some observations on the pigment cells of melanoid structures in a postscript to Schwann's third paper, in Froriep's Not. 1838, April.

tainty whether the increase in number of the pigment cells depends on the production of fresh ones within the parent cell, or whether new cells are formed external to the old ones.

The pigment globules, when very small, display that molecular motion common to all very minute parts, even to the globules of the pigmentum nigrum of the eye. The pigment globules are seen not merely within the cavities of the pigment cells, but also strewn between them, and it is only in the case of these free globules that the molecular motion is observed. The existence of free pigment granules, external to the cells, is perhaps to be attributed to the bursting of the cells and the extravasation of their contents. Many pigment cells are much smaller than others; probably they are young cells which have been set free by the bursting of the older and larger cells, or possibly they may have been formed external to them. Moreover, many cells, and especially many caudate corpuscles, are of so pale a colour, as apparently to be quite destitute of pigment.

In some specimens of melanosis, the author discovered no pigment cells, but all the pigment globules appeared to be free, and dispersed through the meshes of a fibrous tissue. This was the case not merely in diffused melanosis in the human subject, namely, in melanosis of the peritoneum, and of the subserous cellular structure without development of any tumor, but the same was also observed in a preparation of melanoid growths from the prepuce of the horse, which Prof. Gurlt, of the Veterinary School, had the kindness to submit to the author's inspection. The pigment granules bore a great resemblance to those of the choroid coat, and, like them, had a distinct molecular motion. It is probable that in these two cases the formative organs of the pigment granules were dissolved, for the latter are always contained within cells, not merely in diseased structures, but also in healthy tissues.

*Molecular
Motion*

In this place the author has treated of melanosis only in so far as it is related to carcinoma; further remarks must be reserved for the historical part of the work.

V.—OF CARCINOMA MEDULLARE.

FUNGUS medullaris, first described by Mr. Burns* under the name of “spongioid” inflammation; by Mr. Hey†, as “fungus hæmatodes;” by Mr. Abernethy‡, as “medullary sarcoma;” by Dr. Monro§, as “milt-like tumor;” and to which M. Laennec needlessly gave the name of “encephaloid;” appears in the present day to be scarcely employed to denominate other than a softer form of carcinoma. The discussions, whether or no Hey’s fungus hæmatodes and Abernethy’s medullary sarcoma were the same disease, are familiar to every one; as are the erroneous opinions of M. Maunoir||, who confounded fungus hæmatodes with aneurism by anastomosis, and imagined that, in fungus medullaris, there is a production of true nervous matter. English writers have applied the term fungus hæmatodes, as well as that of fungus medullaris, to all varieties of the softer forms of carcinoma, how different soever they might be in colour; and Mr. Wardrop¶ expressly says that fungus hæmatodes may be white, or yellowish, of a reddish or dark red colour, and even brown. Much confusion was afterwards introduced into the subject, owing to some relation which these structures were

* Burns, *Dissertations on Inflammation*, 1800, vol. 1 and 2. *London*.

† Hey, *Practical Observations in Surgery*. *London*, 1803.

‡ Abernethy, *Surgical Observations, &c.* *London*, 1804.

§ Monro, *the Morbid Anatomy of the Human Gullet, Stomach, and Intestines*. *Edinb.* 1811.

|| Maunoir sur le Fongue Médullaire et Hématode. *Genève et Paris*, 1820.

¶ Wardrop, *Observations on Fungus Hæmatodes, &c.* *Edinb.* 1809.

supposed to bear to the vessels and nerves: but it is now allowed on all hands, especially since the appearance of M. v. Walther's* instructive observations, that both names are only different designations for accidental variations of the same structure. The different forms described by Meyent, likewise appear to the author to belong to the same species of morbid growths. This soft cancer, of the consistence of the brain or of the placenta, may have not merely a whitish or yellowish white colour, similar to that of the cerebral substance, or a blood red hue like the placenta, but it is subject to many other variations of colour; and sometimes the same morbid growth will exhibit all varieties of hue in different parts of its substance.

These fungoid growths are highly vascular, and a successful injection makes them appear to be entirely made up of vessels; but in the recent state their other component parts are at once evident to the naked eye. These are, in part, a medullary mass composed of globules or other corpuscles; and partly a tissue made up of delicate fibres, in the meshes of which the medullary portion of the growth is contained.

When perfectly free from other matters, the medullary part of these growths presents a whitish or greyish white colour. If a portion of fungus medullaris is cut in pieces and squeezed under water, the medullary corpuscles, which are very easily soluble, impart to the water a milky hue, more or less tinged with blood. The intensity of the red colour of fungus medullaris depends on the relative proportion of bloodvessels which it contains; but the bloody patches which are sometimes interspersed through the substance of the structure are in part produced by the effusion of blood into the meshes of its tissue.

* v. Graefe's und v. Walther's Journal der Chirurgie und Augenheilkunde, V.B. p. 189.

† Meyen, über die Natur parasitischer Geschwülste, besonders über Mark-und Blutschwamm. Berlin, 1828.

The brownish hue which the ulcerated surface of fungoid growths presents, is probably produced by decomposed blood.

The external form of fungus medullaris is often lobulated: its appearance when cut or broken varies greatly; sometimes it shews no trace of any definite arrangement of fibres, while, at other times, fibres are indistinctly seen either running parallel to each other, or intersecting each other irregularly, and in some instances displaying a radiated or tufted arrangement. In few cases, however, is this fibrous structure very distinct, for the morbid growth may easily be torn in other directions than in that in which the fibres seem to run; and irregular pieces may often be broken off, though it is not possible to tear off a regular tuft of fibres.

Fungus medullaris usually forms large tumors, which increase in size and number with great rapidity. In some rare cases it appears distributed in a great number of very small tumors. Such a specimen once came under the author's notice in the museum at Halle, where it had been deposited by Prof. Blasius. The medullary matter was deposited in innumerable small lobuli upon the omentum, intestines, mesentery, and mesocolon.

Fungus medullaris may form in every organ, and in all the vascular tissues in the human body. It is not prone to attack any part in particular, and is equally common in persons of all ages.

It is sometimes developed on the surface of bones, at other times in their interior. When it appears on the surface of the tubular or flat bones, it receives a slight support from a peculiar skeleton formed of very delicate aciculæ or laminæ of bone, which, proceeding in a radiated manner from the surface of the bone, penetrate into the interior of the soft tumor*. The pre-

* See Carswell's Pathological Anatomy, fasc. 3, plate 4, fig. 1 and 2, and Ebermaier, über den Schwamm der Schädelknochen, etc. *Düsseldorf*, 1829, Taf. vii, viii.

sence of these spiculæ, however, is not an infallible proof of the cancerous nature of a fungoid exostosis. Sir A. Cooper mentions a case of fungus exostosis, containing spiculæ, which grew from the surface of a bone, but was permanently cured by amputation.

If fungus medullaris has its seat in the interior of a bone, not merely does it fill up the cavity of that bone, but induces a state of atrophy in the osseous tissue, and reduces the substance of the bone to a mere shell, so that the slightest cause suffices to produce fracture. The author has seen the whole interior of the bones of the tarsus filled with fungus medullaris, and the remains of their thin external shell surrounded by the soft cerebriform mass*.

When fungus medullaris occurs in the interior of a bone, it does not often happen that the bone becomes distended in a spherical manner, though even of this there are some rare instances. A specimen of this kind is in the museum of St. Bartholomew's Hospital (Morbid Preparations, first series, No. 159, 160); and Sir A. Coopert speaks of fungoid exostosis of the medullary membrane, with distention of the shell of the bone. The relation of medullary sarcoma to scirrhus or carcinoma simplex is displayed by the fact that, after amputation of a scirrhus breast, real fungoid growths may occur in other parts,

* Carswell, in fasc. 3, plate 4, of his work, gives representations of fungus medullaris in the interior of bones. In the specimen there delineated, internal and external fungus medullaris of the bones are combined. Consult also Cruveilhier Anat. Pathol., livr. 20, plate 1.

† Surgical Essays, p. 1, London, 1818. Reference is made to the plate, in which is represented an expansion and partial destruction of a dried portion of bone, the character of the bone not being more minutely described. The expansion is stated to have been produced by a disease of the medullary membrane, but the author doubts whether that disease was fungus medullaris.

as many observations of Langstaff*, Cruveilhier†, and others, abundantly shew. This affinity is likewise further illustrated by microscopic examination, which shews that many structures comprehended under the generic term of fungus medullaris differ greatly from each other, and have nothing in common but the softness of their texture. Several forms, which present no external differences from others, approach very nearly in structure to the most consistent species of cancer, carcinoma simplex, and contain similar cells or formative globules; the softness of their texture being produced by the presence of a great number of these globules distributed through a very delicate tissue. On the other hand, we have seen that carcinoma reticulare, a form of cancer which presents a very peculiar structure, varies in consistence from that of the hardest scirrhus, to that of fungus medullaris. Further, there are varieties of fungus medullaris, the exterior of which presents nothing peculiar or different from other forms, but which shew a great particularity on microscopic examination, appearing then to be formed in a great measure of caudate or spindle-shaped bodies, or of cells, the development of which has been arrested while in the intermediate state between cells and fibres. At first, one might be tempted to separate this form from the rest, under the name of carcinoma closteroides; but more extended investigations prove that this division would be unwarrantable, for cases are met with in which, although the medullary part of the morbid structure is composed principally of formative globules without caudate appendages, yet caudate bodies do occur in greater or less number among the round corpuscles. It will hereafter be seen that this variety of internal structure is met with also in the case of innocent albuminous sarcoma, which is sometimes composed of cells, while, at other times,

* Med. Chir. Trans., vol. ix.

† Anat. Pathol., livr. 23; explanation of Plates 5 and 6.

it consists of caudate and spindle-shaped corpuscles so arranged as to produce the appearance of an imperfectly fibrous structure. This being the case, it appears to the author most proper to employ the term fungus medullaris as a collective name for different forms or stages of development of soft cancer, which undergo imperceptible transitions into each other. The author's observations lead him to refer to this genus the following varieties:—

1. Carcinoma medullare, abounding in roundish formative globules which make up the greater part of the medullary mass, though intersected by a delicate fibrous network*. The specimens which Gluge† examined seem to have been of this kind. The globules which Gluge saw differed in size: the smallest were larger than pus globules, and had a diameter of $\frac{1}{125}$ of a millimetre. They were irregular, though approaching the spherical form; their border was transparent, but dark points and round lines were distinguished on their uneven surface. He likewise observed crystals of various kinds‡ in fungus medullaris. The author regards the formative globules of this variety of morbid structure as very similar to those of common cancer, and to those which constitute the grey mass of carcinoma reticulare: a few points, or very minute granules, were often all that could be detected in their interior, but frequently, on making use of a high magnifying power, a nucleus may be seen just as in other forms of carcinoma. (Plate iii, fig. 6, 7.) The size of

* On a former occasion, the author noticed briefly this form of medullary fungus, in the Bericht über die zur Bekanntmachung geeigneten Verhandlungen der K. Academie der Wissenschaften zu Berlin. December, 1836.

† L'Institut., 1837, No. 191. Auszug der Verhandlungen der K. Academie zu Paris, vom 2 Januar. 1837.

‡ Müller's Archiv. 1837, Heft 5, p. 465.

these globules is about the same as in common cancer, though they are subject to great varieties in this respect. Many of the preparations in the museum at Berlin, and many in Professor Pockels' collection at Brunswick, belong to this class.

2. Carcinoma medullare, with an exceedingly soft cerebriform base, composed of pale, elliptical bodies, without caudate appendages. The author is acquainted with but one specimen, which he can refer to this class: it was a case of cerebriform fungus medullaris of the foot, and of the interior of the tarsal bones. With the exception of the vessels which were distributed to the diseased mass, its substance was almost entirely formed of uniform ellipsoidal corpuscles, which cohered but very slightly with each other. These corpuscles had a very pale hue when looked at under the microscope; they were one-and-a-half or twice as large as the red particles of the blood, and equalled them in breadth. The author in no instance observed a fibril proceeding from these bodies, nor did he ever see a single nucleus or a young cellule in their interior. A few very minute points were all that could be detected by the highest magnifying powers. (Plate iii, fig. 10.)

3. Carcinoma medullare, with caudate or spindle-shaped corpuscles. Sometimes, on tearing a piece of this kind of fungus medullaris, the torn surface will present a resemblance to a fibrous structure. This appearance is owing to several of the caudate corpuscles being arranged in one direction; as was observed in a case related by Valentin*. The author has seen a similar structure in several specimens of fungus medullaris; sometimes interspersed in the midst of round, formative globules, at other times forming the greater part of the growth. Three preparations in the anatomical museum at Berlin belong to this

* Valentin, Repertorium für Anatomie und Physiologie, 1837, 2 Abth p. 277.

class;—No. 9839, an enormous medullary fungus of the leg, and in the abdomen of a female;—No. 10,570, an enormous medullary fungus of the abdominal cavity;—No. 10,571, a medullary fungus of the brain;—No. 10,581, a medullary fungus of the thigh of a child. According to the direction in which the caudate corpuscles are disposed, a radiated appearance is sometimes produced, at other times the structure seems more tufted, while, in other instances the direction of the corpuscles is so various, that the tumor does not display the slightest trace of fibrous texture. It is, indeed, not always easy (even when the caudate bodies are so disposed as to occasion a fibrous appearance) to tear the growth into tufts of fibres, although irregular portions of it may be broken off very readily. Frequently, however, the caudate corpuscles are arranged with great regularity. Their interior presents the appearance already described, namely, it contains either a granular substance without any evident nucleus, or a nucleus with one or more nucleoli may be more or less distinctly seen. (Plate iii, fig. 8, and Plate iv, fig. 9—11.) These corpuscles are prolonged at one or both sides, and in some rare instances at more than two sides into fibrils of different length. They are cells, the development of which has been arrested in the stage of transition from cells to fibres.

It has been already remarked, that there are forms of innocent albuminous sarcoma with caudate corpuscles, incidental both to the soft parts and to bones. In Plates iv, v, and vi, are representations of the internal structure of several such growths. Plate iv, fig. 16, (numbered in the plate, by mistake, fig. 10) represents caudate corpuscles from an albuminous sarcoma of the conjunctiva, extirpated by Dr. Helling; and Plate iv, fig. 17, represents similar bodies, from an osteosarcoma, which M. v. Graefe extirpated. In both cases, the operation was successful.

Plate vi, fig. 17, exhibits caudate corpuscles from the substance of an aneurism by anastomosis.

Since so many fibrous tissues in the embryo are formed from caudate cells, there is evidently nothing extraordinary in the occurrence of caudate corpuscles in morbid growths of very different physiological tendencies; in the innocent, as well as in the malignant; and, consequently, no inferences can be drawn from their presence with regard to the character of the structure in which they occur. It is, however, much to be regretted, that, in the case of morbid growths formed of caudate corpuscles, minute anatomy does not assist in determining their innocent or malignant character. The only guide which remains is afforded by the tendency of cancer to interfere with the natural structure of surrounding parts, while those formations which are of a benignant nature leave the neighbouring healthy tissues unaltered. Thus, in an enormous innocent sarcoma of the conjunctiva, the eye remained unaffected. Since the caudate corpuscles are formed from round cells, the occasional co-existence of round cells with nuclei, and of caudate corpuscles in the same medullary fungus, is not surprising.

In addition to the constituents already described, microscopic examination shews that in all cases of medullary sarcoma fat is present in the form of fat globules which are free, and not enclosed in cells. This element exists in a similar manner in carcinoma simplex and reticulare.

VI.—CARCINOMA FASCICULATUM. (*Syn. Hyalinum.**)

AMONG the structures commonly included under the name fungus medullaris, are some altogether fibrous in their texture,

* Bericht über die zur Bekanntmachung geeigneten Verhandlungen der K. Akademie der Wissenschaften. December, 1836.

and which correspond with other forms of that disease only in the softness of their tissue. The fibrous structure of these growths is immediately evident on breaking or dividing them: when torn they do not crumble, but are readily rent in the direction of their fibres. If examined under the microscope, they display neither the cellular globules of other varieties of carcinoma, nor the caudate corpuscles which give a fibrous appearance to some forms of fungus medullaris. The fibres often have a tufted arrangement, running in a divergent course from a common centre; in which case the masses may be rent into radiated bundles, the apex of which is directed towards their point of insertion, their base towards the uneven surface of the tumor. Or, some of these tufts of fibres are arranged in one way, some in another, large masses of fibres forming but one tuft, while in other places they are divided into many; and all of these bundles of fibres are intertwined with each other, as is seen on attempting to tear their tissue. In this case, the tumor very frequently forms lobules of various sizes, both externally and in its interior. Between the lobules are membranous septa, from some one of which a tuft of fibres springs, and, after running for some distance, curves over, and is inserted into another septum. These lobulated tumors with a soft fibrous structure often attain a very great size. In some instances, however, there is no distinction of the tumor into lobules, but the whole growth is formed of one large tuft of fibres (having a radiated arrangement), and presents only a slightly uneven surface. These growths are extremely vascular, and their vessels follow the same arrangement as the fibres, observing a penecillous distribution through the interior of the structure, and forming a vascular network on its blood-red ulcerated surface. Occasionally, the substance of the growth is transparent, like jelly; it was so in an exceedingly malignant tumor which once

came under the author's observation. A fungous tumor had formed in the breast of a good-looking young woman, who was treated by Professor Dieffenbach, in Berlin, and by Professor Betschler, in Breslau. The disease returned after extirpation; and, after the application of the actual cautery to its neighbourhood and to the axilla, its development proceeded with increased rapidity. Fourteen days before the patient died, she gave birth to a child. On examining the tumor, when first extirpated, it was seen to be composed of fibres which had a tufted arrangement; but the circumstance of its being transparent like glass, induced the author to name it carcinoma hyalinum. Subsequent observation, however, having shewn that transparency is not an invariable character of this form of cancer, the name of carcinoma fasciculatum was adopted as preferable. This form of carcinoma seems to be moderately frequent, for the author has seen many specimens of it in museums in foreign countries. In Meckel's museum, at Halle, are preparations of it in the orbit, in the globe of the eye, and in fungoid carcinoma of the skin.

The fibres of carcinoma fasciculatum are extremely pale and transparent, so that it is only by damping the light very much that they can be distinctly seen under the microscope. Their surface is beset here and there with granules, as with an incrustation: this may be seen in the representation, at Plate iv, fig. 12, of the primitive fibres from the abovementioned tumor of the breast, viewed under the microscope. These fibres have the same diameter as those of cellular tissue, to which, however, they do not in any other point bear the slightest resemblance.

The author is unable to say whether softness is an invariable character of carcinoma fasciculatum, or whether, as indeed is very probable, there are not firmer forms of this structure, as there are of carcinoma reticulare.

In organs affected with cancer, fibrous masses may often be observed, which differ greatly from this fasciculated form of carcinoma; while in the firmness of their substance, and in the complete entanglement of the bundles of fibres of which they are composed, they resemble the benignant fibrous tumors of the uterus, and of other parts. The author once saw such masses in the substance of the uterus, in a case of carcinoma uteri. Sometimes the skin covering cancer of the breast becomes thickened, is rendered more dense than natural, and displays, when divided, a similar complicated intertexture of fibres. Lastly, in cases of cancer of the stomach, in addition to the striated appearance which the swollen muscular coat of that organ usually presents when divided, the author has frequently noticed membranous capsules, containing masses made up of bundles of fibres all arranged in one direction.

OF THE DEVELOPMENT AND SOFTENING OF CARCINOMA.

IN the present state of our knowledge, the development of cancer may be best studied in carcinoma alveolare. (Plate iii, fig. 3. *b.*) This contains within its cells entire generations of younger cells, all of which (as Schwann has shewn to be the case in the early growth of cartilage, and of the chorda dorsalis) are produced from cytoblasts, which, from their large size and dark yellow colour, are easily distinguishable in carcinoma alveolare. The process of development of the other forms of carcinoma cannot be described with the same certainty. It has been already mentioned that, in carcinoma simplex and reticulare, cells are often present which contain one or two smaller transparent vesicles with a minute nucleus. Of course the appearance of the vesicles in the cells is by no means an invariable occurrence, since it depends upon the observer examining the

parent cell at the moment when the young cellules are undergoing the process of development within its interior.

The author is far from supposing that the cells of carcinoma reticulare and carcinoma simplex are invariably developed in this manner from germinal cells formed within the interior of a parent cell, by the bursting or dissolution of which they are afterwards set free, for that occurrence is by no means sufficiently constant to warrant such a hypothesis. Indeed, it so frequently happens that very minute molecules in greater or less number form the only contents of the cells, as to lead us almost unavoidably to the conclusion that the formation of new cellules may take place external to the old cells, no less easily than within their cavity. The young cellules would in this case be developed from nuclei in precisely the same manner as they are when formed within the interior of pre-existent cells. In some instances, indeed, these nuclei may have been set free by the bursting or dissolution of a large cell, but they may also be formed independently of cells, and external to their cavity. This often occurs in healthy tissues; thus, for instance, the cells of the epithelium are certainly not formed within the interior of other cells, although, like others, they have their origin from a nucleus, which remains imbedded in their wall.

In tumors with caudate corpuscles, these bodies are evidently formed from cells with nuclei; for in all growths of this class, the author observed, in addition to the caudate or spindle-shaped corpuscles, a few cells with granular contents more or less evident, often with a distinct nucleus. This form of cell obtains in all parts of the growth which have not a distinctly fibrous structure. Moreover, the spheroidal cells pass into the caudate by imperceptible transitions, while the caudate corpuscles become in their turn transformed into fibres, and are themselves the lowest grade of fibrous structure.

Softening and inflammation are the precursors of the ulcerated state of scirrhus. Sometimes they occur first at one part of the tumor, at other times at another; but the statement that they always commence in the interior is quite unfounded, and instances to the contrary have often come under the author's notice. Often, as in the case of carcinoma mammæ, softening commences in the interior, while the surface of the tumor is still hard and the skin uninjured. In such a case cavities are frequently found in the interior of the growth, filled either with a moderately firm or with a semifluid matter. The more consistent matter is the substance of cancer in a state of softening. The author* ascertained this to be the case in carcinoma reticulare, and he likewise observed some time since, that the white globules which constitute the peculiar network of that structure not merely accumulate during the progress of the disease, but likewise form a main part of the disorganized mass when softening commences. The softened matter, which resembles pus in its appearance, is either contained within large or small cavities, which, in some instances, communicate with each other; or, in cancer of the mammary gland, it occupies the lactiferous tubes and lymphatic vessels, from the divided cavities of which it exudes on pressure.

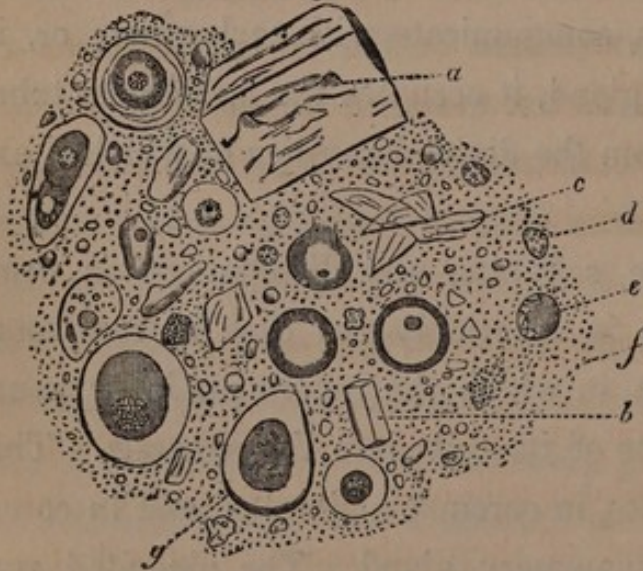
In other instances the softening and disorganization commence on the surface, as is invariably the case in carcinoma alveolare of the stomach, in which the innermost layer pours out the jelly-like contents of its cells into the stomach. This also takes place sometimes in carcinoma simplex, and in carcinoma reticulare of the mammary gland. The ulcerated surface either shoots forth a cancerous fungus, or destruction and disorganization proceed on the surface, unattended by formation of new growths. The latter is often the case in carcinoma of

* Müller's Archiv. für Anatomie und Physiologie, 1836, ccxxi.

the face; more rarely in carcinoma mammæ. An ulceration with an indurated circumference forms on the surface of the hardened mass, and from this ulceration the different elements of cancer are discharged. Valentin detected, in the sanies from a very destructive carcinoma of the face, globules with nuclei, oil globules, and cartilaginous corpuscles*. This discharge of its elements is, however, not peculiar to cancer, but occurs from every ulcerated surface. The pus globules resemble the nucleated epithelium cells: both Henle† and Vogel‡ have noticed this similarity; the latter, indeed, regards the two as identical. Henle§, however, remarks that all vascular granulations of suppurating surfaces are composed of cells containing nuclei; and although their external layer may resemble epithelium, yet it is probable, that (as in the case of carcinoma) portions of the real substance of the part enter into the formation of the pus.

* [The accompanying woodcut, after Professor Valentin, displays the

Fig. 3.



various materials composing the discharge in the case above alluded to. *a*, a large crystal: *b*, a small crystal: *c*, epithelium scales of the epidermis: *d*, pus globules, somewhat altered in form: *e*, a large partially granular globule: *f*, molecular corpuscles: *g*, cartilage corpuscles. The two bodies with dark

circumference are oil-globules.]

† Müller's Archiv. 1837, p. 125.

‡ Physiologisch-pathologische Untersuchungen über Eiter, Eiterung, etc. Erlangen, 1838.

§ Hufeland's Journal, 1838. - Mai.

The surface of an ulcerated carcinoma presents the same structure as the rest of the morbid growth. Thus, in carcinoma reticulare, the author has seen the white network continued even into the smallest inequalities of the ulcerated surface. In carcinoma medullare with caudate corpuscles, though they were not found on the surface of the tumor, yet they gave place to a layer of cellular globules, which are but an earlier stage of the caudate corpuscles. In a specimen of carcinoma of the breast, contained in the museum of the Charité Hospital, the ulcerated surface was covered by a thick layer of a tallow-like substance, formed by polyedrous, cholesteatomatous cells, in which no nuclei were present. No similar case has since come under the author's observation*.

Valentin† saw epithelium scales and crystals in the sanies from a cancer of the face. The author likewise saw (in Meckel's museum, at Halle) a specimen of carcinoma of the cheek, the surface of which was covered by a thick layer of flat, scale-like cells, furnished with nuclei, and resembling epithelium.

Occasionally, ulcerated carcinoma of the breast cicatrizes a short time before death. This circumstance is noticed by Bayle and Cayol‡, who remark that, according to M. Pouteau, such scirrhi are particularly intractable.

CHEMICAL PROPERTIES OF CARCINOMA.

COLD water extracts from carcinomatous growths, when recent, a small quantity of soluble albumen and osmazome; but by far the greater proportion of their substance is formed of a substance resembling albumen, and insoluble by boiling. The

* Müller's Archiv. 1836, cccix.

† Repertorium, 1837, 2. [See Fig. 3, a, b, c.]

‡ Dict. des Sciences Médicales, tom. iii, p. 555.

presence of gelatine in these growths seems to depend on the extent to which cellular tissue enters into their composition. MM. Morin*, Collard de Martigny†, and Hecht‡, mention gelatine as one of the elements of carcinoma; but the author cannot regard this as being always the case, for most specimens of cancer of the breast when thoroughly separated from the skin, and boiled for eighteen or twenty-four hours, or even during a longer time, did not yield any appreciable quantity of gelatine. On the other hand, a very large and firm carcinoma reticulare, situated in the anterior mediastinum, yielded some gelatine after having been boiled for thirty-six hours; and a small quantity of gelatine was obtained from a fungus medullaris of the kidneys by boiling for eighteen hours. Hecht succeeded in extracting gelatine from fungus medullaris while in the crude state, but not after the morbid structure had become fully developed. Wiggers§, however, enumerates gelatine among the constituents of fungus medullaris.

Wiggers, Hecht, and some others, distinguish fibrine and albumen, the former as being a main ingredient of scirrhus, the latter of fungus medullaris. Since, however, we have no unerring means of drawing this distinction, the author does not place very great reliance on the above statement.

In these analyses the presence of caseine is not alluded to, although it is always found in carcinomatous tumors of the breast, and is probably not to be attributed to milk in the remains of the lactiferous tubes, since M. Boutin Limousineau||

* J. de Pharmacie, 8. p. 415.

† J. de Chim. Méd. 4. p. 322.

‡ Lobstein, *Traité d'Anatomie Pathologique*, tom. i, § 442.

§ Mühry ad parasitorum malignorum inprimis ad fungi medullaris oculi historiam symbolæ. *Götting*. 1833.

|| Cruveilhier *Anat. Pathol.*, livr. 21. p. v.

detected it in carcinoma alveolare pultaceum, and the author obtained it from fungus medullaris of the kidney, as also from many other morbid growths. The existence of caseine in decoctions of carcinoma and of fungus medullaris was proved beyond doubt by the following conclusive experiments:—

I.—*Carcinoma Reticulare of the Breast.*

The filtered fluid obtained by boiling for eighteen hours, was rendered turbid by a minimum (about a drop) of acetic acid; but the addition of a larger quantity of acid restored its transparency.

Hydrochloric acid produced the same effects. Solution of alum rendered the fluid turbid; an excess of alum did not restore its transparency. Acetate of lead and bichloride of mercury caused a precipitate. Hydrochlorate of tin caused a precipitate; when added in excess, the precipitate was re-dissolved. Alcohol rendered the fluid turbid.

II.—*Carcinoma Reticulare of the Female Breast.*

The fluid obtained by boiling was rendered turbid by acetic and hydrochloric acids, but an excess of them re-dissolved the precipitate. Acetate of lead rendered it turbid. Alcohol produced but little effect. Corrosive sublimate rendered the fluid very turbid. Tannin caused a copious precipitate. Alum caused a precipitate which was not re-dissolved on adding that substance in excess.

III.—*Fungus Medullaris of the Kidneys.*

The extract obtained by boiling was precipitated by a minimum of acetic acid. Bichloride of mercury caused a copious precipitate; and acetate of lead, one less abundant.

The author never could detect a trace of gelatine in the jelly-like matter of carcinoma alveolare; but both that and collonema

contain a substance akin to salivary matter. In making these experiments, the contents of the cells of cancer alveolaris of the stomach were expressed, and freed as much as possible from the membranous parts of the structure. If the specimen which was the subject of examination had been kept a long time in alcohol, it was already free from osmazome; but when a recent specimen was examined, it was necessary to begin by carefully separating the osmazome.

IV.—*Carcinoma Alveolare of the Stomach.*

The extract obtained by boiling for eighteen hours, and which was afterwards freed from osmazome, was neither precipitated by tannin, nor by most of the metallic salts. Sulphate of copper, chloride of platinum, and sulphate of alum, caused no precipitate; and nitrate of silver, acetate of lead, and bichloride of mercury, rendered the liquid but slightly turbid. Neither acetic, hydrochloric, nor nitric acid caused any precipitate; neither did the hydrate nor the hydriodate of potash; while the ferrocyanate of potash caused no precipitate from the solution of the extract in acetic acid. It was, therefore, only by evaporation that the existence of the substance above referred to could be demonstrated.

V.—*Carcinoma Alveolare of the Stomach.*

The extract obtained from it by long boiling, and which was afterwards freed from osmazome, yielded no precipitate when tested with alcohol, tincture of galls, alum, corrosive sublimate, nitrate of silver, acetate of lead, hydrochloric and acetic acids, nor with any other reagent.

M. Boutin Limousineau detected caseine in the carcinoma alveolare pultaceum of Cruveilhier, while not a trace of it could be discovered in carcinoma alveolare gelatinosum. In one

instance the peculiar white matter which forms the network in carcinoma reticulare could be obtained in sufficient quantity for chemical examination. The person from whom it was taken was a woman aged forty-one years, affected with carcinoma of the breast and of the axillary glands, for which she was operated on by Professor Dieffenbach. The white matter formed large pieces in the substance of the tumor, and a thick layer of it lined a cavity in the mammary gland, and penetrated in a reticulated manner into the grey substance of the carcinoma. After having been separated from the surrounding tissue, the white matter was boiled, and the filtered fluid was tested with acetic acid, corrosive sublimate, and acetate of lead, which occasioned no precipitate, while tannin rendered the fluid but slightly turbid. The white matter itself was scarcely at all altered by boiling. When boiled with alcohol, a very small quantity of fatty matter was dissolved, which was deposited, on cooling, in the form of granules of fat. Acids did not render the substance more pellucid; and after having been kept for a month in acetic acid, it seemed not to have undergone any change.

From these experiments, the matter composing the reticulum would appear to be a substance similar to coagulated albumen.

The grey globules of carcinoma reticulare shewed themselves, on a microscopico-chemical examination, quite as insoluble in acetic acid as the white; neither were they dissolved by water, either cold or boiling. The white corpuscles were not rendered more transparent either by water, alcohol, or acetic acid.

With regard to the fat contained in carcinoma, Collard de Martigny speaks of a soft fat in scirrhous of the breast; Wiggers, of fat containing phosphorus, in fungus medullaris. On the other hand, Gugert detected cholesterine in a fungus medullaris of the eye; Breschet found it in a scirrhous, and Lassaigne in carcino-

matous ulcers of the intestine and mesocolon of the horse. Cholesterine is likewise present in many non-carcinomatous pathological structures*.

NATURE OF CARCINOMA.

THE author presents the following conclusions as the results of what he has learned, with regard to the nature of carcinoma, during many years devoted to the examination of pathological structures, and especially of morbid tumors.

I.—*Carcinoma differs from simple induration not only in its nature, but also in its structure.*

With regard to this statement there can be no doubt, for most pathologists give it their assent.

C. Wenzel† endeavoured to prove that scirrhous and induration are identical, and that carcinoma is merely inflammation in indurated parts.

In this erroneous view of the subject, fungus medullaris and carcinoma alveolare, forms of cancer which differ from their very commencement from induration, are most strangely passed over unnoticed. Even at the very commencement of carcinoma alveolare of the peritoneum, while the disease appears in points no larger than a pin's head, scattered in an isolated manner over the membrane, each of these points is soft, and composed of the cells containing jelly-like matter which are peculiar to this form of cancer. M. v. Walther has set forth most excellently the nature of both forms of disease.

“In induration,” says M. v. Walther, “the degeneration of

* Gmelin's Chemie, 3, p. 405.

† C. Wenzel, über die Induration und das Geschwür in indurirten Theilen. Mainz, 1815.

the substance of the organ, when once it has taken place, remains stationary at the same point; for it is the product of a cause no longer energetic, but which has already ceased to act. It is the result of inflammatory exudation, which sets in with a certain degree and modification of inflammation, and ceases with the cessation of inflammatory action. The exudation, in a more or less high state of organization, unites with the substance of the organ, and forms a mass often not to be distinguished from it: it glues together the most different tissues, nerves, vessels, cellular tissue, &c. in such a manner, that the specific characters of each are no longer to be discerned. But here it comes to a stand; the morbid process has run its course. Induration is the product of an action which has ceased; its distinguishing marks are rest and inaction. From this the progress of scirrhus is widely different. True scirrhus is the product of an ever-working morbid cause; of an activity displaying itself in the formation of diseased structure; of a peculiar dyscrasia, which, unlike the inflammatory process, is not limited in its duration to a certain period of days or weeks. It is a chronic disease, and, when once established, contains within itself the principle of its further development."

This opinion is quite supported by minute examination. Not merely does carcinoma simplex, or scirrhus, develop itself without inflammation, but its structure differs from the very first from that of simple induration. Exuded fibrine always has the same appearance, whether it forms false membranes on the surface of organs, or whether it is deposited in their tissue so as to cause induration. Recent exudations do, indeed, contain small globules, but no cellular globules with germs of new cellules*.

* [It does, however, appear doubtful whether we are warranted in laying down so positively as is here done, by Professor Müller, the distinction between carcinoma and induration. Dr. Henle remarks on this subject,

II.—*Carcinoma differs also in its nature from ulcerations of indurated parts.*

Wenzel* denies that there is any important difference between ulcerations of indurated parts and ulcerated carcinoma; and Andral† even asserts, that the products of all morbid secreting and nutritive processes become cancerous in the stage at which they pass into progressively increasing ulceration. This mode of expression is altogether metaphorical, and belongs, like the word inflammation, entirely to the infancy of science: it does but indicate the common result of very different changes of structure, not one disease *sui generis*; and, did it not emanate from a very distinguished and meritorious writer, it might be passed over without further comment. This confounding of diseases, definite in character, and destructive from their very commencement, with others which prove fatal only by loss of the fluids, and by disturbance of sanguification, seems to the author to be as little of an advance in science, as is that revolution which Andral has sought to bring about in the doctrine of inflammation by his notions about hyperæmia. Most ulcers of a non-carcinomatous nature are ulcers in indurated parts, for exudations often take place in the circumference of abscesses and of ulcers, and thus cause induration of the surrounding parts. Henle's investigations, indeed, have shewn that the granulations of ulcerated surfaces of all sorts are composed of cells resembling that fibrinous exudations contain not merely globules, but also cells, which, though not furnished with germs of young cellules, contain the characteristic nuclei, and at an early period become elongated, and transformed into fibres of cellular tissue, such as constitute the cicatrices of ulcers, &c. See Henle's Observations in Müller's Archiv. 1839. p. 1xxiv.]

* C. Wenzel, Lib. cit. and über die Krankheiten des Uterus. Mainz, 1836.

† Précis d'Anatomie Pathologique, tom. i, p. 191.

bling those in the tissues of the embryo. This cannot, however, be adduced in proof of the similarity of carcinoma and of ulcers in indurated parts, for most benignant tumors are also made up of embryonic cells. Rather, may we say, that the nature of both morbid structures is physiologically different in regard to the productive and destructive powers which each possesses. It is only in carcinoma that the most dissimilar tissues of parts become transformed into tissues identical with those which form the morbid growth.

III.—*Carcinoma is no heterologous structure, and the minutest elements of its tissue do not differ in any important respect from the constituents of benignant growths, and of the primitive tissues of the embryo.*

The proof of this assertion is afforded by the observations already made, as well as by those which follow on benignant tumors. The elements of carcinoma are nuclei, cells, caudate corpuscles which are developed from cells, and fibres which are formed from caudate corpuscles. No other elements occur in benignant tumors. The gelatine—yielding enchondroma and the albuminous sarcoma consist of cells; sarcoma with caudate corpuscles contains the same elements as the corresponding form of fungus medullaris. The gelatine-yielding cellulo-fibrous tumor, the gelatine-yielding tendino-fibrous or desmoid tumor, and the albumino-fibrous tumor, are all, like carcinoma fasciculatum, composed of fibres. The pigment cells of melanosis are repetitions of healthy pigment cells. The peculiar appearance of the white corpuscles in carcinoma reticulatum, and their reticulated arrangement, occurring as they do in but one form of carcinoma, do not warrant us in founding thereon any theory of the heterology of cancer*.

* [This decided rejection of the terms heterologous and homologous is objected to by Dr. Henle. He remarks that the inadequacy of microscopic

IV.—*Neither does carcinoma (independently of the sanies) possess any peculiar chemical constituents.*

The materials observed in carcinoma are albumen, gelatine, caseine, a matter resembling salivary matter, and fat, one form of which is cholesterine. These, however, are all contained in many other non-carcinomatous growths.

V.—*The peculiar nature of the destructive and productive activity of carcinoma does, however, determine in it general anatomical characters which may, in most cases, be distinguished with the naked eye.*

Among these may be reckoned the removal and dissolution of the elements of the affected organs; the transformation of muscles, tendons, nerves, and membranes into the same new mass; the peculiar grouping of the elements of carcinomatous growths, the cerebriform softness of medullary sarcoma, the reticulum of carcinoma reticulare, the production of pigment with the destructive development of melanosis, the peculiar structure of carcinoma alveolare with the same destructive tendency, and others which might be mentioned. Thus may fungus medullaris with caudate corpuscles be distinguished from the corresponding benignant sarcoma, for the latter leaves untouched the different structures in or near the affected organ. A benignant sarcoma

and chemical investigations to detect differences, is far from sufficing to establish an identity of structure between any two tissues. It would, indeed, rather tend to prove that the development of cells, apparently resembling each other, into tissues physiologically dissimilar, must be owing to the existence of some other differences in their component organic matter. Such, too, is the conclusion to which we are naturally led when we observe that the ovum of an insect and that of a mammal, or the primary cells of muscular and nervous tissues, do not present any appreciable difference.—See Müller's Archiv. 1839, p. lxxv.]

of the conjunctiva, though as large as the fist, left the globe of the eye unaltered; while a much smaller carcinomatous growth in the same neighbourhood would occasion the nerves, muscles, and tunics of the eye to swell, and to develop the peculiar morbid structure.

VI.—*The development of carcinoma is the result of a diseased state of the vegetative process; which, whether general or local in the first instance, always tends to involve the whole constitution.*

This is a fact which needs no laboured proof; the history of cancerous disease in thousands of instances has confirmed its truth. The results of extirpation of carcinomatous tumors are so melancholy, that the most experienced surgeons regard cancer in almost every instance as a constitutional disease. Unable to adduce experience of his own with regard to this point, the author relies on that of his much respected colleagues, MM. v. Graefe, Rust, and Dieffenbach. In carcinoma, masses of new structure are developed, which are composed of the elements of tissues in an embryonic state; but this analogy to tissues in their state of original formation occurs also in benignant tumors, and does not constitute the essence of the diseased action in carcinoma. This consists not merely in the formation of new tissues, but in the inability of the constitution to maintain, in such as already exist, their individuality of structure; and hence the muscles, nerves, tendons, bones, &c. all become transformed into the new mass, and form with it one uniform texture.

VII.—*Although in most instances a general disposition to carcinoma exists from the time of its commencement as a local disease, yet it must be owned that a local disposition may give rise to carcinoma, which may afterwards contaminate the whole constitution; and this local disposition has been proved to be, in some instances, the result of certain external agents.*

The general correctness of this statement cannot be disputed, but its application to individual cases requires a minute examination of the boundaries of carcinoma, such as could not be made with certainty, while the structure of morbid growths was but imperfectly understood.

The author thinks it cannot be doubted that true carcinoma has, in some very rare cases, been cured by extirpation. MM. Bayle and Cayol* mention several instances, in which, after cancer had been frequently extirpated, it at length ceased to return. To this class belongs a case, related by M. Sabatier, in which a woman, after having had two operations performed on her breast, remained quite well five years after the second operation. A parallel instance was afforded by an officer, who laboured under a tumor of the breast. M. Lacombe narrates the history of a woman who underwent four operations, and five years afterwards was in the enjoyment of good health. It is, indeed, not quite sure in these cases that the disease was carcinoma, for innocent tumors, when incompletely extirpated, very readily return. Cases which have been operated on once only, and then with perfect success, while the morbid growths have not been anatomically examined, must be left quite out of consideration, since diseases of all sorts have been extirpated for scirrhus and cancer. The author's friend Professor Pockels,

* Dictionnaire des Sciences Médicales, tom. iii, p. 573.

says that once, from among many melancholy cases, he cured a true carcinoma of the breast by extirpation. In this instance, the structure of the tumor was considered by Professor Pockels to be identical with that already described as carcinoma reticulare. Professor Jüngken extirpated, from the orbit of a young woman, a compound carcinoma, partly made up of carcinoma reticulare, partly of carcinoma melanodes: two years have now elapsed since this operation, and the patient continues in perfect health; while other precisely similar cases have had a fatal termination. A carcinoma reticulare of the female breast, which was extirpated by M. v. Graefe, did not return till after the lapse of five years. The author examined the degeneration as it appeared in the breast last affected, and found it to be carcinoma reticulare. Many instances are related in which fungus medullaris has either undergone spontaneous cure, or has been cured by operation. Grossheim* has collected many such cases; but, unfortunately, all of them cannot be relied on, since so many diseases have been confounded with fungus medullaris. The cases on which most dependence can be placed are those in which fungus medullaris of the globe of the eye retroceded, without any operation having been performed, before the cornea had become perforated†. Such cases, indeed, are very rare. The existence, however, of even one single instance in which true carcinoma has been cured by extirpation, proves that it is possible for the disease to be at first merely local, and that removal of the affected part may prevent the constitution from becoming contaminated.

The surest proof of the possibility of the existence of a disposition to carcinoma, at first merely local, although invariably tending to become general, is afforded, according to the experi-

* Medicinische Zeitung des Vereins für Heilkunde in Preussen 1838. N. 11, p. 57.

† v. Ammon's Zeitschrift für Ophthalmologie, B. i, p. 117.

ence of English surgeons, by chimney-sweepers' cancer. Mr. Travers* says, "The chimney-sweeper's is the purest specimen of local cancer. Next to this the cancer of the lip; yet in both the constitution is predisposed, and, unless it be, the occasional cause is ineffectual in producing the disease." According to Mr. Travers, the chimney-sweeper's cancer invariably returns after the affected part has been removed. Although a general predisposition may often precede the production of carcinoma by the irritation of the soot, yet the author cannot agree with Mr. Travers' assertion, that it is absolutely necessary to the production of the disease, since chimney-sweeper's cancer is not invariably fatal. Mr. Langstaff has not seen any person recover from chimney-sweeper's cancer after the affection had implicated the inguinal glands, for then the disease has always extended to the lumbar and abdominal glands. This statement implies that the disease is curable by timely extirpation; and Mr. Earlet maintains this expressly, and mentions a case of chimney-sweeper's cancer of the testicle which was permanently cured by extirpation. The disease, after having lasted for some time, always becomes constitutional.

Sir A. Cooper gives an engraving of chimney-sweeper's cancer, in his work on the testicle†. The minute structure of this disease has not yet been examined‡.

* Medico-Chirurgical Transactions, vol. xvii, p. 411.

† Medico-Chirurgical Transactions, vol. xii, p. 2.

‡ Observations on the Structure and Diseases of the Testis, part ii, plate xii, fig. 3 and 4.

|| [Through the kindness of Mr. Stanley, the translator has had an opportunity of subjecting a portion of chimney-sweeper's cancer to microscopic examination. The disease had not reached the ulcerated stage, but a number of irregular warty excrescences beset the scrotum for a considerable extent. The surface of these excrescences was covered by a thick layer of epithelium cells, in all stages of development; beneath which

Sir A. Cooper and Mr. Keate have seen a few cases in which the ordinary causes had produced chimney-sweeper's cancer in the cheek. This disease throws much light on cancerous affections of the face and lip, which are sometimes cured by local treatment, and the malignity of which must, in those instances, have consisted in a merely local disposition.

Mr. Earle has also made some very valuable observations on those local diseases of the lips and face, which, although they appear to be cancerous, are not so in reality, or, at any rate, are not so at their commencement, and which do not return after the operation, or after local treatment.

It is very difficult, and not always possible, to distinguish, by any peculiarity of structure, cancer of the skin from neglected

were fibres of apparently healthy cellular tissue, intermixed with granules, or small globules, very similar to those figured by Simon in Müller's Archiv. 1839, Plate i, fig. 12. In other parts was a fibrous

Fig. 4.



tissue (see the accompanying woodcut) made up of bodies having a caudate or spindle-shaped appearance, resembling those delineated by Valentin, Repertorium, Bd. iii, tab. i, fig. 1, as being varieties of epithelium, and in Bd. ii, tab. i, fig. 17, as occurring in the substance of fungus medullaris. Similar bodies are likewise represented by Prof. Müller (Plate iii, fig. 8, and Plate iv, fig. 9-11), who detected them in the substance of fungus hæmatodes. This observation favors the supposition that chimney-sweeper's cancer commences by the enlargement, from irritation, of the cutaneous papillæ and their subsequent ulceration. The long time, however, during which the preparation had been kept in spirit, together with the circumstance that only a small and superficial portion of the diseased growth could be submitted to examination, diminish the value of the observation, and render it very desirable that the disease should be examined when recent, and in the ulcerated state, as well as before that change occurs. Mr. Paget's paper on some of the diseases of the papillæ of the cutis, in the Medical Gazette, vol. i, for 1838-9, p. 284; contains much interesting matter which bears upon this subject.]

or mismanaged ulcers of that texture. Here the characteristic forms of cancer are very rare; in one only of many instances was the disease found to be carcinoma reticulare. In no part of the pathology of cancer are our notions more unsettled than in this instance. The mere malignity of a sore is insufficient to stamp on it the carcinomatous character, for then must herpes rodens be cancer. To the idea of a local cancerous affection belong the development of the disease from carcinomatous tubercles; the property, when left to itself, of destroying, without intermission, the structure of all tissues with which it meets, whether muscles, mucous membranes, or bones (the last without the phenomena of ordinary caries or necrosis); and, lastly, the property of giving rise to any of the various forms of carcinomatous degeneration. The diagnosis is still more difficult, if a non-carcinomatous ulceration of the skin should, from the super-vention of a carcinomatous disposition, become converted into cancer, for then we lose the guide afforded by the origin of the disease from a carcinomatous tubercle. In chimney-sweeper's cancer there is no primitive carcinomatous tubercle, for the disease being produced by purely local causes, and prior to the development of local cancerous disposition, the first symptoms are erosion from the action of the soot; but, as the disease progresses, it propagates carcinomatous swellings at a distance from its primary seat, and, at last, not a single symptom of true carcinomatous disease is wanting. With regard to other causes, besides soot, which may produce a local disposition to cancerous degeneration, the author must refer to the essay of M. v. Walther. From his statements it appears probable that these causes are such as, while they are not sufficiently irritating to produce simple inflammation, blunt the irritability of the part by their often repeated impression; or which, from the very first, disturb the harmony between the vegetative activity of

the part and the whole organism; as would be done by a contusion or other violence inflicted on a part. An organ once brought into this state remains incapable of generating simple circumscribed inflammation, when afterwards acted on by causes which would otherwise suffice for its production.

The manner in which the carcinomatous dyscrasia becomes developed from a merely local disposition transcends our researches. It can, however, be easily understood, that, when once cells with a productive tendency have been formed, the reception of the germinal nuclei into the circulation may determine their distribution to some part predisposed to receive them, and may thus give rise to the formation of secondary tumors. How far the appearance of masses of fungus medullaris within the cavities of the large vessels, and especially of the veins, which Sir A. Cooper, M. Cruveilhier, Dr. Carswell, and others, have observed, is connected with this circumstance, must still be a matter of doubt, for it has not yet been determined with certainty whether there exists any organic connexion between these masses and the vessels in which they are contained. No opportunity has occurred to the author for putting this to the test of accurate examination*.

VIII.—*Some tumors which by nature are not carcinomatous, and part of the character of which it is to remain local, may, under certain circumstances, originate the local disposition to cancer.*

Aneurism by anastomosis, and *nævi materni*, must be referred to this class; for M. v. Walther has shewn that, under long-continued irritation from internal or external causes, they may be

* With reference to this subject, consult Cruveilhier, *Anat. Pathol.*, livr. 18; Carswell, *lib. cit.* Fasc. Carcinoma; and Sir A. Cooper, *lib. cit.* part ii, plate 9.

converted into fungoid growths possessed of properties similar to those of cancerous tumors. They are less susceptible than other parts of simple inflammation and its consequences.

IX.—*Many structures differing from carcinoma have, on the other hand, even though repeatedly mismanaged, no inclination to assume the cancerous disposition; or, perhaps, they may be more correctly said to have no greater disposition to pass into the carcinomatous state, than is possessed by many other healthy tissues.*

The simple fatty tumors have been proved to belong to this class, to which Bayle's* observations shew that the tendino-fibrous or desmoid tumors must also be referred. The author's own investigations lead him to conclude that this disposition is not greater in enchondroma, cholesteatoma, and in albuminous sarcoma and osteosarcoma (cellular sarcoma, sarcoma with caudate corpuscles, and fibrous sarcoma). Irritation and partial excision determine, indeed, an increased growth of these tumors; but if perfectly extirpated they cease to be reproduced, and if at any time they exert an injurious influence on the constitution, it is merely by the loss of fluids which they occasion. In the museum of Professor Pockels is a specimen of albuminous sarcoma which had developed itself in the female breast, where it gave rise to most alarming hæmorrhages, but was extirpated with perfect success. A sarcomatous growth of the conjunctiva returned after repeated operations, owing to extirpation having been imperfectly performed, but, after having been extirpated for the third time by Dr. Helling, it never re-appeared. This subject will be spoken of at greater length in a subsequent part of the work.

* Dictionnaire des Sciences Médicales, tom. vii; Corps Fibreux de la Matrice.

X.—*Each form of cancer occurs in persons of all ages, and in all organs, but some organs appear to be especially liable to carcinoma at certain periods of life.*

It has already been long known that fungus medullaris occurs indifferently at all periods of life. Many instances have also occurred to the author which prove that carcinoma reticulare, the most common form of cancerous degeneration in the breast of females advanced in life, is a disease incidental to all ages. The author frequently saw it in the orbit of children, where he has also often met with carcinoma medullare. It is, therefore, incorrect to say, that the ordinary cancer of the breast holds, as a distinct form of cancer, any peculiar ætiological relation to the climacteric years in women; such a relation has reference to the organ attacked, not to the disease by which it is affected. The breast is, like the uterus, more frequently attacked by carcinoma at this period; but this form of cancer occurs at all periods of life.

The assertion has often been made, though without foundation, that certain tissues are affected by peculiar forms of carcinoma. It has, indeed, been allowed, that fungus medullaris may occur in all organs and tissues. In the orbit, it attacks indifferently all parts of the eye. Hence it is evident that the question, whether, in this or the other case, the affection began in the optic nerve, or in the choroid coat, or in some other part of the eye, arises from an erroneous conception of the subject. It is true that in some cases the affection may be particularly well marked in this or in the other part; but there are instances in which the same degeneration becomes simultaneously evident in the muscles of the eye, in the sclerotic, choroid coat, optic nerve, and crystalline lens. Proofs of this are afforded by the numerous writings upon this subject, and the author can substantiate them from the results of his own observations on morbid

growths, extirpated by M. Jüngken. Medullary sarcoma of the bones of the cranium, of the dura mater, and of the brain, sometimes originates in one of these parts, sometimes simultaneously in them all*.

Carcinoma simplex, or scirrhus, has been said to be peculiar to glandular structures. It is well known that it may appear in the bones at the same time with scirrhus in the breast, as well as after its extirpation. J. L. Petit noticed cancer of the bones in a case of carcinoma mammæ, and M. Cruveilhier† saw cancerous degenerations of the bones in cases of carcinoma mammæ, and also after the disease in the breast had been extirpated. He remarks, moreover, that in some of these cases the degeneration of the bones was scirrhus, at other times of an encephaloid nature. In a case of extremely hard scirrhus of the breast, the author observed formative globules precisely the same both in their appearance and in their contents in the substance of the mammary gland and in some very hard tumors which grew from the cancellous structure of the ribs. In another instance, carcinoma fasciculatum was developed in the mammary gland, in the orbit, and in a cancerous fungus of the skin. Carcinoma alveolare and reticulare have likewise a universal distribution; and that this is the case with fungoid melanosis is a fact too well known for it to be necessary that the author should adduce any observations of his own for its confirmation‡.

* See Ebermaier, über den Schädelschwamm, and the article Hirnschwamm and Hirnhautschwamm, in the Encyclopädischen Wörterbuch der Medicinischen Wissenschaften.

† Anat. Pathol. Livr. 20.

‡ In a treatise recently published (on Varicose Capillaries, &c., by T. G. Hake, M.D. London, 1839) Dr. Hake describes a disease to which the liver of the rabbit is subject, and which consists in a dilatation of the hepatic ducts arising from distention of their cavities by a whitish or yellow-

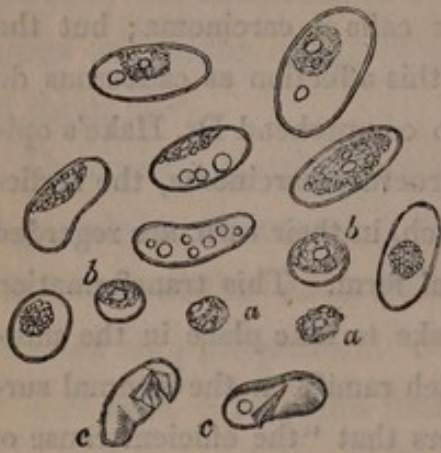ish matter of varying consistency. Dr. Carswell has delineated this disease (Pathological Anatomy, Fasc. Tubercle, plate ii, fig. 6), to which he gives the name of tubercle. Dr. Hake calls it carcinoma; but the reasons which have induced him to regard this affection as cancerous do not appear. It is, indeed, not very easy to comprehend Dr. Hake's opinions; for although he calls the morbid structure carcinoma, the bodies composing it are said to be pus globules, which, in their turn, are regarded as blood globules, altered from their natural form. This transformation of the blood globules is supposed by Dr. Hake to take place in the morbidly dilated portions of the capillaries which ramify on the internal surface of the hepatic ducts; and he considers that "the efficient cause of carcinoma, as existing in the hepatic ducts, is to be found in universal varix of the veins and aneurism of the arteries, as affecting capillaries, and in the simple increase of vessels so affected."

The translator examined the liver of rabbits affected with this disease, and found within the hepatic ducts a white pulpy matter, occasionally tinged with bile. On employing a magnifying power of 180 diameters, this matter was seen to consist of oval cells, imbedded in a granular matter which filled up their interstices. Sometimes the cells were in contact with each other; but that circumstance did not appear to alter their form, which has been faithfully represented by Dr. Hake. In no instance was any considerable thickening of the walls of the cells perceptible. Some of the cells were quite filled with granular matter, and they were almost always furnished with a nucleus, which appeared to be attached to their wall. Nuclei were also seen free; and this circumstance, together with the fact that they were always proportionably largest where the cells were smallest, while their real size varied very slightly, renders it probable that the nucleus is formed before the cell. Walls were not seen surrounding the nucleus, which appeared to be formed of an aggregation of granules of different sizes, one of the largest of which sometimes formed a distinct nucleolus. The nucleolus often resembled an oil globule, and, in some instances, bodies like oil globules were seen in the cells unconnected with the nucleus.

The translator obtained nearly the same results as Dr. Hake, from measurement of these bodies. The long diameter of the cells varied from $\frac{1}{800}$ to $\frac{1}{500}$ of an English inch; their transverse diameter from $\frac{1}{1120}$ to $\frac{1}{1000}$, while the nuclei averaged from $\frac{1}{400}$ to $\frac{1}{244}$ of an inch in diameter.

The woodcut represents some of the chief varieties of the cells and nuclei.

Fig. 5.



a, a, are nuclei around which cells have not yet formed. *b, b,* are cells which have not yet attained their full size, and are observed to present a rounder form than the others. Within their granular nucleus is a nucleolus like an oil globule. *c, c,* are capsules from which the contents have escaped; in the one instance completely, in the other leaving behind a single oil globule. The

other figures display the various forms of the cells, the greater or less abundance of granular matter within them, and the oil globules they contain.

It may not be useless to point out some of the differences between this form of morbid structure and others which it has been supposed to resemble.

1st. The matter contained in the ducts has been regarded as tubercle; but the large oval cells with their granular nuclei differ much from the minute molecules and round granular bodies of tubercle, which more nearly resemble the true pus globule.

2d. The oval cells differ from pus globules in size, form, and in their reaction with acetic acid. They are more than double the size of the pus globule, their oval form is peculiar, and they are unaffected by acetic acid. Dr. Hake, indeed, says that with the aid of slight pressure they may be completely dissolved by acetic acid; but on repeating the experiment the translator did not find any alteration produced by the acid either in the nucleus or capsule.

3d. When carcinoma affects a part, it is not limited to one particular tissue, but involves all alike in one common degeneration. No such change, however, is produced in the rabbit's liver by the disease in question; for the hepatic ducts, although somewhat thickened, presented a fibrous structure, resembling that of healthy cellular tissue, in which no oval bodies were intermixed.

4th. It has been supposed that the oval cells are the ova of animals; but no animalcules have ever been discovered, notwithstanding the countless number of the oval bodies and the various stages of development in which they have been observed.

With regard to the varicose state of the capillaries on which so much stress has been laid, the translator would submit that no proof has hitherto

been adduced of the existence of any thing like the relation of cause and effect between varix of the capillaries and the formation of a peculiar matter in the hepatic ducts. It is natural that where new matter is deposited new vessels should also be formed to nourish it; but as far as we at present know, the duty of the bloodvessels is limited to this conveyance of nutriment. Indeed, we have nowhere any proof afforded us that peculiar forms of morbid structure require a peculiar arrangement of vessels; and the tendency of Prof. Müller's investigations is to conduct us to an opposite conclusion. Moreover, as in some measure explanatory of the varicose state of the capillaries, might be adduced the observations of M. Schwann relative to their formation. From these it would appear, that when first formed they have not a uniform size, but vary in different parts, being in some situations (especially where branches are given off) much wider than capillaries in their natural state, while they speedily contract in caliber, and even become as fine as fibres of cellular tissue. In other words, capillaries, in an early stage of their formation, are, according to M. Schwann, varicose; and if such be the case, it would not be surprising if, in parts where the process of nutrition is so allied as to give rise to the formation of the oval corpuscules, the capillaries did not attain their full development.

) *See errata.*

altered

SECOND PART.

OF THOSE MORBID GROWTHS WHICH MAY BE CONFOUNDED WITH CARCINOMA.

I.—OF CARTILAGINOUS TUMORS. ENCHONDROMA*. (*Synonyms: Sarcoma cartilagineum, chondroides. Tumor cartilagineus.*)

THE term chondroid has been often employed in pathological anatomy, but never in precisely that sense in which it is here made use of to designate cartilaginous tumors, or enchondroma. Heusinger included under the term chondroid, a great variety of pathological structures, and even tubercle. Some have called the tendino-fibrous tumors of the uterus chondroid, on account of their cartilaginous hardness, although in their structure they present no similarity to cartilage. With as little propriety has this term been applied to fibrous tumors in other parts; for instance, in the larynx, or to those pathological productions sometimes found loose in the cavities of joints, and which, though resembling cartilage in hardness, differ from it in structure, and are composed of fibres. The name chondroides, sarcoma chondroides, ought, therefore, to be restricted to tumors identical with cartilage in structure, and presenting the same chemical properties. Since, however, this term has been so often extended to other structures, while the true cartilaginous growths have been misunderstood, treated of under other names, and even arranged among carcinomatous growths, it may, perhaps, be advisable to apply the names of enchondroma, or chondroma, to those true

* From ἐγχοιδῆος, cartilaginous.

chondroid growths described by the author some time since* as presenting a peculiar structure, the nature of which had not always been understood by previous anatomists.

I.—GENERAL DESCRIPTION OF ENCHONDROMA.

Enchondroma is a fungoid growth proceeding from bones, or from soft parts, as, for instance, from glands, and curable by amputation. It forms a spheroidal, not lobulated tumor, which equals or even exceeds the size of the fist. When it appears in soft parts, it is furnished with a thin covering, resembling cellular tissue; in the bones, where its occurrence is more frequent, it retains the periosteum as its investing membrane. This disease presents itself as a soft expansion of the bone, developed either within its interior, or, more rarely, from its periphery. In the former case it is covered not only by the periosteum, but also by the bone itself, which is sometimes expanded to an extreme thinness. In some instances, indeed, this bony shell is not entire, and its only remains are a few thin isolated bony laminae on the surface of the tumor. When the growth springs from the circumference of the bone it does not necessarily have any osseous investment. The articular surfaces of the bones are usually but very little altered by this disease, often they are not at all affected, and even in instances where the phalanx of the finger has been converted into a round tumor as large as an orange, the articular surfaces are in most cases unchanged in structure, and maintain their proper position. How great soever may be the expansion of the bone, the disease seldom advances beyond the articular surface, and if two neigh-

* Rede zur Feier des 42. Stiftungstages des Königl. Med. Chir. Friedrich Wilhelm's Institutes, am 2, August. 1836.

bouring phalanges of a finger form this expansion, the two tumors very rarely become confounded with each other. The occurrence of ankylosis also is unusual, though it took place in a case of enchondroma described by Mery.

The parts covering the enchondroma generally remain unaltered, notwithstanding the large size to which the tumor may attain. This circumstance, together with the slow, painless development of the tumor, and its existence for ten or twenty years without producing any injurious effect on the constitution, sufficiently prove its benignant character. The contents of the tumor are soft: when it is developed in or on the bones small spiculæ of osseous matter are usually intermixed with its tissue, although their presence is not constant. The parenchyma of the growth usually displays, when divided, two different constituents, distinguishable with the naked eye; the one a fibro-membranous substance, the other grey, pellucid, and resembling cartilage or very firm jelly. The fibro-membranous part, which is but seldom absent, forms cells both large and small, some equalling or even exceeding the size of a pea; and the larger cells often containing smaller ones in their cavity. Within these cells is contained the other substance, which is grey, somewhat pellucid, differing from cartilage in being more soft, and more nearly resembling in consistence the soft hyaloid cartilage of cartilaginous fishes: in some instances, indeed, it is not firmer than very firm jelly. These masses are easily removed from the cells, and are then found to be very friable. Like the hyaloid cartilages of cartilaginous fishes, this substance preserves its pellucid character in alcohol. The intervention of membranous structures connects the transparent cartilaginous masses, and imparts to enchondroma a conglomerated appearance, which does not occur in any other form of exostosis.

The slight inequalities which may be seen on the surface of an enchondromatous tumor indicate this conglomerated structure of its interior.

The fibro-membranous part appears, under the microscope, to be composed of an interweaving of transparent fibres; the hyaloid mass, however, so closely resembles cartilage, as to suggest to the author the name he has applied to this form of tumor. Real cartilage, even that of the cartilaginous fishes, contains, scattered through its substance, oval or round semi-transparent cartilage corpuscles,* and cells containing granules, or smaller cellules; and precisely such microscopic corpuscles are contained in the hyaloid mass. But, how similar soever to cartilage the hyaloid mass may appear when viewed by the naked eye, or by the aid of a microscope, yet the fibro-membranous capsules or cells which usually intersect the whole of the tumor distinguish its texture from that of true cartilage. These membranous structures contain bloodvessels, as was shewn by the injection of an enchondromatous tumor which MM. v. Walther and Weber described.†

Previously to the year 1836, the author had observed this form of morbid growth once in the parotid gland, and four times in the phalanges and metacarpal bones of the hand. The structure of that which was developed in the parotid gland differed from that of the others in containing no osseous substance, the presence of which, however, is merely accidental, and results from the tissue in which the tumor is formed. In the first of the cases in which the hand was affected, the tumor began in the phalanges of the index finger, the interior of which was soft-

* These bodies were first observed by Professor Purkinje, in human cartilage, and were described by him in a dissertation by Deutsch, *De penitiori ossium structura observationes*, *Vratisl.* 1834.

† v. Graefe's und v. Walther's *Journal* XIII B. p. 351-374.

ened, and the bony shell of the middle phalanx was expanded so as to form a projection from one side. In the second case, the metacarpal bones and the phalanges of the little finger, and of the finger next to it, formed smooth, spherical enlargements; the thin shell of bone enclosing the matter above described, with which were intermixed fragments of spongy, osseous substance. In the third case, the metacarpal bones and most of the phalanges were converted into spheroidal tumors, which retained nothing of the original form of the bones, excepting at the articular surfaces. A soft mass, without any osseous substance, filled up the interior of these tumors, and thin, isolated laminae were all the remains of the bony shell. In the abovementioned cases, for which the anatomical museum is indebted to M. v. Græfe, the tumors had not burst, nor had ulceration commenced. The muscles and tendons, and all parts covering the bone, present their natural texture, and the skin passes unaltered over the spherical masses. This is characteristic of enchondroma; but although progressing slowly for a number of years, it at length becomes an open sore, as do many other growths, both innocent and malignant. The fourth case, which is taken from Gottl. Walter's collection, affords a specimen of enchondroma in this stage. Some of the round swellings of the phalanges and metacarpal bones have burst; the shell of bone, which in this instance was extremely attenuated, is partially destroyed, its contents have passed into a state of suppuration, and one of the tumors retains nothing but its outer shell, while others are not ulcerated, and are still in a very early stage of their development. Although enchondroma if left to itself will burst in the course of years, and may then occasion death by the local disorganization and loss of the fluids to which it gives rise, yet the disease is curable by amputation. It does not return after amputation to its old seat, nor does it appear in other parts; and

although its simultaneous development in several of the bones of the hand may seem to indicate malignity, yet for the most part this extension of the disease is but the result of the widely spread influence of its exciting cause, which in most instances is a contusion. The specimen of enchondroma of the parotid gland was procured for the anatomical museum from Berger's collection, at Brunswick. The author's much respected colleague, Professor Schlemm, remembers seeing this preparation in Brunswick, and likewise recollects the person from whom it was removed; and is sure that he was completely cured by the operation. It is known that in the three cases which occurred in the surgical clinic connected with this university, the operation was entirely successful; the history of the specimen in Walter's museum is unknown.

The author has since seen many specimens of enchondroma, which presented precisely the same form in different museums both in Germany and England. The author saw one example of it in the collection of Professor Pockles, in Brunswick, who kindly allowed him to make a drawing of it. This specimen is very interesting, and from the manner in which it was prepared, illustrates exceedingly well the alterations in the structure of bones which enchondroma produces when developed within their interior. The soft parts of the tumor have been removed by maceration, so as to display the sieve-like appearance of the thin osseous shell which had once furnished it with a complete investment. Two preparations of enchondroma came under the author's notice in Meckel's museum at Halle, and nine in the London museums. Of these a more minute description will be given in a subsequent page, where mention will be made of the observations of others on this subject. It has already been stated, that the bones are the most frequent seat of this affection; indeed, it was only in four out of

thirty-six cases that enchondroma was found occupying the soft parts. In all of these four cases the parts affected were glandular structures, namely, in one instance the parotid gland, in another the mammary gland, and in the remaining two the testicle. The bones most subject to this disease are the metacarpal bones and the fingers: in fact, five-sixths of the cases of enchondroma in the bones have occurred in those parts. Three cases were observed in the leg, one only in the thigh, one in the os ilium, one in the basis of the skull, and one in the ribs.

II.—DIFFERENT FORMS OF ENCHONDROMA IN THE BONES.

AT the time of the author's first communications with regard to enchondroma in the bones, he was acquainted only with the more common of its varieties, namely, with the central, or that developed in the interior of the bone, and accompanied with expansion of the osseous shell. Since this time he has convinced himself of the existence of a second form, which appears on the surface of the bones unattended by expansion of the bony shell.

A.—*Enchondroma of the Bones with Osseous Shell.*

This is by far the more frequent form in the smaller cylindrical bones, in the metacarpal and metatarsal bones, and in the phalanges of the hand and foot. The alterations which it produces in the bones are best displayed in the accompanying engravings, in which it may be traced in the different bones of the hand, from its first appearance to that stage in which it produces enormous expansion of the shell of the bone. The first changes are softening of the spongy substance in the interior of the bone, the place of which is occupied by the soft mass of enchondroma. While this process is going on, the shell of the bone becomes dilated, as though from the action of some internal force. This distention, however, can be the result only of

some change in the nutritive process, for the attenuated shell does not break, but long maintains its perfect continuity. In proportion as the old bone is destroyed, new bone is deposited on the surface of the tumor, and thus the shell of the bone is the subject of a constant alteration. The progressive growth of the new substance in the interior of the bone dissolves here and there the continuity of the bony shell; and in course of time this shell is reduced to a few thin isolated laminæ on the surface of the tumor, which still retains its smoothness, and spheroidal shape.

This form coincides in many particulars with that which Sir A. Cooper, in his essay on exostosis* terms cartilaginous exostosis of the medullary membrane. Sir A. Cooper divides exostosis into periosteal and medullary, each of which may be cartilaginous or fungoid. He remarks expressly that "in this case the shell of the bone becomes extremely expanded, or rather the original shell is absorbed, and a new one deposited, and within this ossific cavity thus produced a very large mass of cartilage is formed, elastic, firm, and fibrous." This last expression, however, renders it again a matter of doubt whether Sir A. Cooper's cartilaginous exostosis of the medullary membrane belongs to this class, or whether he did not rather intend to describe cases in which a firm fibrous tumor forms within the interior of a bone, the shell of which it distends. The author saw cases of this sort in the museum of St. Bartholomew's Hospital (Morbid Preparations, first series, No. 148, 149). In one of these a fibrous tumor had developed itself in the interior of the lower jaw, as well as on its surface. The growth to which in this work the name enchondroma is applied is never fibrous, but is always composed of an aggregate of cartilaginous fragments. Of the

* Surgical Essays, by A. Cooper and B. Travers, *London*, 1818, Pt. i, p. 169.

two cases detailed by Sir A. Cooper (in both of which the lower jaw was affected), the tumor in one more closely resembled the fibrous or desmoid tumor. The case to which the author refers is that of Sarah Dulwich, of which Sir A. Cooper remarks,* "The tumor originated from the medullary membrane within the cancellated structure of the bone, and was composed of cartilage and bony spiculæ, but upon the surface consisted chiefly of a white fibrous elastic mass resembling the elastic ligament of the body. The shell of the bone was entirely absorbed."

B.—*Enchondroma of the Bones, without Osseous Shell.*

In some bones in which the spongy tissue predominates, enchondroma occasionally becomes developed from their exterior without being invested with a bony shell; thus, for instance, it may be formed from the substance of the pelvis, from the spongy substance of the bones of the cranium, and from that of the ribs. In all instances the internal structure is the same. The tumor is, in these cases, less regularly spheroidal, and its surface less smooth, displaying an agglomeration of roundish bodies, some larger than a pea, others smaller, which are cells containing a soft, grey, cartilaginous mass. The whole tumor is made up of a conglomeration of such cells. The author observed many preparations in the museums in London referrible to this class. In one preparation, contained in the museum of the College of Surgeons, the tumor, which was of a large size, and had a very uneven surface, sprang from the spongy substance of the ribs, and was destitute of any osseous investment. The case had been observed by Sir E. Home, and the superscription on the bottle containing the preparation was "Cartila-

* Surgical Essays, by A. Cooper and B. Travers, *London*, 1818, pl. i, p. 169.

ginous tumor formed on a man's ribs." On dividing the tumor, it presented the ordinary appearance of enchondroma; being made up of round cells of the size of a pea, filled with transparent cartilaginous matter. Professor Owen kindly permitted the author to examine it under the microscope. It was found to contain the ordinary cartilage corpuscles or cells, and here and there remains of the spongy substance of the bone were scattered through the soft mass.

The museum of Saint Bartholomew's Hospital contains (Morbid Preparations, eighteenth series, No. 14) a specimen of enchondroma of the basis of the skull, which appears to have developed itself in the direction of the cranial cavity, as also towards the nose, and which existed for many years without occasioning pain. At length, its situation rendering extirpation impossible, the tumor led to a fatal result, although similar growths have been successfully removed from other parts.

In the museum of the Middlesex Hospital, which Mr. Mayo very politely shewed to the author, is an immense mass growing from the inner surface of the ilium, which presented the structure of enchondroma.

The larger cylindrical bones are also sometimes liable to the exogenous form of enchondroma, especially if that growth is developed in parts where the spongy structure abounds, as in the upper end of the tibia. In such a case, the tumor may be destitute of osseous shell. A preparation of this sort (Morbid Preparations, first series, No. 41) is contained in the museum of Saint Bartholomew's Hospital. The tumor, which is not contained within an osseous cavity, has originated from the outer side of the tibia, and has partly destroyed the fibula. In addition to this enchondroma, however, a very different vascular tumor had been formed in its vicinity. Mr. Stanley, who had the courtesy to shew the author the museum, purposes giving a

more exact description of this case in an illustrated work on the diseases of the bones, which he is preparing for the press. The author owes his best thanks to Mr. Stanley for some of the engravings intended for this work, of which he made him a present on noticing the interest he took in the pathological preparations in the museum. One of these engravings represents the abovementioned preparation.

The museum of Guy's Hospital contains a preparation, numbered in the catalogue 666*, and called an osteo-sarcoma. It is an enchondromatous growth, without a bony shell. Sometimes this growth appears on the leg, encased within a bony shell, at least the examination of two dried preparations in the museum at Berlin seems to warrant this conclusion.

In some rare cases of enchondroma of the phalanges of the finger, the tumor is destitute of bony shell, as may be seen in two preparations of enchondroma, in the museum of Guy's Hospital. The one case is No. 1122 of the catalogue, and is described as an exostosis of the first phalangeal bone of the little finger. In this case the mass of the enchondroma has a lateral direction; in the second case, too, No. 1124, the bony shell is decidedly absent.

To this external form of enchondroma can scarcely be referred those cases which Sir A. Cooper* describes as cartilaginous exostosis between the periosteum and bone, and of which he says that they are curable by operation. On reading his description attentively, it becomes evident that he means only the ordinary external osseous exostosis, with cartilaginous animal basis, which differs from enchondroma. Sir A. Cooper further distinguishes these tumors from fungous periosteal exostoses. The anatomical characters which he gives of them will suffice to shew that he is speaking of a disease differing from enchon-

* Lib. cit. p. 200.

droma. His words are, "Thus, on dissection we discover, 1st, the periosteum thicker than natural; 2d, the cartilage immediately below the periosteum; and, 3d, ossific matter deposited within the cartilage, extending from the shell of the bones nearly to the internal surface of the periosteum, still leaving on the surface of the swelling a thin portion of cartilage unossified." Almost all the cases detailed, with the exception of the tumor of the humerus, described at p. 208, are ordinary exostoses. With regard to the latter, it is said to have consisted principally of cartilage, into which osseous processes extended from the surface of the bone. The tumor was composed of one-third bone and two-thirds cartilage. The engraving of periosteal cartilaginous exostoses, at Plate ix, fig. 5, does certainly not represent enchondroma. The subjects of the engravings, at fig. 3 and 4, might with greater probability be regarded as enchondroma; but they refer to dried preparations contained in museums, and to which no history is attached. Probably, a case mentioned at p. 176, in the introductory remarks on exostoses, belongs to the class of enchondroma. It was an instance of an exostosis, principally cartilaginous, though osseous at its base, which grew from one phalanx of the finger.

III.—MICROSCOPIC EXAMINATION OF ENCHONDROMA.

THE minute structure of enchondroma corresponds exactly with that of cartilage and all that the employment of high magnifying powers has brought to light with regard to the latter substance has been confirmed by examination of the former. The corpuscles which Professor Purkinje* discovered in cartilage have been ascertained to be cells, and, according to the author's observations, the cartilages of the cyclostomata are composed entirely of such cells, forming a tissue resembling

* Deutsch, de Penitori Ossium Structura. Vratisl. 1834.

vegetable parenchyma, which remains in many parts unaltered during the life-time of the animals. These corpuscles may, according to Purkinje, contain others, within which he sometimes detected nuclei*.

Schwann† has directed attention to the correspondence between the embryonic state of cartilage and the cellular tissue of plants. Each cell originally contains a small dark nucleus, situated either in the substance of its wall, or at its inner surface: the same fact is also observed in those cells which are encased within a parent cell. This nucleus is most intimately connected with the origin of the cell, which is either developed out of the nucleus, or is formed around it. At the time of the formation of cartilage, and even during its subsequent development, no intermediate structure intervenes between the cells; but, according to Schwann's observations, it is composed, like many other tissues, entirely of cells. The largest cells are in immediate contact with each other, and thus their walls become more or less flattened. In the large cells smaller cells are contained, and their interior is often occupied by still smaller germinal cells. The smaller cells at first lie loosely within the interior of those which are larger, but, increasing in size, they at length fill up the parent cell. Every, even the most minute, cell has a dark nucleus in its wall, and the smaller the cell is, the larger in proportion is its parietal nucleus. Schwann is of opinion, that the substance which subsequently intervenes between the cells of cartilage is produced either by a thickening of their walls, or, more frequently, by the formation of a new substance between the cells.

The cartilage corpuscles which are seen in the perfectly

* Meckauer, de Penitiori Cartilaginum Structura symbolæ. *Vratisl.* 1836.

† *Frorieps Notizen*, 1838. Januar. No. 3.

formed cartilage, are either the cells themselves, or, if their walls have coalesced with the surrounding substance, their cavities.

The structure of enchondroma resembles more the cartilage in the embryo than in the adult. In most cases cells with nuclei only are seen; the presence of secondary cells is more rare. Usually, the cells are in close contact with each other, and there is no sign of development of intercellular substance, though, in a few cases, a clear substance may be distinguished between the cells. Here and there bundles of fibres are visible.

The size of the cells exceeds several times that of the red particles of human blood. The nuclei, which have a diameter of 0.00032 to 0.00042 of an English inch, are sometimes round, at other times oval, or irregularly elongated. (See Plate v, fig. 4-6.) The nucleus appears somewhat flattened, but its form is often very irregular. In addition to the nuclei, corpuscles are seen here and there, of an irregular form, furnished with spiculated appendages, often of considerable length, and similar to the spiculated osseous corpuscles described by the author*. Occasionally these spiculæ extend over a whole cell, or even further. (See Plate v, fig. 8.)

In most instances enchondroma remains stationary at that stage of development which cartilage attains in the embryo, and presents an almost entirely cellular structure. A very firm and hard cartilaginous tumor of the testicle, however, which once came under the author's notice, shewed a very high degree of development in the intra cellular cartilaginous mass, and closely resembled the natural appearance of those cartilages in which the cellular structure is not permanent.

* For a further account of the spiculated corpuscles, see J. Müller in Poggendorf's Annalen, B. 38, p. 327.

IV.—CHEMICAL ANALYSIS OF ENCHONDROMA.

A.—*Enchondroma of the bones.*

IF portions of enchondroma of an osseous structure are boiled for ten or eighteen hours, they yield a considerable quantity of gelatine, which forms a jelly immediately on cooling, but differs completely in its chemical characters from ordinary gelatine, or *colla*; while it coincides exactly with the peculiar gelatine which the author has discovered in cartilage, and to which he has applied the name of *chondrine*. The author detected it first in enchondroma, afterwards in the permanent cartilages. The results of the examination of this matter have already appeared elsewhere*; they are now republished with some few additions.

There are two kinds of gelatine.

1. *Colla*, common glue, the gelatine obtained from tendons, membranes, bones. The characters of this kind of gelatine are well known, and it is also a fact familiar to all, that isinglass differs from ordinary gelatine, or glue, only in being more soluble in alcohol. Gelatine is precipitated by an infusion of gall nuts, by chlorine, alcohol, corrosive sublimate, and by the sulphate and chloride of platinum; while, on the other hand, muriatic or acetic acid, acetate of lead, alum, sulphate of alumina, and sulphate of iron occasion no precipitate. Sulphate of iron, when first added to common glue, causes no precipitate, but after some time a precipitate forms which is re-dissolved by heat.

This kind of gelatine is extracted, by boiling, from the skin of man or of beasts, from tendon, from fibro-cartilage, from the inter-articular cartilages, from cellular tissue, serous membranes, and from the cartilages of bones after they are ossified; but is not obtained from the permanent cartilages, nor from those of

* Poggendorf's Annalen, Bd. 38.

the bones previously to their ossification. The same kind of gelatine was likewise obtained by boiling from enchondroma of the parotid gland: enchondroma of the bones, however, and of the testicle, became resolved by long boiling into cartilage gelatine or chondrine.

2. Cartilage gelatine, chondrine. This matter exists in the permanent cartilages, with the exception of the tendino-fibrous cartilages; in the cartilages of the larynx, in those of the ribs, and of the joints, and in the cornea; all of which yield it if boiled for ten, fifteen, or eighteen hours, and become wholly converted into it if boiled for a sufficiently long time. A concentrated solution of chondrine is less coloured than a solution of common glue. A solution of it, like a solution of common glue, solidifies in cooling, and forms a clear jelly; if evaporated to dryness, the matter is less brown than ordinary glue. Though chondrine is capable of forming a jelly, though it swells up when moistened with cold water, and is dissolved by hot water, just like ordinary gelatine, and though infusion of gall nuts, chlorine, alcohol, and corrosive sublimate produce the same results with both, yet the former is differently affected by alum, by sulphate of alumina, by acetic acid, acetate of lead, and sulphate of iron. All these matters precipitate chondrine, while they do not produce the slightest effect on ordinary gelatine. The precipitates from alum and sulphate of alumina are most abundant; they form large, white, compact flocculi, which collect into a mass at the bottom of the vessel. The precipitate from acetic acid is in a state of more minute division, and renders the fluid generally turbid and white. The precipitates from acetate of lead and sulphate of iron form larger or smaller flocculi, according to the degree of concentration of their solutions. A very small quantity of a solution of alum or of sulphate of alumina suffices to separate all the chondrine from a fluid in

which it may be dissolved. These precipitates are not soluble either in hot or in cold water, though they may be dissolved by an excess of the solutions of alum or of sulphate of alumina, which ought therefore to be added only drop by drop to any fluid from which it is wished entirely to separate the chondrine. Evaporation of the filtered fluid will shew when the chondrine has been entirely separated; for the fluid then ceases to gelatinize, and, indeed, contains only a minimum of animal matter. Hence it is evident that the presence of chondrine is the cause of the gelatinization of a solution of permanent cartilage, and that chondrine is not contained in it in addition to gelatine, as a sort of subsidiary constituent. Pounded in a mortar, and washed, the jelly from cartilage yields nothing but dissolved chondrine. Probably, the precipitate from alum and sulphate of alumina is a combination of chondrine with either of those substances, which compound is insoluble in hot or in cold water, but is dissolved by an excess of alum, or of sulphate of alumina. The precipitate of chondrine and acetic acid is not dissolved by the addition of more acid; but if the acid is neutralized by adding carbonate of potash, then the precipitate is redissolved. The precipitates produced by alum, by sulphate of alumina, and by acetic acid, are not dissolved by the addition of a small quantity of acetate of potash, by soda, or by chloride of soda, though the addition of a large quantity of those substances will occasion complete solution of the precipitate. The precipitate caused by acetate of lead is not dissolved by adding an excess of that substance. Sulphate of iron produces immediately an abundant precipitate, which is soluble by heat, but not by adding a larger quantity of sulphate of iron.

A minimum of hydrochloric acid added to a solution of chondrine causes a precipitate; but, if more than an exceedingly minute quantity (part of a drop) is added, the chondrine is not

precipitated, and the fluid remains perfectly clear. The solution of chondrine in hydrochloric acid is not precipitated by ferrocyanate of potash.

A concentrated solution of chondrine is not precipitated by liquor potassæ; a slight cloud, indeed, may be produced, but that is immediately redissolved on agitating the fluid, while, on the other hand, the hydrate of potash throws down a copious precipitate from a concentrated solution of gelatine. According to Berzelius, this precipitate contains a large quantity of phosphate of lime. The chloride of platinum causes slight turbidity of a solution of chondrine, but nitrate of silver produces scarcely any effect.

Alcohol precipitates chondrine as well as gelatine; and if it is added to a concentrated solution, it throws down this precipitate in the form of white consistent filamentous flocculi. If the alcohol is filtered, and water added to the precipitate, it becomes quite transparent, and is wholly dissolved in hot water. In this respect, chondrine and colla coincide. The matter which the alcohol extracts (osmazome) is, when evaporated to dryness, again soluble in water, which is rendered turbid by tincture of galls. The alcoholic precipitate from a concentrated solution of chondrine, if dissolved in water, may be again precipitated by alum, sulphate of alumina, acetic acid, acetate of lead, and sulphate of iron. The alcoholic extract of chondrine, however, if evaporated to dryness, and redissolved in water, is not affected by these substances. It would appear, then, that the precipitates thrown down by these substances, contain the same matter as the precipitate obtained by adding alcohol to a concentrated solution of chondrine.

There is another constituent of healthy animal matter, which is likewise precipitated by acetic acid, namely caseine. Chondrine may, however, be distinguished from caseine, by the ge-

latinization of solutions of the former, as well as by the different reactions of the two substances with acetic acid, alum, and ferrocyanate of potash. Berzelius has remarked, that the acid solution of caseine is precipitated by ferrocyanate of potash; which causes no precipitate when added to a solution of chondrine in hydrochloric acid. A minimum of acetic acid precipitates solutions both of caseine and of chondrine; an excess of acetic acid redissolves the former, but exerts no influence on the latter. Alum added in excess redissolves chondrine, but not caseine. The digestive principle contained in the mucous membrane of the fourth stomach of ruminant animals, whence it may be extracted by acids, may likewise be employed to distinguish caseine from chondrine. This principle (pepsin), when employed in the acid state, even in very small quantities, exerts a solvent power on animal matter, and converts coagulated albumen into osmazome and salivary matter*; properties which it retains, even if kept for months. Neutralization does not render pepsin entirely inert, for it will still coagulate milk if mixed with it in certain proportions; but pepsin, if neutralized, does not exert the slightest influence on chondrine. The employment of acetic acid, in the first instance, to detect caseine, requires considerable caution, since it is far from being a sufficient test for that matter†.

The question suggested itself to the author, whether the dif-

* With regard to these properties of pepsin, consult Eberle, *Physiologie der Verdauung, Würzburg*, 1834. J. Müller and Schwann on artificial digestion of coagulated albumen, in Müller's *Archiv. für Anat. und Physiol.* 1836, Heft i; and on the chemical characters of pepsin, Schwann, *ibid.* Heft 1 and 2. See also Müller's *Physiologie*, i B. Dritte Auflage, Nachträge.

† Güterbock states, that both pus and mucus contain a matter which is precipitated by acetic acid and alum, and is not redissolved by adding them in excess. Güterbock, *de pure et granulatione. Berol.* 1837-4.

ferent reactions of glue and chondrine might not result from the manner in which the former is prepared; and whether perfectly pure glue, obtained from fresh parts, might not be affected by precisely the same chemical tests as chondrine; or, lastly, whether chondrine may not be merely ordinary gelatine, modified by long boiling. This difference, however, does not result from the manner of their preparation. It can be easily shewn that long boiling does not cause the peculiarities which distinguish chondrine, for both fibro-cartilage and skin require to be boiled for a long time before they yield any gelatine, which, when obtained, is colla, not chondrine. Moreover, fifteen or eighteen hours cannot be considered to be a very long time for the cartilages of the ribs, or of the larynx to be sodden, when the object is entirely to dissolve those substances; and nevertheless, after having been boiled six or eight hours, these cartilages yield dissolved chondrine in sufficient quantities to be easily demonstrated by chemical tests, although it may not be so abundant as to gelatinize. And further, the most protracted boiling does not at all modify the reactions of the gelatine obtained. Neither is any carelessness in the preparation of common glue the cause of its peculiar reactions, for the differences between isinglass and chondrine are not less distinctly marked than between chondrine and common glue. In order, however, to leave no room for doubt on this subject, the author prepared gelatine from tendon and from skin in a perfectly fresh state. The gelatine thus obtained differed not less strikingly from chondrine, and, save that its colour was somewhat brighter and clearer, it perfectly resembled common glue. Shavings of hartshorn and of bone, or the cartilage of bone, yielded, after extraction of the salts of lime, a gelatine quite unlike chondrine. The next point to determine was, whether the difference between

colla and chondrine might not be occasioned by the combination of a salt or of some other body with one of them; thus, for instance, whether chondrine in combination with a salt did not constitute gelatine. One circumstance which rendered this probable was, that the precipitation of chondrine by alum, sulphate of alumina, and acetic acid, was prevented by the addition of a large quantity of acetate of potash, or of common salt to the solution of chondrine. The large quantity of the salt, however, which is necessary to suspend the peculiar reactions of chondrine, and to render that substance apparently similar to ordinary gelatine, is unfavourable to this hypothesis. On the other hand, this notion derives some support from the statement of Berzelius, that there are compounds of gelatine with salts, as with the acetate and sulphate of potash. Again, it might be supposed that chondrine was a compound of gelatine with some salt. But this hypothesis would not explain how the peculiar reactions of chondrine with alum and acetic acid are prevented by the addition of acetate of potash or chloride of soda. Moreover, the combinations of acetate and sulphate of potash with gelatine have no resemblance to chondrine, for the former is soluble in alcohol, and the latter crystallizes when the water which holds it in solution is evaporated.

Since gelatine contains a large quantity of phosphate of lime, the differences between colla and chondrine might be owing to the presence of this compound. The circumstance that a ley of caustic potash precipitates phosphate of lime from a concentrated solution of colla, while it produces no precipitate from a concentrated solution of chondrine, appears favourable to this opinion. It would be the more desirable to confirm this hypothesis, since not only is the gelatine obtained from tendons and from skin identical with colla, but also that obtained from bones (the

concentrated solution of which is likewise precipitated by hydrate of potash); while the gelatine yielded by the unossified parts of bone, reacts in the same manner as permanent cartilage, and yields chondrine, not colla. Were this theory correct, it would follow, that the nature of chondrine must undergo a change at the time of ossification, owing to the combination of chondrine with phosphate of lime; and during this metamorphosis, which would be necessary to the formation of bone, chondrine would be converted into colla. Enchondroma of the bones might be looked on as exhibiting the converse of this physiological process, for in it colla disappears, and chondrine once more becomes evident. To ascertain how far the notion, that chondrine may be converted into colla by combining with phosphate of lime, was capable of vindication, the author put the question to a test which did not succeed. The author endeavoured to combine chondrine with phosphate of lime, by adding to a solution of chondrine, super-phosphate of lime in which the acid was in excess, and afterwards neutralizing the acid by carbonate of potash, which caused the phosphate of lime to be precipitated. The author expected that a part of the phosphate of lime would have remained dissolved and in a state of combination with the chondrine, and hoped to examine the influence of reagents on this compound; but after having filtered the fluid, it was found to contain no chondrine, for tincture of galls caused no precipitate. An attempt was next made to produce this combination, by mixing a concentrated solution of chondrine with lime water, and then neutralizing it with phosphoric acid. The filtered fluid, however, retained all the characters of chondrine. Chondrine treated with lime water is acted on, as before, by acetic acid, and acetate of lead. The precipitate from sulphate of alumina cannot be adduced here, since, under the circumstances just described, sulphate of lime

is sure to be precipitated. Colla could not be produced by treating chondrine with the ashes of common gelatine.

The following experiments were made, to ascertain the amount of phosphate of lime contained in ordinary gelatine, and the power of combining with it which the latter substance possesses. To a concentrated solution of common glue, liquor potassæ was added, and the precipitate was washed and exposed to the action of fire. The blackening of the powder indicated the presence of a small portion of combined gelatine. In a second experiment, the precipitate of phosphate of lime thrown down by the caustic potash, was washed till tincture of galls shewed no trace of gelatine in the washings. The compound of phosphate of lime and gelatine contained in the precipitate was then boiled for several hours. The author was desirous of knowing whether the animal matter could be extracted by boiling, in the same way as gelatine may be extracted from bone shavings. After boiling for hours, the filtered fluid shewed the slightest possible trace of gelatine, very slight cloudiness being produced by tincture of galls.

The mutual relations of colla and chondrine next occupied the author's notice, and he endeavoured to ascertain whether ordinary gelatine is produced by a combination of chondrine and phosphate of lime. It has already been mentioned, that caustic potash throws down no phosphate of lime from a concentrated solution of chondrine, while it precipitates this substance in abundance from a solution of ordinary gelatine. It is true, that when first added to a concentrated solution of chondrine, liquor potassæ causes a great milkiness, as though it were about to throw down a precipitate; but on agitating the fluid, this cloudiness disappears. The precipitate from a solution of gelatine persists, even though the fluid is diluted with water. Now came the question, whether ordinary gelatine becomes chon-

drine, after the phosphate of lime has been separated? In order to determine this point, a concentrated solution of gelatine was mixed with liquor potassæ, and then filtered; the potash was neutralized with acetic acid, the fluid was evaporated, and alcohol was added to the residue, so as to dissolve the acetates it contained. The fluid was then filtered, and the precipitate again washed with alcohol. The precipitate, thus freed from the acetates, was again dissolved in hot water. It had ceased to gelatinize. Acetate of lead produced an evident precipitate, acetic acid caused slight milkiness, a very minute quantity of alum rendered the fluid slightly turbid, a larger quantity of it produced no effect; sulphate of iron at first occasioned no turbidity, but after a short time a precipitate formed. This experiment, which when repeated yielded the same result, seemed somewhat in favour of the opinion that ordinary gelatine is produced by combination of a certain quantity of phosphate of lime with chondrine. But there are some facts which tend much to weaken this theory. Caustic potash does, indeed, always produce a copious precipitate when added to common glue, and this precipitate is insoluble in water. But isinglass, which in other points coincides with common glue, differs greatly from it in this respect. Caustic potash, added to a concentrated solution of isinglass, produced a precipitate, which, however, was re-dissolved on the addition of water, and consequently could not be phosphate of lime. Isinglass and chondrine resemble each other, in yielding no phosphate of lime, and yet, in other respects, the differences between them are as wide as between common glue and chondrine.

Among the most remarkable chemical changes which any tissue undergoes, are those which ossification produces in the cartilages of bones. According to the author's observations, cartilage becomes changed during this process from chondrine into

gelatine, and this metamorphosis takes place alike in healthy and in morbid ossification. The cartilages of the ribs, larynx, and trachea, and the cartilaginous investments of the articular surfaces, become resolved into chondrine by boiling during fifteen or eighteen hours. The cartilages of unossified bone yield the same substance; but bones, when ossified, do not contain chondrine, but only gelatine. In performing these experiments, it is a matter of indifference whether or no the cartilage is freed from the salts of lime, by means of hydrochloric acid, before boiling; for in either case the gelatine obtained is the same, and resembles common glue. The author examined, 1, Gelatine obtained from the shoulder-blade of a man, from which the salts had been long before extracted by acids. 2, Gelatine obtained from bone-shavings, which did not gelatinize immediately on cooling, but on the following day. 3, Gelatine from stag's horn, which formed a jelly immediately on cooling. 4, Gelatine from fish bones, from the vertebræ of the sword-fish, which resembled ordinary gelatine in every respect, except that it did not gelatinize. Acetic acid and acetate of lead threw down no precipitate from the gelatine of all these parts, and, in most cases, none was produced by alum and sulphate of alumina. In some experiments with No. 2, a very few delicate flocculi were seen in the transparent fluid, on looking at it attentively, but in other cases there was no trace of a precipitate. No. 3 remained perfectly clear in most cases, when alum and sulphate of alumina were added, but sometimes it shewed traces of flocculi, though even fainter than in No. 2. In every instance this cloudiness was so slight, that it might have passed unnoticed; it was probably owing to the existence in the bones of an exceedingly minute quantity of chondrine. The mass of the gelatine from a concentrated solution of bone cartilage is not precipitated by alum; while, from a solution of chondrine, the whole

mass is immediately precipitated. The gelatine from fish-bones reacts in precisely the same way as that from the bones of higher animals. The gelatine from the bones of mammalia was not acted on by sulphate of iron in precisely the same way as common glue; for though a concentrated solution of it was precipitated by the sulphate of iron, yet the precipitate was redissolved by warmth. Gelatine from stags' horns was not precipitated by sulphate of iron, though, after having stood some time, the fluid became turbid. Sulphate of iron is, indeed, by no means a good test for the different kinds of gelatine; even common glue is at first not precipitated by it, though the fluid often becomes turbid after some time. A perfectly concentrated solution of gelatine from bones (like common glue) throws down a copious precipitate on the addition of liquor potassæ. It is evident that a great change takes place in cartilage gelatine at the time of the ossification of bones; whether owing to a change of some of its constituents, or to its combination with new ones, as salts; phosphate of lime for instance. This change seems to be essentially necessary to ossification, for, as far as is yet known, no bone, when ossified, contains an appreciable quantity of chondrine. Even the permanent cartilages lose it during accidental or morbid ossification.

The morbidly ossified cricoid and thyroid cartilages of the human larynx were examined, such parts as preserved their cartilaginous structure being carefully separated before boiling. The gelatine obtained by pounding and boiling the ossified parts was not chondrine, but colla: it was not precipitated by acetic acid, alum, sulphate of alumina, or acetate of lead. The two former reagents produced a few scarcely perceptible isolated flocculi, which were seen only on looking at the fluid with close attention. Since, however, they immediately precipitate chondrine, these flocculi were doubtless traces of it arising from

some imperfectly ossified portions of cartilage. A permanent cartilage, which, as such, contains chondrine, changes that substance (either before morbid ossification begins, or while that process is going on) into bone gelatine, or colla.

Since the cartilage of bone contains chondrine before ossification, but afterwards, when boiled, yields only colla; and since, further, the permanent cartilages during ossification transmute their chondrine into colla, it was natural to suspect that bones which, owing to disease, have lost completely, or in greater part, their salts of lime, would cease to yield colla when boiled, and would give out only chondrine. This, however, is not the case. The alteration which the animal matter undergoes in osteomalacia is of a peculiar kind. The author has examined softened bones in the human subject and in other animals. In both cases, long-continued boiling produced neither colla nor chondrine. The extract continued thin and fluid, did not gelatinize when evaporated, passed turbid through the filter, and, when a finer filter was employed, was seen to be transparent, and of a yellowish-brown colour; it was precipitated by tincture of galls, and by alcohol, but neither by acetic acid, acetate of lead, nor sulphate of iron. Sulphate of alumina did not cause any marked precipitate, but threw down only a few flocculi, which were not seen except by looking attentively, and which were dissolved by adding sulphate of alumina in excess. Liquor potassæ caused a precipitate. It should be observed, that the author speaks here only of the highest degree of osteomalacia, for the bones he examined were perfectly soft and pliable. The spiculated osseous corpuscles are still visible in such bones, although the matter of which they are composed has evidently undergone a peculiar change. In the case of a goat, the pliable pieces of bone became brittle when boiled for a long time, and the water was rendered turbid, and was mixed with much fat.

Portions of the os calcis of a man affected with osteomalacia were still softer, and contained a large quantity of fat in their spongy substance: they were boiled in alcohol to extract the fat, and the structure which remained was membranous, pliable, rendered softer by long boiling, but did not swell. It appears that the cartilage in osteomalacia becomes softened by changes in its constituents, or by combinations with salts, and that a substance remains which may be partially extracted by boiling, but which does not gelatinize. In bones which are less softened, and in rhachitic bones in which the alterations seem to be more inconsiderable, the existence of such a transmutation can scarcely be assumed. The author thought it useless to examine bones crooked by rhachitis, but not in the state of softening; for so soon as the stage of softening has passed, such bones are distinguished from others principally by the permanent deformity which remains.

This examination shews how great is the difference between osteomalacia and those changes in the bones which enchondroma produces. In true softening of the bones, their gelatine completely loses its nature; in enchondroma, on the contrary, there is a new primitive formation of cartilage, exactly similar to its first formation in the embryo; its substance, therefore, bears no chemical resemblance to such as have become ossified, but is real chondrine. On boiling the contents of a very remarkable variety of enchondroma of the bones, the author extracted a quantity of matter which gelatinized completely when cold; but this jelly was chondrine, for its solution was precipitated by alum, acetic acid, acetate of lead, and sulphate of iron; and a few drops of a solution of alum precipitated all the gelatine from a considerable quantity of fluid in large masses, which were not redissolved in hot water. In this disease per-

manent cartilage had become developed, with morbid growth in the interior of the bone.

B.—*Enchondroma of the soft parts.*

On a chemical examination of enchondroma of the soft parts, different results were obtained, nor did any one specimen perfectly resemble another. A very firm cartilaginous tumor of the testicle, which had developed itself in an elderly man, close to a carcinoma reticulare of the same organ, but perfectly unconnected with it, and in which the cartilage cells were separated by the intervention of a firm substance, yielded chondrine when boiled. On the other hand, not only could no chondrine be obtained from the enchondromatous growth of the parotid gland already alluded to, which was remarkable for its soft texture, intersected by many parts of a membranous nature, and made up of cells, exactly resembling those of embryonic cartilage, but the tumor gave out very readily a large quantity of gelatinizing colla. The author is unacquainted with the cause of this difference.

V.—HISTORY OF THE DEVELOPMENT OF ENCHONDROMA.

A.—*The development of Enchondroma, as observed under the microscope.*

THE development of enchondroma is exactly similar to the primitive formation of cartilage. Until lately the cellular structure of cartilage was known only as an isolated phenomenon, observed in some of the permanent cartilages, and in some of the lower orders of vertebrate animals. Miescher discovered cells in the cartilages of the human ear and in the epiglottis, and the author detected them in the softer cartilages of the

cyclostomata; in which animals, indeed, the firmer cartilages are not cellular, and display only the so called cartilage corpuscles scattered through their texture, and separated by a firm intervening substance. By observations on these animals, the author proved that the cellular structure of each cartilage becomes imperceptibly transformed into cartilage corpuscles*. Schwann was, however, the first who not only proved that the cartilages of all animals are originally cellular in the embryo, but who also recognized the principle of their formation from the nuclei of cells, and discovered how young cells are developed within the cavity of older ones; facts which no one before him had observed.

Of all the cartilaginous tumors above described, that of the testicle was the only one which resembled cartilage with isolated cartilage cells and intervening firm substance. The softer tissue of the other tumors presented, almost universally, the embryonic cellular structure.

If the morbid development of cartilage reaches that stage in which the firm intervening substance is formed between the cells, while they shrink into the so called cartilage corpuscles, as in the case of the testicle abovementioned, this substance must be formed either independently of the cells, or by thickening of their walls, which Schwann has shewn to occur in natural cartilage. Preparations do not exist in sufficient number to illustrate this transition in the structure of morbid cartilage. In those cases of enchondroma of the bones examined by the author, the disease had not advanced so far as the formation of the intermediate substance. The analogy between enchondroma and healthy cartilage would lead to the suspicion that the cells

* Vergleichende Anatomie der Myxinoiden. Abhandlungen der Königl. Akademie der Wissenschaften zu Berlin aus dem Jahre 1834, *Berlin*, 1836, p. 133, 134.

in the former are developed from nuclei. In healthy cartilage new cells are formed either from nuclei which become developed within the interior of the old cells, or, in other cases, new cellules are formed by the side of those which previously existed. The author generally observed in enchondroma of the bones, that the cells with their nuclei were merely in contact with each other: it was unusual to see a young cell with its nucleus contained within a parent cell, or to see other nuclei than those which belonged to young cellules. But in many parts of the tumor of the parotid gland this natural encasement of cells within each other was very evident, and in several places it could be distinctly seen that the transparent cells contained within their cavity one, two, or three cellules, each furnished with its nucleus. The more diminutive the cellules were, the smaller were they also in proportion to their nucleus; the nuclei differed far less in size, although those contained in the younger cellules were often less than the others. These facts render the analogy between this form of morbid growth and healthy cartilage extremely probable*.

The chief difference between the morbid and the natural formation of cartilage consists in the persistence, in the former, of that cellular structure which exists in the embryo. Many other tumors afford illustration of this remark. It is not any peculiar form of their elements which stamps upon morbid growths their distinctive character, but it consists partly in the formation of the ordinary primitive structures, where they are not necessary; partly in the imperfect development of these tissues, and its arrest at a stage which, in health, is but transitory. In the healthy primitive formation of cartilage, the vital principle of the whole organism controls the monad state of existence of the

* For minute details concerning the growth of healthy cartilage, see Schwann.

cells, and sets to it bounds which it does not pass. In process of time the walls of the cells thicken, and an interstitial indistinctly fibrous mass of cartilage is formed betwixt the cavities of the germinal cells. In enchondroma, on the contrary, the sunken vitality of the part in which the diseased growth is developed seems to set to it no such limits, but the growth proceeds, slowly increasing to a larger and larger size. Usually the walls of the cells do not thicken; the formative process cannot raise itself above that form of cartilage which first exists in the embryo, but continues without ceasing to reproduce this embryonic structure.

B.—*Duration and termination of Enchondroma.*

The great length of time that these tumors may exist is shewn by the history of many cases of this disease which have been erroneously regarded as cancerous. The case of this disease described by Schaper is one of the oldest upon record. The patient was thirty-eight years old; the tumors had made their appearance on her hand during infancy, they developed themselves without pain for fifteen years, and, even after they had burst, they continued for more than ten years without occasioning suffering. Scarpa had observed enchondroma, to which he gave the name of malignant exostosis; for the round swellings of the fingers and of the metacarpus, of which he gives a drawing, can scarcely have been any thing else than enchondroma. The right hand of a man eighteen years of age had swollen gradually, and with scarcely any pain, until it became one enormous exostosis. At length, after the tumor had been for some time the subject of lancinating pains, it burst at one part, and formed ulcers and fistulous passages, which discharged constantly a large quantity of sanies mixed with gelatinous matter. The hand was amputated, and the patient recovered. In those

tumors which had not ulcerated, the cavities of the cancellous texture of the bone were unusually dilated; the other part of the swellings was soft and pliable, resembling cartilage, and hollow internally, without a trace of osseous tissue, but lined with a membrano-gelatinous matter. To this class may also be referred those tumors which Otto has described and represented as real cancer of the bones, in the phalanges and metacarpal bones of a boy fourteen years old. In this instance, too, the disease originated in a violent contusion which the part had suffered during the boy's infancy. Nine spheroidal tumors covered by the skin sprang from the bones. They were composed of an osseous shell encasing large irregular osseous cells, in the intervals of which were fibro-cartilaginous masses, or cells formed of a tendinous substance, and containing a jelly-like matter. The result of amputation is not stated, but we have the evidence of the long duration of the disease in favour of its having been enchondroma. Klein describes two cases of enlargement of the phalangeal and metacarpal bones cured by amputation. The representation he gives of these tumors shews their identity with enchondroma. Lastly, the roundish tumors of the phalanges of the fingers and of the metacarpus, described by M. v. Walther, evidently belonged to the same disease. In the first case, that of a youth eighteen years of age, the tumor was caused by a bruise received in infancy, and first became evident when he was eight years old. The patient, in the second case, was a man twenty-two years old: the tumors made their appearance in his fifth year, a few months after a fall on the hand. Both cases were cured by amputation. M. Weber has given a minute account, accompanied by a drawing of the tumor in one of these cases. The nerves and vessels were healthy as they usually are in this disease. Of one phalanx nothing remained but the mere shell of the bone and its two extremities.

The remaining part was converted into a reticulated tissue, ossified at but few points, and with its meshes occupied by a greyish white jelly. In all these cases, the long time, often fifteen or eighteen years, occupied by the disease in its development, and the absence of dangerous symptoms during that period, are very striking.

All writers concur in representing the development of these tumors as being unattended by much pain. Mention has already been made of the absence of pain in Schaper's case during more than twenty-five years. Professor Pockels relates a case in which the disease was extirpated at the end of twelve years, without having ever produced pain. His observation refers to a man twenty-four years old, in whose twelfth year these tumors made their appearance. They were situated on the metacarpal bones and on the first and second phalanges of the second and third fingers. The development of the morbid growth was almost painless in Scarpa's case. Mery has drawn and described the hand of a youth, fifteen or sixteen years old, which shews the same disease. In this case all the tumors of the phalanges produced but little pain. Moreover, the skin retained its natural colour, and although the fungous growths had burst, yet the granulations sprouting from them were of a beautiful red, and the bloodvessels around were not dilated. These circumstances induced Mery to regard the tumor as not being of a cancerous nature, and he amputated it with success: the interior of the fungous growths displayed cellular ossifications filled with a gelatinous matter.

The growth of enchondroma may, then, continue for many years without pain, and without causing degeneration of the superincumbent parts. When inflammation is set up in the tumor, it becomes painful, and bursts. The distention of neighbouring parts and accidental injury to the enormous tumors bring on,

in the course of time, inflammation of it and of the neighbouring textures; inflammation is followed by suppuration, the tumor itself discharges sanies, and the bones, the proper structure of which is already destroyed, become necrosed. Such was the state of the disease in the cases described by Mery and Scarpa.

If the part affected by the tumor is amputated, the disease does not return; but if, after the tumor has burst it still remains in connexion with the body, it may, like every extensive local disease, bring with it the ruin of the whole constitution.

VI.—NATURE OF ENCHONDROMA.

THE nature of enchondroma consists mainly in the formation of cartilage resembling the primitive form of that substance in the embryo. Its causes are partly local, partly general.

LOCAL CAUSES.—The local causes of enchondroma of the bones may be stated, with great certainty, to be serious injuries to the vitality of the bones, and, in many instances, mechanical violence. This is confirmed by the cases already related, and will be found to be no less substantiated by the histories of other tumors which older surgeons have written, and in which, though the names applied to them are often very various, yet the characteristic features of enchondroma may be easily distinguished. In the description, by Marcus Aurelius Severinus, of roundish swellings on the fingers of a young man twenty-two years old, which he compares to fruits of different kinds, it is easy to recognize enchondroma. In this instance the cause is not mentioned; but Severinus quotes a second case from Nicolaus Larche, and accompanies it with a drawing which might well serve as a pendant to those at the end of this work. The tumors were quite round, and situated on the phalanges and metacarpal bones of the fingers, and the whole mass weighed seven pounds three

ounces, Romish weight. The tumors had appeared in consequence of the bite of a pig while the patient was young. In Schaper's case the disease was attributed to a bruise, as also in the cases detailed by Otto, Klein, and Ph. v. Walther, which seem to render it tolerably certain that mechanical violence is the exciting cause of enchondroma.

GENERAL CAUSES.—The local causes, just described, appear not to be the only ones influential in producing this disease; indeed, there are cases in which they cannot be shewn to have occurred, and in which enchondroma can scarcely be looked on as a purely local disease affecting certain bones. One of the most important cases in this respect is that which came under the notice of Professor Pockels, and of which a representation will be given in the second part of this work. Here the tumors of the metacarpal bones and phalanges of the fingers had formed not on one hand only, but there was a commencement of the same disease in the other hand; and the most singular fact of all was, that the feet shewed a disposition to become the seat of the same morbid process. The pathological changes in the feet and in one hand were but slight, and did not occasion inconvenience, but the other hand was amputated. The disease did not return; the patient is still alive; his hand and feet are in the same state as before, and probably there is not much reason to dread the further development of the disease, since it had begun in the earliest infancy of the patient, and had progressed very slowly. Ruysch, likewise, has described some cases in which tumors grew from the fingers and metacarpal bones of both hands, and from the toes of both feet. In these instances it is impossible to overlook the existence of a general cause, extending its influence over the whole of the osseous system, and yet by no means of a malignant or cancerous nature; and which, in the consequences it produces, is more akin to the in-

fluence of scrofula on the formation of bone. Both diseases are constitutional, but in no way related to carcinoma, and both are most active during childhood. The observations which have already been adduced suffice to prove that enchondroma occurs most frequently during childhood. Most of the persons in whom it was seen were young men and boys, in whom it had arisen at a very early age; as in the cases related by Schaper, Severinus, Mery, Ruysch, Otto, Scarpa, Pockels, and v. Walther, and most adults affected with it have referred its origin to their childhood. In after-life the general predisposition to enchondroma seems to be extinguished, just as is the case with scrofula. The tumors, which are the effects produced by the previous disease, continue to exist and cannot be removed; but in the adult, after the diathesis has ceased, they continue as merely local affections, which, therefore, do not return after amputation.

There are, however, very sufficient reasons against considering the diathesis which tends to the development of enchondroma as identical with scrofula. Kortum*, indeed, saw in a boy whose abdomen was tumid, and whose cervical glands were swollen, an enlargement of all the fingers, which might possibly have been of an enchondromatous nature, although that is very doubtful. Scrofulous diseases and tumors of the bones are well known, and do not exhibit any similarity to enchondroma, nor do scrofulous growths or tubercles occur in enchondroma. The cause of enchondroma seems to consist rather in a peculiar formative process in the osseous system, in consequence of which, especially when local injuries have been inflicted on the bones, cartilage, in its primitive embryonic state, is developed, and continues to be formed without ever attaining to consolidation or perfect organization. The natural tendency of the part to ossification, and the influence of the whole organism, are un-

* De vitio Scrophuloso. *Lemgovia*, 1790; tom. ii, p. 301.

able to control the growth of enchondroma, which is produced by the innate vitality of the cartilage cells, and their unceasing multiplication. Other alterations of the bones are very rarely combined with enchondroma; indeed, the only instance of it with which the author is acquainted, is that of a hump-backed man, whose case Severinus has related.

Those writers, who were possessed of a general knowledge of this form of morbid growth, have held very discordant opinions with regard to its nature, and consequently it figures in the history of surgery under very different names. Thus, the old writers included this, together with many other most dissimilar structures, under the name of *spina ventosa*. Diseases so various have been described under this name, that it is almost impossible to attach to it any definite signification; indeed, if the term have any distinct meaning, it can be only that of a disease in which all the different results of the inflammation of bone, as suppuration, exudation, and exostosis, are coexistent. At any rate, the name cannot be employed to designate any distinct peculiarity of structure. Marcus Aurelius Severinus called the enchondromatous tumor which he described, "*atheroma nodosum*:" cases of this kind have sometimes been called *osteosteatomata*, a common-place name, which has been applied to various diseases of bone. Scarpa does not sufficiently distinguish between enchondroma which expands the bones and exostosis; he calls this tumor malignant exostosis, which is evidently an erroneous appellation, since enchondroma is a benignant structure, and has no similarity to those really malignant exostoses or fungous growths from bone with which we have recently become better acquainted, through the labours of Ph. v. Walther, Ebermaier, Chelius, and Blasius. Otto applies the name of osteosarcoma to the disease which, in this work, is called enchondroma; but he regards it as being true cancer of the bones. It seems to the author that this term, cancer, ought

to be restricted to fungus medullaris, and other really carcinomatous fungoid growths of bone, which never bear any resemblance to enchondroma. The connexion of enchondroma with bony structures is no essential part of its nature, but only an accidental circumstance; and this affords an additional reason for avoiding such names as exostosis, spina ventosa, osteosarcoma, and osteosteātoma. Mery, and Ph. v. Walther, are the only authors who have duly appreciated the innocent nature of enchondroma. In fact, the amputation of enchondroma is almost invariably successful, as in the cases of Severinus, Mery, and Scarpa, in the two cases related by Ph. v. Walther, in the two which occurred to Klein; in the case of enchondroma of the tibia, the preparation of which is now in the Museum of St. Bartholomew's Hospital; in the case observed by Professor Pockels; and in those which came under the notice of Professor v. Graefe, the preparations illustrating which are now in the museum at Berlin. Of thirty-six cases, the histories of which have been ascertained by the author, two only had a fatal termination: in one of these cases, the tumor, which was situated on the base of the skull, encroached upon the cavity of the cranium, as well as on that of the nose, and proved fatal, owing to its situation. The second case has reference to an enchondromatous tumor of the thigh bone, which is now preserved in the museum of Guy's Hospital, and is numbered 666* in the catalogue. In this instance, the tumor, which probably brought on death by the loss of the fluids which it occasioned, was removed from the body of the patient after he was dead. Mery does not describe minutely the character of those tumors which he considered benignant; but v. Walther remarks expressly, that those tumors which Scarpa, Otto, and he have described, are of a peculiar nature, and have nothing in common either with spina ventosa or with fungus medullaris.

VII.—DIFFERENCES BETWEEN ENCHONDROMA AND OTHER TUMORS TO WHICH THE BONES ARE LIABLE.

THERE are no means by which the characters of any fungous growth can be more certainly determined than by comparing it with other tumors. Enchondroma has no resemblance in structure to those cancerous and medullary tumors which form so interesting a class of the diseases of bone. Albumen forms the basis of all carcinomatous fungoid growths, while they are entirely destitute of that cartilaginous mass, which, when boiled, yields chondrine.

If fungus medullaris is developed in the interior of a bone, it neither perforates it nor expands it in a spherical manner. It is only in very rare cases of medullary sarcoma that real expansion of the bones takes place; a specimen of this, however, is a preparation (Morbid Preparations, first series, No. 159) in the museum of St. Bartholomew's Hospital. Sir A. Cooper* speaks of a fungous exostosis of the medullary membrane, with expansion of the shell of the bone; but the nature of this growth is not very clearly stated.

If fungus medullaris is developed on the surface of a bone, it often contains in its interior delicate acicular, or lamellar spiculæ, which shoot from the surface of the bone. The hardness of numerous forms of scirrhus has led many authors erroneously to compare scirrhus to cartilage; but it has neither the structure nor the chemical characters of scirrhus, for the great mass of the animal basis of scirrhus is an albuminous body, insoluble by boiling. In cancer alveolaris of the stomach and of other parts, cavities may likewise be observed filled with a transparent

* Surgical Essays, part. i, London, 1818.

jelly; but this structure differs both microscopically and chemically, and, when boiled, yields no gelatine.

The bones are subject to another fungous growth, which differs not less widely from enchondroma, and resembles it only in its curability by amputation. The author had an opportunity of studying the characters of this growth, the tumor fibrosus s. desmoides, on a hand which was extirpated with perfect success, by M. v. Graefe. The tumor projected from several of the metacarpal bones, both towards the palm and towards the back of the hand, and presented a lobulated surface and a firm tendinous structure in its interior. When divided, it shewed that white and perfectly fibrous structure whence the tumor derives its name, and which similarity to the glistening satiny tissue of the aponeuroses is characteristic of the desmoid growths. Under the microscope it displayed layers of fibres intertwined, without any trace of cavities or corpuscles. Its base was seated on the surface of the metacarpal bones, from the periosteum of which it was developed; while the bone beneath remained undestroyed, and only slightly rough, as it always is in the neighbourhood of tumors. The arteries of the palm, the muscles, and tendons, ran in the form of an arch over the tumor. The museum of St. Bartholomew's Hospital contains a specimen (Morbid Preparations, first series, No. 148, 149) of this disease in the substance of the lower jaw. The tumor had developed itself in the interior of the bone, and likewise on its surface.

It is not necessary to do more than mention the name of the osteoid tumor of the bones, which is a growth composed entirely of osseous substance.

Enchondroma, and the desmoid and osteoid tumors, are not, however, the only fungous growths from bones, which, though locally destructive, are yet curable by amputation; for there are others which, under the names of osteosarcoma and osteosteato-

ma, are often confounded with cancer of bone. That form of morbid growth usually called osteosarcoma, which is not rare in the bones of the face, and particularly in the lower jaw-bone, is a fungus of a peculiar nature, curable by amputation. Its substance never resembles cartilage, is of a greyish white colour, of an albuminous nature, and cannot be resolved into gelatine by boiling. Examined under the microscope, it presents a structure composed of minute cells furnished with nuclei, or else a soft tissue made up entirely of caudate corpuscles, whose linear arrangement gives it a fibrous appearance. They will be spoken of more at length when albuminous tumors come under consideration: it may at present suffice to remark, that these osteosarcomatous growths are sometimes composed entirely of an albuminous substance, but in other cases they yield some gelatine after long boiling. It is, moreover, far from an easy matter to distinguish between these growths and those tumors of the bones which are really of a cancerous nature.

Enchondroma, which is convertible into gelatine by boiling, is a parallel structure to cartilage. The albuminous cellular osteosarcomatous growths, on the contrary, constitute a structure parallel to that of the chorda dorsalis of cartilaginous fishes, and of the foetus of higher animals. The chorda dorsalis is composed of cells, but is an albuminous body which cannot be converted into gelatine by the longest boiling, and never becomes ossified, although it gives place to ossified cartilage*. The decidua likewise is another parallel structure to the albuminous cellular osteosarcoma, which takes its origin from the medullary membrane of the bones. The decidua consists of cells, like those of

* See J. Müller, *Vergleichende Anatomie der Myxinoiden*, Berlin, 1836, Tab. ix, fig. 1, where a representation is given of the cellular tissue of the chorda dorsalis of *Petromyzon marinus*, which resembles vegetable cellular tissue.

plants, with a parietal nucleus, and distinct nucleoli. It is, like the cellular osteosarcoma, an albuminous substance.

Expansion of the bones is sometimes occasioned by the development within their substance of compound cysts, or of hydatids. The only instance of the former which has come under the author's observation, is contained in the museum of Professor Pockels. In this case, the disease is situated in the os ilium, and the osseous structure is converted into a number of chambers, occupied by cysts which are filled with a jelly-like matter.

Hydatids, when developed in the bones, constitute a destructive disease, which sometimes implicates a great part of the osseous system. Hydatids are formed in the medullary tissue of the bones, and in some instances they expand the bones, while in other cases they do not produce this effect. The spongy bones, as those of the pelvis, or the ribs, are most subject to expansion; and when it does take place, the hydatids are usually found lying in a soft bed abounding in fat, which is a growth from the medullary texture; while the osseous tissue is absorbed, and forms only fragments here and there in the interior of the tumor. The shell of the bone becomes distended in a spherical manner, as in enchondroma. The disease, as might be expected, renders the bones very liable to fracture, and it often leads to a fatal result. A separate article will be devoted to this subject in a subsequent part of the work.

VIII.—HISTORY OF OBSERVATIONS RELATING TO ENCHONDROMA.

IN endeavouring to classify fungoid growths according to their anatomical characters, it is found to be a very difficult task rightly to interpret the synonyms under which they are spoken of by the older writers, while in many instances the imperfection of their descriptions renders the attempt unavailing. This is

especially the case with those tumors which have been confounded with cancerous growths, and with others to which the names of osteosarcoma and osteosteatoma have been applied. The external characters of enchondroma, however, are so well marked, especially when the disease occurs in the bones, that its course, its indolent nature, and its peculiar form, are sufficient to identify it, although badly described; and in every engraving of this disease, the spherical expansion of the bones which it produces is very evident. If a person has once made himself familiar with the characters of enchondroma, he may always recognize it among the preparations in a museum; and the author found, in those instances in which he afterwards had an opportunity of closely examining the growth, that his first diagnosis had never been erroneous.

A.—*Cases of enchondroma on record.*

After having waded through the numerous descriptions of diseases called osteosteatoma and osteosarcoma, the author has related such cases only as can evidently, or with great probability, be referred to the class of enchondroma, while all cases of a doubtful nature have been carefully excluded.

1. The oldest case with which the author is acquainted, which can be determined with certainty to have been enchondroma, is one described, in the year 1698, by Schaper and Below*. The subject of this observation was thirty-eight years old, and referred the disease to a fall when quite a child. For fifteen years the tumor continued to increase without pain, but afterwards it burst, and during the menstrual periods blood used to flow from the surface of the wound. Even then the disease continued

* *Dissertatio de digitis manus dextræ in quadam fœmina per conquassationem nodositate, spina ventosa et atheromate monstrosis. Diss. præ Schaper resp. Below. Rostochii, 1698, 4to.*

painless for ten years more, but afterwards pieces of bone came away in considerable number.

The result of amputation is not mentioned.

2. In a case detailed by Ruysch*, spheroidal tumors were situated on the fingers and on the metacarpus. Ruysch says, "Juvenis 16 annorum—correptus non solum tumoribus magnis in dextra verum etiam sinistra manu uti et in utroque pede, eorumque digitis, qui tumores admodum duri, extrinsecus accurate radices cyclaminis aut potius chrysanthemi americani radices tuberosas æmulabant, sicut in annexis figuris repræsentantur. Reperique illum (tumorem) neutiquam esse glandulosæ indolis, ast cartilagosæ imo et osseæ, eratque quasi ex innumeris minoribus tumoribus partim cartilagineis partim osseis compositus, singuli autem eorum denuo ex innumeris minoribus humore succoso gelatinoso repletis."

3. Mery† relates the history of this disease as he observed it in a young man between fifteen and sixteen years old. All the tumors of the hand gave but little pain. The skin retained its natural appearance, the granulations from the tumor where it had burst were of a beautiful red colour, and the vessels in the neighbourhood were not enlarged. A contusion had been the cause of the development of the tumors, which occupied the first two phalanges of the fifth, fourth, and third fingers, and the metacarpal bones were slightly swollen. The articulations between the first two phalanges of the three fingers were ankylosed. The interior of the tumors was composed of cellular ossifications filled with a gelatinous matter. After amputation portions of the radius and ulna exfoliated; but in the course of three months the patient was perfectly well.

* *Epistola anatomica problematica quarta et decima. Amst. 1714 Opera Omnia, Amst. 1721, 4to.*

† *Mém de l'Acad. Roy. des Sciences, 1720, p. 447.*

4. Two cases of this disease are described by Severinus*. Like Ruysch, he compares the tumors to bulbous roots, and to fruits. In both instances the tumors were situated on the phalanges and metacarpal bones of the hand. "Simile ferme forte Hieronymus Damianus Rochæ Mondraconis, adolescens, vigesimum secundum annum natus, gibber, strigosus et pusillo virium robore, dextram manum secundum quatuor phalangis digitos, gravem ita, ut sustinere non posset, cubans quidem capiti innixam, stans vero subjecta altera manu suffultam gestabat. Comparasses dura tubera partim magnitudine Limoniis corticosis, partim etiam colore non adhuc maturis malis insanis, sic alte turgebant, sic particulis quibusdam livercebant. Una alteris implicata, secundum digitorum nodos excreverant adeo circa extremos unguis, ut hi summis apicibus vix apparerent. Affectum quoad nomen attinet, atheroma nodosum, quod vero figuram, subiit interdum animo mihi comparare vel tuberosis ample difformibusque Chamæirios latifoliæ Lobelii vel fructibus fici Opuntiaë, vel complexur tuberum radiciformium, quæ vocata nostris hispanica, cocta igne sunt esu multis non insuavi; vel monstrosis belluarum secundum digitos nodis, quos sepulcralibus urnis sculptores appingere consueverunt. Tab. ad. p. 174. "Verum enimvero quodcunque vitii fuerit illud, amputatum per nos secundum primos digitorum phalangis articulos ac perustum ad sanitatem integram brevi perduximus. Cæterum materia, quæ sub inciso vitio reperta est, sicuti coctæ carnis bulbi cyclamis apparuit, friabilis insuper et lenissimo quoque contactu cessilis."

Severinus likewise quotes a similar case from Nicolaus Larche, and gives representations of it in three different plates. The tumor occupied the phalanges and metacarpal bones, and

* Marci Aurelii Severini Tharsiensis philosophi de recondita abcessuum natura. Libri viii, *Lugd. Bat.* 1724.

weighed seven pounds four ounces, Romish weight. It appeared in childhood, in consequence of the bite of a pig. It burst, and was amputated; but it is not stated with what success.

5. Vigarous de Montagut* speaks of a peasant who had suffered from early youth from a tumor on the index and ring finger of one hand. The tumor had an osseous shell.

6. Kortum in his history of scrofulat says, "Vidi puerum septennem ventre turgido, glandularum colli tumoribus, omnibusque cachexiæ scrofulosæ indiciis luculentissimis incedentem, cujus omnes decem manuum digitos spina ventosa tumefecerat." The real nature of this case is doubtful.

7. It is doubtful whether the case described by Boyer† ought to be referred to this class. A man, forty-seven years old, was affected with a very large and painful tumor, which, when Boyer saw him, had existed for two years. The deltoid muscle formed a capsule enclosing a gelatinous, tremulous mass of a rather muddy, yellowish-red colour. All that remained of the humerus was a bony plate, which became wider towards the head of the bone. The articular surfaces of the humerus and of the scapula were destroyed. The substance of the tumor contained a large quantity of gelatine, a little albumen, some salts, but no fat.

8. Sir A. Cooper‡ speaks of cartilaginous exostoses arising from the surface of the bones, which, probably, were ordinary exostoses, and not growths of an enchondromatous nature. A few cases which may have been enchondroma have already been mentioned.

* Opuscles sur la Régénération des Os, les loupes osseuses et les hernies, *Paris*, 1788, 8vo.

† De vitio Scrofuloso, *Lemgovia*, 1790, t. ii, p. 301.

‡ Leçons sur les Maladies des Os, *Paris*, 1803.

§ Surgical Essays, Pt. 1, *London*, 1818.

9. Klein* has described and given a drawing of an expansion of the phalanges of the fourth and fifth fingers and of their metacarpal bones, which followed a contusion. Another case is also described by the same writer, who states that in both amputation was successful.

10. Bail† speaks of a man who was rhachitic in infancy, and, while quite a child, began to suffer from expansion of the metacarpal bones and phalanges of the fourth and fifth fingers, on which account M. v. Graefe performed the operation of exarticulation. The preparation is contained in the museum at Berlin, and a drawing of it is given at Plate viii, fig. 3.

11. Otto‡ gives the particulars of a case, in which a boy fourteen years old was affected with tumors of the phalanges and metacarpal bones of the hand. The disease was produced by a bruise of the hand during the childhood of the patient. Nine spheroidal tumors, each covered with skin and cellular tissue, sprang from the bones. They were furnished with an osseous shell, and were made up internally of large bony cells and spiculæ, between which lay masses of a fibro-cartilaginous substance, or tendinous cells filled with jelly-like matter. The latter being transparent, and consequently darker than the bones or cartilaginous masses, they gave to the tumor, even externally, a spotted grey and white appearance. The metacarpal bones and phalanges from which the tumors sprang were almost entirely destroyed, their tissue was unravelled, full of spiculæ, and passing gradually into the substance of the tumor. Of many of the bones a few large spiculæ were the only remains.

* v. Graefe und v. Walther's *Journal der Chirurgie und Augenheilkunde*, Bd. iii, pag. 403, Tab. iii.

† *De luxuriatione ossium*, *Berol.* 1821, 4to, fig. 4.

‡ *Neue seltene Beobachtungen zur Anatomie, Physiologie und Pathologie*, *Berlin*, 1824, 4to, Taf. 1.

12. Scarpa* narrates the case of a youth, eighteen years old, whose right hand began to swell during his childhood, and gradually, and almost without pain, increased in size till it formed an enormous exostosis. The greater part of this tumor continued for many years to present all the characters of benignant exostoses in general, which, after having been soft, gradually acquire the consistence of healthy bone. A small portion of it, however, owing to some unknown cause, began once more to soften, and became the seat of lancinating pain. The soft parts in the neighbourhood began to inflame, the integuments gave way, and, caries having destroyed the walls of the cavities which the tumor contained, ulcers and fistulous passages formed, whence a large quantity of sanies constantly flowed, mixed with gelatinous matter. After the patient had been reduced to a state of extreme weakness by hectic fever, the hand was removed at the wrist joint, and the wound healed in a very short time. The greater part of the tumor had not undergone the process of softening, and, on a section of it being made, its tissue was found to resemble exactly the healthy cancellous texture of bone, except that its cells were much dilated owing to the previous softening and expansion which they had undergone. The other smaller portion of the exostosis, however, was soft and pliable like cartilage, and hollow internally: its interior shewed no trace of osseous tissue, and its exterior was necrosed and covered by a membranous gelatiniform matter.

Several other instances of soft exostoses of other bones are mentioned by Scarpa; but it is doubtful whether they are to be referred to this class.

13. A healthy man, eighteen years old, came under M. Ph. v. Walther's† notice, having when quite a child suffered a contu-

* Ueber die Expansion der Knochen, *Weimar*, 1828, p. 22, tab. 3, fig. 1.

† v. Graefe und v. Walther's *Journal*, Band xiii.

sion of his middle finger. When he was eight years old a nodose swelling of the hand began, and eventually five tumors developed themselves on the metacarpal and phalangeal bones.

The same author describes a similar case of tumors of the metacarpal and phalangeal bones of the hand of a person twenty-two years of age, who fell upon his hand when five years old; a few months after which the first tumor appeared. Professor Weber, of Bonn, made a very minute anatomical examination of these tumors, and found in all of them the nerves, vessels, and tendons perfectly healthy. The shell of the bone and its two extremities were all the remains of one phalanx, the rest of it had become expanded into a sort of network. In a few places only was this network ossified; in the others it was filled with a greyish white jelly, and here and there were extravasations of blood. After injecting the tumor, its sinuses were found lined with an exceedingly delicate and highly vascular membrane. One of the smaller tumors situated on the metacarpal bone of the middle finger was formed not of a soft matter, but of an osseous reticulated tissue, filled with healthy marrow.

14. Mr. Lawrence* has described very minutely a tumor of the tibia, which was cured by amputation, and which appears to the author to have been enchondroma. Mr. Lawrence says of it, "When the integuments and other parts had been removed, the tumor was found to arise from and be inseparably connected with the upper part of the tibia; or it might be said, that the bone, in its upper six inches, was expanded into the morbid growth, as there was a continuity of bony substance between it and the surface of the latter. When the diseased mass and the tibia had been divided by a vertical section, carried from before backwards, it was found that the former had originated in the centre of the tibia; that it consisted partly of a

* Medico-chirurgical Transactions, vol. xviii, page 37.

rough fibrous texture, with bone plentifully deposited in it, partly of a medullary (cerebriform) substance; and that it contained numerous cells, of which the largest were from one to two inches in diameter. These cells, of which the surface was quite smooth, were filled with a transparent yellow fluid, of watery consistence: in some of them was a small portion of coagulated blood, adhering to the surface. Nearly the whole exterior of the swelling, which had been considered to be bony from its hardness, the greater part of the septa between the cells, and the surface of the latter, were made up of the fibrous and osseous texture. The medullary substance, which was whitish, soft, and breaking down into a pulp under slight pressure of the finger, formed the nucleus of the tumor, where it grew out of the bone, and was also deposited partially between the cells. One of the two halves into which the mass had been divided was subjected to maceration. When the soft texture had been completely decayed by putrefaction and removed, it appeared that the upper five or six inches of the tibia had been destroyed by the morbid growth, which had not penetrated the joint, the articular surface being entire, though reduced to a thin shell. The latter was connected to the lower portion of the tibia, by a network of long fibres and plates, forming the skeleton of the tumor, and supplying the place of the bony shaft. There was an exterior thin and imperfect shell growing out of the walls of the bone below, and from the edge of the articular surface above. This was the bony substance which had been felt on the surface of the swelling before the operation. The interior of the space circumscribed by this covering was irregularly traversed by bony productions shooting from the lower end of the tibia, and connected at various points both with the outer shell and with the remnant of the articular surface."

This is, probably, the tumor which is preserved in the museum

of St. Bartholomew's hospital, and of which Mr. Stanley presented the author with a lithographed drawing. The structure of that tumor is undoubtedly enchondromatous.

15. Valentin* has described an enchondroma of the metacarpal bone, and first phalanx of the thumb. The circumference of the tumor of the metacarpal bone at its widest part was 11.75 inches; the circumference of the phalangeal bone 3.5 inches.

The substance of this tumor was composed of a cartilaginous mass, with small longish bodies, pointed at one or both extremities, and containing granules. It was of a bright colour, and more evidently made up of distinct fibres than is the case with cartilage. There were some remains of osseous substance partly in the form of a bony shell, partly as laminæ in its interior.

If portions of the cartilaginous mass were carefully separated from the other tissues and boiled in distilled water for a long time, a fluid was obtained, which, after it had been filtered, was of a slightly opaline colour, and was unaffected by nitric, phosphoric, and hydrochloric acids, by sulphuretted hydrogen, oxalic acid, caustic potash, ammonia, barytes, iodide of potassium, carbonate of potash, phosphate of soda, alum, sulphate of copper, chloride of tin, sulphate of iron, chloride of iron, chromate of potash, and tincture of iodine. On the other hand, sulphuric acid, chloride of barytes, alcohol, and æther, occasioned slight turbidity; acetate of lead, and Goulard's extract threw down a white precipitate very readily soluble in water; acetic acid, nitrate of mercury, and corrosive sublimate, caused a precipitate of a pure yellowish white colour; and ferrocyanate of potash occasioned a similar precipitate, but scanty, and of a more muddy hue. Sulphate of platinum rendered the solution yellow; nitrate of silver caused a white colour, which soon changed to

* Repertorium für Anatomie und Physiologie. 1837, p. 117.

a red, and then to a brown hue. The sulphate of the peroxide of iron caused a yellowish white precipitate; ferro-sesquicyanuret of potash caused one of a green colour; tincture of galls a yellowish white, and solution of chlorine a greyish white precipitate. Its ashes contained phosphate, hydrochlorate, and a small quantity of sulphate of lime, with traces of talc and potash. The articular cartilages of healthy fingers, which were examined for the sake of comparison, contained exactly the same constituents, with the exception of sulphuric acid and of the large quantity of lime.

B.—*Specimens of Enchondroma contained in Anatomical Museums.*

a. *In the Royal Museum at Berlin.*

1. Commencing enchondroma of the phalanges of the index finger; presented to the museum by M. v. Graefe: numbered 9911 in the catalogue.

2. Enchondroma of the metacarpal and phalangeal bones of the fourth and fifth fingers, (see plate viii, fig. 3). The preparation was presented to the museum by M. v. Graefe, and is numbered 8846 in the catalogue*.

3. Enchondroma of most of the phalanges, and of all the metacarpal bones of the hand of a girl, (plate vii, fig. 1, and plate viii, fig. 2). Removed by M. v. Graefe, and presented by him to the museum. No. 8817 of the catalogue.

4. Enchondroma of the phalanges of the first, third, fourth, and fifth fingers of an adult. No. 851 of the catalogue. It formed part of Walter's collection.

5. Enchondroma of the parotid gland; from Berger's museum in Brunswick. No. 4477.

* A short account of this case is given by Bail, in a dissertation de Luxuriatione Ossium. *Berol.* 1821.

6. Enchondroma of the testicle, developed close to a carcinoma reticulare of that organ in an old man. Extirpated by Professor Dieffenbach. No. 10,770.

7. A very large enchondroma, partly covered with a bony shell; from the surgical and ophthalmic clinic of the university. No account of it could be obtained. No. 9581.

8, 9. Two dried preparations of spherical expansion of the upper end of the tibia and fibula of a person eighteen years old probably belong to this class. The preparation of the tibia is numbered 3044, that of the fibula 4917.


b. In the Anatomical Museum at Bonn.

10. Enchondroma of the hand. This is the case described by MM. v. Walther and Weber.

c. In the Anatomical Museum at Halle.

11. Enchondroma of the metacarpal bones of the fourth and fifth fingers, forming an enormous tumor which presents the ordinary structure.

12. Enchondroma of the first phalanx of the middle finger, presenting the ordinary structure. Meckel had called the preparation "Osteosteatoma digiti medii."

13. Enchondromatous degeneration of the mamma of a dog; ossified in parts. 

d. In the Anatomical Museum at Berne.

14. The case described by Valentin. Enchondroma of the metacarpal bone and of the first phalanx of the thumb. II. 49 of the catalogue of the Berne museum.

e. In the Museum of Professor Pockels, at Brunswick.

15. Enchondroma of the metacarpal bones and phalanges of the second and third fingers. The articular surfaces are unde-

stroyed. From a man twenty-four years old, from the thirteenth year of whose age the tumor had been gradually forming; a commencement of similar swellings was evident also on the other hand, and on the toes. The tumor was quite free from pain.

f. In the Museum of the Royal College of Surgeons in London.

16. "Cartilaginous tumor formed on a man's ribs." This is a very large tumor with an irregular surface, without any osseous shell, containing in its interior remains of the spongy substance of the bones. When examined under the microscope, the structure is seen to be the same as that of ordinary enchondroma.

g. In the Museum of Guy's Hospital in London.

17. "Exostosis from the first phalangeal bone of the little finger." Enchondroma. The tumor runs sideways from the bone without causing its expansion. It is numbered 1122 in the catalogue.

18. "Section of a very large osteosarcomatous tumor from the thigh, removed after death from a patient of Mr. Key, Jan. 1832." It is numbered 666* in the catalogue. The growth is enchondromatous, but unattended by spherical expansion of the bone. Here and there, portions of the thigh bone still remain.

19. "Finger amputated by Mr. Key for a considerable tumor growing from the first phalangeal bone: it is of the kind described as gelatinous cancer, and the structure dependent on cysts is very evident. See drawing by Canton." No. 1124 E. of the catalogue. It is an enchondromatous growth arising from the anterior part of the first phalanx; it is round, and unaccompanied by expansion of the bone.

20. "Finger amputated by Mr. Morgan, having a tumor of

considerable size growing from the extensor tendon: the structure dependent on cysts is very evident: it was semitransparent, and was composed of a substance approaching to the character of mucus." No. 1366 A. of the catalogue. It is evidently enchondroma.

21. "Subcutaneous tumor, apparently fungoid." No. 1657 A. of the catalogue. The same disease.

22. "Head of the tibia enlarged and excavated from fungoid disease." This is a dried preparation, but probably is of an enchondromatous nature.

23. Perhaps a tumor of the testicle and epididymis in the museum of Guy's Hospital ought also to be referred to the same class. It is numbered 2362 in the catalogue, and is thus described: "Epididymis greatly enlarged from the general dilatation and development of the seminiferous tubes, which are filled by a semi-transparent substance. The body of the testis appears to be much disorganized."

h. In the Museum of the London University College.

24. Enchondroma of the metacarpus and fingers.

i. In the Museum of St. Thomas's Hospital.

25. "Periosteal fungous exostosis of the finger." No. 947 of the catalogue of the museum. Is distinctly enchondroma.

k. In the Museum of St. Bartholomew's Hospital.

26. Enchondroma of the basis of the cranium.

27. Enchondroma of the tibia, associated with a vascular tumor of a different kind.

l. In the Museum of the Middlesex Hospital.

28. Enchondroma of the inner surface of the os ilium.

II.—OF ADIPOSE TUMORS.

THE cells of adipose tissue are shut sacs, within which the fat is contained. In most animals these sacs are round, but in some, as the sheep and ox, they have a polyedrous form.

M. Raspail* discovered this structure of fat in the sheep and ox, but he was mistaken in supposing that this fat resembles the granules of starch, and that the walls of the cells are composed of stearine, and their interior of eläine. In a natural state all these angular cells are connected together, and are composed of an animal matter quite different from fat. This is beautifully seen by melting out the fat from the adipose tissue of the sheep, or by extracting it by means of boiling æther or alcohol. All the fat cells are then seen closely connected with each other; they imbibe water and spirit of wine, and present their angular form unchanged. This cellular tissue is quite insoluble in æther or alcohol. If, however, the adipose tissue of the sheep is examined with the microscope, without the fat having been previously extracted, the cells are so full, and so distended by their firm contents, that slight pressure suffices to separate them from each other, and to display them as isolated and unsymmetrical bodies.

It is more difficult to detect the nucleus in the wall of adipose cells, than in cells of other tissues; but, even in them, Schwann has demonstrated the existence of nuclei.

Morbid adipose tumors are repetitions, more or less modified, of normal adipose tissue. Some are made up of ordinary fat, such as is found in the healthy adipose tissue of the human subject, while others contain likewise cholesteatoma, and may be distinguished by their laminated structure.

* Breschet, *Repertoire générale d'Anatomie et de Physiologie*, t. iii, p. 2, *Paris*, 1827.

Adipose tumors may be distinguished into three classes. The varieties of lipoma form the first; adipose cysts the second; and the laminated fatty tumor the third. In lipoma the fat is contained in ordinary adipose tissue, and is consequently separated into innumerable isolated compartments by the walls of the contiguous cells. In adipose cysts, the fat is not distributed through small cells, but is contained, partly in a fluid state, partly in the form of fat globules, in the interior of a larger sac, which is generally furnished with thick membranous parietes. In the former, the production of the new fat takes place just as in the healthy body; while in the latter a single fat cell appears to become predominant, and, its walls being thickened, it constitutes an independent cyst.

1.—LIPOMA.

Most specimens of lobulated lipoma resemble in structure ordinary adipose tissue; their cells are of a round or oval shape, and the only distinction between the two consists in the former being made up of a mass of these adipose cells, enclosed by an investment of thickened cellular tissue, while the different lobuli are separated from each other by thinner membranous septa.

The different varieties of lipoma are:—

a. Lipoma simplex. It is to this that the name, lipoma, is usually applied. These growths seem capable of being formed in any part where there is cellular tissue. In Meckel's museum at Halle, the author saw a small adipose tumor, which was situated between the optic nerve and eminentiæ candicantes.

b. Lipoma mixtum. In this case, the interstitial cellular tissue of the adipose tumor is greatly developed, and forms strong membranous septa, which intersect its substance, and thus give

it a much greater degree of firmness than is possessed by simple lipoma. Hitherto the author has met with but two specimens of this form of tumor; once in the spermatic cord of a man, and once between the muscles of the thigh; and in this latter case the tumor had acquired an extraordinary size.

c. *Lipoma arborescens*. This structure consists of arborescent productions, entirely composed of adipose tissue. Growths of this sort occur in the joints, especially in the knee joint, where they spring from the free portion of the synovial membrane. In this situation they are covered by a prolongation of the synovial membrane, and hang loosely into the cavity of the joint, forming arborescent tufts, somewhat swollen at their extremities. A very remarkable specimen of this disease in both knee joints of a man is contained in Meckel's museum, at Halle, and several similar preparations are in the museum of St. Bartholomew's Hospital in London.

II.—ADIPOSE CYSTS.

The ovaries are the most frequent seat of this disease, in which fat, partly in a fluid state, partly in the form of globules and free from adipose cellular tissue, is contained in a large cyst, with dense parietes. In addition to fat, these cysts usually contain hair, either loose within their cavity, or proceeding from their walls; each hair springing from a distinct follicle. In birds, feathers are found in these situations. Gurlt regards the fat in these hair-containing cysts as analogous to that which is formed by the sebaceous follicles of the cutis, and poured by them into the hair follicles. The sebaceous follicles of the skin may themselves become converted into cystoid tumors, and to the accidental occlusion of their orifices many encysted tumors owe their origin. This fact had been rendered probable by M. v. Walther and Sir A. Cooper; and in one instance the author

met with a decisive proof of its truth. In an individual, all the sebaceous follicles of the skin of the nose had become extremely enlarged, and one was converted into an encysted tumor eight lines in diameter. Microscopic corpuscles of irregular polyedrous shape, and resembling epidermoid or epithelium cells, except in being destitute of nuclei, formed the contents of these cysts. These corpuscles are probably produced in a manner similar to epithelium cells.

III.—LAMINATED ADIPOSE TUMOR—CHOLESTEATOMA.

This is a non-lobulated tumor, composed of concentric layers of polyedrous cells, which have a lustre like mother-of-pearl. It is of the consistence of tallow, and is usually invested with a thin membrane which forms a complete cyst. The fat which it contains is not found exclusively within the cells, but is likewise deposited in their interstices. This form of adipose tumor, was formerly but little, if at all known; and M. Cruveilhier was the first who examined its nature with the attention which it deserves*. Dr. Merriman, and MM. Leprestre and Dupuytren, had already seen it; and the accounts of it which they have given are sufficient to shew the identity of the growth which came under their notice with cholesteatoma. In an essay by Dr. Merriman, on tumors obstructing parturition† there is an account of a tumor which it is difficult to regard as having been other than a specimen of cholesteatoma. It was situated between the cervix uteri and the rectum. "The contents of the tumor were regularly disposed in layers, the concave surface of one portion being exactly adapted to the convex surface of the next, and the diameter of each about the breadth

* Anatomie Pathologique, livr. ii, tab. 6.

† Medico-Chirurgical Transactions, vol. x, p. 1.

of a sixpence: their colour resembled tallow, and they appeared to consist of adipocerous matter." In the notice by M. Leprestre* the growth is denominated "tumeur adipociriforme." It had developed itself in the brain, and its external characters are well described. The surface of the tumor was irregular, and beset with pearly granulations, of as glistening appearance as the inner surface of many muscles. Its interior was formed of concentric laminæ, connected together by layers of cellular tissue (?). Its substance was firmer than that of the brain, and it presented no trace of vessels. M. Cruveilhier has given drawings of two cases of lustrous laminated adipose tumor which came under his notice. In both instances the tumor was developed in the brain. Once, likewise, in a cancerous tumor of the testicle, he met with globules of a matter glistening like mother-of-pearl†. He also quotes some notices by M. Dupuytren, of structures which appear to belong to this class, or, at least, where a firm fatty substance was formed in other parts than the brain. Once, a thick layer of a firm fatty substance was found surrounding some carious vertebræ; in another instance, a similar substance had formed in the cancellous structure of the lower jaw, and had distended its internal and external table into a large tumor; and, on a third occasion, the same matter furnished a lining to some old urinary fistulæ. It is not certain that the last mentioned fatty growths, which were found elsewhere than in the brain, were cholesteatomata, although it is probable that they were, since we are unacquainted with any other adipose tumors in the human subject formed of a fat, firm, like the suet of oxen or sheep; and, moreover, the author has met with cholesteatoma under precisely such circumstances.

* Archives générales de Médecine, t. xviii, p. 19.

† Anat. Pathol., livr. v, tab. i, fig. 2.

The author has seen it in the substance of bone, separating from each other the tables of the occipital bone, and once he saw it on the suppurating surface of a carcinomatous ulcer. Barruel examined the chemical characters of these tumors, but no one was acquainted with the peculiarity of their intimate structure till the author gave a short account of his investigations on this subject*.

A.—General Structure of Cholesteatoma.

The author has seen cholesteatoma eight times, and on each occasion he found its structure to be the same when examined by the microscope. The mass is soft, semi-transparent, of the colour of white wax, but glistening like mother-of-pearl. It shrinks much when dried, and at the same time loses its whiteness, and becomes of a yellowish-brown colour, though it still retains somewhat of its glistening appearance. It is usually made up of laminæ no thicker than the finest paper, which are in most instances arranged in a concentric manner, as the author has had an opportunity of observing in tumors of the cerebrum. The tumors are generally round, or oval, or of an uneven though rounded form, and on their surface are seen those small nodules represented by Cruveilhier, the layers of which have also a concentric arrangement. Sometimes fragments of a regularly laminated structure are irregularly intermixed, like broken masses of some stratified rock. Such was the nature of a cholesteatoma in the interior of the cranial bones, the external table of which it had caused to bulge outwards, while it had destroyed the internal table. A distinct membrane enveloped this mass, and, indeed, all the tumors of the brain and of the cranial bones were covered by a very delicate membrane. There are

* See Jahresbericht des Archivs, 1836.

cases, however, as will hereafter be shewn, in which cholesteatomatous matter is deposited in the interior of cysts with thick parietes, or upon the surface of ulcers.

The laminæ which compose these growths may very readily be detached from each other with the point of the scalpel. The dull mother-of-pearl lustre already spoken of is dependent on the "interference" of light, produced by the finely laminated structure of the tumor. If sections are made of the tumor perpendicular to its laminæ, the surface of the sections loses that lustre which is retained by the laminæ, although in a faint degree, when separated from each other.

B.—*Its Microscopic Structure.*

On employing the microscope, the finer elements of cholesteatoma are found to be a cellular tissue, composed of very minute polyedrous cells, which constitute the laminæ, and a crystalline fat deposited in the interspaces between those laminæ.

This cellular tissue bears no resemblance to the adipose cellular tissue which exists naturally in the human subject. Its cells are completely polyedrical, like many pigment cells, and it is exactly analogous to the cellular tissue of plants. It is somewhat similar to the polyedrous cellular tissue of the fat of the sheep, but the cells of cholesteatoma are more than twice as small. The average diameter of the cells of cholesteatoma is 0.00081 of an English inch. The cells are as irregular in form as those of the fat of the sheep, some of them being pentagonal, others hexagonal, and almost all of them having unequal sides, which irregularity in form is produced by the cells being in contact with each other. (Plate v, fig. 9.) A few cells of a more regular, almost dodecahedral form, are occasionally seen. The laminæ, which may be detached from each other with the point of the knife, far exceed in thickness the diameter of a single

cell; consequently, by changing the focus of the microscope, other cells are brought into view. The separation of these tumors into laminæ is probably the result of the successive formation of cells and of the deposit of crystalline fat in their intervals.

The individual cells are easily separated, and, when isolated, they are seen to be very transparent and pale, not containing a nucleus in their wall or cavity, nor a finely granular substance in their interior. It is indeed very difficult to detect any wall to these cells, and consequently there is some doubt whether these bodies are solid or hollow. But the fat cells of the sheep present, when isolated, exactly the same difficulty, although there is no doubt as to their being furnished with walls.

With regard to the substance of the cells, their basis is formed by an animal matter quite distinct from fat. If portions of a cholesteatomatous growth are treated with boiling alcohol or æther, the greater part will remain undissolved, will still retain its laminated arrangement, and will present, although less distinctly, its cellular structure. The same may likewise be observed on heating the substance upon a plate of glass; from which too it acquires, like all animal matter, a brownish tinge. It is probable that a part only of the fat which may be extracted from these growths is contained within the cells.

The crystals situated between the layers of cells are of two kinds, tabular and lamellar; and both forms are easily distinguishable by means of a microscope. The tabular are the most numerous; they are scattered in all directions, and here and there some of them are broken. Their length differs much, in proportion to their breadth; they are often short, broad, and rectangular; but frequently ribbon-like, long and narrow, far exceeding in length the diameter of the cells, and being then very easily broken. The shape of some of the tables seems to be

rhombic; but it is not easy to say whether this is really the case, since rectangular tables, if lying obliquely, would resemble rhombs. These tables are not acted on either by acids or alkalis, and probably consist of pure cholesterine. Pure cholesterine, which the author examined under the microscope, was composed almost entirely of rhombic tables.

The other crystalline bodies which the author saw are less abundant, and are collected here and there into little bundles of lamellæ, which, when seen edgeways, might be taken for aciculæ of stearine. If treated, however, with boiling alcohol or æther, it will be seen, as they are deposited on cooling, that their real form is that of lamellæ, pointed at both ends.

C.—*Its Chemical Relations.*

The chemical relations of cholesteatoma were made the subject of experiment by M. Barruel*. After reducing the substance to powder, he treated it with eight or ten times its weight of boiling alcohol, and then filtered the fluid. The matter which was not dissolved by alcohol absorbed a certain quantity of water, swelled up, and assumed an opaline colour. It was found to possess all the characters of albumen.

The alcoholic solution was evaporated to dryness by a stream of warm air. The scanty residue was white, of the consistence of fat, and contained small glistening scales. On drying it between filtering paper, it imparted to the paper a greasy stain. The paper was treated with boiling alcohol, which left, when evaporated, a trace of a fluid fatty matter. The firm part of the fat was entirely soluble in pure boiling alcohol. When left to evaporate in a watch-glass, crystals formed of a mother-of-pearl lustre; and there likewise remained a coagulated, white, fatty matter. The glistening matter had all the

* Cruveilhier, loc. cit.

characters of cholesterine, while the coagulated fat seemed more to resemble stearine.

The author likewise subjected cholesteatoma to the action of boiling alcohol and æther, both of which, when evaporated, yielded the same residuum. No oil remained, but a finely granular fat, probably stearine. To these granular masses were attached very delicate elongated microscopic lamellæ, of unequal size, slightly bent, and closely resembling the lanceolate leaves of plants (Plate vi, fig. 10). Their edges are convex, and converging meet to form the pointed extremities of the lamellæ. The author is unacquainted with any crystalline form of fat to which these bear a resemblance. Neither the alcoholic nor æthereal solutions yielded any tabular crystals. It is probable that a fatty matter is contained in the cells, although it is partially extracted by keeping the preparation in spirit; for the spirit in which a specimen of cholesteatoma of the cranial bones had been preserved yielded a fatty substance on evaporation, which could not be attributed to the presence of cerebral fatty matter, since the brain formed no part of the preparation.

D.—Of the parts of the body in which Cholesteatoma occurs, and of the different forms which it assumes.

All parts of the body appear to be liable to cholesteatoma. It has been met with twice in the substance of the bones; the author saw it once in the bones of the skull, and M. Dupuytren met with a growth probably of this nature in the lower jaw: he also observed it around some carious vertebræ. Leprestre saw it once in the brain, Cruveilhier twice, and the author three times in that situation. When in the brain, it is situated either on the surface of that organ, as in the cases which occurred to M. Cruveilhier and the author; or in its substance, as in the

case seen by Leprestre. Dr. Merriman met with it between the uterus and rectum. The author saw it once in a cysto-sarcomatous growth of the mammary gland, and thrice in a subcutaneous cyst. This tumor is most frequently observed in the brain, for, of sixteen cases, six occurred in the brain, three in bones, and two on the surface of ulcers.

When this morbid growth forms in the bones, it distends and sometimes bursts their shell, a fact which Dupuytren was witness to in the lower jaw, and the author in the cranium.

The following are the forms under which cholesteatoma appears.

Cholesteatoma in Cysts. Cholesteatoma Cysticum.

In this form, the ordinary cholesteatomatous matter is contained in the interior of a cyst. Even in cholesteatoma of the brain the author observed that the tumor was invested with a delicate membrane. In one of these cases the cyst was imbedded in the surface of one hemisphere of the brain; in the other instance, the cholesteatoma formed a very large irregular tumor in the interior of the lateral ventricles, and above the third ventricle, and was encased within a fine membrane. In the case of cholesteatoma of the occipital bone, there was likewise a very fine membrane separating the tumor from the bony substance of the skull. This membrane had not a cellular structure like cholesteatoma, but was indistinctly fibrous. A cysto-sarcoma of the female breast, which was removed with success by M. v. Brunn of Coethen, contained a large mass, loose within its cavity, which presented all the appearances of cholesterine, and which, when examined under the microscope, displayed the polyedrous cells, and the crystals peculiar to this form of morbid growth. In three instances the author saw cholesteatoma developed in sacs with thick membranous parietes, which were

*Like Mrs. Martin's See case of Brunn
by Hurst.*

situated immediately beneath the skin. In all these cases microscopic examination shewed complete identity of structure.

Cholesteatoma on the Surface of Ulcers.

Of this there are two instances, one of which came under the observation of M. Dupuytren, who found cholesteatoma lining urinary fistulæ, and the other case was seen by the author. The author found, on examining with the microscope a cancerous ulcer of the female breast, that its surface was covered with a layer of a peculiar matter, such as he has never seen, either before or since, in that situation. This substance was composed entirely of the fatty matter of cholesteatoma, and presented the ordinary structure of nucleated polyedrous cells.

E.—*History of the Development of Cholesteatoma.*

It may be assumed, with tolerable certainty, that cholesteatoma is destitute of bloodvessels; for not only have they never been seen, either by the author or by any others who have directed their attention to the subject; but, likewise, the growth of a cholesteatomatous mass by aggregation of successive laminae within cysts, as in cholesteatoma cysticum, suffices to prove that the possession of vessels is not essential to its formation. It must, then, be formed in a manner similar to the yolk cells within the cavity of the yolk bag, and, like the epithelium cells, its increase must take place by the deposit of successive lamellæ. So close, indeed, is the resemblance between the epithelium cells and those of cholesteatoma, that they coincide in all points except in the circumstance that the latter are destitute of a nucleus. The cells of ordinary adipose tissue do, therefore, present less resemblance in the manner of their formation to cholesteatoma than is shewn by the horny structures on the surface of the skin; for the walls of adipose cells are furnished with bloodvessels, which may be demonstrated by minute

injections. This apparent difference, however, diminishes on a close examination of the subject; for the original genesis of all cellular structures takes place independently of bloodvessels, in a manner like to the formation of vegetable tissues. This is illustrated in the structure of epidermis and epithelium; the newly-formed cells removing further and further from the seat of their formation, and losing their vitality, in proportion as new cells are produced in the more deeply seated layers of the epidermis. In the present state of our knowledge the formation of epithelium and of the yolk cells best illustrates the origin and growth of cholesteatoma. It is not probable that the cells of cholesteatoma continue, when once formed, to vegetate like those of other structures, and to produce new cells; for the author never observed in this form of morbid growth young cells encased within older ones, nor any thing approaching to the relation between parent cell and germinal cellule. The cells, when once formed, are moved by the generation of new ones from the place of their original formation, and thus successive laminae are formed, as in all epithelium structures.

F.—*Nature of Cholesteatoma.*

Cholesteatoma is by no means a malignant disease, nor attended with fatal consequences, save in some cases in which its presence in the brain has at length caused death by the pressure it occasioned. The instance in which the author observed the cells of cholesteatoma on the surface of an ulcerated carcinoma mammæ, or that in which Cruveilhier* saw globules of a mother-of-pearl lustre in a carcinomatous tumor of the testicle, are merely accidental complications, and many cases can be adduced to prove that cholesteatoma does not return after extirpation. In confirmation of this, the author might mention several

* Anat. Path., livr. 5, tab. i, fig. 2.

cases of subcutaneous cholesteatoma cysticum, which came under his own notice. M. v. Brunn, of Coethen, extirpated a breast with complete success, in which there was an enormously large tumor, partly of a firm structure, partly of a cystoid nature, one of the cysts containing a large mass of cholesteatoma.

Preparations of Cholesteatoma contained in Museums.

1. Cholesteatoma of the brain, two inches in diameter, situated in the ventricles of the cerebrum. In the anatomical museum at Berlin. Numbered 5761 in the catalogue.

2. Cholesteatoma in the upper and middle part of the right cerebral hemisphere of a woman. In the anatomical museum at Berlin. Numbered 5764 in the catalogue.

3. Cholesteatoma in the inside of the pars occipitalis of the occipital bone. In the anatomical museum at Berlin. Numbered 7072 in the catalogue.

4. Cholesteatoma cysticum, which was situated beneath the skin covering the deltoid muscle. It was extirpated by Dr. Helling, and presented by him to the anatomical museum, in the catalogue of which it is numbered 10,825.

5. Cholesteatoma cysticum, which formed an encysted tumor in the neck of an adult. No. 843 of the catalogue of the museum at Berlin.

6. Cholesteatoma of the brain, in Meckel's museum at Halle. It had been regarded as a specimen of medullary sarcoma.

7. Cholesteatoma in the cyst of a cystosarcoma of the female breast. The breast was amputated by M. v. Brunn, of Coethen, and is preserved in the anatomical museum at Halle.

Like C

Like C
case

Cup

III.—OF COMPOUND CYSTOID AND CYSTOSARCOMATOUS GROWTHS.

I.—OF COMPOUND CYSTOID GROWTHS.

THE profession are indebted to Dr. Hodgkin* for an admirable essay on compound serous cysts. He distinguishes clusters of simple cysts from compound cysts, in the walls of which other cysts are contained. To the former class belong clusters of cysts in the choroid plexus, and probably also the hydatid mole, in which cysts become developed in the flocculi of the chorion of the ovum, and connected by their filaments into clusters like bunches of grapes. The compound cysts have the property of producing other cysts from their walls.

According to Dr. Hodgkin, the compound cysts are of two kinds. In those of the first kind, new cysts develop themselves in the walls of the old one, without growing especially in the direction of its cavity, and without being attached to it by peduncles. A repetition of this process forms a tumor composed entirely of cysts of different sizes. Compound cysts, thus formed of a series of chambers, are frequent in the internal generative organs of the female, and are likewise met with in other situations. Some such growths, of enormous size, are contained in the anatomical museum at Berlin.

The second kind of compound cysts is not thus formed of a series of chambers, but the new cysts are attached by pedicles to the walls of the parent cyst, into the cavity of which they project. These pyriform growths may proceed from one or from several parts of the parent cyst, and may themselves give rise to tertiary growths. Dr. Hodgkin has detailed the history of this structure with great minuteness. The inner membrane

* Medico-Chirurgical Transactions, vol. xv, pt. 2.

of the parent cyst is reflected upon those of secondary formation. These secondary pyriform pedunculated cysts do not contain merely a serous or mucous fluid like that of the parent cyst, but within them are clusters of new growths, which proceed from one or more points of their internal surface, and occupy their cavities. Sometimes the young cysts are attached to the older ones by a thin stalk; at other times they have a broader basis. Sometimes the quantity of fluid contained in the parent cyst is great in proportion to the size of the secondary cysts which sprout from its walls; in other cases the opposite occurs, and the dilatation of the secondary cysts may go so far as not merely to distend the parent cyst, but even to occasion its rupture. The secondary cysts, too, may be ruptured, and then they appear like follicles pouring their contents into the parent cyst. The membranes of these cysts are susceptible of inflammation, which may proceed so far as to cause the adhesion of the secondary cysts to the parent sac. Suppuration, likewise, may take place in these cysts, and, consequently, pus may be found in their cavities.

Whenever the author has had an opportunity of examining compound cysts, he has found these observations of Dr. Hodgkin perfectly correct. But the author cannot coincide with Dr. Hodgkin in his attempt to extend the principle of the formation of compound serous cysts to explain the structure of sarcomatous and carcinomatous tumors. The principle of the development of these latter tumors is, as observations with the compound microscope shew, perfectly different in its character. Their ultimate elements, indeed, are cells, often permanent, so small as to be distinguishable only by employing a high magnifying power; but these cells were never observed by Dr. Hodgkin. These cells, moreover, do not sprout from the parietes of a parent cell, but are developed around nuclei, which

are formed either free in the interior of the parent cells, or external to their cavity. Their development does not differ from the development of the tissues in the embryo.

The substance of the walls of a compound cyst is firm, white, often possessed of a satiny lustre, and is composed of regular layers of fibres. The contents of the sac are sometimes a clear fluid, like mucus, at other times they are formed by a pulpy and turbid matter. If tumors of this kind are preserved in spirits of wine, tabular and rod-shaped crystals may be found in the matter which they contain, as well as granules resembling small vesicles filled with a minutely granular substance.

It is worthy of notice, that the clustered growths which proceed from the interior of compound cysts with endogenous development are, often, almost or altogether solid. Instances of this have frequently come under the author's notice; for instance, in ovarian cysts which were beset internally with clusters of sprouting growths. The interior of these growths was, indeed, soft, but presented no trace of cysts; instead of which it was partly fibrous, and, on a high magnifying power being employed, cells were discovered, such as are found in firm sarcomatous growths; the author, therefore, does not think that the process of development described by Dr. Hodgkin invariably occurs. The same observation has likewise been made by Sir A. Cooper*, with regard to the pedunculated growths sometimes contained in the interior of hydatids of the female breast; for he says that some of them were composed of a cellular tissue, infiltrated with fluid. The converse of the ordinary process may, therefore, sometimes take place, and the pyriform bodies, being first produced, may either remain solid, or become the seat of the development of cysts. In the museums of Germany cysts of this kind, with an internal dendritic structure, are rare, and but few

* Illustrations of the Diseases of the Breast, *London*, 1829, p. 23.

well-marked specimens of it exist; but the museum of Guy's Hospital, in London, contains a great number of most remarkable preparations of this kind. The cysts and the arborescent productions within them are, in most of these specimens, either situated in the ovary, or attached to some part of the female generative organs in its neighbourhood.

The following specimens especially attracted the author's attention :—

No. 2241, A.

“A large compound ovarian cyst, having several tuberosc tumors, some of which present the character of fungoid disease, and others consisting of cysts, containing cysts of an inferior order, filled with mucus or pus. There are, likewise, numerous bunches of highly vascular filaments, attached by very slender peduncles.”

No. 2245, A.

“A cyst of a large size formed in the parietes of the uterus or in one of its appendages, and closely adhering to it. It was filled with numerous bunches of small pedunculated cysts attached to almost every part of its internal surface. There was merely sufficient quantity of mucous secretion to prevent the bunches of cysts from adhering among themselves.”

No. 55.

“Complex cystiform production in the ovary.”

No. 2245.

“One half of a uterus, with its corresponding ovary, tube, and ligaments; to which are attached numerous branches of pedunculated cysts, erroneously called small hydatids, and assuming a cauliflower appearance: they were probably inclosed by a cyst, which has been removed.”

Prochaska* has described and drawn a large growth from the

* *Disquisitio anatom. physiol. organismi, Viennæ, 1812, tab. v.*

ovary, which was of an arborescent form, destitute of investing membrane, and made up of pedunculated nodules. Until the author had seen the preparations just alluded to, and had become acquainted with the conclusions which Dr. Hodgkin has drawn from them, the real nature of this growth appeared to him very questionable. Probably the inclosing cyst was either ruptured or else purposely opened. In the description which accompanies the preparation no mention is made of a cyst.

Cysts sometimes contain fungous growths which proceed from the interior of their parietes. An instance of this is No. 2326 of the museum of Guy's Hospital. "Fungoid cyst from the breast removed by Sir A. Cooper." In the museum at Halle is a tumor cysticus of the thyroid gland, which was extirpated by Professor Blasius. "Tumor cysticus e glandula thyreoidea extirpatus. Dorothea Scharto, 1⁶30." On the inner surface of a large sac are masses which entirely fill up its cavity, and are rooted in its walls. These masses contain many cells, from one to two lines in size, filled with a firm transparent matter, such as is usually found in the cells of a bronchocele. Rod-shaped crystals, discernible only with the microscope, are seen here and there in this matter; in some places, indeed, they are collected together in considerable numbers.

II.—OF CYSTOSARCOMATOUS GROWTHS.

After these preliminary observations on compound cysts, which the author was led to make by the investigations of Dr. Hodgkin, another form of cysts next demands attention.

The author applies the name of cystosarcoma to such tumors as, while they are principally composed of a more or less firm, fibrous, and vascular mass, are yet invariably found to contain solitary cysts in their substance. The fibrous masses are composed of an albuminous substance, and sometimes contain gra-

nules scattered between their fibrils. A person regarding merely the nature of the mass which forms the bulk of the growth, would unhesitatingly refer it to the class of sarcomata; but the presence of cysts is so invariable, and these tumors so often exhibit peculiar forms, as to afford just grounds for forming them into a new species, which, indeed, is rendered more desirable in consequence of the numerous errors to which they have led. The fibrous tissue forms the stroma in which the separate cysts are imbedded. These morbid growths are most frequent in the generative organs; either in the ovaries, or near them, in the testicle, and in the female breast.

Three forms of cystosarcoma have come under the author's notice; the simple cystosarcoma, cystosarcoma proliferum, and cystosarcoma with foliated warty excrescences from its cysts. In cystosarcoma simplex, the cysts contained in the fibrous sarcomatous texture have each their distinct membrane, the inner wall of which is simple, smooth, or at most beset with a few vascular nodules. To this class belong several cases described by Sir A. Cooper as hydatid tumors of the female breast*, and likewise some of the preparations in Guy's Hospital called "cystic tumor of the female breast."

In the second form, the sarcomatous mass is the same, but the cysts within it contain younger cysts in their interior, which are attached to their walls by pedicles. An instance of this is afforded by the case of Mrs. King, described by Sir A. Cooper. This form of morbid growth is a repetition of the cystis proliferata, but imbedded in a sarcomatous mass, which constitutes the chief part of the tumor; and it may, therefore, be termed with propriety cystosarcoma proliferum. The pedunculated offsets from the cysts are hollow, and Sir A. Cooper saw some of them loose

* Illustrations of the Diseases of the Breast, plates i and ii.

† Ibid, p. 41, pl. iii.

7
C. simple

2. C.
proliferum

in the interior of the older cysts. It would likewise appear from an observation of Sir A. Cooper that the young cysts contain cholesteatomatous matter, for he found their interior composed of several laminae, easily separable from each other, and presenting a glistening appearance.

The pedunculated bodies may, however, be sarcomatous; they were so in a case that occurred to Professor Chelius, which will be noticed in a subsequent page.

C. phyllodes
 The third form, cystosarcoma phyllodes, differs greatly from the other two. The tumor forms a large firm mass, with a more or less uneven surface. The fibrous substance which constitutes the greater part of it is of a greyish white colour, extremely hard, and as firm as fibro-cartilage. Large portions of the tumor are made up entirely of this mass, but in some parts are cavities or clefts not lined with a distinct membrane. These cavities contain but little fluid; for either their parietes, which are hard like fibro-cartilage, and finely polished, lie in close apposition with each other, or a number of firm, irregular laminae sprout from the mass, and form the walls of the fissures; or excrescences of a foliated or wartlike form sprout from the bottom of the cavities and fill up their interior. These excrescences are perfectly smooth on their surface, and never contain cysts or cells. The laminae lie very irregularly, and project into the cavities and fissures like the folds of the psalterium in the interior of the third stomach of ruminant animals. In one instance the author saw these laminae here and there regularly notched or crenated like a cock's comb. Sometimes the laminae are but small, and the warty excrescences from the cysts very large, while in other instances both are greatly developed. Occasionally these warty excrescences are broad, sessile, and much indented; others have a more slender base, and somewhat resemble cauliflower condylomata. They are always formed of the

same firm apparently fibro-cartilaginous matter as the non-hydatid portions of the tumor. // The preceding description has been made from a cystosarcoma phyllodes of the female breast, weighing $2\frac{2}{3}$ pounds, which was extirpated by M. v. Graefe, and is now preserved in the museum at Berlin, and is numbered 8906 in the catalogue.

On a microscopic examination of the firm mass, it is seen to have an indistinctly fibrous structure, (Plate ii, fig. 19), but to contain neither cells nor cartilage corpuscles. It is very difficult to distinguish the fibrous texture of the mass; and this circumstance, as well as the difference in the results of chemical analysis, suffice to distinguish the solid mass of cystosarcoma phyllodes from the tumor fibrosus s. desmoides. When boiled for twenty hours it yields no gelatine, and consequently consists of an albuminous substance; but the author never met with any other albuminous body of so great firmness. Whatever may be dissolved by long boiling is precipitated by corrosive sublimate, acetate of lead, tannin, and alcohol, but neither by acetic acid nor by alum. Once the author saw a large mass of cholesteatoma contained free within the cyst of a cystosarcoma phyllodes, which had been successfully extirpated by M. v. Brunn, of Coethen, and which was preserved in Meckel's museum at Halle. Tumors of this kind attain an enormous size; hitherto the author has seen them only in the female breast, nor are they even there of frequent occurrence. They are decidedly innocent, occur earlier than it is usual for cancer of the mamma to develop itself, and sometimes they appear even in youth; they have but little tendency to grow to the skin or to the subjacent muscles, and are not attended with retraction of the nipple. They are not disposed to soften internally, but continue to grow slowly until they have attained an enormous size, when they at length burst, and a very ill-looking suppurating fungus forms upon their sur-

face. Even in this state, however, the operation has been performed with a successful result.

These tumors have been described under very different names. Sometimes they are called steatoma mammæ, more frequently carcinoma mammæ hydatides; and the author, formerly, when he had met with but two cases, of the history of which he was ignorant, regarded them as specimens of carcinoma phyllodes. After having seen the disease more frequently, two specimens of it being contained in Meckel's museum at Halle, and one in London, the author became much interested in the subject, and was very desirous to learn the history attached to the preparations. At length he partly succeeded in this, and found that, in all cases of which it was possible to procure an account, the disease shewed the same benignant tendency, notwithstanding the extraordinary warty or foliated appearance of the excrescences which formed in the interior of the cysts. The author purposes to give the disease the name of cystosarcoma phyllodes, as being very expressive of its peculiar appearance*.

Historical Notices of Observations of this Disease.

The different forms of cystosarcoma phyllodes seem to have been most frequently described under the name of carcinoma mammæ hydatides. The disease, however, which Sir C. Bell* describes as carcinoma mammæ hydatides, may very possibly not have been cystosarcoma phyllodes, but cancer alveolaris,

* Probably only two of the three cases described by the author as carcinoma phyllodes, in the *Archiv. für Anatomie u. Physiologie*, 1836, p. ccxxii, really belong to cystosarcoma phyllodes. The case of degeneration of the axillary glands which the author observed in a carcinoma of the breast, and which he regarded as carcinoma phyllodes, although it presented a foliated structure, had a soft consistence.

† *Medico-Chirurgical Transactions*, vol. xii, pt. 1.

which is likewise formed in part of cells of considerable size. Sir C. Bell says, "This tumor, when cut into, does not exhibit a concentrated mass, but is distinguishable into parts or clusters of lesser tumors. When these subdivisions are cut into, they present the most common carcinomatous appearance, being firm in texture, and having the ligamentous bands, both forming areolæ and diverging lines, and these are distinguishable by their whiteness from the matter they embrace. In the interstices of the tubercles some larger bags or cells are found of a yellowish or amber colour. These cells are of various sizes, and the larger ones contain a dark fluid like blood or bile."

A description by Mr. Travers* may be regarded with greater certainty as referring to this disease. He divides malignant tumors into two original forms, scirrhus, and medullary sarcoma; and when treating of the disease which he regards as the primitive form of cancer medullaris of the mammæ, he says, "The encysted tumor containing a straw or coffee-coloured fluid, with a berry or fringe-like growth from one or more points of its internal surface. The cyst is generally subdivided into compartments, or there are several contiguous cysts. This I regard as the primitive form of medullary cancer, when it appears in the region of the mammæ. The fungus ordinarily commences on the interior of a cyst containing a fluid, from the vascular lining of which it hangs like a fringe; and it is common to find more than one, often several contiguous cysts in the early stage of the disease. As the fungi grow, the cysts burst, and are blended in the same mass." The history of a case then follows, from which, however, it is not clear whether the disease was cured by the operation†.

* Medico-Chirurgical Transactions, vol. xv and xvii.

† Medico-Chirurgical Transactions, vol. xvii, p. 316.

The disease which Chelius* calls sarcomatous or steatomatous degeneration of the mammary gland likewise belongs partly to this class. Chelius observes, that "The sarcomatous or steatomatous degeneration of the mammary gland is one of the most benignant diseases to which that organ is subject, and it is with great impropriety that many have spoken of it as carcinoma mammæ hydatides. It is characterised by the large size and great prominence of the tumor, which is not globular, but four-cornered, and projecting more at one part than another: it does not cause retraction of the nipple, but that part projects and retains its natural appearance. The greatest diameter of the tumor is not at its base, but at a point some distance from the walls of the chest. This disease may be distinguished from scirrhus and fungus medullaris of the mammary gland, partly by the abovementioned signs; but other circumstances which serve still further to distinguish it, are its different consistence at different parts, it being hard at one spot, elastic and tense at another, and even distinctly fluctuating at a third; its mobility in all directions, notwithstanding the great size it attains; the slight influence it exerts on the general health, even after it has continued for a considerable time; and, lastly, the absence of swelling of the axillary glands. Although this tumor is inconvenient to the patient from its size, and painful from its dragging at surrounding parts, yet it does not affect the health." There next follows the description of a tumor which appears to the author to have been a cystosarcoma. With regard to the term sarcomatous or steatomatous degeneration of the mammary gland, the author cannot but remark that it includes various forms of innocent tumors, as albuminous sarcoma, and the fibrous or desmoid tumor, both of which occur in the breast. The case

* *Heidelberger klinische Annalen*, iv, pp. 499, 517.

related by Chelius is transcribed here on account of the many points of interest which it presented. *Case*

“The patient was a person thirty years old, who ten years previously had noticed a slight painless enlargement of the right breast. For about a year the condition of the breast continued the same, but afterwards the tumor gradually increased in size, though it did not become hard, but presented everywhere the same consistence: it continued easily moveable, and the dragging sensation produced by its weight was the only inconvenience which the patient suffered. A quarter of a year before her application to Professor Chelius, the patient experienced a febrile attack, during which the breast became painful, and the menstruation ceased, and did not afterwards return. The tumor now rapidly increased in size, and the breast acquired a circumference of 8 inches from the shoulder to the end of the sternum; from below upwards it measured 1 foot 3 inches, and its greatest circumference was 22 inches. The tumor was of an elongated form; its greatest circumference was about midway between its base and apex, and the base was comparatively narrow. The surface of the tumor was irregular, nodulated, very hard at some parts, and at others soft and fluctuating. The patient was cured by amputation, and has since enjoyed good health.

“The tumor weighed $8\frac{1}{2}$ pounds, and was formed of five separate growths, connected together by condensed fibrous tissue. The topmost tumor was composed of a homogeneous whitish hard mass, in which were some holes filled with clusters of small bodies, some of a white, others of a red colour, which presented a most deceptive similarity to hydatids, but shewed, when divided, a solid lardaceous mass. In the second tumor two substances were distinguishable, the one firm and reticular, the other made up of small globules of a thin fat,

which occupied its interstices. The basis of the whole growth was principally formed by the third tumor, which was vascular, soft, broke down under pressure, and resembled the cotyledons of ruminant animals. The fourth tumor was white, very firm, and almost fibro-cartilaginous, and, when divided, it displayed a texture similar to the arbor vitæ cerebelli. The fifth tumor was of a greenish-yellow colour, and tremulous like jelly, very tough, and almost fibro-cartilaginous, although it gave a sense of fluctuation to the touch. Its section shewed only a few small interspaces, which probably contained a serous fluid that ran out on dividing the tumor. All these tumors were invested with a capsule, to which very few vessels were distributed. This capsule could be divided into two layers: the first appeared to be merely condensed cellular tissue; the second was the real envelope of the tumor."

The fibro-cartilaginous structure of many of the tumors, the clusters of small solid bodies in the walls of the cavity of one tumor, and the foliated appearance of another, like the arbor vitæ in the cerebellum, leave no room for doubting that the tumors described by Chelius belong partly to the cystosarcoma proliferum, partly to the cystosarcoma phyllodes.

Sir A. Cooper has, with great propriety, classed these tumors among hydatid growths, and separated them from the genus of cancerous structures; he has, moreover, adduced a great number of cases in support of his remarks. It would seem, however, as though the cystosarcoma phyllodes with warty and foliated excrescences, and pedunculated growths from its cavities, had never come under Sir A. Cooper's notice, for the cases he describes refer to cystosarcoma simplex and proliferum.

In addition to the preparations of cystosarcoma proliferum and phyllodes, contained in the museums at Berlin and Halle,

the following specimens may be seen in the London museums:—

1. In the museum of St. Bartholomew's Hospital (Morbid Preparations, twenty-eighth series No. 11) is a cystosarcomatous growth, one cyst of which contains small nodulated and foliated bodies which proceed from its walls. The patient recovered after the operation.

2. No. 2291 of the museum in Guy's Hospital. "Tumor removed from the breast, and denominated chronic, as distinguished from malignant. A part at least of its structure presents the encysted form, but there is no appearance of ulceration."

3. No. 2296 in the same collection. "Portion of a tumor considered to be of the hydatid kind, removed from the breast by Sir A. Cooper. It presents very distinctly the kind of structure alluded to."

4. No. 2299 A, in the same collection. "Portion of a very large tumor, removed from the breast by Sir A. Cooper: the structure dependent on pedunculated pyriform bodies is very evident."

On the Curability of the Disease by Operation.

There are many and sufficient observations on record, all of which concur in representing cystosarcoma as curable by extirpation, and as having nothing in common with cancer, notwithstanding the extraordinary appearance which its warty excrescences or its laminæ exhibit. The case described by Chelius was cured by the operation. The same result followed the operation in the case from which the specimen in St. Bartholomew's Hospital was obtained; and amputation cured all the cases of hydatid tumors of the breast described by Sir A.

Cooper. Swelling of the axillary glands is not a common occurrence, and, when it is met with, is the consequence of simple irritation, and subsides after the operation. The extraordinary forms which cystosarcoma phyllodes assumes, at once suggest the notion of its cancerous nature; and yet the disease is perfectly innocent, and as far removed from carcinoma as are those non-suppurating cauliflower condylomata of the penis, and of the female genitals, which have so often been mistaken for cancerous structures. The author has been fortunate enough to learn the history of a case which came under his own observation; and, likewise, of two others, the preparations from which are contained in the anatomical museum at Halle. In all of these the operation was completely successful.

The two specimens in Meckel's museum at Halle were presented by Dr. v. Brunn, of Coethen, to whose kindness the author is indebted for the following details.

“The two breasts were removed from different individuals. The one breast was very large, the other was of moderate size; and the two appeared to me, at the time when I amputated them, to be composed of different structures.

“The first was removed by me, in the year 1817, from an unmarried Jewess, twenty-four years old. It was composed of several nodular growths, resembling encysted tumors (one of which was extremely large, the others were small), intermixed with a considerable quantity of fat. The tumor had not passed into the open state; it was quite moveable upon the pectoral muscles, and was easily removed. The wound healed regularly; the patient has since remained well, and is still alive.

“The second specimen is the breast of a male. It is of moderate size, hard and angular; it had burst, and from its ulcerated surface there grew a spongioid excrescence. It was tolerably

firmly connected to the pectoral muscles, whence it was detached with the knife, and presented on its under surface bundles of firm cellular tissue. The patient from whom it was removed was a labouring man fifty-two years old, who, having fallen sixteen years before upon the edge of a barrel, bruised his right breast. Ever after this accident a hardness remained in the breast, which gradually increased in size until it assumed the appearance just described. The man was in other respects healthy, only somewhat narrow-chested. M. Schmädling amputated the breast in 1825: the wound healed with great rapidity, so that at the end of fourteen days it was almost entirely closed. No relapse took place; the man lived for many years afterwards, and at length died of disease of the lungs."


Two years ago the author received from Dr. Baschwitz, of Driessen, an enormous ulcerated tumor of the female breast which he had removed. The surface of the tumor presented a fungoid growth, which induced the author at first to regard it as cancerous, although it presented considerable similarity to the case of cystosarcoma phyllodes above described. Recently, however, the author wrote to Dr. Baschwitz, stating that he had strong reasons for doubting whether this tumor really was of a cancerous nature, and requesting to know the result of the operation. Dr. Baschwitz replied, that the person in question recovered at the end of six months after the operation, which was followed by the repeated use of the actual cautery, and other external treatment; and that at the time he wrote, which was more than two years afterwards, she continued quite well. The brother of this woman died of cancer of the stomach.

Although it is a well-established fact that these forms of cystosarcoma are innocent, yet it must not be imagined that the appearance of cysts in a parenchymatous tumor necessarily ex-

cludes carcinoma, or a malignant nature. Indeed, just as cysts may be developed in every part of the organism, so it is quite possible that they may be formed in a carcinomatous structure. Among the many cases of innocent hydatid tumors of the breast, Sir A. Cooper mentions one which was malignant, namely, a combination of cancer and hydatids. Moreover, the occurrence of carcinoma alveolare in the breast, although rare, has been observed by the author, and may lead to mistakes. In a carcinoma reticulare, the author saw part of the tumor presenting the ordinary structure of carcinoma alveolare, and containing cells filled with jelly. These cells might very easily have been mistaken for ordinary hydatids.

Carcinoma of the breast never attains that enormous size which cystosarcoma of the female breast sometimes reaches, before it passes into the open state. In Chelius' case the tumor had existed for ten years before the operation was performed, and a cystosarcoma proliferum had lasted for fourteen years before it was extirpated by Sir A. Cooper. The development of the tumor at a period of life when cancer mammæ is infrequent, its tardy progress, the enormous size which it attains without causing pain or producing, at the most, only very slight discomfort, and the fluctuation more or less distinct at the part where some cyst is situated, are points which, even before an operation, may lead to a tolerably certain diagnosis of these growths.

Enchondroma and cystosarcoma are the only forms of benignant tumor of the mammary gland which have hitherto come under our notice. The female breast is liable to innocent tumors of other kinds, which will hereafter claim our attention; as the albuminous and gelatinous sarcoma, and the fibrous tumor, which in the breast, as well as in the uterus, is susceptible of transformation into bone.



habitu persequi, sed proinde non immerita sua ca-
rere, de qua non est dubium, quod non loquar sine
alio, sed de qua agitur de iudicio.

