Johnston's students' atlas of bones and ligaments / by Charles W. Cathcart and F. M. Caird.

Contributors

Cathcart, Charles W.
Caird, Francis M. 1853-1926.

Publication/Creation

Edinburgh ; London : Johnston, 1885.

Persistent URL

https://wellcomecollection.org/works/kzpybd2c

License and attribution

This work has been identified as being free of known restrictions under copyright law, including all related and neighbouring rights and is being made available under the Creative Commons, Public Domain Mark.

You can copy, modify, distribute and perform the work, even for commercial purposes, without asking permission.

Wellcome Collection
183 Euston Road
London NW1 2BE UK
T +44 (0)20 7611 8722
E library@wellcomecollection.org
https://wellcomecollection.org

STUDENTS' ATLAS
OF
BONES AND LIGAMENTS

CATTICART AND CAIRD

24828

22500294598

Med
K29473

STUDENTS' ATLAS

OF

BONES AND LIGAMENTS

JOHNSTON'S

STUDENTS' ATLAS

OF

BONES AND LIGAMENTS

BY

CHARLES W. CATHCART, M.A., M.B., F.R.C.S. Eng. and Edin.

ASSISTANT SURGEON, ROYAL INFIRMARY

FORMERLY LECTURER ON ANATOMY, SURGEONS' HALL, EDINBURGH

AND

F. M. CAIRD, M.B., F.R.C.S.E.

SENIOR ASSISTANT, SURGICAL DEPARTMENT, UNIVERSITY OF EDINBURGH

W. & A. K. JOHNSTON, LIMITED

EDINBURGH AND LONDON

[1885]

2+828



PREFACE.

THE present Work has been undertaken at the request of Messrs W. & A. K. JOHNSTON, who asked us to help them to publish a Series of accurate and artistic Plates illustrative of the Bones and Ligaments of the Human Body. We have had the very ample Lithographic resources of their establishment placed at our disposal, as well as the services of a staff of first-class Artists, and in this way we cannot but feel that the advantages which the work has had have been of a very exceptional kind.

Our duty has been to select and arrange the material, plan out the Plates, superintend the Drawings, and supply the Letterpress and Text. We have tried throughout to ensure accuracy, and have therefore —except in a few cases, chiefly Epiphysis, mentioned in the Text—had the drawings made from actual specimens or fresh preparations. The attachments of muscles to the bones have been marked in after careful and repeated dissection, and in most cases this has been done before the specimen was put into the artist's hands.

The specimens were photographed in the positions we suggested, and the photographs submitted to us for approval; when passed, tracings of them were taken as the basis for the rest of the drawing. The now standard method of marking the origins of the muscles in red, and the insertions in blue, has been supplemented by printing the names of the muscles in corresponding ink, and in washing a shade of blue over the articular surfaces. A similar shade has been used to express the various Ligaments, and in some places a mottling of red has been put in to draw attention to sections through the bone.

Besides Drawings of the important Ligaments, views have been given of the synovial cavities of joints of the limbs, artificially distended with coloured tallow or Plaster of Paris, to illustrate the position assumed in maximum distention, and to show more clearly the exact limits of the synovial cavities.

The Letterpress on each Plate has been used to indicate the various points which the student should remember.

In writing the Text for each Plate, our object has been to help the student to understand the Plate, rather than to explain fully all that it illustrates. This would have necessited writing an additional treatise on the Bones and Ligaments, which is not the purpose of the present Work. We have, however, when possible, tried to direct attention to ways of looking at the parts under consideration, so that the student may be able to study the details with greater ease.

Our thanks are due to Professor Turner for permission to photograph and draw the skeletons figured in the first Plate, and for the use of the injected joint figured on Plate XX.

In conclusion we must express our appreciation of the accuracy and care with which the Publishers have carried out all their part of the work; and we trust that with their aid we have been able—however imperfectly—to clear the way of the much over-taxed Medical Student of the present day.

CHARLES W. CATHCART.
FRANCIS M. CAIRD.

Digitized by the Internet Archive
in 2018 with funding from
Wellcome Library

https://archive.org/details/b2933617x

CONTENTS.

PLATES.

I. Male and Female Skeletons.
II. The Vertebral Column.
III. The Vertebral Column—*continued.*
IV. Ligaments of the Vertebræ.
V. Sternum and Thorax.
VI. Clavicle and Ribs.
VII. Scapula.
VIII. Humerus.
IX. Radius and Ulna.
X. Ligaments of Shoulder and Elbow.
XI. The Bones and Ligaments of the Hand.
XII. Pelvis.
XIII. Os Innominatum.
XIV. Ligaments of the Pelvis.
XV. Femur.
XVI. Ligaments of the Knee.
XVII. Tibia and Fibula.
XVIII. Bones of the Foot.
XIX. Ligaments of the foot.
XX. Synovial Membranes of the Knee and Elbow.
XXI. The Skull—Adult and at Birth.
XXII. Base of Skull.
XXIII. Occipital and Parietal Bones.
XXIV. Frontal and Ethmoid Bones.
XXV. Inferior Maxilla.
XXVI. The Temporal Bone.
XXVII. The Sphenoid Bone.
XXVIII. Superior Maxilla and Palate.
XXIX. Malar, Nasal, and Inferior Turbinate Bones and Sections.
XXX. Sections of Skull.

MALE AND FEMALE SKELETONS.

PLATE I.

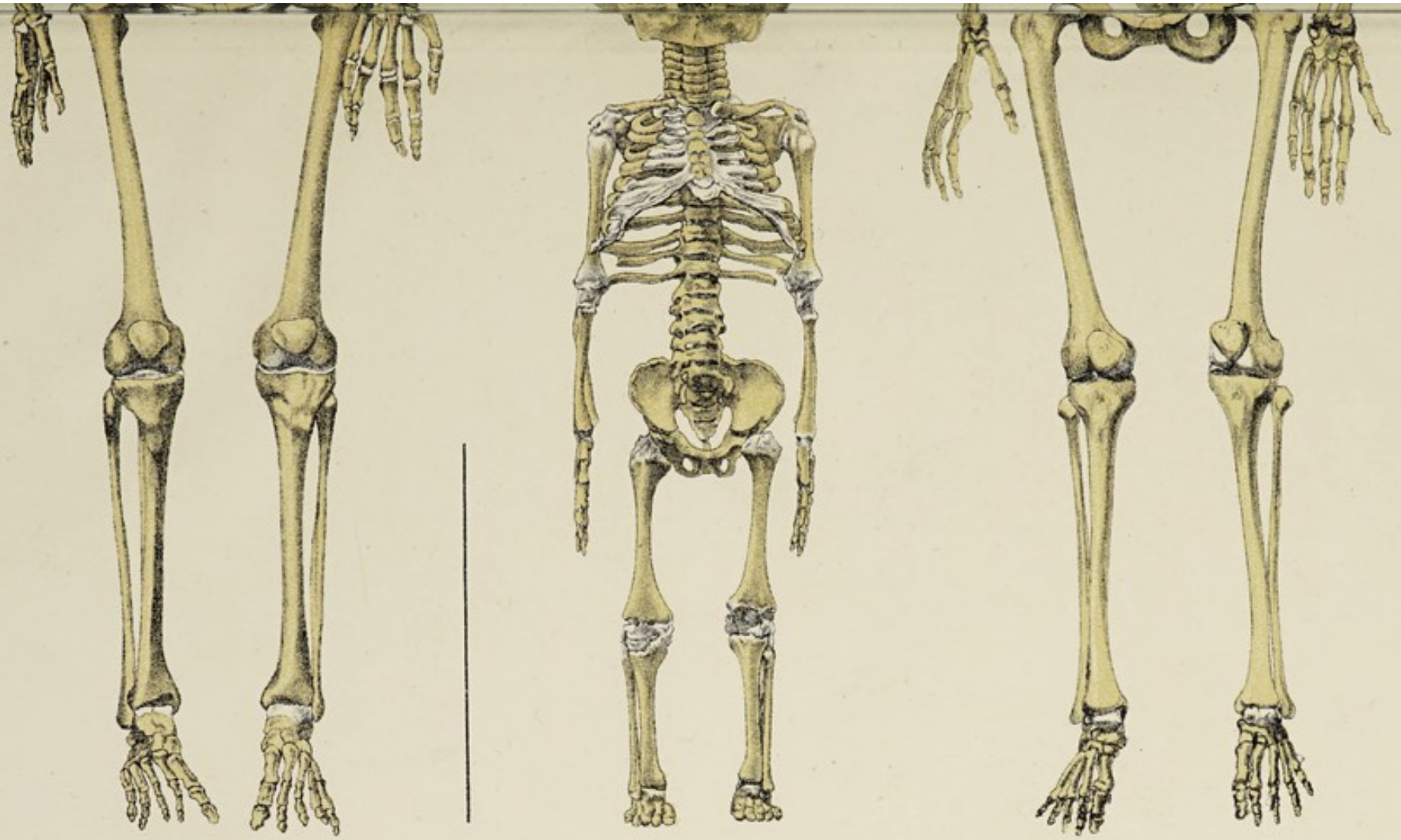

Drawn from nature. & Printed by W. & A. K. Johnston, Edinburgh & London

SPINAL COLUMN AND VERTEBRÆ.

PLATE II.

Fig. 1.
Lateral view of spinal column.

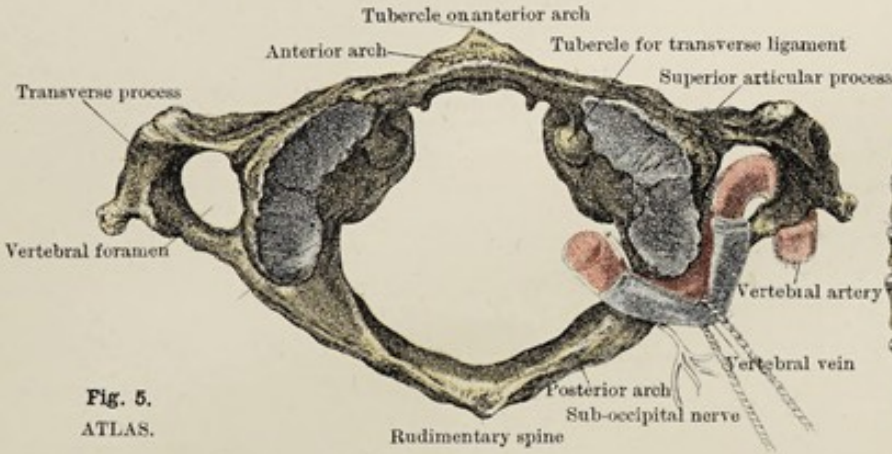

Fig. 5.
ATLAS.

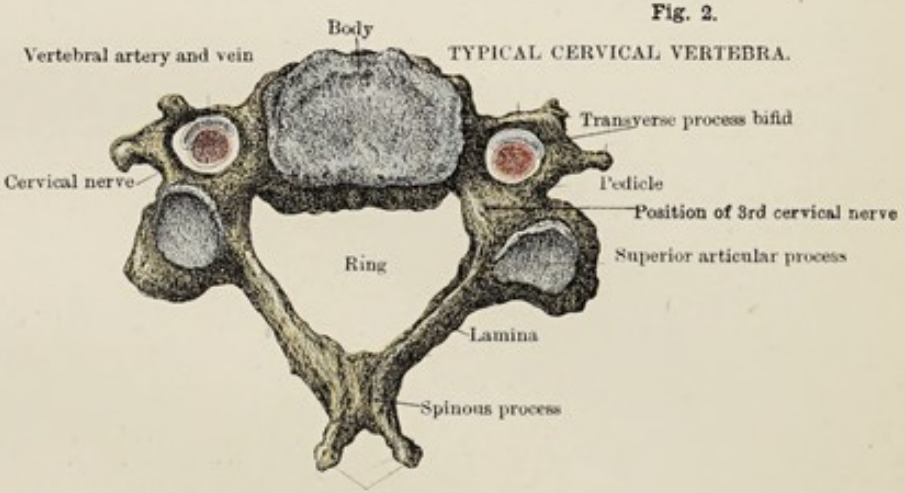

Fig. 2.
TYPICAL CERVICAL VERTEBRA.

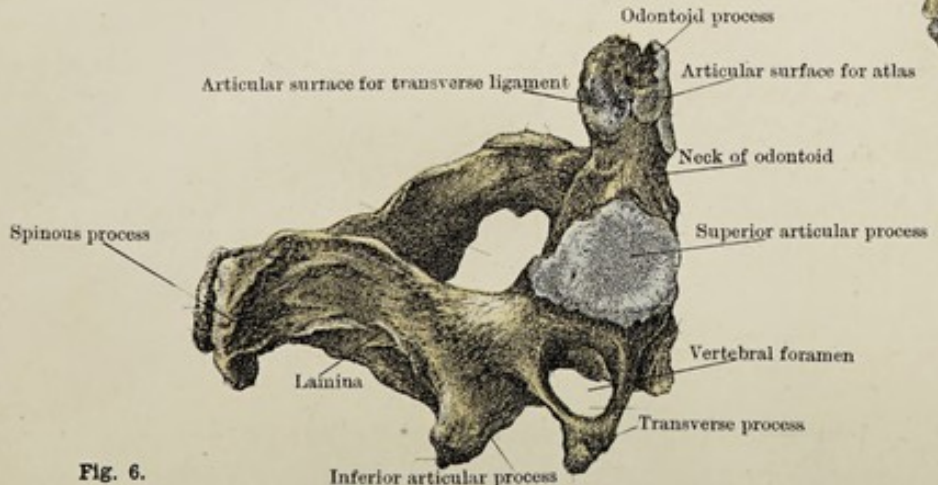

Fig. 6.
AXIS.

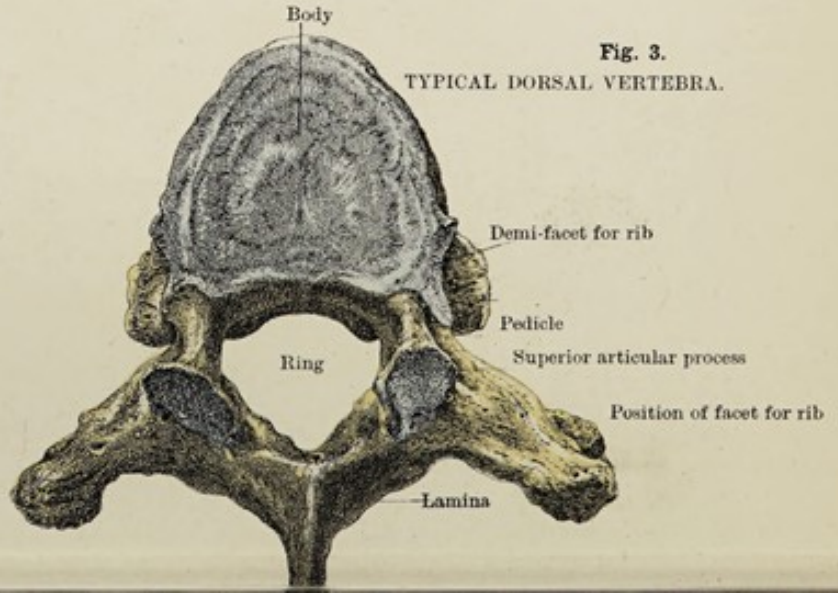

Fig. 3.
TYPICAL DORSAL VERTEBRA.

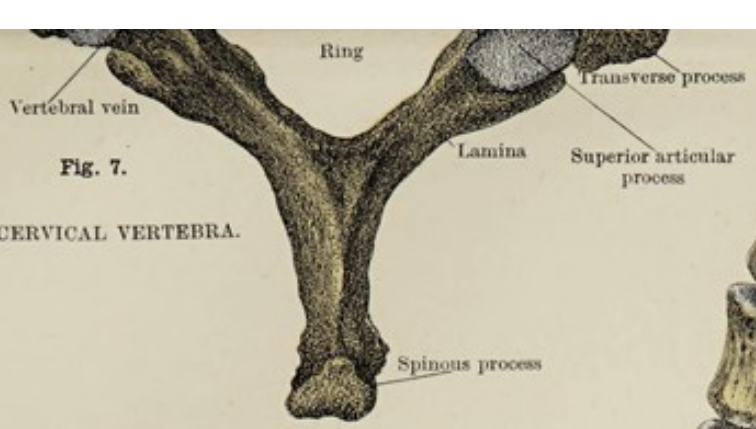

Fig. 7.

7th CERVICAL VERTEBRA.

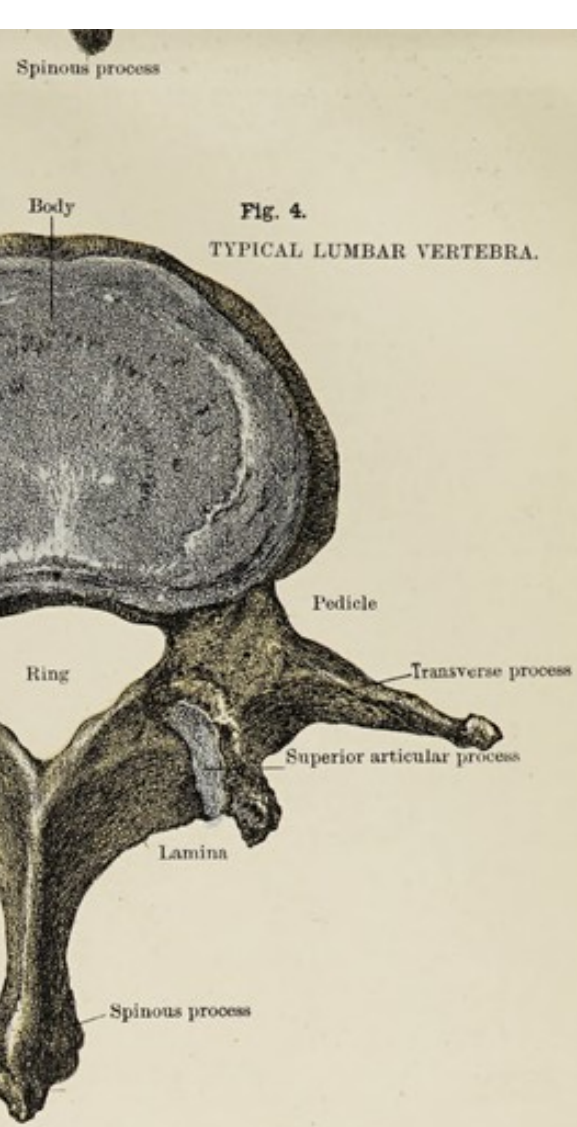

Fig. 4.

TYPICAL LUMBAR VERTEBRA.

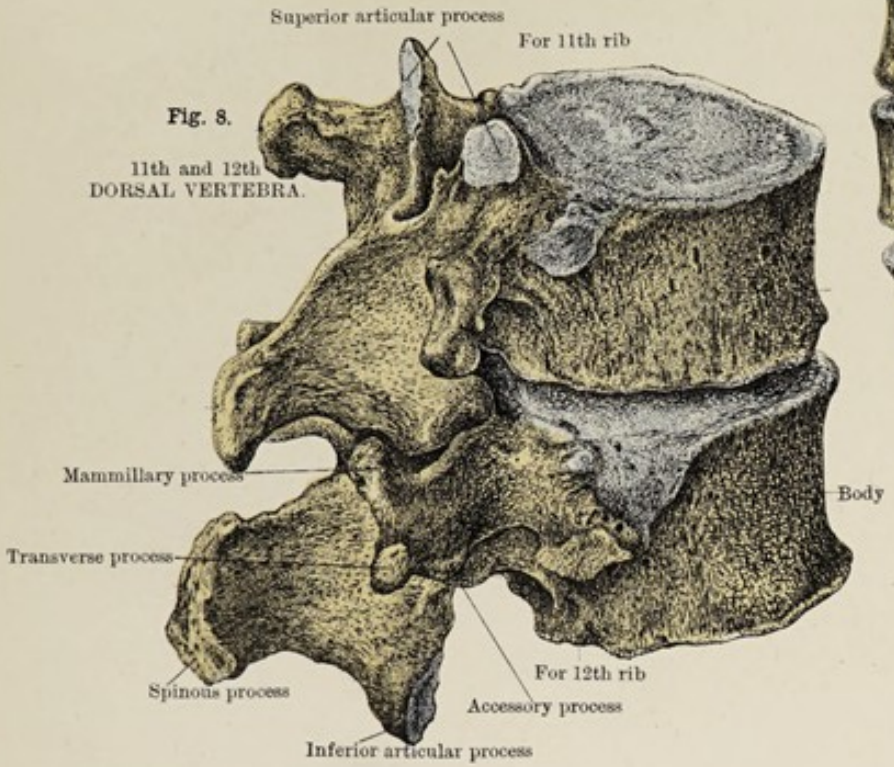

Fig. 8.

11th and 12th DORSAL VERTEBRA.

Drawn from nature & Printed by W. & A. K. Johnston, Edinburgh

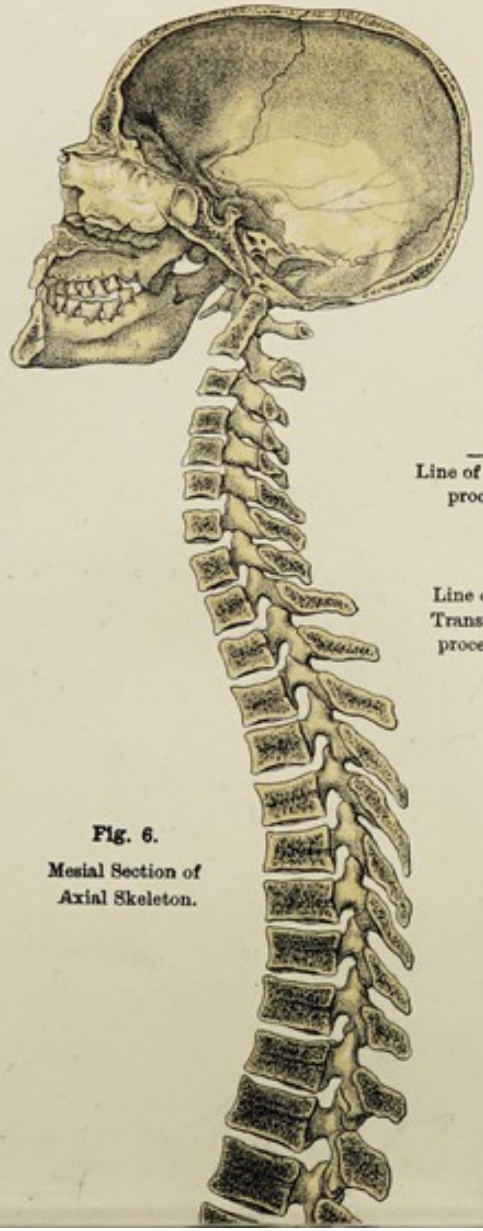

Fig. 6.
Mesial Section of Axial Skeleton.

Fig 7.

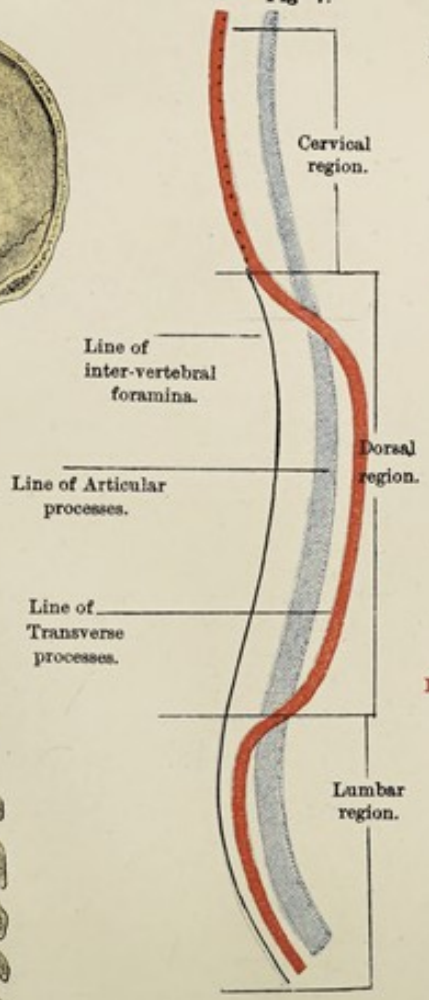

Fig. 1. Sacrum (anterior view).

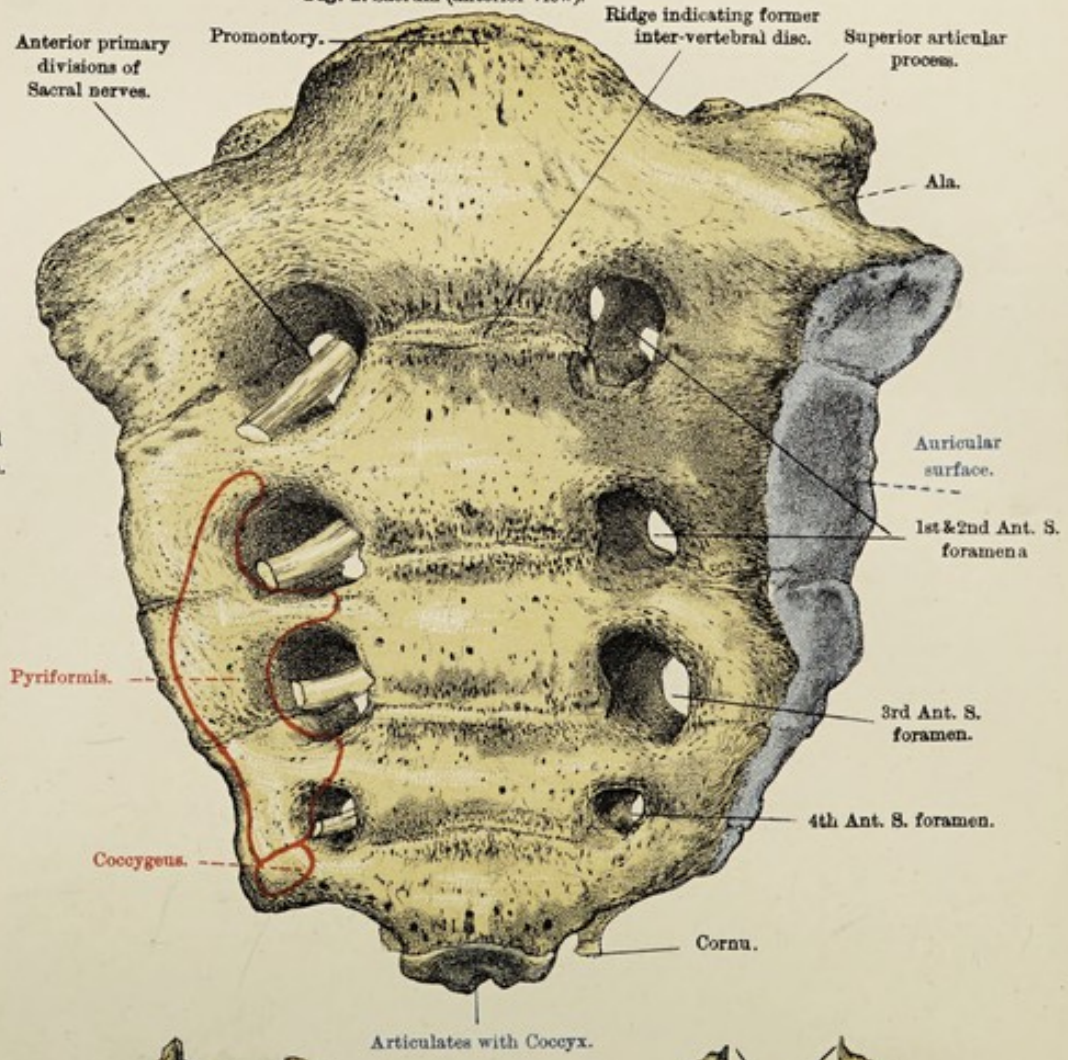

Fig. 4.
Coccyx
(posterior surface).

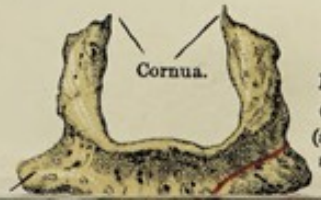

Fig. 3.
Coccyx
(anterior surface).

Fig. 8.

Development of Sacrum.

Fig. 9

Fig. 5.
Anterior view of Vertebral Column.

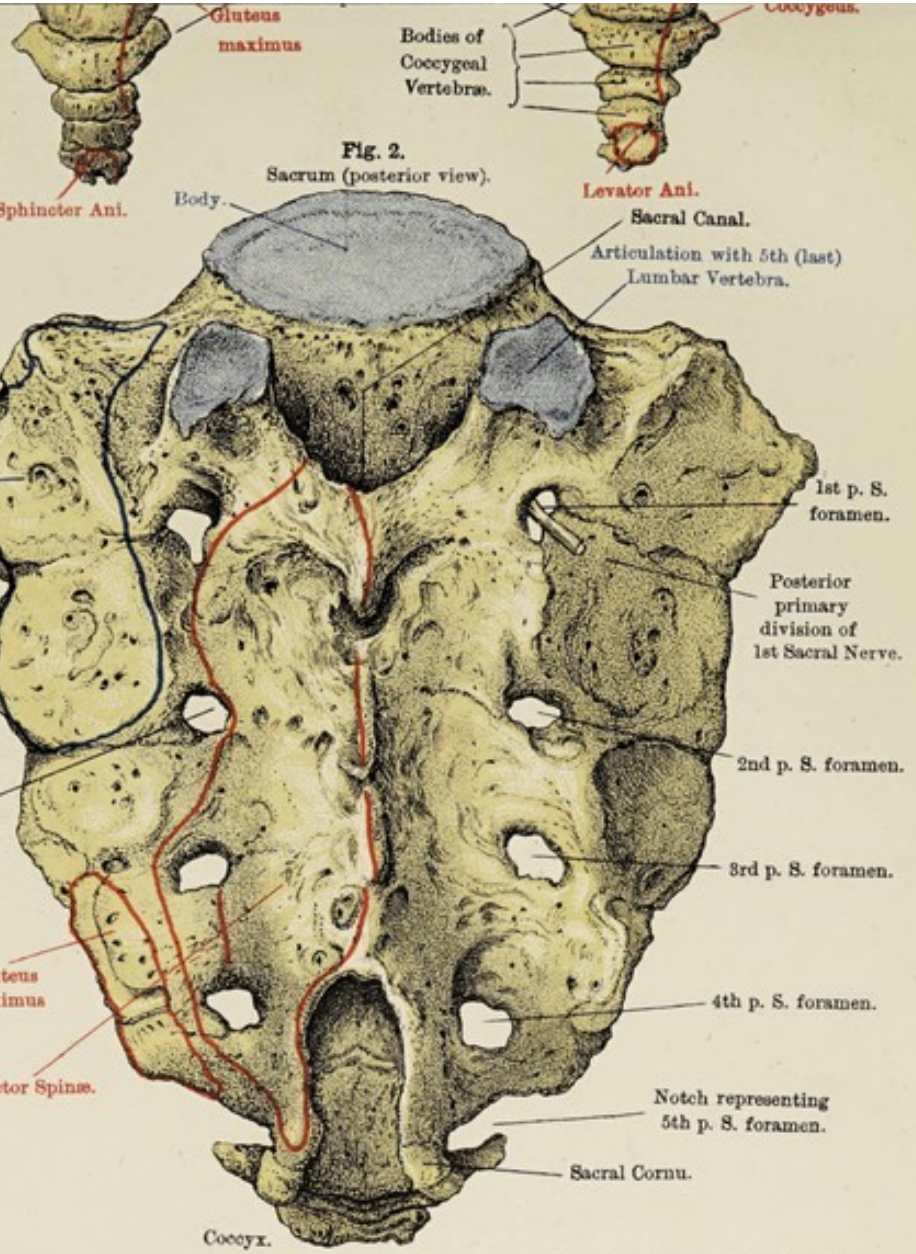

Fig. 2.
Sacrum (posterior view).

Drawn from nature & Printed by W. & A. K. Johnston, Edinburgh & London.

LIGAMENTS OF THE VERTEBRÆ.

PLATE IV.

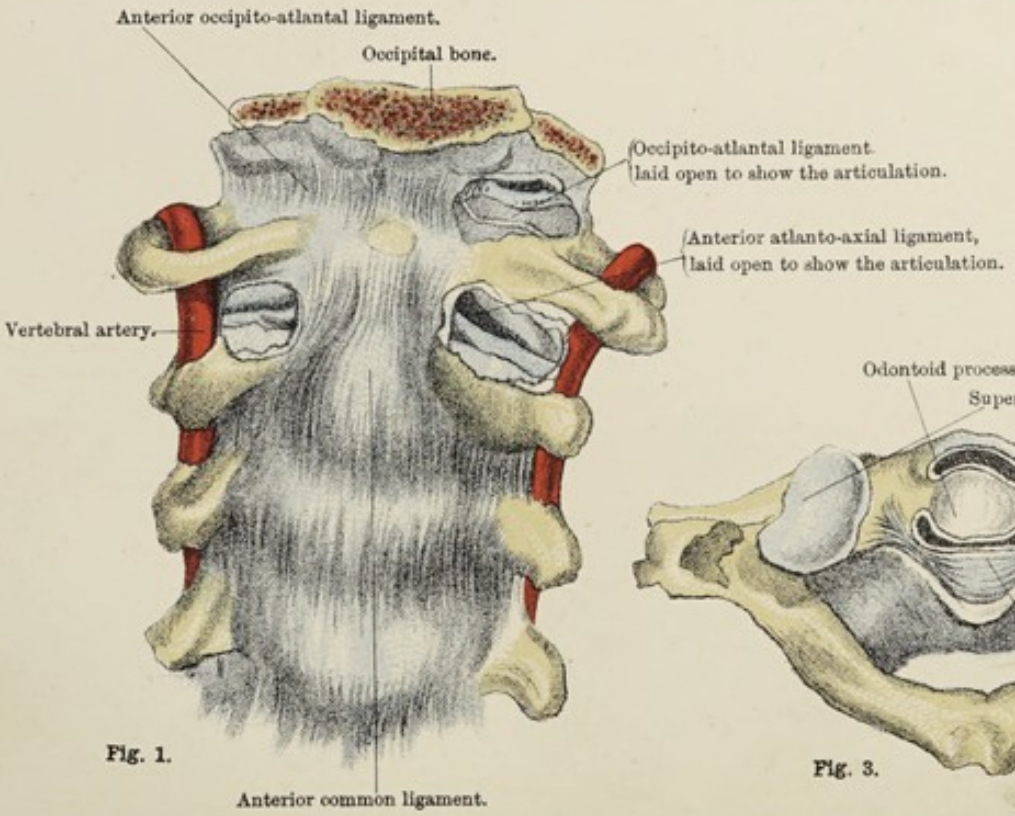

Fig. 1.

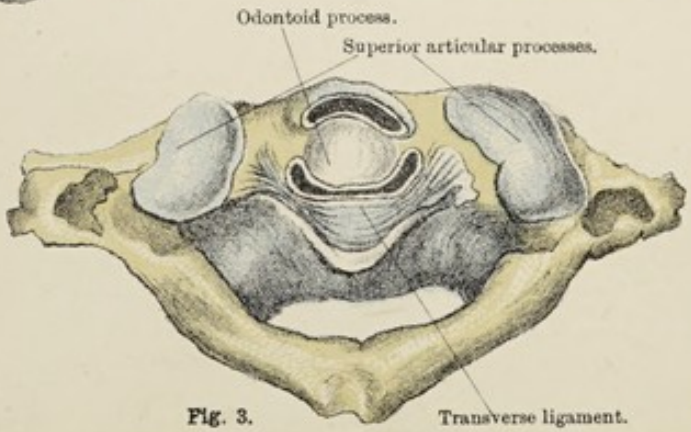

Fig. 3.

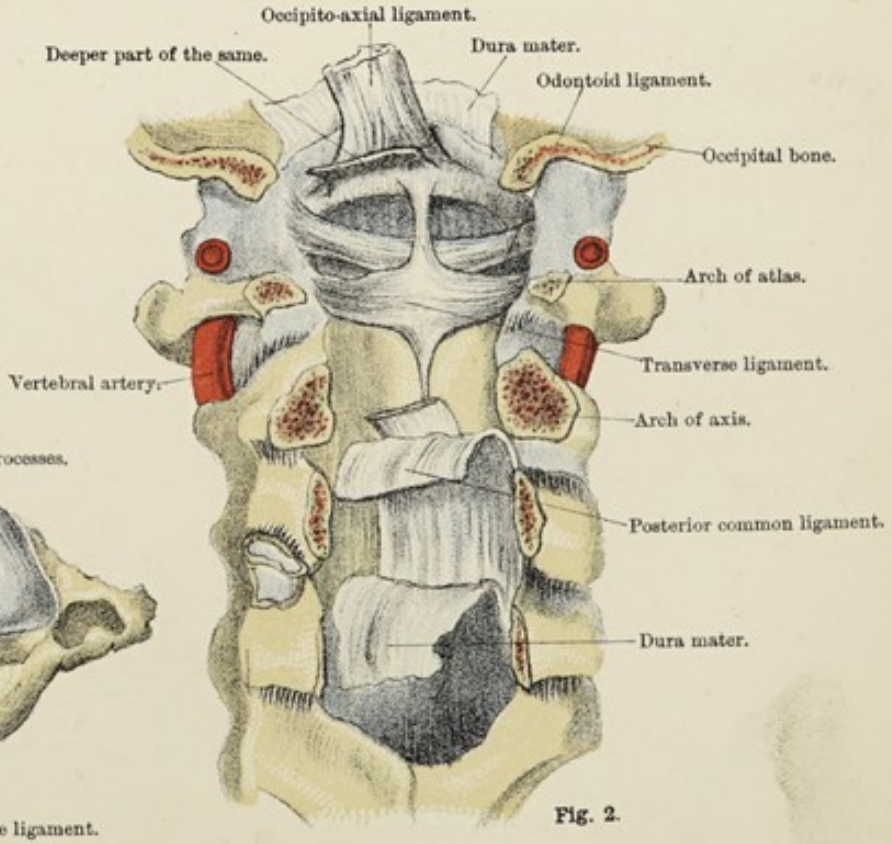

Fig. 2.

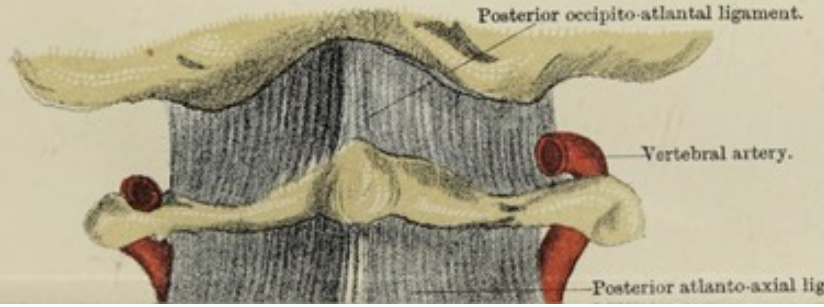

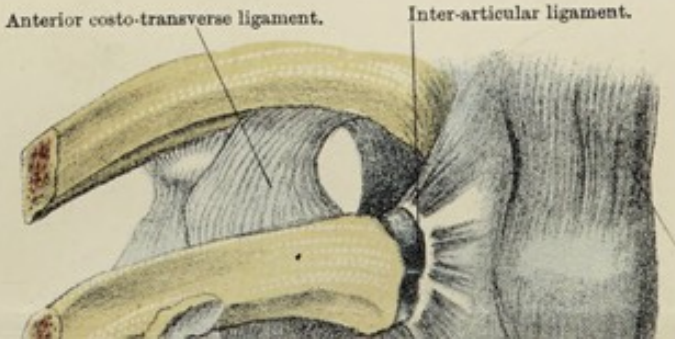

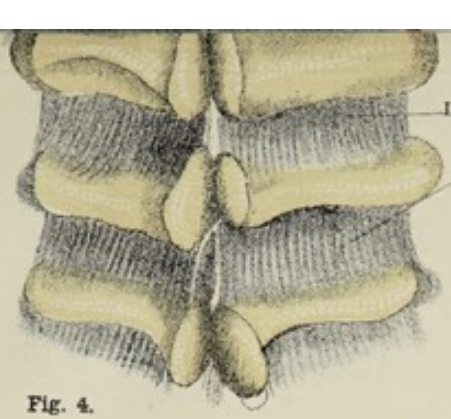

Fig. 4.

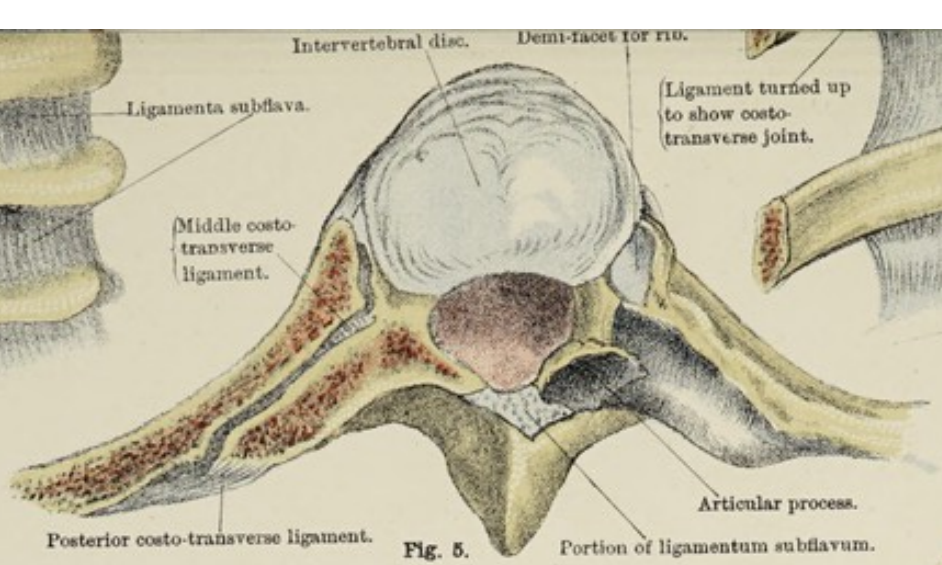

Fig. 5.

Fig. 6.

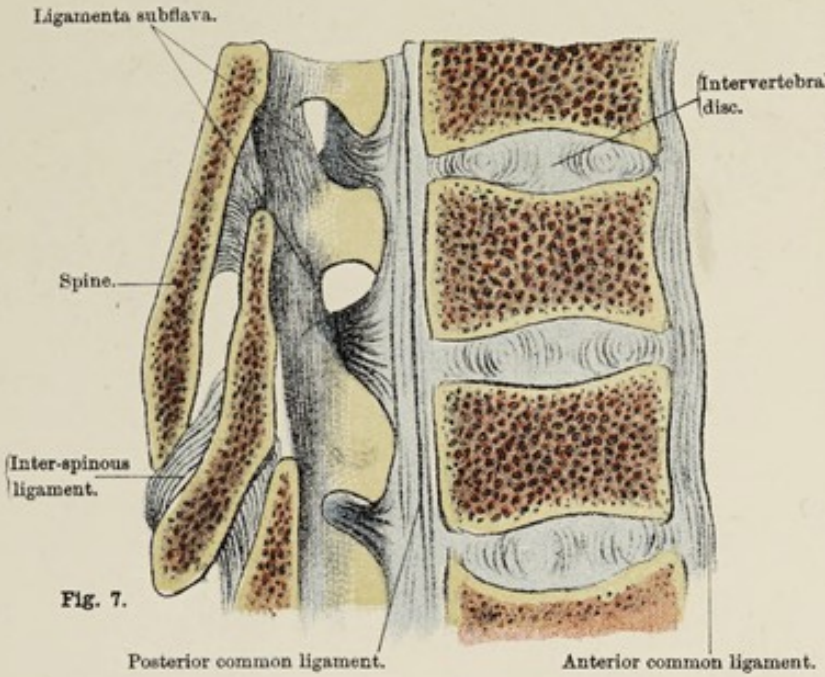

Fig. 7.

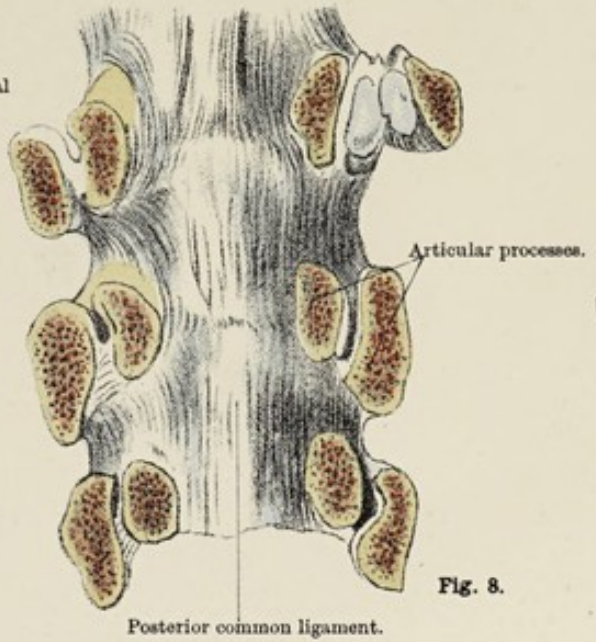

Fig. 8.

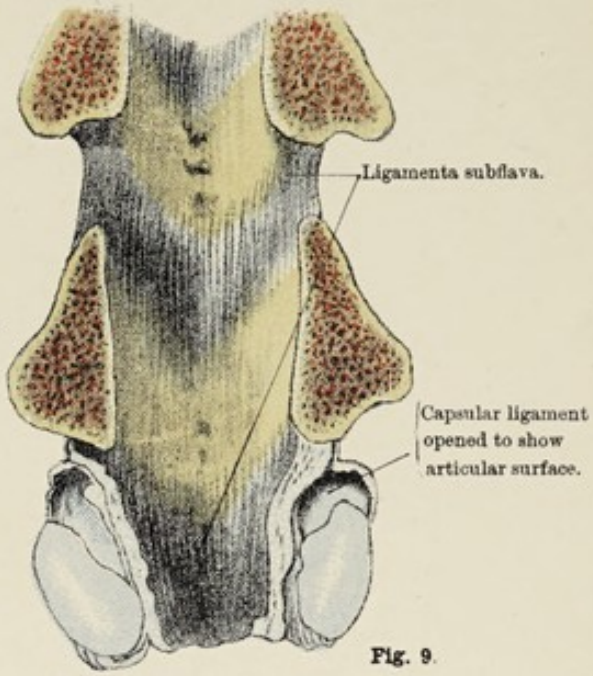

Fig. 9.

Drawn from nature & Printed by W. & A.K. Johnston, Edinburgh & London

STERNUM AND THORAX.

PLATE V.

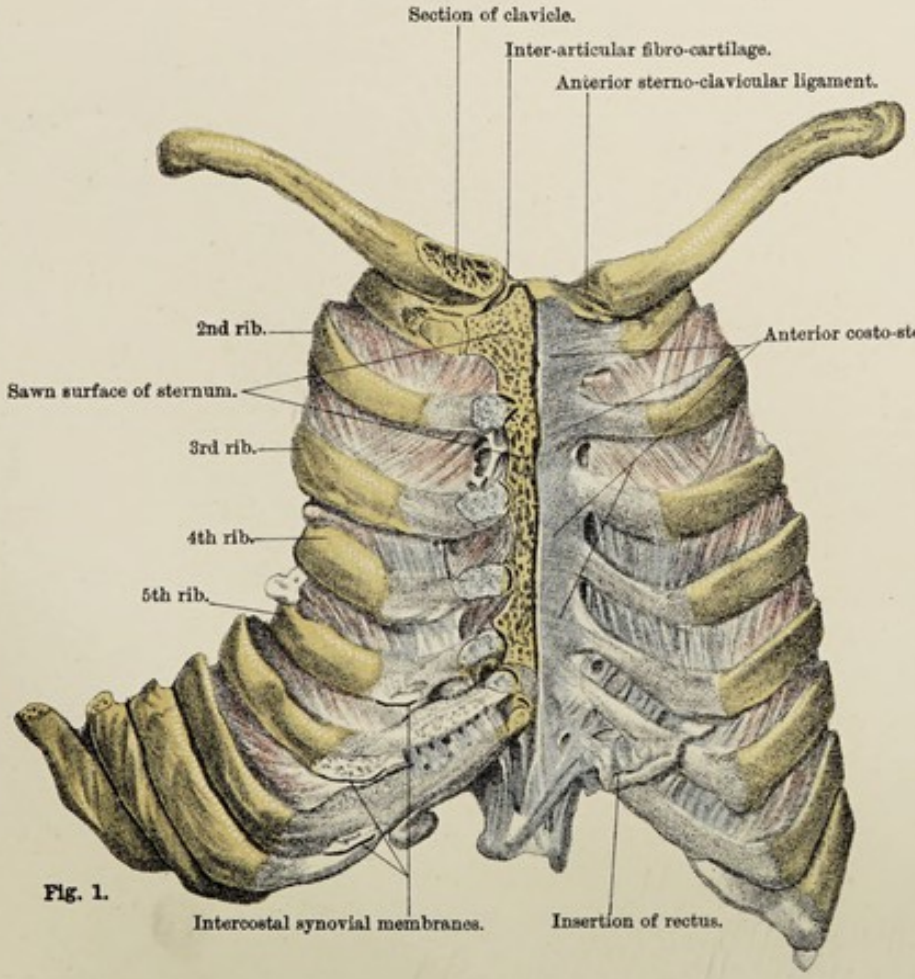

Fig. 1.

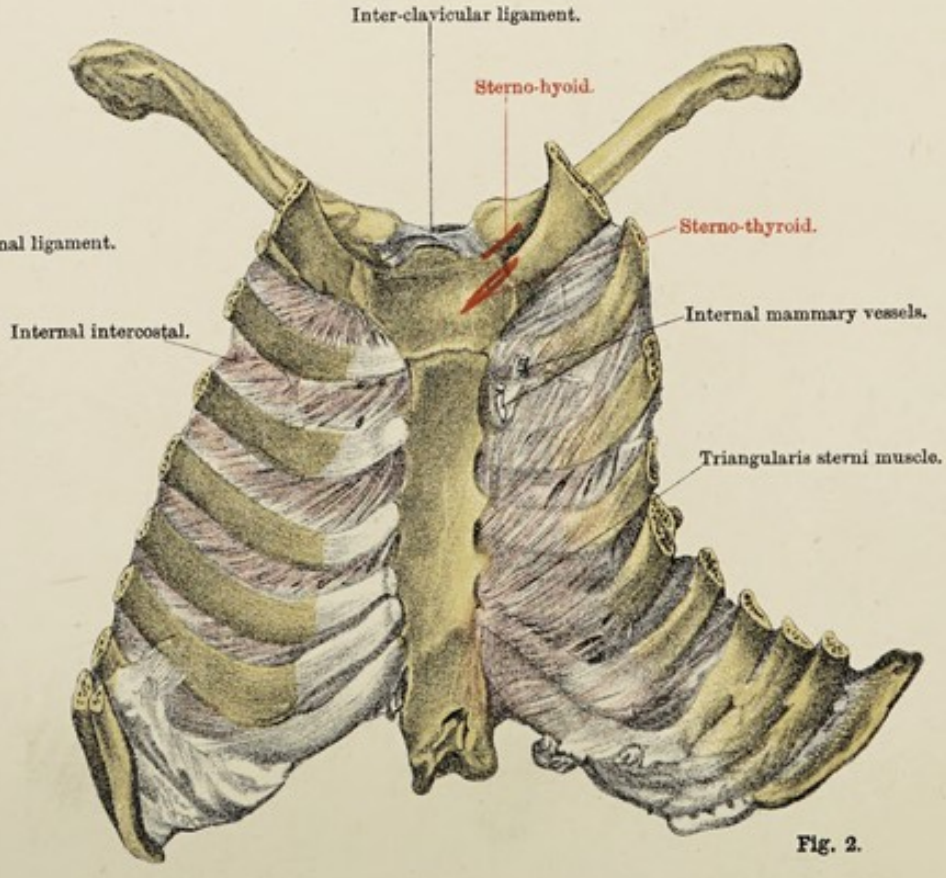

Fig. 2.

Sterno-mastoid.

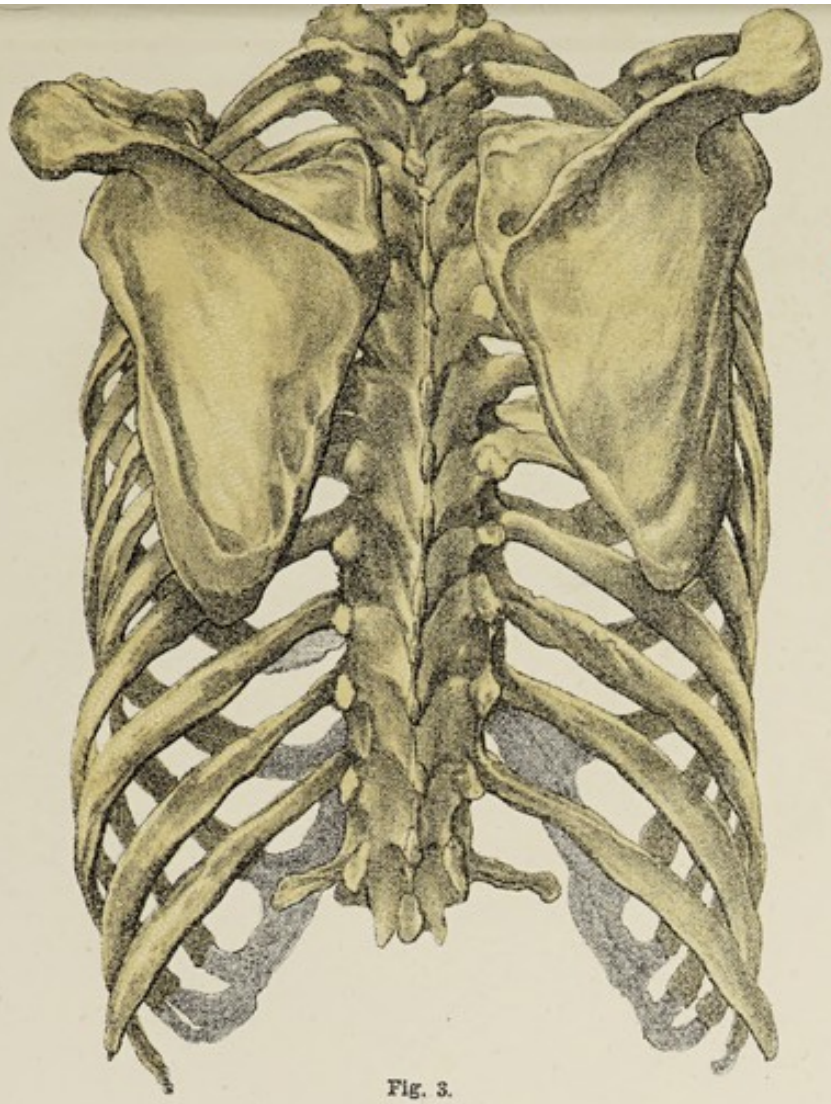

Fig. 3.

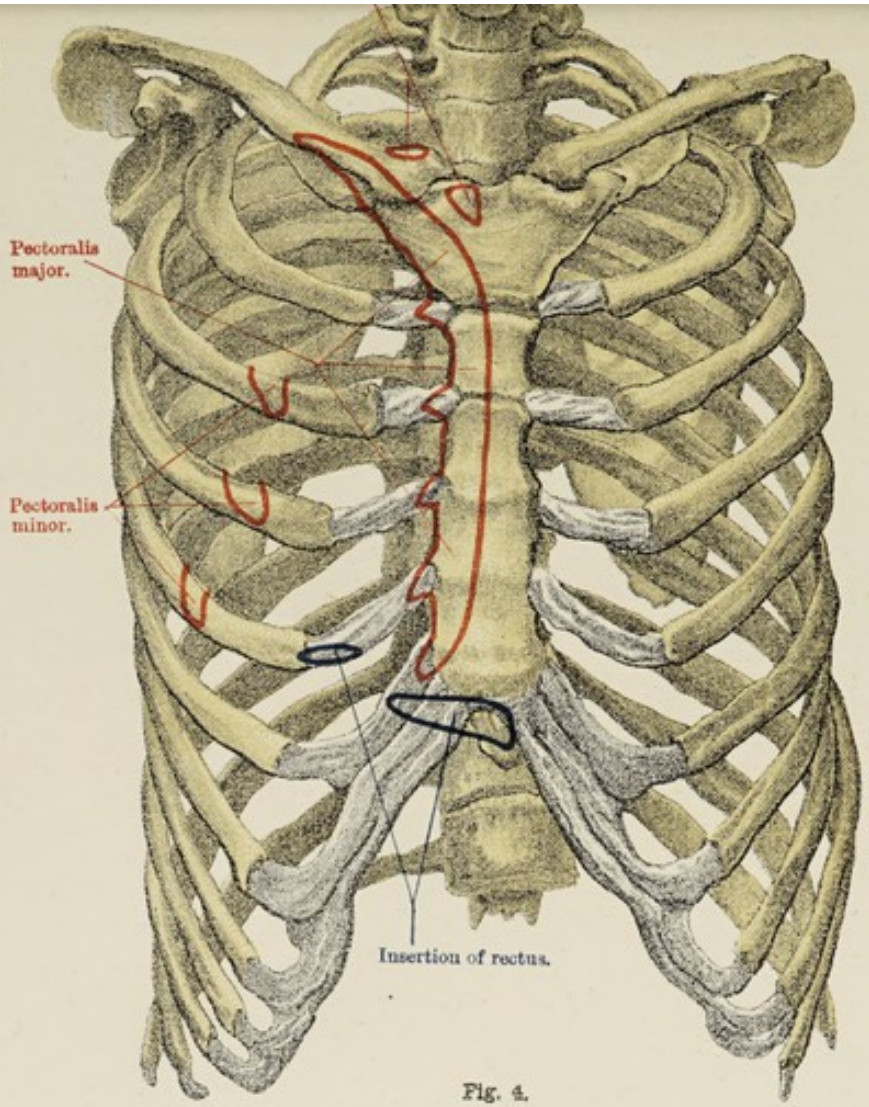

Fig. 4.

Drawn from nature. & Printed by W. & A. K. Johnston, Edinburgh & London

CLAVICLE AND RIBS

PLATE VI.

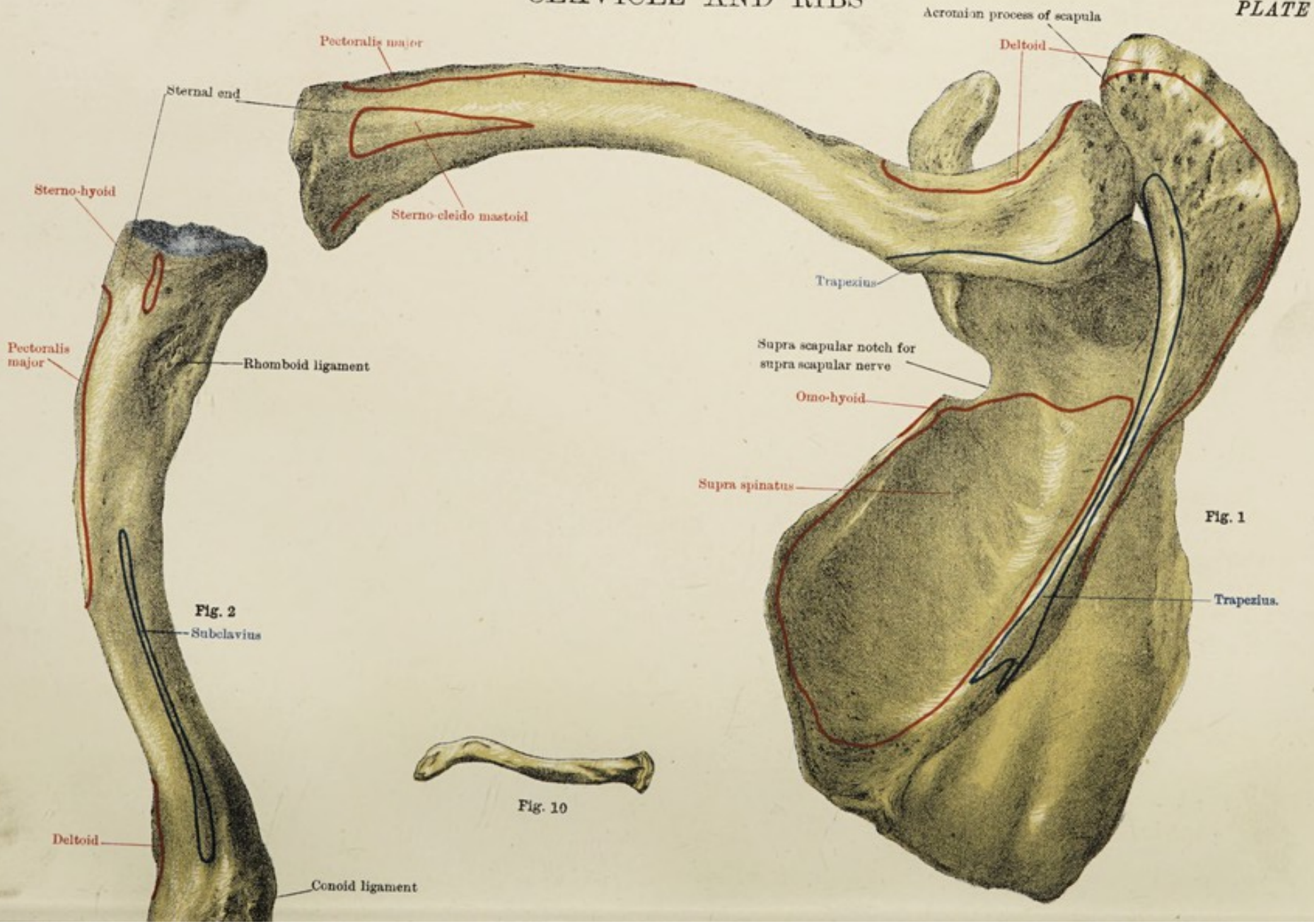

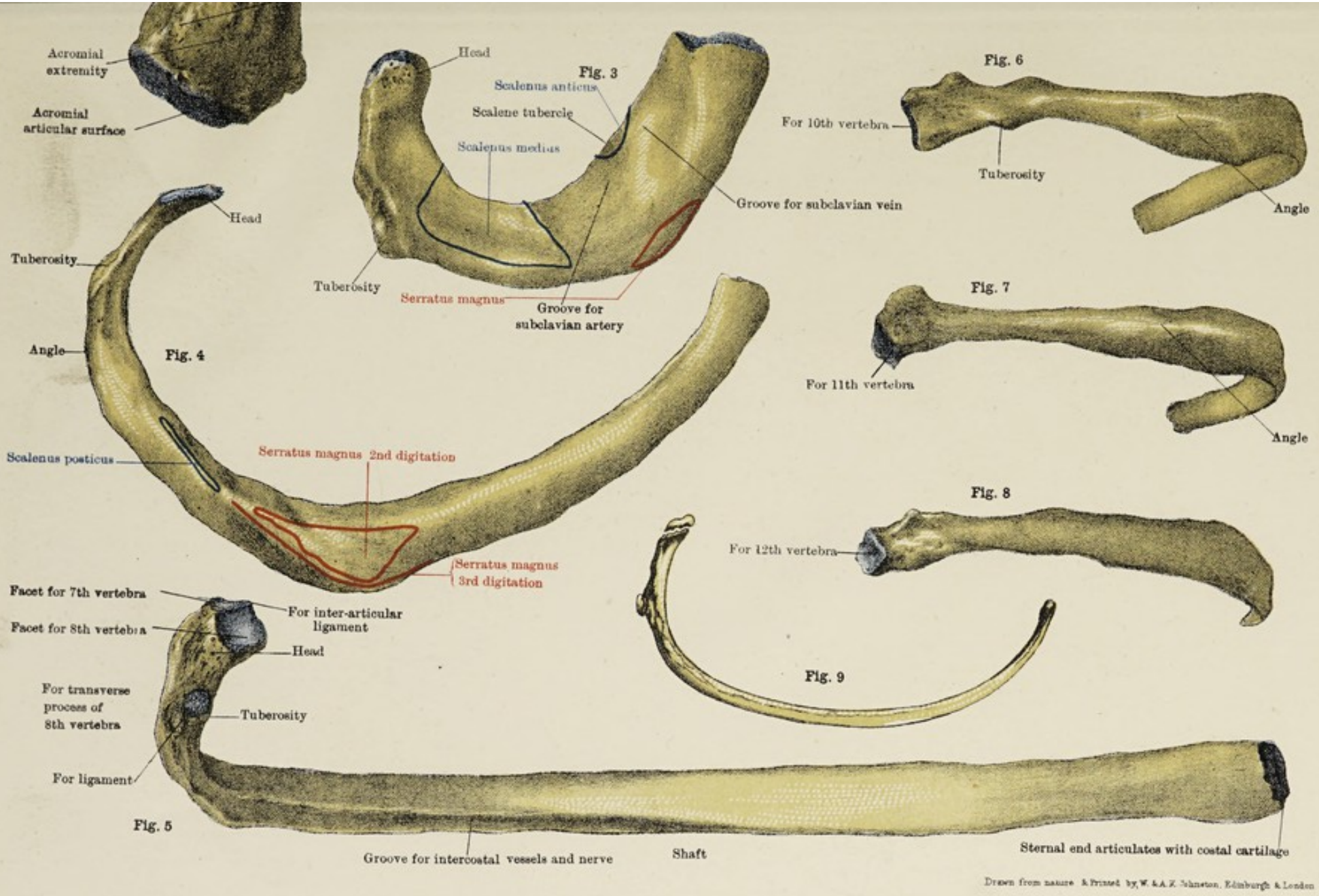

Drawn from nature & Printed by W. & A. K. Johnston, Edinburgh & London

SCAPULA.

PLATE VII

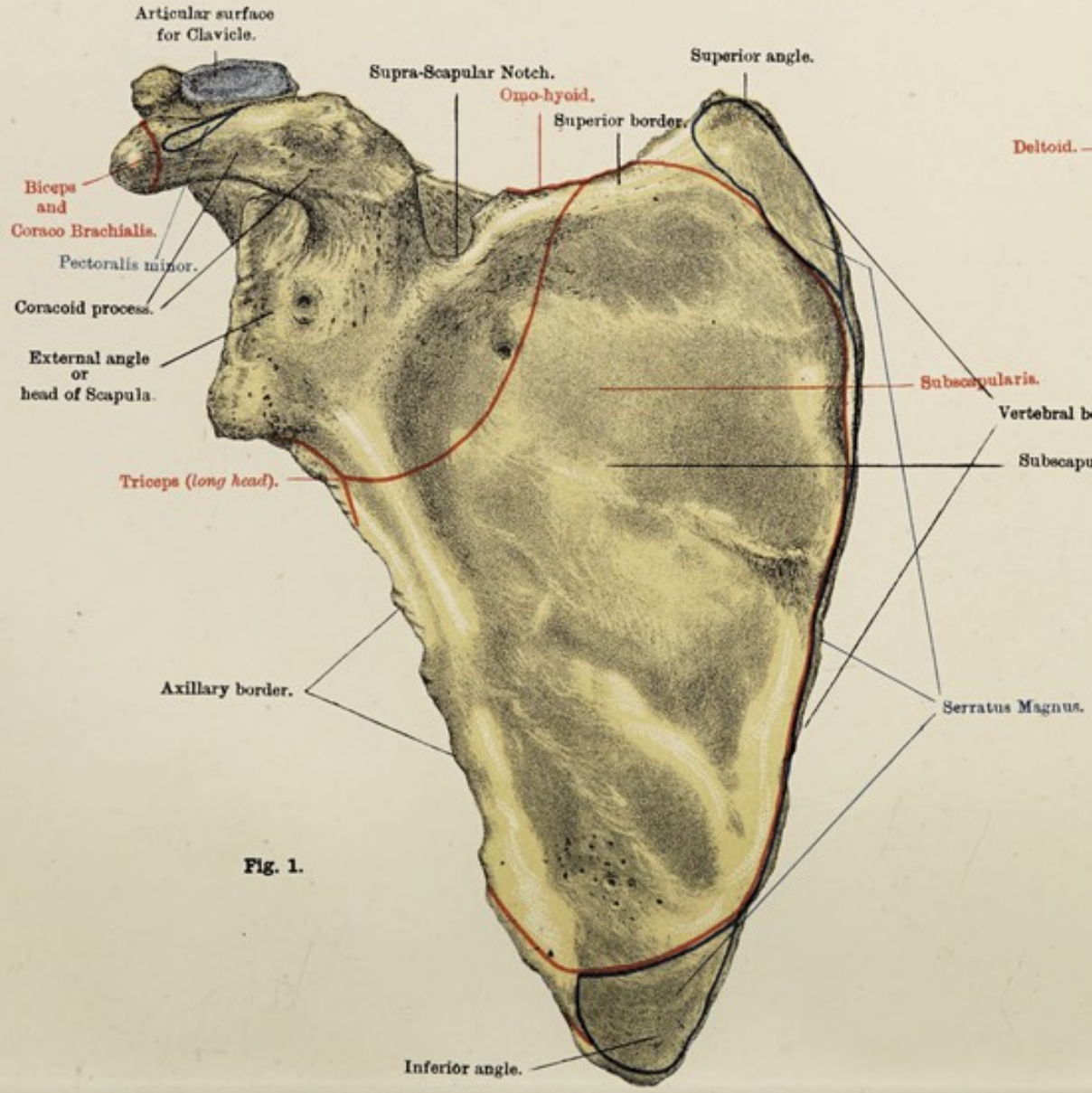

Fig. 1.

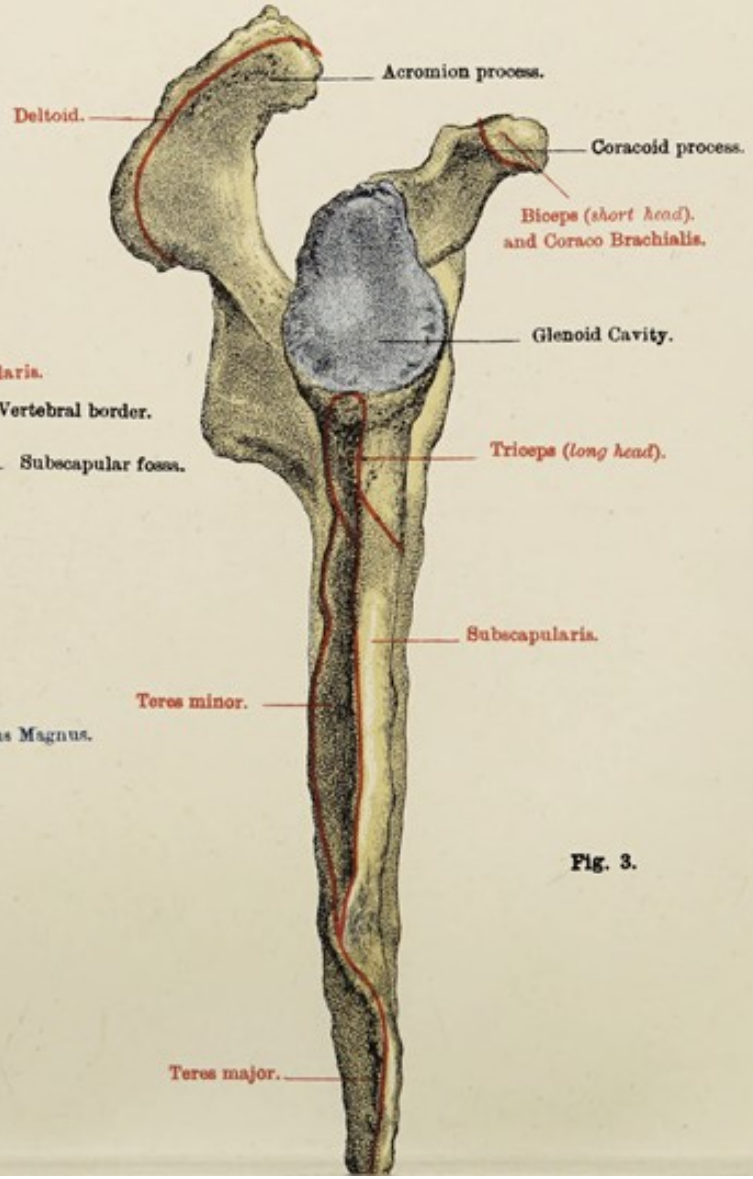

Fig. 3.

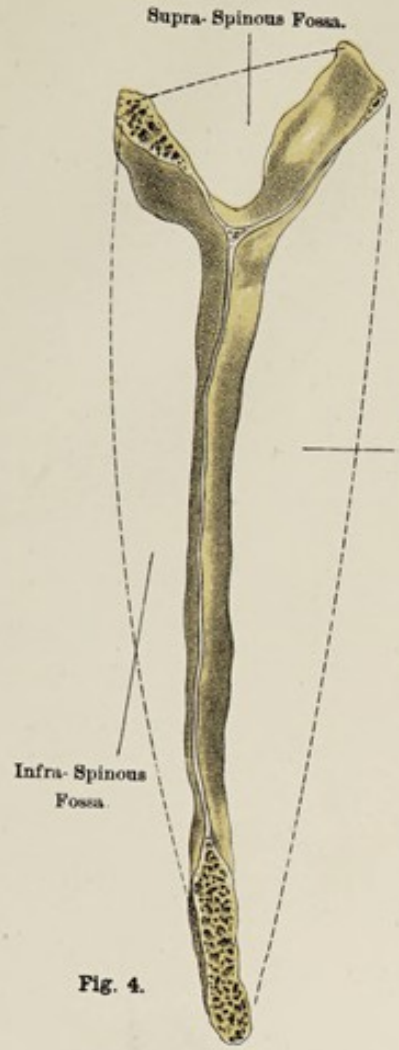

Fig. 4.

Fig. 5.

Fig. 6.

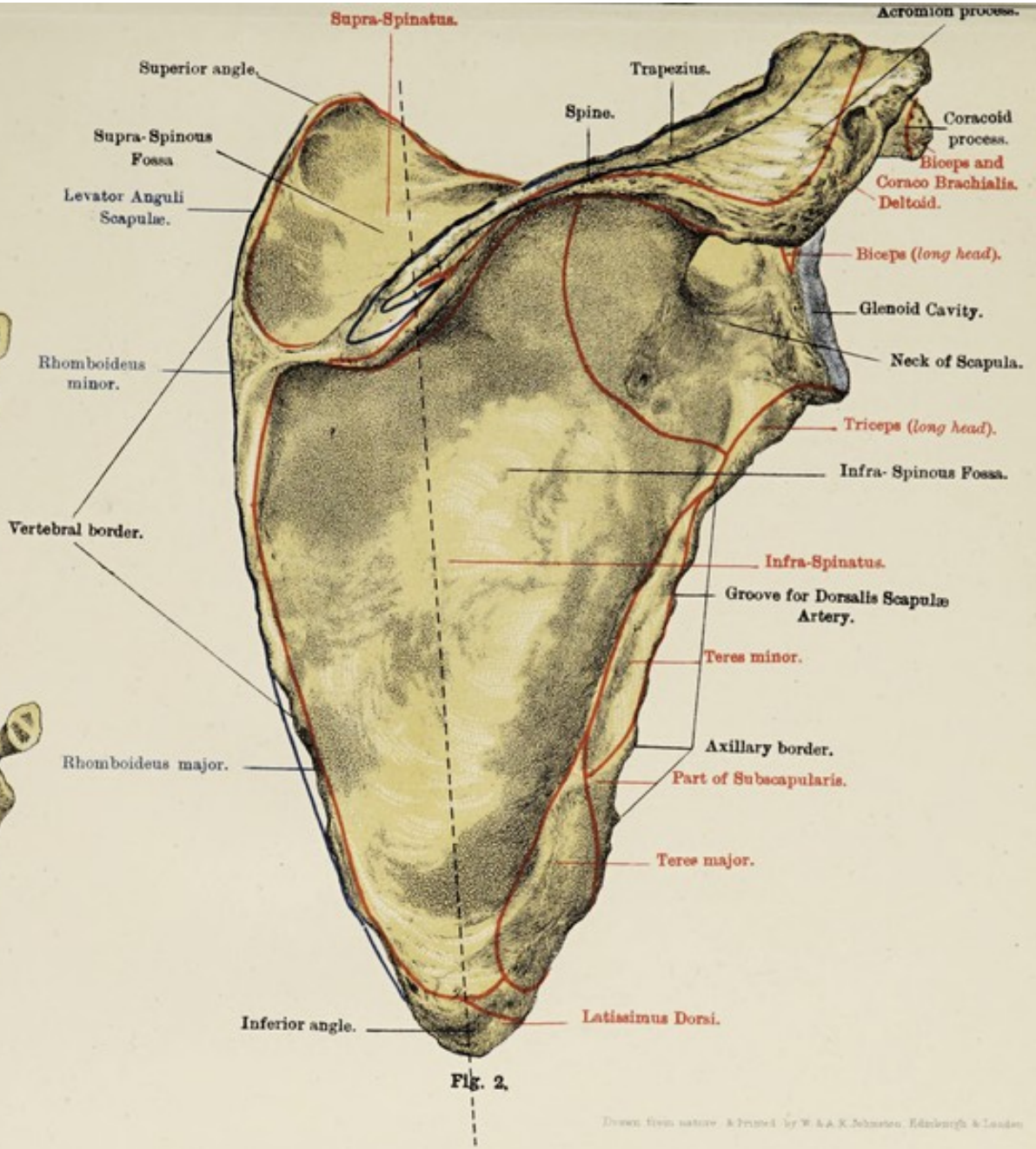

Fig. 2.

Drawn from nature & Printed by W. & A. K. Johnston, Edinburgh & London

HUMERUS.

PLATE VIII.

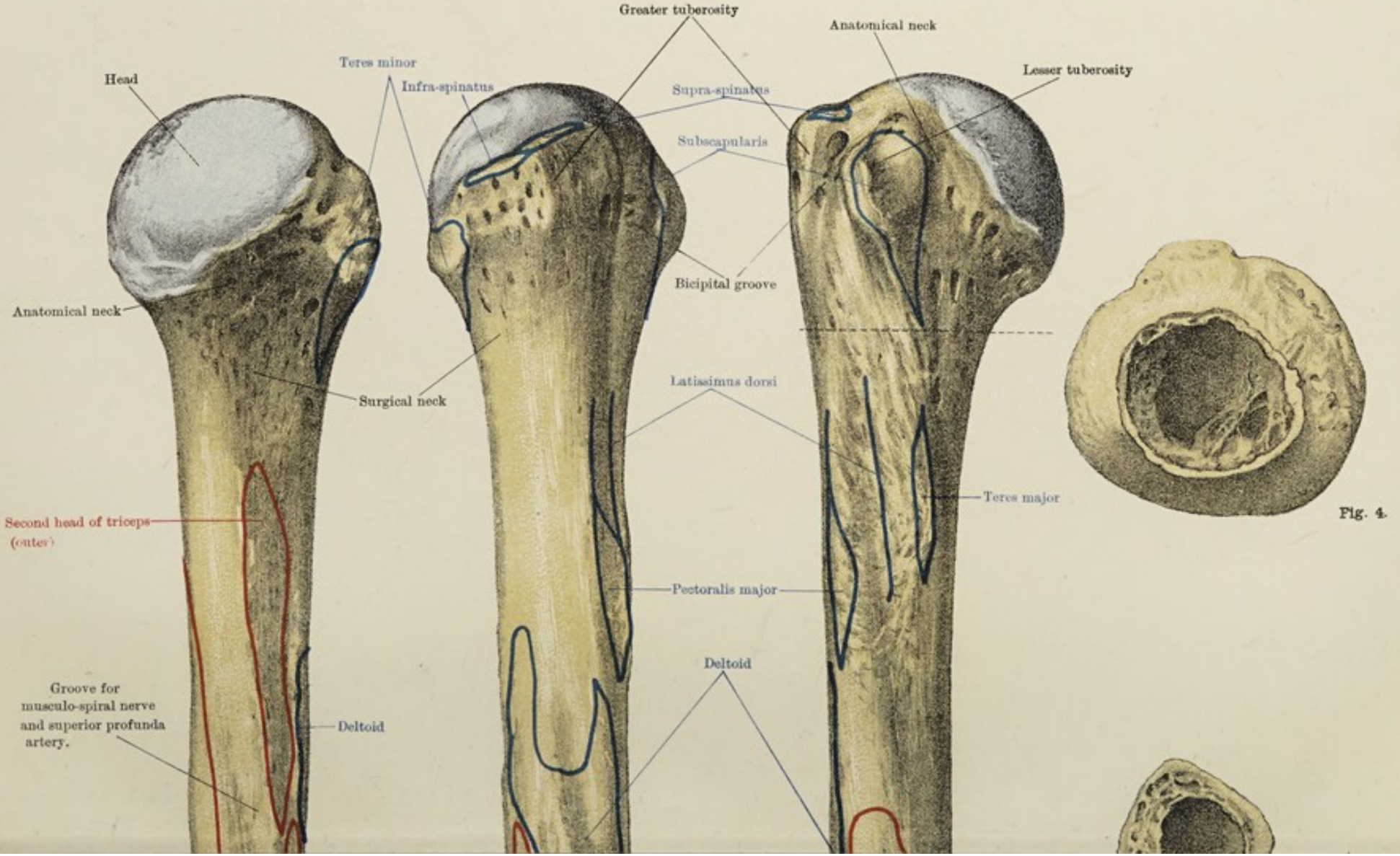

Fig. 4.

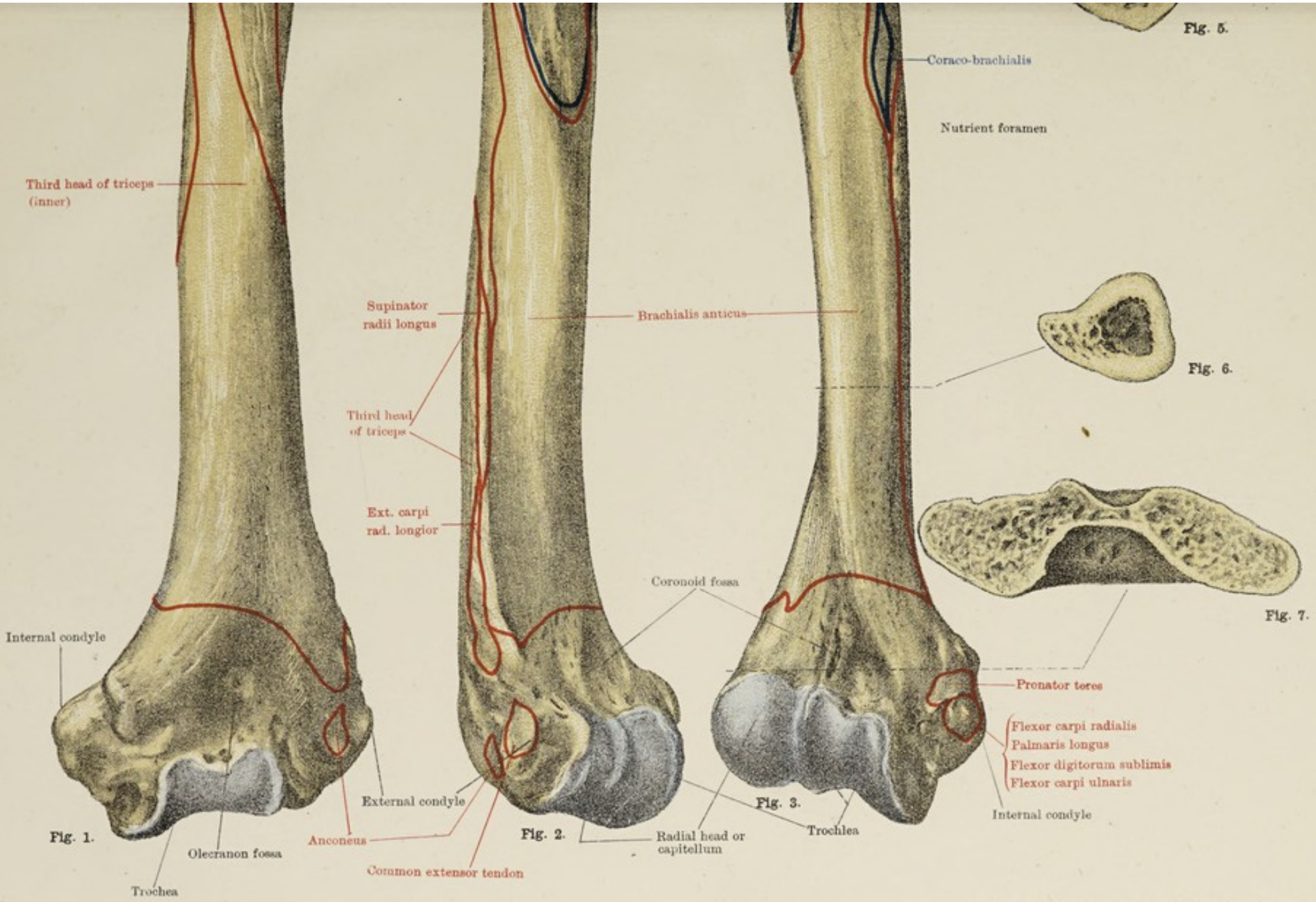

Drawn from nature & Printed by W. & A. K. Johnston, Edinburgh.

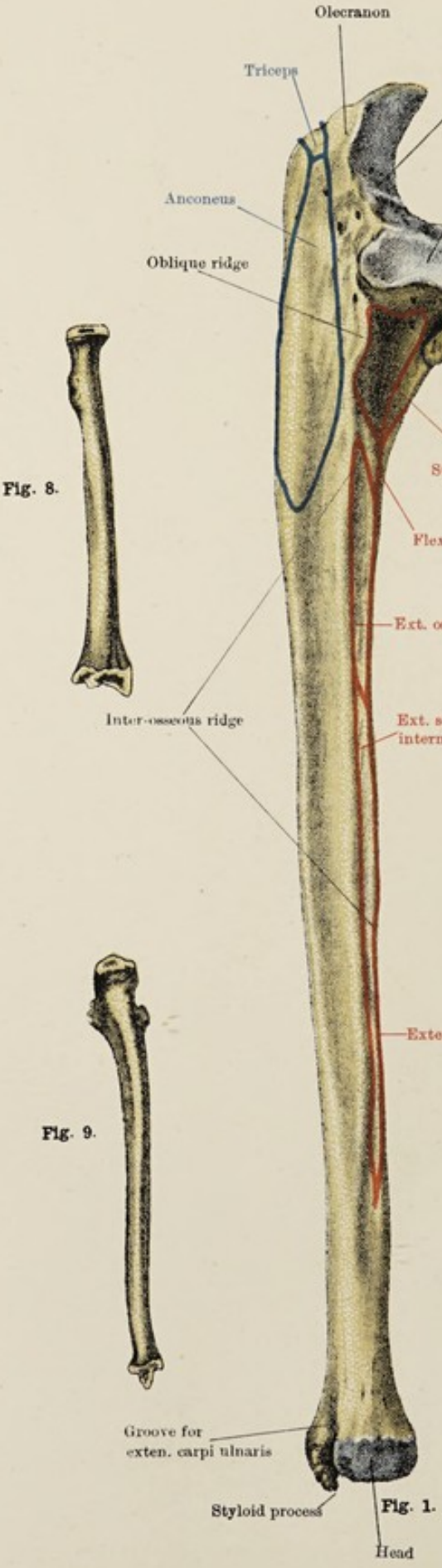

Fig. 1.

Fig. 8.

Fig. 9.

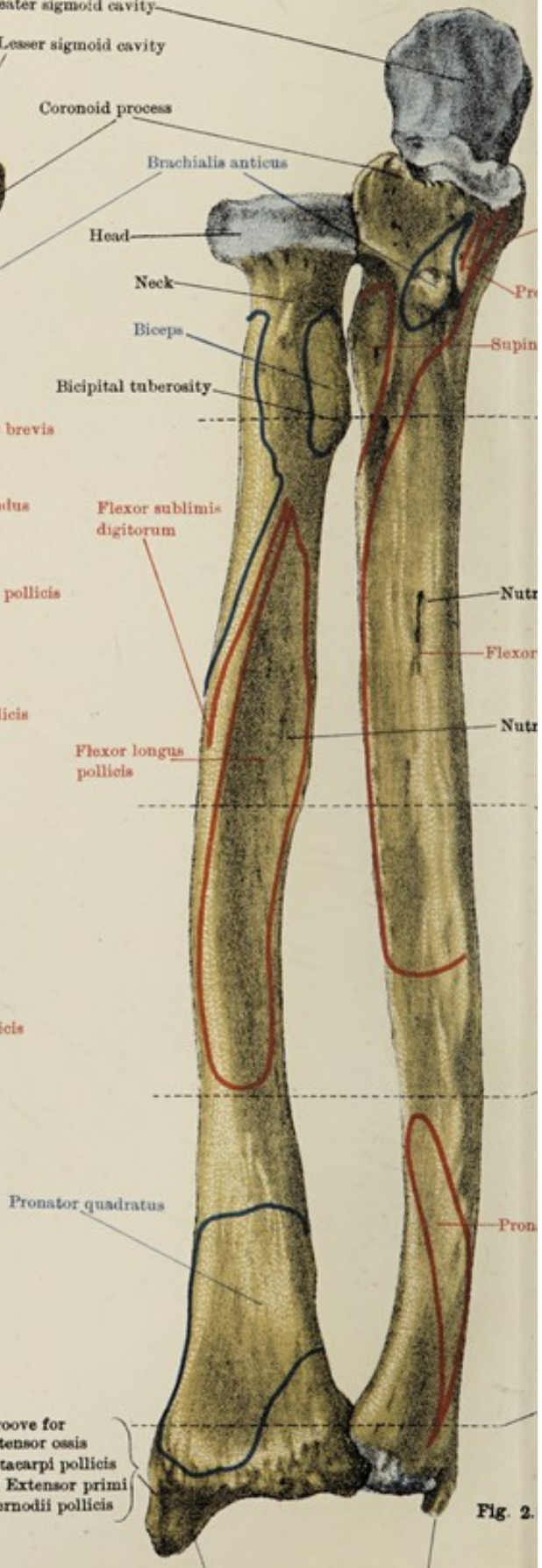

Fig. 2.

exor sublimis
gitorum

or teres

brevis

Fig. 4.

foramen

fundus digitorum

foramen

Fig. 5.

Fig. 6.

quadratus

Fig. 7.

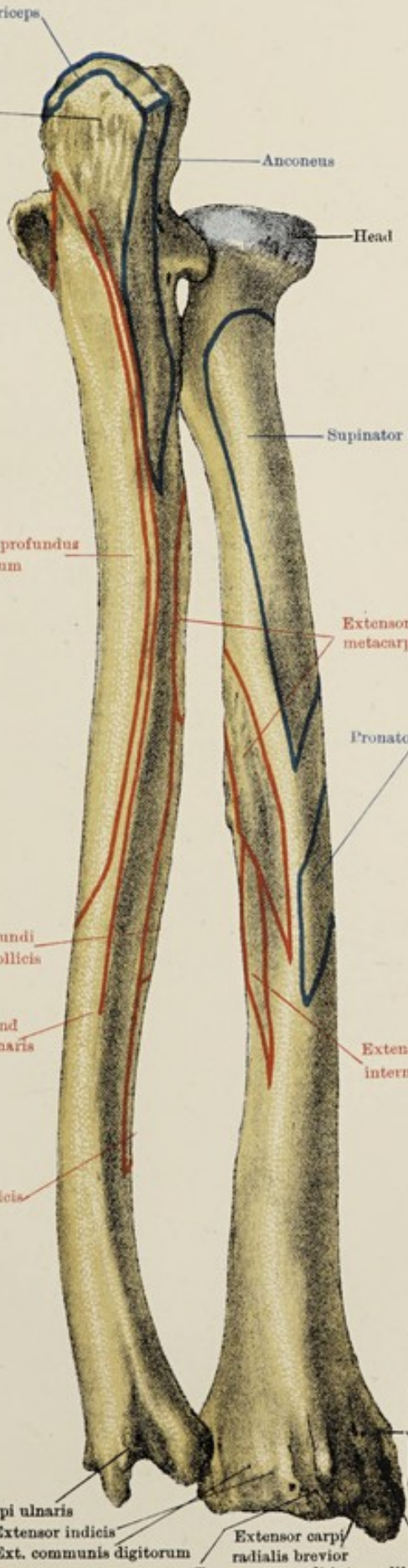

Drawn from nature & Printed by W. & A. K. Johnston, Edinburgh & London

LIGAMENTS OF THE SHOULDER AND ELBOW.

PLATE X.

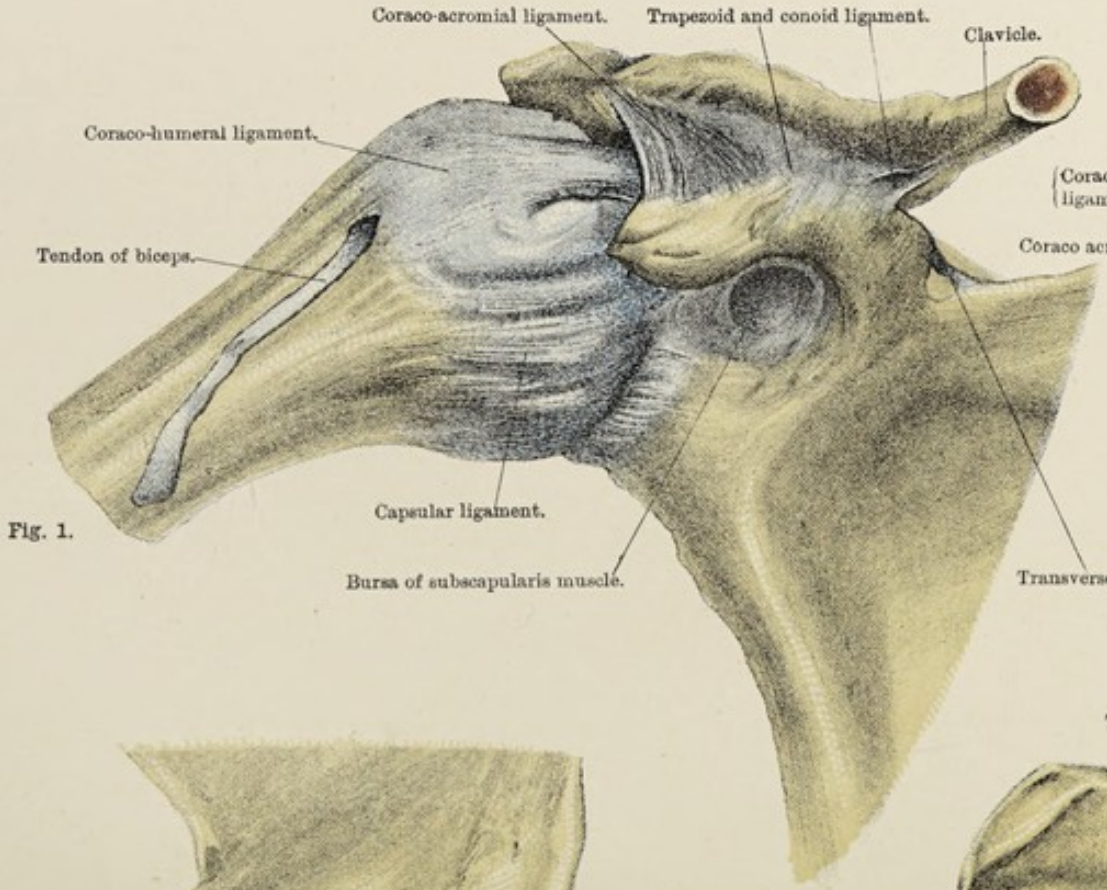

Fig. 1.

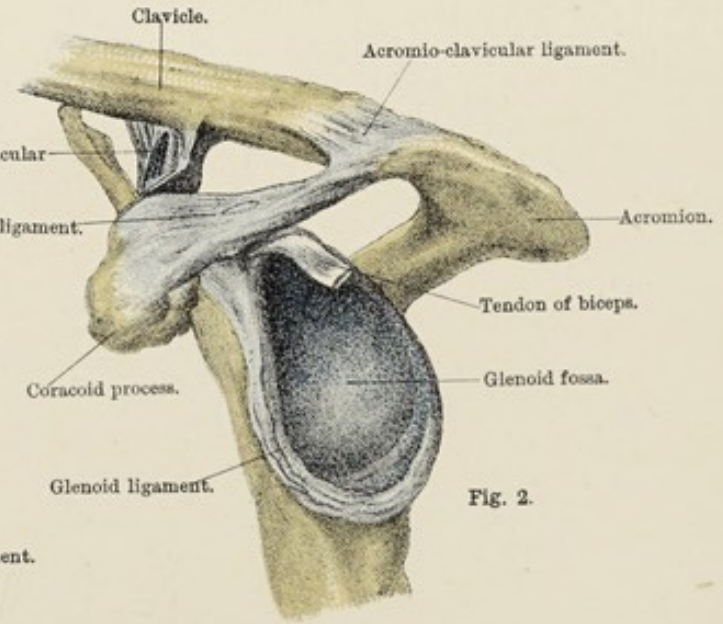

Fig. 2.

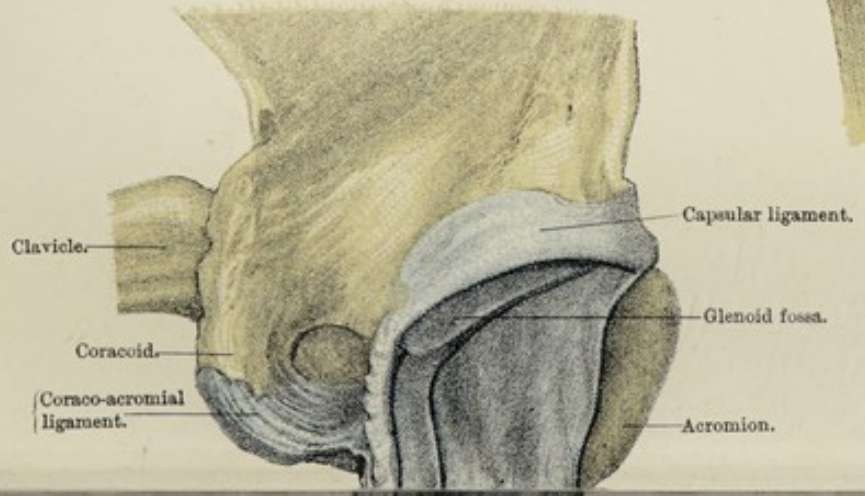

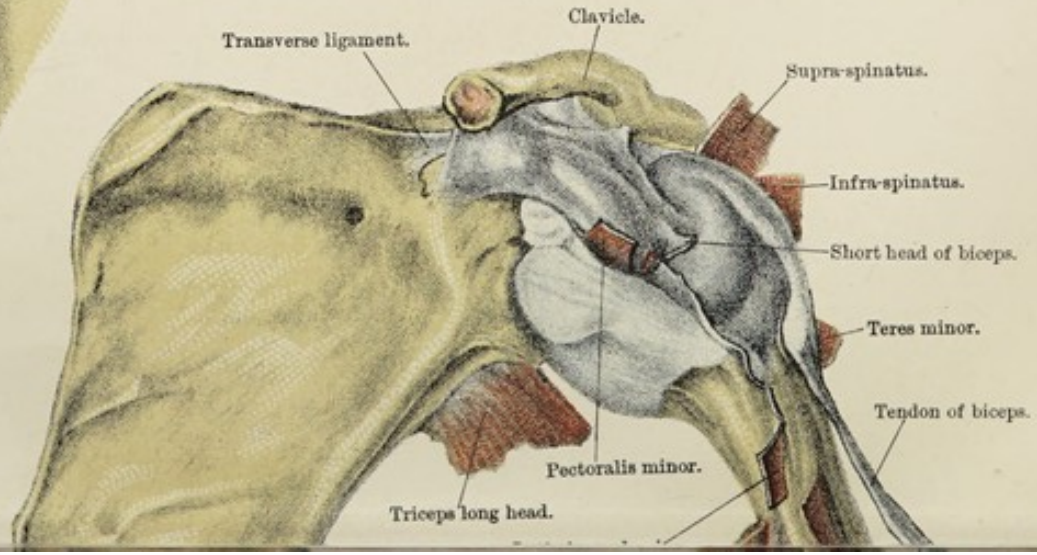

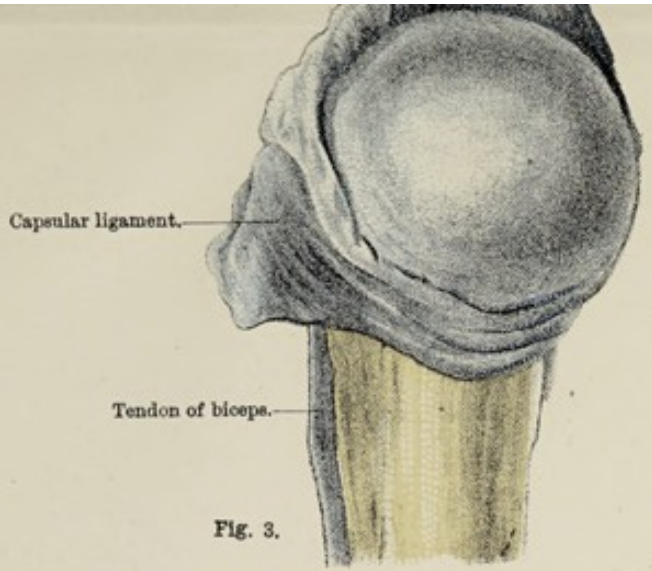

Fig. 3.

Fig. 4.

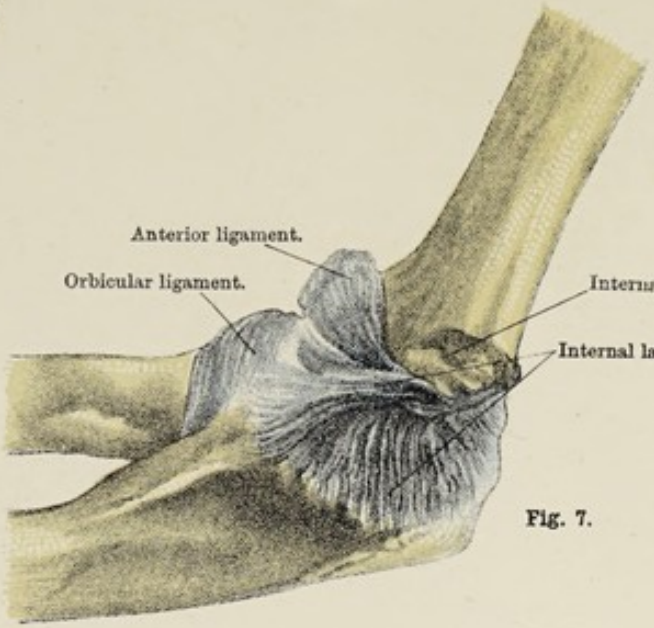

Fig. 7.

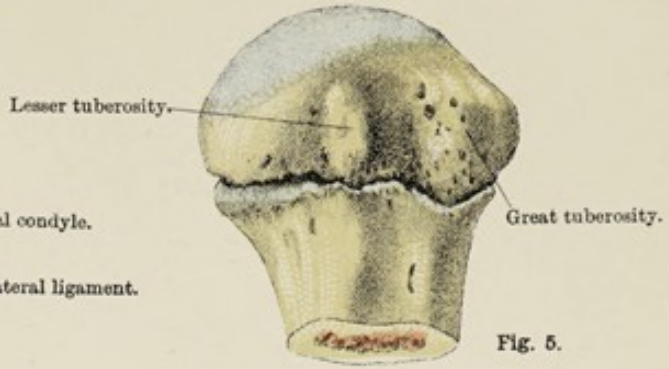

Fig. 5.

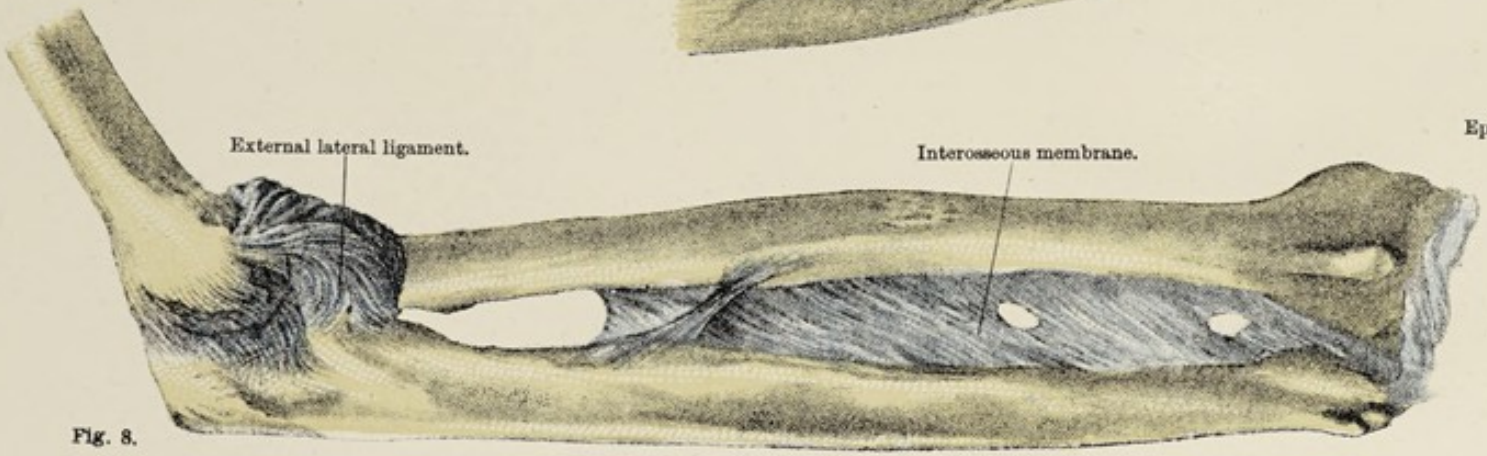

Fig. 8.

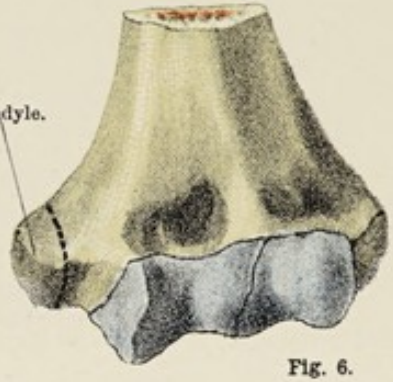

Fig. 6.

Drawn from nature & Printed by W. & A. K. Johnston, Edinburgh & London

Fig. 1

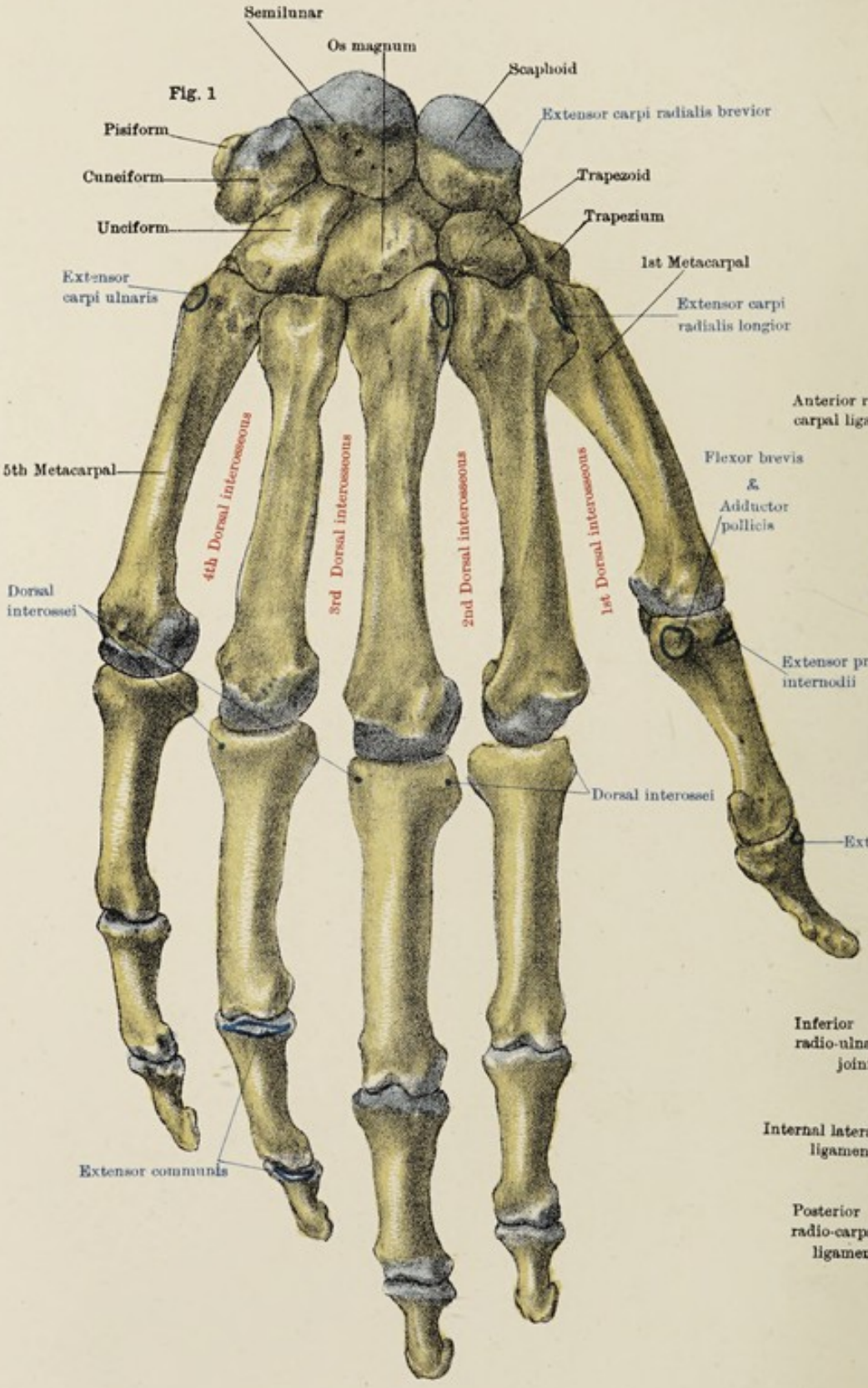
Semilunar
Os magnum
Scaphoid
Pisiform
Cuneiform
Unciform
Extensor carpi radialis brevior
Trapezoid
Trapezium
1st Metacarpal
Extensor carpi ulnaris
Extensor carpi radialis longior
5th Metacarpal
4th Dorsal interosseous
3rd Dorsal interosseous
2nd Dorsal interosseous
1st Dorsal interosseous
Flexor brevis
&
Adductor pollicis
Dorsal interossei
Extensor primi internodii
Dorsal interossei
Extensor secundi internodii
Extensor communis

Fig

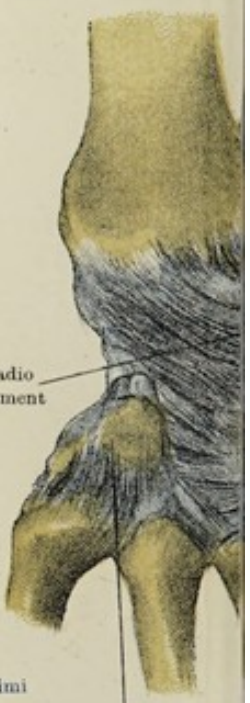
Anterior radio carpal ligament
Joint betwee
of thumb an

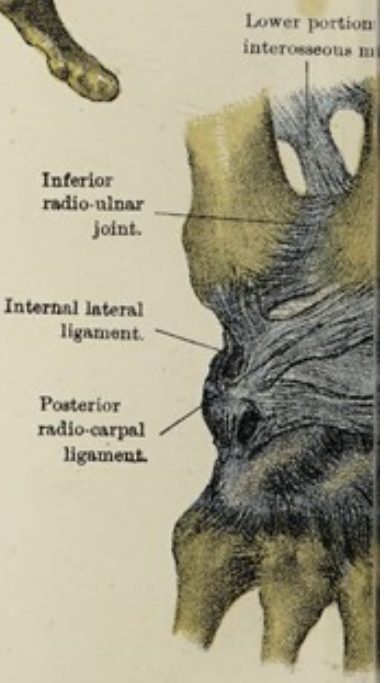
Lower portion
interosseous m
Inferior radio-ulnar joint.
Internal lateral ligament.
Posterior radio-carpal ligament.

Fig

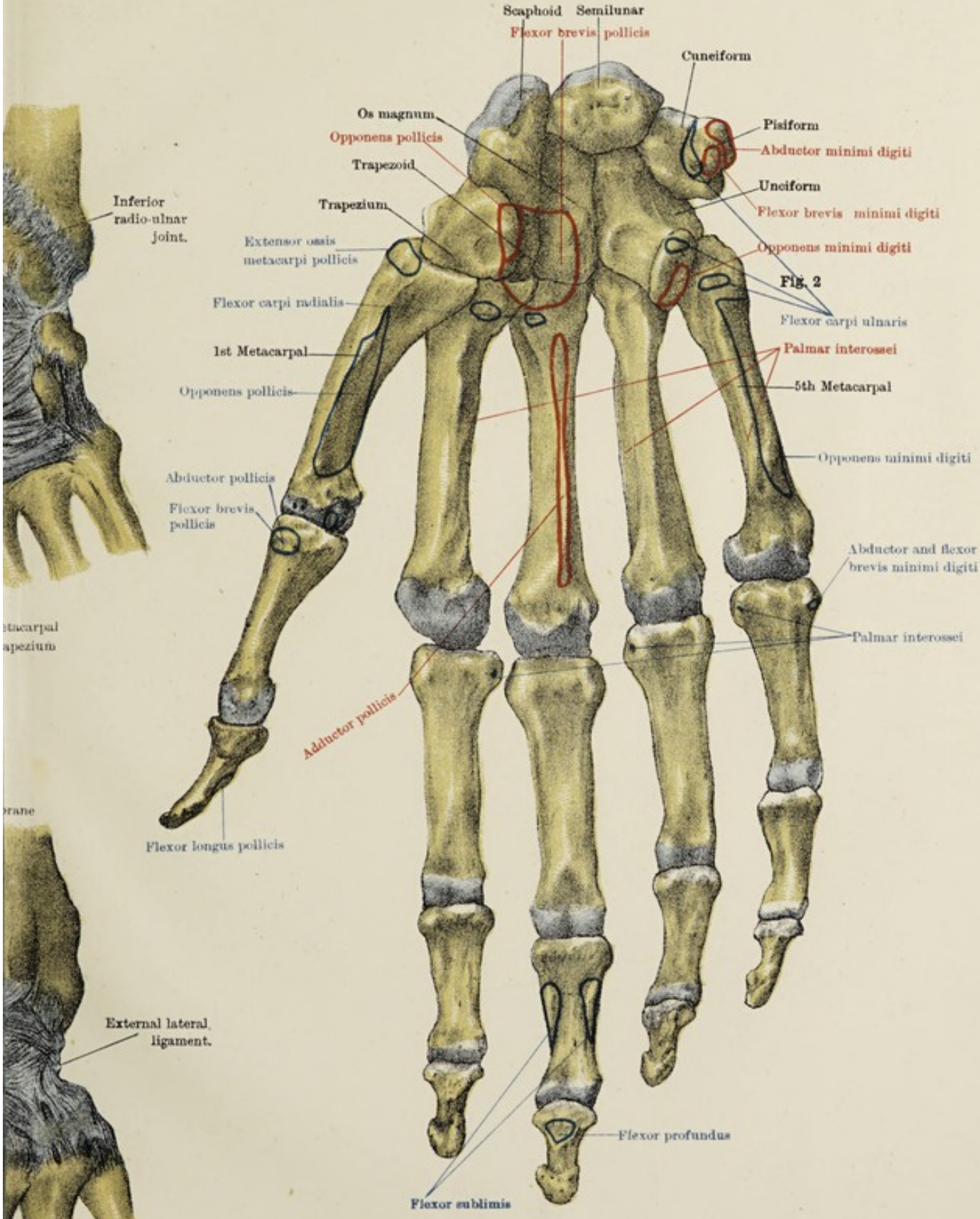

Drawn from nature & Printed by W. & A. K. Johnston, Edinburgh & London.

PELVIS.

PLATE XII.

FEMALE

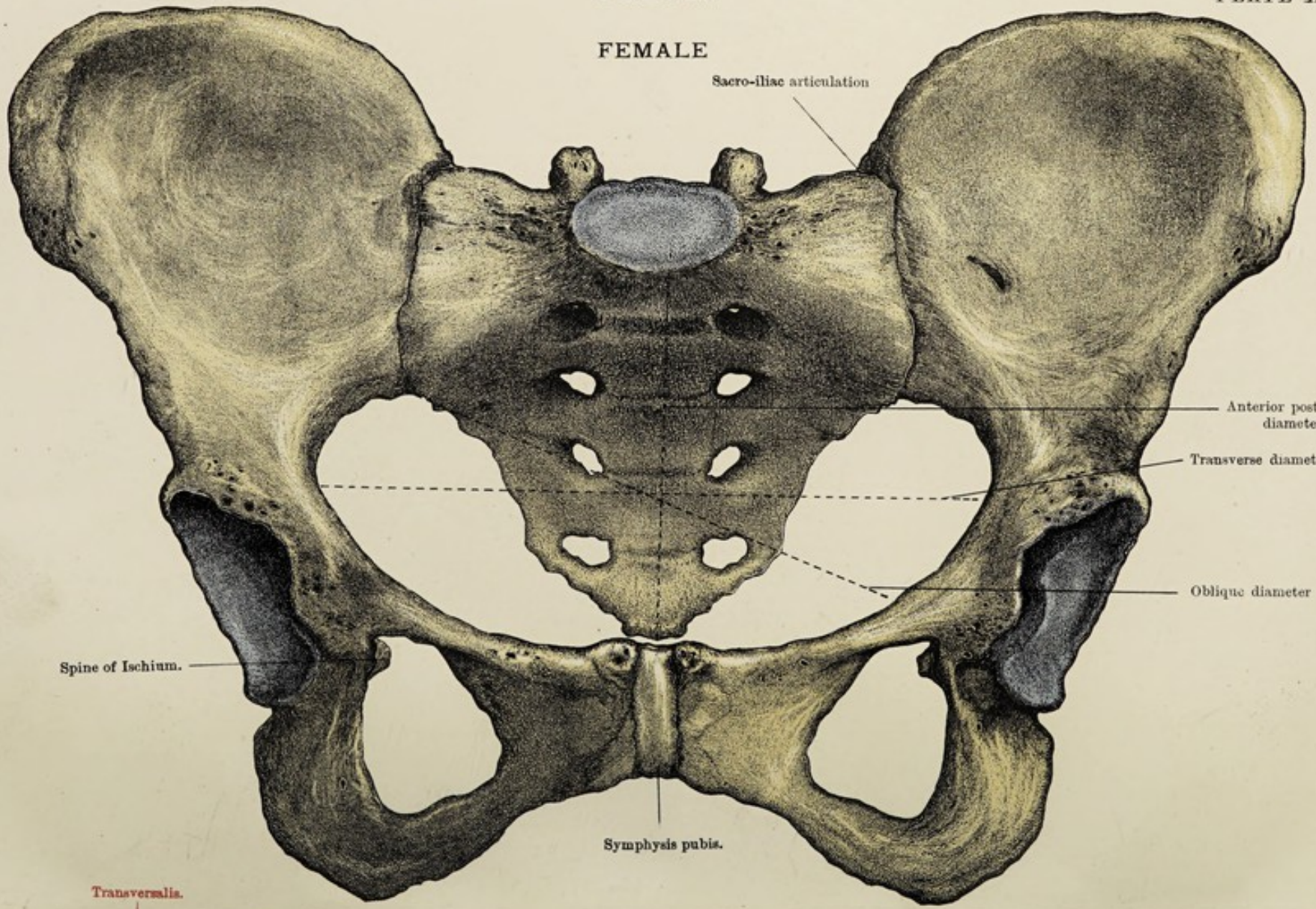

Transversalis.

MALE

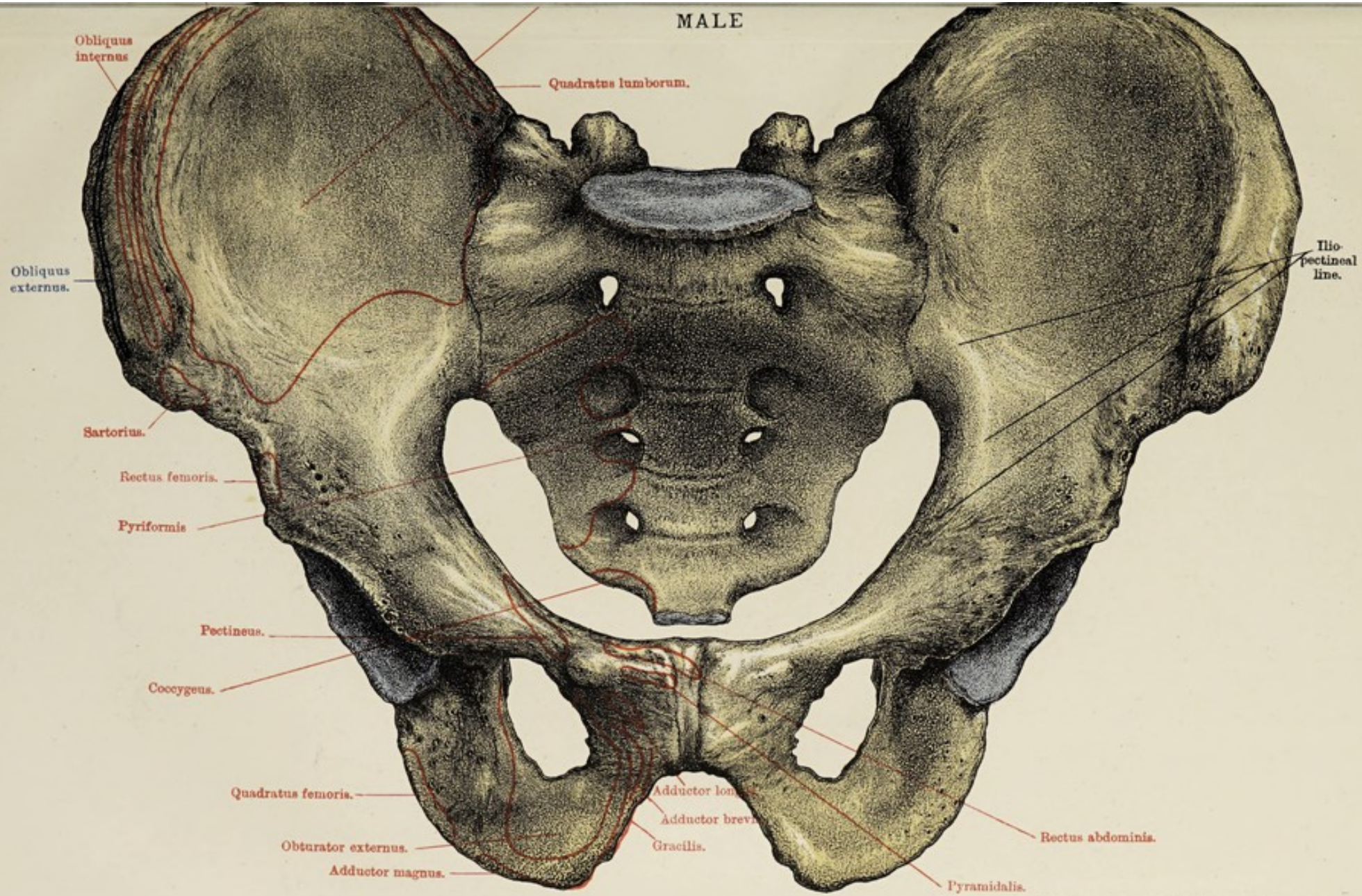

Drawn from nature & Printed by W. & A. K. Johnston, Edinburgh & London

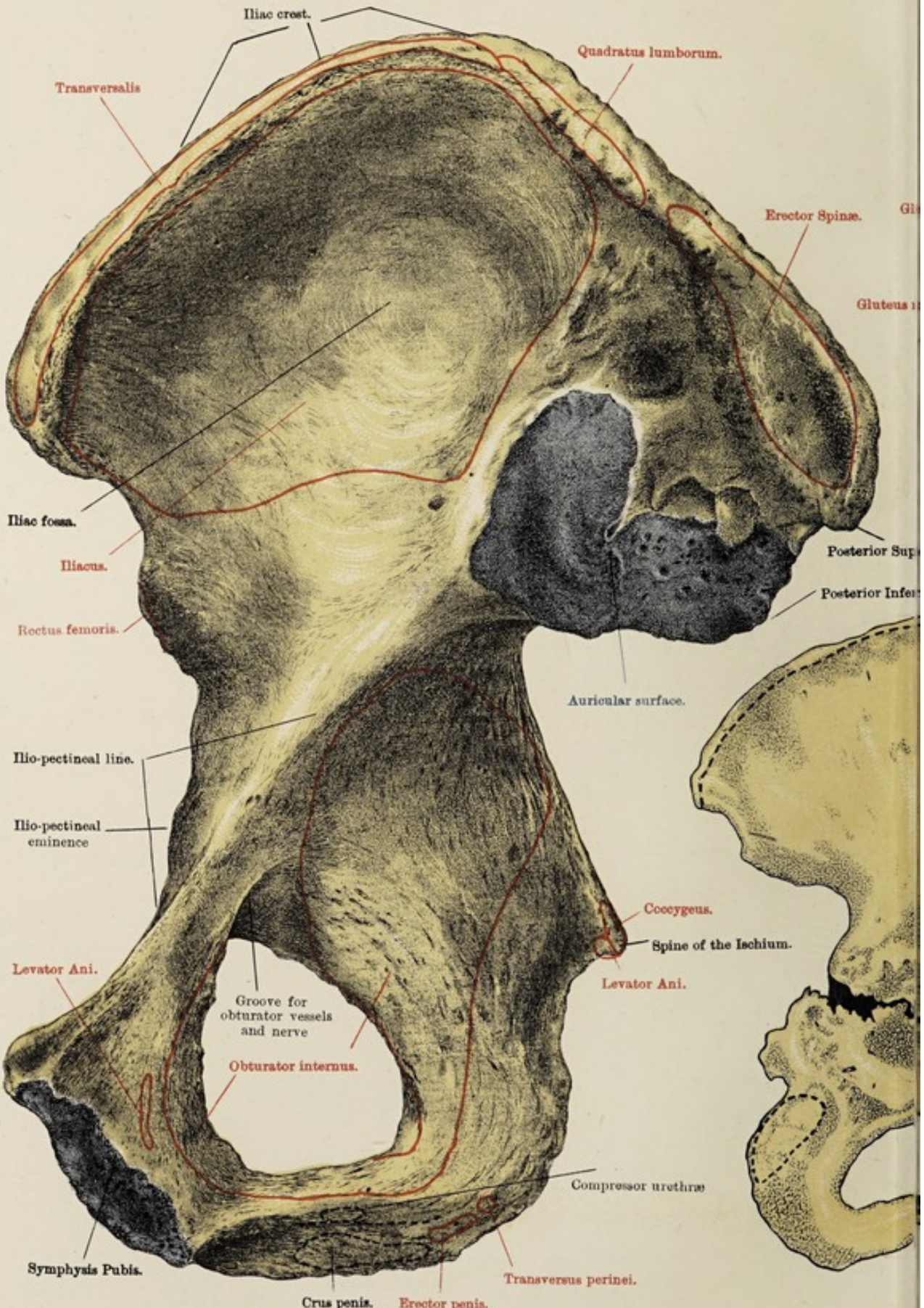

Fig. 1. INTERNAL SURFACE.

Fig. 3.

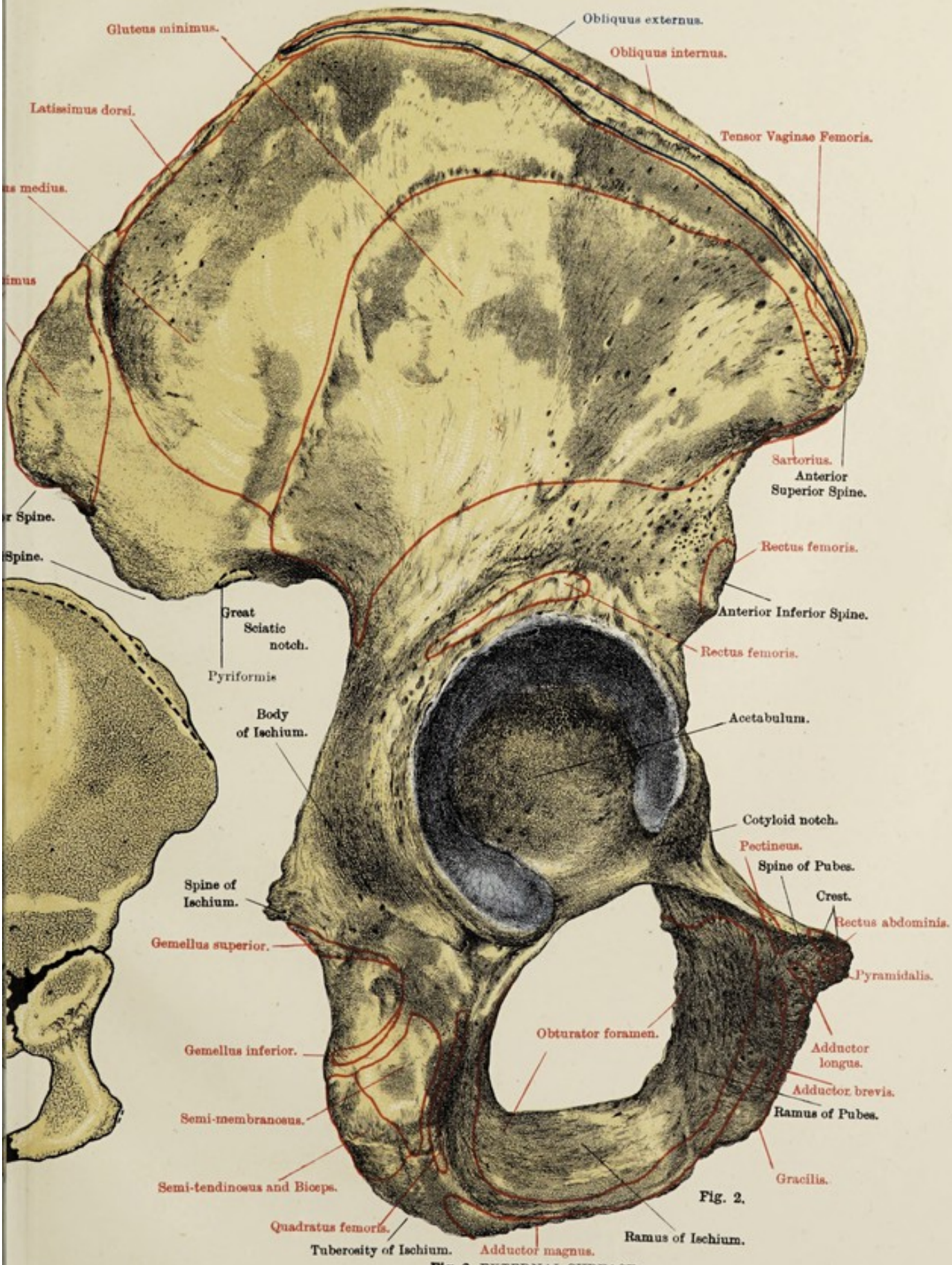

Fig. 2.

Fig. 2. EXTERNAL SURFACE.

Drawn from nature. & Printed by W. & A. K. Johnston. Edinburgh & London.

LIGAMENTS OF THE PELVIS.

PLATE XIV.

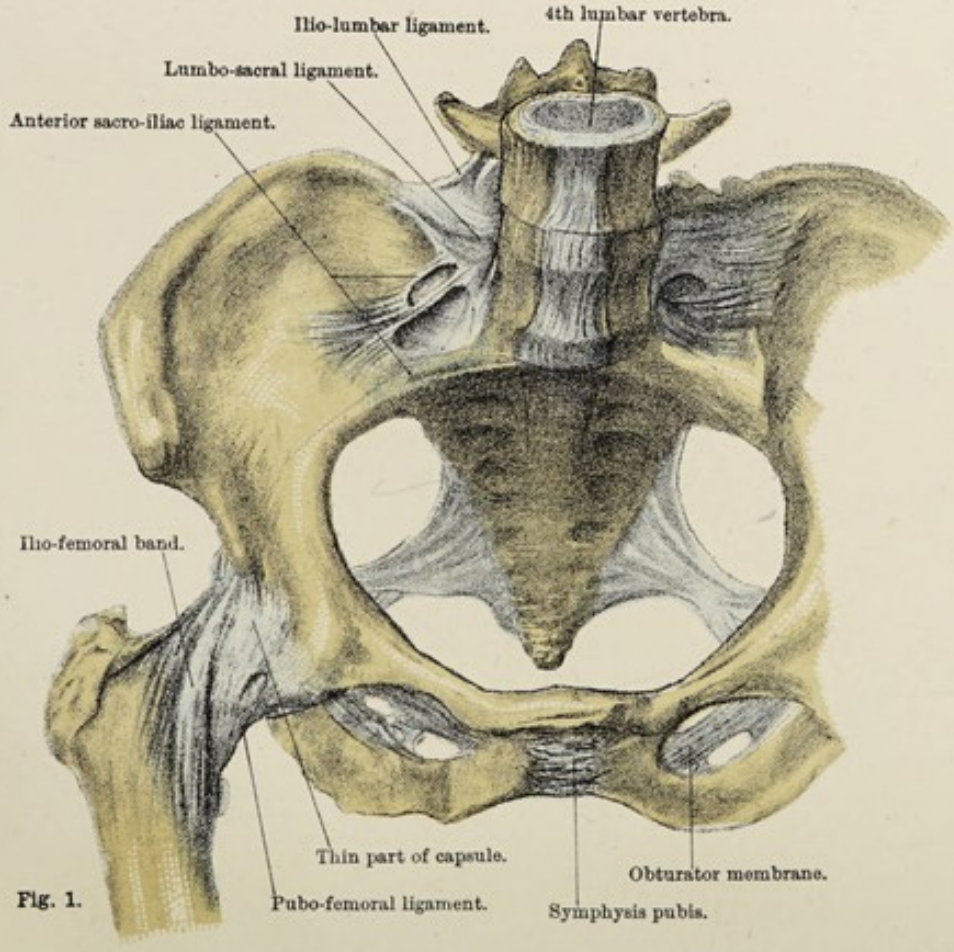

Fig. 1.

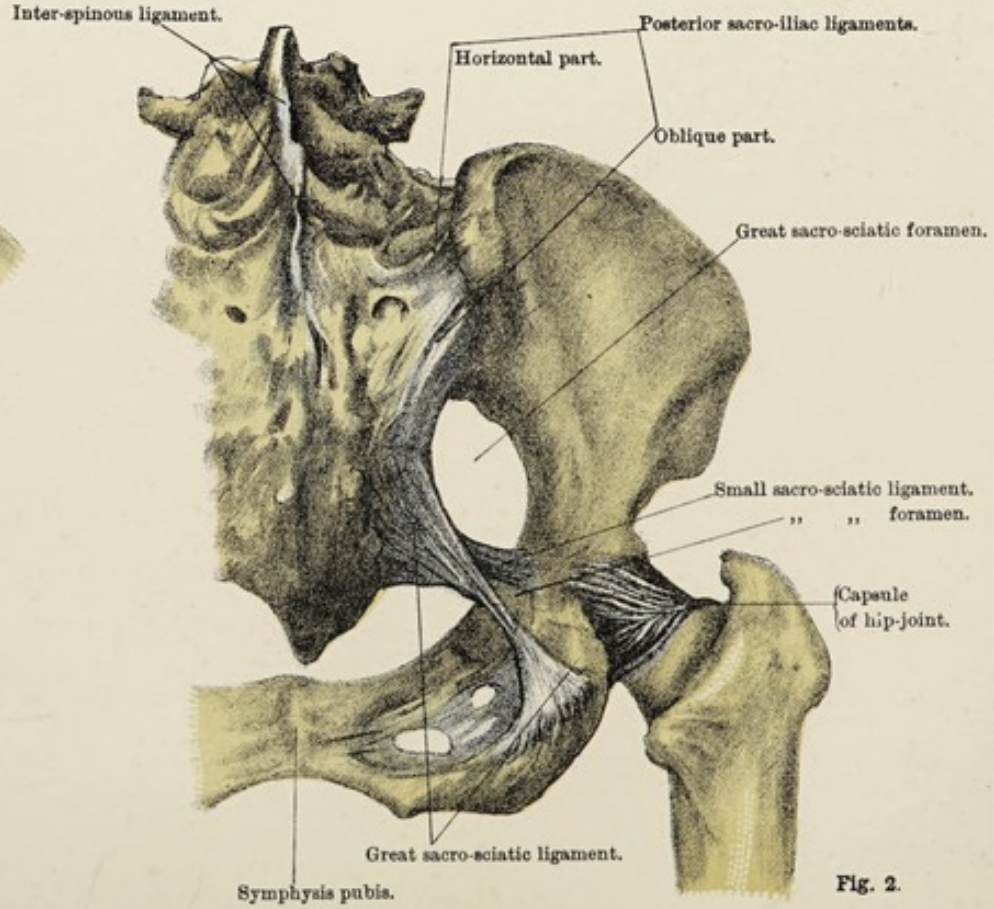

Fig. 2.

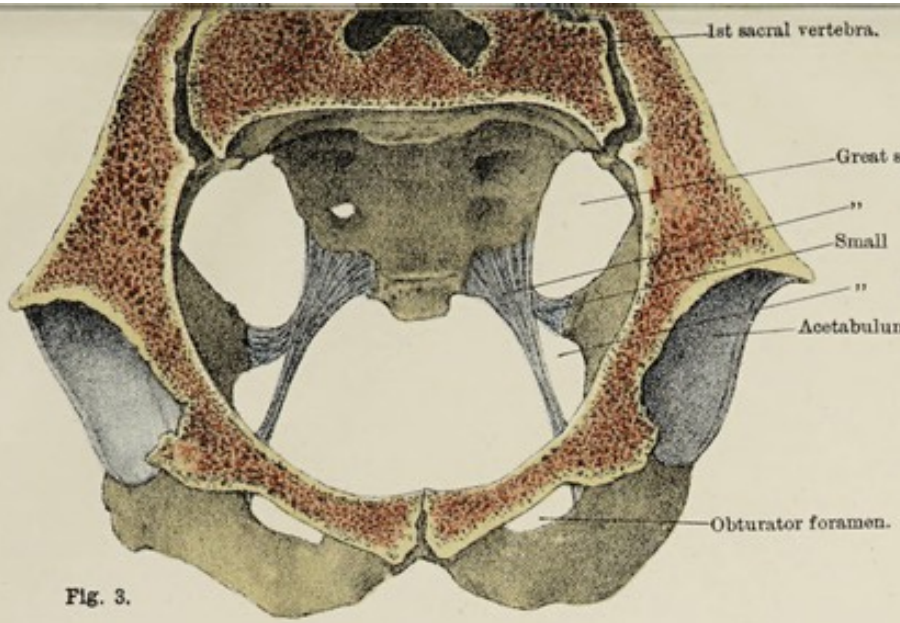

Fig. 3.

Fig. 4.

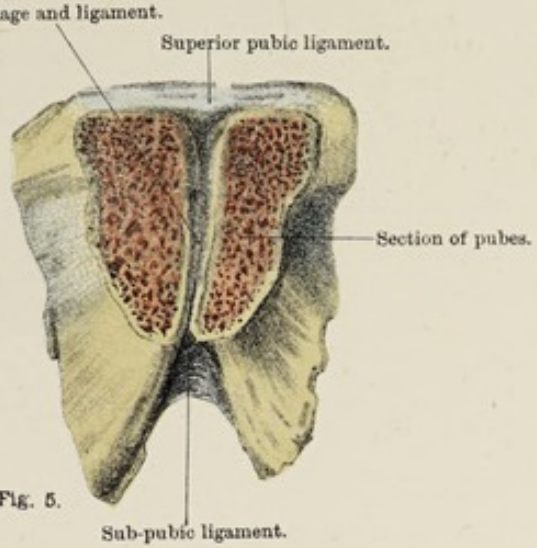

Fig. 5.

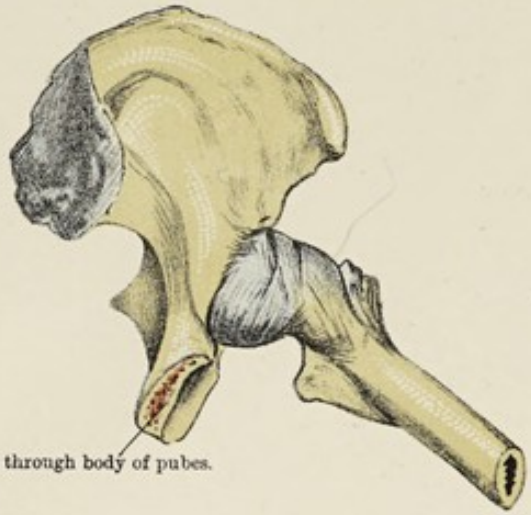

Fig. 6.

Drawn from nature & Printed by W. & A. K. Johnston, Edinburgh & London

FEMUR.

PLATE XV.

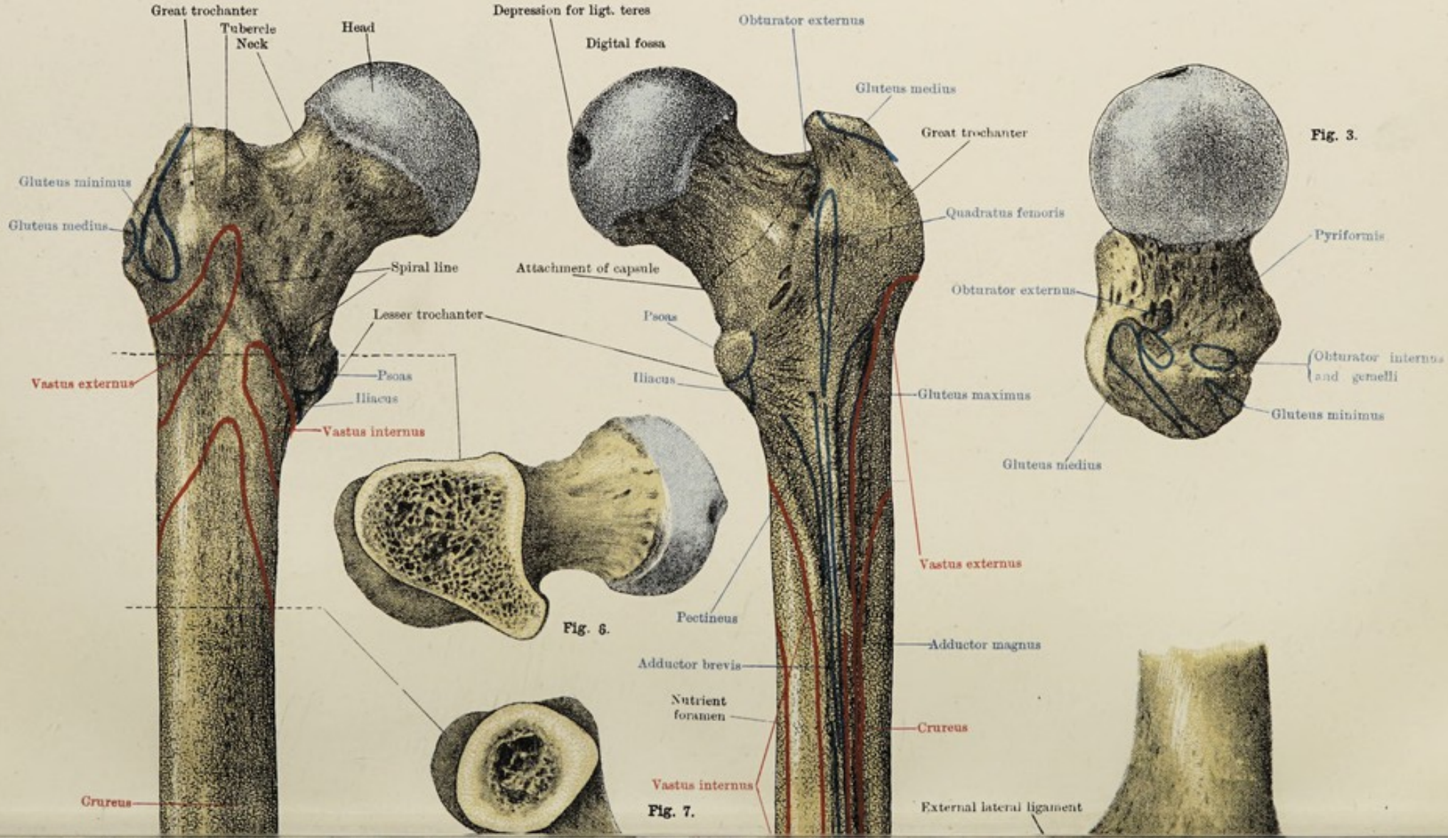

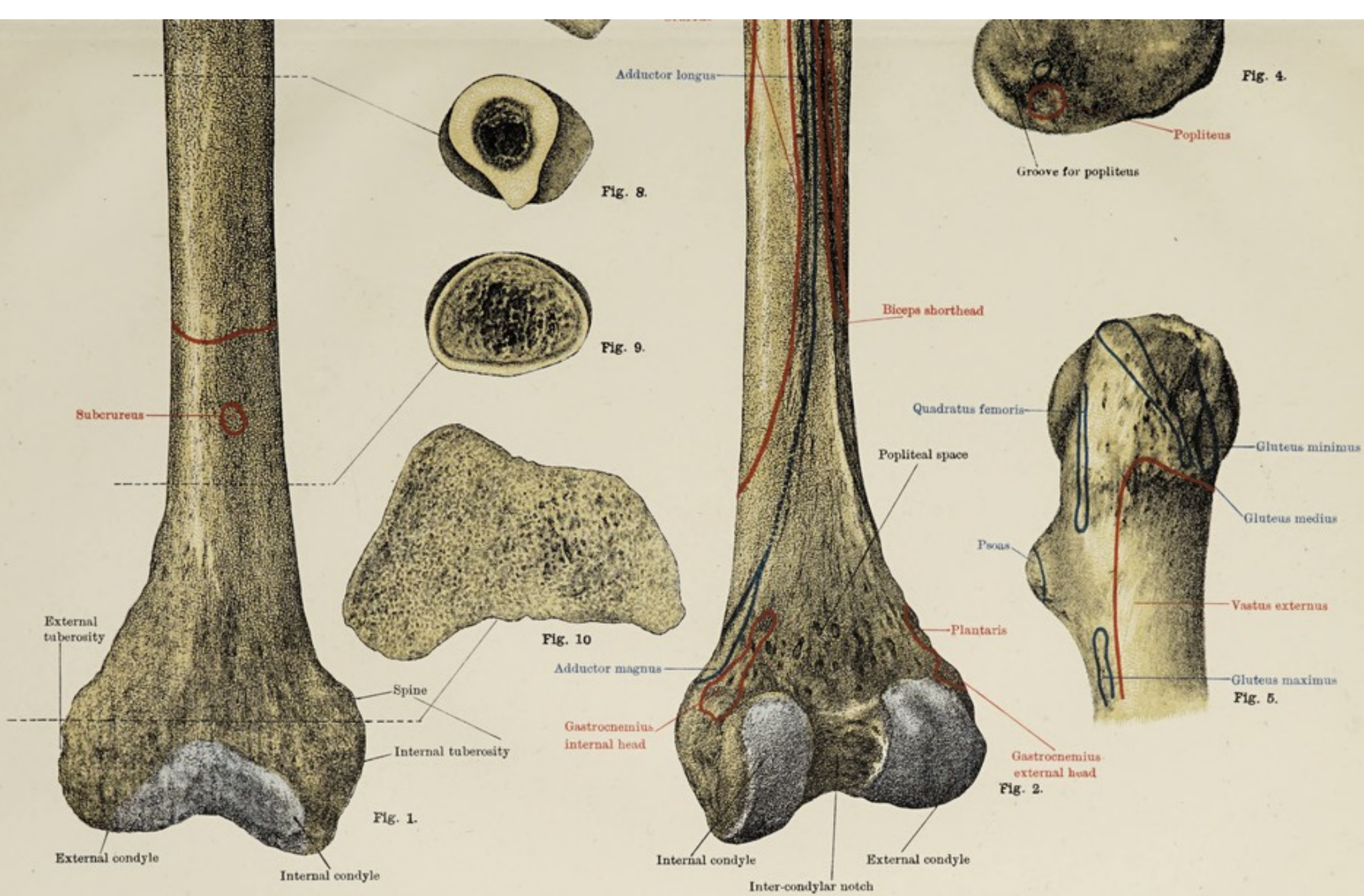

Drawn from nature & Printed by W. & A. K. Johnston, Edinburgh

LIGAMENTS OF THE KNEE.

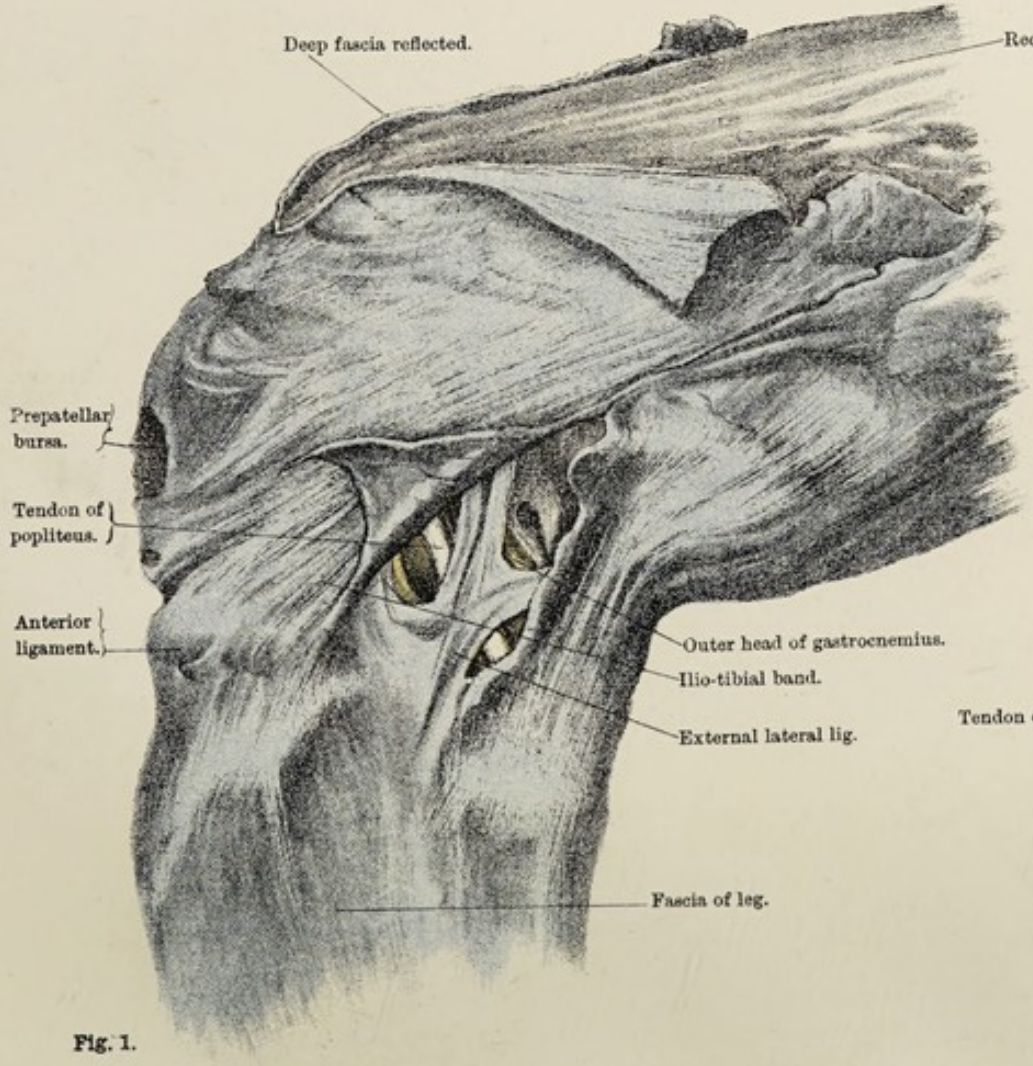

Fig. 1.

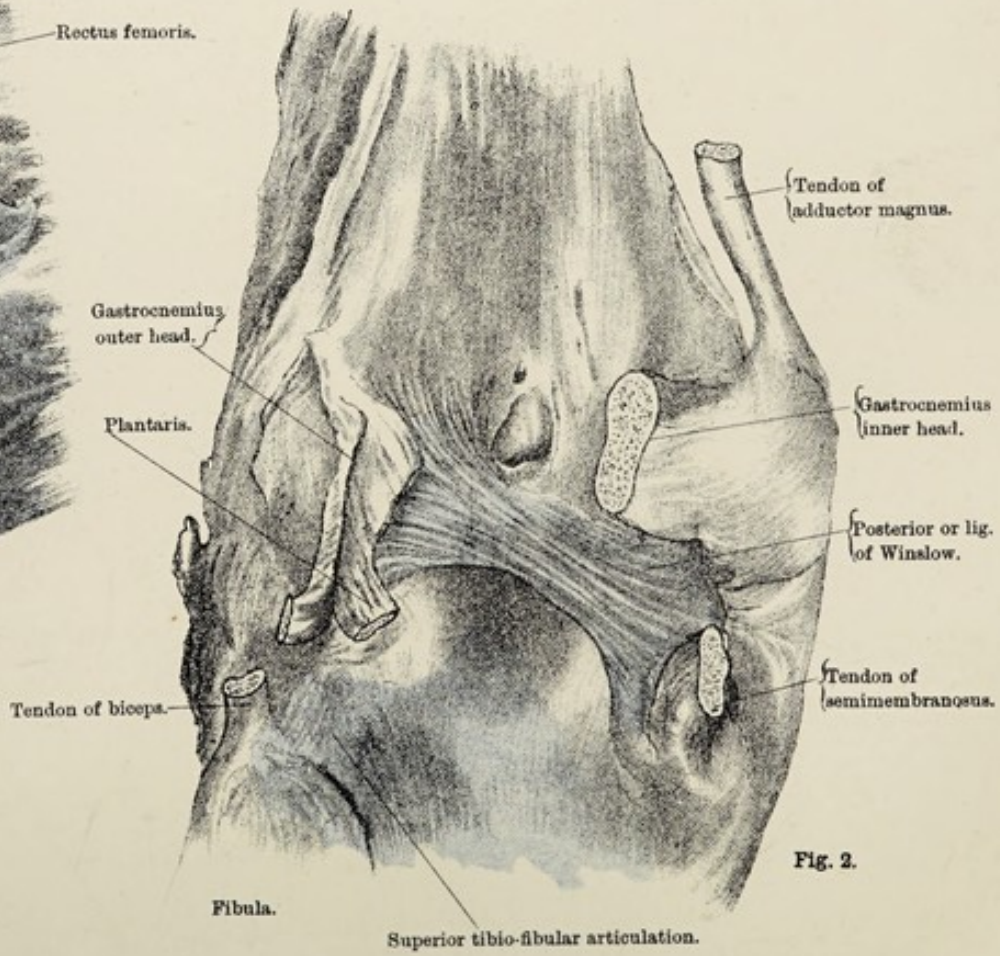

Fig. 2.

Epiphysis of head.

Fig. 3.

Lower epiphysis.

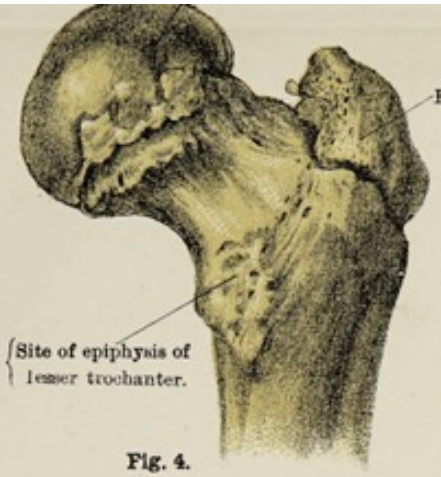

Epiphysis of great trochanter.

Site of epiphysis of lesser trochanter.

Fig. 4.

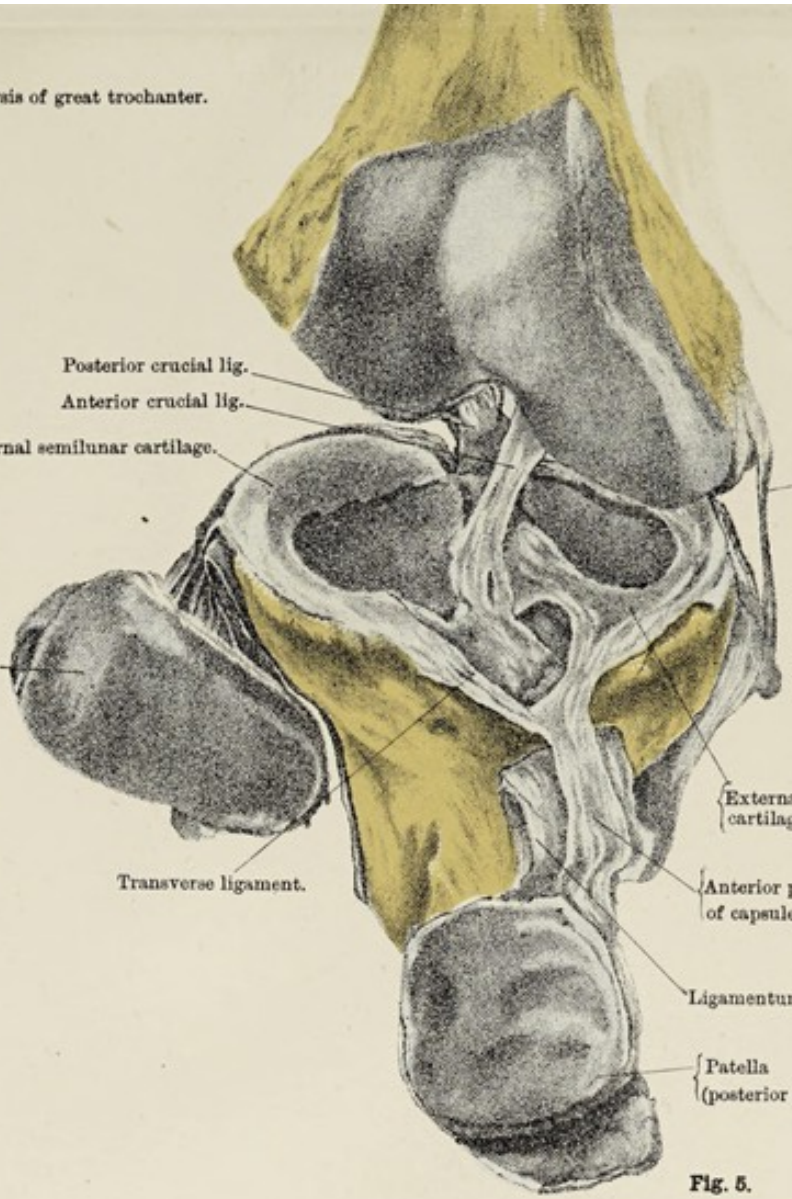

Posterior crucial lig.

Anterior crucial lig.

Internal semilunar cartilage.

Long external lateral ligament.

Inner condyle turned down.

External semilunar cartilage.

Transverse ligament.

Anterior portion of capsule.

Ligamentum patellæ.

Patella (posterior surface).

Fig. 5.

Depression for inner condyle.

Ridge for trochlea.

Depression for outer condyle.

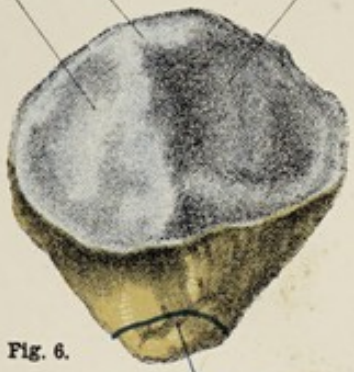

Ligamentum patellæ.

Fig. 6.

Quadriceps extensor.

Fig. 7.

Drawn from nature & Printed by W. & A.K. Johnston, Edinburgh & London

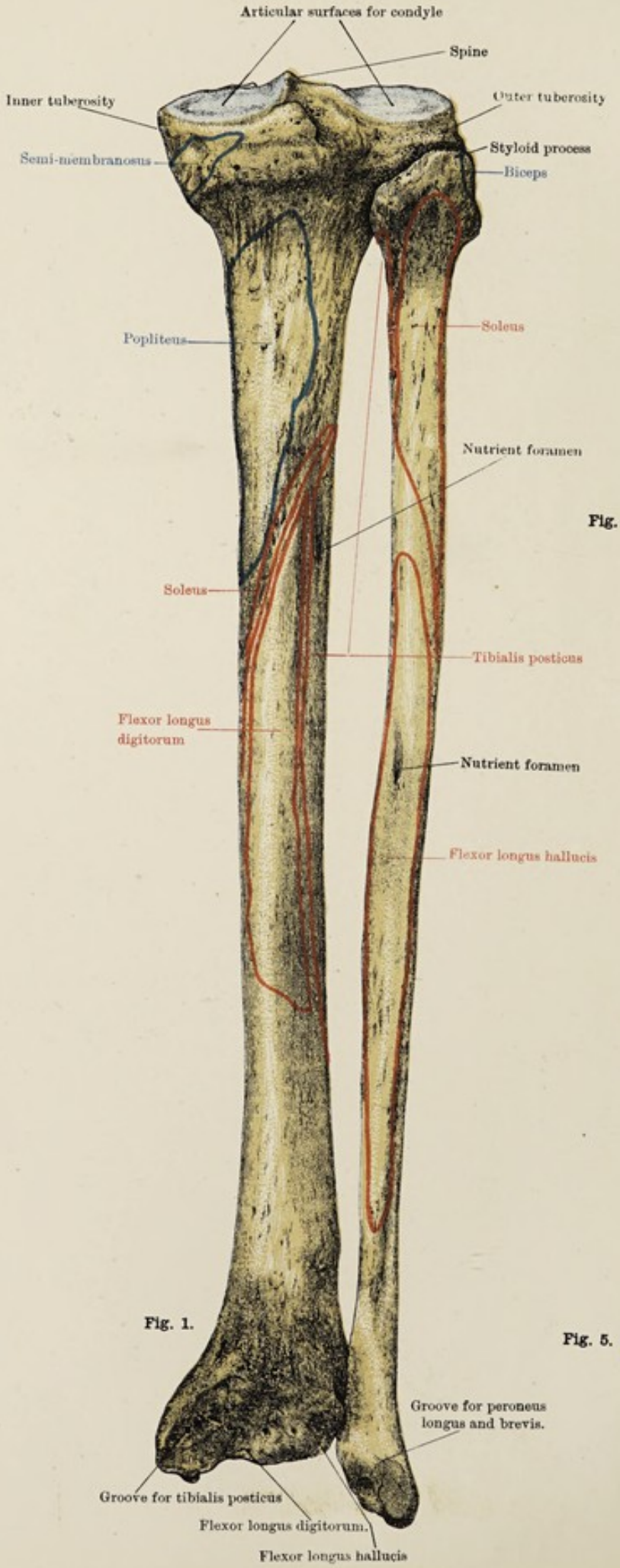

Fig. 1.

Fig. 3.

Fig. 4.

Fig. 5.

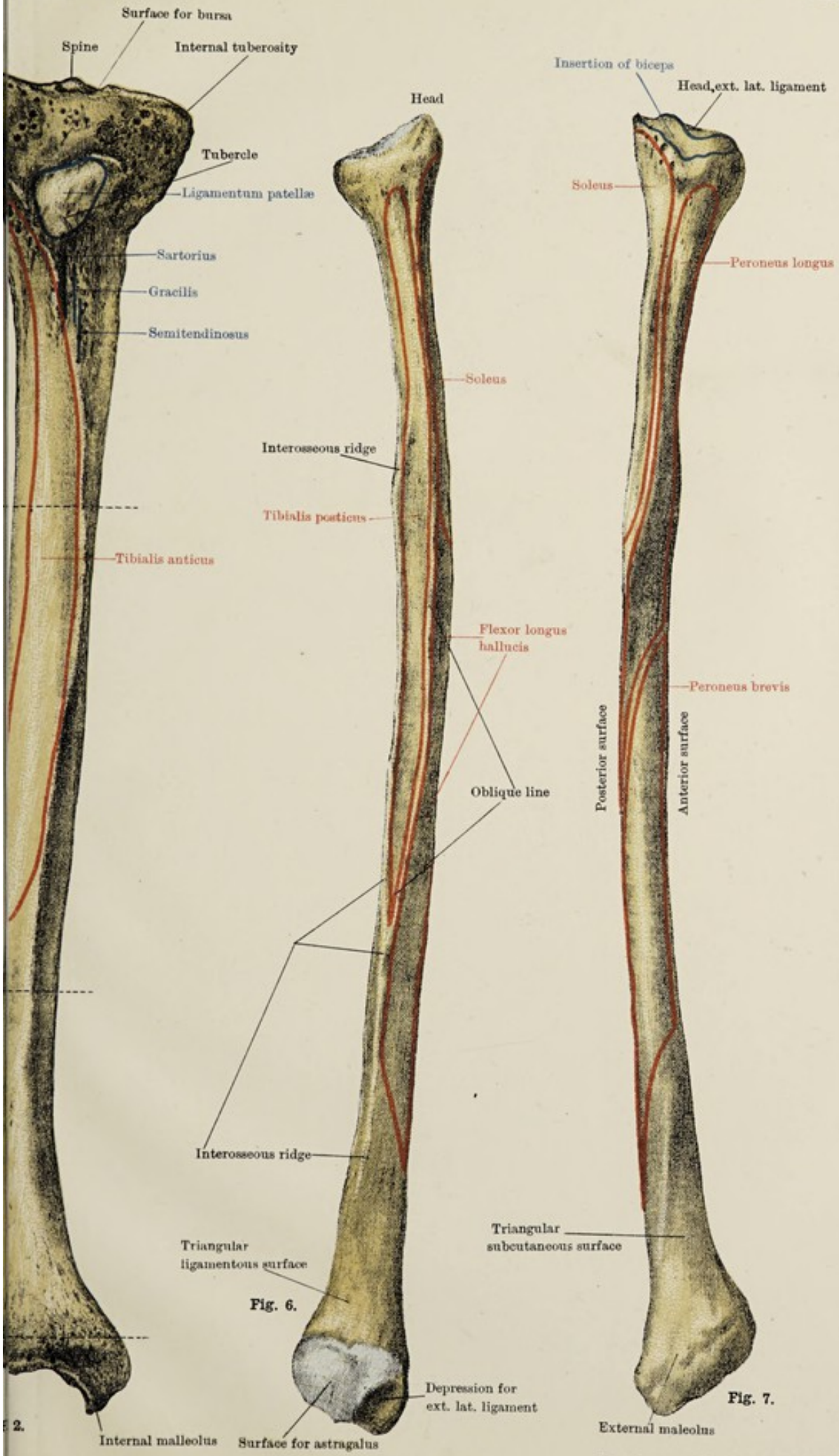

Fig. 6.

Fig. 7.

Drawn from nature. & Printed by W. & A. K. Johnston, Edinburgh & London

BONES OF

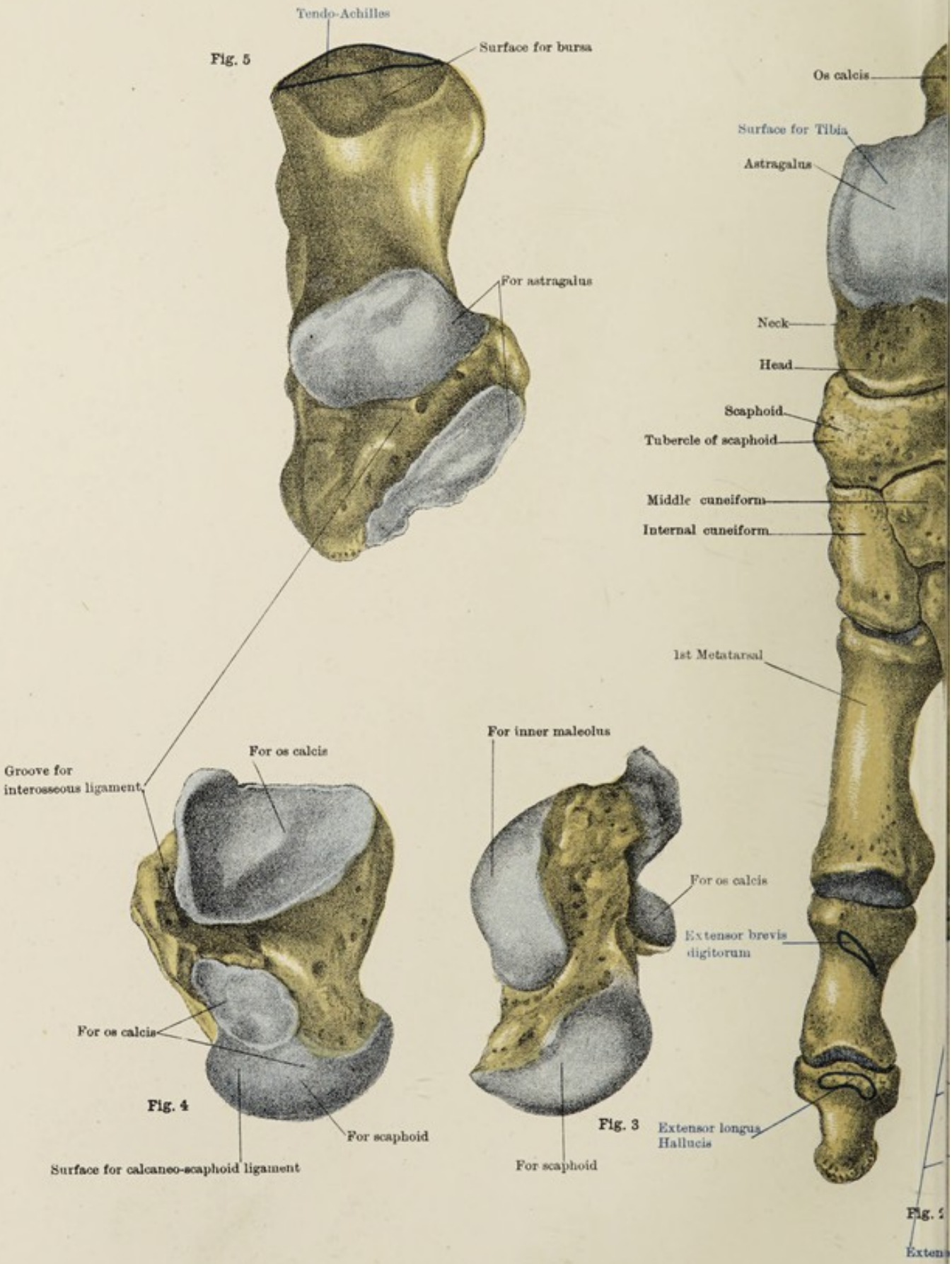

Tendo-Achilles
Surface for bursa
Fig. 5
For astragalus
Os calcis
Surface for Tibia
Astragalus
Neck
Head
Scaphoid
Tubercle of scaphoid
Middle cuneiform
Internal cuneiform
1st Metatarsal
Groove for interosseous ligament
For os calcis
For os calcis
Fig. 4
For scaphoid
Surface for calcaneo-scaphoid ligament
For inner maleolus
For os calcis
Fig. 3
For scaphoid
Extensor brevis digitorum
Extensor longus Hallucis
Fig. 2

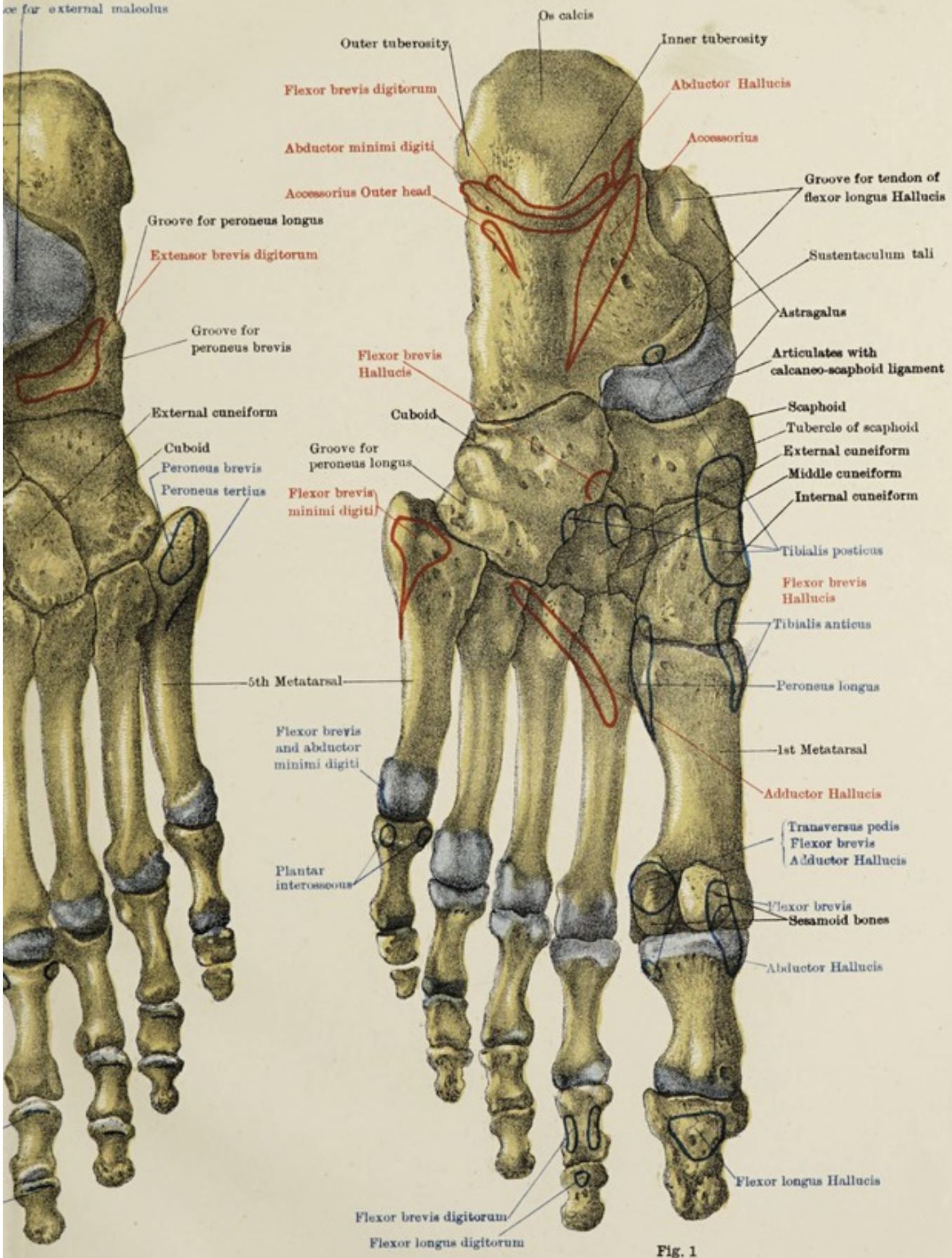

Fig. 1

s longus et brevis digitorum

Drawn from nature & Printed by W. & A. K. Johnston Edinburgh & London

LIGAMENTS OF THE FOOT.

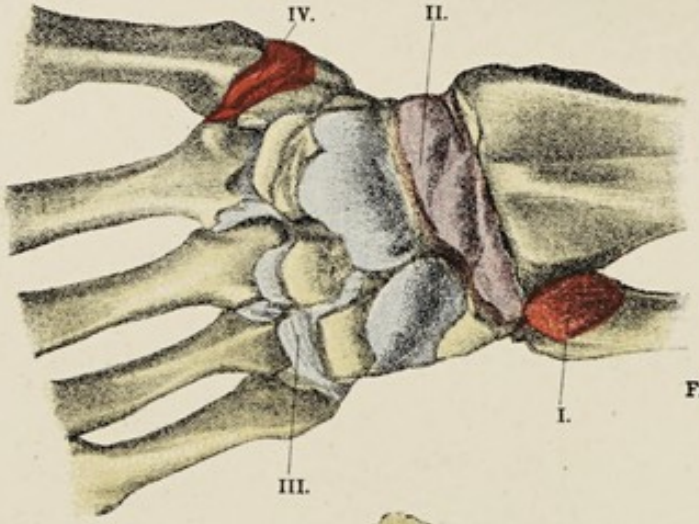

Fig. 1.

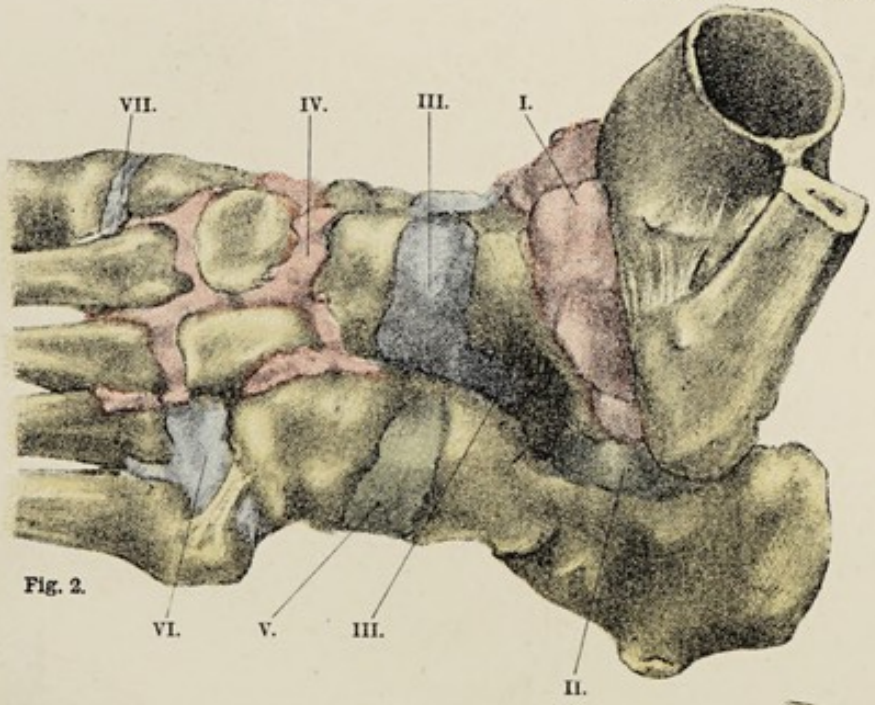

Fig. 2.

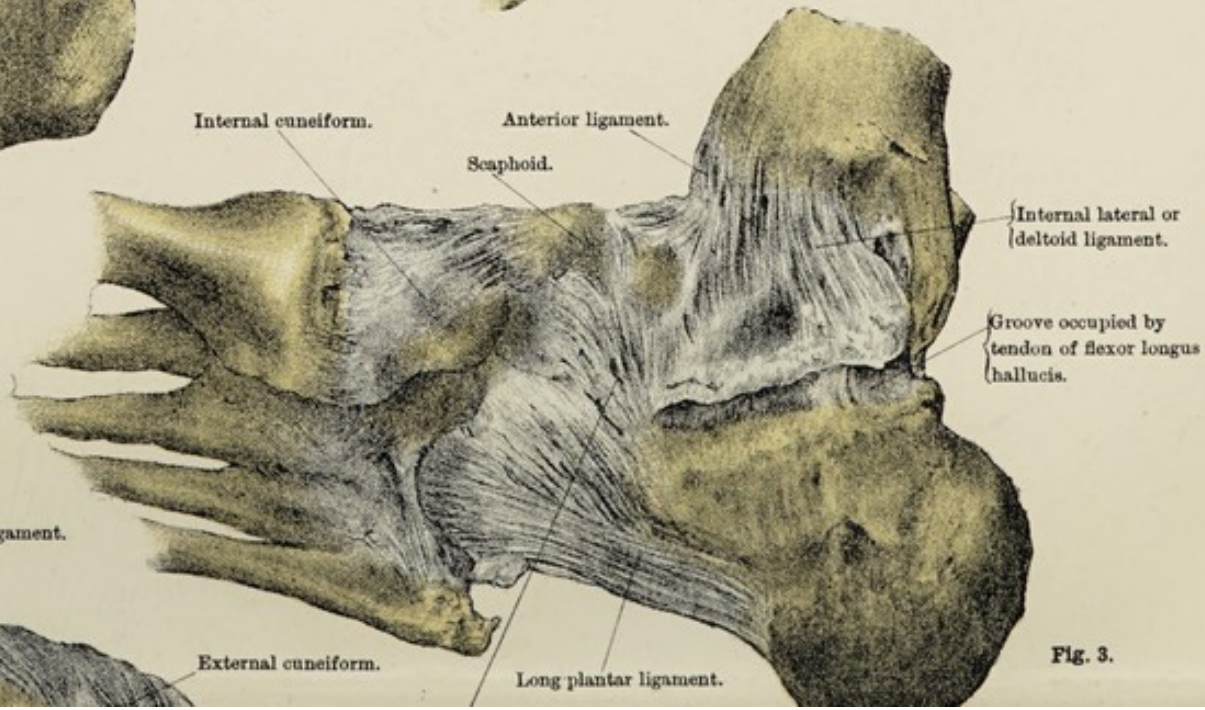

Fig. 3.

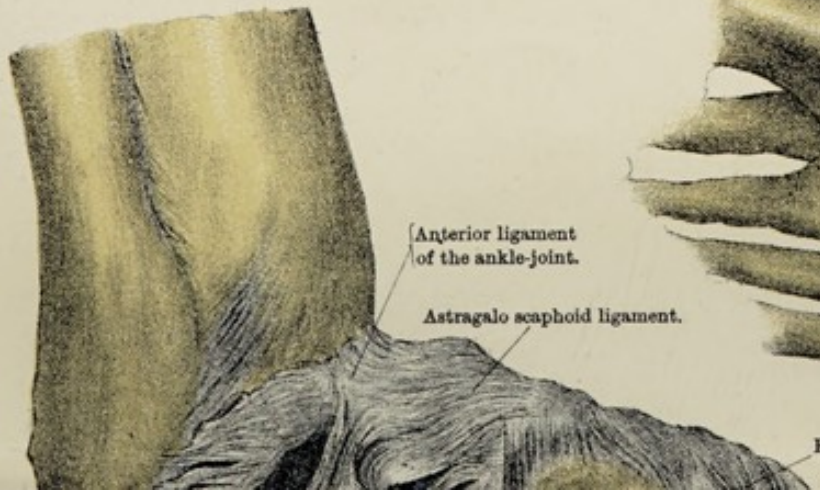

Fig. 4.

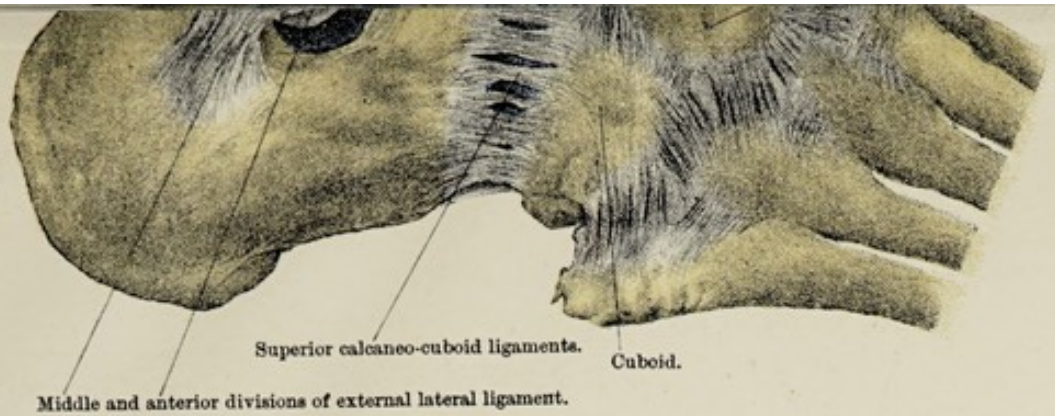

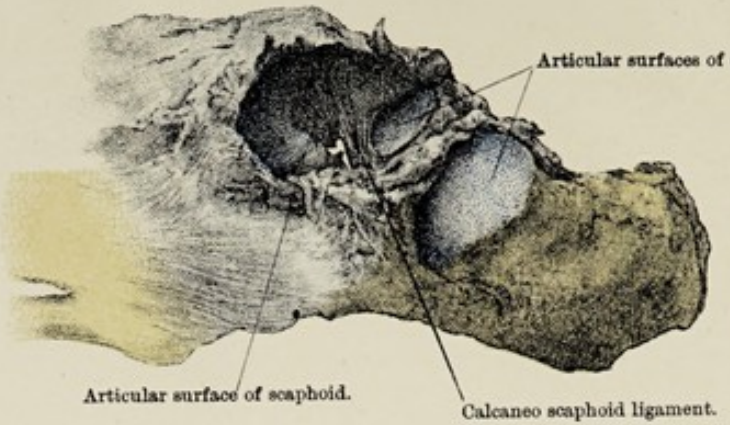

Fig. 5.

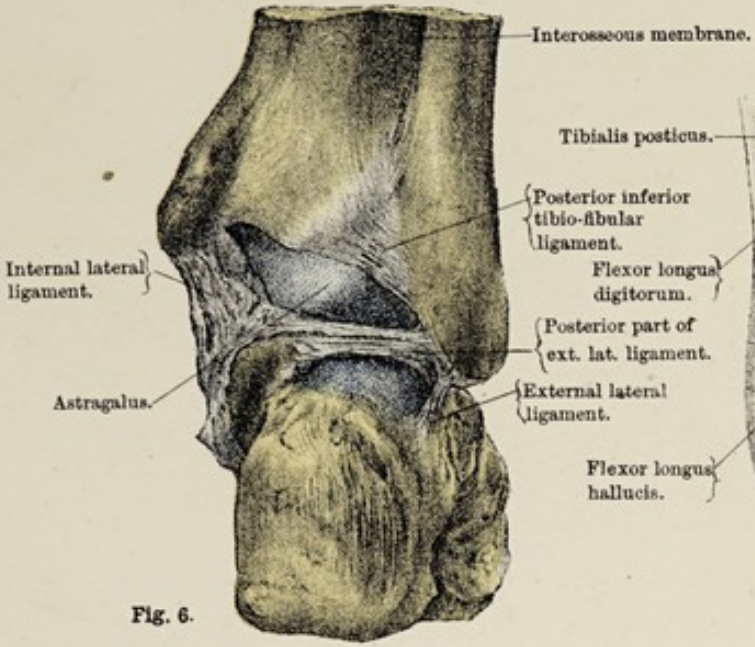

Fig. 6.

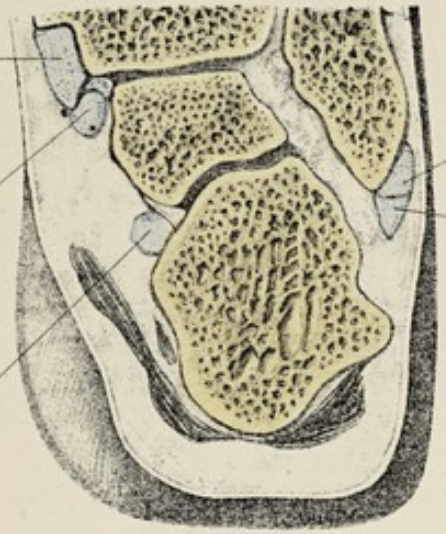

Fig. 7.

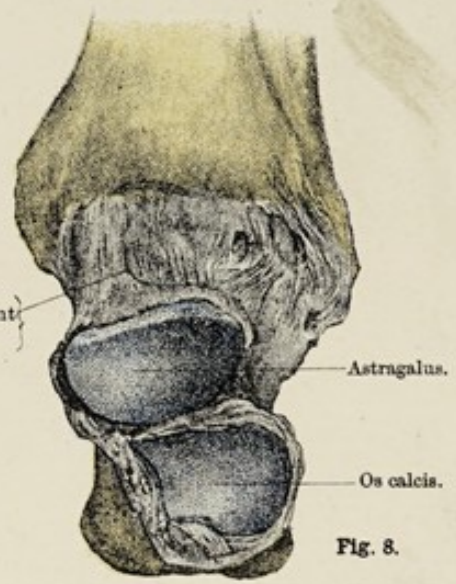

Fig. 8.

Drawn from nature & Printed by W. & A. K. Johnston, Edinburgh & London.

SYNOVIAL MEMBRANES OF THE KNEE AND ELBOW

PLATE XX.

Fig. 1.

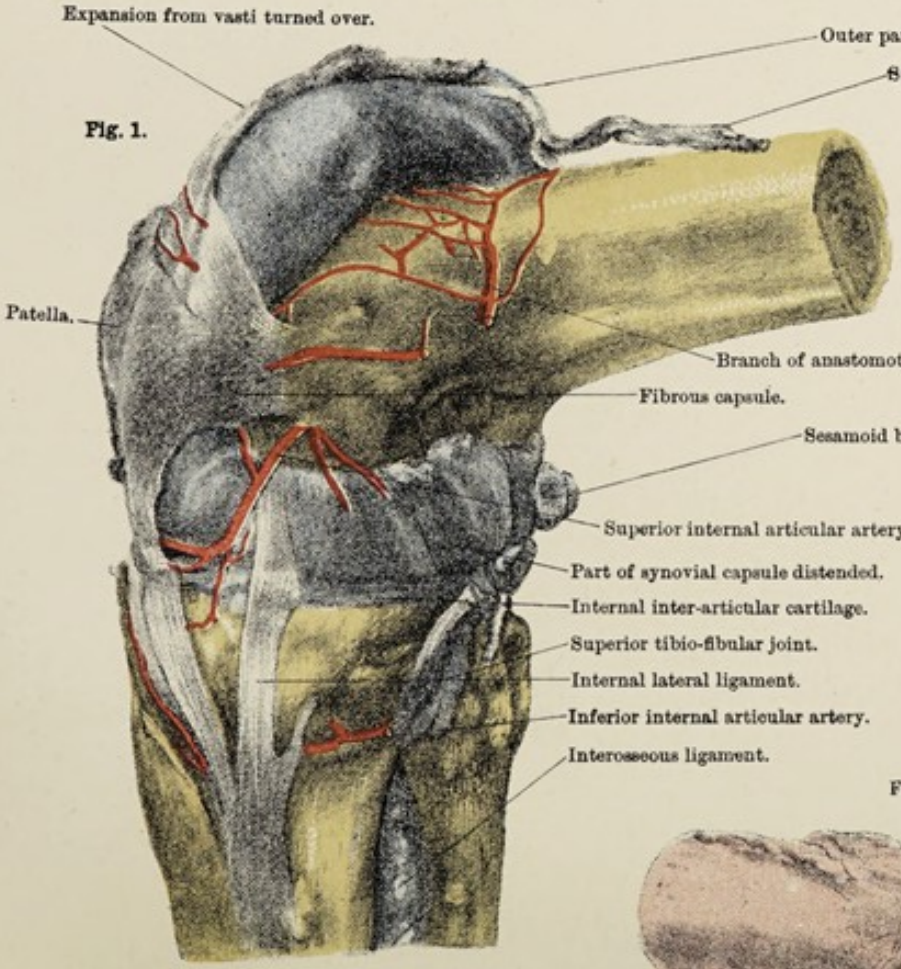

Fig. 2.

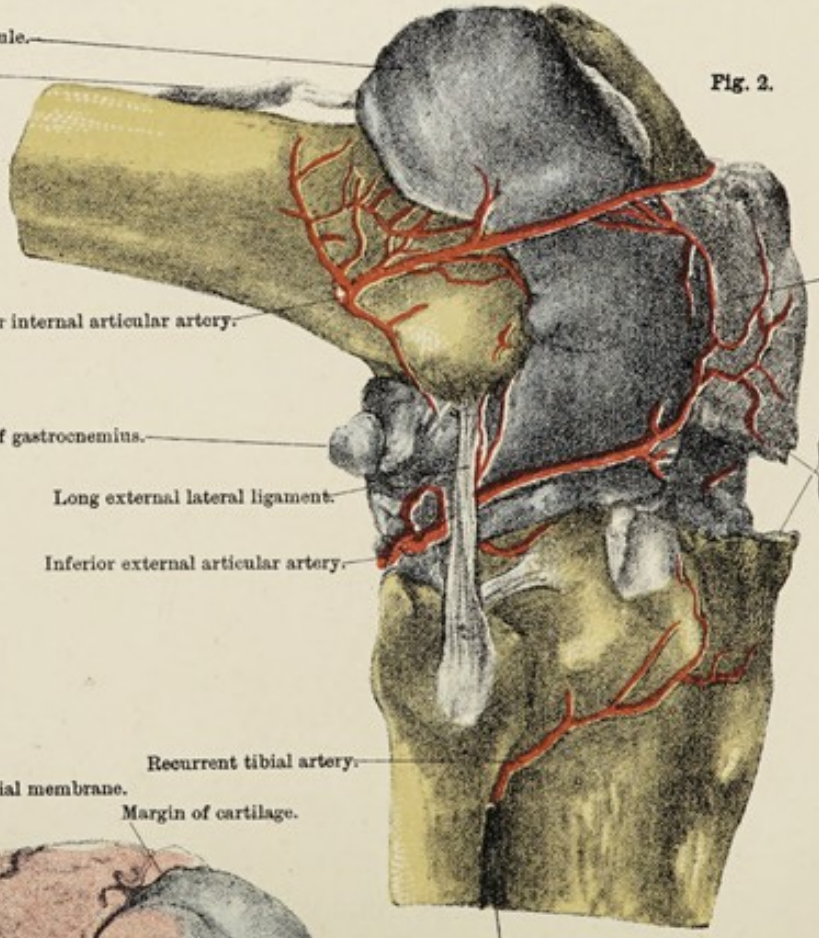

Fig. 4.

Fig. 5.

Fig. 3.

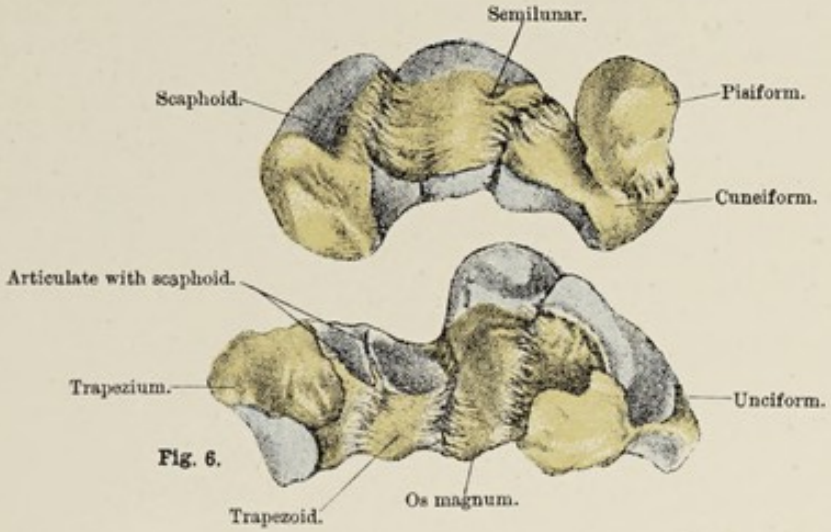

Fig. 6.

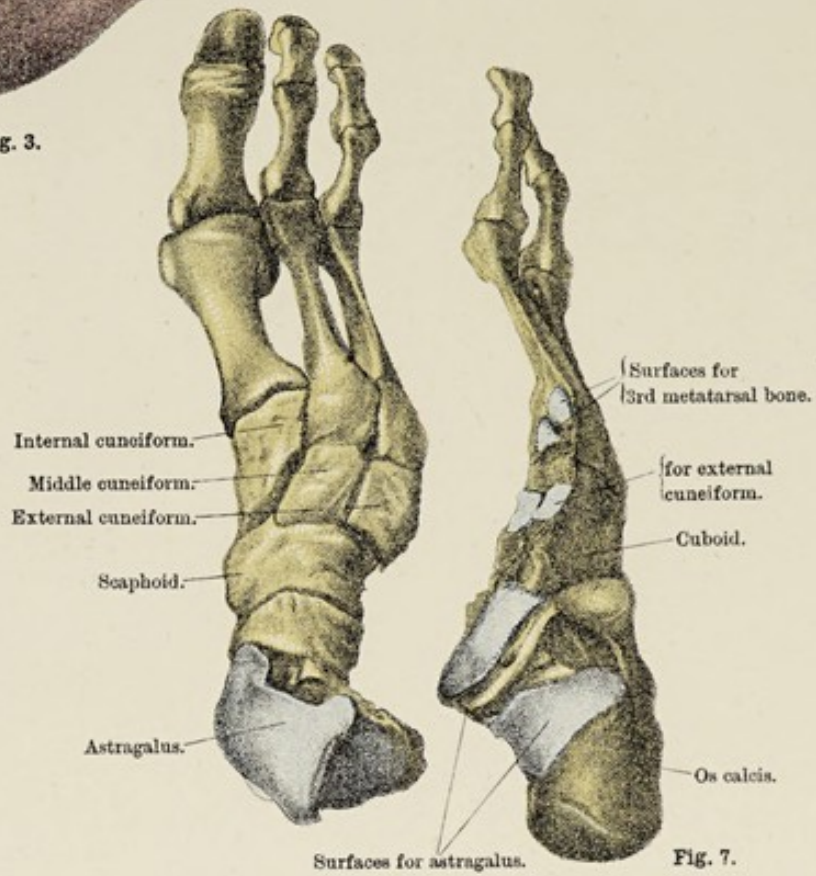

Fig. 7.

Drawn from nature & Printed by W. & A. K. Johnston, Edinburgh & London

SKULL.

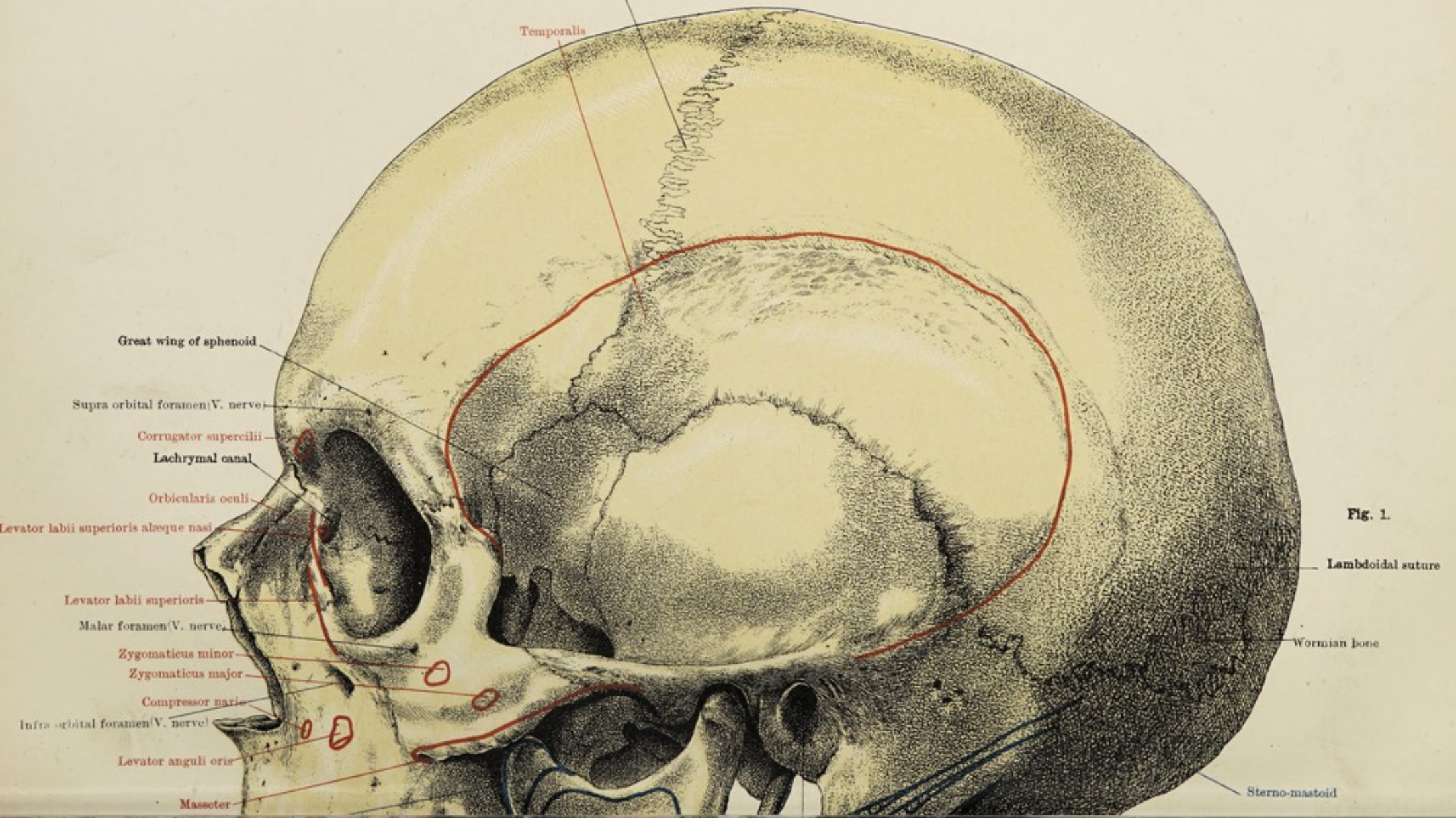
Coronal suture
Temporalis
Great wing of sphenoid
Supra orbital foramen(V. nerve)
Corrugator supercilii
Lachrymal canal
Orbicularis oculi
Levator labii superioris alæque nasi
Levator labii superioris
Malar foramen(V. nerve)
Zygomaticus minor
Zygomaticus major
Compressor nariæ
Infra orbital foramen(V. nerve)
Levator anguli oris
Masseter
Lambdoidal suture
Wormian bone
Sterno-mastoid

Fig. 1.

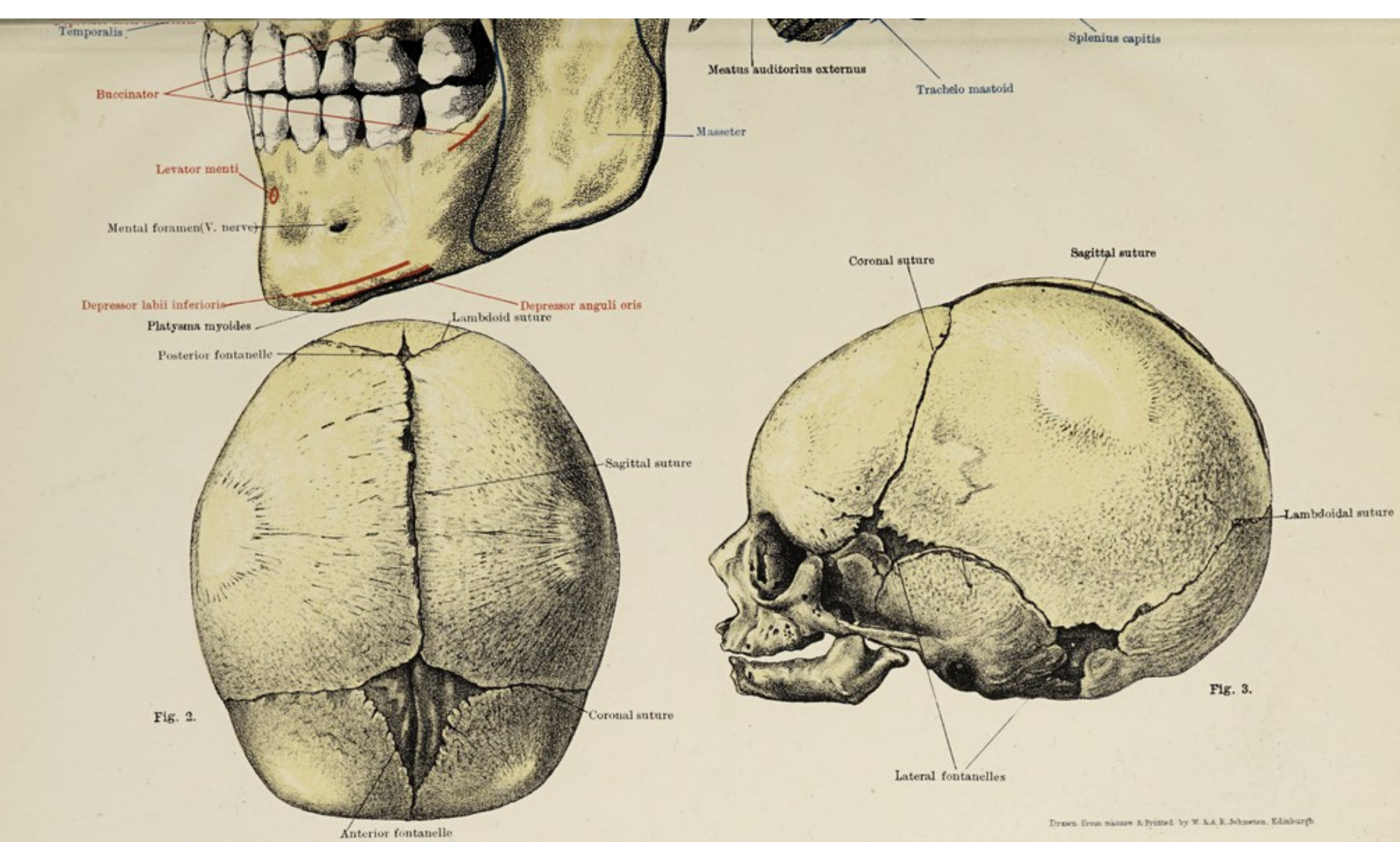

Fig. 2.

Fig. 3.

Drawn from nature & Printed by W. & A. K. Johnston, Edinburgh

BASE OF SKULL.

PLATE XXII.

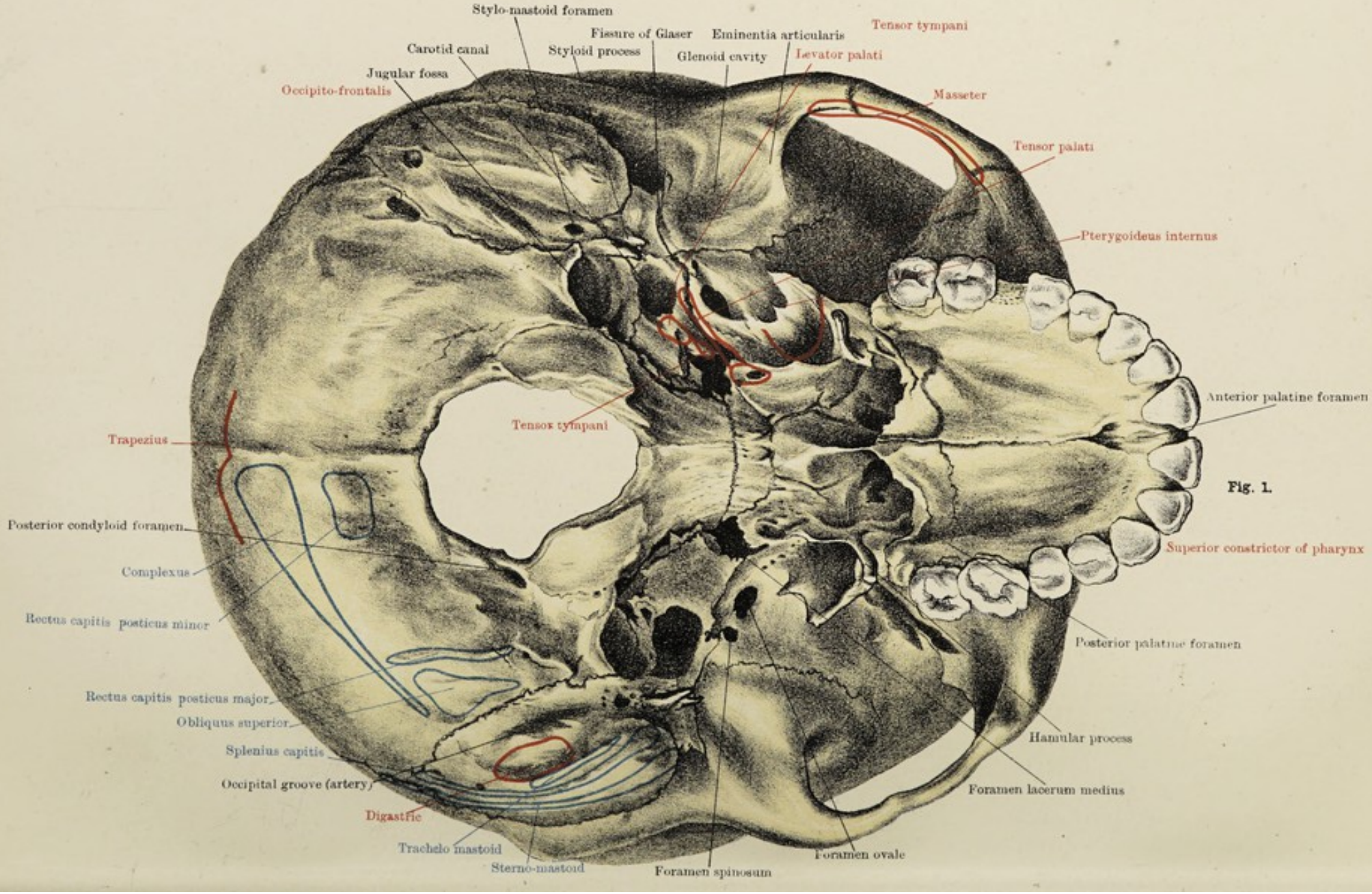

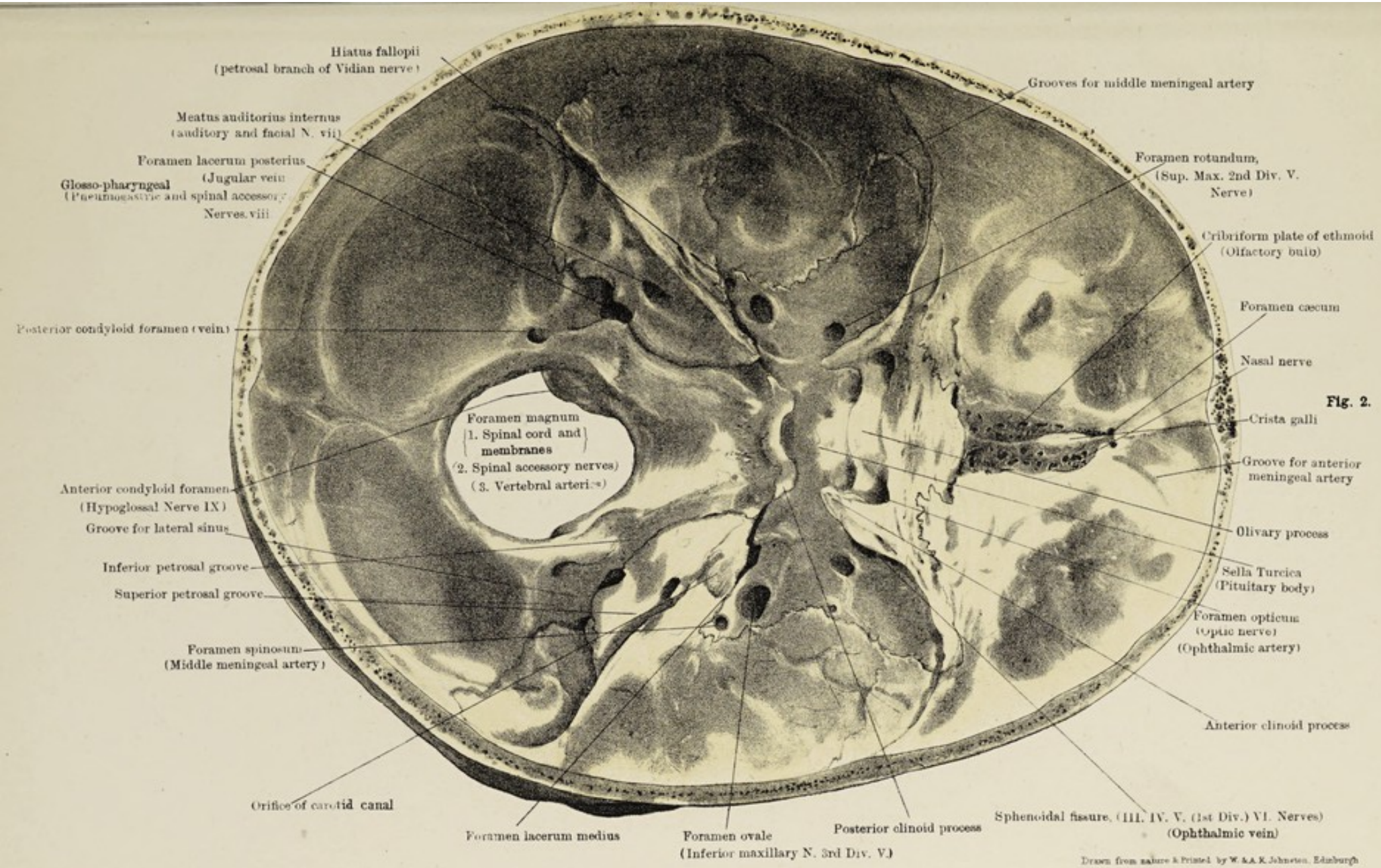

Fig. 2.

Drawn from nature & Printed by W. & A. K. Johnston, Edinburgh

OCCIPITAL AND PARIETAL BONES.

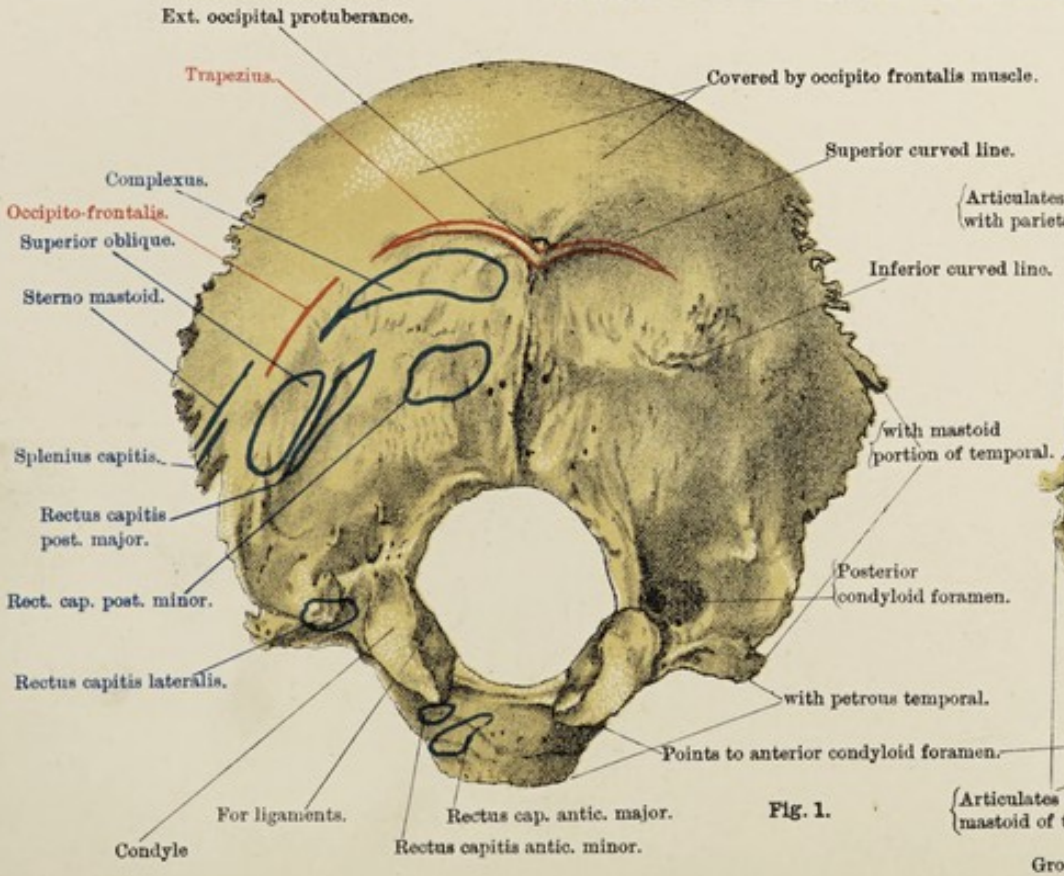

Fig. 1.

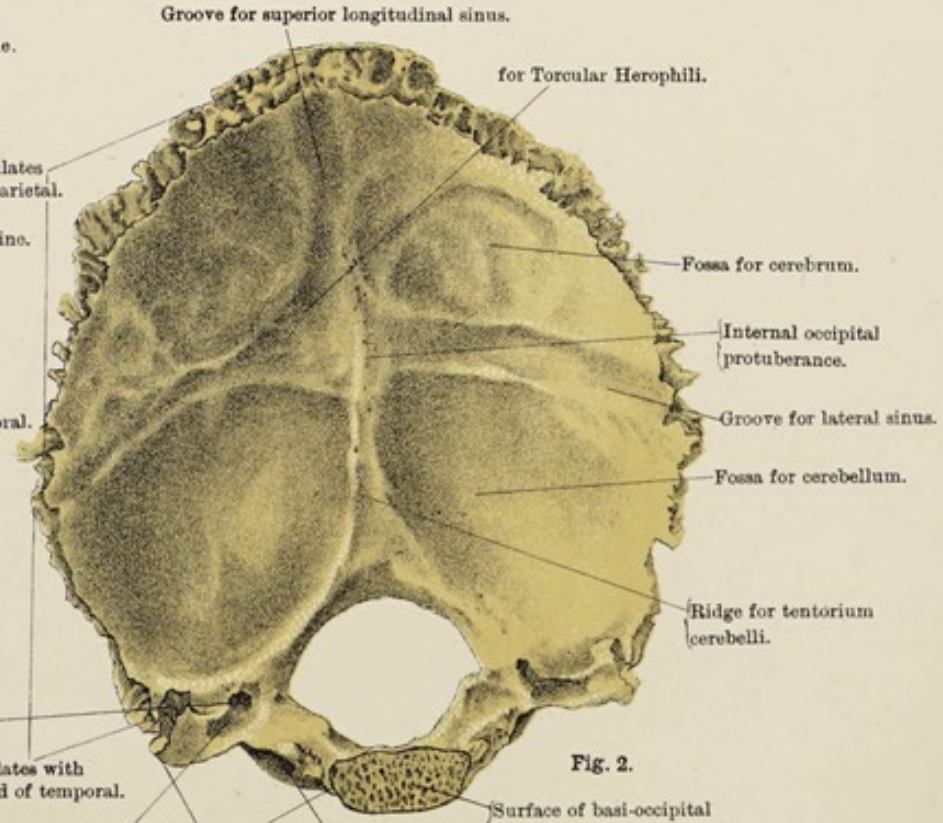

Fig. 2.

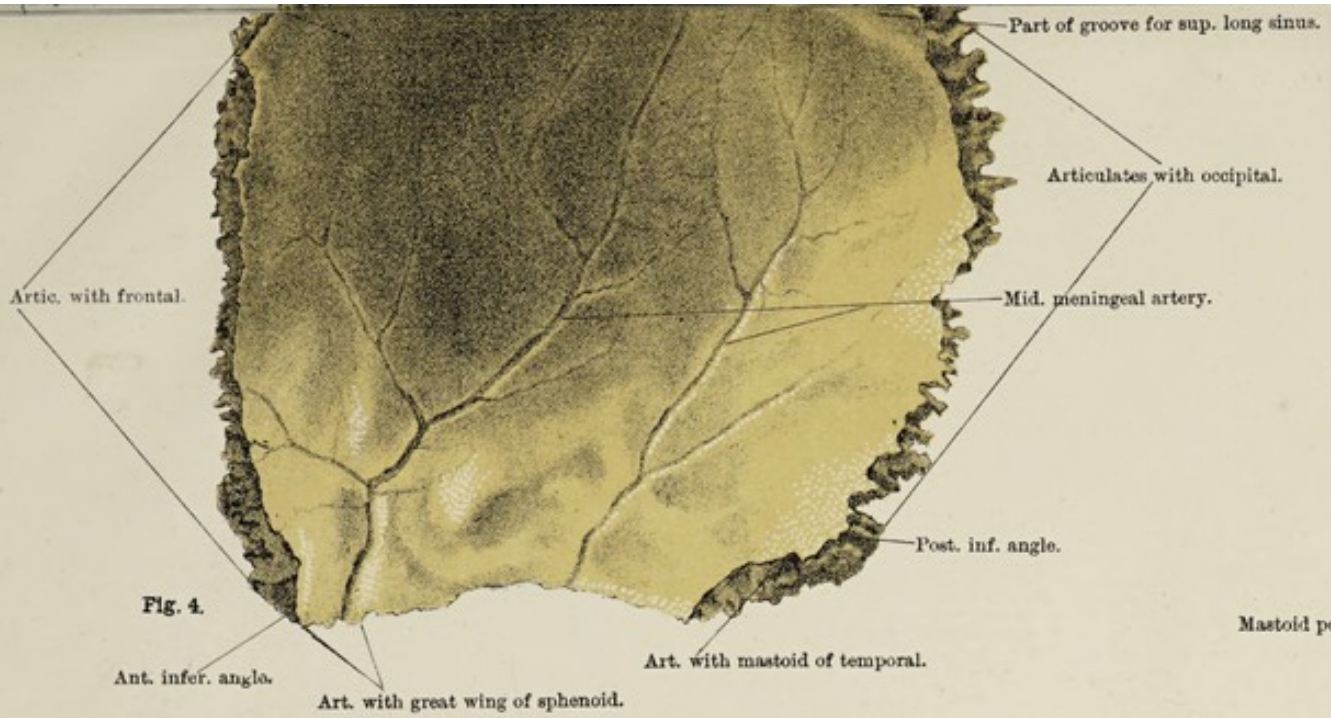

Fig. 4.

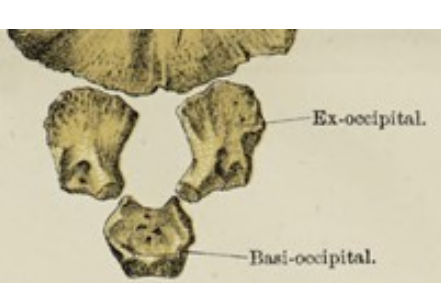

Fig. 3.

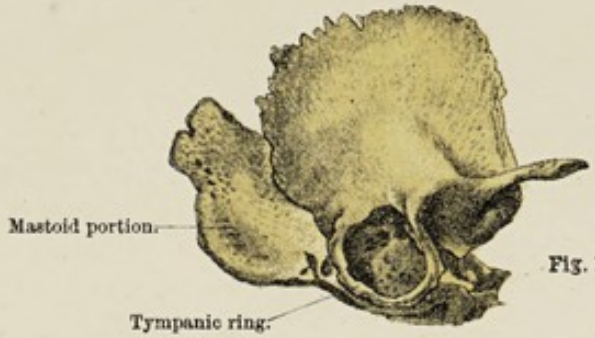

Fig. 10.

Fig. 5.

Fig. 6.

Fig. 7.

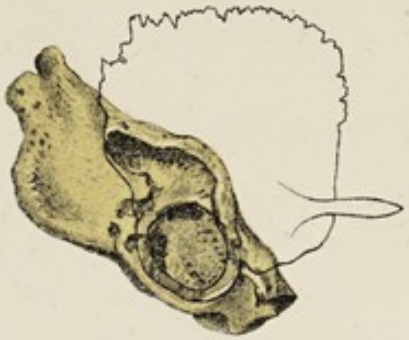

Fig. 8.

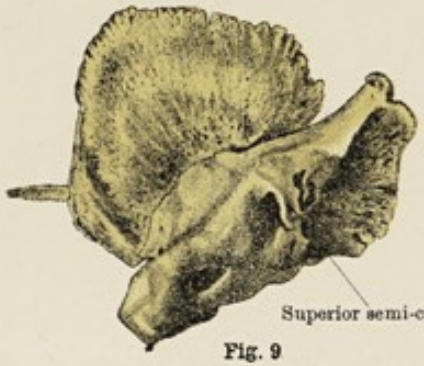

Fig. 9

Drawn from nature & Printed by W. & A. K. Johnston, Edinburgh & London

FRONTAL AND ETHMOID BONES.

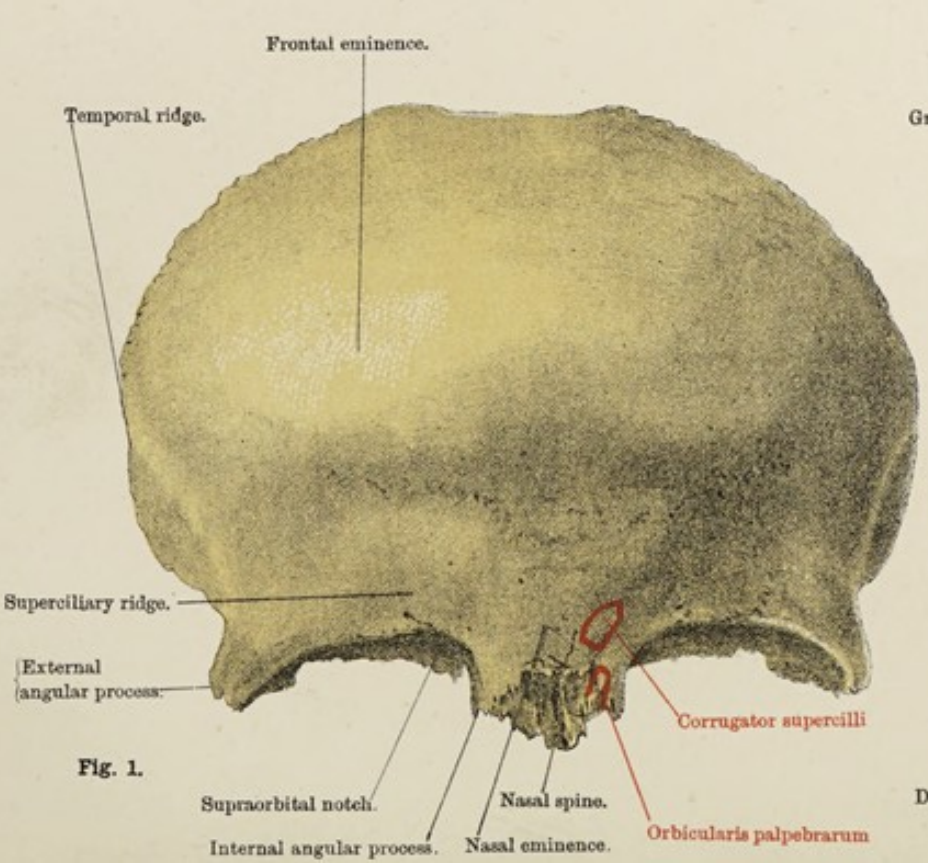

Fig. 1.

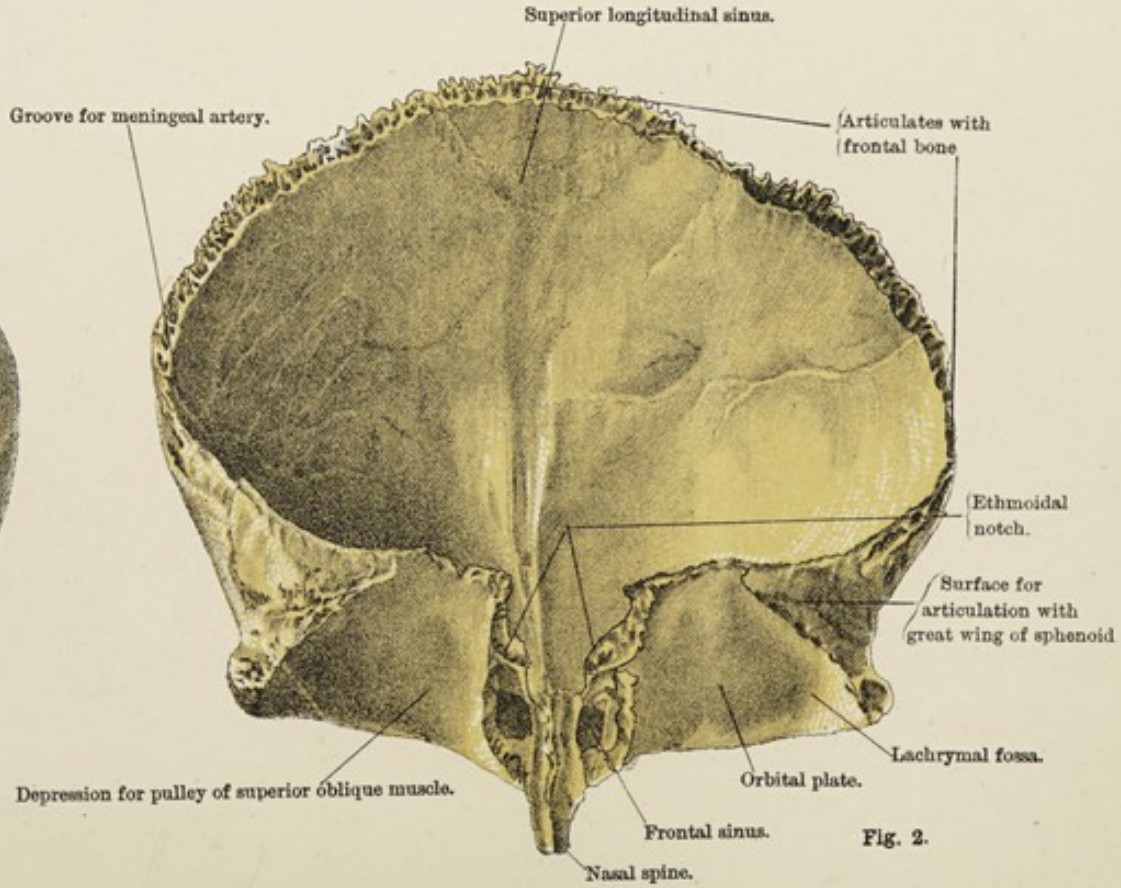

Fig. 2.

Fig. 4.

Infundibulum.

Articulates with sphenoid.

Fig. 3.

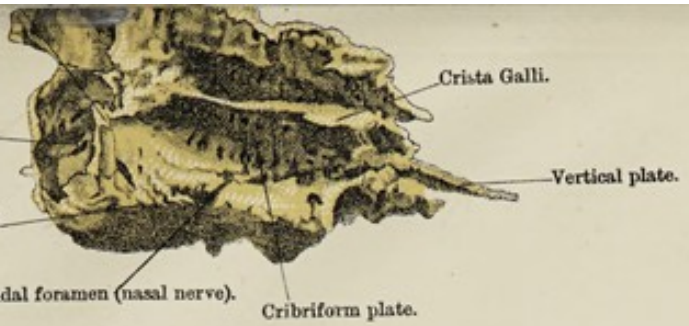

Posterior ethmoidal cells.
Crista Galli.
Vertical plate.
Post. ethmoidal foramen.
Anterior ethmoidal foramen (nasal nerve).
Cribriform plate.

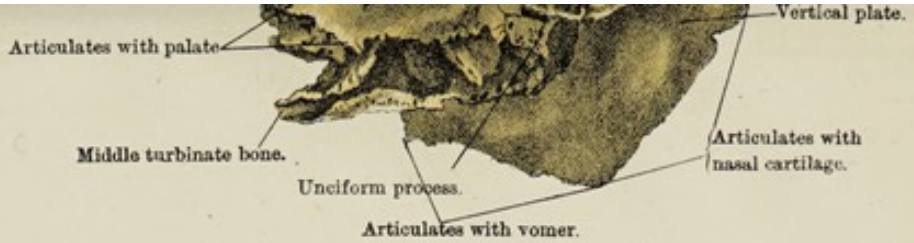

Articulates with palate.
Vertical plate.
Middle turbinate bone.
Articulates with nasal cartilage.
Uncifrom process.
Articulates with vomer.

Superior turbinate bone.
Superior meatus.
Middle turbinate bone.
Middle meatus.
Uncifrom process.
Vertical plate.

Fig. 5.

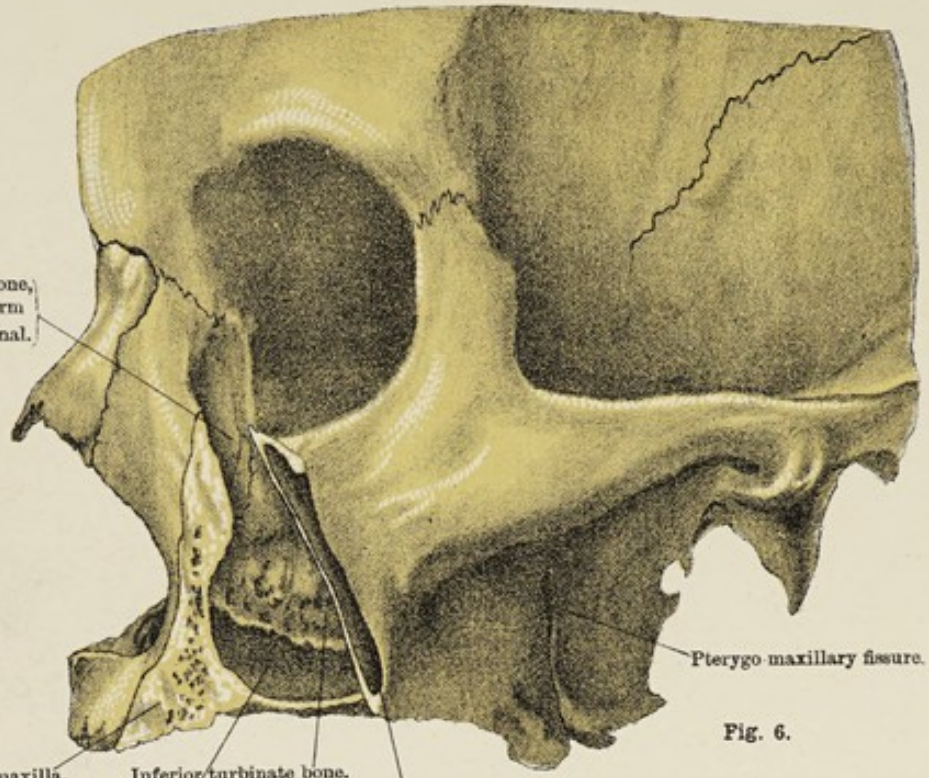

Lachrymal bone, helping to form lachrymal canal.
Pterygo maxillary fissure.
Section of superior maxilla.
Inferior turbinate bone.
Inferior meatus of nose.
Antrum of Highmore.

Fig. 6.

Drawn from nature & Printed by W. & A. K. Johnston, Edinburgh

INFERIOR MAXILLA.

PLATE XXV.

Fig. 1.

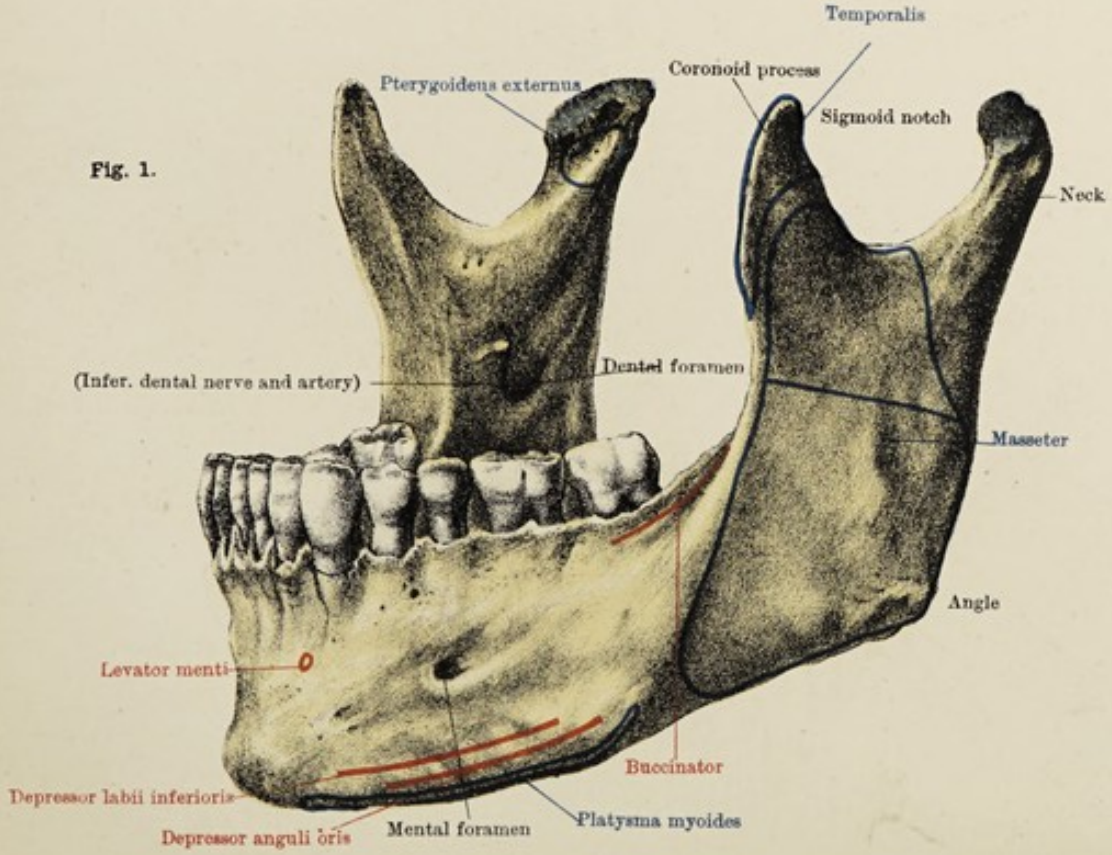

Fig. 10.

Fig. 9.

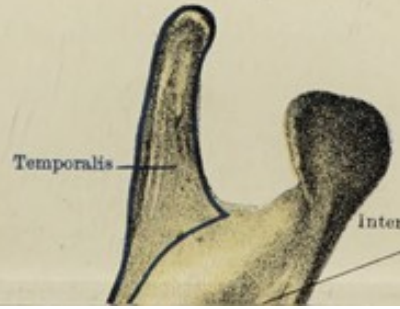

Fig. 8.

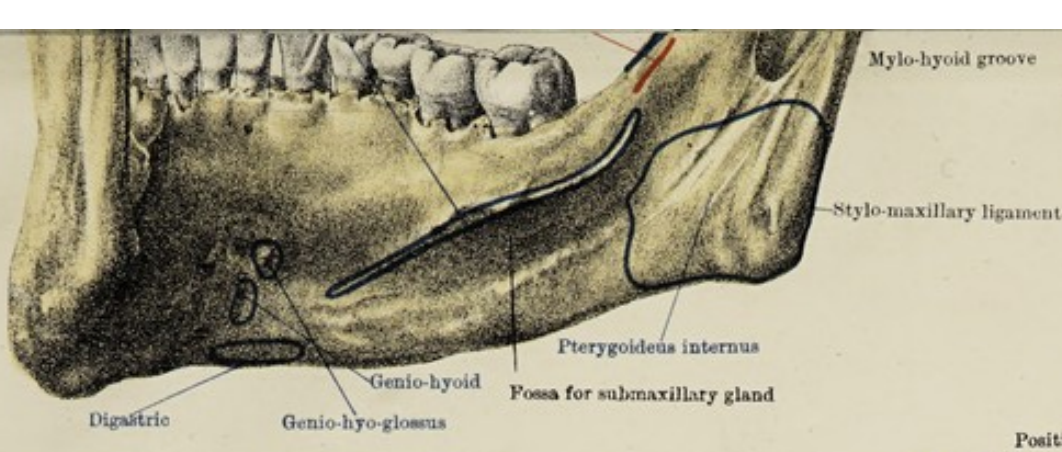

Fig. 2.

Fig. 7.

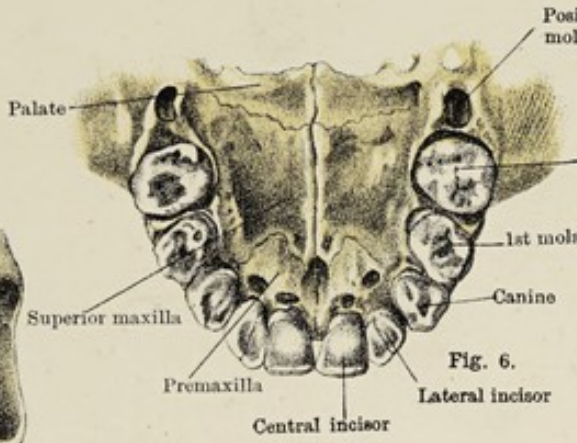

Fig. 6.

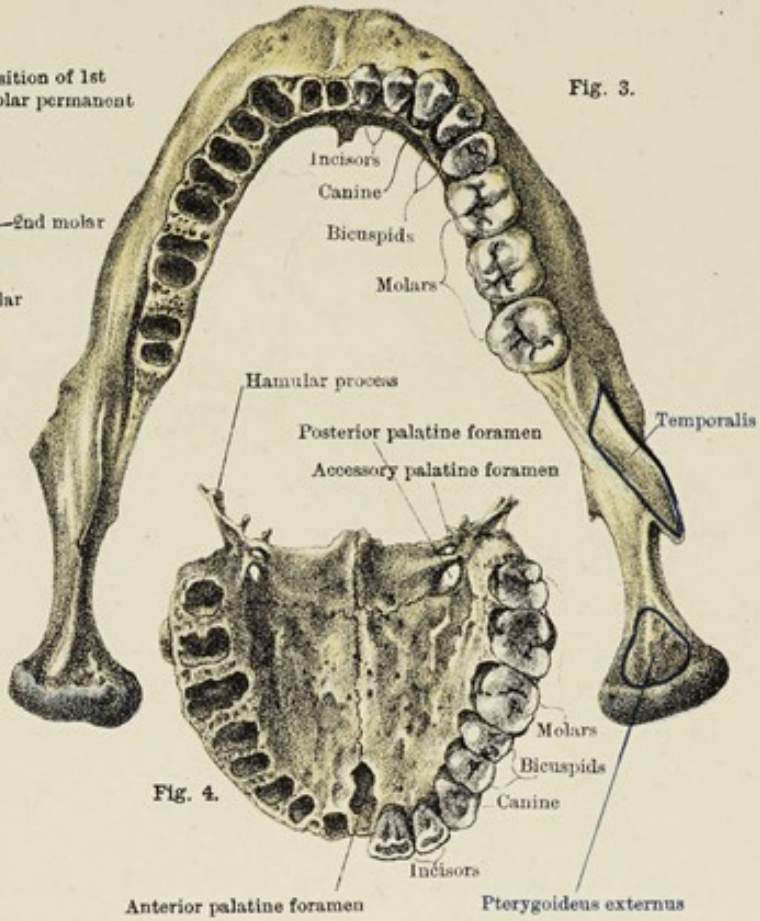

Fig. 3.

Fig. 4.

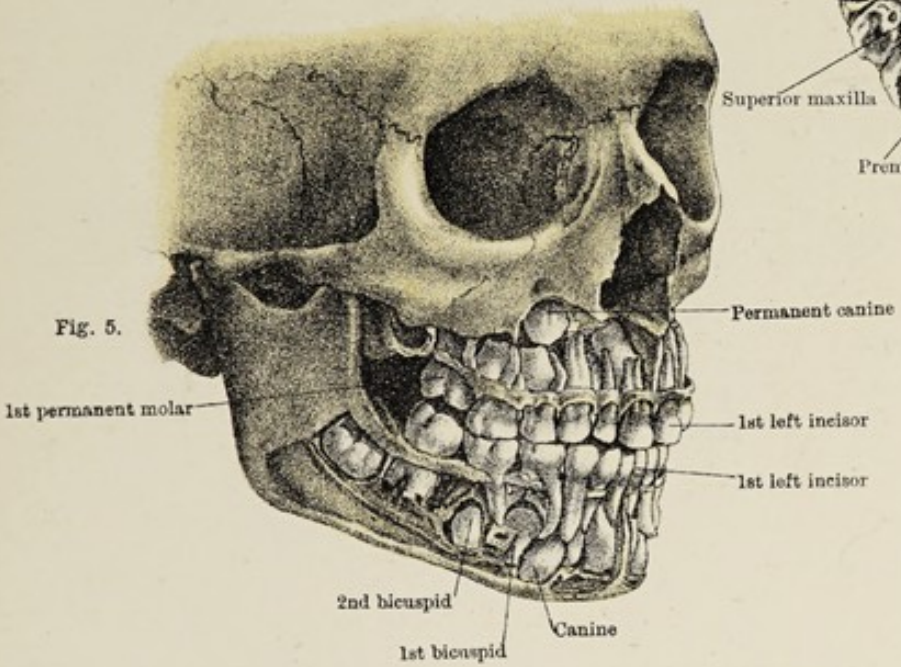

Fig. 5.

Drawn from nature & Printed by W. & A. K. Johnston, Edinburgh

THE TEMPORAL BONE.

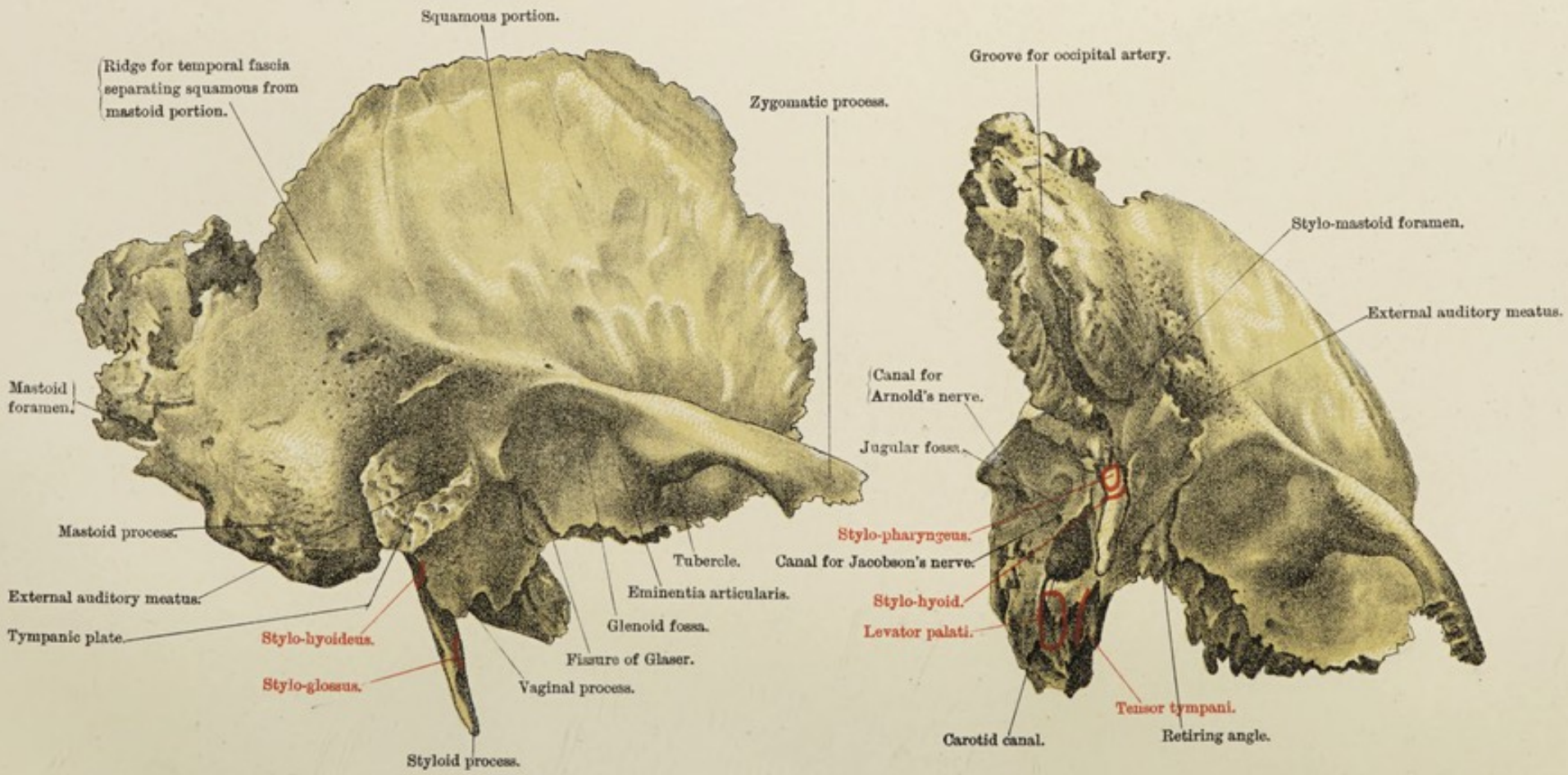

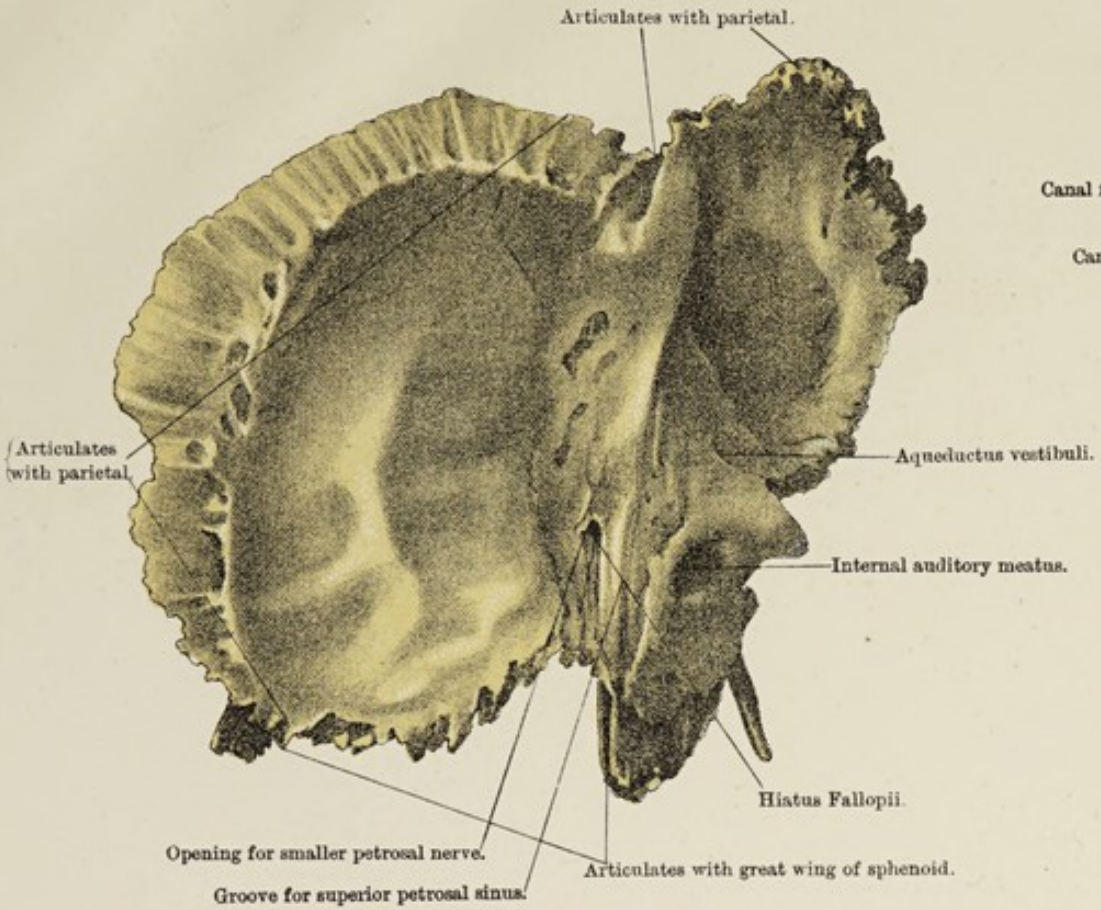

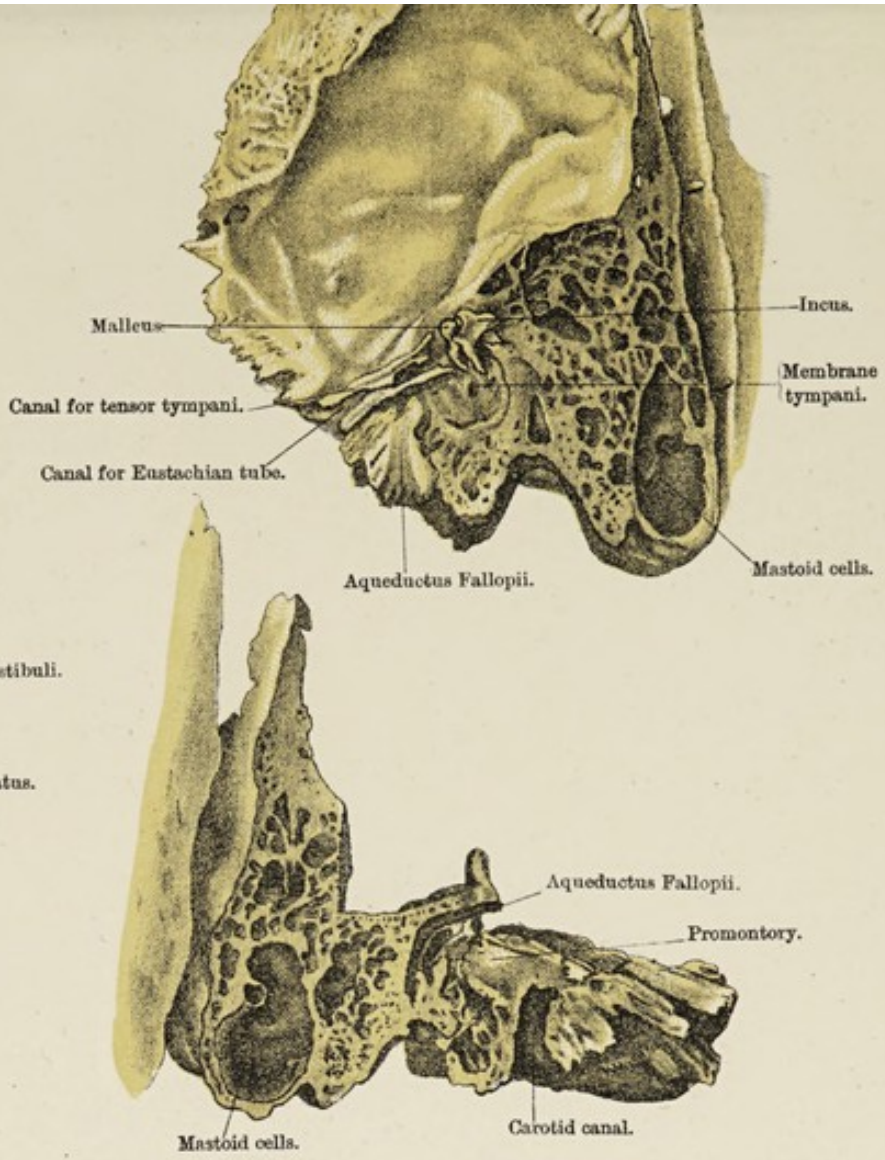

Drawn from nature & Printed by W. & A. K. Johnston, Edinburgh.

THE SPHENOID BONE.

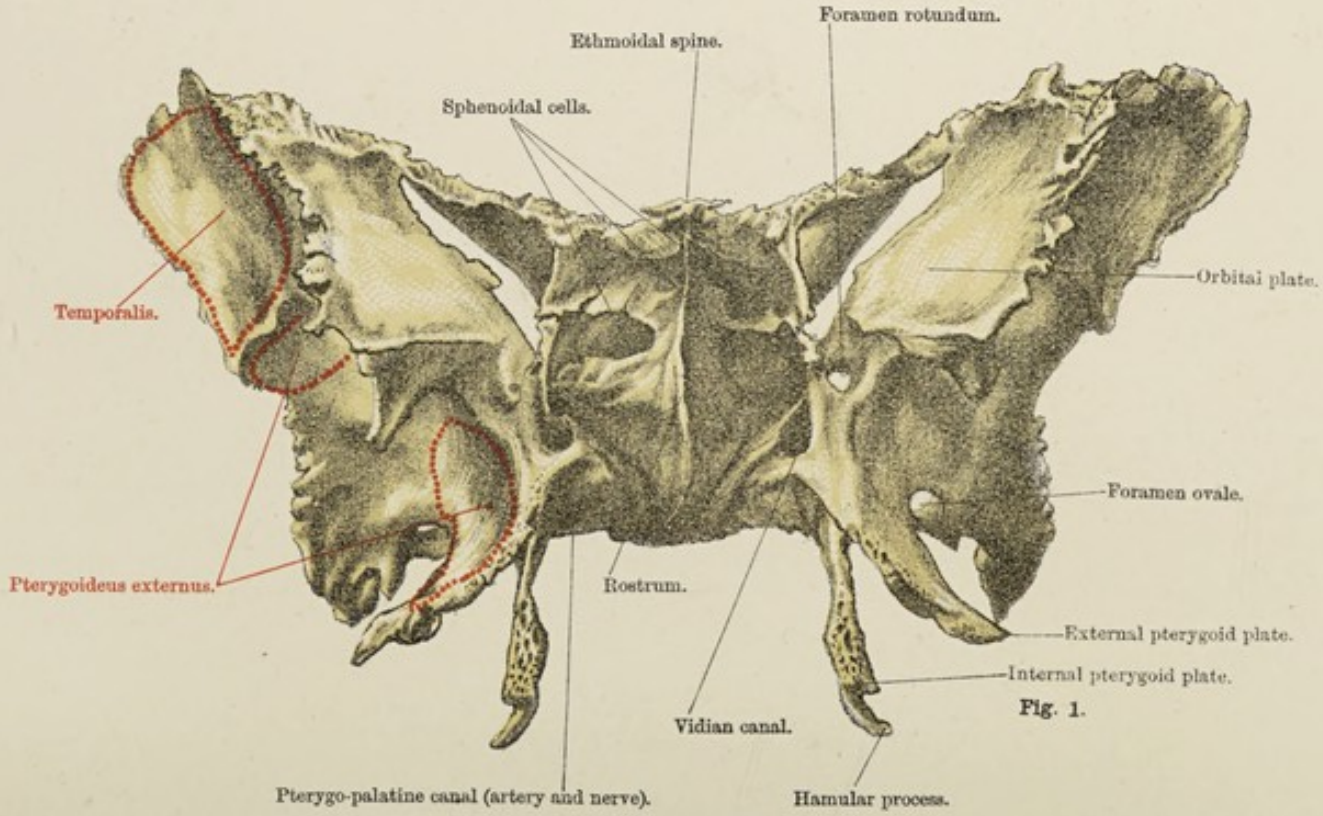

Fig. 1.



Fig. 3.

Fig. 4.

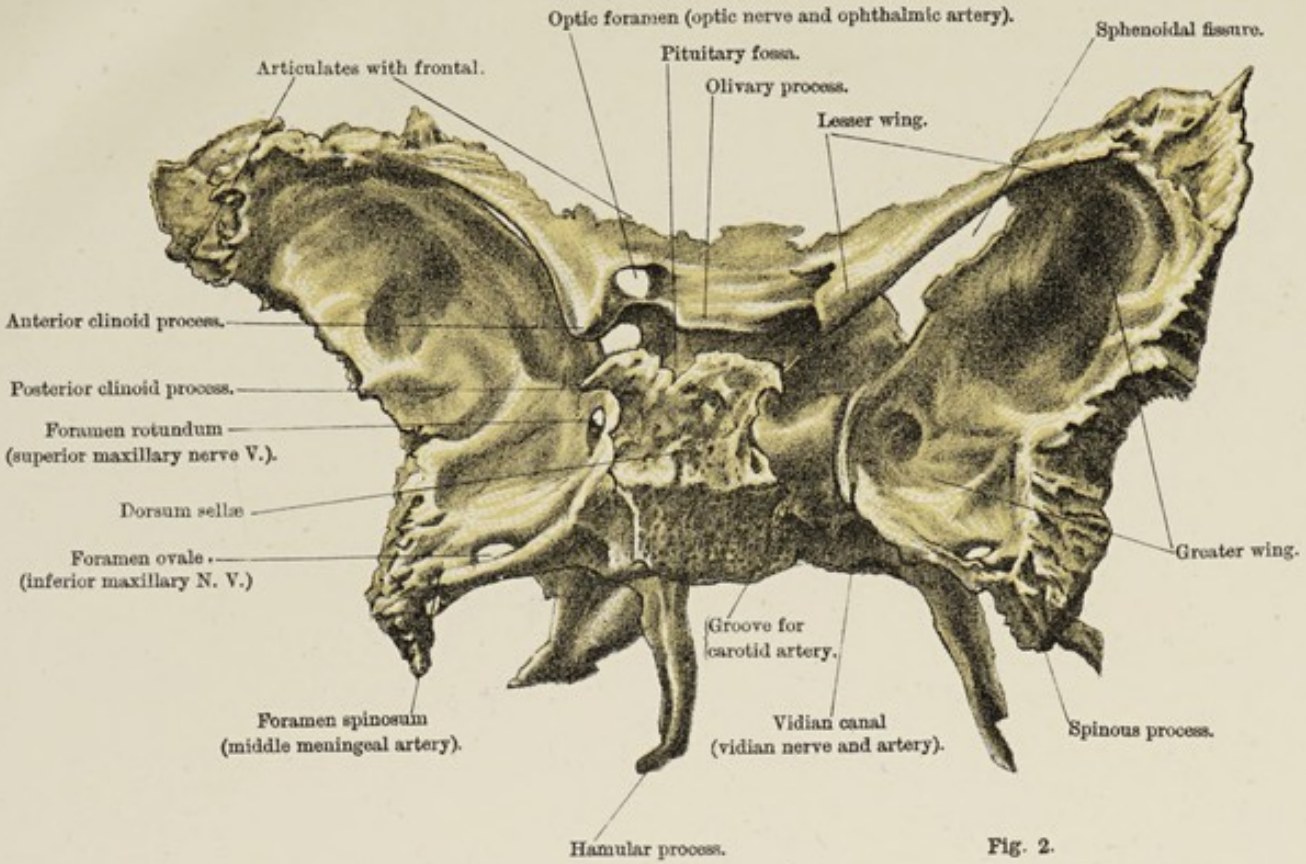

Fig. 2.

Drawn from nature & Printed by W. & A. K. Johnston, Edinburgh & London

SUPERIOR MAXILLA AND PALATE

PLATE XXVIII.

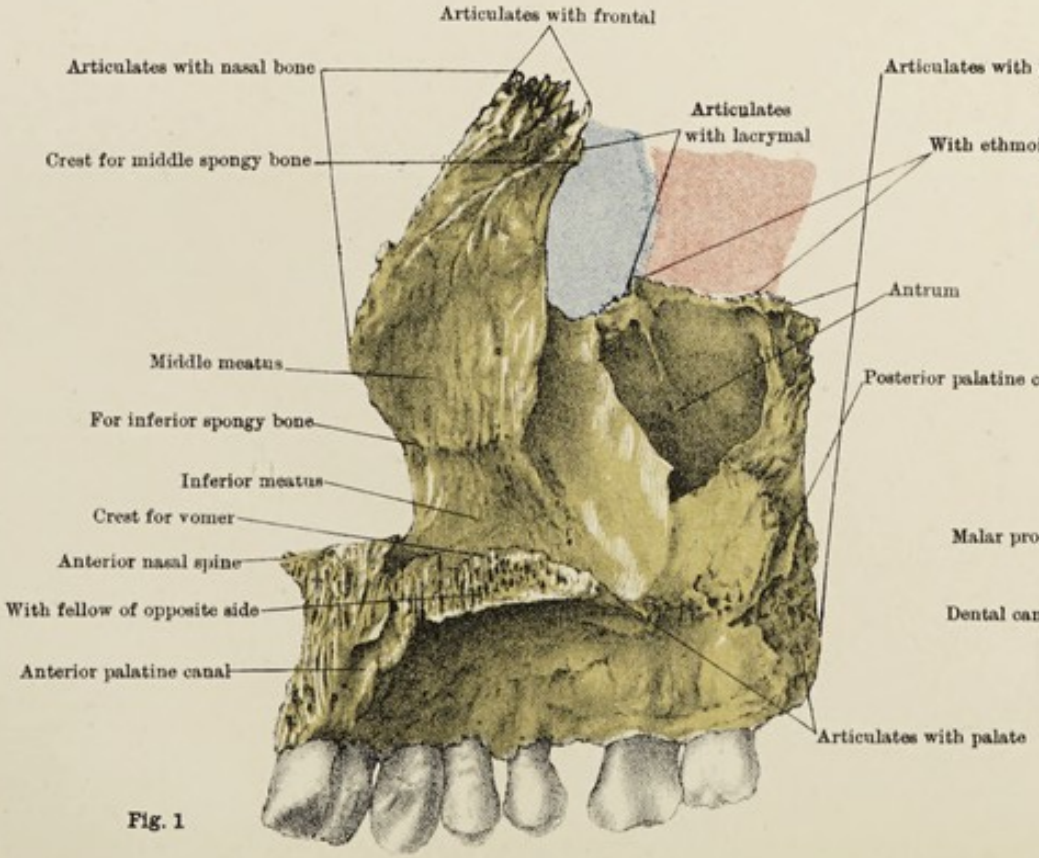

Fig. 1

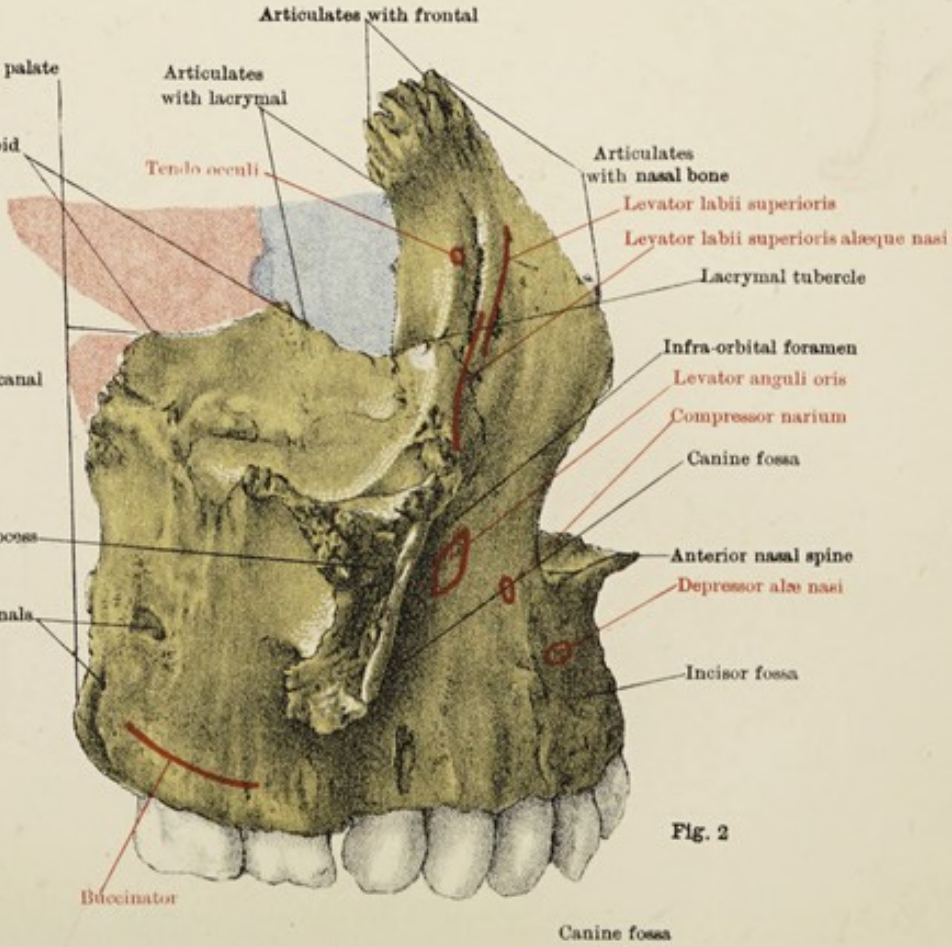

Fig. 2

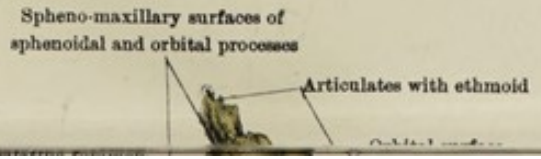

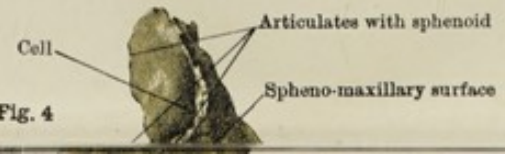

Fig. 4



Fig. 5

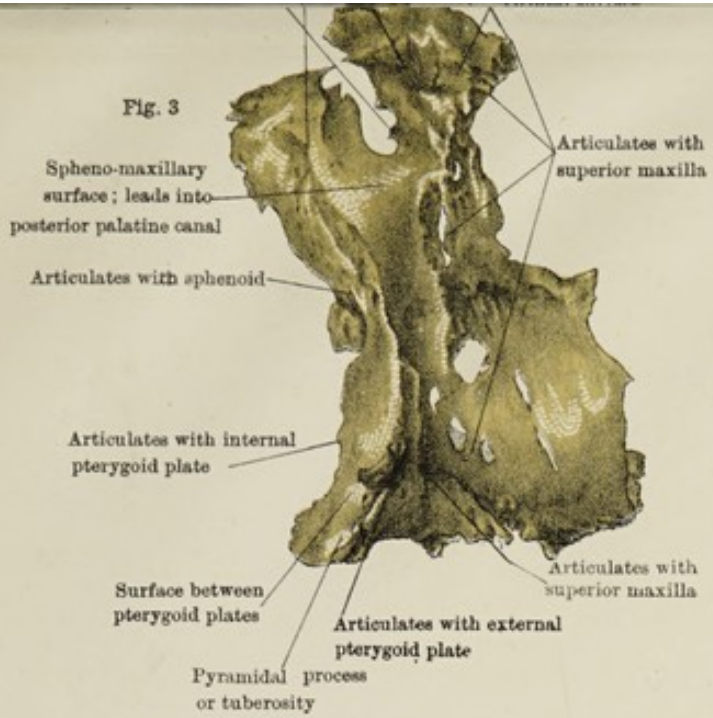

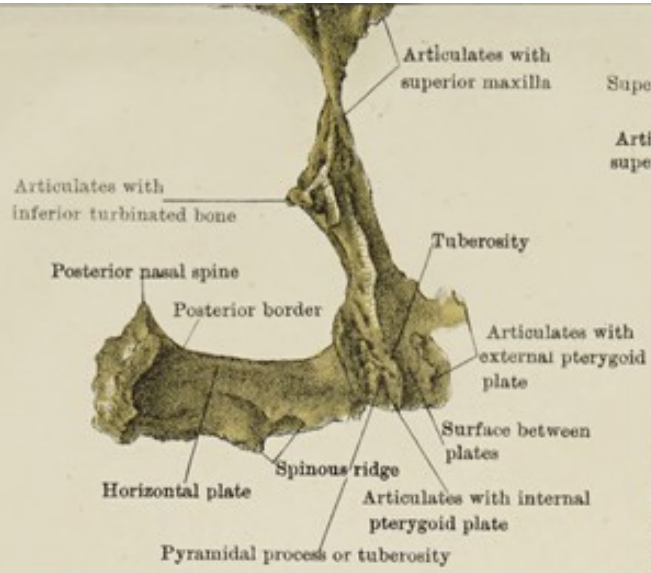

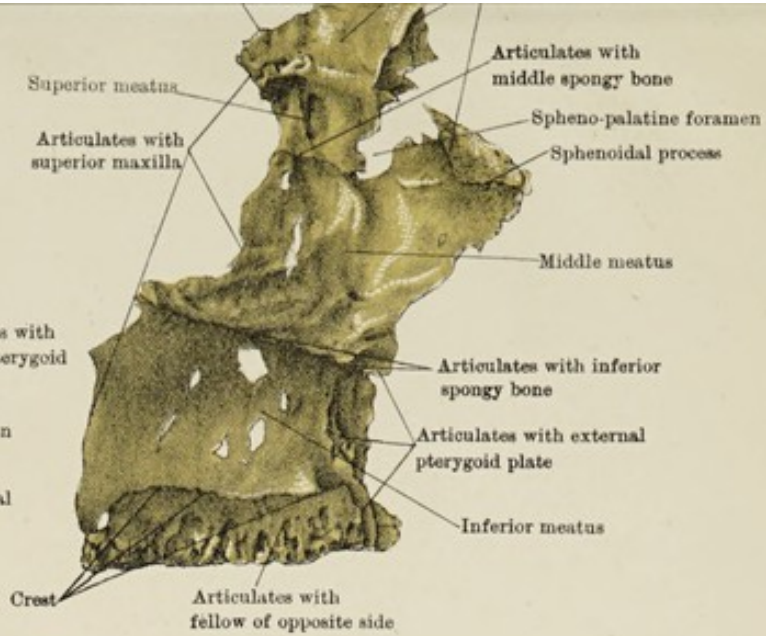

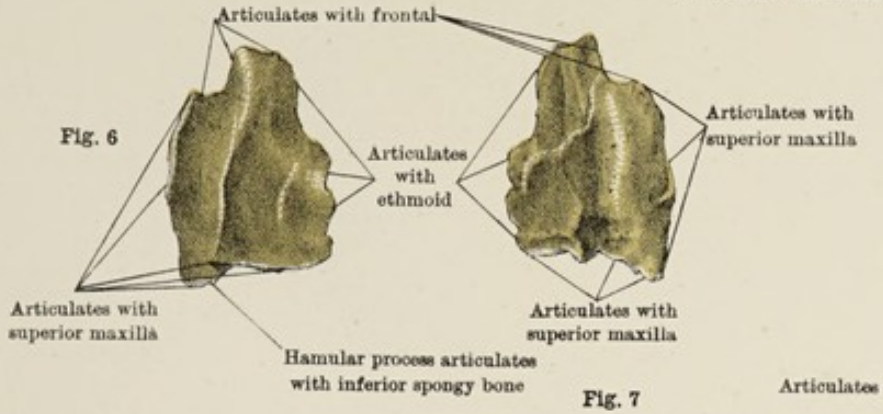

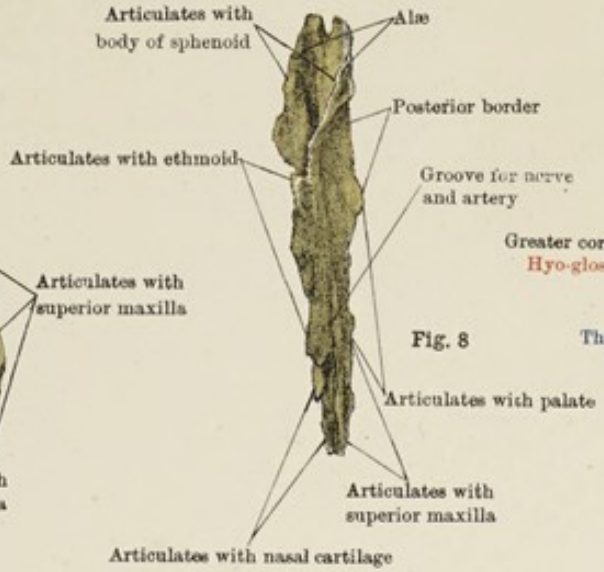

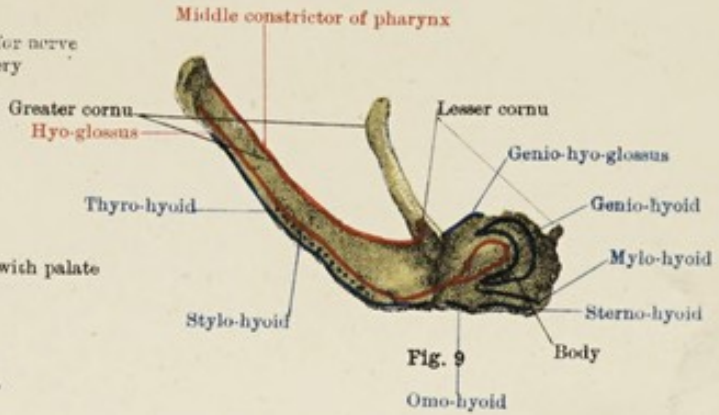

Drawn from nature & Printed by W. & A. K. Johnston, Edinburgh & London

MALAR, NASAL, INFERIOR TURBINATE BONES AND SECTIONS.

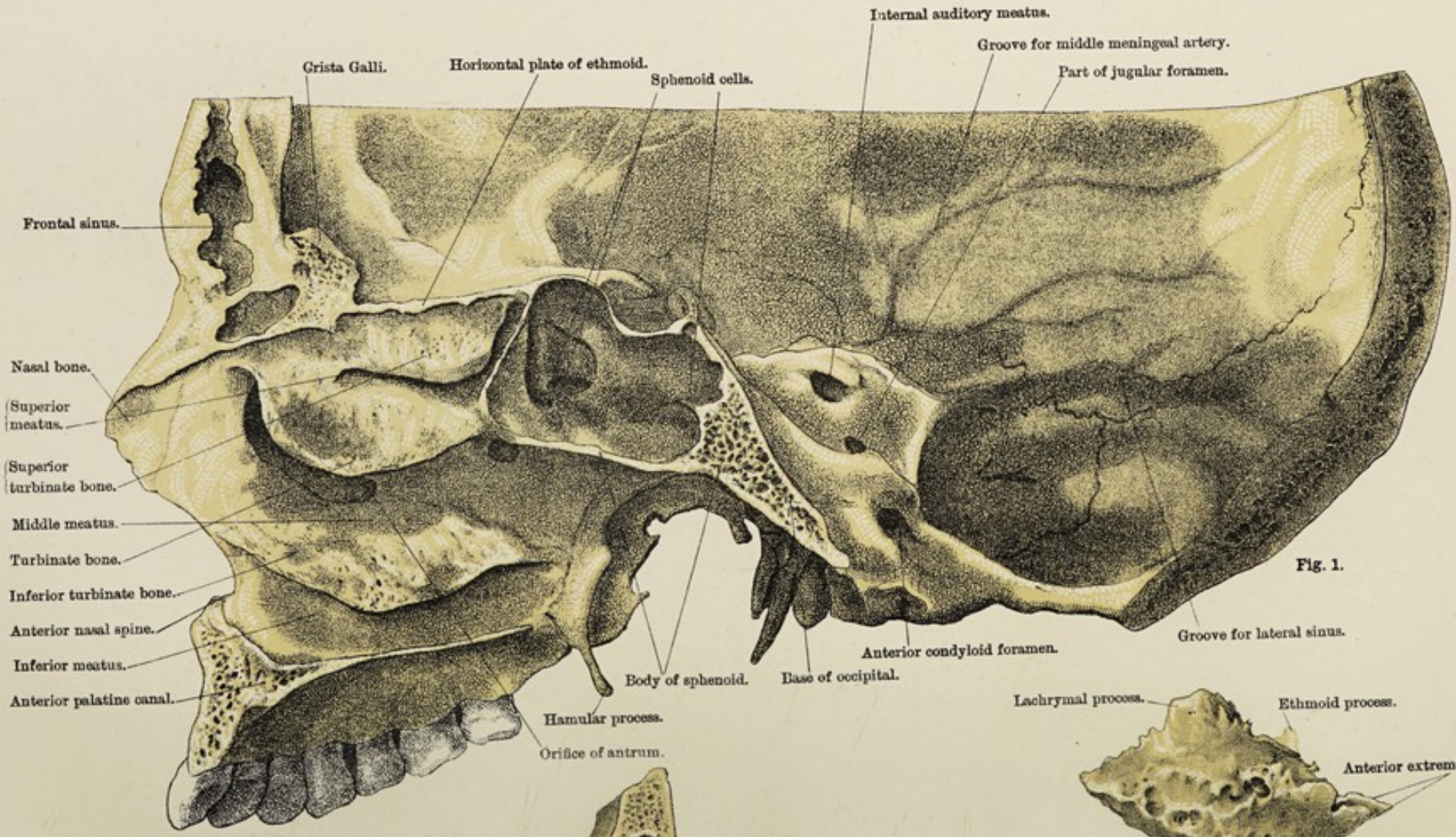

Fig. 1.

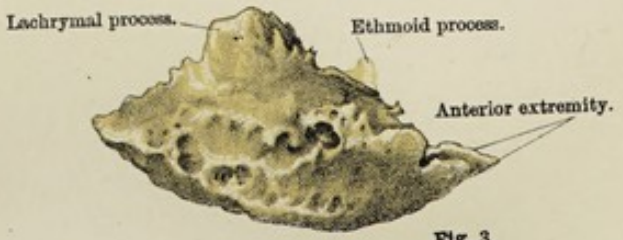

Fig. 3.

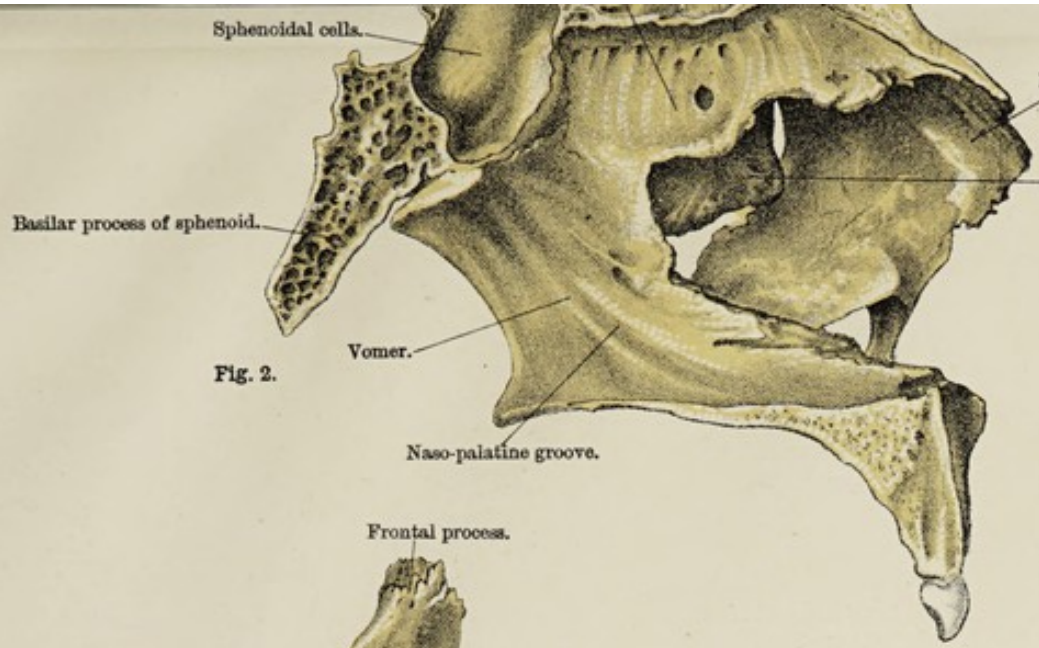

Fig. 2.

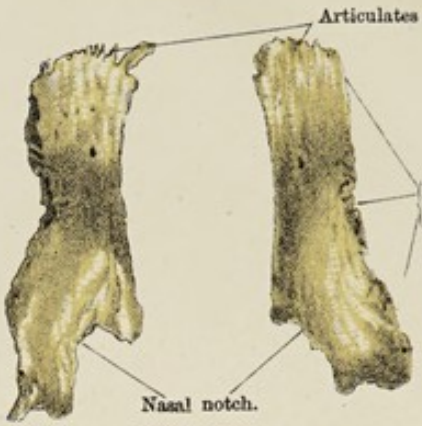

Fig. 7.

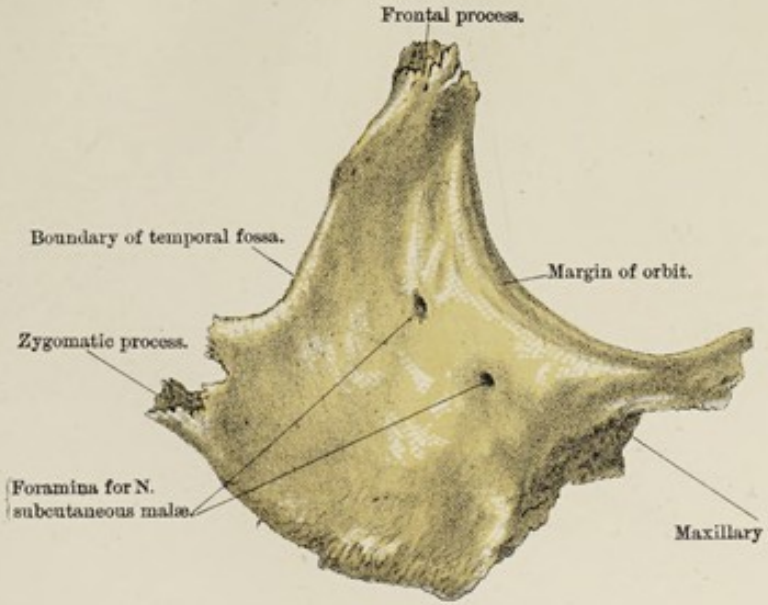

Fig. 4.

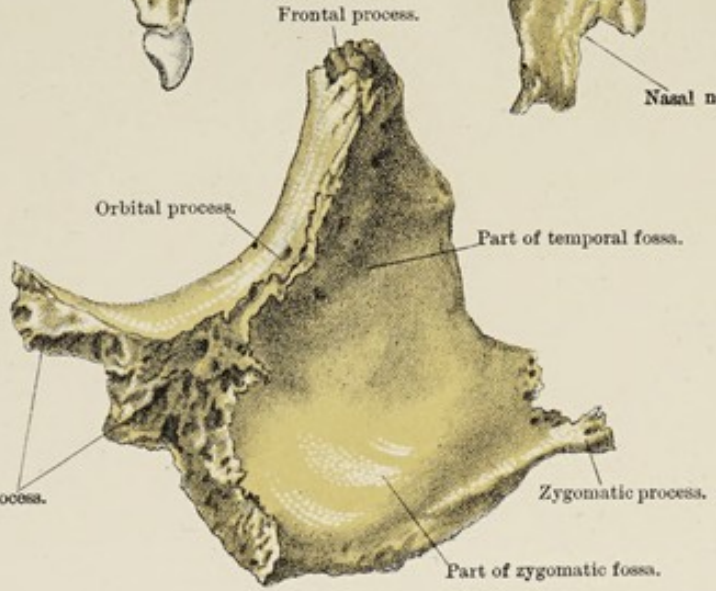

Fig. 5.

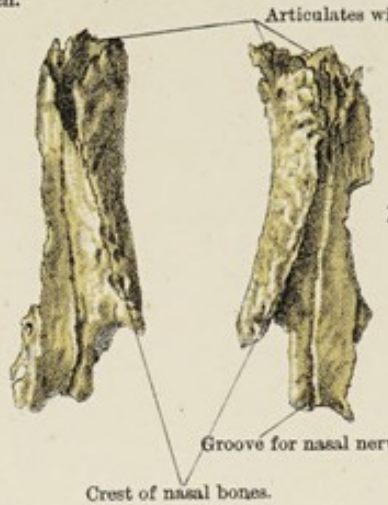

Fig. 6.

Drawn from nature & Printed by W. & A. K. Johnston, Edinburgh & London

SECTIONS OF SKULL, Etc.

PLATE XXX.

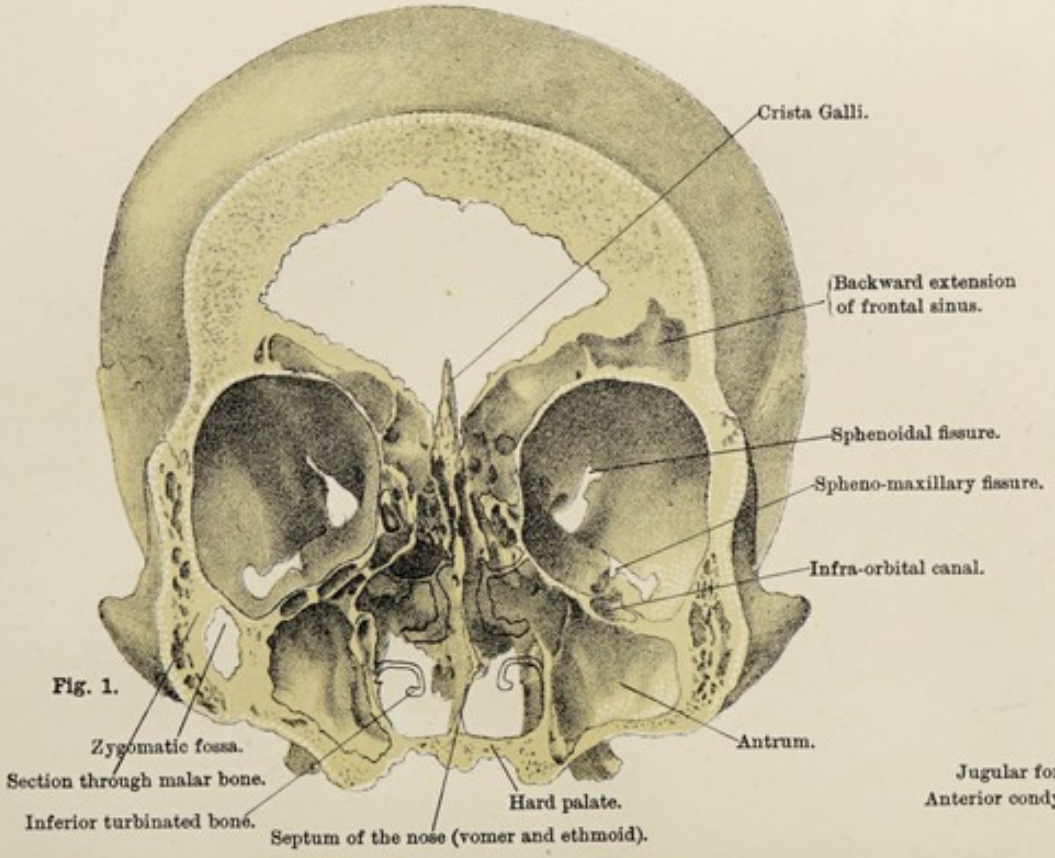

Fig. 1.

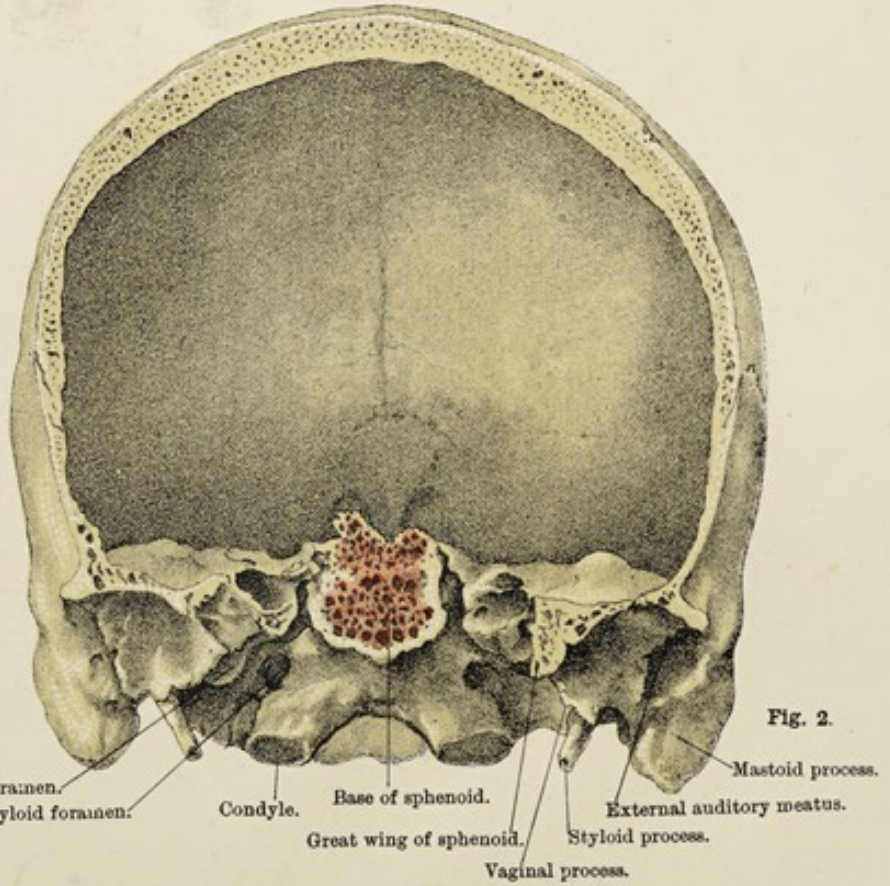

Fig. 2.

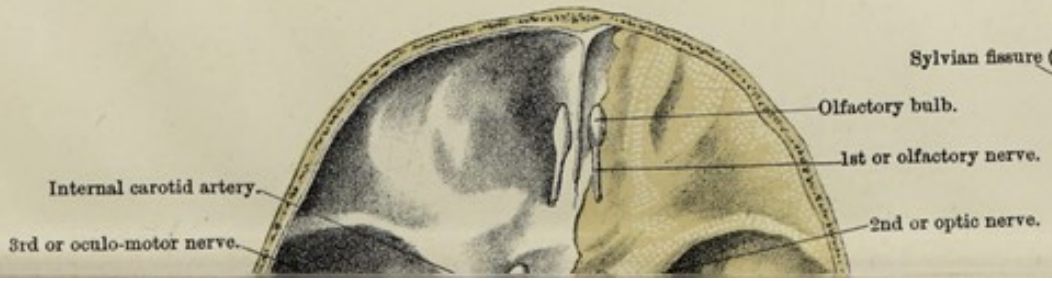

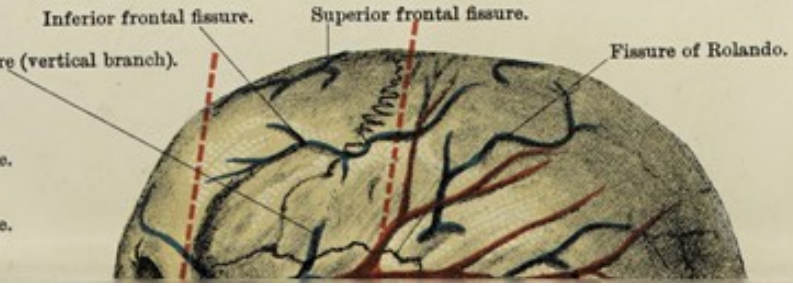

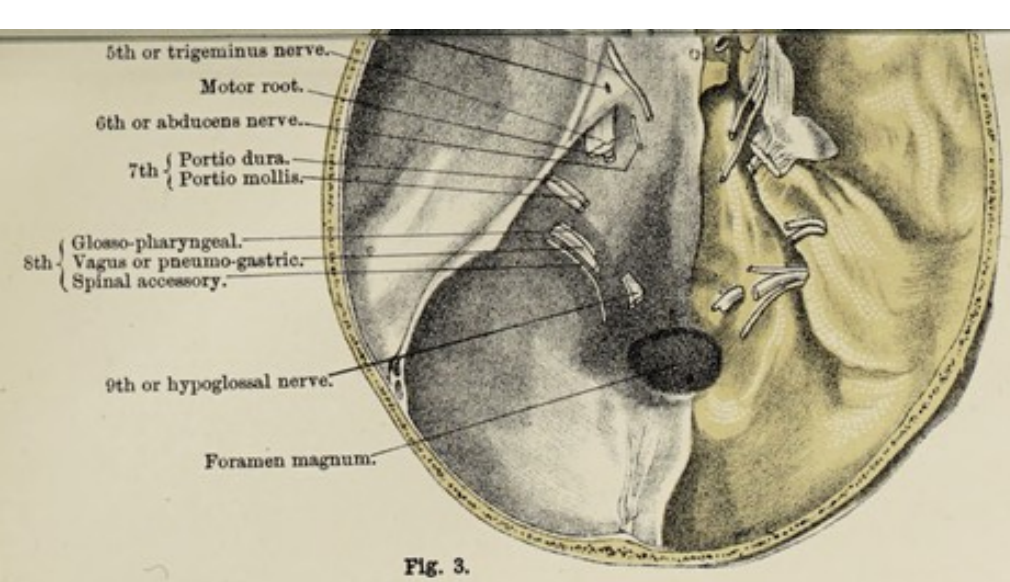

Fig. 3.

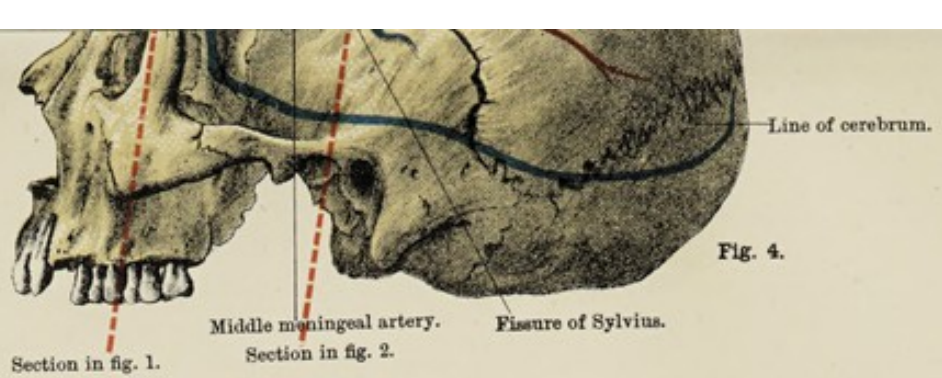

Fig. 4.

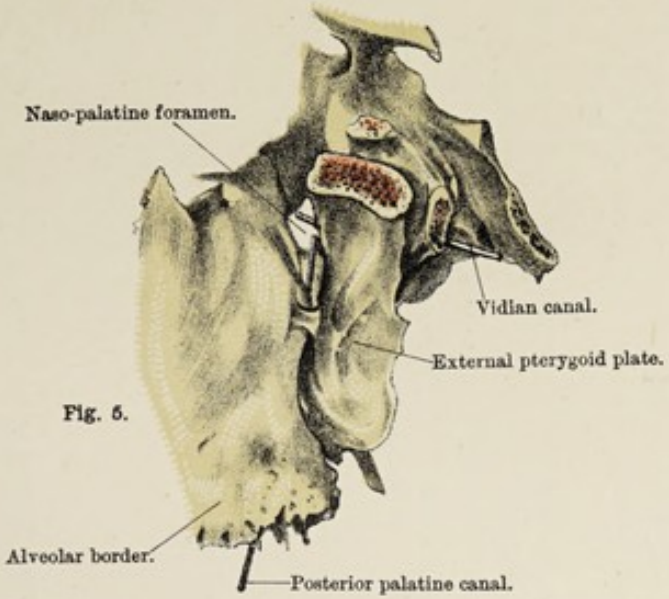

Fig. 5.

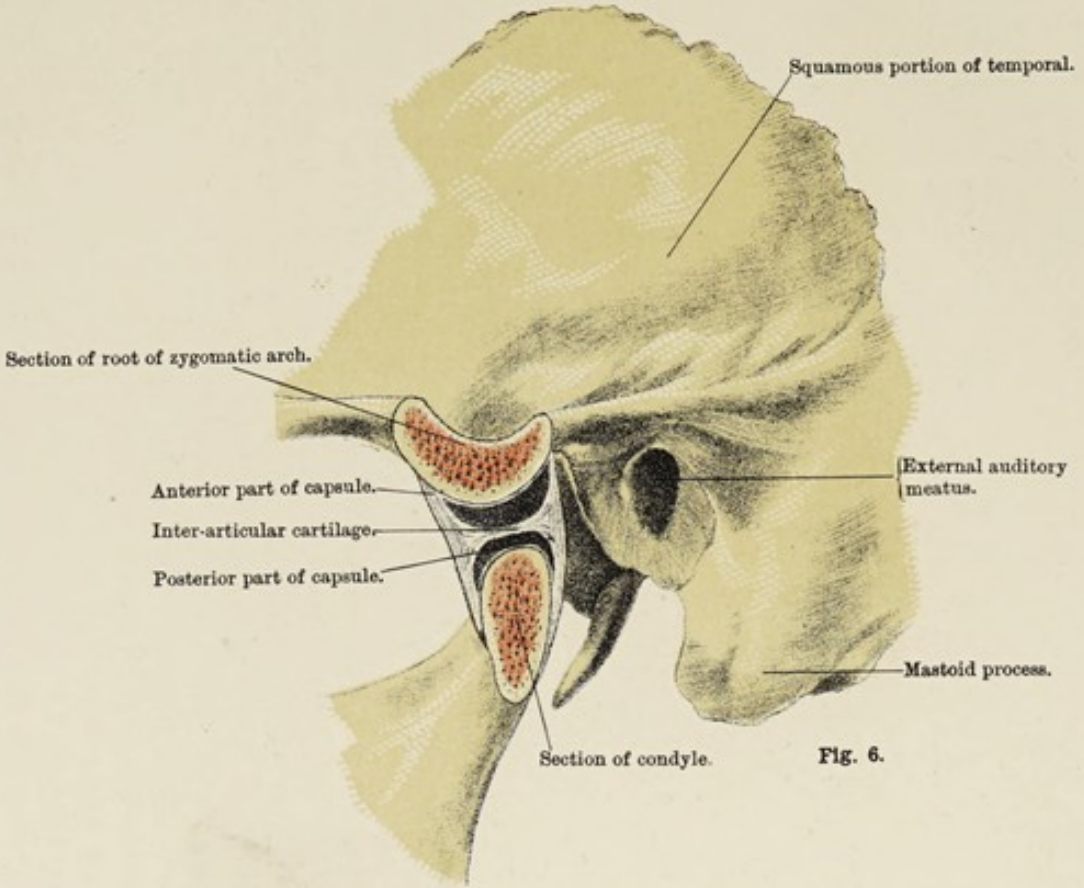

Fig. 6.

Drawn from nature & Printed by W. & A. K. Johnston, Edinburgh & London.

STUDENTS' ATLAS

OF

BONES AND LIGAMENTS

PLATE I.—THE SKELETON.

The Skeletons figured here are drawn, with permission of Professor Turner, from specimens in the collection of the University of Edinburgh.

On comparing the male with the female Skeleton, we find a difference in degree obtains between them. In the male the Skeleton is taller, the bones are larger, better marked, and, speaking generally, have coarser features. The bones of the female are smaller, not so well marked, lighter, and more graceful.

The female Skeleton in addition exhibits characters associated with special sexual functions; thus the pelvis has a larger outlet and is broader, so that the hips are carried further apart than in the male, and, consequently, the angle formed at the junction of the thigh and leg is more acute, and gives rise to a somewhat knock-kneed appearance.

The Skeleton of a child at birth is also introduced in this Plate. It has been enlarged to a greater scale than the adult Skeletons. On the same scale its height would be represented by the vertical black line placed alongside. It has been mounted in the erect posture, a position which, of course, in early infancy is abnormal. It possesses many features which gradually disappear with growth. We may note that the skull is relatively larger than that of the adult. The small size of the chest, its pyramidal form, and the way in which the lower ribs expand, together with the large space left for the abdomen and the small narrow pelvis, all point to the fact that the belly must be large and protuberant, and that the erect position has not yet been acquired whereby important viscera sink into the pelvis. It is also of interest to note that the upper extremities of the infant are relatively longer than those of the adult.

The Human Skeleton differs in many respects from that of the higher apes, and is specially well adapted and modified for the erect position. The skull is carried well above the level of the shoulders, and the face looks directly forwards. The chest is very broad, its antero-posterior diameter is not great. The pelvis is large and roomy, with wide-spreading haunch bones; it contains pelvic organs, and aids in supporting the abdominal viscera. The bones of the lower limbs are longer than those of the ape; they are, moreover, capable of extreme distension, and the foot is commonly used for progression only. While the human spinal column does not vary much in length, the lower limbs do, and are the main cause of individual differences in height In apes the upper and lower extremities are made use of in progression and prehension; the upper limbs are longer, and the lower shorter than in man.

PLATE II.—SPINAL COLUMN AND VERTEBRÆ.

Fig. 1 gives a lateral view of the Spinal Column, including the Sacrum and Coccyx. The vertical blue line indicates the line of gravity of the skull, and renders the antero-posterior curves of the spinal column more apparent. These curves are thus seen to be convex forwards in the cervical and lumbar regions, and convex backwards in the dorsal and sacro-coccygeal regions.

The exact limits of the various curves were carefully examined by Professor Humphry in a specimen specially prepared for the purpose. He found that—

"The Cervical Curve commences at the top of the odontoid process and terminates at the middle of the second Dorsal Vertebra.

"The Second or Thoracic Curve commences at the middle of the second and terminates at the middle of the last Dorsal Vertebra.

"The Third or Lumbar Curve, commencing at the middle of the last Dorsal, terminates at the lower and anterior edge of the last Lumbar Vertebra.

"The Fourth or Pelvic Curve, sharper than either of the others, commences at the upper edge of the Sacrum and terminates at the tip of the Coccyx."

He further found that the line of gravity corresponding with the cords of the first three of these curves, passed from the odontoid process "through the middle of the body of the second Dorsal Vertebra, through the middle of the body of the last Dorsal Vertebra, and through the middle and antero-inferior edge of the last Lumbar Vertebra.

". . . Prolonged further downwards, the plumb line falls just in front of the promontory of the Sacrum, and bisects a line drawn transversely through the middle of the head of the thigh bones, or a very little behind the middle."—Humphry on the Human Skeleton, p. 148. (*These measurements, although not precisely the same in the drawing, are sufficiently near for purposes of illustration.*)

The student will also be able to note from this drawing the shape and direction of the

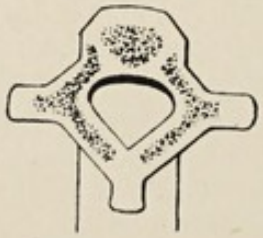

FIG. 1.

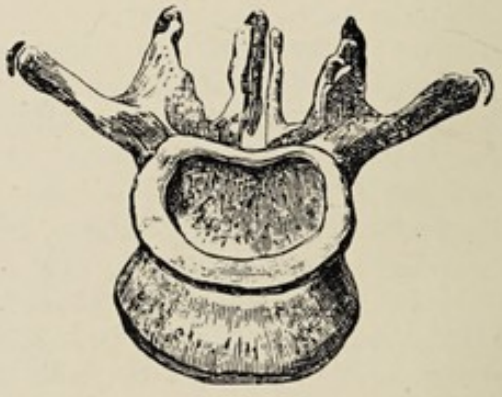

FIG. 2.

spinous and transverse processes, the position of the facets for the ribs, and the mode of formation of the intervertebral foramina.

Figs. 2, 3, *and* 4 giving the view from above of a typical vertebra in each region, should be studied together. The shape, size, and where possible, direction of the various parts should be contrasted with one another, taking in this way the body, pedicles, laminæ, and ring articular transverse and spinous processes. By referring to Fig. 1 many details can be supplied which this view from above cannot give.

Figs. 5 *and* 6 representing the Atlas and Axis, should also be taken together, and the student may observe the contrast which exists between these two vertebræ, parts and processes which are well marked in one being feebly developed in the other. Thus the spinous process and laminæ are small in the atlas (to allow backward movement of the skull) and large in the axis, whose spinous process has important muscular attachments. The transverse process of the atlas, having also special muscles attached to it, is much stronger than the similar process of the axis. The main part of the body of the atlas is attached to that of the axis in the form of the odontoid process.

The student should note that the upper articular processes of the axis and both upper and lower ones of the atlas differ in function from the articular processes of the rest of the vertebral column, in so far that they not only permit of a different kind of movement, and hence have a different shape, but also transmit the weight of the skull downwards, and hence have a different position. They are placed more anteriorly than the other articular processes, and may be looked upon as in the line of the bodies of the vertebræ. Hence the first and second cervical nerves

emerge *behind* their corresponding articular processes, while the succeeding nerves leave at the intervertebral foramina which are *in front* of the articular processes.

Fig. 7 represents the Vertebra prominens or seventh Cervical Vertebra. Its spinous and articular processes should be compared with those of the typical cervical vertebra (Fig. 2). The left vertebral vein, which occasionally passes through the left vertebral foramen, is represented in position.

Fig. 8 gives a view of the eleventh and twelfth Dorsal Vertebræ. The position of the mammillary, transverse, and accessory processes should be noted, also the single facets on the sides of each body for the last two ribs.

The student may find it of some service to trace how the typical character of each region is found in the vertebræ of the region next to it, there being in many points a convergence, so to speak, towards the dorsal region. Thus the lumbar characters are seen in the body and spinous processes of the lower dorsal vertebræ, and in the inferior articular processes of the last; while the cervical character is seen in the shape of the body of the upper dorsal vertebræ, and in the direction of their spines. On the other hand, however, the dorsal characters are found in the shape of the transverse and spinous processes of the seventh cervical vertebra.

The foregoing Woodcuts illustrate the ossification of the Vertebræ.

Fig. 1 (after Quain) shows the central and two lateral nuclei from which the body, pedicles, and laminæ are developed.

Fig 2, from a Lumbar Vertebra, illustrates the additional centres of ossification for the upper and lower margins of the body, and for the tips of the articular, spinous, and transverse processes.

PLATE III.—VERTEBRAL COLUMN—*Continued.*

Fig. 1 represents anterior view of Sacrum, partially turned to the right side to show the Auricular Surface. The anterior primary divisions of the sacral nerves are diagrammatically represented coming through the anterior sacral foramina on the right side of the bone.*

Fig. 2 represents a posterior view of the same bone. The reason why the gluteus maximus begins to take its attachment so low down in the bone will be understood when the place of articulation with the Ilium is remembered, *i.e.*, with the first three pieces of the sacrum.

Figs. 3 *and* 4 represent anterior and posterior views of the Coccyx. The rudimentary articular processes (cornua) can be seen in the first piece, and rudimentary transverse processes in the first two, but the rest show only diminishing representations of the bodies.

Fig. 5. View of Vertebral Column from the front. Shows how the vertebral column forms two main pyramids, with their bases at the sacrum and their apices at the atlas and coccyx respectively; it also shows how the upper pyramid is subdivided into three, two with their apices upwards, extending from the sacrum to the 4th dorsal vertebra, and from the 7th cervical vertebra to the atlas respectively, and the third pyramid with its apex downwards, between the 1st and the 3rd dorsal vertebræ.

The relative length of the transverse processes in the upper three regions can be seen from this figure, and also how the lateral mass of the sacrum may be considered to consist of fused transverse processes of the primitive sacral vertebræ.

Fig. 6 represents a mesial section of the Skull and Vertebral Column. The relative position of the bodies of the vertebræ to the spinal canal is well brought out, also the continuity of the cranial cavity and spinal canal, the mode of formation of the intervertebral foramina, the shape on section of the bodies of the vertebræ, and the size and direction of the spines.

Fig. 7 represents diagrammatically the relative position of the articular and transverse processes, and the Intervertebral Foramina. From this it will be seen that, while the articular processes remain posterior to the intervertebral foramina throughout the three regions (Fig. 6), the relation of the transverse processes to both of these varies in each region, *i.e.*, in the cervical region the transverse processes lie over the intervertebral foramina, in the dorsal region behind

* On Fig. 1 the articular surface for the Ilium is shown to come too low, and should only reach to the level of the 3rd sacral vertebra.

the articular processes, and in the lumbar region between intervertebral foramina and articular processes.

Fig. 8 represents centres of ossification in Sacrum at birth (*after R. Quain*).

Fig. 9 represents condition of ossification of Sacrum at about twenty-three years of age (*after R. Quain*).

PLATE IV.—LIGAMENTS OF THE VERTEBRÆ.

Before considering the special Ligaments of the first two Vertebræ (Figs. 1 to 4), the student should recollect how the Vertebræ are connected together throughout the rest of the Spinal Column. The bonds of union may be taken as those between the bodies, the laminæ, and the articular, transverse, and spinous processes.

Uniting the BODIES there are—

(1.) *Intervertebral Discs* (Figs. 5 and 7).

(2.) *Anterior Common Ligaments* (Figs. 6 and 7).

(3.) *Posterior Common Ligaments* (Figs. 7 and 8).

Uniting the LAMINÆ there are the *Ligamenta Subflava*. These derive their name from containing a large proportion of elastic tissue; their yellow colour, however, could not be specially indicated in the Plate.

Uniting the ARTICULAR PROCESSES there are the fibrous capsules of a diarthrodial joint in each case (Fig. 9).

Uniting the TRANSVERSE and SPINOUS PROCESSES there are bands of fibrous tissue known as the inter-transverse and inter- and supra-spinous ligaments (Fig. 7) in each case.

In the Joints between the Occiput, Atlas, and Axis we must look for modified representatives of the above ligaments, and some additional ones, the key to the understanding of them being a recollection of their functions. The movements are free, hence there are no intervertebral discs. There is antero-posterior movement between the Occiput and Atlas, and lateral rotatory movement between the Atlas and Axis, hence we must look for provision for each of these in the modification of the ordinary ligaments and in the appearance of new ones.

Looking first at the continuation upwards of ligaments from below, we have the *Anterior Common Ligament* continued up as the *Anterior Atlanto-axial*, and the *Anterior Occipito-axial Ligaments* (Fig. 1); the *Posterior Atlanto-axial* and *Occipito-axial Ligaments* (Fig. 4) pass between the *laminæ* of the Atlas and Axis and margin of the Foramen Magnum, and represent the *Ligamenta Subflava*, but without the elastic tissue. The *Posterior Common Ligament* is continued up as the *Occipito-axial Ligament*, which consists of a deep and a superficial part (Fig. 2); there is no attachment to the Atlas in this ligament, because the body of the Atlas posteriorly is represented by the odontoid process of the Axis; anteriorly, however, this bony attachment is represented by the anterior arch of the Atlas. The ligamentum muchæ (not shown in the Plate) represents the inter- and supra-spinous, and a few fibres the inter-transverse ligaments. Further, between the adjacent articular processes of the Atlas and Axis, and between the upper articular processes of the Atlas and the Condyles of the Occipital bone, there are well-marked diarthrodial joints, similar to those between the lower series of articular processes, but permitting of a freer and special range of movement.

The ligaments peculiar to this region are the *Transverse Ligament* of the Atlas (Figs. 2 and 3), which binds the odontoid process in position, and the *Odontoid Ligaments* from the apex of the odontoid process to the margins of the Foramen Magnum (Fig. 2). A synovial sac in front of and behind the odontoid process enables it to glide freely on the anterior arch of the Atlas, and on the transverse ligament (Fig. 3).

In Fig. 4 the place of entrance of the Vertebral artery through the posterior occipito-atlantal ligament is not shown; the coats of the artery blend with the ligament as it passes through.

The student, having now considered these ligaments in contrast to those of other Vertebræ, should next classify them as those which

(1.) Bind the Axis to the Atlas (including the transverse ligament).

(2.) Bind the Axis to the Occipital bone.

(3.) Bind the Atlas to the Occipital bone.

There still remain the joints which unite the ribs to the Vertebræ. These in one of the middle of the series are :—

1. Between the head of the rib and two adjacent bodies, two small synovial cavities separated by an inter-articular ligament (Fig. 6), which binds the head of the rib to the inter-vertebral disc, and in front the anterior costo-vertebral or stellate ligament (Fig. 6).

2. Between the tubercle of the rib and the transverse processes of the *lower* of the two Vertebræ with which the rib articulates, there is a small synovial sac, and *posterior* and *middle costo transverse ligaments* (Fig. 5); the latter is between the neck of the rib and the transverse process.

3. Between the neck of the rib and the transverse process next above, there passes the anterior (or superior) costo-transverse ligament (Fig. 6).

In the 1st, 9th, 10th, 11th, and 12th ribs there are modifications of the above ligaments and joints corresponding to the modifications in the modes of articulation.

PLATE V.—STERNUM AND THORAX.

Figs. 2 and 4 illustrate the Sternum or breast bone. It is a flat bone formed originally of seven pieces, of which the two terminal ones usually remain free and distinct. The five central pieces fuse into one—the Gladiolus (Fig. 4), on whose anterior surface traces of the original separation may still be seen. The uppermost piece, larger and broader than the others, is the Manubrium ; the lowermost, partially covered by the insertion of the rectus muscle, is known as the ensiform process or cartilage, according as it is ossified or not.

The Clavicles join the Manubrium Sterni at the Sterno-clavicular joint. This consists of a capsular joint which contains two synovial membranes separated by a vertical interarticular plate of fibro-cartilage (Fig. 1). The union is greatly strengthened by the interclavicular ligament (Figs. 1 and 2), which passes from clavicle to clavicle and joins the notch of the Manubrium midway.

The junction of the costal cartilages with the Sternum is seen in Fig. 1, where half of the anterior surface of the bone has been removed. By this dissection the joints of the seven true ribs have been opened into. The first has no synovial membrane, the second has two membranes, the remainder one each. This was found to be uniformly the case in the specimens we observed. Intercostal synovial membranes at the articulations of the false ribs are also present. On each side the articulations are as follows: the Manubrium Sterni articulates with one and a half cartilages (the 1st and half of the 2nd); the last piece of the Gladiolus with one (the 8th) and two halves (half of the 7th and half of that common to the 9th, 10th, and 11th); while the remaining pieces of the Gladiolus articulate with two halves (one above and one below) each, and the ensiform cartilage with one half, *i.e.*, the remaining part of that common to the 9th, 10th and 11th.

The shape of the Thorax at its upper part is worthy of note. The thoracic cavity here tapers as it rises above the level of the clavicle, so that the apex of the lungs occupies part of the root of the neck. On account of the breadth of the shoulder girdle and the strong muscles attached to it, this portion of the body has an increased breadth, while the thoracic cavity, as above noted, is really narrowed.

PLATE VI.—CLAVICLE AND RIBS.

In Fig. 1 the right Clavicle, seen from above and behind, is shown in its relations to the Scapula. By this means the attachments of the Deltoid and of the Trapezius to the two bones can be better understood. The Spine and Acromion process of the Scapula may be considered

as forming with the outer end of the Clavicle a roughly-shaped V. From the outer side of this the fibres of the Deltoid take origin; to the inner side of it the fibres of attachment of the Trapezius are inserted.

In considering the Clavicle the student may remember that one of the three surfaces (superior) of the inner prismatic end is continuous with one of the two surfaces (superior) of the outer flattened end; that the two remaining surfaces (anterior and posterior) of the inner end are continuous with the anterior and posterior borders of the outer end, while the remaining surface (inferior) of the outer end is continuous with the inferior ridge of the inner end, thus leaving the anterior and posterior borders of the inner end without exact representatives at the outer end, except so far as they blend with the anterior and posterior borders there. He may also remember that at the inner end of the Clavicle, as in other prismatic-shaped bones, two of the surfaces and two of the borders (anterior and posterior in each case) correspond, while the remaining surface (superior) looks in the reverse direction from the remaining border (inferior). The attachment of the sterno-hyoid muscle to the back of the inner end of the Clavicle is indicated by a single red line. It is better seen on Fig. 2.

The relation of the Coracoid process to the outer end of the Clavicle should be remembered, otherwise the student may have difficulty in finding its position in the living body.

In Fig. 2 the Clavicle is seen from below. The directions of the lines on the bone are given, not as if the bone were lying as at present, but after it has been replaced in its natural position.

Fig. 10, after Quain, shows the single Epiphysis of the inner end of the Clavicle still ununited at twenty-three years of age.

Fig. 5 represents a typical rib, the 7th, taken from within.

Figs. 3 *and* 4 are views from above of the 1st and 2nd Ribs.

Figs. 6, 7, *and* 8 are views from behind of the 10th, 11th, and 12th Ribs.

These latter, *i.e.*, the first two and last three, are exceptional ribs as regards many of their characters. Their peculiarities should be studied along with those of the vertebræ with which they articulate.

Fig. 9, after Quain, represents a typical Rib at twenty years of age, with separate Epiphyses for the head and tubercle.

PLATE VII.—THE SCAPULA.

In each of the figures the right bone is represented.

In studying the Scapula, the student should remember that the bone lies obliquely from behind forwards, not altogether transversely, as he might infer from its position on the Plate. Its mainly transverse position is the reason why the axillary border is also called the external, and the vertebral border the internal; but its slope from behind forwards must also be taken into account as the explanation of the third name, anterior, as applied to the axillary, and posterior, as applied to the vertebral border. These additional names have been omitted from the Plate.

Fig. 1 represents the ventral, anterior, or antero-internal aspect of the bone. Through the supra-scapular notch the spine of the Scapula is seen, and above the coracoid process is the acromion process bearing the articular surface for the clavicle. The spicule of bone projecting over the notch from the root of the coracoid process is an ossified portion of the supra-scapular ligament. The ridges on the subscapular fossa for the fibrous intersections of the subscapularis muscle are well shown. The other parts are sufficiently indicated by the names attached.

Fig. 2 represents the dorsal, posterior, or postero-external aspect of the bone. The doubling round on itself of the insertion of the trapezius near the root of the spine should be noted. Although the insertion of the Rhomboideus major is indicated almost continuously from the root of the spine to the inferior angle, it should be remembered that the muscle is chiefly attached by a fibrous arch which stretches between these two points. Unfortunately, the whole of the origin of the long head of the biceps could not be shown. The small surface from which the tendon arises can be seen on most bones on the upper and posterior margin of the glenoid

cavity. The whole of the origin of the supra-spinatus muscle could not be indicated. It occupies the supra-spinatus fossa, just as the infra-spinatus muscle does its corresponding fossa, and, like it, ceases to take origin from the bone at some little distance from the glenoid cavity. A similar arrangement may be seen in the Os Innominatum and in other bones, where muscular fibres cease to arise from bone when their origin approaches their insertion. In this way a sufficient distance is given for contraction.

Fig. 3 is a view of the Scapula looking directly at the axillary border. The object of this view is to draw attention to the leverage given to some of the muscles acting upon and from the Scapula by the rising out from the bone of the spinous, acromion, and coracoid processes.

Fig. 4. After the diagram given by Ward is the end view of a section of the Scapula taken in the direction indicated by the dotted line in Fig. 2. The mode of formation of the three fossæ for the supra-spinatus, infra-spinatus, and subscapularis muscles is well brought out. It will be seen on examining any scapula that this arrangement is not so distinct near the glenoid cavity.

Figs 5 *and* 6 (*drawn after R. Quain*) represent the Scapula at fifteen or sixteen and at seventeen or eighteen respectively. They show the separate centres at the acromion and coracoid processes, at the vertebral border, and at the inferior angle.

PLATE VIII.—THE HUMERUS (RIGHT).

Figs. 1, 2, *and* 3 are views of the right Humerus from the back, the outside, and the front respectively. By adding an outer view to the anterior and posterior ones generally given, we have been able to give a better representation of the muscular attachments than is otherwise possible.

Figs. 4, 5, 6, *and* 7 are views of the bone in section at the levels indicated by the dotted lines. In each case the section is looked at from below.

Fig. 1 brings out well the direction of the Head looking upwards as well as backwards and inwards. The student should remember that the Scapula is placed obliquely, so that the head of the Humerus and the glenoid cavity look towards one another. Sometimes a difficulty is felt with regard to the outer and inner heads of the triceps. The terms outer and inner are only applicable at the level of the musculo-spiral groove, below that the inner head occupies the whole breadth of the back of the Humerus.

Fig. 2 shows the bone from the outside. To the great tuberosity the supra- and infra-spinatus and teres minor muscles are inserted in the same order from above downwards as they arise from the Scapula (*v.* Plate VII., Fig. 2). The student should note how far the origin of the Brachialis Anticus comes round the bone.

Fig. 3 gives a view of the bone from the front. The nutrient foramen, just below the insertion of the coraco-brachialis, has been obscured by the colour which indicates the attachment of this muscle; like the nutrient foramina of the Radius and Ulna, its direction is towards the elbow-joint.

The drawings of the Epiphyses at the upper and lower ends of the Humerus will be found in the next Plate.

PLATE IX.—THE RADIUS AND ULNA.

In this Plate the bones of the right forearm are represented.

Figs. 2 *and* 3 show the anterior and posterior aspect of the bones in the position of supination. In Fig. 2 the position of the nutrient foramina should be noted. Their direction is towards the elbow joint, as is also that of the nutrient artery of the Humerus. In the bones of the leg and thigh, the nutrient foramina run away from the knee joint.

Fig. 1 displays the Ulna as seen from its outer surface. The tubercle at the insertion of the brachialis anticus is larger than usual.

The interosseous ridge runs in front of the extensor muscles. The upper of the two lines seems to point to the oblique ridge. It should be observed that the oblique ridge divides the surface between the interosseous and posterior ridges into two, a posterior non-muscular and an anterior muscular surface.

Figs. 4, 5, 6, *and* 7 are views of the bones in section. They indicate the position (supine) in which the greatest width of the interosseous space is preserved.

Figs. 8 *and* 9 illustrate ossification ; 8, that of the Radius, with a centre for the shaft and one for each extremity ; 9, that of the Ulna, in every respect similar. These Figs., after R. Quain, are from a boy about twelve years of age.

PLATE X.—LIGAMENTS OF SHOULDER AND ELBOW.

Under the general title " Ligaments of the Shoulder " we have included, besides the proper ligaments of the shoulder joint, (1) those which unite the outer end of the Clavicle to the Scapula, as well as (2) those which pass from one part of the Scapula to another.

(1.) The outer end of the Clavicle is united by a diarthrodial joint to a facet on the acromion process ; there are well-marked *superior acromio-clavicular* fibres (Fig. 2), and a few ill-defined *inferior* ones passing from one bone to the other. A strong set of fibres unites the upper part of the coracoid process to the ridge on under side of the outer end of the Clavicle—the posterior part, Conoid Ligament, and the anterior part, Trapezoid Ligament, are more or less blended—they are shown in Figs. 1 and 2.

(2) Those passing from one part of the Scapula to another are—

a. The Coraco-acromial Ligament (Figs. 1 and 2).

b. The Supra-scapular or Transverse Ligament (Fig. 1).

The Ligaments of the Shoulder Joint consist of a lax capsule with one thickened band above—the coraco-humeral (Fig. 1). This passes from the root of the coracoid process to the fore part of the great tuberosity of the humerus. The rest of the capsule is very thin and lax, and does not aid in keeping the surfaces of the bones in contact, this being done by the action of the muscles and by atmospheric pressure.

The biceps tendon passes through the capsule of the shoulder joint, to be fixed to the scapula above, and to the outside of the glenoid cavity. The synovial membrane forms a little pouch prolonged downwards on the tendon, while within the joint a reflection passes upwards over the tendon as far as its point of attachment. The external relations of the tendon to the joint are seen in Figs. 1 and 3, in the latter of which the synovial membrane is distended, and the separate pouch thus rendered distinct. Within the joint the tendon may be studied in Fig. 3, while its attachment to the scapula is shown in Fig. 2.

A bursal sac is found between the coracoid process and the tendon of the subscapularis muscle ; this is sometimes continuous with the joint, but was not so in the specimen from which the drawing was made, see Fig. 1. Compare also Fig. 4, where the synovial membrane is seen to bulge below the coracoid process.

Fig. 3 is a view of the Right Shoulder Joint, taken from the inside after the capsule has been opened from below and turned back. It shows the tendon of the biceps and the line of attachment of the capsule. The Scapula was placed with the glenoid cavity downwards, and the Humerus was suspended from it by the part of the capsule which was left intact.

Fig. 4 is a view from the inner side of a Left Shoulder Joint distended with tallow. The abducted position of the Humerus, due to the distention, is well shown. (In Fig. 1 the Humerus is also shown abducted, but it was artificially placed so in order to prevent the lower part of the capsule from being unduly folded).

The prolongation of the synovial pouch along the tendon of the biceps is indicated by a lighter colour, and has been already alluded to. Below the coracoid process, *i.e.* in contact with the subscapularis tendon, the capsule is seen to be thin and bulging. The dried remains of the muscular attachments to the Scapula and Humerus are clearly shown in the Figure, and are indicated in the letterpress.

Fig. 5 shows the condition of the upper Epiphysis of the Humerus at fifteen years of age. The Epiphyseal line will be seen to correspond to that of neither the anatomical nor the surgical neck, but partly to both—*i.e.* to the surgical below the Tuberosities, and to the anatomical neck at the lower part of the Head. The upper Epiphysis is developed from one nucleus for the head (second year), another for the great tuberosity (third year), and according to some authorities, a third for the lesser tuberosity (fifth year): these fuse together in the fifth year, and the whole unites to the shaft in the twentieth year.

Fig. 6 is taken from the same bone as Fig. 5. It shows the separate Epiphyses of the trochlea and capitellum and outer condyle not yet united to the shaft, while the Epiphysis for the inner condyle was already united. The order of appearance usually given is capitellum (third year); inner condyle (fifth year); trochlea (eleventh or twelfth year); external condyle (thirteenth or fourteenth year); the nuclei for trochlea, capitellum, and outer condyle unite to the shaft in the sixteenth or seventeenth year, and that for the inner condyle in the eighteenth year. The nucleus for the shaft appears in the seventh week.

Fig. 7 is a view of the Elbow Joint from the inner side. The spreading character of the internal lateral ligament is well seen, also the circular fibres of the orbicular ligament. The thin, lax, anterior ligament is shown bulging in front; the posterior ligament, similar in nature, may be seen behind. The external lateral ligament is shown in Fig. 8. The student may find it easier to remember the ligaments of the Elbow if he keeps in view the movements which take place there—these are flexion and extension of the radius and Ulna on the Humerus, with additional rotation of the radius on the Ulna and on the Humerus. Hence the strong lateral ligaments; the lax antero-posterior ones; the orbicular ligament, forming a collar for the radius, and the external natural ligament attached to this and not to the radius itself, while being also fixed to the ulna.

The Interosseous Ligament is well shown in Fig. 8. The direction of its fibres is such as would make them tense when an upward strain was put upon the radius. The small bundle of fibres running downwards from the ulna was the only representative of the ordinary oblique ligament, which runs from the coracoid process of the ulna downwards to the tubercle of the radius.

PLATE XI.—BONES AND LIGAMENTS OF THE HAND.

Fig. 1, from behind, and *Fig.* 2 from the front, were taken from a strong well-marked hand. The bones were articulated by being glued together. The flexor and extensor tendons are shown attached to only one finger in each hand—these may be taken as representatives for the other fingers. It may be noticed that no flexors or extensors are represented for the first phalanges; they have, however, muscles which perform the function of flexors and of extensors; the long extensors, by their attachment to the capsule of the metacarpo-phalangeal joint, extend the first phalanges, while the interossei and lumbricales produce flexion.

Figs. 3 *and* 4 show the ligaments which bind the radius and ulna to the Carpus, and the bones of the Carpus to one another. The fibrous bands are very numerous, and unite the bones firmly; they keep the bones of the same row together, and hold the rows to one another and to the bones above and below them. Well-marked horizontal fibres bind the bases of the metacarpal bones together in front. Deep interrosseous ligaments unite the bones of the same row together (Plate XX., Fig. 6), as also the bases of the metacarpal bones.

The separate Synovial Sacs at the wrist will be found on Plate XIX., Fig. 1, where they are contrasted with those of the foot.

PLATE XII.—THE PELVIS.

The chief object of the Plate is to contrast the Male and Female Pelvis.

The points of difference may be thus briefly summed up:—

I. Characters corresponding to the greater muscular development of the Male, *i.e.*, greater

density and strength of the bones, greater prominence of muscular impressions and fascial ridges, general ruggedness of contour.

II. Characters of Female Pelvis dependent on its adaptation for parturition.

A. For support of the child while in the abdomen. Greater expansion of the alæ of the Ilium, and increased distance between the anterior-superior spines (hence the greater breadth of the hips in the female).

B. For the passage of the child through the Pelvis.

1. *Depth* of Pelvic Canal less in female as shown in relative measurements of Sacrum, Symphysis Pubis, and Ischium.

2. *Shape* of Canal more suitable, *i.e.*, relative length of diameters more nearly equal in female. Sacro-vertebral angle less prominent. Ischial spines less projecting inwards. Ischial tuberosities wider apart. Pubic arch more opened out and its margins smoother (margins of inlet also smoother in female). Sacrum flatter, especially at its upper part).

3. Capacity greater as shown in increased breadth of Sacrum, mobility of the Coccyx, and actual extent of the diameters.

We may also note that the Thyroid foramina are more triangular in the female. From the greater width between the Acetabula, the femora descend more obliquely inwards in the female, and the internal condyles are consequently more prominent.

Occasion has been taken to indicate some of the muscular attachments in the Male Pelvis, so as to show their relative positions when the bones of the pelvis are articulated together.

PLATE XIII.—OS INNOMINATUM (RIGHT).

The bone is shown in its natural position, with the anterior-superior spine in the same vertical plane as the Symphysis Pubis, and with the most prominent part of the crest over the Acetabulum.

Fig. 1 shows the bone from its pelvic and abdominal aspect. Just above the Crus Penis the triangular ligament is fixed to the Pubes ; above that again is the compressor urethræ. These points are indicated by dotted lines.

Fig. 2 illustrates the outer aspect, the upper part looking backwards and outwards, and the lower part forwards and outwards.

From the Biceps being inserted into the head of the Fibula, and the semi-membranosus into the inner side of the head of the Tibia, the student is sometimes puzzled by the semi-membranosus being external at its origin ; immediately after it arises from the Tuber Ischii, however, it crosses beneath the Biceps and semi-tendinosus to reach the inside.

The occasional origin of fibres of the Pyriformis from the Os Innominatum takes place at the margin of the Great Sciatic Notch.

It is important to observe that the fibres of origin of the Gluteus Medius come as far forward as the anterior-superior spine of the Ilium. It is on this account that the anterior fibres have their power of inward rotation on the Femur.

The origin of the muscles from the body and descending ramus of the Pubes will be better understood by referring to Plate XII.

Fig. 3 is taken from the Os Innominatum of a lad of about fifteen years of age. The black lines indicate the position of cartilage which had not been ossified when the bone was macerated. They show the original separation of the Ilium, Ischium, and Pubes, which do not become finally united till about the seventeenth or eighteenth year. The dotted lines indicate the separate centres of ossification found at the crest of the Ilium, tuberosity of the Ischium, and Symphysis Pubis. These begin to ossify about puberty, and unite to the main bone from the twenty-third to the twenty-fifth year.

PLATE XIV.—LIGAMENTS OF THE PELVIS.

The ligaments of the Pelvis may be conveniently considered under two heads:—

I. Those which bind the Pelvis to the Vertebral Column.

II. Those which bind the various parts of the Pelvis together, or (as in the obturator membrane) fill up apertures and give origin to muscles.

The ligaments which bind the Pelvis to the Femur, although attached at one end to the Pelvis, are considered as Ligaments of the Hip joint.

I. It will probably help the student to remember the ligaments which bind the Vertebral Column to the Pelvis, if he bears in mind that the Sacrum is a series of modified Vertebræ, having their transverse processes represented by the lateral masses, and the other parts, body, articular and spinous processes, laminæ and cervical canal, represented in the Sacrum, with varying distinctness, but all easily traceable by careful examination; further, that the Ilium is an additional point of attachment to all except the last Lumbar Vertebra; and, finally, that from the sudden change in the functions of the first and following Sacral Vertebræ the necessities of the lumbo-sacral joint differ from those of the intervertebral joints. We find therefore, provision for greater mobility in the shorter spines, diminished laminæ, and shapes of articular processes, and for greater mobility and for strength in the structure of certain of the ligaments, passing between the last Lumbar Vertebra and the Pelvis, whose representatives may be easily traced passing between the individual Vertebræ throughout the Spinal Column. Those which would interfere with antero-posterior movement are more lax in texture and arrangement, *i.e.*, inter-spinous, inter-laminal, and inter-articular. Those which permit of antero-posterior movement, yet bind parts together, are stronger, *i.e.*, ligaments from the transverse processes, lumbo-sacral, and ilio-lumbar; and the intervertebral disc is unusually large, while the continuations of the anterior and posterior common ligaments between the bodies are about the same size and strength as their upward continuations.

The Inter-spinous Ligaments are shown on Fig. 2—the somewhat lax inter-articular ligaments and that between the lamina of the last Lumbar Vertebra and corresponding part of the Sacrum, also the continuation of the posterior common ligament could not be shown in the Figure, while prominence was given to more important parts.

The anterior Common Ligament is shown in Fig. 1, passing to the body of the first Sacral Vertebra; its continuation into the Pelvis, however, was removed in cleaning the preparation.

The *Lumbo-sacral* ligament, passing from the strong transverse process of the 5th Lumbar Vertebra to the upper part—ala—of the Sacrum, is represented in Fig. 1. The indicating line ends over the transverse process; although the outline of this piece of bone is hidden by the fibres of the ligament, the *Ilio-lumbar* ligament, continuous with but immediately above this, extends from the same point to the posterior part of the crest of the Ilium.*

II. Ligaments uniting the various parts of the Pelvis together.

1. Between the *Sacrum and Ilium.* There are—

a. Anterior Sacro-iliac, fibres thin and irregular, indicated on Fig. 1.

b. Posterior Sacro-iliac Ligaments, in two parts; deep (Fig. 3), short and strong; and superficial (Fig. 2), less powerful, some fibres being horizontal and others oblique.

c. Sacro-iliac Synchondrosis. In the section (Fig. 3) the parts were too dry to show the cartilaginous structure. Its position is between the cut surfaces of the Sacrum and Ilium, in front of the remains of the posterior Sacro-iliac ligaments.

2. Between the *Sacrum and Coccyx and the Ischium.*

a. Great Sacro-sciatic Ligament. This passes on each side from the side of the Sacrum and Coccyx to the inner part of the Tuber Ischii, blending with the tendons there, and sending a prolongation to the ramus.

b. Lesser Sacro-sciatic Ligament passes from the side of the Sacrum to the tip of the Ischial Spine.

* The line indicating this ligament on the Plate is placed a little too high; it points actually to a ligament which unites the 4th Lumbar transverse process partly to the 5th and partly by a few fibres, also to the crest of the Ilium.

These two ligaments are best seen in Figs. 2 and 3, as well as the foramina of the same name which they help to enclose.

3. Between the Sacrum and Coccyx there are continuations of the anterior and posterior common ligaments, also fibres between the Cornua, but these are not well shown in the Figure, and an intervertebral disc between the bodies of the last sacral and first coccygeal vertebræ.

4. Between the Pubic bones is an amphi-arthrodial joint with (Fig. 5) *anterior*, (Fig. 1) *posterior*, (Fig. 2) *superior*, and *inferior* or *sub-pubic* (Fig. 5) ligaments.

5. Giving attachment to muscles and filling up the obturator foramen is the *obturator membrane* shown in Figs. 1 and 2. The two apertures seen in it are accidental.

Fig. 3 is a section through a dried Pelvis in the plane indicated by the dotted red line in Fig. 4. This plane has been selected as indicating the mechanism of the Pelvis in transmitting the weight of the trunk downwards through the Pelvis to the Femora at the acetabula, and so the strain from the head of the Femur is partly upwards and partly inwards—that upwards is borne on the thicker part of the Ilium shown in the section, and thence transmitted to the Sacrum partly by the interlocking of the Sacrum and Ilium, partly by the firmness of the Sacro-iliac Synchondrosis, and largely by the strength of the posterior Sacro-iliac ligaments. The inward strain is partly also borne by the bonds of union just mentioned, but is chiefly resisted by the anterior arch (not the pubic arch) formed by the horizontal rami and symphysis pubis, and shown continuing the line of section round to the front. In the distorted Pelvis due to rickets, it is the vertical resistance of this Pelvic ring which gives way so as to cause flattening from before backwards, *i.e.*, diminished antero-posterior diameter. In the osteo-malachian distortion, it is the transverse resistance which gives way, and thus there is a diminished transverse diameter, owing to the inward encroachment of the acetabula upon the cavity of the Pelvis.

Fig. 4 is a view of the right half of a mesial section of the Pelvis, placed as nearly as possible in the position it occupies when the body is erect (the tip of the coccyx had been lost from the specimen).

Fig. 5 is a view on a larger scale than the others of the Symphysis Pubis, a slice having been cut off to show the structure of the intervertebral disc. The individual ligaments have already been referred to.

Fig. 6 is a view taken from within of a hip-joint forcibly distended with hot stearine, which was afterwards allowed to solidify in position. The joint was pierced above with an obliquely pointed nozzle, and injected with a small brass syringe. The position of maximum distension is seen to be that of flexion, abduction, and eversion, as in an early stage of acute synovitis.

The Ligaments of the Hip still remain to be noticed, a front view being given in Fig 1 and a back view in Fig. 2. The attachment of the capsule to the spiral line in front, *i.e.*, along the line of junction between the shaft and the neck, and to the neck itself behind, should be noted. It is on this account that an extra-capsular fracture of the neck in front is said to be an anatomical impossibility.

The thickened parts of the capsule are the *Ilio-femoral band* or Y-shaped ligament of Bigelow (Fig. 1). (2) The *Ilio-trochanteric band*, very strong, continuous with the upper branch of the Y, passes from the anterior inferior spine to the upper part of the great trochanter. (3) The *Pubo-femoral band*, comparatively thin (Fig. 1). (4) The *Ischio-capsular band* passes from the Ischium to the back of the capsule. (5) Circular fibres best seen from within when the joint is opened into. (6) *Ligamentum Teres*, within the joint, passing from the pit on the head of the Femur to the depression on the floor of the acetabulum. The thinnest part of the capsule is that which lies internal to the inner branch of the Ilio-femoral ligament (Fig. 1). This is beneath the bursa, below the psoas, and is often perforated so as to be continuous with the bursa itself. The capsule is also relatively thin from this point downwards and round to the back as far as the Ilio-trochanteric band, whence the thick part extends till the lower branch of the Ilio-femoral band is again reached.

PLATE XV.—THE FEMUR.

Fig. 1 shows the right bone from the front. For convenience in arranging the Plate the shaft of the bone has been represented as vertical; in the natural position, however, the bone slopes from above downwards and inwards, so that the internal condyle which here projects below the external is brought on the same plane with it.

The vascular foramina on the front of the neck should be noted. In reference to the muscular attachments on the front and sides of the shaft, which are shown in this Fig. as well as in Fig. 2, it may be mentioned that the crureus arises from the front and outside of the shaft, the vasti, by a narrow origin along each margin of the linea aspera except above where they broaden out, as shown in Fig. 1.

Fig. 2. gives a posterior view of the same bone. The attachment of muscles to the linea aspera may be more easily remembered, after Ward's method, by considering the adductor magnus as dividing the space between the vastus externus and internus into two; on the outside of the adductor magnus is the insertion of the gluteus maximus and the origin of the short head of the biceps, and on the inside of it are the insertions of the pectineus, adductor longus, and adductor brevis. (In the drawing at some places the origins of the vastus externus and crureus run into one another, as in fact the muscles themselves do.)

The greater prominence of the lower and outer branch of the linea aspera is well shown.

Figs. 6, 7, 8, 9, *and* 10 are views from below of sections of the bone made at the levels indicated by the dotted lines. They show well the varying proportion of cancellated and compact tissue in the centre of the shaft and at the extremities, also the alterations in contour seen in following the bone from above downwards. Fig. 10 is especially interesting, as illustrating the triangular shape of the bone at a point only a little below the site of M'Ewan's operation for osteotomy. The triangular shape is found at the seat of operation, and is given as one of the reasons for performing the operation from the inside. The Fig. shows how the triangular shape is obtained by a greater antero-posterior depth above the outer condyle.

Figs. 3 *and* 5 are given to illustrate the attachments of muscles to the great trochanter.

Fig. 4 shows the external condyle from the outside, with the groove for the popliteus tendon when the leg is flexed, and the portion of the origin of the muscle, both of these being within the capsule of the joint. The point of attachment of the rounded portion of the external lateral ligament is also seen.

PLATE XVI.—LIGAMENTS OF THE KNEE.

Fig. 1 represents the left Knee-joint from the outside with its covering of deep fascia. Openings have been made in the deep fascia to show the pre-patellar bursa, the external lateral ligaments, the origin of the outer head of the gastro-cnemius, and within the capsule proper, the popliteus tendon. Contractions of this fascia are apt to produce stiffness of the joint apart from affections of the joint itself.

Fig. 2 is a view of the left Knee-joint from behind. The drawing brings out the attachments of the gastro-cnemius and plantaris muscles and of the semi-membranosus tendon to the capsule.

Fig. 5 shows the interior of the joint after the capsule and synovial membrane have been dissected away. The internal condyle has been sawn through and turned down. The ligamentum mucosum has necessarily been removed in throwing down the patella. It can be well seen in Plate XX., Fig 3.

Figs. 6 *and* 7 are views of the right Patella, from the back and front respectively.

Figs. 3 *and* 4 are from a lad of fifteen. Fig. 3 shows the line of the lower Epiphysis of the right Femur. The sinuous outline at the junction of the Epiphysis and shaft is well brought out; the landmarks usually given for this are seen to be correct, *i.e.* the level of the adductor tubercle, and that of the upper margin of the trochlear surface. This centre of ossification begins just before birth, and is often of service in determining the age of a child in medico-legal cases. It unites to the shaft about the twentieth year.

Fig. 4 illustrates the Epiphyses at the upper end of the Femur. That for the lesser trochanter has been lost in the process of maceration. The centre for the head begins in the first year and unites about the nineteenth ; that for the great trochanter begins in the fourth year and unites about the eighteenth ; and that for the lesser trochanter begins in the thirteenth, or fourteenth year and unites about the seventeenth year. The centre for the head lies within the capsule of the hip-joint, while the Epiphysis at the knee will be included within the capsule in front, but will be united to the shaft at about the same place as that of the attachment of the back part of the capsule.

PLATE XVII.—TIBIA AND FIBULA.

It has been thought better in Figs. 1 and 2 to take the Tibia and Fibula together, as affording a better means of studying their relations and attachments.

Two additional views of the Fibula have been given in order to facilitate the study of this difficult bone.

Fig. 1 shows the Tibia and Fibula from behind. The Tibialis posticus is seen to arise from both bones. The exact origin from the Fibula is best seen in Fig. 6, while from the tibia its origin is defined posteriorly by the red line indicated in the Plate, and is limited in front by the interosseous ridge, which is easily recognised in the Tibia, but could not be shown in the Plate. The relative position of the two nutrient foramina should be noticed, also the muscles within whose origin each lies.

Fig. 2 gives an anterior view of both bones. The student should observe the narrowness of the origins of the extensor longus digitorum and of the extensor longus hallucis (pollicis). Both muscles arise from the very narrow extensor surface between the interosseous and anterior ridges. The portion of the Fibula seen behind these muscles belongs to the flexor surface. The peroneus tertius has not been separately indicated, as it is better to consider it as the lowest part of origin of the extensor longus digitorum. The only muscle which arises from both bones on the anterior aspect is the extensor longus digitorum ; on the posterior aspect there are two muscles arising in this way, *i.e.* the Tibialis posticus and the Soleus.

The sections *Figs.* 3, 4, *and* 5 show the relative amount or cancellated and compact tissue at different levels, also the shape of the bones, their relative position, and size. It will be observed that the small Fibula lies both behind and in front of the corresponding margins of the Tibia. This has to be borne in mind in transfixing the limb from the outside in amputations, otherwise there is a risk of passing the knife between the bones instead of in front or behind them.

Fig. 6 is a view of the right Fibula from the inside, and will be found of special service in illustrating the interosseous and oblique ridges. When the student is tracing the interosseous ridge from below, he has no difficulty in finding where it begins at the apex of the triangular rough surface which surmounts the articular facet. From this point there can be no mistake until he reaches the place where the interosseous and oblique ridges join ; if he keeps to the more anterior of the two, he will trace the interosseous ; if he selects the more posterior, he will be following out the oblique ridge. The posterior surface of the bone in this Figure looks towards Fig. 7 ; the anterior surface looks towards Fig. 2.

Fig. 7 shows the same Fibula from the outside.

PLATE XVIII.—BONES OF THE FOOT.

The bones of the foot, like those of the hand, may be arranged in a triple series.

I. The tarsus, consisting of seven cuboidal bones, named the os calcis or calcaneum, the cuboid, the astragalus, the scaphoid, and the three cuneiform bones.

II. Five long bones forming the metatarsus.

III. Five digits, each consisting of three phalanges, except the first, which has only two.

These bones are closely united by ligaments. If they are examined when so held together *en masse*, they are found to describe a convexity from side to side and from before backwards on

the upper surface, and on the lower surface this arched arrangement presents a concavity in the same directions.

On turning our attention to the articulated foot as it is laid on a plane surface, we may note that it touches the ground at three main points—posteriorly at the tuberosities of the os calcis, anteriorly at the head of the first metatarsal with its sesamoid bones, and the head of the fifth metatarsal. The space included by this bony tripod is practically closed on two aspects; for when we bear weight on the foot it broadens out, and the bases of the toes with their ligaments come in close contact with the ground anteriorly, as also does the outer edge of the sole externally. The floor of the hollow of the foot is closed by fascial bands which stretch from side to side, and from the heel to the toes. Under cover of the os calcis and raised inner margin of the foot, important vessels, nerves, and tendons enter the sole, pass forward to their terminations, and exercise their functions, sheltered from injurious pressure by means of the bony vault above and fascial floor beneath.

The astragalus may be studied in Figs. 1, 2, 3, and 4. Its numerous articular surfaces, one of which is for a ligament, are well represented. *See also* Plate XIX., Figs. 5 and 8.

The os calcis is seen in Figs. 1, 2, and 5. A bony tunnel, occupied in the recent state by the interosseous ligament, is seen to be formed by the apposition of the grooves figured in Figs. 4 and 5.

The lines of articulation, the chief characters of the remaining bones, the size of the first metatarsal, the projecting base of the fifth metatarsal, and the manner in which the base of the second metatarsal is locked between those of its fellows, and the outer and inner cuneiforms may readily be recognised.

Several amputations are practised which correspond more or less to lines of articulation in the foot. Hey's is performed at the level of the tarso-metatarsal joints. In Chopert's all the bones of the foot are removed, save the astragalus or os calcis. The articular surface of the os calcis and astragalus thus exposed are seen in Plate XIX., Fig. 8. Syme's represents a disarticulation at the ankle-joint; but, in addition, the malleoli and articular surface of the tibia are removed.

The bones of the foot may also be studied as forming an outer and inner column. *See* Plate XX., Fig. 7.

PLATE XIX.—LIGAMENTS OF THE FOOT.

The joint of the ankle admits of free flexion and extension; lateral motion is, however, very limited, and only occurs when the foot is fully extended. We are accordingly prepared to find that the lateral aspects of the joint are protected by the malleoli and fortified by strong ligaments, while the anterior and posterior aspects of the joint capsule are lax and comparatively weak.

The external lateral ligament of the ankle-joint is divided into three portions, which pass from the external malleolus as follows: The central to the os calcis (Fig. 4), the anterior (Fig. 4) and the posterior (Fig. 6) to the astragalus, the latter stretching behind the joint.

The internal lateral or deltoid ligament passes from the malleolus to the os calcis, astragalus, and scaphoid (Figs. 3 and 6).

Figs. 3, 4, *and* 8 show the anterior ligament of the capsule of the ankle-joint. Fig. 6 displays the ankle-joint laid open from behind; it is exposed because the thin posterior ligament has been partly removed.

The Tibia and Fibula are united below by anterior and posterior ligaments (Figs. 4 and 6), and also by deep interosseous fibres.

The relation of the tendons at the outer and inner ankles may be studied in Fig. 7.

Attention has been already drawn to the position of the interosseous ligament (Plate XVIII., Figs. 4 and 5), which chiefly binds the astragalus to the os calcis. On the same plate we also saw that surface of the astragalus which articulated with the calcaneo-scaphoid ligament (Figs. 1, 3, and 4). This ligament is displayed in the dissection (Fig. 5), where the astragalus has been removed, and the ligament is seen extending from the sustentaculum tali to the scaphoid. The ligament is again in its turn supported by the tendon of the tibialis posticus. Should tendon or ligament yield, the head of the astragalus will sink and flat foot ensue.

The long plantar or calcaneo-cuboid ligament is seen in Fig. 3. It must be remembered that the various tendons which are inserted into the bones of the foot broaden out and blend with the outer surfaces of the ligaments, thus serving to strengthen the articulations.

Figs. 1 *and* 2 illustrate the synovial membranes of the hand and foot. They were prepared as the knee-joint, etc., in Plate XX.

The hand has five synovial sacs ; only four are seen on the Plate, that between the pisiform and unciform bones on the anterior aspect not coming into view. The foot has seven. The thumb and great toe have each a separate synovial sac (Plate VII., Fig. 2, and Plate IV., Fig. 1), There is an articulation between the radius and ulna at the wrist-joint with a distinct synovial lining (Plate 1, Fig. 1), but that between the Tibia and Fibula is also common to the ankle-joint (Plate I., Fig. 2).

In the hand the remaining two synovial sacs are—(1) Between the radius and triangular fibro-cartilage and the first row of carpal bones (Plate II., Fig. 1). (2) Between the remaining carpal and metacarpal bones (Plate III., Fig. 1).

In the foot, besides those mentioned already, there are—(1) Between the astragalus and the os calcis, behind the interosseous ligament (Plate II., Fig. 2). (2) Between the same bones in front of the ligament, and running also between the astragalus and scaphoid (Plate III., Fig. 2). (3) Between the os calcis and cuboid (Plate V., Fig. 2). (4) Between the cuboid and two outer metatarsal bones (Plate VI., Fig. 2). (5) Between the scaphoid, cuneiform, and remaining metatarsal bones (Plate IV., Fig. 2).

PLATE XX.—SYNOVIAL MEMBRANES OF THE KNEE AND ELBOW.

There are several subjects illustrated in this Plate—The synovial capsules of the Knee and Elbow, the synovial lining of the Knee-joint, and the columns of the Hand and Foot.

Figs 1 *and* 2 are views of the distended capsule of the Knee-joint, while Figs. 4 and 5 are views of a similarly distended Elbow-joint. The preparations were made as follows: While the soft parts were in position, the bones were sawn across above and below the joint, as in the Figures, then a hole was pierced through the bone into the joint, and a nozzle having been inserted, the synovial cavity was forcibly distended with coloured plaster of Paris. The bones were left free during the injection to assume any position that the distention of the capsule disposed them to do. When the injection was complete, the nozzle was rapidly withdrawn, and the plaster was prevented from escaping. The joint was then carefully preserved in its position until the plaster set, after which the soft parts were dissected away. We therefore learn from these preparations (1) the parts of the capsule which admit of distention and its amount ; (2) the position of the joint in which the capacity of the synovial membrane is greatest. This method of studying the capacity of joints has already been followed out by Bonnet and others, and is of value as an explanation of the position of a joint in the early stage of acute synovitis. In the Musée Dupuytren in Paris there are some beautiful specimens of joints prepared in some such way as that just described.

Figs. 1 *and* 2 are taken from a preparation of the right Knee-joint, made by one of the authors, in the museum of the Edinburgh University, and kindly lent by Professor Turner.

Fig. 1 is a view from the inside. It will be seen that the greatest distention is at the front and upper parts of the joint, and that the capsule rises higher at the outside than at the inside. A part of the internal lateral ligament has been left to show its position and relation to the arteries. It should be noticed that the superior internal articular artery descends till it reaches the internal semi-lunar cartilage, and that it then runs forward between the synovial membrane and the fibrous part of the capsule in continuation of the internal lateral ligament. A similar course is to be noted in the *inferior* external articular artery. The capsule is seen to bulge posteriorly, but, being here covered by the structures in the Popliteal space, the distention would not be easily recognised in the living. The synovial cavity of the upper Tibio-fibular articulation was injected from the Knee-joint.

Fig. 2 shows the same preparation from the outside. The external semi-lunar cartilage corresponds to the position of the inferior external articular artery. This has been already referred to. The ligamentum patellæ has been cut away and the top of the bursa beneath can be just made out. It is important to notice that the capsule does not bulge at this point at all, but keeps at the level of the articular surface of the patellæ. The interval between the ligamentum patellæ and the capsule is occupied by the sub-patellar pad of fat. Fluctuation, therefore, need not be looked for here in synovitis.

Fig. 3 is a sketch of a left Knee-joint laid open after minute injection of the vessels with carmine. It is useful as showing the vascularity of the synovial membrane as far as the articular surfaces. The internal condyle has been sawn across and turned up to show the ligamentum mucosum and upper surface of the internal tuberosity of the Tibia.

Figs. 4 *and* 5 are back and front views respectively of the right Elbow-joint. The exact limits of the synovial membranes are clearly marked out. The fibrous portion of the capsule is attached from an eighth to a sixteenth of an inch further on the bone. Corresponding relations in the Knee-joint should be compared with this. The distention below the outer condyle in Fig. 4 should be noticed. This is the place where it is most easily detected in acute synovitis in the living. The swellings in front and behind are obscured by the soft parts, while the firm internal lateral ligament prevents distention on the inside.

Fig. 6 is a view of the two rows of carpal bones. It shows the way in which each row is bound together for articulation with the other row.

Fig. 7 is a view of the bones of the Foot arranged, according to Ward, into an outer supporting column consisting of the os calcis, cuboid, and two outer metatarsal bones with their phalanges, and an inner elastic column, consisting of the astragalus, scaphoid, three cuneiform bones, and three inner metatarsals with their phalanges. The points of usual articulation between the two columns are shown in the outer one by the clearly defined blue surfaces.

The injected synovial cavities of the Hand and Foot will be found in Plate XIX., Figs. 1 and 2.

PLATE XXI.—THE SKULL.

Fig. 1 gives a full-size view of the side of an adult Skull.

Fig. 3 is a similar view of the Skull of a child at birth.

Fig. 2 is a view of the same child's Skull seen from above.

By contrasting Figs. 1 and 3 some of the points of difference between the adult and the child's Skull become at once apparent; one of the chief of these is the much larger proportion which the facial part bears to the rest in the adult Skull, as compared with that of the child. This is partly due to the greater development of the air sinuses in the Frontal and Ethmoid bones, and in the superior maxilla (Antrum of Highmore), but also to the devolopment of the teeth, and increased depth of the alveolar borders of the superior and inferior maxilla. The differences between the lower jaw, at different ages, will be referred to at Plate XXV.

In the temporal bone the difference in development of the mastoid process (below and behind the external auditory meatus) should be observed. This is another example of the formation of air sinuses in the adult which do not exist in the child. The development of the Temporal bone is illustrated on Plate XXIII.

The Plate brings out well a contrast in the surface texture of the two Skulls, also differences along the lines of contact of the individual bones with one another. Both of these may be referred to the fact that the growth of the bones in the child is still going on, while that in the adult has ceased. The roughness of the growing bones is due to the ossification which is going on in the peri-osteum, causing the surface to be irregular, while in the adult the process has been long since finished and the surface rounded off. The differences at the places of contact of the individual bones are due to the fact that the membrane, which precedes the formation of bone, is still present to permit of increased growth in the child's Skull, hence the lines of the future sutures are more or less even and have membrane interposed, while at some places the deficiency is manifest and constitutes what are called Fontanelles. The student should associate these with the four angles of the Parietal bone on each side. Had the Parietal bones not been in contact

along the mesial line above, there would thus have been eight Fontanelles, but as it is, the four mesial ones unite to form two, while the lateral ones remain distinct, two on either side, thus making six in all.

In Fig. 3 the non-union of the frontal bones is well shown, and the consequent shape of the anterior Fontanelle; the prominences of the Frontal and Parietal bones at their centres of ossification should be noted, also the lines of forming bone which radiate out from them in all directions.

PLATE XXII.—BASE OF THE SKULL.

These two views of the skull are taken from a subject under twenty-five years of age. The occipital and sphenoid bones are not united, and the wisdom teeth have not come into their places. The drawings require no special comment beyond what is afforded by the explanatory letterpress, unless a minute description had been attempted, which is not intended here.

Fig. 3, Plate XXX., giving a view of the nerves in position, should be compared with the view of the inside of the skull.

PLATE XXIII.—OCCIPITAL AND PARIETAL BONES.

Fig. 1 shows the Occipital bone from the outer aspect and below. The anterior condyloid foramen will be seen to be present on the right side only. It may be absent from one or both sides.

Fig. 2 gives a view of the bone from within. The student may notice the different character of the articulating border of the Occipital bone, with the Parietal, with the mastoid, and with the petrous parts of the Temporal bone.

Fig. 3, taken from the same skull as Figs. 5-10, shows the state of the ossification at birth. The original growth of the supra-occipital from four centres is indicated by the fissures still traceable at the margin. The ex-occipitals (condylar parts) are still distinct from the basi- and supra-occipital, and with those two parts form the boundaries of the foramen magnum.

Fig. 4 represents the right Parietal bone from the cranial aspect. For the outer view of this bone, *see* Plate XXI., Fig. 1.

Figs. 8, 9, *and* 10 are views of the Temporal bone at birth; the squamous part, carrying the zygomatic process and the typanic ring, is still separate from the fused petrous and mastoid portions. The narrowness of the typanic ring and the want of development of the mastoid process are well brought out. These Figures have been inserted into this plate for convenience in arrangement; they are intended to supplement the views of the adult bone given in Plate XXVI.

Fig. 7 shows the original composition of the Vomer as being of two plates. These afterwards become so fused that in the adult the traces of their original separation are only to be made out where the bone articulates with the base of the sphenoid. (Plate XXVIII., Fig. 8).

Figs. 5 *and* 6, from the same child's skull, are given in this Plate instead of in Plate XXVIII., where they would naturally appear but for want of space. It will be easily seen that they are views of the superior maxilla from the outside and from below. In Fig. 5 the outlines of the teeth can be distinguished in the alveolar process, and it will be seen how close they are to the orbit; the Antrum of Highmore has as yet no place in the bone. In Fig. 6 the alveolar border can be seen from below, hollowed out, and, previous to maceration, containing the pulp cavities of future teeth.

PLATE XXIV.—FRONTAL AND ETHMOID BONES.

The anterior aspect of the Frontal bone is seen in Fig. 1. In this specimen there is no trace left of the original mesial suture which divides the bone into equal halves during early life. (*See* Plate XXI., Fig. 2). The supra-orbital notch is not well marked. The frontal sinuses,

lying above the orbital plates and under cover of the supraciliary ridges, are displayed in section in Plates XXIX., Fig. 1 ; and XXX., Fig. 1. The temporal ridge, Fig. 1, corresponding to the upper margin of the Temporalis muscle, may be fully traced out in Plate XXI., Fig. 1. The Inner or Cerebral surface of the bone is shown in Fig. 2 ; and the cerebral surface of the thin orbital plates, together with the manner in which the Ethmoidal notch is filled, may be seen in Plate XXII., Fig. 2.

Grooves for branches of the Middle Meningeal artery may be seen on the right side of the bone. The main distribution of this vessel, however, is on the inner side of the Parietal bone (Plate XXIII., Fig. 4 ; also Plate XXX., Fig. 4).

The articulations of the Frontal bone may be studied on Plates XXI., XXII., and, with the Nasal bones in the section, on Plate XXIX., Fig. 2.

Ossification begins by two osseous points above the orbits. The suture seen in the fœtal skull, Plate XXI., Fig. 2, sometimes remains distinct in the adult.

The Ethmoid bone consists of a central plate with lateral, spongy, or cell-like masses (Figs. 3, 4, and 5). The central perpendicular plate is seen in Plate XXIX. ; and its relations to the Sphenoid, Vomer, Frontal, and Nasal bones in the middle line are brought out in the section showing the bony nasal septum. The crista galli, its prominent superior point, is figured in Figs. 3 and 4, and in Fig. 2 of Plate XXII. The superior and middle Turbinate bones, which form part of its lateral expansions, are seen in Fig. 5 ; and again in Plate XXIX., where they are seen to form part of the outer wall of the nose. The sectional relations of the perpendicular plate and Turbinate bones in the nose are shown in Plate XXX., Fig. 1. In the same Figure, we may also note the manner in which the inner wall of the orbit is formed by the os planum of the Ethmoid.

Fig. 6 is a dissection in which part of the superior maxilla has been sawn away to show the course of the nasal duct. It will be observed that the Lachrymal bone, Superior Maxilla, and Inferior Turbinate bone help to form this canal. The Antrum of Highmore has been laid open. The duct opens under cover of the Inferior Turbinate bone towards the front of the inferior meatus.

PLATE XXV.—INFERIOR MAXILLA.

Figs. 1 *and* 2 give outer and inner views of the Inferior Maxilla. In Fig. 1 the insertion of the masseter in two parts has been indicated by the blue line running across the ramus. The lower attachment of the temporal muscle on the inner, as compared with that on the outer, aspect of the coronoid process should be noted. Otherwise the drawings require no special comment.

Figs. 7, 8, 9, *and* 10 show the bone at different ages. In the infant's jaw (Fig. 7) no teeth have appeared, although their bulgings may be seen constituting the main thickness of the body of the bone. Had the mental foramen been seen, it would have been found close to the lower border.

Fig. 8 represents a child's jaw (at about five years) with the milk series of teeth complete.

Fig. 9 shows a nearly adult jaw with the last molar or wisdom tooth just beginning to appear.

Fig. 10 shows the jaw of an aged person after all the teeth have fallen out and the alveolar border has been absorbed. The mental foramen is seen therefore close to the upper border. The obtuseness of its angle, as contrasted with that of the adult jaw, is not so distinct as it would have been had the latter been a little older.

Figs. 3 *and* 4 give a surface view of the adult dentition on the right side, with the empty sockets on the left. The two jaws are not taken from the same subject. Fig. 4 shows well the hard palate with its anterior, posterior, and accessory palatine foramina, palatal processes of superior maxilla and palate, and humular process of sphenoid.

Fig. 6 is a drawing of the hard palate and teeth of a child about five years old, the series of milk being complete, and none of the permanent set having yet come through the bone. The foramina shown behind the milk incisor and second molar teeth, however, show where the adult

incisors and first molar would have shortly appeared. This eruption of the adult *behind* the milk incisors is abnormal, usually the former push out the latter. The specimen was selected because the suture which separates the premaxilla from the superior maxilla proper was unusually distinct. It will be seen to pass beween the lateral incisor and canine teeth on each side. According to Professor Albrecht of Brussels, however, an exaggeration of this suture does *not* represent the line of cleft in a hare-lip cleft of the jaw. In these deformities an incisor tooth is, in his view always found in front of the canine tooth, so that the fissure must be through the premaxilla itself.

Fig. 5 is an accurate drawing of a preparation made by M. Vasseur of Paris. The milk teeth are all present, and in addition the first permanent molars in each jaw are seen to be in position. The child has, therefore, been about six years of age. It is at this age that the jaws contain the maximum number of teeth, *i.e.* all the milk set and the future permanent set with the exception of the wisdom teeth—thus forty-eight in all. The bone has been cut away from the alveolar margins so that the permanent series of teeth can be seen coming into their places. The view is taken from the right side of the skull, but the two first teeth seen in the upper jaw and the first three teeth in the lower jaw belong to the left side. The permanent canine tooth just below the infra-orbital foramen should be noted in the upper jaw. In the lower jaw the future bicuspid teeth are seen lying one on either side of the mental foramen; while the permanent canine tooth lies deeply set in the bone, immediately in front of them.

PLATE XXVI.—THE TEMPORAL BONE.

The two upper Figures are views of the Temporal Bone from the outside of the Skull; the one on the left being a lateral view, while that on the right is from below. To avoid multiplying the names attached to the figures, the larger muscular attachments have been omitted; they will be found, however, on Plates XXI. and XXII., where the Skull is considered as a whole.

The lower Figure, on the left, is a view of the same bone from the interior of the Skull; while the two remaining Figures are views of a section through the Mastoid and Petrous parts of the bone, the saw having passed through the cavity of the Tympanum. The upper Figure shows the outer half of the section, with the Membrana Tympani, Malleus and Incus, and Canals for Tensor Tympani and Eustachian Tube. The lower Figure shows the inner half of the section with the Promontory standing out on the inner wall of the Tympanum, having the aqueductus Fallopi above and behind it. This Figure shows the carotid canal in front of the Tympanum, while both Figures show the Mastoid Cells behind it.

PLATE XXVII.—THE SPHENOID.

Fig. 1 shows the bone from below and in front.

Fig. 2 shows it from the right side, above, and behind. The important points are well indicated by the letterpress on the Plate.

Fig. 3 is a view of the sphenoid of a child about full time. It shows the lesser wings and two separate ossific centres for the front of the body, still distinct from the main body of the bone (post-sphenoid). The great wings (ali-sphenoid) are also still ununited. The appearance of the posterior part of the basi-sphenoid shows that the line of junction between this and the basi-occipital has been cartilaginous, and contrasts well with the sawn surface at the corresponding part of the adult bone shown in Fig. 2.

Fig. 4 is a view from below of the same bone as is shown in Fig. 3. The Pterygoid processes seen in perspective are united to one another, but not yet to the rest of the bone. The body is as yet still solid, and is not thorougly opened out by air sinuses until the period of puberty.

PLATE XXVIII.—SUPERIOR MAXILLA AND PALATE.

The views of the Superior Maxilla (Figs. 1 and 2), Palate (Figs. 3, 4, and 5), and Lachrymal bones have been enlarged, in order to facilitate their study. The perspective view of the Vomer and the view of the Hyoid bone are as nearly as possible of natural size.

Fig. 1 shows the right bone from the inside and below.

Fig. 2 shows the same bone from the outside and above.

To help the understanding of the articulations of the orbital plate, some of the articulations have been diagrammatically shaded in colour.

In *Fig.* 3 the right Palate bone is shown from the outside. The greater part of the surface here seen does not come to the outside of the skull, but is in contact with the bones with which it articulates. Those parts which do appear are, the surface between the Pterygoid plates, and the Spheno-maxillary surface; the latter leads on to the sphenoidal and to the orbital processes. The broad, thin plate in front of the Spheno-maxillary surface lies along the inner surface of the posterior part of the Superior Maxilla, and helps to close the inner wall of the Antrum of Highmore.

Fig. 4 is a view of the same bone from behind and slightly below, so that what is seen of the horizontal plate is its under surface. The sphenoidal process should appear to be nearer the eye than the orbital process; in either the inner or the outer view of the bone, however, the relative position of these two can be easily seen.

Fig. 5 shows the same bone from the inside; the anterior part is to the left, the posterior part to the right. Thin though this vertical plate be, it is seen how comparatively large a share it takes in the outer wall of the nostril; this it does by overlapping the Superior Maxilla, as already noticed.

Fig. 6 is a view from the orbital cavity, and *Fig.* 7 a view from the nasal cavity (where it is in relation to the Ethmoid) of the left lachrymal bone. In Fig. 6 we can see a groove in front which helps to form the Lachrymal groove, separated by a ridge from the plane surface behind, which forms part of the inner wall of the orbit.

Fig. 8 represents the Vomer from above and in front. Being a perspective view, the antero-posterior depth requires to be seen also from a side view, such as is given in the drawing of the Nasal septum in the next Plate.

In *Fig.* 9 the hyoid bone is seen from the right side and slightly above. The chief value of this Figure is the exact points of attachments which it shows of the numerous muscles, which either arise or are inserted into this comparatively small bone.

PLATE XXIX.—MALAR, NASAL, INFERIOR TURBINATE BONES AND SECTIONS.

The chief value of Fig. 1, a section of the Skull, is in the view which it gives of the Nasal cavities from the inner side. The student should notice especially the roof, and the Nasal sinuses formed by the Turbinate bones. It will be seen that the roof, which extends from the Nasal bones in front to the back of the body of the Sphenoid behind, may be looked on as in three parts—a central part, higher than the rest, formed by the horizontal or cribriform plate of the Ethmoid; an anterior part, sloping downwards and forwards from this, formed by the Frontal and Nasal bones; and a posterior part, on a much lower level than either of the other two, sloping slightly down from the posterior part of the middle Turbinate bone, and formed by the under surface of the body of the Sphenoid, where it is hollowed out by the large Sphenoidal sinuses. It is of interest to observe the thickness and relations of the roof at the different places, the brain being in relation to the middle and posterior parts, but being separated from them in one place merely by the thin cribriform plate of the Ethmoid, and in the other by the whole depth of the opened-out body of the Sphenoid.

As regards the Turbinate bones, the antero-posterior extent of the inferior one should be observed; and as regards the other two (parts of the Ethmoid), it should be noted that their anterior extremities are farther from the front as they recede upwards towards the cribriform plate.

The relation of the Hamular process of the internal Pterygoid plate may be noticed to the upper teeth. It can be felt from the mouth above and behind the last upper molar.

The figure of the Nasal Septum (Fig. 2) helps the student to understand the relative position of the Vomer and Vertical Plate of the Ethmoid, also of the Nasal cartilage which occupied the interval between them.

Of the two views of the right inferior Turbinate bone (Fig. 3), the upper one shows the bone from the inside; the lower one shows the side which looks towards the outer wall of the nose, with the auricular process which articulates with the Superior Maxilla.

Figs. 4 *and* 5 are somewhat enlarged views of the right Malar bone; Fig. 4 is from the outside; Fig. 5 from the inside.

The two Nasal bones are shown from the posterior or nasal aspect on Fig. 6, and on Fig. 7 from the front or facial aspect. The two adjacent margins articulate with one another, the outer margins with the Superior Maxilla.

PLATE XXX.—SECTIONS OF SKULL, ETC.

Figs. 1 *and* 2 are Sections of an old person's Skull. The teeth had fallen out, and the alveolar border had been absorbed. The frontal sinus was developed backwards over the orbit to an unusual extent. The saw was carried through the bone in the planes indicated by the dotted red lines shown on Fig. 4.

In Fig. 1 the line of section includes both Face and Skull, and is useful in helping to bring out their relations as well as in showing the relations of the various cavities of the face to one another.

In order to preserve the delicate bones which are included in the Section, the nasal and orbital cavities were filled with tallow before the saw was applied. After the Section was made the tallow was melted out again; but, in spite of the precautions taken, some of the more delicate bones were broken off.

The Section of the Cranial Cavity seen at the upper part is less than it would have been otherwise, owing to the backward prolongation of the frontal sinus. The frontal bone seems thicker than it really is, on account of the obliquity of the Section.

The Cristi galli of the Ethmoid, rising into the cranial cavity, is seen to be continuous with the vertical plate of the Ethmoid, and with the vomer. The nasal septum thus formed is, as usual, not quite mesial. The vomer part of it makes two bends, the largest being a convexity to the left opposite the inferior turbinate bones. The middle and inferior turbinate bones were broken by the saw; their position is, however, shown by the hard black lines in the nasal cavity, overhanging on each side their corresponding meatus. The superior turbinate bones could not be clearly defined. The back part of the frontal sinuses and the posterior ethmoidal sinuses are seen to pass irregularly into one another in this specimen. The irregularly four-sided shape of the orbits can be seen, with the inner walls parallel to one another, and the remaining walls oblique. In most cases the roof of the orbit is separated from the Skull by one thin plate of bone; in our present Section this plate is double, owing to the abnormality of the frontal sinus.

The relations of the Antrum of Highmore are important; pressure within the cavity might show itself on the floor of the orbit, on the outer wall of the nasal cavity, or on the cheek; the latter is the common situation when the contents are fluid, but a solid tumour may press in any of the three.

Fig. 2 cuts through the middle vault of the Skull at the apex of the Petrous part of the Temporal bone, and shows the shape of the Skull and the relative thickness of the bone at this level. The thinnest parts are the roof of the Glenoid cavity, and the squamous part of the Temporal.

Fig. 3 is a drawing after one in Henle's Anatomy. Its use is to direct the student's attention to the place where the nerves leave the Skull, as contrasted with where some of them *seem* to leave it when the Dura Mater is in position. Those whose places of exit from Dura Mater and bone correspond are the first, second, seventh, eighth, and ninth ; those where a difference is seen are the third, fourth, fifth, and sixth ; the third, fourth, ophthalmic division of the fifth, and sixth, leave the skull at the sphenoidal fissure, the superior maxillary division of the fifth at the foramen rotundum, and the inferior maxillary division at the foramen ovale. The forward prolongation of the Tentorium Cerebelli makes the anterior and posterior fossæ in the Dura Mater continuous with one another, while the middle fossa is shut off from both. Thus the nerves, which really leave the Skull in the middle fossa, seem to leave it in the posterior (dura matral) fossa, and none seem to leave at the middle fossa. In the Fig., the right third nerve is seen near the cut margin of the Dura Mater, but has not been traced to the sphenoidal fissure ; the position of the other nerves will be easily determined by the descriptive letterpress.

Fig. 4 is taken from a specimen which shows the relation of the brain and its main fissures to the Skull, also—from the outside—the position of the middle meningeal artery. The boundary line of the cerebrum was traced from within. The position of the main fissures was taken from Broca's pamphlet on Cerebral Topography ; and the position of the middle meningeal artery was also traced from within by holding the Skull up to the light.

As already mentioned the dotted red lines indicate the lines of section in Figs. 1 and 2.

Fig. 5 is given to illustrate the spheno-palatine foramen from the outside. The great wing of the sphenoid have been cut away, and rods indicate the foramina so far as they can be seen from this position.

Fig. 6 gives a view or section of the articulation of the lower jaw. The meniscus and anterior and posterior parts of the capsule are well seen. The external lateral ligament consists of fibres descending obliquely from the posterior part of the zygomatic arch to the outer part of the neck.

The internal lateral ligament is a thin band of fibres passing from the spinous process of the great wing of the sphenoid to the projecting lip of the inferior dental foramen (neither of the lateral ligaments is shown on the Plate).