D. G. Campbell
19th March 1908

# FAMINE DISEASES.

# THE DISEASES

OF

# THE MADRAS FAMINE
## OF 1877-78.

BY

ALEXANDER PORTER, M.D., F.R.C.S.I., M.R.I.A.,

BRIGADE-SURGEON, HER MAJESTY'S INDIAN ARMY;
FELLOW OF THE UNIVERSITY OF MADRAS;
PRINCIPAL AND PROFESSOR OF MEDICINE, MEDICAL COLLEGE, AND
SENIOR PHYSICIAN, GENERAL HOSPITAL, MADRAS.

MADRAS:
PRINTED BY THE SUPERINTENDENT, GOVERNMENT PRESS.

1889.

# DEDICATION.

---

To

His Friends in the Profession, especially those of the Madras Medical Service, past and present, the following pages are respectfully inscribed

by

THE AUTHOR.

# TABLE OF CONTENTS.

## CHAPTER VI.



---

## APPENDICES.



---

# LIST OF ILLUSTRATIONS.



All these plates, except No. VII, have been copied from "The Medical and Surgical History of the War of the Rebellion," by Barnes and Woodward, U.S.A.

# PRELIMINARY.

DURING the Madras Famine of 1877-78 the writer had, in addition to his official duties, the charge of the sick of a Famine Relief Camp. It is proposed to give some account in the following pages of the diseases from which these patients suffered and died, basing the narrative mainly on the lines indicated by the pathological appearances observed in 459 consecutive autopsies made as leisure permitted. The details of a few of these cases are also briefly given as a record of the facts observed in each case.

The sheds for Famine sick at the Royapettah Hospital were opened on the 13th December 1876, by the admission of five patients—three men, a woman, and a child—and the numbers steadily increased till, in July 1877, the admissions reached 391. After this they decreased monthly till they were only 49 to the 25th May 1878, when the sheds were closed. The total admissions amounted to 3,250 and the deaths to 1,117, giving a mortality of 34·36 per cent. (*Vide* Appendix A.) The Vellore returns give 1,020 deaths to 3,665 treated, or a death-rate of 27·83 per cent.

The average daily sick increased from 10·65 men, 6·96 women, and 3·77 children, or a total of 21·38 for December 1876, to 48·25 men, 41·89 women, and 30·68 children, being a total of 120·82 for August 1877. After this, it decreased steadily each month till for May 1878 it was only 32·88, consisting of 15·28 men, 12·84 women, and 4·76 children. The average daily sick for the year 1877 was 74·83, consisting of 30·93 men, 26·63 women, and 17·27 children. (*Vide* Appendix B.)

*General state.*

Taken as a whole, these patients were greatly emaciated, the majority had œdema of the feet, and about 10 per cent. suffered from general anasarca. Usually the skin was dry and covered with scurf, but there was seldom any skin disease present, except, perhaps, itch which is so common among natives. The temperature of the body in all

ordinary cases observed was about one degree below normal, the temperature in the rectum being one degree higher than that in the axilla; the latter is the one entered in the record unless otherwise stated. There were bed-sores present in a few cases, and ulceration of the cornea in, perhaps, half a dozen in all; but ulcers on the legs, from the breaking out of old sores, were not very uncommon. In no case were there marked symptoms of scurvy present.

*Measles.*

*Small-pox.*

The Famine was accompanied by epidemics of Cholera, Small-pox, and Measles. Of the last no cases were brought to the sheds, and of small-pox there were only 68 admissions with 5 deaths. This is accounted for by a Small-pox Hospital having been opened on the 8th March 1877, to which all cases were transferred after this date. The first case, a man of about 50 years old, was admitted on the 18th January 1877 with confluent small-pox, and was discharged cured on the 19th February. And on the same day were admitted with *Variola discreta,* another man about 50 years old, 2 young women, and 4 little girls: they all recovered and were discharged in about three weeks. Two other children were admitted in this month in a hopeless condition and died. And of 11 cases admitted in February, 2 died: both were children. After the Small-pox Hospital was opened on the 8th March cases were detained by us only a few hours. The death in April was that of a little boy who was brought in too ill to be sent on, and he died on the same day, so that the average daily sick from this cause for the year 1877 was only 0·85, and of this, children contributed fully one-half, viz., 0·44. But this epidemic does not appear to have been a very fatal one; for, on referring to Appendix C, it will be seen that in 22,936 deaths, small-pox caused only 305, or 1·3 per cent.*

Cholera and the other diseases shown in the returns, (Appendices A, B, and C), are fairly well represented in the subjoined statement.

---

* However Dr. Cornish, the Sanitary Commissioner, reported that during the year 1877, 88,321 deaths from small-pox were registered in the Presidency, against an average number of 29,301 for the previous eleven years.

*Statement of Causes of Death in the 459 Autopsies.*

| —— | Men. | Women. | Children. | Total. |
|---|---|---|---|---|
| The Alvine fluxes ... ... | 166 | 119 | 62 | 347 |
| Cholera ... ... ... | 7 | 4 | 2 | 13 |
| Dropsy ... ... ... | 13 | 6 | 3 | 22 |
| Fever ... ... ... | 3 | 1 | 3 | 7 |
| Acute pneumonia ... ... | 12 | 6 | 3 | 21 |
| Phthisis pulmonalis ... ... | 12 | 7 | ... | 19 |
| Atrophy ... ... ... | 4 | 4 | 4 | 12 |
| Hepatic abscess ... ... | 3 | ... | 1 | 4 |
| Pyæmia ... ... ... | 1 | 2 | ... | 3 |
| Apoplexy ... ... ... | 2 | 2 | ... | 4 |
| Cancer ... ... ... | 1 | 1 | ... | 2 |
| Intestinal ulceration ... ... | ... | 1 | ... | 1 |
| All other causes ... ... | 2 | 2 | ... | 4 |
| Total ... | 226 | 155 | 78 | 459 |

# CHAPTER I.

## THE ALVINE FLUXES.

---

THE statistics in the appendix show that diarrhœa and dysentery constituted the chief cause of death in the Madras Famine. From the following figures (partly taken from the Monegar Choultry returns) it will be seen that this cause furnished nearly two-thirds of the total admissions and deaths, and fully three-fourths of the autopsies :—

| | Total. | Alvine Flux. | Per cent. |
|---|---|---|---|
| Admissions ... ... | 20,348 | 11,871 | 58·34 |
| Deaths ... ... | 28,025 | 17,386 | 62·37 |
| Autopsies ... ... | 459 | 347 | 75·6 |

In these patients the belly often felt hot, and was generally very much retracted, with the walls tensely drawn over the viscera, and tenderness on pressure over the colon was common. It was probably to relieve the tension and pain that these patients adopted the peculiar position in bed they usually assumed—namely, lying on the side with the legs drawn up and shoulders bent forward. Many stated that the disease had begun as dysentery, but in comparatively few were the stools found dysenteric on admission ; these varied greatly in appearance and odour, and this seemingly without any reference to the state of the gut, as found in the autopsy—in fact, some of the most fœtid stools were in cases where the gut was found free from apparent disease, and extensive ulceration has often been found without diarrhœa having been a prominent symptom during life, or even without its having been noticed at all by the hospital staff, who, besides being overworked, had to contend against the persistent endeavours of the patients to conceal any bowel-complaint, lest they should be put upon milk diet and deprived of curry and rice, the only food they considered worthy of the name.

These cases may be divided into those without ulceration, those with ulceration, those with diphtheritic effusion, and those with the two latter characteristics combined, as shown below:—

| | Men. | Women. | Children. | Total. |
|---|---|---|---|---|
| No ulceration ... | 26 | 19 | 19 | 64 |
| Ulceration ... ... | 59 | 52 | 21 | 132 |
| Ulceration and diphtheritic effusion ... | 36 | 19 | 12 | 67 |
| Diphtheritic effusion alone | 45 | 29 | 10 | 84 |
| Total ... | 166 | 119 | 62 | 347 |

## SUB-DIVISION I.

### Alvine Flux without Intestinal Ulceration.

Under this head came 64 out of 347 deaths from bowel-complaints, or nearly one-fifth of the whole.

| | | | Total. | | Per cent. |
|---|---|---|---|---|---|
| Men ... ... ... | 26 | - | 166 | = | 15·6 |
| Women ... ... ... | 19 | - | 119 | = | 16 |
| Children ... ... ... | 19 | - | 62 | = | 30·6 |
| Total ... | 64 | - | 347 | = | 18·4 |

The above figures show the men and women to contribute, in about equal proportions, 16 per cent., while the children are proportionately nearly double this, 30·6 per cent. Of the 19 children, 14 were boys. When duly considered it is sufficiently startling that in deaths from bowel-complaints among children no lesion in the gut should be found in nearly one-third of the cases; and this not resulting from speedy death after attack, for one child had been under treatment in hospital twenty four days, and was said to have been ill a week before admission. However, eight, or nearly one-half of these children, died on the day of admission, but were said to have been ill with the disease on an average over nine days when admitted. The average stay in hospital for the whole 19 children was nearly four days, the average duration of illness before admission being nearly six days.

Again, six, or nearly one-third of the women, and four, or nearly one-sixth of the men, died on the day of admission, after

an antecedent illness of, it was said, fully nine days on an average, the extremes being two days and thirty. The average time in hospital of the 45 adults was nine days, and average duration of illness before admission five-and-a-half days. One man had been under treatment in hospital for sixty-six days, and was ill three days before admission.

*Disease complained of*

The disease complained of on admission was dysentery or diarrhœa in as nearly as possible equal numbers among all three classes—men, women, children.

The nature of the stools varied a great deal, and presented much the same appearance, whether the patient had been admitted complaining of dysentery or diarrhœa. The following is an analysis of the cases noted :—

| | | * Diarrhœa. | Dysentery. |
|---|---|---|---|
| *Stools.* | Thin feculence ... ... ... | 8 | 2 |
| | Do. mud-coloured ... ... ... | 2 | 3 |
| | Yellow water ... ... ... | 1 | 3 |
| | White flocculi in water ... ... | 2 | 2 |
| | Whitish fluid ... ... ... | 1 | ... |
| | Slimy mucus ... ... ... ... | 1 | 2 |
| | Venous blood ... ... ... ... | ... | 1 |
| | Beef-brine-like ... ... ... ... | ... | 2 |
| | Scybala ... ... ... ... ... | ... | 1 |
| | Half-formed fæces, bloody mucus separate. | | 1 |

*Contents, large intestine.*

The contents of the large intestine were found to be similarly characterised as follows :—

| | Diarrhœa. | Dysentery. |
|---|---|---|
| Thin feculence ... ... ... | 2 | 2 |
| White flocculi in water ... ... | 1 | 2 |
| Green fluid ... ... ... ... ... | ... | 2 |
| Blood in clots ... ... ... ... | ... | 1 |
| Ochrey yellow pultaceous matter ... | 2 | ... |
| Green mucus ... ... ... ... | 1 | ... |

In the remainder, forming about four-fifths of the whole, the colon was empty, except gas in extraordinary quantity in two children.

---

* The disease entered is that complained of on admission.

*Contents, small intestine.*

The small intestine also was found empty in nearly half the cases, distension with gas being noted in four cases, three of them children. The contents, when present were :—

| | Diarrhœa. | Dysentery. |
|---|---|---|
| Ochrey yellow pult ... ... | 3 | 5 |
| Do. water ... ... ... | 5 | 1 |
| Mucus ... ... ... ... | 2 | 1 |
| Bloody fluid ... ... ... | 1 | 2 |
| Dark-brown do. ... ... ... | 1 | ... |
| Lumbrici ... ... ... | 14 | 10 |
| Gray fluid ... ... ... | 1 | 4 |
| Green do. ... ... ... | 2 | 4 |
| White flocculi in water ... ... | 1 | 1 |
| Buff or mud-coloured fluid ... | 2 | 1 |
| Tapeworm ... ... ... ... | 1 | ... |

The number of lumbrici present varied from 1 to 13, the average being 3½. In one child (Case XXXII) a lumbricus was lodged in the duct of the pancreas.

This was a boy about six years old, ill a week with dysentery, miserably thin, weighing only 16 lbs., and with a scrofulous-looking ulcer on the chest. His stools were dysenteric, and belly puffy hot and tender. He was admitted on the 10th and died on the 17th August 1877—*Autopsy. Small gut* distended with gas, contained some yellow fluid and two lumbrici, and one was lodged in the duct of the pancreas: all were dead but fresh; coats thin and pale. *Large gut* empty, mucous coat swollen, rosy; the mouths of the follicles red. There was slight lobular pneumonia of both lungs, and the liver and kidneys were very fatty.

*Small intestine, appearances of.*

The walls of the small intestine showed a general thinning of the tissues. In one case there was a diverticulum present, and in two a small fatty tumour was attached to the mucous membrane of the ileum. The appearances noted were as follows :—

| | Diarrhœa. | Dysentery. |
|---|---|---|
| Looked healthy ... ... ... ... | 2 | 3 |
| Pale and thin, like parchment ... ... | 10 | 9 |
| Do., venous radicles showing through... | 1 | 1 |
| Do., closed glands pale and prominent... | 1 | 1 |

| | Diarrhœa. | Dysentery. |
|---|---|---|
| White as milk ... ... ... ... | 2 | 1 |
| Pale rose to pinkish ... ... ... | 3 | 8 |
| Do. valvulæ conniventes white ... ... ... | | 2 |
| Do. do. œdematous ... ... | 1 | 1 |
| Pale rose, villi white, looks sodden ... | 1 | ... |
| Pink, with red puncta or ecchymotic-like blotches and vibices ... ... ... | 1 | 5 |
| Congested more or less deeply ... ... | 6 | 6 |

*Congestion in diarrhœa.*

In the last six diarrhœa cases the congestion was of the deep structures and valvulæ conniventes, the surface of the mucous membrane being white in one case; the congestion was confined to the valvulæ conniventes, Peyer's glands showing as white specks in one case, and in one it was confined to the mouths of the follicles, which showed as minute livid points. In a weakly man, who died in a day from watery purging (not cholera), the congestion was almost livid and the solitary glands prominent, as in cholera, and in one the congestion was in lengths of the mucous membrane.

*In dysentery.*

In one of the dysentery cases the gut was deeply congested and thickened for two feet at both ends; in another there were circular red, swollen spots in the ileum; in one the congestion was confined to lengths of the mucous membrane, as in the diarrhœa case mentioned above; in one there was ecchymotic-like bright red injection in the jejunum, and deep livid injections in the ileum, the solitary glands showing as white spots, but not enlarged; and in one the injection was deep-purple all through, looking like superficial ecchymosis in the valvulæ conniventes, the glands were not prominent; and in one the mucous membrane was uniformly dull-reddish, with deep-red injection in parts.

*Ecchymosis.*

The remains of former congestion was manifested by spots of ecchymosis in three cases of diarrhœa and four of dysentery, and by more or less deep pigmentation of the mucous coat, in whole or in parts, in seven cases of diarrhœa and eight of dysentery.

*Large intestine, appearance of.*

In the large intestine the appearances noted may be grouped as follows:—

| | Diarrhœa. | Dysentery. |
|---|---|---|
| Healthy looking ... ... ... | 2 | 1 |
| Dull-white, looks sodden and thick ... | 2 | ... |
| Thin and gray ... ... ... ... | 6 | 5 |
| Do., venous radicles showing through ... ... ... ... | 1 | 1 |
| Pale rose, turgid and swollen, mouths of follicles red and patulous ... ... | 1 | 2 |
| Do., do., white and patulous. | 2 | 1 |
| Thin and pale, mouths of follicles do. | 2 | ... |
| Rosy with deep-red mottling ... | 1 | 1 |
| Pale, livid points all through, giving gray look ... ... ... ... | 3 | ... |
| Congested or swollen in lower end ... | 2 | 10 |
| Congested in upper end ... ... | 2 | ... |
| Congested all through ... ... ... | | 7 |
| Red, granular, and thickened ... ... | | 4 |
| Œdematous, pale tinged rose or livid. | 3 | 4 |
| Sub-mucous ecchymosis ... ... | 3 | 1 |
| Pigmentation ... ... ... ... | 11 | 9 |
| Cyst forms ... ... ... ... | 2 | 4 |
| Cicatrices ... ... ... ... ... | | 3 |

*Follicles conspicuous.*

Of the above eight cases in which the mucous follicles were markedly patulous and rendered conspicuous by their mouths being either injected or very pale, six were children, and the two in which the mucous membrane was thin and pale, not turgid and swollen, also were children. Where the lower part of the gut only was implicated, in one case of diarrhœa, there was simple lividity of the mucous coat of the rectum, and in the other merely a livid tinge, with swelling; and in four cases of dysentery there was deep venous mottling, with swelling in three, but no swelling in a fourth; deep-red injection and swelling, from transverse colon downwards, in one, simple livid injection in one, redness in one, and rosy hue with swelling in rugæ, in one; in two there was simple thickening of this part of the mucous membrane without injection.

*Lower gut implicated.*

*Caput coli implicated.*

In the two cases of diarrhœa, where the cæcum only was implicated, there was livid injection in both, but swelling in one only.

*Whole length implicated.*

In the seven cases of dysentery with congestion, the injection of the mucous coat was from pinkish-red to deep-purple, and was deepest in the lower end, where the swelling also was most marked; this amounting to œdema in two cases. In one case the mucous coat of the cæcum and ascending colon was of a deep livid purple, and presented two sub-mucous, flat, uncircumscribed abscesses, each about an inch in diameter, containing yellow pus; in the transverse colon it was pale-red and studded with numerous purple spots—the openings of similar abscesses; in the descending colon and rectum it was livid; but in the sigmoid flexure it was pale, and studded with cyst forms and follicles distended with muco-pus. The mucous membrane was not thickened, but the other coats felt so.

*Red, granular, and thickened.*

In the four cases of dysentery where the mucous membrane was injected, granular, and thickened, the lesion extended the whole length of the gut in two, was confined to the ends in one, and to the lower end in one.

*Œdema.*

In the cases of œdema of the mucous coat, in one of diarrhœa, this was pale-rose coloured, and the solitary glands were pink and prominent; in one it was pale-reddish, and the œdema was markedly in transverse folds, and in the third it was red injected in the cæcum, else pale, with a livid tinge.

In the four dysentery cases the mucous membrane looked mottled in one, and was markedly œdematous in two.

*Ecchymosis.*

In the dysentery case the ecchymosis was in sub-mucous, non-prominent blotches, recent in the cæcum, less so in the ascending colon. In the diarrhœa cases it was seen in the lower end of the gut as circular black spots, punctated in the centre in one case.

*Pigmentation.*

The pigmentation was general, giving the mucous coat a more or less deep slate-coloration in four cases of diarrhœa and three of dysentery, affected old spots of ecchymosis in four cases of diarrhœa and one of

dysentery, the mouths of mucous follicles in four cases of dysentery and one of diarrhœa, the mouths of cyst forms in three of dysentery and two of diarrhœa, and cicatrices in three cases of dysentery.

*Cyst forms.*

The "cyst forms" are about the size of small peas, and look like abscesses of the mucous follicles; but in "The Medical History of the American War," edited by Dr. Woodward, they are stated to be dilated growths of the tubular glands extending into the submucosa through the muscle of Brücke and into the solitary glands, and that they mostly contain mucus mixed with altered parenchyma of the glands.

*Diarrhœa and dysentery differentiated.*

In that work it is also stated that the difference between diarrhœa and dysentery lies in the implication in the latter of the part of the gut supplied by the nerves of defæcation, whence arise the symptoms peculiar to the disease. And on examining the present cases this differentiation is borne out, dysentery having been complained of in all cases where marked lesion of the lower part of the gut was found in the autopsy. The two cases of diarrhœa forming apparent exceptions were—one of a child who died on admission, and was said to have been ill four days with diarrhœa. In the autopsy there was found only "some lividity in the rectum, rest of mucous membrane of gut pinkish." The other was the case of a woman who died after being three weeks in hospital with diarrhœa. The autopsy discovered the mucous coat of large gut, "pale, with very slight livid tinge and swelling of folds towards anus," showing the lesion to be so slight in these cases as hardly to constitute an exception.

*Lung complication.*

The most common complication affecting the death-rate was some affection of the lungs. This usually set in when the vital powers of the patient became lowered, and hastened the end. Hence the sub-arrangement of the attached list of cases is in accordance with the nature of the lung complaint found in the autopsy, of which the following is an abstract:—

| | | Cases. |
|---|---|---|
| Lungs healthy ... ... | Men ... ... | 4 |
| | Women ... ... | 8 |
| | Children ... ... | 6 |

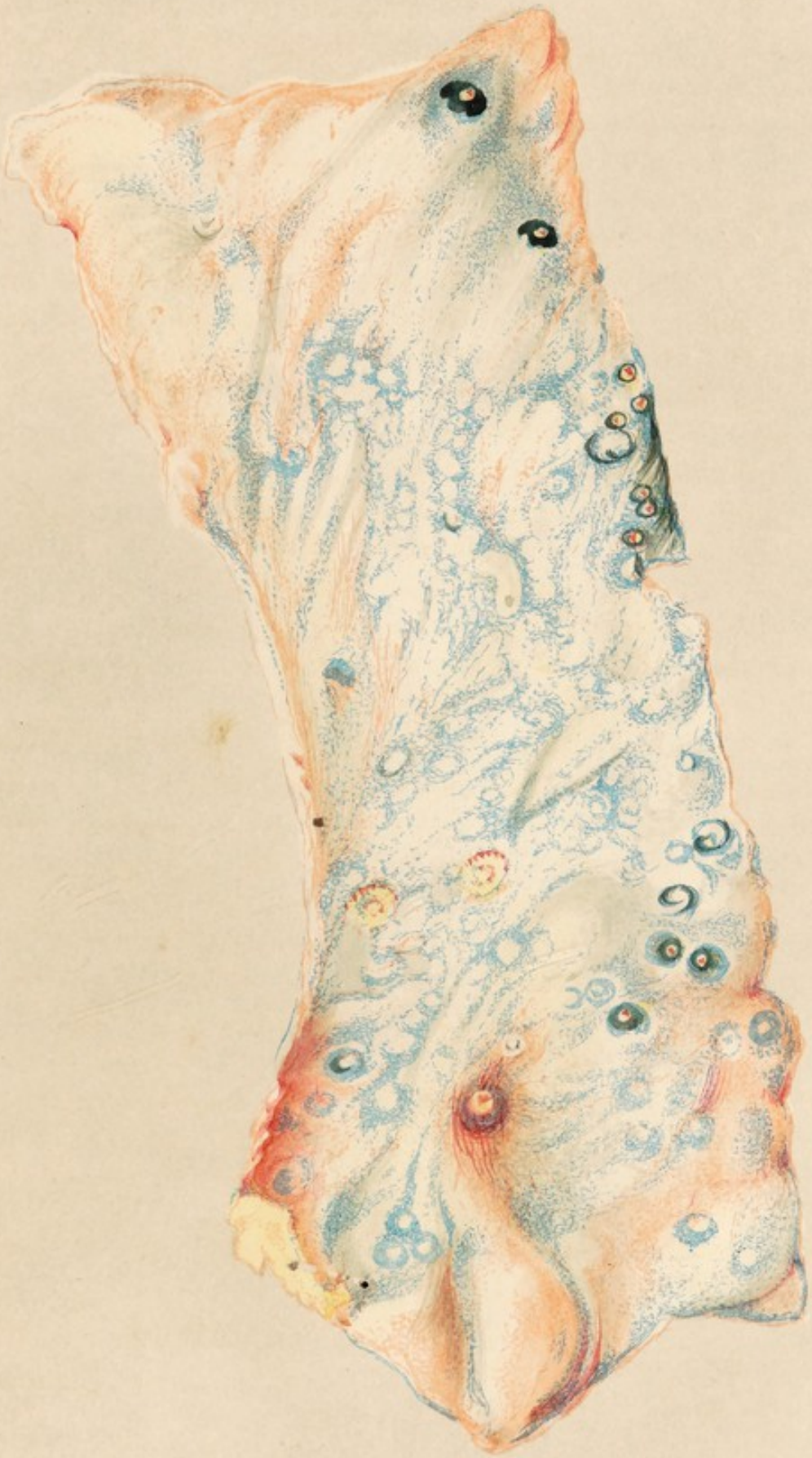

ALEX. BARREN, PINX. ET

CHROMOLITH. MADRAS, 1886

COLLOID CYSTS OF COLON. CHRONIC DYSENTERY.

| | | Cases. |
|---|---|---|
| Pneumonia, acute ... | Men ... ... | 3 |
| | Women ... ... | 1 |
| | Children ... ... | 10 |
| Pneumonic congestion. | Men ... ... | 15 |
| | Women ... ... | 7 |
| | Children ... ... | 2 |
| Other lung complication. | Men ... ... | 4 |
| | Women ... ... | 3 |
| | Children ... ... | 1 |

Subjoined are the last-named cases, eight in number:—

CASE I.—Chengelroy, a potter by caste and calling, about fifty-five years old, from Ochlevakum, two years in Madras, one month on famine relief, and ill ten days with "dysentery" and four with cough; admitted 6th June 1877. Is emaciated, with œdema of feet and face; belly doughy, painful on pressure; stools five last night, a pint of thin yellowish fluid; pulse 100; respirations 28; cough not troublesome; wheeze with expiration in apex of left lung; no dulness on percussion; skin dry and warm (99° F. to 102° F.). Died on 10th June. Autopsy one hour after death. Height, 5 feet 7½ inches; weight, 90 lbs.; body emaciated; no œdema; rigor mortis present. *Skull.*—Scalp and meninges normal; some serum in and beneath arachnoid. *Brain*, 47¾ ozs., firm, rather anæmic, some pale serum in lateral ventricles. *Chest.*—Right lung 14½ ozs.; slight recent adhesions over a livid spot on base, from which frothy fluid flows freely on section, and is studded with thick-walled cavities the size of large peas, containing inspissated mucus and pus; similar cavities, feeling like pellets, in the thin posterior part near apex; rest of lung healthy. *Left pleura*—recent adhesions and false membrane posteriorly; contains nearly a quart of bloody serum. *Lung*, 22⅞ ozs.; similar cavities all through lower lobe, and at apex posteriorly, surrounded by lividity with œdema, one cheesy deposit of same size at root; the other deposits feel hard, and contain sticky thick matter, consisting of granules and masses of epithelial cells. *Pericardium* distended, with dark amber serum, pearly. *Heart*, 6¾ ozs.; little fat; some fluid blood on both sides. *Abdomen.—Peritoneum* pearly, moistened with reddish serum. *Small intestines* contain a quart of ochrey fluid; mucous coat pale; valvulæ conniventes milk white; a rosy tinge in ileum; lots of clear mucus, detached by fingers. *Large intestines* empty; mucous coat of ascending colon dusky pink and œdematous, with one dark old cicatrix; elsewhere rosy and swollen, with minute warty prominences like hypertrophied papillæ, increasing in number and size on rugæ towards rectum. *Stomach* large; full of milky fluid; pale and smooth. *Liver*, 25½ ozs., cirrhotic-looking, 6 + 2 × 5 × 3

inches*; section, pale cirrhotic; very fatty. *Gall Bladder* full of thick dark bile. *Spleen* 1 oz., 3 × 2 × $\frac{3}{4}$ inch, red, not friable, no pulp. *Right kidney*, 2 ozs.; capsule strips easily; medulla, white like fibrous tissue; cortex, pale livid mottled yellow, fatty. *Left kidney*, 1 oz., granular on surface, else like right. *Pancreas*, 1 oz., healthy. *Mesenteric glands* atrophied, a little fat in mesentery.

Case II.—Vyapoora, a weaver, about fifty years old, from Conjevaram, ten days in Madras, three ill with "dysentery." Admitted on 19th August. He is a skeleton; no œdema; pulse 100; respirations 20; belly retracted, soft, not painful on pressure; stools yellow fluid; some nausea; skin clean. 12th September.—Two thin motions daily; urine healthy. Dropsy made its appearance to-day, and increased till death, on the 24th October. Autopsy nine hours after death. Height, 5 feet 5 inches; weight, 101 lbs.; body dropsical; rigor mortis present. *Skull.*—Scalp and meninges pale, 2 ozs. serum in and beneath arachnoid. *Brain*, 45$\frac{1}{2}$ ozs., firm, anæmic, a clot in sulci of convolutions of anterior cornu of left hemisphere. *Chest.*—Right pleura pearly, contains a pint of serum. *Lung*, 11$\frac{1}{2}$ ozs.;† apneumatosis of nearly whole lower lobe, with slight œdema. *Left pleura* like right. *Lung*, 10$\frac{1}{4}$ ozs.; simple apneumatosis of whole lower lobe. *Pericardium*, pearly, moistened with serum. *Heart*, 5$\frac{3}{4}$ ozs.; fluid blood on left side; slight œdema replaces fat on surface. *Abdomen.*—Peritoneum pearly; contains two gallons of serum. *Small intestine* contains some greenish mucus; looks healthy. *Large intestine* empty; mucous coat pinkish red, œdematous in lower end, with pigmentation of the mouths of follicles, many of which are distended with pus; there are also cyst forms here as big as large peas. *Stomach* empty; lining, pale rose, rugose. *Liver*, 18$\frac{3}{4}$ ozs.; margin of left lobe atrophied; a white cloud on capsule, 6 + 1$\frac{3}{4}$ × 5 × 2 inches; section normal; gall-bladder full of pale watery fluid with a green sediment. *Spleen*, 2$\frac{5}{8}$ ozs.; capsule adherent to parietes by firm bands, 3$\frac{1}{2}$ × 3 × $\frac{3}{4}$ in.; section, dark red, not friable, and no pulp exudes on pressure. *Kidneys*, 2$\frac{1}{4}$ ozs. each; capsule partly adherent, section red, cortex paler, structure normal. *Pancreas*, 1$\frac{3}{4}$ ozs., healthy. Slight œdema of mesentery; glands small and pale.

Case III.—Veerasauruy, a Pariah coolie, about fifty-six years old, from Chingleput, two months in Madras, ill five days with "dysentery." Admitted and died on 8th August 1877. Autopsy one hour after death. Height, 5 feet 5$\frac{1}{2}$ inches; weight, 85 lbs.; body thin; no œdema; rigor mortis present. *Skull.*—Scalp and meninges bloody; serum in and beneath arachnoid. *Brain*, 40$\frac{1}{2}$ ozs., surface dusky, veins empty, substance firm, venous hyperæmic like pia mater. *Chest.*—Right pleura healthy. *Lung*, 8$\frac{1}{2}$ ozs., fully collapsed, of livid tinge in

---

* This means breadth of right lobe 6 inches and of left lobe 2 inches, depth of liver 5 inches and thickness 3 inches.

† This term is used in the same sense as in Reynolds' System of Medicine.

upper, with apneumatosis of lower lobe. *Left pleura* healthy. *Lung*, $6\frac{1}{2}$ ozs., less livid than right, and all spongy. *Pericardium*, pearly, contains $\frac{1}{2}$ ozs. serum. *Heart*, $6\frac{5}{8}$ ozs.; fluid blood on right side, fat on surface. *Abdomen.*—Peritoneum healthy; guts distended with gas, reddish. *Small intestine* contains a quart of whitish blood-tinged fluid; mucous coat bright red, ecchymotic-like injection in jejunum, deeply livid in ileum; the solitary glands not enlarged, but appearing as small white dots. *Large intestine* empty; no thickening or mucus present; mucous coat uniformly red injected with a livid tinge and livid mottling in parts. *Stomach* enormous, full of conjee, lining pale and smooth. *Liver*, 30 ozs., conjested, $7 + 2 \times 5\frac{1}{2} \times 3$ inches; cuts soft from hyperæmia; structure normal; gall-bladder full of thick green bile. *Spleen* 3 ozs., flabby, lobulated, $4 \times 3 \times 1\frac{1}{4}$ inch, not friable, and no pulp exudes on pressure. *Right kidney*, $2\frac{1}{2}$ ozs.; capsule strips easily; four small cysts on surface; section uniformly deep red injected; structure normal. *Left kidney*, $2\frac{5}{8}$ ozs., like right. *Pancreas* $2\frac{3}{8}$ ozs., healthy. No fat in mesentery; glands atrophied.

The appearances here were wonderfully like those found in cholera, from the contents of the guts, arterial congestion of its mucous membrane, and conspicuousness of its solitary glands, to the venous congestion of the contents of the cranium, abdomen, and chest, with the fully collapsed lungs.

Case IV.—Veerasauruy, a Vooloocie coolie man, about sixty years old, from Numallay, one month in Madras, ill two days with watery diarrhœa; no vomiting. Admitted and died on 7th July. Is quite a skeleton; no œdema; pulse 92, weak; respiration, 36; some cough for four days; bronchial breathing in right apex; skin scurfy; belly retracted, doughy, painful on pressure. Autopsy six hours after death. Height, 5 feet 5 inches; weight, 75 lbs.; rigor mortis present. *Skull.*—Scalp and meninges bloody; a little serum in and beneath arachnoid; pia mater hyperæmic. *Brain*, 40 ozs., slight dropsy of ventricles; substance firm; hyperæmic. *Chest.*—*Right pleura* healthy. *Lung*, 10 ozs.; a shallow cicatrix on apex, and a small spot of sub-pleural ecchymosis on base; veins engorged, of lower lobe especially. *Left pleura*, firm adhesions all over. *Lung*, $11\frac{3}{4}$ ozs., slight congestion with œdema of posterior border; a hard fibrous deposit occupying nearly the entire apex, and a smaller one in lower lobe; the section looks like chronic pneumonia, the microscopic structure being fibrous tissue, with fat granules intermingled; no sign of tubercles. *Pericardium* pearly, moistened with serum. *Heart*, $6\frac{1}{2}$ ozs.; little fat on surface; dark fluid blood on both sides. *Abdomen.*—*Peritoneum* pearly; intestines and mesentery injected red, as in cholera. *Small intestine* empty; mucous coat reddish; livid at lower end of ileum, with prominence of solitary glands; no mucus. *Large intestine* empty; livid appearance of mucous membrane from deep-seated congestion of venous radicles; no thickening. *Stomach* large, contains some dark fluid; lining in rugæ, pale, with some punctæ. *Liver* $27\frac{1}{2}$ ozs., a deep furrow across right lobe, $5\frac{1}{2} + 3 \times 6 \times 3$ inches; section, dark liver; vessels full

of dark tarry blood; structures normal. *Gall-bladder.*—Quarter full of thin green bile. *Spleen* $1\frac{5}{8}$ ozs., flabby, $4 \times 2 \times \frac{3}{4}$ inch, flaccid, not friable, and no pulp exudes on pressure. *Kidneys*, $2\frac{1}{2}$ ozs. each; capsule strips easily, deeply injected, slightly fatty. *Pancreas* $2\frac{1}{8}$ ozs. healthy. *Mesentery* red injected, devoid of fat; glands atrophied. The appearances in this case were very much those of cholera, although the symptoms were not, and he actually walked to hospital a few hours before death.

Case V.—Ponee, a Pariah coolie woman, about sixty years old, from Palaveram, two months in Madras, ten days ill with "dysentery." She is emaciated with œdema of lower extremities and some ascites; belly painful on pressure; pulse, 88; respirations, 24; skin cool, scurfy. Admitted on 13th August and died on 26th September 1877; the dropsy in the meantime having greatly increased, and bed sores formed on sacrum. Autopsy one hour after death. Height, 4 feet $10\frac{1}{2}$ inches; weight 88 lbs.; body dropsical; rigor mortis present. *Skull.*—Scalp and meninges bloody, 3 ozs. serum in and beneath arachnoid; pia mater anæmic. *Brain* $33\frac{3}{4}$ ozs., firm and pale. *Chest.*—Right pleura pearly, contains a quart of serum. *Lung*, $6\frac{3}{4}$ ozs.; complete apneumatosis of all except apex. *Left pleura* pearly, contains half a pint of serum. *Lung* $6\frac{3}{8}$ ozs., healthy. *Pericardium* pearly, contains 4 ozs. serum. *Heart* $5\frac{5}{8}$ ozs., fluid blood on both sides, only a trace of fat on surface. *Abdomen.*—Peritoneum pearly, contains a gallon of pale serum; intestines collapsed. *Small intestine* contains thirteen lumbrici and a little ochrey fluid; mucous coat pale rose, œdematous, especially on the valvulæ conniventes near upper end. *Large intestine* empty; mucous coat pale red, marked by œdema all through. *Stomach* small; empty; lining pale rosy, rugose. *Liver* $19\frac{1}{2}$ ozs., three furrows across right lobe, $5 + 2\frac{1}{2} \times 5 \times 2\frac{1}{2}$ inches; section fatty nutmeg, very fatty; gall-bladder distended with thin dark-green bile. *Spleen*, $1\frac{1}{2}$ ozs.; has a papillary adhesion to parietes; section red, not friable, and no plup exudes on pressure. *Kidneys*, $1\frac{7}{8}$ ozs. each; capsules strip easily; section pale; cortex, semitransparent, not fatty. *Pancreas* $1\frac{1}{2}$ ozs., healthy. No fat in mesentery; glands small, with concretions in some.

Case VI.—Mariamah, a Pariah coolie woman, about sixty years old, from Acherpaukum, eight days in Madras, and four ill with "dysentery." Admitted on 2nd August. She is a skeleton; no œdema; belly retracted, soft, painful on pressure; pulse, 80; respirations, 24; stools scanty, pale, slimy; skin loose and hanging. Died on 10th August. Autopsy one hour after death. Height 5 feet 1 inch; weight, 59 lbs.; body as above; rigor mortis present. *Skull.*—Scalp and meninges pale; serum beneath tentorium and arachnoid; pia mater hyperæmic; veins full. *Brain* $38\frac{3}{4}$ ozs., firm, hyperæmic; serum in ventricles, normal. *Chest.*—Right pleura pearly; contains a little serum. *Lung*, $9\frac{3}{4}$ ozs.; two depressed cicatrices on middle of lower lobe, and two on upper, over chronic pneumonic tissue, with a few small tubercles around, else healthy. *Left pleura* like right. *Lung* $9\frac{1}{4}$ ozs., pale, spongy, with livid

œdematous spots on section of lower lobe. *Pericardium* pearly; contains 1 oz. serum. *Heart* flabby, fluid blood on both sides, some fat on surface. *Abdomen.*—Peritoneum pearly, moistened with serum. *Small intestine* contains four lumbrici; mucous coat pink, with clear detachable mucus in jejunum; paler in ileum, where there is green mucus sticking closely to it. *Large intestine* empty; mucous coat dusky red; swollen, least so in upper end. *Stomach* small, lining dull pink, mottled darker. *Liver* $28\frac{1}{2}$ ozs., long and narrow, $7 + 3 \times 4 \times 3\frac{1}{2}$ inches; acini bordered yellow; extremely fatty. Gall-bladder wholly protruding beyond liver margin, full of thin dark bile. *Spleen* $1\frac{5}{8}$ oz., flabby, $3\frac{1}{2} \times 2\frac{1}{2} \times 1$ inch; section dark red, not friable, and no pulp exudes on pressure. *Right kidney*, $2\frac{1}{8}$ ozs.; capsule strips; surface granular, with small cysts; section uniformly red, slightly fatty. *Left kidney*, $2\frac{1}{2}$ ozs.; quite like right. *Pancreas* $1\frac{1}{4}$ oz., healthy. A trace of ochrey yellow fat in mesentery; glands atrophied.

Case VII.—Ragachee, a coolie woman of the Pully caste, about fifty years old, from Chingleput, four months in Madras, ten days ill with "dysentery and cough." She is emaciated, has paralysis agitans, stools mud-colored; pulse, 96; respirations, 30; has had a cough for ten months; never spat blood; feels giddy; admitted on 30th August and died on 20th September 1877. Autopsy, nine hours after death. Height, 5 feet; weight, 50 lbs.; body a skeleton; œdema of feet; rigor mortis gone off. *Skull.*—Scalp and meninges pale, a little serum in and beneath arachnoid, lateral veins full. *Brain*, 39 ozs., softish, anæmic. *Chest.*—Right pleura moistened with serum, and slight old points of adhesion behind. *Lung*, $15\frac{1}{2}$ ozs., not collapsed, bronchi exude pus on pressure, upper lobe studded with tuberculoid deposits like fish roe. *Left pleura* pearly, moistened with serum. *Lung*, $11\frac{3}{8}$ ozs., not collapsed, tuberculoid deposits in apex and thin margin of base; some congestion and œdema of posterior border. *Pericardium* pearly, moistened with serum. *Heart*, 5 ozs., cavities full of dark clots, œdema replaces fat on surface. *Abdomen.*—Peritoneum pearly, moistened with red serum. *Small intestine* contains seven lumbrici; mucous coat thin, reddish, deeper red in parts; glands normal, no mucus. *Large intestine* empty, mucous coat congested in points on transverse folds, no thickening or ulceration. *Stomach* small, empty, mucous coat pale in rugæ. *Liver*, 17 ozs.; three furrows across right lobe, $5 + 2 \times 5 \times 2$ inches; section anæmic, acini margined white, decidedly fatty; gall bladder half full of thin green bile. *Spleen*, $1\frac{5}{8}$ oz., $3 \times 2 \times 1\frac{1}{2}$ inch; section red, not friable. *Right kidney*, $2\frac{1}{4}$ ozs.; capsule strips easily, section red, decidedly fatty. *Left kidney*, $2\frac{5}{8}$ ozs., like right. *Pancreas*, $1\frac{5}{8}$ oz., healthy. No fat in mesentery; glands much atrophied.

Case VIII.—Bavyah, the son of a weaver, aged about five years, from Nellore, five days in Madras, and ill one with "diarrhœa." Admitted 20th June 1877. Is quite a skeleton, belly puffed, the coils of intestine seen through the thin abdominal walls; pulse, 100, weak; respirations, 20; said to have had looseness of the bowels yesterday, and no motions since. Died on 22nd June. Autopsy four hours after

death. Height, 2 feet 8 inches; weight, 14 lbs. Body quite a skeleton. No œdema. *Skull.*—Scalp pale, meninges and base of skull bloody, arachnoid normal, pia mater rather minutely red streaked, veins mostly empty. *Brain* 33 ozs., firm, rather hyperæmic. *Chest.*—*Right pleura*, old points of lateral adhesion. *Lung* spongy, 2 ozs., pale, with pink tinge in front, and livid tinge behind; in upper lobe is a largish cavity containing concretions, lining like mucous membrane, but no mucus present, and walls feel hard from old thickening around, but no deposits, some dark red lobules are seen in the section of lower lobe. *Left pleura* healthy. *Lung* $1\frac{3}{8}$ oz., healthy. *Pericardium* pearly, moistened with serum. *Heart* $1\frac{1}{4}$ oz., flabby, no fat on surface, a little fluid blood on both sides. *Abdomen.*—Peritoneum healthy. *Small intestine* contains five lumbrici and some whitish fluid, coats very thin, arborescent injection in ileum showing through, lining rosy, Peyer's patches darker and cribriform; no mucus detachable. *Large intestine* empty, thin and grey, no mucus. *Stomach* small, empty; lining pale rosy, in rugæ. Liver, $7\frac{5}{8}$ ozs.; liver colored with purple tinge on right, and yellow tinge on left lobe, $3\frac{1}{2}+2\times4\times1\frac{1}{2}$ inch, not fatty. *Gall-bladder* full of thin dark bile. *Spleen*, $\frac{5}{8}$ oz., $2\frac{3}{4}\times\frac{1}{2}\times1\frac{1}{2}$ inch; section pale red brown, not friable, and no pulp on pressure. *Right kidney*, $\frac{3}{4}$ oz.; capsule strips easily, anæmic, healthy. *Left kidney*, $\frac{1}{2}$ oz., like right, but some injection of medulla. *Pancreas.*—Three drachms, healthy. *Mesenteric glands* normal; no fat in mesentery.

## Alvine Flux without Lesion of Gut.

*List of Cases, giving Weight of Body and of its Organs, &c.*

| No. | Name. | Caste. | Occupation. | Age. | Sex. | Height. Feet. | Height. Inches. | Weight in lbs. | Weight in ounces of Brain. | Weight in ounces of Right Lung. | Weight in ounces of Left Lung. | Weight in ounces of Heart. | Weight in ounces of Liver. |
|---|---|---|---|---|---|---|---|---|---|---|---|---|---|
| | | | | YRS. | | | | | | | | | |
| 1 | Irchen ... ... ... | Vaden ... | Coolie ... | 60 | Male ... | 5 | 1 | 63 | 39⅜ | 8¼ | 6 | 6 | 21 |
| 2 | Ramadoo ... ... | Cauvary ... | Do. ... | 50 | Do. ... | 5 | 5 | 69 | 44⅞ | 10⅜ | 8¾ | 4¾ | 23½ |
| 3 | Soobroyen ... ... | Moodeliar ... | Do. ... | 65 | Do. ... | 5 | 4 | 87 | 47½ | 9¼ | 9⅝ | 5⅝ | 24¼ |
| 4 | Soobroyen ... ... | Do. ... | Do. ... | 50 | Do. ... | 5 | 5¼ | 75 | 45¾ | 8 | 7⅛ | 9⅛ | 34⅜ |
| 5 | Ellamah ... ... | Pariah ... | Do. ... | 55 | Female... | 5 | 0½ | 62 | 40½ | 14¾ | 10¾ | 6⅝ | 24⅞ |
| 6 | Mootamah ... ... | Pullay ... | Ryot ... | 50 | Do. ... | 5 | 2 | 69 | 36¾ | 7⅞ | 8 | 6 | 38½ |
| 7 | Karambie ... ... | Mahommedan | ... | 60 | Do. ... | 5 | 0 | 62 | 35⅜ | 6⅜ | 7 | 4⅝ | 32½ |
| 8 | Anamully ... ... | Kunkully ... | Weaver... | 40 | Do. ... | 5 | 0½ | 82 | 37½ | 8 | 5¼ | 3¾ | 20¾ |
| 9 | Chengy ... ... | Pariah ... | Coolie ... | 55 | Do. ... | 4 | 9 | 69 | 40 | 8⅞ | 6⅝ | 4⅞ | 18 |
| (a) 10 | Lutchmee ... ... | Cauvary ... | Do. ... | 20 | Do. ... | 4 | 11 | 45 | 33 | 6 | 6⅛ | 3¼ | 21½ |
| 11 | Chengamalam ... | Moodeliar ... | Do. ... | 30 | Do. ... | 5 | 0 | 67 | 39¼ | 18 | 16⅝ | 5¼ | 39¼ |
| 12 | Yellamah ... ... | Pariah ... | Do. ... | 40 | Do. ... | 4 | 7 | 46 | 36½ | 8¾ | 8¼ | 3½ | 17½ |
| 13 | Veeraswamy ... ... | Wadder ... | Wadder. | 5 | Male ... | 3 | 2 | 24 | 31 | 3 | 2¼ | 3 | 9½ |
| 14 | Gungadoo ... ... | Pariah ... | Coolie ... | 12 | Do. ... | 4 | 4 | 37 | 43¼ | 4¼ | 4⅞ | 2⅞ | 14⅞ |
| 15 | Munchee ... ... | Do. ... | Do. ... | 1 | Female... | 2 | 2 | 11 | 24½ | ⅞ | ¾ | ¾ | 5½ |
| 16 | Mooneen ... ... | Do. ... | Do. ... | 3 | Male ... | 2 | 4 | 14 | 36½ | 1⅜ | 1½ | 1 | 8¾ |
| 17 | Chellan ... ... | Irlan ... | Do. ... | 10 | Do. .. | 3 | 8 | 27 | 40⅞ | 3 | 2¾ | 2¼ | 12½ |
| 18 | Moorgun ... ... | Pullay ... | Do. ... | 5 | Do. ... | 2 | 8 | 13 | 34½ | 1¾ | 1½ | 1⅜ | 6¾ |

(a) Lungs, healthy—4 men, 8 women, 6 children.

## ALVINE FLUX WITHOUT LESION OF GUT—*continued.*

*List of Cases, giving Weight of Body and of its Organs, &c.*—continued.

| | No. | Name. | Caste. | Occupation | Age. | Sex. | Height. Feet. | Height. Inches. | Weight in lbs. | Weight in ounces of Brain. | Weight in ounces of Right Lung. | Weight in ounces of Left Lung. | Weight in ounces of Heart. | Weight in ounces of Liver. |
|---|---|---|---|---|---|---|---|---|---|---|---|---|---|---|
| | | | | | YRS. | | | | | | | | | |
| | 19 | Kullen ... ... | Pariah ... | Ryot ... | 55 | Male ... | 5 | 5 | 83 | 43 | 26⅞ | 15½ | 7¼ | 32 |
| | 20 | Moorgun ... ... | Do. ... | Coolie ... | 25 | Do. ... | 5 | 2½ | 88 | 40½ | 13¼ | 29 | 5⅞ | 48½ |
| | 21 | Punthen ... ... | Pullay ... | Do. ... | 20 | Do. ... | 5 | 6 | 67 | 38 | 11⅛ | 13⅛ | 5¼ | 34¼ |
| | 22 | Amanee ... ... | Pariah ... | Do. ... | 20 | Female . | 5 | 3¾ | 61 | 40½ | 15¼ | 16⅞ | 5⅛ | 44½ |
| | 23 | Mooneen .. ... | Pullay ... | Do. ... | 8 | Male ... | 3 | 4 | 23 | 34½ | 9 | 4½ | 1¾ | 13 |
| | 24 | Lutcheegadoo... ... | Yanandy ... | Do. ... | 10 | Do. ... | 3 | 8 | 26 | 41 | 7¼ | 5½ | 2½ | 14 |
| (b) | 25 | Poonun ... ... | Pariah ... | Do. ... | 4 | Do. ... | 3 | ... | 16 | 37⅛ | 5⅛ | 3½ | 1½ | 11⅜ |
| | 26 | Kolandee ... ... | Pullay ... | Do. ... | 7 | Do. ... | 3 | ... | 19 | 35⅛ | 3⅝ | 3⅝ | 1⅞ | 12¼ |
| | 27 | Moorooven ... ... | Pariah ... | Do. ... | 1½ | Do. ... | 2 | 4 | 14 | 25¼ | 2⅞ | 2⅝ | 1⅛ | 7⅞ |
| | 28 | Chungagadoo ... ... | Do. ... | Do. ... | 7 | Do. ... | 3 | 8 | 22 | 40⅜ | 4⅝ | 3⅞ | 2 | 12⅞ |
| | 29 | Kuniamah ... ... | Do. ... | Do. ... | 1 | Female... | 2 | 2 | 14 | 33½ | 2 | 2⅜ | 1 | 7⅜ |
| | 30 | Nagummah ... ... | Cauvary ... | Do. ... | 2 | Do. ... | 2 | ... | 15 | 28¾ | 2¼ | 1¾ | 1⅛ | 10⅛ |
| | 31 | Paupah ... ... | Pullay ... | Do. ... | 5 | Do. ... | 3 | ... | 15 | 33 | 2¾ | 1⅞ | 1⅜ | 9 |
| | 32 | Parthen ... ... | Pariah ... | Do. ... | 6 | Male ... | 3 | ... | 16 | 35½ | 3⅜ | 3¼ | 1¼ | 9¼ |
| | 33 | Moothu ... ... | Do. ... | Do. ... | 50 | Do. ... | 5 | 2½ | 79 | 39½ | 15 | 12 | 5½ | 29⅝ |
| | 34 | Moorthen ... ... | Do. ... | Do. ... | 55 | Do. ... | 5 | 2 | 73 | 36¾ | 14¾ | 8 | 4¾ | 22⅞ |
| | 35 | Karten ... ... | Do. ... | Ryot ... | 60 | Do. ... | 5 | 2½ | 79 | 39¼ | 16½ | 10⅞ | 5⅝ | 29½ |
| | 36 | Chenchi Naidoo ... | Bujlevadoo ... | Teacher .. | 65 | Do. ... | 5 | 5½ | 82 | 33 | 17 | 11½ | 6¼ | 34 |
| | 37 | Mohomed Ghouse ... | Mahommedan. | Fakeer ... | 45 | Do. .. | 5 | 8 | 113 | 46⅜ | 13¼ | 14⅞ | 5½ | 26¾ |
| | 38 | Somiah ... ... | Pariah ... | Coolie ... | 50 | Do. ... | 5 | 4 | 79 | 42 | 24¾ | 12¾ | 6⅜ | 30 |

| | | | | | | | | | | | | | | |
|---|---|---|---|---|---|---|---|---|---|---|---|---|---|---|
| | 39 | Venketswamy ... ... | Do. ... | Do. ... | 40 | Do. ... | 5 | 7 | 69 | 38 | 11¾ | 14¼ | 6¾ | 30½ |
| | 40 | Peeran ... ... | Cauvary ... | Do. ... | 50 | Do. ... | 5 | 7 | 113 | 44½ | 41¼ | 39 | 6¾ | 42¼ |
| | 41 | Venkettachellam ... | Moothree ... | Do. ... | 50 | Do. ... | 5 | 3½ | 66 | 37 | 14 | 12⅜ | 5½ | 28⅝ |
| | 42 | Choudroyen .. ... | Weaver ... | Weaver .. | 50 | Do. ... | 5 | 6 | 81 | 40 | 19 | 15¾ | 7½ | 27 |
| | 43 | Venkettachellam ... | Pully ... | Coolie ... | 35 | Do. ... | 5 | 8 | 68 | 40½ | 18⅛ | 14½ | 6¼ | 26¾ |
| | 44 | Yagan ... ... | Pariah ... | Do. ... | 50 | Do. ... | 5 | 5 | 88 | 38 | 15⅞ | 12¼ | 9⅜ | 28¾ |
| (c) | 45 | Venkatawarda ... | Weaver ... | Weaver... | 40 | Do. ... | 5 | 7 | 69 | 35 | 19¼ | 6⅝ | 5⅝ | 27¼ |
| | 46 | Narain ... ... | Rajoo ... | Farmer... | 35 | Do. ... | 5 | 8 | 93 | 44¼ | 17⅝ | 16⅝ | 6⅝ | 45½ |
| | 47 | Yenkadoo ... ... | Weaver ... | Weaver... | 45 | Do. ... | 5 | 4 | 97 | 47½ | 23¼ | 18 | 7⅛ | 30⅛ |
| | 48 | Moonay ... ... | Koorvah ... | Leaf-seller | 35 | Female... | 5 | 3 | 72 | 38 | 18½ | 15½ | 7 | 28½ |
| | 49 | Thoongay ... ... | Pariah ... | Coolie ... | 45 | Do. ... | 4 | 9½ | 57 | 37½ | 10¾ | 9⅜ | 4¾ | 28¾ |
| | 50 | Mongathy ... ... | Moodeliyar ... | Do. ... | 60 | Do. ... | 5 | 5 | 63 | 42½ | 15½ | 12⅞ | 6⅛ | 49¾ |
| | 51 | Allamaloo ... ... | Pariah ... | Do. ... | 40 | Do. ... | 5 | 2 | 84 | 49 | 16⅛ | 16⅜ | 7⅛ | 25½ |
| | 52 | Latchmee ... ... | Moodelly ... | Do. ... | 30 | Do. ... | 5 | ... | 66 | 36⅝ | 10⅞ | 11¾ | 4⅝ | 20⅜ |
| | 53 | Peruma ... ... | Pariah ... | Do. ... | 50 | Do. ... | 5 | ... | 63 | 40⅛ | 16⅛ | 11½ | 6 | 29¼ |
| | 54 | Moochee ... ... | Do. ... | Do. ... | 40 | Do. ... | 5 | 2½ | 69 | 40⅜ | 17⅜ | 12 | 4¾ | 40⅛ |
| | 55 | Moorooven ... ... | Do. .. | Do. ... | 2 | Male ... | 2 | 10 | 16 | 37¾ | 3¼ | 3 | 1⅜ | 11 |
| | 56 | Mooneeamah ... ... | Do. ... | Do. ... | 7 | Female... | 3 | 4 | 20 | 31¾ | 5½ | 4 | 1¼ | 8¾ |
| | 57 | Chengelroy ... ... | Potter ... | Potter ... | 55 | Male ... | 5 | 7½ | 90 | 47¾ | 14½ | 22⅞ | 6¾ | 25½ |
| | 58 | Vyapora ... ... | Sendie ... | Weaver... | 50 | Do. ... | 5 | 5 | 101 | 45½ | 11½ | 10¼ | 5¾ | 18¾ |
| | 59 | Veeraswamy ... ... | Pariah ... | Coolie ... | 56 | Do. ... | 5 | 5½ | 85 | 40½ | 18½ | 6½ | 6⅝ | 30 |
| | 60 | Veeraswamy ... ... | Voolooin ... | Do. ... | 60 | Do. ... | 5 | 5 | 75 | 40 | 10 | 11¾ | 6½ | 27½ |
| (d) | 61 | Ragachee ... ... | Fully ... | Do. ... | 50 | Female... | 5 | ... | 50 | 39 | 15½ | 11⅜ | 5 | 17 |
| | 62 | Ponee ... ... ... | Pariah ... | Do. ... | 60 | Do. ... | 4 | 10½ | 88 | 33¾ | 6¾ | 6⅜ | 5⅝ | 19½ |
| | 63 | Mariamah ... ... | Do. ... | Do. ... | 60 | Do. ... | 5 | 1 | 59 | 38⅜ | 9¾ | 9¼ | 5 | 28½ |
| | 64 | Baryah ... .. | Weaver ... | Weaver... | 5 | Male ... | 2 | 8 | 14 | 33 | 2 | 1⅜ | 1¼ | 7⅝ |

(*b*) Acute pneumonia—3 men, 1 woman, 10 children. (*c*) Lungs congested—15 men, 7 women, 2 children.
(*d*) Other lung complications—4 men, 3 women, 1 child.

## ALVINE FLUX WITHOUT LESION OF GUT—*continued.*

*List of Cases, giving Weight of Body and of its Organs, &c.*—continued.

| No. | Name. | Weight in ounces of—*cont.* | | | | Date of Autopsy. | Hours after death Autopsy made. | Riger Mortis. | Bodily state. |
|---|---|---|---|---|---|---|---|---|---|
| | | Spleen. | Right Kidney. | Left Kidney. | Pancreas. | | | | |
| 1 | Irchen ... ... ... | 1⅜ | 2½ | 1½ | 1½ | 7 April ... | 4 | Well-marked. | Emaciated; œdema of feet. |
| 2 | Ramadoo ... ... | 1¼ | 2 | 2¼ | 2⅜ | 20 June ... | 14 | Present ... | Quite a skeleton; no œdema. |
| 3 | Soobroyen ... ... | 2¼ | 2⅞ | 2¾ | 2⅝ | 28 Sept. ... | 1 | Do. ... | Emaciated; no œdema. |
| 4 | Soobroyen ... ... | 3⅝ | 2⅝ | 2⅝ | 2⅜ | 10 Oct. 1877 | 8 | Do. ... | |
| 5 | Ellamah ... ... | 2½ | 2½ | 2 | 1⅜ | 5 April ... | 5 | Not well-marked. | Emaciated; œdema of feet. |
| 6 | Mootamah ... ... | 1⅝ | 3⅜ | 3⅜ | 2⅛ | 23 April ... | 4 | Present ... | Emaciated; no œdema. |
| 7 | Karambie ... ... | 1⅜ | 1⅝ | 1½ | 1 | 1 May 1877 | 10 | ... | Thin, not quite devoid of fat; elephantiasis of left leg. |
| 8 | Anamully ... ... | ⅞ | 2⅞ | 3 | 1⅛ | 5 May 1877 | 8 | Present ... | Much emaciated; feet œdematous. |
| (a) 9 | Chengy ... ... | 1 | 2¾ | 2⅝ | 2¼ | 4 June ... | 1 | Do. ... | Emaciated; œdema of feet and legs. |
| 10 | Lutchmee ... ... | 1 | 2¼ | 2¼ | 1¼ | 18 Dec. 1877 | 5 | Do. ... | Quite a skeleton; belly much retracted. |
| 11 | Chengamalam ... | 8⅝ | 3⅝ | 3⅝ | 2⅞ | 27 Dec. 1877 | 12 | Do. ... | Skeleton; no œdema. |
| 12 | Yellamah ... ... | ¾ | 2⅜ | 2½ | 1½ | 10 Jan. 1878 | 4 | Do. ... | Skeleton; œdema of feet. |
| 13 | Veeraswamy ... ... | 1⅝ | 1⅛ | 1¼ | ⅝ | 24 May ... | 2 | Do. ... | |
| 14 | Gungadoo ... ... | 1 | 1¼ | 1¼ | ⅝ | 19 June ... | 11 | Do. ... | Skeleton; no œdema. |
| 15 | Munchee ... ... | ⅜ | ½ | ⅝ | ¼ | 7 Aug. ... | 2 | Do. ... | Skeleton; œdema of feet. |

| | | | | | | | | | | | |
|---|---|---|---|---|---|---|---|---|---|---|---|
| | 16 | Mooneen ... ... | ⅜ | 3¼ | ⅞ | ½ | 25 June ... | 10 | ... | Miserable, pot-bellied; skeleton; no œdema. |
| | 17 | Chellan ... ... | 1⅝ | 1⅛ | 1⅛ | ⅞ | 28 June ... | 4 | Present ... | Skeleton; no œdema. |
| | 18 | Moorgun ... ... | ⅝ | ¾ | ¾ | ½ | 3 Aug. ... | 4 | Do. ... | Skeleton; no œdema; belly puffed. |
| | 19 | Kullen ... ... ... | ¾ | 3 | 3 | 2⅞ | 20 April 1877 | 4 | Do. ... | Emaciated; no œdema. |
| | 20 | Moorgun ... ... | 3 | 3¼ | 3⅞ | 3 | 9 May ... | 2 | Marked ... | In good flesh. |
| | 21 | Punthen ... ... | 4¼ | 2¾ | 2½ | 1⅞ | 18 Dec. 1877 | 1 | Present ... | Quite a skeleton; no œdema; belly retracted. |
| | 22 | Amanee ... ... | 3¼ | 2⅝ | 4⅛ | 2½ | 27 Dec. 1877 | 11 | Do. ... | Skeleton; no œdema. |
| | 23 | Mooneen ... ... | 1⅜ | 1½ | 1½ | ⅝ | 16 June 1877 | 2 | Gone ... | |
| | 24 | Lutcheegadoo ... | ⅞ | 1¼ | 1¼ | ⅝ | 18 June ... | 14 | Gone off ... | |
| (b) | 25 | Poonun ... ... | ⅝ | 1¼ | 1¼ | ⅜ | 3 July ... | 12 | Do. ... | |
| | 26 | Kolandee ... ... | ¾ | 1⅜ | 1½ | 1 | 4 Aug. ... | 2 | Present ... | Skeleton; œdema of feet. |
| | 27 | Moorooven ... ... | ½ | ¾ | ¾ | ½ | 1 Sept. ... | 16 | Do. ... | Skeleton; no œdema. |
| | 28 | Chungagadoo ... ... | ⅞ | 1⅝ | 1¾ | ¾ | 3 Sept. 1877 | 10 | Gone off ... | Skeleton. |
| | 29 | Kuniamah ... ... | ¾ | ¾ | ¾ | ⅜ | 12 June ... | 9 | Gone ... | Skeleton; no œdema. |
| | 30 | Nagummah ... ... | ⅞ | 1 | ⅞ | ½ | 11 July ... | 2 | Present ... | |
| | 31 | Paupah ... ... | ⅞ | ¼ | ¼ | ⅜ | 18 Dec. ... | 7 | Gone off ... | Quite a skeleton; œdema of feet. |
| | 32 | Parthen ... ... | ½ | ¾ | ¾ | ½ | 13 Aug. ... | 9 | Going off ... | Skeleton; scrofulous-looking ulcer on chest; no œdema. |
| | 33 | Moothu ... ... | 1⅜ | 2¼ | 2¼ | 1⅛ | 11 Mar. 1877 | 2 | Present ... | Emaciated; œdema of feet. |
| | 34 | Moorthen ... ... | 1⅛ | 2½ | 2½ | 1½ | 7 April ... | 5 | Well-marked.. | Emaciated; œdema of feet and hands. |
| | 35 | Karten ... ... | 2⅛ | 2⅝ | 2½ | 2⅜ | 19 April ... | 10 | Gone off ... | |
| | 36 | Chenchi Naidoo ... | 7½ | 2¾ | 4¾ | 2 | 20 April ... | 17 | Do. ... | Much emaciated; œdema of feet; a fistulous opening in perinæum. |
| (c) | 37 | Mohomed Ghouse ... | 1⅝ | 3⅛ | 3 | 2½ | 23 April ... | 2 | Present ... | Emaciated; œdema of feet and legs. |
| | 38 | Somiah ... ... | 3⅜ | 3⅛ | 3⅛ | 3 | 9 May ... | 4 | Do. ... | Emaciated; œdema of feet. |
| | 39 | Peeran ... ... | 1⅞ | 2¼ | 2⅛ | 1½ | 17 June ... | 2 | Do. ... | Skeleton; no œdema. |
| | 40 | Venketswamy ... | 8⅞ | 3⅛ | 4¼ | 3 | 21 June 1877 | 2 | Do. ... | Rather thin; œdema of feet. |

(*a*) Lungs, healthy—4 men, 8 women, 6 children. (*b*) Acute pneumonia—3 men, 1 woman, 10 children.
(*c*) Lungs congested—15 men, 7 women, 2 children.

## ALVINE FLUX WITHOUT LESION OF GUT—*continued.*

*List of Cases, giving Weight of Body and of its Organs, &c.*—continued.

| | No. | Name. | Weight in ounces of—*cont.* Spleen. | Right Kidney. | Left Kidney. | Pancreas. | Date of Autopsy. | Hours after death Autopsy made. | Riger Mortis. | Bodily state. |
|---|---|---|---|---|---|---|---|---|---|---|
| | 41 | Venkettachellam ... | $4\frac{1}{2}$ | $2\frac{3}{4}$ | $2\frac{3}{8}$ | $2\frac{5}{8}$ | 14 Aug. .. | 2 | Present ... | Skeleton, } œdema of feet. |
| | 42 | Chondroyen ... ... | $2\frac{3}{8}$ | $2\frac{3}{8}$ | $3\frac{1}{8}$ | $2\frac{1}{2}$ | 24 Aug. ... | 3 | Do. ... | Emaciated, } |
| | 43 | Venkettachellam ... | $2\frac{3}{8}$ | $3\frac{1}{4}$ | $3\frac{1}{2}$ | 3 | 12 Sept. 1877. | 2 | Do. ... | Skeleton; œdema of feet and ascites. |
| | 44 | Yagan ... ... | $2\frac{1}{4}$ | 3 | $3\frac{1}{8}$ | $2\frac{3}{4}$ | 4 Oct. 1877 | 2 | Do. ... | In low flesh; œdema of feet |
| | 45 | Venketawarda ... | $4\frac{3}{4}$ | $3\frac{1}{4}$ | $3\frac{1}{2}$ | 2 | 23 Dec. ... | 8 | Gone off ... | Skeleton; ankylosis of right hip joint; œdema of feet. |
| | 46 | Narain ... ... | $3\frac{7}{8}$ | 3 | $3\frac{3}{8}$ | $3\frac{1}{8}$ | 30 June 1877. | 6 | Present ... | Emaciated; no œdema. |
| | 47 | Yenkadoo ... ... | $4\frac{1}{2}$ | $2\frac{3}{8}$ | $3\frac{1}{2}$ | $2\frac{1}{2}$ | 20 Feb. 1878. | 6 | Do. | Thin; œdema of lower extremities and ascites. |
| (c) con | 48 | Moonay ... ... | $2\frac{3}{4}$ | $2\frac{7}{8}$ | $3\frac{1}{4}$ | 2 | 22 April ... | 8 | Do. | Rather thin; no œdema. |
| | 49 | Thoongay ... ... | $1\frac{1}{2}$ | $2\frac{3}{4}$ | $2\frac{1}{2}$ | $1\frac{1}{4}$ | 27 July ... | 8 | Do. ... | } Skeleton; no œdema. |
| | 50 | Mongathy ... ... | $8\frac{3}{4}$ | $3\frac{1}{2}$ | $3\frac{1}{4}$ | 2 | 15 Aug. 1877. | 16 | Do. ... | } |
| | 51 | Allamaloo ... ... | $1\frac{3}{4}$ | $4\frac{1}{8}$ | $3\frac{5}{8}$ | $3\frac{3}{4}$ | 21 Aug. ... | 7 | Do. ... | Some general anasarca and ascites. |
| | 52 | Lutchmee ... ... | $1\frac{1}{8}$ | $2\frac{3}{8}$ | $2\frac{1}{2}$ | $1\frac{7}{8}$ | 20 Aug. ... | 10 | Gone off ... | Skeleton; œdema of hands, feet and face. |
| | 53 | Peruma ... ... | $1\frac{1}{8}$ | $2\frac{1}{2}$ | $2\frac{3}{4}$ | $2\frac{1}{4}$ | 21 Sept. 1877. | 8 | Present ... | Body emaciated; slight œdema of feet. |
| | 54 | Moochee ... ... | $3\frac{3}{8}$ | $2\frac{7}{8}$ | 3 | $2\frac{1}{8}$ | 30 Oct. 1877. | 15 | Do. ... | Skeleton; no œdema. |

| | | | | | | | | | | | |
|---|---|---|---|---|---|---|---|---|---|---|---|
| | 55 | Moorooven ... ... | $\frac{3}{4}$ | 1 | $1\frac{1}{4}$ | $\frac{5}{8}$ | 1 Sept. ... | 3 | Do. ... | Do. |
| | 56 | Mooneamah ... ... | $\frac{7}{8}$ | $1\frac{1}{4}$ | $1\frac{1}{4}$ | $\frac{3}{8}$ | 17 Oct. ... | 15 | Gone off ... | |
| | 57 | Chengelroy ... ... | 1 | 2 | 1 | 1 | 10 June ... | 1 | Present ... | Emaciated; œdema of feet and face. |
| (d) | 58 | Vyapora ... ... | $2\frac{5}{8}$ | $2\frac{1}{4}$ | $2\frac{1}{4}$ | $1\frac{3}{4}$ | 24 Oct. ... | 9 | Do. ... | Skeleton; no œdema. |
| | 59 | Veeraswamy ... ... | 3 | $2\frac{1}{2}$ | $2\frac{5}{8}$ | $2\frac{3}{8}$ | 8 Aug. 1877 | 1 | Do. ... | Thin; no œdema. |
| | 60 | Veeraswamy ... ... | $1\frac{5}{8}$ | $2\frac{1}{2}$ | $2\frac{1}{2}$ | $2\frac{1}{8}$ | 7 July ... | 6 | Do. ... | Quite a skeleton; no œdema. |
| | 61 | Ragachee ... ... | $1\frac{5}{8}$ | $2\frac{1}{4}$ | $2\frac{5}{8}$ | $1\frac{5}{8}$ | 20 Sept. 1877 | 9 | Gone off ... | Skeleton; œdema of feet. |
| | 62 | Ponee ... ... | $1\frac{1}{2}$ | $1\frac{7}{8}$ | $1\frac{7}{8}$ | $1\frac{1}{2}$ | 26 Sept. 1877 | 1 | Present ... | Emaciated; œdema of lower extremities and some ascites. |
| | 63 | Mariamah ... ... | $1\frac{5}{8}$ | $2\frac{1}{8}$ | $2\frac{1}{2}$ | $1\frac{1}{4}$ | 10 Aug. ... | 1 | Do. ... | Skeleton; no œdema. |
| | 64 | Baryah ... ... | $\frac{5}{8}$ | $\frac{3}{4}$ | $\frac{1}{2}$ | $\frac{3}{8}$ | 22 June 1877 | 4 | Do. ... | Quite a skeleton; no œdema. |

(c) Lungs congested—15 men, 7 women, 2 children.

(d) Other lung complications—4 men, 3 women, 1 child.

## SUB-DIVISION II.

### Alvine Flux with Intestinal Ulceration.

The second division comprises all cases of bowel-complaint with ulceration of the gut only and without diphtheritic effusion. These number 132, or nearly two-fifths of the whole. The following figures show the women to contribute about ten per cent. more than the men or children :—

| | | Total. | Per cent. |
|---|---|---|---|
| Men ... ... ... | 59 | 166 | 35·5 |
| Women ... ... ... | 52 | 119 | 43·7 |
| Children ... ... ... | 21 | 62 | 33·5 |
| | 132 | 347 | 38·0 |

*Disease complained of on admission.*

The disease complained of on admission was dysentery in 36 (or about two-thirds) of the men, in 23 (or about two-fifths) of the women, and in 7 (or one-third) of the children. In the remainder, where diarrhœa was not the disease actually complained of, it was found to be present on examination, and it continued to the end.

*Duration of illness.*

Two men died on the day of admission, having been ill some ten days. The average stay in hospital was 13½ days, the average duration of sickness before admission being 15½ days; one man was as long as two months in hospital, and one said he had been three months ill on admission.

Two women died on the day of admission after a week's illness. The average stay in hospital was 15¼ days, the average duration of illness before admission being 13½ days. One woman was as long as 101 days in hospital, and one had been two months ill before admission she stated.

The children were in hospital 10¼ days on an average, and had been ill twelve on admission. One was five weeks in hospital, and one had been ill two months on admission, the mother said.

*Character of stools.*

The character of the stools varied a good deal, even in the same case, from day to day. The following is an analysis of the cases noted :—

| | * Diarrhœa. | * Dysentery. |
|---|---|---|
| Half-formed fæces ... ... | 1 | 3 [a] |
| Thin feculence ... ... ... | 11 [b] | 4 [c] |
| Bloody fluid ... ... ... | 1 | 5 [d] |
| Melæna ... ... ... | ... | 1 |
| Brown fluid ... ... ... | 3 [e] | 1 |
| Slimy greenish pultaceous matter | 1 | 5 |
| Mud-colored fluid ... ... | 4 | 4 [f] |
| Ochrey yellow fluid ... ... | 4 [g] | 13 [h] |
| Green fluid ... ... ... | 2 | 5 [i] |
| Scybala ... ... ... ... | 1 | 1 |
| White { fluid ... ... ... | 2 | 2 [j] |
| White { do. with sloughs ... | 2 | ... |
| White shreds in serum ... ... | 6 | 3 |

The small intestine was empty in 20 cases of diarrhœa and in 20 of dysentery; 34 were adults and 6 were children, being about a third of either. The contents noted were as follows:—

*Contents of small intestine.*

| | Diarrhœa. | Dysentery. |
|---|---|---|
| Half-digested food ... ... | 2 | 1 |
| Mud-colored fluid ... ... | 13 | 7 |
| Whitish fluid ... ... ... | 3 | 3 |
| Rice-water fluid ... ... ... | 1 | 1 |
| Ochrey-yellow fluid ... ... | 15 | 13 |
| Lumbrici ... ... ... | 30 | 37 |
| Green fluid ... ... ... | 2 [k] | 10 |
| Green pultaceous matter ... | 4 | 6 [l] |
| Red fluid ... ... ... | 6 [m] | 2 |
| Slaty fluid ... ... ... | ... | 2 |
| Gas-distended ... ... ... | 8 | 3 |

Lumbrici to the number of 269 were found in 31 women, giving an average of $8\frac{3}{4}$ each, and of 115 in 24 men, being an

---

* Diseases complained of on admission.

a Slimy.
b Two frothy.
c One frothy.
d Mucus in two.
e One fœtid.
f One frothy.
g One oily looking.
h Two oily looking, seven slimy.
i Three slimy.
j One frothy.
k One oily looking.
l Two slimy.
m One has green flocculi.

average of $4\frac{3}{4}$ each; as many as 63 were found in one woman, not counting three in the stomach. In 12 children 41 were found, being an average of $3\frac{3}{4}$ each; 16 was the largest number found in one child. Cases of distension of the gut with gas were all children except three.

*Contents of large intestine.*

The large intestine was empty in the majority of cases, viz., in about seven-eighths of the adults and in four-fifths of the children. In four children and in two adults it was greatly distended with gas. The contents found may be grouped as follows:—

| | Diarrhœa. | Dysentery. |
|---|---|---|
| Thin pale feculence ... ... | 3 | 2 |
| Half-formed fæces ... ... | ... | 1 |
| Scybala ... ... ... ... | 2 | 1 |
| Ochrey fluid ... ... ... | 2 | 1 |
| Blood and sloughs ... ... | 1 | 1 |
| Red fluid ... ... ... ... | 1 | 1 |
| Brown stinking fluid ... ... | 1 | 1 |
| Gas ... ... ... ... | 4 | 1 |
| Dark green fluid ... ... | 1 | ... |

The walls of the small intestine generally were thin. In one there was a diverticulum an inch long by two lines wide, situated in the ileum about three feet above the valve. There was a smaller diverticulum in one at the upper end of the ileum, and in another about its middle.

*Appearances of small intestine.*

The gut was very wide in one case, and so narrow in another for six inches at the middle of the ileum as hardly to admit the blade of the scissors. The appearances found may be grouped as follows:—

| | Diarrhœa. | Dysentery. |
|---|---|---|
| Healthy-looking ... ... ... | 2 | 2 |
| Injected all through ... ... | 3 | 2 |
| Do. in lengths ... ... | 2 | 3 |
| Injection confined to jejunum ... | 3 | 1 |
| Injection confined to ileum ... | 5 | 7 |
| Rose-colored to white ... ... | 30 | 24 |
| Pale and œdematous ... ... | 5 | 5 |
| Pigmentated ... ... ... | 14 | 20 |

| | Diarrhœa. | Dysentery. |
|---|---|---|
| Sub-mucous ecchymoses ... ... | 8 | 9 |
| Ulcerated ... ... ... ... | 5 | 2 |
| Cicatrices ... ... ... ... | 2 | 2 |

*Peyer's patches.*

Peyer's patches presented the "shaven beard" appearance in two cases of diarrhœa and two of dysentery, were infarcted by tubercle in one of diarrhœa and one of dysentery, swollen and livid in one of diarrhœa, red injected in two of diarrhœa with ecchymotic-like puncta in a third, buff and prominent in one case of diarrhœa, two lowest patches abraded in one and ulcerated in another case of diarrhœa.

*Solitary glands.*

The solitary glands were pale and prominent in two cases of diarrhœa, and were infarcted with tubercle in two cases of dysentery, supervening on chronic phthisis; and in one case of dysentery in chronic pneumonia there were two glands in the jejunum distended with glairy fluid to the size of peas; one of them also contained a concretion.

*Hyperæmia.*

Injection of the mucous coat to a greater or less extent was found as above shown, in 13 cases each of diarrhœa and dysentery, or in about 20 per cent. of the total. Speaking generally the lesion was mostly in the jejunum in the diarrhœa and in the ileum in the dysentery cases; there was no thickening present.

*Hyperæmia of whole mucous coat.*

Where the injection extended the whole length of the gut—in the three cases of diarrhœa it was a deep livid red, being deeper livid in lower six feet, as in cholera, in one; a reddish pink, as in active digestion, being a deeper red in six-inch lengths in one; and a peculiar dusky livid, as in passive congestion, in the third; in the two dysentery cases it was a bright red, being deep claret in the valvulæ conniventes and in parts in one, and a dusky livid, with claret-colored congestion in parts of ileum, in the second.

*Hyperæmia in lengths.*

Where the injection was in lengths—in one case of diarrhœa it was livid, and in the other livid red with red mottles, probably from the large number of lumbrici present; in the three cases of dysentery the congestion was deep livid.

*Hyperæmia of jejunum.*

Where the injection was confined to the jejunum—in three cases of diarrhœa it was livid all through in one, reddish with lividity in lengths in one, with lividity of some valvulæ conniventes only in the third; in the case of dysentery it was reddish in places, probably from the 30 lumbrici present.

*Hyperæmia of ileum.*

Where the injection was confined to the ileum—in the five diarrhœa cases it was livid in lengths in two, both children; dark livid in lengths, with injection of subperitoneal veins, in one, livid in places towards the valve in one, and streaky arborescence of lowest foot in the fifth. In the seven dysentery cases the injection was livid arborescent in lengths in two, reddish livid of spots and parts in two, livid in lengths in one, deep livid of lowest two feet in one, and purple livid of a piece four feet above valve, having four abraded irregularly-shaped spots on surface—one a little thick in the seventh.

*Anæmia.*

Among the cases of pallor of the intestine there were five cases of diarrhœa and four of dysentery in which the coats were thin and quite milk-white, seven of these were children; in five of diarrhœa and three of dysentery the mucous membrane was pale, in fifteen of diarrhœa and fourteen of dysentery it was pale-rose to dull-white, and in five of diarrhœa and three of dysentery it was rose-colored.

*Œdema.*

Where the mucous coat was œdematous, the œdema was confined to the valvulæ conniventes in two cases of diarrhœa and two of dysentery, and it was slight and confined to the jejunum in one case of diarrhœa and one of dysentery, and to the lower end of the ileum in one case of diarrhœa; and in one of dysentery it consisted of white mottles in the ileum from effusion of serum beneath the mucous membrane. In the remaining cases of diarrhœa and of dysentery the œdema was considerable all through, but most marked in the jejunum.

*Pigmentation.*

Pigmentation was found only in adults, was general, giving the mucous coat a more or less deep-slaty coloration, and was usually most marked in the jejunum in 11 cases of diarrhœa and 18 of dysentery; it was confined to cicatrices in one case of diarrhœa and one of

dysentery, to some valvulæ conniventes in one of diarrhœa, to old spots of sub-mucous ecchymosis in one of diarrhœa, and to Peyer's patches in one case of dysentery.

*Ecchymosis.*

Ecchymosis, beneath or into the mucous coat, was found in six or nearly one-third of the children, and in eleven adults. In the former the effusion was sub-mucous, and consisted of a few small flat circular spots in the jejunum in one case of diarrhœa and one of dysentery; and of similar spots in the ileum in one case of diarrhœa and one of dysentery. In one case of diarrhœa the spots were circular, prominent, punctated in the centre, small, from the size of a fleabite to two lines in diameter, and numerous at the middle of the gut, about four to the square inch, but fewer towards the ends where they finally disappeared; and in another case there were four spots in the jejunum, the upper one red and flat, the next venous, rounded, and punctated in the centre, and the lowest two flat and brown. Among adults there was superficial purple effusion into the lowest Peyer's patch in one case of diarrhœa, and numerous similar blotches into the mucous membrane in a case of dysentery. There were a few, one to six, small circular flat spots of sub-mucous ecchymosis in the jejunum in two cases of diarrhœa and in two of dysentery: a large flat blotch near the middle of the gut in one case of diarrhœa and one of dysentery; a dozen small circular flat spots, one prominent, in a case of dysentery; eight prominent circular spots, the size of a florin, in the jejunum and a number of small spots in the ileum, in a case of dysentery; and numerous flat circular livid spots, an inch in diameter, and many small red and livid spots in another dysentery case.

*Adults.*

*Ulcers.*

There was tubercular ulceration of one to four Peyer's patches near the valve in three cases of diarrhœa and two of dysentery supervening on latent phthisis. There was purplish punctated injection, with abrasion of the lowest two Peyer's patches, without thickening, in a young man who died after eleven days' treatment in hospital for diarrhœa with slight lobar pneumonia; and in the case of a middle aged woman, who had been in hospital three weeks with

simple diarrhœa, three Peyer's patches in the jejunum and a number in the ileum were found surrounded by purulent infiltration, the glands being distended with pus; some had burst, leaving circular ulcer-like depressions with no infiltration around; there was no injection present.

*Cicatrices.*

In one of the above cases of tubercular ulceration cicatrices were found in two Peyer's patches; and in an old woman who had been in hospital four weeks with simple diarrhœa, cicatrices binding the mucous to the muscular coat were found extending from the valve upwards for four inches, as well as in the colon also. In a man who had been ten days in hospital with dysentery there was found, six inches above the valve, a blackish cicatrix, irregularly oval transversely, an inch long by three lines wide, and adherent to the middle coat; and in a woman who died from dysentery when two days in hospital there was found a pigmented cicatrix in one Peyer's patch; there was extensive ulceration of the colon in both cases.

*The large intestine.*

The large intestine exhibited more or less injection of the mucous coat in 21 cases of diarrhœa and in 22 of dysentery, or in 38, or about one-third of the adults, and 5, or nearly one-fourth of the children.

| | Diarrhœa. | Dysentery. |
|---|---|---|
| Hyperæmia ... ... ... | 5 | 9 |
| Do. local ... ... ... | 16 | 13 |

*Hyperæmia.*

Where the whole length of the gut was implicated the injection was less marked in the lower end in all cases of diarrhœa except one. It was purple-red to livid, with little or no thickening or swelling in three cases of diarrhœa, one a child, and five of dysentery, pink-red in two of diarrhœa and two of dysentery, and a dirty pale-pink, or livid, in two of dysentery.

The congestion was confined to the upper end in five cases of diarrhœa, two of them children, and four of dysentery, and was of the following characters:—

| | Diarrhœa. | Dysentery. |
|---|---|---|
| Livid ... ... ... ... | 2 | 4 |
| Dull-pink ... ... ... ... | 2 | ... |
| Red ... ... ... ... | 1 | ... |

It was confined to the lower end in six cases of diarrhœa—one a child—and three of dysentery, and was deep livid-red in all except the child and another case of diarrhœa, in which the injection was only slightly livid; and in one case of dysentery in which there were only pink rugæ in the descending colon downwards. It was found in both ends in two cases of diarrhœa and one of dysentery, and was livid in all, except that in one case the rectum was pink; in the case of dysentery there had been bleeding from the rectum.

The congestion was in blotches or patches, which were red to livid in two cases of diarrhœa and four of dysentery, and merely mottling on a rosy mucous membrane in one case of diarrhœa and one of dysentery, the latter a child.

*Swelling.*

The mucous membrane was swollen in three cases of diarrhœa—one a child—and two of dysentery, was slightly thickened in two of diarrhœa and seven of dysentery, was thickened in the upper end in one of dysentery,

*Thickening.*

was thickened in the lower end in five of diarrhœa—one a child—and in five of dysentery, and in both ends in one of diarrhœa and one of dysentery. The thickening was in rugæ in two cases of diarrhœa—one a child—and in two cases of dysentery it was great for the whole

*Œdema.*

length of the gut. Œdema was present in two cases of diarrhœa—one a child—and in two of dysentery; the adults are already included above.

*No thickening.*

The coats were thinned, or at most there was no appreciable thickening in 26 cases of diarrhœa and 15 of dysentery, as given below, or in 32, or about three-tenths of the adults, and in 9, or three-sevenths of the children:—

| | | Diarrhœa. | Dysentery. |
|---|---|---|---|
| *Anæmia.* | Hyperæmia ... ... ... | 7 | 4 |
| | Anæmia ... ... ... ... | 19 | 11 |
| | | 26 | 15 |

*Swelling.*

There was some swelling of the mucous coat in three cases of diarrhœa—two of them children—and in one of dysentery; there was thickening in the upper end of the gut in one case of dysentery and in the lower end in five cases of diarrhœa—two of them children—and in six

of dysentery. There was thickening in wheals or patches in four cases of diarrhœa and two of dysentery—one a child. There was hypertrophy all through of all the coats, which often attained a very considerable thickness, in nine cases of diarrhœa and in nineteen of dysentery—two of them children; and there was œdema of the mucous coat in six cases of diarrhœa—one a child—and in three of dysentery.

*Thickening.*

*Œdema.*

In one case of diarrhœa in latent phthisis there were tubercular ulcers in the ileum, but none in the large gut, only livid congestion in its lower half; and in another there were as well many tubercular girdle ulcers in the lower part of the colon, with black scars lower down. In one case of dysentery in the upper half of the gut the mucous coat was injected bright red, and was studded with large, thick, yellow-based cancroid-like ulcers, and in the lower half it was rosy, with warty fungoid ridges in the rectum, like epithelial cancer in appearance and structure.

*Ulcers.*

In the other cases the lesions may be classed as follows:—

| | Diarrhœa. | Dysentery. |
|---|---|---|
| Abrasion ... ... ... ... | 1 | 4 |
| Circular ulcers ... ... ... | 31 | 18 |
| Oval or irregular ulcers ... ... | 7 | 10 |
| Do., chronic and cicatrising ... | 6 | 11 |
| Sloughing ... ... ... ... | 19 | 22 |

In three of the cases of dysentery with abrasions there was congestion, but little thickening of the mucous coat, and in the fourth there was no congestion, but erosions of thickened rugæ. In the case of diarrhœa there was no thickening, but congestion in spots which were abraded. The circular ulcers were usually small, a line or so in diameter, and often unaccompanied by thickening or congestion, and were usually more or less sparsely studded over the whole surface or confined to the lower end. They appeared mainly to originate in ulceration of, or even tiny sloughs of the mouths of the mucous follicles; but instances of their beginning in the solitary glands, as well as in spots of sub-mucous ecchymosis, were also observed.

*Abrasions.*

*Ulcers, circular.*

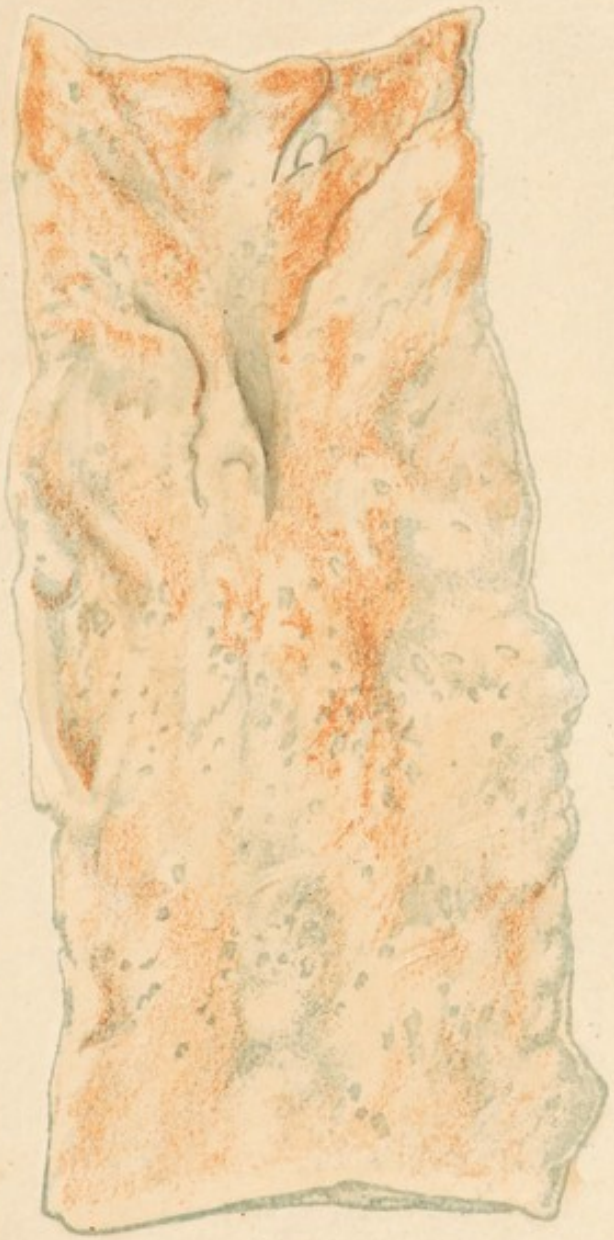

ALEX: BARREN, PINXT. ET.

CHROMOLITHO: MADRAS 1899.

FOLLICULAR ULCERS OF COLON. – CHRONIC DYSENTERY.

The colon is thickened and anæmic.

Ulcers of this sort were the chief characteristic in 38, or fully one-third of the adults, and in 13, or nearly two-thirds of the children.

| | Diarrhœa. | Dysentery. |
|---|---|---|
| Adults ... ... ... ... | 22 | 16 |
| Children ... ... ... ... | 10 | 3 |

There was no thickening of the mucous or other intestinal coats in 24, or nearly one-half these cases, 7 being children; and there was no injection present in 35 cases, of whom nearly one-third were children, 24 were cases of diarrhœa, and 11 were cases of dysentery, as shown in the following table:—

| | Thickened. | | Not thickened. | |
|---|---|---|---|---|
| | Diarrhœa. | Dysentery. | Diarrhœa. | Dysentery. |
| Pale ... | 11 | 5 | 13 | 6 |
| Congested... | 5 | 6 | 3 | 2 |

The ulcers were confined to the upper end in four, to the lower end in 21, and were all through the length of the gut in 26 cases. In two cases of dysentery with congestion, and in four cases of diarrhœa, the ulcers, by sloughing or extension, had lost their peculiar characters at the lower end of the gut.

*Ulcers, irregular.*

There was thickening with congestion or otherwise, as noted below, and oval or irregularly-shaped ulcers, occupying sometimes as much as one-half to three-fourths the total surface, in 10 cases of dysentery—two of them children—and in 7 of diarrhœa—one a child. The ulceration was less extensive in the diarrhœa cases, and was noted absent from the lower end of the gut in the worst case.

| | Diarrhœa. | Dysentery. |
|---|---|---|
| Congested ... ... ... ... | 4 | 5 |
| Anæmic ... ... ... ... | 3 | 5 |

*Ulcers, cicatrising.*

There were chronic ulcers, often cicatrices also, usually with little thickening or congestion, and mostly confined to the lower end of the gut, in nine cases of dysentery and in four of diarrhœa, three of them children. There was no thickening or injection, only some healed and a few unhealed cicatrices, in one case of diarrhœa and in two of dysentery; and in one case of diarrhœa there was a chronic ulcer extending

along the free border of the transverse colon for nearly its whole length; there was some congestion present in this case, but no thickening.

| | Diarrhœa. | Dysentery. |
|---|---|---|
| Congested ... ... ... | 3 | 2 |
| Anæmic ... ... ... | 1 | 7 |

*Sloughing.*

There was sloughing, with usually much hypertrophy of the coats, or œdema, and mostly no injection, in 19 cases of diarrhoea and in 22 of dysentery, two of these children.

| | Thickened. | | Not thickened. | |
|---|---|---|---|---|
| | Diarrhœa. | Dysentery. | Diarrhœa. | Dysentery. |
| Congested. | 2 | 2 | 1 | 1 |
| Anæmic ... | 16 | 18 | 0 | 1 |

*Perforation.*

In many cases the whole mucous tract was one mass of slough, but in only two cases had perforation with effusion of the contents of the gut into the peritoneal cavity actually occurred. One of these was a little girl in whom there was no appreciable thickening of the gut, and only a few congested patches occupied by sloughy ulcers in the transverse colon; one had perforated and killed the child apparently by the shock, for no peritonitis was present. She had been in hospital only two days with dysentery, which was said to have set in three days before admission. The other was the case of a man who had been in hospital nine days with diarrhœa, in which there were sloughs in the transverse colon, one perforating; the lower part of the gut was noted almost healthy looking. However, in seven other cases of dysentery and five of diarrhœa perforation had all but occurred—in fact, it was completed by removing the intestines in three cases of dysentery—and in two other cases of dysentery and one of diarrhœa, peritonitis with lymphy and purulent effusion had been set up; in the remaining two cases of dysentery and in two of diarrhœa adhesive peritonitis was found gluing the surface generally of the transverse colon to the omentum or parietes. In the two cases of diarrhœa perforation occurred in the cæcum in handling.

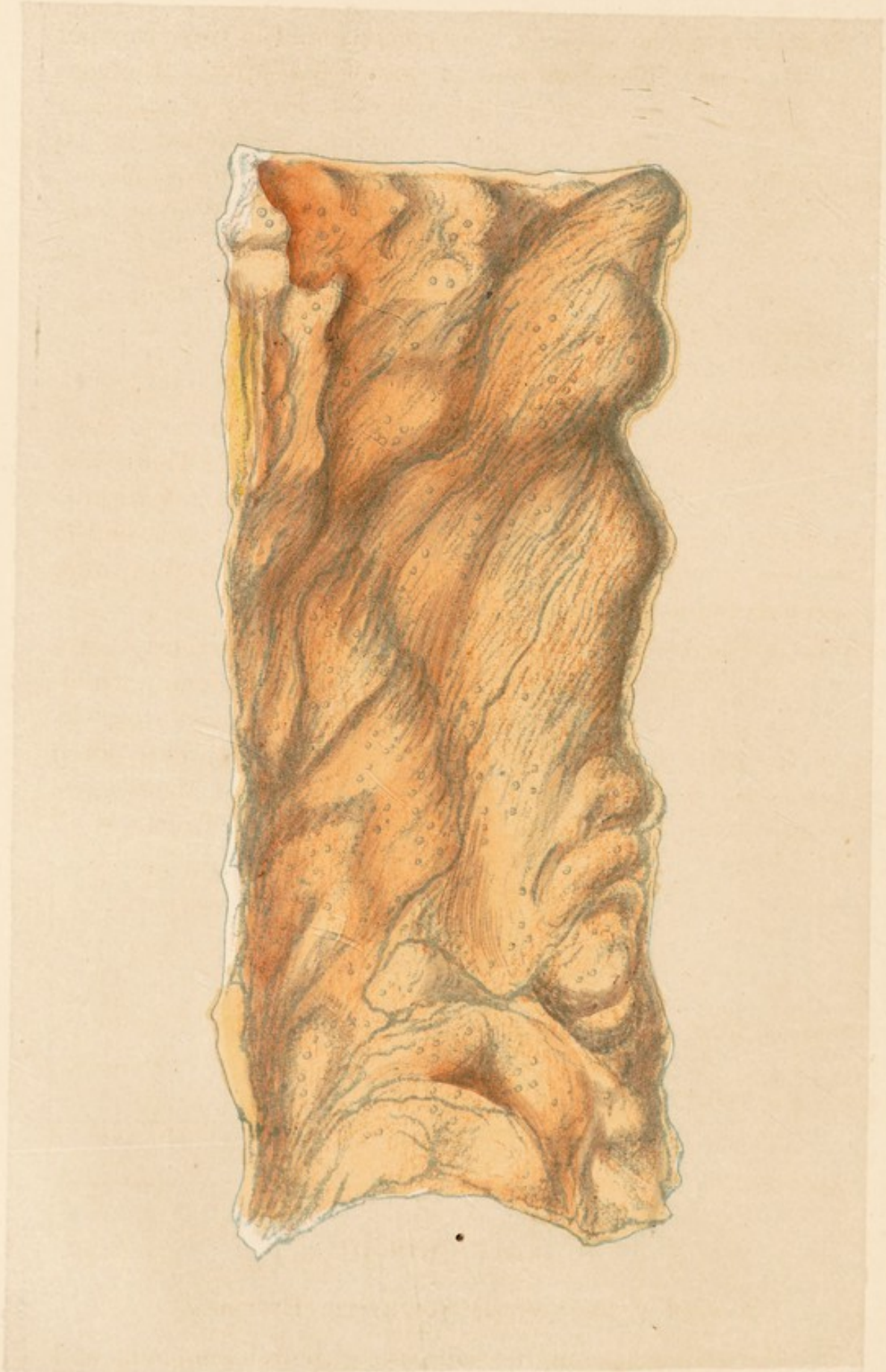

ALEX. HARREN, PINXT. ET

CHROMOLITH: MADRAS, 1889.

COLON WITH PIGMENT DEPOSITS

In and around the solitary Glands.- Dysentery.

*Ecchymosis. Pigmentation.*

Spots of sub-mucous ecchymosis were found in three cases of diarrhœa and in one of dysentery. Pigmentation of the mucous coat, giving it a more or less deep-slaty coloration, was found in 20 cases, and it was confined to cicatrices, ulcers, mouths of follicles, or mottles, in 40 other cases, as noted below, nine in all appearing under two heads—

| | General. | Cicatrices. | Ulcers. | Follicles. | Mottling. |
|---|---|---|---|---|---|
| Diarrhœa ... | 10 | 11 | 5 | 2 | 2 |
| Dysentery ... | 10 | 6 | 11 | 3 | 2 |

*Cicatrices.*

Cicatrices were found in 11 cases of diarrhœa, three of them children, and in six of dysentery. These were confined to the upper end of the gut in three cases of diarrhœa and one of dysentery, and to the lower end in all the rest, except in one case of diarrhœa, in which they were all through the length of the gut.

*Cyst forms.*

"Cyst forms" were noted in four cases of diarrhœa, one a child, and in seven of dysentery, one a child. In several cases the mucous follicles were observed to exude pus on pressure, and in others they were noted red pale or black-mouthed, or patulous. A list of these cases forms Appendix D., of which the following is an abstract :—

| — | Men. | Women. | Children. | Total. |
|---|---|---|---|---|
| Lungs, healthy ... ... ... | 11 | 25 | 7 | 43 |
| Pneumonic congestion ... ... | 25 | 12 | 6 | 43 |
| Pneumonia, acute ... ... | 11 | 2 | 6 | 19 |
| Do. chronic ... ... | 4 | 3 | ... | 7 |
| Phthisis pulmonalis (latent) ... | 6 | 6 | ... | 12 |
| Body, dropsical ... ... ... | 2 | 4 | 2 | 8 |
| Total ... | 59 | 52 | 21 | 132 |

## SUB-DIVISION III.

### Alvine Flux with Diphtheritic Effusion.

The third division comprises all cases of bowel-complaint with an effusion of lymph on some part of the intestinal mucous tract.

These number * 151, being 43·5 per cent. of the total cases of alvine flux. The percentages they bear to the totals under each head are—

| | Diarrhœa. | Dysentery. | Total. |
|---|---|---|---|
| Men ... ... ... | 52·5 | 46·2 | 48·8 |
| Women ... ... | 47·1 | 30·6 | 40·3 |
| Children ... ... | 20·7 | 48·5 | 35·5 |
| | 44·76 | 42·3 | 43·5 |

*Disease complained of.*

Dysentery was the disease complained of on admission by 41 of the 81 men, by 15 of the 48 women, and by 16 of the 22 children. All the rest complained of diarrhœa, except four who were admitted for debility, two for dropsy, and one each for fever and abscess; and one man was brought in dead, it was said, from cholera. All these are included under diarrhœa. The disease often appeared as a complication of some other complaint, setting in as "watery gripes," and proving fatal in a day or two.

---

* Besides these cases, diphtheritic effusion was found in 5 men and 5 women. In these it was confined to the ileum in 1, to the colon in 5, and was present in both in 4, as under :—

| — | Effusion in ileum only. | | Effusion in colon only. | | Effusion in both. | | Total. | |
|---|---|---|---|---|---|---|---|---|
| | M. | W. | M. | W. | M. | W. | M. | W. |
| Cholera ... ... | ... | ... | 1 | ... | 1 | 2 | 2 | 2 |
| Dropsy ... ... | ... | ... | 1 | ... | ... | ... | 1 | ... |
| Pneumonia, acute ... | ... | ... | ... | 1 | ... | ... | ... | 1 |
| Phthisis pulmonalis. | ... | ... | ... | ... | ... | 1 | ... | 1 |
| Pyæmia ... ... | ... | ... | 1 | 1 | ... | ... | 1 | 1 |
| Enteritis ... ... | 1 | ... | ... | ... | ... | ... | 1 | ... |
| Total ... | 1 | ... | 3 | 2 | 1 | 3 | 5 | 5 |

Of the 4 who died from cholera, 1 died in the algide stage, 1 in the stage of reaction, and 2 from cholera during dysentery. Diarrhœa was complained of in the phthisis and pneumonia cases. In the case of enteritis the bowels were costive, and in the remaining 3 cases no bowel-complaint was noticed.

*Duration of illness.*

Eight men died on the day of admission, after an average illness of a fortnight; eight days in hospital and twelve days' sickness before admission were the averages for the 81 men. One was two months in hospital, and one said he had been five months ill on admission. The average stay in hospital for the women was seven days, the duration of illness before admission averaging eight days. One woman was a month in hospital, and one said she had been two months ill on admission. The average stay in hospital for the children was five days, the average duration of illness as reported on admission being nearly thirteen days. Two died on the day of admission, one was as long as sixteen days in hospital, and one was said to have been two months ill on admission.

The characters of the stools noted were as follows:—

*Character of stools.*

| | Diarrhœa. | Dysentery. |
|---|---|---|
| Thin feculence ... ... | 6 [a] | 3 [b] |
| Grumous pulp ... ... | 1 [c] | 1 |
| Whitish serum ... ... | 6 [d] | 4 [e] |
| Do., with shreds or lumps of lymph ... | 3 | 7 [f] |
| Green fluid ... ... | 3 [g] | 8 [h] |
| Buff do. ... ... | 6 [i] | 5 [j] |
| Brown serum ... ... | 4 [k] | 4 [l] |
| Ochrey do. ... ... | 4 [m] | 7 |
| Bloody mucus ... ... | 2 | 2 |
| Watery, passed into bed ... | 5 | 6 |

*Contents of small intestine.*

The small intestine was empty in 29 cases of diarrhœa and in 35 of dysentery; 56 were adults and 8 were children, being more than a third of each. In the remainder the contents were as follows:—

---

[a] Two frothy, one pultaceous. [b] One pultaceous.
[c] Slimy. [d] Undigested food in two, scybala in one.
[e] One bloody, one fœtid. [f] Three bloody. [g] Mucus in one.
[h] One bloody, two pultaceous, one variegated, sediment in two.
[i] One frothy, blood in two. [j] One slimy.
[k] Scybala in one, one offensive. [l] Scybala in one, one slimy.
[m] One frothy.

| | Diarrhœa. | Dysentery. |
|---|---|---|
| Pale buff to mud-coloured fluid ... | 11 [a] | 4 [b] |
| Yellow to ochrey-coloured fluid. | 12 [c] | 10 [d] |
| Green fluid ... ... ... | 8 | 5 [e] |
| Lumbrici ... ... ... | 34 | 36 |
| Brown fluid ... ... ... | 4 | 2 [f] |
| Bloody do. ... ... ... | 4 [g] | 10 [h] |
| Mucus in quantity ... ... | 9 [i] | 7 [j] |
| Gas ... ... ... ... | 2 | 3 |

*Lumbrici.*

Lumbrici to the number of 148 were found in 25 women, being an average of nearly 6 each, and of 166 in 38 men, giving an average of nearly 4 each; as many as 35 were found in one woman, while 16 was the largest number found in one man. In 7 children 24 were found, the greatest number in one case being nine. Distension of the gut with gas were all cases of children except two.

*Contents of large intestine.*

The large intestine was empty in the majority of cases—viz., in about four-fifths of the men, nine-tenths of the women, and ten-elevenths of the children. In one child five lumbrici had reached this part of the gut from the small intestine, where there were still nine found, and in a man two, and in a woman a dozen whip worms (*Trichocephalus dispar*) were found in the cæcum. In the remainder the contents were as follows:—

*Whip worms.*

| | Diarrhœa. | Dysentery. |
|---|---|---|
| Formed fæces ... ... ... ... | ... | 3 |
| Yellow fluid ... ... ... | 6 [k] | 2 [l] |
| Mud-coloured do. ... ... | 2 [m] | 4 [n] |
| Green do. ... ... | 1 | 1 |
| Choleraic do. ... ... | 1 | ... |
| Scybala ... ... ... ... | 2 | 4 |

[a] Two pigmented. [b] One pultaceous.
[c] Two pultaceous, one oily looking. [d] Four pultaceous, one slimy.
[e] Two pultaceous. [f] One black. [g] One pultaceous.
[h] Two like secondary cholera stool, two with shreds of lymph.
[i] Two pigmented, five green, one reddish.
[j] Two pigmented, five green, one pale. [k] Three feculent.
[l] One feculent pulp. [m] One blackish.
[n] Two blackish, one pultaceous, one slimy.

It is worthy of note that in all three cases where the formed fæces were found there was a pseudo-membrane lining at least the lower end of the gut, and in one case there was considerable congestion present besides.*

*Wall of small intestine.*

The walls of the small intestine were, as a rule, thin. In one man the lower end of the ileum was wide and sacculated, and in another, and in a woman, the lumen was so small all through as hardly to admit the blade of the scissors. In one woman there was a diverticulum an inch long in the lower end of the ileum, and in another there were two fatty tumours of the size of peas situated in the duodenum.

The state of injection of the mucous coat was as follows:—

| | Diarrhœa. | Dysentery. |
|---|---|---|
| Healthy looking ... ... ... | 8 | 6 |
| Anæmic ... ... ... ... | 17 | 24 |
| Hyperæmic ... ... ... | 52 | 44 |
| Total ... | 77 | 74 |

It was healthy looking in eight cases of diarrhœa and in eight of dysentery, two of these children. Among the anæmic cases the intestimal coats were quite milk-white, in one case of diarrhœa in a child, and in four cases of dysentery, two of them children. Before analysing the cases of hyperæmia it may be as well to glance at the state of some Peyer's patches and solitary glands. On the three or four lowest Peyer's patches there was a reddish lymphy effusion in two cases of diarrhœa and two of dysentery, three of them children. The patches were conspicuously prominent in three cases of dysentery and one of diarrhœa, a child; and in another case of diarrhœa there was prominence due to sub-mucous ecchymosis. In one case of diarrhœa and two of dysentery, the latter children, some of the lower patches were injected bright red, and in three cases of diarrhœa and one of dysentery they were ulcerated, the ulcers being tubercular in one of each. The "shaven beard" appearance was noted in one case of dysentery, and the cribriform appearance in one case of diarrhœa and of one dysentery, both

*Peyer's patches.*

* See also foot-note to page 38.

children. Small pigmented cicatrices were found in the lowest four patches in a case of dysentery.

*Solitary glands.*

Some solitary glands were prominent and white in congested mucous membrane in three cases of diarrhœa and two of dysentery, and under similar conditions they were prominent and brown-red in one case of diarrhœa and one of dysentery. There was infarction by tubercle of a gland or two in two cases of dysentery, and tubercular ulceration of some half dozen glands in a case of diarrhœa, all in latent phthisis. In a case of diarrhœa there were concretions found in three solitary glands at the upper end of the ileum, and one had been discharged, leaving an ulcer-like cavity.

*Hyperæmia.*

Injection of the mucous coat to a greater or less extent was found in 51 cases of diarrhœa and 43 of dysentery, eight of the latter being children. The ratios per cent. to the total diphtheritic cases are as follows :—

| | Diarrhœa. | Dysentery. |
|---|---|---|
| Men ... ... ... | 88·2 | 58 |
| Women ... ... ... | 57·5 | 66·6 |
| Children ... ... ... | 0 | 50 |
| | 66·2 | 58·1 |

The congestion was continuous all through the length of the small intestine in fully a third of these, was confined to the lower end in less than one-half, was confined to blotches or lengths of the mucous tract in fully a seventh, and was confined to the upper end in the remaining five cases, as follows :—

| | Diarrhœa. | Dysentery. |
|---|---|---|
| All through ... ... ... | 16 | 17 |
| Lower end ... ... ... | 22 | 20 |
| Upper end ... ... ... | 4 | 1 |
| In sections ... ... ... | 9 | 5 |

The character of the injection, where this extended the whole length of the gut, was as follows :—

| | | Diarrhœa. | Dysentery. |
|---|---|---|---|
| | Deep-red ... ... ... | 5 | 5 |
| | Pink ... ... ... | 2 | 5 |
| *All through.* | Reddish ... ... ... | 4 | 5 |
| | Livid ... ... ... | 3 | 1 |
| | Pale livid ... ... ... | 2 | 1 |

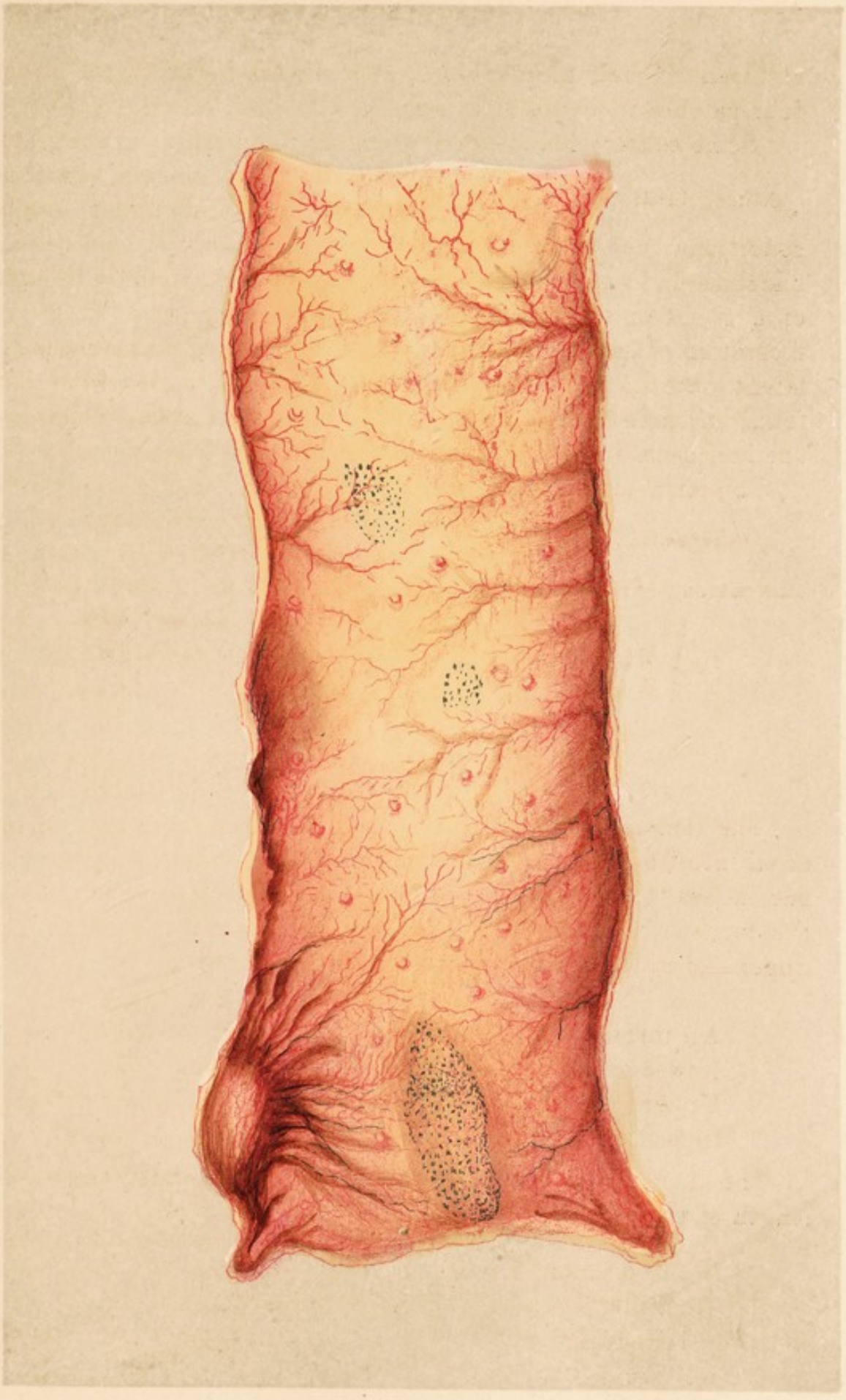

ALEX: BARREN; PINXT. ET

CHROMOLITH: MADRAS, 1889.

PORTION OF ILEUM WITH INFLAMED MUCOUS MEMBRANE,

SOLITARY FOLLICLES ENLARGED, AND SHAVEN BEARD APPEARANCE OF PEYER'S PATCHES.

The injection was deep red in 10 cases; of these, it was paler in the ileum in two of diarrhœa and one of dysentery, and deeper red in the ileum in one case of diarrhœa, and with ecchymotic-like congestion there in transverse lines in two others, and there was markedly deeper injection in parts in two cases of dysentery. Of the seven cases of pink injection, the lower end of the gut was paler in three of dysentery and in one of diarrhœa, and there was purple injection in lengths in the other case of diarrhœa. Of the nine cases of reddish injection, the lower end of the gut was deeper red in one case of dysentery and paler in another, and in a case of diarrhœa; in one case of diarrhœa there were livid mottling in places, and in another there were livid puncta along the free border, and a livid piece at the lower end of the ileum. Of the four cases of livid injection, the lower end of the gut was noted paler livid in one case of diarrhœa and in the case of dysentery. And of the three cases of pale livid injection, the lividity was deeper in the jejunum in one case of diarrhœa and in the ileum in the other. So there are many exceptions to what is apparently the rule that the injection is deeper in the jejunum in diarrhœa and in the ileum in dysentery.

Where the injection was confined to the lower end of the gut its character was livid to deep purple, and it extended from the valve upwards for from a few inches to as many feet, and was mostly lined by a pseudo-membrane, in nine cases of diarrhœa and six of dysentery; and in four cases of diarrhœa and one of dysentery the injection began not at the valve but some little distance above it.

| | | Diarrhœa. | Dysentery. |
|---|---|---|---|
| | Purple ... ... ... ... | 13 | 7 |
| *Ileum.* | Red ... ... ... ... | 3 | 6 |
| | Livid in sections ... ... ... | 6 | 7 |

It was red to pale livid or pink for a variable distance from the valve upwards in three cases of diarrhœa and six of dysentery. And it was livid in sections, often deepest at a foot or so above the valve, in six cases of diarrhœa, and less frequently so in seven cases of dysentery.

*Jejunum.*

In two of the four cases of diarrhœa in which the jejunum was congested there were also the remains of injection with a lymphy effusion just above

the valve, and in the case of dysentery the congestion was confined to some valvulæ conniventes and to four inches of the mucous coat about its middle.

*In sections.*

The injection was reddish to livid and confined to lengths or patches, especially ecchymotic-like in valvulæ conniventes, in 5 cases of dysentery and 9 of diarrhœa; in three of the latter there was purple lividity with effusion in the lower end of the ileum. The other appearances found in the mucous coat of the small intestine were as follows .—

| | | Diarrhœa. | Dysentery. |
|---|---|---|---|
| *Pseudo-membrane.* | Diphtheritic effusion ... ... | 30 | 28 |
| | Thickening ... ... ... | 8 | 10 |
| | Œdema ... ... ... | 8 | 5 |
| | Ecchymosis ... ... ... | 6 | 10 |
| | Pigmentation ... ... ... | 25 | 19 |
| | Ulcers ... ... ... | 7 | 4 |
| | Cicatrices ... ... ... | 1 | 1 |

The diphtheritic effusion was present in this part of the intestinal mucous tract in considerably over one-third of the cases under consideration,* as shown by the percentages, as follows :—

| | Diarrhœa. | Dysentery. |
|---|---|---|
| Men ... ... ... ... | 38·8 | 32·5 |
| Women ... ... ... ... | 42·4 | 46·6 |
| Children .. ... ... ... | 33·3 | 42·7 |
| | 38·9 | 37·8 |

The effusion was a grey, thin pseudo-membrane, extending from the valve upwards on a more or less deeply-purple injected mucous coat, in 14 cases of diarrhœa and in 12 of dysentery; in one of each the membrane was so thin as to appear as a white cloud only. In three cases of dysentery the subjacent injection was only reddish to dull pink, and in three cases of diarrhœa and in four of dysentery there was no injection at all.

The pseudo-membrane, with subjacent purple injection, began some little distance above the valve in five cases of diarrhœa and in one of dysentery. It was confined to congested rugæ in the

* See also foot-note to page 38.

lower end of the ileum in one case of diarrhœa and one of dysentery; and to congested spots or blotches in one case of diarrhœa and three of dysentery; and in three cases of diarrhœa and in two of dysentery it was in the form of a red effusion on two or three of Peyer's patches near the valve; in three cases of diarrhœa and two of dysentery the effusion was into the mucous membrane, and of a green or purple colour.

*Thickening.*

In 7 cases of diarrhœa and in 9 of dysentery the thickening accompanied diphtheritic effusion, but in the eighth case of diarrhœa there was thickening in rugæ at four feet above the valve, with livid congestion without effusion, and in the tenth case of dysentery there was simply ulceration of thickened rugæ situated near the valve.

There was only swelling of the mucous coat in one case of dysentery, and in one case of diarrhœa this was confined to the lower end of the ileum, and accompanied by congestion.

*Œdema.*

The œdema was slight in one case of diarrhœa and in one of dysentery, and was very considerable in six cases of diarrhœa and in one of dysentery; in three of the former it was most marked in the jejunum, especially in the valvulæ conniventes, and was accompanied by congestion in two of these, and in one it was greatest at the ends of the gut. In two cases of dysentery the œdema was confined to the jejunum.

*Ecchymosis.*

Ecchymosis beneath or into the mucous coat was present in 3 children and 13 adults. In the children it consisted of small circular flat spots beneath the mucous coat, undergoing absorption and situated in the jejunum, in one case of diarrhœa and two of dysentery. In the adults the spots were small and numerous in the valvulæ conniventes in one case of diarrhœa; they were few, circular and flat, situated about the middle of the gut in another, and they were prominent near the duodenum in a third case of diarrhœa. There was one prominent spot in the ileum in a case of dysentery, and two prominent spots in Peyer's patches in a case of diarrhœa. It consisted of a flat spot or two in the jejunum in three cases of dysentery, and of numerous small circular flat spots here, and two prominent spots in the duodenum in a fourth case. In two cases of dysentery there were two prominent spots, half-an-inch

in diameter, in the jejunum; these communicated with the gut by small openings in one of them.

The effusion was into the mucous membrane, forming almost a continuous streak along the free border of the gut, made up of distinct points or patches, in one case of diarrhœa; and this was confined to some valvulæ conniventes in one case of dysentery.

*Pigmentation.*

Pigmentation was general, giving the mucous coat a more or less deep-slaty coloration, which was less deep in the ileum in twenty cases of diarrhœa and fifteen of dysentery. In one of the former the valvulæ conniventes were quite black, and in one of the latter they were quite white. In one case of diarrhœa the pigmentation was deepest in the ileum. In two cases of diarrhœa (one a child) and in one of dysentery it was confined to the jejunum, and in two cases of diarrhœa and three of dysentery it was present in some valvulæ conniventes only.

*Ulcers.*

Tubercular ulcers were found in four cases of diarrhœa and in two of dysentery in latent phthisis; these encircled the gut, were girdle ulcers, in only one case, were along the length of the gut in two, and were circular in the remaining three; all had evidently their origin in infarcted Peyer's or solitary glands. In three cases of diarrhœa and one of dysentery ulceration was beginning near the valve in spots of diphtheritic effusion, and in one case of dysentery there was ulceration close above the valve of thickened rugæ without effusion on the surface. In one case of diarrhœa some solitary glands were distended by concretions, and one had discharged its contents, leaving an ulcer-like cavity. In one of the above cases of diarrhœa, beginning in effusion, there was a scar near the ulcers close to the valve, and in one case of dysentery the three lowest Peyer's patches had pigmented cicatricial depressions, the other patches being swollen, and the whole membrane around deeply injected.

*Cicatrices.*

LARGE INTESTINE.

There was narrowing of the calibre of the large gut from cicatrices in the descending colon in a woman who died from dysentery, with tubular sloughing in the cæcum and ascending colon; and narrowing in the sigmoid flexure from cicatrices in a man who died from "dia-

rrhœa," and had scars all through the colon. The lesions found in the large intestines may be grouped as follows:—

| | Diarrhœa. | Dysentery. |
|---|---|---|
| Hyperæmia ... ... ... | 57 | 47 |
| Thickening ... ... ... | 40 | 44 |
| Ulcers ... ... ... ... | 32 | 31 |
| Cicatrices ... ... ... ... | 4 | 7 |
| Swelling ... ... ... ... | 15 | 10 |
| Œdema ... ... ... ... | 7 | 5 |
| Diphtheritic effusion ... ... | 68 | 63 |
| Pigmentation ... ... ... | 15 | 17 |
| Ecchymosis ... ... ... | ... | 1 |
| Cyst forms ... ... ... | 1 | 1 |

There was more or less injection of the mucous coat in 57 cases of diarrhœa and in 47 of dysentery, comprising about two-thirds of the adults and three-fourths of the children. The ratio per cent. to the total diptheritic cases are—

| | | Diarrhœa. | Dysentery. |
|---|---|---|---|
| | Men ... ... ... ... | 86·8 | 60·4 |
| *Hyperæmia.* | Women ... ... ... | 60·6 | 60 |
| | Children ... ... ... | 66·6 | 75 |
| | | 74·0 | 63·5 |

The congestion extended through the whole length of the gut in 32 cases of diarrhœa and 35 of dysentery; nine of the latter were children.

| | Diarrhœa. | Dysentery. |
|---|---|---|
| All through ... ... ... | 32 | 35 |
| Upper end ... ... ... | 8 | 4 |
| Lower end ... ... ... | 8 | 1 |
| Both ends ... ... ... | 2 | ... |
| Blotches or rugæ ... ... | 7 | 7 |
| | 57 | 47 |

The character of the injection was reddish or pale livid in 9 cases of diarrhœa and in 8 of dysentery, red or livid in 14 cases of diarrhœa and 17 of dysentery, and deep red to purple in 9 cases of diarrhœa and 10 of dysentery. It was noted to be deeper in parts in several cases,

*All through.*

and to be less in the lower end, especially in the sigmoid flexure, in six cases of diarrhœa and in five of dysentery, and to be deeper livid in both ends in one case of diarrhœa, and to be less purple in both ends in one case of dysentery.

*Upper end.*

The congestion was considerable and confined to the cæcum or ascending colon, in eight cases of diarrhœa and four of dysentery, one a child in each; and it was confined to the lower end in eight cases of diarrhœa and one of dysentery. In one case of diarrhœa the livid injection was confined to both ends, and in another there was slight lividity in the upper end from injection of the venous radicles, while in the descending colon there was some redness from injection of the mouths of the mucous follicles. The congestion was confined to blotches, rugæ, or mottling in seven cases of diarrhœa and seven of dysentery, two children in each group.

*Lower end.*

*Both ends.*

*Blotches.*

There was thickening of the intestinal coats in 40 cases of diarrhœa and 44 of dysentery, comprising fully half of the adults and nearly three-fourths of the children.

*Thickening.*

| | Diarrhœa. | Dysentery. |
|---|---|---|
| All through ... ... ... | 29 | 33 |
| Lower end ... ... ... | 7 | 9 |
| Upper end ... ... ... ... | 2 | ... |
| Spots ... ... ... ... | 2 | 2 |
| | 40 | 44 |

This was localised in about a quarter of these, and was accompanied by congestion in little over a half, viz., in 22 cases of diarrhœa and 24 of dysentery.

The thickening was through the whole length of the gut in 29 cases of diarrhœa, two of them children, and 33 of dysentery, eight of them children.

*All through.*

| | Diarrhœa. | Dysentery. |
|---|---|---|
| Anæmic ... ... ... | 16 | 14 |
| Hyperæmic ... ... | 13 | 19 |
| | 29 | 33 |

The amount of thickening present was very little in six cases of diarrhœa and four of dysentery, and was very great in seven cases of diarrhœa and seven of dysentery, one a child. It was noted greater in the lower end in two cases of diarrhœa and two of dysentery. It was confined to the lower end in seven cases of diarrhœa and nine of dysentery; two of the former and four of the latter were children.

*Lower end.*

| | Diarrhœa. | Dysentery. |
|---|---|---|
| Anæmic ... ... ... ... | 1 | 5 |
| Hyperæmic ... ... ... ... | 6 | 4 |
| | 7 | 9 |

In two of these the mouths of the mucous follicles were pale and patulous, conspicuously so on the thickened part which was rose-coloured.

The thickening was confined to the upper end, and accompanied by congestion in two cases of diarrhœa, and it was confined to spots or blotches in two cases of diarrhœa and two of dysentery, unaccompanied by congestion in one of each.

*Upper end. Blotches.*

There was swelling of the mucous coat in 15 cases of diarrhœa and 10 of dysentery, with congestion in nearly all.

*Swelling.*

| | Diarrhœa. | Dysentery. |
|---|---|---|
| Anæmic ... ... ... ... | 3 | 1 |
| Hyperæmic ... ... ... | 12 | 9 |
| | 15 | 10 |

The swelling was present throughout the whole length of the gut in 11 cases of diarrhœa and 9 of dysentery, three of them children, and was accompanied by congestion in all except one of each. It was confined to the lower end of the gut, and was unaccompanied by congestion in two cases of diarrhœa, and to the upper end, accompanied by congestion in one case of diarrhœa and one of dysentery, the former a child; and in a case of dysentery it was confined to both ends, and accompanied by congestion.

*Œdema.*

There was more or less marked œdema of the mucous coat all through in six cases of diarrhœa and four of dysentery, unaccompanied by congestion in four of the former and one of the latter.

| | Diarrhœa. | Dysentery. |
|---|---|---|
| Anæmic ... ... ... ... | 5 | 1 |
| Hyperæmic ... ... ... ... | 2 | 4 |
| | 7 | 5 |

The œdema was confined to the lower end of the gut in one case of diarrhœa and one of dysentery, the latter accompanied by congestion.

*Diphtheritic effusion.*

Diphtheritic effusion was found in this (the large gut) in 68 cases of diarrhœa and 63 of dysentery, comprising about seven-eighths of the adults, and all the children except one. The ratios per cent. are as follows :—

| | Diarrhœa. | Dysentery. | Total. |
|---|---|---|---|
| Men ... ... ... | 81·6 | 83·7 | 82·7 |
| Women ... ... ... | 93·7 | 80 | 89·6 |
| Children ... ... ... | 100 | 93·7 | 95·9 |
| Total ... | 88·3 | 85 | 86·7 |

In other words, and speaking accurately, in 13·3 per cent. of the diphtheritic cases the effusion was found in the small intestine without there being any in the large; and this subtracted from 38·3, the total for the small gut before shown, leaves 25 per cent. in which effusion was found in both intestines together.*

The effusion was generally in the form of a pseudo-membrane, lining more or less of the mucous coat; but it was also seen as soft lymph, lying free or as shreds protruding from the mouths of the mucous follicles, and occasionally it appeared as a distinctly granular margin to the mouths of follicles. It was present in the lower end of the gut in nearly the whole of these cases, as well as higher up in a good many. Its distribution is given more in detail as follows :—

---

* See also foot-note to page 38.

ALEX: BARREN, PINXT ET

CHROMOLITH: MADRAS, 1869

PORTION OF DESCENDING COLON

COATED WITH PSEUDO-MEMBRANE

| | Diarrhœa. | Dysentery. |
|---|---|---|
| All through ... ... ... | 35 | 37 |
| Lower end ... ... ... | 24 | 23 |
| Upper end ... ... ... | 8 | 1 |
| Both ends ... ... ... | 1 | 2 |
| | 68 | 63 |

It was in the form of a pseudo-membrane, lining the whole length of the mucous tract, in 28 cases of diarrhœa and 30 of dysentery. The state of the mucous coat as to thickening and congestion was—

| | | Diarrhœa. | Dysentery. |
|---|---|---|---|
| *All through.* | Congestion ... ... ... | 7 | 10 |
| | Thickening ... ... ... | 6 | 6 |
| | Both ... ... ... | 13 | 12 |
| | Neither ... ... ... | 2 | 2 |
| | | 28 | 30 |

*Pseudo-membrane.*

There was no thickening in fully a third of these cases and no congestion in fully a fourth; both were present in less than a half, and in about six per cent. there was neither congestion nor thickening found, In these cases the membrane was generally of some thickness. especially at the lower end of the gut, often of a curdy appearance and in rugæ sometimes, or coloured. In some cases it had been removed in parts by ulceration or had separated in blotches; in one case it had been thrown off the whole length of the sigmoid flexure, forming a tube lying free in its cavity.

*Blotches.*

Effusion all through the gut in blotches or patches, but not forming a continuous membrane, was found in seven cases of diarrhœa and six of dysentery. The state of the mucous coat in these cases as to congestion and thickening was as follows:—

| | Diarrhœa. | Dysentery. |
|---|---|---|
| Congestion ... ... ... | 5 | 4 |
| Thickening ... ... ... | ... | 2 |
| Both ... ... ... ... | 1 | ... |
| Neither ... ... ... ... | 1 | ... |
| | 7 | 6 |

The effusion was pseudo-membrane on patches in one case of diarrhœa and two of dysentery; in the rest it was soft lymph on spots or in furrows; in some manifestly attached by processes running into the mucous follicles; in others granular around their mouths, or forming coloured blotches from effusion into the mucous membrane.

*Lower end.*

Where the effusion was confined to the lower end the state of the mucous coat as to thickening and congestion was as follows:—

| | Diarrhœa. | Dysentery. |
|---|---|---|
| Congestion ... ... ... | 10 | 15 |
| Thickening ... ... ... | 5 | 4 |
| Both ... ... ... ... | 5 | 11 |
| Neither ... ... ... ... | 4 | 3 |
| | 24 | 33 |

Both thickening and congestion were present in only about a third of these cases, no thickening in nearly a half, and no congestion in fully a third, and in about a seventh there was neither congestion nor thickening found. The character of the effusion was soft lymph only in five cases of diarrhœa and two of dysentery, in the rest it was pseudo-membrane lining more or less of the lower end of the gut, often with soft lymph higher up.

*Upper end.*

Where the effusion was confined to the upper end of the gut the state as to congestion and thickening was—

| | Diarrhœa. | Dysentery. |
|---|---|---|
| Congestion ... ... ... | 4 | ... |
| Thickening ... ... ... | 1 | 1 |
| Both ... ... ... ... | 2 | ... |
| Neither ... ... ... ... | 1 | ... |
| | 8 | 1 |

The nature of the effusion was soft lymph in three cases of diarrhœa, shreds and patches in two, and in one of dysentery; and a thin pseudo-membrane lining this part in the other three cases of diarrhœa.

*Both ends.*

Where the effusion was confined to the two ends it was a grey curdy pseudo-membrane in one case of diarrhœa and one of dysentery, and it was specks of lymph in the other case of dysentery. There was no thickening in these cases, but there was congestion present in both cases of dysentery.

*Ulcers.*

There was ulceration or sloughing of the mucous and sometimes other coats in 32 cases of diarrhœa and 31 of dysentery. In the majority of these the diphtheritic effusion was evidently a complication of an ordinary bowel-complaint with ulceration, and had nothing to do with the breach of surface of the intestinal mucous tract, but occasionally, especially in the cases of sloughing, it was otherwise. The lesions found in these cases may be grouped as follows :—

| | Diarrhœa. | Dysentery. |
|---|---|---|
| Abrasions ... ... ... ... | 6 | 7 |
| Circular ulcers ... ... ... | 14 | 8 |
| Irregular do. ... ... ... | 5 | 7 |
| Sloughing ... ... ... ... | 7 | 9 |
| | 32 | 31 |

In six cases of diarrhœa, three of them children, and in seven of dysentery, four of them children, there was abrasion or erosion of the pseudo-membrane, extending in most cases to the mucous coat in the form of circular or irregular ulcers, which were sometimes even pigmented. There were circular ulcers of the character already described * in fourteen cases of diarrhœa and eight of dysentery; in five of these there was no effusion, in six no congestion, and in eleven no thickening :—

*Circular.*

| | Diarrhœa. | Dysentery. |
|---|---|---|
| Effusion ... ... ... ... | 11 | 6 |
| Congestion ... ... ... | 9 | 7 |
| Thickening ... ... ... | 7 | 4 |

The ulcers were confined to the upper end of the gut in four cases of diarrhœa and one of dysentery; to the lower end in five cases of diarrhœa, one a child, and two of dysentery; to both ends

* *Vide* page 34.

in one of each, and they were found all through the length of the gut in four cases of diarrhœa and four of dysentery; two of the latter were children, and in the third there was a large slough in the cæcum.

*Irregular.*

There were irregularly-shaped ulcers, often cicatrices also, and mostly confined to the lower end of the gut in five cases of diarrhœa and seven of dysentery, two of them children; in two of these there was no effusion, in three no congestion, and in four no thickening:—

| | Diarrhœa. | Dysentery. |
|---|---|---|
| Effusion ... ... ... ... | 4 | 6 |
| Congestion ... ... ... | 5 | 4 |
| Thickening ... ... ... | 3 | 5 |

*Sloughing.*

In one case of dysentery there was a livid-edged ulcer with thickening extending along the transverse colon for nearly its whole length; above this there were cicatrices and below it increased thickening with effusion of a rough pale green pseudo-membrane. There was sloughing, with usually much hypertrophy of the coats, but seldom any congestion, in seven cases of diarrhœa and in nine of dysentery, besides the one already mentioned under circular ulcers.

*Perforation.*

In many cases the whole mucous tract was one mass of slough, but in only one instance had perforation actually occurred. This was the case of a young man who had been admitted complaining of dysentery of ten days' standing, and who died two days afterwards. The whole mucous membrane of the colon was found deeply red injected, and lined in the lower end by a pseudo-membrane, which, having become detached, formed a separate tube; higher up the lymph was soft and in patches. In the extreme end of the *cul-de-sac* of the cæcum was an opening leading to a cavity which extended up behind the gut for two inches, and was prevented from communicating with the peritoneal cavity by a tough, white, lymphy effusion, which glued some folds of the ileum to the cæcum and right flank. The redness of the peritoneum extended only to the small gut and over to the left flank, but there was no fluid in its cavity, nor was there loss of lustre of its surface. In two cases of

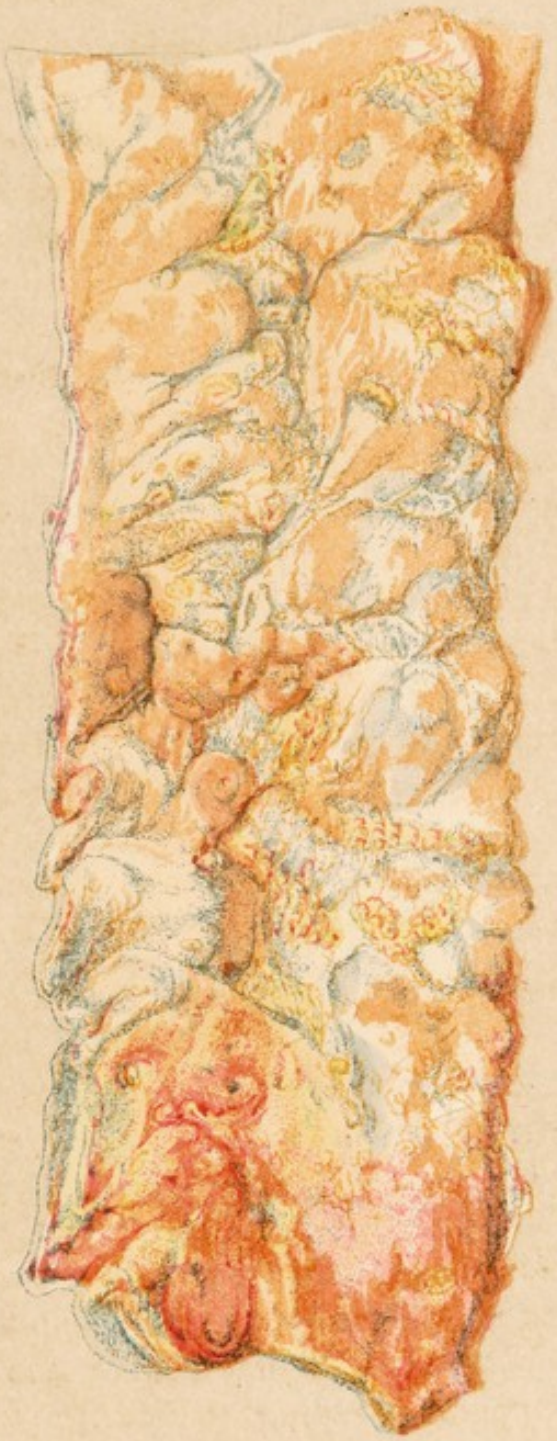

ALEX: BARREN, PINXT ET

CHROMOLITH: MADRAS 1885

FOLLICULAR ULCERS OF COLON – CHRONIC DYSENTERY

The edges of many of the ulcers are fringed with pseudo-membrane

diarrhœa sloughing had gone so far that perforation of the gut occurred on removal, and in one case of diarrhœa and one of dysentery sufficient peritonitis had been set up to glue the appendices epiploicæ to the peritoneum, and in another case of dysentery the sloughing had extended to the peritoneum in the sigmoid flexure without further effect, and in one case of dysentery the slough formed a separate tube in the cæcum and ascending colon.

*Cicatrices.*

Cicatrices were found in four cases of diarrhœa and seven of dysentery, two of these children. They were confined to the upper end of the gut in one case of diarrhœa and one of dysentery, to the middle in one case of dysentery, and to the lower end in one case of diarrhœa and five of dysentery, two of these children. In two cases of diarrhœa they were through the whole length of the gut; in one of these and in a case of dysentery partial constriction of the gut had been induced by the cicatrices, as already mentioned.

*Pigmentation.*

Pigmentation of the mucous coat, giving it a more or less deep-slaty coloration all through, was found in six cases of diarrhœa and five of dysentery; this was confined to the lower end of the gut in one case of diarrhœa, and to spots and lines there in one case of dysentery, both children, and to the upper end in two cases of diarrhœa. It was confined to cicatrices and ulcers in five cases of diarrhœa, two of them children, and in eleven cases of dysentery, five of them children; in one of the former, and in another case of diarrhœa already included, the mouths of some mucous follicles were black.

*Ecchymosis.*

Sub-mucous ecchymosis was found in only one case of dysentery; this consisted of a flat blotch in the transverse colon, about two inches long by one broad, and of a raised circular spot in the descending colon, about an inch and a half in diameter, and punctated in the centre.

*Cyst forms.*

"Cyst forms" were noted in only one case of diarrhœa and one of dysentery. In several cases the mouths of the mucous follicles were observed to be red, or black, or pale, and patulous; some, again, had shreds of lymph protruding from them, while in others the lymph formed a granular margin to their openings.

A list of these cases forms Appendix E, of which the following is an abstract :—

| —— | Men. | Women. | Children. | Total. |
|---|---|---|---|---|
| Lungs, healthy ... ... ... | 26 | 18 | 9 | 53 |
| Pneumonic congestion ... ... | 30 | 19 | 2 | 51 |
| Pneumonia, acute ... ... | 11 | 4 | 10 | 25 |
| Do. chronic ... ... | 5 | 1 | 1 | 7 |
| Phthisis pulmonalis (latent) ... | 5 | 4 | ... | 9 |
| Body, dropsical ... ... ... | 4 | 2 | ... | 6 |
| Total ... | 81 | 48 | 22 | 151 |

## CHAPTER II.

### CHOLERA.

THE epidemic of cholera, unlike that of small-pox, caused a large proportion of the admissions to, and deaths * in the Royapettah sheds, viz., 13·52 per cent. of the former and 23·96 per cent. of the latter; and the mortality was high, being 60·84 per cent. of those treated. (The corresponding figures for Vellore are 7·53; 14·7; and 54·3.)

The first and second cases were admitted on the 29th December 1876, and the admissions increased more or less unsteadily monthly till in July they reached 89; this was also the month in which the greatest number of admission from ordinary bowel-complaints occurred. After this the admissions decreased monthly, and in October they suddenly dropped to five, and subsequently only six were admitted till, and including the last case on, 6th February 1878; the total amount to 439 with 267 deaths (Appendix A.)

The quick and heavy mortality of the disease kept the average daily sick from this cause down to 5·78 for the year 1877, so that while for this year cholera contributed 16·24 per cent. of the average daily admissions, it formed only 7·72 per cent. of the average daily sick; see Appendix B.

The return (Appendix C.) shows cholera to have been not quite so widespread as small-pox, and the number of deaths to have varied from none in two places to 39·35 per cent. of the total in Madura. Of the 22,936 deaths therein given, it caused 1,550, or 6·5 per cent., which is five times the mortality of small-pox there shown. The autopsies amount to 13 in all, consisting of 7 men, 4 women, and 2 children; but although few in number they illustrate some of the most common phases of the disease: patients brought to hospital dead or dying, stricken down from apparent health in a few hours; others attacked while suffering from an

* The total deaths registered as "cholera" in 1877 amounted to 357,430, or in he ratio of 12·2 per mille of population.

ordinary bowel-complaint. Those who consider the disease an aggravated bowel-complaint will find among these cases examples of diphtheritic effusion and other appearances of the severest type of alvine flux; while the advocate of the disease being a sort of sunstroke is not without a case in point in one of the children.

As to causation, those who advocate lumbrici in the intestine as a cause can find lots of evidence of their theory among these cases; while the advocate of the air or water theory would have had as little difficulty in obtaining at the Famine Relief Camp evidence supporting his own particular view. One thing seems certain, viz., that the first case in an outbreak of cholera is always a person who has come from a place where the disease prevails, and somehow from him it spreads; another point observable is that a resident is less liable to be attacked than a stranger who is perhaps only passing through the station or village where the disease is prevalent.

*Duration of attack.*

As to the duration of the attack in the present cases, one man was brought in dead after an illness, it was said, of eleven hours; two died in nineteen, having been ill about four, hours on admission; and one lived seventeen days, having been ill some hours on admission with very marked symptoms of cholera; three men were attacked after an average of nine days in hospital with diarrhœa or dysentery, and died in an average of fifteen hours; one woman was brought in dead, having been ill nearly a whole day, it was said; and one was brought in all but dead, without a history; one died in forty-eight, having been ill on admission about four, hours; and one was attacked after having been four days in hospital with chronic dysentery, and died in thirty-six hours; both children died in thirty-six, having been ill on admission about four, hours.

*Contents of small intestine.*

The small intestine was found empty in one woman and one child; contained "rice-water" fluid in four men and two women; blood-tinged semi-pultaceous fluid in two men and one woman; yellow fluid in one man; and a little green pulp in one child.

*Lumbrici.*

Lumbrici to the number of 95, including those that had reached the mouth or large gut, were

found in five men, three women, and one child. In the child three were in the mouth and three in the small gut. The average for the men was nearly eight and for the women nearly seventeen each; as many as forty were found in one woman, while twelve was the largest number found in one man.

*Contents of large intestine.*

The large intestine was found empty in both children, and in one man and one woman. In the man it was distended with gas, and in the woman it had some red mucus adherent to the mucous coat.

In four men and three women it contained "rice-water" stools, and in two men it contained secondary cholera stools, viz., blood-tinged semi-pultaceous fluid. Lumbrici had reached this part of the gut in three cases, and they were found in the mouth in two cases.

*Walls of small intestine.*

The walls of the small intestine were thin in both children and in two men; in one this was most marked in the lower end of the ileum; and they were anæmic in both children and in two adults. In one child the gut was tinged livid *en masse*, and in the other an odd venous radicle showed through, and the mucous membrane near the valve was white, rugose and somewhat thick. In a man, who had been ill some time with dysentery, the mucous coat was thin and pale, with a livid tinge in the ileum, especially towards the valve, from venous radicles showing through; and in a woman, who also had been ill some time with dysentery, it was anæmic and pigmented pale slate-coloured. In the remaining six men and three women there was congestion of the whole mucous coat, and sometimes of the sub-peritoneal tissues also.

*Anæmia.*

*Hyperæmia.*

The character of the injection was deep rose in a man, reddish pink in a man and a woman, bright red in a man and a woman, red with lengths deeper red to livid in two men, deep red, paler towards valve in a man, and livid, deeper in parts, in a woman.

In three men and three women the peritoneal surface was red to deep livid from injection of the sub-peritoneal vessels. In one of these—a man—the mucous coat was only deep rose-coloured, and in another—a woman—it was anæmic and slate-coloured.

*Peyer's patches.*

Peyer's patches were remarkably prominent in one of the children, and in a man they looked depressed from the prominence of the surrounding membrane, and they were a much paler red than it.

*Solitary glands.*

The solitary glands were pale and prominent and about the size of No. 9 shot in six men, three women, and in both children. Besides, in the children there was no injection of the mucous coat in the case of one man and one woman. The distribution of the enlarged glands was all through the gut in the children and in some adults, but they were always most conspicuous in the ileum.

*Sub-mucous ecchymosis.*

There was a spot or two of sub-mucous ecchymosis in the jejunum in two men, and about a hundred spots (some an inch in diameter and a few prominent) in the jejunum in the woman in whom there was no injection of the mucous coat. And in one of the children the whole mucous tract was studded with punctated ecchymoses each a line or so in diameter.

*Pseudo-membrane.*

A pseudo-membrane was present in this part of the gut in three cases. It was of some thickness, rough, and confined to the lowest two feet of the ileum in the man who died from secondary cholera; it formed a grey film in the ileum, and was removable in places in a woman who died from cholera in forty-eight hours, and it lined the ileum and was unaccompanied by congestion of the mucous coat in another woman, who had been ill a fortnight with dysentery and thirty-six hours with cholera. Pigmentation of the mucous coat was present in the last case and in the case of the man who died from secondary cholera.

*Pigmentation.*

*Large Intestine.*

The walls of the large intestine were thin and pale in both children; in one the mucous coat was dingy with livid mottling from injection of venous radicles, and was stained green. In a man the mucous coat was pale, and in another it was rosy, with the solitary glands prominent and white; in a woman it was dull pink, with pseudo-membrane adherent in the ascending colon, and patches of brown

*Pale.*
*Rosy.*

effusion into the coat in the transverse and descending colon.

*Dull red.*

In a man it was dull red with prominence of solitary glands in the ascending and transverse colon, paler in the descending colon, but deep livid lower down.

*Deep red.*

It was deep red in three men and two women: in one of the former the injection was deepest in the cæcum, and the mouths of the follicles were seen as minute white circles all through, but most markedly in the transverse colon; in one the coat looked as if washed in blood, and in the third there was a pseudo-membrane lining it all through, the injection being absent from the descending colon.

*Dark livid.*

In a man the injection of the mucous coat was dark livid at the end of the gut, paler in the middle, and with filmy patches of pseudo-membrane in the cæcum; and in a woman it was dark livid, deeper in parts, but less so in the sigmoid flexure, and it was lined all through to the descending colon with a pseudo-membrane, which was thick at its termination and seemed recently shed from the lower end of the gut.

*Pseudo-membrane.*

A pseudo-membrane is thus seen to have been present in four cases—two men and two women—three of them the same cases in which we saw this lesion in the small gut, and the fourth a man who had been a week or so ill with dysentery and died from cholera in eighteen hours. This is the case above mentioned in which there were filmy patches on the cæcum.

*Solitary glands.*

And the solitary glands were prominent in the cases of two men and one woman given in detail above.

*Swelling.*

There was some swelling, accompanied by deep congestion of the mucous coat in one of the men who had been under treatment for dysentery, and in the man who was brought in dead; and there was thickening

*Thickening.*

of the tissues at the lower end of the gut in two of the dysentery cases—one a man and one a woman.

*Ulcers.*

Ulcers were found in three men, one woman, and one child. The latter was brought in with his mother, No. 356, without a history, and died in a few

hours. The ulcers were few, small, and circular, about three lines in diameter, appearing to originate in spots of ecchymosis or in the follicular glands, which were patulous. All the other cases were under treatment for bowel-complaint when attacked.

The ulcers were small and circular, confined to the lower end of the gut in a man, and to both ends in a woman. In a man there were three ulcers in the caput coli, livid based, transverse, three inches long by three lines broad, with slightly thickened edges, and a gray slough adherent to one; and in another there were in the cæcum and ascending colon several grey-based, thick-edged, tubercular-like ulcers, some circular, some oval transversely, and in the transverse colon were girdle ulcers encircling three-quarters of the gut. Lower down the ulcers were circular, small, a line in diameter, and healing. No infarcted glands were found, and there was no injection or thickening of the coats generally.

*Sub-mucous ecchymosis.*

Sub-mucous ecchymoses were found in both children. In one they consisted of about a hundred spots, each a line or so in diameter, and scattered over the lower part of the gut, from the transverse colon downwards, and in the other they were seen as small black dots about a quarter of a line in diameter, and all through the gut at about one hundred to the square inch.

Case 348.—Mooneen, a shepherd of the Yeddar caste, about forty years old, was picked up by the police and brought to hospital on the 16th March 1877 with all the symptoms of cholera well marked except vomiting, which was absent; had been attacked during the night, but was too ill to give a full account of himself. He died the next morning. Autopsy two hours afterwards. Height, 5 feet 1 inch; weight, 73 lbs.; body emaciated, with œdema of feet. *Skull.*—Scalp and meninges bloody; pia mater injected; some serum in arachnoid cavity. *Brain.*—37½ ozs., firm, injected. *Chest.*—Right pleura healthy. *Lung*, 8½ ozs.; much collapsed; black tarry blood flows on severing large vessels of root; substance spongy, venous livid, dry on section. *Left pleura* and lung like right; weight, 6½ ozs. *Pericardium* healthy. *Heart*, 5⅞ ozs., full of black blood, with some small yellow clots on right side. *Abdomen.*—Peritoneum reddish pink, glistening. *Small intestine* contains ten lumbrici and a little "rice-water" fluid, reddish pink injected deepest in middle third; Peyer's patches markedly paler, and look depressed from prominence of the surrounding folds; solitary glands full and prominent; lower end of ileum seems very thin. *Large intestine* contains a large quantity of reddish fluid like secondary

cholera stools; coats deeply red congested, deepest in cæcum; mouths of solitary gland showing as minute white circles, most markedly in transverse colon, but sufficiently conspicuous downwards to the rectum, where the injection is less marked. *Stomach* small, contracted; lining pale. *Liver*, 31¼ ozs.; cuts soft; black blood in veins; normal in structure. *Gall-bladder* nearly empty. *Spleen*, 2½ ozs.; flaccid, tough, deficient in pulp. *Right kidney*, 2 ozs.; capsule strips easily; substance healthy. *Left kidney*, 2⅛ ozs., like right. *Pancreas*, 1½ ozs., *Mesenteric glands* normal; some little fat in mesentery. In this case of destitution probably famine diarrhœa preceded the cholera.

Case 349.—Vedamuthoy, a coolie of the Pulley caste, about twenty years old, was brought by the police on the evening of the 28th March 1877, in a state of collapse, having been attacked by cholera about noon, and he died the next morning. Autopsy ten hours after death. Height, 5 feet 3½ inches; weight, 97 lbs.; body plump and well formed; rigor mortis present. *Skull.*—Scalp and meninges bloody; pia mater red injected, and veins full. *Brain*, 42¼ ozs.; softish and rather congested. *Chest.*—Right pleura has old points of adhesion. *Lung*, 11⅛ ozs., injected red, but dry on section. *Left pleura*—Some points of old adhesion laterally. *Lung*, 10¼ ozs.; injection hardly so deep red as in right. *Pericardium* healthy. *Heart*, 7 ozs., flabby, little fat on surface, tar-like blood on right side. *Abdomen.*—Peritoneum pearly; deep injection of small gut. *Small intestine* contains gas and a little pink pulp; peritoneal surface red; mucous coat deep rose-coloured; solitary glands prominent and white. *Large intestine* contains some "rice-water" fluid; mucous coat rosy; solitary glands prominent and white. *Stomach* large, contains some conjee-water; mucous coat smooth, pale buff-coloured. *Liver*, 41 ozs.; veins full of tarry blood; structure normal. *Gall-bladder* half full of bile. *Spleen*, 12¼ ozs.; deeply pigmented, not easily friable and no pulp exudes on pressure. *Right kidney*, 3 ozs.; capsule strips easily; very bloody on section from engorgement of veins. *Left kidney*, 3¼ ozs., like right, but blood almost more tarry. *Pancreas*, 2½ ozs., healthy. Some fat in mesentery; glands large.

Case 350.—Chellan, a Pariah coolie, about thirty-five years old, from Ahtoor, a month in Madras, ill twelve hours with cholera, admitted on the 5th April in a state of collapse, all the symptoms of cholera being well marked. He rallied under treatment, but the purging continued, the stools becoming slimy with blood intermixed, and he died on the 22nd. Autopsy five hours after death. Height, 5 feet 2 inches; weight, 71 lbs.; body emaciated; no œdema; rigor mortis present. *Skull.*—Much blood flows on removing calvarium; pia mater injected, and veins distended with dark blood; bloody serum in arachnoid cavity. *Brain.*—41 ozs.; firm, puncta bleed freely, serum in ventricles. *Chest.*—Right pleura healthy. *Lung*, 7 ozs.; fully collapsed; apneumatosis of posterior border, else pale and pigmented. *Left pleura* healthy. *Lung*, 6 ozs.; quite healthy.—*Pericardium* healthy. *Heart*, small, 4½ ozs.; fluid blood in right side. *Abdomen.*—

Peritoneum healthy; streaky red injection of gut and mesentery. *Small intestines* contain some yellow fluid and gas; mucous coat pale slate, injected red all through, deeper in parts; lowest two feet of ileum lined by a rough pseudo-membrane. *Large intestines* gas-distended; mucous coat injected red all through, except in descending colon, and lined by a dirty green rough pseudo-membrane, which is thickest and most mammillated in lower end. *Stomach* small, empty; mucous coat rugose, quite red. *Liver*, 40 ozs.; large veins full of dark blood, but substance rather pale; structure normal. *Gall-bladder* full of bile. *Spleen*, $2\frac{3}{4}$ ozs.; firm, pigmented; not friable, and no pulp exudes on pressure. *Right kidney*, $3\frac{1}{2}$ ozs.; capsule strips easily; small cysts on surface; substance deeply red injected; structure normal. *Left kidney*, $3\frac{1}{2}$ ozs., like right. *Pancreas*, $2\frac{1}{2}$ ozs., healthy. No fat in mesentery; glands normal.

Case 351.—Chandrayan, a ryot of the Pulley caste, aged about twenty years, an idiot, from Seladoo, a fortnight in Madras, four days on famine relief, admitted with diarrhœa on the 27th April 1877. He was not in good flesh but did not appear ill; his stools were not seen, as he passed them into his bed. On the morning of the 7th May symptoms of cholera set in, and he died in the afternoon of the 8th. Autopsy six hours afterwards. Height, 5 feet $3\frac{1}{2}$ inches; weight, 56 lbs., legs thin; some fat on abdomen; rigor mortis present. *Skull.*—Scalp and meninges bloody; some serum in arachnoid cavity and beneath; pia mater over anterior lobe injected bright red; veins full. *Brain*, $42\frac{1}{2}$ ozs.; firm, hyperæmic. *Chest.*—Right pleura healthy. *Lung*, fully collapsed, $5\frac{1}{2}$ ozs.; rosy-tinged, tarry blood from root. *Left lung*, $4\frac{7}{8}$ ozs., like right, but livid tinge more marked, and two spots of sub-pleural ecchymosis near fissure. *Pericardium* pearly; contains $\frac{1}{2}$ ozs. of straw-coloured serum. *Heart*, small, $3\frac{5}{8}$ ozs.; full of tarry blood; fat on surface. *Abdomen.*—Peritoneum pearly; intestines brightish red. *Small intestine* contains rice-water stools and seven lumbrici; sub-peritoneal veins engorged; mucous membrane brightish red; a spot or two of sub-mucous ecchymosis in jejunum; marked prominence of the solitary glands most seen in ileum. *Large intestine* contains rice-water stools; in caput coli are three livid based transverse ulcers, three inches long by three lines broad, with slightly thickened edges and grey slough adherent to one; mucous membrane of ascending and transverse colon dull red, and solitary glands prominent; of descending colon, paler, but more swollen, and thrown into numerous folds; of sigmoid flexure livid with superficial red mottling; no thickening; and in rectum the whole surface is dark livid red, without ulceration of glands visible. *Stomach* large, distended with rice-water fluid; contains one lumbricus; mucous membrane in rugæ, pale, one venous radicle injected. *Liver*, 22 ozs.; small, $5\frac{1}{2} + 2 \times 4\frac{1}{2} \times 3$ inches; right lobe rounded; capsule pale, cuts soft; section smooth, anæmic; ducts contain bile, slightly fatty under microscope. *Gall-bladder* contains a little green bile. *Spleen*, $3\frac{1}{4}$ ozs., small, $4 \times 3 \times 1$ inch; firm, brown, not friable. *Kidneys*, $2\frac{1}{4}$ ozs.

each; capsule strips easily; injected red. *Pancreas*, an ounce and a half in weight, normal. *Mesenteric glands* slightly swollen; fat in mesentery.

CASE 352.—Perswandroo, Pariah coolie, male, aged thirty-five years, from Pervandrum, two months in Madras, six days on famine relief, admitted 3rd May with dysentery of three days' duration. Is of spare frame, in normal flesh; has frequent mucous stools passed with griping and tenesmus; belly soft, not painful on pressure; pulse 72, small; respiration 18; tongue moist, with buff fur. Ipecac. treatment had stopped the dysentery by the 8th, when there came cough and feverishness; pulse 96, respiration 24. He was attacked by cholera during the night, and he died the next afternoon. Autopsy two hours after death. Height 5 feet 2 inches; weight, 80 lbs; body in fair flesh; rigor mortis present. *Skull.*—Scalp and meninges venous injected; pia mater pale venous; veins full. *Brain*, 42 oz., firm, dark blood from pia mater readily. *Chest.*—Right lung, $6\frac{5}{8}$ ozs.; old points of adhesion at apex; fully collapsed; slightly venous tinged; tarry blood from root. *Left lung*, 7 ozs.; no adhesions, in other respects quite like right. *Pericardium* healthy. *Heart*, $6\frac{1}{8}$ ozs.; fat on surface, right side and coronary veins distended with tarry blood. Peritoneum normal; intestines injected red. *Small intestines* contain two quarts rice-water stools, four lumbrici, and some gas; sub-peritoneal veins full; mucous coat deep red paler towards valve; solitary glands prominent; fewer than usual. *Large intestine* very large and much sacculated; contains three quarts of rice-water stools and four lumbrici; mucous coat of caput coli dark livid, with a filmy patch of grey lymph adherent; of ascending colon pale livid, swollen, thrown into folds; thence downwards pale pink, swollen, and in folds; lower end deep livid brown, thickened, and studded with small grey ulcers. *Stomach* large, full of rice-water fluid; mucous coat pale, smooth. *Liver*, 31 ozs., congested, dark venous and pigmented, $7 + 2 \times 5 \times 2\frac{1}{2}$ inches; left lobe thin atrophied; under microscope nuclei obscured by pigment granules. *Gall-bladder* contains ℥ i. thick dark bile. *Spleen*, 3 ozs., flat, $4\frac{1}{4} \times 2\frac{1}{2} \times 1$ inch; firm, not friable; veins full of tarry blood. *Right kidney*, $2\frac{1}{8}$ ozs.; deeply red injected all through. *Left* $2\frac{1}{2}$ ozs.; capsule strips easily, quite like right. *Pancreas* weighs 2 ounces 3 drachms. *Mesenteric glands* normal; mesentery injected red, contains some fat. The *post-mortem* appearances were markedly choleraic; the remains of the dysentery was still seen in the rectum, and perhaps in caput-coli.

CASE 353.—Burliah, a palki-bearer, aged about seventy years, a resident of Madras since 1860, admitted 30th April 1877 with "dysentery" of two days' duration. A miserably thin little old man; no œdema, skin hanging about him; belly hard, painful on pressure; pulse 84, weak; respiration 22; has had a cough for past year, spits a little phlegm, never blood; has rough breathing over right apex, and pneumonic crepitus over left base, and a crackling sound with the heart's rhythm. 10th May.—Pulse 108, weak; respirations, 26; temperature, 99·2° F.; stools thin and yellow; two passed last night.

12th.—Attacked by cholera during night; died at noon. Autopsy five hours after death. Height, 5 feet $3\frac{1}{2}$ inches; weight, 60 lbs.; body a skeleton; no œdema; rigor mortis present. *Skull.*—Scalp and meninges pale; a little serum in and beneath arachnoid; pia mater pale rose, streaked red; larger veins full. *Brain*, $38\frac{1}{2}$ ozs., firm; section pale buff, punctated; a little pale serum in the lateral ventricles. *Chest.*—Right pleura firm; old adhesions all over broken down with great difficulty. *Lung*, $18\frac{3}{4}$ ozs., somewhat torn; posterior part quite fibrous; section hard and elastic, like white fibrous tissue among pigmented nearly obliterated air cells; some cavities at apex with pigmented mucous contents or empty; no appearance of tubercle anywhere. *Left pleura*—Old adhesions less firm; posteriorly at root a grey granular firm deposit on reddened pleura. *Lung*, 17 ozs.; section like right; cavities five or six, but in apex there are spots of softened tubercle, and the base is congested and studded with miliary tubercles. *Pericardium* pearly; contains 2 drachms of pale serum. *Heart*—Some fat on surface; is flabby, and nearly empty of blood; weighs $6\frac{1}{4}$ ozs. *Abdomen.*—Peritoneum normal; intestines dull white. *Small intestine* contains a quart of "rice-water" stools, and two lumbrici; mucous membrane, thin, pale to livid-tinged in ileum, becoming more decided towards valve from injection of venous radicles; solitary glands prominent only near valve, appearing as clear specks. *Large intestine* contains two quarts of rice-water stools; no injection or thickening of coats generally. In cæcum and ascending colon there are several grey-based, thick-edged tubercular ulcers, some circular, some oval transversely, and in transverse colon are three-quarter girdle tubercular ulcers; lower down the ulcers are circular, small, a line in diameter, with edges not thickened and healing; no infarcted glands found. *Stomach* small, empty; mucous coat pink. *Liver*, $26\frac{7}{8}$ ozs., small, flaccid; two wrinkles half an inch deep run across right lobe, $6 + 2\frac{1}{2} \times 4\frac{1}{2} \times 3$ inches; cuts soft; acini pale-edged, distinct, not fatty. *Gall-bladder* contains 2 drachms of thin green bile. *Spleen* weighs 1 oz., is firm, flesh-coloured, not friable. *Kidneys*, $2\frac{3}{8}$ ozs. each; capsule adherent; section uniformly flesh-coloured, not fatty. *Pancreas* weighs 1 oz. 3 drachms, is healthy. *Mesenteric glands* very visible from complete absence of fat in mesentery, but not enlarged. In this case the tubercular deposit was, no doubt, subsequent to the fibroid pneumonia. With so much tubercular ulceration of the colon it seems strange that none of the solitary glands of the small, or large intestine even, or the mesenteric glands, were found infarcted with tubercles.

Case 354.—Carion, a Pariah coolie man, about thirty years old, from Conjeeveram, three days in Madras, said to have been ill eleven hours with pain in the belly when brought in dead on the 8th June. Autopsy four hours after death. Height, 5 feet 7 inches; weight, 123 lbs.; body plump; rigor mortis well marked. *Skull.*—Scalp and meninges bloody; serum in and beneath arachnoid; veins full. *Brain*, 45 ozs., firm, rather hyperæmic. *Chest.*—Right pleura pearly; half a

pint of dark amber serum in cavity. *Lung*, $10\frac{5}{8}$ ozs., not collapsed, dull pink with a livid tinge; veins full of tarry blood. *Left pleura* and lung quite like right; weight, $9\frac{5}{8}$ ozs. *Pericardium* pearly; contains a little amber serum. *Heart*, $7\frac{1}{2}$ ozs., fat on surface; a little tarry blood in both sides. *Abdomen.*—Peritoneum pearly, moistened with amber serum; intestines reddish pink. *Small intestine* contains twelve lumbrici, and a pint of reddish fluid like secondary cholera stools. Mucous coat brightish red injected, and looking as if washed in blood, with three spots of sub-mucous ecchymosis, half an inch in diameter in jejunum; and deep livid injection in lengths, with prominence of some of the solitary glands in ileum. *Large intestine* also contains reddish fluid; mucous coat has same appearance as in jejunum, is a trifle paler, perhaps, and with numerous rugæ from being swollen; very little mucus is detached by fingers in examination. *Stomach* large, full of dark-coloured fluid containing much black pepper and a little arrack; mucous coat in rugæ pale, tinged livid. *Liver*, 46 ozs., congested, $7 + 2\frac{1}{2} \times 5\frac{3}{4} \times 4$ inches; veins full of tarry blood; substance healthy. *Gall-bladder* full of thin green bile. *Spleen*, $8\frac{7}{8}$ ozs., dark red, $6 \times 3\frac{1}{3} \times 1\frac{1}{2}$ inches; lots of red-brown pulp exudes from cut surface on pressure. *Kidneys*, $3\frac{1}{2}$ ozs. each; capsule strips easily; section uniform livid injection as in cholera; not fatty. *Pancreas*, $3\frac{1}{2}$ ozs., seems healthy. *Mesenteric glands* normal, enveloped in fat. The appearances are more like those of cholera in the second stage than any other disease. He might easily have been ill a couple of days before being picked up by the police. He had not been on famine relief.

Case 355.—Kunnevathee, a coolie woman of the Pariah caste, about thirty-five years old, admitted 1st May with well-marked symptoms of cholera, which set in during the previous night. Is from Chingleput; has been ten days in the Madras Famine Relief Depôt. She remained in a state of collapse, voiceless, pulseless, with much thirst, rice-water vomiting and purging, suppression of urine, cramps, injection of conjunctiva, &c., till death on the morning of the 3rd May. Autopsy three hours afterwards. Body not emaciated; but little fat. Height, 4 feet $11\frac{1}{2}$ inches; weight, 69 lbs.,; rigor mortis well marked; arms bent; eyes injected. *Skull.*—Venous engorgement to smallest capillaries. *Brain*, 36 ozs., firm, venous congested. *Chest.*—Lungs free, shrunken, dull pink, pigmented in front; tarry blood from vessels on separation. *Right Lung*, $6\frac{1}{4}$ ozs., spongy; section dull pink, pigmented. *Left Lung*, $5\frac{1}{2}$ ozs.; some ecchymosed spots under pleura in fissure, else like right. *Pericardium* pearly, empty. *Heart*, distended with tarry blood and soft clots; some fat on surface; weight, $6\frac{1}{2}$ ozs. *Peritoneum* normal, except venous injection to minutest capillaries of parietal, visceral, and mesenteric vessels, making the intestines look claret-coloured. *Small intestine* contains one lumbricus and some whitish and green-tinged mucus adherent to lining membrane, which is uniformly livid, deeper in parts, and valvulæ conniventes prominent; a grey film adherent in ileum, removable in parts; solitary and

Peyer's glands not prominent; sub-peritoneal veins injected to minutest capillaries. *Large intestine* has red-tinged mucus adherent; caput coli like ileum; lividity deeper in parts and film adherent; lividity uniform and deeper in ascending and transverse colon, and adherent film thicker, looking like grey slough; less in descending colon and in sigmoid flexure, which is pale livid, with only spots of effusion; no abrasion, but look of effusion having been detached recently. *Stomach* large; contains one lumbricus and "rice-water" fluid; lining in pale rugæ. *Liver*, 42⅞ ozs.; veins full of tarry fluid; substance pale liver-coloured, as in young people. *Spleen* hypertrophied and pigmented on convexity, not easily friable; weight, 12⅞ ozs. *Right kidney*, 2⅞ ozs.; *Left*, 3 ozs.; deeply venous injected. *Pancreas*, 2¼ ozs.; healthy. *Mesenteric glands* normal; mesentery venous injected; some fat present. The symptoms in this case were markedly those of cholera, while the intestinal lesions were those of diphtheritic dysentery.

Case 356.—Bodyama, a weaver's wife, aged about twenty-five years, was brought to hospital on the 4th May. Said to have been ill twenty-four hours with cholera, and to have died on the way to hospital. Autopsy two hours after death. Height, 4 feet 11½ inches; weight, 101 lbs.; body plump, and a beautiful figure; rigor mortis well marked. *Skull.*—Vessels of scalp and meninges full of dark blood, pia mater pinkish. *Brain*, 38⅞ ozs.; pinkish, punctated, firm. *Right pleura* healthy. *Lung*, 8¼ ozs., not collapsed; lower lobe violet; section dry; tarry blood in veins of root. *Left pleura* healthy. *Lung*, 8 ozs., livid spots of ecchymosis in fissure; section like lower lobe of right. *Pericardium* pearly, empty; veins fully injected. *Heart*, large, fat, 8 ozs.; right side distended with tarry blood. *Peritoneum* normal, but vessels of parietes and viscera injected pink red; lots of fat in mesentery. *Samll intestine* contained forty lumbrici in all, including those found in colon and mouth, and "rice-water fluid;" mucous membrane pink-red, with solitary glands showing as white prominences, the size of snipe-shot. *Large intestines* contain rice-water fluid and some lumbrici; mucous membrane darker red, but solitary glands less prominent than in ileum. *Stomach* small, empty; lining in rugæ, pink. *Liver* large, flabby; veins full of tarry blood, slightly fatty; weight, 42 ozs. *Gall-bladder* full of thickish tarry bile. *Spleen*, 4½ ozs.; veins injected; substance healthy. *Right kidney*, 3 ozs.; deeply venous injected. *Left kidney*, 3½ ozs.; capsule strips easily, quite like right. *Pancreas*, 3½ ozs.; mesentery loaded with fat; glands normal. The absence of collapse of the lungs is unusual; their weight, however, was small.

Case 357.—Muichee, a coolie woman of the Pariah caste, aged about forty years, from Kodambaukum, four months in Madras on famine relief, ill ten days with "dysentery," admitted on the 2nd May 1877. She is emaciated, but has no œdema of ankles; belly soft, tender on pressure; pulse 112, weak, respirations 28; tongue moist, brown-furred; stools mud-coloured fluid tinged with blood, passed with

griping and tenesmus. 6th.—Stools choleraic, suppression of urine; collapse and all symptoms of cholera marked except vomiting. Died on the afternoon of the 8th. Autopsy two hours after death. Height, 4 feet 7 inches; weight, 51 lbs.; body thin, a little fat in cellular tissue. *Skull.*—Scalp and meninges injected, a little serum in arachnoid cavity and beneath it; pia mater veins engorged, streaked red. *Brain*, 37½ ozs., firm, hyperæmic. *Chest.—Right lung* fully collapsed, tarry blood from root, pale with venous tinge, spongy; weight 4¼ ozs. *Left lung*, a few old points of adhesion, but fully collapsed and quite like right, 3⅞ ozs. *Pericardium* normal. *Heart* small, 3 ozs.; some fat on surface; right side and coronary vessels full of tarry blood. *Abdomen.—Peritoneum* normal; veins of mesentery engorged. *Small intestine* contains a quart of white mud-tinged fluid and seven lumbrici; jejunum slaty, with a hundred spots of sub-mucous ecchymosis, some an inch in diameter and a few prominent to the touch; sub-peritoneal venous radicles injected to smallest capillaries; *ileum* also livid, but less slaty, and a grey film adherent throughout; solitary glands markedly prominent as white spots the size of snipe-shot. *Large intestine* contains two lumbrici and some pale fluid; mucous membrane of caput coli dull pink, with one pale, shallow ulcer, half an inch in diameter; patches of grey effusion adherent in ascending colon; mucous membrane of transverse and descending colon, paler venous tinged, thickened, and thrown into numerous folds, with deep red blotches of lymphy effusions into the upper layers of the mucous membrane; a small grey-based superficial ulcer, two lines in diameter on one of these, large red-brown similar patches in sigmoid flexure and rectum, with six or seven similar ulcers on these, the largest half an inch wide. *Stomach* small; mucous membrane in rugæ, pale, tinged green; contents a little green pulp. *Liver*, 20½ ozs. small, 5 + 3 × 4½ × 2 inches; smooth, pale; liver-veins full of tarry blood; slightly fatty. *Gall-bladder* full of dark green bile. *Spleen* small, weighs 1 ounce, 3 × 2 × 1 inch; cut surface brown; is firm not friable. *Right kidney*, 1⅜ oz., small; capsule strips easily; cortex pale, with veins full. *Left kidney*, 2 ozs.; more vascular; non-albuminoid. *Pancreas* weighs only 7 drachms; looks healthy. *Mesenteric glands* slightly swollen, with some fat around.

Case 358.—A woman about forty-five years old was brought to hospital in a dying state on the 6th September 1877, and she died in a few minutes after admission. There was no history, but it looked like a case of cholera. Autopsy one hour after death. Height, 5 feet 1 inch; weight, 75 lbs.; body emaciated; no œdema; rigor mortis present. *Skull.*—Scalp and meninges bloody; serum in and beneath araconoid; veins of pia mater full. *Brain*, 40 ozs.; firm, hyperæmic. *Chest.*—Right pleura healthy. *Lung*, 7⅝ ozs.; very fully collapsed; lower lobe pink, airless; upper healthy. *Left pleura* and lung like right, 6⅜ ozs. *Pericardium* pearly, moistened with serum. *Heart*, 7⅛ ozs.; tarry blood on right side; fat on surface. *Abdomen.*—Sub-peritoneal veins over gut engorged, else healthy. *Small intestines* contain a pint of bloody fluid; mucous coat bright red in ileum, and deep-red like

ecchymosis into the mucous membrane, along free border of jejunum; engorged sub-peritoneal veins seen through; glands near valve prominent, but not conspicuously so. *Large intestine* contains a pint of rice-water stool; mucous coat, deep-red injection of parts like in jejunum. *Stomach* large, full of rice-water fluid; lining pale and smooth. *Liver*, 27 ozs., venous congested, 6 + $2\frac{3}{4}$ × $5\frac{1}{2}$ × $2\frac{3}{4}$ inches; section spotted yellow; dark blood from veins; decidedly fatty. *Gall-bladder* half-full of thin dark green bile. *Spleen* $1\frac{1}{4}$ oz.; white spots on capsule; $3\frac{1}{2}$ × 2 × $\frac{3}{4}$ inch; section red, with white trabeculæ, not friable, and no pulp exudes on pressure. *Right kidney*, $2\frac{1}{4}$ ozs.; capsule partly adherent; section deeply red injected, rather fatty. *Left kidney*, $2\frac{3}{8}$ ozs., like right. *Pancreas*, 2 oz., healthy. No fat in mesentery; glands atrophied. The veins of lungs and liver not so full as usual, nor the solitary glands of ileum so conspicuous, otherwise the appearances are quite those of cholera.

Case 359.—Mugadoo, a weaver's son, aged about five years, brought in with his mother (No. 356) on May 4th, also suffering from cholera with all the symptoms well marked; never rallied; died on night of the 5th. Autopsy seven hours after death; height, 3 feet 1 inch; weight, 30 lbs.; body in fair flesh; no marks; rigor mortis going off. *Skull.*—Scalp and meninges injected, latter pink; a little serum in and beneath arachnoid; pia mater streaked red from injected capillaries. *Brain*, 42 ozs., rather hyperæmic; no serum in ventricles. *Chest.*—Right lung well collapsed; $4\frac{7}{8}$ ozs.; a point of recent adhesion near apex, where frothy fluid flows from section, which is livid; rest reddish and dry on section, with tarry blood from veins. *Left lung* smaller; $4\frac{1}{4}$ ozs.; less venous congestion. *Pericardium* healthy. Heart, no fat; right side and coronary vessels distended with tarry blood; $2\frac{3}{8}$ ozs. *Abdomen.*—Peritoneum healthy; sub-peritoneal veins of jejunum engorged; fat in mesentery. *Small intestine* thin and pale; odd venous radicles injected; marked prominence of solitary glands all through, and numerous punctated ecchymoses, a line or less in diameter; near the valve the mucous membrane is pale, thrown into irregular folds feeling prominent and thickened. *Large intestine* pale; odd venous radicles distended. In transverse colon downwards there are a hundred spots of ecchymosis, apparently into the solitary glands, each about a line in diameter, with a few thick-edged circular ulcers, three lines in diameter, and bases discoloured or pale like the surrounding mucous membrane. The ulcers appear to have originated in the ecchymoses or in the glands, which are patent mouthed. There is no hyperæmia or general thickening of the coat; only the ulcers feel thick-edged. *Stomach* small; mucous membrane in rugæ, very pale livid. *Liver*, $14\frac{7}{8}$ ozs., flaccid, 5 + 2 × 5 × 2 inches; cuts soft; uniform pale red; healthy. *Gall-bladder* full of thickish dark-green bile. *Spleen*, $4\frac{5}{8}$ ozs., large, 3 × 3 × 2 inches, firm; veins injected. *Right kidney*, $1\frac{1}{4}$ oz.; capsule strips easily; cortex pale-rose; medulla blood-red. *Left kidney*, $1\frac{1}{8}$ oz., quite like right. *Pancreas* weighs 1 oz.; looks healthy. Mesenteric glands larger than in adults, with lots of fat around. The

lungs red and intestines rather pale; and the ulceration in the transverse colon and sigmoid flexure are unusual in cholera.

CASE 360.—Moongay, sister of last case, aged about three years, was also brought to hospital on the 4th May in a state of insensibility, said to have been ill with cholera since midnight; pulse 88, good; respiration 40, sighing; vomiting and purging not great; suppression of urine; moans a good deal; never rallied; died on the night of the 5th. Autopsy seven hours after death; height, 2 feet 10 inches; weight, 19 lbs.; body well nourished; rigor mortis going off. *Skull.*—Scalp and meninges bloody; ecchymotic-like injection of pia mater over posterior lobe of brain. *Brain*, 35¼ ozs., rather soft and hyperæmic. *Chest.*—Right pleura healthy; lung, not collapsed, 3¼ ozs., pink red in front, livid posteriorly; tarry blood from veins on section, and some frothy fluid on pressure. *Left lung* adherent to parietes over part of convexity by recent lymphy effusion; no serum, otherwise like right; weight, 3¾ ozs. *Pericardium* healthy. Heart, no fat; right side and coronary vessels distended with tarry blood, 1½ ozs. *Abdomen.*—Peritoneum healthy; intestines pale tinged venous. *Small intestines* contain a little green pulp and three lumbrici, three also were found in the mouth; mucous membrane tinged green; hardly any injection of venous radicles; has a livid tinge *en masse;* Peyer's and solitary glands markedly prominent. *Large intestine* empty; mucous membrane dingy, stained greenish; some livid mottling from injection of venous radicles; studded all over with small black dots, about one hundred to the square inch and a fourth of a line in diameter, looking like pigmented mouths of Lieberkühn's follicles, but no central opening visible; no prominence of solitary glands. *Stomach* small; mucous membrane in rugæ, dingy white, stained greenish. *Liver*, 11⅜ ozs., plump, 5 + 1 × 4 × 2½ inches; pale liver-coloured; veins full of tarry blood. Gall-bladder full of thickish dark bile. *Spleen*, 1 oz. in weight; 3 × 2 × 1 inch; firm; dark liver-coloured. *Kidneys*, 1⅛ ozs. each; capsules strip easily; cortex pale mottled venous; medulla blood-red injected. *Pancreas.*—Weight 5 drachms; looks healthy. *Mesenteric glands* larger even than in last case, with lots of fat surrounding. The pleurisy, injection of the arachnoid, and absence of injection in the gut, with the black punctation, were peculiar.

# CHAPTER III.

## GENERAL PATHOLOGY OF THE ALVINE FLUXES, INCLUDING CHOLERA.

---

THE general pathology of these 360 cases may be now considered. They consisted of 173 men, 123 women, and 64 children. The average height of the men was 5 feet 5 inches nearly, the extremes being 4 feet 7 inches and 5 feet 9 inches; and of the women 5 feet 0½ inch, the extremes being 4 feet 7 inches and 5 feet 8 inches.

*Height.*

No native of the class to which these patients belonged knows his own age, but the average of the ages guessed in each case is 45 years for the men, and 44 years for the women, the extremes in both being 18 and 70 years. The average for the children is 3½ years, the extremes being 1 and 13 years.

*Age.*

The state of the body as to nutrition was that of emaciation, often to a skeleton, in 310 cases; dropsical in 27; and, if not always plump, at least neither emaciated nor dropsical in 23 cases; as shown below:—

| | Men. | Women. | Children. |
|---|---|---|---|
| Emaciated ... ... ... | 151 | 100 | 59 |
| Dropsical ... ... ... | 11 | 13 | 3 |
| Plump ... ... ... | 11 | 10 | 2 |
| | 173 | 123 | 64 |

The weight in the emaciated cases averaged 75¾ lbs. for the men, and 59½ lbs, for the women; in the dropsical, 104 lbs. nearly for the men, and fully 89 lbs. for the women; and in the rest, 92¾ lbs. for the men, and 79½ lbs. for the women.

*Weight.*

The state of the body as to rigor mortis varied a good deal without apparent cause. In some cases it was well marked and remained on for a long time, while in others it hardly appeared at all; for instance, in

*Rigor mortis.*

case 83, an emaciated old woman, about sixty years of age, who died from bowel-complaint with ulceration of the gut, rigor mortis was still present when the autopsy was made fifteen hours after death in the month of June; while in case 172, that of an emaciated old man of about the same age, who died from the same complaint a few days previously, the rigor mortis had gone off when the autopsy was made six hours after death. Again, in case No. 23, that of a boy, about eight years old, who died—a skeleton from pneumonia complicating diarrhœa—the rigor mortis had gone off when the *post-mortem* was made two hours after death.

The skin was covered with scurf in most cases, but in many it was soft and silky, hanging loosely on the emaciated figure.

*Skin diseases.*

Itch is so common in natives that its presence or absence in these cases was not noted. The only skin disease observed was eczema of the scalp in one case, and, in a child, the skin was desquamating after small-pox.

*Ulcers.*

Bed sores were present in only two cases, a man and a woman; ulceration of the cornea in only two, a woman and a child; chronic ulcer of the leg in a woman, and a scrofulous ulcer of the chest in a child.

*Sloughing.*

Sloughing of the instep was seen in a man with œdema of the feet. A slough was found protruding from the anus like a gangrenous prolapsus in a man, and sloughing of the tissues around the anus was seen in another man; neither was a case of diphtheritic dysentery. Cancrum oris was seen in a child; and sloughing of the affected cheek in a woman with facial paralysis; and in another the gums were in a sloughy state—due, she admitted, to mercurial salivation.

*Elephantiasis.*

Elephantiasis of one leg was seen in a man and a woman; and in both legs, with a burrowing abscess around one ankle, in two men. In a woman there was synovitis of the left knee-joint, and in another contusion of the right hip, both the result of accidents.

*Œdema.*

Œdema of the feet was present in two-fifths of the emaciated cases, viz., in 67 men, 57 women, and 16 children; of these, œdema of the hands was present as well in 6 men and 3 women, and of the face as well in 4 men and 2 women; the swelling extended to the knee and

upwards in 3 men and 6 women, and was confined to one foot or leg in 2 men and 2 women.

SKULL. *Scalp.*

The scalp was thin and pale, quite milk-white in some cases, and on removing the calvarium no blood appeared on the meninges, as is usual when the sinuses are full, in 91 men, 68 women, and 54 children. These structures presented about the normal appearance in 11 men, 1 woman, and 1 child, while the scalp was pale and meninges bloody in 2 women and 1 child, and scalp bloody and meninges pale in 5 men and 4 women. A variable amount of blood flowed from the several vessels on cutting through the scalp, and from the surface of the meninges and base of the skull on removing the calvarium and brain, in 66 men, 46 women, and 7 children. The blood flowed in large quantity in 7 men, 2 women and 2 children. The percentages are as follows:—

| | Men. | Women. | Children. |
|---|---|---|---|
| Anæmic ... ... ... | 52·6 | 55·7 | 85·7 |
| Hyperæmic ... ... ... | 36·4 | 37·7 | 11·1 |
| Otherwise ... ... ... | 11·0 | 6·6 | 3·2 |
| | 100·0 | 100·0 | 100·0 |

*Calvarium.*

The calvarium was eroded on its inner surface, difficult to separate from the meninges, requiring a knife in some cases, with deepening of the arterial grooves in 4 men and 2 women.

*Arachnoid.*

On cutting through the meninges, serum was found in the sub-dural space in 145 men, 94 women, and 35 children, and blood with usually bloody fluid was found in 1 man and 1 woman, leaving only 16 per cent. of the men, 22 per cent. of the women, and 44 per cent. of the children with this cavity quite free from effusion.

The quantity effused was considerable in about a sixth of these cases, viz., in 24 men, 16 women, and 6 children; of these, the serum was bloody in 2 men, in the rest it was pale straw-coloured. It was in small amount, being confined to the base of the brain and not appearing till the tentorium had been cut through, in about a third of these adults and a sixth of these children, viz., 48 men, 34 women, and 7 children; of these, the

serum was bloody in 1 man and 2 women, and pale in the rest. In all the other cases the serum was pale straw-coloured, except in 2 men, in whom it was blood-tinged.

*Sub-arachnoid. Serum.*

There was effusion of serum beneath the arachnoid filling up the sulci of the brain, most marked on the vertex, less towards the base, in 122 men, 74 women, and 28 children; this was colourless or pale straw-coloured fluid in all, except that in 1 woman it was bloody. Thus there was no arachnoid or sub-arachnoid serous effusion present in 25 men, 25 women, and 27 children, or about one-sixth of the adults and nearly half of the children; in the latter, however, serum in small quantity would often escape observation, from it being frequently necessary to remove the meninges with the calvarium, from the close adhesion of these structures natural to children.

*Ecchymosis.*

In 17 men, 10 women, and 10 children, there was slight effusion of blood, generally appearing along the course of the veins as dusky red blotches of sub-arachnoid ecchymosis, and usually situated opposite the temples or on the cornua of the hemispheres, and, on dissection, found not to extend into the sulci of the brain or to form clots, except in the cases of 2 men, and 2 women, and 1 child; of these in one man the ecchymosis extended into the sulci along the longitudinal fissure, and in the other it formed a small clot near the tip of the anterior cornu of the left hemisphere; in a woman a thin clot extended from the choroid plexus over the back of the corpus callosum, and, in the other, there was a small soft clot in a sulcus on the anterior part of the right hemisphere.

*Pia mater.*

The larger vessels of the pia mater were found to be full in about a third of the cases, viz., in 66 men, 36 women, and 21 children; in 2 of the women the vessels were greatly distended, but the lateral veins only were full in 6 men, 6 women, and 1 child. There was injection of the capilliaries to pink or red over a greater or less part of the surface of the brain in about a tenth of the cases, viz., in 21 men, 12 women, and 6 children; in 1 of these men the dura mater was injected, dry and lustreless on the inner surface, while the larger vessels of the pia mater were empty, the capillaries being injected; and in a woman the arachnoid

was dry, the pia mater being injected red with livid mottling extending from the vessels of the sulci. In other 9 men, 2 women, and 1 child, the surface of the brain was pink-coloured.

There was a white film over the brain from the visceral layer of the arachnoid being opaque in 8 men and 8 women, and in 2 men and 1 woman this layer was whitish and sodden from a sub-arachnoid serous effusion. In 3 men and 3 women the usual opacity along the longitudinal fissure extended outwards an inch or so beyond its usual limits. The adhesions between the dura mater and arachnoid, and of the latter across the fissure, were greater than usual in 4 men, 2 women and 1 child; in 1 of the men a dropsical ventricle was opened from this cause in removing the brain, and in the child the arachnoid was thickened and adherent to hardened shrunken convolutions over the region of the left temple.

BRAIN.

The subjoined table gives the average weight of the brain, with its ratio to average body-weight, in each of the three classes of adults :—

| Weight. | | Weight of Brain. | | Brain-weight to body-weight, 1 to | |
|---|---|---|---|---|---|
| | | Men. | Women. | Men. | Women. |
| | | ozs. | ozs. | | |
| Emaciated | ... | 40·15 | 35·2 | 30·1 | 27·2 |
| Plump | ... | 40·45 | 38·2 | 36·6 | 33·3 |
| Dropsical | ... | 43·44 | 39·0 | 38·23 | 36·6 |

The extreme brain-weights all fall among the emaciated, naturally so as being by far the most numerous, and were for the men 54 ozs., with a ratio to body-weight of 1 to 28 in a religious mendicant of the Yediar caste, and 32 ozs. in each of two punkah coolies, one of the Reddy and one of the Pariah caste, with a ratio to their mean body-weight of 1 to 38·5; and for the women the extremes were 49·25 ozs., with a ratio to body-weight of 1 to 20 nearly, in a coolie of the Pariah caste, and 27·75 ozs., with a ratio to body-weight of 1 to 37·4 in the wife of a Wuddiar.

From the above results it would appear that the brain wastes like other tissues of the body, but to a less extent, and no doubt to this is due the effusion of serum into the sub-dural and sub-arachnoid cavities so frequently found in these cases. A com-

parison of brain-weights, &c., of Hindus with those of Europeans is reserved for subsequent consideration. The brain was noted rather soft in 52 men, 30 per cent.; 30 women, 24·5 per cent.; and 19 children, 29·7 per cent.

*Soft.*

In 1 man there was a buff depressed convolution on the posterior corner of the right hemisphere, which extended to the ventricles, and cut soft, looking like a half-absorbed abscess, or apoplectic spot, with broken-down brain tissue, and in another there was a depressed convolution on the vertex. It cut firm in 98 men, 56·6 per cent., 76 women, 62·3 per cent., and 33 children, 51·5 per cent. In 2 men it cut almost fibrous, in a child the convolutions on the left side of the hemisphere about its middle were shrunken and hardened, while the rest of the brain was rather soft and anæmic, and in a woman the convolutions were noted as remarkably prominent, while in another they were few and flat.

*Firm.*

The substance was noted anæmic in 60 men, 57 women, and 25 children. Of these, it had all the appearances of being in a state of yellow atrophy in an old man who died from dysentery, with lung, heart, and kidney complications. It was hyperæmic in 31 men, 16 women, and 13 children. The percentages are as follows:—

| | Men. | Women. | Children. |
|---|---|---|---|
| Anæmic ... ... ... | 34·6 | 46·7 | 39·0 |
| Hyperæmic ... ... | 17·9 | 13·0 | 20·3 |

In 2 of the men the colour of the brain was dusky, and in another man and in a woman the surface was distinctly pigmented. In 25 men, 16 women, and 5 children, the injection was noted as normal, and in the rest it was presumably so, since it was not noted otherwise. A little pale serum was found in the lateral ventricle in 41 men, 24 women, and 7 children; and this was in abnormal quantity in 2 men, 4 women, and 1 child. Of these in a man both lateral ventricles, and in a woman the right lateral ventricle, were dilated, with thinned walls, fluctuating to the touch, and containing each about half a pint of pale serum; both died from uncomplicated diptheritic dysentery, and no trace of tubercle was detected in either case.

*Ventricles.*

In the men 26 were found to have both, 23 to have only the right and 33 only the left pleuræ quite healthy, or 15 per cent. of cases in which both and 48 per cent. in which at least one pleura was perfectly healthy; in the women there were 30 with both, 7 with only the right and 16 with only the left pleura quite healthy, or 24·4 per cent. in which both and 43 per cent. in which at least one pleura was perfectly healthy; and in the children there were 39 with both, 7 with only the right and 3 with only the left pleura quite healthy, or 61 per cent. in which both and 76·5 per cent. in which at least one pleura was perfectly healthy. In the men there was an effusion of serum into healthy-looking pleuræ in 20 pairs, 14 right and 20 left pleural sacs. The serum was reddish when in very small, and pale straw-colored when in large, quantity; and it varied in amount from a table-spoonful to a quart, the average quantity found in the right pleural cavity being eight and in the left six fluid ounces. In the women there was a similar effusion in 28 pairs, 6 right and 10 left pleural sacs. In one case the serum was turbid from no apparent cause, in the others it was as in the men. The quantity in the right pleural sac averaged 11 and in the left 10½ fluid ounces nearly. In the children there was a similar effusion in 8 cases into both pleural sacs in all, and in one pair only and one right pleural sac was the quantity as much as half a pint, the average for the whole being fully 4 ounces in the right pleural sac and barely 3 in the left.

CHEST. *Pleura healthy.*

*Hydrothorax.*

In the men there was similar effusion with some old points of adhesion in 7 pairs, 14 right and 11 left pleuræ, the quantity effused averaging fully 7 ozs. for the right and 10 ozs. for the left pleura. In the women there were similar adhesions and effusion in 7 pairs, 7 right and 4 left pleuræ, 7½ ozs. and 5 ozs. being the average amount of serum in each respectively; and in the children there were similar adhesions and effusion in 2 cases only in both pleural sacs, the quantity of serum being small and the points of adhesion rather numerous.

*With adhesions.*

In all there was passive effusion into one or both pleural sacs in 67 men, 38·7 per cent.; 52 women, 42·2 per cent.; and 10 children, 15·6 per cent.; of these both sacs were implicated in 38 men, 22 per cent.; 45 women, 36·6 per cent.; and in all

10 children. In only about two-fifths of these adults, viz., in 28 men and 23 women—was the effusion half a pint and upwards, and in the majority of these, viz., in 18 men and 16 women—it was into both pleural cavities, the quantity in the right sac averaging barely 16 ozs. for the men and fully 23 ozs. for the women, and in the left sac fully 16 ozs. for the men and over 20 ozs. for the women.

In the men there were points of adhesion, easily broken down, of old standing and not extensive, in 18 pairs, 42 right and 24 left pleuræ, in the women there were similar adhesions in 17 pairs, 17 right and 10 left pleuræ, and in the children in 2 pairs, 2 right and 4 left. In the men there were very firm adhesions of old standing, generally extensive and often requiring careful dissection, in 7 pairs, 7 right and 10 left pleuræ, in the women there were similar adhesions in 7 pairs, 7 right and 3 left pleuræ, and in the children in 1 pair, 2 right pleuræ and 1 left pleura. Hydrothorax was present in a certain number of these cases, as has been already seen above.

*Old adhesion.*

In all there were old adhesions present in one or both pleuræ in 106 men, 61·3 per cent.; 61 women, 49·5 per cent.; and 12 children, 18·7 per cent.; both sacs were implicated in about a fourth of these cases, viz., in 25 men, 17 women, and 3 children.

*Summary.*

There were products of recent effusion present in men in 6 pairs, 10 right and 4 left pleuræ, in women in 1 pair, 3 right and 1 left, and in children in two pairs, 1 right and 3 left pleuræ. The nature of the effusion was soft lymphy adhesions in the children, with a little serum besides in 2 cases. In the women there was a mixture of old and recent adhesions in 2 cases, lymphy adhesions with turbid serum in 2, and a quantity of soft lymph with some old adhesions in the remaining case. In the men there was a simple admixture of recent and old adhesions in 5 cases, loss of lustre with injection of the pleura without effusion in 2 cases, points of recent adhesion without marked effusion in 6 cases, recent adhesions with effusion of amber serum, probably of old standing, and averaging half a pint in quantity, in 4 cases, and a quantity of soft lymph with effusion of turbid serum averaging about half a pint in 4 cases.

*Recent effusion.*

*Cicatrices.*

There were cicatrical more or less puckered depressions on the apices of 7 pairs, 3 right and 4 left lungs in men, and of 5 pairs, 1 right and 2 left lungs in women.

*Ecchymosis.*

There were spots or streaks of sub-pleural ecchymosis, mostly situated near the fissures, and often undergoing absorption, appearing as dark red pigmented or yellow streaks or spots—in men, in 1 pair, 2 right and 4 left lungs; in women, in 1 pair, 1 right and 3 left lungs; and in children, in 2 pairs.

LUNGS.

Both lungs were healthy in only 26 men, 15 per cent.; 32 women, 26 per cent.; and 14 children, 22 per cent. The right lung alone was healthy in 6 men and 3 women, and the left lung in 10 men and 9 women, so that at least one lung was healthy in only 24 per cent. of the men and 35·7 per cent. of the women. The average weight of the right lung was 7.77 ozs. in the 32 men, and 6·9 ozs. in the 35 women; and of the left lung, 7·16 ozs. in the 36 men, and 6·2 ozs. in the 41 women.

*Healthy.*

Taking the average weights above given, the ratio of the average weight of the lungs to that of the emaciated bodies is 1 to 81 in the men, and 1 to 72½ in the women; or taking the weights of the pairs of healthy lungs and of their respective bodies, the ratio is 1 to 80 in the 26 men, and 1 to 75 in the 32 women. Contrast the ratios for Europeans—viz., 1 to 37 for men, and 1 to 43 for women (Quain).

*Apneumatosis.*

Simple collapse of the lung tissue, usually of the posterior border of the lower or thin anterior margin of the upper lobe, but sometimes affecting a whole lobe, or even a whole lung, and often accompanied by more or less hydrothorax, was the only abnormal condition found in both lungs in 6 men, 9 women, and 4 children; in the right lung alone in 5 men, 2 women, and 1 child; and in the left lung in 11 men, 5 women, and 1 child. In these the part implicated was usually purplish in colour, tough and airless on section, with at most only a little blood exuding on pressure from cut vessels, the lung remaining of about its normal weight. The average weight of the right lung was 9·63 ozs. in the 11 men, and 7·88 ozs. in the 11

women; and that of the left lung 8·25 ozs. in the 17 men, and 6·94 ozs. in the 14 women.

The whole lung except the apex was collapsed in a right and a left lung in 2 women. The collapse affected the whole lower lobe in both lungs in 3 men and 4 women; in the right lung only in 2 men; and in the left lung only in 3 men and a woman. It was confined to the posterior border in both lungs in 2 men, a woman, and a child; to that of the right lung in 4 men and a woman; and to that of the left lung in 7 men and 2 women; and it was confined to the thin lower margin of both lungs in a child, of the right lung in a child, and of the left lung in 2 women. The collapse was confined to the base of both lungs in a woman; to the inner surface of the left lung in a man, and of the right lung in a woman; to the upper lobe along the fissure in the left lung in a woman; to the thin anterior margin in both lungs in a child; and to lobules and pieces of the thin margin in the right lung in a man and 2 women, and in the left lung in a child. The lower anterior tongue of the upper lobe was the seat of old collapse, with hypertrophy of the fibrous tissue and dilatation of the air-cells and bronchi, which were usually distended with inspissated mucus, in both lungs in a woman and a child. This lesion was also found among cases not grouped under apneumatosis in both lungs in 6 men and 3 women, in the right lung in 2 men and 4 women, and in the left lung in 1 man. In other diseased lungs apneumatosis was found affecting the posterior border of both lungs in 2 women, of the right lung in 3 men and a woman, and of the left lung in 2 men and a woman; and the whole lower lobe was implicated in both lungs in a woman, and in the left lung in another woman. The thin lower margin was collapsed, of the left lung in a man and a woman, and of the right lung in a woman. The collapse was confined to the inner surface of both lungs in a man, and to isolated lobules in various parts of the lung in 4 women.

*Analysis of cases.*

*Apneumatosis in diseased lungs.*

There was simple, generally partial and hypostatic, congestion of both lungs in 6 men, 8 women, and 9 children; of the right lung alone in 4 men and 6 women; and of the left lung alone in 6 men and 2 women. In these cases the lung was little, if at all, above its normal weight;

*Simple congestion.*

the cut surface was dry, yielding no serum, and at most only a little blood on pressure from the congested parts. Most of the acute primary cholera cases come under this description, the lungs being dusky in appearance, tarry blood exuding from the cut vessels of the root, very fully collapsed and consequently of small weight, the left lung in one case being under 5 ozs. The difference in weight between a fully collapsed lung and one not collapsed in the same body was in many cases observed to be fully an ounce and a quarter.

In the children the congestion was often confined to isolated lobules, giving the section of the lung a spotted appearance. The average weight of the right lung was 10 ozs. for the 10 men, and 9·4 ozs. for the 14 women; and of the left lung 9·1 ozs. for the 12 men, and 8·6 ozs. for the 10 women.

*Simple œdema.*

There was simple œdema of the lung, often confined to the dependent parts, and unaccompanied by congestion or softening of the lung tissue, in both lungs in 3 men and 2 women, in the right lung alone in 3 men, and in the left lung alone in 1 man. In these cases the œdematous part pitted on pressure, and pale serum flowed freely from it on section. However, in two men there was an exception—the bronchi of both lungs in one, and of the right lung in the other, being loaded with serous muco-purulent fluid. The average weight of the right lung was 14·5 ozs. in the 6 men, and 15·35 ozs. in the 2 women; and of the left lung 18·7 ozs. in the 4 men, and 10·25 ozs. in the 2 women.

*Apneumatosis with œdema.*

There was serous effusion into collapsed lung tissue in both lungs in 6 men and 4 women; in the right lung alone in 4 men and 2 women, and in the left lung alone in 3 men. The average weight of the right lung was 15·25 ozs. in the 10 men, and 13·6 ozs. in the 6 women; and of the left lung 16·47 ozs. in the 9 men, and 12·46 ozs. in the 4 women. In one case there was some softening of the lung tissue of the left lung in a man.

*Congestion with œdema.*

There was more or less congestion, mostly of dependent parts, with exudation on section of serum and blood from the cut surface without softening of the lung tissue, in both lungs in about a sixth of the adults and a seventh of the children, viz., in 29 men, 21

women, and 9 children; in the right lung alone in 17 men and 7 women, and in the left lung alone in 5 men and 8 women. The average weight of the right lung was 15·14 ozs. in the 46 men, and 12·28 ozs. in the 28 women; and of the left lung 13·17 ozs. in the 34 men, and 12 ozs. in the 29 women. In these cases the congestion and œdema relatively differed very considerably in different cases—in some there was much œdema with little, mostly hypostatic, congestion, while in others the congestion was general and perhaps considerable, but with comparatively little serous effusion.

*Inflammatory œdema.*

There was marked lividity and œdema, mostly of the posterior parts, often of the whole lower lobe, but sometimes of lobules appearing as circumscribed spots, accompanied by softening of the lung tissue in both lungs in 14 men, 3 women, and 1 child; it was confined to the right lung in 8 men and 2 women, and to the left lung in 7 men and 2 women. The average weight of the right lung was 21·9 ozs. in the 22 men, and 12·6 ozs. in the 5 women; and of the left lung 18·2 ozs. in the 21 men, and 12·87 ozs. in the 5 women.

*Acute pneumonia.*

There was acute pneumonia present in both lungs in 9 men, 2 women, and 26 (or two-fifths) of the total children; in the right lung alone in 8 men and 3 women, and in the left lung in 9 men and 2 women. A whole lung was implicated in one or two cases, but in about a third of the adults and three-fourths of the childern the disease was confined to lobules scattered all through the lung; the lower lobe was more frequently affected than the upper. In the majority the disease was in the stage of red hepatisation. The average weight of the right lung in the 17 men was 21·4 ozs. and in the 5 women, 17·3 ozs.; and of the left lung 16·75 ozs. in the 18 men and 18·78 ozs. in the 4 women.

*Chronic pneumonia.*

Chronic pneumonia was present in both lungs in 3 men, 2 women and 1 child; was confined to the right lung in 5 men and 3 women, and to the left lung in 6 men and 1 woman. The disease often occupied a number of contiguous lobules or a whole lobe, converting it into a gray, semi-transparent, solid, tough mass, often containing cavities from dilatation or ulceration of the bronchi, but seldom

presenting any trace of tubercles; in one case the right lung was carnified as well. The average weight of the right lung was 18·5 ozs. in the 8 men, and 12·5 ozs. in the 5 women; and of the left lung 10·8 ozs. in the 9 men and 10·75 ozs. in the 3 women. The cause of the greater weight of the right lung in men is that there was a good deal of œdema conjoined in several cases, and in fact, three of these are returned also under congestion with œdema.

*Gangrene.*

Gangrene was present in both lungs in 2 men, and in the left lung in a third. In one pair of lungs the gangrenous spots were numerous, of the size of a tennis ball, and surrounded by livid œdematous tissue; and in the other pair the spots were little larger than a pea, and they looked like gangrenous tubercles. In the remaining case the gangrene appeared to be an advanced stage of inflammatory œdema, was of the size of a cricket ball and situated on the posterior border of the lower lobe of the left lung, which was so congested and œdematous as to be about four times its normal weight, viz., 30⅛ ozs. The average weight of the 2 right lungs was 15 ozs. and of the 3 left lungs 25 ozs.

*Latent phthisis.*

Tubercular deposits in an inactive or chronic state were found in both lungs in 10 men and 9 women; in the right lung in 2 men, 3 women, and 1 child, and in the left lung in 2 men and 1 woman, and there was a calcified deposit in the apex of the left lung in a man not here included. In the child (a boy about five years old) there was a largish cavity in the apex of the right lung containing concretions but no mucus, and lined by a smooth membrane with some thickening around, but no recent products. In the adults there was generally congestion, œdema, or other recent lesion of the lung also present; hence the average weight of the right lung was 15·17 ozs. in the 12 men, and 11 ozs. in the 12 women; and of the left lung 14·7 in the 12 men, and 9·35 ozs. in the 10 women. Three of the men are also included under congestion with œdema.

*Apoplexy.*

There were apoplectic spots in both lungs in two men, and in the right lung conjoined with lobar pneumonia in a third. The average weight of the 3 right lungs was 14·75 ozs. and of the 2 left lungs 13·6 ozs. The appearances in these cases were—in one pair of lungs,

in the lower posterior margin of each, was a dark-red firm spot like a blood clot, the size of an orange, friable in the centre, and surrounded by pale œdematous tissue; in the other pair the posterior border of each lung was studded with dark-red (nearly black) masses, firm but friable, and surrounded by healthy-looking lung tissue; the lung was about double its normal weight, and similar spots were found in the thin lower margin of the right lung in the remaining case.

PERICARDIUM.

The pericardium was pearly and shining, containing no serum in 17 men, 14 women, and 15 children; and it was equally healthy-looking, but contained serum in 154 men (89 per cent.), 109 women (88·6 per cent.), and 49 children (76·5 per cent.). The sac was distended in 4 men, 3 women, and 13 children; it contained about four fluid ounces in 6 men and 1 woman, and about three ounces in 2 men and 4 women; in the remainder the serum was in small quantity, averaging much less than half an ounce for each. The serum was very pale straw-coloured when in large, and higher-coloured when in small, quantity, with the exception of one case (a man) in which it was smoky, and of another (a woman) in which it was blood-tinged and in large quantity, filling the sac. There were firm old adhesions of the pericardium to the heart all over in one case, and of the pericardium to the apex of the heart in another —both men. There were products of recent inflammation in one case, in which there was firm but recent lymph adherent to the anterior surface of the heart and to the pericardium opposite, with about 3 ozs. of bloody serum in the cavity. This man complained of dysentery, but not of his heart. His pulse was intermittent and flickering on admission, and he soon died in very low flesh with œdema of the feet.

HEART.

The surface of the heart was devoid of fat in about two-fifths of the men, one-fifth of the women, and in nearly the whole of the children, viz., 71 men, 28 women, and 61 children. In 36 of these men and in 20 of the women the fat was replaced by œdema, and in other 5 men and 2 women there was œdema present, making 41 men (23·7 per cent.) and 22 women (17·8 per cent.), in whom there was found effusion of serum into the cellular tissue covering the heart. There was no œdema here in the children.

*Œdema.*

*Fat.*

There was only a trace of fat present in 24 men, 33 women, and 1 child; in 8 men and 15 women it was in considerable quantity, and in 70 men and 47 women it was in moderate amount and confined to the borders of the heart. The white detachable lymphy deposit known as the "soldier's spot" was present in about a sixth of the adults, viz., 28 men and 19 women; of these, in 9 men and 4 women the spots varied in number from two to six, and they were not confined to the anterior surface of the heart.

*Cavities.*

The cavities of the heart were found empty in 48 men (22 per cent.), 49 women (40 per cent.), and 7 children (11 per cent.). In 7 men, 1 woman, and 1 child, the right side was empty, while the left contained dark blood and soft clots; while in 66 men (37 per cent.), 24 women (20 per cent.), and 17 children (26·5 per cent.), the left side was empty and the right contained blood and often pale clots. In 46 men (26·5 per cent.), 42 women, (34 per cent.), and 38 children (59·3 per cent.), there was more or less blood with clots on both sides. In 1 woman and 3 children the cavities were noted distended with blood and clots. The colour of the blood in the cholera cases was very dark, like tar.

*Walls.*

The walls were noted firm in 20 men, 8 women, and 3 children, and flabby in 33 men, 37 women, and 3 children. Among all the fatty-looking hearts examined under the microscope, fatty degeneration was found present in only two men. In 45 per cent. of the men the heart was under 6 ozs. in weight—averaging in fact only 5⅛ ozs.—and in the remainder its weight averaged only 7 ozs.; and in 37·4 per cent. of the women it was under 5 ozs.—averaging indeed only 4·24 ozs.—and in the rest its weight averaged barely 6 ozs. The heart was, of course, weighed empty. For the total men its average weight is 6·17 ozs., with a ratio to average weight of emaciated bodies of 1 to 196, the extremes being 3 ozs., with a ratio to body-weight of 1 to 288 in a young agriculturist of the Komatty caste who died quite a skeleton from diphtheritic dysentery; and 14⅜ ozs., with a ratio to body-weight of 1 to 83·5, in an emaciated cooly of the Pariah caste who died from diarrhœa with kidney disease. For the women the average weight is 5·3 ozs., with a ratio to average

*Weight.*

weight of emaciated bodies of 1 to 180, the extremes being 3 ozs. in 2 cases, with a ratio to mean body-weight of 1 to 269, and 8¾ ozs., with a ratio to body-weight of 1 to 150, in a cooly of the Reddy caste who died from diphtheritic dysentery. Quain gives the ratio for Europeans to be 1 to 158 for men and 1 to 149 for women.

ABDOMEN.

*Peritoneum.*

*Passive effusion.*

The peritoneum was quite healthy in about two-fifths of the adults and two-thirds of the children, viz., in 73 men, 51 women, and 42 children; and it looked equally healthy, but contained serous effusion, in nearly the whole of the remainder, viz., in 97 men, 62 women, and 22 children. The serum was generally more or less pale straw-coloured; but it was whitish in 3 men and a woman, smoky in a man and a woman, turbid in 2 children, and stinking dirty-looking fluid in a third, in which perforation of the gut had occurred at death. No sign of recent peritonitis was present in any of these cases, but in one of the men there were some spots of organised lymph on the parietes and mesentery.

*Quantity.*

The effusion was little more than a mere moistening of the membrane, with a tablespoonful or two collected in the more dependent parts in nearly half these cases, viz., in 40 men, 32 women, and 10 children; in the remaining 57 men the quantity varied from half a pint to two gallons, the average being two quarts; in the 30 women it varied from half a pint to a gallon, the average being two pints and a half; and in the 12 children it varied from an ounce to a pint, the average being eight ounces nearly.

*Old adhesion.*

There were old bands of adhesion between the great omentum and the parietes in the flanks in 2 men and 4 women, and between the transverse colon and parietes on either side in a man. There was injection of the subperitoneal vessels to the minutest capillaries all over the gut, mesentery, and parietes, without serous effusion or loss of lustre of the peritoneum, in 2 women who died from cholera, and less so in a third who died from diphtheritic dysentery, and in a fourth who died from simple diarrhœa. In 2 men and 4 women there was localised peritonitis, originating in approaching perforation of the gut from

*Recent effusion.*

sloughing in the colon; there was little vascularity of the peritoneum, as a rule, in these cases a quantity of whitish serum like thin pus was found in its cavity, and a deposit of lymph in the neighbourhood of the affected gut. In other cases of sloughing the appendices epiploïcæ were dry and adherent to the outer surface of the colon in 3 men and a woman; and the omentum was adherent to the colon in 2 women. In one of the women there was half a pint of pale straw-coloured effusion, but none in the other cases.

STOMACH.

The stomach was noted large in 65 (or about a third) of the men, in 27 (or nearly a fifth) of the women, and in 3 children; of these it was of enormous size in 7 men and 4 women; it was of moderate size in 25 men, 13 women, and 8 children; and small in 82 (or nearly half) of the men, 82 (or nearly two-thirds) of the women, and 51 (or about five-sixths) of the children, of these it was very small and narrow (like a piece of intestine almost) in 3 men and 2 women. It was empty in fully two-fifths of the adults and two-thirds of the children, viz., in 75 men, 58 women, and 40 children; it contained fluid, which was usually tinged with bile in 80 men (46 per cent.), 47 women (38 per cent.), and 16 children (25 per cent.). The fluid was like rice-water in 4 adults who died from cholera, and was reddish to brown in 10 other adults. It contained more or less solid food in only about a tenth of the cases, viz., in 15 men, 15 women, and 6 children; and it was distended with gas in 4 men, 1 woman, and 2 children—all empty stomachs except two. Lumbrici were found in the stomachs of 13 men, varying in number from 1 to 16, the average being nearly 3; in 15 women, varying from 1 to 7, the average being exactly 3; and in 3 children, a total of 4.

*Contents.*

*Mucous coat.*

The mucous coat of the stomach was smooth in 35 men, 25 women, and 19 children, and it was in well-marked rugæ in 104 men, 84 women, and 40 children; in the remainder this was not noted. It was pale and thin and often bile-stained in about half the cases, viz., in 86 men, 72 women, and 32 children; of these there were a few livid spots, mottling or some arborescence, seen mostly on the posterior wall, in 11 men and 5 women; and it was rose-

coloured or had some tinge of pale red in 40 men, 33 women, and 22 children; in 2 of the men and 2 of the women there were some dark livid spots or mottling present also. It was congested in 36 men (20 per cent.), 14 women (11 per cent.), and 7 children (11 per cent.); the injection was confined to spots and patches in 5 men and 1 woman, to rugæ in 3 men and a child, and to the posterior wall in a man; in the remainder it was general and varied in colour from pinkish red to purple or dull red. In 4 men there were spots of congestion having the appearance of superficial ecchymosis into the mucous membrane; and in a woman in whom the mucous coat was pale and emphysematous the peritoneal surface of the stomach looked livid, possibly from *post-mortem* changes, although rigor mortis had not disappeared.

There was more or less well-marked pigmentation of the mucous coat present in 12 men, 1 woman, and 1 child. In an old woman there was a perforating cicatrised ulcer of old standing, closed in by the pancreas, which thus became part of the posterior wall of the stomach.

*Perforating ulcer.*

The intestines have been already described,* but an excerpt from the report of Dr. D. D. Cunningham on similar cases may be here given, as further elucidating especially the microscopic changes observable in the tissues:—

"The tongue in some cases was covered with a thick, creamy white fur; in others this was to a great extent absent, and the surface presented a denuded and raw appearance. Both of these conditions were described as characteristics of the form of disease, and were regarded as indicative of different stages in the morbid process. The majority of the cases admitted into camp, in which the history and general conditions indicated that deprivation of nutritive materials had continued for long, were characterised by presenting the furred condition of the tongue just described. In those cases which progressed favourably this gradually diminished and disappeared, leaving the surface in a normal condition; but in bad cases, in which diarrhœa and dysentery subsequently set in, the fur cleared off, leaving the surface apparently raw and denuded. Numerous careful examinations were made

*Condition of the tongue.*

* See also Intestinal Ulceration, Chapter VI, Section 6.

with a view to determine the nature and origin of these phenomena. The processes which give rise to them, so far as I could ascertain, were analogous to those previously described as occurring in the epidermis, as well as to those still to be described in reference to the intestinal mucous membrane. As in the case of the epidermal tissue, there was no evidence of the occurrence of any special parasitic organisms or of the special prevalence of those forms usually encountered in the locality. The epithelial tissue was very oily, and a true fatty transformation seemed to affect the cells of the deeper layers of epithelium in greater or less extent, leading to an imperfect development of the growing cells and ready detachment of those already formed.

*The stomach, mucous membrane soft and bloodless.*

"The mucous membrane of the stomach was, as a rule, dead-white, quite bloodless, soft and pulpy. It appeared as though in a state of anæmic catarrh. In one case portions of it were variegated with pale pink markings of relative congestion.

*Condition of the duodenum.*

"The duodenum presented the same general features as the stomach, but the softening of the tissue of the mucous membrane was much more pronounced. Only in one instance did the surface present a normal appearance, and in the majority the mucous membrane appeared to be more or less completely disorganised.

*Softening and disintegration of the mucous membrane in the jejunum.*

"The jejunum presented much the same appearance, but in some instances showed distinct evidences of disintegration, and disappearance of the epithelial coat, together with pigmentation and atrophy of the sub-epithelial tissue. In some cases a certain amount of relative congestion appeared in the denuded areas. The pigmentation, where present, caused the surface of the mucous membrane to present a very peculiar aspect, the colouring matter being situated within the villi, so as to appear in fine dark points, as though some dark powder had been sprinkled over the surface.

*Extensive destructive changes in the ileum.*

"The mucous membrane of the ileum presented even more evident signs of change. It was generally characterised by extreme bloodlessness, but faint patches of relative congestion were sometimes present. In all cases, save one, the

epithelial coat was disorganised, and in the majority it appeared to be almost entirely absent. In many instances not only was this the case, but the sub-epithelial tissues were manifestly affected to a serious extent. The solitary glands were either present in very small numbers only, or could not be recognised at all, and Peyer's patches, in place of presenting their normal aspect, appeared as mere empty networks, composed of collections of minute depressions surrounded by slightly elevated ridges. This condition of the patches was very characteristic, and could not be ascribed to causes accidental to the disease, for it appeared as conspicuously in the young children as in the adults or aged people. But the evidences of loss of substance did not end here, for in most cases over considerable areas of the gut, and in some almost universally, the adenoid tissue appeared to be virtually absent. The surface here was quite smooth, the prominences of the villi being almost or entirely unrecognisable, and the muscular coat covered only by a thin membranous investment, seemed to form the inner lining of the tube. Surfaces of this nature corresponded with the transparent slate-coloured areas visible from the exterior of the intestine. This condition was most pronounced over the lower half or two-thirds of the ileum, but in some cases did not extend quite to the ileo-cæcal opening, a small surface intervening where the process did not seem to have progressed so far, and where the mucous membrane was still distinctly recognisable, although in a more or less disorganised and seemingly disintegrating state. In this site, too, a certain amount of relative congestion was sometimes present.

*Results of microscopic examination of the tissues of the mucous membrane.*

"Microscopical examination of the mucous membrane showed that the epithelium, where present, contained a large amount of fat, the cells including large quantities of oil granules. In the neighbourhood of denuded areas only abortive vestiges of cells and free granular matter were present. In places where the epithelium was absent, the sub-epithelial tissue showed more or less distinct evidence of similar changes, the nuclei being affected in varying proportions, appearing granular, and in some cases full of distinct oil granules. This condition of the nuclei may have, to some extent, caused the appearance of pigmenta

tion previously described, but in these cases in which the latter was strongly marked a certain proportion of true pigment granules was associated with the oily materials.

*Pigmentation of the intestinal mucous membrane not uncommon in cases of wasting disease.*

"It is impossible to decide whether this deposit of pigment in the mucous membrane is essentially connected with the morbid processes giving rise to the symptoms of disease in these cases. The phenomenon is not an uncommon one in cases of long-continued wasting disease, and is generally ascribed to the antecedent occurrence of minute extravasations of blood; but in the human subject, in these and in the present cases, the deposit may be due to processes similar to those causing it in the starved amphibian larvæ of the experiments. It may be due to destructive processes in the blood elements generally, rather than to local hæmorrhages and subsequent transformations, the intestinal tissues being merely the special sites of deposit, not the special sites of production of the pigment. In the more advanced stages of atrophy of the mucous membrane the nuclear elements in the villi appeared to be almost entirely absent, and the villi were represented by mere abortive processes containing collections of granular matter.

*Phenomena presented by the mucous membrane of the large intestine.*

"The mucous membrane of the large intestine resembles that of the small one in its extreme general anæmia. Over the greater part of the surface it was dead-white, with faint pink mottling here and there, and as a rule its texture was very soft. In some cases this extreme anæmia and pulpiness formed the only remarkable features—there being no thickening, effusion, or any other evidences of inflammatory action. In other cases there was more or less pronounced thickening, and besides the general softening, distinct evidence of local loss of substance over particular areas was sometimes present. These areas, in some instances, presented characters entitling them to be termed ulcers, but in others they seemed to be merely the result of processes of disintegration and atrophy, like those so strongly developed in the mucous membrane of the small intestine. In such instances there was no evidence of congestion, and the colic lymphatic glands were pale and inconspicuous. The appearances presented by the mucous membrane were some-

times, however, more of the nature of those ordinarily presented in cases of dysentery. In one case this was very decidedly so. In it there was great thickening of the gut, the mucous membrane was broken up into hard rough masses of purple and green colour, distinct ulceration had occurred, there was considerable general congestion, and the lymphatic glands were turgid and of a deep purple colour.

*Cases of so-called famine dysentery really independent of true dysenteric processes.*

"Taking all the phenomena into account, these cases certainly show that fatal cases of so-called 'famine dysentery' may occur in which no true dysenteric processes, as ordinarily understood, are present. The essential process appears to be of the same nature as that affecting the small intestines, but it may be complicated in various degrees by the supervention of true dysenteric changes."

MESENTERY.

There was more or less fat present in the mesentery in 60 men (34·8 per cent.), 56 women (45·5 per cent.), and 8 children (12·5 per cent.). The fat was in large quantity in only 8 men, 12 women, and 2 children, while it was a mere trace, and of a saffron yellow colour, in 29 men, 25 women, and 6 children.

*Œdema.*

There was œdema of the mesentery present in about a fifth of the adults and a fourth of the children, viz., in 34 men, 22 women, and 16 children; of these there was a little fat present as well in 6 men and 5 women.

*Congested.*

It was congested in 22 men and 11 women; in some the injection was confined to the vessels pertaining to, and in the near neighbourhood of, diseased gut, while in others the whole membrane was injected, or at least the larger vessels were engorged. The omentum was congested in 2 men and 5 women.

*Thickening.*

The mesentery was white from some thickening of the peritoneum in 5 men and 3 women; it had white spots of organised lymph on the surface in one case, and it was pigmented in another—both men.

*Glands.*

The mesenteric glands were of normal size in about a third of the adults and five-sixths of the children, viz., in 57 men, 37 women, and 51 children. They were enlarged and swollen in 36, or about a fifth of the men; in 11, or about a sixth of the children; and in 6 women; and

they were so atrophied as to be hardly visible, in some cases even in the absence of all fat, in 73 men (41·6 per cent.), 74 women (60 per cent.), and in 2 children. They were pigmented in 12 men, 8 women, and 2 children, they were injected red in 8 men, 7 women, and 5 children, and livid in 18 men, 11 women, and 7 children.

In some of the glands there were tubercular deposits in 2 men and 4 women; concretions in a woman and syphilitic deposit in a man. Among enlarged glands some had suppurated in a woman, and one was in a sloughy state in a man; and among atrophied glands there was a small cyst in one, in a woman.

LIVER. *Weight.*

The liver weighed, on an average, 32 ozs. in the men, with a ratio to the average weight of the emaciated bodies of 1 to 38 nearly, the extremes being 15¾ ozs., with a ratio to body-weight of 1 to 71, in an old washerman who died quite a skeleton from chronic dysentery; and 58½ ozs., with a ratio to body-weight of 1 to 26·5, in a cooly of the Pully caste who died from diphtheritic dysentery with kidney disease; and in the women 28 ozs., with a ratio to average weight of emaciated bodies of 1 to 34, the extremes being 16 ozs., with a ratio to body-weight of 1 to 55, in an old Pariah woman who died from chronic dysentery; and 57½ ozs., with a ratio to body-weight of 1 to 23·3, in a woman of the Ventham caste who died from chronic dysentery with pelvic peritonitis. It was under 30 ozs. in weight in 84, or nearly half the men, averaging 26 ozs. only, and in 84, or fully two-thirds the women, averaging 23·6 ozs. only; its average weight in the remaining 89 men is 37·7 ozs., and in the 39 women 38 ozs. Although these weights are very low, the ratio to body-weight is much the same as in Europeans, which is generally given as 1 to 36. In wasting disease the liver seems to lose more weight proportionately than the body generally.

*Adhesions.*

There were abnormal adhesions between the liver and surrounding parts in 17, or nearly a tenth of the men; in 16, or fully an eighth of the women; and in one child. The adhesions were of the liver to the parietes over liver abscess in 1 man; they were by points of old standing, with more or less well marked dragging out of the hepatic capsule into teat-like processes, in 8 men and 6 women; they

were flocculent in 4 men and 3 women; very firm all over right lobe in 1 man, and not particularised in 6 women and the child. There was old adhesion between the lower surface of the liver and the colon in a man, and between the fundus of the gall-bladder and the duodenum in a woman. Recent adhesions by quite soft lymph were found in 2 men.

*Scars.*

There were shallow scars on the capsule in 7 men and 2 women, spots of organised lymph in 2 men and 2 women, spots of soft lymph in a man, and white streaks in the course of the vessels on the under-surface of the left lobe in another. The capsule was clouded in 3 men, 5 women, and 1 child, and pigmented in parts in 3 men and 2 women.

*Furrows.*

There were furrows running across the convexity of the right lobe from behind forwards, varying in number from one to three, and in depth from a mere surface-marking to half an inch, in 13 men and in 23 women. In one of these women there was also a furrow across the liver from side to side, evidently arising from habitually wearing of too tight dress. This was broad and shallow, with some whitening of the capsule along its course, characteristics not usual in the other cases; and in the same woman there was a deep angular fissure on the upper part of the right lobe.

*Abnormal shape.*

The right lobe was prominent and projecting against the falciform ligament in 4 men and 5 women, and the left lobe was long and pointed in 6 men, 5 women, and 6 children. In one case there was a ridge on the upper surface of the liver running across both lobes from side to side, in another the liver was remarkably narrow, being only four inches in breadth; and in a third there was a small accessory lobe attached to the left lobe by a fibrous band; all three were women.

*State.*
*Congestion.*

The liver was noted flabby in 22 men, 19 women, and 7 children; plump in 26 men, 18 women, and 12 children; anæmic in 16 men, 31 women, and 12 children; congested in 58, or one-third of the men, 16, or one-eighth of the women, and 16, or one-fourth of the children. Of the congested livers, 1 felt almost like a

bag of blood, and 6 were so much congested as to pit readily on pressure.

*Healthy.*

It was noted healthy in appearance and in microscopic structure in 26 men (15 per cent.), 6 women, and 6 children. Its structure was also normal in congested livers in 11 men and 4 children, and in atrophied livers in 8 men and 2 women. The liver was chocolate in colour, and had all the appearances of red atrophy, in 7 men and 6 women, and it seemed affected by simple atrophy in 4 men and 2 women. There was atrophy of the left lobe, which was reduced to a mere trace, weighing as little as a drachm in one case, and it was cartilaginous in 5 men and 4 women; and in 27 men and 15 women there was a pale atrophied margin to the left lobe. This was usually only a few lines in breadth, and it was sometimes confined to the lower end or to the tip of the lobe. In 5 women there was similar atrophy of the margin opposite the fundus of the gall-bladder.

*Atrophy.*

*Degenerations.*

Fatty degeneration was present in 113 men (65·3 per cent.), 103 women (83 per cent.), and in 50 children (78 per cent.). The liver was only slightly fatty in 21 men, 6 of the women, and 3 of the children; it was usually plump, of a more or less pure saffron yellow colour, and one mass of fat cells in 11 men, 25 women, and 21 children, and in the majority of the rest it was only spotted or mottled yellow, and not quite so extremely fatty. Albuminoid degeneration was looked for in every liver, but found present in none. Microscopic examination was also made of all the livers.

The section of the liver presented a nutmeg appearance in 39 men (22·5 per cent.), 44 women (35·7 per cent.), and in 4 children. In these the acini were distinctly mapped out by a pale margin, and all the livers were markedly fatty, except three in the men; in two of these the lobules were margined a dirty white, and in the third they had very dark red centres with paler margins.

*Cirrhosis.*

There was more or less distinct cirrhosis of the liver in 5 men and 6 women. The hob-nail appearance was tolerably distinct in most of these cases. In one of the women there were small prominences on the surface like the papillæ of the tongue.

Pigmentation was noted in 17 men, 6 women, and one child.

*Abscess.*

Abscess was found in 2 cases—both men. In one it was about the size of a racket ball, situated at the centre of the right lobe, and contained yellow pus, the surrounding tissue appearing healthy. This man had been a week in hospital from bowel-complaint, with much sloughing of the colon, and he said he had had diarrhœa a month on admission. And in the other case it was about the size of a large filbert nut, situated close to the surface which was adherent to the diaphragm over it at the centre of the convexity of the right lobe, and it contained a substance of the consistence and appearance of thick white paint, the surrounding tissue appearing healthy. This man died from diphtheritic dysentery after 10 days in hospital, having been ill 4 on admission.

*Hydatids.*

In one case there was a hydatid cyst, the size of an orange, situated in the gall-bladder fossa, with partially calcified walls, and contents bluish-grey bladders with clear fluid, but no hooklets observable. This man died on the day of admission from diphtheritic dysentery of ten days' standing, complicated with acute pneumonia and disease of left kidney: the liver was greatly congested.

*Cavernoma.*

The structure known as cavernous tumour of the liver was found in 2 men and 3 women. This was usually about the size of a bean, and situated near the surface towards the centre of the convexity of the right lobe. In one of the women there was a second tumour occupying nearly half of the atrophied left lobe, being about the size of an almond in shell.

*Tubercles.*
*Lymphoma.*

There were tubercular deposits in the liver of a woman who died from diphtheritic dysentery with tuberculosis, and lymphomatous growths in another woman who died from diphtheritic dysentery with pneumonic congestion. The latter growths consisted of some white firm tumours, the size of No. 6 shot imbedded in the surface of the liver, and were composed of lymphoid cells with some fat granules.

*Scirrhus ?*

There was a deposit like scirrhus in one case—a man who died from bowel-complaint with sloughing in the colon and bloody flux. He had great

tenderness over the liver during the ten days he was under treatment, but no rise of temperature. By his own account he had been ill with dysentery about three weeks altogether. The liver was somewhat enlarged, and the right end was torn in removal. On section the right half of the right lobe was seen to be occupied by four closely agglomerated masses of tissue of a pale straw colour; the largest was softened into a jelly-like mass; the others were quite fibrous, and seen under the microscope to be composed of indistinct fibres and granules. The rest of the liver was deep red and engorged with blood.

*Gall-bladder.*

The gall-bladder was very large, containing half a pint of dark-coloured bile, in 1 man, and its walls were œdematous in 2 men, 4 women, and 1 child. It was empty in 7 men, 3 women, and 3 children; it contained dark green viscid bile in 32 men (18 per cent.), 35 women (28 per cent.), and 14 children (22 per cent.); and thin green bile in 28 men (16 per cent.), 15 women (12 per cent.), and in 11 children (17 per cent.) The bile was brown and thin in 9 men, 3 women, and 1 child; brown and viscid in 1 man; and it was of the appearance and consistence of olive or linseed oil in 33 men (19 per cent.), 31 women (25 per cent.), and 20 children (31 per cent.), in some of these it was turbid, and in others there was a green cloud or sediment present. It was thin and orange or yellow in 8 men, 5 women, and 2 children; orange and viscid in 4 men and 3 women; yellow and grumous in 8 men, 1 woman, and 2 children; milk-like in 1 child; dark-coloured in 22 men, 15 women, and 5 children; quite tarry in appearance in 2 women and 1 child; water with a green cloud in 2 men and a woman; and colour and consistence not noted in 16 men, 8 women, and 3 children. One gall-bladder was inflamed and distended with serum and pus, one was inflamed and contained pus and gall-stones, and one contained gall-stones and a little thin yellow bile —all three were in men.

SPLEEN.

The spleen varied a good deal in weight, and in 2 cases there was an accessory spleen. In one this weighed ½ oz. and measured 2″ × 1½″ × ½″, the full spleen weighing only 2½ ozs. and measuring 4½″ × 2″ × 1″; in the other case it was of the size of a large pea. It was

lobulated in 9 men, 4 women, and 3 children. The spleens may be divided into hypertrophied, normal, and atrophied.

*Hypertrophied.*

Under hypertrophied may be included in men 16 spleens, varying in weight from 7 to 20⅝ ozs., averaging 11·4 ozs., and giving a ratio to the average weight of the corresponding bodies of 1 to 125; and in women 9 spleens, varying from 6 to 12⅞ ozs., and averaging 8·7 ozs., with a ratio to their average body-weight of 1 to 127.

*Normal.*

Under normal are included in men 22 spleens, varying in weight from 4 to 7 ozs., both weights inclusive, and averaging 4·8 ozs., with a ratio to their average body-weight of 1 to 258; and in women 17 spleens, varying in weight from 3 to 6 ozs., both inclusive, and averaging 4 ozs., with a ratio to their average body-weight of 1 to 279.

*Atrophied.*

Under atrophied are included, in men 135 spleens under 4 ozs. in weight, averaging 2·3 ozs., with a ratio to their average body-weight of 1 to 540; and in women 97 spleens under 3 ozs., averaging 1·83 ozs., with a ratio to their average body-weight of 1 to 558.

The largest spleen, weighing 20⅝ ozs., had a ratio to body-weight of 1 to 71, and was in a young man who said he had been ill three months with fever and cough, and died ten days after admission to hospital, with bases of both lungs consolidated and the colon ulcerated; and the smallest, weighing 3 drachms, had a ratio to body-weight of 1 to 2,645, and was in a woman, about 50 years old, who died from diphtheritic dysentery with pneumonic congestion.

*Capsule.*

The capsule was more or less thickened in 26 men (15 per cent.), 14 women (11·3 per cent.), and in 2 children. This consisted of considerable thickening all over in 2 men and a woman; thickening with adhesions to surroundings in 8 men; a white cloud over the surface in 4 men and 6 women; spots of organised lymph in 9 men, 7 women, and 2 children; flocculi in 1 man, and a reddish effusion in 2 men. There were abnormal adhesions to surrounding parts in all in 24 men (nearly 14 per cent.), 16 women (13 per cent.), and in 3 children. The adhesions were by a point or two in 7 men and 10 women—in 1 of the latter the adhesion was to the colon; by firm bands in 5 men, 4 women, and 3

children; by a greater part of the surface of the capsule in 10 men; and they were flocculent in 2 men and 2 women.

*Pulp.*

The spleen was firm, not friable, and deficient in pulp, with no exudation under pressure, in 113 men (65·3 per cent.) 74 women (60 per cent.), and in 52 children (81 per cent.). It was flaccid in 49 men (28 per cent.), 33 women (nearly 27 per cent.), and in 3 children; and it was plump in only 11 men, 12 women, and 6 children. It was about normally friable in 17 men (10 per cent.), 11 women (9 per cent.), and 4 children; and very friable, breaking up under even slight pressure into brown or red pulp, like thin jam, in 17 men (10 per cent.), 9 women (8 per cent.), and in 1 child. It was pigmented in 22 men (12·7 per cent.), 12 women (10 per cent.), and in 2 children.

*Pigmentation.*

*Deposit.*

In 1 woman there were tubercular deposits of the size of peas all through the substance of the spleen.

*Degeneration.*

Albuminoid degeneration was looked for in every case, but not found present in a single one.

KIDNEYS.

In the men the weight of the right kidney ranged from $1\frac{1}{2}$ oz. to $6\frac{1}{8}$ ozs., the average being 2·87 ozs.; and of the left from 1 oz. to $10\frac{1}{4}$ ozs., the average being 3 ozs. fully: these give a ratio to average body-weight of 1 to 214. In the women there was one horse-shoe kidney, weighing $5\frac{1}{4}$ ozs.; in the remainder the weight of the right kidney ranged from $1\frac{3}{8}$ oz. to $4\frac{3}{4}$ ozs., the average being 2·64 ozs.; and of the left from $\frac{7}{8}$ oz. to $5\frac{3}{8}$ ozs., the average being 2·7 ozs.: these give a ratio to average body-weight of 1 to 192.

*Weight.*

In the men 114 right (67 per cent.) and 97 left kidneys (56 per cent.) were 3 ozs. in weight and under, the average weight of the former being only 2·48 ozs., and of the latter 2·44 ozs.; and in 59 right (33 per cent.) and 76 left kidneys (44 per cent.) the weight was over 3 ozs., the average for the former being 3·6 ozs., and for the latter 3·8 ozs.; and in the women 89 right (73 per cent.) and 76 left kidneys (62 per cent.) were under 3 ozs., the average weight of the former being 2·3 ozs., and of the latter 2·2 ozs.; and 33 right (27 per cent.) and 46 left kidneys (38 per cent.) were 3 ozs. and

upwards, the average weight of the former being 3·5 ozs., and of the latter 3·4 ozs.: although these weights are so low, on account of the extreme emaciation, the ratio to body-weight is higher than for Europeans, as given by Quain, viz., 1 to 240.

*Capsule.*

The capsule was more or less adherent in men in 25 pairs, 8 left and 1 right kidney, 20 per cent.—in one case the outer surface of the capsule of the right kidney was adherent to the colon; and in women in 12 pairs, 1 right and 2 left kidneys, 12 per cent. In all the children the capsule stripped easily. On stripping off the capsule the surface of the kidney was found granular in appearance in men in 6 pairs, 1 right and 2 left kidneys, and in women in 19 pairs and 2 left kidneys; the capsule was adherent as well in 5 of the men and 4 of the women.

Cysts were present in 58 men (33·5 per cent.), and in 33 women (26·8 per cent.). These were confined to the left kidney in 9 men and 5 women, and to the right in 2 men and 3 women. They varied a good deal in number, but they were mostly small and confined to the surface; however, in two or three cases they were of considerable size and formed the chief part of greatly-enlarged kidneys—for instance, one kidney weighing 8¾ ozs. was only 3 ozs. in weight after emptying its cysts. The contained fluid was in all these cases of a pale straw colour.

*Pigmentation.*

There was superficial pigmentation of parts of the cortex in 5 men, 5 women, and 1 child.

*Injection.*

The kidneys were anæmic in 31 men (18 per cent.), 36 women (29 per cent.), and in 14 children (22 per cent.). The cortex was anæmic, while the medulla was injected, in 20 men (11·5 per cent.), 24 women (19 per cent.), and in 11 children (17 per cent.); and the whole substance was congested in 85 men (50 per cent.), 31 women (25 per cent.), and in 13 children (20 per cent.). The injection was normal in the remainder, viz., in about one-fifth of the men, two-fifths of the children, and one-fourth of the women.

*Fatty.*

They were more or less decidedly fatty in 73 men (42 per cent.), 82 women (66·6 per cent.), and 31 children (48·4 per cent.). Of these in 9 men, 17 women, and 10 children they were noted very fatty; and in 40 men, 39 women, and 13 children only slightly fatty.

*Other lesions.*

There was a syphilitic deposit in both kidneys in a man, and in the right kidney only in a man and a woman. This was a grey softish mass in the cortex, composed of nucleated cells and fat granules. There was a small tubercular abscess in the cortex of the left kidney in a woman. In a man the left kidney was half as big again as the right, the capsule was adherent in places, and on removal disclosed small grey sloughy ulcers on the sides, and a slough on the free border of the kidney. In a woman there was suppurative interstitial nephritis of both kidneys. The cortex was semi-transparent in a man and a woman, and fibrous in another man. In the former spherical cells were seen free among the tubes, and in the latter the tubes were empty, and the structure looked like white fibrous tissue.

*Normal.*

In the remainder, viz., in about half the men and children, and in nearly a third of the women, the microscopic structure of the kidney appeared normal, except that in 21 men, 2 women, and 3 children desquamation cells were found in abundance: these kidneys were nearly all congested.

*Pancreas.*

The average weight of the pancreas is 2·26 ozs. for the men, the extremes being 1 oz. and $4\frac{3}{8}$ ozs.; and for the women 1·78 ozs., the extremes being $\frac{7}{8}$ oz. and $3\frac{3}{4}$ ozs. Below is shown its average weight in each of the three classes; its higher weight in the well-nourished bodies is most probably due to the presence of fat between the lobules. Women seem to have a decidedly smaller pancreas than men.

| | Men. | Women. |
|---|---|---|
| | ozs. | ozs. |
| Emaciated ... ... ... ... | 2·2 | 1·8 |
| Anasarcous ... ... ... ... | 2·19 | 1·8 |
| Others ... ... ... ... | 2·97 | 2·2 |
| Average ... | 2·26 | 1·78 |

There were chalky concretions choking up the duct in one case, and a lumbricus lodged in it in another. (See Case at page 8.) In one case a cheesy deposit was situated in the head of the gland, and could be enucleated, it looked tubercular, but the

neighbouring lymphatic glands were not implicated, nor were the lungs, &c., the man having died from diphtheritic dysentery. Under the microscope it was seen to be composed of fat granules and *débris*. In all others the pancreas appeared healthy.

In these cases of alvine flux the complete absence of albuminoid degeneration is noteworthy, while fatty degeneration was so common.

---

# CHAPTER IV.

## GENERAL DISEASES.

UNDER this head are included Dropsy, Atrophy, Fever, and Pyæmia. These caused, in the aggregate, about 10 per cent. of the admissions, deaths, and autopsies.

### 1.—DROPSY.

By dropsy is meant general anasarca with effusion of watery fluid into the serous cavities; this raised the weight of the, generally emaciated, body by about one-third. This state was present in about 10 per cent. of the cases that came under treatment; but the return in Appendix A shows the admissions from this cause to have been only 94, or barely 3 per cent., and the deaths 53, or 4·7 per cent., of the total; the death-rate was 56·3 per cent. of treated.

The average daily sick from this cause was 2·4, or 3·65 per cent. of the total; women contributing 4·5 per cent., men 3·3 per cent., and children 2·9 per cent. See Appendix B.

In Appendix C this disease is not shown separately; but in the Vellore returns it caused 20·6 per cent. of the admissions, and 25 per cent. of the deaths, giving a mortality of 46·4 per cent. of treated. However, this symptom was common in the famine to many diseases which might be returned accordingly as dropsy or otherwise. And the Sanitary Commissioner, Dr. Cornish, reports dropsy to have been, after bowel-complaints, the most common condition of the famine-stricken in hospitals up-country; that it was less prevalent in the early months of the famine, but came on later and was often the fatal ending of cases of malarial fever, or of "famine diarrhœa" apparently cured.

*Disease complained of.*

In the 459 autopsies made, 49 of the bodies were dropsical; of these cases 27 had died from bowel-complaint. The remaining 22, consisting of 13 men, 6 women, and 3 children, it is proposed

to treat of here. The disease complained of on admission was dropsy in all these cases, except three, viz., that of a man, with Bright's disease, who complained of dysentery; of another, with anæmia, who complained of pains all over the body; and of a woman, with heart disease, who complained of cough.

The lesions giving rise to the dropsy may be grouped as under:—

| | Men. | Women. | Children. |
|---|---|---|---|
| Anæmia ... ... ... ... | 3 | 2 | 3 |
| Cirrhosed liver ... ... ... | 4 | ... | ... |
| Bright's kidney ... ... ... | 3 | 1 | ... |
| Heart disease ... ... ... | 3 | 3 | ... |
| Total ... | 13 | 6 | 3 |

*Duration of illness.*

As to the duration of the illness, one man died on the day of admission from Bright's disease after, it was said, an antecedent illness of ten days' duration from dysentery; the average time in hospital of the other men was 11 days, the extremes being 1 and 29 days; the average duration of the dropsy before admission being about three weeks. The average time in hospital of the six women was 15 days, the extremes being 3 and 40 days, the antecedent illness having lasted, on an average, rather under three weeks.

The three children, all girls, had been ill about a month on admission, and lived about nine days in hospital.

*Height.*

The average height of these men is 5 feet 3¾ inches, the extremes being 4 feet 10¾ inches and 5 feet 9 inches; and of the women, 5 feet ½ inch, the extremes being 4 feet 10½ inches and 5 feet 2 inches.

*Age.*

No native of the class to which these patients belonged knows his own age, but the average of the ages guessed in each case is 48½ years for the men, and 46 years for the women; the extremes being 30 and 70 years for the men, and 30 and 60 years for the women; the children's ages were about 1 year, 1½, and 3 years.

*Weight.*

The average weight of the body is 103¾ lbs. for the men, and 101½ lbs. for the women.

On comparing the weight of the dropsical and emaciated, we find the average weight of 24 dropsical men is 104 lbs. nearly,

as against 75¾ lbs. for 151 emaciated; and of 19 dropsical women, 93 lbs. nearly, as against 59½ lbs. for 100 emaciated.

*Rigor mortis.*

Rigor mortis was found present 13 hours after death in one case, and it was absent 10 hours after death in another: the cause of this variation was not apparent.

*Skin diseases.*

Itch is so common among natives that its presence or absence was usually not noted, but no other skin disease was present in these cases; however the skin was mostly found covered with scurf. An ulcer on the right thumb was observed in one case, and sloughing of the skin of the upper of the left foot in another, the case of a child of about 18 months old. Elephantiasis of the scrotum was present in a man of about 50 years of age who died from Bright's disease.

SKULL.

The scalp was thin and pale, quite milk-white in some cases; and on removing the calvarium no blood appeared on the meninges, as is usual when the sinuses are full, in three men, five women, and all three children. These structures presented the normal appearance in one man. Some blood flowed from several vessels on cutting through the scalp, and from the surface of the meninges and base of the skull on removing the calvarium and brain in ten men and one woman: in two of the men the blood was in considerable quantity.

*Arachnoid.*

On cutting through the meninges, serum was found in the subdural cavity in all cases except one, that of a man; and it was found effused under the arachnoid filling up the sulci of the brain in all except the same man, two women, and two children. The serum in, and also that beneath, the arachnoid was bloody only in the case of a man and a woman.

*Pia mater.*

The larger vessels of the pia mater was found full in four * men and three † women, and the lateral veins only were full in six men. In one of the latter there were some blotches of superficial ecchymosis opposite the

---

* Died from anæmia, 2; from cirrhosis liver, 1; Bright's kidney, 1.

† Died from heart disease, 2; Bright's kidney, 1.

right temple in the course of the vessels, not extending into the sulci of the brain, and devoid of clots.

*Brain.*

The average weight of the brain is 42·35 ozs. for the 24 dropsical, as against 40·14 ozs. for the 151 emaciated men; and 39·2 ozs. for the 19 dropsical, as against 35·2 ozs. for the 100 emaciated women. This greater weight in the dropsical cases was probably due to œdema of the brain substance, although any considerable serous oozing from the cut surface was observed in only one case, that of a man, and the effusion into the ventricles amounted to dropsy in only two men, one woman, and two children. The substance was noted soft in nine men, five women, and two children, and firm in three men, one woman, and one child. It was anæmic in six men, four women, and in all the children; and about normally injected in the rest.

CHEST.

*Pleura.*

There was serous effusion into all the pleural sacs, except in a child one left pleura was healthy, and in a man the pleuræ on both sides were so closely adherent all over as to prevent hydrothorax. The serum was pale amber coloured, except in one left pleura it was blood-tinged, and varied in amount from an ounce to a quart, the average quantity found in the right pleural cavity being 17 ozs. for the adults, and 2 ozs. for the children; and in the left pleural cavity 18 ozs. for the men, 17 ozs. for the women, and 1 oz. for the children. In the men, there were old points of adhesion present in four pairs, one right and one left pleura; and in the women in one pair, one right and one left pleura. There were cicatricial more or less puckered depressions on the apices of one pair, and one left lung in men.

*Hydrothorax.*

*Lungs.*

The lungs were quite healthy in only one man and two children; in the former, the weight of the right lung was 8¾, and of the left, 6¾ ozs. The only abnormal condition found was simple collapse of the lung tissue affecting the whole lower lobe of both lungs in a man, and of the right lung only in a man and a woman, and affecting the posterior margin only of the lower lobe of the left lung in the same woman and of the right lung in another man. In these the part implicated was purplish in colour, tough and airless on

section, with at most only a little blood exuding from the cut vessels, the lung remaining of about its normal weight. The right lung weighed $10\frac{1}{4}$ ozs. in the woman, and averaged $10\frac{1}{2}$ ozs. for the two men, while the left lung weighed 8 ozs. in the woman, and averaged 9·3 ozs. for the two men. In other diseased lungs apneumatosis was found affecting the whole right lung in a woman, the whole lower lobe of both lungs in two men, of the right lung only in a man, and of the left lung alone in a man and two women. It was confined to the upper lobe of the right lung in a man, to the posterior border of the lower lobe of the right lung in a woman and a man, and of the left lung in a man, and to the anterior margin and inner surface of the right lung in a man. The collapse was confined to spots through the left lung in a man, and to the lower anterior tongue of the upper lobe of the left lung in a man.

*Apneumatosis.*

There was serous effusion into collapsed lung tissue of both lungs in three men and two women; of the right lung alone in one man, and of the left lung alone in another. The average weight of the right lung is 17 ozs. for the four men, and 11·37 ozs. for the two women; and of the left lung $14\frac{3}{4}$ ozs. for the four men, and 11·7 ozs. for the two women. There was simple œdema of the lung, often confined to the dependent parts, unaccompanied by congestion or softening of the lung tissue in both lungs in two women, and in the left lung alone in one woman. In one case the lungs filled the chest and felt spongy, but in the others the œdematous part pitted on pressure, and in all pale serum flowed freely from the cut surface on section. The average weight of the two right lungs is $17\frac{1}{8}$ ozs., and of the three left lungs, $13\frac{1}{2}$ ozs.

*Œdema.*

There was congestion with œdema of both lungs in a man and a child; in the former, the weight of the right lung was $19\frac{3}{4}$ ozs., and of the left lung, 17 ozs. There was congestion with œdema and softening of the lung tissue in both lungs in two men. The average weight of the two right lungs is $20\frac{1}{2}$ ozs., and of the two left, $16\frac{1}{2}$ ozs.

*Congestion.*

In a case of Bright's disease in a man, case No. 369, both lungs presented consolidation of lobules from chronic pneumonia, besides being congested

*Pneumonia.*

and œdematous. Weight of right lung, 28⅞ ozs., and of left lung, 28⅛ ozs. In another man, case No. 363, who died from cirrhosis of liver, there was a marginal strip of the base of the left lung, two inches square, which was pigmented dull white, tough, firm, fibrous, dry, and airless, like a chronic pneumonic spot compressed. And in another man, case No. 364, who had disease of the kidneys and heart, the lungs, though spongy, were double their usual weight, 21¼ and 14½ ozs., and showed on section blackish brown, tough, airless lobules, with only little serum exuding on pressure in right, as if a combination of apoplexy and chronic pneumonia.

*Apoplexy.*

In a man, case No. 367, who died from anæmia, there was effusion of blood in spots, the size of pigeons' eggs, situated in the thin lower margin of the right lung, apneumatosis with œdema affecting the rest of that lobe; weight of lung, 20 ozs.

*Gangrene.*

In the case above given (No. 363) of chronic pneumonia in cirrhosis of liver, adjoining the pneumonia strip, there was a gangrenous spot on the lung margin of two inches square, the rest of the lobe was in a state of inflammatory œdema and covered by a false membrane with a quart of bloody fluid in the pleural sac. The lung weighed 14½ ozs.

*Latent phthisis.*

Tubercular deposit in an inactive state, forming a few small hard masses in the apex, was found in one right and one left lung, both in men.

*Pericardium.*

The pericardium was healthy in appearance, but contained pale amber serum in all cases. The sac was distended in two men,* one woman,† and one child,‡ contained about four fluid ounces in one woman, and about a fluid ounce on an average in the remainder.

*Heart.*

The surface of the heart was devoid of fat in five men and in all the children; in four of the former the fat was replaced by œdema, and this was present also in two women.

---

* Died from Bright's kidney, 1; anæmia, 1

† Died from Bright's kidney. ‡ Died from anæmia.

There was only a little fat present in two men and two women: it was in considerable quantity in one man and two women, and in moderate amount in four men and one woman.

The white detachable lymphy deposit known as the "soldier's spot" was present in three men; in one of these the spots were three and in another six in number.

The cavities of the heart were found empty in four men, three women, and one child. There was some blood and clots on both sides in five men and one woman, and in the right side alone in four men, two women, and one child. The walls were noted flabby in two men.

*Weight.*

In eight men, the weight of the heart was over 6 ozs., its average weight being 8 ozs., the average weight for the other five men being only 5½ ozs. Its weight was under 5 ozs. in two women and over 7 ozs. in four; average 4 ozs. and 9¼ ozs. respectively. Its average weight for the thirteen men is 7¼ ozs., and for the six women, 7½ ozs. The largest hearts were found in cases of heart and kidney diseases.

ABDOMEN.

The peritoneum was quite healthy in only one man who died with kidney disease, and it was equally healthy in appearance, but contained serous effusion in eleven men and in all the women and children. The serum was turbid in one case, a child, but in all others was pale straw-coloured. In the men it varied in amount from half a pint to two gallons, the average being six pints; in the women, it varied from one to three pints, the average being a quart; and in the children, it averaged nearly 7 ozs. In a man who died from anæmia, the peritoneum was dull white with flakes of lymph adherent, and contained two gallons of turbid serum.

*Peritoneum.*

*Stomach.*

The stomach was noted large in five men and two women, and small in three men and three women. It was empty in six men, three women, and two children; it contained fluid, usually bile-tinged, in six men, two women, and one child, and in a woman it contained food and four lumbrici. The mucous coat was smooth in six men and five women, and it was in well marked rugæ in six men, one woman, and two children. It was pale and thin, and often bile-stained in nine men, four women, and in all the children;

it was pinkish in a woman and congested red in a woman and a man. In a man with heart-disease, there were two soft growths, like fungus hæmatodes, on the posterior wall near the cardiac end, each about the size of a walnut, and dark red as if from ecchymosis; the rest of the coat was pale and the stomach was empty. There was some pigmentation of the coat in a man.

SMALL INTESTINE.

The small intestine was found empty in six men, one woman, and one child, and was noted distended with gas in one woman, one man, and two children.

*Lumbrici.*

The contents when present were white, buff, yellow or green fluid, or in one case lumps of green mucus. Lumbrici were found in eight men and four women, varying in number from one to fifteen, the average being nearly two each for the men, and nearly seven each for the women.

*Diverticulum.*

The walls of this intestine showed a general thinning of the tissues. In one case, No. 369, there was a diverticulum in the ileum, an inch long; in another, No. 363, there was a spiral twist twice round the ileum, and in a third, all men, there was a small fibrous tumour on the peritoneal surface near the duodenum. In one woman the lumen of the jejunum was unusually large.

*Mucous coat.*

The mucous coat was normally injected in four men and a woman; it was pale rose-coloured in five men and two women, and it was pale to milk-white in four men and two women and in all the children: there was passive congestion present in the case of a woman who died with disease of the heart. It was œdematous, more marked in the jejunum, in two men, a woman, and a child, and confined to the lower end of the ileum in a man; in only two of these cases had diarrhœa been present.

*Œdema.*

*Ecchymosis.*

There were three raised spots of submucous ecchymosis in the jejunum in a woman who died from anæmia without bowel-complaint, and several flat spots with prominence of the solitary glands in the lower end of the ileum in a man who complained of dysentery before death.

There was pigmentation present, giving the mucous coat a more or less slaty colouration in five men and three women. This was usually most marked in the jejunum and in Peyer's patches.

There was a tubercular girdle ulcer about half an inch wide encircling the gut in the upper part of the jejunum in a man who died with cirrhosis of the liver, and had some latent tubercles in the apex of the right lung; the rest of the gut looked healthy.

*Tubercular ulcers.*

The large intestine was found empty in ten men, four women, and two children; it contained formed fæces in two men, and yellow or greenish fluid feculence in a man, two women, and a child. The mucous coat was healthy in appearance in three men, and pale to milk-white in eight men, five women, and three children. There was some mottled congestion in the upper end in two men, and passive venous congestion in a woman who died from heart-disease. The mouths of the mucous follicles were patulous in a man (No. 369) and a child, and they were pigmented in a man.

LARGE INTESTINE.

*Mucous coat.*

There was œdema of the mucous coat in five men and two women. Diarrhœa was present at death in four of these cases—two men and two women.

*Œdema.*

There was an effusion of soft lymph on longitudinal folds in the sigmoid flexure in a man, and a reddish pseudo-membrane, lining the lower end of the gut as high as to the transverse colon, in a child; there was no subjacent injection of the gut, and no bowel-complaint was complained of or noted in either case.

*Pseudo-membrane.*

In a man who died with Bright's disease, there were a few small circular, livid-edged, grey-based superficial ulcers scattered through the ascending transverse and descending colon without injection or thickening of the parts; it is noted there was no diarrhœa in this case. In a woman there was a small circular grey-based ulcer in the rectum, and one black-edged ulcer and two cicatrices in the transverse colon; and in another woman there were two small sloughs in the cæcum from strangulation of the tissues by œdema, and some sloughy ulcers in the ascending and transverse colon; diarrhœa was present in both these cases latterly.

*Ulcers.*

*Sloughing.*

There was more or less fat present in the mesentery in six men, all the women, and in one of the children. This was in considerable quantity in three of

*Mesentery.*

the women. There was œdema present in ten men, three women, and two children. The mesentery was white from some thickening of the peritoneum in a man. There was injection of the great omentum in a woman.

The mesenteric glands were of about their normal size in seven men, three women, and two children; they were enlarged and swollen in a man and a child; and in another man they were enlarged, from a granular grey deposit seen under the microscope to consist mainly of fat granules. They were atrophied in three men and two women, and small, with concretions in some, in a man, and with a small abscess in one in a woman. Pigmentation was noted in only one case.

LIVER.

The liver weighed on an average 31⅓ ozs. in the men, and 34½ ozs. in the women. There were abnormal adhesions between its capsule and the parietes by points of old standing, with more or less marked dragging out of the hepatic capsule beneath into teat-like processes, in three men. In one man the adhesion was over a small liver abscess, and in a man and a woman, the liver was adherent all over by flocculent adhesions, and in another by points.

*Adhesions.*

There were shallow scars on the capsule in two men. The left lobe was long and pointed in two men, its margin atrophied in a third, and the whole lobe cartilaginous and reduced to a mere trace in a fourth. The right lobe was prominent and projecting against the falciform ligament in a man.

*Congested.*

The substance was congested in two men, and in a woman the congestion was so great that the liver felt almost like a bag of blood. It was noted anæmic in two men, two women, and a child.

The liver was mostly atrophied. In eleven men it averaged only 27 ozs. in weight, and in four women its average weight was only 29¾ ozs.

*Fatty.*

The substance was of a more or less ochrey yellow colour, and very fatty, in two men and five women, and less fatty in three men and one woman, and only slightly fatty in four men. In two of the fatty livers in men the section showed the acini mapped out by paler margins, giving a nutmeg appearance.

Albuminoid degeneration was looked for in all the livers and found in none.

*Cirrhosis.*

There was cirrhosis of the liver in four men. The "hob-nail" appearance was well seen in three of these, and a history of intemperance was noted in two.

Pigmentation was noted in only one case, that of a woman.

*Abscess.*

In a man who died with Bright's disease, there was a small abscess, the size of a marble, containing a substance like white paint. It was quite superficial and situated on the convexity of the right lobe, which was adherent to the parietes over it.

*Cavernoma.*

The structure known as cavernous tumour of the liver was observed in a man; it was of the size of a bean situated on the margin of the left lobe.

*Gall-bladder.*

There was œdema of the walls of the gall-bladder in two men. It was quite empty in only a man and a child, and contained only a trace of bile in two men. It contained oil-like fluid in two men, a woman, and a child; thin green bile in a man, two women, and a child; thin brown bile in two men; grumous green bile in a man and thick dark bile in a woman. The remaining gall-bladders were simply noted full without specification of contents.

SPLEEN.

The spleens varied a good deal in weight, but may be divided into hypertrophied, normal, and atrophied.

Under hypertrophied come three spleens varying in weight from $7\frac{5}{8}$ ozs. to $12\frac{1}{2}$ ozs., and averaging $9\frac{1}{2}$ ozs., all in men.

Under normal come one spleen, $5\frac{5}{8}$ ozs. in a man; and three spleens, between 3 and 6 ozs. in women, averaging in weight $3\frac{3}{4}$ ozs. Under atrophied are included in men nine spleens under 4 ozs. in weight, averaging $2\frac{1}{4}$ ozs; and in women three spleens under 3 ozs. in weight, averaging $1\frac{1}{2}$ ozs.

*Capsule.*

The capsule was more or less thickened in five men and two women. This consisted of considerable thickening all over in a man, thickening with adhesions to surroundings in three men and a woman, a white cloud over the surface in a woman, and white spots of organized lymph in a man.

The spleen was firm, not friable and deficient in pulp, with no exudation under pressure, in eight men, two women, and a child. It was about normally friable in two men, one woman, and two children, and very friable, breaking up under even slight pressure into a brown pulp, like thin jam, in three men and three women. Albuminoid degeneration was not present in any case.

*Pulp.*

In the men the weight of the right kidney ranged from $1\frac{3}{4}$ to 6 ozs., the average being $3\frac{1}{2}$ ozs., and that of the left kidney from $1\frac{5}{8}$ ozs. to 7 ozs., the average being $3\frac{3}{8}$ ozs. In the women the weight of the right kidney ranged from $2\frac{1}{2}$ ozs. to 5 ozs., the average being $3\frac{1}{2}$ ozs., and that of the left kidney from $2\frac{3}{8}$ ozs. to $4\frac{3}{4}$ ozs., the average being $4\frac{1}{8}$ ozs.

KIDNEYS.

In the men five right and six left kidneys were 3 ozs. in weight and under, the average weight of either being $2\frac{1}{4}$ ozs., and eight right and seven left were over 3 ozs. in weight, the average being $4\frac{1}{4}$ ozs. for the former and $4\frac{3}{8}$ ozs. for the latter. And in the women two right and two left kidneys were under 3 ozs. in weight, the average weight of the former being $2\frac{1}{4}$ ozs. and of the latter $2\frac{1}{2}$ ozs., and four right and four left kidneys were 3 ozs. and upwards, the average weight of either being $4\frac{1}{8}$ ozs.

*Weight.*

The capsule was slightly adherent in one case, but stripped readily in all the others. On stripping off the capsule, the surface of the kidney was found granular in two men and a woman. Small cysts were studded over the surface of both the kidneys in a woman and two men, and of the left kidney in a man.

*Capsule.*

The substance was anæmic in two men and four women, and the cortex was anæmic, and the medulla congested in six men and two women. It was fatty in five men and five women; in three of the latter, it was noted very fatty. Large lymphoid cells, as well as fat granules, were observed in the urinary tubes in three men and one woman, and in three men the structure appeared normal under the microscope.

PANCREAS.

The pancreas weighed on an average 2·4 ozs. in the men and 2·2 ozs. in the women. Its structure appeared healthy in all.

A list of these cases is attached.

### Illustrative Cases.

Case 363.—Narayan, a toddy-drawer by caste and calling, about sixty-five years old, has been ill three months with "pains all over, weakness and starvation;" admitted 1st June 1877 with considerable general anasarca; pulse 100, feeble, respirations 32, laboured; orthopnœa, pleuritic effusion on left side, no bruit with heart's action, urine sp. gr. 1,018, healthy, cough very occasional, short and dry; died on 8th June. Autopsy twelve hours after death. Height 5 feet 6 inches; weight 100 lbs.; body anasarcous; rigor mortis absent. *Skull.*—Scalp and meninges pale, a good deal of serum in sub-dural space and beneath arachnoid, veins nearly empty. *Brain.*—38 ozs., anæmic, some *post-mortem* softening. *Chest.*—Right pleura pearly, contains twelve ounces of dark amber serum. *Lung.*—23 ozs., inflammatory œdema of all except anterior margin. *Left pleura* lined by a false membrane, and contains over a quart of bloody serum. *Lung.*—14½ ozs., small, apex spongy, rest livid and œdematous, but there is apneumatosis with œdema of part of base, embracing a marginal strip four inches by two, one-half of which is gangrenous and the other is pigmented, dull white, tough, fibrous, firm, dry and airless, like a chronic pneumonic spot compressed. *Pericardium.*—Pearly, contains a little pale serum. *Heart.*—very large, lots of fat, 8¾ ozs.; firm clots on right side. *Abdomen.*—Peritoneum pearly, contains six ounces of dark amber serum, intestines pink. *Small intestine* contains three lumbrici and a little yellowish mucoid pulp; a spiral twist twice round ileum; mucous coat rosy pink, paler towards valve, where there is a concretion in one gland. *Large intestine.*—Much œdema of mucous membrane of cœcum with streaky lividity, rest dull white. *Stomach.*—Small, lining pale and smooth. *Liver.*—28¾ ozs., hard, 5 + 3 × 6 × 3 inches,* cuts fibrous, surface nutmeg appearance, a cavernous tumor in left lobe, not fatty. *Gallbladder.*—Full of thick dark bile. *Spleen.*—7⅞ ozs., large, capsule much thickened, fibrous, section soft, easily friable into substance like red currant jam. *Kidneys.*—3½ ozs. each, quite healthy. *Pancreas.*—2 ozs., small, mesenteric glands atrophied in œdematous fat. Probably this man helped himself too freely to toddy, got cirrhosis of the liver, hypertrophy, with dilatation of the heart and serous effusions.

Case 364.—Moonasawmy, a coolie man of the Vanyan caste, about thirty years old, from Pandoor, ten days in Madras, and ill with anasarca; admitted 15th June. Looks plump with puffiness of the face, swelling of hands and feet, and some ascites; pulse 64, respirations 18, rather laboured and wheezy, skin cool, urine pale, and sp. gr. 1018, healthy; bowels said to be costive, tongue white. 18th. Anasarca increasing. Died on 19th. Autopsy nine hours after death. Height 4 feet 10¾ inches; weight 101 lbs. Body looks plump with swelling of hands, feet, and face; rigor mortis present. *Skull.*—

* This means that the breadth of the right lobe was five inches and that of the left lobe three, the length (or depth) of the liver was six inches and its thickness three inches.

Scalp and meninges bloody, ℥ ii of serum in sub-dural space and beneath arachnoid, pia mater streaked red, veins distended. *Brain.*—35½ ozs., softish, watery fluid and blood exudes from cut surface. *Chest.*—Right pluera pearly, contains half a pint of amber serum. *Lung.*—21¼ ozs., not collapsed; upper lobe and many lobules in middle of lower, brown red, airless, tough, exuding serum scantily on pressure. *Left plerua.*—Like right. *Lung.*—Fairly well collapsed, 14½ ozs., dirty looking, showing on section blackish brown, tough, airless lobules in pinkish spongy tissue. *Pericardium.*—Pearly, contains half a pint of amber serum. *Heart.*—8¼ ozs., large, flabby, empty, little fat on surface. *Abdomen.*—Peritoneum pearly, contains a quart of straw-coloured serum, intestines pale. *Small intestine.*—Empty, mucous coat rose-coloured with reddish brown congestion of the villi in blotches in the ileum, each appearing as a minute brown dot, lots of mucus. *Large intestine.*—Empty, rather pale rose, healthy. *Stomach.*—Moderate in size, contains half a pint of brownish fluid, lining in rugæ, dull white. *Liver.*—36½ ozs., livid with yellow mottling, 6 + 3 × 6 × 3 inches, section palish, veins full, slightly fatty. *Gallbladder.*—Half full of thick green bile. *Spleen.*—5⅞ ozs., large, 4½ × 3 × 1½ inches, section brown, not friable but some pulp exudes on pressure. *Right kidney.*—6 ozs., large, capsule strips easily, section shows hypertrophy of cortex with white specks consisting of elongated cells and fat cells and granules. *Left kidney.*—1⅞ ozs., cortex paler and narrower and medulla more livid, else like right. *Pancreas.*—3 ozs., healthy. *Mesenteric glands*, atrophied, much œdema and little fat in mesentery.

Case 367.—Anamally, a coolie of the Moodaliar caste, about thirty-eight years old, from Pullumbaukum, five days in Madras, ten ill with dropsy; admitted on 7th August. There is considerable general anasarca, no diarrhœa, pulse 84, respirations 28, skin cool, urine healthy, appetite bad. He died on 15th. Autopsy two hours after death. Height 5 feet 9 inches; weight 99 lbs.; body anasarcous with some fat; rigor mortis present. *Skull.*—Scalp and meninges bloody, serum in and beneath arachnoid, pia mater anæmic, some veins full. *Brain.*—46 ozs., pale, soft. *Chest.*—Right pleura pearly, contains half a pint of serum. *Lung.*—20 ozs., apoplectic effusion of blood into the thin lower margin seen as dark red hard spots, the size of pigeon's eggs, friable on pressure like blood clots, the rest of lower lobe and posterior of apex spotted red from lobular collapse with œdema. *Left pleura.*—Like right. *Lung.*—13½ ozs., not collapsed, posterior border studded with red œdematous spots. *Pericardium.*—Pearly, contains ℥ i pale serum. *Heart.*—6½ ozs., fluid blood on both sides, fat on surface. *Abdomen.*—Peritoneum pearly, contains two quarts of serum. *Small intestine.*—Empty, mucous coat pale rose, white in ileum and lowest three feet œdematous, lots of clear mucus all through. *Large intestine.*—Empty, mucous coat pale, tinged rose-coloured, markedly œdematous all through. *Stomach.*—Large, contains white fluid, lining pale rose, smooth. *Liver.*—56½ ozs., right lobe projecting over fissure, points of adhesion to parietes; size 7 + 3 × 6 × 5 inches, firm, anæmic, pale yellow, one mass of fat cells; gall-

bladder empty. *Spleen.*—$2\frac{1}{2}$ ozs., plump, $4\frac{1}{2} \times 3 \times 1$ inch, section brown red, friable, but no pulp exudes on pressure. *Right kidney.*—$2\frac{7}{8}$ ozs., capsule adherent on sides, cortex pale yellow, medulla reddish, very fatty. *Left kidney.*—3 ozs., quite like right. *Pancreas.*—$2\frac{1}{8}$ ozs., healthy. Some healthy-looking fat with œdema in mesentery, glands normal. It is strange that there was no diarrhœa in this case.

Case 369.—Moothealoo, a coolie of the Vanyan caste, about forty years old, a Madrasee; ill ten days with "dysentery," some anasarca and great weakness; admitted and died on 3rd September 1877. Autopsy eight hours after death. Height 5 feet $3\frac{1}{2}$ inches; weight 93 lbs.; body anasarcous, not quite devoid of fat; rigor mortis present. *Skull.*—Scalp and meninges normal, ℥ iii serum in sub-dural cavity and beneath arachnoid, pia mater hyperæmic, veins full. *Brain.*—44 ozs., firm, venous injected, ℥ ii serum in ventricles. *Chest.*—Right lung $28\frac{7}{8}$ ozs., firmly adherent all over by old bands, congestion with œdema of posterior border, and chronic lobar pneumonia in places. *Left lung.*—$28\frac{1}{8}$ ozs., like right, the chronic pneumonia being confined to the front lower angle of the upper lobe and to middle of base behind. *Pericardium.*—Pearly, moistened with serum. *Heart.*—$9\frac{1}{8}$ ozs., large, both sides stuffed with white clots, three large soldier's spots, and some fat on surface. *Abdomen.*—Peritoneum healthy, guts gas-distended, slaty. *Small intestine.*—Thin, contains one lumbricus, a diverticulum over an inch long in ileum, mucous coat, pale slate-coloured several spots of submucous ecchymoses, and prominence of the solitary gland near the valve. *Large intestine.*—Empty, pale and thin, the mouths of the follicles wide and very patent, no ulcers. *Stomach.*—Large, full of yellow fluid, lining smooth pale rose. *Liver.*—$52\frac{1}{2}$ ozs., right lobe adherent all over, $6\frac{1}{2} + 4 \times 7 \times 3\frac{1}{2}$ inches, section hyperæmic, acini red, bordered pale, decidedly fatty. Gall-bladder half full of thin grumous yellow fluid. *Spleen.*—$3\frac{1}{4}$ ozs., adherent all over, and white spots of organized lymph on capsule, $4\frac{1}{2} \times 2\frac{1}{2} \times 1\frac{1}{4}$ inches, not friable, and no pulp exudes on pressure. *Right kidney.*—$4\frac{5}{8}$ ozs., capsule strips, section red, cortex streaked paler, rather fatty. *Left kidney.*—$5\frac{1}{8}$ ozs., cysts on surface, else like right. *Pancreas.*—$3\frac{3}{8}$ ozs., healthy. No fat in mesentery; glands of normal size, livid and pigmented.

## DROPSY.

*List of Cases giving Weight of Body and of its different Organs, &c.*

| No. | Name. | Caste. | Occupation. | Age. | Sex. | Height. | | Weight. | Weight in ounces of | | | | |
|---|---|---|---|---|---|---|---|---|---|---|---|---|---|
| | | | | | | Feet. | Inches. | | Brain. | Right Lung. | Left Lung. | Heart. | Liver. |
| | | | | YRS. | | | | LBS. | | | | | |
| 361 | Chiniah ... ... | Pariah ... | Cook's maity. | 55 | Male. | 5 | 4½ | 104 | 46½ | 10⅜ | 10½ | 5⅝ | 30¼ |
| 362 | Poonapey Naick... | Pully ... | Ryot ... | 50 | Do. | 5 | 2 | 88 | 46 | 8¾ | 6¾ | 6 | 17 |
| 363 | Narayen ... ... | Toddy-drawer | ..... | 65 | Do. | 5 | 6 | 100 | 38 | 23 | 14½ | 8¾ | 28¾ |
| 364 | Mooneswamy ... | Vanyan ... | Coolie ... | 30 | Do. | 4 | 10¾ | 101 | 35½ | 21¼ | 14½ | 8¼ | 37½ |
| 365 | Moonean ... ... | Moothrauz ... | Do. ... | 40 | Do. | 5 | 3 | 96 | 45¾ | 12⅝ | 13 | 4⅛ | 25⅝ |
| 366 | Soobroyen ... | Vellaulan ... | Farmer ... | 45 | Do. | 5 | 7 | 105 | 43⅜ | 19 | 20½ | 7 | 20½ |
| 367 | Annamallay ... | Moodelliar ... | Coolie ... | 38 | Do. | 5 | 9 | 99 | 46 | 20 | 13½ | 6½ | 56½ |
| 368 | Ramaswamy ... | Pariah ... | Do. ... | 65 | Do. | 5 | 1¾ | 99 | 44 | 8⅜ | 7⅞ | 6¼ | 17 |
| 369 | Moothealoo ... | Vanyan ... | Do. ... | 40 | Do. | 5 | 3½ | 93 | 44 | 28⅞ | 28⅛ | 9⅛ | 52½ |
| 370 | Kunyan ... ... | Pariah ... | Do. ... | 40 | Do. | 5 | 4 | 116 | 34 | 19¾ | 17 | 6 | 21⅜ |
| 371 | Veeraswamy ... | Washerman. | ..... | 40 | Do. | 5 | 1½ | 83 | 40¼ | 12⅛ | 11⅜ | 6½ | 38 |
| 372 | Thoolcana ... | Fisherman ... | ..... | 70 | Do. | 5 | 4 | 96 | 40 | 18 | 17⅝ | 10⅛ | 38¼ |
| 373 | Tharia ... ... | Pariah ... | Coachman. | 50 | Do. | 5 | 3 | 167 | 41¼ | 15 | 12⅛ | 8 | 23¾ |
| 374 | Lutchmee ... | Cavaray ... | Ryot's wife. | 60 | Female. | 5 | 2½ | 106 | 40 | 18 | 15¼ | 13 | 31½ |
| 375 | Hussain Bee ... | Mahomedan. | ..... | 60 | Do. | 5 | ... | 115 | 41 | 11¼ | 13¼ | 8½ | 44⅞ |
| 376 | Minchee ... ... | Pully ... | Coolie ... | 50 | Do. | 5 | 2 | 125 | 41 | 16¾ | 12 | 8⅝ | 37 |
| 377 | Vellyammah ... | Do. ... | Do. ... | 40 | Do. | 4 | 10½ | 89 | 39 | 10¼ | 8 | 4½ | 22¾ |
| 378 | Moongay ... ... | Cavaray ... | Do. ... | 35 | Do. | 5 | ... | 81 | 38¼ | 16¼ | 13⅜ | 7 | 43 |
| 379 | Venkatammah ... | Gentoo ... | Do. ... | 30 | Do. | 5 | 1 | 92 | 38½ | 11½ | 10⅛ | 3⅝ | 27¾ |
| 380 | Marleeammah ... | Yedyar ... | Do. ... | 3 | Do. | 2 | ... | 20 | 30¼ | 2⅛ | 1¼ | ⅞ | 6½ |
| 381 | Mooneammah ... | Pariah ... | Do. ... | 11/12 | Do. | 2 | 1 | 9 | 17 | 1¼ | 1⅜ | ⅝ | 4¼ |
| 382 | Annamallay ... | Pully ... | Do. ... | 1½ | Do. | 2 | 9½ | 18 | 24¼ | 1½ | 1¼ | 1 | 7¼ |

DROPSY—*continued.*

*List of Cases giving Weight of Body and of its different Organs, &c.*—continued.

| No. | Name. | Weight in ounces of—*cont.* | | | | Date of autopsy. | Hours after death autopsy made. | Rigor mortis. | Bodily state. |
|---|---|---|---|---|---|---|---|---|---|
| | | Spleen. | Right Kidney. | Left Kidney. | Pancreas. | | | | |
| 361 | Chiniah ... ... | 3⅝ | 4¾ | 3⅜ | 2 | 28 April 1877 | 12 | Absent ... | In fair flesh ; some fat with serum in cellular tissue. |
| 362 | Poonapey Naick ... | 1 | 2¼ | 2¼ | 1⅜ | 2 May 1877 | 4 | Present ... | Anasarcous. |
| 363 | Narayen ... ... | 7⅞ | 3½ | 3½ | 2 | 8 June 1877 | 12 | Absent ... | Do. |
| 364 | Mooneswamy ... | 5⅞ | 6 | 4⅞ | 3 | 19 June ... | 9 | Present ... | Plump; swelling of hands, feet, and face. |
| 365 | Moonean ... ... | 1⅜ | 2⅛ | 1⅝ | 1½ | 28 June ... | 13 | Absent ... | Emaciated; much ascites; œdema of feet. |
| 366 | Soobroyen ... | 7⅝ | 3⅛ | 3½ | 3⅛ | 1 July ... | 12 | Do. ... | Thin; ascites; œdema of feet. |
| 367 | Annamallay ... | 2½ | 2⅞ | 3 | 2⅛ | 15 Aug. ... | 2 | Present ... | Anasarcous, with some fat. |
| 368 | Ramaswamy ... | 1 | 1¾ | 2 | 2½ | 22 Aug. ... | 4 | Do. ... | In fair flesh; œdema from the belt down; some ascites. |
| 369 | Moothealoo ... | 3¼ | 4⅝ | 5⅛ | 3⅜ | 3 Sept. 1877 | 8 | Do. ... | Anasarcous; not quite devoid of fat. |
| 370 | Kunyan ... .. | 1⅞ | 2¼ | 2⅜ | 2⅛ | 6 Sept. ... | 12 | Absent ... | Considerable general anasarca and ascites. |
| 371 | Veeraswamy ... | 3⅜ | 6 | 7 | 2½ | 6 Oct. 1877 | 9 | Present ... | Thin; ascites; œdema of feet. |
| 372 | Thoolcana ... | 12½ | 3¼ | 3¼ | 3⅜ | 4 Jan. 1878 | 9 | Do. ... | Somewhat anasarcous. |
| 373 | Tharia ... ... | 2 | 2¼ | 2¼ | 2¼ | 2 Jan. ... | 5 | Do. ... | Anasarcous; elephantiasis of scrotum. |

| | | | | | | | | | | |
|---|---|---|---|---|---|---|---|---|---|---|
| 374 | Lutchmee ... | 3 | $3\frac{1}{2}$ | $3\frac{3}{4}$ | $2\frac{7}{8}$ | 8 April 1877 | 3 | Do. ... | Anasarcous; some fat. |
| 375 | Hussein Bee ... | $2\frac{1}{8}$ | 4 | 4 | 2 | 21 April 1877 | 10 | Do. ... | Obese and dropsical. |
| 376 | Minchee ... ... | $1\frac{1}{4}$ | 4 | 4 | $2\frac{3}{4}$ | 2 June 1877 | 3 | Absent ... | Anasarcous and some fat. |
| 377 | Vellyammah ... | $1\frac{1}{8}$ | $2\frac{1}{2}$ | $2\frac{1}{2}$ | $1\frac{1}{2}$ | 23 June ... | 9 | Present ... | General serous effusion into cellular tissue and serous cavities. |
| 378 | Moongay ... .. | $4\frac{1}{2}$ | 5 | $4\frac{3}{4}$ | $2\frac{3}{4}$ | 11 Oct. 1877 | 10 | Going off ... | Anasarcous. |
| 379 | Venkatammah ... | $3\frac{5}{8}$ | 2 | $2\frac{5}{8}$ | $1\frac{1}{4}$ | 14 Oct. ... | 13 | Present ... | Do. |
| 380 | Marleeammah ... | $\frac{3}{8}$ | $\frac{5}{8}$ | $\frac{3}{4}$ | $\frac{1}{4}$ | 28 April 1877 | 9 | Do. ... | Œdematous extremities. |
| 381 | Mooneammah ... | $\frac{5}{8}$ | $\frac{1}{2}$ | $\frac{1}{2}$ | $\frac{1}{4}$ | 21 May ... | 2 | Going off ... | General anasarca. |
| 382 | Annamallay ... | $\frac{3}{4}$ | $\frac{3}{4}$ | $\frac{3}{4}$ | $\frac{5}{8}$ | 28 Sept. ... | 1 | Present ... | Thin; considerable general anasarca and ascites. |

## 2.—Atrophy.

Many cases were admitted with great emaciation and weakness, but suffering from no appreciable disease. These were generally returned under debility, privation, or atrophy. In Appendix C they are all grouped under "other causes," but in Appendix A debility is shown separately and to have caused 130, or 4 per cent. of the total admissions, and 41, or 3·67 per cent. of the total deaths, and to give a mortality of 31·5 per cent. of treated. The corresponding percentages for Vellore are 16·77, 7·28, and 16·3, if privation there be taken as equivalent to debility.

The average daily sick from this cause was 3·29, or 5 per cent. of the total; women contributing 6·9, men 5, and children 1·8 per cent.

*Disease complained of.*

Among the famine-stricken, four men, four women, and four children, of those who came under observation, may be said to have died from simple atrophy. On admission, two of the men and three of the women complained of debility only; one man and one woman were brought insensible and died directly; one man and one child complained of feverishness of some duration, but showed no rise of temperature after admission; one child was suffering from eczema of the side of face and neck; one had pain in, and irritability of, stomach, which ceased after vomiting a lumbricus; and the remaining child had ophthalmia and ulceration of the scalp.

*Duration of illness.*

As to the duration of the illness, one man died insensible on the day of admission and had no history; the other three had an average of 17 days in hospital and of 19 days' illness before admission. One woman also died insensible on the day of admission and gave no history; the other three had an average of 23 days in hospital, and of 23 days' illness before admission. The children were, on an average, seven days in hospital, and five days ill before admission.

*Height.*

*Age.*

The average height of the men is 5 feet 3 inches, and of the women 4 feet 11 inches. On an average the men were about 42 years of age, and the women about 55 years. Two children were

about a year old, one was about three years, and one was about eight years old. The men weighed on an average 70 lbs. and the women 66¾ lbs.

*Weight.*

Rigor mortis was absent only in one case twelve hours after death; in another it was still present fifteen hours after death. The skin was usually covered with scurf, but the presence of itch was not noted. In a child there was eczema of the side of the face and neck; in another child there was ulceration of the scalp, and in this case and in another child there was injection of the conjunctivæ. There was œdema of the feet present in three men, three women, and a child.

*Rigor mortis.*

*Skin disease.*

The scalp was thin and pale, and on removing the calvarium no blood appeared on the meninges as is usual when the sinuses are full, in two men, all the women, and all the children. In the other two men some blood flowed from the severed vessels on cutting through the scalp, and from the surface of the meninges and base of the skull on removing the calvarium and brain. In one of the other men a quantity of blood flowed from the base of the skull on removing the brain.

SKULL.

On cutting through the meninges serum was found in the sub-dural cavity in all the men, three women, and two children; and it was found effused under the arachnoid filling up the sulci of the brain in three men, three women, and one child. In one of the women the subarachnoid serum was blood-tinged.

*Arachnoid.*

The large vessels of the pia mater were full in a man and two children, and the lateral veins only were full in two men. In one of the latter the membrane was purplish in colour, and in a woman it was whitish, as if sodden by the subarachnoid effusion. In this case there was a hard, round clot, the size of No. 1 shot, on the corpus callosum. In a man there were some blotches of ecchymosis on the sides of the brain; in a child there was slight ecchymosis near the longitudinal fissure in front, and in another the effusion was dark-coloured and considerable in quantity, quite filling the sulci of the posterior part of the right hemisphere of the brain.

*Pia mater.*

*Ecchymosis.*

*Brain substance.*

The average weight of the brain is 39½ ozs. for the men, and 36 ozs. for the women. The substance looked healthy in three men and two children, and it was soft and anæmic in the others. In only one case was there any serum in the ventricles; this was a little whitish fluid, in a woman.

CHEST.

*Pleuræ.*

*Hydrothorax.*

*Adhesions.*

The pleural sacs were quite healthy in all the children, two women, and one man, and they looked healthy but contained a pint of amber serum in a woman. In another woman there was about half a pint of serum in each sac, and in two men the sac was only moistened with serum. There were old points of adhesion in one pair and one right pleura in men, and in one right pleura in a woman; and the adhesions were firm and extensive in one pair and one left pleura in men, and in one left pleura in a woman.

*Lungs.*

The lungs were quite healthy in only one man and three children, and the left lung in a woman. In the man and in the left lung in one of the children the bronchi contained a quantity of muco-purulent fluid; and in another of the children there was some hypostatic congestion present. The weight of the right lung in the man was 10¾ ozs. and of the left lung 10½ ozs.; and of the left lung in the woman 8¾ ozs. In one child the lungs looked healthy, but on section they were studded with red spots, from which could be squeezed some serous fluid, as in incipient lobar pneumonia.

*Congestion with œdema.*

*Apneumatosis with œdema.*

There was more or less lividity with œdema, mostly confined to the posterior border of both lungs in a man and two women. The right lung weighed 13¾ ozs. in the man and averaged 14 ozs. in two women, and the left lung weighed 11⅜ ozs. in the man and averaged 13½ ozs. in the women. There was apneumatosis with œdema of some parts of posterior border—or, in one case, of lobules of the lung—in both lungs in two men and a woman, and of the right lung only in another woman. The average weight of the right lung is 14½ ozs. in the two men, and 11¼ ozs. in the two women, and of the left lung 12¾ ozs. in the two men, and in

the woman it weighed 11⅜ ozs. In one of these men there was a tuberculous deposit in the apex of the left lung of the size of a walnut. It had a cavity in its centre, and the surrounding lung tissue was œdematous, but not congested.

*Tuberculous deposit.*

Pigmentation of the lung tissue was well marked in both lungs in a middle-aged man, and in the right lung in an old woman.

*Pigmentation.*

The pericardium was healthy in a woman and two children, and it looked healthy, but was moistened with serum in three men, three women, and a child; in another child it was distended with pale serum, and in a man it contained two ounces of serum.

*Pericardium.*

The surface of the heart was quite devoid of fat in two men and in all the children, and in the other two men there was only a trace of fat present; in the two former the fat was replaced by œdema.

*Heart.*

In all the women there was a moderate amount of fat present.

*Fat.*

The white detachable lymphy deposit known as the "soldier's spot" was present in two men. In one of these cases it was rather indistinct and situated on the apex of the heart.

*Soldier's spot.*

The cavities of the heart were found empty in a man and three women, and they contained blood and clots in a man and in all the children, and the right side only contained blood or clots in two men and a woman.

*Cavities.*

The average weight of the heart is 4¾ ozs. for the men and 5 ozs. for the women.

*Weight.*

The peritoneum was quite healthy in two men, three women, and in all the children, and it was equally healthy in appearance, but contained serum in two men and a woman; in one of the men the serum was a quart of slightly turbid fluid, in the other it amounted to only half a pint of pale straw-coloured fluid with a cloud of jelly-like lymph floating therein, and in the women it was a pint of pale amber fluid.

ABDOMEN.

*Peritoneum.*

*Ascites.*

The stomach was noted small in two men, three women, and all the children, and large in a woman. It was quite empty in a man, a woman, and three

*Stomach.*

children. It contained fluid, usually bile-tinged, in three men, two women, and one child, and it contained four lumbrici in a woman and much gas in a man.

*Contents.*

The mucous coat was noted smooth in a man, two women, and a child, and rugose in two men, a woman, and three children. It was noted pale and thin in a man, three women, and three children, and congested red to livid in a man and a woman, and a child, and in a man it was pigmented in parts, but otherwise healthy looking.

*Mucous coat.*

The small intestine contained yellow, bluish, or reddish fluid in a man, three women, and a child; in the others it was empty, except being distended with gas in a man and a child, being lined with green mucus in a man and two children, and containing lumbrici in one of these children, in a man, and a woman.

SMALL INTESTINE.

*Contents.*

Lumbrici were found in five cases in all. There were six in a man, one in a child, 103 in a woman, not counting four found in her stomach, and two each in two other women.

*Lumbrici.*

There was some constriction of the ileum four feet above the valve from girdle ulcers encircling this part of the gut in a woman, and in another woman there was a small pedunculated fatty tumour also in the ileum.

The mucous coat was normally injected in two men and a child; it was anæmic in a man, a child, and all the women, and it was hyperæmic in parts of the ileum in a man and two chilrden; in the former there were small spots of submucous ecchymosis in the ileum. In a woman and a child Peyer's patches were felt thickened and were pink to livid in colour. In an old woman there were seven black-based, thick-edged girdle ulcers, about an inch in diameter, and quite encircling the ileum, four were nearly close together at the fourth foot from the valve, and caused partial constriction of the gut. There was pigmentation of parts of the ileum in a man, and all through in a woman. It was slightly œdematous in a woman.

*Mucous coat.*

*Ecchymosis.*

*Tubercular ulcers.*

*Pigmentation, œdema.*

LARGE INTESTINE.

The large intestine contained some fæces in a woman and a child, and in all the others it was empty, except that there were adherent scybala in a man, a film of dry fæces in another, and green mucus in a child, and it was distended with gas in a man and a child. There were two small fatty tumours in the colon in a woman. The mucous coat was normally injected in two men and a woman; in the latter there was some lividity of the cæcum, and the rectum was red and swollen. It was anæmic in two men and two women, and in a woman there were livid spots in the transverse colon, and in a woman livid streaks in the cæcum. It was injected deep rose to red in all the children; in one the mouths of the follicles were red punctated, and in another there was thickening, with papillation in the rectum.

*Mucous coat.*

There was pigmentation, giving the mucous coat a more or less slaty colouration, in a man and a woman.

*Pigmentation.*

In a man there were small superficial livid-edged ulcers, with scybala adherent, in the cæcum and ascending colon, and in another man there were two or three small circular superficial pale-based ulcers in the sigmoid flexure, and in a woman there were similar ulcers of the mouths of a few follicles. Diarrhœa was noted only shortly before death in one of these men, and obstinate constipation of some duration in the other.

*Ulcers.*

There was a little fat in the mesentery of one of the men and three women, but none in the others. In one of the children the fat was replaced by œdema. The mesenteric glands were of about their normal size in a man, three women, and all the children; in one of the latter they were injected red. They were much enlarged in one of the men, and atrophied in two men and a woman.

*Mesentery.*

*Glands.*

The liver was small in all these cases, weighing only 24⅛ ozs. in the men and 28½ ozs. in the women. There was abnormal adhesion between the capsule and parietes by two points of old standing, with dragging out of the hepatic capsule beneath into teat-like processes in a woman. There was atrophy of the margin of the left lobe in three men. The substance was anæmic in all except

LIVER.

*Adhesions.*

one child. Its structure was normal in a man and a child, and in the others it was fatty and of an ochrey yellow colour. In one of the men it was deeply pigmented and less fatty than in the others, and in one of the children a clear fluid flowed from the cut surface, which coagulated on standing, the liver surface being one mass of fat cells. In one of the slightly fatty livers in women the section was pale and studded with small circular spots like fish-roe, the nature of which was not clearly made out by the microscope, and two very fat livers in women looked cirrhotic when cut. Albuminoid degeneration was looked for in all and found in none. The gall-bladder was empty in a man; it contained green bile in two women and three children, thin brown bile in a man, thick tarry bile in a man, oil-like fluid in a man, two women, and a child; in two men and one of the women it was turbid.

*Structure.*

*Gall-bladder.*

The spleen varied in weight in the men from seven drachms to $3\frac{1}{4}$ ozs., the average being $2\frac{1}{4}$ ozs., and in the women from $\frac{1}{2}$ oz. to $5\frac{3}{4}$ ozs., the average being $2\frac{1}{4}$ ozs. The capsule was thickened in points where adherent to parietes in a man. The substance was firm, not friable, and deficient in pulp, with no exudation under pressure in three men, two women, and all the children, and in a man and two women it was easily friable into a brown pulp like thin jam.

SPLEEN.

*Capsule.*

*Pulp.*

In the men the weight of the right kidney ranged from $2\frac{1}{8}$ ozs. to $3\frac{3}{8}$ ozs., the average being $2\frac{5}{8}$ ozs. nearly; and that of the left from $2\frac{1}{4}$ ozs. to $3\frac{3}{4}$ ozs., the average being $2\frac{3}{4}$ ozs. fully. In the women the weight of the right kidney ranged from $1\frac{1}{2}$ oz. to $2\frac{1}{2}$ ozs., the average being 2 ozs. fully, and that of the left from $1\frac{7}{8}$ oz. to $3\frac{3}{8}$ ozs., the average being $2\frac{1}{2}$ ozs. The capsule stripped easily, except in a man it was slightly adherent. The surface was studded with small cysts in two men and a woman. The substance was anæmic and fatty in three men and all the women. Desquamation cells were abundant in a man and a child.

KIDNEYS.

*Weight.*

*Cysts.*

*Substance.*

The pancreas weighed on an average $1\frac{1}{2}$ oz. fully in the men, and $1\frac{3}{8}$ oz. in the women. Its structure appeared healthy in all.

PANCREAS.

## ATROPHY.

*List of Cases, giving Weight of Body and of its Organs, &c.*

| No. | Name. | Caste. | Occupation | Age. | Sex. | Height. | | Weight. | Weight in ounces of | | | | |
|---|---|---|---|---|---|---|---|---|---|---|---|---|---|
| | | | | | | | | | Brain. | Right Lung. | Left Lung. | Heart. | Liver. |
| | | | | YRS. | | FT. | IN. | LBS. | | | | | |
| 383 | Moheedeen Saib ... | Mahomedan... | Coolie ... | 45 | Male. | 5 | 5 | 87 | 43 | 13¾ | 11⅜ | 6⅜ | 22¾ |
| 384 | Lutchmon ... ... | Cavaray ... | Do. ... | 50 | Do. | 5 | 2 | 58 | 37½ | 15½ | 14¼ | 4¼ | 21⅝ |
| 385 | Chenay ... ... | Weaver ... | Weaver... | 45 | Do. | 5 | 0 | 59 | 41 | 13⅝ | 11⅜ | 4⅛ | 19¾ |
| 386 | Ramadoo ... ... | Opera ... | Coolie ... | 30 | Do. | 5 | 5 | 76 | 36¼ | 10¾ | 10½ | 4½ | 32¼ |
| 387 | Narayanen ... ... | Pariah ... | Do. ... | 60 | Female. | 4 | 10 | 60 | 36 | 10⅝ | 11½ | 5 | 21¼ |
| 388 | Ponnee ... ... | Do. ... | Beggar... | 70 | Do. | 4 | 10 | 73 | 35½ | 12 | 8¾ | 5½ | 20⅞ |
| 389 | Fatima Bee ... ... | Mahomedan... | Do. .. | 30 | Do. | 5 | 1½ | 57 | 35 | 12¼ | 12⅝ | 4 | 31½ |
| 390 | Canamah ... ... | Cavaray ... | Coolie ... | 60 | Do. | 5 | 0 | 77 | 36½ | 15¾ | 14⅜ | 5½ | 20⅝ |
| 391 | Kunnee ... ... | Ryot ... | ..... | 1 | Do. | 2 | 0 | 7½ | 20½ | 1 | ⅞ | 4½ | 4⅜ |
| 392 | Lutchmee ... ... | Pariah ... | ..... | 3 | Do. | 3 | 0 | 16¾ | 35 | 2⅛ | 2 | 1 | 8¾ |
| 393 | Venketswamy ... | Cobbler ... | ..... | ⅝ | Male. | 2 | 0 | 8½ | 23 | 1⅛ | 1⅛ | ¾ | 6⅛ |
| 394 | Kollan ... ... | Pully ... | ..... | 8 | Do. | 4 | 1½ | 29 | 45¾ | 4¼ | 3⅜ | 2¼ | 16 |

ATROPHY—*continued.*

*List of Cases, giving Weight of Body and of its Organs, &c.*—continued.

| No. | Name. | Weight in ounces of—*cont.* | | | | Date of autopsy. | Hours after death autopsy made. | Rigor mortis. | Bodily state. |
|---|---|---|---|---|---|---|---|---|---|
| | | Spleen. | Right Kidney. | Left Kidney. | Pancreas. | | | | |
| 383 | Moheedeen Saib ... | 3¼ | 3⅜ | 3¾ | 2¼ | 12 Sept. ... | 6 | Present ... | In low flesh ; œdema of feet ; some ascites. |
| 384 | Lutchmon ... ... | 1⅞ | 2¼ | 2¼ | 1⅜ | 1 Oct. ... | 1 | Do. ... | Skeleton ; no œdema. |
| 385 | Chenay ... ... | ⅞ | 2⅛ | 2¼ | 1½ | 9 Oct. 1877. | 2 | Do. ... | Skeleton ; œdema of feet. |
| 386 | Ramadoo ... ... | 3¼ | 3 | 3¼ | 1⅛ | 13 Dec. ... | 2 | Do. .. | Do. do. |
| 387 | Narayanen ... ... | 1⅝ | 1½ | 1⅞ | ⅞ | 1 April 1877. | 10 | Not well marked . | Emaciated ; œdema of feet. |
| 388 | Ponnee ... ... | 1 | 2 | 2¼ | 1 | 18 June ... | 12 | Absent ... | Do. do. |
| 389 | Fatima Bee ... ... | 5¾ | 2½ | 2½ | 2⅜ | 4 Jan. 1878. | 15 | Present ... | Skeleton ; no œdema. |
| 390 | Canamah ... ... | ½ | 2⅛ | 3⅜ | 1½ | 19 Mar. 1878. | 8 | Do. ... | In low flesh ; œdema of feet. |
| 391 | Kunnee ... ... | ½ | ½ | ½ | ⅛ | 30 April 1877. | 2 | Do. ... | Skeleton. |
| 392 | Lutchmee ... ... | ⅜ | 1¼ | 1⅛ | 1½ | 15 May ... | 2 | Do. ... | Skeleton ; no œdema. |
| 393 | Venkatswamy ... | ¾ | ⅝ | ⅝ | ¼ | 29 July ... | 10 | Do. ... | Do. do. |
| 394 | Kollan ... ... | ¾ | 1⅝ | 1⅞ | ⅝ | 31 Oct. 1877. | 9 | Do. ... | Skeleton ; slight œdema of feet. |

## 3.—Fever.

The admissions under fever were 111, or 3·4 per cent., and the deaths 9, or 0·8 per cent. of the total. The average daily sick was 2·04, or 3·1 per cent. of the total; children contributing 4·5, women nearly 3, and men 2·4 per cent.

The return in Appendix C shows fever to have caused 758 out of 22,939 deaths, or 3·3 per cent. The Sanitary Commissioner (Dr. Cornish) reports that the total deaths registered as fever in 1877 was 469,241, or in the ratio of 16 per mille of population against 7·6 per mille in former years. But I have no doubt that many of these were deaths from pneumonia, for I found pyrexia, nearly always from pneumonia, present in a large proportion of the famine sick; in fact in the *post-mortem* room pneumonia, in a more or less advanced stage, was found in more than one case in every four.

Dr. Cornish also reports that none of the Medical Officers deputed as Sanitary Inspectors was able to find any case of relapsing fever, such as Dr. Vandyke Carter reported to be more or less prevalent on the Bombay side; and that they considered all the fevers they saw malarial in origin.

The low death-rate and short duration of the prevailing fevers seen in the Royapettah sheds are a sufficient indication of their type. Ague and febricula were the most common forms, and no case of relapsing fever occurred. Their prevalence seemed little affected by the seasons.

The following seven were the only cases that came under dissection. The first four were, there is little doubt, cases of enteric fever. The next case, No. 399, looked like malarial fever, although this is not a common disease in Madras, and case No. 400, if not the same disease, was apparently simple continued fever, supposing the history given to be correct. The last case No. 401, was probably sunstroke.

Case 395.—Ragavaloo, a weaver by caste and calling, about twenty years old, admitted on 20th June 1877 with fever of about a week's standing, has had no diarrhœa, but a dry cough set in a day or two ago, pulse 60, respirations 24, temperature 102° F., rising to 104° F. in the evening; is not emaciated. On the morning of the 22nd he was found sitting up in bed with some dyspnœa (R. 36); but not worse in other respects: however towards evening delirium set in, quickly followed by coma, and he died during the night. Autopsy eight hours after death. Height 5 feet 4 inches, weight 87 lbs. Body fairly well nourished, but no fat under the skin; rigor mortis

present; no marks on surface. *Skull*—Vessels of scalp and meninges full of blood, arachnoid normal, veins of pia mater gorged with dark blood. Brain $44\frac{1}{2}$ ozs., cuts softish, hyperæmic. *Chest*—Right pleura pearly, contains four ounces of serum, has slight old adhesions at base. *Lung*—$12\frac{7}{8}$ ozs., well collapsed, livid, section nearly airless, red, dark blood from cut vessels on pressure. *Left pleura*—Pearly, slight adhesions at apex. *Lung*—12 ozs., quite like right. *Pericardium*—Pearly, contains an ounce of amber serum. *Heart*—6 ozs., little fat on surface, some fluid blood on both sides. *Peritoneum*—Healthy, intestines slaty, much distended with gas. *Small intestine*—Empty, distended with gas, mucus adherent, arborescent livid congestion of ileum, and great prominence of the solitary glands. *Large intestine*—Distended with gas and containing a quantity of green pultaceous matter, mucous coat slaty with livid arborescence in cæcum, mouths of solitary gland follicles white and very conspicuous towards lower end. *Stomach*—Enormous, full of gas, contained a quart of milky fluid, lining pale in rugæ. *Liver*—$41\frac{1}{4}$ ozs., congested, $7 + 2\frac{1}{2} \times 5 \times 3\frac{3}{4}$ inches,* section shows deep congestion, slightly fatty. *Gall-bladder*—Quite empty. *Spleen*—$5\frac{1}{4}$ ozs., flaccid, $5 \times 3\frac{1}{4} \times 1\frac{1}{4}$ inches, dark brown pulp exudes on pressure from cut surface. *Right Kidney*—3 ozs., capsule strips easily, section uniformly livid congested; free, and lining the tubes are round nucleated highly refractive cells. *Left Kidney*—$3\frac{1}{2}$ ozs., quite like right. *Pancreas* $2\frac{1}{2}$ ozs., healthy. *Mesenteric Glands*—Normal, enveloped in fat. The high temperature with the congestion of the liver, kidneys, and brain point to a specific poison; the smallness of the spleen discourages the idea of malaria, and the enlargement of the solitary glands suggests enteric fever not yet reached the stage of diarrhœa and ulceration. It is impossible to find out accurately from a native how long he has been suffering from any disease. This man first said a day or two, then a week. The immediate cause of death was apparently apneumatosis of the lungs.

Case 396.—Curpennah, a coolie of the Pully caste, aged about forty years, from Thoornavyalum, nineteen days in Madras, ill seventeen with fever. Admitted on 22nd May. Is in good flesh, pulse 88, respirations 18, temperature 102°8 F., had no diarrhœa before yesterday, when he had six buff-coloured slimy grumous motions, tongue red with a white fur and dry. Has some clonic spasm of the muscles as in chorea: says he has been subject to this about once in five months for the last two years and that arrack cures it! *31st.*—Fever and diarrhœa continue, has some tenderness on pressure over the liver which is not enlarged; some pain on pressure in left flank, no tympanitis, urine free from albumen, sp. gr. 1015. *2nd June.*—Congestion of base of left lung, tongue moist, white furred, stools still thin ochrey fluid, or watery with ochrey sediment. The fever abated on the 12th, but he died on 23rd, worn to a skeleton. The mind was clear all through. Autopsy four hours after death. Height 5 feet 3 inches; weight 73 lbs. Body much emaciated; no œdema; rigor mortis present. *Skull*—

* This means breadth of right lobe 7 inches and of left lobe $2\frac{1}{2}$ inches, depth of liver 5 inches, and thickness $3\frac{3}{4}$ inches.




LOWER END OF ILEUM

SHEWING TYPHOID ULCERS

Scalp and meninges bloody, a little serum in sub-dural cavity, veins full with some ecchymosis in the sulci of vertex. *Brain*—44½ ozs., firm, rather hyperæmic. *Chest* — Right lung 7⅛ ozs., healthy, some circular spots of subpleural ecchymosis two lines in diameter, and thickening of pleura at one point of adhesion. *Left lung*—Firmly adherent to parietes and covered with a false membrane, 6½ ozs., healthy. *Pericardium*—Pearly, moistened with serum. *Heart*—4⅝ ozs , a trace of fat on surface, a little fluid blood on both sides. *Abdomen*—Peritoneum healthy. *Small intestine*—Empty, mucous coat pale slaty, devoid of mucus; three, punched-out like, pale-based, thick dark-edged ulcers close above the valve and three others in the two adjoining Peyer's patches, and a cicatricial circular spot in a patch higher up not adherent to the middle coat. *Large intestine*—With scybala adherent to pale slate dirty-looking unthickened mucous coat of caput and ascending colon; rest swollen, thrown into rugæ pink in furrows and pale on ridges, giving a strange appearance. *Stomach*—Small, empty, pale rose, with ochrey mucus adherent. *Liver*—27¼ ozs., right end of right lobe adherent to parietes, 6 + 2 × 5 × 3 inches, section red nutmeg, but no disease detected by microscope. G.B. full of train-oil-like fluid. *Spleen*—2⅞ ozs., brown red, 4 × 3 × 1 inches, flabby, not friable, and no pulp exudes on pressure. *Kidneys*—2⅜ ozs. each, capsule strips easily, substance deeply red injected, structure normal. *Pancreas*—1½ oz., healthy. *Mesentery*—Has a trace of fat, glands atrophied. In this case the blood was examined for vibriones and none found. The implication of the colon probably dated from about the 3rd of June when some mucus was first noticed in the stools, which were before that quite those of enteric fever only.

Case 397.—Thoyee, the daughter of a coolie of the Pully caste, about thirteen years old, from Conjeeveram, eight months in Madras, ill with fever a month. She is in fair flesh, pulse 120, weak, respirations 36, temperature 104°F., tongue moist and clean; she is irritable and restless, making it difficult to examine her; congestion was detected in base of both lungs; said to have had one loose motion. Admitted on 28th, died on 31st January 1878. Autopsy twelve hours after death. Height 4 feet 8 inches, weight 48 lbs., body as above, rigor mortis present. *Skull*—Scalp and meninges pale, a trace of serum in sub-dural cavity, some spots of subarachnoid ecchymosis and a little serum, surface rosy, veins empty. *Brain*—25⅝ ozs., softish, injection normal. *Chest*—*Right pluera* healthy. Lung 8 ozs., a few spots of lobar pneumonia in posterior border. *Left pleura* healthy. Lung 7⅝ ozs., like right. *Pericardium*—Pearly, contains a little serum. *Heart*—4 ozs., distended with blood, a little fat on surface. *Abdomen*—Peritoneum healthy. *Small intestine*—Lined by ochrey pultaceous matter; mucous coat rosy in upper, livid in lower end, the Peyer's patches all through are thickened and projecting, forming peltate tumours, some are ulcerated in the centre; one ulcer had almost perforated the gut. *Large intestine*—Contains some pieces of fæces, mucous coat pale rosy, two follicles in transverse colon are thickened, and two are ulcerated and injected. *Stomach*—Small, contains a little milky fluid, lining pale pink, in rugæ. *Liver*—35¾ ozs., plump, pale

red, streaked yellow, $6\frac{1}{2} + 2\frac{1}{2} \times 5\frac{1}{2} \times 4$ inches, very fatty; gall-bladder distended with thin green bile. *Spleen*—$9\frac{1}{4}$ ozs., a grey spot on surface two lines thick, $6 \times 4 \times 1\frac{1}{2}$ inches, section red brown, of normal consistence. *Right Kidney*—$2\frac{3}{4}$ ozs., capsule strips easily, section flabby, pale red, slightly fatty. *Left Kidney*—$2\frac{1}{2}$ ozs., like right. *Pancreas*—$2\frac{1}{8}$ ozs., healthy. Little fat in mesentery, glands large pale rose. This girl had been ill probably about a fortnight with enteric fever.

Case 398.—Vythy, daughter of a Pariah coolie, about five years old, admitted and died on 22nd June 1877; said to have been ill ten days with fever. Autopsy five hours after death. Height 2 feet 10 inches, weight 21 lbs. Body quite a skeleton, œdema of feet, rigor mortis gone off. *Skull*—Scalp and meninges rather bloody, serum in sub-dural space and beneath arachnoid. *Brain* $36\frac{1}{2}$ ozs., surface, pinkish streaked red, veins nearly empty, section rather soft and anæmic. *Chest—Right pleura* pearly, contains 1 oz. pale serum. *Lung* 3 ozs., pinkish livid, section red with darker spots, tough, exuding some froth on pressure. *Left pleura* healthy. Lung $2\frac{5}{8}$ ozs. like right, section presenting the variegated appearances of broncho-pneumonia. Two lumbrici in bronchi. *Pericardium*—Pearly, distended with serum. *Heart*—$1\frac{1}{2}$ ozs., no fat on surface; fluid blood in both sides. *Abdomen*—Peritoneum pearly, distended with yellowish turbid fluid with yellow flocculi, sloughy spots on small gut. *Small intestine*—Contains three lumbrici and a pint of yellowish grumous fluid, mucous coat pale slate, tinged yellow; upper Peyer's patches brown, thickened, and adherent to middle coat, showing a tendency to ulcerate, ten lower patches occupied by typical oval typhoid ulcers, each about an inch long by $\frac{1}{2}$ inch broad, six have almost perforated the gut, and are seen on the peritoneal surface as sloughy looking spots. *Large intestine*—Empty, mucous coat dull greyish white to pale slate, no mucus detachable. *Stomach*—Small, empty, lining pale rosy, in rugæ. *Liver*—15 ozs., pale rose tinged, $4\frac{1}{2} + 2 \times 4\frac{1}{2} \times 2\frac{1}{4}$ inches, section fatty nutmeg, very fatty. G.B. half full of olive-oil-like bile. *Spleen*—2 ozs., $3\frac{1}{2} \times 2\frac{1}{2} \times \frac{3}{4}$ inches, brown, tough, not friable, and no pulp exudes on pressure. *Kidneys*—$1\frac{1}{4}$ oz. each, capsule strips easily, section pale livid red; the microscope shows rounded nucleated cells free and lining the tubes. *Pancreas*—Seven drachms, healthy. *Mesenteric glands*—Large and livid, section mottled dark; no fat in mesentery. This was an undoubted case of enteric fever; the duration of the disease can only be guessed at,—"ten days" with a native being any time over a week. The contents of the peritoneum showed actual perforation of the gut had occurred.

Case 399.—Eravareddy, a coolie of the Pully caste, about forty years old, from Conjeeveram, twenty days in Madras, too ill with "diarrhœa": admitted and died on 23rd August 1877. Autopsy ten hours after death. Height 5 feet $4\frac{1}{2}$ inches, weight 81 lbs., body thin, no œdema, rigor mortis present. *Skull*—Scalp and meninges pale, a little serum beneath arachnoid and tentorium, pia mater livid injected, some of the veins full. *Brain*—$41\frac{5}{8}$ ozs., softish anæmic. *Chest—Right lung*—$19\frac{1}{8}$ ozs., slightly torn in removal from old points of adhe-

sion, congestion with œdema of posterior part, anterior part spongy, bright pink on section. *Left Lung*—14⅛ ozs., old points of adhesion posteriorly, apneumatosis with œdema of posterior border, else like right anteriorly. *Pericardium*—Pearly, contains 2 ozs. serum. *Heart*—6¼ ozs. fluid blood on right side, no fat on surface. *Abdomen*—Peritoneum pearly, contains 4 ozs. reddish serum. *Small intestine*—Empty, looks healthy, is rather thin perhaps. *Large intestine*—Contains a quart of formed fæces; mucous coat pale, little mucus, and rather thin perhaps, healthy else. *Stomach*—Small, empty, lining dull rosy, in rugæ. *Liver*—39½ ozs., flabby, 7 + 2 × 7 × 3 inches, section dark liver pigmented; acini not distinct; gall-bladder full of thin dark bile. *Spleen*—23 ozs., adhesions to parietes, 7½ × 5½ × 2½ inches, flabby, easily friable into a dark red pulp. Two additional spleens weigh two drachms; one is the size of a No. 8 and the other of a No. 40 bullet. *Right Kidney*—2¾ ozs., capsule strips, section dark livid red, cortex yellow streaked, much desquamation cells. *Left Kidney*—3⅛ ozs., cysts on surface, less livid; like right. *Spleen*—3¾ ozs., healthy. No fat in mesentery; glands atrophied. This patient cannot have had diarrhœa; the appearances resemble malarial fever with lung complication.

Case 400.—Surruttoo, a grass-cutter, about twenty-five years old, ten days ill with fever, was confined a month ago. She is half unconscious and delirious with much restlessness and jactitation; pulse 144, respirations 44, temperature in axilla 104° F., has pneumonic râles in base of right lung, stools said to be semi-consistent and dark coloured. Admitted on 11th January 1878 and died next day. Autopsy eight hours after death. Height 4 feet 10 inches, weight 63 lbs., body thin, rigor mortis present. *Skull*—Scalp and meninges pale, serum beneath arachnoid and tentorium, veins full with slight ecchymosis at temples. *Brain*—40 ozs., firm, looks healthy. *Chest*—Right pleura healthy. Lung 13¼ ozs., livid especially behind, section spongy, bleeding, with red spots as in incipient lobar pneumonia, no serum or softening. *Left Pleura*—Has firm old adhesions. Lung 11½ ozs., slightly torn in removal, quite similar to right. *Pericardium*—Healthy. *Heart*—5¾ ozs., large, right side full of blood and left of clots, little fat on surface. *Abdomen*—Peritoneum healthy. *Small intestine*—Empty, mucous coat rosy with yellow mucus detachable, rather thin. *Large intestine*—Empty, pale and thin, no mucus. *Stomach*—Small, contains a little green fluid, lining pale rose in rugæ. *Liver*—53¼ ozs., large, of the colour of blue clay, 7 + 3 × 6½ × 4 inches, section pigmented with slight white mottling; microscope shows many pigment cells and few fat granules; gall bladder has only a trace of bile. *Spleen*—11⅛ ozs., pale slate, 7 × 4 × 2 inches, normally friable. *Right Kidney*—3⅝ ozs., capsule strips easily, pale yellowish red, fatty. *Left Kidney*—3⅜ ozs., like right. *Pancreas*—3¼ ozs., large, healthy. A little fat in mesentery; glands of deep purple colour and normal in size. The enlarged pigmented spleen points to former attacks of Malarial fever.

Case 401.—A Hindu girl of about ten years of age was brought to hospital on 31st March 1877 by the police, who had picked her up

on the road insensible, with burning heat of skin (temperature 104° F.); laboured respirations (fifty per minute), is pulseless, restless and moaning; bladder distended, body emaciated, no œdema, extremities cold. She died shortly after admission. Autopsy four hours after death. Body emaciated; height 4 feet 2 inches, weight 45 lbs. *Skull*—Scalp bloody, meninges pink, pia mater injected. *Brain*—39½ ozs., firm rosy, section punctated with a good deal of red blood oozing therefrom, showing active congestion during life. *Chest—Right Lung* 6¼ ozs., moderately collapsed, upper lobe pink, lower livid, but no serum on section. Pleura healthy. *Left Lung*—5 ozs., more fully collapsed and less congested than right, otherwise similar. *Abdomen*—Peritoneum healthy. *Small intestine*—Contains two lumbrici and some green pultaceous matter coats thin and pale, Peyer's patches cribriform, some stained yellow. *Large intestine*—Contains formed fæces; red punctæ on rugæ of transverse and descending colon and arborescent injection of some venous radicles of caput coli; healthy. *Stomach*—Large, contains some grey black mucoid pultaceous matter; lining smooth and pale. *Liver*—23½ ozs., anæmic, healthy. *Gall-bladder*—Nearly full. *Spleen*—4⅜ ozs., firm, corpuscles conspicuous on cut surface. *Right Kidney*—1¾ oz., deeply congested, red blood oozing from cut surface. *Left Kidney*—1⅞ oz., capsule strips easily, quite like right. *Pancreas*—One ounce, healthy. *Mesenteric Glands*—Normal; no fat in mesentery. The apparently sudden death with burning heat of skin and congestion of the brain in this case point to heat apoplexy.

## 4.—Pyæmia.

There were three cases of pyæmia—a man and two women; one of the latter was a Mahomedan, the others were Hindus of low caste. Besides these, Case IV of hepatic abscess probably might be included, as will hereafter be pointed out. These cases are shortly as follows:—

Case 446.—Veeraswamy, a Pariah coolie, æt. 30 years, admitted 4th June 1877 with abscess enveloping left iliac bone of a month's duration, when a sinus in the left groin had closed up; pulse 108, weak; respirations 32, skin scurfy, not hot. The abscess was tapped twice and was finally opened, as the pus had become fœtid. He complained of diarrhœa and sleeplessness from 13th and gradually sank, dying on 22nd June. Autopsy nine hours after death. Height 5 feet 7 inches, weight 89 lbs., body thin, abscess of left buttock with œdema of leg. Brain 43½ ozs., anæmic. Some straw-coloured effusion in all the serous cavities. Apneumatosis with effusion in middle lobe of right lung which weighed 12½ ozs. against 8½ ozs. of left. The liver and spleen were considerably enlarged; the former was fatty, and the latter soft and easily friable. The heart, pancreas, and kidneys were also above normal weight, the last were anæmic, and exhibited under the miscroscope many desquamations, and some round nucleated cells. The alimentary

canal was empty, except four lumbrici in the small gut and one in the stomach. The mucous coat was pale with red puncta on some Peyer's patches and slight pigmentation in the colon. There was a grey pseudo-membrane adherent to three or four livid folds in the cæcum, and thickening in the sigmoid flexure, where there was a communication with the abscess. The iliac and gluted abscesses communicated over the brim of the necrosed ilium and implicated the psoas muscle opposite the opening into the gut. The muscles were quite black from the decomposed pus, and the denuded ilium was movable with grating at the synchondrosis. The mesenteric glands were pale and swollen.

Case 447.—Kalandamah, a coolie woman of Pully caste, æt. thirty years, twenty days ill with sloughing of left parotid gland. Admitted in a weak state on 2nd and died on 3rd November 1877. Autopsy eleven hours after death. Height 5 feet 7 inches, weight 64 lbs., body a skeleton, no œdema, rigor mortis present. Brain $44\frac{5}{8}$ ozs., anæmic. Some congestion with œdema of posterior of lower lobes of both lungs, weight $10\frac{3}{4}$ and 12 ozs. Alimentary tract empty, mucous coat of stomach, small gut, and rectum more or less livid, and in the last there were a few excoriations; colon healthy looking. Liver and spleen somewhat enlarged: the former ochrey yellow and intensely fatty, the latter not easily friable, but pulp exudes under pressure. The kidneys were large, congested, and fatty. Mesenteric glands livid, but of normal size.

Case 448.—Fatma Bee, a Mahomedan woman, æt. thirty-five years, ill three months with sloughy ulcer of right instep which is full of maggots. Admitted in a very low state on 24th and died on 28th February 1878. Autopsy one hour after death. Height 5 feet $\frac{1}{2}$ inch, weight 64 lbs., body a skeleton, rigor mortis present. More or less serum in all the serous cavities, except left pleura: lateral veins of pia mater full with patches of ecchymosis around. Brain $37\frac{7}{8}$ ozs., firm. Grey hepatization of lower lobe of right lung which weighed 22 ozs, against $5\frac{5}{8}$ ozs. of left. The peritoneal cavity contained a pint of yellowish fluid with lymph floating in it. No sign of peritonitis, but there was a small opening leading to an abscess in Douglas's space. The alimentary canal was empty except for five lumbrici in the small gut and a few trichocephali in the cæcum; mucous coat pale red, œdematous, with patches of pseudo membrane adherent in colon, and forming a lining to rectum; liver large and very fatty. Spleen small, not friable and no pulp exudes on pressure. Kidneys small, fatty. Œdema of mesentery, but glands healthy. In this case probably the ulceration of the foot gave rise to thrombosis of the pelvic veins, abscess, and pyæmia.

---

# CHAPTER V.

## LUNG AFFECTIONS.

UNDER this head come Acute Pneumonia and Phthisis Pulmonalis. These contributed about four and a half per cent. of the admissions, seven per cent. of the deaths, and nine per cent. of the autopsies.

### 1.—ACUTE PNEUMONIA.

The admissions from pneumonia were 99, or three per cent., and the deaths 55, or 4·9 per cent. of the total. The disease was rather more prevalent during the three dry, hot months—March, April, and May. The average daily sick from this cause was 2·03, or 3·1 per cent. of the total; men contributing 3·37, women 3·24, and children 2·27 per cent. This disease is not shown in other returns, being no doubt included there under fever.

In the 459 autopsies, inflammatory softening, gangrene, or hepatization of the lung, including chronic pneumonia, were found in 132, or 28·7 per cent. of the cases. In 102 of these, lung disease appeared as a complication of alvine flux, and in 8 it complicated other diseases. The pneumonia was idiopathic in the remaining 22 cases, consisting of 12 men, 7 women, and 3 children; and these cases it is proposed to treat of here.

*Disease complained of.*

Sixteen of these patients were suffering from pneumonia on admission, five others were attacked while in hospital for debility, and the remaining case was brought in dead from cholera, it was said, after an illness of ten hours.

*Duration of the disease.*

As to the duration of the disease, one man was brought in dead, one died on the day of admission, and the others were in hospital on an average fully seven days, the extremes being 1 and 22 days, the average duration of illness before admission being about a fortnight. Of the women, two died on the day of admission,

and the average time in hospital of the others was 9 days fully; the duration of the illness before admission averaged about a week. The three children were said to have been ill only a few days when brought to hospital. Two died on the day of admission, and the third on the day after.

*Height.*

The average height of the men is 5 feet 6 inches fully, the extremes being 5 feet 2 inches and 5 feet 11 inches; and of the women 5 feet $0\frac{3}{10}$ inches, the extremes being 4 feet $10\frac{1}{2}$ inches and 5 feet $2\frac{1}{2}$ inches.

*Age.*

The average of the ages guessed * is $41\frac{3}{4}$ years for the men, with the extremes 30 and 55 years, and $37\frac{1}{2}$ years for the women, the extremes being 15 and 60 years. The ages of the children were about $1\frac{1}{2}$, 3, and 5 years.

*Weight.*

Seven of the men and five of the women were in good flesh; the average weight of the former is 112 lbs. nearly, and of the latter 81 lbs. The average weight of the emaciated men is 74 lbs. nearly, and of the emaciated women $59\frac{1}{2}$ lbs. All the children were emaciated.

*Rigor mortis.*

Rigor mortis was found present nine hours after death in one case, and was absent four hours after death in another; the latter was a child.

*Skin diseases.*

Itch is so common among natives that its presence or absence was not noted in these cases; the only other skin disease present was an herpetic eruption on the nostrils and upper lip in a child. The skin was scurfy in three cases, and in a woman the front of the chest was nearly wholly occupied by a scrofulous-looking scar, and a similar scar was situated on the calf of the right leg. There was œdema of the feet and ankles in six cases, in one of these the hands and face also were œdematous; and in one case the right leg was swollen from a hurt.

SKULL.

The scalp was thin and pale, and on removing the calvarium no blood appeared on the meninges, as is usual when the sinuses are full, in six men, one woman, and in all the three children. These structures

* Natives of the class to which these patients belong do not know their own ages.

presented their normal appearance in only three women. Some blood flowed from the severed vessels on cutting through the scalp, and from the surface of the meninges and base of the skull on removing the calvarium and brain, in six men and three women; in two men and one woman the blood was in considerable quantity.

*Arachnoid.*

On cutting through the meninges serum was found in the sub-dural cavity in seven men, three women, and two children, and it was found effused under the arachnoid, filling up the sulci of the brain, in nine men, three women, and one child. The serum was bloody in only one case.

*Pia mater.*

The larger vessels of the pia mater were found full in all the men except three—in two women and in one child; and in one of these men the smaller vessels also were injected, giving the membrane a reddish appearance. In two men the membrane was covered with a white cloud.

*Brain, weight, state.*

The average weight of the brain is $43\frac{1}{4}$ ozs. for the seven plump as against $39\frac{1}{2}$ ozs. for the five emaciated men, and $36\frac{1}{3}$ ozs. for the five plump as against 37 ozs. for the two emaciated women. The substance appeared healthy in seven men and three women; it was rather hyperæmic in five men and one child and anæmic in three women and two children. There was only a trace of serum in the ventricles in a man and a woman. The substance was noted soft in four men, three women, and one child, and firm in six men, three women, and one child.

CHEST.

Both pleural sacs were quite healthy in only one woman, the right alone was healthy in one man and one child, and the left alone in four men and four women. Both sacs looked healthy, but each contained about an ounce of pale amber serum in one woman and two children, and in a man a healthy-looking right sac contained a pint of pale serum.

*Hydro-thorax.*

*Adhesions.*

In the men there were old points of adhesion present in one pair, three right and one left pleura, and in the women in one right pleura. The adhe-

sions were very firm, requiring a knife for their division in one pair in women, and in one pair and one left pleura in men.

*Recent effusions.*

There were recent adhesions in two pairs and four right pleuræ in men, in one pair and two right pleuræ in women, and in one right pleura in a child. There was recent effusion of serum, the lung being usually at least partially covered with soft lymph, in two pairs, in one of which recent adhesions also were present, in one right pleura which also had recent adhesions, and in three left pleuræ in men; and in one pair, and in one right pleura with old points of adhesion in a woman; in this case the effusion was purulent; in the others it was turbid serum, except in one case it was blood tinged.

*Lungs healthy.*

The healthy lungs were one right weighing 10½ ozs. and one left lung weighing 12¼ ozs. in men, two left lungs weighing each 7½ ozs. in women and one left lung in a child. In another child the only abnormal condition present in the right lung was simple collapse of nearly the whole lower lobe.

*Apneumatosis.*

In only one other of these cases was apneumatosis observed, and it was confined to the anterior tongue of the upper lobe at the fissure in a left œdematous lung in a woman.

In a man the right lung weighing 15¼ ozs. was deeply congested, dark blood but no serum flowing freely from its cut surface, and in a woman there was livid congestion of the left lung, which weighed 10⅜ ozs.

*Congestion with œdema.*

There was congestion, with œdema confined to the posterior border or lower lobe of the right lung in three men and two women, and of the left lung in two men. The average weight of the three right lungs in men was 16⅓ ozs. and of the two left lungs 18½ ozs. The average weight of the right lung in the two women was 13½ ozs.

*Inflammatory œdema.*

There was congestion with œdema and softening of the lung tissue in two pairs, one right and one left lung in men, and in a woman the lesion was confined to the lower lobe of the left lung, (weight 10⅜ ozs.) and was most marked in livid spots, and in another woman

it occupied the whole of the left lung except the anterior border of the upper lobe, weight $14\frac{7}{8}$ ozs. The average weight of the three right lungs is $21\frac{3}{4}$ ozs. nearly, and of the three left lungs in men $21\frac{1}{3}$ ozs.

*Gangrene.*

In a man (case No. 409) the left lung, weighing 13 ozs. had a gangrenous cavity at the base of the lower lobe, the size of a flattened lemon, surrounded by limited inflammatory œdema with soft lymph on the surface, and a pint of bloody fluid in the pleural cavity. In a woman (case No. 418) the hepatized middle lobe of the right lung was passing into gangrene, while there was inflammatory œdema of the lower, and congestion with œdema of the upper, lobe. The weight of this lung was $16\frac{1}{2}$ ozs.

*Abscess.*

In a man the left lung, weighing $15\frac{3}{4}$ ozs., presented two livid spots at the base of the upper lobe, which disclosed on section two cavities full of healthy looking pus: one was as large as a lime, the other smaller and had the appearance of being a dilated bronchus; the surrounding tissue was œdematous, but only slightly congested, being pale livid. In another man the left lung, weighing $18\frac{1}{2}$ ozs., had an abscess, the size of a lime containing yellow pus, situated in the lower posterior margin and surrounded by red hepatized tissue with inflammatory œdema of the rest of the lower lobe, the surface being covered with soft lymph; there was some congestion with œdema of the apex posteriorly. In a third man the right lung weighed 68 ozs., was in a state of grey hepatization, except the thin lower margin which was somewhat spongy and presented a cavity in its posterior part containing a pint of mud-coloured, inodorous fluid, being simply broken down lung tissue.

*Hepatization.*

Including the above three cases there was hepatization of the lung tissue present in four right and four left lungs in men; in one pair, four right and one left lung in women, and in one pair one right and one left lung in children. The average weight of the four right lungs in men is $49\frac{1}{8}$ ozs. and of the four left lungs 34 ozs., and of the five right lungs in women $22\frac{5}{8}$ ozs. and of the two left lungs $14\frac{3}{8}$ ozs.

The disease had, in all the adults except one, reached the stage of grey hepatization, and, on the whole, the right lung was rather more frequently implicated than the left, and the lower

lobe of the lung than the upper; but instances are not wanting where the upper lobe had reached the stage of grey hepatization, while the other parts of the lung were either healthy or only in the first stage of pneumonia. In only one case was there double pneumonia present in adults, and one in children. In the latter the disease was, in all cases, lobular, and had reached only the stage of red hepatization.

*Pericardium.*

The pericardium was healthy in two men and a child, and in all the other cases, except one, it looked healthy, but contained pale amber serum. The sac was only moistened with serum in two men, three women, and one child; it was distended in a woman and a child, and in the others it contained on an average about two ounces of pale amber serum. In one case, that of a man who had grey hepatization of the upper and congestion of the lower lobe of the left lung, the pericardium looked pearly, but was lined with yellow lymph, and contained 4 ozs. of amber serum with jelly like lymph suspended therein.

*Heart, œdema, soldier's spot, cavities.*

The surface of the heart was quite devoid of fat in only one man, one woman, and two children; in the case of the woman the fat was replaced by œdema; there was very little fat present in two men, one woman, and one child; and in the remainder it was often in considerable quantity. The white detachable lymphy deposit, known as the "soldier's spot," was present in a man and a woman, both coolies by trade; in the latter case there was a spot on the back as well as one on the front of the heart. The cavities of the heart were nearly empty in only two women. There was some blood and clots on both sides in seven men, three women, and two children; in the right side alone in four men, two women, and one child; and in the left side alone in one man. The walls were noted firm in four men and flabby in one woman.

*Weight.*

The heart weighed over 6 ozs. in ten men, its average weight being $8\frac{3}{5}$ ozs., while, for the remaining two men, it averaged only $5\frac{1}{2}$ ozs. For the six women its average weight is $6\frac{1}{2}$ ozs. nearly. The largest heart weighed $11\frac{1}{2}$ ozs. in a man, whose liver and kidneys were small and fatty, and who had also suffered from peri-hepatitis. Among the women the largest heart weighed $8\frac{3}{4}$ ozs. in an old Wuddur,

whose liver was small and fatty, and kidneys contracted with the capsule adherent.

ABDOMEN.

*Peritoneum, serous effusion, adhesion.*

The peritoneum was quite healthy in five men, four women, and one child, and it was equally healthy in appearance, but contained pale amber serous effusion, in five men, two women, and two children. In three of the men and in the two children the effusion was in small quantity, in the other two men and in the women it amounted to nearly half a pint. There were old flocculent adhesions over the spleen and kidneys in a man and a woman, and over the liver in another man, the peritoneum was otherwise quite healthly in these cases.

*Stomach, contents.*

The stomach was noted large in three men and two women, and small in five men, two women, and two children, and of moderate size in two men. It was empty in four men, two women, and a child; contained fluid, usually bile-tinged, in four men and two women; and food in three women and two children. The mucous coat was smooth in only one woman, and was in well-marked rugæ in all the rest. It was pale, and often bile-stained, in five men, four women, and two children; in one of the men there were some brown-red ecchymotic-like markings present. It was rosy in seven men, three women, and a child; in two of the men and in one of the women there was stellate congestion of parts.

SMALL INTESTINE.

*Lumbrici.*

The small intestine was found empty in three men, three women, and in all the children; in two of the children it was distended with gas. The contents where present were grey, yellow, or green fluid; this was frothy in one case. Lumbrici were present in nine men, varying in number from one to five, the average being nearly two, in a woman one, and in a child six.

*Diverticula.*

In a woman there were six diverticula in the upper six feet of the jejunum, varying in size from a pea to an almond; one was full of concretions.

*Mucous coat.*

The gut was healthy in appearance in five men, four women, and a child. It was thin and anæmic in three men, a woman, and a child; in the latter it

was parchment-like; in one of the men the valvulæ conniventes were quite white, and in another the mucous coat was pigmented. The injection of the mucous coat was pink, deeper in parts, in a man, and in a woman the injection was confined to the jejunum with circular flat spots of submucous ecchymosis a line in diameter, while the ileum was pale with livid congestion in sections with a few spots of submucous ecchymosis as in jejunum. The mucous coat was injected reddish in a child, and congested in sections and patches in three men and a woman; in one of the men the injection was confined to the duodenum and to the lowest three inches of the ileum, where it was quite purple; in the other two men the injection was almost confined to some valvulæ conniventes; in one of the latter the glands of Peyer's patches were prominent and pellucid, being distended with clear fluid; there was no injection of the ileum in this case, but the mucous coat was so thin that the venous radicles could be seen through it.

*Congestion.*

*Ecchymosis.*

The large intestine was empty in half the men, five of the women, and in all the children; in one of the last it was distended with gas, and contained some green mucus; and in one of the men ground chillies were adherent to the mucous coat. It contained formed fæces in a man, thin feculence in three men and a woman, ochrey fluid in a man, and green fluid in another man, and white fluid in a woman.

LARGE INTESTINE. *Contents.*

The mucous coat was healthy in appearance in two men and two women. It was tinged livid or pink in three men, a woman, and two children; in the woman it looked sodden in the rectum, and in one of the children the upper half of the gut was pale and the mucous follicles conspicuously patent. It was anæmic in four men and three women; in one of the men there was livid mottling with swelling in the lower two feet, and in one of the women there was œdema of the same part. In the latter case and in two men there was more or less deep pigmentation of the whole mucous coat, and in two other men the pigmentation was confined to spots in the sigmoid flexure.

*Mucous coat. Œdema, pigmentation.*

*Congestion, pseudo-membrane, ulcers.*

There was red to livid congestion present in three men and a child; in two of the former this was confined to the upper end of the gut; in a woman the mucous coat was pale rose with spots of yellow lymph effused on brown-red congested transverse patches in the cæcum and transverse colon; in the rest of the colon there was some red mottling, but no effusion; but the rectum was lined by a firm grey pseudo-membrane with black-based ulcers all over, and considerable thickening. In another woman, in whom the mucous coat was pale with livid mottling as above-noted, there was some thickening with pale-based circular ulcers about a line in diameter in the sigmoid flexure and rectum; and in a man, in whom the mucous coat was pinkish as above noted, there were similar ulcers but no thickening in the descending colon, and larger grey-based red-edged ulcers lower down.

*Diarrhœa.*

Diarrhœa was present at the time of death in six adults: in three of these there was ulceration in, and in two others more or less œdema with some congestion of, the mucous coat of the lower end of the large gut; in two of the former there was congestion in lengths and patches of the mucous coat of the small gut, but in the third the patient denied having diarrhœa, nor was any observed till the day of his death; in this as well as in the latter two cases there was no congestion in the small gut. In the sixth case the whole intestinal mucous coat was healthy except being anæmic, the valvulæ conniventes were quite white. This patient was a powerful well-nourished man, the picture of strength, who complained on admission of cough and diarrhœa of eight days' duration, and lived four days in hospital; the stools consisted of thin ochrey fluid.

MESENTERY.

*Œdema, mesenteric glands.*

There was more or less fat present in the mesentery in seven men, six women, and one child; this was in considerable quantity in four of the men and four of the women, while in one of the men and in the child there was only a trace of fat present. In a man and a child the fat was replaced by œdema. In two men the veins of the mesentery were engorged with blood. The mesenteric glands were of normal size in seven men, six women, and in two children, and atrophied in the others; in one of the latter

class they were injected red, and in another pigmented, both men.

LIVER.
*Adhesions, atrophy.*

The liver weighed on an average $45\frac{1}{8}$ ozs. in the men, and $39\frac{1}{7}$ ozs. in the women. There were flocculent adhesions between the capsule and the diaphragm in a man; and in a child, about a year and a half old, the right lobe was adherent to the diaphragm over a surface an inch and a half long by half an inch broad. In the former there was a deep furrow running across the right lobe. The margin of the left lobe was atrophied in a man and a woman, and in another man, with cirrhosis of the organ, the left lobe was atrophied into a fibrous strip weighing under an ounce.

The structure was normal in nine men, a woman, and a child; in four of the former the substance was hyperæmic, and in one, as well as in the child, it was anæmic.

*Fatty, pigmentation.*

The liver was of a more or less ochrey yellow colour and very fatty in one man, three women, and two children; it was less fatty in one woman, and only slightly fatty in a man and two women, and it was cirrhotic in a man; all these livers were anæmic. Albuminoid degeneration was looked for in all cases and found in none. There was some pigmentation present in one of the slightly fatty livers.

*Gall-bladder.*

There was œdema of the walls of the gall-bladder in a child; and in this case, as well as in four men and a woman, the viscus was quite empty, and in another man it contained only a trace of bile. It contained thin green bile in a man and a woman, thin brown bile in a child, brown bile with a sediment in a man, dark bile in a man, and tar-like bile in a man and two women, oil-like fluid in a man and three women, and a trace of orange fluid in a man.

SPLEEN.
*Hypertrophy, atrophy.*

The spleens varied a good deal in weight, but may be divided into hypertrophied, normal, and atrophied. Under hypertrophied came two spleens in men, weighing $7\frac{1}{4}$ and $14\frac{3}{4}$ or average 11 ozs., and one in a woman weighing 7 ozs. Under normal came six spleens in men, varying in weight from $4\frac{1}{4}$ to $6\frac{3}{8}$ ozs., and averaging $5\frac{1}{3}$ ozs., and in a woman a spleen weighing $5\frac{7}{8}$ ozs. Under atrophied are included all spleens under 4 ozs. in weight; these

numbered three in men with an average weight of $2\frac{3}{8}$ ozs., and five in women with an average of $2\frac{1}{2}$ ozs.

*Capsule.*

The capsule had a white cicatrised spot at its lower end in a man, and puckering in places in a woman; it was thickened and adherent to surroundings in points in a man and a woman.

The substance was tough, not friable, and deficient in pulp, with no exudation under pressure in one man, four women, and in all the children; it was easily friable into a red jam-like pulp in four men and a woman, and in the remainder it seemed healthy.

KIDNEYS. *Weight.*

In the men the weight of the right kidney ranged from $2\frac{7}{8}$ to $6\frac{1}{4}$ ozs., the average being $3\frac{3}{4}$ ozs.; and that of the left kidney from $1\frac{3}{4}$ to $6\frac{7}{8}$ ozs., the average being $3\frac{5}{6}$ ozs. In the women the weight of the right kidney ranged from $2\frac{1}{2}$ to $4\frac{5}{8}$ ozs., the average being $3\frac{1}{2}$ ozs.; and that of the left kidney from $2\frac{3}{4}$ to $4\frac{3}{4}$ ozs., the average being $3\frac{5}{8}$ ozs. In the men three right and three left kidneys weighed 3 ozs. or under, the average of the former being $2\frac{7}{8}$ ozs. and of the latter $2\frac{1}{2}$ ozs. nearly; and nine right and nine left kidneys weighed over 3 ozs., the average of the former being 4 ozs. and of the latter $4\frac{1}{4}$ ozs. fully. And in the women three right and two left kidneys weighed under 3 ozs., the average weight of either being $2\frac{5}{8}$ ozs., and four right and five left kidneys weighed 3 ozs. and upwards, the average weight of the former being $4\frac{1}{8}$ and of the latter 4 ozs.

*Capsule, cysts.*

In one case the capsule was somewhat adherent, in all the others it stripped easily. On the capsule being stripped off, the surface was seen studded over with small cysts in one right and one left kidney in men, and in the left kidney in a woman.

*Substance.*

The substance of both kidneys was congested in six men, three women, and a child, and of the left kidney in a woman; it was anæmic in two men, two women, and two children, and the left kidney only was anæmic in a man and the right only in a woman. The cortex was anæmic and medulla congested in both kidneys in two men.

*Fatty.*

The structure was slightly fatty in two men and two children and very fatty in two women. In a man the cortex was of a peculiar orange hue, the

epithelial cells lining the tubes being much swollen; and in a young woman, whose case was finally complicated with diphtheritic dysentery, both kidneys were large, and uniformly flesh-coloured with no demarcation between the medulla and cortex, part of each end was soft and anæmic, being marked off by a red line as if sloughing; in this the microscope disclosed disquamation cells and granules, shreds of epithelial lining with breaking up of the walls of the tubes, but no fat, pus, or cancer cells. In all the other cases the structure of the kidneys was normal.

The pancreas weighed on an average 3½ ozs. in ten men, and 2 ozs. in the women. Its structure appeared healthy in all.

### Illustrative Cases.

Case 409.—Soobein, a Cavaray coolie-man, aged about fifty-five years, from Nellore, four days in Madras, admitted 26th May 1877; has been ill two months with a cough, but no spit till four days ago; never spat blood; appetite good; was fat four months ago, but has been half-starved since then; is now a skeleton with œdema of feet; pulse 124 weak; respirations 36; skin scurfy burning hot (103°2 F.); dulness and pain on percussion over base of left lung, where large crepitating râles and bronchial breathing are heard on auscultation; says he has had no diarrhœa. 28th—Pulse 104; respirations 24; bowels said to be normal. Died on 31st without diarrhœa having been detected till a loose motion ran from the corpse. Autopsy one hour after death. Height, 5 feet 2 inches; weight, 70 lbs.; body a skeleton; œdema of feet; rigor mortis present. *Skull.*—Scalp and meninges pale; 4 ozs. of bloody serum in sub-dural and a little in sub-arachnoid cavaties; pia mater rosy; veins mostly empty. *Brain*, 40 ozs.; a little serum in lateral ventricles; a spot of sub-arachnoid ecchymosis the size of a shilling on the middle lobe close to the fissure of Sylvius. *Chest.*—Right pleura has some points of old adhesion; in other respects normal. *Lung*, 10½ ozs.; quite healthy. *Left pleura* contains half a pint of bloody serum with soft lymph on lower lobe. *Lung*, 13 ozs.; upper lobe healthy; a gangrenous cavity at base of lower lobe, the size of a flattened lemon, surrounded by limited inflammatory œdema; rest of lower lobe pale, yielding some white frothy fluid from bronchi on pressure. *Pericardium* pearly, containing 1 oz. pale serum. *Heart*, 5¼ ozs.; a trace of fat on surface; right side full of fluid blood. *Abdomen.*—Peritoneum pearly; contains 2 ozs. pale straw-coloured serum; intestines dull white tinged rosy. *Small intestine* contains one lumbricus and a little green mucus, lining pale rose-coloured. *Large intestines* empty; mucous coat pinkish with some clear mucus adherent; no thickening or swelling. In descending colon are some pale-based circular ulcers, a line in diameter, and lower down some larger grey-based ulcers with red edges. *Stomach* of moderate size; empty; lining in rugæ, pale rosy with clear mucous adherent. *Liver*, 27 ozs.;

small; $6\frac{1}{2}+1\frac{1}{2} \times 5 \times 3$ inches; * cuts soft, acini small, having a green tinge, hepatic cells look normal under microscope. *Gall-bladder* full of thick tarry bile. *Spleen*, 3 ozs.; plump; $4 \times 2\frac{1}{2} \times 2$ inches; section firm; brown with grey trabeculæ. *Right kidney*, $2\frac{7}{8}$ ozs.; capsule strips; cysts numerous, but small; substance red; structure normal. *Left kidney*, $2\frac{7}{8}$ ozs.; no cysts, else like right. *Pancreas*, 2 ozs.; healthy. A trace of fat in mesentery glands atrophied.

Case 418.—Chinapillay, a young woman of the Yanaudy caste, about fifteen years old, from Nellore, three months in Madras, ill ten days with cough and four with "diarrhœa," admitted on 15th June. Is in fair flesh; cough frequent and short; respirations wheezy 32; pulse 140; belly soft; painful on pressure; skin hot (103°4 F.); crepitus heard in both lungs; most distinct on right side; stools five daily, loose and variable in appearance. Died on 23rd; autopsy nine hours after death. Height, 5 feet; weight, 67 lbs.; body in fair flesh; no œdema; some fat; rigor mortis present. *Skull.*—Scalp and meninges, bloody; a little serum in sub-dural cavity; pia mater with red streaks and some spots of ecchymosis in front; veins empty. *Brain*, 37 ozs., rather soft and anæmic. *Chest.*—Right pleura healthy. *Lung*, $16\frac{1}{2}$ ozs.; middle lobe solid, passing into gangrene; lower lobe livid; upper less so; no œdema. *Left pleura* healthy. *Lung*, $10\frac{3}{8}$ ozs.; simply livid congested. *Pericardium* pearly, distended with serum. *Heart*, $5\frac{1}{2}$ ozs., little fat on surface; dark clots on both sides. *Abdomen*—Peritoneum healthy; guts pale-slate; part of small reddish. *Small intestine* contains some thin grey fluid; mucous coat of jejunum pink with circular unraised spots of ecchymosis, a line in diameter; of ileum grey with livid congestion in lengths; and a few spots of ecchymosis as above. *Large intestine* empty; mucous coat grey, with livid mottling; some thickening with small circular ulcers in sigmoid flexure and rectum. *Stomach* contains a little milk; lining smooth, rosy. *Liver*, 48 ozs.; yellow; $7+3 \times 6 \times 3\frac{1}{2}$ inches; anæmic, one mass of fat. *Gall-bladder* quarter filled with linseed-oil-like fluid. *Spleen*, $2\frac{1}{2}$ ozs.; livid, $3\frac{1}{2} \times 2\frac{3}{4} \times 1$ inch; section purple, not friable and no pulp exudes on pressure. *Right kidney*, 3 ozs.; capsule strips easily; section anæmic with yellow tinge; not fatty. *Left kidney*, $2\frac{5}{8}$ ozs., livid, else like right. *Pancreas*, $1\frac{1}{2}$ ozs., healthy. *Mesentery* contains a little fat; glands of normal size.

The active congestion seen in the small, with the ulceration in the lower end of the large, intestine were probably subsequent to the lung affection as the history indicated, but their relation to each other is not so apparent. The following is the only one of these cases in which the disease had not reached the stage of hepatization.

Case 458.—Koolie Pully, concubine, aged thirty years, a plump well-made woman, brought on 27th March 1877 by the police in a dying state, said to be suffering from diarrhœa, and died almost immediately.

---

* This means breadth of right lobe $6\frac{1}{2}$ and of left lobe $1\frac{1}{2}$ inches, depth of liver 5 inches and thickness 3 inches.

Autopsy twenty-one hours after death. Height, 4 feet 10½ inches; weight, 93 lbs.; no marks on person; rigor mortis absent. *Skull.*—Scalp and meninges pale; pia mater reddish, healthy. *Brain*, 31½ ozs., firm, healthy. *Chest.*—Right pleura has recent points lateral adhesion and contains an ounce of straw-coloured serum. *Lung*, 15½ ozs.; livid red; base of upper lobe semi-solid from œdema. Left pleura recent adhesions all over, surface floccy, jelly-like; an ounce of amber serum in cavity. *Lung*, 14⅞ ozs.; inflammatory œdema of all, except anterior border of upper lobe. *Pericardium* moistened with serum. *Heart*, 7½ ozs.; flabby, empty, covered with fat. *Abdomen.*—Peritoneum pearly, contains 4 ozs. amber serum. *Small intestine* contained a little white fluid; mucous coat pale. *Large intestine* contained a little white fluid; mucous coat pale with sparse arborescent injection. *Stomach* large, full of congee; mucous coat quite white, thin. *Liver*, 30 ozs., saffron yellow, anæmic, very fatty. *Spleen*, 7 ozs., plump, of normal consistence. *Right kidney*, 2¾ ozs., capsule strips easily, flabby, anæmic, fatty. *Left kidney*, 3 ozs.; like right. *Pancreas*, 1¼ ozs.; healthy. Lots of fat in mesentery; glands normal.

## Acute Pneumonia.

*List of Cases giving the Weight of the Body and of its different Organs, &c.*

| No. | Name. | Caste. | Occupation. | Age. | Sex. | Height. | | Weight in lbs. Avordupois. | Weight in Ounces of | | | | |
|---|---|---|---|---|---|---|---|---|---|---|---|---|---|
| | | | | | | Feet. | Inches. | | Brain. | Right Lung. | Left Lung. | Heart. | Liver. |
| | | | | YRS. | | | | | | | | | |
| 402 | Veeraswamy ... | Gentoo ... | ... | 55 | Male ... | ... | ... | ... | 38 | 24 | 25½ | 8 | 34½ |
| 403 | Chenchoo ... ... | Do. ... | Potter ... | 60 | Do. ... | ... | ... | ... | 36 | 14¾ | 15¾ | 6¾ | 31¼ |
| 404 | Chellun ... ... | Pariah ... | Coolie ... | 30 | Do. ... | 5 | 3 | 101 | 39⅜ | 10⅜ | 27¾ | 7⅞ | 44⅞ |
| 405 | Pakivadoo ... ... | Chuckler ... | Cobbler. | 35 | Do. ... | 5 | 9½ | 128 | 44¾ | 15¼ | 46¾ | 7¾ | 61 |
| 406 | Veerabuthrum ... | Vanah ... | Farmer... | 35 | Do. ... | 5 | 11 | 138 | 46¼ | 68 | 12¼ | 10¼ | 65¾ |
| 407 | Rajamen ... ... | Chuckler ... | Cobbler. | 35 | Do. ... | 5 | 8 | 113 | 45½ | 46¼ | 22¼ | 9 | 52½ |
| 408 | Poniah ... ... | Pariah ... | Coolie ... | 35 | Do. ... | 5 | 5½ | 103 | 37¾ | 23½ | 43 | 7 | 54¼ |
| 409 | Soobein ... ... | Cannery ... | Do. ... | 55 | Do. ... | 5 | 2 | 70 | 40 | 10½ | 13 | 5¼ | 27 |
| 410 | Apavoo ... ... | Washerman... | ... | 40 | Do. ... | 5 | 3½ | 68 | 46½ | 23½ | 18½ | 5⅞ | 26½ |
| 411 | Nullathumby ... | Pariah ... | Coolie ... | 50 | Do. ... | 5 | 4 | 83 | 37 | 22 | 19¼ | 11½ | 40 |
| 412 | Nagan ... ... | Do. ... | Do. ... | 40 | Do. ... | 5 | 5½ | 100 | 47 | 19⅝ | 18⅝ | 9½ | 48⅛ |
| 413 | Citadoo ... ... | Washerman... | ... | 30 | Do. ... | 5 | 10 | 100 | 42 | 58¼ | 14¾ | 8¾ | 55½ |
| 414 | Peryanayajee ... | Vullala ... | Butler's wife | 40 | Female... | 5 | 2½ | 84 | 46¼ | 17½ | 7½ | 5¾ | 37 |
| 415 | Lutchmee ... ... | Wudder ... | Beggar ... | 60 | Do. ... | 5 | ... | 77 | 32⅝ | 19⅜ | 12¼ | 8¾ | 38 |
| 416 | Allamaloo ... ... | Bulgee ... | Coolie ... | 38 | Do. ... | 4 | 11 | 59 | 34½ | 11⅛ | 16½ | 5 | 43½ |
| 417 | Sukeenambee ... | Mahomedan... | Do. ... | 40 | Do. ... | 5 | 1 | 84 | 34 | 41½ | 7½ | 7 | 50 |
| 418 | Chinapillay ... ... | Yannady ... | Do. ... | 15 | Do. ... | 5 | ... | 67 | 37 | 16½ | 10⅜ | 5½ | 48 |
| 419 | Nullayee ... ... | Pully ... | Do. ... | 40 | Do. ... | 5 | ... | 60 | 39½ | 18 | 10⅜ | 5¼ | 25¾ |
| 420 | Venketswamy ... | Pariah ... | Do. ... | 1½ | Male ... | 2 | 3 | 12 | 29 | 3 | 3¾ | 1 | 9½ |
| 421 | Kanen ... ... | Do. ... | Do. ... | 5 | Do. ... | 3 | 4 | 24 | 38½ | 3½ | 4⅜ | 2 | 14⅞ |
| 422 | Yetti ... ... | Pully ... | Do. ... | 3 | Female... | 3 | ... | 21 | 32⅝ | 7⅞ | 2¼ | 1¾ | 15¼ |
| 458 | Koolie ... ... | Do. ... | Do. ... | 30 | Do. ... | 4 | 10½ | 93 | 31½ | 15½ | 14⅞ | 7½ | 30 |

ACUTE PNEUMONIA—*continued.*

*List of Cases giving the Weight of the Body and of its different Organs, &c.*—continued.

| No. | Name. | Weight in Ounces of—*cont.* | | | | Date of Autopsy. | Hours after death Autopsy made. | Rigor Mortis. | Bodily State. |
|---|---|---|---|---|---|---|---|---|---|
| | | Spleen. | Right Kidney. | Left Kidney. | Pancreas. | | | | |
| 402 | Veeraswamy ... | 3¾ | 3 | 2¾ | ... | 21 Feb. 1877. | 4 | Present ... | Rather emaciated. |
| 403 | Chenchoo ... ... | 4¼ | 3¼ | 1¾ | ... | 27 Feb. 1877. | 5 | Do. ... | Quite a skeleton. |
| 404 | Chellun ... ... | 3⅜ | 3⅝ | 4 | 4¼ | 19 Mar. 1877. | 2 | Do. ... | Plump; well formed; in splendid condition. |
| 405 | Pakivadoo ... ... | 6 | 3½ | 4¾ | 4 | 25 April ... | 4 | Well marked. | Plump; well nourished. |
| 406 | Veerabuthrum ... | 5 | 6¼ | 6⅞ | 4⅞ | 26 April 1877. | 4 | Present ... | Plump; in splendid condition. |
| 407 | Rajamen ... ... | 14¾ | 4⅞ | 6⅛ | 4½ | 13 May ... | 9 | Well marked. | In splendid condition. |
| 408 | Poniah ... ... | 5⅝ | 3¼ | 3⅛ | 2⅝ | 15 May 1877. | 7 | Do. ... | In good flesh. |
| 409 | Soobein ... ... | 3 | 2⅞ | 2⅞ | 2 | 31 May 1877. | 1 | Present ... | Skeleton; œdema of feet. |
| 410 | Apavoo ... ... | 1⅝ | 2⅞ | 3¼ | 3 | 17 Sept. 1877. | 2 | Not well marked. | Skeleton and slight ascites. |
| 411 | Nullathumby ... | 4⅝ | 3¼ | 3⅛ | 1⅞ | 14 Oct. 1877. | 3 | Present ... | Low flesh; swelling of right leg. |
| 412 | Nagan ... ... | 6⅜ | 3¼ | 3¼ | 2⅞ | 2 Feb. 1878. | 4 | Do. ... | Rather thin, anasarca, œdema of feet. |
| 413 | Citadoo ... ... | 7¼ | 5 | 4¼ | 5½ | 18 Feb. 1878. | 1 | Do. ... | In good flesh. |
| 414 | Peryanayajee ... | 5⅞ | 4¼ | 4¼ | 1½ | 8 Mar. 1877. | 11 | Absent ... | Well nourished; scars, on chest and right calf, of scrofulous ulcers. |
| 415 | Lutchmee ... ... | 1½ | 2¾ | 4 | 1½ | 8 Mar. 1877. | 5 | Present ... | Not emaciated. |
| 416 | Allamaloo ... ... | 3¾ | 4⅝ | 4¾ | 3¼ | 12 May ... | 3 | Do. ... | In moderate flesh; no œdema. |

ACUTE PNEUMONIA—*continued.*

*List of Cases giving the Weight of the Body and of its different Organs, &c.*—continued.

| No. | Name. | Weight in Ounces of—*cont.* | | | | Date of Autopsy. | Hours after death Autopsy made. | Rigor Mortis. | Bodily State. |
|---|---|---|---|---|---|---|---|---|---|
| | | Spleen. | Right Kidney. | Left Kidney. | Pancreas. | | | | |
| 417 | Sukeenambee ... | 4¼ | 4½ | 4⅛ | 2¾ | 20 May 1877. | 2 | Present ... | Fat. |
| 418 | Chinapillay ... ... | 2½ | 3 | 2⅝ | 1½ | 23 June ... | 9 | Do. ... | In fair flesh ; no œdema. |
| 419 | Nullayee ... ... | 2 | 2¼ | 2¾ | 2½ | 20 Oct. 1877. | 7 | Do. ... | Skeleton ; œdema of lower extremities. |
| 420 | Venketswamy ... | 1⅛ | 1 | 1 | ½ | 7 June ... | 4 | Absent ... | Skeleton ; no œdema. |
| 421 | Kanen ... ... | 1⅛ | 1½ | 1⅝ | ⅞ | 26 Aug. 1877. | 5 | Present ... | Quite a skeleton ; slight œdema of feet. |
| 422 | Yetti ... ... | 1¼ | 1⅜ | 1⅜ | ¾ | 13 Sept. 1877. | 6 | Going-off ... | A skeleton. |
| 458 | Koolie ... .. | 7 | 2¾ | 3 | 1¼ | 23 Mar. 1877. | 21 | Do. ... | Plump ; well formed ; no marks. |

## 2. Phthisis Pulmonalis.

This disease caused 51, or 1·57 per cent. of the total admissions, and 22, or 1·88 per cent. of the total deaths. The first cases were admitted in March 1877 and in this and the three following months one-half the admissions and deaths occurred. All were adults. The average daily sick from this cause was 1·58, or 3·06 per cent. of the total adults, men contributing a fraction more than women.

Phthisis pulmonalis does not appear in other returns, deaths from this cause having been probably returned under diarrhœa, or fever (ague).

These patients often did not complain of cough, and more than one case was diagnosed only at the autopsy, for the effects of starvation in deadening the sensibility of the sufferers were perhaps more marked in this disease than in any other.

In the 459 autopsies made, tubercular deposit was found in one or both lungs in thirty men, 13·3 per cent., twenty women, 12·8 per cent., and in one child. The deposit was present in both lungs in eighteen of the men and in sixteen of the women, was confined to the right lung in three of the men, the child, and three of the women, and to the left lung in nine of the men and in one woman. The disease was latent in eighteen men, thirteen women, and in the child; death having been due to alvine flux in all these, except two men who died from dropsy, and one who died from starvation apparently. In the remaining twelve men, 5·3 per cent., and seven women, 4·5 per cent. of the total, death was due to phthisis pulmonalis, and these are the cases of which it is proposed to treat here. It may be noted that in 9,266 admissions to the Royapettah Hospital, 262, or 2·8 per cent. were from this cause. And among 20,492 Natives and 11,706 Eurasians admitted to the General Hospital, Madras, 1,005, or 4·9 per cent. of the former, and 290, or 2·47 per cent. of the latter were from phthisis pulmonalis.

*The disease complained of.*

The disease complained of on admission was cough with dysentery in six cases, cough with fever in three, cough with weakness in one, and simple cough in two cases. Dysentery only was complained of in four cases, diarrhœa in one, and simple weakness in

two; cough was not a prominent symptom in any of these, and in many it was not noticed as being present at all.

*Duration of disease.*

As to the duration of the illness, one man died on the day of admission, having been ill two months it was said with fever and cough; the average stay in hospital of the other men was twenty-nine days, the extremes being three and ninety-one days, the average illness before admission being two months. The average stay in hospital of the seven women was twenty-four days fully, the extremes being eight and sixty days, the antecedent illness having lasted about a month.

*Height.*

The average height of the men is 5 feet 5¾ inches, the extremes being 5 feet 2 inches and 5 feet 9 inches, and of the women 5 feet, the extremes being 4 feet 9 inches and 5 feet 3 inches.

*Age.*

The average of the ages guessed is fully 41 years for the men, with the extremes 20 and 60 years; and nearly 38 years for the women, with the extremes 25 and 60 years.

*Weight.*

The average weight of the men was 76⅚ lbs. One of the women had been obese and still weighed 81 lbs., the average weight of the others was 62 lbs. The autopsy having been made usually shortly after death, rigor mortis was generally found present; but in one case it was absent two hours after death without apparent cause, while in another it was present, when the autopsy was made ten hours after death.

*Skin-disease.*

There was no skin-disease present in these cases, except perhaps itch. There was œdema of the feet and ankles in ten cases; in one of these the swelling extended to the knees, and in two, the hands also were œdematous. In one case the right ankle was swollen from a sprain.

SKULL.

*Scalp.*

The scalp was thin and pale, and on removing the calvarium, no blood appeared on the meninges as is usual when the sinuses are full, in eight men and six women. In the remaining four men and one woman, some blood flowed from the severed vessels on

cutting through the scalp, and from the surface of the meninges and base of the skull on removing the calvarium and brain.

*Arachnoid.*

On cutting through the meninges more or less serum was found in the sub-dural cavity in all except two men; and it was found effused under the arachnoid filling up the sulci of the brain in all except one woman and the same two men.

*Pia mater.*

The larger vessels of the pia mater were full in five men and two women; and in three men the smaller vessels were injected, giving the membrane a pink to a dull reddish appearance.

*Ecchymosis.*

There were dusky red blotches of ecchymosis on the cornua of the left hemisphere in a man and a woman, and along the course of some of the lateral veins in another woman; the effusion was found on dissection not to extend into the sulci of the brain, or to form clots.

There was a white cloud over the brain from the arachnoid being opaque in three men and a woman.

*Brain, weight, state.*

The average weight of the brain is 41⅜ ozs. for the men and 38 ozs. for the women. The substance appeared healthy in four men and two women; it was firm but anæmic in a man and a woman, and soft and anæmic in the remainder; in one of the latter, a man, there was a dark blood-clot in the posterior cornu of each lateral ventricle, and the right optic thalamus was broken up by a clot as large as a marble. There was a little serum in the lateral ventricles in a man and a woman.

CHEST.

*Pleuræ hydro-thorax.*

The pleura was quite healthy only on the right side in two men, and on the left side in another man. There was passive effusion of pale amber serum into both pleural sacs in two men and four women, into the right pleural sac only in a man and into the left in a woman; of these, two right and two left pleuræ looked quite healthy; in the others there were old points of adhesion. The quantity of serum averaged 18 ozs. in the right, and 17½ ozs. in the left pleural sac.

*Adhesions.*

There were points of old adhesion, not numerous, and easily broken down in two pairs, one right and one left pleuræ in men, and in one right pleura in

a woman. The adhesions were very firm, often extensive, and requiring careful dissection, in four pairs, one right and three left pleuræ in men, and in three pairs, one right and one left pleuræ in women; in one of the latter pairs there were some points of recent adhesion also present. In another woman (case No. 438), the right pleura, cut quite cartilaginous in front, was lined with jelly-like matter and lymph, especially over the carnified lung. In a man both pleuræ presented points of recent adhesion and were moistened with serum.

LUNGS.

Three right lungs in men were slightly œdematous, but otherwise healthy, except apneumatosis of a part in two. Their average weight is 13½ ozs. nearly.

*Vomicæ.*

Tubercular deposits with vomicæ were found in both lungs in five men and three women, were confined to the right lung in one woman, and to the left lung in six men. The average weight of the right lung is 27⅗ ozs. for the five men, and 23⅛ ozs. for the four women, and that of the left lung, 24½ ozs. for the eleven men, and 17 ozs. for the three women. These lungs presented various degrees of congestion, œdema, and softening, and in one pair (case No. 430), and one left lung (case No. 426), parts were solid and tough.

*Fibroid phthisis.*

This state of fibroid phthisis was found without vomicæ in one pair (case No. 425), and one right lung (case No. 434) in men, and in one pair (case No. 441) in women. In the former (case No. 425), the bronchial glands were much enlarged, and in only two other cases was this complication observed. The average weight of the two right lungs in the men is 23¼ ozs., and the weight of the left lung is 22¾ ozs., in the woman the right lung weighed 17⅜ ozs., and the left lung 22¼ ozs.

*Miliary deposits.*

There were tubercular, mostly miliary, deposits without vomicæ in two right lungs in men, average weight 15 ozs., and in one pair and one left lung in women; the average weight of these two right lungs is 14¾ ozs., and of the three left lungs 14⅞ ozs.

*Apex not affected.*

Taking the whole phthisical cases, acute and chronic, the deposit was confined to the lower lobe in one pair and one right lung in women, 10 per cent.,

the former an acute case, and in one pair and one left lung in men, 6·6 per cent., the latter an acute case; also in two left lungs in two chronic cases in which the apex and upper lobe of the right lungs were affected as usual. And the deposit was confined to the lower part of the upper lobe adjoining the fissure in one pair and one right lung in women, the former an acute case; also in one left lung in a chronic case in which the right lung was affected as usual; and in men in one pair and one right lung, the latter an acute case, in which the left lung had the upper lobe solid and riddled with vomicæ.

*Pericardium.*

The pericardium was pearly, and only moistened with serum in six men and three women, and it looked equally healthy, but contained serum in five men and four women. The sac was distended in the case of a man (No. 425) and a woman, in the others the quantity averaged about 2 ozs.; the serum was turbid in a man, but in all the others it was clear and pale straw-coloured.

In a man (case No. 426), the pericardium was adherent to the heart all over by old bands, which were tolerably easily broken down.

HEART, *fat, œdema.*

The surface of the heart was devoid of fat in all the men except four, in whom there was a mere trace present, and in all the women except four in whom the quantity present was small. The fat was replaced by œdema in four men and one woman.

*Soldier's spot.*

The white detachable lymphy deposit known as the "soldier's spot" was present in three men, all coolies by trade.

*Cavities.*

The cavities of the heart were found empty in three men and two women. In three men and a woman the left side was empty, while the right contained blood and clots, while in one man and a woman the right side was empty, and left contained clots. In four men and three women there was more or less blood with clots on both sides.

The walls were noted soft and flabby in three men and three women, and firm and hypertrophied in two men.

*Weight.*

The weight of the heart averaged 5⅓ ozs. for six men, and fully 9 ozs. for the other six; its average weight for the whole being 7¼ ozs. nearly,

with the extremes $5\frac{1}{4}$ ozs. and $10\frac{1}{4}$ ozs. In the women three hearts weighed 5 ozs. and under, averaging $4\frac{1}{2}$ ozs., and four weighed over 5 ozs., averaging $6\frac{5}{6}$ ozs., the average weight for the whole is $5\frac{1}{2}$ ozs. fully, the extremes being $4\frac{1}{8}$ ozs. and $8\frac{1}{2}$ ozs.

ABDOMEN.
*Peritoneum, serum.*

The peritoneum was quite healthy in five men and one woman, and it looked equally healthy but contained serous effusion in six men and five women. The serum was in small quantity in four men and a woman, in the others it averaged three and a half pints, and was of a pale amber colour, and clear, except in a man a jelly-like cloud was suspended in it.

*Adhesion.*

There were old bands of adhesion between the transverse colon and the parietes on both sides in a man (case No. 434), a little serum was also present in this case.

*Stomach contents.*

The stomach was noted large in four men, very large in one of these, and small in six men and four women. It was empty in six men and two women, and contained some fluid in three men, and a lumbricus in a fourth. In two women there were six and four lumbrici found, and in two others some milky fluid was present.

*Mucous coat.*

The mucous coat was smooth in three men, and in well-marked rugæ in eight men and six women, in the remainder it was not noted. It was pale, often bile-stained, and thin in six men and five women. It was pale rose-coloured in a man, and injected pink to dull red in five men and a woman. There was pigmentation present in a man, and it was noted healthy in a woman.

SMALL INTESTINE.
*Contents, lumbrici.*

The small intestine was found empty in eight men and four women; the contents when present were green, yellow or mud-coloured fluid. Lumbrici were present in eight men, varying in number from one to three—total twelve, not counting one found in the stomach in one case; and in six women varying in number from two to twenty-four—total fifty, not counting ten found in the stomach in two cases and six found in the common bile duct in one of these. Distension with gas was observed in only one case.

There was a diverticulum nearly an inch in length situated at the lower part of the ileum in a woman (case No. 438). The gut was healthy in appearance in three men and two women; it was anæmic and so thin that the venous radicles showed through in a man and three women. The mucous coat was injected in sections and patches in three men and a woman. It was pale and œdematous in a man and two women, and pigmented in five men and a woman. The pigmentation was confined to spots in two of the men; in the others the coat was of a more or less dark slate colour, which was deeper in the jejunum.

*Diverticulum, congestion.*

Peyer's patches presented the "shaven beard" appearance in one man (case No. 426), and were infiltrated with tubercles in five men and four women. The infiltration had proceeded to ulceration in four of these men and in two of the women, and in a fifth man there were five tubercular ulcers in the lowest three feet of the ileum.

*Peyer's patches, ulcers.*

In a woman (case No. 441), with the mucous coat of the ileum pale and œdematous, there was a soft granular diphtheritic effusion on its lowest four inches.

*Diphtheritic effusion.*

The large intestine was empty in seven men and five women. It contained thin, feculent, yellow or green fluid in three men, and mud-coloured fluid in a woman, formed fæces in a man, scybala in another man (case No. 430), and a layer of ochrey-coloured feculent matter adherent to the mucous coat of the ascending colon in a woman.

LARGE INTESTINE. *Contents.*

The mucous coat was healthy in appearance in a man and a woman; it was injected uniformly pink red in two men, in one of these the mouths of the follicles were conspicuously patulous; it was red and swollen at the two ends in a man, and at the lower end in two other men; in another man the injection was confined to livid blotches, and in another to thickened minutely-ulcerated ridges all through the colon. It was pale in three men and five women, and was also œdematous in two of each sex. It was uniformly pigmented a more or less deep slate colour, in

*Mucous coat, congestion, pale, pigmentation.*

two men, and the pigmentation was confined to scars in three men, and to infiltrated glands or ulcers in two others.

*Ulcers.*

Ulcers were found in five men and three women; in two of the former and in one of the latter they were non-tubercular. Infiltration of the solitary glands was found in two men and a woman; in one of the former there was no ulceration.

*Diphtheritic effusion, scars.*

In a woman (case No. 441) the whole mucous coat was pale red, slightly swollen, and lined by a reddish granular pseudo-membrane which extended through the valve into the ileum. Scars were found in four men and a woman; in three of the former there were no ulcers or glands infiltrated with tubercle present. "Cyst forms" were seen in one case (No. 438), with some follicular ulcers in the lower end of the gut.

*Diarrhœa.*

Diarrhœa was present at the time of death in all these cases except one (case No. 434), and in this the intestines looked healthy.

*Mesentery.*

There was injection of the mesentery in a man, in whom there was much congestion of the small gut; there was a trace of fat present in two men and a woman, and in five men and four women the fat was replaced by œdema.

*Glands.*

The mesenteric glands were of normal size in four men, atrophied in four men and four women, and hypertrophied or swollen in a man and a woman. In three men and two women they were enlarged from deposits of tubercle.

The atrophied glands were pigmented in two women, and injected livid in a third.

LIVER.
*Atrophy.*

The average weight of the liver is 33¼ ozs. for the men, and 26⅔ ozs. for the women. In four men and five women it was under 30 ozs. in weight, the average for the former being 28 ozs. nearly, and for the latter 24 ozs. nearly. The left lobe was long and pointed in a man and a woman, and it was atrophied to under an ounce in weight in two men; and in another man and in two women it had a thin atrophied membranous margin.

*Capsule.*

The capsule was adherent to the parietes all over the convexity in a man (case No. 434); there was a white scar on it in a man, and thickened white spots in a woman. In a man there was a white cloud over, and two furrows running across the convexity of, the right lobe, and in another man there was a similar furrow present in the same position.

*Substance, fatty.*

The structure of the liver was normal in four men and one woman; it was fatty in eight men and five women. In one woman it was cirrhotic, the surface being granular, and the weight of the liver being only 19½ ozs. In this case and in a man, the substance was anæmic. In two men the liver was uniformly congested, and in six men and five women the lobules were margined paler than their centres, giving a nutmeg appearance to the organ; all these were fatty. In only two cases (Nos. 438 and 440) were tubercular deposits found in the liver.

GALL-BLADDER.

*Lumbrici in bile duct.*

In a woman the common bile duct contained six lumbrici, all alive except one. The gall-bladder was empty in a man. It contained green bile in five men and three women; orange bile in a man and a woman; oil-like fluid in a man and two women; brown bile in three men, and a trace of dark bile in a woman. Its walls were œdematous in a man and two women, and they had a cyst filled with watery fluid in two men.

*Cysts.*

SPLEEN.

The spleens varied a good deal in weight, but may be divided into hypertrophied, normal, and atrophied. Under hypertrophied come in men, two spleens weighing 10¾ ozs. and 17⅝ ozs. Under normal come in men, eight spleens varying in weight from 3 ozs. to 4½ ozs., and averaging 3¾ ozs. fully; and in women, three spleens varying in weight from 3½ to 6 ozs., and averaging 4 ozs. fully.

*Weight.*

Under atrophied are included all spleens weighing under 3 ozs. These were two in men, weighing 1½ oz. and 2¾ ozs., and three in women, averaging 2 ozs. fully. In one of these women there were two spleens present, one weighing 1⅜ oz., and the other a drachm.

The capsule had a white thickened spot in a man, and points of thickening were adherent to the parietes in a man (case

No. 434), and a woman. In another man, it was adherent to the omentum without thickening.

*Tubercles.*

The substance was tough, not friable, and deficient in pulp, with no exudation on pressure, in eight men and three women; it was easily friable into a jam-like pulp in two men and a woman, and it appeared healthy in a man and two women. One hypertrophied spleen was less friable than usual. In only one spleen (case No. 438) were tubercular deposits observed; pigmentation also was present in only one case.

KIDNEYS.

In the men the weight of the right kidney ranged from $2\frac{1}{4}$ ozs. to $4\frac{1}{2}$ ozs., the average being $2\frac{3}{4}$ ozs., and that of the left kidney from $2\frac{3}{8}$ to $4\frac{1}{8}$ ozs., the average being 3 ozs. fully. In the women the weight of the right kidney ranged from 2 ozs. to $4\frac{1}{8}$ ozs., the average being 3 ozs. fully, and that of the left kidney from $2\frac{1}{4}$ ozs. to $4\frac{3}{8}$ ozs., the average being $3\frac{1}{4}$ ozs. fully. In the men nine right and five left kidneys weighed 3 ozs. or under, the average weight of former being $2\frac{3}{4}$ ozs., and of the latter $2\frac{3}{4}$ ozs.; and three right and seven left kidneys weighed over 3 ozs., the average weight of the former being $3\frac{3}{4}$ ozs., and of the latter 3 ozs. fully. And in the women two right and two left kidneys weighed under 3 ozs., the average weight of the former being $2\frac{1}{8}$ ozs., and of the latter $2\frac{1}{2}$ ozs., and five right and five left kidneys weighed 3 ozs. and upwards, the average weight of the former being $3\frac{1}{2}$ ozs. nearly, and of the latter $3\frac{1}{2}$ ozs. fully.

*Weight.*

*Cysts.*

In two cases the capsule was adherent; in all the others it stripped easily. On the capsule being stripped off, the surface was seen studded over with small cysts in two cases, both men. The substance of both kidneys was congested in six men and one woman, and of the right kidney alone in a woman; it was anæmic in one man and four women, and the cortex was anæmic, and medulla congested in a man and a woman.

*Fatty.*

The structure was fatty in four men and two women, in the others it seemed healthy, except in a man and two women desquamation cells were present in great numbers.

*Pancreas.*

The pancreas weighed on an average fully 2½ ozs. in the men, and fully 2 ozs. in the women. Its structure appeared healthy in all. A list of these cases is attached.

## Illustrative Cases.

Case 425.—Ragamen, a coolie man of Pariah caste, about twenty years old, from Noveram, a year in Madras, admitted on 8th May 1887 with "cough and weakness." Has been ill six months, first with fever, then with cough for last three months, with only occasional attacks of fever; has had night sweats, but never spat blood. Is rather emaciated, in legs especially; pulse 108; respirations 36; marked dulness on percussion, with clicking râles on auscultation over the apex of right, and base of left, lung; cough very troublesome; spit profuse, mucopurulent; tongue white; appetite good; bowels regular. 15th—Diarrhœa since yesterday, stools thin and green; pulse 120; respirations 48; cough very troublesome; spit profuse. Died on 19th. Autopsy six hours after death: height 5 feet 2 inches; weight 74 lbs.; body emaciated; rigor mortis present. *Skull.*—Scalp and meninges pale, a little serum in sub-dural space and beneath arachnoid, pia mater anæmic. *Brain*, 40½ ozs., firm, anæmic. *Chest.*—Right pleura contains half a pint of straw-coloured serum, firm old adhesions and false membrane present. *Lung*, 25½ ozs.; slightly torn at apex; not collapsed; exsanguineous and semi-solid (except anterior margin); section tough, yellowish-white from a yellowish uniform deposit in the walls of the air-cells doubling their thickness; there are no localised softened masses, although the deposit in places is tolerably like miliary tubercles. *Left pleura* healthy. *Lung*, 22¾ ozs.; apneumatosis of posterior border, otherwise like right; bronchial glands of both large and black. *Pericardium* pearly, distended with serum (a pint or so). *Heart* very large, 10¼ ozs., flabby, no fat on surface, both sides stuffed with firm fibrinous clots, a small "soldier's spot" on anterior surface near root of aorta. *Abdomen.*—Peritoneum pearly; contains two quarts of straw-coloured serum, with a large loose clot or cloud of same colour floating therein. *Small intestine* contains one lumbricus and a little thin reddish fluid; mucous coat, pale rose with ecchymotic-like subepithelial colouration of the valvulæ conniventes, and in corresponding lines and patches in the ileum, no thickening, nor enlargement of Peyer's or solitary glands. *Large intestine* contains a little ochrey fluid; mucous coat in ascending and descending colon, pink, swollen, and thrown into numerous folds; glands not infiltrated with tubercles. *Stomach* of moderate size; empty; mucous coat in rugæ, pink. *Liver*, 38 ozs.; 5½ + 3½ × 6 × 3¼ inches; cuts firm; surface red, with yellow puncta; looks fatty, but not so under microscope. *Gall-bladder.*—Walls œdematous; contains 2 ozs. thin greenish bile. *Spleen* 3½ ozs., flabby; 4 × 2½ × 1½ inches; section dark venous, granular, not friable. *Right kidney*, 2¾ ozs.; capsule strips easily;

substance red, healthy. *Left kidney*, 3 ozs., like right. *Pancreas*, $2\frac{3}{4}$ ozs.; appears healthy. *Mesenteric glands* not enlarged; œdema of mesentery; hardly a trace of fat.

CASE 426.—Mooneswamy, a Cauvery coolie man, about fifty years old, from Conjeeveram, two months in Madras, ill five or six days with troublesome cough, on admission to hospital, 13th May 1877, is much emaciated, no œdema; pulse 136; respirations 44; skin hot; bronchial breathing over dull spot in base of left lung; mucous râles on right side. Bowels loose since yesterday; stools thin, yellow, feculent; belly retracted, not painful on pressure. 14th, stools green mucus, three during night. Died on 18th. Autopsy, twelve hours after death. Height, 5 feet $7\frac{1}{2}$ inches; weight, 74 lbs. Body much emaciated; no œdema; rigor mortis absent. *Skull.*—Scalp and meninges pale; a little serum in sub-dural and arachnoid cavities; pia mater rosy; veins full. *Brain*, $39\frac{3}{4}$ ozs.; anæmic; some *post-mortem* softening. *Chest.*—Right pleura, old adhesions at apex posteriorly. *Lung*, 14 ozs., not collapsed; bronchi full of frothy fluid which exudes on pressure; no congestion. *Left pleura*, old adhesions and false membrane at base posteriorly. *Lung*, 24 ozs., lower lobe livid on surface; solid and tough on section from chronic pneumonia, with three or four cavities and numerous grey deposits which are seen under microscope to consist of nuclei and cells (tubercles); upper lobe congested along fissure, but no deposits. *Pericardium* closely adherent to heart all over by old bands, detachable tolerably easily. *Heart* small, flabby, devoid of fat, empty, $5\frac{1}{2}$ ozs. *Peritoneum* pearly. *Intestines* venous slaty; no fat. *Small intestine* contains one lumbricus and a little green fluid; mucous coat slaty; patches of lividity and arborescent injection of odd venous radicles seen through. "Shaven beard" appearances of Peyer's patches; glands normal. *Large intestine* contains four ounces greenish fluid; mucous coat somewhat swollen, but not enough to be in folds, slate-coloured, with darker spots; some puckered cicatrices, no ulcers or glands infiltrated with tubercles. *Stomach* empty; lining smooth; slaty. *Liver*, $30\frac{1}{4}$ ozs.; surface red with paler small spots $6 + 2\frac{3}{4} \times 5 \times 3$ inches; cuts firm; slightly fatty. *Gall-bladder* full of thin green bile. *Spleen*, 3 ozs., flabby, $4 \times 2\frac{1}{2} \times 1\frac{1}{2}$ inches, not friable, livid. *Right kidney*, 4 ozs.; capsule strips easily, substance red. *Left kidney*, $3\frac{3}{8}$ ozs.; healthy like right. *Pancreas* weighs $2\frac{1}{2}$ ozs.; seems healthy. *Mesentery* devoid of fat; glands normal. This man came in with diarrhœa, but cough was most complained of, and pneumonia was diagnosed. The autopsy showed that he had before suffered from diarrhœa, pericarditis, and chronic pleuro-pneumonia, and the more recent tubercular deposit was confined to the part of the lung then implicated and still unrecovered.

CASE 430.—Venkataram, a Pariah coolie, about thirty years old, from Chingleput, one month in Madras, and two months ill with fever and cough; admitted and died on 13th September 1877. Autopsy six hours after death. Height, 5 feet $6\frac{1}{2}$ inches; weight, 78 lbs.; body a skeleton; œdema of feet; rigor mortis present. *Skull.*—Scalp and

meninges pale; 2 ozs. serum in sub-dural space and some beneath arachnoid; lateral veins full. *Brain*, $39\frac{1}{2}$ ozs.; softish; anæmic. *Chest.*—Right lung, $26\frac{1}{2}$ ozs., firmly adherent all over, torn on removal; upper lobe riddled with cavities, having also semi-transparent solid grey slightly œdematous pieces; lower lobe studded with grey tubercles. *Left lung*, $24\frac{3}{4}$ ozs.; very similar to right. *Pericardium* pearly, contains 2 ozs. serum. *Heart*, $5\frac{3}{4}$ ozs., white clots on both sides, some œdema of surface, no fat. *Abdomen.*—Peritoneum pearly, moistened with serum. *Small intestine* empty; infiltration of solitary glands and of Peyer's patches; some of latter near valve ulcerated. *Large intestine* empty; some tubercular ulcers in cæcum and ascending colon, a few in transverse colon, none lower down. *Stomach* small, empty; lining reddish rugose. *Liver*, $27\frac{3}{4}$ ozs., dark purple, mottled yellow; $6\frac{1}{2} + 2\frac{1}{2} \times 6 \times 2\frac{1}{2}$ inches; section soft, acini margined yellow, decidedly fatty. *Gall-bladder* full of thin brown fluid. *Spleen*, 4 ozs., plump, $4 \times 3 \times 1\frac{1}{2}$ inch, section red, not friable, and no pulp exudes on pressure. *Right kidney*, $2\frac{3}{4}$ ozs., capsule strips easily; section reddish, cortex mottled paler; desquamation, but no fat cells. *Left kidney*, $3\frac{1}{8}$ ozs.; like right. *Pancreas*, $2\frac{1}{2}$ ozs.; healthy. No fat in mesentery; glands normal.

Case 434.—Patchappen, a coolie of the Pully caste, about thirty-five years old, from Paloor, three weeks in Madras, ten days ill with carbuncle on the back, admitted on 29th November. On 24th December he had an attack of remittent fever, which continued for a fortnight. On 7th January pneumonia was discovered in the upper lobe of the right lung, a week afterwards enlargement of the right parotid gland appeared, followed by a discharge from the right ear. He remained weak, and finally died on 28th February. Autopsy one hour after death. Height, 5 feet $3\frac{1}{2}$ inches; weight, 66 lbs.; body emaciated; no œdema; rigor mortis well marked. *Skull.*—Scalp and meninges pale, 4 ozs. serum in sub-dural space and some beneath arachnoid; vessels empty; a cloud over surface. *Brain*, $39\frac{1}{2}$ ozs., firm, anæmic. *Chest.*—Right pleura has old adhesions all over. *Lung*, 21 ozs., upper lobe solid, section grey, semi-transparent, not friable, but a little serum exudes on pressure. *Left pleura* like right. *Lung*, 11 ozs. apex solid with small cavity in centre and two or three shot-like deposits close by, rest pale and spongy. *Pericardium* pearly; contains 2 ozs. serum. *Heart*, $7\frac{1}{4}$ ozs., flabby, thin-walled, fluid blood on right side, œdema replaces fat on surface. *Abdomen.*—Peritoneum pearly, moistened with serum, old bands of adhesion between transverse colon and parietes on both sides. *Small intestine* contains one lumbricus; mucous coat healthy. *Large intestine* contains formed fæces; mucous coat healthy. *Stomach* small, empty, lining red, in rugæ. *Liver*, 38 ozs., firmly adherent to parietes all over convexity $7 + 2\frac{1}{2} \times 6 \times 3$ inches, section flabby, chocolate coloured, fatty. *Gall-bladder* was full of thin orange-coloured fluid. *Spleen*, $17\frac{5}{8}$ ozs., adherent to parietes all over; capsule thickened, $7 \times 5 \times 2$ inches; section dark red, less friable than usual. *Right kidney*, $2\frac{3}{4}$ ozs.; capsule adherent,

cysts on surface; section flabby, red injected, fatty. *Left kidney*, $2\frac{7}{8}$ ozs.; like right. *Pancreas*, $2\frac{5}{8}$ ozs.; healthy. Slight œdema of mesentery; glands pale and atrophied.

CASE 438.—Mongay, grass-cutter, about twenty-five years old, admitted on 15th December 1877, has been ill a fortnight with fever. She is in low flesh, with a dry scurfy skin; pulse 146; respirations 36; tongue moist, with a white fur; bowels loose; says shivering precedes the fever, which comes on daily at 6 P.M. She was found to be suffering from effusion into the right pleural cavity, but complained latterly only of weakness. She died on 13th January. Autopsy two hours after death. Height, 4 feet 9 inches; weight, 52 lbs.; body a skeleton; no œdema; rigor mortis present. *Skull.*—Scalp and meninges pale; serum beneath arachnoid and tentorium; lateral veins full, with slight ecchymosis in their course. *Brain*, 42 ozs., soft, anæmic. *Chest.*—Right pleura quite cartilaginous in front, the cavity full of dark reddish amber serum; a lot of jelly-like matter and lymph adherent to the lung, which is very small, quite carnified and studded with small hard tubercles, mostly immediately beneath the pleura; weight, $11\frac{1}{2}$ ozs. *Left pleura* pearly, contains 2 ozs. serum. *Lung*, 12 ozs., œdema with some congestion of posterior border; a few shot-like miliary tubercles all through. *Pericardium* pearly, contains 2 ozs. serum. *Heart*, $5\frac{5}{8}$ ozs., large and flabby; left side distended with fluid blood; no fat on surface. *Abdomen.*—Peritoneum healthy. *Small intestine* contains seven lumbrici; a diverticulum an inch long in lower end; coats thin, pigmented. *Large intestine* empty; mucous coat pale; a pale ulcer or two and some pigmented cyst-forms in lower end. *Stomach* small, contains six lumbrici and water, lining a dingy grey, in rugæ. *Liver*, $29\frac{3}{4}$ ozs., plump, with yellow spots, $7\frac{1}{2} + 2\frac{1}{2} \times 5\frac{1}{2} \times 2\frac{1}{2}$ inches; section fatty nutmeg, studded with numerous small miliary tubercles; very fatty. *Gall-bladder* contains a trace of dark bile. *Spleen*, $3\frac{1}{2}$ ozs.; purple; $4 \times 2\frac{1}{2} \times 1\frac{1}{2}$ inches; section brown, studded with soft tubercular masses, the size of peas. *Right kidney*, 3 ozs.; capsule strips easily; section dark livid mottled grey, and swollen-looking; numerous globular desquamation cells. *Left kidney*, $3\frac{3}{8}$ ozs.; like right. *Pancreas*, 2 ozs., healthy; no fat in mesentery; glands pale and atrophied.

CASE 440.—Govindama, the wife of a weaver, about forty years old, two months ill with cough and fever, admitted on 19th January 1878. She is a skeleton; pulse 84; respirations 36; has phthisis pulmonalis on both sides; never spat blood; no diarrhœa. The hectic fever continued, profuse expectoration set in; then diarrhœa, and she died on 18th February. Autopsy four hours after death. Height, 5 feet 3 inches; weight, 60 lbs.; body a skeleton; œdema of feet; rigor mortis present. *Skull.*—Scalp and meninges pale, a little serum in and beneath arachnoid; veins empty, but blotches of ecchymosis on posterior of left lobe. *Brain*, 33 ozs., firm, healthy. *Chest.*—Right pleura has very firm adhesion and contains a pint of serum. *Lung*, 29 ozs.;

cavity in apex opened in removal; section solid, friable, pale slate-coloured, studded with tubercles in lower lobe and with cavities in upper. *Left pleura* like right. *Lung*, $18\frac{1}{4}$ ozs.; section pale, œdematous, and softened; tubercles mostly confined to the anterior lower angle of upper lobe. *Pericardium* pearly, contains a little serum. *Heart*, $5\frac{3}{4}$ ozs.; blood and clots adherent on both sides; fat on surface. *Abdomen.* — Peritoneum pearly, contains a pint of serum; intestines reddish. *Small intestine* contains twenty-four lumbrici and a trace of ochrey pultaceous matter; mucous coat rosy with red injection in places; lots of mucus; three solitary glands and four Peyer's patches are infiltrated with tubercles. *Large intestine* empty, except a lot of whip-worms in cæcum; mucous coat pale with a livid tinge and somewhat swollen. *Stomach* contains four lumbrici, lining pale rugose. *Liver*, $30\frac{1}{2}$ ozs.; capsule thickened in spots, $6\frac{1}{2} + 2\frac{1}{2} \times 6 \times 3$ inches; section fatty nutmeg and has a yellow centred softened tubercular deposits, the size of a marble, very fatty. *Gall-bladder* is half full of thin orange fluid; six lumbrici were found in the common bile duct, all alive except one. *Spleen*, 6 ozs.; capsule thickened in points where adherent to parietes, $5\frac{1}{2} \times 3 \times 1\frac{1}{2}$ inch, healthy looking on section. *Right kidney*, $4\frac{1}{8}$ ozs.; capsule strips easily; section reddish, streaked pale, desquamation, no fat cells. *Left kidney*, $3\frac{5}{8}$ ozs., healthy. *Pancreas*, $2\frac{3}{4}$ ozs., healthy; œdema of mesentery; glands enlarged from tubercular deposits.

*Lumbrici in bile duct.*

No. 441.—Thoyee, the wife of a Cauvery coolie, about thirty years old, from Chingleput, twenty days in Madras, eight days ill with cough and diarrhœa. She is emaciated; belly retracted, soft, not painful on pressure; stools thin and yellow; cough troublesome, keeping her awake at night; pulse 104 weak, has pain and swelling of right ankle. Admitted on 2nd, died on 25th March 1878. Autopsy two hours after death. Height, 5 feet 1 inch; weight, 71 lbs.; body as above; rigor mortis absent. *Skull.*—Scalp and meninges pale; serum in sub-dural space and beneath arachnoid; veins empty. *Brain*, 37 ozs., firm, healthy. *Chest.*—Right pleura pearly, contains 4 ozs. serum. *Lung*, $11\frac{3}{8}$ ozs., slight œdema with livid spots in posterior border; lower tongue of upper lobe in front dark red and solid, also a solid brown spot near apex; no sign of tubercles. *Left pleura* has firm adhesions in front and contains a pint of serum. *Lung*, $22\frac{1}{4}$ ozs., upper lobe clay coloured, quite solid, not friable, but some serum exudes on pressure; a cavity of some size near apex, but no sign of tubercles. *Pericardium* pearly, contains 3 ozs. pale serum. *Heart*, $5\frac{3}{8}$ ozs., nearly empty; some œdematous fat on surface. *Abdomen.*—Peritoneum pearly, contains over a pint of serum. *Small intestine* contains four lumbrici only; mucous coat pale, œdematous; a soft granular effusion on lowest four inches; some solitary glands infiltrated with tubercles. *Large intestine* empty; mucous coat pale red, slightly swollen, lined by a granular reddish pseudo-membrane. *Stomach* small, lining rugose pale. *Liver*, $26\frac{1}{2}$ ozs., left lobe long and pointed; $6 + 2\frac{1}{2} \times 6 \times 3$ inches; section fatty nutmeg, very fatty.

*Gall-bladder*, walls œdematous; contents a little oil-like fluid. *Spleen*, $3\frac{1}{8}$ ozs., plump, $3 \times 2\frac{3}{4} \times 1\frac{1}{2}$ inches; section dark red, of normal consistence. *Right kidney*, $3\frac{1}{8}$ ozs.; capsule strips easily; cortex pale; medulla livid, slightly fatty. *Left kidney*, $3\frac{1}{2}$ ozs.; like right. *Pancreas*, $1\frac{3}{4}$ ozs., healthy. Œdema replaces fat in mesentery; glands small and pale.

## PHTHISIS PULMONALIS.

*List of Cases giving the Weight of the Body and of its Organs, &c.*

| No. | Name. | Caste. | Occupation | Age. | Sex. | Height. | | Weight in lbs. | Weight in Ounces of | | | | |
|---|---|---|---|---|---|---|---|---|---|---|---|---|---|
| | | | | | | Feet. | Inches. | | Brain. | Right Lung. | Left Lung. | Heart. | Liver. |
| | | | | YRS. | | | | | | | | | |
| 423 | Veerabudren ... | Pully ... | Ryot ... | 40 | Male ... | 5 | 8 | 89 | 46¼ | 31¾ | 25 | 5⅜ | 35½ |
| 424 | Chinnay ... ... | Pariah ... | Coolie ... | 60 | Do. ... | 5 | 7 | 89 | 41⅝ | 13 | 21½ | 6⅝ | 24⅞ |
| 425 | Ragamen ... ... | Do. ... | Do. .. | 20 | Do. ... | 5 | 2 | 74 | 40½ | 25½ | 22¾ | 10¼ | 38 |
| 426 | Mooneswamy ... | Cauvery .. | Do. ... | 50 | Do. ... | 5 | 7½ | 74 | 39¾ | 14 | 24 | 5½ | 30¼ |
| 427 | Veerasawmy ... | Bulgevadoo. | Do. ... | 46 | Do. ... | 5 | 6½ | 70 | 41 | 18½ | 26½ | 5¾ | 40 |
| 428 | Moonoosawmy ... | Rajoo ... | Do. ... | 50 | Do. ... | 5 | 4¾ | 70 | 43¼ | 28⅝ | 27¼ | 5¼ | 27⅜ |
| 429 | Gooroowadoo ... | Opera ... | Do. ... | 30 | Do. ... | 5 | 4 | 64 | 40 | 11½ | 20⅛ | 5⅜ | 36 |
| 430 | Venkataram ... | Pariah ... | Do. ... | 30 | Do. ... | 5 | 6½ | 78 | 39½ | 26½ | 24¾ | 5¾ | 27¾ |
| 431 | Coleppa ... ... | Do. ... | Pensioned Sepoy. | 50 | Do. ... | 5 | 7 | 86 | 44½ | 28¾ | 29¾ | 6⅛ | 38¼ |
| 432 | Paliathun ... | Do. ... | Coolie ... | 50 | Do. ... | 5 | 4 | 71 | 36¾ | 13¼ | 31⅝ | 6¾ | 27¾ |
| 433 | Veera Raja ... | Raja ... | Do. ... | 35 | Do. ... | 5 | 9 | 91 | 44 | 22½ | 27 | 7¼ | 35½ |
| 434 | Patchappen ... | Pully ... | Do. ... | 35 | Do. ... | 5 | 3½ | 66 | 39½ | 21 | 11 | 7¼ | 38 |
| 435 | Fatma Bee ... | Mahomedan. | ... | 25 | Female... | 5 | 1 | 69 | 39¾ | 21 | 21¼ | 4⅜ | 21½ |
| 436 | Mooneeamah ... | Shepherd ... | ... | 40 | Do. ... | 4 | 9 | 57 | 38 | 24 | 17 | 4⅛ | 22 |
| 437 | Chelly ... ... | Pariah ... | Coolie ... | 45 | Do. ... | 5 | ... | 63 | 36 | 15½ | 13⅞ | 5 | 19½ |
| 438 | Mongay ... ... | Grass-cutter. | ... | 25 | Do. ... | 4 | 9 | 52 | 42 | 11½ | 12 | 5⅝ | 29¾ |
| 439 | Vadootutha ... | Cauvery ... | Coolie ... | 60 | Do. ... | 5 | 1 | 81 | 40¼ | 18⅛ | 14⅜ | 8½ | 35¼ |
| 440 | Govindama ... | Weaver ... | ... | 40 | Do. ... | 5 | 3 | 60 | 33 | 29 | 18¼ | 5¾ | 30½ |
| 441 | Thoyee ... ... | Cauvery ... | Coolie ... | 30 | Do. ... | 5 | 1 | 71 | 37 | 11⅜ | 22¼ | 5⅜ | 26½ |

PHTHISIS PULMONALIS—*continued.*

*List of Cases giving the Weight of the Body and of its Organs, &c.*—continued.

| No. | Name. | Weight in Ounces of—*cont.* | | | | Date of Autopsy. | Hours after Death Autopsy made. | Rigor Mortis. | Bodily State. |
|---|---|---|---|---|---|---|---|---|---|
| | | Spleen. | Right Kidney. | Left Kidney. | Pancreas. | | | | |
| 423 | Veerabudren ... | 3 | 4½ | 4⅛ | 2½ | 4 April 1877 | 2 | Well marked. | Much emaciated ; œdema of feet. |
| 424 | Chinnay ... ... | 1½ | 2¾ | 3⅛ | 1⅝ | 4 April ... | 16 | Absent ... | Much œdema of hands and feet. |
| 425 | Ragamen ... ... | 3½ | 2¾ | 3 | 2¾ | 19 May 1877 | 6 | Present ... | Much emaciated ; no œdema. |
| 426 | Mooneswamy ... | 3 | 4 | 3⅜ | 2½ | 18 May 1877 | 12 | Absent ... | Much emaciated ; no œdema. |
| 427 | Veerasawmy ... | 3½ | 2¾ | 3⅜ | 3 | 15 June 1877 | 15 | Do. ... | Skeleton ; no œdema. |
| 428 | Moonoosawmy ... | 3⅝ | 2⅝ | 2⅞ | 2¾ | 26 Aug. ... | 8 | Present ... | Skeleton ; œdema of feet. |
| 429 | Gooroowadoo ... | 10¾ | 2⅝ | 2¾ | 2¾ | 8 Sept. ... | 4 | Do. ... | Skeleton ; no œdema. |
| 430 | Venkataram ... | 4 | 2¾ | 3⅛ | 2½ | 13 Sept. 1877 | 6 | Do. ... | Skeleton ; œdema of feet. |
| 431 | Coleppa ... | 4⅝ | 2⅞ | 3 | 2¼ | 1 Jan. 1878 | 2 | Do. ... | In low flesh ; œdema of feet and right leg. |
| 432 | Paliathun ... | 2¾ | 2¼ | 2⅜ | 2⅛ | 9 Jan. 1878 | 2 | Do. ... | Skeleton ; œdema of feet. |
| 433 | Veera Raja ... | 4⅞ | 3 | 2¾ | 2⅝ | 12 Jan. 1878 | 7 | Do. ... | Thin ; slight œdema of feet and legs. |
| 434 | Patchappen ... | 17⅝ | 2¾ | 2⅞ | 2⅝ | 28 Feb. ... | 1 | Well marked. | Emaciated ; no œdema. |
| 435 | Fatma Bee ... | 2½ | 3 | 3 | 2¼ | 4 May 1877 | 4 | Present ... | Much emaciated ; œdema of feet. |
| 436 | Mooneeamah ... | 2¼ | 2 | 2¾ | 1⅝ | 10 July ... | 7 | Absent ... | Skeleton ; œdema of feet. |
| 437 | Chelly ... ... | 1⅜, ⅛ | 2¼ | 2¼ | 1⅝ | 10 Dec. ... | 1 | Present ... | Skeleton ; œdema of feet and hands ; some ascites. |
| 438 | Mongay ... ... | 3½ | 3 | 3⅜ | 2 | 13 Jan. 1877 | 2 | Do. ... | Skeleton ; no œdema. |
| 439 | Vadootutha ... | 3½ | 4 | 4⅜ | 2½ | 14 Feb. 1878 | 10 | Do. ... | Rather obese. |
| 440 | Govindama ... | 6 | 4⅛ | 3⅝ | 2¾ | 18 Feb. 1878 | 4 | Do. ... | Skeleton ; œdema of feet. |
| 441 | Thoyee ... ... | 3⅛ | 3⅛ | 3½ | 1¾ | 25 Mar. 1878 | 2 | Absent ... | Emaciated ; no œdema. |

# CHAPTER VI.

## OTHER LOCAL DISEASES.

---

UNDER this head come Hepatic Abscess, Cerebral Hæmorrhage, Aphasia, Cancer, Ulcer, Ulceration of the Intestines, and Enteritis, amounting in all to 14 out of the 97 deaths shown in appendix A under "Other Diseases," wherein are also included the three deaths from pyæmia already treated of.

### 1. HEPATIC ABSCESS.

Abscess of the liver was found in six, or 2·65 per cent. of the men, and in the extremely rare case of a child. Five other cases, four men and a woman, came under treatment, one recovered by the abscess opening into the gut, the others absconded and probably died from the disease; the notes of these cases have unfortunately been mislaid. The total gives 0·37 per cent. on the total admissions.

In three of the men the abscess was insignificant, or in a latent state, and these cases have already been included under alvine flux and dropsy, but are shortly given below, being the first three on the list. In No. IV the abscess was comparatively small, was, I believe, pyæmic in origin like the lesion of the gut, and contributed little to the fatal issue. But in the three remaining cases, death may be fairly attributed to the liver abscess.

*Race.*

Seven is a very much too small a number of cases from which to draw any trustworthy generalization, else the large proportion of Mahomedans might be dwelt upon. This class formed only 6·6 per cent. of the adult males examined, while it contributed some 33 per cent. of these cases, one Mahomedan was a religious mendicant, but the other Mahomedan and the Hindu adults were of a class who indulge in spirituous liquor as often

*Habits.*

as obtainable, but indeed the same might be said of a great many of the other adults in whom no liver abscess was present.

*Age.*

The average age of these adults was about 47 years, the youngest being about 35, and the oldest about 60 years. The age of the child was about a year and a half.

*Disease complained of.*

The disease complained of on admission was diarrhœa in two cases, diarrhœa with cough in one, dysentery in one, dysentery with hepatic pain in one, fever with pains in abdomen in one, and dropsy with loss of appetite in one case.

*Duration of illness.*

The duration of illness given on admission varied from four days to two months, the average being about three weeks for the men; and their average stay in hospital was nine days nearly, the extremes being one and seventeen days. The child died on the day of admission and was said to have been ill only five days.

*Lesions in the colon.*

There was lesion of the mucous membrane of the colon found in all these cases except one, and in that there were pigmented cicatrices found. The form of the lesion was sloughing in three, ulceration in two, and diphtheritic effusion in one case. Viewing these lesions from the standpoint of Budd's theory of the causation of liver abscess by the absorption of morbid products from diseased intestines, it would appear that hardly one of them supports it fully. In case I, it is just possible that this was the sequence of events, but in cases II and III the lesion of the gut was much too recent for this. In case IV the abscess and sloughing in the colon were apparently both due to the same cause, viz., pyæmia set up by the diseased lung. In case V the ulcers in the colon were too recent in appearance to have preceded the liver abscess which dated some three months back, and similarly in case VII the sloughing in the colon was more recent than the liver abscess. In case VI, however, the cicatrices in the colon pointed to ulceration which probably antedated, and so may have caused, the abscesses in the liver. It has also to be remembered that there were 309 other cases in which was found some lesion of the gut, but no abscess in the liver.

*Budd's theory.*

There were abnormal adhesions between the liver and its surroundings in all these cases except one. The adhesions were extensive in the four acute cases. In one, the colon was adherent to the under surface of the liver.

*Liver.*

The liver was small in the three chronic cases, averaging under 30 ozs. in weight and being one-thirty-ninth of their average body weight. In the other three adults, the liver was enlarged, the weight in two being, with the abscess unopened, little over one-twentieth of the body weight. In the child in which the abscess had burst, the liver weighed 9¼ ozs., and was to the body weight as 1 is to 21.

*Size.*

The character of the contents of the abscess was, in the chronic cases, substance of the appearance and consistence of white paint in two, and laudable pus in the third; in the acute cases it was yellow pus in two, in one of these there was a second abscess containing thin reddish fluid with pieces of detached liver tissue intermingled; in the other adult the pus was dirty yellow and fœtid, in the child the pus seemed to have been thin yellow fluid.

The quantity in the acute cases varied from about two pints to some five ounces. In the chronic cases, the largest did not exceed a few drachms.

*Structure.*

The liver structure was noted healthy in three, slightly fatty in two, and congested in one. In one it is not noted.

The gall-bladder contained a little oil-like fluid in the child, and in the man who died from dropsy, in the latter its walls were œdematous. It contained a little thin green bile in the case with double abscess; in the others the character of the contents is not noted.

*Gall-bladder.*

Case I (No. 151).—Ghoolam Dustagheer, a Mahomedan fakeer, about thirty-five years old, 5 feet 2½ inches high, and 75 lbs. in weight, was admitted on the 10th March 1877 with looseness of the bowels of a month's standing, brought on, he said, by having had ground glass put into his food. He was emaciated with œdema of the feet; he appeared rather week minded; but his brain was found above the average in weight, being 41 ozs., and in ratio to body weight, being 1 to 29·2. He died within a week. The liver was small, weighing only 26⅛ ozs., and being only one-forty-fifth of the body weight. There was an abscess situated about the centre of the right lobe, of the size of a racket ball,

and containing yellow pus. The surrounding tissues appeared healthy under the microscope. The gall-bladder was nearly empty; contents not noted. On opening the large gut, the tissues of the caput coli were found greatly thickened, the lining had sloughed off all round forming a separate tube which lay unopened in the lumen of the gut; at one spot the sloughing had penetrated to the peritoneal surface; in the ascending colon there were two gangrenous bands encircling the gut; in the transverse colon there were two small and three larger grey sloughy ulcers; in the descending colon there were one black gangrenous band and four oval black sloughy ulcers; the lining of the lower part of the sigmoid flexure and of the upper part of the rectum formed a gangrenous mass which hung down and partly protruded from the anus. The intervening mucous membrane was wonderfully natural in appearance; it may have been somewhat thickened perhaps. The gut was empty. The small intestine contained some half-digested food and three lumbrici. Its coats were thin, the venous radicles showing through as arborescence in the lowest foot of the ileum.

Case II (No. 250).—Veeraswamy, a Hindu cultivator of the Pully caste, aged sixty years. Height, 5 feet 2½ inches; weight, 56 lbs.; was admitted on the 16th April 1877 for looseness of the bowels of four days' standing. He was much emaciated, but had no œdema. He died on the tenth day. The liver was small, weighing only 25 ozs., but relatively to body weight it was normal, 1 to 36 nearly. It adhered to the diaphragm by a point, about the centre of the convexity of the right lobe, immediately over a small superficial abscess of about the size of a walnut, and containing substance of the appearance and consistence of white paint. The surrounding tissues appeared healthy. *Gall-bladder* full, contents not noted. The large gut was empty; tissues thickened and mucous coat lined all through with a diptheritic effusion, which was black in the upper, ochrey yellow in the middle, and grey in the lower end, of the gut; in the last-mentioned part it was thin enough to allow the congestion of the subjacent mucous coat to be seen through. The small gut was empty, jejunum pale slate, congested in parts; ileum injected quite livid for four feet, one foot from the valve, and lined with a grey aphthous effusion, but not materially thickened; in the less congested parts the distended solitary glands were seen as white circular prominences.

Case III (No. 371).—Veeraswamy, a washerman by caste and calling, aged forty years. Height, 5 feet 1½ inches; weight, 83 lbs.; admitted on 5th October 1877, for dropsy and loss of appetite of five days' standing. He is emaciated, but dropsical; he denied having diarrhœa. He died the next day from Bright's disease. The liver was comparatively large, weighing 38 ozs., and measuring 9″ × 6″ × 3″. There was a small abscess, the size of a marble, containing substance like white paint; it was quite superficial and situated on the convexity of the right lobe which was adherent to the parietes over it. The surrounding tissue was dark liver-coloured, and slightly fatty. *Gall-bladder* half

full of oil-like fluid, walls œdematous. Small gut empty, mucous coat bile-stained. Large gut contained a little greenish pultaceous matter; mucous coat grey with some green mucous adherent; a few circular livid-edged grey-based superficial ulcers in the ascending and transverse colon and in the sigmoid flexture; no thickening. *Right kidney*, 6 oz.; capsule strips easily. Cortex greatly enlarged, pale mottled red and studded with small abscesses; medulla red; decidedly fatty. *Left kidney*, 7 oz.; like right.

Case IV (No. 442).—Meer Gholam Hoosain, a Mahomedan jutka driver, admitted on 8th April 1877, with cough of a month's, and diarrhœa of a week's, duration. Is emaciated; never spat blood. Had been five days under treatment when he died suddenly. Autopsy thirteen hours after death. Height, 5 feet 5 inches; weight, 82 lbs.; body thin; no œdema; rigor mortis present. *Skull.*—Scalp moderately injected; meninges pale. *Brain*, 41 ozs., firm, healthy. *Chest.*—Right pleura healthy. *Lung*, 20 ozs., congested, with some œdema of posterior border. *Left pleura*, firm adhesions over upper lobe which is torn in removal. *Lung*, 19½ ozs., upper lobe quite black, solid, cuts fibrous; is tunnelled with cavities, some containing blackish grumous fluid, some empty with smooth lining; lower lobe healthy; bronchial glands large. *Pericardium* healthy. *Heart*, 6 ozs.; has a firm white clot on right side. *Abdomen.*—Transverse colon adherent to the parietes opposite sloughs of mucous coat, and perforation occurred here in removal; peritoneum healthy; gut bluish grey. *Small intestine* contains a little black grey pultaceous matter; mucous coat nearly black, paler in ileum. Peyer's patches are cribriform. *Large intestine* very large and sacculated, full of thin grey feculence; sloughing of mucous coat almost to perforation in patches 3 inches across in transverse and descending colon, and in rectum, from effusion of pus beneath the mucous coat as seen from a patch in the sigmoid flexure in which the effusion of pus has been too recent to have set up sloughing; the rest of the mucous coat is healthy looking. *Stomach* small; contains a little dark fluid, mucous coat grey, in rugæ. *Liver*, 44¾ ozs.; capsule adherent to parietes by points, an abscess in right lobe containing five ounces of thick yellow pus, surrounding tissue congested, but of normal structure. *Gall-bladder* full. *Spleen*, 3½ ozs.; appears healthy. *Right kidney*, 3⅝ ozs.; capsule strips easily; structure normal. *Left kidney*, 4½ ozs.; quite like right. *Pancreas*, 2⅜ ozs., healthy. No fat in mesentery; glands normal. This case would probably be more correctly classed as pyæmia from chronic lung affection.

Case V (No. 443).—Ragavaloo, a conicoppillay of the Bulywodoo caste, was admitted on 14th February 1877 with dysentery and pains in the right side, the former of about two months', and the latter of one month's, duration; has been rather unhealthy always. He is emaciated and sickly looking; stools slimy, passed frequently and with pain; tenderness over colon; pain in hepatic region increased on pressure and by deep inspiration. On 23rd, stools four, copious, whitish thin feculence; pulse 92; respiration 22; temperature sub-normal. He gradually sank and died on 1st March. Autopsy five hours after death;

body much emaciated; rigor mortis present. *Skull*—Scalp and calvarum healthy; meninges pale; pia mater pinkish. *Brain*, 35½ ozs.: anæmic; rather soft. *Chest.*—Right lung, 9¾ ozs.; firmly adherent all over by old bands requiring careful dissection; upper lobe pale; lower lobe reddish, exuding a little frothy fluid on pressure. Left lung fully collapsed; 6¼ ozs. section pink, deepest behind; not the least serum exudes on pressure. *Pericardium* pearly, contains ℥ i amber serum. *Heart*, 4⅝ ozs., pale, flabby, empty. *Abdomen.*—Peritoneum healthy, except over liver. *Stomach* empty; lining pink. *Small intestine* contained a little pultaceous matter and one lumbricus, mucous coat pink. *Large intestine* thickened; mucous coat in cœum livid with superficial ulcers; in ascending colon pale and pitted, in transverse and descending colon pale and ulcerated, and in sigmoid flexure and rectum pink and swollen; the ulcers were superficial, large, grey based and livid edged. *Liver* adherent to colon below and to diaphragm over convexity of right lobe by four firm bands. Abscess opened in removal giving exit to about a quart of fœtid yellowish pus, leaving the right lobe a mere shell lined by a grey membrane; left lobe dark liver-coloured; weight, 33 ozs. when cleaned of all pus. *Spleen*, 2⅛ ozs.; firm, not friable. *Right kidney*, 3 ozs.; adherent to liver, but structure healthy. *Left kidney*, 3⅛ ozs.; healthy. *Pancreas*, 1¼ ozs.; healthy. No fat in mesentery; glands healthy.

The ulcers in the gut did not look sufficiently chronic to have antedated the liver troubles here.

Case VI (No. 444).—Andrayapen, a gardener of the Narken caste, about fifty years old, from Chingleput, one day in Madras, a fortnight ill with "fever, pain in the belly and œdema of the feet," admitted on 28th February 1878. He is in good flesh; pulse 100 weak; respiration 22; tongue thickly furred; bowels costive; has an asthmatic cough. Diarrhœa set in on 14th and he died on 17th March. Autopsy four hours after death. Height, 5 feet 3½ inches; weight, 92 lbs.; body well nourished; rigor mortis well marked. *Skull.*—Scalp and meninges healthy; ℥ ii serum in sub-dural space and some beneath arachnoid; a white cloud over vertex, veins empty, reddish transudation into the lateral sulci. *Brain*, 39 ozs., soft, anæmic. *Chest.*—Right pleura shows no sign of inflammation, but contains nearly a gallon of amber serum. *Lung*, 8¾ ozs., quite carnified, adherent to diaphragm opposite the liver abscess. *Left pleura* healthy. *Lung*, 12 ozs., spongy, section pink with red mottles; some œdema; and there is softening at one point in the lower lobe. *Pericardium* pearly, moistened with serum. *Heart*, 8 ozs., nearly empty, a soldier's spot and lots of fat on surface. *Abdomen.*—Peritoneum pearly; contains a pint of amber serum. *Small intestine* contains a little yellowish fluid; mucous coat pigmented in upper, rosy in lower, end; little mucus. *Large intestine* empty, pigmented cicatrices in cœcum; lower end of gut slightly swollen, rosy. *Stomach* large, empty, lining smooth, dull yellow. *Liver*, 69 ozs., adherent to diaphragm all over convexity of right lobe, 7″ + 3″ × 7″ × 5.″ Two abscesses occupy the whole breadth and nearly the whole thickness of the right lobe, separated by a thin septum; the left

contained 10 ozs. of thin yellow pus and was lined by whitish lymph; the right had a similar lining and contained 14 ozs. of thin reddish pus with pieces of liver tissue lying loose in the cavity. Section fatty nutmeg. *Gall-bladder* a quarter full of thin green bile. *Spleen*, $2\frac{3}{4}$ ozs.; $3\frac{1}{2} \times 2\frac{1}{2} \times 1$ inch, of normal consistence, section brownish red; pulp exudes on pressure. *Right kidney*, 3 ozs.; capsule strips easily; cysts on surface, section flabby, livid red, not fatty. *Left kidney*, $2\frac{7}{8}$ ozs.; like right. *Pancreas*, $2\frac{1}{2}$ ozs.; healthy. Some fat in mesentery; glands normal.

CASE VII (No. 445).—Peermanah, the daughter of a Pariah coolie, about a year and-a-half old, from Thermaree, two months in Madras, and five days ill with dysentery, was admitted and died on 21st August 1877. Autopsy three hours after death. Height, 2 feet 4 inches; weight, $12\frac{1}{2}$ lbs.; body a skeleton; no œdema; rigor mortis not present. *Skull.*—Scalp pale; meninges normally adherent; serum in sub-dural cavity; pia mater anæmic; veins empty. *Brain*, $26\frac{3}{4}$ ozs.; pale; softish. *Chest.*—Right pleura pearly; moistened with serum. *Lung*, $1\frac{5}{8}$ ozs.; full rose with livid tinge; healthy. *Left pleura* healthy. *Lung*, $1\frac{7}{8}$ ozs.; red hepatized spots at base of upper, and inner side of lower, lobe. *Pericardium* pearly; distended with serum. *Heart*, 1 oz.; blood on both sides; no fat on surface. *Abdomen.*—On cutting through the parietes a thin purulent fluid oozed out above the upper surface of a softish yellowish lymphy membrane which lined the cavity, and on severing this, the intestines were exposed and looked healthy, the injection being confined to the parietal peritoneum. The liver was adherent to the diaphragm all over its convexity. An abscess occupying the left lobe had burst anteriorly, the contents having oozed out between the abdominal wall and the lymphy membrane above described. *Small intestine* empty, except one lumbricus; mucous coat dirty white, thin, no mucus adherent. *Large intestine* empty; mucous coat pale; a thickened livid edged transverse sloughy blotch in the cœcum, two similar sloughs occupied nearly half of transverse colon, small circular thick edged sloughy ulcers intervening; in the sigmoid flexure the mouths of the follicles were red injected and ulcerated. *Stomach* small, empty; lining pale and smooth. *Liver* adherent to parietes $9\frac{1}{4}$ ozs., $6'' \times 3\frac{1}{2}' \times 1\frac{1}{2}''$; left lobe enlarged, being as broad as right, the seat of an abscess cavity, the walls of which are ragged, soft, and yellow to some depth posteriorly; the anterior wall is a whitish yellow substance, like the lymphy membrane sodden with pus; the right lobe is pale red, and healthy in structure. *Gall-bladder* full of fluid like colza oil. *Spleen*, $\frac{5}{8}$ ozs., plump, section dark red, not friable and no pulp exudes on pressure. *Kidneys*, $\frac{3}{4}$ ozs. each; capsule strips easily; section reddish, healthy. *Pancreas*, $\frac{1}{2}$ oz., healthy. No fat in mesentery; glands of normal size, injected livid.

## 2. CEREBRAL HÆMORRHAGE.

Hæmorrhage into the cranial cavity, from rupture of some of the cerebral vessels, was the immediate cause of death in four

cases, two men and two women. In all four the cause as well as the site of the hæmorrhage was different. In only one, case III was the disease true cerebral apoplexy, *i.e.*, the effusion of blood into softened degenerated brain tissue. In case 1 the blood was effused into the left lateral ventricle, and there was ecchymosis into the sulci all over the surface, except on the vertex, but most marked on left side, the cause of the hæmorrhage not being apparent. In case II, the cause was fracture of the skull in an accident, the effusion being beneath the meninges, and into the sub-dural cavity, chiefly. In case IV the blood was effused in considerable quantity into the sub-dural cavity, the hæmorrhage arising from injudicious over-exertion under exposure to the rays of the sun in the heat of the day, the patient being in a chlorotic state.

Case I (No. 449).—Tipoo Saib, a Mahomedan, a coolie, aged fifty years, admitted on the 28th September 1877 complaining of dysentery of five days' standing, but seems slightly off his head; is emaciated, no œdema, belly retracted, hard, tender on pressure; pulse 120; respirations 28. He died on 2nd October. Height, 5 feet 2 inches; weight, 70 lbs.; rigor mortis present; autopsy two hours after death. *Skull.*—Scalp and meninges bloody; a little serum in sub-dural cavity; ecchymosis into sulci of brain all over the surface except vertex; most marked on left side. *Brain,* 42½ ozs, firm, left lateral ventricle filled with rather firm dark clots. *Chest.*—Heart large, 7½ ozs; dark blood on both sides; a little fat on surface; other organs of chest healthy. *Abdomen.*—Stomach contains a little dark reddish fluid. Small gut empty; mucous coat reddish, lined with sticky green mucous. Large gut contains scybala more or less adherent to the mucous coat, which is pale red and rather thin, but not diseased. The solid organs were atrophied, but normal in structure, except liver and kidneys being slightly fatty.

Case II (No. 450).—Chinapayen, a Pariah coolie, aged twenty-two years, a powerful youth in splendid condition, was brought by the police insensible, having been knocked down by a run-away horse. He had a scalp wound and profuse bleeding from the left ear. He died two hours after admission on 11th January 1878. Autopsy six hours after death. Height, 5 feet 2 inches; weight, 107 lbs.; rigor mortis well marked. *Skull.*—Fracture had extended from the occipital into the petrous portion of the temporal bone; blood was effused beneath the scalp and on to the brain which had its convolutions bruised on the left side. *Brain,* 44½ ozs.; firm; bruised on left side. There was ℥ iv pale serum in the peritoneal cavity; 19 lumbrici in the small gut; and some spots of emphysema of the mucous coat of the stomach which was of enormous size and contained food; mucous coat pale. The heart weighed 9½ ozs.; the spleen weighed only 3 ozs.; and the

kidneys only an aggregate of $5\frac{3}{4}$ ozs. All the organs appeared healthy in structure.

CASE III (No. 451).—Sarambee, a Mahomedan widow, aged fifty years, admitted on 3rd March 1877, with hemiplegia of right side of a week's duration, preceded, she said, by fever for some days; the tongue was exempted, but the bladder was paralysed. Spastic paralysis of the muscles of the left side set in on the 8th, when she was observed to have some power over the right side. She died on the 14th. Autopsy two hours after death. Height, 5 feet; weight, 59 lbs. Body emaciated; œdema of face, right eyelid, and left foot. *Skull.*—Scalp and meninges pale; sub-arachnoid effusion of serum near ecchymosed spots in longitudinal fissure. *Brain*, $42\frac{1}{2}$ ozs.; an apoplectic effusion fully the size of a racket ball in the posterior cornu of the left hemisphere extending to the surface of the convexity over a spot about two inches by one-and-a-half inch; a still larger effusion into the white substance of the right hemisphere opposite the corpus striatum and extending through the whole thickness of the lobe from vertex to base. The clots and brain substance were breaking down, the former being bathed in a semi-purulent fluid. The heart was large, weighing $7\frac{1}{4}$ ozs.; contained blood and clots and had some fat on surface. The small gut contained 5 lumbrici and had at the upper end of the ileum a diverticulum an inch in length and distended with gas. The large gut contained a quantity of scybala; the mucous coat was pale, but had a dozen spots of sub-mucous ecchymoses at the splenic flexure of the colon. The liver and kidneys were small and somewhat fatty; the spleen seemed healthy, but weighed only $3\frac{1}{2}$ ozs.

CASE IV (No. 452).—Moongay, wife of a weaver, caste Gentoo, aged twenty years, was in hospital from 21st July to 16th August 1877 for chlorosis. Had a relapse and was readmitted on 27th idem. There was much anæmia, some general anasarca, no bowel complaint, tongue clean, appetite good, pulse 80, respirations 24. She again improved greatly under the treatment of good food and iron. She absconded on September 6th, walked two miles home in the heat of the day, was brought back insensible, and died almost directly. Autopsy fourteen hours after death. Height, 5 feet 1 inch; weight, 73 lbs.; body thin; œdema of feet; ascites; rigor mortis gone off. *Skull.*—Scalp and meninges pale; a large dark clot in the sub-dural cavity covered much of the surface of the brain; there was also a little serum here, and some with a spot or two of ecchymosis beneath the arachnoid on the right side. *Brain*, $35\frac{3}{4}$ ozs.; very white and soft. *Chest.*—*Right pleura* pearly; contains ℥ iv of pale serum. *Lung*, $14\frac{1}{8}$ ozs.; well collapsed; pale with a livid tinge; some œdema; a large apoplectic spot about the middle of the lower lobe on the posterior surface, solid, but friable. *Left pleura* like right. *Lung*, $11\frac{7}{8}$ ozs.; œdema with some lividity of posterior part. *Pericardium* pearly; contains a pint of pale serum. *Heart*, $6\frac{7}{8}$ ozs.; pale, empty; œdema replaces fat on surface and there is a small "soldier's spot" over the anterior coronary vessels. *Abdomen.*—Peritoneum pearly; contains a quart of serum. Small gut empty;

mucous coat pale greyish; some mucus adherent. Large gut empty; mucous coat quite white with dark red edged circular grey sloughs, the size of a six-pence, scattered through its whole length, a score or so in all. *Stomach* small; contained a little water; lining quite white. *Liver*, $46\frac{1}{8}$ ozs.; $6'' + 3'' \times 7'' \times 3''$; section dark livid with prominent yellowish hard spots, the size of small peas all over, the nature of which was not clearly made out by microscope. *Gall-bladder* half full of thin yellow fluid. *Spleen*, $18\frac{1}{4}$ ozs.; $8'' \times 4\frac{1}{2}'' \times 2''$, section dark red with pale hard deposits like those in the liver; substance easily friable, but not into thin pulp. *Right kidney*, $3\frac{3}{4}$ ozs.; capsule strips easily; very anæmic; the microscope discovers numerous lymphoid cells and an odd fat granule. *Left kidney*, $3\frac{7}{8}$ ozs.; quite like right. *Pancreas*, $3\frac{1}{4}$ ozs., appears normal. Œdema replaces fat in mesentery; glands atrophied. There must have been diarrhœa here, although not brought to notice.

### 3. Aphasia.

The following was the only case of this disease that came under notice:—

Case 457.—Patcha Bee, a Mahomedan beggar woman, admitted on 30th May, ill a week from aphasia. She is in low flesh, has partial loss of power of right side not affecting the tongue, understands what is said to her, but articulation monosyllabic and unintelligible; pulse 80; respiration 18; appetite good; bowels regular; her speech improved slightly, but her mental state was unhappy. She died 25th July. Autopsy ten hours after death. Height, 5 feet $6\frac{1}{2}$ inches; weight, 89 lbs.; body thin; œdema of feet; rigor mortis present. *Skull.*—Scalp and meninges pale; ℥ iv serum in sub-dural cavity and beneath arachnoid, surface white; veins nearly empty. *Brain*, $38\frac{3}{4}$ ozs., semi-diffluent; hemispheres flat, soft and anæmic; posterior cornu of left hemisphere yellow on surface, and on section of the consistence of cream, exuding a milky fluid. *Chest.*—Right pleura pearly; contains half a pint of serum. *Lung*, 16 ozs.; congested with œdema. Left pleura some old points of adhesion, else like right. *Lung*, $10\frac{3}{4}$ ozs.; lividity with œdema of posterior border. *Pericardium* healthy. *Heart*, $5\frac{1}{4}$ ozs., flabby, empty, on surface little fat and two large easily removable "soldier's spots." *Abdomen.*—Peritoneum pearly; contains a quart of reddish serum. *Small intestine* contained 15 lumbrici and some yellowish fluid; mucous coat pale slate, growing pale towards valve; lividity in parts. *Large intestine* empty; mucous coat dull grey, some points of lividity, no mucus. *Stomach* small, contains a little milk; lining pale in rugæ. *Liver*, 23 ozs., slaty, fatty; slightly decomposed. *Gall-bladder* full of thin brown bile. *Spleen*, $\frac{3}{4}$ oz.; capsule wrinkled, granular and whitish; section brown, not friable, but some pulp exudes on pressure. *Kidneys*, $2\frac{1}{2}$ ozs. each; capsules strip easily; cortex yellow fatty; medulla livid desquamating. *Pancreas*, $1\frac{1}{4}$ oz., healthy. Mesentery devoid of fat; glands atrophied.

## 4. Cancer.

Two died from cancer, a man and a woman. The man was quite young and had extensive cancerous ulceration of the skin of the left loin; the liver was small and one mass of scirrhus. The woman was middle aged and had cancer of the breast with secondary deposit in the liver which was much enlarged, but not quite wholly cancerous. Besides these there is a case included under alvine flux in which the ulceration of the gut appeared to be cancerous, but there was no deposit elsewhere. This case is shortly given also.

Case I (No. 453).—Chellum, caste Kurayap, a coolie, aged twenty years, was admitted on 31st March 1877 with cancerous ulceration of the skin over the left loin, of two years' duration. The ulcer was some twelve square inches in extent, bounded above by the three lower ribs and below and in front by cicatrices which extended between the crest of the ileum and umbilicus. The glands of the left axilla and groin were cancerous and ulcerated. He was quite plump. He complained chiefly of pain and want of sleep. He died suddenly and unexpectedly three days after admission. Autopsy four hours after death. Height, 5 feet 3 inches; weight, 107 lbs.; rigor mortis slight. *Skull* and contents healthy. *Brain*, 46½ ozs. *Pleuræ* pearly, contain each a quart of serum; some old points of adhesion in right. *Lungs*, 17 ozs; healthy, except apneumatosis of lower lobe in both. *Heart*, 6½ ozs.; healthy, as well as pericardium. *Peritoneum* pearly, contains a gallon of straw-coloured serum. Alimentary canal healthy; two lumbrici in ileum and some thin feculence in colon. *Liver*, 38 ozs.; dull grey, a conglomeration of cancer nodules. Left lobe quite atrophied, hardly any liver tissue discernable. *Gall-bladder* full of bile. *Spleen*, 17 ozs.; upper end rounded, but surface uniform dark brown, hard along convexity, soft as jam along hilus. *Kidneys*, 6⅝ ozs.; anæmic, but healthy. *Pancreas*, 2 ozs., normal. Lots of fat in mesentery; glands normal.

Case II (No. 454).—Perinthayamah, a Malabar woman, aged forty years, admitted on 19th and died on 20th June 1877, from cancer of the left mamna, with secondary deposits in the axillary glands and liver. Autopsy six hours after death. Height, 4 feet 8 inches; weight, 70 lbs.; body in fair flesh; œdema of left arm and right leg; rigor mortis present. *Skull.*—Scalp and meninges normal; serum in sub-dural cavity and beneath arachnoid; veins full. *Brain*, 38½ ozs.; anæmic. *Chest.*—Lungs, 18¼ ozs.; healthy. Left pleura healthy, contains a pint of pale serum; right has firm old adhesions. *Heart*, 4⅞ ozs.; no fat on surface; fluid blood on both sides. *Pericardium* pearly, contains 4 ozs. pale serum. *Abdomen.*—Peritoneum pearly, moistened with amber serum. *Stomach* large, full of green fluid; lining smooth. *Gut* empty; lining pale. *Liver*, 58½ ozs.; surface rough from cancerous deposit $6'' + 4'' \times 7\frac{1}{2}'' \times 4''$; cuts firm; liver tissue about one-third

of whole and fatty; rest hard scirrhus-like cancer, infiltrating tracts; none nodulated or softened. *Spleen*, $4\frac{3}{4}$ ozs., scars on capsule, section firm, red, studded with nodules of cancer eucephaloid in appearance. *Kidneys*, 3 ozs. each; capsule strips easily; substance pale yellowish, fatty; *Pancreas*, 3 ozs.; healthy. Cancerous deposit in a few mesenteric glands; fat in mesentery; right ovary cystic; uterus normal.

Case III (No. 114).—Veerabundrum, a weaver, aged forty-five years, complained of cough, fever and dysentery of five days' duration, was admitted on 27th, and died on 30th June 1877. Autopsy three hours after death. Height, 5 feet 6 inches; weight, 80 lbs.; much emaciated; œdema of feet; rigor mortis present. Gut empty except two lumbrici in jejunum; mucous coat pale rose to dull white in ileum; in upper half of colon it was injected quite red, not swollen, but studded with thick based yellowish cancroid-like ulcers; in lower end it was pale rose with warty fungoid ridges like epithilial cancer in the rectum. The microscope discovered lymphoid and fat cells with granules in sections of both. *Liver* small, $32\frac{1}{2}$ ozs.; $5'' + 3\frac{1}{2}'' \times 6'' \times 3''$; a cicatrix of some depth on convexity of right lobe; substance looks healthy, but is slightly fatty. *Gall-bladder* contained a little thick green bile. *Spleen* atrophied; weighs 1 oz., not friable, and no pulp exudes on pressure. *Kidneys*, $6\frac{5}{8}$ ozs.; healthy; mesentery œdematous; glands atrophied. More or less serous effusion into all the cavities except the pleuræ. *Lungs* pale and œdematous; weigh $19\frac{1}{2}$ and 25 ozs. On both apices were deep white cicatrices very considerably depressed with remains of some deposit degenerated into fatty and calcified matter; œdema replaces fat on heart, which weighs 6 ozs. and has dark blood on right side. *Stomach* large, contained food; lining pale in rugæ. Vessels of scalp and meninges full. *Brain*, 43 ozs.; healthy. *Pancreas*, $2\frac{1}{8}$ ozs.; healthy.

## 5. Ulcer.

In the Vellore returns under ulcer are 292, or nearly 11 per cent. of the total admissions, and 21, or fully 2 per cent. of the total deaths. This disease also appears as assisting to make up the 30·2 per cent. of the total deaths shown in the last column of return in Appendix C. But in the Royapettah sheds the admissions from ulcer were only 45, or 1·35 per cent. of the total, and the following is the only death that could have been returned under this head except perhaps case III of pyæmia. However, ulcer contributed 1·47, or 2·23 per cent., of the average daily sick.

Case (No. 456).—Ramadoo, Pariah coolie, aged fifty years, admitted on 7th April 1877 with gangrene of the skin of nearly the whole of the left thigh, probably the results of phlegmonous erysipelas. The skin is dry and crackles under the touch and smells badly; there is no swelling; emaciation considerable; pulse 80, good; respiration 20. He appeared to be doing well till he was suddenly found dying from

apnœa on 13th April. Autopsy five hours after death. Height, 5 feet 1 inch; weight, 82 lbs.; body emaciated; whole of right thigh denuded of skin; rigor mortis present. *Skull.*—Scalp and meninges healthy; pia mater injected quite red; no fluid in sub-dural space. *Brain*, 40½ ozs., softish, hyperæmic. *Chest.*—Right pleura healthy. *Lung*, 14½ ozs.; lower lobe and posterior of upper livid, spongy; some froth and more blood exude on pressure. Left pleura healthy. *Lung*, 10¾ ozs.; lividity confined to posterior border. *Pericardium* pearly, contains 4 ozs. pale serum. *Heart*, 5¼ ozs.; firm dark clots on right side. *Abdomen.*—Peritoneum pearly, contains a gallon of straw-coloured serum. *Small intestine* contains a little green pultaceous matter; mucous coat pigmented slaty, paler in ileum. *Large intestine* contains a large amount of greenish fluid; mucous coat pale slate-coloured. *Stomach* small, contains a little green fluid; mucous coat in rugæ, anæmic, stained yellow. *Liver*, 26¾ ozs., dark brown, flabby, not fatty. *Gall-bladder* full. *Spleen*, 3⅛ ozs., looks healthy. *Right kidney*, 3 ozs., hyperæmic, otherwise healthy. *Left kidney*, 3¼ ozs., like right. *Pancreas*, 2½ ozs.; healthy. Mesentery œdematous, no fat; glands normal.

## 6. Ulceration of the Intestines.

Only one death is put down to this cause. This was No. 455, a Pariah woman, named Vully, aged thirty-five years, who was admitted on 6th August 1877, for "pains all over the body and swelling of the legs," of ten days' standing. She was emaciated with some ascites and œdema of legs; pulse 84, very small; respiration 18; no diarrhœa. On 8th, she complained of pain in the belly, of having had no motion for three days, and of not having passed urine that morning; there was no vomiting. She died on 10th idem. Autopsy three hours after death. Height, 4 feet 10 inches; weight, 70 lbs.; rigor mortis present; no scrofulous scars on neck or elsewhere. *Abdomen.*—Peritoneum pearly; contained a quart of straw-coloured serum; the free part of the great omentum to nearly as high as the transverse colon was almost devoid of fat, and was injected a deep livid red colour from no apparent cause. *Small intestine* contained a little bloody fluid and four lumbrici; mucous coat in jejunum rosy with fifty circular punctated spots of sub-mucous ecchymosis, one half crowded together in four inches at two feet from its upper end, and with a dozen ulcers in its upper six feet. Three of these were girdle ulcers, two inches across, fully encircling the gut; one was nearly cicatrized, having a thickening pigmented base with spots of ecchymosis thereon; two other ulcers and one livid cicatrix half encircled the gut; the others were smaller and transverse and

appeared to have originated in the spots of ecchymosis; tubercles were not found in all. The mucous coat of the ileum was pale, and that of the lowest foot was slightly œdematous. *Large intestine* empty; mucous coat pale and œdematous. There was a girdle ulcer in sigmoid flexure four inches across, lower half cicatrized, blackish and puckered, upper half pigmented and upper edge thick and livid. There was slight effusion into all the serous cavities. *Brain*, 36 ozs., anæmic. *Lungs*, 9½ and 7⅜ ozs.; apneumatosis of posterior borders; no sign of tubercles. *Heart*, 3¼ ozs., flabby; "a soldier's spot" and some fat on surface. *Liver*, 29 ozs., flabby, very fatty. *Spleen* 3 ozs., white thickened spots on capsule, flesh-like, no pulp. *Kidneys*, 4⅜ ozs., anæmic, desquamation, but no fat cells. *Pancreas*, 1 oz.; healthy. Some fat in mesentery; glands normal; no tubercles.

But while only one death is set down to ulceration of the gut, this lesion itself, varying in extent from a mere abrasion in some, to complete perforation in others, was present in rather more than half the total cases, viz., in 51·4 per cent.; consisting of 50·9 per cent. of the men, 54·1 per cent. of the women, and 47·4 per cent. of the children.

The subjoined table gives the causes of death, the form of alvine flux, if any, complained of, and other details of these cases:—

| — | Men. | | | Women. | | | Children. | | | Total. |
|---|---|---|---|---|---|---|---|---|---|---|
| | Diarrhœa. | Dysentery. | Neither. | Diarrhœa. | Dysentery. | Neither. | Diarrhœa. | Dysentery. | No History. | |
| Alvine Flux, Division II ... | 23 | 36 | ... | 29 | 23 | ... | 14 | 7 | ... | 132 |
| Do. do. III ... | 19 | 17 | ... | 12 | 7 | ... | 4 | 8 | ... | 67 |
| Cholera ... ... ... | 1 | 2 | ... | ... | 1 | ... | ... | ... | 1 | 5 |
| Dropsy ... ... ... | 1 | ... | 1 | 2 | ... | ... | ... | ... | ... | 4 |
| Pneumonia Acute... ... | 1 | ... | ... | 2 | ... | ... | ... | ... | ... | 3 |
| Atrophy .. ... ... | 1 | ... | 1 | ... | ... | 2 | ... | ... | ... | 4 |
| Phthisis Pulmonalis ... | 2 | 3 | 2 | 1 | 2 | ... | ... | ... | ... | 10 |
| Enteric Fever ... ... | 1 | ... | ... | ... | ... | ... | 2 | ... | ... | 3 |
| Hepatic Abscess ... ... | 1 | 1 | ... | ... | ... | ... | ... | 1 | ... | 3 |
| Pyæmia ... ... ... | 1 | ... | ... | ... | ... | 1 | ... | ... | ... | 2 |
| Apoplexy ... ... ... | ... | ... | ... | ... | ... | 1 | ... | ... | ... | 1 |
| Enteritis ... ... ... | ... | ... | 1 | ... | ... | ... | ... | ... | ... | 1 |
| Ulceration of Bowels ... | ... | ... | ... | ... | ... | 1 | ... | ... | ... | 1 |
| Total ... | 51 | 59 | 5 | 46 | 33 | 5 | 20 | 16 | 1 | 236 |

ALEX: BARREN, PINXT. ET

LITHOGR., MADRAS, 1889

TUBERCULAR ULCER OF ILEUM.

The above shows that dysentery was complained of more frequently in the men, and less so in the women and children, than diarrhœa. But if to the latter are added the cases in which looseness of the bowels, though not complained of and often even denied, was found present, then diarrhœa may be said to have been oftener present than dysentery by 117 to 108 cases.

In three men and five women the presence of any bowel complaint was denied and none was discovered, and in two men the bowels were undoubtedly costive. In a child who died from cholera, there is no previous history noted.

SMALL INTESTINE. *Ulceration in—.*

There was ulceration of the small intestine, and in many of these, of this only, in 17 men, 13 women and two children; 15 had complained of dysentery, 13 had diarrhœa, and 4 had no bowel complaint. The ulceration in these cases may be divided into tubercular and non-tubercular.

*Tubercular Ulcers.*

The tubercular ulcers were present in 11 men and 10 women; eight had complained of dysentery, nine had diarrhœa and four had no bowel complaint as shown below:—

| — | Men. | | | Women. | | |
|---|---|---|---|---|---|---|
| | Diarrhœa. | Dysentery. | No Bowel Complaint. | Diarrhœa. | Dysentery. | No Bowel Complaint. |
| Alvine Flux, Division II... ... | ... | 2 | ... | 3 | ... | ... |
| Do. do. III... ... | 2 | 1 | ... | 2 | 1 | ... |
| Dropsy ... ... ... ... | 1 | ... | ... | ... | ... | ... |
| Atrophy ... ... ... ... | ... | ... | ... | ... | ... | 1 |
| Phthisis Pulmonalis ... ... | 1 | 2 | 2 | ... | 2 | ... |
| Ulceration of Bowels ... ... | ... | ... | ... | ... | ... | 1 |
| Total ... | 4 | 5 | 2 | 5 | 3 | 2 |

There was a tubercular deposit in the lungs in all these cases, except two women, one of whom is returned as having died from starvation and the other from the intestinal ulceration.

There was no ulceration whatever of the large intestine in four of these men and in five women; however, in one of the former and in three of the latter there was diphtheritic effusion

here; two had complained of dysentery, five had diarrhœa and two had no bowel complaint. And in only three men and four women was the ulceration in the large gut tubercular in character; three had complained of dysentery, two had diarrhœa and two had no bowel complaint.

On the other hand in cholera case No. VI we have an example of tubercular ulceration of the colon with tubercular deposit in the lung, but none of the small intestine.

*Non-tubercular ulcers in—.*

The ulcers in the small gut were non-tubercular in character in six men, three women, and two children; two had complained of dysentery, and nine had had diarrhœa; three of the latter were cases of enteric fever, all the rest were cases of alvine flux. Ulceration was also present in the colon in all these cases of alvine flux except one, which however had diphtheritic effusion instead, and was present in one case of enteric fever, No. 397, a child, in whom two closed follicles in the transverse colon were infiltrated and ulcerated.

LARGE INTESTINES. *Ulceration of—.*

Ulceration of the large gut was found in 113 men, 50 per cent., 76 women, 49 per cent. and in 36 children, 46·15 per cent.

Of these, 109 had complained of dysentery, 107 had had diarrhœa, eight had had no bowel complaint, and one had no history.

The character of the ulcers, the diseases in which they occurred, the form of alvine flux, if any, complained of, and other particulars, are fully set forth in the subjoined table:—

*Ulcers of Large Intestine, Characters of, &c.*

| — | Abrasions. | | | | | | Small Circular Ulcers. | | | | | | Irregular Ulcers. | | | | | | Tubercular Ulcers. | | | | Sloughing. | | | | | Perforation. | | | Total. |
|---|---|---|---|---|---|---|---|---|---|---|---|---|---|---|---|---|---|---|---|---|---|---|---|---|---|---|---|---|---|---|---|
| | Men. | | Women. | | Children. | | Men. | | Women. | | Children. | | Men. | | Women. | | Children. | | Men. | | Women. | | Men. | | Women. | | Children. | Men. | | Children. | |
| | Diarrhœa. | Dysentery. | Diarrhœa. | Dysentery. | Diarrhœa. | Dysentery. | Diarrhœa. | Dysentery. | Diarrhœa. | Dysentery. | Diarrhœa. | Dysentery. | Diarrhœa. | Dysentery. | Diarrhœa. | Dysentery. | Diarrhœa. | Dysentery. | Diarrhœa. | Dysentery. | Diarrhœa. | Dysentery. | Diarrhœa. | Dysentery. | Diarrhœa. | Dysentery. | Dysentery. | Diarrhœa. | Dysentery. | Dysentery. | |
| Alvine Flux, Division II. | 1 | 2 | ... | 2 | ... | ... | 11 | 12 | 8 | 5 | 10 | 3 | 3 | 13 | 6 | 7 | 4 | 2 | ... | ... | 1 | ... | 8 | 12 | 10 | 8 | 1 | 1 | ... | 1 | 131 |
| Do. do. III. | 2 | 3 | 1 | ... | 2 | 2 | 6 | 5 | 6 | 1 | 1 | 3 | 3 | 3 | 2 | 2 | 1 | 3 | ... | ... | ... | ... | 5 | 6 | 2 | 3 | ... | ... | 1 | ... | 63 |
| Cholera ... ... ... | ... | ... | ... | ... | ... | ... | ... | 1 | ... | ... | †1 | ... | ... | ... | ... | 1 | ... | ... | ... | 1 | ... | ... | 1 | ... | ... | ... | ... | ... | ... | ... | 5 |
| Dropsy ... ... ... | ... | ... | ... | ... | ... | ... | *1 | ... | 1 | ... | ... | ... | ... | ... | ... | ... | ... | ... | ... | ... | ... | ... | ... | ... | 1 | ... | ... | ... | ... | ... | 3 |
| Pneumonia Acute ... | ... | ... | ... | ... | ... | ... | 1 | ... | 1 | ... | ... | ... | ... | ... | 1 | ... | ... | ... | ... | ... | ... | ... | ... | ... | ... | ... | ... | ... | ... | ... | 3 |
| Atrophy ... ... ... | ... | ... | ... | ... | ... | ... | ‡2 | ... | *1 | ... | ... | ... | ... | ... | ... | ... | ... | ... | ... | ... | ... | ... | ... | ... | ... | ... | ... | ... | ... | ... | 3 |
| Typhoid Fever ... ... | ... | ... | ... | ... | ... | ... | ... | ... | ... | ... | 1 | ... | ... | ... | ... | ... | ... | ... | ... | ... | ... | ... | ... | ... | ... | ... | ... | ... | ... | ... | 1 |
| Phthisis Pulmonalis ... | ... | ... | ... | ... | ... | ... | ... | ... | 1 | ... | ... | ... | 1 | 1 | ... | ... | ... | ... | ‡2 | 1 | ... | 2 | ... | ... | ... | ... | ... | ... | ... | ... | 8 |
| Hepatic Abscess ... | ... | ... | ... | ... | ... | ... | ... | ... | ... | ... | ... | ... | ... | 1 | ... | ... | ... | ... | ... | ... | ... | ... | 1 | ... | ... | ... | 1 | ... | ... | ... | 3 |
| Pyæmia ... ... | ... | ... | *1 | ... | ... | ... | ... | ... | ... | ... | ... | ... | ... | ... | ... | ... | ... | ... | ... | ... | ... | ... | ... | ... | ... | ... | ... | 1 | ... | ... | 2 |
| Apoplexy ... ... | ... | ... | ... | ... | ... | ... | ... | ... | ... | ... | ... | ... | ... | ... | ... | ... | ... | ... | ... | ... | ... | ... | ... | ... | *1 | ... | ... | ... | ... | ... | 1 |
| Enteritis ... ... | ... | ... | ... | ... | ... | ... | ... | ... | ... | ... | ... | ... | ... | ... | ... | ... | ... | ... | ... | ... | ... | ... | *1 | ... | ... | ... | ... | ... | ... | ... | 1 |
| Intestinal Ulceration ... | ... | ... | ... | ... | ... | ... | ... | ... | ... | ... | ... | ... | ... | ... | ... | ... | ... | ... | ... | ... | *1 | ... | ... | ... | ... | ... | ... | ... | ... | ... | 1 |
| Total ... | 3 | 5 | 2 | 2 | 2 | 2 | 21 | 18 | 18 | 6 | 13 | 6 | 7 | 18 | 9 | 10 | 5 | 5 | 2 | 2 | 2 | 2 | 16 | 18 | 14 | 11 | 2 | 2 | 1 | 1 | 225 |

* No bowel complaint. † No history. ‡ One had no bowel complaint.

From the above it will be seen that of the 225, in 82, or 36·4 per cent., the ulcers were small and circular, and in 54, or 24 per cent., they were irregular in shape, in 16, or 7 per cent., they were mere abrasions of the mucous coat, while in 67, or 29·7 per cent., there was sloughing; this had extended to actual perforation in four cases, and almost to perforation in some 18 others (*vide* alvine fluxes); and in eight the ulcers were tubercular in character.

*Ulcers. Mode of origin of—.*

The ulcers were observed to originate in nine different ways, omitting those originating through tubercular infiltration, viz., in—

(*a*) Congested spots with little or no thickening.
(*b*) Erosions of thickened rugæ.
(*c*) Erosions of diphtheritic effusion.
(*d*) Ulceration of the mouths of the mucous follicles.
(*e*) Tiny sloughs of the mouths of the mucous follicles.
(*f*) Tumifaction of the solitary glands.
(*g*) Distension of solitary glands with fluid, and concretions.
(*h*) Spots of submucous ecchymoses.
(*i*) Submucous abscess.

I add short abstracts of cases exemplifying each of these modes of origin of ulcers.

*(a) In congested spots, little or no thickening.*

Case 120.—Kallan, Pariah, coolie, aged fifty years, ill ten days with "dysentery;" pulse 64; respirations 20; skin scurfy; belly soft, painful on pressure; stools thin dark mud coloured; admitted on 5th, died on 15th September 1877. Body thin; œdema of feet. Height, 5 feet 6½ inches; weight, 85 lbs. Autopsy three hours after death; rigor mortis present. *Small gut* empty, except one lumbricus; no mucus. Mucous coat dirty livid, claret coloured in parts of ileum. *Large gut* empty; mucous coat livid, with darker livid eroded patches; no appreciable thickening. *Liver* slightly fatty; other organs tolerably healthy. Also see dysenteric cases Nos. 93 and 140.

Case 124.—Irchun, Pully, coolie, aged forty years, ill one day with "diarrhœa;" pulseless, eyes sunken, as in cholera; belly retracted quite to spine, not painful on pressure; admitted on 23rd and died on the 29th September 1877. Autopsy five hours after death. Height, 5 feet 11 inches; weight, 90 lbs.; body thin; no œdema; rigor mortis present. *Small gut* contained some greenish pultaceous matter and one lumbricus; mucous coat dirty slaty, tinged with green in places

and red in others; one Peyer's patch near valve livid and swollen; looks as if going to slough. *Large gut* empty; mucous coat dingy slaty livid, with black submucous patches and superficial abrasions of deeper livid pieces. There was œdema with lividity of the lower lobe of the right lung, less so of the left. The heart was large and flabby, $7\frac{3}{4}$ ozs.; with a large soldier's spot on surface, but no fat. *Liver*, $40\frac{1}{2}$ ozs.; had flocculent adhesions of its right lobe to parietes; slightly fatty. *Gall-bladder* inflamed, distended with pus and serum. *Kidneys*, $9\frac{1}{8}$ ozs.; slightly fatty.

*(b.) Erosions of thickened rugæ.*

CASE 132.—Govinden, Pully, coolie, aged forty years, ill 20 days with "dysentery;" pulse 80; respirations 20; belly retracted, painful on pressure; skin scurfy; stools thin greenish; admitted on 8th, died on 12th September 1877. Autopsy seven hours after death. Height, 5 feet; weight, 65 lbs.; body a skeleton; slight œdema of feet; rigor mortis present. *Small intestine* contained some dirty grey fluid; mucous coat pale, in ileum reddish, and in places slaty. *Large gut* empty; much thickened in rugæ which are eroded all through; intervening mucous membrane pale and swollen. Slight œdema with spots of congestion of posterior border of right lung; less of left. Liver and kidneys very fatty.

CASE 206.—Chenga, Pariah, coolie, aged sixty years, ill a month with "dysentery;" belly retracted, soft, painful on pressure; pulse 96, small; respirations 24; stools like undigested grain in dark greenish fluid; again scanty, mucus in clear fluid; admitted on 19th, died on 25th May 1877. Autopsy two hours after death. Height, 5 feet 3 inches; weight, 70 lbs.; body emaciated; no œdema; rigor mortis present. *Small intestine* contained two lumbrici and a pint of thin brown fluid; jejunum slaty; brown red injected along free border; no thickening, but a thin buff or greenish pseudo-membrane firmly adherent to the injected parts; ileum injected in blotches with coloured pseudo-membrane thereon; this is abraded towards valve, and one circular spot here is also thickened and ulcerated in two places. *Large gut* contained half a pint of thin brown fluid; mucous coat reddish and swollen all through; in cæcum are a few small circular ulcers on thickened red rugæ; in transverse colon is one large livid thickened spot with several small ulcers thereon; rest of mucous coat rugose, reddish, paler towards anus. The liver and kidneys were small and fatty and spleen atrophied. The brain and lungs were healthy; see also case 427, (diarrhœa with pulmonary phthisis.)

*(c) Erosions of Diphtheritic Effusions.*

CASE 197.—Suliman Khan, pensioned sepoy, aged sixty years, ill ten days with "diarrhœa;" belly retracted, hard, hot, not tender on pressure; stools dirty coloured serous fluid; tongue thickly furred; pulse 120, weak; respirations 20; admitted on 24th, died on 28th March 1877. Autopsy four hours after death. Height, 5 feet 5 inches; weight, 70 lbs.; body emaciated; no œdema; rigor

mortis present. *Small intestine* empty; mucous coat pigmented; pink to venous in parts in jejunum, pale in ileum. Peyer's patches injected, and lowest 3 feet somewhat thickened and lined by a venous purple film which is eroded in parts exposing the grey mucous coat; close to the valve the erosion had extended to the mucous membrane forming a few minute ulcers. *Large intestine* contained a little thin mud-coloured fluid; the whole gut much thickened and one mass of greyish black sloughy ulceration like hospital gangrene, except the rectum of which the lining was pale granular and papillated like a cow's tongue. *Liver* congested; kidneys fatty; mesenteric glands enlarged; other organs tolerably healthy. *Vide* also diarrhœa cases Nos. 224, 283, 308, 310, 242, 266 and 267; the last three are children.

Case 293.—Ponen, Pariah, coolie, aged fifty years, ill ten days with "dysentery;" belly retracted, hard, painful on pressure; stools yellow fluid; skin scurfy; pulse 72, weak; admitted on 15th July, died on 1st August 1877. Autopsy three hours after death. Height, 5 feet 6 inches; weight, 71 lbs.; body emaciated; œdema of feet; rigor mortis present. *Small intestine* empty; mucous coat pinkish, stained yellow to green in parts. *Large intestine* empty; mucous coat in upper end livid red with some grey warty dipththeritic effusion ulcerated off in parts, but not much thickening; in lower end mucous coat pale with some chronic ulcers in the sigmoid flexure; serous effusion into all the serous cavities; lobar pneumonia of both lungs; congestion of liver, kidneys, and brain; mesenteric glands atrophied. Also *vide* dysentery cases Nos. 210, 336, 329, 245, 272, 273 and 302; the last four are children.

*(d) * Ulceration of the Mouths of the Mucous Follicles.*

Case 105.—Moonoochee, a little girl of the Pully caste, about eight years old, admitted 9th March 1877, with purging like "watery gripes" which alternated with bloody mucous stools, the purging continued unchecked and paralysis of the bladder set in a few days before death on the 30th idem. Autopsy two hours after death; body a skeleton. Height, 4 feet; weight, 33 lbs.; rigor mortis present. *Small intestines* contain a little reddish pultaceous matter and much gas; mucous coat nearly quite white with circular spots of ecchymoses, some apparently into the solitary glands, from the size of a flea bite to three lines in diameter and prominent to the feel, some are punctated in the centre as if communicating with the gut; they vary in number from one to six in three inches of the length of the gut; none are found at quite the upper or lower ends; they are most numerous about the junction of the ileum with jejunum. Peyer's patches grey not prominent. *Large intestine* contains gas and a little reddish fluid, is quite white on the external and pale rose on the internal surface, on the latter is seen very distinctly ulceration beginning in the mouths of the follicles which appear as circular

* I believe most of the small circular ulcers began in this way.

openings nearly a line in diameter and half that distance apart, the margins not differing in colour from the surrounding mucous membrane. The liver was fatty ; the other organs seemed healthy, but anæmic. See also case of girl Mootialhee, No. 196, whose chief complaint was anasarca and who denied having diarrhœa.

CASE 131.—Hyder Ali, Mahomedan, coolie, aged fifty years, ill four months with "diarrhœa;" stools thin mud coloured ; has bleeding piles ; pulse 90, weak ; respiration 20 ; skin scurfy; admitted 10th, died 18th March 1877. Two days before death a slough formed around anus. Autopsy four hours after death. Height, 5 feet 8 inches ; weight, 77 lbs.; body emaciated; œdema of feet ; rigor mortis present. *Small intestine* empty, except one lumbricus ; mucous coat thin, of a rosy hue. *Large intestine* empty, mucous coat grey ; circular ochrey sloughs in upper end, and ulceration beginning in mouths of mucous follicles all through, other follicles pale open-mouthed ; the rectum is red outside only in the neighbourhood of the ischio-rectal slough. Some serum in all the serous cavities except peritoneum. Apneumatosis with œdema of posterior part of right lung. Liver and kidneys fatty, other organs tolerably healthy—*vide* also cases of diarrhœa, Nos. 138, 185, 191 and 201 and dysentery cases Nos. 304 and 369.

*(e) Tiny Sloughs of Mouths of Mucous Follicles.*

CASE 171.—Latchmee, Pariah, coolie woman, aged seventy years, ill ten days with "dysentery," admitted on 22nd, died on 23rd December 1877. Autopsy ten hours after death. Height, 5 feet ; weight, 52 lbs. ; body a skeleton ; œdema of feet ; rigor mortis present. *Small intestine* empty, looks healthy. *Large intestine* empty ; mucous coat pale pink, œdematous ; a large slough in cœcum had all but perforated the gut and had set up peritonitis ; lower down the mouth of each mucous follicle was margined by a tiny slough mapping out each opening. Left lung had a hard mass, size of an orange in apex, fibrous and semi-transparent on section with a cavity in centre, no tubercles ; there was a pigmented cicatrix on apex of right lung, old standing apneumatosis of lower tongue of upper lobe in both. *Heart*, 4⅝ ozs., flabby, empty, some fat and a large soldier's spot on surface. Peritoneum pink, contains half a pint of purulent fluid and yellow lymph in pelvis. *Liver* small, 22⅝ ozs., congested, fatty. *Spleen* atrophied, ¾ oz. ; surface granular with points of adhesion all over. *Kidneys*, 4 ozs., congested. *Pancreas*, 1⅝ ozs., healthy. No fat in mesentery ; glands injected, of normal size. A small fibroid tumor of uterus.

*(f) Inflammation of Solitary Glands.*

CASE 77.—Iyalandum, Pully, ryot's wife, aged thirty-five years, ill ten days with diarrhœa, stools thin feculence with flocculi, again serum and flocculi, then semi-consistent feculence, finally thin and blood tinged, admitted on 30th March, died on 24th April 1877. Autopsy three hours after death. Height, 5 feet ; weight, 60 lbs. ; body a skeleton ; no œdema; some ascites ; rigor mortis present. *Small intestine* contains a little reddish fluid ; mucous coat of jejunum pink, swollen, punctated ecchymoses of four Peyer's patches, and glands of three others dis-

tended with pus with purulent infiltration around, some glands had burst leaving small circular ulcer-like depressions with no infiltration around, nor injection or discolouration ; ileum pale, similar state of Peyer's patches to that last described, also a spot or two of submucous ecchymosis. *Large intestines* empty ; mucous coat pale, a few solitary glands in descending colon downwards distended, the rest circular clear cut depressions of same colour as pale surroundings. *Brain*, lungs, spleen and pancreas healthy. *Liver* and kidneys fatty. Ascites ; œdema of mesentery ; some mesenteric glands swollen, others suppurated, containing yellow pus. Also see case No. 165 of a boy who died from diarrhœa with pneumonia.

Case 109.—Velloyden, Pully, farm labourer, aged sixty years, ill fifteen days with dysentery, belly soft, painful on pressure; stools yellow serum passed with griping; tongue red ; pulse 88; respiration 20 ; skin cool, scurfy ; admitted on 30th March, died on 20th April 1877. Autopsy three hours after death. Height, 5 feet 5 inches ; body emaciated ; no œdema ; rigor mortis present. *Small intestine* contains one lumbricus and some yellowish fluid ; mucous coat rosy. *Large intestine* empty ; mucous coat pale ; a few solitary glands red and distended in upper end ; ulceration beginning in others in transverse colon ; thickening and irregularly-shaped ulcer in descending colon downwards. Inflammatory œdema of posterior of right lung and a pneumonic spot the size of a lemon in apex of left. *Liver*, fatty. *Spleen* atrophied to under an ounce in weight. *Kidneys*, anæmic ; other organs tolerably healthy. also see case of dysentery No. 83.

*(g) Concretions or Dropsy of Solitary Glands.*

Case 326.—Veeraswamy, Pully, coolie, aged fifty years, ill twenty days with diarrhœa, admitted on 27th February, died 7th March 1877. Autopsy three hours after death ; body a skeleton. Height, 5 feet 3 inches; weight, 58 lbs. ; rigor mortis present. *Small intestine* empty ; mucous coat pink, purple in lengths, this best marked in lowest two feet and for two feet three feet higher up ; an arborescent grey film lines purple parts ; three solitary glands near upper end of ileum distended with white concretions and one had discharged its contents leaving a small circular ulcer-like cavity. *Large intestine* empty ; small circular ulcers on red slightly thickened transverse rugæ in upper end, and on pale mucous membrane in lower end, interspersed with red mamillæ which are also well marked at splenic flexure of colon. *Right lung*, 8½ ozs. ; firmly adherent, spongy, except, apex hard cuts gritty section fibrous, some cavities lined with shining membrane. *Left lung*, 9½ ozs. ; as firmly adherent as right, spongy, size of lime in base of upper lobe solid, fibrous on section, studded with some roe-like deposits and small cavities containing yellow pus. The mesenteric glands were swollen. *Spleen* atrophied ; other organs tolerably healthy.

Case 172.—Chellan, Pariah, coolie, aged sixty years, ill ten days with "dysentery;" stools bloody shreds in serum, passed with griping ; has

ALEX: BARREN, LITHOG:

MADRAS, 1869.

TRANSVERSE COLON WITH ENLARGED GLANDS
ULCERATED AT THEIR APICES.

wheezy cough, with profuse purulent expectoration, never spat blood, has paralysis agitans, admitted on 23rd May, died on 6th June 1877. Autopsy six hours after death. Height, 5 feet 2½ inches; weight, 71 lbs.; body a skeleton; œdema of feet; rigor mortis absent. *Small intestine* contains some yellow fluid; mucous coat dull white, but valvulæ conniventes rosy; two solitary glands distended to the size of peas with glairy jelly-like fluid and a small concretion in one; some arborescent injection in ileum. *Large intestine* contains a little dark grumous fluid; mucous coat œdematous and livid in upper end, paler in middle where are small grey circular ulcers two lines in diameter on transverse ridges, in descending colon are girdle sloughs, and lower down are girdle ulcers on thickened ridges, these are quite close together in the rectum and many show signs of healing; there is no injection but a good deal of thickening of the mucous coat here. In the apex of both lungs is a hard mass, the size of a lime, fibrous on section with small cavity but no sign of tubercle. Serum in all the serous cavities except sub-dural. *Kidneys* congested. *Spleen* and mesenteric glands atrophied; other organs tolerably healthy.

*(h) Spots of Submucous Ecchymosis.*

CASE 68.—Karien, Pariah, coolie, aged forty-five years, ill eight days with "diarrhœa;" belly retracted, soft, painful on pressure; complains of thirst; is pulseless, admitted and died on 20th August 1877. Autopsy ten hours after death. Height, 5 feet 3½ inches; weight, 77 lbs.; body a skeleton; no œdema; rigor mortis present. *Small intestine* contained two lumbrici and three pints of reddish fluid with green flocculi; mucous coat livid red, not swollen, purple near valve, glands not prominent. *Large intestine* empty; mucous coat slaty tinged livid, a few small circular thick-edged ulcers originating apparently in submucous ecchymosis of which there are six circular raised spots close by, each about two lines in diameter; no thickening present. There was hyperæmia of the brain, liver, kidneys and mesentery. The lungs, pancreas and mesenteric glands normal.

*Vide* also cholera case No. 356, diarrhœa cases Nos. 196 and 147.

CASE 252.—Thondroyen, Pariah, coolie, aged fifty years, ill fifteen days with "dysentery" and cough, admitted on 7th, died on 15th June 1877. Height, 5 feet; weight, 67 lbs.; body a skeleton; no œdema; rigor mortis present. *Small intestine* contained two lumbrici and some greenish pultaceous matter; mucous coat pale rose; two spots of submucous ecchymosis three lines across communicating at centre with gut. *Large intestine* empty, dark cicatrices in cœcum, thence to anus increasing thickening in imperfect ridges with ulceration forming a deep livid edged furrow along transverse colon; below this the gut is lined by a rough green-coloured pseudo-membrane. Pneumonic spots in both lungs; liver and kidneys congested; numerous concretions in pancreas; other organs tolerably healthy; mesenteric glands atrophied. See also case No. 91.

*(i) Submucous Abscess.*

CASE 188.—Kamachee, Pariah, coolie woman, aged thirty-five years, ill ten days with "diarrhœa" and "swelling of the legs;" stools watery, greenish, urine contains $\frac{1}{8}$ albumen; admitted on 29th January, died on 18th February 1878. Body emaciated; œdema of legs. Height, 4 feet $11\frac{1}{2}$ inches; weight, 70 lbs.; rigor mortis present. *Small intestine* contained three lumbrici and a little dark fluid; mucous coat pale rose, very œdematous in upper, less so in lower, end; large pigmented tubercular ulcers of four Peyer's patches. *Large intestine* empty; mucous coat pale œdematous; in descending colon is a submucous abscess, and circular thick-edged prominent brown-based ulcers thence downwards to rectum which is one ulcer. A chronic tubercular deposit, size of walnut, in apex of both lungs. Serum in all the cavities. Liver and kidneys fatty, other organs tolerably healthy. Œdema of mesentery, glands livid, of normal size.

Many "cyst forms" were almost undistinguishable from submucous abscesses which had burst and become chronic, for instance—

*Colloid cysts.*

CASE 58. Vyapoora, a weaver, aged fifty years, admitted 19th August 1877, ill ten days with "dysentery." He continued to have two or three watery motions daily. On 12th September, dropsy was first noticed and this increased till death on 24th October. Urine healthy. Body dropsical, weighed 101 lbs. Height, 5 feet 5 inches; rigor mortis present. Small gut looks healthy. Large gut empty; mucous coat pale red, œdematous in lower end, many mucous follicles distended with pus, and with pigmented mouths; there are also several "cyst forms" here as big as large peas and exuding purulent matter on pressure. *Peritoneum* pearly, contained two gallons of pale serum. *Spleen*, $2\frac{5}{8}$ ozs.; adherent to parietes by firm bands. *Liver*, $18\frac{3}{4}$ ozs.; a white cloud on capsule left margin atrophied; structure normal. Serum also in other cavities except pericardium. *Heart*, $5\frac{3}{4}$ ozs.; œdema replaces fat on surface. Apneumatosis of lower lobes of both lungs. *Kidneys*, $5\frac{1}{2}$ ozs.; capsule partly adherent; structure normal. Slight œdema of mesentery; glands atrophied. *Brain*, $45\frac{1}{2}$ ozs.; firm, anæmic; a clot in sulci of convolutions of anterior cornu of left hemisphere. Especially in dysentery case 158, some had grey ragged mouths, exactly like abscesses recently burst, while others further down the gut had the usual pigmented openings. As already shown, besides the above two, in ten other cases of dysentery and seven of diarrhœa among alvine fluxes "cyst forms" were found; only two of these were cases of children. Also they were present in phthisis case No. 438 above given.

*Sloughing modes of origin of—.*

Besides the modes of origin of sloughing in the usual course of ulcerative and diphtheritic inflammation, it arose from strangulation of the tissues by excessive œdema in many cases, *e.g.*, dysentery

cases 172 and 175 above given; diarrhœa cases 141 and 345; and others. It also occurred from effusion of pus beneath the mucous membrane. *Vide* hepatic abscess, case 442 above.

Perforation occurred from without inwards in pyæmia (Case No. 446 above given).

### 7. *Enteritis.*

The following is the only case that comes under this head :—

CASE No. 459.—Chellan, Pariah, a groom, aged forty years, ill two days from violent pain in stomach with constipation. There was some tympanitis and vomiting of dark-coloured fluid; admitted on 23rd, died on 25th February 1878. Autopsy one hour after death. Height, 5 feet 7 inches; weight, 106 lbs.; body plump; rigor mortis well marked. *Skull.*—Scalp congested; on removing calvarum, a large quantity of blood flowed out; serum in sub-dural cavity and beneath arachnoid; larger vessels of pia mater engorged. *Brain*, 40¼ ozs.; firm, congested. *Chest.*—Right pleura healthy. *Lung*, 15½ ozs.; not collapsed, dusky on section; some blood and a good deal of froth exuded under pressure. *Left pleura* healthy. *Lung*, 10⅜ ozs.; like right, with less œdema. *Pericardium* pearly, contains a little serum. *Heart*, 8¾ ozs.; lots of fat on surface, a little fluid blood on left side. *Peritoneum* dull livid injected over gut; mesentery almost black, parietes less livid, a little dirty fluid with some shreds of lymph in cavity. *Small intestine* contained two gallons of thin dark-coloured fœtid fluid like that vomited; mucous coat red in upper end, thence to six inches above valve lined by a thin pseudo-membrane and almost black from capillary injection along the course of the larger vessels, leaving spaces quite white as seen from the peritoneal surface. The injection looked like ecchymosis beneath the mucous coat; this part of the gut was enormously distended; but the distension suddenly ceased with the congestion at six inches above the valve. *Large intestine* contained formed farces; mucous coat pale reddish and healthy in lower end, some thickening with a livid tinge in upper with some livid red sloughy patches in cœcum and transverse colon. *Stomach* large, contained a quart of dark fluid; mucous coat dingy with a livid tinge. *Liver*, 39¾ ozs.; margin of left lobe atrophied $7\frac{1}{2}'' + 2'' \times 6'' \times 3''$, plump, congested, not fatty. *Gall-bladder* distended with thin dark green bile. *Spleen*, 2⅛ ozs.; healthy. *Kidneys*, 3⅜ ozs. each; capsule strips easily; section dusky red, slightly fatty. *Pancreas*, 2⅝ ozs.; healthy. Lots of fat in mesentery which is injected almost black in places; glands livid and swollen.

## OTHER LOCAL DISEASES.

*List of Cases giving Weight of Body and of its Organs, &c.*

| | No. | Name. | Caste. | Occupation. | Age. | Sex. | Height. Feet. | Height. Inches. | Weight. | Weight in Ounces of Brain. | Right Lung. | Left Lung. | Heart. | Liver. |
|---|---|---|---|---|---|---|---|---|---|---|---|---|---|---|
| | | | | | | | | | LBS. | | | | | |
| A | 442 | Meer Ghoolam Hoosein. | Mahomedan... | Jutka driver. | 50 | Male ... | 5 | 5 | 82 | 41 | 20 | 19½ | 6 | 44¾ |
| A | 443 | Ragavooloo ... | Bulgevadoo ... | Cancopillay. | 35 | Do. ... | ... | ... | ... | 35½ | 9¾ | 6¼ | 4⅝ | 33 |
| A | 444 | Audiayapen Naiken. | ... ... | Gardener. | 50 | Do. ... | 5 | 3½ | 92 | 39 | 8¾ | 12 | 8 | 69 |
| A | 445 | Peerenmah ... | Pariah ... | ... | 1½ | Female... | 2 | 4 | 12½ | 26⅜ | 1⅝ | 1⅞ | 1 | 9¼ |
| B | 449 | Tippoo Sahib ... | Mahomedan. | Cooly ... | 50 | Male ... | 5 | 2 | 70 | 42½ | 6⅞ | 8½ | 7½ | 27⅛ |
| B | 450 | Chinnapoyen ... | Pariah ... | Do. ... | 22 | Do. ... | 5 | 2 | 107 | 44½ | 11¾ | 11¾ | 9½ | 45¼ |
| B | 451 | Sarambee ... ... | Mahomedan... | ... | 50 | Female. | 5 | 0 | 59 | 42½ | 8⅜ | 8⅜ | 7¼ | 26¼ |
| B | 452 | Moongay ... ... | Gentoo ... | Weaver... | 20 | Do. ... | 5 | 1 | 73 | 35¾ | 14⅛ | 11⅞ | 6⅞ | 46⅛ |
| C | 453 | Chellun ... ... | Kunyap ... | Cooly ... | 20 | Male ... | 5 | 3 | 107 | 46½ | 8¼ | 8¾ | 6½ | 38 |
| C | 454 | Perinthayamah ... | Malabar ... | ... | 40 | Female. | 4 | 8 | 70 | 38½ | 9½ | 8¾ | 4⅞ | 58½ |
| D | 455 | Vully ... ... | Pariah ... | Cooly ... | 35 | Do. ... | 4 | 10 | 70 | 36 | 9½ | 7⅜ | 3¼ | 29 |
| E | 456 | Ramadoo ... ... | Do. .. | Do. ... | 50 | Male ... | 5 | 1 | 82 | 40½ | 14½ | 10¼ | 5¼ | 26¾ |
| F | 457 | Patcha Bee ... | Mahomedan... | Beggar | 55 | Female. | 5 | 6½ | 89 | 38¾ | 16 | 10¾ | 5¼ | 23 |
| G | 459 | Chellan ... ... | Pariah ... | Groom ... | 40 | Male ... | 5 | 7 | 106 | 40¼ | 15½ | 10⅜ | 8¾ | 39¾ |

A. Hepatic Abscess. B. Apoplexy. C. Cancer. D. Ulceration of Bowels. E. Ulcer. F. Aphasia. G. Enteritis.

OTHER LOCAL DISEASES—*continued.*

*List of Cases giving Weight of Body and of its Organs, &c.*—continued.

| | No. | Name. | Weight in Ounces of | | | | Date of Autopsy. | Hours after Death Autopsy made. | Rigor Mortis. | Bodily State. |
|---|---|---|---|---|---|---|---|---|---|---|
| | | | Spleen. | Right Kidney. | Left Kidney. | Pancreas. | | | | |
| A | 442 | Meer Ghoolam Hoosein. | 3½ | 3⅝ | 4½ | 2⅜ | 13 April 1877 | 13 | Present ... | Thin; no œdema. |
| A | 443 | Ragavooloo ... | 2⅛ | 3 | 3⅛ | 1¼ | 1 Mar. 1877 | 5 | Do. ... | Much emaciated; œdema of feet. |
| A | 444 | Audiayapen Naiken. | 2¾ | 3 | 2⅞ | 2½ | 17 Mar. 1878 | 4 | Well marked. | In good flesh. |
| A | 445 | Peerenmah ... | ⅝ | ¾ | ¾ | ½ | 21 Aug. 1877 | 3 | Absent ... | Skeleton; no œdema. |
| B | 449 | Tippoo Sahib ... | 1⅜ | 3 | 2¾ | 2¼ | 2 Oct. 1877 | 2 | Present ... | Emaciated; no œdema. |
| B | 450 | Chinnapoyen ... | 3 | 2⅞ | 2⅝ | 3⅜ | 11 Jan. 1878 | 6 | Well marked | In splendid condition. |
| B | 451 | Sarambee ... ... | 3¼ | 2⅜ | 2⅜ | 1⅞ | 14 Mar. ... | 2 | Present ... | Emaciated; œdema of face, right eyelid and left foot. |
| B | 452 | Moongay ... ... | 18¼ | 3¾ | 3⅞ | 3¼ | 6 Sept. ... | 14 | Absent ... | Thin; œdema of feet; ascites. |
| C | 453 | Chellun ... ... | 17 | 3⅜ | 3¼ | 2 | 2 April ... | 4 | Not well marked. | Well nourished. |
| C | 454 | Perinthayamah ... | 4¾ | 3 | 3 | 3 | 19 June ... | 6 | Present ... | In fair flesh. |
| D | 455 | Vully ... ... | 3 | 2 | 2⅜ | 1 | 10 Aug. ... | 3 | Do. ... | Emaciated; œdema of legs; ascites. |
| E | 456 | Ramadoo ... ... | 3⅛ | 3 | 3¼ | 2½ | 13 April ... | 5 | Do. ... | Thin; no œdema. |
| F | 457 | Patcha Bee ... | ¾ | 2½ | 2½ | 1¼ | 29 July ... | 10 | Absent ... | Skeleton; œdema of feet. |
| G | 459 | Chellan ... ... | 2⅛ | 3⅜ | 3⅜ | 2⅝ | 25 Feb. ... | 1 | Well marked. | In good flesh. |

A. Hepatic Abscess. B. Apoplexy. C. Cancer. D. Ulceration of Bowels. E. Ulcer. F. Aphasia. G. Enteritis.

## GENERAL REMARKS.

The most notable feature about these patients was their emaciation.

WASTING OF BODY.

While the normal weight of the Tamil men is about from 110 to 120 lbs., the average weight of these 226* men is only 81·38 lbs., their average height being 5 feet 4·84 inches, and apparent age 44½ years; and while Tamil women weigh from about 95 to 105 lbs., these 155† women averaged only 66·14 lbs., their average height being 5 feet 0½ inch, and apparent age 43 years.

If the somewhat plump and the anasarcous cases be separated, the great emaciation of the majority will be still more apparent, as shown below :—

| — | Men. | | | | | Women. | | | | |
|---|---|---|---|---|---|---|---|---|---|---|
| | No. | Age. | Height. | | Weight. | No. | Age. | Height. | | Weight. |
| | | YS. | FT. | IN. | LBS. | | YS. | FT. | IN. | LBS. |
| Plump ... ... | 9 | 30⅞ | 5 | 6⅔ | 113⅔ | 8 | 35⅝ | 5 | 0⅞ | 87½ |
| Dropsical ... ... | 22 | 48 | 5 | 5 1/10 | 105⅔ | 17 | 43⅕ | 5 | 2½ | 95½ |
| Emaciated ... ... | 195 | 44⅘ | 5 | 4 7/10 | 77 | 130 | 43½ | 5 | 0¼ | 60⅔ |

In the above, under plump are included non-dropsical men weighing 100 lbs. and upwards and women weighing 81 lbs.

* The weight and height of four are not noted; and of the 222 others, 15 were Mahomedans of average height 5 feet 5½ inches, weight 79 lbs., and age 45⅔ years, one was anasarcous, the rest emaciated.

† The height and weight of two are not noted; and of the 153 others, 16 were Mahomedans of average height 5 feet 0¼ inch, weight 70¼ lbs., and age 48¾ years, one was plump, three anasarcous, and the rest emaciated, one was not weighed, making 17 in all.

The above averages are scarcely at all affected by excluding these Mahomedans.

and upwards; and under dropsical are included anasarcous men weighing over 90 lbs. and women weighing 81 lbs. and upwards.

It is thus seen that the majority, viz., fully 86 per cent. of the men and 83 per cent. of the women had wasted till they were barely two-thirds of their normal weight. When emaciation has reached this degree life is held by a slender thread which the least untoward circumstance is sufficient to snap.

Many of these patients were in this state when admitted, and besides those who may be said to have died from this cause and are shown above under atrophy, many were carried off by such accidents as that described by Dr. Cornish who tells of having taken into his own house a child of 7 or 8 years old, in the last stage of starvation and emaciation, "to see what care and good "food would do. She lived six weeks under careful nursing, "but never digested, or assimilated food so as to gain flesh, a "storm of rain with a sudden reduction of temperature of the "air by 7 or 8 degrees brought on rapid congestion of the lungs "which destroyed life in a few hours. In this case there was no "pain, no loss of appetite throughout, the circulation was feeble "and the body temperature below the normal standard. Life "hung upon a thread, and the sudden lowering of the tempera-"ture from 85° to 78° Fahr. was enough to sever the frail tie.

WASTING OF ORGANS.

Besides the absorption of the fat and the wasting of the muscular tissues which are chiefly referred to above, the organs of the body, especially the solid organs, also wasted. This was most marked in the spleen which weighed as little as three drachms in one or two cases, and in 109, or two-thirds of the women, its weight averaged only 1½ ozs., with a ratio to the average weight of the respective bodies of 1 to 677; and in 160 men, 70·8 per cent., its average weight was only 2½ ozs., with a ratio to their average body-weight of 1 to 572. The normal ratio for Hindus is not known, but Quain gives the ratio for Europeans to be 1 to 320 or 400.

*Spleen.*

*Brain.*

Wasting was also very noticeable even in the brain. The difference between its average weight in the plump and emaciated being, as shown below, 2·74 ozs. in the men and 2·26 ozs. in the women.

| State. | Men. | | | Women. | | |
|---|---|---|---|---|---|---|
| | No. | Brain in ounces. | Brain-weight to body-weight 1 to | No. | Brain in ounces. | Brain-weight to body-weight 1 to |
| Plump ... ... | 9 | 43·8 | 41·5 | 8 | 39·328 | 35·6 |
| Dropsical ... ... | 22 | 42·8 | 39·4 | 17 | 39·46 | 38·7 |
| Emaciated ... ... | 195 | 41·06 | 29·95 | 130 | 37·0 | 26·2 |
| Europeans ... | ... | 49·5 | 36·0 | ... | 44·0 | 36·5 |

To this wasting of the nervous tissue was no doubt in a great part due the lethargy and great nervous depression depicted in the faces of the famine-stricken, as well as their apathy and unwillingness to use the smallest exertion to help themselves (often taken for obstinacy by the uninitiated); many expressed an indifference to life, and some a desire to die.

The results given above for Europeans are taken from Quain's Anatomy. They are quoted for easy reference and comparison, if such can really be instituted under the circumstances.

*Lungs.*

The lungs also appear to have wasted. The average weight of 33 right lungs in men was 7·8 ozs. and of 36 left lungs 7·1 ozs. each; and of 29 right lungs in women 6·68 ozs. and of 36 left lungs 6·1 ozs. each. These weights give a ratio to the average body-weight of 1 to 87·3 in the men and 1 to 78·8 in the women; or taking the weights of the lungs in the 22 men and 23 women in whom both lungs were found quite free from disease, and of the bodies appertaining thereto, the ratio is 1 to 84·4 in the men and 1 to 78·9 in the women. The standard for Hindus is not known, but Quain gives the weight of the lungs in Europeans to be in men, right lung 24 ozs., left being 21 ozs., and ratio to body-weight 1 to 37; and in women right lung 17 ozs., left lung 15 ozs., and ratio to body-weight 1 to 43. It is not clear why these figures should differ so materially in the cases of Europeans and Hindus, unless it be from the lungs having wasted as well as the bodies in the cases under consideration.

*Heart.*

The average weight of the heart was 8·43 ozs. in the 9 plump, as against 6·1 ozs. in 181 emaciated men, and 7·3 ozs. in the 8 plump, as against 5·2 ozs. in 121 emaciated women. These weights give a ratio to body-weight of 1 to 215·7 for the plump, as against 1 to 202 for the emaciated men, and 1 to 191 for the plump, as against 1 to 189 for the emaciated women. These ratios show the wasting of the heart to have all but kept pace with the wasting of the body generally. For Europeans, Quain gives for men, weight of heart 11 ozs. with the ratio to body-weight of 1 to 158, and for women 9 ozs. with ratio to body-weight of 1 to 149.

*Liver.*

The average weight of the liver was 49·8 ozs. in the 9 plump, as against 31·3 ozs. in 181 emaciated men, and 42 ozs. in the 8 plump, as against 27·06 ozs. in 121 emaciated women. These weights give a ratio to body-weight of 1 to 36·52 in the plump, as against 1 to 39·45 in the emaciated men, and 1 to 33·3 in the plump, as against 1 to 36·4 in the emaciated women. These ratios show that the wasting of the liver was proportionally greater than that of the body generally. Quain gives for Europeans, weight of liver 50 to 60 ozs. with ratio to body-weight of 1 to 36.

*Kidneys.*

The average weight of the kidneys was 4·04 ozs. for the right and 4·24 ozs. for the left kidney in the 9 plump, as against 2·89 ozs. for the right and 2·52 ozs. for the left kidney in 181 emaciated men; and 3·53 ozs. for the right and 3·76 ozs. for the left kidney in the 8 plump, as against 2·6 ozs. for the right and 2·7 ozs. for the left kidney in 121 emaciated women. These weights give a ratio to body-weight of 1 to 219·6 in the plump, as against 1 to 228 in the emaciated men; and 1 to 191·9 in the plump, as against 1 to 185 in the emaciated women. These figures show the wasting of the kidneys to have been somewhat more in the men and less in the women than of the body generally. Quain gives the weight of the kidneys in Europeans to be 4½ to 6 ozs. each in men and 4 to 5½ ozs. in women, the left kidney being heavier than the right by one-sixth of an ounce (Rayer), and the ratio to body-weight as 1 to 240.

*Pancreas.*

The average weight of the pancreas was 3·85 ozs. in the 9 plump, as against 2·2 ozs. in 181 emaciated men, and 2·3 ozs. in the 8 plump, as against 1·8 ozs. in 121 emaciated women. These weights give a ratio to body-weight of 1 to 472 in the plump, as against 1 to 560 in the emaciated men; and 1 to 608·7 for the plump, as against 1 to 539 for the emaciated women. Its greater weight in the well-nourished is no doubt in some part due to the fat deposited between its lobules. Clendinning gives the weight of the pancreas in Europeans to be 2¼ to 3½ ozs.

*Reproductive organs.*

The mammary glands had shrivelled to such a degree in the emaciated women, that their position was only ascertainable by the presence of the nipples; no gland could be seen or felt. Menstruation was not observed in any of these patients, nor was any woman admitted to hospital pregnant.

*Birth-rate.*

The Sanitary Commissioner, Dr. Cornish, records that only 39 births occurred among some 100,000 famine-stricken who passed through the Madras relief camps in 1877. He also shows that the birth-rate began to fall off early in the famine, and steadily decreased, till some nine months after the height of the famine it reached in the famine districts an annual ratio of 4 to 5, against an average of 29 to 30, per mille of the population as per last census (1871), and that for the whole presidency the births in 1878 were barely half the usual average. This is an aspect of the effects of famine that does not appear to have been noticed by former observers. Dr. Cornish, moreover, considers that the wasting of the mammary glands and ovaries had reached such a stage, that in women over 30 years of age they probably never would recover their functions. I regret that this view did not occur to me, else I would have made microscopical examination of these tissues and possibly been able to clear up this point; however, I expect that this view will be found to be incorrect, as I am of opinion that Nature's arrangements for the propagation of the species are more difficult to upset even than the above supposition implies.

DETERIORATION OF THE BLOOD.

Anæmia was another characteristic of the famine-stricken, the emaciation, liability to local œdema, and weakness of the circulation with palpitation of

the heart were all bound up with this state of the blood. There was also a tendency to local effusions of blood such as is seen in purpura. In fact in the cases under consideration sub-mucous, sub-arachnoid, or sub-pleural ecchymoses were found in 45, or 19·9 per cent., of the men, 39, or 26·16 per cent., of the women, and in 26, or one-third of the children. However, unlike in purpura, the ecchymoses in each case were confined to one situation in all except 4 men, 3 women and 2 children, as will be seen by comparing the totals in the subjoined table with the figures above given :—

*Ecchymoses.*

| Ecchymoses. | Men. | Women. | Children. |
|---|---|---|---|
| Sub-mucous ... ... ... | 19 | 19 | 12 |
| Sub-arachnoid ... ... | 21 | 16 | 14 |
| Sub-pleural ... ... ... | 9 | 7 | 2 |
| Total ... | 49 | 42 | 28 |

and purpuric skin eruptions were not noticed by me ; nor were they recorded by any of the Sanitary Inspectors. But the dark colour of the Tamil race, and the scurfy state of the skin may have caused these to have been overlooked ; and may not the ulcers, which were so prevalent in some districts, and more or less so everywhere, have often had their origin in such effusions ?

Dr. Cornish describes as a symptom of this cachetic (scorbutic *he* calls it) state a purplish-blue discolouration and spongy thickening of the gums, most marked in the upper jaw.

The part affected was from one to a few lines in breadth of the gum nearest the teeth. There was no undue sensibility, where ulceration was absent, as was usually the case, but the discoloured portion was sharply defined from the adjacent healthy gum.

*Blue discolouration of the gums.*

I examined all the patients carefully for signs of scurvy such as I witnessed amongst the prisoners in the Akolah Central Jail in 1866, *et seq.*,* but in vain. The discolouration of the gums, such as above described, I may have overlooked, thinking it a

* *Vide* Madras Medical Journal for 1872, Vol. V, page 255. Also Hirsch's Hand-book of Geographical Pathology, Vol. II.

pigmentation natural to some dark-skinned natives. But Dr. Cornish writing from his own experience, and from that of most of the nine Medical Officers who acted as Sanitary Inspectors during the famine, lays considerable stress on this state of the gums, and looks upon it as pathognomic of defective nutrition, probably from some defect in the *quality* of the diet, for it may exist without emaciation. He calculated that 60 to 70 per cent. of the famine-stricken had their gums so affected during the dry hot months of the year 1877.

*Pathognomic of defective nutrition.*

Another and an earlier symptom of this cachetic state he considers to be an aphthous ulceration of the mouth which was not uncommon among children. In adults it appeared as a white coating to the mucous membrane of the mouth, which cracked and peeled off in strips, leaving a glazed red raw and painful surface underneath. This state was not so prevalent in the Royapettah sheds as in the "Monegar Choultry," where it seemed to have some connection with a deficiency of meat and vegetables in the dietary. Among the prisoners in the Coimbatore Jail this aphthous condition is reported to have extended to the gullet, assumed an aggravated form, and caused many deaths.

*Aphthæ.*

Fatty degeneration of the tissues was very common. It was found affecting the liver in 61·94 per cent. of the men, 83·2 per cent. of the women, and 73 per cent. of the children, and in most of these cases, the kidneys and other tissues also were implicated; and we have already seen that Dr. D. D. Cunningham traced most of the intestinal lesions, so common in the famine-stricken, to a fatty degeneration of the mucous membrane.

DEGENERATION OF THE TISSUES.

Also it may be said to have been this form of degeneration of the cuticle that gave rise to the condition of the skin recognised and described by Dr. Donovan in the Irish famine of 1847.* This consisted of a harsh and dry patchy scurf which was darker than the rest of the skin, and was best marked on the neck, chest and back. It had the general appearance of dirt, as if the person had not

*Famine skin.*

* *Vide* Dublin Medical Press for 1848.

washed for some time, but soap and water would not remove it; nothing short of scraping would do this. It would appear that the vitality of the skin was so low as to be unable to throw off the dead epithelium which thus remained firmly adherent to the subjacent tissues undergoing fatty degeneration the while.

*Pigmentation.*

Pigmentary degeneration was found only in connection with old standing bowel-complaint or ecchymoses. In fact the absence of pigment from some parts of the body was a marked feature in the famine-stricken.

*Alteration in the hair.*

This was the most conspicuous among the women and children, a certain proportion of whom exhibited the otherwise black hair of the head tipped red to pale yellow or straw-colour; and in many of these the hair on the body was unusally long and devoid of pigment. The hair was also very dry, and when at all short it was staring and bristly.

*Albuminoid degeneration.*

Albuminoid degeneration was looked for in the liver, spleen, kidneys and intestinal mucous membrane of every case, but found present in none. But there was calcareous degeneration of deposits in the lungs, mesenteric or solitary glands, or pancreas in a few cases.

INTESTINAL PARASITES.

Intestinal parasites, chiefly the *ascaris lumbricoides*, were very prevalent during the famine, but so they are at all times in Madras. In the cases under consideration, lumbrici were found in 108 men, 47·78 per cent.; in 89 women, 57·43 per cent.; and in 31 children, 39·74 per cent. The aggregate number found in the men was 461, giving an average of 4·27 to each; in the women 786, or an average of 8·83 each; and in the children 110, being an average of 3·5 each. The greatest number found in one person was 44 in a man, 107 in a woman, and 14 in a child. The situation in which they were located was usually the small intestine, and if found elsewhere some were here also in all, except 3 men, a woman and a child. But 44 were found in the stomach in 17 men, 61 in 19 women, and 4 in 4 children: 5 were found in the large intestine in 2 men, 5 in 2 women and 5 in a child: and 3 were found in the mouth in a child and 1 in a woman. Six were lodged in the

*Lumbrici in ileum, colon, stomach, mouth, ducts of liver and pancreas, and in bronchus.*

common bile duct of a woman who died from phthisis and had no jaundice, 5 of these were alive and 1 was dead. One was lodged in the pancreatic duct in a child, and one in the bronchus of the left lung of another child; the latter worm was alive.

*Whip-worms.*

Whip-worms (*Trichocephalus dispar*) were found, to the number of three to twelve, in the cæcum, in 3 women and a man; 2 of the women harboured lumbrici also.

*Tape-worms.*

Tape worm was present in only one case, that of a small boy about 3 years old, who had been brought from Nellore a month previously and had been ill only four days with diarrhœa. He died on the day of admission quite a skeleton; weight only 14 lbs.; height 28 inches.

### *Treatment.*

The only effective treatment of famine diseases is the prevention of famine, or, if this be impossible, the efficient organization of famine relief. This to be efficient must be early in the famine, before the famine-stricken have begun to suffer from the disorganisation of the tissues of the alimentary canal, the microscopical appearances of which as described by Dr. D. D. Cunningham will be found at page 89 *et seq.*; while the naked eye appearances of a later stage, as seen especially in the intestines, will be found described under this head in each of the diseases treated of in the foregoing pages.

*Alvine flux.*

The treatment that appeared to succeed best in alvine flux was bismuth subnitras in scruple or half drachm doses combined in some cases with small doses of crude opium, in others with the washing out of the gut with a weak solution of soda followed by a starch and opium enema. No case of acute dysentery for which the ipecacuanha treatment is so suitable was seen. In all cases careful dieting was called for, but difficult to carry out.

*Cholera.*

For cholera I know of no specific, but I think I know how specifics for this disease are discovered; it is in this wise.—When cholera breaks out all the lauded specifics are tried in turn and found wanting, then other remedies are tried till one is found to succeed. By this time the epidemic will be coming to an end, and in reality any

other remedy would have succeeded as well. Nevertheless the last used is looked on as a specific till next epidemic. For the great thirst in this disease, however, the best drink seems to be water acidulated with sulphuric acid.

*Acute pneumonia.*

The treatment best suited to acute pneumonia was the stimulating treatment, viz., bark and ammonia, brandy and egg mixture, and broths.

*Hepatic abscess.*

In hepatic abscess if diagnosed early while the abscess is small using an aspirator gives the best chance of recovery. If, however, the abscess has attained some size before diagnosed or can be operated on, then a free opening dressed antiseptically is best.

---

# APPENDICES.

# APPENDIX A.

*Return showing Admissions and Deaths in the Famine Sheds of the Royapettah Hospital from 13th December 1876 to 25th May 1878.*

| Months. | Bowel-complaints. | | Debility. | | Cholera. | | Dropsy. | | Pneumonia. | | Small-pox. | | Phthisis Pulmonalis. | | Fever. | | Other Diseases. | | Total. | |
|---|---|---|---|---|---|---|---|---|---|---|---|---|---|---|---|---|---|---|---|---|
| | Admissions. | Deaths. | Admissions. | Deaths. | Admissions. | Deaths. | Admissions. | Deaths. | Admissions. | Deaths. | Admissions. | Deaths. | Admissions. | Deaths. | Admissions. | Deaths. | Admissions. | Deaths. | Admissions. | Deaths. |
| December 1876 ... | 20 | 3 | 15 | ... | 2 | ... | 5 | 1 | 1 | ... | ... | ... | ... | ... | 9 | ... | 36 | 3 | 88 | 7 |
| Total ... | 20 | 3 | 15 | ... | 2 | ... | 5 | 1 | 1 | ... | ... | ... | ... | ... | 9 | ... | 36 | 3 | 88 | 7 |
| January 1877 ... | 32 | 21 | 18 | 5 | 42 | 26 | 9 | 6 | 1 | 1 | 10 | 2 | ... | ... | 5 | ... | 25 | 8 | 142 | 69 |
| February ,, ... | 35 | 12 | 10 | 5 | 11 | 5 | 4 | 3 | 4 | 3 | 11 | 2 | ... | ... | ... | ... | 31 | 2 | 106 | 32 |
| March ,, ... | 50 | 11 | 4 | 1 | 27 | 16 | 1 | ... | 13 | 9 | 9 | ... | 5 | ... | 4 | ... | 46 | 2 | 159 | 39 |
| April ,, ... | 58 | 21 | ... | 1 | 75 | 39 | 3 | 2 | 11 | 3 | 13 | 1 | 8 | 4 | 4 | 1 | 49 | 6 | 221 | 78 |
| May ,, ... | 74 | 27 | 1 | ... | 68 | 51 | 2 | ... | 11 | 8 | 3 | ... | 9 | 2 | 7 | ... | 119 | 6 | 293 | 94 |
| June ,, ... | 102 | 49 | 2 | 1 | 39 | 23 | 9 | 2 | 8 | 3 | 3 | ... | 3 | 4 | 8 | 3 | 100 | 10 | 274 | 94 |
| July ,, ... | 133 | 75 | 4 | ... | 89 | 53 | 13 | 8 | 5 | 3 | 2 | ... | 3 | 1 | 5 | ... | 137 | 15 | 391 | 155 |
| August ,, ... | 149 | 86 | 4 | ... | 53 | 35 | 8 | 4 | 8 | 2 | 7 | ... | 5 | 1 | 5 | 1 | 107 | 15 | 346 | 144 |
| September ,, ... | 118 | 69 | 5 | 3 | 22 | 13 | 12 | 6 | 6 | 5 | 8 | ... | 4 | 1 | 9 | ... | 88 | 7 | 272 | 104 |
| October ,, ... | 74 | 53 | 10 | 2 | 5 | 3 | 5 | 7 | 6 | 4 | 1 | ... | 1 | ... | 4 | ... | 78 | 5 | 184 | 74 |
| November ,, ... | 60 | 33 | 21 | 6 | 2 | 1 | 3 | 3 | 5 | 3 | ... | ... | ... | 2 | 9 | ... | 40 | 6 | 140 | 54 |
| December ,, ... | 62 | 36 | 10 | 5 | 2 | 1 | 3 | 2 | ... | 1 | ... | ... | 3 | ... | 8 | 1 | 62 | 2 | 150 | 48 |
| Total ... | 947 | 493 | 89 | 29 | 435 | 266 | 72 | 43 | 78 | 45 | 67 | 5 | 41 | 15 | 68 | 6 | 882 | 84 | 2,678 | 985 |

## APPENDIX A—*continued.*

*Return showing Admissions and Deaths in the Famine Sheds of the Royapettah Hospital from* 13*th December* 1876 *to* 25*th May* 1878—continued.

| Months. | Bowel-complaints. | | Debility. | | Cholera. | | Dropsy. | | Pneumonia. | | Small-pox. | | Phthisis Pulmonalis. | | Fever. | | Other Diseases. | | Total. | |
|---|---|---|---|---|---|---|---|---|---|---|---|---|---|---|---|---|---|---|---|---|
| | Admissions. | Deaths. | Admissions. | Deaths. | Admissions. | Deaths. | Admissions. | Deaths. | Admissions. | Deaths. | Admissions. | Deaths. | Admissions. | Deaths. | Admissions. | Deaths. | Admissions. | Deaths. | Admissions. | Deaths. |
| January 1878 ... | 48 | 26 | 13 | 6 | 1 | ... | 6 | 2 | 2 | 1 | ... | ... | 6 | 3 | 13 | 3 | 62 | 1 | 151 | 42 |
| February " ... | 29 | 14 | 1 | 1 | 1 | 1 | ... | ... | 7 | 3 | 1 | ... | ... | 3 | 6 | ... | 60 | 2 | 105 | 24 |
| March " ... | 21 | 14 | 5 | 1 | ... | ... | 5 | 1 | 7 | 5 | ... | ... | 1 | ... | 5 | ... | 62 | 4 | 106 | 25 |
| April " ... | 12 | 7 | 3 | 3 | ... | ... | 4 | 6 | ... | 1 | ... | ... | 2 | 1 | 7 | ... | 44 | 2 | 72 | 20 |
| May " ... | 15 | 11 | 4 | 1 | ... | ... | 2 | ... | ... | .. | ... | ... | 1 | ... | 3 | ... | 24 | 1 | 49 | 13 |
| Total ... | 125 | 72 | 26 | 12 | 2 | 1 | 17 | 9 | 16 | 10 | 1 | ... | 10 | 7 | 34 | 3 | 252 | 10 | 483 | 124 |
| Grand Total ... | 1,092 | 568 | 130 | 41 | 439 | 267 | 94 | 53 | 95 | 55 | 68 | 5 | 51 | 22 | 111 | 9 | 1,170 | 97 | 3,250 | 1,117 |

# APPENDIX B.

*Return showing the Average Daily Sick in the Famine Sheds of Royapettah, monthly, from 13th December 1876 to 25th May 1878.*

| Months. | Bowel-complaints. | | | Debility. | | | Cholera. | | | Dropsy. | | | Pneumonia. | | |
|---|---|---|---|---|---|---|---|---|---|---|---|---|---|---|---|
| | Men. | Women. | Children. | Men. | Women. | Children. | Men. | Women. | Children. | Men. | Women. | Children. | Men. | Women. | Children. |
| December 1876 ... | 2·15 | 1·94 | 1·10 | 1·31 | ·57 | 1·36 | ·15 | ·15 | ... | ·52 | ·73 | ·21 | ... | ·25 | ... |
| Total ... | 2·15 | 1·94 | 1·10 | 1·31 | ·57 | 1·36 | ·15 | ·15 | ... | ·52 | ·73 | ·21 | ... | ·25 | ... |
| January 1877 ... | 3·67 | 4·06 | 1·32 | 2·80 | 2·06 | 1·70 | 1·87 | 3·29 | 1·64 | ·41 | 1·35 | ·12 | ... | ·25 | ... |
| February " ... | 3·92 | 4·71 | 1·17 | 1·03 | ·39 | ·92 | 1·89 | 1·89 | ... | ·07 | ·85 | ·32 | ·28 | ·21 | ·35 |
| March " ... | 10·25 | 3·12 | 1·80 | ·32 | 1·03 | ·03 | ·74 | 1·12 | ·45 | ·03 | ... | ·03 | 1·00 | ·41 | ·16 |
| April " ... | 15·86 | 7·70 | 3·00 | ... | ·13 | ... | 5·10 | 2·50 | 1·53 | ... | ·20 | ·23 | 2·33 | ·26 | ·13 |
| May " ... | 18·03 | 6·16 | 3·41 | ·12 | ... | ... | 5·74 | 3·00 | 1·41 | ·12 | ·29 | ... | 2·77 | ·51 | ... |
| June " ... | 17·90 | 9·66 | 8·10 | ·03 | ·03 | ... | 2·23 | 2·06 | ·80 | 2·06 | 1·23 | ... | 1·94 | 1·43 | ·03 |
| July " ... | 17·45 | 11·38 | 10·45 | ·29 | ... | ·03 | 4·51 | 5·51 | 3·96 | 1·45 | 2·67 | 1·19 | 1·54 | 1·29 | ... |
| August " ... | 29·35 | 14·64 | 15·64 | ·35 | ·45 | ... | 4·77 | 3·64 | 1·54 | 1·32 | 3·67 | ·35 | 2·19 | 1·58 | ·41 |
| September " ... | 30·06 | 11·73 | 13·00 | ·73 | 2·50 | ... | 3·60 | ·96 | 1·33 | 1·63 | 3·10 | ·93 | 1·63 | 1·70 | ·50 |
| October " ... | 18·77 | 10·22 | 10·74 | 1·45 | 3·87 | ·80 | ·06 | ·22 | ·48 | 2·96 | 1·58 | 1·06 | ... | 1·74 | 2·00 |
| November " ... | 10·16 | 8·70 | 10·23 | 6·30 | 6·90 | ·20 | ·66 | ... | ·60 | 1·23 | 1·20 | ·50 | ·90 | 1·00 | ·96 |
| December " ... | 14·70 | 14·89 | 3·93 | 5·93 | 5·48 | ... | ·41 | ... | ... | ·29 | ... | ... | ·12 | ·93 | ... |
| Average ... | 15·84 | 8·91 | 6·89 | 1·61 | 1·90 | ·30 | 2·63 | 2·01 | 1·14 | ·96 | 1·34 | ·39 | 1·22 | ·94 | ·37 |

## APPENDIX B—*continued.*

*Return showing the Average Daily Sick in the Famine Sheds of Royapettah, monthly, from* 13*th December* 1876 *to* 25*th May* 1878—continued.

| Months. | Small-pox. | | | Phthisis Pulmonalis. | | | Fever. | | | Other Diseases. | | | Average. | | |
|---|---|---|---|---|---|---|---|---|---|---|---|---|---|---|---|
| | Men. | Women. | Children. | Men. | Women. | Children. | Men. | Women. | Children. | Men. | Women. | Children. | Men. | Women. | Children. |
| December 1876 ... | ... | ... | ... | ... | ... | ... | 1·68 | ·43 | ·42 | 4·84 | 2·89 | ·68 | 10·65 | 6·96 | 3·77 |
| Total ... | ... | ... | ... | ... | ... | ... | 1·68 | ·43 | ·42 | 4·84 | 2·89 | ·68 | 10·65 | 6·96 | 3·77 |
| January 1877 ... | 1·03 | ·90 | 1·77 | ... | ... | ... | ·83 | ·16 | ·22 | 3·22 | 5·58 | 2·64 | 13·83 | 17·65 | 9·41 |
| February „ ... | 1·25 | ·82 | 2·71 | ... | ... | ... | ... | ... | ... | 4·71 | 4·03 | 1·50 | 13·15 | 12·90 | 6·97 |
| March „ ... | ·06 | ·06 | ·22 | 1·35 | ·38 | ... | ... | ... | ·77 | 6·06 | 6·03 | ·80 | 19·81 | 12·15 | 4·26 |
| April „ ... | ·16 | ·10 | ·23 | 3·36 | 1·06 | ... | ·36 | ... | ·80 | 4·93 | 5·33 | 2·06 | 32·10 | 17·28 | 7·98 |
| May „ ... | ·03 | ... | ·06 | 2·32 | 1·00 | ... | ·59 | ·25 | ... | 6·70 | 11·06 | 6·96 | 36·42 | 22·27 | 11·84 |
| June „ ... | ... | ·03 | ·06 | ·80 | 1·23 | ... | 1·34 | ·36 | ·50 | 10·43 | 12·56 | 6·60 | 36·73 | 28·59 | 16·09 |
| July „ ... | ... | ·06 | ... | ·45 | ·61 | ... | 1·03 | ... | 1·41 | 6·54 | 17·64 | 11·41 | 33·26 | 39·16 | 28·45 |
| August „ ... | ·06 | ·09 | ·16 | 1·35 | ·09 | ... | ·03 | ·32 | 1·29 | 8·83 | 17·41 | 11·29 | 48·25 | 41·89 | 30·68 |
| September „ ... | ·10 | ·23 | ·10 | ·63 | ·86 | ... | ·43 | 1·20 | 2·23 | 6·30 | 20·10 | 10·36 | 45·11 | 42·38 | 28·45 |
| October „ ... | .. | ·03 | ... | ·09 | 1·03 | ... | ·29 | ·38 | ·48 | 6·38 | 14·09 | 13·74 | 30·00 | 33·16 | 29·30 |
| November „ ... | ... | ... | ... | ... | ·63 | ... | ·80 | 1·34 | ·13 | 6·66 | 9·13 | 9·63 | 26·71 | 28·90 | 22·25 |
| December „ ... | ... | ... | ... | 1·45 | ... | ... | ·87 | 2·39 | ·12 | 11·54 | 6·16 | 8·00 | 35·31 | 29·85 | 12·05 |
| Average ... | ·22 | ·19 | ·44 | ·98 | ·57 | ... | ·54 | ·53 | ·66 | 6·85 | 10·76 | 7·08 | 30·85 | 26·63 | 17·27 |

## APPENDIX B—*continued.*

*Return showing the Average Daily Sick in the Famine Sheds of Royapettah, monthly, from 13th December 1876 to 25th May 1878*—continued.

| Months. | Bowel-complaints. | | | Debility. | | | Cholera. | | | Dropsy. | | | Pneumonia. | | |
|---|---|---|---|---|---|---|---|---|---|---|---|---|---|---|---|
| | Men. | Women. | Children. | Men. | Women. | Children. | Men. | Women. | Children. | Men. | Women. | Children. | Men. | Women. | Children. |
| January 1878 ... | 8·61 | 6·12 | 2·25 | 2·80 | 2·96 | ... | ·12 | ·16 | ... | 1·32 | 1·00 | ·16 | ·25 | ... | ... |
| February ,, ... | 7·39 | 6·85 | ·85 | ·25 | ·57 | ... | ... | ·42 | ... | 1·00 | ... | ... | ·77 | ·50 | ·25 |
| March ,, ... | 5·06 | 5·90 | 1·35 | ·09 | ·90 | ... | ... | ... | ... | ·32 | ... | 1·25 | ·54 | 2·32 | ·77 |
| April ,, ... | 3·46 | 1·36 | ·46 | ·60 | ·33 | ... | ... | ... | ... | 1·33 | ·43 | ·66 | ·06 | ·20 | ... |
| May ,, ... | 3·56 | 1·56 | ·56 | ·44 | ·84 | ... | ... | ... | ... | ·40 | ·72 | ... | ... | ... | ... |
| Average ... | 5·68 | 4·44 | 1·13 | ·86 | 1·15 | ... | ·02 | ·11 | ... | ·91 | ·42 | ·44 | ·35 | ·63 | ·21 |
| Total Average ... | 12·61 | 7·38 | 4·92 | 1·39 | 1·65 | ·26 | 1·83 | 1·43 | ·80 | ·93 | 1·07 | ·40 | ·94 | ·77 | ·32 |

## APPENDIX B—*continued.*

*Return showing the Average Daily Sick in the Famine Sheds of Royapettah, monthly, from 13th December* 1876 *to 25th May* 1878—continued.

| Months. | Small-pox. | | | Phthisis Pulmonalis. | | | Fever. | | | Other Diseases. | | | Average. | | |
|---|---|---|---|---|---|---|---|---|---|---|---|---|---|---|---|
| | Men. | Women. | Children. | Men. | Women. | Children. | Men. | Women. | Children. | Men. | Women. | Children. | Men. | Women. | Children. |
| January 1878 ... | ... | ... | ... | ·67 | ·12 | ... | 1·74 | 2·44 | ·41 | 11·51 | 7·48 | 6·74 | 27·02 | 20·28 | 9·56 |
| February ,, ... | ... | ... | ·35 | 1·00 | 3·10 | ... | 1·75 | 1·82 | ·75 | 15·03 | 10·35 | 7·42 | 27·19 | 23·61 | 9·62 |
| March ,, ... | ... | ... | ·38 | ·25 | ·58 | ... | ·03 | ·58 | ·16 | 14·83 | 9·61 | 2·64 | 21·12 | 19·89 | 6·55 |
| April ,, ... | ... | ... | ... | ·43 | ·63 | ... | 1·00 | ·46 | ·90 | 13·96 | 11·80 | 6·30 | 20·84 | 15·21 | 8·32 |
| May ,, ... | ... | ... | ... | ·84 | ·04 | ... | ... | ·52 | ·92 | 10·04 | 9·16 | 3·28 | 15·28 | 12·84 | 4·76 |
| Average ... | ... | ... | ·15 | ·61 | 1·13 | ... | ·93 | 1·18 | ·60 | 13·15 | 9·67 | 5·31 | 22·51 | 18·73 | 7·84 |
| Total Average ... | ·15 | ·13 | ·33 | ·87 | ·71 | ... | ·69 | ·71 | ·64 | 8·52 | 10·21 | 6·41 | 27·90 | 23·73 | 14·09 |

# APPENDIX C.

*Table showing Causes of Deaths in Relief Camps (taken from a Special Report by the Sanitary Commissioner of Madras, Dr. Cornish).*

| Name of Camp. | Name of the district in which camp is situated. | Total deaths. | Cholera. | Small-pox. | Fevers. | Diarrhœa and dysentery. | Dropsy, debility, privation, ulcer, &c. |
|---|---|---|---|---|---|---|---|
| Red Hills ... | Madras ... | 1,756 | 82 | 44 | 43 | 1,070 | 517 |
| Conjeeveram ... | Chingleput. | 1,304 | 46 | 18 | 4 | 1,124 | 112 |
| Trichinopoly ... | Trichinopoly | 1,171 | 186 | 67 | ... | 888 | 30 |
| Madura ... | Madura ... | 831 | 327 | 45 | 242 | 217 | ... |
| Dindigul ... | Do. ... | 1,029 | 26 | 18 | 23 | 780 | 182 |
| Cuddapah ... | Cuddapah . | 770 | 25 | 42 | 130 | 378 | 195 |
| Madanapalle ... | Do. ... | 4,196 | ... | 5 | 11 | 2,986 | 1,194 |
| Anantapur ... | Bellary ... | 239 | 15 | 2 | 8 | 126 | 88 |
| Vellore (Sathoo-vanacharry). | N. Arcot ... | 3,673 | 396 | 40 | 129 | 586 | 2,522 |
| Chalk Hills ... | Salem ... | 3,890 | 9 | 11 | 7 | 2,944 | 919 |
| Coimbatore ... | Coimbatore. | 589 | 20 | 4 | 101 | 252 | 212 |
| Udamalpet ... | Do. ... | 975 | ... | 3 | 7 | 785 | 180 |
| Tirupúr ... | Do. ... | 379 | 1 | 1 | 44 | 173 | 160 |
| Vellore (Civil dispensary). | N. Arcot ... | 1,020 | 150 | ... | ... | 521 | 349 |
| Royapettah Hospital sheds. | Madras ... | 1,117 | 267 | 5 | 9 | 568 | 268 |
| | Total ... | 22,939 | 1,550 | 305 | 758 | 13,398 | 6,928 |
| Ratio to Total Deaths ... | | ... | 6·5 | 1·3 | 3·3 | 58·4 | 30·2 |

# APPENDIX D.

## Alvine Flux with Intestinal Ulceration without Diphtheritic Effusion.

*List of Cases giving Weight of Body and of its Organs, &c.*

| No. | Name. | Caste. | Occupation. | Age. | Sex. | Height. | | Weight. | Weight in ounces of | | | | |
|---|---|---|---|---|---|---|---|---|---|---|---|---|---|
| | | | | | | Feet. | Inches. | | Brain. | Right Lung. | Left Lung. | Heart. | Liver. |
| | | | | YEARS. | | | | LBS. | | | | | |
| 65 | Mooneah ... ... | Pariah ... | Coolie ... | 60 | Male ... | 5 | 2 | 57½ | 34¼ | 7¼ | 7½ | 4¾ | 20¼ |
| 66 | Moothoo ... ... | Do. ... | Do. ... | 50 | Do. ... | 5 | 3½ | 83 | 40⅝ | 7¾ | 8¼ | 7⅛ | 34 |
| 67 | Mooneappen ... | Reddy ... | Do. ... | 50 | Do. ... | 5 | 6 | 88 | 43⅜ | 9⅛ | 7⅜ | 6⅜ | 45 |
| 68 | Karien ... ... | Pariah ... | Do. ... | 45 | Do. ... | 5 | 3½ | 77 | 44⅝ | 7⅜ | 6⅝ | 6 | 26½ |
| 69 | Govinda ... ... | Pully ... | Do. ... | 40 | Do. ... | 5 | 5½ | 89 | 46½ | 10¾ | 10¾ | 5¾ | 33 |
| 70 | Irchian ... ... | Do. ... | Do. ... | 25 | Do. ... | 5 | ... | 83 | 46¼ | 7¼ | 7¼ | 6¾ | 28 |
| 71 | China Naik ... | ..... | Farmer... | 50 | Do. ... | 5 | 2 | 84 | 42½ | 7½ | 6¼ | 6¼ | 28 |
| 72 | Kullathan ... ... | Pully ... | Coolie ... | 50 | Do. ... | 5 | 5 | 85 | 39⅛ | 8⅝ | 7⅛ | 6⅛ | 38⅝ |
| 73 | Tooben ... ... | Moodeliar ... | Do. ... | 30 | Do. ... | 5 | 2 | 58 | 38¾ | 6¾ | 7¼ | 4 | 33¼ |
| 74 | Munean ... ... | Pariah ... | Do. ... | 40 | Do. ... | 5 | 2½ | 80 | 39¼ | 9 | 8½ | 5⅜ | 35¾ |
| 75 | Mootooswamy ... | Pully ... | Do. ... | 50 | Do. ... | 5 | 5 | 86 | 44½ | 8½ | 7⅜ | 6¼ | 35 |
| 76 | Thannay ... ... | ..... | ... | 55 | Female... | 5 | 2 | 58 | 33 | 8 | 6½ | 5⅛ | 27¼ |
| 77 | Iyalandum ... ... | Pully ... | Ryot ... | 35 | Do. ... | 5 | ... | 60 | 36 | 7¼ | 7¼ | 5 | 23¼ |
| 78 | Alamaloo ... ... | ..... | ... | 32 | Do. ... | 5 | 1½ | 84 | 46½ | 9½ | 8¾ | 6¼ | 57½ |
| 79 | Vully ... ... | Pully ... | Coolie ... | 20 | Do. ... | 4 | 11 | 58 | 42 | 8¼ | 6¼ | 5 | 30¼ |
| 80 | Divamy ... ... | Fisherman ... | Fisherman | 65 | Do. ... | 4 | 10 | 46 | 33 | 10¼ | 9⅞ | 4¾ | 21¼ |
| 81 | Moothiama ... ... | Pariah ... | Coolie ... | 60 | Do. ... | 4 | 11¾ | 76 | 38½ | 7¼ | 6¾ | 6½ | 40¼ |
| 82 | Lutchmee ... ... | Cavaray ... | Do. ... | 40 | Do. ... | 5 | ... | 66 | 42½ | 8½ | 6¾ | 4⅞ | 25¾ |
| 83 | Ponee ... ... | Pariah ... | Do. ... | 60 | Do. ... | 5 | ... | 59 | 36½ | 9¼ | 9 | 5 | 29 |
| 84 | Rally ... ... | Do. ... | Beggar ... | 65 | Do. ... | 5 | ... | 54 | 36 | 6½ | 5¼ | 5 | 24½ |

| | | | | | | | | | | | | | | |
|---|---|---|---|---|---|---|---|---|---|---|---|---|---|---|
| 85 | Hussan Bee ... | Mahomedan | Coolie ... | 60 | Do. ... | 5 | 1 | 56 | 36 | 7⅜ | 5⅝ | 5⅛ | 25½ |
| 86 | Veelamah ... ... | Pully ... | Do. ... | 60 | Do. ... | 4 | 10¾ | 47 | 36⅞ | 5⅛ | 4½ | 6 | 17½ |
| 87 | Mulavy ... ... | Do. ... | Do. ... | 50 | Do. ... | 4 | 11 | 55 | 39¾ | 8⅜ | 8 | 5 | 26½ |
| 88 | Sanjee ... ... | Do. ... | Do. ... | 36 | Do. ... | 5 | 2½ | 89 | 39½ | 9½ | 8½ | 7⅝ | 53¾ |
| 89 | Mooneamah ... | Malabar ... | Do. ... | 20 | Do. ... | 5 | ... | 58 | 33¼ | 3⅞ | 3½ | 4 | 33½ |
| 90 | Ayee ... ... | Pully ... | Do. ... | 60 | Do. ... | 5 | 2 | 66 | 40⅜ | 8¼ | 6 | 4 | 26⅞ |
| 91 | Chelly ... ... | Pariah ... | Do. ... | 60 | Do. ... | 5 | ... | 65 | 37½ | 6½ | 5½ | 5¾ | 22¾ |
| 92 | Yellamah ... ... | Do. ... | Do. ... | 40 | Do. ... | 4 | 11½ | 54 | 37 | 8¾ | 8¼ | 5 | 22 |
| 93 | Lutchumee ... | Do. ... | Do. ... | 50 | Do. ... | 4 | 11 | 56 | 29½ | 6¼ | 5¼ | 5⅝ | 24 |
| 94 | Lutchmee ... ... | Cavaray ... | Do. ... | 65 | Do. ... | 5 | 2½ | 65 | 31½ | 7½ | 7⅜ | 5¾ | 30 |
| 95 | Allamalloo ... ... | Pariah ... | Do. ... | 35 | Do. .. | 4 | 10 | 48 | 38⅝ | 5 | 4⅜ | 6 | 23¼ |
| 96 | Ponee ... ... | Do. ... | Do. ... | 50 | Do. ... | 5 | 3 | 52 | 39¼ | 6⅜ | 5¾ | 4⅛ | 26⅝ |
| 97 | Allamaloo ... | Do. ... | Do. ... | 30 | Do. ... | 5 | 1 | 75 | 36½ | 8⅞ | 9 | ¾ | 30½ |
| 98 | Thoolassee ... | Do. ... | Do. ... | 30 | Do. ... | 4 | 11¾ | 57 | 38¾ | 7⅜ | 6¾ | 4¾ | 27¾ |
| 99 | Venketama ... | Pully ... | Do. ... | 25 | Do. ... | 5 | 1 | 73 | 34¼ | 9 | 7⅛ | 4¼ | 32 |
| 100 | Kunachee ... ... | Weaver ... | Do. ... | 35 | Do. ... | 4 | 10 | 55 | 33⅜ | 5 | 4¼ | 4¾ | 21¾ |
| 101 | Thumboo ... ... | Pariah ... | Do. ... | 7 | Male ... | 3 | 4 | 23 | 33½ | 2 | 1½ | 2⅜ | 11 |
| 102 | Moorgasen ... | Moodelliar ... | Do. ... | 2 | Do. ... | 2 | 7 | 14 | 33½ | 1⅝ | 1¼ | 1⅜ | 6 |
| 103 | Kanapathy ... | Do. ... | Do. ... | 6 | Do. ... | 3 | 5 | 22 | 38⅝ | 2¼ | 2 | 1¾ | 11¼ |
| 104 | Ayamah ... ... | Pully ... | Do. ... | 8 | Female. | 3 | 11 | 27 | 34 | 3⅞ | 3½ | 2⅛ | 12⅜ |
| 105 | Moonoochee ... | Do. ... | ... | 8 | Do. ... | 4 | ... | 33 | 34½ | 3⅜ | 3⅜ | 2½ | 17½ |
| 106 | Asoree ... ... | Pariah ... | Coolie ... | 3 | Do. ... | 3 | ... | 19 | 36 | 2⅜ | 2⅜ | 1⅜ | 10¾ |
| 107 | Lutchmee ... ... | Shepherd ... | ... | 8 | Do. ... | 3 | 9 | 23 | 34⅝ | 2⅝ | 2⅜ | 1⅜ | 10⅝ |
| 108 | Venkut Rumboo ... | Wudder ... | Beggar... | 60 | Male ... | ... | ... | ... | 37½ | 24⅜ | 8½ | 7½ | 20 |
| 109 | Velloyden ... ... | Pully ... | Laborer. | 60 | Do. ... | 5 | 5 | 73 | 39 | 17 | 10¾ | 5 | 24 |
| 110 | Chelladoo ... ... | Washerman. . | ... | 63 | Do. .. | 5 | 3½ | 69 | 36¾ | 16 | 10¼ | 4⅞ | 15¾ |
| 111 | Thanadoo ... .. | Wudder .. | Navvy ... | 36 | Do. ... | 5 | 9 | 92 | 45 | 23⅓ | 30⅛ | 8¼ | 38⅞ |
| 112 | Nynapa ... ... | Pully ... | Coolie ... | 55 | Do. ... | 5 | 6 | 59 | 42¼ | 24 | 14¾ | 4¾ | 31½ |
| 113 | Veeran ... ... | Pariah ... | Do. ... | 50 | Do. ... | 5 | 6½ | 91 | 40¼ | 11½ | 14⅞ | 6¼ | 23 |
| 114 | Veerabudrum ... | Weaver ... | ... | 45 | Do. ... | 5 | 6 | 80 | 43 | 19½ | 25 | 6 | 32½ |
| 115 | Soobiah ... ... | Edyar ... | Fakheer . | 48 | Do. ... | 5 | 9¾ | 99 | 54 | 27½ | 24 | 7 | 26½ |
| 116 | Hullavadoo ... | Yanathy ... | Coolie ... | 20 | Do. ... | 5 | 3 | 70 | 38 | 17 | 21 | 4½ | 37 |
| 117 | Nynapah Reddy ... | Vanyan ... | Do. ... | 55 | Do. ... | 5 | 7 | 89 | 42 | 24 | 14¼ | 8 | 34 |
| 118 | Vadagherry ... | Pundarum .. | Do. ... | 70 | Do. ... | 5 | 2½ | 96 | 46¼ | 14½ | 9⅞ | 7¾ | 43½ |
| 119 | Moonean ... ... | Pariah ... | Do. ... | 60 | Do. ... | 5 | 3½ | 77 | 36½ | 25½ | 22 | 14⅜ | 27 |
| 120 | Kallan ... ... | Do. ... | Do. ... | 50 | Do. ... | 5 | 6¼ | 85 | 44 | 9¾ | 10 | 6¾ | 33¾ |

## APPENDIX D—*continued.*

### ALVINE FLUX WITH INTESTINAL ULCERATION WITHOUT DIPHTHERITIC EFFUSION—*continued.*

*List of Cases giving Weight of Body and of its Organs, &c.*—continued.

| No. | Name. | Caste. | Occupation. | Age. | Sex. | Height. | | Weight. | Weight in ounces of | | | | |
|---|---|---|---|---|---|---|---|---|---|---|---|---|---|
| | | | | | | Feet. | Inches. | | Brain. | Right Lung. | Left Lung. | Heart. | Liver. |
| | | | | YEARS. | | | | LBS. | | | | | |
| 121 | Royappen ... ... | Pariah ... | Coolie ... | 60 | Male ... | 5 | 5¼ | 68 | 46⅜ | 10½ | 14⅜ | 5⅛ | 25½ |
| 122 | Manakum ... ... | Do. ... | Do. ... | 30 | Do. ... | 5 | 8 | 80 | 45¼ | 11¾ | 10¼ | 5⅜ | 40¼ |
| 123 | Moonean ... ... | Do. ... | Do. ... | 60 | Do. ... | 5 | 6½ | 85 | 40¾ | 12⅛ | 13¾ | 6⅛ | 21¼ |
| 124 | Irchen ... ... | Pully ... | Do. ... | 40 | Do. ... | 5 | 11 | 90 | 48 | 24⅝ | 11¼ | 7⅜ | 40½ |
| 125 | Chellam ... ... | Pariah ... | Do. ... | 60 | Do. ... | 5 | 5 | 81 | 37½ | 14¾ | 12¼ | 5⅜ | 25½ |
| 126 | Cunamadoo ... ... | Do. ... | Do. ... | 30 | Do. ... | 5 | 2 | 68 | 44 | 10⅝ | 18 | 5½ | 36½ |
| 127 | Rampursad ... | Rajpoot ... | Fakheer. | 20 | Do. ... | 5 | 8½ | 75 | 42½ | 16¼ | 14 | 5⅜ | 40¾ |
| 128 | Perumal ... ... | Pariah ... | Coachman | 65 | Do. ... | 5 | 6 | 96 | 47 | 28 | 21 | 10¾ | 30 |
| 129 | Ponappen ... ... | Moodeliar ... | Coolie ... | 60 | Do. ... | 5 | 9 | 79 | 43⅝ | 28¼ | 26⅝ | 5⅜ | 24 |
| 130 | Pursooram ... ... | Pariah ... | Do. ... | 50 | Do. ... | 5 | 5 | 94 | 43 | 12 | 9⅛ | 5½ | 19¾ |
| 131 | Hyder Ali ... ... | Mahomedan... | Do. ... | 50 | Do. ... | 5 | 8 | 77 | 42½ | 18½ | 7½ | 6¾ | 35½ |
| 132 | Govindoo ... ... | Pully ... | Do. ... | 40 | Do. ... | 5 | ... | 65 | 40¾ | 14½ | 11¼ | 5¼ | 26¼ |
| 133 | Mariamah ... ... | Pariah ... | Do. ... | 50 | Female... | 5 | 3 | 80 | 44½ | 14 | 22½ | 5 | 27½ |
| 134 | Mootiamah ... ... | Pully ... | Do. ... | 50 | Do. ... | 5 | 2 | 65 | 39½ | 10¼ | 10 | 5¾ | 28¼ |
| 135 | Chelly ... ... | Pariah ... | Do. ... | 65 | Do. ... | 5 | 2 | 70 | 38⅜ | 13 | 6¾ | 4½ | 27 |
| 136 | Hooroythya .. | Do. ... | Do. ... | 60 | Do. ... | 5 | ... | 50 | 34⅝ | 13 | 16½ | 6¼ | 26½ |
| 137 | Sundrum ... ... | Cavaray ... | Do. ... | 60 | Do. ... | 5 | ... | 52 | 34½ | 10¼ | 9⅜ | 5 | 21¾ |
| 138 | Venkatamah ... | Aperah ... | Do. ... | 20 | Do. ... | 5 | 3½ | 69 | 40⅝ | 11¼ | 13⅜ | 4¼ | 29⅜ |
| 139 | Atchee ... ... | Do. ... | Do. ... | 30 | Do. ... | 5 | 3 | 72 | 40½ | 11½ | 12 | 5¼ | 31 |
| 140 | Chandrama ... ... | Shepherd ... | Shepherd. | 40 | Do. ... | 5 | 2½ | 67 | 40 | 13½ | 20¼ | 6⅛ | 40½ |

| | | | | | | | | | | | | | | |
|---|---|---|---|---|---|---|---|---|---|---|---|---|---|---|
| 141 | Lutchee ... ... | Weaver ... | Weaver... | 40 | Do. ... | 4 | 8 | 61 | 29 | 12 | 10¾ | 4½ | 19⅜ |
| 142 | Mootamah ... ... | Pariah ... | Coolie ... | 40 | Do. ... | 5 | 1 | 56 | 32⅝ | 10 | 6¼ | 5¼ | 19½ |
| 143 | Iyamah ... ... | Do. ... | Do. ... | 40 | Do. ... | 5 | 0¾ | 68 | 40⅝ | 12½ | 15½ | 5½ | 40½ |
| 144 | Yellah ... ... | Do. ... | Do. ... | 30 | Do. ... | 5 | ... | 48 | 36 | 8⅞ | 9¼ | 4⅛ | 27 |
| 145 | Moorgum ... ... | Do. ... | Do. ... | 6 | Male ... | 3 | ... | 19 | 37½ | 3⅜ | 2¾ | 1⅛ | 8⅝ |
| 146 | Permaul ... ... | Cavaray ... | Do. ... | 2½ | Do. ... | 2 | 6 | 17 | 37½ | 2½ | 2⅜ | 1⅛ | 9¾ |
| 147 | Ramadoo ... ... | Operah ... | Do. ... | 3 | Do. ... | 3 | 4 | 23 | 38½ | 3⅝ | 3¼ | 1¾ | 9¾ |
| 148 | Lutchmee ... ... | Pully ... | Do. ... | 8 | Female... | 3 | 6 | 29 | 39⅝ | 4½ | 3⅞ | 1⅞ | 11¼ |
| 149 | Kally ... ... | Do. ... | Do. ... | 8 | Do. ... | 3 | 8 | 26 | 33¼ | 4 | 3⅛ | 1¾ | 10¼ |
| 150 | Lutchmee ... ... | Pariah ... | Do. ... | 7 | Do. ... | 3 | 7 | 22 | 35¼ | 3⅞ | 3½ | 1½ | 14¼ |
| 151 | Ghoolam Dustaghir... | Mahomedan | Fakheer... | 35 | Male ... | 5 | 2½ | 75 | 41 | 13⅞ | 12½ | 5¾ | 26⅛ |
| 152 | Moodeen ... ... | Pully ... | Coolie ... | 45 | Do. ... | 5 | 5 | 96 | 43¾ | 25 | 19¼ | 7⅞ | 40⅜ |
| 153 | Moorgum ... ... | Pariah ... | Do. ... | 20 | Do. ... | 5 | 5 | 84 | 44¼ | 21½ | 18½ | 6¼ | 52 |
| 154 | Gungadoo ... ... | Do. ... | Do. ... | 50 | Do. ... | 5 | 5 | 94 | 38 | 28½ | 8⅞ | 8 | 38½ |
| 155 | Venketachellum ... | Naicker ... | Do. ... | 50 | Do. ... | 5 | 7½ | 74 | 40 | 17 | 12¾ | 6½ | 33 |
| 156 | Chellan ... ... | Pariah ... | Do. ... | 30 | Do. ... | 5 | 2 | 62 | 41 | 16 | 14 | 4¼ | 39½ |
| 157 | Kallapah ... ... | Barber ... | Barber ... | 50 | Do. ... | 5 | 4 | 81 | 46¼ | 23¾ | 13⅞ | 9 | 43½ |
| 158 | Moonean ... ... | Pully ... | Coolie ... | 30 | Do. ... | 5 | 2¾ | 72 | 45 | 20⅝ | 18⅛ | 5¾ | 32 |
| 159 | Gopal ... ... | Weaver ... | Weaver... | 20 | Do. ... | 5 | 4 | 68 | 37 | 10¼ | 11¾ | 5⅜ | 31 |
| 160 | Syed Cawder ... | Mahomedan... | Coolie ... | 35 | Do. ... | 5 | 4½ | 92 | 36 | 21 | 26½ | 7¼ | 52¾ |
| 161 | Rungee ... ... | Cavaray ... | Do. ... | 35 | Do. ... | 5 | 7 | 78 | 39½ | 13¼ | 14 | 6¼ | 34½ |
| 162 | Suka Bee ... ... | Mahomedan... | Do. ... | 60 | Female... | 4 | 9 | 50 | 35 | 10⅝ | 20½ | 3 | 21⅞ |
| 163 | Lutchmee ... ... | Washerwoman | Dhobie... | 39 | Do. ... | 5 | 8 | 90 | 33¼ | 10¾ | 22½ | 7¼ | 31½ |
| 164 | Velloy ... ... | Pariah ... | Coolie ... | 5 | Male ... | ... | ... | 16 | ... | 3 | 2¾ | 1⅛ | 6¼ |
| 165 | Chenty ... ... | Do. ... | Do. ... | 4 | Do. ... | 3 | 4 | 18 | 37½ | 4½ | 3¼ | 1½ | 10⅜ |
| 166 | Chinacolandy ... | Do. ... | Do. ... | 9 | Do. ... | 3 | 8 | 36½ | 35 | 5½ | 4¾ | 2⅜ | 22 |
| 167 | Yellamah ... ... | Pully ... | Do. ... | 6 | Female... | 2 | 6 | 13 | 29 | 1⅞ | 1⅜ | ⅞ | 6⅜ |
| 168 | Ragava ... ... | Pariah ... | Do. ... | ½ | Do. ... | 1 | 10 | 6½ | 17 | 1½ | 1¼ | ½ | 6½ |
| 169 | Lutchmee ... ... | Pully ... | Do. ... | 2 | Do. ... | 2 | 5 | 13 | 24½ | 2⅝ | 2 | 1 | 6¼ |
| 170 | Kunny ... ... | Do. ... | Do. ... | 26 | Male ... | 5 | 4 | 76 | 43½ | 19⅝ | 18½ | 7¼ | 38¾ |
| 171 | Shaik Emam ... | Mahomedan .. | Do. ... | 70 | Do. ... | 5 | 5½ | 85 | 44 | 23½ | 17¼ | 6⅞ | 35 |
| 172 | Chellan ... ... | Pariah ... | Do. ... | 60 | Do. ... | 5 | 2½ | 71 | 37 | 12½ | 9½ | 5½ | 21 |
| 173 | Mylapen ... ... | Cavaray ... | Do. ... | 60 | Do. ... | 5 | 4 | 66 | 32 | 23¾ | 10¼ | 6 | 20½ |
| 174 | Soobee ... ... | Weaver ... | Weaver... | 30 | Female... | 4 | 9 | 50 | 37 | 10 | 8⅞ | 4 | 39½ |
| 175 | Lutchmee ... ... | Pariah ... | Coolie ... | 70 | Do. ... | 5 | ... | 52 | 36¾ | 9⅜ | 9½ | 4⅝ | 22⅝ |
| 176 | Mungay ... ... | Pully ... | Do. ... | 55 | Do. ... | 5 | 1½ | 63 | 34 | 8¾ | 8⅛ | 6 | 22¼ |

## APPENDIX D—*continued.*

### ALVINE FLUX WITH INTESTINAL ULCERATION WITHOUT DIPHTHERITIC EFFUSION—*continued.*

*List of Cases giving Weight of Body and of its Organs, &c.*—continued.

| No. | Name. | Caste. | Occupation. | Age. | Sex. | Height. | | Weight. | Weight in ounces of | | | | |
|---|---|---|---|---|---|---|---|---|---|---|---|---|---|
| | | | | | | Feet. | Inches. | | Brain. | Right Lung. | Left Lung. | Heart. | Liver. |
| | | | | YEARS. | | | | LBS. | | | | | |
| 177 | Venkatasen ... | Pariah ... | Coolie ... | 50 | Male ... | 5 | 6 | 70 | 44 | 14½ | 15 | 5 | 29 |
| 178 | Poneah ... ... | Do. ... | Do. ... | 50 | Do. ... | 5 | 4 | 63 | 36¼ | 15¾ | ... | 4½ | 30½ |
| 179 | Moonean ... ... | Do. ... | Do. ... | 60 | Do. ... | 5 | 6 | 63 | 38½ | 10¾ | 10¾ | 6½ | 35 |
| 180 | Venketswamy ... | Cavaray ... | Do. ... | 35 | Do. ... | 5 | 8 | 70 | 52 | 20¾ | 16 | 5⅝ | 34⅝ |
| 181 | Ramalayan ... ... | Pully ... | Do. ... | 60 | Do. ... | 5 | 5½ | 80 | 44½ | 22½ | 16⅛ | 6½ | 27 |
| 182 | Golanda ... ... | Potter ... | Potter ... | 38 | Do. ... | 5 | 4 | 63 | 38 | 7½ | 9½ | 4⅞ | 26¼ |
| 183 | Ragava ... ... | Pariah ... | Coolie ... | 50 | Female... | 5 | 1 | 55 | 35 | 6¾ | 5⅝ | 4½ | 16 |
| 184 | Cunniamah ... ... | Pully ... | Do. ... | 50 | Do. ... | 5 | 1 | 54 | 31½ | 10¼ | 6⅜ | 6½ | 27 |
| 185 | Ponee ... ... | Pariah ... | Do. ... | 35 | Do. ... | 5 | 1 | 43 | 37½ | 8 | 9⅛ | 4⅛ | 25¾ |
| 186 | Ungoor ... ... | Mahratta ... | Do. ... | 45 | Do. ... | 5 | 1 | 55 | 34½ | 12¾ | 17⅝ | 4⅝ | 23¾ |
| 187 | Allamalloo ... ... | Pariah ... | Do. ... | 37 | Do. ... | 5 | 3 | 70 | 38 | 9⅝ | 9 | 5¼ | 56 |
| 188 | Kamachee ... ... | Do. ... | Do. ... | 35 | Do. ... | 4 | 11½ | 70 | 30½ | 11⅝ | 9½ | 4⅜ | 23 |
| 189 | Rungen ... ... | Wudder ... | Navvy ... | 46 | Male ... | 5 | 2¾ | 100 | 42½ | 17 | 15½ | 5 | 16⅛ |
| 190 | Soobroyen ... ... | Pully ... | Coolie ... | 40 | Do. ... | 5 | 7 | 96 | 44 | 18¼ | 14⅛ | 7⅛ | 25⅝ |
| 191 | Ootakota ... ... | Pariah ... | Do. ... | 40 | Female... | 5 | 1 | 90 | 46½ | 8⅞ | 9 | 4¼ | 25 |
| 192 | Ammanee ... ... | Pully ... | Do. ... | 30 | Do. ... | 5 | 2½ | 127 | 41¾ | 15⅛ | 13⅛ | 6¾ | 33 |
| 193 | Rajoo ... ... | Shoe-maker ... | Chuckler. | 25 | Do. ... | 5 | 4 | 75 | 36½ | 8¼ | 6¼ | 5 | 54 |
| 194 | Kaucotchee ... | Pariah ... | Coolie ... | 26 | Do. ... | 5 | 3 | 88 | 39 | 9½ | 9 | 5½ | 37½ |
| 195 | Moothen ... ... | Do. ... | Do. ... | 8 | Male ... | 3 | 9½ | 35 | 40¼ | 2⅞ | 2½ | 1⅞ | 10⅛ |
| 196 | Mootiathee ... ... | Do. ... | Do. ... | 4 | Female... | 2 | 10½ | 26 | 30½ | 2½ | 2 | 1⅛ | 7½ |

## APPENDIX D—*continued.*

### Alvine Flux with Intestinal Ulceration without Dipththeritic Effusion—*continued.*

*List of Cases giving Weight of Body and of its Organs, &c.*—continued.

| No. | Name. | Weight in ounces of—*cont.* | | | | Date of autopsy. | Hours after death autopsy made. | Rigor mortis. | Bodily state. |
|---|---|---|---|---|---|---|---|---|---|
| | | Spleen. | Right Kidney. | Left Kidney. | Pancreas. | | | | |
| 65 | Mooneah ... ... | 1⅝ | 1½ | 1⅜ | 2⅛ | 13 Mar. 1877. | 1 | Present ... | Quite a skeleton ; no œdema. |
| 66 | Moothoo ... ... | 2⅛ | 1⅞ | 1⅞ | 2⅛ | 11 July 1877. | 1 | Do. ... | In fair flesh ; but little fat. |
| 67 | Mooneappen ... | 6¼ | 2⅝ | 2⅞ | 2⅝ | 19 Aug. ... | 3 | Do. ... | Much emaciated ; œdema of feet. |
| 68 | Karien ... ... | 2 | 2⅝ | 3 | 2½ | 20 Aug. ... | 10 | Do. ... | Quite a skeleton ; no œdema. |
| 69 | Govinda ... ... | 2½ | 2½ | 2¾ | 2¼ | 30 Aug. ... | 2 | Do. ... | Emaciated ; œdema of feet. |
| 70 | Irchian ... ... | 3 | 3¼ | 3¼ | 2¼ | 21 Aug. ... | 6 | Do. ... | Thin ; œdema of feet. |
| 71 | China Naik ... | 2½ | 2¾ | 3¼ | 2⅝ | 12 July | 4 | Do. ... | Do. do. |
| 72 | Kullathan ... ... | 2¼ | 5 | 4⅜ | 3½ | 24 Aug. 1877. | 2 | Do. ... | Emaciated ; no œdema. |
| 73 | Tooben ... ... | 2⅛ | 3⅛ | 3⅛ | 2⅝ | 5 Oct. 1877. | 6 | Do. ... | Skeleton ; no œdema. |
| 74 | Munean ... ... | 3¾ | 2¾ | 3¼ | 2¾ | 5 Mar. 1878. | 4 | Do. ... | Thin ; no œdema. |
| 75 | Mootooswamy ... | 2⅜ | 4⅛ | 3¼ | 2⅛ | 30 Oct. 1877. | 3 | Do. ... | Do. do. |
| 76 | Thannay ... ... | 7½ | 3⅜ | 3⅞ | 1⅜ | 9 April 1877. | 3 | Do. ... | Emaciated ; œdema of feet. |
| 77 | Iyalandum ... ... | 3¼ | 2⅞ | 2⅞ | 1 | 24 April 1877. | 3 | Do. ... | Skeleton ; some ascites ; no œdema. |
| 78 | Alamaloo ... ... | 11½ | 3 | 3½ | 1¾ | 29 July ... | 1 | Do. ... | In good flesh ; lots of fat. |
| 79 | Vully ... ... | 2⅝ | 2⅞ | 3⅛ | 2⅛ | 22 Aug. ... | 7 | Absent ... | Skeleton ; no œdema. |
| 80 | Divamy ... ... | 1¼ | 2 | 2⅛ | 2 | 3 Aug. ... | 16 | Present ... | Skeleton ; œdema of feet. |
| 81 | Moothiama ... | 1⅝ | 2½ | 2⅞ | 2⅛ | 7 July 1877. | 9 | Do. ... | In fair flesh. |

## APPENDIX D—*continued.*

### Alvine Flux with Intestinal Ulceration without Diphtheritic Effusion—*continued.*

*List of Cases giving Weight of Body and of its Organs, &c.*—continued.

| No. | Name. | Weight in ounces of—*cont.* | | | | Date of autopsy. | Hours after death autopsy made. | Rigor mortis. | Bodily state. |
|---|---|---|---|---|---|---|---|---|---|
| | | Spleen. | Right Kidney. | Left Kidney. | Pancreas. | | | | |
| 82 | Lutchmee ... ... | 5 | 3 | 3⅜ | 2 | 8 May 1877. | 12 | Absent ... | Emaciated; ascites; œdema of feet. |
| 83 | Ponee ... ... | 2⅛ | 2¼ | 2⅜ | 1½ | 11 June ... | 15 | Present ... | Skeleton; œdema of feet. |
| 84 | Rally ... ... | 2 | 3 | 3⅜ | 1½ | 15 June ... | 6 | Do. ... | Do. do. |
| 85 | Hussan Bee ... | 2⅞ | 3⅞ | 4¼ | 1¼ | 22 June ... | 1 | Do. | Quite a skeleton; no œdema. |
| 86 | Veelamah ... ... | 1⅛ | 2⅜ | 2 | 1¼ | 29 June ... | 1 | Do. | Skeleton; no œdema. |
| 87 | Mulavy ... ... | 1⅛ | 2⅞ | 3 | 1⅜ | 29 June ... | 6 | Do. | Do. do. |
| 88 | Sanjee ... ... | 6¾ | 4¾ | 5⅜ | 3¼ | 5 Aug. ... | 9 | Do. | In good flesh. |
| 89 | Mooneamah ... | 2⅛ | 2⅝ | 2½ | 1⅜ | 10 Jan. 1878. | 5 | Do. | Emaciated; œdema of face and feet. |
| 90 | Ayee ... ... | ⅞ | 2⅞ | 2⅞ | 1⅜ | 23 Oct. ... | 5 | Do. | Skeleton; œdema of feet. |
| 91 | Chelly ... ... | 1 | 1¾ | ⅞ | 1⅞ | 11 July ... | 1 | Do. | Skeleton; no œdema. |
| 92 | Yellamah ... ... | 1⅞ | 2¾ | 2⅜ | 1⅜ | 1 Aug. ... | 5 | Absent ... | Do. do. |
| 93 | Lutchumee ... | 1⅛ | 2⅜ | 2 | 1½ | 3 Aug. 1877. | 2 | Present ... | Thin; no œdema. |
| 94 | Lutchmee ... ... | 1¾ | 2½ | 2⅞ | 2 | 16 Aug. ... | 4 | Absent ... | Emaciated; œdema of feet. |
| 95 | Alamaloo ... ... | 1⅛ | 1⅞ | 2 | 1⅜ | 19 Aug. ... | 2 | Present ... | Skeleton; œdema of feet. |
| 96 | Ponee ... ... | 1⅛ | 1¾ | 2⅜ | 2⅛ | 6 Sept. ... | 10 | Absent ... | Quite a skeleton; slight œdema of feet. |
| 97 | Allamaloo ... ... | 1¾ | 3¼ | 3¼ | 1¾ | 30 Sept. 1877. | 5 | Present ... | Skeleton; œdema of feet. |

| | | | | | | | | | |
|---|---|---|---|---|---|---|---|---|---|
| 98 | Thoolassee ... ... | 1¾ | 3 | 2⅞ | 1⅜ | 2 Oct. ... | 7 | Do. | Ulceration of both cornea; no œdema; skeleton. |
| 99 | Venketama ... ... | 4⅛ | 2⅝ | 3⅜ | 1¼ | 4 Oct. 1877. | 9 | Do. | Thin; œdema of feet. |
| 100 | Kunachee ... ... | 1¾ | 2 | 2 | 1⅛ | 21 Oct. ... | 2 | Do. | Skeleton; œdema of feet. |
| 101 | Thumboo ... ... | 2⅛ | 1¼ | 1⅝ | ⅞ | 21 May 1877. | 2 | ... | Emaciated; some œdema of feet. |
| 102 | Moorgasen ... | ⅞ | ⅞ | 1 | ⅜ | 27 Aug. ... | 11 | Absent ... | Skeleton; slight œdema of feet. |
| 103 | Kanapathy ... | 1 | 1½ | 1½ | ⅝ | 13 Oct. 1877. | 8 | Going off ... | Skeleton; œdema of feet. |
| 104 | Ayamah ... ... | 2⅜ | 1½ | 1⅝ | ⅞ | 27 Oct. ... | 9 | Present ... | Skeleton; no œdema. |
| 105 | Moonoochee ... | 2 | 2¼ | 2⅜ | ¾ | 30 Mar. 1877. | 2 | Do. ... | Skeleton; no œdema. |
| 106 | Asoree ... ... | ½ | 1⅛ | 1¼ | ⅝ | 10 July ... | 12 | Absent ... | Quite a skeleton; œdema of feet. |
| 107 | Lutchmee ... ... | ⅞ | 1½ | 1⅝ | ¾ | 26 Sept. 1877. | 12 | Do. ... | Do. no œdema. |
| 108 | Wenkut Rumboo ... | 1½ | 2⅝ | 2½ | 2¼ | 26 Feb. 1877. | 1 | Well marked. | Very much emaciated. |
| 109 | Velloyden ... ... | 1 5/16 | 2½ | 2⅝ | 1⅞ | 20 April ... | 3 | Present ... | Emaciated; no œdema. |
| 110 | Chelladoo ... ... | 1½ | 2¼ | 2⅛ | 1½ | 13 April 1877. | 3 | Do. ... | Skeleton; œdema of feet. |
| 111 | Thanadoo ... ... | 11⅛ | 3⅛ | 4¼ | 2⅛ | 19 April 1877. | 6 | Do. ... | Much emaciated; no œdema or fat. |
| 112 | Nynapa ... ... | 2¼ | 2⅞ | 2⅞ | 1⅜ | 25 April 1877. | 3 | Well marked. | Skeleton; no œdema. |
| 113 | Veeran ... ... | 1 | 3⅛ | 3 | 3 | 9 June 1877. | 7 | Present ... | Emaciated œdema of feet. |
| 114 | Veerabudrum ... | 1 | 3⅛ | 3½ | 2⅛ | 30 June ... | 3 | Do. ... | Skeleton; œdema of feet. |
| 115 | Soobiah ... ... | 2⅞ | 5 | 4 | 2⅜ | 7 May 1877. | 10 | Do. ... | Emaciated; ascites; no œdema. |
| 116 | Hullavadoo ... ... | 3 | 3¼ | 3½ | 1½ | 11 May 1877. | 4 | Do. ... | In fair condition. |
| 117 | Nynapah Reddy ... | 3¼ | 3 | 2⅝ | 2⅝ | 4 June ... | 3 | Do. ... | Emaciated; œdema of feet and ankles. |
| 118 | Vadagherry ... | 1⅜ | 3½ | 3½ | 2¾ | 1 Aug. ... | 10 | Do. ... | Emaciated; œdema of face. |
| 119 | Moonean ... ... | 4 | 1⅞ | 1⅞ | 2¼ | 3 Aug. ... | 5 | Do. ... | Miserably thin; œdema of face and feet. |
| 120 | Kallan ... ... | 3⅜ | 2⅝ | 2¼ | 2¼ | 15 Sept. 1877. | 3 | Do. ... | Emaciated; œdema of feet. |
| 121 | Royappen ... ... | 2⅛ | 2⅛ | 2 | 1⅞ | 28 Aug. ... | 14 | Absent ... | Do. do. |
| 122 | Manakum ... ... | 2⅝ | 4 | 4⅜ | 2¾ | 31 Aug. ... | 8 | Present ... | Skeleton; no œdema. |
| 123 | Moonean ... ... | 1½ | 2⅝ | 3⅜ | 2⅜ | 25 Sept. ... | 2 | Do. ... | Thin; some œdema of feet. |
| 124 | Irchen ... ... | 4½ | 4½ | 4⅝ | 3¾ | 29 Sept. 1877. | 5 | Do. ... | Thin; no œdema. |
| 125 | Chellam ... ... | 3¼ | 2¾ | 10¼ | 2½ | 24 Oct. ... | 10 | Do. ... | Thin; œdema of feet. |
| 126 | Cunamadoo ... | 4 | 4½ | 4½ | 2⅛ | 8 Jan. 1878. | 2 | Do. ... | Skeleton; no œdema. |
| 127 | Rampursad ... ... | 14¼ | 3⅝ | 4⅛ | 2¼ | 23 Jan. 1878. | 15 | Do. ... | Skeleton; œdema of feet. |
| 128 | Perumal ... ... | 5½ | 2½ | 2½ | 2⅞ | 28 Jan. ... | 9 | Do. ... | Thin; no œdema. |
| 129 | Ponappen ... ... | 1⅞ | 2⅝ | 2½ | 2⅜ | 31 Jan. ... | 9 | Do. ... | Skeleton; œdema of feet. |

## APPENDIX D—*continued.*

### ALVINE FLUX WITH INTESTINAL ULCERATION WITHOUT DIPHTHERITIC EFFUSION—*continued.*

*List of Cases giving Weight of Body and of its Organs, &c.*—continued.

| No. | Name. | Weight in ounces of—*cont.* | | | | Date of autopsy. | Hours after death autopsy made. | Rigor mortis. | Bodily state. |
|---|---|---|---|---|---|---|---|---|---|
| | | Spleen. | Right Kidney. | Left Kidney. | Pancreas. | | | | |
| 130 | Pursooram ... ... | 3 | 2 | 2⅜ | 2½ | 19 Sept. ... | 9 | Present ... | Emaciated; œdema of feet. |
| 131 | Hyder Ali ... ... | 3¾ | 2½ | 3⅛ | 2 | 18 March ... | 4 | Absent ... | Do. do. |
| 132 | Govindoo ... ... | 1⅛ | 2½ | 2⅜ | 2⅜ | 12 Sept. ... | 7 | Present ... | Skeleton; slight œdema of feet. |
| 133 | Mariamah ... ... | 3 | 3½ | 3 | ⅞ | 16 June ... | 14 | Absent ... | Emaciated; œdema of hands and feet. |
| 134 | Mootiamah ... ... | 1⅝ | 4 | 3 | 2¼ | 30 June ... | 8 | Present .. | Emaciated; œdema of feet. |
| 135 | Chelly ... ... | 2⅛ | 4¾ | 4¾ | 2 | 30 June ... | 12 | Absent ... | Do. do. |
| 136 | Hooroythya ... | 1½ | 2⅝ | 2⅝ | 2 | 4 July | 1 | Well marked. | Skeleton; œdema of feet. |
| 137 | Sundrum ... ... | 2 | 2⅜ | 2½ | 1⅝ | 12 Aug. ... | 15 | Absent ... | Do. no œdema. |
| 138 | Venkatamah ... | 8½ | 8¼ | 8¼ | 1⅜ | 14 Aug. .. | 12 | Present ... | Skeleton; œdema of lower extremities. |
| 139 | Atchee ... ... | 3⅝ | 2⅜ | 2⅛ | 1½ | 16 Sept. ... | 9 | Going off ... | Emaciated; no œdema. |
| 140 | Chandrama ... ... | 3⅛ | 4¼ | 4⅝ | 2 | 28 Sept. ... | 5 | Present ... | Skeleton; swelling of left leg. |
| 141 | Lutchee ... ... | 1⅜ | 2⅝ | 2½ | 2 | 24 Oct. ... | 5 | Do. ... | Emaciated; œdema of lower extremities. |
| 142 | Mootamah ... ... | 1 | 2⅝ | 2⅝ | 1⅞ | 21 Dec. ... | 11 | Do. ... | Skeleton; no œdema. |
| 143 | Iyamah ... ... | 2¼ | 3¾ | 3½ | 2¼ | 30 Dec. ... | 2 | Do. ... | Thin; œdema of feet. |
| 144 | Yellah ... .. | 2 | 2⅛ | 2½ | 1⅝ | 23 Jan. ... | 3 | Do. ... | Skeleton; bed-sores on sacrum; no œdema. |
| 145 | Moorgum ... ... | 1 | 1⅛ | 1 | ⅝ | 1 Aug. ... | 10 | Absent ... | Skeleton; no œdema. |

| | | | | | | | | | |
|---|---|---|---|---|---|---|---|---|---|
| 146 | Permaul ... ... | $\frac{7}{8}$ | 1 | 1 | $\frac{1}{2}$ | 30 Sept. ... | 3 | Present ... | Skeleton; œdema of feet. |
| 147 | Ramadoo ... ... | $\frac{3}{4}$ | $1\frac{1}{8}$ | $1\frac{1}{4}$ | $\frac{3}{4}$ | 16 Aug. ... | 12 | Absent ... | Skeleton; no œdema. |
| 148 | Lutchmee ... ... | $\frac{3}{4}$ | $1\frac{1}{4}$ | $1\frac{1}{2}$ | $\frac{3}{4}$ | 3 Sept. ... | 14 | Do. ... | Skeleton; œdema of feet. |
| 149 | Kally ... ... | $\frac{5}{8}$ | $1\frac{1}{8}$ | $1\frac{1}{8}$ | $\frac{7}{8}$ | 21 Sept. 1877. | 10 | Present ... | Skeleton; little œdema of feet. |
| 150 | Lutchmee ... ... | $\frac{5}{8}$ | $1\frac{1}{4}$ | $1\frac{3}{8}$ | $\frac{5}{8}$ | 4 Oct. 1877. | 11 | Absent ... | Skeleton; no œdema. |
| 151 | Ghoolam Dustaghir... | $1\frac{3}{8}$ | $2\frac{3}{4}$ | $2\frac{3}{4}$ | $1\frac{1}{2}$ | 16 Mar. 1877. | 4 | Present ... | Emaciated; œdema of feet. |
| 152 | Moodeen ... ... | $2\frac{7}{8}$ | 3 | 3 | $2\frac{7}{8}$ | 17 Mar. 1877. | 8 | Going off ... | Rather muscular, but no fat. |
| 153 | Moorgum ... ... | $1\frac{5}{8}$ | $4\frac{7}{8}$ | $4\frac{7}{8}$ | $2\frac{1}{8}$ | 26 April ... | 4 | Well marked. | Skeleton; no œdema. |
| 154 | Gungadoo ... ... | 3 | $2\frac{3}{4}$ | $2\frac{7}{8}$ | $2\frac{7}{8}$ | 12 May ... | 3 | Present ... | In fair flesh with fat on mesentery; feet œdematous. |
| 155 | Venketachellum ... | $1\frac{1}{2}$ | 3 | 3 | $1\frac{3}{8}$ | 22 May 1877. | 2 | Going off ... | Emaciated; no œdema. |
| 156 | Chellan ... ... | $3\frac{1}{4}$ | $2\frac{3}{8}$ | $2\frac{3}{8}$ | $1\frac{3}{8}$ | 12 July ... | 5 | Present ... | Skeleton; no œdema. |
| 157 | Kallapah ... ... | $5\frac{7}{8}$ | $3\frac{7}{8}$ | $4\frac{1}{4}$ | $2\frac{1}{8}$ | 25 Aug. ... | 6 | Do. ... | Skeleton; œdema of feet. |
| 158 | Moonean ... ... | $7\frac{1}{4}$ | $3\frac{1}{8}$ | $3\frac{3}{8}$ | $1\frac{7}{8}$ | 31 Aug. .. | 12 | Absent ... | Emaciated; no œdema. |
| 159 | Gopal ... ... | $3\frac{1}{4}$ | $3\frac{7}{8}$ | $4\frac{3}{8}$ | $1\frac{5}{8}$ | 21 Jan. 1878. | 6 | Present ... | Emaciated; no œdema. |
| 160 | Syed Cawder ... | $20\frac{5}{8}$ | $3\frac{5}{8}$ | $3\frac{7}{8}$ | 3 | 8 Mar. 1878. | 9 | Well marked. | In fair flesh; no œdema. |
| 161 | Rungee ... ... | $4\frac{1}{4}$ | $3\frac{3}{4}$ | $3\frac{7}{8}$ | 2 | 4 April 1878. | 8 | Present ... | Skeleton; œdema of feet. |
| 162 | Suka Bee ... ... | $\frac{5}{8}$ | $2\frac{1}{2}$ | $2\frac{1}{8}$ | $1\frac{1}{2}$ | 29 April 1877. | 14 | Absent ... | Skeleton; œdema of feet. |
| 163 | Lutchmee ... ... | $4\frac{7}{8}$ | $2\frac{7}{8}$ | $2\frac{7}{8}$ | $2\frac{1}{8}$ | 15 Aug. ... | 7 | Present ... | Thin; œdema of legs. |
| 164 | Velloy ... ... | $\frac{3}{4}$ | ... | ... | $\frac{1}{2}$ | 16 April 1877. | 2 | Do. ... | A mere skeleton. |
| 165 | Chenty ... ... | $\frac{3}{4}$ | $1\frac{1}{8}$ | 1 | $\frac{5}{8}$ | 24 May 1877. | 5 | Do. ... | Skeleton; no œdema. |
| 166 | Chinacolandy ... | $2\frac{1}{4}$ | $1\frac{1}{4}$ | $1\frac{1}{8}$ | $\frac{7}{8}$ | 7 June 1877. | 4 | Do. ... | Skeleton; œdema of feet. |
| 167 | Yellamah ... ... | $\frac{3}{8}$ | $\frac{5}{8}$ | $\frac{5}{8}$ | $\frac{1}{4}$ | 13 Aug. ... | 3 | Do. ... | Skeleton; no œdema. |
| 168 | Ragava ... .. | $\frac{1}{4}$ | $\frac{5}{16}$ | $\frac{5}{16}$ | $\frac{1}{16}$ | 17 Aug. ... | 4 | Absent ... | Quite a skeleton; no œdema. |
| 169 | Lutchmee ... ... | $\frac{1}{2}$ | $\frac{5}{8}$ | $\frac{5}{8}$ | $\frac{1}{2}$ | 15 Oct. ... | 3 | Present ... | Skeleton; œdema of face and of lower extremities. |
| 170 | Kunny ... ... | 2 | $4\frac{3}{8}$ | $5\frac{1}{4}$ | $2\frac{3}{8}$ | 30 July ... | 15 | Do. ... | Low-flesh; œdema of feet. |
| 171 | Saik Emam ... ... | $3\frac{1}{4}$ | $3\frac{1}{4}$ | 3 | $2\frac{1}{2}$ | 25 April 1877. | 6 | Do. ... | Emaciated; some fat; œdema of feet. |
| 172 | Chellan ... ... | 1 | $2\frac{1}{2}$ | $2\frac{3}{4}$ | 1 | 6 June 1877. | 6 | Absent ... | Skeleton; œdema of feet. |
| 173 | Mylapen ... ... | $3\frac{1}{2}$ | $2\frac{5}{8}$ | $2\frac{3}{4}$ | $1\frac{7}{8}$ | 11 July ... | 6 | Present ... | Emaciated; œdema of feet. |
| 174 | Soobee ... ... | 2 | $2\frac{5}{8}$ | $2\frac{5}{8}$ | $1\frac{3}{8}$ | 15 Dec. ... | 3 | Going off ... | Skeleton; no œdema. |
| 175 | Lutchmee ... ... | $\frac{3}{4}$ | 2 | 2 | $1\frac{5}{8}$ | 23 Dec. 1877. | 10 | Present ... | Skeleton; œdema of feet. |
| 176 | Mungay ... ... | $2\frac{1}{4}$ | $2\frac{3}{8}$ | 3 | $2\frac{1}{8}$ | 5 Feb. 1878. | 8 | Do. ... | Emaciated; œdema of feet. |
| 177 | Venkatasen ... ... | $4\frac{3}{8}$ | $3\frac{1}{2}$ | $8\frac{3}{4}$ | $1\frac{1}{8}$ | 30 May 1877. | 16 | Absent ... | Skeleton; no œdema. |
| 178 | Poneah ... ... | $2\frac{1}{4}$ | 3 | 3 | 2 | 4 June 1877. | 6 | Present ... | Do. do. |

## APPENDIX D—*continued.*

### ALVINE FLUX WITH INTESTINAL ULCERATION WITHOUT DIPHTHERITIC EFFUSION—*continued.*

*List of Cases giving Weight of Body and of its Organs, &c.*—continued.

| No. | Name. | Weight in ounces of—*cont.* | | | | Date of autopsy. | Hours after death autopsy made. | Rigor mortis. | Bodily state. |
|---|---|---|---|---|---|---|---|---|---|
| | | Spleen. | Right Kidney. | Left Kidney. | Pancreas. | | | | |
| 179 | Moonean .. ... | 2⅛ | 2¾ | 2¾ | 2⅜ | 15 June ... | 8 | Absent ... | Skeleton; no œdema. |
| 180 | Venketswamy ... | 3¼ | 3⅛ | 3⅝ | 2⅜ | 6 July ... | 9 | Do. ... | Do. do. |
| 181 | Ramalayan ... ... | 3⅝ | 2⅞ | 3¼ | 2 | 9 Aug. ... | 6 | Present ... | Emaciated; œdema of feet and hands. |
| 182 | Golanda ... ... | 2¾ | 2⅛ | 2¼ | 2¼ | 28 Sept. 1877. | 4 | Do. ... | Skeleton; no œdema. |
| 183 | Ragava ... ... | ½ | 1⅜ | 1⅜ | 1¼ | 12 June ... | 8 | Do. ... | Skeleton; œdema of feet. |
| 184 | Cunniamah ... ... | 4⅞ | 3⅞ | 4⅝ | 1¾ | 2 July ... | 1 | Well marked. | Do. do. |
| 185 | Ponee ... ... | 1½ | 2¼ | 2⅜ | 1⅞ | 27 Aug. ... | 16 | Absent ... | Much emaciated; no œdema. |
| 186 | Ungoor ... ... | 2¼ | 2⅛ | 1¾ | 1⅜ | 7 Oct. 1877. | 3 | Present ... | Skeleton; œdema of feet. |
| 187 | Allamalloo ... ... | 4⅝ | 3⅜ | 3 | 1⅜ | 6 Dec. ... | 4 | Do. ... | Anasarcous; some fat. |
| 188 | Kamachee ... ... | 2 | 2⅜ | 2¼ | 1½ | 18 Feb. 1878. | 2 | Do. ... | Emaciated; œdema of lower extremities. |
| 189 | Rungen ... ... | ⅞ | 2 | ... | 1⅜ | 22 April 1877. | 6 | Do. ... | Anasarcous; bed-sores over sacrum. |
| 190 | Soobroyen ... ... | 4 | 3¼ | 3¼ | 2¼ | 15 Oct. ... | 16 | Do. ... | Dropsical. |
| 191 | Ootakota ... ... | 2 | 2¼ | 1¾ | 1⅜ | 23 Aug. ... | 6 | Absent ... | Anasarcous; some fat. |
| 192 | Ammanee ... ... | 1¾ | 2⅞ | 3 | 2 | 3 Oct. ... | 13 | Present ... | Considerable general anasarca. |
| 193 | Rajoo ... ... | 3¾ | 3¼ | 2¾ | 1½ | 21 Jan. 1878. | 6 | Do. ... | General anasarca. |
| 194 | Kaucotchee ... | 2⅜ | 2⅞ | 3⅛ | 1⅜ | 25 Jan. 1878. | 11 | Absent ... | Considerable general anasarca. |
| 195 | Moothen ... ... | ⅞ | 1⅜ | 1⅝ | ⅞ | 2 Nov. 1877. | 12 | Present ... | Anasarcous. |
| 196 | Mootiathee ... ... | 1 | ⅞ | 1 | ½ | 13 Sept. 1877. | 6 | Do. ... | General anasarca. |

# APPENDIX E.

## Alvine Flux with Diphtheritic Effusion.

*List of Cases giving Weight of Body and of its Organs, &c.*

| No. | Name. | Caste. | Occupation. | Age. | Sex. | Height. | | Weight. | Weight in ounces of | | | | |
|---|---|---|---|---|---|---|---|---|---|---|---|---|---|
| | | | | | | Feet. | Inches. | | Brain. | Right Lung. | Left Lung. | Heart. | Liver. |
| | | | | YEARS. | | | | LBS. | | | | | |
| 197 | Suliman Khan ... | Mahomedan... | Sepoy ... | 60 | Male ... | 5 | 5 | 70 | 41¾ | 9⅞ | 9 | 8⅛ | 38 |
| 198 | Yagambaram ... | Moodelliar ... | Carpenter... | 26 | Do. ... | 5 | 2 | 68 | 40½ | 7⅙ | 7⅞ | 4⅜ | 29 |
| 199 | Nagacowary ... | Shepherd ... | Shepherd... | 60 | Do. ... | 5 | 4½ | 73 | 39 | 9¼ | 5¼ | 6¾ | 22¼ |
| 200 | Shaikmoodeen ... | Mahomedan... | Coolie ... | 37 | Do. ... | 5 | 5 | 83 | 46¼ | 7½ | 6½ | 4⅞ | 24½ |
| 201 | Valarian ... ... | Pariah ... | Do. ... | 55 | Do. ... | 5 | 3 | 79 | 41¼ | 9¼ | 7¼ | 7⅞ | 41½ |
| 202 | Yettian ... ... | Pully ... | Do. ... | 40 | Do. ... | 5 | 9 | 97 | 44½ | 8 | 7¾ | 8 | 58½ |
| 203 | Permaul ... .. | Washerman... | Washerman | 42 | Do. ... | 5 | 3¾ | 67 | 41¾ | 10 | 8¾ | 5¾ | 37¼ |
| 204 | Savathy ... ... | Reddy ... | Coolie ... | 55 | Do. .. | 5 | 6 | 88 | 32 | 9⅛ | 11 | 7¼ | 35 |
| 205 | Mauray ... ... | Pariah ... | Do. ... | 40 | Do. ... | 5 | 2 | 66 | 41 | 8 | 7 | 4¾ | 32½ |
| 206 | Chenga ... .. | Do. ... | Do. ... | 60 | Do. ... | 5 | 3 | 70 | 40½ | 7⅝ | 6⅝ | 7¼ | 26 |
| 207 | Irchan ... ... | Do. ... | Do. ... | 50 | Do. ... | 5 | 6 | 71 | 40 | 12¼ | 9⅝ | 7 | 35 |
| 208 | Moonean ... ... | Do. ... | Do. ... | 40 | Do. ... | 5 | 2 | 70 | 43 | 9 | 8 | 5⅜ | 32⅞ |
| 209 | Sutharo ... ... | Do. ... | Do. ... | 30 | Do. ... | 5 | 2 | 88 | 35⅝ | 7⅝ | 7⅜ | 7⅛ | 46¾ |
| 210 | Karean ... ... | Do. ... | Do. ... | 38 | Do. ... | 5 | 8½ | 96 | 47¾ | 9⅝ | 7½ | 6⅛ | 34½ |
| 211 | Ramaswamy ... | Shepherd ... | Shepherd... | 35 | Do. ... | 5 | 2½ | 84 | 48 | 10 | 8½ | 6¼ | 38 |
| 212 | Basaven ... ... | Cavaray ... | Coolie ... | 36 | Do. ... | 5 | 5½ | 69 | 42¼ | 7¾ | 7⅜ | 6 | 30 |
| 213 | Moothun ... ... | Pully ... ... | Do. ... | 23 | Do. ... | 4 | 11 | 60 | 41½ | 6 | 5 | 5⅜ | 37⅝ |
| 214 | Rungadoo ... ... | Opera ... | Do. ... | 32 | Do. ... | 5 | ... | 86 | 42¾ | 7⅜ | 5 | 6 | 36½ |
| 215 | Thoolkana ... | Pariah ... | Do. ... | 60 | Do. ... | 5 | 6 | 76 | 39½ | 7⅞ | 7 | 5½ | 27½ |

## APPENDIX E—*continued.*

### ALVINE FLUX WITH DIPHTHERITIC EFFUSION—*continued.*

*List of Cases giving Weight of Body and of its Organs, &c.*—continued.

| No. | Name. | Caste. | Occupation. | Age. | Sex. | Height. | | Weight. | Weight in ounces of | | | | |
|---|---|---|---|---|---|---|---|---|---|---|---|---|---|
| | | | | | | Feet. | Inches. | | Brain | Right Lung. | Left Lung. | Heart. | Liver. |
| | | | | YEARS. | | | | LBS. | | | | | |
| 216 | Permaul ... ... | Pariah ... | Coolie ... | 50 | Male ... | 5 | 6 | 81 | 38 | 8¼ | 8⅜ | 6 | 40 |
| 217 | Thumboorgee ... | Malabar ... | Do. ... | 45 | Do. ... | 5 | 4 | 81 | 37½ | 9⅞ | 9⅞ | 7⅞ | 39 |
| 218 | Yellan ... ... | Pariah ... | Do. ... | 40 | Do. ... | 5 | 6 | 80 | 41⅜ | 11⅛ | 9¼ | 6 | 36⅜ |
| 219 | Mooneyan ... | Moodely ... | Do. ... | 45 | Do. ... | 5 | 2 | 70 | 36¾ | 6 | 5⅛ | 4⅝ | 22⅜ |
| 220 | Anauchan ... | Pariah ... | Do. ... | 35 | Do. ... | 5 | 7½ | 75 | 35 | 7¾ | 7¼ | 4¾ | 22⅞ |
| 221 | Thoolkanah ... | Do. ... | Do. ... | 50 | Do. ... | 5 | 3 | 65 | 45 | 7¾ | 7⅛ | 4⅞ | 22 |
| 222 | Ponen ... ... | Do. ... | Do. ... | 25 | Do. ... | 5 | 3½ | 81 | 36¾ | 9 | 7¾ | 5⅜ | 45 |
| 223 | Murreensab ... | Mahomedan... | ... | 60 | Female... | ... | ... | ... | ... | 10¼ | 9 | 7½ | 24 |
| 224 | Romboy ... ... | Do. ... | Coolie ... | 60 | Do. ... | 4 | 8 | 71 | 33⅜ | 6¼ | 4⅝ | 4⅞ | 24 |
| 225 | Ponee ... ... | Pariah ... | Do. .. | 45 | Do. ... | 4 | 11 | 73 | 33 | 5½ | 5¼ | 6⅛ | 33⅛ |
| 226 | Coopoochee ... | Toty ... | ... | 40 | Do. ... | 5 | 1 | 49 | 36 | 7 | 6¾ | 3⅜ | 21 |
| 227 | Lutchmee ... | Pully ... | Coolie ... | 60 | Do. ... | 5 | 3½ | 57 | 34½ | 6⅝ | 6⅛ | 6½ | 24½ |
| 228 | Mootiamah ... | Pariah ... | Do. ... | 55 | Do. ... | 4 | 10 | 45 | 31½ | 7⅛ | 6⅞ | 4⅜ | 21½ |
| 229 | Koolum Bee ... | Mahomedan... | Mendicant.. | 40 | Do. ... | 4 | 10½ | 70 | 34 | 9⅝ | 8¾ | 6¾ | 30½ |
| 230 | Chelly ... ... | Pariah ... | Coolie ... | 40 | Do. ... | 5 | 1 | 59 | 36¼ | 5⅜ | 4⅞ | 5⅛ | 26⅞ |
| 231 | Mungathoy ... | Pully ... | Do. ... | 50 | Do. ... | 4 | 9½ | 47 | 34½ | 9¾ | 7⅜ | 6¼ | 24½ |
| 232 | Thanacooty ... | Moodeliar ... | Do. ... | 35 | Do. ... | 5 | 3 | 74 | 38¼ | 6⅝ | 6¾ | 4⅝ | 25 |
| 233 | Ponee ... ... | Pariah ... | Do. ... | 40 | Do. ... | 4 | 11 | 47 | 34½ | 8½ | 7 | 5⅛ | 26⅛ |
| 234 | Moongay ... ... | Pully ... | Do. ... | 40 | Do. ... | 4 | 10 | 57 | 39 | 5⅝ | 4 | 4 | 16¾ |

| | | | | | | | | | | | | | | |
|---|---|---|---|---|---|---|---|---|---|---|---|---|---|---|
| 235 | Pongee ... ... | Pariah ... | Do. ... | 25 | Do. ... | 5 | 2 | 72 | 38¼ | 8¼ | 7 | 5⅛ | 42½ |
| 236 | Chelle ... ... | Do. ... | Do. ... | 72 | Do. ... | 4 | 11¾ | 53 | 35¼ | 7¾ | 6 | 5¼ | 23⅜ |
| 237 | Mungama ... | Wuddur ... | Navvy .. | 20 | Do. ... | 4 | 11 | 65 | 27¾ | 6½ | 6 | 4¾ | 30⅛ |
| 238 | Chelly ... ... | Pariah ... | Coolie ... | 50 | Do. ... | 5 | 3 | 61 | 49¼ | 8¾ | 7⅝ | 6¼ | 25¼ |
| 239 | Chinnamah ... | Malabar ... | Peasant ... | 55 | Do. ... | 5 | 5 | 63 | 42 | 7⅜ | 6½ | 5¾ | 29 |
| 240 | Thoyee ... ... | Shepherd ... | Shepherd.... | 30 | Do. ... | 4 | 11 | 74 | 37¼ | 6⅝ | 5½ | 5 | 47⅝ |
| 241 | Ponun ... ... | Pariah ... | Coolie ... | 4 | Male ... | 3 | 2 | 17½ | 38 | 2½ | 1⅝ | 1⅛ | 9 |
| 242 | Moreen ... ... | Vanyan ... | Do. ... | 2 | Do. ... | 2 | 7½ | 14 | 36 | 2⅝ | 2 | 1 | 9⅛ |
| 243 | Thoyee ... ... | Pully ... | Do. ... | 1 | Female... | 2 | 4 | 8 | 24⅛ | 1¼ | 1⅛ | ¾ | 4⅜ |
| 244 | Moorooven ... | Do. ... | Do. ... | 5 | Male ... | 3 | ... | 15 | 35 | 1⅞ | 1⅝ | 1⅜ | 11⅜ |
| 245 | Ramakesh ... | Pariah ... | Do. ... | 2 | Female ... | 2 | 4 | 13 | 27½ | 1½ | 1⅛ | ¾ | 5⅞ |
| 246 | Irchun ... ... | Do. ... | Do. ... | 6 | Male ... | 3 | 8½ | 30 | 42½ | 4¼ | 3½ | 2½ | 16 |
| 247 | Casism Saib ... | Mahomedan... | Do. ... | 3 | Do. ... | 2 | 5 | 17 | 34¼ | 1⅛ | 1⅜ | 1⅛ | 9⅜ |
| 248 | Kunan ... ... | Pariah ... | Do. ... | 5 | Do. ... | 3 | 1½ | 21 | 43½ | 3⅛ | 2⅝ | 1¾ | 13¾ |
| 249 | Veeraswamy ... | Opera ... | Do. ... | 5 | Do. ... | 3 | 9 | 25 | 30¼ | 2¾ | 2¼ | 2 | 10¾ |
| 250 | Veeraswamy ... | Pully ... | Farmer ... | 60 | Do. ... | 5 | 2½ | 56 | 34⅞ | 6⅜ | 9⅜ | 5 | 25 |
| 251 | Basavadoo ... | Shepherd ... | ... | 35 | Do. ... | 5 | 6 | 77 | 44¼ | 10 | 7 | 6¼ | 42½ |
| 252 | Shondroyen ... | Pariah ... | Coolie ... | 50 | Do. ... | 5 | 1 | 67 | 40 | 20¾ | 12¼ | 8¼ | 33¼ |
| 253 | Vurdapah ... | Yanaudy ... | Weaver ... | 50 | Do. ... | 5 | 3 | 72 | 38⅝ | 27½ | 16 | 6 | 36⅞ |
| 254 | Moonean ... ... | Pariah ... | Coolie ... | 50 | Do. ... | 5 | 6½ | 89 | 49 | 19¾ | 32¼ | 7½ | 40¼ |
| 255 | Narayen ... ... | Pully ... | Do. ... | 32 | Do. ... | 5 | 6 | 61 | 40¾ | 13⅛ | 9¾ | 5 | 30 |
| 256 | Soobroyen ... | Do. ... | Do. ... | 45 | Do. ... | 5 | 5 | 76 | 45¼ | 11½ | 14½ | 6¾ | 35 |
| 257 | Abdool Rhymon ... | Mahomedan... | Do. ... | 24 | Do. ... | 5 | 5½ | 64 | 44 | 10½ | 7¾ | 4¼ | 40⅝ |
| 258 | Arnachellum ... | Pully ... | Do. ... | 50 | Do. ... | 5 | 6½ | 75 | 36½ | 16⅜ | 27½ | 7⅛ | 33¼ |
| 259 | Ramadoo ... ... | Cavaray .. | Do. ... | 40 | Do. ... | 5 | 7 | 70 | 12⅞ | 23⅞ | 5 | 5 | 42½ |
| 260 | Govindardozen ... | Do. ... | Bhang Seller. | 65 | Do. ... | 5 | 8½ | 83 | 39½ | 37¼ | 15 | 7¾ | 34½ |
| 261 | Atchammah ... | Gentoo ... | ... | 60 | Female. | ... | ... | ... | 41 | 15½ | 16 | 8 | 31 |
| 262 | Moonay ... ... | Pariah ... | Beggar ... | 60 | Do. ... | 5 | 3 | 66 | 38 | 24 | 20¾ | 5 | 34 |
| 263 | Lutchmee ... | Vanyan ... | ... | 25 | Do. ... | 5 | 2 | 67 | 37 | 18 | 17 | 5 | 37½ |
| 264 | Chelly ... ... | Pariah ... | Coolie ... | 35 | Do. ... | 5 | 1½ | 72 | 42⅜ | 15⅛ | 10⅜ | 5¾ | 28⅞ |
| 265 | Lutchmana ... | Moothai ... | Do. ... | 4 | Do. ... | 2 | 8 | 17 | 36½ | 2¾ | 2¼ | 1⅛ | 8¼ |
| 266 | Chelly ... ... | Pully ... | Do. ... | 5 | Do. ... | 3 | 4 | 23 | 32 | 4½ | 3¼ | 1⅜ | 13¼ |
| 267 | Gooroovy ... ... | Pariah ... | Do. ... | 6 | Do. ... | 3 | 4 | 22 | 38⅞ | 3½ | 3 | 1⅜ | 13 |
| 268 | Chelly ... ... | Do. ... | Do. ... | 9 | Do. ... | 3 | 8 | 38 | 50¾ | 8 | 6 | 3 | 14½ |
| 269 | Moorgun ... ... | Do. ... | Do. ... | 5 | Male ... | 2 | 10 | 20 | 41 | 3⅛ | 2⅞ | 1½ | 8 |

## APPENDIX E—*continued.*

### Alvine Flux with Diphtheritic Effusion—*continued.*

*List of Cases giving Weight of Body and of its Organs, &c.*—continued.

| No. | Name. | Caste. | Occupation. | Age. | Sex. | Height. | | Weight. | Weight in ounces of | | | | |
|---|---|---|---|---|---|---|---|---|---|---|---|---|---|
| | | | | | | Feet. | Inches. | | Brain. | Right Lung. | Left Lung. | Heart. | Liver. |
| | | | | YEARS. | | | | LBS. | | | | | |
| 270 | Mooroogan ... | Pariah ... | Coolie ... | 4 | Male ... | 2 | 10 | 19 | 35¾ | 3½ | 3¼ | 1⅜ | 11¼ |
| 271 | Venkutee ... | Do. ... | Do. ... | 10 | Female... | 4 | 4½ | 37 | 35¾ | 4⅞ | 3⅜ | 2⅝ | 20⅝ |
| 272 | Kunny ... ... | Pully ... | Do. ... | 2 | Male ... | 2 | 7½ | 13 | 28½ | 3⅜ | 3½ | ⅞ | 7⅜ |
| 273 | Naraien ... ... | Do. ... | Do. ... | 5 | Do. ... | 3 | 2 | 21½ | 37⅝ | 4⅜ | 3⅞ | 1⅝ | 13¼ |
| 274 | Mooroonen ... | Washerman... | Washerman | 2½ | Do. ... | 2 | 8 | 16 | 37½ | 4 | 4 | 1¼ | 8⅜ |
| 275 | Thoolkhana ... | Pariah ... | Gardener ... | 55 | Do. ... | 5 | 5 | 83 | 37½ | 16⅛ | 20⅝ | 4⅝ | 22¼ |
| 276 | Koomarapan ... | Pully ... | Coolie ... | 50 | Do. ... | 5 | 3 | 89 | 39¾ | 13½ | 18⅜ | 5⅛ | 17¼ |
| 277 | Paupiah ... ... | Weaver ... | Weaver ... | 40 | Do. ... | 5 | 8 | 74 | 44¾ | 15¾ | 13¾ | 5⅝ | 37½ |
| 278 | Maree ... ... | Pariah ... | Labourer ... | 55 | Do. ... | 5 | 8 | 85 | 40 | 19 | 16½ | 8 | 28 |
| 279 | Candan ... ... | Naickun ... | Coolie ... | 35 | Do. ... | 5 | 1 | 61 | 39 | 15½ | 8⅞ | 4⅝ | 27⅛ |
| 280 | Moothun ... ... | Pariah ... | Do. ... | 50 | Do. ... | 5 | 3¾ | 76 | 40¼ | 29½ | 8½ | 6¾ | 29¾ |
| 281 | Kullan ... ... | Pully ... | Do. ... | 60 | Do. ... | 5 | 5 | 73 | 37 | 11⅜ | 11⅝ | 6⅞ | 24⅛ |
| 282 | Gooria ... ... | Opera ... | Do. ... | 20 | Do. ... | 5 | 9 | 93 | 46 | 17¼ | 18⅝ | 7⅝ | 43½ |
| 283 | Narainen ... ... | Pully ... | Do. ... | 25 | Do. ... | 5 | 1¾ | 61 | 38¾ | 15¼ | 16¼ | 5⅛ | 36¼ |
| 284 | Moorooven ... | Do. ... | Do. ... | 22 | Do. ... | 5 | 6 | 82 | 43¼ | 18⅛ | 10¾ | 4⅞ | 31⅞ |
| 285 | Padavalum ... | Pariah ... | Do. ... | 50 | Do. ... | 5 | 4 | 81 | 42¼ | 13 | 13¾ | 7⅛ | 29½ |
| 286 | Pariathumby ... | Pully ... | Do. ... | 30 | Do. ... | 5 | 4½ | 80 | 42 | 12⅝ | 10 | 6⅜ | 47 |

| | | | | | | | | | | | | | |
|---|---|---|---|---|---|---|---|---|---|---|---|---|---|
| 287 | Moothen ... ... | Pariah ... | Do. ... | 30 | Do. ... | 5 | 2 | 56 | 38½ | 8 | 6½ | 4¼ | 24¼ |
| 288 | Sabapathy ... | Water-carrier. | Water-carrier | 40 | Do. ... | 5 | 3½ | 62 | 39¾ | 10⅝ | 8¾ | 4¾ | 37½ |
| 289 | Adam Sheriff ... | Mahomedan. | Sepoy ... | 55 | Do. ... | 5 | 6½ | 70 | 40½ | 15⅞ | 12¾ | 5⅜ | 26¼ |
| 290 | Paynee ... ... | Pariah ... | Labourer ... | 30 | Do. ... | 5 | 7 | 68 | 44½ | 15 | 12 | 5¼ | 26¾ |
| 291 | Appavoo ... ... | Moodaliar ... | Coolie ... | 35 | Do. ... | 5 | 5 | 86 | 46 | 10 | 7⅝ | 6 | 28½ |
| 292 | Runganadoo ... | Yanathy ... | Agriculturist. | 18 | Do. ... | 5 | 3½ | 54 | 40 | 11⅝ | 14⅞ | 3 | 27 |
| 293 | Poonen ... ... | Pariah ... | Coolie ... | 50 | Do. ... | 5 | 6 | 71 | 43½ | 12½ | 14⅜ | 5½ | 27 |
| 294 | Paradoo ... ... | Toty ... | Sweeper ... | 50 | Do. ... | 5 | 9 | 105 | 41½ | 19¾ | 15⅞ | 6½ | 38¼ |
| 295 | Mauree ... ... | Pully ... | Coolie ... | 55 | Do. ... | 5 | 4½ | 83 | 42½ | 16 | 17⅝ | 5⅜ | 28 |
| 296 | Oonamally ... | Pariah ... | Do. ... | 40 | Do. ... | 5 | 7½ | 83 | 44½ | 11⅞ | 14¼ | 5¼ | 36¾ |
| 297 | Moonean ... ... | Do. ... | Do. ... | 32 | Do. ... | 5 | 8 | 90 | 43¼ | 18⅞ | 11½ | 6¼ | 41¾ |
| 298 | Periathamby ... | Do. ... | Do. ... | 60 | Do. ... | 5 | 5 | 78 | 38 | 9⅛ | 7¼ | 6 | 26½ |
| 299 | Moorooven ... | Moodaly ... | Do. ... | 35 | Do. ... | 5 | 7 | 71 | 39½ | 22¼ | 19¼ | 7⅞ | 31¼ |
| 300 | Thoolkana ... | Pully ... | Do. ... | 45 | Do. ... | 5 | 5½ | 77 | 43⅝ | 17¼ | 18 | 8¼ | 35⅞ |
| 301 | Moothen ... ... | Do. ... | Do. ... | 55 | Do. ... | 5 | 3 | 81 | 37½ | 13¼ | 9¾ | 5⅜ | 29½ |
| 302 | Moonoosawmy ... | Do. ... | Do. ... | 50 | Do. ... | 5 | 6½ | 73 | 44⅝ | 10⅛ | 9⅛ | 6⅜ | 33⅛ |
| 303 | Ponapen ... ... | Do. ... | Do. ... | 40 | Do. ... | 5 | 5 | 86 | 40½ | 16¼ | 18¼ | 6¾ | 25½ |
| 304 | Vengan ... ... | Pariah ... | Do. ... | 60 | Do. ... | 5 | 6 | 65 | 40¼ | 11¼ | 18¾ | 4¾ | 31¼ |
| 305 | Ahmeda Bee ... | Mahomedan... | Beggar ... | 45 | Female... | 4 | 7 | 45 | 38¾ | 12⅛ | 7⅞ | 4½ | 17⅝ |
| 306 | Ameer Bee ... | Do. | ..... | 40 | Do. ... | 5 | 3 | 75 | 39¼ | 12½ | 14 | 7⅝ | 30 |
| 307 | Ayee ... ... ... | Pariah ... | Coolie ... | 45 | Do. ... | 5 | ... | 52 | 35¼ | 14¾ | 8⅜ | 4⅝ | 22½ |
| 308 | Venkatamah ... | Cavaray ... | Do. ... | 45 | Do. ... | 5 | 1 | 83 | 44 | 12 | 10¾ | 7⅛ | 33⅝ |
| 309 | Moothee ... ... | Pariah ... | Do. ... | 26 | Do. ... | 5 | 1½ | 46 | 45 | 9⅛ | 6⅛ | 3⅜ | 29½ |
| 310 | Lutchmee ... ... | Pully ... | Do. ... | 60 | Do. ... | 5 | 4 | 69 | 35½ | 14⅜ | 16⅝ | 6¼ | 24 |
| 311 | Allamaloo ... ... | Weaver ... | ..... | 50 | Do. ... | 4 | 7 | 40 | 37¼ | 4¾ | 7¼ | 4⅛ | 20¼ |
| 312 | Allamaloo ... ... | Pariah ... | Coolie ... | 55 | Do. ... | 4 | 8 | 50 | 33¾ | 17¼ | 8½ | 5¼ | 18 |
| 313 | Ayee ... ... ... | Do. ... | Do. ... | 30 | Do. ... | 4 | 10½ | 70 | 37½ | 12½ | 11 | 6¾ | 41 |
| 314 | Ankama ... ... | Weaver ... | ..... | 60 | Do. ... | 4 | 10½ | 70 | 37 | 16¼ | 14½ | 7⅛ | 19½ |
| 315 | Cunnamah ... ... | Reddy ... | Coolie ... | 55 | Do. ... | 5 | 2½ | 84 | 40½ | 13 | 8⅜ | 8¾ | 25⅛ |
| 316 | Ammanee ... ... | Palikar ... | Ryot's wife. | 60 | Do. ... | 5 | 5 | 70 | 33½ | 12½ | 12 | 6½ | 31 |
| 317 | Gungee ... ... | Pariah ... | Coolie ... | 60 | Do. ... | 5 | 2 | 62 | 34½ | 11 | 12⅛ | 5⅝ | 33½ |
| 318 | Mooneamah ... | Pully ... | Do. ... | 45 | Do. ... | 5 | ... | 55 | 33⅛ | 14 | 9¾ | 4½ | 18½ |
| 319 | Vellamah ... ... | Do. ... | Do. ... | 30 | Do. ... | 5 | 3½ | 47 | 40¼ | 8⅛ | 10 | 3⅜ | 20⅞ |
| 320 | Ponee ... ... | Pariah ... | Do. ... | 45 | Do. ... | 4 | 8½ | 46 | 36 | 11¼ | 8¾ | 4¼ | 25 |
| 321 | Lutchmee ... ... | Do. ... | Do. ... | 50 | Do. ... | 5 | 2 | 62 | 36¼ | 11 | 11⅝ | 4¼ | 19 |

## APPENDIX E—*continued.*

### ALVINE FLUX WITH DIPHTHERITIC EFFUSION—*continued.*

*List of Cases giving Weight of Body and of its Organs, &c.*—continued.

| No. | Name. | Caste. | Occupation. | Age. | Sex. | Height. | | Weight. | Weight in ounces of | | | | |
|---|---|---|---|---|---|---|---|---|---|---|---|---|---|
| | | | | | | Feet. | Inches. | | Brain. | Right Lung. | Left Lung. | Heart. | Liver. |
| | | | | YEARS. | | | | LBS. | | | | | |
| 322 | Venkatamah ... | Cavaray ... | Coolie ... | 70 | Female... | 5 | ¾ | 68 | 31½ | 8 | 5½ | 6 | 16⅝ |
| 323 | Minchee ... ... | Pariah ... | Do. ... | 22 | Do. ... | 5 | 1 | 81 | 37¾ | 13 | 7⅛ | 6¾ | 30½ |
| 324 | Poonee ... ... | Do. ... | Do. ... | 1 | Male ... | 2 | 6 | 10¾ | 27¾ | 2⅜ | 2⅜ | 1 | 6¼ |
| 325 | Puckerdeen ... ... | Mahomedan. | Do. ... | 8 | Do. ... | 3 | 9½ | 26 | 44 | 4¾ | 3⅞ | 2 | 12¼ |
| 326 | Veeraswamy ... | Pully ... | Gardener ... | 50 | Do. ... | 5 | 3 | 58 | 40⅛ | 8½ | 9½ | 3¾ | 25 |
| 327 | Chengun ... ... | Reddy ... | Coolie ... | 55 | Do. ... | 5 | ... | 74 | 41 | 9⅛ | 7¼ | 6⅞ | 36 |
| 328 | Chengelroyan ... | Vanyan ... | Do. ... | 55 | Do. ... | 5 | 7 | 88 | 40¾ | 22¾ | 11½ | 7¼ | 28¼ |
| 329 | Narainswamy ... | Pariah ... | Do. ... | 50 | Do. ... | 5 | 4½ | 81 | 40¾ | 28½ | 15¼ | 5¼ | 26¾ |
| 330 | Ponapen ... ... | Pully ... | Do. ... | 50 | Do. ... | 5 | 7 | 79 | 45 | 11¼ | 10¼ | 5⅜ | 36½ |
| 331 | Allamaloo ... | Do. ... | Do. ... | 50 | Female... | 5 | 3 | 61 | 40 | 17¾ | 14½ | 5¾ | 30¾ |
| 332 | Moothen ... ... | Pariah ... | Do. ... | 10 | Male ... | 4 | 2¾ | 30 | 33½ | 5¾ | 4¾ | 2⅛ | 14½ |
| 333 | Sheik Daud ... | Mahomedan. | Do. ... | 50 | Do. ... | 5 | 9 | 89 | 39 | 10¼ | 7¼ | 9¼ | 31 |
| 334 | Nallan ... ... | Pully ... | Do. ... | 60 | Do. ... | 5 | 6 | 77 | 39 | 9¼ | 8⅜ | 7⅜ | 34 |
| 335 | Maike Moodelly ... | Moodelly ... | Do. ... | 45 | Do. ... | 5 | 3 | 74 | 44½ | 14 | 16½ | 6¾ | 34¼ |
| 336 | Shaik Booden ... | Mahomedan. | Do. ... | 45 | Do. ... | 5 | 4 | 56 | 45 | 19 | 16⅛ | 5 | 28 |
| 337 | Permaul ... ... | Pariah ... | Do. ... | 50 | Do. ... | 5 | 3½ | 65 | 38½ | 18 | 15¾ | 5⅝ | 28 |
| 338 | Paupee ... ... | Do. ... | Do. ... | 38 | Female... | 5 | 5 | 59 | 36½ | 14⅝ | 6¾ | 4⅝ | 24 |
| 339 | Minchee ... ... | Pully ... | Do. ... | 26 | Do. ... | 4 | 11½ | 49 | 36¼ | 12¼ | 6⅝ | 3½ | 20½ |

| | | | | | | | | | | | | | |
|---|---|---|---|---|---|---|---|---|---|---|---|---|---|
| 340 | Moothee ... ... | Pariah ... | Do. ... | 50 | Do. ... | 5 | ... | 50 | 34¾ | 8¼ | 5⅜ | 5½ | 21½ |
| 341 | Ameerghat ... | Mahomedan. | Do. ... | 50 | Do. ... | 5 | 4 | 93 | 39¼ | 16⅝ | 13⅛ | 6⅞ | 35 |
| 342 | Venkadoo... ... | Washerman... | Washerman | 45 | Male ... | 5 | 7½ | 113 | 38 | 42¾ | 12⅝ | 8⅞ | 56 |
| 343 | Veeraswamy ... | Shepherd ... | Shepherd ... | 60 | Do. ... | 5 | 6 | 111 | 53 | 7¾ | 6⅜ | 5¾ | 22⅝ |
| 344 | Veerabudrum ... | Pully ... | Coolie ... | 48 | Do. ... | 5 | 8 | 107 | 37½ | 9¼ | 9 | 5¾ | 20 |
| 345 | Mungaldoss .. | Rajpoot ... | Fakheer ... | 50 | Do. ... | 5 | 7 | 102 | 39 | 17½ | 14¼ | 7⅞ | 33½ |
| 346 | Hossein Bee ... | Mahomedan. | Coolie ... | 50 | Female... | 5 | 4¼ | 88 | 36½ | 13⅜ | 7 | 5¾ | 39¾ |
| 347 | Mungathoyen ... | Cavaray ... | Do. ... | 40 | Do. ... | 5 | 7 | 102 | 32⅝ | 9½ | 7½ | 5 | 26 |

## APPENDIX E—*continued.*

### ALVINE FLUX WITH DIPHTHERITIC EFFUSION—*continued.*

*List of Cases giving Weight of Body and of its Organs, &c.*—continued.

| No. | Name. | Weight in ounces of | | | | Date of autopsy. | Hours after death autopsy made. | Rigor mortis. | Bodily state. |
|---|---|---|---|---|---|---|---|---|---|
| | | Spleen. | Right Kidney. | Left Kidney. | Pancreas. | | | | |
| 197 | Suliman Khan ... | 2⅝ | 3¼ | 3⅜ | 2½ | 28 Mar. 1877. | 4 | Present ... | Much emaciated; no œdema. |
| 198 | Yagambaram ... | 2 | 3 | 2⅝ | 1⅜ | 31 Mar. 1877. | 3 | Not well marked. | Skeleton; no œdema. |
| 199 | Nagacowary ... | 1⅝ | 1⅞ | 2⅜ | 1¼ | 10 June ... | 5 | Well marked ... | Emaciated; no œdema. |
| 200 | Shaikmoodeen ... | 5⅛ | 3⅜ | 3⅛ | 2⅛ | 3 Aug. ... | 8 | Absent ... | Thin; œdema of left foot. |
| 201 | Valarian ... ... | 3¾ | 3⅛ | 3¼ | 2⅞ | 15 Aug. ... | 2 | Present ... | Skeleton; œdema of lower extremities. |
| 202 | Yettian ... ... | 5⅛ | 6⅛ | 6⅛ | 3½ | 18 Aug. ... | 2 | Do. ... | In fair flesh; right leg slightly swollen. |
| 203 | Permaul ... ... | 1½ | 2⅞ | 3¼ | 2⅝ | 21 Aug. ... | 6 | Do. ... | Skeleton; no œdema. |
| 204 | Savathy ... ... | 2 | 3¼ | 3⅜ | 2¼ | 25 Mar. 1877. | 3 | Do. ... | Emaciated; no œdema. |
| 205 | Mauray ... ... | 1⅛ | 2⅝ | 2½ | 1½ | 7 May 1877. | 10 | Do. ... | Emaciated; œdema of ankles. |
| 206 | Chenga ... ... | 1 | 2¼ | 2⅝ | 2½ | 25 May 1877. | 2 | Do. ... | Emaciated; a trace of fat in cellular tissue; no œdema. |
| 207 | Irchan ... ... | 2¼ | 2¼ | 2⅜ | 2 | 11 July 1877. | 10 | Do. ... | Skeleton; no œdema. |
| 208 | Moonean ... ... | 3⅛ | 2⅝ | 2⅞ | 1⅝ | 27 June 1877. | 9 | Do. ... | Do. do. |
| 209 | Sutharo ... ... | 3½ | 2⅞ | 3⅛ | 3 | 3 July ... | 4 | Do. ... | In good flesh. |
| 210 | Karean ... ... | 2¼ | 2¼ | 2⅝ | 2¼ | 31 July ... | 1 | Do. ... | Low flesh; œdema of feet; sloughing of left instep. |
| 211 | Ramaswamy ... | 2¾ | 2⅞ | 3⅛ | 2⅝ | 1 Aug. ... | 10 | Absent ... | Thin; no œdema; no fat. |
| 212 | Basaven ... .. | 4 | 2¾ | 3 | 2¼ | 5 Aug. ... | 3 | Present ... | Skeleton; no œdema. |

| | | | | | | | | | |
|---|---|---|---|---|---|---|---|---|---|
| 213 | Moothun ... ... | 1½ | 2⅛ | 2⅝ | 1½ | 7 Aug. ... | 3 | Do. ... | Do. do. |
| 214 | Rungadoo ... ... | 2½ | 3⅜ | 3 | 2½ | 8 Aug. ... | 2 | Do. .. | In low flesh ; no œdema. |
| 215 | Thoolkana... ... | 1¼ | 1¾ | 1⅞ | 2½ | 10 Aug. ... | 3 | Do. ... | Skeleton ; œdema of feet. |
| 216 | Permaul ... ... | 2⅜ | 2½ | 2½ | 2 | 13 Aug. 1877. | 2 | Do. ... | Emaciated ; no œdema. |
| 217 | Thumboorgee ... | 1⅛ | 2⅜ | 2¾ | 4⅜ | 23 Aug. 1877. | 2 | Do. ... | Emaciated ; œdema of feet. |
| 218 | Yellan ... ... | 4¼ | 2¾ | 2⅜ | 2 | 7 Sept. ... | 2 | Do. ... | Thin ; not quite devoid of fat. |
| 219 | Mooneyan ... | 1 | 2⅝ | 2⅝ | 1⅜ | 7 Sept. ... | 3 | Do. ... | Emaciated ; œdema of lower extremities. |
| 220 | Anauchan .. | 2⅛ | 2⅝ | 2¾ | 2⅜ | 28 Oct. ... | 11 | Do. ... | Skeleton ; œdema of feet. |
| 221 | Thoolkanah ... | 1⅛ | 2¼ | 2 | 1¾ | 30 Oct. 1877. | 1 | Do. ... | Do. no œdema. |
| 222 | Ponen ... ... | 15¼ | 4¼ | 4⅜ | 2¼ | 27 Dec. 1877. | 2 | Do. ... | In good flesh ; some fat ; no œdema. |
| 223 | Murreensab ... | 1 | 2½ | 3 | ... | 18 Feb. 1877. | 13 | Going off ... | Quite a skeleton. [accident. |
| 224 | Romboy ... ... | ⅞ | 2½ | 2⅞ | 1 | 21 April ... | 5 | Not well marked. | Rather obese ; right eye lost by |
| 225 | Ponee ... ... | 1¼ | 1⅝ | 1¾ | 2 | 5 May1877. | 1 | Present ... | Some fat ; œdema of right foot ; contusion of right hip. |
| 226 | Coopoochee ... | ¾ | 2⅛ | 2⅝ | 1⅛ | 31 May 1877. | 8 | Absent ... | Skeleton ; œdema of legs. |
| 227 | Lutchmee ... | 1½ | 2¾ | 2⅜ | 2 | 3 June 1877. | 9 | Well marked ... | Skeleton ; no œdema. |
| 228 | Mootiamah ... | 1⅛ | 3¼ | 3⅜ | 1¼ | 11 July ... | 1 | Present ... | Emaciated ; œdema of feet and right leg. |
| 229 | Koolum Bee ... | 2 | 2¼ | 2⅛ | 2⅜ | 13 Aug. ... | 4 | Do. ... | Looks thin, but some fat over abdomen. |
| 230 | Chelly ... ... | 1⅜ | 1⅝ | 1¾ | 2¾ | 24 Aug. ... | 1 | Do. ... | Skeleton ; no œdema. |
| 231 | Mungathoy ... | 2½ | 2⅜ | 2⅝ | 2¼ | 26 Aug. ... | 6 | Do. ... | Do. do. |
| 232 | Thanacooty ... | 1⅜ | 3 | 3⅛ | 1⅝ | 5 Oct. 1877. | 2 | Do. ... | Emaciated ; œdema of feet. |
| 233 | Ponee ... ... | ¾ | 1⅞ | 1⅜ | 1 | 30 Oct. ... | 8 | Do. ... | Skeleton ; no œdema. |
| 234 | Moongay ... ... | 1¾ | 2 | 1¾ | 1⅛ | 19 Dec. ... | 2 | Do. ... | Do. œdema of extremities and ascites. |
| 235 | Pongee ... ... | 2 | 3¼ | 3½ | 2 | 20 Jan. 1878. | 5 | Do. ... | Thin ; no œdema. |
| 236 | Chelle ... ... | 1⅜ | 2⅛ | 2½ | 1¼ | 20 Feb. 1878. | 4 | Do. ... | Quite a skeleton ; œdema of feet. |
| 237 | Mungama ... | 7⅜ | 2¾ | 2½ | 1⅞ | 23 Feb. ... | 5 | Absent ... | Thin ; some anasarca. |
| 238 | Chelly ... ... | 1⅜ | 1⅝ | 2 | 2⅞ | 12 July. ... | 4 | Present ... | Skeleton ; no œdema. |
| 239 | Chinnamah ... | 1⅛ | 5¼ | | 2⅝ | 13 Aug. ... | 4 | Do. ... | Do. œdema of feet. |
| 240 | Thoyee ... ... | 4½ | 4½ | 4½ | 2¼ | 31 Aug. ... | 8 | Do. ... | Some fat on abdomen. |
| 241 | Ponun ... ... | ⅝ | 1 | 1 | ⅝ | 15 May. ... | 2 | Do. ... | Skeleton ; no œdema. |

## APPENDIX E—*continued.*

### ALVINE FLUX WITH DIPHTHERITIC EFFUSION—*continued.*

*List of Cases giving Weight of Body and of its Organs, &c.*—continued.

| No. | Name. | Weight in ounces of | | | | Date of autopsy. | Hours after death autopsy made. | Rigor mortis. | Bodily state. |
|---|---|---|---|---|---|---|---|---|---|
| | | Spleen. | Right Kidney. | Left Kidney. | Pancreas. | | | | |
| 242 | Moreen* ... ... | ¾ | 1 | 1⅛ | 1½ | 16 May 1877. | 6 | Absent ... | Skeleton; no œdema. |
| 243 | Thoyee ... ... | ⅜ | ⅝ | ½ | ⅜ | 6 Aug. ... | 3 | Present ... | Do. do. |
| 244 | Moorooven ... | ½ | 1⅛ | 1⅛ | ⅝ | 9 Aug. ... | 7 | Do. ... | Do. do. |
| 245 | Ramakesh ... | ½ | ⅝ | ⅝ | ⅜ | 4 Sept. ... | 11 | Absent ... | Do. œdema of feet. |
| 246 | Irchun ... ... | ⅞ | 1⅝ | 1½ | 1¼ | 7 Sept. ... | 5 | Present ... | Do. no œdema. |
| 247 | Cassim Saib ... | ⅞ | 1¼ | 1¼ | ½ | 20 Sept. 1877. | 3 | Not well marked. | Do. œdema of feet. |
| 248 | Kunan ... ... | 1⅛ | 1⅜ | 1½ | ⅜ | 24 Oct. 1877. | 13 | Present ... | Miserably thin; pigeon-breasted; no œdema. |
| 249 | Veeraswamy ... | 1¾ | 1½ | 1½ | ¾ | 25 Oct. 1877. | 14 | Absent ... | Skeleton; œdema of feet; some ascites. |
| 250 | Veeraswamy ... | 2⅛ | 1½ | 1¾ | 1⅞ | 16 April 1877. | 3 | Present ... | Emaciated; no œdema. |
| 251 | Basavadoo ... | 7⅝ | 3 | 3 | 2½ | 31 May 1877. | 9 | Do. ... | Skeleton; no œdema. |
| 252 | Shondroyen ... | 2½ | 2⅝ | 2¾ | 3 | 15 June 1877. | 2 | Do. ... | Do. no œdema. |
| 253 | Vurdapah ... | 1 | 2⅝ | 2⅝ | 2½ | 25 June 1877. | 7 | Do. ... | Do. do. |
| 254 | Moonean ... ... | 3½ | 3½ | 4¾ | 2½ | 27 July 1877. | 9 | Absent ... | Thin; some œdema of feet. |
| 255 | Narayen ... ... | 1⅝ | 2⅛ | 2⅝ | 1⅞ | 13 Aug. ... | 8 | Present ... | Skeleton; œdema of feet. |
| 256 | Soobroyen ... | 3½ | 2½ | 2¾ | 2½ | 25 Aug. ... | 5 | Do. ... | Emaciated; no œdema. |
| 257 | Abdool Rhymon ... | 10⅞ | 3½ | 3⅝ | 1⅝ | 25 Aug. ... | 13 | Do. ... | Skeleton; no œdema. |
| 258 | Arnachellum ... | 3¼ | 3¼ | 3⅛ | 2⅜ | 2 Oct. 1877. | 3 | Do. ... | Do. do. |

| | | | | | | | | | |
|---|---|---|---|---|---|---|---|---|---|
| 259 | Ramadoo ... ... | 10¼ | 3½ | 3¼ | 2⅝ | 11 Feb. 1878. | 4 | Do. ... | Do. do. |
| 260 | Govindardozen ... | 3⅞ | 3⅜ | 4 | 2½ | 17 Mar. 1878. | 4 | Do. ... | Emaciated; elephantiasis of right leg; œdema of feet. |
| 261 | Atchammah ... | 2 | 3¾ | 3¾ | ... | 20 Feb. 1877. | 14 | Going off ... | Much emaciated. |
| 262 | Moonay ... ... | 2 | 3⅜ | 4⅛ | 1½ | 21 April 1877. | 5 | Present ... | Emaciated; œdema of feet. |
| 263 | Lutchmee ... | 1⅛ | 3 | 3½ | 2¼ | 27 July ... | 2 | Do. ... | Skeleton; no œdema. |
| 264 | Chelly ... ... | 1⅜ | 2⅝ | 2⅜ | 1⅝ | 29 Aug. 1877. | 9 | Do. ... | Emaciated; œdema of feet. |
| 265 | Lutchmana ... | ⅝ | 1 | ⅞ | ½ | 31 May 1877. | 3 | Absent ... | Skeleton; no œdema. |
| 266 | Chelly ... ... | ⅞ | 1⅜ | 1¼ | ⅞ | 3 June 1877. | 3 | Present ... | Do. no œdema, except of the face. |
| 267 | Gooroovy ... ... | ⅞ | 1⅛ | 1¼ | ¾ | 8 June ... | 4 | Do. ... | Skeleton; œdema of feet. |
| 268 | Chelly ... ... | 1 | 2 | 1⅝ | ⅞ | 8 June 1877. | 12 | Absent ... | Emaciated; no œdema. |
| 269 | Moorgun ... ... | ½ | 1 | 1 | ⅜ | 8 June 1877. | 9 | Do. ... | Skeleton; no œdema. |
| 270 | Mooroogan ... | 1 | 1½ | 1¾ | ¾ | 15 June ... | 5 | Do. ... | Do. œdema of feet. |
| 271 | Venkutee ... | 7 | 1½ | 1⅞ | 1½ | 20 Aug. 1877. | 9 | Present ... | Do. no œdema. |
| 272 | Kunny ... ... | ⅜ | ⅞ | ¾ | ⅜ | 2 Sept. ... | 10 | Absent ... | Do. œdema of feet. |
| 273 | Naraien ... ... | 1⅛ | 1⅛ | 1⅛ | ½ | 3 Sept. ... | 10 | Do. ... | Miserably thin; pigeon-breasted; œdema of feet. |
| 274 | Mooroonen ... | ¾ | 1¼ | 1¼ | ½ | 25 Sept. 1877. | 11 | Present ... | Quite a skeleton; no œdema. |
| 275 | Thoolkhana ... | ¾ | 2⅞ | 3¼ | 1¼ | 5 March ... | 2 | Do. ... | Thin; elephantiasis of both feet and ankles. |
| 276 | Koomarapan ... | 1¾ | 2⅜ | 2⅛ | 1¾ | 30 March ... | 8 | Do. ... | Emaciated; œdema of face and limbs, and ascites. |
| 277 | Paupiah ... ... | 5⅜ | 3 | 3½ | 2¼ | 31 March 1877 | 12 | Absent ... | Skeleton. |
| 278 | Maree ... ... | 2⅞ | 2⅞ | 3 | 2¾ | 13 April ... | 15 | Do. ... | Much emaciated; no œdema. |
| 279 | Candan ... ... | 1 | 3 | 2⅞ | 1½ | 26 May 1877. | 10 | Present ... | Skeleton; œdema of feet and hands. |
| 280 | Moothun ... ... | 2½ | 2 | 2⅛ | 2⅞ | 3 Aug. ... | 4 | Do. ... | Skeleton; œdema of feet. |
| 281 | Kullan ... ... | 1⅛ | 1¾ | 2 | 1⅞ | 14 Aug. ... | 9 | Do. ... | Emaciated; no œdema. |
| 282 | Gooria ... ... | 17¼ | 4⅝ | 5⅛ | 3⅝ | 25 Aug. ... | 6 | Absent ... | Do. œdema of feet and legs. |
| 383 | Narainen ... ... | 2¾ | 2¾ | 2⅝ | 2¾ | 10 Sept. ... | 12 | Do. ... | Emaciated; no œdema. |
| 284 | Moorooven ... | 5⅛ | 3⅝ | 3¾ | 2¾ | 10 Sept. ... | 10 | Present ... | Thin; œdema of feet and face. |
| 285 | Padavalum ... | 1⅝ | 3 | 3⅜ | 1¾ | 20 Oct. 1877. | 10 | Do. ... | Thin; slight œdema of feet. |
| 286 | Pariathumby ... | 9¾ | 3⅝ | 4⅛ | 2½ | 4 Nov. 1877. | 4 | Do. ... | Thin; no œdema. |

## APPENDIX E—*continued.*

### ALVINE FLUX WITH DIPHTHERITIC EFFUSION—*continued.*

*List of Cases giving Weight of Body and of its Organs, &c.*—continued.

| No. | Name. | Weight in ounces of | | | | Date of autopsy. | Hours after death autopsy made. | Rigor mortis. | Bodily state. |
|---|---|---|---|---|---|---|---|---|---|
| | | Spleen. | Right Kidney. | Left Kidney. | Pancreas. | | | | |
| 287 | Moothen ... .. | 1½ | 1¾ | 1¾ | 2 | 5 Dec. 1877. | 6 | Absent .. | Skeleton; no œdema. |
| 288 | Sabapathy ... | 1¾ | 2½ | 2¼ | 2½ | 9 Dec. ... | 14 | Going off ... | Do. œdema of feet. |
| 289 | Adam Sheriff ... | 1½ | 2¾ | 3 | 1¾ | 7 Jan. 1878. | 1 | Present ... | Do. no œdema. |
| 290 | Paynee ... ... | 2½ | 3¼ | 3¼ | 2⅛ | 13 Jan. 1878. | 12 | Do. ... | Do. do. |
| 291 | Appavoo ... ... | 5 | 3¼ | 2⅞ | 1⅞ | 20 Feb. 1878. | 8 | Absent ... | Do. œdema of hands and feet. |
| 292 | Runganadoo ... | 1 | 2⅛ | 2½ | 1 | 30 April ... | 11 | Do. ... | Do. no œdema. |
| 293 | Poonen ... ... | 1⅜ | 3 | 3 | 2 | 1 Aug. ... | 3 | Present ... | Emaciated; œdema of feet. |
| 294 | Paradoo ... ... | 7¾ | 3⅜ | 4 | 2⅜ | 2 Aug. ... | 5 | Do. ... | Thin; œdema of left foot. |
| 295 | Mauree ... ... | 4½ | 2⅝ | 2½ | 2¼ | 4 Aug. ... | 11 | Going off ... | Emaciated; œdema of hands and feet. |
| 296 | Oonamally ... | 2⅜ | 2⅜ | 2⅞ | 1⅝ | 6 Aug. ... | 9 | Present ... | Emaciated; œdema of feet. |
| 297 | Moonean ... ... | 2½ | 2½ | 3 | 1⅞ | 7 Aug. 1877. | 3 | Do. ... | Do. no œdema. |
| 298 | Periathamby ... | 1⅛ | 3⅛ | 3⅛ | 2¼ | 8 Aug. ... | 2 | Do. ... | Do. œdema of feet. |
| 299 | Moorooven ... | 2⅛ | 3¼ | 3⅛ | 2⅛ | 28 Aug. ... | 14 | Do. ... | Do. no œdema. |
| 300 | Thoolkana... ... | 4¼ | 3 | 3⅛ | 3¼ | 29 Aug. ... | 8 | Do. ... | Do. do. |
| 301 | Moothen ... ... | 2⅜ | 2⅝ | 2⅞ | 2 | 30 Aug. ... | 9 | Absent ... | Emaciated; œdema of feet; some ascites. |
| 302 | Moonoosawmy ... | 1⅛ | 2⅜ | 2⅞ | 2⅜ | 5 Sept. 1877. | 6 | Present ... | Much emaciated; no œdema. |
| 203 | Ponapen ... ... | 2¼ | 2¾ | 2⅝ | 2½ | 28 Sept. 1877. | 1 | Do. ... | Emaciated; œdema of feet. |
| 304 | Vengan ... ... | 2⅜ | 2 | 2⅛ | 2⅜ | 2 Oct. 1877. | 9 | Do. ... | Skeleton; no œdema. |

| | | | | | | | | | |
|---|---|---|---|---|---|---|---|---|---|
| 305 | Ahmeda Bee ... | 1⅞ | 1¾ | 2½ | 1½ | 30 June ... | 6 | Absent ... | Skeleton; œdema of feet. |
| 306 | Ameer Bee ... | 2¼ | 2⅛ | 2⅛ | 2½ | 11 June ... | 7 | Present ... | Not greatly emaciated; no œdema. |
| 307 | Ayee ... ... | 1⅞ | 2¼ | 2½ | 2 | 21 Aug. 1877. | 10 | Going off ... | Skeleton; no œdema. |
| 308 | Venkatamah ... | 6¼ | 3 | 2½ | 2⅞ | 27 Aug. 1877. | 8 | Present ... | Emaciated; œdema of feet and legs; some ascites. |
| 309 | Moothee ... ... | 1½ | 2¼ | 2¼ | 1⅜ | 18 Oct. 1877. | 9 | Do. ... | Skeleton; no œdema. |
| 310 | Lutchmee ... | 1⅜ | 2⅝ | 2⅝ | 2¼ | 11 Dec. ... | 8 | Absent ... | Quite a skeleton; œdema of feet. |
| 311 | Allamaloo ... | ¾ | 1½ | 1 | 1⅛ | 15 Dec. 1877. | 15 | Do. ... | Skeleton; no œdema. |
| 312 | Allamaloo ... | ⅞ | 1⅝ | 1¾ | 1½ | 26 Nov. 1877. | 1 | Not set in ... | Do. œdema of feet. |
| 313 | Ayee ... .. | 5⅞ | 2¾ | 3 | 2⅜ | 25 Jan. 1878. | 15 | Present ... | In low flesh; no œdema. |
| 314 | Ankama ... ... | 1¼ | 3⅜ | 3⅝ | 2 | 20 Feb. 1878. | 2 | Do. ... | Thin; œdema of feet. |
| 315 | Cunnamah ... | 1½ | 1¾ | 1¾ | 1⅝ | 24 Feb. 1878. | 9 | Well marked ... | Do. do. |
| 316 | Ammanee ... | 2½ | 2⅞ | 3½ | 2 | 22 April ... | 3 | Present ... | Skeleton; œdema of feet. |
| 317 | Gungee ... ... | 2 | 2¼ | 2⅞ | 2⅛ | 22 Aug. 1877. | 5 | Do. ... | Do. slight œdema of feet. |
| 318 | Mooneamah ... | 1½ | 2¼ | 2⅜ | 2 | 26 Aug. 1877. | 9 | Do. ... | Do. œdema of feet. |
| 319 | Vellamah ... ... | ⅞ | 2¼ | 2⅛ | 1⅜ | 11 Sept. ... | 9 | Absent ... | Do. do. |
| 320 | Ponee ... ... | 1⅞ | 2⅜ | 2¾ | 1½ | 17 Sept. 1877. | 9 | Present ... | Do. do. |
| 321 | Lutchmee ... ... | ⅜ | 2⅛ | 2⅛ | 1⅝ | 2 Oct. 1877. | 2 | Do. ... | Do. do. |
| 322 | Venkatamah ... | ⅝ | 1¾ | 2 | 1½ | 19 Dec. 1877. | 2 | Do. ... | Emaciated; œdema of feet. |
| 323 | Minchee ... ... | 3¾ | 2 | 2⅛ | 2⅝ | 27 Dec. 1877. | 12 | Do. ... | In good flesh. |
| 324 | Poonee ... ... | ¾ | ⅝ | ⅝ | ½ | 5 Aug. ... | 14 | Absent ... | Quite a skeleton; œdema of feet. |
| 325 | Puckerdeen ... | 4 | 1½ | 1⅝ | ⅞ | 10 Oct. 1877 | 6 | Present ... | Quite a skeleton; no œdema. |
| 326 | Veeraswamy ... | 1¼ | 2¼ | 2 | 1¼ | 7 March 1877 | 3 | Do. ... | Quite a skeleton; no œdema. |
| 327 | Chengun ... .. | 5 | 2¾ | 1½ | 2½ | 20 June ... | 2 | Do. ... | Thin; no œdema. |
| 328 | Chengelroyan ... | 2 | 3½ | 4¼ | 3½ | 5 Sept. ... | 1 | Do. ... | In low flesh; œdema of feet. |
| 329 | Narainswamy ... | 1½ | 2¾ | 3½ | 2⅜ | 6 Oct. 1877. | 2 | Do. ... | Thin; œdema of feet. |
| 330 | Ponapen ... ... | 1½ | 2¾ | 3¼ | 1⅞ | 15 Oct. 1877. | 6 | Do. ... | Do. do. |
| 331 | Allamaloo ... | 1¾ | 2⅜ | 2⅜ | 1⅝ | 13 Oct. 1877. | 2 | Do. .. | Skeleton; œdema of feet. |
| 332 | Moothen... ... | 2¼ | 1⅝ | 1½ | ⅞ | 13 Dec. 1877. | 5 | Absent ... | Skeleton; no œdema. |
| 333 | Sheik Daud ... | 3¼ | 4 | 4½ | 2¾ | 3 June 1877. | 3 | Present ... | Emaciated; œdema of feet. |
| 334 | Nallan ... ... | 1 | 2¼ | 2⅝ | 2⅝ | 20 June ... | 5 | Do. ... | Skeleton; no œdema. |
| 335 | Maike Moodelly ... | 3⅜ | 4 | 3⅝ | 3 | 4 Aug. ... | 9 | Do. ... | Do. do. |

## APPENDIX E—*continued.*

### ALVINE FLUX WITH DIPHTHERITIC EFFUSION—*continued.*

*List of Cases giving Weight of Body and of its Organs, &c.*—continued.

| No. | Name. | Weight in ounces of | | | | Date of autopsy. | Hours after death autopsy made. | Rigor mortis. | Bodily state. |
|---|---|---|---|---|---|---|---|---|---|
| | | Spleen. | Right Kidney. | Left Kidney. | Pancreas. | | | | |
| 336 | Shaik Booden ... | 1½ | 2¼ | 2½ | 2 | 15 Sept. 1877. | 8 | Present ... | Skeleton; on œdema. |
| 337 | Permaul ... ... | 2⅝ | 3⅛ | 3¼ | 1¾ | 2 Nov. 1877. | 10 | Do. ... | Emaciated; no œdema. |
| 338 | Paupee ... ... | 2¼ | 2 | 3 | 2½ | 22 Aug. ... | 3 | Do. ... | Skeleton; œdema of hands and feet. |
| 339 | Minchee ... ... | 3½ | 1⅞ | 2 | 1⅛ | 26 Oct. ... | 2 | Do. ... | Skeleton; œdema of feet. |
| 340 | Moothee ... ... | 1⅝ | 2⅜ | 2½ | 1¼ | 11 Jan. 1878. | 4 | Do. ... | Quite a skeleton; no œdema. |
| 341 | Ameerghat ... | 1¾ | 3½ | 3⅞ | 2⅛ | 30 Jan. 1878. | 10 | Do. ... | In low flesh; œdema of left lower extremity and of right foot and ankle; some ascites. |
| 342 | Venkadoo ... ... | 17⅛ | 3¾ | 4⅜ | 3 | 2 July ... | 1 | Well marked ... | In fair flesh; some general anasarca. |
| 343 | Veeraswamy ... | 2¾ | 3½ | 3½ | 2 | 4 Aug. ... | 1 | Present ... | Anasarcous. |
| 344 | Verabudrum ... | 1½ | 2⅜ | 2½ | 2 | 12 Aug. ... | 9 | Do. ... | Emaciated; considerable ascites; much anasarca of legs and dependant parts. |
| 345 | Mungaldoss ... | 6¼ | 3⅜ | 3⅝ | 3¼ | 20 Jan. 1878. | 1 | Do. ... | In low flesh; œdema of hands and feet. |
| 346 | Hossin Bee ... | 1¾ | 4 | 4⅜ | 2¼ | 17 Aug. ... | 3 | Do. ... | Considerable general anasarca and ascites. |
| 347 | Mungathoyen ... | 2½ | 2¾ | 2⅜ | 2¼ | 28 Jan. 1878. | 1 | Do. ... | Thin, with ascites; œdema of lower extremities. |

# INDEX.

A.