

**A vade-mecum of morbid anatomy, medical and chirurgical; : with pathological observations and symptoms. Illustrated by upwards of two hundred and fifty drawings.**

**Contributors**

Money, William.

**Publication/Creation**

London : Burgess and Hill, Great Windmill Street, Haymarket, 1830.

**Persistent URL**

<https://wellcomecollection.org/works/yhx9np5s>


**License and attribution**

This work has been identified as being free of known restrictions under copyright law, including all related and neighbouring rights and is being made available under the Creative Commons, Public Domain Mark.

You can copy, modify, distribute and perform the work, even for commercial purposes, without asking permission.



Wellcome Collection  
183 Euston Road  
London NW1 2BE UK  
T +44 (0)20 7611 8722  
E [library@wellcomecollection.org](mailto:library@wellcomecollection.org)  
<https://wellcomecollection.org>





EPB Supp/B

60552/B


A. B. Stewart

3  
DR. BILL WHIMSTER  
72 FOYLE ROAD  
BLACKHEATH  
LONDON SE3 7RH  
TEL: 01-858 4684

By Wm Money

£2





A  
VADE-MECUM  
OF  
MORBID ANATOMY.

W. D. GILL

MORRIS A. TOM

MEDICAL AND SURGICAL

PATHOLOGICAL ANATOMY

W. D. GILL

MORRIS A. TOM

THE HISTORY AND PRESENT STATE

OF

THE HISTORY AND PRESENT STATE

OF



A  
VADE-MECUM  
OF  
MORBID ANATOMY,  
MEDICAL AND CHIRURGICAL;  
WITH  
PATHOLOGICAL OBSERVATIONS  
AND  
SYMPTOMS.

ILLUSTRATED BY UPWARDS OF  
TWO HUNDRED AND FIFTY DRAWINGS.

---

LONDON:  
BURGESS AND HILL, GREAT WINDMILL STREET,  
HAYMARKET.

1830.

YADON M. L. L. M.

MORRIS AND TOMMY

MEDICAL AND SURGICAL

The following is a list of the names of the  
persons who have been admitted to the  
profession of medicine in the year 1870.  
The names are arranged in alphabetical order.  
The names of the persons who have been  
admitted to the profession of medicine in  
the year 1870 are as follows:—

---

James Bulcock,  
4, Furnival's Inn Court, Holborn.



## PREFACE.

---

THIS Vade-mecum is neither intended nor calculated to supersede any of the standard works on Morbid Anatomy, by which medical science has been enriched during the last thirty years. To furnish a concise and faithful transcript of the labours of all the eminent morbid anatomical writers, and to illustrate the productions of his more elaborate predecessors, are objects which the Author has most zealously endeavoured to achieve. He has not, however, confined his task merely to the transcribing and illustrating of what others have seen, and of which others have written ; but he has blended in the work some account of what he has himself observed, during many years of close application to this subject. The work contains, Observations on, with Illustrations of, the Changes of Structure found in the Brain, Thoracic, Abdominal, and Pelvic Viscera, and of the Organs of Generation in both sexes. It likewise gives the Pathological Symptoms, by which we judge of disease during



life, and a true Description of the Morbid Changes that are exhibited after death.

The Sketches are made either from diseased parts in the Author's Museum, or from recent dissection; and it is hoped, the arrangement will render the work convenient, both for occasional reference and regular perusal.

It has not been deemed necessary to give Cases, nor to introduce all the strange appearances that are occasionally found after death: the Author has preferred a brief Statement of Symptoms and Morbid Phenomena in Diseases the most likely to fall under the daily notice of the Practitioner, than to any speculative hypothesis, or rare or doubtful subjects.

The Author, although his name is not appended to the work, is however happy in having this favourable opportunity of publicly returning his sincere thanks for the kindness he has received from his numerous medical friends; and he cannot conclude this short Preface without presenting to those who have executed the Sketches, his grateful thanks for the faithfulness and ability with which they are depicted.

*London, 1830.*






Fig. 1.

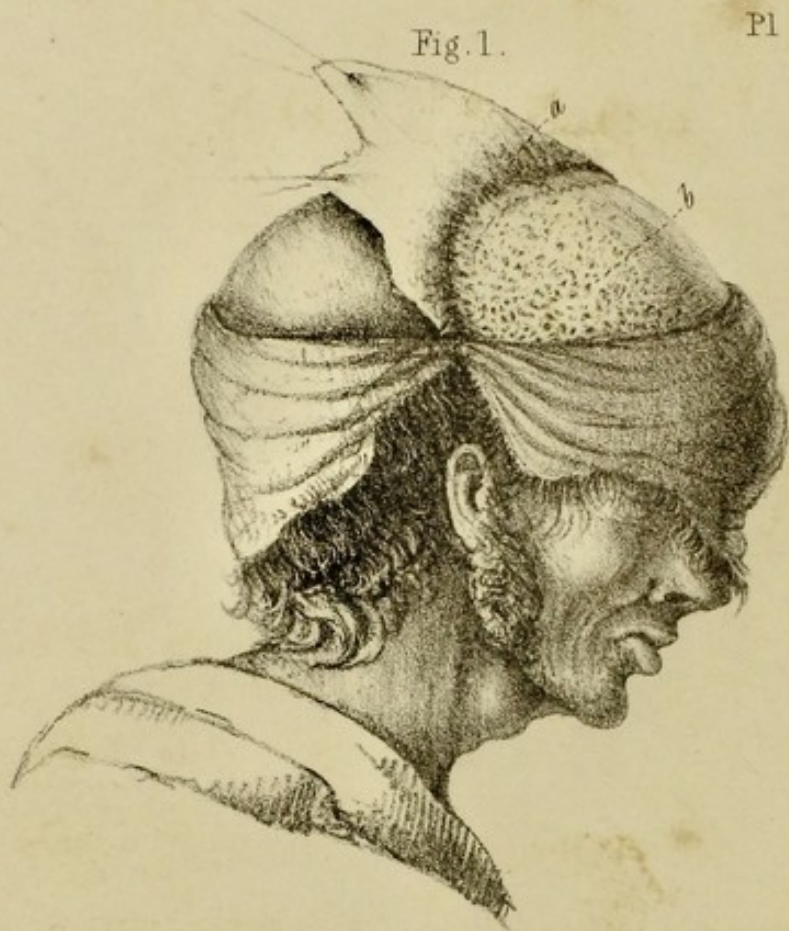

Fig. 2.

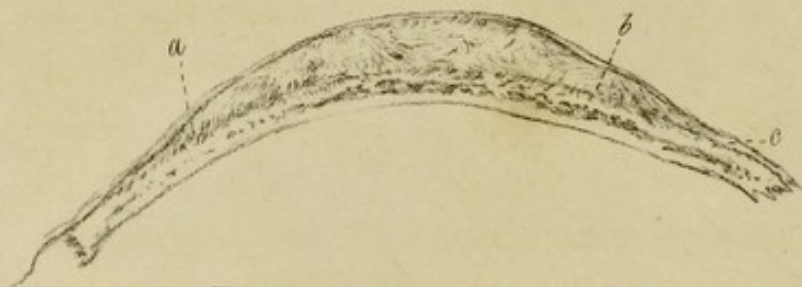

Fig. 3.

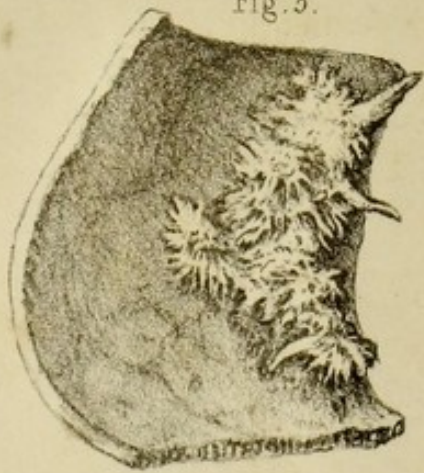
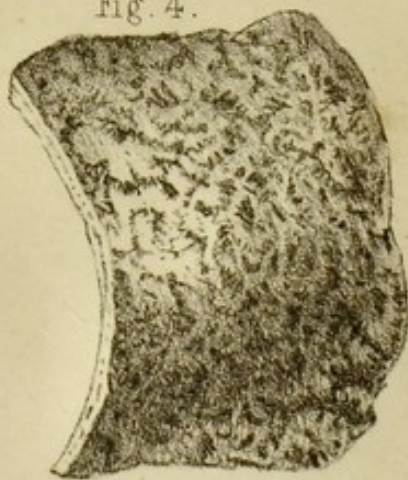
Fig. 4.





# EXPLANATION

OF

## THE PLATES.

---

### PLATE I.

THIS Plate represents simple abrasion of the bones of the head, thickening of the pericranium, and mercurial skull.

*Fig. 1. a* Thickening and fibro-cartilaginous state of the pericranium.

*b* Simple absorption, or erosion of the parietal and frontal bones.

*Fig. 2.* Fibro-cartilaginous state of the pericranium.

*a* The fibro-cartilaginous matter dipping into, and firmly adhering to the abraded bone.

*b* Outer table of the bone completely destroyed.

*Fig. 3.* Spiculæ of bone arising from the inner table of the parietal bone.

4. A portion of mercurial cranium.

**SYMP.** Dull heavy pain, with soreness of the integuments covering a particular part or parts of the head, accompanied with a puffiness of the scalp; pulse small and frequent, tongue moist, and covered with a whitish fur; sometimes an erysipelatous state of the head and face, sickness, constipation of the bowels, restless nights, coma.

**MORBID ANAT.** The pericranium is generally found thickened, and firmly attached to the bones of the head. In some cases it presents quite a cartilaginous texture,



nearly three quarters of an inch in thickness; when removed from the skull, the bone or bones are found to be very much destroyed by absorption, particularly the outer table, and its texture resembles that of coarse sponge, but very white.

In such cases you generally find some organic derangement within the cranium.

---

## PLATE II.

ACUTE and chronic inflammation of the dura mater are represented in this Plate.

*Fig. 1.* Exhibits at one view acute inflammation and softening of the dura mater, and an enlarged state of the pacchionian glands, situated within the longitudinal sinus.

- a* Longitudinal sinus split open.
- b* Softening, lesion, and separation of the laminæ composing the dura mater.
- c* Injected and arborescent state of the venous capillary vessels of the dura mater.

SYMP. Nausea, thirst, headach; quick, full, and hard pulse; restlessness, pain, and corded sensation of the head.

MORBID ANAT. The dura mater presents a degree of redness more or less intense, and the venous capillary vessels are seen to be dilated and loaded with blood of a vermilion colour. Sometimes lymph is found effused on its surface, but more frequently pus, particularly so if an injury has been the exciting cause.

The dura mater is sometimes found firmly united to the inner table of the cranium, and sometimes to the arachnoid membrane and pia mater. Softening of the dura mater is not a very common affection, although I have met with several cases within the last ten years.



a Fig. 1.

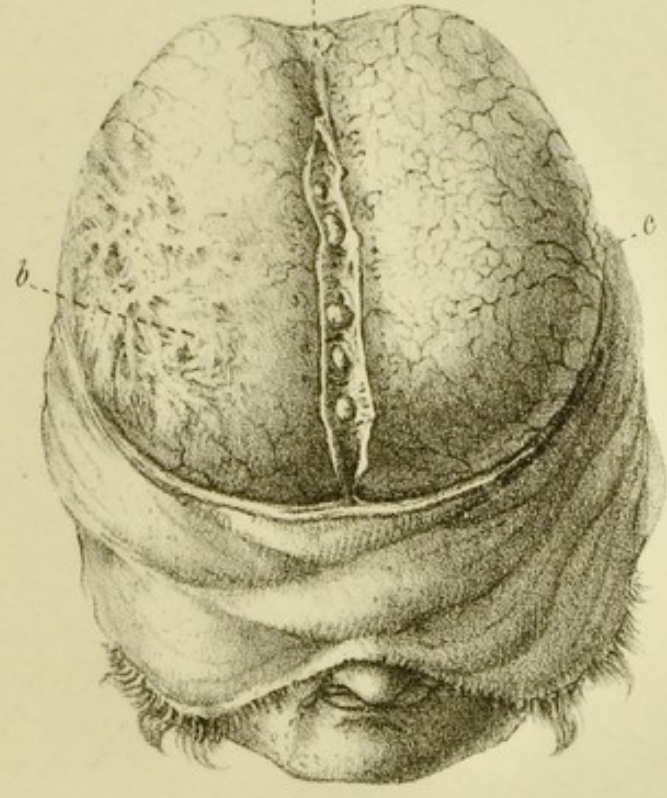


Fig. 5.

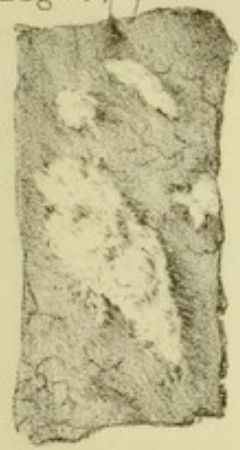

Fig. 2.

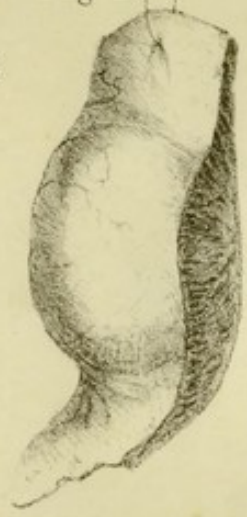

Fig. 4.

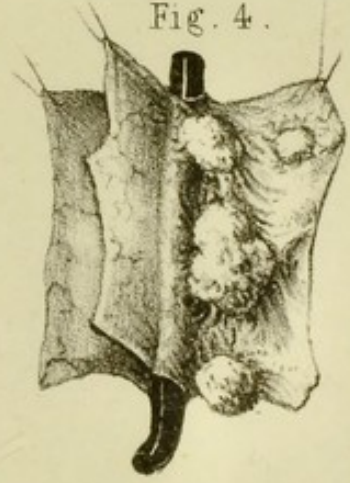


Fig. 6.

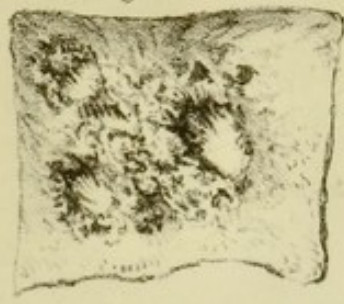


Fig. 5.

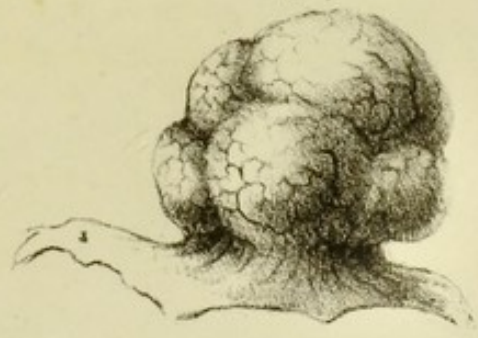








Fig. 1.

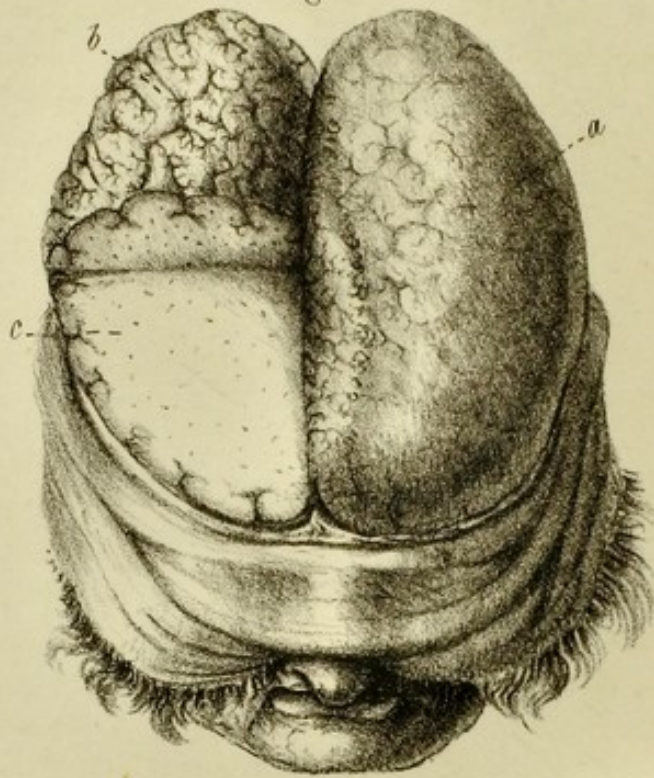


Fig. 3.

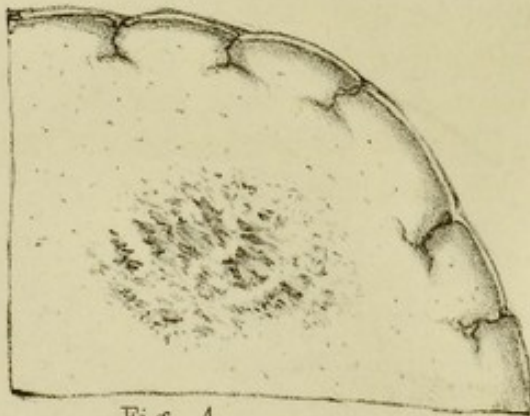


Fig. 2.

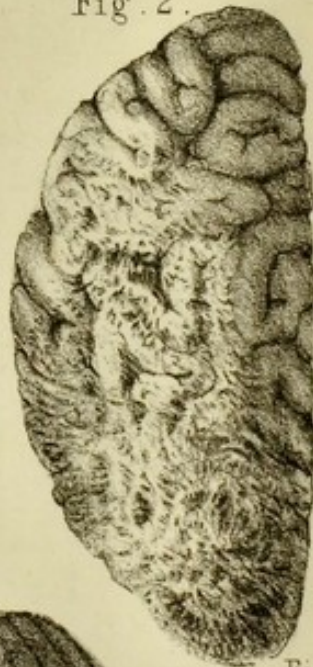

Fig. 4.

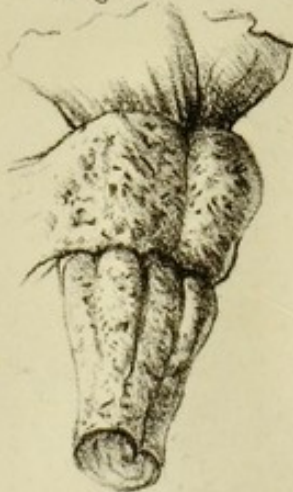

Fig. 5.



Fig. 6.


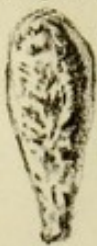


Fig. 7.





*Fig.* 2. Fibro-cartilaginous state of the cellular tissue between the laminæ of the dura mater.

3. Ossific depositions between the arachnoid and dura mater.
4. Fungoid tumours arising from the under surface of the dura mater.
5. Encephaloid tumour arising from the under surface of the tentorium cerebelli.

SYMP. of 2, 3, 4, and 5 are, long and continued headach, accompanied, at times, with the ordinary symptoms of epilepsy or apoplexy.

MORBID ANAT. Deposition of ossific matter is frequently found between the arachnoid membrane and dura mater; the patches of bone are generally small, scaly, and irregular in their shape; the falx cerebri and tentorium have been found completely ossified.

Fungoid tumours are pulpy to the touch, and of a fibrous texture. In some points they become softened, and broken down, with blood effused into their substance.

The dura mater is also subject to ulceration, and some say gangrene. Scrofulous tumours are found adhering, and sometimes passing through the texture of this membrane; also small indurated fleshy tumours, of the size of peas, are met with.

---

### PLATE III.

REPRESENTS inflammation of the pia mater, arachnoid membrane, and substance of the brain, and also softening of the cortical and medullary substance of the same organ.

*Fig.* 1. Shows at one view inflammation of the arachnoid membrane, pia mater, and substance of the brain.

- a* The arachnoid membrane thickened and opaque, and the convolutions of the brain imperfectly seen through it.



- b Highly injected state of the vessels of the pia mater, with a deposition of lymph between the convolutions of the brain.
- c Bloody points in the substance of the hemisphere.

SYMP. *Arachnitis*—Headach, sense of constriction over the eyebrows, injected state of the eyes, heat of the scalp, nausea, agitation.

*Pia Mater*—Intense throbbing pain in the head, increase of heat, flushing of the face, injected state of the eyes, disturbed functions, want of sleep, delirium.

*Substance of the Brain*—Weight and sense of heaviness in the head, numbness of one or more of the extremities, ringing in the ears, irritability of the retina, deceptive vision, convulsions, paralysis, coma.

MORBID ANAT. Thickening of the arachnoid membrane is generally the consequence of chronic inflammation. It has sometimes acquired the thickness of the pleura, of the pericardium, of the dura mater, and even as thick as the coats of the stomach.

*Inf. of the Pia Mater*—The minute capillary vessels are much more numerous than in its natural state, are filled with florid blood, and form, by their anastomosis, a beautiful network.

*Substance of the Brain*—The inflamed portion becomes of a red colour, although this is seldom very intense; when cut into, the colour is found to arise from a great many small vessels which are filled with blood. The part which is inflamed has no peculiar hardness, but yields nearly the same sensation to the touch as it would do in a healthy state.

- Fig. 2.* Extensive softening of the cortical and medullary substance of the left hemisphere of the brain.
3. Softening of the medullary matter of the right hemisphere.
  4. Softening of the pons varolii, corpora pyramidalia, olivaria, and medulla oblongata.
  5. Complete destruction of the right hemisphere of the cerebellum by the softening process.





Fig. 1.



Fig. 2.

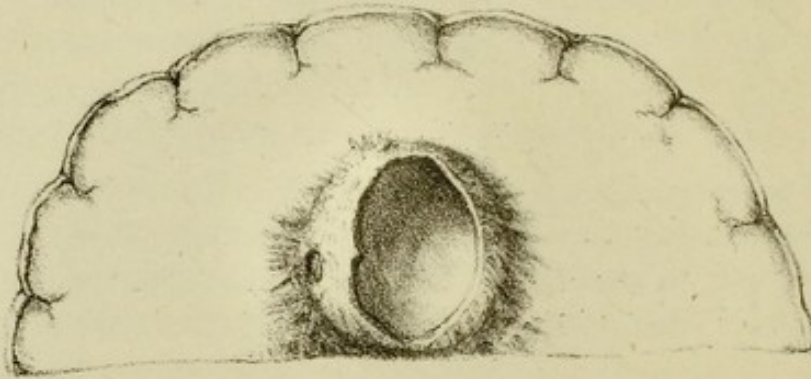


Fig. 3.

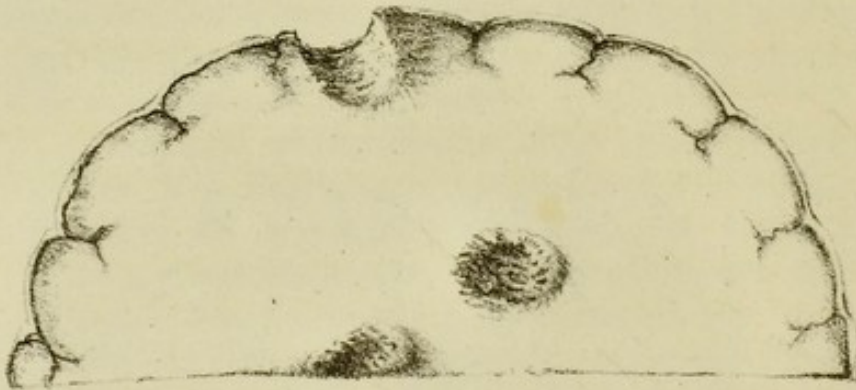
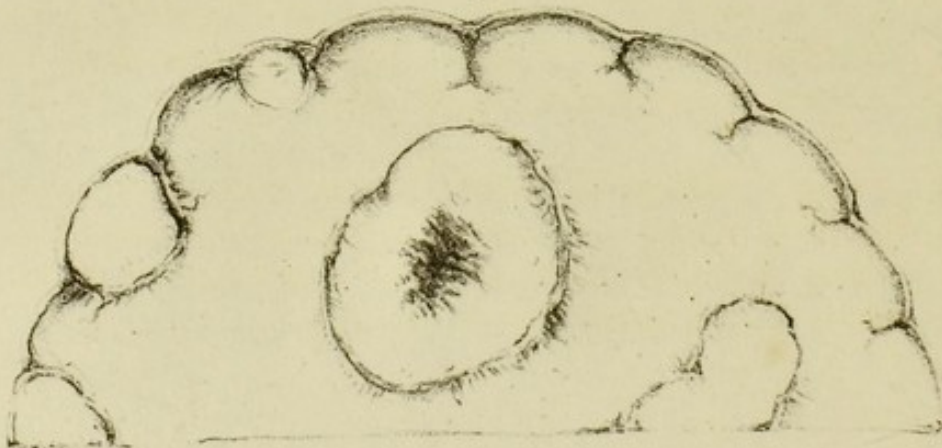


Fig. 4.





*Fig. 6.* Pulpy state of the cerebral matter within the serrated body.

7. Softening of the corpus olivare.

**SYMP.** *Softening of the brain*—Long and severe attacks of headach, occurring at distinct intervals, obscure vision, loss of memory, deafness, rheumatic pains in the limbs, sleepiness, paralysis of some part or parts, coma.

**MORBID ANAT.** Softening, to a greater or less degree, of the cortical or medullary matter, without any traces of vascularity or perceptible change of colour; the medullary portion being of a dull white and homogeneous, whilst the grey substance remains in its natural state, whatever be the degree of softening.

---

## PLATE IV.

THIS Plate represents abscess, cyst, ulceration, and scrofulous tubercles.

*Fig. 1.* An abscess in the substance of the brain; it contained a small quantity of pus.

2. A large cyst of a fibro-cellular texture, situated in the medullary substance of the right hemisphere of the brain.

3. Ulceration of the cortical and medullary substance of the right hemisphere, from long and protracted inflammation of the organ.

4. Encysted scrofulous tubercles, situated in the substance of the left hemisphere of the cerebrum of an infant who died of *tabes mesentericæ*. The centre of the large tubercle is softened, and presents the curd-like appearance.

**SYMP.** Violent pains in the head fixed to a particular spot, disturbed sleep, convulsions of the extremities, involuntary piercing cries, dejected countenance, accompanied with a lemon tint of the skin.



*Ulceration*—Pain and weight in the head, with a sense of tightness, nausea, vomiting, giddiness, twitching, paralysis.

---

## PLATE V.

THIS Plate represents the morbid appearance in Apoplexy.

*Fig. 1.* An extravasation of blood between the dura mater and the pia mater, from a rupture of one of the veins.

*a* The convolutions of the anterior and lateral part of the right hemisphere, completely covered by a mass of effused blood.

*b* Shows the turgescient state of the vessels of the pia mater.

*Fig. 2.* An effusion of blood under the pia mater, the patient died of typhus fever (hæmorrhagic brain).

*a* The anfractuositities of the brain filled with fluid blood.

*b* A large mass of dark blood lying on the centre of the hemisphere.

*c* Pia mater, dissected and reflected back from the brain. The vessels of the membrane were loaded with blood.

*Fig. 3.* Complete destruction of the wall of the left ventricle, thalamus, and corpus striatum, by the softening process.

*a* An attenuated and softened state of the corpus callosum.

*b* Corpus striatum.

*c* Softening of the crus cerebri and thalamus. The ventricles were filled with blood.

*SYMP.* *Apoplectic effusion*—The pulse is firm and vibrating under the finger; face swollen, and of a brick red colour; stertorious breathing, with a frothy white fluid issuing from the mouth and nostrils; paralysis, coma.



Fig. 3.

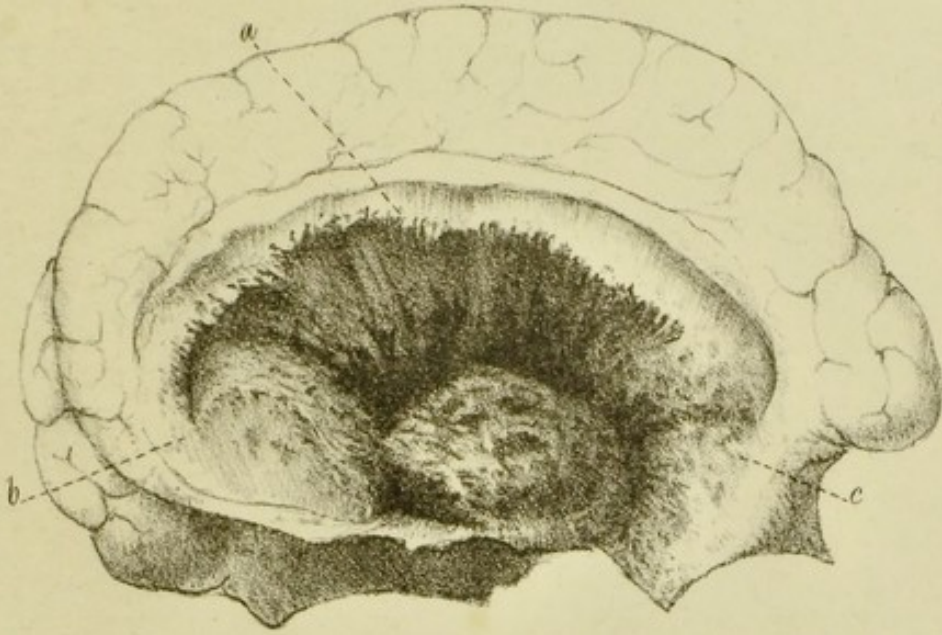


Fig. 1.

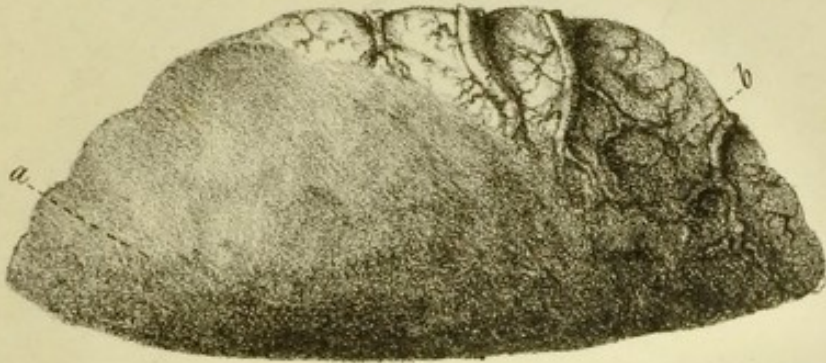
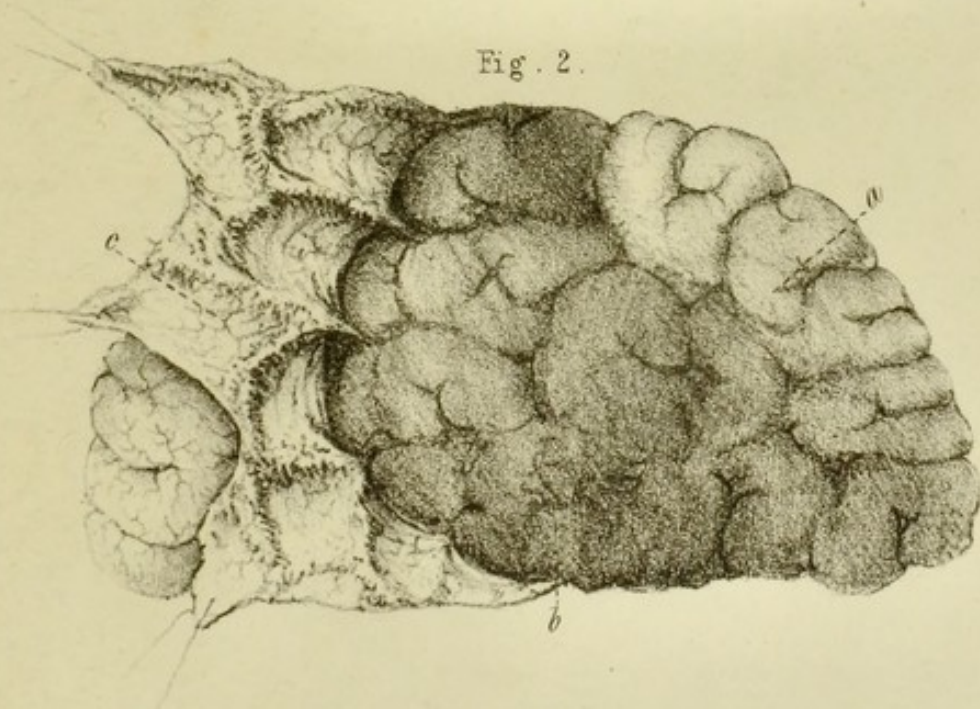



Fig. 2.










Fig. 1.

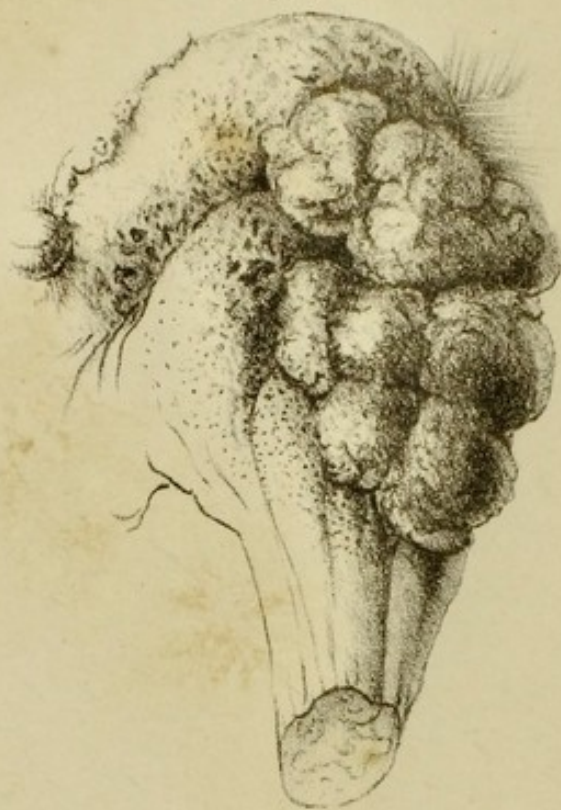

Fig. 2.

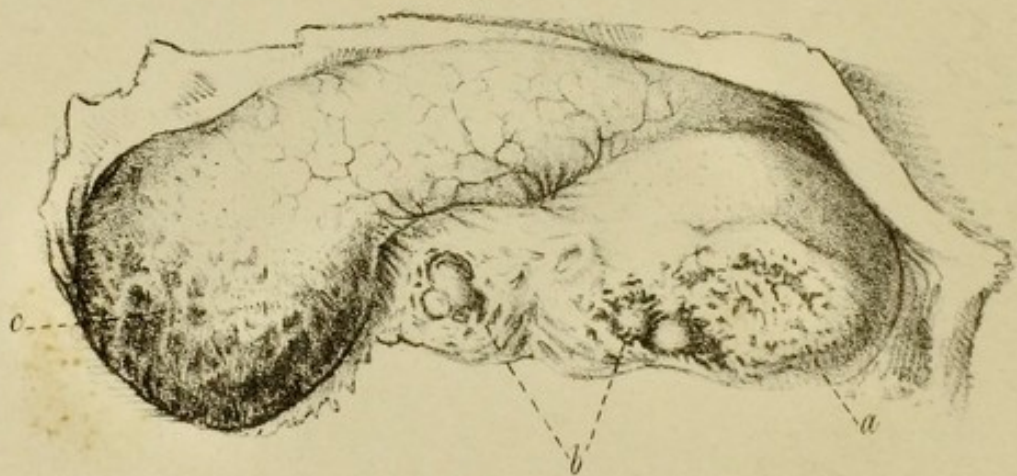
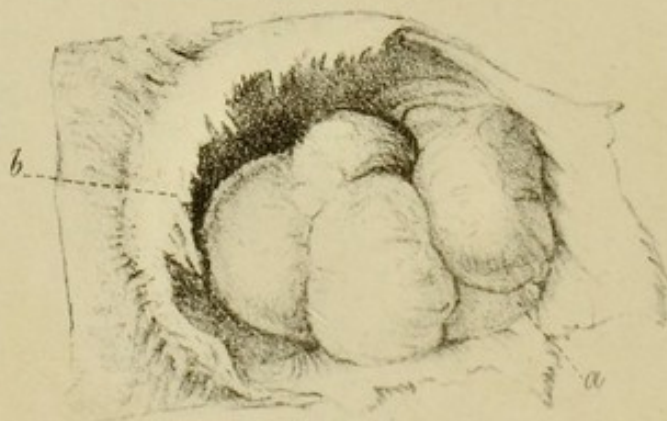


Fig. 3.








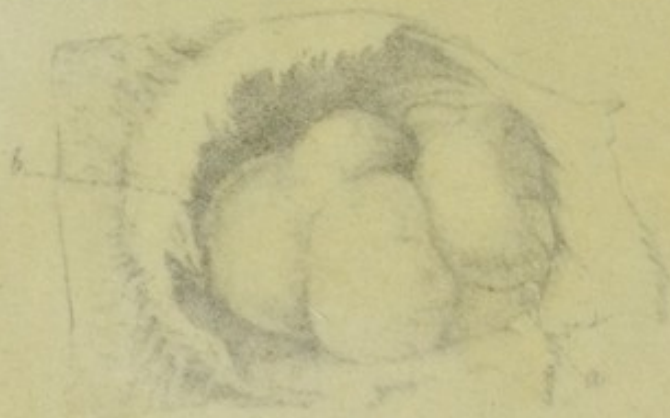
Fig. 1.



Fig. 2.

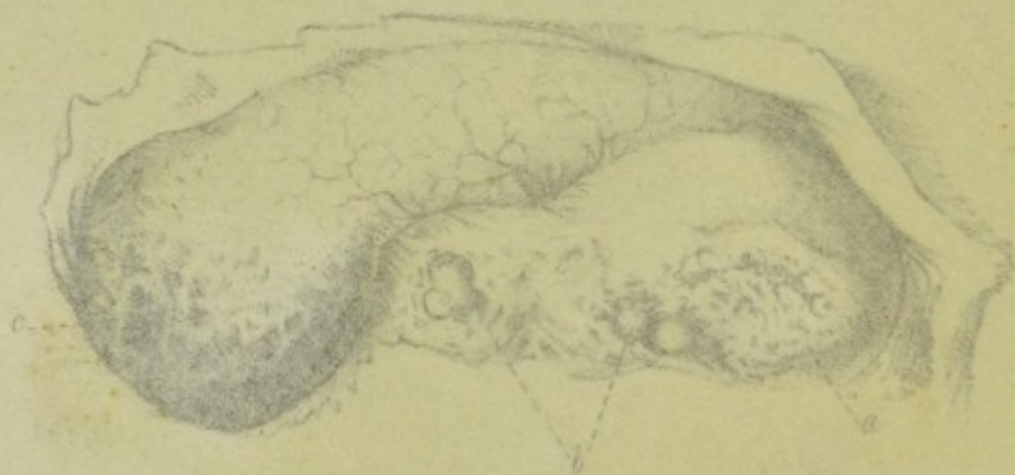

Fig. 3.








Fig. 1.

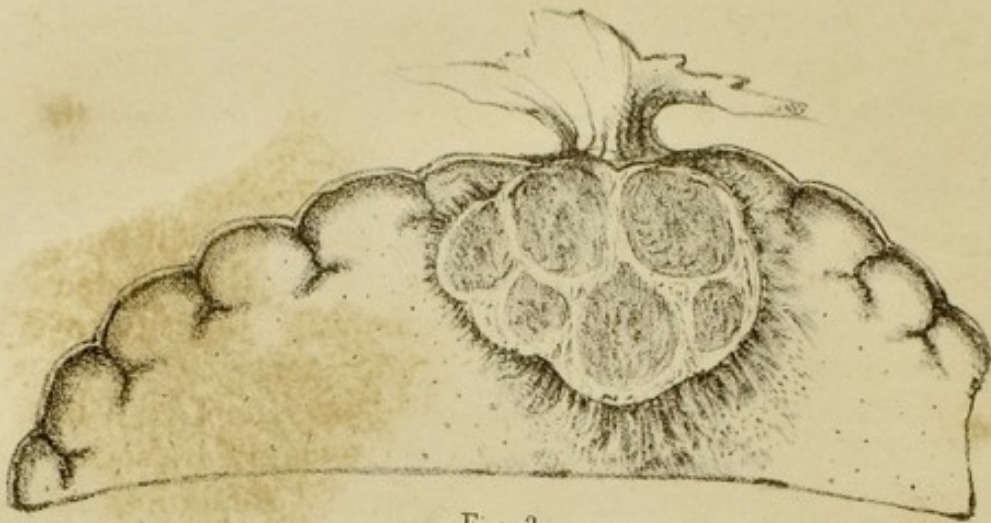


Fig. 2.

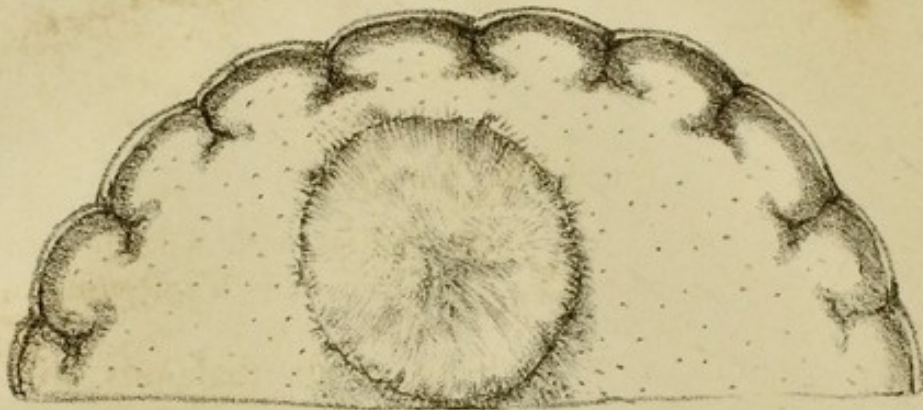


Fig. 3.

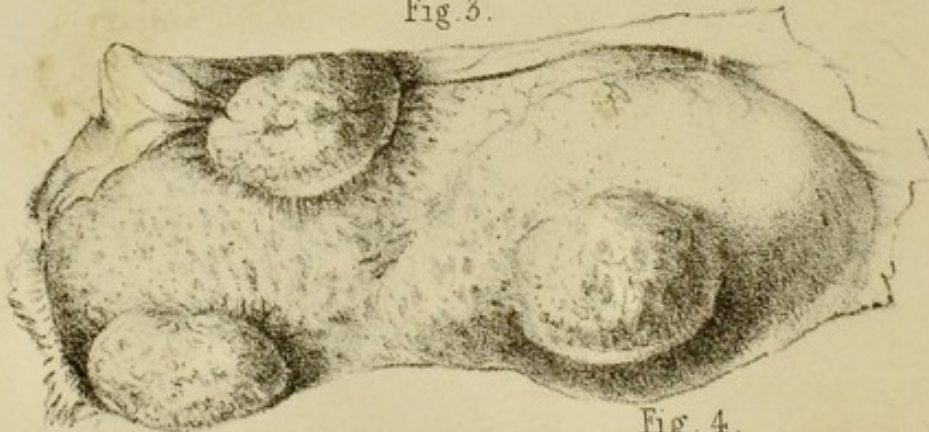
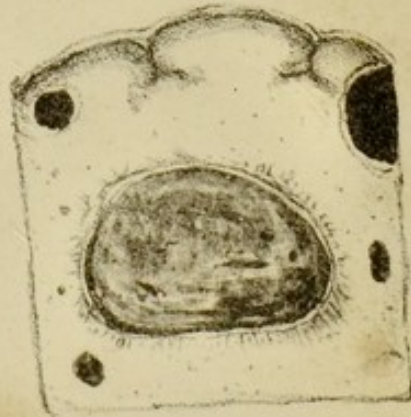
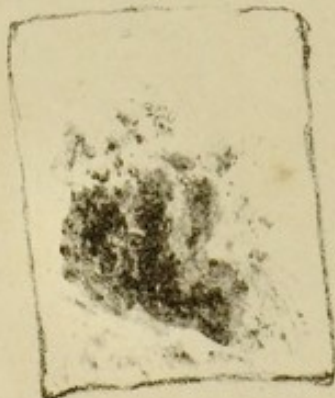

Fig. 4.

Fig. 5.





**MORBID ANAT.** Between the pia mater and tunica arachnoides there often is to be observed a serous effusion, which in some bodies is colourless, in others turbid, bloody, or even mixed with streaks of coagulable lymph. With respect to the substance of the brain, it is sometimes found unusually firm; and when cut into, the numerous points of blood show that the divided vessels are enlarged. A considerable quantity of serous fluid is also found in the ventricles.

For the most part extravasated blood is met with in the cranium; sometimes between the membranes, sometimes in the substance of the brain, and sometimes in the ventricles.

---

## PLATE VI.

*Fig.* 1. A PORTION of apoplectic brain, with a large clot of blood at its base, accompanied with softening of the crura cerebri and cerebelli.

2. An apoplectic cyst formed in the thalamus, with softening of the corpus striatum.

*a* Curd-like appearance of the softened medullary matter of the thalamus.

*b* Dark brown clots within the cyst.

*c* Softening of the anterior and inferior portions of the corpus striatum.

*Fig.* 3. An old apoplectic cyst with a recent coagulum.

*b* The cyst formed by condensed cellular tissue.

*a* The clots of blood or coagula.

---

## PLATE VII.

IN this Plate tubercles in the substance of the brain, with circumscribed and diffused melenosis, are depicted.

*Fig.* 1. An encephaloid tumour, situated in the substance of the right hemisphere of the brain; it was lobu-



lated, indurated, intersected by bands of cellular tissue, and of a greyish white colour.

*Fig. 2.* Cancillated scirrhus tumour, as large as a pigeon's egg, in the substance of the right hemisphere of the brain.

3. Scrofulous tumours, situated within the lateral ventricle, and arising from the thalamus and corpus striatum.

4. Circumscribed melenosis of the cerebral texture.

5. Diffused melenosis of the substance of the brain.

**SYMP.** *Of Tumours within the Cranium*—Severe headachs, continued or intermittent, with twitching of one or more of the extremities, pallid countenance, convulsions, loss of memory, paralysis, epilepsy, coma, hydrocephalus.

**MORBID ANAT.** Scirrhus tubercles and encephaloid tumours are found in the form of round irregular masses, varying from the size of a pea to that of a hen's egg, either of a greyish or reddish colour, and sometimes nodulated on the external surface. The nature of the tumour can be determined only by cutting into it; the interior is sometimes found softened, and contains some effused blood. The medullary matter surrounding the tumour is generally found softened.

---

## PLATE VIII.

**THIS** Plate represents the encephaloid and scirrhus tumours, also depositions of calcareous and bony matters in the substance of the cerebrum and cerebellum.

*Fig. 1.* An encephaloid tumour at the posterior part of the medulla oblongata. Two are softened and have a flocculent appearance; they are adhering to the pia mater, covering the right lobe of the cerebellum, and receive their vessels from the same.



Fig. 1.

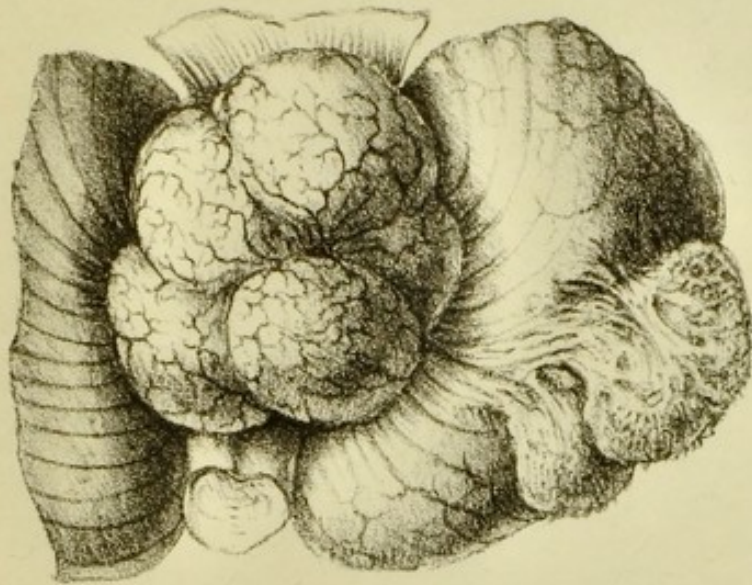


Fig. 2.

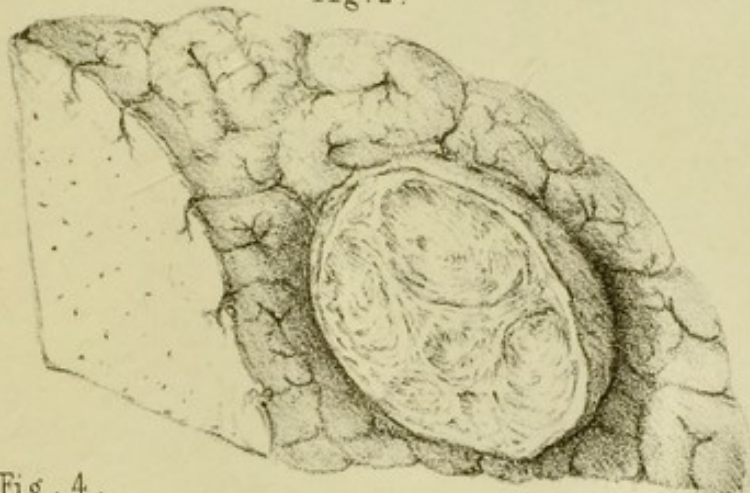


Fig. 4.




Fig. 5.

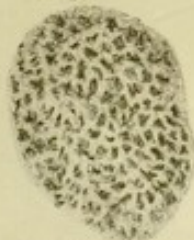

Fig. 3.

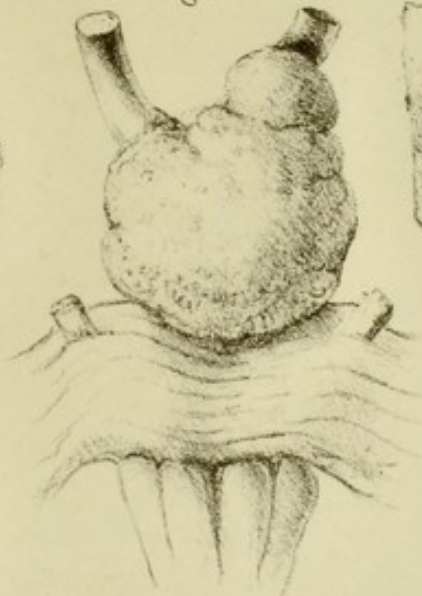

Fig. 6.

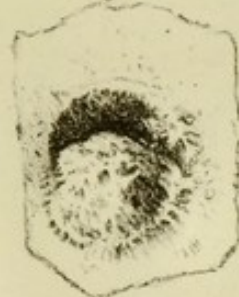

Fig. 7.









Fig. 1.

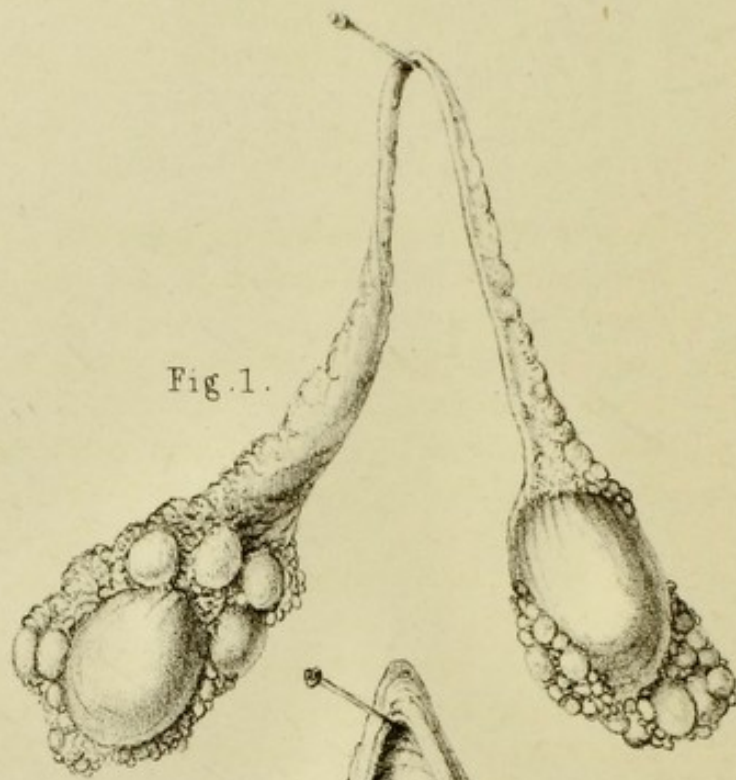


Fig. 2.

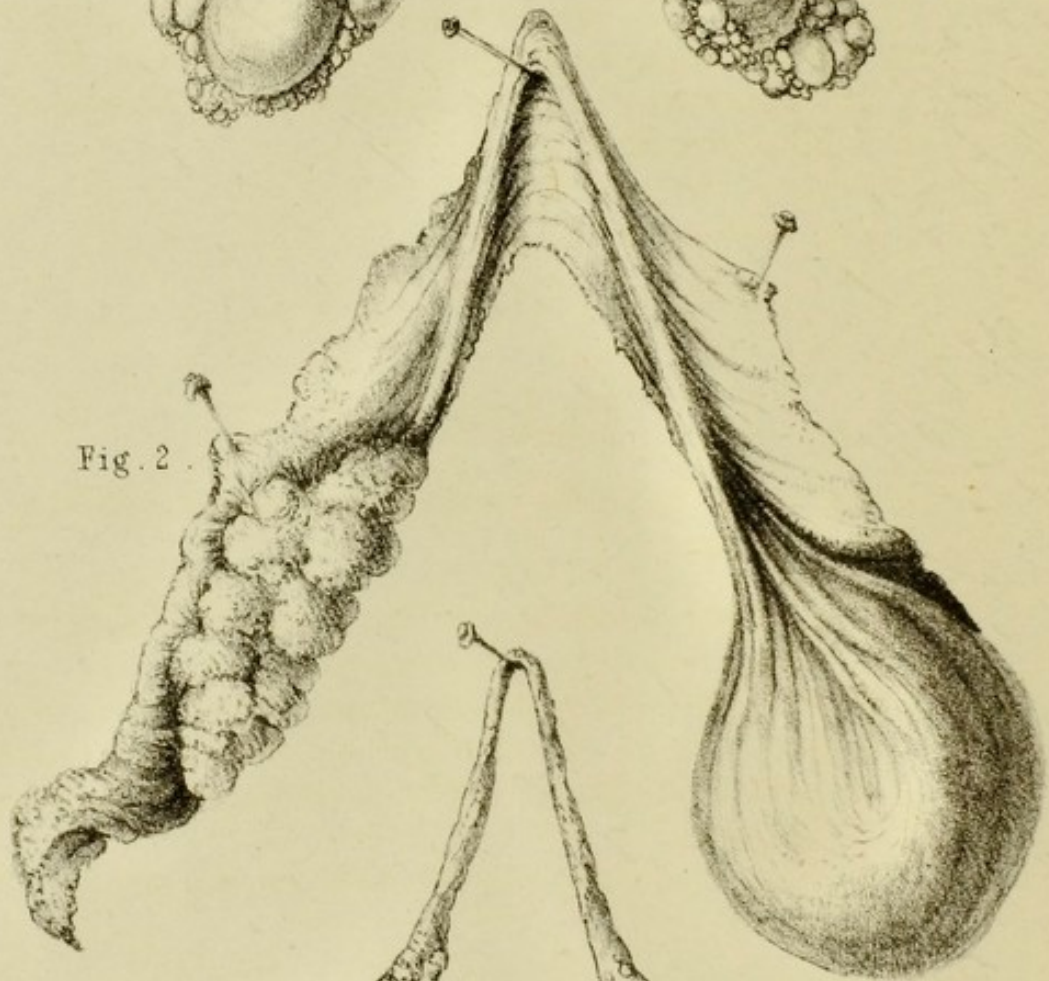
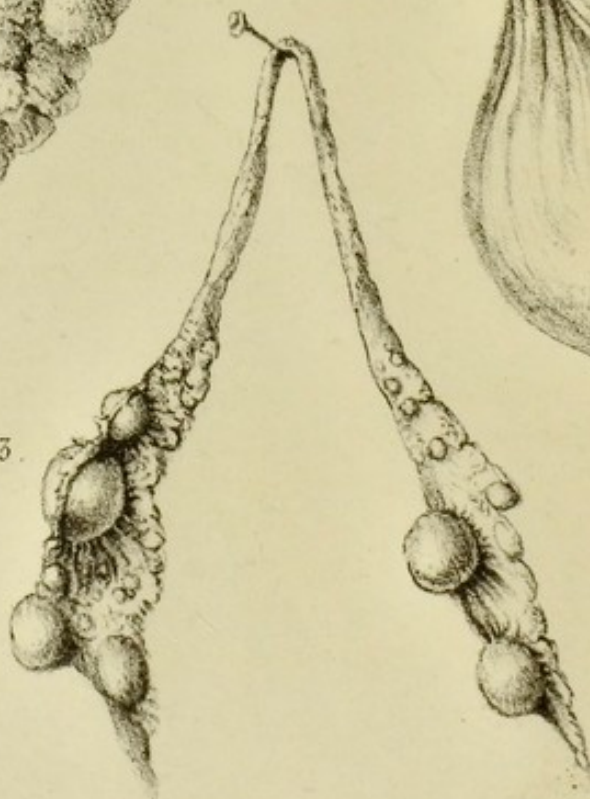


Fig. 3.





- Fig. 2.* Section of an indurated encephaloid tumour, situated on the cortical matter of the left hemisphere of the brain.
3. An indurated tumour, situated on the crura cerebri and optic nerves.
  4. Appearance of the cancellated scirrhus tumour, taken from the left hemisphere of the brain.
  5. Macerated portion of the above, showing its cancellated texture when the intervening matter is washed away.
  6. A large calcareous mass taken from the substance of the right hemisphere of the brain of an idiot.
  7. A portion of bone embedded in the substance of the cerebellum.

---

## PLATE IX.

HYDATIDS, cysts, tubercles, and fleshy tumours adhering to the choroid plexus.

- Fig. 1.* Hydatids adhering to the plexus choroides of an infant who died of hydrocephalus.
2. A large cyst, firmly attached to the plexus of the left ventricle. To the right ventricle were adhering several masses of flesh, somewhat of a fibrous character.
  3. Extensive tuberculated state of the plexus choroides.

SYMP. *Of Hydatids and Cysts*—Dull obscure pain in the head, with a sense of compression, giddiness, tendency to sleep, numbness of the extremities, convulsions.

*Tuberculated state of the Plexus*—Great emaciation, loss of appetite, vomiting, moaning, ptosis of the upper eyelids, starting in sleep, with a constant inclination to lie down, pallid countenance.



MORB. AP. *Of Hydrocephalus*—On removing the scalp the bones are found to be very thin, and there are frequently broad spots of membrane in them. These appearances are however only to be observed when the disease has been of long continuance. In some cases, where the quantity of water is not great, the substance of the brain appears to be indurated, and in others softened. We frequently find within the cranium the veins, particularly those of the membranes on the surface of the brain and lining of the ventricles, gorged with dark blood; sometimes considerable adhesions and thickening of the membranes and minute and florid vessels upon the pia mater: collections also of a viscid tenacious matter have been discovered, in cysts, upon its external surface, and tumours have been found attached to its substance.

---

## PLATE X.

*Fig. 1.* AN extensive deposition of a calcareous matter in the substance of the striated body, and in the thalamus.

*a* Chalky concretion embedded in the substance of the thalamus.

*b* Irregular and serrated appearance of the earthy matter deposited into and on the surface of the corpus striatum.

*Fig. 2.* A deposition of chalky matter in the substance of the quadrigeminal bodies.

3. A very large hydatid, with a great many smaller ones, situated in the substance of the left hemisphere of the cerebrum.



Fig. 1.

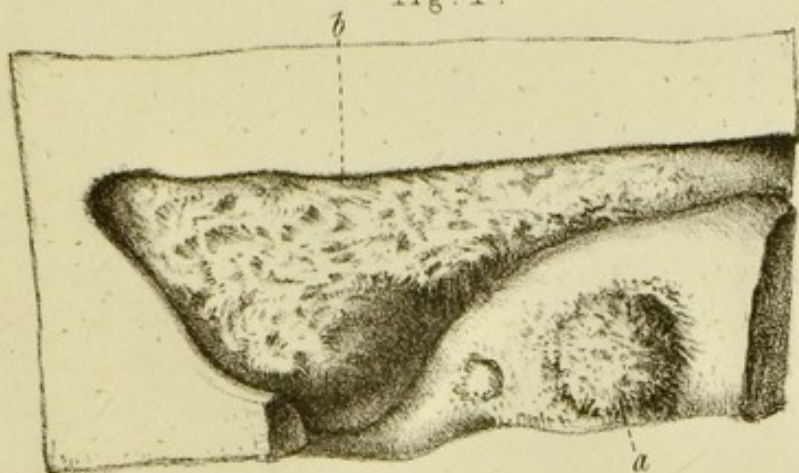


Fig. 2.

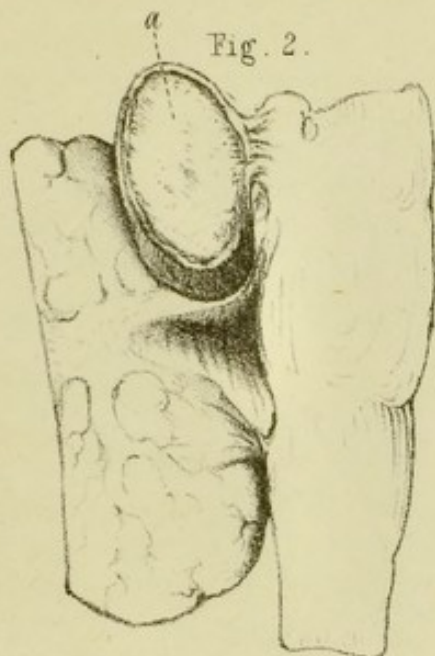


Fig. 3.

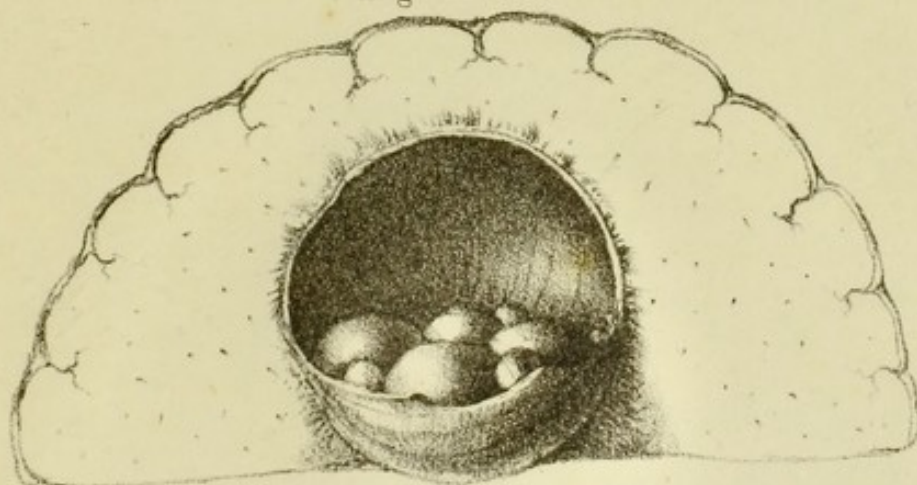








Fig. 1.

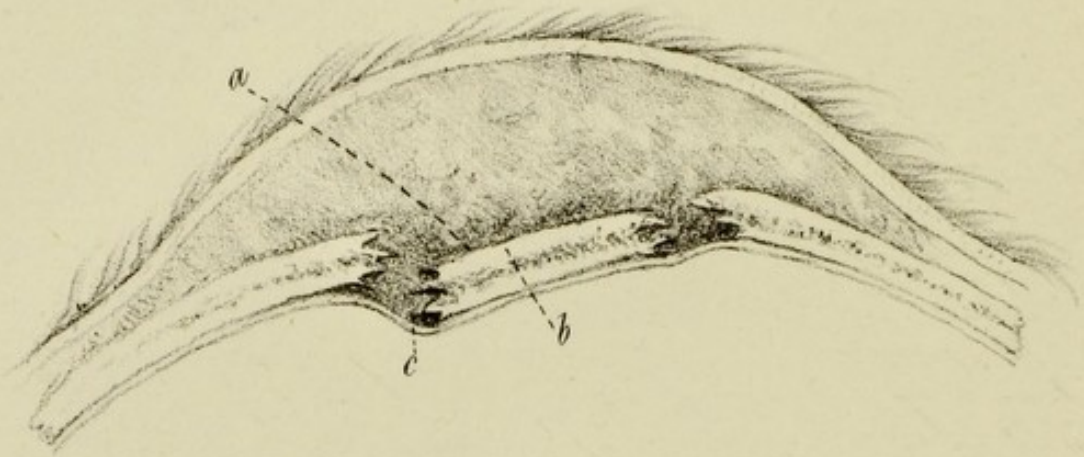


Fig 2.

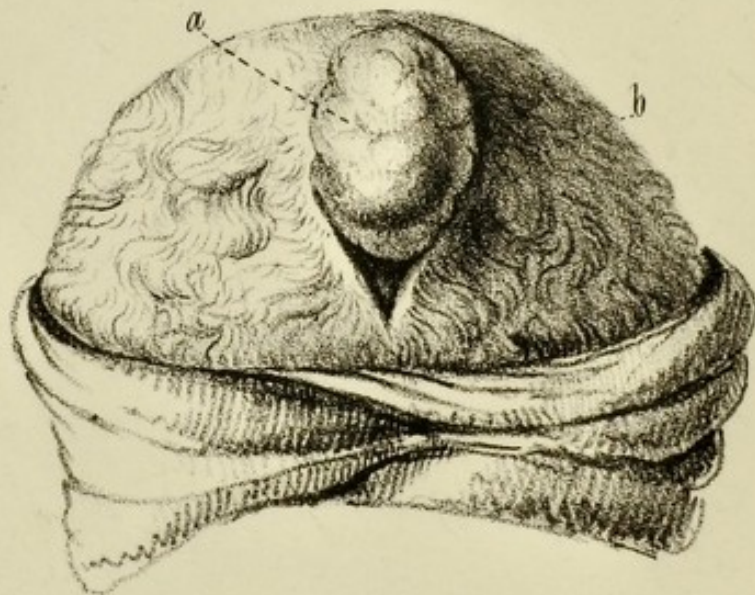


Fig. 3.

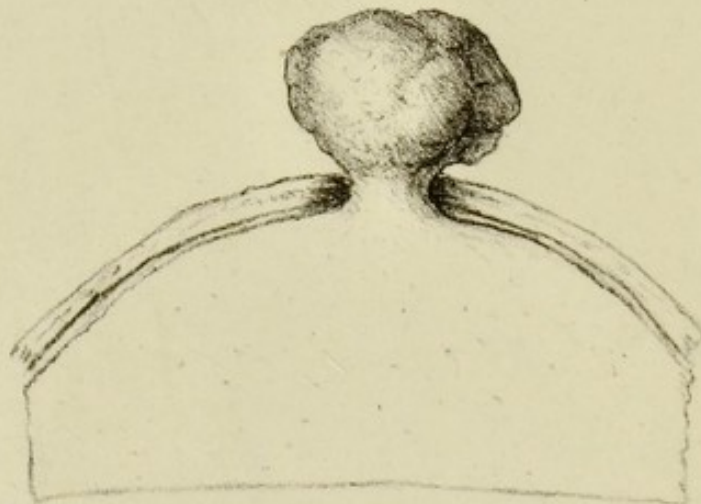






Fig. 1 .

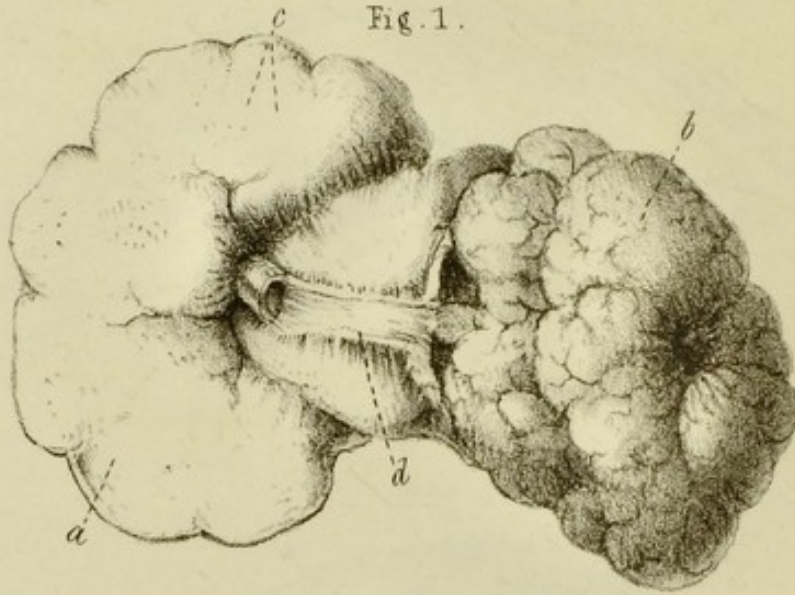


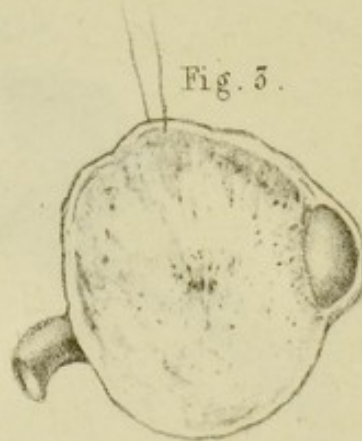
Fig. 2 .

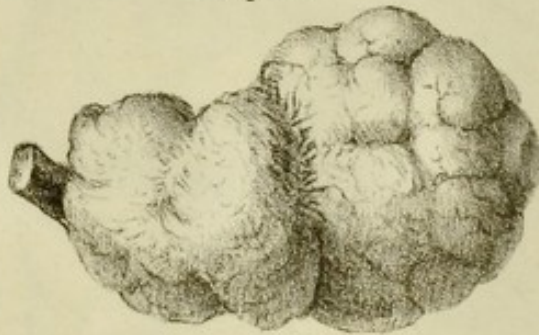

Fig. 4 .

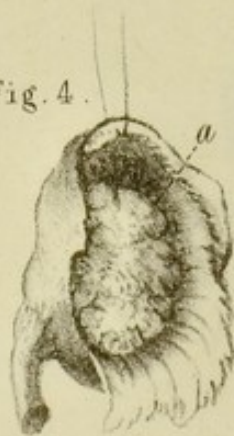

Fig. 5 .





## PLATE XI.

FRACTURE of the bones of the head and fungus cerebri.

*Fig. 1.* Fracture of the skull.

*a* Extravasation of blood between the pericranium and bone.

*b* Depressed portion of bone.

*Fig. 2.* Fungus cerebri, from an injury of the bones of the head.

3. Fungus cerebri, in consequence of a complete destruction of the bone and membranes of the head from syphilis.

## PLATE XII.

*Fig. 1.* COMPLETE destruction of the eye and all its external appendages within the socket, by an extensive encephaloid tumour.

*a* Encephaloid mass removed from the anterior lobes of the brain.

*b* External and lobulated appearances of the tumour, as seen when projecting from the socket.

*d* Section of the optic nerve compressed and embedded in the substance of the encephaloid mass.

*Fig. 2.* Lobulated state of the eye from a deposition of encephaloid matter within the sclerotica; also a large tumour, situated externally, of the same nature.

3. The whole cavity of the eye filled up with encephaloid matter, but in its centre and on its edges are seen depositions of melenotic matter.

4. A small encephaloid mass seen arising from the vessels of the retina.

*SYMP.* *Fungus Hematodes*—Diminution of sight, amaurosis, dilatation and immobility of the pupil, deeply seated

Fig. 1.

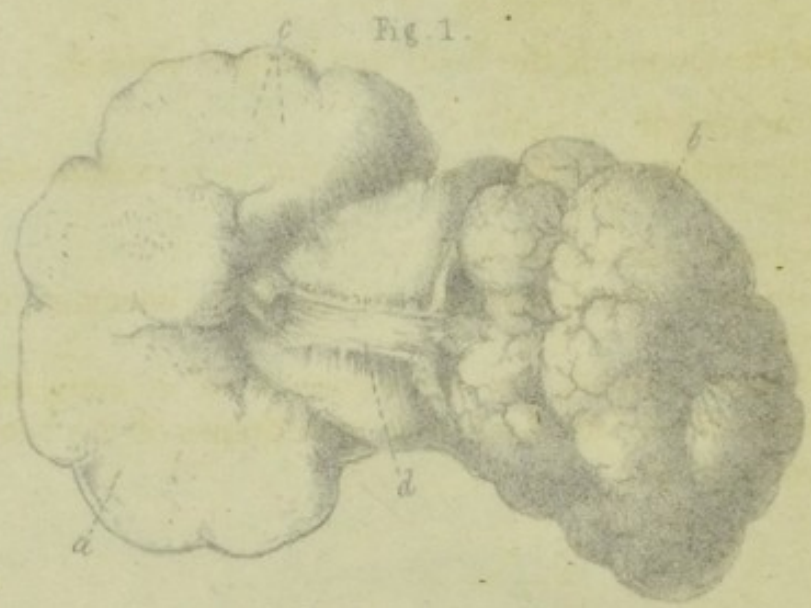

Fig. 2.

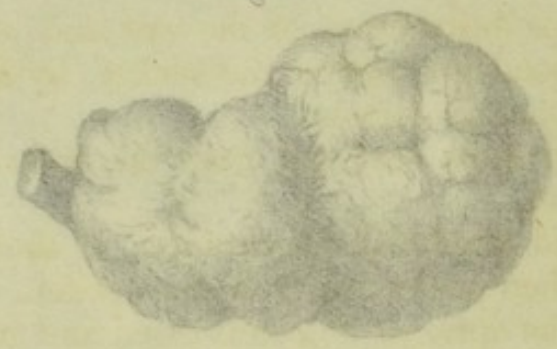

Fig. 4.

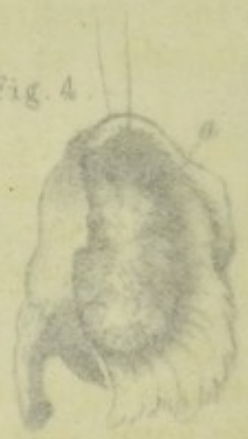
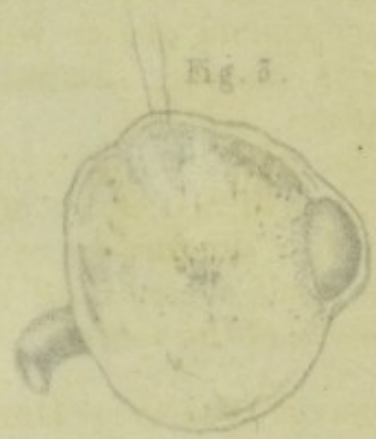
Fig. 5.





## PLATE XI.

FRACTURE of the bones of the head and fungus cerebri.

*Fig.* 1. Fracture of the skull.

*a* Extravasation of blood between the pericranium and bone.

*b* Depressed portion of bone.

*Fig.* 2. Fungus cerebri, from an injury of the bones of the head.

3. Fungus cerebri, in consequence of a complete destruction of the bone and membranes of the head from syphilis.

## PLATE XII.

*Fig.* 1. COMPLETE destruction of the eye and all its external appendages within the socket, by an extensive encephaloid tumour.

*a* Encephaloid mass removed from the anterior lobes of the brain.

*b* External and lobulated appearances of the tumour, as seen when projecting from the socket.

*d* Section of the optic nerve compressed and embedded in the substance of the encephaloid mass.

*Fig.* 2. Lobulated state of the eye from a deposition of encephaloid matter within the sclerotica; also a large tumour, situated externally, of the same nature.

3. The whole cavity of the eye filled up with encephaloid matter, but in its centre and on its edges are seen depositions of melenotic matter.

4. A small encephaloid mass seen arising from the vessels of the retina.

SYMP. *Fungus Hæmatodes*—Diminution of sight, amaurosis, dilatation and immobility of the pupil, deeply seated



and constant pain in the eye, white shining metallic appearance in the fundus of the eye, opacity of lens, eyeball enlarged, deep leaden colour of sclerotica, dilated and varicose state of vessels of the conjunctiva, countenance pallid, bowels torpid, coma.

**MORB. ANAT.** The eyeball, optic nerve, and in many cases the brain itself, are all involved in the disease. The morbid growth has, in almost every instance, the appearance of medullary matter. It is chiefly composed of an opaque, whitish, homogeneous matter, having the same degree of pulpy softness and tenacity with the brain, mixed with a filamentous substance, resembling the cellular membrane.

---

### PLATE XIII.

**SKETCHES** of chronic inflammation of the fauces, enlarged, indurated, and ulcerated tonsils.

- Fig.* 1. Chronic inflammation of the mucous tissue of the palate and fauces.  
 2. Enlarged and indurated tonsils.  
 3. Extensive ulceration of the tonsils, uvula, and mucous tissue of the fauces.

**SYMP.** Tickling in the throat, attended with great heat and a peppery taste in the mouth, cough, expectoration of mucus, sometimes blood; the tonsils are enlarged, and of a dark red colour. The uvula is soft and papulous, as if composed of a clot of blood. The capillary veins are distended, and the soft vascular network spread over the palate gives it the appearance of a well injected tissue of blood vessels.

**MORBID ANAT.** *Cynanche maligna*—The fauces are inflamed, suppurated, and gangrenous; and the trachea and larynx are likewise in a state of inflammation, and lined with a viscid fetid matter.



Fig. 1.

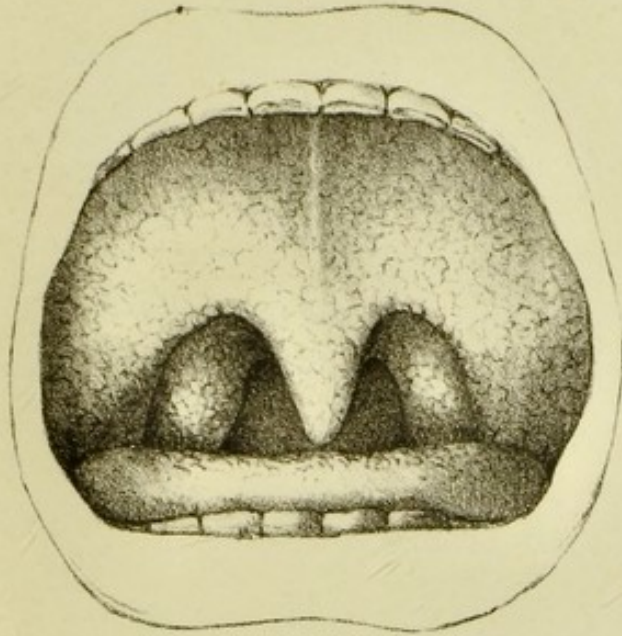


Fig. 2.

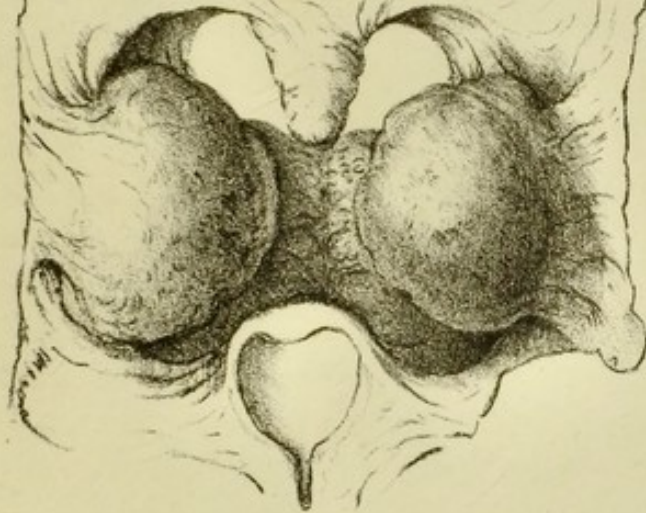
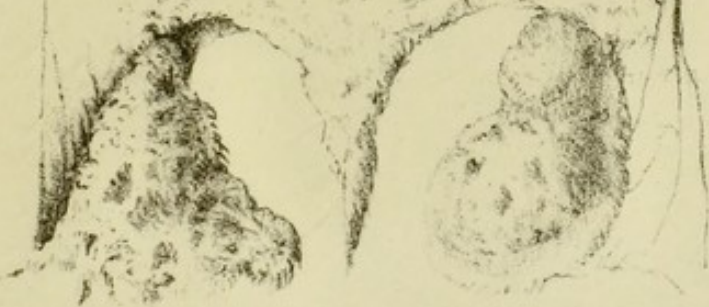

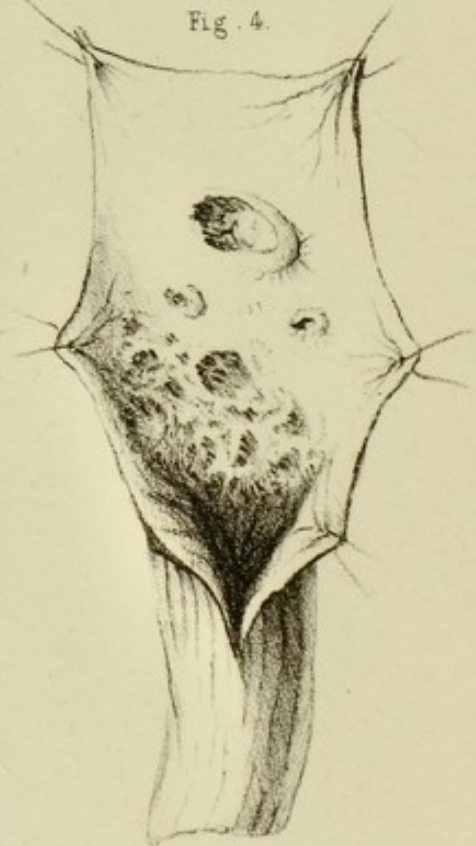
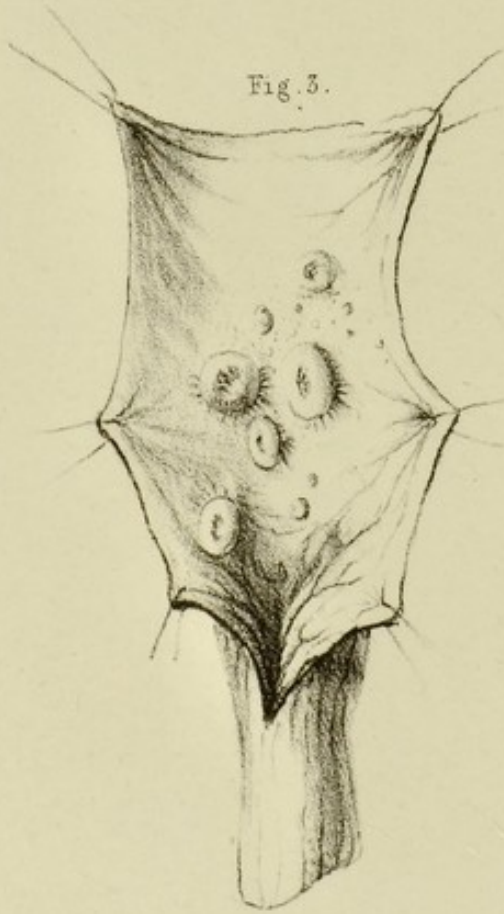
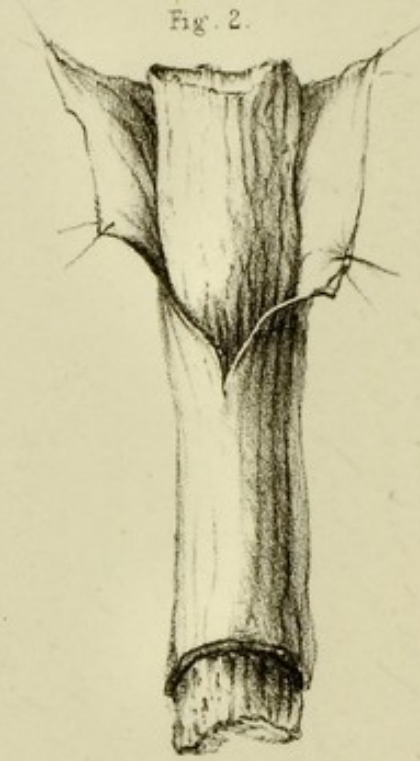
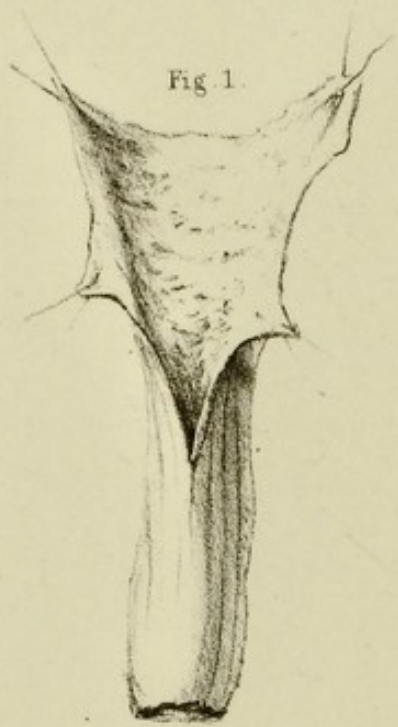
Fig. 3.















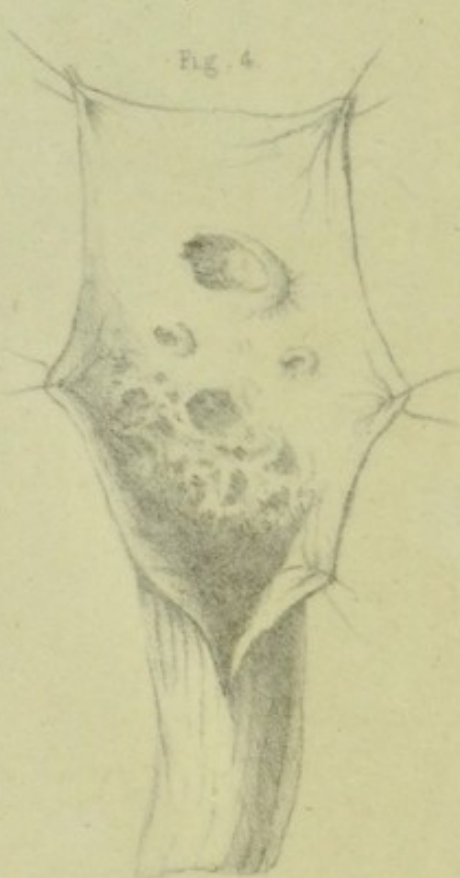
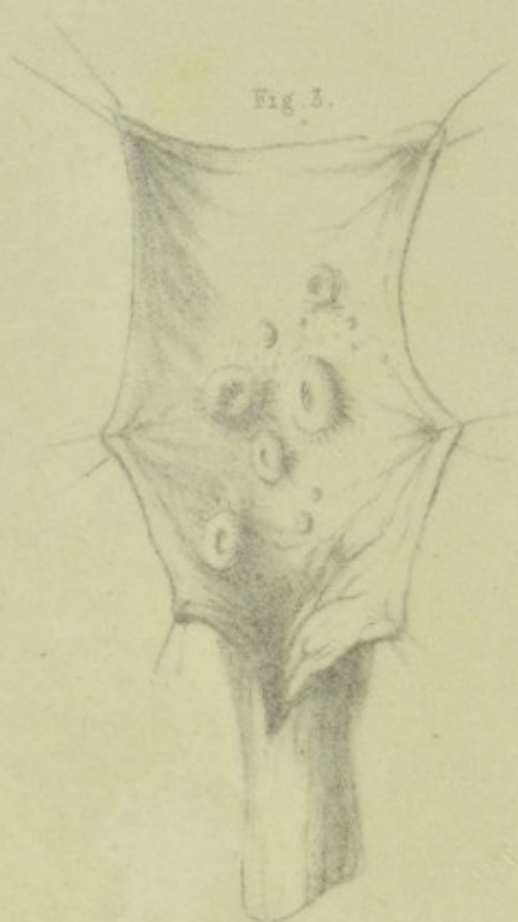
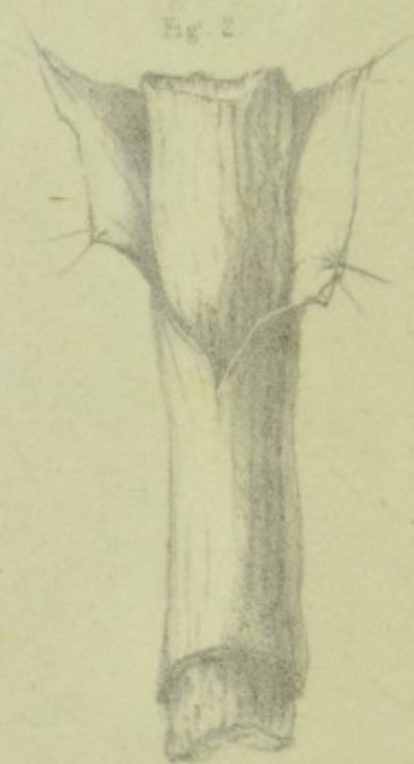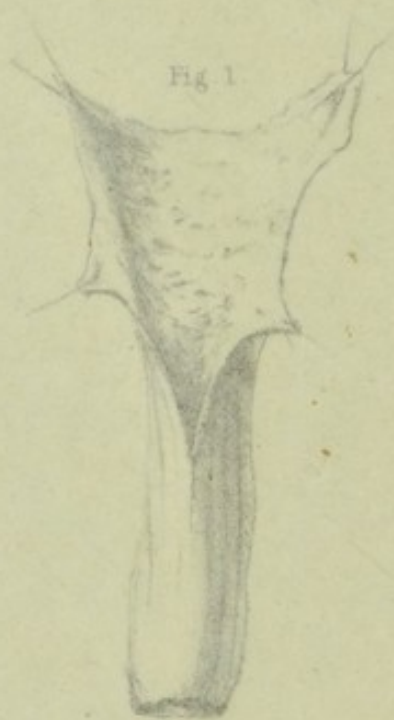






Fig. 1.

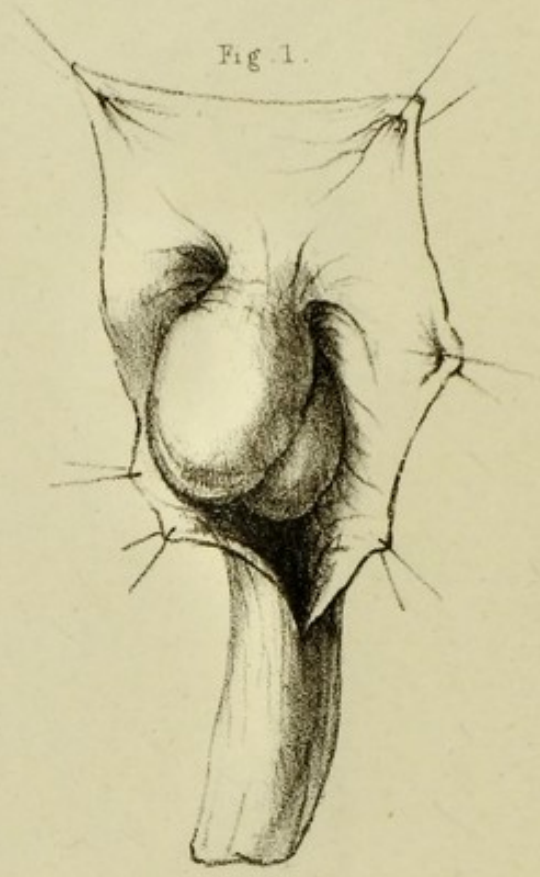


Fig. 2.

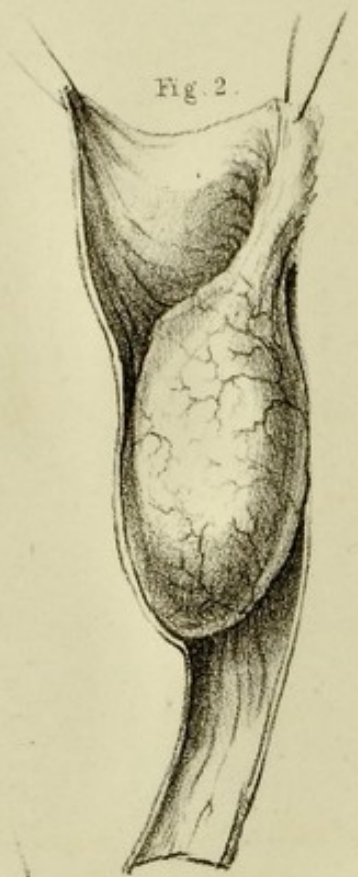


Fig. 3.

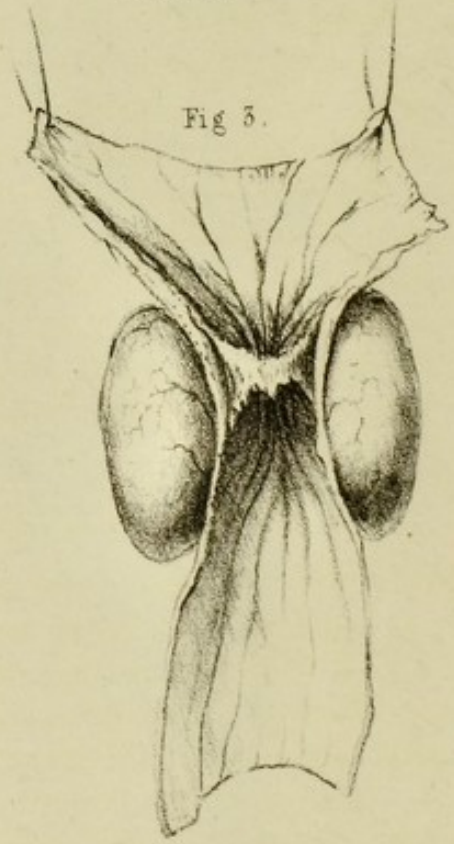
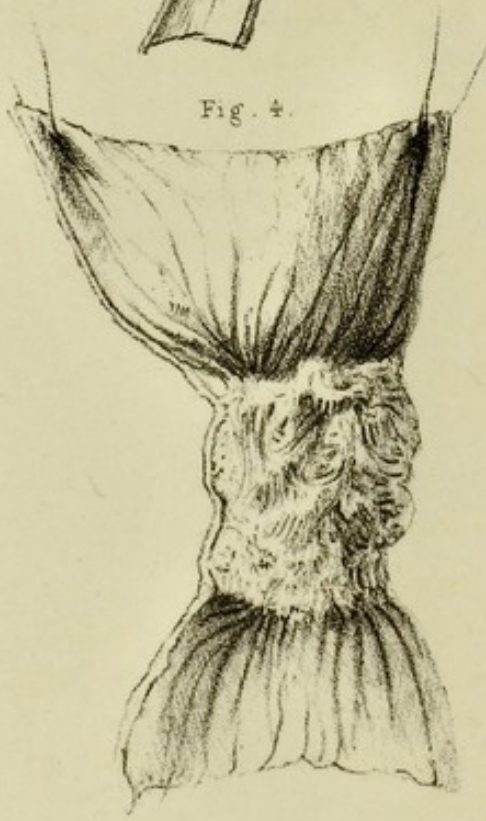

Fig. 4.





## PLATES XIV. XV.

THESE Plates represent acute and chronic inflammation of the œsophagus and its effects.

## PLATE XIV.

- Fig.* 1. Acute inflammation of the mucous tissue of the œsophagus.
2. Fibrine deposited in the œsophagus; it was moulded to the calibre of the tube, and slightly adhered to its mucous tissue.
  3. An enlarged state of the mucous glands situated in the œsophagus.
  4. Extensive ulceration of the mucous follicles of the œsophagus.

SYMP. *Inflammation of the Œsophagus*—Burning sensation on taking food, pain in the neck, particularly so in the side, which is increased on pressure, dryness of the fauces, regurgitation of the food through the nostrils.

*Ulceration*—An uneasy sensation in some part of the œsophagus, which is aggravated after eating, or after drinking ardent spirits; a lancinating or burning sensation in one or more parts of the tube; slight cough, cardialgia, repeated efforts to clear the throat of a tough dirty-coloured matter.

## PLATE XV.

- Fig.* 1. Two tumours of a fibro-cartilaginous nature, arising from the mucous tissue of the œsophagus.
2. A tumour of the encephaloid character, arising from the mucous tissue of the œsophagus.
  3. Stricture of the œsophagus, from chronic inflammation of the mucous tissue.
  4. Stricture of the œsophagus, from ulceration of the mucous tissue, produced by the swallowing of sulphuric acid.



SYMP. *Stricture of the Œsophagus*—Dyspnœa, difficulty in swallowing, nausea, vomiting, eructation, sense of hunger, bowels constipated, dejected and pallid countenance, cramp and spasms, both at the seat of stricture and in the stomach.

MORBID ANAT. The mucous membrane is generally found pulpy and red, and its capillary vessels are very distinctly seen loaded with blood; sometimes it is lined with a false membrane. Ulcers of the œsophagus are generally surrounded with indurated and everted edges; the erosion sometimes is very deep, sometimes superficial.

---

## PLATE XVI.

THIS Plate exhibits the effects of contraction of the chest consequent on pleurisy.

- Fig.* 1. Anterior view.  
2. Posterior view.

---

## PLATE XVII.

INFLAMMATION and ulceration of the trachea, with deposition of fibrine; also an enlarged thyroid gland.

- Fig.* 1. An extensive inflammation of the mucous tissue of the trachea, with a deposition of fibrine, which is firmly adhering to the inside of the tube.  
2. Fibrine moulded to the shape of the trachea, and bifurcation of the bronchia of an old man who died of laryngitis.  
3. Fibrine expectorated in a severe case of pneumonia.  
4. An enlarged and scirrhus state of the thyroid gland.



Fig. 1.

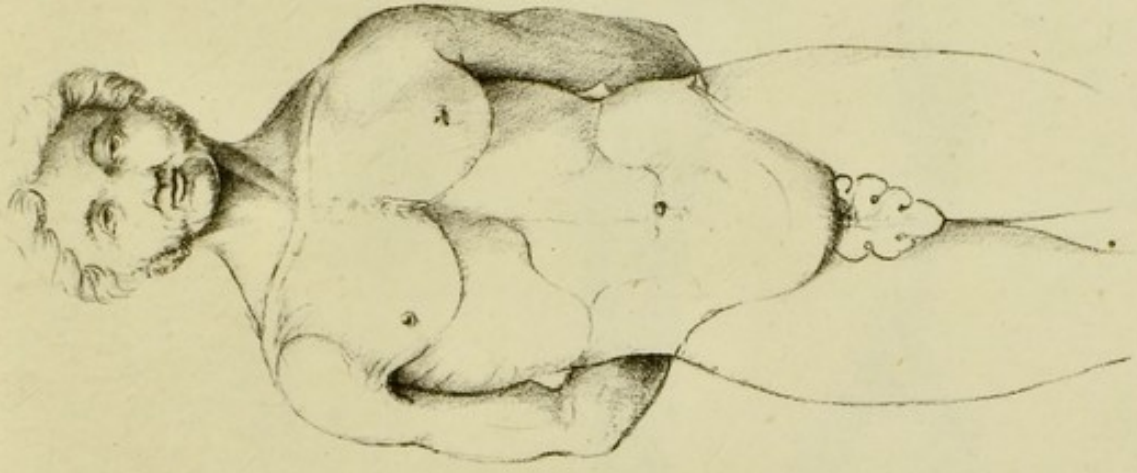


Fig. 2.

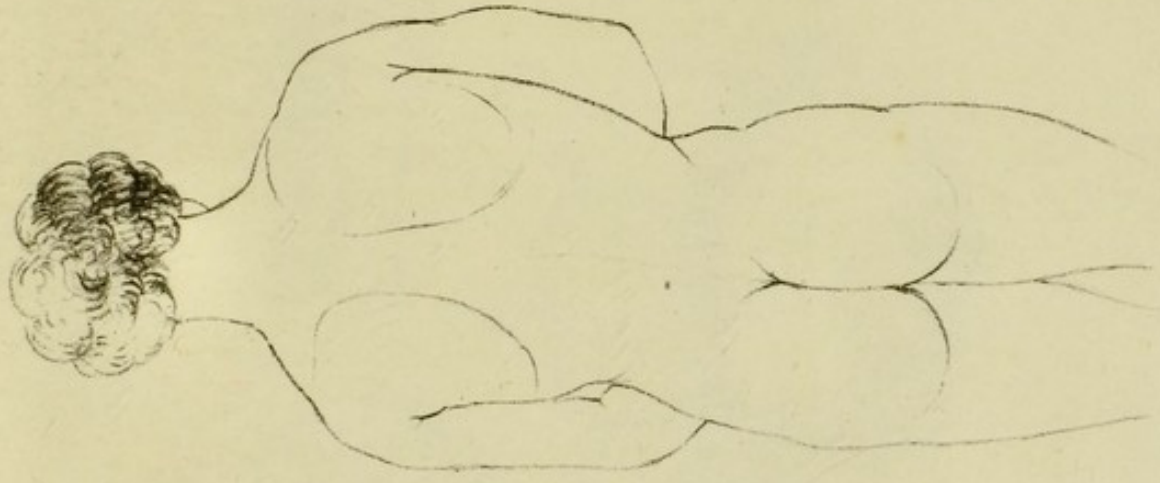






Fig. 1.

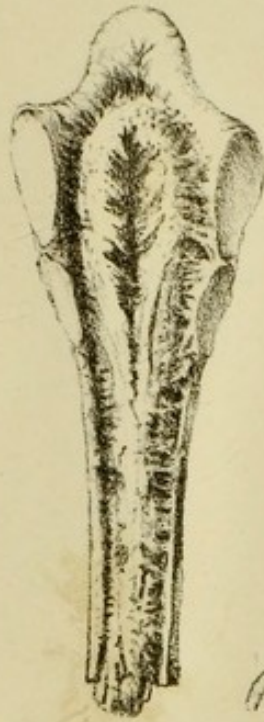

Fig. 2.

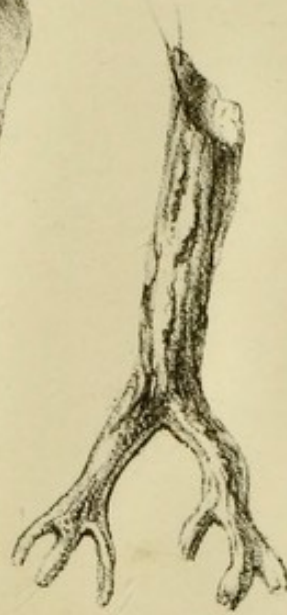


Fig. 3.

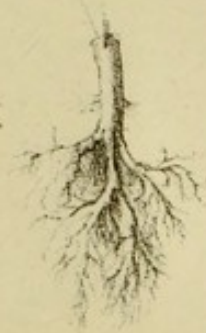

Fig. 3.

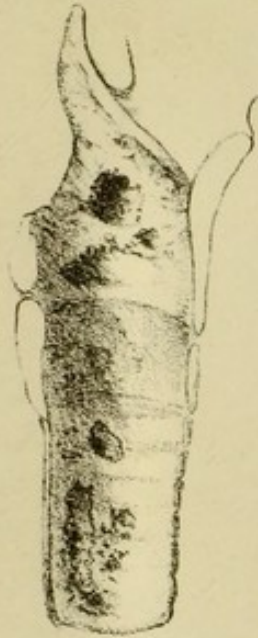


Fig. 4.

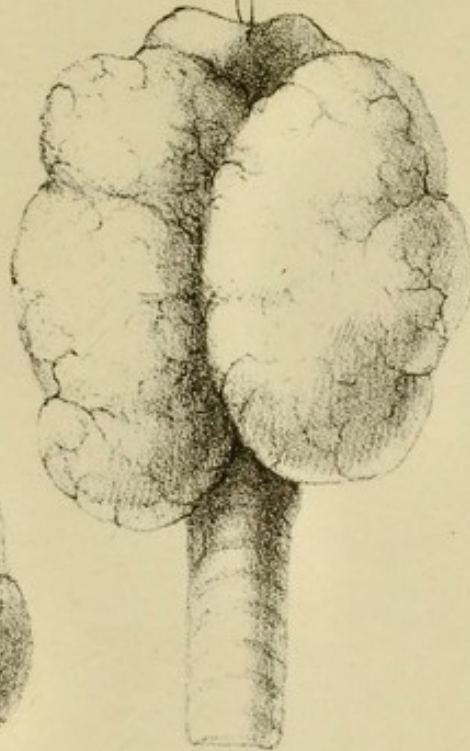
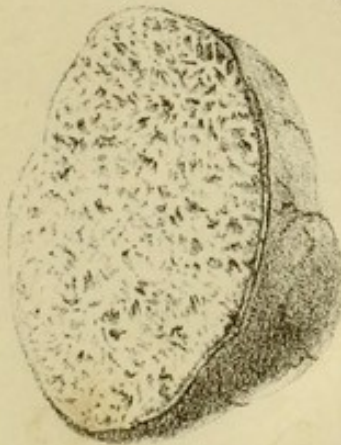



Fig. 5.









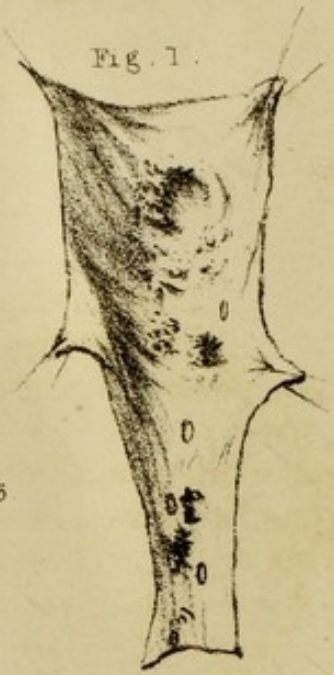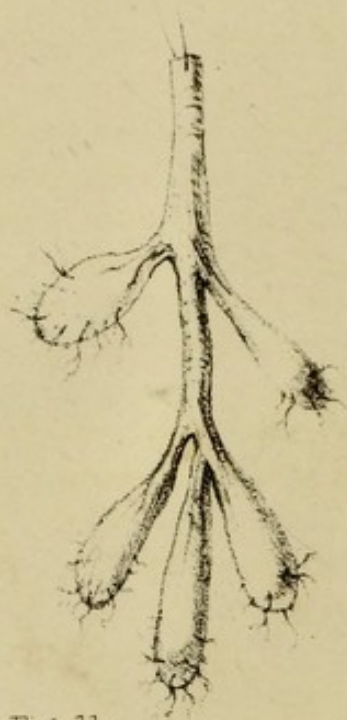


Fig 3

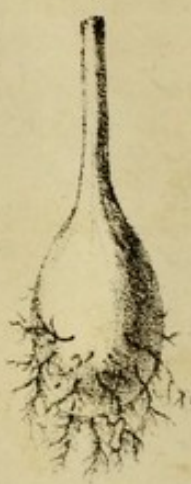

Fig. 11.

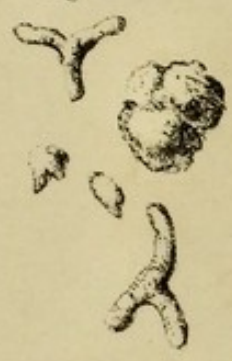

Fig. 4.



Fig. 7.



Fig 8.

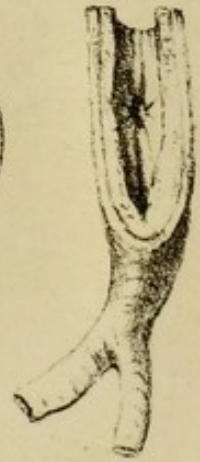

Fig. 9.

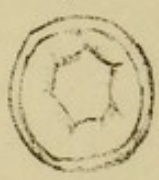

Fig. 5

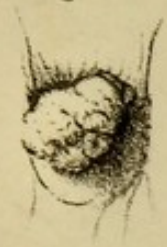

Fig. 10.

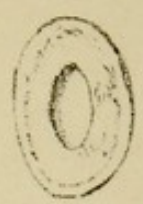

Fig. 6.

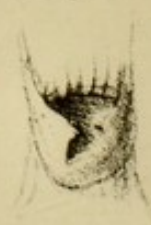
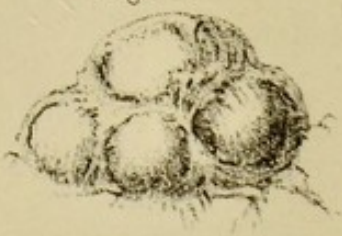
Fig. 12.




Fig. 13.





*Fig. 5.* Section of the thyroid gland, to show its cancellated structure.

6. Extensive ulceration of the mucous tissue of the larynx and trachea.

SYMP. *Croup*—Harsh, dry, metallic cough, dyspnoea, shrill voice, flushed face, veins of the head and neck turgid, and violent action of the muscles of the throat; asphyxia.

*Trachitis*—Heat, pain, soreness in the trachea, dryness of the mucous tissue of the windpipe, followed by copious mucal expectoration, cough.

*Bronchocele*—At first the swelling is without pain, but as the tumour increases in size it grows hard and irregular, the skin acquires a yellow colour, and the veins of the neck become varicose; flushing, headach, and lancinating pains in the tumours.

*Ulceration of the Larynx*—Fixed pain in the seat of this organ, difficulty of breathing, and the patient can only speak in a whisper.

MORB. ANAT. In croup there is generally an exudation of lymph, which, becoming concrete at the very moment of its formation, lines the inner surface of the trachea to a greater or less extent. When this false membrane is removed, the subjacent tunic is found of a deep, vivid, red colour, occasionally livid and somewhat thickened.

This colour is commonly uniform over the whole space covered by the false membrane, but is also frequently unequal, and occasionally altogether wanting.

---

### PLATE XVIII.

THIS Plate represents the diseases of the bronchial membrane and tubes.

*Fig. 1.* Extensive ulceration of the mucous tissue of the right bronchial tube.



*Fig. 2.* Dilated bronchia—ramifications, which, in the natural state, would scarcely admit a fine probe, acquire a diameter equal to that of a crow-quill, or a goose-quill, or even of the finger.

3. A dilated bronchial tube terminating in a cul-de-sac.
4. Ulceration of the bronchial valve and mucous tissue lining the edge of the tube.
5. Fungoid excrescence arising from the edge of one of the bronchial apertures.
6. Rupture of the delicate membrane forming the bronchial valve.
7. A small fleshy excrescence arising from the mucous tissue of the bronchial membrane.
8. The calibre of the left bronchus and its bifurcations diminished from a thickening of the mucous tissue.
9. A transverse section of the lower end of the trachea, showing its calibre reduced in size from thickening of the mucous membrane.
10. The calibre of the left bronchus reduced in size by a deposition of a fibro-cartilaginous matter between the laminæ of the mucous tissue.
11. Concretions expectorated from the lungs.
12. A large chalky concretion expectorated from the pulmonary organ.
13. Lobulated hydatid taken from the substance of the lungs of a person who died of phthisis.

**SYMP.** *Bronchitis*—Dyspnœa, loose, deep, and diffused cough, accompanied with a stuffing noise, copious and loose expectoration, purple, violet, or leaden colour of the lips and cheeks, soft and compressible pulse.

*Dilatation of the Bronchia*—Over the seat of the principal dilatations pectoriloquism, more or less perfect, is perceived, together with a loud mucous rattle, precisely like the cavernous rattle of phthisis.

**MORB. ANAT.** The bronchial membrane is generally covered with mucus, and if you wipe that off with a sponge,



you will find the membrane highly injected, and generally of a dark colour, which soon becomes more red on being exposed to the air, when the mucous secretion is removed. The substance of the lung itself is gorged with venous and arterial blood. If you press the end of your finger upon the part most affected, the impression remains. If you slice the lung, and squeeze the divided portions, a mucus or muco-purulent fluid will issue from the cut surfaces, similar to that contained in the bronchial passages.

**SYMP.** *Of Pneumonia*—Dyspnœa, accompanied with a weight and sense of oppression in the thoracic cavity, metallic cough, expectoration of a dark yellowish, or yellowish green lymph, which adheres firmly to the sides of the vessel, crepitation in some part or parts of the chest, flushed countenance.

**MORBID ANAT.** The lung is heavier than in its natural state, and presents on its surface a livid or violet colour, and a degree of firmness much greater. It is, however, still crepitous; but when pressed between the fingers it is very apparent that it is gorged with a fluid, and that the crepitation is much less than in the healthy state. When cut, its tissue appears of a livid red, and altogether filled with a serous fluid, more or less bloody and frothy, which exudes in abundance from the divided surfaces. In the second stage there is no crackling whatever of the lung on its being pressed between the fingers, and it then acquires a degree of firmness and solidity similar to that of the liver.

In the third stage the pulmonary tissue preserves the same firmness and granular appearance, assumes a pale yellow colour, and pours out, in greater or less abundance, from its divided surfaces, a yellow, opaque, viscid, and evidently puriform matter.



## PLATE XIX.

THIS Plate represents emphysema and apoplexy of the lungs.

- Fig.* 1. General emphysema of the lung.  
 2. Dried portion of the same lung.  
 3. Diffused apoplexy of the lung.  
 4. Circumscribed apoplexy of the lung.

SYMP. *Emphysema*—Dyspnœa, wheezing inspiration, oppression and stricture across the chest, cough, mucous expectoration, lassitude, torpor; pulse generally regular, lips violet-coloured, thick, and swollen.

*Apoplexy*—Dyspnœa, cough, oppression at the chest, expectoration of a bright and frothy, or black and clotted blood, quite pure, or merely intermixed with saliva, or some bronchial or guttural mucus; pulse frequent, full, and vibrating under the finger.

MORBID ANAT. *Emphysema*—The pulmonary vesicles on the surface of the lungs are distended, their size varies from that of a millet seed to a nut; the partitions separating them are ruptured, hence the contained air is readily extravasated. The small bronchial ramifications of the affected part are also dilated.

*Apoplexy*—The lung is generally found gorged with dark venous blood; when sliced, it presents an appearance similar to indurated liver, and the minute vessels and bronchial tubes are completely buried in the bloody mass. On the pleura pulmonalis are seen a great many ecchymose spots. Sometimes the blood is found diffused, sometimes circumscribed.



Fig. 1.

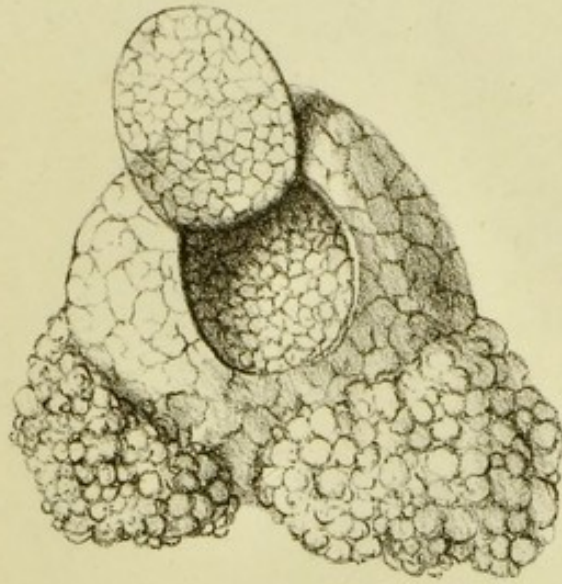


Fig. 3.

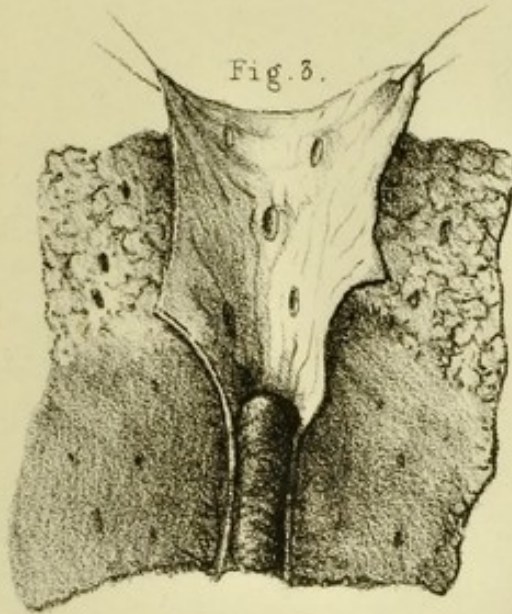


Fig. 4.

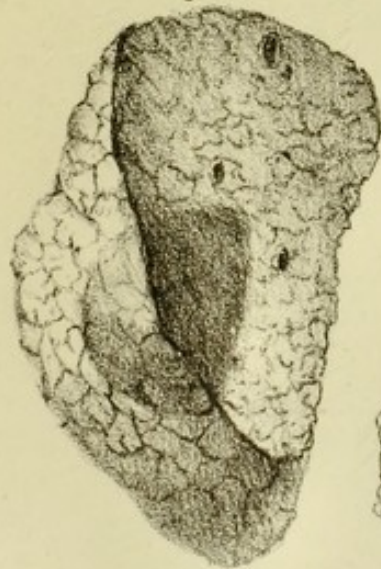

Fig. 2.

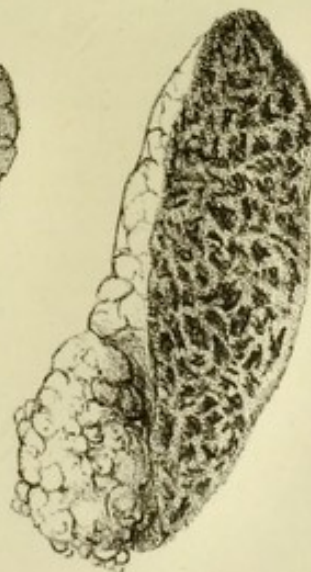







Fig 1.

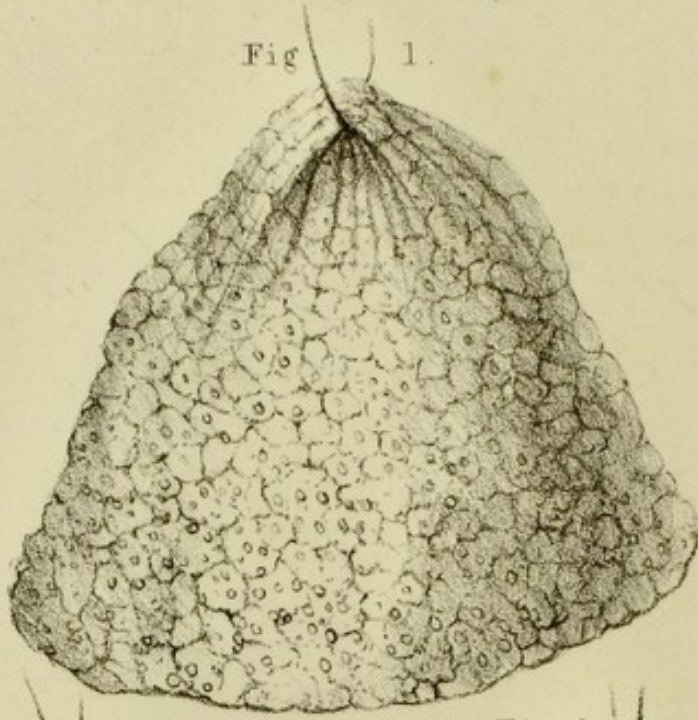


Fig. 3.

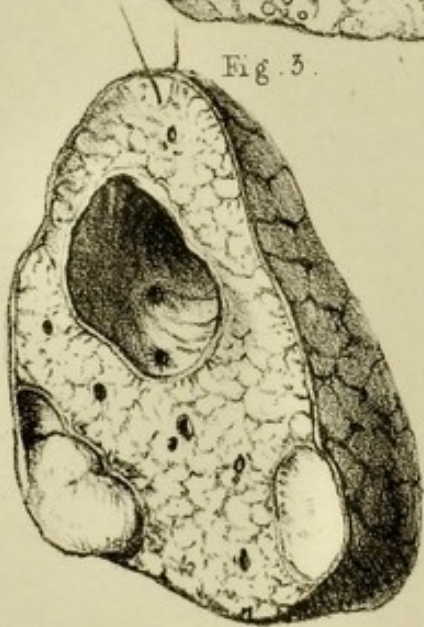


Fig. 2.

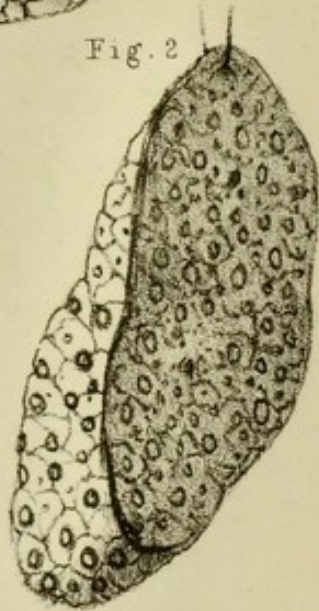


Fig. 5.

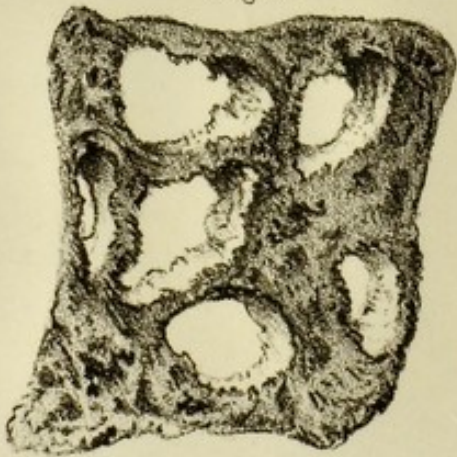
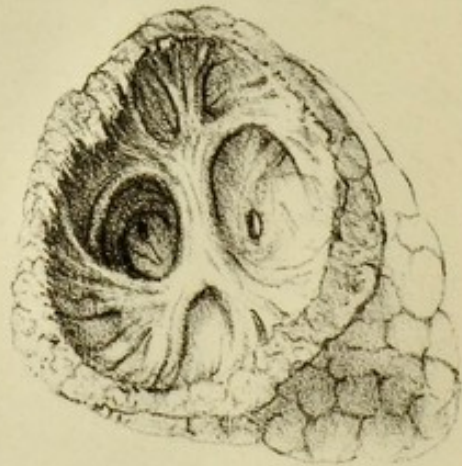


Fig. 4.





## PLATE XX.

MILIARY, indurated, and suppurative tubercles, and vomicæ of the lungs.

- Fig.* 1. A portion of lung loaded with miliary tubercles.  
 2. A portion of lung studded with indurated miliary tubercles.  
 3. A portion of the left lung considerably reduced in size, with a large tuberculous excavation in the superior part of it, and other smaller cavities filled with cheese-like matter.  
 4. One very large tuberculous excavation, with a fibro-cartilaginous state of the bands crossing it.  
 5. Vomicæ, with condensation of the intervening tissue of the lung.

SYMP. *Incipient Tubercles*—Short dry cough, dyspnœa, dull heavy pain at the scrobiculus cordis; fatigued on the slightest motion; venous inactivity around the nasal and ocular portions of the face; dry skin, with a florid state of the mucous tissue of the lips.

*Suppurative Tubercle*—Increased cough, accompanied with copious expectoration of a muco-purulent matter, suppression of the catamenia, colliquative perspiration, and diarrhœa; skin pale, shrivelled, and sometimes dry; intense heat in the soles of the feet and palms of the hand; nose sharp, cheeks prominent, with a purplish blush; pearly appearance of the conjunctiva of the eyes; nails elongated and curved; tormina.

MORBID ANAT. On the surface and in the substance of the lung are generally found the vesiculated, granular, or indurated cheese-like tubercle; sometimes all these might be met with in the same lung; after the vesiculated stage is past, they have the appearance of indurated glands, are of different sizes, and are often found in clusters. Their firmness is usually in proportion to their size, and when laid open in this state they are of a white colour, and of a consistence nearly



approaching to cartilage. Although indolent at first, they at length become inflamed, and at last changed into little abscesses or vomicæ, which breaking and pouring their contents into the bronchia, give rise to purulent expectoration.

---

## PLATE XXI.

ENCEPHALOID, scirrhous, and melenotic state of the lungs, also vomicæ.

- Fig.* 1. An extensive vomica, lined with a membrane of a fibro-cartilaginous texture.
2. A vomica communicating with a dilated bronchial tube.
  3. A fibro-cartilaginous state of the lung, which has destroyed the minute bronchial texture, and produced condensation through compression.
  4. Encephaloid tumours embedded in the parenchymatous texture of the lung.
  5. An extensive deposition of melenotic matter into the substance of the lung.

SYMP. Dyspnœa, cough, expectoration, with slight oppression at the chest.

*Melenosis of the Lung*—Dyspnœa, cough, which is often dry, but sometimes attended by a mucous expectoration, intermixed with some puriform sputa.

---

## PLATE XXII.

HYDATIDS, cysts, bony and chalky concretions in the substance of the lung; also ossific, calcareous, and scrofulous depositions in and on the surface of the bronchial gland.

*Fig.* 1. Section of a large and an encysted tumour, situated



Fig. 1.

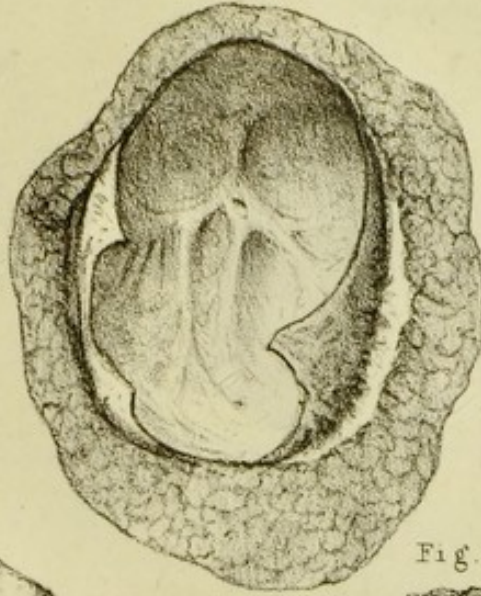


Fig. 2.

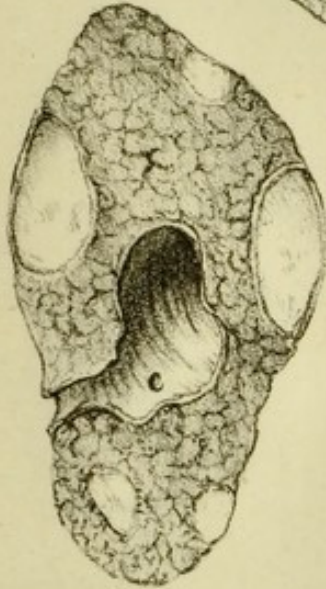


Fig. 3.

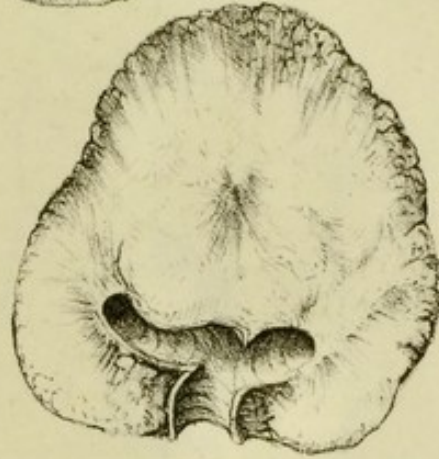


Fig. 5.

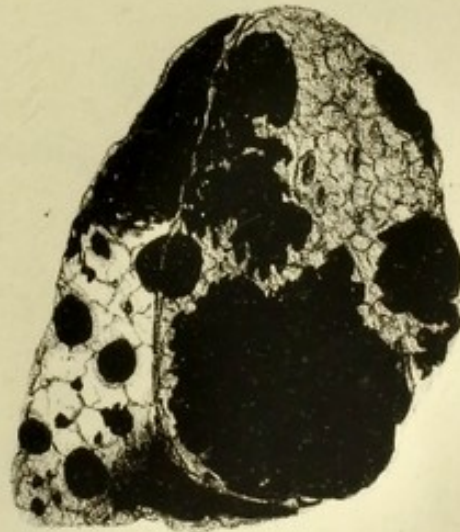


Fig. 4.

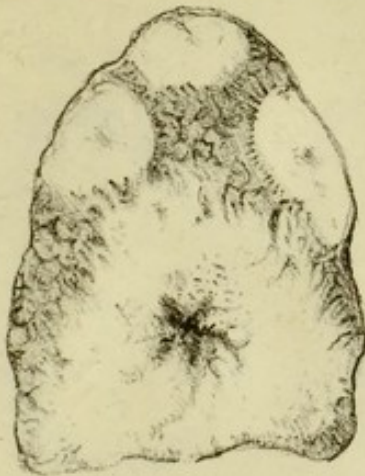






Fig. 2.

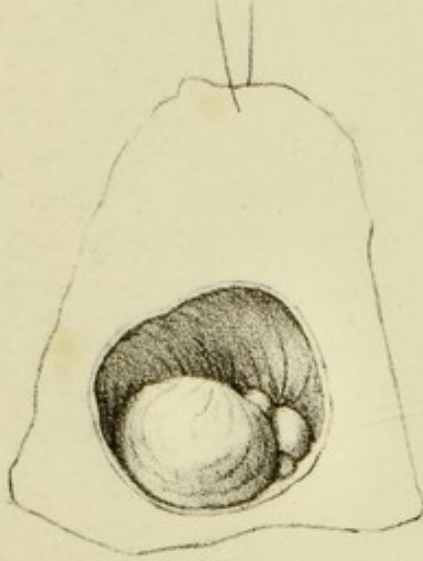


Fig. 1.

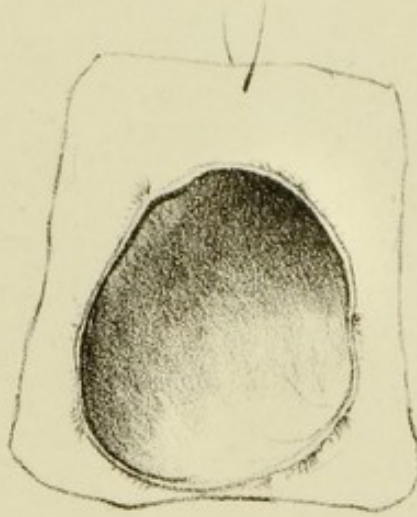


Fig. 4.

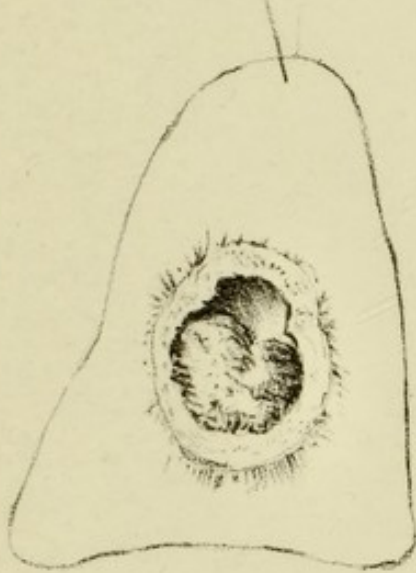


Fig. 3.

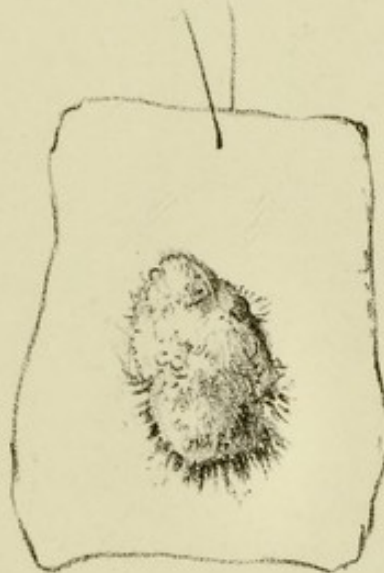


Fig. 7.

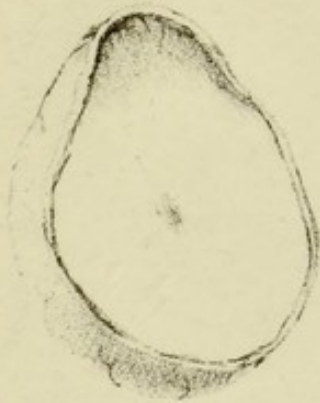


Fig. 6.

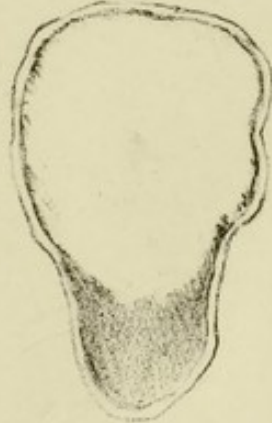


Fig. 5.









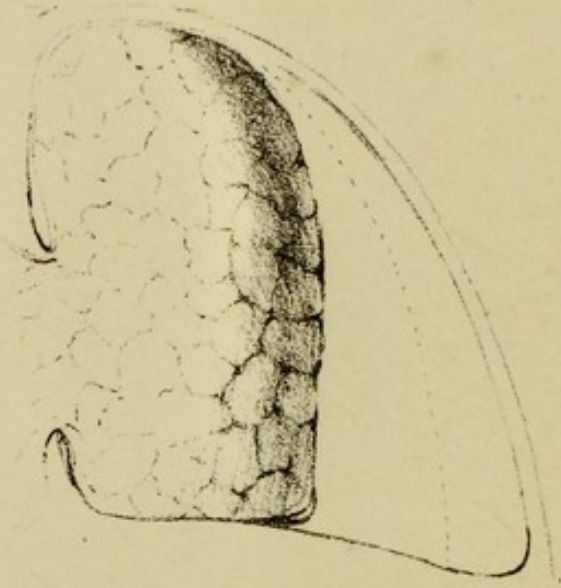


Fig. 4.

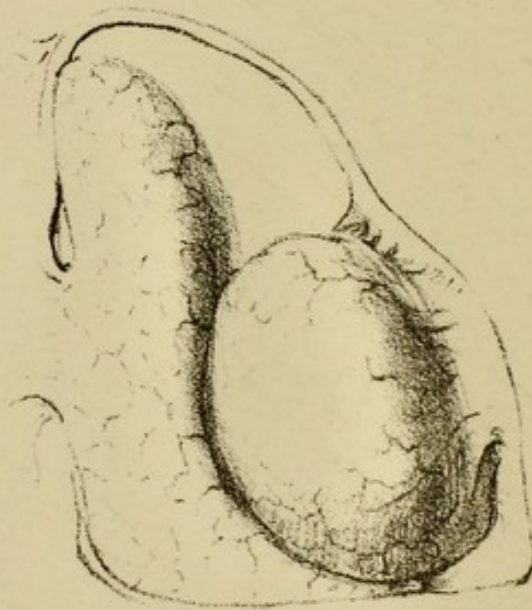


Fig. 5.

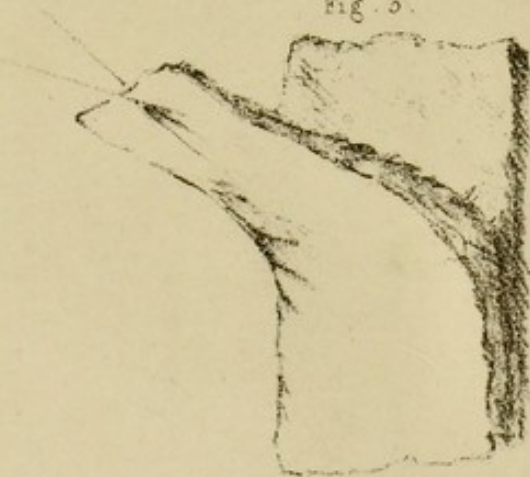


Fig. 2.





in the lower portion of the parenchymatous texture of the lung.

2. Hydatids, situated in the substance of the lung of a youth twelve years old.
3. A large chalky concretion, embedded in the substance of the lung of an old man who died of phthisis.
4. Fibro-cartilaginous state of the capsule of an old hydatid, from chronic inflammation.
5. Bone deposited on the superior and lateral part of a bronchial gland.
6. Chalky concretion, deposited within the capsule of a bronchial gland.
7. An enlarged and scrofulous state of a bronchial gland.

---

## PLATE XXIII. XXIV.

REPRESENT diseases of the pleura pulmonalis and costalis.

### PLATE XXIII.

- Fig.* 1. Condensation or compression of the lung by a fluid, in the cavity of the chest, produced by inflammation of the pleura.
2. Deposition of ossific matter on the pleura costalis.
  3. Fibro-cartilaginous state of the pleura costalis.
  4. The lung compressed by a tumour of the encephaloid character, arising from the pleura costalis.

**SYMP.** *Pleuritis*—Acute pain in the side or sides, difficulty of breathing, dry cough; deep inspirations increase the pain and produce a catch in the side; inability to lie on the side affected.

*Hydrothorax*—Dyspnœa, numbness of one or both arms, sense of suffocation on lying down, frightful dreams, weight and oppression at the chest, urine high



coloured and scanty, anasarca of the extremities; the chest sounds dull on percussion, and the respiration is inaudible.

**MORBID ANAT.** When the pleura is inflamed, it becomes thicker than it is naturally, and in some degree pulpy. There are also interspersed through it a great number of very small vessels containing florid blood, and a layer of coagulable lymph is at the same time formed upon its surface.

#### PLATE XXIV.

- Fig.* 1. EXTENSIVE adhesion of the pleura costalis to the pleura pulmonalis by strong cellular bands.
2. Complete union of the pleura pulmonalis to the pleura costalis.
  3. Small indurated fleshy tubercles arising from the pleura costalis.
  4. Tumours of an albuminous nature arising from the pleura costalis.

---

#### PLATES XXV. XXVI. XXVII. XXVIII.

REPRESENT the effects of acute and chronic inflammation of the pericardium and substance of the heart.

- Fig.* 1. Pericarditis, with an extensive deposition of lymph on the heart and inner surface of the pericardium.
2. The surface of the heart firmly fixed to the pericardium by strong cellular bands.
  3. Perfect adhesion of the pericardium to the surface of the heart.

**SYMP.** *Acute Pericarditis*—Heat and soreness of the integuments covering the pericardial region, with acute pain in the anterior mediastinal space, particularly so on taking a deep inspiration; firm pulse, wiry, and re-



Fig. 1.

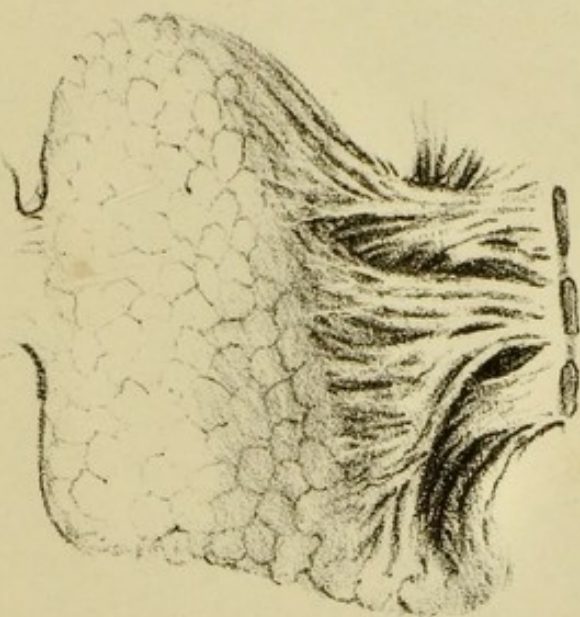


Fig. 2.

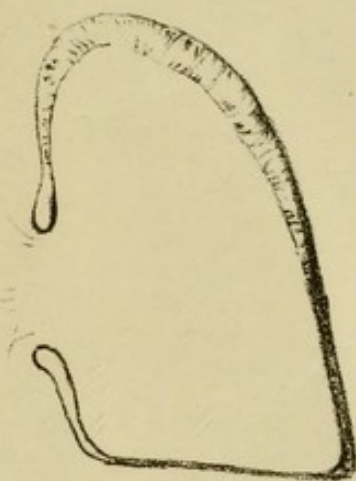


Fig. 3.

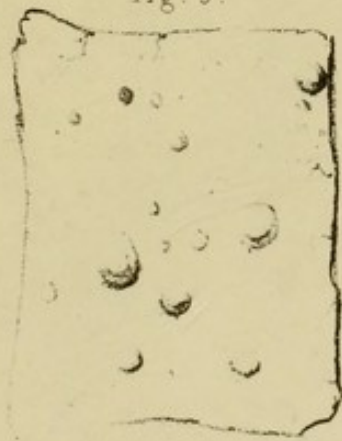
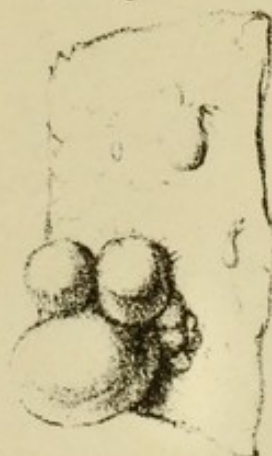


Fig. 4.








Fig. 1.

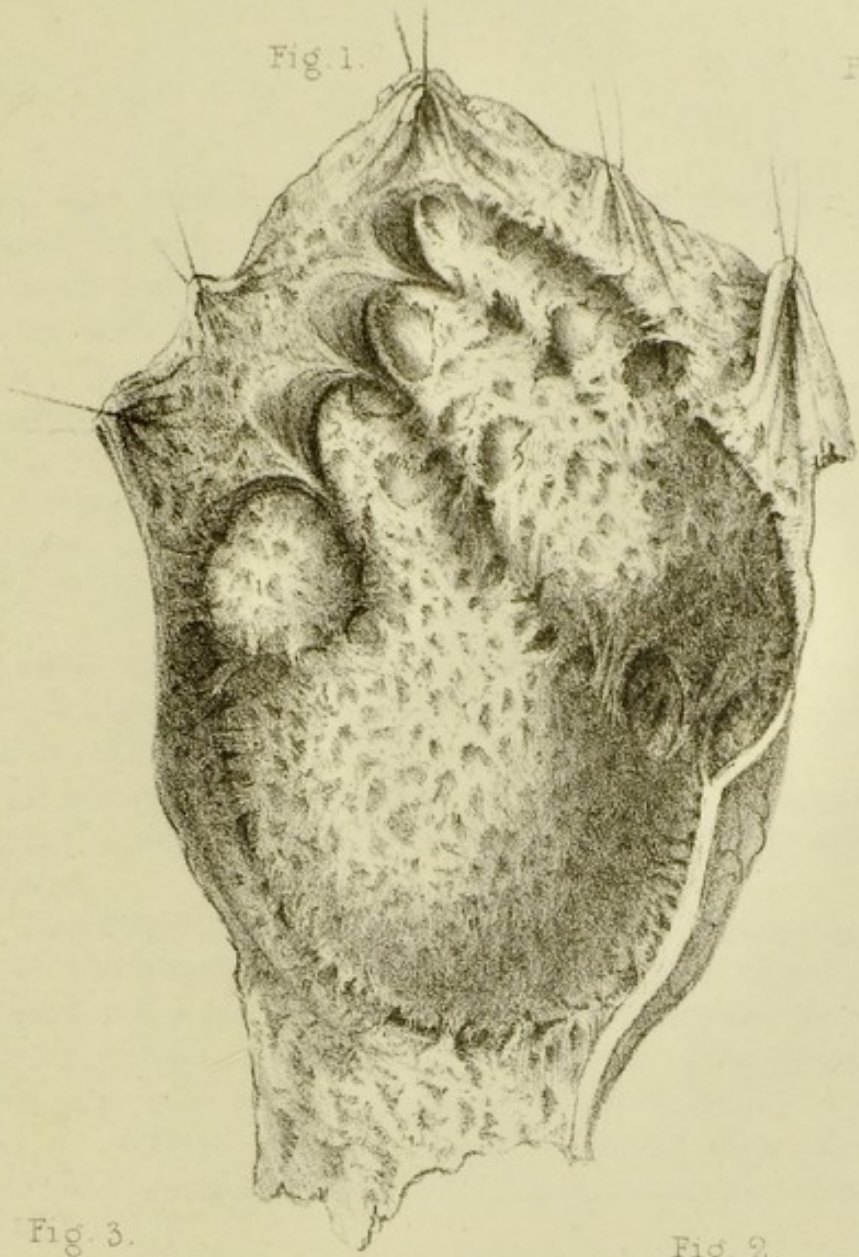


Fig. 3.

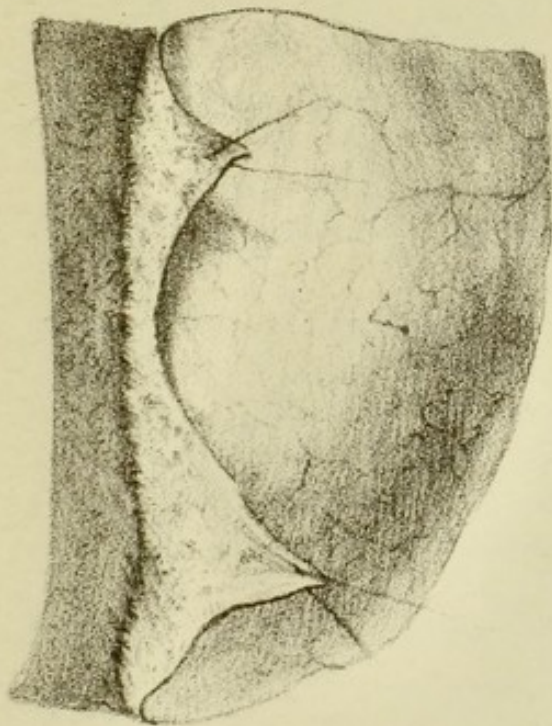
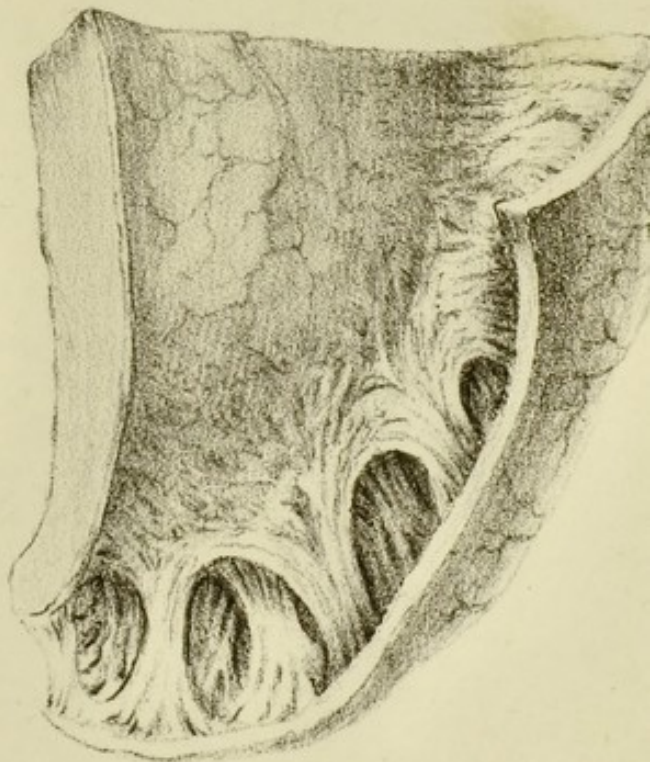


Fig. 2.





## PLATE XXVI.

- Fig.* 1. Several indurated pearly tubercles arising from the serous membrane of the heart.
2. Deposition of a cartilaginous matter into the cellular tissue, between the laminæ of the pericardium reflected on the heart.
  3. Ulceration of the reflected portion of pericardium and muscular substance of the heart.
  4. A great many small cysts attached to the pericardium; they contained a small quantity of limpid fluid of a faint straw colour.
  5. Deposition of bony matter between the laminæ of the pericardium reflected on the heart.

*SYMP. of Ulceration*—Palpitation, fatigued by the slightest exertion, pulse small but quick, constant weight and sense of burning in the regions of the heart.

*MORBID ANAT.* Ulceration of the heart is a very rare disease; I have seen but two cases in twenty years: the subjects were young women, disease asthma. The ulcer was situated in the muscular substance of the ventricle of the heart; it appeared of a dark colour, surrounded by an irregular edge, and bordered with an inflamed areola. One part of the surface of the ulcer had a tough cheese-like matter adhering to it. When first examined, the pericardium contains a quantity of blood-like serum, and very offensive.

## PLATE XXVII.

- Fig.* 1. Chronic inflammation of the serous membrane lining the cavity of the left ventricle, with thickening, and a deposition of cartilaginous matter between its laminæ.
2. Recent effusion of imperfect lymph on the surface of the serous membrane lining the heart (chronic rheumatism).



Fig 2

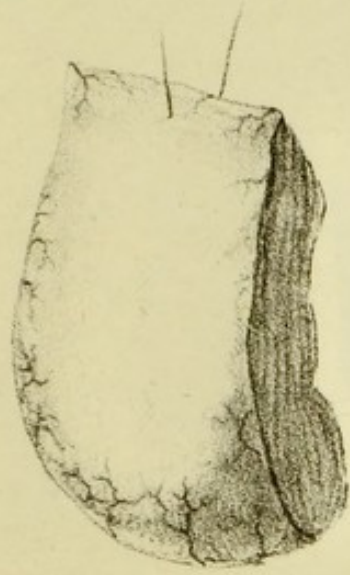


Fig. 1

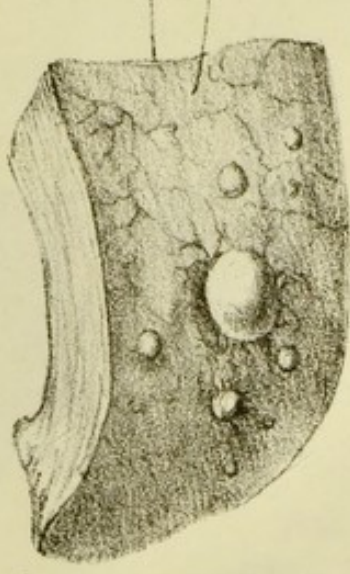


Fig. 3.

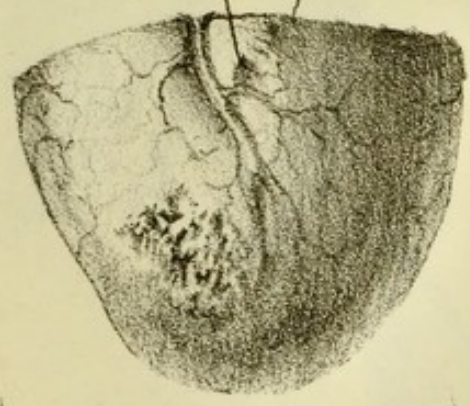


Fig 5

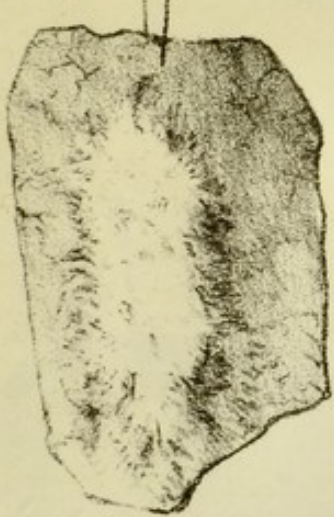


Fig 4

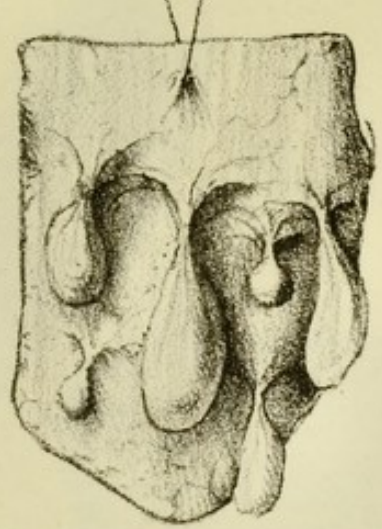






Fig. 1.

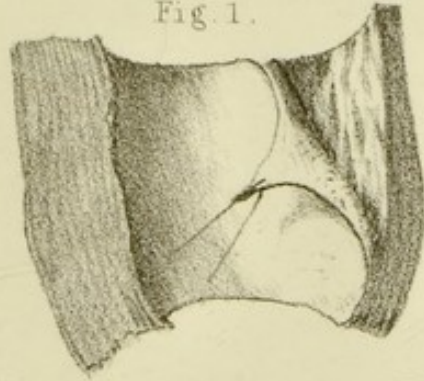


Fig. 2.

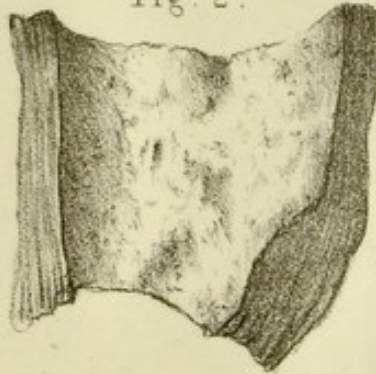


Fig. 3.

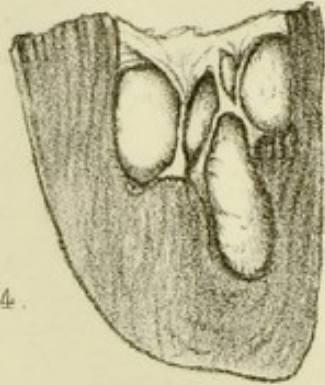


Fig. 4.

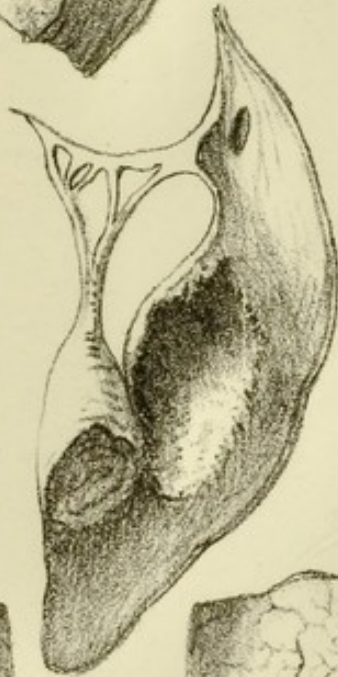


Fig. 6.

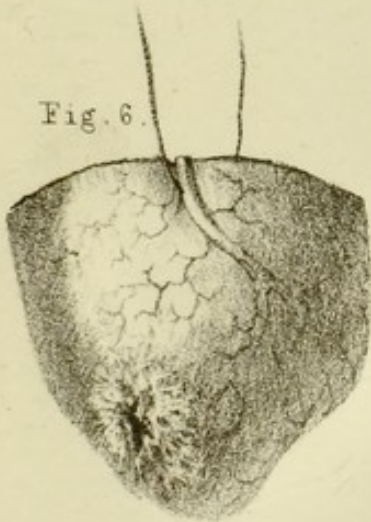


Fig. 5.

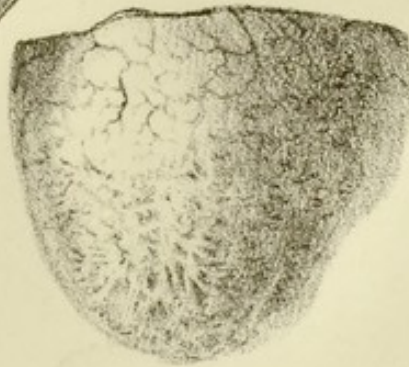







Fig 1

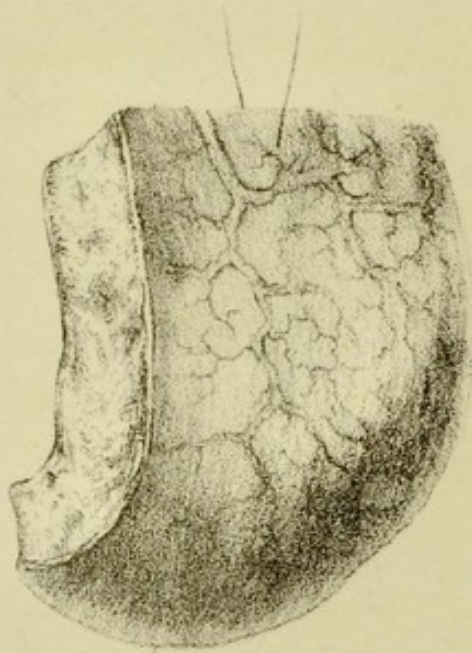


Fig 2

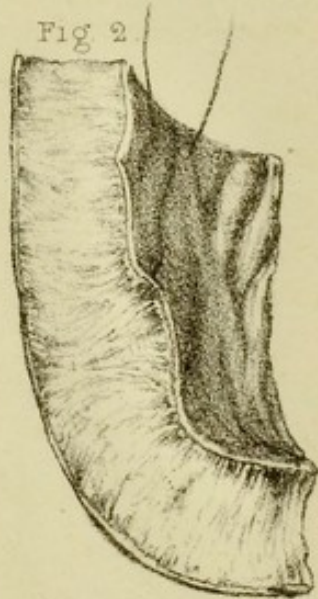
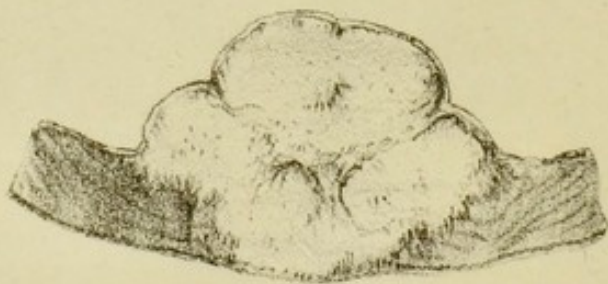


Fig 3.





3. The cavity of the heart filled with coagulable lymph.
4. A large abscess situated in the muscular substance of the left ventricle, the effect of acute inflammation.
5. Softening of the muscular fibres of the lower and lateral portion of the right side of the heart.
6. Softening, attenuation, and rupture of the muscular fibres of the apex of the heart.

SYMP. *Inf. internal Lining*—Agonizing pain in the pericardial region, dyspnoea, concentration of heat over the site of the organ; jactitation, with great expression of distress depicted in the countenance; pulse full, quick, and wiry.

*Softening of the Heart*—Dull obscure pain in the region of the heart, pallid countenance, pulse small and soft, and sometimes intermittent; slight exertion at times produces syncope; the lips are seldom purple, and still more rarely swollen, but on the contrary almost always colourless.

*Polypus*—In cases where the heart has been acting regularly, if the pulsations suddenly become anomalous, obscure, and confused, so as not to be analyzed, we may suspect the formation of a polypus. If the disordered action exists on one side of the heart only, we may consider the thing as almost certain.

MORBID ANAT. *Of Softening*—The muscular fibres are soft, and easily torn; sometimes the softening takes place only on one side of the organ. It is of a dark red or brown colour in the acute stage, pale and yellowish in the chronic.

#### PLATE XXVIII.

- Fig. 1.* DEPOSITION of an earthy matter in the muscular substance of the heart.
2. A fibro-cartilaginous state of the wall of the left cavity of the heart.
  3. An encephaloid tumour arising from the muscular substance of the left ventricle.



## PLATE XXIX.

CARTILAGINOUS and bony deposition on the valves of the heart.

- Fig.* 1. An extensive dilatation of the foramen ovale.  
 2. A mulberry-like tumour, the size of a pigeon's egg, firmly attached to the inner surface of the auricle.  
 3. An opening in the septum ventriculorum.  
 4. Cartilaginous state of the corpora sesamoidea, and a reticulated state of the semilunar valves.  
*a b* Reticulated portions.

- Fig.* 5. The superior margins of the semilunar valves completely encased in bone.  
 6. A deposition of cartilaginous matter between the layers of the serous membrane forming the mitral valve.  
 7. Ossific and cartilaginous deposition in the substance of the tricuspid valve.

SYMP. Blue or violet colour of the skin and mucous tissue of the body, dyspnœa, palpitation of the heart, syncope.

*Ossif. of Semilunar Valves*—Dyspnœa, aggravated on motion, palpitation, intermittent pulse, face generally violet or brick-red colour.

*Ossif. of Mitral and Tricuspid Valves*—Dyspnœa, increased on the slightest motion, irregular action of the heart at its pericardial region, while the pulse at the wrist is small and feeble; purplish hue of countenance.

MORBID ANAT. Tumours situated in the auricles generally have a proper capsule, besides the envelope they receive from the serous lining of the heart. The proper capsule is smooth externally, but internally it has more the character of loose cellular tissue, and apparently enters into the composition of the tumour. The sub-



Fig. 1.



Fig. 2.

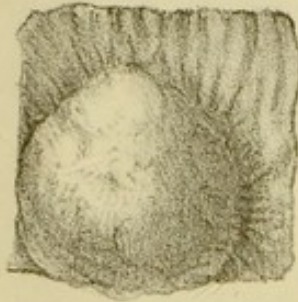

Fig. 3.

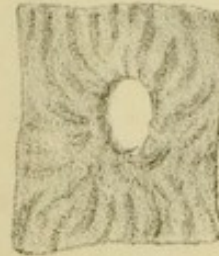


Fig. 4.

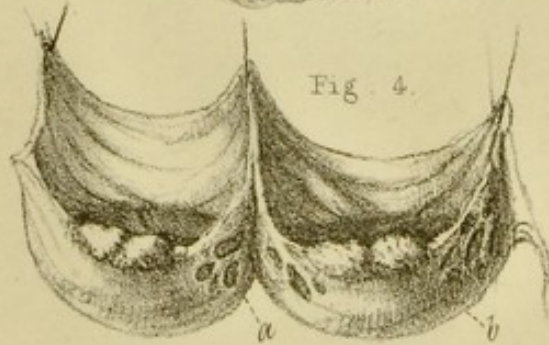


Fig. 5.

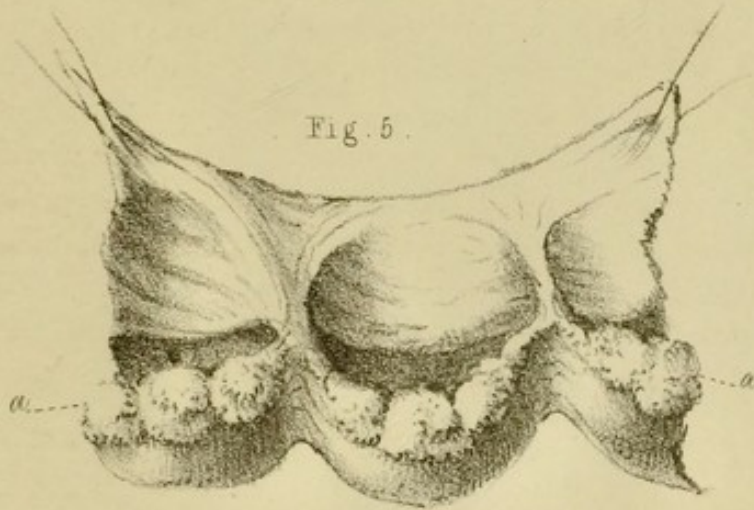
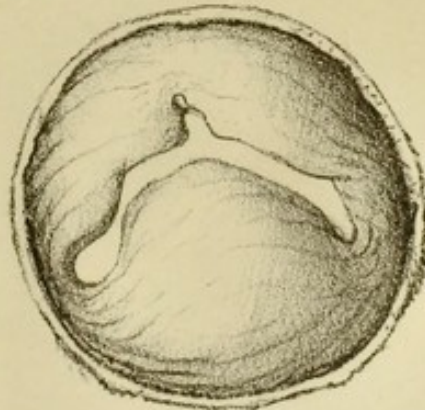


Fig. 7.

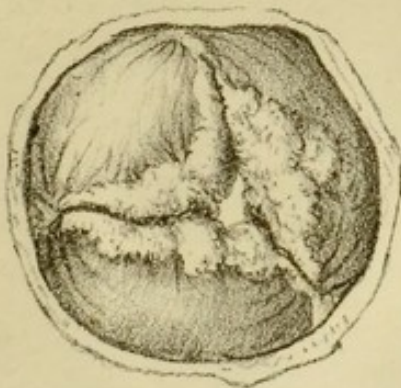

Fig. 6.










Fig. 2

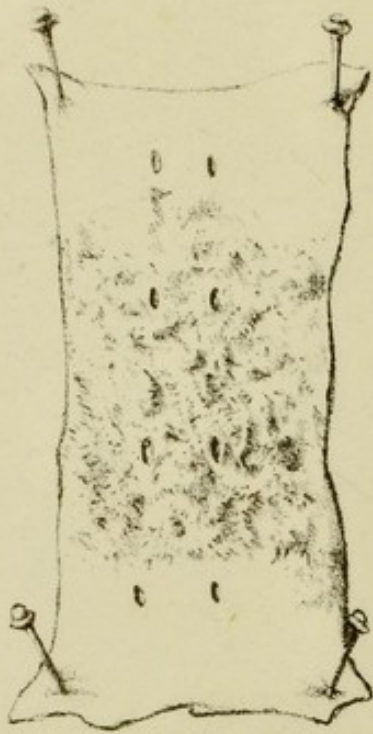

Fig. 1.

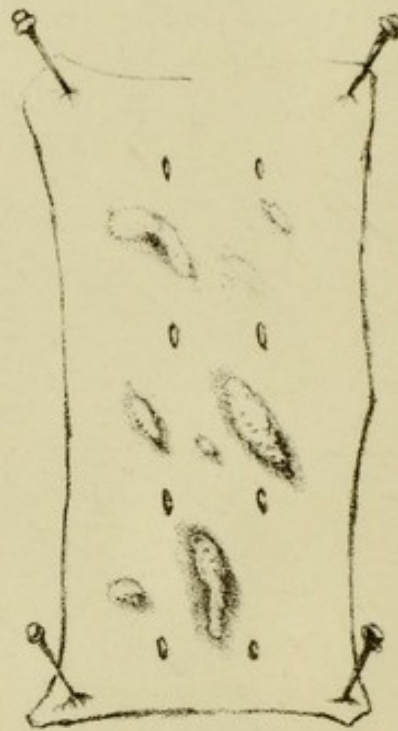

Fig. 4.

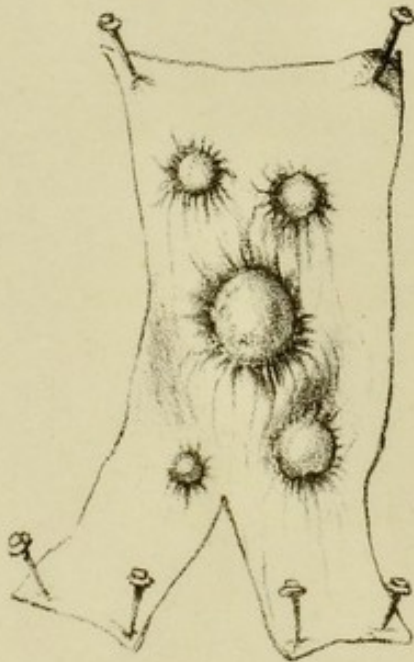


Fig. 3

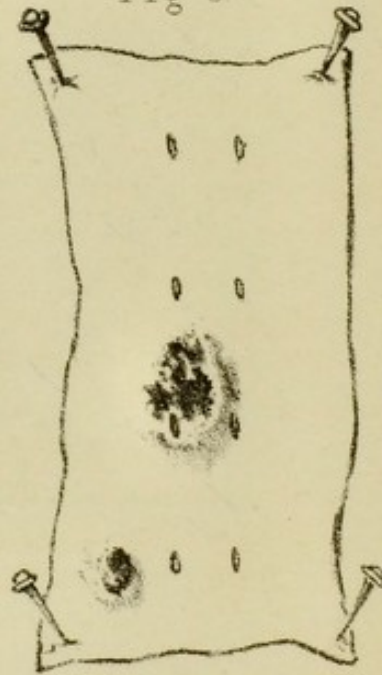
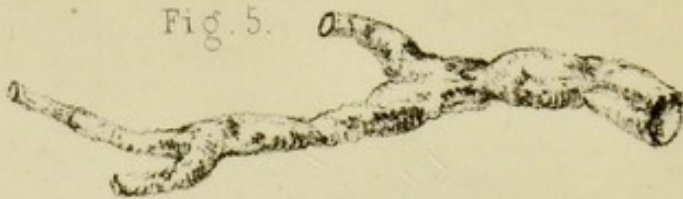

Fig. 5.





stance of the tumour is composed of fibrine, partially organized, and intersected with patches of coagulated blood, of a purplish red colour; sometimes there is a matter in its substance similar to the earthy-like matter formed on the external surface of the aorta.

---

### PLATE XXX.

DEPOSITION of calcareous and bony matter, and ulceration and tumours on the serous surface of the aorta.

- Fig.* 1. Deposition of ossific and cartilaginous matter on the thoracic aorta.
2. Chronic inflammation of the serous tunic of the thoracic aorta, with a deposition of a cheesy or earthy-like matter.
  3. Ulceration of the serous and muscular tunics of the thoracic aorta.
  4. Several tumours of an indurated fleshy structure, arising from the serous membrane of the abdominal aorta.

SYMP. *Inf. of the Serous Memb. of the Aorta*—Strong pulsation in the heart's region, coming on suddenly, dyspnœa, great anxiety, sighing, pulse strong and full, face florid, jactitation.

*Chronic*—Sense of weight in the pericardial region, anxiety, and depressed countenance; dyspnœa, bronchitis, pulse slow and weak, disposition to syncope on motion.



PLATES XXXI. XXXII. XXXIII. XXXIV.  
XXXV. XXXVI.

THESE plates represent the effects of acute and chronic inflammation of the serous and mucous membrane of the stomach; XXXV. contains a tuberculated state of the spleen, with a bony and cartilaginous deposition on its capsule.

PLATE XXXI.

- Fig.* 1. This patch represents the vessels in congestion; the larger vessels are distended to their utmost extent, and the capillary vessels are empty.
2. This figure represents the arborescent state of vessels in acute inflammation of the serous tunic of the stomach.
  3. Appearance of the capillary vessels in chronic inflammation; they are enlarged, tortuous, and filled with blood.
  4. Tubercles arising from the serous tunic of the stomach.
  5. Melenotic state of the serous membrane of the stomach.

SYMP. *Sero-Gastritis*—Pain in the region of the stomach, anxious and hurried breathing, hot skin, pulse quick and small, tongue covered by a whitish fur, nausea, sometimes actual vomiting.

*Chronic*—More or less pain at the scrobiculus cordis, aggravated on pressure and accompanied by a sense of distension and confinement after any food has been taken, emaciation, a yellow, clay-like appearance of the skin, tongue broad and soft, pale tip and edges, and covered with a whitish fur.

MORBID ANAT. The serous membranes of all the organs in acute inflammation, present an arborescent state of the minute serous vessels; there is also an infiltration of



Fig. 2.

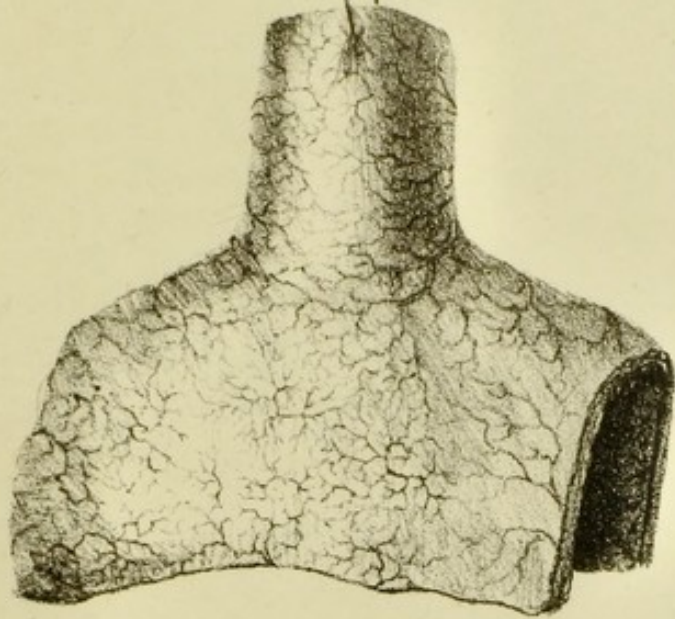


Fig. 3.

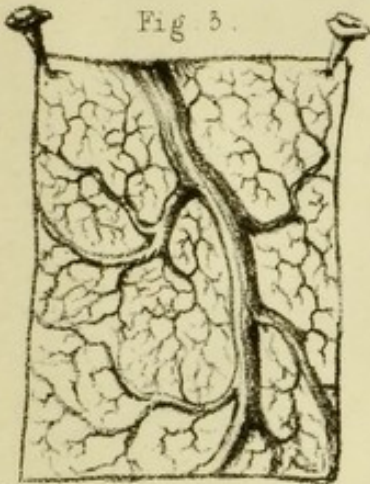


Fig. 1.

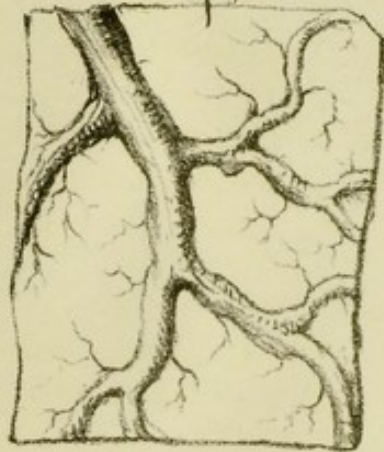


Fig. 5.

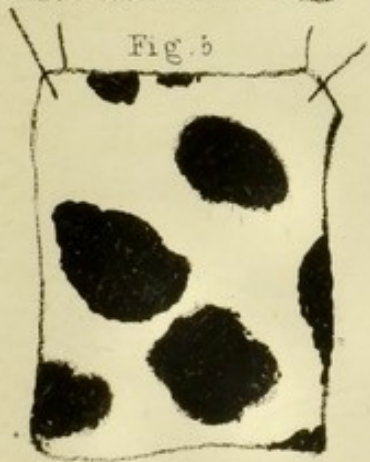
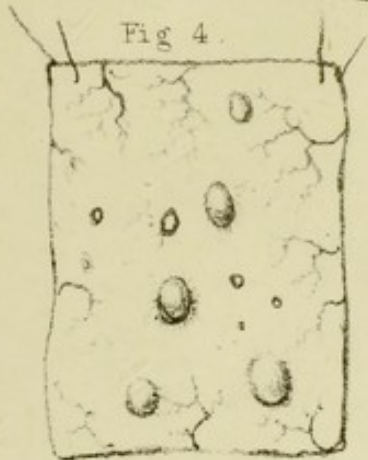


Fig. 4.










Fig. 1.

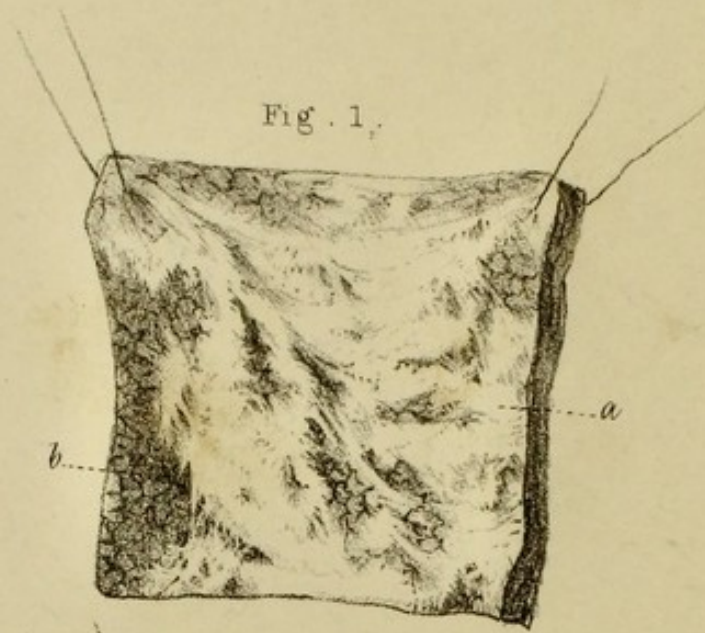


Fig. 2.

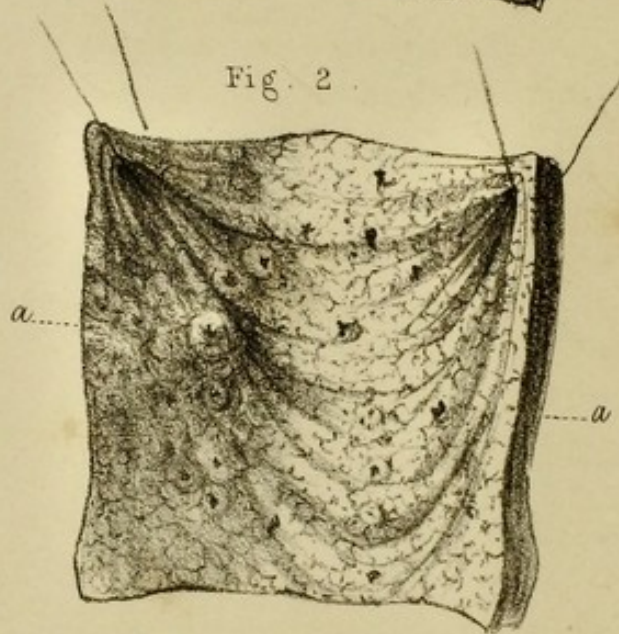
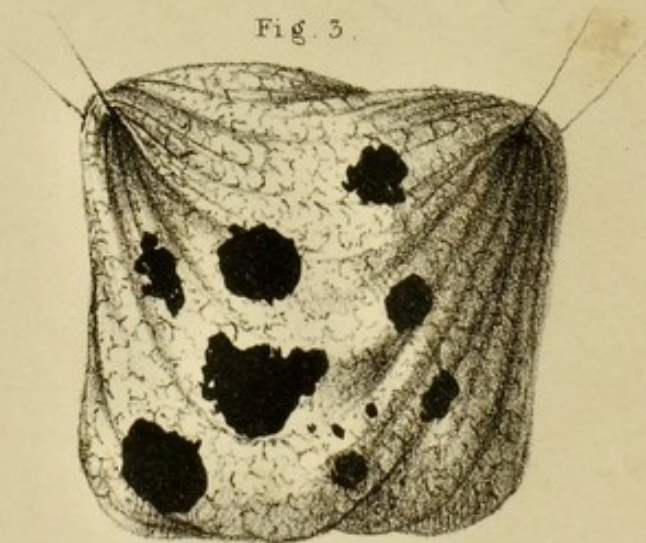


Fig. 3.





lymph between its laminæ, and a larger quantity of blood allowed to circulate through the larger capillary vessels; it also becomes thickened, softer, and less transparent.

*Chronic*—The veins are observed to be enlarged, and their capillary vessels dilated and loaded with a red-coloured blood.

### PLATE XXXII.

*Fig. 1.* A deposition of lymph on the mucous surface of the stomach in acute gastritis.

*a* Lymph firmly adhering to the villi of the stomach.

*b* Lymph removed, shewing a red and pulpy surface.

*Fig. 2.* Minute ulceration of the mucous follicles of the stomach.

*a a* The ulcerated points.

*Fig. 3.* Melenotic state of the mucous tissue of the stomach; those parts unoccupied by the black matter are white and corrugated, and the stomach was very much attenuated.

**SYMP.** *Acute Muco-Gastritis*—Nausea, vomiting; full, hard, and quick, sometimes small and contracted pulse; tongue white, with red tip and edges; concentration of heat about the scrobiculus cordis, great prostration of strength, pain increased on pressure, desire for cold fluids.

*Chronic Muco-Gastritis*—Sense of heat and pain in the stomach after eating, nausea, constipation of bowels, cardialgia with acid eructation, dejected countenance, dyspnœa, cough, palpitation, emaciation, œdema of the lower extremities, tongue covered with a white varnish and red tip and edges, skin cold and harsh to the touch.

**MORBID ANAT.** The mucous membrane of the stomach is sometimes studded with red dots, or covered by patches arising from the effusion of blood into the substance of the membrane itself; at other times a uniform redness



is diffused over its whole extent, being particularly conspicuous, and of a deeper shade, around the cardia and pylorus.

### PLATE XXXIII.

- Fig.* 1. Thickened and pulpy state of the mucous membrane, with a deposition of lymph between it and the muscular fibres of the stomach.
2. An attenuated state of stomach, from long and protracted inflammation.
  3. An attenuated state of stomach, with the solution of its mucous and muscular parietes.

**SYMP.** Nausea, vomiting after meals, pain in the region of the stomach, increased on pressure, cardialgia, prostration of strength, pulse small and quick, tongue red tip and edges, skin dry and husky.

**MORBID ANAT.** The mucous coat softened, varies in colour from white, or grey, to the deepest shade of red; scraped with a knife it is easily detached in the form of a pulpy matter, occasionally it presents slight erosions.

*Perforation*—The edges are thin, soft, fringed, sometimes with a blackish line more or less marked. It presents no appearance of thickening or inflammation. In perforation from caustic poisons, the edges are of the same thickness as the organ; sometimes they are hard and callous.

### PLATE XXXIV.

- Fig.* 1. An encephaloid tumour embracing the lower and external portion of the œsophagus.
2. An encephaloid tumour arising from the mucous membrane of the stomach; it is partially softened, and the flocculent appearance arises from the vessels which formed the tumour.
  3. Encephaloid tumours in the pyloric extremity of the stomach.



Fig. 1.

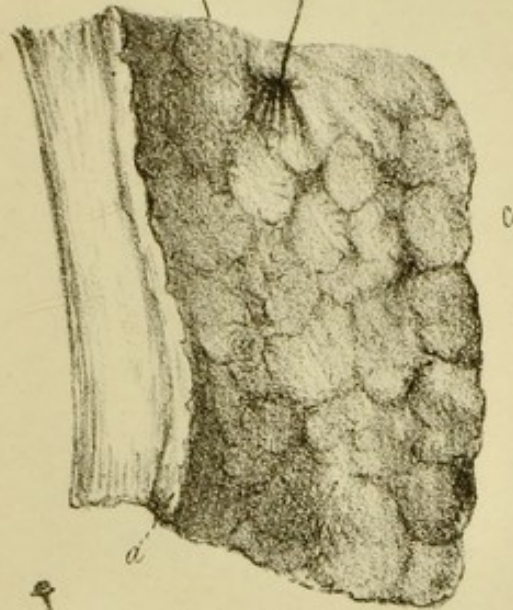


Fig. 2.

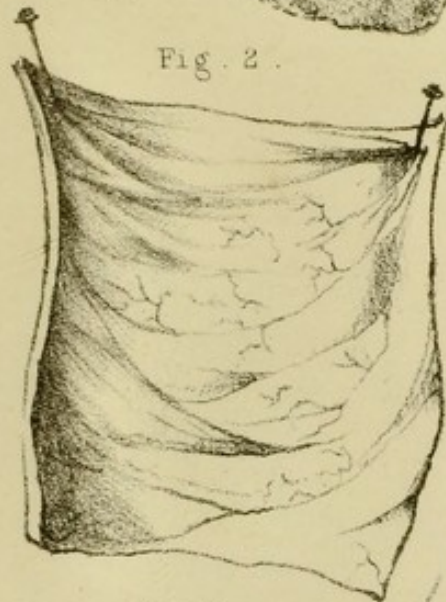
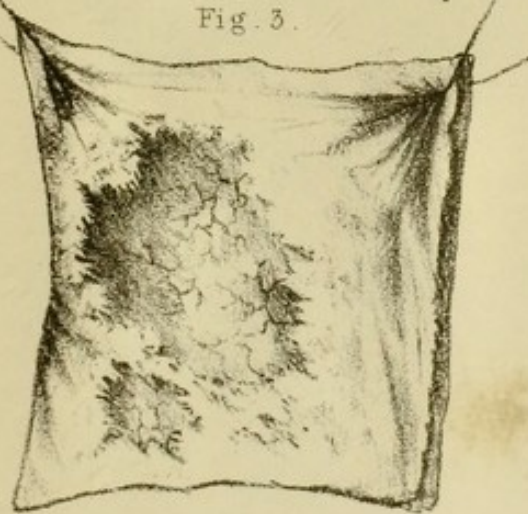


Fig. 3.








Fig. 1.

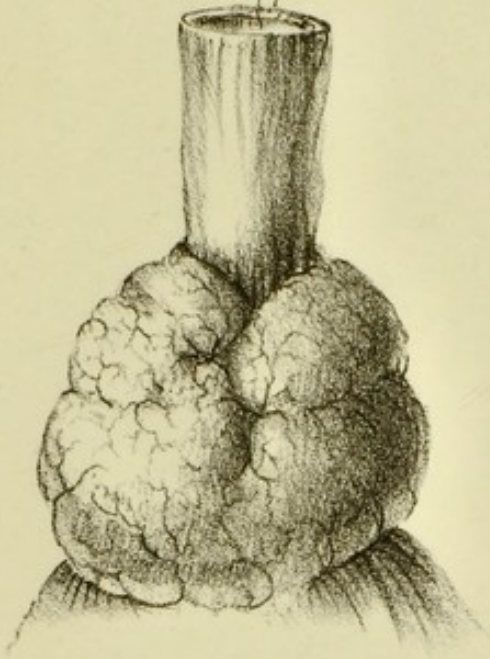


Fig. 2.

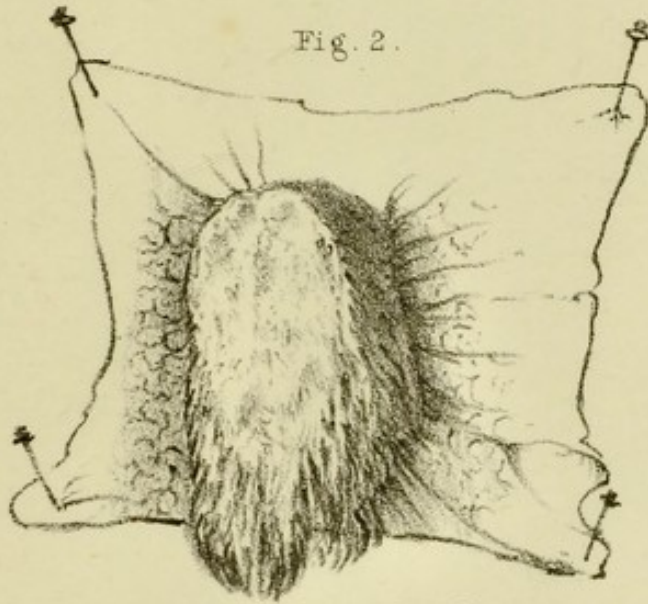



Fig. 3.

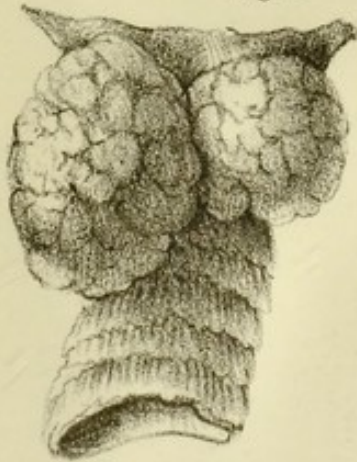








Fig. 1.

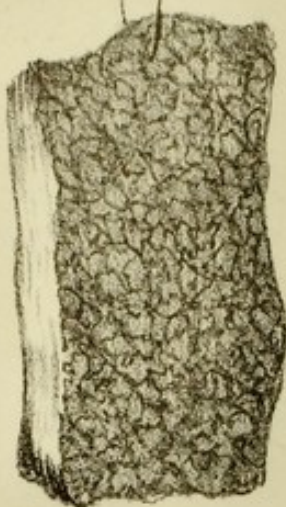


Fig. 2.

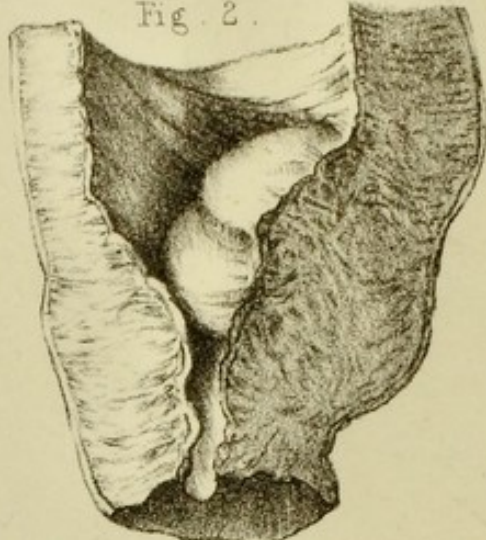

Fig. 4.

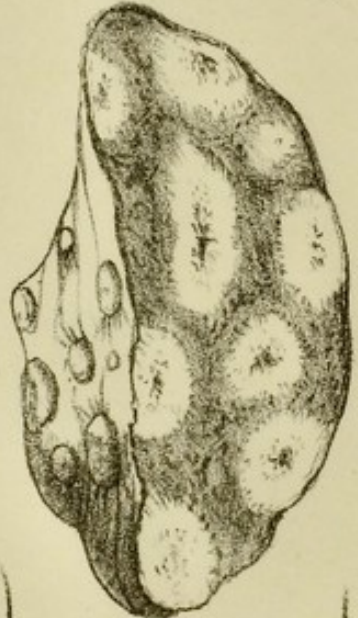


Fig. 3.

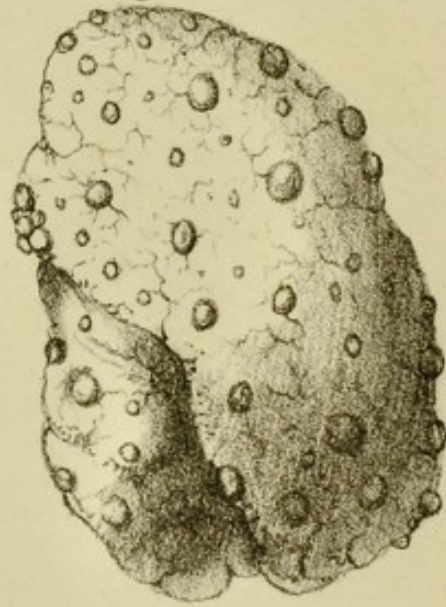


Fig. 5.

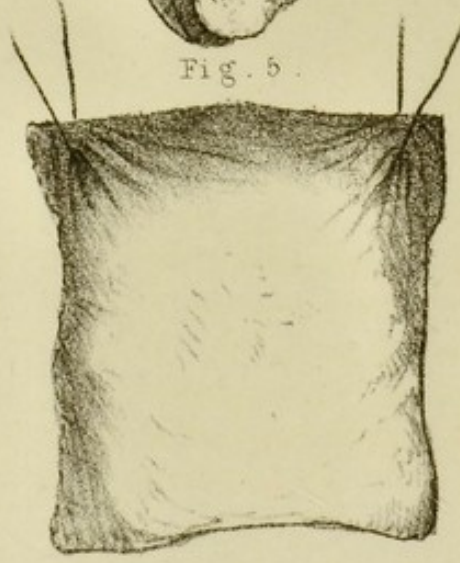
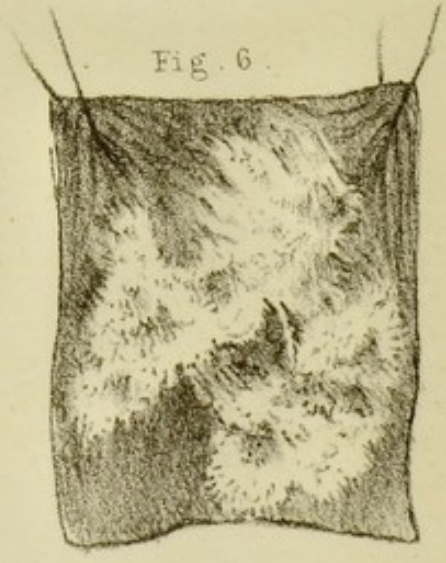


Fig. 6.





SYMP. *Tumour at the Cardia*—Pain in the epigastric and dorsal regions; regurgitation of food; sometimes a small quantity of matter, similar to a solution of arrowroot in water, is ejected.

*Tumours in the Stomach*—Vomiting, particularly after eating, and distension of the epigastric region.

*Rupture of the Stomach*—Suddenly seized with the most acute and unremitting pain in the stomach, and a rigidity and contraction of the abdominal muscles.

### PLATE XXXV.

*Fig. 1.* A portion of scaly scirrhus stomach. In this case the villi were matted together and of a fibro-cartilaginous texture.

2. A deposition of a fibro-cartilaginous matter between the several tunics of the stomach.
3. A tuberculated state of the spleen, taken from a child who died of tabes mesenteria.
4. Section of a tuberculated spleen.
5. A cartilaginous state of the proper capsule of the spleen.
6. Ossific deposition between the laminæ of the capsule of the spleen.

SYMP. *Fungus and Scirrhus*—Pain after eating, nausea, sometimes vomiting, great emaciation, dull, earthy colour of the skin, pulse small and quick, tongue clean at its tip and edges, but the base is generally covered with a dirty, yellowish fur; matter ejected is dark, acrid, and sometimes very offensive.

MORBID ANAT. In the fibro-cartilaginous state, the part is harsh and firm, it feels like bone, and, when cut, presents a light greyish surface, minutely intersected with whitish bands of a cartilaginous texture. If a portion be macerated for some time in water and vinegar, the intervening jelly-like substance is freed from the mass, and the indurated cellular tissue is seen crossing in every direction.



## PLATE XXXVI.

- Fig.* 1. An enlarged state of the mucous glands of the stomach.
2. Solution of the substance of the mucous glands of the stomach.
  3. Extensive phagedenic ulceration of the mucous tissue of the stomach.
- 

## PLATE XXXVII.

THIS Plate represents the effects of acute and chronic inflammation of the serous membrane, and the parenchymatous texture of the liver.

- Fig.* 1. An extensive deposition of lymph on the serous membrane of the liver.
2. Adhesion of the upper part of the liver and the diaphragm, and laterally to the abdominal muscles.
  3. Thickening of the diaphragm and close adhesion to the liver.
  4. Deposition of bone, the size of a bean, surrounded by a false membrane, which has become organized and attached to the peritoneal surface of the abdominal muscles.
  5. A deposition of cartilaginous matter between the laminæ of the serous membrane.
  6. An abscess in the substance of the liver.
  7. A portion of indurated liver from acute inflammation.
  8. Softened state of the parenchyma of the liver.
  9. Incipient fatty, or light nutmeg-coloured liver.
  10. Dark brown nutmeg-coloured liver.
  11. Melenotic nutmeg liver.
  12. Circumscribed melenosis on the serous surface of the liver.



Fig. 1.

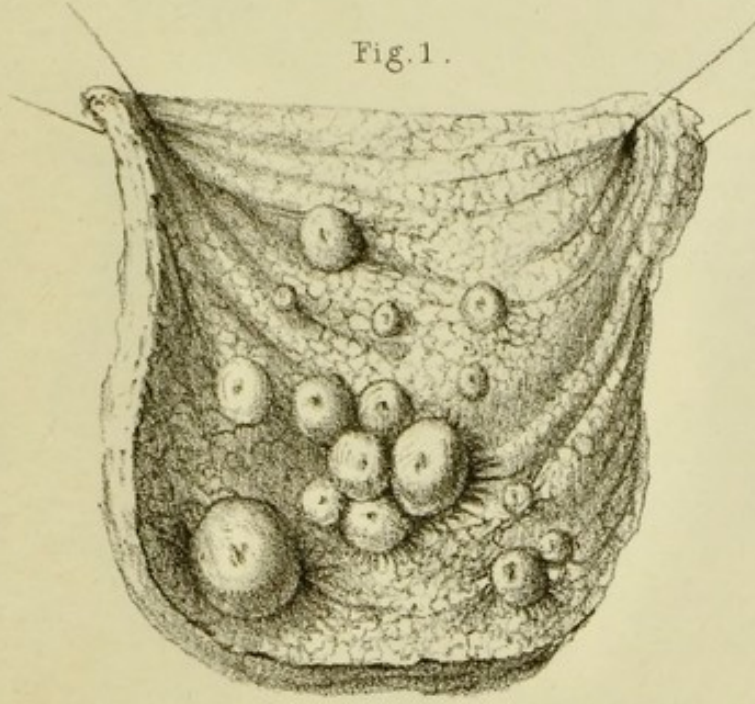


Fig. 2.

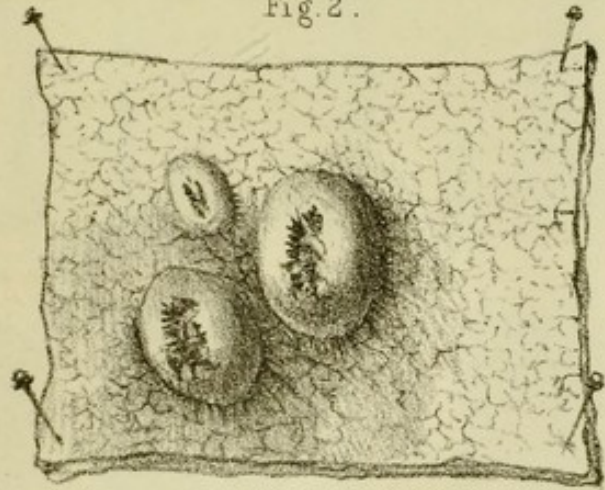


Fig. 3.

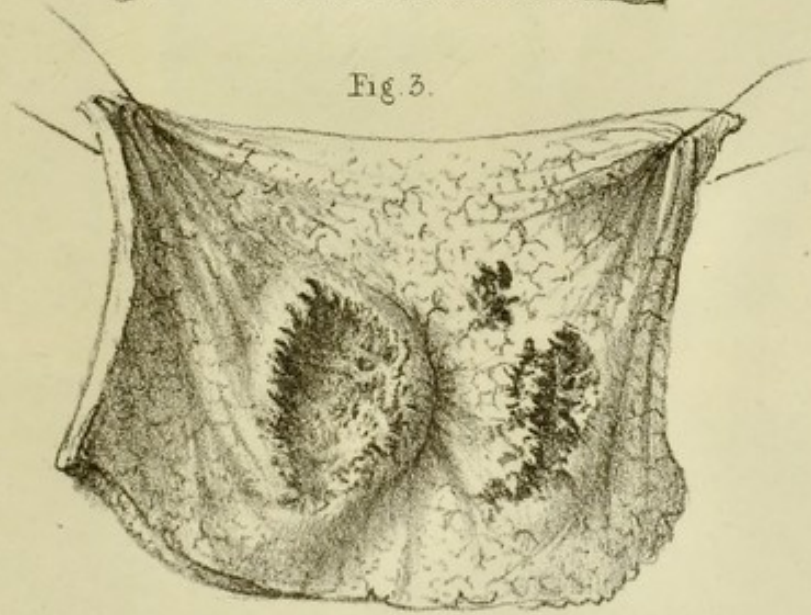






Fig. 3

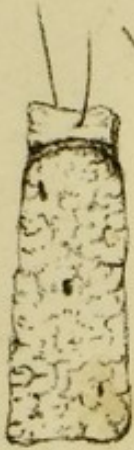

Fig. 2

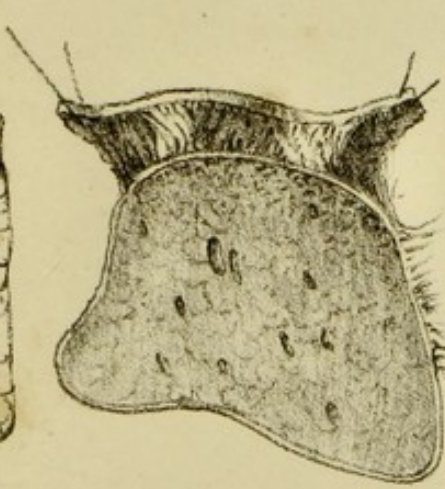


Fig. 1

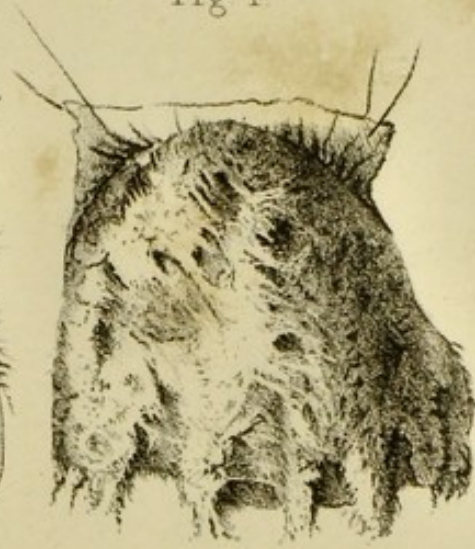

Fig. 4

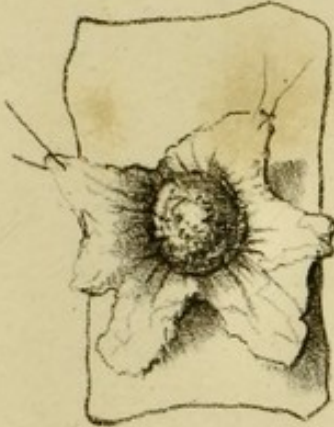

Fig. 5

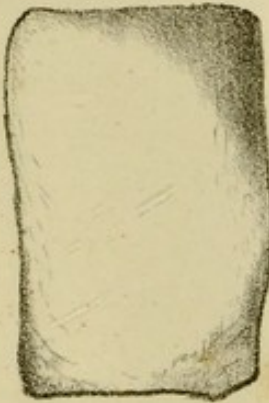

Fig. 6

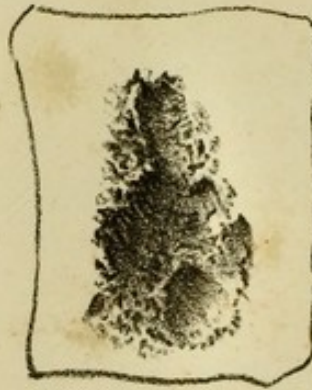

Fig. 9



Fig. 8

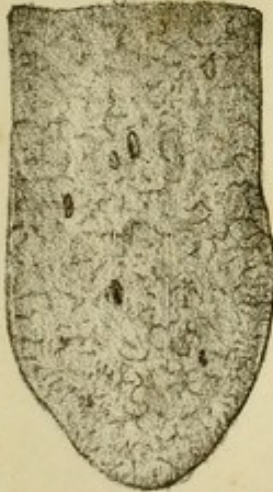

Fig. 7

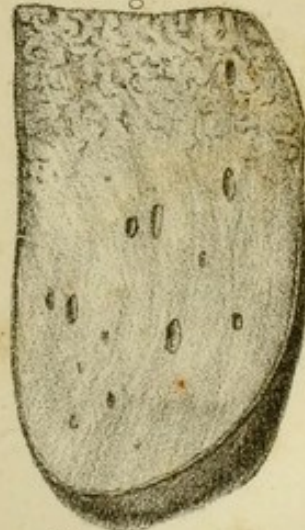


Fig. 10



Fig. 12

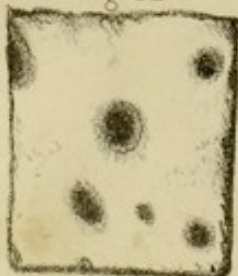




Fig. 11





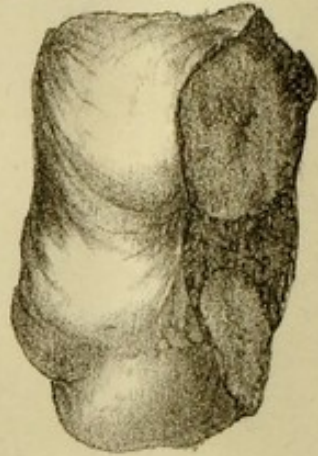


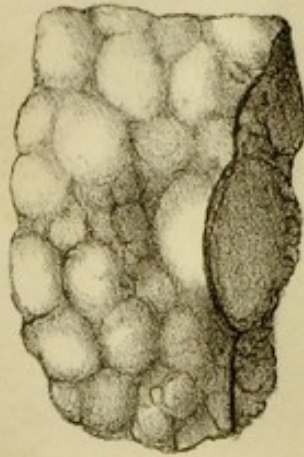
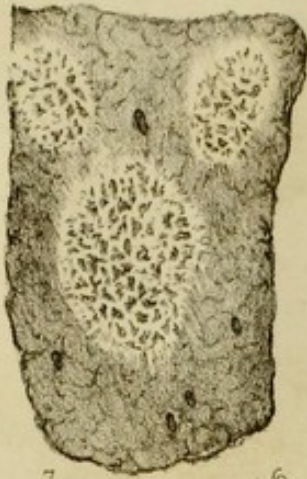


Fig 3

Fig 2

Fig 1

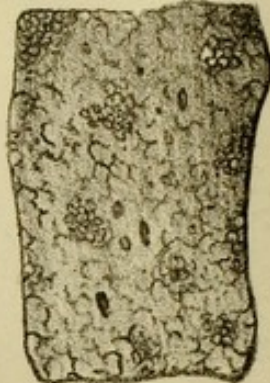
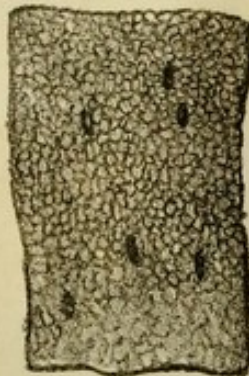
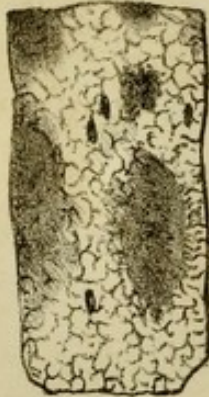


7

6

5

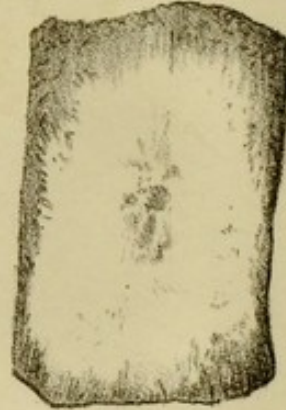
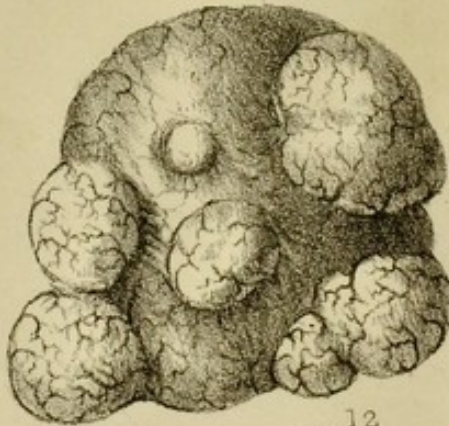
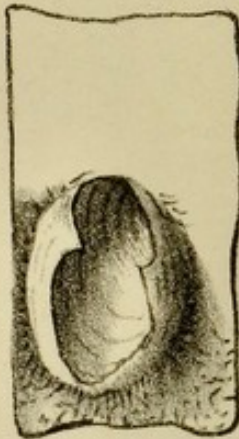4



10

9

8

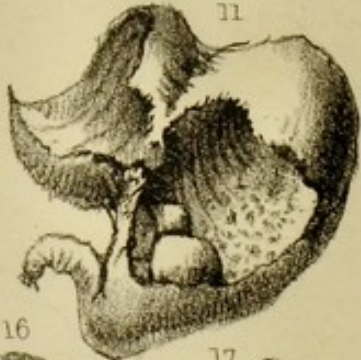
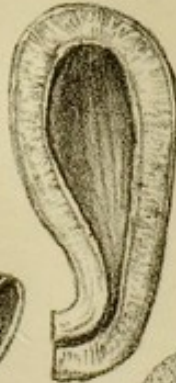
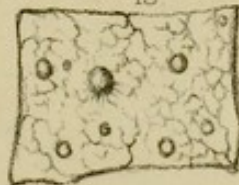
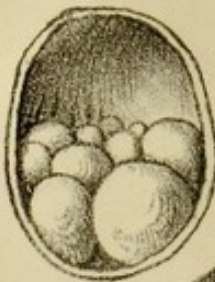14

13

12

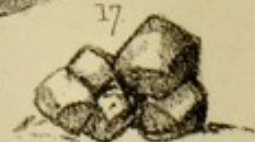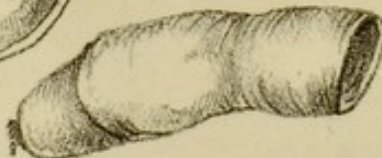
11



15

16

17





**SYMP. Hepatitis.**—Pain in the side, increased on pressure, nausea, vomiting; hurried respiration; yellow tint of the skin; unable to lie on the left side.

*Chronic*—An uneasy sensation in the side, sallow countenance, nausea, dyspepsia; high coloured urine; tongue covered with a dark yellowish fur.

**MORBID ANAT. Acute Inf.**—Its size is generally increased, it cuts solid, and its substance is of a bright purple colour.

*Abscesses* are sometimes found in the substance of the liver, containing a large quantity of pus.

*Softening*—In this state the parenchyma is dissolved, and a larger quantity of fluid is deposited in the substance of the liver. The veins are also found thickened, and their coats either inflamed or of a pearly white colour.

*Hepatic Apoplexy*—The vena porta and hepatic veins are loaded with dark blood, and in different parts of the liver are to be seen circumscribed spots of blood of greater or less size.

*Ossific and calcareous depositions* take place on the serous surface, and in the substance of the liver.

*Exsanguinated liver* is generally found to exist in subjects who die of marasmus, or long and protracted ascites. The texture of the liver is healthy, but quite bloodless.

## PLATE XXXVIII.

- Fig. 1.* Scirrhous tubercles situated in the substance of the liver.  
*2.* Scirrhous tubercles in the substance of the liver.  
*3.* Macerated portion of liver, containing scirrhous tubercles.  
*4.* Light granulated state of liver.  
*5.* Dark granulated state of liver.

Fig 3

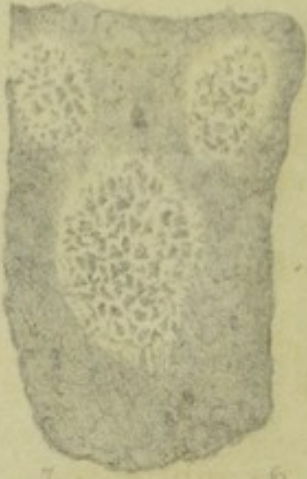

Fig 2

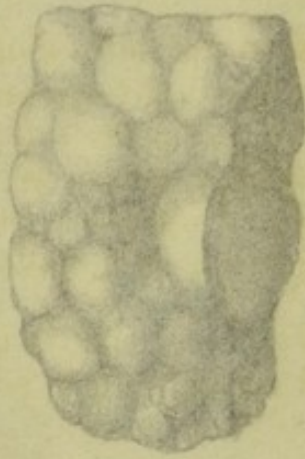
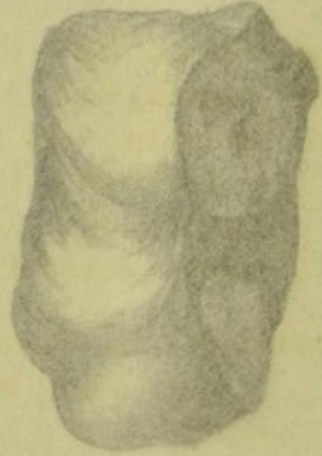
Fig 1



7



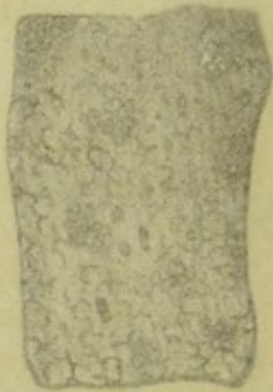6



5



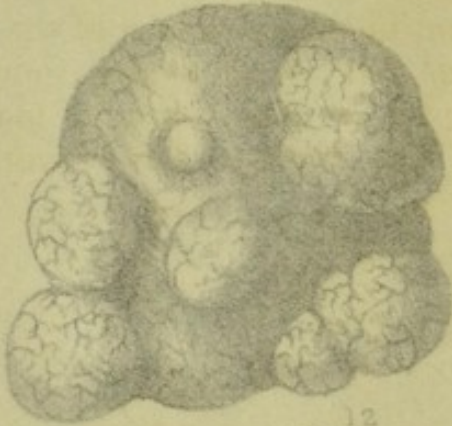4



10



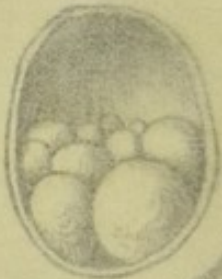9




8



14



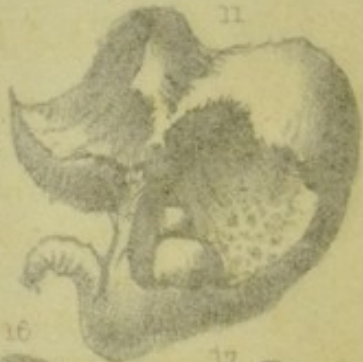15



12



11



13



16



17





SYMP. *Hepatitis*.—Pain in the side, increased on pressure ; nausea, vomiting ; hurried respiration ; yellow tint of the skin ; unable to lie on the left side.

*Chronic*—An uneasy sensation in the side, sallow countenance, nausea, dyspepsia ; high coloured urine ; tongue covered with a dark yellowish fur.

MORBID ANAT. *Acute Inf.*—Its size is generally increased, it cuts solid, and its substance is of a bright purple colour.

*Abscesses* are sometimes found in the substance of the liver, containing a large quantity of pus.

*Softening*—In this state the parenchyma is dissolved, and a larger quantity of fluid is deposited in the substance of the liver. The veins are also found thickened, and their coats either inflamed or of a pearly white colour.

*Hepatic Apoplexy*—The vena porta and hepatic veins are loaded with dark blood, and in different parts of the liver are to be seen circumscribed spots of blood of greater or less size.

*Ossific and calcareous depositions* take place on the serous surface, and in the substance of the liver.

*Exsanguinated liver* is generally found to exist in subjects who die of marasmus, or long and protracted ascites. The texture of the liver is healthy, but quite bloodless.

---

## PLATE XXXVIII.

- Fig.* 1. Scrofulous tubercles situated in the substance of the liver.  
 2. Scirrhus tubercles in the substance of the liver.  
 3. Macerated portion of liver, containing scirrhus tubercles.  
 4. Light granulated state of liver.  
 5. Dark granulated state of liver.



- Fig.* 6. Soft dark brown tubercles, situated in the substance of the liver.
7. Melanotic state of liver.
  8. An encephaloid tumour situated in the substance of the liver.
  9. The external and internal surface of the liver studded with encephaloid tumours.
  10. Softening of the parenchyma of the liver, with a large cyst in its centre.
  11. Ulceration of the gall-bladder and stomach.—The gall-bladder was firmly united to the small curvature of the stomach; ulceration and perforation had taken place at the point of union; the gall-bladder contained several gall-stones.
  12. The proper tunics of the gall-bladder thickened to six times their natural size.
  13. Tuberculated state of the serous membrane of the gall-bladder.
  14. A nest of hydatids taken from the liver.
  15. Dilatation of the ductus communis choledochus.
  - 16, and 17. Gall-stones.

**MORBID ANAT.** Granulated liver is very common; but differs from tubercle in many respects. Granules begin in clusters, and seldom increase in size individually, although the liver will become one perfect mass of them. In slicing this state of liver, the knife grates, as if cutting a sandy substance. The cellular connecting membrane is more or less of a fibro-aponeurotic structure.

*White or scirrhous Tubercle*—The part is hard, and cuts solid; its colour is of a dirty white, or bluish grey.

When macerated, the parenchyma can be washed away, and nothing but its beautiful and cancellated structure is to be seen.

*Encephaloid*—The colour of the liver, in which these tumours are found, is of a purplish brown; and its texture is generally softer than usual. Sometimes they are softened, and of a darker colour than the substance of the liver, in consequence of an effusion of blood from some of the veins.






Fig. 3.

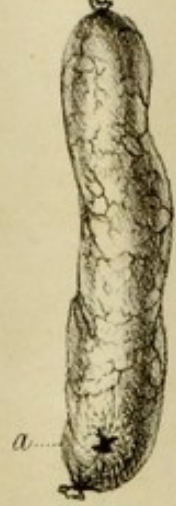

Fig. 2.

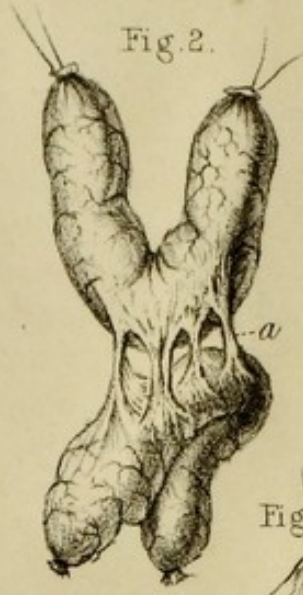

Fig. 1.

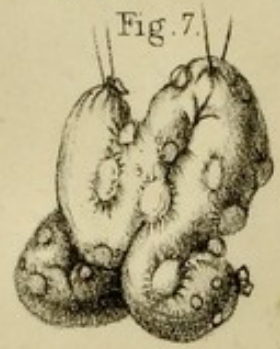
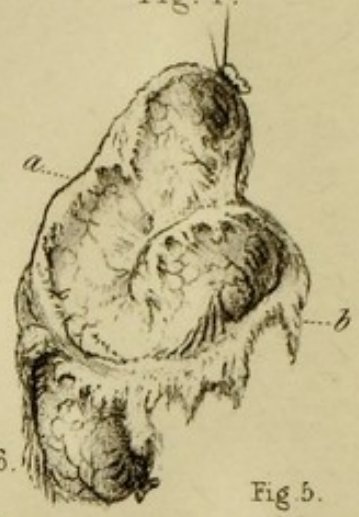
Fig. 7.

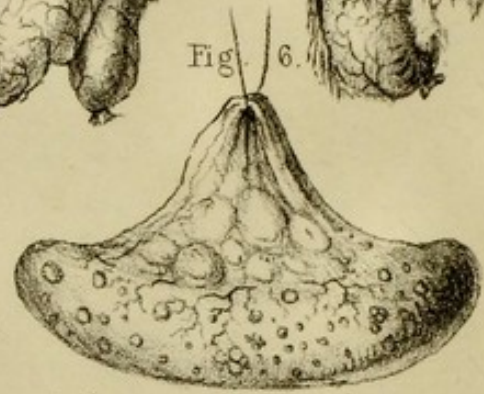


Fig. 6.

Fig. 5.



Fig. 4.



Fig. 8.

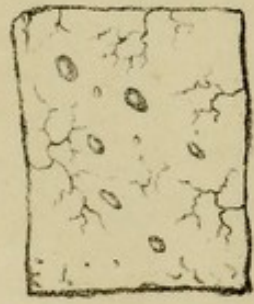


Fig. 12.

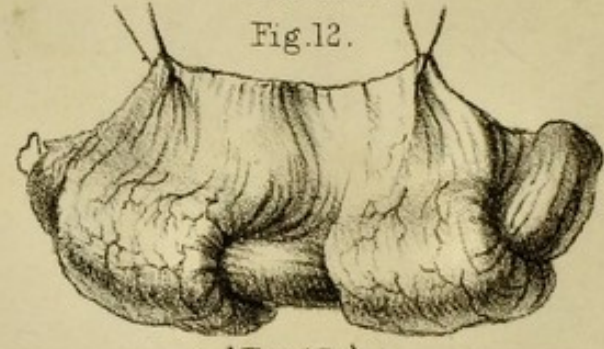


Fig. 11.

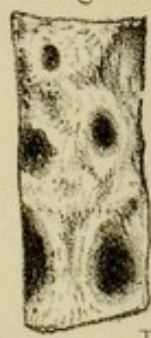

Fig. 9.

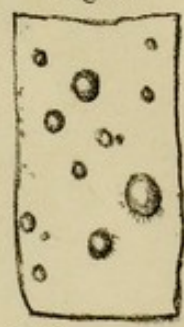


Fig. 13.

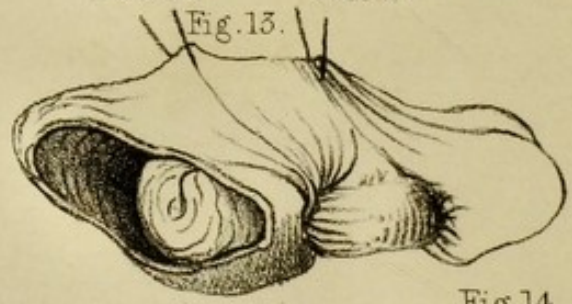

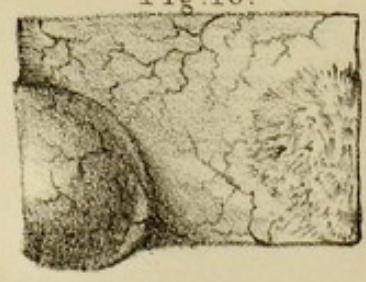
Fig. 15.

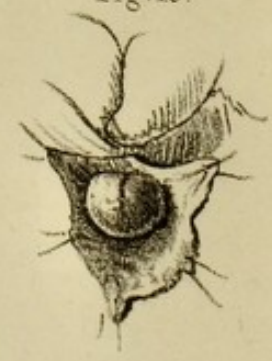

Fig. 14.

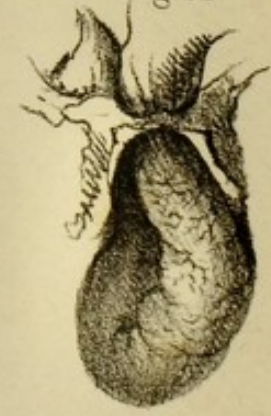

Fig. 10.





*Melenosis*—Sometimes the liver presents a black lobulated mass, intersected by a dark brown and dirty yellowish substance. At times the liver is found loaded with melenotic matter, and softer than usual. Sometimes the matter is circumscribed in the substance, and on the serous membrane of the viscus.

---

## PLATE XXXIX.

THIS Plate shows the effects of acute and chronic inflammation of the serous membrane of the intestines, also intussusceptions and herniæ.

- Fig.* 1. Extensive inflammation of the serous membrane of the ileum, with a deposition of lymph.
- a.* An injected and arborescent state of the minute capillary veins.
  - b.* Lymph lying on the surface of the intestines.
- Fig.* 2. Chronic inflammation of the serous membrane of the ileum, with adhesions of the intestines, by cellular bands.
- a.* Bands.
- Fig.* 3. Ulceration and perforation of the serous membrane of the ileum, close to the caput coli.
- a.* The perforation.
- Fig.* 4. Vesicular, or first stage of tubercle.
- 5. Fibro-cartilaginous tubercle, taken from the intestine of a patient who died of marasmus.
  - 6. Tuberculated state of the serous membrane of the intestine, and an enlarged state of the mesenteric glands.
  - 7. Scrofulous tubercle, arising from the serous tunic, with adhesion of the folds of the intestine.
  - 8. Small fleshy tubercles, arising from the peritoneal surface of the abdominal muscles.
  - 9. Enlarged and indurated tubercles, arising from the peritoneal surface of the abdominal muscles.



- Fig.* 10. Scirrhous tumours, embedded in the cellular tissue, between the abdominal muscles and peritoneum, on the left side.
11. Melenotic matter deposited between the abdominal muscles and reflected peritoneum.
  12. A portion of the ileum, showing two intus-susceptions, taken from an infant.
  13. Section of an intus-susception, showing the invaginated portion.
  14. Strangulated hernia, exhibiting gangrene of the intestines.
  15. A portion of strangulated intestine: the stricture is seated in the neck of the sac.

**SYMP.** *Acute Sero-enteritis*—Extreme prostration of strength; nausea, vomiting; intense pain in the abdomen, particularly so about the navel; concentration of heat in the umbilical region; tympanitic state of bowels, constipation; tongue flaccid, broad, and white; urine high coloured.

*Chronic*—Pain and distension of the abdomen; nausea; tongue broad, and covered with a whitish fur; pulse is jerky, and the face pale and swollen; emaciation of the body.

*Tubercles in the Peritoneum*—Swollen and board-like feel of the abdomen, tender to the touch; pain increased on pressure; cough, skin dry and harsh; blanched conjunctiva; tongue covered with dirty white varnish, and red tip and edges; great emaciation.

*Intus-susceptio*—Constipation, irregular and swollen state of the abdomen; nausea, hiccough, colic pains, great prostration of strength: pain in a particular part of the abdomen; vomiting of a mucous, bilious, or stercoraceous matter.

**MORBID ANAT.** *Acute Inf.*—The peritoneum becomes thick, soft, and of a bright red colour. The veins of the part are also distended with blood; and the redness of the inflamed part is often increased by an effusion of blood into the cellular substance, under the peritoneum, in the form of streaks or patches. Sometimes it is of a



greenish colour, when its vessels are loaded with venous blood, and an effusion of lymph has taken place. The thickness of the lymph varies, according to the degree of inflammation, from a line to a quarter of an inch.

*Chronic*—The peritoneum is generally found thickened, either by a deposition of lymph on its external surface, or an infiltration of lymph between its laminæ; it is also white, red, or bluish, with an injected and dilated state of the venous capillaries of the part. There is generally found in the cavity a quantity of fluid, of a light straw colour, or a blood-like serum with patches of lymph floating in it.

*Intus-susceptio*—In the infant it is not uncommon to meet with three, four, or even five intus-susceptions, at the same time; but they are generally unaccompanied with inflammation.

*Inflammatory Stage*—The intestines, above the intus-susception, are greatly distended and inflamed; they are of a brownish red colour: and if the inflammation has continued long, purulent matter is mixed with serum in the belly. When the distended bowels are laid aside, we find a knot of intestines, which may be called the vaginal portion; these are of a pale yellow, with black spots upon them; and the track of the canal below the obstruction is pale, compared with the portion above,

*Strangulated Hernia*—If the stricture be of recent date, the portion of intestine is of a dark or petechial red colour, and the incarcerated portion is much thicker than natural, from an infiltration of lymph between its laminæ. The veins are dilated and minutely injected, and some petechial points are to be seen. When gangrene has actually commenced, the part becomes more of a chocolate colour, or of a reddish purple tint, and an indistinct appearance of the capillary vessels of the part. Complete mortification of a portion of intestine is demonstrated by the part presenting a dull dark brown colour, with dark patches of a bluish green upon it; the surface is abraded and softened, and when punctured no fluid appears.



*Tubercles*—Of the peritoneum are found as small as millet seed, and as large as pigeon's eggs; they are generally of a greyish, but sometimes of a yellowish white colour, and of a cheese-like consistence; their centres, when large, are generally found softened.

---

## PLATE XL.

AN enlarged and ulcerated state of Brunner's and Payer's glands; perforation, and an encephaloid tumour and stricture of the rectum.

- Fig.* 1. Chronic inflammation of the mucous tissue of the ileum, and an enlarged and ulcerated state of Brunner's glands.
2. An enlarged state of Payer's and Brunner's glands in the ileum.
  3. An enlarged and ulcerated state of Payer's gland.
  4. Chronic inflammation, with ulceration of the mucous texture of the colon.
  5. Extensive ulceration of the mucous and muscular tunics of the ileum, and perforation of the peritoneal coat.
  6. Ulceration of the caput coli, from a phthisical patient.
  7. An encephaloid tumour arising from the serous tunic of the colon.
  8. Hemorrhoids situated in the cellular tissue, between the muscular and mucous tunics.
  9. An encephaloid tumour, arising from the mucous texture of the colon.
  10. Stricture of the rectum, from a puckering and thickening of the mucous and muscular tunics of the gut.
  11. A great deposition of scirrhus matter into the cellular texture of the rectum.
  12. A stricture of the rectum, from a deposition of



Fig. 1.

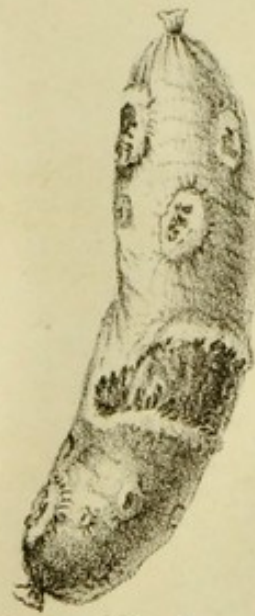

Fig. 2.

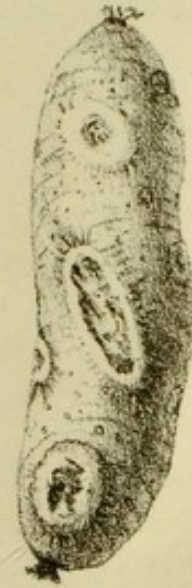

Fig. 3.

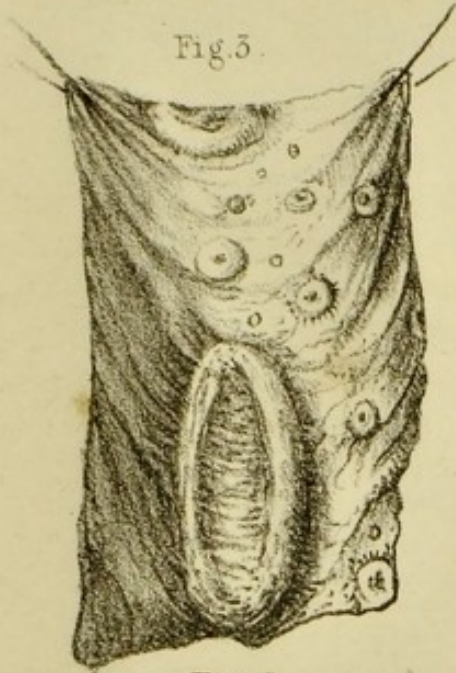

Fig. 4.

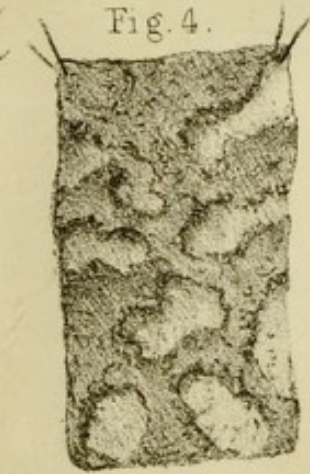


Fig. 5.

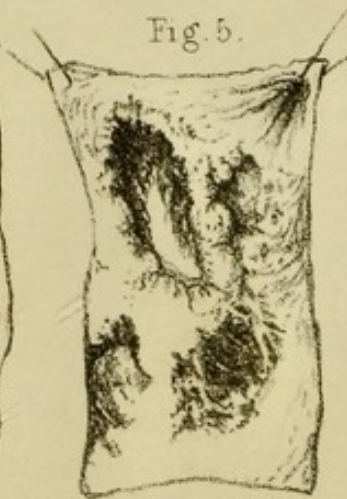

Fig. 6.

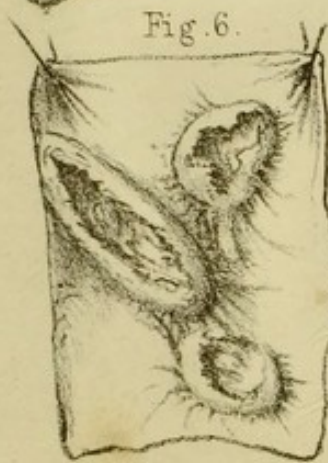

Fig. 7.

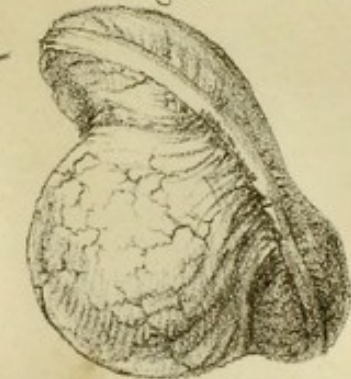


Fig. 8.

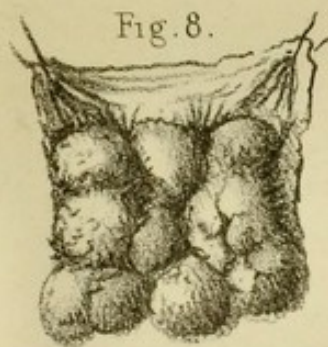


Fig. 9.

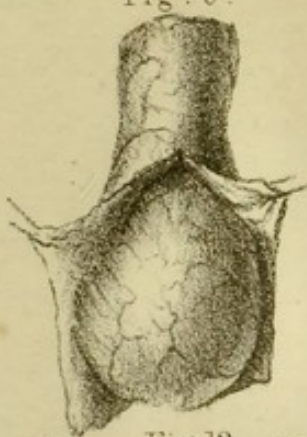


Fig. 10.

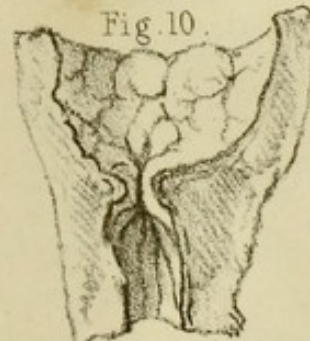


Fig. 11.

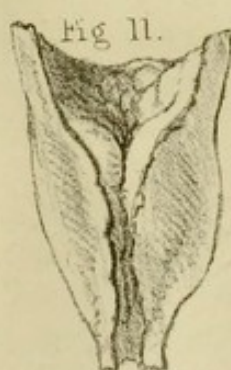
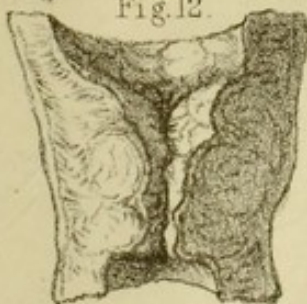



Fig. 12.







a fibro-cartilaginous matter into the cellular tissue of the gut.

*Fig. 13.* Specimen of internal piles.

**SYMP.** *Acute Muco-Enteritis*—Compressed state of the abdomen, pain in the region of the navel; nausea, vomiting, slight tormina; jelly-like evacuations; tongue covered with a whitish fur, red tip and edges; pulse soft and compressible.

*Chronic, with Ulceration*—Cough; rigors with alternate flushes of heat; jelly evacuations, mixed with pus or blood; tongue covered with a dirty yellowish fur, red tip and edges, pulse soft and compressible, pain on pressure just above the pubis; belly becomes flatter, the face more sunk, and the cheeks and eyes more hollow.

*Mucous Memb. of the large Intestines*—Tormina, tenesmus; scanty evacuations of feculent matter, blended at times with mucus, pus, or blood; pulse quick and full, tongue white, with slight red tip and edges.

*Stricture of the Gut*—Pain and sense of weight in the loins, which sometimes extends to the rectum and thighs; obstruction to free evacuation, with a thready and compressed appearance of the feculent matter; pallid countenance; if of long standing, great emaciation.

*Cancer of the Rectum*—Severe pain, darting through the pelvis to the bladder and the groin. The countenance is of a sallow leaden colour.

**MORBID ANAT.** The parts are redder than usual, and the vessels are seen to course in an arborescent manner; there is an œdematous and puffy state of the part, which is produced by an infiltration of fluid into the cellular connecting membrane. Lymph is sometimes found adhering to its surface. The redness in acute inflammation has no line of demarcation, but vanishes gradually from a dark red to a faint flesh colour.

*Chronic*—The mucous tissue is thickened, attenu-



ated, softened, indurated, or ulcerated; and the colour of the parts varies considerably, being at times blue, red, green, yellow, white, or black.


Encephaloid tumours differ in their structure from fungus hæmatodes, and likewise in their manner of destroying parts. These tumours are found to be of a medullary consistency, and protected by one or more tunics, according to the part affected. The capsules are bountifully supplied with arteries and nerves, and the venous capillary vessels are seen to form complete masses of vessels on their external surface. Some of the vessels enter into the substance of the tumour. Sometimes the medullary matter occupies one cell only; sometimes six or eight, so as to form one tumour, hence the lobulated appearance.

The intervening cellular tissue is matted together by chronic inflammation, so as not to be separated without the greatest difficulty. In the substance of these tumours there is most commonly found a small quantity of blood.

*Fungus Hæmatodes*—has no proper capsule, and possesses the peculiar power of changing every portion of the human frame to its own nature; and this occurs without that thickening or hardening of the cellular tissue which generally accompanies chronic inflammation.

In ulceration, the capillary vessels of the venous system form a perfect net-work; and these minute vessels press into larger branches of the venous system: it is to the varicose and partial lesion of these vessels, that the edges and inferior surface of the ulceration owe their dark ruby colour. If the ulceration be extensive, the destruction of veins is very great, and hemorrhage is the consequence.





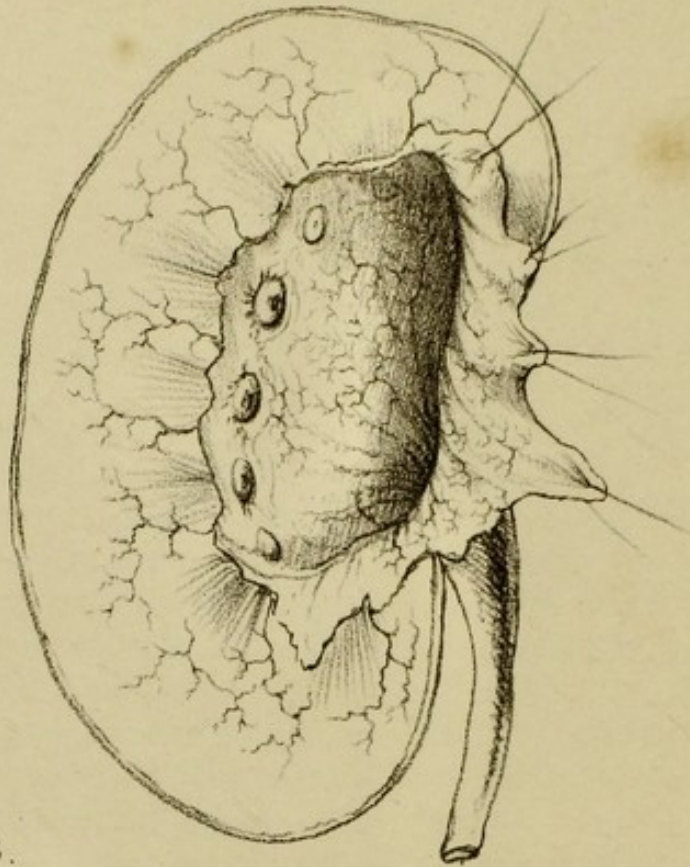


Fig. 3.

Fig. 2.

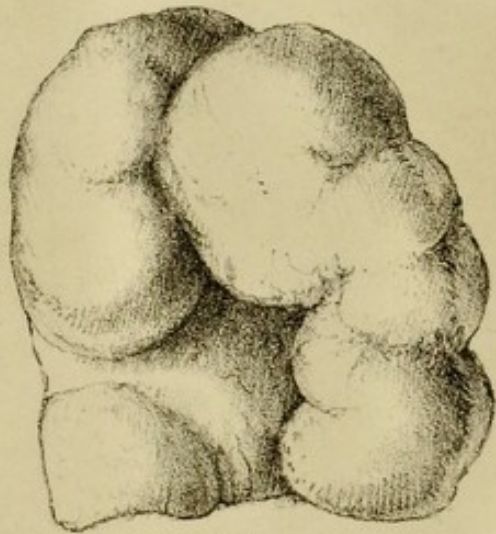
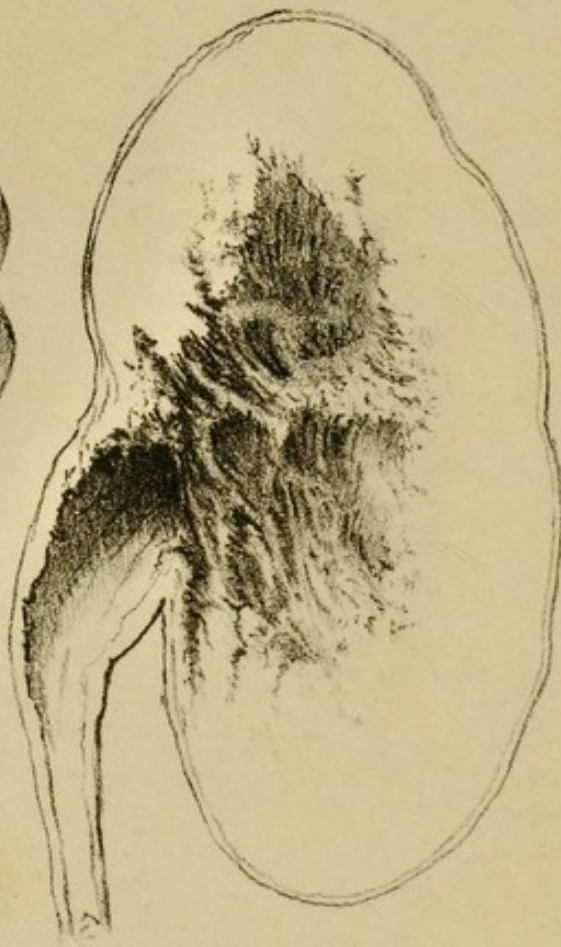
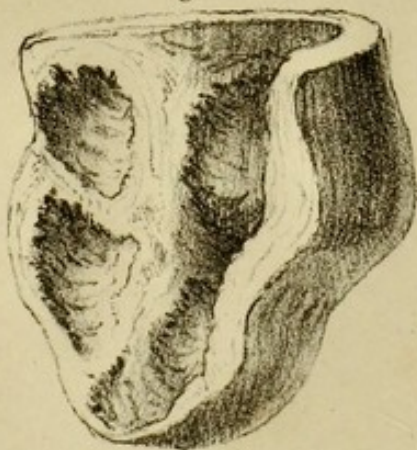


Fig. 4.








Fig 1

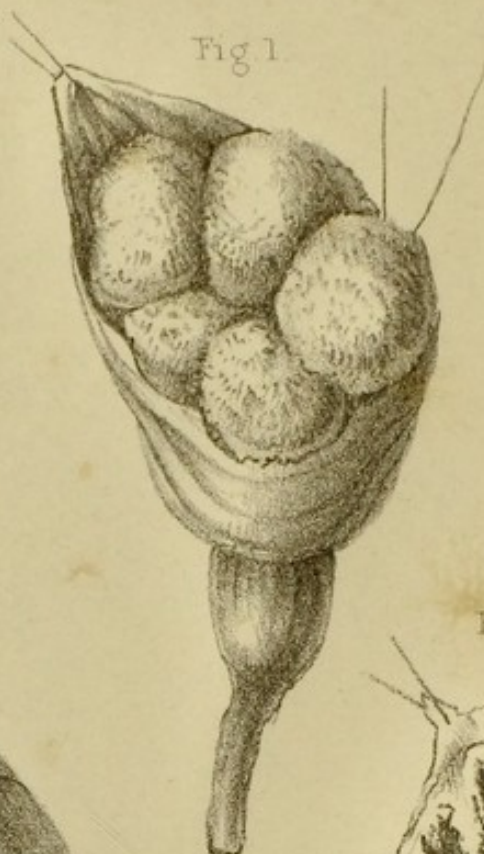


Fig 3

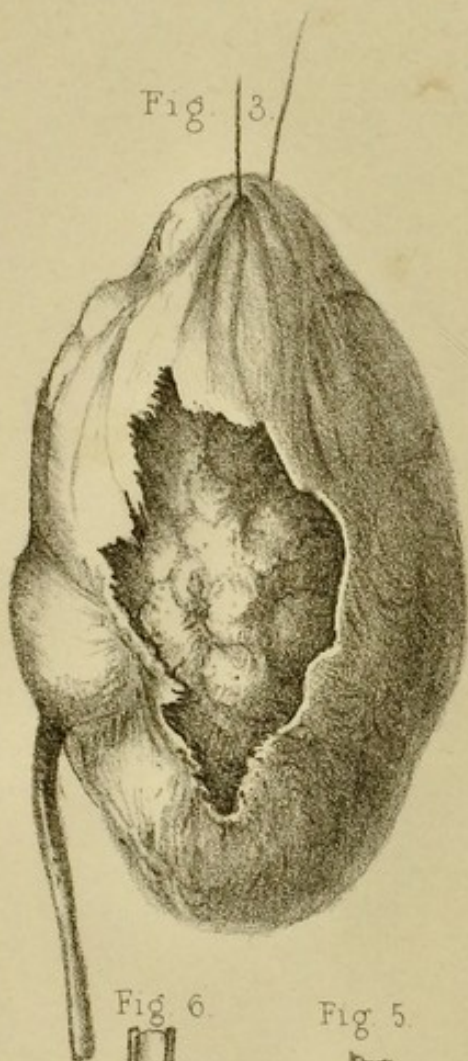

Fig 2

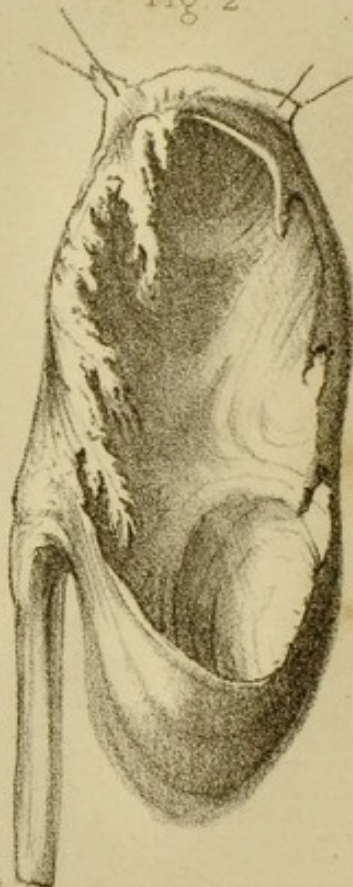

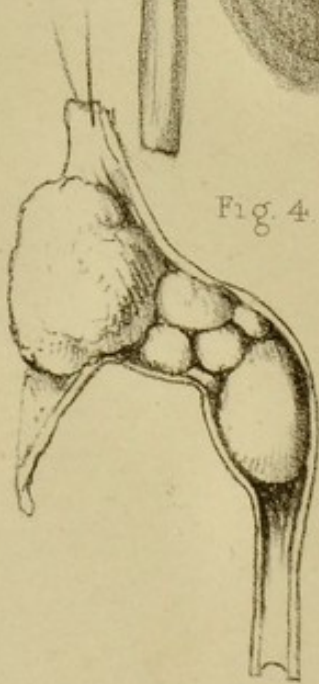
Fig 6

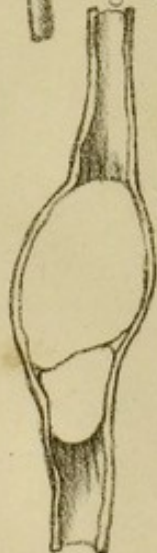


Fig 5

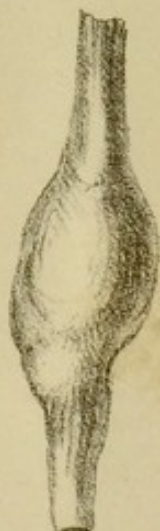

Fig 4







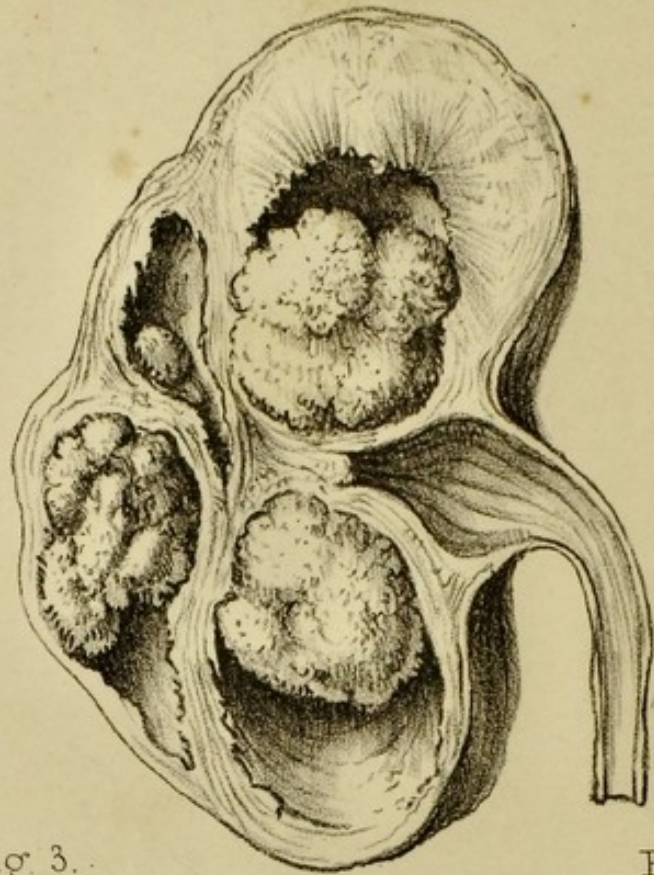


Fig 3.

Fig 2

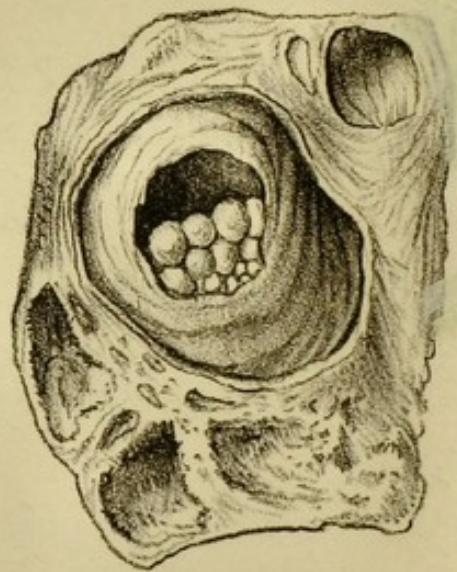
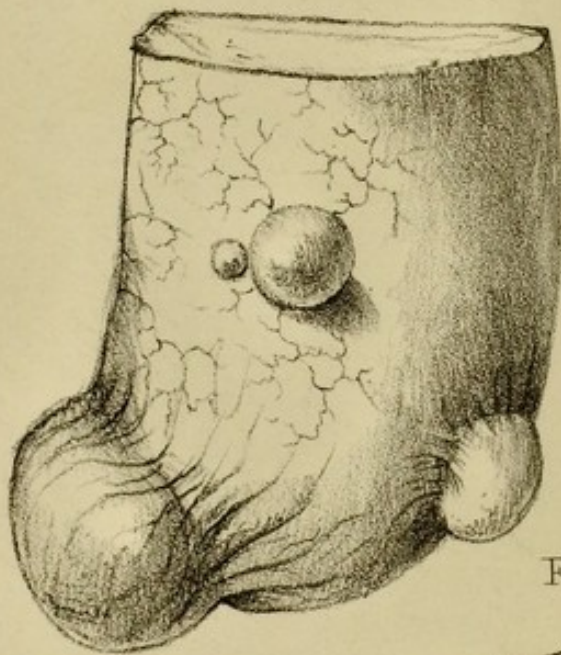
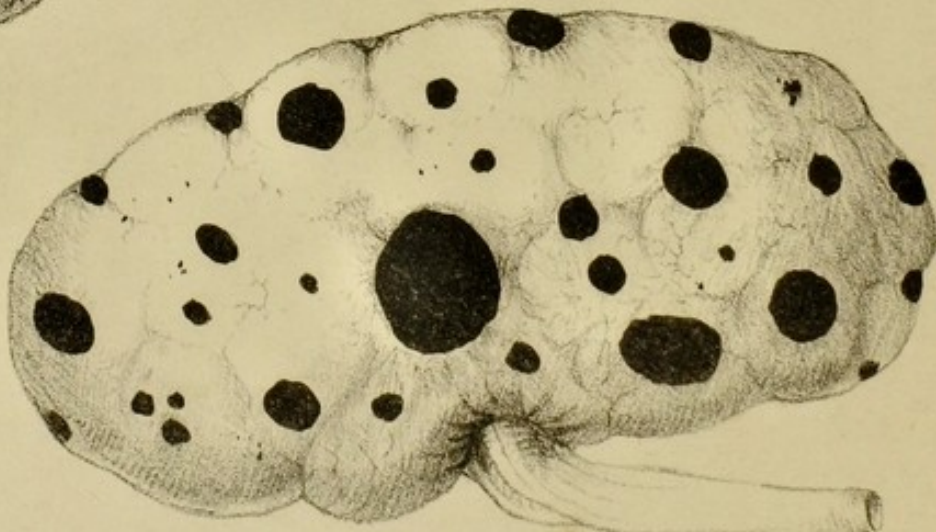


Fig 4.





## PLATES XLI. XLII. XLIII.

ACUTE and chronic inflammation of the kidney ; calculi in its substance and ureters ; also hydatids, and a deposition of melenotic matter.

## PLATE XLI.

- Fig.* 1. Inflammation of the membrane lining the pelvic portion of the kidney and its substance.
2. Extensive destruction of the parenchymatous structure of the kidney, from long and protracted inflammation.
3. External appearance of the scrofulous abscess formed in the kidney.
4. A section of the scrofulous kidney, showing the destruction of its internal texture.

## PLATE XLII.

- Fig.* 1. Pelvic portion of ureter loaded with calculi.
2. Extensive dilatation of the pelvic portion of ureter, from a large calculus.
3. A very large calculus, situated in the pelvis of the kidney.
- 4, 5. Calculi in the ureter, at its upper extremity, and in the middle.
6. Section of ditto.

## PLATE XLIII.

- Fig.* 1. Several calculi formed in the substance of the kidney, accompanied with destruction of the medullary and cortical part of the kidney.
2. Hydatids in the substance of the kidney, taken from a patient supposed to be labouring under chronic hepatitis.
3. Several cysts formed on the surface, and in the parenchymatous texture of the kidney.
4. Deposition of melenotic matter in the substance and on the surface of the kidney, taken from a patient who had been affected with chronic inflammation of the air passages.



SYMP. *Nephritis*—Pain in the region of the kidney, increased on pressure; micturation, dysuria, nausea, vomiting; urine of deep red colour, constipation, retraction of the testicles.

*Chronic*—All the symptoms milder in character; of several months' duration.

*Abscess*—All the above symptoms increased in violence for a time, accompanied with chilliness and shivering, and a dull deep-seated pain in the loins.


*Calculi in the Kidneys or Ureters*—Dull heavy pain in the loins, accompanied with spasmodic twitches about the superior portions of the ileum and lumbar region internally; pressure on the abdomen produces pain in the course of the anterior crural nerve; nausea, vomiting; pain in the testicles, irritation of the glans penis; skin pallid; lithic acid blood, or pus, mixed with the urine; bent position produces great pain in the loins.

*Hydatids*—Dull obscure pain in the loins, with slight irritation of the bladder and glans penis; a discharge of hydatids from the urethra.

MORBID ANAT. In acute inflammation of the kidney, the surface is covered with dilated minute capillary vessels, beautifully arborescent; it cuts more solid, and its vessels contain more blood; yet it is not increased much in size, in consequence of the inelastic state of its capsule; hence the acute pain. Sometimes the kidney is found to be of a fibro-cartilaginous texture, and when cut, presents a surface similar to a cut turnip. The scirrhus kidney is of a light greyish, or dirty yellow ochre colour, harder than natural; and when cut, presents a homogeneous appearance; but if macerated for a short time, a quantity of chalky or clay-like fluid can be pressed from it, and it presents a beautiful reticulated appearance.

Sometimes a quantity of adipose matter is found deposited in the substance of the kidney; it is generally very soft and flabby. Sometimes there is a deposition of an ochre-coloured matter, of the consistency





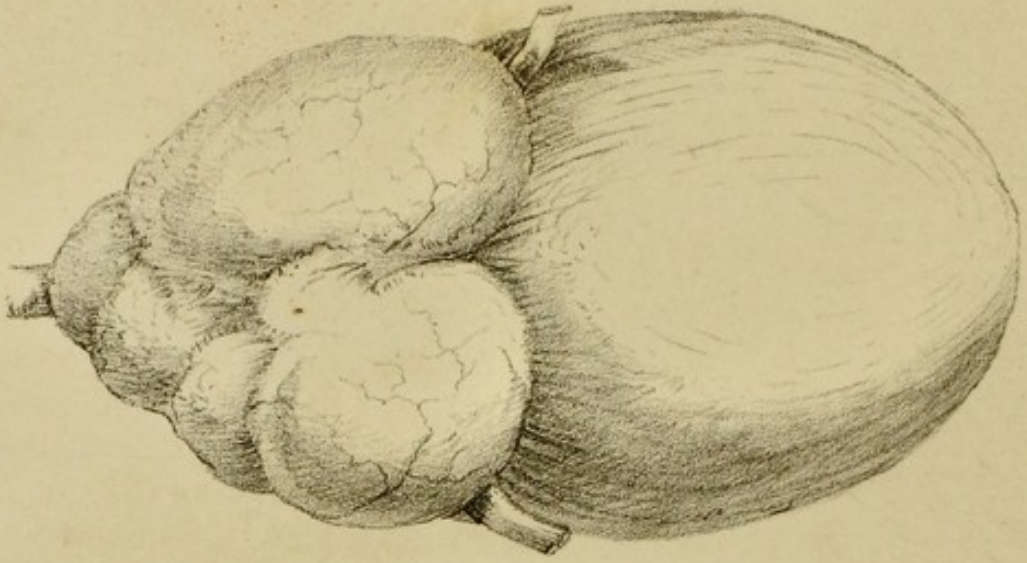


FIG 2.

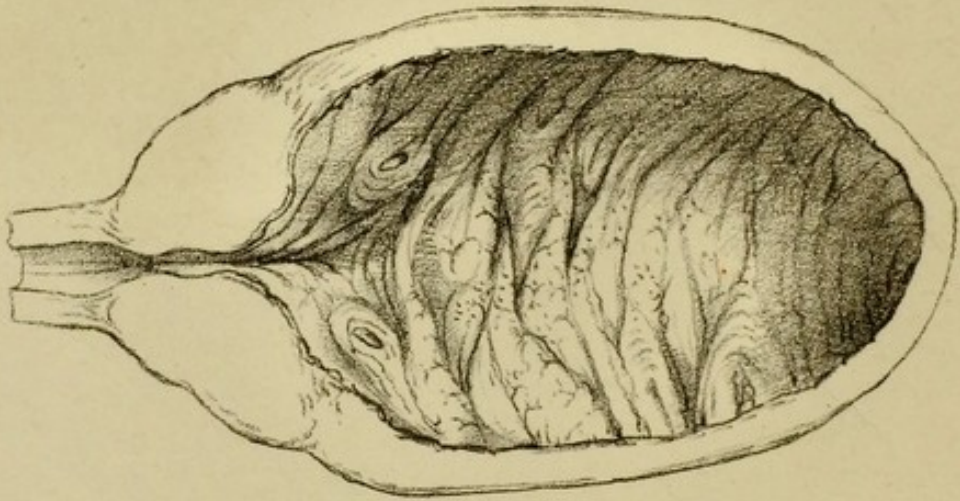


FIG. 3.

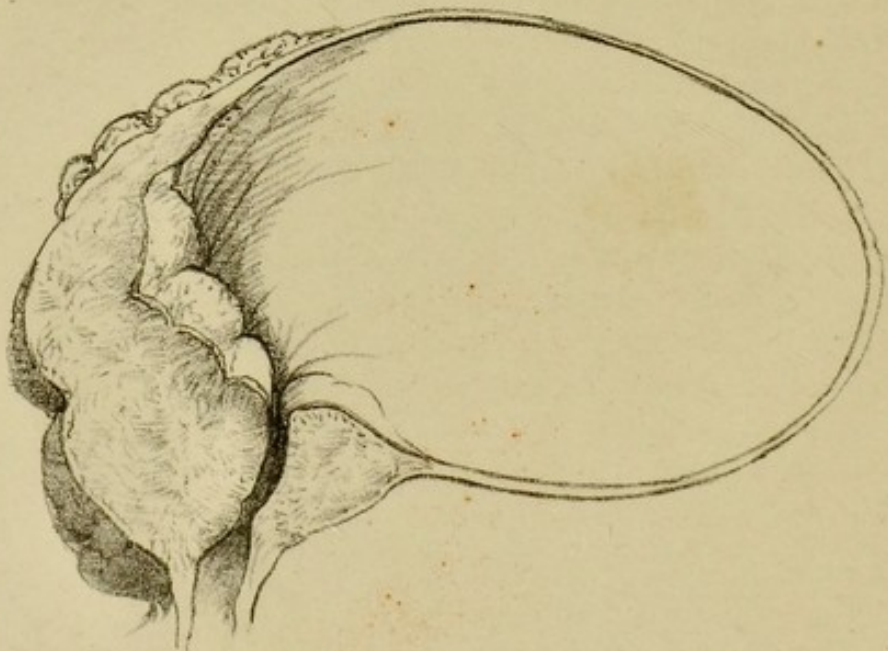


FIG 1.



of tallow, between the calices; and sometimes the posterior half of the organ externally is buried in this substance.

*Ossification*—of the substance is a very rare disease; but bony depositions on its fibrous tunic are not unfrequently found. It is sometimes converted into a cheese-like matter, and enlarged to twice its natural size, its capsule thickened, and of a fibro-cartilaginous texture.

*Hydatids* are found adhering to its surface, and embedded in its substance.

*Sacculated Kidney*—arises from various causes; but the most common is from the formation of calculi in the different compartments of the organ; which, from their pressure and irritation, produce rapid absorption of the medullary and cortical parietes of the viscus, leaving nothing but the capsule filled with calcareous matter.

Hypertrophia and atrophia of this organ, as well as every organ in the body, is at times found to exist.

---

## PLATES XLIV. XLV. XLVI.

DISEASES of the prostate gland, vesiculæ seminales, bladder, and urethra.

### PLATE XLIV.

- Fig. 1.* An enlarged state of the prostate gland, from simple infiltration of lymph into its substance, accompanied with induration.
2. An enlarged prostate gland, taken from a patient who had been the subject of diseased urinary organs upwards of ten years.
  3. Thickened and corrugated state of the bladder, with simple increase in the size of the prostate gland.



## PLATE XLV.

- Fig.* 1. Extensive ulceration and thickening of the mucous and muscular tissue of the bladder.
2. Calculi in the bladder of a youth, fourteen years old.
3. Fungi in the bladder, taken from a gentleman aged eighty years.
4. Abscess of the vesiculæ seminales and prostate gland: the latter is divided into two distinct lobes, and filled with a thick curd-like matter.
5. Ulceration of the vesicula seminales of the right side.
6. Calculi in the substance of the vesicula seminales.
7. Hydatids in the substance, and on the surface of the vesicula seminales.
8. Fibro-cartilaginous state of the vesicula seminales, taken from a young man, who was addicted to onanism, and who hung himself.

SYMP. *Inf. of the Prostate*—Pain and heat in the perineum and rectum; tenesmus; constant desire to pass the urine, without the power to do so; acute pain on pressure of the gland.

*Scirrhus*—Lancinating pains darting through the gland; dysuria, tenesmus, and an inability to bring the thighs close to each other; constipation.

*Ulceration*—Frequent desire to pass urine; micturation, tenesmus, burning sensation in the perineum, with pain of the meatus urinæ; ardor urinæ; discharge of matter per urethra; emaciation; dejected and pallid countenance; gland painful to the touch.

*Abscess of the Vesicula Seminales*—All the symptoms of inflammation of the prostate, with increased pain and irritability of the testes; tenesmus, shivering.

*Ulceration*—Pain, deep seated and lancinating; tenesmus, ardor urinæ, extreme irritability of the testes; great emaciation.

*Cystitis*—Heat and pain in the hypogastrium; frequent attempts to make water, which is evacuated in



Fig 4

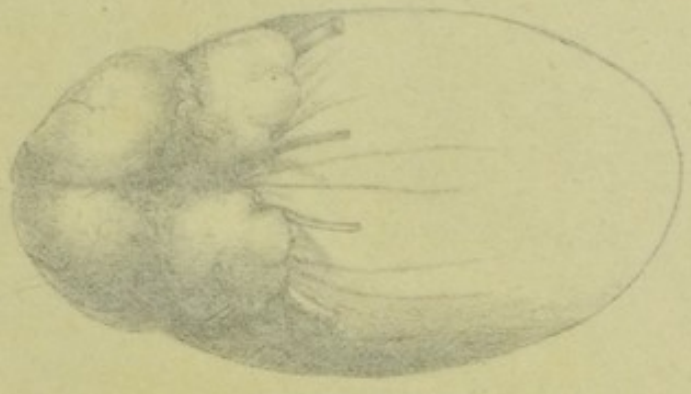

Fig 1

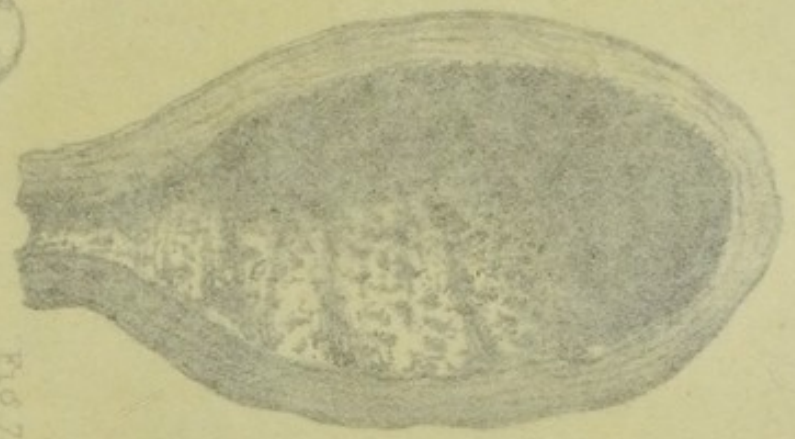


Fig 2

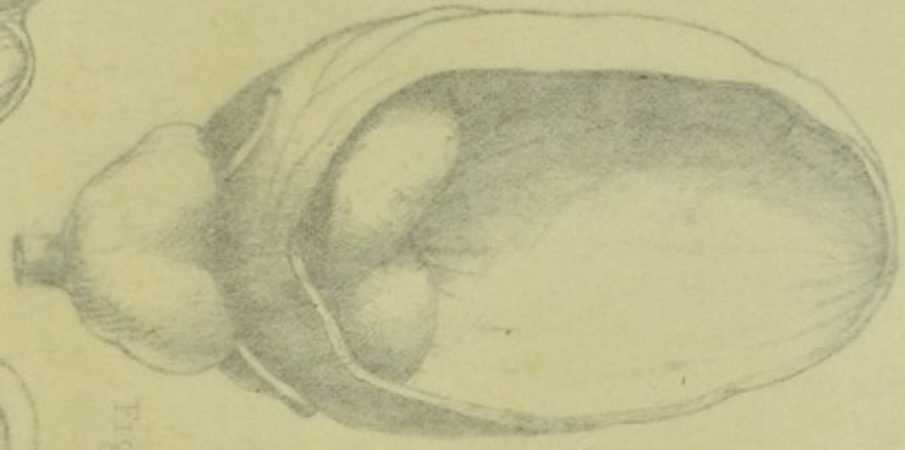


Fig 3

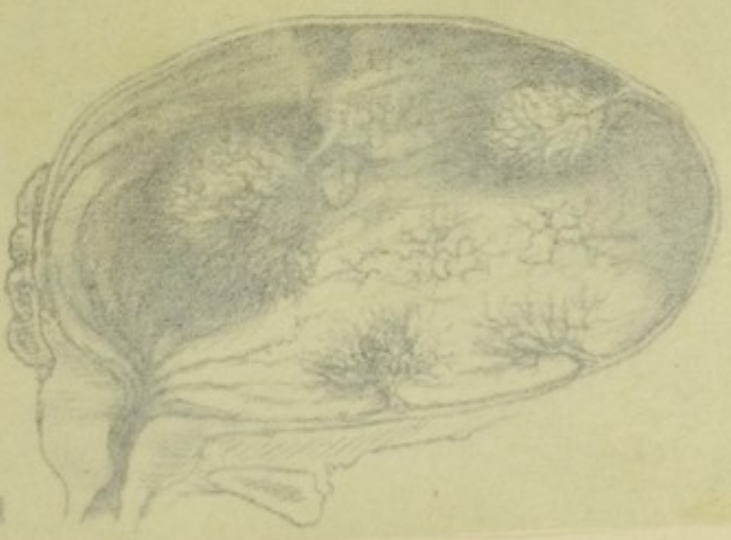

Fig 8

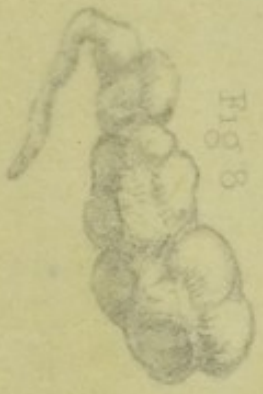

Fig 7

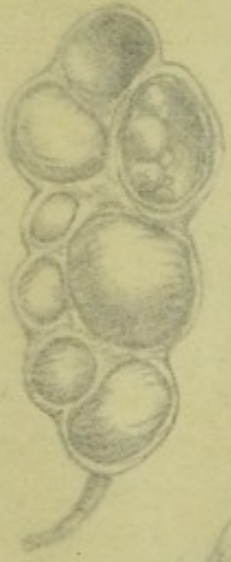

Fig 6

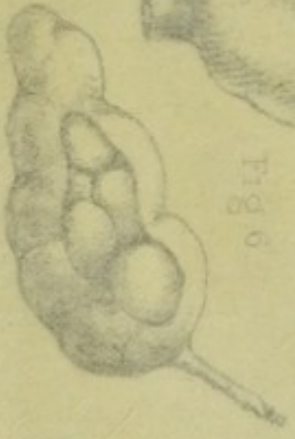
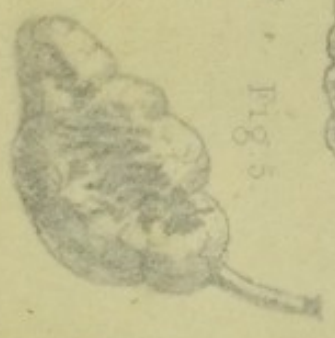
Fig 5



## PLATE XLV.

- Fig.* 1. Extensive ulceration and thickening of the mucous and muscular tissue of the bladder.
2. Calculi in the bladder of a youth, fourteen years old.
3. Fungi in the bladder, taken from a gentleman aged eighty years.
4. Abscess of the vesiculæ seminales and prostate gland: the latter is divided into two distinct lobes, and filled with a thick curd-like matter.
5. Ulceration of the vesicula seminales of the right side.
6. Calculi in the substance of the vesicula seminales.
7. Hydatids in the substance, and on the surface of the vesicula seminales.
8. Fibro-cartilaginous state of the vesicula seminales, taken from a young man, who was addicted to onanism, and who hung himself.

*SYMP. Inf. of the Prostate*—Pain and heat in the perineum and rectum; tenesmus; constant desire to pass the urine, without the power to do so; acute pain on pressure of the gland.

*Scirrhus*—Lancinating pains darting through the gland; dysuria, tenesmus, and an inability to bring the thighs close to each other; constipation.

*Ulceration*—Frequent desire to pass urine; micturition, tenesmus, burning sensation in the perineum, with pain of the meatus urinare; ardor urinæ; discharge of matter per urethra; emaciation; dejected and pallid countenance; gland painful to the touch.

*Abscess of the Vesicula Seminales*—All the symptoms of inflammation of the prostate, with increased pain and irritability of the testes; tenesmus, shivering.

*Ulceration*—Pain, deep seated and lancinating; tenesmus, ardor urinæ, extreme irritability of the testes; great emaciation.

*Cystitis*—Heat and pain in the hypogastrium; frequent attempts to make water, which is evacuated in



Fig 4

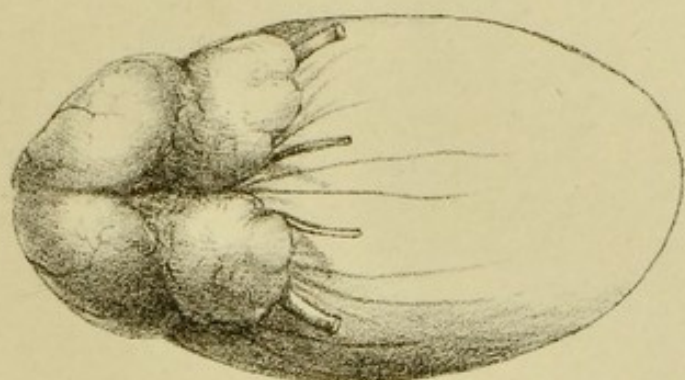


Fig 1

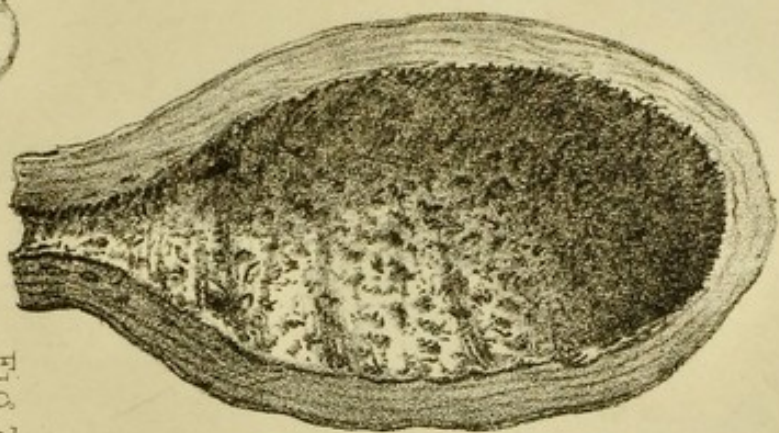


Fig 2

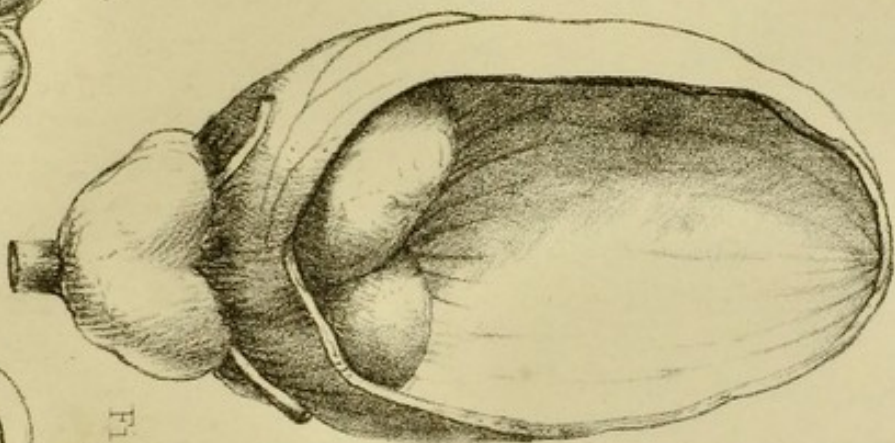


Fig 3

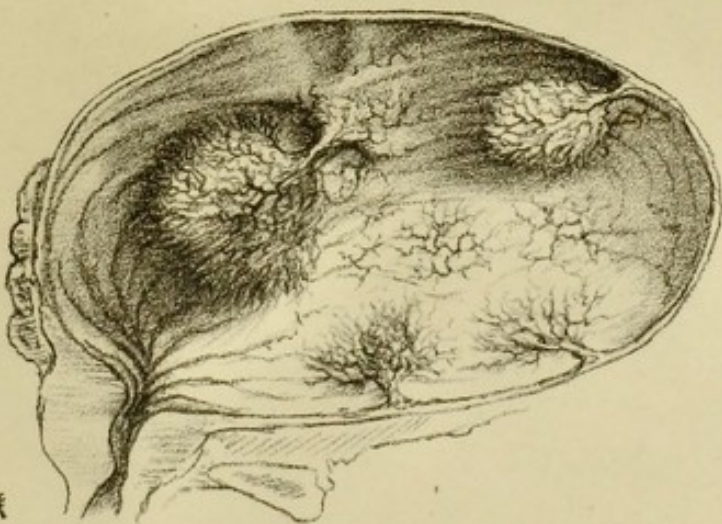


Fig 8

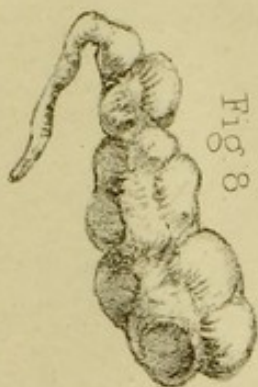

Fig 7

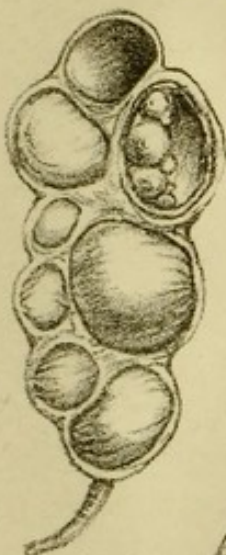


Fig 6

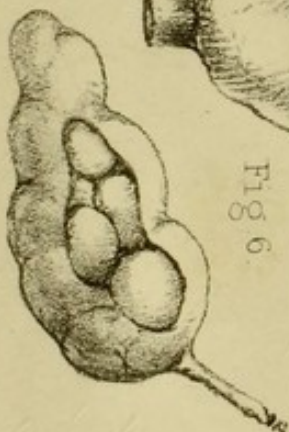
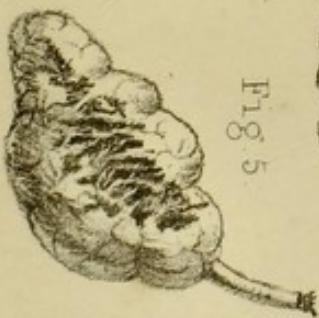



Fig 5







small quantity, and with great pain; or there is a total retention of the urine, with a strong desire to void it; the urine, at first limpid, becomes turbid and reddish.

*Chronic*—Dull heavy sensation behind the pubis, with sense of weight in the perineum; slight tenesmus; constipation; difficulty in passing urine; it is generally loaded with mucus or pus.

*Ulceration*—The discharge is generally mixed with blood, sometimes with a greenish foetid matter; great emaciation.

*Fungi*—Dull pain, with a constant desire to pass urine; a sensation as if girt with a cord at the hypogastric region; weight and uneasiness about the kidneys; aching pain in one or both testicles; discharge of pure blood, or blood and mucus; itching at the meatus; constipation.

*Inflammation of the Corpora Carnosa*—Deep seated pain in the pelvis, with a sense of weight, and constant desire to pass urine.

*Ulceration*—Pain, deep seated and lancinating; and if the ulceration be extensive, tenesmus, and ardor urinæ, with wasting of the body.

*Calculi*—Frequent inclination to pass urine, dysuria, itching or pain at the meatus urinare externis; nausea, vomiting; increased pain after discharging the water; tenesmus; violent exercise increases the pain, and is generally followed by bloody discharge from the bladder, pulling the prepuce over the glans penis; muco-purulent discharge.

**MORBID ANAT.** When the mucous tissue of the bladder is acutely inflamed, there is a suffused redness of the part, with bloody points, more or less mucus adhering to its healthy surface.

Ulceration sometimes advances so far as to destroy a portion of the bladder entirely, and to form a communication between it and the neighbouring parts, as the abdominal cavity, rectum in the male, and vagina in the female. Sometimes the inner surface of the bladder



is lined with a cheese-like substance, but not uniform on its free surface, but divided into innumerable irregularities.

The mucous, muscular, and peritoneal coats are thickened.

*Corpora Carnosa*—Are found at times enlarged, ulcerated, scirrhous, or ossified.

*Hydatids*—have been found adhering to the inner surface of the bladder.

*Fungi*—Arise from several parts of the internal membrane at the same time; the nuclei of these tumours are capillary veins, which are enlarged, and intersect each other, so as to form an imperfect lace-work; from this matting arise thousands of minute pencillated vessels, which are so intimately woven together as to give *character* to the tumour during life, but which disappears at death, and presents nothing more than macerated cellular membrane.

Sometimes there are fungoid tumours met with, that are pulpy to the touch but fibrous in texture, and preserve their appearance after death.

The fibro-cartilaginous, scirrhous, and corrugated state of bladder, are met with; also hypertrophia and atrophia, melenotic deposition, &c.

*Calculi* are found in the bladder.

Sacculated state of bladder arises from a separation or lesion of some of the muscular fibres, and the mucous texture passing through the preternatural aperture and carrying before it the peritoneal coat, which forms a perfect sac or pouch.

#### PLATE XLVI.

- Fig.* 1. Extensive ulceration of the posterior portion of the prostate gland, with an enlarged and indurated state of the vesiculæ seminales.
2. An enlarged and scirrhous state of the prostate gland.
  3. Fibro-cartilaginous state of the cellular tissue, surrounding the entrance of the ureter into the bladder.



FIG. 8.

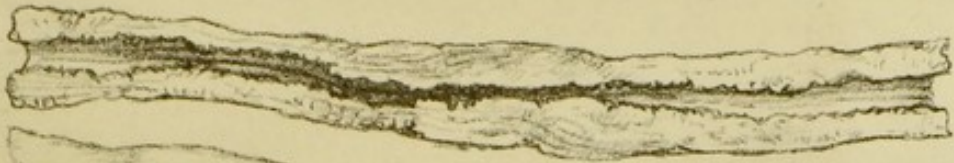

FIG. 9.

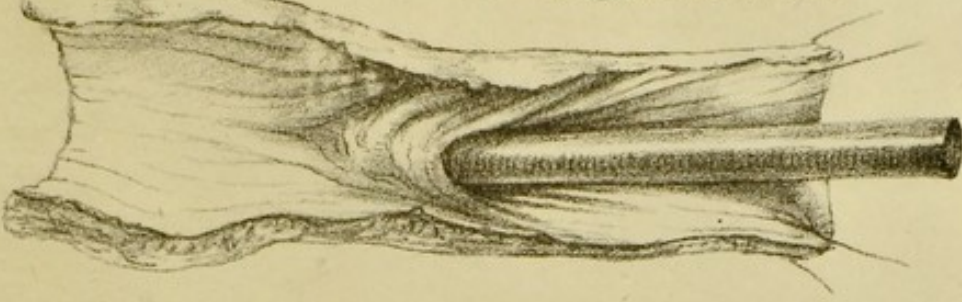


FIG. 7.

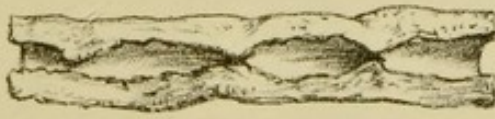

FIG. 6.

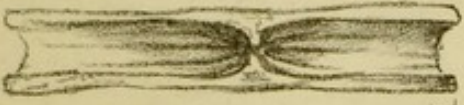

FIG. 3.



FIG. 1.

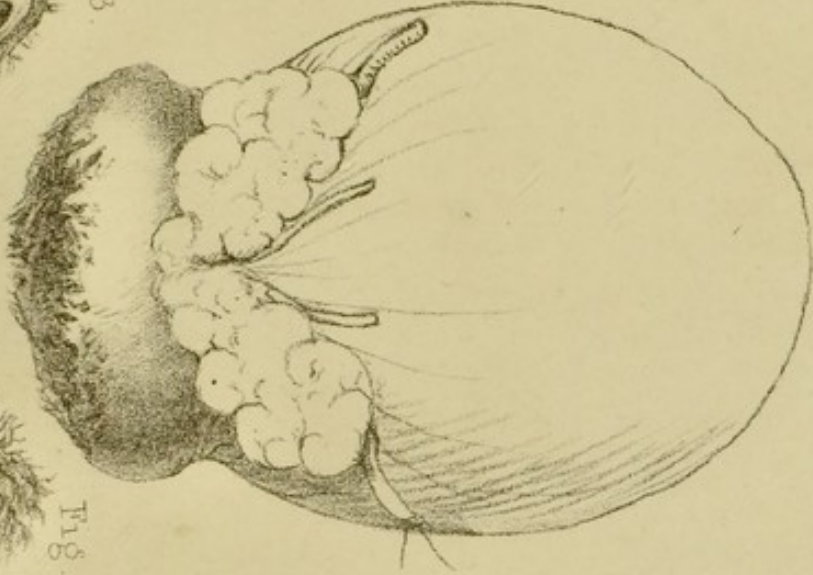


FIG. 4.

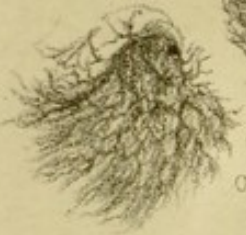

FIG. 2.

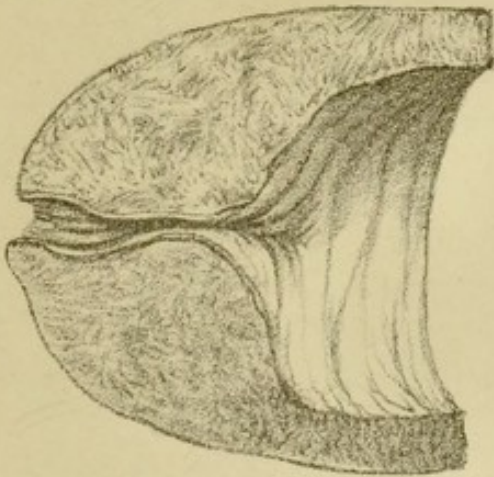
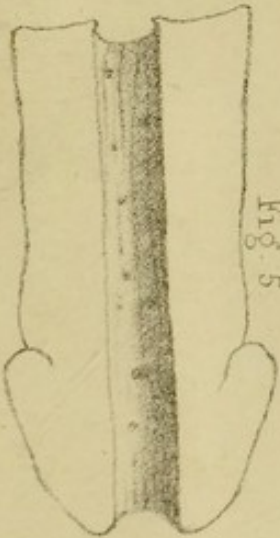



FIG. 5.







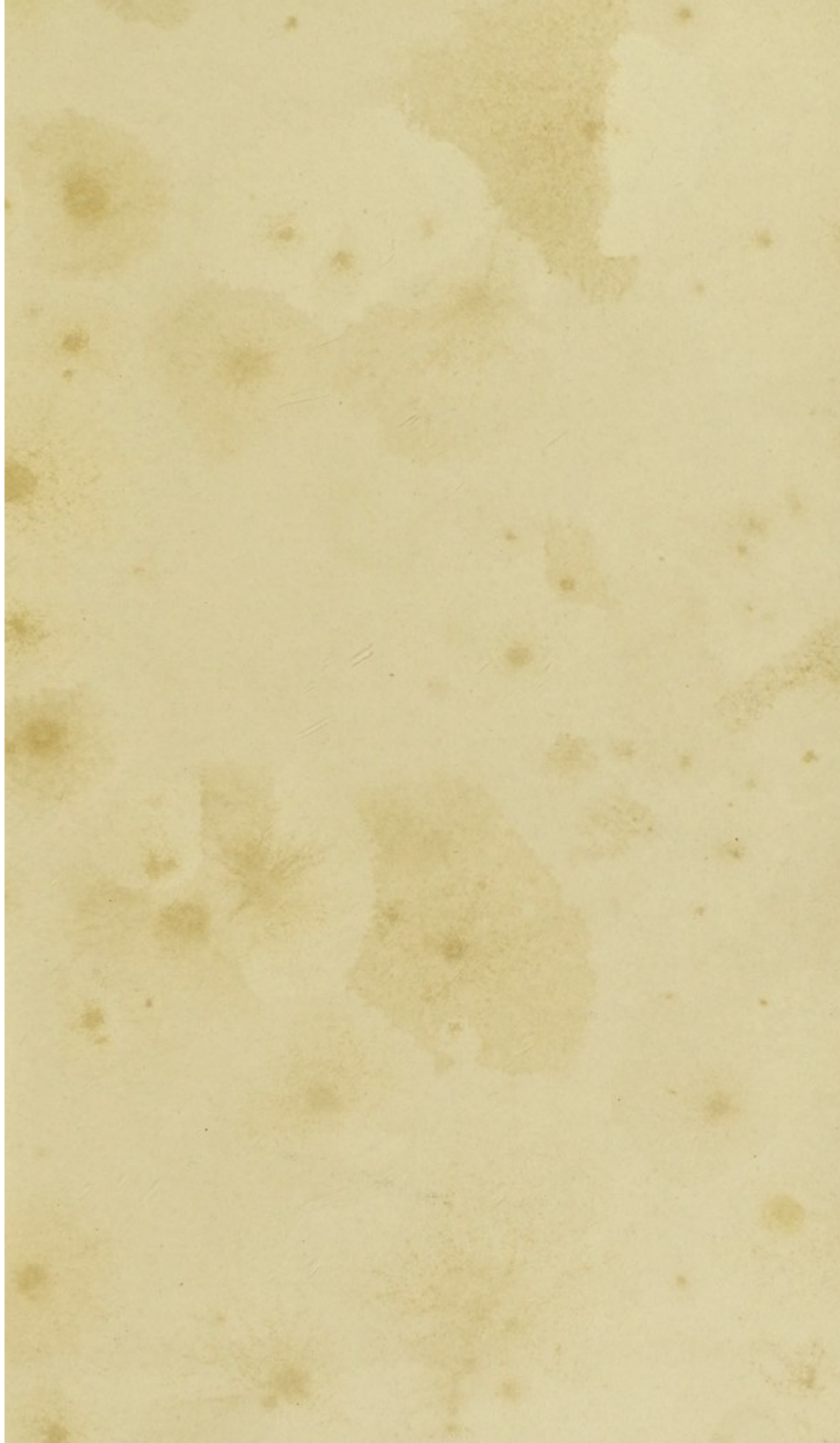


Fig. 1.

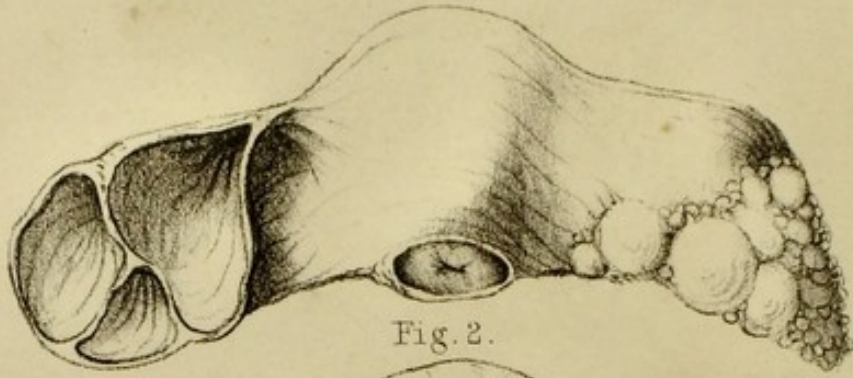


Fig. 2.

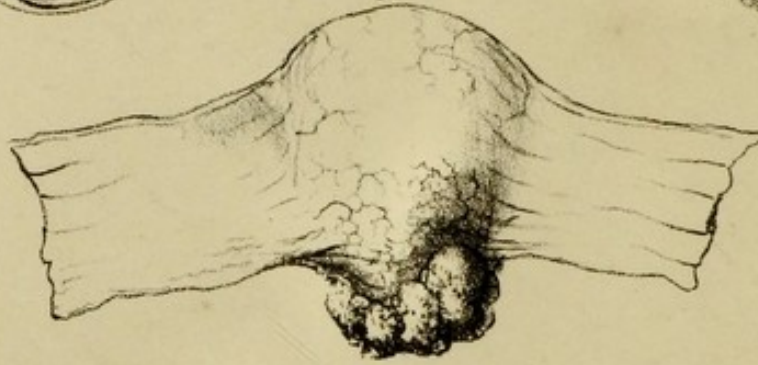


Fig. 3.

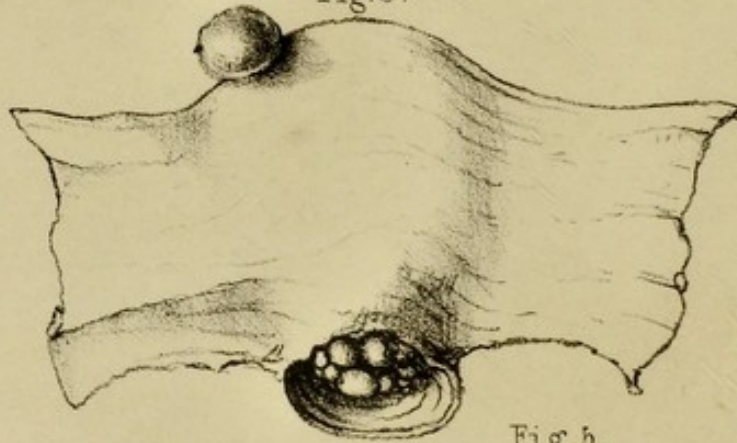
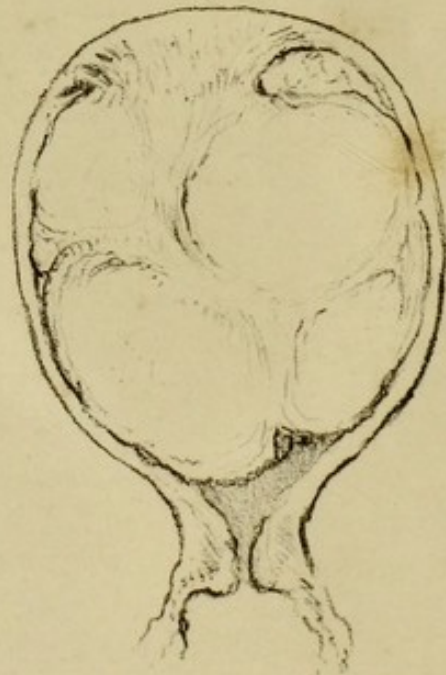
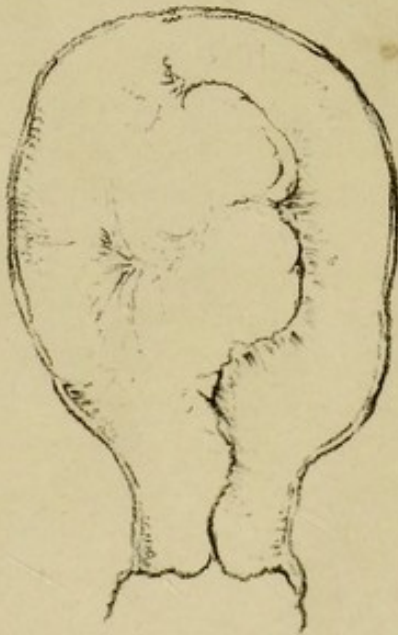


Fig. 4.

Fig. 5.





- Fig. 4.* Fungoid excrescence, arising from the right side of the corpus carnosum, which entirely obstructed the flow of urine into the bladder, and produced an enlargement of the ureter on that side.
5. Inflammation of the mucous tissue of the urethra and mucous follicles.
  6. Approximation of the sides of the canal, forming stricture.
  7. Irregular stricture, or callous state of the urethra.
  8. The calibre of the urethra diminished, and a fibro-cartilaginous state of the spongy body of the penis.
  9. A false passage made by the improper use of the bougie.

---

## PLATE XLVII.

THIS Plate represents cancer, tubercles, and hydatids of the uterus.

- Fig. 1.* Hydatids adhering to the fallopian and ovarian extremities of the uterus: on the left side a section is made to show its compartments.
2. Cancerous tumour arising from the cervix uteri.
  3. Tubercles arising from the cervix and fundus uteri.
  4. An encephaloid tumour, arising from the mucous tissue of the uterus.
  5. Scirrhus tumour filling the cavity of the uterus.

SYMP. *Inf. Mucous Tissue of the Uterus*—Dull heavy pain, referred to the os pubis, with a circumscribed burning heat in the centre of the pelvic and vaginal portion of the uterus; dryness of the parts. The pubic portion of the abdomen appears as if flattened and sunk towards the back; and the veins, coursing over the inguinal and hypogastric regions, are swollen; tense pain in the back, pelvis, and thighs; constipation, tenesmus, dysura; pulse full and soft; examination per vaginam produces pain.



*Irritable Uterus*—Fulness, and an uneasy feeling in the centre of the pelvic viscera, accompanied with a degree of heat, and a dull aching pain and sense of weight in the lumbar and sacral regions; slight discharges of mucus; sometimes the parts are quite dry, as if scorched by heat; soreness about the pubis, particularly at the insertion of the round ligaments; swelling and puffiness of the labiæ, with irritation about the bladder and rectum; examination per vaginam causes exquisite pain; the patient becomes very irritable, and ultimately disagreeable.

*Cancerous Tumours*—Dull heavy pain in the loins, accompanied, at times, with acute and lancinating pains in the uterus; an offensive discharge of sanious matter; examination per vaginam gives pain; dysuria; constipation.

*Phagedenic Ulceration*—Pressure on the organ gives pain; discharge of a bloody or greenish yellow matter, which is very offensive, but different in smell to the discharge from true cancer; dysuria; constipation; sickness; tenderness at various points of the abdomen; great distress, both of body and mind; emaciation.

*Hydatids*—There are no symptoms which will enable us to elucidate their first formation.

MORBID ANAT. *Acute Inf.* Mucous tissue presents a thickened and pulpy state; the veins are dilated, and their inner surface very red, and sometimes obstructed by a coagulum of blood and pus. In very severe cases lymph is found adhering to the mucous texture of the uterus, and its follicles enlarged and very red.

*Ulceration*, as far as I have observed, arises mostly in females of strong venereal appetites, or in those who have suffered from the effects of syphilis or mercury.

The ulcers have been situated about the os internum and internal portion of vagina.

*Phagedenic* presents a livid or purplish red colour of the part, with an increased state of the venous



capillaries; vesication of various sizes, and an abrasion of the part by the ulcerative process. The ulcer is generally very deep.

*Cancerous*—The ulceration presents an uneven, ragged, and excavated surface, the edges of which are hard to the touch; sometimes the surface is covered with bloody patches, or black masses. The discharge from this kind of ulcer is very offensive, it smells like rotten eggs.

*Irritable Uterus*—Fulness and varicose state of the veins situated on the lateral portions of the cervix uteri externally, and an œdematous state of the os internum, with a fulness and slight vascularity of the follicles situated between the rugæ formed by the folding of the mucous texture within the cervix uteri. Sometimes this portion of the uterus is scirrhus.

*Bleeding Encephaloid*—It is generally lobulated, and its texture firm and apparently fleshy; when cut, it presents a bright red, intersected by bluish or purplish patches. Its capsule is bountifully supplied with tortuous vessels; and sudden distension or lesion of these vessels cause the hemorrhage which so often occurs in this disease.

*Placental Polypus*—is generally situated at the lateral or fundal surfaces of the mucous texture of the uterus; it presents an irregular hemorrhagic coagulum, with several shreds or patches of a loose membranous texture, which lay collapsed on its surface. This substance, when sliced, presents a dark purple or reddish cancellated texture, and its parenchyma bears a great resemblance to the spleen.

The perfect conception is distinguished from the imperfect or uterine growths, by its not receiving its origin from the mucous texture, or fibrous texture of the uterus.

*Scirrhus*—The uterus enlarges to nearly six times its natural size; and when cut, presents a greyish or yellowish white structure, and is intersected by bands of a whiter appearance than its intermediate substance.

The cavity of the uterus is sometimes found oblite-



rated; sometimes the os internum only. I have found bone deposited on the fundal surface of the organ.

The mucous texture of the uterus is occasionally lined with a calcareous matter. Hydatids frequently adhere to the substance of the uterus and its appendages, and large masses of them are sometimes found in the cavity of the uterus. Rupture of the uterus is of rare occurrence.

---

### PLATE XLVIII.

HYDATIDS in the substance of the testicle, encephaloid and scirrhus state of the same organ.

- Fig.* 1. External appearance of the testicle from hydatids in its substance.
2. Section of the testicle, showing the fibrous texture of the capsules of the hydatids.
  3. Extensive encephaloid tumour, situated in the body of the testicle.
  4. Section of an encephaloid tumour, situated in the body of the testicle.
  5. An enlarged and scirrhus state of the whole body of the testicle.
  6. Section of a scirrhus testicle.
  7. Section of a fibro-cartilaginous state of testicle.

SYMP. *Hydatids*—The disease is attended with obscure fluctuation; but it is rather a yielding at the part compressed with the finger, than an extensive fluctuation from one extremity of the swelling to the other. If the diseased part be firmly compressed, it gives the sensation of squeezing the testis; pain in the loins.

*Encephaloid*—An enlarged and indurated state of testicle; the enlargement proceeds generally rapidly; lancinating pains in the substance of the organ; want of appetite, emaciation of the body, pains in the



Fig 2

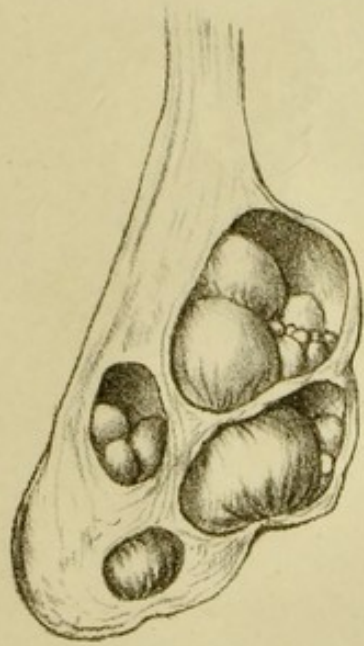


Fig 1

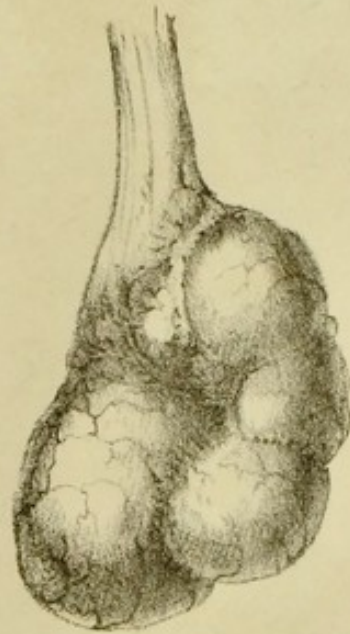


Fig 4

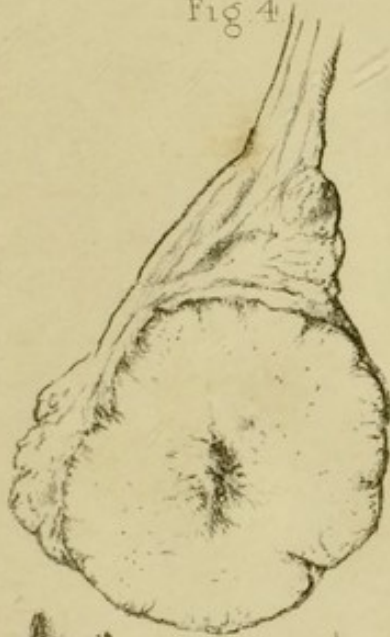

Fig 3

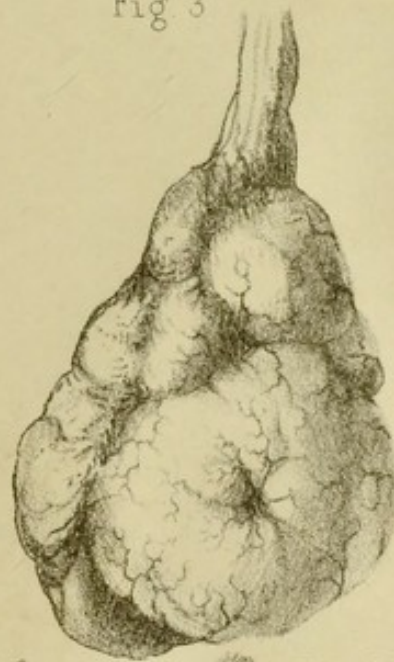


Fig 7

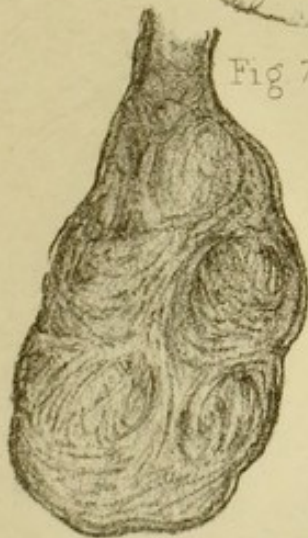

Fig 6

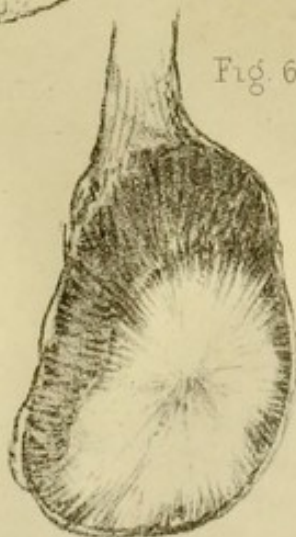
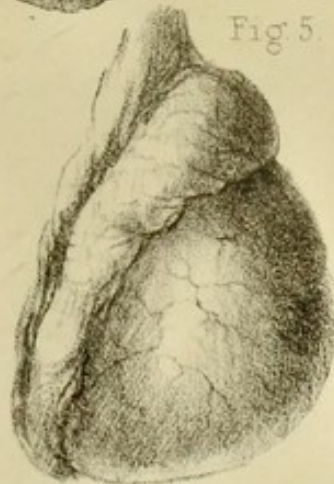



Fig 5







thighs and legs; wan and leaden appearance of the countenance.

*Scirrhus*—The stony hardness, the imperceptible growth at first, the lancinating pain in this part extending to the loins, and the tuberculated feel of the testicle, form the most distinguishing characters of scirrhus.

**MORBID ANAT.** The testis in its centre; is filled with numerous cysts, of various sizes, some small as the head of pins, others the size of peas, and the largest about an inch in diameter; as they vary in size, so the fluid they contain differs in appearance.

*Encephaloid*—A secretion of a soft pulpy matter, looking something like brain, is found deposited in the midst of the semeniferous tubes, in its early stages; and, as the disease advances, and the testicle becomes enlarged, the semeniferous tubes are absorbed, and the peculiar secretion of this disease occupies their natural situation. The tumour is partially vascular in some parts; the vessels are very numerous; in others, they do not enter the mass.


*Scirrhus*—When the testicle is cut open, the tunica vaginalis and tunica albuginea are thickened; and instead of tubes, which form the secreting structure of the testicle, a hard white mass is found, in lobes or tubercles, which are harder than the other parts; and in which cartilaginous, and sometimes ossific matter, are deposited.




*Symptoms of Acute and Chronic Inflammation of the following  
Organs :*

	Page		Page
AORTA . . . . .	27	Kidney . . . . .	42
Arachnoid Membrane . . . . .	4	Abscess . . . . .	42
Brain, Substance . . . . .	4	Calculi . . . . .	42
Softening . . . . .	5	Hydatids . . . . .	42
Abscess . . . . .	5	Liver . . . . .	33
Ulceration . . . . .	6	Larynx, ulceration . . . . .	15
Apoplexy . . . . .	6	Lungs . . . . .	17
Tumours . . . . .	8	Incipient Tubercle . . . . .	19
Hydatids and Cysts . . . . .	9	Suppurative Tubercle . . . . .	19
Tubercles of the Plexus Choroides . . . . .	9	Apoplexy . . . . .	18
Bronchocele . . . . .	15	Emphysema . . . . .	18
Bronchitis . . . . .	16	Melenosis . . . . .	20
Bronchia, dilatation of . . . . .	16	Tumours . . . . .	20
Blue disease . . . . .	26	Œsophagus . . . . .	13
Bladder . . . . .	44	Ulceration . . . . .	13
Calculi . . . . .	45	Stricture . . . . .	14
Ulceration . . . . .	45	Ossification of the Valves of the Heart . . . . .	26
Fungi . . . . .	45	Pia Mater . . . . .	4
Corpora Carnosa . . . . .	45	Periosteum . . . . .	1
Ulceration . . . . .	45	Pleura . . . . .	21
Croup . . . . .	15	Pericardium . . . . .	22
Dura Mater . . . . .	2	Prostate Gland . . . . .	44
Eye, fungus of . . . . .	11	Scirrhus . . . . .	44
Fauces . . . . .	12	Ulceration . . . . .	44
Hydrothorax . . . . .	21	Stomach, Serous Membrane . . . . .	28
Heart . . . . .	23	Mucous Membrane . . . . .	29
Softening . . . . .	25	Tumours in the . . . . .	31
Internal Lining . . . . .	25	Fungus and Scirrhus . . . . .	31
Ulceration . . . . .	24	Rupture of the . . . . .	31
Polypus . . . . .	25	Trachea . . . . .	15
Ossification of Valves . . . . .	26	Testicle, Hydatids . . . . .	50
Intestines, Serous Membrane . . . . .	36	Encephaloid . . . . .	50
Mucous Membrane . . . . .	39	Scirrhus . . . . .	51
(large) . . . . .	39	Vesicula Seminales, Abscess . . . . .	44
Tubercles . . . . .	36	Ulceration . . . . .	44
Structure . . . . .	39	Uterus . . . . .	47
Ulceration . . . . .	39	Irritable . . . . .	48
Cancer . . . . .	39	Cancerous . . . . .	45
Intus-susceptio . . . . .	36	Phagedemi, Ulceration . . . . .	48
		Hydatids . . . . .	48









The Pancreas has been purposely omitted, the author not feeling sufficiently satisfied with the value and importance of the specimens which have fallen under his own observation to allow him to make them a part of this work.

ERRATA.

Page 23, line 36, should be read thus:  
constipated; pain in some cases relieved, in others aggravated

Page 39, omit line 3.

Page 51, line 8, omit the semicolon.

