

**Report ... on the Asiatic cholera, together with a report of the City Physician on the Cholera Hospital.**

**Contributors**

Committee of Internal Health (Boston, Mass.)

**Publication/Creation**

Boston (Mass.) : J.H. Eastburn, 1849.

**Persistent URL**

<https://wellcomecollection.org/works/gvfv8w3d>


**License and attribution**

This work has been identified as being free of known restrictions under copyright law, including all related and neighbouring rights and is being made available under the Creative Commons, Public Domain Mark.

You can copy, modify, distribute and perform the work, even for commercial purposes, without asking permission.



Wellcome Collection  
183 Euston Road  
London NW1 2BE UK  
T +44 (0)20 7611 8722  
E [library@wellcomecollection.org](mailto:library@wellcomecollection.org)  
<https://wellcomecollection.org>





58,466/.3 Suppl



ACCESSION NUMBER

310556


PRESS MARK

~~FK 615~~

Suppl / BOSTON


22101254 968

BOSTON (Mass.), Committee of  
Internal Health



Digitized by the Internet Archive  
in 2016 with funding from  
Wellcome Library

<https://archive.org/details/b28740816>



REPORT  
OF THE  
COMMITTEE OF INTERNAL HEALTH  
ON THE  
ASIATIC CHOLERA,  
TOGETHER WITH A  
REPORT OF THE CITY PHYSICIAN  
ON THE  
CHOLERA HOSPITAL.



BOSTON:  
1849.  
J. H. EASTBURN, CITY PRINTER.



STON: Cholera: 19 cent.

CHOLERA: U.S.A.: 19 cent.

~~FK. 615~~



310 556

*In the Board of Mayor and Aldermen, }  
December 31, 1849.*

Accepted and ordered to be printed.

Attest:

S. F. McCLEARY, *City Clerk.*

# REPORT.

---

*In the Board of Mayor and Aldermen, }  
Monday, Dec. 31st, 1849. }*

THE Committee on Internal Health, who have had under their charge the various arrangements which have been made by the Board of Health for the preservation of the City from Asiatic Cholera, and for the succor of persons attacked by the disease, beg leave to present the accompanying Report, prepared by Dr. Henry G. Clark, the City Physician, and Drs. Charles E. Buckingham, John C. Dalton, and Henry W. Williams, his associates in the care of the Cholera Hospital. It will be found to embrace every thing of interest to the public or the medical profession, relating to the exciting causes, peculiar characteristics, localities, treatment, and cure of this mysterious epidemic in Boston. It also furnishes a statement of deaths properly classified under the heads birth-place, age, and general habits, when known; and a detailed account of a considerable number of post mortem examinations. For this document, bearing upon its pages, as it does, the marks of unusual care and fidelity, the community is greatly indebted to the above named gentlemen, and especially to Dr. Clark, who has had the principal hand in getting



it up ; and the obligation is increased by the consideration that this labor is in addition to a great amount of arduous and unrequited professional service, rendered during the whole period of the prevalence of the epidemic.

In addition to this document, the Committee are of opinion that nothing further is required than a brief statement of the precautionary measures taken by the City authorities to prevent the approach or allay the virulence of the disease,—an estimate of the expenses incurred,—and some account of the sanitary state of certain localities and the steps that should be taken to prevent a recurrence of future attacks from this and other epidemics ; and to these points they at once proceed.

The attention of the Municipal authorities was called to the subject of Asiatic Cholera as early as September, 1848, by a communication from the Board of Health of Philadelphia. A Joint Committee of the City Council was immediately raised to consider the matter and the Consulting Physicians were requested to give their opinion upon the probability of the approach of the disease and the preparatory steps that should be taken in reference to it. Their report was published in the newspapers, and notices were sent out and left at all residences of the inhabitants, calling their attention to the state of their houses and yards.

In addition to these measures, the City Council resolved themselves into special joint committees, and to each of them, was assigned the custody of one of the wards of the City, for greater facility in examination, and reporting cases of nuisance. Special agents were also employed in the most exposed districts during the month of December, and much valuable work throughout the City was accomplished before the close of the year. The



further active prosecution of sanitary proceedings was suspended, during the winter months, in consequence of the coming in of a new City Government, and the diminished probability of a speedy approach of the epidemic within our limits. But, early in the spring, the attention of the authorities was again called to the subject, by the arrival of the disease at New York. The old arrangement of joint committees of the City Council having been found practically inconvenient and cumbersome, the Board of Health, consisting of the Mayor and Aldermen, undertook the sole charge and responsibility of all future measures in reference to this matter. For greater convenience, the City was divided into districts, each of which was placed under the particular care of a member of the Board, with power to obtain from the Police and Internal Health Departments as large a force as should be necessary for the effective and thorough cleansing of his district. All nuisances, not removable in a summary way, were reported to the Board, which passed the necessary orders and carried them into effect through this Committee.

The Board commenced their labors by republishing the report of the Consulting Physicians in the public journals, and leaving printed notices at each house, in the City, requesting the inhabitants to thoroughly cleanse their houses, yards, privies, and drains, and deposit all decayed vegetable and animal matter, and other deleterious substances in the streets opposite their dwellings, on certain specified days. The requisition was very generally complied with, and a large number of carts were at once employed to carry off what had thus been collected. The Police, under the City Marshal, were then detached, in squads proportioned to the size of the respective districts, to carefully inspect, from garret to cellar, every building in the City; to order and



see to the removal of every offensive substance which could readily be removed; and to report all cases of important or permanent nuisance to this Committee. They performed the laborious service with great fidelity and in the most quiet and gentlemanly manner; and, it is proper to state, that the inhabitants, everywhere, received them with kindness, and seemed anxious to aid them in the proper discharge of their duties. After this examination had been completed, and sufficient time allowed for the removal, by the authorities, of what had been collected, the whole force of the Police and Health Departments, with such other assistance as was required, were turned to the immediate removal of the nuisances which had been reported to the Board. In addition to an immense amount of filth, of all sorts, removed from houses, yards, and streets, several thousand vaults were emptied, and many scores of drains cleansed, repaired, or newly constructed. In consequence of these efforts, the City was soon in a greater state of cleanliness, it is believed, than it ever had been since its foundation; but, in order that the labor which had been expended, might not be lost, the Police were again detailed in squads to visit, in daily rounds, every part of their respective districts, and carts were assigned to them for the immediate removal of any offensive substance which they might find. Every street was swept, and the house dirt and offal were carried off from each dwelling, twice a week, through the Health Department; and, in the exposed localities, these precautionary labors were performed daily, under the direction of the Police. Many yards, lanes, and by-places, in different places, were also daily drenched with Cochituate water. The services were continued through the whole summer; and too much praise can hardly be given to the City Marshal and his numerous assistants, for the zeal, fidelity



and promptitude with which they carried out every order, or even suggestion, which they received from this Board.

On the approach of the Cholera, several additional measures were undertaken. Printed notices were published in the journals and posted up in various places, containing directions as to regimen, diet, clothing, and the treatment to be pursued on the discovery of premonitory symptoms. The Police were directed to see that houses and cellars, in exposed places, were white-washed. Large quantities of disinfecting substances were purchased, and freely distributed wherever they were required. The inhabitants were notified to cleanse their house drains with Cochituate water, and the common sewers were ordered to be washed, at different periods, during the summer. The Board directed the large tract of marshy land, constituting the Back Bay, to be flooded from the ocean, and the water to be retained at as great a height, as the drains flowing into it, would permit. By a special order, all vessels arriving in the harbor with fruits, or other objectionable substances, were ordered to report themselves to the Hospital Physician at Deer Island, by whom they were thoroughly examined; and all decayed or deleterious portions of their cargoes were removed, or thrown overboard, before a permit was granted to come up to the City.

For the relief of the poorer classes, the Board fitted up a large building on Fort Hill, formerly a gun house, as a Cholera Hospital, and placed it in the charge of this Committee. A medical staff, under the direction of Dr. Clark, the City Physician, and all necessary nurses and attendants were speedily provided, and the whole establishment was ready for the reception of patients before its use was required. As a further measure, your Committee, with the consent of the Board and the ap-



proval of the Consulting Physicians, appointed special physicians for each ward, who were required to visit and prescribe for Cholera patients at their own dwellings, and be at their service, both day and night; with power to procure nurses and medicine. By this means great additional medical aid was afforded, and the first stages of the disease were more effectually watched and checked.

The thanks of the Board and of the whole community are due to the medical gentlemen and all their assistants, at the Hospital and elsewhere, for their promptitude, judgment, humanity, skill, and fidelity, during the whole progress of the disease. Their labors were arduous and unremitted, day and night, and those rendered at the Hospital were wholly without pecuniary compensation.

From the above account, it will be seen that the City was well prepared for the Cholera before its arrival; and, though the precautionary measures which had been taken, did not prevent the anticipated attack, there is every reason to believe that they were effective in checking its progress and diminishing its virulence. As is well known, most persons, throughout the City, were more or less, affected by the Cholera atmosphere; but few cases of the actual disease, and still fewer deaths, occurred in any of the more dry and airy portions of the metropolis. As will be seen by the topographical map, appended to the medical report, the epidemic made its first attack and spent its force, in those localities which were nearest to the level of the sea, and, in fact, rescued from it by filling up with dock mud; which were the least perfect in drainage, the worst ventilated, and the most crowded and filthy. And, though its fatality in these districts was considerable, it cannot be doubted that it would have been much more so, except for the extraordinary care and vigilance which had been



taken to put and keep them in as good condition as circumstances would permit. It ought also to be added, that personal habits seemed to be quite as important as locality, in determining an attack of the complaint. For the most part, the temperate, the moral, the well conditioned, escaped; whilst the imprudent, the vicious and the poorly fed, succumbed to its insidious influences.

The number of *cases* of Asiatic Cholera in the City cannot be given, as no account is known to have been taken of them; but, as all *deaths* are required to be reported at the Registrar's office before any permit for burial is granted, their number can be accurately ascertained. From his records, it appears that the first death from this disease occurred on the third of June, at No. 11 Hamilton street, in the person of an Irishman, and the last on the thirtieth of September, at the Cholera Hospital, in that of an Irish woman from Wharf street. The whole number of deaths between these dates was six hundred and eleven, of which one hundred and sixty-three were Americans, and seventy-nine Bostonians. The first patient at the Cholera Hospital was Rosanna Norris, an Irish woman, from Allen's Block, received June 29th; and from that time to November 15th, when the establishment was closed, the whole number of persons received were two hundred and sixty-two, of whom one hundred and sixty-six died, and ninety-six recovered: two hundred and eighteen foreigners and forty-four Americans. For detailed statements of the cases, treatment and autopsies at the Hospital and elsewhere, as well as for many interesting facts and observations in relation to the nature and progress of the disease, we must refer to the annexed medical report.



The expenses incurred on account of the Cholera Hospital, are as follows:

For fitting up,	-	\$898 02
“ furnishing,	- -	2,055 90
“ wages,	- -	2,299 03
“ stores and provisions,		997 86
“ medicines,	- -	375 72
“ board of children,		139 14
“ carriages, horses, &c.		82 64
“ sundries,	- -	55 28
		—————\$6,903 59

The expenditure for account of physicians, employed at large in the districts, and for nurses and medicine, was 1,342 28

The cost of cleansing the City and carrying out the precautionary measures, adopted by the Board of Health, cannot be ascertained with precision, for the reason that the whole service was undertaken by the Police and Health Departments, and no special account was kept of the expenses which were properly chargeable to Cholera. From a pretty careful examination, however, of the several charges in the books, we estimate the outlay of the City, over and above what is above given, at \$20,000, thus making the whole expenditure \$28,245 87; and we are of opinion that it does not exceed this sum.

The account books used at the Cholera Hospital, and a small book, containing an accurate schedule of all the furniture and property within its walls, remaining on hand on the day the building was closed, are herewith delivered to the Board.

Before closing their report, your Committee deem it their duty to call the special attention of the Board of Health, and their successors in office, to the present



unhealthy condition of many of the streets, in the lower parts of the City. They refer, particularly, to portions of the Neck and Harrison Avenue ;—to the South Cove, —the territory bordering on the water, from South Boston upper Bridge to State Street,—the neighborhood of Ann Street,—a part of the Mill Pond lands,—and certain tracts on the northerly side of Cambridge Street, near the river. In all these localities, there are many streets, courts, and lanes which are exceedingly contracted, ill ventilated, and dirty ; without any proper grade and with no, or very insufficient sewerage. This state of things is mainly owing to the fact of their having been originally laid out by private speculators, whose only object was to make a profitable investment for themselves, and who paid but very slight attention to the health or comfort of those who have to reside upon them. But in some cases, it arises from the great increase of population, which renders the space and accommodation, originally provided for a limited number of residents, wholly insufficient for the proper supply of the present necessities. In certain localities, as on the South Cove, the marshy and new made ground has settled, and the imperfect sewerage which was originally provided, has become nearly useless. The great body of the streets alluded to are private ways, over which the City exercises no special care or custody ; and the policy, hitherto pursued by it, has been to refuse to accept them, until they are graded and put in good order by the abutters. It may be questioned whether this policy is a sound one. The public interest would seem to require that the Board of Health should have the power to cause all streets and ways to be laid out, of a suitable width, and to be properly graded and provided with ample sewerage, constructed and laid down in the best manner, before any buildings are erected upon them.



And, in case of neglect or refusal to comply with their requisitions, they should be authorised to proceed by their own agents; and the adjacent territory should be held answerable for the payment of the necessary expenses.

The Committee consider that the whole subject of streets and ways, in respect to width, ventilation, grade, and drainage, is one of very great and increasing importance. They would urge strongly the necessity of enforcing all existing statutes and ordinances; and, where a deficiency of power is apprehended, the propriety of an immediate application to the legislative power. A great deal, undoubtedly, has been done in reference to this subject, during the last few years, but very much still remains undone; and it is only by a long continued system of measures, patiently persevered in, that we can expect to arrive at that point of practical perfection which will secure the health and comfort of our inhabitants.

We would now refer to another subject which, in our view, also demands the attention and action of this Board. We allude to the very wretched, dirty and unhealthy condition of a great number of the dwelling houses, occupied by the Irish population, in Battery-march, Broad, Wharf, Wells, Bread, Oliver, Hamilton, Atkinson, Curve, Brighton, Cove, Ann, and other streets. These houses, for the most part, are not occupied by a single family, or even by two or three families; but each room, from garret to cellar, is filled with a family consisting of several persons, and sometimes with two or more families. The consequence is an excessive population, wholly disproportioned to the space or the accommodations.

From the very necessities of the case, these residences soon become polluted with all manner of bad odors.



In such a state of things, there can be no cleanliness, privacy, or proper ventilation, and little comfort; and, with the ignorance, carelessness, and generally loose and dirty habits which prevail among the occupants, the necessary evils are greatly increased both in amount and intensity. In Broad street and all the surrounding neighborhood, including Fort Hill and the adjacent streets, the situation of the Irish, in these respects, is particularly wretched. During their visits the last summer, your Committee were witnesses of scenes too painful to be forgotten, and yet too disgusting to be related here. It is sufficient to say, that this whole district is a perfect hive of human beings, without comforts and mostly without common necessities; in many cases, huddled together like brutes, without regard to sex, or age, or sense of decency; grown men and women sleeping together in the same apartment, and sometimes wife and husband, brothers and sisters, in the same bed. Under such circumstances, self-respect, forethought, all high and noble virtues soon die out, and sullen indifference and despair, or disorder, intemperance and utter degradation reign supreme.

The houses above alluded to are also insufficiently provided with the necessary in and out of door conveniences, which are required in every dwelling place. The great mass of them, particularly in the region last referred to, have but one sink, opening into a contracted and ill constructed drain, or, as is frequently the case, into a passage way or street, and but one privy, usually a mass of pollution, for all the inhabitants, sometimes amounting to a hundred. Some of them have neither drain nor privy; and the tenants are obliged to supply their necessities as best they can. Many of them were originally designed for warehouses, and have been converted to their present uses as eco-



nomically as possible ; whilst others, which were once well fitted for the accommodation of a single family, have become wholly inadequate to meet the wants of the large numbers that now crowd into them. A great portion of those in Broad street and Fort Hill are lofty buildings from three to six stories high, and contain from forty to one hundred inhabitants. The rent for each room ranges from one dollar to one dollar and a half ; and is generally collected by a man who hires the whole building, or several buildings, and enforces prompt payment under the threat always rigidly executed, of immediate ejection.

Appended to the medical report is a sketch of Half Moon Place, which is probably the worst locality in the City. Here the houses are built around an area from which air is almost totally excluded by the perpendicular wall of Fort Hill on one side, and the lofty buildings of Broad street on the other. A large part of the area is occupied by some twelve or fourteen privies, constantly overflowing, and by ill constructed and worn out sinks and drains, into which are hourly thrown solid substances, of all sorts, which choke them up and cause the liquid parts mixed with them to run over. Into the area there is a narrow entrance from Broad street, whilst a steep and crazy staircase affords a passage to Humphrey place, some fifty feet above. Side by side with the staircase, and fully exposed, a large, square, plank drain makes a precipitous descent, conducting, half hidden, half revealed, not only the waste water of the houses in Humphrey place, but, also, the contents of its privies to the area below ; which, as may be supposed, is redolent of the fact.

Your Committee have already, in a former communication, described to the Board the state of the cel-



lars under the houses, above described; but the importance of the subject, as well as the consideration that the duties of the existing Board will soon be transferred to others, seem to require some notice of them here, even at the risk of repetition. These cellars are generally entirely beneath the surface of the ground, and, to most of them, the only entrance for light or air, is by the passage, or cellar door way, leading down to them by steps from the sidewalk above. They are crowded with families, which lodge there and make them their sole place of abode. Besides a dwelling house, these places very generally serve the purposes of a grocery and vegetable shop; and, not unfrequently, a groggery and dancing hall are added. As might be expected, intemperance, lewdness, riot and all the evil spirits, to which poor humanity is at any time subject, enter in and dwell there. Few of the cellars have either drains or privies. Some of them are divided off into one or more rooms, into which hardly a ray of light, or breath of air passes, and where notwithstanding, families consisting of several persons reside. How the lamp of life, under such circumstances, holds out to burn, even for a day, is, perhaps, as great a wonder as that such a state of things should, in this community, be suffered to exist. That such residences become the permanent abode of fever, in some of its forms, is well known to the medical men who visit them; and, that they tend to shorten life, we may clearly infer from the statistical tables of Mr. Shattuck, who states that the average age of Irish life in Boston, does not exceed fourteen years. The number of cellars, used as dwelling houses, is, according to the return of the City Marshal, five hundred and eighty-six; and the number of persons occupying them varies from five to fifteen.

The Committee would gladly have been excused from



the task of setting before you the above most painful details, but it has been forced upon them by a sense of duty and the hope and belief that, for the large portion of the evils complained of, some adequate remedial measures can and ought to be found by the City. Great public considerations seem to them to demand, that every dwelling house should be provided with sinks, drains, and privies, that are adapted, in size, number, and construction, to the number of individuals who shall occupy it; that the owners should be compelled by law, to construct them, under the direction of the Board of Health; and, in case of neglect or refusal, that the estate itself should be held liable for the payment of all expenses which may be incurred by the City in making such provision. As to the health and comfort of the poorer classes, as well as to the rights of tenants, who are unable to prosecute them, would also make it reasonable, that every landlord should be required to fit his building properly to the purposes for which it is to be used, in respect to light, air, and necessary conveniences; and that some provision of law should be made by which the number of tenants should be apportioned to its size and general arrangements. And, especially is it important, that some legal power, sanctioned by penalties sufficiently stringent, should be obtained, to prevent entirely the occupation of under-ground cellars as dwelling houses.

Your Committee submit the above subjects to the serious consideration of the Board of Health, and they recommend that an early application be made to the Legislature for such additional powers, as may be needed to abate the evils complained of.

In behalf of the Committee,

HENRY B. ROGERS,

*Chairman.*

## CITY PHYSICIAN'S REPORT.





CITY PHYSICIAN'S OFFICE,

DECEMBER 24, 1849.

*To the MAYOR AND ALDERMEN, Health Commissioners of  
the City of Boston.*

GENTLEMEN :

HAVING been charged by your order of July 2d, with the care, (under the direction of the Committee on Internal Health) of superintending the "CITY HOSPITAL FOR CHOLERA," during the continuance of that disease;—I have thought it an appropriate mark of respect to the Board,—an act of justice to the Physicians, whom I had the pleasure to associate with me,—and to myself,—to present you an account of my proceedings under the said order;—that you may judge for yourselves of the manner in which this trust has been fulfilled.

For this purpose, I have the honor to submit to you a detailed Report, containing a history of the Hospital and of the epidemic itself, so far as it has been connected with it.

In making this Report, I have been very much indebted to my associates; and while this insures more full and perfect statements in its various departments, it will also account to the reader for some want of unity

in its style and arrangement. Dr. Buckingham has prepared the account of the cases, and their treatment, from the Hospital records. Dr. Dalton furnishes the important portion, relating to the pathology of the disease; while Dr. Williams has supplied the topographical statistics; so that it will be seen little else has been left for me beyond the general plan of the Report, the arrangement of its materials, and its formal presentation to the City Government.

The drawings are by Mr. Billings, and are most faithful representations of the scenes they are intended to exhibit.

We have endeavored to present, in the plainest manner, the facts which have fallen under our observation, in order that they may be available in case of the recurrence of Cholera, if indeed they cannot be made more directly useful to the sanitary improvement of our City.

I have the honor to be,

Gentlemen, with great respect,

Your obedient servant,

HENRY G. CLARK,

*City Physician.*



# R E P O R T .

---

## THE HOSPITAL AND ITS ORGANIZATION.

THE Hospital was fitted up under the supervision of the City Physician, and in its arrangements, no necessary expense was spared. The building was formerly used as a gun-house, by the Washington Artillery, and required extensive alterations to prepare it for occupation. A large ventilating stove was placed in the centre of the main building, and two large ventilators were put upon the top. Twenty beds were placed in it, and at a later period eight others were provided. At one time these were all filled, and by the permission of the Committee on Public Buildings, a door was cut through the wall, between the yard of this building and the yard of the Boylston School House, enabling the attendants to have free access to the Ward Room under that School House. When the Hospital was full, about a dozen beds were placed in the ward room, and occupied by convalescents and nurses. At one end of the gun house, the officers' room was fitted up, as a Dispensary, and in this room two medical students slept at night. At the other end of the house a kitchen was built, and adjoining it, in front, a space was roofed over and floored, for a dining room, the front of which was closed by sail cloth, which, during the



warm and pleasant weather, was drawn aside. The cellar beneath the house, which was filled with rubbish before its occupation as a Hospital, was cleansed, and about eighteen inches in depth of dirt, tar, &c., was dug out, and its place supplied with gravel. Over the gravel a new plank floor was built. The cellar was used as a wash room, bathing room, dead house (for the temporary deposit of the dead, until the bodies could be removed by the undertaker,) closets, &c., in various divisions. The ward of the Hospital was thoroughly cleansed and whitewashed. The floor was whitewashed as often as once in two days, during the season.

During the first week or two of the epidemic, the beds, which were palm-leaf mattresses, upon common cot bedsteads, were covered with vulcanized rubber cloth, sheets, and quilts. Subsequently the quilts were removed and thick woolen blankets substituted. An unlimited supply of these and unbleached cotton sheets was provided by the Cholera Committee. Nothing, in fact, which was desired by the medical officers, for their own comfort, or for the comfort of the patients, was refused.

For the first ten days of the epidemic, Dr. Clark had charge of the Hospital, with the assistance of Mr. H. B. C. Greene and Mr. Charles T. Hildreth, medical students. After this time the following gentlemen were on duty at the house.

HENRY G. CLARK, M. D., *City Physician.*

CHARLES E. BUCKINGHAM, M. D.	}	<i>Associate Physicians.</i>
JOHN C. DALTON, JR., M. D.		
HENRY W. WILLIAMS, M. D.		

HENRY B. C. GREENE,	}	<i>Resident Students.*</i>
RICHARD M. HODGES,		

\* Mr. A. F. SAWYER was also a part of the time acting as assistant.



The morning visit, at 9 o'clock, was made by Dr. Clark, the afternoon visit, at 4 o'clock, by Dr. Buckingham. To these visits all medical men were invited. Another visit was made at 9 o'clock, P. M., by all the Physicians, and this visit was private. It was the duty of Dr. Williams to remain in the house as much of the time as possible, for the purpose of visiting reported cases of Cholera in the neighborhood. To Dr. Dalton was assigned the duty of making the autopsies, and a later portion of this report will exhibit the faithfulness with which this duty was performed. Too much credit cannot be given to the resident students for their zeal and self-devotion to their duties. They were often out of bed until one o'clock in the morning, and it was not unfrequently the case that they were at their work by daybreak, besides being often called upon in the night.

No medical men could have been more united in their opinions, nor more willingly united in their action than the Hospital Staff. Their final separation was the only circumstance, which they regretted at the close of the epidemic.

It is our duty to express our satisfaction with the drugs, which were always well and punctually supplied by Mr. Thomas Restieaux.

We feel greatly indebted to the Cholera Committee of the Board of Health, and particularly to Henry B. Rogers, Esq., their Chairman, for the willingness with which our calls were answered, and the readiness with which the sick and their families were assisted.

To the Consulting Physicians of the City, who were frequently at the Hospital, we acknowledge ourselves under great obligation for the very courteous and considerate manner in which they were always ready to



favor us with their opinions and advice whenever called upon.

To his Honor the Chairman of the Board, for the very cordial support which he was at all times prompt to render, we return our sincere thanks. He was very often at the Hospital, and visited also in person many of the bad localities which originated some of the worst cases, putting into effect the most energetic measures for their removal.

The Catholic Clergy of the City have our warmest thanks for their energy and activity in their efforts to prevent the spread of the sickness among the class of persons over whom they had especial influence. Rev. Mr. O'Brien, of that Church, was almost daily in the Hospital, sometimes much more frequently, and by his advice and co-operation with us, we were often enabled to remove patients to the Hospital, who would otherwise have died at their miserable homes, neglected and forsaken.

The publishers of the several newspapers which were furnished gratuitously at the Hospital during the whole period of its continuance, will please accept our thanks for the very acceptable favor. The Police department has already been referred to by Mr. Rogers, in a manner which has our cordial endorsement.



## MEDICAL HISTORY OF THE DISEASE.

---

### CAUSES.

ON the 29th of June, the day of its completion, the first patient was received at the Hospital; and the last patient was discharged on the 15th of November. During this period of time, there were under treatment in all, two hundred and sixty-two patients; of these, one hundred and sixty-six died and ninety-six recovered. Up to the 5th of July, there was not a large number of sick received. On that day five were admitted. After this until August 2d, the average number of patients was small, on some days one or two, and on others none being admitted. On the 2d of August the number of admissions was four, and on the succeeding day, which it will be remembered was the day of fasting appointed by President Taylor, the number of admissions suddenly increased to fifteen. For several days after the admissions varied from five to twelve, except on the 4th, when there was one admission only. On the 15th of August there were but three admissions. After this date the number of patients again began to increase, until the 1st of September, on which day eight were admitted. From this date the number gradually fell off again till the 19th of September, when one only was admitted, and after that day till the 29th, when the last Cholera patient was admitted, there were only five admitted in all.



It is perhaps difficult to say, what was the cause of these apparent exacerbations and remissions of the disease. We shall subjoin an account of the meteorology of this city during the epidemic, from which readers may draw their own conclusions. Days of public fasting have always been noticed in other places, as occasions for increased severity of this disease, but the cases of Cholera in this city were chiefly among that class of the inhabitants, foreigners, who pay but little attention to our public fasts. It is more likely that, as they were mostly intemperate subjects, the fast day was made with them a day of general relaxation from their usual labors, and that there was really more than the usual amount of indiscretion among them. One fact, however, is worthy of note, that at this time, Rev. Theobald Mathew was in this city, upon his temperance mission, and many of the subjects of Cholera had lately taken the pledge, had at once lost their appetites and become affected with diarrhœa, one of the first and most marked symptoms of Cholera.

No class of the inhabitants of Boston was perfectly free from the attack of Cholera, though the number of those in easy circumstances attacked was so small, that they might almost be overlooked, in the history of the epidemic.

The general opinion of physicians in this city seems to be against the contagious nature of the disease, and we have seen no reason to differ from their opinion. There were about twenty-five attendants in the Hospital exclusive of medical officers, at different times, all of whom were more or less constantly in proximity to the subjects and their excretions, and many of them were only for a very few hours at a time out of the ward. Four physicians and four medical students were engaged in the duties of the Hospital; two of the latter for a



short period only. Of the others, the students were untiring in their devotion to the sick, often irregular in their meals, and having a much smaller allowance of sleep than nature is supposed to require. The physicians spent from six to eight hours daily in the house, until about the close of the epidemic, and when the number of patients was large, were often engaged in the duties properly belonging to nurses. Of all these attendants, but two had the symptoms of the disease, and in one of these (Mr. Greene) they were not all present, and in the other (Mr. Ripley) the most marked early symptom (rice water discharges) was entirely wanting. Two of the attendants had Cholera at the time they entered the house, and neither of these had any return of the disease. The diet of the attendants was not restricted. Meat, fruit, vegetables, even salad, puddings, &c. were freely partaken of.

#### SYMPTOMS.

The symptoms of Cholera in our patients did not differ from those reported in other places. It usually began with purging of a yellowish fluid, with or without flocculi, soon followed by vomiting. The cramps generally began at the time of the vomiting. In some of the cases, the discharges were described as "at first bilious." Patients came in generally so late in the course of the disease, that we had no chance of seeing the early symptoms, except in private practice. In many cases, the hearing was early impaired, and always upon being particularly questioned, they expressed a sense of noise in the head, at the commencement. The sight we know but little of. The eyes were always injected, often dry, always sunken and surrounded by a dark areola. The tongue was almost always dry, when we first saw it, there being seldom enough moisture



upon it to act upon test papers. When this was not the case, the tongue was generally strongly acid. The thirst was always excessive, and was never relieved wholly by drinks. Restlessness in the fatal cases was one of the most marked symptoms, it being impossible to keep any bed-clothing upon the patients, except by a resort to the bed-strap. The voice was early husky, and towards the close, in fatal cases, was hardly perceptible. There did not seem to be any direct relation between the dryness of the fauces and the aphonia. In the favorable cases, the voice soon became improved. The urine was declared scanty in almost every case, or entirely wanting for hours previous to entrance. After it re-appeared, patients with few exceptions recovered from Cholera; those who died after its re-appearance, went into a febrile state, which lasted from one to four or five days. The first urine it was not generally our good fortune to collect, though it was attempted, as it was passed with the dejections. When examined, it was never found highly charged with albumen, sometimes not at all; its specific gravity was high, and its reaction acid. The rice water dejections were not always marked. The late period in the disease, at which we saw patients, may account for this, but in those cases when they were not seen, the dejections were frequent and liquid, with a deposit of broken down blood, resembling the grounds of an infusion of black tea, with a peculiar fleshy odor, which it was not easy to mistake or to forget. These dejections were sometimes pints in quantity, and lasted for several days before bile was excreted.

Apparent narcotism was noticed in many of the fatal cases upon entrance. The patients who exhibited this symptom had generally been many hours under treatment before entrance, and from many of them we learn-



ed that excessive doses of opium had been taken. In most of these patients there was a contracted pupil, not influenced by light or darkness, stertorous breathing, difficulty of hearing, together with the customary evacuations and occasional cramps. These appearances were the more remarkable, because in the generality of fatal cases, patients were decidedly active and intelligent until within a short time of death, which in these cases was always the speedy result.

The pulse was usually accelerated to more than one hundred in the minute, and feeble. In many cases it could not be counted, when the patients entered. Notwithstanding this, the action of the heart was violent and the external vessels of the head were much congested. In a large number of the cases, no pulse could be felt at the wrist at the time of entering, these patients being yet able to walk into the house and raise themselves without apparent effort. This was marked in one patient in whom the pulse afterwards returned. But he was very restless, constantly rising in bed. He died suddenly while drinking some water, which he got out of bed to obtain, during the momentary absence of the nurse. In one woman who recovered, no pulse could be distinguished at the wrist for two days.

The shrivelled, cold and clammy skin and its livid color were never absent throughout the whole course of the disease in any patient.

Secondary fever was almost always present in the favorable cases, and in many of the fatal ones. It was more marked in the intemperate. In the latter, whether they lived or died at a late period, delirium resembling *mania a potu* was generally present at night. The amount of valerian, brandy and opium taken by some of these patients before sleep was produced was almost incredible. In one patient (Coolidge) who died, this delirium was very remarkable, continuing without ces-



sation for several days. He was always in fear, but could be easily quieted until the last day, when his struggles and outcries were intolerable. One patient (Rogers) came into the house drunk twice, before she was admitted with Cholera. She recovered after a long illness, but for two or three days and nights she had no sleep. No patient is known to have died, except from the fever, who slept without opium.

One of the most peculiar points noticed by us in this disease, was the appearance in three patients who recovered, of a rash exactly resembling the rash of the typhus or ship fever, which prevailed here the last year and the year previous. In one case, (that of Dill) the whole body was so thickly studded with the eruption that a pin's head could not have been placed between any two of the blotches, although in most parts it was distinct. This lasted in his case for four days and was accompanied with paralysis of the bladder, rendering the employment of the catheter necessary for several days. A peculiarity noticed in this eruption was, that it was not seen, except in Dill's case, on parts when first exposed to the light. After a half minute's exposure, however, the surface became quite dusky red and again regained its former color, when recovered.\* This eruption was seen also in three out-patients who recovered, and who were treated by Dr. Williams.

The perspiration was remarkable, in almost every case which lasted for several days, for staining the bed clothes of a reddish brown. It had a strong, sickly odor.

#### TREATMENT.

We can hardly presume to recommend any method of treatment, nor can we say positively what was the

\* In this patient the desquamation of the cuticle was very remarkable.



invariable effect of different remedies. Patients came in, almost always so far gone in collapse, that we expected them to die at any rate. With this feeling it was in several instances judged best to give them no medical treatment, but to let them follow their own inclinations. In no one case, where this practice was followed, did the patient recover. Early in the epidemic a circular was issued to physicians requesting them to send their cases early, if at all. We believe, that there was hardly a fatal case when this request was acceded to. We feel it our duty to mention this, because we believe that Cholera, if early treated, is almost as manageable as any of the severe epidemic diseases, but that the stage in which it is manageable is of very short duration. One physician is reported to have said that more than three quarters of all the Cholera patients who were under his sole charge were saved, while of a large number sent by him to the Hospital not one recovered. The latter part of this statement is perfectly correct, and it is equally so, that not one patient came from him to the Hospital, who was not moribund at the time of entrance, or became so very shortly after. The cases that could not be kept under regular treatment, those which were already hopeless, were sent to the City Hospital. We should not feel that we were doing ourselves justice, if we suffered our large bill of mortality to be publicly exhibited without this correlative fact.

The remedies which were used were numerous. Of some of them it may be well to speak in detail.

*Narcotics* totally failed of any beneficial effect. Opium in no case, either single or combined, arrested the vomiting or purging, and it was often thought to hasten the fatal termination. *Camphor* always failed except perhaps to relieve the cramps, which it was sometimes



thought to do. In two patients, to whom it was exhibited, the whole surface became before death very dark, and the lips actually black. In these cases narcotism was very evident.

*Stimulants* almost always failed. To some patients brandy and water was freely given. Three of these recovered after a severe secondary fever. Very few were relieved at all, and almost every patient treated in this way had secondary fever. The same may be said of the various preparations of ammonia, of the astringent stimulants, of coffee and of tea. Those who drank freely of strong coffee and tea and had no other treatment except external heat, died early. *Electricity* failed entirely.

*Emetics.* The usual emetic dose was ipecac: and capsicum in powder, about forty grains to a drachm each. This was always exhibited in the early cases, and at least with temporary benefit. The pulse, which was often gone, returned at the wrist, and with it, the warmth of surface. How much our omission of this treatment, if any thing, had to do with the greater mortality in later cases, we are unable to say.

*Calomel* was given alone, in large doses, in a few cases. We could not perceive that it had any effect. It has been said, that if you ever give a Cholera patient a mercurial sore mouth, he will recover. This is undoubtedly true, and is equivalent to saying, that if a patient lives long enough, he will get well.

*Quinia*, in the form of the sulphate, was used in a very few cases. We are not positive that these patients died any sooner than others: none of them recovered. The drug was administered in five, ten, and twenty grain doses.

*Tannic Acid* was frequently used in enemata, in proportions of five or six grains to the ounce of fluid,



and almost always with temporary relief of the purging. By the stomach in doses of two or three grains it sometimes appeared to check vomiting.

The astringents and aromatics had usually but little if any effect. *Ginger* was almost always immediately rejected, in whatever form used. *Cinnamon* in tincture fared but little better. The aromatic powder of the United States Dispensary was oftener retained. But upon none of these drugs do we place any reliance.

*Ether*, could be given in large enough doses by inhalation to relieve the cramps, but we are not aware that any patient recovered, who used it to this extent, or that others were benefitted by it.

*Cathartics* were never used until the dangerous period was supposed to have passed. *Elaterium* was suggested by one of the Consulting Physicians, as possibly having the power to set up a new action. It was administered in one instance, but without any apparent effect.

*Venous Injection.* Several solutions of alkaline salts were injected into the veins, as recommended by Dr. Stevens, of the West Indies, and in one or two cases simple warm water was injected. One patient, the first one upon whom this treatment was tried, after he had become apparently moribund, lived and appeared well for two days; but the secretion of urine never returned, and he died comatose. In one or two other cases there was temporary relief, but death invariably followed shortly after. We were not inclined to make new trials of this mode of treatment after the first six weeks of the epidemic.

*External Heat* was freely applied, by mustard, hot sand, hot bottles, and by dry heat from a furnace; but generally after collapse was marked, none of these had any other effect than to annoy and irritate the patients. Those patients who could be induced to re-



main covered with blankets fared the best; with or without other artificial heat. Those who were restless and threw off the clothing invariably died. On this account the bed-strap was sometimes used with advantage, and we can but regret, that, notwithstanding the apparent cruelty of confining the limbs of a sick man, it was not oftener applied.

*Drinks*, of whatever nature, were useless. Those, who drank the least, vomited and purged the least. The call was always for cold water. When taken in quantities of more than a teaspoonful, it was speedily rejected. A draught of half a pint was sure to be followed by the ejection of a pint and a half. Those patients to whom drink was steadily refused, neither vomited nor purged freely afterwards, often, not at all. They more speedily grew warm, and those who for an hour were kept closely enveloped in blankets, took no medicine, and got no drink, suffered the least, and were the most likely to recover.

*Hot baths* were painful to the patient, and they generally sank speedily after their use. *Cold sponge baths* were more grateful, and even during collapse they seemed for a short time to revive the patients. Bladders of ice to the head, and the *cold affusion*, were resorted to advantageously, in cases of violent delirium.

*The wet sheet*, (packing, so called,) was tried faithfully, but every patient upon whom it was tried, died. Reaction did not take place in any one of them, and we soon ceased to resort to it. Our experience is against the free exhibition of water either within or without.

*Bleeding* by the lancet and by cups, was several times resorted to. In that stage of the disease before the cramps have gone off, great relief was experienced from the lancet. Later, like other remedies, it was of little avail, though we cannot say that the life of any patient



was shortened by it. An absent pulse sometimes returned, during bleeding, and several patients dated their relief from the opening of the vein. Several who were collapsed are among these, and two of the male nurses are examples of its innocuousness, at least. The opening of a vein was never followed by a stream of blood, but sometimes, by kneading and rubbing the limb, a thick, tarry blood was expressed, which was followed after an ounce or two was drawn, by more fluid blood. In such cases the heart which was almost always beating strongly, lost its excessive action, the pulse returned, the cramps, if they existed, disappeared, and the patient, if inclined to recovery, speedily rallied, and if inclined to die, was relieved of those terrible cramps, which no one can imagine till he has seen them. Of bleeding, in an early stage of the disease, we are inclined to speak quite favorably, though not with so much enthusiasm, as many East Indian surgeons do. The extraction of blood from the nape of the neck by cups, was, in a few cases, useful.

*Kreasote* was used at first in many cases. It sometimes seemed to relieve the vomiting, but of its power to do this we cannot speak so favorably as of the

*Wood Naphtha.* In no case, and there were many in which this was administered, did it fail, after the second or third dose, to relieve the vomiting perfectly. It was given in various doses, clear, from twenty minims to a drachm. Even, in cases which ultimately proved fatal, we were perfectly satisfied of the power of this drug to check vomiting speedily.

Much benefit was thought to be derived from the exhibition of *Saline medicines*. Stevens's mixture of the chlorate of potash, in solution, with the hydrochlorate and bicarbonate of soda, was the form in which salines were usually given. We used larger doses of



the chlorate generally than Stevens recommends, but are not able to say that this was an advantage.

*Homœopathic Treatment.* As the stimulating plan of treatment, the Hydropathic, and that called Allopathic, had been fairly tried, it might be asked, why we did not practice Homœopathy, in some cases. The truth is, that no one of our number understood it, and, notwithstanding offers were made to several Homœopathic practitioners, we could not find among those any, who were willing to come into the Hospital, upon equal terms, and take charge of an equal number of patients with ourselves.

Several complications ought not to be passed by without notice. We refer to pregnancy and menstruation. One woman, who was brought into the Hospital after suffering two days from Cholera, was delivered of a dead child, having the appearance of collapse, and died herself in about twenty-four hours. One woman died pregnant. One other woman miscarried, and recovered. A third, who was pregnant and nursing at the time of entrance, retained her foetus, and the secretion of milk continued till after the stage of collapse had passed. She then had fever, delirium, and recovered. She was treated at first with stimulants, and after the first day with salines. She was intemperate.

Several women menstruated soon after entrance. They all recovered.

It was remarked that but a very small number of the children who were admitted, died. In them the state of the skin and the discharges were decidedly choleric, the cramps alone not being well marked. This is the more strange because many of them were collapsed on entrance.

*Post mortem contractions* were seen or could be excited in every fatal case; the time of their commence-



ment being about fifteen minutes after death. In one case the muscular action was so great, that the nurses supposed the man to be alive, thirty minutes after actual death. The external muscles in this man were in constant action, the motions being like tides regularly progressing from one to the other of their extremities. They were strongest in the extensor muscles of the thighs.

#### PATHOLOGY.

Although the morbid appearances after death from Cholera are not such as to demonstrate, to any great extent, the pathology of the disease, they are yet sufficiently peculiar to deserve a large share of attention. Even purely negative facts, such as the absence of inflammation, &c., though not so satisfactory, are surely quite as important as positive ones would be. Indeed, a proper attention to the post mortem appearances, imperfect as they are, would have prevented some very serious errors which have occasionally been entertained with regard to the course and treatment of the disease. Thus, it has been supposed that an attack of Cholera was necessarily accompanied by a suppression of bile; owing probably to the circumstance, that the bile, though present in the discharges to its normal amount, was yet diluted with such an excessive quantity of fluid as not to be recognized by its color. It will be seen, however, by an examination of the following autopsies, that bile is very frequently found after death in the duodenum and stomach, almost always in the gall-bladder, and that it can generally be expressed from the small ducts in the interior of the liver without difficulty.

In the accounts of post mortem investigations, made previously to the epidemic of 1849, there has been considerable discrepancy. Some writers have even considered their results as altogether trifling and inconclusive.



In the Report of a Committee to the French Academy of Medicine, made July, 1831, it is stated that "The profound study of a great number of statements of post mortem examinations leads to the following results:

I. The pathological changes found after death by Cholera are slight, variable, different, and even opposite.

II. In a stated system of organs, these lesions have no fixed seat, and still less a determinate character.

III. In a great number of cases the most exact observers state that no important alteration has been found."

So also in Scutteten's History of the Cholera, (Boston, 1832,) page 27, it is said that "numerous post mortem examinations have revealed to M. Gravier a violent inflammation of the œsophagus and inner membrane of the stomach;" while no fact is more completely established by other observations, made in this City and elsewhere, than that there are, as a general rule, no constant traces of inflammatory action visible anywhere. It is notorious, that redness of the intestinal canal, though unaccompanied by any other alteration, is often reported as "inflammation." The experiments of M. Magendie, with regard to this point, were repeated by M. Contour at Moscow in 1848. "Like the learned French physiologist, he saw, in injecting water into one of the gastro-epiploic arteries, the blood give place to the injected fluid, and the redness of the mucous membrane disappear; a proof that it was caused simply by a sanguineous stagnation by congestion, and not by vascular obliteration from inflammation." (Tardieu, Bigelow's Translation, page 36.)

Some of these discrepancies, no doubt, are owing to hasty or inaccurate observation. Others may be explained, by the rapidity and violence of a disease, in which death often ensues before any marked alteration can be



produced in the solid textures. It must be recollected, also, that, from the first moment of attack a process is going on within the body which rapidly passes through its successive stages; so that a patient who dies after one day's illness may present an assemblage of morbid appearances quite different from those which would have been discovered, had he lived six hours longer. We should also take into consideration the possible variation of the morbid appearances of different epidemics, or of the same epidemic in different countries. It is even quite certain that such variations take place during the course of the same epidemic in the same place. Several were noticed during the course of the Cholera last summer in this City.

Nevertheless, while making allowance for all these causes of difference, we are confident that the morbid appearances of Cholera are not, by any means, so slight and variable as they have sometimes been represented. Though there is no single lesion of any particular organ which is characteristic of the disease, yet the whole series of appearances, taken together, are sufficiently well marked and distinctive, to enable one accustomed to them to decide with certainty that such a patient died of Cholera. The disease was, in fact, thus recognized in one of the following autopsies, the case of Mary Ann Maran. This patient was in the Hospital for nine days without any choleric appearances, and with only such symptoms as were referable to a disease of the liver. She was suddenly attacked, in the night of September 7th, with purging and signs of collapse, and died early the next morning. Most of her discharges having been involuntary, and passed in the bed clothes, their precise character was not ascertained; and, as she had been in a feeble state for some time previously, no surprise was excited by the fatal termination



of her illness. She was not supposed to have been necessarily affected with Cholera. Yet the appearances at the autopsy were such as to demonstrate, beyond a doubt, that she died of a sudden attack of Cholera, which had supervened upon the old hepatic disease.

The morbid appearances are, then, sufficiently constant and peculiar. If their study has not, as yet, thrown much light on the essential nature of Cholera, perhaps the investigation of symptoms during life has, in this respect been, so far, equally unsuccessful; and although the rapidity and obscurity of the disease hitherto presents unusual difficulties to the observer, it is to be hoped that these will rather stimulate perseverance than discourage it.

The most remarkable and constant appearances were the following.

1. An unusual dryness of the pleura, particularly where the anterior edges of the lungs overlap the pericardium; so that, on raising them, the two pleural surfaces separated from each other with some difficulty, and presented a dry and wrinkled appearance, instead of their usual moist and polished aspect.

2. A nearly empty condition of the pericardium; that cavity often containing not more than eight or ten drops of fluid.

3. The peritoneum was smeared with a thin layer of slimy opaline secretion, which was drawn out into minute threads on separating the convolutions of the small intestines. When this substance was not in sufficient quantity to be visible on the peritoneal surface, it could be collected by drawing a few coils of intestine through the fingers, when its slimy, sticky feel was easily recognisable.

4. A moderate swelling and opacity of Peyer's patches, and of the solitary glands in the lower part of the



small intestines ;—in the large intestine, a similar development of the mucous follicles, the mouths of which were often widely open, and sometimes marked by a black point.

5. A shrivelled condition of the spleen with deficiency of blood.

6. A completely contracted and empty state of the urinary bladder, the mucous surface of which was smeared with a thickish, creamy secretion, sometimes abundant, sometimes moderate in amount.

7. The mucous surface of the vagina was smeared with a somewhat similar secretion, but thicker and less opaque than that in the bladder ; rather like thick starch in consistency and aspect.

The whole number of recorded autopsies was 33. Of these subjects 12 were males and 21 females. The large majority were adults. The youngest was 8, the oldest 60 years of age. Several of the females presented signs of recent menstruation. One was in the 8th month of pregnancy. In 15 cases, there were marks of previous disease ; mostly tubercular deposits, peritoneal adhesions, fibrous tumors of the uterus, &c., &c. In this list, however, are not included such alterations as old pleuretic adhesions and simple ovarian cysts ;—these lesions being everywhere so frequently met with. In five cases only, was there any previous disease, in an active condition ; viz., two of pulmonary phthisis, one of tubercular pleurisy, one of cirrhosis of the liver, and one of a fibrous tumor of the uterus, which had induced redness and softening of part of the uterine substance.

*Rigor mortis* was established in every instance. In one case it was slight, and in a few unusually strong ; generally, neither deficient nor excessive.

Besides those already mentioned, several other points deserve particular attention.



I. *Blood.* The blood was not so much altered, in its gross appearances, as might have been expected from previous accounts. It has been represented as quite fluid and destitute of coagula. In point of fact the coagulum was, as a general rule, remarkably deficient in quantity, or consistency, or both; but, not by any means, universally. In two cases, the coagulum in the heart was unusually abundant, and of firm consistency;—in eight, it was moderate in amount, and of natural firmness; and, in twenty, it was “small,” “trifling,” or “insignificant” in quantity, and loose, gelatinous, or semifluid. In three cases, only, was it entirely wanting. Coagula, however, often existed in the heart, when they were not to be found in any other part of the body.

The consistency of the fluid part of the blood after death varied considerably. In some cases no remarkable alteration was observed; in some, it was recorded as natural;—and, in two or three, it was unusually thin and fluid. In fifteen cases it was more or less thick and tarry, either throughout the system, or in particular situations. For, what was sufficiently remarkable, the consistency of the blood often varied in different vessels in the same subject. Thus in the case of Sarah Hill, the blood in the left cavities of the heart was thick, but that in the right cavities, thin. So, in the case of Andrew Patterson, the right cavities of the heart contained “fluid blood of natural consistency,” but that in the left auricle and pulmonary veins was “dark and thickish.” In the case of Mary Ann Maran, the blood in the vessels of the neck was observed to be thinner than that in the heart.

No constant relation was found to exist between the consistency of the coagula, and the length of time the patient had been ill.

It will be noticed, in the case of Catharine Hurley,



who died pregnant, that the coagulum in the heart of the fœtus was of moderate consistency, while that of the mother was "very black and soft."

In five cases, there was a dusky red staining of the endocardium, or some of the lining membrane of the vessels, owing to the solution of the blood globules, and consequent imbibition of the coloring matter. This took place occasionally, in certain situations, while the remainder of the vascular membrane was free from alteration. Thus the "right cavities of the heart, and the heart, and the veins throughout the chest were stained of a deep red color;"—while the "left cavities were natural." (Case of Calvin Castleman.) The "lining membrane of the venæ cavæ, and of both right cavities of the heart, was stained of a purplish red; that of the left auricle, quite white and healthy; that of the left ventricle, slightly stained in some parts." (Case of Manus McCarty.) This process had apparently some connexion with the consistency of the blood; though not, perhaps, precisely that which we should expect; the staining sometimes being most strongly marked when the blood was thickest. Thus, in the case of Margaret Ince, the "aorta was stained dull red in its thoracic portion, where it contained dark fluid blood. In the lumbar region it contained some dark brownish and slate colored blood, almost as thick as putty; and at this spot the walls were stained of a corresponding dusky red and slate color. Below this the internal surface was natural."

II. In fourteen cases, *Ecchymoses* were observed in various situations;—mostly on the pericardium and external surface of the heart, or internally, immediately beneath the endocardium;—occasionally in the cellular tissue of the lungs, on the surface of the kidney, and between the lobules of the pancreas.



III. *The Brain* was almost universally natural in color, vascularity, and consistency. In three cases, only, was there any appreciable softening of the cerebral substance, and in three, some bloody engorgement;—viz., in one case, of the hemispheres generally; in one, of their superficial parts; and in one, of the lining membrane of the ventricles. The effusion of clear or reddish fluid into the arachnoid cavity, among the meshes of the pia-mater, and into the lateral ventricles, was a much more common occurrence. This, however, was moderate in amount;—the fluid in the ventricles varying from a few drops to two drachms. In three cases, only, was the quantity of fluid in the ventricles considerable;—in one, these cavities were said to be “filled” with fluid; in another the quantity was estimated at one ounce.

The most remarkable circumstance noticed in the head, was the presence of a quantity of dark, thick, bloody fluid in the arachnoid cavity, over the posterior part of the convexities of the hemispheres, just sufficient to smear the arachnoid surfaces; the arachnoid itself remaining, at the same time, quite natural. This appearance presented itself in fifteen cases. When first observed, it was so remarkable and unexpected, that it was thought the blood might have escaped accidentally from ruptured vessels, through some carelessness in separating the skull from the dura-mater;—but it occurred so frequently afterward, and always in the same situation, as to leave no doubt that it was a true morbid appearance, and a consequence of the disease. Considering its constant situation at the most dependent parts of the brain, and the fact that the arachnoid membrane itself always retained its natural transparent and polished aspect, this appearance seemed to be, in all probability, rather a post-mortem transudation, owing to the peculiar condition of the blood, than any effusion which had



taken place during life. Pains were taken to determine this point in the case of Margaret Flarnegan. This patient lay upon her back until the moment of death. The body was then immediately turned upon its left side, and kept in that position, till the autopsy, sixteen hours afterward. In almost every other case, the exudation was similar on the two sides of the brain. In this, it was "trifling, light colored and thin" to the right of the longitudinal sinus, but on the left side "copious, dark-colored, and thick." In one case, however, (Ellen Dorety) beside the above effusion, there was a thin plate of red *coagulum* on the superior surface of the cerebellum, which had taken the form of the cavity into which it was effused. This effusion, apparently, must have taken place during life, and at an early period of the disease;—since the coagulum was considerably firmer than that in any other part of the body."

Nothing was observed in any instance like the "sticky varnish" described (by Tardieu) as coating the surfaces of the arachnoid.

IV. *The Spinal Cord* was examined in two cases. In the first, that of Ellen McCann, who died in the choleric stage, it was absolutely natural in every respect. In the other, John McCarthy, who died in the febrile stage, it was decidedly softened in the cervical portion, and a little, also, in the dorsal, with some bloody œdema of the adjacent cellular tissue. These were the only alterations observed.

V. *Congestion.* Though congestion of the heart and lungs may very possibly exist during the early stages of the disease, yet it was not generally found to any great extent after death. In a majority of cases the lungs were natural in appearance, except for that moderate degree of engorgement of the dependent parts, which we are not surprised to see in any subject.



In three cases there were marks of unnatural congestion. In six, the lungs are spoken of as "deficient in fluids," "dryish," "much collapsed," and "shrivelled." In one case, there was general emphysema; in two, ecchymoses; and in one, John McCarthy, who had secondary fever, pneumonia.

The right cavities of the heart, contained a moderate quantity of blood, in fifteen cases; and in thirteen, they were "full." They were absolutely distended, in only three; but these were not the same three cases in which the lungs were congested. In two cases, the quantity of blood in the heart, was deficient.

The left ventricle of the heart was firm and thoroughly contracted, in nine cases. It was more or less deficient in firmness, in thirteen; and, in ten, it was completely flaccid. In one case its condition was only remarked as "natural."

VI. *Contents of the alimentary canal.* These varied greatly in quantity, color and consistency. They were thick, thin, gruelly, grey, yellow, yellowish white, pink, reddish, or puriform. They were sometimes like soap and water; sometimes thickish, and dull red in color, as if "mixed with red paint." Sometimes, they presented the appearance of true "rice water;" i. e., a thin, whitish, opaline fluid, which deposited a quantity of very fine white flocculi, looking, when collected at the bottom, like a layer of pure pus. Almost always, the contents of the stomach, and the small and large intestines, differed from each other in color, consistency, or both. Thus, in the case of Ellen Dorety, they were "reddish" in the small intestines, "grey" in the large. In the case of Michael Desmond, the small intestines contained a "thin, dingy, light-colored fluid, with flocculi of a wood-brown color." The frequent occurrence of the coloring matter of bile has already been noticed.



On several occasions, the ordinary re-agents showed the presence of albumen in the fluid part of the intestinal contents, in considerable or moderate quantity. Examined by the microscope, the flocculi, suspended in the rice-water fluid, invariably consisted of columnar epithelium, floating about in larger or smaller masses, or as detached cells. These epithelium-cells were so abundant and well defined, as to leave no doubt that they constituted nineteen-twentieths of the mass of the flocculi. This extensive exfoliation of epithelium, in Cholera, has been pretty thoroughly investigated by Dr. Ludwig Boehm, who considers it as one of the most characteristic phenomena of the disease. Dr. W. T. Gairdner, of Edinburgh, however, takes a different view of the matter. He considers the exfoliation as entirely a post-mortem occurrence, owing to the maceration of the intestinal mucous membrane by the contained fluid. He states, that the Cholera stools, passed during life, contain almost no perfect epithelium; and, also, that ordinary maceration will produce upon healthy mucous membrane a separation of epithelium, entirely similar to that which is found to have taken place in the intestines of Cholera patients. If maceration, however, is the only cause of the separation of such an enormous quantity of epithelium, how shall we explain its occurrence in other situations, where no unusual amount of fluid has existed? The mucous surfaces of the vagina, and of the urinary bladder are invariably smeared with a thick, whitish, pasty, or creamy secretion, which, on microscopic examination, is seen to consist entirely of detached epithelium-cells, mostly perfect in shape, and generally distinctly nucleated. But *these* passages have not been subjected to maceration. The urinary bladder, indeed, is completely empty, and, from the first moment of disease, has been deprived of the fluid which it



contained in health. Dr. Gairdner's opinion does not, therefore, seem entirely well founded. The fact, that epithelium-cells are not so distinctly recognisable in the Cholera stools passed during life, is probably to be explained by the circumstance, that, in their passage through the intestinal canal, they become, to a certain extent, disintegrated. We have sometimes seen, mixed with the columnar epithelium, "small roundish bodies, like the nuclei of destroyed or unformed epithelium-cells." Since the violent purging, in Cholera, very commonly ceases during the last hours of life, we can easily understand why the epithelium-cells, thrown off after that period, should remain uninjured. The bowels are then comparatively quiet, and they are not so much exposed to the causes of injury, as those which were evacuated in the earlier stages of the disease.

Beside the intestinal secretions, remains of food, undigested or indigestible, were not unfrequently found in various parts of the alimentary canal. In several instances, there were cherry-stones in the intestines; in one case, as many as thirteen. Bits of wood, small seeds, potato, bits of egg shell, &c., were among the articles found. In one case there was, both in the stomach and colon, a considerable quantity of fish-bones, of irregular, angular shapes, sharp pointed and jagged; some of them between  $1\frac{1}{2}$  and 2 inches long. In one case there were several lumbrici in the small intestine, and in one, the cæcum contained about twenty *tricocephali dispares*.

VII. *The internal surface of the stomach and intestines* was almost universally pale, or natural in color. Its usual appearance was that of general paleness, with "slight," or "moderate" redness in some parts. It was very common to find the small intestines, generally pale, stained yellow at their upper extremity, and moderately



reddened toward the lower part of the ileum. In no instance was the redness general. The intestinal villi were almost always unusually distinct, appearing tumefied, and whitish opaque in color. The spots of redness, were not unfrequently produced, as in the case of Margaret Harnegan, by scarlet coloration of the villi, while the rest of the mucous membrane retained its natural paleness. This condition was very readily distinguishable on close examination.

VIII. *The kidneys* did not usually present any remarkable alterations in appearance;—the most common being flaccidity of tissue, without noticeable increase or diminution in volume. Beside this, the kidneys were occasionally entirely destitute of their ordinary renal odor, and exhaled from their cut surfaces, a very distinct and peculiar smell, resembling that of molasses. This was noticed in only four instances; but as our attention was not directed to this circumstance until a late period in the epidemic, it may have existed more frequently.

It might, perhaps, be expected that we should discover some relation between the condition of the heart, the fluidity of the blood, and the duration of the disease. No such relation, however, existed, as will appear from the following table.

Case.	Left Ventricle.	Coagulum.	Duration of Disease.
No. 1.	Firm.	Abundant and firm.	12 hours.
2.	Flaccid.	Moderate in amount and consistency,	13½ “
3.	Firm.	“ “ “ “ “	“
*4.	“	Deficient and loose.	“
*5.	Deficient.	Moderate.	31½ “
*6.	Flaccid.	“	“
*7.	“	Deficient.	13¼ “
*8.	Deficient.	“	12 “
*9.	“	Entirely absent.	33½ “
10.	“	“ “	48 “

Case.	Left Ventricle.	Coagulum.	Duration of Disease.	
11.	Deficient.	Deficient.	15	hours.
*12.	"	Moderate.	53	"
13.	Firm.	Deficient.	52	"
14.	Deficient.	"	10	"
*15.	Firm.	"	15 $\frac{1}{2}$	"
16.	"	Abundant and firm.	17 $\frac{1}{2}$	"
17.	"	Deficient.	17	"
18.	Flaccid.	Moderate.	240	"
19.	<i>Natural.</i>	Deficient	15	"
20.	Deficient.	"	10 $\frac{1}{2}$	"
21.	Flaccid.	"	150	"
22.	Firm.	"	96	"
*23.	Deficient.	"	42	"
24.	Flaccid.	Moderate.	24	"
25.	"	Deficient.	28	"
26.	Deficient.	"	20	"
27.	Firm.	"	12	"
28.	Flaccid.	"	19	"
29.	"	"	18	"
30.	Deficient.	Moderate.	108	"
31.	"	Entirely absent.	12 $\frac{1}{2}$	"
*32.	"	Deficient.	30 $\frac{1}{2}$	"
33.	Flaccid.	"	9 $\frac{1}{2}$	"

The cases marked (\*) are those which presented more or less abundant ecchymoses on the heart.

Three of the cases presented peculiar appearances, in consequence of the disease, or its sequelæ, being unusually prolonged, in one, to the tenth day, in another, to the fifth, and, in another, to the seventh.

The first of these patients, John McCarthy, was in the Cholera stage for three days. He then passed into a typhoid condition, with dry tongue and skin, epistaxis, sordes upon the lips and teeth, bilious discharges, a dusky paleness of the countenance and gradually increasing stupor.† Death took place after this condition

† He did not have the typhus eruption.



had lasted for a week. At the autopsy, the whole interior of the body presented, in a marked degree, the appearances of a septic, unhealthy process, which had depressed the vital powers, as if by the influence of a specific poison. This was evident, from the dusky, leaden hue of the peritoneum and air-passages, the pneumonia unaccompanied by active pleurisy, the early generation of gas in the cellular tissue of the mediastinum, and in the blood contained in the heart; and the disagreeable putrefactive odor, and dingy brown color, of the fluid which was effused into the cavity of the chest. The deposite of ammonio-magnesian phosphate, in a chrystalline form, is also attributed by Vogel to the developement of ammonia by decomposition.

The spleen was enlarged and engorged, presenting an appearance quite different from that usual in Cholera. The appearance of the mucous surface of the small intestines was also most remarkable, as showing the close pathological connexion between the secondary stage of Cholera and spontaneous typhoid affections. The patches of Peyer, situated at the *lower* part of the ileum, were inflamed and deeply ulcerated;—two of them showing an abundant deposite of typhus matter, which projected into the intestinal cavity, like loose, granular coagula. The description, given by Rokitansky, of the patches in an advanced stage of the “typhus process” corresponds so precisely with their appearance in the case of John McCarthy, that I cannot do better than to introduce it in this place.

“The most remarkable change is now effected in the typhus patches, and in the mesenteric glands; they soften. The patches become more tumefied, and if the softening process does not affect them uniformly, they acquire an uneven, tuberculated surface. The deposite



is converted into a grayish-red, medullary mass; this may, from the imbibition of bile, be at once metamorphosed into a dirty-yellow or brown slough, involving the investing mucous membrane. The slough shrivels up in a vertical and lateral direction, becoming loose at the edges and pultaceous, splitting in various directions, and detaching itself from the lowest stratum of submucous cellular tissue, by which means it is wholly or in part discharged; or the morbid product degenerates, when the epidemy is of very intense character, *into a loose, vascular, fungous growth, which is traversed by streaks of extravasated blood*, or is entirely saturated with blood; it is the chief source of profuse intestinal hæmorrhages, and is generally discharged piecemeal without antecedent sloughing." (Rokitansky's Path. Anat., Sydenham Ed., p. 70.)

In this instance, the peculiar morbid appearances of Cholera were entirely wanting; but in the second case, that of Andrew Patterson, several remained distinct. He was sick four and a half days with symptoms somewhat mixed, but still decidedly choleric. This patient never fairly passed into the secondary stage. His was in reality a prolonged case of Cholera; and although his skin at one time became warm, and the secretion of urine was re-established, yet he never entirely lost the choleric voice and aspect. In him, the dryness of the pleura, the empty condition of the pericardium, the slimy secretion on the peritoneum, and the moderate enlargement and opacity of Peyer's patches, were all present. This case, however, corresponded with the former, in presenting an abundant secretion of bile, and decided bloody congestion of the lower parts of the alimentary canal.

In the third case, that of J. G. Coolidge, it was not



absolutely certain that the patient had had Cholera, though the account given of his condition previous to entrance, made it altogether probable. A few marked signs of the disease existed, however, on entrance; some moderate coolness of the skin being the most prominent symptom. The succeeding affection in this patient was not typhous, but presented in a high degree the characters of *delirium tremens*;—i. e., a capricious, talkative insanity, in which the patient was often suspicious that some injury was intended him by the bystanders, and frequently referred to transactions in which he had previously been engaged. Beside the serous effusion, &c., in the brain, there were almost no well marked, recent alterations discoverable at the autopsy; dryness of the pleura and deficiency of fluid in the pericardium, being the only appearances referable to Cholera. In this instance, the secondary disease did not appear to be a true sequela of Cholera, but merely an accidental consequence. The *delirium tremens*, followed the attack of Cholera, just as it might have followed an attack of bronchitis, or the fracture of an arm.

It is sufficiently worthy of notice, that decided variations took place during the course of the epidemic, in the frequency of certain post-mortem appearances, as well as of some of the symptoms during life. It will be seen, by a reference to the foregoing table, that, at first the coagula in the heart were not unfrequently moderate in quantity and consistency, and sometimes even remarkably abundant and firm. Afterward, however, they were almost invariably deficient and loose, or even entirely wanting. In the early part of the epidemic, also, spots of ecchymosis on the heart, externally or internally, were an almost constant symptom; at a later period this appearance was rarely met with. In the



above table, those cases which presented ecchymoses on the heart have been marked with an asterisk, in order to show their great preponderance in the early periods.

A similar variation was noticed by Dr. C. Müller in his second report on Cholera, (1848) quoted in the *Medico Chirurg. Rev.* Jan. 1849. He says "at the commencement of the epidemic, the small intestines were generally found pale and anæmic; afterward appeared throughout the whole small intestine, intense hyperæmia."

The most correct account of the post-mortem appearances of Cholera, or at least that which agrees most completely with the results of the following autopsies, is that given by Dr. W. T. Gairdner, Pathologist to the Royal Infirmary at Edinburgh.

It was published, in the *Monthly Journal of Medical Sciences* for July, 1849, and quoted in the *American Journal of Medical Sciences* for October of the same year. He notices, the occasional firm and abundant coagulation of the blood, and the fact, that it is not by any means so universally thick and tarry as had been formerly represented. He alludes, also, to the absence of pulmonary and cardiac congestion, the occasional tendency to ecchymosis in various parts, and to the frequent occurrence of bile, in the intestines and gall-bladder;—points which had not been distinctly noticed by previous observers.

Two or three circumstances, not connected with Cholera, which were observed in the course of the post-mortem examinations, are of sufficient importance to receive particular attention.

I. In the case of Nancy McFarland, a woman 60 years of age, there existed at the apex of the right lung, an old tubercular cavity, large enough to contain half an



ounce of fluid, which presented every appearance of having remained inactive for a long time.

II. In the case of Mary Ann Maran, who had disease of the liver, the tissues generally were wasted so as to give the body the appearance of advanced emaciation, there was yet a superabundance of fat in all parts of the body. The liver was also remarkable as exhibiting two different stages of the same disease (cirrhosis;) the right lobe being enlarged, the left atrophied.

III. In the case of Margaret Harnegan, a girl 22 years of age, whose body presented every appearance of perfect developement and robust health, there existed an abscess in the parietes of the chest containing one and a half ounces of pus; which apparently was remaining perfectly quiescent in its position, without any tendency to discharge itself, either externally or internally.

---

### *THE AUTOPSIES.*

The following autopsies are arranged in the order of their occurrence; each one being preceded by a brief summary of the most important circumstances of the case previous to death. This method was preferred as more concise and convenient, and, on the whole, quite as likely to be useful, as a more detailed history of the symptoms and treatment.

onset of which which presented every appearance of having remained inactive for a long time.

II. In the case of Mary Ann Martin, who had the apex of the liver, the finger normally was wasted so as to give the body the appearance of advanced emaciation, there was not a superabundance of fat in all parts of the body. The liver was also remarkably as exhibiting two different stages of the same disease (atrophy); the right lobe being enlarged, the left atrophied.

III. In the case of Margaret Harman, a girl 23 years of age whose body presented every appearance of perfect development and robust health, there existed an abscess in the trunk of the chest containing one and a half ounces of pus; which apparently was remaining perfectly quiescent in its position, without any tendency to discharge itself either externally or internally.

IV. In the case of John Smith, a boy 15 years of age, who had been ill for several months, and who was found to have a large abscess in the chest, containing one and a half ounces of pus; which apparently was remaining perfectly quiescent in its position, without any tendency to discharge itself either externally or internally.

## THE LARYNX.

The following larynges are arranged in the order of their occurrence; each one being preceded by a brief summary of the most important circumstances of the case previous to death. This method was preferred as more concise and convenient, and on the whole, quite as likely to be useful, as a more detailed history of the symptoms and treatment.



## I.

NANCY MCFARLAND. Aged 60. Widow. Irish. In- JULY 7.  
temperate. Cholera for 12 hours, preceded by four  
days' diarrhœa. Treatment; opium, brandy, capsicum and cinnamon, freely. Insensibility for last two  
hours of life. Autopsy 17 hours after death.

*Rigor mortis* natural. Much purplish discoloration of skin; not particularly of dependent parts. Abdomen prominent, resonant, but not tympanitic;—has upon it many cicatrices of pregnancy. Muscles red. Fat rather abundant.

*Chest.* Pericardium natural. Heart of good size, moderately contracted. Left ventricle round and prominent. Right cavities contain an unusual amount of dark red, and fibrinous coagula, of moderate consistency. Left ventricle nearly or quite empty. Left auricle filled with a dark red, moderately firm coagulum. No ecchymoses on heart.

Both lungs have nearly universal old adhesions. Moderate sanguineous engorgement of posterior parts. Left lung crepitates well every where, but has a few well-defined, inactive tubercles scattered through its substance. Right lung is solidified at apex, to the extent of three cubic inches, at which part pleuritic adhesions are particularly firm. Solidified portion is occupied at its upper part by a roundish cavity, capable of containing, at least, half an ounce of fluid. The walls of this cavity are quite smooth, reddish in color, and smeared over with a very small quantity of thin puriform fluid. The whole has an entirely inactive appearance. A bronchus, one line in diameter, opens into cavity. No other abnormal appearances in lung. Tuberculous cavity healed.

*Abdomen.* Peritoneum natural. Stomach and intestines, pale externally, with slight rosy tinge. Stomach contains about half a pint of turbid greyish



fluid. Mucous membrane pale; thinned and softened in cœcal extremity. No other remarkable appearance.

Small intestines moderately distended with air and fluid;—contain in all perhaps ten ounces of “rice water” fluid. Mucous membrane shows nothing unusual, except a little red injection in duodenum. Peyer’s patches distinct, not much altered. Solitary glands not seen.

Colon rather distended in ascending portion, contracted in transverse, and moderately full in descending. Rectum nearly empty. Mucous membrane of large intestine quite pale and smooth.

Peritoneal adhesions.

Liver of natural size, with numerous old, and somewhat firm, adhesions to diaphragm, and some to stomach. Rather red externally. Internally it presents, in various parts, ill-defined spots of anæmia. Consistency of liver generally a little soft.

Gall bladder contains a drachm or two of green bile, of ordinary consistence.

Spleen very soft; otherwise natural.

Disease of kidney.

Left kidney natural. Right kidney much smaller than left; of a dark, rather slaty color. Its surface shows numerous strongly marked depressions, produced by atrophy, of cortical substance, which is here transformed into a finely granular mass, entirely distinct from remaining healthy parts. No marked difference in color. Lining membrane of pelvis natural. Urinary bladder completely contracted.

M. glands tuberculous.

Mesenteric glands generally enlarged and tuberculous, rather soft and cheesy, but enclosed in a thick double layer of fat.

Fibrous tumor.

The uterus has a fibrous tumor in the thickness of its walls, which is globular in shape, and about the size of a filbert. It is otherwise natural.

Right ovary, atrophied, to a considerable extent.

Ovarian cyst.

Left ovary completely atrophied, and its place occupied by a firm cyst, somewhat lobulated externally, but having a single cavity, capable of containing one ounce of fluid. This cavity encloses about half an ounce of thickish, opaque, yellowish, fluid (consisting



of water, albumen, and oil,) a mass of semi-solid, granular fat, almost completely soluble in ether; and a loose knot of tangled, reddish hair. Walls of cyst, firm, and about one eighth of an inch in thickness. Internal surface, smooth and polished, and of a red color over greater part; but there is one spot, occupying about one sixth of the whole, which is rough and yellowish.

The fluid, both from the stomach and intestines, in this case, was examined. It contained albumen, chloride of sodium, and the earthy phosphates. That from the intestines was more strongly albuminous than that from the stomach.

The flocculent deposit, under the microscope, consisted almost entirely of epithelium.

The earthy phosphates were precipitated from the filtered fluids, by ammonia, in the following crystalline forms:—

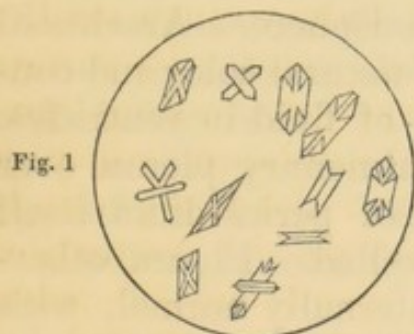


Fig. 1

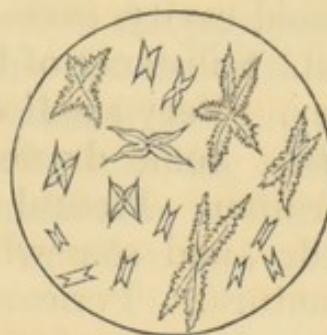


Fig. 2

A drop of that taken from the stomach, evaporated on a slip of glass, left the following deposit, (principally chloride of sodium.)

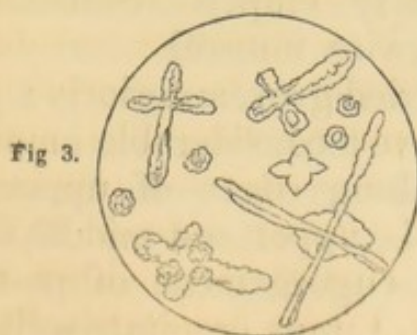


Fig 3.

## II.

JULY 14. ISABEL HASSEN. Aged 45. Married. Irish. Temperate. Cholera for 13½ hours. Slight previous diarrhœa. Severe cramp. Insensibility, for last seven hours of life. No medicine given, owing to insensibility. Marked post-mortem contractions, and heat of body, 15 to 20 minutes after death. Autopsy 17½ hours after death.

*Rigor mortis* well developed. Purplish discoloration very moderate. Sclerotics, when exposed to the air, dry and brownish. Corneæ not shrivelled. Nails dark purple. Skin of fingers shrivelled. Abdomen of moderate resonance, neither distended nor sunken. Muscles red.

*Head.* Dura-mater natural. A little fluid blood in longitudinal sinus. A small amount of fluid in arachnoid cavity, over each hemisphere. Arachnoid natural. Substance of brain, of natural color and consistency. Very small quantity of fluid in ventricles.

*Chest.* Some dryness of pulmonary pleura over pericardium. Pleural surface of pericardium itself quite dry, and somewhat shrivelled. Pleura otherwise natural. Pericardium internally normal, with ordinary amount of clear fluid. No ecchymoses on heart. Great veins about heart moderately distended.

*Pleura dry.*

*Heart flaccid.* Heart flaccid. Right cavities contain a moderate amount of dark fluid blood and reddish coagula, of good consistence. Blood not particularly thick. Left cavities nearly empty. Substance of heart rather soft; otherwise natural.

Lungs, of a mottled grey, anteriorly; purplish, posteriorly. Both have a considerable amount of vesicular emphysema along edges of upper and middle lobes; (upper of L, upper and middle of R.) Moderate sanguineous engorgement of posterior part of both lower lobes. Lungs crepitate well every where.



Some softening of substance universally; otherwise Lungs soft. natural.

Larynx, trachæa, and bronchi, pale internally; smeared with a very small quantity of thickish, creamy fluid.

*Abdomen.* Peritoneum, which lines upper and anterior part of abdominal parietes, is rather dry;—elsewhere moist and shining. No unusual secretion on peritoneum any where.

Small intestines, show a moderate pinkish injection externally, and are everywhere about equally distended with air and fluid. They contain one pint (by estimate) of thin, reddish-grey, turbid fluid, with a faintly acid reaction. Fluid in duodenum has a slight greenish tinge, and a neutral reaction.

Small intestines pale internally. Duodenal glands not unusually developed. Peyer's patches, moderately developed towards lower part of small intestines, and a little softened. Solitary glands not seen. There is a considerable amount of sub-mucous emphysema, which commences three feet below the pylorus, and extends four inches downward;—the mucous membrane being raised in small bullæ, which are easily made to change their situation by scraping with the edge of the knife. Mucous membrane at this part, as in others, absolutely natural in color and consistence.

Large intestine, pale externally;—contains about one pint of greyish white, "gruelly" fluid. Internally, pale. Mucous follicles not noticeable.

Stomach contains about half a pint of dingy, olive-colored fluid, thinner than that in remainder of alimentary canal. Mucous membrane generally pale;—gelatinized (cadaveric alteration) over nearly whole of posterior half of organ, less universally, over anterior;—not otherwise remarkable.

Liver, of natural size and consistence;—mottled red and purplish, externally; brownish red, internally. Sallow color of gall-ducts, in interior of organ, well marked.



Gall-bladder contains half an ounce of rather thin, dark, olive-colored bile.

Spleen, small, firm, blue, externally. Peritoneal coat can be stripped off, leaving surface of organ smooth.

Both kidneys rather flabby;—otherwise natural. Urinary bladder not contracted, but collapsed and empty;—contains only a few drops of thickish creamy fluid.

Vagina, smeared with a whitish, sticky substance, like starch. Os uteri, reddish-purple; has imbedded in its substance several small hard nodules, which prove to be cysts, containing a gelatinous fluid. There is a similar cyst, but pedunculated, growing from inner surface of the cervix. Cavity of uterus is occupied by a purple-colored, fleshy, polypus, about the size of a raisin, which is attached to fundus of cavity by a broad base. Uterus otherwise natural. Ovaries, atrophied.

---

### III.

JULY 15. ROGER RYAN. Aged 50. In Hospital, for 6½ hours, with Cholera. No previous history obtained, owing to patient's deeply collapsed situation. Treatment;—strong coffee, freely, (three pints, in 6½ hours;) warmth to the feet, and inhalation of ether, with relief to cramps. Pupils dilated, for last half hour of life. Autopsy, 17½ hours after death.

Cadaveric rigidity strongly developed. Very moderate cyanosis, except of finger nails, where the blue color is strongly marked. Fingers wrinkled. Conjunctivæ, sclerotics, and corneæ, which have remained covered by the lids, natural in appearance. Abdomen not prominent.



Muscles have a slight slaty color.

*Head.* Brain and its membranes everywhere quite healthy.

*Chest.* Dryness of the pleura, which covers pericardium and diaphragm on right side, sufficiently marked. Pericardium, natural, internally. No ecchymoses on heart. Right auricle much distended. Both right cavities, pulmonary artery, and venæ cavæ, distended with dark fluid blood, and a large proportion of soft, red, and fibrinous coagula. Right ventricle rather flabby. Left ventricle firm, nearly empty. Left auricle contains a moderate quantity of fluid and coagulated blood. Whole heart, somewhat hypertrophied;—otherwise natural.

Both lungs similar in appearance;—mottled greyish and black, anteriorly; purplish, posteriorly. Some vesicular emphysema at upper and anterior parts of each. Moderate sanguineous engorgement of posterior portions of lower lobes. Both lungs crepitate everywhere, and are of natural consistence.

Larynx, trachea, and bronchi, internally pale. Mucous membrane covered, from immediately below vocal chords to small ramifications, with numerous minute drops of yellowish viscid secretion, which at first appear like small vesicles, but can be easily brushed off from mucous membrane. Dotted secretion in air passages.

*Abdomen.* Peritoneum, a little dryish where it lines anterior wall of abdomen;—elsewhere sufficiently moist. No unusual secretion on surface. Small intestines decidedly reddish, externally;—moderately distended with air;—contain a few ounces of yellowish-white, turbid fluid, with a large amount of flocculent matter. Mucous membrane generally pale;—somewhat reddened in several spots. Consistence generally natural. Duodenal glands not remarkably developed. Solitary glands visible, but not enlarged, in lower part of ileum;—not elsewhere. Peyer's patches moderately developed, and slightly softened, in ileum, to number of eight or ten. No



other remarkable appearance. Fluid in duodenum has a decided greenish color.

Large intestines, pale externally;—contain a moderate amount of air, and about one pint of thin, reddish, turbid fluid. Mucous membrane pale and smooth. Mucous follicles not seen. A few fragments of egg shell toward lower part of intestine.

Mesenteric glands not remarkable.

Stomach contains from one pint to three half pints of thin yellowish fluid, with brownish yellow flocculi, and having an odor of gastric acid. There are also a number of softish yellow masses, like half-digested cheese, or yolk of egg. Mucous membrane universally softened;—almost entirely destroyed on posterior half, toward cœcal extremity. No other morbid appearance.

Liver large, smooth, and pale;—of natural consistence.

Gall bladder contains about one ounce of very thin, fluid, greenish bile.

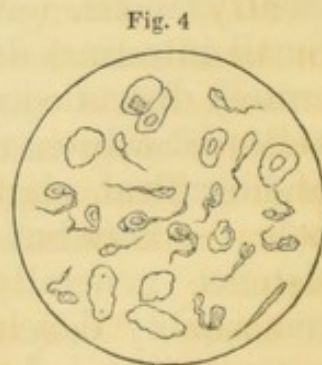
Spleen small, bluish externally; a little soft, otherwise natural.

Pacreas natural.

Kidneys, natural, except that rather more blood than usual flows from cut surface of right.

Urinary bladder, moderately contracted and empty, except for about half a drachm of whitish creamy fluid.

The creamy-white substance from the bladder, examined under microscope, showed a multitude of flat, irregular, and elongated cells, most of them distinctly nucleated. (Epithelium from the urinary passages.)



The fluid from the stomach, examined under microscope, contained irregular masses of epithelium, oil globules, and a chain-like, cellular, vegetable (?)



growth. Chemically examined, it contained no albumen, or other protein compound, but a large amount of some chlorine compound, probably chloride of sodium. No sulphates; no triple phosphate.

---

#### IV.

MARY P. SPALDING. Aged 42. American. *Prostitute. Intemperate. In Hospital for two hours, with Cholera. No previous history. Treatment,—one dose of capsicum and brandy, and one of sodæ bicarb. one drachm. Ice to epigastrium and to back of neck. Coma for last half hour of life. Post-mortem contractions. Autopsy, 21½ hours after death.* JULY 16.

*Rigor mortis* moderate. Very little cyanosis, generally, but finger-nails are dark blue. Fingers somewhat shrivelled. Sclerotics dryish where they have been exposed to the air, but not discolored. A little œdema of both legs;—none elsewhere. Abdomen, prominent, tympanitic.

Muscles a little slaty in color.

*Head.* Dura-mater natural. A little fluid blood in longitudinal sinus. Arachnoid healthy. Some sub-arachnoid œdema over both hemispheres. A few bubbles of air in superficial vessels over right hemisphere. Brain slightly engorged with blood;—equally so on both sides. Consistence and color every where natural.

*Chest.* Well marked dryness of pleura covering pericardium on left side, but none on right. Pleuræ elsewhere quite moist and shining.

General, old, moderately firm, pleuritic adhesions on right side; none on left.



Ecchymoses.

Pericardium natural internally. No ecchymoses on external surface of heart. Right cavities rather flabby; contain a considerable amount of dark blood, mostly fluid, with a little coagulum, decidedly wanting in firmness. Left ventricle firm, well contracted;—contains a drachm or two of dark fluid blood. Aorta also contains a considerable amount of similar blood. Some ill-defined ecchymoses beneath lining membrane of left ventricle. Heart otherwise healthy.

Both lungs crepitate well every where. Upper portions of both upper lobes do not collapse, and have a lighter and more spongy feel than ordinary. Moderate sanguineous engorgement of posterior parts. No tubercle, or other morbid appearance anywhere.

Mucous follicles in lateral pouches of pharynx, and at base of tongue, hypertrophied.

Congestion.

Lining membrane of larynx and trachea generally pale;—but there is a circular spot of strongly marked local congestion, almost like ecchymosis, underneath mucous membrane of right side of larynx, just below vocal chords. Some redness, not excessive, of bronchi, internally, below bifurcation. A moderate amount of frothy, thickish, white secretion, in air passages.

Adhesions.

*Abdomen.* Peritoneum generally natural in appearance. Old, but delicate, and rather tender, cellular adhesions of liver to diaphragm and to transverse colon. Also of several convolutions of small intestine to each other.

Stomach much distended with air;—contains also about twelve ounces of turbid reddish fluid, having a faintly acid reaction, and an odor of spearmint. Mucous membrane universally somewhat softened. Brownish gelatinization in great pouch. Vessels along large curvature strongly marked, and the blood in them colored brown. At pyloric extremity, vessels strongly marked, and evidently altered by post-mortem changes, but quite red in color. No other morbid appearance.



Small intestines moderately distended with air. Contain rather more than two pints of thickish, turbid, yellowish-white fluid, without fecal odor. Mucous membrane generally pale; slightly reddened in lower eight or ten feet. Universally softened, but not any where to extent of disorganization. Duodenal glands visible, natural. Solitary glands not seen. Peyer's patches very moderately developed, to number of five or six; not particularly softened or otherwise altered. No greenish color to contents of duodenum. Mesenteric glands not remarkable.

Mucous  
membrane  
soft.

Large intestine pale, externally and internally;—contains a little over two pints of true “rice water” fluid, i. e. a thin, whitish, opaline fluid, which, on standing, deposits a layer of fine whitish flocculi, like pure pus.

Mucous follicles of large intestine visible, but not altered. Nothing else remarkable.

Liver rather pale and yellowish in color; of natural consistence. Rather over medium size.

Gall bladder contains about half an ounce of dark olive-colored bile, of usual thickness.

Spleen small, flabby; of natural consistency.

Pancreas natural.

Both kidneys quite natural, except that right has a spot of dark sanguineous congestion, about the size of half a dime, occupying whole thickness of corticle portion, at lower and posterior part of organ.

Congestion.

Urinary bladder, collapsed and empty. Has only a little whitish creamy secretion, smeared over internal surface.

Uterus has a very small, purple colored polypus, hanging from internal surface of neck.

Polypus.

Ovaries each contain one or two cavities, lined with a delicate, thin, very vascular, serous membrane, and containing a few drops of thin watery fluid. Genital organs otherwise quite healthy.

Ovarian  
cysts.

The secretion lining the inner surface of the bladder, examined under microscope, was entirely similar

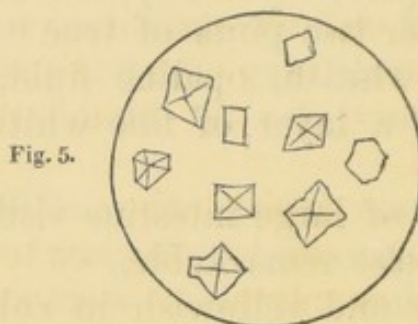


to that described as found in the bladder of *Roger Ryan*.

The flocculent deposit from the intestinal fluids was composed entirely, or nearly so, of columnar epithelium, in larger and smaller masses.

The fluid from the large intestine, when filtered, had a light amber color. It was moderately albuminous, and ammonia produced a light precipitate of the earthy phosphates.

A drop, evaporated on a slip of glass, left the following chrystalline deposit. (Chloride of sodium.)



## V.

JULY 19. DELIA McLAUGHLIN. Aged 35. Married. Irish. Intemperate. Cholera for 31½ hours, with some previous diarrhœa. Treatment,—opium and tannin, moderately; afterward, wine. Veins injected with saline solution three hours before death, with temporary reappearance of pulse. Coma for last 2½ hours of life. Autopsy 20 hours after death.

*Rigor mortis* moderate;—most firm in hands and feet. No blue discoloration, except a little in dependent parts. Considerable heat about chest and lumbar region. Face and extremities cool. Corneæ, which have remained covered, a little dryish and

Post-mortem heat.



shrunk. Sclerotics natural. Abdomen somewhat prominent, moderately resonant.

*Head.* Dura-mater natural. Moderate quantity of red and yellowish coagula in longitudinal sinus. Arachnoid cavity contains a very little serum. Some sub-arachnoid œdema. Arachnoid healthy. Substance and color of brain and cerebellum generally natural. Lateral ventricles contain about two drachms of clear serous fluid. Lining membrane natural. No vascularity of surrounding parts, which, as well as medulla oblongata and pons varolii, are quite firm. Middle commissure requires some force to tear it apart. Nothing else remarkable.

*Chest.* No dryness of pleura. Pericardium contains normal amount of clear fluid, together with a small shreddy, yellowish coagulum, floating loose in the fluid. A few, sharply-defined, oblong spots of ecchymosis, one line in length, clustered together underneath lining membrane of pericardium, where it lies over anterior aspect of heart. One or two, also, circular in shape, and less defined, at junction of ascending and descending venæ cavæ.

Venæ cavæ moderately full of dark fluid and coagulated blood. Right cavities and pulmonary artery full of sufficiently firm fibrinous and red coagula. Left ventricle moderately firm;—contains a small dark red coagulum. Left auricle contains dark and fibrinous coagula. Lining membrane, valves, and substance of heart, natural.

Pleura healthy. No adhesions. A very little vesicular emphysema of anterior surface of upper right lobe. Both lungs crepitate well everywhere, and are firm in texture;—contain a moderate amount of fluids and air. No tubercles.

Trachea and bronchi contain a very frothy fluid, slightly tinged with red. Lining membrane of air-passages pale, down to lower part of trachea;—below that, considerably reddened;—otherwise natural.

*Abdomen.* Peritoneum natural. Small intestines ruddy, externally; moderately distended, with *pale*



*contractions* at some parts;—contain about six ounces of thick green, curdy fluid. Contents more yellow and fluid at upper part of intestine; more green and fluid below. Mucous membrane generally pale; in some spots moderately reddened; every where of good thickness and consistency. Duodenal glands natural. Solitary glands visible, moderately developed at lower part of small intestines. Peyer's patches same.

Green fluid  
in intestines.

Large intestine contains a moderate quantity of greenish-olive, pasty, fœces. Mucous membrane natural.

Liver, of moderate size and natural consistency; generally rather of a pale red color, with irregular, tolerably well-defined spots of anæmia on anterior surface.

Gall bladder contains about one ounce of very black, rather fluid bile.

Stomach contains three to four ounces of fluid, rather thin, in consistency, less green than that in intestines, but more of a yellowish-brown color. Mucous membrane has a considerable amount of bloody congestion, principally along great curvature; redder toward pyloric extremity, more brownish toward cardiac. Mucous membrane generally rather soft; natural near pylorus, softened and thinned in great pouch; not otherwise remarkable.

Congestion.

Spleen rather small, and a little flabby; not otherwise unnatural.

Both kidneys somewhat pale; and lining membrane of pelvis very much so. Organs otherwise healthy.

Urinary bladder contains about half an ounce of watery, reddish-yellow, turbid fluid, without urinary odor.

False corpus  
luteum.

Uterus somewhat tumefied and congested, with considerable softening and vascularity of internal surface. Right ovary natural; but left contains a rather recent-looking spurious corpus luteum, from



which the coloring matter of the blood has been nearly absorbed. (Patient menstruated June 15th.)

The fluid from the bladder, examined by the microscope, presented the same appearances as in the case of *Roger Ryan* and *Mary P. Spalding*.

That from the small intestines showed some fragments of columnar epithelium, but was, in general, too much broken up to be distinctly recognized.

---

## VI.

ROBERT SHEA. Aged 31. Laborer. Irish. Intemperate. In Hospital, with Cholera, for 4¼ hours. JULY 22.  
Previous diarrhœa, for one week. Treatment,—venesection, to eight ounces, followed by two doses of brandy, one ounce each. Coma, for last two hours of life. Autopsy 20 hours after death.

*Rigor mortis* moderate; blue discolorations also moderate; most marked on ends of fingers. Sclerotics and corneæ, which have remained covered, nearly or quite natural. Genital organs very dark colored. Muscles red.

*Head.* Longitudinal sinus empty. A little bloody effusion in arachnoid cavity, over posterior part of right hemisphere. Some sub-arachnoid œdema on both sides; also bubbles of air in meshes of pia-mater. Substance of brain natural. A few drops of fluid in lateral ventricles;—surrounding parts pale, and firm in consistency. Cerebellum and medulla oblongata also natural.

*Chest.* Dryness of pleura, on both sides, well marked, but not excessive. Dryness confined to



that part where the lung overlies the pericardium. Elsewhere pleura quite smooth and moist.

Pericardium contains not more than two drachms of fluid, slightly reddish in color. A few minute, *Ecchymosis.* circular spots of ecchymosis on lower and anterior part of right ventricle, near point of heart; none elsewhere. Right auricle moderately full of dark fluid blood, and dark red coagulum. Right ventricle, which is flabby, contains also fibrinous clots, of moderate consistency, which extend into pulmonary artery. Left ventricle entirely uncontracted; has a "doughy" feel when kneaded with the fingers;—contains nothing. Endocardium and valves natural. Substance of heart rather soft.

Lungs natural in appearance;—crepitate well everywhere;—moderately filled with blood and air.

Trachea and bronchi contain a little frothy fluid, slightly tinged with red. Mucous membrane pale at upper part, somewhat dusky below; otherwise natural. Larynx natural.

*Abdomen.* Peritoneum natural;—contains about *Fluid in peritoneum.* two ounces of reddish colored fluid.

Small intestines greenish and reddish-yellow externally, not morbid in appearance;—considerably distended with air till within five feet of cæcum, when they suddenly become quite shrunk, collapsed, and empty; but retain their ruddy color. Intestine contains a very small quantity, not over two ounces, of whitish fluid, rather thick with yellow flocculi; beside which, inner surface of intestine is, at some parts, plastered over with moist masses of similar flocculi. Réaction decidedly acid. Internal surface of intestine generally pale or greenish;—decidedly reddened in last eight or ten feet. *Sub-mucous emphysema.* Prominent masses of sub-mucous emphysema, in circular or irregularly oval spots or clusters, having a base of three quarters of an inch diameter, downward, and resembling much in appearance the pulmonary tissue of a reptile. There is no alteration of the mucous membrane, or other intestinal coats, at these points,



in color or consistence. One of these patches is situated in the duodenum, two in the jejunum, one in the ileum. Duodenal glands well developed. No greenish contents in duodenum. Nineteen Peyer's patches visible, of which only the last eight are rather more developed than ordinary. Solitary glands moderately developed in lower portion.

Large intestines contain but little air, and no fluid. A little thin, yellowish-brown substance at lower portion, and just enough to smear the walls above. There are small black specks, like minute bits of charcoal, scattered over most of internal surface. About three inches below cæcum there is a strip of fibrous, woody substance, like half-chewed liquorice-root, or slippery-elm bark,  $2\frac{1}{2}$  inches long by  $\frac{1}{4}$  inch wide, lying transversely in the intestine. Four inches lower down, there are three other similar strips,  $2\frac{5}{8}$  inches long, but narrower than the others, lying diagonally. These strips are all quite firm, and not at all digested. No appearance of irritation about intestinal walls in their neighborhood.

Strips of  
wood (?) in  
intestine.

About twenty "tricocephali dispaes" in cæcum; *Tricocephali*. none in other parts of intestine. One of the largest of these worms is  $1\frac{3}{8}$  inches in length.

The appendix (cæci), contains a little pasty fæces at its upper part.

Mucous membrane of large intestine generally pale or greenish. A few minute red circles in middle portion, apparently the reddened edges of the orifices of dilated mucous follicles. No ulceration or other morbid appearance.

Stomach contains six ounces of thin, yellowish, dingy, turbid, flocculent fluid, with a fœtid odor and a decided acid reaction. It has, floating about in it, some small undigested bits of green leaves, like parsley. Mucous membrane, considerably thinned and gelatinized, with brownish discoloration, almost everywhere; only just at pylorus it retains its natural firmness. No other morbid appearance.

Liver, pale yellowish red, externally. Internally,



of a dusky color, inclining to olive; consistence natural. Not much blood.

Spleen small, blue externally; somewhat wrinkled and flabby. Contains less than normal amount of blood. Consistence firm. Pancreas natural.

Kidneys natural, externally. Cut surface quite bloody. Color and consistence natural. Urinary bladder collapsed; contains only a little whitish, creamy, pus-like fluid, just sufficient to smear its walls. Mucous membrane reddened near orifice of urethra. Otherwise natural. Abdominal vessels natural internally.

The fluid from the stomach, next morning, still retained an acid reaction.

Filtered clear, it was of a light yellowish color, like the serum of blood.

Albumen.

It became opaline by heat, and the opalescence was cleared up by liquor potassæ. It was not precipitated by dilute or concentrated acetic or muriatic acid; but after the addition of these acids, ferro cyanide of potassium produced a feeble turbidity.

Nitric acid caused a faint white deposit.

Nitrate of silver produced a copious white deposit, which became dark on exposure to light; soluble in ammonia, insoluble in nitric acid. (Chlorine—compound.)

Chloride of barium caused a moderate whitish precipitate. (Sulphates.)

Ammonia threw down a faint precipitate of earthy phosphate, in the following crystalline forms:

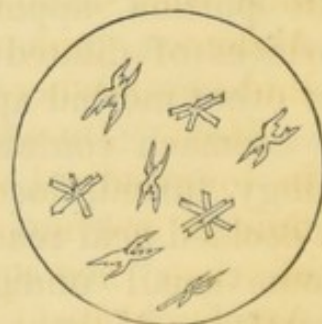


Fig. 6.

The flocculent deposit from the intestinal fluids showed, under microscope, evident columnar epithelium, but much broken up.



That from the stomach showed no distinct epithelial structure.

The creamy secretion from the bladder consisted of nucleated epithelium scales, and elongated cells, as heretofore, together with many small circular, or oval bodies, apparently the cells of a *Torula*.

## VII.

MANUS MCCARTHY. Aged 45. Laborer. Irish. Intemperate. Cholera for  $13\frac{1}{4}$  hours. Previous diarrhœa for one week. Collapse excessive. Treatment; external heat and sinapisms. Venous injection of 20 ounces saline solution, with temporary re-establishment of pulse. Afterward, venesection to 10 ounces, and saline injection repeated, with similar effect. Second injection  $3\frac{1}{4}$  hours before death. Insensibility for last two hours of life. Autopsy 13 hours after death. JULY 27.

*Rigor mortis* well established. Fingers shrivelled, and finger-nails deep blue. Elsewhere, cyanosis not considerable. Corneæ, which have been covered, somewhat shrunken, but not dry. Sclerotics natural. Abdomen, prominent, tense, tympanitic. Body and limbs everywhere cool.

*Head.* Dura-mater natural. A little fluid blood in longitudinal sinus. A small amount of bloody fluid in arachnoid cavity, spread out over convexities of each hemisphere. No sub-arachnoid œdema. Arachnoid itself healthy. Substance of brain, has a natural aspect, externally. Amount of blood, in substance of brain, normal. About one drachm of bloody fluid in ventricles. Lining membrane of ventricles pale. Choroid plexus natural. Fornix, corpora

Bloody fluid  
in arachnoid,

and in  
ventricles.



Brain  
softened.

striata, optic thalami, and whole cerebral substance at base of brain, considerably softened, but not so much as to destroy its shape at any part. Upper parts of hemispheres of natural consistence. Cerebellum also softened in the same manner as the cerebrum; otherwise natural. Medulla oblongata sufficiently firm.

Ecchymosis.

*Chest.* Dryness of pleura, only on anterior surface of pericardium, beneath lung; there, it is sufficiently well marked. Pulmonary pleura covering pericardium has nearly, or quite, its natural moisture. Pericardium contains about half an ounce of yellowish fluid; presents numerous spots of ecchymosis underneath the lining membrane; both beneath that portion lining sac, and that covering heart and large vessels. These spots are red or purple, mostly collected into groups of five or six, and about one sixteenth to one twelfth of an inch in diameter. They have almost no appreciable thickness. There are two or three, however, on posterior aspect of aorta, before it leaves the cavity of the pericardium, which have a diameter of three eighths of an inch, and some thickness. These are quite dark and purple in color. Pericardium otherwise natural.

Endocardium stained.

The right ventricle is full of a dark, granular coagulum, very deficient in firmness. It is flabby, and contains a little dark coagulum. Venæ cavæ contain mostly dark fluid blood, with some soft coagula. Lining membrane of venæ cavæ and both right cavities of heart, stained purplish red by coloring matter of blood. Lining membrane of left auricle quite white and healthy; that of left ventricle slightly stained in some parts;—elsewhere natural. Left ventricle not contracted, but soft, and “doughy” to the feel;—empty. Left auricle contains a little soft, red, and some yellowish, coagula. Valves all healthy.

Both lungs crepitate well throughout; somewhat dryish and emphysematous in upper lobes; dark red, rather soft, and abundant in fluids in lower lobes. No tubercles.



General pleuritic adhesions of right lung, not very firm; none of left.

Larynx, trachea, and bronchi, natural internally. Trachea contains only a very little colorless froth; Bronchi contain some yellowish watery fluid, which can be pressed up from lung.

*Abdomen.* Peritoneum natural. Small intestines of a pale ruddy color externally, considerably distended with air and fluid—contain nearly two pints of a yellowish, thin, flocculent fluid, of which the flocculi have a much stronger yellow color than the fluid in which they are suspended. Neutral reaction. Mucous membrane of small intestines pale;—stained of a bright yellow color in duodenum and upper two feet of jejunum; moderately reddened, in lower part of ileum. About one foot above ileo-cæcal valve, there is a circular spot, ill-defined, of a dark purple-red color, which shows through on outside of intestine, and which presents, internally, two or three small spots of ecchymosis beneath mucous membrane. M. M. everywhere of medium thickness and consistence. Duodenal glands natural. Peyer's patches visible, to number of seventeen or eighteen, the lower six or eight of which are moderately developed; not softened or reddened. Solitary glands visible, moderately developed, in last few feet of ileum. No other remarkable appearance.

Large intestine of a slaty hue, externally and internally; somewhat distended with air. It contains about half a pint of thinnish, grey, flocculent fluid, without any yellow tinge; neutral, without odor. On standing, the flocculent portion is deposited greyish white, and the fluid part has a darker, dingy-brownish color. About midway between cæcum and anus, there is a single cherry-stone; no other solid contents. Mucous membrane of natural thickness and consistence. Mucous follicles, developed in sigmoid flexure and upper part of rectum;—not elsewhere.



Stomach contains ten ounces of a reddish-brown, watery, slightly flocculent fluid, neutral, without odor. Mucous membrane, pale and natural, near pylorus; shows red, dotted, vascular injection along small curvature and on anterior wall; moderate dusky color and gelatinization in great pouch and on posterior wall. Nothing else remarkable

Esophagus generally pale internally; but, one inch above cardiac orifice, there commences a very dark slaty, almost black, discoloration of blood in vessels beneath mucous membrane. This extends upward for two inches. Its limits are not very well defined. Mucous membrane natural.

Liver, of natural size and consistence, and with a moderate supply of blood. Mottled, red, pale, and yellowish, externally; internally, it has a universal slaty-olive color.

Gall bladder contains about half an ounce of greenish-black fluid bile.

Spleen quite small, blue externally, sufficiently firm; contains less than normal quantity of blood.

Pancreas natural.

Both kidneys entirely natural in appearance. Urinary bladder contains about three drachms of thin, yellowish white, flocculent fluid, without urinary odor.

The vena porta contains only dark fluid blood.

Abdominal vena cava and iliac veins stained purplish-red internally. Aorta similarly stained in abdominal portion, yellow and natural in thoracic.

Staining of  
vessels.

The fluid from the stomach deposited a fine, whitish, pus-like sediment, which, under the microscope, exhibited many oval, nucleated, epithelium cells, together with numerous small, oval, granular corpuscles, (which were unaffected by acetic acid) like the nuclei of disintegrated or unformed cells. Little or no columnar epithelium.



When filtered clear, the fluid had a red, clarety color. It contained a considerable quantity of albumen, and ammonia caused a faint precipitate of the earthy phosphates, as follows:—

Fig. 7.

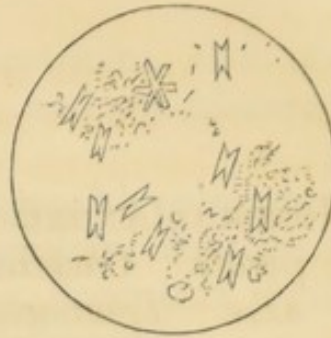
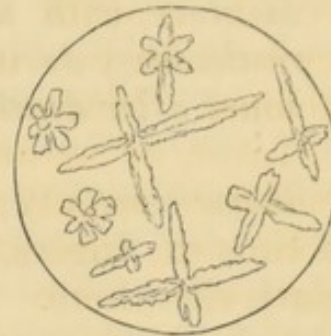


Fig. 8.

A drop evaporated on a slip of glass, left the following deposite. (Chloride of sodium.)



The flocculent deposite, from the small intestine, consists principally of long, narrow strips of columnar epithelium, with smaller detached masses of the same.

That from the large intestine, shows also columnar epithelium, but in smaller masses.

The fluid from the urinary bladder shows an abundance of elongated epithelium cells, similar to those already represented; but, for the most part, not so distinctly nucleated.



## VIII.

JULY 29. NICHOLAS ANDREWS. Aged 35. American. Intemperate. Cholera for 12 hours, without previous illness. Treatment,—External heat and sinapisms; Saline Mixture by mouth, (one ounce every 15 minutes,) and venous injection of 30 ounces Saline Mixture, with temporary relief to collapse. Much restlessness during last hours of life. Autopsy 14 hours after death.

*Rigor mortis* very firm. Strong blue discoloration of ends of fingers, and of penis and scrotum; not much elsewhere. Body and limbs everywhere cool. Muscles red.

*Head.* Longitudinal sinus contains fluid blood. A little sub-arachnoid œdema over posterior lobes; in some spots reddish. Substance of encephalon natural in color and consistence. Little or no fluid in ventricles.

*Chest.* Dryness of pleura well marked on both sides of mediastinum, particularly on surface of pericardium, which is slightly shrivelled. Pericardium natural internally; no ecchymosis; contains about one drachm of clear, yellowish fluid. Right cavities of heart flaccid; contain a considerable quantity of dark, very fluid blood, with a minute quantity of loose red and yellowish coagula. Great veins contain dark fluid blood. Left ventricle moderately firm, well-contracted and empty. Left auricle and pulmonary veins contain dark red, quite fluid blood. Aorta contains also a considerable quantity of similar blood. A few spots of dark purple discoloration in interior of left auricle, caused by ecchymosis in substance of heart, beneath lining membrane, extending sometimes to the depth of about one line. No stain-



ing of any part of lining of membrane of heart, aorta, or venæ cavæ.

Both lungs crepitate well everywhere, but are unusually full of thin frothy fluid, and considerably softened in texture. No tubercles.

Larynx natural. Trachea and bronchi, pale internally, with slight greyish discoloration; contain a large amount of thin, dingy, frothy, flocculent fluid, much like that which existed in the stomach.

*Abdomen.* Peritoneum natural. Small intestines light colored externally; uniformly distended; contain about two and a half pints of thin, yellowish, flocculent fluid. Mucous membrane generally pale. In duodenum, where contents were of a more decided yellow color than elsewhere, mucous membrane is also stained yellow. It is reddish in lower part of ileum. Duodenal glands natural. Peyer's patches visible to number of twenty-five,—the lower thirteen of which are somewhat developed, but not decidedly softened, or reddened. Solitary glands visible, moderately developed in lower three and a half feet of ileum. Nothing else remarkable.

Large intestines, greyish externally; contain a moderate quantity of air, and about half a pint of thin, greyish-white, flocculent fluid; also, a single cherry-stone. Mucous membrane natural. Mucous follicles considerably developed at lower part of intestine. *Appendix cæci* contains, at its upper part, some fæces, bits of egg-shell, and some minute, black, hard seeds. A few bits of egg-shell, and similar little hard seeds also in colon.

Mesenteric glands generally not remarkable; one or two moderately enlarged; not softened or reddened.

Stomach, seems rather vascular, externally; contains about six ounces of thin, dingy-reddish fluid, with pus-like flocculi floating on surface, and a considerable quantity of oil globules. Mucous membrane natural near pylorus; very little softened in great pouch, where there is also brown discoloration of



Redness of  
mucous  
membrane.

blood in vessels; but all along large curvature it is of a uniform bright scarlet tinge, without any appreciable softening, or other alteration of its substance. On close inspection, the redness is seen to be occasioned by injection of vascular-looking tufts (villi ?) in mucous membrane. Nothing else remarkable.

Liver mottled, purplish and yellowish-red, externally; internally, reddish-brown. Consistence natural. Gall bladder contains about one ounce of thin, blackish bile.

Spleen quite small, blue, and much wrinkled. Internally, red, firm, and very deficient in blood.

Pancreas natural. Supra-renal capsules also natural.

Anomaly of  
kidney.

Both kidneys quite natural in appearance, except that the left has the following anomaly: viz.—the longitudinal fissure, which receives the vessels and ureter, is not continuous; but is broken in its middle by interposed cortical substance of kidney, so that there are two ureters, and two sets of vessels, which emerge from upper and lower fissures, to join themselves over intervening substance of kidney.

Urinary bladder, completely contracted; contains a few drops of thin whitish substance.

The deposite, from the intestinal fluid, consisted entirely of very distinct and uninjured columnar epithelium, mostly in larger and smaller patches, partly in detached "columns," or cells.

The whitish fluid from the bladder contained scaly and elongated epithelium cells as heretofore; but many of the narrow, slender, elongated cells were collected into groups, and arranged side by side, as if still attached to a basement-membrane. There were also smaller, globular, un-nucleated cells, some transparent, some granular.



## IX.

MARGARET BAKER. Aged 19. Cholera for 33½ hours, without previous diarrhœa. Venesection to four ounces, followed by stimulants, and "Saline Mixture" by mouth. Temporary improvement in pulse. Venous injection of 20 ounces of Saline Mixture, followed, in course of an hour, by coma, which continued till death. Autopsy 13¼ hours after death.

JULY 31.

*Rigor mortis* strong. Much lividity of lips and ends of fingers; none else. Body quite warm about lumbar region; elsewhere cool.

Muscles red.

*Head.* Longitudinal sinus empty. Dura-mater natural. Posterior part of hemispheres smeared over with bloody fluid. Arachnoid itself natural. Similar bloody fluid over cerebellum. Substance of brain natural in consistence, and the amount of blood is normal. No fluid in ventricles. Lining membrane pale. There is a cyst, about the size of a pea, containing clear fluid, in posterior part of pineal gland. Brain and membranes otherwise natural.

*Chest.* No dryness of pleura, but some of pericardium, in centre of anterior aspect, immediately behind mediastinum. Pericardium contains less than half an ounce of clear fluid. Numerous minute spots of dark purple ecchymosis along anterior edge of heart, and on posterior surface. Right ventricle is flaccid, and, as well as the auricle and great veins, contains only a small quantity of dark, fluid blood, without any coagula. Left ventricle, moderately, but not perfectly contracted. Left cavities of the heart also contain a quantity of perfectly fluid blood. No



staining of endocardium. Blood elsewhere in body also quite fluid.

Lungs, natural in appearance, but rather deficient in crepitation; they have somewhat of a solid feel, but the texture is unaltered throughout. Cut surfaces red, but yielding less than the usual quantity of fluids. Trachea pale; at lower part, slaty in color. Small bronchi reddish. Larynx natural. Trachea and bronchi contain a large quantity of dingy, watery, nearly colorless fluid.

*Abdomen.* Peritoneum natural. Small intestines pale-ruddy externally, with a greenish tinge in some parts; contain about one pint of thick, yellow, flocculent fluid. Mucous membrane generally pale; yellowish in duodenum, reddish in lower part of ileum. Twelve Peyer's patches visible, the lower eight of which are moderately developed. Solitary glands prominent in the last seven feet of ileum. Mucous membrane natural in thickness, and consistence. A very little sub-mucous emphysema in lower part of ileum. Large intestines contain yellowish, dingy, flocculent fluid. Mucous membrane pale and natural in appearance.

Sub-mucous  
emphysema.

Mesenteric glands moderately enlarged; some yellowish-white in color, some slightly reddened. None softened.

Stomach contains rather less than two ounces of a thin, dingy fluid. Moderate softening of mucous membrane, especially in great pouch, without any undue vascularity, or other morbid appearance.

Liver, brownish; externally and internally. Natural in consistence.

Gall bladder contains about one ounce of thin, dark colored bile.

Spleen blue, not particularly wrinkled; natural in size and consistence. Contains the usual amount of blood.

Both kidneys quite natural in appearance. Urinary bladder, collapsed and much shrunken, nearly



empty; contains just enough of the whitish, creamy fluid to smear its walls.

Much vascularity of uterus and neighboring parts. Both ovaries are pale externally, and contain several cysts. One of them contains, also, a somewhat recent false corpus luteum. Internal surface of uterus, softened and vascular.

---

## X.

JOSHUA COOPER. Aged 25. Seaman. Indian. Temperate. Cholera for 48 hours, with two days previous diarrhæa. Venesection to 16 ounces, followed by saline mixture and carbonate of ammonia. Excessive vomiting. Much pain at epigastrium; relieved by leeches. Venous injection of 20 ounces saline mixture, with great improvement in pulse. Sensible till within half an hour of death. Autopsy 20 hours after death. JULY 31.

*Rigor mortis* sufficiently strong. No blue discoloration perceptible. Finger nails pale. No heat about body or limbs. Muscles red.

*Head.* Longitudinal sinus empty. Some bloody fluid in arachnoid cavity, over posterior part of hemispheres; also some over cerebellum. Substance of brain, of natural consistence, but rather pale. Small amount of clear fluid in ventricles; lining membrane not discolored. Nothing else remarkable in head. Bloody fluid.

*Chest.* Moderately firm, cellular, pleuritic adhesions at edges of anterior mediastinum on both sides.

Pericardium, natural internally; no ecchymosis;



Blood fluid.

but about half an ounce of fluid. Right cavities of heart contain a small quantity of dark, fluid blood, absolutely without coagula. Same in left. Left ventricle, round and prominent, but not quite firm and hard; has a little doughy feel, on pressing it. No staining of endocardium. Blood, elsewhere in body, quite fluid.

Both lungs natural in appearance externally, and crepitate well everywhere; contain a sufficient amount of fluid. Trachea pale internally.

Mucous membrane thin.

*Abdomen.* Peritoneum has a very little colorless, sticky, secretion on surface, just enough to pull out into slender threads, on separating the convolutions of the small intestines, which are pale and thin-looking externally. They contain about one pint of thin, greyish-white, gruelly fluid; internally pale, but stained yellow in upper two inches of duodenum. Mucous membrane very thin, so that transverse muscular fibres of intestine are very noticeable through it.

Peyer's patches, visible, to the number of seventeen. The lower seven of them are highly developed and reddish. Solitary glands, visible in lower part of intestine, but not remarkably developed.

Mesenteric glands not remarkable.

Old disease of cæcum.

Large intestines contain about twenty ounces of gruelly fluid, similar to that already described, but thicker. Mucous membrane smooth and pale. In the cæcum it is raised into numerous folds and ridges, and small elevations of considerable firmness, which are, for the most part, colored black, or dark purple. This has all the appearance of a chronic alteration. Nothing else remarkable in large intestine.

Stomach contains one pint of fluid, similar to that in small intestine. Mucous membrane pale, moderately softened; no vascularity.

Liver, natural in appearance, of proper consistence. Gall bladder contains about one ounce of blackish, fluid bile.

Spleen small, blue, wrinkled; internally, red, moderately soft, and quite deficient in blood.



Both kidneys rather pale; of very firm consistence; otherwise natural.

Urinary bladder, shrunk and collapsed, contains about half a drachm of thin, dingy-looking fluid.

In this case, there was great heat of all the internal organs, though the exterior of the body was cool.

---

## XI.

ELLEN KEITH. *Intemperate. Cholera 15 hours, with* AUGUST 3.  
*two days previous illness. In hospital one hour,—*  
*during which time she took opium, camphor, capsic-*  
*um, and brandy, freely. No reaction. Autopsy*  
*17¼ hours after death.*

*Rigor mortis* sufficiently strong. Slight general lividity of face, and some of lips. Hands and feet pale. A little œdema of both legs. Abdomen natural in form, moderately resonant. Body and limbs everywhere cool.

*Head.* Dura-mater adhered with great force to skull-cap, so that arachnoid cavity was torn open in removing latter, and it could not be ascertained whether any fluid existed in its cavity. Arachnoid natural. Substance of brain and cerebellum everywhere of good consistence and color, but lining membrane of all the ventricles is unusually vascular; otherwise healthy. Lateral ventricles contain a drachm or two of fluid. Nothing else remarkable. Congestion.

*Chest.* Dryness of pleura well marked, particularly on right side, where it covers the pericardium, which is natural in appearance. No ecchymoses; but about one drachm of clear, serous fluid in cavity.



Right cavities and venæ cavæ, filled with dark fluid blood, and a very little dark red, and yellowish, soft, gelatinous coagula. Left ventricle moderately well contracted; contains, as well as auricle, a small quantity of dark fluid blood. No staining of endocardium or lining membrane of vessels. Blood elsewhere quite fluid.

Tubercle.

Ecchymosis  
in lung.

Both lungs crepitate well, and have generally a natural appearance. A few, small, firm, inactive, encysted, semi-tuberculous looking masses at each apex. No alteration of pulmonary texture in vicinity. On posterior aspect of upper and lower left lobes there are several dark purple stains, which extend some distance ( $\frac{1}{4}$  to  $\frac{3}{4}$  inch) into substance of lung. These spots are very dark in color, sufficiently well defined, and very distinguishable from the surrounding red, healthy pulmonary tissue. Structure of lung, at these spots, is not materially altered, being of natural consistence and not entirely deficient in crepitation. Excised portions float in water. These spots are apparently produced by ecchymosis into the cellular tissue. There is little or no engorgement of posterior parts. Larynx natural. Trachea and bronchi moderately reddened; contain a little dingy, frothy fluid.

*Abdomen.* Peritoneum, dryish at upper and anterior part of abdomen; otherwise natural. Small intestines rather pale externally, and somewhat distended with air and fluid at upper part, but comparatively empty at lower. Whole of small intestines contain about one pint of moderately thick, greyish, gruelly fluid, without fœcal odor. Mucous membrane pale, with very little reddening in lower portion of intestine; of natural thickness and consistence throughout. Some red injection of villi in duodenum. No yellowish contents in this part, nor staining of mucous membrane. Twenty of Peyer's patches visible; none of them remarkably developed. Solitary glands slightly developed in lower portion of ileum. Duodenal glands natural.



Large intestine pale greenish externally and internally; contracted through greater part of its extent; contains ten ounces of thin, greyish, flocculent fluid, with a faint fœcal odor. Mucous membrane generally of natural appearance, but along middle part of intestine there is an appearance of its being deficient in minute, irregular, circular, or oval spots, as if worm-eaten. On scraping away mucous membrane, it is evidently partially or entirely deficient at these points. At one spot, a mucous follicle is visible, surrounded by a narrow zone or *trench*, where mucous membrane is wanting. Appendix cœci nearly empty; has a Peyer's patch on its internal surface.

Deficiency  
of mucous  
membrane.

Mesenteric glands not remarkable.

Stomach contains about ten ounces of thin, dingy-reddish fluid. Mucous membrane natural toward pylorus; softened toward cardiac extremity over about one half its surface. Proceeding from pylorus toward cardiac extremity, softening is marked first by red injection of mucous membrane, then by blackish, ill-defined discoloration of blood in larger vessels, and finally by brownish, gelatinous disorganization of mucous membrane.

Liver quite pale; of natural consistence. Gall bladder contains about one and a half ounces of dark, yellowish-brown bile, of ordinary thickness.

Pancreas has much dark purple ecchymosis in cellular tissue on surface and in interior between lobules, but the pancreatic tissue itself is not altered. Ecchymoses occupy left half of organ.

Ecchymosis.

Spleen of moderate size, blue, quite flabby. Internally red and rather soft. Deficient in blood.

Both kidneys flabby and rather pale. Left has on upper part of anterior aspect a small, dark, ecchymosis. Capsules separate with great ease from both organs, leaving surfaces quite smooth and polished. Calyces and pelves smeared with a thin, purulent-looking fluid. Urinary bladder contracted and empty; only its walls are smeared with the puriform secretion.



Uterus natural excepting some redness of its lining membrane. Ovaries contain each several serous cysts. There is also in each organ a cyst, containing dark red coagulum, the color of which shows through peritoneal covering. Nothing else remarkable.

---

## XII.

AUGUST 6. SARAH HILL. Aged 28. Prostitute. Cholera for 53 hours. In Hospital 10¾ hours. Treatment—"Saline mixture" every hour. Sage tea ad libitum, and cold bath to arms. Autopsy thirteen hours after death.

*Rigor mortis* slightly developed. Hands and feet much shrivelled, and nails blue. Body and limbs everywhere cool.

Abdomen prominent, tympanitic.

Muscles red.

Mammæ moderately full; internally they are reddish and granular, and contain a considerable quantity of milk.

Strong puerperal odor about body, externally and internally.

*Head.* Longitudinal sinus contains a little fluid blood. Arachnoid natural. A very little bloody fluid smeared over posterior part of right hemisphere. Purplish discoloration of sub-arachnoid cellular tissue in left temporal region. Slight sub-arachnoid œdema; also a little emphysema in same situation, and some bubbles of air in veins on surface. Color and consistence of brain and cerebellum everywhere natural. Trifling amount of clear fluid in lateral ventricles; lining membrane pale.



*Chest.* Pericardium contains about half a drachm of clear fluid. (Hygrometric condition of pleura not noticeable, owing to adhesions.) A few small purple ecchymoses along edges and on posterior surface of right ventricle. Right cavities filled with dark red and fibrinous coagula and dark fluid blood. No coagula in venæ cavæ. Left ventricle rather deficient in firmness. Left cavities contain a moderate quantity of dark fluid blood, of thick consistence. (But fluid blood on right side is thin.) No staining of endocardium. Substance of heart a little soft.

Aorta contains dark fluid blood, and a tolerably firm, fibrinous clot.

Moderately firm, universal, cellular adhesions of right lung; very limited ditto of left. Both lungs crepitate well everywhere, but there is a remarkable difference in their color and appearance. The right is smaller than the left, in consequence of a contraction of chest. (?) It is of a healthy red color externally and internally. The left is red only at apex of upper lobe; elsewhere throughout of a very dark brownish purple, deepest at lowest part of lower lobe; contains a sufficient amount of air and fluids, but not much blood. No tubercle anywhere. Texture of left lung somewhat soft, but not otherwise altered; that of right lung natural.

Difference  
in color of  
lungs.

Larynx healthy. Trachea and bronchi pale; contain a little frothy fluid.

*Abdomen.* Close adhesions (old) of anterior edge of right lobe of liver to colon; also short, shaggy excrescences on peritoneum in immediate neighborhood, like the remains of old lymphatic effusion. Close adhesion of sigmoid flexure of colon to posterior abdominal wall, just in front of bifurcation of aorta. No recent disease of peritoneum.

old peritonitis.

Small intestines pale greenish externally; considerably distended; contain about two pints of yellowish white, flocculent fluid, without remarkable odor, and without reaction on test-paper. Mucous membrane generally pale; moderate yellow staining in duode-



num, and a little reddening in lower part of ileum. Mucous membrane everywhere of natural thickness and consistence. Villi quite visible in all parts of intestine. Twenty-four Peyer's patches counted; the lower eighteen very moderately developed. Solitary glands developed, but not remarkably altered, in lower three feet.

Lymph (?)  
on mucous  
membrane.

About four inches above cœcum there is, on internal surface of ileum a patch of soft, yellowish transparent substance, one and a quarter inches in diameter, about two lines in thickness, entirely resembling fresh lymph in appearance. It is easily separated from mucous membrane, which presents the same appearance underneath patch as in surrounding parts.

Large intestine light-colored externally. Cœcum, which is large and full of fluid, occupies almost whole of cavity of pelvis, rectum and bladder being both empty. Colon contains in all about one pint of thin, yellowish, semi-purulent looking fluid, without odor and neutral in reaction. Mucous membrane pale, of good consistence and thickness. Mucous follicles everywhere very distinct. No other remarkable appearance.

Dark spots  
in stomach.

Stomach contains ten ounces of thick, brownish-yellow fluid, moderately alkaline, and with a disagreeable odor. Moderate softening of mucous membrane generally; considerable brown discoloration at cœcal extremity, without disorganization of mucous membrane. There is one patch, situated on large curvature, irregularly oval in shape, very well defined, which is of a very dark brown, almost black color, and perfectly distinct from surrounding parts. It has a pulpy appearance, but on scraping it, is found to be as firm, or a little more so, as parts in immediate neighborhood. There are two or three smaller similar spots near it. Mucous membrane generally much wrinkled. Nothing else remarkable.

Mesenteric glands generally enlarged, but of natural color and consistence.



Liver pale externally, with spots of well-marked anæmia. Internally of a natural brownish-red color. Bright yellow bile can be expressed from cut ends of ducts in substance of organ. Gall bladder contains about one ounce of rather thin bile.

Pancreas pale; otherwise natural.

Spleen small, wrinkled. Internally red and softish, but deficient in blood.

Both kidneys pale and flabby; otherwise natural. Lining membrane of pelvis pale, and smeared with a puriform fluid.

Urinary bladder collapsed; contains about two drachms of thin turbid fluid, without any appearance of urine.

Abdominal vessels natural internally. Blood everywhere fluid, excepting a very little soft coagulum; not particularly thick.

Uterus somewhat vascular and tumefied; and with ovaries, shows signs of recent menstruation.

---

### XIII.

JEREMIAH MULLEN. Aged 26. Cholera for 52 hours, AUGUST 7.  
with some previous diarrhœa. Reported bloody vomiting and dejections, previous to entrance. In Hospital nine hours. Treatment; "Saline mixture" every half hour, and external heat. Autopsy 13½ hours after death.

*Rigor mortis* sufficiently strong. Lips pale. Fingers much shrivelled, and nails dark blue. Body



and limbs everywhere cool. Abdomen natural in shape, moderately resonant.

Muscles have a slight slaty tinge.

*Head.* A little fluid blood in longitudinal sinus. A little bloody fluid smeared over posterior part of hemispheres. (This appearance is probably a post-mortem effect of the fluidity of the blood, and is favored by the dependent position of the head in first parts of autopsy.) Arachnoid perfectly natural in appearance. Substance of brain rather soft toward central parts, but no undue vascularity, or other morbid appearance.

Bloody fluid also over surface of cerebellum, and a very little in cavity of ventricles.

*Chest.* Dryness of pleura strongly marked, not only over pericardium, but also down on each side on anterior portions of diaphragm. Pericardium natural internally; no ecchymosis; contains not more than one drachm of clear fluid.

Right cavities of heart filled with dark, fluid, thickish blood, with almost no coagula. Left ventricle firm, sufficiently well contracted; contains, with auricle, dark fluid blood, moderate in quantity. Interior of heart natural; no staining nor ecchymoses. Substance also natural.

Both lungs crepitate well everywhere; light rosy in color, externally and internally, excepting some dark sanguineous engorgement of posterior parts. Texture unaltered. Two greyish yellow, firm, encysted, perfectly inactive masses of tubercle, three eighths of an inch in diameter, in left apex; at which spot there is a moderately firm pleuritic adhesion. Nothing else unusual.

Abscess (?)  
in thyroid.

Trachea and bronchi, natural internally; contain some frothy fluid. Thyroid cartilage has an enlargement on left side, occasioned by a cavity in its substance, large enough to hold a pea, and containing a gelatinous fluid, with small, dark clots of blood. There is no cyst, but walls of cavity are composed of



softened cartilaginous substance. Larynx otherwise natural.

*Abdomen.* Peritoneum dryish over stomach, liver, and great omentum ; but underneath omentum, among convolutions of small intestine, it has its natural moisture.

Small intestines light colored externally, not much distended ; contain about one and a half pints of thickish, stone-yellow, flocculent fluid, neutral in reaction, and without remarkable odor. Mucous membrane yellow in duodenum, pale in jejunum, moderately reddened in greater part of ileum ; everywhere of natural thickness and consistence. Villi perfectly visible in all parts of intestine. Twenty-nine Peyer's patches counted ; the lower eighteen moderately developed. Solitary glands visible in last foot or two of ileum. No other remarkable appearance.

Large intestine contains rather over two pints of thin, greyish fluid, without odor, or reaction on test-paper. It contains also a quantity of fish-bones, of <sup>Fish-bones in colon.</sup> various sizes and shapes. Some are long, slender, and sharp-pointed, as much as one and three-quarter inches in length, others thin and broad, others apparently parts of the jaw, as they are more solid in texture, and thickly set with small conical teeth. There are also undigested pieces of fish. These articles are chiefly collected in cæcum, but are scattered at intervals also from there down to middle of colon. Appendix cæci contains also, at its blind extremity, a few small bits of similar bone.

Mucous membrane everywhere pale, and without any appearance of irritation, only mucous follicles are developed, and their orifices, for the most part, marked by a black speck.

Mesenteric glands generally enlarged, and of natural color and consistence.

Stomach contains one and a half pints of thin dingy <sup>Fish-bones, &c., in stomach.</sup> fluid, with a slight acid reaction, and a faint smell of beer ; also a quantity of bones, similar to those in



colon, and more large pieces of fish, entirely undigested. Mucous membrane stained yellow near pylorus, elsewhere pale; and almost entirely unaltered by softening or thinning of substance. In cæcal extremity, however, there are a number of small whitish bodies, visible just beneath mucous membrane, like the solitary glands of the small intestine.

Ecchymosis  
in œsophagus.

There is a considerable amount of dark purple ecchymosis beneath mucous membrane of œsophagus, just above its termination in cardia, extending nearly or quite round œsophagus and for about three-quarters of an inch in an upward direction. Œsophagus otherwise natural.

Liver reddish externally; dusky and granular internally. Natural in consistence. Bile can readily be expressed from mouths of ducts of cut surfaces.

Gall bladder contains about one and a half ounces of rather thin bile, natural in color.

Pancreas natural.

Spleen large; six and three quarter inches long, and broad and thick in proportion; blue externally, not wrinkled. Internally red and softish, well supplied with blood.

Beside this, there is a supplementary spleen, one inch in length.

Both kidneys natural in appearance, but hard. Puriform fluid is smeared over lining membrane of pelvis, and can be expressed from papillæ.

Urinary bladder shrunken and contracted; contains about half a drachm of thinnish, turbid fluid.

Abdominal vessels natural internally, but contain no coagula. Blood generally rather thickish.



## XIV.

ELLEN McCANN. Aged 19. Domestic. Irish. Tem- AUGUST 8.  
perate. Cholera for ten hours. In Hospital four  
hours. Treatment—"Saline mixture" every half  
hour. Autopsy 20 hours after death.

*Rigor mortis* sufficient. Some lividity of finger nails; not much elsewhere. Abdomen natural in shape.

Spinal cord (examined first) every way natural. A drachm or two of clear serum in cavity of sheath, which collects at bottom of cord. Sheath and arachnoid quite pale and healthy looking. Cord has a natural degree of vascularity, and its substance is everywhere of proper color and consistence.

*Head.* Dura-mater and arachnoid natural. Bloody fluid, as before, just sufficient to smear posterior part of hemispheres. Color of brain natural; consistence firm. Ventricles contain little or no fluid; lining membrane pale. Medulla oblongata also natural.

*Chest.* No dryness of pleura in front, but a very little on diaphragmatic surface of right lung. Pericardium natural internally; no ecchymoses; contains a about half a drachm of clear serum. Right cavities of heart filled with dark, fluid, rather thickish blood, with trifling, soft coagula. Adjacent veins contain same. Left ventricle tolerably firm; contains, with auricle, a moderate quantity of dark fluid blood.

Heart natural internally; no staining.

Aorta contains much dark fluid blood, absolutely without coagula.

Both lungs crepitate well everywhere, and are of a natural red color externally and internally. There are some dark patches on the posterior surface of right, like those described in the case of *Ellen Keith*,



but not so large. No tuberculous or other alteration of pulmonary tissue.

Larynx natural. Trachea and bronchi pale-dusky internally; contain a little frothy fluid. Mucous membrane not altered in structure.

*Abdomen.* Peritoneum natural. Small intestines light-colored externally, moderately distended; contain one pint of thickish, yellowish-grey fluid, without odor. Mucous membrane considerably reddened and *browned* in duodenum, (upper 3 or 4 inches;) elsewhere pale; in all parts of intestine of natural thickness and consistence. Villi everywhere visible. Peyer's patches moderately developed in lower part of intestine. Solitary glands same. No ulceration or other morbid appearance.

Large intestine contains one pint and a half of thinner greyish fluid, with white cheesy-looking specks floating about in it. No other unusual contents. Mucous membrane pale, natural in texture. Mucous follicles everywhere very visible, and their orifices apparent; not otherwise altered.

Mesenteric glands not remarkable.

Stomach contains about one pint of thin dingy fluid, with a smell of beer, or fermenting vegetable juices. Mucous membrane nearly natural in consistence. Brown discoloration of blood, arranged in streaks and ridges, very marked in left half of organ. Toward pyloric extremity, sub-mucous tissue is thickly strewn with whitish, firm, round bodies, having much the appearance of Brunner's glands in the duodenum, only rather larger and more distinct. Nothing else remarkable.

Liver reddish-brown externally and internally. Consistence natural. Ducts in organ yield bile by pressure. Gall bladder contains about six drachms of thinnish bile, of natural color.

Pancreas natural.

Spleen small, blue, flabby. Internally reddish, rather soft, and tolerably well supplied with blood.

Kidneys about equal in size. Right a little pale;



left contains normal amount of blood. Otherwise both healthy.

Urinary bladder much shrunk and collapsed, and is absolutely empty. Only a little of the puriform secretion can be obtained by scraping its walls with the edge of a knife.

Uterus pale and small, without any appearance of activity. Internal surface slightly red and soft. Ovaries natural externally; contain internally several cysts; one of them having rather thick, yellow walls, and bloody contents.

---

## XV.

KATHARINE HURLEY. *Aged 30. Pregnant. Cholera for 15½ hours, with three days previous diarrhœa. In Hospital four hours; collapse complete on entrance. Treatment—External heat, sinapisms “saline mixture” every 15 minutes, and brandy and water freely. No reaction. Autopsy 19 hours after death.* AUGUST 9.

*Rigor mortis* moderate. Fingers blue and shrivelled. Some heat about anterior part of abdomen, which is of natural form, but firm and resisting. Elsewhere, body and limbs cool.

Muscles red.

Pupils equally dilated. A spot of bright-red congestion in right sclerotic, just where it joins outer edge of cornea. Sclerotics otherwise natural.

Skin of abdomen seamed with numerous scars of pregnancy.

Mammæ flaccid; neither of them much developed, nipples show signs of previous nursing. Mammæ



internally granular. Left contains a moderate quantity of thin opaline fluid, like milk much diluted. Right contains a more abundant, opaque fluid, of a yellow color, appearing as if it contained a large amount of oil.

Sub-arachnoid ecchymosis.

*Head.* Dura-mater natural, well-marked sub-arachnoid ecchymosis, or rather infiltration of bloody fluid into pia-mater, over upper and anterior surface of hemispheres. Arachnoid natural. Substance of brain natural in color, but very firm in texture, particularly toward central parts, so that it requires some force to tear apart middle commissure. No other alteration of texture. Ventricles contain a very little clear fluid. Lining membrane pale. Medulla oblongata firm, like the brain, but otherwise natural.

*Chest.* No dryness of pleura, except a little on right diaphragmatic surface. Pericardium natural internally; only one or two ecchymoses, very small and ill-defined, on posterior surface of heart. Pericardium contains not more than one drachm of clear fluid. Right cavities, together with large veins of chest and neck, filled with an abundant, very black, soft coagulum, and some dark fluid blood. Left ventricle well contracted and firm. Left cavities contain a moderate quantity of blood, similar to that in right. Internal surface and substance of heart natural.

Both lungs crepitate sufficiently well everywhere, but are very dry; almost entirely deficient in blood and other fluids, so that they become collapsed and shrink up to an excessive degree, on being removed from the chest. Color of a natural light-red, freckled with black. No tubercle. No congestion, even at posterior parts. Larynx natural. Trachea and bronchi empty; pale internally.

*Abdomen.* Peritoneum covered with a colorless, slimy, sticky secretion, just sufficient in amount to smear surfaces and to be drawn out into slender threads, on separating intestinal convolutions. Small



intestine is also somewhat roughened in various parts of its surface; and this roughness is not removable by scraping with edge of knife. No other alteration of peritoneum.

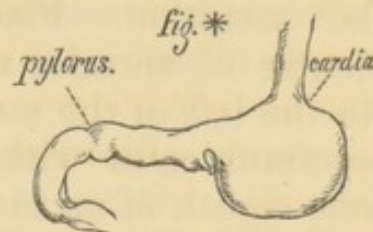
Small intestines of natural appearance externally; contain about ten ounces of thickish, yellowish-grey, flocculent fluid, without remarkable odor. Mucous membrane rather pale in upper portions, considerably reddened throughout ileum. Redness is situated altogether in the villi, which are distinctly seen of a bright red color. Mucous membrane otherwise unaltered. Peyer's patches moderately developed in lower portion.

Large intestine contains half a pint of similar fluid to that in small. Mucous membrane generally pale and of natural consistence and thickness. Mucous follicles distinct everywhere, and their orifices slightly open. No other remarkable appearance. Mesenteric glands not remarkable.

Stomach of a very peculiar shape; it suddenly becomes contracted at its middle part, and continues so as far as pylorus; pyloric half being reduced to calibre of duodenum, while the cardiac half is of natural size. No external redness, exudation, or other mark of irritation about contracted part.

Great pouch contains about two ounces semi-transparent, stringy, mucous-looking fluid, colored yellow with bile. Contracted portion nearly empty, with the mucous membrane thrown into strong longitudinal rugæ, the prominent edges of which show a bright-red vascular injection, the intervening spaces remaining pale. In uncontracted portion, the mucous membrane is thrown into irregular convolutions, the prominent edges of which are also red, but brownish in cœcal extremity. Mucous membrane very slightly softened. Œsophagus natural.

Liver natural in color and consistence. Gall bladder contains about one ounce of very dark bile.





Pancreas natural.

Spleen rather small, blue ; internally red, of natural consistence ; somewhat deficient in blood.

Both kidneys natural. Urinary bladder contains about one drachm of light-colored turbid fluid, and is much shrunken.

Uterus comes up exactly to level of umbilicus. It occupies almost the entire cavity of pelvis, the bladder being collapsed, the rectum empty, and the remainder of intestines above and behind it. It is pear-shaped, and inclined to the right side, so that full two thirds of the organ lie to the right of the median line. It has a dull reddish vascularity on external surface. Fluctuation of liquor amnii can readily be felt through walls of uterus, as also limbs and head of foetus. Uterus (with contents) measures, longitudinally, nine and a half inches ; transversely, six and a half inches. Cervix uteri (which is included in the above measurement,) one inch in length. Os uteri has a somewhat tumefied appearance, and a dark purplish color. Its substance is filled with follicles which are distended with a yellowish, glairy, tenacious secretion. Cavity of cervix filled with a similar secretion. Placenta is attached to about the centre of anterior uterine wall, only a little inclined to the left of the median line. Cavity of cervix uteri communicates with cavity of body by an opening, one eighth of an inch, or a little more, in diameter.

Internal surface of uterus moderately red and shaggy ; external surface of chorion, ditto. Chorion and amnion completely in contact.

Liquor amnii about fourteen ounces in amount, slightly turbid, of a yellowish color, neutral, and of a specific gravity (at 71° F.) 1010. Strongly albuminous.

Right ovary contains a corpus luteum, measuring half an inch through its short axis, and five sixteenths through its long. Nothing remarkable about other uterine appendages.



*Fœtus of Katharine Hurley. Examined next day, AUGUST 10.  
at 12 o'clock, M.*

Fœtus measures fourteen inches in length. Weight, with one inch of cord, three pounds and five and a half ounces.

Skin of a rosy hue, in some parts pale; sufficiently thick and tough; covered, over greater part of surface, with fine, white, short hairs.

Head covered with fine, dark hair, a quarter of an inch in length.

Nails distinct; reach nearly, but not quite, to ends of fingers.

Umbilicus situated one inch above pubes, and three quarters of an inch below middle point of body. Quite a thick layer of sebaceous matter on back.

Eyelids in contact; adhering, but easily separated.

Slight opacity of corneæ.

No pupillary membrane.

No rigor mortis.

Strongly marked, distinct, purple, "tiger-lily" spots of ecchymosis on internal surface of pericardium. Some, also, on each pleura, particularly along sides of spinal column. Ecchymosis.

Both ventricles of heart white, and well contracted, while the dark color of the blood shows through the thin walls of the auricles. All the cavities of heart contain dark coagula, of moderate consistency; also, the veins of the chest and neck.

Foramen of Botal, a quarter of an inch in diameter; can be completely covered, from left side, by valve.

Arterial duct appears like the continuation of the pulmonary trunk, while right and left pulmonary arteries seem to be only small branches.

Heart, natural internally.

Lungs of a dull reddish color, rather purplish posteriorly, smooth, but with interstices between



lobules distinctly apparent. Lungs sink in water. A very moderate inflation is sufficient to change color of whole lungs to a bright rosy red, to bring out vesicles, and to make lung so much lighter, that it will float on water, even with the other, uninflated, still attached to it.

Lung, thus inflated, can be compressed in hand without much difficulty, so as to become again heavier than water.

Tongue white. Caliciform papillæ large and distinct. Mucous follicles at base, visible, but very small. Filiform papillæ also distinct.

Superior borders of larynx of a bright vermillion color. Larynx, trachea, and bronchi, pale internally. Longitudinal fibres of bronchi well developed.

Peritoneum natural. Liver of a dark-red color; soft and grumous internally, like spleen. Lower border comes down to five eighths of an inch above umbilicus. Gall bladder comes nearly, but not quite, to anterior edge of liver; contains a few drops of thin brownish fluid, with small yellowish flocculi.

Stomach, pale internally; contains a small quantity of thin yellowish, flocculent fluid. No softening of mucous membrane.

Small intestine six and a half feet in length; contains a little light olive-colored substance, of same consistency as meconium. No valvulæ conniventes. Brunner's glands visible; also Peyer's patches, which are very distinct. Solitary glands not seen.

Large intestine fourteen inches in length; round and smooth, not marked by either longitudinal or transverse bands. It is distended with dark greenish, almost black, meconium, from ileo-cæcal valve to within seven eighths of an inch of anus. Appendix also full of meconium.

Kidneys lobulated; rather larger than supra-renal capsules, but the *length* of the two bodies is the same, viz., one and an eighth inches.

Urinary bladder, one and an eighth inches long; empty. Its cavity is not extended at all into urachus.



Uterus, three quarters of an inch in length, and nearly cylindrical. Lips of os uteri thin and sharp. Internally, arbor uterina extends nearly up to fundus uteri.

Upper part of vagina distended with a whitish, soft substance, in appearance much like half-congealed starch. Internal labia pudendi much developed, and project beyond the outer ones.

Three points of ossification in sternum.

Calcaneum has one point of ossification, well advanced.

Astragalus has one point of ossification, just commenced.

Axis has a point of ossification, well advanced, in body, and another in odontoid process.

Fœtus is therefore, probably, seven and a half months old.

---

## XVI.

MICHAEL DESMOND. Aged 27. Laborer. Irish. In-temperate. Cholera for 17½ hours, with three or four days previous diarrhœa. In Hospital seven hours. Emetic of capsicum and ipecac. Saline mixture, one ounce, and chloric ether, one drachm; every hour. Autopsy 9½ hours after death. AUGUST 12.

*Rigor mortis* well developed. Clubbed appearance of ends of fingers, with incurvation of nails and lividity. No œdema. No heat. Pupils equal, natural in size. Abdomen of natural form, tense, tympanitic.

*Head.* Dura-mater natural. A little bloody sub-arachnoid œdema over upper and anterior part of



right hemisphere. Slight bloody effusion in arachnoid cavity, farther back on left side. Arachnoid natural. Substance of brain also natural everywhere in color and consistence. A very little clear fluid in ventricles. Lining membrane pale. Medulla oblongata natural.

*Chest.* No dryness of pleuræ observable, owing to adhesions. Pericardium natural internally. Heart of good size, well contracted and firm. Right cavities almost completely filled with a firm fibrinous coagulum; contains also some dark coagulum and fluid blood. Yellowish coagula extend into veins of neck. Left cavities contain a moderate quantity of similar coagulum. Internally heart natural, except that one of aortic valves has a little thickening along semi-lunar ridges, not sufficient to interfere with its proper action. Substance of heart natural.

*Phthisis.*

Extensive and firm pleuritic adhesions at upper portions of both lungs. Lungs crepitate well everywhere on surface, but upper portion of each is filled internally with tubercular masses of various sizes, most of them unsoftened. There is one cavity at right apex, capable of containing half an ounce of fluid. The walls of this cavity are soft, and irregular, variegated grey and red. There is another cavity, about half the size of that first mentioned, at posterior part of upper left lobe; but this has a distinct, nearly healthy-looking lining membrane, and has the appearance of a dilated bronchus. No engorgement of posterior parts of lungs. No appearances of recent inflammatory action anywhere.

Larynx natural. Trachea and bronchi pale internally, and their surfaces covered with minute drops of clear fluid, having the appearance of being left after evaporation. Mucous membrane natural in texture, except for two tuberculous ulcers on posterior surface of trachea; the first situated immediately behind upper extremity of sternum, oval in shape, one quarter of an inch in its longest diameter. Mode-

*Tuberculous  
ulcers.*



rate tubercular deposite round edges of ulcer. The second is situated a little below the first, also on posterior surface, and is somewhat smaller. It is a smooth, roundish mass of deposite, with ulceration just commenced on prominent part. No inflammatory appearances in neighborhood of either ulcer.

The larger part of each lung is still in a healthy and serviceable condition.

*Abdomen.* A very little of the sticky secretion on peritoneum, between intestinal convolutions. Intestines of a natural color externally, considerably distended.

Numerous small, hard, tubercular deposites in peritoneum of mesentery, most abundant as we approach ileo-cæcal valve. There are also a very few on surface of small intestine; a considerable number on left side of abdomen, behind spleen and along spine; and cavity of pelvis is completely lined with them, whole of peritoneal surface being speckled with small, hard, white, cartilaginous, or fibrinous-looking masses. Those on mesentery are generally white, but a few of them are red.

Tubercular  
disease of  
Peritoneum.

No fluid in peritoneal cavity, or other sign of inflammatory action.

Small intestines contain one half pint, of thin, dingy, light-colored fluid, with large abundant flocculi, of a wood-brown color. Mucous membrane of duodenum very pale and greyish, with a look as if it had been macerated for a considerable time in water. Below this, mucous membrane pale but of natural appearance; moderately reddened in lower part of ileum, everywhere somewhat softened, but not actually disorganized. Twenty-four Peyer's patches counted, none of them excessively developed. Villi visible in all parts of intestine. Redness in ileum in this instance is not seated in villi, but these are distinctly seen of a white color, on a red ground. No other remarkable appearance in small intestine.

Large intestines contain one pint of fluid, similar



## Ulcers.

to that in small, only rather deeper colored. Mucous membrane pale throughout. Mucous follicles visible, natural in lower part. Cæcum and upper part of colon have a considerable number of small irregular ulcers, with abrupt edges, many having penetrated the whole thickness of mucous membrane. These ulcers have no appearance of tubercular deposit about them. Many are elongated transversely to axis of intestine, occupying the free edge of a transverse fold of mucous membrane. No redness about ulcers. Appendix cæci has also many similar ulcers on mucous surface, and toward cæcal extremity a small, oval, prominent collection of pus, which has not yet escaped from beneath mucous membrane.

Stomach contains one pint and a half of fluid, thinner than that in intestines; otherwise similar. Moderate softening of mucous membrane, with brown discoloration of blood.

Mesenteric glands a little enlarged and yellowish, but not tuberculous.

Liver large and smooth, with a lardaceous feel and rounded anterior edge; rather pale. No fat extracted by heat. Consistence about natural. Gall bladder contains half an ounce of dark, thin bile. Common duct large, and filled with same. Ducts in interior of liver yield thin yellow bile by pressure.

Lymph on  
Spleen.

Pancreas natural. Spleen of natural size, smooth, and firm; natural internally; posterior surface smeared with softish lymph, easily removable.

Degenera-  
tion of kid-  
neys.

Both kidneys of full size, rather pale, of a lardaceous feel, like the liver, and decidedly morbid in appearance. Very slightly nodulated on surface. They are not flabby, but have a peculiar *clumsy* feel, similar to that of india rubber. Internally cortical portion abundant, pale, and with a confused, degenerated appearance. Tubular portion natural. Lining membrane of pelves pale. A few minute, globular, tuberculous looking masses scattered through substance of kidney.



Urinary bladder contains two ounces of thin, yellowish, flocculent fluid, with all the gross appearances of urine; highly albuminous. Abdominal vessels natural internally.

Albuminous  
Urine.

## XVII.

MARGARET BURKE. Aged 30. Irish. Intemperate. AUGUST 13

*Cholera 17 hours, with one day's previous diarrhœa. In Hospital two hours. Much lividity. Bled to ten ounces, and ordered saline mixture every fifteen minutes. An hour and a half afterward patient rose from bed, drank half a pint of water, and almost immediately expired. Autopsy 13 hours after death.*

*Rigor mortis firm. Much lividity and shrivelling of fingers. Well-marked lividity also of face. Abdomen rather prominent. Pupils equal, a little dilated.*

*Muscles red.*

*Blood exceedingly fluid; trifling soft coagula in heart being the only ones found.*

*Head.* Dura-mater exceedingly adherent to skull. A very little clear serous fluid, not at all bloody, in arachnoid cavity, most on right side. Moderate sub-arachnoid œdema. A drachm or two of clear fluid also in ventricles. Substance of brain and cerebellum every way natural. Lining membrane of ventricles pale, but vein running along inner border of choroid plexus is turgid with blood. Medulla oblongata natural.

*Chest.* Dryness of pleura well-marked on left side, doubtful on right. Pericardium natural internally, but empty: contains not more than five or six



drops of fluid. Heart much loaded with fat, but left ventricle well contracted. Cavities contain a considerable quantity of very fluid, dark blood, of moderate consistence. Internal surface of right auricle stained of a dark purplish-red, but other cavities are of natural color and appearance. Consistence of heart natural; valves, &c. healthy.

Both lungs have a remarkably full, healthy appearance. They collapse but little, crepitate perfectly everywhere, and are throughout of natural consistence. Color light-grey, mottled with red and black. Absolutely no sanguineous congestion, lower and posterior parts being, in fact, lighter colored and dryer than upper. They contain little blood, but a sufficient quantity of fluid. A minute round, smooth, encysted, calculous concretion just underneath pleura, at right apex. No other morbid deposit.

Larynx natural. Trachea pale internally; contains a little frothy fluid. Bronchi also pale generally, except those distributed to left apex, which are very slightly reddened. Thickness and consistency of mucous membrane unaltered.

*Abdomen.* Peritoneum natural. No sticky secretion visible, but intestines have a slimy feel. Drops of oil exude from peritoneal surface of liver, stomach, and small intestines, and reappear after they have been wiped away; most abundant on liver.

Small intestines of a light rosy hue externally; contain about two pints of thickish, grey, gruelly fluid. Mucous membrane generally pale or light-rosy, with very moderate redness in lower part. Peyer's patches visible to number of twenty; none of them remarkably developed. Solitary glands visible, somewhat enlarged, near ileo-cæcal valve. Mucous membrane natural in thickness and consistence. No bile in duodenum. Large intestines contain half a pint of fluid, similar to that in small. No evident morbid alteration of mucous membrane.

Stomach contains one pint of rather thin, dingy



fluid. Mucous membrane moderately thinned and softened in cœcal extremity, and slightly brownish over most of surface; otherwise natural.

Esophagus natural.

Mesenteric glands not remarkable.

Liver mottled red and yellowish externally; internally, of natural color, rather soft; ducts contain a little yellow bile.

Gall bladder contains about half an ounce of thin, dark-brownish bile. Common duct rather collapsed; contains bile similar to that in bladder.

Pancreas natural.

Spleen not much enlarged, but full of blood; tense and elastic, like india rubber.

Kidneys small and flabby; of a dark-red color, natural in consistence.

Urinary bladder empty, excepting a little puriform secretion.

Both ovaries contain serous cysts of various sizes. One has, beside, a cyst, containing a brownish, old-looking coagulum. Old adhesions of right ovary to portion of wall of pelvis and of oviduct to ovary. Left oviduct free. Uterus somewhat reddened and softened internally, but reddened part can easily be scraped away, leaving internal surface smooth and pale.



## XVIII.

AUGUST 15. JOHN McCARTY. Aged 20. Temperate. Cholera for three days. Secondary fever for one week. Treatment; at first, chlorate of potass, chloric ether, and hot brandy and water, ad libitum. After reaction, effervescing drinks, and finally wine and quinine. Autopsy about 20 hours after death.

*Rigor mortis* moderate. Some lividity of fingers, but no marked shrivelling. Body and limbs everywhere cool. Much dark brown sordes about teeth and lips. Strong smell about body, like that of rabbits' urine. Muscles rather soft, mostly red.

Spinal cord (examined first.)

Softening of  
cord.

Considerable bloody œdema of cellular tissue in interior of spinal canal, along sides of cord, in dorsal and lumbar regions. None in cervical. Considerable, but not excessive, quantity of clear fluid in cavity of sheath. No undue vascularity about sheath, or cord, in any part. Cord everywhere of natural form and color, both internally and externally; but there is decided softening of cervical enlargement, though not enough to destroy texture. Dorsal portion very slightly softened; lumbar, quite firm and healthy. Nothing else remarkable.

*Head.* Dura-mater natural. Moderate quantity of red coagulum in longitudinal sinus. Arachnoid natural; no effusion. Substance of brain everywhere of natural firmness and color, unless cortical portion is rather pale. A little clear fluid in ventricles. Lining membrane pale. Medulla oblongata quite natural.

*Emphysema.*

*Chest.* No dryness of pleura. Considerable emphysema of cellular and adipose tissue about anterior mediastinum. Pericardium natural internally;



contains from three to four drachms of fluid. Heart rather pale; contains almost no blood, but what there is, has due proportion of coagulum. Right ventricle moderately distended, principally with air; contains also, together with auricle and adjacent veins, a small quantity of dark red coagulum, with a little fluid blood. Air in heart.

Left ventricle relaxed, and empty. Left auricle contains a little blood, as on right side. Aorta contains some dark red coagulum. Lining membrane of heart rather dusky, but not actually stained. Substance of heart, valves, &c., natural. Blood also deficient, in amount, in all parts of the body.

Lungs natural in appearance, anteriorly; rather darker, posteriorly. They generally crepitate sufficiently well, but there is a spot of hepatization at lower part of right upper lobe posteriorly, and another at upper part of left lower lobe, also posteriorly. Pneumonia. Solidified portions each occupy a space of about five to six cubic inches. At these points the lung is full and smooth externally, without crepitation, and has a dense, resisting feel. Excised portions of it sink rapidly in water. Cut surface has a deeper red color than surrounding healthy parts, with a granular appearance, and a texture something like that of liver. Not much fluid exudes. Hepatized portions sufficiently well defined.

Left cavity of pleura contains five and a half ounces of dark brownish, dingy, thin fluid, with a disagreeable odor. Effusion. Right cavity contains rather less of a similar fluid. A little soft, greenish-yellow lymph, smeared over costal pleuræ, at each apex.

On each pulmonary pleura, directly over hepatized portions of lung, there is an appearance as if fine sand had been sprinkled over the membrane, which is owing to the deposit of numerous small crystals of ammonio-magnesian phosphate upon the surface of pleura, giving it a finely granular, gritty feel to fingers. Crystalline  
deposit on  
pleura.



Larynx, trachea, and bronchi, of a dark, dusky hue internally. Mucous membrane otherwise natural.

*Abdomen.* Peritoneum natural; contains no fluid. Small intestines of a very dark leaden color externally; contain a moderate quantity of thin, pasty, greenish substance, which grows more yellowish as we go downward, and finally becomes dark brown in lower part of ileum. Twelve Peyer's patches counted, nearly or quite natural in appearance, but below this their places are occupied by oval or irregularly circular ulcers, varying in size from a quarter of an inch diameter downward, with thick, rounded, swollen edges, and for most part penetrating quite through thickness of mucous membrane. The first three of these ulcers are distinctly seen to be situated in the substance of swollen Peyer's patches; but below this, structure of patches is no longer recognizable at ulcerated points. Two of the ulcers are covered on their surface with roundish, red and yellow, granular coagula, which project into cavity of intestines, and can be separated from ulcer without much difficulty.

*Ulcers.*

The ulcers in all are fourteen in number, and are entirely confined to lower two feet of ileum.

Mucous membrane generally of natural thickness and consistence; stained dull greenish, yellowish, or brown, according to color of contents in different parts. Solitary glands visible in lower part of ileum, not altered.

*Redness of intestine.*

Large intestine contains a considerable quantity of consistent, dark brown, thick, pasty, homogeneous substance, like altered blood. Mucous membrane much reddened in upper third, where there are also a few small, purple, circular spots of ecchymosis in its substance. In lower two thirds, mucous membrane paler, and mucous follicles moderately enlarged, with their openings marked by a black speck. No other morbid appearance.

Mesenteric glands generally enlarged, red, and somewhat soft.



Stomach contains about one ounce of a yellowish fluid. Mucous membrane discolored, of a strong slaty-brown, in cæcal extremity, but without any marked thinning or softening. Very remarkable appearance of œsophagus, mucous membrane of which is entirely destroyed in lower half, by irregular cor-  
Corrosion of  
œsophagus.  
 roding ulcers, except a narrow strip on one side of the tube, which remains healthy. Healthy and ulcerated parts covered with a rather tough, opaque, yellow, flaky exudation, removable without much difficulty. Ulcers penetrate, at many points, quite through mucous membrane, and have much the aspect of corrosions. No ecchymosis, but some reddening of parts.

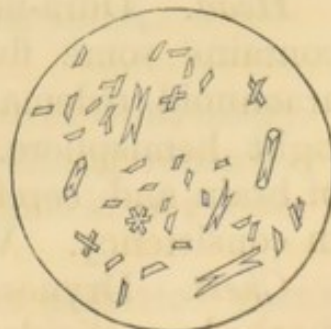Liver natural in color, somewhat soft. Gall bladder contains about two ounces of thin, dark bile.

Pancreas natural. Spleen large and full; rather heavy. Internally natural, with normal amount of blood, or a little more.

Both kidneys large, pale, and flabby, without any other morbid alteration. Urinary bladder contains from one and a half to two pints of clear, light colored urine. Mucous membrane very pale, as if macerated.

The crystals of ammonio-magnesian phosphate, adhering to the pleura, could not be distinctly recognized as such by direct examination under the microscope, owing to their being somewhat enveloped in lymph. They were insoluble in distilled water, but soluble in dilute acetic acid, and were precipitated from this solution by ammonia, in minute crystals of the following form:—

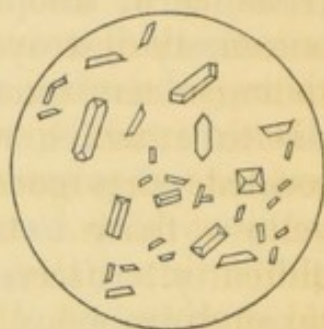
Fig. 9.





The fluid taken from the left chest was moderately alkaline, with a specific gravity (at 80° F.) of 1026, and strongly albuminous, as to become opaque, and nearly solid by heat. Under the microscope it contained an abundance of well defined crystals of triple phosphate, varying in size, as follows:—

Fig. 10.



## XIX.

AUGUST 18. CALVIN CASTLEMAN. Aged 21. *Intemperate. Cholera for 15 hours, without previous illness. In Hospital seven hours. Venesection to 16 ounces. Sinapisms, external heat, and saline mixture with six grains of carbonate of ammonia, every half hour. Cold bath. Death half an hour after cold bath. Autopsy 16½ hours after death.*

*Rigor mortis* very strong. Much shrivelling and blueness of fingers. No heat about body.

*Head.* Dura-mater natural. Longitudinal sinus contains some fluid blood. A little bloody sub-arachnoid œdema at anterior and superior part of right hemisphere. Arachnoid natural. Substance of brain and cerebellum little, or not at all, altered in consistency. Vascularity normal.

*Chest.* Dryness of pleura over pericardium well marked, particularly on right side. Pericardium natural internally. No ecchymoses. Right cavities



contain a moderate quantity of thick, dark, sticky blood, with coagula similar in appearance and consistence to black currant jam. Lining membrane stained of a dark purple, as also that of veins up as far as neck, and throughout chest. Left cavities contain similar blood to that on right side. Heart otherwise natural.

Staining of heart, &c.

Both lungs crepitate well everywhere. Very moderate engorgement of posterior parts. No deficiency of fluids. Larynx, trachea and bronchi dark-colored internally, but mucous membrane smooth and shining. A thickish, opaline secretion can be expressed from tracheal glandules, a clearer one from bronchial.

Nothing else remarkable about chest.

*Abdomen.* Peritoneum natural. Small intestine contains about two pints of thickish, yellowish-grey, flocculent fluid, without remarkable odor, slightly alkaline; also five lumbrici, most of them alive, the largest ten and five-eighth inches in length. Mucous membrane almost universally pale, and in some parts decidedly thinned, so that muscular fibres can be distinctly seen through it. Mucous membrane also perceptibly softened throughout. Twenty-five Peyer's patches counted, all of them somewhat swollen and softened. Solitary glands moderately enlarged in lower six feet of intestine.

Lumbrici.

Thinning of mucous membrane.

Large intestine contains one pint and a half of thin, grey, flocculent fluid, and thirteen cherry-stones. Mucous membrane pale, of natural thickness and consistence. Mucous follicles everywhere visible, their orifices being marked by a black speck.

Cherry-stones.

Mesenteric glands natural.

Stomach contains about one pint of thin, dingy, semi-transparent, neutral fluid. Nothing remarkable about mucous membrane of stomach or œsophagus.

Liver decidedly soft, especially at posterior part of left lobe; everywhere very dark-colored, owing to staining of hepatic veins with the coloring matter of

Staining of veins.



the blood. Ducts in interior contain an abundance of greenish bile. Gall bladder and common duct contain a moderate quantity of dark, rather thin bile.

Pancreas somewhat dark-colored, from the staining of veins, as in liver.

Spleen rather small ; otherwise not remarkable.

Both kidneys pale and flabby. Renal veins stained, as the others. Urinary bladder contains from one and a half to two drachms of thin, light-colored, flocculent fluid, without any aspect of urine.

The fluid taken from the large intestines in this case, was examined for urea, without affording any trace of that substance. It contained an abundance of oil, and while evaporating gave off a strong odor of gluten. It was very moderately albuminous.

---

## XX.

AUGUST 21. ELLEN BARRETT. *Aged 30. Widow. Irish. Intemperate. Cholera for 10½ hours, without previous illness. In Hospital 8¾ hours. Thorough collapse at entrance. Treatment—Sulphate of Quinine, five grains every half hour, for four hours ; afterward ten grains every 15 minutes. Autopsy 13 hours after death.*

*Rigor mortis* natural. Shrivelling and lividity of fingers well marked. Pupils equal, natural. No remarkable heat about body. Abdomen rather full, but lax ; moderately resonant. Numerous scars of pregnancy.

Mammæ sufficiently full. A moderate quantity of



normal-looking milk can be expressed in jets from each nipple. Muscles red.

*Head.* Dura-mater natural. Some coagulum in longitudinal sinus. Some bloody fluid (or fluid blood) smeared over posterior and superior part of left hemisphere. A very little also on right side. Arachnoid quite healthy. No other unnatural appearance about any part of brain or membranes, except a moderate quantity, perhaps one and a half drachms of clear fluid in lateral ventricles.

*Chest.* Dryness of pleura well marked on left side, over pericardium. No fluid in pericardium, or only just enough to lubricate surfaces. Unusually large white spot on anterior surface of right ventricle; also a few small circular spots, similar in structure, on posterior aspect of ditto. Pericardium otherwise natural.

Right cavities of heart, as well as adjacent veins, considerably distended with dark, thick blood, and blackish, jelly-like coagula; left ventricle somewhat, but not perfectly contracted; nearly empty. Left auricle contains a considerable amount of blood, similar to that on right side. Lining membrane, valves, and substance of heart natural.

Both lungs crepitate well everywhere. Left quite light and healthy in appearance. Right rather more purplish and engorged, (as if from patient's lying on right side,) but nowhere altered in texture. No tubercles.

Trachea and bronchi quite pale internally; contain a little frothy fluid.

*Abdomen.* A little sticky feel to intestinal peritoneum. Peritoneal surface of mesentery presents numerous small spots of short reddish *tufts*, as if the products of old inflammatory effusion, become organized and engorged with blood. The whole inner surface of the pelvis, also, presents an abundance of these tufts, which, in this situation are colored, not red, but dark brown. Upper and posterior surface

Old  
Peritonitis.



of spleen also presents a few spots of somewhat old lymphatic deposite, but not colored.

Small intestines light colored and fair externally ; contain about three pints thin, yellowish, flocculent, neutral fluid, without remarkable odor. Mucous membrane universally pale, excepting some brownish discoloration of duodenum ; everywhere of natural thickness and consistence. Twenty-five Peyer's patches counted, most of which are slightly swollen and opaque. *The lower seven, however, are entirely free from alteration.* Solitary glands not visible.

Large intestine contains two and a half pints of thin, grey, flocculent, neutral fluid, without odor ; and some half-digested bits of food. Mucous membrane pale, and not altered. Mucous follicles just visible in cœcum.

Mesenteric glands natural.

Stomach contains about six ounces of thin, dingy, semi-transparent, slightly acid fluid, and a considerable quantity of undigested bits of potato, quite recognizable. Mucous membrane moderately softened and thinned in cœcal extremity ; not otherwise remarkable.

Liver natural externally ; rather dusky colored internally. Yellowish bile flows readily from ducts interior. Consistence of organ natural.

Gall bladder contains about one ounce of quite dark, rather thin bile.

Pancreas natural. Spleen nearly of natural size, but flabby and wrinkled on surface. Internally rather dry ; otherwise natural.

Left kidney somewhat dark-colored internally. Right paler. They are both flabby, and afford an abundance of puriform fluid from papillæ, by pressure. Nothing else remarkable.

Urinary bladder quite contracted and empty ; only smeared with the puriform fluid. Internal surface natural.

Blood everywhere of same character as in heart. No staining of lining membrane of vessels.



Uterus somewhat tumefied and reddened internally, and right ovary contains a somewhat recent corpus luteum, from which the blood has not yet been entirely absorbed.

## XXI.

JOSEPH COOLEGE. Aged 29. Intemperate. Cholera AUGUST 22.  
*for one day. (Only a few hours previous diarrhœa.)*  
*Afterward delirium (tremens?) for five days. Treat-*  
*ment—at first saline mixture; then valerian and*  
*chloric ether; and during the last day of life bran-*  
*dy and water every three hours. Autopsy 16 hours*  
*after death.*

*Rigor mortis* well established. Considerable lividity of ends of fingers, but no shrivelling. Pupils equal, natural. No remarkable heat about body. Abdomen natural in form, moderately resonant.

Muscles red.

*Head.* Dura-mater natural. Longitudinal sinus empty. A very little clear fluid over both hemispheres in arachnoid cavity. Much sub-arachnoid œdema everywhere; in three or four small spots bloody. Arachnoid healthy in appearance. Substance of brain everywhere of natural vascularity; a little firmer than usual. Effusion in Arachnoid.

Lateral ventricles filled with clear serous fluid. Lining membrane not vascular, but otherwise presents a very remarkable appearance. All over both corpora striata, and on floor and roof of both posterior cornua, there is an abundance of thickly-set, minute, roundish, colorless, shining prominences, like small, bloodless granulations, of same consistence as Brain firm.  
Granulation and ulceration of ventricular membrane.



cerebral substance. On each side of septum lucidum there are some of these granulations, and also several roundish, and irregular abrasions or ulcerations, very shallow, and without any induration or redness of base. The surface of most of these abrasions is smooth; that of some of them set with granulations. No granulations on surface of optic thalami, but they are abundant on floor of fourth ventricle, at its lower extremity. No abrasions except on septum lucidum. No remarkable appearance at base of brain, except that pia-mater adheres with somewhat unusual tenacity. Medulla oblongata firm; natural in appearance.

*Chest.* Dryness of pleura very well marked, over and about pericardium. Well marked, broad, white spot on posterior aspect of right ventricle; another, smaller and thinner, on anterior surface of left ventricle. Several others, small but quite opaque and well defined, on internal surface of pericardium, over right auricle. Pericardium otherwise healthy; contains hardly half a drachm of clear fluid.

Right cavities of heart moderately full of dark fluid blood, and soft, jelly-like coagula. Left ventricle, not at all contracted, but quite collapsed and flabby; contains, with auricle, a moderate quantity of blood, similar to that on right side. No staining of endocardium. Valves all healthy, except aortic; these present each a decided thickening along festooned borders of fibrous portion, and aurantian corpuscles are hypertrophied to five or six times their natural size. Cavities of heart of natural size, and substance healthy.

Both lungs of a very light mottled-grey anteriorly; posteriorly, moderately engorged with blood; crepitate well everywhere, but collapse rather more than ordinary. Structure natural. No tubercle. Larynx, trachea, and bronchi natural internally, except that lower ramifications of the bronchi, on both sides, are somewhat stained with the coloring matter of the blood.



*Abdomen.* Peritoneum natural. Small intestines light-greyish externally. Upper part contains a moderate quantity of rather thin, green, bilious matter; this becomes thicker as we go downward, and alters in color; first to yellow, then to brownish. Mucous membrane rather thin, otherwise natural; stained throughout nearly upper half with bile. No vascularity. Peyer's patches visible, but not altered. Solitary glands, the same.

Large intestine contains pasty yellowish fæces; at one spot, about commencement of lower third of intestine, stained with blood; elsewhere, natural. Mucous follicles generally visible; natural.

Mesenteric glands natural.

Stomach contains an ounce or two of dingy, slightly yellowish fluid; presents nothing remarkable, except that mucous membrane is stained with bile in cæcal extremity; of natural color toward pylorus.

Œsophagus natural internally; contains, about six inches above cardiac orifice, a tortoise-shell ring; (which patient had worn, and probably swallowed in last hours of life.) The ring is enveloped in a greyish, stringy, moderately tough exudation, but there is no other mark of irritation of mucous membrane in neighborhood.

Liver natural in appearance; contains bile in ducts. Kidneys sufficiently firm, and well supplied with blood. Urinary bladder contains about three ounces of turbid urine, moderately coagulable by <sup>Albuminous</sup> nitric acid. <sub>urine.</sub>

Other abdominal organs not remarkable.



## XXII.

AUGUST 23. CATHARINE McCARTY. Aged 30. Married. Irish. Intemperate. Cholera 96 hours. In Hospital eight hours. Treatment—Emetic of ipecac: and magnesia; afterward, chlorate of potass ten grains, with bicarbonate of soda, half a drachm every hour. Autopsy  $7\frac{1}{2}$  hours after death.

*Rigor mortis* natural. Some heat about chest and abdomen; none elsewhere. Blueness and shrivelling of fingers well marked. Pupils equal, slightly dilated. Countenance natural.

*Head.* Longitudinal sinus empty. Arachnoid quite natural, and no effusion into its cavity, or beneath it. Substance of brain everywhere unaltered. Moderate amount of clear fluid (half a drachm?) in lateral ventricles. No vascularity. Medulla oblongata natural.

*Chest.* Dryness of pleura sufficiently well marked, but not excessive. Pericardium natural internally; contains about one drachm, or less, of clear fluid; Right cavities of heart, moderately full of dark fluid blood, quite thick and tarry, with insignificant amount of coagula. Left ventricle perfectly firm, well contracted, and empty. Left auricle contains blood as on right side. Lining membrane, valves, and substance of heart healthy, excepting a trifling amount of cartilaginous deposite on one of the aortic valves.

Blood generally thick and tarry, and without coagula; but no staining of vessels noticed.

Both lungs crepitate pretty well everywhere, but collapse much, and have something of a dry, leathery feel; rather deficient in fluids; no tubercle; but just at anterior part of lower edge of left lower lobe there is an irregularly roundish, hard, light-colored, encysted calculus, about three eighths of an inch in diam-

Concretion.



eter. Pulmonary tissue in neighborhood unaltered. Larynx, trachea, and bronchi pale internally; contain a little frothy fluid; no particular morbid appearance.

*Abdomen.* Peritoneum dryish at upper and anterior part. Some roughness of peritoneal surface of intestines, and a perceptible amount of sticky, slimy secretion. Peritoneum otherwise natural.

Small intestines contain two pints of rather thickish, flocculent, bright yellow fluid, with distinct alkaline reaction, but no remarkable odor. Internally, intestines pale, with some yellowish staining at upper part of duodenum. Slight reddish discoloration in one or two spots below. Mucous membrane everywhere of natural thickness and consistence. A few Peyer's patches moderately swollen and opaque; otherwise natural. Solitary glands more than usually developed in lower foot and a half of ileum. Nothing else remarkable.

Large intestine contains one pint of greyish, flocculent fluid, having an odor and appearance like that of soap and water. Reaction moderately alkaline. Mucous follicles everywhere considerably developed. Mucous membrane pale and natural.

Mesenteric glands somewhat enlarged and yellowish in color. Stomach contains about five ounces of dingy, alkaline fluid. Moderate softening of mucous membrane, without any other remarkable appearance.

Esophagus natural.

Liver of natural color and appearance; sufficiently well supplied with blood. Green bile can readily be expressed from ducts in interior of organ.

Gall bladder contains a moderate quantity of dark, thickish bile.

Spleen rather small, blue and wrinkled; internally, not remarkable. Pancreas natural.

Kidneys rather dark-colored, sufficiently large, somewhat flabby; firm in texture. Papillæ afford an unusual amount of puriform fluid on pressure.



Urinary bladder contracted; contains only a little puriform secretion.

Menstruation present.

Uterus somewhat tumefied, and together with vagina and external organs shows a considerable amount of menstrual fluid, which is smeared over labia and walls of vagina, and mixed with the mucus which fills the os uteri.

Left ovary contains a false corpus luteum, half an inch in diameter.

---

### XXIII.

AUGUST 26. BRIDGET BLACK. Aged 38. Married. Irish. Cholera 42 hours. In Hospital 14 hours. Saline treatment, with external heat. Autopsy 6½ hours after death.

*Rigor mortis* natural. Blueness and shrivelling of fingers moderate. Some turgidity of superficial veins in neck. Muscles of natural color.

*Head.* Longitudinal sinus empty. Thickish bloody fluid smeared over posterior part of left hemisphere, in most dependent situation. None elsewhere. Arachnoid natural. No effusion other than that mentioned. Lateral ventricles contain a very moderate quantity of clear serum. Color and consistence of brain everywhere natural.

Medulla oblongata natural.

*Chest.* Dryness of pleura distinct, but not excessive. Sticky secretion, also, on pleura, in minute quantity, similar to that on peritoneum. Pericardium empty of fluid. Distinct, irregular, sharply defined, white spot, on anterior aspect of right ventricle; also others, similar in appearance, but smaller,



on internal surface of pericardium. A few minute spots of ecchymosis on free edge of right ventricle. Pericardium otherwise natural.

Right cavities of heart moderately filled with dark, thick blood, with loose, jelly-like coagula, and some firm, stringy, yellowish clots, entangled among tendinous cords. Left ventricle moderately well contracted, nearly empty. Left auricle contains dark blood, with jelly-like coagula. One of the aortic valves has a prominent, well defined, cartilaginous thickening, in the form of a double festoon, arranged in a transverse direction. Interior and substance of heart otherwise natural.

Both lungs crepitate everywhere, but collapse rather more than natural. No alterations in texture, except one or two small concretions at left apex.

Larynx, trachea, and bronchi, pale and natural in appearance.

*Abdomen.* Peritoneum of intestines moderately smeared with slimy secretion; otherwise natural.

Small intestines contain from three to four pints of yellow, bilious-looking, flocculent fluid. That in duodenum is of a bright yellow, and evidently bilious. Mucous membrane of a dull red color in some spots, apparently from settling of blood in dependent parts of convolutions; thickness and consistence not altered. Several Peyer's patches, toward lower part of intestine, moderately swollen and opaque; others quite natural. Solitary glands not remarkable.

Large intestine nearly empty; contains only a very little thin, yellowish, flocculent fæces. Mucous membrane pale and natural. Mucous follicles visible, and not remarkably altered.

Mesenteric glands somewhat enlarged, but not reddened or softened.

Stomach contains nearly one pint of dingy, greenish, bilious-looking fluid. Mucous membrane very moderately softened; not otherwise altered.

Pancreas natural. Spleen of natural size, flabby and wrinkled. Internally, rather deficient in blood,



Liver of its ordinary reddish-yellow color, internally and externally. Ducts stained bright yellow, but do not yield much bile on pressure.

Gall bladder contains about one and a half ounces of dark, thin bile.

Horse-shoe  
kidney

Kidneys connected with each other on median line, at their lower extremities, by a band of corticle substance. Band about one inch broad on median line, and of proportionate thickness. It is constricted just at its middle, and here several fibres of the sympathetic nerve pass in front of it downward toward pelvis. The two kidneys have separate pelves and ureters, the latter of which pass downward in front of kidneys, in company with the uterine veins. Internally, kidneys not remarkably altered in structure. Lining membrane of pelves smeared with a creamy secretion. Urinary bladder contracted and empty; walls smeared with the same creamy secretion.

Uterus retroverted, so that its fundus is directed downward and backward. Posterior parietes somewhat reddened and soft, but organ otherwise unaltered. Internal surface pale. A very little stringy, uncolored secretion in cervix.

Both ovaries healthy in appearance; contain only serous cysts.

Abdominal vessels natural internally. No staining anywhere. Blood generally thick, and very deficient in coagulum.



## XXIV.

MARY O'NEIL. Aged 57. Married. Temperate. AUGUST 28.  
*Cholera 24 hours. No previous diarrhœa. In Hospital 11½ hours. Treatment; 80 grains of calomel in divided doses. Carbonate of ammonia, five grains, every 15 minutes. Autopsy 15 hours after death.*

*Rigor mortis* very moderate. Excessive lividity and shrivelling of fingers; none of importance elsewhere. Abdomen of natural form, rather resonant. No heat about body or limbs. Muscles red.

*Head.* Dura-mater natural. Longitudinal sinus full of dark colored fluid blood and gelatinous coagula. Some effusion of serum in cavity of arachnoid: no blood. Decided sanguineous congestion of superficial parts of brain, but, internally, amount of blood natural. Considerable amount of serous effusion also into ventricles, sufficient to produce fluctuation, but not enough to distend ventricular parietes. Moderate softening of central parts, particularly of fornix. Cerebellum also a little softened. Encephalon otherwise natural.

*Chest.* Pericardium natural internally; contains about half an ounce of clear serum. Right cavities of heart, particularly auricle, as well as venæ cavæ and internal jugulars distended by a very dark, tolerably consistent coagulum, with a small portion colorless, and a very little fluid blood. Left ventricle relaxed; contains a little dark, fluid blood. Left auricle contains dark fluid blood, with gelatinous coagula. Lining membrane, valves, and substance of heart natural.

Both lungs have extensive, moderately firm, cellular, pleuritic adhesions. They crepitate tolerably well except just at lower edge of right lower



lobe. Here crepitation is very deficient, and texture of lung redder and more compact than natural, but not at all softened. The intimate structure does not seem altered. Excised pieces float in water. The unnatural appearance is apparently owing to confinement by adhesions. Lungs otherwise quite natural.

Larynx and trachea pale internally, covered with small drops of thickish, semi-transparent secretion from laryngeal and tracheal glandules. Bronchi pale, except that going to right lower lobe; this is somewhat reddened, and contains a little puriform secretion.

No other abnormal appearance about lungs.

*Abdomen.* No slimy secretion over greater part of intestinal convolutions, but a very little in some spots. Small intestines, light greyish-red externally; moderately distended with air, but nearly empty of fluid. They contain not more than six ounces of thickish, flocculent fluid, of a dull red color, (as if from the admixture of red paint, and with a moderately alkaline reaction. Mucous membrane generally pale, stained yellow in duodenum. In upper part of duodenum, some injection of vessels of mucous membrane; in one or two spots, an approach to ecchymosis. Eighteen Peyer's patches counted, all slightly swollen and opaque, but not otherwise altered. Solitary and duodenal glands natural.

*Congestion.*

*Deficiency  
of mucous  
membrane.*

Large intestine contains about twelve ounces of reddish-brown, gruelly fluid, moderately alkaline, with slight fecal odor. Mucous membrane pale, but presents, over greater part of its extent, an appearance of "deficiency," as in the case of *Ellen Keith*. As in her case, also, it seems most marked immediately round mucous follicles, as in scraping up mucous membrane, (which is very easily accomplished,) the follicles are often left adhering to the cellular coat. Mesenteric glands not remarkable.

Stomach contains rather more than one pint of a dingy, green, bilious fluid, neutral in reaction, with



an odor of fermenting beer. There is also a considerable quantity (one scruple?) of heavy, dark, slate-colored powder, like the sediment of black wash, resting on mucous membrane, but not strongly adhering to it. There is a little of it toward pylorus, quite white, and like calomel in its physical properties. Calomel in Stomach. Mucous membrane considerably thinned and gelatinized over surface of posterior wall, but otherwise not remarkable. Œsophagus natural.

Liver stained dark slate color on under surface, elsewhere reddish-yellow, externally and internally. Ducts stained bright yellow, and yield a moderate quantity of greenish bile, by pressure.

Gall bladder pale and much atrophied, and contracted round a gall-stone which occupies its cavity Calculus. toward outlet. Cystic duct quite impervious. Gall bladder contains, beside calculus, about half a drachm of turbid, yellowish-white fluid, rather thinner than bile.

Hepatic duct hypertrophied to five or six times its natural size.

The calculus is irregularly ovoid in shape, five eighths of an inch in its largest diameter, and covered with ridges of transparent, tubular crystals, arranged with their broad faces opposed to each other, so as to form long blocks, or ridges.

Pancreas natural. Pancreatic fluid, clear, distinctly acid in reaction, can be expressed from duct.

Spleen quite small, flabby, and deficient in blood.

Kidneys firm in texture, and moderately supplied with blood. Fluid expressed from papillæ, not thick and creamy, but reddish and semi-transparent. Urinary bladder contracted, empty; and smeared internally with a little creamy fluid.

Both ovaries atrophied to a few small, firm, cartilaginous nodules, connected by a little reddish tissue. Uterus considerably enlarged, by reason of three rounded fibrous tumors, which occupy its walls. Fibrous tumors of Uterus. Two of them, on the right side and posteriorly, are about the size of walnuts. The third is



four or five times as large, and projects into cavity of uterus, covered only by mucous membrane, while the muscular fibres of the uterus are spread out over its body.

Lining membrane of uterus considerably reddened, but not otherwise altered. Cavity of cervix occupied by two small, softish, purple, pedunculated polypi. Os uteri and vagina natural.

---

## XXV.

AUGUST 31. MARGARET INCH. Aged 31. Married. Irish. Intemperate. Cholera 28 hours, without previous diarrhœa. In Hospital eight hours. Cramps very severe. Venesection to six ounces, which produced syncope; afterward to three ounces. Saline mixture every 15 minutes. Autopsy 26 hours after death.

*Rigor mortis* moderate. Excessive shrivelling, with blueness of fingers. Abdomen rather collapsed, flabby. No heat about body.

*Head.* Dura-mater healthy. Arachnoid same. No bloody or other effusion in arachnoid cavity. Some clear sub-arachnoid œdema. Substance of brain and cerebellum everywhere firm and of natural color. Firmness perhaps greater than natural, considering time since death. Moderate serous effusion in lateral ventricles. Several small, firm, colorless, "miliary" granulations on free surface of posterior pair of tubercular quadrigemina. No inflammatory or other morbid appearances in neighborhood. Tubercula-quadrigemina natural internally. No other unusual appearance about brain.

Medulla oblongata healthy.



*Chest.* Moderate dryness of pleuræ, most marked on left side. Pericardium natural, internally, but contains nearly one ounce of thin, bloody effusion. Right cavities of heart distended, principally with air; contain a moderate quantity of dark, thick blood, with soft gelatinous clots, mixed with a great abundance of small air-bubbles. Left ventricle relaxed; contains a little dark blood, fluid. Endocardium of right side stained dark-brownish red; of left side stained little or none. Substance of heart natural.

Air in  
heart.

Both lungs crepitate well. Moderate sanguineous congestion of lower lobes at posterior part. No other remarkable appearances. Larynx, trachea and bronchi pale internally, and without any unnatural appearance, except slight duskiness.

*Abdomen.* A little roughness, in some parts of peritoneum, over intestinal convolutions; but no noticeable amount of slimy secretion. Small intestines a little dusky externally; contain about twenty ounces of greyish, gruelly fluid. Mucous membrane pale, with a little yellow stain in duodenum. Peyer's patches moderately enlarged and opaque. Solitary glands same in lower part of ileum. Beside these there are numerous whitish specks in substance of mucous membrane, throughout most of its extent, somewhat smaller than solitary glands, but otherwise of similar appearance. Mucous membrane everywhere of natural thickness and consistence.

Large intestine contains twelve ounces of greyish-brown, flocculent fluid, with slight fœcal odor. Mucous membrane everywhere pale and natural in appearance. Mucous follicles generally a little enlarged, and their mouths open. Nothing else remarkable. Mesenteric glands generally natural; some enlarged, but not softened.

Stomach contains one pint of dingy, brownish fluid. Mucous membrane considerably softened, and has marked brownish discoloration, particularly on posterior wall. Nothing else remarkable.

Œsophagus natural.



Pancreas natural. Pancreatic fluid can be expressed from duct, clear and natural in appearance, distinctly acid in reaction.

Spleen under natural size ; quite flabby, wrinkled, and dry.

Left kidney small and flabby. Internally of natural appearance, but has quite a strong smell of molasses. Right kidney contains more blood than left, and is without melassic odor ; otherwise same. Both pelves pale internally. Both capsules strip off readily, and external surface of each kidney shows several small, whitish spots of emphysema in substance of cortical portion.

*Emphysema.*

Urinal bladder empty, contracted. Puriform secretion smeared over walls has some reddish discoloration, as if from blood.

Liver light reddish-yellow externally ; somewhat dusky internally. Ducts stained yellow, and yield a sufficient quantity of rather thin bile. Substance of liver somewhat softened.

Gall bladder contains about one ounce of dark, brown-yellow bile, of natural consistence.

Portal veins in liver stained brownish by blood. Hepatic veins natural.

Abdominal vena cava stained internally of a very dark brownish-red. Aorta stained dull red in thoracic portion, where it contains a dark fluid blood. In lumbar region it contains some very dark-brownish, and slate-colored blood, almost as thick as putty ; and here, walls are stained of a corresponding dusky red and slate-color. Below this, the color of internal surface of aorta is natural.

Vagina smeared with a thick white secretion, like starch. Os uteri somewhat open. Uterus internally somewhat softened and vascular, and right ovary shows a recent-looking false corpus luteum, a little over one quarter of an inch in diameter. Left ovary contains only serous cysts.



## XXVI.

JANE COLLINS. Aged 38. Married. Irish. Intemperate. Cholera 20 hours. In Hospital 3½ hours, Catamenia present. Saline mixture every half hour, with efferverscing drinks. Autopsy 23½ hours after death. SEPT. 4.

*Rigor mortis* moderately strong. Some shrivelling and much blueness of fingers. Abdomen of natural form, moderately resonant. Walls rather flaccid, as if from former pregnancies. Mammæ of natural size, white and firm internally, with a smooth section; contain no milk.

Muscles red.

*Head.* Dura-mater natural. Some bloody sub-arachnoid œdema over posterior part of hemispheres. Brain everywhere rather more vascular than natural, Vascularity. especially toward central parts, where substance is also somewhat softened, but nowhere so much as to destroy texture. Some effusion into lateral ventricles. Brain and membrane otherwise healthy.

*Chest.* Moderate dryness of pleura, most marked on left side. Pericardium contains eight or ten drops of serous fluid. Small, irregular, white spot on anterior surface of right ventricle, and faint indication of a similar one on posterior. Pericardium otherwise natural.

Right cavities quite full of dark, rather thickish, fluid blood, with trifling amount of dark and fibrinous coagula. Left ventricle tolerably well contracted; contains a little dark fluid blood. Left auricle same. No staining of endocardium anywhere. Valves on right side natural. Mitral valves somewhat thickened, and have on their free edges a few small, firm, cartilaginous excrescences, not sufficient to interfere



with action of valves. Aortic valves also a little stiffened, and aurantian bodies hypertrophied, but not to a serious extent.

Morbid de-  
posite in  
lungs.

Lungs light-greyish anteriorly, purplish posteriorly; moderately engorged with blood, and infiltrated with fluid. Crepitate generally well, but along lower edge of lower left lobe, pulmonary tissue is indurated, being somewhat stiff, nearly but not quite destitute of crepitations, with a solidified appearance, and an indistinctly lobulated feel externally. Excised pieces sink in water. The section shows numerous greyish-yellow, irregularly globular, tuberculous-looking deposits, varying from one quarter of an inch diameter downward, mostly encysted, and enucleated without much difficulty, leaving a smooth, red, vascular-looking surface. Immediately around these tuberculous or fibrinous deposits there is more or less induration of the pulmonary tissue, as in ordinary hepatization, thus giving the indistinct lobulated feel externally. There is one similar deposit in lower edge of lower right lobe, and another in lower edge of right middle lobe, but this last is surrounded by grey (tubercular?) infiltration, instead of hepatization. Both apices quite healthy, and free from any morbid appearance. Pleura covering left lung shows some signs of old inflammatory disease, and just along edge of lower lobe there is a small flake of recent yellow lymph. No other mark of pleurisy. Bronchi pale internally; contain a little frothy fluid, tinged with red. Larynx and trachea quite natural.

*Abdomen.* Peritoneum a little dryish at upper and anterior part. Very little slimy secretion on intestinal convolutions, perceptible only to the feel. Small intestines light-colored externally; contain about one pint of thick, gruelly, whitish fluid, with distinct alkaline reaction. Mucous membrane shows a little red injection in upper part of duodenum; elsewhere pale. Thickness and consistence natural. Twenty-three Peyer's patches visible, the lower twenty of



which are moderately swollen and opaque; not softened or reddened. Solitary glands not remarkable.

Large intestine contains also about one pint of thin gruelly fluid, with an alkaline reaction. Mucous membrane pale, of natural thickness and consistency. Mucous follicles generally developed, and their mouths open. Nothing else unusual. Mesenteric glands not remarkable.

Stomach contains about ten ounces of dingy, yellowish, alkaline fluid. Mucous membrane mostly pale, moderately softened in cardiac half, without remarkable discoloration. Otherwise natural.

Liver of a natural reddish-yellow externally, with spots of anæmia. Internally rather dusky, inclining to olive. Somewhat soft. Ducts stained yellow, and yield readily greenish bile by pressure.

Gall bladder and duct contains about one ounce of brownish green bile, which shows, through coats, of a pure green color.

Pancreas natural. Fluid, which is distinctly acid, is readily expressed from duct.

Spleen small, blue, and wrinkled externally. Internally natural in appearance.

Kidneys everywhere natural as to consistence, vascularity, aspect, &c. Urinary bladder empty and contracted; walls smeared with puriform fluid.

Vagina smeared with menstrual fluid. Uterus natural. Right ovary contains a large, very recent bloody cavity. Nothing else remarkable.



## XXVII.

SEPT. 5. JAMES McCARTY. Aged 8 years. Cholera for 12 hours, (after eating rotten fruit.) In Hospital four hours. Saline mixture, half an ounce every half hour, and two doses of *naphtha ligni*, half a drachm each. Autopsy 18 hours after death.

*Rigor mortis* natural. Eyes sunken, but face quite full. Fingers blue, not shrivelled. Abdomen natural in form. No heat about body.

*Head.* Longitudinal sinus contains dark fluid blood. Dura-mater natural. Considerable exudation of dark, thickish, bloody fluid over posterior part of hemispheres, and over surface of cerebellum. Substance of brain and cerebellum sufficiently firm, natural in color. Moderate amount of clear fluid in lateral ventricles. Lining membrane pale. Both corpora striata shew internally ill-defined tracts of light greyish, or opaline color, similar in texture to remaining portions. Medulla oblongata quite firm. Nothing else remarkable.

*Chest.* Moderate dryness of pleura on left side; not observable on right, owing to adhesions. Pericardium natural internally; contains three to four drachms of serous fluid. Right cavities of heart filled with dark, softish coagulum, and a little fluid blood; also a trifling quantity of colorless, firm coagulum. Left ventricle perfectly contracted, and empty. Left auricle contains a little dark fluid blood. Blood in *venæ cavæ* and internal jugulars fluid; not remarkable in consistence. Endocardium, valves, and substance of heart, natural.

Right lung has universal, moderately firm, cellular, pleuretic adhesions, so that cavity of pleura is entirely obliterated. Adhesions everywhere occupied by numerous firm, yellowish tubercles, varying from three

Tubercular  
pleurisy.



or four times the size of a pin's head downward. One is half the size of a hazel-nut. These all remain attached to thoracic parietes, none of them coming off with lung when it is removed. Lung generally deficient in crepitation, and has a somewhat solid feel, as if partially carnified, in consequence of these adhesions. There is one globular, firm, yellowish tubercle, cheesy in centre, situated just beneath surface of lung, at lower part of right middle lobe. Pulmonary texture in neighborhood of a grey color and natural consistence. No tubercular deposit in any other part of lung.

Left lung quite natural everywhere.

Larynx, trachea and bronchi pale internally, with mucous membrane of natural appearance.

*Abdomen.* Very slight roughness of peritoneum which covers intestinal convolutions. No perceptible slimy secretion. Small intestines light greyish and rosy externally; contain about three ounces of thick, dark, greyish fluid, alkaline in reaction, somewhat resembling mucus in consistency. Mucous membrane generally pale. Thirty-eight Peyer's patches counted, all more or less swollen and opaque; none excessively so; some white, others reddened. Solitary glands visible; moderately developed throughout whole extent of small intestine; in lower part of ileum much enlarged. Some of them are encircled by a very narrow zone of redness. No other alteration.

Large intestines contains about three ounces of greyish, alkaline fluid, thinner than that in small. Mucous membrane pale, natural, but mucous follicles are generally enlarged and their mouths open; often marked by a black speck. Mesenteric glands almost all enlarged; not softened. Some of them show small tubercular deposits in interior.

Stomach contains from three to four ounces of a thin greyish fluid, with distinct acid reaction. Mucous membrane pale, extensively thinned and gelatinized toward great pouch, particularly on posterior



surface. There are, in great pouch, and universally about cardiac orifice, many minute white granules, apparently in substance of mucous membrane. None elsewhere.

Œsophagus natural.

Liver reddish yellow externally; internally somewhat slaty. Ducts yield thin yellowish bile by pressure. Consistence natural. Gall bladder and duct contain about half an ounce of bile, which shows, through coats, of a pure green color; but when let out, is of a natural dark brownish-yellow. Duct of natural size.

Pancreas natural. Spleen about natural in size, very slightly wrinkled; internally rather pale, and deficient in blood.

Both kidneys absolutely natural. Urinary bladder contracted; contains about half a drachm of thin turbid fluid, and some of the puriform secretion on walls.

Thymus gland four inches in length.

Right testicle in scrotum; left in groin.



## XXVIII.

MARY ANN MARAN. Aged 40. Married. Irish. Intemperate. In Hospital 10 days, with debility, slight stupor, yellowness of skin, and palpable enlargement of liver. Soft souffle with first sound of heart, but both valvular sounds distinct. Pulse moderate. Cholera came on suddenly in night, and continued seven hours. Death on morning of eleventh day. Treatment, after Choleric attack—External heat, sinapisms, brandy, and musk. Autopsy 24 hours after death.

*Rigor mortis* moderate. Some shrivelling of fingers of both hands, and considerable lividity of those of left. None elsewhere. No heat about body. Abdomen flattened, considerably resonant, except over region of hepatic enlargement. Here resonance deficient, but nowhere quite absent. Skin of abdomen marked with numerous scars of pregnancy. SEPT. 9.

Subject has the appearance externally of advanced emaciation, but fat is nevertheless everywhere quite thick under integuments.

*Head.* Dura-mater natural. Longitudinal sinus empty. Considerable clear fluid in arachnoid cavity, at base of brain, and some also over hemispheres. No exudation of blood. Much sub-arachnoid œdema. Internally, substance of brain natural as to color and vascularity. Lateral ventricles distended with a considerable amount (one ounce?) of limpid serum. No vascularity of lining membrane. Some moderate softening of central parts, particularly on left side. Cerebellum and medulla oblongata natural. Serosus effusion.

*Chest.* Dryness of pleura well marked. On left side it has gone so far as to give pericardium a translucent appearance when held up to the light, like oiled paper, in one spot immediately beneath which



Fat abund-  
ant.

surface of heart is somewhat discolored. Pericardium contains about half an ounce of clear fluid. Heart perfectly loaded with fat, so that few or none of muscular fibres are visible externally. Large lobules of fat also in anterior mediastinum and on upper surface of diaphragm.

Right cavities of heart contain a moderate quantity of dark, fluid, thickish blood, with one or two trifling, soft, yellowish coagula. Left ventricle flaccid; contains, with auricle, a little dark fluid blood. Aorta contains also considerable dark fluid blood.

Heart fatty.

Disease of  
valve.

Heart of natural size, or a little less. Substance everywhere soft. Muscular fibres of right ventricle have undergone fatty degeneration to considerable extent, and there is no distinct dividing line between them and layer of fat on external surface. Left ventricle is dark-red in color, and distinction between muscular and fatty layers perfectly well marked. Lining membrane natural, but on one of aortic valves there is a prominent, semi-lunar cartilaginous induration, with a serrated free edge. Valves otherwise natural. Aorta natural.

Blood in vessels of neck rather deficient in amount, thinner than that in heart. Blood generally dark, thickish, and entirely destitute of coagula.

Both lungs light-colored and spongy at upper and anterior parts, but below and posteriorly they are darker, with deficient crepitation, and a flabby, leathery feel. Consistence natural. No very unusual sanguineous congestion. Excised portions float in water. One cheesy tubercle, without signs of active disease in neighborhood, in upper left lobe. None else.

Larynx and trachea pale internally. Trachea has on its mucous surface small globules of thickish, opaline exudation from tracheal grandules. Same secretion exists, more abundantly, in bronchi. Mucous membrane of bronchi mostly pale, in some parts rosy; everywhere of natural texture.

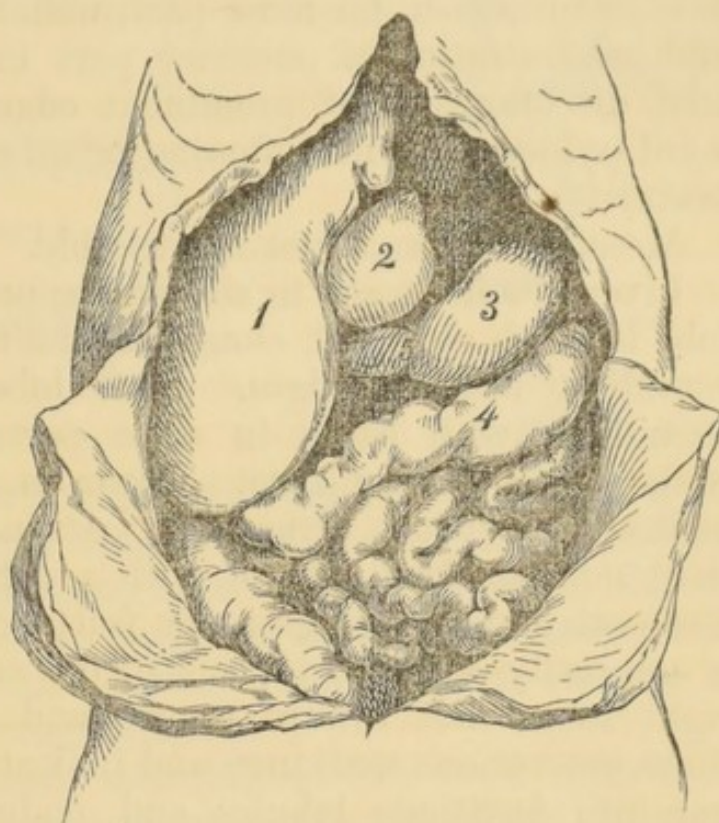
*Abdomen.* Peritoneal surface of small intestines



slightly roughened in parts, just enough to lose its natural polish, and is covered with a sufficient amount of slimy secretion. Position of abdominal organs, somewhat altered by the enlargement of

Fig. 11.

1. Right lobe of liver.
2. Gall bladder.
3. Stomach.
4. Transverse colon.
5. Pylorus and commencement of duodenum.



right lobe of liver, which extends downward one and three quarter inches below level of umbilicus. Gall bladder situated a little to the left of median line. Pylorus also a little to the left, and pushed upward.

Small intestines light rosy and greyish externally; contain a moderate amount of air and about eight ounces of very thick, flocculent fluid, colored strongly yellow, as if with bile, and neutral in reaction. Mucous membrane generally pale; in some parts pinkish; stained yellow in duodenum; of natural thickness and consistency. Eighteen Peyer's patches counted, all moderately swollen, white and opaque. No softening. Solitary glands also moderately enlarged in lower part of ileum, not elsewhere. No other remarkable appearance.

Large intestine contains one pint of thinner, yellowish, flocculent, moderately alkaline fluid, without remarkable odor. Mucous membrane pale and nat-



ural in appearance, excepting that mucous follicles are rather enlarged, and their mouths open.

Stomach contains about four ounces of dingy, olive-colored, faintly acid fluid. Mucous membrane pale or brownish, for most part, with some thinning and gelatinization of posterior part in cardiac half. Red discoloration of prominent edges of plicæ, toward pylorus, but no softening or other alteration of texture.

Mesenteric glands not remarkable.

Cirrhosis;  
commencing  
in right lobe,  
and advanced  
in left.

Liver much altered in size and appearance. Right lobe is much enlarged, elongated and thickened, with roundish, massive edges. Left lobe considerably shrunk, with edges in some parts thinned and reduced to a fibrous seam. Organ is generally pale yellow, (somewhat variegated) externally and internally; firmer than natural, with a dense, solid feel, a smooth section and granular fracture. Its surface is generally smooth, especially on anterior part of right lobe; but toward fissure and over left lobe, there are various markings and indications of a division into factitious lobules and nodules, owing to streaks of dirty white, condensed fibrous tissue, running in various directions. Also spots where surface is distinctly granular both to sight and touch. There are a few bands of adhesion between anterior surface and abdominal walls, and also some plates of old inflammatory thickening of peritoneum.

The variegation of color on surface is apparently produced by a convoluted mass of distended capillary gall ducts, causing a yellow spot in the centre of each acinus; which spot is surrounded by the pale color of remainder of acinus.



The condensation of fibrous tissue and consequent partial nodulation, is chiefly confined to the left lobe.

Antero-posterior diameter (right lobe,) . . . 10 1-2 inches.

Greatest transverse diameter, . . . " 10 1-8

Greatest thickness, (right lobe,) . . . 4 1-4 "

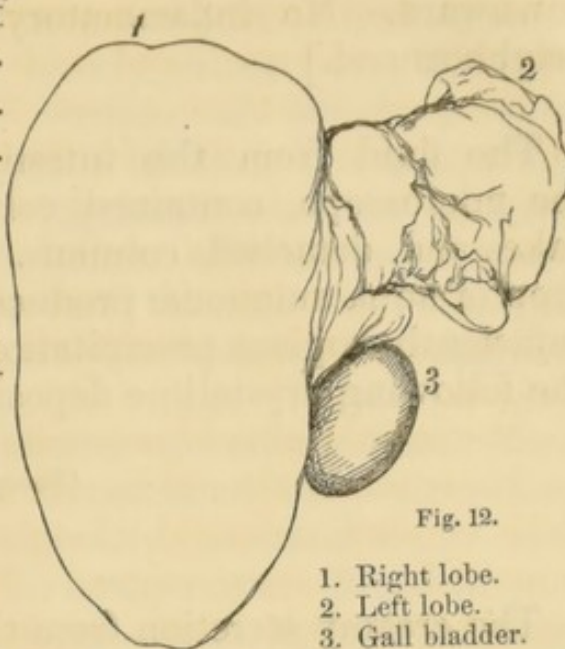


Fig. 12.

1. Right lobe.
2. Left lobe.
3. Gall bladder.

Gall bladder somewhat distended with thin yellowish bile. Proper duct of gall bladder is of natural size, but common and hepatic ducts are much dilated; five or six times as large as natural, containing bile similar to that in bladder. All the ducts interior of liver are also much dilated.

Pancreas mostly natural, but in several spots it is much firmer than ordinary, and granulated in same manner as parts of liver, by condensation of fibrous tissue. No alteration of color.

Spleen rather small, blue and wrinkled; flabby. Internally softish.

Both kidneys rather flabby, somewhat dark-colored, and sufficiently well supplied with blood. Both give out strong melassic odor from cut surface. Consistence natural. Puriform fluid expressed from papillæ.

Urinary bladder contracted, empty. Walls smeared with puriform secretion.

Vagina smeared with a moderate quantity of starchy secretion. Uterus of natural appearance, quite smooth, pale and firm internally. Ovaries somewhat atrophied, white and firm, with numerous deep scars.

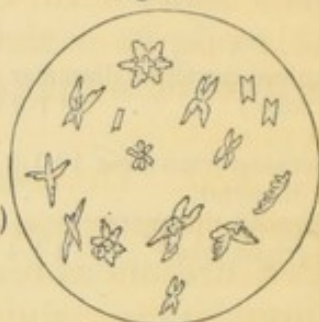
[There were two intus-susceptions in upper part of jejunum, each about one inch long, directed from above



downward. No inflammatory appearance in their neighborhood.]

The fluid from the intestines, examined under the microscope, contained columnar epithelium, in flakes and detached columns. A drop of aqua ammoniæ produced a sufficiently copious precipitation of the following crystalline deposite;

(Phosphatic.)



The creamy secretion from the bladder showed an abundance of elongated cells, as in the case of *Isabel Hassen, &c.*

## XXIX.

SEPT. 12. ELLEN DORETY. Aged 36. Single. Irish. Intemperate. Cholera 18 hours, without previous illness. In Hospital 12½ hours. Saline mixture and tincture of ginger, every half hour. Effervescing mixture, every two hours. Afterward, half a drachm of *naptha ligni*. Autopsy 29 hours after death.

*Rigor mortis* moderate. Much lividity and shrivelling of hands. No heat anywhere, but skin damp and cold. Acid odor of cholera quite strong.

Abdomen of natural shape and resonance. Fat tolerably abundant beneath integuments.

*Head.* Excessively firm adhesion of dura-mater to cranium, so that it is impossible to remove skull cap without laceration of dura-mater. Moderate



bloody exudation over posterior part of hemispheres, but there is abundant bloody effusion over the cerebellum, the superior surface of which is even covered with a thin plate of dark red coagulum, which has evidently coagulated since its effusion. Coagulum on cerebellum. Arachnoid natural. Substance of brain not remarkably vascular; but rather soft throughout. A drachm or two of serum in lateral ventricles. Nothing else remarkable.

*Chest.* Dryness of pleuræ excessive on both sides, producing translucent appearance of pericardium. Pericardium natural internally; contains six or eight drops of clear fluid. No ecchymosis. Right cavities of heart, with veins of chest and neck, contain a very moderate quantity of dark, thickish blood, with trifling fibrinous clots; also dark red, loose, gelatinous, coagula. Left ventricle flaccid; contains a little fluid blood. Left auricle and aorta contain dark, fluid, thickish blood, with loose gelatinous coagula. Blood in system generally has the same character, but coagulum on surface of cerebellum is considerably firmer than that elsewhere. Endocardium and valves natural. Substance of heart a little soft. Aorta and veins natural internally.

Lungs light grey and spongy anteriorly; purplish, and considerably engorged with fluids, posteriorly; crepitate well everywhere;—collapse but little. A little emphysema along free edges of lower lobes. Nothing else remarkable.

Larynx, trachea and bronchi, pale internally, and contain a little thickish secretion, not standing in globules, but smeared over mucous membrane.

*Abdomen.* Peritoneal surface of intestines has a perceptible quantity of slimy secretion. Small intestines, rosy externally, at upper portion; dusky greyish in lower. They contain about fourteen ounces of thin, reddish, alkaline fluid, with white flocculi. Mucous membrane mostly pale, with a little red injection and some yellow staining in duodenum; generally softened, (as if a little macerated,) but of



natural thickness and texture. Peyer's patches moderately swollen and opaque as usual. Solitary glands in lower part of ileum.

Large intestine contains ten ounces of thin, grey, alkaline fluid. Mucous membrane of natural appearance. Mucous follicles visible, and not remarkably altered.

Stomach contains one pint of dingy, alkaline fluid. Mucous membrane has a moderate red injection along most of small curvature and over about two thirds of anterior wall; in whole of great pouch, and over most of posterior wall, it has a dingy brownish discoloration. It is thinned and softened in great pouch, with sub-mucous vessels colored black. No other alteration.

Mesenteric glands not remarkable.

Liver dark brownish red externally; dusky internally. It is flabby and "doughy" to the feel;—otherwise natural. Gall bladder contains about one ounce of dark brown bile, of ordinary appearance.

Pancreas natural. Fluid, having a faintly acid reaction, can be expressed from duct, in minute quantities.

Spleen of moderate size. Capsule strips off with the greatest readiness, leaving organ with a smooth surface, and looking much like a large coagulum. Rather soft internally. Close old adhesions between posterior surface and diaphragm.

Kidneys of natural appearance and consistence; sufficiently full of blood. Puriform secretion can be expressed from papillæ, but not abundantly. Distinct melassic odor in left, not perceptible in right.

Urinary bladder contains a few drops of thin puriform fluid.

Vagina smeared with a moderate quantity of starchy secretion; but, in extreme upper part, this has more of a muco-purulent appearance.

Uterus rather slender and small; firm and pale anteriorly. It has a well defined, globular, fibrous-looking tumor, imbedded in its posterior wall, about



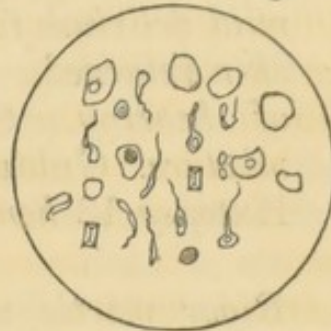
a quarter of an inch in diameter, and distant a quarter of an inch from external surface of uterus. Uterine tissue, posterior to plane of tumor, is soft, dark reddish in color, and shows uterine veins much dilated. Substance of uterus elsewhere natural.

Right ovary contains a recent false corpus luteum. Abdominal vessels natural internally.

The fluid from the bladder, examined under microscope, contained as before small, elongated, nucleate and non-nucleate cells, with larger, flat, irregular epithelium scales, and a very few small round globules, of slightly granular aspect. There were also one or two small prismatic crystals of triple phosphate.

Fig. 14.

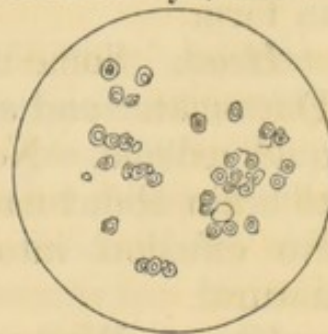
(260 diameters.)



The fluid expressed from papillæ of kidneys, showed only small, slightly granular, but transparent, globular cells, with very distinct oval nuclei.

Fig. 15.

(260 diameters.)





## XXX.

SEPT. 14. ANDREW PATTERSON. Aged 45. Irish. Intemperate. Cholera  $4\frac{1}{2}$  days. In Hospital four days. Symptoms at first not very severe. Passed urine occasionally. Saline mixture, naphtha ligni p.r.n for vomiting, and application of liniment of ammonia to chest and back. Considerable improvement on third day, and large quantity of urine. On fourth day, mild delirium followed by somnolence. Coolness of skin returned. Difficulty of swallowing and dulness of hearing. Stimulants, alternating with saline mixture. Gradual failure of vital powers and death. Autopsy 13 hours after death.

*Rigor mortis* moderate. Well marked, but not excessive, shrivelling of fingers. Abdomen natural in form.

*Head.* Some dark coagulum in longitudinal sinus. Dura-mater and arachnoid natural. Much sub-arachnoid œdema. No bloody transudation. Substance of brain about natural in consistence, but rather pale. No effusion into ventricles. Medulla oblongata natural.

*Chest.* Well-marked dryness of pleura. Pericardium empty; natural internally, excepting a small white spot on anterior surface of right ventricle, and another, smaller, on internal surface of pericardium over same. Right cavities contain a sufficient amount of dark-red and firm fibrinous coagulum, with some fluid blood of natural consistence. Dark coagula, of considerable firmness, extend up into subclavian and internal jugular veins, and fibrinous coagula into pulmonary arteries. Left ventricle rather flaccid; contains dark fluid blood. Blood in left auricle and pulmonary veins dark and thickish, with loose, dark coagula. Lining membrane, valves, and substance of



heart natural. Foramen of Botal sufficiently open to allow a moderate-sized boagie to pass from right auricle into left. Opening perfectly valvular.

Both lungs light grey anteriorly; purplish and considerably engorged with fluids posteriorly. They crepitate well everywhere, and have a natural feel, except at lower part of right, where there are abundant old pleuretic adhesions and a great deal of fluid engorgement, so that lung does not collapse at this part, and has a somewhat dense and resistant appearance. Texture somewhat friable, but crepitation remains, and excised pieces float in water. Lungs otherwise natural.

Larynx natural. Trachea and bronchi pale above, dusky, or dull-reddish in color below. Texture of mucous membrane unaltered. Trachea covered internally with thickly-set globules of thickish, opaline secretion from grandules. Bronchi contain a more abundant, dull reddish-grey, muco-purulent secretion, in some parts evidently mixed with blood. Nothing else remarkable.

*Abdomen.* Very slight amount of slimy secretion on surface of intestines. Small intestines externally of a dull rosy hue, slaty, and dusky-greenish. They contain a moderate quantity of air, and about twelve ounces of very thick, yellow, bilious fluid, about the consistency of mucus. Mucous membrane stained bright yellow above; below, pale in spots; elsewhere shows dark-red congestion. Surface of mucous membrane everywhere natural in appearance. Consistence natural in upper third of intestine; below this, moderately softened. Peyer's patches and solitary glands moderately enlarged, and opaque as usual. No other change.

Large intestine contains a considerable amount of soft greenish fæces; no fluid. Mucous membrane shows dark-red congestion in cæcum, with some spots <sup>Congestion.</sup> approaching to ecchymosis. Congestion most marked on prominent edges of membranous folds. A similar tract of congestion a foot or two lower down. Mu-



cous membrane elsewhere pale ; texture unaltered. Mucous follicles natural.

Mesenteric  
glands  
enlarged.

Mesenteric glands generally enlarged. Those corresponding to upper part of intestinal canal are nearly or quite natural in color and consistence ; those corresponding to lower part, have the enlargement more marked, and are also decidedly reddened and softened.

Congestion.

Stomach contains half a pint of thin, yellow, bilious-looking fluid. Réaction neutral. Mucous membrane has much dark-red congestion over about one quarter of anterior wall, and two thirds of posterior ; deepest on posterior in great pouch, where there is also moderate softening, but no thinning. Beside this, there is a general yellow (bilious) staining of surface. Otherwise natural.

Liver somewhat turgid, smooth and flabby ; dull-reddish in color internally and externally ; a little soft. Thin, bright-yellow bile can be readily expressed from ducts in interior.

Gall bladder distended ; contains about two and a half ounces of very thin, nearly colorless fluid, like water, with a small quantity of yellowish flocculi diffused through it.

Pancreas rather firm, with something of a granulated feel.

Spleen of full size, dark-red, not wrinkled ; internally, grumous.

Kidneys rather turgid, and a little softened. Copiously supplied with blood. No melassic odor. External capsule strips off, leaving surface smooth, Puriform secretion can be expressed from papillæ.

Urinary bladder contains about one pint of light-colored urine. Mucous membrane pale, with a flabby, macerated appearance.

Albuminous  
Urine.

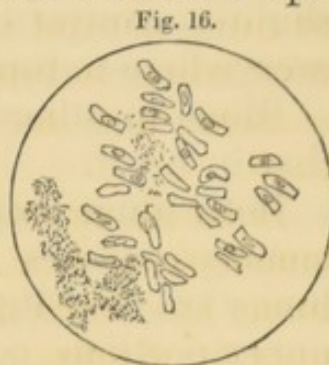
The urine had a distinctly acid réaction, and was moderately albuminous. Under the microscope it showed a few of the variously shaped epithelium cells,



similar to those contained in the creamy secretion in other cases.

The fluid from the gall bladder contained bright-yellow granules, and an abundance of columnar epithelium, mostly in detached cells, nucleated, considerably larger than those from intestines.

(260 diameters.)



### XXXI.

HONORA McCAWLEY. Aged 37. Irish. Intemperate. SEPT. 16.  
*Cholera 12½ hours, with some previous diarrhœa.*  
*In Hospital 4½ hours. Saline mixture with six grains of carbonate of ammonia every hour. Effervescing mixture every two hours. Autopsy 18 hours after death.*

*Rigor mortis* natural. Abdomen prominent, rather tympanitic, not tense. Some scars of pregnancy.

*Head.* A very little fluid blood in longitudinal sinus. Dura-mater and arachnoid quite natural in appearance. Exudation of dark, thickish, bloody fluid in arachnoid cavity, over posterior part of hemispheres, and over cerebellum; not elsewhere. Substance of brain natural in color, a little soft. Lateral ventricles contain a small quantity of serum, but are not at all distended. Medulla oblongata natural.

*Chest.* Dryness of pleura well marked. Pericardium natural internally; contains only about four or



five drops of serum. Right cavities of heart contain a moderate quantity of dark fluid blood, of natural fluidity and consistence, without the least trace of coagula. Left cavities same. Left cavities very slightly contracted. Valves and lining membrane everywhere natural. Substance a little soft.

Blood in other parts of body of same character as that in heart.

Both lungs emphysematous throughout; i. e. pulmonary vesicles are everywhere visible on surface, lungs are very light-colored and dry. At anterior and upper portions, collapse very little, and after opening  
*Emphysema,* of chest are still so prominent as nearly to cover heart and to overlap each other to considerable extent. Abundant crepitation everywhere. Lower lobes are more moist than upper—somewhat friable, and have a dingy brown color internally, while upper and middle lobes are dry, firm, and of a clear reddish-gray color.

Trachea and bronchi contain some frothy, flaky fluid, probably introduced from stomach. Mucous membrane of trachea, and that of bronchi distributed to lower pulmonary lobes of a uniform slaty-brown color, but retains its natural thickness and polish. Drops of thickish, opaline fluid readily expressed from tracheal glandules. Mucous membrane of bronchi distributed to upper and middle lobes, light-reddish in color. Nothing else remarkable.

*Abdomen.* Almost no slimy secretion on surface of intestines. Peritoneum generally of natural appearance and polish. Numerous old, cellular, bridge-shaped adhesions of upper surface of liver to diaphragm. A few of posterior surface of spleen to ditto. Numerous white, firm, fibrinous-looking deposits, of minute size, on peritoneal surface of anterior wall of  
*Old peritonitis.* great pouch of stomach. There are also firm, close, cicatrix-like adhesions of small intestines to surface of descending colon in left inguinal region, just above commencement of sigmoid flexure. These adhesions are nine in number, and so close and firm



that intestines are separated by dissection with considerable difficulty. The first occurs at a point a little over ten feet below pylorus; the remainder at various distances below. The third adhesion includes a minute fistula between cavity of small intestine and that of colon; the others are quite solid and impervious. Adhesions all at nearly same point on colon.

There is also a communication at this point between cavities of cœcum and descending colon, by a fistulous passage three quarters of an inch in length, and large enough to allow the passage of an ordinary sized bougie. Cœcum occupies cavity of pelvis and communication runs across pelvis from right to left.

*Bi-mucous  
fistula.*

There is also a close adhesion, at the same point, between left ovary and colon. Colon itself is here pretty firmly adherent to anterior and lateral wall of abdomen. About one inch below this, there is a firm rounded cord of adhesion inserted, which thence runs across hypogastric region, to be inserted into abdominal walls at a corresponding point on opposite side. Several folds of intestine are bound down, and more or less constricted by this bridle, beside which small intestines are variously involved and entangled among themselves by numerous other cellular adhesions, less close and firm than those already described. Uterus is drawn out of its normal position in median line, and held firmly against left side of pelvis, while right lateral ligament is stretched across cavity of pelvis, like a curtain, between cœcum and bladder. No signs of recent inflammatory action anywhere.

Small intestines light-rosy externally at upper part, dull-greenish below; contain half a pint of thick, pinkish, alkaline, flocculent fluid, with some few yellow shreds. Contents of duodenum entirely yellow. Mucous membrane of usual appearance, with ordinary amount of tumefaction and opacity in Peyer's patches and solitary glands. Surface of patches covered by abundant, tumid, opaque, white villi, and shows also numerous blackish dots and markings.



Large intestine contains about one pint of thin, semi-purulent, alkaline fluid. Mucous follicles, toward lower part, rather enlarged, and their mouths open. Lining membrane of fistula, between cœcum and colon smooth and shining.

Mesenteric glands a little enlarged ; some reddish, others of natural color.

Stomach contains six ounces of thin, light-greyish, turbid fluid, with lumps of undigested food. Réaction of fluid, acid. Mucous membrane shows a slaty-brown discoloration of blood in vessels, over most of great pouch, and some moderate softening. On small curvature, two inches from pylorus, there is an irregularly globular, pendulated tumor of the mucous membrane, about the size of a hazel-nut, projecting into cavity of stomach. It consists of a softish tissue, resembling hypertrophied mucous membrane, containing several small cavities, filled with a transparent, glutinous fluid. Nothing else remarkable.

Liver dark-reddish brown, externally and internally, rather soft and flabby, without remarkable odor.

Gall bladder contains one and a half to two drachms of very thin, yellowish bile.

Pancreas natural, only somewhat reddish and flabby.

Spleen small, blue, and wrinkled ; internally dark-red, softish, with moderate amount of blood.

Both kidneys flabby, dark-red in color, and fluid blood readily follows incision. No melassic odor. Puriform fluid readily expressed from papillæ.

Urinary bladder collapsed, and partly contracted ; empty. Walls pale, but with some dark-red discoloration of prominent ridges of mucous membrane. Puriform secretion as usual.

Vagina smeared with starchy secretion. Uterus not remarkable.



## XXXII.

MARGARET HARNEGAN. Aged 22. Irish. Temperate. Cholera 30 hours, without previous illness. In Hospital 10¾ hours. Treatment; before entrance, brandy and water, ad libitum; after entrance, external heat, sinapisms and saline mixture every two hours, alternating with effervescing mixture. Noise in ears, and congestion about head. Dry cupping to back of neck and spine, with considerable relief. Failed suddenly, and died four hours after. Autopsy 16¼ hours after death. Ever since death, body kept lying on left side. Previously, patient lay constantly on back. SEPT. 17.

*Rigor 'mortis* natural. Body presents the most perfect appearance of health, being finely developed, and all the limbs full and rounded. Considerable amount of fat beneath integument. Abdomen of natural form, or a little prominent. Mammæ full and round. Nipples deficient.

*Head.* Dura-mater and arachnoid natural. Exudation of bloody fluid, but thin, light colored, and trifling in amount over middle part of right hemisphere, adjacent to longitudinal sinus. On left side, exudation is in a corresponding situation, but quite copious, dark colored, and thick. Little or no exudation over cerebellum. No sub-arachnoid œdema. Brain of natural consistence and color; from one to one and a half drachms of clear fluid in lateral ventricles.

Medulla oblongata natural.

*Chest.* Dryness of pleura trifling. Pericardium natural internally; contains eight or ten drops of clear fluid. Abundant, large, irregular, dark purple ecchymoses on surface of heart, both anteriorly and posteriorly, along free edge, and over left ventricle, but most abundant on right side, over situation of Ecchymoses.



auriculo ventricular orifice. The largest of these ecchymoses is a little over a quarter of an inch in diameter. Right cavities of heart contain a moderate amount of dark fluid blood, not very thick, with a little gelatinous coagula, and numerous small bubbles of air. Left ventricle rather flaccid, contains dark fluid blood. Left auricle contains fluid blood, with gelatinous coagula. Endocardium natural excepting a few faint, dark reddish stains in some parts, approaching to ecchymoses. Valves and substance of heart healthy.

Nearly universal old, close, cellular, pleuritic adhesions of right lung, and in separating these adhesions (which are most firm at lower part) an abscess is opened, situated in substance of false membrane. Abscess commences at anterior part of chest, at level of third intercostal space, and thence extends downward and backward five inches. Its cavity is flat and ribbon-like in shape, two inches broad at upper and anterior extremity, and thence gradually tapering nearly to a point. It contains about one ounce and a half of thick, yellow, natural-looking pus, and some masses of soft, granular, cheesy matter, also yellow. Walls of abscess are covered mostly by layers of this last mentioned substance, which adhere with some tenacity. Where exposed, internal surface of abscess is dark purplish in color, with smooth, rounded eminences, like flabby granulations.

Right lung crepitates well everywhere, allowing for adhesions, but contains two tubercles; one in lower part of lower lobe, near abscess, rather superficial in situation, encysted, cheesy. The other, smaller and drier, is situated in lower part of middle lobe. No signs of recent inflammatory action anywhere.

Some small tubercular deposits, also, in bronchial glands of this side. Other bronchial glands enlarged and soft.

Left lung everywhere natural; no adhesions. Larynx, trachea, and bronchi, everywhere pale, or a little reddish, internally; of natural appearance.



*Abdomen.* Minute quantity of slimy secretion on surface of small intestines. These have externally a dingy pinkish color, at upper part, approaching to green below. They contain a considerable quantity of air, and only about four ounces of a very thick, pinkish, alkaline fluid. Mucous membrane mostly pale, but in several parts of intestine there are limited tracts where villi are of a bright red color; rest of mucous membrane remaining natural. Thickness and consistence everywhere normal. Tumefaction of Peyer's patches and solitary glands as usual.

Large intestine contains only about two ounces of thin, puriform, alkaline fluid. Internal surface stained of a deep red near upper part of rectum, owing to redness of villi, but in centre of this tract injection is so intense that mucous membrane appears completely permeated by blood. Elsewhere pale. Consistency, &c. natural. Mucous follicles more and more developed, from cæcum downward.

Stomach has a strongly marked annular contraction about its middle part, which, however, is completely removed by forcible inflation, and original shape of organ restored. Mucous membrane shows no remarkable appearance.

Liver dark reddish-brown, internally and externally, soft and flabby. Yellowish bile easily expressed from ducts.

Gall bladder contains about one ounce of natural-looking bile.

Pancreas reddish and flabby; otherwise natural.

Spleen small, but quite smooth and fair externally; internally natural.

Kidneys firm, not flabby, moderately supplied with blood. Distinct melassic odor. Puriform fluid, thinner than usual, can be expressed from papillæ. Lining membrane of pelves pale.

Urinary bladder contains about half a drachm of thinnish, turbid fluid.

Venæ cavæ natural internally. Lining membrane of aorta natural in chest and upper part of abdomen,



but in lower part stained a little purplish-red and dingy. Blood here thick and somewhat tarry; elsewhere quite fluid and thin.

Vagina smeared with starchy secretion. Uterus somewhat reddened and softened internally. Left ovary contains a recent-looking false corpus luteum. (Patient menstruated two weeks previously.)

---

### XXXIII.

SEPT. 19. BRIDGET GILMORE. Aged 28. *Sempstress. Irish. Intemperate. Cholera 9½ hours. In Hospital six hours. Saline mixture; also tincture of cinnamon, and turpentine, and a little coffee occasionally. Hot-air bath. Autopsy 20½ hours after death.*

*Rigor mortis* sufficiently strong. Lividity and shrivelling of hands well marked. Abdomen prominent, tympanitic. Muscles rather slate-colored.

*Head.* Longitudinal sinus empty. Considerable exudation of thickish, purple-red, bloody fluid over posterior part of both hemispheres in arachnoid cavity; same on the two sides. Arachnoid natural. No sub-arachnoid œdema. Substance of brain rather soft, natural in color. Lateral ventricles contain a very little clear serum. Nothing else remarkable. Medulla oblongata natural.

*Chest.* Dryness of pleura well marked. Pericardium natural internally; contains about three ounces of serum. Right cavities of heart contain a moderate quantity of dark fluid blood, of ordinary consistence. Left ventricle perfectly flaccid. Blood in left cavities, fluid and thickish, with dark gelatinous coagula. Endocardium, valves, and substance of heart natural.



Lungs light-colored anteriorly, a little engorged posteriorly; crepitate well everywhere, and have a natural appearance.

Larynx, trachea and bronchi pale internally at upper part, dusky below. Nothing else remarkable.

*Abdomen.* Almost no slimy secretion on peritoneum. Small intestines much distended with air; contain also two pints and a half of thin, "rice-water," alkaline fluid. Mucous membrane mostly quite pale; a little red injection in duodenum. Enlargement and opacity of Peyer's patches and solitary glands, as usual. Consistence and thickness of mucous membrane natural. Large intestine contains from three to three pints and a half of fluid, similar to that in small. Mucous follicles moderately enlarged, with open mouths. Nothing else remarkable.

Mesenteric glands generally much enlarged, but white and natural in consistence.

Stomach contains not more than two ounces of a thickish grey fluid, more strongly alkaline than that in lower parts of intestinal tube. Mucous membrane extensively softened, with dusky discoloration; otherwise natural.

Liver brownish-red externally and internally; softish. Yellow bile can be expressed from ducts.

Gall bladder contains about half an ounce of natural-looking bile.

Pancreas natural. Secretion faintly acid.

Spleen rather small, but plump and smooth on surface. Internally red and dry.

Kidneys firm, not flabby, and fluid blood readily follows incision. No distinct puriform fluid is to be expressed from papillæ, but that which flows from them rather resembles turbid urine. Sufficiently distinct renal odor; no melassic.

Urinary bladder contracted and quite empty, excepting a puriform secretion smeared over walls.

Uterus and appendages not remarkable.

NOTE. The microscopic and pathological drawings are from the pencil of Dr. Dalton.







## TOPOGRAPHY,

WITH A CHART OF THE CITY PROPER.

---

As this epidemic has, in a very remarkable manner, domiciled itself, so to speak, in localities, nearly all of which have in common certain easily recognizable and well-defined peculiarities, we have procured some perspective drawings and plans of several of them, as specimens of the rest. They will, we think, give a sufficiently accurate impression of the uniformly crowded state of the buildings; of their inaccessibility to air; and the apparent impossibility of arresting the spread of disease in such situations, or of treating satisfactorily in them, any of its victims.

We have appended to this Report a chart or block-plan of the City proper, in which the original location of all the cases which were received at the Hospital, and all the *fatal* cases, so far as they are known, are carefully indicated. This method was preferred to an attempt, which must have failed, for obvious reasons, to trace the origin of those also which recovered in private practice. So that, if this statement seems to fall short of what is desirable in this respect, it will be free from the gross inaccuracies into which the widely varying reports, from a large number of observers, many of whom have no uniform or well-defined standard of diagnosis, must inevitably have led. Besides, as a gen-



eral rule, the tables of mortality will always give a very good idea of the character and extent of any prevailing epidemic.

The subjoined statistics furnish the history of the origin of 707 cases—611 of which were fatal. The sources of information are the records of the Hospital, and the books of the City Registrar, at the City Hall.

The reports of the office of the City Registrar, being made mostly by the undertakers of funerals, and not by medical authority, are not of course entitled to implicit confidence; but we have no doubt that they give a very fair approximation to the exact truth.

There were doubtless some cases reported as Cholera, which were not so, especially of children under ten years of age; as our experience at the Hospital gave us the impression that it was seldom fatal in this class of subjects. These may fairly be offset by the deaths among adults, from drunkenness, or by drinking cold water, which were reported as Cholera.

The exact age was also evidently only approximately given, the foreign population being very illy informed in regard to their advance in life. This fact is indicated, upon the records, by the large numbers reported as having died at the ages of 25, 30, 35, 40, &c.; showing that the persons were *estimated* to be about those periods of life. But while this renders the statement uncertain for a particular year, (of the age,) it does not affect the results for periods of five years.

Of the 707 cases, 385 were males, and 322 females. Their birth-places and ages are given in the accompanying tables.

Isolated instances of the disease were noticed in even the most salubrious portions of the City, but with a very



few exceptions, the disease was confined to unhealthy, ill-ventilated and crowded localities. The lower parts of the City, where the drainage is difficult and the cellars more or less invaded by the back-water; those reclaimed from the ocean, and those in the vicinity of marshes, were invaded by the pestilence. As instances in point, we may cite the cases which occurred in the new streets, upon the Neck and the South Cove; Church street; Sea and East streets; Battery-march\* street; Broad, Wharf, Well and Bread streets; Ann street and its neighborhood; Nashua and Brighton streets, and South and East Boston.

In nearly all these localities, an over-crowded population, bad ventilation, insufficient and unwholesome diet, *intemperance*, and the entire absence of cleanliness, have been most efficient adjuvants in assisting the operation of other causes.

As examples of the influence of filthy habits, deficient ventilation, &c. in what would be considered as healthy situations, may be mentioned the cases which originated in Oliver and Hamilton streets; Sullivan place; and Atkinson, Hanover, West-Cedar, Southac, and May streets. So many instances might be cited, from our personal knowledge of the localities where the majority of the cases occurred, that we are quite certain that the influences alluded to above are, as a universal rule, the exciting cause of the disease, with the occasional exception of those cases which are evidently produced by an unusual indulgence or excess.

The City Institutions at South Boston furnish evidence of the liability of persons of enfeebled constitutions to be attacked by the disease, even when removed

\* Formerly Battery-Marsh street—a name which is quite appropriately descriptive.



to a healthy location, and furnished with clean rooms and a regulated diet.

A considerable number of deaths are reported from these institutions, especially from the House of Industry, notwithstanding the great advantages enjoyed by the medical officers, in being able to place the patients under treatment from the first moments of the appearance of the disease.

The exact place, whenever it could be ascertained, where each case originated, has been indicated, so that, if the epidemic should réappear, as it is certainly not unlikely to do, the Health Commissioners may have it in their power to ascertain at once, not only what streets, but what particular buildings will be likely to require the process of purification. In cases where the number of the house is not designated, as in portions of those reported in Broad, Cove, Sea, and some other streets, it is presumed that most of the cases originated, directly or otherwise, in the houses which were known to be the chosen foci of the disease.

Most of the worst localities are easily to be recognized upon the chart, or on the accompanying list. Among them, as conspicuously bad, may be cited the houses in the rear of 136 Hanover street;\* Mechanics court; No. 14 Battery-march street; Humphrey place; Burgess' alley; Cross, Broad, Well, and Wharf streets.

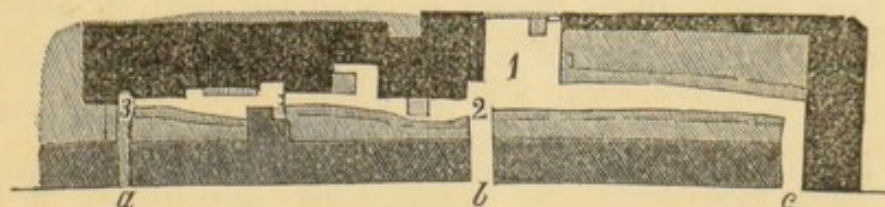
At East Boston there were quite a number of fatal cases, in or near Liverpool street; in every instance, as far as can be ascertained, the houses which were visited with the pestilence, were without proper *drains*, while others, in the same locality, and in otherwise the same circumstances, but *well-drained*, entirely escaped.

\* It is worthy of note that a few years since, typhus or typhoid fever prevailed here to an unusual extent.



It will be observed that the Hospital was located near the scenes of the greatest ravages of the disease. This was most appropriately done. That it did not itself constitute a focus of contagion, may be proved from the circumstance that several cases originated in its vicinity, before it was occupied by patients from other parts of the City, as also by the fact that the disease was not manifested in all directions around it. *No cases occurred in the houses upon the square.* They were limited entirely to the houses, (on the northeasterly side of the hill,) which were occupied by the most miserable portion of our population, living in the most miserable manner; while those residing, under better circumstances, in the opposite direction from the building, were entirely exempt from the visitation of the malady.

It will be observed that about two hundred cases occurred within a circle, having a radius of a few rods only, whose centre was in Broad street, near Burgess' alley. The population of this district is enormous. The following is a plan of Half-moon place, with Burgess' and Baker's alley, showing the entrances from Broad street.\*




*No. 1. Half-moon place. No.'s 2 and 3. Burgess' alley.*

- a.* Entrance through arch to Burgess' alley.
- b.* Entrance through Half-moon place from Broad street.
- c.* Entrance to Baker's alley.

The dark-colored parts represent the brick blocks. The *darkest* colored, the houses where the worst cases occurred. The lighter colored tints represent the sheds and out-houses.

\* See Shattuck's "Census of Boston."



*View of Half-moon place.*

Half-moon place is situated in the rear of Broad street, and is formed by a kind of excavation into the side of Fort Hill; the houses which form its semicircular side being built either against the hill, or separated from it by a space of a few feet. It has two narrow entrances between blocks of houses, on Broad street, and "Jacob's Ladder," which, at the time of the prevalence of Cholera, was a very dilapidated stair-case, that connects it with Humphrey place, and thus with the higher streets upon the hill. Baker's alley, one of its entrances, forms its northern boundary, and Burgess' alley extends from its southern extremity. The cut represents a portion only of the place, and conveys, as do the others, but an imperfect idea of the near proximity of the houses, and the utter want of any circula-




tion of air. The side towards Broad street, from which the view is taken, is formed by the sheds in the rear of the houses on that street, with extremely dirty backyards, and a fair proportion of privies.

To the right of "Jacob's Ladder," as represented in the cut, is a cluster of six privies, situated nearly in the centre of the place. At the time of the epidemic, these were greatly out of repair, and the ground about them was covered with their overflowing contents, removed only by evaporation. They have since been repaired, so as to present a better outward appearance. A fence has since been erected, as a screen, at the side of the "Ladder," to hide the naked deformity of its neighborhood. At the foot of the drain are two more clusters of privies, six in number. The open space likewise presents three cesspools, intended to convey off the dirty water; but which were choked by all sorts of vegetable matters, as fragments of cabbage and potatoes. As these accumulated, they were scooped out and thrown upon the ground near them, which was thus plentifully bestrewed with putrefying vegetable matters. With these were mingled no small proportion of substances still more loathsome.

The houses to the left, are from four to six stories in height, and were crowded with inhabitants. Their rear was only separated from the stone-wall which supported the side of the hill, by a space of a few feet, and here the contents of drains from above found a receptacle, creating a perpetual humidity which must have reminded the tenants of their native land.




*Burgess' alley. North view.*


From point marked 2, on plan.

Burgess' alley runs from the southern extremity of Half-moon place, and its houses, fruitful sources of examples of the disease, are destitute of any opening whatever in their rear—being built against the hill, and in front are separated from the rear of the houses on Broad street by merely the width of the alley and a row of narrow sheds and privies.





*Burgess' alley. South view.*

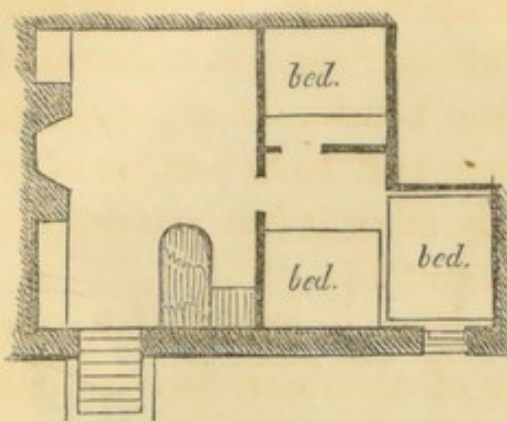


*Entrance to Burgess' alley.  
(Looking out.)*

The sketches can convey a faint idea, only, of the actual narrowness of the limits occupied by an immense population, and the utter impossibility of a healthy circulation of air in such locations, where a free ventilation is especially demanded by the supreme filthiness of the persons who occupy them.

The plan which is given of a triple cellar, would scarcely be believed to represent a reality, by those unacquainted with some of these localities. The principal



*Plan of cellar in Bread street.*

were crowded, served as the family sleeping-room, whilst the third, a dungeon six feet square, and the same in height, (with no aperture for the admission of air, save the narrow door, which was closed at night,) served to accommodate boarders.

The landlord said the tide came through the floor of his rooms but rarely! We have procured a sketch of

*Subterranean bedroom in Bread street.*

the appearance of one of these subterranean apartments. It gives a fair idea of the mode of stowing the bedsteads, and of its contracted dimensions; but cannot give an adequate impression of its darkness and its loathsomeness. The family was warned by

visiting physician of the district not to permit these inner rooms to be occupied; yet he was called, a few nights after, to see a man in this very den, who, two or three hours previously, was in apparent good health, but had then already reached the stage of hopeless collapse.

One cellar was reported by the police, to be occu-

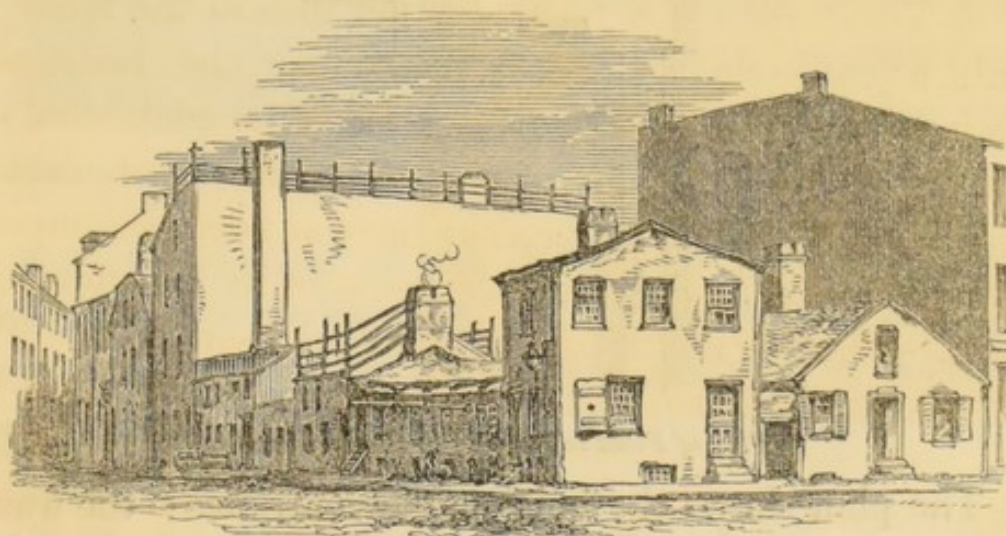
tenant considered his accommodations of the most desirable character. The first cellar, from the street, was occupied, in one corner, by a bar for the sale of refreshments, and served as kitchen and parlor. The second, into which two beds



pied nightly, as a sleeping apartment, by thirty-nine persons ! In another, the tide had risen so high that it was necessary to approach the bedside of a patient by means of a plank, which was laid from one stool to another ; while the dead body of an infant was actually *sailing* about the room in its coffin !

Many of the inhabited cellars in this vicinity are inundated by the back-water of the drains during high-tides ; and being entirely below the level of the sidewalks, they are necessarily, therefore, almost entirely without light or ventilation. But, far from being considered a hardship, a residence in them is considered preferable to loftier apartments. They are said to be cooler in summer and warmer in winter, and consequently command higher rents.

Another locality, which furnished quite a number of victims, is shown in the following view. It is a nest of miserable tenements at the easterly corner of Stillman and Endicott streets.



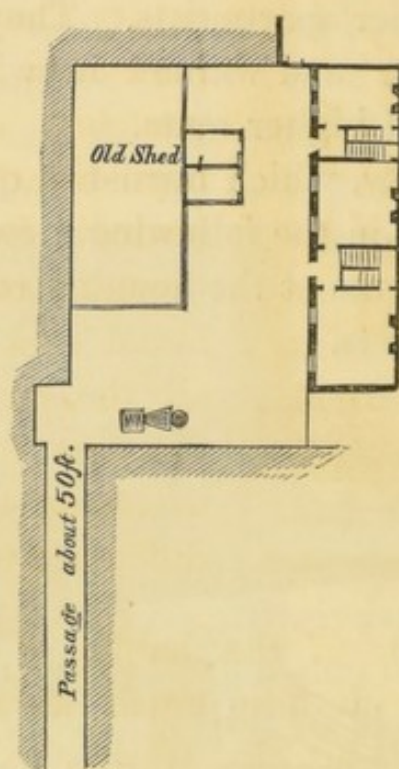
*View of tenements in Stillman street.*

They are filled to overflowing with a most vicious and miserable population. Even the cellars, under the long low building, near which the two figures are seen, and



into which it is very difficult to *crawl*, are inhabited, although the crazy timbers overhead threaten each moment to entomb, or the waters beneath to drown them.

We give but one illustration more: it is the place in the rear of 136 Hanover street, which was inhabited chiefly by the unfortunate "Crowe" family. It will be recollected that some of the earliest cases occurred here, and the victims were seized and died in such rapid succession as to attract special attention to the spot. There were something like twelve deaths here, in a period of little more than two days, out of a population of less than fifty persons.




*Plan of Place in rear of 136 Hanover street.*

The plan shows the long narrow entrance; the want of any passage beyond; the entire absence of any yard in the rear; and the reason, therefore, why all the excrementitious matters, the refuse vegetables, &c. should be constantly accumulated in the centre of the place. Nothing arrested the fearful progress of the disease,



here, but the immediate removal of all the inmates, and a thorough cleansing of the premises.

The large house, in the left foreground, was in tolera-



House in rear of 136 Hanover street.

bly good repair, but excessively crowded with inmates. The farther building on the right, was formerly the rear wing of a larger house. It is a very dilapidated and incommodious building, with very low and narrow rooms. It was with the greatest difficulty that the people were persuaded to leave these wretched quarters. The horse-litter\* was sent repeatedly for them, and, although some of them were found sick upon the floor, all the energy of the authorities was required to overcome their listless indifference to their fate.

An examination of the habits of the victims of Cholera, shows with how much discrimination they were selected for its attack; while the rate of mortality, among those who were intemperate, is still more remarkable.

Of the whole number of patients at the Hospital, (262,) one hundred and fifty-four were known to be intemperate, and one hundred and eight who were *supposed* to be temperate.

\* An easy covered carriage, (containing a bed,) for the conveyance of patients, which was constantly in readiness, day and night, in the Hospital yard.



The whole number of deaths there was		166
Of those who were temperate, - -	37	
“ “ intemperate, - -	129	
	—	166
The whole number of recoveries was	-	96
Of the intemperate, - - -	25	
Of the temperate, - - -	71	
	—	96

The experience of this epidemic has certainly given most satisfactory evidence of the power and value of sanitary measures: for, as we have stated in the early part of this report, while no person was attacked without some obviously exciting cause, so, in every case in which those much exposed were removed from these deleterious influences, and provided with cleanly, airy apartments, and suitable food, an attack of the disease was averted.

The laws of nature, although immutable, are beautifully adapted to the welfare and happiness of mankind. In nothing can this fact be more strikingly illustrated than in its relation to the public health, in a City whose natural advantages, for improvement, in this respect, are not surpassed by any other.

Modern science has demonstrated that the most malignant epidemics may be greatly controlled by efficient sanitary reforms: It is not unreasonable, therefore, that, for the future, the legal custodians of the public health, (the necessary means being first placed at their disposal,) should be held to a strict accountability for its conservation.

For the Medical Staff of the Hospital.

HENRY G. CLARK,

*Superintendent.*



# LIST OF LOCALITIES,

WITH THE NUMBER OF CASES OCCURRING IN EACH.

The following list of locations in which cases occurred, commences at the south end of the City, and proceeds nearly regularly, according to the map, towards the north and west:

	Cases.		Cases.
Allen's block, Arnold street,	7	1 Utica street,	1
Concord street,	1	49 " "	1—2
13 Hamburg street,	1	East street,	3
Fabin street,	1	17 East street,	1—4
West Dedham street,	1	Sea street,	21
Middlesex street,	1	4 Sea street,	1
Suffolk street,	1	13 " "	1
Erie street,	1	21 " "	1
East Orange street,	1	26 " "	1
20 " "	1—2	39 " "	1
705 Washington street,	1	43 " "	1
Corey avenue, Ash street,	1	45 " "	1
98 Warren street,	1	64 " "	1
Knox street,	1	75 " "	7
Church street,	3	101 Sea street,	1
3 " "	1	107 " "	1
" " cor. Cedar,	1—5	113 " "	1
Marion street,	1	118 " "	1
Shaving street,	4	122 " "	1
Cove street,	11 }	130 " "	1
46 Cove street,	1 }	136 " "	1
Cove place,	7 }	150 " "	1—44
2 " "	1 }	South street,	3
3 " "	1 }	3 " "	1—4
5 " "	3 }	Essex street,	1
Eliot street, } 2		7 Oliver place,	1
59 " " } 1		Ætna place,	1
1 Foster place,	2	36 High street,	1
La Grange place,	1	86 Federal street,	1
Fayette court,	1	Sullivan place,	3
Kneeland street,	2	14 " "	1—4
Albany street,	2	Fort Hill Hospital,	2



	Cases.
Atkinson street,	1
11 " "	1
22 " "	1
31 " "	1—4
Washington avenue,	6
Leman's alley,	1
Purchase street,	3
48 " "	1
120 " "	1
143 " "	1
173 " "	1—7
Hamilton street,	11
2 " "	3
3 " "	1
8 " "	1
11 " "	1
15 " "	1
18 " "	1
19 " "	1
69 " "	1—21
Hamilton court,	1
4 Humphrey place,	7
2 Hamilton alley,	2
Wendell street,	1
Oliver street,	7
7 " "	2
8 " "	1
9 " "	1
29 " "	1
31 " "	1—13
Battery-march street,	12
12 " "	1
14 " "	6
cor. Hamilton,	4—23
New Broad street,	2
Broad street,	28
3 Broad street,	1
6 " "	1
9 " "	2
74 " "	2
79 " "	1
82 " "	1
84 " "	1
86 " "	3
87 " "	1
89 " "	2
91 " "	2
92 " "	2
96 " "	1
98 " "	2
99 " "	1
104 " "	4
107 " "	2
111 " "	2
116 " "	1
118 " "	1
163 " "	3
164 " "	1
211 " "	1—65
Burgess' alley, Broad st.	16
Baker's alley, "	7

	Cases.
Marsh's alley, Broad st.	1
Wharf street,	4
1 " "	2
2 " "	1
5 " "	1
7½ " "	2—10
Well street,	7
5 " "	1—8
Bread street,	5
6 " "	1—6
Milk street,	2
120 Milk street,	1—3
7 Harvard place,	1
Commercial street,	1
38 " "	1—2
Commercial wharf,	2
Fulton street,	1
Cross street,	3
13 " "	3—6
Ann street,	10
54 Ann street,	1
106 " "	2
108 " "	1
110 " "	1
112 " "	2
126 " "	1
136 " "	1
152 " "	1
155 " "	1
175 " "	4
191 " "	1
252 " "	3
310 " "	1
324 " "	1—31
Keith's alley, Ann st.	3
5 " " "	1—4
Mechanics' street,	6
Mechanics' court,	6
3 Lewis street,	1
Moon-street court,	1
Hatters' square,	2
Richmond street,	4
49 Hanover street,	1
115 " "	1
136 " "	13—15
Hanover avenue	1
1 Lime alley,	1
143 Charter street,	1
19 Tileston street,	1
Prince street,	22
" cor. Salem,	1
3 Prince street,	1
4 " "	1
5 " "	1
8 " "	2
23 " "	1
26 " "	1
36½ " "	1
37 " "	1
75 " "	1—13
Salem street, cor. Prince,	1



	Cases.
3 Bartlett place,	1
North Margin street,	2
31 North Margin street,	3
Endicott street,	5
37 " "	1
38 " "	1
83 " "	1—8
Stillman street,	1
38 " "	1
83 " "	1—3
1 Thacher street court,	1
Thacher street avenue,	1
7 Charlestown street,	1
Causeway street,	1
28½ Portland street,	1
54 " "	1—2
Deacon street,	1
38 Merrimack street,	1
Andover street,	1
13 Nashua street,	1
79 " "	1
96 " "	1—3
9 Lowell street,	1
Cotting street,	1
Wall street,	1
14 " "	1—2
11 South Margin street,	1
44 " "	3
48 " "	1—5
29 Gouch street,	1
Pitts street,	1
11 " "	1—2
Ivers street,	1
Distil-house square,	1
Cambridge street,	1
8 Staniford street,	1
19 Temple street,	1
23 Belknap street,	1
South Russell street,	1
North Russell street,	2
6 " "	2
12 " "	2
17 " "	1—7
64 Allen-street place,	1
Lovett place, Poplar street,	1
Sprong street,	1
17 " "	1—2
3 Milton street,	1
Brighton street,	2
6 Brighton street,	1
42 " "	1—4
12 Fruit street,	1
Fruit-street place,	1
Bridge-street court,	1
8 Cyprus street,	1
North Grove street,	1
8 " "	1—2
10 Grove place,	1
Butolph street,	1
6 West Centre street,	1
James place, W. Centre st.	1
Southac street,	2

	Cases.
May street,	1
15 " "	1—2
May-street court,	1
West Cedar street,	4
56 " "	1—5
54 Mount Vernon street,	1
36 Charles street,	1
" "	1—2

*South Boston.*

No location mentioned,	21
House of Industry,	23
Lunatic Hospital,	10
House of Correction,	4
2d street,	5
3d " "	7
4th " "	2
5th " "	2
A " "	4
C " "	1
Silver street,	1
Wright's court,	1
Swan street,	5
Athens street,	1
250 Broadway,	1
465 " "	1—2
South Boston Point,	1
Deer Island Hospital	28
From shipboard,	10

*East Boston.*

Location not reported,	26
Centre street,	1
Lexington street,	1
London street,	3
Maverick street,	2
Marion street,	1
Liverpool street,	5
Havre street,	1
Kelley place,	1
	—
	687

Location unknown,	20
	—
Total,	707
Recovered,	96
	—
Total Deaths,	611



## PLACE OF BIRTH.

Ireland,	-	-	-	-	-	-	-	-	-	-	-	460
Children of Irish parents,	-	-	-	-	-	-	-	-	-	-	-	49
England,	-	-	-	-	-	-	-	-	-	-	-	18
Scotland,	-	-	-	-	-	-	-	-	-	-	-	14
British Provinces,	-	-	-	-	-	-	-	-	-	-	-	18
Continent of Europe,	-	-	-	-	-	-	-	-	-	-	-	11
Jamaica,	-	-	-	-	-	-	-	-	-	-	-	1
St. Helena,	-	-	-	-	-	-	-	-	-	-	-	1
Boston,	-	-	-	-	-	-	-	-	-	-	-	42
Massachusetts,	-	-	-	-	-	-	-	-	-	-	-	42
New England,	-	-	-	-	-	-	-	-	-	-	-	39
Other States,	-	-	-	-	-	-	-	-	-	-	-	12
												707

## AGES.

Years.	Years.	Years.	Years.	Years.	Years.
1 13	11 4	21 10	31 10	41 4	
2 13	12 5	22 14	32 7	42 12	5,—63
3 8	13 2	23 8	33 15	43 5	5 to 10,—40
4 11	14 4	24 11	34 13	44 8	10 to 15,—18
5 18—63	15 3—18	25 25—68	35 42—87	45 23—52	15 to 20,—36
6 12	16 3	26 7	36 18	46 7	20 to 25,—68
7 1	17 5	27 16	37 11	47 4	25 to 30,—101
8 14	18 9	28 15	38 14	48 5	30 to 35,—87
9 4	19 10	29 17	39 9	49 7	35 to 40,—87
10 9—40	20 9—36	30 46—101	40 35—87	50 16—39	40 to 45,—52
103	54	169	174	91	45 to 50,—39
					50 to 55,—22
					55 to 60,—19
51 6	61 3	71 0	81 0	91 0	60 to 65,—18
52 4	62 4	72 0	82 0	92 0	65 to 70,—6
53 1	63 2	73 0	83 1	93 0	70 to 75,—1
54 6	64 2	74 1	84 0	94 1—1	75 to 80,—2
55 5—22	65 7—18	75 0—1	85 0—1		80 to 85,—1
56 8	66 4	76 0	86 0		85 to 90,—0
57 2	67 0	77 1	87 0		90 to 95,—1
58 1	68 0	78 0	88 0		
59 1	69 0	79 0	89 0		661
60 7—19	70 2—6	80 1—2	90 0—0		Unknown, 46
41	24	3	1		707



# WEATHER TABLE.—JUNE.

D. of mo.	Sun-rise.	M.	Sunset.	Kept at the Institution for the Blind.*	Mean Temperature.	Minimum of Thermometer.	Maximum of Thermometer.
1	52	60	54	Cloudy, clear, S, SE.	64.76	Sunrise, 52	82 ab. z.
2	62	64	64	Clear, S, SE.	63.46	Noon, 54	91 ab. z.
3	66	76	72	Cloudy, calm, SSE, S.	63.7	Sunset, 53	88 ab. z.
4	66	76	68	Cloudy, fair, cloudy, SSW, SW.			
5	60	65	64	Clear, WNW, NW, SW.			
6	58	68	70	Fair, W, NW, W.			
7	62	69	68	Light clouds, NW, SW.			
8	62	54	52	Cloudy, calm, W, NE, NNE.			
9	58	64	62	Clear, cloudy, NW, E.			
10	64	62	64	Cloudy, calm, SE and E.			
11	56	60	58	Fair, N, E.			
12	56	60	58	Fair, cloudy, wind E all day.			
13	56	67	60	Cloudy, fair, W, SW.			
14	62	68	66	Fair, SW, E, SE.			
15	62	74	70	Cloudy all day, SW, SSW, SW.			
16	68	83	80	Clear, WSW, SW, NW.			
17	64	73	72	Clear, NW, SE.			
18	64	80	77	Clear, light clouds, wind variable.			
19	68	86	88	Clear, clouds, SW and W.			
20	74	84	80	Light clouds, NW and SE.			
21	80	88	84	Fair, W, SE, SSW.			
22	82	81	88	Clear, WSW, SSW.			
23	80	88	87	Light clouds all day, W.			
24	72	82	68	Cloudy, rain, NW, E and S.			
25	70	80	78	Clear, W, NW and W.			
26	70	80	74	Clear, W, N.			
27	64	79	81	Clear, cloudy, WNW, NW.			
28	67	70	62	Cloudy, rainy, NE and SE.			
29	58	59	58	High wind, cloudy, E and N.			
30	60	76	74	Calm, SW.			
					Mean Temperature.	Minimum of Thermometer.	Maximum of Thermometer.
					Sunrise, 52	Sunrise, 52	Sunrise, 52
					Noon, 54	Noon, 54	Noon, 54
					Sunset, 53	Sunset, 53	Sunset, 53
					Rain during month, 1.27 inches.		
					Mean Heat of month, 65.97.		

# WEATHER TABLE.—JULY.

D. of mo.	Sun-rise.	M.	Sunset.	Kept at the Institution for the Blind.	Mean Temperature.	Minimum of Thermometer.	Maximum of Thermometer.
1	67	70	70	Cloudy, fair, N and NW.	67.45	Sunrise, 67	92 ab. z.
2	60	66	62	Clear, cloudy, NE and N.	77.45	Noon, 60	93 " "
3	56	60	64	Clear, N and SE.	70.32	Sunset, 62	80 " "
4	64	67	62	Clear, cloudy, SE, SSW.			
5	58	62	62	Cloudy, N, NE, calm.			
6	61	78	75	Cloudy, NW, W, and SW, calm.			
7	70	77	73	Cloudy, SW all day.			
8	75	82	76	Calm, light clouds, W, SE.			
9	66	71	69	Cloudy, calm, E, all day.			
10	72	80	76	Cloudy, clear, W, S, SW, SSW.			
11	68	87	85	Cloudy, clear, SW, WSW.			
12	76	92	88	Clear, WSW, calm.			
13	79	93	92	Clear, W, WNW.			
14	80	81	66	Cloudy, high wind at sunset, N.			
15	58	67	66	Clear, cloudy, NW, N.			
16	58	74	72	Clear, cloudy, wind variable.			
17	66	78	76	Clear, cloudy, SW.			
18	65	83	74	Calm, clear, SW all day.			
19	70	85	78	Calm, cloudy, fair, SW.			
20	70	85	78	Cloudy, fair, cloudy, SW.			
21	72	78	75	Calm, cloudy, fair, W, and NW.			
22	77	80	75	Cloudy, calm, clear at noon, W.			
23	67	70	66	Light clouds, calm, NE, E.			
24	65	70	66	Clear, NW, nearly calm.			
25	65	70	64	Cloudy, E, and ESE.			
26	66	76	77	Cloudy, SSE, SW.			
27	70	85	78	Clear, cloudy, SW.			
28	64	80	78	Cloudy, WNW, calm.			
29	58	81	76	Clear, WSW, ESE.			
30	64	82	78	Nearly clear, high wind, SW.			
31	73	85	73	Clear, cloudy, SW, calm.			
					Mean Temperature.	Minimum of Thermometer.	Maximum of Thermometer.
					Sunrise, 67	Sunrise, 67	Sunrise, 67
					Noon, 60	Noon, 60	Noon, 60
					Sunset, 62	Sunset, 62	Sunset, 62
					Rain during month, 4-10 inches.		
					Mean Heat of month, 71.74.		

\* Elevation 115 feet above the level of the sea.



# WEATHER TABLE.—AUGUST.

D. of mo.	Sun-rise.	M.	Sunset.	Kept at the Institution for the Blind.	Mean Temperature.
1	61	78	68	Cloudy, clear, calm, wind variable.	65.65
2	60	74	70	Cloudy, NW and SE, calm.	66
3	61	77	69	Clear, WSW and SE.	66
4	68	76	72	Fair, cloudy, SW and SE.	66
5	70	74	68	Cloudy, fair, wind variable.	66
6	64	75	72	Calm, cloudy, SE and N.	66
7	67	78	76	Cloudy, rain, fair, W, NW.	66
8	67	77	70	Clear, NW, SE.	66
9	62	77	77	Slightly cloudy, SW and SE.	66
10	66	74	68	Cloudy, violent thunder-storm, SE.	66
11	66	75	67	Cloudy, SE.	66
12	65	66	62	Cloudy, E, and N, calm.	66
13	66	76	66	Cloudy, clearer, at sunset, S.	66
14	66	72	64	Cloudy, calm, E, foggy.	66
15	63	73	68	Clear, high wind, SW and NW.	66
16	60	72	78	Clear, NW, all day.	66
17	64	78	74	Cloudy, wind variable.	66
18	66	76	72	Cloudy, clear, SSW.	66
19	64	72	66	Cloudy, clear, cloudy, NE, calm.	66
20	64	74	68	Cloudy, clear, NE, E, SE.	66
21	61	76	62	Light clouds, calm, wind variable.	66
22	70	80	78	Slightly cloudy, W all day.	66
23	66	76	64	Cloudy all day, NE.	66
24	62	70	66	Cloudy, clear, N, NW, W.	66
25	76	62	75	Fair, W, NW, W.	66
26	68	82	78	Calm, clear, W and SW.	66
27	66	*	74	Clear, cloudy, S, SSW.	66
28	70	83	77	Clear, cloudy, SW.	66
29	70	82	74	Calm, cloudy, wind variable.	66
30	70	78	72	Cloudy, clear, SSW, SE.	66
31	70	85	74	Cloudy, S and SSW.	66

# WEATHER TABLE.—SEPTEMBER.

D. of mo.	Sun-rise.	M.	Sunset.	Kept at the Institution for the Blind.	Mean Temperature.
1	54	64	64	Wind high, cloudy, NE and E.	54.8
2	54	63	62	Clear, windy, NW all day.	54.8
3	50	66	62	Calm, fair, NW, SE.	57.5
4	52	73	62	Clear, cloudy, calm, S.	57.5
5	62	73	68	Calm, S, cloudy, clear.	57.5
6	64	73	66	Fair, NE and SE.	57.5
7	66	80	66	Cloudy, SE, SW, NW.	57.5
8	54	63	59	Clear, NW and SE.	57.5
9	52	64	62	Perfectly clear all day, SE and NW.	57.5
10	52	66	60	Perfectly clear all day, wind calm, NW, [SE.]	57.5
11	56	66	60	Fair, NW, E.	57.5
12	54	70	66	Cloudy, clear, calm, S.	57.5
13	60	74	67	Clear, calm, SW and S.	57.5
14	67	62	70	Calm, clear, cloudy, NE, SE.	57.5
15	60	69	68	Cloudy, SW, W, S.	57.5
16	62	70	71	Cloudy, clear, SE and S.	57.5
17	68	77	74	Cloudy, nearly calm, SW.	57.5
18	62	69	63	Nearly clear, NW and N.	57.5
19	48	58	52	Fair wind, N, NW, NE.	57.5
20	48	58	54	Calm, cloudy, clearer, wind variable.	57.5
21	54	60	56	Cloudy, NE all day.	57.5
22	52	64	60	Cloudy, calm, NNE and SE.	57.5
23	62	70	60	Cloudy, rain, S and W.	57.5
24	50	61	56	Clear, cloudy, W.	57.5
25	54	68	58	Clear, cloudy, W all day.	57.5
26	60	74	67	Cloudy, clear, SW, WNW.	57.5
27	50	57	66	Clear, calm, SW all day.	57.5
28	60	66	62	Nearly clear all day, WNW, NW.	57.5
29	52	66	52	Fair, NW, NE.	57.5
30	52	51	46	Cloudy, E, ENE.	57.5



# COURSE OF CHOLERA IN BOSTON IN 1849.

## CHART

showing the locations in which all the cases of Cholera at the Hospital & all the fatal cases elsewhere originated.

The dark spots give the localities, & the figures, the number of cases which occurred at that location.

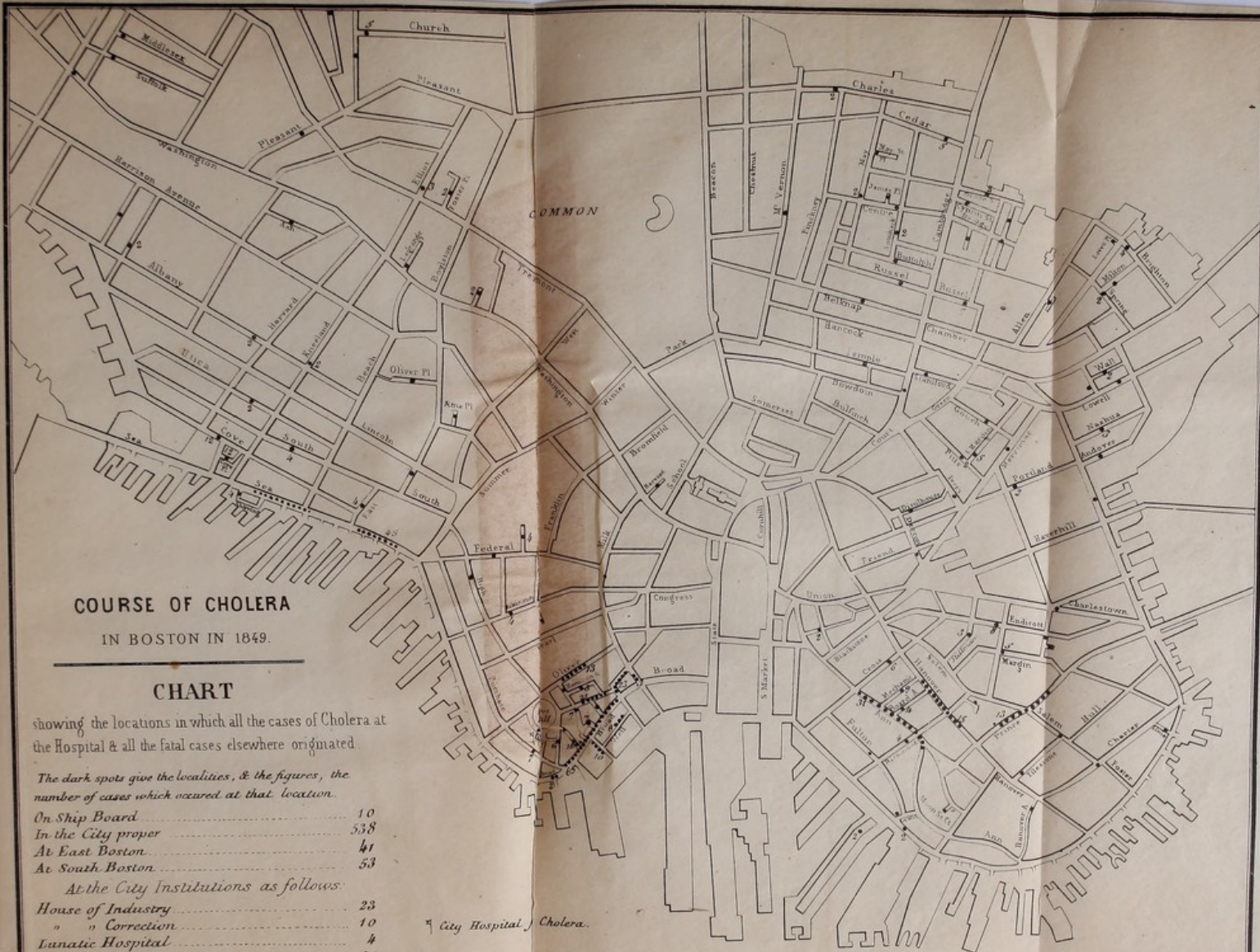On Ship Board	10
In the City proper	538
At East Boston	41
At South Boston	53

At the City Institutions as follows:

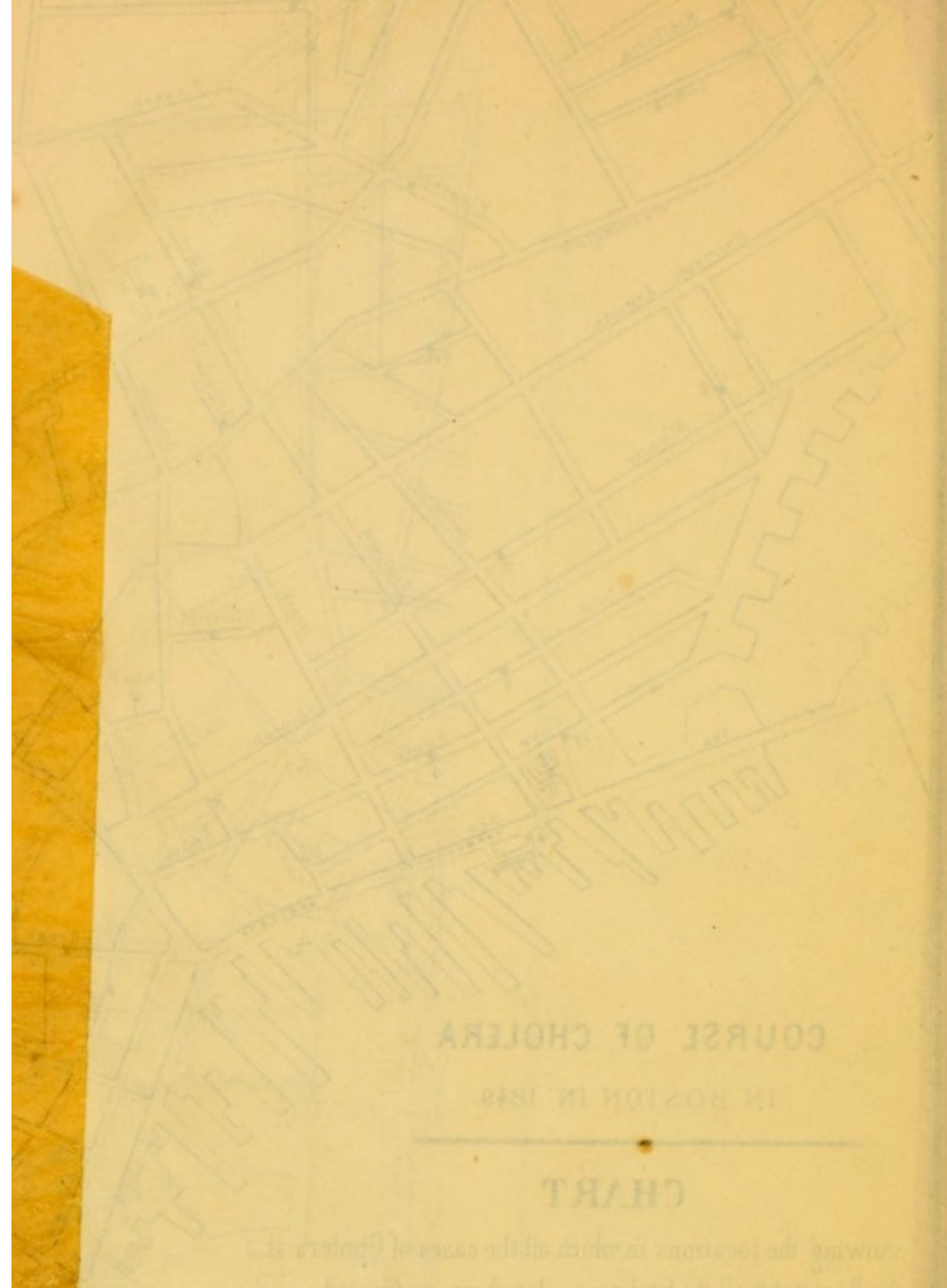
House of Industry	23
" " Correction	10
Lunatic Hospital	4
At Deer Island	28

Fatal cases 611. 707.

City Hospital, Cholera.







# COURSE OF CHOLERA

IN BOSTON IN 1849

## CHART

Showing the locations in which all the cases of Cholera at the Hospital & all the fatal cases elsewhere originated

The chart also gives the duration of the disease, the number of cases which occurred at each location

10	Ship Board
15	in the City
20	at the Hospital
25	at South Boston
30	at the City
35	at the City
40	at the City
45	at the City
50	at the City
55	at the City
60	at the City
65	at the City
70	at the City
75	at the City
80	at the City
85	at the City
90	at the City
95	at the City
100	at the City







