

Tumour of lateral portions of the lower jaw removed without external wound / by C.F. Maunder.

Contributors

Maunder, C. F. 1832-1879.

Publication/Creation

London : J. & A. Churchill, 1874.

Persistent URL

<https://wellcomecollection.org/works/gsu2c38c>

License and attribution

This work has been identified as being free of known restrictions under copyright law, including all related and neighbouring rights and is being made available under the Creative Commons, Public Domain Mark.

You can copy, modify, distribute and perform the work, even for commercial purposes, without asking permission.



Wellcome Collection
183 Euston Road
London NW1 2BE UK
T +44 (0)20 7611 8722
E library@wellcomecollection.org
<https://wellcomecollection.org>

MAUNDER
ON
REMOVAL OF TUMOUR
OF PORTIONS OF THE
LOWER JAW.

TRO
RAMC
Coll.
MAU



22101955862




3

e

With the Authors Recd. Regards

TUMOUR

L. Langmore



LATERAL PORTIONS OF THE

LOWER JAW

REMOVED WITHOUT EXTERNAL WOUND

BY

C. F. MAUNDER,

SURGEON TO THE LONDON HOSPITAL; FORMERLY DEMONSTRATOR
OF ANATOMY IN GUY'S HOSPITAL.

LONDON

J. & A. CHURCHILL, NEW BURLINGTON STREET

—
1874

BY THE SAME AUTHOR.

A Translation of Ricord's Lectures on Chancre.
Operative Surgery. Second Edition. 165 Woodcuts.

PRO
RANC
all.
MAU



PREFACE.

I AM led to bring the subjoined method of operation to the notice of the Profession, because I feel that the practice of our art will have one horror less for a patient, who can be assured that no unsightly scar will disfigure his face.

C. F. MAUNDER.

16, QUEEN ANNE STREET, CAVENDISH SQUARE, W.

July, 1874.



Digitized by the Internet Archive
in 2016

<https://archive.org/details/b28709482>

TUMOUR OF THE LOWER JAW.

So far as I am aware, the instructions usually given by authors to guide surgeons in the removal of portions comprising more or less of the whole depth of the lower jaw, when the seat of tumour, not being merely the symphysis, involve section of the skin. Some advise certain incisions to be traced so as to form a flap; in one case to be turned up, in the other to be turned down, in order to expose the condemned piece of bone. Some, in making the flap, carry the incision into the mouth, either at its angle or some point of the lower lip, and thus deform this feature. Others are content with incision of the cheek, leaving the mouth untouched. Many of the instructions if followed, must disfigure the patient very seriously. Free incision of the cheek, as is recommended, entails free bleeding and delay in arresting it, the formation of unsightly scars, and an unnecessary interference with the nervous supply to the muscles of expression. The mode of proceeding which I have practised in two instances is here described, and the result illustrated.

CASE I.

MYELOID TUMOUR OF LOWER JAW.

The patient, Sarah C——, ten years of age, was referred to me by Mr. Owen, of Leatherhead. The left base of the jaw was enlarged to the size of a hen's egg, the swelling projecting outwards, and inwards to the floor of the mouth, displacing the tongue somewhat, and deforming the lower part of the face. The tumour had a history of two years, was painless, smooth on the surface, and hard and resistant to the touch, and gave one the impression that a growth within was expanding the jaw. It had enlarged rather quickly of late. The teeth usually found at that age were present. I did not pretend to make a diagnosis beyond suggesting that it was probably benign. I thought it possible that I might have to deal either with a cyst or with a fibrous or cartilaginous growth; and if so, that I might be able to evacuate the one and enucleate the other, and, at the same time, preserve the line of the jaw unbroken; but in this I was disappointed.

Operation.—*March 9th, 1870.*—The child being under the influence of chloroform, recumbent, with the head well forwards, I penetrated the tumour at the most resilient spot with a drill by way of exploration. A little blood only flowed. With a chisel and mallet I perforated the thin, bony wall at this spot, and extracted a small portion of a growth. This was at once submitted to a microscopic examination by Dr. Sutton and Mr. Tay, and pronounced to be myeloid. The bleeding from the growth, now increasing, was checked by the introduction of a bit of sponge. I determined to remove the portion of bone containing the growth, and if possible through the mouth and without cutting the skin of the cheek and lip at all.

Standing somewhat behind, and on the right side of the patient, the integuments of the chin, including muscular attachments and periosteum, were first turned down off the symphysis, partly with a scalpel and partly with a raspator, so as to expose the right side of the jaw opposite the right canine tooth (which was then extracted by Mr. A. W. Barrett), to the action of the saw and cutting forceps. At the back of this position the soft parts were also detached from the bone, and the floor of the mouth was perforated so as to admit of the introduction of a narrow spatula passed behind the bone to protect the soft parts from injury by the saw. The section here being completed, the mucous membrane and

periosteum covering the tumour both in front of and behind the alveolus, as well as along the lower half of the anterior edge of the ramus, were severed down to the bone; and a raspatory introduced separated the periosteum, and with it muscular attachments to the required extent. By a little manœuvring the end of the raspatory was made to pass round the base of the jaw and to appear under the floor of the mouth, and with the aid of the forefinger similarly introduced, the soft parts on the deep surface of the bone were detached from it. It was found to be possible to turn the soft parts covering the chin literally inside out. While the bone was being cut by the forceps the thin shell containing the tumour cracked, and so the condemned fragment came away in two portions. This fracture did not facilitate the operation. The next step consisted in cutting across the ramus about its middle, and this was effected with forceps alone (guided into position by the point of the left forefinger) but not without some longitudinal splintering. During the operation the mouth was kept open by a gag. Before detaching the *frænum linguæ* and muscles at the back of the symphysis, the tongue was secured by a ligature passed through it near the tip, and held by an assistant to prevent the possibility of the organ falling back upon the larynx. Also, before the patient left the theatre the tongue was firmly secured with its raw surface in apposition with the

raw surface of the integuments of the chin by a hare-lip pin, and also by fastening the ends of the ligature previously passed through the tip of the organ on either side to either end of the pin.

Bleeding was trifling, no ligature being requisite.

Progress of Case.—During the early days following operation there was a good deal of swelling about the mouth with foetid discharge. The child was sustained in a semi-recumbent posture with the head well forwards. The buccal cavity was repeatedly syringed with Condyl's Fluid and water, and liquid nourishment was plentifully administered. The case progressed favourably throughout; and before three weeks had elapsed, she could protrude her tongue tolerably well and articulate, and was running about the ward. Subsequently a very small piece of necrosed bone came away from the sawn surface of the remnant of the base.

Examination of Bone.—My colleague, Mr. Barrett, examined the diseased bone, and discovered a misplaced second bicuspid tooth; it was lying at right angles to its natural position. This malplaced organ may have been the cause of the growth; but inasmuch as the corresponding tooth was also absent, the fact was comparatively valueless from an etiological point of view.

Remarks.—The patient was recumbent during the operation, but no sign of danger from blood passing into the larynx was exhibited. Bleeding was comparatively trifling, the blood coming chiefly from the tumour when this had been broken into, but this was arrested at once by the introduction of a piece of sponge. A groove in the gum having been made with a scalpel so as to admit the end of the raspatory, the periosteum and chief muscular attachments, such as those of the masseter and internal pterygoid, were separated; and the bone being bared, awaited section only.

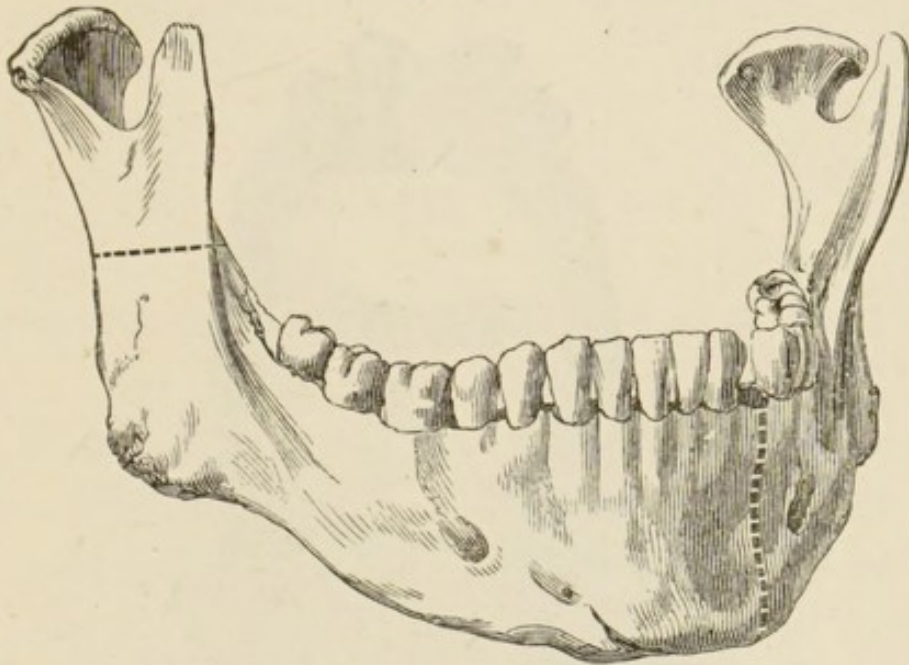
By this proceeding a very large piece of the lower jaw (Fig. 1),* containing a growth of the size of a hen's egg, was removed through the mouth, without any section whatever of skin; with trifling bleeding, and without division either of the facial artery or of branches of the facial nerve. And what is of great importance in the female, at all events, there is *no* scar.

Postscript.—*April 19th, 1874.*—To-day, in company with Mr. Owen, I visited the child, the subject of the above remarks, and who had been operated upon rather more than four years ago (March 9th, 1870). I found her wonderfully grown, being

* Shows on the healthy jaw, included by the dotted lines, the extent of bone removed. By an error of the artist the right instead of the left side of the jaw is represented.

unusually tall for her age, but thin. Although possessed of only three teeth in the remnant of the

FIG. 1.




right half of the lower jaw, she masticates tolerably well, and enjoys good health. She works at her needle many hours daily; and notwithstanding this cramped position she carries herself well, being very upright.

Twenty months subsequent to the operation, when her photograph was taken, of which the woodcut (Fig. 2) is a copy, the deformity was comparatively slight; but now, by lapse of time, growth and development, the upper part of the face has become enlarged in all directions, while the remnant of the lower jaw has probably remained nearly stationary.

The immediate effect of the operation was (two-

thirds of the semi-circle of bone being removed) to allow the remnant to fall in towards the centre

FIG. 2.



of the mouth, and to make the chin somewhat pointed. Now, by reason of her growth, the pointed chin is more marked, as though she were the subject of a congenital want of development of the lower jaw, whilst when the muscles about the mouth are in a state of repose, the mouth falls away to the left. Her mother says this is especially evident during sleep. This maximum of deformity will be reached when the patient is full grown, and may be expected, if the operation be performed in early life, while the minimum will accrue to an adult submitted to a similar operation.

CASE II.

FIBROUS EPULIS.—(*Reported by Mr. J. H. Turtle.*)

F. S., aged 35, married, was admitted into the London Hospital on the 15th May, 1873, having been referred to Mr. Maunder by Dr. Dove, of Pinner.

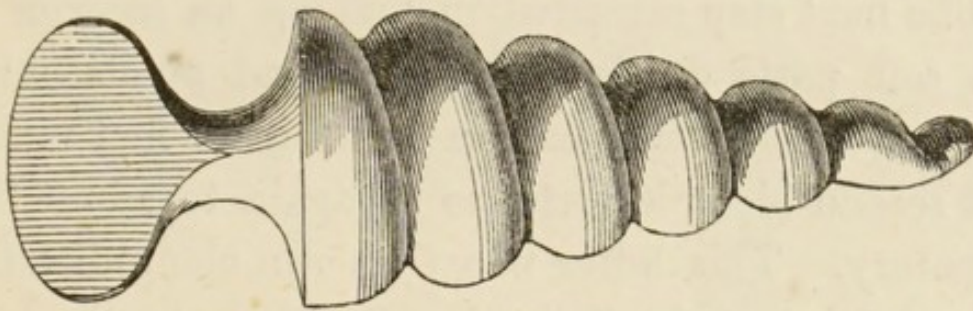
History.—She stated that about a year and nine months ago she noticed a decayed molar tooth on the right side of the lower jaw. She removed a portion of it at the time, and not long afterwards observed a growth springing from the situation of the decayed tooth. It gradually extended itself along that side of the jaw. A surgeon removed the tooth which was believed to be the cause of the growth, and afterwards the tumour. In six weeks from the time of removal it appeared again, and was a second time removed. It made its appearance a third time, and has gradually increased in size. She has been free from pain throughout.

On examination the growth was found to occupy the original site of the molar teeth. It had very much the appearance and consistence of gum tissue hypertrophied and indurated. It encroached considerably on the bone below the level of the alveolus, especially on the inner side; was very firmly adherent to it throughout its extent, as though growing from it, and the surface was continuous with the mucous membrane lining both the cheek and the floor of the mouth. Thus, only some portion of the outer surface and the mere line of the base of this part of the bone were free from the growth. There was no evidence of glandular affection, nothing to contra-indicate an operation, although the patient had not a robust appearance.

Operation.—*May 21st, 1873.*—The patient was seated in a dentist's chair, and the head comfortably and conveniently supported, in order that blood should readily flow out at the mouth rather than pass backwards towards the larynx and pharynx. Chloroform having been administered, the mouth was fixed open by the screw-gag (Fig. 3), introduced and held by an assistant at the left commissure of the lips. This gag had also the beneficial effect of depressing the tongue. The operator standing in front, and somewhat to the left of the patient, placed the tip of his left forefinger on the anterior

sharp edge of the right ramus immediately above the natural position of the last molar tooth. Along this, as a guide, a scalpel, its edge protected by adhesive plaster to within half an inch of the point,

FIG. 3.



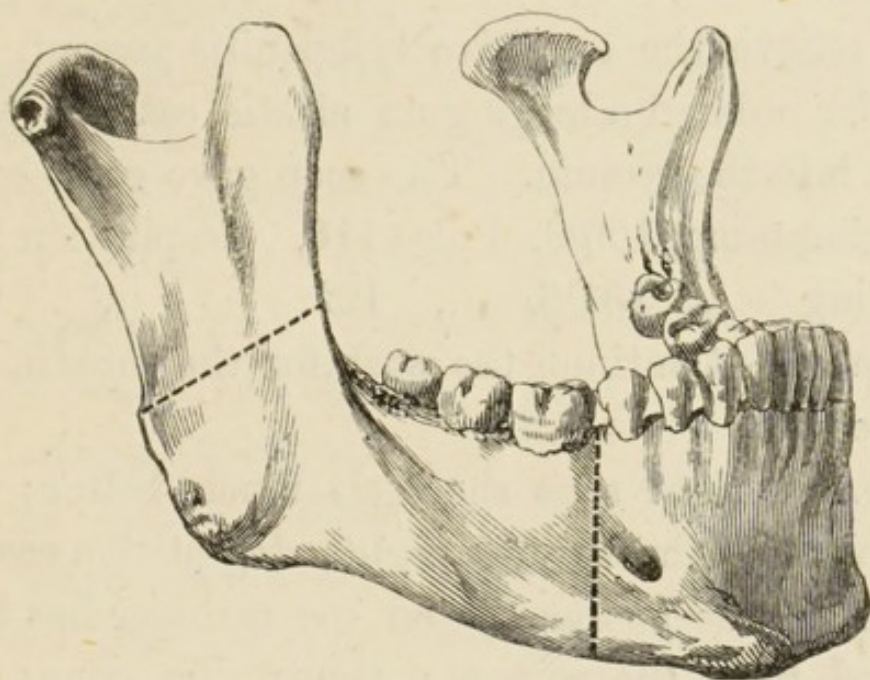
was carried and made to sever the soft parts down to the bone, just enough to admit the raspatory. The point of this latter was now passed through the wound made by the scalpel and pushed between the periosteum and bone, so as to separate the former from the latter, first on one side of the ramus and then on the other. In this way, also, the portions of the masseter and internal pterygoid muscles attached to condemned bone were separated. The cutting forceps, guided by the left forefinger, were next carried to this spot, and by a little care a blade was passed on each side of the ramus, but the bone could not be cut through at this stage. The possibility of this failure had been foreseen and provided against by a small stout, straight, narrow-bladed saw, blunt at the extremity, but without

a button. This instrument, having been placed under the periosteum, upon the outer surface of the ramus, was worked through the mouth, so as to cut a groove in the bone and prepare the way for the cutting forceps, which now with some difficulty completed the section.

The next step consisted in making an incision in the soft parts down to the bone and on its outer surface, opposite the position between the first molar and second bicuspid teeth, so as again to admit the raspatory. This latter was then run along directly towards the angle of the jaw, to separate the soft parts, and manipulated so as to turn round the base and come up under the floor of the mouth with a similar object. The raspatory withdrawn, the forefinger completed the further separation of the internal pterygoid and stylomaxillary ligament, &c The anterior surface of the bone was now cleared opposite the original interval between the teeth mentioned, and having been partially severed by the saw used perpendicularly, its section was completed by forceps. It was now found that the means which had been employed to separate the periosteum and muscles from the bone had likewise nearly separated the growth from the bone, leaving the former almost solely connected with mucous membrane. There remained then only to divide the mucous membrane, reflected on the one side from the cheek, and on the other from the

floor of the mouth, and the operation was finished. While the saw was being used the jaw was steadied by the finger and thumb of an assistant grasping it on the cutaneous surface. The bleeding was slight and soon ceased. (Fig. 4.) *

FIG. 4.



22nd.—Slept for a short time during the night; swallows with difficulty; complained of slight pain in the abdominal region, which is tympanitic.

Ordered.—The mouth to be often washed out with a mixture of Condyl's Fluid and water, 1 drachm of the former to a pint of the latter. Should the deglutition become more painful enemata only are to be used, consisting of half a pint of milk and half an ounce of brandy, every four hours.

* Shows, on a healthy jaw, the extent of bone removed.

Morning temp. 102·9. Pulse 136. Respiration 36.

Evening „ 101·8. „ 120. „ 22.

23rd.—Can swallow a little to-day, but the enemata are being used. Pain in the abdomen is very acute, and on inquiry it was found that a large quantity of air had been pumped into the bowel with the enemata.

To relieve the excessive tympanitis present, Mr. Maunder ordered a large gum elastic catheter to be passed into the rectum. This soon gave great ease.

Morning temp. 100·8. Pulse 116. Respiration 22.

Evening „ 101·6. „ 122. „ 20.

Ordered.—Continue the wash for the mouth, also the enemata.

24th.—Patient says she feels much better; has slept tolerably through the night; deglutition easier; no pain in the abdomen, and the catheter has been removed from the rectum; tympanitis gone; can put the tip of her tongue out without pain. There is a free discharge from her mouth of rather an offensive character.

Morning temp. 102·8. Pulse 124. Respiration 26.

Evening „ 101·4. „ 114. „ 24.

Ordered.—The enemata to be discontinued. To take freely of beef tea and milk. Continue the wash for the mouth.

25th.—Complained of a slight pain on the right side of her face, otherwise doing well; bowels have not been relieved since the operation.

Morning temp. 99·4. Pulse 106. Respiration 20.

Evening „ 100·4. Pulse 110. „ 16.

Ordered.—An enema of soap and water.

26th.—Pain in the face is worse. She describes it as a continued aching pain located principally in the right ear and extending down the side of the neck about two inches.

Morning temp. 100·6. Pulse 110. Respiration 18.

Evening „ 99·8. „ 106. „ 22.

Ordered.—A hot fomentation to the neck.

27th.—Has had a fair night; pain in the face and neck is much relieved; the discharge from the mouth has still an offensive odour. Partook of some minced meat to-day.

30th.—Patient looks decidedly better; can put her tongue out a little more.

June 10th.—Up to to-day, when the patient got up for a short time, she has progressed favourably. She can masticate a little.

11th.—Has had pain on the right side of the face and chin since last night, which has been very acute, the latter being swollen and tender to the touch.

Morning temp. 100. Pulse 96. Respiration 18.

Ordered.—A hot fomentation.

20th.—Gets up daily; some induration and tenderness still about the chin; scarcely any discharge from the mouth now.

28th.—Goes home to-day, but there is still

swelling, induration, and slight tenderness about right side of the chin.

Here Mr. Turtle's report ends.

Postscript.—*July 25th.*—To-day Mrs. S—— came up from the country to see me, her general health being very much improved. Just under the chin to the right side of the middle line there is a small wound, which had been artificially made a fortnight previously, and also about a fortnight subsequent to her leaving the hospital, to evacuate a small abscess. From this opening, and also from within the mouth, three or four small sequestra had come away, and even then a probe introduced detected a small portion of dead bone.


Between this date and October 16th, when the wound closed, two or three small fragments of bone came away. Doubtless the fact that the process of exfoliation occupied so long a period is in great measure due to the existence of pregnancy, the patient having been confined on November 21st, six months subsequent to operation.

The symphysis being unsupported on the right side has a tendency to that direction, and consequently, excepting during mastication, the teeth in the two jaws do not accurately correspond. Still she masticates well. (Fig. 5.)*

* A copy (not flattering) of a photograph of the patient, taken twelve months subsequent to operation.

Remarks.—The growth was doubtless fibrous epulis, sessile and, as already remarked, attached to a large surface of bone, so much so, that it appeared

FIG. 5.



impossible to remove the whole growth, and yet leave the line of the jaw unbroken; also two operations to eradicate the tumour had already been performed elsewhere. As a rule epulis is pedunculated, and can be cut away without external wound with suitable forceps with the portion of bone involved; and I need scarcely suggest that such should be the practice.

It is scarcely necessary to suggest that in all surgical operations as little blood as possible should be lost; for two reasons, one in the interest of the

patient, the other in the surgeon's behalf. In many operations the presence of blood embarrasses the operator by interfering with his sight, even though it be only present in small quantity; and in operations about the mouth the flow of blood also adds to this anxiety, lest any find its way into the larynx. The surgeon, therefore, will take care to select the most favourable position for his patient in which to favour the ready escape of blood by the mouth, and will so time his incisions and limit their extent with similar objects in view. It will thus be observed that the order in which the respective steps of the two operations above recorded were carried out differs.

The first operation was, as it were, tentative or experimental, inasmuch as although when contemplating the case, I determined to endeavour to remove the required extent of bone through the mouth; yet having never practised it on the dead subject, it was only by degrees as the operation progressed that the possibility of removing so large a portion of the lower jaw with a growth expanding its walls became evident. In the first case, the chief question was—How to lay bare the bone in order to bring the saw and cutting forceps to act upon it without serious injury to the soft parts.

In the second case the chief difficulty appeared to be, and proved to be—The section of the ramus.

In the first case a free separation of the cheek and

chin from the tumour favoured the turning down of the chin with unexpected facility, and the raspatory readily separated the periosteum from the ramus. All this being accomplished, the bone of the young subject was cut readily. Having thus acquired some experience, I reversed the steps of the operation in the case of the adult, in some measure, only cutting so much of the mucous and submucous tissues as were essential to the use of the forceps and saw; and reserving the division of the mucous membrane reflected from the cheek and from the floor of the mouth to the growth, till the bone had been divided. By this plan, although in neither instance was there hæmorrhage in the ordinary sense of the term, still I was less embarrassed by blood in the latter case. The report of the adult case is—"The hæmorrhage was comparatively slight." No artificial means were required to arrest bleeding.

In the case of the child an ordinary pair of cutting forceps was sufficient, but a similar instrument employed on the adult failed to divide the ramus. This portion of the bone is thin, but hard and brittle, and the aid of the saw is necessary. I employed the saw to make a groove in the bone, but of course to what depth it penetrated I could only surmise. I then completed the section with the forceps, but not without difficulty. My impression at the time was that the portion of bone left *in situ*, besides being a little rough at the cut surface,

might be splintered longitudinally. At any rate I tacitly determined, on a future occasion, to use the saw more thoroughly, and the forceps perhaps not at all.

With regard to the dimensions of a tumour of the lower jaw, which may be removed without division either of the cheek or lip, my impression is, that such as do not prevent depression of the chin so that the mouth can be opened, or do not fill the cavity of the mouth so as to prevent the finger and instruments from reaching the ramus, may be so treated. Indeed, I should expect that in this latter event, section of the base of the bone having been effected at the required spot, the tumour and diseased portion of bone might then be so much depressed as to allow the operator to get at the ramus and divide it with a saw. Again, a tumour growing in a certain direction forwards, outwards, and downwards, as in the child above-mentioned, rather aids the operator by enlarging the buccal orifice as it drags upon the lower lip.

It has been suggested that it is more desirable to remove the whole rather than to leave the upper portion of the ramus. If in an individual case it be thought desirable to act on this suggestion, my experience would lead me to make the attempt, with the prospect of success. Next in importance to the saving of life and of the blood of a patient, stands the prevention of deformity, especially on the face of the

female. Ugly scars are to be avoided, and nerves supplying muscles of expression are to be scrupulously preserved. All three desiderata are, in great measure, obtained by this method of operation.

Throughout the operations my anxiety was to save the whole of the periosteum. Apparently I did so, the bone in each instance coming away quite bare. To my disappointment, the reproduction of bone in the child amounts only to a thin scale, about an inch long and half an inch wide, situated in the middle of the gap caused by the removal of bone. This new production, however, is not connected with either fragment of jaw—a thin, fibrous band alone connects these latter.

In each case when the patient was convalescent, some tenderness and swelling occurred about the chin; and, after a time, small fragments of bone either came away or were removed. In the child one very small piece exfoliated, in the adult several. In this latter complete recovery was long delayed by this process of necrosis, and a small abscess formed under the chin. In both instances the small exfoliations took place at the margin of the cut “body,” and not at the damaged ramus; as sometimes happens to the edge of a bone divided by amputation. Possibly this drawback may be prevented by a more free use of the saw and less of the cutting forceps, but it cannot be insured against. At any rate, should abscess form in connection with necrosis, every effort should be made

to open it within the mouth rather than externally, in order to avoid even a small scar. The knowledge of the fact that this complication arose in the progress of both cases will put the surgeon on the alert. I might also add that both patients in the early days after the operation occupied a semi-recumbent posture, and were encouraged to favour the out-flow of secretions from the wound by the mouth rather than to swallow them.

In contemplating sub-periosteal ablation of large portions of the lower jaw, I anticipated the reproduction of a good portion of new bone as a foundation for a dental appliance, more especially in the young subject. In neither instance has my hope been realized, nor can I expect now that it will be, four years in the case of the child and one year in the instance of the adult having elapsed.

Although in these two cases the periosteum was preserved and practically no new bone was produced, yet some, at present unknown, accidental (and possibly in the future appreciable and avoidable) cause may have led to this; it would, therefore, be rash to come to a positive opinion on the subject from what might be regarded as insufficient data. If I were myself to hazard an opinion concerning the non-production of bone in these instances, I should suggest that inflammatory action subsequent to operation very probably destroyed the periosteum.

The pain in the ear complained of in the adult was probably reflex, and consequent on irritation of the divided inferior dental nerve. The absence of bleeding from the inferior dental artery was doubtless due to the division of it by laceration.

In proposing to remove large lateral portions of the lower jaw, it must be distinctly understood that I refer only to cases in which the bone is the seat of tumour and not in a state of necrosis. In the latter disease the dead bone, when operative interference is called for, is no longer in continuity with living structures, but is generally retained in its position by more or less new bone, which has been formed to replace it. To remove this sequestrum is a matter, as is well known, of comparative facility. Nature has in great measure anticipated the work of the surgeon.*

* While these pages are going through the press (June 17, 1874), I have removed, through the mouth of course, and without external wound, the greater part of the lower jaw of a male adult, the subject of phosphorus necrosis. With a raspatory I separated the new bone and periosteum from the dead, and then, having divided the ramus on each side with saw and cutting forceps, extracted the sequestrum in one piece.

