

**Contributions to teratology : undescribed malformation of the lower lip occurring in four members of one family / by J. Jardine Murray.**

**Contributors**

Murray, John Jardine.  
Royal College of Physicians of London

**Publication/Creation**

London : Savill and Edwards, 1860.

**Persistent URL**

<https://wellcomecollection.org/works/bpskuvnq>

**Provider**

Royal College of Physicians

**License and attribution**

This material has been provided by This material has been provided by Royal College of Physicians, London. The original may be consulted at Royal College of Physicians, London. This material has been provided by Royal College of Physicians, London. The original may be consulted at Royal College of Physicians, London. where the originals may be consulted. This work has been identified as being free of known restrictions under copyright law, including all related and neighbouring rights and is being made available under the Creative Commons, Public Domain Mark.

You can copy, modify, distribute and perform the work, even for commercial purposes, without asking permission.



Wellcome Collection  
183 Euston Road  
London NW1 2BE UK  
T +44 (0)20 7611 8722  
E [library@wellcomecollection.org](mailto:library@wellcomecollection.org)  
<https://wellcomecollection.org>

# Contributions to Teratology:

5

UNDESCRIBED MALFORMATION OF THE LOWER LIP  
OCCURRING IN FOUR MEMBERS OF ONE FAMILY.

BY

J. JARDINE MURRAY, F.R.C.S.E.,  
BRIGHTON.

---

LONDON :

PRINTED BY SAVILL AND EDWARDS, CHANDOS STREET,  
COVENT GARDEN.

1860.

✓





## CONTRIBUTIONS TO TERATOLOGY.

---

HAVING lately found in four members of one family instances of a singular malformation of the lower lip, which does not seem to have been alluded to by any writer on teratology, I purpose in this paper first, to describe the malformation, and then to consider the various possible explanations which might account for its occurrence. And as in the same family there are other important defects of formation, which, viewed collectively and in their relations to each other, afford interesting illustrations of the fundamental laws of teratology, I shall notice the individual peculiarities in the order in which they came under my observation.

In May, 1859, Dr. Thomson, Physician to the Royal Maternity Hospital of Edinburgh, requested me to see J. H., whose parents were anxious that he should immediately undergo an operation for the cure of hare-lip. The little patient was a well-developed and vigorous child, aged eighteen months. The fissure in the lip was confined to the left side,\* but extended quite into the nostril; and on this side, also, the anterior part of the hard palate was cleft from want of union between the intermaxillary bone and the left superior maxilla. The intermaxillary bone was twisted on itself, so that the incisor teeth were placed at an angle with the line of their ordinary direction, and partly bridged over the gap in the alveolar ridge. This twisting caused the portion of the alveolar ridge formed by the intermaxillary bone to overlap that portion formed by the inferior maxilla. The

\* It is worthy of remark, that Nélaton, Chelius, Fergusson, and others, have observed that in cases of single hare-lip the cleft is usually on the left side. "Vices of formation," such as hare-lip, are properly instances of arrested development, due in the great majority of cases to insufficient formative power in the embryo; and it has been asserted by Otto and others that the left side of the body is not only more frequently the subject of malformations, but that, being weaker, it is also more prone to disease than the right side.



little patient had been brought up at the breast; but, in consequence of the above malformation, he had only been able to apply himself to the left nipple.



Fig. 1.—J. H. (the eighth child), before operation. The condition of the Mouth is well shown in this woodcut from a careful sketch. The marks on the lower lip indicate the openings of sacculi to be hereafter described.

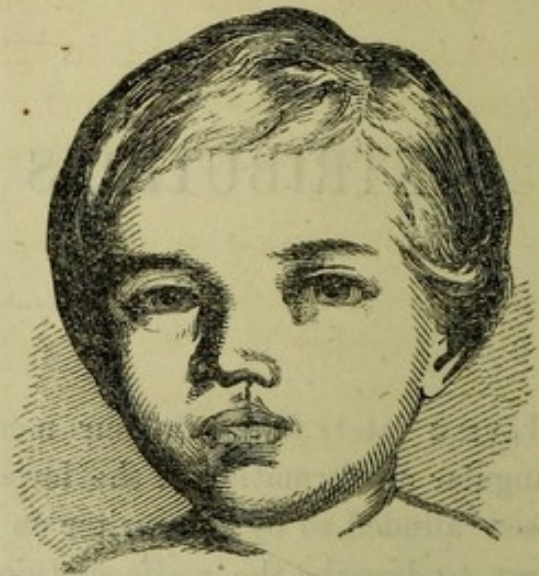

Fig. 2.—The same, some months after operation. As nearly the entire intermaxillary bone has been preserved, the upper lip is normally prominent.

I believe that if the surgeon can choose his own time, in hare-lip he ought either to operate soon after birth, or wait till the child is two or three years old. But in this case there did not appear to be any reason to fear constitutional disturbance from dentition, which had been somewhat irregular. Both parents were extremely anxious that the operation should not be delayed; for the mother was again pregnant, and both she and her husband firmly believed that the daily contemplation of the infant's hare-lip would have such an effect on the mother as to produce a similar malformation in her yet unborn child. With the assistance of my friends Drs. Pow and Messer, I accordingly performed the operation on the 14th May, 1859. After extracting the incisor teeth, I pared off a small portion of the prominent angle of the alveolar ridge, hæmorrhage from the gum being readily controlled by means of a hot wire. I next dissected the lip from the gum for some little distance on each side of the fissure. Then, having put the lip on the stretch by grasping the angle with catch forceps, I removed a crescentic portion from each margin of the fissure, and brought the edges together by means of two needles of soft steel and two sutures of silver wire. On the fourth day the needles were removed, and the cicatrix protected by a layer of col-



lotion. During the following week, the cheeks were supported by a strip of adhesive plaster placed across the face.

The operation was entirely successful, and afforded the father so much satisfaction that he brought me another of his children, aged three years, who had been born with webbed fingers, and requested me to perform any operation I might think proper for the removal of the deformity.

On the left hand, the middle and ring fingers were closely united as far as their utmost tips; while, on the right hand, the like fingers were joined together by a web which did not extend much beyond the middle joint. It appeared that the bones and tendons of each finger were perfect, and that two fingers were merely wrapped in a common envelope of skin.

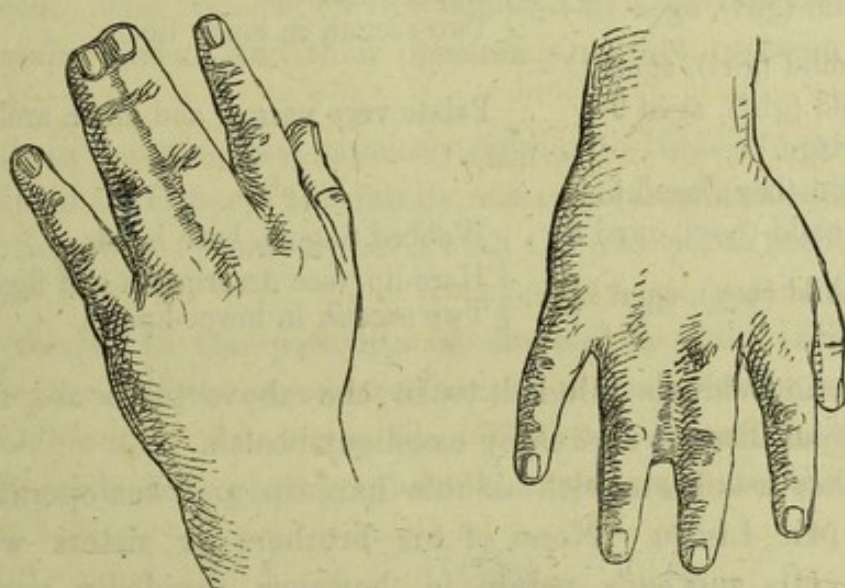


Fig. 3.—Left hand. Webbed Fingers. Right hand.

This Boy (the seventh child) was not the subject of any other malformation:

This malformation really consists in absence of fission, and is properly an arrest of development; for in the embryo the rudiments of hands and feet do not at first present any division of the fingers and toes.

I dissected the fingers from each other, and dressed each hand on a Y-shaped splint of gutta percha, the wrist being bandaged to that portion of the splint corresponding with the stem of the letter, and the middle and ring-fingers being respectively placed on the portions representing its arms. Thus, the undesirable re-formation of the web by cicatrization at the angle of divertication of the fingers, which has such a strong tendency to occur in these cases, was effectually



prevented. A month afterwards the wounds were entirely healed, the fingers were almost free from stiffness, and the little fellow was using his hands as freely as any child of his age. Neither he nor any of his relatives have webbed toes.

Being now much interested in the peculiarities of this family, I was permitted to examine each of its members in turn; and I am thus enabled to construct the following table, which exhibits in a very striking manner the hereditary nature of physical malformations:—

Father's mother, aged 65 . . .	Palate very narrow and much arched.
Father, aged 41 . . . . .	{ Double hare-lip.
	{ Two sacculi in lower lip.
*Mother, aged 37.	
First child (girl), aged 17 . . .	Two sacculi in lower lip.
*Second child (girl), aged 15+.	
Third child (girl), aged 13+ . .	{ Double hare-lip.
	{ Two sacculi in lower lip.
*Fourth child (girl), aged 11—.	
Fifth child (girl), aged 9+ . . .	Palate very narrow and much arched.
[Miscarriage.]	
*Sixth child (boy), aged 5.	
Seventh child (boy), aged 3 . . .	Webbed fingers, both hands.
Eighth child (boy), aged 1½ . .	{ Hare-lip (see description and figs. above).
	{ Two sacculi in lower lip.

All the individuals alluded to in the above table are free from constitutional disease, and enjoy excellent health.

The father was born with double hare-lip, and was operated on by the late Mr. Liston. None of his brothers or sisters were thus affected. His mother's palate is, however, decidedly narrow and unusually arched in formation; and while she was somewhat eagerly accounting for the existence of hare-lip in her son, by the circumstance that, shortly before his birth, she had been frightened by an elephant in Wombwell's menagerie, I was forcibly reminded of Mr. Fergusson's remark that—'Often, while listening to a mother's story about some conjectural cause for her infant's deformity of face, he has thought that a glance at her own features in the looking-glass might have given her a more plausible reason for the condition of her offspring.'†

In the contracted formation of the palate, the fifth child exactly resembles her paternal grandmother.

\* The mother is in every respect well formed, and her second, fourth, and sixth children are also quite normal in development. She does not inherit any tendency to malformations such as are found among her children.

† Practical Surgery, p. 584, 1852; p. 564, 1857.



The seventh child, as already mentioned, was born with the middle and ring finger of each hand closely united by skin.

The eldest child, aged seventeen, is quite womanly in appearance. She is in every respect well-formed, save that in the lower lip there are present two pouches or sacculi, which constitute the interesting congenital peculiarity now to be described.

The under lip is full and fleshy. About a quarter of an inch from the external edge of the pink mucous membrane of the prolabium are two crescentic openings, exactly similar in appearance and symmetrical in position, one placed on either side of the mesial line. The horns of the crescent are directed forwards, and a little outwards. A probe inserted into one of these openings passes downwards on the inner side of the lip under a considerable thickness of mucous membrane, to the depth of half-an-inch. Into each pouch a split pea might readily be introduced. The pouches do not communicate with each other; they secrete glairy mucus, and their presence does not occasion any inconvenience.

Sacculi in every respect precisely similar to these are present in the under-lips of the father of this family, and of his third and eighth children, all of whom were, however, born with the additional malformation of hare-lip.

By referring to the portraits of the eighth child (Figs. 1 and 2), the indications of the crescentic mouths of the sacculi may be seen on the prolabium of the lower lip. The two following woodcuts are carefully made from photographs of the father and his third daughter.

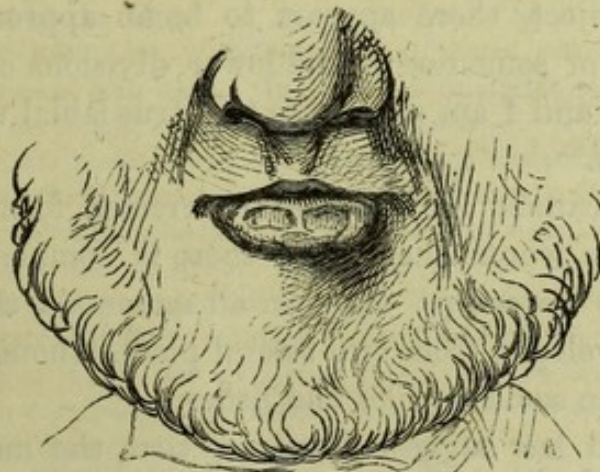

Fig. 4.—The lower portion of the face of the Father, aged forty-one. He was born with double harelip, and at the age of thirteen was operated on by the late Mr. Liston. The prominence of the under-lip is due to the scantiness of the upper lip, which is drawn tightly over the gap caused by the removal of the intermaxillary bone. The crescentic openings of the sacculi on the prolabium of the under-lip are faithfully represented.



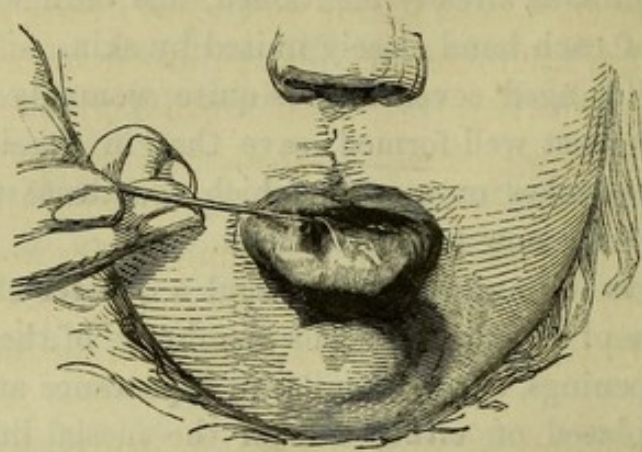


Fig. 5.—The lower portion of the face of the third child, aged thirteen. She was born with double harelip, and was operated on in infancy. The intermaxillary bone has been removed, and the upper lip is tightly stretched over the gap in the jaw thus created. The openings of the sacculi are well shown. The mucous membrane round the opening of the sacculus to the right of the mesial line is represented as it appeared when put on the stretch by means of a probe.

How, then, are we to account for this malformation in the lower lip?

1. The malformation is evidently not consequent on the occurrence of hare-lip; for although the father and the third and eighth children were born with hare-lip, and also sacculi in the lower lip, the eldest child has the sacculi in the lower lip very large, while her mouth is in every other respect well formed.

2. The sacculi might possibly be ascribed to the erratic development of tooth-sacs in the under lip. But in all so-called "freaks of Nature" in the human subject, there appears to be an approximation to the normal condition of some one of the lower divisions of the vertebrate animal kingdom; and I am not aware that true labial teeth are present even among fishes.

3. The sacculi cannot be ascribed to arrested formation, for in all the four persons in whom they occur there is complete union in the mesial line of the lower lip. And in all mammals, the under lip and lower jaw are developed from two lateral pieces, though the formation is more complex in some reptiles and fishes.

4. Dr. Ormerod has suggested to me, that the malformation may possibly be explained by some peculiarity in the development of the frænum. The crescentic form of the mouths of the sacculi, and their perfectly symmetrical character, render the suggestion well worthy of consideration. But, in other respects, the formation and position of the sacculi do not appear to accord with this explanation.



5. Are the sacculi the result of intra-uterine disease of the labial glands? Some considerations favour this view. Surgeons are aware that the labial, like other mucous glands, are frequently the seat of cystic disease. In the 'Guy's Hospital Reports' for 1859, Mr. Birkett has recorded an interesting case of labial cyst, occupying the middle of the prolabium of the lower lip, a little to the left of the mesial line.\*

The peculiarly wide and crescentic openings of the sacculi, however, and the fact that in all four individuals they are so perfectly uniform in appearance and symmetrical in position, seem opposed to such an explanation.

Congenital malformations are sometimes evidently due to disease of the ovum or foetus, and probably are often to be attributed to the male and female reproductive elements having been affected prior to the act of conception; but assuredly the most common explanation is to be found in impeded or arrested development of the foetus, from some remote or unknown cause. Now, if we suppose the sacculi to be consequent on intra-uterine disease of the labial glands, it is to be noted that in each of three members of the family which forms the subject of this paper, we have two malformations—one (hare-lip) due to arrest of development, and the other (sacculi in lower lip) caused by intra-uterine disease. But there is ample proof that intra-uterine disease may co-exist with arrested development of the foetus.†

At my request, Professor Goodsir very carefully examined the sacculi; and, while he concurred with me in thinking them ex-

\* Guy's Hospital Reports, third series, vol. v. pp. 266, 267.

† Malformations due to arrested development may co-exist with malformations caused by intra-uterine disease of the foetus. In April, 1857, while house-surgeon in the Royal Maternity Hospital of Edinburgh, I delivered a half-witted girl of a monstrous child, presenting malformations of both kinds. As the case is interesting and illustrative, I may be permitted to insert the following extract from my notes:—

"J. J., aged twenty, has never previously had a child or miscarriage. Labour tedious; after the head and arms had been expelled, the greatly enlarged abdomen of the child remained firmly impacted within the maternal passages, and considerable extractive force had to be employed in order to remove the mass. Patient recovered without a bad symptom. Child still-born, full-grown, female. It is the subject of several malformations. There is what may properly be regarded as spina-bifida of the occiput, arising from deficiency of the occipital bone. On each hand there is an additional finger, but without any additional metacarpal bone. There is fissure of the soft palate. A fleshy tumour is attached to the margin of the tongue. But the most remarkable feature of this case is the enormous size of the abdomen, caused by cystic disease of the kidneys. Both kidneys are affected in a manner precisely similar, and they are of equal size. The right kidney, being carefully dissected from its position, is found to have its vessels and ureter quite normal in size and appearance. The peritoneal covering and the fibrous coat are readily separated from the uniformly smooth external surface of the organ. This kidney weighed 13 oz. 63 29. On making a clear section, the whole substance



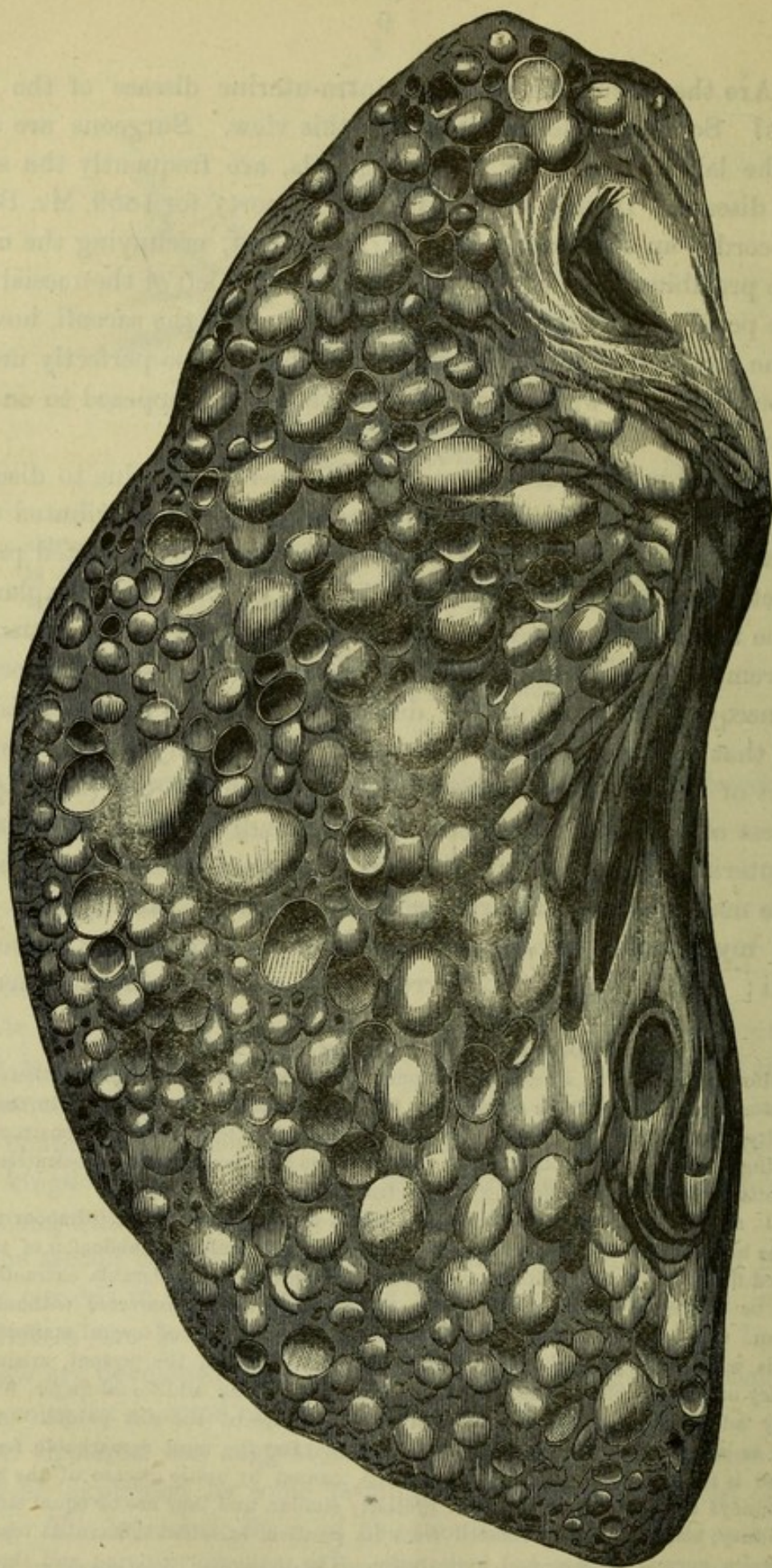


Fig. 6.—Full-size representation of section of the right kidney, showing the enormous development of cysts throughout its substance. The presence of these growths is evidently due to intra-uterine disease of the fœtus.—See the description of this case in the foot-note to p. 9.



tremely interesting and remarkable, he confessed himself unable to account for their existence. I have since communicated with Professor Owen, Dr. Simpson, Mr. Paget, Mr. Green, Mr. Quekett, and others whom I thought likely to throw light on the subject. But I believe that a careful record of facts and description of appearances will better fulfil the requirements of science, than a painstaking advocacy of any one possible explanation of this interesting malformation.

seems to consist of pearly cysts containing serous fluid. The cysts vary somewhat in size, the average being that of a pea. Other viscera healthy; bladder empty."

Whatever the special pathology of these renal cysts may be—and to discuss the subject here would be out of place—there can be no question that they are consequent on intra-uterine disease of the fœtus; and the tumour on the tongue has doubtless a like origin. The spina-bifida of the occiput and the cleft palate are admitted defects of formation. The redundant fingers and the enormously increased growth of the kidneys are also interesting, as they show that defective development of one portion of the body in the fœtus is sometimes accompanied by excess of development or by increased growth of other parts.

THE END.



LONDON :  
SAVILL AND EDWARDS, PRINTERS, CHANDOS STREET,  
COVENT GARDEN.