

**A series of engravings : accompanied with explanations, which are intended to illustrate the morbid anatomy of some of the most important parts of the human body; divided into ten fasciculi / by Matthew Baillie.**

### **Contributors**

Baillie, Matthew, 1761-1823.  
Royal College of Physicians of London

### **Publication/Creation**

London : printed by W. Bulmer and Co. for J. Johnson, St. Paul's Churchyard; and G. and W. Nicol, Pall-Mall, [1799]-1803.

### **Persistent URL**

<https://wellcomecollection.org/works/xpmcdh5a>

### **Provider**

Royal College of Physicians

### **License and attribution**

This material has been provided by This material has been provided by Royal College of Physicians, London. The original may be consulted at Royal College of Physicians, London. This material has been provided by Royal College of Physicians, London. The original may be consulted at Royal College of Physicians, London. where the originals may be consulted. This work has been identified as being free of known restrictions under copyright law, including all related and neighbouring rights and is being made available under the Creative Commons, Public Domain Mark.

You can copy, modify, distribute and perform the work, even for commercial purposes, without asking permission.



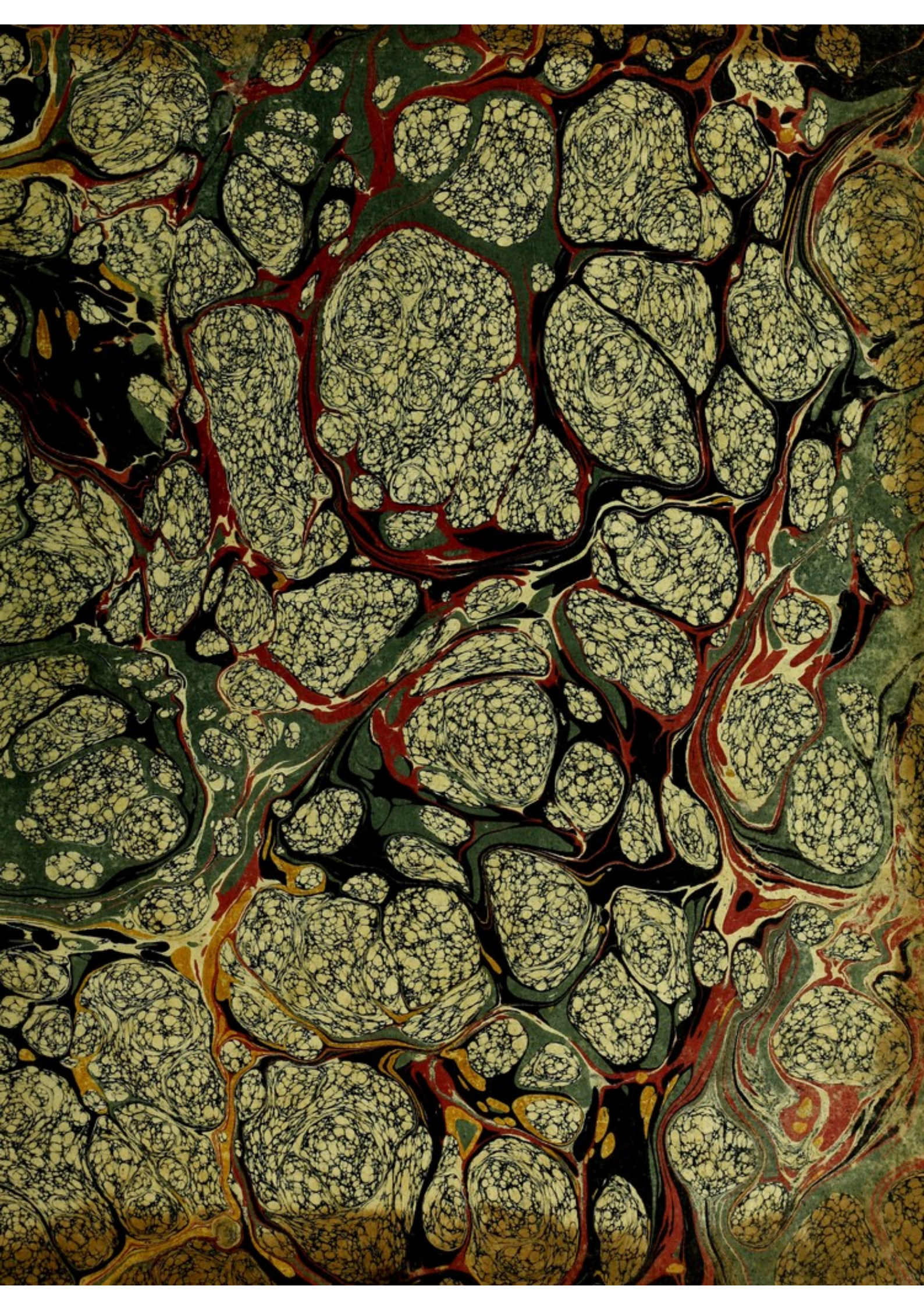
Wellcome Collection  
183 Euston Road  
London NW1 2BE UK  
T +44 (0)20 7611 8722  
E [library@wellcomecollection.org](mailto:library@wellcomecollection.org)  
<https://wellcomecollection.org>













1

6-11

*W Baillie*





Digitized by the Internet Archive  
in 2016

<https://archive.org/details/b28518445>

A  
SERIES OF ENGRAVINGS,  
ACCOMPANIED WITH  
EXPLANATIONS,  
WHICH ARE INTENDED TO ILLUSTRATE  
THE MORBID ANATOMY  
OF SOME OF THE MOST IMPORTANT PARTS OF THE  
HUMAN BODY.

---

FASCICULUS I.

COMPREHENDING  
THE CHIEF MORBID APPEARANCES OF THE HEART,  
AND OF THE AORTA NEAR ITS ORIGIN.

---

By MATTHEW BAILLIE, M.D. F.R.S.  
FELLOW OF THE ROYAL COLLEGE OF PHYSICIANS, AND  
PHYSICIAN TO ST. GEORGE'S HOSPITAL.

---



PRINTED BY W. BULMER AND CO.  
AND SOLD BY J. JOHNSON, ST. PAUL'S CHURCH-YARD;  
AND G. NICOL, PALL-MALL.

1799.



SERIES OF ENGRAVINGS

ILLUSTRATED WITH

EXPLANATIONS

AND A COMPLETE INDEX

THE MORBID ANATOMY

OF THE HUMAN BODY

BY WILLIAM B. RAY

LONDON

1854

PRINTED BY

JOHN JOHNSON, ST. PAUL'S CHURCH-YARD

AND OF THE NEW YORK OFFICE

OF THE NEW YORK OFFICE

OF THE NEW YORK OFFICE

OF THE NEW YORK OFFICE

OF THE NEW YORK OFFICE

OF THE NEW YORK OFFICE

OF THE NEW YORK OFFICE

OF THE NEW YORK OFFICE

OF THE NEW YORK OFFICE

OF THE NEW YORK OFFICE

OF THE NEW YORK OFFICE

OF THE NEW YORK OFFICE

OF THE NEW YORK OFFICE

OF THE NEW YORK OFFICE

OF THE NEW YORK OFFICE

OF THE NEW YORK OFFICE

OF THE NEW YORK OFFICE

OF THE NEW YORK OFFICE

OF THE NEW YORK OFFICE

OF THE NEW YORK OFFICE

OF THE NEW YORK OFFICE

OF THE NEW YORK OFFICE

OF THE NEW YORK OFFICE

OF THE NEW YORK OFFICE

ROYAL COLLEGE OF PHYSICIANS LIBRARY	
CLASS	616-091/084
ACCN.	19678
SOURCE	
DATE	

TO  
**DAVID PITCAIRN,**

M. D. F. R. S. &c.

MY DEAR SIR,

I BEG leave to inscribe to you the Fasciculi of Engravings upon Morbid Anatomy, which I have just finished. They are to be considered as illustrations addressed to the eye, of the subject upon which I published a treatise some years ago, and may, I hope, be useful to those who have not an opportunity of examining the diseased appearances themselves.

Although you have been obliged, by want of health, to decline the more laborious duties of your profession, yet your energy is not abated in promoting every plan, which may conduce to the improvement of medicine; and you enjoy one of



the purest satisfactions, in feeling that you retain the full and undiminished confidence, not only of the public, but of the great body of medical men, who are best able to appreciate your merit. That your health may continue to improve, and that the public may long reap the great advantage of being aided by your sagacity and experience, is the sincere wish of your

faithful and obliged friend,

M. BAILLIE.

*Great Windmill Street,  
October 30th, 1802.*

## ADVERTISEMENT.

---

NO Work has been published in this, nor, I believe, in any other country, in which the principal Morbid Changes of Structure, affecting the most important parts of the Human Body, have, as far as they admit of it, been illustrated by a regular Series of Engravings.

Whatever has been hitherto done upon this subject, has been without any regular plan, and scattered over various works, some of which are expensive, and others difficult to be procured. It seemed to me, therefore, to be an important desideratum in Anatomy, to comprehend in one work, upon some regular plan, Engravings of the chief Morbid Changes of Structure in the most essential parts of the human body, which are capable of this kind of illustration. I have, therefore, ventured to undertake such a Work; but only propose to proceed in it a little way, till the opinion of the Public with regard to it



is collected. If that shall be favourable, it will encourage me to advance with earnest diligence, in an undertaking both attended with difficulty and considerable expence; and if it shall be otherwise, there will at least be the comfort of reflecting, that I have made an attempt to promote the cultivation of a Science, upon which the health and life of mankind so immediately depend.

In the plan which I propose to follow, more attention will be paid to express accurately by Engravings, the exact Changes of Structure which take place in the most important parts of the body, than has hitherto been done. The greater number of engravings upon this subject which I have seen, represent rather the general external appearance of morbid parts, than the real changes of structure which are produced by disease. This defect I shall attempt in some measure to remedy, by representing commonly, Sections of Morbid Parts; but the art of engraving is perhaps incapable of arriving at such a degree of perfection, as to represent very accurately many of the finer changes of structure which various parts of an animal body undergo by disease.

It does not seem to be useful to represent by engravings, every diseased change of structure to which the internal and more important parts of the body are subject. Some are of so



little consequence as not to be worth representing ; others can be so clearly understood from description, as not to require being illustrated by engravings ; and others still may be of such a nature as not to be capable of being adequately represented by this kind of art. It is proposed, therefore, in the following Work, to give Engravings only of the principal Morbid Changes of Structure affecting the most important parts of the human body, which are either capable of being illustrated, or of being more distinctly impressed upon the mind by figures of them being exhibited to the eye. These will comprehend a large proportion of the chief diseased appearances of the Thoracic and Abdominal Viscera, of the Organs of Generation in both sexes, and of the Brain.

The order of the Engravings will correspond very much with that of the description of diseased changes of structure, in my book upon Morbid Anatomy ; but the two works will be made independent of each other. The Engravings will be accompanied with such a Description as to be perfectly understood, without any reference to the volume upon Morbid Anatomy ; so that a person may possess the one work, without being obliged to purchase the other. It is impossible to determine at present the exact limits of this work ; but I think it may probably be comprehended in Ten Fasciculi, each of



which will contain about five, or sometimes six Plates. Two Fasciculi are intended to be published every year, if the Public shall approve of the Work; and I propose to publish Two Fasciculi as a trial of their opinion, the first of which comprehends the chief diseases of the Heart, and of the Aorta near its origin, and the second, the chief diseases of the Lungs.

The Engravings will be principally taken from preparations in Dr. Hunter's and Mr. Hunter's Museum, and also from preparations in a collection of my own which has now become extensive. It is probable also, that such of my medical friends and acquaintances as may have in their possession a preparation illustrating very clearly any particular disease, will allow, for the advantage of the Public, an engraving to be taken from it.

The size of the Plates is proposed to be a large Quarto, as being much more convenient than a folio size; and many of the Plates will contain several Figures, in order to bring the Work into a smaller compass, and thereby to diminish the expence of it to those who may wish to become purchasers.

The Drawings will be made by a young man, who is not only very well skilled in his own art, but who possesses a considerable share of knowledge in Anatomy. This last circum-



stance is of great importance in giving to Anatomical Drawings distinctness and fidelity of representation. The Engravings will be made by artists who are well known to the Public, more especially for the excellence which they have attained in Anatomical Engraving, and who are ambitious of increasing their reputation by the attention which they propose to bestow upon this Work.



stance is of great importance in giving to Anthropological Drawings distinctness and fidelity of representation. The Engravings will be made by artists who are well known to the Public, more especially for the excellence which they have attained in Anatomical Engraving, and who are ambitious of increasing their reputation by the accuracy which they propose to bestow upon this *History*.

It is not only the accuracy of the Engravings, but the manner in which they are arranged, and the manner in which they are printed, that will give to this *History* the value which it is intended to possess. The Engravings will be arranged in a manner which will be most convenient for the Reader, and the manner in which they are printed will be such as to give to the Engravings the value which they are intended to possess. The Engravings will be arranged in a manner which will be most convenient for the Reader, and the manner in which they are printed will be such as to give to the Engravings the value which they are intended to possess.

The Engravings will be arranged in a manner which will be most convenient for the Reader, and the manner in which they are printed will be such as to give to the Engravings the value which they are intended to possess.







Fig. 1.

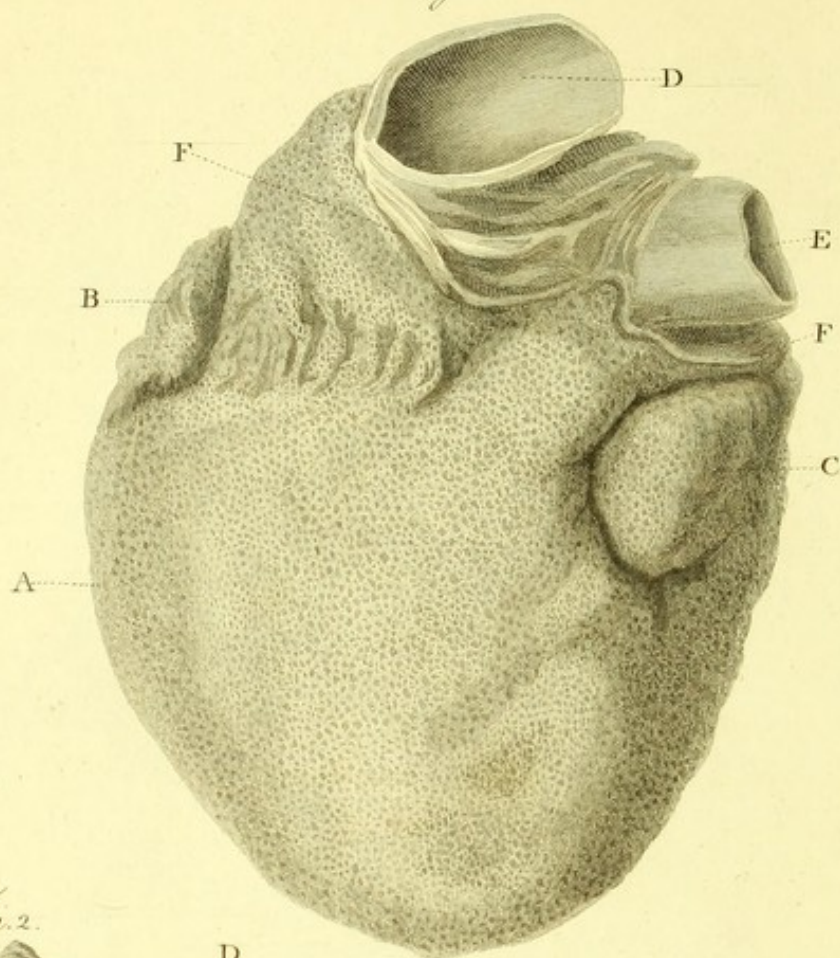


Fig. 2.

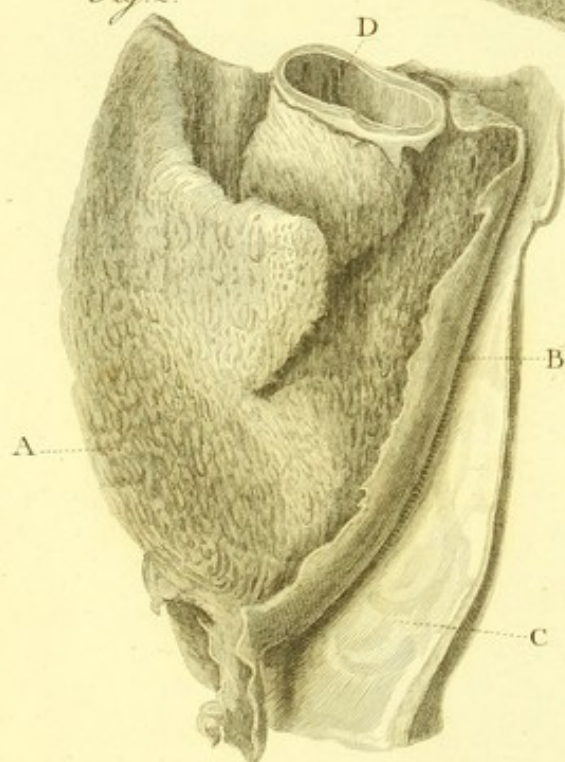
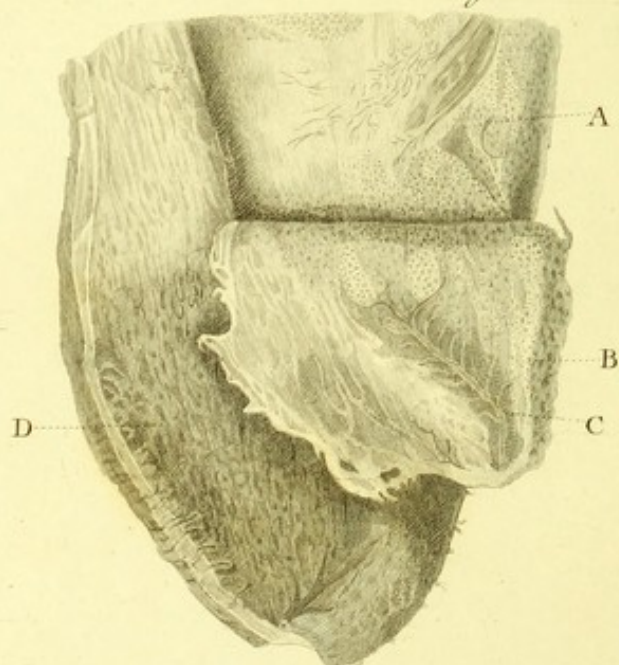


Fig. 3.





## PLATE I.

THIS Plate is intended to exhibit some variety in the appearance of the layer of the coagulable lymph, which is formed by a violent inflammation of that part of the pericardium immediately adhering to the heart. It is occasionally full of pores upon its surface, bearing a resemblance to some kinds of lace, but more frequently it throws out from its surface small floculi. In many cases the layer of coagulable lymph, which is formed by an inflamed membrane, is smooth; but this I think I have observed more frequently in inflammation of the pleura and the peritonæum, than in inflammation of the pericardium. Its colour is a very light yellow, or buff colour, and it generally adheres slightly to the surface of the inflamed membrane upon which it lies.

## FIG. I.

- A. The anterior surface of the heart covered with a layer of coagulable lymph, which is porous upon its surface, resembling lace.
- B. A part of the right auricle thickened from inflammation, and covered with the coagulable lymph.
- C. A part of the left auricle having undergone the same change, and covered with the same matter.
- D. An oblique section through the aorta near its origin.



- E. A section of the left branch of the pulmonary artery near its origin.
- FF. The upper edge of the coagulable lymph, where it had been cut off along with that part of the pericardium, which surrounds the heart like a bag.

The heart is here represented as of a smaller than the natural size, in order to be accommodated to the size of the Plate.

*From the Author's Collection.*

### FIG. II.

- A. A portion of coagulable lymph covering a section of the heart, with small processes or flocculi arising from its surface.
- B. Shewing a part of it turned up from the pericardium.
- C. The pericardium immediately adhering to the heart, thickened by inflammation.
- D. A section through the aorta near its origin which has been by some accident compressed, so as to exhibit a narrow oval aperture.

*From Dr. Hunter's Museum.*

### FIG. III.

- A. A portion of a heart, from which a layer of coagulable lymph is partly turned off, and is partly left adhering to it. Some fine blood-vessels are seen ramifying upon the surface of the heart.



- B. That part of the coagulable lymph which is turned off.
- C. A small blood-vessel distinctly ramifying in it.
- D. That part of the coagulable lymph which is left adhering to the heart.

*From Dr. Hunter's Museum.*



PLATE I

- B. That part of the root of the lymph which is turned off.  
C. A small blood-vessel directly ramifying in it.  
D. That part of the lymphatic branch which is left adhering  
to the heart.

From Dr. Hunter's Museum.







Fig. 1.

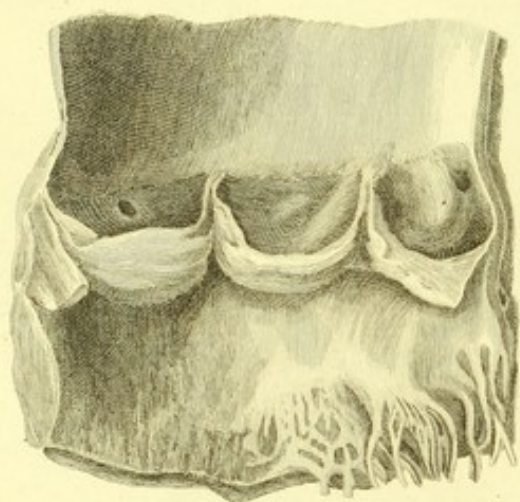


Fig. 2.

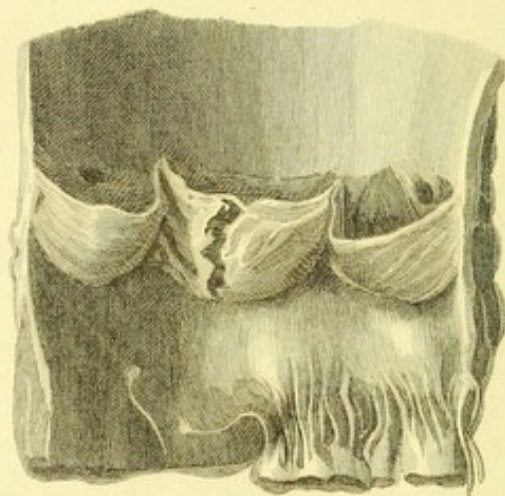


Fig. 3.

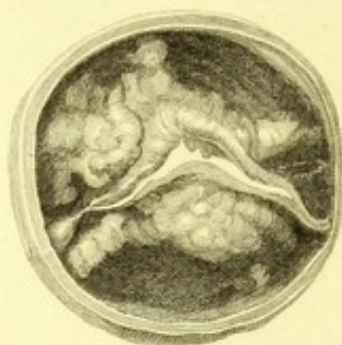

Fig. 4.

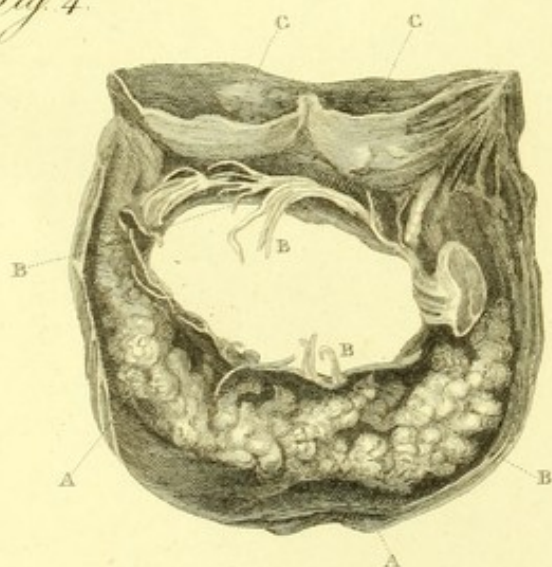
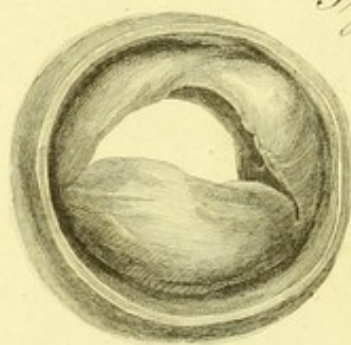


Fig. 5.





## PLATE II.

THIS Plate is intended to illustrate the diseased alterations of structure, to which the valves of the heart are subject. These consist chiefly in the valves becoming thick and opaque, or becoming ossified. The valves at the origin of the aorta are more liable to be affected with both kinds of disease, than those at the beginning of the pulmonary artery, and are more particularly subject to ossification, than the valves between the auricles and the ventricles.

## FIG. I.

Shews the three semilunar valves at the origin of the aorta, shortened in their depth, and considerably thickened. It is obvious that such valves must perform their office very imperfectly.

*From Mr. Hunter's Museum.*

## FIG. II.

Shews one of the valves at the origin of the aorta thickened and ruptured. The other two valves are in their natural state.

*From Dr. Hunter's Museum.*

## FIG. III.

Shews the semilunar valves at the origin of the aorta, much ossified. The separation between two of the valves is in a great measure obliterated. *From Mr. Hunter's Museum.*

## FIG. IV.

Shews the valve, between the left auricle and the left ventricle, much ossified.

A A. The irregular masses of bony matter.

B B. The edge of the membrane of the valve, with some divided portions of the chordæ tendineæ still attached to it. C C. Two valves at the origin of the aorta in their natural state. *From Dr. Hunter's Museum.*

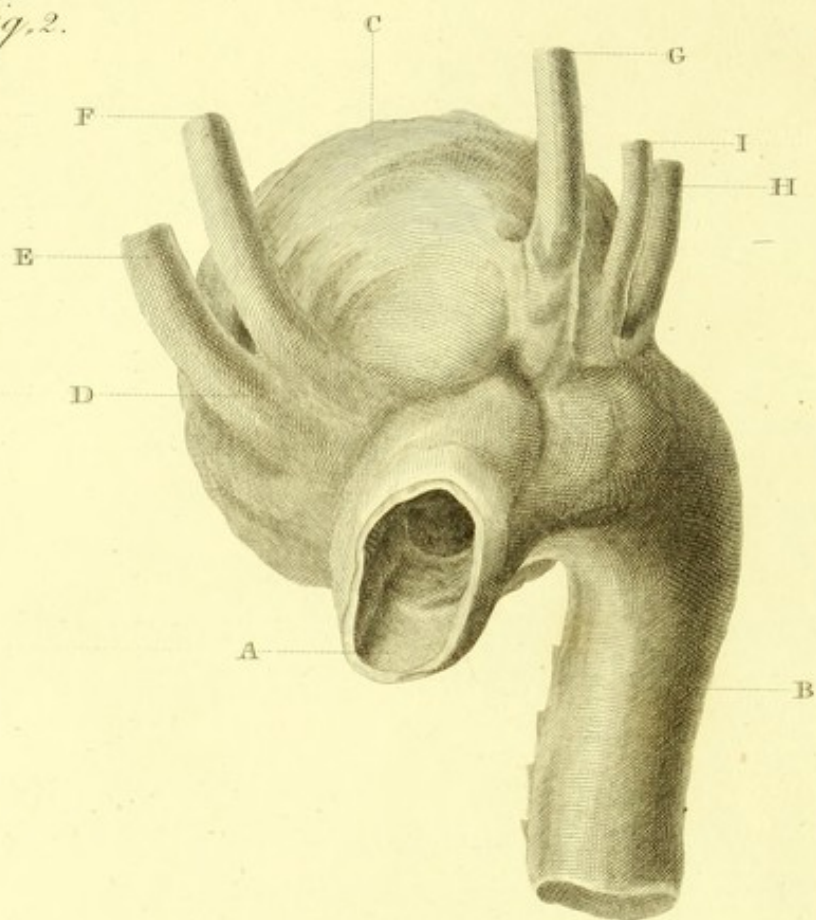
## FIG. V.

A section of the aorta with two semilunar valves at its origin instead of three, and these are also thickened. The valves are viewed upon their convex surface, on the side next the left ventricle. This variety in the number of the valves is very uncommon. *From Mr. Hunter's Museum.*

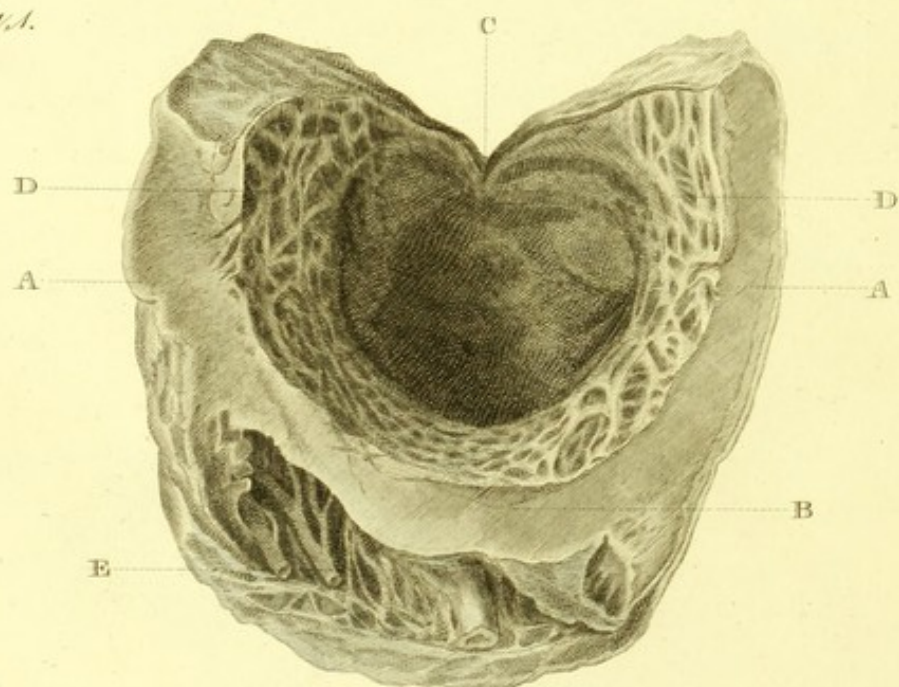




*Fig. 2.*



*Fig. 1.*





# PLATE III.

THIS Plate is intended to represent the swelling or sac which is formed in aneurysm. Aneurysm of the heart, which is exhibited in Fig. I. is very rare ; but aneurysm of the arch of aorta, represented by Fig. II. is not uncommon.

## FIG. I.

Represents an oblique section through the ventricles of the heart, where a part of the left ventricle near the apex was dilated into an aneurysmal sac.

- A A. The thick fleshy parietes of the left ventricle.
- B. A part of the septum.
- C. The cavity of the aneurysmal bag, which is lined with a thick smooth membrane.
- D D. A part of the natural fasciculated structure upon the inside of the left ventricle.
- E. A small part of the fasciculated structure of the right ventricle, near the apex of the heart.\*

*From Dr. Hunter's Museum.*

\* In the preparation, from which this Figure was taken, the section has been made nearer to the diseased part, than could have been wished. It would have given a dis-

## FIG. II.

This Figure represents the outward appearance of an aneurysm of the arch of the aorta, where the sac had not been dilated to a very large size.

- A. A section of the ascending aorta just where it is beginning to form the arch.
- B. A part of the descending aorta.
- C. The aneurysmal bag arising from the arch.
- D. The common trunk of the right carotid, and right subclavian arteries.
- E. The right subclavian artery; F the right carotid artery.
- G. The left carotid artery; H the left subclavian artery; and I the left vertebral artery, which sometimes arises from the arch of the aorta.

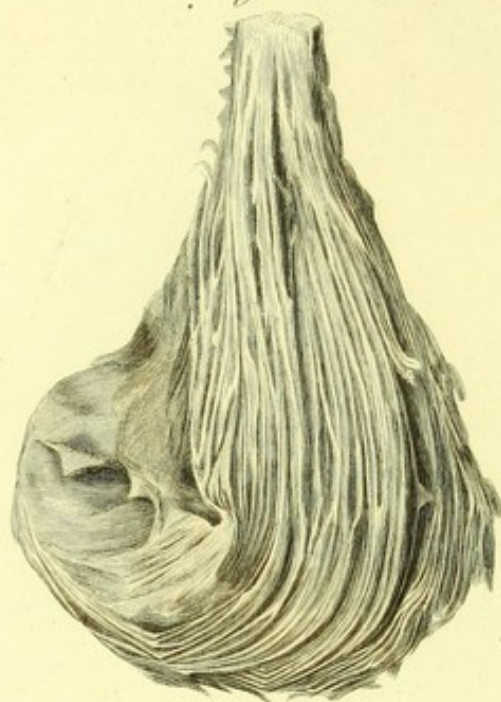
*From Dr. Hunter's Museum.*

tincter idea of the disease, if more of the natural structure of the heart had been preserved. The preparation, however, was made many years ago, without there being any intention of presenting it, by an engraving, before the public eye. In the course of this Work defects will sometimes occur in the representations of morbid parts, arising from the same general cause, and which can neither be remedied nor avoided.

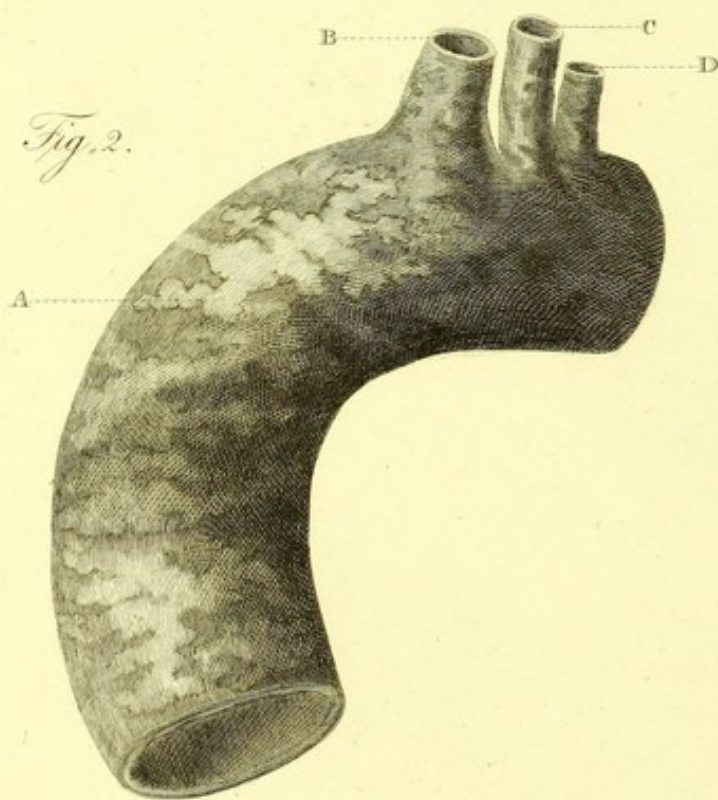




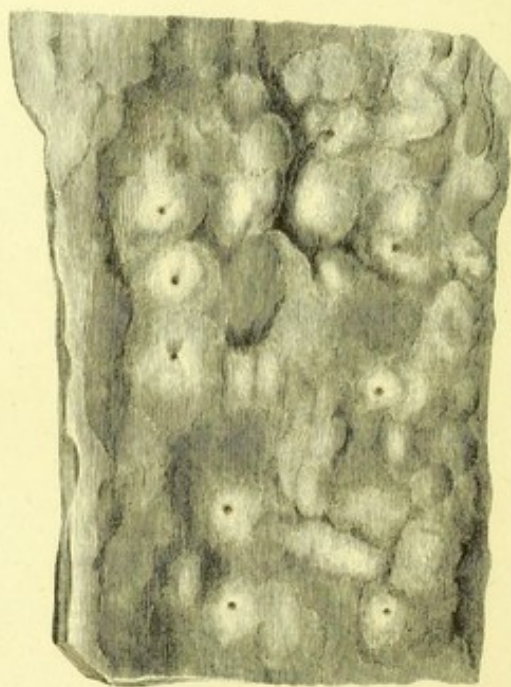
*Fig. 1.*



*Fig. 2.*



*Fig. 3.*





## PLATE IV.

THE object of this Plate, is to shew the appearance which coagulated blood puts on in the sac of an aneurysm, and also to illustrate the diseased structure of aneurysmal arteries. This consists in ossifications being formed behind the inner membrane of the arteries, and in the inner membrane itself being thickened, with small irregular protuberances on some parts of its surface.

## FIG. I.

Represents a portion of coagulated blood, taken out of a large aneurysmal sac. It is always formed into laminæ, which may be said to be concentric, and is found in greater or less quantity in every aneurysmal sac, which has arrived at any considerable size.

*From Dr. Hunter's Museum.*

## FIG. II.

Represents the arch of the aorta, with a number of irregular spots of bone in it. The artery was dry from which this Figure was taken, in order to shew the spots of bone more distinctly. In a wet preparation of this kind, the spots of bone are hardly observable.

- A. The arch of the aorta, with a number of irregular bony spots in it. B. The common trunk of the right carotid and right subclavian arteries. C. The left carotid artery. D. The left subclavian artery.

*From the Author's Collection.*

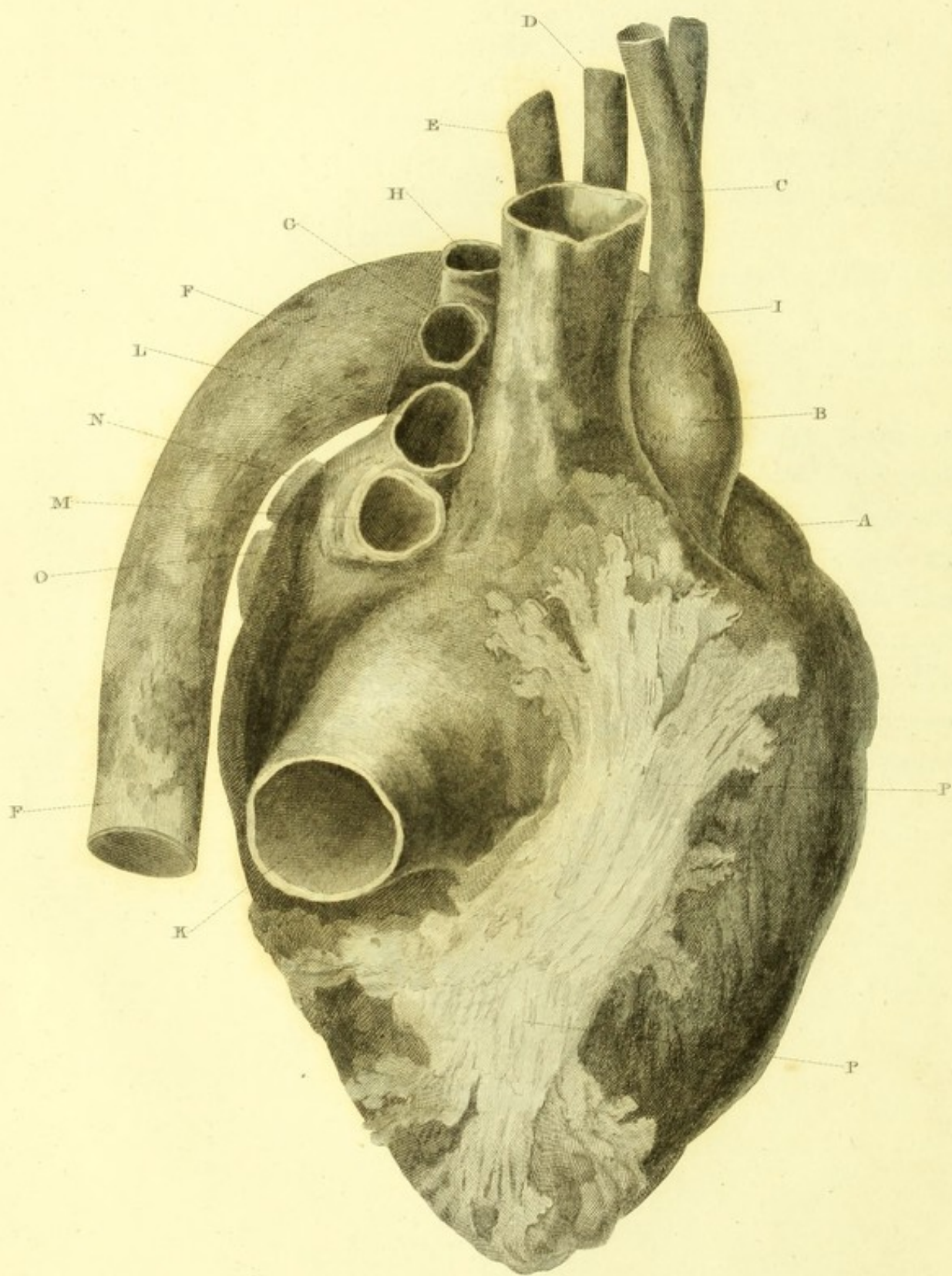
FIG. III.

Represents a part of the descending aorta, cut open and expanded. It is intended to shew the inner membrane thickened and raised in many places into irregular protuberances. This change takes place, more or less, in all aneurysmal arteries; but it was more strongly marked in the artery from which this Figure was taken, than is usual. The small openings are the orifices of some of the intercostal arteries. The aorta had been enlarged, by the progress of the disease, beyond its natural size.

*From Dr. Hunter's Museum.*









## PLATE V.

THE object of this Plate is to represent a large ossification upon the surface of the heart. Ossification of the pericardium, or of the muscular structure of the heart, occurs very rarely, although ossification of the valves, more especially at the origin of the aorta, is not uncommon.

- A. A part of the right ventricle, just at the origin of the pulmonary artery.
- B. A part of the ascending aorta, as it is about to form the arch.
- C. The common trunk of the right carotid and right subclavian arteries.
- D. The left carotid artery.
- E. The left subclavian artery.
- HG. Two branches of the right branch of the pulmonary artery.
- FF. Part of the descending aorta, which is smaller than the natural size. This had been occasioned by the blood being propelled into it from the left ventricle, in less than the natural quantity, and by a feeble exertion.
- I. The vena cava superior, somewhat enlarged beyond the natural size.
- K. The vena cava inferior.

LM. The pulmonary veins of the right side, at their entrance into the left auricle.

NO. The pulmonary veins of the left side.

PP. A large irregular ossification, covering a considerable part of the right ventricle and of the right auricle, rendering the limit between the two in some degree indistinct.

The heart from which this Figure was taken, appeared somewhat larger than the natural size; and this may have arisen from the blood being accumulated in it in consequence of the extent of the ossification, which was so great as to prevent the full degree of contraction. It is dried, and is here represented in an oblique posterior view, in order to shew the ossified part more distinctly.\*

*From Mr. Heaviside's Museum.*

\* This heart has been already engraved, and an account of the case has been given by Dr. Samuel Foart Simmons; and of the dissection after death, by the late Mr. Watson, Surgeon of the Westminster Hospital. See Medical Communications, Vol. I. p. 228.





Fig. 1.

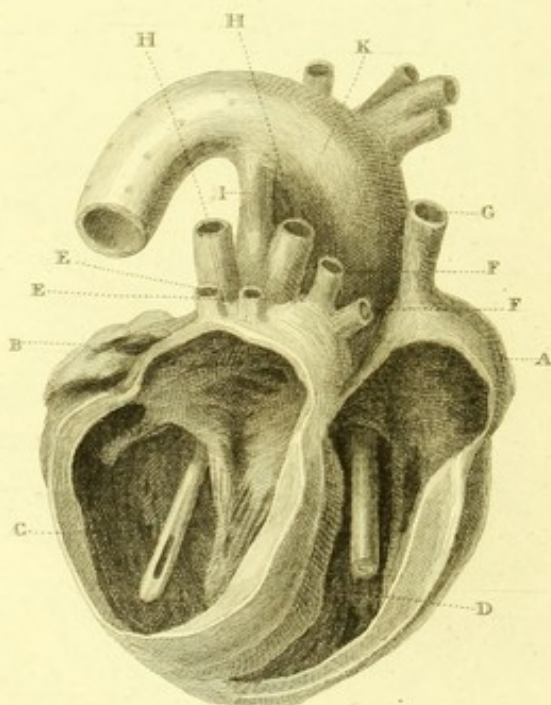
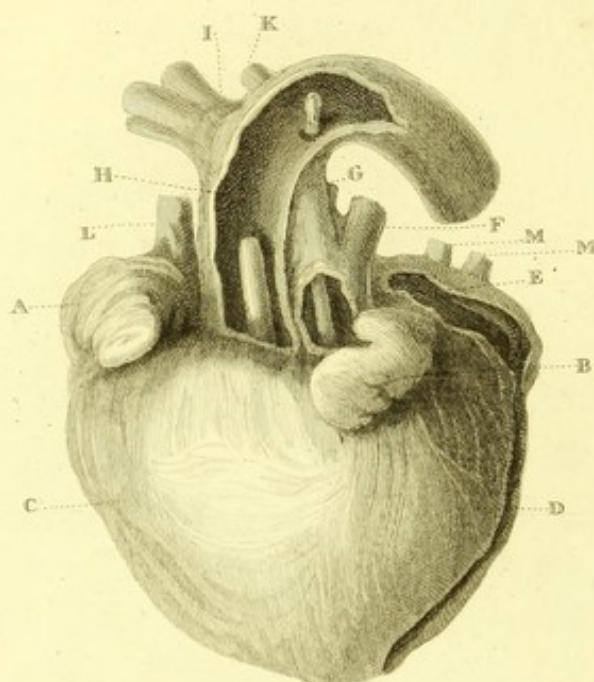


Fig. 2.



## PLATE VI..

It does not form strictly a part of our plan, to illustrate by engravings the various original deviations from the natural structure, to which the more important parts of the body are subject; but the heart, which is represented in this Plate, is so singular an instance of monstrosity, that we have been induced to give an engraving of it in two points of view.

## FIG. I.

Represents the anterior view of the heart.

- A. A part of the right auricle.
- B. A part of the left auricle.
- C. The anterior surface of the right ventricle.
- D. The anterior surface of the left ventricle.
- E. The trunk of the pulmonary artery laid open, shewing a probe in it: it arises from the left ventricle.
- F. The left pulmonary branch.
- G. The ductus arteriosus, through which a probe is passed into the aorta.
- H. The ascending aorta and its arch laid open, in a part of which is seen the extremity of a bougie. This artery arises from the right ventricle.

- I. A common trunk of the right subclavian, and the two carotid arteries. This variety in the origin of the large branches from the arch of the aorta, is rare.
- K. The left subclavian artery.
- L. The vena cava superior.
- MM. The two left pulmonary veins.

## FIG. II.

Represents the posterior view of the heart.

- A. A part of the right auricle laid open.
- B. A part of the left auricle laid open.
- C. The left ventricle laid open ; in which there is the extremity of the same probe that is seen in Fig. I. in the pulmonary artery, and the ductus arteriosus.
- D. The right ventricle laid open ; in which there is a part of the same bougie which, in Fig. I. is seen in the aorta. The parietes of the right ventricle are thicker than those of the left, as in the child to whom this singular heart belonged, the right ventricle was the principal agent in propelling the blood over the whole body.
- EE. The two left pulmonary veins.
- FF. The two right pulmonary veins.
- G. The vena cava superior.
- HH. The two branches of the pulmonary artery.



I. The ductus arteriosus.

K. The posterior view of the arch of the aorta.

It is evident from the structure of this heart, that florid blood must have always been circulating in the child to whom it belonged, between the lungs and the left side of the heart, except for the small proportion of black blood which passed from the right auricle into the left through the foramen ovale.

It is also evident, that a dark coloured blood must have been constantly circulating between the right ventricle and the general mass of the body, except for the small quantity of florid blood which passed from the pulmonary artery into the aorta through the ductus arteriosus. The child was about two months old when it died.

*From the Author's Collection.*







Fig. 1.

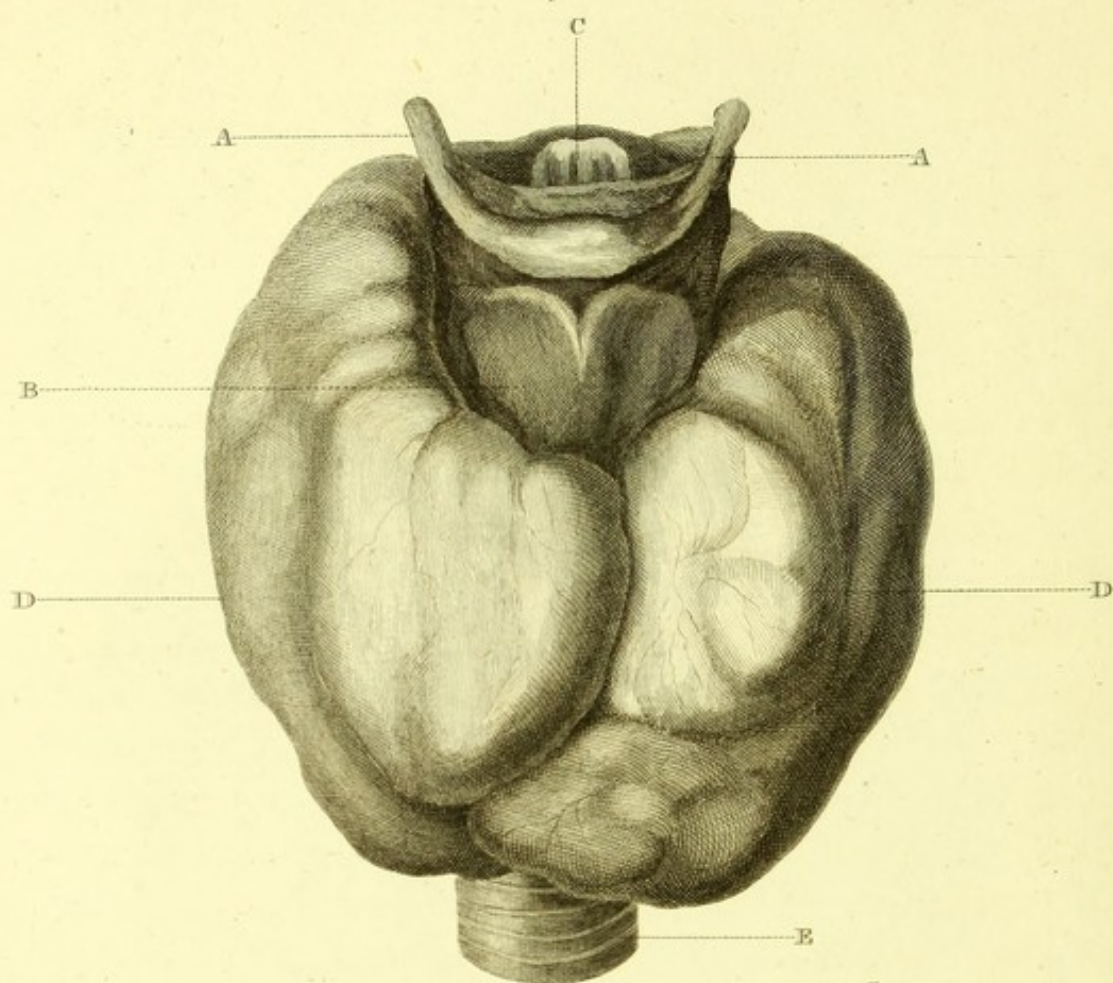


Fig. 2.

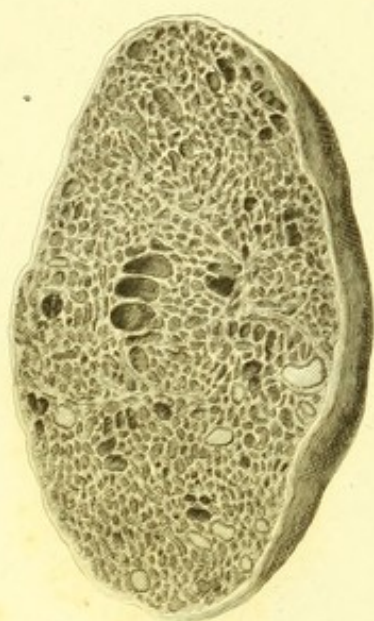
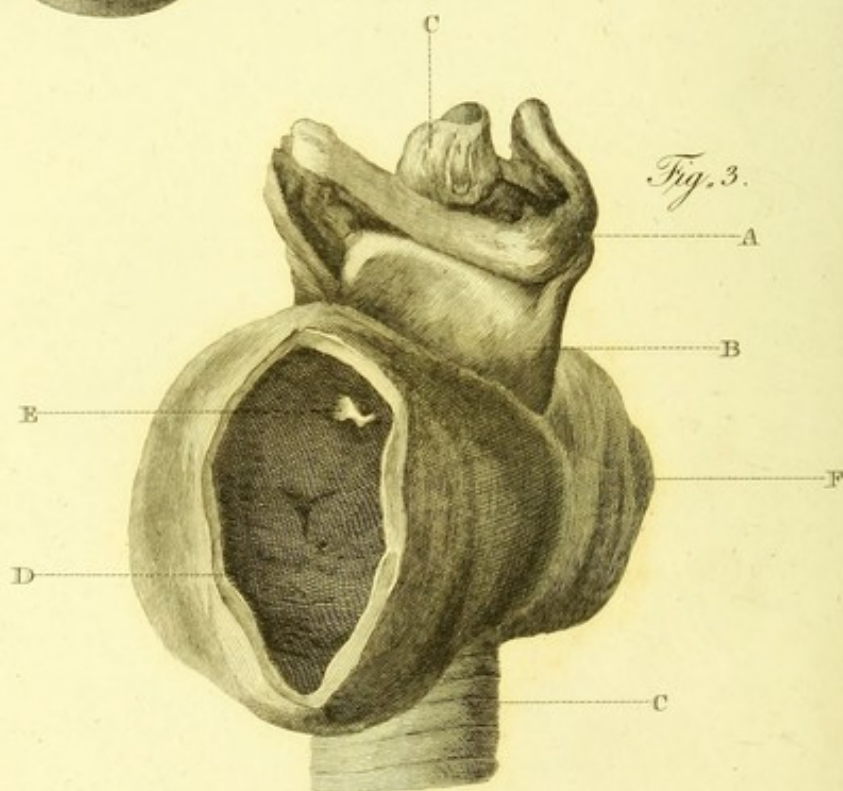


Fig. 3.





THE  
SECOND FASCICULUS.

---

IN the second Fasciculus, we propose to illustrate, by Engravings, the Chief Morbid Appearances of the Lungs, and of the parts which are intimately connected with them. These are the Thyroid Gland, the Larynx, the Trachea, and the Pleura. We shall begin with the diseased changes to which the Thyroid Gland is subject.

PLATE I.

THIS Plate is intended to illustrate the principal diseased appearances of the thyroid gland. The most common is known by the name of bronchocele, in which this gland is much enlarged beyond its natural size, and formed into a great number of cells, containing a very viscid fluid. This fluid becomes solid like a jelly, when the gland has been kept for some time in proof spirits.

## FIG. I.

- A A. The os uoides.
- B. The thyroid cartilage.
- C. The extremity of the epiglottis.
- DD. The thyroid gland much enlarged.
- E. Some of the rings of the trachea.

*From Dr. Hunter's Museum.*

## FIG. II.

Represents a section of the thyroid gland, affected with bronchocele. On the cut surface of this section many cells are observable, which vary a good deal in their size, and are filled with a kind of jelly. A few of the cells are filled with a pretty hard whitish matter.

*From Dr. Hunter's Museum.*

## FIG. III.

Represents an abscess laid open in the right side of the thyroid gland.

- A. The os uoides.
- B. The thyroid cartilage.
- C. A part of the epiglottis.



- D. The cavity of the abscess.
- E. An opening of communication formed by ulceration between the cavity of the abscess and the cavity of the trachea, by which the pus had been evacuated into the trachea, and had suffocated the patient.
- F. The left side of the thyroid gland.
- G. Some rings of the trachea. *From Dr. Hunter's Museum.*

- D. The cavity of the space.  
 E. An opening of communication formed by elevation in  
 between the cavity of the space and the cavity of the  
 trachea, by which the gas had been separated from the  
 trachea, and had collected in the space.  
 F. The left side of the thyroid gland.  
 G. Some rings of the trachea.





Fig. 1.

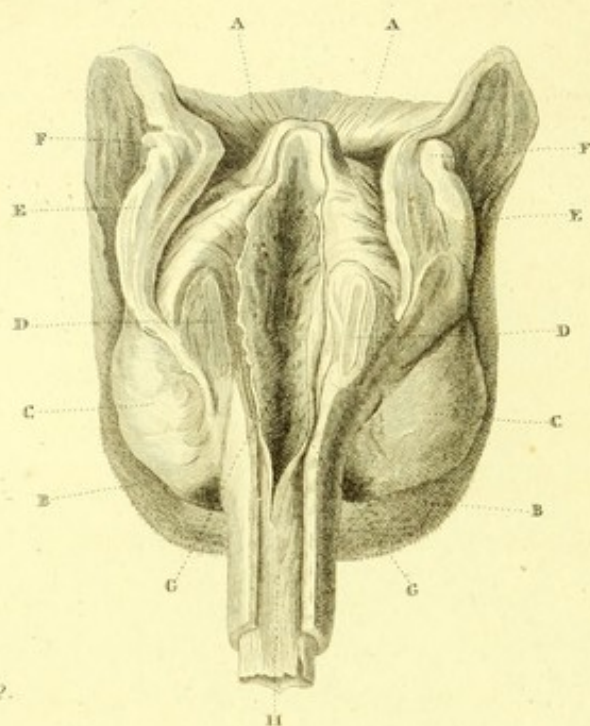
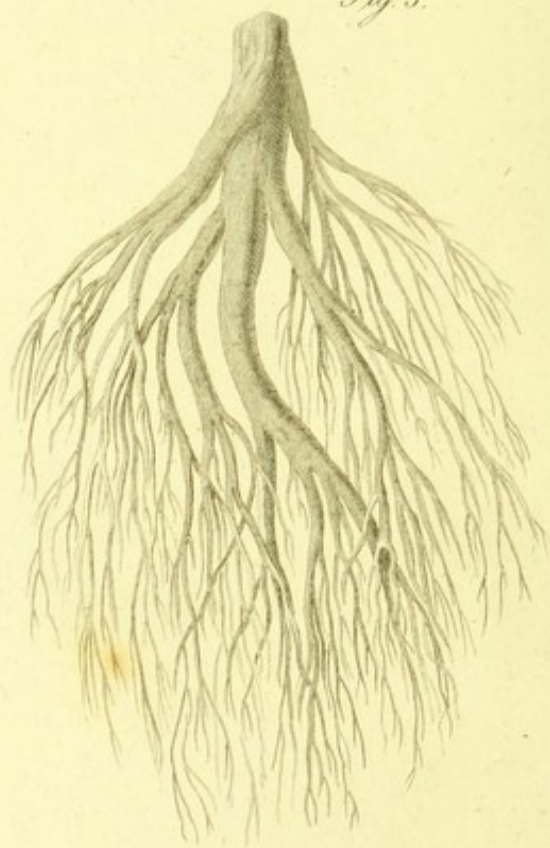


Fig. 2.

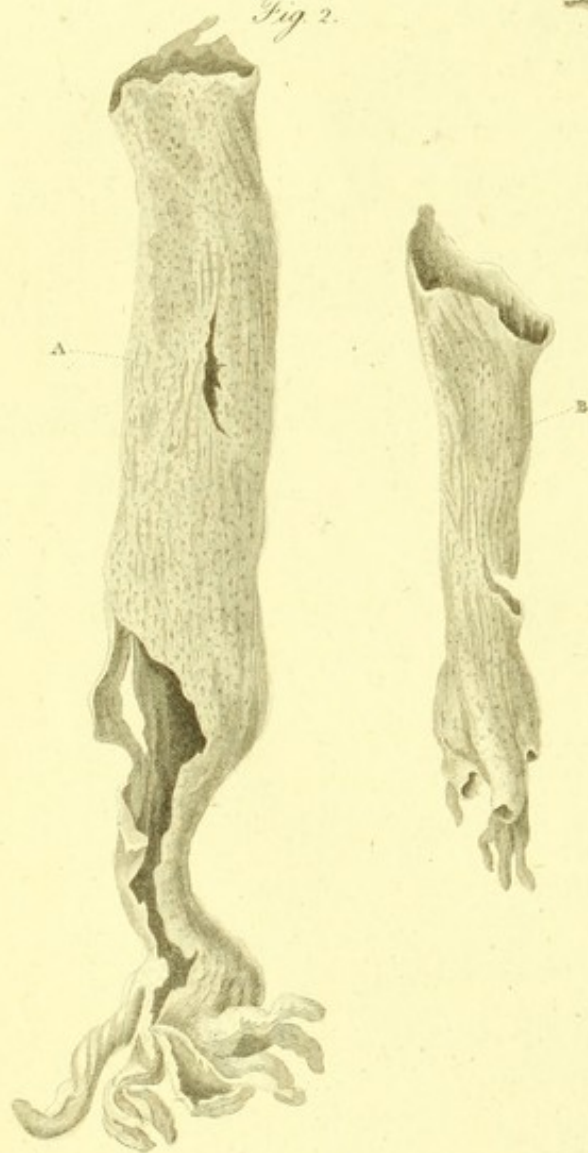

Fig. 3.





## PLATE II.

THE object of this Plate is to illustrate the chief morbid appearance which takes place in croup, and also the tubular and solid polypi which sometimes are formed in the trachea and its branches.

## FIG. I.

This Figure is intended to represent the layer of coagulable lymph which is formed in croup by the inflammation of the inner membrane of the larynx and the trachea. The inflamed appearance of the membrane itself cannot be distinctly preserved in a preparation, and therefore cannot be represented in any engraving taken from one.\*

AA. The upper surface of the tongue, very near the epiglottis.

BB. The edge of the tongue near its tip.

\* The colour of an inflamed membrane, or indeed of any structure whatever, can only be represented by a coloured drawing, or a coloured engraving. The colour of parts, however, is in a great measure lost in all wet and dry preparations. In a work, therefore, in which the engravings must almost all be taken from preparations, the colour must have been chiefly represented from memory, and of consequence very imperfectly. On this account we thought it much better that the engravings should not be coloured.



- CC. The posterior and lateral portions of the thyroid gland.  
DD. The cut edges of the cricoid cartilage.  
EE. The upper processes of the thyroid cartilage, which had not been distinctly exposed to view by dissection.  
FF. The posterior extremities of the horns of the os uoides.  
GG. The coagulable lymph lining, as an adventitious membrane, the inner surface of the larynx and the epiglottis.  
H. A portion of the same coagulable lymph lining a part of the trachea, where its tubular shape is preserved. It extends in croup into the branches of the trachea; but this appearance cannot be preserved in a preparation to any minuteness, without great difficulty.

*From Mr. Cline's Collection.*

## FIG. II.

- A. A large portion of a tubular polypus, which had been coughed up from the trachea. In some parts it is broken, so as to discover its cavity or tubular shape. Its colour and consistence resemble exactly those of the coagulable lymph of the blood when coagulated, and it is slightly irregular upon its external surface.  
B. A smaller portion of the same polypus.

*From Dr. Hunter's Museum.*



## FIG. III.

This Figure illustrates the appearance of a solid polypus which had been coughed up. Its branches are very numerous, and had occupied some very minute ramifications of one of the bronchia. Its colour was somewhat whiter than is usual in the coagulable lymph of the blood, but its texture was exactly the same as that of this lymph coagulated.

*From the Author's Collection.*

This figure illustrates the appearance of a cell, polygonal in shape, which has been stained with the fast blue. The nucleus is visible as a dark spot in the center of the cell. The cytoplasm is filled with fine granules. The cell is surrounded by a thin layer of fluid. The overall appearance is that of a typical epithelial cell.

The cell is shown in a cross-section, revealing its internal structure. The nucleus is centrally located and contains a prominent nucleolus. The cytoplasm is densely packed with organelles, giving it a granular appearance. The cell membrane is clearly defined, separating the cell from its surroundings.

The figure also shows the arrangement of multiple cells, which are closely packed together. The cells exhibit a variety of shapes, from rounded to more elongated, reflecting their natural state in tissue. The staining highlights the cellular boundaries and internal components.

The overall image provides a detailed view of cellular morphology and organization. The use of fast blue staining allows for the clear visualization of the nucleus and cytoplasmic details, facilitating the study of cellular structure and function.

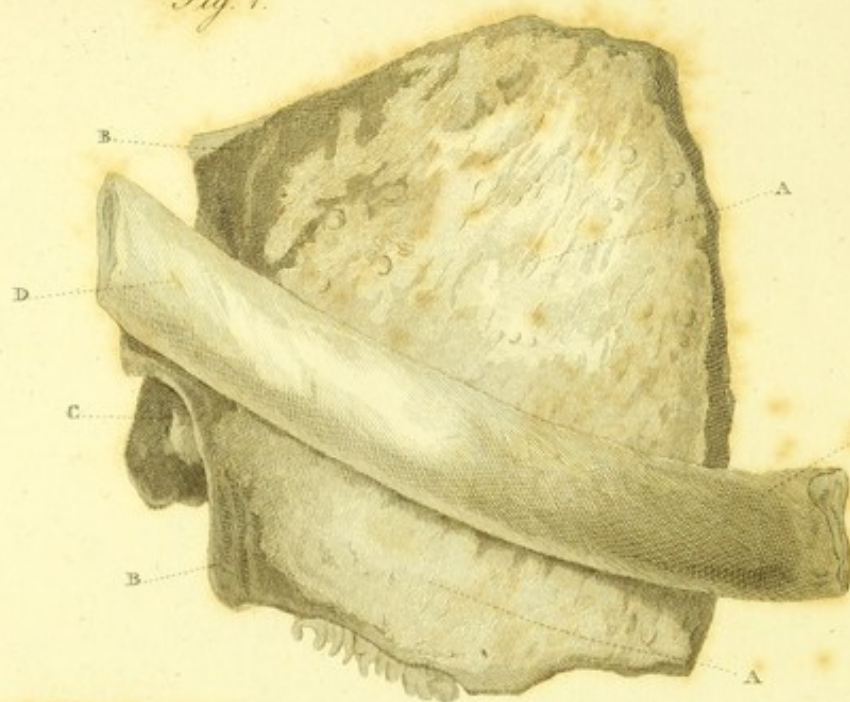The figure is a high-magnification micrograph, showing individual cells and their interactions within a tissue sample. The clarity of the image allows for the identification of specific cellular features and the overall architecture of the tissue.

The image is a black and white reproduction of a stained glass slide, showing the same cellular structures as described above. The contrast is slightly different, but the overall morphology and organization remain consistent with the color image.

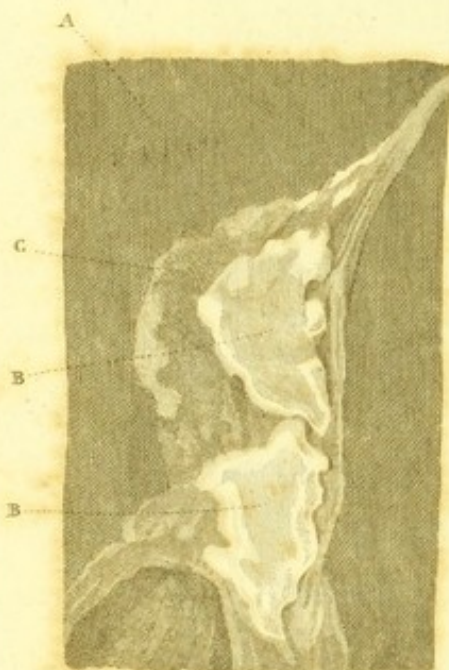





*Fig. 1.*



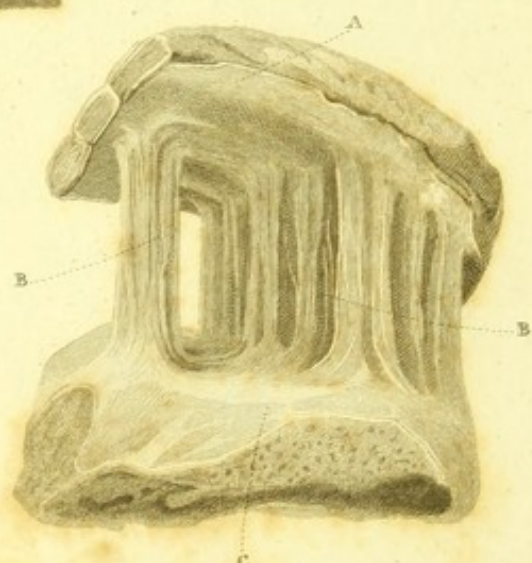*Fig. 2.*



*Fig. 3.*



*Fig. 4.*





# PLATE III.

THIS Plate is intended to illustrate the more considerable diseased appearances of the pleura.

## FIG. I.

In this, and Fig. II. is represented an ossification of the pleura.

AA. An ossified part of the pleura, of considerable extent.

BB. A part of the pleura not converted into bone.

C. A small portion of the lungs dried, and adhering upon the inside of the pleura.

DD. A part of a rib adhering upon the outside of the pleura.

The preparation from which this figure is taken was dry, in order to shew the ossification more distinctly.

*From the Author's Collection.*

## FIG. II.

A. A portion of the pleura in its natural state.

BB. Two considerable ossifications in it.

- C. A portion of the pleura thickened, in which some very small ossified spots are beginning to be formed.

Ossification of the pleura is a rare morbid appearance, although it more commonly occurs in it than in the peritonæum, or any other membrane of a similar structure.

*From Dr. Hunter's Museum.*

FIG. III.

This Figure illustrates inflammation of the pleura.

- A. A portion of the pleura thickened from inflammation, which may be judged of from the thickness of the edge of the membrane.
- B. A portion of the layer of coagulable lymph which is formed by inflammation of the pleura. The greater part of its surface is rough, bearing some resemblance to lace; but a part of the surface at the lower end is smooth, an appearance which is not uncommon.

*From the Author's Collection.*

FIG. III.

This Figure exhibits an example of adhesions in the chest;



which is perhaps the most common morbid alteration of structure found upon examining dead bodies. They are formed by a gradual change of the layer of coagulable lymph, thrown out during the inflammation, into a membrane. This membrane is of the same kind with the common cellular membrane of the body.

A. A portion of three ribs.

B B. Adhesions of considerable length between that portion of the pleura which lines the ribs, and that other portion of it which covers the lungs.

C. A portion of the lungs with the pleura upon its surface, thickened by a former inflammation, which was probably the same that produced the adhesions.

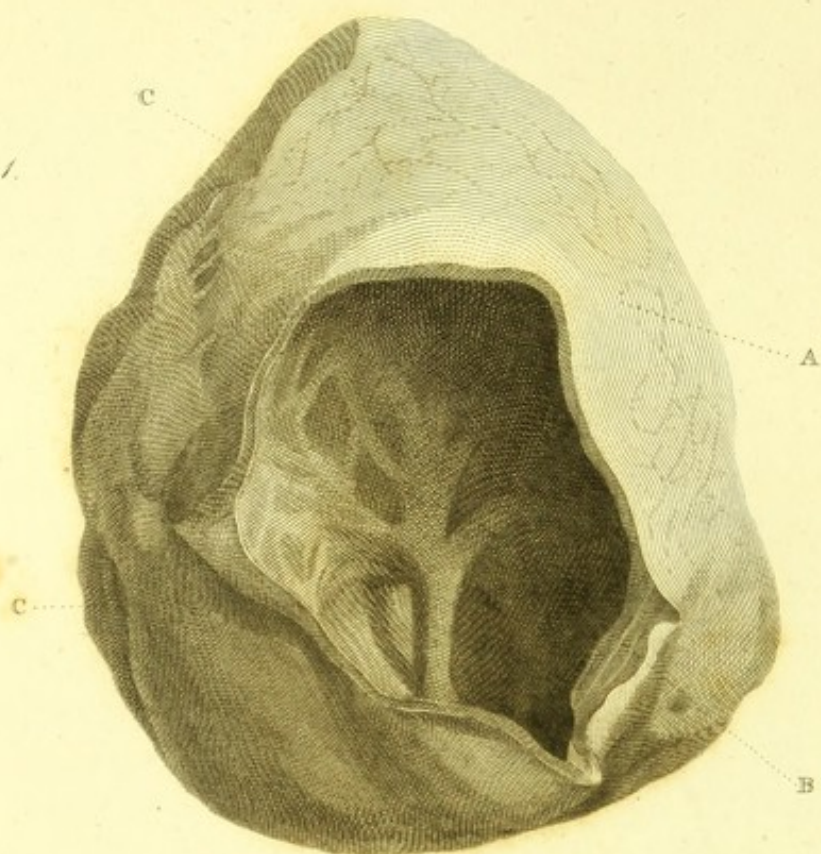*From the Author's Collection.*



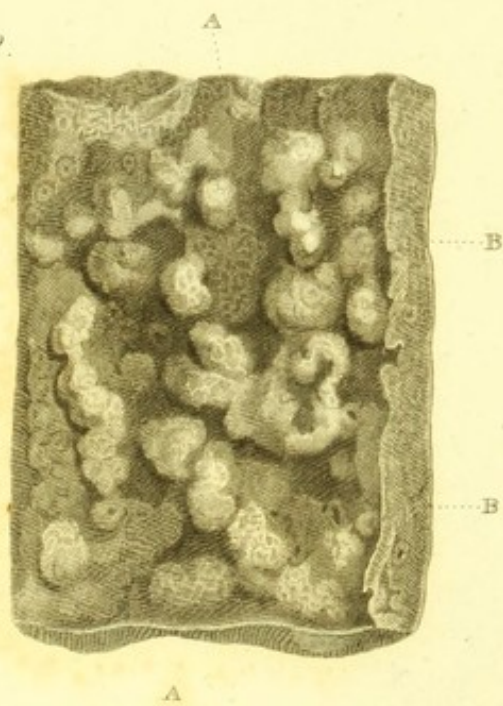




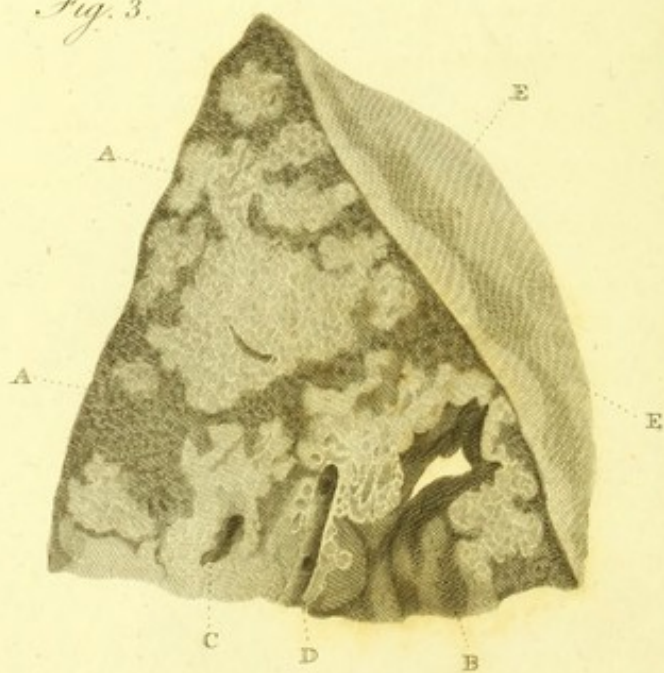
*Fig. 1.*



*Fig. 2.*



*Fig. 3.*





## PLATE IV.

IN this Plate are illustrated the more common diseases to which the lungs are subject. These consist of abscess, and of that particular species of tubercles, which lays the foundation of pulmonary consumption.

### FIG. I.

Exhibits a portion of one of the lungs, with a large abscess in it.

- A. The external surface of the lungs.
- B. The cavity of the abscess.
- CC. The edge where this part of the lungs had been cut off from the rest.

Inflammation of the lungs which has not advanced to form pus, is not capable of being adequately represented by an engraving, otherwise a representation of it would have preceded this figure. *From the Author's Collection.*

### FIG. II.

Represents a portion of the lungs studded with tubercles. These vary a good deal from each other in their size, and



had none of them advanced to suppuration. No part of the external surface of the lungs is here presented to view, but a part of their substance or internal structure.\* In frequent examinations of the lungs, when affected with tubercles, there is an opportunity not only of observing a great variety in the size of tubercles, but also in some other particulars. The tubercles, in some cases, are very numerous, and in others comparatively few; in some cases they are quite separate or distinct, and in others many of them are joined together. In some almost all the tubercles have run more or less into suppuration, and in others this process has not at all begun. When the disease has made any considerable progress, there is commonly in this respect, a mixed appearance; some of the tubercles being in a state of suppuration, and others having not yet advanced so far as this state. It would require several Figures to represent all of these varieties: in this and the following Figure we have only represented those which are the most important.

A A. A part of the substance of the lungs, studded with tubercles.

B B. A part of the edge of the lungs near their external surface, shewing the natural structure.

*From the Author's Collection.*

\* The natural structure of the lungs has been a good deal removed by dissection from the outer surface of the tubercles, in order to render their appearance more distinct,



## FIG. III.

Represents a section of a part of the lungs, shewing tubercles in a more advanced progress, and abscesses in some places being formed.

A A. A section of the lungs, shewing tubercles of various sizes, and some of them coalescing together.

B. An abscess formed in consequence of some tubercles having advanced to suppuration.

C. A very small abscess.

D. One of the pulmonary vessels laid open by a section of this part of the lungs.

E E. A part of the external surface of the lungs.

*From the Author's Collection.*

The figure shows a section of a part of the large, elongated structure in a more advanced stage than the one shown in figure 1, the difference being that the structure is now more elongated and the internal structure is more complex.

A. A section of the large, elongated structure, showing the internal structure and the arrangement of the various parts. The structure is elongated and the internal structure is more complex than in figure 1.

B. A section of the large, elongated structure, showing the internal structure and the arrangement of the various parts. The structure is elongated and the internal structure is more complex than in figure 1.

C. A section of the large, elongated structure, showing the internal structure and the arrangement of the various parts. The structure is elongated and the internal structure is more complex than in figure 1.

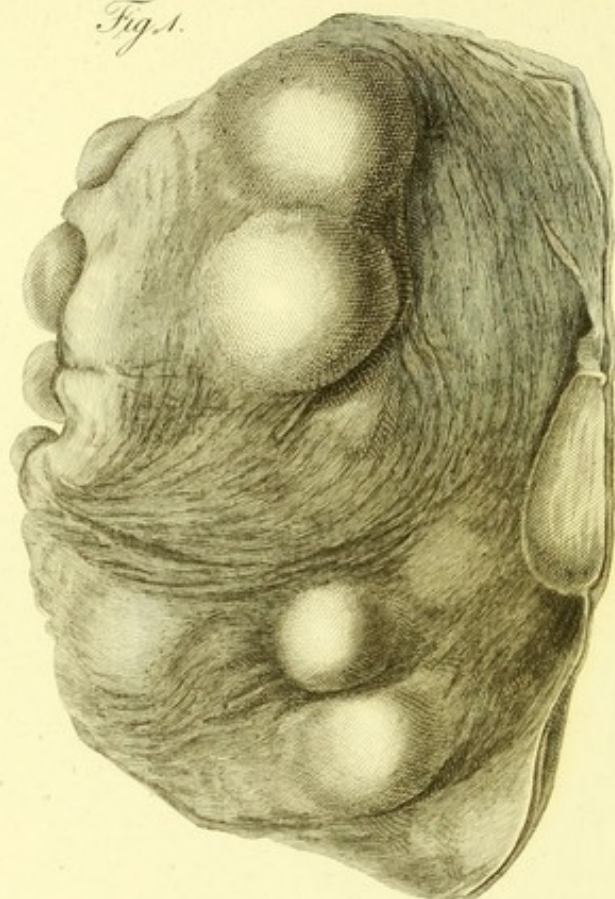
D. A section of the large, elongated structure, showing the internal structure and the arrangement of the various parts. The structure is elongated and the internal structure is more complex than in figure 1.

E. A section of the large, elongated structure, showing the internal structure and the arrangement of the various parts. The structure is elongated and the internal structure is more complex than in figure 1.

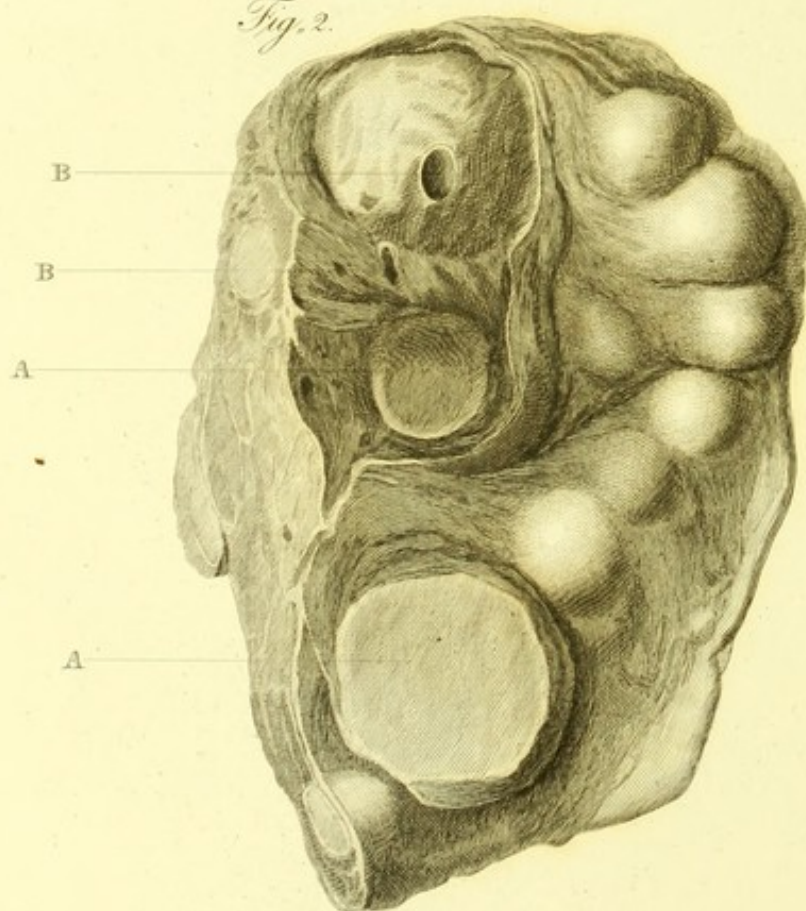




*Fig. 1.*



*Fig. 2.*





## PLATE V.

THIS Plate is intended to represent a very uncommon sort of tubercles in the lungs. They are of a considerable size, and are chiefly formed near the surface of the lungs, rendering it irregular. They consist of a light brown soft matter, very uniform in its texture, and the substance of the lungs in the interstices is perfectly sound. At present nothing is known with regard to the tendency of this species of tubercles to run into suppuration.

### FIG. I.

Represents a part of the convex surface of the lungs, with several pretty large tubercles formed on it.

*From Dr. Hunter's Museum.*

### FIG. II.

Represents the concave surface of the same portion of the lungs with a greater number of tubercles formed on it.

A A. Two tubercles cut transversely, to shew the appearance of the light brown matter of which they consist.

B B. The orifices of two divided blood vessels in the lungs.

PLATE V

This Plate is intended to represent very common sort of tubercles in the lungs. They are of a conical, lobed, and are chiefly found near the surface of the lungs, extending to irregular. They are of a light brown color, rather very uniform in its texture, and the substance of the lungs in the immediate vicinity of the tubercles is known to be perfectly healthy. The tubercles are known with regard to the texture of the lungs to run into suppurative.

FIG. 1

Represents a part of the surface of the lungs, with several pretty large tubercles, taken from a young Dr. Wright's Alaskan.

FIG. 2

Represents the surface of a lung, showing the position of the lungs with a great number of small tubercles on it.

A. A. The tubercles are generally in the appearance of the lungs, and are of a light brown color, and are of a conical shape. B. B. The surface of the lungs, showing the position of the lungs.

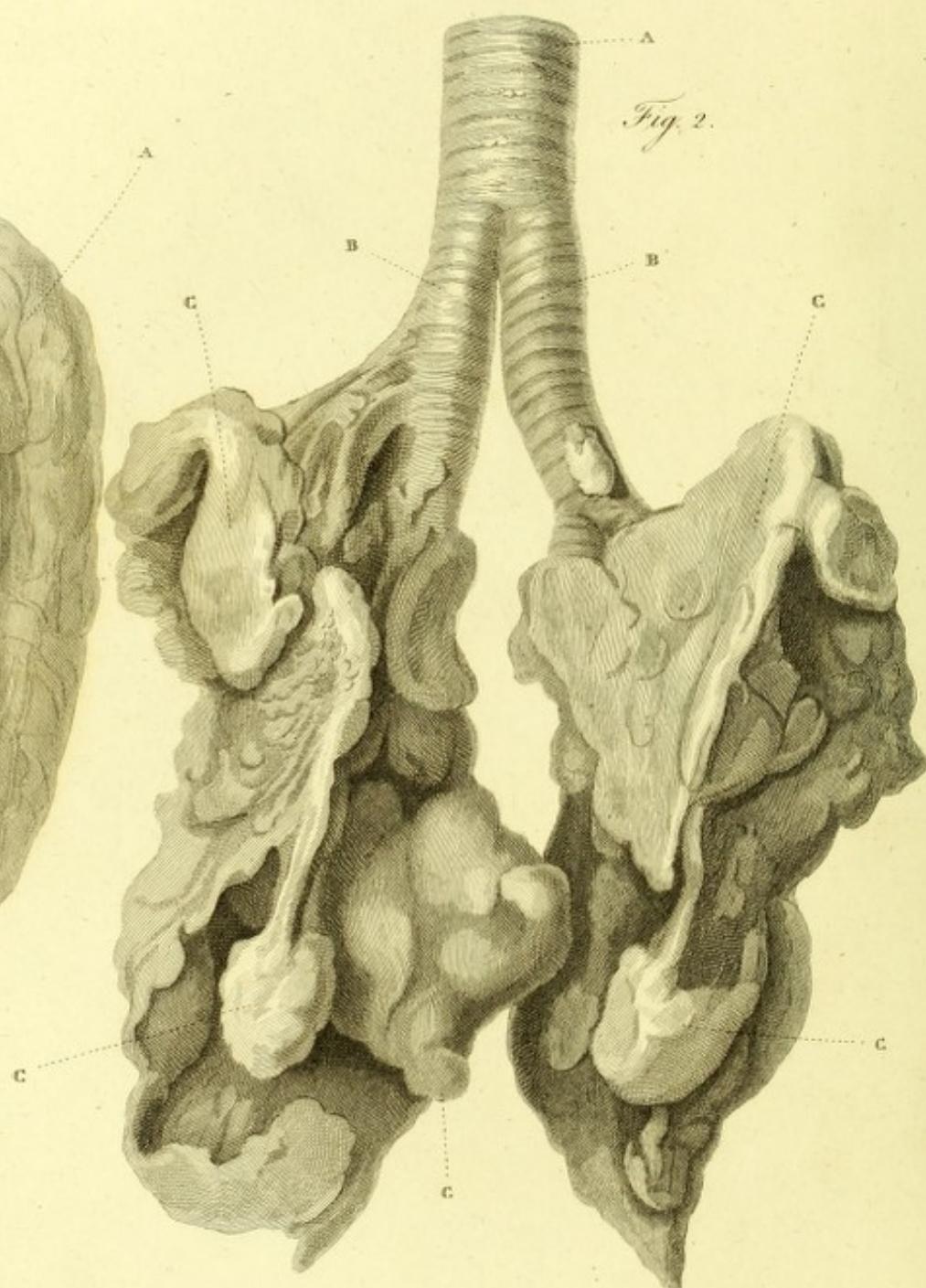




Fig. 1.

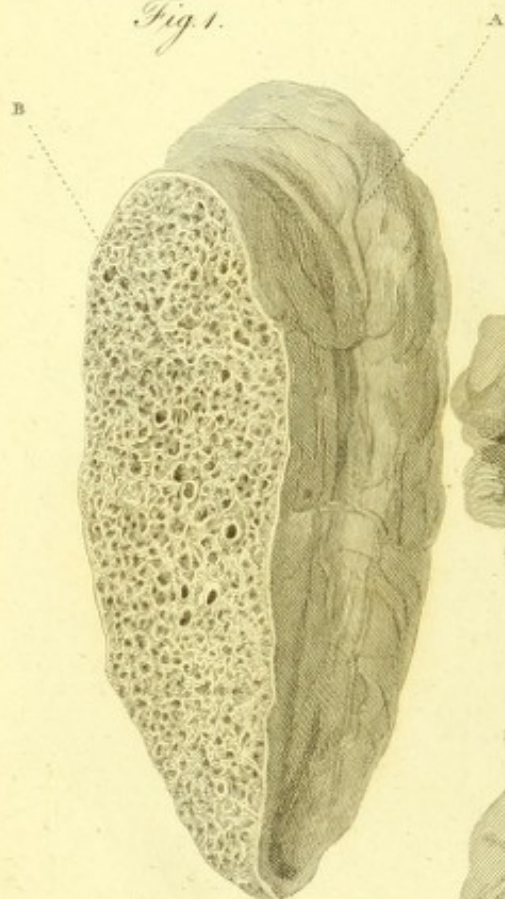

Fig. 2.





## PLATE VI.

IN this Plate are exhibited two very rare diseased appearances of the lungs, the one an enlargement of their cells, and the other an ossification of their substance.

### FIG. I.

Represents a section of one of the lungs, exhibiting the first kind of disease. In this section the air-cells are seen much enlarged beyond their natural size, so as to resemble the air-cells of the lungs in amphibious animals.

- A. The external surface of this section of the lungs.
- B. Its cut edge, shewing a large cellular structure. The very dark cavities, which are about ten in number, are the orifices of some divided branches of the pulmonary blood vessels and the trachea. *From the Author's Collection.*

### FIG. II.

Represents lungs which had been ossified to a great extent.

- A. The trachea.
- B B. The two bronchia.
- CCCCC. The ossified portions of the lungs.

The parts which appear of a dark colour, consist of the natural substance of the lungs dried. The lungs are here represented as being considerably smaller than the natural size; but this was necessary, in order that they might be adapted to the size of the Plate. *From Mr. Hunter's Museum.*

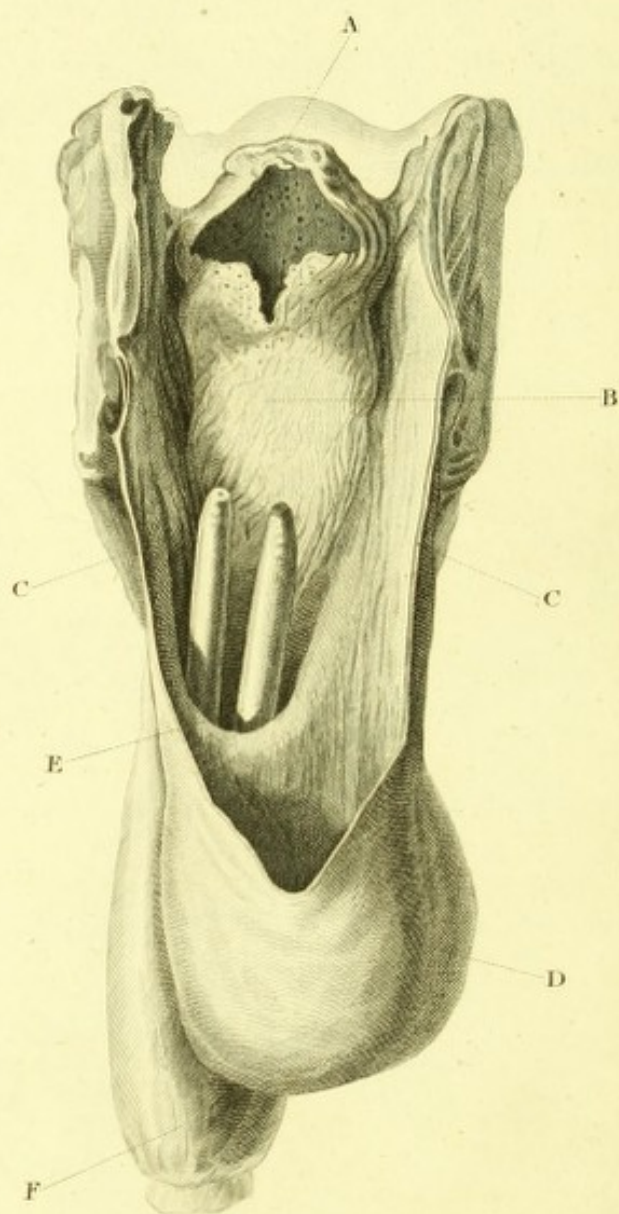




Fig. 1.

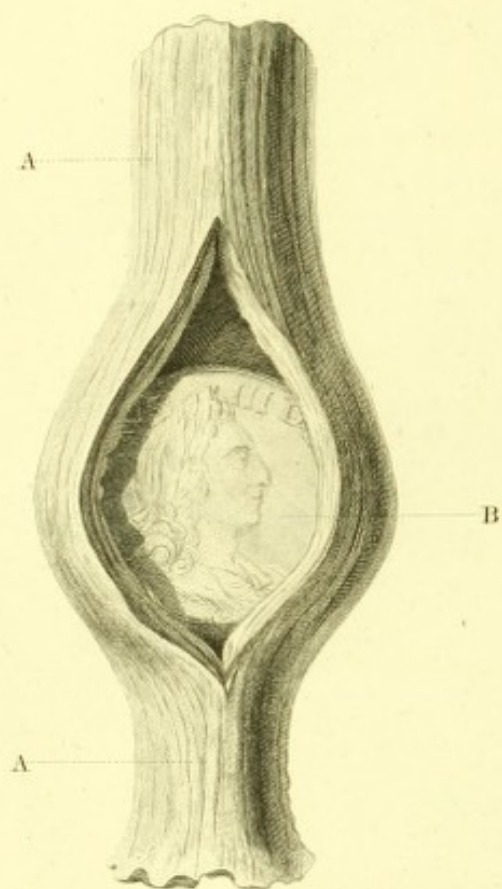

Fig. 2.





THE  
THIRD FASCICULUS.

---

IN this Fasciculus we propose to illustrate the more important Morbid changes of Structure, which affect the Pharynx, the Œsophagus, and the Stomach. The Œsophagus is found to be most liable to disease at its upper and lower extremities ; and the Stomach at its small end. We shall begin with the diseases of the Pharynx and the Œsophagus.

PLATE I.

Is intended to illustrate some circumstances depending upon extraneous bodies having got into the pharynx, or the œsophagus.

FIG. I.

In this figure is represented a half crown of William the Third sticking in the œsophagus. It could neither be got up,

ner could it pass into the stomach, and the patient was carried off in a few days, a large quantity of blood having been previously thrown off from the stomach.

A A. A part of the external surface of the œsophagus, in which the longitudinal muscular fibres of the œsophagus are seen unusually strong. It is probable that the fibres may have become thicker and stronger from the violent efforts to action which the œsophagus would be excited to make, after the half crown had been swallowed, notwithstanding that the patient survived the accident but a few days.

B. The half crown, in which the countenance of William the Third, and part of the superscription, are very readily distinguishable. The surface of the half crown had become almost black from the action of the juices upon it, which are secreted in the mouth and the œsophagus.\*

*From Dr. Hunter's Museum.*

## FIG. II.

This figure represents a pouch which had been formed in the lower end of the pharynx, by a cherry stone having rested there for three days, and formed a little recess for itself. This

\* The œsophagus is sometimes so large in an adult, as to allow a half crown to pass through it without injury, and it has afterwards been evacuated by the rectum. A half crown which had made this journey, is preserved in Dr. Hunter's Museum.



recess was gradually enlarged during the course of five years, by a part of the food constantly passing into it, and for some time remaining in it, till it arrived at the size which is represented in the figure. The food at last was all detained in the pouch or bag, and none of it passed into the œsophagus. The case is related in Vol. III. of the Medical Observations, and an engraving has also been given of the preparation, in different points of view. In the present figure there is only represented one view of the preparation, but it is sufficient to illustrate clearly the nature of the disease.

- A. The epiglottis lying over the aperture into the larynx. Upon its internal surface, some follicles are very observable.
- B. That part of the pharynx lying next to the larynx, upon the upper surface of which, may also be observed a few follicles.
- C C. The cut edges of the pouch which is formed by a dilatation of the pharynx: these have been rendered thin by long and gradual stretching.
- D. The lower end of the pouch.
- E. The valvular-like communication of the œsophagus with the pouch, through which are passing two quills in order to render it more conspicuous. It is obvious that neither food nor drink could pass under these circumstances from the pharynx into the œsophagus.
- F. A part of the œsophagus. *From Dr. Hunter's Museum.*

was gradually enlarged during the course of five years by a part of the food constantly passing into it and for some time remaining in it till it arrived at the size which is represented in the figure. The food at last was all detained in the pouch for five and a half years into the crop again. The case is related in Vol. III of the Medical Observer, and an engraving has been given of the preparation, in different points of view. In the present figure there is only a representation and view of the preparation; but it is sufficient to illustrate clearly the nature of the disease.

A. The preparation lying over the aperture into the pouch upon the internal surface. Some fat is also visible.

B. That part of the preparation lying next to the pouch, upon the upper surface of which may also be observed a few follicles.

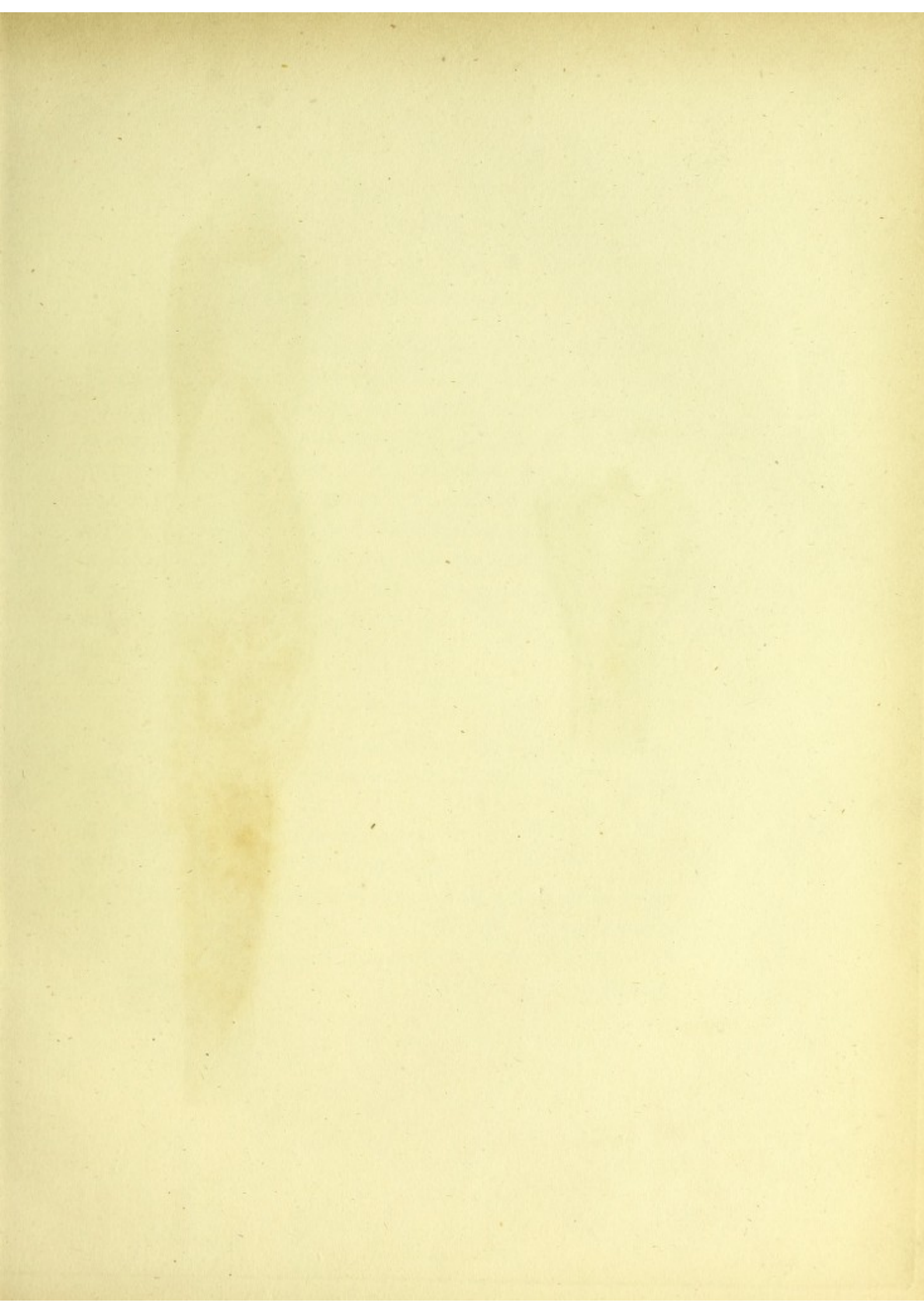
C. The cut edge of the pouch which is formed by a dilatation of the pharynx: there have been several thin longitudinal folds and several stretching.

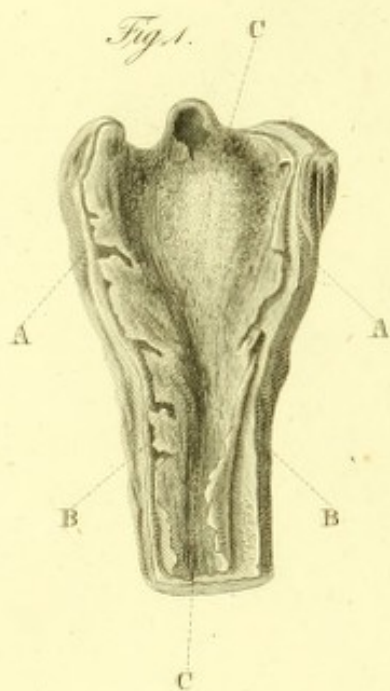D. The lower end of the pouch.

E. The exterior of the preparation of the preparation with the pouch, showing the position of the pouch in order to be seen in the preparation. It is observed that neither food nor drink could pass under these circumstances from the pharynx into the crop.

F. A part of the preparation. From the Medical Observer.

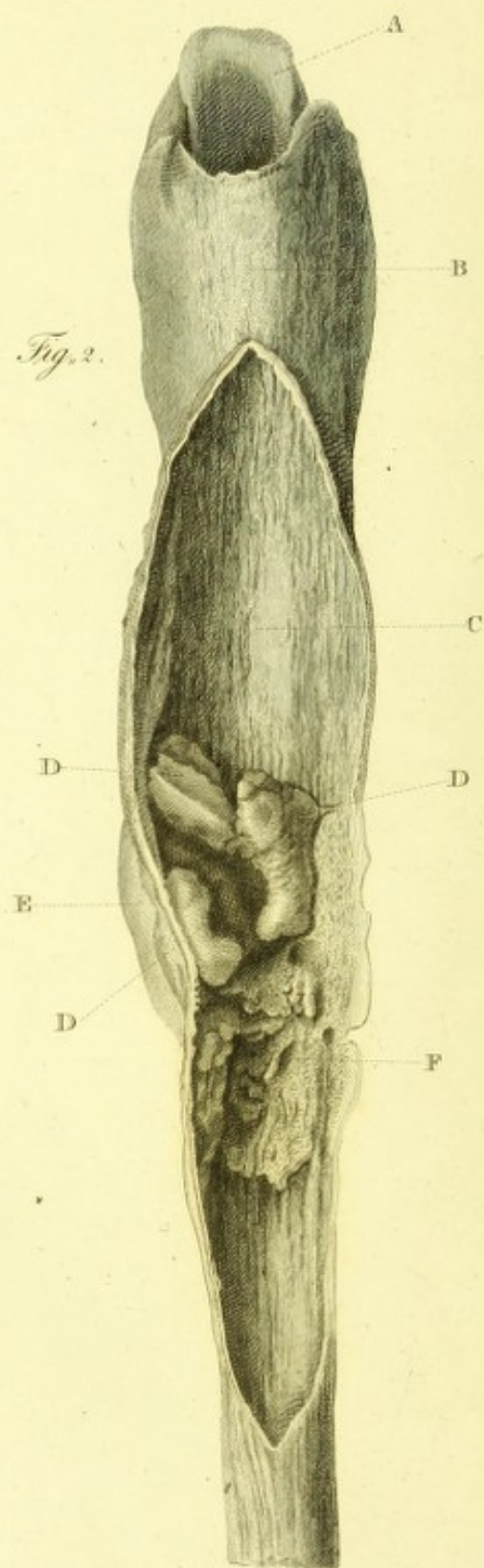






*W. C. del.*

*Fig. 2.*



*A. F. del.*

*J. B. sculp.*



## PLATE II.

THIS Plate represents the layer of white matter which is formed by the thrush in the pharynx and the œsophagus. The matter bears a very strong resemblance to the coagulable lymph which is formed upon many inflamed surfaces in the body, but the former is generally whiter in its colour and more brittle in its texture than the latter. It may be considered not improperly, as the coagulable lymph peculiarly modified by the action of the blood-vessels which separate it from the mass of blood in this disease. The same Plate too represents some tumours in the cavity of the œsophagus, forming a cause of obstruction in that canal which is very uncommon.

## FIG. I.

Represents the layer of white matter which lines the cavity of the pharynx, and the œsophagus in thrush.

- A A. The cut edges of the pharynx.
- B B. The cut edges of the œsophagus.
- C C. The layer of white matter turned up a little at the edges in order to be viewed more distinctly. In some places it is cracked, a circumstance which depends upon its brittle texture.

*From Dr. Hunter's Museum.*

## FIG. II.

Is chiefly intended to represent three hard tumours which had grown from the inner surface of the œsophagus, and which must have necessarily impeded very much deglutition.

A. The epiglottis.

B. The posterior surface of the pharynx.

C C. The œsophagus laid open through nearly the whole of its extent.

D D D. The three tumours which were growing from its inner surface.

E. A lateral projection, or bulging of a part of the œsophagus, occasioned by the growth of one of these tumours.

F. An ulcerated surface, near which the parietes of the œsophagus are a little thickened.\*

*From Dr. Monro's Museum.*

\* An engraving of this preparation has been published by Dr. Monro, junior, in his Inaugural Dissertation.





Fig. 1.

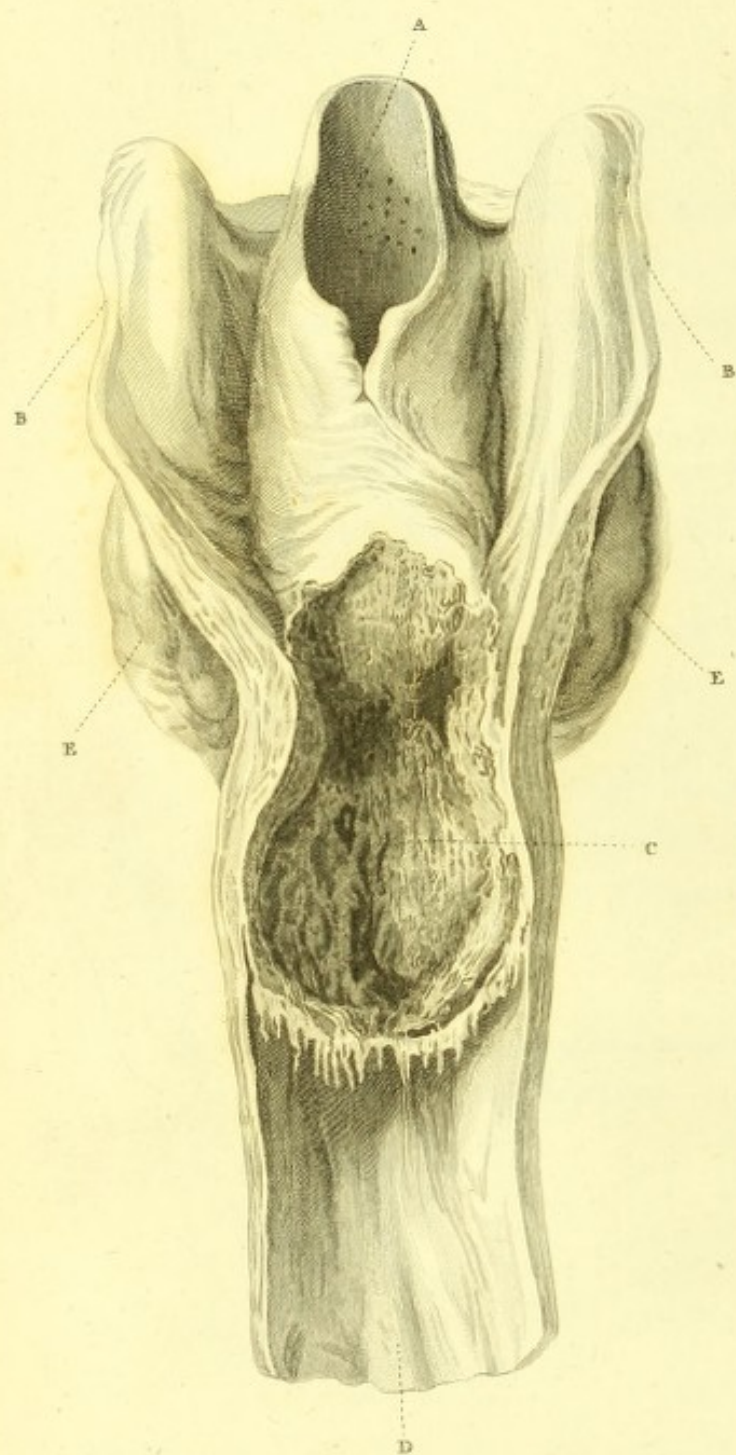
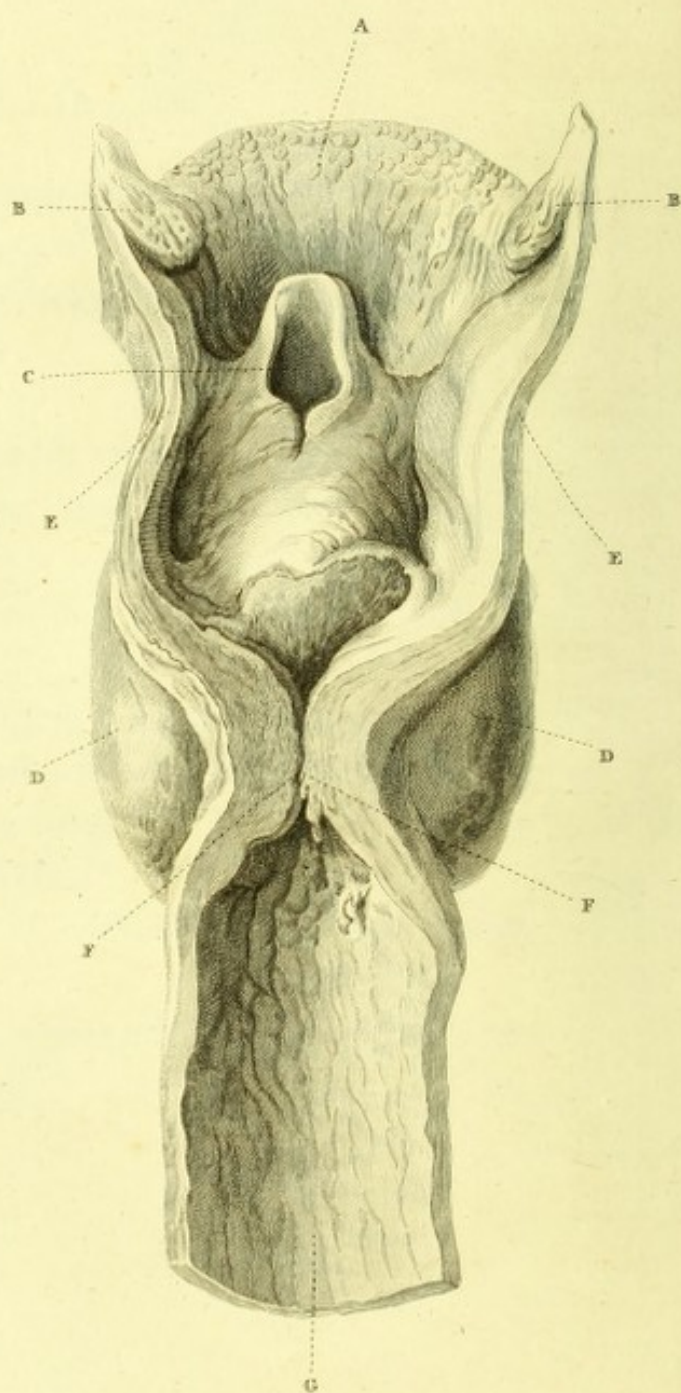


Fig. 2.





### PLATE III.

THIS and the following Plate are intended to illustrate the most important circumstances which are observable in ulcers and strictures of the œsophagus. Ulcers more commonly take place at the upper and lower extremity of the œsophagus, than in any other part of it. The parts surrounding an ulcer are sometimes but little thickened, and in such cases there is no stricture; but more commonly the surrounding parts are a good deal thickened, and very frequently have a gristly hardness. In these cases there is stricture, and where the hardness is strongly marked, the disease is to be considered as of a cancerous nature. Where an ulcer takes place at the upper extremity of the œsophagus, the thyroid gland is frequently enlarged beyond its natural size, and rendered somewhat harder in its texture. There is also sometimes a hard thickening of a part of the œsophagus without ulcer, which may be considered as analogous to scirrhus in glandular parts.

#### FIG. I.

A. The epiglottis with the aperture into the larynx seen under it.

- B B. The cut edges of the pharynx which is laid open.  
C. A large ulcer in the lower part of the pharynx, and the upper part of the œsophagus, with the surrounding parts but a little thickened.  
D. A part of the œsophagus under the ulcer in a sound state.  
E E. The posterior surface of the sides of the thyroid gland, which is somewhat enlarged in its size.

*From Dr. Hunter's Museum.*

FIG. II.

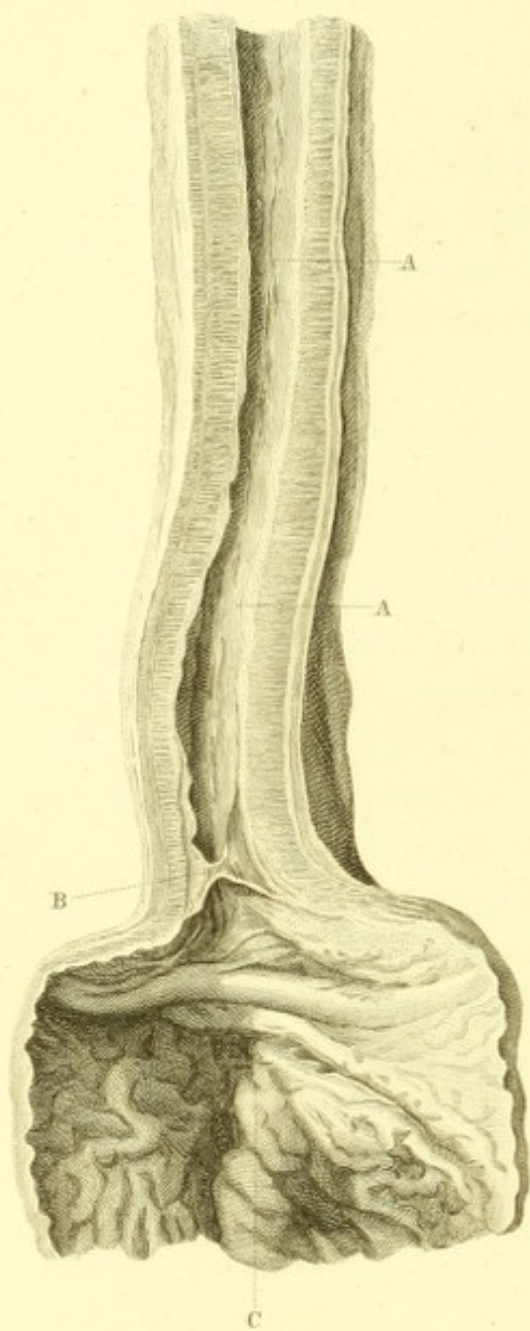
- A. The upper surface of the posterior part of the tongue, which is crowded with follicles.  
B B. The two tonsils.  
C. The epiglottis, with the aperture into the larynx.  
D D. The posterior surface of the sides of the thyroid gland, which is a little enlarged.  
E E. The cut edges of the pharynx, which is laid open.  
F F. An ulcer at the upper extremity of the œsophagus, with the sides a good deal thickened: the stricture therefore in this case was considerable.  
C. A part of the œsophagus under the ulcer, where the structure is sound.

*From Mr. Hunter's Museum.*

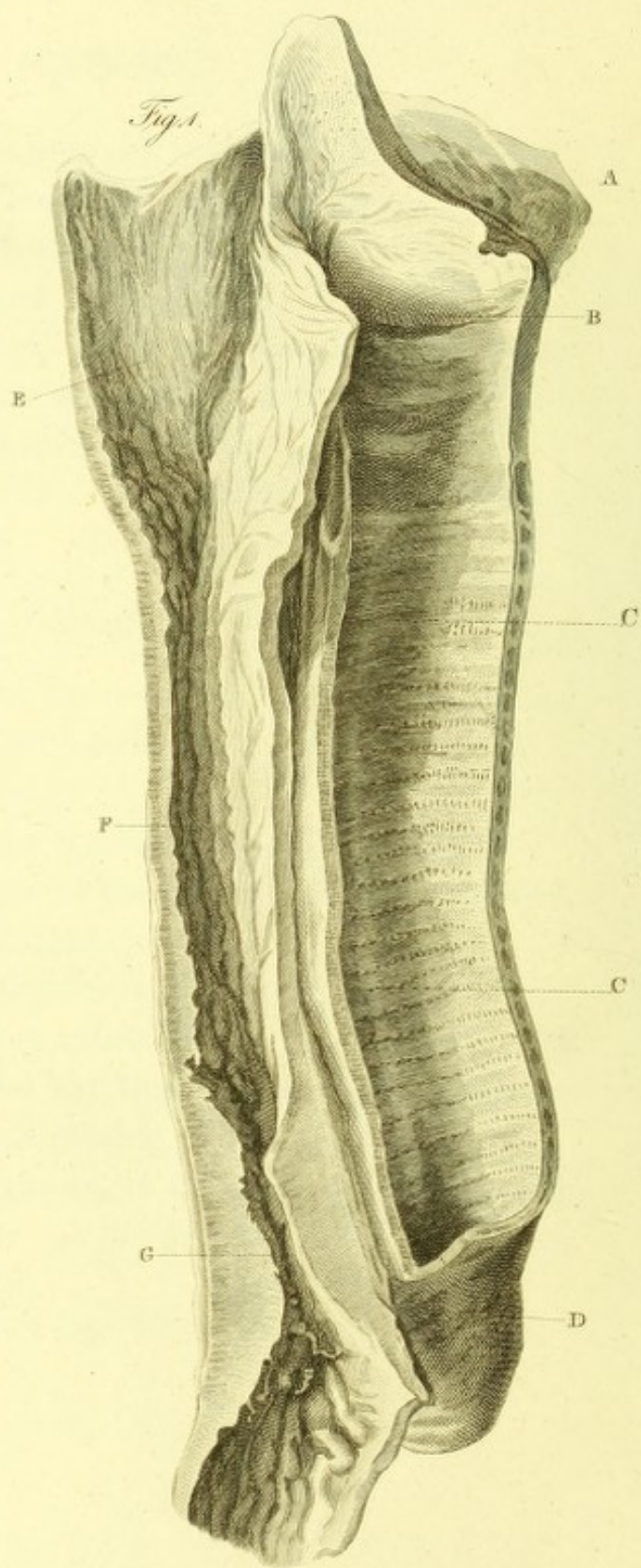




*Fig. 2.*



*Fig. 1.*





## PLATE IV.

IN this Plate an illustration of the same subject is continued, from Plate III.

## FIG. I.

Represents a stricture in the œsophagus near the cardia.

- A. A part of the body of the os uoides, covered from view by the muscles which are attached to it.
- B. A lateral view of the cavity of the larynx.
- C C. A lateral view of the cavity of the trachea.
- D. A part of the left bronchia.
- E. A lateral view of the cavity of the pharynx.
- F. A lateral view of a part of the œsophagus in a sound state.
- G. A stricture near the cardia, where the sides of the œsophagus are very thick and hard, and where there is some degree of ulceration upon the internal surface.

*From Dr. Hunter's Museum.*

## FIG. II.

Represents a stricture in the œsophagus of great extent, not attended with ulceration. The coats of the œsophagus are very

hard and much thickened, and upon the cut surface may be observed many white transverse lines. These represent the cellular membrane interposed between the muscular fibres, thickened from disease. This preparation may be considered as affording a good example of scirrhus in muscular parts.

- A A. A considerable portion of the œsophagus contracted in its cavity, and thickened in its substance.
- B. Shewing the canal to be very narrow at the cardia.
- C. A small part of the inner surface of the stomach, near the cardia, sound in its structure, and exhibiting some rugæ.

*From Mr. Hunter's Museum.*





Fig. 1.

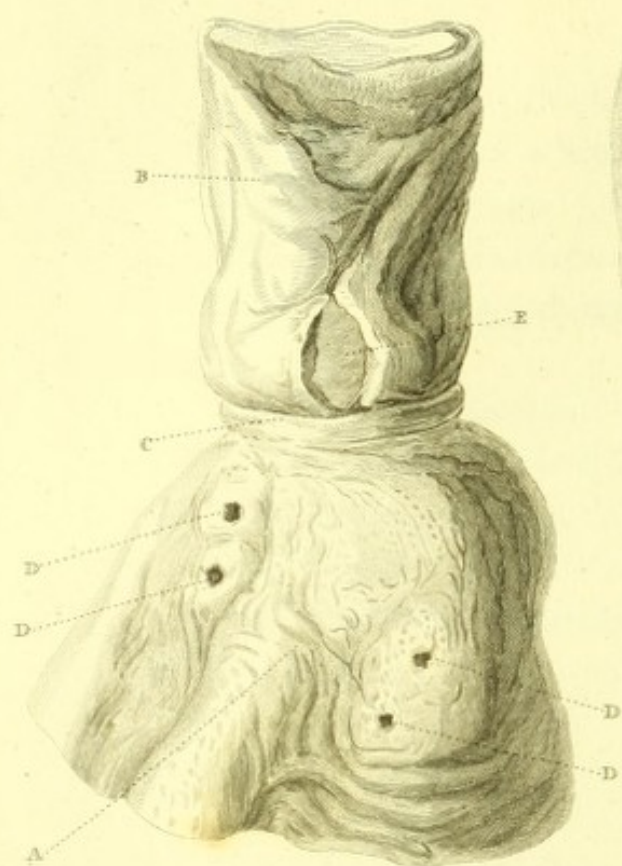


Fig. 3.

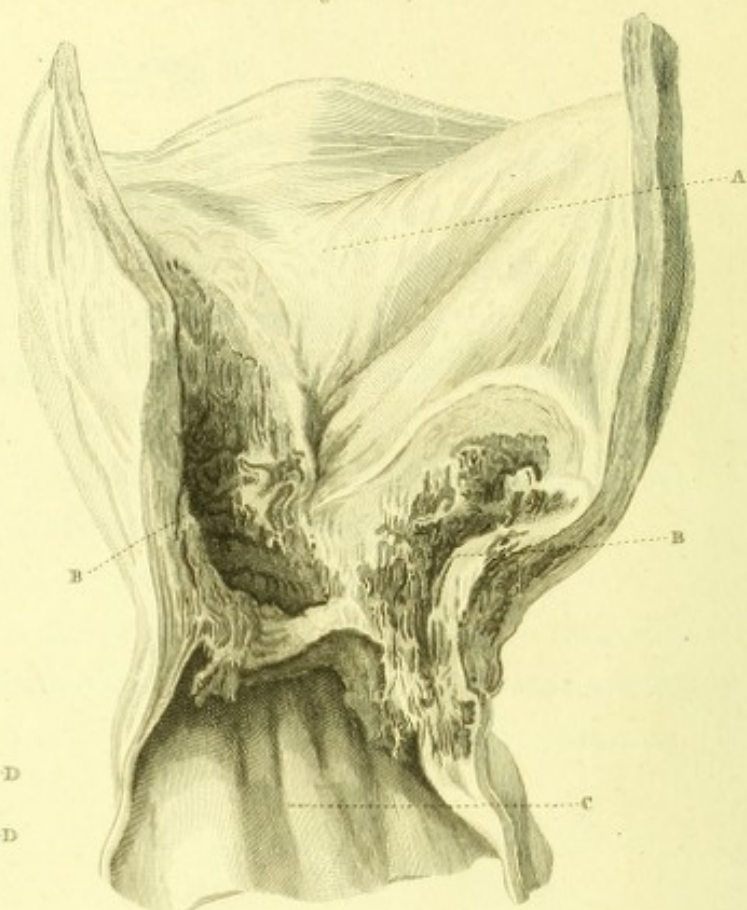
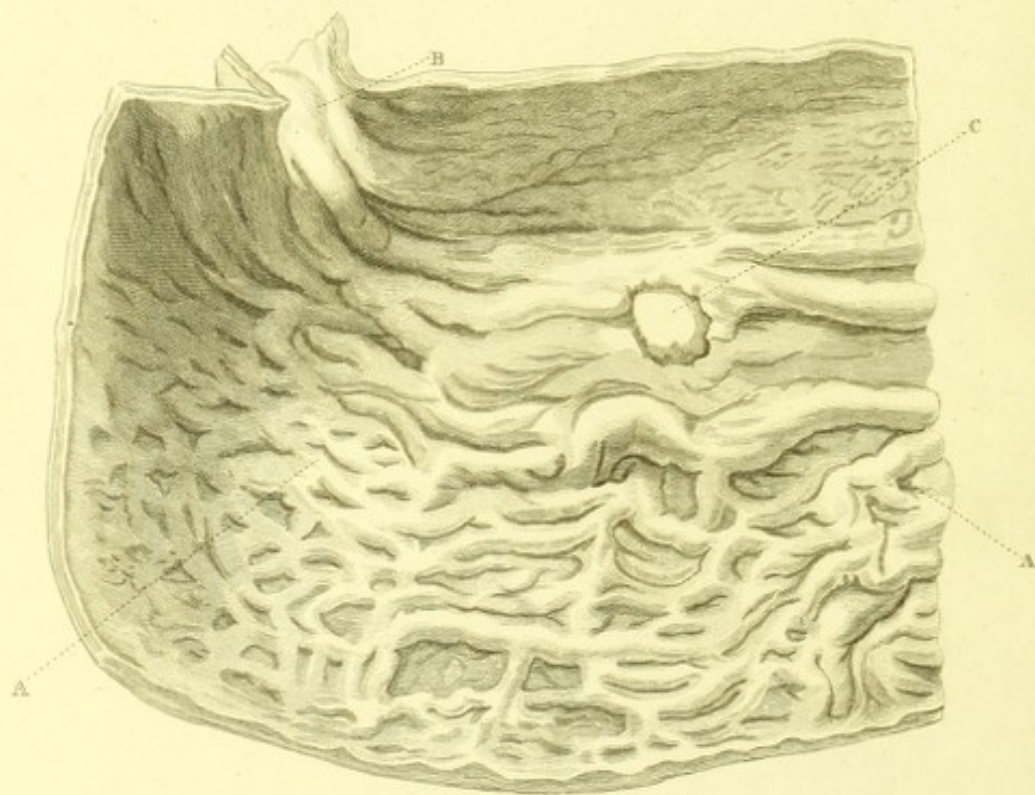


Fig. 2.





## PLATE V.

THIS Plate is intended to illustrate the principal varieties which are observable in ulcers of the stomach. Ulcers in this organ are sometimes very small, with smooth edges which are but little thickened, and seem as if a small portion had been cut out from the inner surface of the stomach with a knife. They are sometimes of considerable extent, with an irregular ragged surface, and the surrounding parts are more or less thickened. Ulcers are commonly found to have destroyed only a part of the internal coat of the stomach, but sometimes they destroy a part of all its coats, and a communication is formed between the cavity of the stomach, and the general cavity of the abdomen.

Inflammation of the stomach, which has not advanced to form an ulcer, is not capable of being adequately represented by an engraving, otherwise it would have been represented in this Plate.

## FIG. I.

Represents some small ulcers in the stomach with smooth edges, where the inner coat only is destroyed.

A. A part of the inner surface of the stomach near the pylorus, in a sound state.

B. A part of the inner surface of the duodenum.

C. The ridge of the pylorus.

D D D D. Four small ulcers in the stomach.

E. A considerable ulcer in the duodenum, which had destroyed a part of all its coats.

*From the Author's Collection.*

### FIG. II.

Represents an ulcer which had destroyed a part of all the coats of the stomach.

A A. A part of the inner surface of the stomach near its great end, strongly marked with rugæ.

B. The cardia.

C. An ulcer of a round shape which had eat through a part of all the coats of the stomach. Its edge is almost smooth, and the parts immediately surrounding it, are nearly of their natural thickness. *From Mr. Hunter's Museum.*

### FIG. III.

Represents two large ulcers of the stomach, near the pylorus.

A. A part of the stomach near the small end, in a sound state.



- B B. The two ulcers. They are very irregular or ragged upon their surface, and the surrounding parts are somewhat thickened.
- C. A part of the duodenum, free from disease.

*From Dr. Hunter's Museum.*

PLATE V.

B. B. The two ulcers. They are very irregular or ragged upon their surface, and the surrounding parts are somewhat thickened.  
C. A part of the abdomen, free from disease.  
From Dr. Hunter's Museum.





Fig. 1.

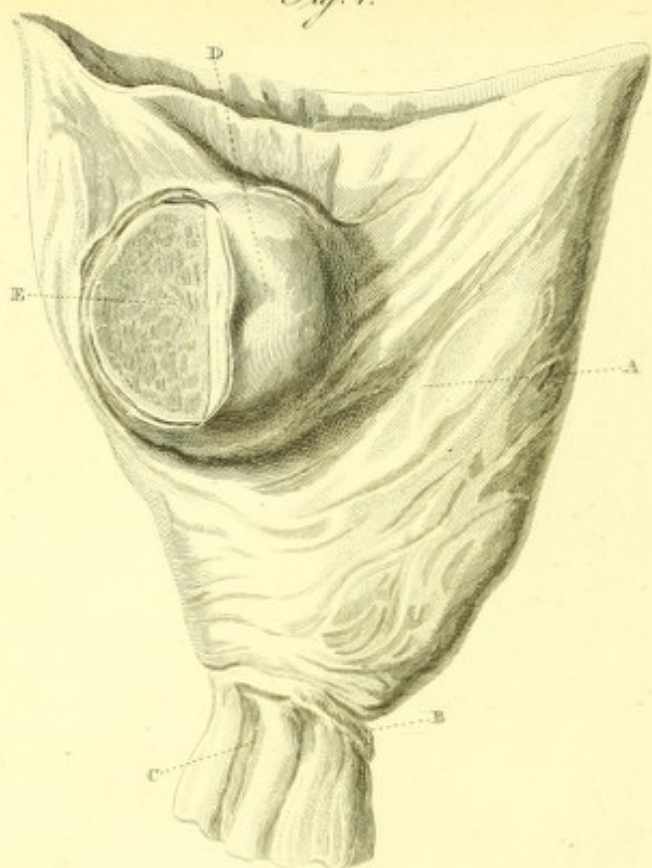


Fig. 2.

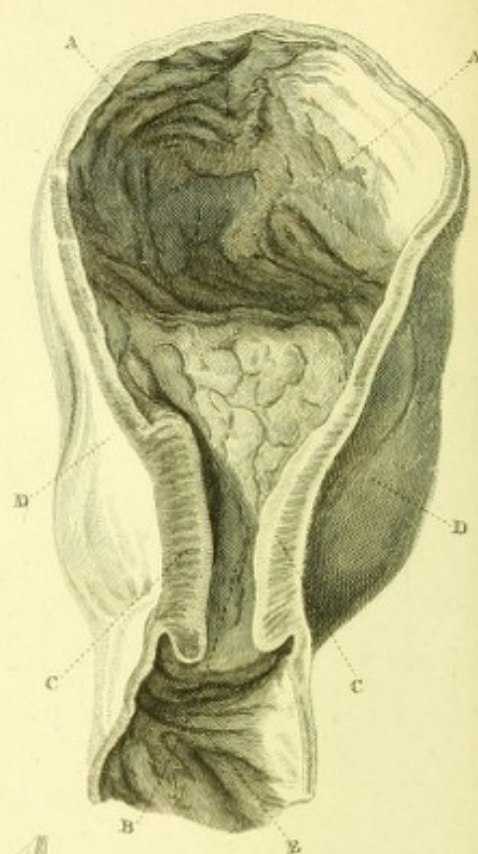
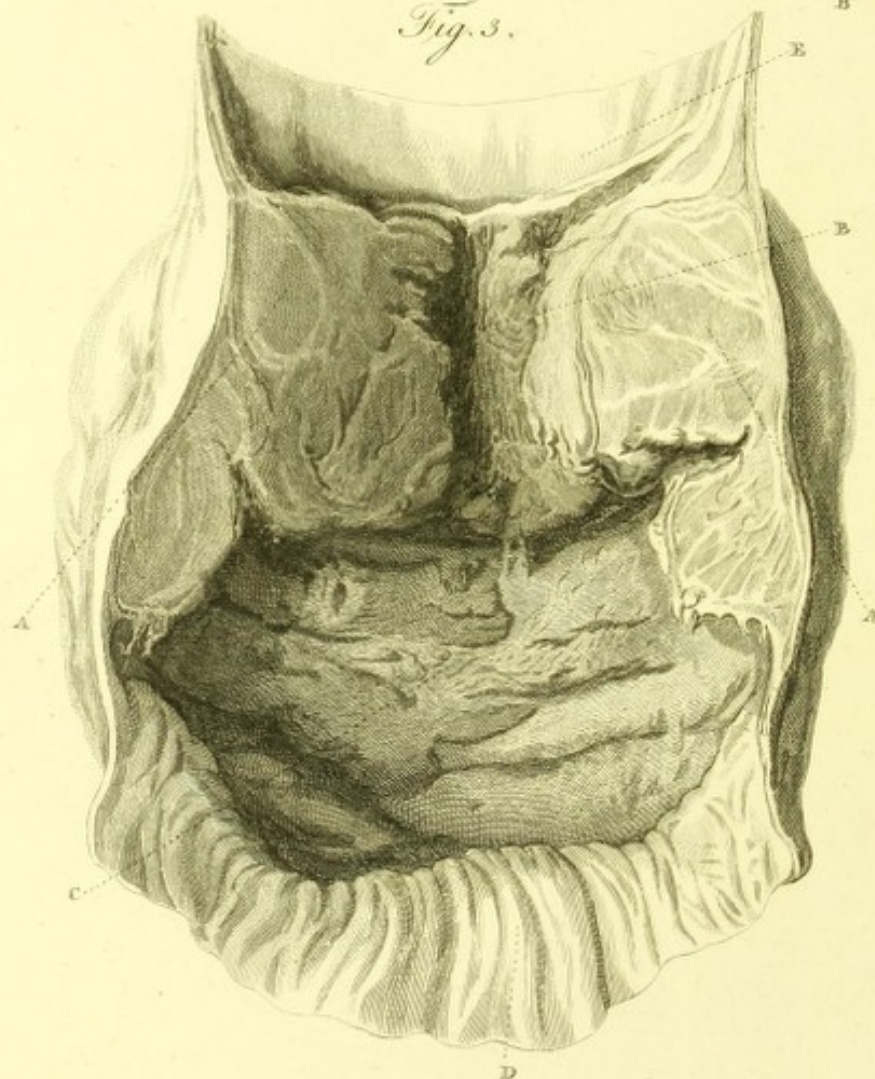


Fig. 3.





## PLATE VI.

THIS Plate is intended to illustrate some of the appearances of scirrhus and cancer in the stomach. These two names are to be considered as applicable to the same disease in different states of its progress. The disease is more apt to take place in the small end of the stomach, than in any other part of it. It sometimes consists of a hard circumscribed tumour growing in the stomach, but this is uncommon: more frequently the coats of the stomach at their small end, for some extent become thick and hard, and ultimately run into ulceration.

## FIG. I.

Represents a circumscribed scirrhus tumour in the stomach, the neighbouring parts being quite sound in their structure.

- A. The inner surface of the stomach at its small end, free from disease.
- B. The ridge of the pylorus.
- C. A small portion of the duodenum in a healthy state.
- D. The circumscribed tumour which is covered by the inner membrane of the stomach. In its centre there is a small aperture.



- E. A section of this tumour, in order to illustrate its structure. It consists of a whitish substance, having a gristly hardness, and in some parts it is slightly intersected by membrane.

*From Dr. Hunter's Museum.*

### FIG. II.

Represents a stricture near the pylorus, produced by a scirrhus thickening of the coats at the small end of the stomach. The scirrhus had not advanced to form an ulcer.

- A A. A part of the inner surface of the stomach, where the coats are sound.
- B. The cavity of the stomach near the pylorus, much contracted, forming a stricture.
- C C. The cut edges of the stomach at the stricture, shewing its coats to be much thickened. The distinction between the external, the muscular, and the villous coat of the stomach is very well marked, and some transverse white lines are observable, dividing the muscular coat. These consist of thickened cellular membrane.
- D D. A swelling formed round the small end of the stomach by the scirrhus thickening of its coats.
- E. A small part of the duodenum, in a sound state.

*From the Author's Collection.*



## FIG. III.

Illustrates cancer of the stomach, or scirrhus advanced to suppuration.

- A A. A section of the stomach near the pylorus, shewing its structure very much thickened by this disease.
- B. A very foul ulcer formed in the thickened part.
- C. A part of the stomach more remote from the pylorus, irregularly thickened and ulcerated.
- D. A part of the stomach in a sound state.
- E. A small portion of the duodenum, sound in its structure.

*From Dr. Hunter's Museum.*

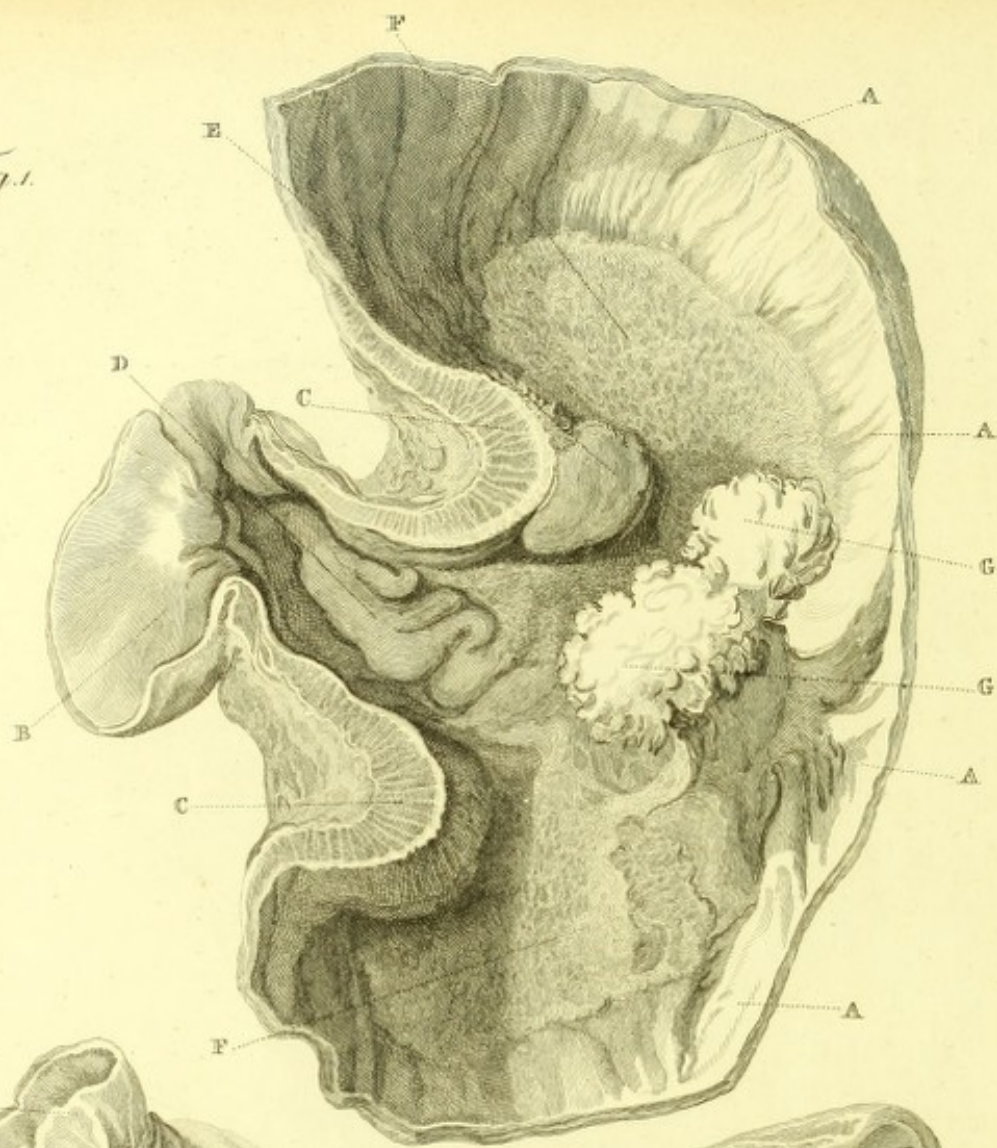
Illustrates cancer of the stomach, or scirrhus, advanced to suppuration.

- A. A. A section of the stomach near the pylorus, showing its structure very much thickened by this disease.
  - B. A very foul ulcer formed in the thickened part.
  - C. A part of the stomach more remote from the pylorus, irregularly thickened and ulcerated.
  - D. A part of the stomach in a sound state.
  - E. A small portion of the duodenum, sound in its structure.
- From Dr. Hunter's Museum.

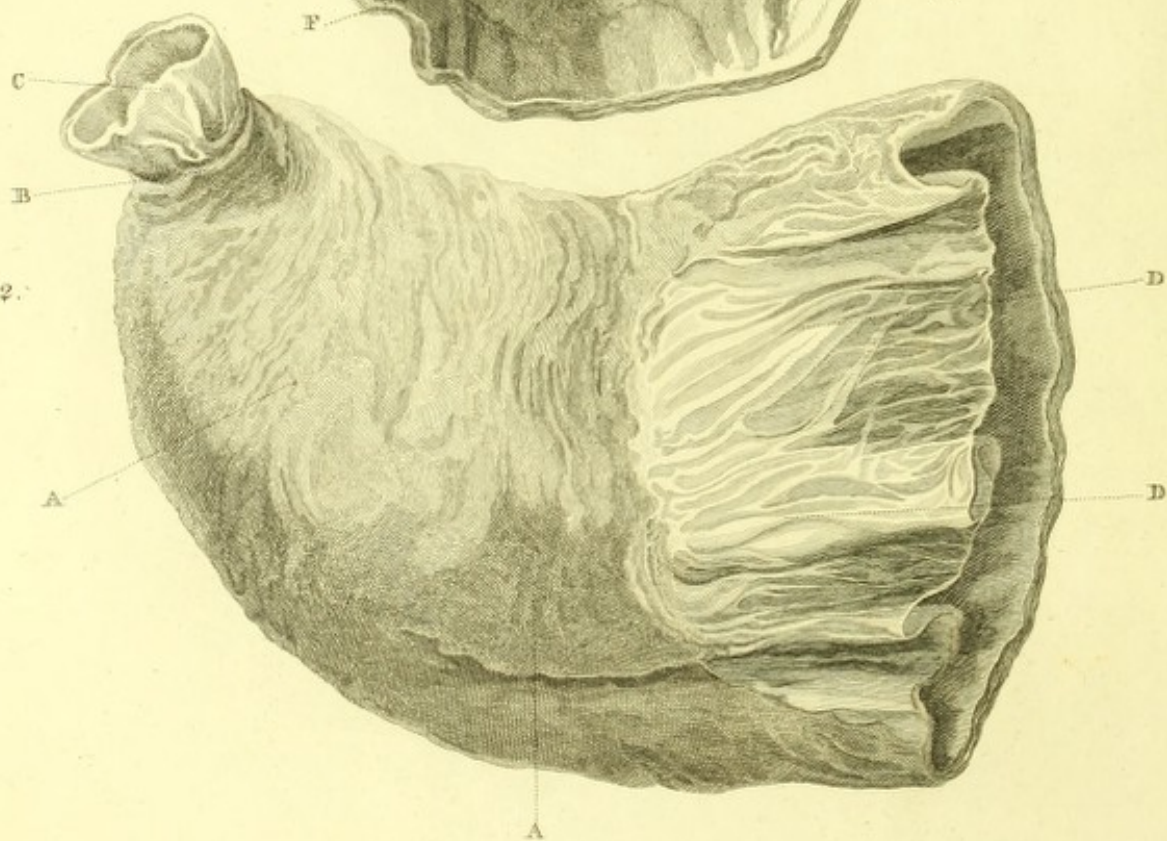




*Fig. 1.*



*Fig. 2.*





## PLATE VII.

THIS Plate is intended to exhibit a further illustration of the effects produced by cancer on the stomach; and also to represent the change which the coats of the stomach undergo by the action of the gastric juice upon them. It rarely occurs that this change is to be observed in any striking degree, because in almost all diseases which terminate fatally, the powers of digestion are very much impaired before death. When a person dies suddenly, who has just before been in good health, or has been destroyed by external violence, the effect of the action of the gastric juice upon the coats of the stomach, is often very remarkable.

Even in persons, however, who have been carried off by diseases in the common way, the influence of the gastric juice upon the stomach is sometimes observable, although it is but slightly marked.

## FIG. I.

Represents a section of the stomach near the pylorus, affected with cancer. It is laid open, so as to exhibit the inner surface.

A A A A. A part of the stomach, sound in its structure.



- B. A small part of the duodenum laid open at the pylorus, which is also free from disease.
- C C. The cut edges of the stomach near the pylorus. The texture is of a gristly hardness, and the three coats of the stomach are much thickened. The change produced in the muscular coat of the stomach is here chiefly observable. The muscular Fasciculi are not only thickened, but also the cellular membrane interposed between them, has undergone the same change, putting on the appearance of white transverse lines.
- D. An irregular fold of the inner membrane of the stomach, hard, and much thickened by this disease.
- E. A hard excrescence growing from the inner membrane of the stomach.
- F F. Two ulcers of considerable extent.
- G G. Two rounded masses, consisting of very short processes supported upon a broad stalk, or process, which grows from the inner surface of the stomach.

*From Dr. Hunter's Museum.*

FIG. II.

Represents a section of the stomach inverted, where in one part its coats had been a good deal affected by the action of the gastric juice.



- A A. A sound part of the stomach, next to the pylorus.  
B. The pylorus.  
C. A small portion of the duodenum.  
D D. A part of the stomach affected by the action of the gastric juice. It is rendered very soft, thin, and transparent, and all distinction between the different coats of the stomach is obliterated. It exhibits the same appearance as if a part of the stomach had been steeped for some time in an acid, and looks very different from any change which is produced by disease.

*From Dr. Hunter's Museum.*

A. A. A sound part of the stomach, next to the pylorus.  
 B. The pylorus.  
 C. A small portion of the duodenum.  
 D. D. A part of the stomach affected by the action of the gastric juice. It is rendered very soft, thin, and transparent, and all distinction between the different coats of the stomach is obliterated. It exhibits the same appearance as if a part of the stomach had been steeped for some time in an acid, and looks very different from any change which is produced by disease.

From Dr. Hunter's Museum.





Fig. 1.

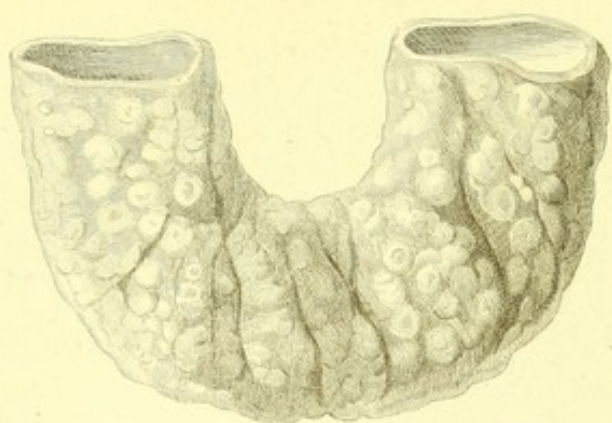


Fig. 2.

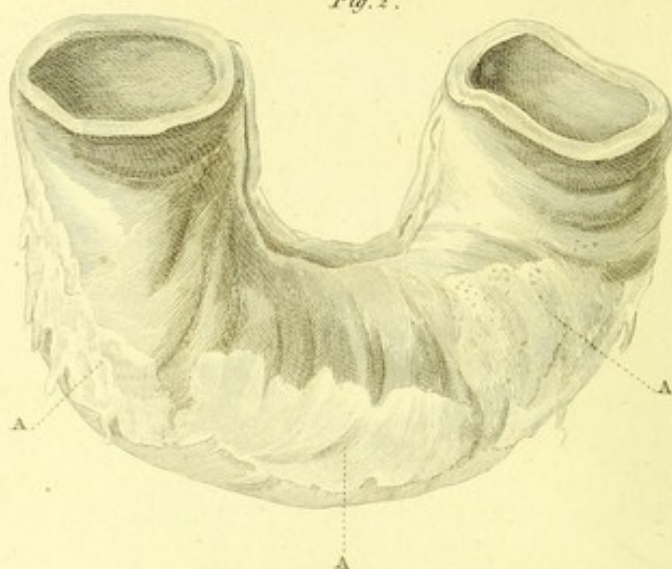

Fig. 3.

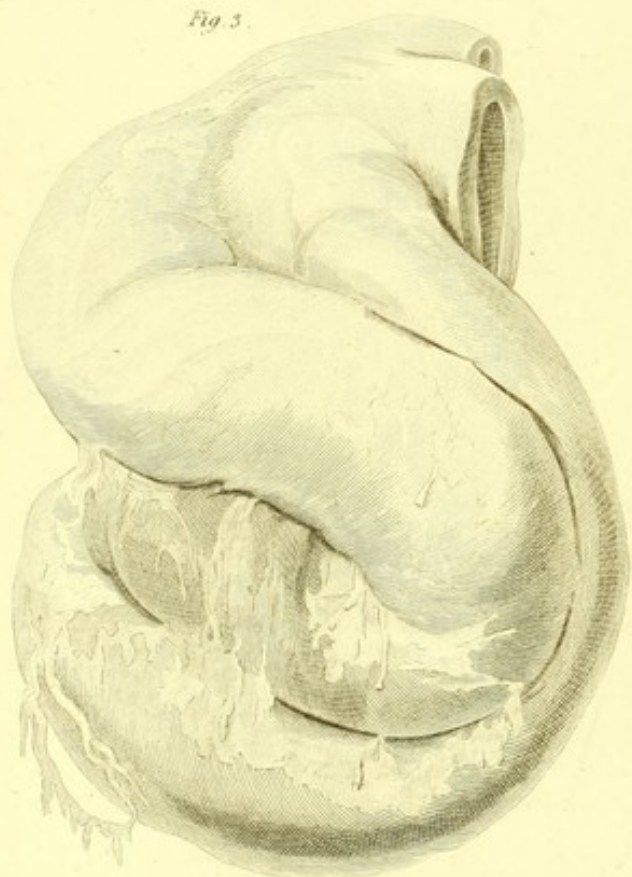
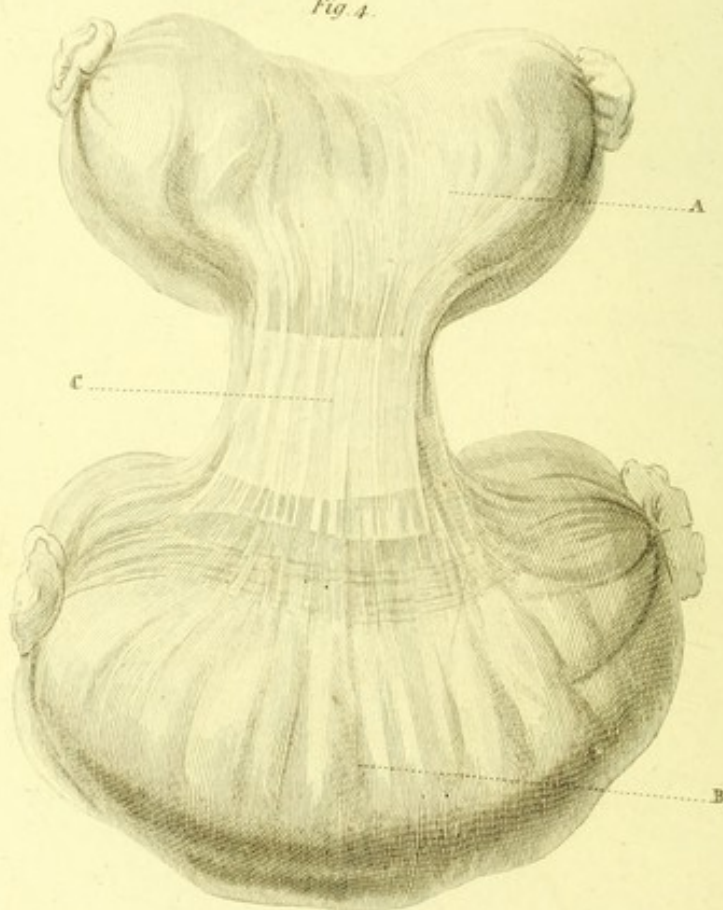


Fig. 4.





THE

## FOURTH FASCICULUS.

---

IN this Fasciculus it is proposed to illustrate the chief Morbid appearances which are found in the small and the great Intestines. These are very various, and depend not only upon a morbid alteration of structure, but frequently upon a change of situation, as in the different kinds of Hernia. The Intestines too, under certain circumstances, form a nidus for the evolution and growth of some animals of a low order in the scale of nature, which necessarily claim our attention in this Fasciculus.

### PLATE I.

THIS Plate is intended chiefly to illustrate the various effects of inflammation upon the outer surface of the intestines.

It exhibits also some small scrofulous masses upon the outer surface of the intestines, which constitute an uncommon appearance of disease.

## FIG. I.

Represents a portion of the jejunum, with a great number of scrofulous masses covering its external surface. They adhere immediately behind the peritonæum, and resemble in their texture a scrofulous absorbent gland, which is just beginning to suppurate. These masses are generally found to adhere not only to that part of the peritonæum which covers the intestines, but to every other part of it, and especially the omentum.

*From the Author's Collection.*

## FIG. II.

Represents a portion of the jejunum affected with inflammation, where the inflammation had begun upon the outer surface, and had spread inwards.

A A A Shew three portions of the coagulable lymph which had been formed by the inflammation of the external surface of this part of the small intestines. All the coats are thickened, as may be seen by looking upon the cut edges of the intestine, and this proves that the inflammation had spread from the outer surface through its whole substance.

*From the Author's Collection.*



## FIG. III.

Shews some convolutions of the small intestines adhering together, in consequence of inflammation upon their outer surface. The adhesions are formed by the coagulable lymph thrown out during the inflammation, which glues (as it were) the convolutions to each other. On different parts of this Figure representations of coagulable lymph are to be seen in scattered portions. The inflammation had in this case been so violent as to pervade all the coats of the small intestines.

*From Dr. Hunter's Museum.*

## FIG. IV.

Represents a membrane of adhesion between a part of the small and the great intestines. This membrane is transparent, is formed from the coagulable lymph of the blood thrown out during an inflammation upon the outer surface of the intestines, and corresponds in its texture with the common cellular membrane of the body. The membrane is gradually elongated by the motion of one part of the intestines upon another, till the motion of the intestines is not impeded or restrained by it.

A, A portion of the small intestines.

B, A portion of the great intestines.

C, The membrane of adhesions a good deal elongated.

*From Dr. Hunter's Museum.*

## FIG. III

Shows some convolution of the small intestine adhering together in consequence of inflammation upon the mesentery. The adhesions are formed by the coagulable lymph thrown out during the inflammation, which glues the parts of the convolutions to each other. On different parts of the figure representations of coagulable lymph are to be seen in scattered positions. The inflammation had in this case been so violent as to pervade all the coats of the small intestine.

From Dr. Williams's Museum.

## FIG. IV

Represents a miniature of adhesion between a part of the small and the great intestine. This miniature is transparent, is formed from the coagulable lymph of the blood thrown out during an inflammation upon the entire surface of the intestine, and corresponds in its texture with the common cellular membrane of the body. The membrane is gradually absorbed by the action of one part of the intestine upon another, and the motion of the intestine is not impeded or retarded by it.

A. A portion of the small intestine.  
B. A portion of the great intestine.  
C. The membrane of adhesion, a good deal enlarged.  
From Dr. Williams's Museum.





Fig. 1.

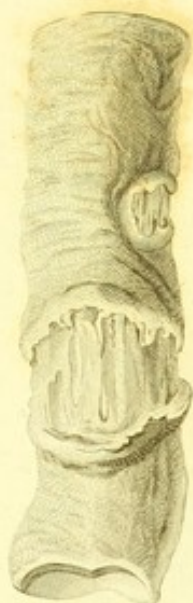

Fig. 2.

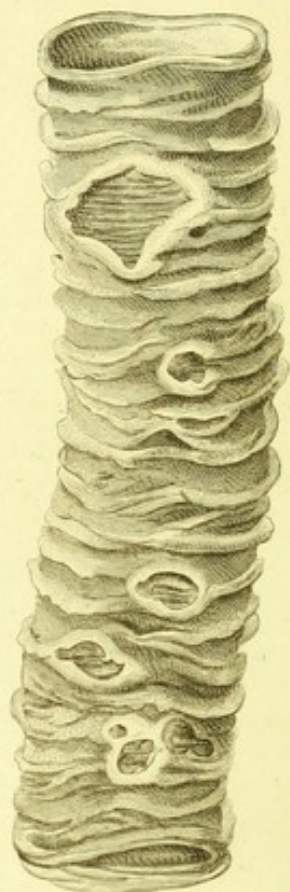

Fig. 3.

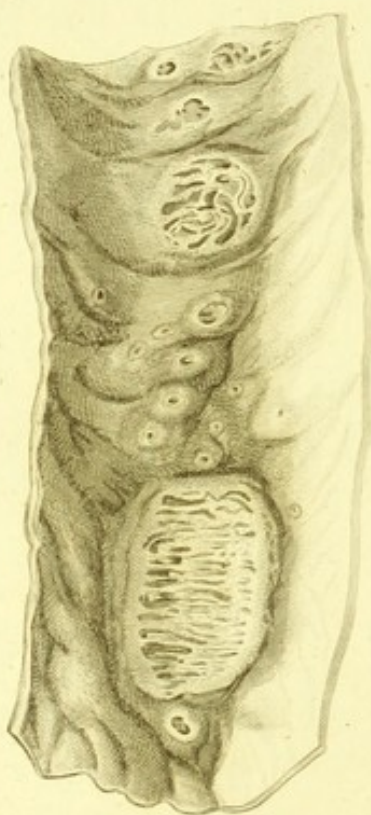


Fig. 4.

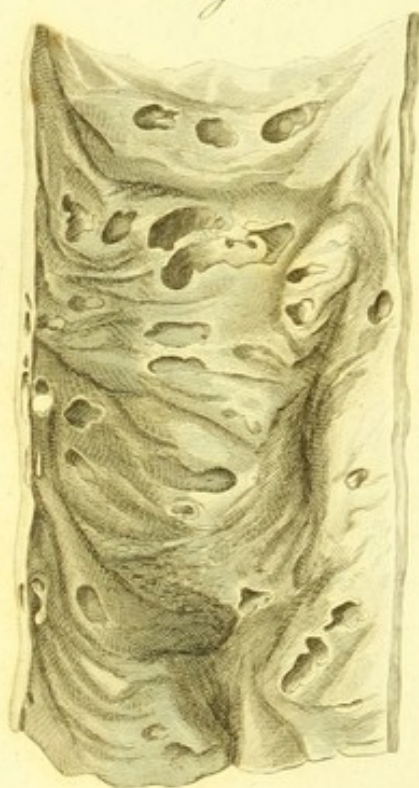
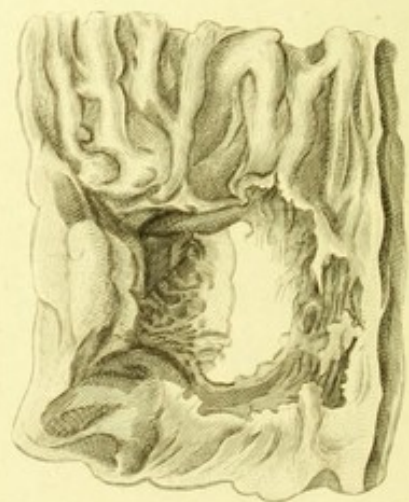
Fig. 5.





## PLATE II.

THIS Plate exhibits the different appearances of ulcers upon the inner surface of the intestines.

### FIG. I.

Represents a small portion of the ilium inverted so as to exhibit its inner surface. Two ulcers are observable, which had destroyed the villous coat, but not entirely the cellular membrane, that is interposed between the villous and muscular coats. They have an irregular, ragged appearance.

*From Dr. Hunter's Museum.*

### FIG. II.

Represents a portion of the jejunum inverted: upon its inner surface several ulcers are observable. The villous coat in these places has not only been destroyed by ulceration, but the cellular substance also lying behind it, so that the circular muscular fibres of the intestine come into view. These ulcers have smooth edges, a little thickened.

*From the Author's Collection.*

## FIG. III.

Represents the internal surface of a part of the ilium. It is intended to exhibit a number of small ulcers in the glandulæ aggregatæ. Ulceration is more apt to attack these glands than the ordinary structure of the villous coat.

*From Mr. Hunter's Museum.*

## FIG. IV.

Represents the inner surface of a part of the great intestines, in which may be seen a number of small ulcers. Most of them are oval in their shape, and have thin smooth edges. They had begun in the solitary glands of this part of the intestines.

*From Mr. Hunter's Museum.*

## FIG. V.

Represents the inner surface of a part of the great intestines with a large ragged ulcer, which had destroyed a part of all the coats, whereby a communication had been formed between the cavity of the intestine and that of the abdomen. The internal coat surrounding the ulcer is puckered, or thrown into small rugæ from the contraction of the muscular coat, and the whole substance of the intestine is a little thickened.

*From Dr. Hunter's Museum.*





Fig. 1.

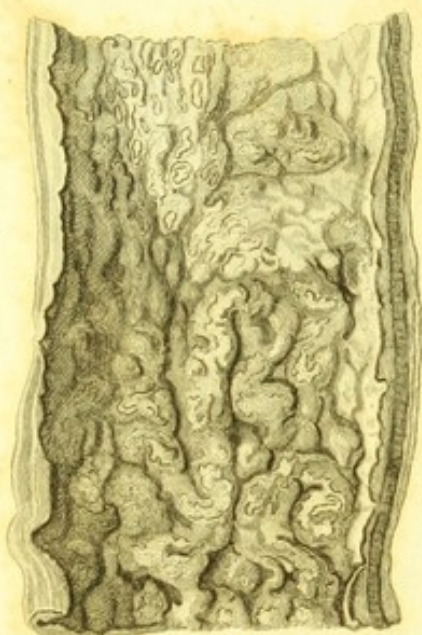

Fig. 2.

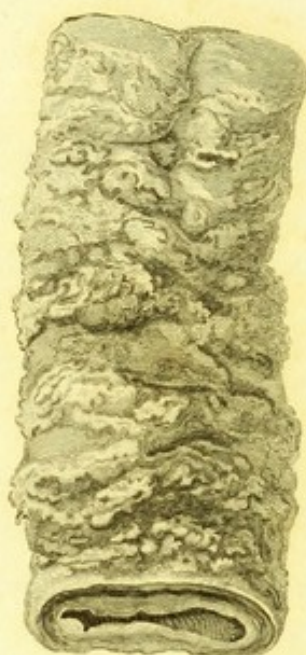
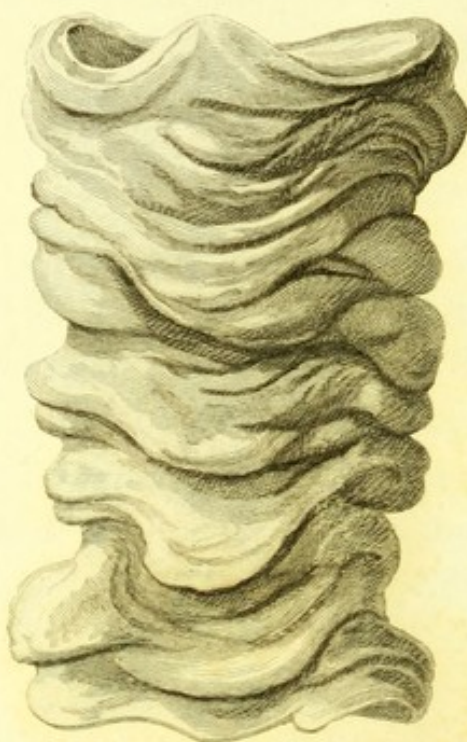
Fig. 3.





## PLATE III.

IN this Plate it is proposed to illustrate the morbid appearances observable in the great intestines of persons who have been carried off by that fatal species of dysentery which too often arises in camps.

An uncommon morbid change in the great intestines is also represented in this Plate, by which the inner membrane is formed into a number of thick folds.

## FIG. I.

Represents the inner surface of a part of the great intestines from a person who had been destroyed by camp dysentery. The inner membrane of the intestine is thickened, and raised into a number of tubercles. The other coats of the intestine are also thickened, as may be seen from the thickness of its cut edge.

*From Dr. Hunter's Museum.*

## FIG. II.

Represents a portion of the great intestine inverted, from a person who died of camp dysentery. Many irregular excrescences are observable, somewhat resembling warts, and the

inner member in some places appears abraded. The other coats of the intestine are thickened, as may be seen at the lower extremity, where it is cut off, and the cavity of the intestine is considerably contracted within its natural size.

*From the Author's Collection.*

### FIG. III.

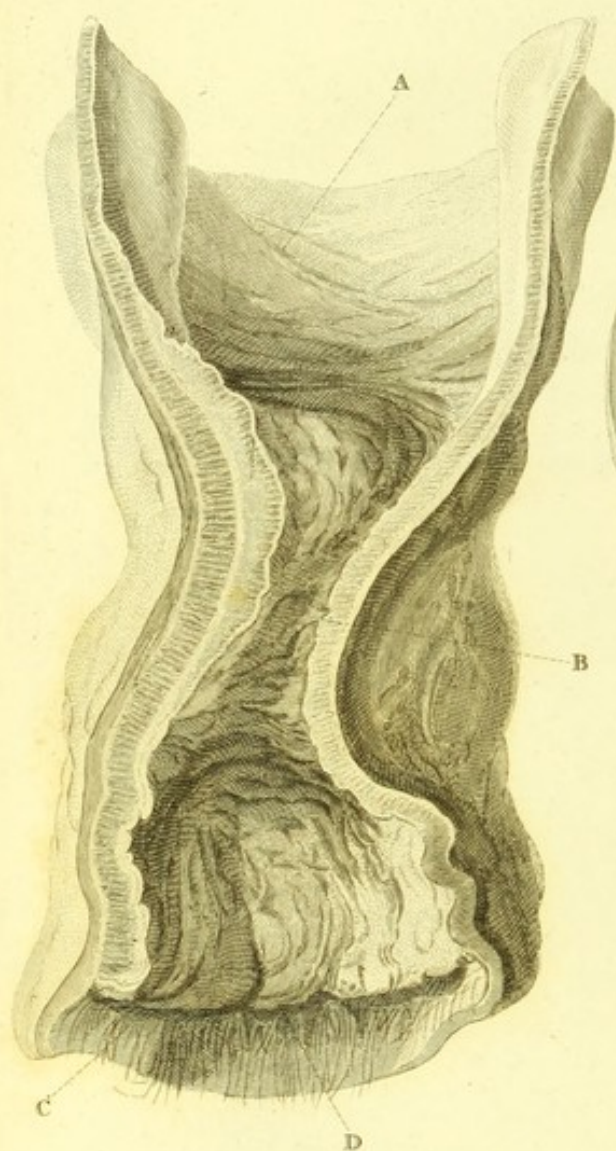Represents a part of the great intestine inverted, shewing its inner membrane formed into a great number of large or massy folds. These bear some remote resemblance to the valvulæ conniventes of the jejunum.

*From Dr. Hunter's Museum.*

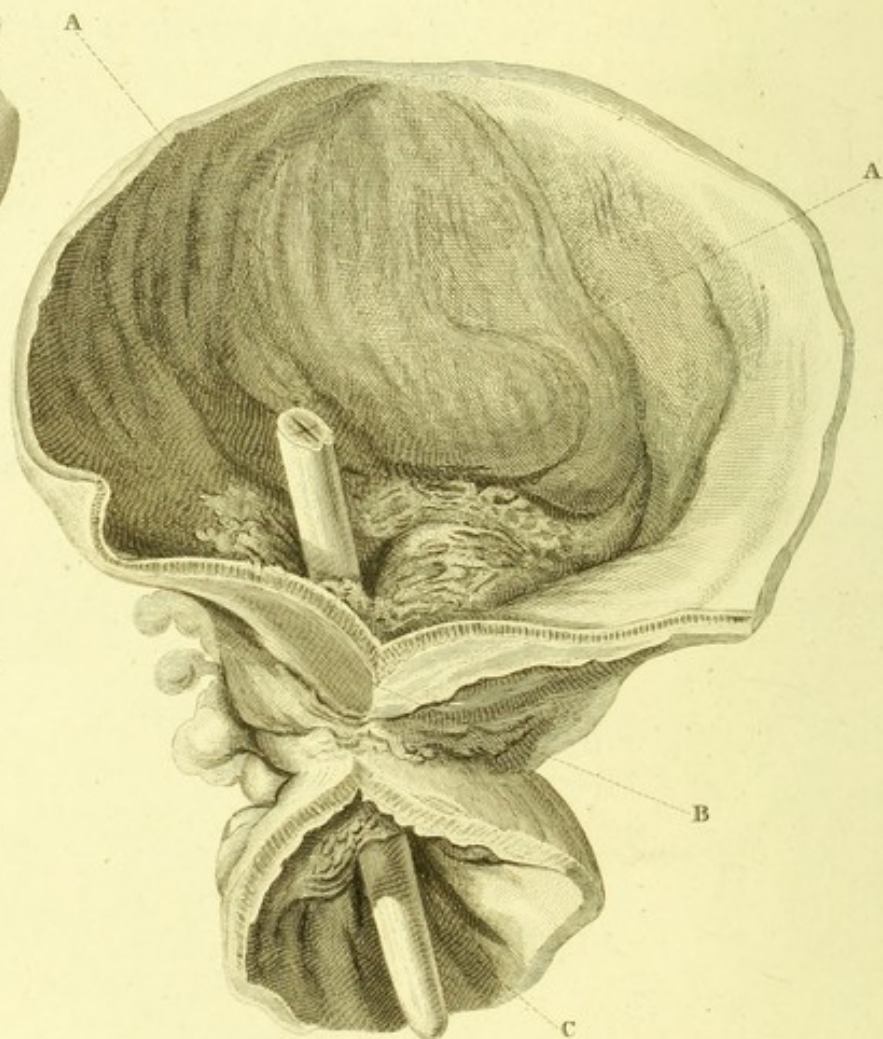



*Fig. 1.*



*Fig. 2.*





## PLATE IV.

THIS Plate illustrates the most important morbid changes of structure belonging to scirrhus and cancer of the rectum.

## FIG. I.

Represents a stricture in the rectum, about two inches above the anus, occasioned by a scirrhus thickening of its coats.

- A. A portion of the rectum above the stricture, which is sound in its texture, but enlarged in its capacity, on account of the frequent accumulation of the fæces above the stricture.
- B. The part where the stricture is. The coats of the rectum here are very thick and hard, exhibiting the usual appearance of scirrhus structure in membranous and muscular parts. One side of the rectum at the stricture is considerably thicker than the other. Upon the inner surface there is no distinct mark of ulceration.
- C. A part of the rectum under the stricture, which is nearly sound in its texture.
- D. The verge of the anus.

*From Dr. Hunter's Museum.*

## FIG. II.

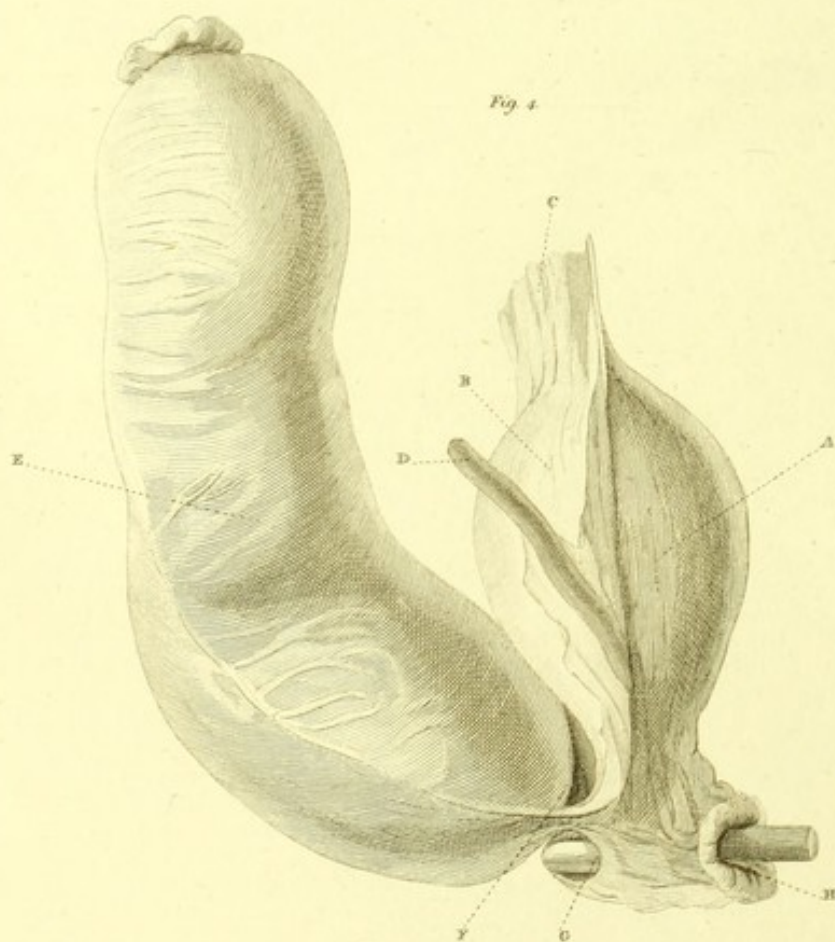
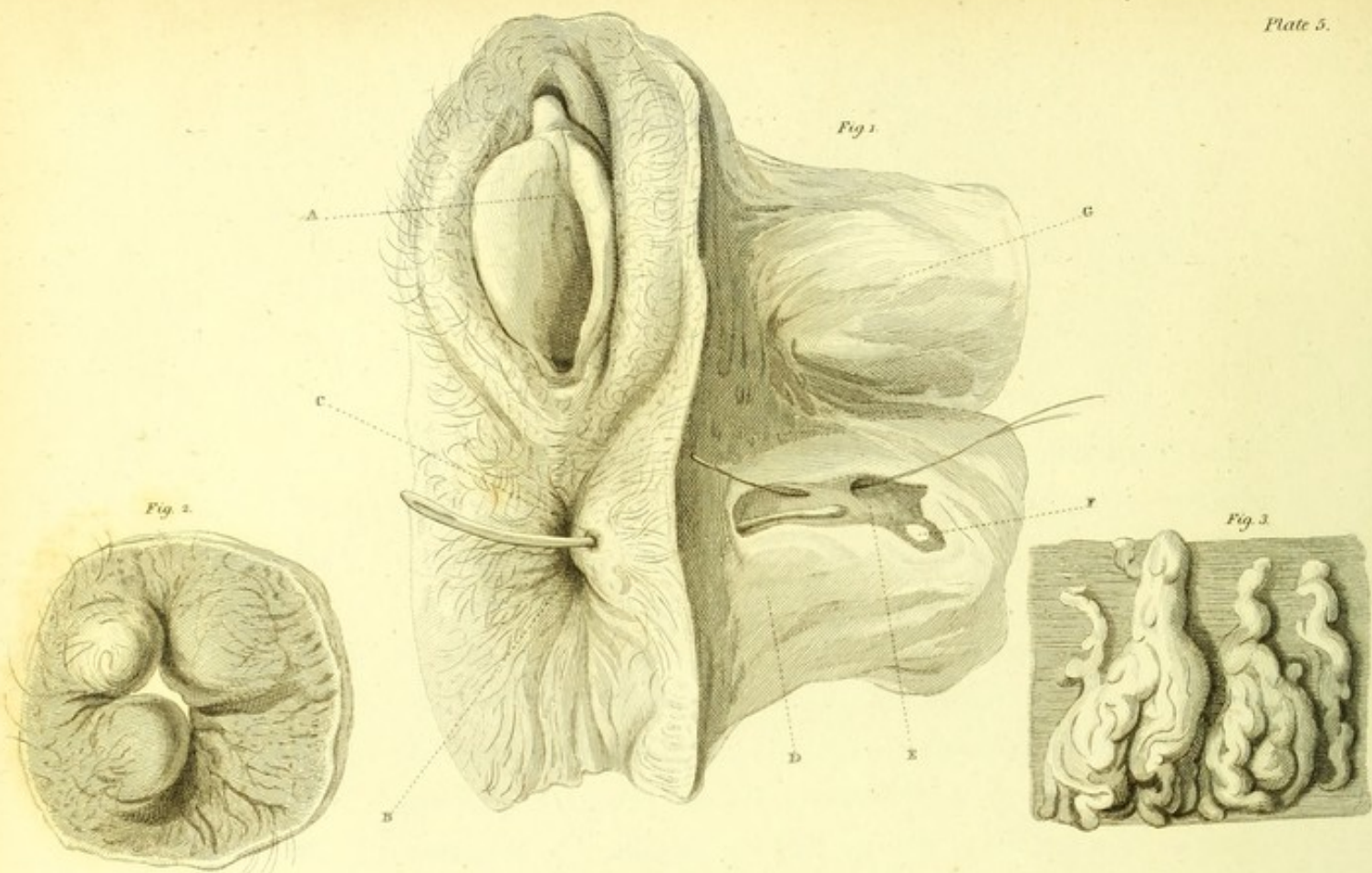
Represents a stricture of the rectum, accompanied not only with much thickening, but with ulceration of the parts, which may be considered as an illustration of cancer.

- A A. A part of the rectum above the stricture, sound in its texture, but much dilated, in consequence of the great accumulation there of the fæces, the stricture being so narrow as hardly to allow any fæces to pass through it.
- B. The strictured part, where the cavity is so narrow as just to admit a goose-quill to pass through it. At the upper part of the stricture ulceration is very observable.
- C. A part of the rectum under the stricture, free from disease.

*From Dr. Hunter's Museum.*









## PLATE V.

THIS Plate is intended to illustrate some of the most important morbid changes of structure which take place at the lower end of the rectum. These are fistula in ano, and piles ; to which we have thought proper to add that malformation in which the rectum is imperforated, or ends in a cul-de-sac.

### FIG. I.

Represents the most important circumstances attending fistula in ano.

- A. The external organs of generation in a female.
- B. The anus.
- C. The external opening of a fistula, through which a probe has been passed.
- D. A lateral view of the outer surface of a part of the rectum.
- E. The fistula, which is about two inches in length, with a smooth internal surface. A very small canal communicates with it, in which a bristle has been put, and very near its internal extremity there is an opening, marked F, by which it communicates with the cavity of the rectum.
- G. A view of the outer surface of a part of the vagina.

*From Dr. Hunter's Museum.*

## FIG. II.

Represents an external view of the anus, with three considerable tumours, which are piles.

*From Dr. Hunter's Museum.*

## FIG. III.

Represents a part of the rectum at the anus, with the inner membrane dissected off. This dissection brings into view some varicose veins of a considerable size, and demonstrates the true nature of piles. These veins, when covered by the inner membrane of the rectum, appeared exactly like common piles. The transverse or circular muscular fibres of the rectum behind the veins, are very observable.

*From the Author's Collection.*

## FIG. IV.

Represents an imperforated rectum, where its lower extremity terminates in a cul-de-sac.

A. The anterior surface of the urinary bladder.

B. The posterior surface of the urinary bladder, covered by a reflected portion of the peritonæum.



- C. A part of the peritonæum passing up from the fundus of the bladder, in order to line the internal surface of the recti abdominis muscles.
- D. A part of one of the ureters.
- E. The rectum.
- F. The termination of the rectum in a cul-de-sac.
- G. A short narrow canal leading from the external anus to the blind extremity of the rectum, in which a part of a bougie has been put, in order to shew it more distinctly.
- H. The external anus.

*From Dr. Hunter's Museum.*

C. A part of the peritoneum passing up from the fundus of the bladder, in order to line the internal surface of the recti abdominalis muscles.

D. A part of one of the ureters.

E. The rectum.

F. The termination of the rectum in a cul-de-sac.

G. A short narrow canal leading from the external anus to the blind extremity of the rectum in which a part of a bougie has been put, in order to show it more distinctly.

H. The external anus.





Fig. 1.

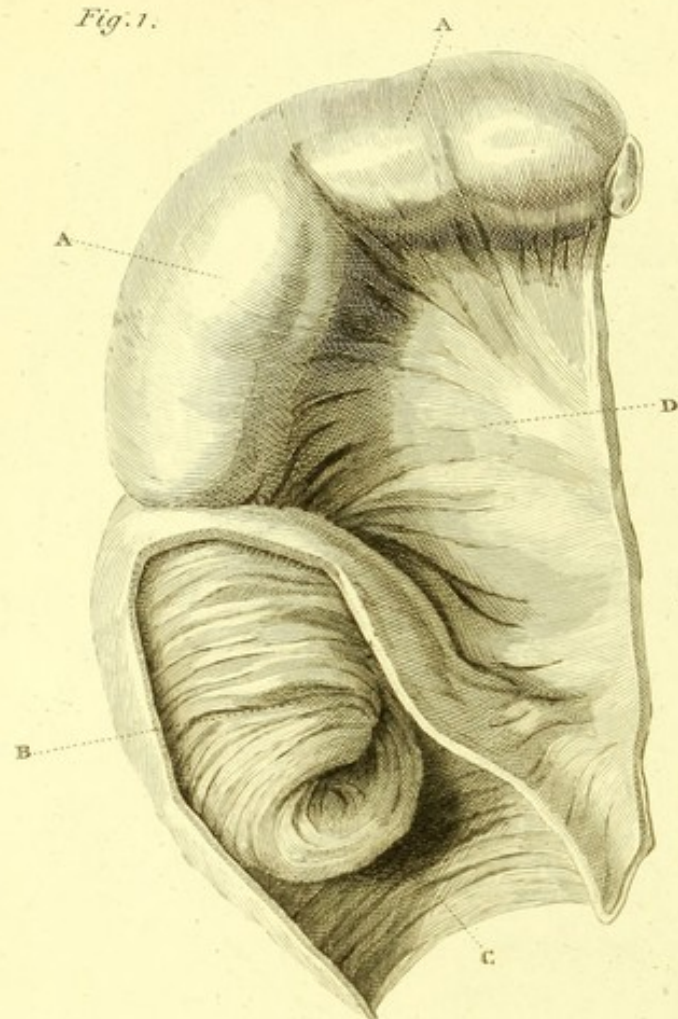


Fig. 2.

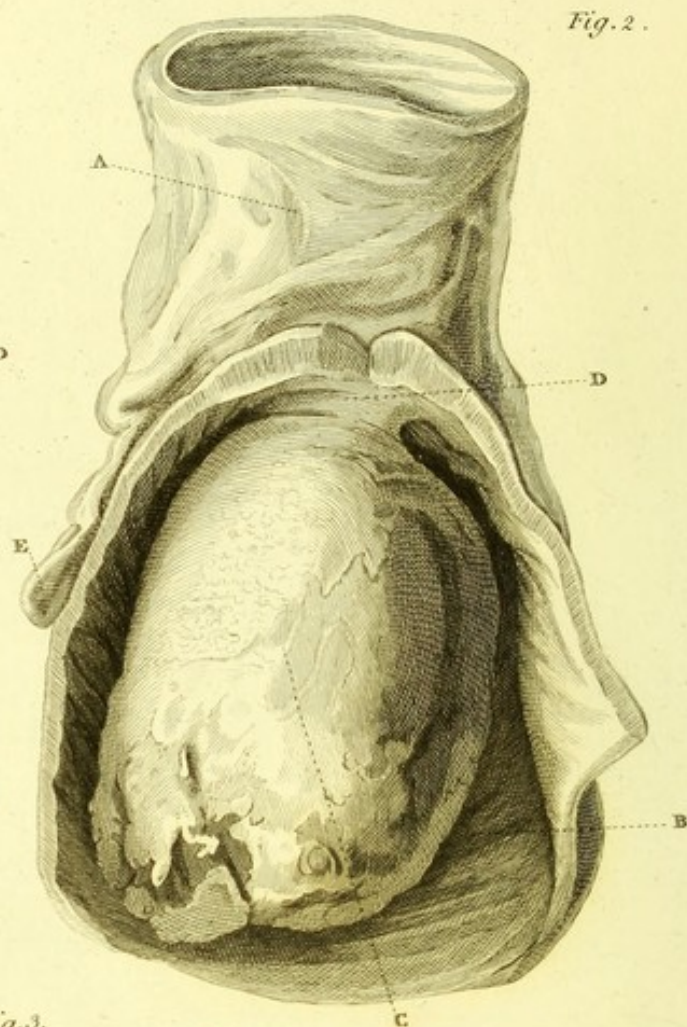
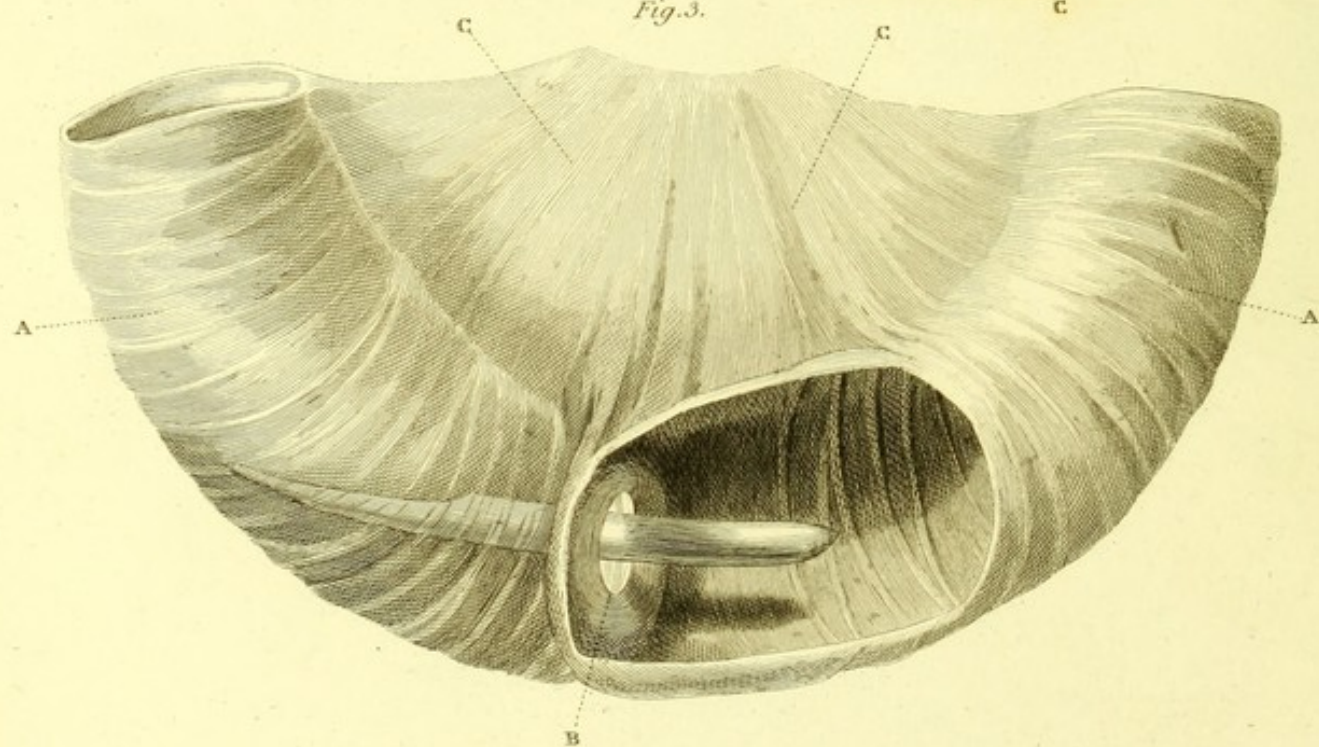


Fig. 3.





## PLATE VI.

THIS Plate illustrates three causes of obstruction in the bowels, two of which are very uncommon.

## FIG. I.

Represents an intus-susceptio in the jejunum, or in the upper part of the ilium.

A A. A part of the intestine contracted within its usual size by the action of its muscular fibres, and passing down towards the part where the intus-susceptio is formed.

B. A part of the bowel inverted, passing for about an inch and a half within another part of the same bowel, and forming the intus-susceptio.

C. The part of the bowel which receives the other, and which is a little distended.

D. A part of the mesentery, of which a small portion is dragged into the cavity of the bowel, where the intus-susceptio takes place.

*From Dr. Hunter's Museum.*

## FIG. II.

Represents a considerable polypus which had grown in the sigmoid flexure of the colon, forming a cause of obstruction there which is very uncommon.

- A. A part of the colon in a sound state.
- B. A part of the colon laid open, in order to bring the polypus into view.
- C. The polypus.
- D. The neck of the polypus : the coats of the colon near the neck of the polypus are a little thickened.
- E. One of the appendiculæ epiploicæ.

*From the Author's Collection.*

## FIG. III.

Represents a part of the jejunum, in the cavity of which a membranous process had grown from original malformation, resembling in its shape a ring, or the valve of the pylorus. It appears to have laid the foundation of no disease in the bowels. If the person, however, in whom there was this *lusus naturæ*, had swallowed any substance of a considerable size, not capable of being digested in the stomach, as a large stone of some fruit, or a piece of money (as a shilling), it could not have passed



this ring, but would have been arrested there, and would have formed a fatal cause of obstruction.

A A. A part of the jejunum in a natural state.

B. The præternatural process or ring, through the cavity of which a quill passes.

CC. A part of the mesentery.\*

*From Dr. Hunter's Museum.*

\* The preparation from which this drawing was taken, is preserved dry, and hence in the engraving, as well as the drawing, there is some appearance of transparency.





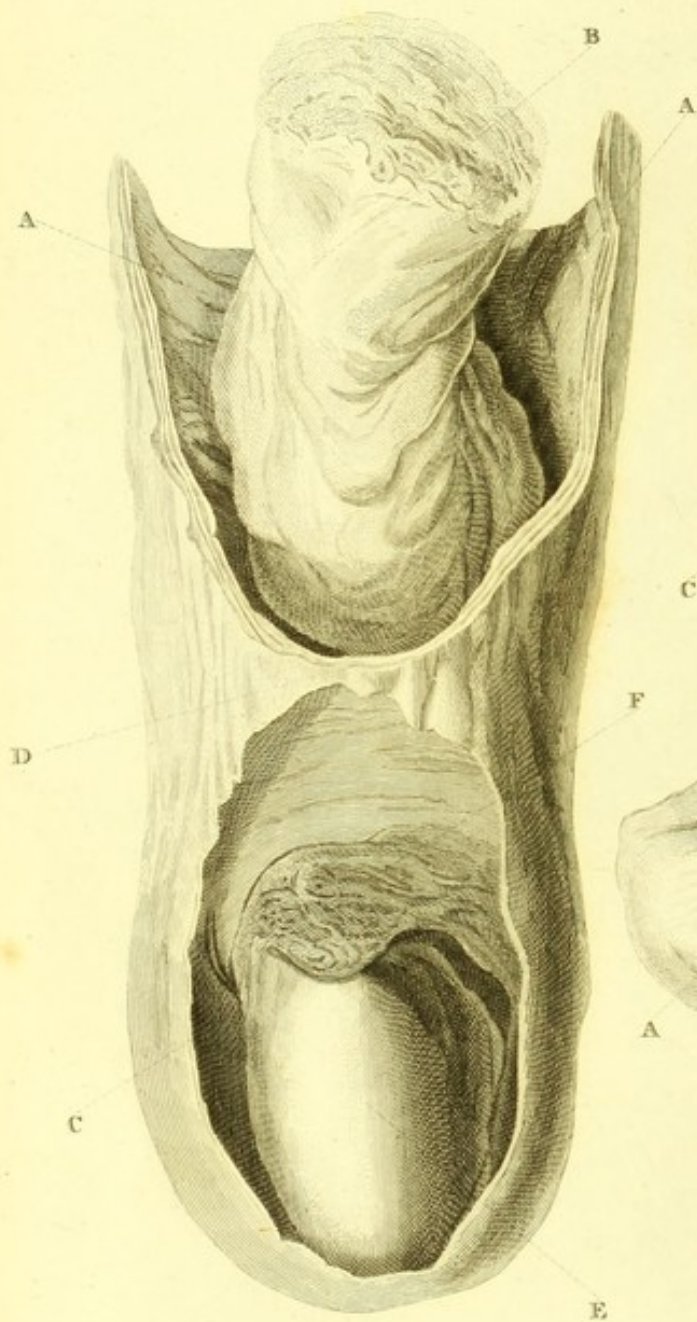




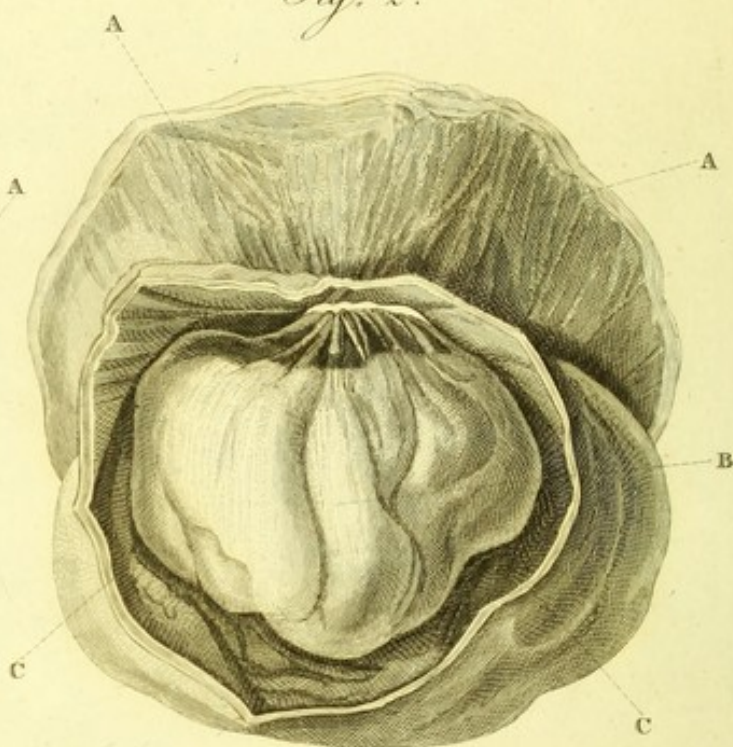




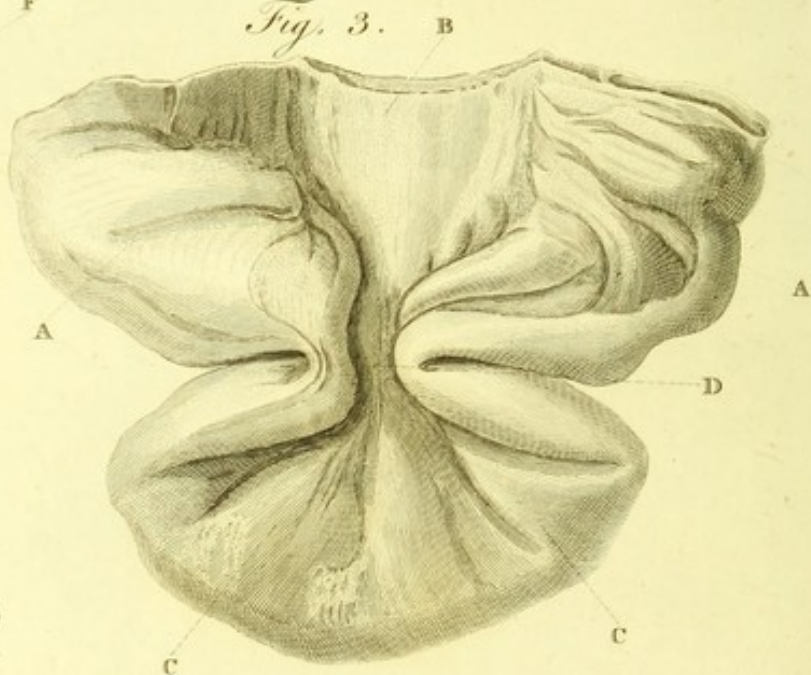
*Fig. 1.*



*Fig. 2.*



*Fig. 3.*





## PLATE VII.

IN this Plate it is proposed to illustrate some of the most important circumstances belonging to herniæ.

## FIG. I.

Represents a scrotal hernia, in which the sac contains a part of the omentum.

- A A. The sac of the hernia laid open anteriorly.
- B. A part of the omentum changed into a long rounded mass, lying in the sac, and adhering to it by its posterior surface.
- C. The cavity of the tunica vaginalis testis laid open to view, and distended in order to shew its full size.
- D. The separation or septum between the sac of the hernia and the tunica vaginalis.
- E. The body of the testicle.
- F. A considerable part of the epididymis.

*From the Author's Collection.*

## FIG. II.

Represents another specimen of hernia, in which the sac contains a portion of the small intestines.

- A A. A part of the parietes of the abdomen.
- B. A portion of the small intestines, with a very small part of the mesentery in the cavity of the hernial sac.
- C C. The cut edge of the hernial sac, the anterior part of which had been removed, in order to shew its contents.

*From Mr. Heaviside's Museum.*

## FIG. III.

Represents a portion of the small intestines which had been lodged in a hernial sac, and where a stricture had been formed by strangulation.

- A A. A part of the small intestines above the stricture.
- B. A part of the mesentery.
- D. The place where the stricture had been formed.
- C C. The part of the small intestines under the stricture, which had been inflamed, and somewhat thickened.

*From Mr. Hunter's Museum.*





Fig. 2.

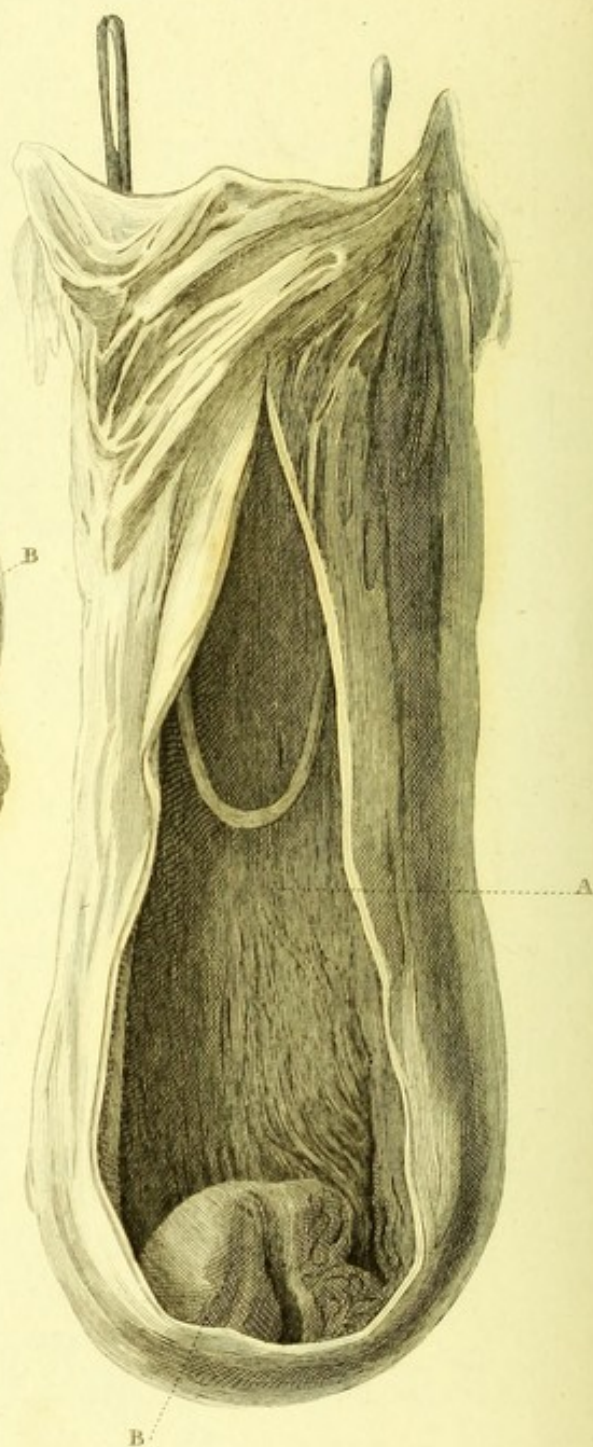
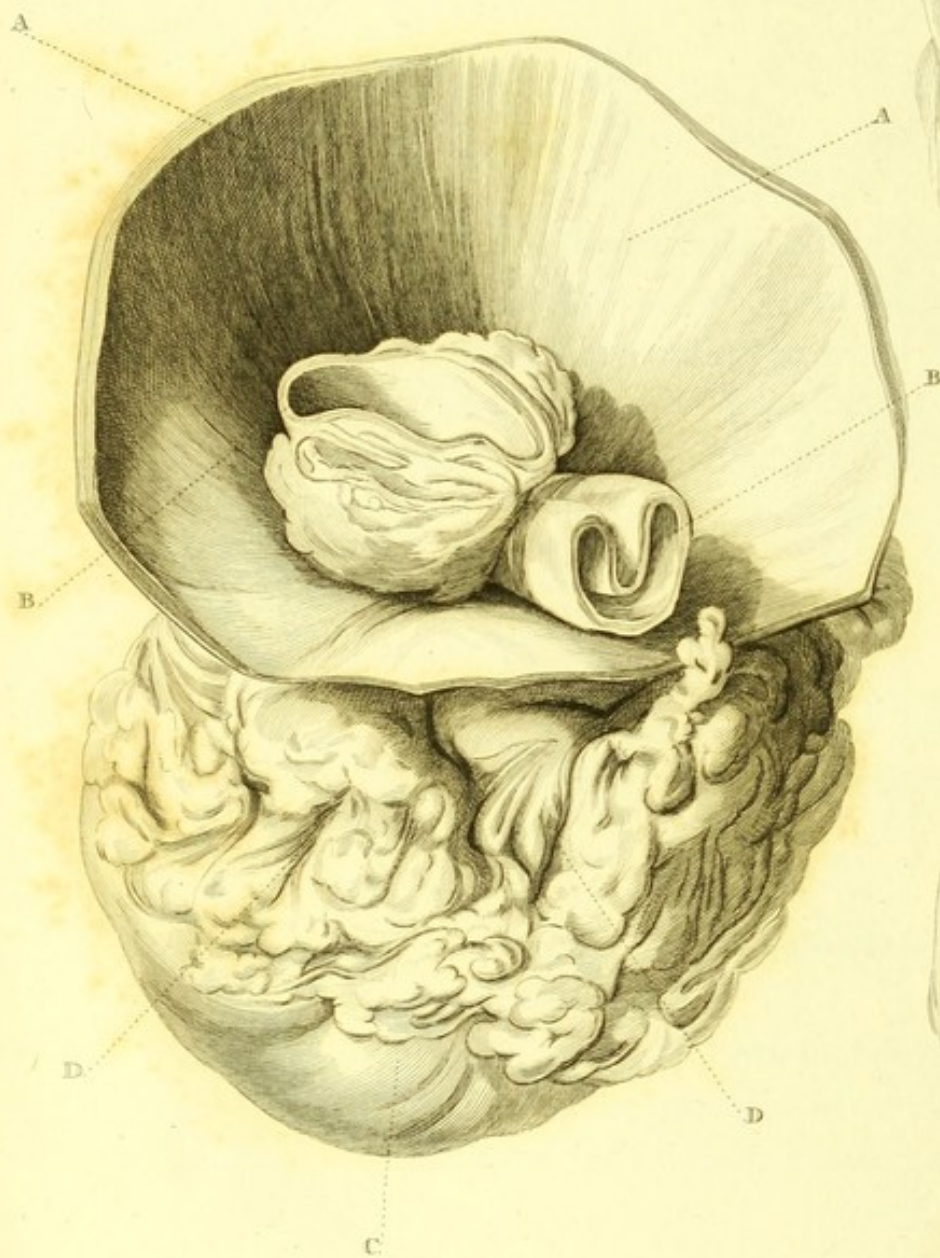


Fig. 1.





## PLATE VIII.

IN this Plate are illustrated two uncommon species of hernia, viz. the hernia congenita, and that through an opening in the diaphragm, which may be called by way of distinction, the diaphragmatic hernia. Of these the latter is much more rare than the former. The hernia congenita depends upon the communication between the tunica vaginalis testis and the cavity of the abdomen not being closed a little before the time of birth, so that a part of the omentum or of the intestines may protrude into the cavity where the testicle is lodged. The diaphragmatic hernia depends upon a malformation of the diaphragm. This malformation is an opening in or near the tendinous part of the diaphragm, through which a part of the intestines or the omentum may be protruded into the cavity of the chest. When this præternatural opening is very large, so much of the viscera of the abdomen passes into the cavity of the chest as to prevent the expansion of the lungs necessary in breathing, and therefore children with this malformation die immediately at birth. When the aperture is small, the lungs remain capable of carrying on their function; but it lays the foundation of this very singular hernia, which is illustrated in the following figure.



## FIG. I.

Represents the hernia through the diaphragm.

- A A. A portion of the tendinous part of the diaphragm viewed upon its concave surface, or that next the abdomen.  
B B. Two cut extremities of a part of the transverse arch of the colon.  
C. A part of the transverse arch of the colon which had passed through the aperture of the diaphragm into the cavity of the chest, and had been strangulated.  
D D. A part of the omentum which had passed also into the cavity of the chest.\* *From the Author's Collection.*

## FIG. II.

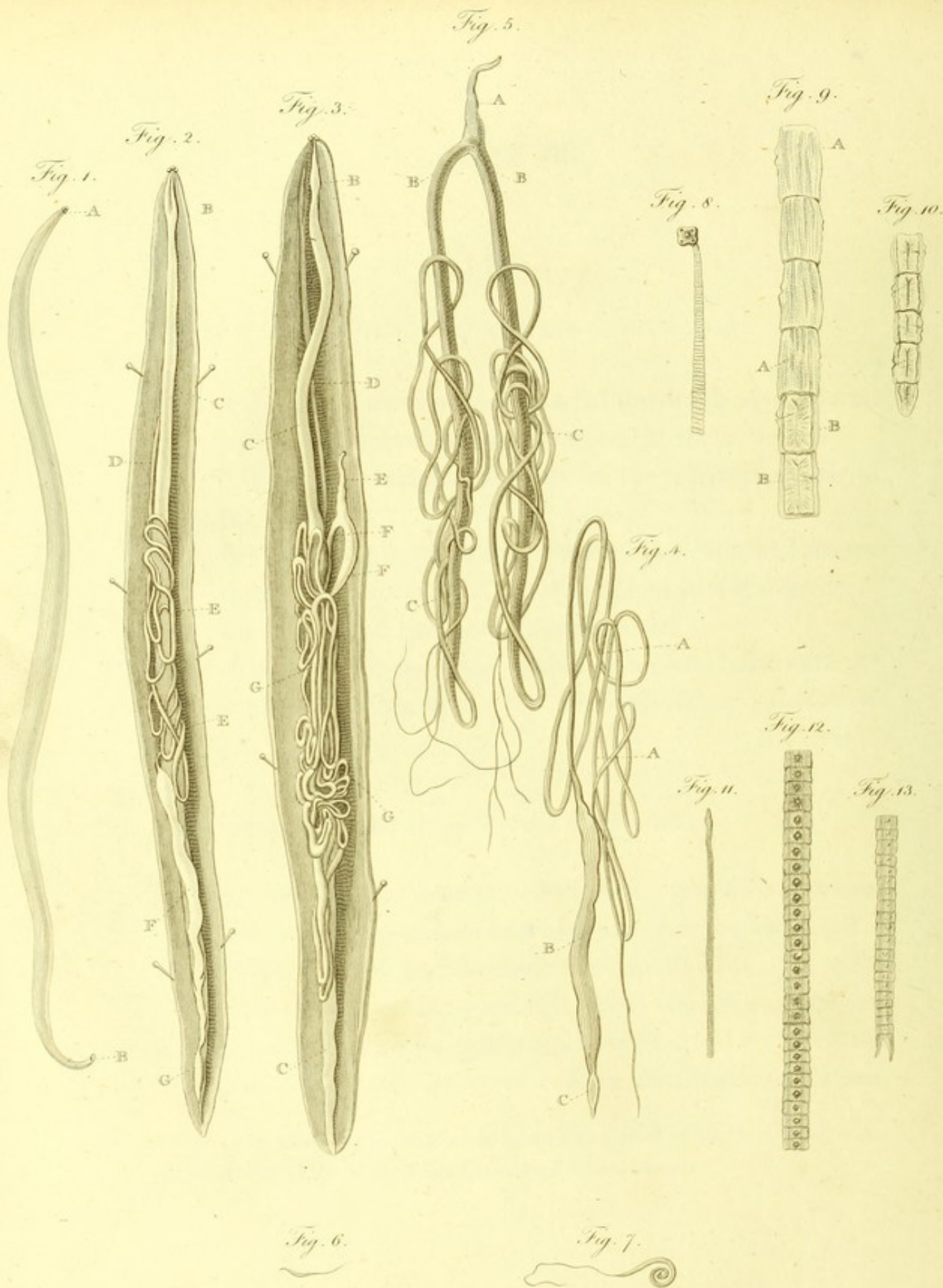
Represents the sac of the hernia congenita.

- A. The cavity of the sac exposed to view. There is a curved probe in it, the extremities of which may be supposed to be in the cavity of the abdomen, thereby illustrating the communication between this cavity and that of the sac.  
B. The testicle, with its epididymis seen at the bottom of the sac. *From Dr. Hunter's Museum.*

\* An engraving of this hernia has been lately published by Dr. Clarke, in the second volume of the Medical and Chirurgical Transactions.









## PLATE IX.

IN this Plate are represented the different species of worms which are bred in the human intestines. These are, the lumbricus teres, ascaris, trichuris, tænia solium, and tænia lata. The two first are very common in this country, but the trichuris is not only rare in this country, but, I believe, in every other. The tænia solium is occasionally met with in Great Britain, but it may still be said to be rare; in other parts of Europe it is much more common, especially in Germany. The tænia lata occurs more rarely in Great Britain than the tænia solium, but it is very common in Switzerland. We have attempted to illustrate the most important circumstances in the anatomical structure of the lumbricus teres, the tænia solium, and the tænia lata, but it is foreign from our purpose to enter into it minutely, and indeed it may still be said to be imperfectly known.\* The ascaris and the trichuris are so small, that we have only attempted to represent their external form.

\* Dr. Hooper has lately published, in the fifth volume of the Memoirs of the Medical Society of London, a very good account of the worms inhabiting the human intestines, which has enabled me to give a more satisfactory description of these worms, in some particulars, than otherwise I could have done.



## FIG. I.

Represents a lumbricus teres of the common size and shape.

- A. The anterior extremity, where the head is observable, consisting of three round tubercles, with an intermediate cavity.
- B. The posterior extremity, or tail; and very near the end of it a fissure may be perceived, which is the anus of the worm.

## FIG. II.

Represents a male worm laid open so as to exhibit its internal structure.

- A. The head.
- B. The beginning of the intestinal tube, which may be called the œsophagus.
- C. The intestinal tube.
- D. One of the two white lines which pass along the whole length of the worm.
- E E. A small convoluted tube which terminates in the large canal, F. This convoluted tube may be considered as analogous to the vas deferens, and perhaps also to the tubuli testis.



- F. The large canal or reservoir, which may be considered as a vesicula seminalis.
- G. The penis.\*

## FIG. III.

Represents a female worm laid open, exhibiting its internal structure.

- A. The head.
- B. The œsophagus.
- C C. The intestinal tube.
- D. One of the white lines which pass along the whole length of the worm.
- E. The vagina and the uterus.
- F F. The horns of the uterus near their bifurcation.
- G G. Small convoluted tubes connected with each horn of the uterus, which have been considered as analogous to the fallopian tubes.

\* There are very few male worms in comparison of the number of female, but in this species of worm there is undoubtedly a distinction of sex. Werner has given an engraving of the internal structure of a male worm, from which this figure has been copied; and I have in my possession a specimen of it, in which, however, the parts are not very perfectly preserved.

## FIG. IV.

Represents the male organs taken out of a worm in order to be viewed more distinctly.

- A A. A small convoluted tube, which is analogous to the vas deferens.
- B. A large canal or reservoir, which is considered as similar to the vesiculæ seminales.
- C. The penis.

## FIG. V.

Represents the female organs taken out of a worm, in order to allow of a more distinct examination. They are of a large size.

- A. The vagina and uterus.
- B B. The horns of the uterus near their bifurcation.
- C C. Two small convoluted tubes arising from the small extremity of each horn of the uterus, which have been considered as fallopian tubes.

## FIG. VI.

Represents an ascaris of the natural form and size. Its tail is filiform; and the extremity where the head is situated, is somewhat smaller or narrower than the body.



## FIG. VII.

Represents a trichuris. It is much larger than the ascaris, and is often found coiled up into a spiral form. Its tail is very long and filiform, and at its head there is a small process, which has been called a proboscis: this is hollow, and communicates with the intestinal tube. In many of these worms it is not visible, but in such cases it may be supposed to be retracted within the head.

## FIG. VIII. IX. AND X.

Represent different parts of the tænia solium.

## FIG. VIII.

Represents the head of this worm, and some of the small joints upon which it is supported. The head is somewhat of a square form, in the centre of which there is a projection and aperture: this is called the proboscis, and is surrounded with a double row of very small processes. The projection can not be distinctly seen, unless when the head is viewed laterally. At each of the four angles of the head there is a round aperture.

## FIG. IX.

Represents some joints from the body of the worm : these are flat, of an oblong shape ; and on the alternate edges of each joint there is a small projection and aperture.

A A. Represent some of these joints in their natural state.

B B. Represent two joints so prepared as to shew their anatomical structure. In the middle of these joints may be observed an arborescent distribution of small vessels. These are sometimes seen filled with a brownish-white fluid, and are supposed to be the ovaria. A small tube is seen running from the aperture in the edge of these two joints, and communicating with the arborescent distribution of vessels. Through this the ovula are supposed to be ejected from the parent worm. Two vessels may likewise be observed running longitudinally near the edges of the joints, which communicate together at the upper and lower ends of the joints by a cross canal. This apparatus is extended through the whole length of the worm, and is supposed to be its alimentary canal.



## FIG. X.

Represents some joints at the tail of the solium. The only circumstance to be particularly remarked is the rounded, or rather parabolic shape of the last joint, which wants also the aperture at its edge.

## FIG. XI. XII. AND XIII.

Represent different parts of the tænia lata.

## FIG. XI.

Represents the head of the worm, with some of the small joints which support it. The head is somewhat of an oblong shape ; but its minute structure is not here exhibited, because it could not even be perceived with a magnifying glass of considerable power.

## FIG. XII.

Represents a number of joints from the body of the worm. These are short and broad ; and in the middle of the flattened surface of each joint there is a circular aperture, surrounded with short stellated tubes. These are supposed to be the ovaria.

## FIG. XIII.

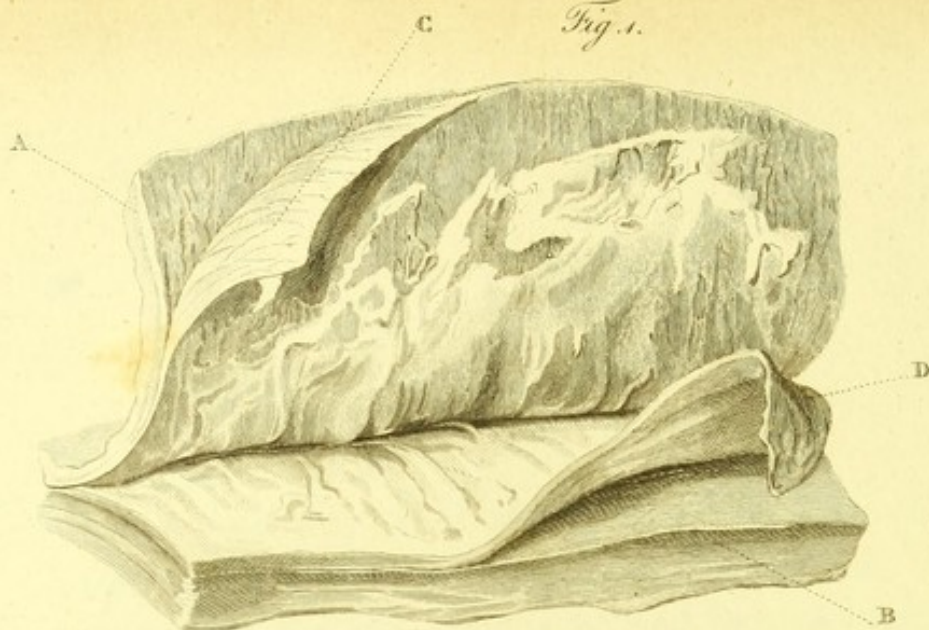Represents the tail of the *tænia lata*. The joints here are longer and narrower than in the rest of the worm, with smaller oscula; and the last joint is formed into two processes, one of which is longer than the other. In five worms of this species I have had an opportunity of examining the tail, and in all of them it consisted of two processes, as are represented in this figure.\*

\* Fig. II. III. IV. V. and X. were copied from Werner's excellent Treatise upon Worms, with the permission of Sir Joseph Banks, who obligingly lent the book to the Author. The other figures in this Plate have been drawn from preparations in Dr. Hunter's Museum, and the Author's Collection.

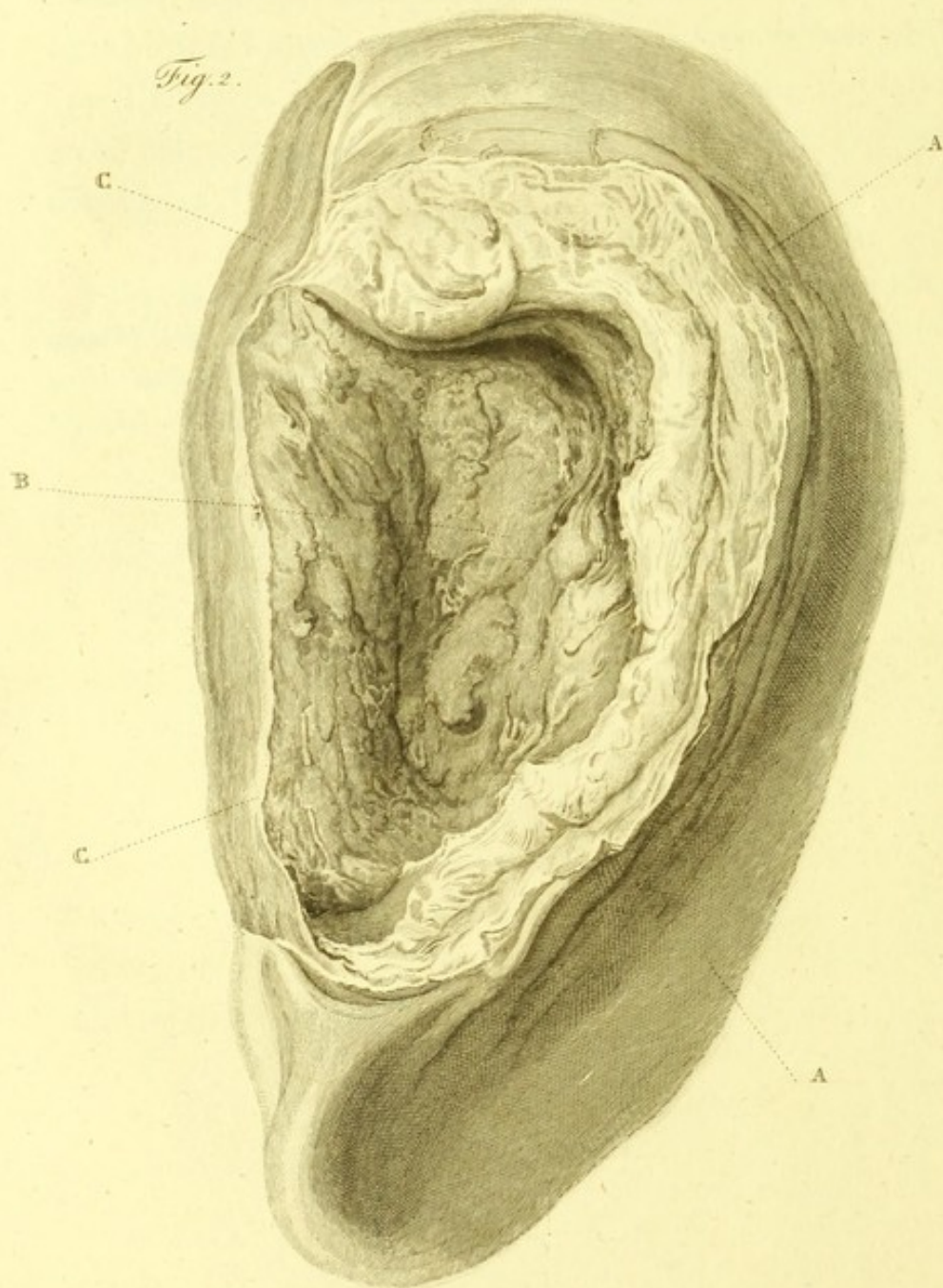




*Fig. 1.*



*Fig. 2.*





## FIFTH FASCICULUS.

It is proposed in this Fasciculus to illustrate the most important Morbid changes of structure which occur in the Liver and the Pancreas. In the former they are perhaps more various than in any other gland of the body: but some of them are, fortunately, very rare, as they are of such a nature as hardly to admit of much relief from medicine. In the Pancreas, the morbid changes of structure are very few in number; and some of these occur so rarely, as seldom to have fallen under the observation even of the most experienced anatomists.

## PLATE I.

THIS Plate is intended to illustrate inflammation of the capsule of the liver, and an abscess in its substance. The first is not unfrequently observed, because every part of the peritonæum has a considerable tendency to be inflamed; the second occurs more rarely, at least in the inhabitants of this country.

## FIG. I.

Represents inflammation of that part of the capsule which covers the anterior surface of the liver, and of a portion of the peritonæum lining the diaphragm.

- A. A part of the diaphragm, with its peritonæum inflamed.
- B. A part of the substance of the liver, with its capsule inflamed.
- C. A layer of the coagulable lymph in part adhering to, and in part turned off, from the inflamed portion of the peritonæum lining the diaphragm.
- D. A similar layer of coagulable lymph partly adhering to, and partly turned off, from the inflamed capsule of the liver.

If the person in whom this disease occurred had lived a few weeks longer, these layers of coagulable lymph would have been changed into a transparent membrane, joining the anterior surface of the liver to the diaphragm.

*From Dr. Hunter's Museum.*



FIG. II.

Represents a portion of the liver, with a large abscess in it.

A A. A part of the liver in a sound state.

B. A part of a large abscess, with a very irregular surface.

C C. The cut edge of the liver.

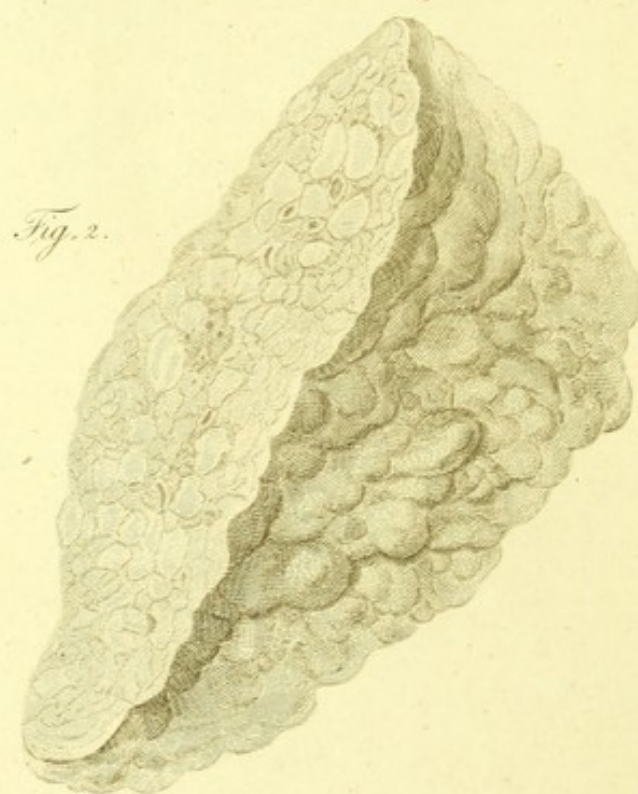
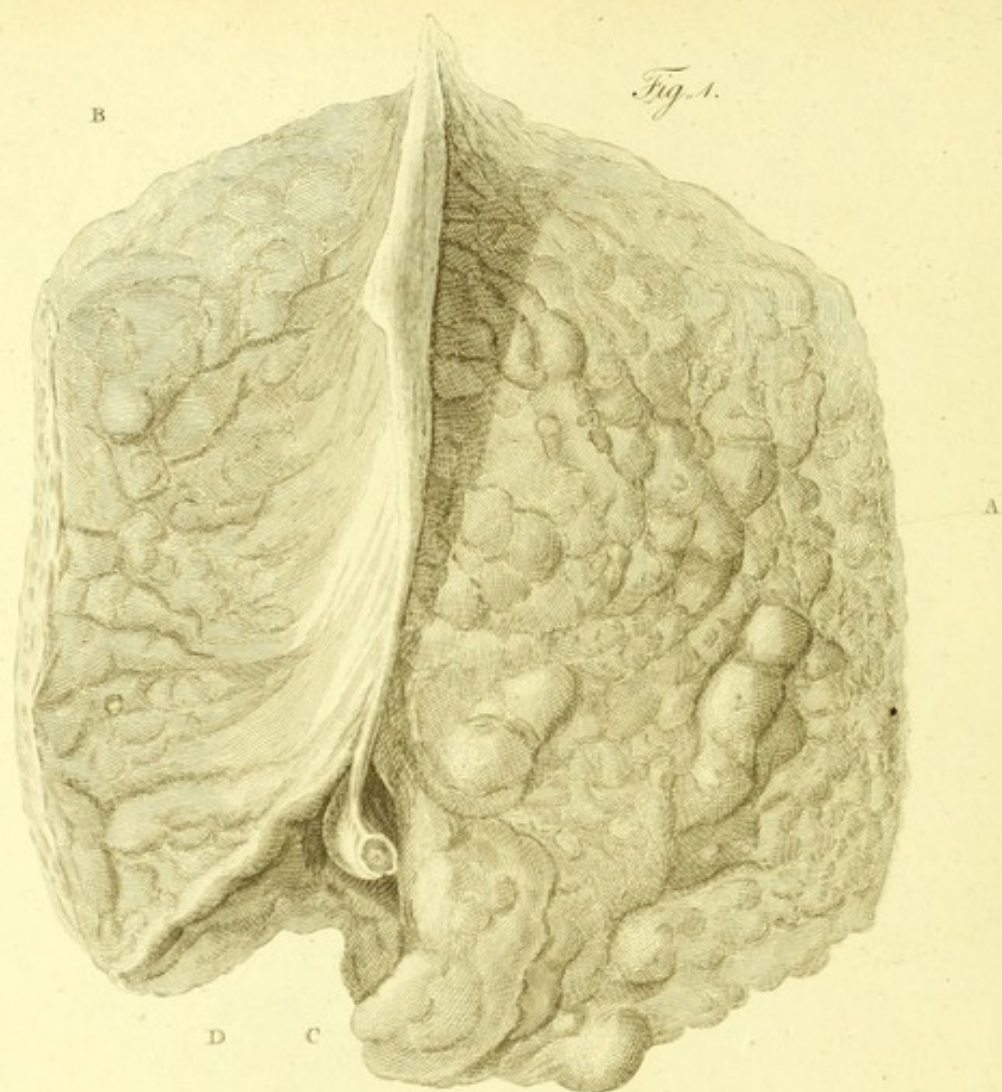
*From Mr. Heaviside's Museum.*

FIGURE

Representing a portion of the river with a large island in it  
 and in addition a large island in the river and a large island in the river  
 A.A. A part of the river in a straight line, with a large island in it  
 B. A part of a large island, with a very irregular outline  
 C. The river in a straight line, with a large island in it  
 D. A part of a large island, with a very irregular outline  
 E. A part of a large island, with a very irregular outline  
 F. A part of a large island, with a very irregular outline  
 G. A part of a large island, with a very irregular outline  
 H. A part of a large island, with a very irregular outline  
 I. A part of a large island, with a very irregular outline  
 J. A part of a large island, with a very irregular outline  
 K. A part of a large island, with a very irregular outline  
 L. A part of a large island, with a very irregular outline  
 M. A part of a large island, with a very irregular outline  
 N. A part of a large island, with a very irregular outline  
 O. A part of a large island, with a very irregular outline  
 P. A part of a large island, with a very irregular outline  
 Q. A part of a large island, with a very irregular outline  
 R. A part of a large island, with a very irregular outline  
 S. A part of a large island, with a very irregular outline  
 T. A part of a large island, with a very irregular outline  
 U. A part of a large island, with a very irregular outline  
 V. A part of a large island, with a very irregular outline  
 W. A part of a large island, with a very irregular outline  
 X. A part of a large island, with a very irregular outline  
 Y. A part of a large island, with a very irregular outline  
 Z. A part of a large island, with a very irregular outline









## PLATE II.

THIS Plate is intended to illustrate the most common kind of tubercles formed in the liver. The process by which they are formed is very slow, although it varies in this respect a good deal in different individuals, and it is commonly produced by a long habit of drinking spirituous liquors. When the liver has undergone this change, it is commonly said to be scirrhus, but the morbid appearance is very different from what is observed in the genuine scirrhus of other glands. It should rather be considered as a disease *sui generis*.

## FIG. I.

Represents a considerable portion of the liver studded with tubercles.

- A A. A part of the anterior surface of the liver, rendered very uneven from the irregular elevation of the tubercles.
- B. A part of the suspensory ligament of the liver.
- C. A section of the ligamentum teres, which, before birth, constituted a part of the umbilical vein. Although it has got the name of ligament, yet it does not change into a true ligamentous substance, but retains very much the

original structure of a vein, the cavity only being obliterated.

D. The lower end of the deep fissure which separates the right and the left lobe of the liver from each other.

*From Mr. Heaviside's Museum.*

### FIG. II.

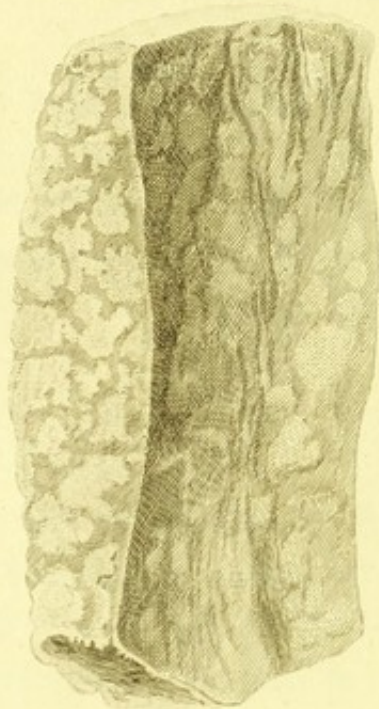
Represents a smaller section of the liver affected with the same disease. It is intended to shew that the tubercles are not merely formed near the surface of the liver, but throughout the whole of its substance, as may be distinctly perceived through the whole extent of its cut edge. In the cut edge may also be seen a few round cavities, which are sections of veins. The liver in this disease is not enlarged in its size, but is, on the contrary, somewhat diminished.

*From the Author's Collection.*

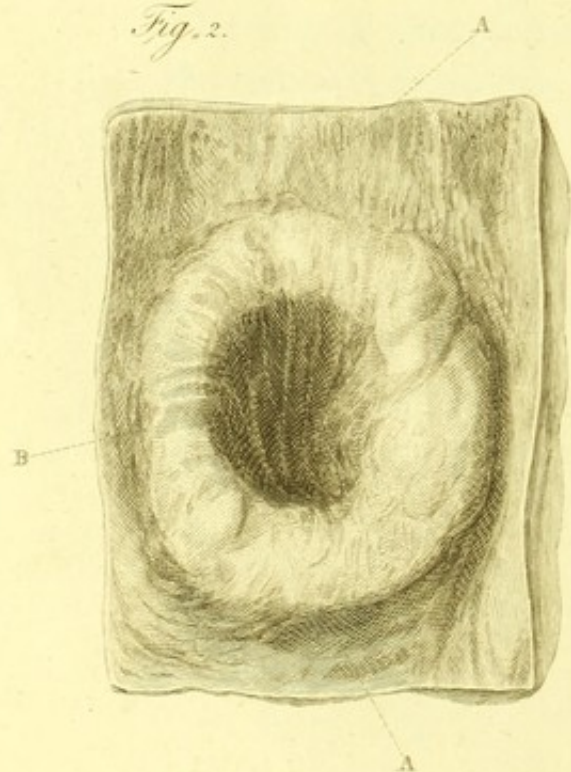




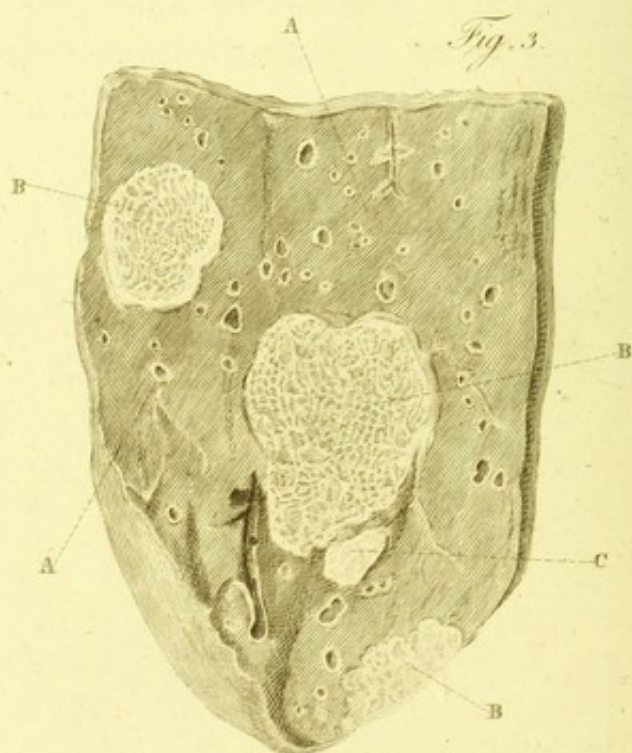
*Fig. 1.*



*Fig. 2.*



*Fig. 3.*





## PLATE III.

THIS Plate represents two species of tubercles, which are different from that exhibited in the former Plate.

## FIG. I.

Represents a small section of a liver affected with scrofulous tubercles. They resemble exactly in their texture a scrofulous absorbent gland, and are spread throughout the whole substance of the liver, but produce little irregularity upon its surface. They sometimes are converted into a scrofulous pus, but by no means so frequently as the tubercles of the lungs.

*From the Author's Collection.*

## FIG. II.

Represents a large tubercle formed in the liver. This is different in its appearance from either of the two species of tubercles which have been already illustrated. It is firm in its texture, is generally depressed upon its external surface, and large portions of the liver in a sound state are interposed between the different tubercles of this species. If a judgment were to be formed concerning the nature of this tubercle, merely

from its texture, it would be considered as scirrhus ; but in one or two instances I have seen some tubercles of this kind converted into a thick curdly pus, similar to that of a scrofulous gland. When such tubercles are formed, the liver is commonly enlarged beyond the natural size.

A A. A part of the liver in a sound state.

B. The external surface of a large tubercle somewhat hollowed or depressed. *From the Author's Collection.*

### FIG. III.

Represents a portion of the liver with the cut surface exposed to view, in order to shew the general size and texture of these tubercles.

A A. The sound portion of the liver, in which may be observed various apertures, being the orifices of divided blood-vessels.

B B B. Three tubercles of a considerable size. Their texture consists of a pretty hard white substance, variously intersected with membrane.

C. A smaller tubercle. *From the Author's Collection.*





Fig. 1

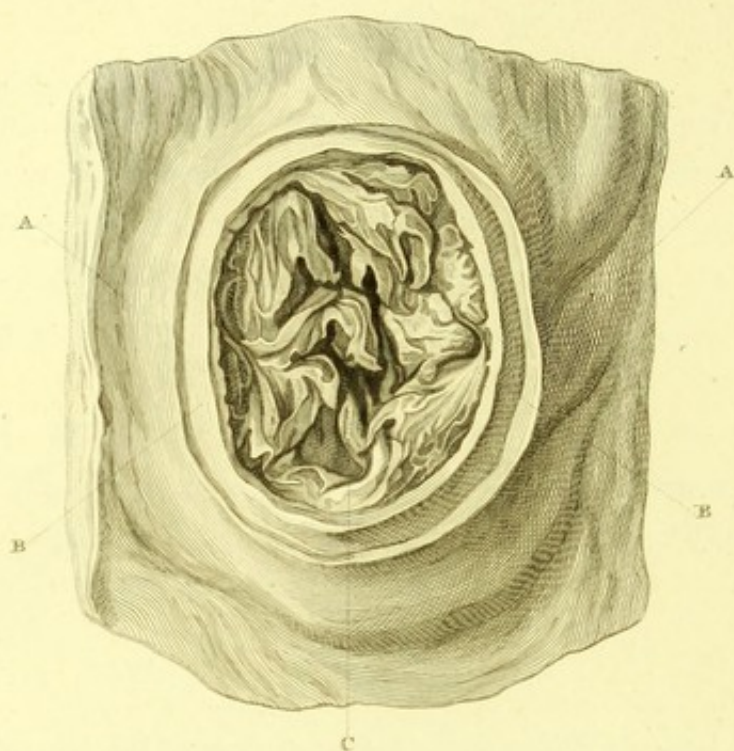
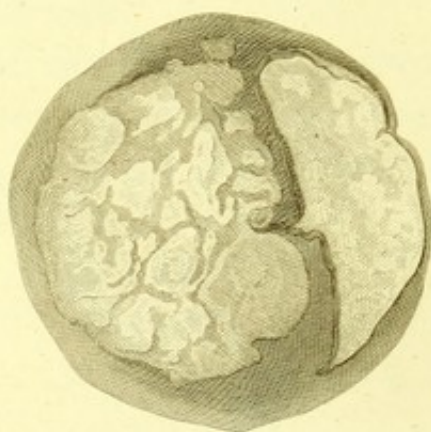


Fig. 2





## PLATE IV.

THIS Plate is intended to illustrate a cyst of a peculiar kind, which sometimes, although very rarely, is formed in the liver. The cyst is composed of a cartilaginous substance, intermixed with bone, and contains a smooth, soft, whitish earth, a good deal blended with transparent laminæ, of a substance which resembles the coats of an hydatid. The liver in every other part is sound, except where the cyst is formed; and the progress of the growth of this cyst, as well as the exact nature of its contents, are at present imperfectly known.

## FIG. I.

Represents one of these cysts laid open, in order to shew what is contained in it.

A A. A part of the liver in its sound state.

B B. A part of the cyst.

C. The contents of the cyst, which it is very difficult to express accurately in an engraving. Still, however, some irregular laminæ of a membranous substance are observable, and the interstices between them seem to be filled up with a different kind of matter, which is the earth formerly explained.

*From the Author's Collection.*

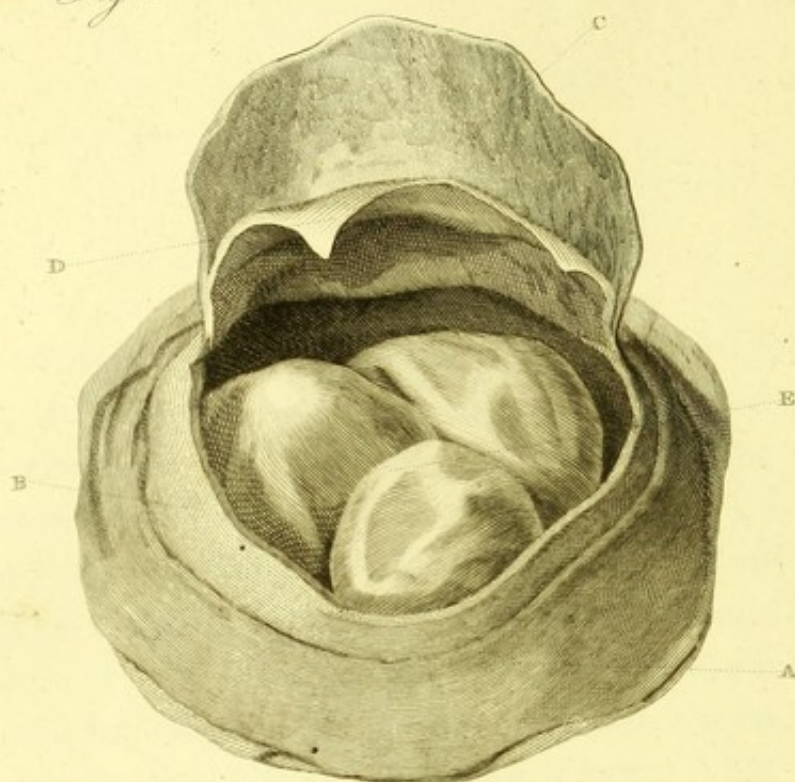
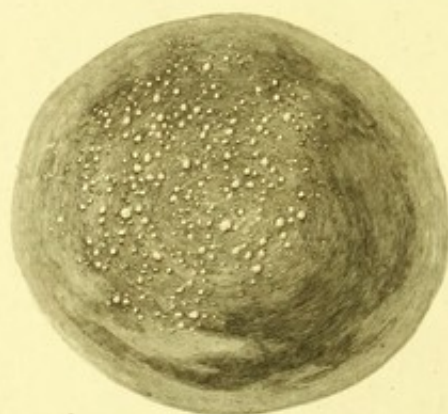## FIG. II.

Is intended to illustrate more distinctly the nature of the cyst, and with this view it was taken from a dried preparation possessing a certain degree of transparency. The white spotted part consists of bony matter, and the other part of cartilage, An oblong opening may be observed in the cyst, which was made for the purpose of removing its contents, and of allowing the cyst to be dried. In this way only can the exact proportion of bony and cartilaginous substance in the composition of the cyst be distinctly perceived by the eye.

*From the Author's Collection.*





*Fig. 1.**Fig. 2.**Fig. 3.**Fig. 4.**Fig. 5.*



## PLATE V.

IN this Plate are represented some hydatids of the liver. These consist of spherical bags of a white or light amber colour, more or less transparent, and are lodged in cartilaginous cysts. The cysts are lined with a brownish pulpy membrane, resembling very much the coagulable lymph of the blood ; but this membrane is more or less distinctly marked in different cases. The cysts are sometimes surrounded on every side by the substance of the liver, and sometimes are formed at the surface, so as to be partially seen without dissection. The hydatids themselves contain a transparent fluid, which is capable of being coagulated by heat, and by acids, and sometimes contain also smaller hydatids floating in this fluid. On many occasions very small hydatids are found adhering to the coats of the larger hydatids, and appear to the eye like small pearls. Hydatids of this species would seem to be animalcules of a very simple structure, and although they are not often formed in the liver, yet they grow more frequently in this gland, than in any other of the body.\*

\* The hydatids which most commonly are found in the kidneys, are very different from the hydatids here described.

## FIG. I.

Represents a cyst containing three hydatids.

- A. A part of the substance of the liver.
- B. A part of the cartilaginous cyst.
- C. Another part of the cyst turned upwards, in order to discover its cavity.
- D. A part of a membrane lining the cysts, which resembles the coagulable lymph of the blood.
- E. The cavity of the cyst, in which may be observed three hydatids.

*From Dr. Hunter's Museum.*

## FIG. II.

Represents an hydatid of a considerable size, with a number of very small hydatids adhering to its coats, resembling pearls.

*From Dr. Hunter's Museum.*

## FIG. III. IV. AND V.

Represent three hydatids, varying a good deal in their size.\*

*From the Author's Collection.*

\* If the ground of this Plate had been dark, the transparency of the hydatids would have been much more observable; but this colour could not have been given consistently with that of the other plates.





Fig. 1.

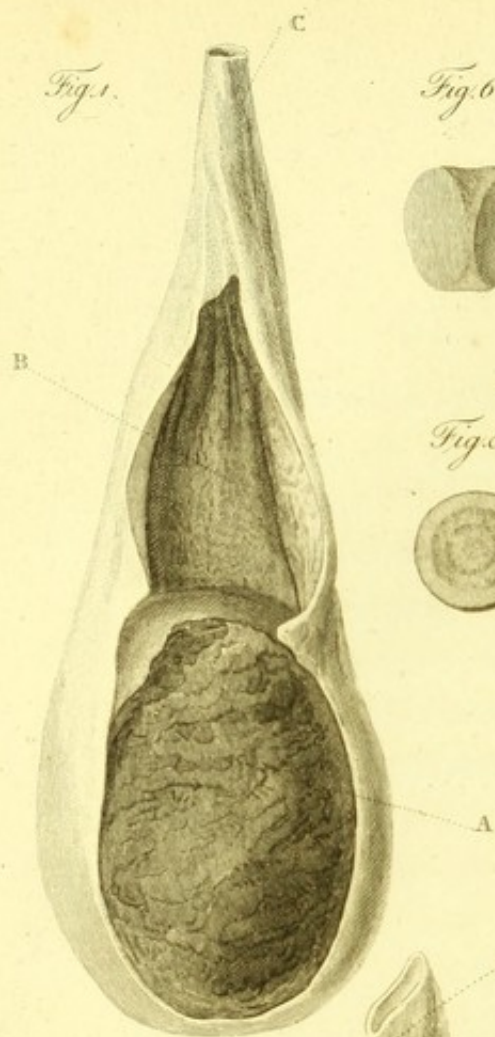


Fig. 6.



Fig. 5.



Fig. 7.



Fig. 2.

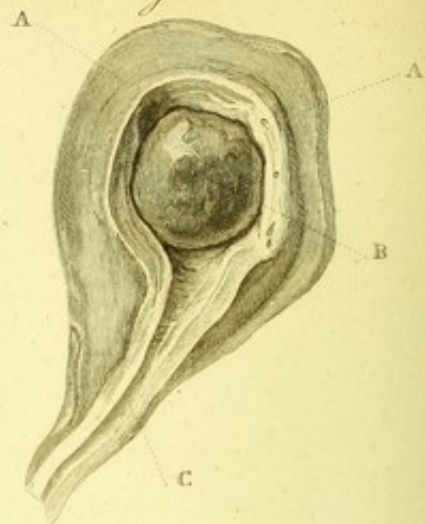

Fig. 8.



Fig. 4.

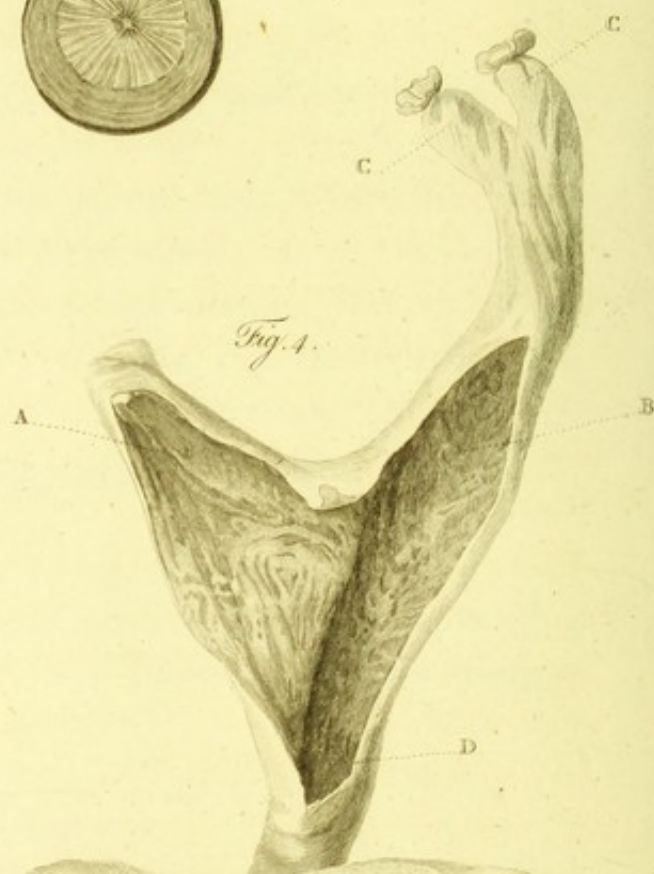
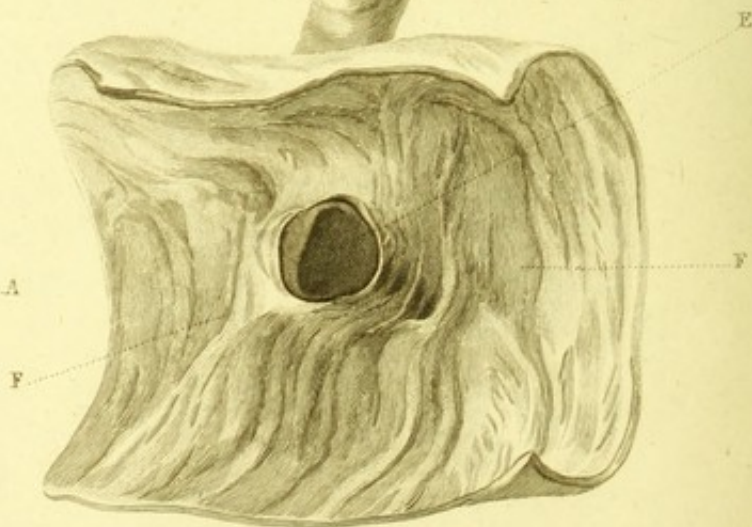
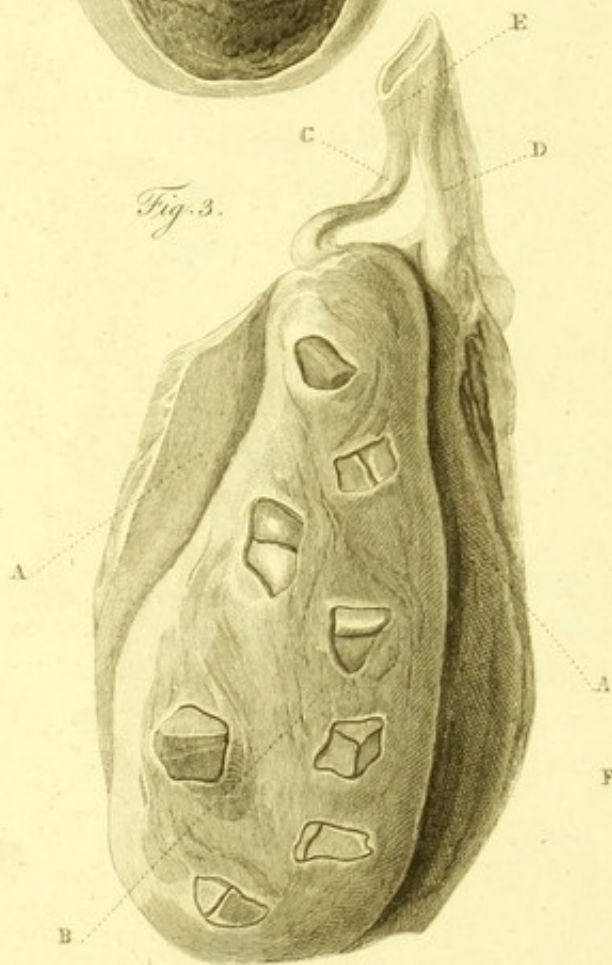


Fig. 3.





## PLATE VI.

IN this Plate it is proposed to illustrate the most important circumstances observable in biliary calculi. These vary in their colour, their shape, their size, and their texture. Most of them are of a brown colour, which differs very much in its shade ; but this cannot be illustrated in a colourless engraving. When there is but one calculus in the gall-bladder, it is oval in its shape, and commonly more or less uneven upon its surface ; when the calculi are in considerable numbers, they are of an irregular shape, having several flattened sides, with a surface smooth or polished. There is a great deal of difference in the size of biliary calculi : some are not larger than the head of a pin, while others have been known to be as large as a pullet's egg of a common size. Their texture consists of concentric laminæ upon the outside, with radiated crystallizations in the centre ; but this is much more distinctly marked in one calculus than another. Biliary calculi, too, have some variety in their situation : they are generally found in the gall-bladder, but not unfrequently they are met with in some of the biliary ducts, which are capable of being so much distended as to allow calculi of a large size to pass into the duodenum.

## FIG. I.

Represents a gall-bladder containing a gall-stone of the size of a pullet's egg. The gall-bladder is a good deal enlarged in its capacity, from the accumulation of bile in it, and the space necessarily occupied by so large a calculus.

- A. A large calculus of an oval shape, filling up the whole fundus of the gall-bladder.
- B. A part of the gall-bladder, in which the bile was accumulated, and which was capable of containing nearly the usual quantity of bile which is received into this reservoir.
- C. The beginning of the ductus cysticus, which is a good deal enlarged in its size. *From Dr. Hunter's Museum.*

## FIG. II.

Represents a section of a gall-bladder very much thickened in its coats, and embracing closely a calculus.

- A A. The thickened coats of the gall-bladder.
- B. The calculus.
- C. The ductus cysticus. *From Dr. Hunter's Museum.*



## FIG. III.

Represents a gall-bladder completely filled with gall-stones.

A A. A part of the substance of the liver.

B. The gall-bladder filled with gall-stones. Little openings have been made in it, in order to bring some of the gall-stones into view. They are very numerous, and have a number of smooth sides, produced by friction, by which they become adapted in their shape to each other. The gall-bladder is a little thickened in its coats, partly from pressure, and probably also in part from unusual exertions of its contractile power.

C. The ductus cysticus.

D. The ductus hepaticus enlarged in its size.

E. The junction between these two ducts, where they form the ductus communis choledochus.

*From Dr. Hunter's Museum.*

## FIG. IV.

Represents the biliary ducts much enlarged, and a gall-stone ready to drop into the cavity of the duodenum.

A. A part of the ductus cysticus laid open and enlarged.

- B. The ductus hepaticus enlarged.
- CC. The two tubes which unite to form the ductus hepaticus, enlarged also in their size.
- D. The ductus communis choledochus, likewise increased in its capacity.
- E. A gall-stone which had passed through these ducts, and was just ready to be discharged into the duodenum.
- FF. A part of the duodenum laid open, in which the valvulæ conniventes are formed very imperfectly, a circumstance belonging to the natural structure of this part of the small intestines.

*From Dr. Hunter's Museum.*

FIG. V.

Represents a gall-stone of an oval shape, and an irregular surface. It had been lodged by itself in the gall-bladder, and therefore its surface had neither been smoothed nor flattened by its friction against other calculi.

FIG. VI.

Represents a gall-stone smooth on its surface, and with flattened sides, from rubbing against other gall-stones.



## FIG. VII.

Represents a transverse section of a gall-stone, in order to shew its texture. Upon the outside it consists of concentric laminæ, and upon the inside of radiated crystallizations. The laminated texture was composed of a brown substance, and the radiated of a white splendid matter, like spermaceti, or mica. It happens almost constantly that the colour and the arrangement of structure, in the outer and inner part of a gall-stone, differ very much from each other.

## FIG. VIII.

Represents a transverse section of a smaller gall-stone. The radiated crystallizations are not so distinctly marked as in the gall-stone represented in Fig. VII. There is much variety in the distinctness of this structure in different gall-stones, and in some it is hardly observable. The appearance too of concentric laminæ upon the outside cannot be distinguished.\*

\* Fig. V. and VI. are taken from gall-stones in the Author's Collection; and Fig. VII. and VIII. are taken from gall-stones in Dr. Hunter's Museum.

Fig. VII. A transverse section of a gallstone, showing its structure.

FIG. VII

Representing a transverse section of a gallstone, so ordered to show its texture. Upon the outside it consists of a concentric lamina, and upon the inside of radiated crystalline lines. The laminae are composed of a heavy substance, and the radiated lines of a white crystalline matter. The specimen is mica. It happens, however, frequently that the colour and the arrangement of the laminae in the outer and inner part of a gallstone, differ very much from each other.

FIG. VIII

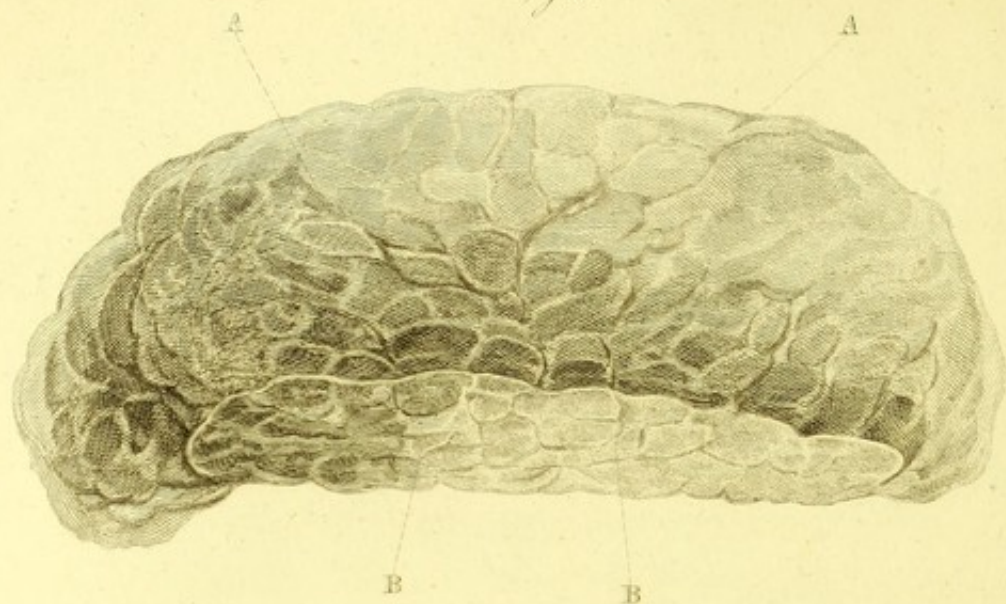
Representing a transverse section of a smaller gallstone. The radiated crystalline lines are not so distinctly marked as in the gallstone represented in Fig. VII. This is because the laminae of this minute specimen are thicker and denser, and in some it is hardly observable. The appearance, however, of concentric laminae upon the outside cannot be distinguished.

The gallstones in the Appendix, Figs. V and VI are taken from the same patient, and Figs. VII and VIII are taken from another patient.





*Fig. 1.*



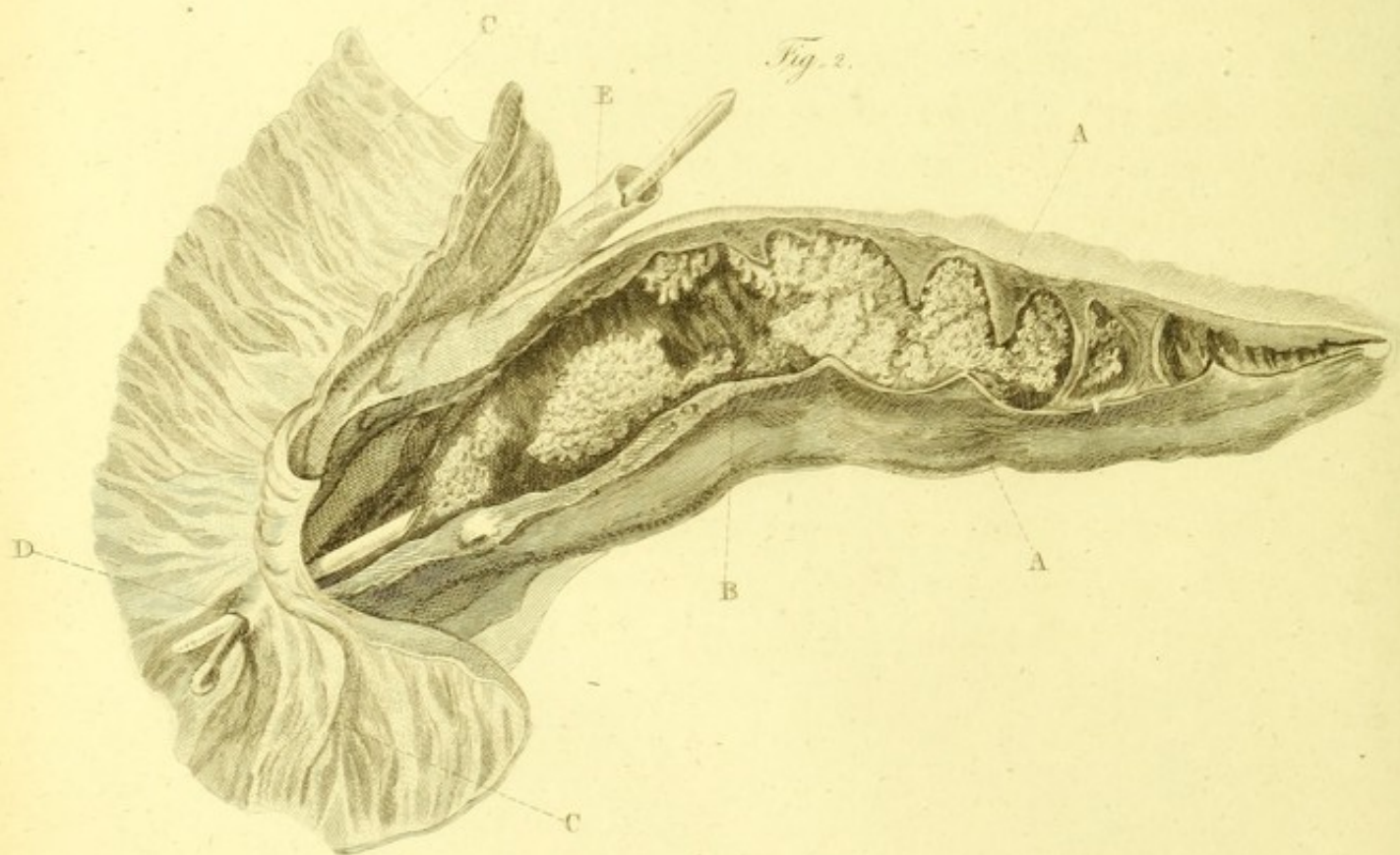*Fig. 3.*



*Fig. 4.*



*Fig. 2.*





## PLATE VII.

IN this Plate are exhibited two diseases of the Pancreas; the one consists in its structure becoming hard, while the appearance of its being composed of minute lobules is still sufficiently distinct to the eye. Of this I have had an opportunity of observing several instances, and the pancreas under such circumstances has been considered as scirrhus. The other disease consists in small calculi being formed in the duct of the pancreas and its branches. I have only seen one instance of this diseased change in the pancreas, which is represented in Fig. II.; and the stones in this case were very white in their colour, and irregular upon their surface.

Diseases of the pancreas occur so rarely, that I have not seen any other specimen of disease in this gland, preserved in the various collections of anatomical preparations which I have had an opportunity of consulting.

## FIG. I.

Represents a large portion of a pancreas which had become very hard in its texture. It had become at the same time thick and broad, but the small lobules of which it was originally composed, still remain very distinct.



- A A. The anterior surface of the pancreas.  
B B. One of the edges of the pancreas, which had been cut, in order to shew more distinctly its increased thickness, and the structure of the gland.

*From the Author's Collection.*

FIG. II.

Represents a pancreas, the excretory duct of which is prodigiously widened, and filled with a number of calculi. These had been gradually formed in the duct, distending it in proportion to the increase of their growth, were of a white colour, and of a very irregular shape. The irregularity of the shape was probably in some measure owing to their shooting, during their growth, into the small branches of the excretory duct, which are very numerous.

- A A. The pancreas.  
B. Its excretory duct, very much distended, and filled with calculi of an irregular shape.  
C C. A part of the duodenum laid open, so as to shew its internal surface.  
D. The opening in the duodenum common to the duct of the pancreas, and the ductus communis choledochus. A crow quill is put into the duct of the pancreas, and a small probe into the other duct.



E. A part of the ductus communis choledochus, into which a silver probe has been put.

*From Dr. Hunter's Museum*

FIG. III. AND IV.

Represent two calculi from the pancreas, which had been taken out, and drawn separately, in order to give a more distinct idea of their irregular form.

*From Dr. Hunter's Museum.*







Fig. 1.

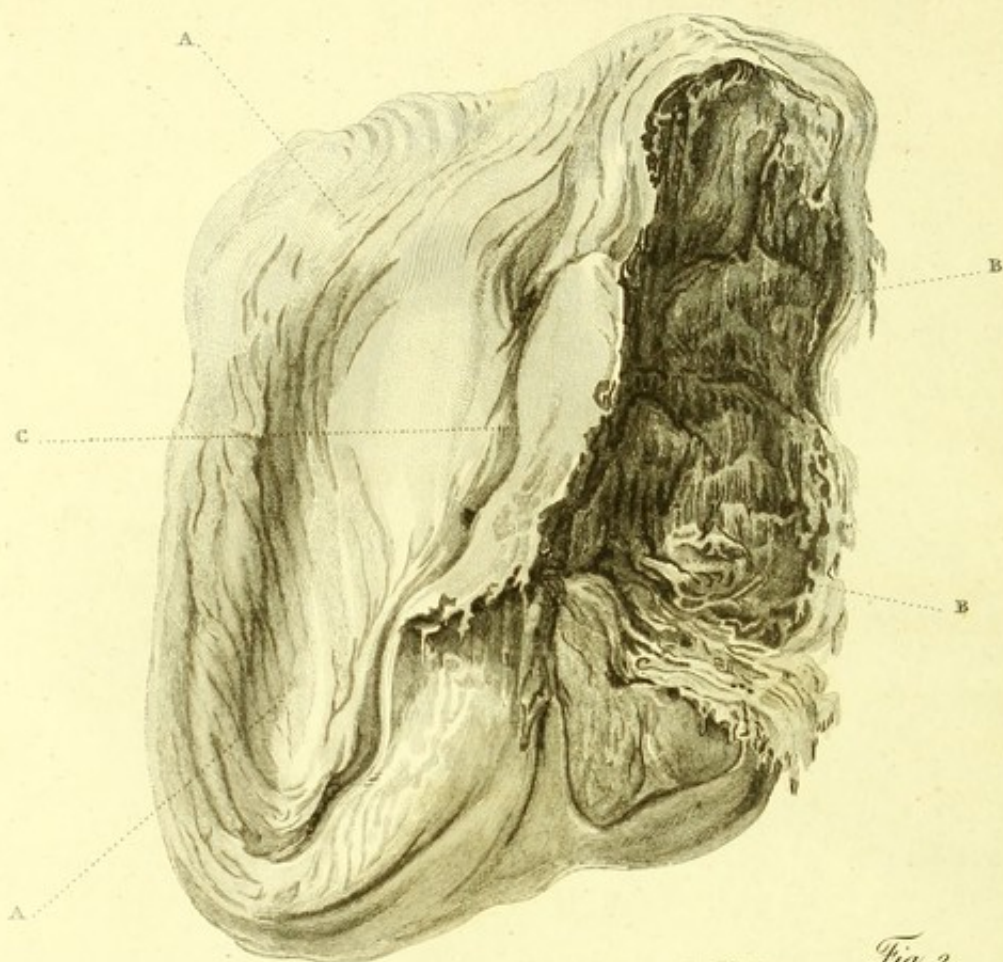
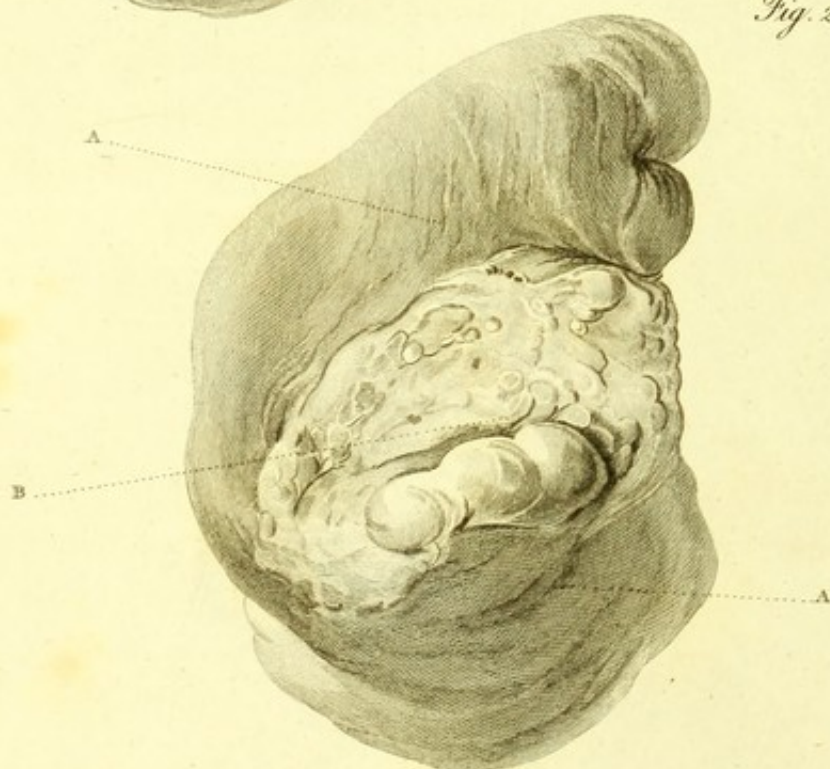


Fig. 2.





THE

## SIXTH FASCICULUS.

---

It is proposed in this Fasciculus to illustrate the chief Morbid appearances of the Spleen and the Kidneys.

In the former the diseased changes of structure are few in number, but in the latter they are numerous, and exhibit also a good deal of variety in the progress of the same diseases.

### PLATE I.

THIS Plate is intended to illustrate an abscess in the spleen, and also a diseased change which occasionally takes place in its coats. Although inflammation of the coats of the spleen is not uncommon, yet it rarely happens that inflammation takes place in the substance of the spleen to so violent a degree as to terminate in suppuration.

The diseased change in the coats of the spleen, which is illustrated in this Plate, is a conversion of them into a soft cartilage. This change may be said to be almost peculiar to

the spleen ; at least it occurs in the coats of the spleen much more commonly than in the coats of any other gland in the body.

### FIG. I.

Represents that surface of the spleen which is partly in contact with the great end of the stomach, and partly rests upon that portion of the diaphragm which covers the side of the spine.

A A. Represents that part of the surface which rests upon the diaphragm as above described : it is sound in its structure.

B B. Represents that other part of the surface of the spleen which lies in contact with the great end of the stomach : it is ulcerated through its whole extent.

C C. The ridge and fissure where the blood vessels, lymphatics, and nerves enter into, or pass out of the spleen.

*From Mr. Heaviside's Museum.*

### FIG. II.

Represents the broad convex surface of the spleen, where a part of its coats is converted into cartilage. The spleen was, in this case, as it often is under such circumstances, smaller



than its usual size, but this had no necessary connection with the change in its coats. Many instances occur of this change, where the spleen is fully as large as it commonly is.

A A. A part of the convex surface of the spleen, where its coats are sound.

B. A part of the coats converted into cartilage. The cartilage is generally soft, and forms a smooth layer, but in this case it was irregularly elevated.

*From Dr. Hunter's Museum.*

than the usual size, but this had no necessary connection with the change in the shape. Many instances occur of this change, where the species is fully as large as it commonly is.

A. A. A part of the convex surface of the epidermis, where its costs are found.

B. A part of the cost, rounded into a convexity. The convexity is generally small, and forms a small protuberance. In this case it was irregularly shaped, and was not a true cost.

C. A part of the cost, rounded into a convexity. The convexity is generally small, and forms a small protuberance. In this case it was irregularly shaped, and was not a true cost.

D. A part of the cost, rounded into a convexity. The convexity is generally small, and forms a small protuberance. In this case it was irregularly shaped, and was not a true cost.

E. A part of the cost, rounded into a convexity. The convexity is generally small, and forms a small protuberance. In this case it was irregularly shaped, and was not a true cost.

F. A part of the cost, rounded into a convexity. The convexity is generally small, and forms a small protuberance. In this case it was irregularly shaped, and was not a true cost.

G. A part of the cost, rounded into a convexity. The convexity is generally small, and forms a small protuberance. In this case it was irregularly shaped, and was not a true cost.

H. A part of the cost, rounded into a convexity. The convexity is generally small, and forms a small protuberance. In this case it was irregularly shaped, and was not a true cost.

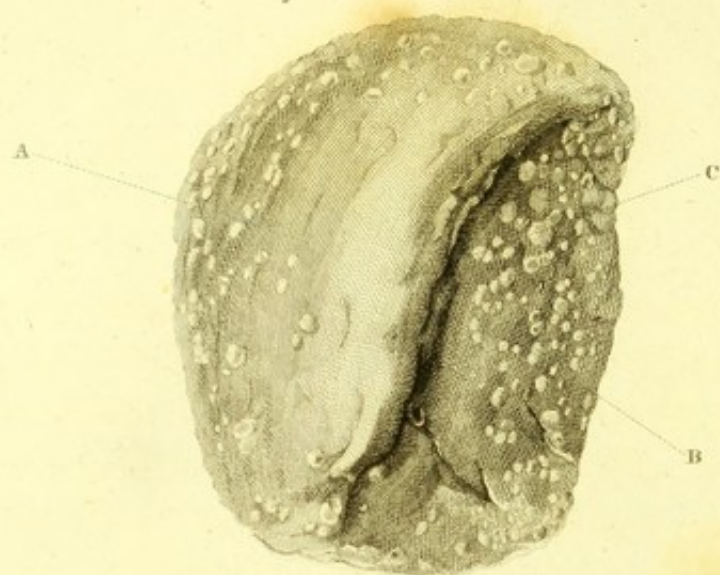
I. A part of the cost, rounded into a convexity. The convexity is generally small, and forms a small protuberance. In this case it was irregularly shaped, and was not a true cost.

J. A part of the cost, rounded into a convexity. The convexity is generally small, and forms a small protuberance. In this case it was irregularly shaped, and was not a true cost.

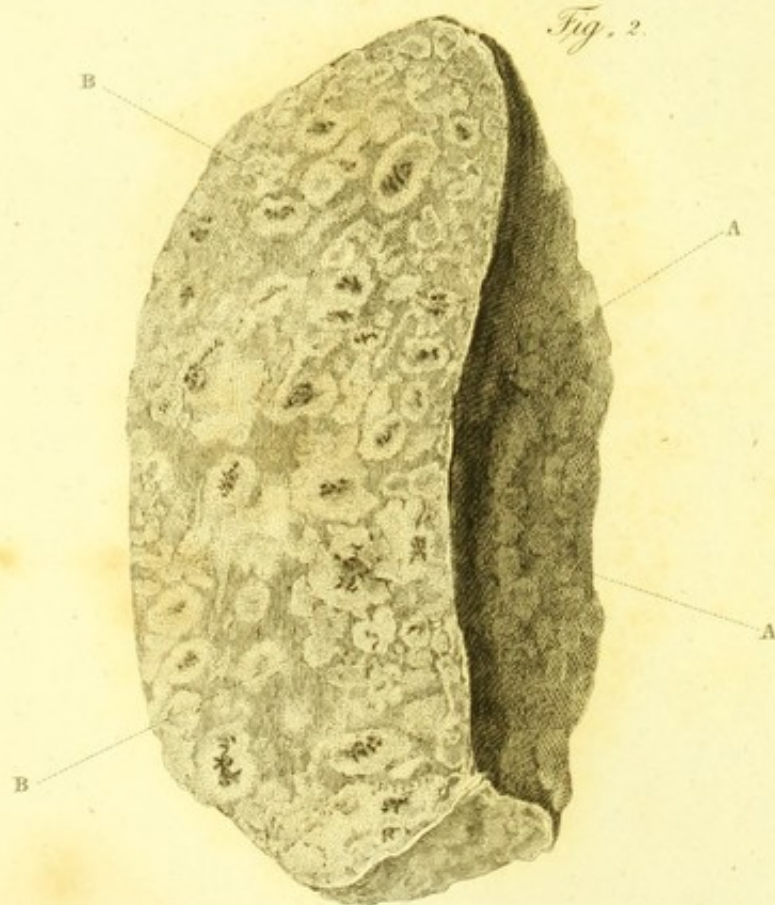



*Fig. 1.*



*Fig. 2.*





## PLATE II.

THIS Plate is intended to illustrate scrofulous tubercles in the spleen. These are much more rarely formed in the spleen than in the lungs, but they are precisely of the same nature in both. The scrofulous tubercles of the spleen, I am inclined to think, are less disposed to suppurate than those of the lungs.

## FIG. I.

Represents a spleen from a young child, which is studded with scrofulous tubercles.

- A. The surface of the spleen which rests upon that part of the diaphragm covering the side of the spine.
- B. The small hollow surface which lies in contact with the great end of the stomach.
- C. The ridge and fissure for the entrance and egress of the blood vessels, lymphatics, and nerves, of the spleen.

*From the Author's Collection.*

## FIG. II.

Represents a section of a spleen from an adult, with scrofulous tubercles formed in it. These pervade the whole substance of the spleen, and many of them had suppurated. The tubercles which had suppurated are distinguished from the others by having irregular cavities. The spleen from which this section was taken, was larger than the usual size, but the size of the spleen is not necessarily connected with the formation of tubercles.

A A. The outer surface of this section of the spleen, where the tubercles are seen obscurely under its capsule.

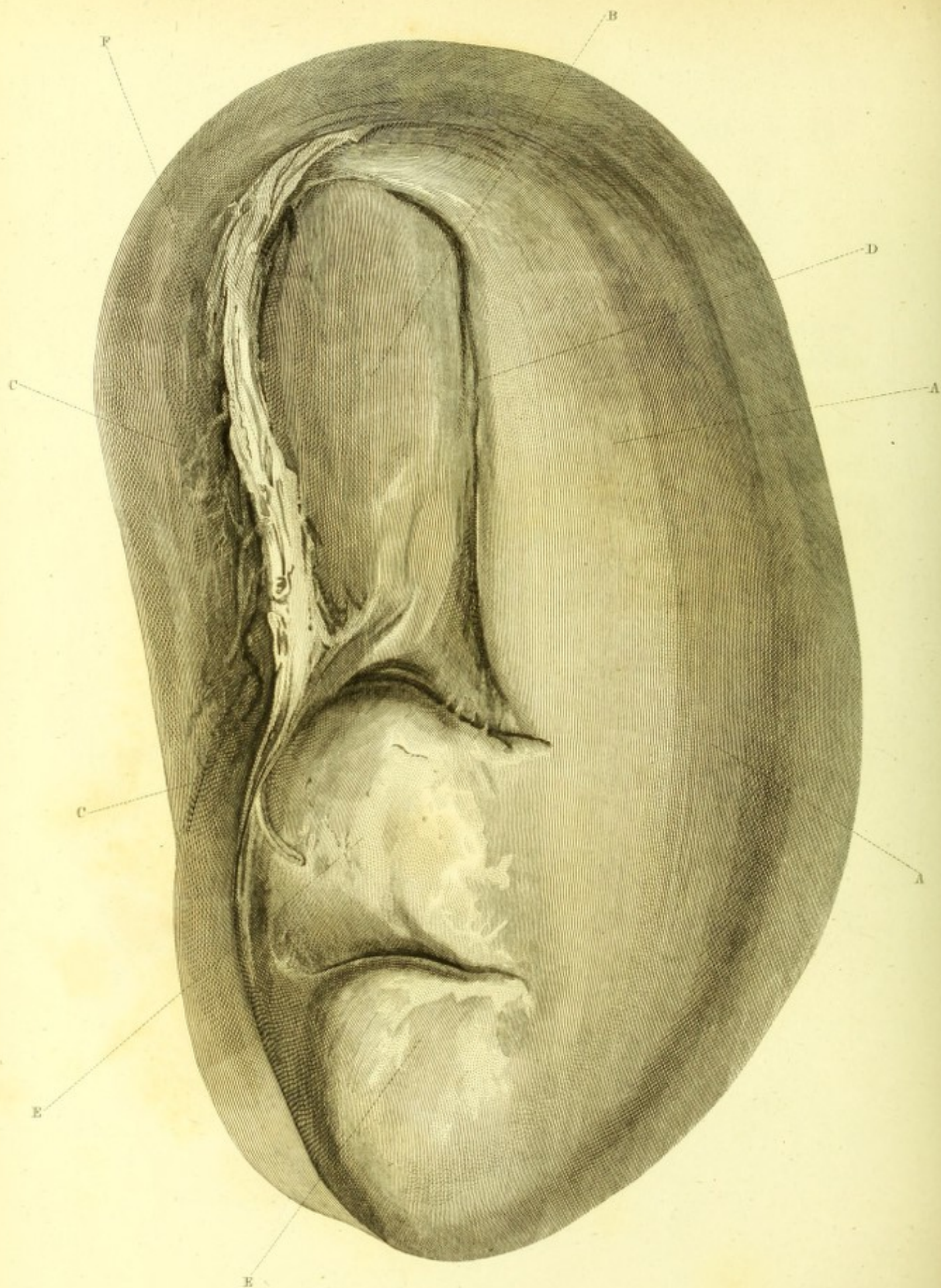B B. The cut surface, shewing a very great number of tubercles, and many of them in a state of suppuration.

*From the Author's Collection.*











## PLATE III.

THIS Plate represents an enlarged spleen. It is, at least, three times as large as the usual size, and was hard in its texture. A spleen in this state does not become tuberculated, but exhibits, in every part, an uniform solid structure, which is not disposed to run into suppuration. The spleen in this Plate is represented in an oblique view, so as to exhibit a part of all its sides.

- A A. The large convex surface of the spleen.
- B. A part of the small concave surface of the spleen, which lies in contact with the great end of the stomach.
- C C. A part of the surface of the spleen which rests upon that portion of the diaphragm covering the side of the spine.
- D. The edge of the spleen separating the convex from the concave side.
- E E. Two small lobules or eminences in the edge of the spleen, which make a very common variety in its shape ; it being very usual for this edge of the spleen to be marked by projections and deep notches.
- F. The ridge and fissure for receiving or giving out the blood vessels, lymphatics, and nerves of the spleen.

*From Mr. Hunter's Museum.*

PLATE III

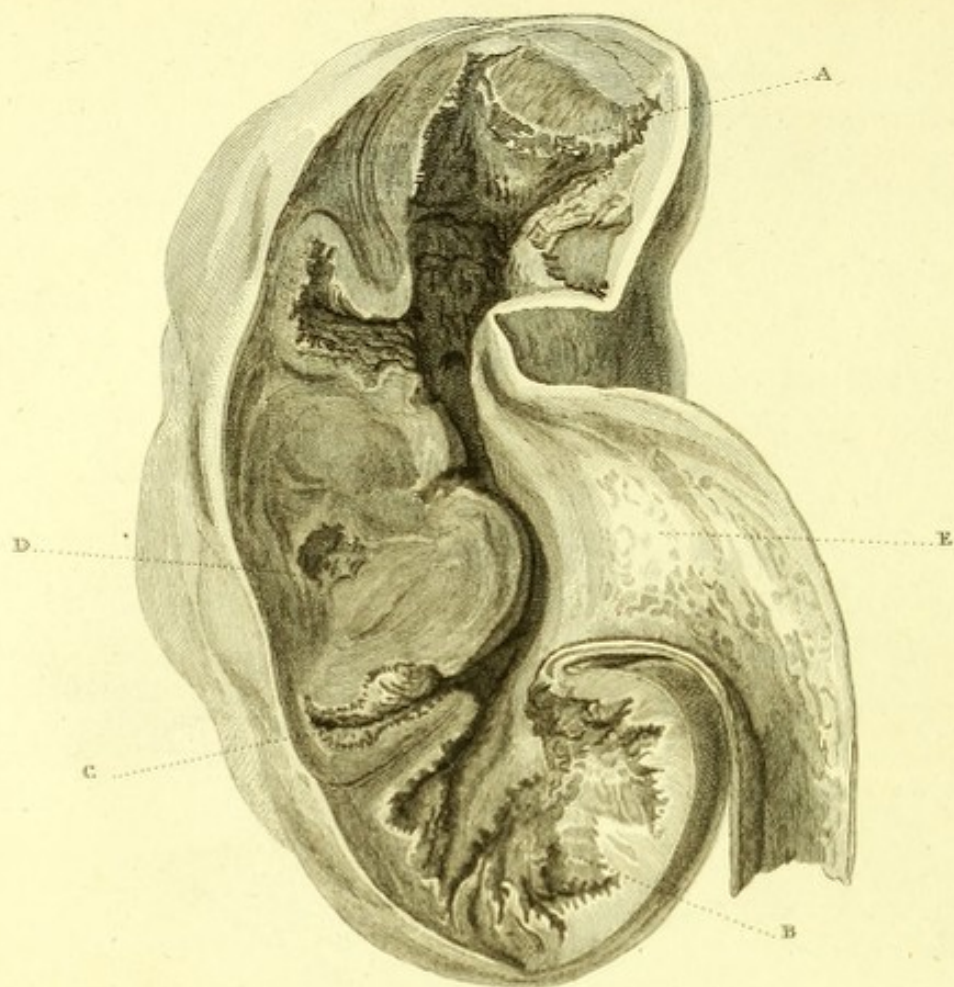
This Plate represents an enlarged view of the ...  
times as large as the actual size, and was found in the ...  
A specimen of this material has not been submitted, but ...  
hiding in every part an uniform solid structure, which is ...  
not adapted to run into suspension. The ...  
This is represented in an oblique view, so as to exhibit a part ...  
of all its sides.

- A. The large convex surface of the ...  
B. A part of the small convex surface of the ...  
C. A part of the surface of the ...  
D. The ...  
E. The small ...  
F. The ...  
G. The ...  
H. The ...  
I. The ...  
J. The ...  
K. The ...  
L. The ...  
M. The ...  
N. The ...  
O. The ...  
P. The ...  
Q. The ...  
R. The ...  
S. The ...  
T. The ...  
U. The ...  
V. The ...  
W. The ...  
X. The ...  
Y. The ...  
Z. The ...

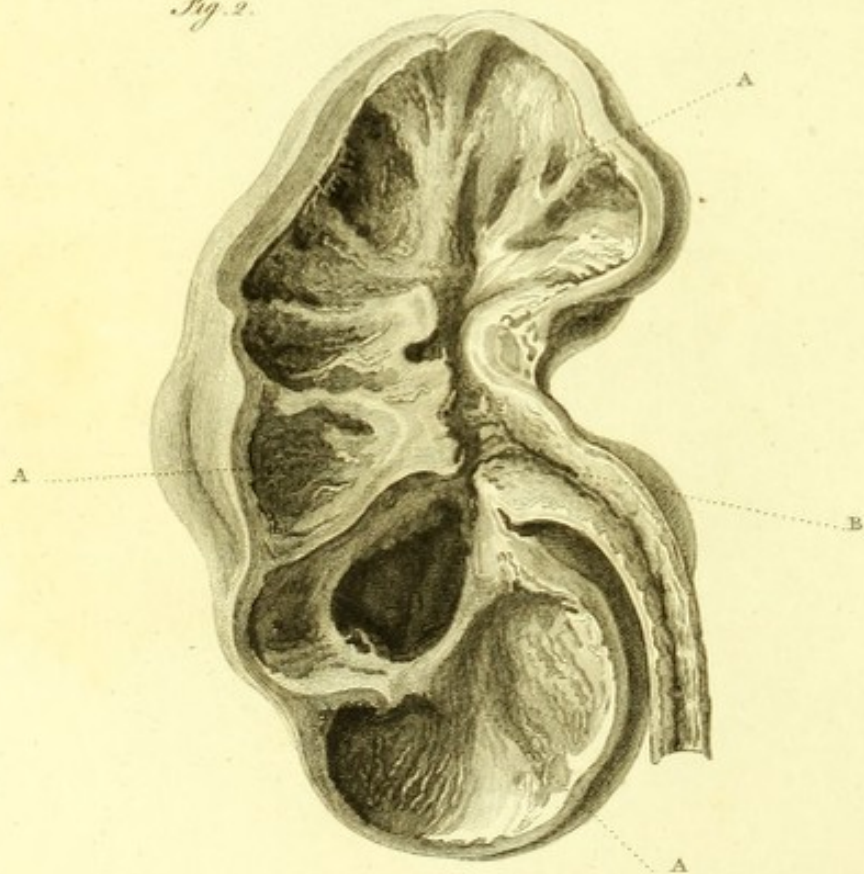




*Fig. 1.*



*Fig. 2.*





# PLATE IV.

THIS Plate is intended to represent the chief varieties which occur in abscesses of the kidneys. It sometimes happens that abscesses are formed in the kidneys from the progress of common inflammation, but much more frequently they possess a scrofulous taint.

## FIG. I.

Represents a section of a kidney with several abscesses in it, which were, in some degree, scrofulous.

- A. A considerable abscess at the upper end of the kidney.
- B. A considerable abscess at the lower end of the kidney.
- C D. Two smaller abscesses: the remaining part of the substance of the kidney was sound.
- E. A section of the pelvis of the ureter, the coats of which have been a little thickened by the inflammation.

*From Dr. Hunter's Museum.*

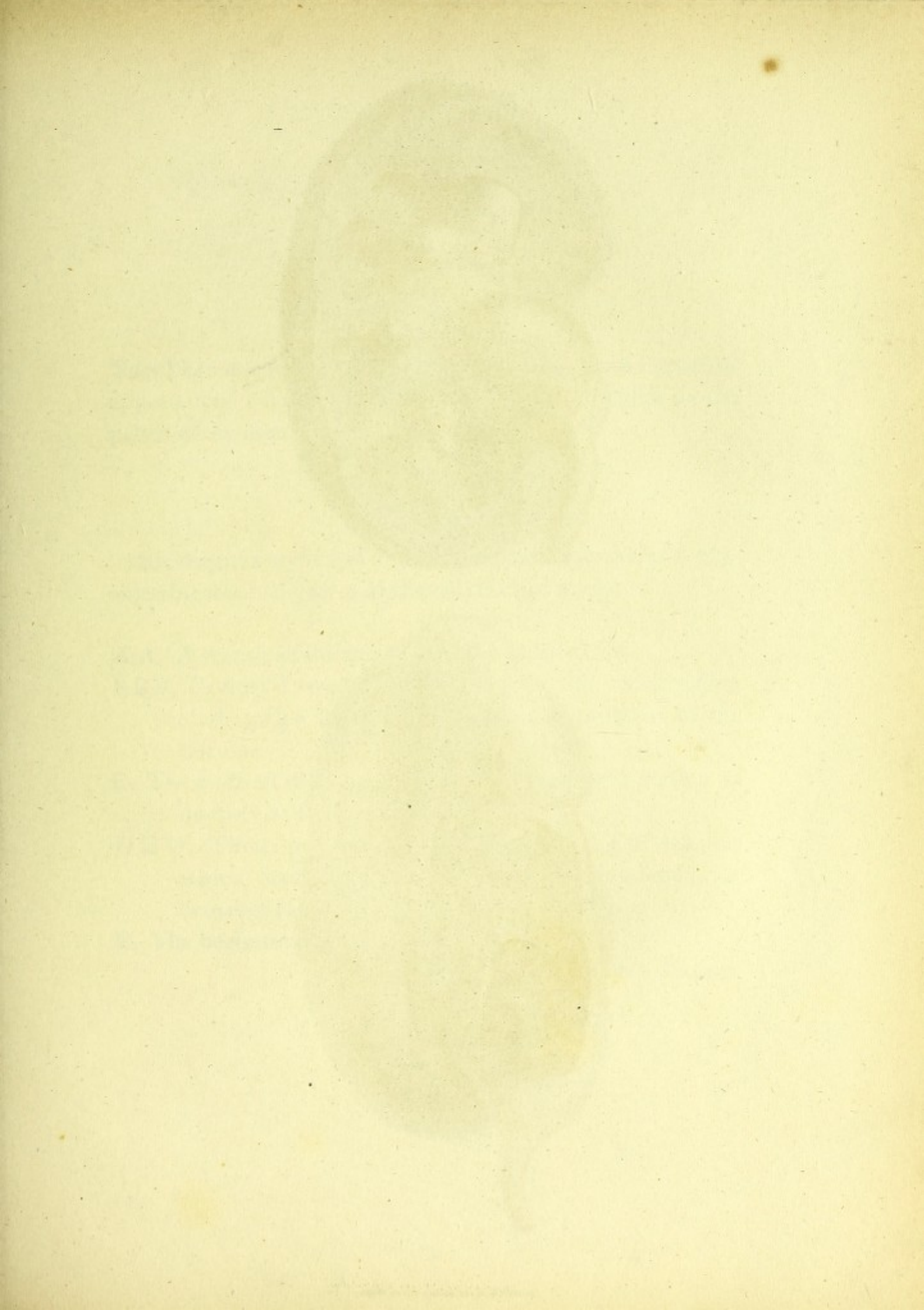
## FIG. II.

Represents a section of another kidney, of which almost

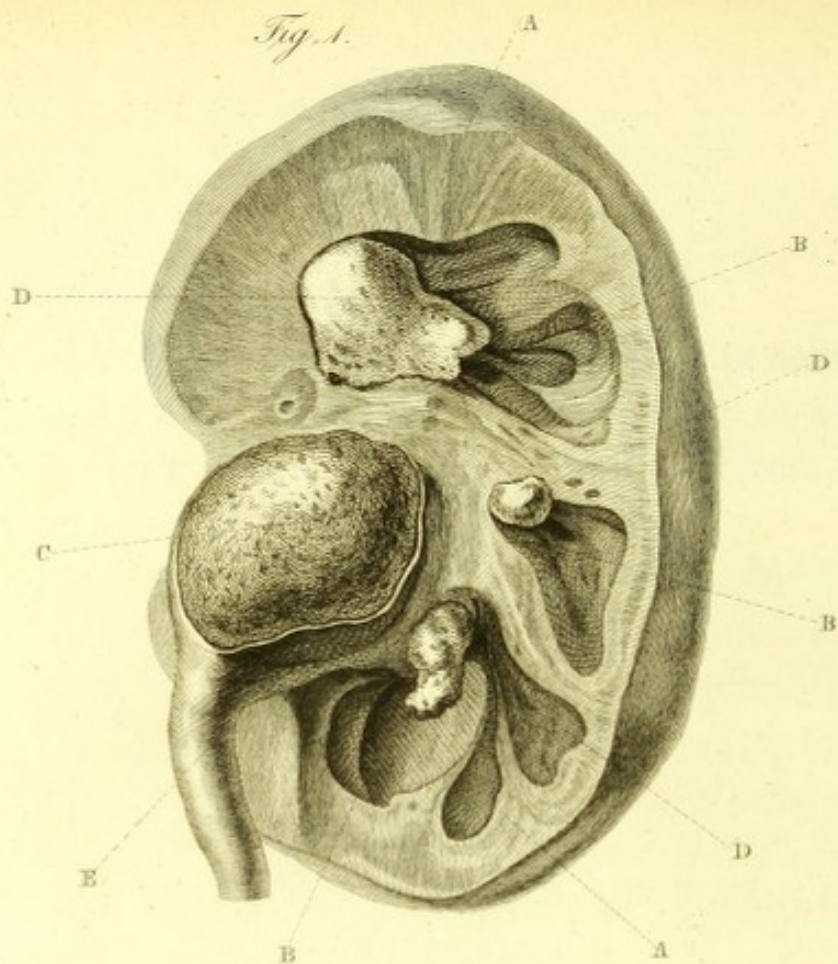
the whole substance has been destroyed by scrofulous sup-  
puration. It is converted into a number of cells, which  
communicate with each other, and some of these still contain  
a quantity of soft curdly scrofulous matter.

*From Dr. Hunter's Museum.*

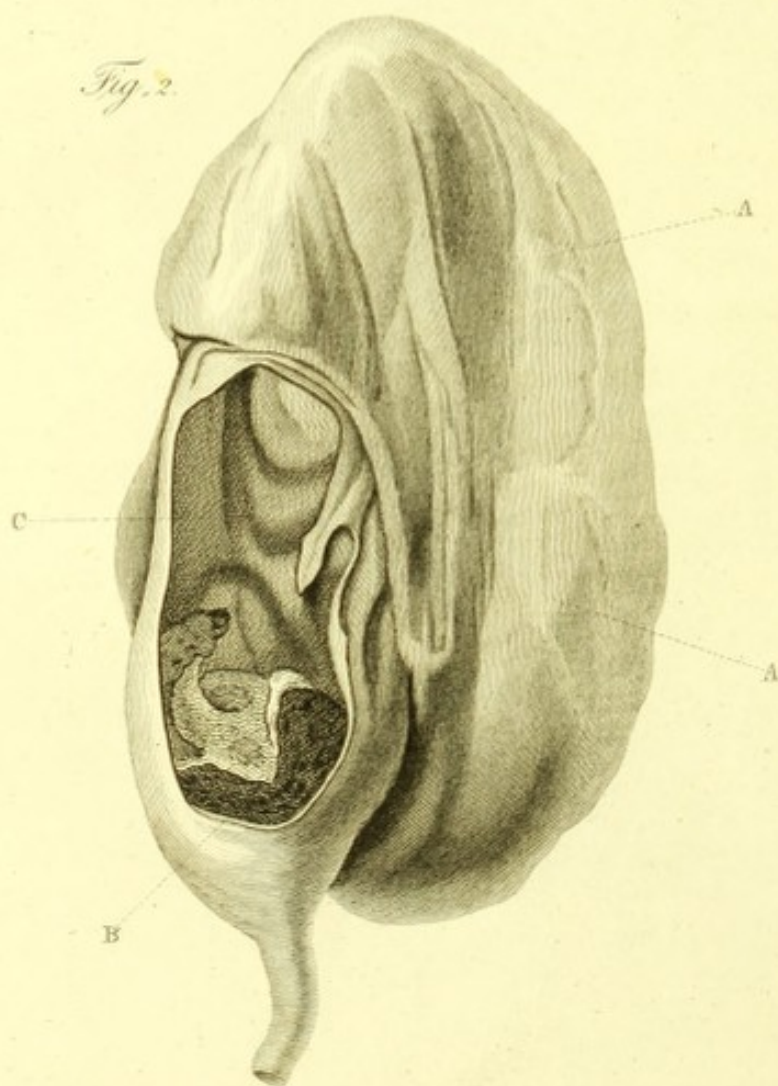




*Fig. 1.*



*Fig. 2.*





## PLATE V.

THIS Plate is intended to illustrate some of the most important appearances belonging to the growth of a calculus in the pelvis of the ureters.

### FIG. I.

Represents a section of a kidney where a calculus of a considerable size had grown in the pelvis of its ureter.

A A. A section of the substance of the kidney.

B B B. Cavities formed in the kidney by the accumulation of the urine behind the branches or processes of the calculus.

C. The body of the stone brought into view by a portion of the pelvis of the ureter being cut off.

D D D. Three processes or ramifications of the calculus which had filled up three of the infundibula, or branches of the pelvis of the ureter.

E. The beginning of the ureter.

*From Dr. Hunter's Museum.*

## FIG. II.

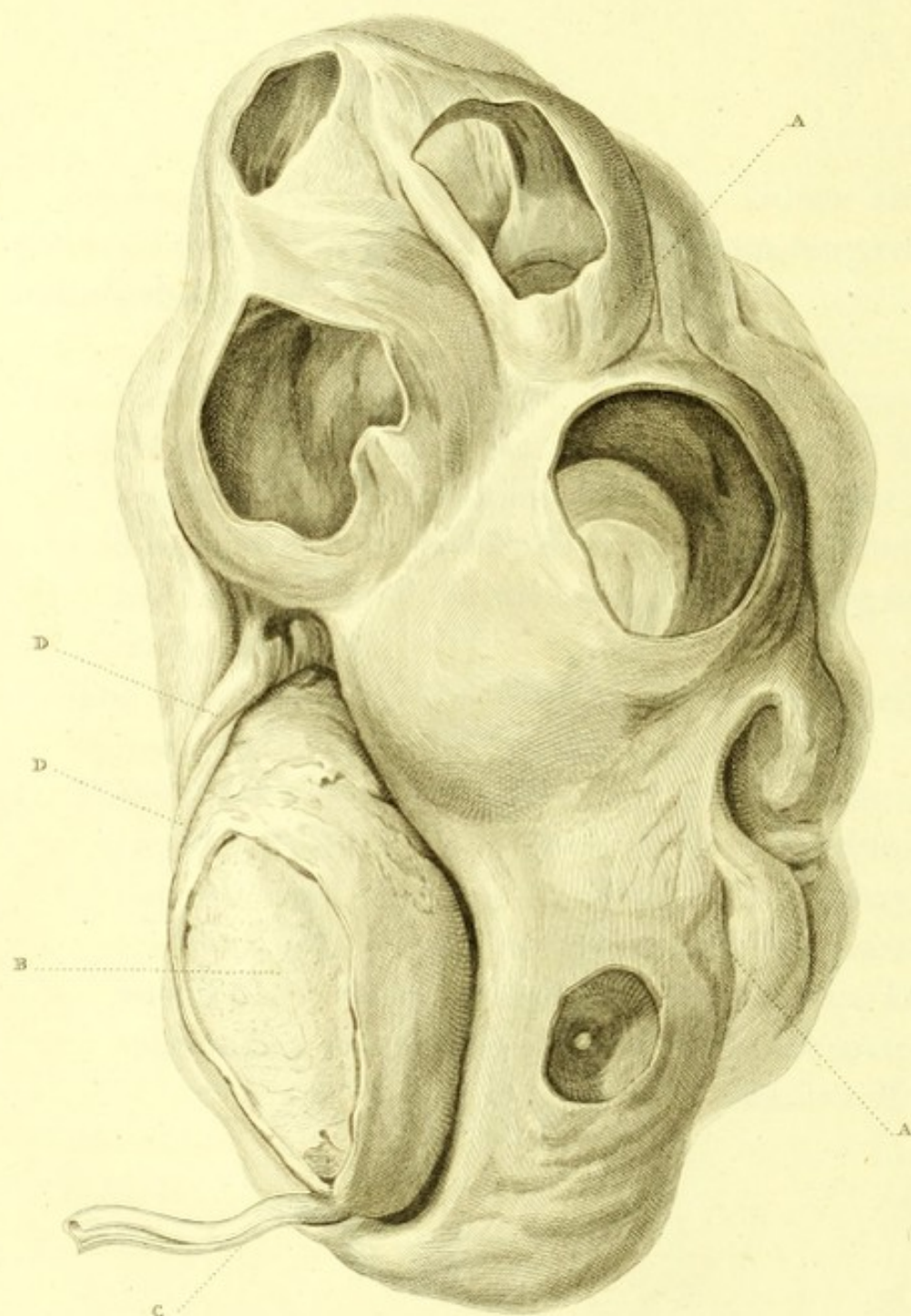
Represents some further changes in the kidney and the pelvis of the ureter, from a stone having been long resident in the pelvis.

- A A. the substance of the kidney. This had been very much thinned, with a large cavity formed in it, in consequence of the accumulation of the urine above the stone. The pressure produced by the accumulation of the urine had made a part of the substance of the kidney be gradually absorbed.
- B. The calculus which had filled up very completely the lower end of the pelvis of the ureter.
- C. The pelvis of the ureter laid open. It is very much enlarged from the accumulation of the urine, and is thrust out, as it were, from the substance of the kidney. At the upper part there is an appearance of transparency, which shews the thinness of the substance of the kidney surrounding this portion of the pelvis of the ureter.

*From Dr. Hunter's Museum.*









## PLATE VI.

THIS Plate illustrates the same subject as the preceding one, and exhibits a striking example of the degree of change which the kidneys are capable of undergoing in consequence of a stone being lodged in the pelvis of the ureter. When a stone lodged in the pelvis of an ureter is not very large, a great part of the urine escapes over its surface, passes into the ureter, and is conveyed into the bladder. The accumulation therefore of the urine in the infundibula, above the stone, is not very considerable, and little change is produced upon the substance of the kidney by the pressure of the urine. When the stone, however, is large, so as to fill up completely, or nearly so, the pelvis of the ureter, the whole, or almost the whole, of the urine, separated by the kidney, is accumulated above the stone. Under these circumstances, it first distends the infundibula, then by pressing upon the substance of the kidney, it excites the deeper seated absorbent vessels, to take up or absorb a part of it. This process goes on very gradually, till at length the substance of the kidney sometimes becomes as thin as a membrane, and then it consists of a number of cells which communicate with each other. The thin part of the substance which remains, is still capable of separating urine, because its minute structure



is the same with that of a natural kidney. As it is impossible for a kidney in this state to contain all, or almost all, the urine which may be separated in a given time, as, for instance, during the space of a few days, the absorbents of the kidney must be partly employed in absorbing the urine after it is separated. The absorbents of the kidney, therefore, in this state, are employed in a double office, viz. that of partly absorbing the substance of the kidney, to make room, in a certain degree, for the urine, and partly absorbing a portion of the urine itself.

A A. A kidney much enlarged and converted into a number of cells in consequence of the urine being accumulated above a large stone, which is lodged in its pelvis.

A number of openings have been made into it, in order to shew these cells, and to point out the thinness of its substance. It is, in fact, converted into a substance not thicker than a shilling.

B. A very large stone in the pelvis of the ureter, and filling up the pelvis completely. A part of the pelvis is cut off, in order to shew the stone.

C. A part of the ureter which is contracted in its size, because no urine at all, or almost none, had for some time passed through it.

D D. A part of two blood vessels belonging to the kidney.

*From Dr. Hunter's Museum.*







Fig. 1.

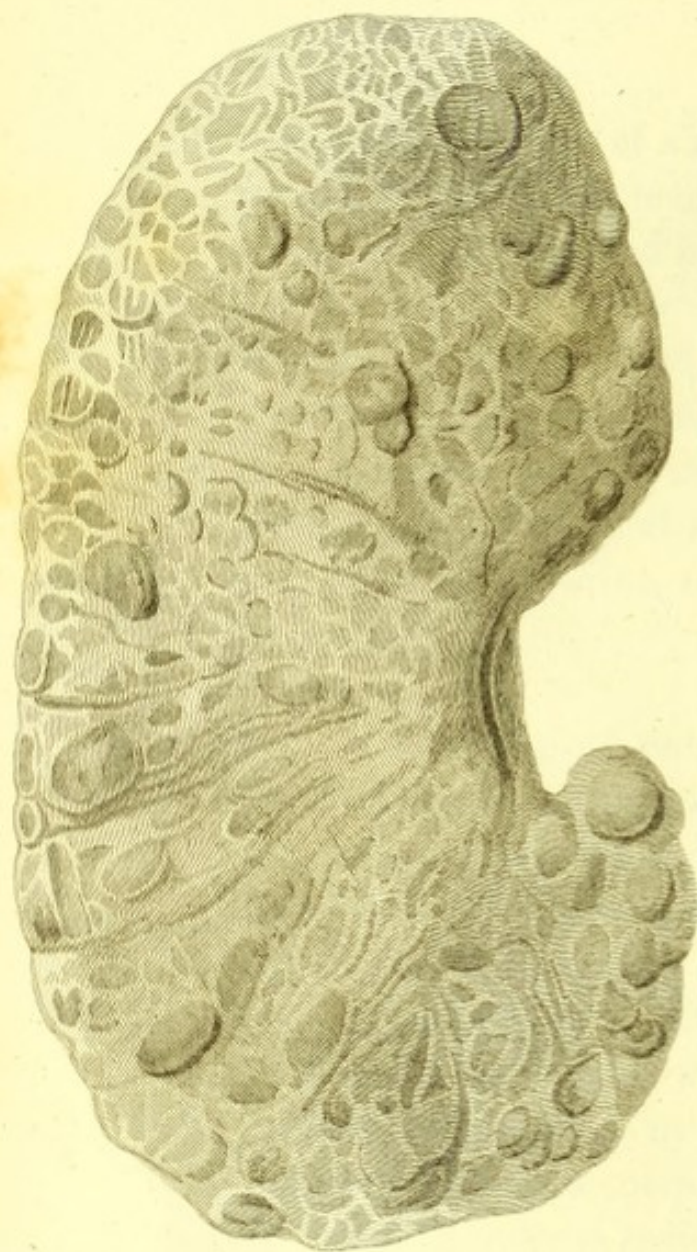

Fig. 2.

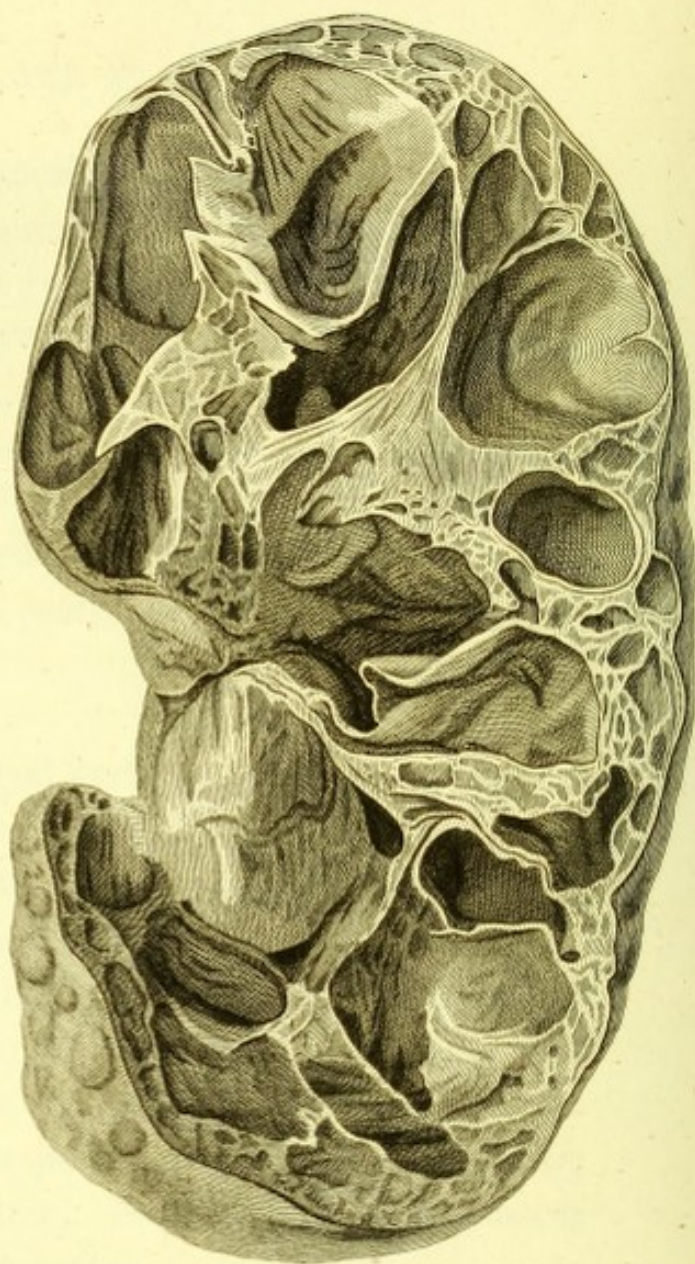


Fig. 3.

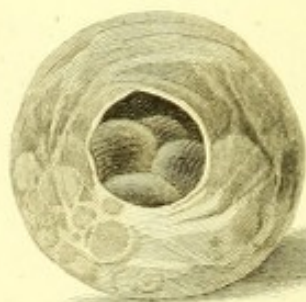

Fig. 4.





## PLATE VII.

THIS Plate illustrates the formation of one species of hydatids in the kidneys. The hydatids which are formed in this gland would seem to be of two species, the one resembling in all its characters the hydatids formed in the liver, and the other having appearances peculiar to itself. The first may be called the genuine, and the second the spurious, hydatid. The genuine hydatid is sometimes formed in every part of the substance of the kidney, so that the whole of the natural structure of the kidney appears to be lost, and the kidney thus changed is a good deal enlarged beyond its natural size. Sometimes there is a bag or cyst formed in the kidney, which contains a number of hydatids. These hydatids have white semi-opaque coats, like the hydatids of the liver, contain a fluid capable of being coagulated by heat or acids, and possess the power of forming smaller hydatids. These smaller hydatids are sometimes attached to the coats of the larger ones, and sometimes float loose in their cavities. The spurious hydatid possesses characters peculiar to itself, but these will be taken notice of when we come to explain the succeeding plate where it is represented.



## FIG. I.

Represents the external surface of half a kidney, in every part of which genuine hydatids are growing. The kidney is considerably enlarged beyond its usual size, and the appearance of its natural structure is altogether obliterated.

## FIG. II.

Represents the cut surface of the same portion of the kidney. It shews in a most conspicuous manner, that hydatids had been formed in every part of it, and that there was no vestige any where of the natural structure of the kidney. The hydatids which had been formed in the centre of this kidney appear to have been a good deal larger than those formed at its surface.

*From Dr. Hunter's Museum.*

## FIG. III.

Represents an hydatid of a considerable size which had been found in a cyst of a kidney containing a great number of hydatids. This hydatid contained several small hydatids which were not attached to its inner surface, but which floated loose in its fluid. An opening has been made into this hydatid, in order to shew the small hydatids more distinctly.

*From the Author's Collection.*



## FIG. IV.

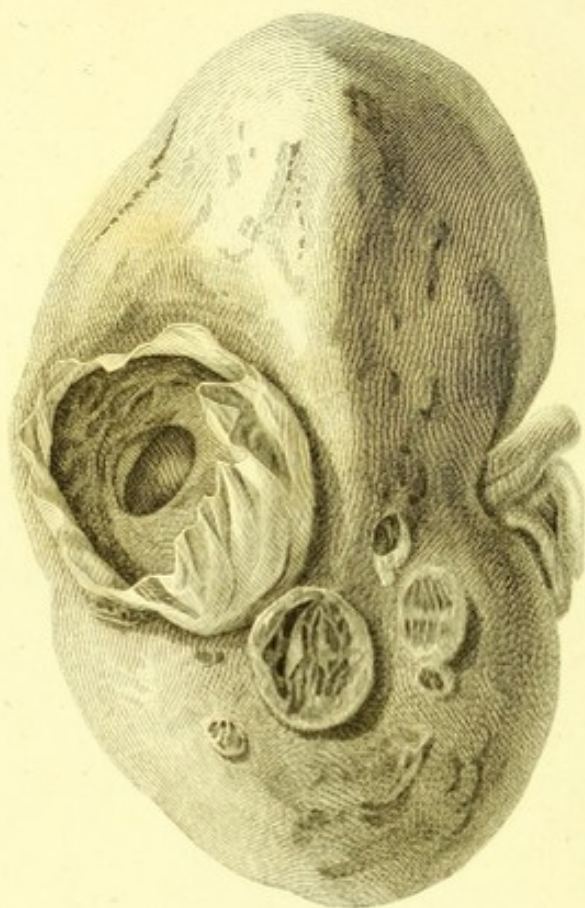
Represents a smaller hydatid, which was found in the same cyst with that represented in Fig. III. No opening has been made into it, but there may be seen obscurely through its coats some very small hydatids, which floated loose in its fluid. These were at one time attached to the larger hydatid, but this attachment had at length been dissolved, and each hydatid began then to carry on an independent growth. Small hydatids have often been found adhering to hydatids of a larger size; and indeed it is only by means of this adhesion or attachment, that their formation can at all be explained.

*From the Author's Collection.*

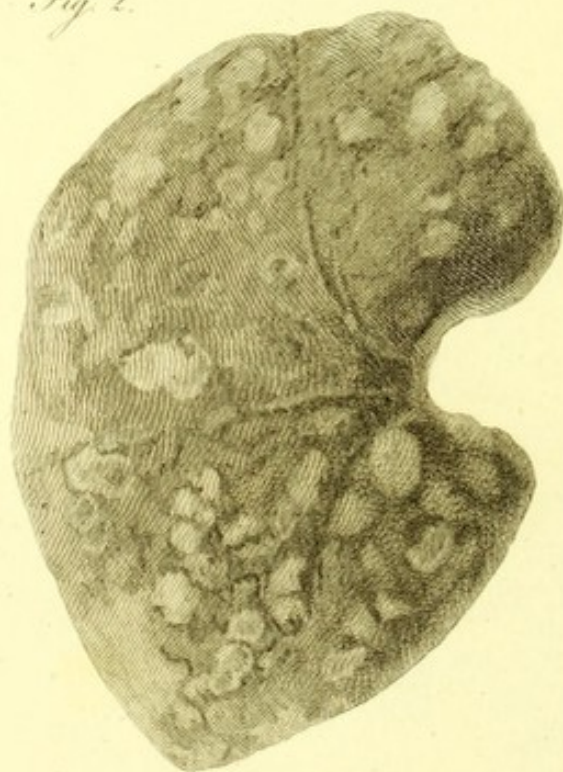








*Fig. 2.*





## PLATE VIII.

IN this Plate are represented hydatids of the kidney, which may be considered as spurious. These occur more frequently in the kidneys than the genuine hydatids, and differ from them in several essential circumstances. They are situated upon the surface of the kidneys, and are neither interspersed through their substance, nor are contained in firm cysts, as the genuine hydatids. They are composed of a very fine transparent membrane, and are much thinner than the genuine hydatids. They have no power of forming smaller hydatids; and they never pass through the ureters into the bladder, as the genuine hydatids sometimes do, but continue always adhering to the kidneys.

In this Plate too are represented some scrofulous tubercles of the kidneys. These are exactly of the same kind with the scrofulous tubercles of the lungs. They occur in the kidneys very rarely, although abscesses of the kidneys very commonly possess a scrofulous disposition.

### FIG. I.

Represents a kidney, with some spurious hydatids formed upon its surface. They are composed of a very fine membrane,

and had been filled with a transparent fluid capable of coagulation. Some are of a very small size, but the largest had been nearly equal in bulk to a pullet's egg. Its capsule had been ruptured; and at its posterior surface may be seen a small oval cyst, communicating with its cavity.

*From Dr. Hunter's Museum.*

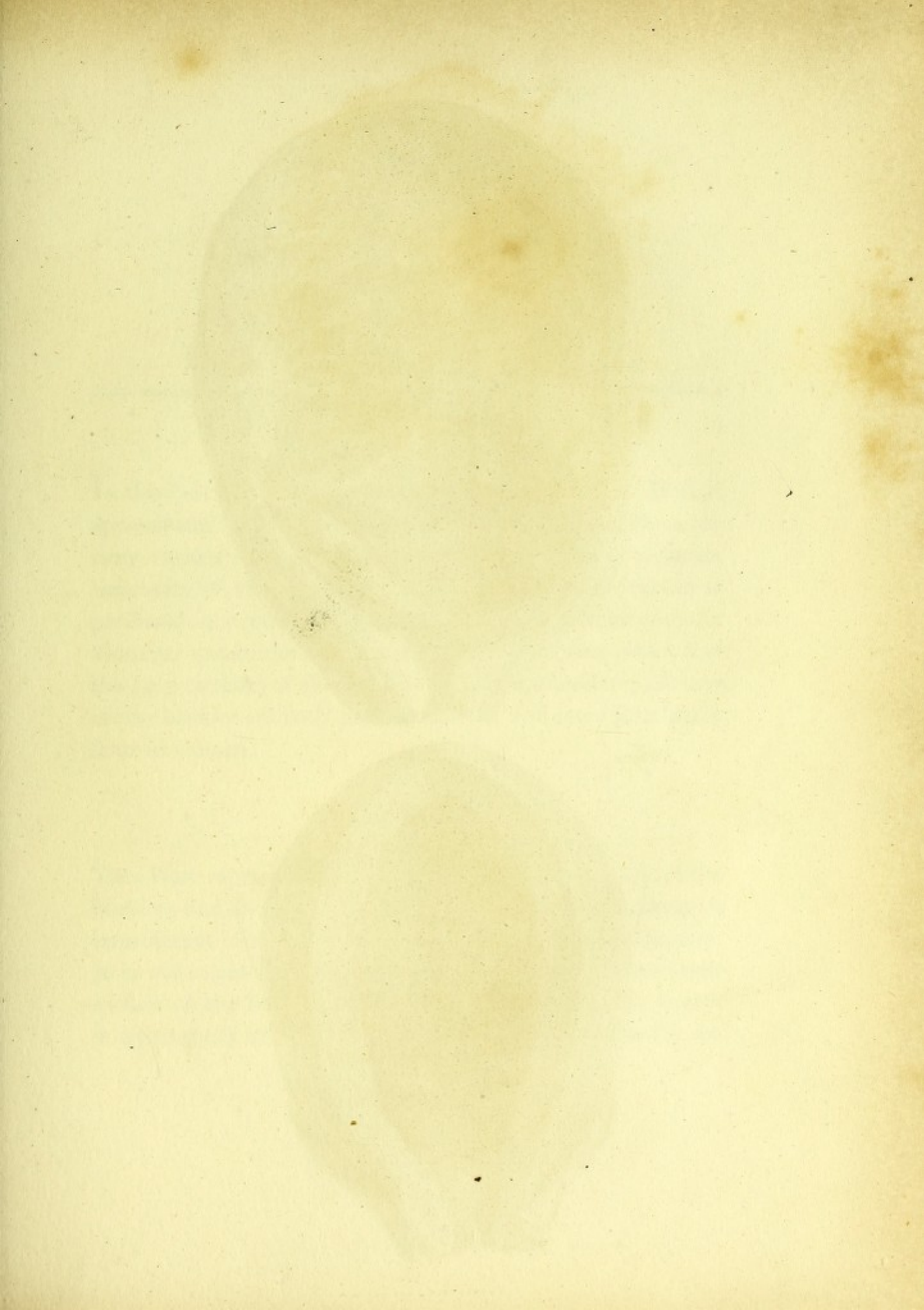
## FIG. II.

Represents a portion of a kidney, with a number of scrofulous tubercles formed in it. It is viewed upon its external surface, which is rendered in some degree irregular or uneven. The tubercles were of a scrofulous nature, but none of them had suppurated.\*

*From the Author's Collection.*

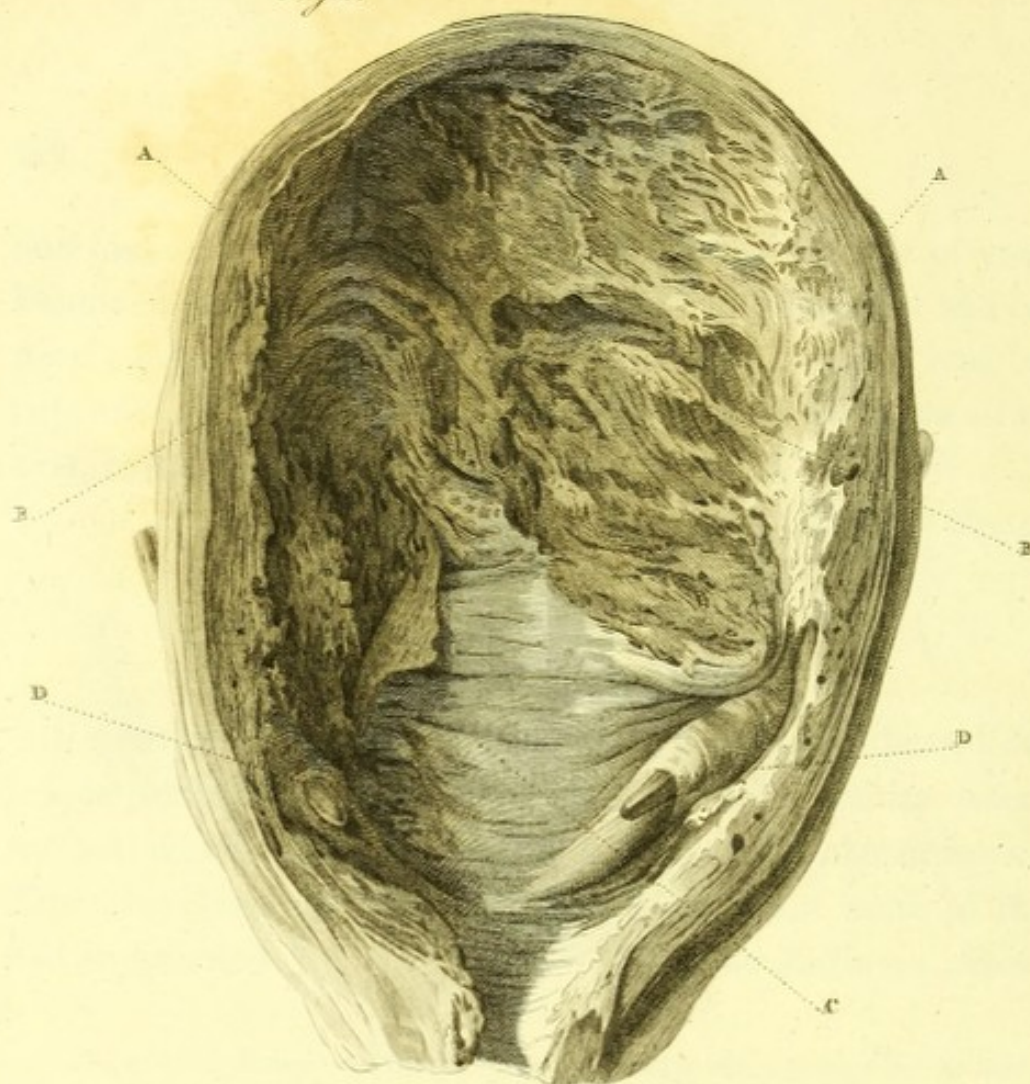\* The morbid changes of structure in the renal capsule, are very few in number. I know but of one instance of a preparation shewing any disease in it, which consists in a scrofulous enlargement of this gland. It seemed hardly worth while to add another plate merely to represent this solitary specimen of disease, and therefore the morbid changes of structure in the renal capsule have been omitted altogether.



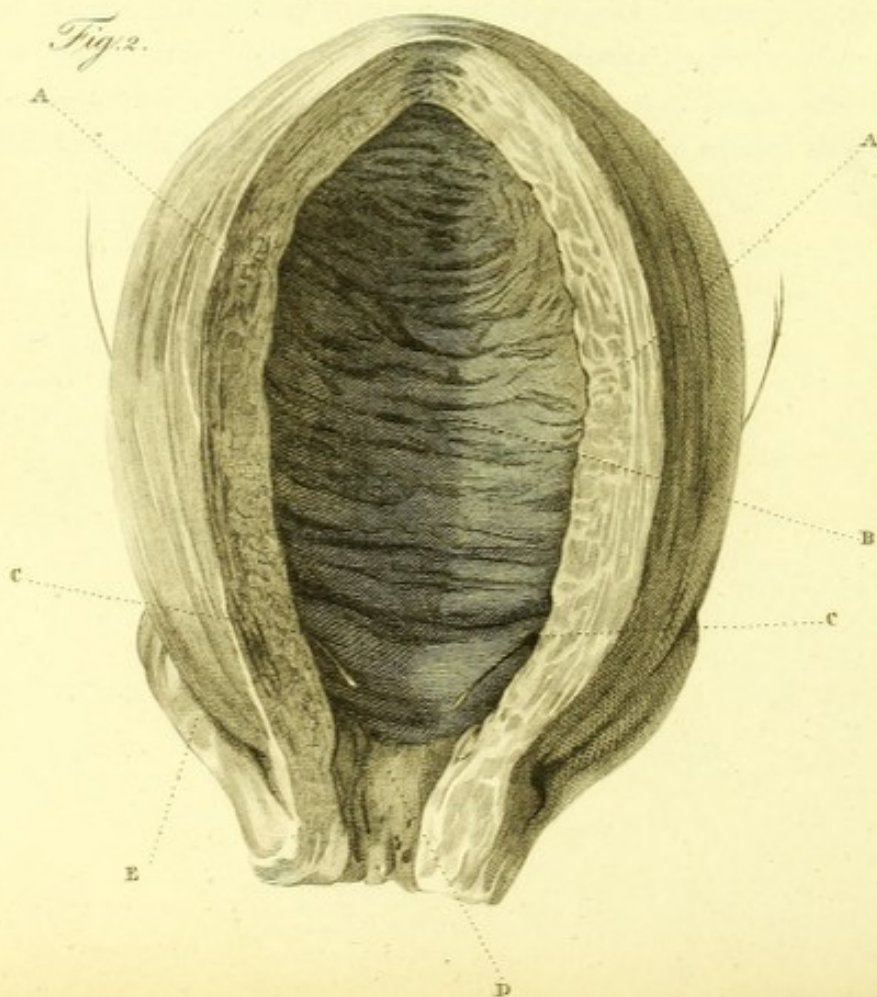

*Fig. 1.*

*Pl. I.*



*Fig. 2.*





THE

## SEVENTH FASCICULUS.

---

**I**N this Fasciculus it is proposed to illustrate the chief Morbid appearances which belong to the Urinary Bladder. These are more various than might have been expected either from the simplicity of its structure, or of its function. This variety is produced in a considerable degree, by its connection with the kidneys; and in the male sex too, with the prostate gland, and the long channel of the urethra. In men, therefore, diseases of the bladder are both more numerous and more formidable than in women.

### PLATE I.

**T**HIS Plate represents ulceration upon the inner surface of the bladder; and also a bladder thickened and contracted, from an impediment in the passage of the urine through the urethra. It is not common for ulceration to take place upon the inner surface of the bladder, more especially to the extent which is represented in this Plate; but it is very common for the

bladder to become thickened in its coats, and contracted in its capacity.

### FIG. I.

Represents a section of the urinary bladder, exhibiting an extensive ulceration upon its inner surface.

- A A. The cut edge of the bladder, shewing its coats somewhat thicker than natural.
- B B. The irregular ulcerated surface.
- C. The only remaining part of the inner membrane of the bladder, which is sound in its structure.
- D D. The openings of the two ureters into the bladder, into which two quills have been inserted.

*From the late Mr. Cruikshank's Collection.*

### FIG. II.

Represents a section of a thickened and contracted bladder.

- A A. The cut edge of the bladder, shewing its coats to be three or four times thicker than in the healthy state.
- B. The cavity of the bladder, which is a good deal contracted within its natural size. There is an appearance of rugæ upon the inner surface, which are formed by the



projections of the thickened fasciculi of the muscular fibres, lying immediately behind the inner membrane of the bladder. This appearance is much more strongly marked in one bladder than another.

C C. The two ureters opening into the bladder, into which have been inserted two bristles.

D. The cavity of the prostate gland.

E. The edge of one of the vesiculæ seminales.

*From the Author's Collection.*







Fig. 1.

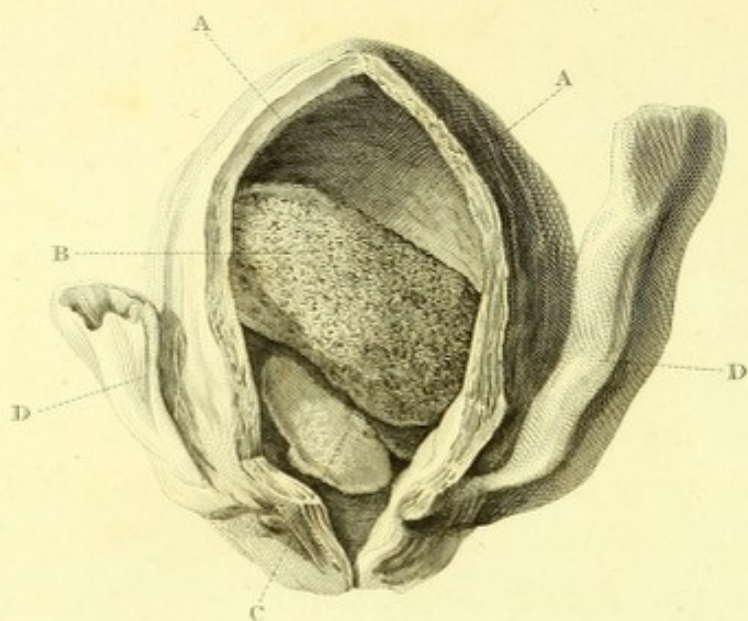


Fig. 3.

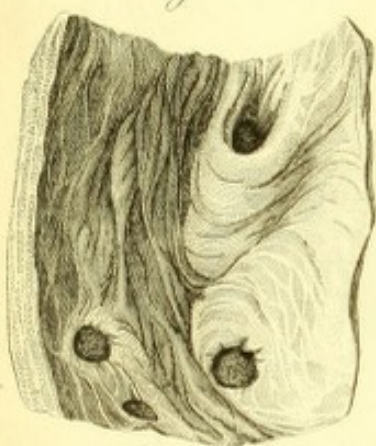
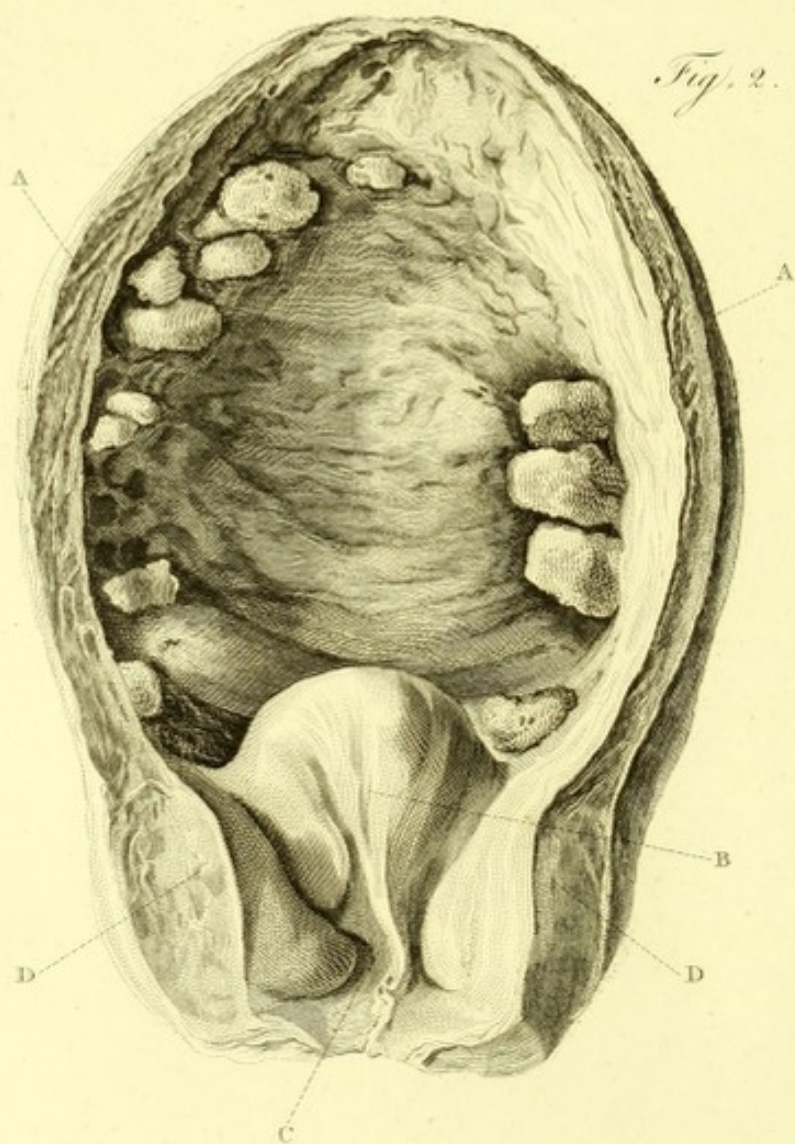


Fig. 2.





## PLATE II.

THIS Plate represents the principal varieties which are observable when calculi are lodged in the urinary bladder.

### FIG. I.

Represents the urinary bladder of a child, with two calculi in it, one of which is of a considerable size.

- A A. The urinary bladder, which is somewhat thickened in its coats, and contracted in its cavity.
- B. A stone of a considerable size, lying in some measure transversely within the bladder.
- C. A stone of a smaller size.
- D D. The two ureters much enlarged in their size. This shews that these stones had passed, when pretty large, from the kidneys into the bladder.

*From Mr. Heaviside's Museum.*

### FIG. II.

Represents a section of the urinary bladder from an adult, shewing a number of small calculi, lodged in pouches within

the bladder. These pouches are formed by the calculi being pressed into the interstices, between the fasciculi of its muscular fibres.

A A. The cut edge of the bladder, shewing it to be much thickened in its coats. Within the cavity of the bladder, on each side, may be seen a number of small calculi, which are lodged in recesses, or pouches, formed in its inner membrane.

B. The posterior and inner part of an enlarged prostate gland, which makes a considerable projection into the cavity of the bladder.

C. The cavity of the prostate gland, near the beginning of the urethra.

D D. The cut edges of the prostate gland, shewing it to be considerably enlarged beyond its usual size.

*From Dr. Hunter's Museum.*

### FIG. III.

Represents a small portion of the urinary bladder, viewed upon its inner surface, exhibiting four small pouches which had contained calculi. These are occasionally so complete as almost to surround the calculi, and exclude them, as it were, from the general cavity of the bladder. They are commonly of a small size; but a few instances have occurred of their



being so large as to be capable of containing a pullet's egg. The bladder is often much thickened where these pouches exist ; but frequently, too, it retains nearly its natural thickness ; and this variety may be supposed to depend upon the greater or less difficulty, with which calculi are pressed into little recesses, between the fasciculi of its muscular fibres.

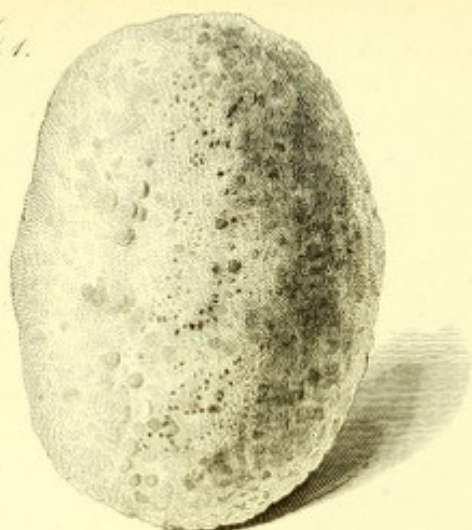
*From Dr. Hunter's Museum.*



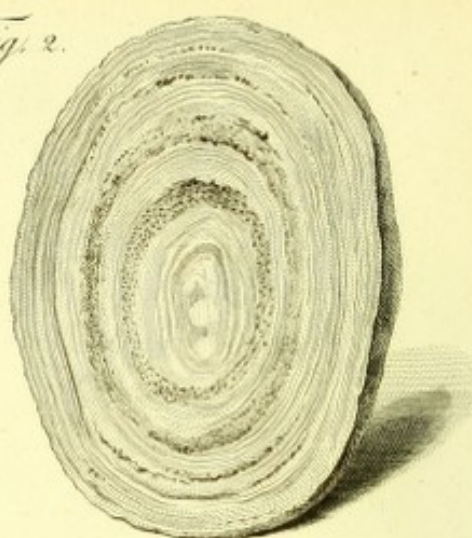



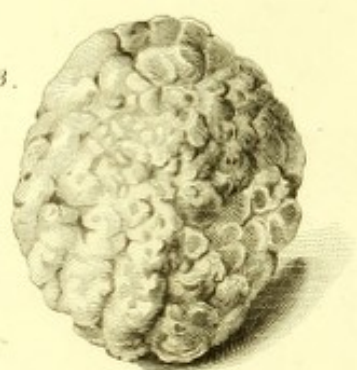
*Fig. 1.*



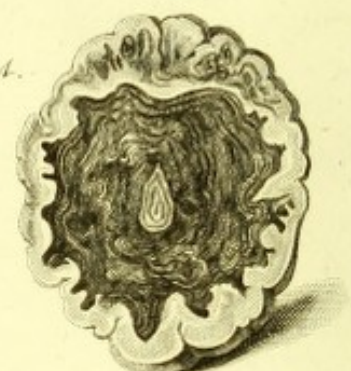*Fig. 2.*



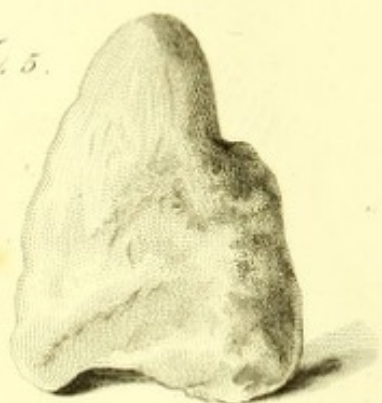*Fig. 3.*



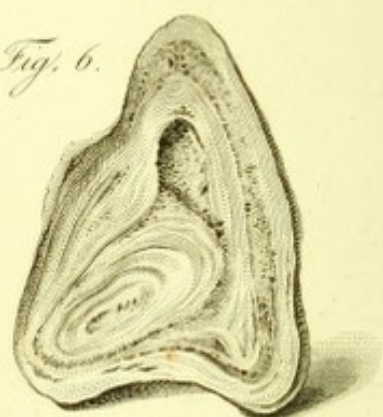*Fig. 4.*



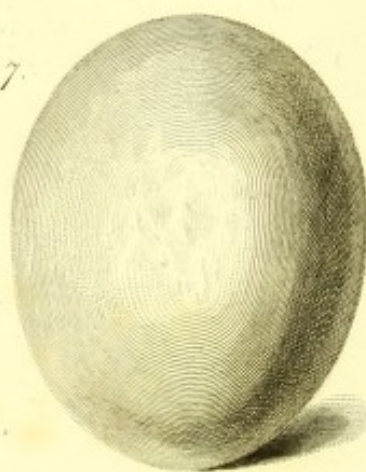*Fig. 5.*



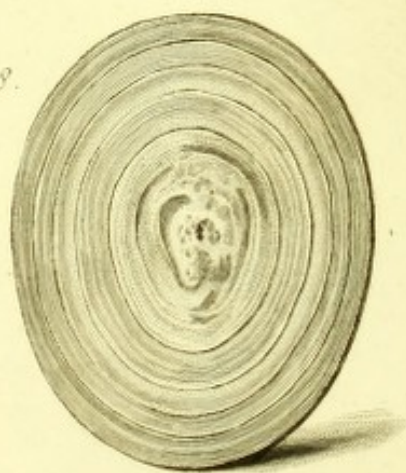
*Fig. 6.*



*Fig. 7.*



*Fig. 8.*





## PLATE III.

THIS Plate represents the chief varieties of calculi which are found in the urinary bladder. It is but a few years since the composition of the most common calculus was accurately ascertained; and very lately, indeed, that the other varieties have been properly investigated.\*

## FIG. I.

Represents the outer surface of the most common calculus. It is oval in its shape, and somewhat rough upon its surface. There is a good deal of variety in the smoothness or roughness of this species of calculus, and also in its colour. The colour is generally brown, varying in the depth of its shade, and having sometimes a tinge of yellow.

## FIG. II.

Represents a section of the same calculus, in order to shew its internal structure. It evidently consists of concentric laminæ, with a porous texture interposed between them, and

\* See a valuable paper upon this subject, by Dr. William Hyde Wollaston, in the Philosophical Transactions for the year 1797.

there is much variety in the proportion of this porous texture in different calculi. This species of calculus is composed of lithic acid, animal matter, and a very minute proportion of calcareous earth.

### FIG. III.

Represents an external view of the mulberry calculus. It is irregularly protuberant, or knotted upon the outside, like a mulberry, from whence it has derived its name. Its colour is generally dark-brown throughout the greater part of its mass, and is lighter near the external surface.

### FIG. IV.

Represents a section of the same calculus. There may be seen a small nucleus in the centre, a number of irregularly projecting concentric laminæ, of a brown colour, surrounding it, and near the outer surface irregular laminæ, of a lighter colour. This species of calculus has been found to consist of the acid of sugar, and the acid of phosphorus, combined with lime, together, generally, with some lithic acid in the interstices.

### FIG. V.

Represents the outer surface of the white calculus. It is generally either smooth upon its outer surface, or has but



little roughness. Its shape is more irregular than that of the other calculi, for it frequently deviates from the oval form.

## FIG. VI.

Represents a section of the same calculus. It is composed of irregular concentric laminæ, with an intervening porous structure. This species of calculus is fusible by the blow-pipe, and consists of crystals, formed by the combination of phosphoric acid with magnesia and volatile alkali. These are mixed with some phosphorated lime, and generally some lithic acid.

## FIG. VII.

Represents the outer view of the bone-earth calculus. It is generally smooth upon its external surface, and is of a pale-brown colour.

## FIG. VIII.

Represents a section of the same calculus. It consists of regular concentric laminæ, which very slightly adhere to each other, so as to be easily separated. This species of calculus is found to consist entirely of phosphorated lime.

*All these Specimens are from Dr. Hunter's Museum.*







Fig. 1.

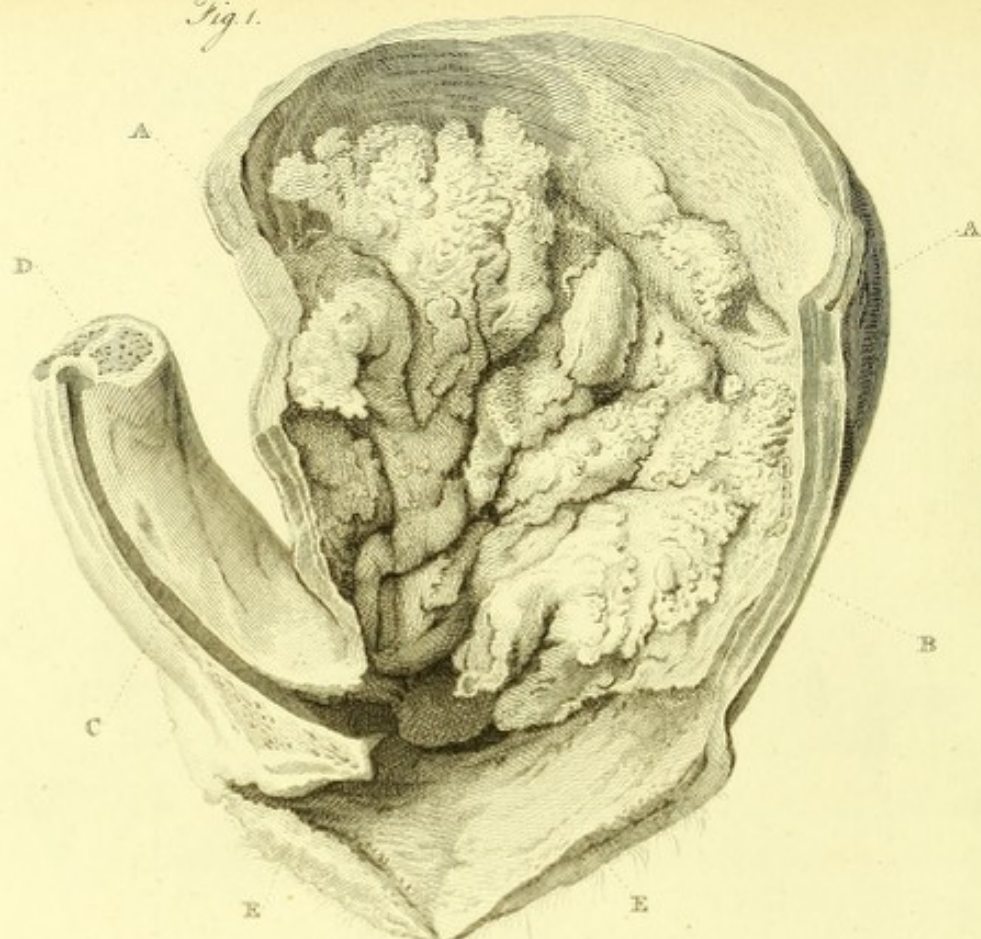
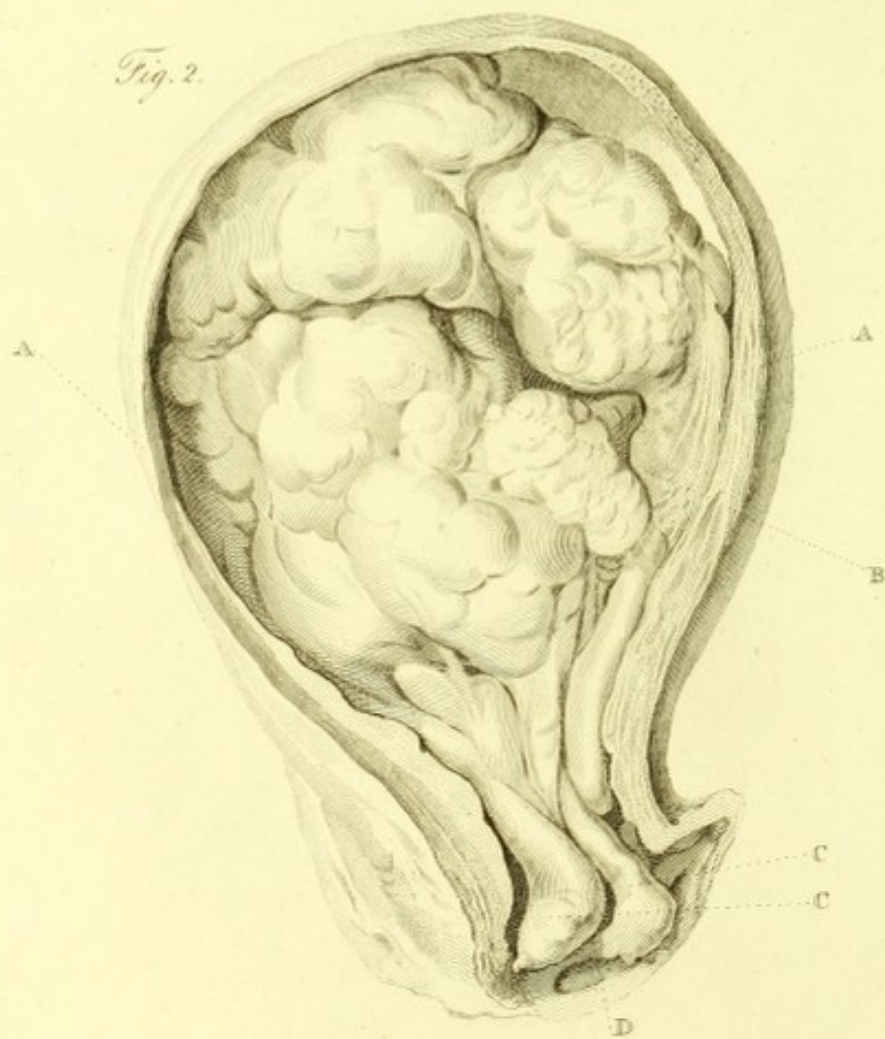


Fig. 2.





## PLATE IV.

IN this Plate is represented a substance resembling the coagulable lymph of the blood, which had been formed in the cavity of the bladder, near its neck, and is incrustated with calculous matter. It consists of a great number of irregular processes, to which a stone had once adhered. This was extracted by an operation, but the wound never closed, and the man at length died, in consequence of the very diseased state of his bladder.

This Plate represents, too, a very large polypus growing within the bladder. It is a very rare disease; and, indeed, I have not seen any other example of it than in the preparation from which Fig. 2 of this Plate was taken.

### FIG. I.

Represents a lateral section of the urinary bladder of a male, in which calculous matter had been deposited, upon a substance resembling the coagulable lymph of the blood.

A A. A section of the coats of the bladder, which are a little thickened.

B. The substance, resembling the coagulable lymph, which is formed into many small projecting masses, and is incrustated with calculous matter.



- C. A portion of the urethra laid open.  
D. A section of the corpora cavernosa.  
E E. The edges of an incision at the neck of the bladder, where the wound had never closed, but had become fistulous.\*

*From Mr. Hunter's Museum.*

FIG. II.

Represents a section of the bladder of a child, by which is brought into view a very large polypus, filling up its cavity. The polypus consists of several large projecting irregular masses, and two long processes had grown from it, shooting through the urethra as far as its external orifice, and distending very much this canal.

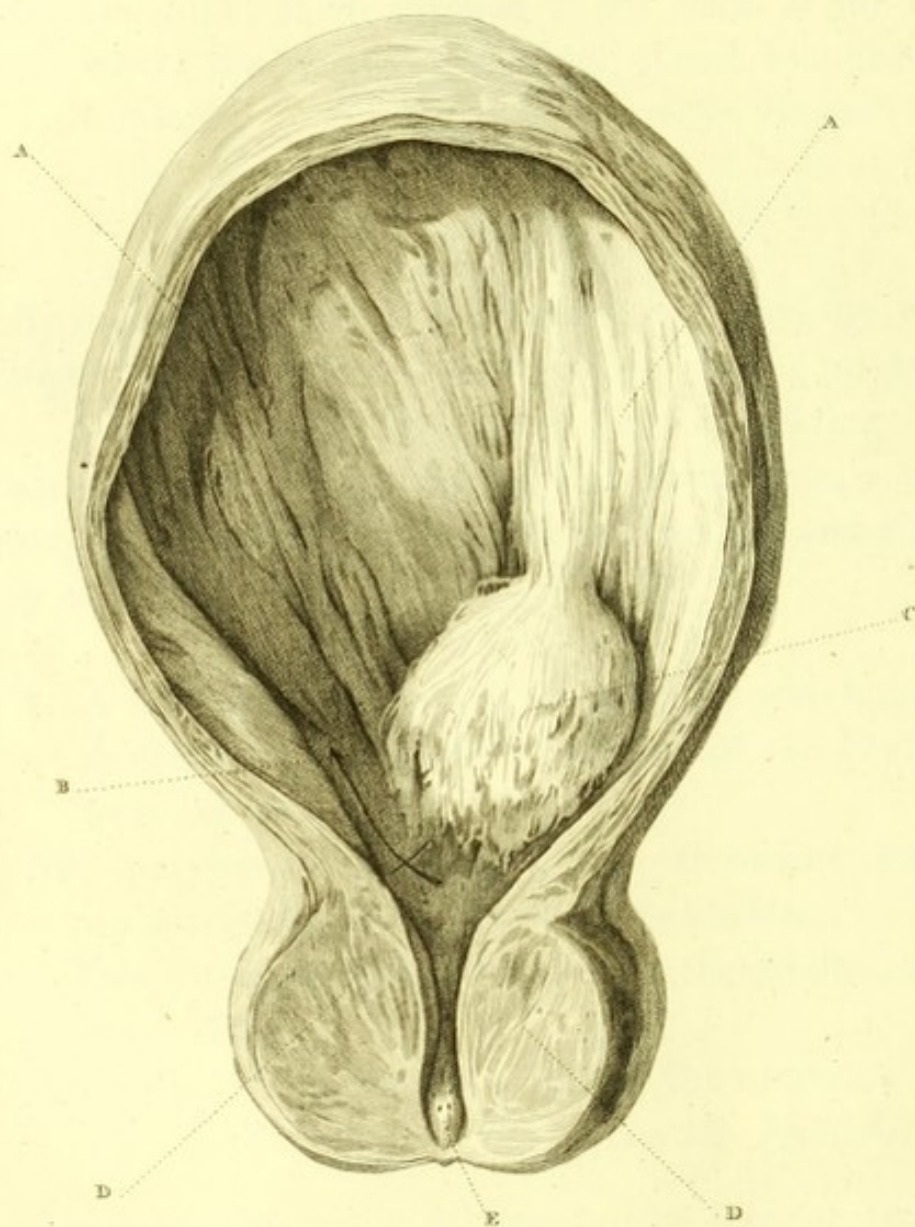
- A A. A section of the coats of the bladder, which are a little thickened. The anterior surface of the bladder had been cut off.  
B. The polypus, very irregular upon its surface, and filling up nearly the whole cavity of the bladder.  
C C. Two processes of this polypus in the urethra, which is much dilated.  
D. The edge of the external orifice of the urethra.

*From Mr. Hunter's Museum.*

\* The bladder represented by this figure has been already engraved and published in the second edition of Mr. Home's Treatise upon Strictures, where an account of the case is also given.









## PLATE V.

THIS Plate represents a spongy tumour, growing from the inner surface of the bladder. Tumours of this kind are seldom formed in the bladder, but still they are not so rare as polypi. They consist, commonly, of a very loose fibrous structure, and must produce more or less impediment to the passage of the urine towards the urethra, in proportion to their size and their situation, as being less or more remote from the neck of the bladder.

- A A. The cavity of the bladder exposed to view.
- B. The opening of the right ureter, in which a bristle has been inserted.
- C. The spongy tumour, growing from the inner membrane of the bladder, a little above the insertion of the left ureter, which is hid from view by it. Its fibrous texture is very distinctly marked.
- D D. The sides of the prostate gland, which is of the usual size, and healthy in its structure.
- E. The Caput Gallinaginis, where the openings of the ducts of the vesiculæ seminales, and of some of the ducts of the prostate gland, are observable.

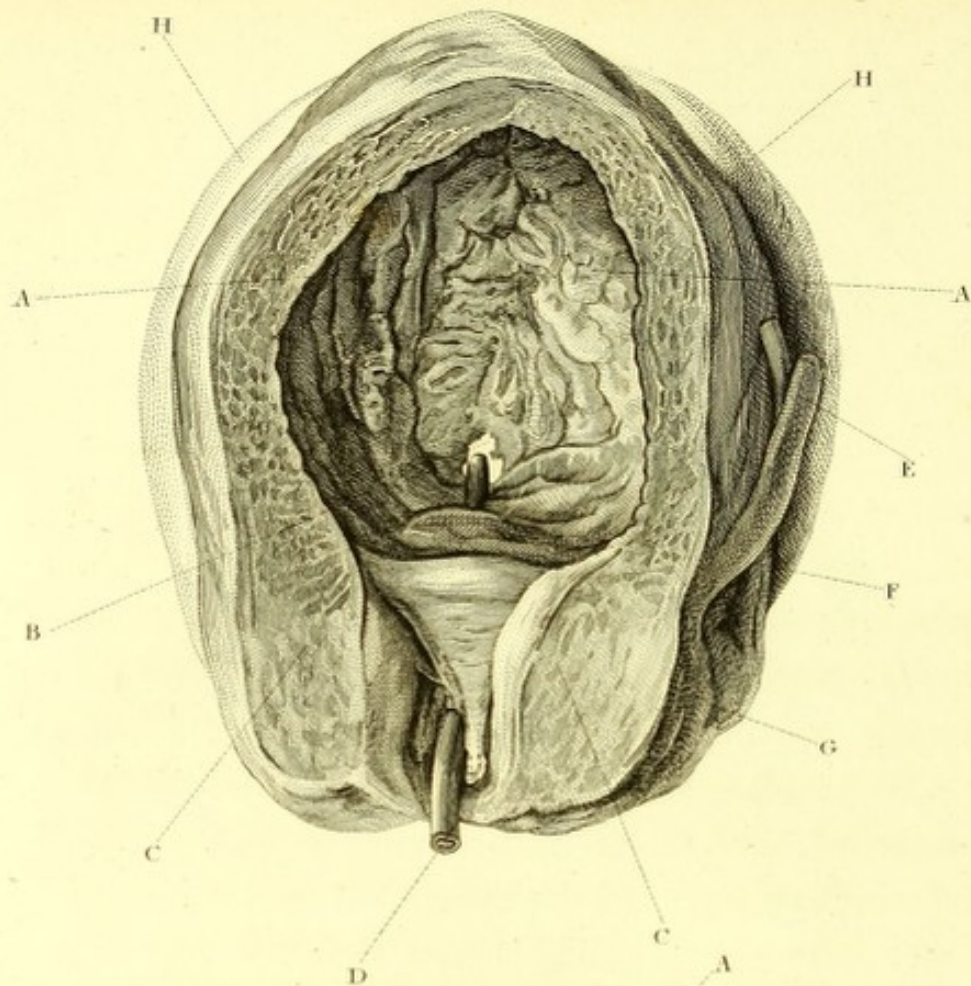
*From the late Mr. Cruikshank's Collection.*



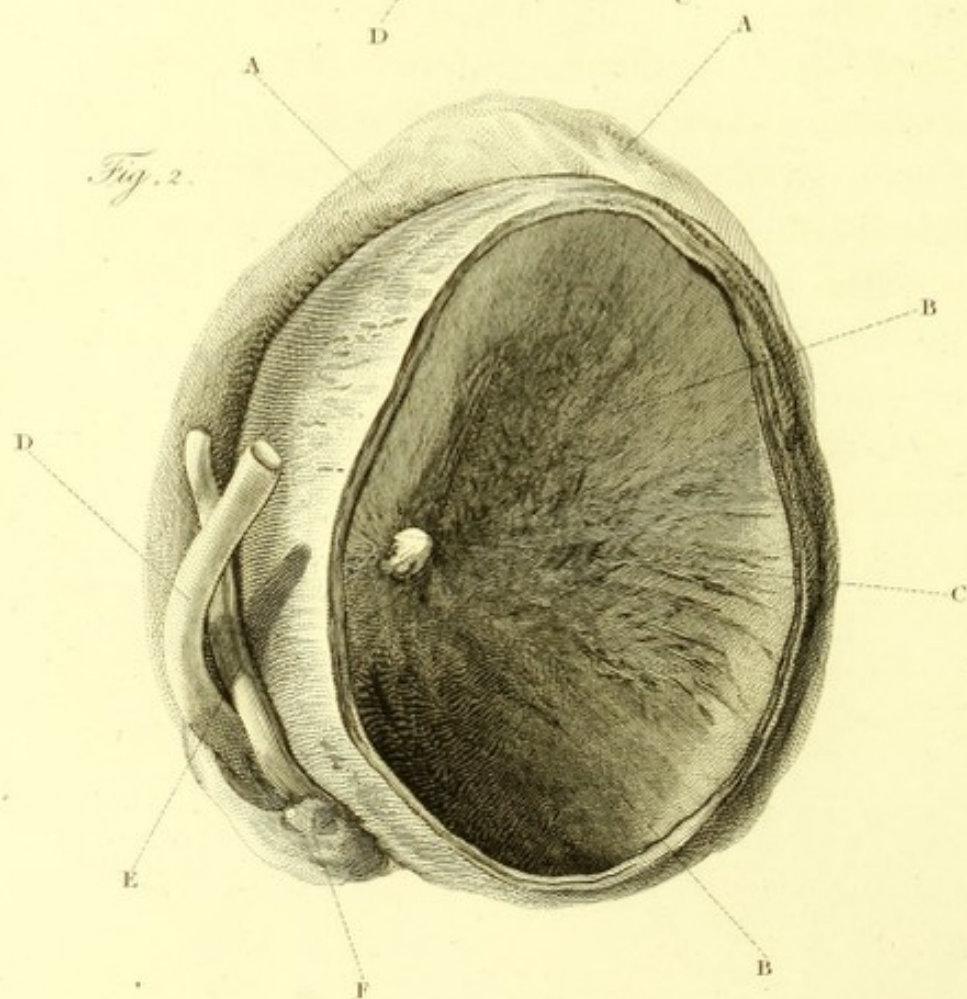




*Fig. 1.*



*Fig. 2.*





## PLATE VI.

THIS Plate represents a very large cyst, communicating with the urinary bladder. The cysts which most commonly communicate with the urinary bladder are formed, by the pressure of calculi into recesses of its inner membrane, between the Fasciculi of the muscular fibres. These cysts are generally of a small size, although some instances have occurred, as we have lately mentioned, of their being so large as to be capable of containing a pullet's egg. In the case of the cyst represented in this Plate, there was no calculus, and the cyst was larger than the bladder itself, in its diseased state. There was an opening of communication between the bladder and the cyst, so that the urine readily passed from the one cavity into the other, and towards the latter part of the disease a larger quantity of urine must have been lodged in the cyst than in the bladder. It is probable that this cyst was formed in consequence of the urine being pressed, during the contraction of the bladder, into some little recess between the Fasciculi of the muscular fibres, which recess became gradually larger, till it arrived at the present size of the cyst. In the present case, however, some circumstances must have occurred very favourable to the original formation of the recess; otherwise, a communicating cyst would be very common whenever there was any



considerable difficulty in the expulsion of the urine, and the muscular coat of the bladder became thickened, from its increased exertion. But it is well known, that a cyst of this nature is extremely rare.

FIG. I.

This figure represents a section of the bladder, with a small portion of the cyst seen behind it.

A A. The bladder, with its cavity exposed to view. It is very thick in its coats, and is much contracted in its capacity. The rugæ, likewise, upon its inner surface are very observable.

B. An opening of communication between the bladder and the cyst, by which the urine readily passed from the one to the other.

C C. The sides of the prostate gland, a little enlarged in size.

D. A bougie put into an opening, or short canal, in the substance of the prostate gland, which had been made in attempting to pass a catheter into the bladder.

E. The left ureter.

F. The left vas deferens, thrust a little to the left side, out of its natural situation, by the cyst.

G. A part of the left vesicula seminalis.

H H. A part of the outer surface of the cyst.



## FIG. II.

Represents the cyst lying behind the bladder, and adhering to it.

- A A. A part of the outer surface of the urinary bladder.
- B B. The cyst laid open. Its inner surface is very smooth, and its structure consists of membranes applied together, so as to form a coat of considerable thickness.
- C. The opening of communication between the cyst and the bladder.
- D. The left ureter, seen upon its posterior surface.
- E. The left vas deferens, seen from behind.
- F. A part of the left vesicula seminalis.

*From Mr. Hunter's Museum.*





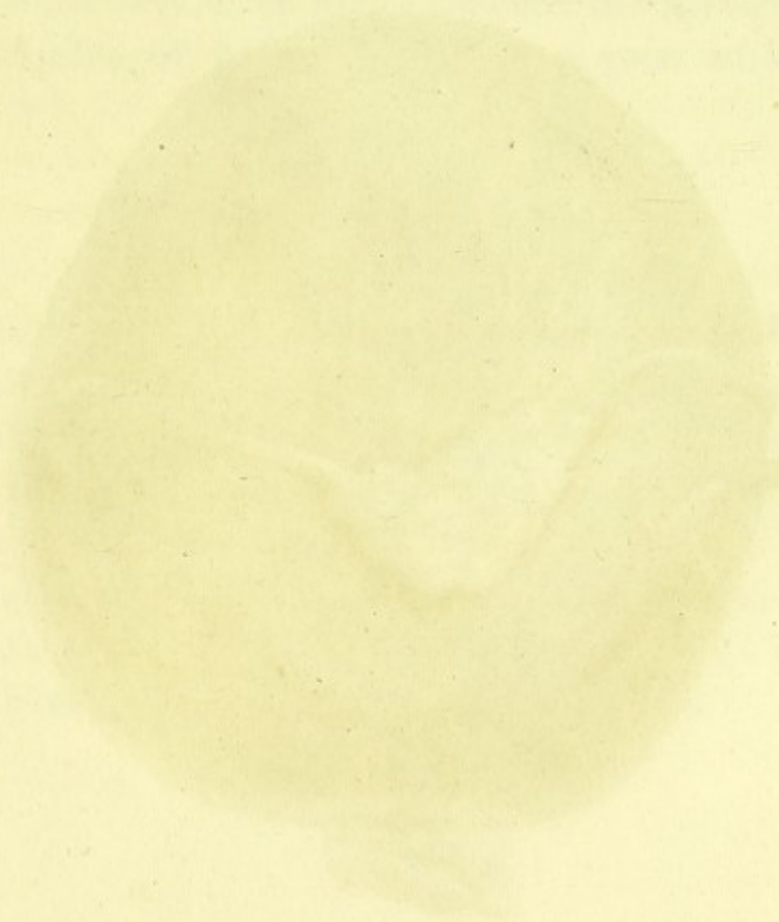
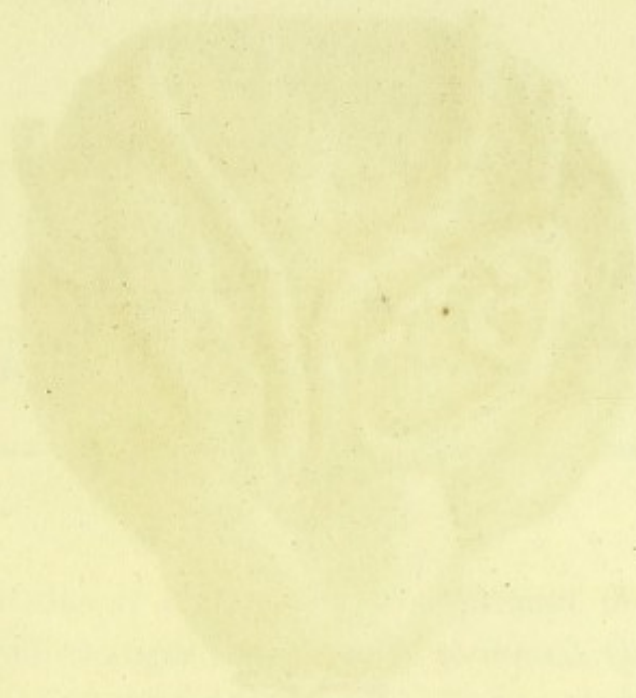
Fig. 1.

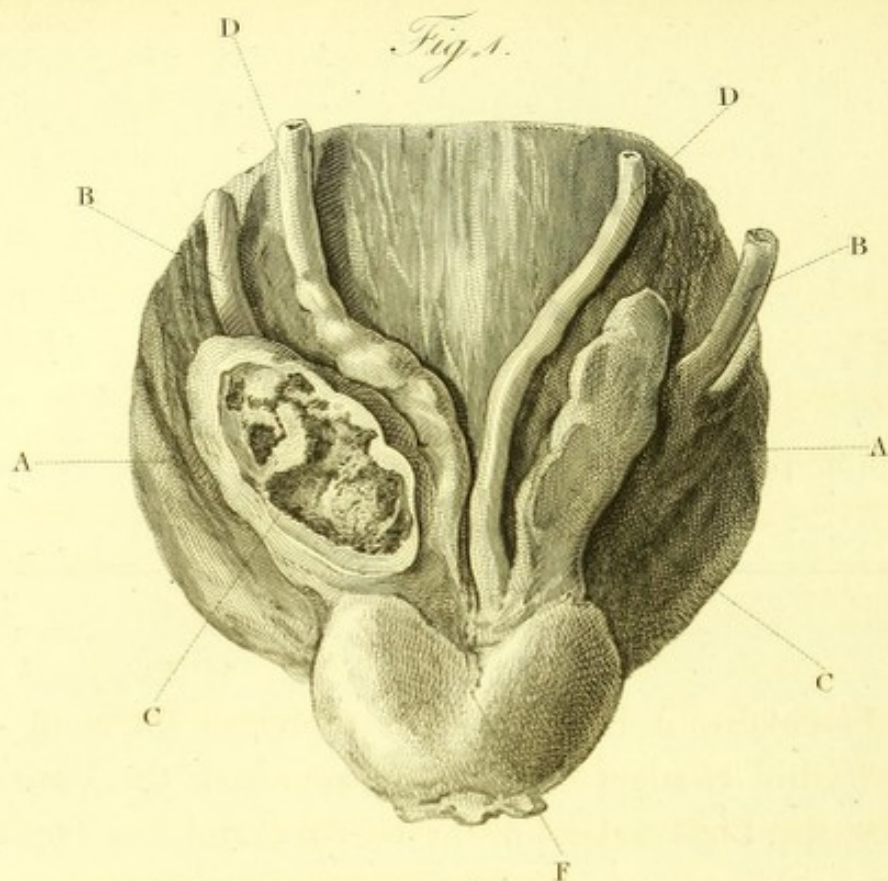
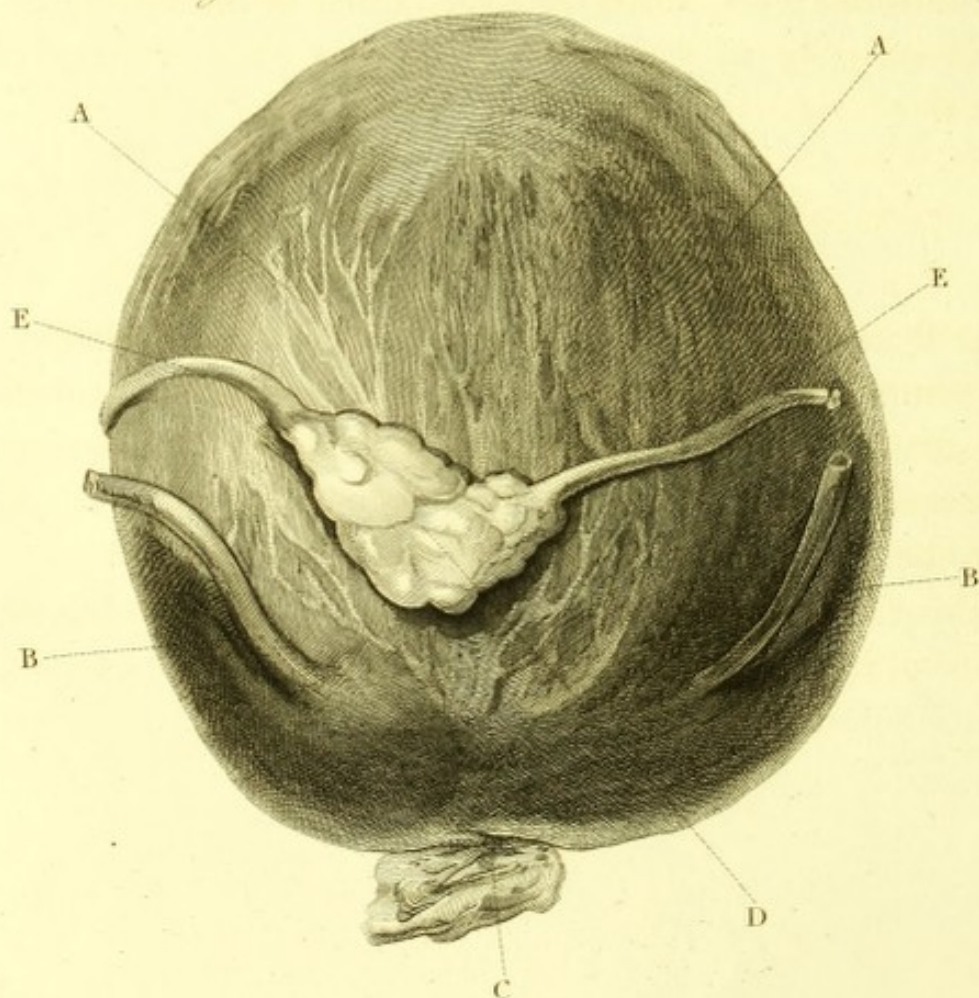


Fig. 2.





THE

## EIGHTH FASCICULUS.

---

IN this Fasciculus it is proposed to represent the most important Morbid changes of structure, to which the Vesiculæ Seminales, the Prostate Gland, the Urethra, and the Testicles are subject. These parts are associated together in their functions, but differ very much from each other in their structure, and are capable of being affected by a great variety of diseases.

## PLATE I.

IN this Plate is represented a scrofulous ulcer in the left vesicula seminalis. Common inflammation sometimes spreads to the vesiculæ seminales from the urinary bladder or the rectum, but very rarely originates in them, and indeed they would seem to be liable to few diseases.

In this case the inflammation had been decidedly scrofulous, the coats of the left vesicula had become a good deal thickened, and its different cells were filled with a curdly pus.



In this Plate is also represented a very singular *lusus Naturæ* in the *vesiculæ seminales*. It is so rare, and at the same time so important, as having interrupted one of the principal functions in the animal *œconomy*, that I was induced to deviate from the general plan of this work, and to give an engraving of it.

## FIG. I.

Represents the left *vesicula seminalis* affected with *scrofula*.

- A A. A portion of the external surface of the bladder at its posterior and depending part.
- B B. The two ureters at their insertion in the bladder.
- C C. The *vesiculæ seminales*. A section has been made of the left one, in order to shew that its coats are much thickened. It was filled with *scrofulous* pus, and some of the grosser parts of it still adhere to the inside of its cavities.
- D D. Portions of the two *vasa deferentia*. That upon the left side is thickened and had partaken of the same *scrofulous* affection with the *vesicula seminalis*.
- E. The prostate gland, of its usual size, and sound in its structure.

*From the Author's Collection.*



## FIG. II.

Represents a very uncommon *lusus Naturæ* in the *vesiculæ seminales*. The two are joined together, forming an irregular mass, and want entirely the excretory ducts. They are situated to one side and upon the posterior surface of the bladder, at a considerable distance from the depending part, instead of being close to this part, which is their natural situation.

A A. The posterior surface of the bladder.

B B. The two ureters near their insertion.

C. A small portion of the penis dried near the neck of the bladder.

D. The two *vesiculæ seminales*, shewing the *lusus* above described.

E E. The *vasa deferentia* which in this case terminate in the upper and posterior edge of the *vesiculæ seminales*.

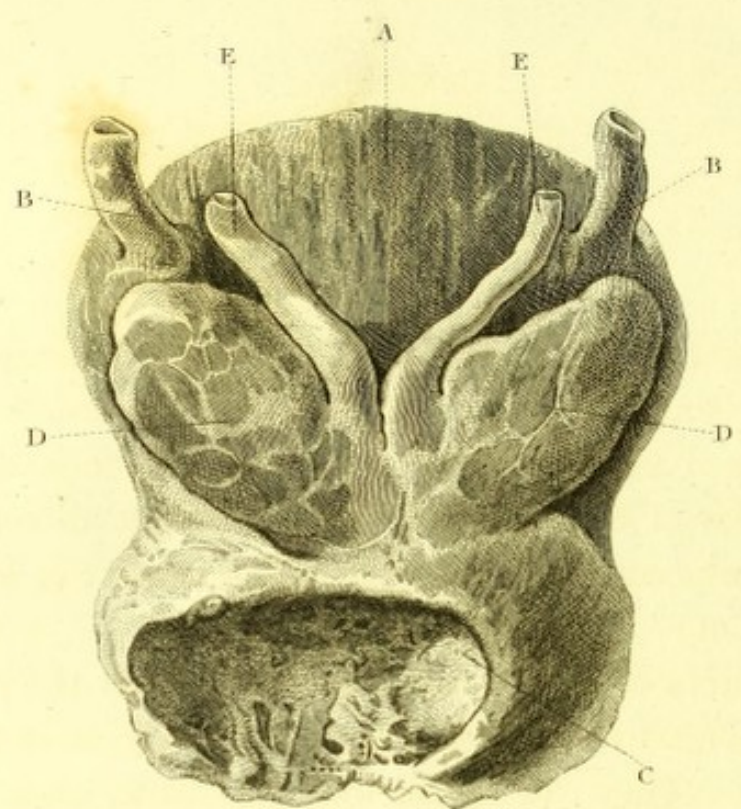
*From Dr. Hunter's Museum.*



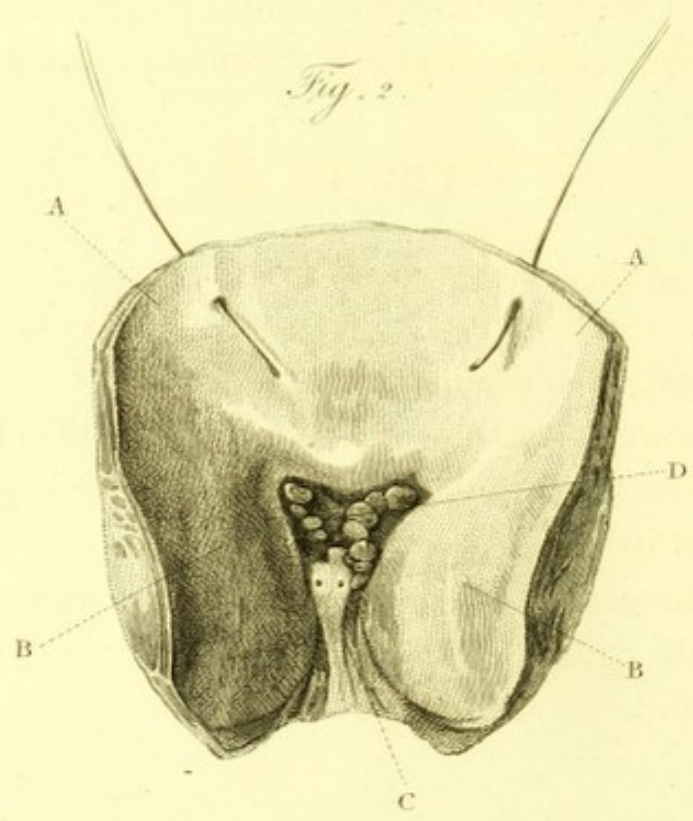




*Fig. 1.*



*Fig. 2.*





## PLATE II.

IN this Plate are represented two diseases of the prostate gland. The one consists of an ulcer in the prostate gland, and the other of small calculi which had been formed in its ducts. Ulcers of the prostate gland are not at all common, and when they occur, they generally possess more or less of a scrofulous taint.

The formation of small calculi in the ducts of the prostate gland is very far from being common, although it is not extremely rare. They are round in their shape, of a brown colour which varies in its shade, and have been found to consist of phosphoric lime in the state of neutralization.

## FIG. I.

Represents an ulcer in the prostate gland.

- A. A small portion of the urinary bladder.
- B B. The two ureters at their insertion into the bladder.
- C. An ulcer in the prostate gland, which is a good deal enlarged in its size.
- D D. The two vesiculæ seminales thickened and enlarged, evidently partaking of the same disease with the prostate gland.

E E. The two vasa deferentia, also a little thickened from the same cause. *From the Author's Collection.*

FIG. II.

Represents the prostate gland with a number of small calculi in its cavity, which had been formed in its ducts.

A A. A small portion of the bladder cut off near the insertion of the ureters, through which two bristles have been passed.

B B. The lateral eminences of the prostate gland.

C. The caput gallinaginis in its cavity, with the two small openings of the ducts of the vesiculæ seminales very observable.

D D. The small calculi.

*From Dr. Hunter's Museum.*





Fig. 1.

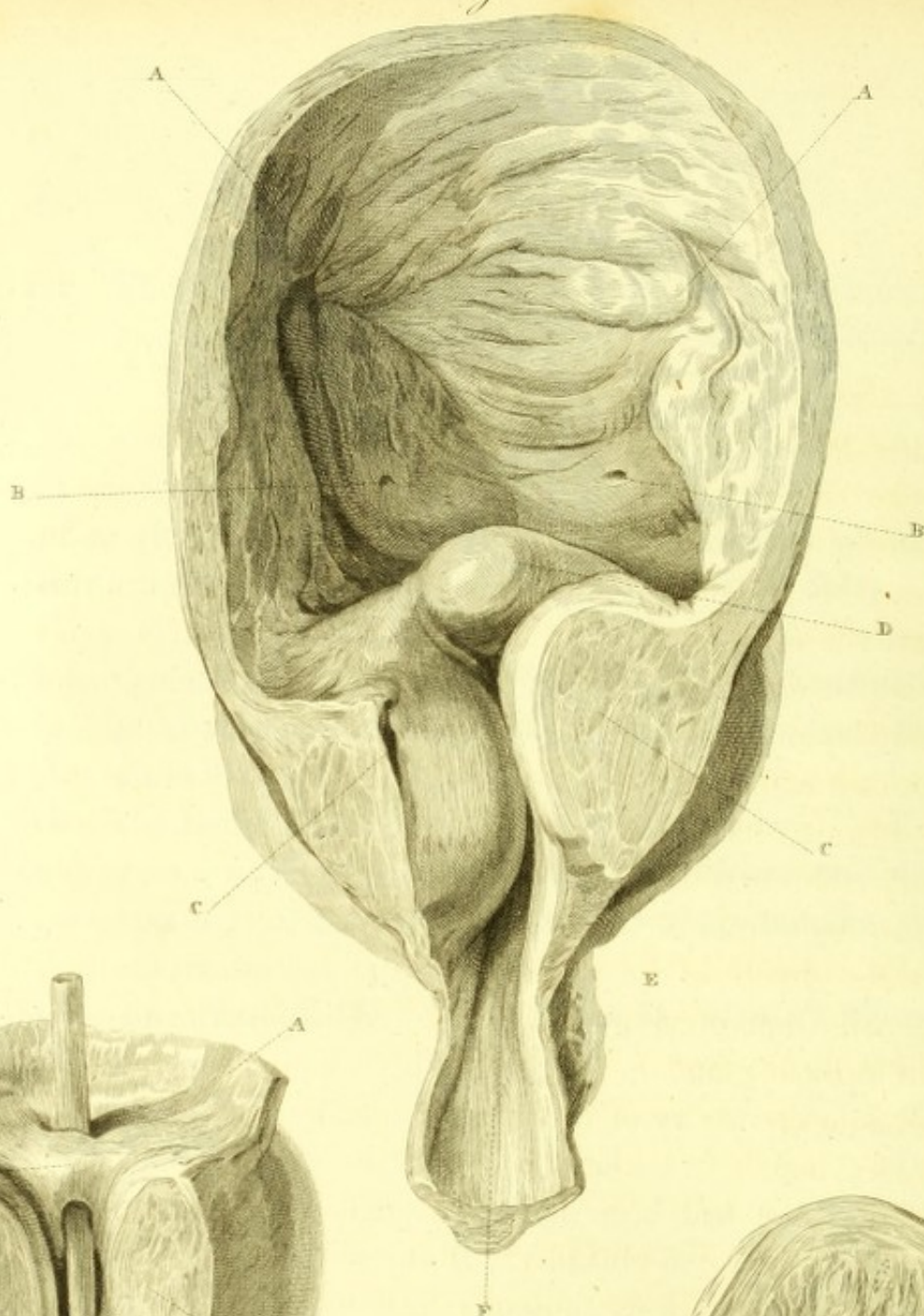


Fig. 2.

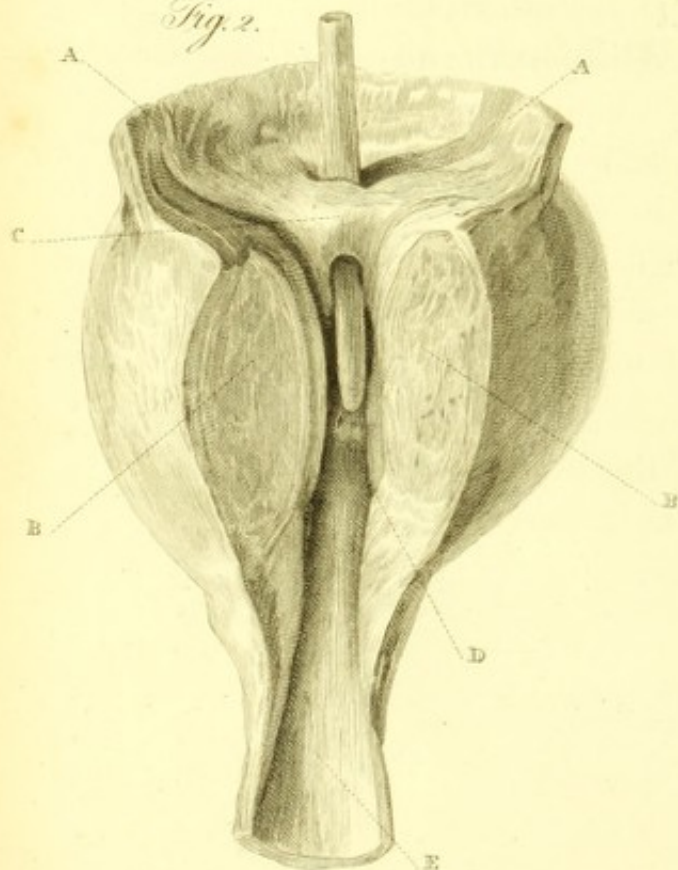
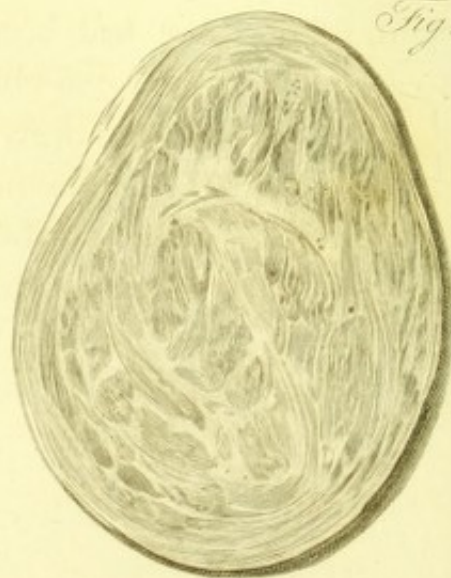

Fig. 3.





## PLATE III.

IN this Plate is represented a scirrhus enlargement of the prostate gland. It is the most common morbid change to which the prostate gland is liable, and it occurs chiefly at an advanced period of life. The enlargement of the gland in this disease is sometimes so great as to exceed the size of a man's fist, and it often grows irregularly, the one side being more enlarged than the other. The posterior part of the gland also makes sometimes a high projection into the cavity of the urinary bladder. When the enlargement of the gland is considerable, there is always more or less difficulty in introducing an instrument into the bladder, but this difficulty is increased when the growth of the gland is irregular, because its cavity is necessarily then of an irregular form. The posterior part too of the prostate gland has sometimes been known to project so much into the cavity of the urinary bladder, that the extremity of a bougie or catheter could not be elevated above the projection, but had been forced through it, before it could reach the cavity of the bladder. In the scirrhus enlargement of the prostate gland, its substance feels hard, but the disease has little tendency to run into ulceration. It must therefore be considered as not being exactly of the same nature with that kind of scirrhus which terminates in cancer.



## FIG. I.

Represents a prostate gland enlarged from scirrhus. It is at least four or five times larger than its natural size, and had grown irregularly, the right side of it having protruded more into the cavity of the gland than the left side. Hence the cavity, instead of being straight, is winding in its course. The posterior part of the gland had also grown so as to project a good deal into the cavity of the urinary bladder. This must have produced a great additional difficulty in attempts to pass into the bladder an instrument for drawing off the urine.

- A A. A section of the urinary bladder much thickened in its muscular coat, from the great efforts which it had been often forced to make in expelling the urine.
- B B. The openings of the two ureters into the bladder.
- C C. The two sides of the prostate gland much enlarged, and the right side projecting very much into the cavity of the gland.
- D. The posterior projecting part of the prostate gland.
- E. The cavity of the prostate gland curved in its shape.
- F. The urethra at the bulb laid open, which is sound in its structure.

*From Dr. Hunter's Museum.*



## FIG. II.

Represents an enlarged prostate gland, in which a bougie had been passed through a part of its substance, in an attempt to draw off the urine.

- A A. A very small portion of the bladder near the prostate gland.
- B B. The two sides of the prostate gland, which are much enlarged in size, but they had grown regularly.
- C. The portion of the prostate gland through which the bougie had been forced: a quill has been put into it.
- D. The cavity of the prostate gland which is straight in its direction; in it the caput gallinaginis, and the openings of the ducts of the vesiculæ seminales are very observable.
- E. A part of the urethra at the bulb, in a healthy state.

*From Dr. Hunter's Museum.*

## FIG. III.

Represents a lateral section of a prostate gland, very much enlarged from scirrhus. It is intended to give an accurate idea of its structure, which consists of a whitish firm substance, intersected in various directions by thick membranes.

*From Dr. Hunter's Museum.*





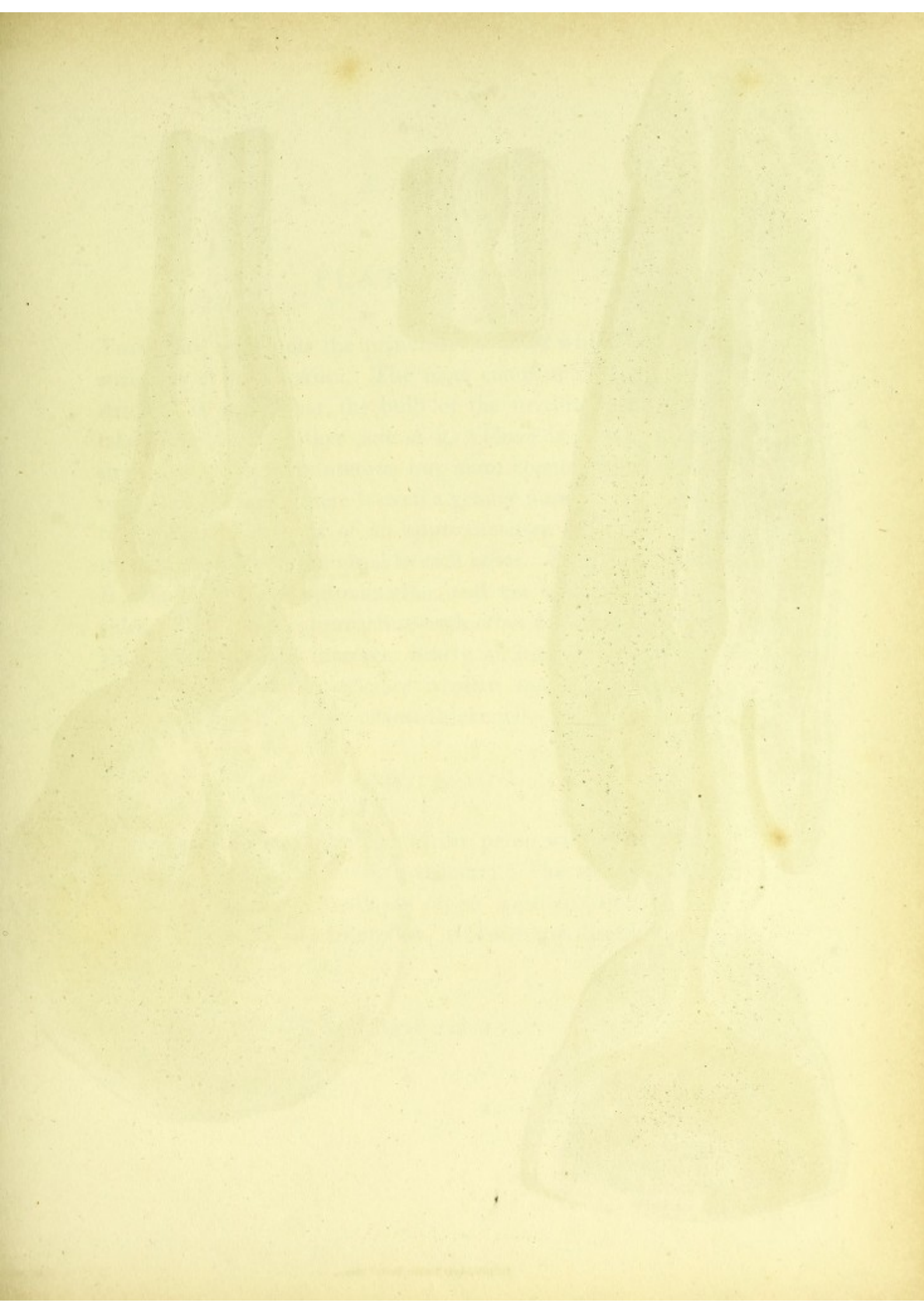
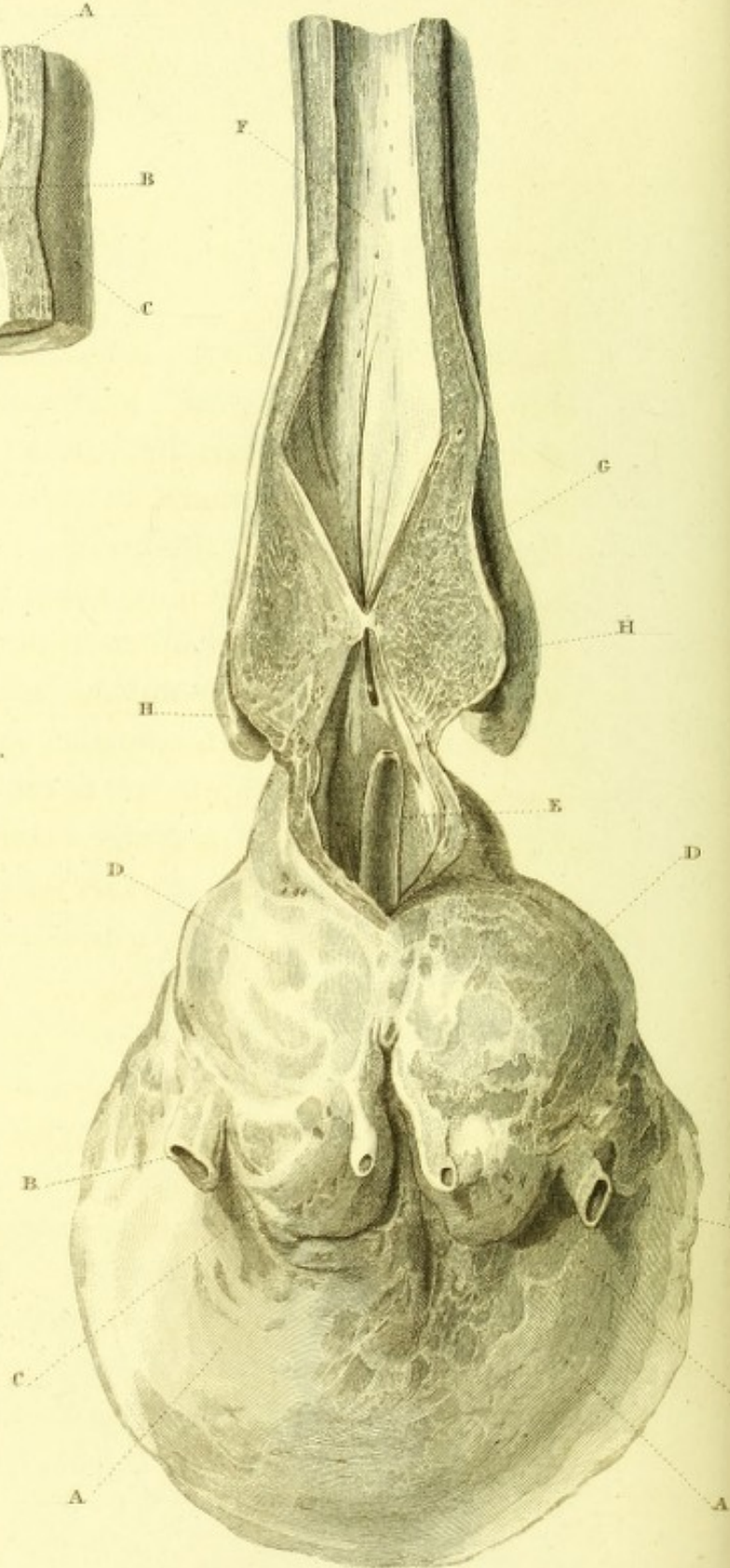
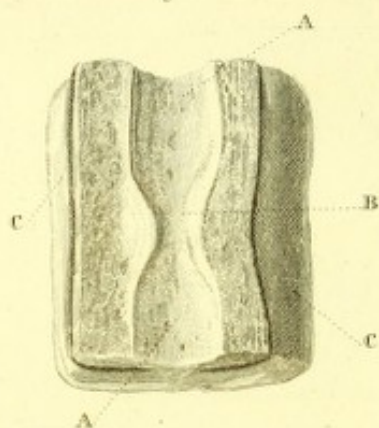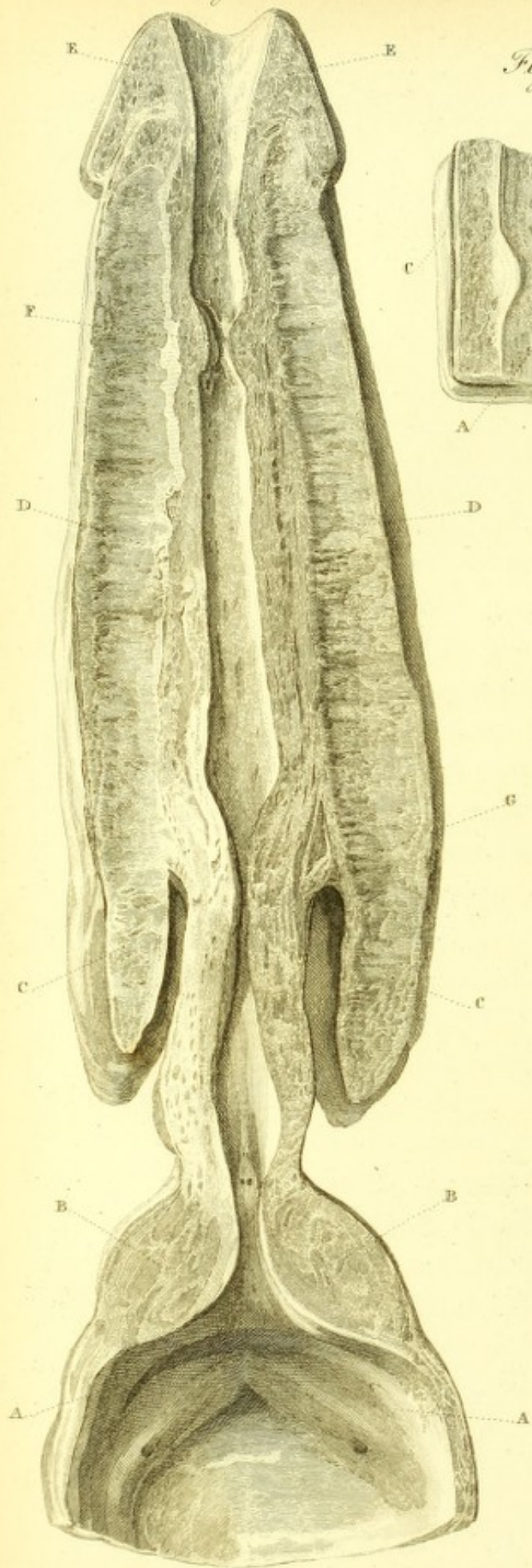


Fig. 2.

Fig. 1.

Fig. 3.





## PLATE IV.

THIS Plate represents the principal varieties which occur in strictures of the urethra. The most common situation of a stricture is at, or near, the bulb of the urethra, but it may take place in any other part of it. There is often but one stricture in the same urethra, but more commonly there are two, and sometimes there is even a greater number. A stricture generally consists of an approximation, for a short extent, of the sides of the canal to each other. Sometimes there is a mere line of approximation, and not uncommonly the sides of the urethra approach to each other for some considerable length, as, for instance, nearly an inch. The surface of the urethra at the stricture is often sound, but not uncommonly too, it is more or less thickened.

## FIG. I.

Represents a small portion of the penis with the urethra laid open, so as to discover a stricture. The stricture is of small extent, consisting simply of an approximation of the sides of the canal of the urethra, without any disease in the organization of the part.

A A. The urethra of its natural width.

B. The stricture.

CC. A part of the corpora cavernosa.

*From Dr. Hunter's Museum.*

FIG. II.

Represents two strictures in the urethra. The one is near the bulb, and the other is within two inches of the orifice of the urethra.

A A. A small portion of the bladder, a little thickened in its coats, with the insertion of the ureters very observable.

B B. The two sides of the prostate gland in a sound state.

C C. The crura of the corpora cavernosa penis divided.

D D. The corpora cavernosa themselves divided.

E E. The glans penis also divided.

F. The anterior stricture, which is of short extent, but the inner membrane of the urethra is a little irregular and thickened.

G. The stricture near the bulb, which is nearly an inch in length ; the rest of the urethra is in a healthy state.

*From Dr. Hunter's Museum.*



## FIG. III.

Represents a stricture at the bulb of the urethra, where the sides of the urethra had approached each other nearly in a point, and where the stricture is so narrow, as just to allow a bristle to pass through it.

- A A. The posterior surface of the bladder, which is contracted and thickened in its coats.
- B B. The two ureters near their insertion.
- C C. The two vesiculæ seminales with the vasa deferentia, not very accurately dissected.
- D D. The prostate gland, somewhat enlarged in its size.
- E. The urethra at the membranous part laid open, and sound in its structure. A quill has been put into it, leading on to the bladder.
- F. The urethra near the anterior extremity of the penis, in a healthy state.
- G. The stricture at the bulb of the urethra so narrow as just to allow a bristle to pass through it.
- H H. A part of the crura of the corpora cavernosa.

*From Dr. Hunter's Museum.*









Fig. 1.

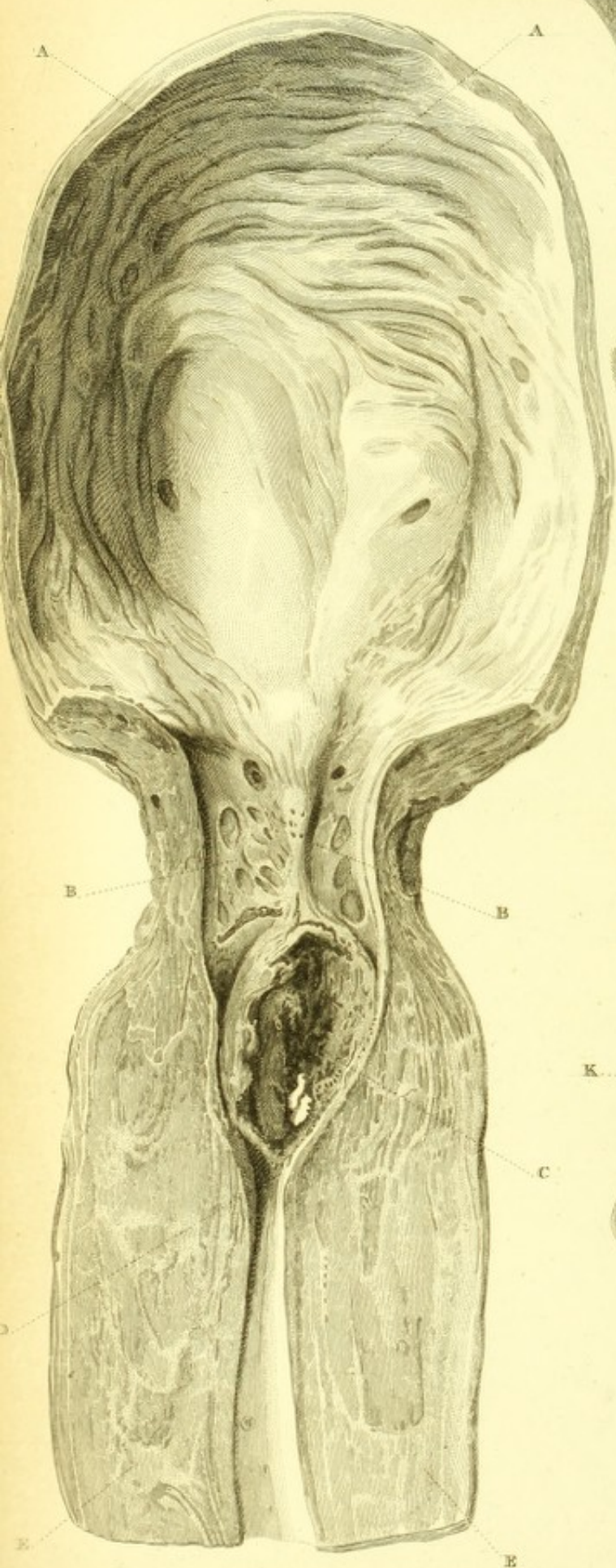
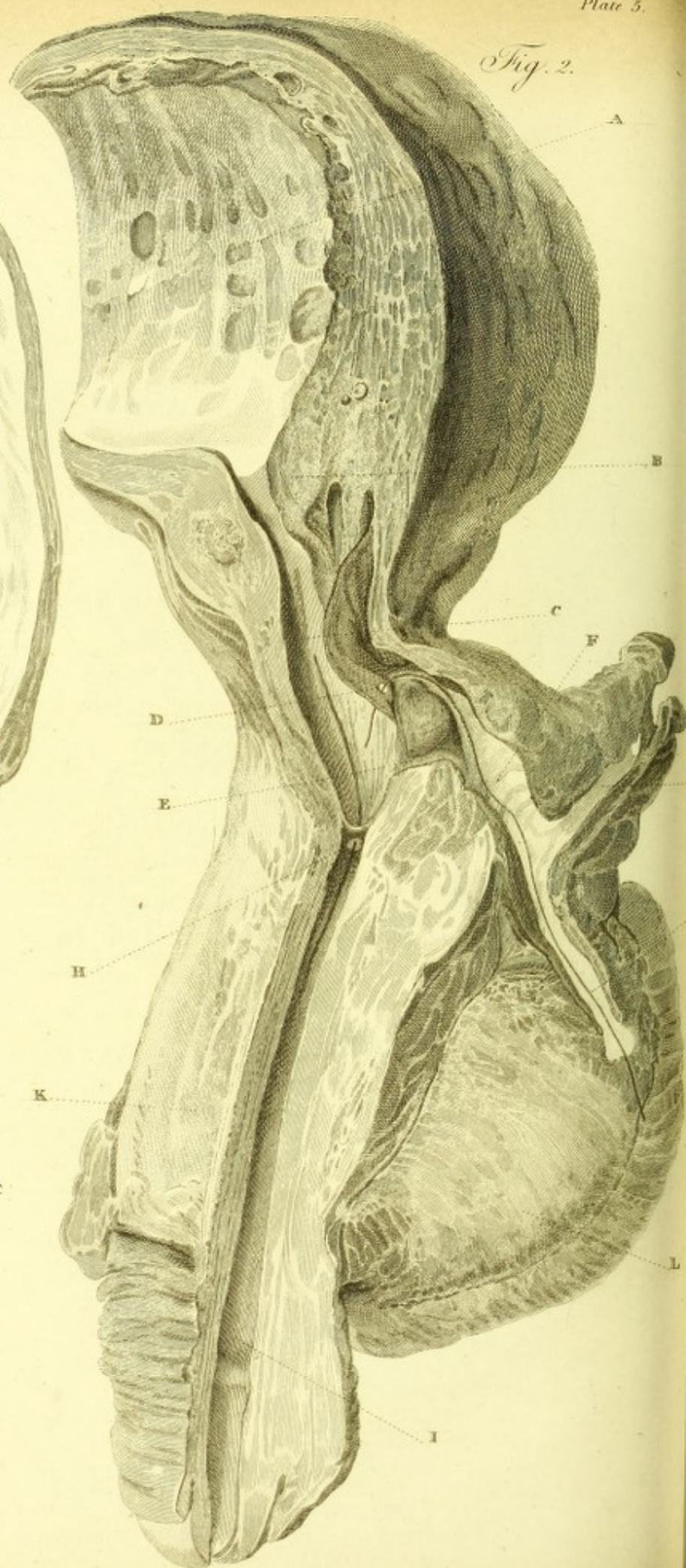


Fig. 2.





## PLATE V.

THIS Plate is intended to represent an ulcer of the urethra near the prostate gland, and a fistula in perinæo. These are not uncommonly the consequences of a very narrow stricture.

## FIG. I.

Represents an ulcer in the membranous part of the urethra. It is of considerable extent, and had destroyed not only the coats of the urethra, but the integuments at this part.

A A. A portion of the bladder considerably thickened, with the fasciculi of its muscular fibres strongly mark'd.

B B. The cavity of the prostate gland, enlarged from distension in consequence of the accumulation of the urine behind the ulcer. The ducts of the prostate gland may be seen very much enlarged from the same cause.

C. The ulcer in the membranous part of the urethra.

D. A narrow part of the urethra, immediately before the ulcer, which had been a part of the stricture destroyed by the process of ulceration.

E E. A part of the corpora cavernosa.

*From Dr. Hunter's Museum.*

## FIG. II.

Represents a fistula in perinæo.

- A. A section of the bladder very much thickened in its coats.
- B. A section of the prostate gland, which from the thickened state of the bladder, is very obscurely marked.
- C. The cavity of the prostate gland, and of the membranous part of the urethra.
- D. A fistulous orifice leading to a long fistulous canal.
- E. Another orifice, or rather short duct, communicating with the same canal.
- FF. The fistulous canal itself, in which there is a long slender bristle leading from the orifice D. It has one of its terminations in the scrotum.
- G. Another termination of the fistulous canal in the perinæum.
- H. The stricture in the urethra, through which a bristle is passed.
- I. The remaining part of the urethra.
- K. A part of one of the corpora cavernosa.
- L. The scrotum somewhat corrugated.

*From Mr. Hunter's Museum.*





- C. The testicle enlarged in its size, but flattened from the pressure of so large a quantity of water as had been accumulated in the cavity of the tunica vaginalis. Its form is also obscured from the thickness of the coats which surround it.
- D. Some veins passing up to the spermatic chord, enlarged and tortuous.
- E. A small portion of the spermatic chord.

*From Dr. Hunter's Museum.*

### FIG. III.

Represents a hydrocele combined with hernia, a combination which is not very rare.

- A. The cavity of the tunica vaginalis laid open, which had been enlarged from the accumulation of the water to a considerable size.
- B. The testicle somewhat enlarged.
- C. A part of the hernial sac laid open.

*From Dr. Hunter's Museum.*





Fig. 1.

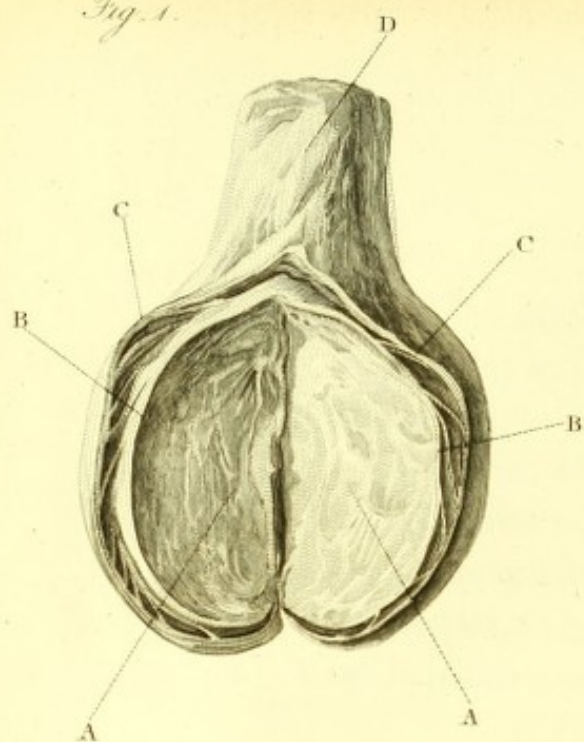


Fig. 2.

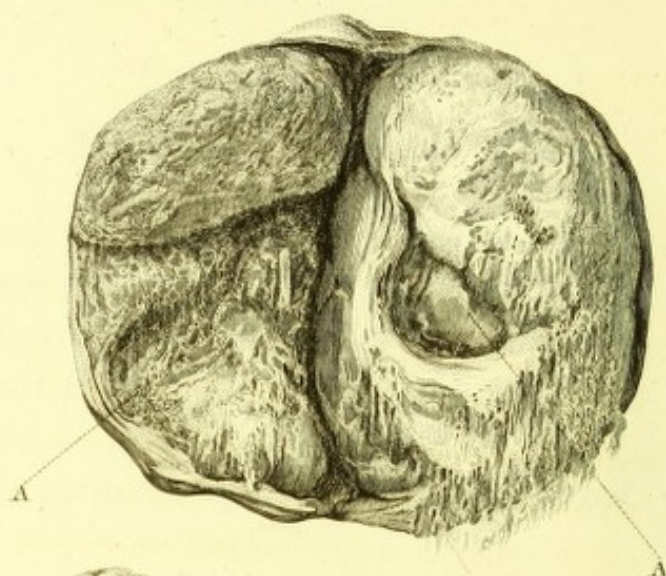
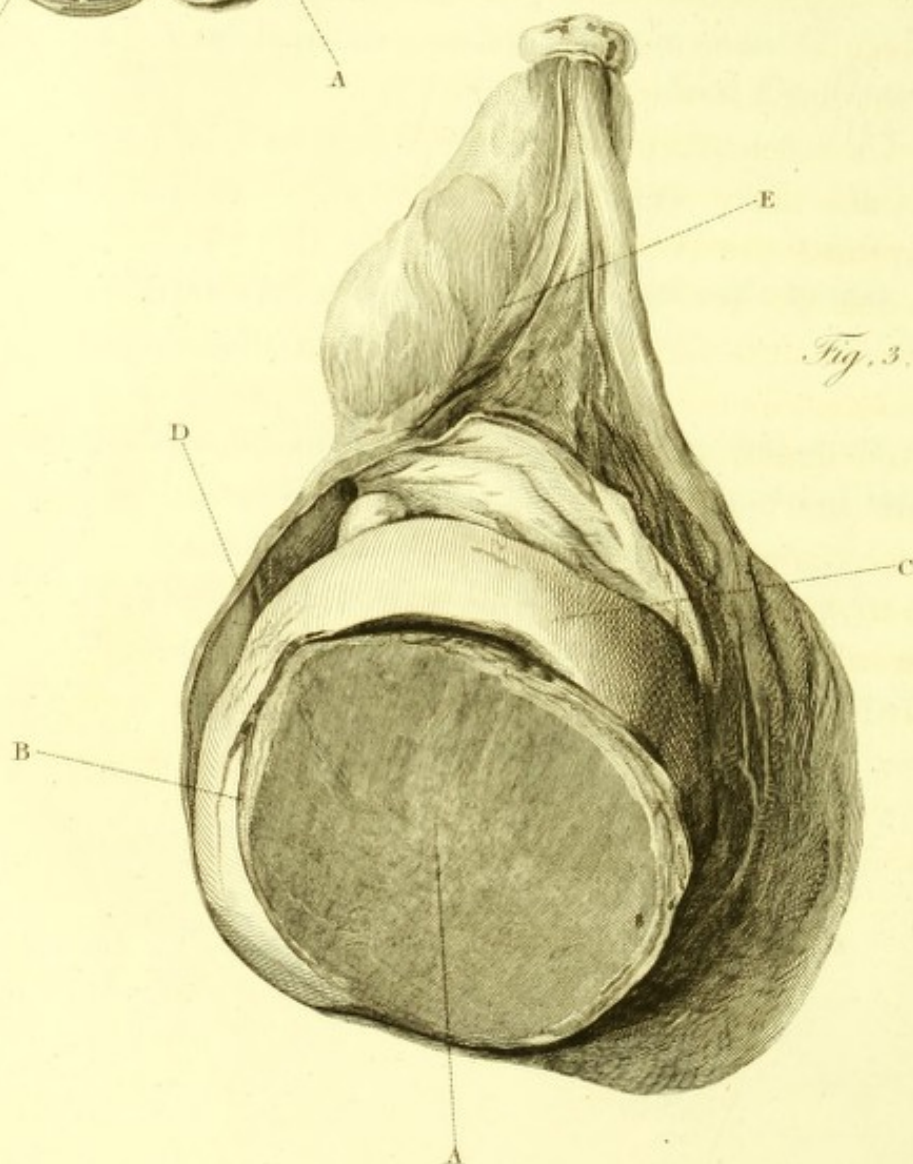


Fig. 3.





## PLATE VII.

IN this Plate are represented adhesions of the tunica vaginalis testis to the body of the testicle, an ulcer in the substance of the testicle, and a testicle enlarged and pulpy. The first morbid change of structure is common, and arises from inflammation having taken place in the cavity of the tunica vaginalis. The second is not so common, but is very far from being rare, and is often attended more or less with a scrofulous taint. The third also is not very unusual: the testicle in this case is changed into a tender substance of an uniform texture in which the healthy or natural organization is entirely lost. It is much enlarged in its size, but preserves its smooth round figure. This disease has sometimes been confounded with the scirrhus testicle, and sometimes with the true scrofulous one. The pulpy testicle however is very different in its texture and other circumstances from the first, but it is probably nearly allied in its nature to the second, although its texture be somewhat different,\* and it be very little disposed to suppurate.

\* The structure of a true scrofulous testicle resembles exactly that of a scrofulous absorbent gland, but the pulpy testicle consists of a tender flesh. This difference however cannot be properly represented in an engraving, and therefore it has not been attempted.

## FIG. I.

Represents adhesions of the tunica vaginalis testis to the body of the testicle. These adhesions appear to extend over the whole of the surface of the testicle, and therefore the whole of the cavity of the tunica vaginalis must at one time have been in a state of inflammation.

A A. The body of the testicle divided.

B B. The outer surface of the testicle.

C C. The tunica vaginalis. Between this and the outer surface of the testicle fine membranes may be observed to pass, by which they adhere to each other.

D. A part of the spermatic chord.

*From Dr. Hunter's Museum.*

## FIG. II.

Represents an ulcer in the substance of the testicle. The testicle is enlarged in its size, and is divided nearly into two halves, by which the ulcer is exposed to view.

A A. Represents the part chiefly affected by the ulcer.

*From Dr. Hunter's Museum.*



## FIG. III.

Represents an enlarged and a pulpy testicle.

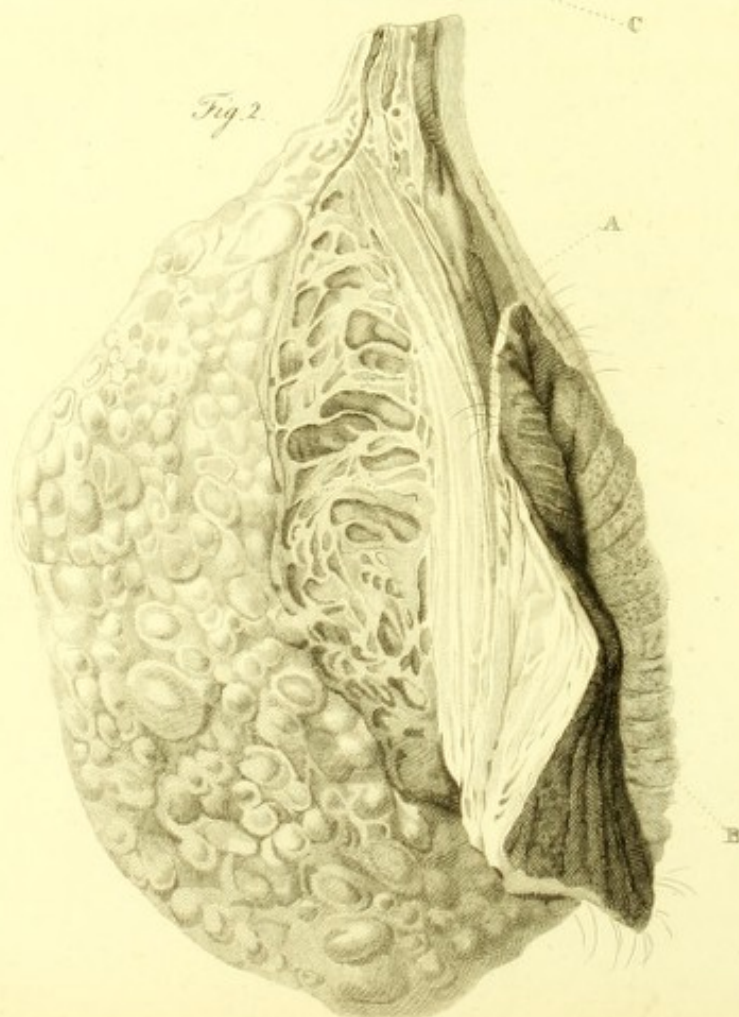
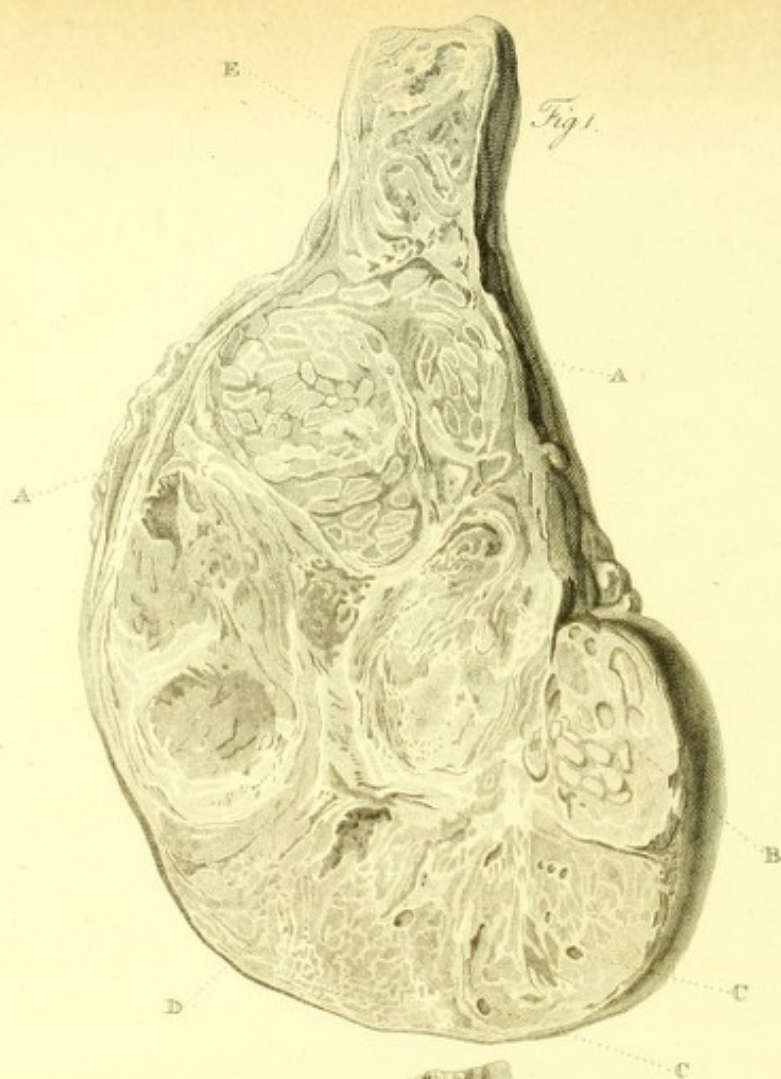
- A. Represents the body of the testicle. A section has been made of it at this part, in order to shew the uniformity of its texture. It consists of a smooth tender flesh, which gives the sensation of moderate firmness upon pressing or handling it.
- B. The tunica albuginea. This is fully of its natural thickness notwithstanding the enlargement of the testicle, and therefore it must have had a growth corresponding to the growth of the testicle.
- C. The epididymis, enlarged in its size.
- D. The tunica vaginalis testis, which is of a natural thickness, and therefore it must have kept pace in its growth with the testicle.
- E. The spermatic chord. It is sound in its structure, but appears larger than usual, from its vessels being increased in size, and being filled with injection.

*From Mr. Heaviside's Museum.*











## PLATE VIII.

THIS Plate is intended to represent a scirrhus testicle, and also a testicle converted into a mass of hydatids. The first disease is unfortunately not uncommon, but the last is very rare.

## FIG. I.

Represents a section of a testicle affected with scirrhus. It is very much enlarged in its size, and its natural structure is entirely lost. It is converted into a hard substance, intersected in various directions by thick membranes, and in some parts intermixed with soft cartilage.

- A A. Represents this part of the testicle which has a considerable mixture of cartilage. The cartilage consists of small masses, which appear to the eye somewhat like seeds that are embedded in this part of the testicle.
- B. Another portion of the testicle, shewing several oval cavities which are filled with a substance a good deal like the coagulable lymph of the blood.
- C C. Two small round cavities, which had probably contained a serous fluid.

- D. A larger cavity, somewhat irregular in its shape.  
E. A portion of the spermatic chord, affected also with  
scirrhus. *From Dr. Hunter's Museum.*

## FIG. II.

Represents a large portion of a testicle, which had been converted into a mass of hydatids. These are not collected into considerable cysts as in the liver, but pervade the whole mass of the testicle, as they sometimes do in the kidneys.

- A. A section of these hydatids, to shew their accumulation  
and their size more distinctly.  
B. A part of the skin of the scrotum corrugated, and some-  
what thickened. *From Mr. Hunter's Museum.*





Fig. 2.

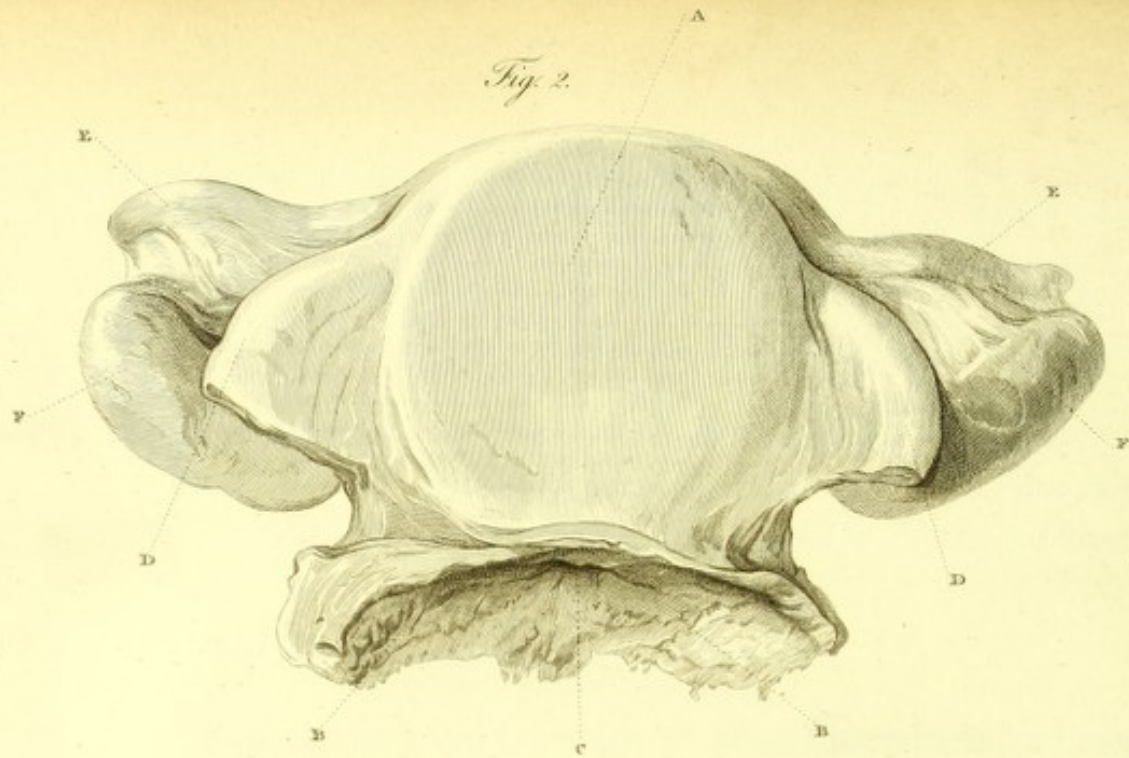


Fig. 1.

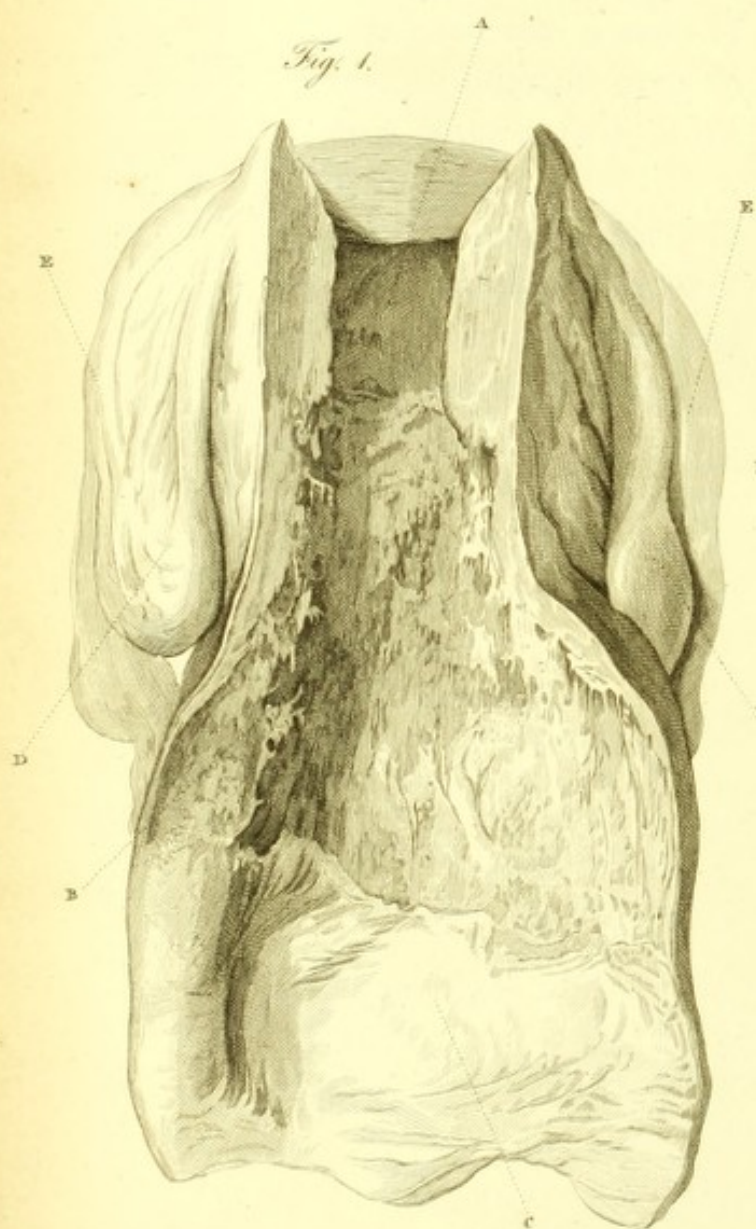


Fig. 3.

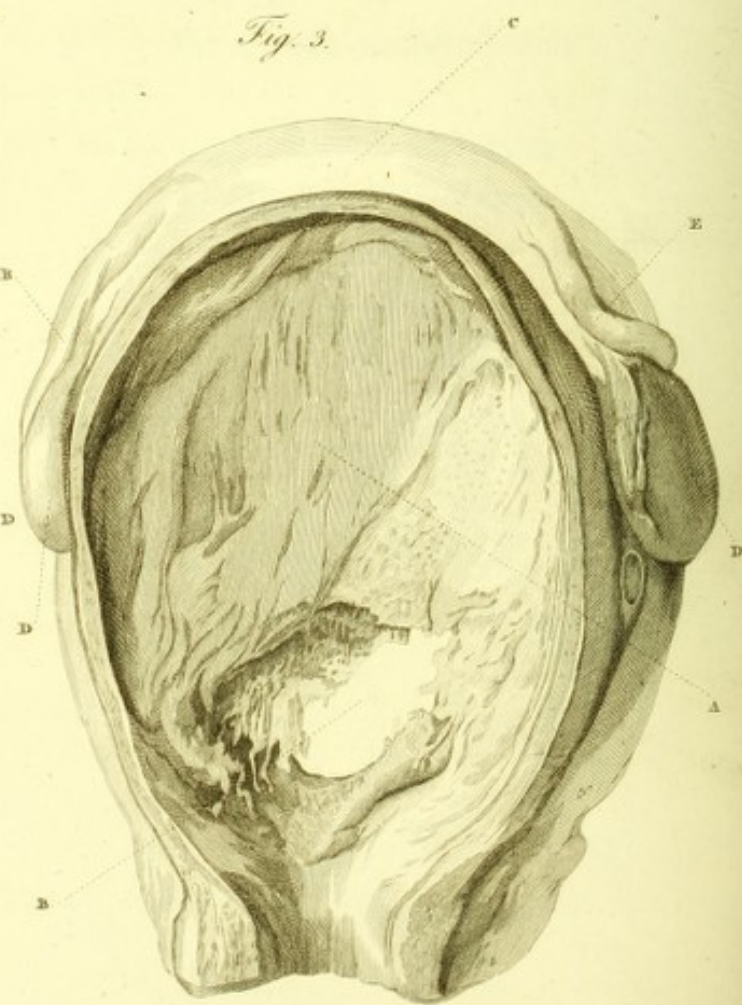



PLATE I.

THE

NINTH FASCICULUS.

---

IN this Fasciculus are represented the most important changes of structure from disease, to which the Female Organs are subject. These are more various than what occur in many other parts of the body, and this variety depends upon their structure, their situation, and their functions.

PLATE I.

THIS Plate represents an ulcer of the uterus of a malignant nature, which has commonly been considered as cancerous. This disease is certainly as formidable as cancer, because it always terminates fatally, but its progress is different from that of cancer in other parts of the body, and the uterus does not undergo the same changes of structure. There is but little enlargement of the uterus in this disease; and when ulceration has once begun, it proceeds regularly till a great part of the uterus is destroyed, without forming either fungus or cysts, as happens very commonly in cancer of other parts. The disease

begins in the cervix uteri; and when it has made a great progress, the contiguous parts, as the rectum and the urinary bladder, are often involved in it. The ulceration spreads to the one or the other from the uterus, and communications are thereby formed between them.

---

FIG. I.

Represents an uterus with an ulcer in its cervix, which had spread some way into the vagina. The disease had been in an early stage when the person died, so that little of the substance of these parts had as yet been destroyed.

- A. The cavity of the uterus at its fundus exposed to view. It is still sound, and exhibits the smooth natural surface. The substance of the fundus too is not enlarged beyond the natural size.
- B. The ulcer which is of considerable extent, but is superficial.
- C. A portion of the vagina free from disease.
- D D. The two ovaria, not very distinctly marked.
- E E. The two Fallopian tubes.     *From Dr. Hunter's Museum.*



## FIG. II.

Represents an uterus, in which the ulceration had made so great a progress, as to destroy the whole of the cervix.

- A. The fundus of the uterus, a little enlarged beyond its natural size.
- B. The ulcer, which extends across the whole of the uterus, and had destroyed the cervix.
- C. The cavity of the uterus.
- D D. Portions of the two round ligaments.
- E E. Portions of the two Fallopian tubes.
- F F. The two ovaria.

*From the Author's Collection.*

## FIG. III.

Represents an ulcer which had spread from the uterus to the urinary bladder, forming a communication between them. In the same manner a communication is sometimes formed between the uterus and the rectum.

- A. The urinary bladder with its inner surface exposed to view.
- B. A large ulcer, which communicates with the uterus and the beginning of the vagina.

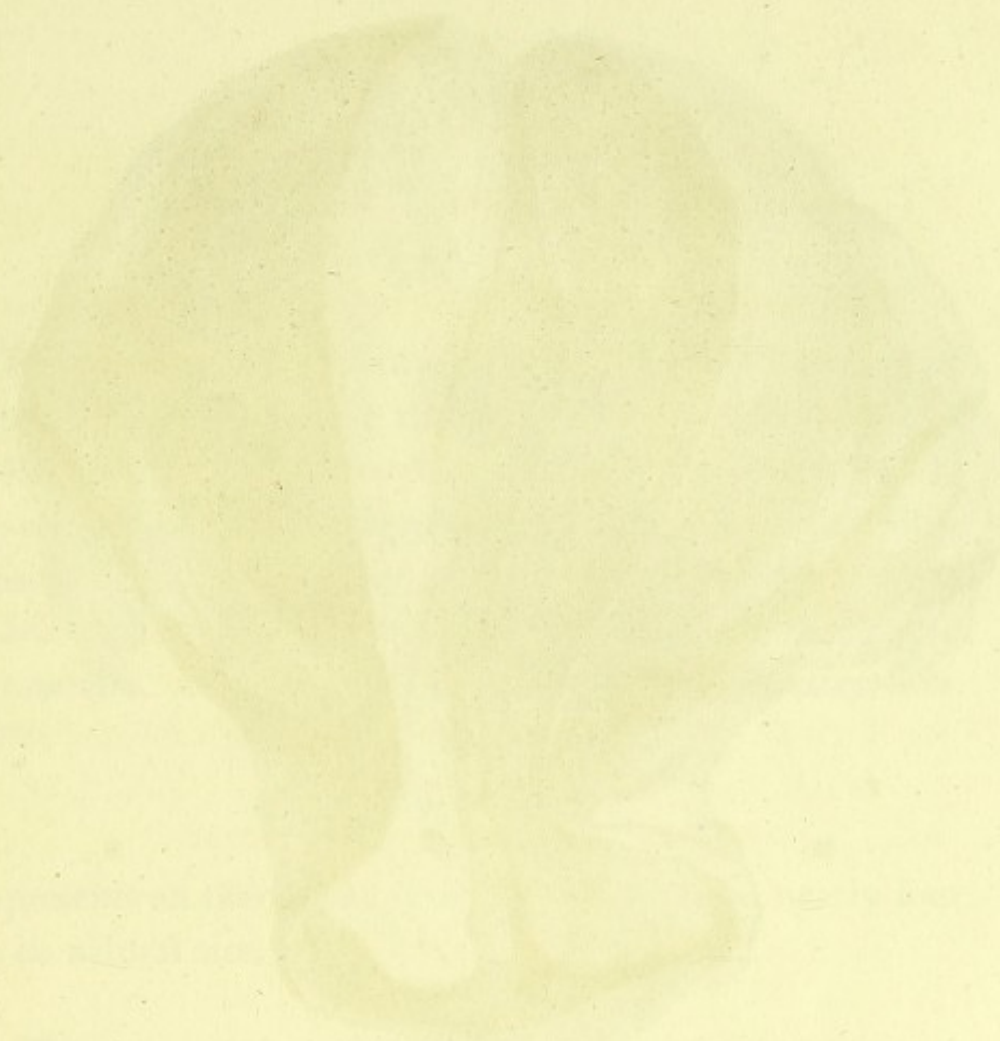
C. A portion of the fundus uteri, which is somewhat enlarged in size.

D D. The two ovaria.

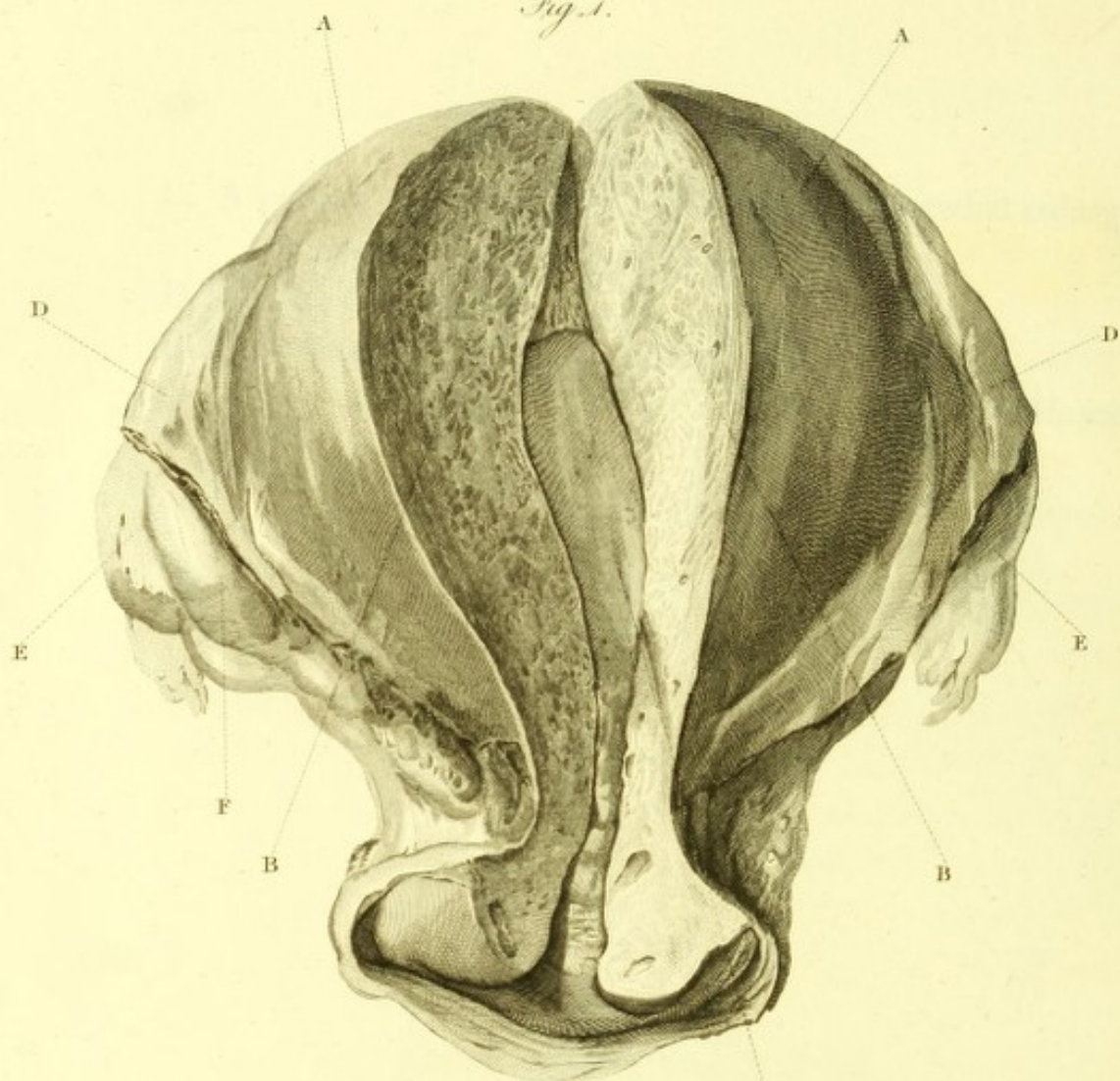E E. Portions of the two Fallopian tubes.

*From Dr. Hunter's Museum.*

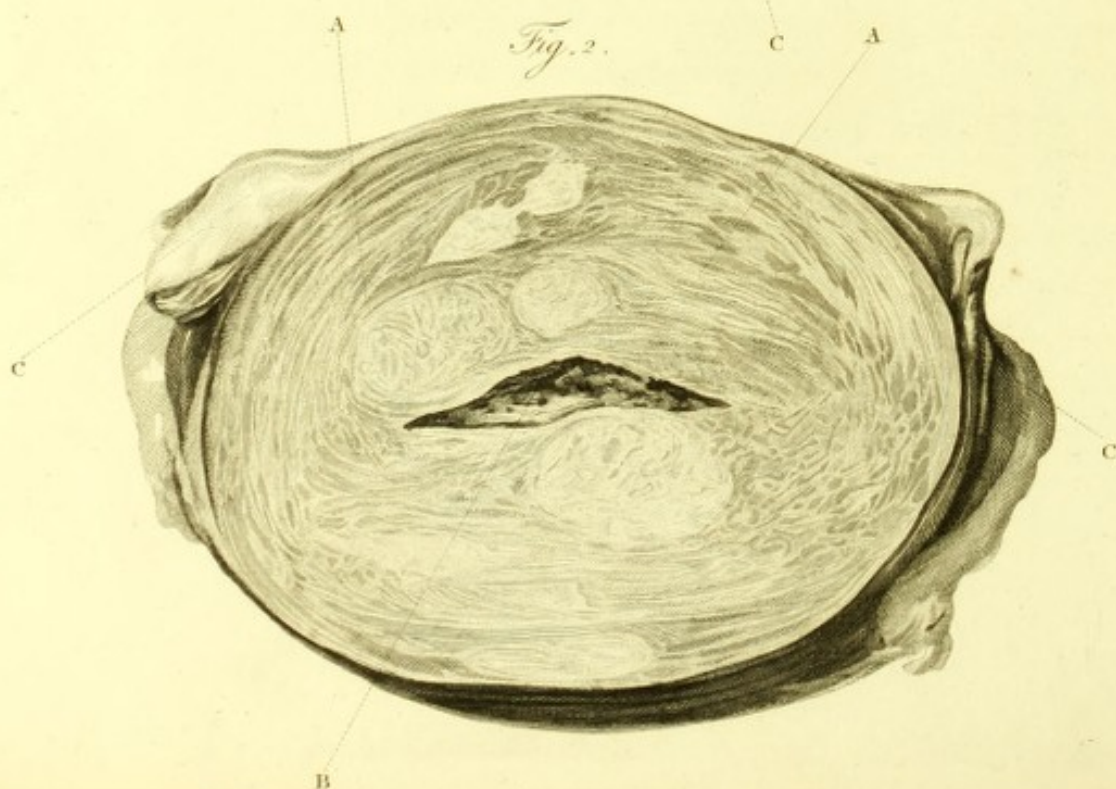



*Fig. 1.*



*Fig. 2.*





## PLATE II.

THIS Plate is intended to illustrate a scirrhus enlargement of the uterus. In this disease the uterus sometimes grows to a very large size, so as not merely to fill the cavity of the pelvis, but to occupy a considerable part of the cavity of the abdomen. It consists of a hard substance intersected in various directions by thick membranes, and has sometimes imbedded in it round hard tumours. It is but little disposed to run into ulceration.

## FIG. I.

Represents an uterus enlarged from scirrhus to nearly four times its natural size.

- A A. The outer surface of the fundus uteri.
- B B. A longitudinal section of the uterus, shewing its texture, and the thickness of its substance.
- C. The inner surface of the cavity of the uterus, which is smooth and natural.
- D D. A part of the round ligaments.
- E E. The Fallopian tubes.
- F. The ovarium of the right side.

*From the Author's Collection.*

## FIG. II.

Represents a transverse section of a scirrhus uterus. It is intended principally to shew the texture of the uterus in this disease. A prodigious number of membranes may be seen intersecting its substance in various directions, and several tumours are imbedded in its substance.

A A. The surface of the transverse section, shewing the circumstances just described.

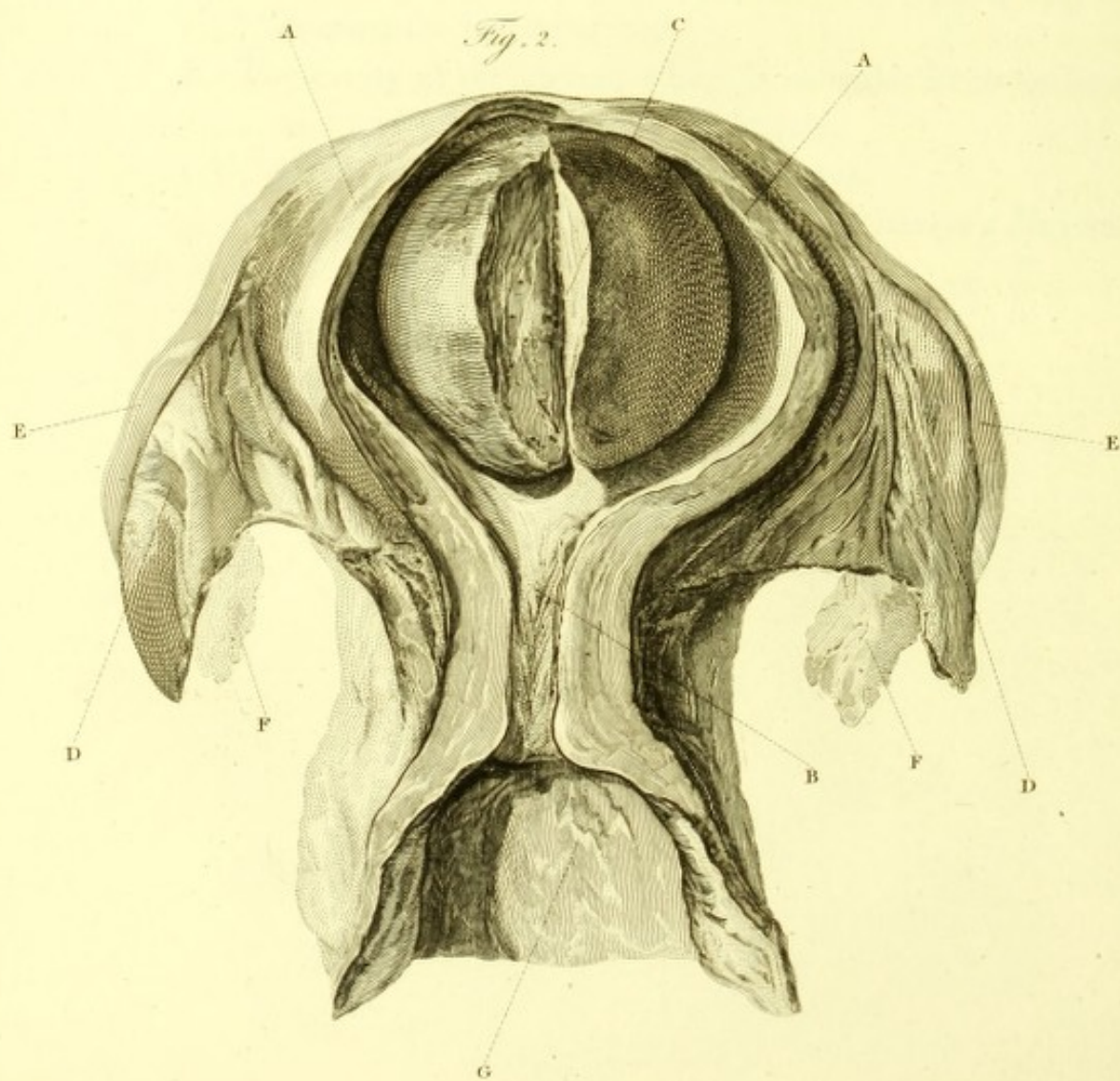
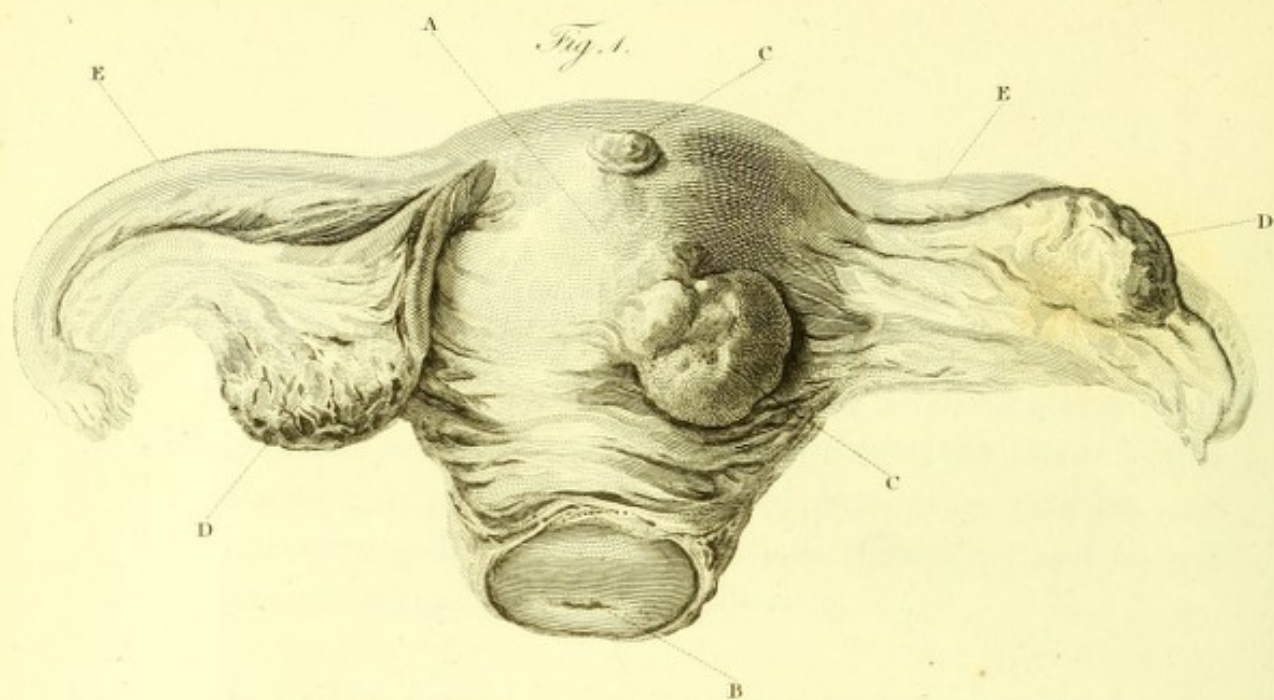
B. The cavity of the uterus, which is irregular in its surface, and had probably begun to ulcerate.

C C. A part of the appendages of the uterus.

*From Dr. Hunter's Museum.*









## PLATE III.

THIS Plate represents the tubercles which are sometimes formed upon the outer surface, and in the cavity of the uterus. They vary a good deal in their size, some being smaller than a hazel nut, and others being larger than an orange. They are hard in their texture, and consist of a white substance intersected by strong membranes. The tubercles upon the outer part of the uterus are generally more or less of a rounded form, and often knotted on their surface. Those in the cavity of the uterus are more accurately globular in their shape, with a surface that is smooth. They are loosely connected to the inner surface of the uterus by cellular membrane, and can be easily separated from it. The tubercles in either situation are not disposed to ulcerate, and the structure of the uterus itself is generally healthy. When tubercles grow imbedded in the substance of the uterus, this organ is commonly enlarged in its size, and diseased in its structure, as is illustrated in Fig. II. of the preceding Plate.

## FIG. I.

Represents two tumours growing upon the surface of the uterus. They are covered by the external membrane of the uterus, lying between it and the muscular structure.

- A. The posterior surface of the uterus.
- B. The os uteri.
- C C. The two tumours, the largest of which is knotted upon its external surface.
- D D. The two ovaria.
- E E. The two Fallopian tubes. *From Dr. Hunter's Museum.*

## FIG. II.

Represents a tumour growing in the cavity of the fundus uteri. It is very round in its shape, is smooth upon its external surface, and is but loosely connected by cellular membrane to the uterus.

- A A. The substance of the fundus uteri rendered thin by distention, in consequence of the growth of the tumour, but sound in its structure.
- B. A section of the cervix uteri in a natural state.
- C. The tumour, which had been divided by a longitudinal incision in order to examine its structure.
- D D. The round ligaments.
- E E. The bodies of the Fallopian tubes.
- F F. The fimbriated extremities of these tubes.
- G. A part of the vagina. *From Dr. Hunter's Museum.*



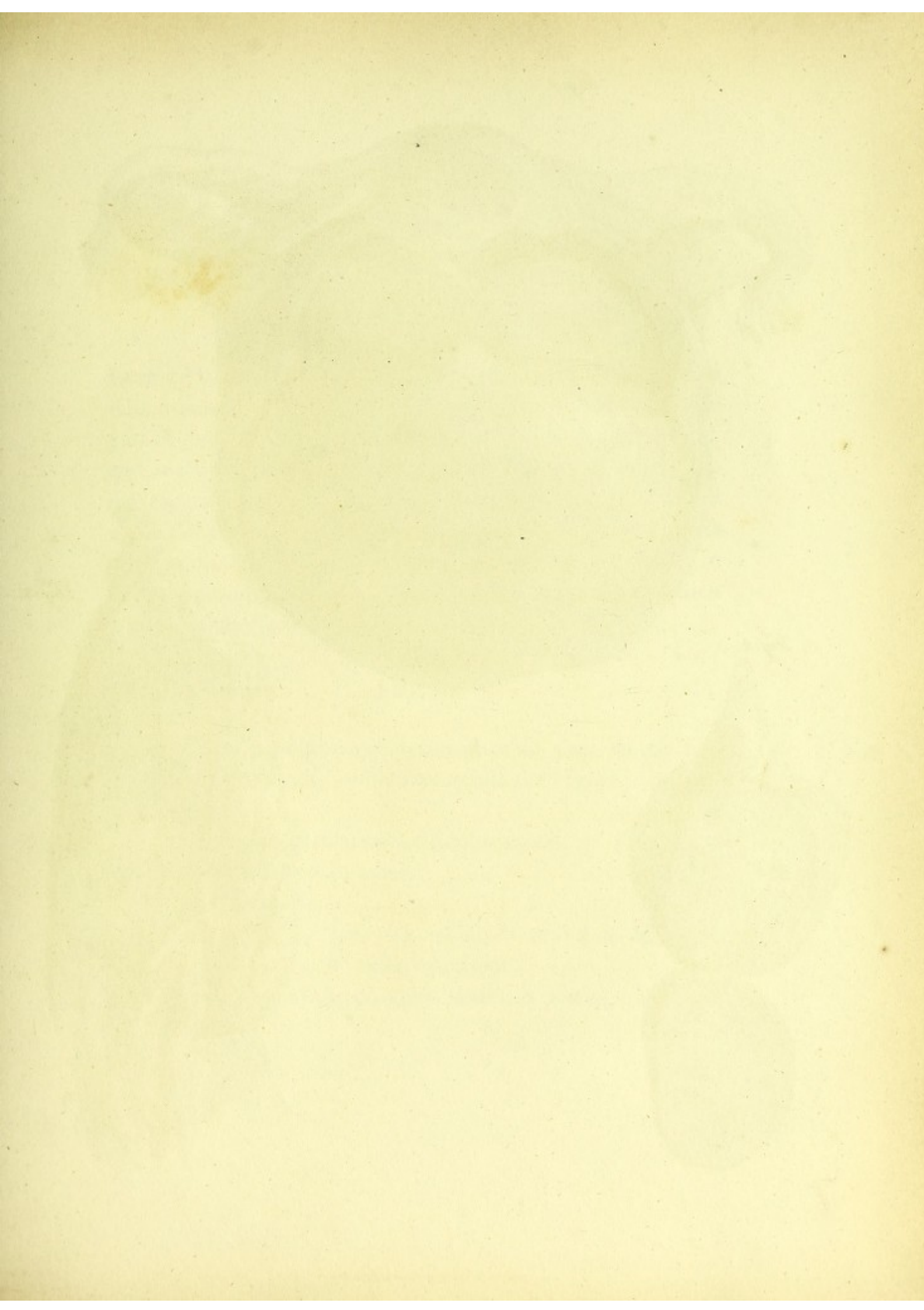


Fig. 1.

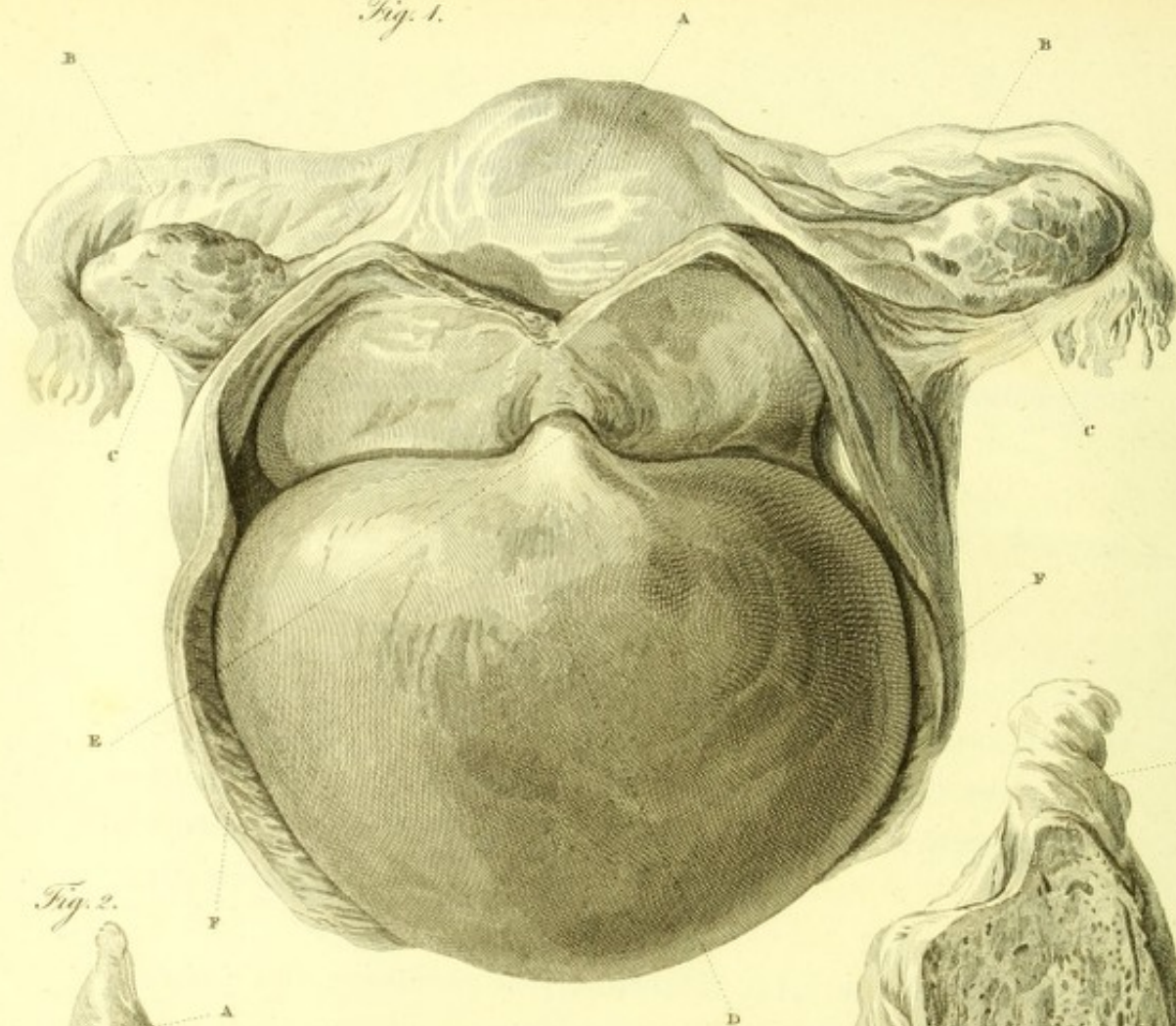

Fig. 2.

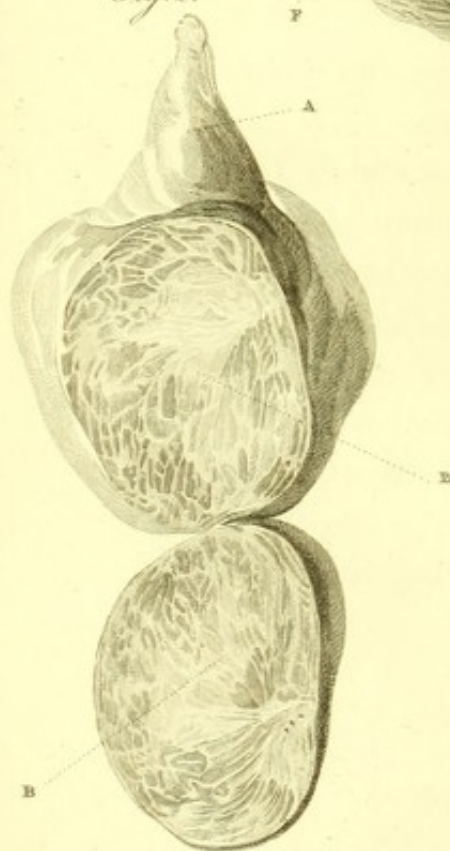
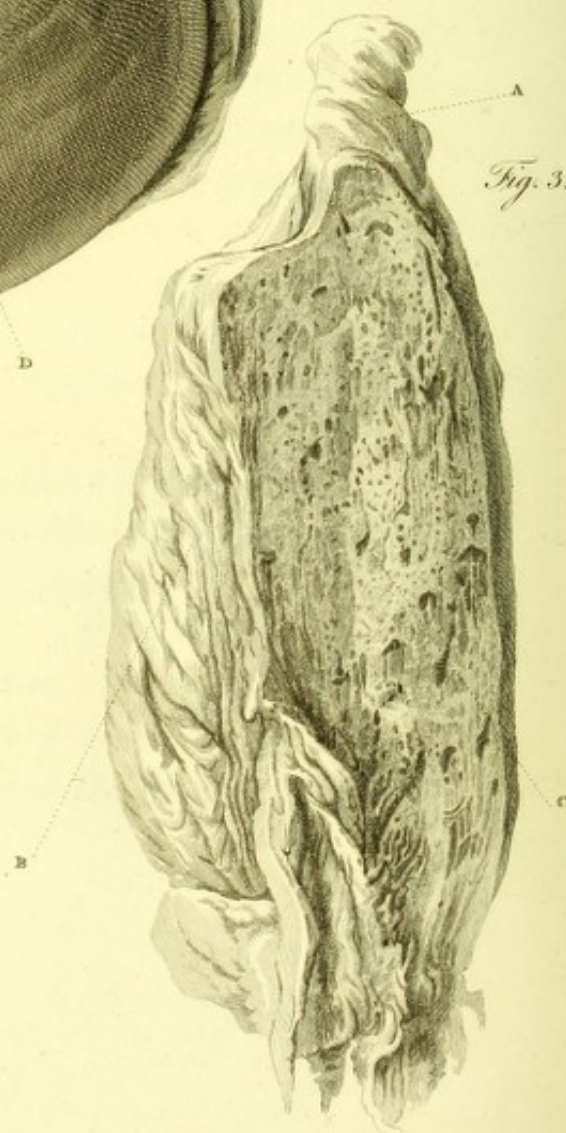
Fig. 3.





## PLATE IV.

IN this Plate are illustrated the most important circumstances which belong to polypi of the uterus. They grow from some part of the cavity of the uterus by a narrow neck or peduncle, and as they increase in size, they pass out of the uterus into the vagina. They are generally round in their shape, and consist of a firm substance, which is intersected by membranes running in various directions. Sometimes they are oblong in their shape, and consist of a loose irregular substance, in which there are many interstitial cavities.

## FIG. I.

Represents a polypus of a considerable size, which had passed from the cavity of the uterus into the vagina.

- A. The posterior surface of the fundus uteri.
- B B. The two Fallopian tubes.
- C C. The two ovaria.
- D. The body of the polypus, which is round in its shape and smooth on its external surface.
- E. The peduncle of the polypus, which is passing out of the os uteri.

FF. The vagina, which is much stretched by the size of the polypus. *From Dr. Hunter's Museum.*

FIG. II.

Represents a small polypus separated from the uterus.

AA. The peduncle by which it adhered to the cavity of the uterus.

BB. A section of the body of the polypus, in order to illustrate its structure, which consists of a firm whitish substance, intersected in various directions by membranes.

*From Dr. Hunter's Museum.*

FIG. III.

Represents a section of the spongy polypus.

A. Its peduncle.

B. The external surface of its body, which is oblong and irregular.

C. A section of the body of the polypus in order to illustrate its structure, which consists of a loose substance, with many interstitial cavities in it.

*From Dr. Hunter's Museum.*





Fig. 1.

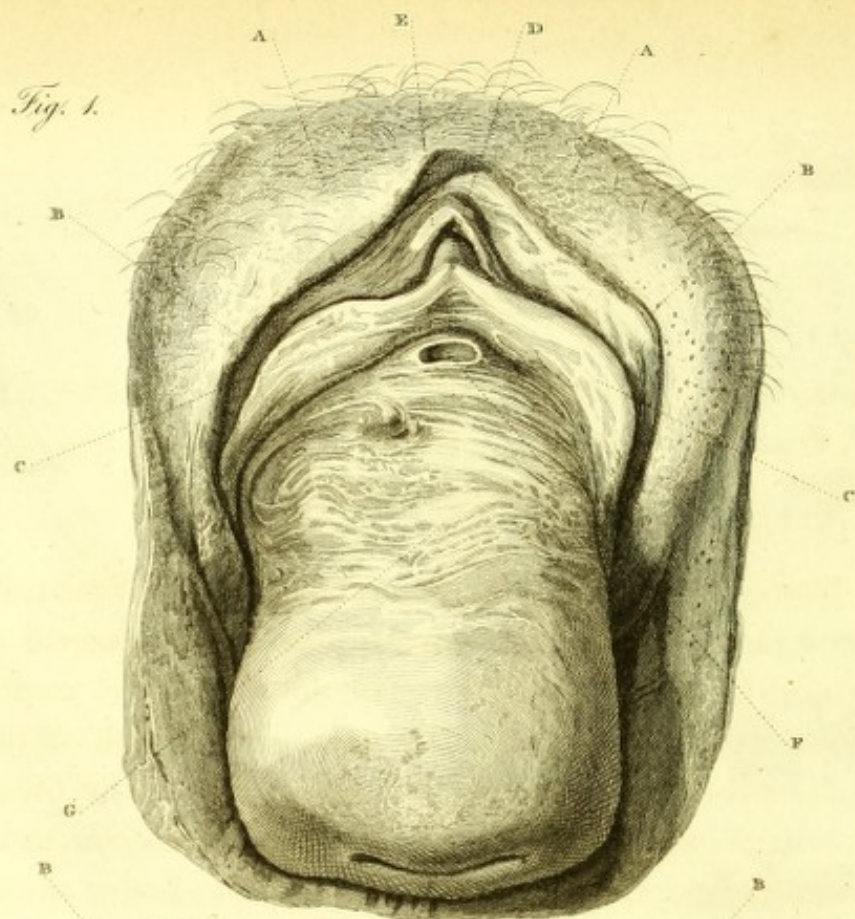
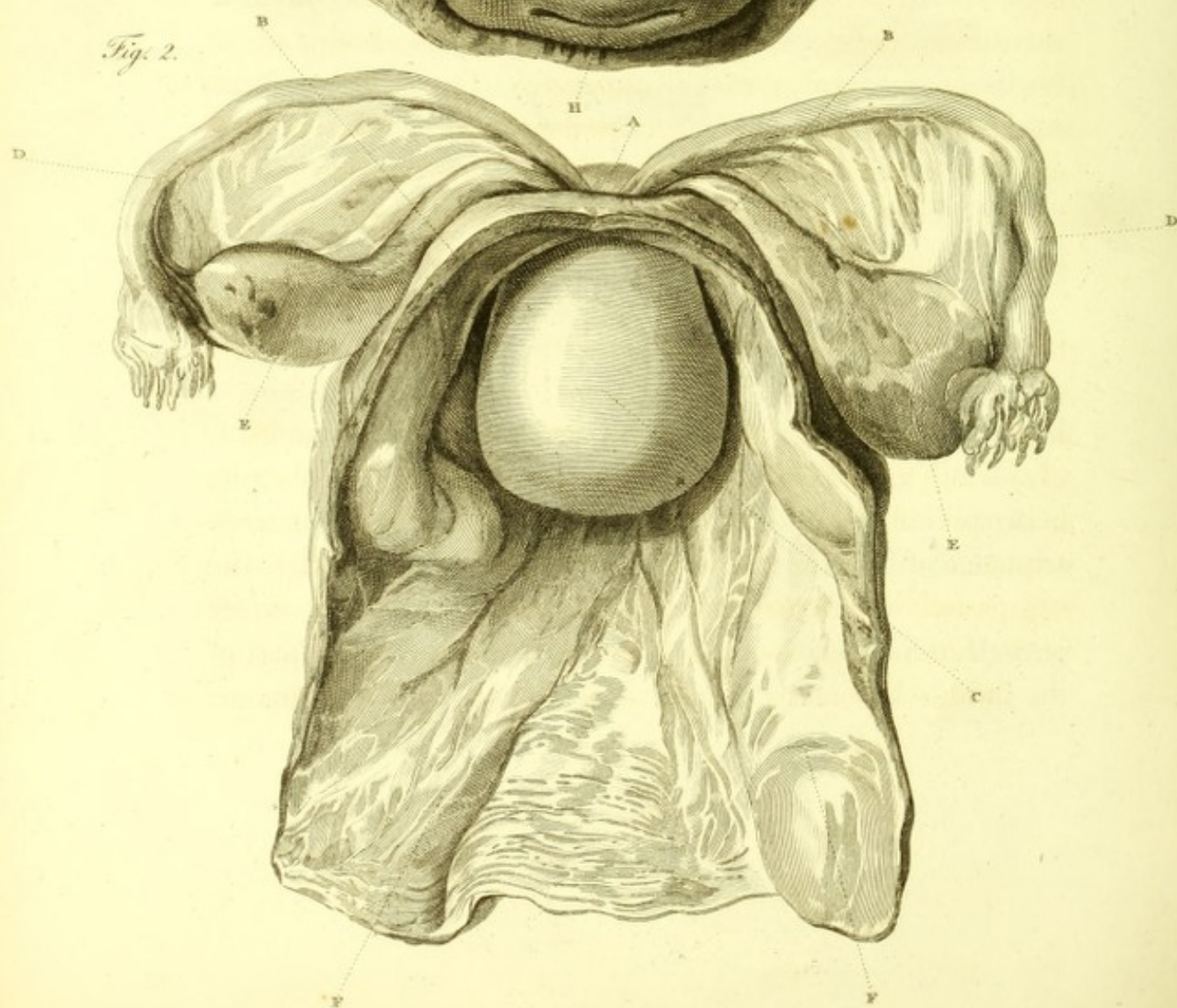


Fig. 2.





## PLATE V.

IN this Plate are represented the two diseases called Prolapsus Uteri, and Inversio Uteri. It is not unusual for the uterus to leave its ordinary situation, and to fall down into the cavity of the vagina. This is occasioned partly by the width of the vagina and pelvis, and partly by the relaxation of the broad ligaments of the uterus. When these circumstances concur in an eminent degree, the uterus passes out of the body, and it constitutes a complete case of prolapsus. The prolapsus forms a tumour of a different size and shape in different cases. It is sometimes more round and sometimes more elongated in its form. Where the tumour is long and narrow, the prolapsus has sometimes been mistaken for an hermaphrodite structure.

The inversio uteri consists either in a part of the fundus passing within the cavity of the uterus, and forming a tumour there; or the whole of the uterus may be inverted, making a large swelling in the cavity of the vagina, and on the outside of the vulva. This last change is produced by the placenta being pulled away too forcibly after a child is born, in consequence of which the fundus uteri is dragged through the vagina and the external parts. In this swelling the inner surface of the fundus uteri is exposed to view, and the upper part of the fundus becomes the most depending part of the tumour.



I know of no preparation which shews this complete inversion, but an engraving of it has been published by Ruysch.\*

FIG. I.

Represents a prolapsus uteri.

A A. A part of the skin at the pubes.

B B. The external labia.

C C. The two nymphæ.

D. The head of the clitoris.

E. The prepuce of the clitoris.

F. The orifice of the urethra.

G. The inner surface of the vagina, which is inverted from the prolapsus of the uterus.

H. The os uteri.

*From Dr. Combe's Collection.*

FIG. II.

Represents an inversion of the uterus; the vagina and a part of the uterus have been cut open upon their posterior side, in order to bring the inverted portion of the uterus into view.

A. A small part of the anterior portion of the uterus, just where the inversion is beginning to take place.

\* Vide Tom. I. Observat. X.



- B B. The posterior part of the uterus cut open, in order to shew the inverted portion of it.
- C. The inverted portion of the uterus, forming a tumour.
- D D. The two Fallopian tubes drawn in along with the inverted part of the uterus.
- E E. The two ovaria.
- F F. A part of the vagina laid open.\*

*From Dr. Combe's Collection.*

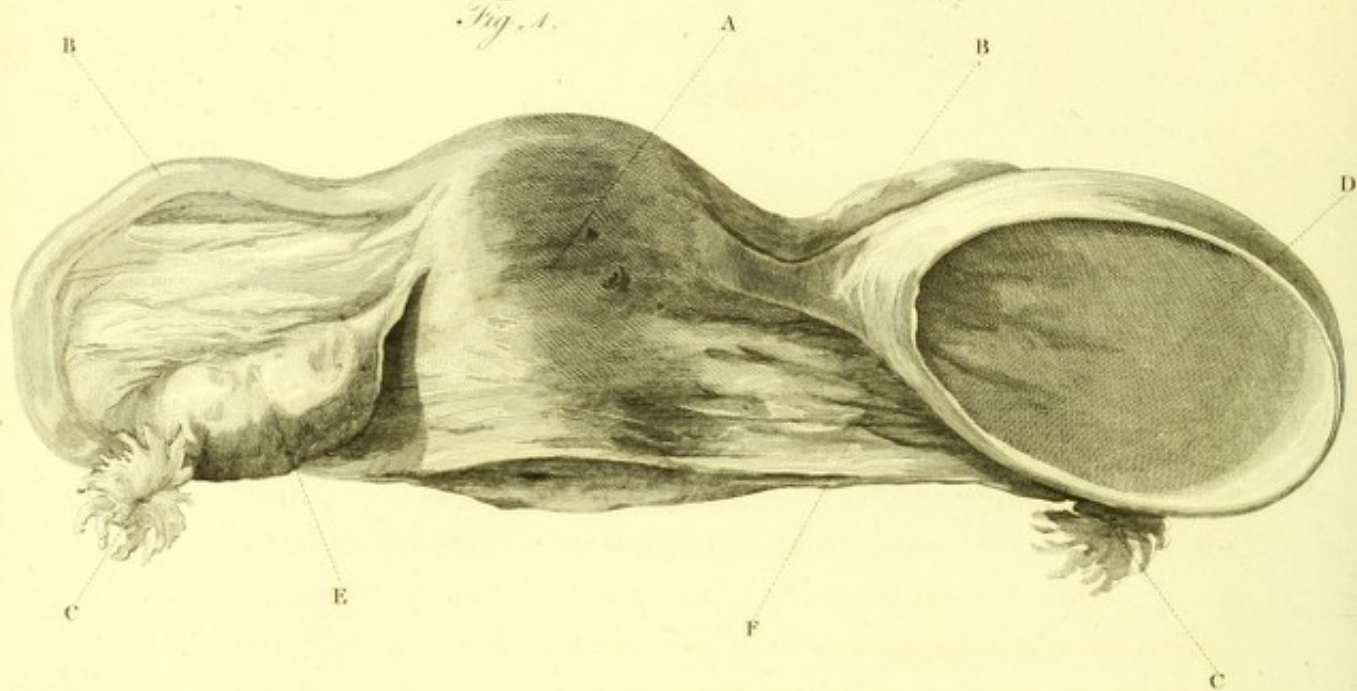
\* An excellent engraving of the same diseased parts has been lately published by Dr. Denman in the last edition of his *Introduction to the Practice of Midwifery*. The drawing from which his engraving was made, was taken from the parts when fresh, but the drawing from which the present engraving was made, was taken from the parts when formed into a preparation. There is a little difference in the representation given by the two engravings, because the position of parts, at the time of the two drawings being taken, was not exactly the same.



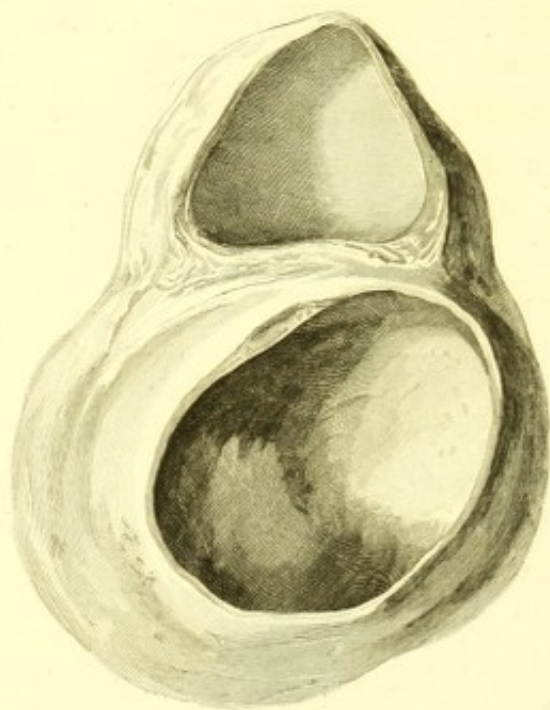




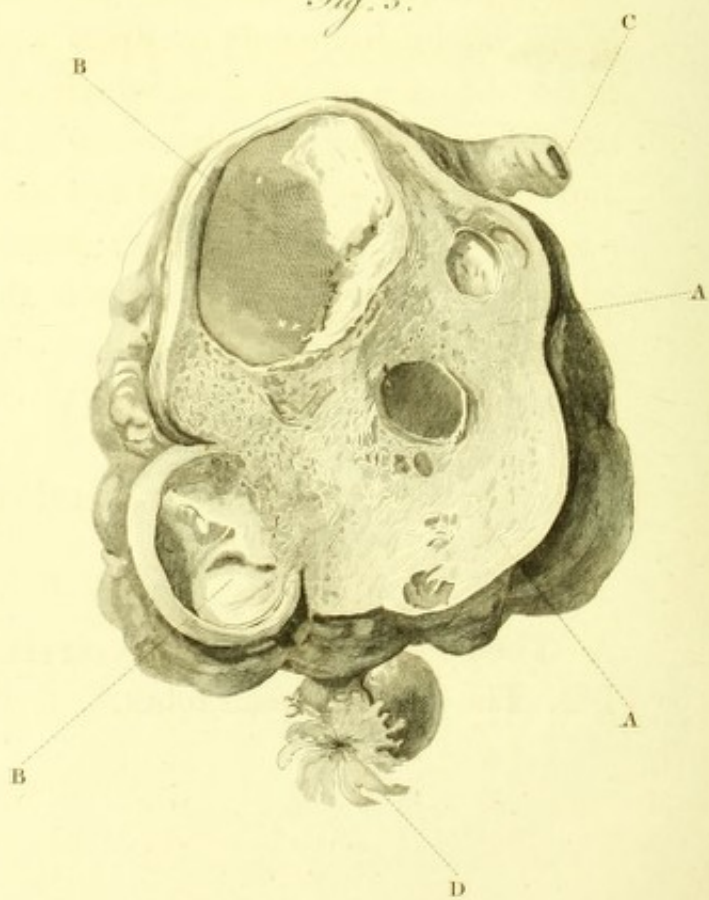
*Fig. 1.*



*Fig. 2.*



*Fig. 3.*





## PLATE VI.

THIS Plate represents the chief varieties which are observable in dropsical ovaria. The natural substance of an ovarium is sometimes changed into a cyst or bag of a large size, containing a fluid: more commonly it is converted into a number of bags, which either communicate together, or each bag is complete, having no communication with the others. It is also not unusual for an ovarium partly to consist of a solid uniform flesh, and partly of a number of bags. In whatever way the ovarium is changed as above described, it is often very much enlarged in size, and it frequently occupies the greater part of the cavity of the abdomen. The fluid which a dropsical ovarium contains, is sometimes merely serous, sometimes viscid or ropy, and sometimes gelatinous. When an ovarium is composed of a number of cysts which have no communication with each other, it will sometimes happen that different cysts will contain a different fluid.

## FIG. I.

Represents an ovarium converted into a cyst or bag which had contained a serous fluid.

A. The body of the uterus, its cervix having been cut off.

B B. The two Fallopian tubes.



- C C. The fimbriated extremities of the Fallopian tubes.  
D. The right ovarium converted into a bag about the size of a large hen's egg, which consists of a firm white membrane.  
E. The left ovarium in a healthy state.  
F. The broad ligament of the uterus upon the right side, extended.

*From Dr. Hunter's Museum.*

### FIG. II.

Represents a small portion of a very large ovarium, which had been converted into a great many cysts. These are composed of a firm white membrane, and do not communicate with each other. I do not perfectly recollect what was contained in the cysts of this ovarium, but some of them, I believe, contained a serous fluid, and others a jelly.

*From the Author's Collection.*

### FIG. III.

Represents a section of an ovarium, which is partly composed of a solid substance, and partly of cysts or bags.

- A A. The solid substance.  
B B. Two considerable cysts.  
C. The body of the Fallopian tube cut through.  
D. Its fimbriated extremity.

*From the Author's Collection.*






Fig. 1.

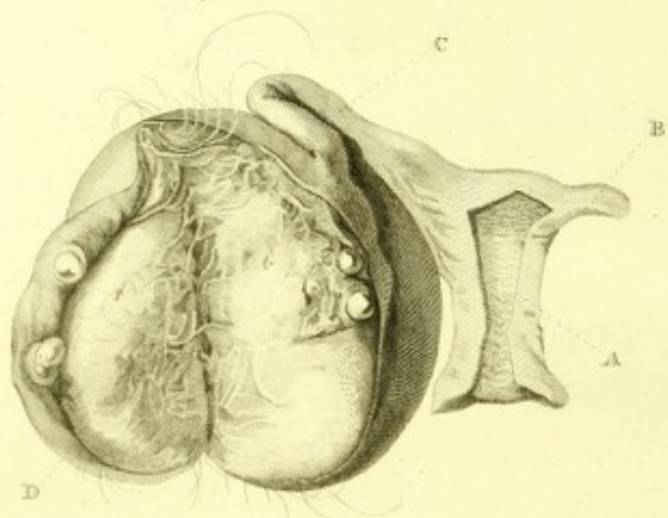
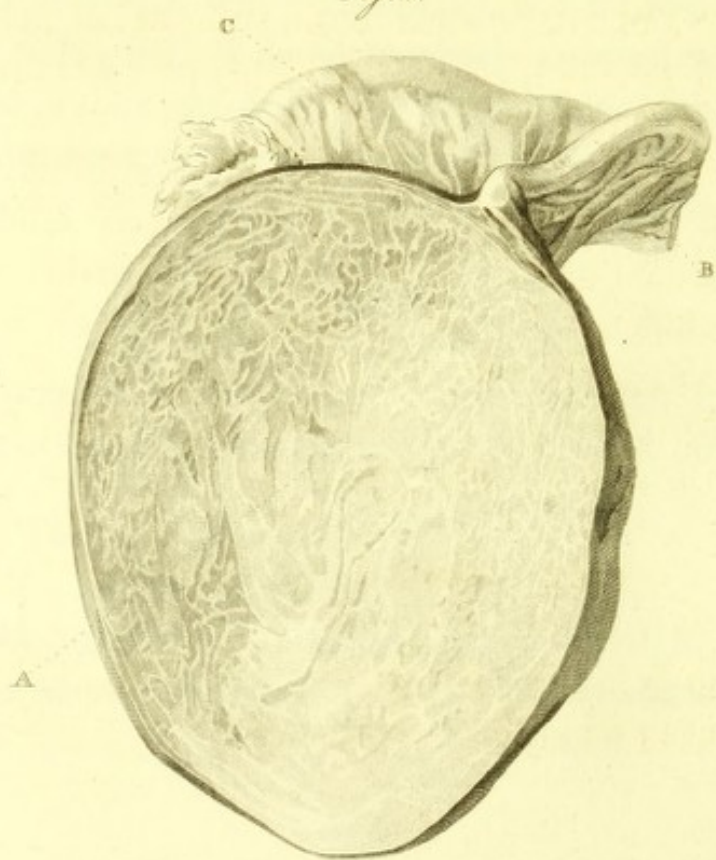


Fig. 2.





## PLATE VII.

IN this Plate is represented a very uncommon change of structure in an ovarium, by which it is converted into a membranous bag containing a suetty matter, hair, and some teeth imperfectly formed. This change has been generally considered as the very imperfect rudiments of a foetus which had been formed in the ovarium. As, however, this change can take place in the ovarium, before the uterus would appear capable of these functions which begin at the age of puberty, and where the hymen is entire, it is highly probable that it is independent of impregnation.

In this Plate, too, is represented a scirrhus ovarium. It is much enlarged in its size, and consists of a very solid substance intersected by membranes, which run in various directions. It resembles exactly in its texture the tumours which grow upon the outside of the uterus, and, I believe, has very little tendency to inflame or suppurate. The ovaria are but seldom affected with this disease.

## FIG. I.

Represents an ovarium containing a suetty matter, hair, and the rudiments of four teeth. It belonged to a girl, who, from

the appearance of the pubes, and the uterus, could not be more than twelve or thirteen years of age, and whose hymen was perfect.

- A. The uterus laid open. It is evident that it had not undergone that process of enlargement which takes place at puberty, and is in fact as small as the uterus of a child at birth.
- B. The cut extremity of one of the Fallopian tubes.
- C. The other Fallopian tube.
- D. The ovarium which contains the suetty substance, hair, and the rudiments of four teeth. The hair is pretty long, and had grown from the inner surface of the membrane containing the suetty matter, with which it is intermixed. There are four teeth imperfectly formed, the fangs being wanting. These were each of them inclosed in proper capsules, which, in order to shew the teeth, have been cut off.\*

*From the Author's Collection.*

## FIG. II.

Represents a section of a scirrhus ovarium.

\* A more particular account of this preparation was presented by the Author to the Royal Society, and printed in their Transactions for the year 1789.



- A. The section of the ovarium. It is much enlarged in its size, and consists of a solid matter intersected by membranes, which are distinctly represented in the engraving.
- B. The ligament of the ovarium, which appears to be a little thickened.
- C. A part of the Fallopian tube.

*From Dr. Hunter's Museum.*

A. The section of the ovum, it is much enlarged in its size, and consists of a solid mass, intersected by membranes, which are distinctly represented in the engraving.

B. The ligament of the ovum, which appears to be a little thickened.

C. A part of the Fallopian tube.

From Dr. Hunter's Museum.





Fig. 1.

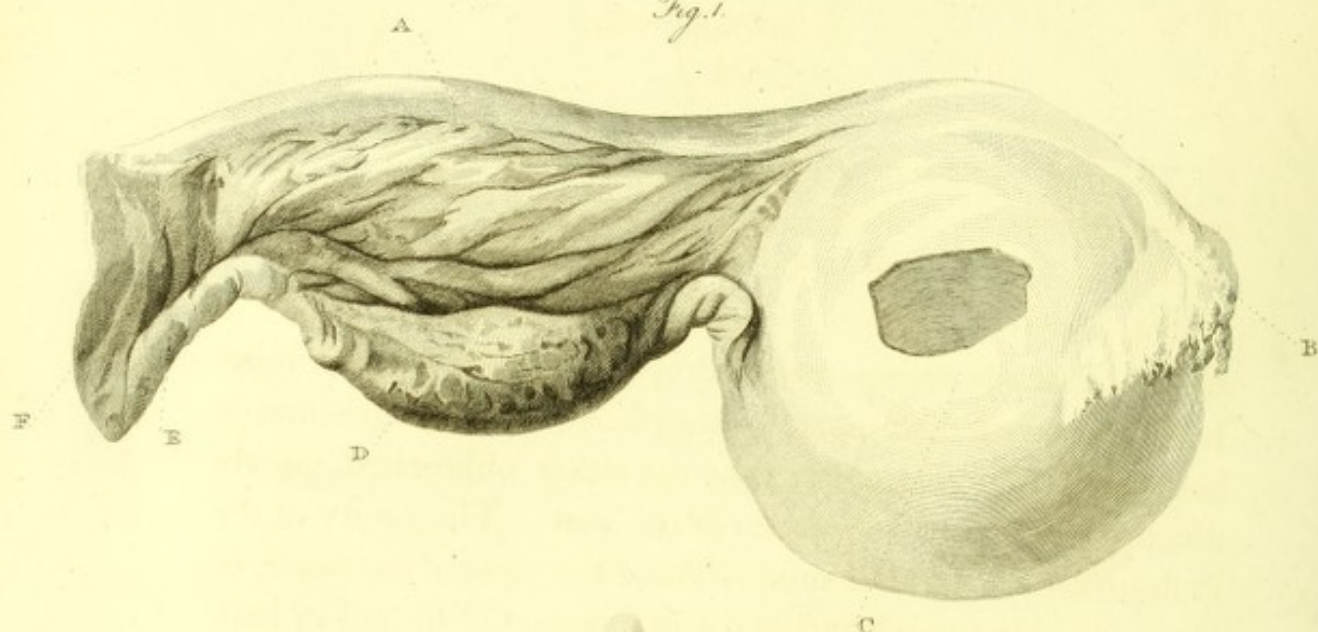
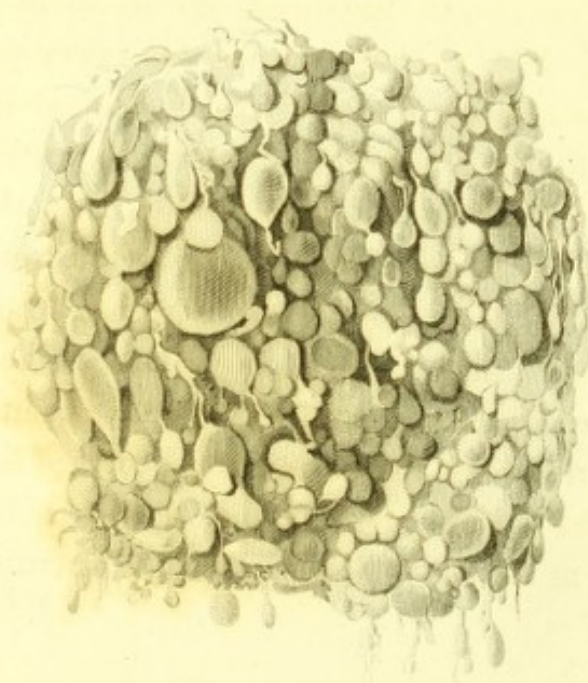


Fig. 3.



Fig. 2.





## PLATE VIII.

IN this Plate is represented a dropsy of the Fallopian tube. It is a very rare disease, and takes place when the apertures at both ends of a Fallopian tube are either obliterated, or are much narrower than in their natural state. The cavity of the Fallopian tube is either much dilated throughout its course, or a considerable tumour is formed in one part of it, and in both cases the swelling contains a serous fluid. The last form of swelling only is represented in this Plate.

In this Plate, too, a portion of a placenta is represented, which had been converted into hydatids. It had belonged to an ovum which was not far advanced, viz. to about the third or fourth month. It is not uncommon for every part of an ovum, except the foetus, to have hydatids formed in it, and these put on a different appearance from the hydatids which grow in the human liver. They are oval in their shape, and have a very narrow neck or process running out from one extremity of them. Their coats are thinner than those of the hydatids of the liver, and they are not inclosed like them, in hard cysts. They possess a procreative power, and smaller hydatids are often to be seen attached to the coats of larger ones. They appear to have the same claim with hydatids of the liver, to be considered as animals of a very simple structure.



It does not fall strictly within our plan, to represent the hydatids of the ovum, because they properly belong to diseases connected with pregnancy ; but still we have not wandered far out of our road, and we thought it would be agreeable to most of the purchasers of this work to possess an accurate engraving of them.

### FIG. I.

Represents a dropsical tumour of the Fallopian tube.

- A. The portion of the Fallopian tube, next to the uterus.
- B. Its fimbriated extremity.
- C. The tumour, into which an opening has been made : it is of the size of an orange, and contained a serous fluid.
- D. The ovarium.
- E. The ligament of the ovarium, where it arises out of the uterus.
- F. A very small portion of the uterus.

*From Dr. Hunter's Museum.*

### FIG. II.

Represents a portion of the placenta at an early period of pregnancy, converted into hydatids. These are small in their size, of an oval shape, with small processes or stalks



arising from one extremity of them, and have thin transparent coats.

*From the Author's Collection.*

FIG. III.

Represents a few of these hydatids detached from the rest, in order to shew smaller hydatids adhering to larger ones. They adhere to each other by slender processes.

arising from one extremity of them, and have thin transparent coats.

## FIG. III.

Represents a few of these hyaline detached from the rest, in order to show smaller hyaline adhering to larger ones. They adhere to each other by slender processes.





Fig. 1.

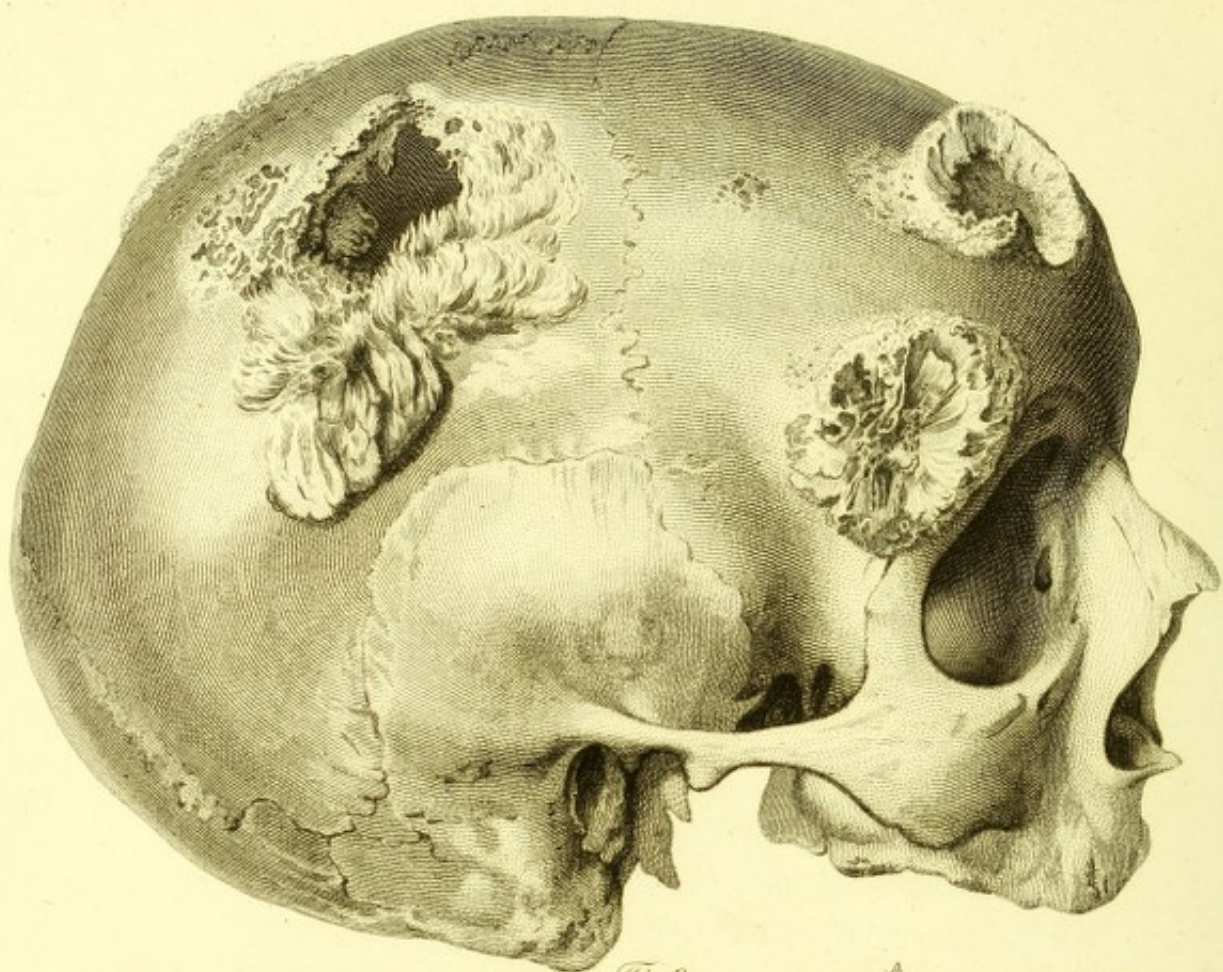
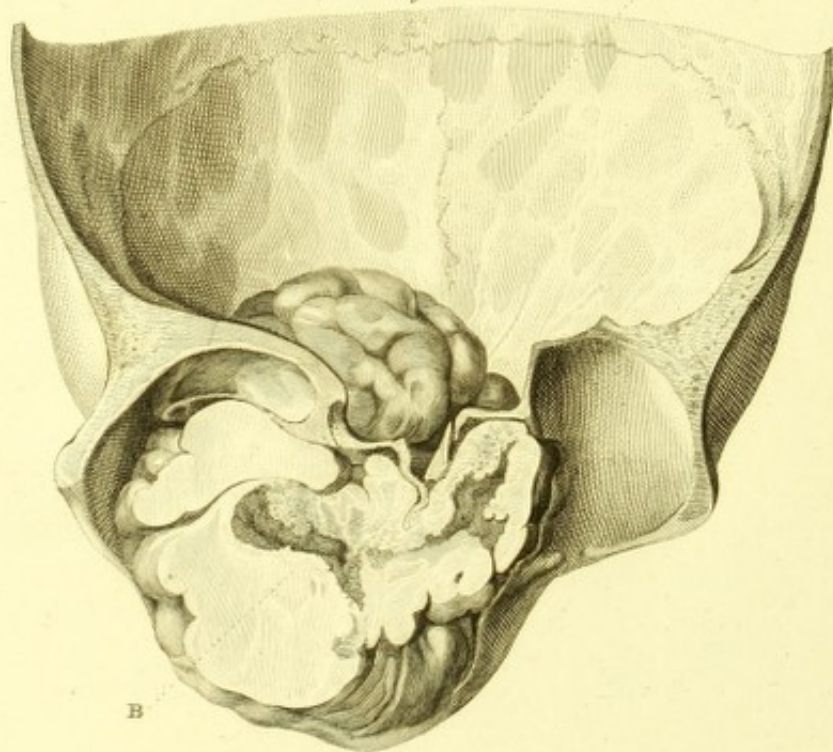


Fig. 2.





THE  
TENTH FASCICULUS.

---

IN this Fasciculus it is proposed to illustrate the principal morbid changes of structure, which occur in the cranium, the brain, and its membranes. The diseases of the cranium may appear at first sight hardly to fall within the plan of this work, but they cannot properly be omitted, as they very often have a powerful influence upon the functions of the brain. The morbid changes of structure, to which the brain is subject, possess a good deal of variety, but some of them cannot be represented at all by engravings, and others will admit of a less distinct representation, from the peculiar texture of the brain, than the morbid appearances which take place in most other parts of the body.

PLATE I.

IN this Plate are represented two diseases of the cranium. The one consists of bony excrescences, which assume a sort of oval form. These are composed of bony spicula resembling



crystallizations, which grow from the outer, and also from the inner surface of the cranium. The original bone of the cranium at these places is absorbed, and in this disease a double process would appear to be going on at the same time, viz. the absorption of the original bone, and the formation of new bone in the shape of spicula or crystals. Of the nature of this disease nothing is accurately known, but it has been sometimes regarded as cancerous.

The other disease of the cranium, represented in this Plate, consists of a substance which exactly resembles ivory in the compactness of its texture, and it is extremely rare.

#### FIG. I.

Represents the right side of the cranium, in which four excrescences of bone composed of spicula may be distinctly seen. The greater number of these shoot outwards, but some are also directed into the cavity of the cranium.

*From Dr. Hunter's Museum.*

#### FIG. II.

Represents an inner view of a section of the forepart of the cranium. The section has been made at such a level, as to include a small part of each orbit. It is intended to represent a considerable tumour, which occupies the left orbit and



shoots for some way into the cavity of the cranium. This tumour has the texture of ivory.

A. The inner surface of the anterior part of the cranium.

B. The tumour resesembling ivory.

*From Mr. Hunter's Museum.*

shows for some way into the cavity of the cranium. The  
tunnel has the texture of ivory.

A. The inner surface of the posterior part of the cranium.

B. The anterior view of the cranium.

From the *Alouatta* *fulva*.

The cranium is shown in the same position as in the  
figure, and is the same as in the figure.

The cranium is shown in the same position as in the  
figure, and is the same as in the figure.





Fig. 1.

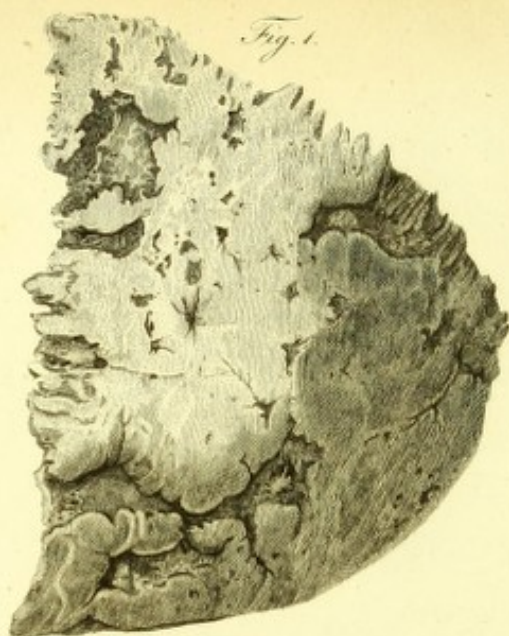
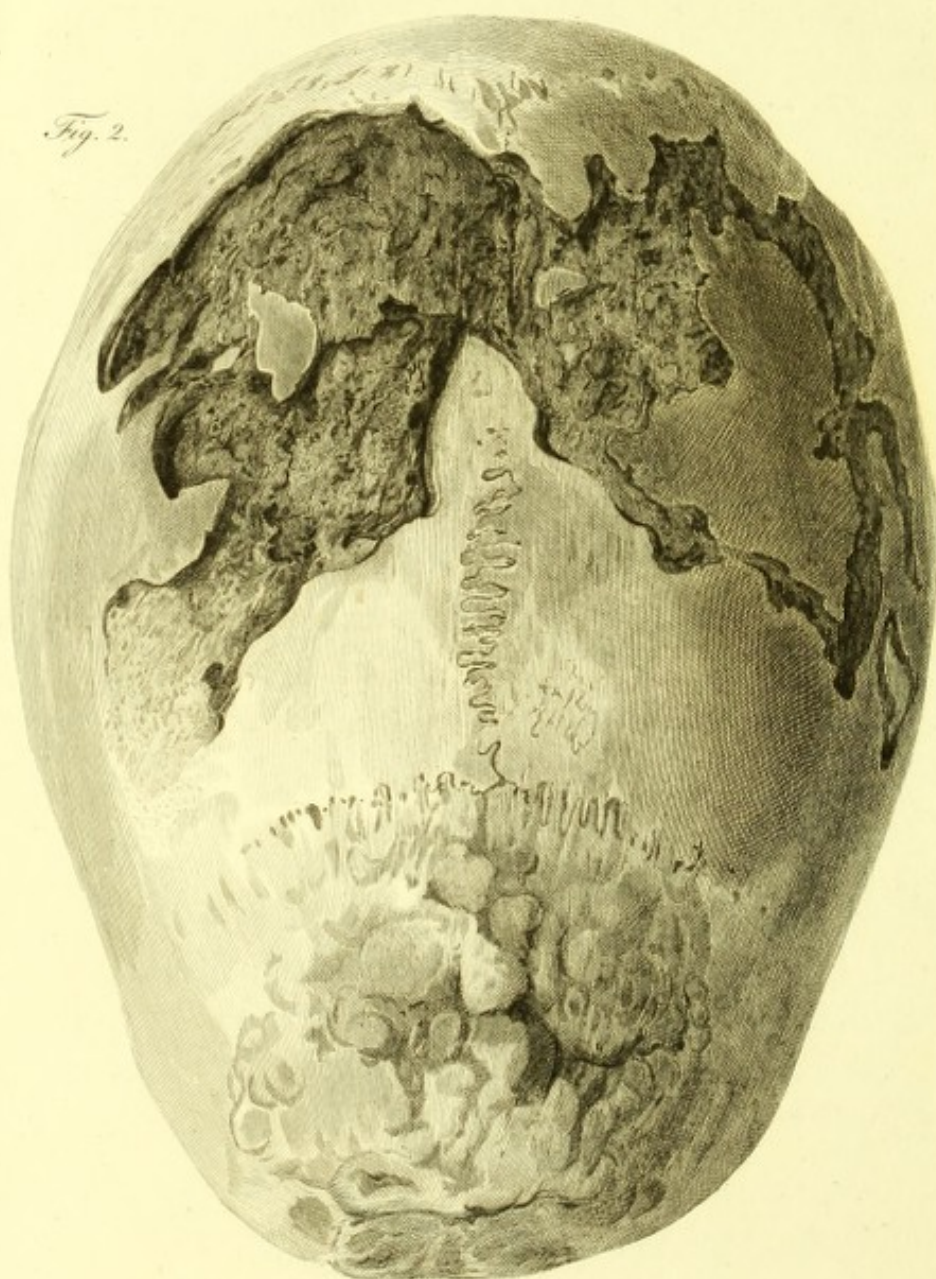
Fig. 2.





## PLATE II.

THIS Plate represents the effects which the venereal disease commonly produces upon the bones of the cranium. They generally become heavier in this disease, from a deposition of bony matter into the diploe of the bones. They become ulcerated upon their external surface, and the ulcers are very irregular, having more the appearance of the bones being worm-eaten, than of the ulcers being produced by the action of absorbent vessels. Sometimes there are protuberances on the bones of the cranium, but these are seldom much elevated above the general surface.

## FIG. I.

Represents a small portion of the left side of the frontal bone, which in this case was divided from the right side by a frontal suture. Upon its external surface many irregular ulcers are observable, which look very much as if the parts had been worm-eaten.

*From Dr. Hunter's Museum.*

## FIG. II.

Represents the outer surface of the upper part of the cranium. It shows a very large and irregular ulceration of the parietal bones, and on the frontal bone a number of small irregular protuberances.\*

\* This engraving was taken from a preparation belonging to Mr. Pearson, who had the patient under his care in the Lock Hospital.

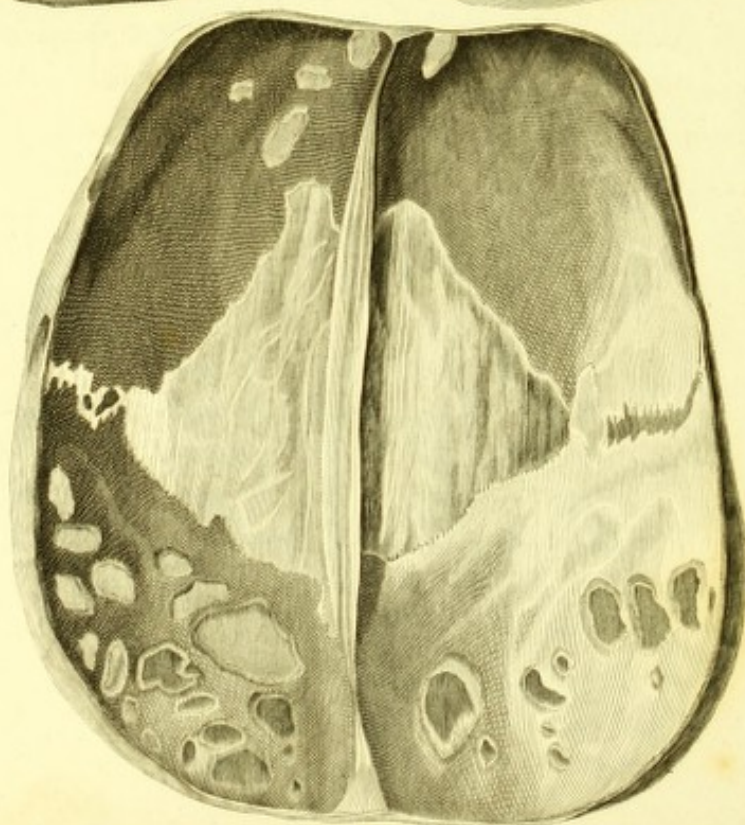




Fig. 1.

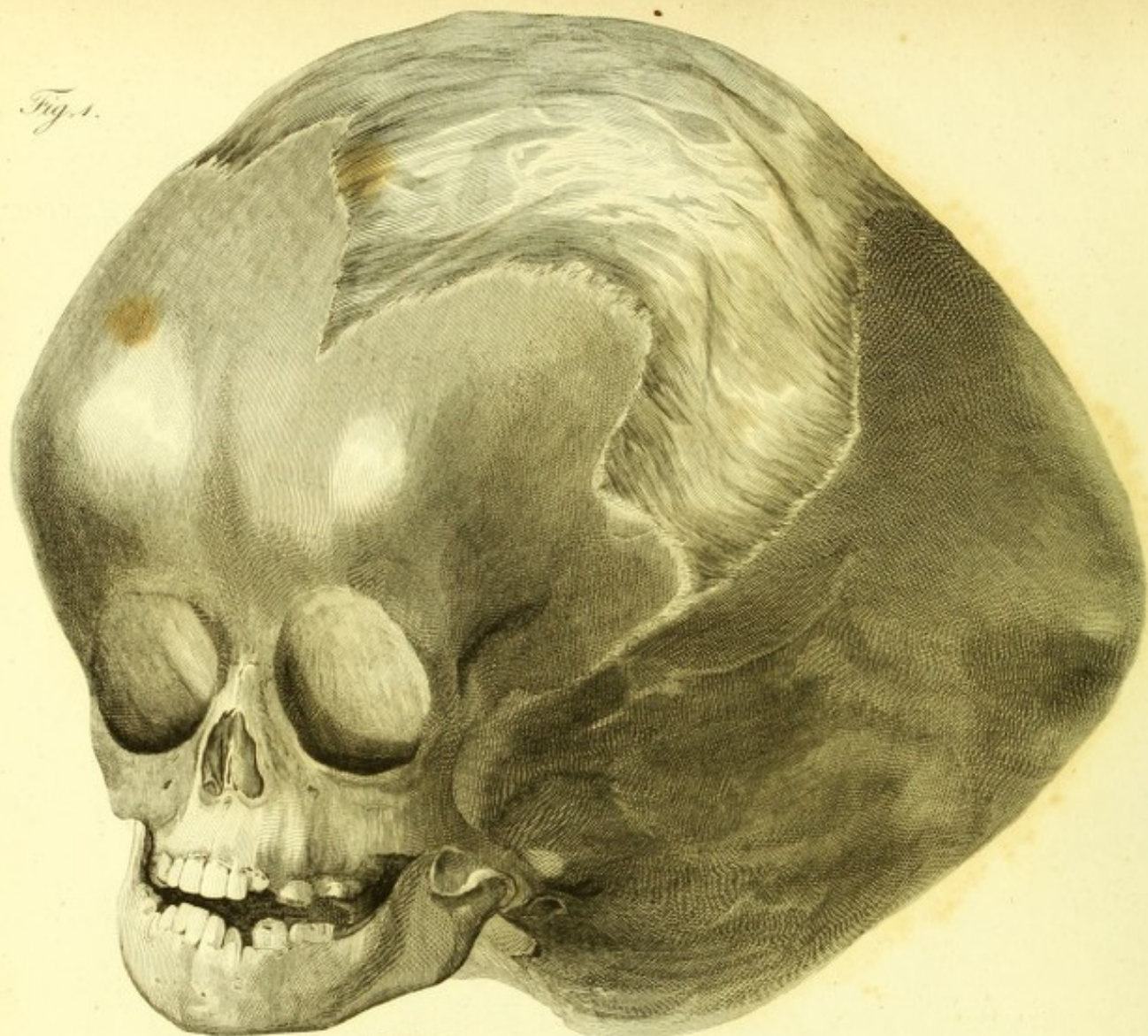

Fig. 2.





## PLATE III.

THIS Plate is intended to illustrate the external appearances of the cranium in a young child, when affected with hydrocephalus of a long standing. The cranium, in this stage of the disease, is very much enlarged in size, bearing a monstrous proportion to the upper and lower jaws. The bones at the upper part of the cranium are widely separated from each other, exhibiting a great extent of membranes. The frontal, the parietal, and occipital bones have strongly-marked projections at their centres of ossification, and frequently show spots of membrane not converted into bone. Where the cranium is very much enlarged in hydrocephalus, the brain is thinned by absorption into a pulpy bag, and the corpus callosum is burst, so that the water deposited in the ventricles comes in contact with the dura mater at the upper part of the cranium. In this way an hydrocephalus originally internal, becomes in part external. When the bones of the cranium have been united together, before water begins to be accumulated in the ventricles of the brain forming hydrocephalus, they are never separated by that accumulation, and the external form of the head remains the same. The water which is accumulated in hydrocephalus is always limpid; but it varies a good deal in different cases, in the quantity of coagulable matter which



it holds in solution, and sometimes this matter is altogether wanting.

FIG. I.

Represents the head of a child, about two years old, who had probably hydrocephalus from its birth. The cranium is very much enlarged, the projections at the centres of ossification in the frontal and parietal bones are very strongly marked, and there is a wide expanse of membrane at the anterior fontanelle. The upper and lower jaws bear a very diminutive proportion to the size of the cranium.

*From Dr. Hunter's Museum.*

FIG. II.

Represents the inner surface of the upper part of the cranium from a hydrocephalous child. It is intended to show the extreme thinness of the bones of the cranium in this disease at a very early period of life, and to show also many spots of membrane, that had been left from a deficiency in the progress of ossification, which could not keep pace with the accumulation of the water.\*

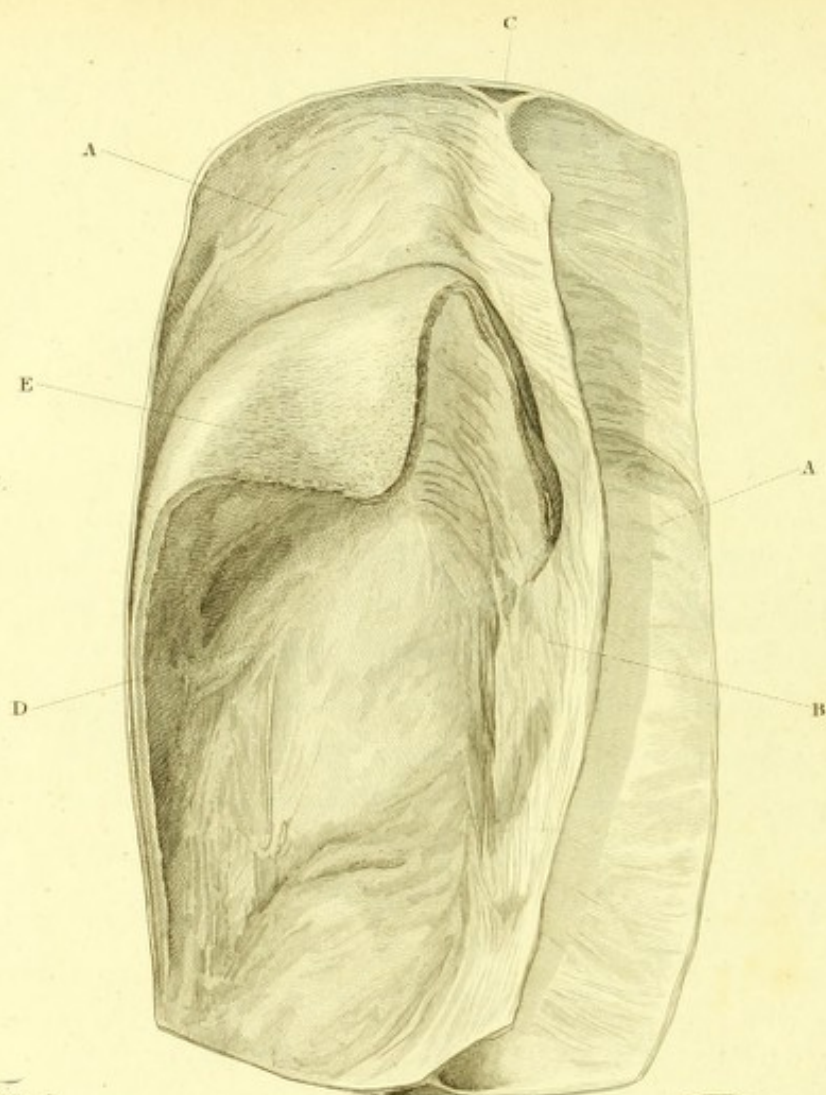
*From Dr. Hunter's Museum.*

\* Both figures in this Plate are considerably less in size than the preparations which they represent, in order to be adapted to the size of the paper; but in other respects they are very faithful.

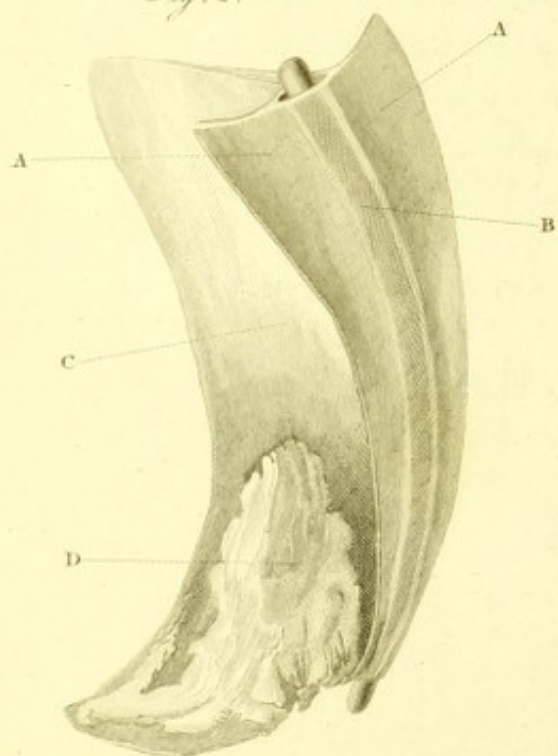




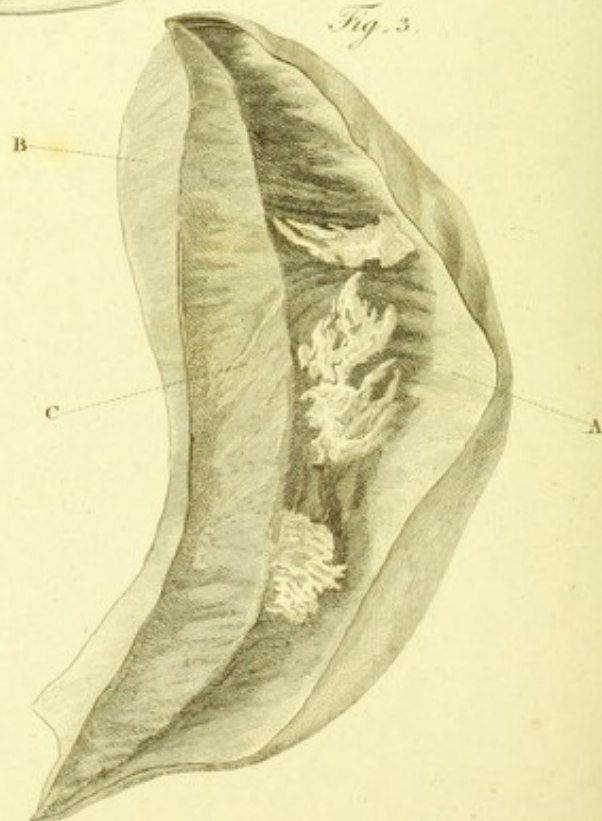*Fig. 1.*



*Fig. 2.*



*Fig. 3.*





# PLATE IV.

THIS Plate represents two morbid appearances of the dura mater. The first is an inflammation of this membrane, which had been so violent as to form a layer of coagulable lymph upon its inner surface. Inflammation of the dura mater very seldom advances so far as to produce this effect; but when it takes place, the layer of coagulable lymph exactly resembles that which is formed upon the surface of an inflamed pleura or peritonæum.

This Plate too represents some ossifications of the dura mater. These are very rarely of a large size, and are almost always found either in the falciform process, or in its immediate neighbourhood.

## FIG. I.

Represents a considerable portion of the dura mater in an inflamed state, which had covered the upper part of the brain.

A A. The portion of the dura mater, which lay upon the upper surface of the two hemispheres of the brain.

B. The falciform process.

C C. The superior longitudinal sinus.

- D. The layer of coagulable lymph lying in contact with the dura mater
- E. A portion of this layer separated from the dura mater, and turned down in order to be seen more distinctly.

*From Dr. Hunter's Museum.*

### FIG. II.

Represents an ossification in the falciform process of the dura mater.

- A A. A small portion of the dura mater, which had covered the upper surface of the brain.
- B. The longitudinal sinus, in which a bougie has been put.
- C. The falciform process.
- D. An ossification in it of a large size.

*From the late Mr. Cruikshank's Collection.*

### FIG. III.

Represents another example of ossification in the dura mater. The ossification consists of three or four distinct irregular masses, which are formed very near the upper edge of the falciform process, but not in the process itself.

- A. A portion of the dura mater which had covered the upper



surface of one of the hemispheres of the brain in which these ossifications are formed.

B. Another portion of the dura mater covering the upper surface of the other hemisphere of the brain.

C. The falciform process. *From Mr. Heaviside's Museum.*







Fig. 1.

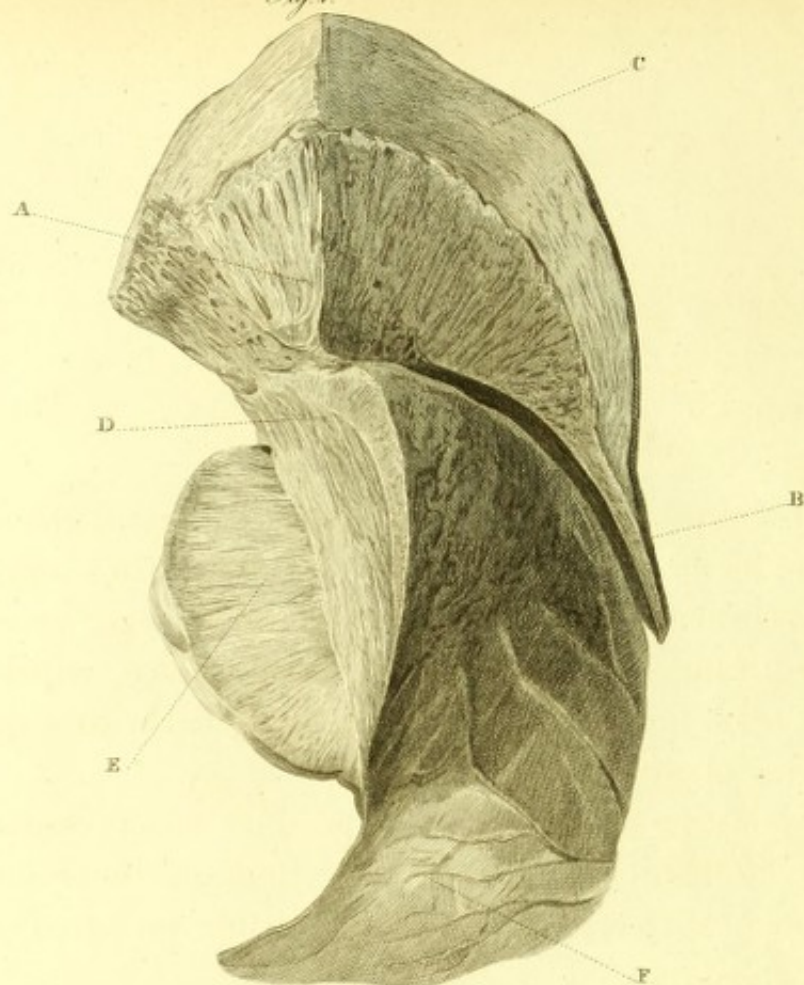
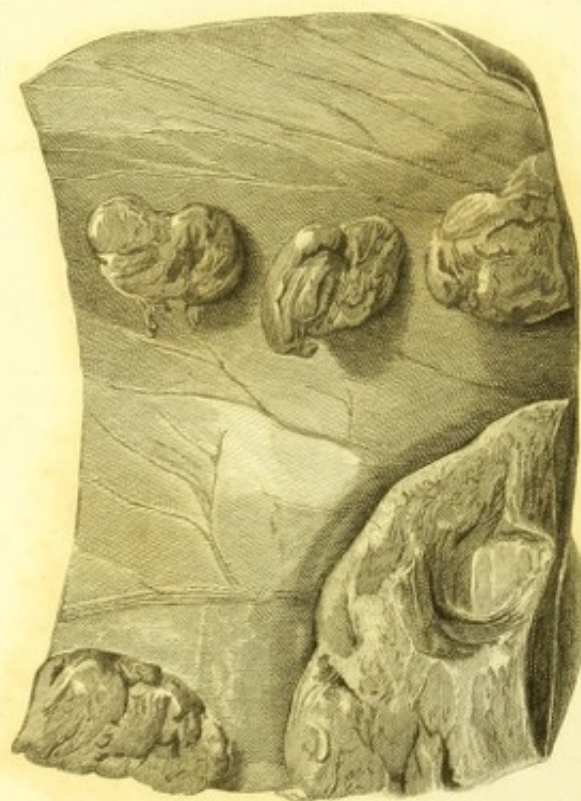

Fig. 2.





## PLATE V.

THIS Plate represents two very uncommon diseased changes of structure in the dura mater. The one consists in a portion of the dura mater being very much thickened, together with a spongy tumour growing from its inner surface, which had pressed upon the brain. This was connected with a spongy thickening of a part of the cranium.

The other morbid change of the dura mater consists in several scrofulous tumours growing from its inner surface. These are of such a size as to have probably produced considerable pressure upon the brain.

## FIG. I.

Represents a part of the dura mater very much thickened, with a spongy tumour growing from its inner surface.

- A. The thickened spongy part of the cranium.
- B. The sound part of the cranium.
- C. A fleshy tumour covering the spongy texture of the diseased portion of the cranium.
- D. The thickened part of the dura mater.
- E. The spongy tumour, which is fibrous in its texture, and

the fibres arise nearly at right angles from the inner surface of the diseased portion of the dura mater.

F. A part of the dura mater, sound in its structure.

*From Dr. Hunter's Museum.*

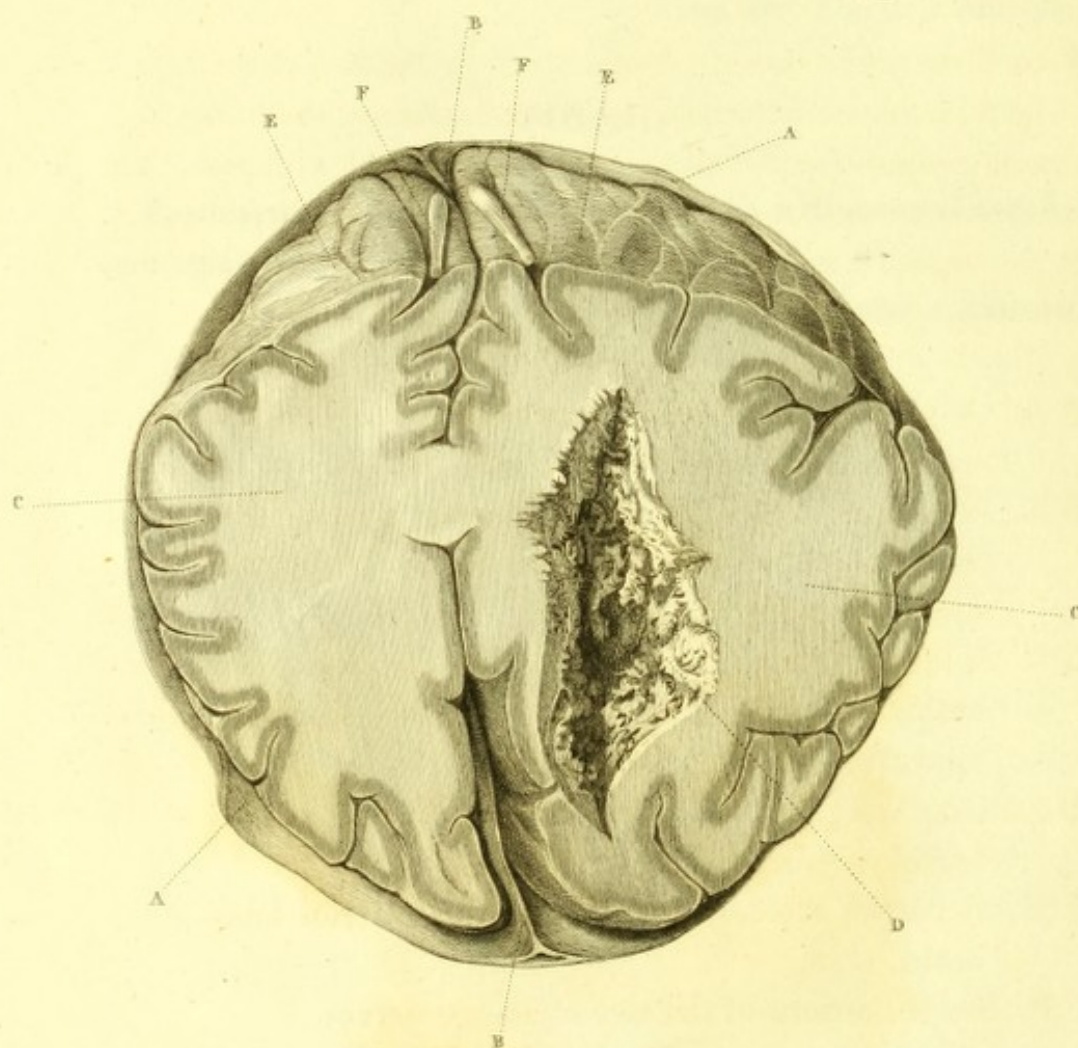
# FIG. II.

Represents a portion of the dura mater with several scrofulous tumours growing from its inner surface.

*From Mr. Hunter's Museum.*









## PLATE VI.

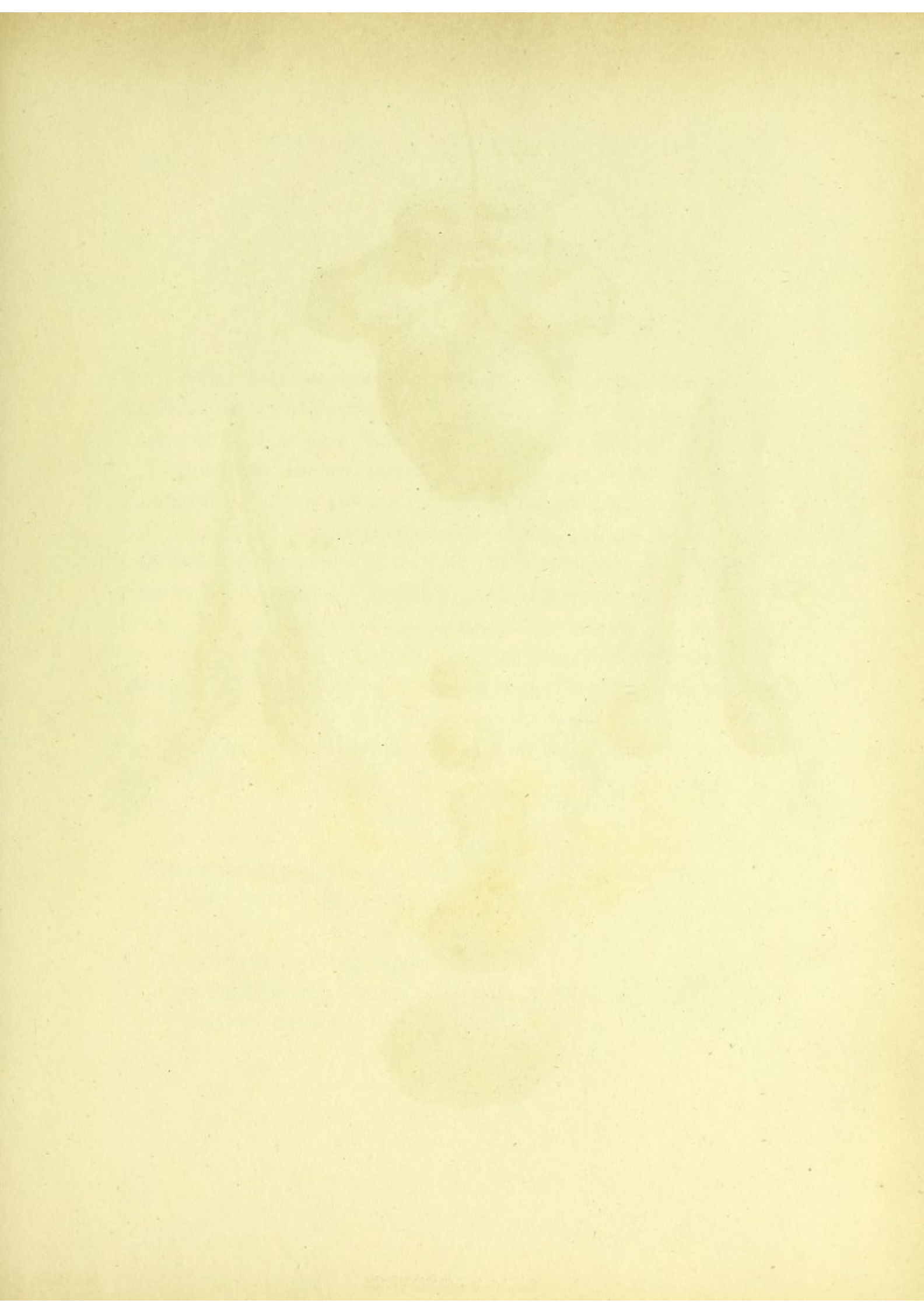
THIS Plate represents an abscess in the substance of the brain. When an abscess is formed upon the surface of the brain, it is almost constantly the effect of some external violence; but when it is formed at a considerable depth within the substance of the brain, it is often independent of this cause. The first situation of abscess is much more common than the second.

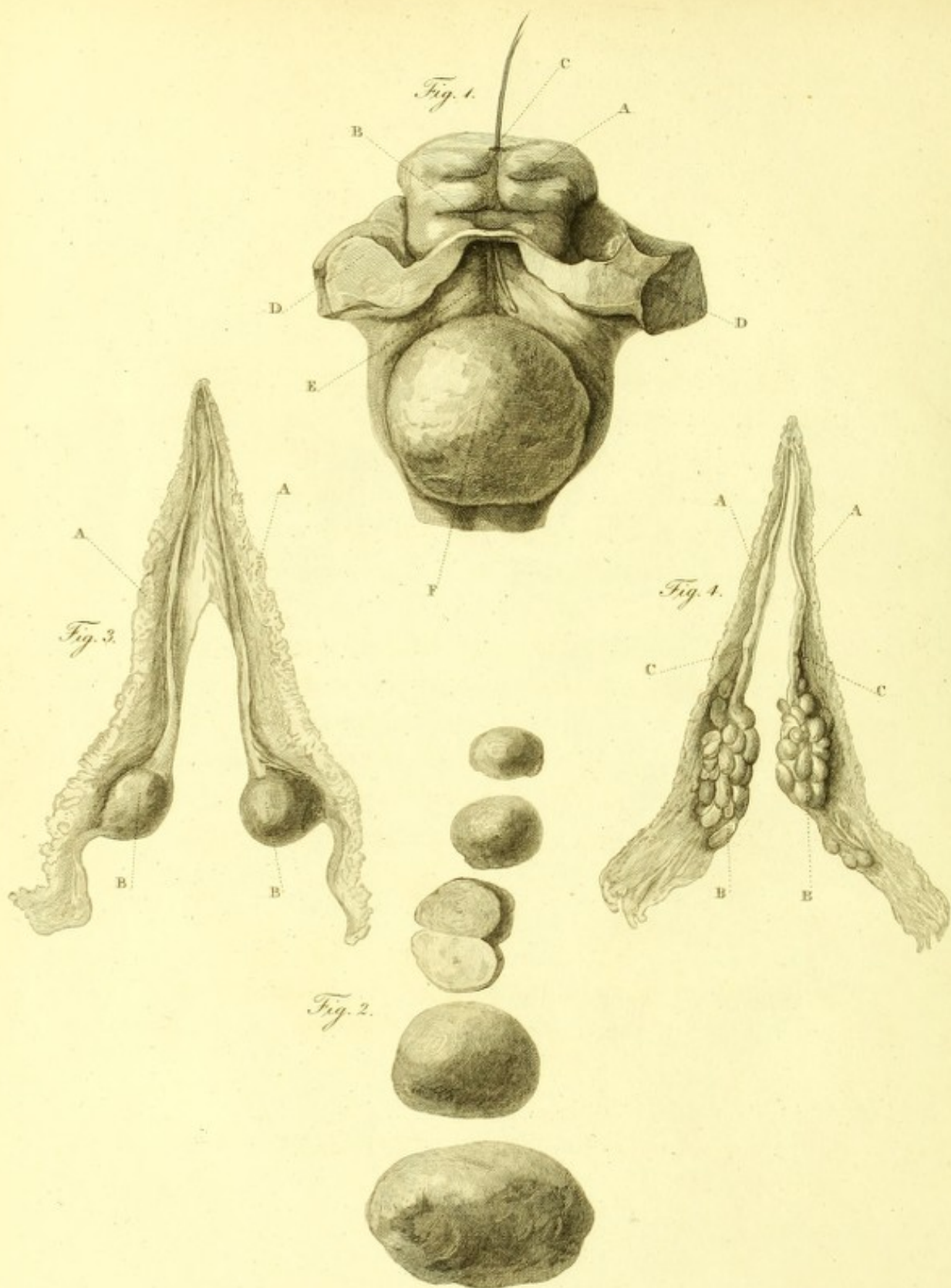
- A A. A portion of the dura mater, which covers the upper surface of the hemispheres of the brain.
- B B. A portion of the falciform process of the dura mater which separates the two hemispheres of the brain from each other.
- C C. A section across the substance of the brain, somewhat oblique in its direction, so that the left hemisphere appears larger than the right.
- D. A large irregular abscess in the medullary substance of the left hemisphere of the brain.
- E E. A part of the lower surface of the anterior lobes of the brain.
- F F. Small portions of the two olfactory nerves.

*From Mr. Hunter's Museum.*











## PLATE VII.

THIS Plate represents the tubercles which are sometimes formed in the substance of the brain. These are white in their colour, are round in their form, and are of a scrofulous nature.

In this Plate also are represented two diseases of the plexus choroides. The one consists of little transparent bags, which have commonly been considered as hydatids, and are attached to the edge of the plexus choroides; the other consists of small round scrofulous tubercles, which grow in this vascular membrane. The first diseased appearance is very common, and the other is very rare. The little bags named hydatids, I have sometimes inflated with air from the vein which runs along the edge of the plexus choroides, so that they would appear to be varicose veins, although I do not recollect to have seen them filled with blood.

### FIG. I.

Represents a pretty large round tubercle, which had grown in the lower part of the fourth ventricle of the brain.

A. The corpora quadrigemina.

B. A part of that thin stratum of medullary substance, which has been called the valvula major.

- C. A bristle which is passed through the canal, named the  
iter a tertio ad quartum ventriculum.  
D D. A part of the crura of the cerebellum.  
E. A part of the cavity of the fourth ventricle.  
F. The tubercle. *From the late Mr. Cruikshank's Collection.*

## FIG. II.

Represents five tubercles of this sort, which had been separated from the brain. They vary in their size, and one of them is divided to show its structure. Its substance is very smooth, and uniform in its texture, and in the centre of it there is a small hole or cavity. *From Dr. Hunter's Museum.*

## FIG. III.

Represents the plexus choroides with two small scrofulous tubercles formed in it.

- A A. The plexus choroides.  
B B. The two small tubercles. *From Dr. Hunter's Museum.*

## FIG. IV.

Represents the plexus choroides with the small transparent bags.



A A. The plexus choroides.

B B. The transparent bags.

C C. The two veins at the edge of the plexus choroides, and which are beginning to become varicose before they reach the bags. In this case, the bags could be readily inflated from the two veins.

*From Mr. Hunter's Museum.*

PLATE VII.

- A.A. The pharynx choroides.  
B.B. The nasopharynx.  
C.C. The two veins at the edge of the pharynx choroides, which are beginning to become separate before they reach the pharynx. In this case the veins could be readily detached from the two veins.  
From the Library of the





Fig. 1.

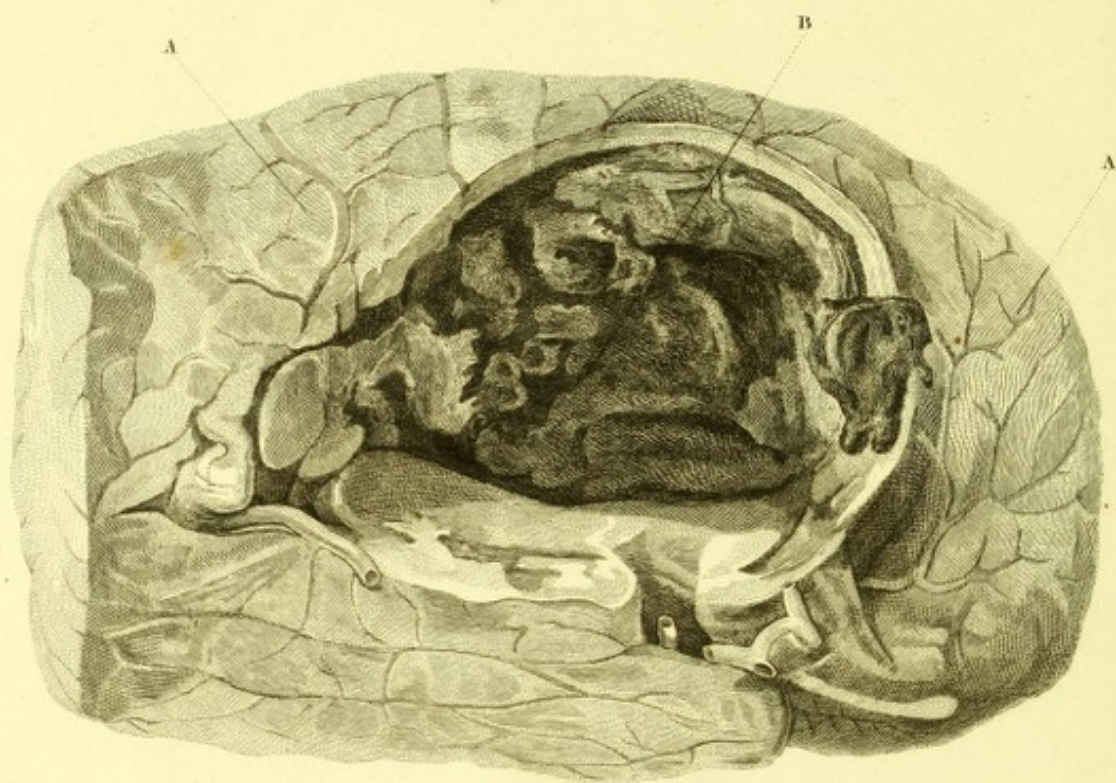
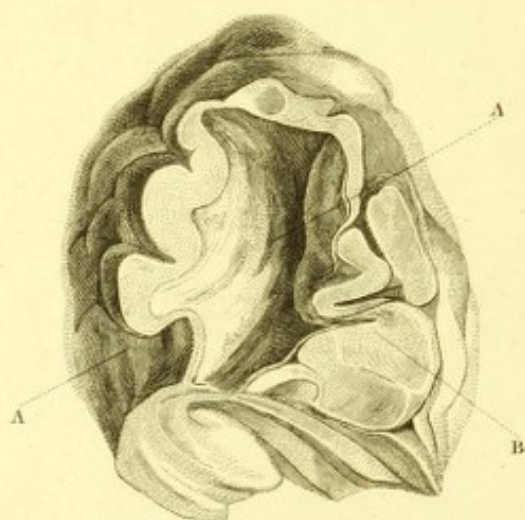


Fig. 2.





# PLATE VIII.

THIS Plate represents the most important diseased appearances which are discoverable in apoplexy.

In apoplexy an extravasation of blood takes place, from the rupture of a blood vessel into some part of the substance of the brain. The part where it more commonly occurs, is the medullary substance of the brain near the lateral ventricles, and some portion of the blood often escapes into these cavities.

Where a person has survived a fit of apoplexy for a considerable time, as for some months, the extravasated blood would seem to be absorbed, and a serous fluid to be substituted in its place. The substance of the brain immediately surrounding this serous fluid, becomes tough and firm, so as to resemble a good deal in its appearance a membrane.

## FIG. I.

Represents the greater part of the half of the cerebrum upon the right side, its anterior extremity being cut off. The flattened side of the hemisphere is presented to view, viz. that which lies in contact with the falciform process of the dura mater.

- A. A. The flattened surface of the right hemisphere of the cerebrum.
- B. A large mass of extravasated and coagulated blood. The blood during its extravasation had broke down a considerable part of the medullary substance of the hemisphere, and had burst into the right ventricle.\*

## FIG. II.

Represents a cavity in the cerebrum which contained a serous fluid, but had formerly been filled with extravasated blood during a stroke of apoplexy.

- A A. A transverse section of the anterior lobe of the cerebrum.
- B. The cavity which contained the serous fluid. It appears to be lined by a membrane, but this is only the substance of the brain condensed. *From the Author's Collection.*

\* This drawing was taken from a very fine preparation presented to the Author by Dr. Hooper.

FINIS.





# THE

THE

THE

THE

THE

THE

THE

# THE

THE

THE

THE

THE

THE

THE

THE

THE

THE

THE

THE

THE

THE









Ind 60-  
Ref 7/1/72



