

Abdominal sections in the women's ward Saint Bartholomew's Hospital for the year 1892 / by Harrison Cripps.

Contributors

Cripps, Harrison 1850-1923.

Publication/Creation

London : Smith, Elder & Co., 1894 (Edinburgh : Ballantyne, Hanson and co..)

Persistent URL

<https://wellcomecollection.org/works/h4qa277e>

License and attribution

This work has been identified as being free of known restrictions under copyright law, including all related and neighbouring rights and is being made available under the Creative Commons, Public Domain Mark.

You can copy, modify, distribute and perform the work, even for commercial purposes, without asking permission.



Wellcome Collection
183 Euston Road
London NW1 2BE UK
T +44 (0)20 7611 8722
E library@wellcomecollection.org
<https://wellcomecollection.org>


ABDOMINAL SECTIONS
IN THE
WOMEN'S WARD
SAINT BARTHOLOMEW'S HOSPITAL
FOR THE YEAR 1892

HARRISON CRIPPS, F.R.C.S.



22102139020

Med
K32035



With the Authors names registered

ABDOMINAL SECTIONS

IN THE

WOMEN'S WARD

SAINT BARTHOLOMEW'S HOSPITAL



FOR THE YEAR 1892.

F/2

BY

HARRISON CRIPPS, F.R.C.S.

ASSISTANT-SURGEON TO THE HOSPITAL, AND OPERATOR FOR THE OVARIAN
CASES, ETC., IN THE WOMEN'S WARD.

REPRINTED FROM SAINT BARTHOLOMEW'S HOSPITAL
REPORTS.

LONDON:

SMITH, ELDER, & CO., 15 WATERLOO PLACE.

1894.

27 191 776

WELLCOME INSTITUTE LIBRARY	
Coll.	welMOMec
Call	
No.	W1



Digitized by the Internet Archive
in 2016

<https://archive.org/details/b28141593>

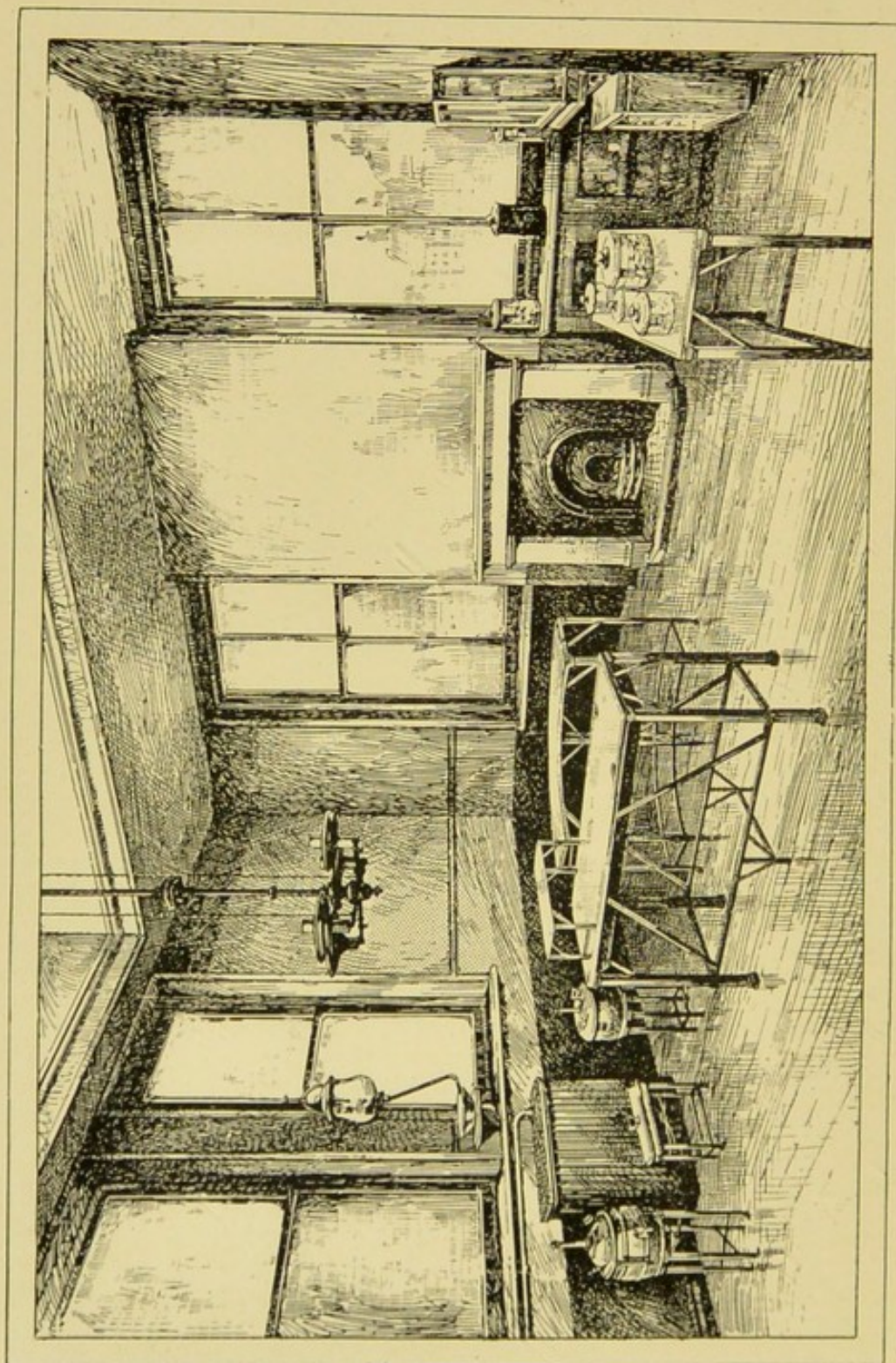


FIG. 1.—Interior of Operating Theatre attached to Martha Ward, showing the position of the tables, the sterilisers, the windows, and the skylight.

To face page 3.

ABDOMINAL SECTIONS

It may interest old Bartholomew's men to have some account of twelve months' abdominal work in Martha Ward. I venture, therefore, to give a brief sketch of the manner in which it is done, with an Appendix of the cases.

Martha Ward is under the care of my colleague, Dr. Champneys, and my duty is to undertake, after consultation, such abdominal sections as, in his opinion, are required. This dual arrangement works smoothly, and, I believe, with advantage to the patients, who have the benefit in consultation of an entirely unprejudiced opinion as to the propriety of any surgical interference. I must also acknowledge the great advantage which these consultations have afforded me in the diagnosis and treatment of difficult cases.

Martha consists of one large ward and three separate rooms, each containing two beds. These rooms are set apart for special cases, and in them the majority of the abdominal sections are nursed. These rooms contain no furniture beyond the bed, a chair, and table for dressings. The floors are laid with close-fitting English oak with a polished surface.

Theatre.—Our operating theatre (Fig. 1), which is reserved entirely for the Martha cases, is fairly

complete, but would have been greatly improved had it been specially constructed for the purpose. The floor in the theatre is of teak laid in closely-fitting narrow boards. Good floor as this makes, some absolutely insoluble material, such as a finely-laid mosaic in cement, would have been preferable, while the walls would have been greatly improved were they lined with accurately-fitting light-coloured Minton's tiles.

The theatre is nearly square, 19 feet by 18 feet, and 19 feet 5 inches high to the top of the skylight. It has two large windows facing south and a cross light to the east. It has a lantern skylight, which occupies about half the area of the ceiling. This light is provided with outside blinds for summer use. The theatre is heated by hot-water coils under the east window, and by a fireplace between the southern windows, and thus efficient ventilation is maintained. Hot and cold water are laid on to a marble washing-basin, the waste pipe of which is unenclosed, so that the slightest leakage can be detected. This waste pipe is carried directly through the wall, and discharges into the open air, so that there can be no possible sewer communication. Above the washing-basin is a glass shelf, which supports two glass barrels holding three gallons each. One of these is for carbolic lotion, the other for corrosive sublimate.

Operating Table (Fig. 2).—This is simple, and is made of a light framework of polished brass. The top of the table consists of a shallow copper tray 3 inches deep, forming a hot-water reservoir. Over this tray is an inch-thick plate-glass slab. This can

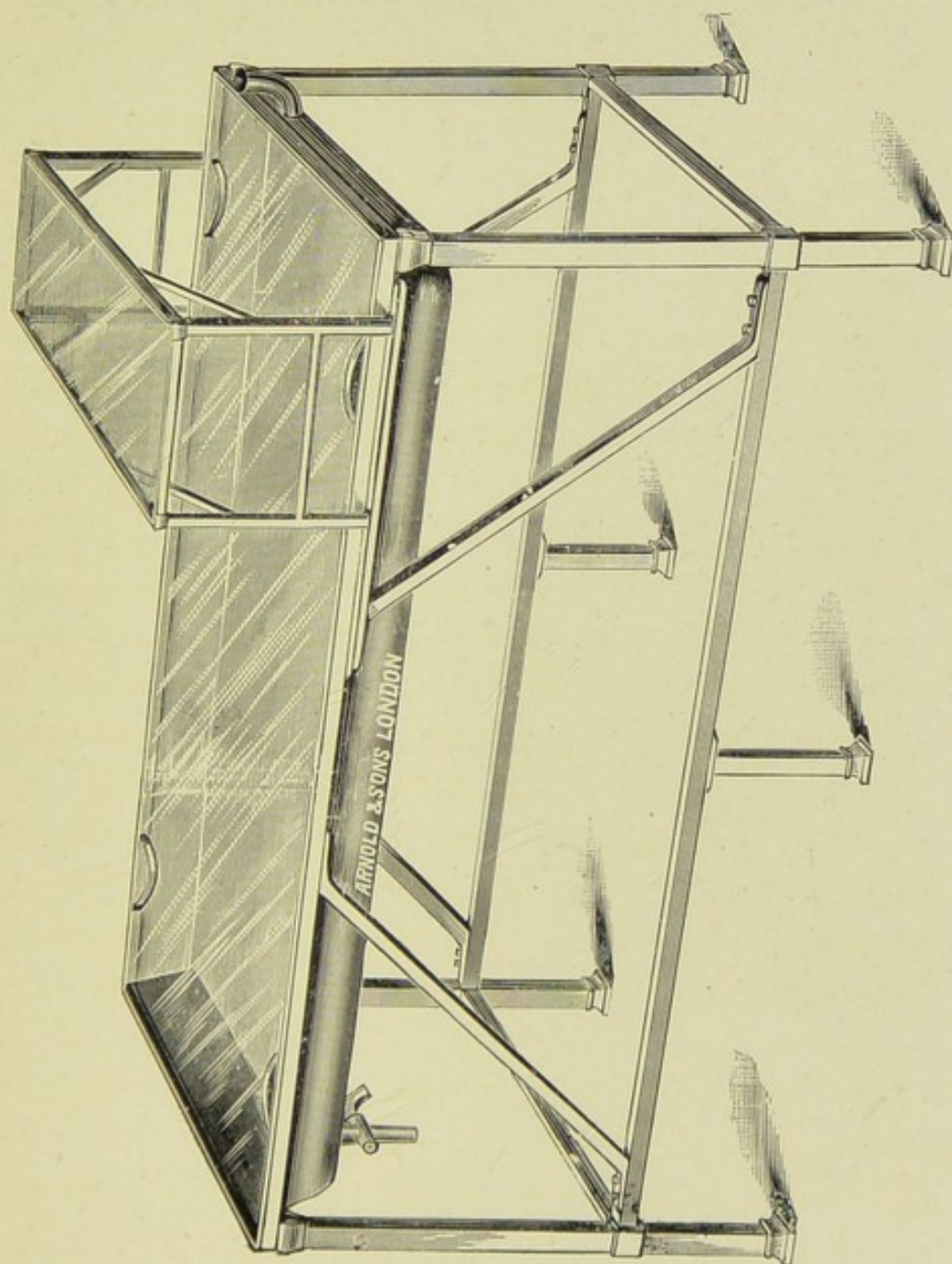




FIG. 2.—Plate-glass operating table with hot-water tray. The small glass shelf A goes over the patient's knees, and can be slid backwards and forwards at pleasure.

To face page 4.





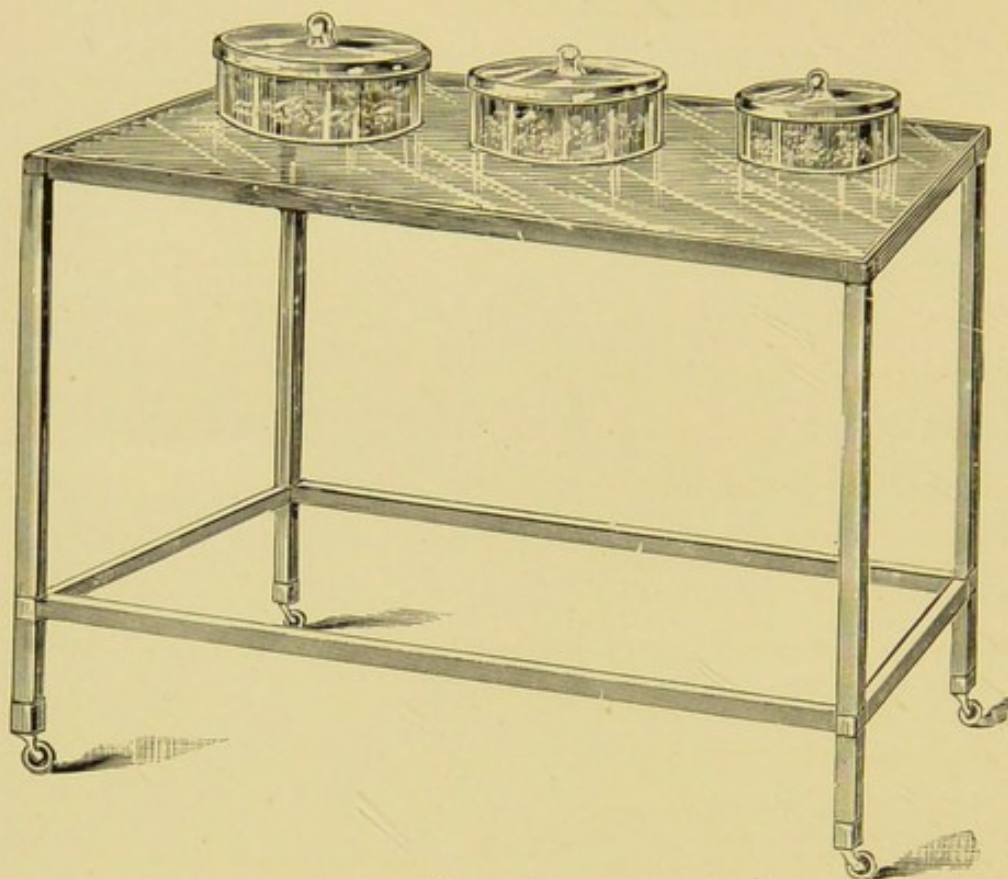


FIG. 3.—Glass table for dressings.

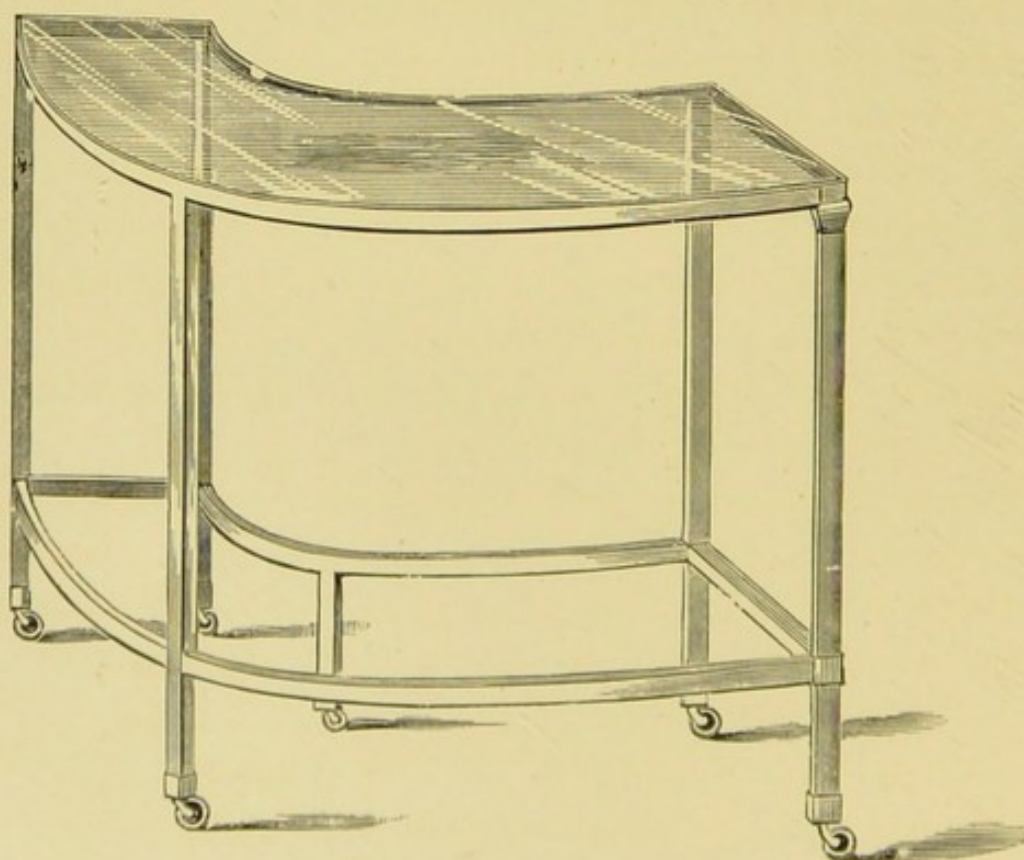


FIG. 4.—Semicircular glass table for instruments.

To face page 5.

be lifted on and off for the cleaning of the tray underneath, but the tray is so arranged with a small funnel at one end and a tap at the other, that the water can be changed without removing the glass lid. The width of the table is 1 foot 10 inches, the length 5 feet 3 inches, and the height 2 feet 10 inches. Fitted to slide along the table is a plate-glass tray 12 inches wide, and the same length as the table's width. When the patient is on the table, the glass tray supported by four uprights fits over the patient's knees. The supports of the tray rest upon a projecting slot which enables it to be slid backwards and forwards at the surgeon's convenience. It is most handy for placing the sponge-bowl and the instrument in actual use whilst operating.

Before operating, the copper tray of the table is filled with water at the temperature of 130° , and although there is no provision for keeping it heated, it only loses a few degrees of its temperature even during a prolonged operation. I am confident that the warm water table is of considerable service in reducing the shock where the nature of the operation involves a long exposure. Over the glass top is laid a narrow, perfectly clean folded blanket, on which the patient is placed.

Tables for Dressings and Instruments.—The dressings are cut and placed on a glass table (Fig. 3) on polished metal legs; the glass plate is $\frac{3}{4}$ of an inch thick, and measures 4 feet by 2 feet 2 inches, and 3 feet high. The table for the instruments (Fig. 4) is very convenient, and, like the rest of the furniture, is of plate glass on metal supports with india-rubber castors, so it is easily moved. It is made in a semi-

circle, with a radius of about 6 feet. The width is 1 foot 2 inches, and length 4 feet 6 inches.

When the surgeon takes his stand on the right side of the patient, the semicircular table fits round him, and brings all the instruments within easy reach, while at the same time it has the advantage of being a polite method of preventing spectators crowding over the operator's shoulder.

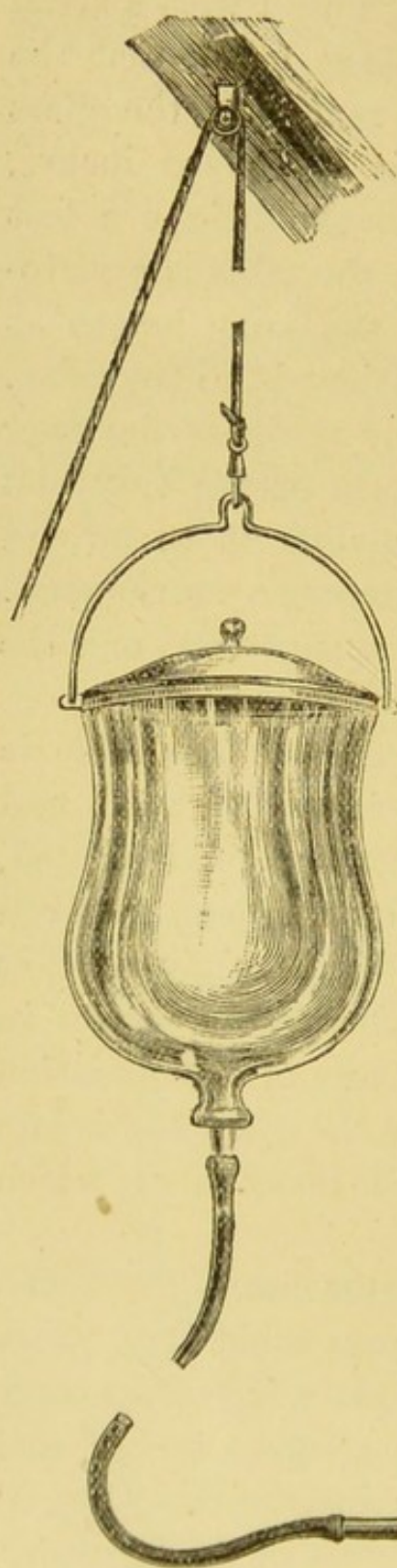



FIG. 5.

Irrigator (Fig. 5).—This, which is so important an item in modern abdominal surgery, consists of an ordinary bell-glass, which when inverted holds three gallons. Through the knob a 1-inch hole is drilled, slightly conical. Into this a glass stopper with a glass tube through its centre is accurately fitted; the tube projecting a couple of inches, allows the adjustment of the india-rubber tube

over it. Round the rim of the bell-glass is a brass



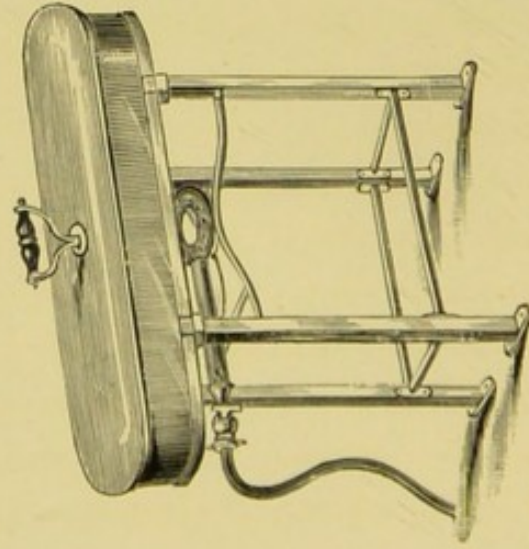


FIG. 7.—Steriliser for instruments.

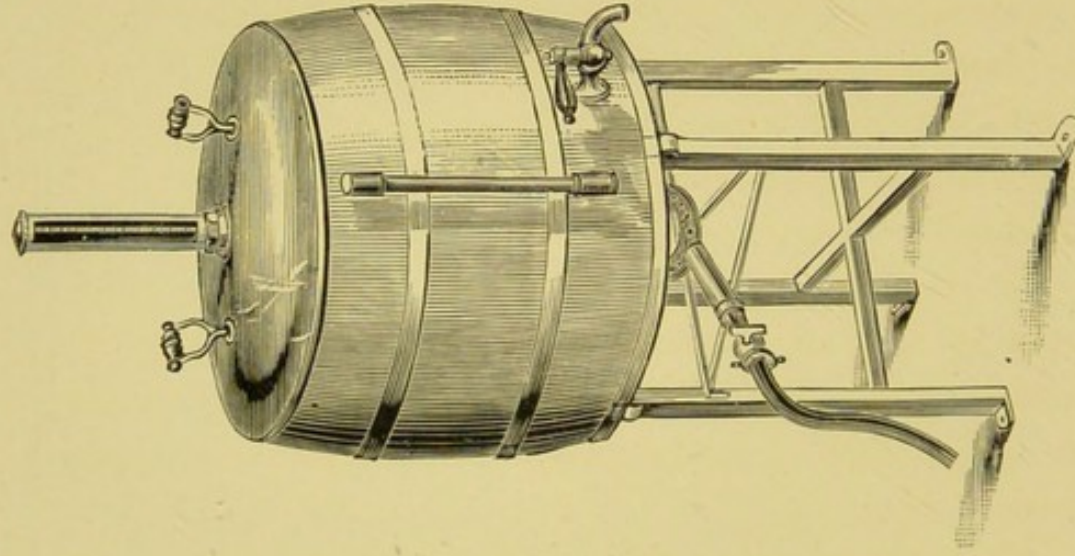


FIG. 6.—Boiler for sterilising water.

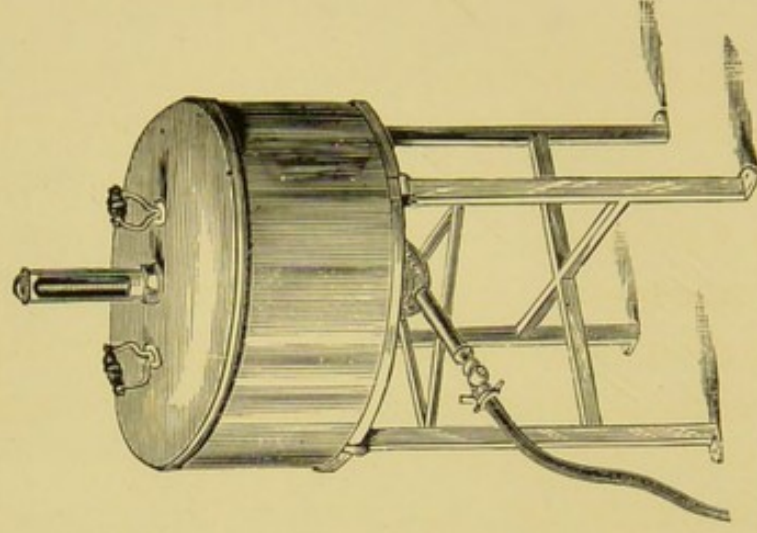


FIG. 8.—Dry steriliser for dressings.

band to which a bucket-shaped handle is attached. A pulley fixed in the roof allows the irrigator to be raised or lowered to the necessary height for filling or flushing.

Sterilisers.—Fixed in the theatre, and heated by Argand burners, are three sterilisers, for the water, for the instruments, and for the dressings respectively. These are made of fine polished copper on brass supports.

The first is a boiler (Fig. 6) containing eight gallons. It is made barrel-shaped, and is fitted with a water-gauge and a thermometer. The tap is at the bottom, and the lid is the full diameter of the barrel, so as to offer every facility for cleaning the interior. All water used at the operation is thus previously boiled in the room.

The second (Fig. 7) is for the instruments, and consists of a shallow copper tray 18 inches long, 6 inches wide, and 4 deep. In this all instruments are boiled before being put away in their air-tight case.

The third steriliser (Fig. 8) for the dressings is an oval copper pan $46\frac{1}{2}$ inches in circumference and 8 inches in depth. In the lid is fixed a properly protected thermometer registering 400° . Within the pan is a perforated false bottom 4 inches above the real bottom. This is necessary to prevent the dressings from being scorched. On the outer and under surface of the steriliser is fixed a steel plate to protect the copper bottom from burning. This steriliser requires considerable care in using. If the gas be turned on too full, the dressings become scorched, notwithstanding that the thermometer is

not raised above 350° . This arises from the copper becoming more rapidly heated than the contained air, and hence the dressings resting in contact with it become singed. If, however, the gas be turned on slowly, the temperature of the air is gradually raised without the copper bottom becoming too hot. In the hands of an intelligent nurse the steriliser acts admirably.

Instruments.—All the instruments, which are thickly nickel-plated except the cutting edges, are made to take to pieces, while the handles of knives, needles, &c., are made in one piece with the rest of the instrument. After using, every instrument is taken to pieces and well scrubbed with soap and cold water to dissolve out all blood. They are then boiled, dried, and polished, and replaced in their case. Our case in Martha (Fig. 9) is 3 feet long, 2 feet 6 inches high, 10 inches wide, and made absolutely air-tight. In one half of the case are glass shelves for knives, trocars, &c., while the other half is fitted with metal hanging pegs, on which forceps and other instruments of the kind are arranged. This is a much better plan than keeping the instruments in drawers. All that are likely to be required can easily be picked out before the operation, while, owing to the glass front, should any further instrument be required during the operation, the surgeon can immediately recognise what it is he wants. Beneath the case is a drawer for india-rubber tubing, &c. If india-rubber is kept in the same case with the instruments, the latter will rapidly get tarnished.

Sponges.—The sponges used at an operation are twelve in number, six flat ones and six round ones.

The flat sponges should be thin, and of as uniform a thickness throughout as possible, for if they have to be sheared down with scissors, the softness of their surface is lost. I have found oblong pads knitted with a double thickness of soft wool, varying from 4 to 10 inches in diameter, of great service. They will not last, however, for more than four or five operations, as they gradually become hard from

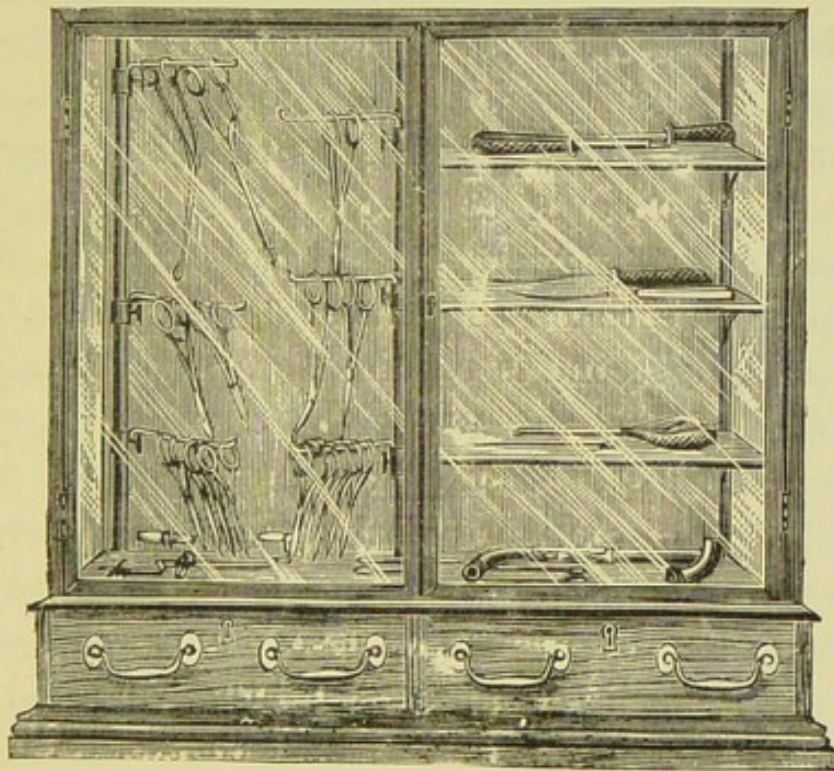


FIG. 9.

boiling and washing. These pads are knitted by the patients in the ward, so that they can be easily and cheaply renewed. Before using on the first occasion, they should be passed lightly through the flame of a spirit-lamp to remove fluffy particles. Before commencing an operation, I always count the sponges out loud, and the number is written down on a board provided for the purpose by the patient's dresser, and the same precaution is taken with the

forceps. The sponges and forceps are again counted before closing the wound. Unless an operator invariably takes this precaution, he runs the risk of a sponge turning up in the *post-mortem* room.

Preparation of the Patient.—I am indebted to Sister Martha for the following description of the method employed in preparing patients for ovariotomy. The operations are performed at 2 P.M. "Great attention is given to the action of the bowels and diet during the previous week, or as long before the operation as possible. A good daily action is obtained. At mid-day preceding the day of operation half-an-ounce of castor-oil is given. At 8.30 A.M. on the day of operation the patient has a soap-and-water injection; one is usually sufficient, but occasionally a second is required. A good breakfast at 6 A.M., and at 10 A.M. eight ounces of mutton essence. This is the last food taken. On each night of the previous week, or as many nights as possible before the operation, the patient is bathed, and the abdomen carefully washed with soap and water, after which dry sterilised gauze is lightly bandaged on, so that no personal linen comes in contact with the skin. The night before the operation a dressing of lint soaked in 1 in 20 carbolic is put on instead of the dry dressing. On the morning of the operation the patient is washed all over with carbolic (1 in 20), the hair being rubbed with the same and quickly dried. A dry dressing of sterilised gauze replaces the lint of the night before, and the patient is put into clean fresh linen. An operating gown of clean white flannel is then put on, with knitted woollen stockings, and a catheter is passed just

previous to the operation. The foregoing is in the case of a patient who is in good health coming in for an operation. It has to be modified in the case of a feeble and ailing woman."

Preparation of the Theatre.—"The previous evening and night ventilators and windows are widely opened, the floor repolished, and again dusted over the next morning with a damp cloth. On the morning of the operation the walls of the theatre, bowls, trays, basins, and all measures are thoroughly cleansed, and afterwards washed with 1 in 1000 of perchloride of mercury solution and dried. All syringes and tubes are changed into fresh 1 in 20 carbolic lotion. All water to be used for the operation is boiled. Water needed cold is drawn off into covered vessels. The dressings are heated in the steriliser for twenty minutes to 356° ; the gas is then turned off, but the dressings are not taken out till the moment of using. Sponges and pads, if they have been in contact with pus, are never used a second time, otherwise they are thoroughly rinsed with cold water and allowed to soak for twenty-four hours. They are then boiled, and kept in 1 in 20 carbolic ready for use."

I am strongly of belief that septic conditions are introduced whilst the abdominal cavity is opened at the time of operation, and that for good or evil, the patient's fate is practically sealed when the wound is closed; so that, having taken all possible precautions as regards the patient, the theatre, the sponges and instruments, it remains for the surgeon to be particularly careful as to the cleanliness of his own person and hands. I make a point myself of

changing all my clothes in the ante-room of the theatre, and find that nothing is so comfortable to operate in as a clean thin white flannel shirt.

Anæsthetics.—Unless there is any special reason to the contrary, I prefer chloroform to ether. Some patients—no matter how skilfully the ether is administered—never seem entirely to lose muscular rigidity, and the operator may be considerably handicapped if there is any tightness about the recti muscles. Another objection to ether is that it has undoubtedly a greater tendency to produce venous congestion, which, should the operation involve the separation of extensive adhesions, causes continuous oozing. Perhaps, however, the most serious drawback to ether if administered during a long operation is its direct effect upon the lungs. I have seen several cases of severe bronchitis follow upon its prolonged use, and felt convinced that the trouble was to be attributed to the ether, rather than from any cold contracted from the exposure of the patient. Lastly, the face-piece and apparatus necessary for its administration is objectionable. The operator has complete control over his own instruments, and knows how to ensure absolute cleanliness, but he has no knowledge as to the previous history of the complicated face-piece, or as to the nature of the previous case for which it was used, and possibly herein lies the explanation of some cases of acute bronchitis.

The administration of the anæsthetic is commenced before the patient is brought into the theatre, and completed after she has been placed on the table, and during this time the mackintosh sheeting, &c., can be arranged and time saved.

Operation.—The patient, lying flat on the operating table with a small pillow under her head, the antiseptic dressing is removed, and the night-dress pulled well up out of the way. The abdomen is covered with a thin mackintosh sheet; the hole in this should be 8 inches by 6. If cut too narrow, the adhesive plaster makes a mess just where the sutures have to be passed, but a 6-inch opening will bring the plaster well outside the line of sutures. To the under-surface of the sheeting, round the margin of the hole, is fixed a piece of strapping an inch and a half wide. The removal of the antiseptic dressing, the arrangement of the patient, and the mackintosh sheet should be done by the nurse, otherwise the operator and his assistant risk contaminating their fingers.

The Abdominal Incision.—Many operators attach much importance to the opening being made exactly between the recti muscles, so as not to interfere with their sheaths. I do not consider this to be a matter of the slightest importance. In many of my operations the sheath has been opened, in others not, and the wounds heal equally well in either case. The length of the incision must depend on the work in hand. In thin subjects a long incision probably entails a very slightly increased risk. In fat patients, owing to the thickness of the walls, each inch in length means many square inches of surface to unite, and in theory a corresponding strain on the patient. I say in theory, for I cannot call to mind any case where the length of the incision has unfavourably affected the result. So far as a ventral hernia is concerned, it is doubtful whether a patient would be

more liable to it after a long than after a short incision. Herniæ nearly always occur at the lower angle, while long incisions are extended upwards. In the first instance a 3-inch opening is sufficient, and if the tumour prove to be a simple cyst, may be long enough for the completion of the operation. Should it become necessary to pass the hand into the abdomen, the cut must be extended to $4\frac{1}{2}$ inches, for an attempt to pass the hand through a smaller opening detaches the peritoneum and bruises the tissues. If the tumour prove to be solid, if it be complicated with dense adhesions, or should it require to be shelled out of the broad ligament, I like plenty of room. Half the secret of successful surgery is to see what you are doing, and not to drag and tear important tissues by working in the dark at the bottom of a deep wound; and in difficult and complicated cases, the advantages gained by a long incision far more than outweigh any harm that may arise from it.

In making the cut, the knife should be kept as horizontal as possible, for it cuts far cleaner in this way than when held perpendicularly, and the centre of the incision should be a little nearer the umbilicus than the pubes. Care should be exercised not in any way to dissect the various layers the one from the other. To the inexperienced it is not always easy to identify immediately the peritoneum, and this is especially the case when there is a thin layer of subperitoneal fat, which, showing through a transparent layer of fascia, looks not unlike the omentum. A little investigation puts the operator right. On reaching the peritoneum, it is best divided by lifting it up with two forceps off the subjacent structures,

and making a small cut between them. Before opening the peritoneal cavity, the vessels in the walls of the incision are clamped. The forceps should be put on by the operator, who, being on the right side of the patient, and using his right hand, can place them so that the handles lie downwards. If the assistant puts them on, the forceps will have to be turned round after the vessel is seized, a clumsy manœuvre, which unnecessarily lacerates the fat.

If there has been a history of inflammation, the possibility of the cyst-wall being adherent to the peritoneum in the line of incision must be remembered. If there is any doubt whether the fluid that is let out comes from the cyst or peritoneal cavity, it is better at once to enlarge the incision sufficiently to make the point quite clear. No separation should be commenced until the operator is quite certain that he is in the line between the cyst and the peritoneum, otherwise the peritoneum may be extensively stripped off before the mistake is detected. Sir Spencer Wells' suggestion of extending the incision upwards beyond the adhesion is generally the best plan. In a case, however, in which I recently operated, I could find no sign of division after a considerable extension of the cut upwards, but found it with comparative ease on prolonging the incision downwards.

On opening the abdominal cavity, the first thing to be done is to verify the diagnosis, to note the character of the tumour, its situation, and the adhesions, if any, it has formed to surrounding parts. The white pearly-looking surface of an ovarian cyst

is very characteristic. If, however, the cyst be thin, it may look dark from the contained fluid being seen through the almost transparent walls. If the cyst be situated in the broad ligament, it may be covered by a thin adherent membrane in which vessels and decussating fibres may be seen. This is the peritoneal surface of the broad ligament stretched over the cyst, which has grown between its layers, a condition of things which generally means that some shelling out will be necessary. When the cyst is small and deeply situated in the pelvis, it may not come into sight, being covered by the intestine and omentum; and should there have been any inflammation, the latter may be plastered down and adherent, forming a sort of lid over the contents of the pelvis. Should there be no adhesions, and the pedicle of a moderate length, the operation becomes extremely simple. A small flat sponge is tucked into the lower angle of the wound to catch any material trickling in this direction, and another somewhat larger should be held in readiness over the upper angle of the wound to keep back the intestines should they protrude as the cyst is withdrawn.

The trocar should be about the size of the little finger, and is pressed into the cyst, and the fluid allowed to flow through the india-rubber tube into the pan. As the cyst becomes flaccid, it is seized on each side of the trocar by good-sized pressure forceps. By pulling on these, and taking a fresh hold, if necessary, the emptied cyst can be drawn through the incision. When the cyst is completely withdrawn the pedicle comes into view.

The Pedicle.—It is necessary to tie the pedicle

not only free of the cyst, but to allow sufficient material to form a good button beyond the ligature to prevent it slipping, but unless absolutely necessary, it is not desirable to tie so close to the uterus and reflexion of the broad ligament as to put these too tightly on the stretch. The assistant supports the cyst in such a way as to give the operator a good view of the pedicle in the untwisted state. As the chief vessels enter the cyst along the outer border of the pedicle, these can be tied separately from the main portion. A good view being obtained so as not to perforate a vein, a small needle threaded with No. 4 silk is passed through the pedicle just internal to the vessels, which can be seen and felt in the outer border; the ends of the ligature are then brought round the outer border and tied, the vessels being thus secured. The main bulk of the pedicle is now ligatured, and this is done by transfixion with a blunt needle armed with No. 4½ silk. The loop of the silk is then cut and the needle withdrawn. The threads are now interlaced and tied, care being taken that the outer thread is tied into the same groove as the smaller ligature, which has already been applied to the vessels. In making the first half of the knots, I interlace the thread twice, believing that thus managed it is less liable to slip whilst the second half of the knot is being completed.

After tying the second thread, some operators bring its two ends completely round the whole pedicle, which is thus again tied *en masse*. I do not, as a rule, do this, seeing no necessity for this additional amount of silk being left in the abdomen.

Should, however, a vein have been perforated, or the pedicle at all split in the transfixion, the manœuvre may be adopted. At the moment of tightening the ligatures the assistant should relax the cyst, so that the parts are as little on the stretch as possible. The ends of the ligatures are now cut off short, and a pair of pressure forceps applied below the ligature to the pedicle on each side. The cyst is cut away about three-fourths of an inch from the ligatures. If cut closer than this, sufficient material to form a good button is not left. Should the pedicle be a short one, it may be found after cutting away the cyst that a portion of its wall is still adherent to the distal side of the pedicle. This must be carefully dissected out, and if in doing so there is any suspicion of the ligatures being loosened, it is better to transfix and tie the stump a little below the loosened ligatures.

If the stump be of any size, its peritoneal borders may be sewn across with three or four of the finest silk sutures; the amount of raw surface to which adhesions might form is thus materially diminished. The stump being carefully examined to make sure that all is tight, the forceps are removed, and it is allowed to drop back into the pelvis.

Multilocular Cysts.—After tapping the main cyst, the remaining cysts, if small, would not prevent the tumour being delivered, but if they are large they must be broken down. Should there be only one or two, on the trocar being withdrawn the finger is introduced into the main cyst. If these secondary cysts are numerous with tough walls, the opening into the main cyst is enlarged sufficiently to admit

the whole hand. In this way the remaining cysts can easily be broken down. Should the cysts contain much solid intercystic growth, care must be exercised not to break this down too freely, otherwise considerable hæmorrhage may occur before the pedicle can be secured. I prefer, therefore, rather than run this risk, to enlarge the abdominal wound sufficiently to extract the tumour *en masse*.

Cysts Burrowing beneath the Broad Ligament.—These present a class of cases in which some difficulty often arises in their removal. The broad ligament varies a good deal in its behaviour to tumours commencing within it or burrowing beneath it. In many instances a cyst will form between the layers, and gradually expand the upper or free portion of the ligament without in any way separating the lower parts, which remain in contact, and form as good a pedicle as can be desired. In other instances the layers of the broad ligament will be opened out at their base by the tumour insinuating itself between them. It would appear as if the posterior layer were more easily lifted up than the anterior, for though they may be both lifted right off the pelvis, it is often to a greater extent backwards and upwards than forwards, where the attachments to the bladder and uterus are firmer. I have seen this stripping up of the posterior peritoneal layer extend on the right side so as to lift up the cæcum, and on the left the rectum and sigmoid flexure. If on opening the abdomen the tumour be found to have separated the broad ligament so much as to make a pedicle impossible without opening it, the tumour must be shelled out, either completely or

partially, from between its layers. At first sight some of these cases look very impracticable, but, with a little experience as to how they shall be done, they are often not so formidable as at first would appear. I generally commence by making the cut through the anterior layer of the ligament on the front surface of the tumour, extending it horizontally round from this. The vessels of the broad ligament capsule are chiefly on its outer side, and bleed very freely when divided, so that it becomes a matter of cut and clamp. The chief difficulty is to cut to the proper depth, so as to find the right line between the tumour and the expansion of the ligament over it. If this can be hit off, the peeling back of the broad ligament from the cyst is comparatively easy. On the other hand, if this natural line of separation be missed, the operation becomes very difficult from the close adhesion and the constant dividing of small vessels. The mistake that I most generally myself fall into has been not seeking for the line of separation sufficiently near the tumour. In some of these cases the actual cyst itself is so extremely thin that the operator, in his anxiety not to cut into it, does not really get completely through the broad ligament capsule, and this accounts for the troublesome bleeding. It sometimes happens that after a certain amount of shelling out has been done, that a sufficient pedicle can be obtained by transfixion in such a way as to include the edges of the opened peritoneal layer; more generally, however, the cyst must be shelled out before any pedicle is formed.

It may happen that after the removal of the

tumour the edges of the opened ligament can be gathered together like a bag purse, transfixed and tied. In this way of course all bleeding from the cut edges is secured, and the part again completely shut off from the peritoneal cavity. This, however, is not generally practicable. Bleeding vessels in the edges of the opened ligament can be secured with fine silk, and should the margins of the capsule be superfluous or damaged, they may be trimmed off. Sometimes after the cyst has been removed the opened ligament seems naturally to fall together in a good position, or it may be sutured across by fine silk. I think it of great importance that all bleeding should be stopped before any attempt is made to sew the layers across. If I had any doubt as to the continuation of the oozing, I should not completely close the ligament, but allow sufficient room for the glass drainage-tube fitting closely into it between two of the stitches.

One of the most valuable and complete works that we have on ovariectomy is that by Alban Doran. This surgeon, with an almost unique experience in the number of operations he has either performed or in which he has assisted others, advises that the edges of the open capsule should be brought up, and attached by suture to the borders of the lower part of the abdominal wall, and a glass drainage-tube passed into the capsule. The practice of so experienced an operator deserves the greatest respect; but, for my own part, I cannot believe that such a procedure is sound in principle. What is the object of thus draining the interior of the capsule? Surely, if the whole tumour has been shelled out from within

it, and the operation conducted aseptically, everything is most favourable for the clean, raw under-surface of the capsule to lie flat on and unite with the fascia underneath. Thus there is no cavity at all, in the ordinary sense, left, and all that is to be feared may be a little extravasation of blood. Is it for fear of this that the capsule is to be drawn up and stitched to the skin? If so, why not pass the drainage-tube so that its end lies just between the edges of the capsule as they lie *in situ* behind the intestines in the pelvis? It is difficult to conceive any more unnatural position than the capsule drawn up in this way and stitched to the abdominal walls. I suppose after this procedure, if we could look inside, we should see the capsule thus treated looking like a soldier's tent, the apex of which is permanently fixed to the abdominal walls. In this way an artificial cavity is produced in the capsule where none would naturally exist. Further, is there no risk in such a case of intestine subsequently finding its way between this attached portion and the pubes, with a liability to strangulation? I know that in inguinal colotomy where the bowel is fixed to the skin, death has resulted by a piece of bowel slipping and becoming strangulated between the attached bowel and the side of the abdomen.

Adhesions.—These, varying as they do from a slight gluing together of the adjacent structures to the cyst-wall to the densest fibrous adhesions, require different treatment. The slighter adhesions to the abdominal parietes can be readily detached by gently sweeping the hand round the tumour, and the slight recent adhesions of the omentum or intestines can be

wiped away with the finger or a sponge as the cyst is withdrawn. Should the adhesions be of a firmer nature, more room is obtained for dealing with them by first emptying the cyst, and not hesitating to prolong the abdominal incision sufficiently to obtain plenty of room. Omental adhesions, if firm, are best dealt with by following them up and ligaturing the omentum above the adherent portion. When small and narrow, a simple transfixion is all that is required. If the omentum be of any width, it should be tied by transfixion in several portions; it is then cut across below the ligatures, the adherent part being removed with the tumour. Intestinal adhesions, when firm, require the most cautious treatment. By using the cutting edge of the knife sparingly, and gently separating with the fingernail, the intestine can be detached. When the adhesions are so firm as to risk the bowel being torn open if the whole thickness of the cyst-wall be removed, it is better to leave a portion of the outer layer of the cyst-wall adherent. When the separation has been carried as far as seems safe, the part that is intimately adherent is probably a very small portion; and provided that no part of the internal lining of the cyst be allowed to remain, I believe that no harm will result from a portion of the outer cyst-wall being left. In one of the cases recorded in the Appendix, a suppurating dermoid cyst had burst into the rectum, and was subsequently opened into the vagina. I found at the operation, performed some months later, a suppurating cyst firmly adherent in the pelvis. With considerable difficulty it was detached from the uterus

and vagina. On separating it from the vagina, of course there was the hole into the latter. This was easily closed with a suture or two. The cyst was so tightly adherent to the rectum behind, at the site of the opening where it had formerly burst into it, that it was obvious that it could not be removed without cutting out a portion of the rectal wall. At the bottom of a deep pelvis it would have been quite impracticable to have securely closed such an opening, the walls of the rectum being densely indurated. I separated the cyst as close to the adhesion as possible and then cut it off. A portion, consisting of the whole thickness of the cyst-wall, of an area the size of half-a-crown, was left on the rectum. The soft suppurating lining of the cyst was scraped away with a Volckmann spoon, and the raw surface lightly touched over with the actual cautery, with a view to destroying any septic or secreting surface that might be left. The patient made an excellent recovery.

In cases where extensive adhesions of the mesentery and omentum have been separated, the separated portions should be carefully examined to see if there are any window-holes in the membranes. If so, these must be closed with fine silk, otherwise intestines may slip through them and get into trouble.

There is one form of cyst of which I have a wholesome horror. It is when there is a cyst, usually of small size, situated right at the bottom of the pelvis, beneath the broad ligament, which is expanded over its summit. The contents of the cyst have suppurated, and foetid pus has been discharged from

time to time into the rectum. Such a cyst, from its deep situation and from the dense adhesions formed by inflammation, is extremely difficult to remove, and, of course, notwithstanding the utmost care, when the cyst is eventually got out, there remains the hole, of greater or less size, into the interior of the rectum. Such a hole is through the portion of rectum lying behind the peritoneum. In this situation the hole is difficult to find, and it has to be sought for entirely by the finger-tip. The part round the hole is soft and rotten from inflammation, and even with the utmost gentleness it will hardly hold a suture. In such a case every effort should be made to close the opening, but success is most doubtful, and the operator has to rely upon one of two alternatives: he can either pass a drainage-tube down through the open layers of the broad ligament into the bottom of the cavity, and then suture the ligament across *in situ*, so as to fit tightly round the tube, or the edges of the open ligament might be drawn upwards and sutured to the peritoneum and skin at the bottom of the abdominal incision, and a drainage-tube kept within it. The latter alternative is the safer, if only it can be accomplished, but this is not always possible, as was the case in one of my operations, where, owing to the depth of the opened ligament, the distance was so great as to make it quite impracticable to unite it with the skin. It happens that during the last year I have had to deal with three cases in which there was a communication between the interior of the cyst and the rectum at the bottom of the pelvis. The first case was the one in which

the particulars are given in the Appendix (Case XX.). The second was a case of extra-uterine foetation, also occurring at St. Bartholomew's Hospital. The third was a case in private practice. The two former recovered, the latter died. In the first case, after the abscess had discharged itself two or three times into the rectum, it was opened by puncture through the vagina, and a glass drainage-tube kept in for some time. The effect of draining in this way was that matter soon ceased to pass by the rectum, and the opening spontaneously closed, so that when the operation was eventually performed, there was no actual opening from the rectum into the cyst, and, as described in the Appendix, the portion of cyst-wall adherent to and covering the site of the opening was left on the bowel at the time of operation, being merely treated with the cautery. The patient made a perfect recovery. The second case was one of extra-uterine foetation, the foetus being dead and softened, and on the point of discharging itself through the rectum. When the remains of the tube and the foetus had been removed, a small opening was discovered in the rectum by some faecal material oozing through it. Fortunately the hole was small, and sufficiently high to enable me to pass three fine sutures, and thus temporarily to close it, and the patient recovered. The third case was that of a lady who was emaciated to the last degree from hectic fever, the temperature having ranged from 101° to 104° during the previous three months, during the whole of which time she had had a copious discharge of foetid pus by the rectum. The cyst, about the size of a cricket-ball, was at the

bottom of the pelvis and below the ligament. It had insinuated itself almost behind the rectum.

After opening the broad ligament by a linear incision, I was eventually able, after considerable difficulty, to remove the entire cyst. I could then feel an opening into the rectum which would admit the tip of my finger. The opening was apparently in the posterior part of the rectum, and although it could be felt distinctly, it was quite impossible to get a view of it. Guided by feel, I was enabled by means of a fine curved needle set in a long handle to pass two silk sutures across the opening, and as I hoped succeeding in closing it. A drainage-tube was passed into the cavity from which the tumour had been shelled out, and the opened edges of the broad ligament sutured across, so as to fit tightly against the glass tube. Owing to the depth, it did not seem practicable to unite the cut edges to the peritoneum or skin. Fæcal material passed freely through the tube on the fourth day. The patient died on the fifth day. The patient had no rise of temperature, no distension or abdominal tenderness, so that she may have died from simple exhaustion, which, as already stated, was considerable previous to operation, or there might have been peritonitis, due to a leakage by the side of the tube, or to a septic infection from the extremely foetid pus, some of which came in contact with the peritoneum at the time of operation. Seeing the extremely foetid nature of these suppurating cysts communicating with the rectum, it is a matter of grave consideration whether the tentative treatment adopted in the first case, of draining the cyst into

the vagina with a view to obtaining the spontaneous closure of the rectal communication prior to undertaking the radical cure, is not the better mode of procedure. I trust in a future communication to have an opportunity of further considering this question.*

Treatment of the Peritoneum.—In simple cases, where no blood or doubtful fluid from the cyst has escaped into the abdominal cavity, the peritoneum is not touched either by sponging or flushing. A small flat sponge is merely laid within the wound to guard the intestines, and to catch the blood from the needle-pricks in sewing up the wound. If pus, sebaceous material, cyst contents, or blood-clot lie amongst the intestines, a thorough flushing is resorted to with water of the temperature of 100° which has been previously boiled. The water has a fall of about 4 feet through an india-rubber tube, one end of which is fixed to the irrigator, and the other fitted over a glass cannula 10 inches in length, with half-a-dozen holes at its extremity. This is passed into Douglas's pouch, and the flushing continued till all the débris and blood-clot are washed away, the intestines being gently kneaded by the left hand in the abdominal cavity during the washing. The amount of water used varies from a few pints to several gallons. After the flushing the india-rubber tube is slipped off the glass cannula, and by pressure on the abdominal walls the water is pressed out through it, and the adjustment of the sutures is now proceeded with. During this time the glass cannula remains in Douglas's pouch, and a small india-rubber

* See Paper in *British Medical Journal*, Feb. 10, 1894.

tube is passed down to the bottom of it, and by means of syphon action, or a glass syringe, the remainder of the water is abstracted, whilst the operator is closing the abdominal wound. Before tying the last suture the glass cannula is removed, if temporary drainage is not to be resorted to.

It is impossible to over-estimate the value of this flushing if pus or other septic material has escaped into the abdominal cavity; and I consider that of all the many improvements introduced by Lawson Tait into abdominal surgery, none exceed in practical importance this simple means of ensuring cleanliness.

Drainage.—In the majority of cases this is not resorted to, but it is adopted in the following circumstances: If there has been much oozing from torn adhesions or separated broad ligaments: if pus or suspicious débris has escaped into the abdominal cavity: if there has been any injury to the continuity of the intestine, especially of the rectum. There is no difficulty in closing any wound of the intestine if within reach by Lembert's sutures; but if a cyst has burst into the rectum, or become so adherent to it that the bowel is opened on separating the cyst, it is extremely difficult, for mechanical reasons, completely and soundly to close the opening by sutures. In these circumstances, after the opening has been closed as well as it can be, it is wise to leave a small drainage in the neighbourhood of the injured rectum. For the first twelve hours the fluid should be drawn out, and the sponge changed every three hours. After this, if the amount of fluid be small, the intervals may be six hours. At the first draining off there is usually a very con-

siderable quantity of blood-stained fluid; but this chiefly consists of the remains of the water used for flushing, and soon becomes absorbed, so that at the subsequent dressings the fluid is of relatively small amount. If at the end of twenty-four or thirty-six hours the fluid drawn off is fairly clear and less than half an ounce, the tube may be removed; but if it has been used for an injured bowel, or if there is the slightest suspicion of the fluid not being perfectly sweet, the tube must be left in for at least some days. It is certainly desirable to take the tube out so soon as it seems safe to do so. Notwithstanding all antiseptic precautions, there must always be some risk of septic infection through this highway into the centre of the body. Apart from this fear of infection, I believe that the tube occasionally presses against some loop of bowel, and gives rise to partial obstruction. In one case, where considerable abdominal pain and distension accompanied some nasty retching, on the evening of the third day the symptoms completely disappeared on removal of the tube, and soon afterwards the patient passed a considerable quantity of wind, which she had not done previously.

The tubes used in Martha are half an inch in diameter, and made in progressive lengths of a quarter of an inch from 4 to 9 inches. I prefer their being rounded and closed at the bottom, for if open there is always a possibility of a piece of omentum or intestine slipping into and becoming strangulated in the open extremity. For the same reason the holes in the sides of the tube should be quite small, not more than the twelfth of an inch in

diameter. It is surprising the ease with which omentum can insinuate itself through holes a little larger than this. The disadvantage of the tube being closed at the end is, that should it be desirable to change it, it cannot be withdrawn over a guide; but since it is so rarely necessary to replace a tube after removal, it is not a matter of great importance. It is not necessary to put any stitch into the skin-hole left on removal of the tube. A pad of dry sterilised gauze placed over it is all that is wanted. In a few hours the hole is closed by the contraction of the tissues round.

Closure of the Abdominal Wound.—Silkworm gut is the best material, and should be of the stoutness of the best salmon-gut. To those who are not salmon-fishers, and not therefore accustomed to buy this article, I may mention that gut varies from three shillings to four pounds a hank; but the price does not depend on the thickness, but on the length, and the short lengths (8 to 9 inches) do perfectly well for the purpose in question. Silkworm gut always requires to be well soaked for some hours before use, when it loses its harshness and becomes as soft and plastic as silk. The gut is entirely spoilt by boiling, or even placing in very hot water, but it will soak for an indefinite time in cold carbolic lotion without detriment. The sutures are passed through the whole thickness of the abdominal walls, including skin, muscles, and peritoneum. Some surgeons use a suture threaded at both ends, each needle being passed through the peritoneum from within the abdomen out through the muscles and skin. It

is simpler and more expeditious to use only one needle, which is passed from without inwards on one side, and from within outwards on the other. The distance of the sutures from the edge of the cut should be half an inch, while the distance from each other should be about three-quarters of an inch. If closer, the edges have too much of their blood supply cut off. All the sutures are best passed before tying them up, unless the incision is very long, when a few of the upper ones may be tied at once, to prevent prolapse of the intestine, should the patient strain or vomit. The sutures should be tied just so tightly as to bring the sides of the incision accurately together; if tied too tightly the tissues are strangulated. If there is not much tension on the stitches, I prefer not to tie them in a double knot, but to fasten them by twisting them round in making what would be the first half of the knot, and leaving them like this. The ends will, if fastened in this manner, lie quite flat.

Dressings.—In last year's volume of the Hospital Reports I drew particular attention to the value of dry dressings. I may here repeat that the dressings for the abdominal wound which we now use in Martha are of the simplest description, and consist of a few strips of very soft gauze. The strips are 2 inches wide and 6 long, laid across the wound at right angles. Over the gauze is placed a single moderately thick layer of cotton-wool about 10 inches square. No strapping is used, the dressings being kept in place by a many-tailed bandage of domette; each strip is 5 inches wide and 4 to 5

feet in length. This admits of each strip being crossed in front and well tucked down on either side. The strips thus arranged form a tight and even support to the abdominal walls. The dressings of plain absorbent wool and gauze are placed in the steriliser and heated to a temperature of 350° or 400° for twenty minutes; they are left in the steriliser until the moment for use, the heat having been previously turned off. They are applied, of course, perfectly dry. If a drainage-tube is employed, it is protected with a Keith's dressing; and in order to prevent the end of the tube being pressed against Douglas's pouch, after the sponge is wrapped up in the india-rubber sheeting, four thick rolls of lint are placed on each side of it, forming a square nest, the edges of which take the pressure of the bandage. A single layer of gauze is laid over the cotton-wool and india-rubber before the domette bandages are applied; this prevents the cotton-wool sticking to the bandage. I find the best way of getting at the sponge is, after the whole bandage has been applied, to cut a small window-hole in it, about 3 inches square, immediately over the site of the sponge. It is thus readily accessible without disturbance to the main part of the bandage.

After Treatment.—If the operation has been prolonged or the shock great, an injection of one ounce of brandy and three of hot water is administered before the patient is lifted off the operating table. The patient is placed in bed on her back, the head low and a pillow under the knees. During the first twenty four hours the patient has nothing by the mouth except a little hot water, at the rate of a

teaspoonful every hour. During the second twenty-four hours the quantity is increased to a table-spoonful hourly, half milk and half water. After this the quantity of fluid is gradually increased, and consists of a little mutton-broth or Valentine's juice, milk, and tea. Such a small quantity of fluid during the first forty-eight hours of course keeps the patient thirsty, but I have no doubt that it promotes the rapid absorption of any fluid that may be left in the abdominal cavity, and thus removes a possible source of trouble. There is also less vomiting or abdominal distension when patients are thus starved than when allowed to take fluids freely. In ordinary patients a four-ounce nutrient injection is given every eight hours for the first two days; if the patient is old and feeble, at more frequent intervals. After the fourth day, when the bowels have been opened, solid food in the way of bread or toast and butter may be given, while by the sixth day a little fish, and gradually back to a regular diet. If the patient requires it, during the first thirty-six hours, a little brandy can be added to the nutrient injection. If stimulant is given by the mouth, champagne seems to answer better than anything else.

I have the greatest dislike to morphia after any surgical operation, particularly after ovariectomy. It stops secretion, makes the tongue dry, and often produces vomiting. It is seldom used in Martha. If, however, the pain is very great during the first night, a quarter of a grain is given subcutaneously, but is not repeated. I prefer patients to lie on their backs for the first few days, but do not make a point of this. Old people, however,

stand the dorsal position badly, so they are allowed to turn partly on their side, and to have the head and shoulders well raised up with pillows.

In an ordinary case, the gut sutures are removed on the ninth day; but if the wound be very long, or the patient troubled with cough, every alternate suture is left for some days longer. The silkworm gut very seldom produces the slightest irritation of the wound.

Dressings.—If no drainage-tube has been used, and if there is no abdominal tenderness or rise of temperature, I do not remove the gauze over the wound till the fifth day, but take care each day to see that the many-tailed bandage has not become loose, and if it has, readjust it. On the fifth day the gauze is gently removed; the wound is not moistened or cleaned, but dusted over with a little powder consisting of equal parts of iodoform and boracic acid, and a clean layer of gauze replaced over the wound. After the stitches have been removed it is comfortable to the patient to have the wound attended to once daily. It may be washed over with soap and water, using a soft badger's-hair shaving-brush for the purpose; bathed with carbolic lotion, and thoroughly dried and clean gauze applied. Strapping is seldom used, the support afforded by a well-applied many-tailed flannel bandage being preferable. If, however, the wound be a long one, and if there be any cough, a few strips of one and a half inch strapping going well across from either loin gives additional security.

Bowels.—On the morning of the fifth day an injection of soap and water is given. If this acts well, no medicine is required; if it does not, two

to four teaspoonfuls of castor-oil are given on the sixth morning. A soft rectal tube passed occasionally during the first few days gives relief to wind that the patient has not the power herself to expel through the sphincter.

In simple cases the wound is practically healed at the end of a fortnight. A trouble that occasionally follows ovariectomy is a hernia through the cicatrix. One of the causes of this is allowing the patient to get about too soon without adequate support to the abdomen. So long as she retains the recumbent position, there is but little distensile force from the viscera. In the sitting or upright position the pressure is considerably increased. All scar-tissue in its earlier days is comparatively soft, and will slowly yield to anything like constant pressure; on the other hand, after a while it becomes one of the firmest and least yielding structures in the body. A carefully-made abdominal belt will be sufficient protection after a while. But for the first three months it is most desirable that the patient should apply three or four turns of a thin roller bandage, five inches wide, round the abdomen firmly on rising in the morning. Such a bandage can be worn beneath the belt, and fits more accurately and gives better support than any other appliance. The patient should be enjoined to keep the recumbent position as much as possible, and avoid any exercise that causes undue action of the abdominal muscles. A little patience and care in this respect during the first few months, while the cicatrix is soft, is well repaid by allowing it to become permanently firm and unyielding.

Death Rate.—At St. Bartholomew's Hospital, for some years past, the number of cases in which abdominal section has been performed in the women's ward has gradually increased, and, coincident with the progressive improvements of modern surgery, the rate of mortality has slowly diminished. During the year, excluding abdominal sections performed in Martha for explorations, peritonitis, pelvic abscesses, and abdominal obstruction, there remain 28 cases in which one or both ovaries were removed for disease, 3 cases of hysterectomy for large fibroids, and a case in which the ovary and tube were removed for ruptured ectopic gestation. Of these 32 cases, 29 recovered and three died. One of these cases cannot properly be regarded as death from ovariectomy, for the patient was admitted for acute general peritonitis, and was nearly *in extremis*, but it was considered right to give her the chance of an operation, at which it was found that the cause of the peritonitis was a suppurating ovary. If this case be included, we have a death-rate of 9.12, or, if we exclude it, a death-rate of 6.4.

Mortality rates following abdominal section, to be of substantial value, require a larger series than a single year affords, for it may happen that an operator, by good fortune, may have a series of simple and straightforward cases, or, on the other hand, he may have a few consecutive cases of extreme danger and difficulty. There is still room for improvement, but I doubt whether the death-rate after ovariectomy in a long series of cases, provided the operator refuses no case in which there is a possibility of saving life, will ever fall substanti-

ally below 5 per cent. Certainly my experience in general surgery teaches me that after all severe operations a certain number of fatal complications inevitably occur, and are such that no care or foresight can entirely eliminate. In a large general hospital the mortality must of necessity be somewhat higher than in special hospitals in which ovarian cases only are received. Cases of desperate illness from peritonitis are admitted into the medical wards of a general hospital. A certain proportion of these prove to be due to ruptured or suppurating cysts; an operation has to be undertaken on patients so ill as to render the chance of success remote, and, as every operator knows, that is just the class of cases which swells the mortality table.

Of the two remaining deaths mentioned in the Appendix, only one could probably have been avoided. This was Case VII., and arose from some septic condition beneath the lower angle of the wound. The patient was an alcoholic subject, such as was likely to afford good soil if a septic germ of any sort found entrance, but that it found a resting-place at all in the wound I believe could and should have been avoided, the water used in this case not being sterilised. In Case XI. it is doubtful if any care on the operator's part could have prevented death. The patient was a feeble old woman of seventy, and the tumour of an enormous size. When admitted to the Hospital, she was suffering from bronchitic symptoms. The diagnosis was doubtful between an ovarian tumour and malignant disease. It was thought that a few days' rest might improve her condition, so as to warrant an explora-

tory incision, but it soon became evident that her breathing troubles were increasing from the pressure of the tumour. The operation was therefore undertaken as one of immediate necessity. She somewhat improved during the first few days. The breathing then became gradually more embarrassed, and she died from bronchitis on the eighth day. At the *post-mortem* the abdominal wound was perfectly sound, and not a sign of anything wrong could be found in the abdominal cavity.

In most modern tables of abdominal sections a certain number of cases of oöphorectomy for fibroids, pain, &c., are recorded. It will be observed that no operation of this nature was performed during the year in Martha. My colleague, Dr. Champneys, is not much in favour of the removal of the ovaries except when manifestly diseased, or when a serious and persistent hæmorrhage is produced by a fibroid, which, on exploration, might prove impracticable for removal. In the cases of hysterectomy for large fibroids causing hæmorrhage, it was found in each case that the entire tumour could be removed, otherwise oöphorectomy would have been performed as a palliative.

I cannot close this article without expressing my thanks to my colleague Mr. Bruce Clarke for his excellent assistance at the operations, and to Mr. Eccles and Mr. Morrison, our midwifery residents, to whom no time or trouble seemed too much when taking care of difficult cases, while only those connected with the work in the ward can adequately appreciate the devotion of Sister Martha to the welfare of her patients.

APPENDIX OF CASES.

The following cases were admitted under Dr. Champneys, or, during his absence, under Dr. Griffith, and were subsequently transferred to my care for operation.

CASE I.—**Cystic Disease of both Ovaries.**

History.—M. A. W., aged 28, was well till four years ago, when she was admitted into Martha for a thick discharge from the uterus, and has ever since had pain in the lower part of the abdomen. Has kept her bed for the last ten months. Has never been pregnant, and is addicted to alcohol.

Present condition.—Is a stout, well-nourished woman; no tumour can be discovered on examining the abdomen. There is much pain on firm pressure over the right inguinal region. Per vaginam: Cervix points downwards to the left; on left side towards the front is an elastic swelling; on the right side a tender movable body the size of a plover's egg. Uterus is somewhat fixed; sound passes $2\frac{1}{2}$ inches, and movement causes pain.

Operation.—A five-inch incision having been made, a cyst the size of an orange was found on the left side. This was tapped, and a clear straw-coloured fluid evacuated. The cyst was deeply situated, and was adherent both to the bladder and rectum, and was removed with considerable difficulty. After its removal a second smaller cyst was discovered deeply situated on the right side. This was removed, and had to be shelled out from beneath the broad ligament. A glass drainage-tube

was inserted. The first three days there was slight flatulence and vomiting. On the seventh day the fluid drawn off from the tube had a decided smell. The following day it was again sweet. The tube was not permanently removed until the nineteenth day.

Result.—Recovery.

CASE II.—Unilocular Cyst—Twisted Pedicle.

History.—A. L., aged 28, first noticed her present trouble a year ago, and has had considerable pain in the right pelvic region ever since. Menstruation has been regular, but during the last few months has had considerable difficulty in passing her water. Eight days ago, after a hard day's washing, she had very severe pain radiating from the lumbar region. Pain has continued, and she has been unable to pass any water except by the catheter.

Present condition.—Abdomen very tender and distended by an elastic swelling reaching as high as the navel. Per vaginam: Sound passes easily backwards and behind the tumour. Uterus is rather fixed; abdominal swelling cannot be felt. Per rectum: The abdominal swelling can be just felt high up.

Operation.—A three-inch incision. A non-adherent cyst containing eight pints of slightly blood-stained fluid was removed. The pedicle was twisted one complete turn.

Result.—Recovery.

CASE III.—Multilocular Ovarian Cyst.

History.—F. B., aged 62. Menopause fourteen years ago. The abdomen has been slowly enlarg-

ing for about twelve years, but rapidly for the last three months.

Present condition.—Abdomen enormously distended by a tumour rising to the ensiform cartilage. It is elastic in some parts and hard in others. Circumference at umbilicus 45 inches. Per vaginam: No part of tumour can be felt in pelvis.

Operation.—Abdominal incision $4\frac{1}{2}$ inches. An omental-like membrane was lying over the tumour. This was divided between ligatures. There were no other adhesions, and the supposed omentum was a thinned out tube.

Result.—Recovery.

CASE IV.—Unilocular Cyst.

History.—E. A., aged 32. After birth of last child, nine years ago, abdomen began to swell, and has grown gradually larger; is now 35 inches round.

Present condition.—Large free unilocular cystic tumour, reaching nearly to ensiform cartilage, and just dipping into pelvis behind; no trouble with micturition.

Operation.—Three-inch incision. Tumour smooth and glistening presented in the wound. Fluid opalescent; pedicle easily found and transfixed, and cut about an inch beyond the ligature. No flushing, sponging, or drainage. Wound closed with silk sutures.

Result.—Made an excellent recovery.

CASE V.—One Ovary Cystic, the other Papillomatous.

History.—M. B., aged 35. Five years ago first noticed small lump in left iliac region, in which she

has always had pain. Three years ago noticed lump in lower right side of abdomen, also painful. Nine months ago taken with sudden severe pain and a yellow discharge from vagina for two days; not seen since. For three years pain when the bladder is full; for three months dysmenorrhœa.

Present condition.—Abdomen uniformly distended, not semi-globose; in left iliac fossa, rising to level of iliac crests, is a rounded body, size and shape of an unimpregnated uterus, and a somewhat similarly situated mass, only larger, on the right side; both are hard, elastic, dull, and tender. Cervix to right pointing downwards, and to left one finger's-breadth behind symphysis; rest of excavation filled by dense, not quite immovable resistance, slightly elastic. Has considerable bronchitis.

Operation.—This was delayed a fortnight on account of the bronchitis. On opening the abdomen, a right ovarian cyst was found burrowing under the broad ligament. The cyst was shelled out without much difficulty. The cyst contained a considerable quantity of intra-cystic papillomatous growth. After removing the cystic ovary, the left ovary, the size of a hen's egg, was found entirely covered with papillomatous growth, which gave it a cauliflower appearance. There was considerable oozing from where the right cyst was removed. The abdomen was washed out and a drainage-tube inserted. For some days a considerable quantity, amounting to two or three ounces daily, of nearly pure blood was withdrawn from the tube, which was kept in till the seventh day. The day following the operation the bronchitis became acute, and for ten days the temperature

varied from 100° to 104° , and the pulse from 100 to 140. Even during the third week the evening temperature was 104° . The patient ultimately did well.

Fig. 10 shows the two ovaries, the one on the right filled with intra-cystic growth, that on the left having the same papillomatous condition on the surface.

Result.—Recovery.

CASE VI.—Multilocular Cyst.

History.—C. A., aged 33, has had eight pregnancies and eight children, last seven weeks ago. After last confinement, when she got up she first noticed the abdomen larger than usual, with some pain in the lumbar and umbilical regions; the swelling continued to increase more at first than lately. Micturition natural.

Present condition.—Patient looks ill. The abdomen is more than half globose, tender all over, resonant in the flanks; circumference round navel, 37 inches. Per vaginam: Cervix high up; the roof of pelvis is occupied by an elastic resistance, communicating impulse to the abdominal swelling.

Operation.—Under ether, three-inch incision. The cyst presented, and had some slight adhesions to the omentum.

Fluid, sp. gr. 10.30, thick, creamy, and of a greenish-white colour. The pedicle was easily reached and ligatured, and peritoneal cavity flushed with water at 100° F., and glass tube and Keith's dressing applied. Three days later tube removed.

Result.—Made a good recovery.

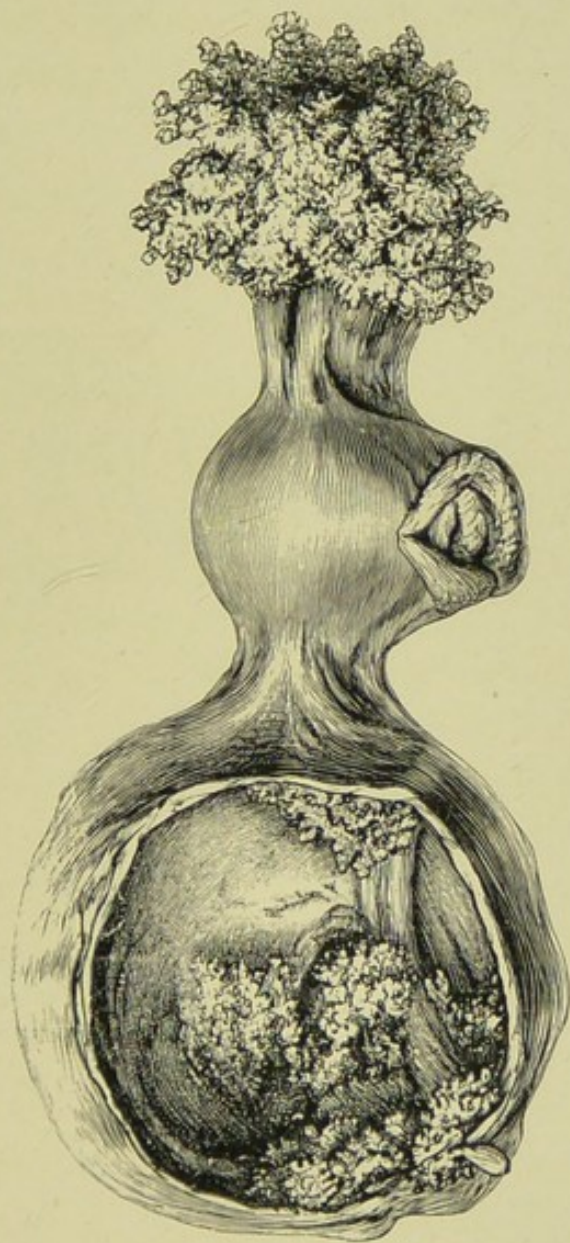



FIG. 10.—Illustrating the condition found in Case V. The cyst on the left side contains about two pints of fluid, and bunches of papillomatous growths are seen springing from its walls. The ovary on the left side is not cystic, but is covered with papillomatous growth on the surface.—St. Bartholomew's Museum, Specimens Nos. 2913a and 2913b.



CASE VII.—Broad Ligament Cyst.

History.—M. F., aged 44, addicted to alcohol. Pregnancies, four; last, fourteen years ago, after which laid up four months with "inflammation." Last recognised period, Nov. 1891; Dec. 11, 1891, severe hæmorrhage, which came on when she got up in the morning, and has continued ever since.

Present condition.—Not anæmic. Micturition frequent, has to get up at night. Breasts both tender, and there is secretion in the right one. The abdomen is swelled by a large mass = size of child's head, giving impulse to a smaller one in the left posterior quarter; the whole freely movable, elastic, fluctuating, and dumb. Uterus displaced in front and to left.

Operation.—A five-inch incision. The tumour, which was a broad ligament cyst, had to be shelled out of the ligament. The operation was difficult and prolonged, no washing or drainage. Abdomen closed with silk sutures. The patient had a restless night, and in twenty-four hours there was much abdominal distension, which, however, was almost entirely relieved by the rectal tube. The pulse-rate steadily increased to the fourth day, when it was 135. Temperature rose on the second day to 102° , and then fell to 99.5° , and it never again rose beyond one degree above this. On the fifth day the abdomen was again slightly distended; the manner was very restless. During the next two days the pulse became more rapid (140) and very feeble; there was no sickness.

Result.—Death on the eighth day.

Post-mortem.—Suppuration in lower half of abdominal wound. Intestines much distended with gas. Between the bladder and uterus was a collection of $1\frac{1}{2}$ oz. of pus. There was no general peritonitis.

CASE VIII.—Broad Ligament Cyst.

History.—M. G., aged 37, single. Pregnancies none; catamenia regular till two and a half years ago. Since that time they have not been so regular. During the same period she has had more or less pain in hypogastrium, worse on exertion and at monthly periods. Micturition difficult at times, and defæcation painful. Patient still has pain and discomfort, but has not herself noticed any tumour.

Abdominal examination.—There is a soft swelling, with a distinct sense of fluctuation, extending 4 inches above the pubes. Per vaginam: Uterus fixed; swelling can be felt in front of it.

Operation.—A four-inch incision. An extremely thin-walled cyst in the broad ligament to the right of the uterus; no adhesions. It was tapped and drawn up, and it was found possible to make a broad pedicle without shelling it out of the ligament; no washing or drainage.

Result.—Recovery.

CASE IX.—Unilocular Cyst and Dermoid.

History.—S. M., aged 31, married. One child, one miscarriage. Catamenia regular and normal. Five years ago first noticed swelling the size of an orange in the right iliac fossa, with pain. Very little increase noticed till three months ago, when

pain became severe with vomiting. No trouble in defæcation or micturition.

Present condition.—Firm swelling, chiefly occupying the right side, so firm as to suggest a fibroid tumour. On the outer border a hard offshoot can be felt. Per vaginam: Uterus moves freely.

Operation.—A four-inch incision. A cyst with very thick walls, containing four pints of thin clear fluid, came into view. In the wall of the cyst, partly projecting into it, but chiefly bulging from its surface, and forming the offshoot previously alluded to, and not communicating with the main cyst, was a dermoid cyst the size of a cricket-ball. On the interior surface of this cyst was a piece of skin, looking almost normal, two inches square, and from this was growing a long coil of fine hair. No drainage or flushing.

Result.—Recovery.

CASE X.—Multilocular Ovarian Cyst.

History.—J. N., aged 49. Catamenia regular till twelve months ago, then absent for six months; since then irregular, clear intervals not more than two days. A year ago noticed pain on standing, especially in the left iliac fossa. Since then the pain has increased, and has noticed the abdomen steadily enlarging; has lost flesh for the last few months. Defæcation and micturition natural.

Present condition.—Large swelling occupies abdomen and pelvis; greater part contains fluid, and some very hard nodules can be felt in right flank. Uterus much fixed. Sound passes $2\frac{1}{2}$ inches.

Disease was suspected to be malignant, with free fluid.

Operation.—Six-inch incision. A large multilocular cyst, dipping down into pelvis. No adhesions. Good pedicle. The hard nodule mentioned was found to be on the outer wall of the cyst, and half the size of a tennis-ball. It cut very hard, suggesting the possibility of a scirrhus. Washed out and drained.

Result.—Recovery.

N.B.—1893, patient readmitted with malignant disease of uterus.

CASE XI.—Large Multilocular Ovarian Cyst.

History.—S. T., aged 70, married. Pregnancies, none. Catamenia normal till fifty years, then menopause. Fourteen months ago noticed swelling of the abdomen, also some swelling of the legs. The swelling has gradually increased, more quickly lately; has lost flesh within the last six months; has had some difficulty in breathing on lying down.

Present condition.—Is very thin; legs much swollen; has considerable bronchitis, with impaired resonance and râles at bases. Has considerable dyspnœa. Abdomen 41 inches. Veins enlarged. Hard masses felt through abdominal wall. Some amount of free fluid. Per vaginam: Douglas's pouch depressed.

Diagnosis.—Thought very probably to be malignant disease, but that an exploratory incision should be made with a view of confirming the diagnosis

and relieving the dyspnœa, which was becoming urgent, by letting out the fluid.

Operation.—A five-inch incision. Slight recent adhesions almost universal between the cyst and parietal peritoneum. After breaking down a large number of secondary cysts within the main one, the entire cyst was removed without much difficulty. Some torn adhesions over the common iliac vessels bled freely, and there was a considerable amount of oozing from the general parietal surface. Cavity flushed and glass drainage-tube inserted. Tube removed on second day. The operation had been postponed some ten days on account of bronchitis, from which the patient suffered on her admission. The patient did well for the first three days. The bronchitis then gradually became more and more troublesome. By the sixth day there was great difficulty in expectoration, the secretion being copious and thick. She slowly sank, and died on the eighth day.

Result.—Death.

Post-mortem. — Abdominal wound completely healed; there was no sign of peritonitis, and everything seemed perfectly right in the abdominal cavity. Left lung, and to some extent the right, showed signs of severe bronchitis.

CASE XII.—Multilocular Cyst (slipped Pedicle).

History.—Married. Pregnancies, fifteen. Children, ten. Catamenia regular; the last period a few days ago. Ten months ago first noticed swelling of the abdomen on the left side. Pain and loss

of flesh for the last four months. Three weeks ago was tapped by a physician, but nothing came through the cannula.

Present condition.—Abdomen greatly distended, and dull all over, except deep in the flanks. Distinct rubbing sound can be felt and heard over the left part of the tumour on deep inspiration. Per vaginam: Uterus slightly movable; firm elastic swelling occupying Douglas's pouch. This swelling can be pushed slightly upwards.

Operation.—A four-inch incision. Left multilocular cyst with slight recent adhesions. Uterus much enlarged. A very short pedicle. The ovarian vessels were tied separately with fine silk. The remainder of the pedicle was transfixed and tied in two portions. After tying one of these, it was apparent that it was not sufficiently tight; a separate ligature was therefore passed round the whole pedicle, and was of necessity tied very close to the uterine tissue. Half-an-hour after being placed in bed, the patient vomited, and a few minutes later suddenly became collapsed. Within a quarter of an hour the abdomen was reopened by my colleague Mr. Bruce Clarke, who found that the pedicle had retracted from its ligature. There was about 8 ounces of clotted blood in the abdomen. Mr. Bruce Clarke resecured the pedicle, and though the patient was somewhat collapsed, she gradually rallied. For three weeks the patient had an irregular temperature with some symptoms of pneumonia. These gradually passed off, and she ultimately made a good recovery.

Result.—Recovery.

CASE XIII.—Multilocular Ovarian Cyst.

History.—E. O., aged 25, single. Catamenia regular. Ten months ago noticed pain in left lower abdomen, and a month later first observed a swelling, which has gradually increased up to the present time.

Present condition.—Abdomen much distended. Flanks resonant. Hard movable mass can be felt beneath some fluid. Per vaginam: Cervix lying low close behind the symphysis. Movements of tumour, especially those of hard body mentioned, communicated to the cervix. Sound passed 3 inches.

Operation.—On opening the abdomen by a $3\frac{1}{2}$ -inch incision, a considerable quantity of clear viscid fluid was found in the abdominal cavity. A multilocular cyst the size of an adult head then came into view. No adhesions. The pedicle transfixed and ligatured, abdominal cavity washed out with water; no drainage. The source of the viscid fluid in the abdominal cavity could not be ascertained, but its character suggested that it might have come from a ruptured cyst.

Result.—Recovery.

CASE XIV.—Multilocular Ovarian Cyst.

History.—E. L., aged 50, single. Catamenia regular; menopause seven years ago. Eleven months since first noticed increase in size of the abdomen. No pain. Retention of urine three times.

Present condition.—Elastic fluctuating tumour,

which reaches nearly to the costal arch. Marked procidentia; sound passes $4\frac{1}{2}$ inches.

Operation.—A three-inch incision. No adhesions. Multilocular cyst. Good pedicle. Bladder much distended at the time of operation.

Result.—Recovery.

CASE XV.—Multilocular Ovarian Cyst.

History.—C. E. T., aged 60, married. No pregnancies; catamenia regular. Menopause eight years ago. Has not noticed the swelling of the abdomen herself, nor has she had any pain.

Present condition.—Abdomen much distended; fluctuates in all directions. Dull on percussion. Resonance in right flank; left dull. Per vaginam: Cervix high up. No part of tumour to be felt in the pelvis. Sound, $2\frac{1}{2}$ inches.

Operation.—Incision, $3\frac{1}{2}$ inches. Walls fat and vascular. No adhesions. Cyst contained a gallon and a half. No flushing or drainage.

Result.—Recovery.

CASE XVI.—Suppurating Ovarian Cyst in Broad Ligament.

History.—E. M., aged 38, married, six children. Catamenia regular; last period three weeks ago. Was in good health until a miscarriage seven years ago. Laid up after this for a whole year. Five years ago had severe pain in left iliac region. Was then told at a London Hospital that she had a tumour, probably fibroid, the size of an egg. Swell-

ing has slowly increased, and a fortnight ago she had severe pain and vomiting.

Present condition.—The lower half of the left side of the abdomen is occupied by a rounded, smooth, tender, elastic swelling; dull on percussion. Per vaginam: Cervix high up; movements of the tumour downwards and forwards are communicated to the cervix, but not those downwards and backwards. Sound passes 3 inches.

Operation.—Incision, $5\frac{1}{2}$ inches. Abdominal walls very fat. Tumour, of dark red aspect, without superficial adhesions, was seen in the broad ligament. This was opened after tapping the cyst. The cyst was partly dissected out of the broad ligament. A pedicle was made of the remaining part of the broad ligament on the uterine side. No attempt was made to suture the open part of the ligament. Abdomen flushed; glass drainage-tube used, the end being placed in the hole in the broad ligament. There was a pretty free discharge through the tube, which became distinctly purulent on the fourth day. For over a week purulent fluid was drawn out through the tube, but it remained perfectly sweet. An examination of the cyst showed that it was roughened and inflamed on the outer surface, with a considerable number of flakes of lymph and pus in its interior.

Result.—Recovery.

CASE XVII.—**Large Multilocular Ovarian Cyst**
(Adhesions).

History.—L. S., aged 48, twelve children. Catamenia regular. Well until two years ago; pain then commenced in lower part of abdomen. Noticed swell-

ing a year later. Has had much severe pain since, and has lost flesh.

Present condition.—Looks old and worn. Abdomen greatly distended by a large swelling. Fluctuation not distinct; hard masses can be felt on the right side of the tumour. Per vaginam: Cervix natural situation; uterus not enlarged. Sound passes $2\frac{1}{2}$ inches.

Operation.—A large thickened omentum was lying over and adherent to the cyst. The transverse colon and its mesocolon was also firmly adherent. On separating the mesocolon, a large opening was made through it, which was sewn up with silk. Peritoneum flushed; drainage-tube inserted. The cyst, which was multilocular, with its contents, weighed 26 lbs.

Result.—Recovery.

CASE XVIII.—Acute Peritonitis from Ovarian Cyst with Twisted Pedicle.

History.—R. B., aged 44, married; eight children, last nine years ago. Catamenia ceased seven years ago. Said to have noticed the swelling from that time, but has increased rapidly the last eight months. A week ago, whilst washing, had sudden pain in the abdomen, followed by faintness and nausea. The pain continued very severe, and for the last three days there has been frequent vomiting.

Present condition.—Abdomen greatly swollen and mottled, with dusky redness; exquisitely tender, so that no pressure can be borne. When admitted, was

in a state of much collapse. Pulse very irregular, 135; scarcely perceptible at the wrist. On consultation it was decided that the patient had acute peritonitis from a ruptured or twisted cyst. It was decided that her present condition was too grave for any operation, but that if she rallied at all an exploration should be made. Eight hours later, she had somewhat improved; pulse was more regular, and could be felt at the wrist. It was not considered desirable to lift her off the bed. Ether was administered and the abdomen opened by a five-inch incision. A large multilocular cyst was exposed, twisted one and a half times on its axis. The cyst was adherent to the intestines by a layer of recent lymph. Its whole surface was acutely inflamed, the inflammation had extended to the intestines and parietal peritoneum. The intestines were red and distended, and plastered here and there with patches of thick yellow lymph. Cyst removed and abdominal cavity washed out. Patient somewhat rallied for a few hours after the operation, and then quickly sank.

Result.—Death.

CASE XIX.—Multilocular Cyst with Dermoid.

History.—I. A. G., aged 45, single. Catamenia absent, except for three slight shows, for twelve months. Swelling first noticed in the lower part of right side eighteen months ago. A year since was thrown out of a trap. Swelling has increased more rapidly since then; she also dates her pain from that time.

Present condition.—Healthy-looking. Abdomen pretty uniformly distended by a fluctuating tumour. Flanks resonant. Per vaginam: Cervix fixed. On the right side a swelling can be felt, to which an impulse is communicated from the abdominal swelling.

Operation.—Incision, $4\frac{1}{2}$ inches. No adhesions; tumour was partly beneath the broad ligament on the right side. After partly dissecting out, a fair pedicle was obtained. Peritoneal cavity flushed; no drainage-tube. The cyst on examination proved to have been a multilocular ovarian cyst. One of the secondary cysts the size of a tennis-ball was dermoid.

Result.—Recovery.

CASE XX.—Broad Ligament Cyst with Suppurating Ovary communicating with Rectum.

History.—N. A., aged 26. Six months ago felt ill with feverish symptoms, with night temperature of 102° . A month later noticed slight enlargement of abdomen. Two months after this, for over a week had severe pain in left iliac fossa. After this a discharge of nearly a pint of pus by the rectum. Abdomen distended; pain in left fossa. Per vaginam: A lobulated tumour was felt in Douglas's pouch. Per rectum: About 4 inches up the rectum the finger-tip entered a ragged opening in the anterior wall, which apparently led into the tumour. During the next fortnight the patient steadily lost ground, and as the swelling was considered to be a partly-filled abscess, an opening was made into

it by the vagina, and a glass tube inserted for drainage. In a fortnight the discharge was practically nothing. The tube was removed and she left the Hospital. Six weeks later, a slight discharge having continued by the vagina, but none by the rectum, and feeling ill, she was again admitted. Last three periods regular.

Present condition.—Has improved in general health. In the middle line of the abdomen, and extending nearly as high as the umbilicus, is an elastic swelling the size of a foetal head. Per vaginam: Cervix fixed an inch behind symphysis. Behind in left posterior quarter is a round hole admitting tip of finger; rest of vaginal roof occupied by a tender hardness. Bimanually the mass occupies the left iliac fossa and hypogastrium; the summit reaches to the navel.

Operation.—Five-inch incision. Walls thick and very tight. On opening the abdominal cavity, a thin-wall cyst presented itself, spreading up the left side under the parietal peritoneum (broad ligament). This was tapped and two pints of clear fluid let out. At the bottom of this cyst another, with very thick walls, could be felt firmly fixed between the uterus and rectum. This was tapped through the cyst already mentioned; four ounces of greenish pus and some gas escaped; the whole cyst was well flushed out. The upper cyst was then drawn up and dissected out of the broad ligament. The deeper cyst was then separated with difficulty, partly by the finger, partly by cutting. At the point where it opened into the vagina the opening was closed with fine silk sutures. The posterior part of the cyst was

firmly fixed to the rectum over an area $2\frac{1}{2}$ inches in diameter. The adhesion was dissected off till not more than a square inch was left. To have removed this would certainly have opened the rectum, for it corresponded with the old opening into the bowel. The cyst was cut off, and the surface of the still attached portion seared over with the actual cautery. Abdomen flushed out and drained.

The upper cyst was a broad ligament cyst; the lower a distended and suppurating ovary.

Result.—Recovery.

CASE XXI.—Ovarian Cyst—Double Pedicle.

History.—E. S., married, aged 54; six children, last nineteen years ago. Catamenia regular. Menopause seven years ago. First noticed abdomen slowly enlarging two years since. Increased more rapidly of late. For the last month has had incontinence of urine.

Present condition.—Abdomen greatly distended by uniform swelling, which extends to the costal arch; fluctuation. Per vaginam: Cervix freely movable; tumour cannot be felt in pelvis. Sound $2\frac{1}{2}$ inches.

Operation.—Four-inch incision. No adhesions; tapped; 18 pints of fluid drawn off. There appeared to be a double pedicle, each being quite separate and about equal size, lying one in front of the other. The front one was obviously the broad ligament, &c. The nature of the other was doubtful.

Result.—Recovery.

CASE XXII.—**Multilocular Ovarian Cyst.**

History.—S. C., aged 45, single. Catamenia regular. Five months ago first noticed swelling, which has gradually increased; no pain.

Present condition.—Abdomen greatly distended by fluctuating swelling. Per vaginam: Uterus normal; tumour cannot be felt. Patient a healthy-looking woman.

Operation.—Four-inch incision. No adhesions. Tumour had burrowed under broad ligament of right side, lifting up the cæcum. At first it appeared as if the cæcum was attached to the tumour by adhesions, but further examination showed that the tumour had separated the layers of the mesocolon. One layer was divided and the tumour shelled out. The opened mesocolon was sewn up. Abdomen flushed and drained for twenty-four hours.

Result.—Recovery.

CASE XXIII.—**Unilocular Cyst containing Pus.**

History.—E. Q., aged 33, married; five children, youngest two years old. Quite well till six months ago, when she had her last regular period. Missed period for next two months, then a miscarriage (?) and loss of blood for seven days; nothing since. Three months ago noticed swelling in left iliac region; continued since to get weaker, with much pain.

Present condition.—Lower half of abdomen occupied by elastic thick-walled swelling. Alters in shape during manipulation. More prominent in left than right side, feels like gravid uterus at six months.

Tumour dumb. Difficulty and pain on passing water. Has lost flesh. Per vaginam: Cervix very short, in natural position; not softened. Sound passes $2\frac{1}{2}$ inches.

Operation.—Incision, $3\frac{1}{2}$ inches. Abdominal walls very thin. A few slight adhesions. A thick-walled cyst. Tapped, and four pints of sweet greenish pus evacuated. Good pedicle. Abdominal cavity flushed out, but no drainage.

Result.—Recovery.

CASE XXIV.—Multilocular Ovarian Cyst.

History.—K. H., aged 32, married; no pregnancies. Catamenia regular up to present time. First noticed swelling two months ago; getting larger ever since. Pain for three weeks only.

Present condition.—A healthy-looking woman. Abdomen distended, but not uniformly, up to costal arches, by a mass which reaches $4\frac{1}{2}$ inches above umbilicus. Crepitation felt and heard over a portion of the tumour. Tumour consists of several lobes of varying consistency. Left loin dull; right and upper border of tumour resonant. Per vaginam: Cervix low down and forwards, freely movable. Into Douglas's pouch an elastic swelling protrudes, to which an impulse is communicated from abdominal tumour. Sound passes $2\frac{1}{2}$ inches.

Operation.—Incision, 5 inches. A large multilocular cyst of left side. No adhesion. Pedicle very short and thick. Owing to straining, intestines much protruded. Abdominal cavity flushed and drained for twenty-four hours.

Result.—Recovery.

CASE XXV.—**Suppurating Ovarian Cyst.**

History.—J. P., aged 25; four children, last one three months ago. Catamenia regular. Never well since six weeks before her last confinement. Much pain in abdomen and back; for the last fortnight has felt ill with high temperature.

Present condition.—Abdomen distended by a tense tumour, reaching to left costal angle. Tenderness over whole of abdomen, most marked in left half. Tumour elastic, except at one spot on the left side, which is hard. Can be moved beneath abdominal walls. Per vaginam: Cervix to the left; in front is a rounded hard swelling like an anteflexed uterus. It is movable. Sound passes $2\frac{1}{2}$ inches.

Operation.—Four-inch incision. Omentum firmly adherent to top of tumour. Intestines also adherent. The cyst was on the right side. Adherent structures being separated, the cyst was tapped, and some pints of pus let out; cyst-wall soft and inflamed; fair pedicle. After removing the cyst a large quantity of thickened omentum was tied and cut off. Abdomen thoroughly flushed; drainage for four days.

Result.—Recovery.

CASE XXVI.—**Unilocular Ovarian Cyst.**

History.—A. C., aged 24, unmarried. Catamenia regular till admission. Noticed the swelling for a year; it has increased a great deal the last few months. No pain.

Present condition.—Abdomen uniformly distended by a fluctuating swelling. Dull all over, except in

the right flank. Per vaginam : Cervix natural and slightly movable. Sound passes $2\frac{1}{2}$ inches. Per rectum : The whole roof of the pelvis occupied by an elastic hardness.

Operation.—Incision, $2\frac{1}{2}$ inches. Walls very vascular ; a large thin-wall cyst found occupying greater part of abdomen. No adhesions. Tapped, 16 pints of clear fluid. Very thin but broad pedicle. The tumour consisted of right ovary and tube ; no flushing nor drainage.

Result.—Recovery.

CASE XXVII.—Broad Ligament Cyst—Enucleation.

History.—E. C., aged 40, married ; never pregnant. Catamenia regular. Had pain about lower abdomen for six years ; for the last three years frequent micturition and incontinence ; has only noticed swelling for three months.

Present condition.—Abdomen occupied by elastic mass extending to navel, dull on percussion. Per vaginam : Uterus fixed, and whole pelvic roof occupied by a dense fixed hardness.

Operation.—Six-inch incision. Walls very fat. Cyst when exposed showed a dark bluish-red. Tapped, and some pints of greenish fluid drawn out. The cyst was dissected out with much difficulty, being intimately adherent to the bladder and uterus ; it had also extended upwards behind the posterior layer of the broad ligament. Neither the ovary nor tube could be made out. Abdomen flushed, and drainage-tube removed on fourth day.

Result.—Recovery.

CASE XXVIII.—Broad Ligament Cyst.

History.—S. W., aged 62, married ; eight children. Menopause sixteen years ago. Had a slight bloody discharge two months ago, and first noticed tumour at that time. Has been quickly getting larger.

Present condition.—Right side of abdomen occupied by a fluctuating swelling. Per vaginam : Uterus displaced to the left.

Operation.—Three-inch incision. No adhesion. Cyst unilocular, containing thick viscid fluid. Good pedicle. No flushing nor drainage.

Result.—Recovery.

CASE XXIX.—Uterine Fibroid—Hysterectomy.

History.—E. L., aged 40. Noticed pain in the right iliac fossa five years ago. A month later a tumour the size of an orange was observed. Since then it has steadily increased in size, and now causes her considerable inconvenience and prevents her doing her work. Menstruation has always been regular, lasting four days. No clots or membranes.

Present condition.—Abdomen pretty uniformly distended up to costal arch, and occupied by a densely hard insensitive tumour, moving beneath the abdominal walls. Tumour dull, and dumb to auscultation. Resonance in both flanks. Per vaginam : Cervix low ; uterus retroverted. No part of tumour felt in pelvis. Sound passes concavity to left and backwards $2\frac{1}{2}$ inches. Nearly fixed move-

ment of tumour does not immediately affect it. Per rectum : No part of tumour can be felt.

Operation.—Incision, nine inches long, made in linea alba. Tumour proved to be a large fibroid. On lifting it out of the abdomen, some very large thin-walled vessels were seen running into the broad ligament on each side. The outer edge of this, containing the vessels, was transfixed on both sides and tied with silk, the distal part being secured with large pressure forceps. The intervening portion was then divided, which enabled the tumour together with the ovaries to be lifted well up. A fair pedicle was secured across the upper part of the uterus. The pedicle was transfixed with two pins, and the silk rope of the *serre-nœud* was tightened. The lower part of the peritoneum was stitched across to the uterine pedicle, and the rest of the wound closed. Tumour weighed 18 lbs.

Result.—The patient made an uninterrupted recovery.

CASE XXX.—**Hysterectomy for Multinodular Uterine Myoma (22 lbs.).**

History.—E. B., aged 43, single. Pregnancies, 0. Menstruation regular till two years ago ; since then profuse ; only five days' interval.

Present condition.—Thin and worn ; good colour. The abdomen is filled with a number of hard irregular masses, and is about half globose. Per vaginam : The cervix cannot be reached.

Operation.—A nine-inch incision. On exposing the abdomen, the tumour was found to consist of

seven or eight partly pedunculated lobes. The bladder was drawn up on the tumour, so that it lay half way between the pubes and umbilicus. The upper lobes passed up under the liver; the lower dipped down to the bottom of the pelvis. The tumour shelved off on both sides into the broad ligament, but more so on the left than on the right. An incision six inches long was made transversely through the peritoneum between the tumour and the bladder. The latter was then peeled off the tumour, the hand being passed above the upper lobes; the whole tumour was partly turned out of the abdomen. It was held, however, by the tightly stretched broad ligaments. The ovaries were seen situated high up on the tumour. Running up the ligaments towards the ovaries and tumour were some large veins, the size of the little finger. Commencing at either end of the transverse incision, the finger was tunnelled beneath the broad ligaments, and by keeping close to the tumour the veins were all kept to the outer side. The broad ligaments, with their vessels, were now transfixed and tied, the distal or tumour ends being clamped. After this the ligaments were divided between the ligatures and clamp. On completing this, the tumour could be lifted well out of the abdomen. A silk cord of the thickness of a No. 6 catheter was passed round the pedicle of the tumour at about the level of the upper part of the cervix; the pins were then passed, and the pedicle fixed with very little tension. No flushing nor drainage.

The pedicle was kept dry and perfectly sweet, and separated on the eighteenth day.

There was never any rise of temperature nor untoward symptom.

Result.—Recovery.

CASE XXXI.—**Hysterectomy for Uterine Myoma.**

History.—M. C., aged 36, married; three children, youngest five years old. Commenced to feel pain six years ago about the back of pelvis. Catamenia have been regular, but more profuse and lasting longer than usual.

Present condition.—Abdomen irregularly distended. Umbilicus everted; large irregular modulated masses felt, varying in consistency. Mass extends to ensiform cartilage, and spreads into both flanks. Souffle heard in several places. Per vaginam: Cervix cannot be reached. Post-vaginal wall bulged forwards against symphysis.

Operation.—Incision, 11 inches in length. It was then seen that the tumour was a fibroid, extending laterally into the broad ligaments, and backwards under the posterior layer of the parietal peritoneum. The tumour was firmly fixed. By manipulation the upper portion was partly raised out of the abdomen. A cut 10 inches long was made through the capsule above the bladder, which was spread out on the lower anterior surface of the growth. The bladder was then peeled off well down to the front. A second cut, 12 inches long, was now made low down across the tumour behind, and the capsule stripped back. A large mass of blood-vessels could be seen entering the capsule and tumour on each side, corresponding with the apex of the broad ligament. The ovaries

were lying high up on the tumour. The forefinger was inserted from the end of the anterior cut beneath the mass of lateral vessels, as yet undivided, emerging at the extremities of the posterior cut. A silk ligature was passed by transfixion around each lateral mass of vessels, that on the right was tied at once, that on the left being left untied for the return of venous blood. At this point the hæmorrhage was very free, so an elastic band was passed round the tumour outside the capsule as low as possible. The ligatures on the left side were now tightened, the distal end clamped and divided. The tumour at once became far more free and manageable. By a little more manipulation and freeing of the capsule, the tumour was lifted sufficiently out of the abdomen to admit of the silk-cord of the *serre-nœud* being placed around it well below the elastic band. This was screwed up tight, and the tumour, weighing 30 lbs., cut off three inches above it. The blood was now washed out of the abdomen. The pins being passed, the stump was trimmed down to an inch above the pins. There was great tension on the pedicle, which was $3\frac{1}{2}$ inches in diameter. The abdominal wound was closed with salmon-gut sutures. A considerable amount of blood was lost during the operation, which lasted an hour and forty minutes.

Great care was taken to keep the large stump sweet. It was washed daily with equal parts of spirit and water, and dusted with iodoform and boracic acid. Day by day large portions were cut off with scissors, the pins being taken out on the eighth day, the silk-cord on the ninth. The stump gradually sank deep back into the pelvis, at least

four inches from the surface, and the last portion separated as an inodorous slough on the twenty-first day.

It was found, on examination of the vagina and tumour, that the pedicle had included, about the upper end of the vagina, the whole uterus, ovaries, &c., being completely removed. On the twenty-third day a small amount of urine passed by the wound, apparently the right ureter having been opened by the sloughing of the pedicle. By injection, &c., we pretty clearly made out that the leak was from the ureter, and not the bladder.

When discharged from the Hospital, a small amount still escaped from the upper part of the vagina, but caused remarkably little inconvenience.

Result.—Recovery.

CASE XXXII.—Ruptured Tubal Gestation.

History.—L. J., aged 24 ; no history of gonorrhœa. Three children, last two years ago ; labour with forceps ; very ill afterwards for a month. Catamenia regular ; last passed four months ago ; then amenorrhœa for six weeks. Ten weeks ago sudden pain in lower abdomen, stabbing and shooting into loins and perineum ; then rather free loss for seven days, clots being passed, with frequent attacks of pain and bleeding and a feeling of faintness. Fourteen days ago at 9 A.M. sudden acute pain in lower abdomen ; no loss ; pain lasted till two days ago, but not so severe. Yesterday had another sudden severe attack of pain.

Present condition.—Anæmic, with rapid feeble

pulse; has an anxious, distressed look. Abdomen distended; resonance in flanks impaired. Per vaginam: Cervix backwards to the left; not soft; movable high up in right anterior quarter; vague resistance. Seen by Dr. Champneys and Mr. Harrison Cripps at 8 P.M., at which time she showed marked symptoms of collapse.

Operation.—Chloroform. Five-inch incision. Abdominal walls fat. On opening peritoneal cavity, a large quantity of dark-coloured blood and clots poured out. The hand was at once passed down to the uterus and along to the ovaries. In the position of the right tube a tumour the size of a plover's egg could be felt. This was drawn into the wound and proved to be the centre of the right tube dilated by a firm mass. On the posterior peritoneal surface was a small ragged opening the size of a threepenny-piece, which was plugged with a portion of soft coagulated blood. The tube was ligatured with silk close to the uterus, and the remainder, including the foetal cyst and ovary, removed after tying the broad ligament. The ovary contained a large corpus luteum.


The abdominal cavity was filled with an enormous amount of clot and fluid blood, the former being all apparently recent. As much as possible of the clot was scooped out with the hands, and then the abdominal cavity was thoroughly washed. The washing took half-an-hour before the last of the clots could be got out and the water came back clear. Sponges were not used, nor was a drainage-tube inserted.


The patient stood the operation well. The next day the temperature was normal; the pulse 130.


Patient very pallid ; complained of much pelvic pain ; during the next two days she had much vomiting. On the second day after the operation, she passed per vaginam a complete cast of the uterine cavity. On the sixth day the temperature began steadily to rise, reaching 103.6° in twenty-four hours. A slight smelling discharge was then noticed from the vagina. The vagina was well douched out with 1 in 2000 perchloride of mercury. The discharge became sweet and the temperature rapidly fell to normal.

Patient discharged in three weeks perfectly well.

Result.—Recovery.









WITHDRAWN

R. L. Hufferdum.

