

A text book of veterinary ophthalmology / by Geo. G. Van Mater.

Contributors

Van Mater, George G., 1863-

Publication/Creation

New York : W.R. Jenkins, 1897.

Persistent URL

<https://wellcomecollection.org/works/ax3jg45d>


License and attribution

This work has been identified as being free of known restrictions under copyright law, including all related and neighbouring rights and is being made available under the Creative Commons, Public Domain Mark.

You can copy, modify, distribute and perform the work, even for commercial purposes, without asking permission.

**wellcome
collection**


Wellcome Collection
183 Euston Road
London NW1 2BE UK
T +44 (0)20 7611 8722
E library@wellcomecollection.org
<https://wellcomecollection.org>



156 B

Mr. Denton

20 Penworthby




Coach




22101850895

Med
K53653

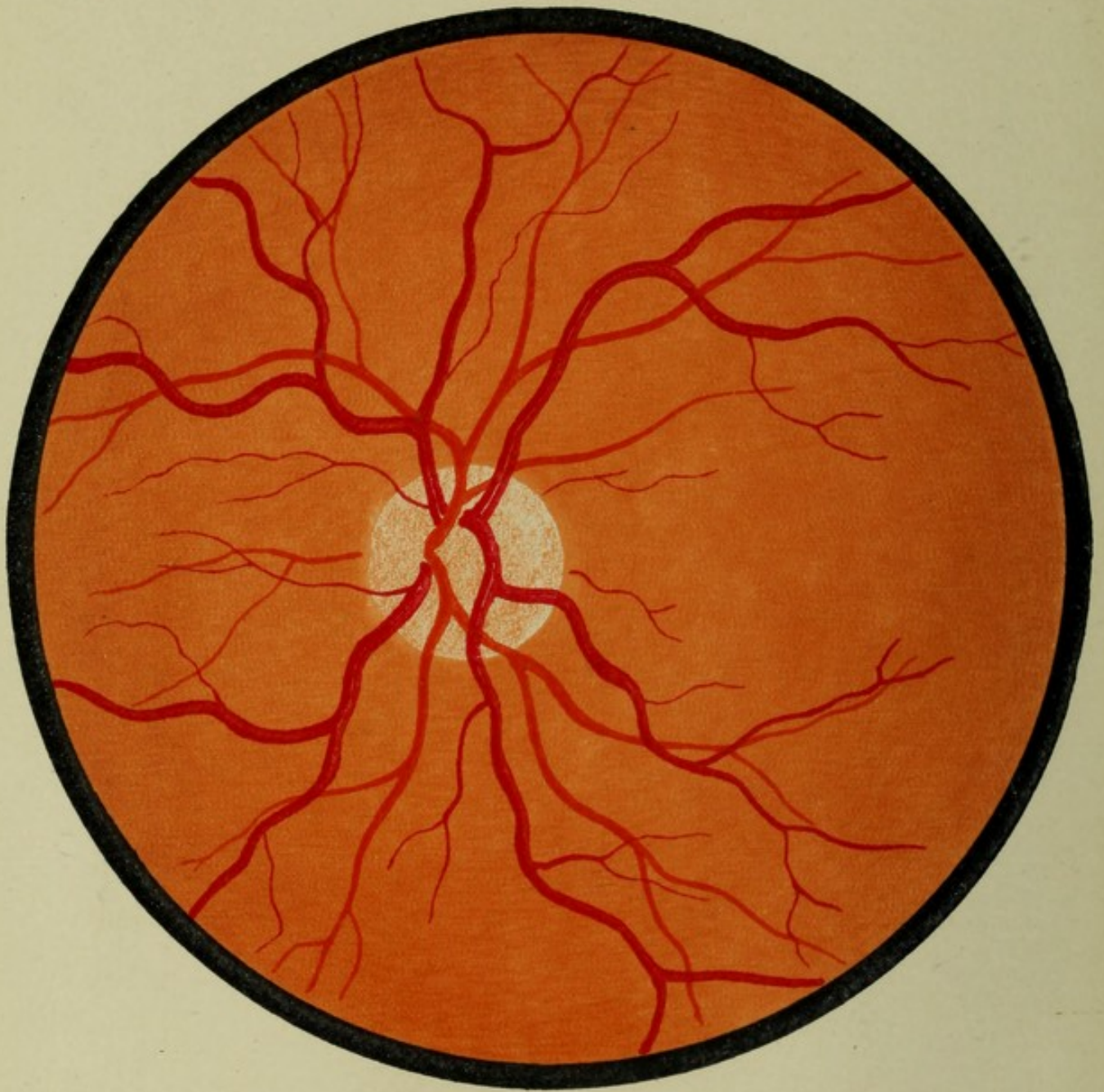












THE NORMAL FUNDUS OF THE EYE.



A TEXT BOOK
OF
VETERINARY OPHTHALMOLOGY

BY
GEO. G. VAN MATER, M.D., D.V.S.

*Professor of Ophthalmology in the American Veterinary College;
Oculist and Aurist to St. Martha's Sanitarium and Dispensary;
Consulting Eye and Ear Surgeon to the Twenty-sixth Ward Dispensary; Eye and Ear Surgeon,
Brooklyn Eastern District Dispensary, Etc.*

ILLUSTRATED BY ONE CHROMO LITHOGRAPH PLATE AND
SEVENTY-ONE ENGRAVINGS



NEW YORK:
WILLIAM R. JENKINS,
VETERINARY PUBLISHER AND BOOKSELLER,
851 & 853 SIXTH AVENUE.
1897.


COPYRIGHT, 1897, BY WILLIAM R. JENKINS.

All Rights Reserved.

PRINTED BY THE
PRESS OF WILLIAM R. JENKINS,
NEW YORK.

WELLCOME INSTITUTE LIBRARY	
Coll.	welM0mec
Call	
No.	V

THIS BOOK
IS
AFFECTIONATELY DEDICATED
BY THE AUTHOR
TO
HIS MOTHER.




PREFACE.

MY excuse for perpetrating this work consists in shifting the blame on the students who so often have asked me to recommend something that could be studied without necessitating the perusal of many pages. And so this is the result. I lay claim to but little originality, although what I have told is the result of conscientious study, supplemented by practice, both private and clinical, and careful observation. Let me hope, therefore, that my motives will be taken into consideration by any critic who may deem this publication worthy of notice.

BROOKLYN, Jan. 1st, 1897.

354 Macon Street.



A TEXT BOOK
OF
VETERINARY OPHTHALMOLOGY

INTRODUCTION.

THE visual apparatus consists of the eyeballs and their accessory parts. The means of communication to the brain are the optic nerves. Each eyeball (*Bulbus*) forms a hollow spherical box, blackened interiorly, with a system of convex lenses, in front, for forming images of external objects, and the retina behind, which is the perceptive membrane. The whole

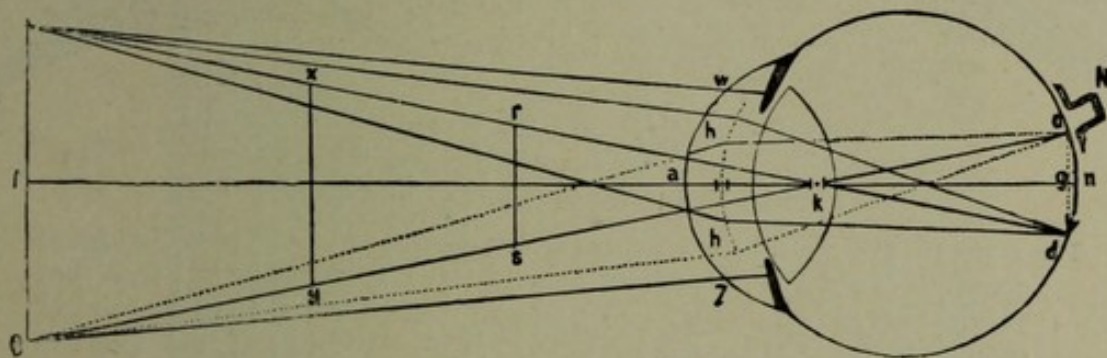


Fig. 1.—Formation of an image in the eye. (*Landois.*)

By following the rays from the object A B, it may be seen that they are brought to a focus on the retina, where a small inverted image is formed.

is likened to a camera obscura. A camera obscura is an optical apparatus, consisting of a darkened chamber, at

the top of which is placed a box or lantern containing a convex lens and sloping mirror, or a prism combining the lens and mirror. The rays of light from surrounding objects are received by the lens, and the mirror reflects images of the scenery downwards on a table placed underneath (invented by Batista Porta in the end of the 16th century). Now the light passes through the cornea, aqueous humor, lens and vitreous humor, and is focussed on the retina. The retina appreciates both intensity and color. Images which are formed on the

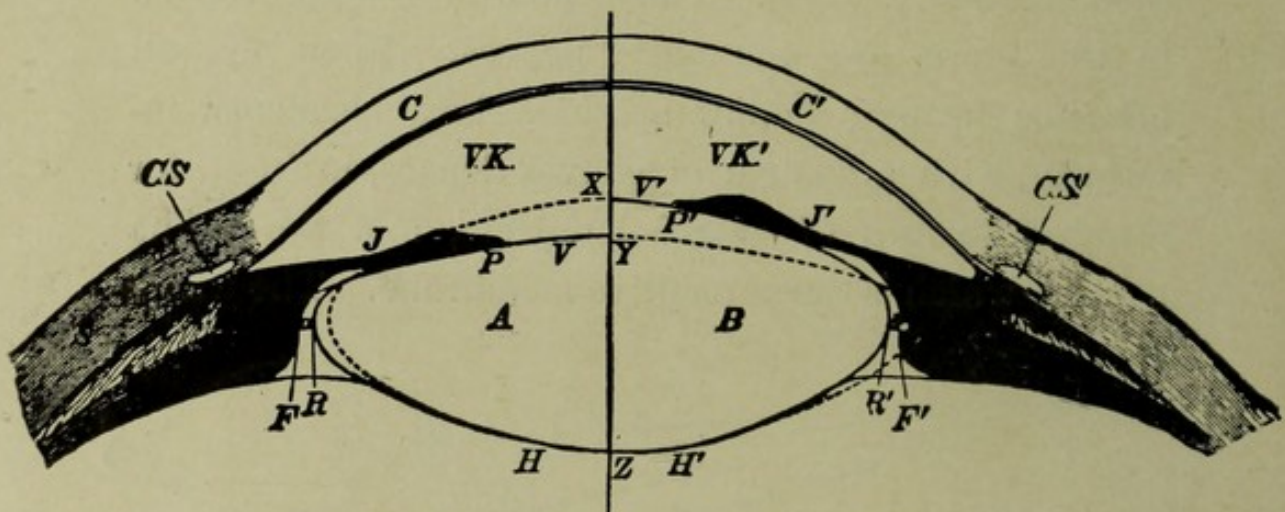


Fig. 2.—Scheme of accommodation. (*Landois.*)

The right side of the figure represents the condition of the lens during accommodation for a new object, and the left side when the eye is at rest. The letters indicate the same parts on both sides; those on the right side are marked with a stroke. A, left, B, right half of the lens; C, cornea; S, sclerotic; CS, canal of Schlemm; VK, anterior chamber; J, iris; P, margin of the pupil; V, anterior surface; H, posterior surface of the lens; R, margin of the lens; F, margin of the ciliary processes; A B, space between the two former; the line Z X indicates the thickness of the lens during accommodation for a near object; Z Y the thickness of the lens when the eye is passive.

retina are inverted. (Fig. 1.) These impressions are conveyed to the brain by the optic nerves, and thence

we have resulting—vision. Vision in all animals depends on the sensibility of the retina (optic nerve filaments) to the vibration of luminous rays. The amount of light admitted to the eye is regulated by a curtain, the iris, the movements of which are reflex. The eye adjusts itself (*accommodation*) for distances, so that the retina is properly focussed for distance and for objects near by. (Fig. 2.) At the base of the horse's eye is found a collection of pigment cells—brilliant—called the *tapetum*, and in a darkened stall one may get the reflex from the eye, bluish in color, more of a yellow in the ox and reddish-yellow in the cat.

In the horse the eyes are placed in their orbits inclined toward the sides. Only a portion of a view is




Fig. 3.

perfectly appreciated at one time, the surrounding being less and less distinct, but from the perfect action

of the extrinsic muscles the bulbi are rotated so extensively and with such harmony that the field is quite extensive. Where rays of light proceed from a luminous body, they always pass in straight lines, forming in their divergence a cone, the apex of which is the luminous body, and the base any plane which may intercept them. So long, then, as they travel in a medium of uniform density, so long will they travel in straight lines. Rays passing from a rarer to a denser medium are bent toward the perpendicular *at* the point of incidence. (Fig. 3.) Should they fall upon a *polished* surface perpendicularly, they will be *reflected* in a straight

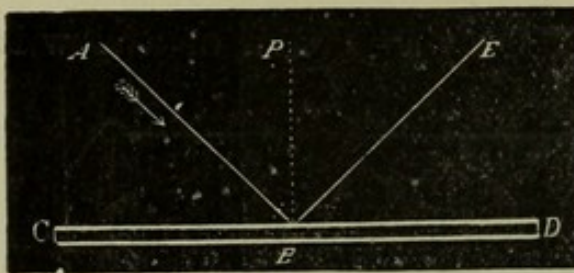


Fig. 4.

line. If obliquely, they will be reflected, and the angle of reflection is equal to the angle of incidence. (Fig. 4.) If they pass from a denser to a

rarer medium, they will be bent from the perpendicular (see Fig. 3).

If a luminous ray passes through a piece of glass, the ray striking obliquely, it will be bent toward the perpendicular, but, on its passing from the glass to the air (denser to rarer), it will be bent *away* from the perpendicular. We have seen rays of light passing through plane surfaces. Let us see it through curved surfaces. It is supposed the circumference of a circle is made up of a number of small, straight lines. Take

a double convex lens. (Fig. 5.) Rays of light passing through this are bent *toward* the perpendicular, and

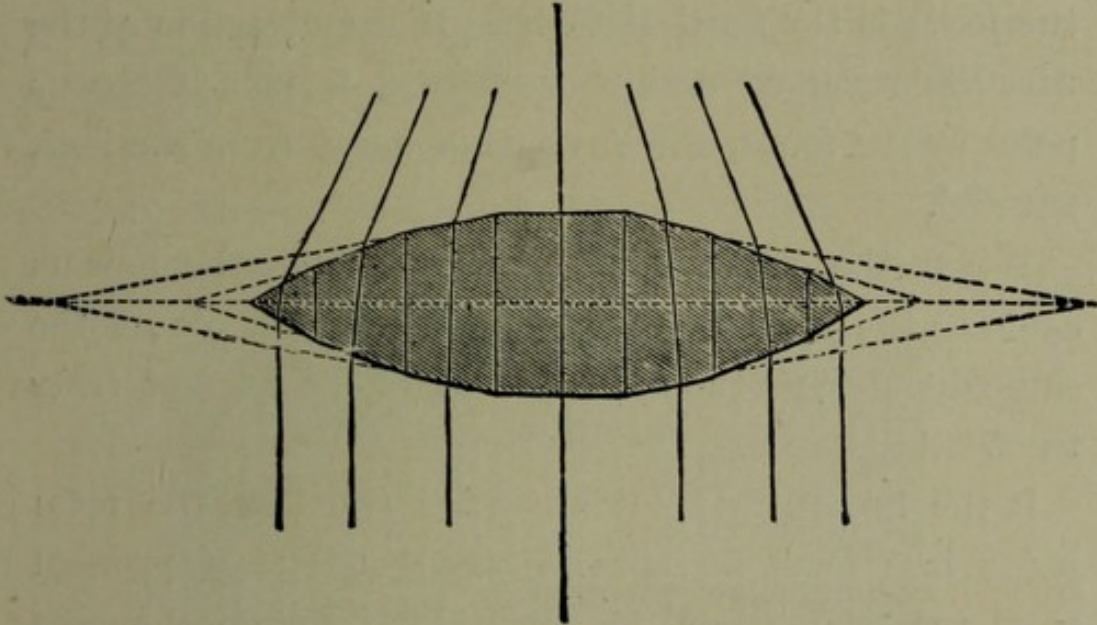


Fig. 5.

Diagram illustrating the composition of a convex lens of a number of plane surfaces.

therefore these rays come to a focus; and where the focus is, we will find light and heat, because of the num-




Fig. 6.

ber of light and heat rays converged at one spot. Remember that a ray striking a plane perpendicularly

will not be acted upon, but will pass through unchanged, and this is the *chief axis*.

The distance between the central point of the lens and the focus is the focal distance. If the direction of the rays are reversed and they proceed from a luminous point at the focus, the rays will emerge from the lens, parallel.

When the distance of the light from the lens is *equal* to the focal distance, the focus will lie at the same distance on the opposite side of the lens, or *twice* the focal distance.

If the luminous point approach the lens, the focal point is moved farther away. If the rays proceed from a chief point on the chief axis between the lens and principal focus, they will diverge on the opposite side of the lens, and *not* come to a focus. (Fig. 7.) In

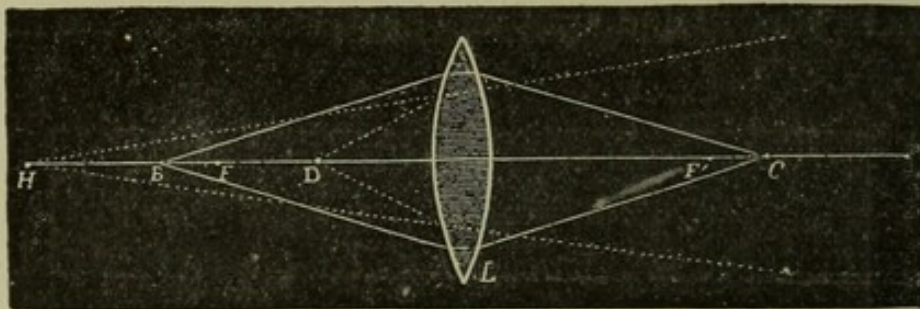


Fig. 7.

ordinary lenses, the refraction is not equal in amount at the center and periphery.

Rays passing through the optical center are not refracted, while those which pass near the center are less

refracted than those which pass near the circumference ; so, you see, the nearer the circumference, the more the amount of refraction. This is called spherical aberration, which may be corrected as follows :—Increase the density of the central part of the lens, which will cause it to act more strongly on the rays. Now see : this is just what the lens (crystalline) does in the eye, as it is more dense in its center than periphery. Or,

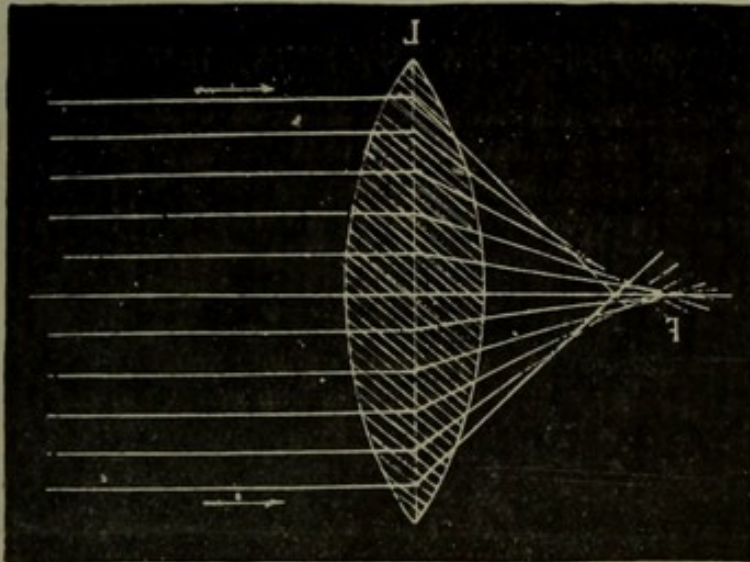


Fig. 8.

The rays passing through the edges of the lens have a shorter focal distance than those passing nearer to the center.

placing a diaphragm between the object of which the image is to be formed and the lens, thus cutting off those rays which pass through the peripheral portion of the lens, the image therefore being formed by the rays passing through the center. This is also a condition existing in the eye, for have we not the iris, and what is the iris but a diaphragm, which is capable of modification? Now, light, after all, is a composite

affair, being composed of seven colors,—violet, indigo, blue, green, yellow, orange and red. One may demonstrate this by using a triangular piece of glass—a prism—and intercepting a beam of light, which will be split up into its component parts, the red rays being

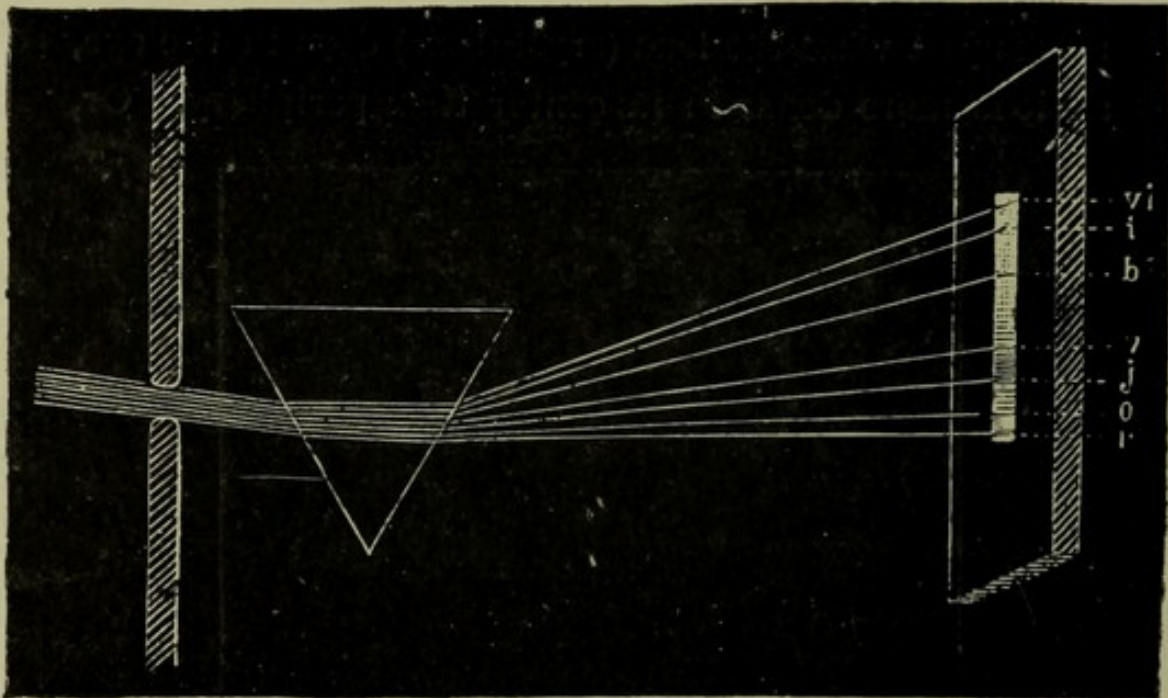


Fig. 9.

Diagram illustrating the decomposition, in passing through a prism, of white light into the seven colors of the spectrum (*Biclard*): r, red; o, orange; j, yellow; v, green; b, blue; i, indigo; vi, violet.

refracted the least and the violet the most. It is not the province of a small compilation, such as is represented by this little work, to give full details in the physiology of sight. That must be culled from your various text-books on physiology. That point at which the image is focused on the retina is called the "field of projection." Here the visual purple becomes bleached

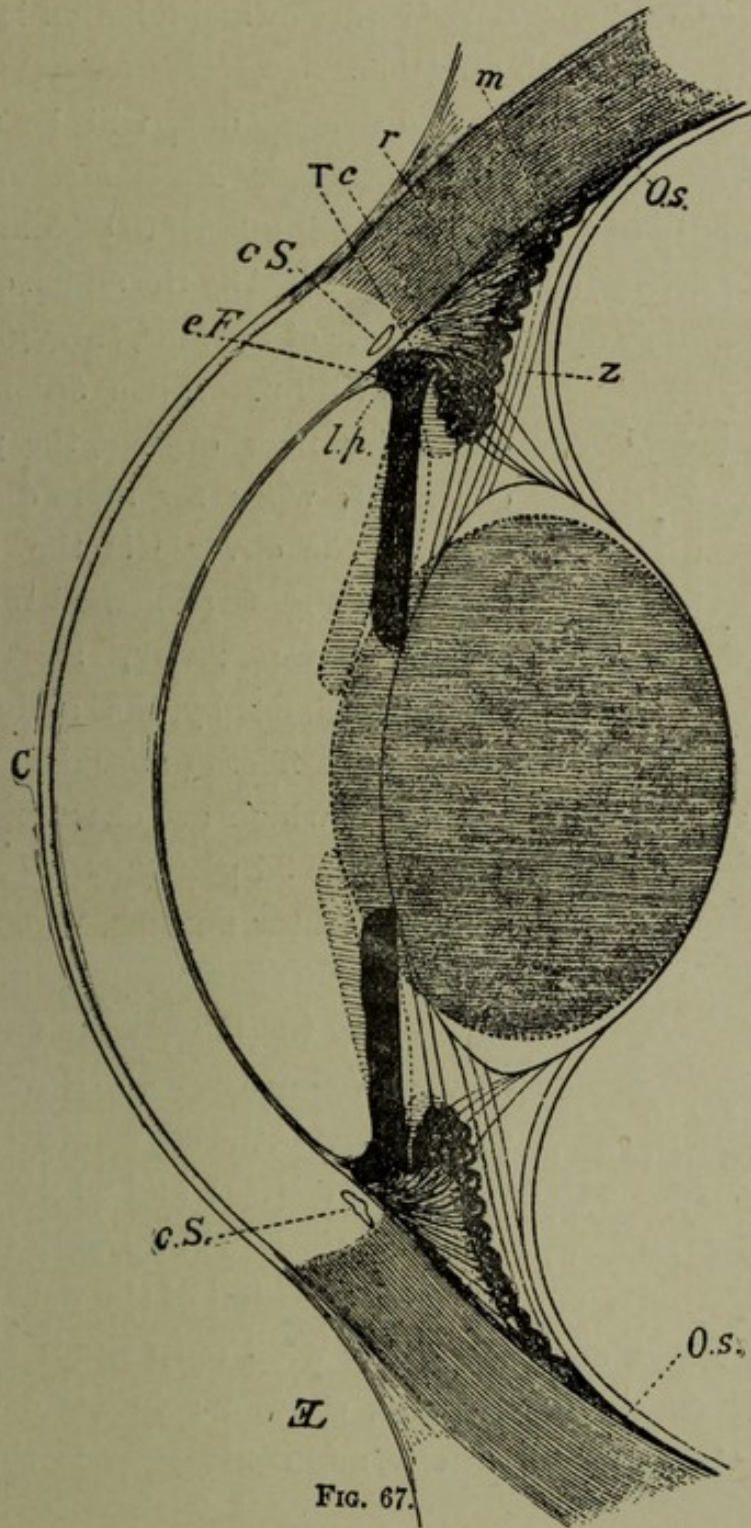


FIG. 67.

Fig. 10.

Anterior portion and ciliary region of the eye. C, cornea; cS, Schlemm's canal; Os, *ora serrata*; lp, pectinated ligament; eF, Fontana's space; T, tendinous ring; m, meridional fibers; c, circular fibers of the ciliary muscle; Z, zone of Zinn. The full lines indicate the crystalline lens, iris, and ciliary body in a state of rest, the dotted lines show the same in a state of accommodation.

—undergoes change—and its action and function is now the subject of much question.

The question of inverted images, etc., will be more fully dealt with in the lecture-room. *Accommodation* is that faculty of the eye of adapting itself to distances of varying degree, and is accomplished by the action of the ciliary muscle upon the capsule of the lens, through the

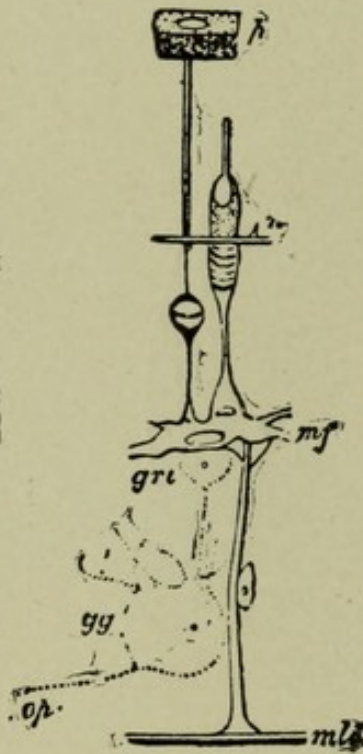


Fig. 11.

P, pigment cell of the retina connected with a rod. n, Cone seated on the membrana limitans externa.

zonule of Zinn. When accommodated for near objects, the pupil contracts; when for more distant objects, the obverse is the case. These changes (contraction and dilation) are reflex, and are brought about by the action of two sets of fibers (muscular)—the sphincter, which are circular, supplied by the 3d pair (motor-oculi); and the dilator pupillæ, which are the radiating fibers, supplied almost entirely by the trigeminus and the cervical sympathetic. Now, suppose we divide the 3d, what results?

Dilates of course; and why? The sympathetic gets in its work and is in full possession of the field; the dilator fibers contract, and a wide open pupil is the result. On the other hand, cause a solution of continuity in the sympathetic, and contraction is the re-

sult. The sphincter fibers contract and narrow down the pupil. If both nerves be stimulated simultaneously, we will observe that the sphincter set are the more powerful, for contraction will ensue. In the presence of bright light we have contraction. Stimulation in the floor of Aqueduct of Sylvius causes contraction. Pupillary caliber is modified by action of certain drugs, of which more hereafter. The retinal action and its results are far from being satisfactorily explained to the ophthalmic student, as yet. We know that it is the rod and cone layer only, which is concerned in the formation of the image. The most acute vision is at the *macula lutea*, or yellow spot. We will speak of only the rod and cone layer in this part of our little brochure, and under the retina will delve deeper into its layers.

The external layer, consisting of rods and cones closely packed together, *i. e.*, small transparent rods, end on, close together, and scattered among them without regularity, a cone here and there. At the macula we find numerous cones and an absence of rods. Also at this place, find ganglionic and yellow pigment cells. Now, remember, *light is a sensation only*.

Remember, also, we spoke of the visual purple. As yet we know not of its precise function, but that it is concerned in the perception and recognition of light, there is no reasonable doubt.

The movements of the bulbus in its socket are of

the universal order known as ball-and-socket joint. Luminous impressions upon the retina continue for a short time after cessation of light. If a bright point, like a smouldering or glowing match end, be waved around in a circle, the eye follows it throughout, but if the rapidity of its motion be increased it appears drawn out into a curved line, and with higher motion, very fast, it becomes a complete ring of light. Sparks from a knife-grinder's wheel become a stream of light. A circular saw with large teeth presents a smooth edge when revolving rapidly, and the spokes of a rapidly-turning wheel assume the appearance of a glimmering disc.

A brilliant light leaves a longer impression than a dim one. When an electric spark is seen, it has already come to an end, the interval elapsing before its perception by the observer being greater than its actual duration. The momentary closing of the eyelids in winking is unnoticed, and why? Because the visual impression of external objects continues unimpaired during the interval occupied by the movements of the lids. The eyes of the horse, remember, are set obliquely. Only in man, apes and some night-birds are the eyes so set as to permit visual lines directly ahead in parallels.

The bulbus has its poles. An imaginary line from pole to pole is its axis. The equator is at right angles to the axis, so we may have meridians. The visual

axis corresponds to the *macula lutea*, while the optic axis extends from pole to pole.

We are not aware of an image being on the retina, nor of its position there, but only of the stimulus produced on the perceptive nerve elements of the retina. So, understand, we do not see the image, but the object from which the rays emanate, and we refer the sensations in their direction. For instance, if an image is formed on the *upper* and *outer* quadrant of the retina, we refer it *downward* and *inward*, from which direction the rays *must* have come. At this point a word on inverted images:—The great advantage of inverted images is, that for a given-size pupil a much larger picture can be formed on the retina than would be the case if no inversion took place, for in the latter case all images must necessarily occupy a *much smaller place* upon the retina than the *size of the pupil*.

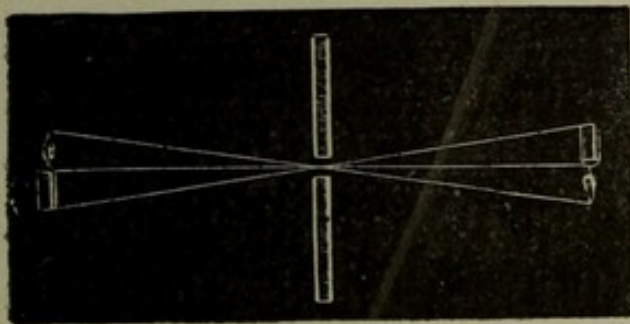


Fig. 12.

Color is analagous to pitch, violet corresponding to the high, and red to the low tones. Intensity of color, as of sound, depends upon the amplitude of the

vibrations. When a body absorbs all the colors of the spectrum except blue, we call it a blue body. Red glass has the power of absorbing all the colors except

the red, which it transmits. If any body or thing reflects *all* colors, we have white. Should all the colors be absorbed, we have black. Light travels 186,000 miles per second (discovered by Roemer in 1676). Scientifically this is of great moment, but to us the rate is so great that, for all distances on earth, it is instantaneous. The globe would be girt by a sunbeam quicker than we could wink. The theory of to-day as regards light is the undulatory theory. The earth is supposed to be bathed, embalmed, enveloped by a fluid termed Ether, which is very subtle. Suppose a luminous body sets in motion waves of this Ether which go in every direction, moving, remember, at the rate of 186,000 miles per second. Well, these waves breaking upon the retina cause the molecular disturbance termed "sight." This wave motion is like that of sound, except that the vibrations are transverse—cross-wise. "The sunbeam comes to the earth as simply motions of Ether-waves, yet it is the grand source of beauty and power. Its heat, light and chemical force work everywhere the miracle of life and motion. In the growing plant, the burning coal, the flying bird, the glaring lightning, the blooming flower, the rushing engine, the roaring cataract, the pattering rain, we see only varied manifestations of this one all-energizing force." *

* Steele.

CHAPTER I.

ORBITAL CAVITY.

Orbital cavity.—According to Chauveau, this cavity is irregularly circular in outline and circumscribed by the orbital process of the frontal bone, the lachrymal

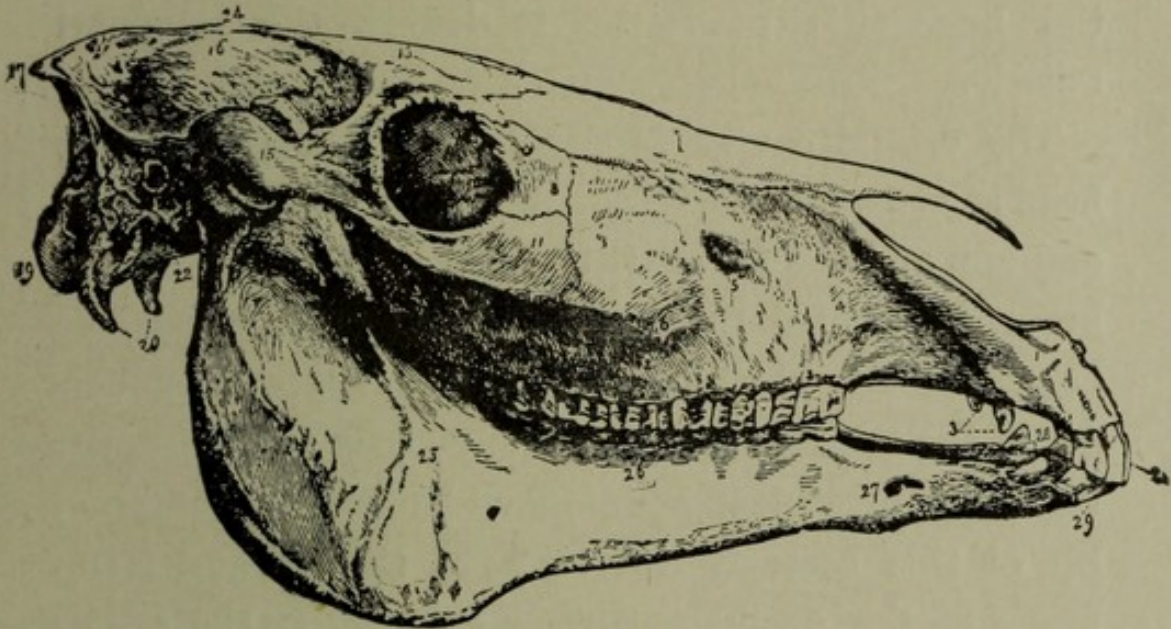


Fig. 13.

and malar bones, and the summit of the zygomatic process. At the bottom, which shows the maxillary and orbital hiatus, it is confounded in the skeleton with the temporal fossa.* It lodges the globe of the

* A fibrous membrane, the *ocular sheath*, isolates it from the temporal fossa in the majority of mammiferous animals. Only in

eye and the muscles which move it. Some organs accessory to the visual apparatus, such as the lachrymal gland and the membrana nictatans, are also contained in this cavity. The temporal fossa surmounts the orbit and is incompletely separated from it by the orbital arch (or process). Oval in shape, lying obliquely from above to below, and from within outwards, on the sides of the cranium, the temporal fossa is limited, within by the parietal ridge, and outwardly by the anterior border of the longitudinal root of the zygomatic process. It lodges the temporal muscle.

The orbital cavity is situated at the side of the head at the point corresponding to the union of the cranium and the face. It is lined by a fibrous membrane, designated the ocular sheath (ocular membrane or periorbita), which is attached posteriorly to the border of the orbital hiatus and anteriorly to the upper lip of the orbit, being prolonged beyond the external lip of this osseous rim to form the fibrous membrane of the eyelids. Strong externally, the ocular sheath is thin within the cavity, composed of elastic and inelastic fibers (unstriped muscular fibers have also been included in its composition), traversed by vessels and nerves. Thus completed, the orbital cavity has the form of a regular hollow cone, open at its base, man and the quadrumana has the orbital cavity complete bony walls.

closed at the apex, which corresponds to the orbital hiatus. In the ordinary position of the head the opening of this cone is directed forward, downward and outward. The bones which go to make the orbital cavity are the frontal, sphenoid, superior maxillary, malar, palate, ethmoid and lachrymal. The optic foramen, situated at the apex of the cone, transmits the optic nerve and ophthalmic artery. The superior orbital fissure transmits the third, fourth and sixth nerves, ophthalmic branch of the trigeminus and the superior and inferior ophthalmic veins. The inferior orbital fissure gives passage to the malar and infra-orbital nerves, and a facial branch of the ophthalmic vein. (See Fig 41.) The supra-orbital notch, at the upper and inner margin of the orbit, contains the supra-orbital nerves and artery as they pass to the forehead. In addition to the bulbus, muscles, vessels, etc., the orbit contains much adipose tissue.

There is a limiting membrane between the globe and conjunctiva and the cellulo-fatty tissue, called Tenon's capsule. To some extent it ensheaths the muscles, nerves and vessels that pass through it, and is continuous with the periosteum of the orbit, as well as with the conjunctiva. It is somewhat analogous to the pleura, and serves as a cup in which the globe revolves. It constitutes a secondary attachment for the ocular muscles. The dura mater is firmly attached at the sphenoidal fissure and optic foramen, and is continuous

with the outer sheath of the optic nerve and with the periosteum of the orbit.

Orbital cellulitis.—*Diseases of the orbit* may be either simple œdematous cellulitis or phlegmonous cellulitis. In the œdematous form there will be bulging forward of the bulbus. Little pain on pressure occurs in the young and subsides in a few days. The phlegmonous form is much more severe; swelling of the lids, especially the upper; pain, which may be intense and will tolerate no pressure on the globe; eye is protruded directly forward.

Exophthalmus.—In some severe cases have absolutely no motion; * will have chemosis of conjunctiva; symptoms almost always acute, and the crisis is reached in 8 to 14 days. Tissues on palpation will be found firm, tense and hard. All this may go on, the bulbus become involved and have inflammation of all parts of the eye—*panophthalmitis*. When pus forms, as it may, fluctuation may be found behind the lids. Abscess may burst through conjunctiva or lids. May result from injuries, periostitis and inflammation of lachrymal gland.

TREATMENT.—Antiphlogistics early. Should suppuration occur, poultices and incision through conjunctiva between the lids. Exploration is *good* when in doubt, and better to use knife too early than too late. A large majority of these cases recover, and about the

* Compare periostitis.

only untoward results are abscess of brain and meningitis. Don't be fooled, when the whole thing may be a simple foreign body, the removal of which will dissipate the alarming symptoms.

Periostitis of the Orbit is generally limited to the margin of the orbit. It *may* arise idiopathically in the rheumatic. Some swelling and redness of the lids and a slight exophthalmus, generally to one side. Sometimes slight elevation of temperature. Pus *may* form beneath the periosteum. In the chronic form there is simply slight swelling of the upper lid and supra-orbital pain, and a little local swelling. This form is very tedious, running months, and ending in caries, deformities, etc.

TREATMENT.—As in cellulitis. If, however, it has gone on to necrosis, etc., the chisel and gouge come into play, and a thorough removal of and curetting is applied to the carious parts.

Tumors of the Orbit.—Both benign and malignant. May develop primarily in the orbit or spread from the face. Cause more or less exophthalmus and its consequences.

TREATMENT is excision. Sometimes it is necessary to remove bulbus also: (*Eneucleation.*)

CHAPTER II.

EYELIDS.

THE eye is protected and covered by two membranous, movable curtains—the palpebræ—superior and inferior. They serve to protect the eye and to exclude excessive light. Another function is to secrete and distribute a moisture to the eye. Their movements are both voluntary and involuntary, the involuntary due to the orbicularis muscle. The levator palpebræ superioris opens the eyes by lifting the upper lid. The space between the free margins of the lids is the palpebral fissure. The angles of junction between the lids are the *canthi*, the external being the most acute. At the inner canthi are found two small elevations, one on each lid—the *punctum lachrymale*—which are the beginnings of the canals, or *canaliculi*, leading to the tear sac. The eyelids are composed of four layers : (1) the integument, (2) layer of muscular fibers, (3) the tarsus, and (4) the conjunctiva. The muscular fibers consist of the orbicularis palpebrarum, a wide, thin sphincter common to both lids, having tendinous attachments at the angles of the lids, the tendons together with some muscle-

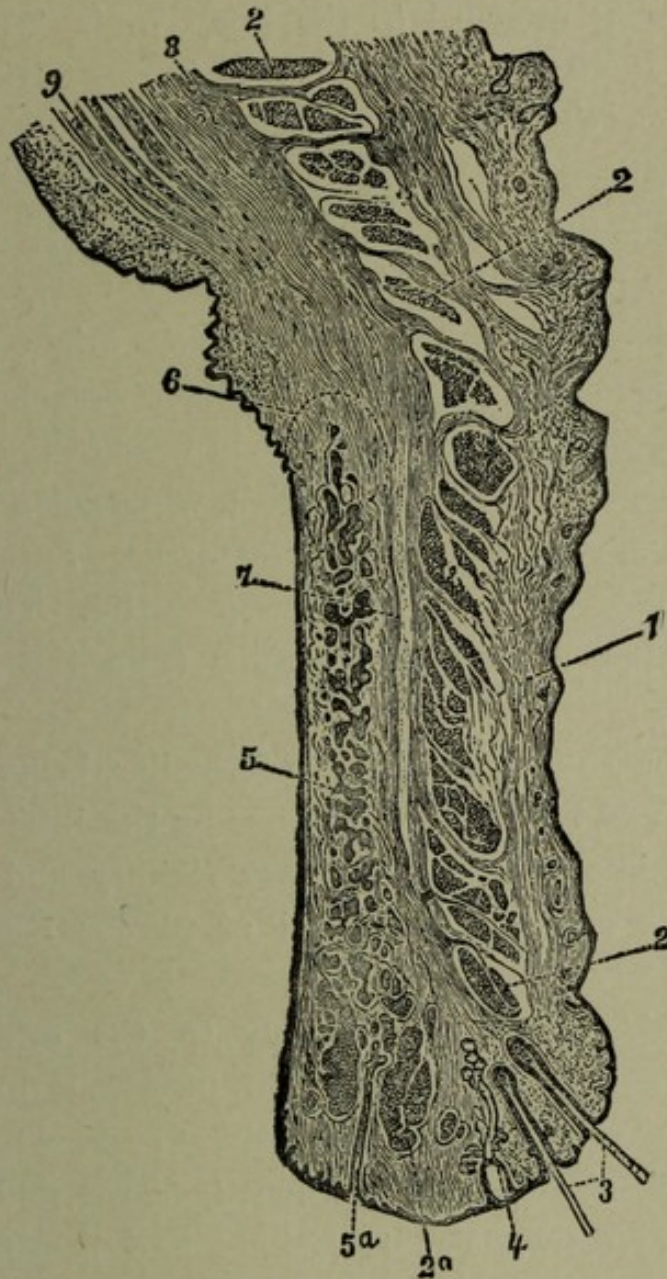


Fig. 14.

Saggital Section through the upper eyelid. 1, skin; 2, palpebral portion of the musculus orbicularis oculi; 2a, its inner portion, designated as the musculus ciliaris Riolini; 3, cilia; 4, gland of Moll, opening into a hair follicle; 5, Meibomian gland; 5 a, its orifice; 6, indication of the ill-defined limit of the tarsus; 7, loose connective tissue between tarsus and anterior insertion of the tendon of the musculus levator palpebrae superioris; 8, anterior connective-tissue-like insertion of the tendon of the musculus levator palpebrae superioris; 9, its middle layer, non-muscular, called the musculus palpebralis superior.—*H. Muller.*

fibers being attached to the bony wall. There are certain bundles of the orbicularis fibers—involuntary—known as the *ciliary muscle of Riolini*. The orbicularis is adherent to the skin, but glides smoothly and loosely over the tarsus. The contraction of this muscle closes the palpebræ.

The *Levator Palpebræ Superioris* arises at the orbital apex, passing along the upper wall, becoming intermingled with the orbicularis in front of the tarsus. Some fibers go to the conjunctiva, while some become attached to the upper edge of the tarsus. Supplied by the motor-oculi. Function to raise the lid. The lower lid is supplied by a prolongation from the inferior rectus.

The Tarsi.—The framework of the lids, being united together and to the adjacent bone by the internal and external lateral ligaments, gives rigidity and stability to the eyelids. Composed of fibrous condensed tissue.

The Skin adheres intimately to the orbicularis muscle; smooth and covered with numerous fine short hairs. In the fœtus, at the orbital arch, where the skin everywhere else is without hair, we find a well marked eyebrow. Fat is *never* found beneath this skin.

The Conjunctiva is a delicate mucous membrane, which commences at the free border of the lid where it is continuous with the skin. It lines the inner surface

of the lids and is reflected upon the globe, over which it passes and becomes continuous with the cornea. The palpebral portion is thicker and more vascular than the ocular, and is firmly attached to the tarsus. Where it passes from the lids to the globe it is thin and very loose and forms the *fornix conjunctivæ*.

Now, as its name indicates, it joins the bulbus and palpebræ together. It envelops, in addition to the above,

the anterior portion of the haw (*membrana nictatans*) in a particular fold, and covers the *caruncula lachrymalis* and enters the puncta. At the margin of the cornea one may not trace it, although it is represented by a layer of pavement epithelium. At the surface of the caruncle it shows some very fine hair bulbs. (See conjunctiva.)

Eyelashes (cilia.)—Two rows, at free borders of the lids. Act as a shield against foreign particles, dust, etc. Their follicles are surrounded by sebaceous glands and the glands of Moll (which are small tubular glands resembling ceruminous glands.)

These various glands serve to lubricate the eye by

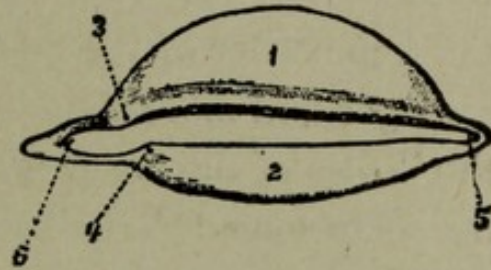


Fig. 15.

The tarsi seen from behind. They have been isolated from other tissues and remain joined at the external and internal angles by the lateral ligaments, external and internal: 1, Posterior surface of tarsus superior; on its edge the openings of the Meibomian follicles; 2, tarsus inferior; 3 and 4, punctum lachrymale superior and inferior; 5, external angle; 6, internal angle.

their secretions, which emerge by minute orifices on the free border of the lids. The lashes are longer and stronger and more abundant in the upper lid. Though the lashes of the lower lid are few, they are reinforced by some long bristly hairs, which are just like the tentacular of the lips.

The Meibomian Glands.—Analogous to sebaceous. They are lodged near the posterior surface of the tarsus, arranged like currants on a stem. They open by minute orifices upon the free border of the lids behind the cilia. Each gland consists of a central tube with a number of openings around its sides. The unctuous matter they secrete facilitates the retention of the tears over the conjunctivæ. Supra-orbital, lachrymal and orbital branch of the superior dental arteries, forming thick network indirectly connected around the cornea with the ciliary system, through the episcleral, are the arteries. Lymphatics form a close network around the cornea. Nerves from the fifth pair enter at inner and outer angles of the eye, form a thick plexus and end free—some by club-shaped expansion. These nerve fibers are non-medullated.

Membrana Nictatans.—“*Third or winking eyelid.*”—*Haw.* At the inner angle of the eye. Its composition is of a fibro-cartilaginous framework, elastic, irregularly shaped, prismatic at its base, which is thick, and thin anteriorly, where it is covered by the conjunctiva. Behind is a strong cushion of adipose tissue, which is

insinuated *between* all the muscles of the eye. The movements of the haw are mechanical, and no muscle directly causes them. When the eye is in repose but a small fold of conjunctiva is seen; the rest is in its fibrous case. When the eye is withdrawn into the orbit by contraction of the recti muscles, the globe compresses the fatty cushion belonging to the cartilage; this cushion, pressing outwards, pushes the *membrana* before it, and the latter then entirely conceals the front of the eye. This movement is instantaneous, but it may be momentarily fixed by pressing gently on the eye when the animal retracts it within the orbital cavity. The use of the *membrana* is, as will be seen from the above, to maintain the healthy condition of the eye by removing any matters that have escaped the eyelids; and what clearly demonstrates this function is the inverse relation that always exists between the development of this body and the facility with which animals can rub their eyes with their anterior limbs; so it is that, with the horse and the ox, whose thoracic member cannot be applied to this purpose, the *membrana* is very highly developed, and in the dog, which may use its paw to some extent when it requires to brush its eye, it is smaller; in the cat it is still less, while in the monkey and in mankind, whose hands are perfect, it is rudimentary. In tetanus, the *membrana nictatans* often remains permanently over the eye in consequence of the continued contraction of

the recti muscles.* The gland of Harder, situated on the outer face of the haw, is a reddish-yellow gland, covered by fibrous membrane and surrounded by fat. Secretes a thick unctuous matter, which gains exit on the inner face of the membrana by three or four openings.

DISEASES OF THE LIDS.

Acute Blepharitis.—Abscess of the lids. Is an acute phlegmonous inflammation of the lids; usual cause is of a traumatic nature. May accompany strangles or follow it; adenitis simple. Will have great swelling with the cardinal symptoms; apt to have conjunctivitis accompany this. May have fluctuation early. This might go on to gangrene. If early enough, cold applications to abort. If later, and suspect formation of pus, *hot* applications, and get the matter over with. Of course, as soon as fluctuation is felt, open freely and *make the incision parallel* with the lid border. Evacuate freely, using antiseptics and asepsis (and Boric acid solution is good and safe about the eye) for patient and instruments. Do not use Hydrar for instruments, as you'll dull the edge quicker than it can be restored, and not more powerful than 1 to 5000 about the eye, unless great care is taken to prevent its entrance into the conjunctival sac. May suture if you think necessary; compress bandage to insure first intention.

* F. Lecoq in Chauveau's Anatomy.

Blepharitis Ciliaris (*Blepharitis Marginalis, Tinea Tarsi, Ophthalmia Tarsi*).—Rarely met with in equine patients, but when it is, it is long-lasting and very rebellious. This may be merely a slight, scarcely perceptible redness of the lid margin, while again it may be very severe—ulcerations, or thickened everted edges. Caused by smoke, dust, cold winds, bright light and too much of it. Lids are apt to be agglutinated. Edge or margins scaly and scabby. Photophobia and lachrymation. Hair follicles may be destroyed and the cilia fall out. The thickening and eversion of lids may cause ectropium.

Always assure yourself it is not the result of Phthiriasis, for, if it is, it will be necessary to eradicate them before attempting a cure of the Blepharitis. Use Merc. ung. Fungus growths in the hair follicles are also said to cause this disease. Remove the hairs by epilation, and go on to cure. Lachrymal catarrh, and particularly catarrh of the lachrymal sac, with stricture of the duct; the tears, unable to get through into the nose, flowing over the lids. Tears being retained, inflammation ensues. In such cases open the canaliculus into the sac and give free passage for the tears, then go on and treat as a simple case. It is very necessary to observe *cleanliness*. Removal of scales and scabs—*without* force. If can not get them away easily, poultice the eyes for fifteen or twenty minutes. Then proceed: Vaseline. Boric ac. and vaseline; gr.—xxx.

to one ounce;—Oxide of zinc ointment. If it has gone on to ulceration, after removing the crusts gently, use hydrar. ox. flav. grs. two to vaseline one dram;—or citron ointment x or xx grs. to the dram, of vaseline. May cauterize the ulcers with a fine point of lunar caustic.

Stye (*Hordeolum*). Acute inflammation of cellular tissue of the lids, with suppuration and pointing at the

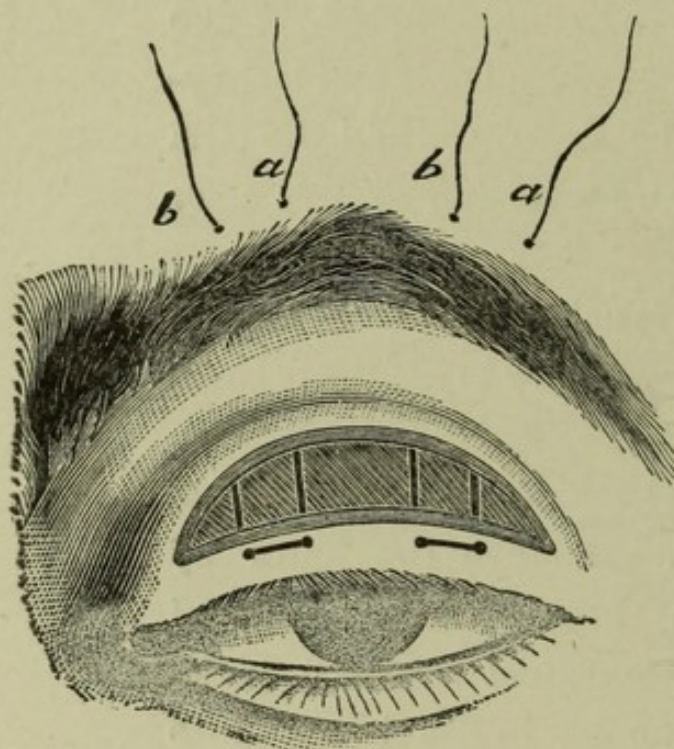


Fig. 16.

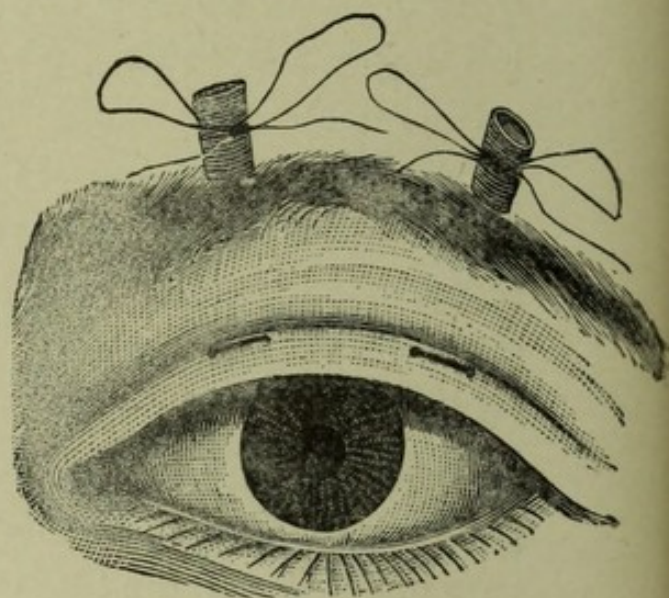


Fig. 17.

edge of the lids. This usually is found around a hair follicle and first appears as a circumscribed swelling. Some cases go on and involve the entire lid, which becomes swollen and œdematous. Much severe *throbbing* pain. Often multiply and may return in successive crops. Usually break in a week. Some are absorbed and do not break. Incise if pointed, and evacuate.

Will just mention here a drooping of the lid, due either to partial or complete paralysis of the levator palpebræ superioris. Is called Ptosis. If you should desire to correct, remove an elliptical portion of the skin and muscular fibers, and suture. (See Figs. 16 and 17). There is another condition which may be met with, called *Blepharospasmus*, and it is a spasmodic closure of the lids. May be due to a foreign body, ulcus corneæ, iritis. Carious teeth. May be tonic; or clonic, lasting but a few seconds at a time. Remove the cause of irritation, which is the only treatment. Another rarity, called nictitation, which is a constant blinking, may be due to some irritation in the eye, or of a reflex character, from worms, decayed teeth, etc. Remove cause.

Blepharophimosis is a narrowing of the palpebral opening, usually the result of chronic trachoma, and can be relieved by canthotomy, performed by inserting blunt pointed scissors in outer canthus and snipping as far as desired.

Trichiasis and Distichiasis.—The first is an irregularity in shape and disposition of the cilia. The second is a double row of cilia.

TREATMENT: epilation.

Entropium is an inversion of the eyelid, spasmodic and cicatricial. First usually in the lower lids; comes from keratitis, foreign bodies, etc. Second is the result of granular and diphtheritic conjunctivitis, burns, etc.,

where there has been loss of substance in the conjunctiva. In the spasmodic form may use adhesive plaster; paint with collodion and keep the lid in position.

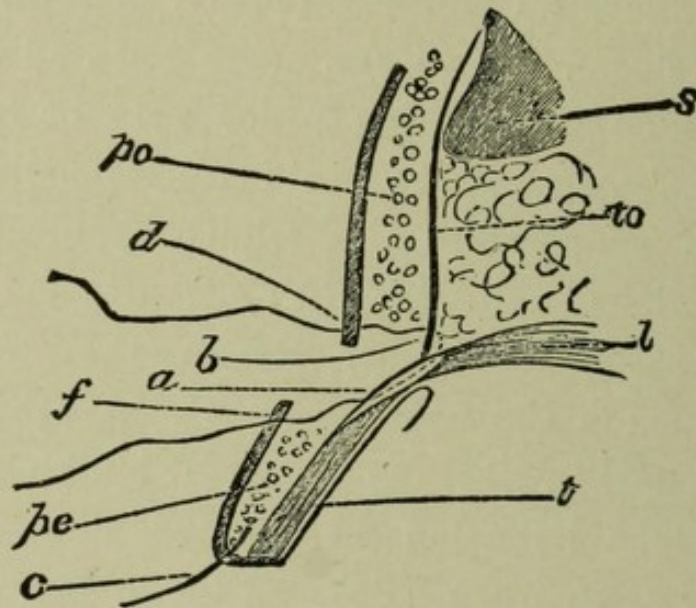


Fig. 18.

Represents a vertical section of the upper eyelid. S, supra orbital margin; to, fascia tarso-orbitalis; po, pars orbitalis; pc, pars ciliaris of orbicularis muscle; t, tarsus; c, eyelash; f, lower border; d, upper border of the wound; a b, passage of suture through aponeurosis.—Noyes.

In cicatricial, operative interference consists in removing a slight strip of skin parallel with the lid margin and suturing, entering the suture on the conjunctival side of the lid and drawing the lips of the incision together. This will evert the lid. (See Fig. 18.)

Ectropium.—Eversion of the eyelid may be slight or great. Two forms—*cicatricial*, due to contraction after burns, abscesses, wounds, etc.; *conjunctival*, when due to chronic inflammation and swelling of the conjunctiva, which separates the lid margin from

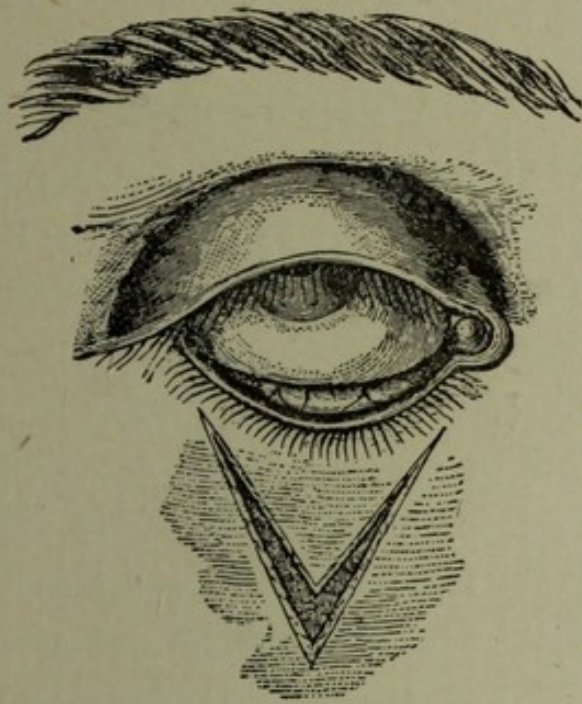


Fig. 19.

the eye, sometimes aided by relaxation of the skin and spasm of the orbicularis muscle. The best results are obtained by the removal of a V-shaped piece of skin, and dissecting it away. Bring the edges together so as to *push* and support the eyelid in its proper position, causing the sutures to assume a Y-like appearance. This

is the Wharton Jones operation. (See Figs. 19 and 20.)

When we find an eyelid fast to the eye-ball the condition is known as *Symblepharon*. Is the result of burns, severe inflammations, such as conjunctivitis, or anything which will cause the destruction of the mucous membrane. This growing together may be

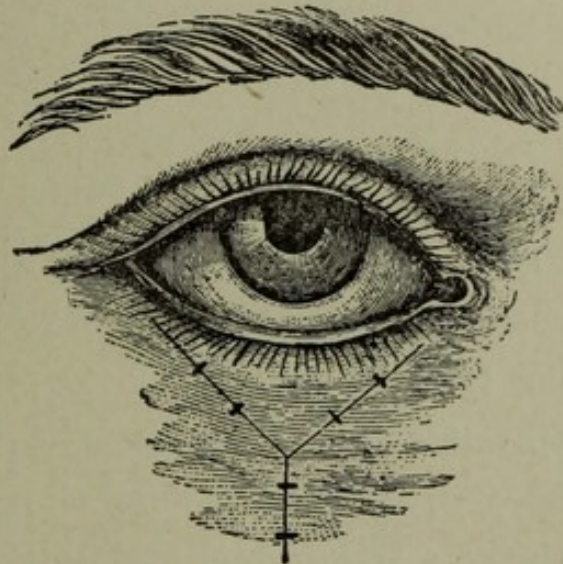


Fig. 20.

partial, or, we should say, of more or less extent. For instance, the entire lid may be adhered to the

globe, and again it may be only a thread-like attachment. The treatment is to separate and keep apart until the parts are healed over. This may necessitate transplantation from other portions of the globe, or borrow from a rabbit's eye. An adhesion, growing together, of the *lid margins*, is *Anchyloblepharon*, complete or partial.

TREATMENT is division. (See Fig. 21.)

Chalazion is obstruction of some of the follicles of the tarsus with retention of its secretion. The diagnostic point is that the skin is *freely* movable *over* it. Vary in size, and are apt to come in crops. Fluctuation is never felt. Excision is the treatment.

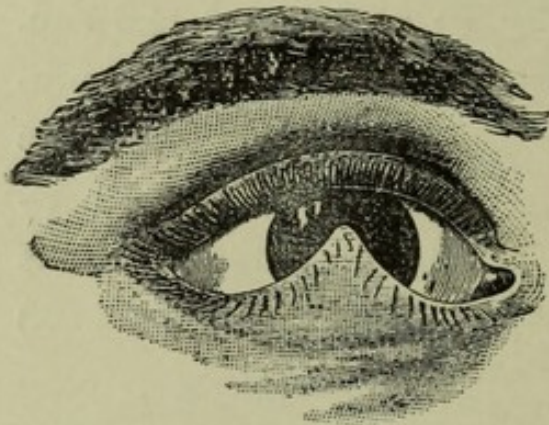


Fig. 21.

Make the primary incision on the skin surface—*parallel* to the lid border. May open on the inside if it points that way. This has a sac wall, remember, which must be either removed or *thoroughly* scraped, curetted, spooned out. Cocaine will be the only anæsthetic needed, dropping some of a 4 per cent. solution into the conjunctival sac and hypodermically injecting some alongside the tumor, which will render the operation almost painless. May lightly touch with lunar caustic to insure healing. All operations upon the lids are

productive of free hemorrhages, which may be very successfully controlled by using a clamp such as this.

Contusions should be treated as contusions elsewhere.

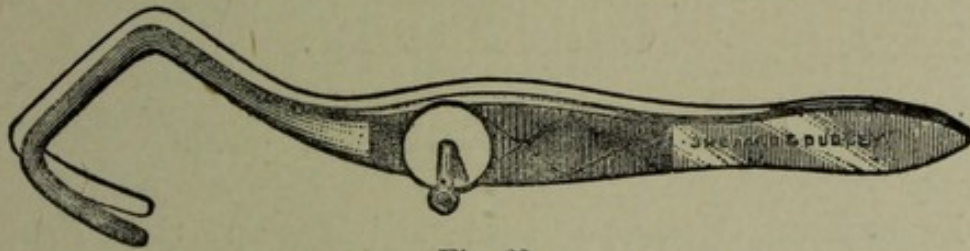


Fig. 22.

Immediately after a contusion, cold compresses, firm bandaging, cooling and soothing lotions, etc.

Burns and Scalds.—The great care is prevention of adhesions. If lime is the burning cause, antidote it immediately with acids, vinegar, etc., or protect with oil, freely used. Do not wash out the conjunctival sac unless you have *plenty* of water. A small amount would but aggravate the condition by slaking the lime.

Wounds.—Treat as elsewhere; cleanliness, antisepsis. Carefully inquire into the condition of the parts severally and as a whole. Careful coaptation of the wound's lips, intelligent suturing, and watch out for adhesions always.

CHAPTER III.

THE LACHRYMAL GLAND.

Lachrymal Gland.—Situated between the orbital process and upper part of the eyeball and close to its interior margin, convex superiorly, concave inferiorly. Is an acinous gland, formed of small granulations,

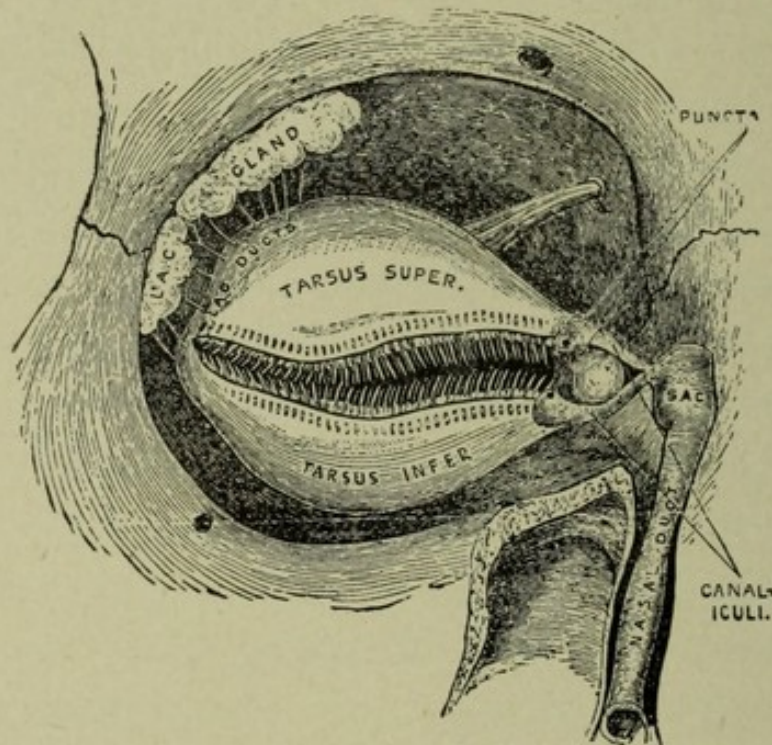


Fig. 23.

whose junction forms ducts called hygrophthalmic canals. These run to the upper and outer portion of

the superior fornix of the conjunctiva. Secretion is alkaline, moistens anterior surface of the eye, passing off by means of the puncta, canaliculi, lachrymal sac and nasal duct to the nose. The puncta are two openings of the canaliculi, at the inner canthus, a short distance from the commissure. Function, to collect the tears. The canaliculi extend from the puncta to the lachrymal sac, and these canaliculi join before reaching the lachrymal sac. The lachrymal sac is the upper dilated portion of the nasal duct, which is situated in a groove or osseous canal in the lachrymal bone. Terminates between the two turbinated bones. The balance of the canal is under the nasal mucous membrane, passes to inner surface of outer wing of the nostril, terminating by an orifice (sometimes two) toward the lower commissure, where the line of demarcation between the skin and rosy mucous membrane presents.

The tears are forced into the excretory passage by muscular action and some kind of suction caused by the muscular fibers of the puncta and canaliculi.

Dacryoadenitis.—Very rare indeed. Symptoms of the acute form are great swelling and redness of the upper lid at its outer angle. The gland will be pushed out of its fossa downwards, by the inflammation and swelling, and may be recognized on everting the lid. The swelling may be so great as to displace the globe

down and inward. Suffering is pronounced. May have an accompanying conjunctivitis, chemosis, etc. Sometimes confounded with periostitis. May have suppuration. Generally of traumatic origin.


TREATMENT—If early, ice may abort. So soon, however, as there is suppuration, aid the formation with heat. Free incisions through the conjunctiva.

Dislocation of the gland has been seen and *hypertrophy* of the gland is exceedingly rare. This structure may be the seat of new growths, as glandular structures, in other parts of the body, and should be treated as elsewhere, *i. e.*, extirpation of entire gland.

CHAPTER IV.

EXCRETORY APPARATUS.

Excretory Apparatus (Diseases of).—As a result of inflammations; of the conjunctiva and lids; wounds of the lid; narrowing and stoppage of the canaliculus; may have watering of the eye (*Epiphora*). If *obstruction* of the canaliculus, slitting the canal with a knife modeled by and bearing the name of Agnew is the treatment. This is a narrow-bladed, probe-pointed



Agnew's Canaliculus Knife

Fig. 24.

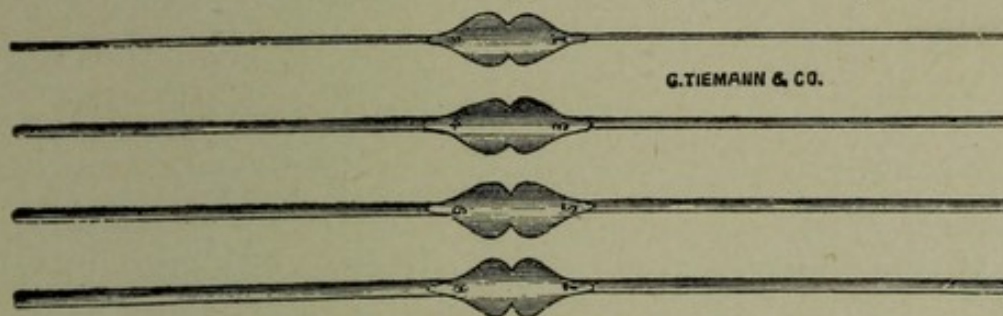
knife. Enter the puncta with its probe point, *vertically*. Remember the anatomical disposition of the canaliculus in the angle of the lid and *follow* it. The idea is to open the *already existing*, but obstructed passage, and *not* to establish a new one. When entered vertically,—and that takes patience, but the sphincter will yield to persevering pressure—*depress* the handle of the knife until it is horizontal. Push *inward* until you reach the inner wall, keeping the lid on the

stretch. Bring the knife straight up and down and cut the whole length of the canaliculus. This is difficult of accomplishment in the horse, owing to the length of the canal; but a knife with a malleable shank will facilitate matters much. Remember and divide the canaliculus close to the juncture of skin and mucous membrane, so that its function of collecting the tears may be as little interfered with as possible, close coaptation to the conjunctiva being one of the factors of that important function.

Stricture of the Lachrymal Duct.—Most common of all the lachrymal affections. Its one symptom is a flowing of tears—Epiphora. May be result of catarrh, trauma, carious teeth, pressure from tumors, and periorbitis.

Dacryocystitis Catarrhalis.—Seldom recognized before the chronic stage. Practically no difference between this and catarrh. Will find a swelling at the inner angle of the eye, caused by a retention of secretion from the catarrhal inflammation, and swelling, lessening the caliber of the excretory ducts. Firm pressure on this swelling will cause mucous to flow from either the canaliculus or down the duct, into the nasal cavity. The swelling is generally painless. Keeping the sac empty affords some relief. Have generally a coexisting blepharitis marginalis. The secretion after a time becomes irritating, and this is especially the case when it is permitted to remain quiet some time in the sac.

Then it sets up conjunctivitis. It becomes infectious, and if it gain entrance to a wound of the cornea is apt to cause suppuration. In diagnosing, the *question of tears* decides. For instance, the tumor will be lessened by pressure and the contents come upwards through the puncta or descend to the nose. This might be the result with a *very* tight stricture, but of less degree, or the sac-walls may be very thick, but remember the tears—Epiphora—and *that* is decisive. These conditions are rebellious—may continue for months. The cure of the underlying catarrh is imperative. Any *cause* must be removed. Strictures must be dilated. May have to precede dilation by slitting the canaliculus, but *don't* slit the puncta if can avoid. Take, by preference, a pair of fine iridectomy forceps, and, gently insinuating the closed points into the puncta, dilate the sphincter until it relaxes, and will then be able to introduce a small probe (Bowman's). Then



Bowman's Set of Probes, Nos. 1, 2, 3, 4, 5, 6, 7, 8

Fig. 25.

introduce a Stilling's knife and slit the stricture, using




Fig. 26.

same method as in probing. This knife being triangular, after introduction it is simply necessary to turn it in different directions and force it down two or three times. Blood issuing from the nose is proof of an open passage. In some instances it is impossible to gain entrance into the canaliculi without nicking the puncta, but remember that you are apt to destroy the normal function of the parts, impairing its suction powers. Electrolysis has produced good results—introducing a probe until reaching the stricture and attaching the negative pole; apply the positive to the temple and make gentle pressure as the stricture yields. Repeat this until permanent results are achieved.

Lotions on the lids, astringents to the conjunctiva, are good. Arg. nit. gr. v to $\bar{3}$ i. Watch and treat the nasal catarrh. Dobell's sol. is nice and successful.

R. Sod. bibor., $\bar{3}$ iv.

Glyc., $\bar{3}$ i.

Sod. bicarb.,

Ac. carb., aa $\bar{3}$ ss.

Aq., $\bar{3}$ vi.

If this condition continues, becomes phlegmonous, it is called *Dacryocystitis Phlegmonosa*, and is a higher stage of the preceding. Have much swelling and extreme sensibility. Usually much infiltration of the surrounding parts. Constitutional symptoms very often. Conjunctiva may be inflamed and even chemosed.

Must differentiate between this and abscess of the cellular tissue. In abscess, pressure will not reduce it, while in *dacryocystitis phlegmonosa* the contents will be forced through the puncta or down into the nose. And remember the previous history of long lachrymation.

TREATMENT is incision into the sac, and in advanced cases (which are the only ones you will meet) this is the only treatment. Thrust the knife perpendicularly down to the bone and carry the incision down as far as necessary. Keep the incision open with lint. If it has opened spontaneously, poultice for twenty-four hours, but not too long; maybe forty-eight hours of hot poulticing, but no longer. After this opening has closed it will be necessary to open the nasal duct and establish a passage for tears. Don't probe until subsidence of inflammation.

Lachrymal Fistula.—Result of an illy-healed abscess, and indicates the existence of a permanent stricture. Rarely seen. If possible, the re-establishment of the proper channel for the passage of tears should be the primary care. Then the fistula can be easily healed, treating as you would a sluggish fistula anywhere, stimulating its edges with lunar caustic, etc.

CHAPTER V.

MUSCLES OF THE EYE.

Muscles of the Eye.—Seven—posterior, superior, inferior, external and internal recti, and superior and inferior oblique.

Posterior Rectus Retractor Oculi, as its name implies, pulls the bulbus backward. Is a muscular sheath,

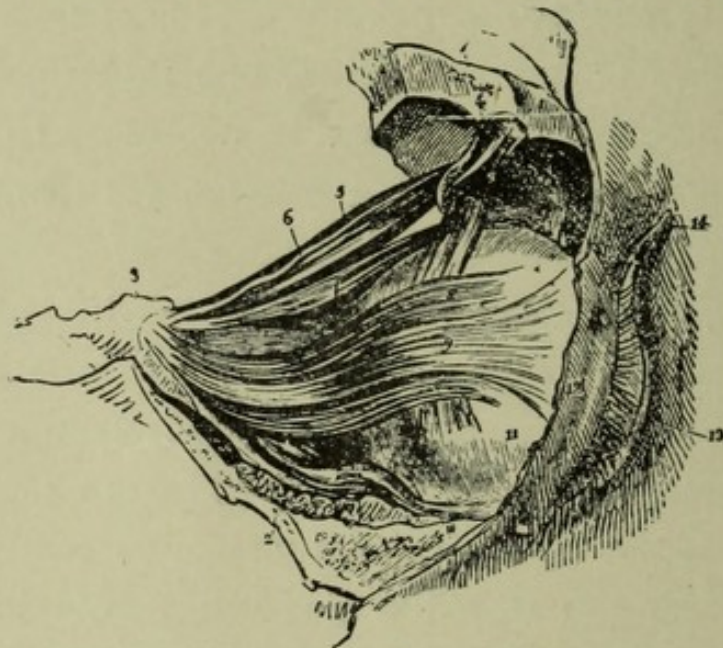


Fig. 27.

with fibers disposed longitudinally ; arises from around the optic foramen and inserted into the posterior part of the external face of the sclerotic. May be dissected into four bundles. *Superior, Inferior, External, and In-*

from one another and the posterior by the fat belonging to the membrana nictatans. They act according to position, and, as I have demonstrated upon the board, according to concerted action.

Superior Oblique, or Great Oblique.—This arises from the back of the orbit and passes forward against the inner wall to pass through a strong fibro-cartilaginous pulley, which is attached to the frontal bone at the base of the orbital process; then, bending outward, passes beneath the superior rectus near its attachment and inserts itself into the sclerotic between the superior and external rectus. Consequently this muscle pivots the eye inward and upward, carrying the outer aspect of the globe upwards and its lower part outwards.

Inferior or Small Oblique Muscle.—Thicker and shorter than the superior; is nearly parallel to the *reflected* portion of the superior. Arises in the lachrymal fossa, passes outward and is inserted in the sclerotic between the external and inferior recti. In action it antagonizes the great oblique. The movements of the bulbus correspond to a ball and socket joint. The center of rotation is a short distance behind the center of the eye.

The oculo-motor nerve, or third pair, supplies all the muscles of the eye except the external rectus and superior oblique, which are supplied by the sixth and fourth pair respectively. These muscles are susceptible to

paralysis, individually and collectively. When individual muscles are affected we find restricted motion—converse to the action of the muscle when physiologically exerted. If complete paralysis of the third pair occurs, then have ptosis, some exophthalmus, ditto dilatation of the pupil and accommodation paralyzed. Movements restricted in all directions, except directly outward.

Strabismus or Squint.—Many varieties. Usually mono-lateral, which is a faulty position of one eye. May be alternating—the ability to fix with either eye. Also have intermittent or constant.

TREATMENT is operative; divide the tendon of the contracting muscle.

CHAPTER VI.

THE CONJUNCTIVA.

Conjunctiva.—A delicate, fine mucous membrane; lines the inner surface of the lids. From the lids it is reflected upon the bulbus and extends to the cornea, covering the sclerotic. It is continuous with the cornea. Consists of three layers—external being epithelial, the intermediate being the proper tissue and the subconjunctival tissue. The palpebral conjunctiva especially contains numerous lymphatics and glandular structures. The conjunctiva in its reflection from lid to bulbus forms the cul-de-sac or fornix. Highly supplied with nerves from the fifth pair (trigemini). Also well furnished with blood, and especially so around the limbus. The conjunctiva has the important function of *lubrication*. The membrane is divided into three distinct portions: Tarsal, which is smooth, and fits the tarsi (the Meibomian follicles may be seen through it) the fornix, sinus and cul-de-sac being the reverse, loosely attached and easily movable, and is dark in color, while the tarsal is of a light yellow; and third, the ocular portion which lies loosely, but smoothly, upon the globe, and this fact aids in

diagnosing between conjunctivitis and inflammations of a deeper nature.

Conjunctivitis Catarrhalis.—*Purulent* (which may be idiopathic or gonorrhœal, *Diphtheretic*, *Granular*, *Phlyctenular*, these are some of the forms of inflammation of the conjunctiva, one of which may run into another. The discharge from one kind may reproduce itself or one of another form. They are contagious and infectious. May occur epidemically. Pink-eye is but an epidemic catarrhal conjunctivitis. A differential diagnosis is often impossible early.

Catarrhal Conjunctivitis.—Catarrhal ophthalmia is the mildest form. Caused by injuries, exposure, bad hygiene, exanthematous diseases, etc. Again, it may be secondary to other inflammations. Among the symptoms we find smarting preceded by itching, lachrymation, sensation of sand or of some other foreign body in the eye. Have increased vascularity, causing partial or uniform redness of the ocular conjunctiva and imparting to the palpebral conjunctiva a velvety, roughened appearance. Œdematous swelling of the conjunctiva and subjacent tissue, which may go on to chemosis, causing the cornea to look sunken. Redness, swelling and stiffness of the lids. Mucus or muco-purulent discharge, with tendency toward agglutination of the lids, especially succeeding sleep. Both eyes usually participate, although one eye may go free. This form is amenable to treatment and not *very* apt to invade the cornea.

Now, when the front of the eyeball is red, it is important to know whether the congestion is *superficial* or *deep*. If superficial, the redness will be conjunctival and will appear as a coarse network of blood vessels running over the sclerotic very irregularly and in no order at all, or by a more uniform redness which nearly conceals all the white of the globe. If the congestion and swelling are not very great, the edge of the lower lid rubbed against the globe by the finger may be seen to move the vessels over the sclerotic and to press the blood out of them. The inner surface of the lids will be congested also, and there will be a mucous or muco-purulent discharge, with probably not very much photophobia. In deep, or *ciliary* congestion, there is a rosy zone of straight, fine vessels, as I here draw upon the blackboard, and, as you see, resembling the rays of a brilliant sun. Very regular, straight as an engraver's lines, totally different from conjunctival injection, which is highly irregular and of a grape-vine order. These straight fine lines radiate *from* the corneal margin. They are *immovable* under pressure through the lower lid, while the conjunctival, remember, are *movable*, and the blood may be pressed out of them. On close inspection the rosy zone is seen to lie *beneath* the conjunctiva, in the sclerotic. When we find this form of congestion, although it may be very slight, there will be, usually, pain, photophobia and *profuse* lachrymation, and the tears will be *hot*.

This picture indicates ciliary irritation and an affection of the cornea or of some of the deeper structures. Of course the two kinds of congestion are often found combined. When the exit of venous blood from the interior of the eye is impeded, large dark, tortuous veins will appear running over the sclerotic, which they penetrate near the edge of the cornea. It is important to learn, in the presence of inflammation, as to the existence of pain, tenderness in the ciliary region, which is the name given that region immediately surrounding the cornea. To this end, make gentle pressure over the closed lids about this region using the index finger of each hand and palpating, as if for suspected abscess, for instance. Examinations are somewhat difficult owing to the photophobia. Will be facilitated by a drop or so of cocaine 4%. Use oblique illumination, as I have demonstrated in the clinic. Notice the mobility of the pupil and intra-ocular tension.

TREATMENT: *extreme* cleanliness, hygienic precautions, attention to general health. Topically, some mild astringent lotion every few hours. A caustic applied at the outset may abort. Cold applications in the early stages are very good; catarrhal conjunctivitis is, however, a self-limited affair, which often requires very little local treatment, and which, with good hygiene, terminates in complete recovery. However, do not be too sanguine, but temporize, as it may extend a week or so longer than you expect, and so, give no definite prognosis as to time.

℞ Sulph. Zinc. grs. ij to the oz. of distilled water;

℞ Boric. ac., 4 %

Sig. Gtt. j t. i. d., or oftener; *or*,

℞ Ac. Boric., gr. xij.

Aq. Camph.

Ag. destill. āā ʒ ij.

M. Sig. Gtt. i. t. i. d. or oftener.

Purulent Conjunctivitis, Blepharorrhœa, Contagious Ophthalmia.—This is like the catarrhal, but with intensification of all the symptoms. Due to the same causes. It often appears as an epidemic, where numbers are crowded together with poor hygiene. Is met with in the Asiatic countries especially. The discharges are thick, purulent and *very* contagious. Very great danger of invasion of the cornea, which results in ulceration, sloughing and probable loss of the eye, within a short time.

TREATMENT. — Mild cases should receive same treatment as the catarrhal form. Severe cases require isolation, darkness and quiet; and, first, last and all the time, watch the pus, which *must not* be allowed to accumulate. Sometimes cleansing is needed every few minutes. Application of cold, bleeding, scarification of the conjunctiva, if the swelling be pronounced and chemosis be present, and, if the lids press greatly upon the globe, canthotomy. When the discharge appears, astringent lotions every few

hours and some caustic application, such as lunar caustic, to inner surface of lids, twice daily, or possibly once will suffice; cold compresses, continuous or changed for warm ones if you like. Atropine if the cornea becomes involved. If one eye only be affected, the other must be guarded. May be sealed hermetically. When a case is seen at the very outset, *thorough* cleansing and a caustic application to the lids (palpebral conjunctiva) seems to abort.

Gonorrhœal Conjunctivitis.—Gonorrhœal ophthalmia. This does not differ, except in manner of origin, from any other purulent conjunctivitis, and of course in the equine race the groom must be looked to for an explanation. It is an *extremely* violent purulent inflammation, caused by inoculation from the urethral discharge. It may destroy the eye in a few hours. Still another form of inflammation, in the newly-born, called

Ophthalmia Neonatorum.—This form is a catarrhal or purulent conjunctivitis, usually appearing shortly after birth and caused by contact with the vaginal discharges of the mother. May also occur from other causes, such as exposure and filth, and not appear until several weeks after birth. Assumes all grades of severity.

TREATMENT.—Same as in similar conditions in the adult, and should be regulated by the severity of the attack. It is believed by many that caustics are

needless in the very young. Even claim they are injurious, and that a mild astringent application is all that is necessary. In practice among physicians the method of Credè is largely employed, which consists in dropping into the eye of a newly-born one drop of a 2% solution of Arg. nit.; and it seems to me if there is any apprehension the same could be done by the veterinarian.

Diphtheretic Conjunctivitis is peculiar in that it may result from the *same cause* as the other forms. This begins with great heat, redness, swelling and *tenderness* of the lids, with rigidity from fibrinous infiltration. Have firm swelling of conjunctiva from the same cause, and a pale, smooth, glistening appearance of its surface. Sometimes have a grayish exudation membrane on the conjunctiva, *which may be stripped off*. Discharge of flakes of lymph. Advanced stage is marked by softening of the parts and from the disappearance of fibrinous matter and by discharge of pus. Great tendency to shrinking and formation of cicatrices of conjunctiva in healing. The cornea is apt to suffer, and constitutional disturbance is often marked. This form is very destructive, and, fortunately, is rare in this country and England.

TREATMENT not very effectual. In the first stage ice compresses, local bleeding, etc.; astringents and caustics in the purulent stage. Atropine should be used throughout.

Take a case, for example : Diagnosis has been satisfactorily made. The eye is cleansed *thoroughly*. If much pain and restlessness present, instill a drop of cocaine 4% three times, at five-minute intervals. If the case has been brought you while young (*i. e.*, the case, not the patient), evert the lid and paint the palpebral conjunctiva with a strength suitable to the severity of the presenting symptoms, of nitrate of silver solution, even using the stick form in aggravated cases, *neutralizing it with a saturated solution of Sod. Chloride, before the lid returns to its normal position*. Then commence cold applications, which may be in the form of cracked ice, or pieces of *clean* cloth which have been laid on ice. Atropine, one to one hundred and twenty (1-120) p. r. n., *i. e.*, from every thirty minutes to once daily. Also, employ any of the collyria mentioned through the lectures you may see indications for. As a result of one of the previously described inflammations, we may have :—

Granular Lids (*Granular conjunctivitis, Granular ophthalmia, Trachoma*).—Generally the result of one of the previously described inflammations, and is especially a *chronic condition*, although sometimes associated with acute symptoms. The palpebral conjunctiva presents almost exclusively the granulations, of which we have chiefly two kinds, to wit., enlarged conjunctival papillæ and the frog-spawn granulations. These latter are grayish bodies resembling sago grains, and

are composed of lymphoid cells and connective tissue. Both varieties may be seen separately, but more often combined.

Symptoms are those of an annoying conjunctivitis, and may be more or less severe. If the process is not checked the cornea becomes ulcerated and *vascular* from the constant irritation from friction of the roughened lids upon it. The conjunctiva and tissue of the lids may become atrophied and cicatricial, leading to entropion, symblepharon, xerophthalmia, etc. This disease is more often found in the poorly nourished, bad hygiene, etc. Runs an exceedingly tedious course.

TREATMENT.—Locally, astringents and caustics, sulphate of copper crystal being the favorite one, nitrate of silver, alum, and many more. Applications may lose effect through toleration, and change becomes necessary, and regular treatment for a long period will be necessary to establish cure. Before beginning any astringent treatment of a trachoma, it may be necessary to use hot water, atropine, cocaine, until the great irritation, photophobia, etc., subside. Then may begin with a mild astringent, alum, spray of tannin and glycerine, xx. grs. to the oz. or the like. In very obstinate cases, after a fair trial with other remedies, jequirity bean (*abrus precatorius*), used as follows, as prepared by De Wecker of Paris. The bean is to be powdered and mascerated for three hours, in water, at ordinary

temperature, and of a 3% concentration. The recent infusion is best, as it loses power with age. With a camel's-hair pencil, it is applied to the lids, two or three times. Reaction should be present within twenty-four hours. If not, repeat application. This is painful in

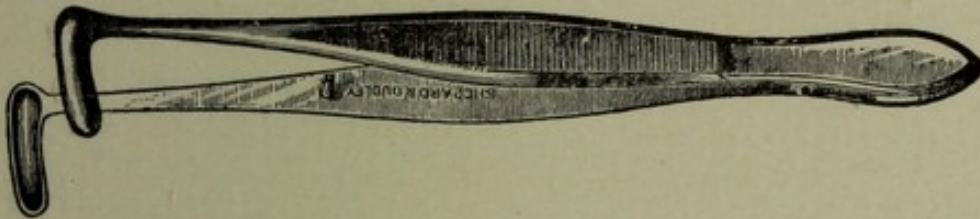


Fig. 29.

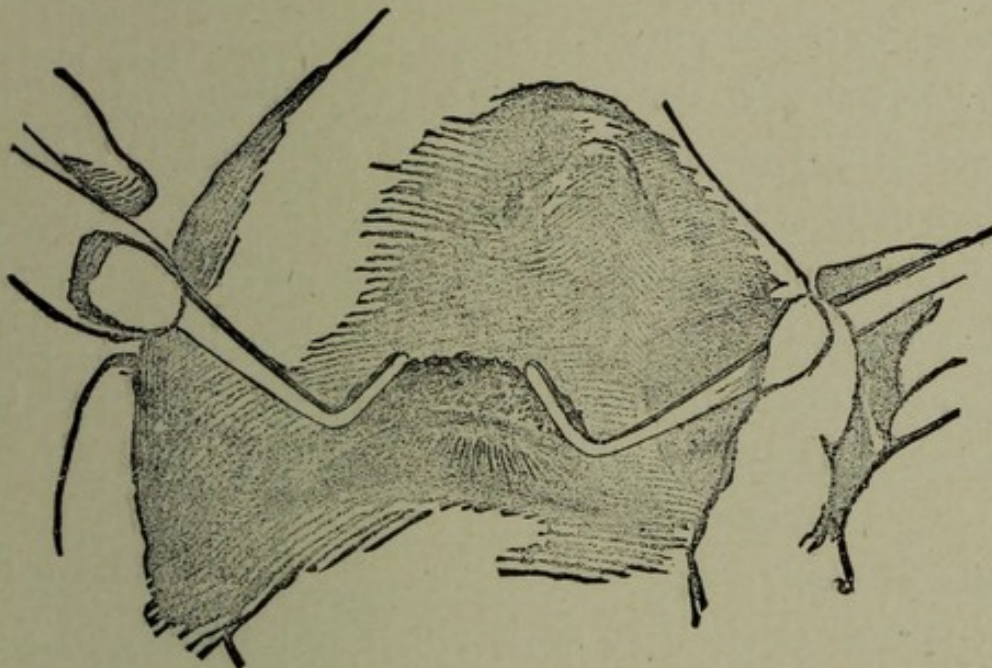


Fig. 30.

action, and ice-water bags, etc., should be employed. The inflammation will last for at least two weeks. Keep patient in dark stall, and quiet. As soon as the inflammatory membrane has appeared, use the cold application until reaction has abated. Treat the case as

one of acute trachoma, when sulphate of copper crystal may be used until the cure is complete. When the granulations are *large* and numerous, they may be torn out and destroyed by forceps, and as this is a very delicate operation great care is to be exercised. The lid being everted, the granules are *stripped* off. As may be readily appreciated, the reaction is superb, and is to be carefully treated with ice, antiseptics, etc. To do this, an anæsthetic should be used. Now, in simple chronic blennorrhœa, or chronic conjunctivitis, *do not use* the above infusion. The results are apt to prove disastrous.

Phlyctenular Conjunctivitis. (Pimple, Gr.) — This form is characterized by a small yellowish-red elevation, or phlyctenule, on the summit of which a serous vesicle forms, which vesicle bursts, and leaves a small ulcer. *One* or *several* of these bodies may be present, and are generally situated near the margin of the cornea. Duration about ten days; but there always is great tendency to relapse. The injection of the conjunctiva may be *general* or *partial*. A triangular leash of vessels runs up to each phlyctenule, with its base pointing toward the retrotarsal fold. The appearance of the phlyctenule is attended by pain, which is burning; photophobia and lachrymation. Often associated with phlyctenular keratitis.

TREATMENT.—Particular attention is to be paid to the general condition. Atropine 1 to 120. In some cases,

application of a mild irritant, such as calomel or ox mercury, ungu., etc.

Now for a word on *diagnosis* of a *differential* character. In catarrhal conjunctivitis, the injection is general over the conjunctiva, and on pressure, through the lower lid, the injected vessels are seen to move over the sclerotic with the membrane, (*i. e.*, the conjunctiva). There is *always* redness of the fornix conjunctiva, and usually of the palpebral ditto. There is a muco-purulent discharge, more or less profuse, dependent on degree. The iris is clear and bright, the pupil reacting readily to light, and *the cornea is clear and transparent*. In *Iritis*, the injection is *deep-seated*, surrounding the cornea as a rosy zone. This is *not* accompanied by redness of the fornix, or palpebral conjunctiva. The injected vessels are beneath the conjunctiva, and do *not* move with it. The iris is discolored, the pupil sluggish and inactive, and vision is impaired. There is usually very severe pain in the eye and head, generally worse at night. In *Trachoma*, the upper lid, and particularly the free border of the tarsus, is affected; the granule is oval, grayish-red, and opaque. It is imbedded *in* the membrane, and is *less* prominent than the follicles. They may be found on the ocular conjunctiva, and *even the cornea*. In the granular variety, the affection usually takes on the mixed form, presenting follicular and papillary hypertrophy in addition to

the new growth. There is also general lymphoid infiltration of the conjunctiva and of the deeper tissues of the lid, including the tarsus, also great proliferation of epithelia and formation of new vessels. In *papillary* trachoma, the location is predominately over the surface of the tarsus, instead of its borders. The enlarged papillæ are bright-red, or sometimes red with a bluish cast. *Follicular Conjunctivitis* especially affects the lower lid, and particularly the cul-de-sac. The follicle is round, or elongated, pale and semi-transparent. Is more prominent and sharply raised above the surface of the conjunctiva, and can be removed or separated from it. Its general arrangement is in rows parallel to the free margin of the lids.

Pterygium (a little wing, Gr.). — Quite a common

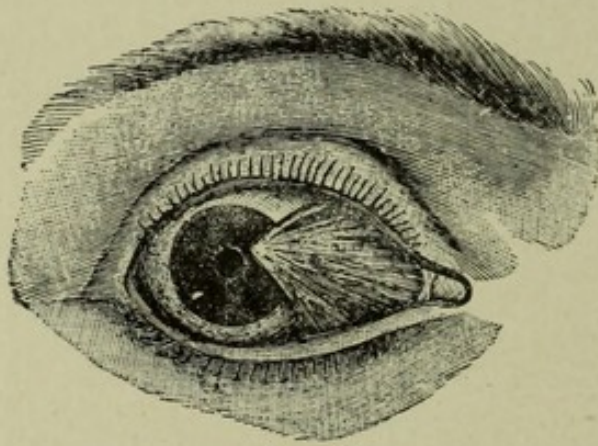


Fig. 31

affection, result of inflammation and from constant exposure. Consists of hypertrophy of conjunctiva, and sub-conjunctival tissue. In form it is a triangular vascular prominence, generally at the nasal side of

the eye, with the base toward the inner canthus and its rounded apex at the edge of the cornea, or encroaching more or less *upon* the cornea. We notice two forms,

or one form of different degree—*i. e.*, a thin (*tenue*), and a thick (*crassum*). Requires no treatment unless it extends upon the cornea so as to obstruct vision. May then be removed by (1) *excision*, which is dissecting the growth off of the cornea and sclerotic, to a point near the canthus, and uniting the conjunctival wound by sutures; (2) *transplantation*, which is performed by dissecting it off up to the base and then inserting it into an incision made in the conjunctiva, parallel to the lower edge of the cornea and retaining it there by sutures; or (3) *ligature* thread passed around the growth at two or more points, so as to cause strangulation.

As the result of severe chronic conjunctivitis we meet with *Xerophthalmia*. Dryness of the eye. This is an atrophied condition, and of cicatricial change in the cornea, conjunctiva and sub-conjunctival tissues. The surface is of a dirty greenish or grayish color, or tendinous appearance. Also is dry, scaly, and stiff from destruction of secretory apparatus. Obliteration of the palpebral folds, and more or less adhesion of lid to globe.

TREATMENT is inefficient. The dryness may be alleviated by bland applications, such as milk, glycerine, vaseline, etc.

Tumors of the Conjunctiva.—*Pinguecula*; a small yellowish tumor, fatty in appearance, situated near the corneal margin, and chiefly seen in the aged; con-

sists of hypertrophied conjunctiva and epithelium; they are harmless and need no treatment. *Dermoid* tumors, smooth and yellowish, covered with conjunctiva and perhaps with short hairs; composed of connective tissue and fat; generally congenital. Excise them. *Warts*, similar to those on prepuce, may occur on any part of the conjunctiva; snip off with scissors.

Cancer should be treated as elsewhere.

CHAPTER VII.

THE CORNEA.

Cornea is elliptical in shape, is perfectly transparent, which is due to the arrangement as well as the transparency of its individual parts. It closes the anterior opening of the sclerotic and forms one-fifth of the external envelope which it completes. It fits into the sclerotic like the crystal of a watch into its case, the cornea being beveled on its outer edge. The cornea is composed of five layers: (1) The *anterior epithelial* layer is, as its name indicates, composed of epithelia disposed in layers and continuous with that of the conjunctiva. (2) *Bowman's membrane*. A very elastic tissue which possesses a tendency to curl up. Neither acids or boiling renders this layer opaque as it does the other layers. This layer has no lacunæ nor lymph canals, but contains fibrillæ and fasciculi. Has no fixed cells or movable corpuscles. Is intimately adherent to the parenchyma. Cannot be separated as a distinct layer. (3) The *parenchyma* is composed of fine fibrillæ united into fasciculi, bound together by a cement matter. Has a system of canals which are a continuation of lymphatic spaces. These lymphatic

canals contain cells. The fasciculi are in layers, one above the other. The canals in the cornea are hollowed out of the tissue formed by the cement and fasciculi, and may be resolved into shallow spaces, very numerous and communicating with each other by canaliculi, which vary in size and form a net-work throughout the parenchyma, penetrating between the fibers and ramifying from layer to layer. Their function is to convey the nourishing lymph. Three varieties

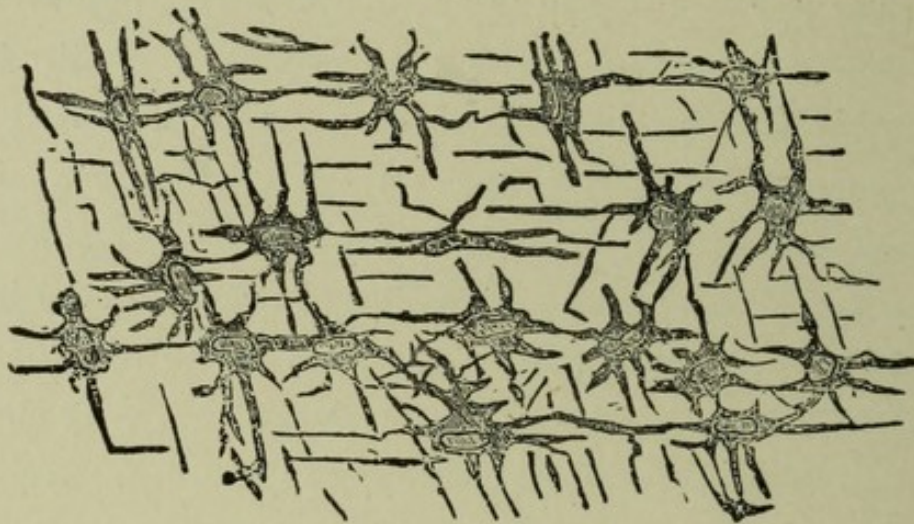


Fig. 32.

of cells may be found in these canaliculi, fixed, wandering and pigment. The *fixed* lie in the lacunæ, and send prolongations out into the canals. The *wandering* are brighter, larger, and, as the name implies, have power of motion. The *pigment* is found only at the periphery of the cornea. On the inner side of the tissue proper of the cornea is a lining membrane called (4) *Descemet's*. It is firm, elastic, glossy in appearance and

highly refractive. Then the (5) *endothelial* layer, composed of a single layer of cells. This layer is reflected on the anterior surface of the Iris. In or on the cornea *are no blood vessels*. The anterior ciliary arteries furnish branches, which *approach* the limbus, forming loops. Blood vessels on the cornea are indicative of either a pathological condition or an attempt of nature to repair. The nerves come from the ciliary, which pass the ciliary body and form a plexus around the border of the cornea. Their terminal fibrillæ are most abundant in the epithelium and anterior layers of the cornea. Some few twigs come from the conjunctival nerves.

Injuries and Wounds.—Many varieties—clean cut, contused, scraped, etc. Clean cut, if not too large, usually heal and leave no trace. Contused wounds are apt to cause suppuration.

The great danger is of injury to the lens, which would be apt to result in cataract, or to the iris, which may prolapse, or, becoming adhered to the corneal puncture, cause staphyloma.

TREATMENT—The *primary treatment* is to place the eye in a state of rest and allay irritation by soothing applications. Atropine and cocaine should be applied several times daily; atropine 1 to 120, or stronger if need be; cocaine 4%. Cold compresses if seen early enough. If the epithelium is abraded a few drops of olive oil allays irritation. The compress bandage re-

strains motion and so is useful; also excludes light. If the corneal wound be central, use atropine, and *quick*. If peripheral, eserine $\frac{1}{2}\%$.

Foreign bodies are of frequent occurrence, the most common being dust, glass, metal, etc., and they cause *severe* reaction according to the depth to which they penetrate and length of time they remain. Exceptionally, the reverse may be the case. They are seen easily, generally, and oblique illumination will facilitate a search. If superficial, remove with a spud. If firmly imbedded, use forceps or a needle. To avoid a deeply seated particle falling *backwards* into the anterior chamber during attempts at removal, a broad needle may be passed into the anterior chamber so as to form a base on which to work. Cocaine 4% must be used, and an eye-speculum will insure better results if used.

Burns, injuries, from chemical agents, etc., are apt to cause sloughing and permanent opacities. Use oil, cocaine; wash the eye thoroughly, and neutralize acids by alkalis—for instance, soda, dram to the ounce. Should the offending matter be *lime*, use vinegar and water, oil, and, above all, don't put a *little* water into the eye.

Abrasions of epithelium appear as a roughened, glistening facet, and are very painful. Use oil collyria.

Keratitis (inflammation of the cornea.) Result of injuries, exposure, constitutional diseases, mal-nutrition,

inflammation of adjacent parts, etc.; is one of the most frequent diseases of the eye. It leads to vascularization, cell proliferation and suppuration, each of these conditions being more or less prominent according to the *kind* of inflammation present. Attending these conditions we find the vision is impaired, ciliary irritation, which is *always* ominous (a zone of fine vessels appearing around the corneal margin), pain, photophobia, lachrymation, conjunctival congestion and contraction of the pupil. The cornea will be turbid and swollen. If ulcerated, it becomes thinned, and perhaps rupturing permits deeper parts to become prolapsed or escape. If thinned or softened it may bulge forward from intra-ocular pressure, forming staphyloma. After recovery, indelible opacities and alterations of curvature may remain, with corresponding loss of vision. In treating acute corneal inflammations it is the cardinal rule to *avoid* all *irritants* and *caustics* and to pay special attention to hygiene and general health.

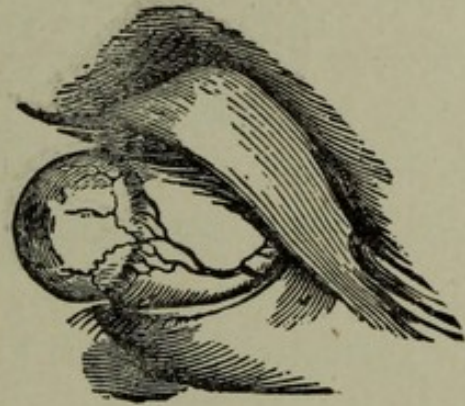


Fig. 83.

Atropine, darkness, and rest of the eye are always proper. Cold and local bleeding may be tried if symptoms are very acute. When the disease does not improve under this treatment, or becomes chronic, the proper treatment requires special experience. Where

there is great photophobia, or spasm of the orbicularis, the cold douche, forcible stretching apart of the lids, canthoplasty, insufflations of calomel, ointments of mercury, etc., are employed.

Keratitis Vasculosa.—This is characterized by a grayish cloudiness of the cornea with network of vessels in the affected region. The epithelium may be shed, causing great pain from the exposure of nerves. Under favorable circumstances, tends to recovery. May, however, run on into other forms and be combined with them.

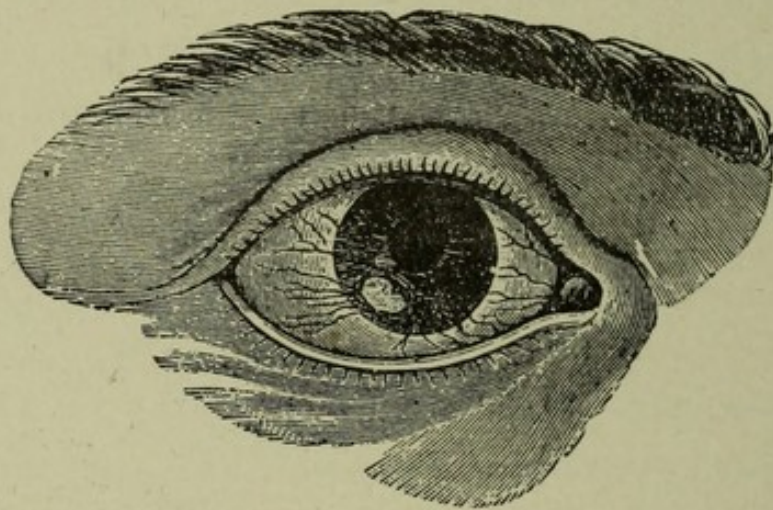


Fig. 34.

Phlyctenular Keratitis is characterized by phlyctenules in the superficial layers of the cornea like those in phlyctenular conjunctivitis. These phlyctenules appear as inflammatory nodules, singly or in groups, on *any* part of the cornea, but most often at the margin. May be surrounded by vesicles, which vesicles may

burst and leave a ring of ulcers. A triangular network of vessels will be seen running toward phlyctenule, its base towards the retrotarsal fold and its apex *at* the phlyctenule, if this is at the edge of the cornea. If, however, the phlyctenule lies some distance from the corneal border, the apex of the triangle appears cut off at the edge of the cornea, thus leaving a space of clear tissue intervening between *it* and the phlyctenule. If the attack is severe, vascular keratitis may supervene, vessels then would extend upon the cornea quite up to the phlyctenule. The secretions from the eye irritate and excoriate the parts over which they flow.

Interstitial Keratitis.—Also termed *Parenchymatous* and *Diffuse*. Will have swelling and diffuse cloudiness, which cloudiness usually extends from *margin* to *center*, and *very* rarely the reverse. May be very slight, and again may be very dense, simulating ground glass. May be irregular in density, causing white and grayish patches. The corneal surface usually loses its polish and assumes a dull stippled appearance, due to loss of epithelium. Vessels may appear in the corneal substance, running from margin toward center, and are sometimes numerous enough to cause a bright red reflex. Happily, there is very little tendency toward ulceration. This form is tedious, taking months to cure.

Suppurative Keratitis.—The inflammatory infiltra-

tion becomes changed to pus, which pus shows as a yellow opacity in the corneal tissues. The suppuration may be limited, or the entire cornea may be involved. If inclosed by corneal tissue, forms an abscess; if superficial, an ulcer. Sometimes the pus sinks down between the layers, forming an onyx from its resemblance to the lunula of the finger-nail. Often will see hypopyon in the anterior chamber, caused by the pus settling to its bottom. These two conditions may co-

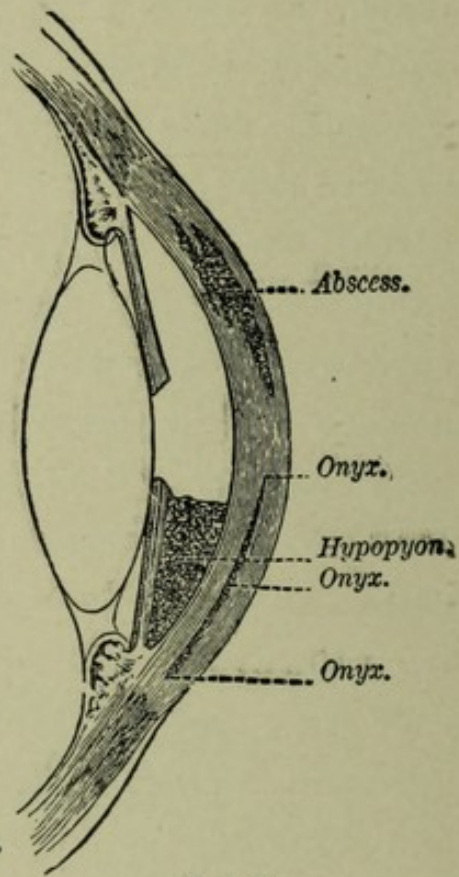


Fig. 35.

exist. Vascularity may attend the suppuration, and with acute symptoms, or there may be very little pain and vascularity, which latter form is very dangerous from death of tissue and sloughing. Abscesses may be absorbed or burst open, or pus may undergo fatty or chalky degeneration, leaving dense opacities. An ulcer may be an *opened* abscess. But, remember, superficial ulcers may occur without a primary abscess. Ulcers are of variable size, shape and depth, and are dangerous according to their location. The crescentic marginal is exceedingly dangerous from its tendency to *encircle* the cornea and thus deprive the central cornea of nutri-

tion. If an ulcer extend deep enough to reach the membrane of Descemet, it may bulge forward through the ulcer like a vesicle, and thus form a hernia of the cornea or *keratocele*, and is usually followed by perforation. Larger ulcers generally lead to staphyloma. When perforation does occur, there is escape of the aqueous and a carrying forward of the iris and lens. If the iris becomes fast into the wound, it forms an *anterior synechia*. If perforation is large enough, the iris may *protrude*, becoming adherent around the edges, leaving synechia. Sometimes, after healing of the ulcer, there will be re-accumulation of aqueous and tearing loose of the adhesions through the action of the pupillary muscles, the iris then assuming its freedom, floating in the aqueous. As before mentioned, the lens may also be carried forward *against* the perforation, and if it return to its position we may see some matter deposited on its anterior capsule, thus constituting anterior *capsular* cataract. Remember that adhesions sometimes formed may never be broken, and the anterior chamber may be never re-established.

If the aperture, resulting from ulcer and sloughing, be extensive enough to allow of escape of all the contents of the eye, atrophy of the globe will result. The rule in healing of ulcers is that some trace be left, from a slight cloud to a dense opacity, and are variously termed, according to degree—*nubecula*, a mist; *nebula*, a cloud; *macula*, a spot. And

often a cloudiness which will be prominent during convalescence will clear up to a very satisfactory degree. But the reverse may obtain. During the healing process vessels may be seen traversing the cornea, but this is physiological and necessary to absorption. Suppurative inflammation may result from many and identical causes with other forms, and is the dread of operators. Bruised and lacerated wounds are also apt to give rise to suppuration. Cases of *severe* conjunctivitis sometimes result so.

TREATMENT includes the ordinary remedies for keratitis, remembering to *avoid all irritants*. Even large hypopyon are absorbed, and it is *very seldom necessary* to evacuate. Paracentesis may be frequently repeated in cases of increased tension. Hot fomentations are often useful, especially in asthenic cases, where there is danger of death of tissue. In *deep* ulcers it is better to perform paracentesis through their base than to permit spontaneous perforation. In ulcers that are *superficial* and *indolent*, *Sæmisch's operation* is indicated and performed as follows:

Introduce (after cocaine) a spring speculum; grasp the conjunctiva opposite point of counter puncture with fixation forceps, (fig. 37) enter the cornea at right angles with a Graefe's knife (fig. 38) thus dividing the minimum amount of tissue; then turn the knife inward, *avoiding the iris and lens*. Make this primary incision inside the ciliary region, on account of risk

of sympathetic ophthalmia.

This primary incision should be about two mm. from the edge of the ulcer and brought out about the same distance on the other side. The knife then cuts its way out through the bottom of the ulcer.

The incision may be kept open by passing a fine probe through it daily, using extreme asepsis and antisepsis, and the tension kept down until repair begins. Corneal abscess may be treated in a similar manner. You remember my speaking of *paracentesis*

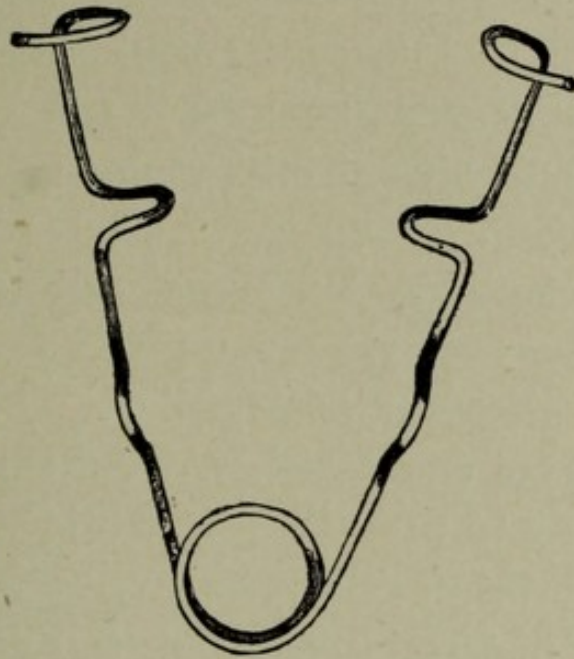


Fig. 36.

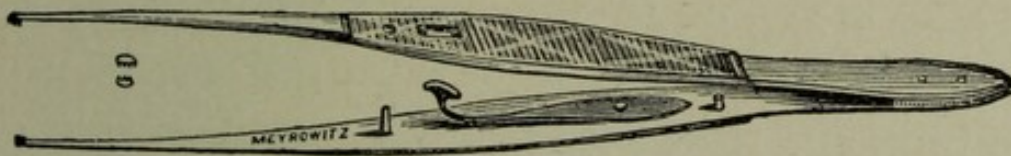
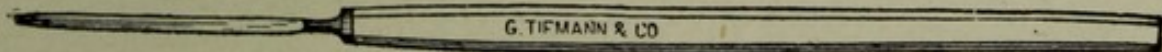

Fig. 37.

of the cornea,—it is performed as follows: Introduce a needle or blade of an iridectomy knife through the cornea near its margin and allow the aqueous to drain



Fgi. 38.

off *slowly* alongside the instrument. The one care in this is to avoid too sudden an escape of the fluid and possible prolapse of the iris. Again, a too sudden diminution of intra-ocular tension is apt to result in shock.

Pannus.—A vascular opacity of the cornea, non-inflammatory. A new growth—neoplasm—the result of a preceding inflammation. The term is applied also to acute and chronic vascular keratitis where the formation of new tissue is still in progress. A part or the entire cornea may be involved. Two forms, remember, I spoke of—*tenue*, thin, and *crassum*, thick (or beefy).

In extreme degrees the cornea may appear decidedly red and fleshy, and this condition may continue for months and years with no change. The rarity is complete cure, for usually a *good* cure leaves opacities of different degrees. The cornea may become thin and bulge forward. Trachoma is the cause of the majority of cases of pannus, and these cases may present corneal granulations similar to those upon the lids. It may be traumatic from long continued irritation, such as that from foreign particles, inverted cilia, etc.

TREATMENT.—After removing the cause, hasten resolution of the opacity, and to this end, if no inflammation be present, irritating powders and unguents are used. Sometimes a too constant application of a remedy wears it out and a change becomes necessary. If the entire cornea be involved, the pannus in a high state

of vascularity, and *no ulcers existing*, the Jequirity infusion offers good results. *Opacities* are frequently the result of corneal inflammations and cicatricial deposits. While they are classified according to degree, they are practically divided into superficial and deep, the former affecting the epithelial layer, the latter the parenchyma. A faint superficial opacity is

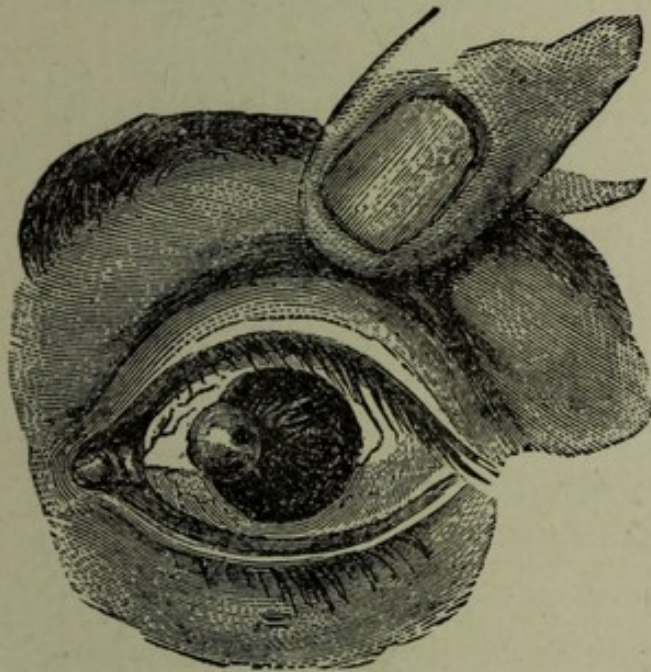


Fig. 39.

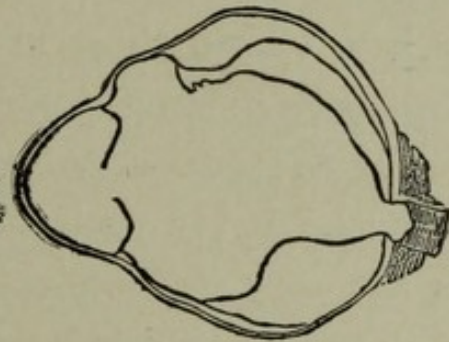


Fig. 40.

called nebula (L. fog), a thick dense one leucoma (Gr. white). A cicatrix *combined* with *prolapse* and *adhesion* of the iris is called leucoma adherans. May see white, chalky deposits, which may be the result of an application of lead lotion where ulceration was present in the corneal tissues. Many opacities disappear spontaneously in the young and robust. As a rule the more recent and *superficial* the opacity the better the

chance for removal. The application of *finely* powdered calomel will assist absorption by exciting hyperæmia and increased tissue change. Deposits of lead may in some cases be scraped away, and the ulcer which results *may* be filled up with transparent tissue.

Cicatricial Staphyloma is generally the result of ulceration, for the floor of an ulcer, being very thin, is therefore very apt to yield to the intra-ocular pressure and bulge.

In the process of healing the bulged portion is apt to be covered with cicatricial tissue, and a staphyloma is left, bluish-white in appearance. Remember the leucoma adherans, which may be a complication.

Kerato-conus.—Conical cornea is a cornea cone-shaped. It is a protrusion of the cornea, and its cause is not very well understood. Usually congenital, but *may* appear after inflammations.

Fistula of the cornea may be the result of a perforation, ulcer or wound. Difficult of cure, indeed. Continual irritation from the constant dribbling of aqueous. Pacquelin's cautery, carefully cauterizing the edges of the fistula, or a delicate probe dipped in carbolic acid and lightly touched to the opening. Atropine, etc. A compress bandage, enjoining rest, from quiet and gentle pressure.

CHAPTER VIII.

THE SCLERA.

The Sclera is a tough, dense, fibrous structure, continuous with the cornea. Is a little elastic. Possesses blood vessels, in which it differs from the cornea. Its fibrillæ are gathered into bundles and cross each other indiscriminately. Lymph canals ramify through these. The cells are fixed, wandering and pigment. Loose connective tissue covers the sclera in front, and is called episcleral, and this in turn is covered by the conjunctiva. The sclera is pierced at the *inner* side of the axis by the optic nerve. This entrance is also *below* the exact center. This place of entrance is sieve-like and is called the *lamina cribrosa*, in the center of which is a larger opening, the *porus opticus*, through which passes the *arteria centralis*. *Surrounding* the optic nerve the sclera is perforated by vessels and nerves called posterior or short ciliary, which go to the choroid, ciliary body and iris. In front it is pierced by the anterior ciliary vessels. In front the sclera presents an elliptical opening, whose greatest diameter is transverse and whose border is bevelled on the inner side (remember the bevelling of the cornea), and fits

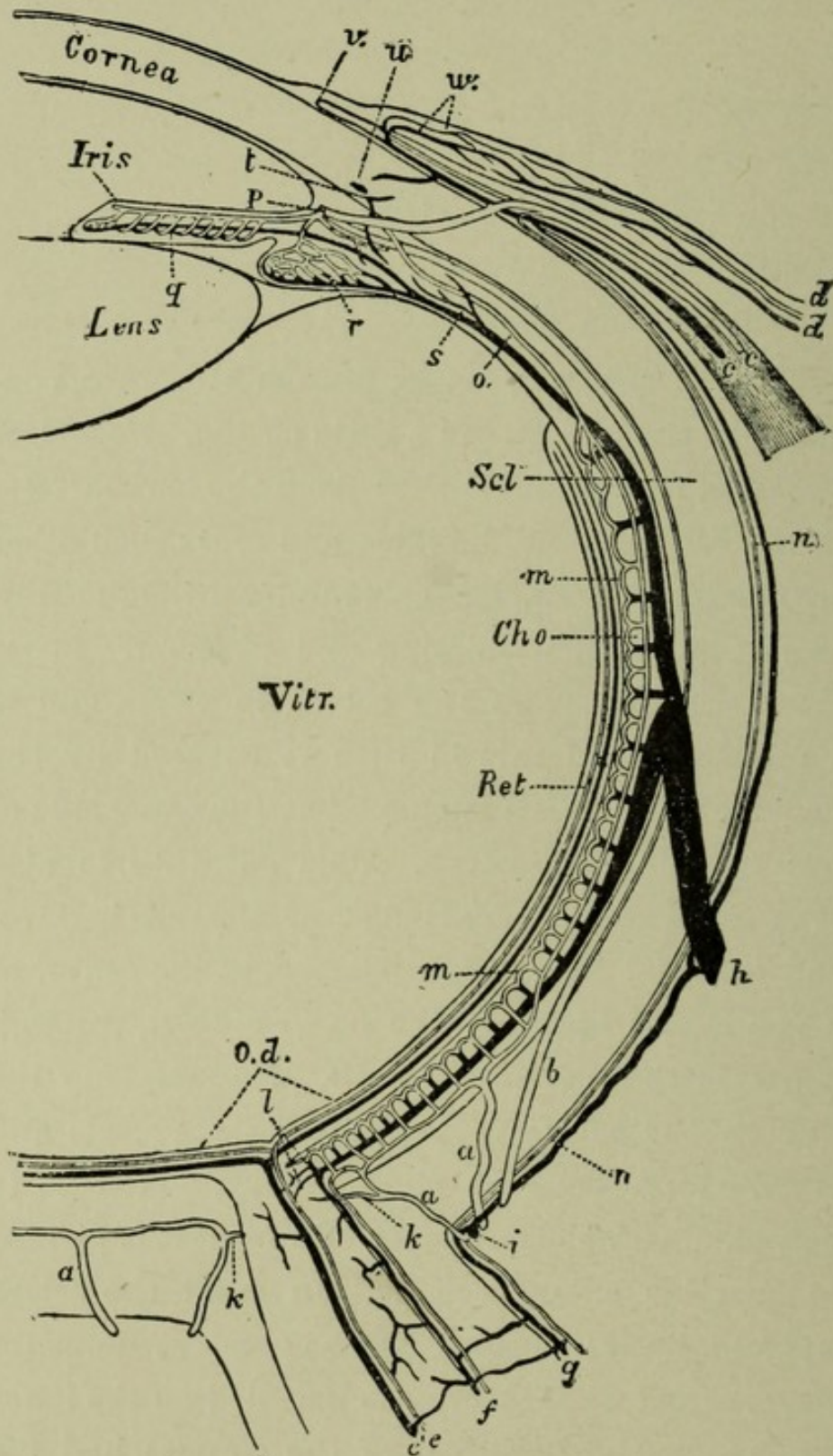


Fig. 41.

nicely over the corneal circumference. The sclera is thickest around the optic nerve entrance, grows thinner at the equatorial region and thicker again anteriorly. The existence of nerves in the sclera is denied by some.

Episcleritis appears as a swelling near the cornea, dusky red in color and most frequently seen over the insertion of the rectus externus muscle. Gives no evidence of tendency to ulceration or suppuration and looks like a phlyctenule. Irritation and tenderness. Rebellious to treatment. Met with in those of rheumatic tendencies principally, and therefore constitutional remedies are the most valuable, (*i.e.*, remedies for rheumatism), and, locally, atropine, and pilocarpin hypodermically administered.

Staphlyoma of the Sclerotic.—Before describing this form will mention *Scleritis*, which appears as a general faint pinkish tinge, due to injection of superficial vessels of the sclera. In its later and severer stages this becomes more bluish. If seen early it is hard to distinguish between it, iritis, and conjunctivitis, but the aqueous is *clear* and no *adhesions* are present, and that throws out iritis; and having no secretion, there can be no conjunctivitis. This is another rheumatic accompaniment, and De Wecker of Paris says in the human being it accompanies the *articular* rheumatism by preference. Now this inflammation of the sclera, from weakening and consequent thinning, may lead to staphyloma, and

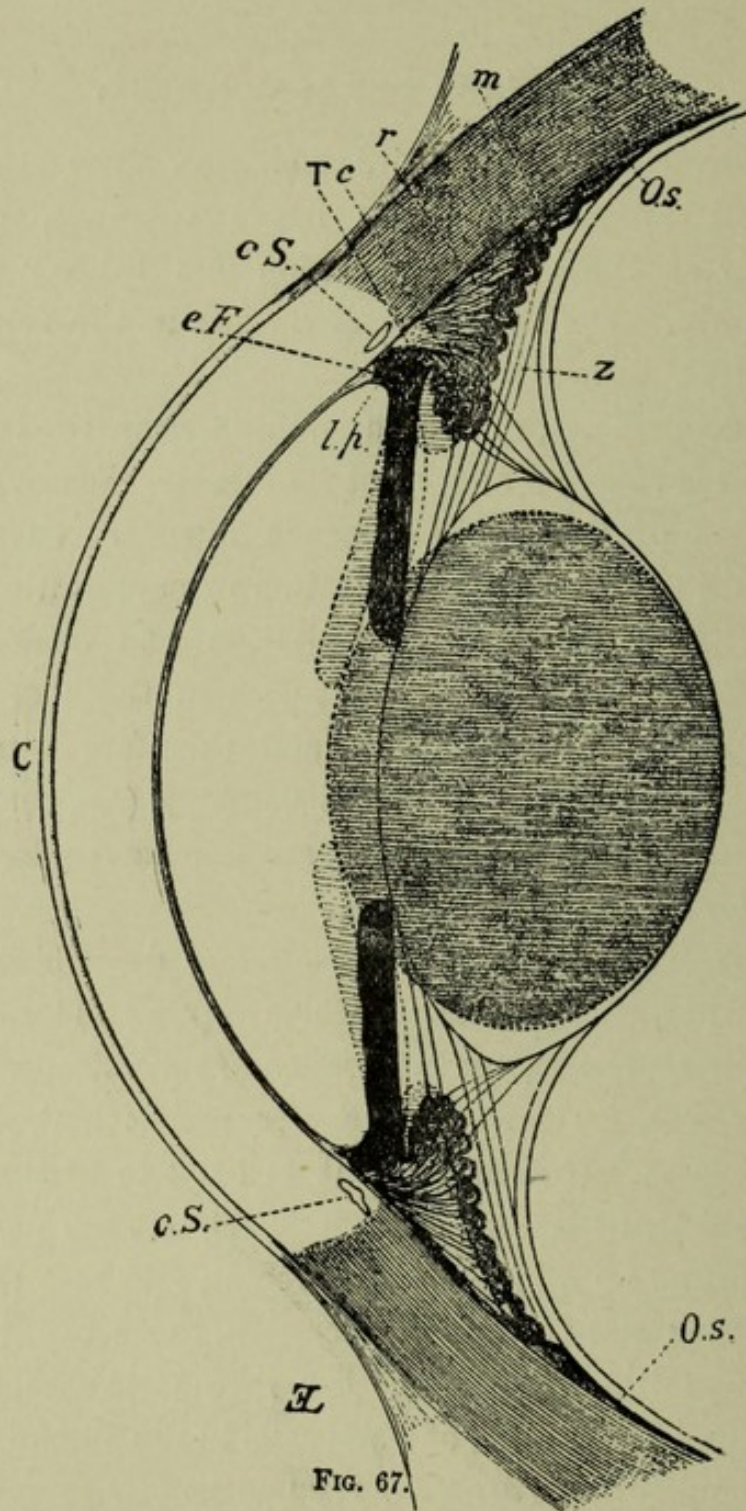


FIG. 67.

Fig. 42.

Anterior portion and ciliary region of the eye. C, cornea; cS, Schlemm's canal; O s, *ora serrata*; i p, pectinated ligament; e F, Fontana's space; T, tendinous ring; m, meridional fibers r, radiating fibers; ; c, circular fibers of the ciliary muscle; Z, zone of Zinn. The full lines indicate the crystalline lens, iris, and ciliary body in a state of rest, the dotted lines show the same in a state of accommodation.

so here we are. It may be complete or partial. Again, it may be anterior, between the cornea and the equator or posterior, around the optic nerve. Anterior staphyloma has a dirty bluish color from the choroid shining through, and is of variable size, sometimes, indeed, involving the whole front of the eye. Where the tumor is small, paracentesis with pressure may check further progress. If very extensive it may be necessary to enucleate the eye. When the bulging extends all around the sclera is called *annular staphyloma*, and when complete may protrude so far as to be called *buphthalmus*.

Injuries of the Sclera.—Dangerous, as they complicate adjoining tissues and as they permit contents of the eye to escape. Small wounds may heal readily. Clearly cut, may be united by a fine suture; any *protruding* choroid or vitreous *must be cut off* with scissors first. Patient kept quiet, and ice compresses employed. If the wound is extensive and in the ciliary region, enucleate and thus avoid sympathetic trouble.

CHAPTER IX.

THE IRIS.

Iris.—The *Iris* forms in the interior of the eye, in front of the crystalline lens, a veritable diaphragm, with a central opening—the pupil. Is a beautifully colored and contractile membrane. It is attached at its periphery to the sclera through the fibers of the *ligamentum pectinatum*. The shape of the iris is elliptical. It rests (the pupillary margin) posteriorly, on the lens capsule. Its anterior surface is free. The iris is continuous with the ciliary body and choroid, and *together* these constitute the *uveal tract*, upon which the aqueous humor, the lens and vitreous, depend for nourishment. The iris divides the space between the cornea and the anterior face of the lens and internal extremities of the ciliary processes into two compartments of unequal size—the anterior being the larger and the posterior having only a virtual existence, as the iris *rests* upon the lens capsule. Both the anterior and posterior chambers contain the aqueous humor in which the iris floats free. The anterior surface of the iris is lined with a layer of epithelial cells, which are continuous with those on the posterior sur-

face of the cornea. On the back of the iris is a thicker layer containing pigment, which is continuous with that of the ciliary body and choroid. Now, this layer of pigment, the *uvea*, may be frequently seen as small bodies on a pedicle or stem in the pupillary aperture. Indeed, they may pass through and show in the anterior chamber. Called soot-balls (*corpora nigra*). More often seen at the upper (pupillary) border.

In color they are brownish-black. Unstriped muscle fiber is the predominating constituent of the iris, contained in a stroma of connective tissue, which also contains the vessels, nerves, lymph spaces and cells. Around the pupil some certain fibers are arranged circularly. This is the

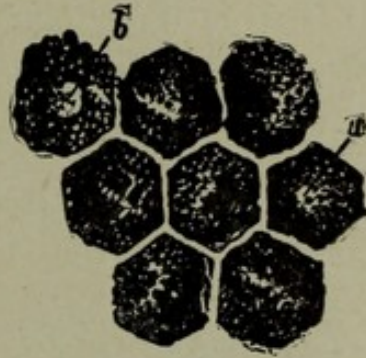


Fig. 43.

sphincter pupillæ, and the *dilator* of the pupil is formed of radiating fibers. The peculiar disposition or juncture of these two sets of fibers is that they join each other near the pupil in curves, as I here depict. The sphincter governed by the third pair, the dilator by the sympathetic. The iris has three different classes of nerves sent to it from the ciliary ganglion, which ganglion has three roots—sensitive, motor and sympathetic. The twigs which emanate from this ganglion pass to the sclera, surrounding the optic nerve. These are named the short ciliary. The two long *posterior*

ciliary arteries form the *circulus iridis major* by uniting with the branches of the *anterior* ciliary arteries. From these we have branches which form another ring, the *circulus iridis minor*, formed by anastomosing. The major is formed at the ciliary region. The minor gives off capillaries, which in turn become veins, and, the circulation being established, is returned in the same manner as above described. The

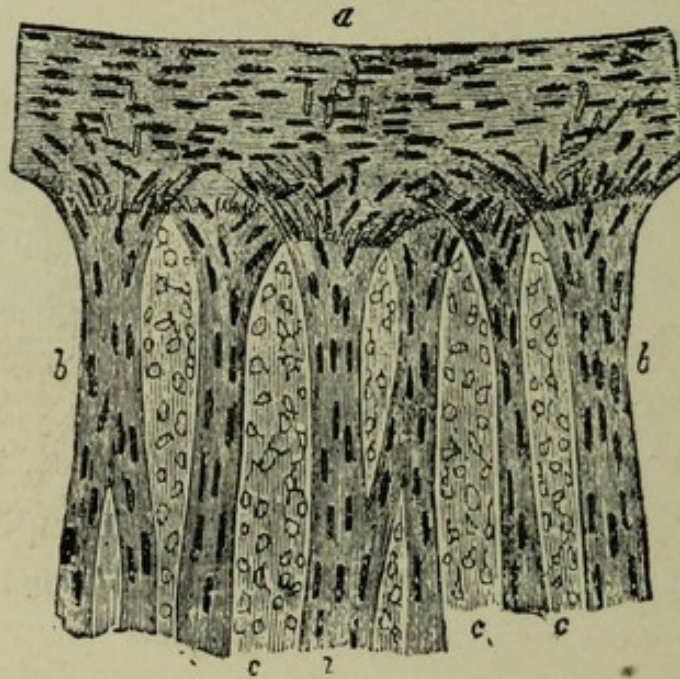


Fig. 44.

The iris regulates the amount of light admitted to the eye's interior, and by excluding peripheral rays admits of acute vision.

Iritis. — Inflammation of the iris is the result of injuries, cold, rheumatics, extension of inflammation from other parts, etc. Three principal divisions: (1) plastic, (2) purulent, and (3) serous, but a description of one

general case will suffice for the general practitioner. With the appearance of inflammation, and its symptoms, will have an exudate showing at the margin of the pupil. This may go on to such a degree that the aqueous shows decided

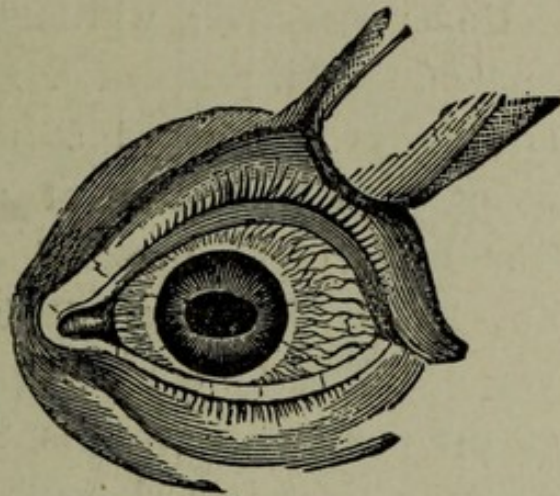


Fig. 45.

turbidity, iris becomes discolored and *sluggish* in its movements and much swollen. Now, this exudate I spoke of, in some forms especially, is sticky, adherent

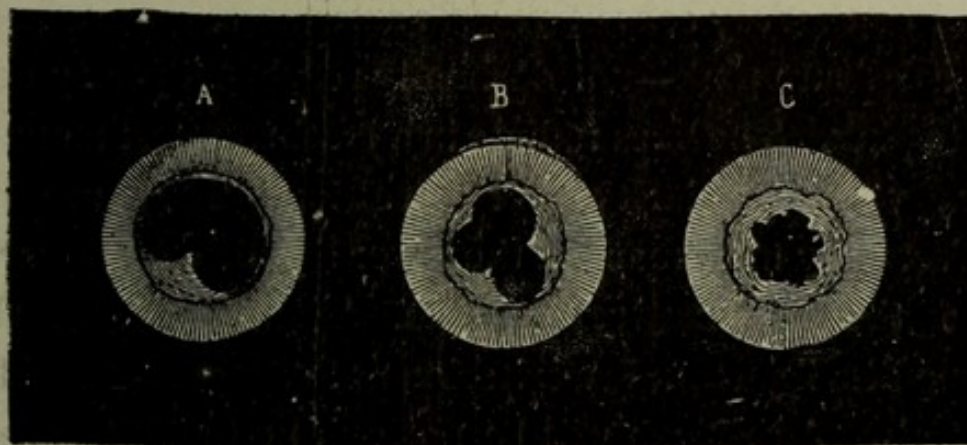


Fig. 46.

in its nature, and is the cause of the decided adhesions between the lens capsule and the iris (*synechia*). This condition may be readily broken up, but if the exudate is of an organized character, *i.e.*, vascular, fibrous, etc., then the adhesions are correspondingly firm.

Under *symptoms*, will find photophobia and lachrymation, frontal pains of a lancinating nature, which are *always* aggravated at night, the degree of pain being some indication of the severity of the case. The lids will be involved to some degree, usually but slightly, however. Careful examination will reveal a dull, rusty appearing iris, with often turbidity of the aqueous. The iris from infiltration will respond to light in a sluggish manner. There will be conjunctival and sub-conjunctival injection, which is represented by irregularly scattered vessels, which *may be moved with the conjunctiva* by rubbing on the lower lid, remember, and these vessels may be so enlarged and engorged as to present chemosis. The point will be the *rosy zone* of vessels surrounding the cornea, of a delicate pink—not decidedly red, but a pretty delicate pink. The lines radiate in a mathematical manner, *i.e.*, with regularity and precision. They are not affected by movement of the lower lid with the finger as are the conjunctival vessels. The degree of this zone-like injection is a criterion as to the severity of the attack. Adhesions will be noticed, and may be slight or very pronounced, from a slight synechia to complete occlusion of the pupil. If they are not seen or easily diagnosed, the instillation of atropine will discover any, no matter the degree, by irregularities of the pupil. (See Fig. 46.) Not wise to expect resolution this side of six weeks. May be met within one or both

eyes. The *one* condition, remember, which will cause a doubtful prognosis is *synechia*, otherwise, with a reasonably robust patient, the prognosis is good. There is a special form of iritis called *purulent*, and

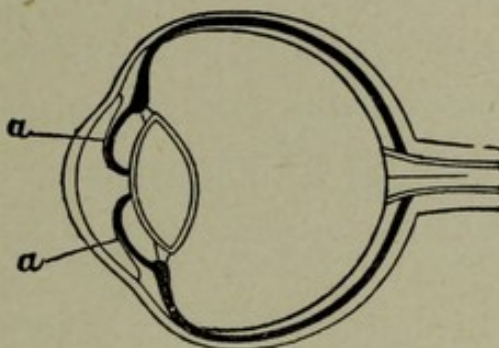


Fig. 47.

its most prevalent cause is trauma. Follows operations on the eye. This form is accompanied by the formation of pus usually, and which may be in such degree as to collect at the bottom of the anterior chamber, forming hypopyon. This may run on to panophthalmitis or general suppuration of the eye.

TREATMENT.—Assure yourself that no exciting cause remains in the eye. Then *atropine* till full mydriasis is secured. If 1% be not strong enough, use stronger and stronger solutions until the effect is accomplished, even to the crude drug. Then maintain it by a weaker solution. The patient must be kept quiet in darkened stall and not overfed. *Cold* applications are the most recent and successful method of treatment of cases with rheumatic complications. But in using very cold applications, watch out for haziness of the cornea, when they must be discontinued (Helfrich, Schenck). Now, though this seems paradoxical, warmth is a valuable means of treatment in some cases, and is especially valuable in relieving the pain at night. Let it be *dry* rather than

moist heat. If it has been found that a previously existing synechia is an exciting cause, an iridectomy will be in order, and also later, if other treatments are ineffectual. Of course the underlying cause must be cared for, whatever it may be.

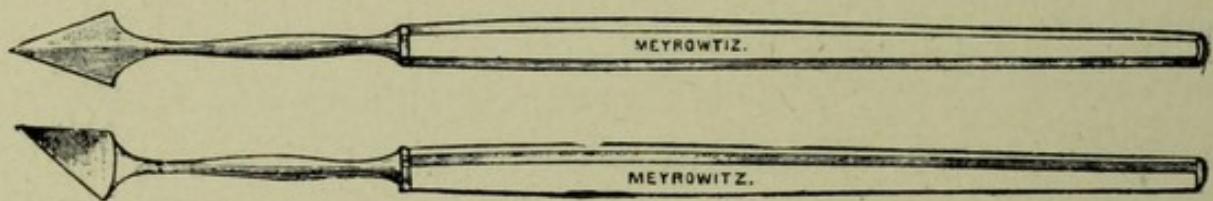


Fig. 48.

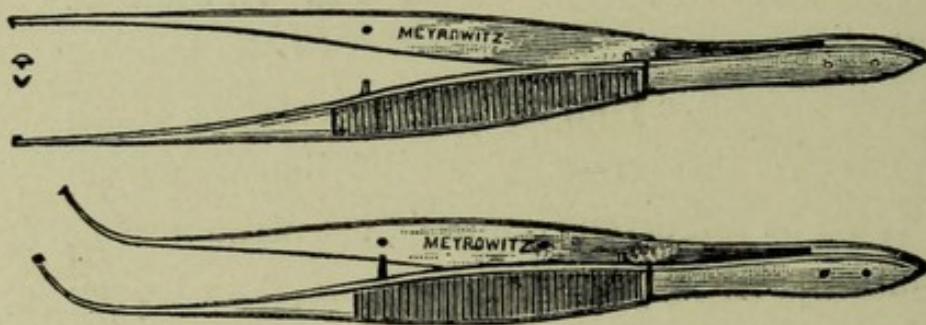


Fig. 49.

Tumors.—Not much to be done. Simple and malignant, as met with elsewhere. If of sufficient import to render it necessary, excise them. Avoid, if possible, in excising cysts, rupturing their walls, if of a serous nature, for the serous cyst is simply distended iris tissue, and is translucent in appearance.

There is a condition rarely, very rarely, met with, which I merely mention, called *Membrana Pupillaris*

Persistans. During gestation the pupil is closed by a membrane, and occasionally some part or all of it remains.

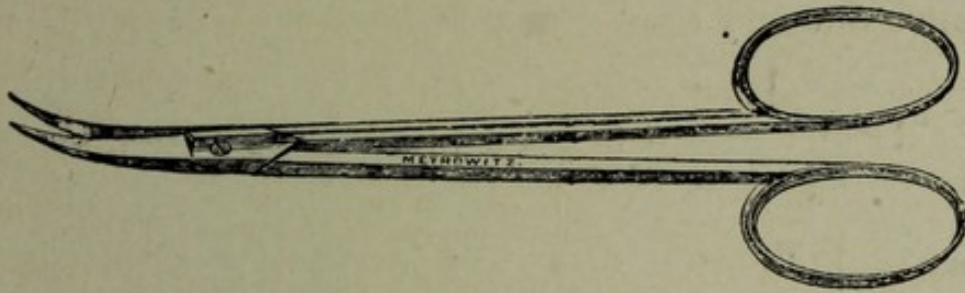


Fig. 50.

Iridectomy.—(Excision of a portion of the iris; removal of the entire iris is iridavulsion.) Iridectomy

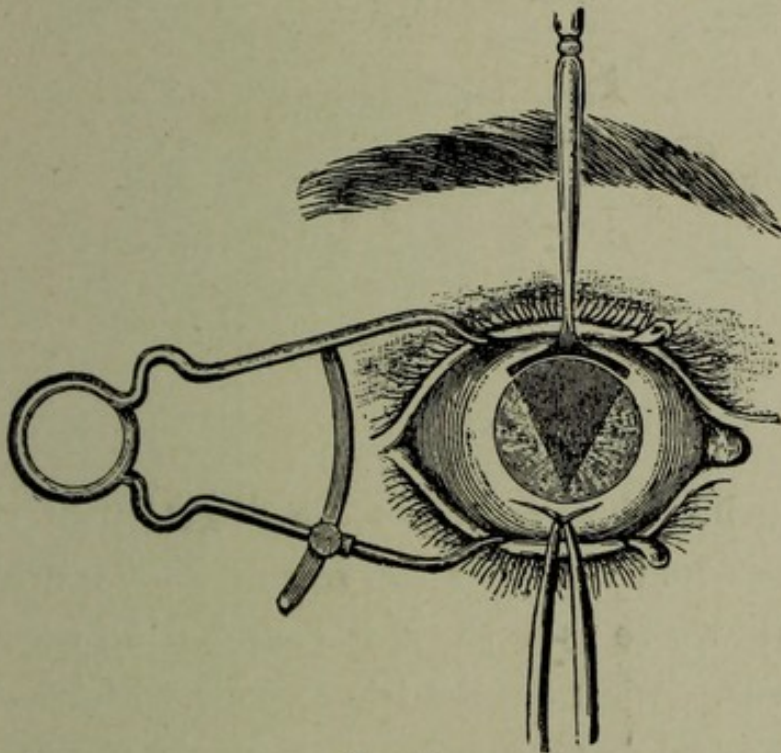


Fig. 51.

demands a speculum, fixation forceps, an angular or straight keratome, or Græffe knife, iris forceps and

iris scissors, and cocaine 4%. Introduce between the lids the speculum. With the fixation forceps grasp the conjunctiva directly opposite the point of incision (on the opposite side of the cornea, understand), and thus control the eyeball. (A full dose of chloral hydrate is good in irritable patients). The keratome is inserted about a line from the corneo-scleral margin into the cornea, and introduce the blade so as to divide as little tissue as pos-

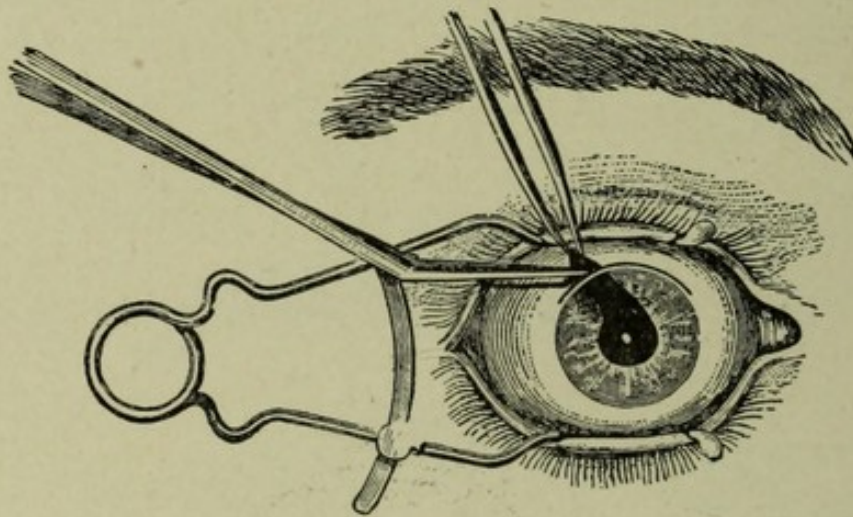


Fig. 52.

sible. When introduced change the direction of the knife so as to avoid touching the iris or lens. Withdraw knife slowly so as to avoid too sudden an escape of the aqueous. With curved iris forceps withdraw a portion of the iris, having grasped it at its *pupillary edge*. Cut it off with the scissors. *See that none of the iris remains in the wound.* Compress, bandage. Maintain asepsis and antisepsis, and instil $\frac{1}{2}$ per

cent. sol. Eserine immediately to draw iris away from puncture and thus prevent prolapse or synechia, etc.

Great care is to be taken not to injure the lens or iris. For should you hit the lens, cataract is apt to ensue, or glaucoma, with its horrible consequences. The cutting of the iris may be followed by a little hemorrhage, which will be absorbed. Be guarded also, in withdrawing the keratome, that a too sudden evacuation of the aqueous does not occur, as the sudden diminution of intra-ocular tension might be followed by hemorrhage into the vitreous, and this is serious.

CHAPTER X.

THE CILIARY BODY.

Ciliary Body.—Between the iris and the ora serrata (anterior limit of the retina) lies the ciliary body, which consists of the ciliary processes and muscles. It is the source from which the lens and vitreous derives nourishment largely. Is composed of two portions—(1) a muscular and (2) a pigmented and vascular portion. Around the crystalline lens there is a wide black circle, the ciliary processes, forming regular radiating folds, which project by their inner extremities inward. There

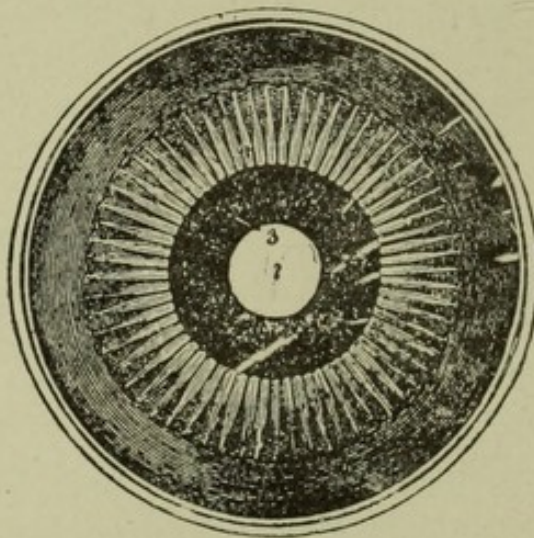


Fig. 54.

are about 120 of these folds, composed of connective tissue, which is continuous with that of the iris and pectinate ligament; also of blood vessels, convoluted, and covered over all by a layer of pigment. From the furrows that separate these processes posteriorly we see a hyaline structure extending, that constitutes the zonule of Zinn, which goes

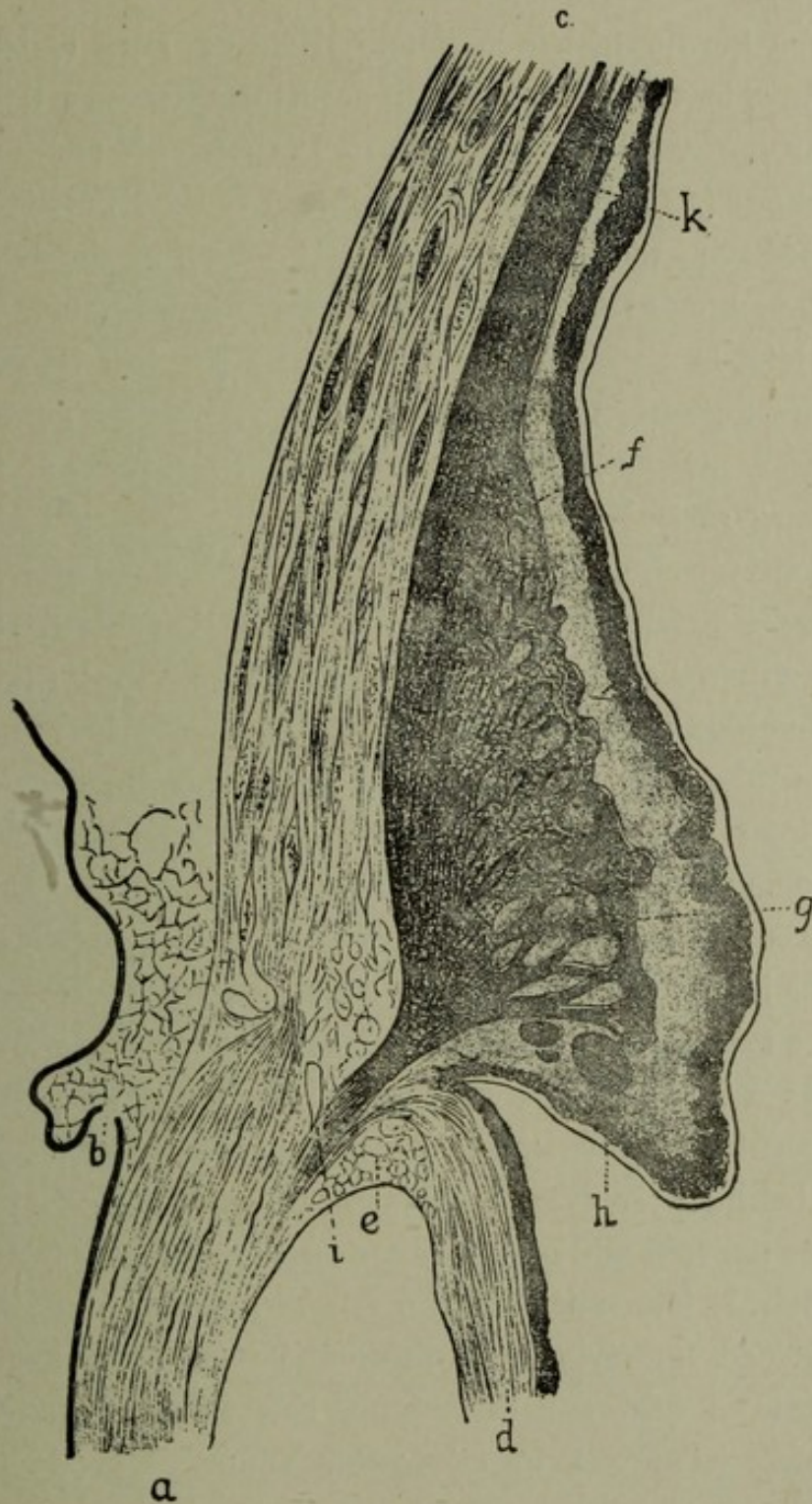

Fig. 53.

Ciliary muscle, after Iwanoff ; a, cornea ; b, corneal limb ; c, sclerotic ; d, iris ; e, Fontana's Spaces.

to the border of the lens and, dividing, goes to each surface, leaving between its separating surfaces a triangular space, called the canal of Petit. This pectinate ligament (*Ligamentum Pectinatum*) is that portion of connective tissue where the iris is joined to the sclera at the edge of the cornea. The suspensory ligament of the lens is permeable, transfusion from the vitreous to the aqueous taking place. Chauveau says: "The anterior or ciliary zone includes two parts: the 'ciliary circle' (or ligament) and the 'ciliary body.' The ciliary circle, ligament or muscle (*annulus albidus*) varies in width from one to two millimetres; its external face adheres closely to the sclerotic and its internal is confounded with the ciliary body; the posterior border is continuous with the choroid zone near the canal of Fontana (ciliary canal). The anterior border gives attachment to the greater circumference of the iris." This is a portion of Chauveau which I will explain later, for as it now stands it is not over easily grasped. To quote still further: "The ciliary body (*corpus ciliare*) forms a kind of zone or ring, wider than the ciliary ligament, and consequently overlaps the latter before and behind. It extends on one side on the inner face of the choroid and on the other on the posterior face of the iris." The fibers of the ciliary muscle are of the unstriped variety, and in different parts of the muscle they take different directions, the whole combined making a muscle of triangular shape. This is the

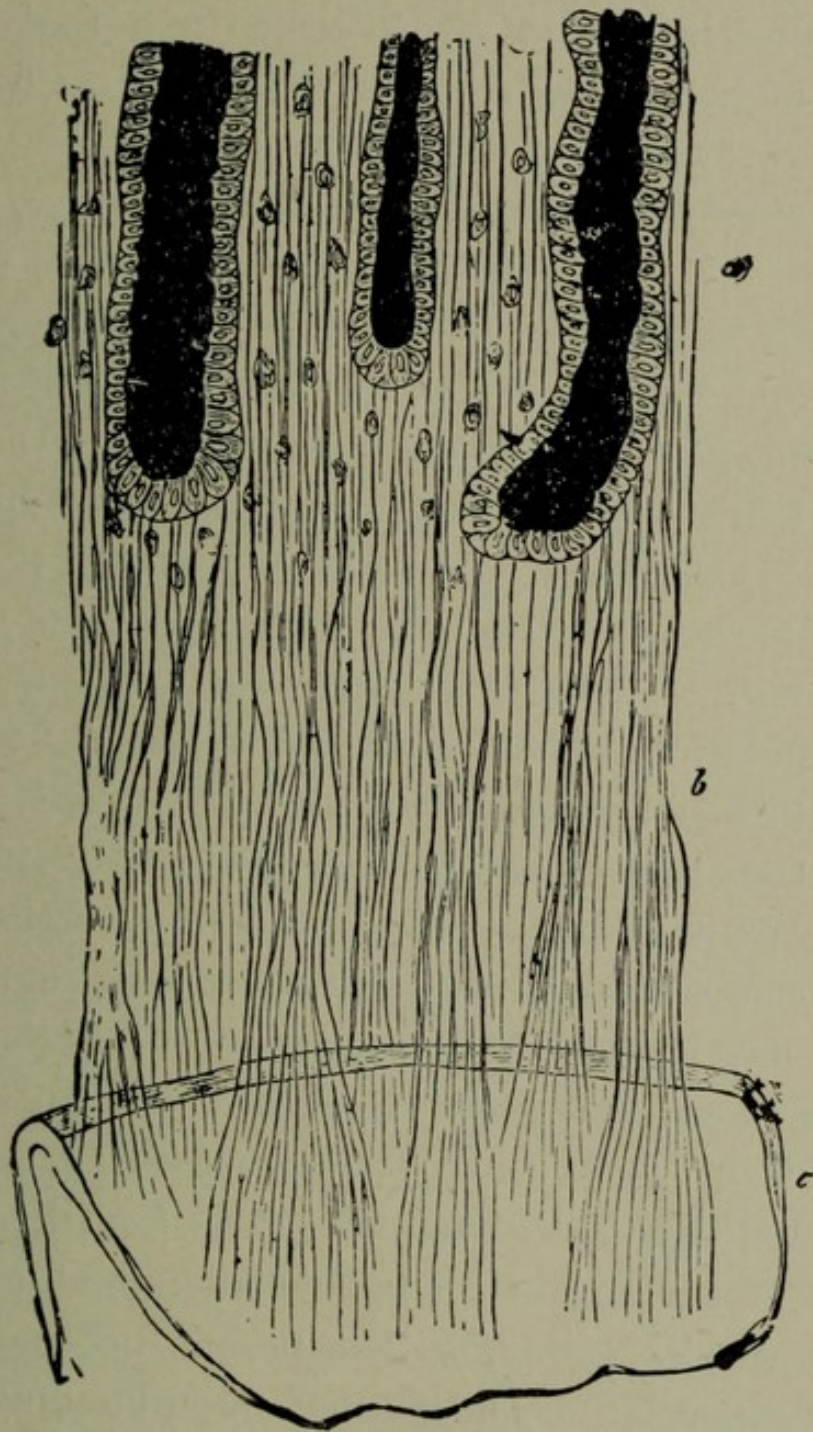


Fig. 55.

Insertion of the zone of Zinn upon the crystalline lens, seen from in front.
 The pigment of the detached ciliary processes has remained adherent
 to the non-plicated portion (a) of the zone of Zinn.

muscle of accommodation. Vessels are the anterior

and posterior ciliary, which come from the ocular branch of the ophthalmic, which in turn comes from the internal carotid. The nerves are from the ciliary, which contain ganglion cells containing sensitive, motor and sympathetic filaments, and these pass to ciliary body, iris and cornea. These nerves, you understand, come from the ophthalmic division of the fifth, and the fifth is peculiar in its origin—to wit., from the floor of the fourth ventricle and side of the pons and the Gasserion Ganglion (this is sensory), and from the floor of the fourth ventricle and side of the pons for its motor root. Contains also sympathetic filaments. The ophthalmic branch enters by the sphenoidal fissure.

Cyclitis.—Inflammation of the ciliary body. The ciliary body is seldom involved alone. Usually the contiguous parts participate. Is as a rule an extension of iritis; choroiditis. If the result of operation, or injury, then it may be alone involved.

Under *Symptoms* will have ciliary injection accompanied by chemosis, pain. The eye will be *intolerant of touch*, and that is *the* symptom. The iris will appear rusty. This may go on to inflammation of all parts of the eye—*panophthalmitis*. Prognosis is not good.

TREATMENT.—Hot fomentations, local bleeding, atropine, anodynes, etc. If the attack prove rebellious, as is often the case, enucleation, for the safety of the other eye, which, through sympathy, may participate. *Injuries* are dangerous, principally because of giving origin to

sympathetic ophthalmia. So, if the eye be injured to a grave degree, enucleation is the word.

Irido-choroiditis, Periodic Ophthalmia, Reccurrent Ophthalmia, Moon blindness, (Irido-cyclitis). — This affection is intimately related to certain climates, systems and soils, and shows a strong tendency to recur again and again. Usually terminates in blindness from cataract. Its causes may be said to be, primarily, in the soil—on frequently submerged grounds; on marshy and clayey grounds; on coasts. Also wet, damp climates, which produce lymphatic constitutions. Again, rank, watery foods. This affection is usually seen during the dentition and breaking period; therefore are apt to see it between two and five or six. Among local causes would be smoke, acrid vapors, dust, etc. No *one* of these is sufficient to cause this disease. To-day a microbe is the alleged cause, or the product of a microbe. This product may be preserved in the marshy soil. The presence of a definite germ has not been demonstrated as yet.

Heredity is one of the most potent causes we know. This is very positively demonstrated when both parents have suffered. In support of this, we know if a mare had borne a number of foals, all sound, and then suffered an attack of periodic ophthalmia, the subsequently born would also suffer. The study of atavism presents many interesting facts in these matters. And yet if the foals of diseased parents be

transferred to high, dry ground they will nearly all escape. In France, the government rejects all unsound stallions and refuses service to any mare that *has* suffered. Unwholesome food and errors in feed are undoubtedly predisposing causes, for in a given district those fed with judgment will be granted immunity in a large proportion over those badly fed. Intestinal parasites, over-work, debilitating diseases and causes of every kind that weaken the vitality.

The *symptoms* vary according to the severity of the attack. Some present marked exacerbation of temperature, and again it may be entirely absent. But there *always* is evidence of general disorder, lack of vitality. Locally, symptoms are those of internal ophthalmia with the addition of increased tension or hardness of the bulbus. This may be due to effusion into its cavity. The contracted pupil does not expand much in darkness nor even under the action of a mydriatic. Opacity advances over the cornea commencing at the limbus, and may be partial or complete. And so long as it is transparent the aqueous will be seen turbid, with sometimes flocculi. The iris will appear rusty and dullish. The lens will be clouded and will observe a greenish-yellow reflection from the eye. From the fifth to the seventh day the flocculi precipitates, the lens and iris are more plainly seen, and the commencing absorption may be complete in twelve to fifteen days. The recurrence is *the* characteristic of the affection. And

it will recur again and again and in the same eye until total loss of sight ensues. These attacks may occur at intervals of a month or so, but they show *no relation* to any particular phase of the moon, as the name would lead one to suppose. These recurrences are determined, more likely, by some periodicity of the system. From five to seven or eight attacks usually suffice in resulting blindness, and then the second eye is liable to attack with the same result. Between the attacks some latent symptoms tell the story, and these symptoms become more marked with each successive attack. Even after the *first* attack there can be seen a bluish ring around the corneal margin, the eye therefore seeming smaller; and after several attacks it *is* smaller from atrophy. The upper eyelid, in place of presenting a uniform continuous arch, has about one-third from its inner angle an *abrupt* bend caused by the contraction of the levator muscle. The pupil is contracted *except* in advanced cases, where, with an opaque lens, it will be widely opened, dilated. The animal will carry his ears erect and forward to compensate for his waning vision. Now, this is a general picture, but that the attacks vary with different cases must be remembered. The recurrence, however, is characteristic, and all alike lead to cataract and intra-ocular effusion, giving rise to T +, with pressure on the retina and resulting blindness. The *prevention* of this disease is the great object, and to accomplish this

most desirable end, we must go back to the starting wire and have careful and discriminating breeding, feeding, stabling, etc., *ad infinitum*.

TREATMENT is UNSATISFACTORY. Some are benefited by colchicum in scruple doses where rheumatic tendencies are evinced, or two-dram doses of salicylate of soda twice daily. If the tension is increased to a marked degree paracentesis or iridectomy has been attended with good results.

When convalescing, tonics—

Oxide of iron, \times ʒ ij.

Nux vom, gr. x.

Sulphate of soda, $\bar{\text{z}}$ j. daily.

There is an affection of the eye which has been and is the subject of great speculation and discussion:

CHAPTER XI.

SYMPATHETIC OPHTHALMIA.

Sympathetic Ophthalmia.—Supposed to be due to a pre-existing inflammatory condition of the other eye. At its inception there is some photophobia, some injection and lachrymation. With the ophthalmoscope will find opacities floating in the vitreous. Pain in the ciliary region, especially is it painful to *touch*. The haziness of the aqueous will be from the exudation from the ciliary processes. Occlusion of the pupil is a common accompaniment. Tension will be increased and loss of sight will be complete. The causes which are responsible for many such cases are injury, trauma, especially in the danger zone, *i. e.*, the ciliary region; an operation for cataract with the incision too far back of the corneo-scleral margin, for instance; previous inflammations, followed by or resulting in atrophy, etc. The period of danger, *i. e.*, when one eye may sympathetically suffer from another, is variously estimated at from two weeks to *any* period. The most frequent period is from one to two months. The method and means of transmission is as yet an open question, and space forbids entering into the many

theories. Prognosis is unfavorable, especially in animals, as the affair is well established and effusion has taken place, by the time we are rendered cognizant of its presence.

TREATMENT.—Enuceate the exciting eye, and if done early enough, the inflammation will be checked. The sympathetic eye must be treated as a case of internal ophthalmia; to wit., atropine 1 to 120. Hot fomentations, moist or dry, as you choose, etc.

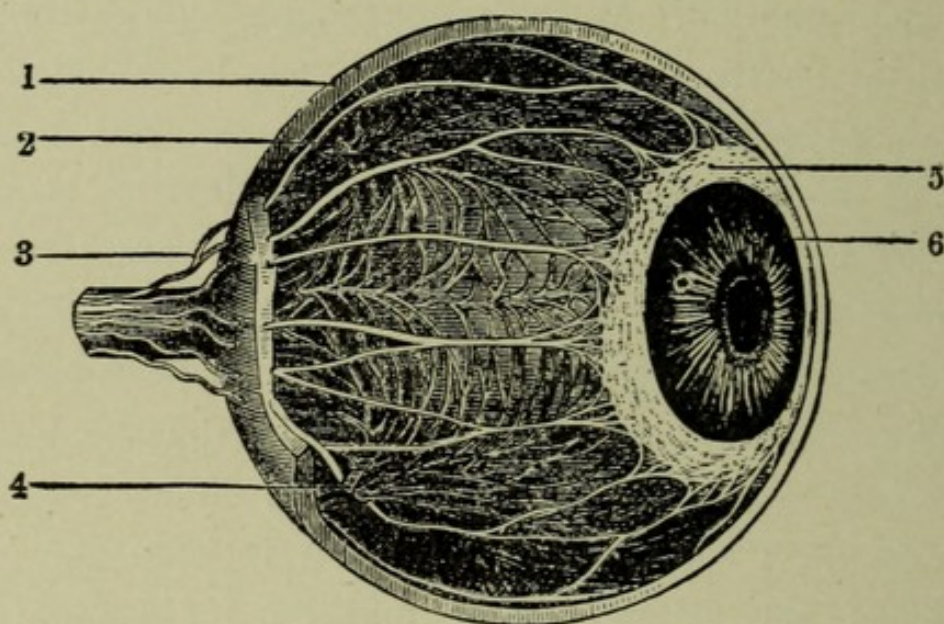


Fig. 56.

CHAPTER XII.

THE CHOROID.

The Choroid is a thin, dark-colored membrane situated between the sclera and the retina. Extends from corpus ciliare to the optic nerve. Made up of vessels, pigment, and some connective tissue. The blood comes from the short posterior ciliary arteries which anastomose with the long posterior and anterior ciliary arteries. The veins begin as capillaries and take on a peculiar form. Resemble as much as anything else a weeping willow, and these uniting, form the *venae vorticosæ*, emptying into the ophthalmic vein. The anterior ciliary vein drains the anterior portion. The long and short ciliary nerves form plexuses in the choroid and contain a number of ganglionic cells. Between the retina and choroid there is a layer of pigmented epithelium. The inner face of the choroid is not uniform in color, being perfectly black in the lower part of the eye. This is abruptly terminated at a horizontal line about the eighth or ninth part of an inch above the optic papilla. From this line on the segment of a circle from $\frac{4}{10}$ to $\frac{6}{10}$ of an inch in height, it shows most brilliant colors; at first

blue, then an azure-blue, afterwards a brownish-blue, and after this the remainder of the eye is occupied by

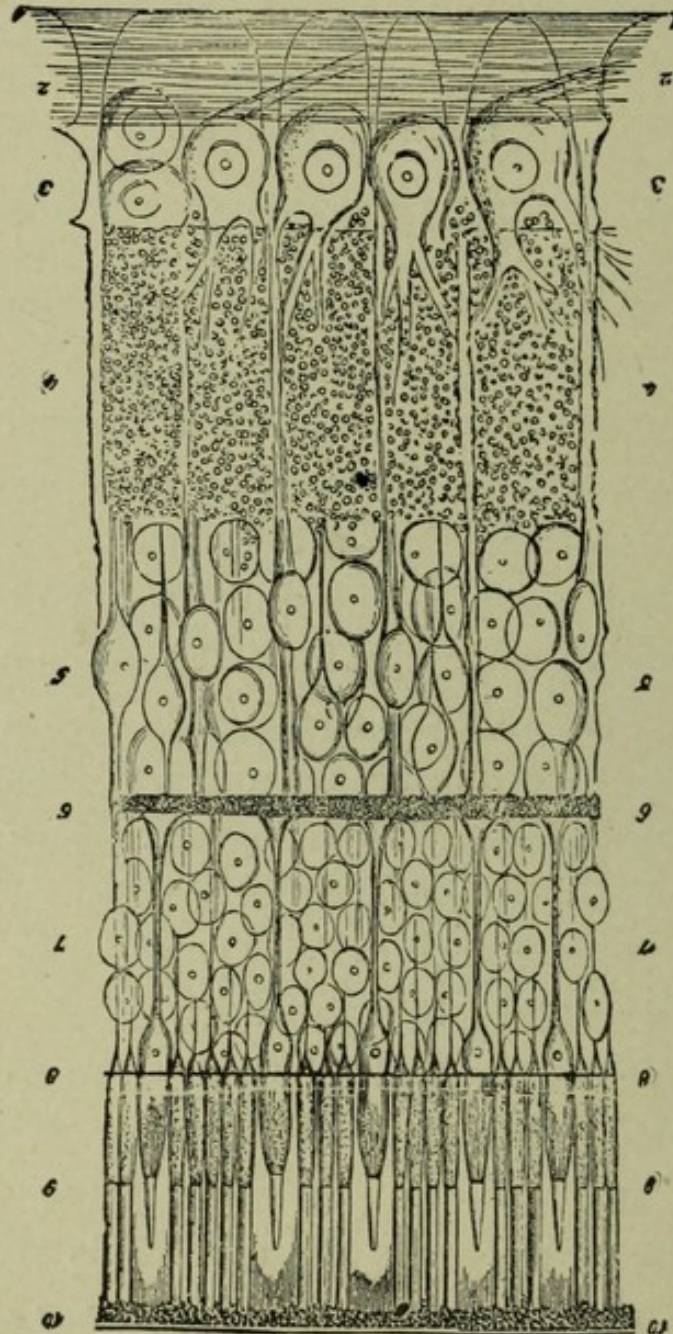


Fig. 57.

an intense black. The bright portion is the tapetum.
The **Retina** lies between the choroid and vitreous.

Extends from the optic nerve to the ciliary processes, where it is called the *ora serrata*. Consists of ten layers. (1) *The internal limiting membrane*, separates the nerve fiber layer from the vitreous, and the fibers of Müller terminate in this layer. (2) *The nerve fiber layer*, consists of the axis-cylinder of the optic nerve fibers, which run in a radiating direction to the *ora serrata*, where they terminate. At the macula lutea these fibers are bent into arches, and this arrangement permits a larger number to reach the yellow spot than if they approached in a radiating direction. (3) *The layer of ganglion cells*, composed of multipolar cells, each with a nucleus and nucleolus. A nerve fiber enters each of these cells, and one or more prolongations extend out into the inner molecular layer. These ganglionic cells are arranged closer around the optic nerve than at the *ora serrata*. (4) *The internal molecular layer*, one of the thickest, granulous in appearance. Consists principally of fine fibers from the layer of ganglion cells. (5) *The internal granular layer*, composed of two kinds of cells with nuclei. The larger are nerve cells, having *two* offshoots, one passing into the inner granular layer, anastomosing with offshoots of the ganglionic cells, the other out to the external molecular layer and supposed to anastomose with fibers from the layer of rods and cones. The smaller cells of this layer are connected with the fibers of Müller. (6) *The external molecular layer*. Very thin and is made up of

the fibers just mentioned with some molecular matter.

(7) *The external granular layer.* Composed of both nerve and connective tissue elements. Former consists of bi-polar cells, from which offshoots pass out to the rod and cone layer and inward to the internal granular layer.

(8) *The external limiting membrane,* formed by the terminal extremities of Müller's fibers.

(9) *The layer of rods and cones.* The rods commence as fine fibers in the outer molecular layer, pass through the outer granular, and just beneath the external limiting membrane begin to increase in size, forming the rod granule, and some distance after passing through this membrane they taper down into cylindrical-shaped rods which extend outward to the pigment layer. The cones also commence as a cone-shaped swelling in the outer molecular layer, where they are in direct communication with the fibers from the internal granular layer. The cone fiber becomes thinner until, just underneath the external limiting membrane, it again swells rapidly and there forms the cone itself, which contains a large oval nucleus and nucleolus. The cones are shorter and thicker than the rods, and are of a bottle-shaped appearance. The rods and cones are arranged perpendicularly to the plane of the retina, and may be divided into an inner and outer part. The inner is thickest and appears granulated; the outer is broken up into highly refracting lamellæ, appearing like superposed discs or piles of coins.

(10) *The pig-*

ment layer, is a single layer of hexagonal nucleated cells, the inner surface of which is loaded with pigment

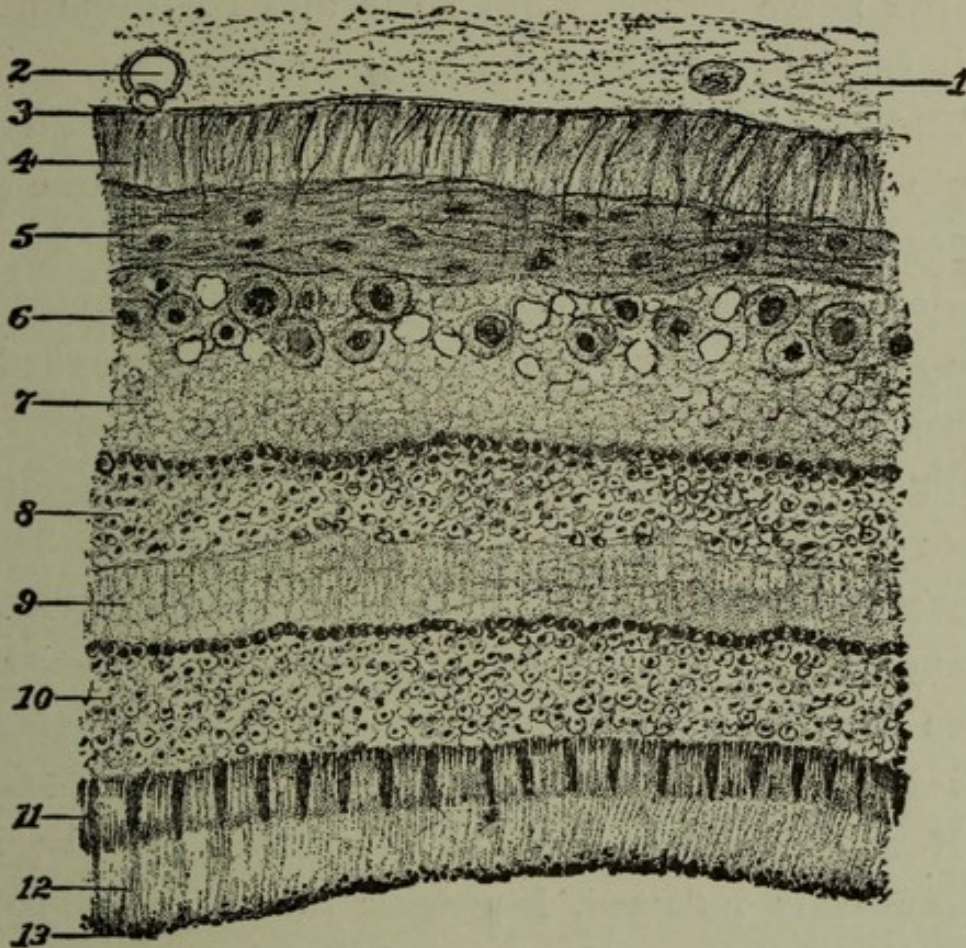


Fig. 58.

Section of Normal Retina X 350.—Eye removed for Sarcoma, Retina detached but almost normal.—1, Vitreous ; 2, hypertrophied cells of vitreous ; 3, membrana limitans interna ; 4, fibers of Müller (they are slightly hypertrophied)—they are part of the connective tissue frame work ; 5, layer of optic nerve fibers, nuclei more numerous than usual ; 6, layer of ganglion cells, some of them having undergone colloid degeneration ; 7, internal molecular or reticular layer ; 8, layer of inner granules ; 9, external molecular reticular layer—in this as in the internal molecular layer the fibers of Müller are abnormally distinct ; 10, layer of outer granules ; 11 and 12, layers of rods and cones, in which a distinction is made between the body of each element, 11, and the process 12, which is its continuation ; 13, layer of epithelial pigment in polygonal cells.—(Noyes).

granules. The fibers of Müller form the connective

tissue framework as they traverse the various layers and spread out in its membranes. At the *ora serrata* all the nerve elements disappear and the connective only continues, forming the zonule of Zinn.

The *Macula lutea*, or yellow spot, is the seat of most acute vision. The macula contains no rods, while the cones are longer and narrower than elsewhere. At the center all the retinal layers are thinned, and this is called the *fovea centralis*. The retina possesses a particular vascular distribution. The *arteria centralis retinae* with its vein enters the optic *nerve* at a short distance from the globe, and *with* it passes into the eye. They traverse the papilla and immediately divide into two branches, one up, the other down. These branches then turn out, but *none of its capillaries extend into the fovea*.*

Now, though the choroid and retina may be independently inflamed, I propose to describe inflammation of both under *Internal Ophthalmia*. Severe blows, punctures, foreign bodies, sudden transition from darkness to brilliancy, glare of snow, cold and dampness, high winds, (front of ferryboats, for instance), rain, exposure when heated, and many general diseases, among which are rheumatism and influenza. Met with during dentition. There are not many external symptoms, *unless* the cause was

* The above description of the retina was taken largely from Norton's excellent work.

external, such as a blow, puncture, etc., in which case the lids and conjunctiva would participate to a marked degree. Otherwise the symptoms would be deep. The anterior edge of the sclerotic where it overlaps the cornea will remain white, when posterior to it will show congestion; and this is caused by the fact that the arteries (ciliary) penetrate the sclera behind its anterior border. This many times cannot be seen, owing to pigmentation. The opacity of the cornea may be confined to its outer margin. The aqueous will be turbid and will see yellow-white flakes floating in it. These may deposit and form hypopyon. The iris will be dull and rusty, as in iritis. Intense photophobia. Watch out for adhesions. In taking the tension will find it plus, even to + 3. In severe attacks the formation of pus in the choroid (and iris), which escaping sinks to the bottom of the anterior chamber, forming hypopyon, as above stated. In nearly *all* cases cataract results.

TREATMENT.—Quiet, rest, *darkness*. May give a purge, if patient is robust. If any rheumatic tendency, colchicum, ʒ ss and Sod, salicyl, ʒ ss, daily. You will treat the eye much as for conjunctivitis. Astringents—Boric ac. 4%; Zinc, sulph. one to two grs. to the ʒ, and *never forget the instillation* of atropine 1%, using an eye dropper. Some advise use of a feather, but that is apt to carry foreign matters with it, so don't. In cases of severe pain, cocaine 4% is

good. Local bleeding and blisters, the bleeding being accomplished by shaving the part desired and applying leeches.

A word or two anent the *Vitreous humor*. It occupies all that portion of the eye *behind* the lens. Has a depression in front called the lenticular fossa or *fossa patellaris* in which rests the crystalline lens. It (the vitreous) is adherent to the optic nerve and ciliary body and has *no other* attachments. It is contained in the hyaloid membrane, and this membrane forms the zonule of Zinn, and it is between the layers of the zonule and *around* the circumference of the lens that we have the canal of Petit. Now through the center of the vitreous may be discovered a canal, the canal of Cloquet, for the hyaloid artery during foetal life. This is sometimes (very rarely) seen after birth, and is then termed Persistent Hyaloid Artery, and it has no attendant vein. The

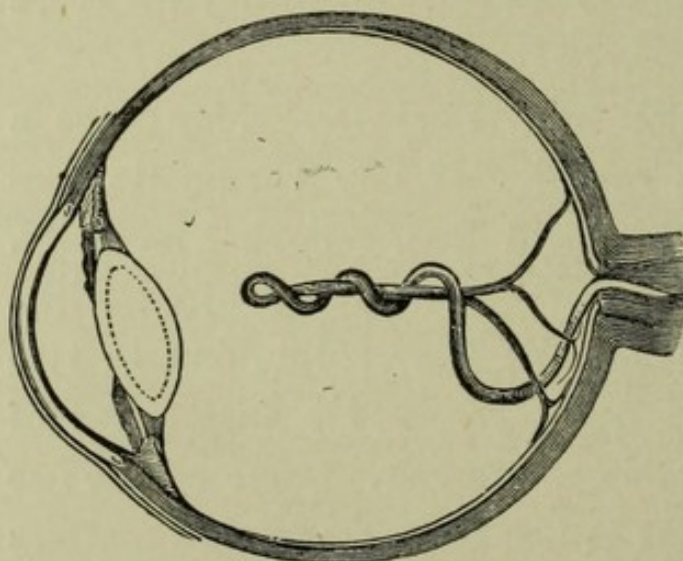


Fig. 59.

vitreous humor has neither blood vessels nor nerves, but it must be classed with organized structures because of the cells it always contains. These cells have no definite form, being

round, star, spindle, etc.

CHAPTER XIII.

CRYSTALLINE LENS.

Crystalline Lens.—A transparent, biconvex body, solid and inclosed in a membrane which is transparent and called its capsule. According to Chauveau the measurements are vertically $\frac{6}{10}$ of an inch; transversely $\frac{5}{10}$. The posterior face, measuring transversely $\frac{4}{10}$, is the more convex, for the anterior transverse diameter is but $\frac{3}{10}$. The lens is enveloped in its capsule but *not* adherent to any part of it, and this capsule is of uniform thickness. Is composed of an elastic homogeneous membrane, being lined anteriorly with a layer of cells which give nutrition to the lens. The zonule of Zinn or suspensory ligament supports the lens, maintaining it in its position. This ligament, you will remember, is the continuation of the membrana limitans of the retina which passes over the ciliary process to the border of the lens and separately passes to the front and rear of the capsule, thus enveloping it and making a capsule. The canal of Petit, you see, is the space between the dividing surfaces and the circumference of the lens. Function of this canal is in doubt; supposed, however, to convey

nourishment to the lens. The zonule has control over the accommodative changes of the lens. The tissue proper of the lens is composed of concentric layers, and each layer is composed in turn of a single layer of

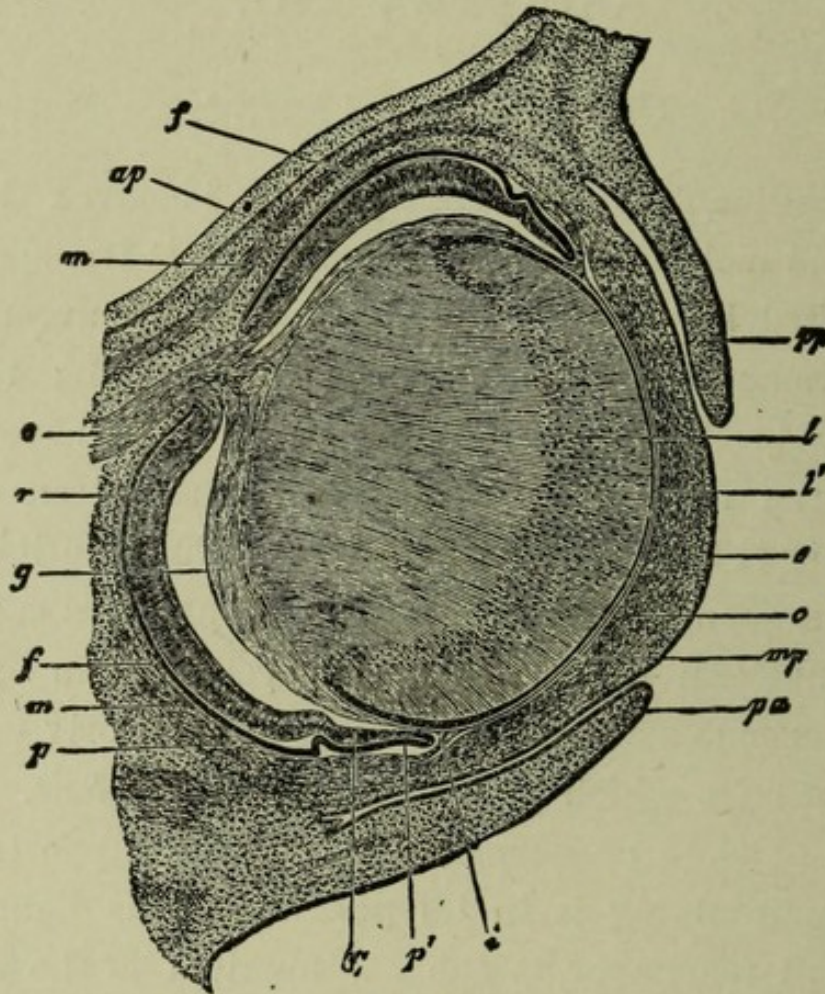


Fig. 60.

Eye of calf—third month (Kölliker). pp, lower lid; pa, upper lid; m, mesoderm not yet differentiated; c, cornea; mp, membrana pupillaris; i, place of iris; chc, chorio-capillaris; g, vitreous; p, pigment layer or proximal lamella of the secondary eye vesical; r, its distal lamella, composing the retina.

fibers with a cementing substance. These fibers have each an oval nucleus. Now, each fiber runs from the anterior to the posterior surface in a meridional manner, the ends meeting at the poles of the lens in such a manner as to form a star-like figure. Taking the lens

as a whole, it is divided into a nucleus and a cortex. A single layer of fibers under the microscope will be seen to lie parallel and each measure about $\frac{1}{5000}$ of an inch in thickness. They unite with each other by serrated borders, by dovetailing. The lens acts as any plus lens, bringing light to a focus. Cataract is the common result of internal ophthalmia and is an opacity

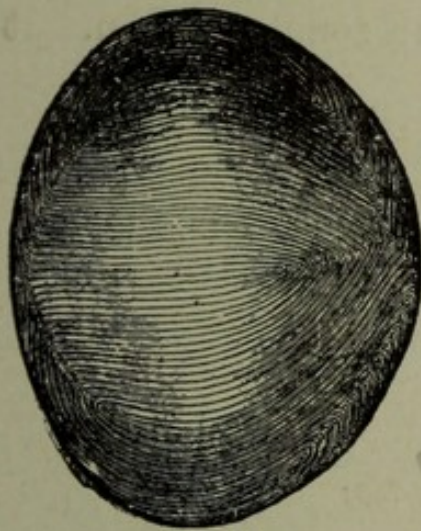

Fig. 61.

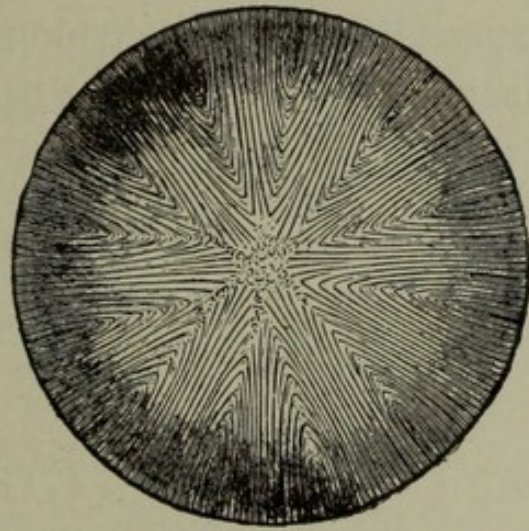


Fig. 62.

of the crystalline caused by interference with its nutrition. Ergotism is a cause, but we don't know how. Cataract may occur at any age. Sometimes congenital. Two principal divisions, hard and soft cataract. There is a peculiar form called *morgagnian*, and is a hard nucleus or a fluid cortex, or a cataractous lens floating in a fluid medium. Traumatic cataract is a soft cataract following trauma. The detection of cataract is by oblique illumination. The extraction of the cataract will not improve vision, and as its appear-

ance is not marked, operative interference is not imperative. The horse would be a shy after removal, as the rays of light would *not be focused* on the retina. *Reclination* or depression of the lens into the vitreous has been done, but it is dangerous, the lens being apt to set up hyalitis, etc.

Ectopia Lentis or dislocation of the lens, is generally the result of injury. May be spontaneous and has been congenital, from weakening of the zonule of Zinn. It may also be complete or partial.

CHAPTER XIV.

THE OPTIC NERVE.

The Optic Nerve.—Of this we will have but little to say. The anatomy of the nerve is so well laid down in Chauveau and the various works on anatomy that I will proceed at once to an affection called *Amaurosis* (*Amblyopia*). Palsy of the nerve. The term amblyopia is used when there is some impairment of vision for which we can ascribe no cause. Vision is often thus defective where the eye has long been disused—amblyopia from disuse or *ex anopsia*. In anæmia subsequent to severe illness or hemorrhages, *anæmic* amblyopia. In lead poisoning. From exposure to prolonged glare, as in snow-blindness. From irritation of the fifth pair, as in neuralgia; overdosing with quinine. Also tumors and other diseases of the brain implicating the roots of the optic nerve. Injury to the nerve between the brain and eye. Retinitis. Undue pressure upon the retina from dropsical or inflammatory effusion. Also occurs from overloaded stomach, even from pressure of the gravid uterus.

Symptoms.—The pupils are dilated widely and do not react to light. A feint to strike does not cause the

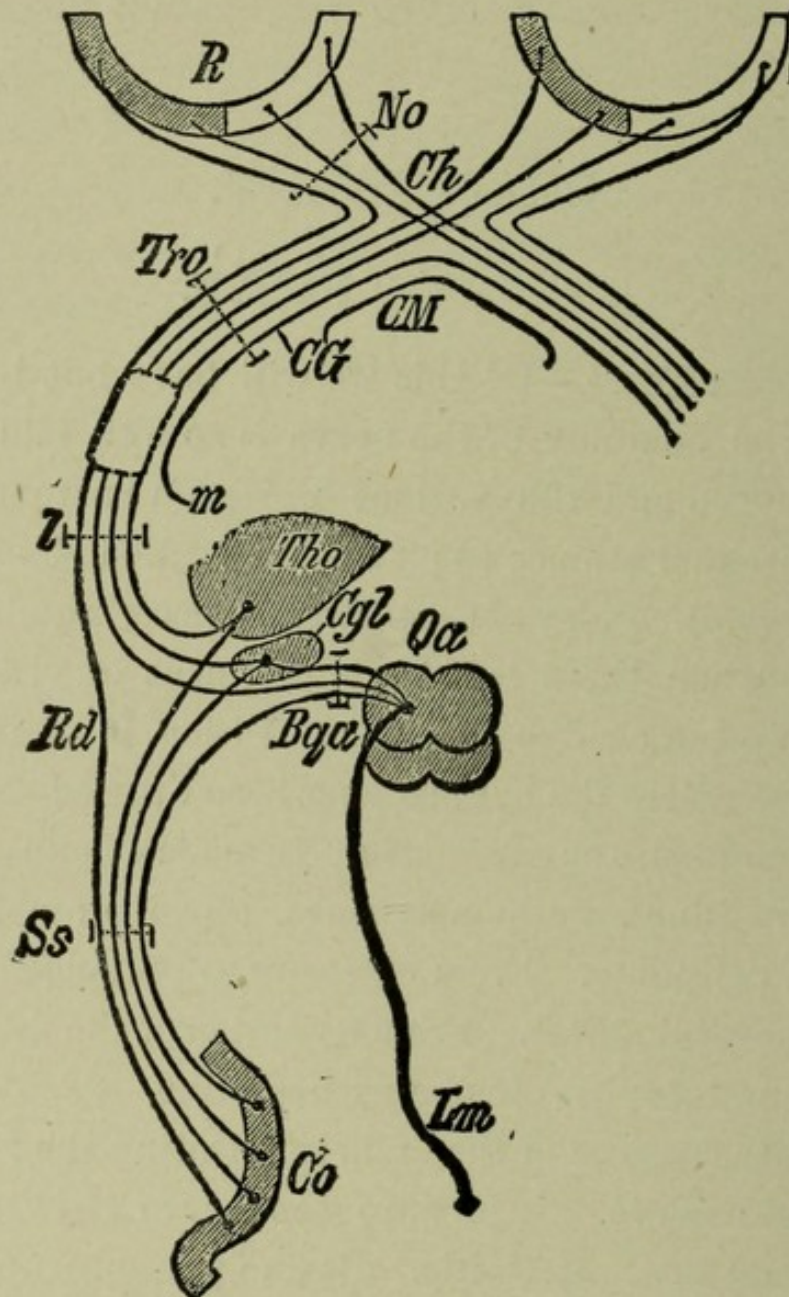


Fig. 63.

Scheme of the Central Visual Apparatus.—R, Retina, shaded where it is innervated by the left, clear where innervated by the right hemisphere : No, Optic Nerve ; Ch, chiasma ; Tro, Tractus Opticus ; CM, Meinerts commissure ; CG, Gudden's commissure, b, lateral tract root ; m, median tract root ; Tho, thalamus opticus ; Cgl, corpus geniculatum laterale ; Qa, notes ; Bqa, brachia anterior ; Rd, direct cortical tract root ; Ss, sagittal medullary layer of occipital lobe ; Co, cortex (chiefly of the cuneus) ; Lm, median tract.—(Schleife).

horse to swerve. And here a word. In making these feints, be sure you do not cause a current of air to strike the animal which would cause him to start and so possibly deceive. The ears are held erect and move quickly on appreciating any sound. He will also step high.

TREATMENT is useful only when the disease is symptomatic of some removable cause. Should the condition persist after the subsidence of the supposed cause, try blister, (post auricular,) and give 3 ss doses of nux vomica daily.

Atrophy of the Optic Nerve. This may be the occasion of the condition above described and (fig 64) is to be watched for, especially on passing horses. So it is imperative to know and handle the ophthalmoscope intelligently. The *general* symptoms are as described under Amaurosis. The *ophthalmoscopic* symptoms are here the interesting ones. The disk is almost always white—decidedly so—but may be grayish, and the lamina cribrosa may be distinguished. The blood supply is lessened, with consequent paleness, and the *larger vessels* will be lessened in caliber. Thus is it very evident that the student *must know the appearance* of a normal fundus. (See colored plate.) Colored crayons and a blackboard will not convey the required picture, be they ever so happily depicted.

The disk will be sharply outlined, and often this outline will be pigmented. If this atrophic condition

succeeds an inflammatory attack, the outlines will be ragged and ill-defined. The duration of a case of atrophy is tedious, very, months and years being

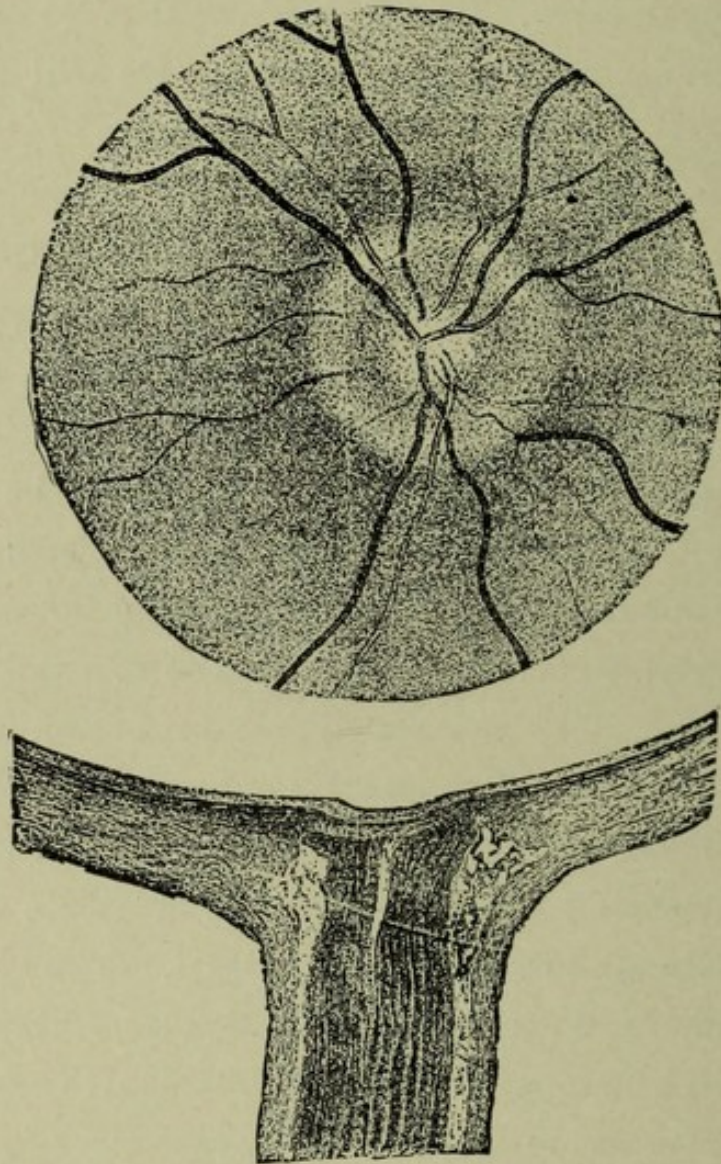


Fig. 64.

usual time of duration of a case. Occurs at all ages and may be congenital. Prognosis is unfavorable.

TREATMENT.—Little or none. Strychnia may be used, hypodermically, about the temple.

CHAPTER XV.

GLAUCOMA.

Glaucoma.—Norton defines glaucoma as “an excess of pressure within the eye, plus the causes of and consequences of that excess.” That place where the tissue of the iris, the cellular stroma of the ciliary body and the posterior and external portions of the cornea and sclera intersect, is known as the iritic angle (see fig. 53). This juncture combines to make a tissue of a fenestrated nature. These fenestra or openings are the Fontana spaces. The meshes of this tissue (just imagine a coarsely meshed fisher’s net) merge into Descemet’s membrane and form the *ligamentum pectinatum* iridis. In the sclerotic is formed, by the same means, the canal of Schlemm (see fig. 42), and all of these spaces, etc., are connecting and are of the lymphatics. The canal of Schlemm communicates with the sclerotic veins, and thus the connection between the anterior chamber and the circulation is established. Blood is never found in these spaces physiologically. The zonule of Zinn, which you remember extends from the ciliary processes (posterior surface) to the

lens, is a readily transfusible membrane. The pressure in the aqueous and vitreous are equal, and this equilibrium must be maintained to have a *normal* eye. The slightest excess will destroy its function in corresponding degree. This equilibrium is rendered stable by due secretion and excretion of the fluids. The intra-ocular fluids flow from the blood stream.

The ciliary body supplies the fluid to the vitreous, aqueous and lens. Most of the secretion passes directly to the aqueous by means of the pupil and filtration angle. A very much smaller portion passes backward and out through the papilla. The most important change which takes place in glaucoma will be found at the iritic angle, affecting the vessels composing or entering into Schlemm's canal. These are inflammatory, and the iris becomes adherent to the cornea and *closes up* Fontana spaces partially or wholly, thus hindering the *excretion* of the fluids, and so augments the condition. The fibers of the optic nerve become inflamed, and atrophy, in the later stages. There may be fluidity and detachment of the vitreous and cataract of the lens.

Symptoms.—Take the tension, gently palpating with finger tips, using both hands, and it may be any thing, *i. e.*, + or —. Palpate through the sclera back of the cornea. Cases will be met with where the tension will be stony in its degree of hardness. Haziness of the cornea is usually present, and

the cornea will also present anæsthesia. Dilation and inactivity of the pupil is a constant symptom.

The word glaucoma means green, and so we do get a greenish reflex in glaucomatous eyes. The pain may be slight or severe, and may have general symptoms of fever, etc. Swelling of the lids, chemosis and protrusion (exophthalmus) are all due to infiltration from pressure. Glaucoma comes in relays, *i. e.*, have a prodromal stage of a variable duration, weeks, months; and then a *sudden* attack, lasting from a few hours to days, and then the eye returns to normal or *nearly so*. These attacks return, and the intervals become *shorter* and *shorter*, and finally, chronic or absolute glaucoma. Some cases go right from an acute to absolute with no rebatement of symptoms. Glaucoma tends to absolute blindness. Any condition causing vascular turgescence may cause gout, rheumatism, fever. The use of atropine *has* caused it. Prognosis is always bad. I had the pleasure last year of showing the class a case of *Glaucoma secundarium* in one of the clinics. One of the patients from the Broadway car stables was pointed out to me as having an interesting eye, and so it was. *Secundarium* means increased intra-ocular tension, consequent to some other disease. This case presented total occlusion of the pupil, the pupil being fast completely around to the lens capsule. (See Fig. 47.) The eye was *buphthalmic* and *hydrophthalmic*. The whole globe was enlarged, and the cornea especially was

distended, resembling, indeed, a soap-bubble. The lens might have been of ground glass for all its transparency. Nothing could be done.

I have said Atropine *has* caused. Since then, investigations have led to the use of Scopolamine Hydrobromate, which we have reason to believe does *not* increase intraocular tension. Therefore, use in place of Atropine (in strength 1 to 200) wherever have cause to suspect *any increase* in tension. Another point. In making up collyria, use Trikresol 1 to the 1000 (in place of distilled water only as this will not decompose and is harmless to the eyes).

TREATMENT.—The only medicinal remedy is Eserine Sulph. $\frac{1}{2}\%$ every couple of hours, and must be used early. In veterinary practice the opportunity to use it does not occur, as the condition is well advanced by the time it is diagnosed. The eserine, you know, will contract the pupil and thus tend to freeing the iritic angle. Also constricts the vascular system, diminishing secretion.

Don't use atropine. *Iridectomy*, introduced in '57 by Von Græfe, is *the* operation for glaucoma. The incision should be in the sclera, and allow the aqueous to drain away *gradually*, and be *sure* that no remnants of the iris remain in the wound. The eye is not exempt from parasites, and we meet with *Acari* (mites), and nothing need be further said, as you all know of them and have suffered from their getting in the eye.

Filaria lachrymalis.—A white worm, about an inch in length, found in the lachrymal duct and under side of the eyelid and membrana nictatans. Their presence sets up a conjunctivitis spoken of as a *verminous* conjunctivitis. Remove and treat. *Filaria papillosa.* A silvery delicate worm, about two inches long. Seen in the aqueous and is very active. This was Barnum's famous "Snake in the Eye." Sets up inflammation and has to be removed. Best to make incision in upper half of cornea near the scleral border. Then treat the inflammation. The *Echinococcus*, the larval state of the tape-worm of the dog has been found in the eye.

Cysticercus has its origin between the choroid and the retina, and causes detachment of the latter, finally perforates it and enters the vitreous, and entering the vitreous, sets up an irido-cyclitis and goes on to destruction of the eye.

Pentastoma Tænioides has been found by Stitten in the horse's eye, but this case stands alone.

CHAPTER XVII.

ENEUCLEATION.

Eneucleation. — Instruments necessary will be curved blunt-pointed scissors, speculum, fixation forceps and a strabismus hook. The administration of chloral hydrate in full doses, and also cocaine 4 per cent., is necessary to this operation. Separate at the corneal margin the conjunctiva from the globe, going *completely around*, of course. Then divide the attachment of the superior straight, *after* catching it on the strabismus hook. Have an assistant hold the wound open with this hook, while you take another and insert it under the insertion of the internal straight, and so proceed with the balance of the muscles. Some divide the obliques previous to the optic nerve, and others, the reverse—protruding the eye by pressure—dividing the obliques and then the nerve. Do whichever method comes the more natural to you, and as the exigencies of the case present. With the scissors *closed*, push, probe and separate your way back, until the nerve is reached on the inner side, and, with one cut, divide the nerve. Will have an immediate flow of blood, which is easily controlled by pressure. This operation is followed, as

may be easily imagined, by considerable reaction, sometimes fatal. There is a method ascribed to Liebold which is followed by less reaction and is called *Exen-*

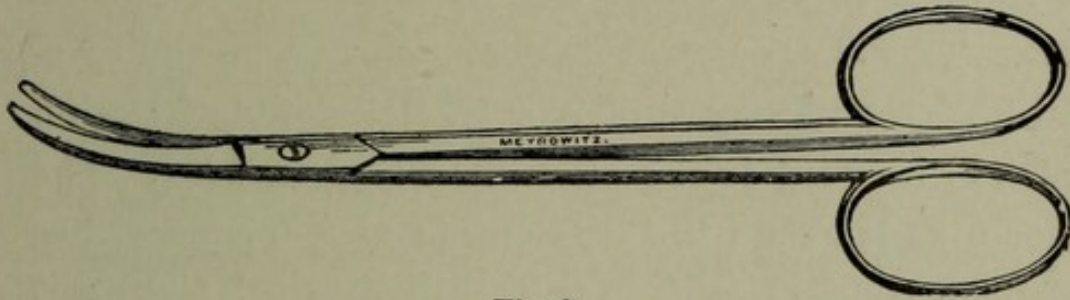


Fig. 65.




Fig. 66.

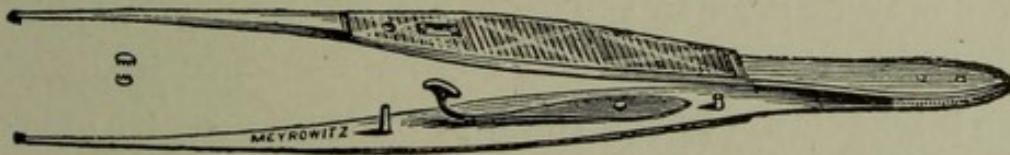


Fig. 67.

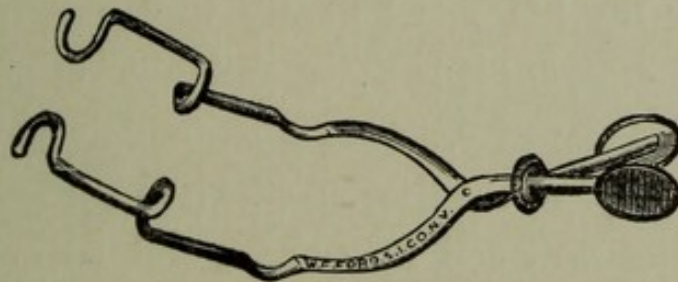


Fig. 68.

teration, and consists in opening the eye by excising the cornea at its limbus and removing the entire contents. When these cases have been fatal, has been by

meningitis mostly. Still, with asepsis and antisepsis closely observed, there need be no hesitation in performing this operation.

A word or two anent the *Ophthalmoscope* and its use. This instrument was the result of long and careful investigation by Professor H. Helmholtz of Berlin. Was introduced to the scientific world in 1851. The scope, as it exists to-day, consists of a mirror, either plane or concave, with a perforation called the sight hole. Also generally there is an object lens. The mirror is *the* essential. Usually we use a lamp for light, and have it held behind and to one side of the eye we wish to examine. The examiner should keep both eyes open, for the same reason that a sailor will keep both open when using the telescope, and whatever may be seen by the other eye must be disregarded. The first thing noticed will be a *red* reflex, where before the introduction of the beam of light all seemed black. Having succeeded this much, the student will try and make up his mind finally that this particular eye has no disc, *but* it is there, and that is the objective point. Find the disc. Just when one decides to "let go" and postpone the search, like a moon in a brilliant sky, the disc will sail into sight, and as quickly sail *out* of view. However, we have demonstrated to our own satisfaction that it is there, and that gives one the needed stimulus to go on and patiently endure disappointment after disappointment, until, as always, success crowns

our efforts and we are astonished and pleased with our ability to locate the disc and study its condition at will. We cannot tell our patients to look upward, down-

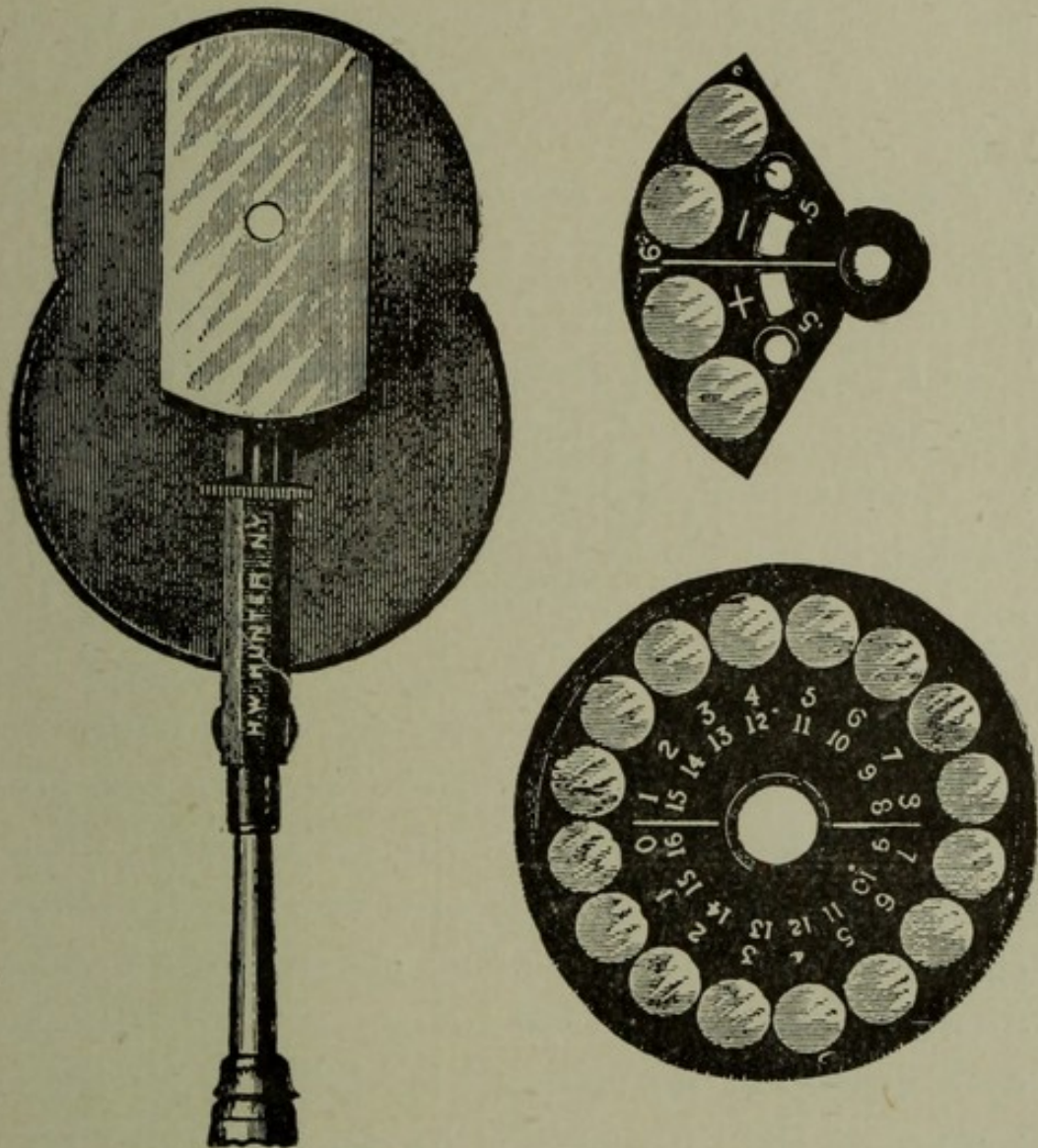


Fig. 69.

ward, to the right, to the left, and thus bring into the field each and all portions of the fundus. Therefore we do the see-sawing, and, having gotten the focus,

slide your head, (and with it your eye) *with the scope in position*, to the right and left, upward and downward. There are two methods of examining the fundus—direct and indirect. In the direct method, the *image* (that which we see and appreciate, at the bottom or fundus of the eye, is the image), will be erect, *i. e.*, it will have suffered no inversion, as is the case when the *indirect* method is employed, for there we interpose a biconvex lens between the eye examined and our own, thus *inverting* the image. This I demonstrated early in the session upon the blackboard diagrammatically. Now, if you, for experiment, will take a piece of card-board and drive a pencil through it, you will find on looking through the resulting hole that the nearer your *own* eye you bring the card the larger will be the field of vision. Yes? So with the eye of the subject, for the pupil represents the hole in the cardboard. But there is a bar here which can be overcome only by experienced pilots. The observer must put his own eye in a condition equivalent to his looking at an object in the distance—twenty feet—*i. e.*, *his* eye, to see the fundus (the accommodation of the observed eye being suspended, at rest) must be in a condition to receive parallel rays. Fortunately, the horse under examination being in a semi-darkened room, relaxes his accommodation, and thus one factor is overcome. This is to be accomplished only by *practice*, and like all good things is

gained only by patient application. The observer's eye must be normal, *i.e.*, neither hyperopic, myopic or astigmatic, and if such conditions do exist they must be corrected by a proper glass. The *indirect method*, (*the inverted image*.) To use this, the examiner holds in front of the observed eye a biconvex lens of $2\frac{1}{2}$ or $3\frac{1}{2}$ inch focus, and does not bring the scope *nearer* than one foot, and he may draw gradually back until the proper view is obtained, the top of the scope

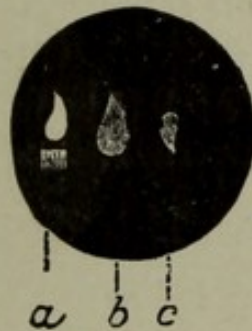

Fig. 71.

touching the eyebrow. This biconvex lens condenses the light which the mirror throws to the eye, and of necessity (light returning in the same direction in which it came) passes through the lens, becoming *inverted* and forming an image *between* the *lens* and *mirror*, in the air, and is thus an aerial image. An important aid to diagnosis is the $2\frac{1}{2}$ inch lens which accompanies the ophthalmoscope, and which we use in the indirect method, and also for oblique illumination. In olden times, before oblique illumination, the catoptric test was used to detect cataract, etc., in the lens, but where it was most desir-

able, *i.e.*, in the very obscure and slight cases, it was of little use. It is still useful in determining the presence or absence of the lens, and depends upon the fact that the surfaces of the cornea and lens reflect images and consists of the following manœuvres: Hold a candle, lighted, before an eye in a darkened room, and you will observe three distinct images—the anterior, bright, erect and distinct from the *anterior* surface of the *cornea*; an intermediate, slight, smaller, inverted, and fairly distinct from the *lens' posterior* capsule, which is concave; and a posterior, indistinct and erect from the surface of the *lens' anterior* capsule. To return to oblique illumination, and this is of extreme applicability. While being very easy, the veriest novice having it at his command, it is decidedly thorough, one being enabled by its mediation to discern the slightest opacities and striæ of incipient cataract, etc. For this test, need but a 2½ inch lens and a candle flame. To be thorough, the use of cocaine, atropine, or scopolamine is necessary. Have the candle placed on one side of the head and concentrate its rays by means of the lens so as to focus upon the eye, and then the cornea, the pupil, the iris and the lens may be very thoroughly studied. For the examination of the anterior parts and chamber, the lens is sufficient, but there *it ends* and the ophthalmoscope comes into play. If we take a small box and punch a hole in the top, through which we send a pencil of light by means

of our $2\frac{1}{2}$ inch lens, we illuminate the interior, and can study its every part. Well, then, why not the same with the eye? The eyeball is not a box simply. It contains a lens, *and that* is why. If you throw a pencil of light into the eye it will be brought to a focus by the lens. That is not the case in a simple box. The light has to come back again and emerge from the eye. So if the lens (biconvex) brings the entering rays to a focus, it does the same for those emerging. (See figs. 6 and 7.) But the entering rays were parallel and brought to a focus through the mediation of the lens, whereas the emerging rays, coming from a focus, were rendered parallel. Let us go a little further. Suppose divergent rays be the case, as they will pass to the lens and on *returning* will be converged and made to meet at a focus in front of the lens. As the rays primarily were *not* parallel, but divergent, the focus at which they meet after passing through the lens will not be at the same distance, as you see. They will be further than the focus for parallel rays. If one of the foci be brought nearer the lens the other will be further off and are called conjugate foci. Now, please notice that although conjugate they maintain a certain distance between each other, for as you approach one foci the other recedes. So, all rays emanating from the eye take a direction toward the conjugate focus, and if one attempts using this ray to see the fundus he must necessarily bring

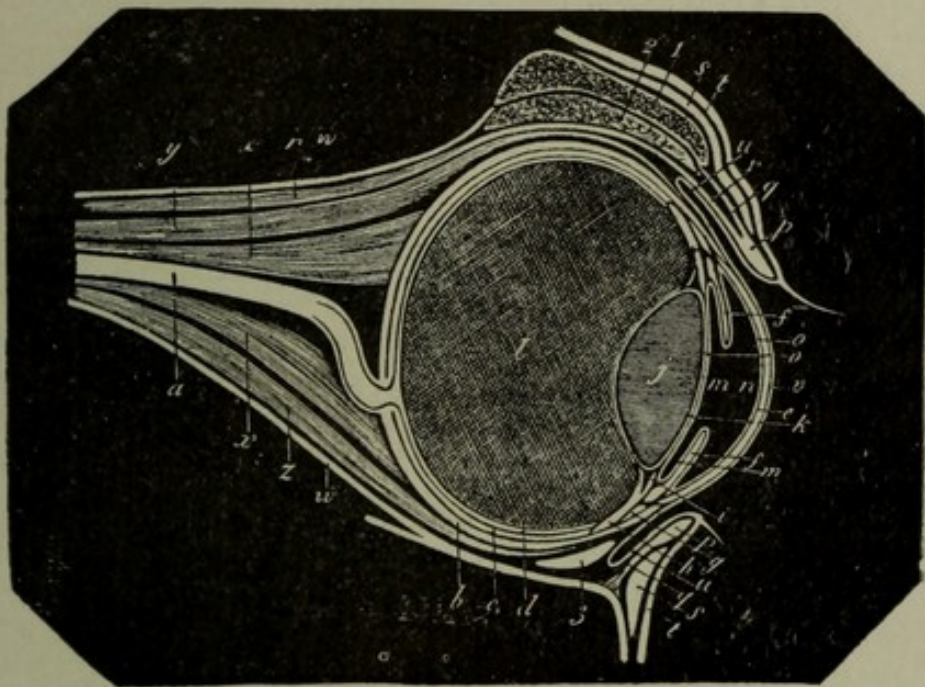
his eye into *their* line. Then what happens? The line occupied by these rays is the same that was taken by the *entering* rays, and if no rays enter the eye, none will emerge. And when you try to intercept the rays coming *from* the eye so as to make use of them in viewing the fundus, you get in the path of the lines of light which *enter* and of course your head intercepts them. Consequently, having cut off the source of light, the result is darkness. For example, a candle a couple of feet from the eyes will give divergent rays, which will enter the eye, be refracted and focus on the retina, forming an image of the candle-flame. The rays will undergo reflection, and being reflected back through the lens, will be again refracted, and you will find at the candle-flame an image of the fundus, and *at* the candle-flame is one of the conjugate foci. Of course, if you interpose your head between the eye and the candle, the rays emanating from the candle will be cut off and, in place of the observed eye being illuminated it will be in a shadow of your own head. If you try to look from the other side of the flame, *i. e.*, having the flame between you and the patient's eye, you will be dazzled by the flame, as it radiates light in all directions though in straight lines. And there the matter stood until, in 1851, Helmholtz, after careful study evolved the Ophthalmoscope. What was wanted was a something which would allow an observer to bring his head into *his own light*. This the mirror, which is a


part of the ophthalmoscope, does, being a mirror pierced by a hole for observation. An ophthalmoscope consists principally of two parts—a mirror and a lens, and the mirror is the essential part, everything else being accessory.

“ Find out the cause of this effect,
Or rather say the cause of this defect,
For this effect defective comes by cause.”

Hamlet.


FINIS.







BIBLIOGRAPHY.

- Ophthalmic and Otic Memoranda..... ROOSA.
Encyclop. Brit. Article Optics.
Physiology of Domestic Animals.....SMITH.
Ocular Therapeutics.....DE WEAVER.
Diseases of the Eye.....NOYES.
Physics.....STEELE.
Ophthalmic Diseases and Therapeutics...NORTON.
Comparative Anatomy of the Domestic
animals.....CHAUVEAU.
Popular Scientific Lectures.....HELMHOLTZ.
Six Lectures on Light.....TYNDALL.
Journal of Ophthalmology, Otology and
Laryngology, N. Y.
Vade mecum of Equine Anatomy.....LIAUTARD.
Diseases of the horse, B. A. I., 1890.....LAW.
Pathology and Treatment of Glaucoma...SMITH.
Lectures on the Human Eye.....ALT.
Diseases of the Eye.....BERRY.
Diseases of the Eye.....NETTLESHIP.
American Journal of Ophthalmology.....ST. LOUIS.







INDEX OF ILLUSTRATIONS.

	PAGE.
Action of ocular muscles.....	47
Apparatus, lachrymal.....	38
Agnew's canaliculus knife.....	41
Anterior staphyloma	69, 77
Abscess, corneal.. ..	72
Accommodation.....	82
Angle of incidence.....	8, 9
Angle of reflection.....	8, 9
Anterior portion and ciliary region.....	13, 82
Angular keratome.....	90
Artery, persistent hyaloid.....	112
Body, ciliary.....	82, 94
Lowman's probes.....	43
Corneal cells.....	66
Corneal abscess.....	72
Clamp forceps.....	37
Canals, hygrophthalmic.....	38
Canaliculi.....	38
Canaliculus knife, Agnew's.....	41
Ciliary body.....	82, 94
Cornea	82
Canal, Schlemm's	82
Circular fibers of ciliary muscle.....	82
Ciliary muscle, circular fibers of.....	82
Crystalline lens.. ..	82, 115

	PAGE.
Cells, corneal	66
Cells, pigment, of iris	85
Corpus, ciliare	94
Ciliary processes	94
Ciliary muscle	95
Cornea	95
Colored plate	Frontispiece
Choroid	104
Ciliary region	13, 82
Cell, pigment, of retina	14
Cavity, orbital	19
Cartilages, tarsal	27
Coat, choroid	104
Cells, ganglion	109
Central visual apparatus	118
Catoptric test	131
Candle test	131
Decomposition of light	12
Dilator pupillae	86
Duct, nasal	38
Disc	120
Eye, third month	114
External molecular layer of retina	109
Eye of calf at third month	114
Embryological eye	114
Enucleation scissors	127
Eyelid, sagittal section of upper	25
Eye, muscles of	46
Eye, general scheme of (tailpiece)	80
Formation of image	4
Foci of rays	10, 11
Fontana's spaces	82

INDEX OF ILLUSTRATIONS.

139

	PAGE.
Fibers, meridional, of ciliary muscle.....	82
Fibers, radiating, of ciliary muscle.....	82
Forceps, fixation.....	75, 90, 127
Fontana's spaces.....	95
Forceps, iris.....	90
Fibers, circular, of ciliary muscle.....	82
Fibers of Muller.....	109
Fixation forceps.....	75, 90, 127
Fixation speculum.....	127
Forceps, trachoma.....	59
Forceps, clamp.....	37
Gland, lachrymal.....	38
General scheme of the eye.....	80
Ganglion cells.....	109
Hyaloid artery, persistans.....	112
Hook, strabismus.....	127
Hypopyon.....	72
Hygrophthalmic canals or lachrymal ducts.....	38
Image, inverted.....	17
Iris.....	82, 95
Iris, pigment cells of.....	85
Iritis.....	87
Iris forceps.....	90
Iris scissors.....	91, 92
Iridectomy.....	91
Insertion of zonule of Zinn.....	97
Inverted image.....	17
Internal molecular layer of retina.....	109
Internal granular layer of retina.....	109
Jaeger's keratome.....	90
Jones-Wharton, operation of.....	35
Knife, Agnew's canaliculus.....	41

	PAGE.
Knife, Stilling's.....	43
Keratitis, phlyctenular.....	71
Knife, Saemische's	75
Keratome	90
Lachrymal ducts or hygrophthalmic canals.....	38
Lid, saggital section of upper.....	25
Ligament, pectinated.....	82
Layers of retina.....	106
Layer of optic nerve fibers.....	109
Layer of rods and cones.....	109
Lens, crystalline... ..	82, 115
Loring's ophthalmoscope.....	129
Lid, vertical section of upper.....	34
Lachrymal apparatus.....	38
Lachrymal gland.....	38
Lachrymal sac.....	38
Muscles of eye	46
Muscles, scheme of action of ocular.....	47
Muller, fibers of.....	109
Muscle of accommodation.....	82
Meridional fibers of ciliary muscle.....	82
Muscle, ciliary.....	95
Nerve, optic	118
Normal fundus of eye.....	Frontispiece
Normal retina, section of.....	109
Nasal duct.....	38
Ocular muscles, scheme of action.....	47
Onyx	72
Operation, Wharton-Jones.....	35
Optic nerve fibers, layer of.....	109
Outer granular layer of retina.....	109
Optic nerve.....	118

INDEX OF ILLUSTRATIONS.

141


	PAGE.
Optic disc	120
Ophthalmoscope.....	129
Ora serrata.....	82
Occlusion of pupil.....	89
Orbital cavity.....	19
Operation for ptosis.....	32
Pencil of rays of light....	9
Prismatic spectrum.....	12
Pigment cell of retina	14
Ptosis, operation for.....	32
Pectinated ligament.....	82
Pigment cells of iris.....	85
Pupil, sphincter of.....	86
Posterior synechia.....	89
Pupil, occlusion of.....	89
Pupil, dilator of.....	86
Processes, ciliary	94
Pigment, epithelial of retina	109
Persistent hyaloid artery	112
Pterygium	62
Phlyctenular keratitis	71
Puncta.....	38
Probes, Bowman's.....	43
Retina, reticular layer of.....	109
Retina	106
Retina, section of normal.....	109
Reticular layer of retina.....	109
Ring, tendinous, of ciliary muscle.....	82
Retina, internal molecular layer.....	109
Radiating fibers of ciliary muscle.....	82
Retina, inner granular layer	109
Refracted ray of light.....	7, 9

	PAGE.
Retina, external molecular layer.....	109
Region, ciliary.....	13, 82
Retina, pigment cell of.....	14
Retina, outer granular layer.....	109
Rods and cone layer.....	109
Retinal layer of epithelial pigment.....	109
Scheme of the central visual apparatus.....	118
Scissors, Enuclation.....	127
Schlemm's canal.....	82
Section, sagittal, of upper lid.....	25
Space, Fontana's.....	82, 95
Strabismus hook.....	127
Section of normal retina.....	109
Synechia.....	87
Speculum, fixation.....	127
Serrata, ora.....	82
Sphincter pupillae.....	86
Synechia, posterior.....	89
Scissors, iris.....	90
Spaces, Fontana's.....	82, 95
Scheme of accommodation.....	6
Seven primary colors.....	12
Spectrum, prismatic.....	12
Sagittal section of upper lid.....	25
Section, vertical of upper lid.....	34
Symblepharon.....	36
Sac, lachrymal.....	38
Stilling's knife.....	43
Scheme of action of ocular muscles.....	47
Staphyloma, anterior.....	69, 77
Spring speculum.....	75
Saemische's knife.....	75

INDEX OF ILLUSTRATIONS.

143

	PAGE.
Speculum, spring	75
Scheme, general of the eye.....	80
Tarsi.....	38
Trachoma forceps.....	59
Tendinous ring of ciliary muscle.....	82
Tarsi.....	27
Third month, eye at.....	114
Test, catoptric.....	131
Tailpiece.....	136
Test, candle.....	131
Upper lid, saggital section of.....	25
Upper lid, vertical section of.....	34
Venae vorticosae.....	104
Vitreous.....	109
Vertical section, upper lid.....	34
Wharton-Jones operation.....	35
Zonule of Zinn.....	82, 97



INDEX.

	PAGE.
Annulus albidus.....	96
Accommodation.....	7, 14, 97
Arteria centralis retinae.....	79, 110
“ hyaloid.....	112
Acari.....	124
Angle, iritic.....	121
Abrus precatorius.....	58
Abscess of cornea.....	72
Anteria synechia.....	73
“ capsular cataract.....	73
Annular staphyloma of Sclera.....	83
Agnew.....	41
Abscess of lids.....	30
Anchyloblepharon.....	36
Axis, optic.....	16
Artery, Ophthalmic.....	21
Angle of reflection.....	8
“ “ incidence.....	8
Axis, Chief.....	10
Aberration, spherical.....	11
Aqueduct of Sylvius.....	15
Amaurosis.....	117
Amblyopia.....	117
Atrophy of optic nerve.....	119
Blindness, snow.....	117
Bibliography.....	137

	PAGE.
Body, ciliary.....	94
Blindness, moon.....	99
Cupthalmus.....	83
Blenorrhœa.....	54
Bean, Jequirity.....	58
Bowman's membrane.....	65
Burns of cornea.....	68
Blepharitis, acute.....	30
" ciliaris.....	31
" marginalis.....	31
Blepharospasmus.....	33
Blepharophimosis.....	33
Burns of lids.....	37
Bulbus.....	15, 16
Baptista Porta.....	6
Binocular vision.....	7
Color.....	17
Cavity, orbital.....	19
Chauveau.....	19, 96, 113
Capsule, Tenon's.....	21
Cellulitis, orbital.....	22
Canaliculi.....	24, 39
Ciliary muscle of Riolini.....	24
Conjunctiva.....	26, 50
Conjunctival fornix.....	27, 50
Cilia.....	27
Chalazion.....	36
Contusions.....	37
Canals, hygrophthalmic.....	38
Canal of Petit.....	96, 112, 113
Conjunctivitis catarrhalis.....	51
" purulenta.....	54

INDEX.

147

	PAGE.
Contagious ophthalmia.....	54
Canal of Cloquet.....	112
Crede's method.....	56
Cloquet, canal of.....	112
Conjunctivitis diptheretica.....	56
" trachomatosa.....	57
Crystalline lens.....	113
Conjunctivitis phlyctenulosa.....	60
Cataract.....	115
Conjunctival tumors.....	63
Cancer.....	64
Cornea.....	65
Corneal injuries.....	67
Canal of Schlemm.....	121
Corneal wounds.....	67
" burns.....	68
" abrasions.....	68
" epithelium.....	68
Conjunctivitis verminosa.....	125
Cornea, inflammation of.....	68
" staphyloma of..	69
Cysticercus.....	125
Corneal abscess.....	72
" ulcer.....	72
Catoptric test.....	131
Cataract, anterior capsular.....	73
Conjugate foci.....	133
Cicatricial staphyloma.....	78
Corpora nigra.....	85
Ciliary nerves, short.....	85
Circulus iridis major.....	86
" " minor.....	86

	PAGE.
Ciliary body.....	94
Canal of Fontana.....	96
Ciliary canal.. ..	96
Corpus ciliare.....	96
Camera obscura.....	5
Chief Axis.....	10
Center, optical.....	10
Colors, primary	12
Cyclitis.....	98
Choroid.....	105
Canthi	24
Distance focal.....	10
Dilator pupillae.....	14, 85
Duration of luminous impressions.....	16
Degree " " "	16
Duret—stricture of lachrymal.....	42, 43
Dacryocystitis catarrhalis.....	42
" phlegmonosa.....	44
Diffuse keratitis.....	71
Differential diagnosis between—	
Conjunctivitis.....	}
Scleritis.....	
Iritis.....	
Distichiasis	33
Diphtheritic conjunctivitis.....	56
Duct—nasal.....	39
Dacryoadenitis.....	39
De Wecker.....	58, 81
Dislocation lachrymal gland.....	40
Differential diagnosis between—	
Conjunctivitis catarrhalis....	}
Iritis.....	
Trachoma.....	
Conjunctivitis folliculosis....	

INDEX.

149

	PAGE.
Dermoid tumor.....	64
Decemet's membrane.....	66
Equator.....	16
Ether waves.....	18
Eyelids.....	20, 24
Exophthalmus.....	22, 123
Enucleation.....	23, 99, 125
Eyelashes.....	27
Ectropium.....	31, 34
Epilation.....	31
Ectopia lentis.....	116
Entropium.....	33
Excretory apparatus.....	41
Epiphora.....	41, 42
Echinococcus.....	125
External rectus muscle ..	47
Exenteration.....	127
Episcleritis.....	81
Fontana's spaces.....	121
Fornix.....	50, 27
Filaria lachrymalia.....	125
" papillosa.....	125
Fistula lachrymaria ..	45
Fontana, canal of.....	96
Focal distance.....	10
Field of projection.....	12
Fovea centralis.....	110
Fossa, temporal.....	20
" patellaris.....	112
Foramen, optic.....	21
Glands of Moll.....	27
Glands, meibomian.....	28

	PAGE.
Gland of Harder.....	30
Gland, lachrymal.....	20, 38
Great oblique muscle.....	48
Gonorrhoeal conjunctivitis.....	55
“ ophthalmia.....	55
Granular lids.....	57
“ conjunctivitis.....	57
Glaucoma.....	121
Humor, vitreous.....	112
Hyaloid membrane.....	112
Haw.....	20, 28
Hyaloid artery.....	112
Hiatus, orbital.....	20
Helmholtz.....	128
Harder's gland.....	30
Hordeolum.....	32
Hygrophthalmic canals.....	38
Hypertrophy of lachrymal gland.....	40
Hypopyon.....	72
Hernia of cornea.....	73
Introduction.....	5
Image, inverted.....	5, 15, 17
Interstitial keratitis.....	71
Incidence, angle of.....	8
Iris.....	11, 84, 86
“ sphincter muscle of.....	14
Impressions, luminous.....	16
Image, position of.....	17
Inverted image.....	5, 15, 17
Injuries of sclera.....	83
“ “ cornea.....	87
Inflammation of cornea.....	68

INDEX.

151

	PAGE.
Inferior rectus muscle.....	46
Internal " "	47
Inferior oblique "	48
Iritic angle.....	121
Iridectomy.....	91, 124
Irido-cyclitis.....	99, 125
Iris, tumors of.....	90
Iridavulsion.....	91
Irido, choroiditis ..	99
Internal ophthalmia	110
Jequirity bean.....	58
" infusion.....	77
Keratitis.....	68
" vasculosa.....	70
" phlyctenulosa.	70
" interstitialis	71
" diffusa.....	71
" parenchymatosa.....	71
" suppurativa.....	71
Keratocele	73
Lamina cribrosa.....	79
Lids, Abscess of.....	30
Ligamentum pectinatum	84
Lachrymal gland	20, 38
" " dislocation of	40
" sac.....	39
" gland, hypertrophy of..	40
" duct.....	42, 43
" fistula.....	45
Luminous impressions.....	16
Lids, granular.....	57
Levator palpebrae superioris muscle.....	24, 26

	PAGE.
Light.....	8, 11, 18
Lens.....	113
Ligamentum pectinatum iridis.....	96, 121
Liebold.....	127
Lenticula fossa.....	112
Leucoma.....	77
“ adherans.....	77
Muscle—Ciliary, of Riolini.....	24
Posterior rectus.....	46
Retractor oculi.....	46
Superior rectus.....	46
Inferior “.....	46
Internal “.....	47
External “.....	47
Superior oblique.....	48
Inferior “.....	48
Temporal muscle.....	20
Obicularis.....	24
Levator palpebrae superioris.....	24, 26
Muscle of accommodation..	97
Meibomian follicles.....	50
Moll, glands of.....	27
Meibomian glands.....	28
Membrane nictatans.....	20, 28
Method, Crede's.....	56
Membrane, Bowman's.....	65
“ Decemet's.....	66
“ Hyaloid.....	112
“ Ocular.....	20
Meridians.....	16
Mites.....	124
Motor-oculi nerves.....	14

INDEX.

153

	PAGE.
Macula lutea.....	15, 73, 110
Membrana pupillaris persistans.....	90
Moon blindness.....	99
Nubecula.....	73
Nebula... ..	73, 77
Nictatans, Membrana.....	20
Nerve, optic.....	79, 117
" oculo-motor.	48
Nerves, short ciliary.....	85
" fifth pair.....	98
Nictitation.....	33
Nasal duct.....	39
Oblique illumination..	132
Optic nerve.....	21, 79, 117
" " atrophy of.....	119
" axis.....	16, 17
" foramen.....	21
Optical center.....	16
Orbits.....	7
Orbital cavity.	19
Ocular sheath.....	20
" membrane.....	20
Orbital hiatus.	20
Ophthalmic artery	21
Orbital cellulitis	22
" periostitis.....	23
" tumors.....	23
Ophthalmoscope.....	128
Orbicularis muscle	24
Ora serrata.....	94, 107
Ophthalmia, sympathetic.....	99, 103
" tarsi.....	31

	PAGE.
Ophthalmia, periodic.....	99
Operation, Wharton Jones	35
Ophthalmia, internal	110
Oculo-motor nerve.....	48
Onyx	72
Operation, Saemisches.....	74
Ophthalmia contagiosa	54
" catarrhalis	51
" gonorrhoeal	55
" neonatorum.....	55
Phlyctenular conjunctivitis.....	60
" keratitis	70
Punctum lachrymalia.	24
Parenchymatous keratitis	71
Phtheriasis.....	31
Paracentesis.....	74, 75
Ptosis.....	33
Pannus	76
Puncta.....	39
Porous opticus.....	79
Phlegmonous dacryocystitis.....	44
Posterior retractor oculi muscle.....	46
Pink eye.....	51
Paralysis of muscles.....	48
Purulent conjunctivitis.....	54
Poles of the eye.....	16
Petit, Canal of.....	112, 113, 96
Panophthalmitis.....	22, 98
Position of image.....	17
Periorbita.....	20
Pterygium.....	62
Pinguecula	63

INDEX.

155


	PAGE.
Periostitis—Orbital.....	23
Palpebrae	20, 24
Preface.....	4
Persistent hyaloid artery.....	112
Prism	12
Primary colors.....	12
Projection, field of.....	12
Purple, visual.....	12
Pentastoma Tænoides.....	125
Periodic ophthalmia	99
Pectinate ligament.....	96
Reflection, angle of.....	8
Rods and cones	15
Riolini, ciliary muscle of.....	24
Recurrent ophthalmia	99
Retina.....	106
Roemer.....	18
Sound waves.....	18
Squint	49
Staphyloma of cornea	69
Suppurative keratitis.....	71
Spherical aberration.....	11
Superior rectus muscle.....	46
Staphyloma, cicatricial.....	78
Sphincter muscle of the iris.....	14
Simpathetic cervical	14
Sylvius, aqueduct of.....	15
Sclera	79
Staphyloma of sclerotic.....	81
Sight	18
Steele	18
Sheath, ocular.....	0


	PAGE.
Sclerotic, staphyloma of.....	81
Scleritis	18
Sclera, annular staphyloma of.....	83
Sebacious glands.....	27
Staphyloma, annular of sclera.....	83
Stye.....	32
Symblepharon.....	35
Sac, lachrymal ..	39
Soot-balls.....	85
Sphincter pupillae.....	85
Short ciliary nerves.....	85
Stricture, lachrymal duct.....	42, 43
Synechia.....	87
Superior oblique muscle.....	48
Small " "	48
Strabismus.....	49
Sympathathic ophthalmia	103
Snow blindness.....	117
Spaces of Fontana.....	121
Synechia, anterior.....	73
Saemische's operation.....	74
Schlemm, canal of	121
Tinia tarsi.....	31
Tarsi	26
Tumors of conjunctiva.....	63
Tract, uveal	84
Third pair of nerves.....	14
Tumors of iris.....	90
Tapetum	7
Test, catoptric.....	131
Trigeminus	14
Temporal fossa.....	20


INDEX.

157

	PAGE.
Tumors, dermoid	64
Tenon's capsule	21
Tumors of orbit	23
Trachoma	57
Trichiasis	33
Uveal tract	84
Uvea	85
Ulcer cornea	72
Visual purple	12
Vision	7
Visual axis	16
Vascular keratitis	70
Venae vorticosae	105
Vitreous humor	112
Von Graefe	124
Warts	64
Wounds of cornea	67
" " lids	37
Xerophthalmia	63
Yellow spot	15, 17, 110
Zinn, zonule of	14, 94, 112, 113







WILLIAM R. JENKINS'
Veterinary Books.

1897.

(*) *Single asterisk designates New Books.*

(**) *Double asterisk designates Recent Publications.*

- ANDERSON.** "Vice in the Horse" and other papers on Horses and Riding. By E. L. Anderson. Demy, 8vo, cloth.....2 00
- "How to Ride and School a Horse." With a System of Horse Gymnastics. By Edward L. Anderson. Cr. 8vo 1 00
- (**) **BACH.** "How to Judge a Horse." A concise treatise as to its Qualities and Soundness; Including Bits and Bitting—Saddles and Saddling, Stable Drainage, Driving One Horse, a Pair, Four-in-hand, or Tandem, etc. By Captain F. W. Bach. 12mo, cloth, fully illustrated \$1 00; paper.....50
- BANHAM.** "Tables of Veterinary Posology and Therapeutics," with weights, measures, etc. By George A. Banham, F.R.C.V.S. 12mo, cloth.....75
- BAUCHER.** "Method of Horsemanship." Including the Breaking and Training of Horses.....1 00

BELL. "The Veterinarians Call Book (Perpetual)."

By Roscoe R. Bell, D.V.S., Professor of Materia Medica, Therapeutics and Hygiene in the American Veterinary College, New York; President of the Long Island Veterinary Society; late U. S. Government Veterinary Inspector, etc.

A visiting list, that can be commenced at any time and used until full, containing much useful information for the student and the busy practitioner. Among contents are items concerning: Veterinary Drugs; Poisons; Solubility of Drugs; Composition of Milk, Bile, Blood, Gastric Juice, Urine, Saliva; Respiration; Dentition; Temperature, etc., etc. Bound in leather, with flap and pocket 1 25

(*) **BRADLEY.** "Outlines of Veterinary Anatomy."

By O. Charnock Bradley, Member of the Royal College of Veterinary Surgeons; Professor of Anatomy in the New Veterinary College, Edinburgh.

The author presents the most important facts of veterinary anatomy in as condensed a form as possible, consistent with lucidity. 12mo, cloth.

PART I.: *The Limbs* 1 25
 PART II.: *The Trunk* 1 25

CLEMENT. "Veterinary Post Mortem Examinations."

By A. W. Clement, V.S. Records of autopsies, to be of any value, should accurately represent the appearances of the tissues and organs so that a diagnosis might be made by the reader were not the examiners conclusions stated. To make the pathological conditions clear to the reader, some definite system of dissection is necessary. The absence in the English language, of any guide in making autopsies upon the lower animals, induced Dr. Clement to write this book, trusting that it would prove of practical value to the profession. 2mo, cloth, illustrated 75

(**) **CADIOT.** "Roaring in Horses." Its Pathology and Treatment. This work represents the latest development in operative methods for the alleviation of roaring. Each step is most clearly defined by excellent full-page illustrations. By P. J. Cadiot, Professor at the Veterinary School, Alfort. Trans. Thos. J. Watt Dollar, M.R.C.V.S., etc. Cloth.....75

CHAUVEAU. "The Comparative Anatomy of the Domesticated Animals." By A. Chauveau. New edition, translated, enlarged and entirely revised by George Fleming, F.R.C.V.S. 8vo. cloth with 585 Illustrations 5 75

CLARKE. "Horses' Teeth." A Treatise on their Anatomy, Pathology, Dentistry, etc. Revised and enlarged. By W. H. Clarke. 12mo, cloth.....2 50

— "Chart of the Feet and Teeth of Fossil Horses."25

CLEVELAND. "Pronouncing Medical Lexicon." Pocket edition. Cloth.....75

COURTNEY. "Manual of Veterinary Medicine and Surgery." By Edward Courtney, V. S. Crown, 8vo, cloth.....2 75

(**) **COX.** "Horses: In Accident and Disease." The sketches introduced embrace various attitudes which have been observed, such as in choking; the disorders and accidents occurring to the stomach and intestines; affection of the brain; and some special forms of lameness, etc. By J. Roalfe Cox, F.R.C.V.S. 8vo, cloth, fully illustrated1 50

CURTIS. "Horses, Cattle, Sheep and Swine." The origin, history, improvement, description, characteristics, merits, objections, etc. By Geo. W. Curtis, M.S.A. Superbly illustrated. Cloth, \$2 00; half sheep, \$2.75; half morocco.....3 50

DALZIEL. "British Dogs." Describing the History, Characteristics, Points, and Club Standards, etc., etc. With numerous colored plates and wood engravings. By Hugh Dalziel. Vol. I., \$4 00. Vol. II., 8vo.4 00

— "The Fox Terrier." Illustrated. (Monographs on British Dogs).....1 00

— "Fox Terrier Stud Book." Edited by Hugh Dalziel.

Vol. I. Containing Pedigrees of over 1,400 of the best-known Dogs, traced to their most remote known ancestors1 00

Vol. II. Pedigrees of 1,544 Dogs, Show Record, &c.1 00

Vol. III. Pedigrees of 1,214 Dogs, Show Record, &c.1 00

Vol. IV. Pedigrees of 1,168 Dogs, Show Record, &c.1 00

Vol. V. Pedigrees of 1,662 Dogs, Show Record, &c.1 00

— "The St. Bernard." Illustrated.....1 00

— "St. Bernard Stud Book." Edited by Hugh Dalziel.

Vol. I. Pedigrees of 1,278 of the best-known Dogs, traced to their most remote known ancestors, Show Record, &c.....1 00

Vol. II. Pedigrees of 564 Dogs, Show Record, &c.,1 00

851-853 Sixth Avenue (cor. 48th St.), New York. 5

- "The Diseases of Dogs."** Their Pathology, Diagnosis and Treatment, with a dictionary of Canine Materia-Medica. By Hugh Dalziel. 12mo, paper, 60c. ; cloth, 80
- **"Diseases of Horses."** 12mo, cloth.....1 00
- **"Breaking and Training Dogs."** Being concise directions for the proper education of dogs, both for the field and for companions. Second edition, revised and enlarged. Part I, by Pathfinder; Part II, by Hugh Dalziel. 12mo, cloth, illus....2.60
- **"The Collie."** Its History, Points, and Breeding. By Hugh Dalziel. Illustrated, 8vo, paper, 50c., cloth 1 00
- **"The Greyhound."** 8vo, cloth, illus.....1 00
- DANCE.** **"Veterinary Tablet."** Folded in cloth case. The tablet of A. A. Dance is a synopsis of the diseases of horses, cattle and dogs with the causes, symptoms and cures.....75
- DANA.** **"Tables in Comparative Physiology."** By Prof. C. L. Dana, M.D.....25
- DAY.** **"The Race-horse in Training."** By Wm. Day, 8vo3 50
- (**)**DUN.** **"Veterinary Medicines, Their Actions and Uses."** By Finlay Dun, V.S. Revised edition (almost entirely re-written) 8vo, cloth.....3 50
- DWYER.** **"Seats and Saddles."** Bits and Bitting, Draught and Harness and the Prevention and Cure of Restiveness in Horses. By Francis Dwyer. Illustrated. 1 vol., 12mo, cloth, gilt.....1 50

- (*)**FLEMING.** "**Veterinary Obstetrics.**" Including the Accidents and Diseases incident to Pregnancy, Parturition, and the early Age in Domesticated Animals. By Geo. Fleming, F.R.C.V.S. With 212 illustrations. *New edition revised*, 226 illustrations, 758 pages...6 25
773 pages, 8vo, cloth (old edition)3 50
- "**Rabies and Hydrophobia.**" History. Natural Causes, Symptoms and Prevention. By Geo. Fleming, M. R.C.V.S. 8vo, cloth.....3 75
- "**Propagation of Tuberculosis.**" Stating Injurious Effects from the consumption of the Flesh and Milk of Tuberculous Animals. By Geo. Fleming, M.D., M.R.C.V.S., and others. 8vo, cloth.....1 50
- "**A Treatise on Practical Horseshoeing.**" By George Fleming, M.R.C.V.S. Cloth.....75
- "**Tuberculosis.**" From a Sanitary and Pathological Point of View.....25
- "**The Contagious Diseases of Animals.**" Their influence on the wealth and health of nations. 12mo, paper 25
- "**Operative Veterinary Surgery.**" Part I, by Dr. Geo. Fleming, M.R.C.V.S. This valuable work, the most practical treatise yet issued on the subject in the English language, is devoted to the common operations of Veterinary Surgery; and the concise descriptions and directions of the text are illustrated with numerous wood engravings. 8vo, cloth.2 75

Orders are now received for the second volume, which is expected by December.

851-853 *Sixth Avenue (cor. 48th St.), New York.* 7

- “**Human and Animal Variolæ.**” A Study in Comparative Pathology. Paper25
- “**Animal Plagues.**” Their History, Nature, and Prevention. By George Fleming, F. R. C. V. S., etc. First Series. 8vo, cloth, \$6.00; Second Series. 8vo, cloth.....3 00
- “**Roaring in Horses.**” By Dr. George Fleming, F.R.C.V.S. A treatise on this peculiar disorder of the Horse, indicating its method of treatment and curability. 8vo, cloth, with col. plates1 50

(**)**FLEMING-NEUMANN.** “**Parasites and Parasitic Diseases of the Domesticated Animals.**” A work which the students of human or veterinary medicine, the sanitarian, agriculturist or breeder or rearer of animals, may refer for full information regarding the external and internal Parasites—vegetable and animal—which attack various species of Domestic Animals. A Treatise by L. G. Neumann, Professor at the National Veterinary School of Toulouse. Translated and edited by George Fleming, C. B., L.L. D., F.R.C.V.S. 873 pages, 365 illustrations, cloth.7 50

FRIEDBERGER - FROHNER. “**Pathology and Therapeutics of the Domesticated Animals.**” Translated by Prof. L. Zuill, M. D., D. V. S. 2 vol.....12 00

GRESSWELL. “**The Diseases and Disorders of the Ox.**” By George Gresswell, B.A. With Notes by James B. Gresswell. Crown, 8vo, cloth, illus....3 50

- “**Diseases and Disorders of the Horse.**” By Albert, James B., and George Gresswell. Crown, 8vo, illustrated, cloth.....1 75

- GRESSWELL.** Manual of "The Theory and Practice of Equine Medicine." By J. B. Gresswell, F.R.C.V.S., and Albert Gresswell, M.R.C.V.S., second edition, enlarged, 8vo, cloth. 2 75
- "Veterinary Pharmacology and Therapeutics." By James B. Gresswell, F.R.C.V.S. 16mo, cloth . . . 1 50
- "The Bovine Prescriber." For the use of Veterinarians and Veterinary Students. By James B. and Albert Gresswell, M.R.C.V.S. Cloth. 75
- "The Equine Hospital Prescriber." Drawn up for the use of Veterinary Practitioners and Students. By Drs. James B. and Albert Gresswell, M.R.C.V.S. Cloth. 75
- "Veterinary Pharmacopœia, Materia Medica and Therapeutics." By George and Charles Gresswell, with descriptions and physiological actions of medicines. By Albert Gresswell. Crown, 8vo, cl. 2 75
- (**) **GOTTHEIL.** "A Manual of General Histology." By Wm. S. Gottheil, M.D., Professor of Pathology in the American Veterinary College, New York; etc., etc.
- Histology is the basis of the physician's art, as Anatomy is the foundation of the surgeon's science. Only by knowing the processes of life can we understand the changes of disease and the action of remedies; as the architect must know his building materials, so must the practitioner of medicine know the intimate structure of the body. To present this knowledge in an accessible and simple form has been the author's task. 8vo., cloth, 148 pages, fully illustrated. . . 1 00

(*)**HASSLOCH.** "A Compend of Veterinary Materia Medica and Therapeutics." By Dr. A. C. Hassloch, V.S., Lecturer on Materia Medica and Therapeutics, and Professor of Veterinary Dentistry at the New York College of Veterinary Surgeons and School of Comparative Medicine, N. Y. 12mo, cloth, 225 pages ..1 50

HAYES. "Veterinary Notes for Horse-Owners." An every day Horse Book. Illustrated. By M. H. Hayes. 12mo, cloth.....5 00

— "Riding." On the Flat and Across Country. A Guide to Practical Horsemanship. By Captain M. H. Hayes. Second edition, 16mo, cloth.....4 25

— "Illustrated Horse Breaking." By Captain M. H. Hayes. 12mo, cloth, illustrated.....8 40

— "The Horsewoman." By Captain M. H. Hayes and Mrs. Hayes. 12mo, cloth, illustrated.... 4 25

(**) **HEATLEY.** "The Stock Owner's Guide." A handy Medical Treatise for every man who owns an ox or cow. By George S. Heatley, M.R.C.V. 12mo, cloth1 25

— "The Horse Owner's Safeguard." A handy Medical Guide for every Horse Owner. 12mo, cloth1 50

— "Practical Veterinary Remedies." 12mo, cloth...1 00

HILL. "The Principles and Practice of Bovine Medicine and Surgery." By J. Woodroffe Hill, F.R.C.V.S. Cloth. (Temporarily out of print).

HILL. "The Management and Diseases of the Dog." Containing full instructions for Breeding, Rearing and Kenneling Dogs. Their Different Diseases. How to detect and how to cure them. Their Medicines, and the doses in which they can be safely administered. By J. Woodroffe Hill, F.R.C.V.S. 12mo, cloth, extra fully illustrated..... 2 00

HINEBAUCH. "Veterinary Dental Surgery." For the use of Students, Practitioners and Stockmen. 12mo, cloth, illustrated..... 2 00
Sheep..... 2 75

(**) **HOARE.** "A Manual of Veterinary Therapeutics and Pharmacology." By E. Wallis Hoare, F.R.C.V.S. 12mo, cloth, 560 pages..... 2 75

"Deserves a good place in the libraries of all veterinarians. * * * Cannot help but be of the greatest assistance to the young veterinarian and the every day busy practitioner."—*American Veterinary Review.*

(*) **KOBERT.** "Practical Toxicology for Physicians and Students" By Prof. Dr. Rudolph Kobert, Director of the Pharmacological Institute, Dorpat, Russia. Translated and edited by L. H. Friedburg, Ph.D., of Dept. of Chemistry, College of City of New York, Prof. of Chemistry and Toxicology at the American Veterinary College, New York, and New York Homœopathic Medical College and Hospital. Authorized edition. (In press.)

KOCH. "Etiology of Tuberculosis." By Dr. R. Koch. Translated by T. Saure. 8vo, cloth 1 00

KEATING. "A New Unabridged Pronouncing Dictionary of Medicine." By John M. Keating, M.D., LL.D., Henry Hamilton and others. A voluminous and exhaustive hand-book of Medical and scientific terminology with Phonetic Pronunciation, Accentuation, Etymology, etc. With an appendix containing important tables of Bacilli, Microcci Leucomaines, Ptomaines; Drugs and Materials used in Antiseptic Surgery; Poisons and their antidotes; Weights and Measures; Themometer Scales; New Officinal and Unofficinal Drugs, etc., etc. 8 vo, 818 pages.....5 00

LAMBERT. "The Germ Theory of Disease." Bearing upon the health and welfare of man and the domesticated animals. By James Lambert, F.R.C.V.S. 8vo. paper.....25

LAW. "Farmers' Veterinary Adviser." A Guide to the Prevention and Treatment of Disease in Domestic Animals. By Professor James Law. Illustrated. 8vo, cloth.....3 00

LIAUTARD. "Median Neurotomy in the Treatment Chronic Tendinitis and Periostosis of the Fetlock." By C. Pellerin, late Repetitor of Clinic and Surgery to the Alfort Veterinary School. Translated with additional facts relating to it, by Prof. A. Liautard, M.D., V.M.

Having rendered good results when performed by himself, the author believes the operation, which consists in dividing the cubito-plantar nerve and in excising a portion of the peripheral end, the means of improving the conditions, and consequently the values of many apparently doomed animals. Agriculture in particular will be benefited.

The work is divided into two parts. The first covers the study of Median Neurotomy itself; the second, the exact relations of the facts as observed by the author. 8vo., boards.....1 00

- (**) **LIAUTARD.** "Manual of Operative Veterinary Surgery" By A. Liautard, M.D., V.M., Principal and Professor of Anatomy, Surgery, Sanitary Medicine and Jurisprudence in the American Veterinary College; Chevalier du Merite Agricole de France, Honorary Fellow of the Royal College of Veterinary Surgeons (London), etc., etc. 8vo, cloth, 786 pages and nearly 600 illustrations.....6 00
- "Animal Castration." A concise and practical Treatise on the Castration of the Domestic Animals. The only work on the subject in the English language. Illustrated with forty-four cuts. 12mo, cloth...2 00
- (*) "Vade Mecum of Equine Anatomy." By A. Liautard, M.D.V.S. Dean of the American Veterinary College. 12mo, cloth. New edition, with illustrations....2 00
- "Translation of Zundel on the Horse's Foot." Cloth2 00
- "How to Tell the Age of the Domestic Animal." By Dr. A. Liautard, M.D., V.S. Profusely illustrated. 12mo, cloth50
- "On the Lameness of Horses." By A. Liautard, M.D., V.S.2 50
- LONG.** "Book of the Pig." Its selection, Breeding, Feeding and Management. 8vo, cloth4 25
- (**) **LUPTON.** "Horses: Sound and Unsound," with Law relating to Sales and Warranty. By J. Irvine Lupton, F.R.C.V.S. 8vo, cloth, illustrated.....1 25
- "The Horse." As he Was, as he Is, and as he Ought to Be. By J. I. Lupton, F.R.C.V.S. Illustrated. Crown, 8vo1 40

851-853 Sixth Avenue (cor. 48th St.), New York. 13

MAGNER. "Facts for Horse Owners." By D. Magner. Upwards of 1,000 pages, illustrated with 900 engravings. 8vo, cloth, \$5.00; sheep, \$6.00; full morocco..7 50

MAGNER. "Veterinary Diagrams." (1) The Structure of Horses Feet (in colors). The Structure of Horses Feet (Effects of Bad Treatment of the Feet). Mounted and Varnished.....2 00
(2) The Shoeing of the Horse. The Education of the Horse. Mounted and Varnished.....2 00

MAYHEW. "The Illustrated Horse Doctor." An accurate and detailed account of the Various Diseases to which the Equine Race is subject; together with the latest mode of Treatment, and all the Requisite Prescriptions written in plain English. By E. Edward Maynew, M.R.C.V.S. Illustrated. Entirely new edition, 8vo, cloth.....2 75

McBRIDE. "Anatomical Outlines of the Horse." 12mo, cloth.....2 50

McCOMBIE. "Cattle and Cattle Breeders." Cloth.1 00

M'FADYEAN. "Anatomy of the Horse." A Dissection Guide. By J. M. M'Fadyean, M.R.C.V.S. This book is intended for Veterinary students, and offers to them in its 48 full-page colored plates numerous other engravings and excellent text, the most valuable and practical aid in the study of Veterinary Anatomy, especially in the dissecting room. 8vo, cloth5 50

— "Comparative Anatomy of the Domesticated Animals." By J. M'Fadyean. Profusely illustrated, and to be issued in two parts. Part I—Osteology, ready. Paper, \$2 50; cloth.....2 75
(Part II. in preparation.)

MILLS. "How to Keep a Dog in the City." By Wesley Mills, M.D., V.S. It tells how to choose manage, house, feed, educate the pup, how to keep him clean and teach him cleanliness. Paper.....25

(**) **MOLLER.** "Operative Veterinary Surgery." By Professor Dr. H. Moller, Berlin. Translated and edited from the 2d edition, enlarged and improved, by John A. W. Dollar, M.R.C.S.

Prof. Moller's work presents the most recent and complete exposition of the Principles and Practice of Veterinary Surgery, and is *the standard text-book on the subject throughout Germany.*

Many subjects ignored in previous treatises on Veterinary Surgery here receive full consideration, while the better known are presented under new and suggestive aspects.

As Prof. Moller's work represents not only his own opinions and practice, but those of the best Veterinary Surgeons of various countries, the translation cannot fail to be of signal service to American and British Veterinarians and to Students of Veterinary and Comparative Surgery.

1 vol., 8vo. 722 pages, 142 illustrations5 25

MORETON. "On Horse-breaking." 12mo, cl...50

MOSSELMAN-LIENAU. "Veterinary Microbiology." By Professors Mosselman and Liénaux, National Veterinary College, Cureghem, Belgium. Translated and edited by R. R. Dinwiddie, Professor of Veterinary Science, College of Agriculture, Arkansas State University. 12mo, cloth, 342 pages.....2 00

851-853 Sixth Avenue (cor. 48th St.), New York. 15

(**) **NOCARD.** "The Animal Tubercloses, and their Relation to Human Tuberculosis." By Ed. Nocard, Professor of the Alfort Veterinary College. Translated by H. Scurfield, M.D. Ed., Ph. Camb.

Perhaps the chief interest to doctors of human medicine in Professor Nocard's book lies in the demonstration of the small part played by heredity, and the great part played by contagion in the propagation of bovine tuberculosis. It seems not unreasonable to suppose that the same is the case for human tuberculosis, and that, if the children of tuberculosis parents were protected from infection by cohabitation or ingestion, the importance of heredity as a cause of the disease, or even of the predisposition to it, would dwindle away into insignificance. 12mo, cloth 143 pages.....1 00

PEGLER. "The Book of the Goat." 12mo, cloth.1 75

PELLERIN. "Median Neurotomy in the Treatment of Chronic Tendinitis and Periostosis of the Fetlock." By C. Pellerin, late repetitor of Clinic and Surgery to the Alfort Veterinary School. Translated, with Additional Facts Relating to It, by Prof. A. Liautard, M.D., V.M. 8vo, boards, illustrated.....1 00

See also under Liautard.

PROCTOR. "The Management and Treatment of the Horse" in the Stable, Field and on the Road. By William Proctor. 8vo..... 2 40

PETERS. "A Tuberculous Herd—Test with Tuberculin." By Austin Peters, M. R. C. V. S., Chief Inspector of Cattle for the New York State Board of Health during the winter of 1892-93. Pamphlet....25

REYNOLD. "Breeding and Management of Draught Horses." 8vo, cloth.....1 40

ROBERTSON. "The Practice of Equine Medicine."
A text-book especially adapted for the use of Veterinary students and Veterinarians. By W. Robertson, Principal and Professor of Hippopathology in the Royal Veterinary College, London. 8vo. cloth, 806 pages, revised edition.....6 25

(**) **ROBERGE.** "The Foot of the Horse," or Lameness and all Diseases of the Feet traced to an Unbalanced Foot Bone, prevented or cured by balancing the foot. By David Roberge. 8vo, cloth5 00

(**) **SMITH.** "A Manual of Veterinary Physiology."
By Veterinary Captain F. Smith, M.R.C.V.S. Author of "A Manual of Veterinary Hygiene."

Throughout this manual the object has been to condense the information as much as possible. The broad facts of the sciences are stated so as to render them of use to the student and practitioner. In this second edition—rewritten—the whole of the Nervous System has been revised, a new chapter dealing with the Development of the Ovum has been added together with many additional facts and illustrations. About one hundred additional pages are given. *Second edition*, revised and enlarged, with additional illustrations3 75

(**) **SMITH.** "Manual of Veterinary Hygiene." 2nd edition, revised. Crown, 8vo, cloth3 25

STORNMOUTH. "Manual of Scientific Terms." Especially referring to those in Botany, Natural History, Medical and Veterinary Science. By Rev. James Stornmouth.....3 00

(**) **STRANGWAY.** "Veterinary Anatomy." New edition, revised and edited by I. Vaughn, F.L.S., M.R.C.V.S., with several hundred illustrations. 8vo, cloth5 00

(*) **SUSSDORF.** Colored Plates specially for Lectures. Size 40x27. By Professor Sussdorf, M.D. Translated by Prof. W. Owen Williams, of the New Veterinary College, Edinburgh.

Plate 1.—"Diagram of the Horse." Left or near side view.

Plate 2.—"Diagram of the Mare." Right side view.

Plate 3. "Anatomy of the Cow," showing the position of the viscera in the large cavities of the body. Price, unmounted.....1 75 each
" mounted on linen, with roller...1 75 extra "

Plate 4. "The Ox." Showing right side view of the position of the viscera in the large cavities of the body.

VETERINARY DIAGRAMS in Tabular Form. Size, 28½ in. x 22 inches. Price per set of five... 4 75

No. 1. "The External Form and Elementary Anatomy of the Horse." Eight coloured illustrations—1. External regions; 2. Skeleton; 3. Muscles (Superior Layer); 4. Muscles (Deep Layer); 5. Respiratory Apparatus; 6. Digestive Apparatus; 7. Circulatory Apparatus; 8. Nerve Apparatus; with letter-press description1 25

No. 2. "The Age of Domestic Animals." Forty-two figures illustrating the structure of the teeth, indicating the Age of the Horse, Ox, Sheep, and Dog, with full description75

No. 3. "The Unsoundness and Defects of the Horse."

Fifty figures illustrating—1. The Defects of Conformation; 2. Defects of Position; 3. Infirmities or Signs of Disease; 4. Unsoundnesses; 5. Defects of the Foot; with full description..... 75

No. 4. "The Shoeing of the Horse, Mule and Ox."

Fifty figures descriptive of the Anatomy and Physiology of the Foot and of Horse-shoeing.75

No. 5. "The Elementary Anatomy, Points, and Butcher's Joints of the Ox."

Ten coloured illustrations—1. Skeleton; 2. Nervous System; 3. Digestive System (Right Side); 4. Respiratory System; 5. Points of a Fat Ox; 6. Muscular System; 7. Vascular System; 8. Digestive System (Left Side); 9. Butcher's Sections of a Calf; 10. Butcher's Sections of an Ox; with full description 1 25

WALLEY. "Hints on the Breeding and Rearing of Farm Animals." 12mo, cloth.....80

— **"Four Bovine Scourges."** (Pleuro - Pneumonia, Foot and Mouth Disease, Cattle Plague and Tubercle.) With an Appendix on the Inspection of Live Animals and Meat. Illustrated, 4to, cloth..6 40

— **"The Horse, Cow and Dog."** By Dr. Thomas Walley. A poetical account of the "Troublous Life of the Horse"; "The Life of a Dairy Cow," and "The Life of a Dog"; with an article on Animal Characteristics. 12mo, cloth,80

(*) **WALLEY.** "A Practical Guide to Meat Inspection."

By Thomas Walley, M.R.C.V.S., formerly principal of the Edinburgh Royal (Dick) Veterinary College; Professor of Veterinary Medicine and Surgery, etc. *Third Edition*, thoroughly revised, with forty-five coloured illustrations, 12mo, cloth.....3 00

An experience of over 30 years in his profession and a long official connection (some sixteen years) with Edinburgh Abattoirs have enabled the author to gather a large store of information on the subject, which he has embodied in his book. Dr. Walley's opinions are regarded as the highest authority on Meat Inspection.

(**) **WILLIAMS.** "Principles and Practice of Veterinary Medicine." New author's edition, entirely revised and illustrated with numerous plain and colored plates. By W. Williams, M.R.C.V.S. 8vo., el. .6 00

— (**) "Principles and Practice of Veterinary Surgery."

New author's edition, entirely revised and illustrated with numerous plain and colored plates. By W. Williams, M.R.C.V.S. 8vo, cloth.....6 00

ZUNDEL. "The Horse's Foot and Its Diseases." By

A. Zundel, Principal Veterinarian of Alsace Lorraine. Translated by Dr. A. Liautard, V.S. 12mo, cloth illustrated.....2 00

ZUILL. "Typhoid Fever; or Contagious Influenza in the Horse." By Prof. W. L. Zuill, M.D., D.V.S.

Pamphlet25



