Descriptive catalogue of specimens in the museum of human anatomy. Pt. 2, The comparative osteology of man and the higher apes / by W.L.H. Duckworth.

Contributors

Duckworth, W. L. H. 1870-1956.

Publication/Creation

Cambridge : The Anatomy School, 1908.

Persistent URL

https://wellcomecollection.org/works/qk5bat4u

License and attribution

Conditions of use: it is possible this item is protected by copyright and/or related rights. You are free to use this item in any way that is permitted by the copyright and related rights legislation that applies to your use. For other uses you need to obtain permission from the rights-holder(s).

wellcome collection

Wellcome Collection
183 Euston Road
London NW1 2BE UK
T +44 (0)20 7611 8722
E library@wellcomecollection.org
https://wellcomecollection.org

22500447987

Med
K7578

DESCRIPTIVE CATALOGUE OF SPECIMENS

IN THE

MUSEUM OF HUMAN ANATOMY.

PART II.

THE COMPARATIVE OSTEOLOGY OF MAN AND THE HIGHER APES.

BY

W. L. H. DUCKWORTH, M.D., Sc.D.,

University Lecturer in Physical Anthropology and Senior Demonstrator of Anatomy.

THE ANATOMY SCHOOL,

CAMBRIDGE,

1908.

31053696

WELLCOME INSTITUTE
LIBRARY

Coll.	WelMOmec
Coll.	
No.	QS

UNIVERSITY
COLLEGE LONDON
LIBRARY

100101

Descriptive Catalogue of Specimens in the Museum of Human Anatomy.

PART II.

THE COMPARATIVE OSTEOLOGY OF MAN AND THE HIGHER APES.

BY

W. L. H. DUCKWORTH, M.D., Sc.D.,

University Lecturer in Physical Anthropology and Senior Demonstrator of Anatomy.

In a former publication (*Proceedings of the Anatomical Society*, July, 1899) I provided a general sketch of the contents of the Cambridge Museum of Anatomy. The present account deals with recent additions which illustrate the comparative osteology of Man and the anthropoid apes. The specimens now to be described are arranged in six cases, and the descriptions will therefore follow the numerical order of the latter. It is hoped that the illustrations which accompany these notes will render them useful to other students besides those who have access to the original specimens. These consist principally of casts and of sections of bones; with one or two exceptions, they were prepared and arranged by myself, with assistance from the Museum attendant. The contents of the cases may be summarized in the following manner:—

Case 1 contains casts of heads, and also actual crania, of the larger anthropoid apes. In addition to these, casts of the hand and foot of an adult male Gorilla are exhibited here.

Case 2 is devoted to specimens illustrative of different degrees of the facial angle. With these skulls are arranged others divided in the *median longitudinal plane*, and showing various forms of modification of the cranial base and the cranio-facial axis.

Case 3 contains sections, in *horizontal planes*, of the

skull of a Gorilla; the mandible is also shown, and, for economy of space, some pelves are placed in the same case.

Case 4.—Sections of the facial part of the skull, in the *coronal plane*, are exhibited here; with these are arranged specimens to illustrate some features of the internal surface of the skull. Preparations of the mandible of various Primate forms follow. The study of other parts of the skeleton than the skull is then commenced, and the characteristic anthropoid conditions are illustrated by bones of a large male Orang-utan.

Case 5.—Here are arranged sections of the upper limb-bones, and of the lumbar vertebræ and sacrum, of Man and of the anthropoid apes. In this case space was found for a number of sections of endocranial casts, illustrative of the form and proportions of the cerebrum in the Gorilla and in two human racial types.

Case 6.—This is set apart for sections of the lower limb-bones in Man and the anthropoid apes, with especial reference to points illustrative of the erect and the semi-erect attitudes characteristic of the two forms.

The contents of these cases will be described in detail in the following paragraphs :—

Case 1.—A fair idea of the external configuration of the head in the Gorilla and Chimpanzee may be obtained from the examination of the two casts exhibited in the first case, and this study should be commenced with the head of the male Gorilla (fig. 1). It should be noted that both this head and that of the Chimpanzee (fig. 2) are represented without the hairy covering which modifies and obscures the actual contour in the living animal.[1]

In the head of the Gorilla, the chief points of interest to be noted are the prominent brow-ridges, the flatness of the nose, the remarkable elevations on each side of the

[1] The Gorilla and Chimpanzee are "anthropoid" apes found in Africa. Two other anthropoid apes, the Orang-utan and the Gibbon (of the latter, various species exist), are Asiatic. The four anthropoid apes constitute the Family *Simiidæ* in zoological classification. Some account of their anatomy will be found in the writer's book on "Morphology and Anthropology," and the literature relating to them up to 1897 was collected by Dr. Keith and published in articles contributed to *Natural Science* in that year.

Digitized by the Internet Archive
in 2016

https://archive.org/details/b28131824

nasal aperture, the short but prominent upper lip, and the small ears with inconspicuous lobules. The nuchal region is not depressed as in Man, for in the Gorilla the great development of the muscles of the back of the head fills up the space between the head and shoulders.

FIG. 1.—Head of adult male Gorilla (Holt Don., Mus. Anat. Cant.).

FIG. 2.—Head of adult female Chimpanzee (Mus. Anat. Cant.).

The corresponding skull (fig. 3) presents the usual characters of that part of the skeleton in the Gorilla. It should be noted that the prominent osseous crests which project from the cranial surface are not perceptible in the head of the living animal (reference to the first cast should be made), for the intervening spaces are well filled by the great temporal muscles on either side and by the nuchal muscles behind.

The head of the Chimpanzee (figs. 2, 6, 7, 8, 9) presents some points of contrast with that of the Gorilla. The head is smaller and rounder, and though the brow-ridges are very prominent and the upper part of the nose depressed, yet the physiognomy is very different, owing mainly to the much smaller size of the nasal alæ (the elevations at the sides of the nostrils) and the long protruding upper lip. The ears are very different, too, being very large. In a large female Chimpanzee in the Cambridge Collection, some accident has caused the loss of the upper part of the right ear, the small size of which is quite abnormal (*cf.* fig. 6). The left ear is of the usual dimensions. In this specimen (fig. 2) there is a slight but

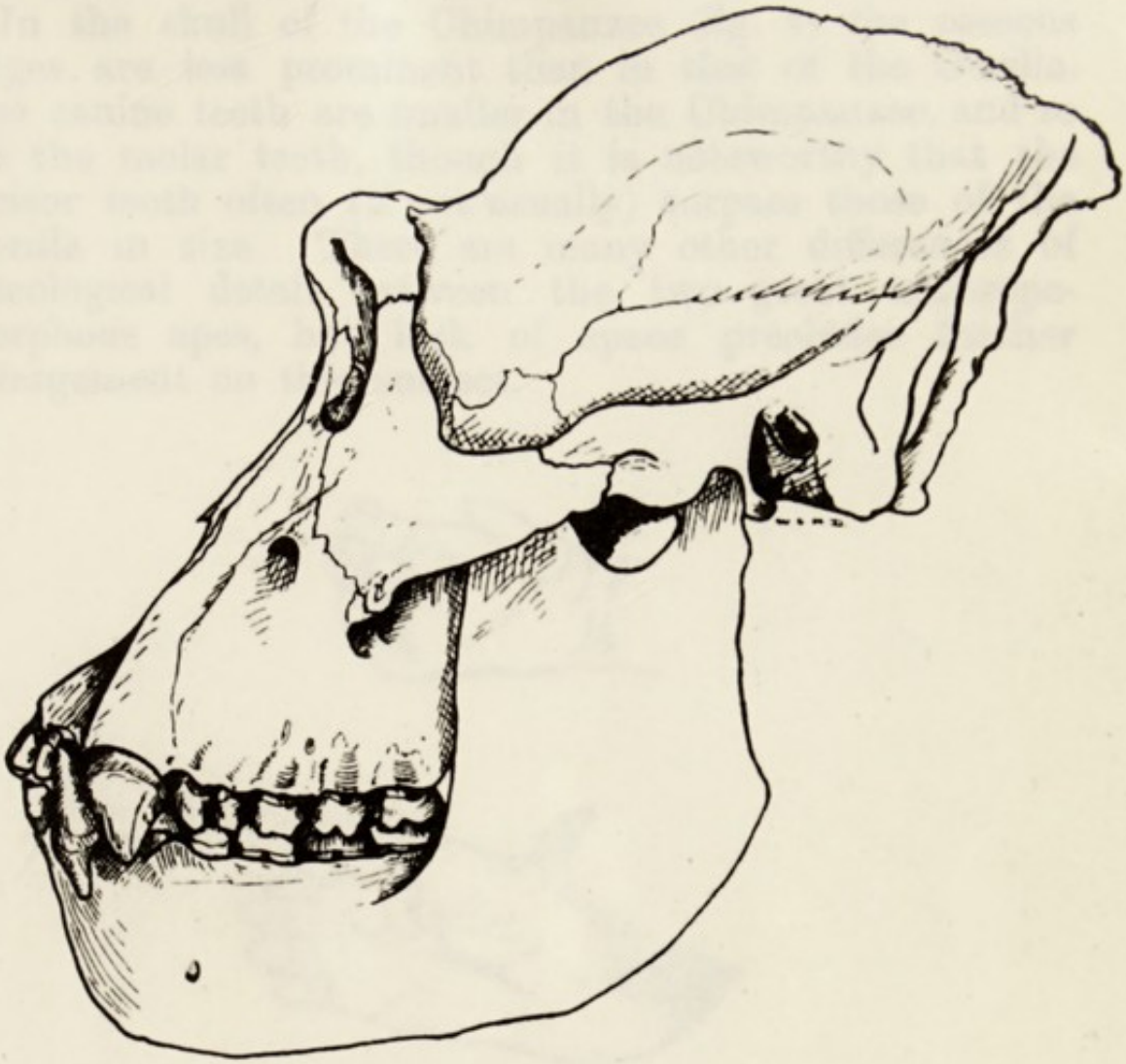

FIG. 3.—Cranium of adult male Gorilla. One-third of natural size.

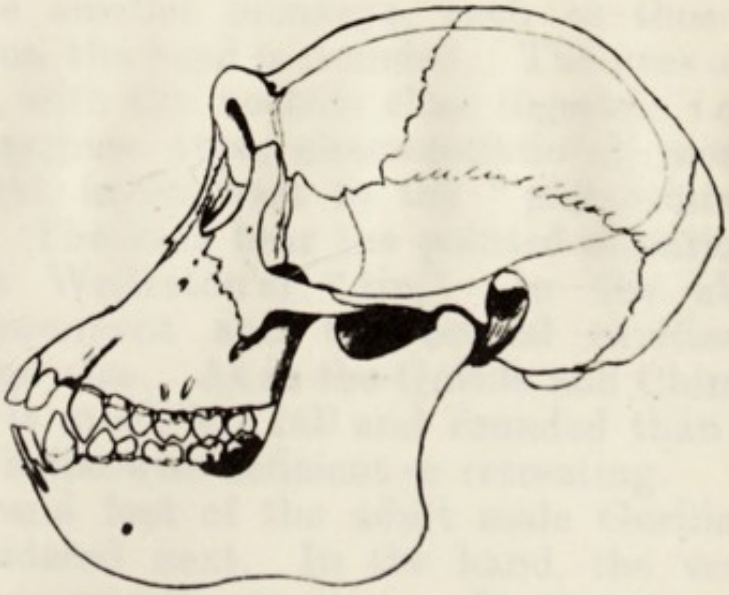

FIG. 4.—Cranium of adult female Chimpanzee (Mus. Anat. Cant.). One-third of natural size.

distinct nuchal depression (at the back of the neck), and herein lies another contrast with the Gorilla.

In the skull of the Chimpanzee (fig. 4) the osseous ridges are less prominent than in that of the Gorilla. The canine teeth are smaller in the Chimpanzee, and so are the molar teeth, though it is noteworthy that the incisor teeth often (if not usually) surpass those of the Gorilla in size. There are many other differences of osteological detail between the two great anthropomorphous apes, but lack of space precludes further enlargement on this subject.

FIG. 5.—Hand and foot of adult male Gorilla.

Among the smaller monkeys, such as those of the genus Macacus, the head is rounded. The eyes are large, the nose flat, with the nostrils close together, *i.e.*, of the so-called catarrhine type, characteristic of monkeys of the Old World, in contrast to the "platyrrhine" New World apes. The ears bear the pointed elevation called Darwin's (or Wollaston's) "tip." In the skull the muzzle is prominent and the orbital cavities are of relatively large size. As in the Gorilla and Chimpanzee, the forehead is much less full and rounded than in Man, and the chin is likewise deficient or retreating.

The hand and foot of the adult male Gorilla (fig. 5) may be considered next. In the hand, the very small thumb at once arrests attention. In the second place,

FIG. 8.—Adult female Chimpanzee (Mus. Anat. Cant.). The arrows denote the direction of the hair tracts.

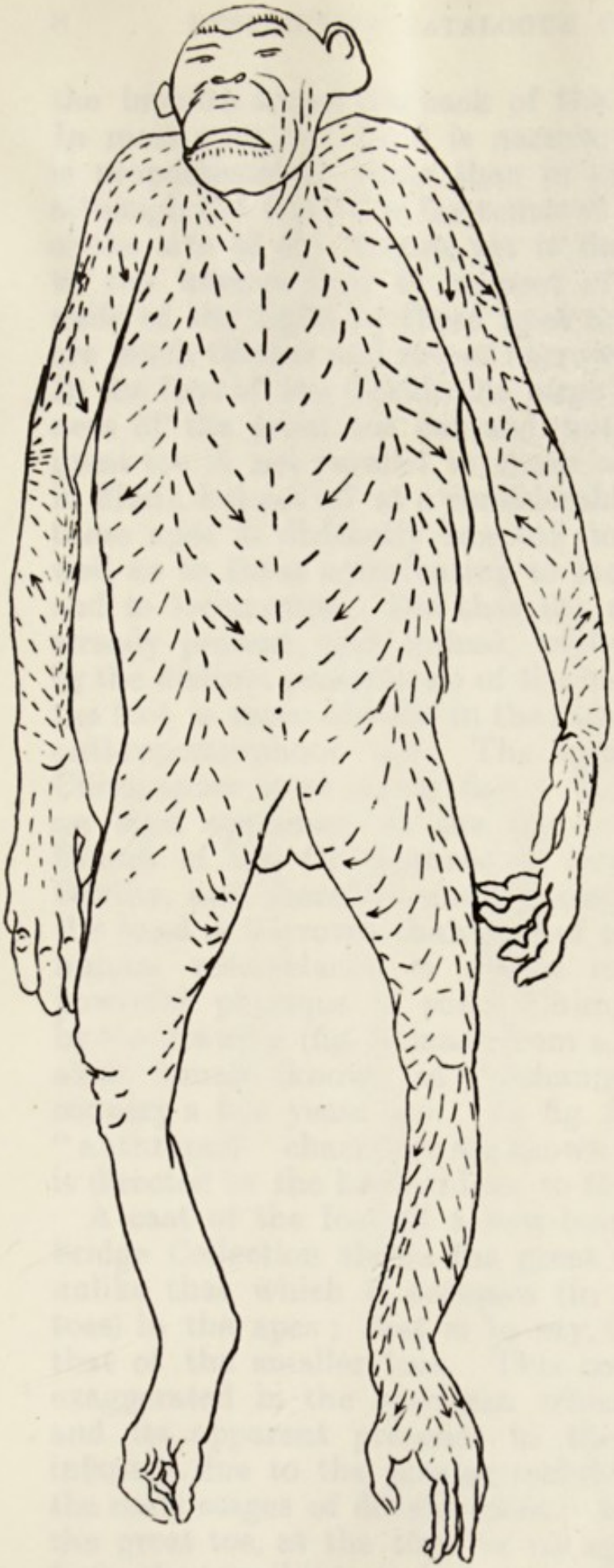

FIG. 6.

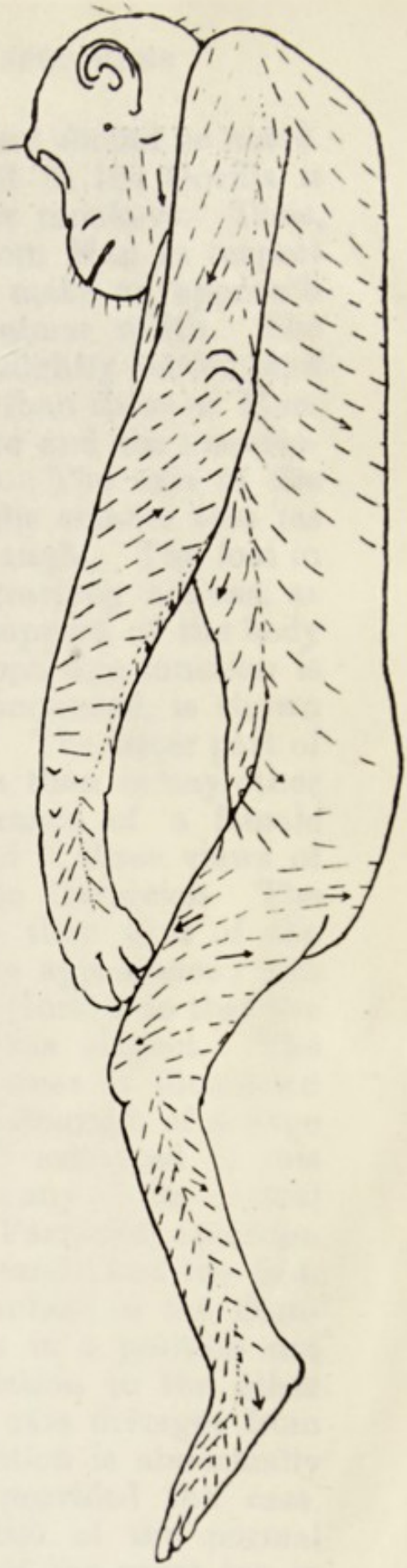

FIG. 7.

FIGS. 6 and 7.—Adult female Chimpanzee (Mus. Anat. Cant.). The arrows denote the directions of the hair tracts.

the breadth across the back of the hand should be noted. In most apes the hand is narrow, but in the Gorilla it is proportionately wider than in other monkeys. Thus, although the Gorilla is far removed from Man in respect of the size of the thumb, yet it does make an approach to the human type in respect of palmar width. The nails of the digits in these apes are slightly curved, and are much thicker and rather narrower than those of Man. In the foot of the Gorilla the large size and the massiveness of the great toe demand notice. The axis of the great toe is not parallel to those of the smaller toes (as in Man), but set off at a considerable angle. The foot in these apes is distinctly adapted to grasping actions, as well as to those contributing to the support of the body and to locomotion. But that the supporting function is already present, and, indeed, well-pronounced, is shown by the distinct prominence of the heel. The latter part of the foot is more distinct in the Gorilla than in any other anthropomorphous ape. The appearance of a female Chimpanzee is shown in figs. 6, 7, and 8, three views of an aged specimen in the Cambridge Collection. The thumb of the Chimpanzee is longer than that of the Gorilla, and therefore more human in appearance: but the hand is narrower than that of the Gorilla, so that the human resemblance is absent in this respect. The powerful physique of some Chimpanzees is illustrated by the drawing (fig. 9) made from a photograph of a large adult female (known as "Johanna") exhibited in this country a few years ago. In fig. 9 many of the typical "anthropoid" characters are shown. Particular attention is directed to the brow-ridges, to the hands, and the feet.

A cast of the foot of a new-born infant in the Cambridge Collection shows the great toe in a position not unlike that which it occupies (in relation to the other toes) in the apes; that is to say, its axis diverges from that of the smaller toes. This condition is abnormally exaggerated in the specimen which provided the cast, and its apparent presence in the foot of the normal infant is due to the greater mobility of the great toe in the early stages of development. In the human embryo, the great toe, at the time of its appearance, is divergent from the smaller toes, but the typical human conformation is very quickly acquired while embryonic life is still incomplete.

FIG. 9.—Adult female Chimpanzee ("Johanna").

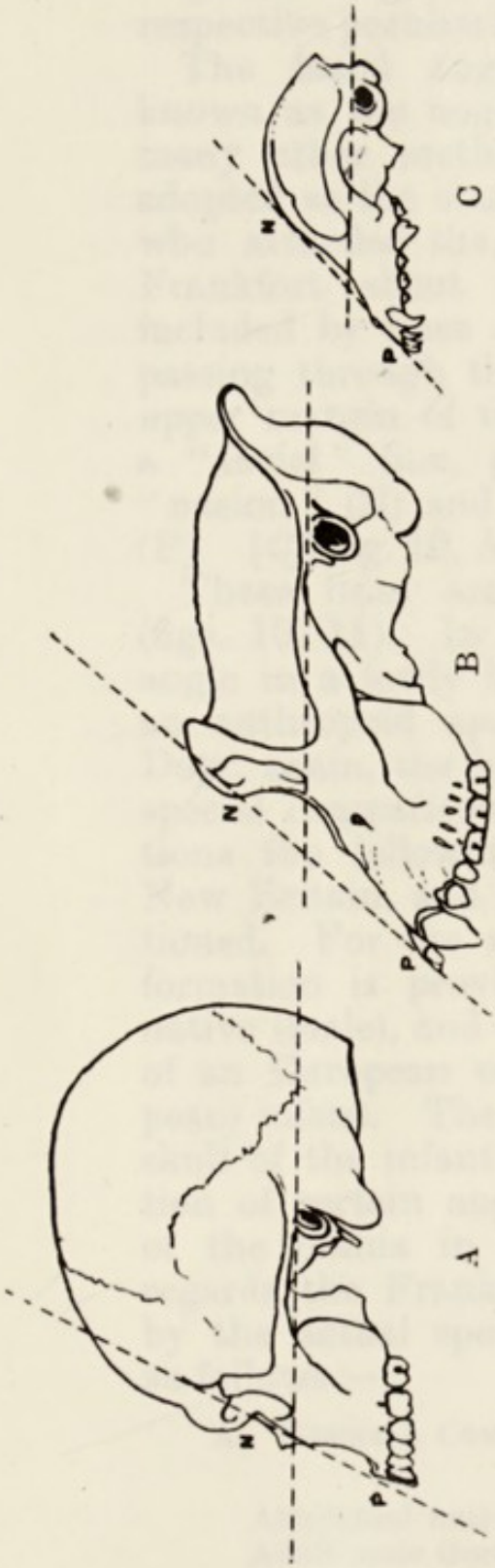

FIG. 10.—The facial angle of the Frankfort Agreement is shown in the crania of (A) a New Britain native (male); (B) a Gorilla (male); (C) a Dog.

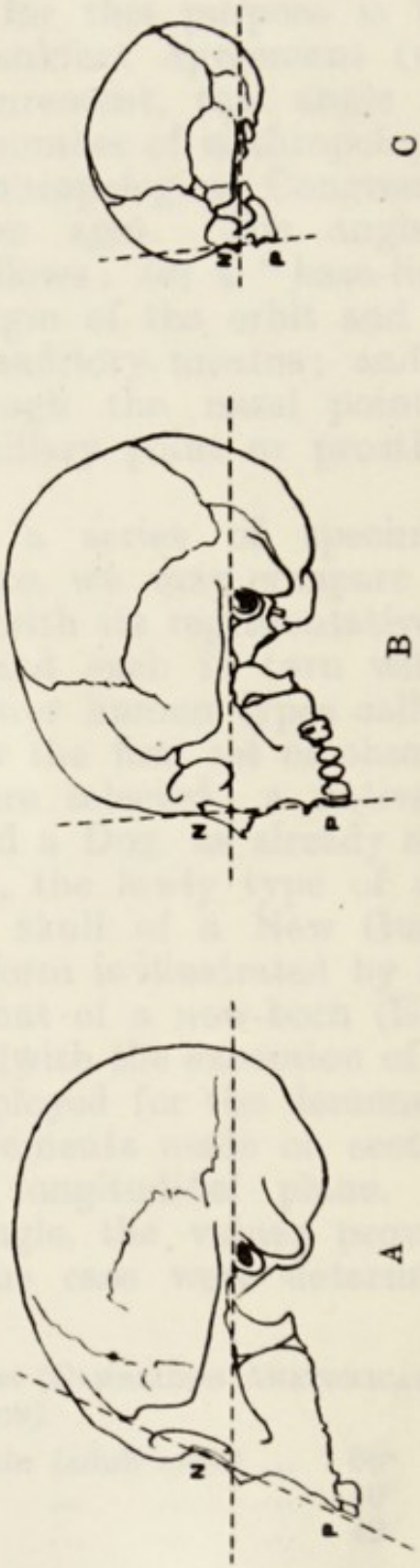

FIG. 11.—The facial angle of the Frankfort Agreement is shown in the crania of (A) a New Guinea native; (B) an European (woman); (C) a new-born infant.

CASE 2.—A comparative study of the crania of Man and the apes involves some reference to the so-called "facial" angles, and the light they throw upon the respective peculiarities of cranial development.

The facial angle selected for this purpose is that known as the angle of the Frankfort Agreement (with many other methods of measurement, this angle was adopted as the standard by a number of anthropologists who attended the German Anthropological Congress at Frankfort about twenty years ago). The angle is included by lines drawn as follows: (*a*) a "base-line," passing through the lower margin of the orbit and the upper margin of the external auditory meatus; and (*b*) a "facial" line, passing through the nasal point or "nasion" (N) and the pre-maxillary point or prosthion (P). [*Cf.* fig. 10, A.]

These lines are shown in a series of specimens (figs. 10, 11). In the first place, we may compare the angle in a lowly human type with its representative in an anthropoid ape (Gorilla), and each in turn with a Dog; again, the higher and lower human types call for special comparisons. Thus, for the first set of observations the following crania were selected: a native of New Britain, and a Gorilla and a Dog, as already mentioned. For the second series, the lowly type of conformation is provided by the skull of a New Guinea native (male), and the higher form is illustrated by that of an European woman and that of a new-born (European) infant. The same series (with the exception of the skull of the infant) is also employed for the demonstration of certain angular measurements made on sections of the crania in the median longitudinal plane. As regards the Frankfort facial angle, the values provided by the actual specimens in the case were determined as follows:—

A. GENERAL COMPARATIVE SERIES (CAMBRIDGE ANATOMICAL COLLECTION).

Aboriginal native of New Britain (adult male) ...	68°
Adult male Gorilla	50°
Dog	42°

B. HUMAN SERIES.

Adult European (female)	93°
European new-born infant (or fœtus of 9 months)	93°
Aboriginal native of New Guinea (adult male) ...	75°

In each series, the lower numerical value of the facial angle denotes an inferior evolutionary status, but it should be noticed that the infant skull provides a high value, so that this character is attained at an early age in the European, and is also a feature of the infantile cranium of all races.

Other angles, no less instructive, and indeed more easy to determine with accuracy than the facial angles, are measured upon the plane surface exposed when a skull is split longitudinally into symmetrical halves. Such sections are shown in the second case, and the including lines of two angles are represented on the sections. These angles are known as the spheno-ethmoidal angle and the spheno-maxillary angle respectively. They provide a definite and accurate means of comparing the sections of crania divided in the median longitudinal plane (figs. 12, 13).

The spheno-ethmoidal angle is included by lines drawn from the point called prosphenion (the foremost and uppermost point on the sphenoid bone) to the basion (or basal point) and the nasion (or nasal point) respectively.

The values of the spheno-ethmoidal angle, as measured on the specimens exhibited in the Cambridge Anatomical Collection, are given in the following tables:—

A. General Comparative Series.

Aboriginal native of New Britain	147°
Adult male Gorilla	180°
Adult Dog	238°
	(greater than two right angles.)

B. Human Series.

Adult European (female)	145°
Aboriginal native of New Guinea	162°

The second angle is called spheno-maxillary. It is included by the line drawn from the basal point to the prosphenion (as described in the preceding paragraph), and by a second line drawn through the prosphenion and the pre-maxillary point (or prosthion). This angle (like the facial angle, to which, however, it is regarded as distinctly superior and preferable) gives a measure of prognathism. The values, as measured on the above-mentioned crania, are given in the following tables:—

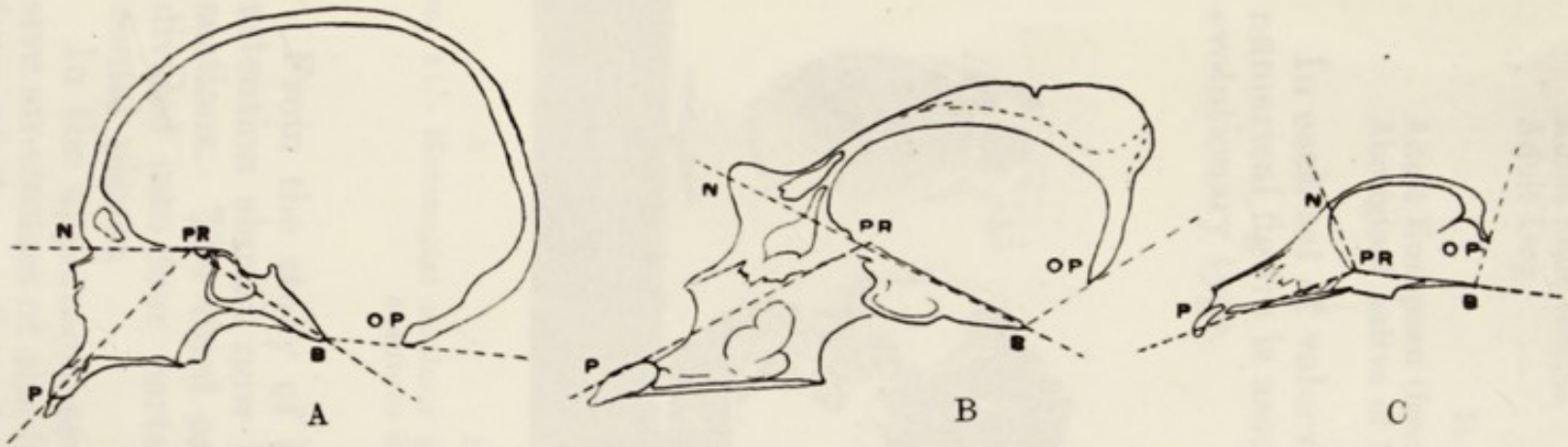

FIG. 12.—The spheno-ethmoidal, spheno-maxillary, and foramino-basal angles are shown in the crania of (A) a New Britain native (male); (B) a Gorilla (male); (C) a Dog. N, PR, B, Spheno-ethmoidal angle; P, PR, B, spheno-maxillary angle; PR, B, OP, foramino-basal angle.

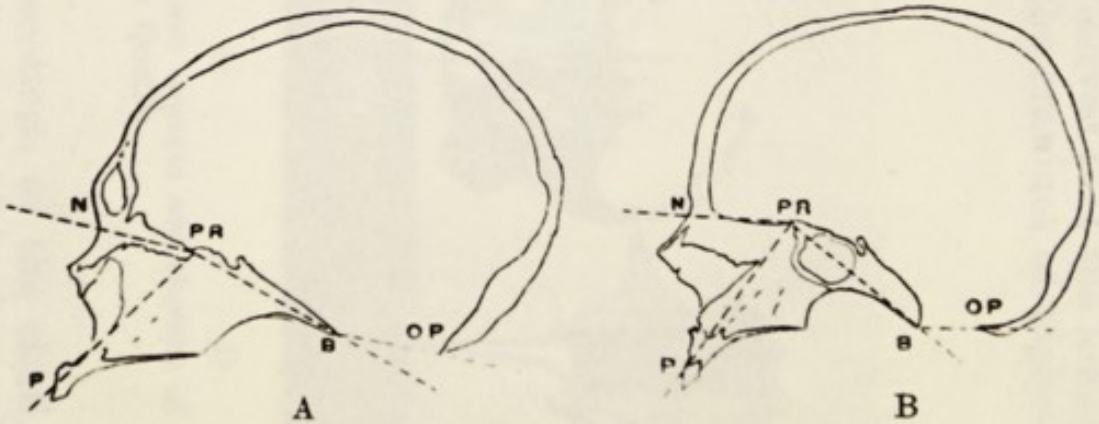

FIG. 13.—The spheno-ethmoidal, spheno-maxillary, and foramino-basal angles are shown in the crania of (A) a New Guinea native (male); (B) an European woman. N, PR, B, spheno-ethmoidal angle; P, PR, B, spheno-maxillary angle; PR, B, OP, foramino-basal angle.

A. General Comparative Series (Cambridge Anatomical Collection).

Aboriginal native of New Britain	95°
Adult male Gorilla	125°
Adult Dog	150°

B. Human Series.

Adult European (female)	85°
Aboriginal native of New Guinea	104°

In each set of values, it will be observed that the lower numerical figure is associated with the cranium of higher evolutionary type.

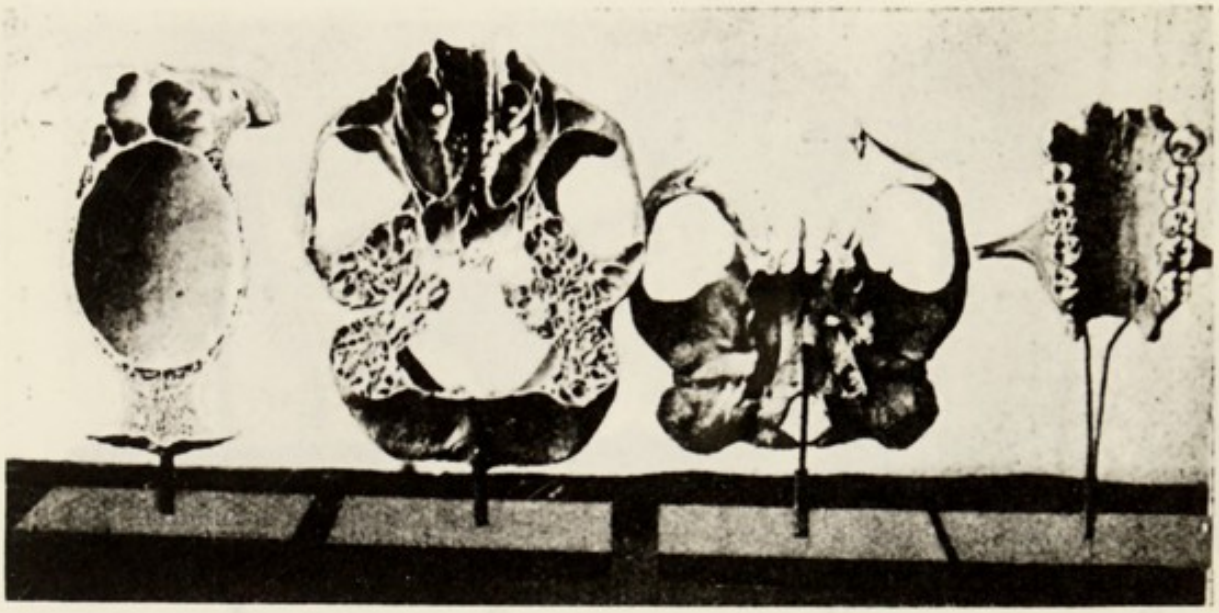

A B C D

Fig. 14.—Horizontal sections (of which the lower aspects are shown) of the cranium of an adult male Gorilla.

From the study of longitudinal sections of the skull, attention should now be diverted to that of horizontal sections. The third case contains the skull of a Gorilla divided into four parts by successive divisions in horizontal planes.

In the uppermost section (fig. 14, A) notice the extensive air-sinuses of the frontal bone, and the extraordinary form of the section, due largely to the sudden narrowing of the skull just behind the brow-ridges. Contrast the European human skull with that of the Gorilla in this respect, and note that the essential factors are two, viz.,

(*a*) the growth of the temporal muscles, and (*b*) the growth of the frontal lobe of the brain. The gap between European Man and the Gorilla in these respects is bridged over to some extent, the intermediate forms being the negro races of Man, and the Chimpanzee and Gibbon (especially in their immature stages) among the apes.

The second section (fig. 14, B) shows the enormous extent of air-sinuses in the Gorilla skull. A communication between the nasal fossæ and the sinuses of the temporal bone is strongly suspected, but has not yet been demonstrated. Notice the remarkable dilation of the nasal duct, a characteristic of the Gorilla.



A B C D

FIG. 15.—(A) Mandible of an adult male Gorilla; (B) pelvis of a male Bush native (South Africa); (C) pelvis of a male Orang-utan; (D) pelvis of a male Macacus monkey.

In the third section (fig. 14, C), the lower aspect may be studied. Notice the contrast with the human skull in the following points: (*a*) shallowness of the glenoid fossa; (*b*) large endo-glenoid and post-glenoid tubercles; (*c*) non-ossification of the styloid process.

The fourth section (fig. 14, D) reveals the extent of the maxillary antrum (in the upper jaw) forwards and backwards. The maxilla greatly exceeds that of Man in bulk. The canine tusks and diastema are shown, and the prominent cusps of the molar teeth should be noted. The dental formula is like that of Man (I. $\frac{2}{2}$, C. $\frac{1}{1}$, Pre. $\frac{2}{2}$,

M. $\frac{3}{3}$). The palate is shallow and long in proportion to its length. The two rows of teeth (behind the canine tusks) converge as they are traced backwards.

The mandible (fig. 15, A) is of corresponding dimensions to the maxilla. In the male Gorilla the jaw is much larger than in the female, and a corresponding, though far less striking difference obtains between man and woman. The chin is curiously indefinite, and behind the mandibular symphysis a deep pit often replaces the genial tubercles. The molar teeth should be examined, and the numerous cusps (even six may be present) should be remarked. The first pre-molar tooth imitates the canine in shape. The region of the angle is remarkable, for though this part projects, the contour is rounded, so that the region of transition does not admit of very accurate determination of the exact site of the "angle."

It is necessary now to digress for a moment, and to pass from the study of skulls to that of the pelves, which (on account of the exigencies of space) are placed in this case. For the sake of rendering comparisons the more easy, the pelves here shown are those of :—

(*a*) A male Bush native (South Africa) (fig. 15, B).
(*b*) An adult Orang-utan (male) (fig. 15, C).
(*c*) An adult Macacus monkey (male) (fig. 15, D).

The general characters of the three specimens should first be studied. In the human pelvis, transverse width is the prominent feature; in the Orang-utan, and still more in the Macacus monkey, the pelvis is narrowed transversely, but in compensation for this the diameter is increased in the direction of the vertebral axis. The index of the pelvis (whereby height and width are compared, *i.e.*, index $= \frac{\text{height of pelvis} \times 100}{\text{width of pelvis}}$) brings out this difference in a numerical form :—

PELVIC INDEX.

Example.	*Value of Index.*
European female	74 (av.) [Verneau] *i.e.*, height = 74 % only of width, so that the latter is to the height as 100 to 74.
European male...	79 (av.) [Verneau].
Bush native (male)	82·4 (specimen in Case 3).
" " "	91 (Turner).
Orang-utan (male)	95·7 (specimen in Case 3).
" "	95 to 103 (range of variation).
Macacus monkey and allies ...	134 (average).
" " (male) ...	160·4 (specimen in Case 3).

Other instructive comparisons result from the study of the form of the pelvic brim. In the European female pelvis, the sagittal (or conjugate) axis of the brim falls far short of the transverse axis. But in the lower human races, and especially in males, the difference is lessened; in the apes the proportions are reversed. The index of the pelvic brim (index $= \frac{\text{sagittal diameter of brim} \times 100}{\text{transverse diameter of brim}}$) provides the following figures:—

BRIM-INDEX OF PELVIS.

Example.	*Value of Index.*
European female	74
European male	92·6
Bush native (male)	94·8
Orang-utan (male)	141·8
Macacus monkey (male)	122·8

The height and width of the innominate bone may also be compared usefully in these types of pelvis. The innominate index ($= \frac{\text{iliac width} \times 100}{\text{innominate height}}$) gives the following figures:—

INNOMINATE INDEX.

Example.	*Value of Index.*
European female	79
European male	74·5
Bush native (male)	70·7
Orang-utan	46·7
Macacus monkey	24·6 (or 38·9 if measurement of iliac width is exactly from the anterior to the posterior superior iliac spine).

The sacrum will be dealt with in connection with specimens in Cases 4 and 5.

CASE 4.—Resuming the study of the skull, we come to specimens illustrating certain points in the anatomy of the face as seen in coronal sections.[1] If a facial coronal section be made so as to pass throughout the length of the nasal ducts, the maxillary antrum and nasal fossa will be exposed on each side. Such sections have been made in crania of lower and higher human types (viz., of

[1] This method of study was recommended by Dr. Keith in the *Proceedings of the Anatomical Society*, May, 1902.

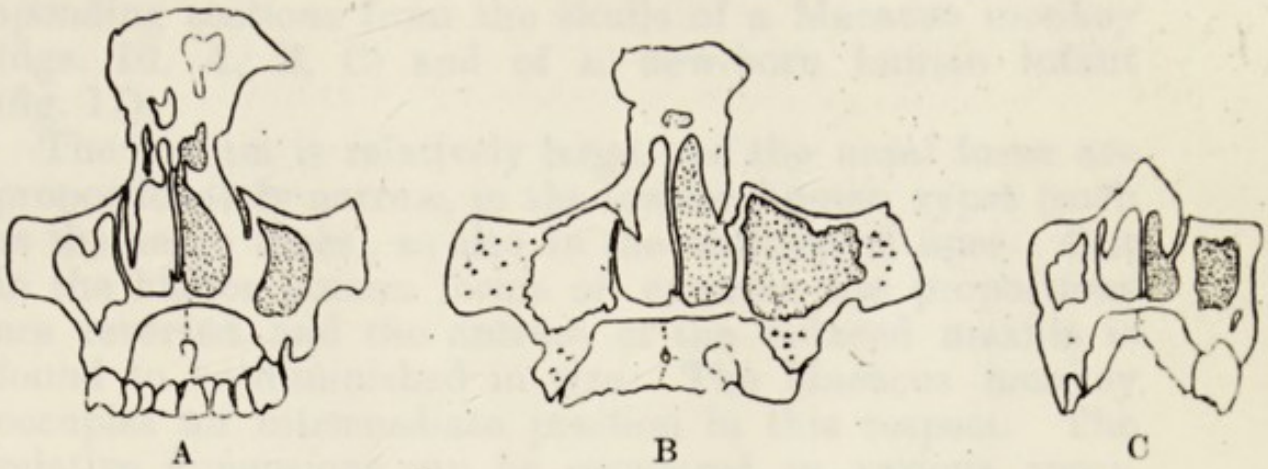

FIG. 16.—Coronal sections (traversing the nasal duct) of the facial skeleton of (A) European (male); (B) New Guinea native (male); (C) Macacus monkey. The nasal fossa and maxillary antrum of the right side are stippled.

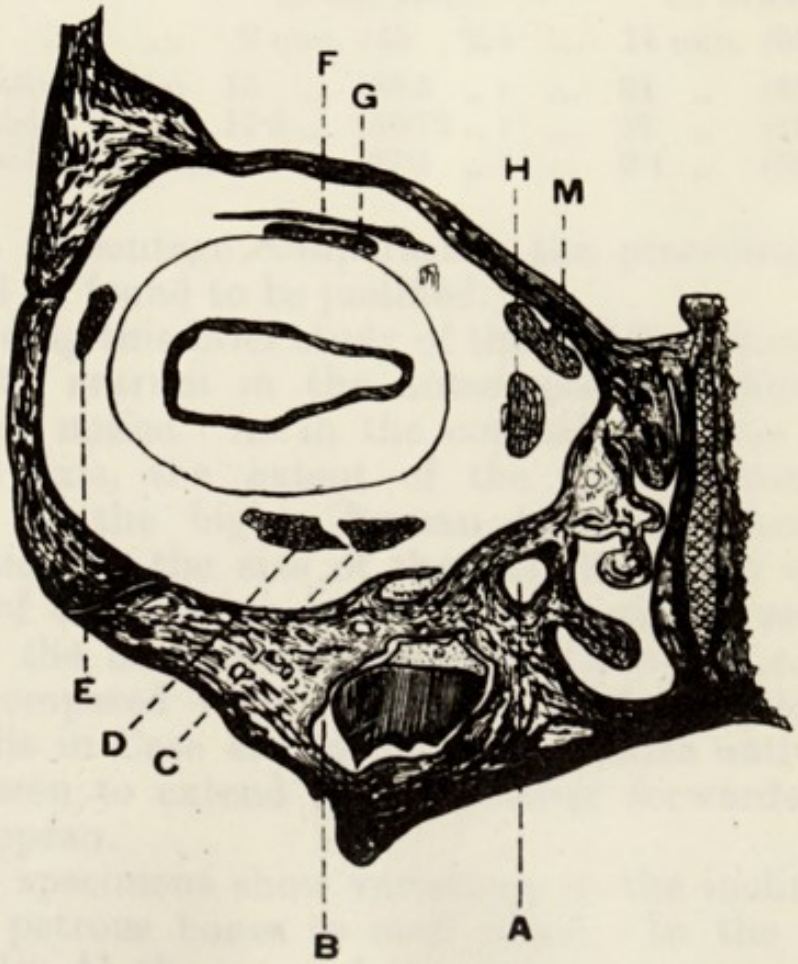

FIG. 17.—Coronal section (× 2) of the facial skeleton of a new-born infant. (A) Maxillary antrum; (B) tooth-cavity; (C–M) orbital muscles.

an adult male New Guinea native and of an adult male European), which are to be compared with the corresponding sections from the skulls of a Macacus monkey (figs. 16, A, B, C) and of a new-born human infant (fig. 17).

The antrum is relatively large, and the nasal fossæ are proportionately narrow, in the lowlier human types (such as the negro races), as also in the anthropoid apes. But in the higher human forms of cranium the proportions are reversed, and the antrum of the reduced maxilla is found to be diminished in size. The Macacus monkey occupies an intermediate position in this respect. The relative dimensions can be compared in various specimens by measuring the widths of the nasal fossa (of one side) and that of the antrum of the corresponding side in the same section. In the specimens here considered these measurements are as follows:—

Specimen.	*Width of nasal fossa on one side.*	*Width of antrum on same side.*
Macacus	9 mm. (45 %) ...	11 mm. (55 %)
New Guinea native (male)	15 ,, (38·5 ,,) ...	24 ,, (61·5 ,,)
European (male)... ...	17·5 ,, (50·72 ,,) ...	17 ,, (49·28 ,,)
European (new-born infant)	5 ,, (67·5 ,,) ...	2·4 ,, (32·5 ,,)

From the percentage comparisons, the preceding conclusions will be found to be justified.

In concluding this brief study of the facial sections, the extent of the antrum in the antero-posterior direction also demands notice. As in the coronal direction, so in the sagittal axis, the extent of the antrum tends to diminution in the higher human types concurrently with reduction in the size of the maxilla. The extent (forwards) of the antrum in the Gorilla can be seen by reference of the horizontal sections in Case 3 (*q.v.*), and should be compared with the extent in the sections of human skulls in Case 4. In the New Guinea native the antrum is seen to extend rather further forwards than in the European.

The next specimens show variations in the inclination of the two petrous bones to each other. In the lower types (fig. 18, A) the axes of the petrous bones are inclined at an acute angle salient forwards. In the higher forms (fig. 18, B), and with the transverse expansion of

the brain, the sides of the skull separate and each petrous bone rotates about a vertical axis; the angle of inclination enlarges to a corresponding extent. Measurements were made with the following results :—

Example.	*Angle of inclination of petrous bones.*
Macacus monkey	68°
Chimpanzee (young)	82°
New Guinea native (adult male)	100°
European (adult male)	101°
[Human embryo of 7 weeks (v. Noorden) ...	45°]

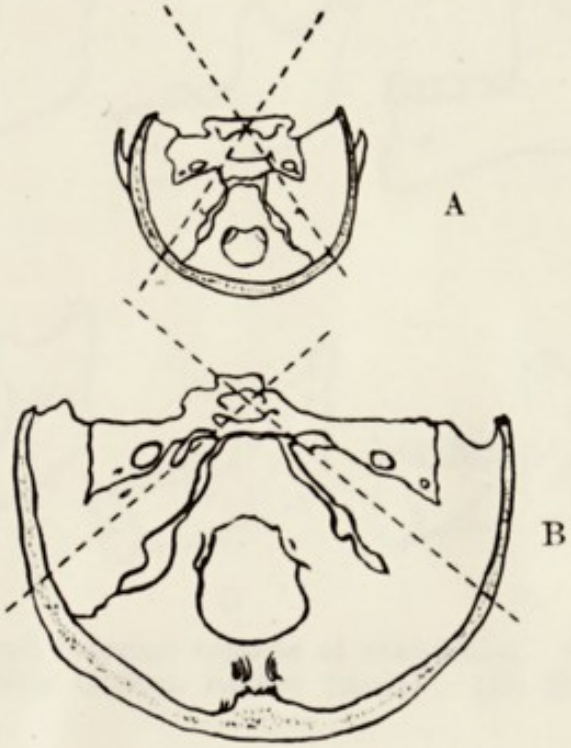

FIG. 18.—Horizontal sections through the posterior part of the cranium (A) of a Macacus monkey; (B) of a New Guinea native (male).

The same specimens reveal the differences in the thickness of the brain-case which occur in different human crania and in different regions of one and the same skull. Measurements of the thickness of the skull-wall in different regions provide the following results. The influences of race, age and sex must all be taken into account in comparisons of this kind.

SUBJECT : The skull-wall differs in thickness from :—

Macacus	1 mm. to 2·5 mm.
Chimpanzee (juv.)	1 ,, ,, 3·5 ,,
New Guinea native (male)	1 ,, ,, 18·0 ,,
European (adult male)	1 ,, ,, 11·5 ,,

The mandibles shown in this case are those of a Macacus monkey (fig. 19, A); a Chimpanzee (adult) (fig. 19, B); two New Guinea natives (adult males) (fig. 19, C); male European (adult) (fig. 19, D); female European (adult) (fig. 19, E); new-born European infant. In the upper row the external aspect is shown; the lower row shows the internal aspect. In the lower row special

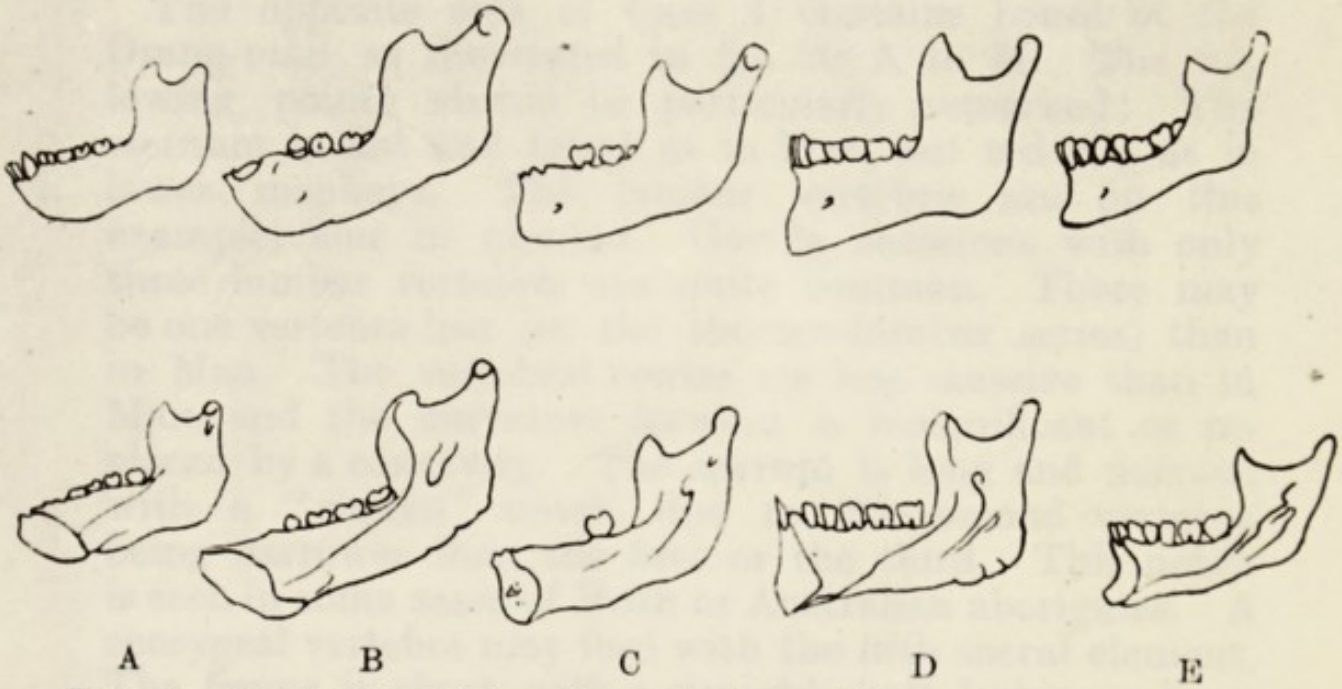

FIG. 19.—External and internal aspects of mandibles. (A) Macacus monkey; (B) Chimpanzee; (C) New Guinea native (male); (D) European (male); (E) European (female).

attention is directed to the form of the section at the symphysis, and the gradual change in sectional contour with the evolution of the chin in the European type. The symphysial angle measures the degree of obliquity of the chin. The angle is included by (*a*) the lower border of the mandible, and (*b*) the anterior surface of the symphysis. The greater numerical value of the angle denotes the lower evolutionary stage, in which the chin is absent or insignificant. The following table gives some data illustrative of this statement :—

Specimen	*Symphysial angle*
French (av. of 31 Auvergnats and Bretons)[1]	66°
African Negroes (av. of 47)[1]	82°
New Hebrides natives (av. of 15)[1]	87°
Infant Gorilla (Mus. Anat. Cant.)[2]	97°
Orang-utan (adult male, Jena)[2]	113°
Chimpanzee (adult male, Lübeck)[2]	125°
Macacus Monkey (adult male)[2]	140°

Other important features are the ascending ramus, in respect of width, height and obliquity, and also of depth of the sigmoid notch and the consequent prominence (or the reverse) of the neck and condyle. The direction of the lower incisor teeth also varies, being more vertical in the human jaw.

The opposite side of Case 4 contains bones of the Orang-utan as illustrated in fig. 20, A to M. The following points should be particularly remarked: The sternum is flat and broad as in Man, not rod-like as in lower monkeys. The lumbar vertebræ are (in this example) four in number. Gorilla skeletons with only three lumbar vertebræ are quite common. There may be one vertebra less (in the thoraco-lumbar series) than in Man. The vertebral centra are less massive than in Man, and the curvature forward is insignificant or replaced by a concavity. The sacrum is long and narrow, with a "simian" notch, due to the second vertebra being narrower than the first or the third. This notch is seen in some sacra of Bush or Australian aborigines. A coccygeal vertebra may fuse with the fifth sacral element. The femur is short, with a straight shaft lacking a linea aspera, and a round head devoid of a digital impression for the ligamentum teres (which is absent).

The patella of the anthropoid ape is intermediate in form between those of men and those of the lower apes, which in turn closely resemble the lower mammals in possessing a narrow patella. In the anthropoid ape the bone already exhibits increased width, and this increase attains a further stage in Man.

The skeleton of the foot demands particular notice. The tarsus is shorter, and the metatarsus relatively longer, than in Man. The toes are very long, and there is a wide

---

[1] *Cf.* Topinard, *Éléments, &c.*, p. 898.
[2] Measurements by the writer.

space between the hallux and the second digit. All these points are associated with the function of the foot as a

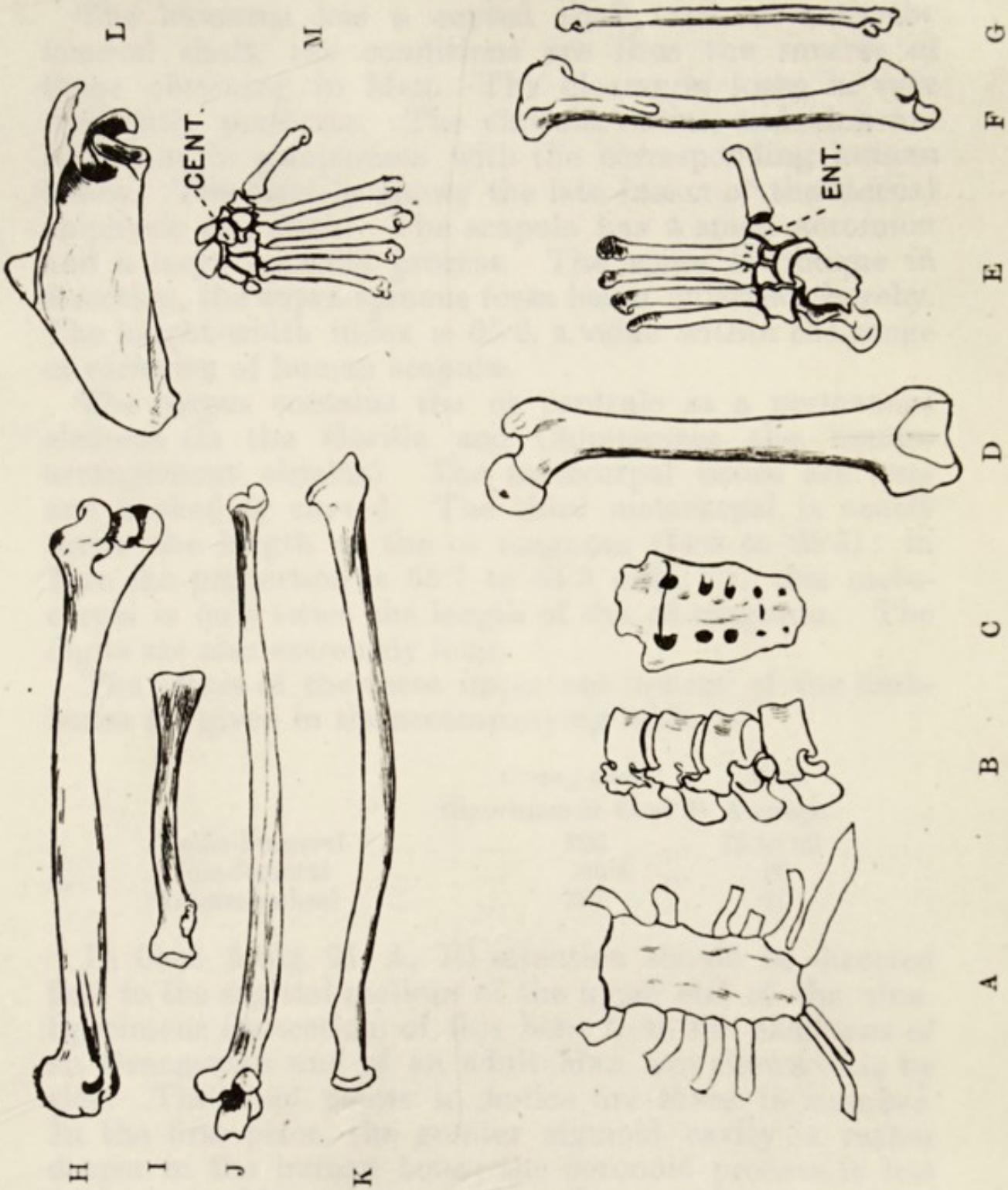

FIG. 20.—Skeleton of an adult male Orang-utan. (A) Sternum with costal cartilages; (B) lumbar vertebræ (four); (C) sacrum; (D) left femur; (E) left tarsus and metatarsus (ENT., entocuneiform bone); (F) left tibia; (G) left fibula; (H) right humerus; (I) right clavicle; (J) right ulna; (K) right radius; (L) right scapula; (M) right carpus and metacarpus (CENT., os centrale carpi).

prehensile rather than a supporting organ. The interosseous muscles are grouped about the third metatarsal bone and digit, as in the hand.

The tibia and fibula will be considered in connection with their sections shown in Case 6.

The humerus has a curved shaft, and, as with the femoral shaft, the conditions are thus the reverse of those obtaining in Man. The olecranon fossa is very frequently perforate. The clavicle, radius, and ulna are enormous in comparison with the corresponding human bones. The clavicle shows the late fusion of the sternal epiphysis and shaft. The scapula has a small acromion and a large coracoid process. The spine is oblique in direction, the supra-spinous fossa being enlarged thereby. The height-width index is 65·6, a value within the range of variation of human scapulæ.

The carpus contains the os centrale as a permanent element (in the Gorilla and Chimpanzee the human arrangement obtains). The metacarpal bones are long and hooked or curved. The third metacarpal is nearly thrice the length of the os magnum (74·5 to 25·5); in Man the proportion is 65·7 to 34·3 only, *i.e.*, this metacarpal is only twice the length of the os magnum. The digits are also extremely long.

The values of the three important indices[1] of the limb-bones are given in the accompanying table:—

	Orang-utan. (Specimen in Case 4)	*Man.* Average
Radio-humeral	106 ...	75 to 80
Tibio-femoral	86·4 ...	80
Intermembral	137 ...	70

In Case 5 (fig. 21, A, B) attention should be directed first to the sagittal sections of the upper end of the ulna. Specimens (in section) of this bone from the skeletons of an Orang-utan and of an adult Man are shown side by side. The chief points to notice are three in number. In the first place, the greater sigmoid cavity is rather deeper in the human bone; the coronoid process is less massive in Man, appearing in the section as a sharp spinous projection; and there is an important difference in the olecranon process in the two bones. In the Orang-utan (fig. 21, A) the olecranon process is not quite so hook-like as in Man, and the process in Man (fig. 21, B) is more massive. The last point is well illustrated by

[1] See "Morphology and Anthropology," pp. 328-340, for other examples.

the comparison of measurements made on the surfaces of these sections. In the Orang-utan the area of that part of the ulna which may be termed the true olecranon process is 251·5 sq. mm. In the human bone the sectional area of the corresponding part is 383 sq. mm. The difference is accounted for chiefly by the extent of the posterior and upper part of the human olecranon, as may be seen when the sections are compared.

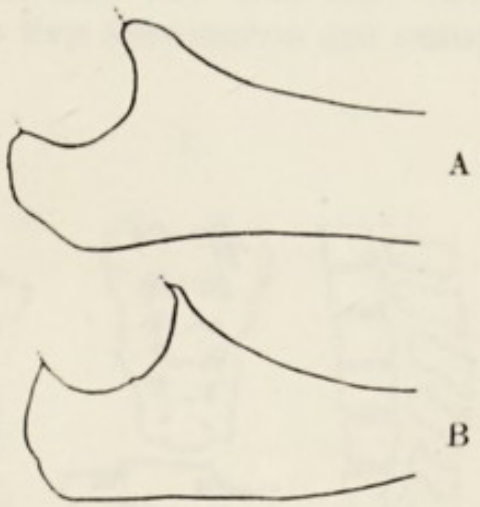

FIG. 21.—Tracings (× ½) of upper end of ulna in (A) Orang-utan (male); (B) Man.

The humerus of the Orang-utan provides an interesting comparison with the human humerus when the coronal sections through the upper and lower ends are respectively compared. In the sections through the heads of the humeri, the chief difference depends on the more definite constriction in the Orang-utan's humerus at the region known as the "anatomical neck" of the bone. The anatomical neck is thus more distinct in the Orang-utan. The upper part of the shaft, known as the "surgical neck," is stouter in the humerus of the Orang-utan. At the lower ends of these humeri differences again occur. In the Orang-utan the outline of the lower articular surface is distinctly more undulating than in the humerus of Man, wherein the capitellum and the two parts of the trochlea are not so clearly demarcated and defined. This difference leads to the conclusion that the joint in the Orang-utan is better protected against lateral strain and stress than the elbow-joint of Man. In the

ape the elbow-joint is above all a hinge-joint, the movements of pronation and supination being less prominent than in Man, for in the latter one result of the acquisition of his erect attitude is to set free the upper limb, and this in turn allows of other movements at the elbow than the simple primary actions of flexion and extension.

The human characteristic of sudden expansion of the lower part of the humerus, with an abrupt transition between the shaft and the articular end of the bone, is evident when the two specimens are compared.

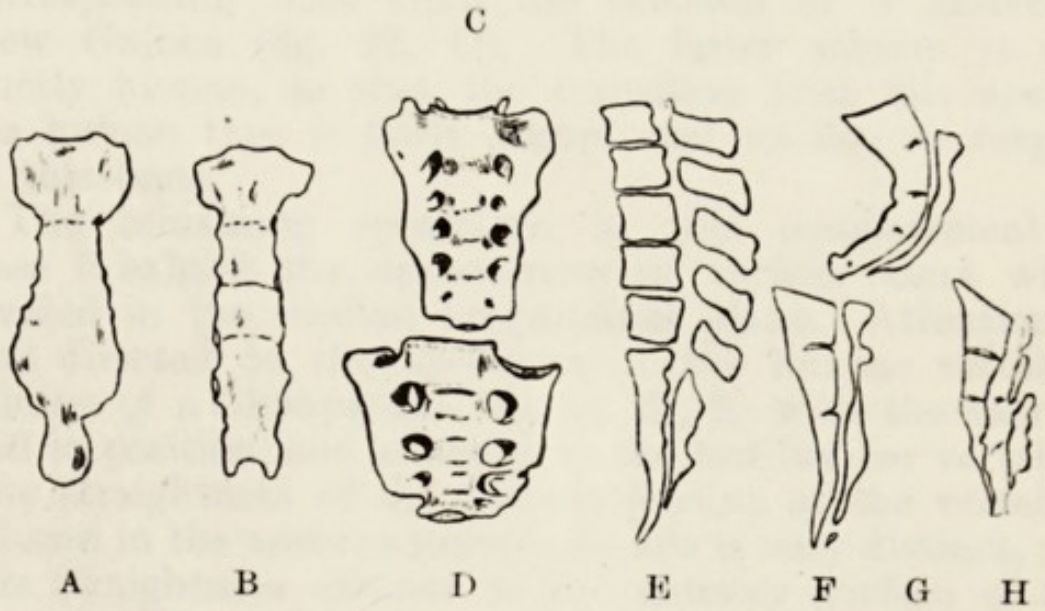

FIG. 22.—(A) Sternum of European (male); (B) sternum of New Guinea native (male); (C) sacrum of Chimpanzee; (D) sacrum of New Guinea native (male); (E) mesial section of lumbar vertebræ and sacrum of Chimpanzee; (F) mesial section of sacrum of New Guinea native (male); (G, H) mesial sections of extreme forms of European sacra.

In the next compartment of Case 5 (fig. 22, A, B) specimens of the sternum in an adult European and a native of New Guinea are placed side by side. The great length of the specimen from New Guinea is unusual, but by no means outside the range of variation in European examples. Following these specimens we must pass to the opposite side of the case to compare with them the short broad sternum of an Orang-utan (in which traces of the serial or segmental arrangement of the sternal elements still persists), and for purposes of contrast the almost rod-like sternum of a Macacus monkey has been mounted beside the preceding example. The latter type of sternum

is associated with what has been well termed the "pronograde" attitude, the broad "latisternal" type occurring only in the highest apes and in Man. From some points of view the broad type may be considered the more primitive, for comparative anatomy shows that a broad sternum appears early in the vertebrate series. The same compartment of Case 5 contains some examples of the sacrum in various types. The long narrow sacrum (associated with a tall narrow pelvis) of the Orang-utan has been the subject of comment in connection with the specimens in Cases 3 and 4. Here the sacrum of a Chimpanzee is shown (fig. 22, C), and beneath it the corresponding bone from the skeleton of a native of New Guinea (fig. 22, D). The latter sacrum is distinctly human, so that the transition from the ape to the human type is fairly abrupt and sudden in respect of this bone.

The remaining specimens in this compartment of Case 5 exhibit the appearances of various sacra when divided in the median longitudinal plane. Attention is first directed to the specimen of the lumbar vertebral column of a Chimpanzee (see fig. 22, E) with the sacrum still in position, and attached to the last lumbar vertebra. The straightness of the lumbar portion of the vertebral column in the anthropomorphous ape is very distinct, and this straightness extends to the anterior surface of the sacrum. The adult human sacrum, on the other hand, is deeply concave; in women the concavity is more marked than in men; in the higher or white types of mankind, the concavity is more marked than in the lower races, here exemplified by the sectionized sacrum of a native of New Guinea (fig. 22, F), and in the adult human being the concavity is more distinct than in the fœtal and infantile phases of life. Thus the factors of sex, race, and age all play parts in determining this character in the sacrum. But varieties occur among human adults, and these range from the extremes of exaggerated curvature, on the one hand, to instances of obliteration of the normal concavity forwards, or even of its replacement by a slight forward convexity. The two specimens from the dissecting room, shown in fig. 22, G, H, exemplify these extremes, so that yet another factor, that of variation within physiological and pathological limits, must also be taken into account.

The curvature of the sacrum may be measured and the result set forth in a numerical form. This enables the observer to make comparisons with greater exactness. As examples of this method of comparison the following data may be quoted :—

ANTERIOR SACRAL LENGTH.

	Rectilinear.	*Curvilinear.*	*Difference.*
	mm.	*mm.*	*mm.*
European (female)	83 ...	109 ...	26
European (male)	104 ...	120 ...	16
New Guinea native (male) ...	101 ...	107 ...	6
Orang-utan (Mus. Anat. Cant., No. 1, male)	99 ...	102 ...	3
Gorilla (Mus. Anat. Cant., female)	115 ...	116 ...	1

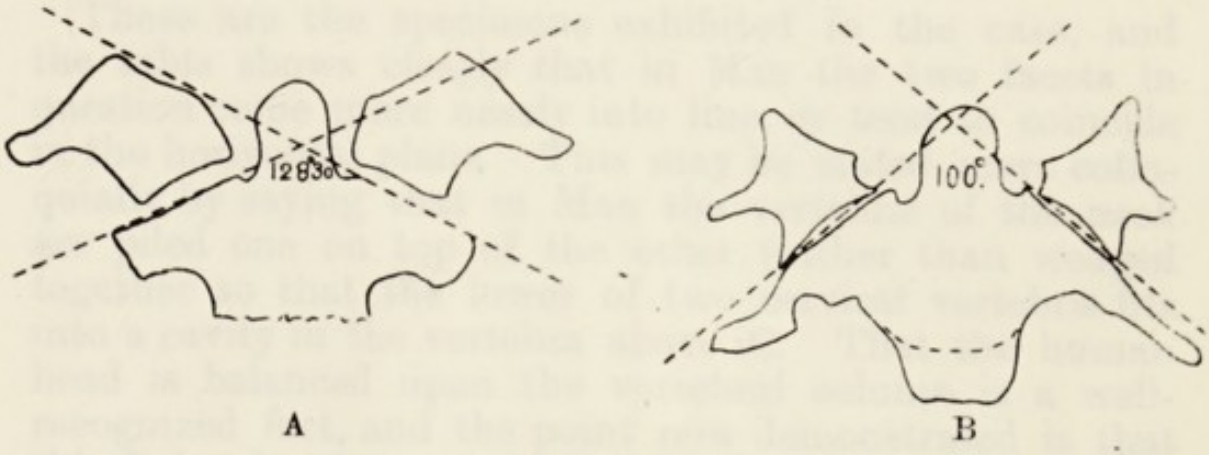

FIG. 23.—Vertical sections through the atlas and axis vertebræ of (A) a New Guinea native (male); (B) an Orang-utan.

The third part of this case contains the broad flat sternum of an Orang-utan, and next to it will be seen the rod-like sternum of a Macacus monkey. These types of sternum have been described as the (latisternal) orthograde and the pronograde forms respectively. The remaining specimens (fig. 23, A, B) in this part of Case 5 are all coronal sections through the two upper cervical vertebræ, and in two examples the lower part of the skull with the first five cervical vertebræ have been divided thus (coronally) while still in apposition. The object with which these sections were made is to demonstrate the differences between the higher apes and Man in respect of the articulations (*a*) of the skull with the atlas vertebra, (*b*) of the atlas vertebra (C. I.) with the axis vertebra (C. II.). Particular attention is here called to the joints

between the atlas and axis, *i.e.*, between the articular processes of those vertebræ. If the articular facets of the upper articular processes of the axis vertebra are examined, it is at once evident that they are nearly flat surfaces, and that the planes of the two facets are inclined upwards and inwards so as to intersect somewhere near the top of the odontoid process. The angle of inclination of the planes of these facets gives the following values:—

The angle of inclination in the			Macacus monkey is	93°
,,	,,	,,	Orang-utan (fig. 23, B) is ...	100°
,,	,,	,,	Ancient Egyptian is	126°
,,	,,	,,	New Guinea native is (fig. 23, A)	128° 30′
,,	,,	,,	European (adult male) is ...	128°
,,	,,	,,	European fœtus (9 months) is ...	130°

These are the specimens exhibited in the case, and the table shows clearly that in Man the two facets in question come more nearly into line, or tend to coincide in the horizontal plane. This may be stated more colloquially by saying that in Man the vertebræ of the neck are piled one on top of the other (rather than wedged together so that the lower of two cervical vertebræ fits into a cavity in the vertebra above it). That the human head is balanced upon the vertebral column is a well-recognized fact, and the point now demonstrated is that this balancing is accompanied by a distinct and special inclination of the facets on the lower surface of the atlas vertebra and the upper surface of the axis vertebra.

The series of endocranial casts (figs. 24, 25, 26) were made from crania of (*a*) an ancient Egyptian, (*b*) an aboriginal native of Australia, (*c*) an adult male Gorilla. The Gorilla, though probably exceeding in bulk and weight both the human representatives, has by far the smallest endocranial cavity.

Each cast has been cut transversely to the long axis of the cerebrum, and the surfaces at three different levels are shown. Careful tracings were made of each section at the mid-point of the extreme length of the cast, and also at the mid-point between each pole of the hemisphere and the first section. Thus the levels correspond to distances of one quarter, one half, and three quarters of the total length measured from the frontal end. Such sections are therefore comparable in the three specimens.

The endocranial cast of the Australian aboriginal skull provides sections (fig. 25) which are curiously pointed in the upper part. This pointed appearance is due to a flattening of the surface which is clearly revealed in the sections. In comparison with these, the sections of the endocranial cast of the skull of the Egyptian are rounded and full. The outline of the brain is thus shown to be



FIG. 24.

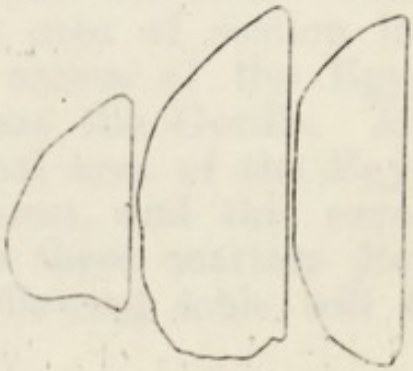

FIG. 25.



FIG. 26.

FIG. 24.—Coronal sections of an endocranial cast (cranium of Ancient Egyptian man). In this and the two following figures the sections were made at equal distances along the antero-posterior axis of the hemisphere. The smallest section is the most anterior, the largest is intermediate. (× ¼.)

FIG. 25.—Coronal sections of an endocranial cast of an aboriginal native of Australia (male). (× ¼.)

FIG. 26.—Coronal sections of an endocranial cast of an adult male Gorilla. (× ¼.)

different in the two crania, and the "scaphoid" character of the skull of the Australian aboriginal must therefore also correspond to a peculiar formation of the cerebral surface, viz., with a marked area of flattening near the great longitudinal fissure. This flattening is not, however, a primitive, *i.e.*, a simian feature, since the endocranial cast of the Gorilla does not exhibit it, being in fact intermediate in type and proportions (though not in

absolute size) between those of the Egyptian and of the Australian aboriginal. The latter must be regarded as "specialized" in this respect, and not necessarily pithecoid or ape-like.

Nevertheless, the Australian encephalon is smaller than that of the Egyptian. The measure of the contents of the skull is one way of showing the differences. But the area of the sections also brings out the same point. Now as a matter of fact, if the sections at the level of one quarter of the length of the axis (measured from the frontal pole) be compared, the area of section in the Australian cast is slightly in excess of the Egyptian example, while both far surpass the Gorilla. At the mid-point, however, the sectional area of the Egyptian specimen is decidedly the greatest, and this excess is reproduced at the level of the three quarters distance from the frontal end. The following table will bring out these facts more clearly :—

Position of plane of section, with reference to the long axis of the cerebrum.	Description of skull whence the cast is derived.		
	Ancient Egyptian	*Australian Aboriginal*	*Gorilla*
	Area in sq. mm.	Area in sq. mm.	Area in sq. mm.
At one quarter of the length of the axis, as measured from the frontal pole	2025 (100)	2057 (101·5)	1344 (66·37)
At one half of the length of the axis, as measured from the frontal pole	4667 (100)	4402 (94·3)	2398 (51·3)
At three quarters of the length of the axis, as measured from the frontal pole	3607 (100)	3341 (92·9)	2172 (70·8)

The figures in parentheses represent these values reduced to terms of those provided by the Egyptian cast, taken as = 100 in each case.

CASE 6.—This case contains sections of portions of the lower limb-bones, which may be classified in the following way :—

Sections of the left femur :—

(1) Upper end : head, neck, and trochanter : coronal sections { Man (European) / Orang-utan } (fig. 27, A, B).

(2) Upper end : head, neck, and trochanter : sagittal sections { Man (European) / Chimpanzee } (figs. 28, 29).

(3) Lower end: condyles: coronal sections { Man (European) / Chimpanzee } (fig. 30, A, B).

(4) Lower end: condyles: sagittal sections { Man (European) / Orang-utan } (figs. 31, 32).

(5) Shaft: mid-portion: longitudinal mesial section { Man (New Guinea native). / Orang-utan. }

(6) Shaft: 4 cm. above adductor tubercle: transverse section { Man (New Guinea native). / Orang-utan. }

Sections of the tibia:—

(7) Upper end: right tibia: coronal sections { Man (European) / Chimpanzee } (fig. 33).

(8) Upper end: left tibia: sagittal sections { Man (European) / Orang-utan } (fig. 34).

(9) Lower end: left tibia: sagittal sections { Man (European). / Orang-utan. }

(10) Lower end: right tibia with fibula: coronal sections { Man (European). / Orang-utan. }

(11) Lower end: left tibia with fibula: coronal sections { Man (European) / Orang-utan } (figs. 35, 36).

(12) Shaft: left tibia, level of nutrient foramen: transverse sections { Man (New Guinea native) / Orang-utan } (figs. 37, 38).

A few remarks will now be added in reference to the foregoing series of sections. In general, it should be remembered that the difference in function between the femur and tibia of the Orang-utan, on the one hand, and of Man on the other, is very great. In the Orang-utan the lower limb is largely prehensile, and as a weight-supporting piece of mechanism is quite contemptible in comparison with the human lower limb. The latter has, however, gained its peculiar and special character at the expense of the prehensile function, which has been sacrificed almost completely.

In comparing the bones of the lower limb of the apes with those of Man, the difference of function must be

held continually in mind. In the human bones we shall expect to find provision for supporting, unaided, the superincumbent weight of head, trunk, and upper limbs, in the form of larger bones, more extensive articular surfaces, and more prominent crests and ridges for the attachment of the powerful muscles demanded by the strain thrown on the several parts in movement. With such considerations in view the various preparations may now be studied in some greater detail.

FIG. 27.—Tracings (× ½) of coronal sections through the left femur in (A) an European (male); (B) an Orang-utan (male).

It will be noticed that the apes are represented in most instances by the Orang-utan; in two or three cases the bones of Chimpanzees have been substituted owing to lack of material from skeletons of Orang-utans. The object of the selection of the Orang-utan in these series has been to provide a comparison between terrestrial man and a definitely arboreal ape; for the Chimpanzee and Gorilla are not so distinctly confined to life among trees as is the Orang-utan. The result is that in these African anthropoid apes the more purely arboreal characters are already a little blurred. This very fact places them in a position nearer to Man than is the Orang-utan (despite a statement which has crept into books on this subject and is based upon too narrow an anatomical survey). With these introductory remarks, the study of the

sections may be commenced. For convenience of reference, the various points will be set out in a tabular form.

(1) Femur: upper end: coronal sections (fig. 27 A, B).

In the human femur: The head, neck, great trochanter, and shaft are larger; the angle at the neck is nearer 90°. In the Orang-utan the bone is smaller.

(2) Femur: upper end: sagittal sections (figs. 28, 29).

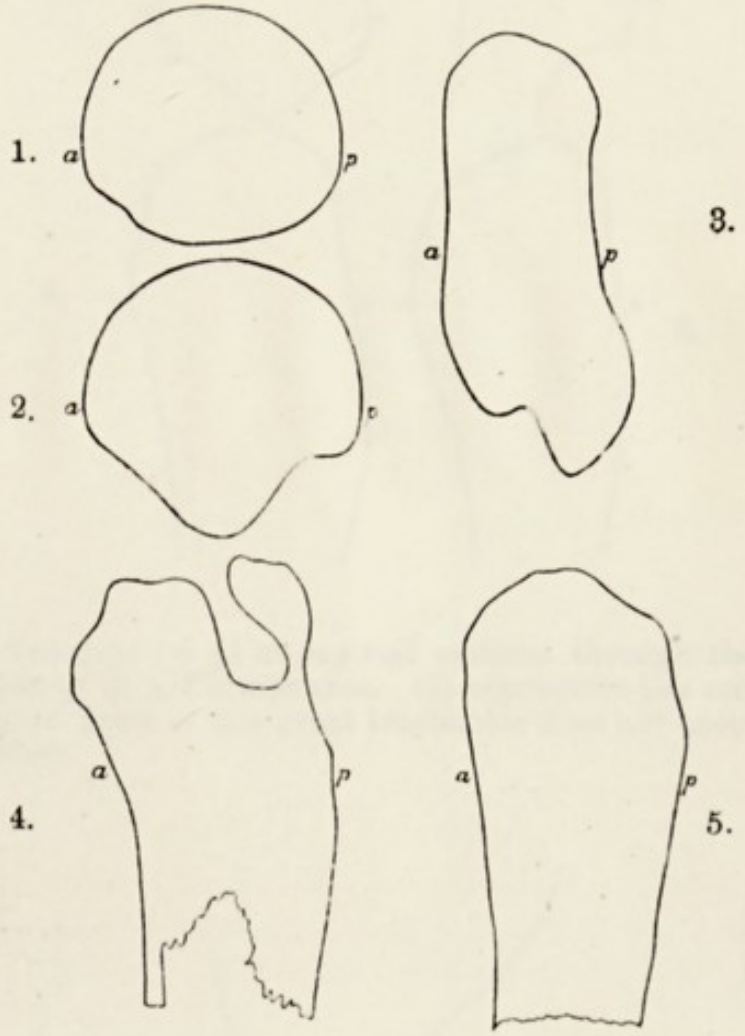

FIG. 28.—Tracings (× ½) of sagittal sections through the upper part of the right femur of an European (male). (5) represents the outermost section.

In the human femur a massive buttress-like flange supports the inner part of the head; this flange is rudimentary in the simian bone. In Man (in contrast to the Chimpanzee) the digital fossa extends further outwards beneath the great trochanter.

(3) Femur: lower end: coronal sections (fig. 30, A, B).

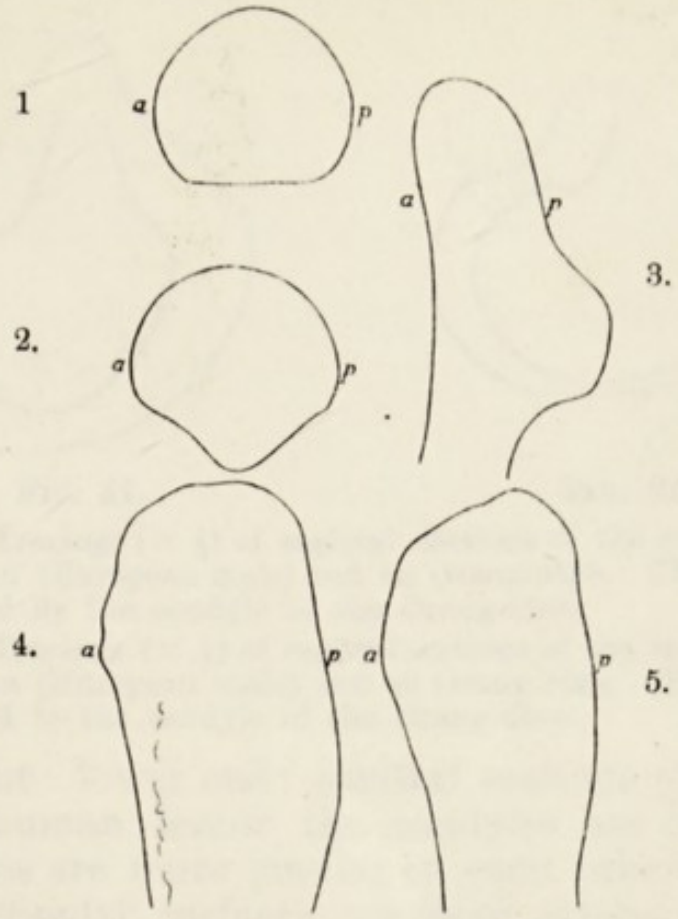

FIG. 29.—Tracings (× ½) of sagittal sections through the upper end of the right femur of a Chimpanzee. (5) represents the outermost section. The digital fossa of the great trochanter does not extend outwards so far as in Man.

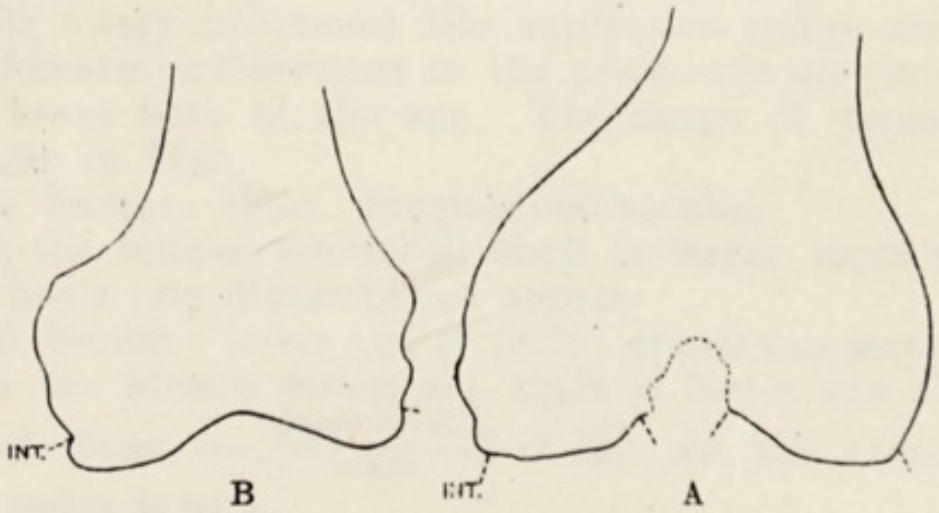

FIG. 30.—Tracings (× ½) of coronal sections of the femoral condyles of (A) European (male); (B) Chimpanzee. In this and figs. 31 to 34 inclusive, the dotted lines mark the limits of articular surfaces.

In the human femur the condyles are larger; they

are more definitely contrasted in shape; a deep notch separates the two weight-bearing surfaces.[1]

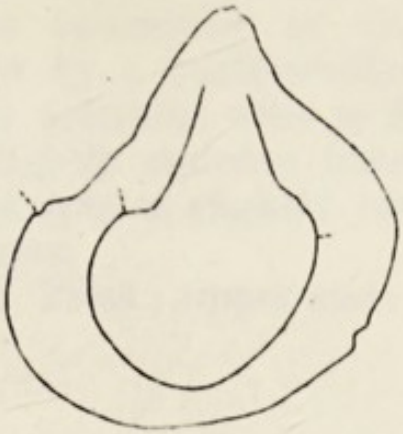

FIG. 31.

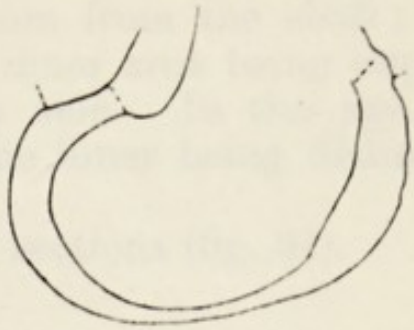

FIG. 32.

FIG. 31.—Tracings (× ½) of sagittal sections of the outer left femoral condyle of Man (European male) and an Orang-utan. The smaller tracing is provided by the condyle of the Orang-utan.

FIG. 32.—Tracings (× ½) of sagittal sections of the inner left femoral condyle of Man (European male) and an Orang-utan. The smaller tracing is provided by the condyle of the Orang-utan.

(4) Femur: lower end: sagittal sections (figs. 31, 32).

In the human femur the condyles are larger; their contour-lines are more similar to each other than in the ape; the articular surfaces are more extensive, the outer forming a segment of a circle of much larger radius than in the Orang-utan; the inner condyle has an area of condylar flattening. These contrasts between Man and the anthropoid ape are associated with functional differences, the human femur being specialized for weight-bearing, while the anthropoid femur is adapted in form to the rotary movement (like supination and pronation in the forearm) subservient to the prehensile movements of the lower limb of the ape. The range of extension is greater in Man.

(5) Femur: shaft: longitudinal section.

In the human femur the shaft is larger, more curved, and has a very distinct linea aspera.

(6) Femur: lower end of shaft: transverse sections.

In the human femur the shaft is larger and the sectional index ($= \frac{\text{depth} \times 100}{\text{width}}$) is 85. In the Orang-utan this index is 64·4.

[1] In the outer condyle the cancellous septa are coarse and their direction is vertical: in the inner condyle the cancelli are finer and in direction are irregular. The simian femur does not show such differences, which are related to the necessity (in Man) for supporting the weight of the body.

(7) Tibia: upper end: coronal sections (fig. 33).

In the human tibia the head is much larger; the outer tuberosity is much more effectively supported below by a buttress-like projection from the shaft; the outer articular area is flat, the inner area being cupped or slightly concave from side to side. In the ape the outer area is slightly concave, the inner being distinctly concave.

(8) Tibia: upper end: sagittal sections (fig. 34).

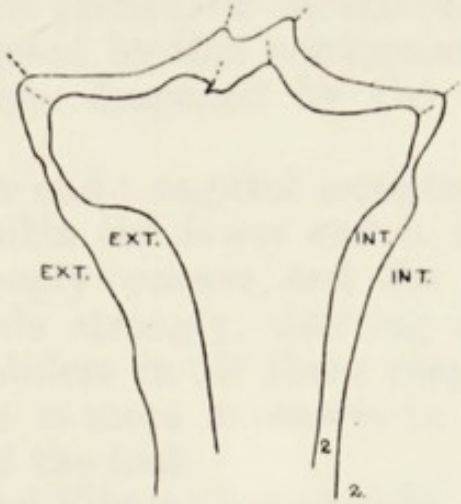

FIG. 33.—Tracings (× ½) of coronal sections of the head of the right tibia of Man (European male) and a Chimpanzee. The smaller tracing is provided by the tibia of the Chimpanzee.

FIG. 34.—Tracings (× ½) of sagittal sections of the head of the left tibia of Man (European native) and an Orang-utan. The bone of the latter provided the smaller tracing.

In the human tibia the upper end is larger, the inner tuberosity has a larger supporting base, and bears an articular area slightly concave in the sagittal (as in the coronal) plane. The apex of the spine is posterior to the long axis of the shaft. The outer tuberosity bears an articular area flattened in the sagittal (as in the coronal) plane, and it extends far above the head of

the fibula. In the Chimpanzee, the inner condylar surface is concave, but the outer surface is slightly convex in the sagittal plane, and does not lie so far above the head of the fibula. The spine is placed almost in the long axis of the shaft.

The important point is the conformation of the outer condylar surface in the anthropoid tibia; this surface is saddle-shaped, *i.e.*, slightly concave from side to side and convex from before backwards. As in the case of the femoral condyles, the difference is intelligible when one reflects that the prehensile movements at the knee of the ape are facilitated by this conformation. The joint-cavity is, of course, deepened by the semilunar fibro-cartilages.

(9) Tibia: lower end: sagittal sections.

In the human tibia the lower end is much larger; the lower surface is deeply concave, and the posterior margin projects downwards strongly, limiting extension at the ankle. The ape differs in all these respects, and movement at the ankle is more extensive in correlation with grasping actions of the foot.

(10, 11) Tibia and Fibula: lower ends: coronal sections (figs. 35, 36).

In the human tibia and fibula the malleoli are larger; the internal malleolus in particular is longer and more pointed. The articular surfaces for the reception of the astragalus are three in number, viz.:—

(*a*) Inner: on the outer aspect of the internal malleolus.

(*b*) Intermediate: on the inferior aspect of the tibial shaft.

(*c*) Outer: on the inner aspect of the external malleolus.

Tracings were carefully made both of the human and the ape bones, and the angles of inclination between (*a*) and (*b*) and also between (*c*) and (*b*) were carefully measured (figs. 35, 36). If the joint were a perfect mortise-joint, then (*a*) should be at right angles (90°) to (*b*), and so also (*c*) should be at right angles (90°) to (*b*). The greater the excess of either angle over 90°, the more free will lateral movements be (in the perfect mortise-joint no lateral movement occurs), and the greater the facility for grasping movements on the part of the foot. We may therefore expect to find that the values of the

angles between (*a*) and (*b*), as also between (*c*) and (*b*), prove greater in the ape than in Man.

In Man (in the left ankle), (*a*) is inclined to (*b*) at an angle of 122°, and (*c*) is inclined to (*b*) at an angle of 98°.

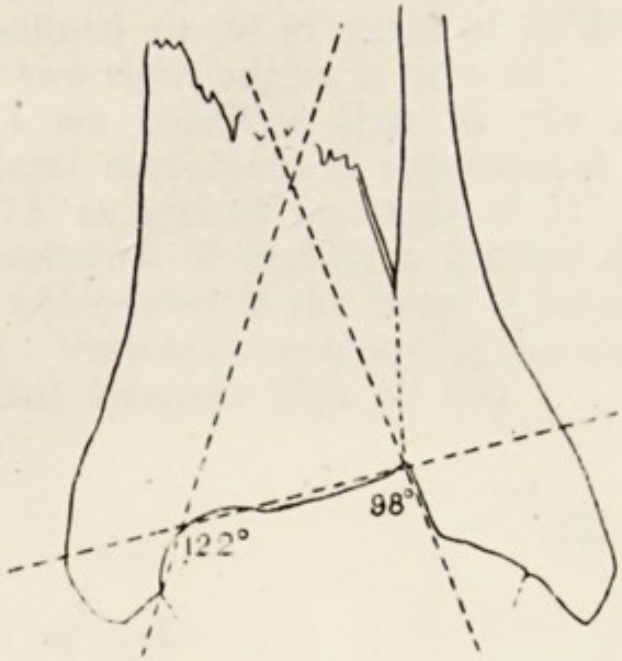

FIG. 35.—Coronal section through the lower ends of the left tibia and fibula of Man (European male).

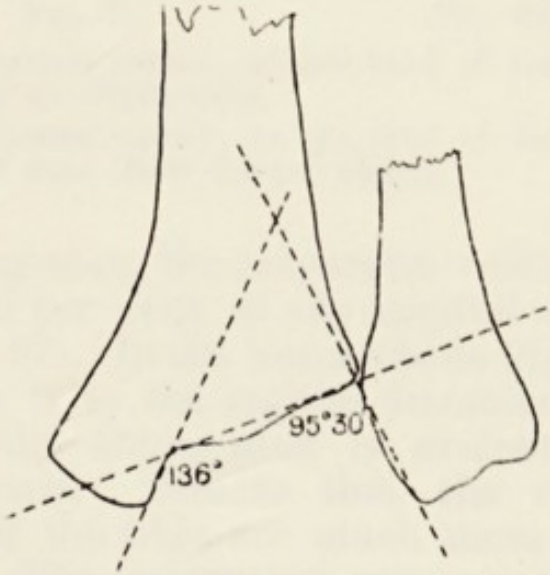

FIG. 36.—Coronal section through the lower ends of the left tibia and fibula of an Orang-utan.

Therefore the excess over 90° is 32° for (*a*) to (*b*), and 8° for (*c*) to (*b*), the total excess over 180° or two right angles being therefore 40°. In the bones of the right limb the angles are as follows: (*a*) to (*b*) = 116°30';

(*c*) to (*b*) = 110°. The excess over 180° (or two right angles) is here 46°30′. We may take the mean from these excess values for right and left limbs as a fair average value, and this gives 43°15′ for Man.

In the Orang-utan the corresponding angles were measured: (*a*) is inclined to (*b*) at an angle of 136°; and (*c*) is inclined to (*b*) at angle of 95°30′. The excess over 180° or two right angles is here 51°.

From this we conclude that at the ankle-joint the range of lateral movement is represented in Man by an angle of 43°15′ as against an angle of 51° in the ape; so that the expectation of finding a greater range of movement in the ankle-joint of the latter is hereby confirmed.

(12) Tibia: transverse sections of the shaft at the level of the nutrient foramen (figs. 37, 38).

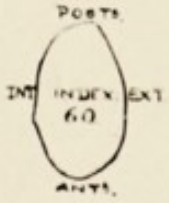

Fig. 37.



Fig. 38.

Fig. 37.—Transverse section, at the level of the nutrient foramen, of the left tibia of an Orang-utan.

Fig. 38.—Transverse section, at the level of the nutrient foramen, of the left tibia of man (New Guinea native).

In the Orang-utan, the transverse width of the bone at this level is 60 per cent. of the sagittal diameter at the same level (fig. 37). In the human bone (fig. 38), the transverse diameter is to the sagittal diameter as 68·1′ to 100. The tibia of the Orang-utan is evidently narrower or more *platycnemic*. Besides this, the various surfaces and margins of the tibia are much more distinct in the human bone. The percentage proportion of the sagittal diameter that is given by the transverse diameter is called the platycnemic index, and in the human (European) tibia its value is usually about 88, so that the human specimen exhibited is unusually flattened from side to side.

Bale, Sons and Danielsson, Ltd., Printers, London, W.

WELLCOME
LIBRARY
INSTITUTE