

The student's guide to dental anatomy and surgery / by Henry Sewill.

Contributors

Sewill, Henry.

Publication/Creation

London : J. & A. Churchill, 1883.

Persistent URL

<https://wellcomecollection.org/works/xdpm6abx>


License and attribution

This work has been identified as being free of known restrictions under copyright law, including all related and neighbouring rights and is being made available under the Creative Commons, Public Domain Mark.

You can copy, modify, distribute and perform the work, even for commercial purposes, without asking permission.



Wellcome Collection
183 Euston Road
London NW1 2BE UK
T +44 (0)20 7611 8722
E library@wellcomecollection.org
<https://wellcomecollection.org>



K. x
19/5



22101920365

Med
K49336

STONY BROOK
LIBRARY AND MUSEUM

THE
STUDENT'S GUIDE
TO
DENTAL ANATOMY AND SURGERY

THE

STUDENT'S GUIDE

DEPARTMENT OF HISTORY AND GEOGRAPHY

UNIVERSITY OF TORONTO

1911




W. H. BURNETT

84392

THE
STUDENT'S GUIDE
TO
DENTAL ANATOMY AND SURGERY

BY
HENRY SEWILL
MEMBER OF THE ROYAL COLLEGE OF SURGEONS AND
LICENTIATE IN DENTAL SURGERY,
FORMERLY DENTIST TO THE WEST LONDON HOSPITAL, ETC.

SECOND EDITION



LONDON
J. & A. CHURCHILL
11, NEW BURLINGTON STREET
1883

PREFACE



Digitized by the Internet Archive
in 2016

<https://archive.org/details/b28129362>

PREFACE

TO

THE FIRST EDITION.

No department of physiology or surgery has of late years made greater progress than that connected with the teeth, and this advance has been necessarily attended by a corresponding increase in the literature of the subject, which has now become so voluminous as to form a source of embarrassment to those who are entering upon a course of dental education. Under these circumstances the projectors of the "Students' Guide" manuals have considered a work on Dental Anatomy and Surgery a desirable addition to the series. It is designed that these manuals should be free from needless technicalities; that they should facilitate the labours of the student; and that whilst each volume—although presenting merely an outline of the subject—should be complete in itself, it should at the same time lead the reader to desire, and direct him in seeking, the fuller knowledge afforded by more extended treatises. These designs I have striven to accomplish in this volume.

It must, however, not be supposed that the student can profitably peruse even the most rudimentary textbook on any special branch of physiology or surgery without an adequate knowledge of the fundamental principles of those sciences; and evidently it can but confuse him to encounter such terms as "nucleus" and "cell," or "inflammation" and "abscess," unless he have a clear conception of their signification. Such knowledge must be obtained previously from elementary works on physiology and surgery.

Whilst in a work of this kind it is essential that, as far as practicable, facts only should be laid before the student, it is not possible to avoid altogether the discussion of controverted points, or at least the description of subjects that have as yet been insufficiently investigated. Amongst these subjects must be placed the development of the teeth. The description of this process, which is found in physiological textbooks, even the latest editions, is entirely based upon the investigations of Goodsir, which were published by him in the "Edinburgh Medical and Surgical Journal," in the year 1838. Since that date the subject has been investigated by numerous physiologists, among whom may be specially mentioned Marcusen, Dursy, Kölliker, and Waldeyer, and they are agreed with regard to the main facts of the process. Aided by the advance of microscopical science since the time of Goodsir, they have traced the phenomena of dental evolution from a period of embryonic life much earlier than that at which it was supposed to

commence by that renowned physiologist, and have thus necessarily overthrown much of his theory.

Messrs. Legros and Magitot have issued the latest monograph on the subject—a most elaborate and minute description, entirely based upon original observations—and the corroboration it receives from previous investigations, leaves no doubt that it is substantially accurate. The section which I have in this manual devoted to the development of the teeth is merely a summary of the work of these physiologists.

The histogenesis of the dental tissues—the changes which take place in the tooth-germ by which its elements are gradually converted into these tissues—has been, like the preceding subject, investigated by numerous physiologists, and like it has given rise to considerable difference of opinion. The majority of more recent observers (Lent, Kölliker, Marcusen, Huxley, Robin, Magitot, Tomes, and Waldeyer) are, however, in accord with regard to essential points, and in the account which I have given I have attempted to epitomize the main facts elucidated by these authorities without entering upon controverted topics.

The theory of the etiology and pathology of caries which I have adopted, is entirely based upon generally admitted facts; it is that which I believe can alone be arrived at by reasoning upon such facts; it is that which recently has been enunciated by the best authorities, and eventually must be, in my opinion,

universally accepted. It will be perceived that decay of the teeth is a process entirely dissimilar to caries of bone, and that although the term caries is retained for the sake of convenience, it is not really indicative of the true character of the disease.

No more than passing reference has been made to those injuries and diseases of the mouth and jaws that are not intimately associated with dental pathology. Although these affections necessarily fall much under the notice of the dental surgeon, who is therefore required to possess a knowledge of their nature, their discussion belongs more properly to works on general surgery than to those devoted entirely to dental subjects.

A knowledge having been obtained of the principles upon which operative procedures are carried out, and of the materials and instruments employed, the student cannot commence too soon to acquire skill by practice and experiment. This practice is easily obtained by the dental student. He may begin by plugging with tin-foil cavities cut in bone or ivory or in extracted teeth, each stopping after completion being carefully broken up to discover in what detail it has failed, or in what direction it is capable of improvement. In the same way such operations as capping the pulp and fang-filling may also be practised. As soon as the student can with rapidity and certainty fill difficult cavities in extracted teeth fixed in a vice, he may safely proceed to operate upon simple cavities in the mouth of the living subject. Similar remarks may be made

with regard to the operation of extraction. The anatomy of the teeth and of the parts around being understood, the student may proceed to apply the forceps to the different kinds of teeth, and familiarize himself with the mode in which the instrument is held, the tooth grasped, and the force applied. Every student should subsequently go through a course of extracting operations on the dead subject, opportunities for which are afforded at every school of medicine.

Of the illustrations some are original, some are copied, and some are borrowed from works the property of the publishers. Those illustrating the development of the teeth are copied from Messrs. Legros and Magitot's monograph. For some of the most valuable I am indebted to the admirable works of Messrs. Tomes, Mr. Christopher Heath, and Mr. Salter. Figs. 34, 36, and figs. 74 to 78, are taken by permission from the "Transactions of the Odontological Society." Among the original engravings, those in the sections on preparing cavities and gold filling, have been most kindly contributed by my friend Mr. Howard Mummery. The cuts of the instruments have been supplied by the eminent and well-known firm of Ash and Sons, of 7, Broad Street, Golden Square.

6, WIMPOLE STREET, W.

Feb. 1876.

CONTENTS

1	ANATOMY AND HISTOLOGY OF THE TEETH
16	DEVELOPMENT OF THE TEETH
28	GROWTH OF THE PULP PULPITIS
	ABNORMALLY FORMED TEETH. IRREGULARITIES OF THE
42	TEETH
73	CARIES
80	TREATMENT OF CARIES
134	EXPOSURE OF THE PULP. DISEASES OF THE PULP
	DENTAL PERIODONTITIS. ALVEOLAR ABSCESS. PERIODONTITIS
	AND PERIOSTITIS OF THE MAXILLA. DENTAL EXOSTOSES
	TOOTH AND NERVOUS. ABSCESSION OF ALVEOLAR
	CHRONIC SUPPURATIVE WASTING OF ALVEOLAR AB-
152	SORPTION OF ROOTS OF REMNANT TEETH
160	DISEASES OF THE GUMS AND GREAT MUCOUS MEMBRANE
	ABRASION OF THE TEETH. EROSION. MECHANICAL IN-
173	JURIES
177	SALIVARY CALCULI OF VARIETIES

CONTENTS.

	PAGE
ANATOMY AND HISTOLOGY OF THE TEETH	1
DEVELOPMENT OF THE TEETH	16
GROWTH OF THE JAWS. DENTITION	28
ABNORMALLY FORMED TEETH. IRREGULARITIES OF THE TEETH	42
CARIES	73
TREATMENT OF CARIES	96
EXPOSURE OF THE PULP. DISEASES OF THE PULP . .	134
DENTAL PERIOSTITIS. ALVEOLAR ABSCESS. PERIOSTITIS AND NECROSIS OF THE MAXILLÆ. DENTAL EXOS- TOSIS AND NECROSIS. ABSORPTION OF ALVEOLI. CHRONIC SUPPURATIVE WASTING OF ALVEOLI. AB- SORPTION OF ROOTS OF PERMANENT TEETH . . .	152
DISEASES OF THE GUMS AND ORAL MUCOUS MEMBRANE	169
ABRASION OF THE TEETH. EROSION. MECHANICAL IN- JURIES	173
SALIVARY CALCULUS OR TARTAR	177

	PAGE
MORBID GROWTHS CONNECTED WITH THE TEETH . . .	180
DISEASES OF THE ANTRUM	190
PIVOTING TEETH	193
NEURALGIA AND DISEASES OF THE NERVOUS SYSTEM .	196
EXTRACTION OF TEETH	203

LIST OF AUTHORS.

1. ARKÖVY . . . Trans. Internat. Congress, 1881.
2. BÖDECKER . . . Dental Cosmos. 1874-1880.
3. CATTLIN . . . { Accidents in Dental Surgery.
Trans. Odont. Soc. New
Series.
4. HEATH. . . . { Injuries and Diseases of the Jaws.
1868.
5. HUTCHINSON,
JONATHAN . . . } Path. Trans., 1875.
6. LEBER and ROT-
TENSTEIN . . . } Caries der Zähne. 1867.
7. LEGROS and
MAGITOT . . . { Origine du Follicule Dentaire.
Journal de l'Anatomie, 1873.
8. MAGITOT . . . Traité de la Carie Dentaire.
9. MASON { Irregularities of the Teeth. Trans.
Odont. Soc. Vol. V. New
Series.
10. NEUMANN, E. . . { Archiv für klinische Chirurgie,
Bd. VI.
11. SALTER Dental Pathology and Surgery.
12. SEWILL { Irregularities of the Teeth. Lan-
cet, 1870.
13. „ { Alcohol in Dental Operations.
Trans. Odont. Soc. Vol. VII.
New Series.

14. SEWILL . . . { Etiology and Pathology of Dental
Diseases. Journal of Brit. Dent.
Assoc., Sept. and Oct. 1882.
15. TOMES, CHAS. S. { The Attachment of Teeth. Trans.
Odont. Soc. Vol. VII. New
Series.
16. " " . Dental Anatomy. 2nd Edit. 1881.
17. TOMES, J. & C. S. System of Dental Surgery. 1873.
18. UNDERWOOD, A. Brit. Med. Journal, 1880.
19. " " . Journal of Brit. Dent. Assoc., 1882.
20. UNDERWOOD, A. }
and MILLES, W. . } Trans. Internat. Congress, 1881.
21. WALDEYER . . { Structure and Development of the
Teeth. Stricker's Histology.
22. WEDL . . . Pathology of the Teeth.

THE STUDENT'S GUIDE
TO
DENTAL ANATOMY AND SURGERY.

ANATOMY AND HISTOLOGY OF THE TEETH.

HUMAN TEETH are hard structures of a bony character, implanted in the alveoli along the margins of the jaws for the purpose of triturating the food preparatory to its passage into the stomach, and solution by the gastric juice. Two sets of teeth are developed during life—the first, the temporary, deciduous or milk teeth, ten in each jaw, and the second or permanent teeth, sixteen in each jaw.

The teeth are divided into classes according to their function and external configuration, but they have all certain characters in common. Every tooth consists of a *crown*, the portion which appears above the gum, a *root* or roots imbedded in the jaw, and a *neck*, the portion which unites the crown and root, and which is surrounded by the free edge of the gum.

The permanent set is made up of four incisors,

formed for cutting, two canines for cutting and tearing, and four bicuspids and six molars for grinding the food.

The upper incisors have chisel-shaped crowns, the front surface convex, the back concave. Viewed laterally the crown is wedge-shaped, the base of the wedge being at the gum, the apex at the cutting edge. The cutting edge is horizontal, its distal angle being rounded, its mesial acute. Before becoming worn by mastication the edge is marked by three small tubercles, which give it a serrated appearance. The root is single, conical, and slightly compressed laterally. The central are about one-third larger than the lateral incisors.

The lower incisors are similar in shape to the upper, but they are smaller, the root is more flattened at the sides, both angles of the cutting edge are acute, and unlike the upper teeth the central is less in size than the lateral.

The canines, or eye teeth, are stronger than the incisors, to which they bear a general resemblance. The crown is convex anteriorly, concave posteriorly, and may be compared to that of an incisor with the angles bevelled off, and terminating in a sharp central cusp. These teeth have one root which is stronger and longer than any other of the set. It is conical in shape and slightly more flattened laterally than that of an incisor.

The lower canines are smaller than the corresponding upper teeth, the cusp is more obtuse, the root more flattened at the sides.

The upper bicuspids viewed from the front, bear a close resemblance to the canines, than which however they are smaller. The crown springs vertically

from the neck, its labial and lingual aspects being convex, its mesial and distal surfaces somewhat flattened. Its long diameter is across the jaw. The masticating surface is divided by a deep antero-posterior groove into two cusps, of which the inner is the smaller. The root is conical, and more compressed laterally than that of either the incisor or canine. It is deeply grooved and often bifid, the cleft occasionally dividing the root throughout the greater part of its length.

The lower bicuspids are smaller than the upper, the internal cusp is less well marked, and the root is much compressed, and rarely bifid.

The molars have crowns of a cube-like form, the labial and lingual aspect rounded, the mesial and distal flattened. The grinding surface is divided by grooves into tubercles or cusps. The neck is rounded and well defined. The molars of each jaw decrease in size from before backwards.

The masticating surface of an upper molar has four cusps, one at each angle, but in the third molar or wisdom tooth the internal cusps are blended into one mass. The first and second upper molars have three conical roots, two external spreading apart upwards towards the antrum, and one, the smallest, directed towards the palate. The latter is occasionally bifid. The root of the wisdom tooth is, as a rule, single, forming an irregular conical mass, which is often either deeply grooved or shows traces of subdivision into three roots. The crowns of the lower molars are a little larger than those of the upper jaw, and they are surmounted by five cusps, one at each angle, and the fifth between the two posterior cusps rather nearer the labial surface. The anterior internal is

always much the largest, and is in the upper molars connected by a ridge of enamel with the posterior external cusp. Owing to the manner in which the upper teeth meet the lower, the inner cusps of the lower molars are higher (less worn down) than the outer, while the reverse is the case in the upper—*i.e.*, the inner cusps become always most worn down by use in mastication. The first and second lower molars have each two roots, one anterior and one posterior. They are broad, compressed, and grooved on the surfaces turned towards each other, and they have an inclination slightly backwards in the jaw. The root of the lower wisdom tooth, like that of the upper, is often connate, but occasionally it is bifid or divided into distinct fangs.

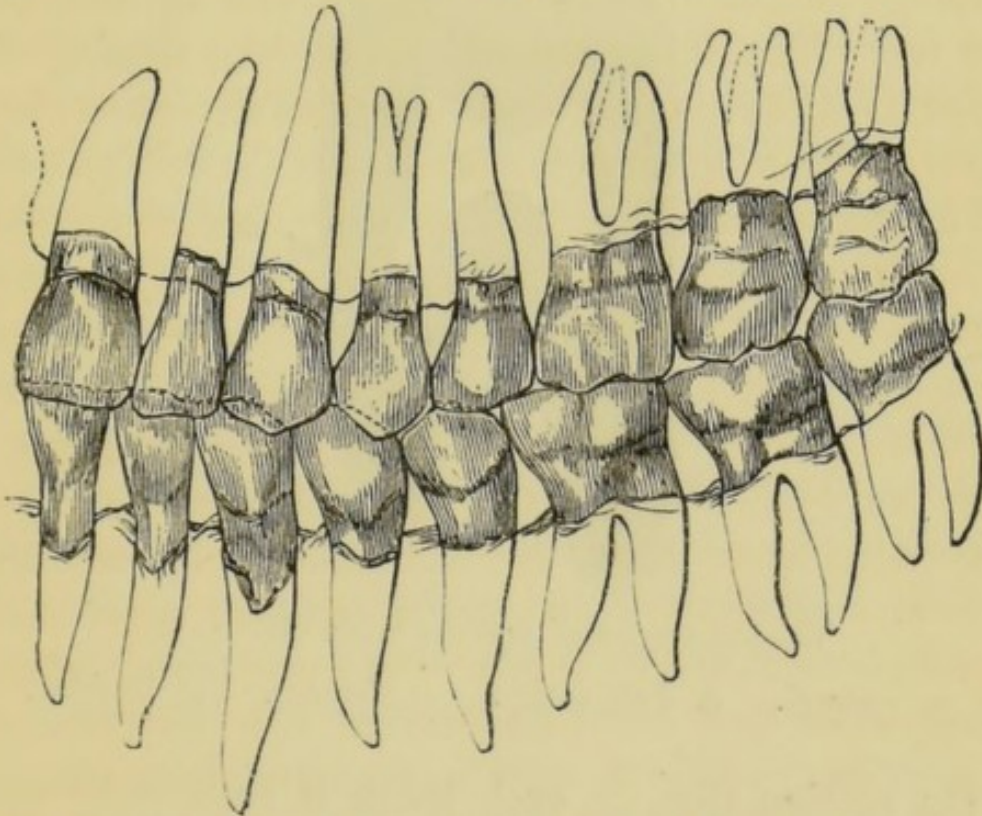
The entire set of teeth in each jaw are arranged in an elliptical curve, the incisors, canines and bicuspid forming an almost perfect semicircle, the molars and bicuspid continuing the lines backwards. The lower teeth are placed vertically in front and looking somewhat inwards at the sides and behind, whilst the corresponding upper teeth have an inclination forwards in front and outwards behind, so that the upper teeth slightly overhang the lower. In consequence of this arrangement and the difference in size between the teeth of the two jaws, each upper tooth on closure of the jaws, impinges partly on the corresponding lower tooth and partly on the tooth next following; but the upper dental arch being larger than the lower, and the upper molars being smaller than those of the lower jaw, the upper wisdom teeth do not extend backwards beyond the range of the lower teeth.

The teeth are fixed in position by the implantation of their roots in the alveoli of the jaws, the bone,

lined with periosteum, investing and accurately fitting them and providing a separate socket for each root. This form of articulation has been termed *gomphosis*, from its resemblance to the impaction of a nail driven into wood.

The annexed diagram from Wedl (21) (fig. 1), shows at one view the form and character of a normal set of teeth, the direction and arrangement of the roots within the bone, and the relation of the upper and lower sets to each other when closed.

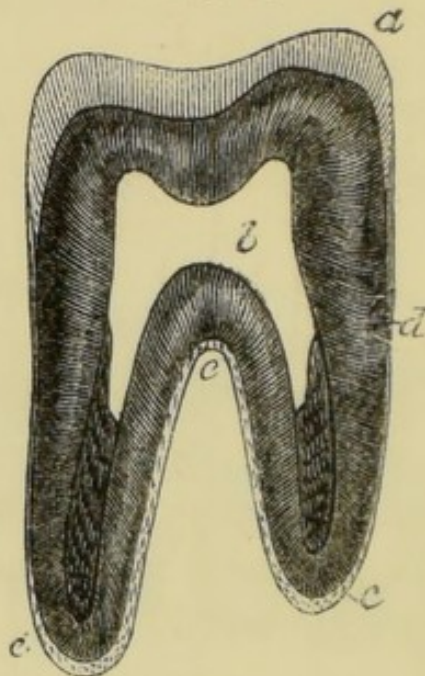
FIG. 1.



The temporary teeth resemble the permanent set, but are considerably smaller. There are no bicuspids in this set. It is made up of four incisors, two canines, and four molars. The first upper molar is smaller than the second, and has three cusps, two external, one internal. The second upper molar has four cusps. The first lower molar is smaller than the second, and has four cusps. The second lower molar has five

cusps, three external, two internal. The roots of the temporary set are similar to those of the corresponding permanent teeth. The fangs of the molars are, however, more divergent from the neck of the tooth, and are hollowed on their inner aspect to afford space for the crypts of the developing bicuspid situated beneath them. In the temporary set the enamel ends in an abrupt ridge at neck of the tooth beneath the free edge of the gum.

FIG. 2.



Vertical section of a molar tooth (HUXLEY).

a. Enamel. *b.* Pulp cavity. *c.* Cement. *d.* Dentine.

On section (fig. 2), each tooth is seen to be composed of three tissues, distinct in structure, but intimately united with each other, the enamel which covers the crown, the cement which coats the roots, and the dentine which forms the great bulk of the organ. When the teeth first make their appearance the enamel is covered by a thin layer of peculiar tissue, the cuticula dentis or Nasmyth's membrane, which, however, becomes soon worn off by mastication.

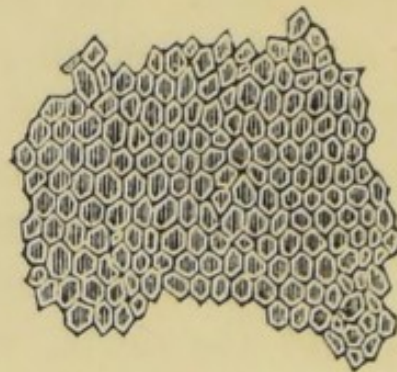
tion. In the centre of the tooth is the pulp cavity, a chamber similar in shape to the external outline of the tooth, and containing a vascular and nervous structure, the dental pulp. The vessels and nerves of the pulp enter the chamber through foramina in the apices of the roots.

The enamel forms a cap or layer adapted to the surface of the dentine. It attains its greatest thickness on the cutting edges and summits of the masticating surface of the teeth, whence gradually decreasing, it slopes towards the neck and terminates beneath the free edge of the gum, where it is slightly overlapped by the cement. It is an extremely hard translucent substance, either of a yellowish or of a bluish white colour. It is the hardest tissue of the body, ranking in density with limpid quartz, and emitting a spark when struck with steel. It contains not more than from one to five per cent. of organic matter, ninety per cent. of calcium phosphate, with a trace of fluorine, and four to five per cent. of calcium carbonate, the remainder being made up of traces of magnesium phosphate and other salts. It is entirely soluble in acids, leaving but the smallest trace of organic matter. Enamel is devoid of sensibility.

Examined microscopically enamel is found to consist of solid fibres or prisms mostly hexagonal, but some nearly square, others nearly circular (fig. 3), lying parallel side by side, probably without any intermediate substance. Dr. Bödecker claims to have demonstrated an intervening substance, but his observations have not yet been confirmed. The fibres spring from depressions on the surface of the dentine, and radiate outwards in an undulating course towards the exterior of the tooth, so that their direc-

tion varies between vertical at the masticating surface and horizontal at the sides. Most of the fibres extend

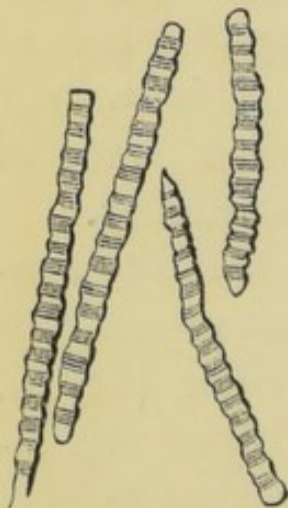
FIG. 3.



Enamel fibres, viewed in transverse section.

through the whole thickness of the tissue; and although they cannot be demonstrated, there must exist, probably, shorter fibres to fill up the intervals which would otherwise exist in consequence of the divergence of the longer prisms in their outward course. The diameter of the prisms is about $\frac{1}{5500}$

FIG. 4.



Enamelled prisms separated and viewed laterally.

of an inch. They are mostly marked at short regular intervals by transverse striæ, so that each fibre resembles a sheath containing a line of granular masses, but this condition is not very visible in young and in dense well-formed tissue. The prisms (fig.4) also show at intervals slight bulgings or varicosities. No generally accepted explanation of the origin of the striæ and varicosities has yet been made.

They perhaps constitute the remaining trace or expression of the soft cell elements in which the tissue existed before calcification. The apparent decussation of the prisms, a peculiar pattern exhibited by enamel in

section beneath the microscope, is not real. The tissue is made up of many layers, the fibres in each layer being parallel, but the direction pursued by fibres of different layers varying considerably. The appearance of decussation is visible only under a high magnifying power, in a thin section which is made up of several layers of prisms, and which is of course transparent. Hence the crossing of fibres, which actually lie on different planes, gives rise to the apparent free decussation of prisms lying on the same plane.

Dentine or ivory forms the great bulk of the tooth, and encloses the central cavity. It is a yellowish-white elastic tissue, presenting a finely fibrous fracture, and intermediate in hardness between enamel and dense bone, which latter it resembles somewhat in its general aspect and chemical characteristics. It contains twenty-eight per cent. of animal and seventy-two of earthy matter. Treated with acids the earthy constituents are dissolved, and there remains a material called dentinal cartilage, which retains the form of the tooth, and which is precisely similar to the animal basis of ordinary bone tissue. The seventy-two per cent. of earthy constituents are made up of 64 parts of calcium phosphate, 5 of calcium carbonate, and 3 of magnesium phosphate and other salts, with a trace of fluorine. It will perhaps assist the reader's memory to consider these chemical compositions side by side in a tabulated form :—

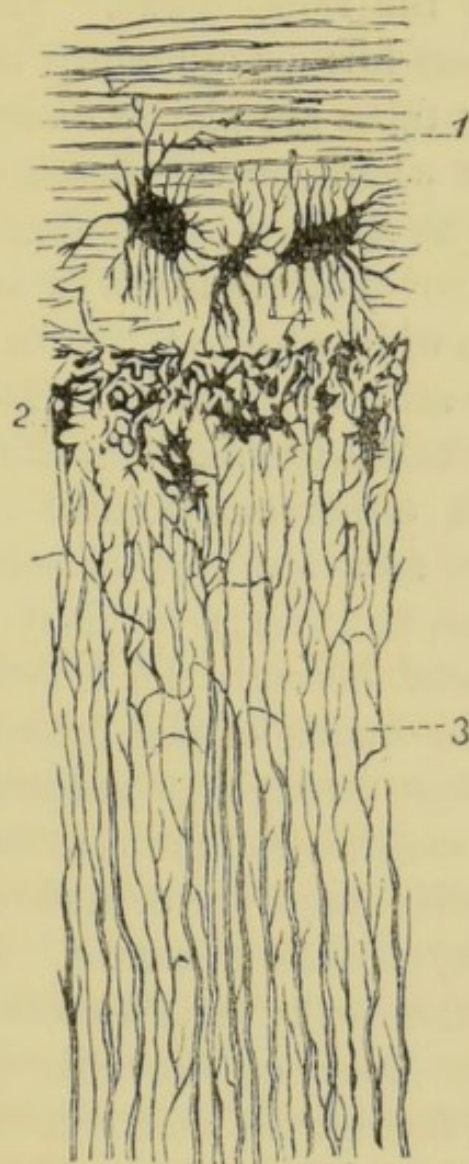
TABLE OF CHEMICAL COMPOSITIONS OF DENTINE, ENAMEL,
AND BONE.

	Enamel.	Dentine.	Cementum-Bone.
Organic matter . . .	3.50	28.00	33.30
Calcium phosphate and fluoride	90.00	64.00	53.04
Calcium carb.	4.50	5.50	11.30
Magnesium phosphate	1.50	1.00	1.16
Other salts (chiefly sodium)50	1.50	1.20
	100	100	100

Examined microscopically (fig. 5), dentine is found to consist of innumerable minute tubes having apparently distinct walls, and running close together through an intermediate substance—the intertubular substance or matrix. Commencing by open orifices on the walls of the pulp cavity, the tubes radiate outwards in an undulating course, giving off numerous branches, which freely anastomose. In the upper part of the crown they have a vertical direction, towards the sides they become oblique, then horizontal, finally incline downwards towards the point of the root. Each tube as a rule extends throughout the whole thickness of the tissue. Their diameter is about $\frac{1}{4500}$ of an inch, being larger at the inner ends than at a distance from the pulp cavity. They are also more close together near the pulp, there being less matrix between them. The distance between

adjacent tubes is about two or three times their width. The tubes and their branches are occupied by soft fibrils which anastomose; and Bödecker has shown, by staining the soft parts with chloride of

FIG. 5.



Transverse section of the root of a canine tooth.

1. Cement. 2. Granular layer. 3. Dentine.

gold, that they form a perfectly continuous network. These fibrils proceeding from the central pulp are elongated processes of the odontoblasts, the special cells of the pulp. The tubes surrounding the fibrils are called the dentinal sheaths or sheaths of Neuman.

These sheaths are probably in an intermediate condition between the fully calcified matrix and the wholly uncalcified fibril. It is stated that the only difference between these three tissues, matrix, tube, and fibril, is that they represent different degrees of calcifications of the same tissue. That there must, however, be some further difference is obvious from the fact that the tubes are plainly discernible in interglobular spaces where no calcification whatever has taken place. The sheaths can be demonstrated most clearly after removal of the fibres by maceration, and they remain as a white fibrous felt even after boiling in strong muriatic acid, or in caustic alkalies.

The dentinal tubes terminate in the crown by fine processes which either anastomose or become extremely minute, and are lost beneath the enamel, into which tissue, however, a few may penetrate. In the root they end beneath the cement, by opening into the irregular spaces of the granular layer, and frequently passing through to anastomose with the contents of the canaliculi of the cementum.

The intertubular substance or matrix is translucent and without any visible structure. It contains the greater part of the earthy constituents of the dentine.

The granular layer of the root (fig. 5), which exists between the dentine and cement, may be said to constitute the line of transition where these tissues blend. The layer is made up of granules or minute globules, and contains numerous spaces apparently due to imperfect coalescence of these elements. Into these spaces (as above mentioned) the dentinal tubes open, and the spaces are again connected with the lacunæ of the cement by fine canaliculi.

Dentine is endowed with a considerable amount of

sensibility, due to the soft fibrils which permeate its tubes, and which, as we have seen, directly emanate from the pulp. It is more sensitive immediately beneath the enamel than deeper, until the pulp chamber is approached. The sensibility disappears when death of the pulp takes place.

The Cement forms a thin layer, which, commencing at the neck, where it slightly overlaps the enamel, gradually increases towards the apex of the root. It is a true bone structure, having the same chemical and microscopical characters as that tissue. Existing only in a thin layer in man, cement is, however, destitute of Haversian canals. It contains, as a rule, canaliculi throughout, and lacunæ at its thicker parts, enclosing during life protoplasmic contents which form by anastomosis a complete continuous network. Canaliculi and lacunæ may be wanting where the tissue is extremely thin. In the latter case it presents on section a perfectly homogeneous appearance.

The cement is invested with periosteum which is directly continuous with periosteum of the jaw. It unites the cementum to the socket, and consists of a single layer, not two as used to be supposed. The fibres of this periosteum run obliquely upwards from the cement to the socket, so that when in periostitis the tooth is forced outwards from the socket, the periosteum allows the outward movement without tearing. It is a delicate connective-tissue membrane, containing abundance of vessels and nerves, which are derived from those of the submucous tissue, from those which supply the pulp, and from those of the contiguous alveolar wall.

Nasmyth's membrane is an extremely thin homogeneous layer, covering the enamel. It exists only

on young teeth which have not been long used in mastication. It resists the action of the strongest mineral acids, but softens when boiled in caustic potash. Although other theories as to its nature exist, the majority of authorities are agreed that Nasmyth's membrane is merely a thin layer of cement modified in structure, and exactly homologous with the thick coronal-cement found on the teeth of herbivorous animals. This theory has lately been confirmed by the investigations of Mr. Charles Tomes (16), who has especially pointed out that coronal cement of well-marked structure, containing lacunæ and canaliculi, occasionally occurs in human teeth, and that when such a layer does not exist it may be often found that fissures of the enamel are filled with a bone-like tissue continuous with Nasmyth's membrane.

The dental pulp which occupies the central cavity constitutes the remains of the original papilla from which the dentine was developed. It consists of fine fibrous connective tissue, containing numerous cells, and is well supplied with blood-vessels and nerves, which enter the cavity through small orifices in the apices of the roots. The outermost cells of the pulp—that is, those that immediately line the dentine, are of a special form, larger and more regular than the others, and are called collectively the *membrana eboris*, or odontoblast layer, because of the important part they play in the formation of dentine. Each odontoblast is oval or pear shaped, with a well marked nucleus at the end farthest from the dentine, and has several sets of processes; some of these processes penetrate the canals in the dentine and become the fibrils, others connect the cell with its odontoblast neighbours on

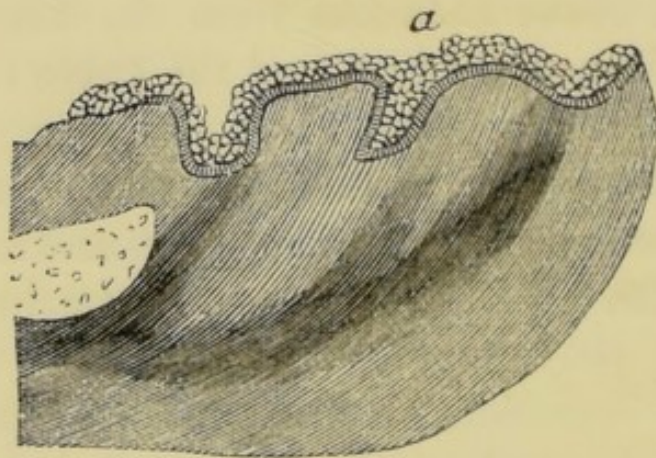
either side, while others again join the processes of underlying pulp cells. By means of these last mentioned anastomoses, it may be presumed the odontoblast layer is directly continuous with the terminal nerve filaments in the pulp, while, in the other direction, their prolongation, reach, as fibrils, through the dentine and join the protoplasmic network in the cement. Lymphatics have not yet been demonstrated in the pulp.

As age advances, gradual calcification of the pulp takes place, until at last it is reduced to a few fibrous filaments, with the remains of vessels and nerves. The tissue resulting from this calcification is called secondary dentine. In some cases the process commences in the external layer of odontoblasts, and the new formed tissue coalesces from the first with the previously formed dentine, and the tubes of the two are continuous. In other cases secondary dentine is deposited in isolated nodules scattered through the pulp. These nodules sometimes unite and form larger masses, which again may become attached to the walls of the pulp cavity. The masses of secondary dentine are occasionally traversed by canals containing blood-vessels, and surrounded by concentric lamellæ, like the Haversian canals of bone. At the same time that the slow conversion of the pulp is taking place, the dentinal fibrils also become impregnated with earthy matter and solidified.

THE DEVELOPMENT OF THE TEETH.

THE first trace of dental development in man is visible to the naked eye as early as the seventh week of intra-uterine life, when the embryo is not more than one inch and a quarter in length. This trace consists of a smooth oval ridge ex-

FIG. 6.



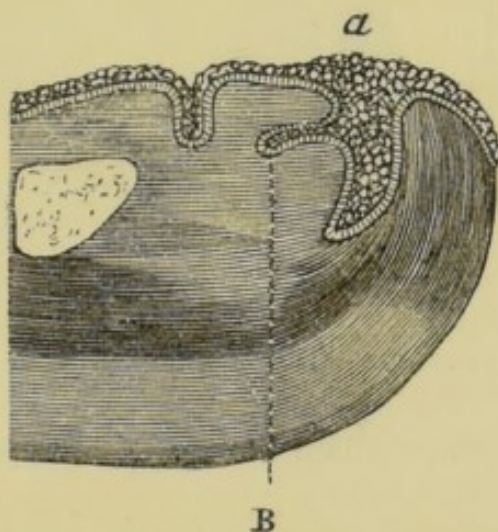
Section of the incisive region of the lower jaw of an embryo sheep, magnified eighty diameters. (Dental development in the sheep and in man are identical.)

- a.* Epithelial ridge or band which extends the whole length of the maxillary arch, but of which the section only is here visible. From this band the epithelial lamina will be given off later.

tending along the whole length of the rudimentary alveolar border (*a*, fig. 6). Section of this ridge shows it to be a continuous vertical band composed of a thick layer of epithelial cells, and it is, in fact, a prolongation of the epithelial layer of the mouth

which has sunk into the embryonic tissue of the jaw. Before the end of the eighth week there has become developed, at about the middle of the buried or deep surface of the ridge, a projection or lamina (B, fig. 7), which, like the layer from which it is derived, extends the whole length of the maxillary border. Its shape

FIG. 7.



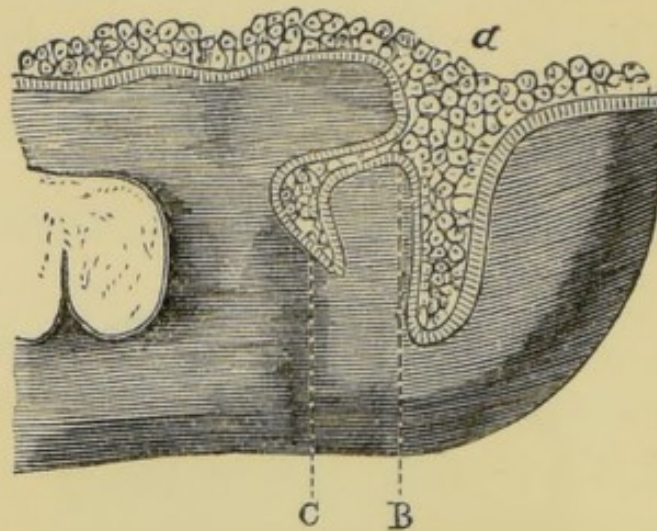
Section of the incisive region of the lower jaw of an embryo sheep, magnified eighty diameters.

- A. Epithelial ridge.
- B. Epithelial lamina originating from the epithelial ridge.

is a little flattened from above downwards, with its extremity rounded and curved in the form of a crook. It is composed externally of columnar cells of the deep or Malpighian layer of the mucous membrane, internally of squamous cells. Within a few more days there can be demonstrated along the border of epithelial lamina in each jaw a series of ten small club-shaped enlargements (c, fig. 8). These enlargements or buds are the rudimentary enamel organs of the temporary teeth, and they are situated at intervals corresponding to the position of the future teeth. The shape of each bud is at first like the finger of a

glove pushed into the submucous tissue, then the end swells, becoming much bigger than the neck, and it

FIG. 8.

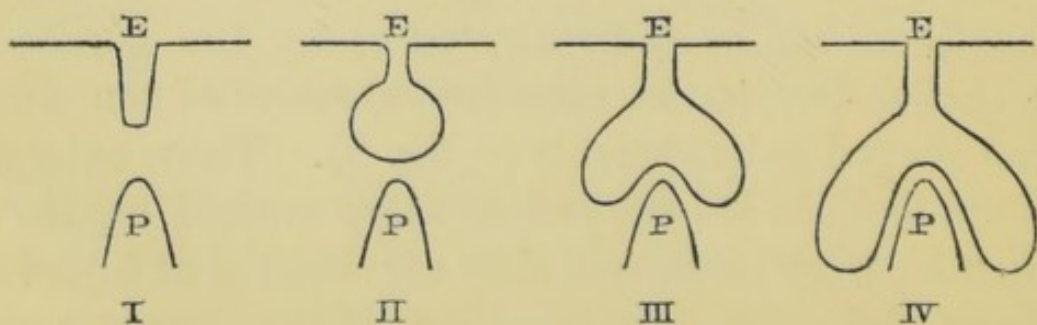


Section of the ramus of the lower jaw of an embryo sheep, magnified eighty diameters.

- A. Buccal epithelium and epithelial ridge.
- B. Epithelial lamina.
- C. First appearance of the enamel organ.

is flask-shaped, with its central or lowest point directly over the future dentine papilla. The apex of this future papilla arrests the further descent of this central part, but the sides continue to descend all round the papilla, enveloping it in a double layer, and assuming the same shape that an india-rubber ball takes if a finger be pushed against it.

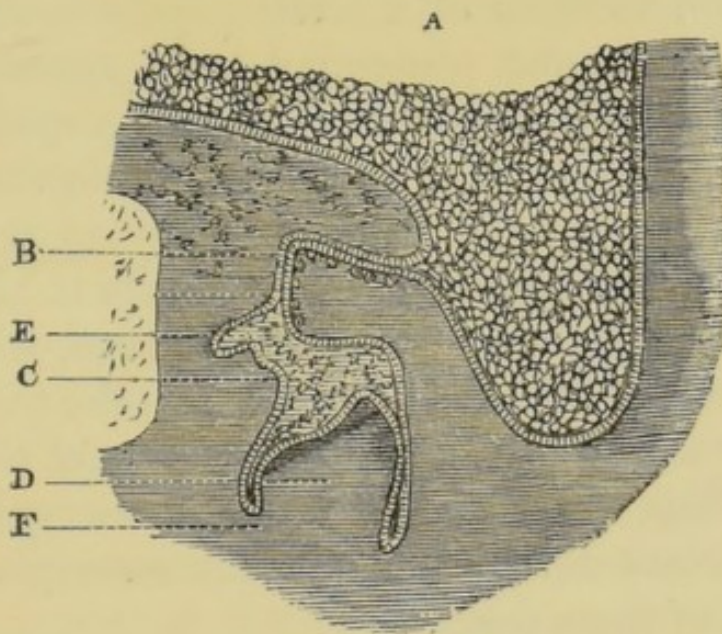
FIG. 9.



The annexed drawing (fig. 9) represents diagram-

matically four stages of the descent of the follicle or enamel organ on to the dentine papilla. It must be borne in mind that this is supposed to be only a section of the object, and also that the papilla is not visibly differentiated so early. The buds are composed of the same epithelial elements as make up the lamina, and they are destined by subsequent deposit of cal-

FIG. 10.



Section of the ramus of the lower jaw of an embryo sheep, magnified eighty diameters.

- | | |
|---|-----------------------|
| A. Buccal epithelium. | B. Epithelial lamina. |
| C. Enamel organ. | D. Dentinal pulp. |
| E. First appearance of the enamel organ of the permanent tooth. | |
| F. Fibrous tissue whence is derived the dental sac. | |

careous matter to become the external or enamel layer of the crown of the tooth. They remain for some time united to the lamina by a narrow portion in the form of a neck, which grows longer as the enamel organ increases in size. The enamel organs soon begin to assume the form of the crowns of the future teeth, but at first their shape is not well defined, and

resembles a cap with the concavity directed towards the depths of the jaw.

By this time (the ninth week) the first appearance of the dentinal pulp may be detected. This pulp (D, fig. 10) eventually becomes converted by calcification into the dentine or ivory forming the bulk of the tooth. Its elements first manifest themselves in the depths of the jaw independently of the enamel organ, but directly contiguous with its deeper surface. The pulp at first consists of a small papilla composed of nucleated cells, and penetrated by a vascular loop, and it is, in fact, at this stage merely a special division of the mucous tissue unusually rich in vessels and cells. Later on, when it has assumed more definite shape, nerve filaments can be traced into it. It grows until it impinges upon the enamel organ, which becomes moulded upon it like a cap, whilst the papilla gradually assumes the form of the crown of the future tooth. Thus, for the incisors it becomes conical, and for the molars develops outgrowths corresponding to the cusps of these teeth.

By the beginning of the fourth month each rudimentary temporary tooth has become enveloped in a distinct closed sac composed of sub-epithelial connective tissue. This sac begins to appear as soon as the dentinal pulp is slightly advanced in development. An opaque fibrous outgrowth springs from each side of the base of the pulp, and grows towards the summit of the tooth, where it unites with that of the opposite side, and so forms the dental sac. By this time the connection between the enamel organ and the epithelial process from which it emanated has become severed, owing to resorption of the uniting neck or band of epithelium at the surface of

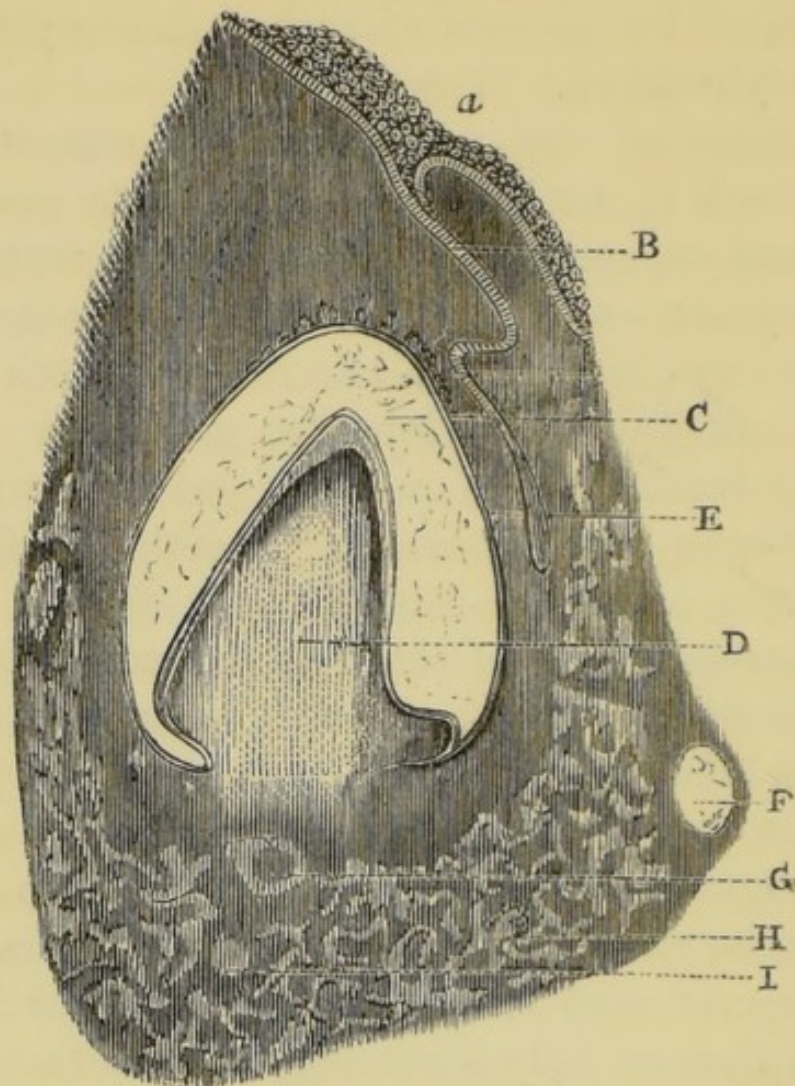
the sac, and this resorption slowly progresses until the whole of the process disappears, leaving the sac completely isolated.

The origin of the permanent set, consisting of sixteen teeth in each jaw, has now to be described. The enamel organs of the ten teeth which replace the temporary set—namely, the incisors, canines, and bicuspids—originate from a bud for each tooth, which is given off from the elongated extremity of the epithelial lamina at its point of junction with the enamel organ of the temporary tooth (E, figs. 10 and 11).

The enamel organ of the first permanent molar is given off from the posterior extremity of the same epithelial band as gave origin to the temporary tooth. From the epithelial process of this enamel organ a bud springs for the second permanent molar in exactly the same manner as the permanent successors of the temporary set were evolved from the epithelial processes of that set. In a precisely similar fashion the enamel organ of the third molar, or wisdom tooth, arises from the epithelial process of the second molar.

These sixteen germs in each jaw constitute the first traces of the permanent teeth, and they each pass through the same phases of development as we have seen undergone by the germs of the temporary set, these phases being the appearance of the dentinal pulp, its junction with the enamel organ, and their enclosure in the sac. The only further difference to be noted between the development of the permanent and deciduous teeth is in the time which particular teeth take to pass through the successive stages of evolution. For example, the temporary teeth are usually all cut by the third year, whilst the first per-

FIG. 11.



Section of the incisive region of the ramus of the lower jaw of a human embryo. (In this preparation of the epithelial cord or process whence is developed the enamel organ of the permanent tooth, is seen partly isolated from its origin in the follicle of the temporary tooth.)

- A. Buccal epithelium.
- B. Epithelial process or cord of the temporary follicle.
- C. Enamel organ.
- D. Dentinal pulp covered by a small cap of dentine.
- E. Epithelial cord, whence is developed the enamel organ of the permanent tooth.
- F. Rudimentary cartilage of the jaw.
- G. Section of the dental artery.
- H. Traces of ossific matter in the jaw.
- I. Section of the dental nerve.

manent molar, although its germ appears at the fifteenth week of foetal life, is not erupted until the

sixth year. Similar remarks apply to the rest of the permanent set; but it will suffice now to give the dates of the phases of their development so far as above described. The enamel organs of the incisors, canines, and bicuspid make their appearance about the sixteenth week of intra-uterine life; those of the first permanent molars about the fifteenth week; those of the second molars about the third month after birth; and those of the wisdom teeth can be demonstrated towards the third year. The dentinal pulps of the ten first-mentioned teeth appear at the twentieth week; those of the first molars at the seventeenth week; those of the second molars about the first year after birth; and those of the wisdom teeth towards the end of the sixth year. The complete closure of the sacs of these teeth is accomplished in the order in which they have been above mentioned at the following dates—9th month, 20th week, 1st year and 6th year.

The histological changes which take place in the tooth germ by which its elements are gradually converted into the dental tissues, must be now more fully described.

It has been seen that the enamel organ when first formed is composed entirely of epithelial cells—externally of the columnar, internally of the squamous variety. It retains its epithelial nature throughout the process of calcification. This process begins at the surface of the dentine, and progresses outwards. Prior to the deposition of earthy matter the columnar cells immediately in contact with the dentine increase greatly in length, and form six-sided prismatic bodies so arranged as to constitute a columnar epithelium, which, according to Waldeyer, is the most beautiful

and regular found in any part of the animal body. This layer is called the internal epithelium of the enamel organ. The external cells of the enamel organ (termed external epithelium) are shorter and more cubical in form. Numerous vascular papillæ, arising from the contiguous tissue of the dental sac, penetrate to a slight depth the external epithelium, and serve doubtless to provide nutriment to the developing tissue. The cells forming the interior of the organ undergo transformation during the formation of the enamel. At first small and round, they soon become stellate in form, united with each other by their processes, and from the cells of this layer (called *stratum intermedium*), in contact and united with the internal epithelium, a continuous development of columnar enamel cells proceeds.

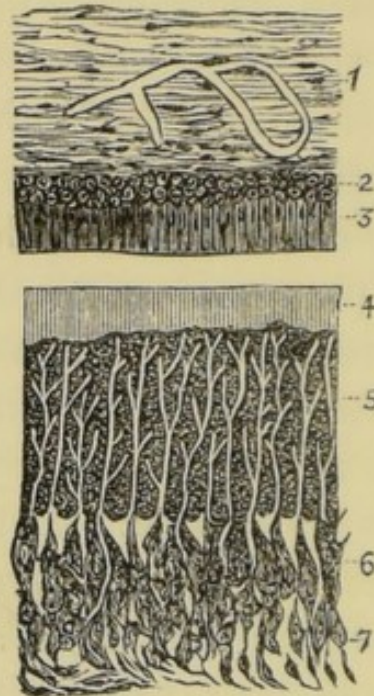
It has been just stated that the deposition of calcareous matter commences in the enamel organ at the surface of the dentine and proceeds outwards. The completed tissue results from the direct calcification of the internal epithelium. The calcification progresses from the periphery of each cell towards its centre, at the same time uniting together the contiguous columns. Prior to the completion of the enamel the external epithelium and remaining portion of the *stratum intermedium* undergo atrophy. These cells ultimately disappear, or perhaps, as some observers state, they take part in forming Nasmyth's membrane (*cuticula dentis*), the thin layer of tissue which envelops new-formed enamel.

Calcification of the dentinal pulp begins before that of the enamel organ. The process by which the conversion is effected closely resembles the histological formation of bone. It commences at the surface and

proceeds inwards, the central portions with the vessels and nerves remaining to constitute the persistent dental pulp or "nerve" of the tooth. The dentinal pulp (as already mentioned) at first consists of a special division of the rudimentary mucous tissue, rich in vessels and cells. Its fibrous elements consist of a fine connective tissue, through which the cells are scattered. When the pulp has arrived at a certain stage of development the cells begin to be specially organized and arranged. By this time the pulp contains numerous nerve fibrils besides blood-vessels. The latter form a plexus close to the surface. The specialized cells are termed odontoblasts. They are developed from the cells lying at the periphery, where they become arranged in a layer so as to form a kind of columnar epithelium. This layer is termed the *membrana eboris*. The cells are finely granular, have no membrane, and contain a large rounded nucleus. They are each provided with numerous processes, which unite them with the contiguous odontoblasts, and with subjacent developing cells. The nuclei of the odontoblasts disappear, and they become converted into a gelatinous material which undergoes direct calcification, and forms the whole of the hard constituents of the dentine. The changes take place from the periphery of each cell towards the centre. The central portion of each cell remains uncalcified, and forms the soft fibril which occupies the completed dentinal tube. The *membrana eboris* is constantly fed from the deeper layer of cells, which, united with the odontoblasts by means of their processes, form an uninterrupted series, and provide for the continuity of the dentinal tubes and fibrils. The layer of matrix immediately around the fibrils be-

comes converted into the dentinal sheaths—the lining walls of the tubes. It has not yet been ascertained whether the sheaths are calcified or not, since their structure cannot be examined except after maceration

FIG. 12. From Waldeyer (1).



Longitudinal section of a milk-tooth from the fœtal sheep carried through the margin of the dentinal pulp and adjoining portion of the enamel organ, magnified 200 diameters.

1. Dental sac.
2. External epithelium of enamel organ.
3. Internal epithelium of enamel organ.
4. Young layer of enamel detached from the enamel cells.
5. Dentine.
6. Odontoblasts.
7. Part of the dentinal pulp.

or incineration of the tissue. M. Magitot denies the existence of sheaths, regarding them as the products of the re-agent employed to remove the matrix, of the same nature in fact as the *membrana præformativa*; and certainly it does not appear that there is more evidence of their distinct structure than of the existence of that hypothetical tissue.

By the end of the seventeenth week of intra-uterine life a cap of dentine may be demonstrated on the pulps of all the temporary teeth. By the sixth month the first permanent molar has advanced to a similar stage of development. By the first month after birth the permanent incisors and canines are advanced to the same stage; and at the third year and twelfth year respectively, calcification has commenced in the second molars and wisdom teeth.

The entire crown of each tooth is represented in soft tissue before the deposition of earthy salts commences, and as the tooth elongates by growth of the pulp from below, successive portions undergo calcification to form the root.

The development of the cement, or *crusta petrosa*, has not been made out beyond dispute. It probably takes place in a matrix formed by the investing fibrous coat of the dental sac. A special cement pulp has not been demonstrated in man. Cement is, in fact, a thin layer of bone, and the process of its formation is doubtless similar to intra-membranous ossification of other bones of the body.

The *cuticula dentis* (Nasmyth's membrane), already mentioned, is believed by some authorities to be formed from the residuum of the pulp of the enamel after the completion of that tissue. It is, however, much more probable that it is merely a thin layer of modified osseous tissue continuous with the cement, having a similar origin, and homologous with the coronal cement found on the teeth of certain herbivorous animals.

GROWTH OF THE JAWS.

FIRST AND SECOND DENTITION.

COMMENCING as early as the fifth week of foetal life, ossification of the maxillary bones proceeds rapidly, and is well advanced at birth. The lateral halves both of the upper and lower jaws at this period are, however, still united by cartilage, and the alveoli of the temporary teeth are represented by a deep trench, divided by incomplete bony plates into large crypts, in which the teeth lie enclosed by the dental sac and submucous tissue. The temporary teeth are represented by their partly calcified crowns, the stage of development varying in the different teeth according to the period at which their eruption is destined to take place. Thus the crowns of the central incisors are nearly complete, whilst the apices alone of the rudimentary crowns of the canines have become converted into a cap of calcified material.

During the first few months after birth, the development of the maxillæ is most active at the surface adjacent to the connecting cartilages and at the alveolar border. The alveoli increase in depth, and by the growth of their free margins overhang and protect the contained teeth. A little later they become nearly closed.

The age at which the eruption of the temporary teeth commences varies somewhat in different individuals, but it is rarely earlier than the fifth, or later

than the ninth month. The eruption of the teeth is a process of gradual elongation of the teeth on the one hand, and of simultaneous absorption of the superimposed tissues on the other. The absorption commences first in the overhanging margins and front walls of the alveoli, which gradually disappear until room is afforded for the free passage of the advancing tooth. The growth of the tooth keeps pace with this absorption, and the crown at length pressing against its membranous coverings these undergo atrophy, and, becoming by degrees thinner, and at last transparent, give way and disclose the advancing crown.

It occasionally happens that these various actions are not perfectly harmonious in their course, the advance of the tooth being more rapid than the disappearance of the enclosing bony and soft tissues. The tooth is thus mechanically held in position, and irritation is set up, which manifests itself by inflammation and induration of the gums, and even by reflex nervous disorders, and constitutional disturbance of various kinds. It is for the relief of such diseases that the operation of lancing the gums of infants is performed. This operation has for its object the division of the abnormally indurated gum, and the release of the advancing tooth. It is obvious that the utility of this procedure must be extremely doubtful when it is carried out prior to the passage of the tooth through the contracted bony orifice of the alveolus; but that it may be reasonably expected to afford relief in cases where the advancing tooth can be distinguished beneath the indurated, tense and swollen gum.

The order in which the temporary teeth are erupted

seldom varies. The lower central incisors are the first which appear. They are followed, after an interval varying between a week and two or three months, by the corresponding members of the upper set. After another similar lapse of time, the lower, quickly followed by the upper lateral incisors, present themselves. Next, after like intervals, the first molars, and then the canines are protruded. Lastly, the second molars take their places, and complete the series. By the time that the eruption of the temporary teeth is completed (between the second and third years), considerable progress has been made in the development both of the jaws and permanent teeth. The maxillæ have increased in size, and the fibro-cartilages uniting the lateral halves are completely ossified; the alveoli which had been absorbed to give exit to the teeth, have since grown up with the advancing organs, and now closely invest them; the angle of the lower jaw, which recently after birth is very obtuse, has become more acute, coincident with the development and lengthening of the ramus, and of the articular and coronoid processes. Excepting those of the wisdom teeth, the crowns of the permanent set are all well advanced in calcification, their progress being, however, proportionate to the respective periods of their evolution. The incisors, canines, and bicuspid are completely enclosed in bony crypts. The incisors are situated in the upper jaw above and behind, and in the lower jaw below and behind the roots of the teeth, which subsequently they respectively replace. The canines are deeply placed between the crypts of the lateral incisors and first bicuspid. The bicuspid lie within the divergent roots of the temporary molars. The

molars, surrounded by incomplete casings of bone, occupy the portion of jaw posterior to the temporary set, extending into the ramus of the inferior, and the tuberosity of the superior maxilla. The anatomy of the jaws at this period is admirably displayed in

FIG. 13.

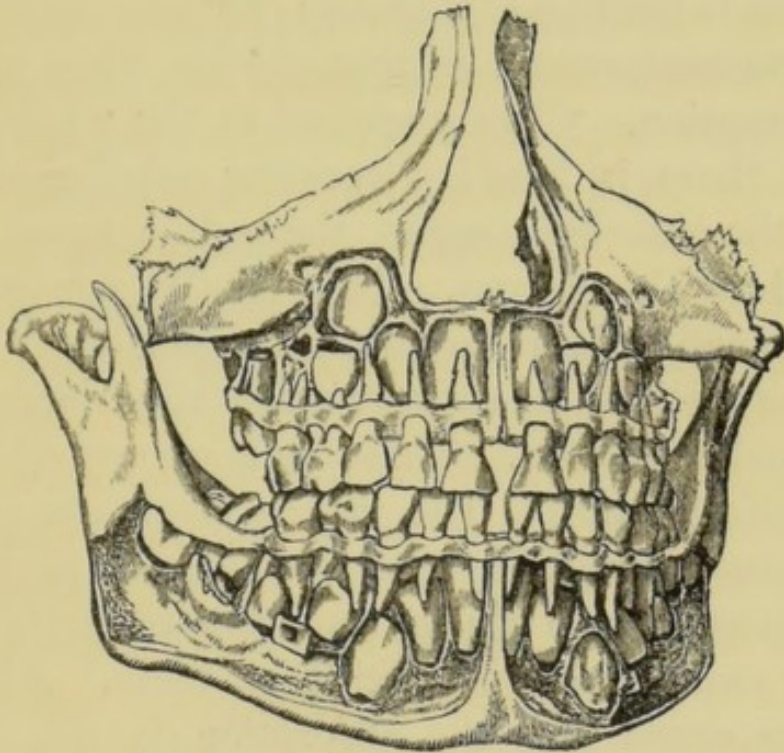


fig. 13, from Mr. Tomes' work (17). It may be noted that this is the epoch at which the greatest number of teeth are held in the jaws at one time. The whole of the deciduous set, and the whole of the permanent set, are present, and of these the wisdom teeth alone are still totally uncalcified.

Within two years after the completion of the temporary set a process is commenced by which their roots are gradually removed by absorption, until in time the teeth lose their attachment to the jaws, and are cast off one by one, to be afterwards replaced by the advancing members of the permanent set. The

absorption does not begin simultaneously throughout the whole set, but attacks the teeth according to the order in which they are to be shed. It commences and proceeds, as a rule, at that part of the root towards which the permanent tooth is advancing, but occasionally it affects other parts at the same time. The wasting surface, which on examination is found irregular in outline and broken up into minute pits or depressions, resembles that of bone when undergoing absorption. Closely applied to the whole of this surface there is found a vascular papilla of slight depth, the absorbent organ, the active agent in the removal of the tissues. This papilla consists of a vascular and cellular structure, the portion in contact with the teeth being entirely made up of large multi-form nucleated cells. These cells occupy the pits in the wasting tissues. The papilla originates from the contiguous vascular layer of the alveolar periosteum, and it constitutes a special provision in the economy for the removal of the deciduous teeth. Abundant evidence exists that the absorption is not (as was once supposed) due to the pressure of the advancing permanent teeth, and the following are some of the main facts composing this evidence:—1st. In some of the lower animals, notably in the serpent, conditions exist during the evolution of successive sets of teeth, which prove beyond doubt that absorption of deciduous teeth, similar to what occurs in man, takes place independently of pressure. This fact has been recently demonstrated clearly by Mr. Charles Tomes (15). He has pointed out that the succession of teeth in snakes is endless, new teeth continuing to be developed at the inner side of the teeth already in place throughout the lifetime of the animal; that

when a tooth is about to be shed, both it and the bone at its base are attacked by absorption, this taking place at its inner side before the outer side is at all involved; and that the advancing tooth moves forward, the delicate cells of its enamel organ remaining *in situ*, even after absorption has been effected to such an extent that the inner side of the old tooth has been cut away, and the successional tooth has passed into the space thus gained. "It is obvious that if the successional tooth had ever come into contact with its predecessor, these cells, at the point of impact, could not have escaped destruction."

2nd. Absorption of a human temporary tooth occasionally goes on at points remote from the permanent successor.

3rd. The permanent do not impinge upon the temporary teeth during their advance, and, on the contrary, they are separated from them throughout by the bony walls of the crypts in which they are enclosed.

The process of the eruption of the permanent teeth closely resembles that which has been described as occurring in the first dentition. By the time each temporary tooth is shed, absorption has commenced in the plate of bone which up to this period has closed the crypt of the permanent successor, and this absorption proceeds until the opening is large enough to permit the free passage of the emerging crown. When the crowns of the teeth are fully protruded the development of the alveoli again becomes active, and the bone in time firmly embraces the necks of the teeth, and invests the roots in accurately fitting sockets.

The age at which second dentition commences

varies, like the first, in different individuals, but the order in which the teeth appear is rarely irregular. The following may be taken as average dates at which the eruption of the different teeth is completed. The teeth of each class appear somewhat later in the upper than in the lower jaw :—

	YEARS
First molars	} 5 to 7
Central inferior incisors	
Central superior incisors	6 to 8
Lateral incisors	7 to 9
Anterior bicuspids	8 to 10
Canines	9 to 12
Posterior bicuspids	10 to 12
Second molars	12 to 14
Wisdom teeth	17 to 25

The eruption of the permanent teeth is seldom attended with constitutional disorders due to reflex nervous disturbance, such as commonly accompany first dentition ; and local irritation is rare, except in the case of the lower wisdom teeth. The protrusion of these teeth is, however, often attended by considerable suffering. They make their appearance after the completion of dentition, at the time when, owing to insufficient backward development of the horizontal ramus of the jaw, crowding of the teeth frequently exists, and the space which should remain for their reception is encroached upon by the second molar. The wisdom teeth in their advance thus become wedged between the posterior surface of the second molar and the coronoid process, and give rise to pressure upon the overhanging mass of gum and mucous membrane. This condition is alone some-

times enough to give rise to considerable swelling and inflammation of the gum, and the mischief becomes aggravated when the opposing teeth of the upper jaw come forcibly in contact with the swollen tissues in mastication. The inflammation spreads to the alveolar periosteum, and to the uvula, soft palate, and tonsil, and the neighbouring lymphatic glands become swelled and painful. The pain is severe, often throbbing in character, and is increased by attempted movements of the jaw and by swallowing. These symptoms are attended with considerable febrile disturbance. If the disease run on suppuration takes place, and an abscess forms and discharges within the mouth at some point about the swollen gum or adjacent structures. From this time the symptoms may slowly subside, or the inflammation may remain chronic, increasing again into the acute form from time to time under the influence of cold or other irritation.

Treatment.—If the other teeth of the affected side be sound, and the space is too small to allow the emerging wisdom tooth to rise in time clear of the gum and mucous membrane which overlays it behind, it should be at once extracted. This operation should also be performed without hesitation, in order to cut short the patient's suffering, should extensive acute inflammation exist. If the tooth, as sometimes happens, be misplaced, and with the crown so directed as to render it useless in mastication, it should be removed. It often happens, however, in these instances, that the tooth is so impacted as to render its extraction extremely difficult or impossible. This is especially the case where the tooth is advancing in an oblique direction—sometimes it may be nearly

horizontal—and with the anterior margin of the crown impinging upon the distal surface of the second molar. In one or two cases of this kind, the author has succeeded in breaking the crown from the root, the patient being under the influence of an anæsthetic, and extracting the root in a second operation. But, with few exceptions, cases of impacted lower wisdom teeth, in which relief afforded by space is called for, are best treated by extraction of the second molar. This allows the impacted tooth to advance slowly into the vacant space. Where the second molar is extensively carious, there seldom need be hesitation in proposing this operation. Under other circumstances the preservation of the tooth may be attempted. In some cases the excision of the gum covering the tooth will suffice to give relief. The flap of gum should be seized with a dissecting forceps, and cut away with a small bistoury. The mere lancing or division of the gum rarely does much good, as the divided parts fall again at once into contact, and become rapidly united. After the extraction of the tooth or excision of the gum the persistent application of warm fomentations within the mouth usually soon effects a subsidence of the inflammatory symptoms.

Throughout the entire period of their growth the process by which the maxillæ are moulded into their destined form is similar to that which takes place in all developing bones. It consists, on the one hand, of continuous deposition of bone, and on the other of occasional absorption. It has been already explained how the processes of growth and absorption alternate during the process of dentition and the development of the alveolar border of the jaws. The enlargement

of the maxillary arch is produced mainly by deposition of bone upon the facial surface, and as the new layers of bone are deposited absorption takes place upon the lingual surface. In the same way in the development of the posterior portion of the lower jaw, whilst the ascending ramus is increasing in size by the deposition of bone upon the posterior surfaces of the coronoid and the condyloid processes, absorption is going on upon these parts anteriorly, and thus the bones are moulded into their destined form. The deposition of new material is principally subperiosteal, but it also takes place beneath the articular cartilage of the lower jaw, and at the surfaces contiguous to the cartilages, which in the infant unite the separate portions of bone in both maxillæ ; and the increase in the bulk of the jaws is thus entirely affected, not by interstitial growth or expansion of the bones, but by constant additions to the external surfaces.

Up to a certain period in the growth of the jaws, as previously mentioned, there is not sufficient room in the alveolar arch for the crypts of the developing permanent molars, which, therefore, are enclosed in the base of the coronoid process of the lower, and in the tuberosity of the upper jaw. The space taken up by the ten anterior permanent teeth almost exactly corresponds to that occupied by the milk teeth, and it is, therefore, in the backward direction that the required increase in size of the arch takes place. The depth of the bones becomes greater in accordance with the dental and muscular development. Examination of a large series of human maxillæ of different ages, enabled Mr. Tomes to demonstrate the fact, first pointed out by John Hunter, that the growth of the

alveolar border, both during the first and second dentition, follows and is dependent upon the growth of the teeth, and that the position of the teeth is not, as was once believed, predetermined by independent growth of the bone. This fact has also lately received confirmation from the observations of Mr. Chas. Tomes, upon the mode of attachment of the teeth in fishes and reptiles. He has proved that in the attachment of a tooth by simple ankylosis, or by ever so rudimentary a socket, as it takes place in the varied species, the bone is modelled to the tooth in full subserviency to the position of that tooth, and that the tooth does not come to take its place upon a spot predetermined for it by any disposition of the bone, made prior to its advent.

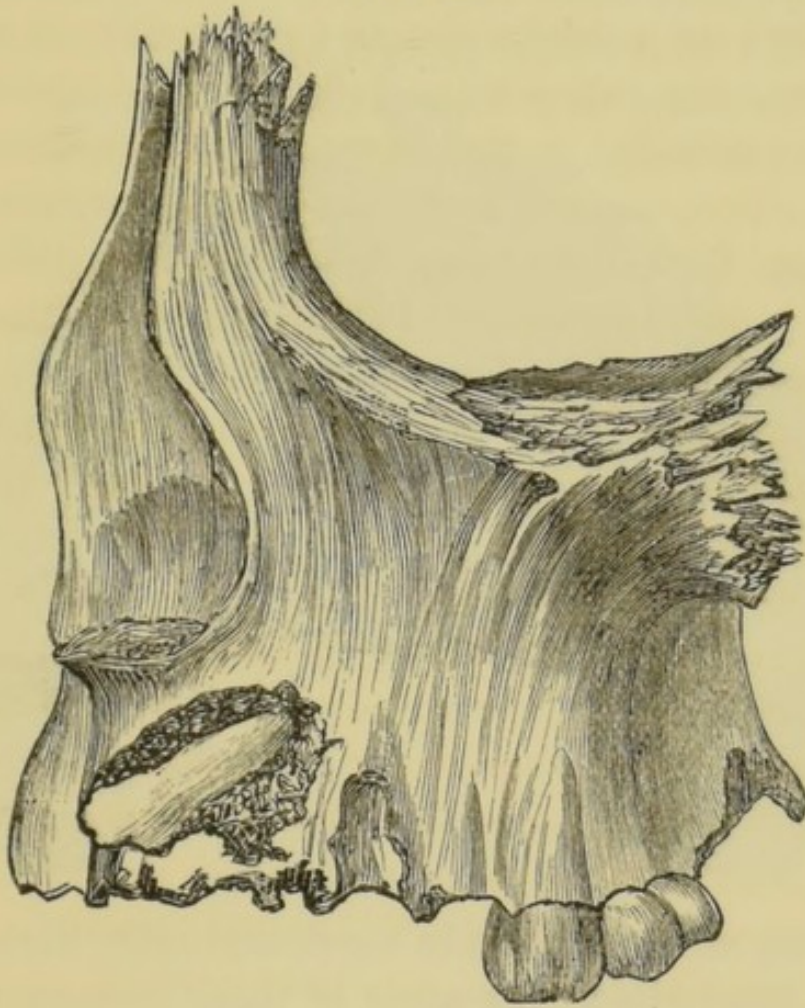
The portions of bone which give attachment to the muscles of mastication increase in bulk as these organs develop in size and power.

When the teeth are lost from age or other causes, the alveoli waste by absorption; and at the same time mastication being gradually discontinued, the muscles, together with the portions of bone to which they are attached, undergo atrophy, and the jaws assume the peculiar form characteristic of age.

It happens occasionally that permanent teeth remain imbedded within the jaws instead of making their appearance at the natural epoch of their eruption. It has been just explained, and illustrated in fig. 13, that at one period in the growth of the maxillæ, before the jaws have attained their full size, enough space for the extended arrangement of the set in an unbroken arch does not exist, and the teeth are therefore crowded within the jaw, the canines and bicuspid being deeply placed, whilst

the upper and lower wisdom teeth are situated in the tuberosity of the upper and in the ramus of the lower jaw respectively. If, owing to arrest of development or other cause, the jaws remain unduly small or contracted, there may never be enough room for the entire set of teeth to be erupted in the dental

FIG. 14.

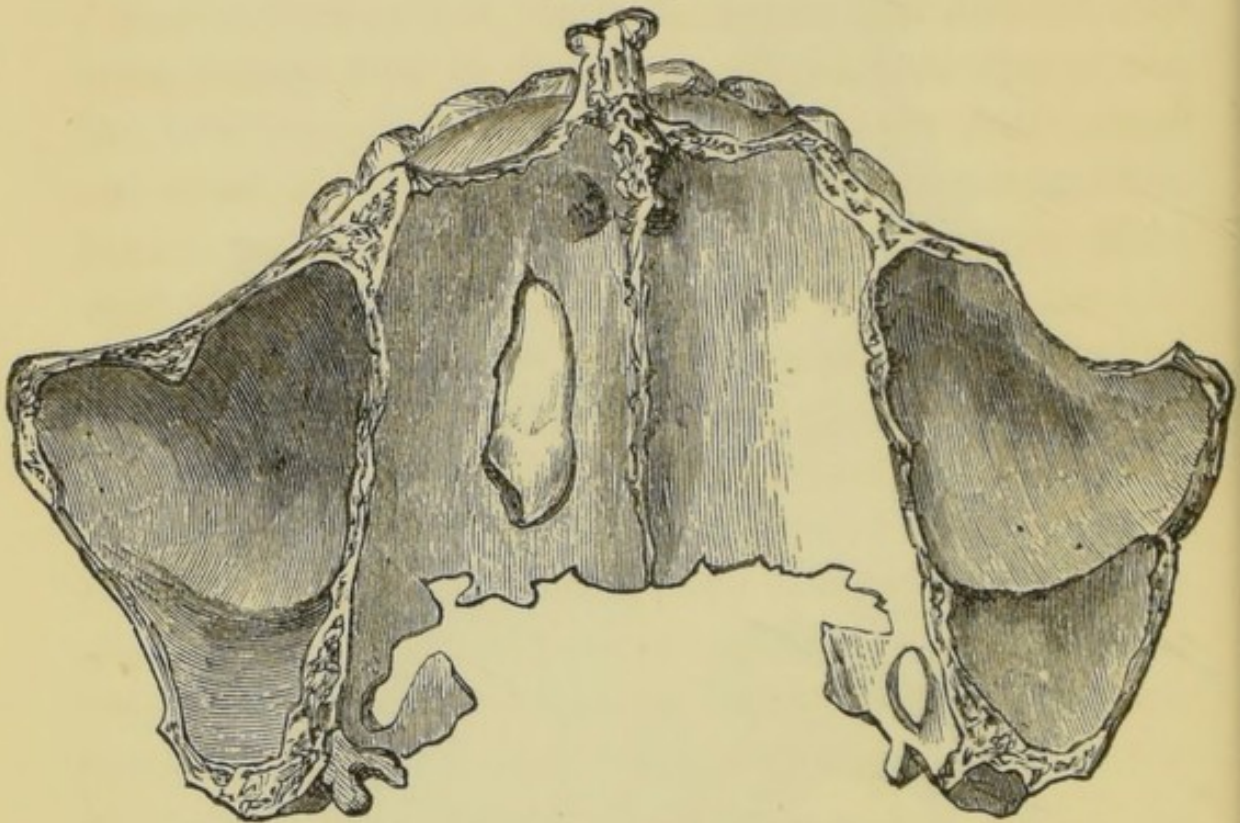


arch, and some of the set, although fully formed, may remain buried within the bone. This condition, although it may happen in the case of any tooth, most commonly arises, as might be expected, with those teeth—such as wisdom teeth, canines, and bicuspid— which are cut at a late stage of dentition, when the whole available space in an abnormally

small maxilla may be taken up by the rest of the set. The eruption of such teeth may be also in the same way prevented by the presence of supernumerary teeth or by persistent temporary teeth holding their position after the time at which they ought to be cast off.

In another class of cases imbedded teeth hold such abnormal positions within the bone that, although

FIG. 15.



room may exist for them in the dental arch, their eruption is impossible. In some of these instances there is evidence that the malposition is due to deflection of the growing tooth from its normal course by obstacles, such as temporary teeth, or supernumerary teeth, but in others the tooth is situated far from the alveolus, and its misplacement cannot be accounted for. Fig. 14, from Mr. Heath's work (4), shows an upper canine situated within the jaw in a position which it may have possibly assumed in consequence of want of space,

whilst fig. 15 from the same work, exhibits an inexplicable misplacement of an upper canine, which lies horizontally in the floor of the nose, with the crown directed backwards. Specimens are preserved in the Museum of the College of Surgeons, showing teeth imbedded in almost every position in the maxillæ. Imbedded teeth, especially those regularly situated within the bone, sometimes make their appearance after a lapse of time when room is afforded by the loss of other teeth, and the eruption of such teeth late in life has given rise to the unfounded belief in the occasional occurrence of a third dentition.

In the majority of instances, imbedded teeth remain through life, without the patient being aware of their existence, but in some few individuals they become the centre of cystic disease or of other morbid growths. Such growths connected with teeth are described in a later section.

ABNORMALLY FORMED TEETH.
IRREGULARITIES OF THE TEETH.

Syphilitic and Honeycombed Teeth.—Of the innumerable deviations from a typically formed tooth that are constantly brought under observation, many are so slight as not to call for notice here, others though curious have no pathological interest, for they give rise to no symptoms and call for no interference. There are, however, certain abnormalities in the formation and growth of permanent teeth that are the constant sources of disease and disfigurement, and the exact nature of these it is important to understand. The temporary teeth never present any peculiarities worthy of description.

There are two great classes of imperfectly formed teeth—those in which the imperfections are due to inherited syphilis, and those in which development has been arrested or interfered with by external influences affecting the individual after birth, such as the administration of mercury or the direct effect of stomatitis.

Syphilitic teeth, as they are called, show the deformity most in those parts of the tooth, the tips and cusps, which are first formed. As development proceeds the taint seems to wear itself out, and the last stage, namely, the deposition of enamel, is fairly well performed. The whole tooth is, however, profoundly

modified in shape by the disease. The cutting edge of a normal upper central incisor is broader than the neck, so that between the two centrals there is a V-shaped space at the line of the gum. In syphilitic teeth, however, the cutting edge which is first developed is narrow, concave, and notched. The effects of the syphilis lessen as the tooth formation proceeds, so that the neck is little less than normal; and the space between the central incisors appears very great, because they do not approach each other at the cutting edge. The central incisors are the teeth which show most characteristic signs of inherited syphilis. They are generally short and narrow, have a broad vertical notch in their cutting edge, and their corners rounded, giving them a peg shape. Horizontal notches or furrows often exist on the same teeth, but these may not be syphilitic in origin.

The enamel formation, being a final stage in the tooth development, does not show marked deformity; it may be smooth, white and normal, unless other causes, afterwards to be described, should have interfered to arrest its development.

A striking connection has been observed between syphilitic deformity of the teeth and a syphilitic disease of the cornea, known as interstitial keratitis, a connection of the highest interest, though liable to many exceptions. Many honeycombed and defective teeth closely resemble in appearance syphilitic teeth, and great caution is necessary in pronouncing a diagnosis from the evidence of such teeth alone.

Imperfections of the second class—namely, those due to causes that begin to affect the teeth after

birth, consist mainly of arrest of the enamel formation to which the names honeycombed, pitted, rocky or ridged teeth have been given. Their history is probably very simple. The early administration of mercury as a remedy for convulsions, or in some of the innumerable "teething powders" (most of which contain the drug), or any of the ordinary varieties of stomatitis so common amongst ill-nurtured children, would be amply sufficient to account for the temporary arrest of the deposition of enamel. The first permanent molars are always most affected, then the incisors; the bicuspid usually escape entirely. Again, in this class, as in the syphilitic teeth, there is a notable coincidence with an eye affection. A peculiar zone of opacity in the lens, called a lamellar cataract, not congenital, and certainly not syphilitic, has been observed to occur in intimate connection with infantile convulsions, and such children are conspicuously subject to honeycombed enamel.

To sum up these facts it would appear:—

1. That syphilitic teeth are mostly accompanied by other evidences of the inherited taint, such as skin affections and interstitial keratitis, while honeycombed teeth are associated with a non-syphilitic eye disease, lamellar cataract, with infantile convulsions, and with mercurial treatment during the enamel forming period.

2. That in inherited syphilis the teeth most affected are the upper incisors, the honeycombed condition being most conspicuous in the first molars.

3. That these conditions may both be present in the same individual.

4. It by no means happens that every case of inherited syphilis is marked by typical mal-development

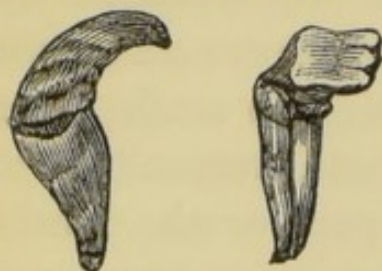of the teeth; many instances occur in which no characteristic defect is visible.

Dilaceration.—When the mode of development of the teeth is considered, and it is remembered that they are liable to injury at the period when they are but partially calcified, it is easy to understand why teeth are occasionally met with the crowns and roots of which are more or less distorted. In such cases some force—such as a blow—has been transmitted to the developing organ, by which a part or the whole of the crown has become displaced, without severance of its connection with the uncalcified portion of the pulp, and has become subsequently fixed in its malposition by the completion of the process of calcification. This kind of injury has been termed dilaceration. Section of such teeth displays evident marks of the bending which the tissues underwent in the soft state. It is possible that a tooth might be distorted during growth to the extent of dilaceration in consequence of crowding and pressure within the jaw from want of space, and this opinion is strengthened by the fact that the deformity seldom or never occurs except in teeth situated at the front of the jaw where a crowded condition is common.

Teeth which have undergone dilaceration are of course easily recognized when the injury affects the tissues of the crown, but when the crown is well formed and merely bent at an angle with the root, careful examination is sometimes required to distinguish the case from one in which a well formed tooth is lying in an abnormal position. The latter case might be amenable to treatment, which would be inapplicable to dilaceration. Teeth the subject of dilaceration often present marked bulgings upon

either surface close to the neck, which is frequently constricted and well defined; they occasionally display marked mobility under slight pressure, and the distorted root may be in some cases traced by

FIGS. 16 and 17.

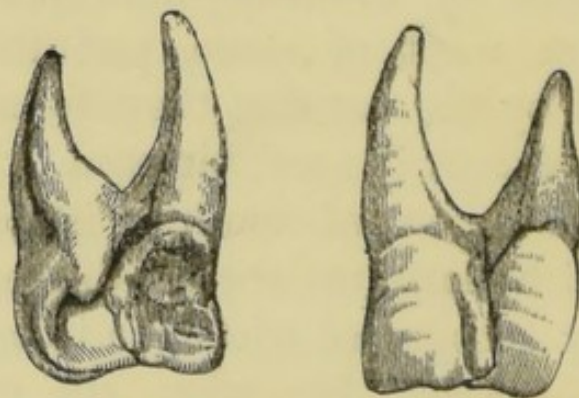


the finger through the alveolar wall. Fig. 16, from Wedl, represents a case of dilaceration or flexion occurring in an upper central incisor, of which a side view is presented. The crown is perfectly developed, but the root is

short and thick and much curved, its apex being directed towards the lips. Fig. 17, from Wedl, shows a lower central incisor the seat of dilaceration, the crown is bent at a right angle to the root, and the cutting edge is directed towards the lips.

Gemination, or organic union of two neighbouring teeth, sometimes occurs, due to coalescence of con-

FIG. 18.



tiguous primitive pulps during development. It rarely affects any but incisors, and the union may extend through crowns and root, or may effect only a part of the teeth. Blended crowns contain as a rule a common pulp cavity, but in blended roots the chamber is divided or distinct. Gemination does not necessarily give rise to marked deformity in the ap-

pearance of the teeth. Fig. 18, from Tomes, exhibits a lingual and labial view of two incisors of the upper jaw, the crowns of which are thus united.

Supernumerary teeth are frequently met with. They are as a rule easily recognized, being mostly of an irregular conical form, unlike any member of the normal set of teeth. Their most common situation is towards the front of the mouth, where they are usually placed irregularly among the other teeth. Sometimes a supernumerary tooth is both placed within the dental arch and symmetrical in form, and hardly distinguishable from its neighbours—an individual in this way possessing an extra or supplemental incisor or canine.

Other abnormal teeth, presenting several forms, varying between so-called warty teeth, studded with nodules of enamel, and monstrous teeth, mere shapeless masses of dental tissue, must be considered identical with the morbid growths termed odontomes, the nature of which will be described in a future section.

The sole treatment available in each variety of the above described abnormalities is the extraction of the deformed teeth, an operation which may be called for when the faulty tooth is unsightly, or when it is causing displacement of adjoining teeth.

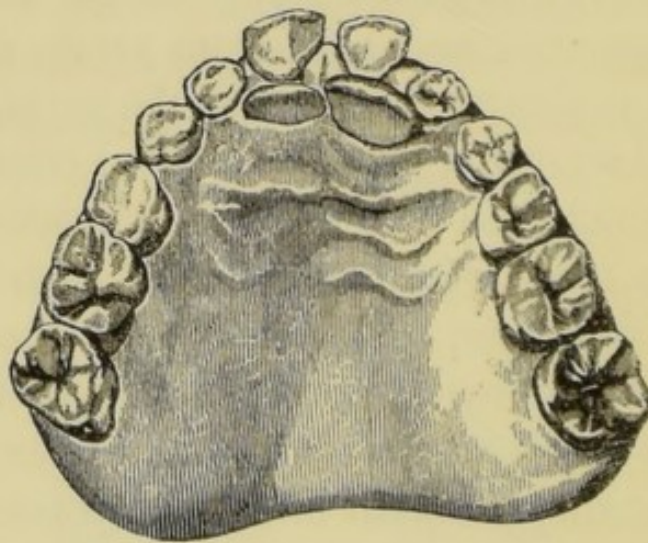
Irregularities of the teeth may be divided into two great classes. 1st. Those in which teeth occupy abnormal positions in well-formed jaws; 2nd, those associated with malformation either of the alveolar border or of the body of the jaw,

The first class of irregularities rarely occurs in deciduous teeth, for the reason that in this case the chief cause of irregularity—obstruction by preceding

teeth—is absent. Instances of the second class in the infant, although seldom manifest to casual observation, are often perceptible to careful examination, especially when the deformity affects the jaw generally. Irregularities of the temporary teeth, whatever their character, are, however, of little practical importance, since the teeth are shed in early life, and the deformities do not call for treatment.

It was explained in the previous section that, during the process of eruption the teeth are not closely embraced by bone, and that it is not until some time after the crowns have fully emerged from the wide orifices of the crypts that the alveoli become fully formed, and invest closely the necks and roots of the teeth. During

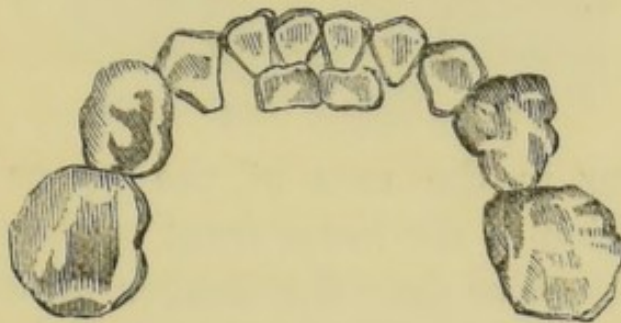
FIG. 19.



this stage of growth, when the advancing teeth are surrounded by soft, readily yielding tissues only, any slight obstacle to their progress suffices to divert them from their proper direction, and to retain them in a wrong position. The most frequent of such obstacles consist of temporary teeth, or decayed portions of temporary teeth, which have retained their places, after the time at which they ought to have been cast

off. The most common example of this kind of irregularity, is illustrated in fig. 19 (Tomes), where the permanent incisors of the upper jaw are seen to occupy a posterior position, owing to the persistence of the temporary teeth. A corresponding irregularity occurring in the lower jaw, is shown in fig. 20.

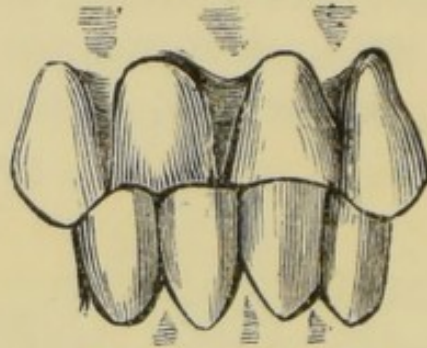
FIG. 20.



By similar causes teeth may be twisted upon their axes, crowded together so as to overlap, or displaced in almost any direction. In such cases if the temporary teeth be extracted sufficiently early, those that are displaced tend spontaneously to assume their proper positions; but should the deformity be allowed to continue for any great length of time, the teeth become fixed, either by the consolidation of the bone of the jaw, by the advance of the contiguous teeth, or by the locking together of the upper and lower sets when closed. For example, the prompt extraction of the temporary teeth in the case depicted in fig. 19, would enable Nature to effect a cure; but if the operation were delayed until the permanent teeth were fully protruded they would pass, as seen in fig. 21, on closure of the jaws, behind instead of in front of the lower incisors, and an impediment to their forward movement would be thus constantly opposed. This impediment could then be overcome only by the mechanical means to be presently described. Simi-

lar remarks apply to the corresponding irregularity of the lower teeth. Delay here is, however, not so

FIG. 21.



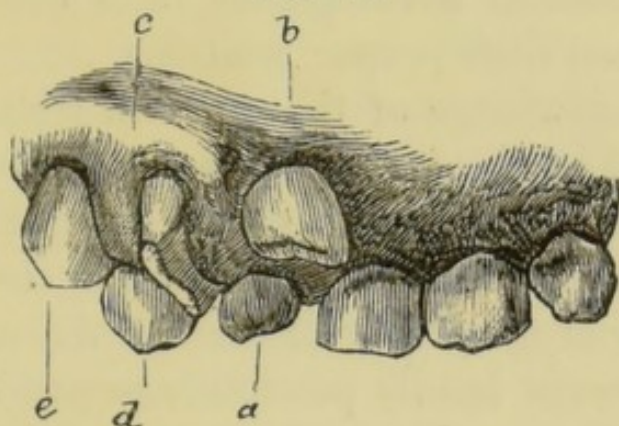
dangerous as in the case of the upper set. The normal position of the lower front teeth being behind those of the upper jaw the danger of locking does not exist; and after the extraction of the temporary teeth mechanical treatment is rarely required. This operation nevertheless should not be too long delayed, lest the adjoining teeth, taking a forward position, prevent the advance of those that are displaced.

Other causes of the class of irregularities at present under consideration are to be found in injuries, such as blows upon the mouth, the presence of supernumerary teeth, or constant pressure, such as is kept up in thumb-sucking—a habit sometimes acquired by children. Then again, alveolar abscess connected with a temporary tooth may cause displacement of the developing permanent successor; whilst lastly, some cases of simple displacement of one or more teeth alone, in well formed jaws, can be traced to hereditary predisposition, or to other causes acting prior to the eruption of the teeth.

Fig. 22, from Wedl, exemplifies the form of displacement of the upper front teeth, produced partly by the persistence of temporary teeth, and partly by the pre-

sence of a supernumerary tooth. The supernumerary tooth (*a*) presented itself within the dental arch upon

FIG. 22.



the right side, adjacent to the left central incisor, and thus caused a displacement of the right central incisor (*b*) upwards and forwards. The lateral incisor (*c*) is twisted on its axis, and the permanent canine (*e*) pushed somewhat outwards, in consequence of the retention of the temporary canine (*d*).

It is of course not necessary to describe in detail all the varieties of displacement of teeth of the kind under discussion. The preliminary treatment of them all is the same—namely, the prompt removal when possible of the cause.

And it may be here remarked, that whilst uncalled-for interference should be guarded against, there need be no hesitation in extracting temporary teeth, the removal of which is necessary for the cure of irregularities. It is a somewhat popular belief that the premature extraction of these teeth may act as a cause of subsequent contraction of the jaw, and thus of irregularity of the teeth. This belief is refuted by physiological fact, as well as by practical experience. The growth of the alveoli of the permanent teeth (as pointed out on a previous page)

goes on quite independently of the temporary set ; and cases are on record in which even after the premature loss of the entire temporary set the jaw attained its normal development, and the permanent teeth assumed their proper positions.

With a knowledge of the order in which the teeth are erupted, and of the characteristics which distinguish the permanent from the temporary set, the mistake of extracting one of the former instead of one of the latter is not likely to occur. An error of this kind is, however, hardly possible, except in the case of the incisors and canines. The permanent molars may be known from their position posterior to the temporary teeth ; whilst the bicuspid may be easily recognized, since no such tooth exists in the deciduous set. The permanent, if present during the persistence of the temporary, incisors will be found posterior to the teeth which they replace, and their cutting edges are serrated, whilst those of the temporary set by this time are worn smooth. The permanent canines may be distinguished by their great size in comparison with the corresponding temporary teeth, and by their position, which is external and prominent, the root being perceptible as a vertical projecting ridge on the external alveolar wall.

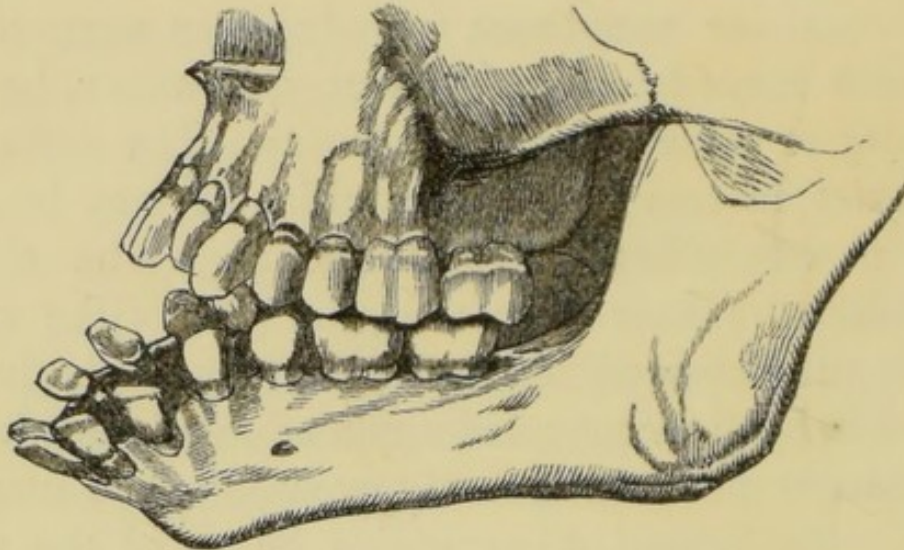
Irregularities due to malformations of the alveoli or of the body of the jaws themselves have now to be described. It has been before stated that the normal dental arch is semi-elliptical in shape. The front portion of the figure, containing the incisors, canines, and bicuspid, forms an almost perfect semicircle ; whilst the portions containing the molars continue the line backwards at each side. Flattening or contraction of this arch, or abnormal development of any

part of it, necessarily give rise to irregularities of the teeth. This class of irregularities is most commonly congenital, and at the same time often hereditary, a peculiar abnormality in the form of the jaws being in this manner sometimes reproduced in many members of a large family. They may, however, be due to injury or other accidental causes. The deformity may exist in one or both maxillæ, or may be confined to one side only of the bone. The almost marvellous manner in which the jaws (like other bones) may be modified in shape, especially during early life, by the continued application of force in one direction, is not uncommonly exemplified in surgical cases. The sequel of extensive burns of the neck occasionally furnishes a striking instance in point. The cicatrix resulting from such an injury has a constant tendency to contract, and unceasingly drawing the chin towards the chest, causes the body of the jaw gradually to curve downwards. In cases from time to time met with, the curvature is so great that the alveoli are completely everted, and the teeth directed outwards, or even downwards. One of these cases is figured in the annexed engraving (fig. 23), taken from Mr. Tomes' work.

The nature of these irregularities, associated with malformations of the jaw, will be rendered evident by a few typical examples. Fig. 24 represents an extreme instance of a common variety, a protrusion of the central incisors apparently due to an abnormal outgrowth of the anterior portion of the alveolar processes. A somewhat similar deformity of the lower jaw (fig. 25) (Tomes), gives rise to projection of the lower beyond the upper front teeth. An individual affected with this deformity is said to be underhung.

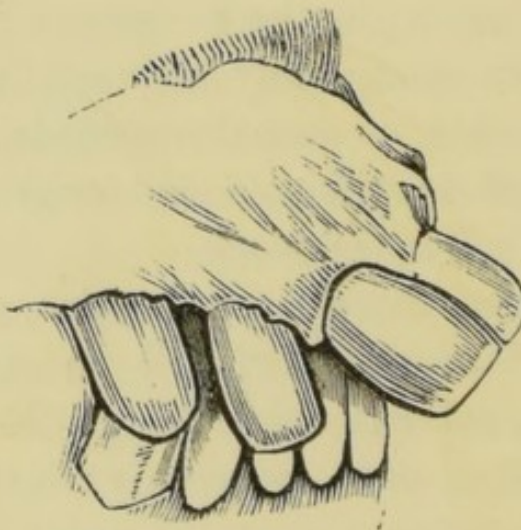The V-shaped or contracted arch, instances of which daily present themselves, is illustrated in fig. 26.

FIG. 23.



This deformity gives rise to almost endless varieties of displacements of the teeth. The incisors or bicuspid

FIG. 24.



are often forced inwards, and the canines, appearing after these are in position, remain external and prominent. The deformities due to crowding in that class of case in which a small though well-shaped jaw

contains disproportionately large teeth, closely resemble those occurring in the V-shaped maxilla

FIG. 25.

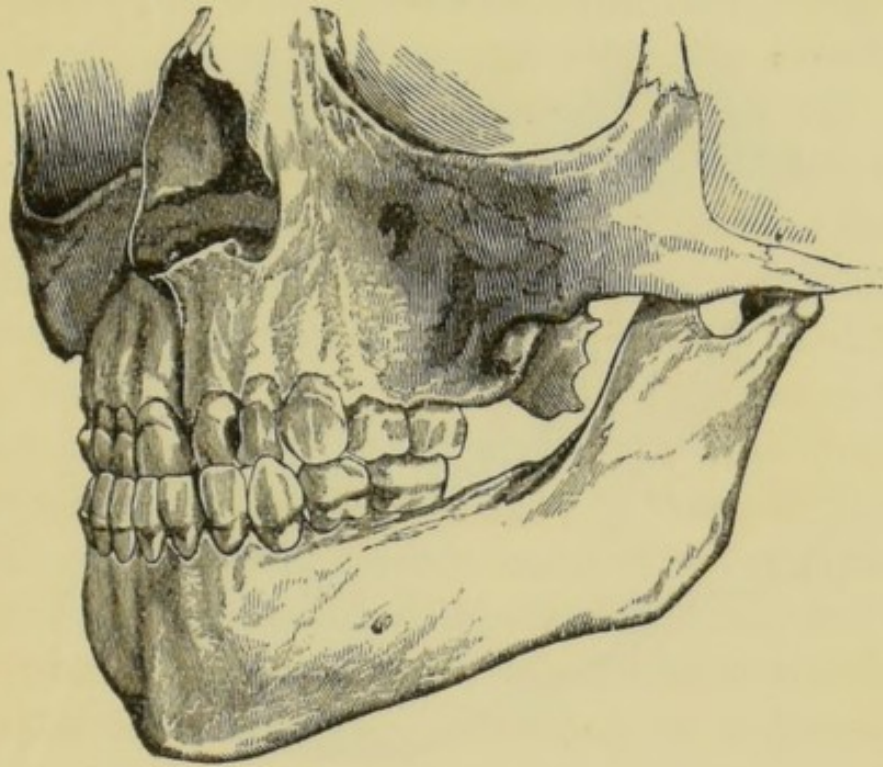
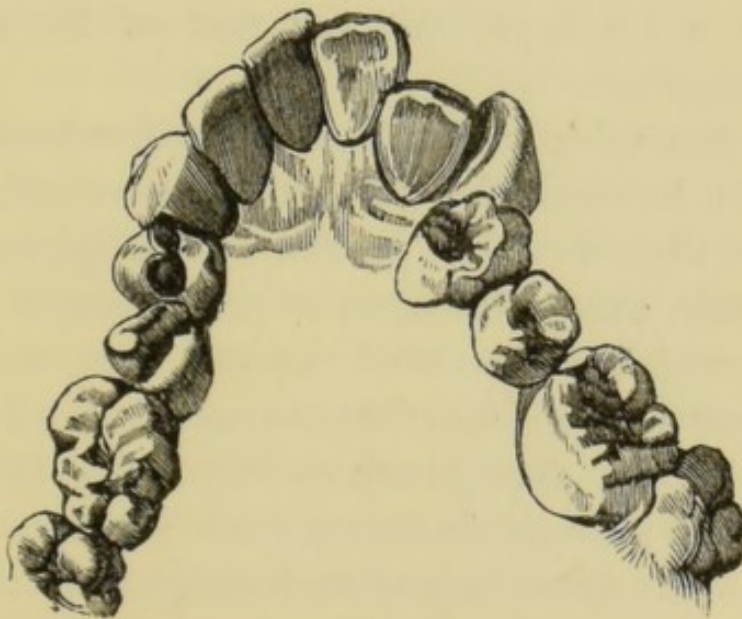


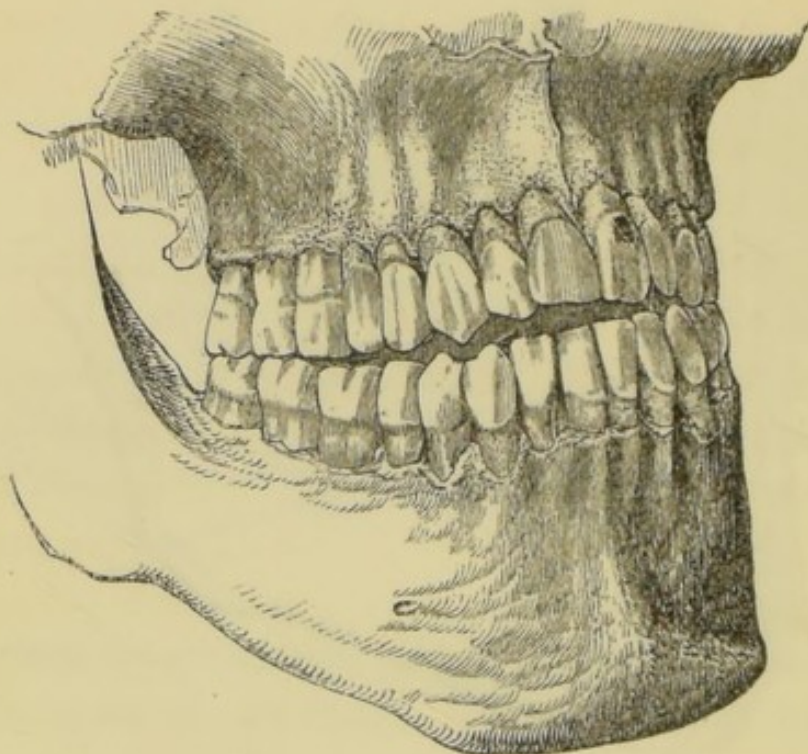
FIG. 26.



In a somewhat rarer example of deformity (fig. 27) (Tomes) the molars alone approximate on closure of the jaws, and the incisors remain apart and cannot be

brought into contact. This is in consequence of a malformation of the posterior portion of the lower

FIG. 27



jaw, as a result of which the molars, being placed on too high a level, prevent the rest of the set from coming together.

These examples will suffice to render manifest the distinction between the two great classes of irregularities, and little would be gained by multiplying them. In any case, except the simpler instances of the first class, in which removal of the cause is enough to bring about a cure, it may be necessary in the first place to consider the expediency of extracting permanent teeth for the sake of obtaining space; next comes the question of the extraction of such malplaced teeth as are not amenable to mechanical treatment; and lastly, there is the construction and application of a mechanical apparatus when it is required for the completion of the treatment. With regard to the extraction of perma-

ment teeth for the sake of affording room, it may be at once stated that the sacrifice of an incisor or canine is rarely necessary or justifiable. They are the most durable of the teeth, they contribute most to the symmetry of the dental arch, and moreover a tooth may generally be chosen, the removal of which will better serve towards the desired end. The choice will as a rule fall upon the first molar. This tooth is the most liable to decay, and even in early life is often so extensively carious as to require extraction, or at least is in a condition so defective that it cannot be expected to last many years. After the extraction of a tooth from a crowded jaw the pressure is relieved; and the teeth spread equally apart until in a comparatively short time (very rapidly in early life) the space previously occupied by a large tooth becomes obliterated. In most cases to relieve crowding it is desirable to remove a tooth at each side of the jaw. If only one tooth be extracted, the movement of the crowded members takes place towards that side, and the regularity of the dental circle is disturbed. It is advisable in most cases to postpone the extraction of the first molars until the complete eruption of the second molars at about the twelfth year. The first molars if carious may be filled and preserved till that period. If they be extracted earlier, as is sometimes unavoidable, it often happens that the second molars incline forwards as they advance, and occupy the place of the extracted teeth; and thus prevent the backward movement of the crowded front teeth.

Nothing conduces more to the onset and rapid advance of decay than a crowded, irregular condition of the teeth, and when this condition exists the removal of one or two even sound teeth has a highly beneficial

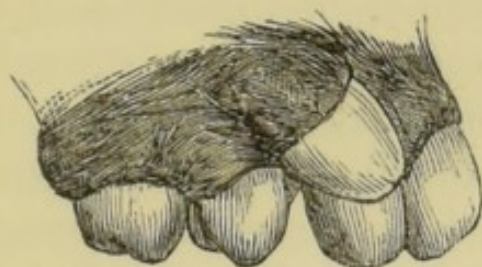influence over the future health of the rest of the set, and on this ground alone the operation is often advisable.

Should the first molar be free from defect, any other tooth which shows signs of decay, or of imperfect structure, may of course be chosen instead, and where doubt exists, the relative liability of the different classes of teeth to decay will govern the choice. This liability has been ascertained from carefully collected statistics. The first molars, as just stated, are much more often attacked by decay than any others of the teeth; next in this respect come the second molars; after these the second bicuspid; fourthly, the first bicuspid; fifthly the lateral incisors; sixthly, the canines; and lastly, the central incisors are less frequently the seat of caries than any other teeth of the set. Space having been obtained by the extraction of teeth, Nature may be trusted unaided to effect a cure in some few cases of irregularity due to crowding alone, in which the direction of the teeth is good, and where they are not locked in their malpositions by those of the opposing jaw; but in many cases mechanical treatment will be necessary.

Numerous instances, however, present themselves in which one or more teeth are so far displaced as to preclude the possibility of their reduction by any means to their proper positions. Such instances are specially those in which not only the crown, but the entire root is out of its normal situation. For example, an upper canine being erupted after the lateral incisor and bicuspid are in position, often presents itself external to and prominent over the space between these teeth, which is too narrow to contain it. When the direction of the canine is correct it will in time take its

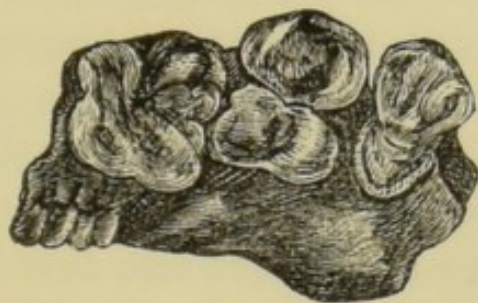proper place if room be afforded, but should it appear in an oblique direction and with its root lying at an angle across the alveolar border, as in the case depicted in fig. 28, it is unlikely that it could be brought into

FIG. 28.



the desired position even were mechanical treatment employed. In such cases the extraction of the malplaced tooth is the sole resource. An example of an irremediable displacement of a bicuspid of a kind which is also frequently met with in the case of other teeth is shown in fig. 29, from Wedl. The wisdom

FIG. 29.



teeth more than any other of the set are liable to total displacement of this kind, for the reason which has been mentioned in a previous section, in speaking of the eruption of these teeth—namely, that they make their appearance after the rest of the teeth are in place, and when insufficient room in the jaw for their normal progress remains. Displaced wisdom teeth do not call for interference unless they constitute a source of discomfort or give rise to irritation. When

this occurs extraction may be performed without hesitation, the tooth from its position being useless in mastication.

Instruments for the purpose of regulating the teeth are constructed to fulfil several objects—to prevent the locking together of the teeth or closure of the mouth, and to exert such continued pressure or traction on those that are displaced, that they may be gradually compelled to assume their normal positions. It has been seen that irregularities vary between the simplest kind—mere slight displacements of growing teeth—and the severest form associated with malformation of the maxilla. It will be understood, therefore, that the effect required to be produced in different cases by mechanical treatment varies also considerably; and it will be perceived also that the treatment can be carried out much more rapidly and effectually in the child than in the adult. At the former period of life when the alveoli are in process of growth a malplaced tooth can be drawn into position in a short time, and with the exercise of but slight force, whereas at a later date, the jaw having become consolidated, the treatment becomes long and tedious. It will be evident also that in the simplest cases the instrument is not required to do much more than guide the developing tooth in the desired direction, whilst in the more difficult, it will be necessary to keep up such pressure as shall cause absorption of the bone which opposes the movement of the tooth. To give rise to absorption by continued pressure, it is well known, is not difficult either in the jaw or in other bones. The precaution must be taken in dental cases not to cause irritation sufficient to pass into destructive inflammation. Some amount of con-

gestion or perhaps even inflammation of the slightest extent must necessarily accompany the absorption, but it is not difficult to arrange the apparatus to exert with great nicety any amount of force required, without exciting inflammation of undesirable severity. The more slowly the teeth are moved the less danger will there be of mischief arising. It is only experience in each case that can determine the degree of force which may be safely applied, and it is well, therefore, to commence always with a small amount, and gradually increase it.

That the movement of teeth under the influence of pressure must be accompanied in some instances by absorption of bone is beyond doubt, but from the fact that the opportunity for post-mortem examination never presents itself during the treatment of these cases, the exact mode in which the changes in the tissues are effected cannot be ascertained, and for a similar reason it is impossible to explain the well-known circumstance that even after the absorption of bone has been apparently induced, and the teeth have taken the desired positions, they tend invariably to fall back into their former situation unless mechanically fixed by the teeth of the opposing jaw, or retained for a considerable time by an instrument constructed for the purpose. Thus in the case shown on a previous page, fig. 21, the treatment might cease safely so soon as the upper teeth had been pushed into their normal position, in front of the corresponding lower teeth when closed; whilst in such a case as depicted in fig. 24, if after the reduction of the deformity the treatment were discontinued a relapse would speedily take place. In all such cases as the latter, after the irregularity is cured, a plate must

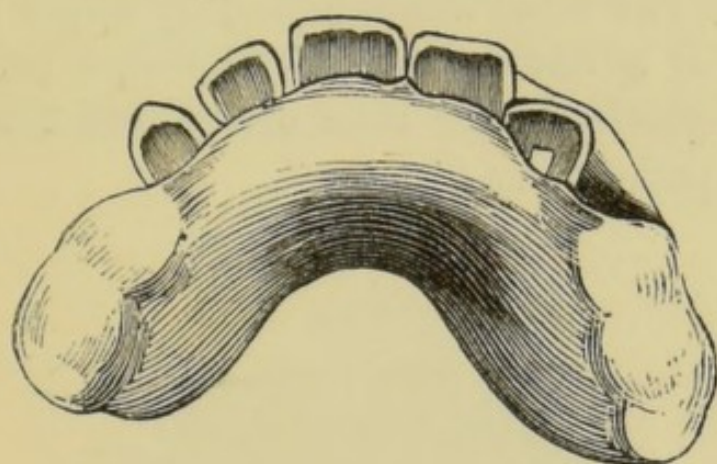
be arranged to hold the teeth in their new positions, and must be worn from six months to two years, according to the age of the patient and the severity of the deformity.

The simplest form of regulating apparatus consists of a plate accurately adapted to the teeth and gums, the crowns of the molars being covered when desirable with a sufficient thickness to prevent the upper and lower front teeth from meeting. A fixed point is thus provided to which screws, springs, or levers, elastic bands, or wedges of wood, may be attached to act upon the teeth in any desired direction. The material of which the plate is constructed may be either metal (gold or silver) or vulcanized india-rubber. Either of these materials answers well, some operators prefer one, some another. The author considers that vulcanite has some great advantages over metal. It is easier to make it firm in the mouth. If a perfect model be taken and the plate vulcanized upon it, the accuracy of the fit alone in most instances will suffice to fix it in the mouth. Additional rigidity may be obtained by paring the model slightly at the necks of the temporary molars before vulcanizing, and after this it is never necessary to attach the plate by ligatures, an expedient which must be adopted frequently where metal is used. Vulcanite again affords a more congenial surface for mastication than metal, and it is less liable to chafe the surface and injure the enamel of the teeth with which it is in contact.

Of whatever material the plate is constructed it ought to be removed at intervals, as frequent as possible, for the purpose of thoroughly cleansing it as well as the crowns of the teeth which it envelops.

The plate causes accumulation of particles of food over the surfaces of the teeth which it covers. These particles, if allowed to remain, speedily decompose, and thus give rise to decay of the teeth. Where the teeth are of inferior formation, decay may under these conditions progress with great rapidity, and prove disastrous to several of the set. Tooth-powder, such as prescribed on a later page, may be used with advantage during wearing of regulating plates; and the teeth may in addition be brushed with a weak carbolic acid lotion, with which the mouth can also be frequently washed, during the time the plate is in position.

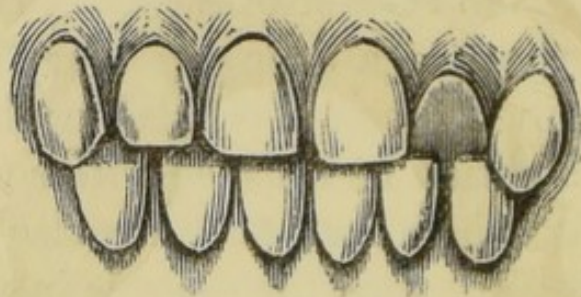
FIG. 30.



In order to make the character of these instruments clearly understood, the description of two or three cases will suffice. Fig. 30 shows in position the instrument employed in the regulation of the case represented in fig. 31. This was an irregularity of a simple kind, one upper lateral incisor being displaced inwards, and held in its malposition by the lower teeth. The plate covering the molars kept the jaws sufficiently apart to prevent the front teeth from meeting, and the obstacle to the forward movement of the tooth being in this way removed, but a slight

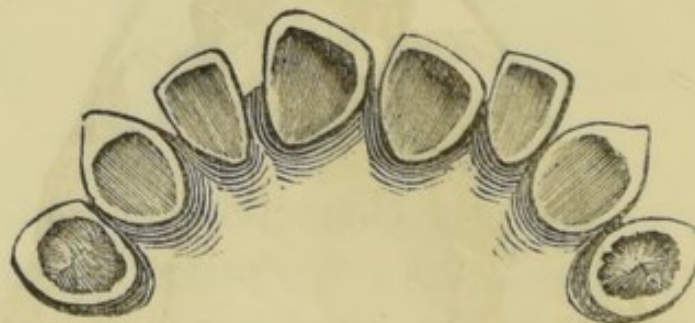
amount of pressure was required to force it into its right position. The pressure was obtained by a wedge of compressed hickory fixed in a chamber in the vulcanite behind and in contact with the irregular tooth, the moisture of the mouth causing the wood to

FIG. 31.



expand and in expanding to push the tooth slowly forward. The wood was renewed by larger pieces at intervals of a day or two, as the cure progressed, until the tooth having been driven sufficiently outward the patient was dismissed.

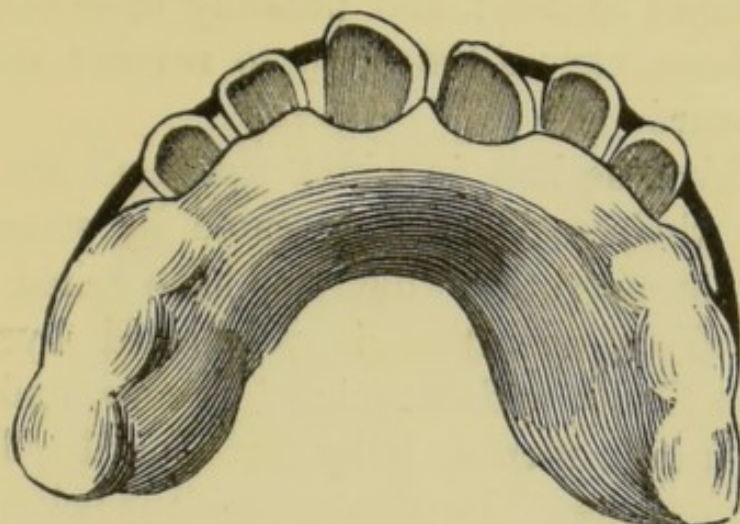
FIG. 32.



The next case (fig. 32) was of a somewhat different character. The irregularity consisted of a twisting of the central incisors on their axes. It was probably of congenital origin. The instrument with which it was treated is shown in position in fig. 33. It consisted of a vulcanite frame closely in contact with the inner angles of the twisted teeth, but clear of the rest of their surfaces. From each side of this frame there

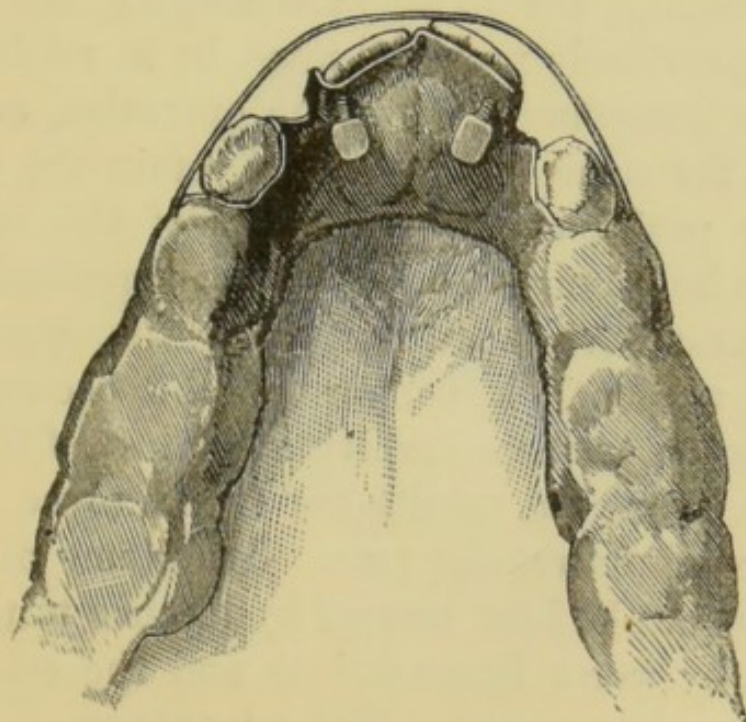
proceeded a flat spring of hard gold wire, and these extending round in front were so arranged, that their

FIG. 33.



free extremities kept up constant pressure on the prominent edges of the incisors. In this way the distorted teeth were compelled gradually to revolve, and the

FIG. 34.



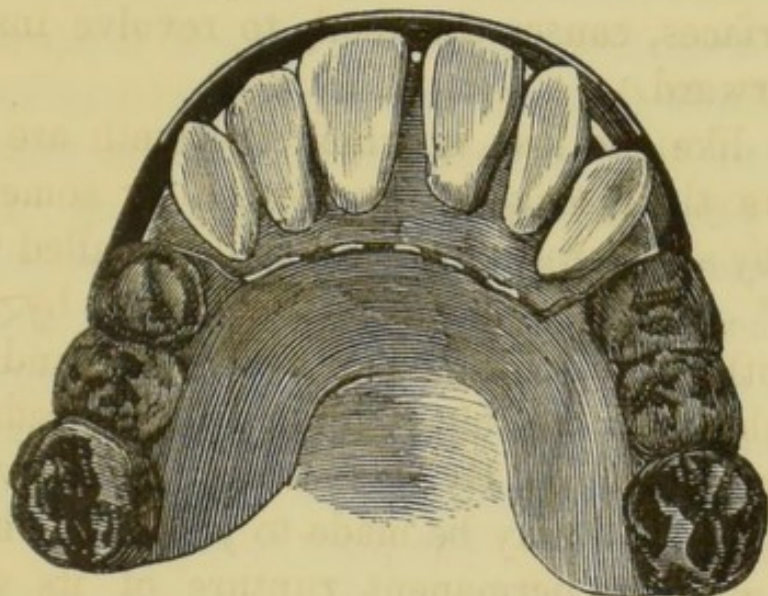
deformity was in time entirely removed. Fig. 34, from Mason (9), illustrates another method of treating these

irregularities. A metal plate is fitted to the mouth, backing the twisted incisors, and carrying screws to act upon the inverted angles, whilst a metal bar passing round in front, and pressing upon the prominent surfaces, causes the teeth to revolve instead of move forward.

Cases like the last, in which the teeth are merely turned in their sockets, are treated by some practitioners by an operation which has been called "actual torsion." This operation is performed by seizing each tooth firmly with a pair of forceps, and slowly and deliberately turning it by force, until reduced to its proper position. By this means it is believed that the alveolar wall may be made to yield, and the tooth turned without permanent rupture of its vascular connections, or injury to its vitality. The forceps ought to be specially constructed with broad flat blades lined with leather, or better, with lead, so as to avoid crushing the tooth or damaging the enamel. A plate previously prepared must be in readiness for insertion immediately after the operation, and must be worn for some few months to retain the teeth in the new position. The subjects of this operation ought to be young children in good general health. There must obviously exist, after the operation of "actual torsion," a danger of the occurrence of inflammation, perhaps involving the loss of the tooth, but such untoward results are stated to be in well-chosen cases extremely rare. Symptoms of inflammation would be best treated by leeches to the gum, followed by warm fomentations and the administration of a saline purge. The advantage of "actual torsion" consists in the rapidity with which a cure is accomplished, but in proposing the operation it must

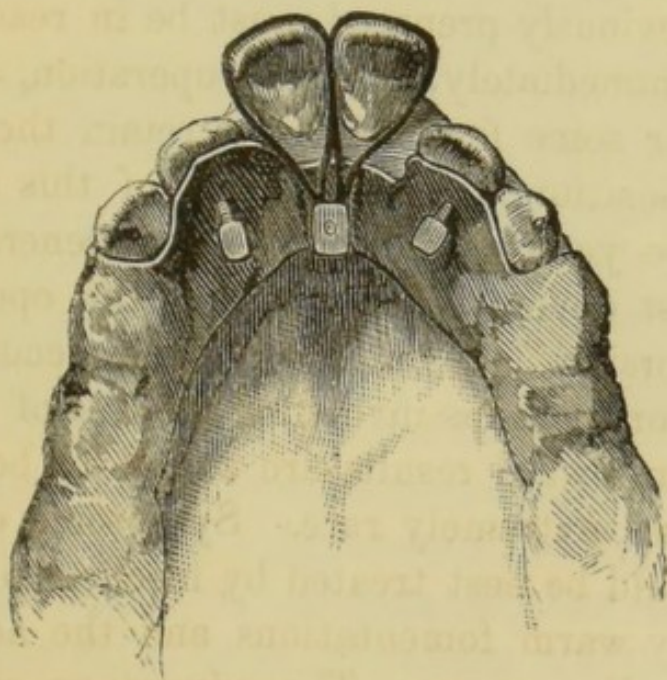
be borne in mind that it involves unquestionably a risk, whilst the desired effect can be produced with

FIG. 35.



certainly by other means, without any danger whatever.

FIG. 36.



Cases similar to that shown in fig. 24 may be treated by an instrument (fig. 35) much the same as

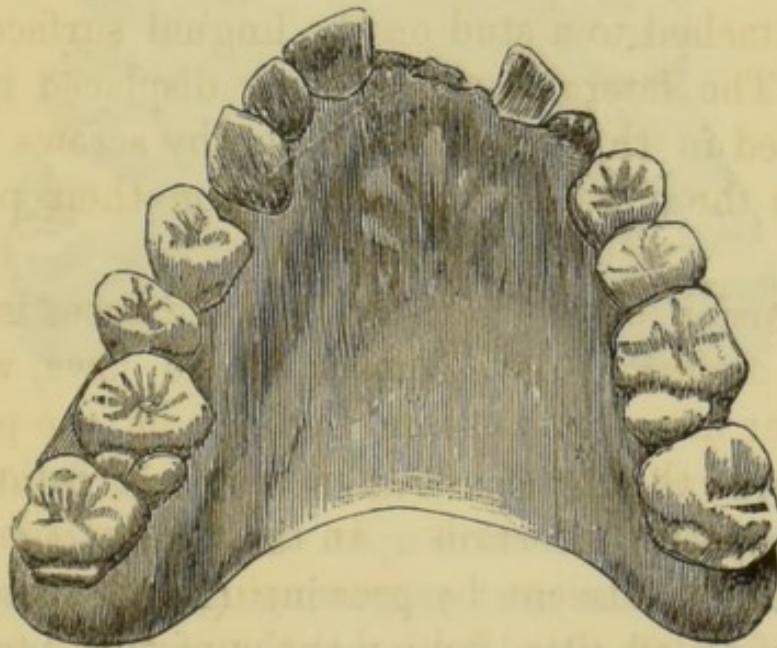
in that illustrated in fig. 33. In these cases, however, the gold wires are made to terminate in front of the canine teeth, and each has affixed at its extremity a small gold stud or hook. An elastic band stretched between these hooks over the faces of the protruding teeth, affords the pressure necessary to reduce them in time to their proper position. The same effect may be produced equally well by means of elastic bands passed over the teeth, and attached behind to the surface of the plate, but this method sometimes causes discomfort by interfering with the movements of the tongue, or with the lower teeth during mastication. An apparatus of this kind is depicted in fig. 36, from Mason (9). The plate is of metal. The projecting central incisors are acted upon by elastic ligatures attached to a stud on the lingual surface of the plate. The lateral incisors being displaced inwards, are forced in the desired direction by screws passing through the plate, and pressing upon their posterior surface.

Protrusion of the incisors in some cases is clearly due to abnormal development of the jaws, whereby the lower incisors in biting impinge on the posterior surfaces of the upper teeth in such a direction as to force the latter outwards. In such cases it is well to commence treatment by preventing this pressure by means of a plate fitted behind the upper teeth to receive the impact of the lower incisors. At the same time the molars are left uncovered. These teeth are thus kept apart, and in growing subjects, under this treatment, they gradually rise, until they articulate again with their opponents. When this is accomplished, the lower incisors, which have been meanwhile prevented by the plate from advancing,

no longer impinge on the upper teeth, and these may then be acted upon and drawn inwards with comparative rapidity and ease.

The following case, the models of which are in the museum of the Odontological Society, illustrates several points in the treatment of irregularities. In June, 1873, a young lady, then aged fourteen, received a blow in the mouth which caused a fracture extending vertically through the crown of the left upper central incisor. In January, 1875, she was seen by the author, who, finding the fracture involved the root, and rendered its preservation impossible, extracted the tooth. The accompanying cut (fig. 37)

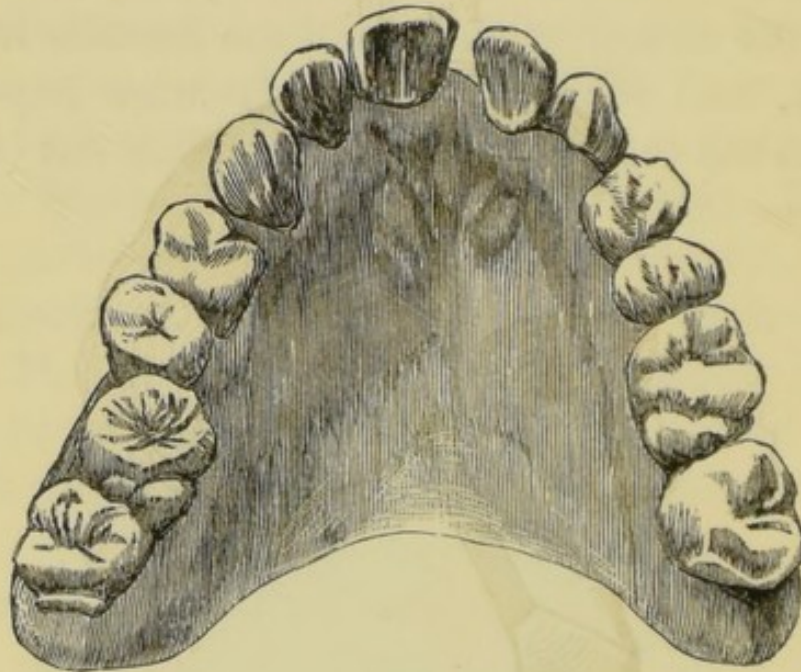
FIG. 37.



shows exactly the appearance of the upper jaw after this operation. The right central and lateral incisors, and the left canine fell considerably beyond the range of the lower teeth on closure of the mouth, whilst the right canine and first molar were displaced inwards, the cusp of the former locking within the lower teeth. Considering all the circumstances, it was deemed pre-

ferable to attempt to regulate the teeth, and to bring about at the same time closure of the gap in front, rather than to condemn the patient to wear an artificial tooth. An apparatus was accordingly made to exert constant outward pressure by means of wooden wedges, on those teeth which were within the normal dental circle, and flat springs of hard gold

FIG. 38.

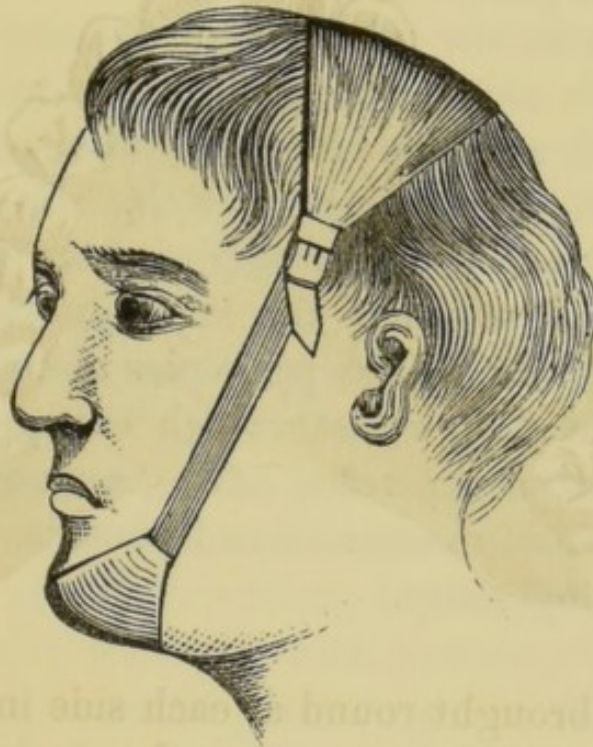


wire were brought round at each side in front, to act in the opposite direction upon the projecting incisors and canine. The next engraving (fig. 38) shows the effect produced after three months of this treatment, by the exercise of an amount of force so slight as to give rise throughout to no irritation, beyond a trivial passing tenderness of some of the teeth. The rapid favourable progress of this case was due to a great extent to the youth of the patient, and to the ample room which the loss of the incisor provided for the spreading apart of the crowded teeth, and their move-

ment in the desired directions. The case under this treatment, showed in a short time still greater improvement in the arrangement of the teeth.

By contrivances similar in action to those already described, the entire alveolar border of the jaw might be modified in form. For instance, in the contracted or V-shaped palate, an apparatus would be made to maintain equal pressure from within outwards along the alveolar margin of the jaw, until in time the re-

FIG. 39.



quired expansion of the arch could be accomplished. Perhaps the simplest apparatus for this purpose is that devised by Mr. Coffin. It consists of a perfectly fitting vulcanite frame, capping the molars and covering the palate. The frame is divided into two equal parts along the central line of the palate. The halves are then connected by a spring of steel pianoforte wire. The spring is in shape like the letter W, and has its free ends attached one to each half of the

divided plate, upon which it closely lies. The spring can be adjusted so as to exert with great nicety the slight outward pressure, which being sufficiently prolonged, is enough gradually to cause the needed expansion of the arch. Some few cases may be advantageously dealt with by instruments fixed externally. Thus, the case depicted in fig. 27, would be treated by constant upward traction of the chin, a cap of leather adapted to that part being attached to a strap across the head by strong elastic bands at each side, as seen in fig. 39.

It is not within the scope of this manual to enter further upon a description of all the numerous expedients which may be adopted in the devising of instruments for regulating the teeth. Enough has been said to make clear the principles upon which the construction and action of the apparatus are uniformly based, and indeed these principles alone being understood, there are few cases which can present serious difficulty to any operator having an adequate knowledge of dental mechanics and possessing a moderate amount of ingenuity.

CARIES.

CARIES, or decay of the teeth, must be defined as a process of disintegration commencing invariably at the surface and proceeding inwards, affecting dentine more rapidly than enamel, and due entirely to external agencies. Caries is not an inflammatory process, and it does not depend upon the tooth's vascular or nervous connection with the rest of the body. Caries may occur in extracted natural teeth retained in the mouth by artificial means, as on a denture or pivot.

The onset of the disease is favoured, and its progress is hastened primarily, by certain structural defects in the enamel and dentine, and secondarily, by some diseases of the oral mucous membrane and some derangements of the general health.

With rare exceptions, caries, unless checked by art, having once attacked a tooth, advances towards the interior, forming a cavity which increases in size until the crown, and even the greater part of the root also, are destroyed. It is attended with pain, which often commences in a mild form as soon as the dentine is slightly penetrated, and becomes most severe when the central chamber is laid open, and the pulp, being exposed to the action of external irritants and to injury, becomes the seat of inflammation.

To understand the pathology of caries it is necessary first to bear in mind that enamel and dentine are soluble in acids which may be present in the mouth, and that structural defects, presently to be described,

both furnish lodgment for acid-forming substances, and render the ill-formed portions of the teeth easily acted upon and destroyed.

The active agents in caries are acids and living organisms. The acids, principally malic, butyric, and acetic, are mainly the products of chemical change and fermentation, set up in fragments of organic matter, food, mucus, and epithelial scales, which are commonly present in the mouth.

Acid may be derived from several other sources. It may be secreted by the mucous membrane. The normal secretion of the membrane is small in quantity and slightly acid. In health the acid is at once neutralized by the alkaline saliva, with which it mingles; but when the membrane is congested or inflamed the mucus increases in quantity, and becomes more strongly acid in character. This may be proved by experiment. If a small pellet of cotton wool, or other foreign substance, be forced between two teeth, and left so as to press upon the gum, the secretion from the mucous membrane at that point will be found in the course of a few hours increased in quantity and strongly acid; and it will be seen after a short time that the enamel of the adjacent teeth is undergoing slow solution. Many forms of organisms themselves produce acids. Acid is eructated in many gastric disorders. Saliva has an acid instead of an alkaline reaction in several diseases; in others acid mucus is secreted by the gums. The solubility of dentine and enamel in acids not more powerful than would be derived from the several sources named can be demonstrated. The organisms active in caries consist of micrococci, oval and rod-shaped bacteria, and a fungus called *leptothrix buccalis*. These organ-

isms—except leptothrix, which is peculiar to the mouth—are such as are always present in fermentation and putrefaction. Fermentation may be regarded as the result of proliferation of certain organic forms present in the dust floating in the atmosphere. If this dust be excluded, putrefaction or fermentation do not occur.

The factors in the direct causation of caries are, first a weak point in the enamel, or the retention of acid-forming agents in contact with its surface; secondly, acids and organisms in sufficient quantity to effect the disintegration of the tissues. That acids alone do not produce all the phenomena of caries is obvious, from the fact that in the progress of the disease destruction of dentine is more rapid than of enamel, whereas acid acting alone would completely destroy the enamel, but only partially destroy dentine. It is, on the other hand, inconceivable that micro-organisms acting alone could gain access to the dentine without the assistance of an acid capable of perforating the enamel. Three facts should be borne in mind in this connection:—(1) Micro-organisms are always present in the canals of carious dentine, numerous in proportion to the extent of the disease; (2) acid buccal secretions and acid decomposition products, if in constant contiguity with the enamel, decalcify it, and hasten the commencement of decay; (3) experimental decalcification and disintegration of extracted teeth by acids present no resemblance to caries, but simply destroy the enamel first, and render the dentine soft and elastic by removing its lime salts.

Caries may commence on a sound unbroken surface of the tooth, especially on the lateral aspects, close

to which acids and organisms are constantly generated by the decomposition of particles of food and irritation of the mucous membrane, and where the shelter afforded by the chinks between adjacent teeth allows foreign particles to remain undisturbed for lengthy periods. Caries frequently has a starting-point at some part of the enamel and dentine, the seat of structural defect. Imperfections in structure, from which few sets of teeth are altogether free, may be owing to defect either in the quantity or in the quality of the tissues. Defects in quantity have been referred to in the chapter on abnormally formed teeth, where the typical syphilitic tooth and the honey-combed tooth were described. They consist of pits and fissures in the enamel and dentine. These vary in extent between minute cracks perceptible only under the microscope, and cavities plainly visible by the naked eye. They may penetrate the enamel alone, or may extend to a greater or less depth into the dentine also. Their most common situation is in the depths of the natural depressions in the contour of the tooth, as for example between the cusps of the molars, but they are also not unfrequently found on the lingual surface of upper incisors. The one notable fact about these pits is that they occur at about the same period of development in all the teeth. Fissures which involve the dentine as well as the enamel are the most favourable to the attacks of caries.

Defects in the quality of the tissues may affect the whole body of the tooth, or may be confined to certain spots in the enamel and dentine. The fact is well known that the durability of the dental tissues varies considerably in different individuals—in one the teeth withstand the extremest hard usage combined with

neglect, in another they show traces of disease within the earliest years of childhood, and are destroyed sooner or later even in spite of active treatment. If the enamel and dentine of such delicate teeth be examined, it will be found that they present well marked evidences of imperfect formation. The enamel instead of appearing a densely hard, almost homogeneous mass, is comparatively soft owing to imperfect calcification and porous in consequence of incomplete coalescence of its formative elements. It retains a marked fibrous character. The fibres are imperfectly blended; their transverse striæ are clearly evident, and they are often penetrated at their centres by tubes or small cavities. At parts the fibrous character may be altogether lost, the tissue consisting of an imperfectly united granular mass.

The dentine in addition to undue softness exhibits throughout its structure, and especially immediately beneath the enamel, patches of defective tissue similar in character to the granular layer which in well-formed teeth exists only at the point of juncture with the cement. In the spaces within this defective tissue—sometimes called interglobular spaces—the tubes end, or they may even run on and terminate in dilated extremities within the substance of the enamel.

It does not always happen by any means that all the structural defects which have been just mentioned in the quantity and quality of the dental tissues exist together in one tooth. Their degree and character vary considerably. It is not uncommon to find in teeth of otherwise good organization one or two pits or fissures, or small patches of defective tissue; whilst in teeth of generally inferior structure there are often to be discovered portions of still feebler formation.

The local and constitutional diseases which favour the onset and progress of caries are those which are accompanied by, or which tend to aggravate inflammation of the oral mucous membrane, and those which give rise to the formation or deposit of acid or excessive accumulation of decomposition products within the mouth. Among the former may be particularly enumerated all the varieties of stomatitis; among the latter scrofula, syphilis, phthisis, diabetes, chlorosis, and chronic alcoholism. These constitutional affections exert their baneful effect upon the teeth in great part by reason of the chronic inflammation of the gums, the vitiation (even general acidity) of the secretions of the mouth, and the dyspepsia with which they are all so commonly accompanied. For the same reason caries is frequently active during pregnancy. During febrile diseases, in which the secretion of saliva is scanty and the teeth remain coated with sordes, accumulations of epithelial scales, viscid mucus and other foul secretions, crowded with bacteria, caries, as might be expected, is often originated, and when previously present is always accelerated. It has frequently been suggested that these effects are due to morbid influences acting on the teeth through the general system, but there is no evidence in support of this statement, and moreover the facts are fully accounted for by the external influence of the vitiated secretions always present in diseases which promote caries.

The facts that enamel and dentine are soluble in the acids the presence of which in the mouth commonly arises from various sources, and that structural defects in the enamel and dentine not only furnish places favourable for the lodgment of acid-forming

substances, but at the same time render those portions of the teeth more readily acted upon than others, suffice in most cases to explain both the origin of caries and why the disease commences at certain isolated spots, and does not affect uniformly and at once the entire surface of the crowns of the teeth.

The physical signs of caries, consisting mainly of discoloration and softening of the tissues, bear a general resemblance in every case. They differ only in consequence of the mode of onset, the situation, and rapidity of the disease. The discoloration in the incipient stage on an unbroken surface of enamel usually amounts to no more than slight opacity of that tissue, a condition which also as a rule prevails throughout the later stages on the borders of the cavity of decay. When the disease begins in a fissure, and when a cavity is formed, the discoloration is more marked, the softened dentine assuming a brown tint, or becoming stained to a blackish hue. This discoloration—the author suggests—is probably due to the presence of pigment-forming bacteria. It has been proved that bacteria produce pigment, and moreover that each variety of germ produces its own particular pigment, one kind red, another yellow, another green. Wherever the germs can live there will their special pigment appear and stain the neighbouring tissues. Cavities in which the disease is progressing rapidly show least discoloration.

The softening or disintegration perceptible in the successive stages of caries varies considerably. When a surface of enamel is first affected it appears eroded, rough, and full of small holes, and is readily scraped away by a steel instrument. When the mischief has commenced in a fissure, but little soften-

ing may be apparent for a time at the surface, until later the undermined enamel breaking down or being cut away discloses a cavity in the dentine filled with disorganized tissue. Such a cavity is formed in every case in the later stages of the disease. Carious cavities are often cone-shaped, the apex of the cone being at the surface. The enlargement of the cavity in the deeper parts is due to the fact that caries destroys dentine more completely than enamel, it has been even known to completely hollow out the dentine of a tooth, leaving the enamel covering almost intact. This circumstance is explained by the fact that organisms flourish most in the dentine, in the organic basis of which they find their pabulum. Then again when caries penetrates to a mass of interglobular substance, it is easy to understand how the disease advances with greater rapidity at that part than at the superficies. The differences in the physical character of the disease have given origin to such distinctive terms as "spreading," "penetrating," "soft," and "hard" caries.

Microscopical examination of carious teeth shows the tubes to be filled with micro-organisms which can be seen very plainly when stained with methyl violet (or any of the aniline dyes). They appear to penetrate the canals at first in single file, and then accumulating in vast numbers to encroach upon the matrix until the canals are so enlarged that two adjacent often amalgamate and form one irregular tube full of organisms. Organisms can be seen in the branches of the tubes; and beyond the sphere of visible decay, in tissue which to the naked eye shows no trace of commencing caries, the microscope discovers here and there a narrow line of bacteria or

micrococci penetrating like the advance guard of an army. Besides the disintegrated tissues and foreign particles, there is to be found by the microscope in most carious cavities abundance of the peculiar fungoid growth, *leptothrix buccalis*, similar to that which is deposited upon the surfaces of the teeth in all mouths in which the most extreme care is not taken in frequently cleaning the teeth. *Leptothrix* assumes the appearance of minute threads projecting from the surface of the carious dentine in enormous numbers. It never penetrates below the surface, and it is difficult to see how it can produce any effect on the deeper portions of the affected tissues. It has been supposed by some few observers that the *leptothrix*, if not the exciting cause of the disease, takes the principal part in promoting the advance of caries. There is no more than the slightest evidence to support the former part of this opinion, and but little to substantiate the latter. It can be conceived, however, that the growth may have some share in hastening the destruction of the already decomposing tissues.

The exact stages of the progress of caries are probably as follows:—The enamel is first perforated by acid, the organisms then find their pabulum in the fibrils of the dentine and destroy them, encroaching upon the matrix, the acid they themselves generate no doubt contributing to dissolve the lime salts. In this manner the more organic tissue, the dentine, is eaten away, whilst the enamel, partly dissolved and undermined, either remains as a shell or breaks away for lack of support.

Examination of carious teeth in various stages of decay demonstrates the fact that certain changes

apparently take place prior to actual disintegration in that portion of dentine through which the disease is advancing, and which is situated immediately contiguous to the already disorganized tissue. This altered dentine has a translucent appearance, and forms either a regular zone, or exists in isolated patches around the walls of the cavity. The appearance was once thought to indicate invariably a vital or pathological action, a natural effort to arrest the disease by calcification of the dentinal fibrils, similar to that which occurs as a natural phenomenon as age advances. Such a change does doubtless really occur in some cases, especially in slowly advancing caries in teeth of good formation, and it renders the tissue harder and better able to resist the progress of decay, and even sometimes to arrest it altogether. It is found, however, that a precisely similar translucent appearance is always produced during the gradual softening of dentine by acid, and to this softening and not to consolidation, the appearance in caries is due in the majority of instances.

The account which has been here given of the etiology, pathology, and morbid anatomy of caries, seems to the author to furnish a sufficiently complete and satisfactory theory of the disease. The theory is entirely based upon facts—facts which have been demonstrated and verified by many independent observers. These facts are enough to account for all the fundamental phenomena without the introduction of any unsupported hypothesis; and none of the facts are in the least irreconcilable with any phenomenon of the disease which yet remains without full explanation. It is of course possible that some details may need modification, as more light is thrown upon

the minute changes which the affected tissues undergo; but the student may note that, with scarcely an exception, observers of weight and authority are agreed upon these main essential points—namely, that caries is due solely to causes acting externally to the teeth; and that the disease consists of passive disintegration of enamel and dentine, the initial stage of which is caused by acid.

The part played by micro-organisms in caries has been but lately investigated afresh by Messrs. Arthur Underwood and Milles (19)—on whose research the account of caries in this work is mainly based—and these investigations have not, in consequence of their recent publication, been yet verified by other authorities. It is certain that the facts discovered by these observers will lead to modification of the opinions held by earlier investigators.

The views of some of the highest authorities who base their opinions on original investigations may now be briefly summarized. Messrs. J. and C. S. Tomes (17) believe “that caries is an effect of external causes, in which so called ‘vital’ forces play no part; that it is to a great extent due to the solvent action of acids which have been generated by fermentation going on in the mouth, the buccal mucus probably having no small share in the matter; and when once the disintegrating process is established at some congenitally defective point, the accumulation of food and secretions in the cavity intensify the mischief by furnishing fresh supplies of acid.” The presence of globular masses of calcareous salts, which are sometimes found in dentinal tubes near a carious cavity, and which are relied upon by some writers as evidence of vital action, they regard as probably depositions

from solutions of salts, and not the results of vital action; and they maintain that even if it were conclusively shown that dentinal fibrils became obliterated by calcification, this would not be absolute proof of vital action; for they point out that albumen, even when out of the body, is able to form with calcareous salts combinations having a definite structure. The zone of altered dentine surrounding the cavity where caries is advancing, they demonstrate is present in caries of extracted teeth retained in the mouth; and they show that this appearance, which was once thought to indicate pathological action, is due merely to passive decomposition of the tissue. Inasmuch as no characteristic appearances can be found to distinguish caries occurring in living from that in dead teeth, the hypothesis of vital action in any way modifying the disease must be abandoned *in toto*, and "dental caries cannot, strictly speaking, be said to have any 'pathology.'"

Messrs. Tomes regard as the main predisposing cause of caries structural imperfections in the tissues (such as are described on previous pages); and they recognize that the physical signs visible at the onset of the disease vary mainly in consequence of the disintegration commencing sometimes on an unbroken surface, sometimes on a surface the seat of congenital defect, as, for example, on a patch of porous enamel, or in a fissure. The other great predisposing cause is vitiation of the secretions of the mouth.

The mucous membrane, when irritated or inflamed, throws out an acid secretion capable of injuring susceptible teeth. They prove by experiment that this secretion is alone enough to give origin to caries. Other sources of acid are the saliva, which in some

conditions of health has instead of an alkaline a strong acid reaction; fermentation of particles of food lodged about the teeth gives rise to acid; and lastly, acid may be eructated from the stomach.

The appearances visible to microscopical examination during the progress of the disease Messrs. Tomes regard as governed by the physical characters of the tissues. For instance, in the enamel the central portion of the fibres is the first to undergo decomposition. In the dentine they consider that, as a rule, the connecting material (the matrix) is the first, the walls of the tubes (the dentinal sheaths of Neumann) the last to undergo disintegration.

They recognize the presence of leptothrix. They state that it insinuates itself along the dentinal tubes and into fissures to a considerable depth. They doubt whether it has any active part in disintegration of the tissues, and suggest that it is deposited in the carious cavity just as it is deposited in other parts of the mouth favourable for its collection.

Wedl's observations (21) agree substantially with the views of Messrs. Tomes. He classes caries under the heading "Anomalies of the Secretions," considering the disease to be due to the effect of morbid secretions. Caries, he says, has its origin chiefly in abnormal secretions of the gums, of the oral mucous membrane, and salivary glands. He looks upon the secretion of the gums as most active, this secretion coming in immediate contact with and forming a viscid covering on the teeth. Commencing at favourable points on the exterior of the tooth, the disease spreads in the direction of the pulp-cavity. In consequence of decomposition of the secretions acids are formed, which extract the calcareous salts from

the hard tissues, and give rise to disintegration of the affected portions of the latter. These tissues are passive under this disintegrating process, and show no vital reaction, and no change whatever of an inflammatory character. He draws a distinction between dental caries and caries of bone. The latter is an inflammatory process which originates in the soft parts of the bone and erodes its hard tissues. Dental caries, on the other hand, commences in the hard tissues and spreads to the vascular pulp. The destructive process is promoted essentially by the accumulation of secretions and particles of food; and opportunity is afforded for the proliferation of *leptothrix buccalis* in the dead and softened dentine. The absence of acid (alleged by some observers) in some cases of well-marked chronic caries he denies, and considers the absence of acid in any case of caries is not established on scientific grounds. Wedl fully recognizes the part played by inherent structural defects of the tissues as predisposing causes of caries, and especially dwells upon the occurrence of cracks or fissures in the enamel in connection with the development and extension of the disease. During life these flaws are observed very frequently in otherwise healthy sound teeth. The other main predisposing causes are found in those diseases of the general system, during the existence of which the mixed saliva generally acquires an acid reaction. These diseases include many forms of dyspepsia, cancer of the stomach, diabetes, scrofula, rickets, phthisis, and stomatitis. Wedl also notes that in certain conditions of health, such as pregnancy, there is frequently an increased secretion from the gums of viscid mucus, which is often acid even

without the presence of débris of food; and the action of this upon the teeth causes caries in many instances to assume a more or less acute character.

With regard to the minute phenomena occurring in the tissues in caries, Wedl observes in the enamel, as an early change, the presence of pigment of varying shade, such as the author of this work suggests is probably deposited by bacteria. The persistence of the contours of the prisms in places—that is, the more rapid solution of their centres than peripheries by the acid—he considers at present unexplained, but thinks it possibly due to proliferation of a mass of leptothrix into the decalcified enamel. In the dentine he recognizes two stages in the progress of the disease, which, however, cannot always be nicely discriminated—a preparatory stage of decalcification and softening, and a stage of direct disintegration. During the latter stage the tubes become enlarged and varicose and filled with leptothrix, which also he believes may be found in all the ramifications of the carious cavity, although he has not discovered its presence in the earliest stages of the disease. The increased transparency (zone) of the dentine round the focus of caries, said by some to be due to calcification of the dentinal fibrils and consolidation of the dentine, and regarded by these writers as a vital process, Wedl does not consider as such; and although it cannot be denied that the living pulp does react against external agencies, still, he says, the interpretation of writers, according to whom an inflammation of the pulp can manifest itself by pathological effects on the dentine, is incorrect. Carious dentine of reinserted human teeth, and of artificial teeth made from the ivory of the

hippopotamus, presents the same appearances as are formed in ordinary caries, in respect of pigmentation, granular condition of dentinal fibrils, and thickening and varicose enlargement of the latter. The phenomena ascribed to inflammation do not therefore really belong to such a pathological process.

Leber and Rothenstein's work (6) goes to prove the entire identity of caries of extracted teeth and of teeth made of ivory with caries of living teeth; and they deny that any recorded observations authorize the assumption of any vital reaction, or anything to be compared to an inflammatory process in the affected tissues of living teeth. The initial stage of caries is due to the solvent power of acid, and when, in consequence of this, the enamel and dentine have lost somewhat their power of resistance, or a breach of substance, however small, has been produced upon the surface of the dentine, the fungoid growth, *leptothrix*, penetrates into the interior of the tissues, and by proliferation, particularly in the dentine, occasions more rapid progress of the softening and disintegration than would have been the case under the action of acid alone.

Magitot (8) holds the opinion that caries is due to purely chemical action upon the enamel and dentine. He describes a large number of his experiments, proving that enamel and dentine are soluble in acids not more powerful than such as may be formed and deposited in the mouth. He believes that in extracted teeth, submitted experimentally to the action of such acids out of the mouth, he has produced all the phenomena of caries with the exception of the zone of altered dentine so often already mentioned. This zone he considers due to vital action on the part of the

dentine, and regards it as due to consolidation of the dentinal fibres, and as an attempt at natural arrest of the disease.

Messrs. Westcott, Allport, and Mantegazza have each independently proved the destructibility of the dental tissues by acids and decomposition-products such as are commonly present in the mouth.

To this evidence may be added a brief account of some of the more important investigations of Messrs. Underwood and Milles, in order to afford additional proof that caries is due entirely to external influences.

The more important portion of these investigations consists of microscopical examinations of carious dentine stained with an aniline dye. These examinations have been carefully carried on for several years, and with at least one perfectly constant result—namely, that in every section observed under an eighth with transmitted light, micro-organisms have been found inside the canals in more or less number according to the degree of softening and disintegration of the tissue. The presence of these micro-organisms has proved so far to be invariable in natural caries, and the number of sections, cut and examined, is now so enormous, that the observers feel justified in assuming that the presence of organisms is indispensable to the process. They do not remain like leptothrix on the outskirts of the diseased tissue, but penetrate as far as the disease, and even seem to extend slightly beyond the limits of the tissue recognizable by the unaided senses as carious. Another direction in which these observers have obtained a valuable negative result, is that although a weak acid is able to dissolve out the lime salts from enamel and dentine, the result of such solution is not in the least like caries, either in its

mode of attack, its colour, consistency, naked-eyed appearances, or microscopical appearances. This statement may be verified by experimentally decalcifying a healthy tooth in an acid bath. It will be found that the enamel is completely destroyed *first of all*, and reduced to a condition in which it can be removed with a paint brush, and afterwards that the dentine is rendered elastic. The negative evidence was further strengthened by submitting a number of teeth to the action of malic and butyric acids, and even of saliva under aseptic conditions—*i.e.*, in boiled flasks capped under the carbolic spray, both the fluid and the teeth having been previously purified. Two years' exposure in these fluids produced no caries. In some septic flasks some apparently very conclusive positive results were obtained, but the whole of the flask experiments are being repeated with many elaborations, and pending the results of these investigations, the observers do not wish to make any further statement until they are able to support what they may say with a sufficient accumulation of evidence.

With regard to the pigment formation, if some of the organisms be put on a slice of potato, and kept at a temperature of about 90°–100° F., they will soon form the characteristic brown pigment on the surface.

Lastly, the presence of micro-organisms is absolutely indispensable to putrefaction—that is, nothing can putrefy without the presence of micro-organisms; but the presence of leptothrix is not in any sense necessary to the process. Leptothrix is in all probability a fungus, and Messrs. Leber and Rothenstein in their careful observations, of 1868, probably by mistake, classed all micro-organisms under the common heading of leptothrix, simply because the general knowledge of micro-organic life was in its infancy, and the germ

theory had not then attracted the attention of the scientific world.

In face of the overwhelming mass of proof that caries is due entirely to causes arising external to the teeth, and that the sole predisposing causes are, first, structural defects in the enamel and dentine; and, secondly, such general or local diseases as favour the formation of acid and products of decomposition within the mouth; there are some few writers, not more than one or two very recent, who adhere to the opinion that caries is largely, if not solely, due throughout to vital pathological changes in the enamel and dentine. These writers follow Neumann, who maintained that the distinction between caries of teeth and of bone is purely formal, depending upon the difference between the forms of the cellular elements contained in each of the tissues respectively, the roundish bone-cells on the one hand and the elongated dentinal fibres on the other, which latter become thickened and detached. He observed calcification of the dentinal fibres in only one instance, and believed this condition to be referable to the deposit of calcareous salts at the expiration of an inflammatory process, a phenomenon which is observed in bone. Some writers, who believe that caries can be due to pathological conditions arising within the teeth, are led to the conclusion also that the disease may be excited by causes acting upon the teeth through the general system. It may be well, therefore, once more to summarize the main arguments against all these views:—

First. The anatomical characters of dentine render it almost inconceivable that such a tissue can be the seat of a vital morbid process of the nature of inflam-

mation; it is still less conceivable that enamel, a densely hard, almost homogeneous calcareous mass, can be the seat of such action; and it is in this tissue that caries, unless located in a fissure, invariably commences.

Second. If caries were inflammatory in its origin, or due to causes acting through the vascular system, it might be expected that a disturbance in the pulp or other vascular connections of the tooth would be discoverable during the progress of the disease, and that caries would often commence in that part of the dentine which is nearest the vessels, and not, as it always does, in that which is furthest off. Any such vascular phenomena are unknown.

Third. The occurrence of caries in extracted teeth retained in the mouth, and even in artificial teeth made of ivory, shows that neither inflammation nor any other vital action is in any way essential to the disease.

Fourth. The success of the operation of filling teeth furnishes corroboration to these arguments. This operation in the vast majority of cases when perfectly performed arrests decay. This could hardly happen if caries were due to internal causes. The fact, moreover, that enamel and dentine passively submit to the presence of a foreign body like a filling wedged into their substance, and do not resent its presence by pathological action, seems alone enough to prove that their vitality is of so low a character as to render them incapable of such action under any circumstances. The operation of filing the teeth affords similar evidence of the dependence of caries upon external influences. It often happens that the contiguous surfaces of incisor teeth are attacked by decay, and when this is discovered in an early stage, before the mischief has advanced further

than through the enamel, it is in many cases good practice to file down the affected surfaces until sound tissue is reached, and to polish them, leaving them of such shape that particles of food, or shreds of mucus, cannot adhere. This operation is one of the most permanently efficacious in arresting decay; but it is hard to understand how mere removal of the surface as described could succeed in any case if caries were due to pathological changes beginning within the tooth.

Lastly, the coincidence of caries with disorders of the general health and various cachexiæ can be accounted for fully by the vitiation of the secretions of the mouth and deposit of the products of decomposition upon the teeth during the progress of such diseases.

Enamel being devoid of sensibility the pain during caries (as already stated) does not begin before the dentine is affected, and it is due in the earlier stages of the disease solely to the exposure of this sensitive tissue to sudden changes of temperature and pressure of foreign particles and contact with irritating substances. In the later stages pain arises from the transmission of similar irritation to the pulp, when that structure is either insufficiently protected by a layer of dentine, or actually exposed. Finally, if the disease runs on, there is added the pain due to the extension of the inflammation from the pulp to the peridental membrane.

The amount and character of the pain in all the phases of caries are much diversified in different persons. In some there is almost from the beginning constant pain of a dull aching character, augmenting from time to time as decay advances into severe or even agonizing paroxysms, whilst in others the teeth

are altogether destroyed without any suffering beyond slight occasional aching and uneasiness. It is impossible to account for this difference, but it may be noted that the very young suffer as a rule more acutely than adults or the aged, and that in certain conditions of health, of which pregnancy furnishes the most striking instance, toothache, if it occurs, is usually of the severest kind. Leaving out such exceptional cases it may be broadly stated, however, that in the vast majority of instances there comes on from time to time, after the dentine is affected, slight attacks of transient aching, particularly after entry into the cavity of irritating substances, such as sugar and salt; and a smart pang slowly subsiding is often inflicted when a hard fragment of food is forced in during mastication.

The symptoms and pathology of irritation and inflammation of the pulp and of dental periostitis associated with caries are discussed in a later chapter. It may be repeated that the most severe pain which arises during the progress of caries is due to inflammation of the pulp. It is by the extension of this inflammation that the dental periosteum becomes involved. When periostitis has supervened the tooth becomes slightly loosened, and exquisitely sensitive to the touch.

It is a remarkable fact, and one that has some practical application (as was seen in a preceding section), that the teeth are not all equally liable to be affected by caries. Series of cases have been tabulated from time to time by various observers, and these agree in the main with each other. The following statistics of 10,000 cases collected by Magitot, show the relative frequency of caries in the different kinds of permanent teeth :—

Central incisors	642	{ Superior	612
		{ Inferior	30
Lateral incisors	777	{ Superior	747
		{ Inferior	30
Canines	515	{ Superior	445
		{ Inferior	70
First bicuspid	1310	{ Superior	940
		{ Inferior	370
Second bicuspid	1310	{ Superior	810
		{ Inferior	500
First molars	3350	{ Superior	1540
		{ Inferior	1810
Second molars	1736	{ Superior	690
		{ Inferior	1046
Third molars	360	{ Superior	220
		{ Inferior	140
	<hr/>		<hr/>
	10,000		10,000

The first point which attracts attention in these tables is the great relative frequency of caries in the first molars; the next the much greater frequency of the disease in the front teeth of the upper than in those of the lower jaw. The latter circumstance may perhaps be accounted for by the fact that the lower front teeth are protected from the action of acid by the saliva with which, owing to their position, they are constantly bathed; but it must be admitted that no entirely satisfactory explanation of the ratio of frequency presented by the several classes of teeth has yet been afforded. The localisation of caries is, however, most probably determined mainly by the presence of inherent flaws in the teeth attacked; but we cannot yet fully account for the fact that certain classes of teeth are more than others the seat of these defects.

TREATMENT OF CARIES.

PREVENTIVE—THE INCIPIENT STAGE—THE OPERATION OF FILLING THE TEETH.

Preventive Treatment.—The pathology and etiology of dental caries being understood, it will be obvious that much can be done to prevent attacks of the disease, and to delay its progress. The treatment of constitutional conditions predisposing to decay of the teeth, falls beyond the province of the dentist, and although it can be therefore only mentioned here, too much stress cannot be laid upon its importance. If it be omitted, the most active local measures may prove in some cases ineffectual.

Locally, the prophylaxis of caries in part consists in combating diseased conditions of the mucous membrane of the mouth, which are attended with vitiation of the secretions, but as these conditions are discussed in later pages, there need be considered here only the means which are available locally in preventing the formation of acid, the active agent in caries, in neutralizing it, and in preventing its hurtful effects upon the teeth. Foremost among these means, must be placed the maintenance of the mouth in perfect cleanliness. The teeth should be carefully brushed, at least twice daily, and the patient should be taught not only to cleanse the exposed surfaces, but to apply the brush to every

part which it can reach. The spaces between the teeth should be frequently freed from the particles of food which lodge there. For this purpose a few threads of floss silk, or a fold of any similar soft material slipped into the spaces, and rubbed briskly to and fro answers well. A quill toothpick may be used with advantage; those of metal should be avoided, being capable of scratching and injuring the surface of the tooth. Tooth powders and lotions are of considerable value. Tooth powders ought not to be made of materials like levigated pumice, which are often used to whiten the teeth, and which produce this effect by grinding away the enamel, but should be composed of alkaline, bland, and soluble substances, having no more mechanical power than enables them to remove the well-known soft fur which coats the surfaces of the teeth in most mouths, even within a few hours after every application of the tooth-brush. The desired objects are well fulfilled by such a mixture as that of precipitated chalk and soap, commonly known as saponacious tooth powder. The author's routine prescription for tooth powder for ordinary use, which is liked by most patients, is as follows:—

R. Pulv. sapon. Castil. ℥ij.
 Pulv. Iridis ℥ss.
 Sodæ bibor. ℥ij.
 Cretæ precip. ℥ij.
 Ol. caryoph. ℥ij.
 Ol. lavand. ℥x.
 Otto rosæ ℥v.
 M. ft. dentifricium.

A powder having as its principal ingredients chalk

and a soluble alkali, such as carbonate of soda, is almost equally efficacious, and may be prescribed in the few cases of patients who dislike the slight soapy lather which the other powder produces.

Mouth washes may be composed with advantage of tincture of myrrh or of rhatany. The spirit which these tinctures contain, besides rendering them more astringent, is antiseptic, and it is a good plan to use them to moisten the floss silk, or other material which is employed in cleansing the spaces between the teeth. With the same design Eau de Cologne, lavender water, and similar perfumes are pleasant applications. With these lotions there may be combined carbonate of soda, or other soluble alkalies, when the acidity of the secretions is great, or where the patient is obliged to take acid medicines.

In fevers or other diseases, when the patient is either too feeble or too listless to clean his teeth for himself, this should be done by an attendant. A soft tooth-brush frequently dipped in a weak lotion of permanganate of potash or carbolic acid should be used; and the patient's mouth should also be frequently well washed out with the same lotion.

Perhaps the most beneficial procedure that can be adopted for the prevention of caries, in cases in which the teeth are of a generally defective structure, and *where great crowding of the teeth exists*, is the extraction of two or more permanent teeth from each jaw during the period of second dentition. In such cases, but if possible not before second molars are in place, for reasons explained in chapter on irregularities, the first, which are often extensively carious, can be well spared, but even when sound their sacrifice will be repaid in many instances by the improved condition

of the remainder of the set. Not only does the room afforded by the equal spreading apart of the teeth render the origination of caries less possible, but it enables the cleansing of the interstices to be easily performed, and affords the dentist the opportunity of detecting, and dealing with the decay in these difficult situations, in its incipient and most tractable form.

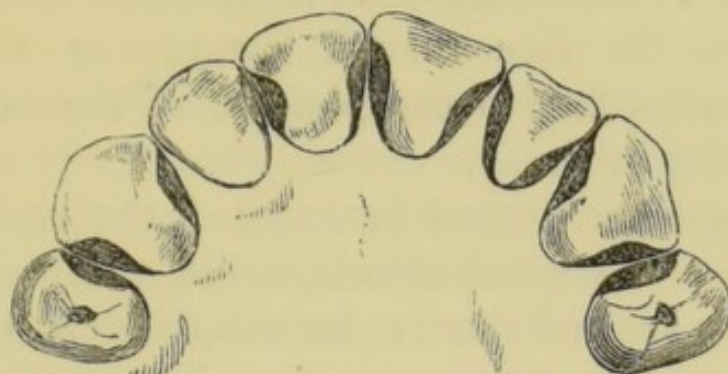
The treatment of incipient caries may be confined in many instances to cutting away the diseased tissues, polishing the surface, and leaving it of such a form that it may be readily cleansed, and not allow of the adhesion of decomposing particles of food. This procedure is in imitation of an operation which is sometimes effected accidentally during the progress of the disease, and which suffices to arrest permanently the process of carious disintegration. The disease occasionally commences on the grinding surface of a tooth, only the external portion of which is of defective structure. This portion having been destroyed, the denser subjacent tissue is laid bare, and becomes smoothed and highly polished by mastication, whilst at the same time calcification of the dentinal fibrils gradually takes place, and renders the surface extremely hard.

The treatment of caries by the simple operation of excising the diseased tissue is applicable only in rare cases to the grinding surfaces of the teeth, but is commonly resorted to with success in dealing with decay of the contiguous surfaces, especially those of the incisors and canines. The operation is performed under the most favourable circumstances when the enamel alone is affected, but it may be often carried out with permanent advantage even when the dentine

has been penetrated to some slight depth. As a rule it should not be undertaken in mouths where chronic inflammation and sponginess of the gums prevail; neither should it be proposed in any case when the carious surface extends below the gum. At the level of the gum it is desirable in most cases that a portion of sound tissue should remain projecting from each tooth, so as to prevent their surfaces from coming into close apposition. The rest of the surfaces should be left perfectly plane, and with such an inclination towards each other that the space between them is V-shaped, the wider part so directed as to be easily accessible to the tooth-brush and to the tongue, and subject to the constant beneficial friction of mastication. In forming the surfaces in this manner it is sometimes necessary to cut away a considerable quantity of sound tissue. The amount which may be safely removed varies with the size of the tooth, but it must be borne in mind throughout, that if too much be removed the tooth may be left unbearably sensitive, owing to near exposure of the pulp. In the case of the incisors and canines the excision of tissue may be confined always to a great extent, and sometimes entirely, to the lingual aspect of the teeth, which are thus preserved from perceptible disfigurement. The instruments required in the operation consist of enamel chisels and files; with the chisels—when applied in the direction of the enamel fibres—the decayed tissue may be rapidly and painlessly broken down; with files of different degrees of coarseness the operation may be continued, and the surface made ready for the final polishing. This latter process is accomplished by rubbing the surfaces first with finely powdered pumice, carried on

ape or on a strip of cane, to remove the file-marks, and afterwards with a strip of wet slate-stone, to make it perfectly smooth. Fig. 40 (from Arthur) shows the

FIG. 40.



most favourable form in which the interstices of the teeth can be left after this treatment. The slight sensibility in the exposed dentine, varying in amount in different cases, which often remains for a time after the operation, may be rapidly diminished by the occasional application of solution of chloride of zinc, or the use of a lotion containing spirit.

The Operation of filling the Teeth.—When, owing to its extent or to other circumstances, caries cannot be dealt with by the method just described, it must be treated by the operation of plugging or filling the tooth. This operation comprises cutting out the diseased tissues and forming the cavity for the retention of the filling, drying the cavity, and filling it with some suitable material. It is conducted always on the same principles, but its details vary somewhat according to the position, character, and extent of the decay. The present section will be restricted to the treatment of cases in which the central chamber of the tooth has not yet been laid open by the caries, and in which the dental pulp is free from disease.

The operation of filling, throughout all its details, is

much facilitated by the use of a dentist's chair, which allows the patient to be firmly and comfortably placed in the most suitable position, raised when a tooth of the upper jaw, and lowered when a tooth of the under jaw, is to be filled, with the head tilted forwards or backwards, the face turned towards or from the operator, according to the position of the tooth and of the cavity of decay.

The instruments used in excising the carious tissues consist of enamel chisels, drills, and excavators. The chisels are sufficiently described by their name, both as regards their nature and use. They are made with blades of different sizes, bent at various angles, so as to reach the decay wherever situated. With them the carious enamel of the walls of cavities can be speedily broken down with but little pain to the patient. The chisel should be held firmly with the handle in the palm of the hand, the thumb being lodged securely against the tooth to control the instrument and to prevent it from slipping. It should be applied in the direction in which the enamel fibres run.

Dental drills are of two kinds, the rose or bur-head, and the sharp-pointed drill. The cutting point of the rose-head forms a circular or conical file. It is used to open up the ragged orifices of cavities and to grind away the carious tissues within. The sharp drills serve to open up small cavities and fissures in the enamel, to shape the cavity, and to cut retaining points into which the filling is to be dovetailed. These drills are now commonly employed in conjunction with the burring engine. This instrument consists of a flexible shaft rotated by a band, which is driven by a treadle and fly-wheel. The

extremity of the shaft carries burs, grinding wheels, or drills of any desirable size and shape, and, revolving with great rapidity, enables the operator to excise the tissues with great nicety, and speedily to reduce to smoothness the ragged or rough surfaces.

Excavators serve to pare away the dentine. They are made of all sizes, some with flat blades, some spoon-shaped, and others sharp-pointed, and they are curved and bent at various angles to reach the differently situated cavities.

With regard to the performance of the preliminary step in the operation of filling, at present under discussion, it may be laid down in the first place as a rule, subject to important exceptions to be mentioned further on, that the whole of the carious structures should be removed. If the margin at least of the cavity be not formed of sound tissue, decay will proceed unchecked after the insertion of the filling. At this part of the cavity the beginner is much more liable to err, by too limited than too free use of the chisel and excavator. In the next place it must be observed, that although the sensibility of the teeth varies in a great degree in different individuals, the excision of the carious tissues is always a more or less painful operation. In most cases, however, it will be found that it inflicts no more than an easily bearable amount of pain, when it is done rapidly with instruments thoroughly sharp. The suffering may be lessened in the few cases in which the patient cannot endure the pain, by applications which diminish the sensibility of the dentine. Amongst the most useful of these applications in common use, may be mentioned chloride of zinc and arsenious

acid. The cavity may be swabbed with a strong solution of the former, or a minute quantity of the latter may be applied, and this will usually have the desired effect. These remedies, especially the latter, must be used with great caution when the pulp is nearly approached by decay, lest they penetrate to that structure and excite inflammation.

The exceptions to the rule with regard to the excision of the whole of the carious tissues present themselves in cases in which the pulp cavity is closely approached by the decay and when the pulp is free from disease. In such cases the greatest care must be exercised to avoid laying open the chamber, for, if this accident happen, the chances of saving the tooth are much diminished. When danger of the accident exists, the softened dentine must be slowly and cautiously removed, and for this purpose excavators with spoon-shaped blades should be used, to avoid the danger of a sharp point cutting through the softened tissues. If it be found that the excision of all the affected dentine cannot be accomplished without risk, it is better to leave a layer of partly decayed tissue of sufficient thickness in the depths of the cavity. Carious dentine in the earlier stages of decay may be, in fact, always left with safety in the deeper parts of large cavities, and in the later stages, unless utterly disorganized, it can be brought into such a condition, and placed under such circumstances, as will prevent it from decaying further. Caries—it has been shown—cannot go on without the influence of external agencies, and all that is wanted in the case in question, is in fact to harden so far as possible the diseased tissue, to abstract completely its moisture, to render it perfectly aseptic, and to

protect it by a permanent filling from the action of these external agencies. Partially disorganized dentine may be hardened by filling the cavity with a plug of cotton wool, saturated with a solution of gutta-percha and tannin in chloroform, or gum mastic in spirits of wine—a dressing of wool with carbolic acid, or a paste composed of iodoform and eucalyptus oil being applied beneath, and the whole being renewed at intervals of a few days, over as long a period as necessary. In many cases the drying alone of the tissues by means of a hot-air syringe, or better, by the application of alcohol, will suffice. This process is described on a later page.

There are no grounds upon which the deliberate exposure of a healthy pulp during the process of excavation can be justified. It is probable that a healthy pulp, exposed to the atmosphere alone, and no other irritation, will certainly pass into a condition of disease if not kept in aseptic by art. This always happens in the case of a joint or other analogous part of the body wounded in a like manner. The condition of an exposed pulp might be fairly compared to that of the tissues exposed in such a wound or in a compound fracture. The difficulties of rendering an exposed wounded pulp aseptic, and of keeping it in that condition during and after the filling operations are very great. These are spoken of under the heading of treatment of exposed pulp. The existence of a layer of partly disorganized tissues treated as described, and enclosed beneath a filling in the depths of a cavity, can be productive of no harm. If it be cut away it must be afterwards replaced by a cap—an artificial substitute, the application of which is difficult, which often sets up irritation, and which

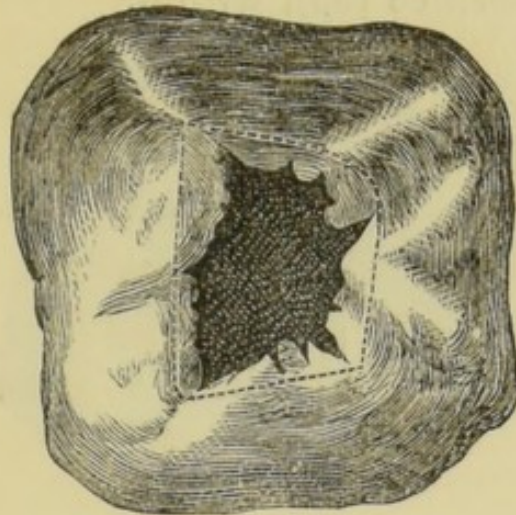
even if of the most perfect construction, must be necessarily less adapted to its purpose than a layer of imperfect dentine.

In excavating the tissues preparatory to the insertion of filling it is necessary not only to remove decay but to adapt the cavity for the retention of the plug. It will be presently seen that with one exception none of the materials used in filling teeth adhere as cements to the walls of the cavity—they are all retained by either plugging, wedging, or dovetailing. The simplest kinds of cavities are such as after removal of the decay assume the form of a hole or trench with vertical walls; and those which require most modification are such as have a narrow irregular orifice, and those which either wholly or partly take the form of a shallow saucer-shaped excavation. It being impossible to pack a filling beneath the overhanging margins of a cavity, these portions must be, when necessary, freely cut away, whilst, as it is also impossible to fix a plug upon a shallow concave depression, the walls of such a cavity must be rendered either vertical or slightly undercut, or retaining points must be formed. Retaining points are made by drilling small pits in different parts of the cavity. Into these pits portions of filling are packed, and to these portions more and more being securely joined, the whole mass is fixed immovably in position. The number, size, and depth of the retaining points must be regulated according to the circumstances of the case. They need never be very deep, and of course due care must be taken in using drills to avoid laying open the pulp cavity.

The annexed enlarged diagrams may serve to make this subject more clearly understood. Fig. 41

exhibits the aspect of the commonest form of simple cavity in the grinding surface of a molar. Such a

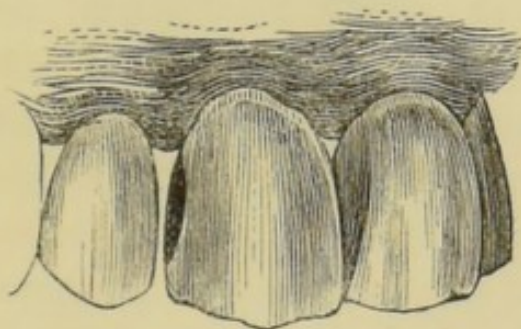
FIG. 41.



cavity after the excavation of the carious tissues, including the enlargement of the orifice to the extent indicated in the dotted lines, would require no further modification to fit it for the reception of a filling.

Fig. 42 shows a cavity after excavation on the lateral

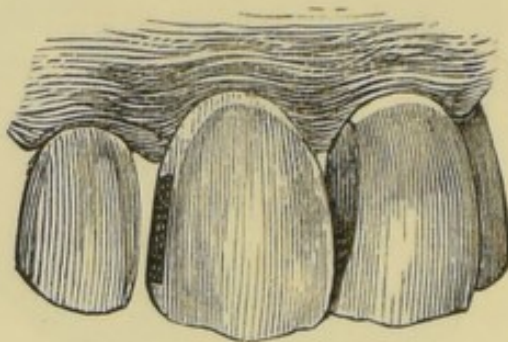
FIG. 42.



surface of an incisor. The cavity is of some depth towards its centre, but from that point slopes gradually in every direction towards the lingual and labial margins, and towards the cutting edge and neck of the tooth. It forms, therefore, a uniformly concave saucer-shaped cavity incapable of retaining a

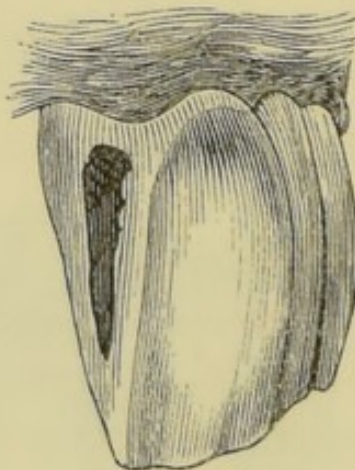
filling. Such a cavity might well be prepared by giving it the form of a trench, as shown in fig. 43, with slightly undercut walls, rendering it a little smaller at the orifice than within.

FIG. 43.



The next diagrams illustrate the formation of retaining points. A cavity of typical character on the lateral surface of an incisor is shown in fig. 44.

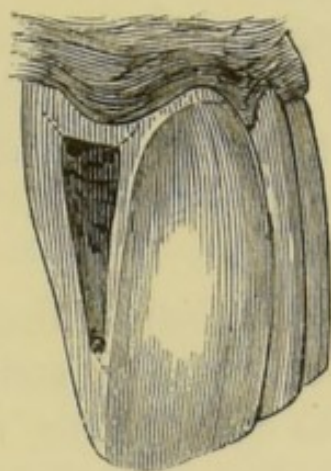
FIG. 44.



After removal of the carious tissues, it forms a shallow concavity, broad at the upper part and sloping and narrowing towards the cutting edge of the tooth, near which point it terminates. The preparation of such a cavity would consist, after slightly deepening the labial and lingual walls, in drilling two pits (as shown in fig. 45) in the upper

aspect, and one in the lower angle, of the depth and in the direction indicated by the dotted lines.

FIG. 45.



The later section on gold filling will be further explanatory of this subject.

The difficulties which present themselves in dealing with cavities, which, being situated on the contiguous surfaces of teeth, are neither fully visible nor sufficiently accessible, must be overcome either by free chamfering, or by temporarily forcing the teeth apart. The beneficial effect of permanently separating teeth was explained in the section on the treatment of incipient caries, and the procedure there described must be adopted in the majority of cases preparatory to the filling of the cavities in question. In treating the incisors and canines the plan described in the section on incipient caries must be adhered to, and the chamfering must be as far as possible confined to the lingual aspect of the teeth. This suffices in most cases to render the cavity accessible to the filling instruments from behind, whilst the labial surface remaining intact, the normal appearance of the tooth is preserved, and the filling, unless large, is rendered invisible to casual observation. The instances in

which it is better to force the teeth temporarily apart are those in which small cavities exist in teeth—especially front teeth—of otherwise sound structure, and where permanent separation would cause disfigurement. Sometimes the plan may be well adapted of chamfering the affected surfaces to some extent, and pressing the teeth apart in order to obtain the further space necessary for the use of the filling instruments.

The temporary separation of teeth is easily effected by slipping between them a strip of india-rubber, and allowing it to remain for twenty-four hours. A very slight amount of pressure suffices for the object; the rubber should not therefore be thicker than the space which it is desired to make, and this space should not be greater than suffices to allow the use of the necessary instruments. If much force be exercised great pain is set up, and the presence of the rubber soon becomes intolerable. After the removal of the rubber the teeth fall together again in the course of a few hours, and the tenderness which the process has caused also rapidly subsides.

A similar effect can be produced by packing a plug of cotton wool, saturated with mastic cement, between the teeth, and allowing it to remain for a few days, renewing it at intervals till the desired effect is produced. This plan is preferable in cases in which a mass of swollen gum projects into the cavity, the pressure of the plug causing the mass to sink, and forcing it out of the way of the instruments.

During the subsequent steps of the filling operation, the insertion of a wooden wedge between the necks of the defective teeth is often useful. A piece of com-

pressed hickory of suitable size is cut so as to fit with a moderate degree of tightness the V-shaped space which naturally exists between the necks of the teeth. This is steadily pushed between the teeth, and the ends being cut short, it is allowed to remain until the filling is completed. The use of a wedge alone in this manner, in some cases in which the teeth are not closely in contact, is sufficient to afford room for the satisfactory performance of the filling operation. The wedge often also subserves the purpose of forcing away the gum and preventing it from bleeding, and from being wounded by the files and other instruments. It also often serves to hold in position the rubber dam.

Drying the cavity.—The cavity having been prepared for the reception of the filling, the next step consists in drying it and guarding against the access of moisture until the completion of the operation. The difficulty in accomplishing the latter part of this process is much greater in every case at some positions in the mouth than at others, whilst the extremely profuse flow of saliva in certain patients is even under favourable circumstances hard to control. The teeth situated at the anterior part of the upper jaw are the most easily managed, the orifices of the salivary glands being distant, and the fluid naturally gravitating towards the back of the mouth. In most cases during the filling of upper incisors, canines, or bicuspid, the cavity may be kept dry by the insertion of a roll of cotton wool beneath the lip, a fold of napkin being at the same time laid across the lower front teeth, to prevent the tongue from carrying up moisture from beneath. Absorbent cotton wool—wool prepared so as to have the property of

rapidly absorbing moisture—renders these procedures more efficacious.

The duct of the largest salivary gland—the parotid—opens through the mucous membrane of the cheek, where it lies against the upper molars, and its flow must therefore be directed or controlled before these teeth can be dried. Where the flow is not profuse, and the cavity is situated on the masticating surface, precautions such as described for the front of the upper jaw may suffice. In other cases these measures may be supplemented by the temporary closure of the orifice of the duct. This may be accomplished by the application of clamps specially contrived for the purpose, or the exit of saliva may be sometimes prevented temporarily by a small patch of impervious sticking plaster.

In the lower jaw the exclusion of the saliva during plugging presents more difficulties than in the upper. The saliva naturally accumulates in the floor of the mouth, and the movements of the tongue and the efforts of swallowing have a constant tendency to throw it over the crowns of the teeth. In patients who cannot swallow with the mouth open the difficulties are increased. Where the tooth has to be kept dry for no more than a few minutes, the influx of saliva may be guarded against by the insertion of a roll of absorbent wool or of bibulous paper beneath the tongue, and another between the cheek and side of the jaw, these rolls being firmly held in position by the fingers of the left hand. In more prolonged operations the tongue depressor is extremely useful. By it the tongue can be held down, and any desirable amount of pressure can be kept upon the ducts of the glands which open in the floor of the mouth.

Patients may often be trusted to assist the operator by holding a pad of cotton wool beneath a fold of napkin firmly on the floor of the mouth under the tongue.

It will be found in the majority of cases possible to keep the faulty tooth dry during the insertion of a filling by the means just described, which were those alone available until late years. There has, however, been recently introduced the contrivance known as the rubber dam. This simple invention, for which the profession is indebted to Dr. Barnum, of the United States, enables the dentist to keep the tooth perfectly dry throughout the most prolonged operation. The dam is formed of a thin sheet of india-rubber specially prepared for these operations. A piece is taken a few square inches in size, and towards its centre is punched a small hole, one about as large as an ordinary pin-head being big enough for a molar. This hole is stretched and slipped over the tooth, so that the rubber closely embraces the neck and leaves the crown surrounded by an impervious dam. In practice it is well to make a series of holes in the rubber the same distance apart as the crowns of the teeth adjoining the one to be operated upon, and to pass the rubber over them also. By this means the rubber is securely fixed and kept effectually out of the way.

Difficulties in applying and securing the dam arise where the teeth are in extremely close contact, and where, from the conical shape of their crowns, the elasticity of the rubber causes it to spring off. The first of the difficulties may be overcome by forcing down the highly stretched rubber by a thin strand of waxed floss silk. It is found that by the pressure of

the tense thread the teeth can be forced slightly apart at the point where their crowns are in contact at the masticating surface, and this point being passed, the rubber is readily carried down to the gum, at which position an interval invariably exists between the teeth. To prevent the dam from springing off the tooth a steel clamp of suitable design may be used. This clamp grips tightly the neck of the tooth, and forms a projecting flange, under which the rubber slips, and is thus held secure. The same purpose is fulfilled by the insertion of wooden wedges between the teeth after the dam is applied. The dam having been fixed by one of these methods, the borders of the rubber projecting from the mouth may be turned back and held out of the way by hooks attached to elastic bands passing over the patient's head. The rubber dam gives less annoyance to the patient, whilst answering the purpose better than any other contrivance of the kind, besides which it leaves both hands of the operator free for the manipulation of the stopping instruments.

The influx of saliva having been guarded against, the cavity has next to be dried, a comparatively easy matter. It may be done roughly by wiping the surface with absorbent cotton wool, or with bibulous paper, or amadou. It is, however, by no means easy to procure perfect dryness by mere wiping with these materials. Better to achieve this end several varieties of hot-air syringes have been devised, by which the moisture may be driven off by a current of heated air. These instruments are superseded by the use of absolute alcohol, in the manner first suggested by the author. When applied to a wet surface, the alcohol, having a great affinity for water, combines with it,

and if exposed to the atmosphere evaporates. In this way it not only carries off the superficial moisture, but it also abstracts the water which the tissues intrinsically contain. Cavities to be dried with this fluid should be first wiped out with wool and then swabbed with a small pellet saturated with alcohol. After a pause of a moment to allow the spirit to unite with the water, the cavity can be again wiped with dry cotton, and this will leave a surface as dry as could be obtained by the hot-air syringe. Rectified spirits of wine of ordinary strength, freely used, suffices for the purpose where the tissue to be dried is healthy, and not softened or saturated with water. The swabbing and wiping can be repeated when called for, as in those cases already referred to under a previous heading, in which it is desired to harden a layer of carious dentine, which to avoid exposure of the pulp must be left in the depths of a cavity beneath a filling. Like every other fluid which has a strong affinity for water, absolute alcohol will of course produce irritation if allowed to flow upon the skin or mucous membrane, although this will be but slight if the surface be wet and the quantity of spirit small. Accidents of this kind need not occur if ordinary care be taken.

The materials used in filling teeth may be conveniently arranged for the purpose of description according to their durability in the mouth. One (gold) only is practically imperishable, several others, although subject to slight physical and chemical changes, are sufficiently lasting to deserve the name of permanent filling, whilst a third group, being liable to rapid decomposition, must be classed as temporary fillings. Permanent fillings are, of course, always

intended to act as substitutes for the tissues destroyed by disease. Temporary fillings—as was noted incidentally in the section on excavating the carious tissues—are used in the preparatory treatment of cavities. Further explanation of their employment in the same and in other ways will appear in later chapters.

With regard to the choice of materials in cases ready for the reception of permanent fillings, it may be said that there occur few cavities in which the insertion of a gold plug is impossible, and regarded from a merely theoretical point of view the instances are rare in which the use of any other material as a stopping intended to be permanent is justifiable. Practically, however, it is often necessary to employ inferior and less durable substances. In the first place the expense of gold puts it beyond the reach of the lower and of the poorest classes. In the next place, the operation of gold filling in large and difficult cavities is long, tedious, and, frequently, painful, and there are many patients who either cannot or will not submit to it. Lastly, exceptional cases occasionally present themselves, as for example, in neglected caries of a front tooth, in which the crown—the preservation of which is of great importance—is so extensively excavated as to form a mere thin shell of enamel, incapable of withstanding the force required in gold filling. In all such instances the substitute for gold best adapted to the circumstances must be employed. With Sullivan's cement, the author in hospital practice alone has filled and saved in a useful condition numbers of grinding teeth which must have been lost had there not been available any such material, at once inexpensive and rapid of application; whilst he has seen an equal number of fragile front

teeth preserved for years by such comparatively perishable materials as oxychloride of zinc, and especially gutta-percha.

The gold used for filling teeth is pure—without any alloy whatever—for in this condition alone it possesses the qualities necessary for the production of perfect plugs. It is prepared by the manufacturers in two forms—in foil and in a spongy mass. The leaves are produced by beating, the sponge is formed by precipitating the metal from a solution. The leaf gold suitable for filling teeth is much thicker than that which is used in gilding, and comes to hand in sheets about four inches square, the lightest of which weigh four grains. Thicker qualities are made to suit the fancy of different operators, and the exigences of cases. Sheets from four to six grains in weight are the most generally useful. Two qualities of gold foil are manufactured for dental purposes, non-adhesive and adhesive, and these differ in the fact that pieces of the former pressed together do not cohere, whilst portions of the latter forced closely into contact become inseparably united. These peculiarities are due to difference in the molecular condition of the foils, the adhesive variety being more crystalline in character than the non-adhesive. The adhesive quality of all foils is increased by annealing, and the non-adhesive variety may be rendered adhesive by the same operation. The adhesive property of pure gold (when in a certain molecular condition) is one that it possesses in common with some other metals, such as platinum, silver, tin, and lead, which are comparatively soft at ordinary temperatures. The adhesion is in fact due to welding, the metals being capable of union of this kind when in their cold

state, just as iron, and some others are when rendered plastic by heat. Sponge gold, owing to its perfectly crystalline form, is the most adhesive variety prepared for dental purposes. The adhesive property of gold is destroyed by moisture, but can be again restored by annealing.

Tin foil, of which permanent fillings can be made, is composed of the pure metal. It is sent out by the manufacturers in leaves of the same size as the gold foil, and in thickness about the same as six grain sheets of that metal. Pure tin, as just mentioned, can be welded in the cold state, but the union cannot be brought about, unless the surfaces of the separate portions are bright and free from oxidation. This chemical change affects tin foil after a few hours' exposure to the atmosphere, and destroys to a great extent its cohesive property. This does not however much lessen its usefulness as a filling material. In plugging it is manipulated in the same way as non-adhesive gold foil.

Amalgam fillings come next to gold and tin in point of durability. These are all formed by combination of mercury, either with a single metal or with an alloy of several. Perhaps one of the first of these compounds used in dentistry was that composed of coin silver and mercury. The silver, reduced to filings was rubbed up in a mortar with mercury, until a stiff pasty mass was formed, which became hard in the course of a few hours. This amalgam, although of considerable durability under favourable conditions in the mouth, had the disadvantages of becoming itself blackened by oxidation, and of gradually staining the tooth in which it was inserted. In spite of numerous attempts to do away with them, either or both of these imperfections in a greater or less degree

are common to all the amalgams since introduced. Most of these have as their basis silver alloyed with small quantities of tin, gold, and platinum, the alloy being reduced to filings to facilitate union with mercury.

Palladium amalgam, and copper amalgam, or Sullivan's cement, are each composed of pure metals with mercury. The palladium is manufactured for the purpose by precipitation, which produces a fine powder. Sullivan's cement is supplied to the dentist in the form of small solid pellets—masses of amalgamated copper and mercury. To prepare it for use, a sufficient quantity is placed in an iron spoon, and held over the flame of a spirit lamp, until globules of mercury appear on the surface. It is then ground down in a mortar and forms a smooth paste, with an evident excess of mercury. It is then folded in wash leather, and forcibly squeezed until much of the mercury having escaped, the mass assumes a drier and somewhat granular character. This amalgam more than any other is subject to the disadvantage that in time it discolours and blackens the tooth. This bad effect is much lessened if the filling be well washed with spirit of wine. A table-spoonful of spirit can be poured on to the softened pellet in the mortar before the excess of mercury is forced out, and thoroughly washed through with the effect of removing a large quantity of metallic oxide. The mass can be then squeezed in a fold of wash leather, which, while removing the mercury, forces out the remaining spirit, which may not have already escaped by evaporation.

A copper amalgam (Steward's) of purer composition than Sullivan's is now to be obtained.

It has been proved by the experiments of Mr.

Charles Tomes that all the amalgams in common use contract during the process of hardening, although the extent to which this occurs varies considerably in the different compounds. The amount of contraction has been closely ascertained, by obtaining the specific gravities of masses of the amalgams when recently mixed, and afterwards when hardened. In the former state their density is found to be always less than in the latter, the difference being, of course, due to contraction. It is obvious that when the shrinkage is more than infinitesimal in amount a permeable space must be formed between the filling and wall of the cavity after the hardening of the amalgam, and in such a case the stopping must necessarily fail to arrest decay.

The following table from Mr. Tomes' paper exhibits a comparison of the weight gained (*i.e.*, shrinkage) by different amalgams while hardening:—

Palladium037
Sullivan's07
*Ash's14
*Smale's14
Tin and silver (55 to 45)35
Tin and silver (equal parts)38

The compounds marked with an asterisk may be taken as fair specimens of the amalgams in ordinary use, composed mainly of silver and tin, with a slight admixture of gold or platinum. These experimental results accord in the main with those of practice. Palladium amalgam and Sullivan's cement, when packed with due care, form plugs of greater durability than those composed of any other amalgam. In theory it would appear that the contraction which

accompanies the hardening of most amalgams must be alone an insuperable objection to their use for fillings; but practically in well chosen cases amalgams manipulated with due skill and care endure for an indefinite period. The most favourable cases are those in which the general structure of the teeth is of good quality; the most favourable cavities such as are situated on the grinding surfaces of the teeth, or in situations where they are constantly subject to friction by the tongue or in mastication. The durability of an amalgam filling largely depends upon the amount of care which is bestowed on the preparation of the cavity. It must be borne in mind that amalgam does not adhere to the walls of a cavity, but is held as a plug by packing alone. It must, therefore, be thoroughly supported by solid walls, and fixed in position by well planned retaining points where needful. Too much care cannot be taken in finishing the orifice of the cavity, and by means of corundum points and the burring engine in rendering the inner margins perfectly smooth.

Many points with regard to the properties of amalgams are still undecided. Among them the question as to the proportion of mercury which it is best to use with the different compounds is still an open one, the balance of evidence being, however, in favour of the admixture of a quantity no greater than will suffice to produce a friable mass, which, under slight pressure, becomes coherent.

In the case of those amalgams whose basis is an alloy, the mercury should not be added in excess, and then squeezed out. The error should be corrected by the gradual addition of more filings. If the mercury be pressed out of such an amalgam it carries with it

an undue proportion of those of the constituent metals that are most soluble in it, and so the chemical character of the resulting compound is altered. Palladium and copper amalgam, on the other hand, may be freely mixed with an excess of mercury, care being afterwards taken to expel sufficient to reduce them to the proper degree of dryness.

In addition to staining the tissue, some amalgams have the effect of rendering the surface of dentine against which they rest extremely hard. This appears due to the saturation of the tissue to some slight depth by the metallic salts set free during the oxidation of the amalgam. In the case of Sullivan's cement the tissue in time becomes so hard as to resist effectually the further inroads of caries, and this effect doubtless has a share in increasing the permanence of this amalgam as a filling, counterbalancing the effect of the slight contraction which it undergoes whilst hardening.

Among filling materials of a more perishable nature than the metallic compounds just described, to gutta-percha may be assigned the first place; indeed, although its physical characters render it unfit to sustain the wear of mastication, its durability as a filling in proper situations is very great. For dental purposes gutta-percha is prepared in the form known as Jacobs' and Hill's stoppings. These consist of gutta-percha bleached and intimately blended with silica, or some like substance, in the form of an impalpable powder, to render the material harder and more durable.

There has been introduced during late years a numerous class of useful compounds for temporary fillings, amongst which those known as Robert's,

Guillois', and Fletcher's cements are of the most value. These are all mainly composed of oxide of zinc mixed either with silica or marl. This pulverulent mixture, when required for use, is worked into a paste with a strong solution of zinc chloride. Chemical combination takes place, and a hard mass is rapidly formed, consisting of oxychloride of zinc, with the earthy ingredients mechanically mixed. These latter serve to impart greater hardness to the filling.

For the purpose of sealing up cavities in the teeth for a few hours or days, nothing answers better than a pellet of cotton wool saturated with a solution of gum mastic in spirit, or of gutta-percha in chloroform. After the insertion of the pellet the fluid evaporates, leaving a tough mass impervious to moisture.

Instruments used in filling teeth.—A pair of plugging tweezers, a set of 18 pluggers on Dr. Butler's pattern (fig. 46), and a mallet, will be found sufficient in filling the vast majority of cavities with gold. The tweezers (fig. 47) are for the purpose of carrying portions of gold into the cavity and fixing them there prior to consolidation. Of the pluggers seven or eight will have serrated wedge-shaped points, of various sizes, and bent at different angles convenient for reaching cavities wherever situated. These are used for carrying gold into position and in packing or welding it there. Six foot-pluggers of different patterns will be included in the set. These serve to consolidate the component parts of the plug. In addition there will be four or five instruments with working extremities flat faced and serrated, and so bent or twisted on the shaft as to reach cavities to which straight foot-pluggers could not be applied.

Lastly, there will be provided a burnisher, having a rounded highly polished steel point. The mallet especially useful with adhesive gold foil, supplements pressure of the hand in consolidating the filling and in uniting its component portions. The same set of

FIG. 46.

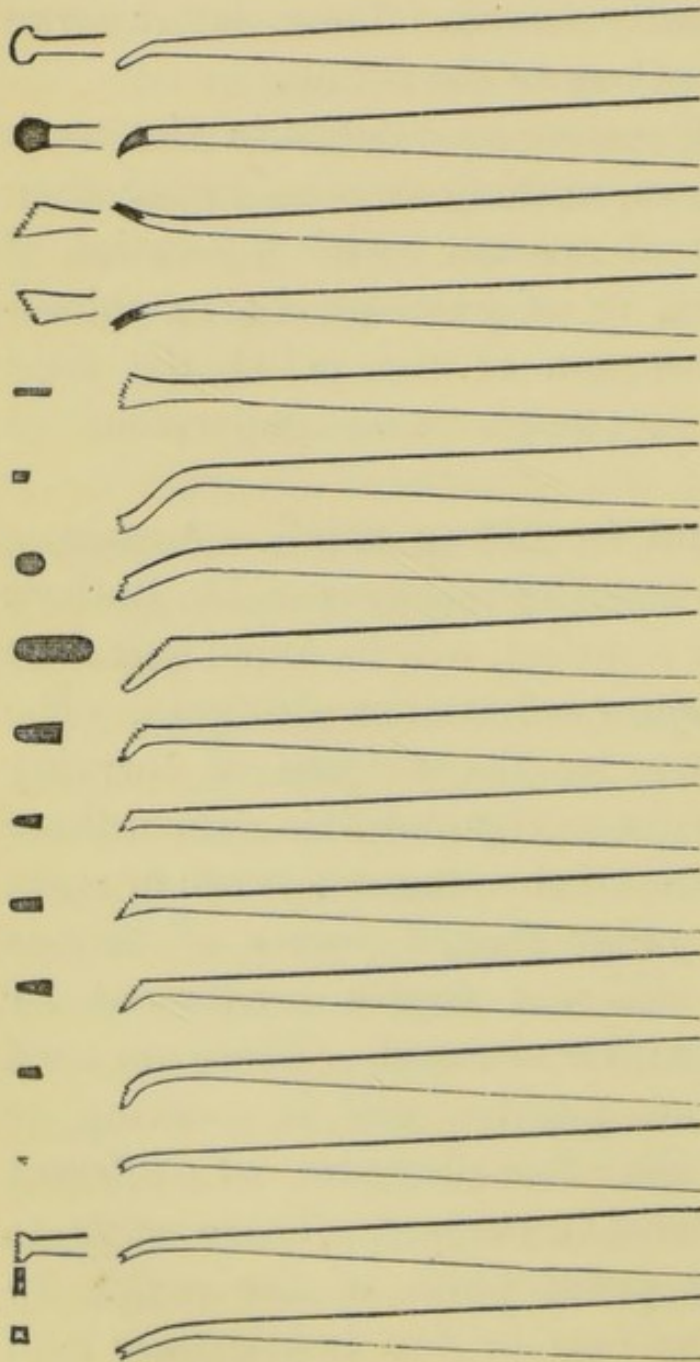


FIG. 47.



instruments serve in filling with tinfoil. A set of instruments (six or eight) with smooth round steel

points are most suitable for packing amalgams. If the points which are used with these materials be serrated, the rough surface soon becomes clogged with amalgam, which lodges and hardens there, forming a layer, which softened again by the mercury, is apt to mingle with an amalgam of another kind on a subsequent occasion.

A set of small spatulas are required for the insertion of oxychloride of zinc cement, and the blades of these may be advantageously made of silver or platinum, steel being rapidly oxidized and destroyed by these fillings. A similar set with smooth steel blades will suffice in packing gutta-percha, or inserting temporary plugs of cotton wool and cement.

Filling with gold.—It has been already stated that two varieties of gold—non-adhesive and adhesive—are used in filling teeth, and that their difference consists in the fact that fragments of the former kind do not cohere when pressed together, whereas separate portions of the latter may be welded and united into a solid mass. Plugs of non-adhesive gold must be formed always by the wedging together of folds or layers of foil; whilst on the other hand, in fillings composed of adhesive gold, the mode of arrangement of the successive portions is of little importance, provided they be made to unite with each other. Although portions of non-adhesive foil do not actually coalesce under pressure, they become sufficiently dense to take a high polish, to resist mastication perfectly, and to constitute a stopping absolutely impermeable to moisture. Indeed it is much easier to make a water-tight plug of non-adhesive than of adhesive gold. An adhesive gold plug can be perfectly built up only when it is composed of small pieces slowly and thoroughly

welded together. If an attempt be made to consolidate a mass of adhesive foil it condenses on the surface beneath the instrument and no amount of force which can be safely applied to a tooth is sufficient afterwards to affect the deeper portions which therefore remain imperfectly united and porous. The presence even of a trace of moisture, such as is liable to be deposited on the surface of the gold from the breath of the patient during the operation also prevents perfect welding from being accomplished. Either variety of gold, adhesive or non-adhesive foil or sponge, can be used exclusively in almost any cavity, but the properties of non-adhesive foil make it most useful in simple cavities—*i.e.*, those of the form of a hole or trench with vertical or nearly vertical walls—whilst the peculiar qualities of adhesive gold render it invaluable in irregular, difficult cavities, and where a plug has to be built up from a limited foundation. It is in many cases good practice to combine two kinds of foil, commencing with non-adhesive and using adhesive to build up the plug, or to key together securely the separate portions.

If the cavity be small in size and simple in form, the following method may be adopted. A sufficient quantity of non-adhesive foil—four to six grain sheets—is folded lengthwise by means of a spatula into narrow ribbons, each containing a third or a quarter of a sheet. These ribbons are next cut into short strips, which may be conveniently spread upon a wooden tray covered with smooth woollen cloth. The point of a wedge-shaped plugger is next pressed upon a few of the strips one after the other, which are thus fixed lightly to the instrument. The gold is thus carried into the tooth and lodged, so that one

extremity of the folds rests on the floor of the cavity and the other protrudes from the orifice. Portion after portion of gold is inserted in the same way, and forced against the walls of the cavity, until it becomes difficult to make the instrument enter. A smaller point is then used, and this is forced into the centre of the filling, the hole so formed being again filled with strips. The surface of the filling is next compressed by a broad, followed by a small, pointed instrument. Finally it is filed smooth, and then polished by means of slate stone and water followed by a burnisher. The surface of gold fillings should be left convex in shape, and slightly above the level of the surrounding tooth, unless the projection interfere with the bite. They should not overlap the margin of the cavity.

This procedure may be varied by the use of adhesive gold towards the end of the operation to fill the holes made by the perforating instrument. Again the entire cavity can be filled with adhesive gold. A loosely folded ball or pellet is packed on the floor of the cavity, and consolidated, and to this piece after piece is added, each being thoroughly welded or kneaded to the mass by means of small pointed serrated instruments. Adhesive gold in the form of foil may be prepared for use in strips similar to those of non-adhesive foil, just described, and like them may be carried into position on the point of a plugger; or portions of the foil or fragments of sponge may be torn from the leaf and fixed by the plugging tweezers, and afterwards condensed by other instruments.

Large cavities of simple form may be most rapidly and effectually plugged with cylinders or rolls of non-adhesive foil. The cylinders are to be obtained of the foil makers, or they may be prepared by the

operator. They are formed by winding a ribbon of foil round the point of a thin broach. They should be of such a size that several are required to fill the cavity, and of such a depth that when inserted endwise they project slightly from the orifice. Those used to commence the plug should be loosely rolled so as to be soft and malleable, but those for the latter part of the operation may advantageously be rolled more solidly or compressed slightly before insertion. In commencing the filling one of the cylinders is carried by the plugging forceps into the cavity and gradually condensed against one of the walls by a foot-plugger. Another and another are then introduced in the same way until the cavity is full. A wedge-shaped instrument is then forced between the two last inserted cylinders, and the hole so made is filled with strips either of non-adhesive or adhesive foil. The rest of the surface may be next tested by a sharp pointed plugger, and at any point at which it can be made to enter gold is added. The surface of the plug is finally filed down and polished.

In cases in which adhesive gold is to compose the whole or the greater bulk of the filling, the first and most important step consists in fixing portions of gold securely in the cavity. Upon these portions fragments of foil or sponge are successively welded until the cavity is filled with a solid plug. In many instances the shape of the cavity after excavation allows of the secure formation of the foundation of the filling, or affords suitable positions for the packing of retaining points without further preparation, and the filling is commenced with strips, pellets, or cylinders. In some cases small pits, or retaining points of the kind already described must be cut, into which the gold

being packed, the completed filling becomes dove-tailed immovably in position.

The operation of filling with cylinders is illustrated in figs. 48, 49, 50. In the first of these the com-

FIG. 48.

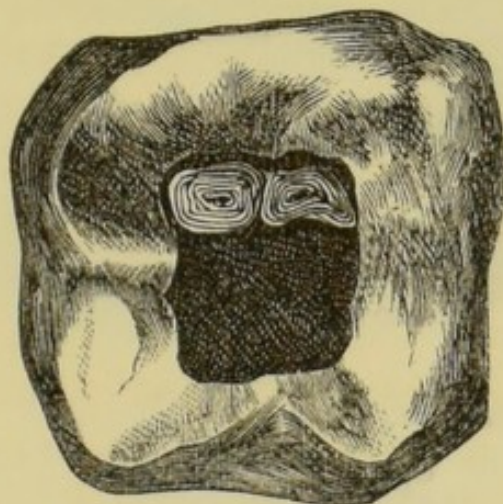
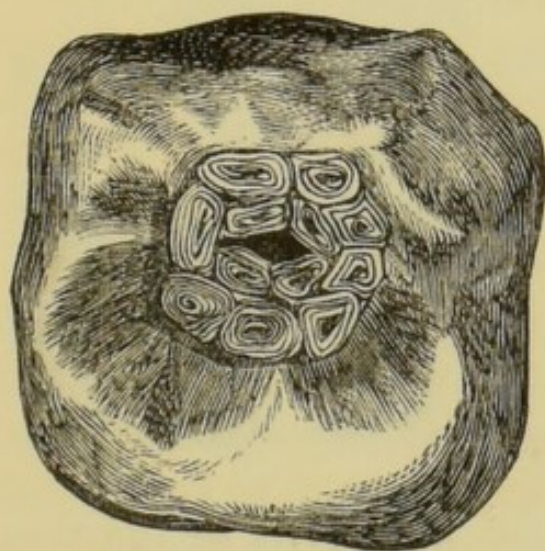


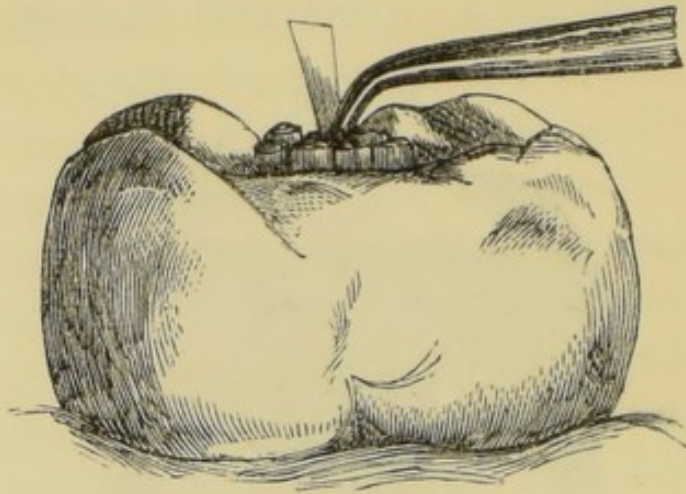
FIG. 49.



mencement of the filling is seen, two soft cylinders having been placed in position by the plugging forceps ready for consolidation, by the foot-plugger, against the wall of the cavity. The next diagram (fig. 49) shows a later stage of the operation. The filling now approaches completion, the masses of gold

are condensed, and a small central space alone remains to be plugged with strips of non-adhesive or

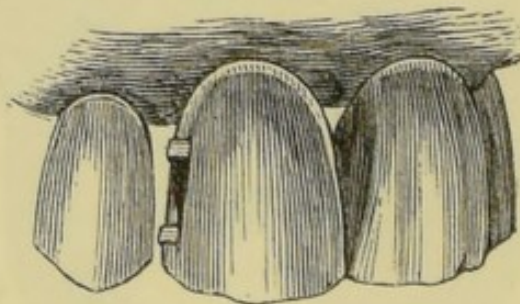
FIG. 50.



fragments of adhesive foil. Fig. 50 exhibits this latter process in operation, and it also shows the proportionate extent to which a plug should project from the cavity before the surface is finally consolidated, filed smooth, and polished.

Fig. 51 shows a mode of beginning a filling with

FIG. 51.

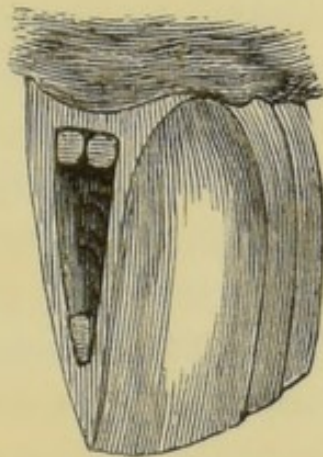


non-adhesive foil in a cavity of the trench-like form already described, and illustrated in figs. 42 and 43. The filling is commenced by fixing a mass of gold in the upper and lower extremity of the cavity. These masses may be composed of strips or small cylinders, and are made to project slightly from the mouth of the cavity. The filling is completed by packing between these buttresses successive portions of foil in

strips in the manner described in speaking of small simple cavities. If adhesive foil be used, either partly or entirely, the filling may be commenced in the same way, or a loosely rolled pellet may be packed on to the floor of the cavity, and the plug completed by welding to the first securely fixed masses, portion after portion of foil in the form of strips, pieces of loosely rolled ropes of foil, or fragments of sponge or crystal gold.

Fig. 52 shows the commencement of a filling in the cavity already illustrated in fig. 45, three portions of

FIG. 52.



gold being fixed in the retaining points there displayed. Each of these pits or points has been separately dealt with as a simple cavity, and packed with strips, each mass of gold projecting beyond the orifice of the main cavity. This part of the operation being accomplished, the construction of a plug on one of the methods already described presents no difficulty. The same principles are applied to the filling of more complicated cavities in which retaining points are necessary, or in cases in which a plug has to be built up from a limited foundation. The first thing to be done is to form the points of support,

anchorage, or foundation, care being taken that the masses of gold extend into the main cavity or project beyond its orifice when a filling on the wedging system is to be inserted.

In the construction of adhesive and non-adhesive gold fillings the consolidation and the welding of the metal is much facilitated by the aid of the mallet, an instrument which has come into general use in late years. A quick succession of sharp blows, carefully regulated, and given by a mallet of proper weight, does not inflict more pain upon the patient than the pressure of the hand alone, whilst the effect is to weld and condense the foil more rapidly and thoroughly. The heads of the hand mallets which are manufactured for this purpose are made of lead or some such soft metal, and weigh about 2 ozs. In order to facilitate the use of the mallet, and to leave one hand of the operator free, automatic instruments are now constructed to which a series of plugging points of various sizes and shapes can be adjusted as required.

Filling with tinfoil.—This material is manipulated and packed in precisely the same way as non-adhesive gold foil.

Filling with amalgams.—Many of the remarks which have been made with regard to gold apply equally to amalgams. It has been already remarked in a previous page that the durability of these materials as fillings depends very much upon the mode in which they are manipulated. They should never be inserted in a mass, but should be thoroughly packed piece after piece, and retaining pits should be freely used on shallow sloping surfaces. It is important in packing to obtain absolute contact of the amalgam with the walls of the cavity, and to prevent a layer of mercury

(which is often squeezed from the mass) from remaining around the forming plug. These objects are best achieved by rendering the cavity absolutely free from moisture, using the pluggers with a rubbing movement, and adding portions of the dryer amalgam to absorb the mercury as it oozes towards the centre of the cavity.

It is of the utmost importance after the amalgam has hardened to file it level with the margin of the cavity, and to polish it. If this precaution be neglected the overlapping portions of the filling in time break away, and leave a rough surface around, which favours the adhesion of decomposing particles, and soon becomes the seat of carious action. This precaution is even more important when *oxychloride of zinc* is employed as a filling. This material is used as a mortar or cement. It attaches itself with great tenacity to any surface which is perfectly free from moisture; it is the only filling which can be securely fixed by mere adhesion to the walls of the cavity; it forms a perfectly water-tight stopping; it is a non-conductor of heat, and were it not for its perishable nature it would perhaps constitute a more perfect substitute for the lost dental tissues than any other substance at present available.

In plugging with gutta-percha, pellets are softened on a metal tray over the flame of a spirit lamp, and packed into the cavity by means of heated instruments, great care being taken, while making the mass sufficiently soft, not to injure its texture by overheating or burning it.

EXPOSURE OF THE PULP. DISEASES OF THE PULP.

Exposure of the pulp.—In the last section the treatment of caries uncomplicated with exposure of the pulp was discussed, and the precautions were described which ought to be taken to prevent the laying open of the central cavity of the tooth during the excavation of carious tissue. This event is, however, sometimes unavoidable, owing to the complete disorganization of the dentine. Its occurrence will be known by the characteristic sharp pang which it inflicts, whilst on examination the exposed surface—from which, if wounded, slight bleeding takes place—is visible. If in such a case the pulp be free from disease the operation of “capping” the pulp, followed by filling, should be performed. The healthiness of the pulp may be inferred from the history of the case, and the absence of the signs and symptoms of irritation and inflammation to be presently mentioned.

The object of capping an exposed pulp is to provide a covering which shall protect the sensitive structure from pressure and from changes of temperature. Various materials, such as gold, platinum, quill, parchment paper, gold-beater's skin, or thin sheet cork, are used for the purpose by different operators, and any one of them answers well. When the exposure is but slight some are content with laying a few folds of gold foil over the surface. The hæmorrhage having ceased, the

cavity should be freely washed out by means of a syringe with warm water containing a small quantity of carbolic acid (1 in 40), and should then be dried. In this latter part of the operation in these cases alcohol must not be used. Next a piece of the chosen material having been cut of suitable shape and size, is carefully fixed by the plugging tweezers over the opening into the pulp cavity, resting upon the margin of the opening and closely in contact with, whilst at the same time not pressing upon, the subjacent pulp. The cap being thus arranged, the filling of the tooth may be proceeded with. The success of the operation no doubt depends on the preservation of the pulp in a perfectly aseptic condition, and in the arrangement of a cap which while protecting shall not press upon the pulp. The cap and everything which is brought into contact with the pulp ought, therefore, to be rendered aseptic by dipping in eucalyptus oil or solution of carbolic acid (1 in 40); and the cavity should be repeatedly syringed with the same solution. Seeing that even in the best managed cases irritation, or even inflammation, of the pulp sometimes follows this operation, and that the danger of this mishap is increased after insertion of a metal plug, which requires great pressure in packing, besides being a rapid conductor of heat, it appears desirable after capping to employ temporarily materials, such as gutta-percha or one of the cements now to be had, which do not contain chloride of zinc; this substance having a very irritating effect upon the pulp. These fillings are non-conductors, are inserted without pressure, and are readily to be removed on the occurrence of untoward symptoms. The author prefers such plastic cements, particularly in cavities on masticating sur-

faces. In these situations the filling may be trusted to endure at least for a few months; and within that time, if all go well, it may be excavated, with the exception of a protective layer over the depths of the cavity, and may be replaced by a more lasting material. In many cases the cap may be composed of thin sheet cork, which is to be obtained for the purpose, or of parchment. A piece of suitable size and shape being prepared, is rendered aseptic by soaking in carbolic acid, or better, in eucalyptus oil, and carefully placed in position over the exposed surface. A filling of plastic cement is then inserted. Later, this can be cut away; a protective layer being alone left, and, as just described, a more durable material substituted to form the external portion of the filling.

Diseases of the Pulp. Irritation.—It has been seen that the dentine is intimately connected with the pulp by means of the fibrils which permeate it and endow it with vitality and sensibility. This connection renders intelligible the facts, firstly, that influences may be communicated through the dentine to the pulp in consequence of disease or injury affecting that tissue; and secondly, that the condition termed irritation of the pulp occasionally is produced during the progress either of caries or of abrasion of the tooth long before the central chamber has been nearly approached or opened. When the pulp is insufficiently protected only by a thin layer of dentine it is of course liable to be acted upon directly by external agencies; and it is possible for bacteria or other septic agents to find a way to the pulp, through a slight covering of partly disorganized dentine. Irritation of the pulp is manifested by one symptom alone—namely, more or less dull aching pain, asso-

ciated sometimes with a feeling of tenderness in the tooth, and increased sensibility to changes of temperature, and it is not always easy to distinguish between this pain and the aching arising solely from exposed dentine. Sympathetic toothache, or that occurring in a sound tooth in the neighbourhood of others the seat of advanced caries, has been ascribed to irritation of the pulp, but the pain in most of such instances is more probably neuralgic.

Irritation of the pulp is pathologically nothing more than slight hyperæmia involving consequent pressure upon the nerve fibrils, and the condition may change to more pronounced inflammatory action, especially in cases of caries, in which the dentine displays exalted sensibility, and in which metallic fillings, rapid conductors of changes of temperature, have been inserted without previous treatment. If a pulp could be examined during an attack of irritation it would be found the seat of increased vascularity, disappearing with the cessation of the attack. Pulps which have been subject to long-continued irritation almost always become more or less calcified. The newly-formed tissue is identical in structure with that already described as secondary dentine, and like it may be developed either in a layer organically united with the pre-existing tissue, or in isolated nodules scattered throughout the substance of the pulp. When a layer of secondary dentine becomes developed over the surface of the pulp it protects the latter structure, and where waste of the hard tissues is in progress owing to attrition or to caries, it prevents the exposure of the pulp, which would be otherwise in the end surely brought about. Secondary dentine of this kind is often displayed in

teeth which have been gradually ground down to the level of the central chamber by mastication.

The treatment of irritation of the pulp varies somewhat in different cases, but the indications always are to remove the cause by protecting the exposed tissues from irritating influences, and to diminish the sensibility of the dentine. Where the dentine has been laid bare, owing to fracture of the tooth or to attrition, and must remain ever after exposed, its sensibility may be often destroyed at once by solid chloride of zinc. The same effect may be more slowly produced by frequent friction of the surface with spirits of wine, or better, by the occasional application of absolute alcohol, and with this treatment may be advantageously combined the use of tooth powders containing astringents such as tannin, with alkalies like carbonate of soda.

When irritation of the pulp exists in connection with caries, the permanent filling of the cavity is in the great majority of cases sufficient to effect a cure. Caution must, however, be exercised where abnormal sensibility of the dentine exists, and it must be remembered that in some few individuals the insertion of a filling even in a cavity of slight depth in the dentine is enough to excite acute inflammation of the pulp. This danger is necessarily increased with the extent of the decay, and where the pulp is nearly approached, it is well to shield it by a layer of oxide of zinc cement, in the manner which has been already described. The sealing up of a cavity for a few months with a non-conducting filling material is often alone sufficient both to abate sensibility of the dentine and to cure irritation of the pulp.

Inflammation.—This is the commonest affection of the dental pulp. Its most frequent cause by far is

caries which, having laid open the central chamber of the tooth, has exposed the sensitive structure within to the action of the atmosphere and external irritants. It may arise (as was mentioned in the preceding section) from irritation communicated through the dentine when that tissue has been penetrated to a greater or less extent. In rare cases it originates as an extension of inflammation which, having commenced in the periosteum, has involved the dental vessels and nerves in their passage to the pulp cavity through the foramina of the root. A blow on a sound tooth, loosening it or partly dislocating it, will occasionally be followed, sooner or later, after lapse of time, by acute inflammation of the pulp.

Inflammation of the pulp assumes either an acute or chronic form, and it gives rise to pathological changes in the tissues essentially similar to those occurring in other like structures of the body, the pulp's very cellular structure rendering it peculiarly liable to exhibit inflammatory changes rapidly and violently. Suppuration, ulceration, gangrene, or outgrowth of new tissue, or degeneration may result.

Pain is the most prominent symptom of *acute inflammation* of the pulp. It varies in amount according to the extent and intensity of the inflammatory action, is more severe in some individuals than in others—in the young than in the old—and in all is increased by some derangements of the general health, of which pregnancy affords the most remarkable example. At the commencement of an attack it is dull and aching, confined to the affected tooth, soon assuming a more intense lancinating or throbbing character, and finally becoming almost intolerable, it appears to spread to the adjoining teeth and to the

whole side of the head and face. The pain of this form of toothache is more severe than arises in any other dental disease, and its severity is accounted for by the fact that the pulp, a highly vascular and nervous substance, is confined within the rigid walls of a chamber where swelling is impossible, and whence the inflammatory exudations cannot freely escape.

The diagnosis of acute inflammation rarely presents any difficulty. The character of the pain can hardly be mistaken, whilst in the vast majority of cases there exists a carious cavity in which after excavation of the softened dentine the pulp is exposed and visible. Where the opening is extensive the surface of the pulp may be seen red and injected with blood or dotted with suppurating points, and it bleeds readily and freely if touched. From dental periostitis it may be distinguished by the fact that in that disease the earliest symptom is tenderness upon pressure, and slight elevation of the tooth in the socket, whilst, where the pulp is alone inflamed, it is not until a later stage of the affection—when in fact the inflammation has extended to the periosteum—that these symptoms are displayed. When the intimate connection of the vessels entering the pulp with those of the periosteum is considered, it will be obvious that some periostitis must often accompany inflammation of the pulp; and care must be taken in diagnosis not to mistake the case for one of periostitis alone.

The tendency of acute inflammation of the pulp, which runs on unchecked, is to terminate in gangrene or sphacelus, but this termination is of most frequent occurrence when the pulp cavity is but slightly

opened, or where the pulp is altogether confined beneath a layer of dentine, or beneath a filling. Under such circumstances, there being no room for swelling, and little or no escape for the inflammatory exudations, such constriction is produced as causes death of the whole mass. Death of the pulp may be recognized by the cessation of the pain, the insensibility of the dentine during excavation, whilst on examination the pulp is found devoid of sensation, softened and discoloured, and emitting a characteristic fetid odour. The entire tooth at the same time assumes a darker tint, and occasionally becomes stained to various hues in consequence of the diffusion of the colouring matter of the blood of the pulp through the dentine.

An attack of acute inflammation when the pulp is freely exposed rarely produces gangrene of the entire structure. The inflammation is sometimes limited to the exposed surface alone. In many cases swelling having taken place, and the exudation having found vent, the attack slowly subsides and assumes a chronic form, to be renewed again and again from time to time under the influence of increased irritation.

If a pulp, the seat of acute inflammation, be examined recently after the extraction of a tooth the affected portion will be found deeply red in colour, the vessels being visibly injected, and small patches of extravasated blood will be observed upon the surface. Where swelling has been possible a red œdematous mass, studded with suppurating patches, is found projecting into the carious cavity through the opening into the pulp chamber. Some amount of suppuration is almost always present, but it is generally confined to the exposed surface, and abscess in the substance

of the pulp is rarely formed. The general characteristics of a pulp in which gangrene has supervened have been already mentioned. Close examination shows that the tissues in this condition are reduced to a semi-fluid mass of a dirty reddish-grey or yellow colour, with a marked gangrenous odour. In this mass portions of the disintegrated walls of the blood-vessels, with numerous fat cells interspersed, and disorganized nerve fibrils, may be traced by the microscope.

The treatment of acute inflammation of the pulp must be modified in accordance with the circumstances of the case and the phase which the process has assumed. In some instances the extraction of the tooth is called for; in others the reduction of the inflammation and the conservation of the complete vitality of the tooth may be reasonably aimed at; whilst in a third group the extirpation of the pulp is the sole resource.

The extraction of the tooth is most frequently required in childhood. At this period an attack of acute inflammation usually runs a rapid course, the pain becomes excruciating, the inflammation quickly spreads to the periosteum, and the tooth becomes so exquisitely sensitive to the touch that manipulation of any kind is unbearable. The rapid spread of the inflammation in these cases is accounted for by the yet incomplete condition of the roots, the apices of which are represented by a portion of uncalcified pulp, freely communicating with the alveolar tissues. This condition renders inadmissible any attempt at the destruction of the pulp by means of escharotics in the manner presently to be described, whilst the advantages previously referred to, which in many

cases accrue from the extraction of the first permanent molars (the teeth by far the most frequently the seat of caries in children), render their preservation inexpedient. In the temporary teeth, the roots of which are undergoing absorption, the course of acute inflammation of the pulp closely resembles that which takes place in the permanent teeth at the same age. The treatment of the affection, except by the extraction of the tooth, is in most cases unsatisfactory.

In the case of children, as in every other case of acute inflammation of the pulp in its earlier stages, the attack may be often cut short by removing the cause. With this view the cavity should be excavated, and in doing this with proper care it is possible to avoid wounding the pulp and inflicting (besides the injury) severe suffering upon the patient. Foreign particles pressing upon the pulp may be dislodged by the excavator, aided by the syringe and warm water, the free use of which should be continued to encourage bleeding from the exposed surface, should it occur. The cavity may be then lightly filled with a temporary plug of cotton wool saturated with mastic solution, over a pellet of wool moistened with carbolic acid, and external irritation being thus guarded against, the inflammation will often subside. The temporary filling may be renewed at intervals of a few days. When all symptoms have disappeared the operation of capping the now healthy pulp and filling the tooth may be proceeded with. The cases favourable for this treatment are those in which the periosteum is unaffected, and in which the pulp fully retains its vitality, not having been partly destroyed by gangrene or ulceration, resulting from former attacks of inflammation.

In acute inflammation of pulp following upon insertion of a permanent filling, as sometimes happens after capping, or when the pulp has been protected but by a thin layer of dentine, the tooth often passes in a few hours into a condition of such exquisite tenderness as to make the removal of the filling unbearable. In such cases it is good practice to drill a small hole through the tooth or stopping into the pulp cavity. This gives vent to the inflammatory effusions and relieves the pain. The filling being removed later the pulp can be dealt with as circumstances direct. This operation is also called for in those cases mentioned above, in which acute inflammation of the pulp occurs after injury in teeth in which no cavity exists. In these cases, there being absolutely no vent for inflammatory exudation, the pulp will often, after a short course of the disease, be found sphacelated on opening the tooth.

In cases in which preservation of the pulp is contraindicated the treatment consists in destroying its vitality by means of arsenious acid, in extirpating it, and afterwards permanently filling the chamber and root canals, as well as the external cavity of decay. A very minute quantity—less than $\frac{1}{20}$ th of a grain of the escharotic—is sufficient to destroy the vitality of the pulp of the largest molar. The mode of applying it is as follows. The cavity having been excavated and dried, the arsenic is carried to the exposed surface of the pulp by means of a few filaments of cotton wool saturated with carbolic acid, and is then at once sealed in by a wool and mastic or gutta-percha filling. It is important to apply sufficient arsenic to devitalize the pulp, and not merely to set up inflammation, and no harm need be feared if the dose be thoroughly

sealed within the tooth. If too small a quantity be applied, and the effect limited to promotion of inflammation, this, in some cases, extending to the periosteum, leads to suppuration and loss of the tooth. Continued pain would indicate that the arsenic was not effectual, and a renewed careful application ought then to be made. The addition of a small quantity of morphia to the escharotic appears to prevent increase of the pain from this application. The pain is, however, rarely severe, and often altogether absent. The action of the arsenic being rapid, the treatment often, indeed, serves to arrest almost instantly the suffering arising from an aggravated attack of inflammation of the pulp. There are some disadvantages attending the use of wool with mastic solution or gutta-percha as a covering for the escharotic. It is sometimes difficult to avoid pressure upon the exposed pulp, an accident which is attended with great pain, whilst the liquid constituents tend to wash away the pulp-destroying dose. These disadvantages are overcome by the use of bees'-wax as a temporary filling. A small piece of wax is carried by the tweezers to the cavity, and by means of a small heated spatula is melted over the orifice, so as to effectually exclude the saliva for a few hours. The spatula should have a wooden handle and a short metal blade, so as to avoid burning the patient's lips. The effects of arsenic upon the pulp are stated by Dr. Arkövy (1) to be as follows:—It first produces hyperæmia followed by thrombosis; it is then taken up by the vessels, producing granular degeneration of their contents, and finally shrinkage and collapse of the vessel walls. The connective tissue and odontoblasts are unaltered, the other cells swell to three or four

times their natural size. The axis cylinders of the nerves undergo granular degeneration. Arsenic has practically no effect upon dentine.

The temporary filling may be removed in about twenty-four hours, when it will be usually found that the pulp has lost its vitality, and that no pain results from probing the canal. It happens, however, occasionally that in consequence of the smallness of the opening into the pulp cavity, or of the presence of nodules of secondary dentine preventing the free access of the escharotic, the deeper portion of the pulp will be found to retain its vitality. In these cases the opening into the chamber can be enlarged, and a second effectual application of arsenic can be made.

The devitalization of the pulp of single rooted teeth—incisors and canines—can be effected instantaneously by means of instruments alone, and the pain of this operation, especially where the pulp has been previously destroyed to some extent by disease, is not so severe as might be supposed. The operation is performed by thrusting rapidly a thin flexible broach to the apex of the canal, and rotating it, so as to sever at once the vascular and nervous connections of the pulp.

The next step consists in removing the dead pulp. This is, as a rule, accomplished with little difficulty by means of the barbed pulp extractors especially made for the purpose. One of these instruments passed into the canal and manipulated entangles the pulp and brings it away on withdrawal. The operation is much facilitated by the free cutting away of the crown of the tooth where necessary, to render visible—or at least to render accessible—the orifices of the canals, whilst if difficulty arise in consequence

of smallness of the canals or the presence of nodules of secondary dentine, they must be overcome by the use of fine flexible broaches. Some slight hæmorrhage from the canal usually follows the extraction of the pulp. When this has ceased the filling of the canals may be proceeded with. Gold may be employed for this purpose, but the author has no hesitation in affirming that other materials available are much to be preferred. Among these oxychloride of zinc is one of the best. In using it it is rarely necessary to enlarge the pulp cavity, as it can be made to flow into any canal into which a fine flexible wire will pass. The canals, after cleansing by the syringe and warm water, should be dried, and absolute alcohol is valuable in this part of the process. Shreds of cotton wool soaked in the fluid should be passed into each root and allowed to remain for a few moments. By this means not only are the canals more thoroughly dried than is possible by any other means, but any minute particle of soft tissue which has escaped the nerve extracting instruments is shrivelled by the spirit and left in a condition in which, after insertion of the filling, decomposition is impossible. The oxychloride cement is next mixed to the consistency of cream. A few filaments of cotton wool saturated with the fluid are then taken on the point of a wire or root-plugger of suitable size, and passed to the apex of the canal, portion after portion being afterwards carried in in the same way until the root is filled. The wool is used to facilitate the insertion of the cement, as it is often difficult to force the fluid alone into the depths of the canals. This, however, may be sometimes accomplished by carrying a portion of the liquid cement to the orifice of

the root, and then with a pumping action, by means of a wire, having a few threads of wool fixed at its extremity, causing it to flow into the canal. After the cement has hardened the external cavity may be filled with a more durable material. The advantages of oxychloride of zinc over other substances used in fang filling are the following. It is antiseptic in its properties; it forms a perfectly water-tight filling; it is a non-conductor of heat; it can be applied, as a rule, without enlarging the canals and without other manipulation likely to set up irritation; and lastly, it can be easily removed by a drill and excavator, should it be necessary. The objection to the filling owing to its perishable nature, which holds good in ordinary situations, does not apply in root filling where the material remains buried deeply beneath a plug and protected from the action of decomposing agencies. Wool soaked in eucalyptus oil, or a paste made of eucalyptus oil and iodoform, will remain perfectly unaltered in a fang, and will prevent any further changes taking place, provided the stopping sealing it in be perfect. Shreds of wool so prepared can be passed without difficulty into the canals, and the orifices of the canals in the pulp chamber being enlarged for some little depth, each can be sealed with a pellet of Jacob's gutta-percha, and the filling completed with any suitable material. This treatment seems even less likely to give rise to an untoward result than that with the oxychloride cement; in use of which there is a danger of setting up periodontitis, if oxychloride by accident be forced through the foramen of a root in pumping in the liquid stopping. Mr. A. Underwood and the author have extensively adopted the wool filling plan, with good results.

Filling fangs with gold is a more laborious operation and presents no advantages over that just described. It is often necessary to open up the canals to a considerable extent before plugging instruments to carry in the gold can be made to enter. Gold is, moreover, a rapid conductor of heat; it is extremely difficult to remove when once packed, and in the author's experience its use in fang filling is often followed by periostitis, a result which very rarely follows the employment of the other materials.

Chronic inflammation of the pulp arises from the same causes which originate acute inflammation, by far the most common being the exposure of the pulp by caries. It often remains as a sequel to an acute attack, and again assumes a more active character from time to time under the influence of increased irritation.

The pain, usually of a dull aching or gnawing kind, is less severe than in acute inflammation, it may be almost altogether absent if there be a free vent for the discharges, or may be manifested at a distance in the form of neuralgia. The exposed surface is red, swollen, and pours out a thin puriform or serous secretion, having a characteristic phosphatic odour. On examination, the redness due to injection is found to be confined to the superficial portion alone of the pulp. This condition may resolve itself into a process of ulceration under which the pulp gradually disappears; in other cases degeneration and atrophy ensue, and effect complete destruction of the pulp, often without the occurrence of any pain.

In a certain number of instances chronic inflammation gives rise to the development of new tissue in the form of polypus of the pulp. This occurs mostly in

young subjects, in teeth the crowns of which are extensively excavated by caries and with the pulp fully exposed. The new growth consists of a rounded fleshy mass, red or bluish-red in colour, occupying or projecting from the cavity of decay, and may attain a size between that of a small pea and a Spanish nut. It is usually covered with an offensive muco-purulent secretion. It bleeds readily if wounded, but displays but little sensibility. Examination shows that polypus is united with the pulp, from which it springs, and that it consists of a mass of rounded and spindle-shaped cells, supported by a small quantity of fibrous tissue, and provided with numerous comparatively large blood-vessels.

Treatment.—In cases of uncomplicated chronic inflammation of the pulp in which there is neither an outgrowth of new tissue (polypus), nor loss of substance from ulceration or gangrene, nor periostitis of marked extent, an attempt may be made to bring the structure into a healthy condition. With this object the cavity having been excavated and cleansed, a dressing of carbolic acid on cotton wool may be lightly applied to the pulp, covered by a temporary filling. Later this may be followed by similar treatment with eucalyptus oil, the dressing being renewed at intervals of a day or two until all symptoms of inflammation have subsided. The operation of capping the pulp and filling the carious cavity must then be carried out in the manner already described.

In cases in which there has occurred an outgrowth of new tissue sufficient to constitute a polypus, the extraction of the tooth is the sole treatment that can be recommended.

The treatment of a pulp partly destroyed by

ulceration must be directed to the destruction of the remainder by arsenious acid, extirpation of the mass, and the subsequent filling of the fangs and cavity by the method already explained. It will sometimes happen (as before stated) that after repeated attacks of acute or long-continued chronic inflammation the pulp is entirely destroyed, and on examination the canals are found to contain merely a semi-fluid mass of decomposing tissues. The treatment in these cases consists in thoroughly clearing out the canals, and in disinfecting them by the application of some antiseptic agent, eucalyptus oil being the most powerful and least injurious. A thin paste of iodoform with eucalyptus oil on wool is preferred by the author; and, while renewing dressings and temporary fillings, it is well to exclude saliva by the rubber-dam. It is in most of such cases well to dress the canals at intervals during a week or more (keeping in a temporary filling), until all danger of periostitis, which sometimes supervenes, has passed away. This is a precaution which may well be adopted before fang filling, in all cases in which the occurrence of unfavourable symptoms appear probable. The fangs can subsequently be filled in the usual way. Throughout the treatment of every case of exposed, diseased, or dead pulp, antiseptic precautions must be adopted. Every nerve extractor or other instrument passed ought to be dipped in eucalyptus oil; and the cavity may be freely swabbed with the oil, so as to keep it in an aseptic condition.

DENTAL PERIOSTITIS. ALVEOLAR ABSCESS.
 PERIOSTITIS AND NECROSIS OF THE
 MAXILLÆ. DENTAL EXOSTOSIS AND
 NECROSIS. ABSORPTION OF ALVEOLI.
 CHRONIC SUPPURATIVE WASTING OF
 THE ALVEOLI. ABSORPTION OF ROOTS
 OF PERMANENT TEETH.

Periostitis.—Inflammation of the dental periosteum may be confined to one or two teeth, or may involve many or all the teeth of each jaw. The former variety is that most frequently met with, the commonest cause being the extension of inflammation from the diseased dental pulp. Periostitis also often arises after the filling of a cavity in which portions of suppurating or decomposing pulp have been improperly left, and in which the matter, not finding any escape, penetrates to the depths of the root canals, reaches the periosteum and sets up irritation. It may extend from one tooth, to those adjacent through the periosteum of the jaw, or may spread from the gums, inflammation of which indeed if at all extensive, always in some degree involves the periosteum. Periostitis may result from mechanical injuries of the teeth or alveoli, it may be caused by the continued inhalation of fumes of phosphorus, or may arise from rheumatism, syphilis or scrofula, or from cold, or from the effects of mercury upon the system (when however it is an extension from the gums), or from debility; whilst finally cer-

tain cases of general subacute or chronic periostitis, associated with absorption of the alveoli, frequently present themselves, in which the cause cannot be satisfactorily ascertained. Periostitis due to constitutional causes usually affects several or all of the teeth of one or both jaws.

The symptoms of *acute periostitis* commence with a feeling of uneasiness in the affected tooth, which increases in the course of a few hours into aching pain, accompanied by tenderness of the tooth, especially when pressed into the socket as in mastication. If allowed to continue these symptoms increase in intensity. The pain becomes severe, and the sensibility of the tooth extreme; and the tooth is felt evidently protruded to a small extent from the alveolus, and slightly loosened owing to swelling of the lining membrane of the socket. The neighbouring teeth become tender, the inflammation involves the neighbouring gum and spreads thence to the palate and cheek, which becomes swollen and œdematous—the œdema often extending to the eyelids when an upper front tooth is the centre of the disease. With these symptoms more or less febrile disturbance is associated in accordance with the extent of the inflammation and the condition of the patient's general health. The tongue is foul, the breath tainted, the skin is hot, and there are thirst and headache. At this stage supuration takes place, pus is formed, points and finds its way to the surface, and this is followed at once by diminution of the pain and by slow subsidence of all the symptoms. The acute stage of such an attack, uninfluenced by treatment, usually lasts from six to ten days. Perfect recovery may take place, the inflammation may remain chronic, it may end in partial

or complete necrosis of the tooth, or spreading to the periosteum of the jaw, may cause necrosis of the bone to a greater or less extent.

On the extraction of a tooth the seat of acute periostitis, the periosteum in the early stage of the attack is found thickened, red, and injected; later it presents patches of lymph, and when pus has formed it is not uncommon to find a distinct sac containing matter attached to the extremity of the fang. This arises from suppuration of the internal layer of the periosteum, which becomes detached from the cement, thickened and dilated, and filled with purulent matter.

The treatment of acute periostitis must be governed by the cause of the disease and other circumstances, and although the great majority of cases yield to active treatment, the question of the extraction of the tooth will sometimes arise. Teeth or roots which have been long the seat of previous chronic inflammation, or alveolar abscess, or which are loose owing to absorption of their alveoli, may be often extracted without hesitation on the appearance of an attack of acute periostitis, whilst it is sometimes necessary to sacrifice a tooth to cut short the attack and avert the dangers of suppuration. And it may be here pointed out that if extraction be deemed desirable there need be no hesitation in performing the operation at any stage of the affection. There is a popular error on this subject, which prevails to some extent even among the more intelligent classes. The belief is, that it is both difficult and dangerous to remove a tooth when great swelling and inflammation of the soft parts are present, but there are no grounds whatever for such belief. The tooth is, under these

circumstances, always loose and protruding from the socket, in consequence of the swelling of the periosteum, and there are, therefore, no special difficulties attending its extraction. No harm can possibly arise from the operation, whilst, on the contrary, in cases in which it is called for, much good must follow it, since the tooth constitutes the sole cause of the mischief.

If it be resolved to save the tooth, and the case be seen during the earliest premonitory symptoms, the gums may be painted with a mixture of equal parts of tincture of iodine and tincture of aconite. Local abstraction of blood and the assiduous use of warm fomentations are of the first importance in the next stages of the attack. One or two leeches can be easily applied to the gum over the affected tooth, and fomentation can be practised by the patient washing the mouth with warm water. The carious cavity and the exposed pulp must be dealt with conformably to the circumstances by the methods described in the previous sections.

In most cases the administration of a brisk purge will be found beneficial. In some patients an ordinary saline draught, such as a Seidlitz powder, will suffice; to others, with muddy complexion, foul tongue, and constipation, calomel or blue pill, with colocynth, may be administered, followed by a saline draught if necessary.

So soon as swelling occurs, and even before pus can be detected, free incisions should be made through the gum down to the bone at the position where it appears probable matter may form, whilst at the same time the warm fomentations are persevered with.

Chronic dental periostitis may arise from any of the causes which originate the acute form of the disease. It often remains as a result of an acute attack, whilst periostitis due to constitutional causes is generally chronic, and rarely passes at all beyond a subacute stage. The symptoms comprise in a modified degree those present in acute inflammation. The teeth are tender on pressure, they are the seat of a varying amount of pain, they are more or less loosened and raised from their sockets, owing to the swelling within; and they are surrounded by reddened and swollen gum. On pressing the mucous membrane in some cases either pus or muco-purulent matter oozes from around the necks of the teeth, or escapes through a fistulous opening in the gum. These symptoms may continue for months or years, until becoming completely loose, in consequence of absorption of the alveoli, the teeth are at last lost.

Roots, the seat of chronic inflammation, exhibit various pathological changes. The periosteum is always thickened and more or less injected, and covered with patches of lymph. A complete sac, containing pus similar to those occurring in acute inflammation, is often found attached to the apex. In the same situation there are often found masses of fibrous tissue—hypertrophied root membrane—which are often undergoing ossification at the point of junction with the cement. In other cases partial necrosis exists, and the effects of absorption of the cement and dentine, indicated by a rough excavated surface, are commonly observable.

Treatment.—The question of the extraction of the affected tooth will arise in many instances, and must be decided in accordance with the circumstances of

the case. The condition of the carious cavity (when one exists), the degree of loosening of the tooth owing to absorption of the alveolus, and the presence of symptoms indicating pathological changes in the cement, will determine whether there is a fair prospect of bringing the organ into a useful condition.

The first step in the treatment will consist in removing the cause—when discoverable—of the disease. When the inflammation is associated with disease of the pulp, that structure must be dealt with by appropriate measures. Sources of local irritation, such as tartar deposited upon the necks of the teeth or necrosed roots, must be removed. Local depletion is of considerable service, and the blood may be abstracted by incising deeply with a scalpel the swollen gum occupying the spaces between the teeth. When the gum is separated from the necks of the teeth, and a purulent discharge is poured out, the part should be swabbed frequently with a solution of chloride of zinc—20 grains to an ounce—by means of a small probe and a pellet of cotton wool, passed beneath the free edge of the gum. Lotions of permanganate of potash or carbolic acid may be used to overcome the fetor of the breath. An attempt has lately been made to revive Hunter's old operation of replantation or transplantation. Some practitioners advocate the extraction of teeth subject to chronic periostitis, removal of the diseased portion, including the periosteum and the end of the fang, the insertion of any fillings that may be necessary, and replantation of the tooth, which, it is stated, becomes reunited to the socket. That such cases so treated have run a satisfactory course is attested by unimpeachable authorities. Hunter, and almost every one since Hunter, has had

some successes; but it is equally plain that the chance of success lies in the amount of healthy tissue that is left uninterfered with, and must always be very problematical. Of late, this mode of treatment has been gaining advocates, and, perhaps, deserves consideration; but evidently it ought to be practised only as a last resource, and after failure of ordinary methods of treatment.

In periostitis due to or aggravated by constitutional causes, attention must be directed to the general health—rheumatism, syphilis, debility, and mercurialization, each receiving its appropriate treatment.

Alveolar Abscess.—Certain phases of the suppurative stage of dental periostitis constitute the conditions most commonly spoken of under the designation of alveolar abscess. This class of abscess is seen in its simplest and most familiar form in the ordinary gum-boil, which consists of a collection of pus between the gum and the bone, external to the root of the tooth from which the disease originates. In severer forms of the same affection the cheek having become involved in the inflammation, great swelling having taken place, and suppuration to considerable extent ensuing, the matter, if it do not find a ready exit into the mouth, may point and burst externally. Thus there results a fistulous tract between the diseased tooth and the surface of the cheek, which remains open and discharging as long as the inflammation continues. This termination, although it occasionally supervenes upon suppuration around other teeth, much more commonly follows alveolar abscess connected with the lower molars. Suppuration in alveolar abscess always commences in the socket at the surface of the tooth, but as soon as matter forms absorption of the bone is set

up and the matter escapes into the surrounding tissues. The external alveolar plate being the thinner, is almost invariably alone perforated, and the perforation often takes place with great rapidity, a few hours sufficing for the formation of a hole in the bone of considerable size. In some cases the thin alveolar plate becomes dilated and forms a bony sac around the abscess.

Abscesses connected with diseased teeth are usually traceable without difficulty to their origin. The matter does occasionally, however, burrow through the soft tissue and appear about the palate, cheek, or jaws in situations so unusual that the relation of the discharge to the teeth is not at first sight suspected. In cases of abscess about the mouth or face, the origin of which is not otherwise evident, it is therefore desirable that an examination of the teeth should be made.

When the matter escapes through the cheek the symptoms closely simulate necrosis of the jaw. The orifice of the sinus is surrounded by granulations, which often increase so as to form a papilla-like projecting mass, and from it issues a more or less constant secretion of purulent fluid. Such a case may be distinguished from necrosis of the bone by the following circumstances—firstly, that there is as a rule but one sinus when a tooth alone is implicated, whereas when a sequestrum exists there are several; secondly, dead bone may be detected by the probe; and thirdly, if necrosis have not taken place the symptoms, as a rule, speedily disappear on the extraction of the tooth.

The treatment of alveolar abscess is necessarily associated in many cases with that of dental periost-

titis, which has been already described. In the acute stage free incisions into the swelling within the mouth and warm fomentations are the principal measures called for. Poultices and warm applications to the cheek should be avoided, as they encourage the escape of the matter through the skin. Painting the surface with tincture of iodine may assist in averting this danger. It must be remembered that although most cases either yield to treatment or subside after running a certain course, the progress of the disease may be arrested at once by the extraction of the tooth—an operation which may be performed without hesitation when the tooth is useless owing to chronic disease or extensive decay, or when the abscess threatens to burst externally. This latter event will be known to be imminent when fluctuation close to the surface is recognizable, and when the skin over the pointing abscess looks dusky or livid, and feels thin, and ready to give way. If the escape of pus through the skin appears inevitable, the abscess should not be allowed to burst spontaneously, but should be opened as soon as symptoms of pointing appear, in order to prevent the disfiguring cicatrix which must otherwise result in consequence of destruction of a portion of skin. Abscesses or fistulous tracks, opening externally, must be treated by dressing and syringing with solution of carbolic acid, 1 in 40, or with eucalyptus oil. In cases where no dead bone exists such treatment, with the extraction of the tooth, which in these cases is always called for, rarely fails to bring about a rapid cure.

The treatment of chronic alveolar abscess must be directed first to the tooth and the exposed and inflamed or gangrenous pulp. The abscess having

been then laid open by the bistoury, may be mopped out or syringed daily with a solution of carbolic acid, 20 grains to the ounce, or chloride of zinc, 20 grains to the ounce; or better still, perhaps, eucalyptus oil, which is as antiseptic as carbolic acid, when diluted with five or six times its bulk of olive oil. The abscess may be swabbed out with this mixture, which may also be passed up the root canals and pumped through, so as to enter the abscess, and escape externally; thus ensuring antiseptic treatment of the whole suppurative track.

These measures will in most cases suffice to effect a complete cure. In some instances, however, in which necrosis of the apex of the root exists, a small fistulous orifice remains permanently in the gum, from which a minute quantity of pus is constantly discharged, which causes no inconvenience to the patient, who, indeed, often remains ignorant of its existence.

The operation of replantation, already described, has been practised for the cure of chronic alveolar abscess as well as for chronic periostitis, and the remarks which were made under the head of the latter disease equally apply to that under consideration—the operation can only be considered as a last resource when other measures have failed.

Periostitis and Necrosis of the Maxillæ.—The slight limited periostitis of the alveolus or jaw, which, from the intimate relation of the parts, is necessarily associated with the dental diseases just described, subsides in most cases on the removal of the cause; but in some instances the inflammation continues or extends, and may terminate in suppuration, followed

sometimes by necrosis, to a greater or less extent, of the bone, in consequence of separation of the periosteum. On the other hand, cases occur in which inflammation, involving both teeth and bone, originates, independently of the teeth, in the periosteum of the maxilla. This form of inflammation may be caused by injury, such as fracture of the alveoli during extraction in an unhealthy subject, or by any of those constitutional conditions which give rise also to dental periostitis, and which have been already enumerated. C. O. Weber and Salter have both observed and recorded cases of a form of necrosis, which the latter has termed exanthematous necrosis. It occurs at the period of the commencement of second dentition in children, especially such as are badly nourished, who have been debilitated by attacks of the eruptive fevers. The necrosis in these cases is usually confined to the alveoli of the temporary teeth, the bone being exfoliated and thrown off together with the teeth which it supports.

The symptoms of periostitis of the jaw resemble in an aggravated form those attending the dental disease. There are violent pain and great swelling, and œdema accompanied by fever. The occurrence of suppuration is marked by rigors, and is often attended with increase rather than diminution of pain, unless the matter find immediate vent. The skin assumes a shining, erysipelalous aspect, and pits on pressure, and after a time the abscesses point and discharge pus through openings corresponding to the position of the diseased bone, to which they lead by fistulous passages. These openings are similar to those described as occurring in alveolar abscess discharging through the cheek. When

necrosis has supervened the rough denuded surface of bone can be felt by probing.

In exanthematous necrosis the symptoms commence in the gum, which, with the periosteum, ulcerates and lays bare the bone. It is accompanied by a discharge of fetid pus. It gives rise to little or no pain.

The treatment of periostitis of the jaw consists of local bleeding by means of leeches, and free incisions through the gum down to the bone, with assiduous application of warm fomentations. All sources of irritation, such as hopelessly decayed and necrosed teeth, must be removed. As soon as matter forms it must be evacuated by the bistoury. The general health will of course receive due attention.

When necrosis has supervened the treatment is directed to maintaining a free vent for the discharges, destroying their fetor by antiseptic lotions, and removing the dead bone. In exanthematous necrosis the amelioration of the general health is the first care, locally detergent lotions are called for, but incisions or bleeding are not required.

Detergent lotions may be composed of carbolic acid, two grains to the ounce of water, or of Condy's fluid, half a drachm to the ounce; and it is a good plan not only to wash the mouth frequently with these fluids, but also to inject them by means of a syringe into the sinuses when these exist.

No attempt should be made to remove the dead bone until it has become detached from the living tissue, which event may not occur for many weeks or months, and will be known by the mobility of the sequestrum on examination. It is especially important that force should not be applied in extracting the

dead bone in the case of children, lest the rudimentary permanent teeth lying within the jaw be injured or removed in the operation.

By the time the sequestrum has become detached the orifices of the sinuses have usually become so enlarged as to allow the mass to be readily withdrawn by means of a pair of sequestrum forceps, but in some cases a few touches of the scalpel may be required to complete the operation. To avoid subsequent disfigurement the necessary incisions should be confined to within the mouth.

Dental exostosis consists of outgrowth of osseous tissue from the surface of the cement, and takes the form either of prominent rounded nodules or of smooth and regular masses connected with a large portion of the root. These outgrowths are in most cases situated towards the apex of the root. The new tissue is similar in structure to ordinary cement, except that the lacunæ are generally coarser, larger, and closer together, but when developed in a considerable quantity it is frequently penetrated by vascular canals, which, proceeding from the exterior, give off branches throughout the mass.

The cause of exostosis is chronic periostitis. In this disease—as we have seen—the periosteum becomes thickened and vascular, and coated with masses of lymph. If the inflammation continue the lymph becomes organized into fibrous tissue, which, under favouring circumstances, undergoes ossification. The ossification commences upon the surface of the root, and proceeds outwards, the soft tissues becoming dense and almost cartilaginous in texture prior to impregnation with earthy matter. It happens occasionally that roots of adjacent teeth become sur-

rounded and united by the same inflammatory exudation, and when this exudation becomes subsequently organized and ossified organic union of the teeth is brought about. Adjacent lower molars thus united are shown in fig. 78 in a later page. The symptoms of dental exostosis are almost identical with those of periostitis, and it is often difficult to distinguish between the two diseases. Exostosis may, however, exist without any distinct symptoms being apparent, except, perhaps, slight congestion of the gum around the tooth; and teeth the seat of hypertrophy of the cement, although they may be the seat of no pain, sometimes give rise to facial neuralgia.

The only available treatment is extraction, an operation which must be performed when the tooth is the seat of severe or persistent pain, or is in any way a source of constant annoyance to the patient.

Necrosis.—The teeth derive their vitality from two sources—the central pulp and the periosteum. When from any cause the pulp has been destroyed and the cementum denuded of periosteum complete necrosis of the tooth results, and it is reduced to the condition of a foreign body. Complete necrosis of this kind is occasionally met with, but cases are much more common in which the necrosis is only partial. The pulp may be destroyed, whilst the connection of the cementum with the periosteum remains intact; or the pulp may retain its vitality, whilst the cementum has to a greater or less extent lost its connection with the periosteum.

A tooth entirely necrosed becomes speedily loosened and cast off, but if the necrosis affect a small portion only of the cementum, the tooth—whether the pulp be living or not—may remain useful for an indefinite

time without giving rise to important pain or irritation.

The causes, symptoms, and treatment of gangrene of the pulp have been described in a previous section.

The most frequent cause of necrosis of the cement is periostitis. It is sometimes due to absorption of the gums and alveoli, and it may arise, especially in the case of the front teeth, from an injury, such as a blow, which has partly dislocated the tooth and severed at once its vascular connections.

Necrosis of the cement manifests itself by suppuration, the amount varying, of course, with the extent of the disease. The matter escapes through a fistulous opening in the gum, or wells up around the root from within the alveolus.

The surface of necrosed roots is rough and discoloured. The roughness is due to the denudation of the periosteum and to absorption, which almost always affects to some extent the necrosed cement. In cases where the periosteum is entirely detached a thin probe can be passed along the root within the alveolus to near the apex. Roots in this condition exposed to the access of saliva become coated with tartar or studded with small nodules, and the deposit is usually of the hard black variety.

The sole treatment of necrosis of the cement is extraction, but the operation is, of course, not called for so long as the tooth remains useful and free from severe pain.

Absorption of the roots of permanent teeth is a common accompaniment of chronic periostitis and of necrosis. If the roots, especially the apices, of teeth affected with these diseases be examined after

extraction it will be found that they often display patches of roughened excavated surface closely resembling that presented by bone and by the roots of temporary teeth when undergoing absorption. Although several are recorded, cases of complete or even of considerable absorption of the roots of permanent teeth are rare—no doubt, because the teeth are usually lost before the process is far advanced. The disease, when extensive, manifests itself by loosening of the tooth. Extraction is the sole treatment.

Absorption of the alveoli occurs in many cases as an accompaniment of chronic dental periostitis, and calls for similar treatment.

Chronic suppurative wasting of the alveoli seems, if not a disease of modern life to be at least, on the increase at the present time. The symptoms commence with inflammation appearing to affect simultaneously the free edge of gum and the alveolar periosteum. There is a discharge, usually slight in quantity, of muco-pus from within the edge of the gum. The gum and alveolus slowly waste until the tooth is lost; the bone in many cases wasting more rapidly than the gum. There is in most cases, although not invariably, deposit of tartar, often in the form of hard nodules around the denuded surface of the tooth, and beneath the swollen and loosened margin of the gums. The disease may affect one tooth only, but more commonly attacks several at the same time, subsequently extending to the whole set. The inflammation is usually extremely chronic, with occasional subacute and, in later stages of the disease, acute exacerbations.

It is not known whether this malady is of local or constitutional origin; and it is not known in which

tissue it has locally its starting-point. It has been stated, but without any verification of the statement, that the affection is really due to either ulceration or caries of the alveoli progressing from their edges onwards to the depths.

The treatment consists in removing tartar with great care. The pouched interval which exists between the swollen margin of the gum and the tooth should be swabbed at intervals of a few days with pure carbolic acid, care being taken to prevent the application from flowing over the gums, and causing unnecessary irritation. This may be accomplished by using a thin silver probe, having its end bound with a small quantity of cotton wool to convey the carbolic acid to the part. Teeth which become so loose as to be constant sources of irritation should be extracted. Where several teeth have been lost, great comfort will often be afforded by the adaptation of a perfectly-fitting frame of vulcanite to embrace the necks of all the teeth, and to hold artificial substitutes in the vacant places. The frames, which for the upper jaw should be on the "suction" plan, must closely surround the teeth without causing any strain upon them.

DISEASES OF THE GUMS AND ORAL MUCOUS MEMBRANE.

Inflammation of the gums may be due to various causes. Some amount always accompanies dental periostitis, and reference has been made to this variety in previous sections. It may arise from the irritation of tartar accumulated around the necks of the teeth, or from the presence of necrosed teeth and roots; it may be associated with disorders of the digestive organs, especially such as occur in pregnancy and gouty subjects, and in those who habitually take alcohol to excess. It is also often caused by constitutional syphilis, it forms a prominent symptom in ptyalism and in chronic mercurialization, and it is present in diseases which, like scurvy, are due to a depraved state of the blood.

The inflammation may involve a small part only of the gum or may attack the whole surface in each jaw. The limited variety is most commonly occasioned by local irritation; general inflammation of the gums generally arises from constitutional disorder.

Symptoms.—The gums are deep red or purple in colour, swollen, spongy, and tender, and they bleed on the slightest touch. Pus oozes or can be squeezed from around the teeth at the free edge of the gum, where ulceration also often occurs. If the disease continue for any length of time, it always spreads to the dental periosteum, rendering the teeth loose and tender, and leading to absorption of the alveoli.

Chronic inflammation sometimes leads to hypertrophy of the gum. The outgrowth is at first soft, but after the lapse of time may become hard and fibrous in character.

The treatment must be first directed to the removal of the exciting cause, and all sources of local irritation must be done away with, tartar and hopelessly loose and necrosed teeth being at once removed. The gums may be unloaded by free scarification, followed by warm fomentation, in the acute stage, and by astringents, such as tannin, in the chronic form. Where a fetid discharge exists detergent lotions may be prescribed, and the necks of the teeth may be swabbed with solutions of chloride of zinc or carbolic acid. Where the inflammation is associated with constitutional disorder local treatment is of secondary importance, and the remedies must be applied to the amelioration of the general health.

Thrush is an inflammation of the mouth occurring in infants. The entire mucous membrane is reddened and studded at parts with vesicles, especially inside the lips and on the tip of the tongue. These vesicles give place to patches of exudation, which are thrown off, leaving the membrane exposed and deeply red in colour beneath. With these symptoms there is fever and often diarrhœa. The treatment must be directed to the general health. Locally, soothing applications, such as lotions of glycerine or borax and honey, are most useful.

Aphthous, or follicular ulceration, occurs both in adults and in children. The first stage of the malady takes the form of simple inflammation of the mucous membrane. In the next stage small, round, transparent vesicles appear, which burst, leaving small spreading

ulcers with red and swollen margins. Both in this disease and in thrush, in some cases, the ulcers become coated with a layer of a microscopical parasite (*oidium albicans*). Besides constitutional treatment, which is of the first importance in this affection, the ulcers may be touched with sulphate of copper or nitrate of silver, and a lotion may be prescribed to destroy the vegetable parasite composed of sulphate of soda $\bar{3}j$ to $\bar{3}j$.

Ulcers of the tongue and lips often originate from friction against the ragged edges of broken and decayed teeth, and ulcers in these situations arising from other causes—such as syphilis and dyspepsia—are frequently aggravated by similar irritation. Ulcers due to irritation of ragged teeth vary in size with the length of time they have existed, and they may attain large dimensions. They are of irregular form, with slightly hardened bases, and are situated, as a rule, on the surface of mucous membrane lying against the faulty tooth, those on the tongue appearing on the side and under surface. These ulcers when neglected may assume an aspect closely simulating epithelioma, and the resemblance is rendered more complete in some cases by the induration of the glands beneath the jaw, which accompanies them.

In all cases of ulcers in the neighbourhood of decayed teeth it is desirable to file down and polish the rough and ragged surfaces. Should the ulcer be of a simple character it will then soon heal. The cure may be hastened by the use of astringent lotions, such as nitrate of silver, two grains to the ounce of water.

One of the commonest symptoms of constitutional syphilis is the occurrence of ulceration of the mucous

membrane of the mouth, which assumes various forms, sometimes not easily distinguishable in appearance from the varieties above described, due to other causes. Such cases can be diagnosed by the presence of other symptoms indicative of syphilis, and by their obstinacy under any but specific treatment.

Cancrum Oris.—This comparatively rare disease is confined entirely to young ill-fed children inhabiting low crowded neighbourhoods. The disease may be well defined as sloughing phagedæna of the gums and cheeks. It may begin at any part of the mucous membrane, but in many cases makes its appearance at the edge of the gum about the necks of the central incisors, in the form of a yellowish or ash-coloured ulcer. Thence it spreads with great rapidity and speedily attacks the inside of the cheek, which is, however, often swollen, and the seat of ulceration from the first. The ulceration extends in the direction of the sockets of the teeth, destroying the gums and periosteum, and causing necrosis of the teeth and bone. The affected soft parts slough, and a large ragged ulcer of a dirty blackish appearance is formed, which perforates the cheek. A profuse discharge of fetid purulent fluid and saliva accompanies the progress of the ulceration. In the early stages, and until sloughing has commenced, there is little or no pain. The disease often ends fatally, the patient dying from exhaustion.

The treatment consists in supporting the patient's strength by nourishment, together with quinine, ammonia, and brandy. Locally, the sloughing surface must be destroyed by nitric acid or acid nitrate of mercury, whilst detergent lotions are employed to destroy the fetor of the discharges.

ABRASION. EROSION. MECHANICAL
INJURIES.

Abrasion.—As age advances the teeth become ground down by mastication. The enamel is first worn off, next the dentine suffers, and in time the pulp would be laid bare were it not that it almost invariably undergoes calcification on the surface *pari passu* with the slow destruction of the hard tissues. The amount of abrasion in every case depends of course on the density of the teeth, and on the kind of usage to which they are subjected, and to some extent on the bite—the manner in which the teeth articulate. If the bite be normal, abrasion of the front teeth rarely becomes excessive, but if these teeth meet edge to edge they are worn down, sometimes even to the level of the gum. In rare cases, from some **unexplained** cause, the front teeth are ground down more rapidly than the molars, so that after a time, on closure of the mouth, the incisors of the opposing jaws cannot be brought into contact. Abrasion of the teeth of this slow kind is in most instances unattended with suffering, but it is occasionally accompanied by tenderness or pain due to exposure of sensitive dentine, or to approaching exposure of the pulp.

The treatment of abrasion of this kind is the same as that prescribed in a previous section for sensitive dentine and irritated pulp.

Erosion is a term used to designate a slow wasting of certain surfaces of the teeth, occurring mostly along the necks, where it forms grooves of characteristic form. Erosion is distinct from, although sometimes mistaken for caries, and perhaps a summary of the points in which it differs from caries would contain almost all the knowledge we possess upon the matter. Like caries it is a destructive process proceeding from without inwards, but there the resemblance ceases. In erosion the tissue that suffers most is the enamel; in caries, the dentine. Erosion scarcely ever forms an undercut cavity; caries almost always does so. The eroded surface is always hard and polished; the carious surface is always more or less soft and rough. Erosion shows no preference for fissures or sheltered crevices, but freely destroys those surfaces most readily washed by the tongue and saliva. It has often very much the appearance of the effect of the friction of a band, but since it is often found in mouths where no artificial denture has been worn, this hypothesis does not explain its presence. It cannot be due in many cases to the use of tooth-brushes or tooth-powders, for it is common amongst those who never clean their teeth. It is not due to the friction of opposing teeth, for it often attacks lingual, labial, proximal, and distal surfaces of the same tooth simultaneously. The suggestion that it is the effect of acids—acid saliva or acid mucus secreted by the gums—is plausible, but requires investigation. It has this in its favour that the morbid process is precisely similar to decalcification, if the decalcifying surface be kept polished by constant friction. It is certain that erosion can be due alone to some such chemical and

mechanical causes acting externally to the teeth ; but it is not known why it attacks certain teeth by preference in each case, and why certain surfaces only of those teeth.

The treatment consists in use of alkaline tooth-powder, such as prescribed at p. 97, and in lessening the sensibility of exposed dentine by application of strong solution of chloride of zinc. Where the erosion takes the form of grooves across the face of the teeth, it is good practice in later stages of the disease to undercut the margins of the excavations and fill them with gold. This often permanently arrests the destructive process.

Fracture of the teeth may arise from injury, such as a blow upon the mouth, or may occur during mastication, as when a fragment of bone, a small gritty particle, or a shot in game is bitten upon. If the fracture, however caused, do not lay open the pulp cavity it will often suffice to file down the rough surface, and carefully polish it. In other cases, if the fractured surface is of such a shape as to form a cavity, or so situated that this appears desirable, a filling may be inserted. If the pulp be exposed by the injury, and the fracture extend in a vertical direction into the root, the extraction of the tooth will be called for, but if the fracture involve only the crown an attempt may be made to save the tooth, or at least the root. The pulp in most cases must be at once destroyed, after which fang-filling may be performed; or should the tooth be an incisor or canine, an artificial crown may be attached to the root in the manner elsewhere described. If the root be transversely fractured in the socket, it may be induced, if kept at rest by some mechanical contrivance adapted to

the case, to so far reunite as to remain a useful member for many years.

Dislocation of the teeth, and more particularly front teeth, is not an uncommon effect of blows upon the mouth. Sometimes the tooth is only started from the socket or partly dislocated; sometimes it is completely dislodged.

Treatment.—If partly dislocated the tooth must be pushed back into the socket. In complete dislocation, if the case be seen within a few hours, the tooth may be replanted in the socket. The socket should be first washed out with syringe and warm water, to clear it of coagulated blood, and the tooth having been also cleansed, should be replaced in the socket. If but a short time has elapsed after the tooth was knocked out, if great care be taken to support the tooth by ligatures and to guard it from injury, it will in favourable cases regain its attachment to the socket, and may remain firm for years. After this treatment, as also after replacement of a partly dislocated tooth, there may supervene an attack of acute periostitis, which must be treated in the manner described on another page.

SALIVARY CALCULUS OR TARTAR.

SALIVA, among its other constituents, holds in solution a small proportion of earthy salts, and these salts are very liable to be deposited upon the teeth in the form of a concretion—salivary calculus or tartar. There are indeed few mouths, however healthy, which are absolutely free from deposit of tartar, whilst in some individuals with disordered health, and with local conditions favourable to the formation, it accumulates in enormous quantities. In health the saliva secreted by the parotid, sublingual and submaxillary glands, is alkaline, while that secreted by the buccal glands is acid.

Diseases associated with disorders of the digestive organs and with vitiation of the secretions of the mouth predispose to the formation of tartar. It is deposited upon teeth which are not subject to the friction of mastication, and it is common to see the teeth of one side of the jaw covered by the concretion when the presence of tender teeth compels the patient to use the other side alone. It accumulates often in great masses around teeth the alveoli of which are undergoing absorption. The accumulation is always greatest upon the external labial surfaces of the upper molars and on the lingual aspects of the lower front teeth, owing to the proximity of these surfaces to the orifices of the salivary ducts.

The density and colour of tartar vary considerably. When rapidly deposited it is soft and friable, and

light yellow in colour; when slowly formed it is hard and darker in colour—brown, greenish, or even quite black.

Analysis of tartar shows its composition to be as follows:—

Earthy phosphates	79·0
Salivary mucus	12·5
Ptyalin	1·0
Animal matter	7·5

This analysis must be understood as only approximate, the composition of tartar being very inconstant. When recently deposited the animal matter which chiefly consists of micro-organisms is greatly in excess. If allowed to remain, this animal matter dries up and the mass comes to consist mainly of lime salts.

According to Tomes, salivary calculus differs somewhat in chemical composition according to the situation in the mouth where it is deposited. Thus that formed near Steno's duct contains most carbonate of lime, whilst in that deposited on the lower incisors phosphate of lime preponderates.

Microscopical examination shows that the animal matter entering into the formation of tartar is made up of micro-organisms of every variety from huge bacilli to micrococci, and the débris of broken-down epithelial cells, whilst numerous filaments of leptothrix are always present in the mass.

The peculiar green discoloration occurring upon the teeth of children, and most frequently affecting the labial surfaces of the front teeth, appears to be due to staining of Nasmyth's membrane, or possibly to a deposit of leptothrix. The discoloration

produced by the bacteria most commonly present in the mouth is brown or yellow.

Deposition of tartar occasionally begins around the necks of the teeth beneath the free edge of the gum, and, acting as a foreign body, it keeps up chronic inflammation of the gums and periosteum, and thus may constitute in numerous instances the sole cause of absorption of both gums and alveoli.

Treatment.—Careful use of the toothbrush and due exercise of the teeth in mastication will do much to retard and prevent the deposition of tartar, but where these measures fail the deposit, if of great extent, must be removed by suitable scaling instruments. The blade of an instrument should be inserted beneath the edge of the tartar around each tooth below the gum, and levered outwards. By this means it is possible in many cases to detach the concretion in scaly masses, leaving the enamel smooth and intact beneath. Flat thin-bladed instruments are required to pass between the teeth and dislodge the deposit which occupies the interstices. In some cases, being densely hard and adhering with great tenacity, the tartar can be removed only by gradual scraping. Superficial discoloration—such as occurs in children—is best removed by pumice powder, with water, and a wooden or cane point.

In the operation of scaling it is of the utmost importance that every particle of tartar be removed, and that the surface of the tooth be left perfectly smooth, since a rough surface favours rapid re-deposition. The teeth, when necessary, can be polished after the operation by pumice powder, followed by chalk or slate stone.

MORBID GROWTHS CONNECTED WITH THE TEETH.

Odontomes.—Under this name there have been classed and described during late years several varieties of malformed and monstrous teeth and tumours composed of confused masses of dental tissues. The etiology of these morbid products has not yet been clearly made out. It appears, however, certain that they can originate only during the development of the teeth. At this period (as we have seen) the teeth are represented by soft tissues, which gradually assume the form of the future organs, and become calcified. During this stage of growth the formative elements may become the seat of partial or general hypertrophy, or atrophy, or other morbid action, followed by more or less complete calcification. The morbid process may be confined to the enamel organ, or to the dentine pulp, or may involve all the tissues of the tooth. The most simple form of these morbid growths is displayed in what have been called warty teeth—teeth which present nodules or excrescences projecting from some part of the surface. The excrescences most frequently spring from the neck of the tooth below the gum, and occasionally they assume the appearance of a supernumerary tooth lying in contact with the tooth to which they are attached. Section of these outgrowths shows them to be composed of dentine coated with enamel, and they sometimes con-

tain a pulp cavity continuous with that of the tooth. The roots of warty teeth are often well formed, but in some cases, especially where numerous excrescences exist on the crown, the root is stunted and ill-formed. In these cases, along with hypertrophy of the tissues of the crown, there appears to have occurred arrest of development of the root.

On the other hand, cases sometimes occur in which the crown of the tooth is normal in form, whilst the root is abnormally large, and is composed of a confused mass of dentine and osseous tissue (cement), enclosing a vascular structure, doubtless the hypertrophied dentinal pulp.

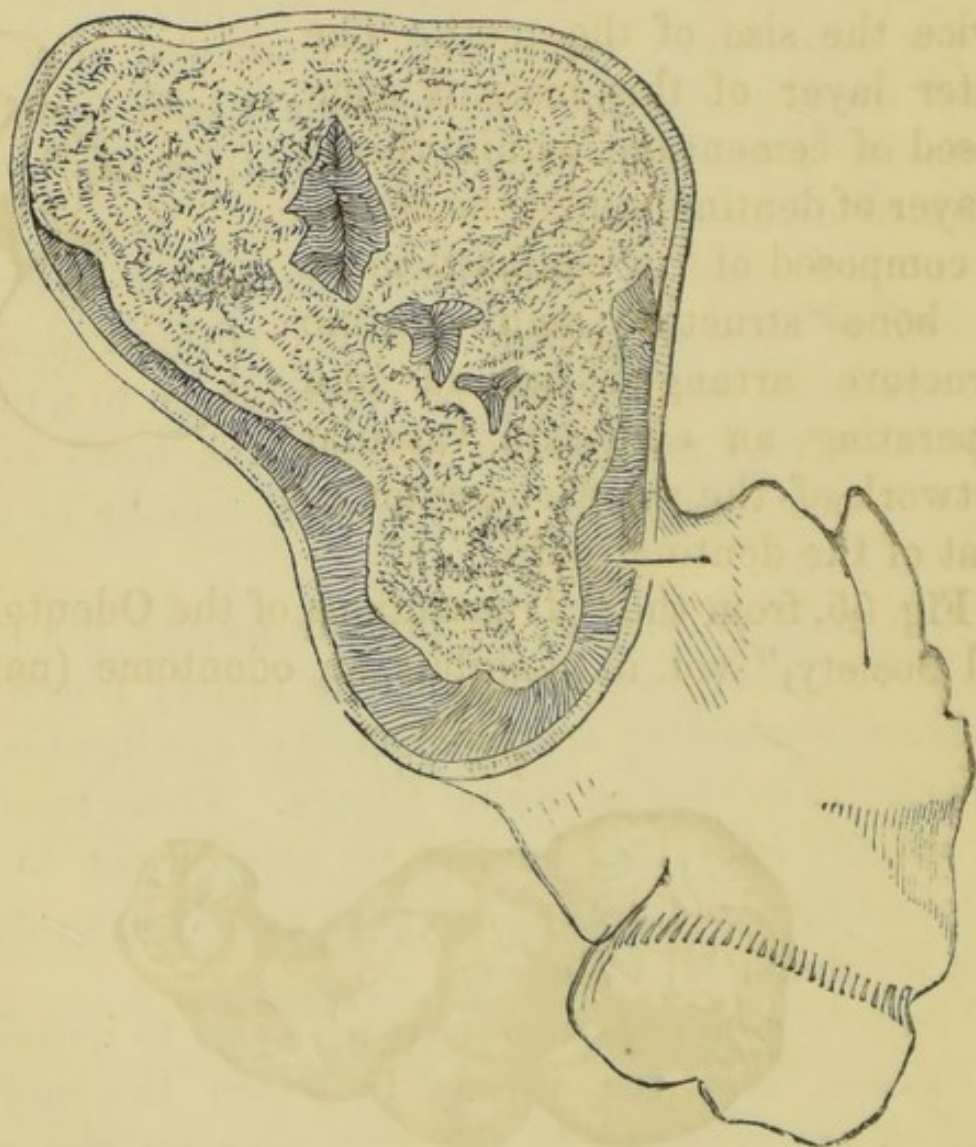
Another class of odontome consists of irregular masses of dental tissues mingled without definite arrangement, and bearing no resemblance to a tooth. The mass may not exceed in bulk the tooth whose place it occupies, or it may form a tumour of considerable size.

Still another variety of tumour having the same origin as those just mentioned is mainly fibrous in structure, containing scattered spots of calcification or imperfectly developed dental tissues. These tumours are usually encysted, having no attachment to the surrounding structures except such as may have arisen from inflammatory adhesion.

Odontomes do not necessarily give rise to irritation or disease, and the variety in which the morbid changes are confined to the root may, on the contrary, remain in position for years, serving the purpose of a tooth. Should they, however, constitute a deformity, become a source of irritation, or the centre of inflammatory action, they must be removed. Their extraction can be accomplished in some cases by

means of an ordinary tooth-forceps, and, should it be necessary, the bone may be divided by the bone-forceps to facilitate the operation. The fibrous variety may be removed by similar means. The cyst having been laid open, the mass may be turned out with the handle of a strong scalpel. It may be here remarked that in all cases of tumour of the jaw of doubtful

FIG. 53.



diagnosis exploratory incisions—within the mouth if possible—ought to be made to ascertain the true character of the disease, before a formidable operation like excision of the jaw is proposed. An operation of this magnitude and severity was not infrequently

performed for the removal of odontomes in former times before the real nature of these growths was recognized.

Fig. 53, from Mr. Salter's work (11), shows a magnified section of an odontome in the Museum of the College of Surgeons, of which the natural size is displayed in fig. 54. The crown of the tooth, a molar, is normal in size, but the root is enlarged into a mass more than twice the size of the tooth. The outer layer of this mass is composed of cementum, within this is a layer of dentine, whilst the centre is composed of "a confused mass of bone structure and dentine structure arranged around and separating an elaborate vascular network of the same character as that of the dentinal pulp."

FIG. 54.

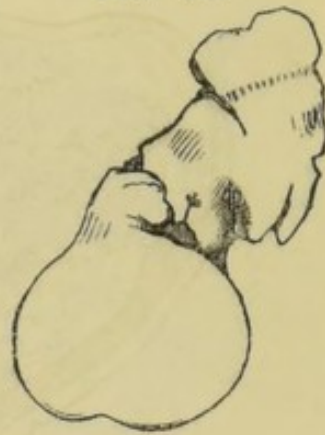
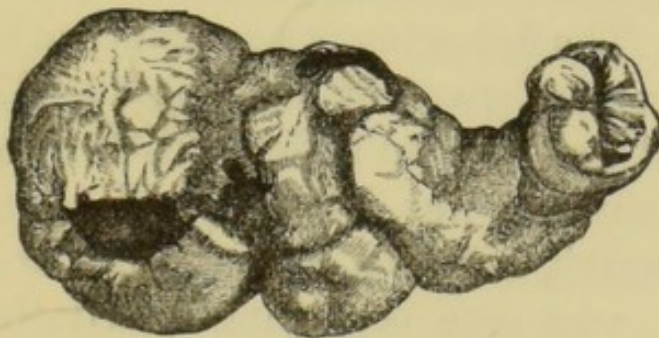

Fig. 55, from the "Transactions of the Odontological Society," vol. iii., exhibits an odontome (natural

FIG. 55.

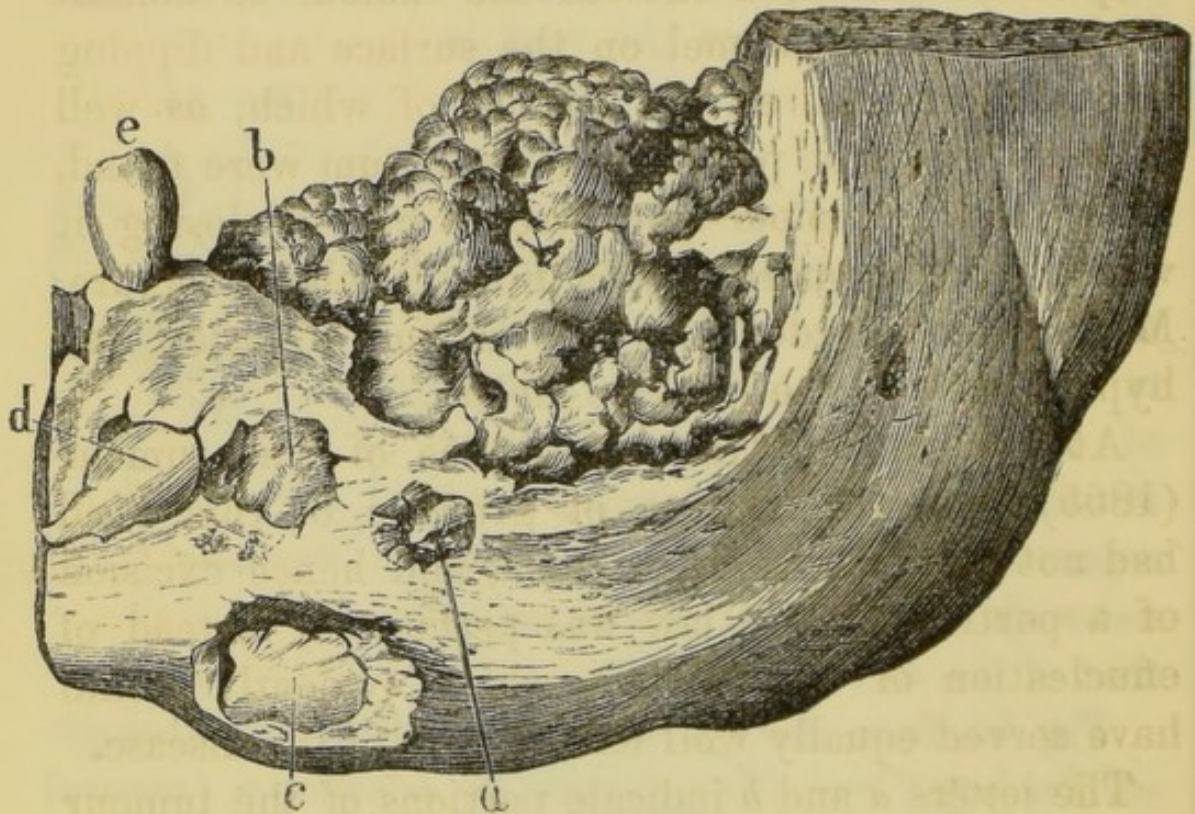


size) removed by Mr. Hare, of Limerick, from the upper jaw of a man. The growth occupied the position of the antrum, in which situation pain had long existed and where suppuration had occurred, leading to the

formation of a fistulous opening through the cheek. Its structure is identical in its main features with that of the specimen in the College of Surgeons Museum.

The engraving (fig. 56) from Mr. Heath's work (4),

FIG. 56.



exhibits an odontome occupying the left side of the lower jaw. The following is a summary of the account of this tumour as given by Mr. Heath:—The patient, a man aged twenty, had suffered with disease of the lower jaw since he was five years old. Upon looking into the mouth, a round, smooth tumour, hard and unyielding, was seen occupying nearly the whole of the left side of the jaw. None of the teeth, beyond the first bicuspid, were present. The portion of jaw shown in the engraving was removed by operation by M. Forget, under whose care the case came. Examination of this portion showed that the jaw

between the first bicuspid and the ramus was converted into a cavity which was occupied by a hard, oval mass of the size of an egg, having an uneven surface covered here and there with minute tubercles which were invested by a layer of enamel penetrating into the substance of the bone. Section and microscopical examination showed the tumour to consist of dentine with enamel on the surface and dipping into the crevices, at the bottom of which, as well as in other parts, portions of cementum were found. Between the tumour and osseous cyst enclosing it was a thick membrane of a fibro-cellular structure. M. Forget regarded the case as one of fusion and hypertrophy of the last two molars.

At the date of the occurrence of this tumour (1855) the exact nature of growths of this kind had not been clearly ascertained, and hence excision of a portion of the jaw was performed, instead of enucleation of the tumour, which evidently would have served equally well for the cure of the disease.

The letters *a* and *b* indicate portions of the tumour projecting through the bone; at *c*, where the enclosing bone is cut away, the crown of an inverted molar is seen lying between the tumour and the jaw; *d* is the second bicuspid lying beneath the first, *e*.

Cysts of the jaw may be either simple or dentigerous—that is, containing one or more complete or rudimentary teeth. They may occur in either jaw, and are usually situated towards the posterior part of the bone. They are more common in the young than in the aged.

Cysts commence as a gradual painless enlargement of the bone, and may in time attain a great size. Sometimes they inflame and suppurate. On manipu-

lation in some cases the expanded walls of the cyst yield to pressure, and give beneath the fingers a stiff parchment-like crackling; but in other instances they are so hard as to resemble solid growths. When the tumour is punctured a serous fluid escapes. The course and symptoms of simple and dentigerous cysts are alike, and it is often impossible to distinguish between them except by exploratory incisions. Dentigerous cysts, however, generally occur during childhood, often commencing at the period of second dentition, and when teeth are missing from their position after the time when they should appear, a clue to the nature of the case is afforded. These cysts are almost always connected with permanent teeth, but they may contain temporary or supernumerary teeth. In most cases the cyst contains only a single tooth, but instances are recorded in which many supernumerary teeth have been found in one tumour. Cysts of the jaw may contain only one cavity, or may be multilocular—that is, made up of several small cells separated by osseous or fibrous walls. The etiology of simple cysts is not clear, but there is evidence that they may in some cases be caused by dental disease. It has been before mentioned that in ordinary alveolar abscess the bone often expands and encloses the accumulating pus, and it is easy to perceive how such a cyst might attain a considerable size, and might commence to secrete serous fluid, and still progress after the suppurative process was arrested.

The origin of dentigerous cysts is more evident. Each developing tooth at one stage of its progress is enclosed in a complete bony cyst, and it is not difficult to understand that if the eruption of the tooth be prevented, and from any cause fluid be slowly poured out

within the cavity, the bony walls gradually expand and a tumour is formed. Mr. Tomes has pointed out that when the developing crown of a tooth is completed a small quantity of fluid is to be found between the surface of the enamel and the investing soft tissue, and he believes that it is the gradual secretion and collection of this fluid in abnormal quantity which causes expansion of the bone.

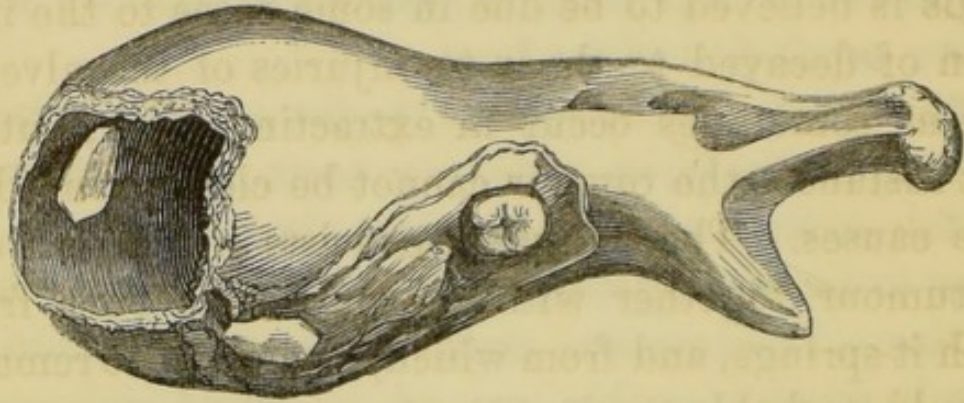
The treatment of cysts of the jaw consists in laying them open freely, in removing teeth when these are contained within, and plugging the cavity with lint, so as to set up suppuration and destroy the secreting surface. The incisions ought to be made within the mouth when possible, so as to avoid subsequent deformity.

The following case, with the illustration taken from Mr. Heath's work (4), will serve to exemplify the common course and history of dentigerous cysts, and also to make evident the importance of the rule already mentioned, that in cases of doubtful diagnosis the nature of tumours of the jaws should be ascertained by incisions and explorations before further operative procedures are undertaken.

In this case the cyst occurred in the lower jaw, and gave rise to a general expansion of the bone rather than a distinct tumour, and the disease was mistaken for a solid tumour of the lower jaw. The patient was a girl aged thirteen. The tumour was large and resistant, and occupied the left side of the lower jaw, and had been growing six months. No opening could be detected in the tumour, though there was a constant offensive discharge from the surface. The surgeon in charge of the case removed the left half of the jaw, from the symphysis to the

articulation. "The tumour (fig. 57) gave exit to a quantity of foetid pus on being opened, and it proved to be a bony cyst formed by the expansion of the two plates of the jaw. The cavity was lined with a thick vascular membrane, and at the bottom the canine

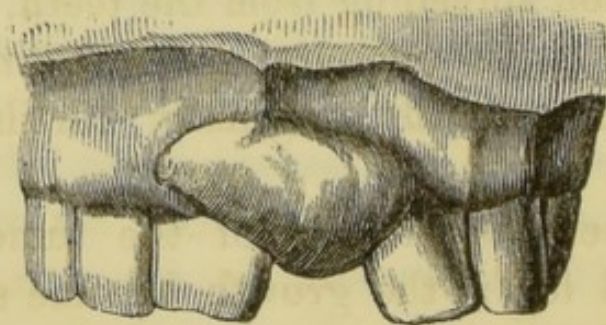
FIG. 57.



tooth was seen projecting from the wall. The case was evidently, therefore, one of dentigerous cyst due to the non-development of the canine tooth, the contents of which had from some cause become purulent."

Epulis is a fibro-plastic or fibrous tumour attached to and springing from the maxillary periosteum. It generally commences between two teeth, which become gradually pushed apart and loosened; but it sometimes springs from a part of the bone distant from the teeth. It grows slowly and painlessly,

FIG. 58.



forming a firm, rounded, often lobulated mass, covered with mucous membrane. A case of epulis in its

simplest form is shown in fig. 58, from Mr. Heath's work. It sometimes reaches an enormous size, encroaches upon the cavities of the nose and eye, and produces great deformity. In the later stages it may ulcerate, and frequent hæmorrhages taking place, the growth closely stimulates malignant disease. Epulis is believed to be due in some cases to the irritation of decayed teeth or to injuries of the alveoli, such as sometimes occur in extracting teeth, but in most instances the tumour cannot be clearly traced to these causes. The treatment consists in cutting out the tumour, together with the portion of bone from which it springs, and from which, if allowed to remain, it would probably again grow.

Osseous tumours, or exostoses of the jaws, are occasionally met with. The most common situation of exostoses is on the inside of the lower jaw, where they form hard, round, smooth protuberances. They sometimes spring from the angle, and they may also grow from the neighbourhood of the antrum and other parts of the upper jaw. Osseous tumours are slow in growth and painless, and are not commonly developed to such an extent as to cause inconvenience. Their cause is obscure, but in some few cases they would appear to be associated with persistent irritation spreading from the teeth. There is evidence that these tumours are sometimes due to ossification of growths originally cartilaginous in structure.

The treatment is excision of the tumour, which may be called for if the growth become a source of deformity or inconvenience.

DISEASES OF THE ANTRUM.

Inflammation of the antrum is by no means common. It arises sometimes from injury, or from the presence of a foreign body, such as a tooth fang which has been pushed into the cavity in an attempted extraction, but it is more commonly caused by the irritation of decayed teeth—molars and bicuspid—the roots of which either enter or approach closely the floor of the cavity. The symptoms are acute throbbing pain, with great swelling of the cheek, accompanied by more or less feverishness. If the disease run on, the pain becomes more severe, extending to the nose and frontal sinus, and an erysipelatous blush appears on the skin. The gums are red, spongy, and swollen, and sometimes there is a discharge of pus from the nostril of the affected side. The formation of pus is attended by rigors. If the matter find vent the pain and other symptoms may subside, but if it do not find an exit the symptoms persist, and the walls of the antrum become distended, and encroaching upon the neighbouring cavities occasion pressure upon the contents of the orbit, with protrusion of the eyeball, closure of the lachrymal duct, and blocking up of the nostril.

Inflammation of the antrum, except in its severest symptoms, resembles some cases of dental periostitis, and it is indeed often merely an extension of that

disease to the contiguous lining membrane of the cavity.

Treatment.—Foreign bodies are best removed by opening the cavity freely and syringing with warm water. The exciting cause must be removed, whether it be a root lodged within, or a decayed tooth in the neighbourhood of the cavity. The extraction of the tooth will often be followed by subsidence of the symptoms, the matter, if suppuration have occurred, escaping through the alveolus. If the antrum remain distended, the matter not freely escaping, the opening may be enlarged by pushing a trocar through the bone in the apex of the alveolus, or an opening may be made through the external wall of the cavity. This operation must be followed by warm fomentations and the injection of warm water into the cavity. If the discharge continue after subsidence of the acute symptoms, lotions of nitrate of silver or chloride of zinc may be thrown into the cavity.

Dropsy.—When the natural outlet of the antrum becomes from any cause obstructed, an accumulation of fluid may take place, causing gradual distension of the walls of the cavity, and giving rise to considerable deformity. The disease is usually slow in progress and unattended with pain. A puncture with an exploring needle, or an incision, will establish the diagnosis where doubt exists.

Treatment.—A free vent for the fluid having been afforded by one of the methods already mentioned, the cavity must be frequently injected with a lotion composed of chloride of zinc, 3 grains to the ounce of water, nitrate of silver, 2 grains to the ounce, or tincture of iodine, 1 drachm to the ounce.

The antrum is sometimes the seat of dentigerous

cystic, fibrous and other tumours, which call for few special observations here after the general remarks upon morbid growths of the maxillæ which have been made in a previous section.

A frequent sign of tumour of the antrum is protrusion or displacement of the molar teeth. To establish a diagnosis, it is often a good plan to extract one of these teeth and explore the antrum through the alveolus. In this way the author has, in several cases, detected the character of a morbid growth in an early stage—a matter of extreme importance where the tumour is of malignant nature. In one instance (reported in the "Trans. Odont. Soc.") this procedure led to the discovery of a medullary cancer occupying the antrum, and enabled the performance of excision, before the deeper structures had become invaded by the rapidly increasing tumour.

PIVOTING TEETH.

AFTER the partial or complete destruction of the crown of a tooth by injury or disease, it is possible in many cases to attach permanently an artificial crown to the root by means of a peg or pivot fixed in the pulp canal—the pulp having been, of course, previously removed. The incisors and canines are, as a rule, alone suitable for this operation, but it may occasionally be practised successfully upon the bicuspids. The root should be free from disease. If periostitis exist, it must be treated, and even in cases where no symptoms are apparent, it is good practice to dress the canal with carbolic acid or eucalyptus oil, and to plug it for a few days before permanently closing it by the pivot. An attack of acute periostitis will often follow the operation if this precaution be not observed.

In preparing the tooth the remaining portion of the crown must be excised. This is accomplished by means of a small saw, cutting forceps and suitable files. The edge of the root must be reduced to the level of the gum and its surface should be concave. The depth of the canal having been ascertained by probing, it must be reduced to an equal calibre throughout, to near the apex. The most suitable calibre for the canal is one that will admit a wire of ordinary dental pin size. It often happens, however, that the canal has been already enlarged to a greater

size by decay, and in such cases the softened tissue must be cut away, and the walls of the cavity rendered smooth. The canal in some of these cases must remain tapering in form.

A model of the part should then be taken by the following method. A wooden pin is cut to fit the canal and long enough to project slightly beyond the orifice when inserted. With this peg in place an impression of the root and adjacent teeth is taken in the usual way (plaster of Paris is preferable for the purpose), and in this the pin comes away. The cast which is prepared from the impression shows, on withdrawal of the peg, the size and diameter of the canal, and an artificial crown can be fitted to the root and attached to a pin in the patient's absence. In the case of bicuspid, it is sometimes a good plan to fill one division of the bifid pulp cavity with gold and attach the new crown by a single pin. Sometimes a split pin or two pins may be used.

The material of which the pivot is made will depend on the size of the canal. If it be small, metal—gold or platinum—answers best, if large, a piece of compressed hickory is more suitable, or perhaps better, a metal pin may be screwed into the wood which can be filed down to the desired size.

If wire alone, the pin should fit the canal accurately, but not tightly. It should be roughened by the file and covered with a thin even layer of floss silk. The canal having been thoroughly dried, the silk should be saturated with solution of gum copal in ether or mastic in spirit, and the pivot tooth may be then pushed firmly into place.

If a wooden or a wood-coated pin be used, the procedure is the same, save that no cement or silk is

used. The pin should fit the canal so tightly as to require a moderate amount of force to drive it home. When there the moisture of the mouth causes the wood to expand, and binds it with great firmness in position.

Root canals much enlarged by decay may often be made to securely hold a pivot by plugging. Gold or amalgam—copper amalgam answers well—may be employed. An iron pin may be inserted and the filling packed around. When the filling has hardened the pin can be withdrawn and a tooth prepared; the pivot, where amalgam is used, being of platinum. A more beautiful operation consists in inserting a gold tube and packing gold around; and in every case where a pivot is inserted it is good practice to seal the depths of the root canal for a short length with a plug of gold-foil.

Pivot teeth should be so arranged as to escape contact with the teeth of the opposing jaw during mastication. Where the bite is close, a flat tooth mounted on a plate covering the surface of the root is most suitable; where the bite is free, a tube tooth or a pivot tooth may be employed.

NEURALGIA AND DISEASES OF THE NERVOUS SYSTEM.

Facial Neuralgia.—The fact is well known that irritation of a nerve commonly manifests itself by pain at some point distant from, instead of at, the seat of injury or disease. This phenomenon cannot be accounted for, yet nevertheless presents itself daily to clinical observation, and may be exemplified by the case of an inflamed liver giving rise to pain about the right shoulder, a diseased hip-joint producing pain at the knee, and an irritated tooth-pulp exciting pain at remote parts of the head and face. Pain of this reflected or sympathetic character is called neuralgia. Neuralgia, or nerve pain in a part may also occur without the existence of any discoverable lesion. It may be caused by debility, by cold, or by malaria, or it may accompany pregnancy. It may be due to disease of the great nerve centres, the brain or spinal cord. Finally lesions of nerves not necessarily painful may give rise to neuralgia in consequence of disorder of the general health—thus cases are met with frequently in which the diseased nerves of carious teeth, previously the seat of little or no pain, give rise to severe neuralgia when the patient has become lowered by disease or by exhaustion.

Neuralgic pain is usually of a plunging, lancinating or burning character, following the course

of the nerve branches. It occurs in paroxysms which are often regularly periodic, the pain commencing at a particular hour of the day, lasting a certain period and then disappearing completely for a time.

The pathology of neuralgia has not yet been clearly made out, and the causation of the disease is often extremely obscure. When we remember the physiological fact mentioned at the opening of this section, and consider that the fifth nerve which supplies the teeth is distributed also to nearly the whole of the head and face, it is at least not difficult to understand that diseases of the teeth may act as frequent exciting causes of facial neuralgia. And since, as is pretty generally acknowledged, there are no symptoms which serve to distinguish neuralgia due to constitutional causes from that set up entirely by local disease, it is impossible to overrate the importance of searching for lesions of the nerve in all cases in which doubt exists.

Any of the pathological conditions of the teeth which have been described in preceding sections are capable of giving rise to neuralgic pain, but among them all chronic inflammation of the pulp is the most frequent cause. In every case of facial neuralgia a careful examination of the teeth should be made. It is not sufficient to take the patient's assurance that his teeth are not decayed, or that he does not suffer from toothache. Patients are often unconscious of the presence of disease, and teeth which do not ache are frequently the excitants of neuralgic pain. The isolated nodules of secondary dentine which are not infrequently found in the pulps of externally healthy teeth, seem often associated with acute neuralgia,

though their existence can never be demonstrated till the tooth has been extracted and split open. The pulps of such teeth are probably sometimes the seat of irritation or extremely mild inflammation, due to some obscure cause. In examining a case of neuralgia it is necessary that every tooth be examined separately. Cavities hidden in the interstices or below the gum must be sought for, and the signs of necrosis, exostosis, inflammation, and thickening of the dental periosteum must not be overlooked. Decayed and broken down wisdom teeth (common causes of neuralgia and especially of pain in the ear) are often, owing to their position, difficult to discover. They are in many instances placed at the extremity of the alveolar ridge, and in the upper jaw are invisible except with a mouth mirror; whilst in the lower jaw they are commonly hidden by folds of the cheek or by overhanging gum. Decaying in many instances before they are completely erupted, these teeth after the destruction of their crowns by caries are occasionally quite invisible, and their presence in the sockets can be ascertained only by passing a probe through the small fistulous tract in the gum which covers them. A condition similar to this may also exist in the case of any other tooth, and buried roots, especially when the seat of exostosis, are the excitants of neuralgia in numerous instances.

Although in cases of obstinate neuralgia there can be no doubt of the propriety of removing such diseased teeth as cannot be brought by treatment into a healthy state, it must be borne in mind that all decayed teeth need not be condemned to extraction. Neuralgia may be often cured by destroying inflamed pulps, and guarded against by filling decayed cavities and pro-

protecting the sensitive structures of the teeth from irritation. In these operations care should be taken to avoid increasing the susceptibility of the teeth to changes of temperature. For this purpose any of the white cements not containing chloride of zinc answer admirably, and in cases in which the pulp is exposed or protected only by a thin layer of dentine a layer of this material should be applied to the bottom of the cavity in the manner described in a former page.

There are other surgical diseases besides those of the teeth which involve branches of the fifth nerve, and which may therefore originate neuralgia, and in every case of doubtful diagnosis it is necessary to examine as far as possible the whole course of the nerve. The nerve, or its branches, may be compressed by a tumour or aneurism, or be affected by the inflammation, exostosis, or necrosis of the bony canals through which they pass. Inflammation of the mucous membrane of the antrum may include the superior dental nerves. Disease in the orbit may affect the first division of the fifth. One case is reported by Niemeyer in which a foreign body was imbedded in a branch of the nerve. Syphilitic nodes of the head are accompanied by pain, with nightly exacerbations of a character similar to neuralgia.

The discovery and removal of the exciting cause (as above remarked) must be the first care in dealing with neuralgia, but the treatment of the predisposing causes must not be overlooked. It has been already pointed out that the state of the general health often determines whether we have to attack slight local pain or severe neuralgia. Conversely, with improvement of the general health the pain frequently dis-

appears, although the exciting cause may remain. If the disease has been developed by any form of debility, or by malaria, full doses of quinine give almost always excellent results, and where this drug fails Fowler's solution of arsenic is said to prove effectual. Chloride of ammonium, 10 grs. every hour gives often good results, and gelseminum and Tonga are valuable remedies. Anæmia, rheumatism, and syphilis will each receive their appropriate treatment.

In those cases (by no means unknown) in which the cause of the neuralgia, whether local, central, or constitutional, cannot be discovered, an attempt alone can be made to destroy the excitability of the painful nerves. For this purpose electricity in various forms is employed. Cold, which diminishes for a time the excitability of the nerves, may be applied to the skin by means of ice or evaporating lotions; and ointments of aconite or veratria, or lotions of belladonna and chloroform, produce similar effects.

The division of the nerve at some point between the seat of pain and the brain, or (as section would be speedily followed by reunion) the cutting out of a portion of the nerve, is a procedure which theoretically seems likely to prove efficacious by preventing communication between the affected nerve and the brain. The operation is sometimes attempted, especially when the pain appears to have its seat in the ramifications of the mental nerve. It is, however, seldom followed by good results, and for three reasons, first, because it is difficult to pick out the nerve which is really the seat of pain, secondly, because it is difficult to get at and divide a part of the nerve between the brain and seat of the disease which excites the neuralgia, and lastly, because the divided

parts very soon reunite. The point where division would succeed is doubtless often so deeply placed that, even if discoverable, to reach it would be impossible. Stretching the nerve is considered by some most efficacious, but the second or third divisions of the fifth are very inaccessible for this operation.

Nervous Disorders.—Irritation of a peripheral nerve, besides exciting distant pain, may give rise to reflex irritation, or to functional disturbance of the brain or other great nerve centres, resulting in various phases of morbid action; and although dental diseases no doubt rarely excite nervous affections of a nature more grave than neuralgia, yet there is abundant evidence that neuroses of the severer kind do occasionally result from irritation of the dental nerves. Reflex irritation may be transmitted both to motor and sympathetic fibres. Severe neuralgia of the face, for example, is sometimes accompanied by convulsion of the facial muscles, together with profuse flow of tears, saliva, and mucus, and perspiration on the skin at the seat of pain.

Esquirol and Ashburner relate somewhat doubtful cases in which mania and delusions accompanied difficult eruption of wisdom teeth, and were apparently cured by incisions into the gum over these teeth. Mr. Tomes reports two cases of epilepsy believed to be consequent upon diseased teeth, the seat of exostosis. Many cases of amaurosis due to diseased teeth are recorded, and these have been accounted for on the supposition that irritation of dental branches of the fifth nerve may be transmitted through the ciliary system to the retina, producing hyperæmia and inflammation.

These affections call only for the same remark which was made with regard to neuralgia—viz., that in every case of doubtful diagnosis a careful examination of the teeth should be made, with a view to the removal of every cause of nerve irritation due to dental disease.

EXTRACTION OF TEETH.

DURING the operation of extraction the dentist stands on the right side of the patient, who is placed low when a tooth of the under jaw is to be drawn, and raised when an upper tooth is to be removed. The instrument is held in the right hand, whilst the left hand, fingers, and arm are employed according to circumstances, in steadying the head, grasping and fixing the lower jaw, drawing back the commissure of the lips, and assisting to direct the instrument.

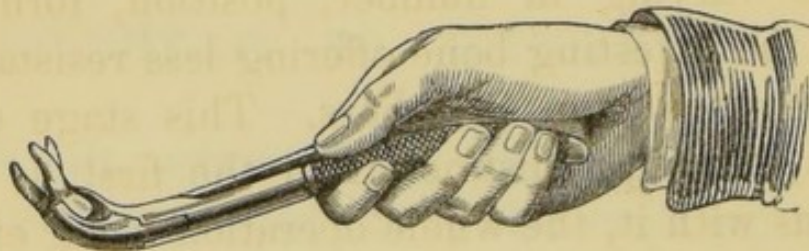
The instruments employed almost exclusively are forceps. These are made with blades of various patterns adapted to fit the different classes of teeth, and to grasp without crushing them. Their edges are sharp that they may be readily insinuated between the free edge of the gum and the neck of the tooth, and forced towards the socket.

The operation consists of two distinct actions, firstly, the seizure of the tooth, and secondly, the loosening of its connections, and its withdrawal from the socket.

The seizure of the teeth of each class is effected in the same manner. The forceps is lightly applied to the neck, and then forcibly pushed along the root until it becomes stopped at or within the edge of the alveolus. The grasp is then tightened, but not to such an extent as to crush the tooth, and the next

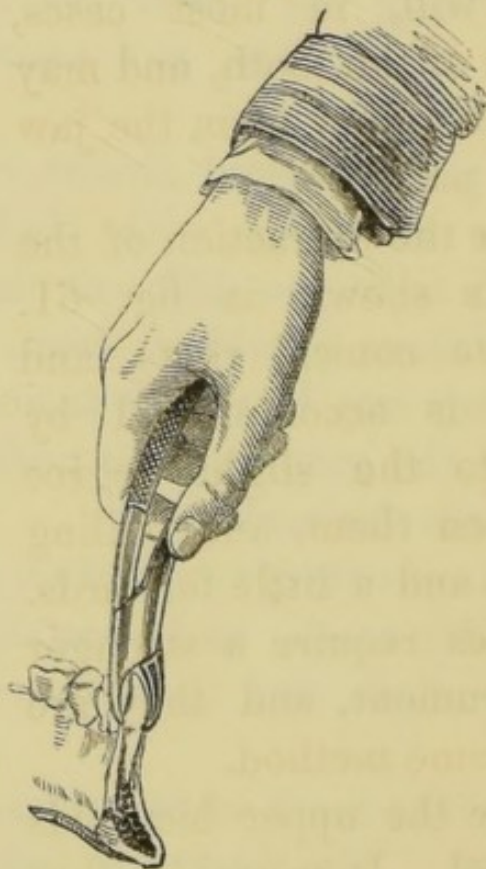
step of the operation is proceeded with. As soon as the tooth is felt to yield the forceps may be pressed still deeper, so as to embrace the tooth within the

FIG. 59.



socket; to obtain more power over it, and to avoid breaking off the crown. It is not necessary to separate the gum from the neck of the tooth by means of

FIG. 60.



the lancet before applying the forceps—a proceeding recommended by some authors. The connection of these parts is slight, and they are readily divided by

the cutting edges of the forceps. The mode of holding the forceps and applying them to the teeth is shown in figs. 59 and 60 from Druitt.

In the second stage of the operation the method of applying the force is modified with each class of tooth, the roots varying in number, position, form, and size, and the investing bone offering less resistance in some directions than in others. This stage of the operation, although distinct from the first, is really continuous with it, the whole operation being effected with one even movement. It may be performed rapidly by a practised hand, but it must be remembered that an attempt to wrench a tooth from its socket by force, either wrongly directed or indiscriminately applied, will, in most cases, result in fracture of the tooth, and may also inflict severe injury upon the jaw and surrounding parts.

The forceps for the extraction of the upper incisors is shown in fig. 61. These teeth have conical roots, and their extraction is accomplished by rotating them to the slight degree necessary to loosen them, and pulling them downwards and a little forwards. The upper canines require a stronger but similar instrument, and they are removed by the same method.

The forceps for the upper bicuspid is shown in fig. 62. It resembles that used for the incisors and canines, but has narrower blades, and handles bent to clear the lower teeth. The upper bicuspid having

FIG. 61.



roots flattened laterally cannot be rotated. They are loosened by forcing them steadily outwards. They are then moved to and fro from within outwards, and pulled downwards. Two forceps are required for the upper molars, one adapted to the teeth of the right side, one to those of the left (figs. 63, 64). The outer

FIG. 62.

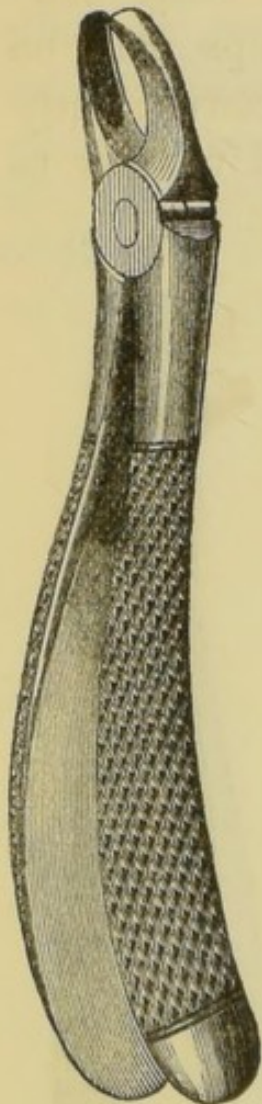


FIG. 63.

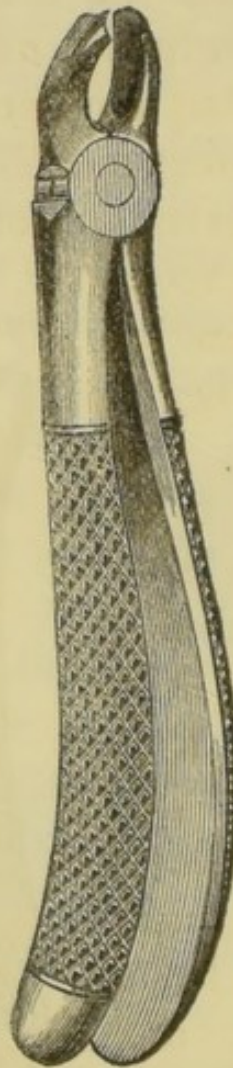
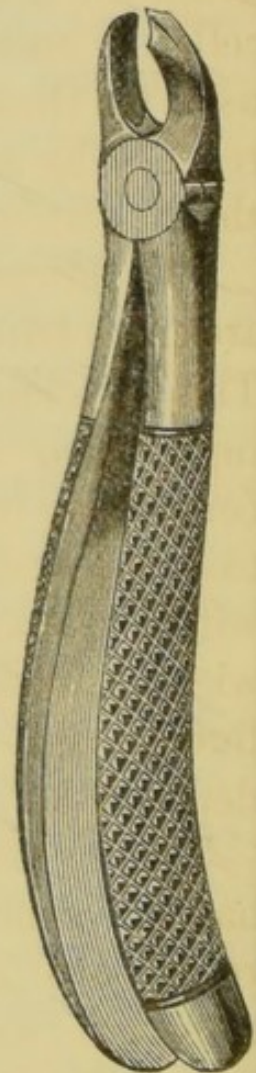


FIG. 64.



blade is formed in two curves to contain the external roots, the inner blade is designed to grasp the internal root. The force in extracting these teeth is first applied in the outward direction, for the reason that the external alveolar plate offers less resistance than the inner, while the direction of the

palatine root is such that it is likely to be snapped in an attempt to move the tooth inwards. As soon as the tooth yields it is moved from side to side, and pulled downwards.

The upper wisdom teeth are extracted in the same way as the upper molars. The removal of these teeth, however, rarely requires great force, their roots being often connate and the bone around being cancellated and soft. Ordinary molar forceps may be used for these teeth, but they are more conveniently reached by an instrument specially curved to pass to their position at the extremity of the jaw.

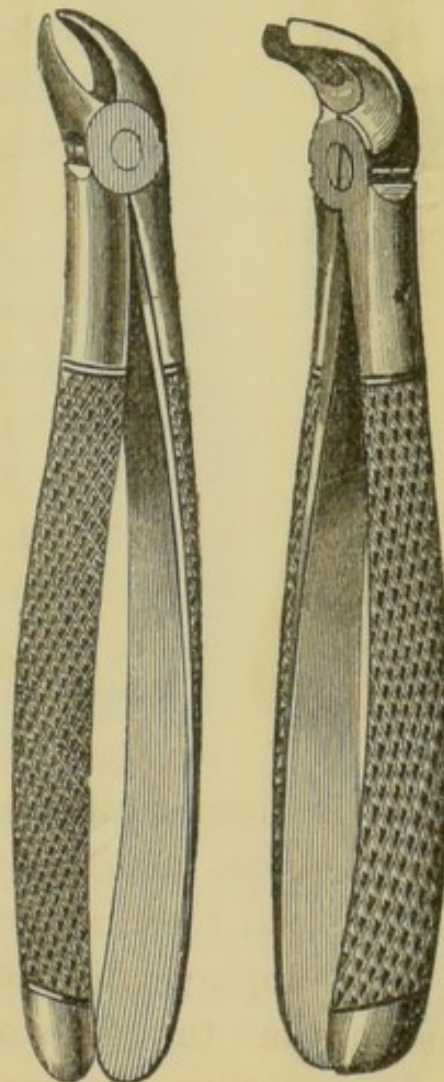
The lower incisor roots are much flattened laterally. They are loosened by bending them forwards and completely detached by a to-and-fro movement from within outwards, combined with an upward pull. The forceps for these teeth is depicted in fig. 65.

The lower canines, having somewhat conical roots, are loosened by a rotatory movement, and drawn by an upward pull. The forceps closely resemble those used for the incisors.

The lower bicuspid, having roots flattened laterally, are extracted by forcing them outwards until they

FIG. 65.

FIG. 66.



are felt to give, then moving them from side to side and at the same time drawing them upwards; the forceps is shown in fig. 66.

In applying the forceps to the lower bicuspid and molars the point of the thumb of the left hand may be placed over the joint of the instrument whilst the fingers press the jaw upwards from beneath. In this way the forceps is guided in the desired direction, enough power is obtained to drive it home, and the instrument is prevented from coming into violent contact with the upper jaw at the moment the tooth leaves the socket, whilst at the same time the danger of dislocating the jaw is guarded against. This accident has occurred in some cases.

FIG. 67.



The lower molars are loosened by force directed first in the outward direction. They are then moved to and fro from within outwards, and pulled upwards. Should the tooth offer great resistance, a backward and forward movement may be adopted, the better to free the roots, which are curved more or less in the backward direction. The forceps for these teeth is shown in fig. 67. The lower wisdom teeth are extracted by the same method as the first and second lower molars, than which, however, they require usually less force. A forceps is provided with the blades bent at such an angle to the shafts as permits their ready application to these teeth.

Extraction of the roots of incisors, canines, and bicuspid, the single-

fanged teeth of both the upper and lower jaws, is carried out on the principles already described—that is to say, the forceps is steadily pushed along the root, and a sufficient grip upon a sound portion obtained before an attempt is made to complete the operation. As the root yields, the thrusting

FIG. 68.

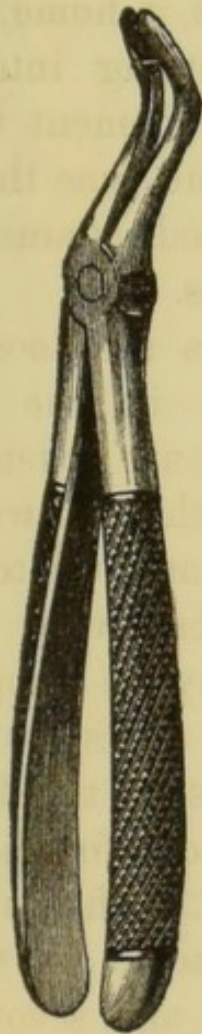
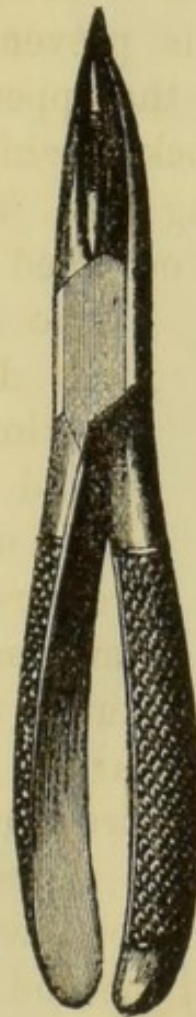

FIG. 69.



of the instrument deeper may be continued, and by giving the forceps at this time a slightly rotary movement, the blades are made to penetrate more readily. When the root is extensively decayed or broken within the alveolus, forceps are used with smaller and more slender blades (fig. 68),

that they may be more easily passed into the socket and insinuated between the root and the surrounding bone.

Fig. 69 represents a forceps designed for the extraction of roots of upper front teeth, which are

FIG. 70.

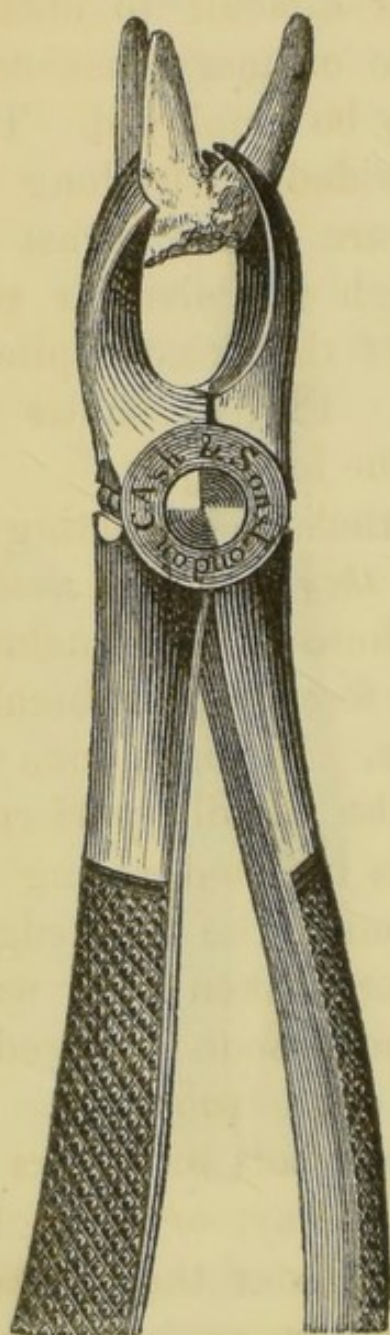
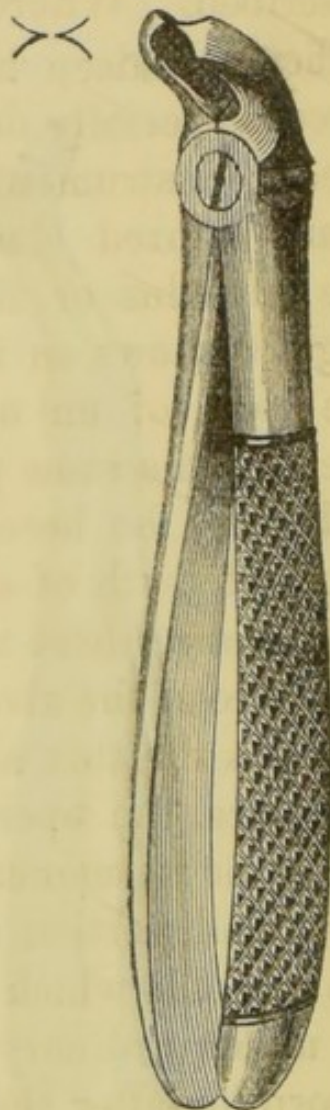


FIG. 71.



so extensively excavated by caries as to be readily crushed by the ordinary instrument. They are provided with a screw, which is inserted into the cavity

before the blades, between which the screw slides, are forced into the alveolus.

In extracting the roots of molars the procedure is guided by the extent of the decay. If the roots are still firmly united together they may be removed by the ordinary forceps, used in the manner already described. Where it appears difficult to obtain a sufficiently deep hold with the ordinary instrument, forceps specially designed may be employed. These special instruments are provided with long and sharp-pointed blades, which are either thrust into the alveolus or forced through the alveolar plate. Fig. 70 shows an instrument of this kind applied to the roots of an upper molar. Fig. 71 shows that used for the same purpose in the lower jaw.

It may be here remarked that in extracting the roots of teeth of any class, *if they cannot be seized by other means*, there need be no hesitation in including the edge of the alveolus in the forceps, or in breaking through the thin alveolar walls. If this is done with due care the operation may be rapidly performed, whilst no permanent damage is inflicted, seeing that the small portion of bone forming the thin edge of the alveolus which is injured or broken away would be under ordinary circumstances soon removed by absorption after the extraction of the root.

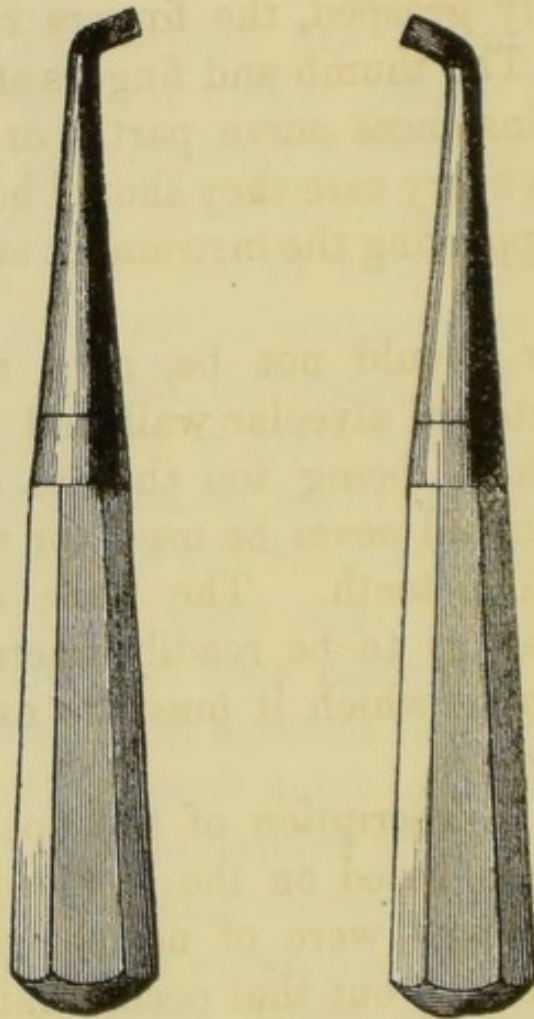
In those cases in which the roots of molars are detached from one another by decay, or so slightly united as to preclude the possibility of their removal in a mass, they must be extracted separately. Root-forceps (similar to those in fig. 68) are used. They are thrust as deeply as possible into the socket. The roots of the upper teeth, being conical, may be detached by a rotary movement; those of the lower,

owing to their flattened shape, require a rocking movement from within outwards.

Roots which are so deeply buried in the sockets as to be with difficulty reached with the forceps may be extracted with the elevator. This instrument consists of a stout handle carrying a steel shaft, which terminates in a narrow blade. The blade is thin,

FIG. 72.

FIG. 73.



and concave on its inner surface, and has either a spear-shaped or a sharp horizontal edge. Various patterns are used by different operators, but the right and left instruments depicted in figs. 72 and 73 suffice for all ordinary purposes. In applying the elevator the blade is thrust into the socket along the root until a solid surface is reached. The handle is

then turned, so that the point of the blade impinges upon the root, and by a levering movement prizes it from the socket. In this procedure the fulcrum is necessarily formed, altogether or to a great extent, by the alveolar wall or by the adjoining tooth, and as the force exercised by the elevator is great, unless care be taken the former may be extensively fractured or the latter dislodged. The elevator should be, therefore, firmly grasped, the fingers reaching close to the blade. The thumb and fingers of the left hand may in some instances serve partly or entirely as a fulcrum, and in every case they should be employed in guiding and supporting the instrument and controlling the force.

The elevator should not be, as a rule, inserted between the external alveolar wall and the root, this part of the bone being too thin to sustain much pressure. It should never be used for the extraction of upper wisdom teeth. The bone around these teeth is so weak as to be readily fractured by force in the direction in which it must be exerted by the elevator.

The foregoing description of the operation of extraction has been based on the supposition that the teeth to be removed were of normal character. It must be now pointed out that occasionally difficulties arise in consequence of irregular formation of the roots. Thus they may be so curved or, in the case of molars, so spread as to require more than ordinary force to remove them; indeed, the roots are sometimes so placed in the jaw that it is impossible to remove the tooth without snapping one or more of the roots or breaking away a portion of the alveolus. The portion of the alveolus most liable to be thus frac-

tured is the septum between the roots of the molars, and especially the lower molars. The roots of these teeth, wide apart at the neck, sometimes converge towards their apices, and cannot be separated from the plate of bone which they enclose.

If unusual resistance be met with, an abnormal arrangement of the roots may be suspected. Such being the case, the operator must proceed cautiously and deliberately to exercise a sufficient amount of force to overcome the obstruction; and as it is impossible to ascertain the precise form of the irregularity, it will be found safer in applying this extra force to follow the directions given for the extraction of a normal tooth. In spite of due care it will happen sometimes that a portion of a root is left in the socket. The broken piece is commonly loosened, and may be picked out with the root-forceps or elevator; but should the fragment, consisting only of the apex of the fang, remain fixed in its original position, it may be in some cases better to leave it rather than to inflict the injury upon the bone which its withdrawal would entail. It rarely gives rise to irritation, but in due course the changes which take place in the surrounding bone lead to its loosening or extrusion. The separation of a small portion of the alveolar process during extraction, which is sometimes inevitable where the roots are twisted, is a matter of little or no importance.

Figs. 74, 75, and 76 show teeth with roots in such conditions as to give rise to unusual difficulties in their extraction. The canine (fig. 74) obviously could not be removed without either leaving the curved extremity behind in the socket or extensively breaking away the investing bone. The lower molar

(fig. 75) exemplifies the "dovetailing" of the roots of these teeth with the bone, which occasionally occurs. The presence of exostosis at the apices of the fangs of this specimen would render its removal entire hardly possible. Fig. 76 exhibits upper molars with

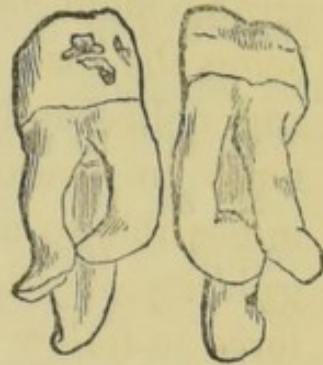
FIG. 74.

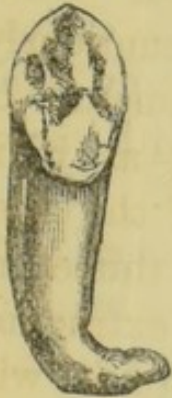

FIG. 75.

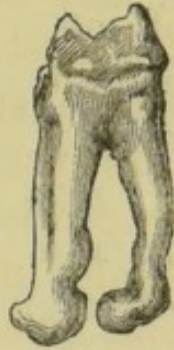

FIG. 76.



similar irregularity of the roots, and fig. 77 exhibits an upper molar of great size with unusually divergent roots. The difficulties which might arise in extracting a tooth organically united to its neighbour, as

FIG. 77.

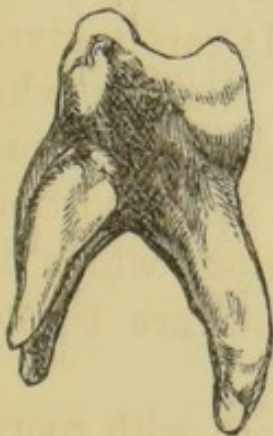
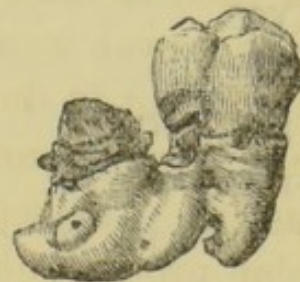

FIG. 78.



illustrated in fig. 78, and in fig. 18 on a previous page, are obvious.

It sometimes happens that a molar with abnormal roots of these kinds may be loosened, so as to move

readily from side to side, but yet cannot be drawn by any amount of force which can be safely applied. In such cases it has been recommended that the fangs of the teeth should be separated by cutting-forceps, and removed one by one. Forceps with blades fitted to be thrust into the alveolus are made for this purpose. It is often good practice to adopt a similar procedure in the removal of molars in which caries has advanced so far as completely to destroy the crown and to render the union of the roots with each other at the neck of the tooth but slight. If an attempt in these cases be made to extract the mass at once, the decayed tissues often give way, and render it difficult afterwards to grasp the broken fangs; but if the roots be first separated from each other, they may be easily removed one by one by the stump-forceps or the elevator.

The Casualties of Tooth-Extraction.—On this subject Mr. Salter writes: “In estimating the casualties which may arise in extracting teeth it is well to consider the essential nature of the operations themselves. They are different from all or nearly all other surgical proceedings. In removing a tooth the operator wrenches or tears an organ from its living connection with the rest of the body, frequently by the exercise of great force. And this force is often applied with little intelligence—the operator being necessarily ignorant, from the hidden and varying nature of the parts, of many of the conditions with which he has to deal. I would not for a moment imply that the extraction of teeth does not require the application of dexterity with anatomical knowledge, but where great force has to be applied, that *per se* is adverse to mechanical delicacy. The force

which the operator has to expend in removing a tooth is often very great indeed, occasionally one has to exercise the whole muscular power of the hand and forearm. It would be difficult to estimate, in measure of so many pounds, what is the force thus sometimes employed, but it must be immense; and with the exception of the reduction of dislocations of the larger joints, is probably in excess of that which is used in all other operations of surgery."

From these remarks it may be inferred that accidents in the operation of tooth extraction may occasionally happen, even in the hands of the most experienced, and therefore they must occur much more frequently in those of the unskilful.

The following list, compiled by Mr. Salter, probably includes every variety of casualty of this kind on record. Several of them have been already sufficiently referred to; others it will suffice merely to enumerate; the remainder will bear some further observations. 1. Breaking of tooth. 2. Breaking of jaw. 3. Taking out wrong teeth. 4. Taking out two teeth instead of one. 5. Removing capsule of growing permanent tooth in extracting its temporary predecessor. 6. Tearing gum. 7. Wounds produced by slipping of elevator. 8. Extracted tooth falling into air passages. 9. Extracted tooth falling into pharynx and being swallowed. 10. Crushing the inferior maxillary nerve. 11. Dislocating the lower jaw. 12. Breaking one tooth in extracting another. 13. Cutting lip in removing a jagged extracted tooth. 14. Forcing tooth or tooth-fang into the antrum. 15. Forcing tooth-fang into an abscess excavation in maxilla.

Fractures involving the alveolus only to a slight

extent occasionally occur, and are rarely followed by an untoward result. Fractures extending through the ramus of the lower jaw, or completely severing a considerable portion of the upper maxilla, have in rare instances been caused by the extraction of a tooth. This accident might happen either in consequence of inherent weakness of the bone or the existence of some abnormal form of the fangs of the tooth, such as already exemplified. This accident, like most of those in the above list, could be guarded against only by the application of the principles already inculcated in the general observations upon the extraction of teeth. The treatment of fractured jaw due to this cause would not differ from that arising from other forms of violence, and requires therefore no description here.

The possibility of the occurrence of the third accident has been casually alluded to in a previous section, where it was pointed out that the pain arising from an inflamed pulp sometimes becomes neuralgic in character and manifests itself in a neighbouring tooth, whilst the seat of disease remains free. Patients thus frequently present themselves and request that a certain tooth be extracted which on examination is found to be sound, or at least not the source of pain. In all cases in which doubt exists a careful inspection must be made to discover the offending tooth before an operation is attempted. The extraction of a wrong tooth in consequence of the slipping of the instrument is an inexcusable accident. Should the instrument become displaced, the operation should be stopped until it is readjusted.

The accidental extraction of two teeth instead of one may occur when force, as in using the elevator,

is improperly exerted on an adjoining tooth when the latter is already loose, or when the teeth are organically united. The author and others have recorded ("Trans. Odont. Soc.") cases in which this accident has happened, although the utmost care was taken to avoid it—the movement of the condemned tooth forcing the adjacent one, usually either a bicuspid or molar, from its socket. The accidentally extracted tooth, in such cases, should be instantly returned to its socket and pressed home. It will, in most instances, reunite within a few days, and remain apparently uninjured.

Some few cases are recorded in which, in extracting a temporary molar, the rudimentary permanent bicuspid, which lies within the diverging fangs of that tooth, has been also brought away. In such instances adhesion between the two teeth had probably existed as a result of previous inflammatory action.

Laceration of the gum, common with the obsolete key, ought not to occur with the forceps. It sometimes happens, however, that a tooth or root has become attached to the gum by strong fibrous adhesions, which are discovered when, on loosening its bony connections, it still remains attached to the soft tissues of the jaw. In these cases, if the tooth were torn away, an extensive laceration of the gums might ensue. This is to be prevented by dividing the adhesions by a scalpel or scissors.

Several cases are reported in which, after the extraction of a lower molar, sensation was lost at that part of the face supplied by the inferior dental nerve, which had evidently received some injury in the operation. This accident would arise from abnormal proximity of the nerve to the fang of the tooth.

In one case under care of the author the roots of a lower wisdom tooth (now in Museum of Odontological Society) contained a groove and a foramen through which the inferior dental nerve had evidently passed. Complete loss of sensation occurred at once on extraction of the tooth, but after lapse of a few months sensibility was again slowly but completely restored. No treatment was attempted.

The pain following the extraction of a tooth is rarely severe, unless periostitis exist. It is best treated by warm fomentations within the mouth. Mr. Tomes states that relief is often afforded by plugging the alveolus lightly with wool saturated with the following solution, after washing away the blood-clots:—℞ Acidi carbolicæ glacialis, liq. potassæ āā ʒj, aquæ, ʒj.

The hæmorrhage which follows the extraction of teeth in most cases is slight, and continues but for a few minutes. Occasionally, however, oozing goes on for a considerable time, whilst in rarer instances the flow is so severe as to require active measures for its arrest. The bleeding may be due to a hæmorrhagic condition of the patient, or may result from laceration of an artery. The former variety, which usually takes the form of general capillary oozing, is by far the more common, but the latter, in which the blood issues in a jet, or in a full florid stream, is not unknown. The vessel liable to be wounded in extracting a tooth is the dental artery, or one of its branches, which may run in abnormal proximity to the root; but it must be remembered that in consequence of periostitis which has existed for a long period, capillary vessels, previously too minute to give rise to more than trivial bleeding,

may become enlarged, so as to pour out when lacerated a considerable stream. It occasionally happens that hæmorrhage, which has ceased for a time after the extraction of a tooth, recurs with severity after an interval of hours or days.

Treatment.—Slight hæmorrhage may be usually arrested by cold—the mouth being freely rinsed with cold water, or better with iced water. Should the flow persist in spite of these measures, or should it be copious or arterial in character from the first, the alveolus must be at once firmly plugged. The clots having been removed by syringing with cold water, a narrow strip of lint is taken and tightly packed into the alveolus by a blunt probe, fold upon fold, care being taken to pass it to the bottom of each division of the socket. A compress of lint is then placed in position, and pressure is kept up by causing the patient to bite forcibly upon it, and fixing the jaw by a bandage passed over the head and beneath the point of the chin. The plug—which often gives rise to considerable irritation—may be carefully withdrawn after the lapse of twenty-four to forty-eight hours.

Seeing how effectually pressure may be maintained upon the whole bleeding surface by plugging the socket in the manner described, the instances must be extremely infrequent which call for other treatment. Such cases are, however, recorded. The treatment to be adopted would consist in the application of powerful styptics and the internal administration of tincture of steel, or acetate of lead with opium, to promote coagulation of the blood. The best local styptic is perchloride of iron, and it may be applied upon strips of lint packed into the alveolus. This application

excites inflammation, and should therefore be used only in the severe cases in question. In cases which resist this treatment the actual cautery may be resorted to, the iron being used at a black heat. Instances, although extremely rare, are recorded, in which every effort to arrest the hæmorrhage, including the last resource, ligature of the common carotid artery, has failed, and the patient being of hæmorrhagic diathesis has at last perished from the loss of blood.

INDEX.

- :—
- ABNORMAL development of jaws, 46
Abnormally formed teeth, 42
Abrasion of the teeth, 173
Absorption of alveoli, 167
 ,, roots of permanent teeth, 166
 ,, ,, temporary teeth, 31
Alveoli, growth of, in first dentition, 37
 ,, ,, second dentition, 37
Amalgams, 118
Amaurosis, due to dental disease, 201
Antrum, diseases of, 190
Arsenious acid in treatment of inflamed pulp, 144
 ,, ,, sensitive dentine, 103
- BURIED teeth, 38
- CALCIFICATION of cement, 27
 ,, dentine, 24
 ,, enamel, 23
 ,, pulp, 15, 137, 173
Cancrum oris, 172
Capping the pulp, operation of, 134
Caries, 73
 ,, acid in, 74
 ,, comparative liability of different teeth to, 94
 ,, consolidation of fibrils in, 82
 ,, incipient treatment of, 99
 ,, in dentine, 80
 ,, in enamel, 79
 ,, organisms in, 80

- Caries pain during, 93
 - „ preventive treatment of, 9
 - „ zone of transparency in, 82
- Cavities, preparation of, for filling, 102
- Cementum, development of, 27
 - „ exostosis of, 164
 - „ necrosis of, 165
 - „ structure of, 13
- Chronic inflammation of dental periosteum 156
 - „ „ pulp, 149
 - „ suppurative wasting of alveoli, 167
- Copper amalgam, 119
- Crystal, gold, 117
- Cuticula dentis, 6, 13, 27
- Cylinder fillings, 127
- Cysts of the jaws, 185

DECUSSATION of enamel prisms, 8

- Defective dentine, 77
 - „ enamel, 77
- Dentigerous cysts, 185
- Dentinal cells, 25
 - „ fibrils, 11
 - „ tubes, 10
- Dentine, defects in structure of, 185
 - „ development of, 24
 - „ papilla, 18
 - „ secondary, 15, 137
 - „ sensibility of, 12
 - „ structure of, 10
 - „ treatment of, sensitive, 101, 103 73
- Dentition, permanent, 31
 - „ temporary, 28
- Development of jaws, 28
 - „ teeth, 16
- Dilaceration, 45
- Dislocation of teeth, 176

ELEVATORS, 212

- Enamel, defects in structure of, 77
 - „ development of, 17 23
 - „ structure of, 7
- Epilepsy, due to dental disease, 201
- Epulis, 188
- Erosion 173
- Eruption of permanent teeth, 33
 - „ temporary teeth, 28

- Exanthematous necrosis, 162
 Excavators, 103
 Exostosis of cement, 164
 ,, jaws, 189
 Extraction of teeth, 203
 ,, difficulties in, 213
 ,, hæmorrhage following, 220
 ,, pain following, 220
 Eye, amaurosis of, 201
- FANG filling, 147
 Fangs, union of, 46, 164, 215
 Filing in treatment of incipient caries, 99
 Filling, materials used in, 115
 ,, operation of, 101
 ,, with amalgams, 132
 ,, ,, gold, 125
 ,, ,, gutta-percha, 133
 ,, ,, oxochloride of zinc, 133
 ,, ,, tin, 132
 Fistulous openings on face, 159
 Follicular ulceration, 170
 Forceps, extracting, 203
 ,, plugging, 123
 Fracture of teeth, 175
- GEMINATION of teeth, 46
 Gold, filling with, 125
 ,, instruments used in filling with, 123
 ,, used in filling teeth, 117
 Gumboil, 158
 Gums, diseases of, 169
 Gutta-percha filling, 133
- HÆMORRHAGE after tooth extraction, 220
 Histology of dental tissues, 7
 Hypertrophy of gums, 170
 Honeycombed teeth, 42
- INFLAMMATION of alveolar periosteum, 152
 ,, gums, 169
 ,, periosteum of jaw, 161
 ,, pulp, 138
 Interglobular spaces, 12
 Irregularities of teeth, 47

- JAW, tumours of, 180
 Jaws, growth of, 28
 „ necrosis of, 161
- LANCING gums, 29
 Leptothrix buccalis, 74
- MAXILLÆ, development of, 28
 „ V shaped, 54
 Mechanical injuries to the teeth, 175
 Membrana eboris, 25
 Membrane, Nasmyth's, 6, 13, 27
 Microscopical character of carious tissues, 80, 82
 Moisture, methods of excluding, 111
- NASMYTH'S membrane, 6, 13, 27
 Necrosis, exanthematous, 162
 „ of jaw, 161
 „ teeth, 165
 Nervous disorders connected with the teeth, 201
 Neuralgia, 196
- ODONTOBLASTS, 25
 Odontomes, 180
 Operation of extraction, 203
 „ filling, 101
- PALLADIUM amalgam, 119
 Papilla, dentinal, 18
 Periosteum, dental, 13
 „ inflammation of, 152
 „ of jaw, inflammation of, 161
 Permanent teeth, 1
 Pivoting teeth, 193
 Plugging, operation of, 101
 Polypus, 149
 Pulp, atrophy of, 149
 „ calcification of, 15, 137, 173
 „ dentinal, 20
 „ exposure of, 134
 „ gangrene of, 140
 „ inflammation of, 138
 „ irritation of, 136
 „ polypus of, 149

- Pulp, structure of, 14
 ,, ulceration of, 149
- RETARDED eruption of teeth, 38
 Reunion of dislocated teeth, 176
 Roots of teeth, absorption of, 31
 Rubber dam, use of, 113
- SALIVARY calculus, 177
 Second dentition, 31
 Secondary dentine, 15, 137
 Sensitive dentine, treatment of, 101, 103, 173
 Separation of teeth, 99, 110
 Shedding of temporary teeth, 31
 Silver amalgam, 118
 Sinus opening through cheek, 159
 ,, ,, ,, gum, 159
 Sponge gold, 118
 Stumps, extraction of, 208
 Sullivan's cement, 119
 Supernumerary teeth, 47
 Sympathetic toothache, 137
 Syphilitic teeth, 42
- TARTAR, 177
- Teeth, abrasion of, 173
 ,, anatomy and histology of, 1
 ,, development of, 16
 ,, dislocation of, 176
 ,, eruption of permanent, 33
 ,, ,, temporary, 28
 ,, fracture of, 175
 ,, gemination of, 46
 ,, honeycombed, 42
 ,, imbedded, 38
 ,, irregularities of, 47
 ,, malformations of, 42
 ,, permanent, 1
 ,, supernumerary, 47
 ,, syphilitic, 42
 ,, temporary, 5
- Teething, disorders due to, 29
 Temporary fillings, 123
 Thrush, 170
 Tongue, ulcers of, 171
 Torsion, actual, 66

Transparency, zone of, in caries, 82

Tumours, cystic, 185
,, dentigerous, 186
,, fibrous, 188
,, osseus, 189

ULCERATION of gums, 170
,, ,, lips, 171
,, ,, pulp, 149
,, ,, tongue, 171

WISDOM teeth, eruption of, 34

ZONE of transparency in caries, 82

THE END.



J. & A. CHURCHILL'S
MEDICAL CLASS BOOKS.

ANATOMY.

BRAUNE.—An Atlas of Topographical Anatomy, after Plane Sections of Frozen Bodies. By WILHELM BRAUNE, Professor of Anatomy in the University of Leipzig. Translated by EDWARD BELLAMY, F.R.C.S., and Member of the Board of Examiners; Surgeon to Charing Cross Hospital, and Lecturer on Anatomy in its School. With 34 Photo-lithographic Plates and 46 Woodcuts. Large Imp. 8vo, 40s.

FLOWER.—Diagrams of the Nerves of the Human Body, exhibiting their Origin, Divisions, and Connexions, with their Distribution to the various Regions of the Cutaneous Surface, and to all the Muscles. By WILLIAM H. FLOWER, F.R.C.S., F.R.S., Hunterian Professor of Comparative Anatomy, and Conservator of the Museum, Royal College of Surgeons. Third Edition, containing 6 Plates. Royal 4to, 12s.

GODLEE.—An Atlas of Human Anatomy: illustrating most of the ordinary Dissections and many not usually practised by the Student. By RICKMAN J. GODLEE, M.S., F.R.C.S., Assistant-Surgeon to University College Hospital, and Senior Demonstrator of Anatomy in University College. With 48 Imp. 4to Coloured Plates, containing 112 Figures, and a Volume of Explanatory Text, with many Engravings, 8vo, £4 14s. 6d.

HEATH.—Practical Anatomy: a Manual of Dissections. By CHRISTOPHER HEATH, F.R.C.S., Holme Professor of Clinical Surgery in University College and Surgeon to the Hospital. Fifth Edition. With 24 Coloured Plates and 269 Engravings. Crown 8vo, 15s.

ANATOMY—continued.

HOLDEN.—A Manual of the Dissection of the Human Body. By LUTHER HOLDEN, F.R.C.S., Consulting-Surgeon to St. Bartholomew's Hospital. Fourth Edition. Revised by the Author and JOHN LANGTON, F.R.C.S., Surgeon and Lecturer on Anatomy at St. Bartholomew's Hospital. With Engravings. 8vo, 16s.

By the same Author.

Human Osteology: comprising a Description of the Bones, with Delineations of the Attachments of the Muscles, the General and Microscopical Structure of Bone and its Development. Sixth Edition, revised by the Author and JAMES SHUTER, F.R.C.S., Assistant-Surgeon to St. Bartholomew's Hospital. With 61 Lithographic Plates and 89 Engravings. Royal 8vo, 16s.

ALSO,

Landmarks, Medical and Surgical. Third Edition. 8vo, 3s. 6d.

MORRIS.—The Anatomy of the Joints of Man. By HENRY MORRIS, M.A., F.R.C.S., Surgeon to, and Lecturer on Anatomy and Practical Surgery at, the Middlesex Hospital. With 44 Plates (19 Coloured) and Engravings. 8vo, 16s.

The Anatomical Remembrancer; or, Complete Pocket Anatomist. Eighth Edition. 32mo, 3s. 6d.

WAGSTAFFE.—The Student's Guide to Human Osteology. By WM. WARWICK WAGSTAFFE, F.R.C.S., late Assistant-Surgeon to, and Lecturer on Anatomy at, St. Thomas's Hospital. With 23 Plates and 66 Engravings. Fcap. 8vo, 10s. 6d.

WILSON — BUCHANAN — CLARK.—Wilson's Anatomist's Vade-Mecum: a System of Human Anatomy. Tenth Edition, by GEORGE BUCHANAN, Professor of Clinical Surgery in the University of Glasgow, and HENRY E. CLARK, M.R.C.S., Lecturer on Anatomy in the Glasgow Royal Infirmary School of Medicine. With 450 Engravings, including 26 Coloured Plates. Crown 8vo, 18s.

NEW BURLINGTON STREET.

BOTANY.

BENTLEY.—A Manual of Botany. By Robert BENTLEY, F.L.S., M.R.C.S., Professor of Botany in King's College and to the Pharmaceutical Society. With 1185 Engravings. Fourth Edition. Crown 8vo, 15s.

BENTLEY AND TRIMEN.—Medicinal Plants: being descriptions, with original Figures, of the Principal Plants employed in Medicine, and an account of their Properties and Uses. By ROBERT BENTLEY, F.L.S., and HENRY TRIMEN, M.B., F.L.S. In 4 Vols., large 8vo, with 306 Coloured Plates, bound in half morocco, gilt edges, £11 11s.

CHEMISTRY.

BERNAYS.—Notes for Students in Chemistry; being a Syllabus of Chemistry compiled mainly from the Manuals of Fownes-Watts, Miller, Wurz, and Schorlemmer. By ALBERT J. BERNAYS, Ph.D., Professor of Chemistry at St. Thomas's Hospital. Sixth Edition. Fcap. 8vo, 3s. 6d.

By the same Author.

Skeleton Notes on Analytical Chemistry,
for Students in Medicine. Fcap. 8vo, 2s. 6d.

BLOXAM.—Chemistry, Inorganic and Organic; with Experiments. By CHARLES L. BLOXAM, Professor of Chemistry in King's College. Fourth Edition. With nearly 300 Engravings. 8vo, 16s.

By the same Author.

Laboratory Teaching; or, Progressive Exercises in Practical Chemistry. Fourth Edition. With 83 Engravings. Crown 8vo, 5s. 6d.

CHEMISTRY—*continued.*

BOWMAN AND BLOXAM.—**Practical Chemistry,** including Analysis. By JOHN E. BOWMAN, formerly Professor of Practical Chemistry in King's College, and CHARLES L. BLOXAM, Professor of Chemistry in King's College. With 98 Engravings. Seventh Edition. Fcap. 8vo, 6s. 6d.

CLOWES.—**Practical Chemistry and Qualitative Inorganic Analysis.** An Elementary Treatise, specially adapted for use in the Laboratories of Schools and Colleges, and by Beginners. By FRANK CLOWES, D.Sc., Professor of Chemistry in University College, Nottingham. Third Edition. With 47 Engravings. Post 8vo, 7s. 6d.

FOWNES AND WATTS.—**Physical and Inorganic Chemistry.** Twelfth Edition. By GEORGE FOWNES, F.R.S., and HENRY WATTS, B.A., F.R.S. With 154 Engravings, and Coloured Plate of Spectra. Crown 8vo, 8s. 6d.

By the same Authors.

Chemistry of Carbon - Compounds, or Organic Chemistry. Twelfth Edition. With Engravings. Crown 8vo, 10s.

LUFF.—**An Introduction to the Study of Chemistry.** Specially designed for Medical and Pharmaceutical Students. By A. P. LUFF, F.I.C., F.C.S., Lecturer on Chemistry in the Central School of Chemistry and Pharmacy. Crown 8vo, 2s. 6d.

TIDY.—**A Handbook of Modern Chemistry,** Inorganic and Organic. By C. MEYMOTT TIDY, M.B., Professor of Chemistry and Medical Jurisprudence at the London Hospital. 8vo, 16s.

VACHER.—**A Primer of Chemistry, including Analysis.** By ARTHUR VACHER. 18mo, 1s.

CHEMISTRY—*continued.*

VALENTIN.—Introduction to Inorganic Chemistry. By WILLIAM G. VALENTIN, F.C.S. Third Edition. With 82 Engravings. 8vo, 6s. 6d.

By the same Author.

A Course of Qualitative Chemical Analysis.

Fifth Edition. By W. R. HODGKINSON, Ph.D. (Würzburg), Demonstrator of Practical Chemistry in the Science Training Schools. With Engravings. 8vo, 7s. 6d.

ALSO,

Chemical Tables for the Lecture-room and Laboratory. In Five large Sheets, 5s. 6d.

CHILDREN, DISEASES OF.

DAY.—A Treatise on the Diseases of Children.

For Practitioners and Students. By WILLIAM H. DAY, M.D., Physician to the Samaritan Hospital for Women and Children. Crown 8vo, 12s. 6d.

ELLIS.—A Practical Manual of the Diseases

of Children. By EDWARD ELLIS, M.D., late Senior Physician to the Victoria Hospital for Sick Children. With a Formulary. Fourth Edition. Crown 8vo, 10s.

SMITH.—Clinical Studies of Disease in

Children. By EUSTACE SMITH, M.D., F.R.C.P., Physician to H.M. the King of the Belgians, and to the East London Hospital for Children. Second Edition. Post 8vo. *[In preparation.]*

By the same Author.

On the Wasting Diseases of Infants and

Children. Third Edition. Post 8vo, 8s. 6d.

STEINER.—Compendium of Children's Dis-

eases; a Handbook for Practitioners and Students. By JOHANN STEINER, M.D. Translated by LAWSON TAIT, F.R.C.S., Surgeon to the Birmingham Hospital for Women, &c. 8vo, 12s. 6d.

DENTISTRY.

SEWILL.—**The Student's Guide to Dental Anatomy and Surgery.** By HENRY E. SEWILL, M.R.C.S., L.D.S., late Dental Surgeon to the West London Hospital. With 77 Engravings. Fcap. 8vo, 5s. 6d.

STOCKEN.—**Elements of Dental Materia Medica and Therapeutics, with Pharmacopœia.** By JAMES STOCKEN, L.D.S.R.C.S., late Lecturer on Dental Materia Medica and Therapeutics and Dental Surgeon to the National Dental Hospital. Third Edition. Fcap. 8vo. [In the press.]

TAFT.—**A Practical Treatise on Operative Dentistry.** By JONATHAN TAFT, D.D.S., Professor of Operative Surgery in the Ohio College of Dental Surgery. Third Edition. With 134 Engravings. 8vo, 18s.

TOMES (C. S.).—**Manual of Dental Anatomy, Human and Comparative.** By CHARLES S. TOMES, M.A., F.R.S. Second Edition. With 191 Engravings. Crown 8vo, 12s. 6d.

TOMES (J. and C. S.).—**A Manual of Dental Surgery.** By JOHN TOMES, M.R.C.S., F.R.S., and CHARLES S. TOMES, M.A., M.R.C.S., F.R.S.; Lecturer on Anatomy and Physiology at the Dental Hospital of London. Second Edition. With 262 Engravings. Fcap. 8vo, 14s.

EAR, DISEASES OF.

BURNETT.—**The Ear: its Anatomy, Physiology, and Diseases.** A Practical Treatise for the Use of Medical Students and Practitioners. By CHARLES H. BURNETT, M.D., Aural Surgeon to the Presbyterian Hospital, Philadelphia. With 87 Engravings. 8vo, 18s.

DALBY.—**On Diseases and Injuries of the Ear.** By WILLIAM B. DALBY, F.R.C.S., Aural Surgeon to, and Lecturer on Aural Surgery at, St. George's Hospital. Second Edition. With Engravings. Fcap. 8vo, 6s. 6d.

EAR, DISEASES OF—*continued.*

JONES.—A Practical Treatise on Aural Surgery. By H. MACNAUGHTON JONES, M.D., Professor of the Queen's University in Ireland, Surgeon to the Cork Ophthalmic and Aural Hospital. Second Edition. With 63 Engravings. Crown 8vo, 8s. 6d.

By the same Author.

Atlas of the Diseases of the Membrana Tympani. In Coloured Plates, containing 59 Figures. With Explanatory Text. Crown 4to, 21s.

FORENSIC MEDICINE.

OGSTON.—Lectures on Medical Jurisprudence.

By FRANCIS OGSTON, M.D., Professor of Medical Jurisprudence and Medical Logic in the University of Aberdeen. Edited by FRANCIS OGSTON, Jun., M.D., Assistant to the Professor of Medical Jurisprudence and Lecturer on Practical Toxicology in the University of Aberdeen. With 12 Plates. 8vo, 18s.

TAYLOR.—The Principles and Practice of Medical Jurisprudence. By ALFRED S. TAYLOR, M.D., F.R.S., late Professor of Medical Jurisprudence to Guy's Hospital. Second Edition. With 189 Engravings. 2 Vols. 8vo, 31s. 6d.

By the same Author.

A Manual of Medical Jurisprudence.
Tenth Edition. With 55 Engravings. Crown 8vo, 14s.

ALSO,

On Poisons, in relation to Medical Jurisprudence and Medicine. Third Edition. With 104 Engravings. Crown 8vo, 16s.

TIDY AND WOODMAN.—A Handy-Book of Forensic Medicine and Toxicology. By C. MEYMOTT TIDY, M.B.; and W. BATHURST WOODMAN, M.D., F.R.C.P. With 8 Lithographic Plates and 116 Wood Engravings. 8vo, 31s. 6d.

HYGIENE.

PARKES.—A Manual of Practical Hygiene.

By EDMUND A. PARKES, M.D., F.R.S. Fifth Edition by F. DE CHAUMONT, M.D., F.R.S., Professor of Military Hygiene in the Army Medical School. With 9 Plates and 112 Engravings. 8vo, 18s.

WILSON.—A Handbook of Hygiene and Sanitary Science.

By GEORGE WILSON, M.A., M.D., Medical Officer of Health for Mid Warwickshire. Fourth Edition. With Engravings. Crown 8vo, 10s. 6d.

MATERIA MEDICA AND THERAPEUTICS.

BINZ AND SPARKS.—The Elements of Therapeutics:

a Clinical Guide to the Action of Medicines. By C. BINZ, M.D., Professor of Pharmacology in the University of Bonn. Translated and Edited with Additions, in conformity with the British and American Pharmacopœias, by EDWARD I. SPARKS, M.A., M.B., F.R.C.P. Lond. Crown 8vo, 8s. 6d.

OWEN.—Tables of Materia Medica; comprising the Contents, Doses, Proportional Composition, and Methods of Manufacture of Pharmacopœial Preparations.

By ISAMBARD OWEN, M.B., M.R.C.P., Lecturer on Materia Medica at St. George's Hospital. Fifth Edition. Crown 8vo, 2s. 6d.

ROYLE AND HARLEY.—A Manual of Materia Medica and Therapeutics.

By J. FORBES ROYLE, M.D., F.R.S., and JOHN HARLEY, M.D., F.R.C.P., Physician to, and Joint Lecturer on Clinical Medicine at, St. Thomas's Hospital. Sixth Edition. With 139 Engravings. Crown 8vo, 15s.

THOROWGOOD.—The Student's Guide to

Materia Medica and Therapeutics. By JOHN C. THOROWGOOD, M.D., F.R.C.P., Lecturer on Materia Medica at the Middlesex Hospital. Second Edition. With Engravings. Fcap. 8vo, 7s.

WARING.—A Manual of Practical Therapeutics.

By EDWARD J. WARING, C.B., M.D., F.R.C.P. Third Edition. Fcap. 8vo, 12s. 6d.

MEDICINE.

BARCLAY.—A Manual of Medical Diagnosis.

By A. WHYTE BARCLAY, M.D., F.R.C.P., late Physician to, and Lecturer on Medicine at, St. George's Hospital. Third Edition. Fcap. 8vo, 10s. 6d.

CHARTERIS.—The Student's Guide to the

Practice of Medicine. By MATTHEW CHARTERIS, M.D., Professor of Materia Medica, University of Glasgow; Physician to the Royal Infirmary. With Engravings on Copper and Wood. Third Edition. Fcap. 8vo, 7s.

FENWICK.—The Student's Guide to Medical

Diagnosis. By SAMUEL FENWICK, M.D., F.R.C.P., Physician to the London Hospital. Fifth Edition. With 111 Engravings. Fcap. 8vo, 7s.

By the same Author.

The Student's Outlines of Medical Treat-

ment. Second Edition. Fcap. 8vo, 7s.

FLINT.—Clinical Medicine: a Systematic Treatise

on the Diagnosis and Treatment of Disease. By AUSTIN FLINT, M.D., Professor of the Principles and Practice of Medicine, &c., in Bellevue Hospital Medical College. 8vo, 20s.

HALL.—Synopsis of the Diseases of the Larynx,

Lungs, and Heart: comprising Dr. Edwards' Tables on the Examination of the Chest. With Alterations and Additions. By F. DE HAVILLAND HALL, M.D., F.R.C.P., Assistant-Physician to the Westminster Hospital. Royal 8vo, 2s. 6d.

SANSOM.—Manual of the Physical Diagnosis

of Diseases of the Heart, including the use of the Sphygmograph and Cardiograph. By A. E. SANSOM, M.D., F.R.C.P., Assistant-Physician to the London Hospital. Third Edition. With 47 Woodcuts. Fcap. 8vo, 7s. 6d.

WARNER.—Student's Guide to Medical Case-

Taking. By FRANCIS WARNER, M.D., Assistant-Physician to the London Hospital. Fcap. 8vo, 5s.

MEDICINE—continued.

WHITTAKER.—Students' Primer on the Urine.

By J. TRAVIS WHITTAKER, M.D., Clinical Demonstrator at the Royal Infirmary, Glasgow. With Illustrations, and 16 Plates etched on Copper. Post 8vo, 4s. 6d.

MIDWIFERY.

BARNES.—Lectures on Obstetric Operations,

including the Treatment of Hæmorrhage, and forming a Guide to the Management of Difficult Labour. By ROBERT BARNES, M.D., F.R.C.P., Obstetric Physician to, and Lecturer on Diseases of Women, &c., at, St. George's Hospital. Third Edition. With 124 Engravings. 8vo, 18s.

CLAY.—The Complete Handbook of Obstetric

Surgery; or, Short Rules of Practice in every Emergency, from the Simplest to the most formidable Operations connected with the Science of Obstetricy. By CHARLES CLAY, M.D., late Senior Surgeon to, and Lecturer on Midwifery at, St. Mary's Hospital, Manchester. Third Edition. With 91 Engravings. Fcap. 8vo, 6s. 6d.

RAMSBOTHAM.—The Principles and Practice

of Obstetric Medicine and Surgery. By FRANCIS H. RAMSBOTHAM, M.D., formerly Obstetric Physician to the London Hospital. Fifth Edition. With 120 Plates, forming one thick handsome volume. 8vo, 22s.

REYNOLDS.—Notes on Midwifery: specially

designed to assist the Student in preparing for Examination. By J. J. REYNOLDS, M.R.C.S. Fcap. 8vo, 4s.

ROBERTS.—The Student's Guide to the Practice

of Midwifery. By D. LLOYD ROBERTS, M.D., F.R.C.P., Physician to St. Mary's Hospital, Manchester. Second Edition. With 111 Engravings. Fcap. 8vo, 7s.

SCHROEDER.—A Manual of Midwifery; includ-

ing the Pathology of Pregnancy and the Puerperal State. By KARL SCHROEDER, M.D., Professor of Midwifery in the University of Erlangen. Translated by CHARLES H. CARTER, M.D. With Engravings. 8vo, 12s. 6d.

MIDWIFERY—*continued.*

SWAYNE.—Obstetric Aphorisms for the Use of Students commencing Midwifery Practice. By JOSEPH G. SWAYNE, M.D., Lecturer on Midwifery at the Bristol School of Medicine. Seventh Edition. With Engravings. Fcap. 8vo, 3s. 6d.

MICROSCOPY.

CARPENTER.—The Microscope and its Revelations. By WILLIAM B. CARPENTER, C.B., M.D., F.R.S. Sixth Edition. With 26 Plates, a Coloured Frontispiece, and more than 500 Engravings. Crown 8vo, 16s.

MARSH.—Microscopical Section-Cutting: a Practical Guide to the Preparation and Mounting of Sections for the Microscope, special prominence being given to the subject of Animal Sections. By Dr. SYLVESTER MARSH. Second Edition. With 17 Engravings. Fcap. 8vo, 3s. 6d.

MARTIN.—A Manual of Microscopic Mounting. By JOHN H. MARTIN, Member of the Society of Public Analysts, &c. Second Edition. With several Plates and 144 Engravings. 8vo, 7s. 6d.

OPHTHALMOLOGY.

DAGUENET.—A Manual of Ophthalmoscopy for the Use of Students. By Dr. DAGUENET. Translated by C. S. JEAFFRESON, Surgeon to the Newcastle-on-Tyne Eye Infirmary. With Engravings. Fcap. 8vo, 5s.

HIGGENS.—Hints on Ophthalmic Out-Patient Practice. By CHARLES HIGGENS, F.R.C.S., Ophthalmic Surgeon to, and Lecturer on Ophthalmology at, Guy's Hospital. Second Edition. Fcap. 8vo, 3s.

JONES.—A Manual of the Principles and Practice of Ophthalmic Medicine and Surgery. By T. WHARTON JONES, F.R.C.S., F.R.S., late Ophthalmic Surgeon and Professor of Ophthalmology to University College Hospital. Third Edition. With 9 Coloured Plates and 173 Engravings. Fcap. 8vo, 12s. 6d.

OPHTHALMOLOGY—continued.

MACNAMARA.—A Manual of the Diseases of the Eye. By CHARLES MACNAMARA, F.R.C.S., Surgeon to, and Lecturer on Surgery at, Westminster Hospital. Fourth Edition. With 4 Coloured Plates and 66 Engravings. Fcap. 8vo, 10s. 6d.

NETTLESHIP.—The Student's Guide to Diseases of the Eye. By EDWARD NETTLESHIP, F.R.C.S., Ophthalmic Surgeon to, and Lecturer on Ophthalmic Surgery at, St. Thomas's Hospital. Second Edition. With 137 Engravings, and a Set of Coloured Papers illustrating Colour-blindness. Fcap. 8vo, 7s. 6d.

WOLFE.—On Diseases and Injuries of the Eye: a Course of Systematic and Clinical Lectures to Students and Medical Practitioners. By J. R. WOLFE, M.D., F.R.C.S.E., Senior Surgeon to the Glasgow Ophthalmic Institution, Lecturer on Ophthalmic Medicine and Surgery in Anderson's College. With 10 Coloured Plates, and 120 Wood Engravings, 8vo.

PATHOLOGY.

JONES AND SIEVEKING.—A Manual of Pathological Anatomy. By C. HANDFIELD JONES, M.B., F.R.S., and EDWARD H. SIEVEKING, M.D., F.R.C.P. Second Edition. Edited, with considerable enlargement, by J. F. PAYNE, M.B., Assistant-Physician and Lecturer on General Pathology at St. Thomas's Hospital. With 195 Engravings. Crown 8vo, 16s.

LANCEREAUX.—Atlas of Pathological Anatomy. By Dr. LANCEREAUX. Translated by W. S. GREENFIELD, M.D., Professor of Pathology in the University of Edinburgh. With 70 Coloured Plates. Imperial 8vo, £5 5s.

VIRCHOW.—Post-Mortem Examinations: a Description and Explanation of the Method of Performing them, with especial reference to Medico-Legal Practice. By Professor RUDOLPH VIRCHOW, Berlin Charité Hospital. Translated by Dr. T. B. SMITH. Second Edition, with 4 Plates. Fcap. 8vo, 3s. 6d.

WILKS AND MOXON.—Lectures on Pathological Anatomy. By SAMUEL WILKS, M.D., F.R.S., Physician to, and late Lecturer on Medicine at, Guy's Hospital; and WALTER MOXON, M.D., F.R.C.P., Physician to, and Lecturer on the Practice of Medicine at, Guy's Hospital. Second Edition. With 7 Steel Plates. 8vo, 18s.

PSYCHOLOGY.

BUCKNILL AND TUKE.—A Manual of Psychological Medicine: containing the Lunacy Laws, Nosology, Ætiology, Statistics, Description, Diagnosis, Pathology, and Treatment of Insanity, with an Appendix of Cases. By JOHN C. BUCKNILL, M.D., F.R.S., and D. HACK TUKE, M.D., F.R.C.P. Fourth Edition, with 12 Plates (30 Figures). 8vo, 25s.

PHYSIOLOGY.

CARPENTER.—Principles of Human Physiology. By WILLIAM B. CARPENTER, C.B., M.D., F.R.S. Ninth Edition. Edited by Henry Power, M.B., F.R.C.S. With 3 Steel Plates and 377 Wood Engravings. 8vo, 31s. 6d.

DALTON.—A Treatise on Human Physiology: designed for the use of Students and Practitioners of Medicine. By JOHN C. DALTON, M.D., Professor of Physiology and Hygiene in the College of Physicians and Surgeons, New York. Seventh Edition. With 252 Engravings. Royal 8vo, 20s.

FREY.—The Histology and Histo-Chemistry of Man. A Treatise on the Elements of Composition and Structure of the Human Body. By HEINRICH FREY, Professor of Medicine in Zurich. Translated by ARTHUR E. BARKER, Assistant-Surgeon to the University College Hospital. With 608 Engravings. 8vo, 21s.

SANDERSON.—Handbook for the Physiological Laboratory: containing an Exposition of the fundamental facts of the Science, with explicit Directions for their demonstration. By J. BURDON SANDERSON, M.D., F.R.S., Jodrell Professor of Physiology in University College; E. KLEIN, M.D., F.R.S., Assistant-Professor in the Brown Institution; MICHAEL FOSTER, M.D., F.R.S., Prælector of Physiology at Trinity College, Cambridge; and T. LAUDER BRUNTON, M.D., F.R.S., Lecturer on Materia Medica at St. Bartholomew's Hospital Medical College. 2 Vols., with 123 Plates. 8vo, 24s.

SURGERY.

BRYANT.—A Manual for the Practice of Surgery. By THOMAS BRYANT, F.R.C.S., Surgeon to, and Lecturer on Surgery at, Guy's Hospital. Third Edition. With 672 Engravings (nearly all original, many being coloured). 2 vols. Crown 8vo, 28s.

SURGERY—continued.

BELLAMY.—The Student's Guide to Surgical

Anatomy; a Description of the more important Surgical Regions of the Human Body, and an Introduction to Operative Surgery. By EDWARD BELLAMY, F.R.C.S., and Member of the Board of Examiners; Surgeon to, and Lecturer on Anatomy at, Charing Cross Hospital. Second Edition. With 76 Engravings. Fcap. 8vo, 7s.

CLARK AND WAGSTAFFE. — Outlines of

Surgery and Surgical Pathology. By F. LE GROS CLARK, F.R.C.S., F.R.S., Consulting Surgeon to St. Thomas's Hospital. Second Edition. Revised and expanded by the Author, assisted by W. W. WAGSTAFFE, F.R.C.S., Assistant-Surgeon to St. Thomas's Hospital. 8vo, 10s. 6d.

DRUITT. — The Surgeon's Vade-Mecum; a

Manual of Modern Surgery. By ROBERT DRUITT, F.R.C.S. Eleventh Edition. With 369 Engravings. Fcap. 8vo, 14s.

FERGUSSON.—A System of Practical Surgery.

By Sir WILLIAM FERGUSSON, Bart., F.R.C.S., F.R.S., late Surgeon and Professor of Clinical Surgery to King's College Hospital. With 463 Engravings. Fifth Edition. 8vo, 21s.

HEATH.—A Manual of Minor Surgery and

Bandaging, for the use of House-Surgeons, Dressers, and Junior Practitioners. By CHRISTOPHER HEATH, F.R.C.S., Holme Professor of Clinical Surgery in University College and Surgeon to the Hospital. Sixth Edition. With 115 Engravings. Fcap. 8vo. 5s. 6d.

By the same Author.

A Course of Operative Surgery: with

Twenty Plates drawn from Nature by M. LÉVEILLÉ, and Coloured by hand under his direction. Large 8vo, 40s.

ALSO,

The Student's Guide to Surgical Diag-

nosis. Fcap. 8vo, 6s. 6d.

MAUNDER.—Operative Surgery. By Charles

F. MAUNDER, F.R.C.S., late Surgeon to, and Lecturer on Surgery at, the London Hospital. Second Edition. With 164 Engravings. Post 8vo, 6s.

SURGERY—continued.

PIRRIE.—The Principles and Practice of Surgery. By WILLIAM PIRRIE, F.R.S.E., late Professor of Surgery in the University of Aberdeen. Third Edition. With 490 Engravings. 8vo, 28s.

SOUTHAM.—Regional Surgery: including Surgical Diagnosis. A Manual for the use of Students. Part I., the Head and Neck. By FREDERICK A. SOUTHAM, M.A., M.B. Oxon, F.R.C.S., Assistant-Surgeon to the Royal Infirmary, and Assistant-Lecturer on Surgery in the Owen's College School of Medicine, Manchester. Crown 8vo, 6s. 6d.

TERMINOLOGY.

DUNGLISON.—Medical Lexicon: a Dictionary of Medical Science, containing a concise Explanation of its various Subjects and Terms, with Accentuation, Etymology, Synonymes, &c. By ROBLEY DUNGLISON, M.D. New Edition, thoroughly revised by RICHARD J. DUNGLISON, M.D. Royal 8vo, 28s.

MAYNE.—A Medical Vocabulary: being an Explanation of all Terms and Phrases used in the various Departments of Medical Science and Practice, giving their Derivation, Meaning, Application, and Pronunciation. By ROBERT G. MAYNE, M.D., LL.D., and JOHN MAYNE, M.D., L.R.C.S.E. Fifth Edition. Fcap. 8vo, 10s. 6d.

WOMEN, DISEASES OF.

BARNES.—A Clinical History of the Medical and Surgical Diseases of Women. By ROBERT BARNES, M.D., F.R.C.P., Obstetric Physician to, and Lecturer on Diseases of Women, &c., at, St. George's Hospital. Second Edition. With 181 Engravings. 8vo, 28s.

COURTY.—Practical Treatise on Diseases of the Uterus, Ovaries, and Fallopian Tubes. By Professor COURTY, Montpellier. Translated from the Third Edition by his Pupil, AGNES M'LABEN, M.D., M.K.Q.C.P. With Preface by Dr. MATTHEWS DUNCAN. With 424 Engravings. 8vo, 24s.

DUNCAN.—Clinical Lectures on the Diseases of Women. By J. MATTHEWS DUNCAN, M.D., F.R.C.P., Obstetric Physician to St. Bartholomew's Hospital. 8vo, 8s.

WOMEN, DISEASES OF—continued.

EMMET.—The Principles and Practice of

Gynæcology. By THOMAS ADDIS EMMET, M.D., Surgeon to the Woman's Hospital of the State of New York. With 130 Engravings. Royal 8vo, 24s.

GALABIN.—The Student's Guide to the Dis-

eases of Women. By ALFRED L. GALABIN, M.D., F.R.C.P., Assistant Obstetric Physician and Joint Lecturer on Obstetric Medicine at Guy's Hospital. Second Edition. With 70 Engravings. Fcap. 8vo, 7s. 6d.

REYNOLDS.—Notes on Diseases of Women.

Specially designed for Students preparing for Examination. By J. J. REYNOLDS, M.R.C.S. Fcap. 8vo, 2s. 6d.

SMITH.—Practical Gynæcology: a Handbook

of the Diseases of Women. By HEYWOOD SMITH, M.D., Physician to the Hospital for Women and to the British Lying-in Hospital. With Engravings. Second Edition. Crown 8vo. [*In preparation.*]

WEST AND DUNCAN.—Lectures on the Dis-

eases of Women. By CHARLES WEST, M.D., F.R.C.P. Fourth Edition. Revised and in part re-written by the Author, with numerous additions, by J. MATTHEWS DUNCAN, M.D., F.R.C.P., Obstetric Physician to St. Bartholomew's Hospital. 8vo, 16s.

ZOOLOGY.

CHAUVEAU AND FLEMING.—The Compara-

tive Anatomy of the Domesticated Animals. By A. CHAUVEAU, Professor at the Lyons Veterinary School; and GEORGE FLEMING, Veterinary Surgeon, Royal Engineers. With 450 Engravings. 8vo, 31s. 6d.

HUXLEY.—Manual of the Anatomy of Inverte-

brated Animals. By THOMAS H. HUXLEY, LL.D., F.R.S. With 156 Engravings. Fcap. 8vo, 16s.

By the same Author.

Manual of the Anatomy of Vertebrated

Animals. With 110 Engravings. Post 8vo, 12s.

WILSON.—The Student's Guide to Zoology:

a Manual of the Principles of Zoological Science. By ANDREW WILSON, Lecturer on Natural History, Edinburgh. With Engravings. Fcap. 8vo, 6s. 6d.

