

Hand atlas of human anatomy / by Werner Spalteholz ; edited and translated from the fourth German edition by Lewellys F. Barker.

Contributors

Spalteholz, Werner, 1861-1940.
Barker, Lewellys F. 1867-1943

Publication/Creation

Philadelphia ; London : Lippincott, [1906?]

Persistent URL

<https://wellcomecollection.org/works/utb2vtpd>

License and attribution

You have permission to make copies of this work under a Creative Commons, Attribution, Non-commercial license.

Non-commercial use includes private study, academic research, teaching, and other activities that are not primarily intended for, or directed towards, commercial advantage or private monetary compensation. See the Legal Code for further information.

Image source should be attributed as specified in the full catalogue record. If no source is given the image should be attributed to Wellcome Collection.



Wellcome Collection
183 Euston Road
London NW1 2BE UK
T +44 (0)20 7611 8722
E library@wellcomecollection.org
<https://wellcomecollection.org>

WERNER SPALTEHOLZ
HAND ATLAS OF
HUMAN ANATOMY

SECOND EDITION VOL. III.

DA C. (2)



22500302874

Med
K8215

HAND-ATLAS
OF
HUMAN ANATOMY

BY
WERNER SPALTEHOLZ

EXTRAORDINARY PROFESSOR OF ANATOMY IN THE UNIVERSITY AT LEIPZIG

EDITED AND TRANSLATED FROM THE FOURTH GERMAN EDITION

BY
LEWELLYS F. BARKER

PROFESSOR OF THE PRINCIPLES AND PRACTICE OF MEDICINE, JOHNS HOPKINS UNIVERSITY, BALTIMORE;
FORMERLY PROFESSOR OF ANATOMY IN THE UNIVERSITY OF CHICAGO AND RUSH MEDICAL COLLEGE

WITH A PREFACE

BY
FRANKLIN P. MALL

PROFESSOR OF ANATOMY IN THE JOHNS HOPKINS UNIVERSITY AT BALTIMORE

SECOND EDITION IN ENGLISH

VOL. III
VISCERA, BRAIN, NERVES, SENSE-ORGANS

PHILADELPHIA AND LONDON
J. B. LIPPINCOTT COMPANY

[1906?]

DA.C(2)



ALL RIGHTS RESERVED

302840

WELLCOME INSTITUTE LIBRARY	
Coll.	WelMOMec
Coll.	
No.	QS

CONCLUSION.

Almost eight years have elapsed since the first part of the Atlas appeared. When I began the preliminary work connected with it I did not think it possible that so long a time would be required to complete the book, and subsequently I have often been surprised at the expenditure of time which has been necessary. The cause of the long intervals between publications of the single parts lay essentially in the fact that special dissections had to be made for the Atlas. Only in the parts dealing with the bones and ligaments could I use directly, to any great extent, the specimens in our collection. In all other portions of the anatomy there were only single specimens which were suitable for use as a basis for an illustration; by far the largest part had to be made new, especially for this purpose, and usually more than one specimen had to be prepared for each illustration. Aside from individual exceptions, I have prepared these specimens entirely alone, a circumstance which, on the one hand, contributed much to the delay, but on the other has insured as a result an even treatment of all regions and has done much to favor the truth and accuracy of the illustrations.

The illustrations of the muscles have all been taken from formalin preparations and therefore present somewhat more rigid forms than we were accustomed to see in cadavers preserved by other methods. In the short description of the muscles accompanying the plates I have included notes on their action, though these could by no means be exhaustive. Thus, for example, the recently established fact that muscles acting on two joints may, in certain cases, act in other ways than those hitherto assumed, and that muscles can cause movements even in joints over which they do not extend, could, unfortunately, receive no attention in this cursory description. The description given concerns therefore only the influence which the muscles

Conclusion.

exert upon those joints over which they extend and neglects the deviations in the action which appear in muscles extending over two joints in certain initial positions.

In the work on the central nervous system I have been fortunate in the friendly support of my colleague H. Held, whom I here wish to thank most heartily; all the figures either for which he has placed preparations at my disposal, or which have been drawn at his direction, as well as the next belonging to them have been accredited in each single case to his name. In Figs. 723—743, the experiment has been made of introducing colors, without sacrificing accuracy, in the reproduction of the specimen in order to make it more easily possible to grasp the position of the motor nuclei of origin and the sensory nuclei of termination of the cerebral nerves and the course of some of the larger conduction paths. For permission to use the preparation for Fig. 743 I am indebted to Professor Flechsig; I am no less under obligation to him for revising Figs. 755 and 756 dealing with the extent of the sense centers and association centers. Thanks are further due to Professor P. Eisler of Halle, who at my request supplemented his plexus schemata (Figs. 786 and 812) and placed them, in the original, at my disposal, and to Professor Sattler who has been good enough to permit me to use some drawings of the eye made under his direction and several microscopic preparations from his collection.

The schematic drawings illustrating the domain of distribution of the cutaneous nerves of the arm and leg (Figs. 806, 807, 827 and 828) have been prepared by myself from original preparations and from those illustrations of cutaneous nerves in the literature which are free from objection. They are based on the mode of representation of R. Zander, (see Fig. 772) and show the overlapping of the nerve areas and also approximately their extent of variation; what they lose in clearness, as compared with other illustrations with sharply delimited areas, they have certainly won in accuracy.

The index has been prepared here by two medical students Messrs. P. Rosenhauer and A. Strobel; both these gentlemen have carried on this large task with great conscientiousness. I wish to thank them sincerely for their help.


Finally I desire to repeat again here my heartiest thank to Professor His for placing at my disposal without reserve the material and the collections of the Anatomical Institute. I am no less grateful to Mr. G. Hirzel who has given me an entirely free hand with regard to the size of the book and the use of colored illustrations; he has spared neither work nor expense to make the book the best possible.

Conclusion.

Of the drawings of the last volume those of Figs. 725—743 have been made by Mr. Albert Fiebiger and others by Mr. H. Unger and other gentlemen; but by far the greatest number of them come from the hand of Mr. B. Héroux who is therefore responsible for the largest part of the artistic work. That Mr. B. Héroux has been extraordinarily successful in accomplishing the tasks set him, some of them very difficult, everyone can easily convince himself by looking through the Atlas. To him especially and also to the other gentlemen who have helped in the preparation of the illustrations, I wish here to offer my best thanks.

Leipzig, July 31, 1906.

W. Spalteholz.

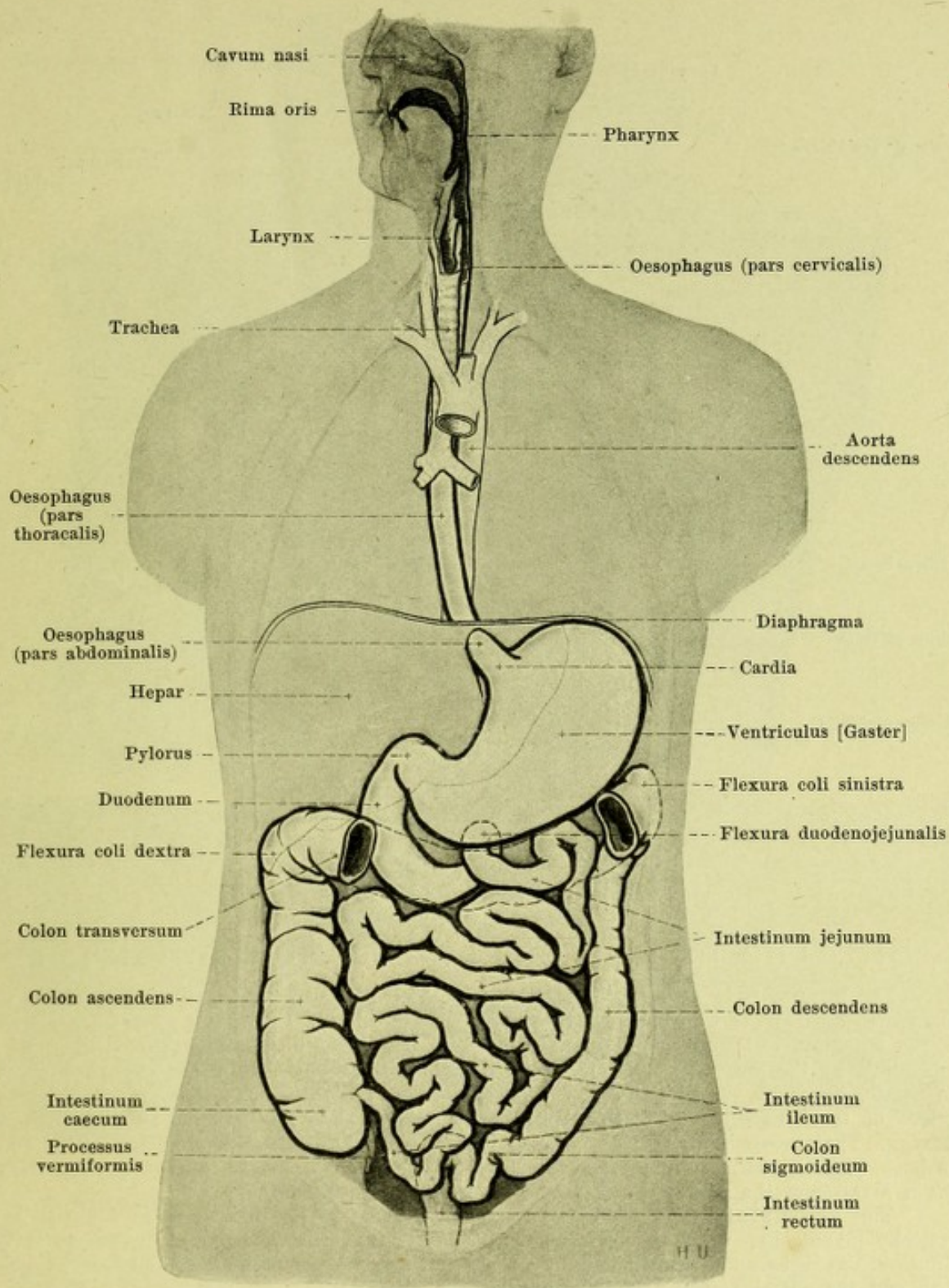


Digitized by the Internet Archive
in 2016

https://archive.org/details/b28128692_0003

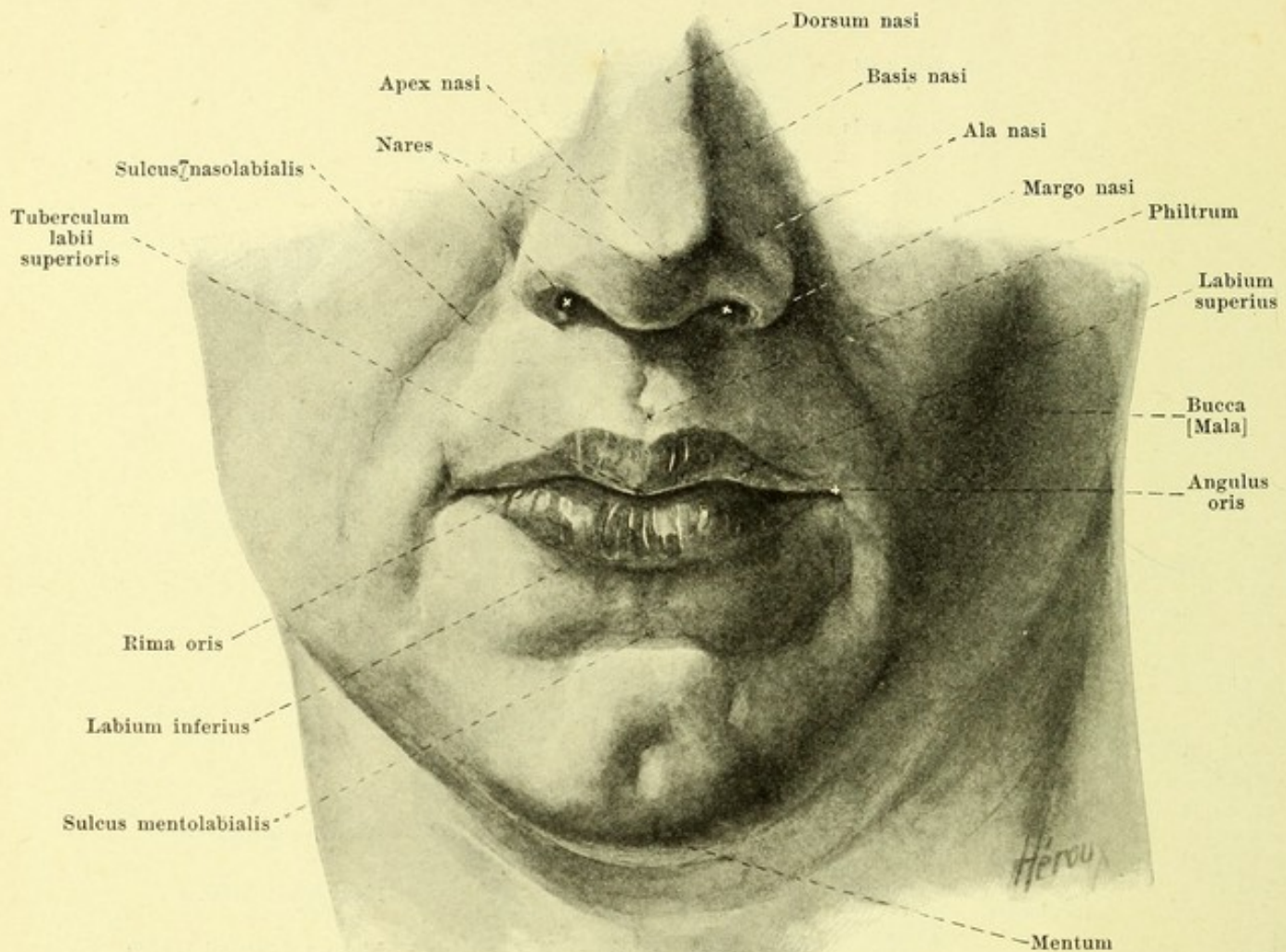
III.

Viscera, Brain, Nerves, Sense-
Organs.



512. General view of the digestive tube, somewhat schematic.

(The stomach is represented in this drawing without regard to its exact true position; see p. 513. A piece has been cut out of the transverse colon, its course being indicated by dotted lines. The inferior margin of the liver is indicated by a fine dotted line.)

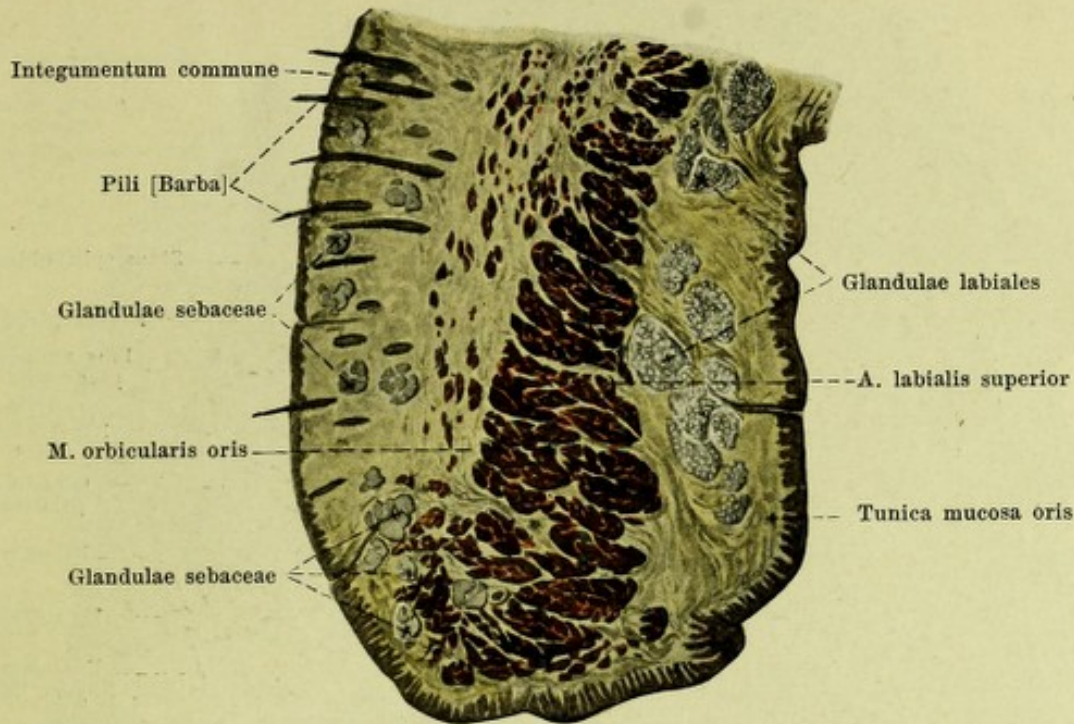


513. The mouth-slit and its surroundings.

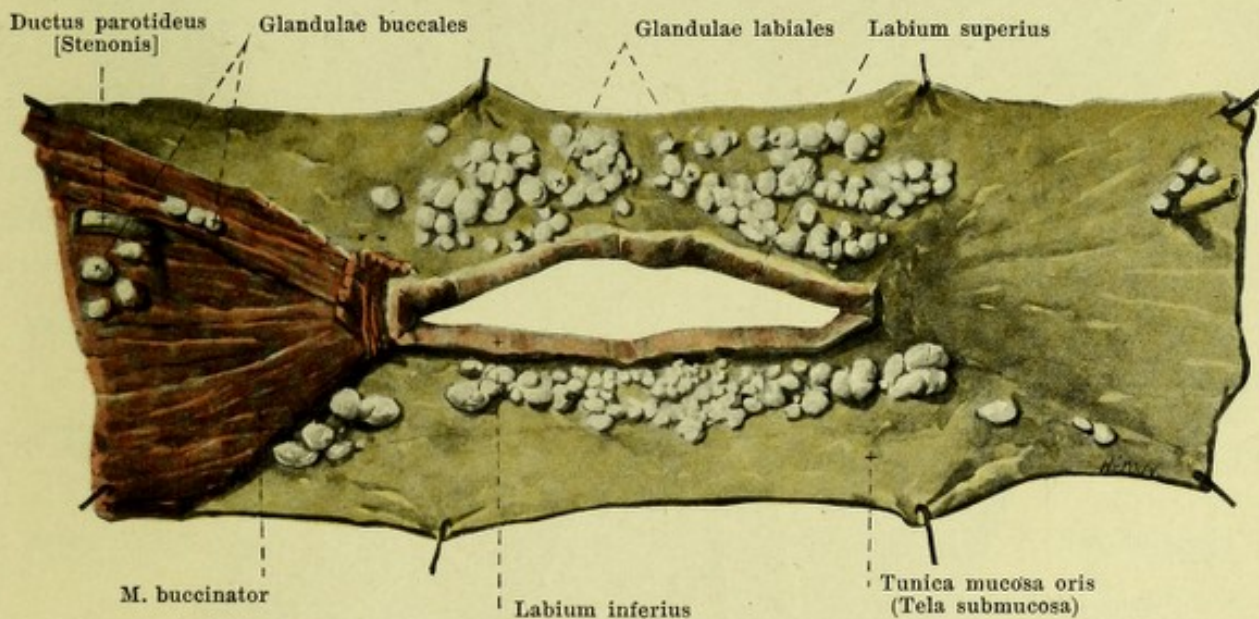
The **cavum oris** (*mouth cavity*) (see Figs. 516, 517 and 543) is the beginning of the *apparatus digestorius* (digestive tube) but serves also as a path for the respiratory air and for the formation of sounds of speech. It opens in front through the mouth-slit; in front it is bounded by the mucous membrane of the lips, lateralward by that of the cheeks, above by the palate, below by the tongue and by the mucous membrane which extends from the under surface of the tongue to the gums; behind it is connected by the *isthmus faucium* with the pharynx. The *processus alveolares* of the upper jaw-bones and the *pars alveolaris* of the lower jaw-bone with the teeth fixed in them separate an anterior and lateral, narrow portion (*vestibulum oris*) from the mouth cavity proper (*cavum oris proprium*).

The **vestibulum oris** when the mouth is closed and lips and teeth in contact, is a vertically placed slit, which is connected with the mouth-cavity proper only by means of the minute spaces between the teeth and by a somewhat larger space between the hindermost molar teeth and the anterior margin of the ramus of the lower jaw.

The **lips** (*labia oris*) (see also Figs. 514—516, 538 and 543) are folds which are covered on the outer surface by skin, on the inner by the *tunica mucosa oris* and which contain, between these, the *m. orbicularis oris* (see p. 245). As *upper* and *lower lip* (*labium superius*, *labium inferius*) they bound the *rima oris* (*mouth-slit*) and go over into one another on each side, lateralward from its extremity (*angulus oris*, *angle of the mouth*), by means of the *commissura labiorum*. In the median plane from the posterior surface of each a small perpendicular fold of mucous membrane (*frenulum labii superioris*, *frenulum labii inferioris*) extends to the anterior surface of the jaw-bones. Between the muscular layer and the mucous membrane in the *tela submucosa* lie numerous mucous glands (*glandulae labiales*), some as large as a pea; their ducts open upon the surface of the mucous membrane.



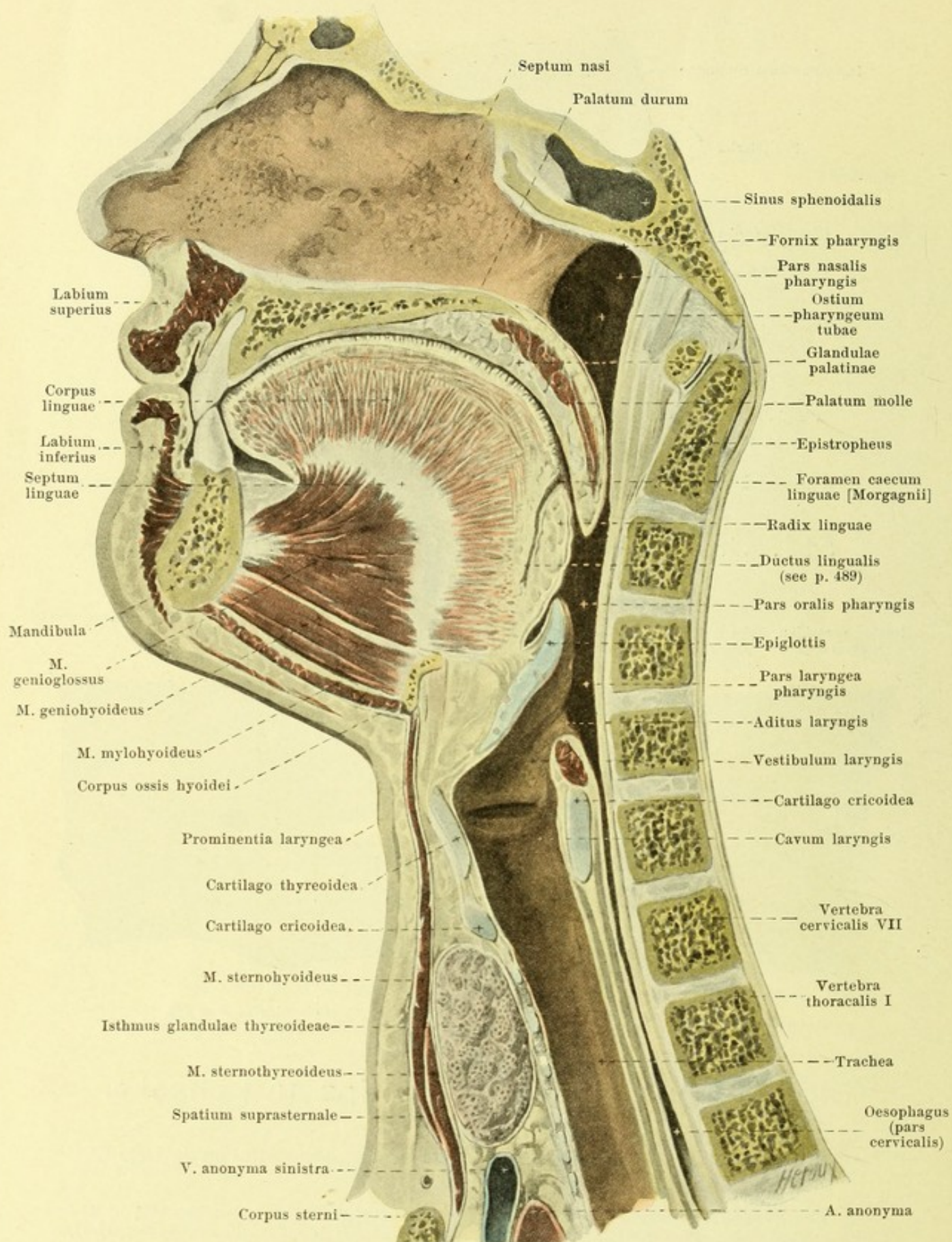
514. Cross section through the upper lip.
Magnification 4 : 1.



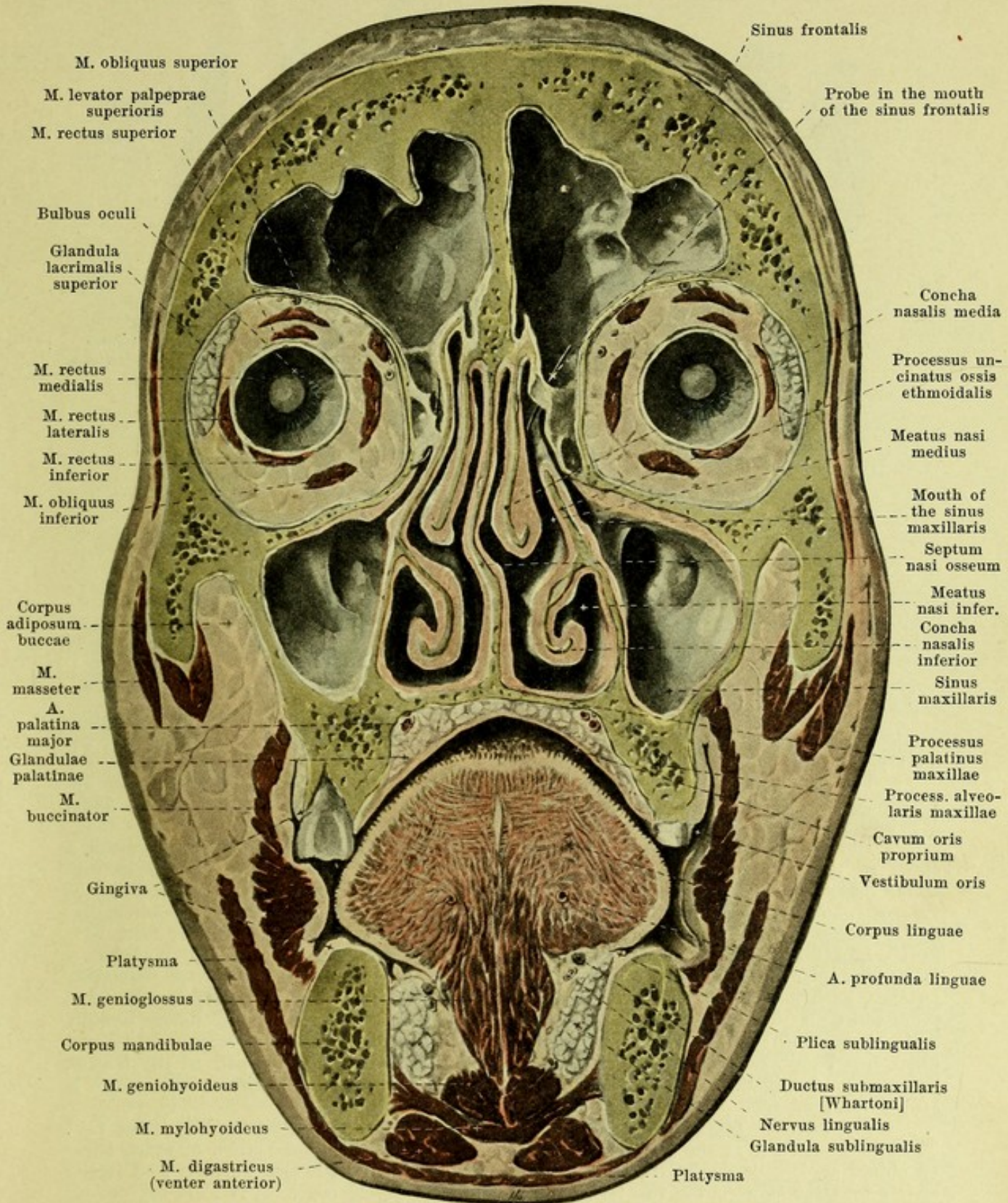
515. Mucous glands of the lips and cheeks,
viewed from in front.

(The external skin has been completely, the musculature of the mouth-slit in large part, removed.)

The **cheeks** (*buccae*) are lined internally in the region of the vestibulum oris by the tunica mucosa oris. They contain a smaller number of mucous glands (*glandulae buccales*), which lie partly between the mucous membrane and the m. buccinator, partly upon the lateral surface of the latter; two or three glands situated beneath the mucous membrane in the region of the last molar tooth are called *glandulae molares* (not illustrated).

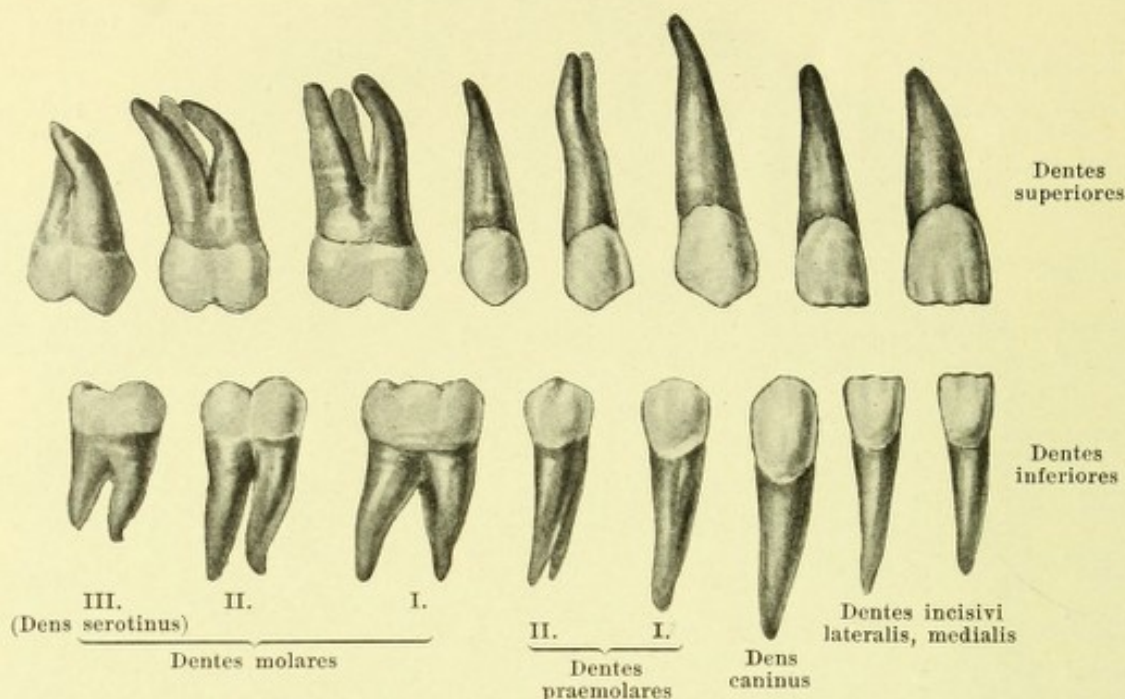


516. Median section of the head and neck, right half, viewed from the left (partly after W. Braune).



517. Frontal section of the head,
viewed from behind (after W. Braune).

The **mucous membrane of the mouth cavity** (*tunica mucosa oris*) lines the inner surface of the lips and cheeks and is reflected upon the jaw-bones at about half the height of the roots of the teeth. It there forms the *gums* (*gingiva*), is high, dense, immovable and arranged around the neck of the teeth in the form of wall-like elevations (see also Figs. 523 and 543).



518. Permanent teeth, right side,

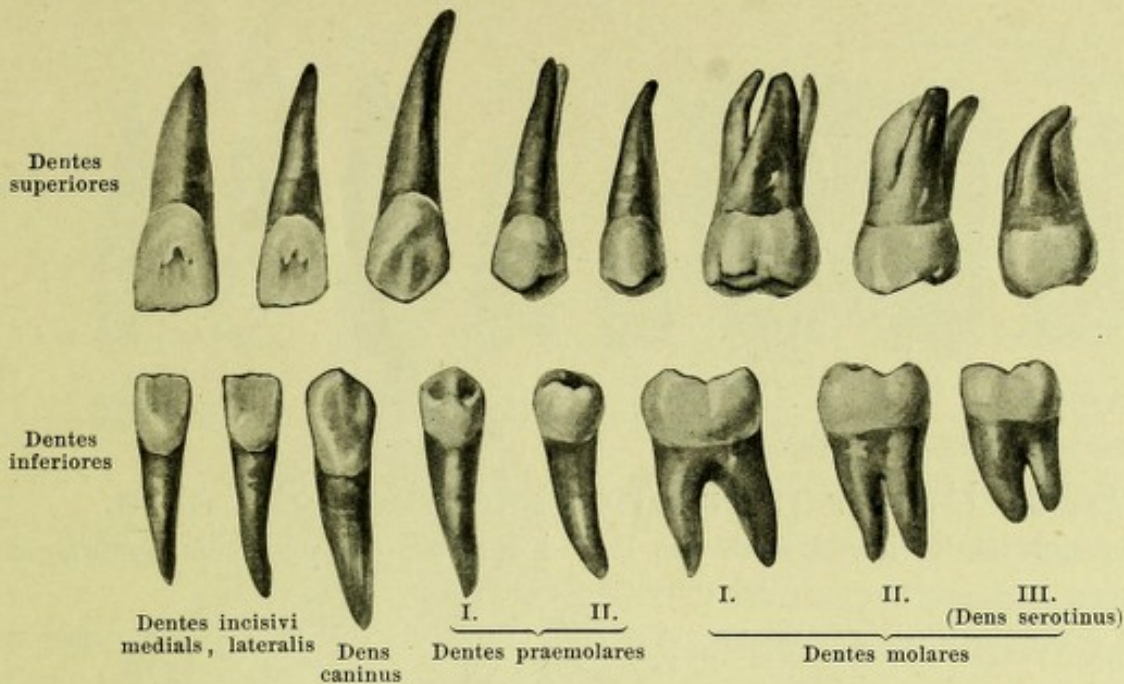
viewed from the lip or cheek surface.

The **teeth** (*dentes*) appear in two successive series called dentitions. The first dentition consists of *twenty milk teeth*, the second of *thirty-two permanent teeth*, which appear for the most part in the place of the milk teeth.

The **permanent teeth** (*dentes permanentes*) (see also Figs. 519—521, 527—529) are present in the upper and lower jaws, eight on each side: *2 incisor teeth*, *1 canine tooth*, *2 premolar teeth* and *3 molar teeth*.

The **incisor teeth** (*dentes incisivi*) possess a crown which in general resembles a chisel so that its free end is formed by a straight edge, the cutting edge. The facies contactus (facies medialis et lateralis) are approximately triangular, the facies labialis et lingualis are somewhat narrowed toward the root. The labial surface is approximately quadrangular and possesses usually three low longitudinal ridges, which correspond, when the teeth have freshly broken through, to three rounded jags on the cutting edge. The lingual surface is more triangular and markedly concave lengthwise; it ends at the neck in a very blunt projection. Each incisor tooth has only one root, which is inclined somewhat lateralward ("root characteristic"). The roots are conical, compressed somewhat from right to left (more markedly in the lower teeth) and usually slightly grooved on the medial and lateral surfaces. The root canal (see Figs. 523 and 525) is single. The superior medial incisor tooth is the largest, then follow usually the superior lateral, the inferior lateral and the inferior medial, which is always the smallest.

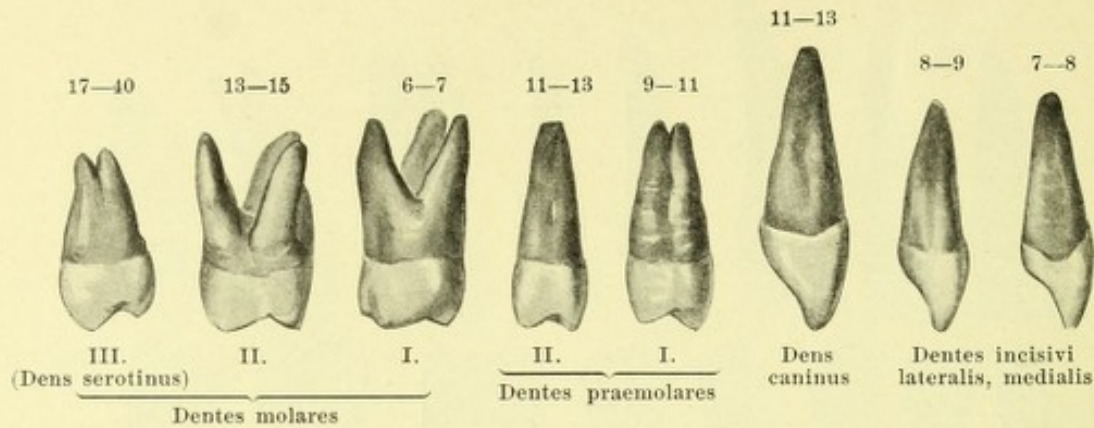
The **canine teeth** (*dentes canini*) are the strongest and longest teeth with one root. The crown runs out at the free end into an edge, the medial shorter portion of which forms an obtuse angle with the lateral longer portion. The labial surface is approximately pentangular and is broadest between the two terminal points of the cutting edge. It is markedly convex, especially in transverse direction. The lingual surface of the upper canine tooth presents a blunt nodule on its neck, from which a strong longitudinal ridge extends to the medial angle of the chewing edge. Medial and lateral from this ridge lies a shallow groove. The lingual surface of the inferior canine tooth is slightly concave, its nodule projecting but little or not at all. The crown of the inferior canine tooth is the narrower and longer. The roots are single, flattened and grooved, like those of the incisor teeth; that of the inferior is not seldom bifurcated; they are inclined somewhat backward, especially toward the apex. The root canal is single.



519. Permanent teeth, right side, viewed from the lingual surface.

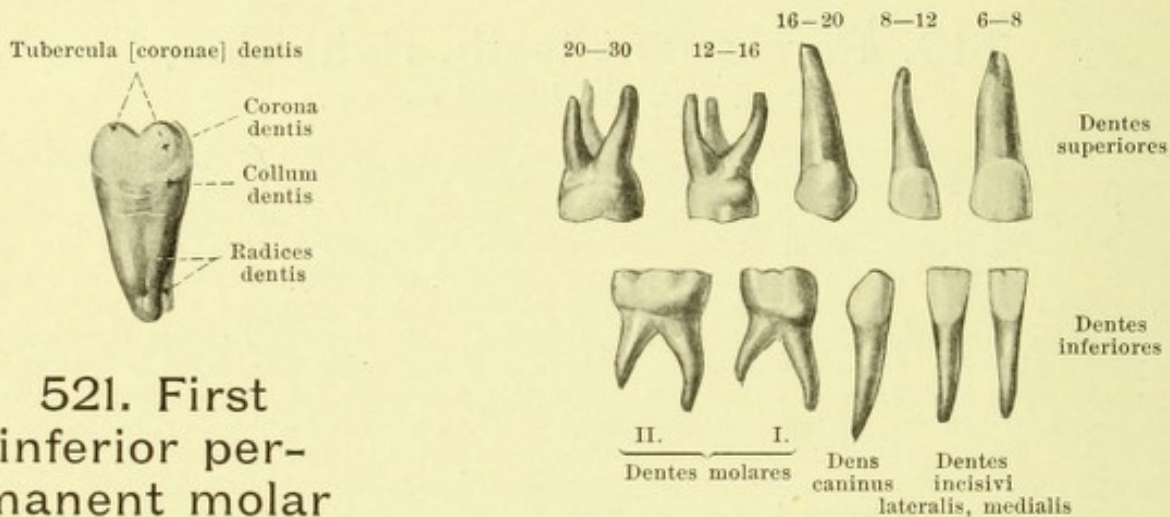
The **premolar teeth** (*dentes praemolares*) possess a broad, uneven, rounded-off quadrangular chewing-surface, which is divided by a groove running from before backward into a larger buccal and a smaller lingual tubercle: the tubercles are of the same height on the second superior premolar tooth; on the other premolars the lingual tubercle is lower. On the inferior teeth the two tubercles are frequently connected by a ridge of enamel. The buccal and lingual surfaces are convex transversely and longitudinally and each of them helps to form one of the declivities of the tubercles mentioned; thus the buccal surface resembles in its form that of the corresponding canine tooth. The root is single and curved backward; on the upper teeth it is flattened from before backward and presents flat grooves on the anterior and posterior surfaces, the marked development of which leads frequently to a bifurcation of the root of the first superior premolar tooth; the roots of the inferior teeth are more rounded. The pulp-cavity is a narrow slit-like space, compressed from before backward, and possesses two diverticula corresponding to the two tubercles; the first superior premolar tooth has, almost constantly, two root canals, one buccal and one lingual, the others have one slit-like canal.

The **molar teeth** (*dentes molares*) are the strongest teeth and have (especially in the lower jaw) a more cubical crown. On the first superior molar tooth the chewing-surface is rhombic and divided by an **H**-like asymmetrically arranged groove into four tubercles of unequal size, of which two lie upon the buccal surface and two upon the lingual surface; the anterior lingual tubercle is the largest, the posterior the smallest. The buccal and lingual surfaces are convex and are subdivided by a longitudinal groove; the lingual surface frequently possesses a small (fifth) tubercle in front; it is often merely indicated and only very rarely reaches the chewing-surface. The anterior and posterior (contact) surfaces are convex. The second upper molar tooth has either four tubercles like the first, or only three, in which case the posterior lingual tubercle is merely indicated or entirely absent. The third upper molar tooth (*dens serotinus*, *wisdom tooth*) varies extremely in form and size. The crown in many ways resembles that of the second; it possesses usually three tubercles, sometimes more, sometimes fewer; it may be very much reduced in size. The upper molar teeth have three roots; the two buccal roots run approximately parallel to one another, are flattened from before backward and bend somewhat backward at the apex; the third lingual (palatal) root is rounded and diverges from the other two. The buccal roots have usually anterior and posterior longitudinal grooves, the palatal root is often manifoldly grooved on its lingual surface. The roots of the wisdom tooth are more or less fused with one another. The pulp cavity is large, somewhat narrowed from before backward and possesses as many processes as there are nodules present (3—4). Each root has a single canal. The first molar tooth is usually the largest, the third the smallest.



520. Upper permanent teeth, right side,
the anterior teeth viewed from the lateral surface, the posterior teeth from
the posterior surface.

(The Arabian numerals give the time of eruption of the individual teeth in years [after E. Zuckerkandl].)



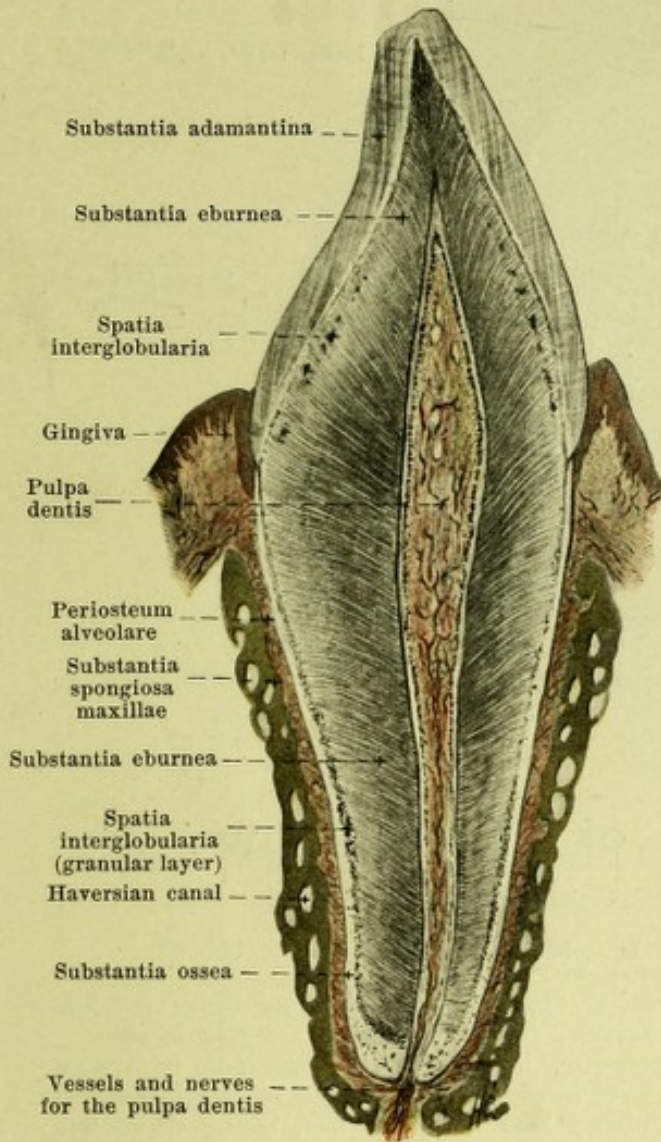
**521. First
inferior per-
manent molar
tooth, right
side,**

viewed from in front.

522. Milk teeth, right side,
viewed from the labial or buccal surface.

(The Arabian numerals give the time of eruption of the individual teeth in months [after Fr. Hesse].)

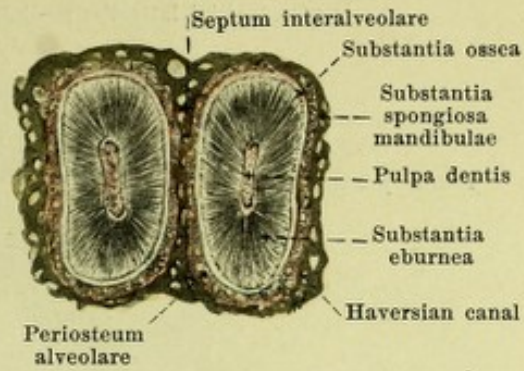
The **molar teeth** (continued). The inferior molar teeth are larger and more powerful than the superior. Their chewing surfaces are rectangular and are somewhat longer from before backward than in the frontal direction. Each surface is divided by a fairly symmetrical + -shaped groove into 4-5 tubercles, namely 2-3 buccal and 2 lingual, of which the latter are a little the higher; the anterior tubercles are somewhat larger than the posterior. The buccal surface is more markedly convex than the lingual. The first molar tooth almost always presents five tubercles, the second usually four, often five. The third (wisdom tooth) varies very much, but in general is not so rudimentary as in the upper jaw; it has usually 5 or 4 tubercles. Each tooth possesses two roots, an anterior broader and a posterior; both are flattened from before backward and usually present longitudinal grooves on the broad anterior and posterior surfaces. The anterior root is usually directed vertically, the posterior obliquely backward; either of these may be bifurcated. The roots of the wisdom teeth are very different, frequently fused. The pulp cavity (see Fig. 526) resembles in shape that of the crown. The anterior root usually has two canals, a buccal and a lingual, the posterior usually only one (sometimes also two). The wisdom tooth presents three or two root canals or even only one. The first molar tooth is usually the largest, the third the smallest.



523. Sagittal section of an upper incisor tooth and its surroundings.

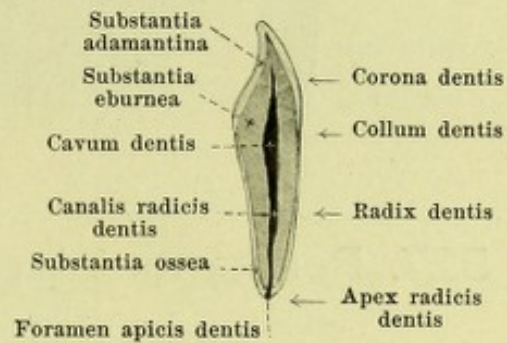
Magnification 5 : 1.

(In Figs. 523 and 524 the drawings of the teeth have been made from air-containing ground sections.)

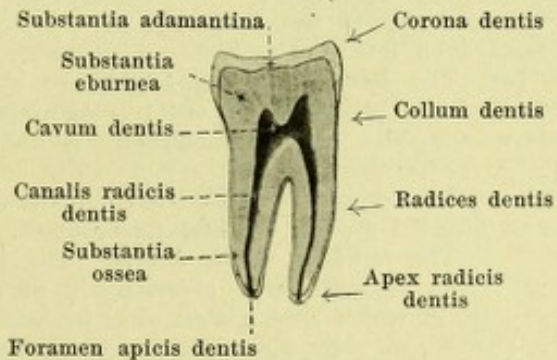


524. Transverse section through the roots of two lower incisor teeth and their surroundings.

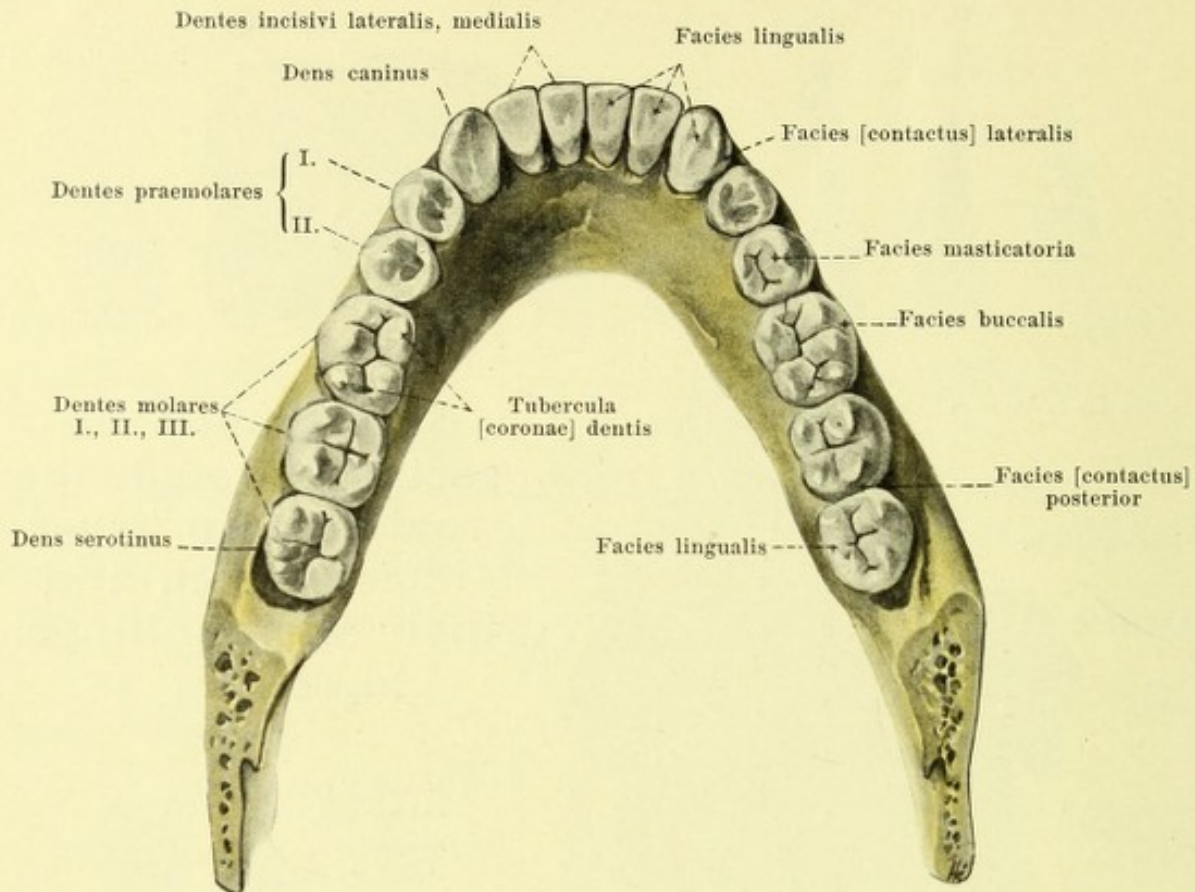
Magnification 5 : 1.



525. Sagittal section through an upper incisor tooth.



526. Sagittal section through a lower molar tooth.



527. Permanent teeth of the lower jaw *in situ*, viewed from above.

(The rami mandibulae have been sawed away.)

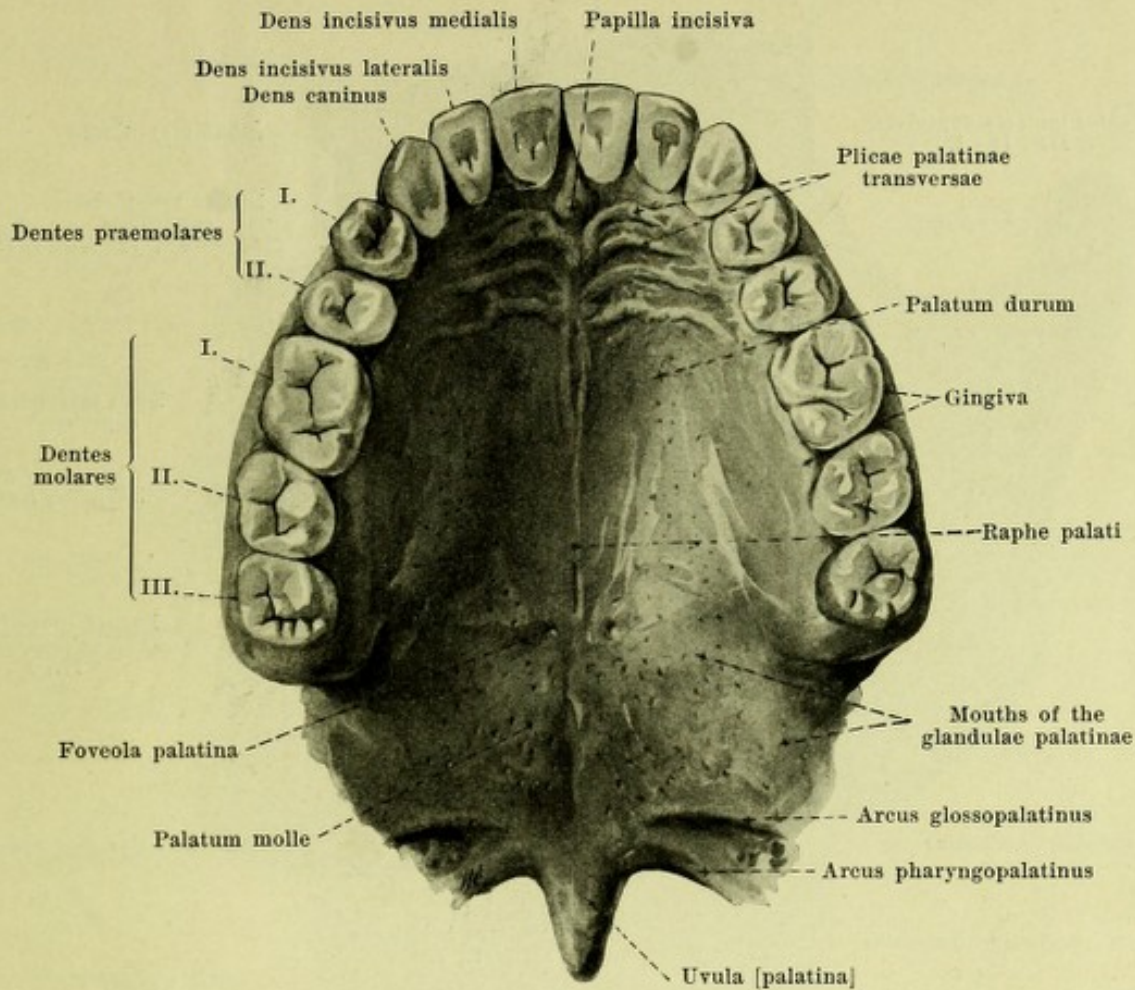
The **milk teeth** (*dentes decidui*) (see Fig. 522) are situated in the upper and lower jaws, five on each side as follows: 2 *incisor teeth*, 1 *canine tooth* and 2 *molar teeth*.

With the exception of the first molar teeth, in the main they resemble in form the corresponding permanent teeth, but are, however, in general smaller and more delicate. The crowns of the incisor and canine teeth are relatively broader and shorter, their roots are fairly long and very delicate. The milk teeth stand more perpendicularly in the jaws. Especially characteristic is the markedly developed ridge-like enamel border with which the crown is marked off from the root.

The **incisor milk teeth** are in their crowns very similar to the permanent. The root of the upper medial one is somewhat flattened from before backward, that of the other is round. The "root characteristic" is distinctly marked on the upper teeth, but on the lower it is inconstant.

The **canine milk teeth** resemble the permanent very closely; the roots are round and directed toward the first molar tooth.

The **molar milk teeth**. The first upper molar occurs in two forms. Either it resembles in its crown, especially in its chewing surface, the first permanent premolar very closely, in which case the chewing surface is triangular and divided by a sagittal groove into a buccal and a lingual tubercle; or the chewing surface is broader from before backward, the buccal tubercle runs out more into a cutting edge, and behind the lingual tubercle a second smaller one appears. The buccal surface regularly presents a blunt nodular projection in front just over the neck of the tooth. The upper second molar milk tooth resembles throughout the first permanent upper molar tooth. Both upper molar milk teeth possess three roots, which in position and form are in general like those of the permanent teeth; but at their tips they diverge widely from one another.

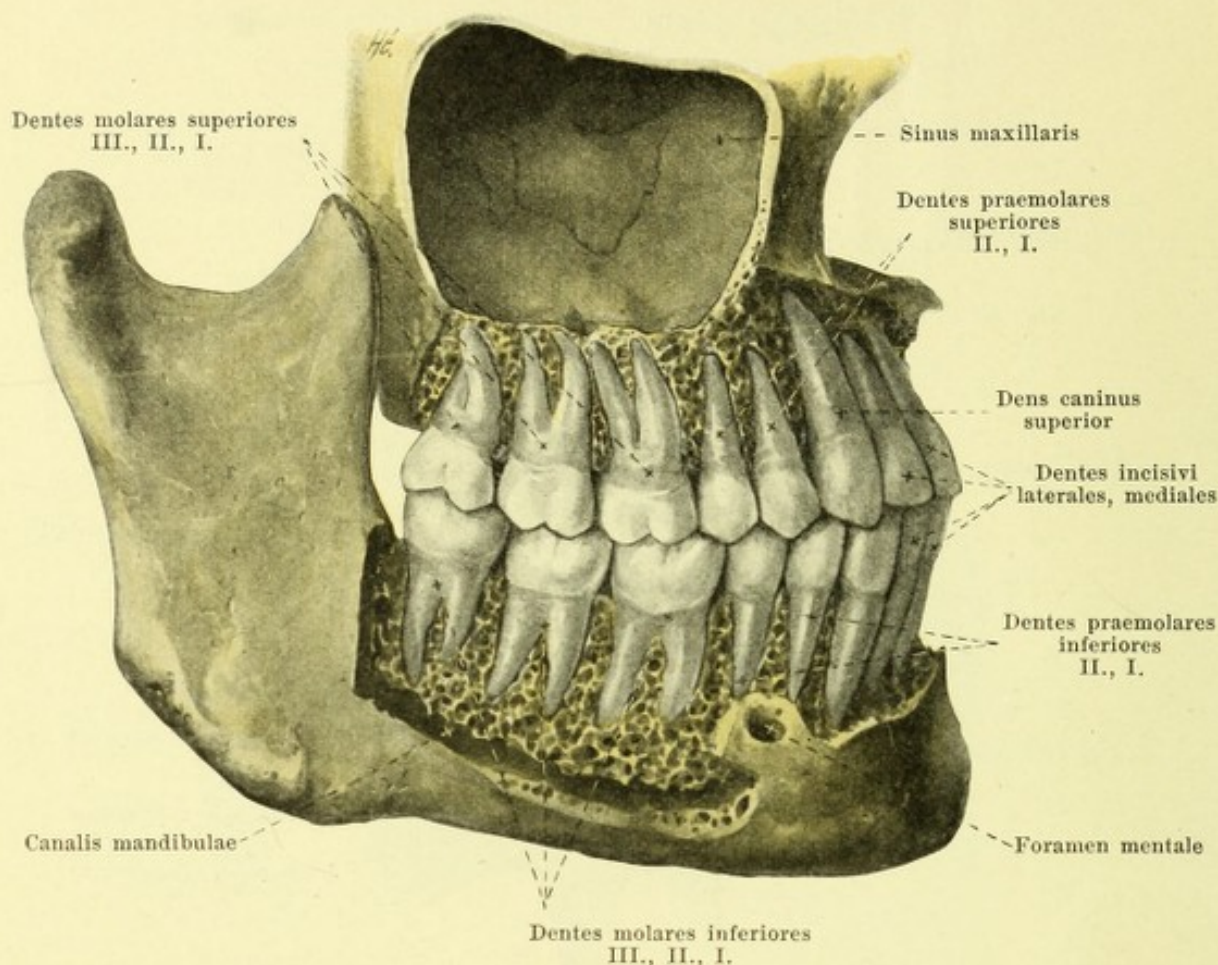


528. Permanent teeth of the upper jaw *in situ*

with the mucous membrane of the palate, viewed from below.

Molar milk teeth (continued). The first lower molar tooth has a quadrangular chewing surface, which is drawn out lengthwise from before backward. It presents four or five tubercles, two lingual, sharp, and two or three buccal, lower, separated from the former by a sagittal furrow. The first lower tooth bears on its buccal surface a projection analogous to that seen in the first upper tooth. The second lower molar milk tooth resembles throughout the first permanent lower molar tooth. Each of the two lower molar milk teeth has two broad roots, which diverge markedly from one another, and only at their tips are bent somewhat toward one another; otherwise, however, they resemble those of the permanent teeth.

General statements regarding the teeth (see Figs. 521, 523—526). Each tooth consists of *dentine* (*substantia eburnea*), *enamel* (*substantia adamantina*) and *cement* (*substantia ossea*). The dentine forms the main mass and gives the tooth its form, the enamel covers the free part of the tooth superficially, the cement the parts hidden in the bone and gum. According to form are distinguished the *crown of the tooth* (*corona dentis*), the *neck of the tooth* (*collum dentis*), and the *root of the tooth* (*radix dentis*). The crown of the tooth is the thickest part projecting free into the mouth cavity. The root of the tooth, often multiple, is the longest portion, is situated for the most part in the correspondingly shaped alveolus of the jaw and is there held firmly in place by the fibers of the *root membrane* (*periosteum alveolare*) which for the most part run transversely; a narrow region of the root, however, projects beyond the free margin of the bone, is covered only by the gum and constricted more markedly in teeth with several roots than in teeth with one root; it is called the neck of the tooth. Within the dentine lies a cavity which resembles the external form of the tooth; the larger portion of the cavity situated in the crown and in the neck is called the *pulp cavity* (*cavum dentis*); this narrows down to a slender *root canal* (*canalis radialis dentis*) which runs in every root and opens at the tip of the root (*apex radialis dentis*) by means of a fine opening (*foramen apicis dentis*). The whole cavity is completely filled by the *pulp of the tooth* (*pulpa dentis*), rich in blood vessels and nerves.

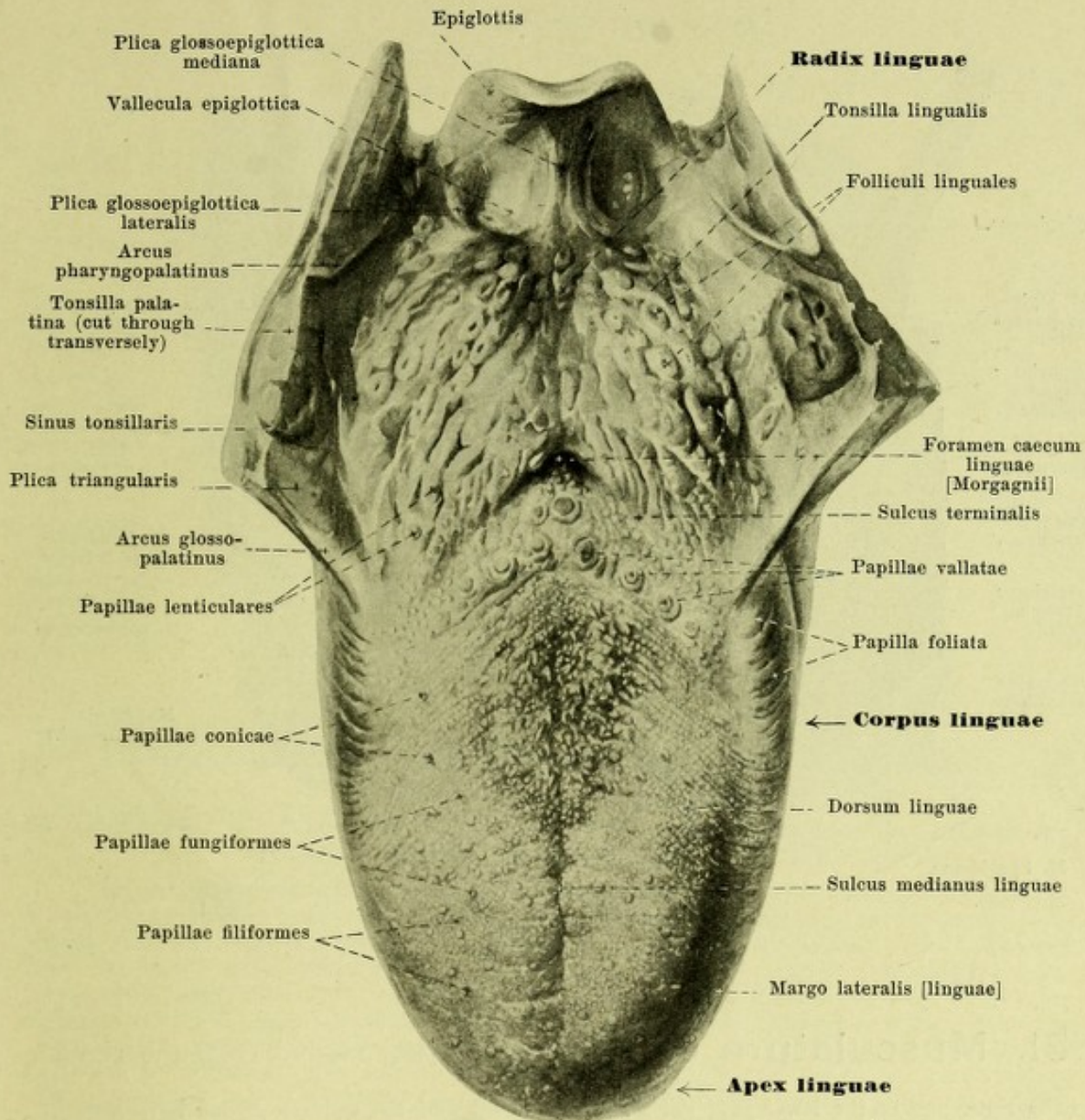


529. The permanent teeth, viewed from the right.

(The external layer of bone has been partly removed and the sinus maxillaris has been opened.)

On the *crown of the tooth* (see Fig. 527) five surfaces can be distinguished. The external surface of the incisor and canine teeth is covered by the lips (*facies labialis*), of the premolar and molar teeth by the cheeks (*facies buccalis*). The inner surface belonging to the concave side of the tooth-arch is the *facies lingualis*. The two surfaces, by which the tooth touches its neighbors are called the *facies contactus* and on the incisor and canine teeth are distinguished as the *facies medialis* and *facies lateralis*, on the premolar and molar teeth as the *facies anterior* and *facies posterior*. The fifth surface (*facies masticatoria*) when the jaws are closed is in contact with the corresponding surface of the other row of teeth; on the incisor teeth it is reduced to a cutting edge, but on the other teeth it has one or several tubercles (*tubercula [coronae] dentis*).

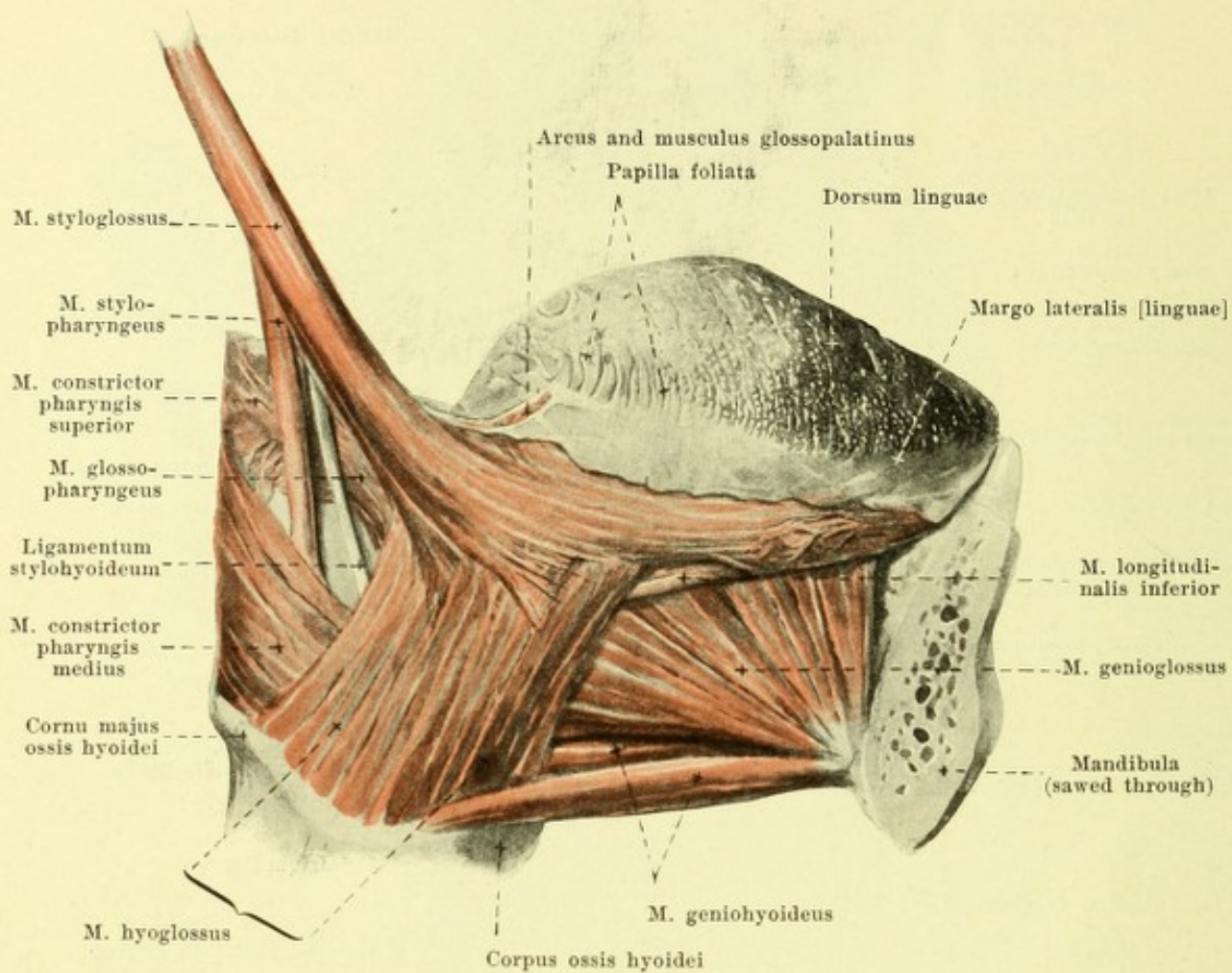
The *lower row of teeth* or *tooth-arch* (*arcus dentalis inferior*) (see Fig. 527) resembles a parabola in its curvature, the *upper row* (*arcus dentalis superior*) (see Fig. 528) forms half an ellipse. Since the two rows of teeth differ from one another and since, besides, the teeth in the two jaws present differences in form and size, the teeth of the same name in the upper and lower jaws do not come into contact with one another in their corresponding portions. The *articulation of the rows of teeth*, occurs rather as follows: The upper teeth which *in toto* are directed with their long axes somewhat obliquely outward and downward, project lateralward somewhat over the lower teeth, the long axes of which run more inward and upward. As a result of this the upper anterior teeth cover somewhat the free ends of the lower teeth from in front (the upper teeth bite over the lower) (see also Fig. 516), while the buccal tubercles of the other upper teeth lie somewhat lateralward as regards the same tubercles of the lower teeth, and the lingual tubercles of the lower teeth lie in the grooves between the buccal and lingual tubercles of the lower teeth. The rows of teeth are also displaced from before backward as regards one another. Especially since the upper incisor teeth are considerably broader than the lower, the upper canine tooth lies between the lower canine and the first premolar, touching both; similarly the upper premolar and molar teeth are displaced backward; the upper wisdom tooth, smaller than the lower, is the only one that does not project over behind the lower.



530. Tongue, viewed from above.

(The palatine arches and the palatine tonsils have been cut through transversely.)

The **tongue** (*lingua*) is a flat, oblong body consisting mainly of muscles and is fastened below to the floor of the mouth. It ends in front in a flat rounded tip (*apex linguae*). Following upon this without being sharply differentiated from it is the body of the tongue, *corpus linguae*. This in turn is bounded behind by the *sulcus terminalis*, the right and left limbs of which run obliquely backward toward the median plane and meet in the *foramen caecum linguae [Morgagnii]*; the latter is represented usually by a small depression and in an early embryonal period is the opening of the ductus thyreoglossus, the terminal portion of which may still be met with in variable length in the adult as the *ductus lingualis* (see Fig. 516). The region behind the *sulcus terminalis* is called the *radix linguae* (root of the tongue). The upper surface of the tongue (*dorsum linguae*) (see also Figs. 516 and 517) is curved in a sagittal and frontal direction so as to be convex upward and presents in the median plane especially in front a shallow groove, the *sulcus medianus linguae*. At the root of the tongue it goes directly over into the medial surface of the palatine arch and the tonsil (see also Fig. 545). The body of the tongue is bounded lateralward by the blunt *margo lateralis [linguae]*. The inferior surface (*facies inferior [linguae]*) lies free only along its lateral margins and below the anterior portion of the tongue (see also Figs. 516, 517 and 538).



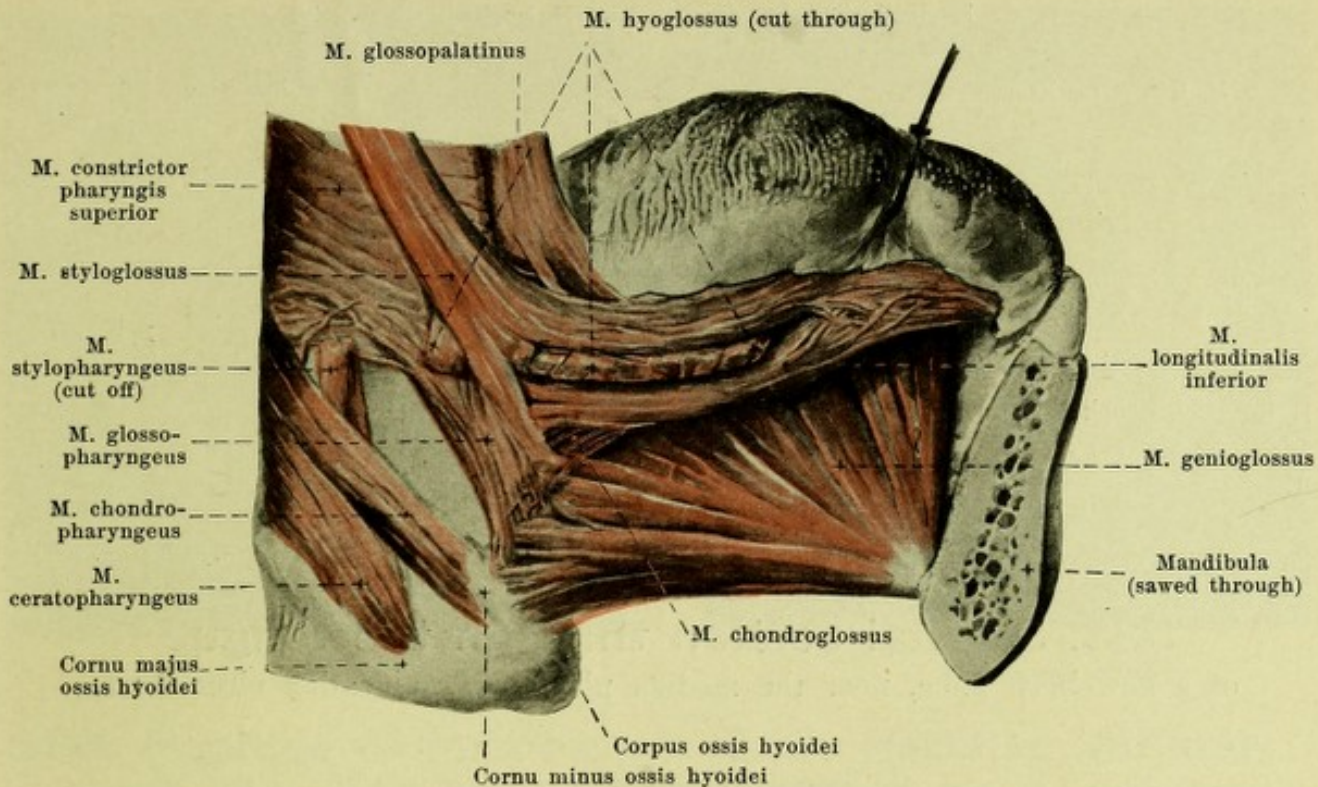
531. Musculature of the tongue, viewed from the right.

(The right half of the lower jaw, the m. mylohyoideus and the salivary glands have been removed.)

Muscles of the tongue (*musculi linguae*):

M. styloglossus (see also Figs. 532, 534, 539 and 555). Form: long, narrow and flat. Position: medianward from and above the m. stylohyoideus, between the a. carotis externa and interna, medianward from the mandibula and m. pterygoideus internus, covered by the glandula parotis. Origin: processus styloideus and ligamentum stylohyoideum. Insertion: it runs obliquely downward, forward and medianward to the lateral surface of the m. hyoglossus and there divides into two bundles; the larger lateral upper bundle goes on the lateral surface of the m. hyoglossus and m. longitudinalis inferior beneath the lateral margin of the tongue toward the tip of the tongue; the smaller medial inferior bundle perforates the m. hyoglossus and turns medianward in the posterior part of the tongue. Action: it draws the tongue, especially the radix linguae, upward and backward. Innervation: n. hypoglossus.

M. hyoglossus (see also Fig. 532). Form: flat, quadrangular. Position: medianward from and above the glandula submaxillaris and m. mylohyoideus, medianward from the mandibula. Origin: upper margin of the corpus and cornu majus ossis hyoidei. Insertion: it extends upward and somewhat forward and plunges between the bundles of the m. styloglossus; the fibers then bend around forward between the lateral bundle of the m. styloglossus and the m. longitudinalis inferior and run longitudinally in the tongue toward the apex. Action: it draws the tongue backward and downward. Innervation: n. hypoglossus.



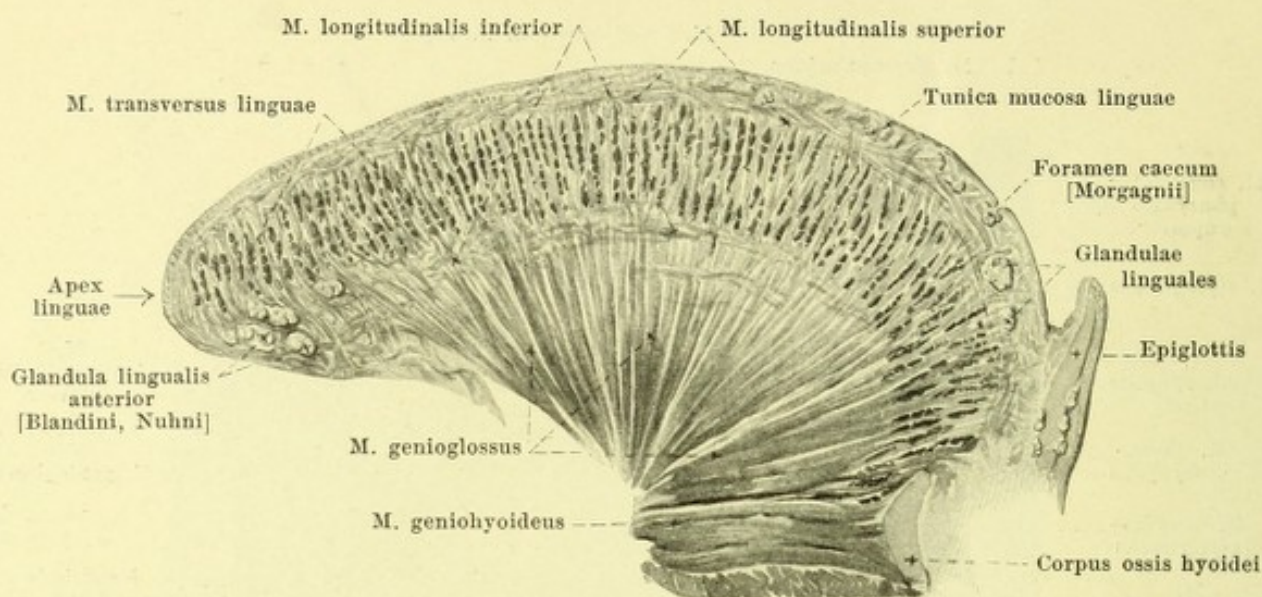
532. Deep musculature of the tongue, viewed from the right.

(As in Fig. 531; in addition the mm. geniohyoideus and hyoglossus have been removed and the tongue has been drawn upward and to the left.)

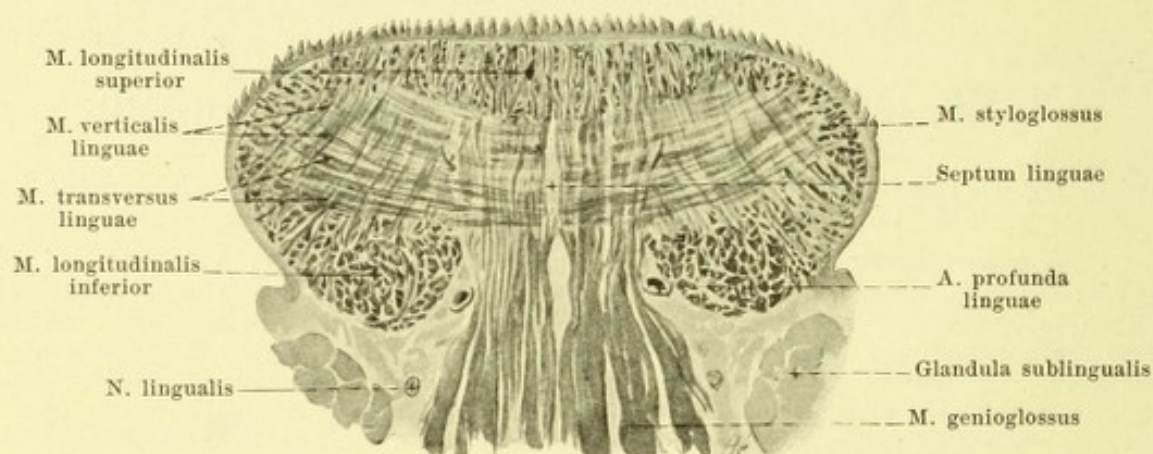
M. genioglossus (O. T. geniohyoglossus) (see also Figs. 531, 533, 534 and 539). Form: approximately quadrangular, thick, placed sagittally. Position: in the depth of the tongue, just above the m. geniohyoideus close to and parallel to the median plane, separated from the muscle of the other side only by loose connective tissue and by the septum linguae (see p. 493); lateralward partly covered directly by the mm. longitudinalis inferior, hyoglossus, styloglossus and the glandula sublingualis. Origin: by a small triangular tendon from the spina mentalis mandibulae, just above the m. geniohyoideus. Insertion: the fibers diverge backward and upward. The lowermost fibers go backward parallel to the m. geniohyoideus and are attached partly to the corpus ossis hyoidei, partly to the epiglottis; the other fibers radiate fan-like toward the dorsum linguae in the whole length of the tongue and accordingly decussate in layers with the fibers of the m. transversus linguae. Action: it draws the tongue forward and downward. Innervation: n. hypoglossus.

M. longitudinalis inferior (O. T. inferior lingual) (see also Figs. 531, 534 and 539). Form: long and narrow. Position: in the depth of the tongue, in front between the mm. genioglossus and styloglossus, behind between the mm. genioglossus and hyoglossus. Origin: in the mucous membrane of the root of the tongue. Insertion: the fibers pass downward in the form of a curve and collect on the medial surface of the m. hyoglossus in the form of a well isolated muscle-belly. Fibers which arise from the cornu minus oss. hyoidei (*m. chondroglossus*) partly lie upon this muscle belly below, partly extend upward and forward between the bundles of the m. genioglossus and join the m. longitudinalis superior. The main mass of the m. longitudinalis inferior runs straight forward and ends in the mucous membrane of the facies inferior linguae; only a small part bends upward to the mucous membrane of the dorsum of the tongue. Action: it shortens the tongue in the longitudinal direction. Innervation: n. hypoglossus.

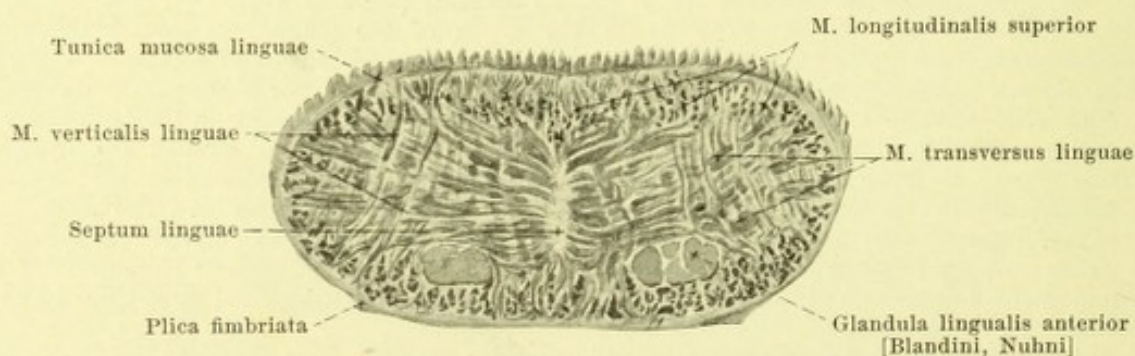
M. longitudinalis superior (O. T. superior lingual) (see Figs. 533—535), just beneath the mucous membrane of the whole of the dorsum of the tongue, strengthened behind by a part of the fibers of the m. chondroglossus. The fibers run in the longitudinal direction, are stretched out in bundles in short arches, concave above, between points of the mucous membrane, the different bundles decussating with one another. Action: it bulges the tongue upward in the longitudinal direction. Innervation: n. hypoglossus.



533. Sagittal section through the tongue
of a new-born babe, near the median plane. Magnification circa 3 : 1.

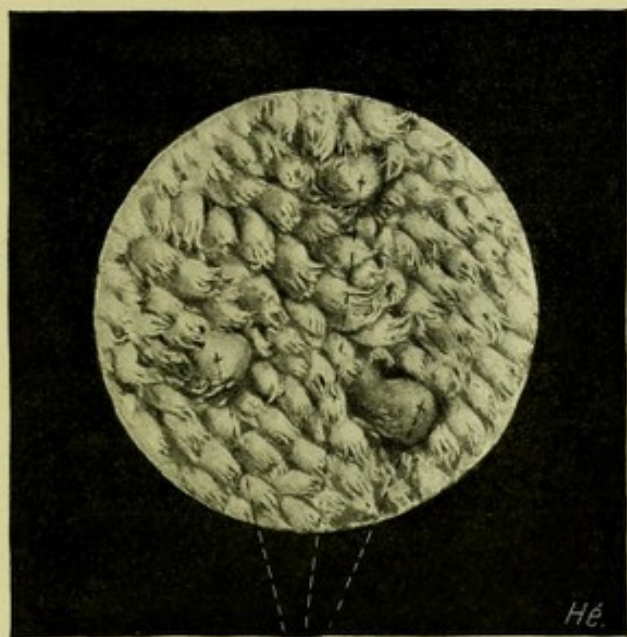


534. Frontal section through the body of the tongue of a new-born babe. Magnification circa 3 : 1.

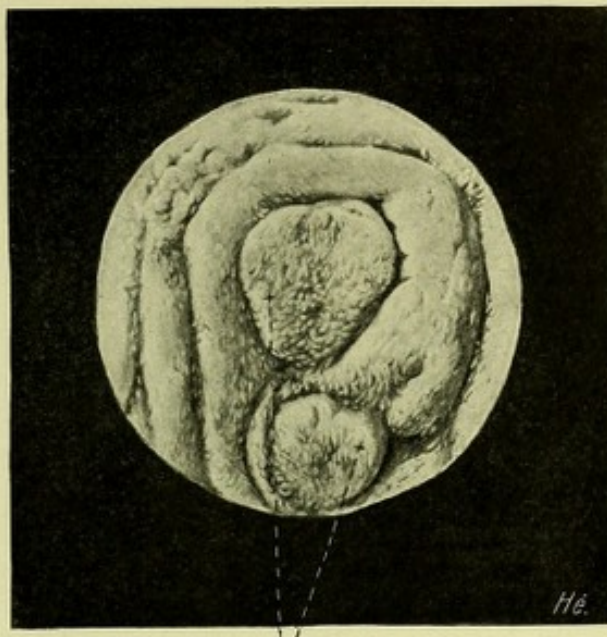


535. Frontal section through the apex of the tongue of a new-born babe. Magnification circa 3 : 1.

(Figs. 533—535 after preparations of Fr. Hesse.)



Papillae fungiformes



Papillae vallatae

536. Papillae filiformes, viewed from the surface.

Magnification 7 : 1.

537. Papillae vallatae, viewed from the surface.

M. transversus linguae (see Figs. 533—535), in the whole extent of the tongue. It consists of layers placed perpendicularly to the surface alternating with the lamellae of the *m. genioglossus*; in these layers the fibers run in a transverse direction and have a fan-like distribution to the mucous membrane of the dorsum and lateral margin of the tongue; some of the fibres of the muscle arise from the septum linguae, others perforate it. Action: it bulges the tongue upward in the transverse direction. Innervation: *n. hypoglossus*.

M. verticalis linguae (see Figs. 534 and 535) is formed of bundles of fibers, which pass directly from the superior to the inferior mucous membrane of the tongue especially in the neighborhood of its lateral margin. Innervation: *n. hypoglossus*.

Septum linguae (see Figs. 516, 534 and 535) is a small, narrow, leaf of connective tissue which runs from before backward in the median plane and is surrounded on all sides by muscles; it is curved in a zigzag fashion to the right and to the left and multiply perforated.

The **tunica mucosa linguae** (*mucous membrane of the tongue*) (see Fig. 530) is covered on the dorsum of the tongue by numerous small elevations, the *papillae linguales* (*papillae of the tongue*). These are:

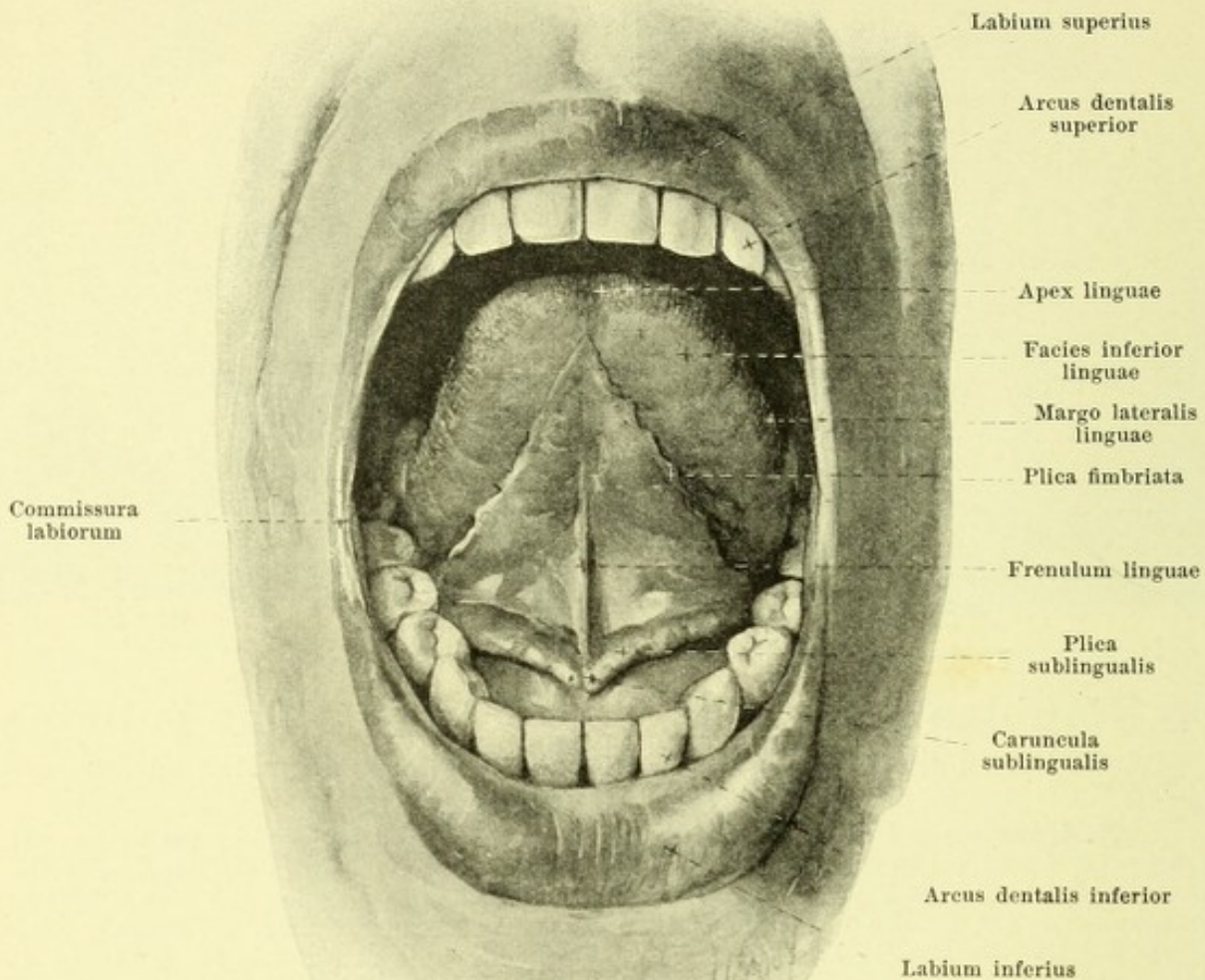
1. *Papillae filiformes*, narrow wedge-shaped elevations, with brush-like epithelial appendages, of whitish color, present on the whole of the dorsum of tongue, on its lateral margins, and at its tip. They are best developed in the middle, a little in front of the papillae vallatae. Among them are scattered *papillae conicae*, which are larger and longer but otherwise similar to them.

2. *Papillae fungiformes*, flask-like projections, of reddish color, larger than the preceding, scattered between them, especially in the anterior half of the tongue. On the lateral margin of the tongue especially they are often markedly flattened and are then called *papillae lenticulares*.

3. *Papillae vallatae* (O. T. circumvallate papillae), the largest of all, 7—11, are situated almost parallel to and in front of the sulcus terminalis in the form of a Λ , so that the most posterior is situated a little in front of the foramen caecum. They are short, cylindrical elevations, which are surrounded by a circular groove and a ridge of mucous membrane and project slightly above their surroundings.

4. *Papilla foliata*, on each side on the margo lateralis linguae, a little in front of the beginning of the arcus glossopalatinus, is very variable and consists of from 5—8 nearly vertically placed folds separated by grooves and projecting but little above the surroundings.

Folliculi linguales are lens-shaped elevations of the mucous membrane, variable in size, situated over the whole of the root of the tongue visible behind the sulcus terminalis as far as the epiglottis. They are often distributed lateralward as far as the palatine tonsils and are themselves grouped together as the *tonsilla lingualis*. Each presents a small depression in its middle.



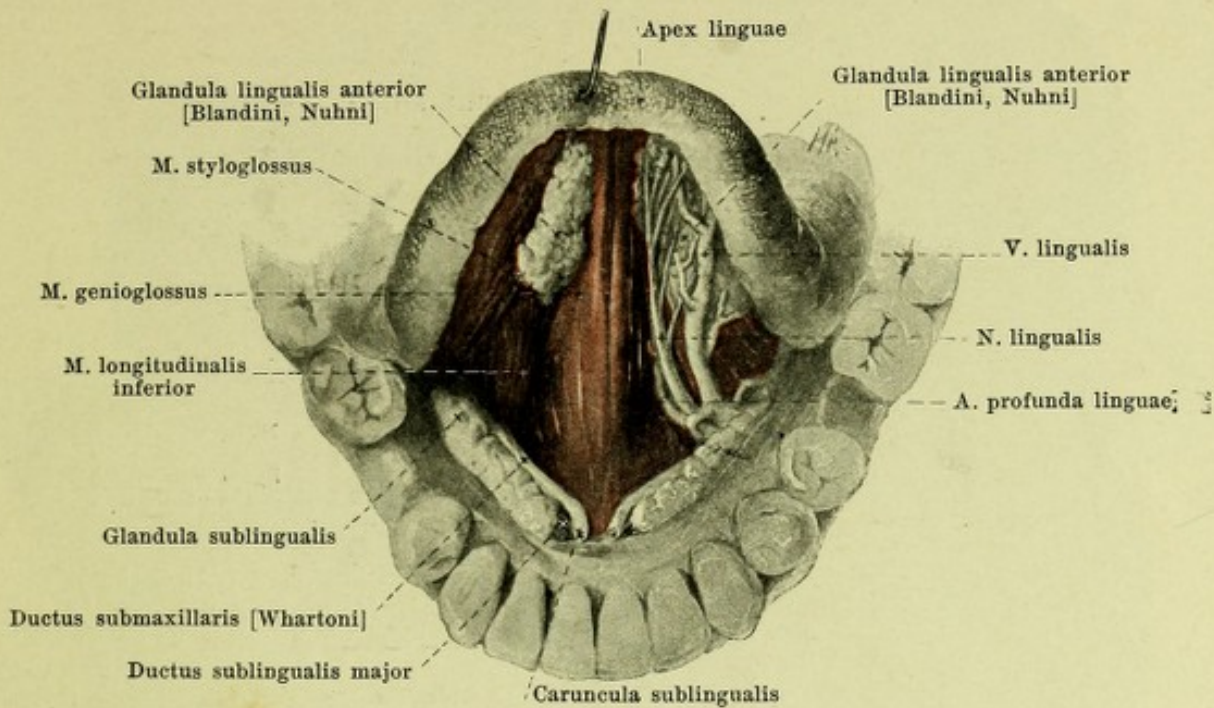
538. Inferior surface of the tongue and its surroundings, the tip of the tongue being elevated.

Mucous membrane of the tongue (continued). Passing out from the root of the tongue (see Fig. 530) in the median plane is a large fold of mucous membrane, *plica glosso-epiglottica mediana* (median glosso-epiglottidean fold), and lateralward from it on each side a smaller, *plica glossoepiglottica lateralis*; these folds extend to the anterior surface of the epiglottis. Between them on each side lies a fossa-like depression, *vallecula epiglottica*.

The mucous membrane of the *facies inferior linguae* is smooth and presents only two symmetrical low narrow folds, *plicae fimbriatae*, which converge in front; the free margin of each fold is for some distance finely jagged. These folds are more distinct in the new-born and in children than in the adult. In the median plane extending from the inferior surface of the tongue to the gums is a fold of mucous membrane, the *frenulum linguae*; close to it on each side lies a small round nodule, *caruncula sublingualis*, which contains the opening of the ductus submaxillaris. On the region between the frenulum linguae and the arcus glossopalatinus the mucous membrane goes over in a flat curve upon the gums; at the point where it covers the glandula sublingualis it is elevated to form a long nodular ridge, the *plica sublingualis* (sublingual fold), which runs from the caruncula sublingualis on backward and lateralward; along this ridge open the ductus sublinguales minores.

The *glandulae linguales* (see Fig. 533) lie just beneath the mucous membrane, and are especially numerous beneath the tonsilla lingualis, the papillae vallatae and the papillae foliatae.

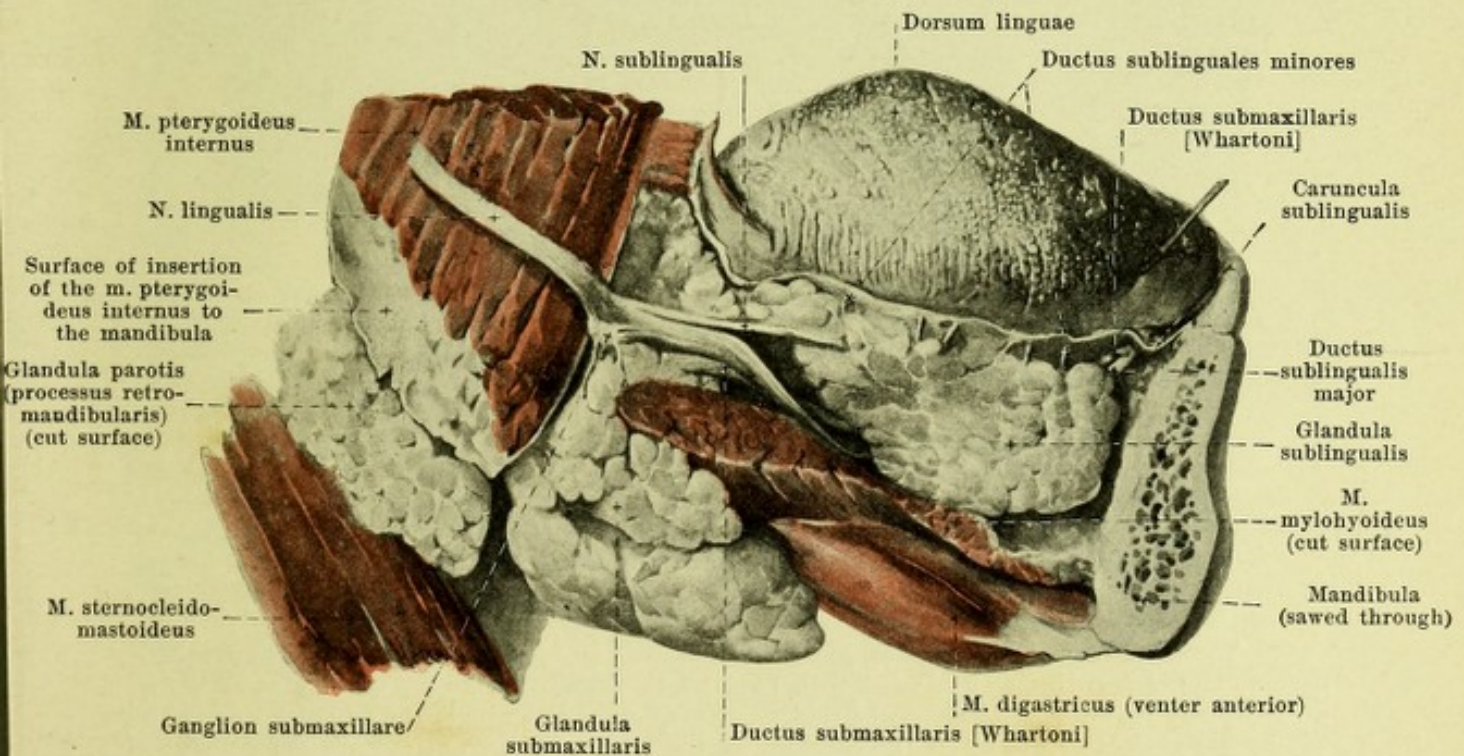
The *glandula lingualis anterior* [Blandini, Nuhn] (O. T. gland of Nuhn) (see Figs. 535 and 539) is an oblong body on each side lying lateralward from the anterior extremity of the m. genioglossus close behind the tip of the tongue; it is covered on its inferior surface by some fibers of the mm. styloglossus and longitudinalis inferior. Its ducts open along the plica fimbriata.



539. Inferior surface of the tongue,

after removal of the mucous membrane, the tip of the tongue being elevated.

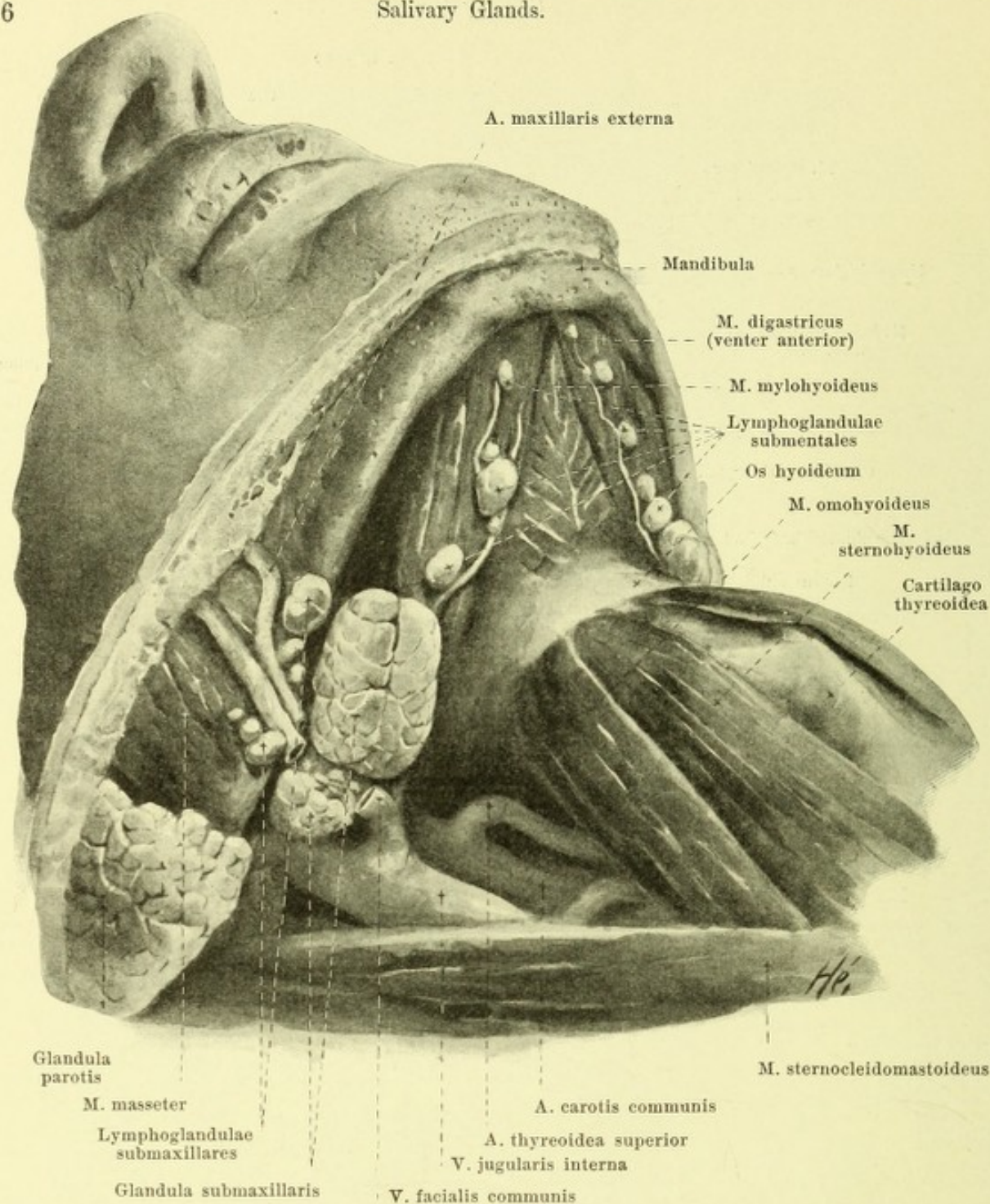
(On the right the blood vessels and nerves have been removed, as have also the superficial fibers of the mm. styloglossus and longitudinalis inferior as far as they cover the glandula lingualis anterior.)



540. Salivary glands of the right side,

after removal of the right half of the lower jaw, viewed from the right.

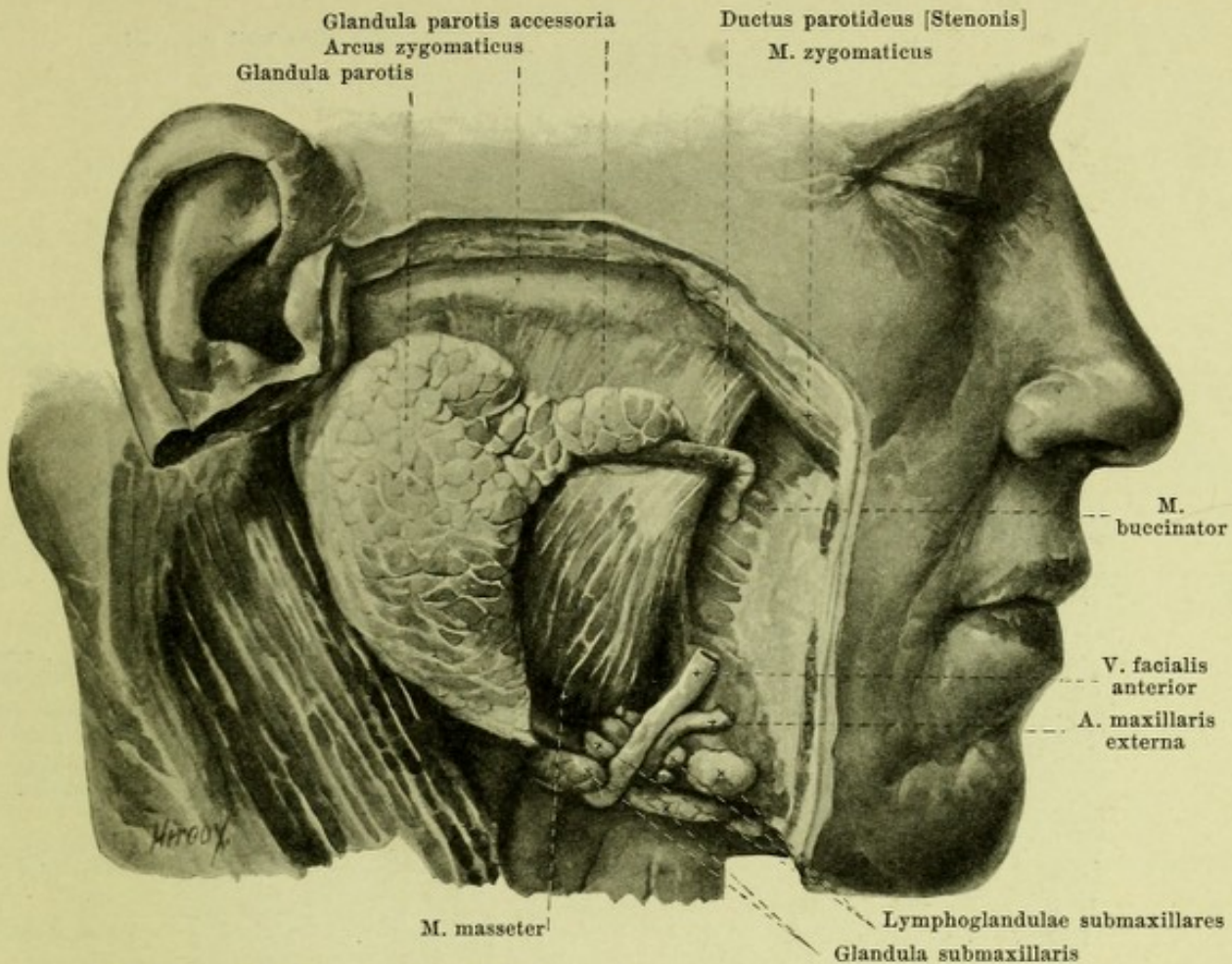
(The glandula parotis has been in large part removed.)



541. Right submaxillary gland and its neighborhood, viewed from the right and below.

(The platysma has been removed.)

The **glandula sublingualis** (*sublingual gland*) (see Figs. 517, 539 and 540) is oblong, narrow, longer from before backward than from above downward. It lies directly upon the m. mylohyoideus between the mm. geniohyoideus, genioglossus and hyoglossus on the one hand and the medial surface of the corpus mandibulae on the other and lies in the fovea sublingualis of the latter; above it is directly covered by the mucous membrane of the mouth and there causes the plica sublingualis to project (see Fig. 538). Behind it is adjacent to the glandula submaxillaris. It opens by several narrow and short ducts, *ductus sublinguales minores*, upon the plica sublingualis; sometimes there is also a larger duct, the *ductus sublingualis major*, which runs forward and upward on the medial surface of the gland beneath the ductus submaxillaris and either goes into the latter or opens close to it upon the caruncula sublingualis.

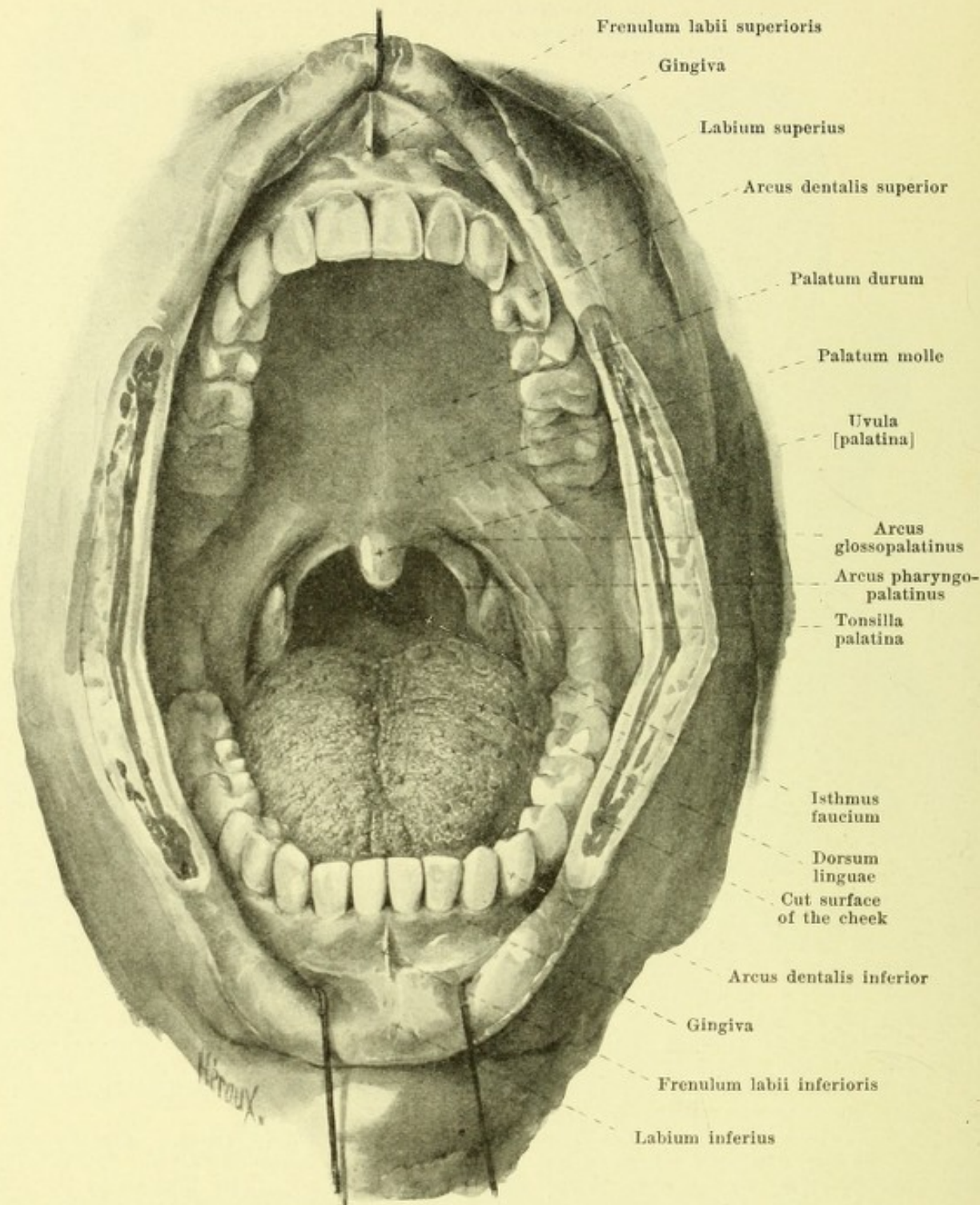


542. Right parotid gland, viewed from the right.

(The platysma and the nerves have been completely removed; the vessels have been partially removed.)

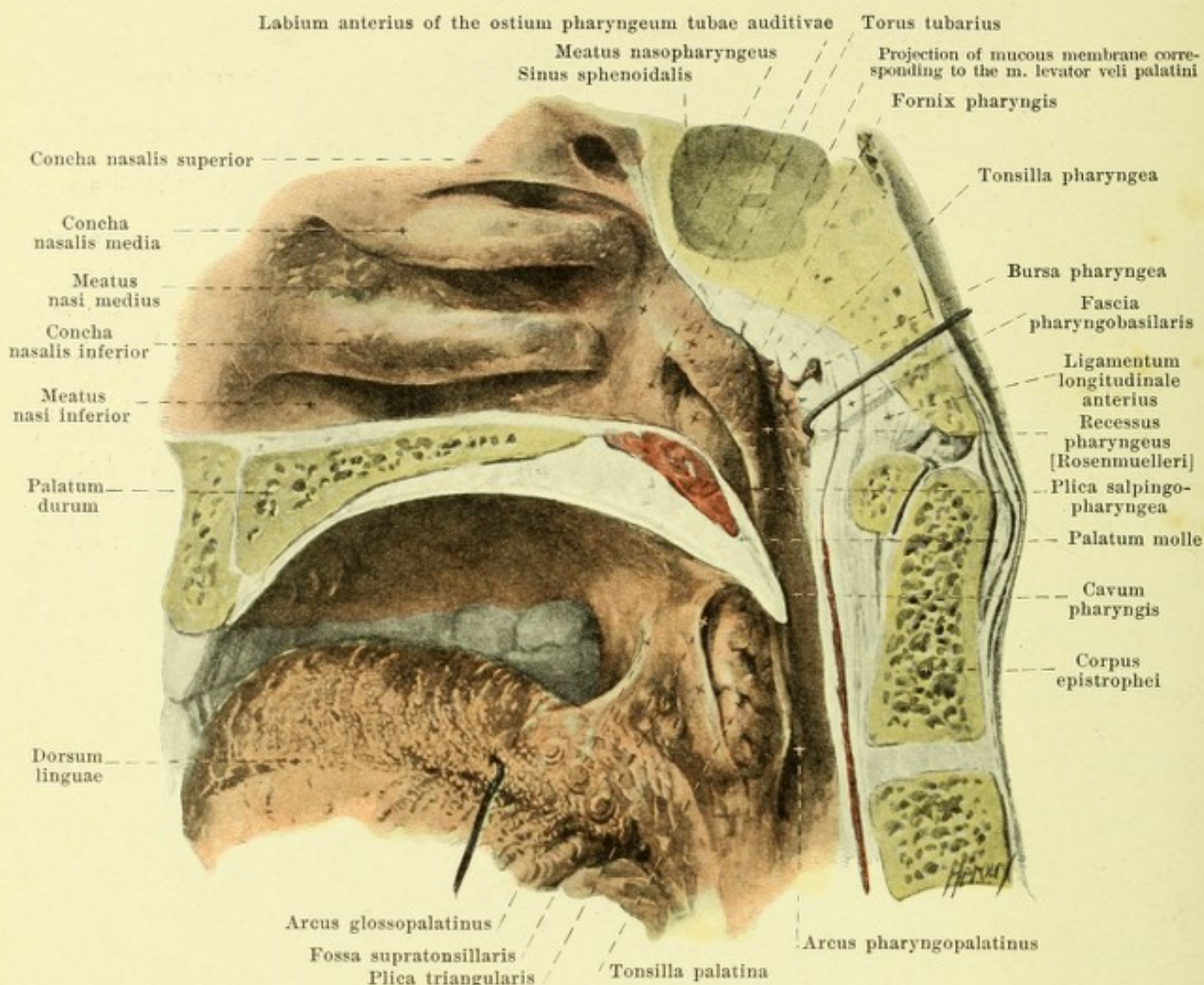
The **glandula submaxillaris** (*submaxillary gland*) (see also Figs. 540 and 541) has the shape of a flattened egg. It lies in the fossa which is bounded above and lateralward by the fovea submaxillaris of the mandibula, elsewhere by the mm. digastricus and stylohyoideus. Above and medially it is in contact with the inferior surface of the m. mylohyoideus and sends around its posterior margin to its upper surface a process of variable size which reaches the glandula sublingualis and comes in contact medianward with the m. hyoglossus; out of this goes the duct. Behind it often reaches as far as the glandula parotis and touches the m. pterygoideus internus. Its free surface is crossed by the v. facialis anterior and covered by the platysma. The excretory duct, *ductus submaxillaris* [*Whartoni*] (see Figs. 517, 539 and 540) runs forward and upward on the medial surface of the glandula sublingualis and opens into the caruncula sublingualis.

The **glandula parotis** (*parotid gland*) (see also Fig. 541) is approximately triangular on its lateral slightly convex surface. With its medial, narrowed portion, *processus retro-mandibularis* (see Fig. 540), it fills up the fossa which is bounded in front by the posterior margin of the ramus mandibulae and the m. pterygoideus internus, behind by the pars tympanica oss. temporalis, by the cartilago meatus acustici as well as by the anterior margin of the proc. mastoideus and of the m. sternocleidomastoideus; in the depth it comes into contact with the proc. stylohyoideus, the mm. stylohyoideus and styloglossus, the a. carotis interna and the v. jugularis interna. Lateralward it passes forward upon the ramus mandibulae and m. masseter and reaches almost as far as the arcus zygomaticus. Below it tapers out and terminates close beneath the angulus mandibulae and often touches the glandula submaxillaris. Inside the gland run for some distance the a. carotis externa and several of its branches, the v. facialis posterior as well as the n. facialis and its peripheral branches. The duct, *ductus parotideus* [*Stenonis*], goes off from the upper portion of the anterior margin, runs approximately horizontally forward upon the lateral surface of the m. masseter, then bends medianward, perforates the m. buccinator obliquely and opens in the vestibulum oris opposite the second upper molar tooth (see Fig. 544); upon the m. masseter there often lies on the duct a *glandula parotis accessoria* which is of variable size.



543. The mouth cavity, viewed from in front, after deep incisions in the cheeks (starting from the angles of the mouth) forced wide open.

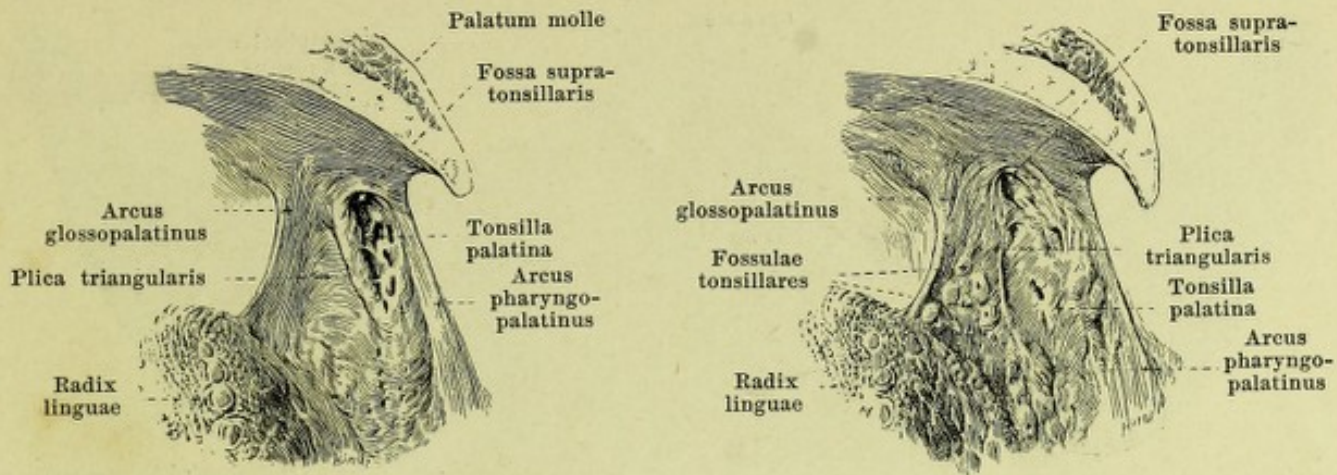
The roof of the mouth cavity is formed by the **palate** (*palatum*) (see also Figs. 516, 517, 528, 544 and 545), which is curved so as to be more concave from the right to the left than from before backward. The substratum of the palate is bony in front (*palatum durum*) and consists there of the processus alveolares and palatini of the upper-jawbones and the partes horizontales of the palate bones (see also Figs. 59 and 60); in the posterior part it is muscular (*palatum molle*). The mucous membrane, very firmly attached to the substratum especially in the hard palate, is in general smooth and goes directly over forward and lateralward into the gums, behind into the uvula and the palatal arches.



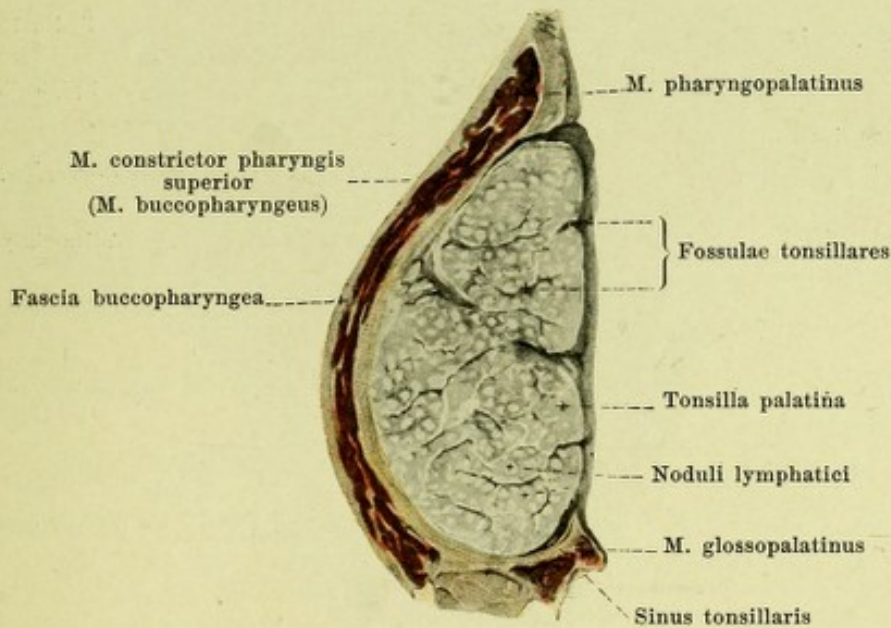
545. Right half of the pharynx and its neighborhood, viewed from the left.

(The head has been cut in two in the median plane; the tongue has been drawn downward.)

The **soft palate** (*palatum molle*) (see also Figs. 516, 543 and 549) is a thick transversely placed membrane, which contains within it the expansion of several muscles (see p. 506). The anterior portion connected with the hard palate is placed nearly horizontally, the posterior portion, *velum palatinum* (*palatal sail*), is directed obliquely backward and downward, terminating (see also Fig. 528) behind and lateralward on each side in a free margin, the *arcus pharyngopalatinus*; in the middle it is drawn out to form the small, conical, very variable, *uvula* [*palatina*]. The mucous membrane which covers the inferior surface of the soft palate is directly continued at its free margin upon the upper surface into the mucous membrane of the pharynx and of the nasal cavity. The *arcus pharyngopalatinus* (*posterior palatal arch*) (see also Fig. 549) is thicker above, thinner below where it has almost a sharp edge; from the lateral margin of the uvula it bends so as to be markedly concave downward and a little backward and becomes lost in the lateral wall of the *pars laryngea* pharyngis. Arising from the lower surface of the *velum palatinum* on each side a little in front of the base of the uvula (see also Figs. 528 and 543) is a fold of mucous membrane, the *arcus glossopalatinus* (*anterior palatal arch*), which, curved so as to be slightly concave, extends downward and lateralward and unites behind the *papillae foliatae* with the lateral margin of the root of the tongue (see also Fig. 530). From the posterior surface of this anterior palatal arch a thin triangular fold of mucous membrane, the *plica triangularis*, passes dorsalward; it is narrow at its beginning above but is broad at its attachment to the lateral margin of the tongue. Lateralward from and behind it, reaching behind as far as the *arcus pharyngopalatinus*, lies, in the foetus, a deep fossa, the *sinus tonsillaris*, from the bottom of which the *tonsilla palatina* develops.



546 and 547. Right palatine tonsils, unequally developed, viewed from the left (see Fig. 545).

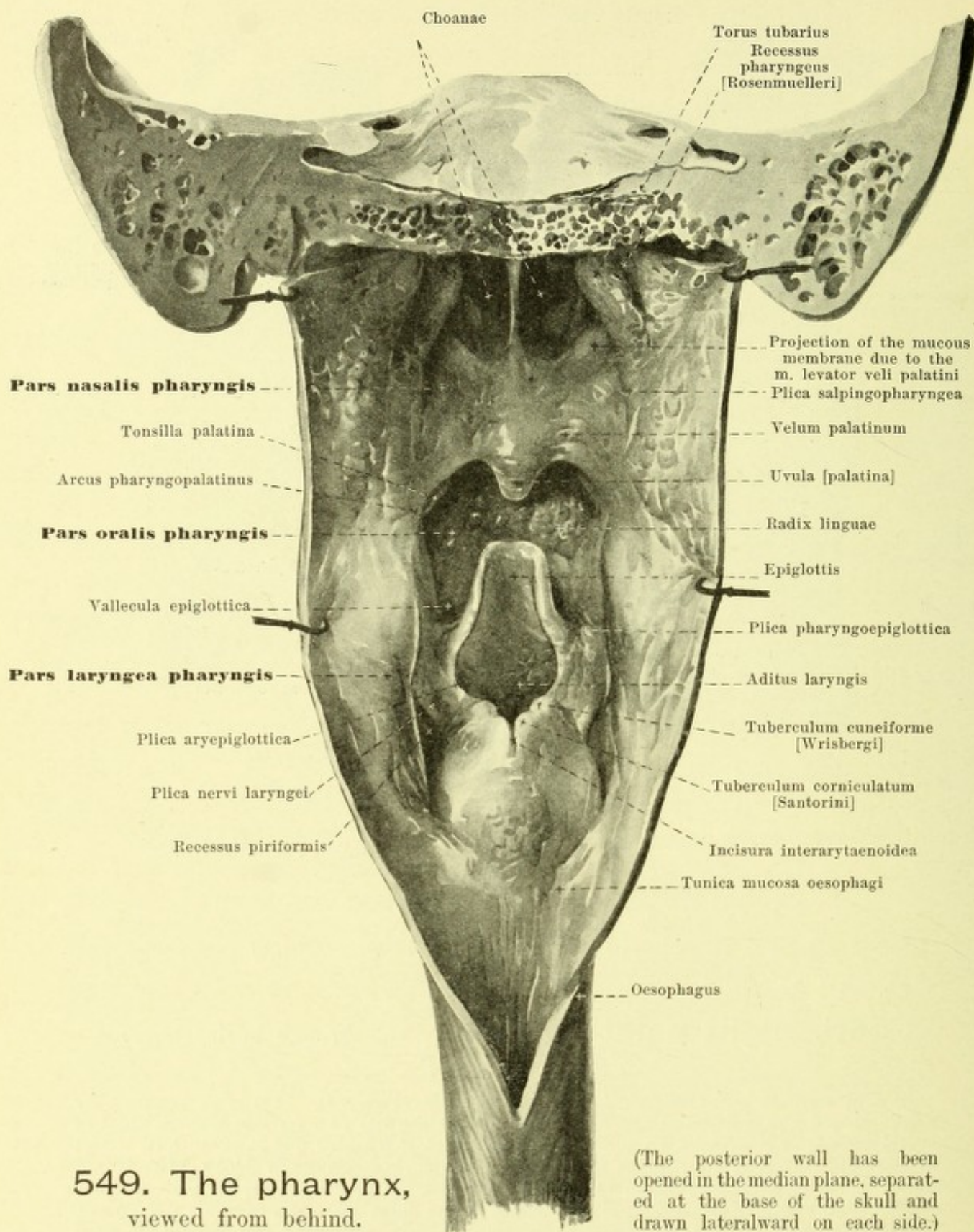


548. Right palatine tonsil, cut through horizontally.

Magnification 2 : 1.

The *tonsilla palatina* (*palatine tonsil*) (see also Figs. 543—545) is an oblong body usually shaped like a flattened egg, of variable size, which lies on each side between the two palatal arches; it is bounded lateralward by the *m. buccopharyngeus* and looks, with its medial nodular surface, free into the mouth cavity. From this surface rounded or oblong openings lead into slits, the *fossulae tonsillares*, in the walls of which are situated numerous lymph nodules (*noduli lymphatici*). The tonsil is often confined to the sinus tonsillaris only (see p. 500) and leaves free above it a *fossa supra-tonsillaris*, which extends lateralward and forward for some distance (see Fig. 545); in other cases, however, the plica triangularis fuses with the free surface of the tonsil, and sometimes there is even a development of the lymph nodules also on the medial surface of the plica triangularis itself, so that the boundaries of the fold may vanish entirely (see Figs. 546 and 547).

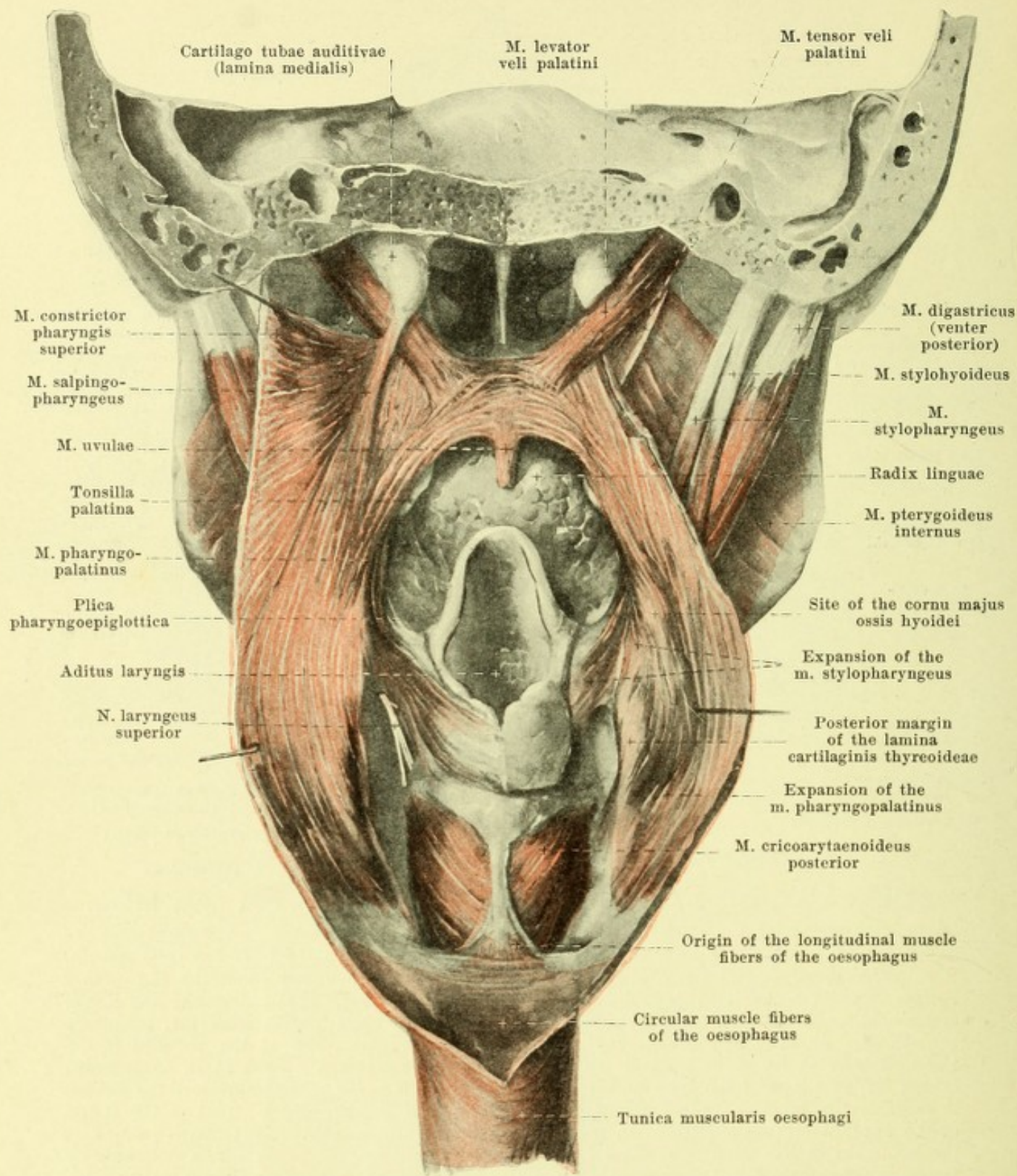
The space enclosed by the soft palate, the palatal arches, and the root of the tongue, is called the *isthmus faucium* (see Fig. 543).



549. The pharynx,
viewed from behind.

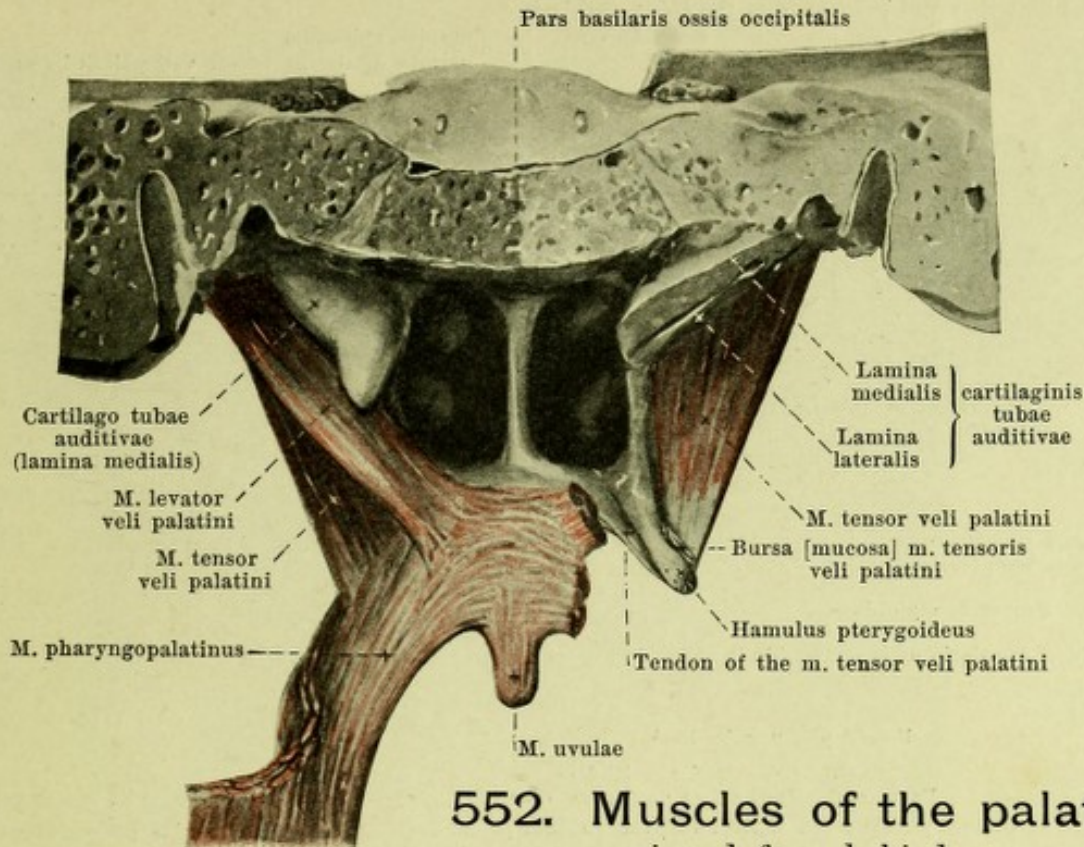
(The posterior wall has been opened in the median plane, separated at the base of the skull and drawn lateralward on each side.)

The **pharynx** (see also Figs. 516 and 545) is an unpaired, tube-like cavity which is situated behind the nose, mouth and larynx; it is correspondingly divided into three portions, which however are not sharply separable from one another: *pars nasalis*, *pars oralis* and *pars laryngea*. The cavity surrounded by its walls, *cavum pharyngis*, is connected in front with the three cavities mentioned.



551. Muscles of the palate and pharynx, viewed from behind.

(The pharynx has been opened as in Fig. 549; the tunica mucosa and tela submucosa have been dissected away, except for a small area of the pars laryngea. On the right side the m. salpingo-pharyngeus, a part of the m. constrictor pharyngis superior and one corner of the cartilago tubae auditivae have been removed.)



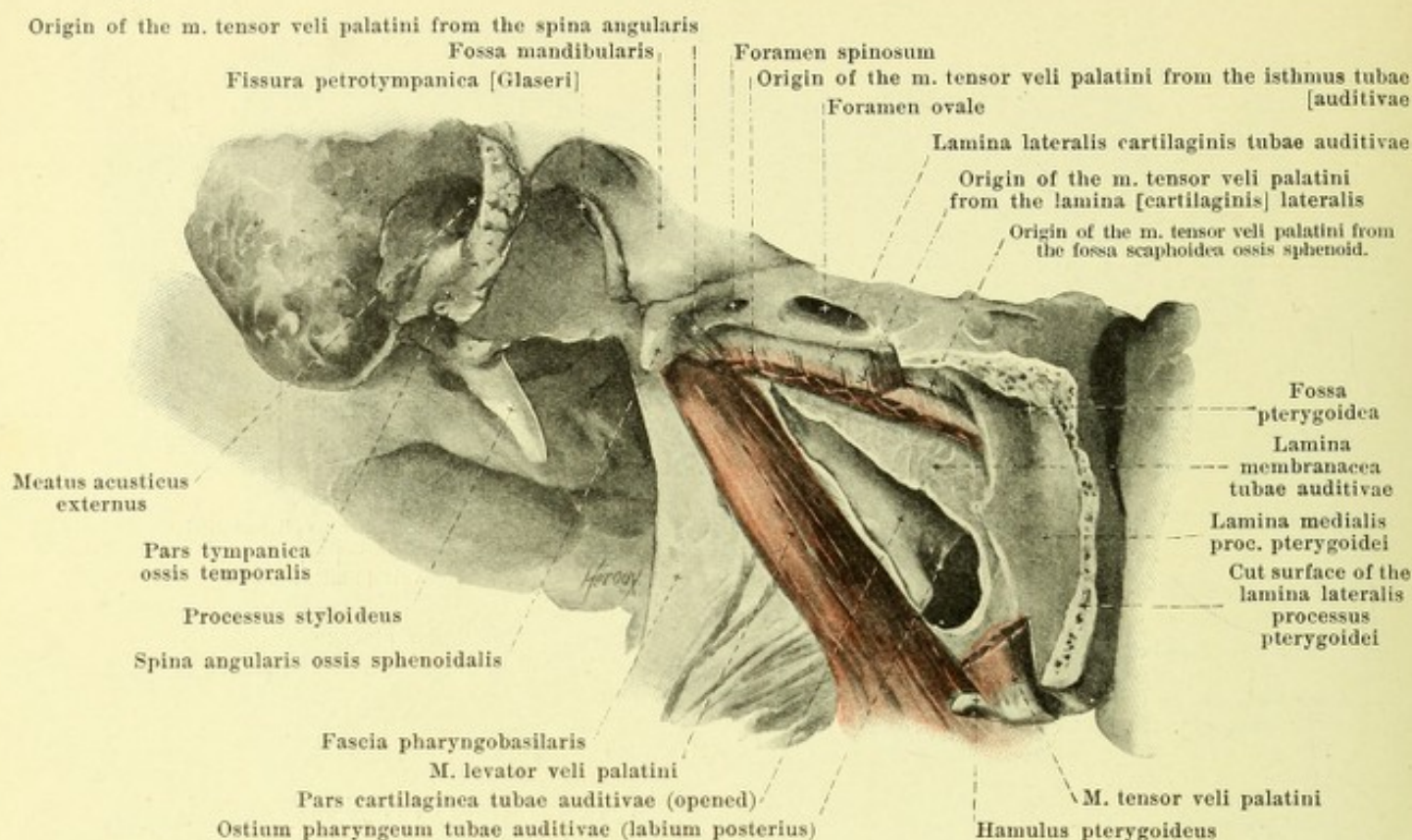
552. Muscles of the palate, viewed from behind.

(On the right side the *m. levator veli palatini* and the *m. pharyngopalatinus* have been removed. In addition the lamina medialis of the cartilago tubae auditivae has been partially cut away and the pars cartilaginea of the Eustachian tube has been opened for a corresponding length.)

In the pars nasalis pharyngis (see Figs. 545, 549, 550, 923 and 924) on each side lateralward, behind the insertion of the inferior turbinate bone, is visible the sickle-shaped *ostium pharyngum tubae auditivae*; it is surrounded above and behind by a horseshoe-shaped ridge. The anterior part of the ridge, *labium anterius*, is the smaller; the upper and posterior part (*labium posterius*) is thicker and harder, being made prominent by the lamina medialis of the cartilago tubae auditivae (see p. 816) whence it is also called the *torus tubarius*. The opening is encroached upon from below by a projection caused by the *m. levator veli palatini*. From the lower end of the labium posterius a fold of mucous membrane, *plica salpingopharyngea*, extends downward for a variable distance on the lateral wall. Behind the torus tubarius, extending far lateralward, is a pocket, usually slit-shaped, the *recessus pharyngeus* [*Rosenmuelleri*] (pharyngeal recess of Rosenmueller). The partition between the pars nasalis and the pars oralis, formed by the velum palatinum, is indistinct and incomplete. Lateralward in the pars oralis is the arcus pharyngopalatinus; the pars oralis is not sharply marked off from the pars laryngea. In the pars laryngea (see Fig. 549), extending lateralward from the lateral margin of the epiglottis, is the low *plica pharyngoepiglottica*. Below and behind it on each side between the plica aryepiglottica and the lamina cartilaginis thyreoideae, which is covered directly by the mucous membrane, lies a deep fossa, the *recessus piriformis* (O. T. sinus pyriformis) which runs downward in the form of a groove; a fold, *plica nervi laryngei*, runs obliquely downward and medianward in its most anterior part. Scattered in the tela submucosa are mucous glands, *glandulae pharyngeae* (not illustrated), more numerous behind the tonsilla pharyngea and in the recessus pharyngeus.

Muscles of the palate (*musculi palati et faucium*) (see also Figs. 544, 551 and 553).

M. pharyngopalatinus (O. T. palatopharyngeus). Form: triangular, thin, long. Position: for the most part in the arcus pharyngopalatinus. Origin: broad in the tela submucosa of the posterior wall of the pars laryngea pharyngis and from the posterior margin of the lamina cartilaginis thyreoideae in front of the *m. constrictor pharyngis inferior* (see also Fig. 554). Insertion: the fibers, converging, run in front of the *m. constrictor pharyngis medius* upward, first lateralward, then medianward, and radiate out transversely into the palate; some fibers go to the hamulus pterygoideus, others as the *m. salpingopharyngeus* (see Fig. 551) in the plica salpingopharyngea to the lower end of the lamina medialis cartilaginis tubae auditivae. Action: it approximates the pharyngopalatine arches, and elevates the inferior part of the pharynx and larynx. Innervation: rami pharyngei n. vagi.



553. Cartilaginous part of the right Eustachian tube, viewed from the lateral surface and somewhat below and behind.

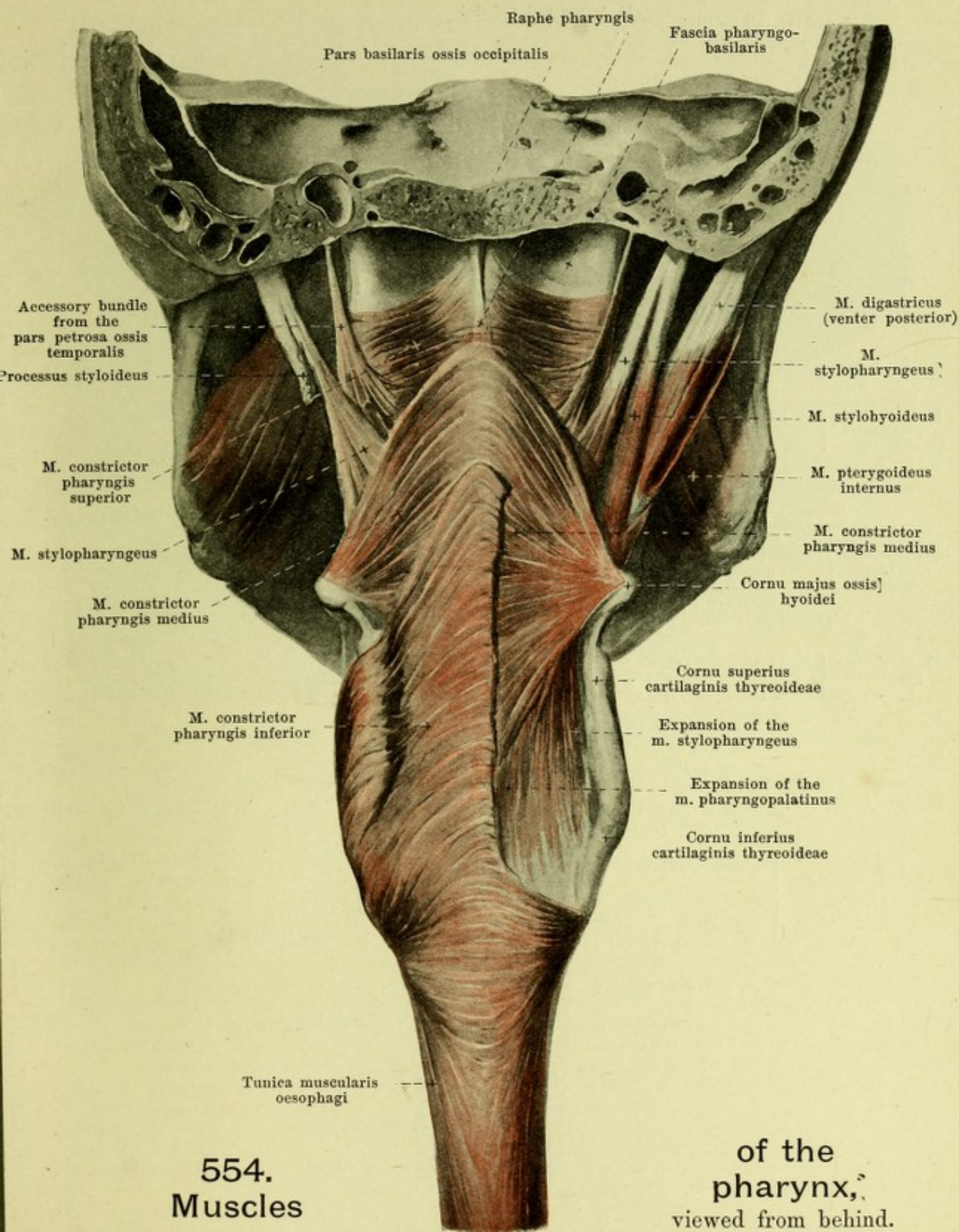
(The lamina lateralis of the processus pterygoideus, the m. tensor veli palatini and the lamina membranacea of the tuba auditiva have been partially removed.)

M. glossopalatinus (O. T. palatoglossus). Form: narrow, long. Position: in the arcus glossopalatinus. Origin: at the lateral margin of the tongue from fibers of the latter which run transversely (see also Fig. 532). Insertion: curving upward it radiates out transversely in the soft palate. Action: narrows isthmus faucium. Innervation: rami pharyngei n. vagi.

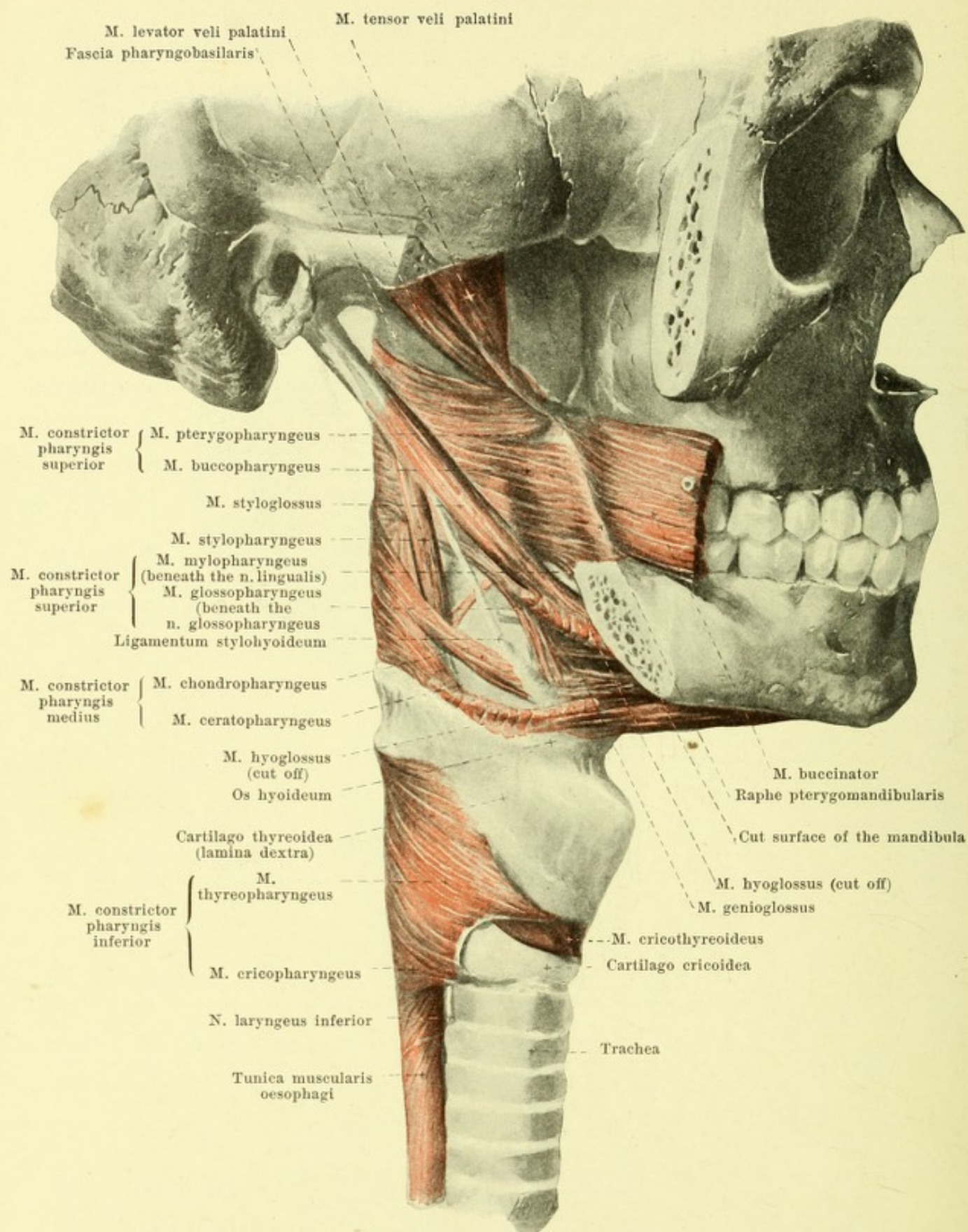
M. uvulae (O. T. azygos uvulae). Form: narrow, oblong; frequently paired. Position: in uvula, nearer upper surface, partly behind other muscles. Origin: tendinous expansions of mm. tensores veli palatini. Insertion: backward and downward to tip of uvula. Action: shortens uvula and draws it backward and upward. Innervation: rami pharyngei n. vagi.

M. levator veli palatini (O. T. levator palati) (see also Figs. 550—552, 555, 895—898). Form: flat-cylindrical. Position: in the uppermost part of the lateral wall of the pharynx, directly in front of the recessus pharyngeus. Origin: facies inferior pyramidis ossis temporalis, just in front of the foramen caroticum externum; some fibers go from the lateral end of the lamina medialis of the cartilago tubae. Insertion: the fibers are parallel to the inferior margin of the lamina medialis of the cartilago tubae, run downward, medianward and forward, causing a projection of the mucous membrane at the ostium pharyngeum tubae (see Figs. 545 and 549) and go to the soft palate. They are there interwoven with the other muscles and unite mainly with the same muscle of the other side. Action: it lifts the velum palatinum, narrows the ostium pharyngeum and widens the isthmus tubae. Innervation: rami pharyngei n. vagi.

M. tensor veli palatini (see also Figs. 544, 550—552, 555, 895—898). Form: triangular, flat, thin. Position: lateral from the lamina membranacea tubae auditivae and the m. levator veli palatini, medial from the m. pterygoideus internus. Origin: fossa scaphoidea ossis sphenoidalis, lamina [cartilaginis] lateralis and lamina membranacea (at the isthmus) tubae auditivae, spina angularis ossis sphenoidalis. Insertion: the fibers converge and run downward and forward to a small tendon which forms a loop around the sulcus hamuli pterygoidei (here is situated the *bursa m. tensoris veli palatini*, see Fig. 552) and radiates out medianward into the soft palate; there (see Fig. 544) it becomes attached partly to the posterior margin of the pars horizontalis ossis palatini, and becomes connected partly with the fibers of the muscle of the other side (see Fig. 544). Action: it makes the anterior portion of the soft palate tense and opens the tuba auditiva. Innervation: n. tensoris palatini (from the n. mandibularis).



(On the right side most of the m. constrictor pharyngis inferior has been removed, on the left side the mm. digastricus and stylohyoideus have been removed.)



555. Muscles of the pharynx, viewed from the right.

(The arcus zygomaticus and ramus mandibulae have been completely, the m. hyoglossus has been partially, removed.)

The **tunica muscularis pharyngis** (see p. 505) consists mainly of the three *mm. constrictores pharyngis* (constrictors of the pharynx), which surround the posterior and lateral walls, and of which the lower one in each case partly covers the next upper from behind; in addition, this muscular tunic contains the terminal expansions of the *mm. pharyngopalatinus* (see p. 505) and *stylopharyngeus*. The constrictors of the pharynx of the two sides partly fuse behind in the median plane, in part, however, they are connected with a band of connective tissue, the *raphe pharyngis* (see Fig. 554); this raphe is usually distinct in the uppermost part only and is attached to the tuberculum pharyngeum oss. occipitalis. The uppermost constrictor of the pharynx does not reach as far as the base of the skull but leaves an area of variable size free on each side on the posterior and lateral walls in which the tela submucosa pharyngis is visible; it is thicker here and is called the *fascia pharyngobasilaris* (see Figs. 554 and 555).

M. constrictor pharyngis superior (see Figs. 551, 554 and 555) arises from several parts of the head. It is divided into:

1. *M. pterygopharyngeus*. Origin: posterior margin of the lamina medialis of the processus pterygoideus and hamulus pterygoideus.
2. *M. buccopharyngeus*. Origin: raphe pterygomandibularis (see p. 247), partly connected with fibers of the m. buccinator.
3. *M. mylopharyngeus*. Origin: posterior end of the linea mylohyoidea mandibulae in the region of the third molar tooth.
4. *M. glossopharyngeus* (see also Fig. 532). Origin: from fibers running transversely in the root of the tongue, which appear between the posterior bundles of the m. genioglossus, and, covered by the m. hyoglossus, extend obliquely upward.

The fibers run for the most part horizontally backward; the upper ones extend chiefly somewhat upward (see Fig. 554) and becoming tendinous may reach the base of the skull; the lower ones curve behind somewhat downward. The muscle is partly covered behind by the m. constrictor pharyngis medius. Accessory bundles (see Fig. 554) frequently arise at the anterior margin of the foramen caroticum externum, descend behind the muscle at the junction of the lateral and posterior wall and finally turn around into the horizontal direction.

M. constrictor pharyngis medius (see Figs. 531, 532, 554 and 555) arises from the hyoid bone in two parts as the

1. *M. chondropharyngeus*. Origin: cornu minus ossis hyoidei.
2. *M. ceratopharyngeus*. Origin: cornu majus ossis hyoidei.

The fibers arising most anteriorly are covered by the m. hyoglossus; behind, the middle fibers run horizontally, the others diverge upward and downward and may, above, even reach the base of the skull. The muscle is covered in its lower larger part by the m. constrictor pharyngis inferior.

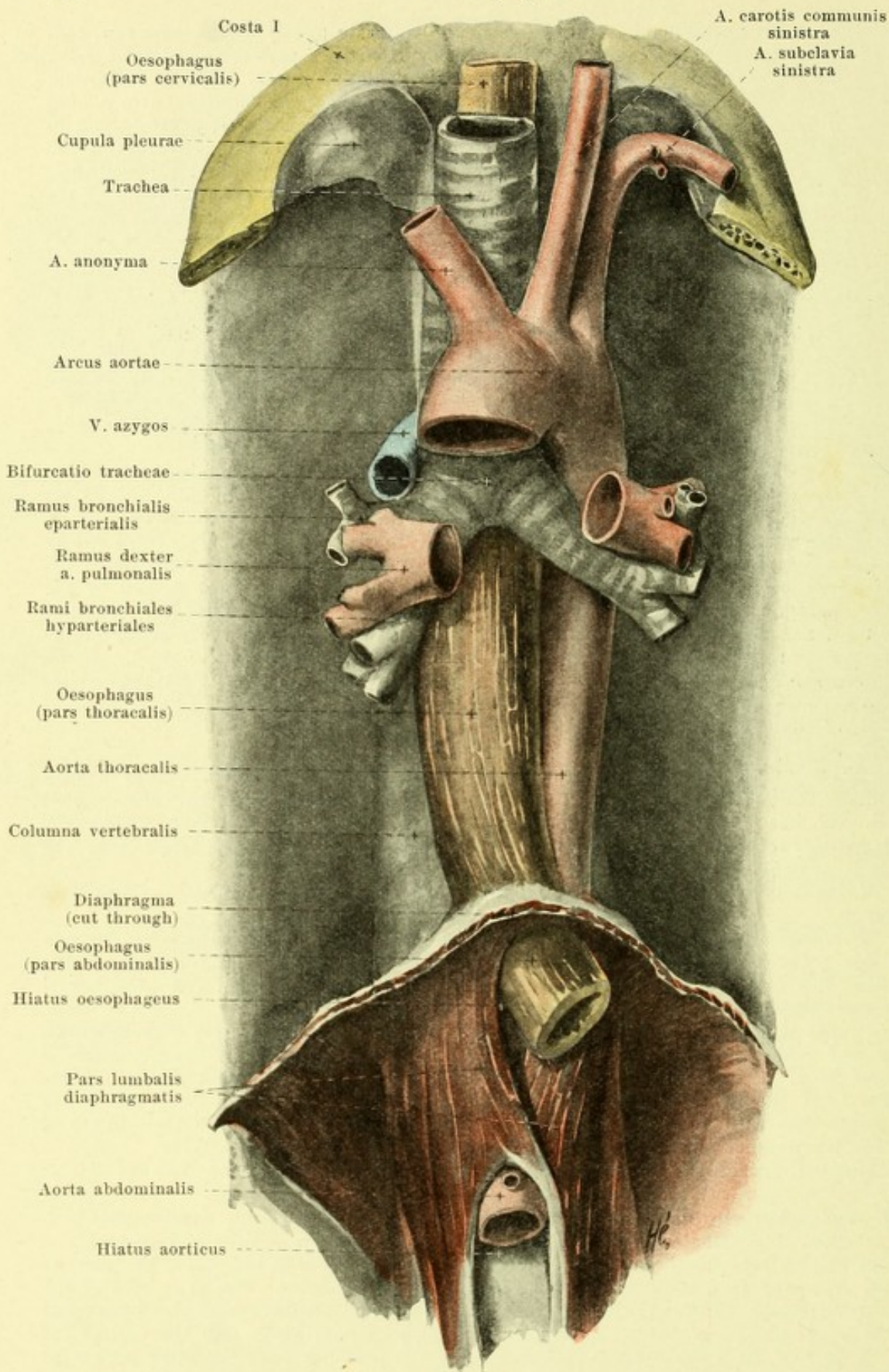
M. constrictor pharyngis inferior (see Figs. 554 and 555) arises from the larynx. It is divisible into:

1. *M. thyropharyngeus*. Origin: lateral surface of the lamina cartilaginis thyroideae (linea obliqua).
2. *M. cricopharyngeus*. Origin: from a tendinous arch convex backward, which is stretched out between the tuberculum thyroideum inferius and the lateral surface of the cartilago cricoidea and partially bridges over the m. cricothyroideus, and from the lateral surface of the cartilago cricoidea.

The upper larger mass of fibers forms a loop around the posterior margin of the cartilago thyroidea and runs medianward and upward, diverging somewhat. The inferior bundles of fibers extend more horizontally but so that they mostly form convex arches with the fibers of the other side; these arches are curved partly upward, partly downward; those which are curved upward fuse with the circular muscle layer of the oesophagus between the bundles of origin of the longitudinal muscle fibers of the oesophagus as these converge below.

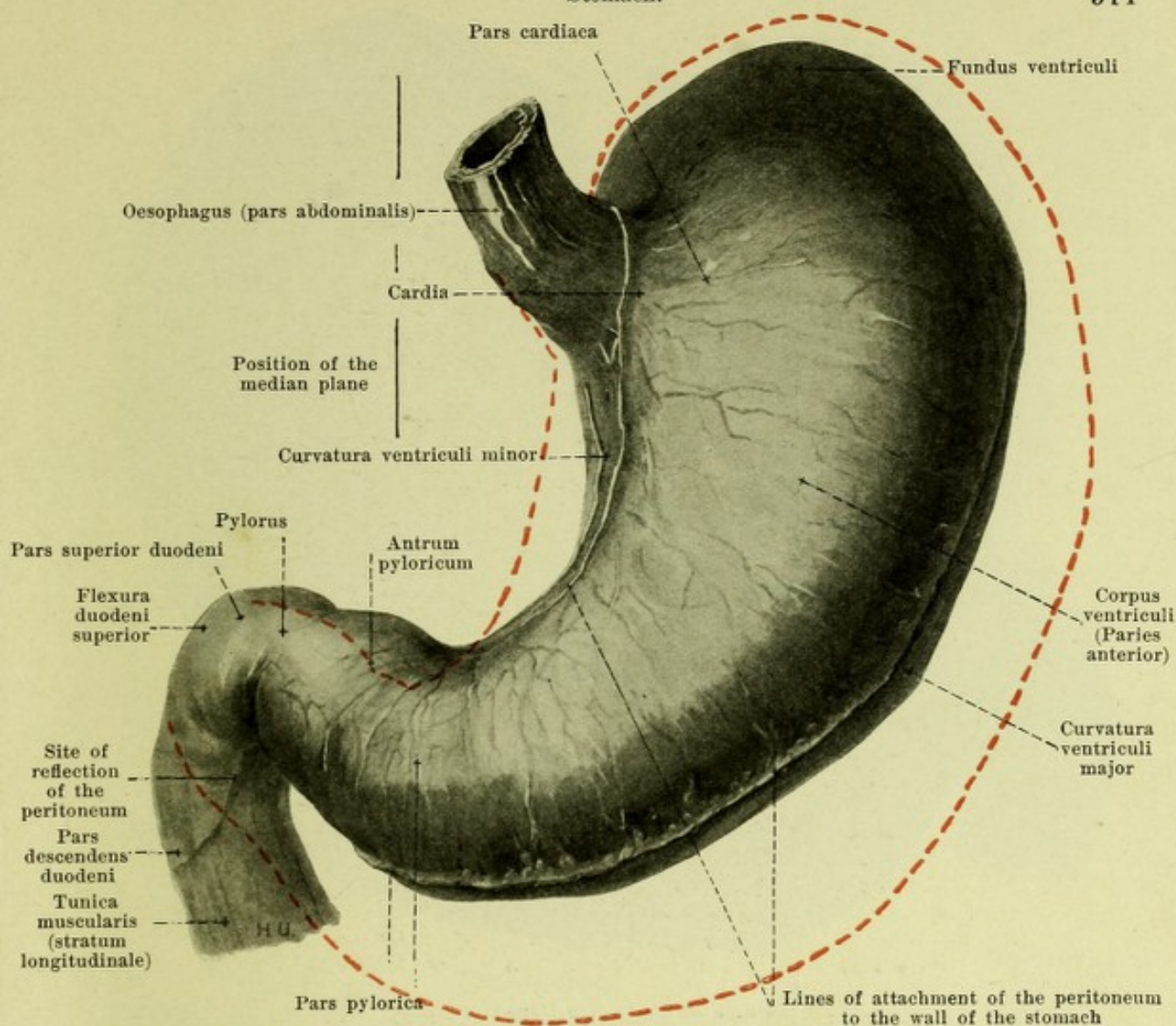
Action of the constrictor muscles of the pharynx: they narrow the pharynx. Innervation: rami pharyngei n. vagi.

M. stylopharyngeus (see Figs. 531, 551, 554 and 555). Form: slender, flattened. Position: above it is situated between the m. constrictor pharyngis superior and the m. stylohyoideus, as well as between the a. carotis interna and externa, below in the wall of the pharynx medianward from the mm. constrictores pharyngis medius et inferior. Origin: root of the processus stylohyoideus. Insertion: it extends downward and medianward and, diverging in front of the upper margin of the m. constrictor pharyngis medius, sinks into the wall of the pharynx. A part of the fibers extends medianward to the posterior wall, the other part runs farther downward and (see Fig. 551) arrives in front of the m. pharyngopalatinus partly in the plica pharyngoepiglottica to the anterior surface of the epiglottis, partly in the plica aryepiglottica to the m. aryepiglotticus (see p. 556) and the thyroid and cricoid cartilage, partly (see Figs. 551 and 554) to the upper margin of the lamina cartilaginis thyroideae. Action: it widens the pharynx and elevates the pharynx and larynx. Innervation: rami pharyngei n. vagi.



556. Oesophagus and trachea with surrounding tissues, viewed from in front.

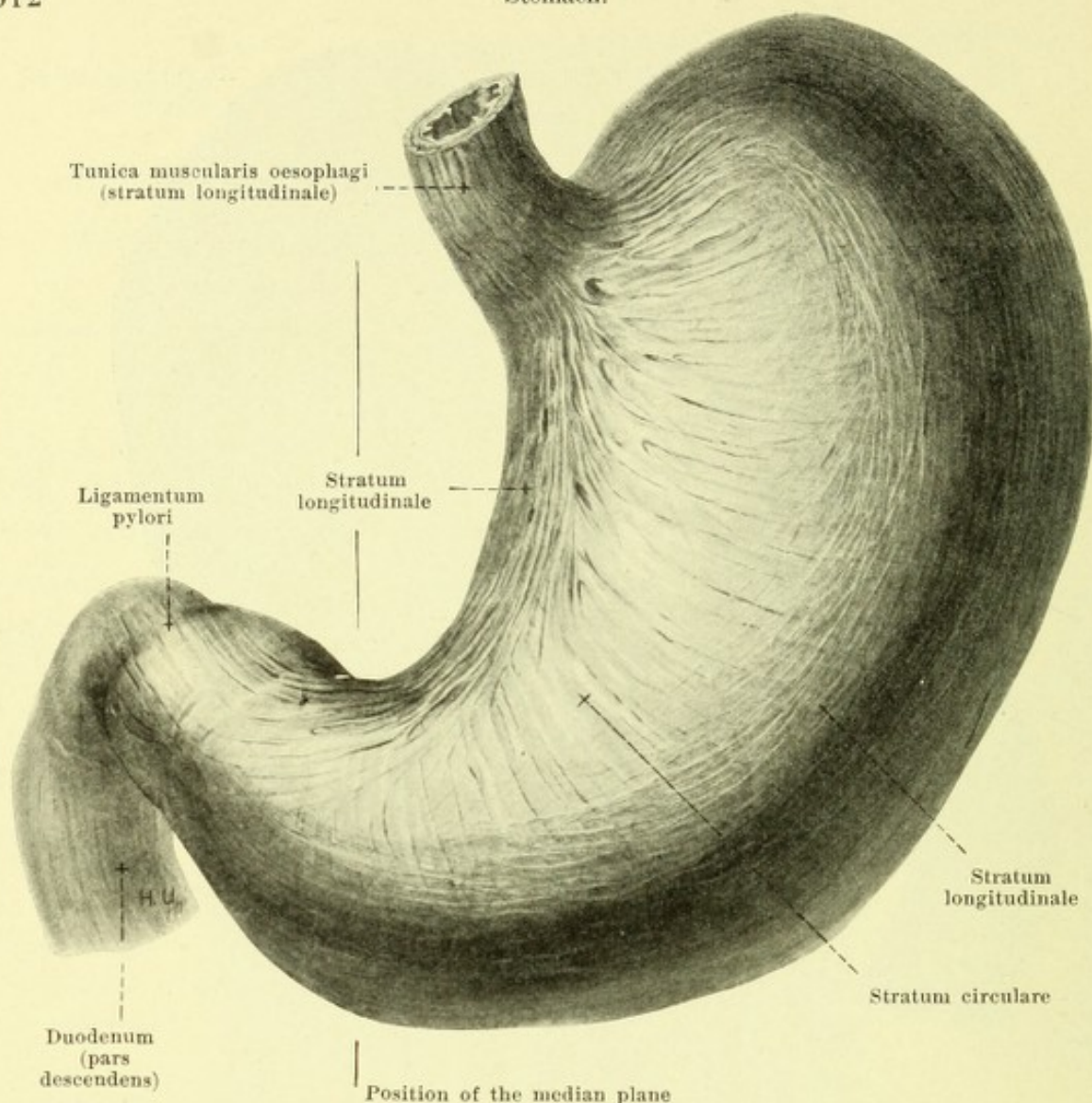
(The pleura with the exception of its uppermost part has been removed on each side.)



557. The stomach, partly filled, viewed from above and in front.

(The red line indicates the form and position of the stomach when more markedly distended.)

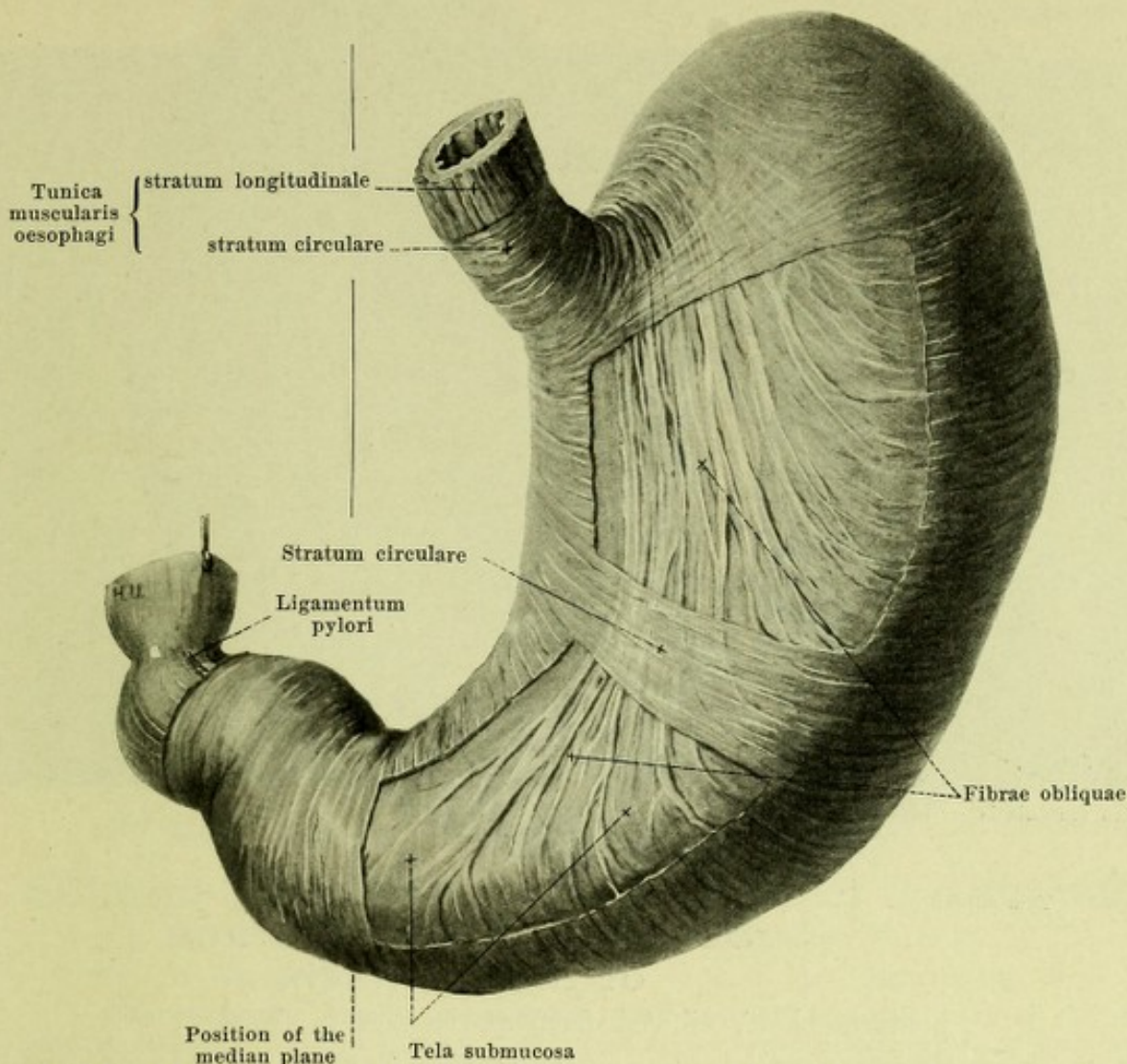
The **oesophagus** (*gullet*) (see also Figs. 307, 512, 516, 549, 556, 629—631) is a muscular tube and in man averages 25 cm in length. It begins as the continuation of the pharynx behind the cartilago cricoidea, in front of the 6th cervical vertebra (*pars cervicalis*), runs downward through the spatium mediastinale posterius of the thorax (*pars thoracalis*), passes through the hiatus oesophageus diaphragmatis into the abdominal cavity (*pars abdominalis*) and opens into the cardia of the stomach at the level of the 10th or 11th thoracic vertebra. In its course it lies, with the exception of its lowermost portion, directly in front of the spinal column, in its upper half also behind the trachea, in the lower part of the *pars thoracalis* behind the pericardium and the left atrium. It runs nearly straight in front of the middle of the spinal column, deviating above a little to the left, in the middle a little to the right where it passes on the right anterior surface of the aorta thoracalis, and on the left side of the v. azygos; in the lowermost part of the *pars thoracalis* it extends, turned slightly to the left and forward, on the anterior surface of the aorta and goes in front of this, somewhat to the left of the median plane, obliquely through the diaphragm. In the lowermost part of the *pars thoracalis* the oesophagus approaches for a short distance very close to the pleura mediastinalis sinistra, in the middle part its posterior wall especially lies for a long distance close to the pleura mediastinalis dextra. The *pars abdominalis* is very short and runs to the left and downward in front of the pars lumbalis diaphragmatis, directly behind the impressio oesophagea of the liver. The oesophagus when empty is markedly flattened above from before backward, its lumen being a frontally placed slit; in the whole thoracic portion it is wide open during life. Its diameters increase on the average from above downward; circular constrictions can however be made out, oftenest in three situations: behind the cartilago cricoidea, behind the bifurcatio tracheae and in the hiatus oesophageus of the diaphragm; the uppermost is very frequently the narrowest.



558. Superficial muscular layer of the stomach, viewed from above and in front.

The *wall of the oesophagus* consists of three layers. Nearest the lumen lies the mucous membrane, *tunica mucosa*, of a greyish red to a whitish color; beneath it is the connective tissue, *tela submucosa*. Scattered throughout the latter are mucous glands, *glandulae oesophageae*; in the upper and lower parts of the oesophagus however the mucous membrane possesses in addition glands which differ from these in their structure. The outermost layer, *tunica muscularis*, is composed of an inner circular and an outer longitudinal layer (see also Figs. 551, 554, 555 and 559). The bundles of the latter arise from the posterior surface of the cartilago cricoidea, surround in part the lateral surface of the oesophagus and spread out upon the whole circumference of the latter. At the cardia the longitudinal fibers go over into the superficial muscular layer of the stomach, the circular fibers (see Fig. 559) into the middle and deep muscular layers. The longitudinal layer is connected usually by very variable narrow bands of fibers (not illustrated) with the posterior surface of the trachea, of the left bronchus (*m. bronchooesophageus*), with the pleura mediastinalis sinistra (*m. pleurooesophageus*) and with the muscle fibers which surround the hiatus oesophageus.

The **stomach** (*ventriculus, gaster*) (see also Figs. 512, 557 and 560) is an unpaired, saccular dilatation of the alimentary canal connecting above with the oesophagus, below with the duodenum. In it can be distinguished an upper surface directed at the same time forward and to the right (*paries anterior*) and a lower surface directed at the same time backward and to the left (*paries posterior*); these go over into one another to the right and behind at the *curvatura ventriculi minor* which is convex to the right and concave to the left, and to the left and in front at the convex *curvatura ventriculi major*. At the upper end of the *curvatura minor* the oesophagus enters the wall of the stomach (*cardia*); the blind-sac-like portion projecting higher up and situated to the left of the cardia is called the *fundus ventriculi*.



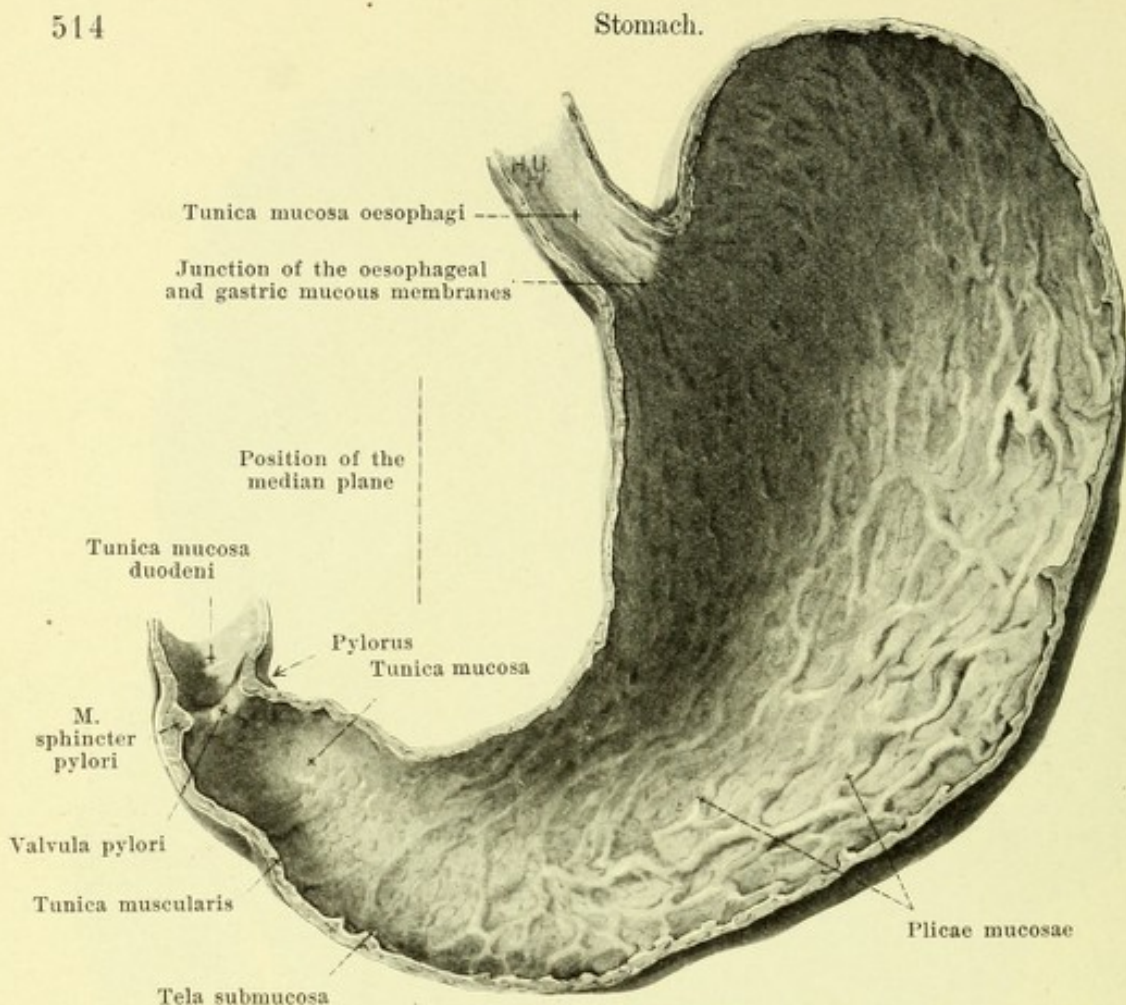
559. Middle and deep muscular layers of the stomach, viewed from above and in front.

(The superficial layer has been completely, the middle partly, cut away.)

Stomach (continued). The middle, largest portion is called the *corpus ventriculi*, the part adjoining the cardia being known as the *pars cardiaca*. The body is continued into the *pars pylorica* by an obtuse-angled or right-angled bend, which causes a distinct furrow at the *curvatura minor*. The more cylindrical terminal portion of the latter, *antrum pyloricum*, is often indistinctly bounded on the left at the *curvatura major* by a furrow; toward the duodenum, however, it is sharply marked off by a circular constriction which indicates the position of the *pylorus*.

The empty, contracted stomach is approximately cylindrical; it is somewhat broader above than below and the fundus is but little marked; the lumen on cross-section is stellate.

Position of the stomach (see Figs. 465, 497, 591—593). A plane drawn through the two curvatures looks upward, forward and to the right, but approaches more to the transversal than to the vertical plane; when the stomach is distended less than when it is empty. In this plane the stomach lies in the form of a semicircle, with its convexity directed arch-like forward around the *pars lumbalis* of the diaphragm, around the *tuber omentale* of the pancreas and around the *tuber omentale* and the *processus papillaris* of the liver. The long axis of the corpus is directed forward, to the right and somewhat downward; the deepest point is situated at the junction of the corpus with the *pars pylorica* and the latter passes again backward, somewhat to the right and somewhat upward, but even at the pylorus does not again reach the level of the cardia. The pylorus lies farther forward than the cardia, at the level of the 11th or 12th thoracic or the first lumbar vertebra, and when the stomach is empty at the same time in the median plane or slightly to the left of it; when the stomach is full it passes markedly to the right and at the same time becomes lower by about the level of one vertebra. The main mass of the stomach accordingly lies in the left half of the body.



560. Mucous membrane of the stomach,

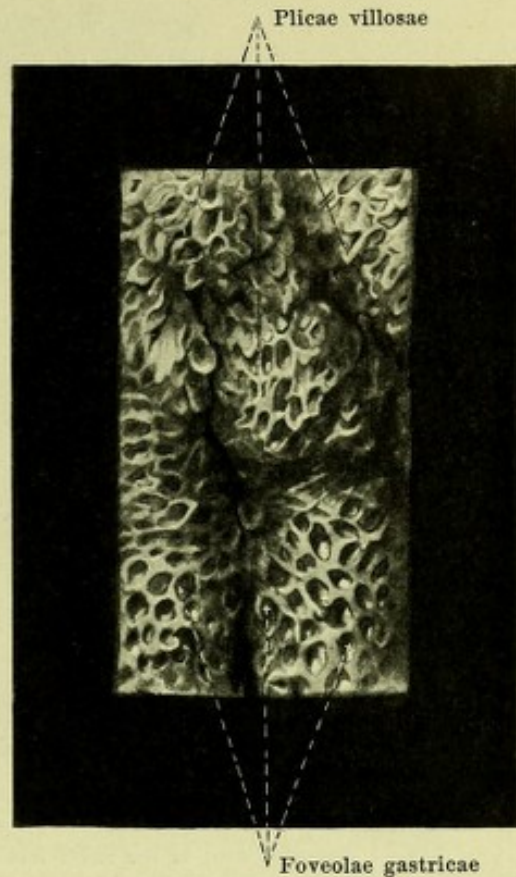
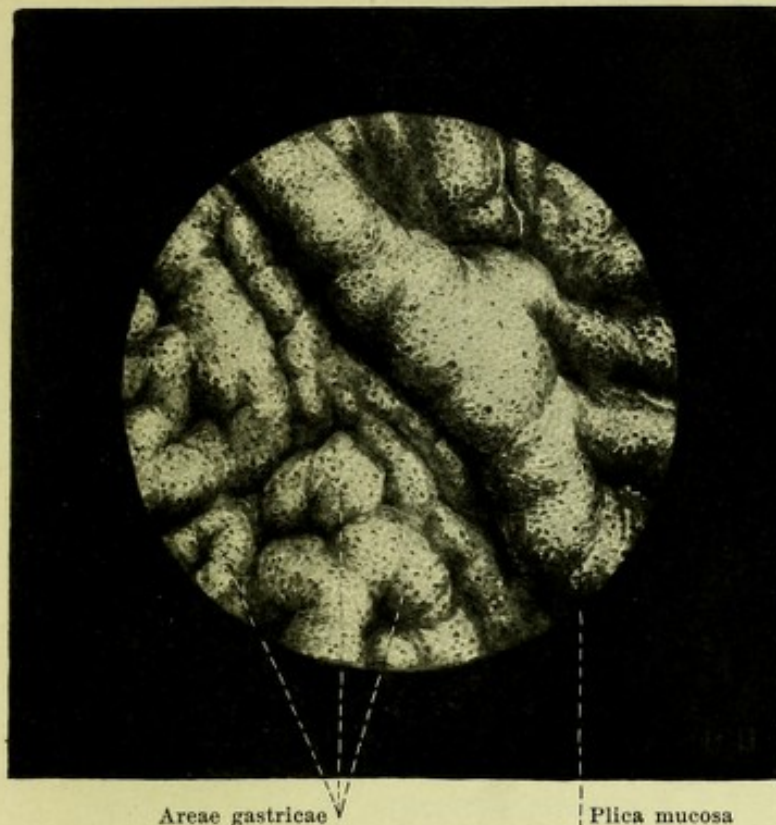
posterior half, viewed from above and in front.

(The moderately distended stomach has been cut through along the greater and lesser curvatures.)

Position of the stomach (continued) (see Figs. 592 and 593). The fundus is bounded directly above by the cupola of the diaphragm, to the left and behind by the facies gastrica of the spleen. The paries posterior is in contact with the facies anterior of the glandula suprarenalis sinistra, with the facies anterior (impressio gastrica) of the left kidney and with the facies anterior of the pancreas; it is partly separated from these organs by the bursa omentalis. The paries anterior is in contact with the impressio gastrica of the lobus sinister and of the lobus quadratus as well as with the tuber omentale of the liver and, when the stomach is empty, is almost completely covered by these parts. When the stomach is full the paries anterior is in contact on the left side in still greater extent with the diaphragm; in addition, a triangular area of the corpus and pars pylorica lies directly against the anterior abdominal wall in the regio epigastrica beneath the margo anterior of the left lobe of the liver and to the right of the 8th (9th) costal cartilages of the left side (see Fig. 591).

The external surface of the stomach is covered by the *tunica serosa* (*peritoneum*) (see Fig. 557). Two narrow strips running from the cardia to the pylorus alone remain free from it. One of these extends along the curvatura minor; near it is attached the ligamentum hepatogastricum. The other stretches behind the fundus and along the curvatura major; near it goes off the lig. gastrolienale, the omentum majus and the lig. gastrocolicum.

Beneath the peritoneal covering lies the *tunica muscularis*. It consists of three layers. The outermost layer, *stratum longitudinale* (see Fig. 558) is a continuation of the longitudinal muscle fibers of the oesophagus. It forms a narrower, more powerful, complete band of fibers along the curvatura minor, while a broader but feebler band passes over the fundus and the greater curvature; in addition fibers diverge from the cardia to the corpus and bend partly into the second layer also. Both bands of fibers converge toward the pylorus, cover the antrum pyloricum as a continuous layer and go over into the longitudinal fibers of the duodenum. The bundles upon the upper and lower surfaces are especially tense and closely arranged and are designated the *ligamenta pylori*.



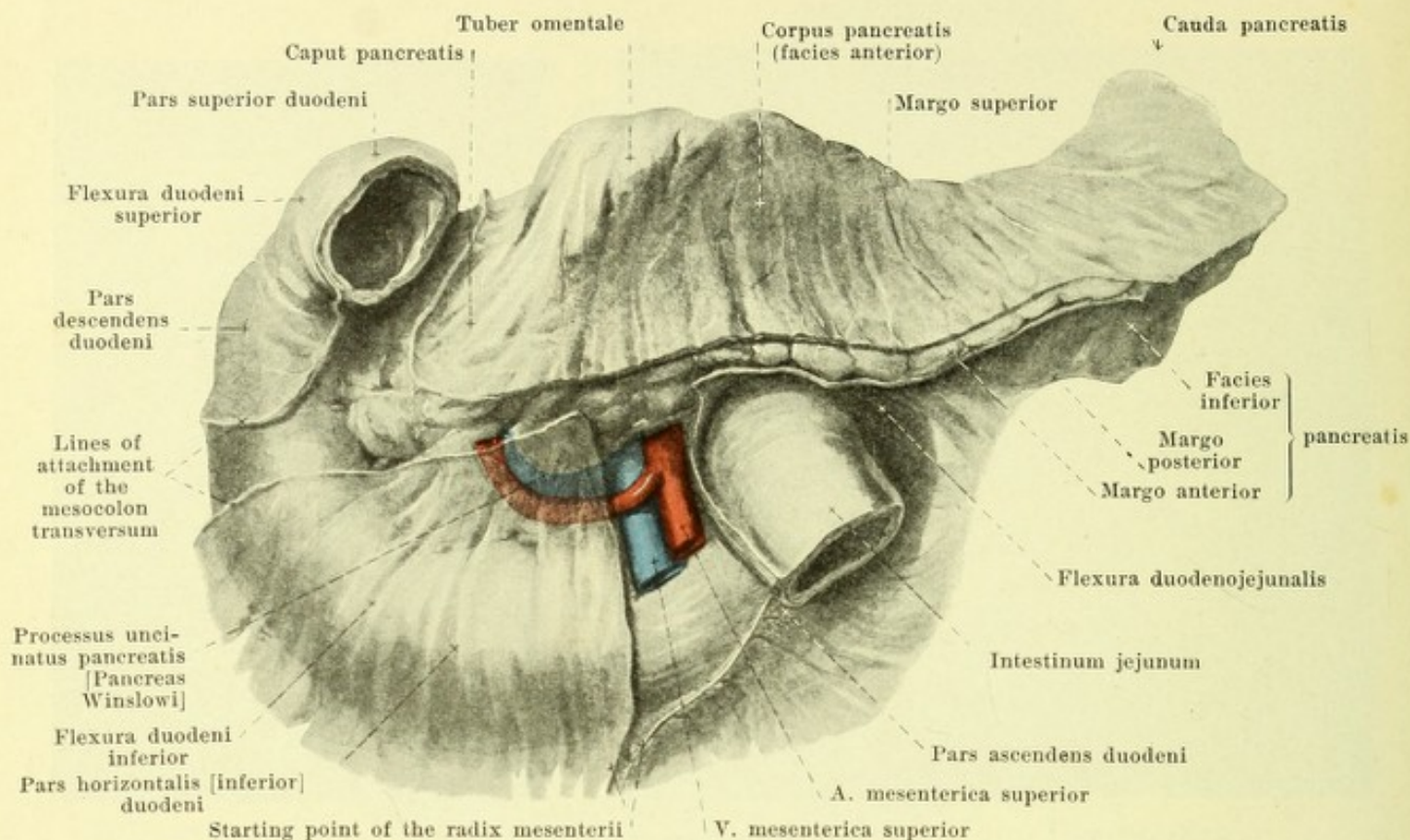
561 and 562. Mucous membrane of the stomach, from the pars pylorica, viewed from the surface.

Magnification 5:1.

Magnification 16:1.

The **stomach. Tunica muscularis** (continued). The second layer of the same, *stratum circulare* (see Figs. 558 and 559) in the form of even circular bands of fibers covers the whole stomach with the exception of the fundus; the uppermost fibers arising at the right side of the cardia form only incomplete rings. The layer is directly connected with the circular layer of the oesophagus and of the duodenum and projects at the pylorus into the interior of the stomach as an especially thickened ring, *m. sphincter pylori* (see Fig. 560). The third, deepest layer *fibrae obliquae* (see Fig. 559) is connected at the left side of the cardia with the circular layer of the oesophagus. Thence the fibers diverge upon the paries anterior and posterior so that the first run parallel to the *curvatura minor* and pass almost as far as the *pars pylorica*, the last run more transversely to the long axis; all the fibers bend around finally in the direction of the *stratum circulare* and are partly continued into this. To these fibers are added, on the left side and above, those which encircle the fundus in concentric rings.

The **tunica mucosa (mucous membrane)** of the stomach (see also Fig. 560) is separated from the *tunica muscularis* by the *tela submucosa*. It is of a greyish red or rose color and is marked off at the cardia by a sharp jagged line from the more whitish mucous membrane of the oesophagus. When the stomach is contracted it forms with the *tela submucosa* numerous folds, the *plicae mucosae* (O. T. *rugae*); the largest of these frequently radiate from the cardia or run approximately parallel to the long axis in the corpus and in the *pars pylorica*, always connected by smaller transverse folds. These folds vanish entirely when the stomach is markedly distended. At the pylorus there is always a fold, usually circular, the *valvula pylori*, which is shoved forward by the *m. sphincter pylori* and surrounds an oval opening. Besides the larger folds of the stomach there are still smaller elevations, *areae gastricae*, incompletely separated from one another by a large number of irregular furrows of varying depth; they differ markedly from one another and each has an area of several square millimeters. Over the whole mucous membrane with the aid of a hand-lens can be seen minute depressions, *foveolae gastricae*, in which open the glands of the stomach, *glandulae gastricae [propriae]* and *glandulae pyloricae*. The thin walls intervening between these depressions present, especially in the *pars pylorica*, small oblong flat villous processes, the *plicae villosae*.

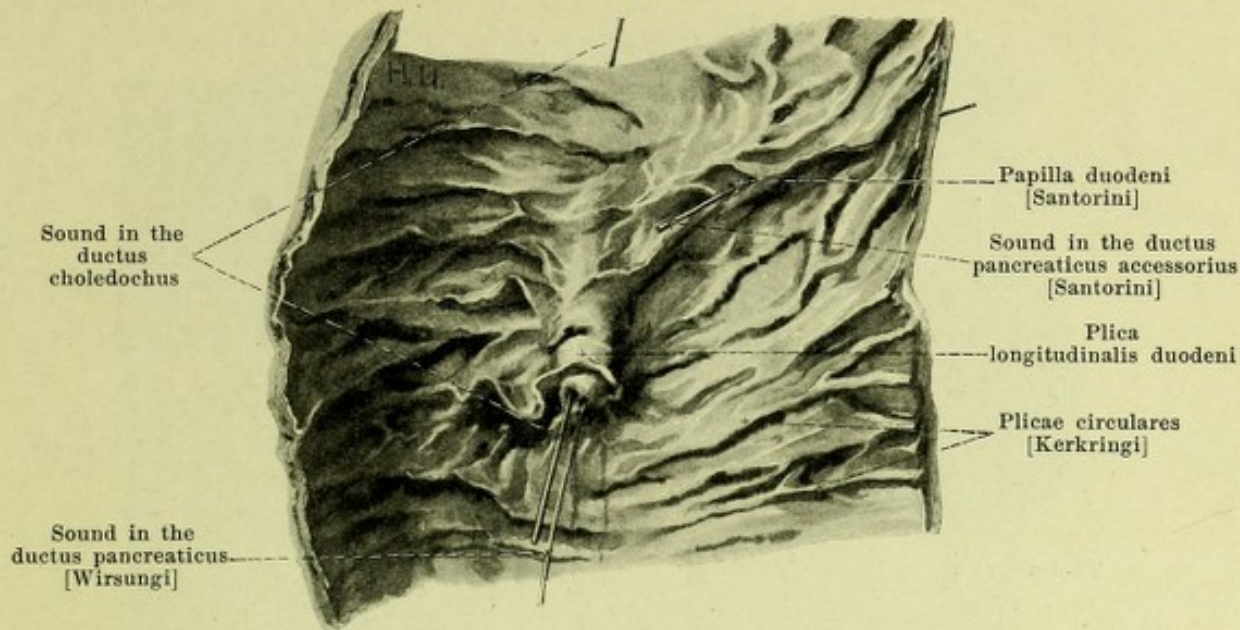


563. Duodenum and pancreas, viewed from in front.

(A piece of the pars superior duodeni has been cut off. The peritoneum has been cut away exactly at the point where it turns away from the two organs.)

The **small or thin intestine** (*intestinum tenue*) (see Fig. 512) is a cylindrical tube; it begins at the pylorus, fills up a large part of the abdominal and pelvic cavities with its numerous convolutions and ends by opening into the large intestine. Its diameter gradually diminishes from above downward. The small intestine is divisible into the *duodenum* and the *intestinum tenue mesenteriale*.

The **duodenum** (see also Figs. 584, 585, 591—594) is the name given to the first portion of the small intestine which is directly and firmly attached to the posterior abdominal wall. It forms a spirally curved ring, open to the left and above, in the concavity of which the pancreas is inserted and the terminal points of which lie closer to one another when the stomach is empty than when it is full. It presents for examination a *pars superior*, *pars descendens* and *pars inferior*. The *pars superior* is the shortest portion and runs approximately horizontally and backward; when the stomach is empty it extends at the same time from left to right, when the stomach is full it extends exactly sagittally from before backward or it may even pass from right to left. It lies to the right and in front of the pars lumbalis of the diaphragm, of the v. portae, a. hepatica and ductus choledochus, behind and below the lobus quadratus of the liver, crosses the porta hepatis and by means of the *flexura duodeni superior* bends around beneath the processus caudatus of the liver into the *pars descendens*. This runs downward and somewhat to the left in front of the medial margin of the right kidney (somewhat nearer the median plane when the colon ascendens is full than when it is empty), to the right of the v. cava inferior, behind the left portion of the right lobe of the liver, behind the gall-bladder and behind the colon transversum and goes over by means of the *flexura duodeni inferior* into the *pars inferior*. The latter extends transversely to the left at first (*pars horizontalis inferior*) in front of the body of the 3rd or 4th lumbar vertebra and in front of the v. cava inferior and then turns abruptly upward and somewhat to the left (*pars ascendens*) in front of the aorta abdominalis. This last portion runs behind the a. and v. mesenterica superior, crossed by the radix mesenterii, as far as the left side of the body of the 2nd lumbar vertebra and as far as the facies inferior pancreatis and there, covered by the stomach, suddenly bends around markedly to the right and forward (*flexura duodenojejunalis*), to go over into the *intestinum jejunum*. Sometimes no marked *pars horizontalis inferior* is present; the pars descendens then forms a V with the pars ascendens.



564. Mucous membrane of the pars descendens of the duodenum.

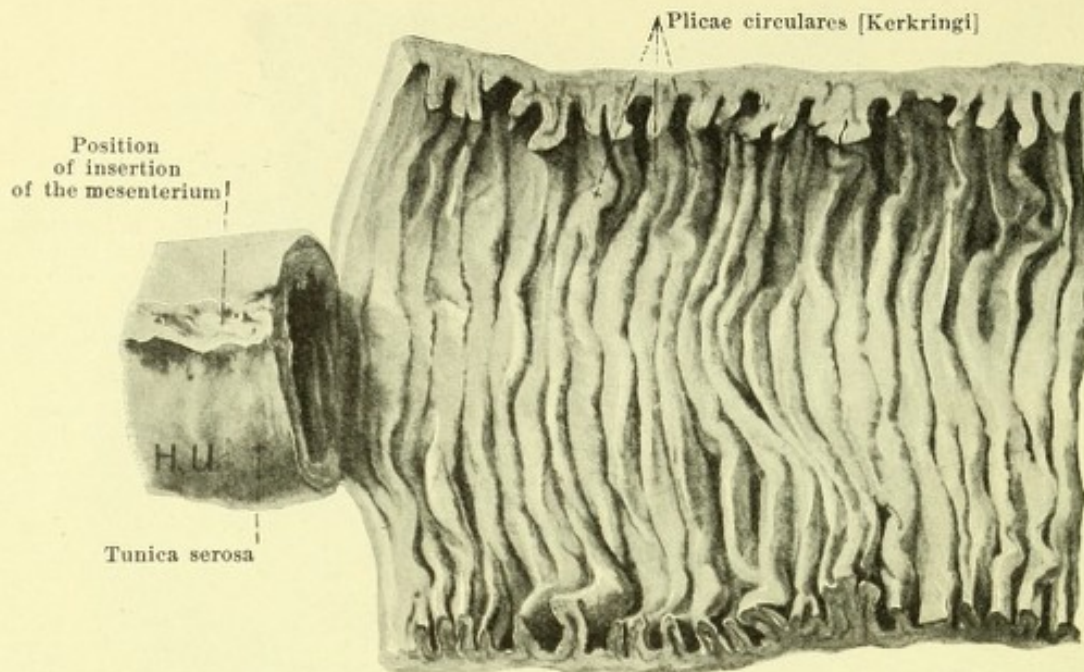
(The piece of intestine has been cut open along its right side and spread out.)

Duodenum (continued). The flexura duodenojejunalis is firmly attached to the diaphragm by means of the *m. suspensorius duodeni* (see Fig. 633). This small, flat, triangular muscle consisting of smooth muscle fibers arises directly above the hiatus aorticus from the bands of fibers of the pars lumbalis diaphragmatis. It runs downward in front of the plexus coeliacus and behind the pancreas, its fibers diverging downward; it lies to the left of the a. coeliaca and a. mesenterica superior and is strengthened by fibers from the neighborhood; at the flexure it radiates out into the longitudinal and circular muscle bands of the intestine.

The *tunica serosa* (peritoneal covering) is present only in part of the duodenum (see Figs. 563, 593 and 594). A part of the left wall of the pars superior looks into the bursa omentalis and is covered by its peritoneum; the right and upper walls are completely covered by peritoneum, the latter except for a narrow strip, from which the ligamentum hepatoduodenale goes off. The pars descendens possesses a serous covering on its right and anterior walls, and only the area between the lines of attachment of the mesocolon transversum is free from it. The pars horizontalis [inferior] is covered by peritoneum in front and below, the pars ascendens in front and to the left, the latter with the exception of the spot where it is crossed by the radix mesenterii.

The *tunica muscularis* in detail, the *tunica mucosa* in general, resembles that of the rest of the small intestine. But the mucous membrane possesses in the pars descendens certain special structures in addition (see also Fig. 584). In that region, at the junction of the posterior with the left wall, it is elevated by the *ductus choledochus* to a longitudinal fold more distinct below, the *plica longitudinalis duodeni*; in its lower part this presents a small projection upon which open the *ductus choledochus* and the *ductus pancreaticus* [Wirsungi] either close to one another with two openings or, when they have previously united, by a common opening. Somewhat above and in front of this spot there is constantly to be found a smaller rounded elevation, *papilla duodeni* [Santorini], with the opening of the *ductus pancreaticus accessorius* [Santorini].

The *intestinum tenue mesenteriale* (see Figs. 512 and 589) by means of numerous convolutions fills up the space which is bounded on the right by the colon ascendens, above by the colon transversum and mesocolon transversum, to the left by the colon descendens; it is shoved into the right and left partly in front of the organs mentioned and extends below into the cavity of the small or true pelvis. In the posterior wall of this space, covered by the peritoneum, lie the bodies of the two inferior lumbar vertebrae, the pars inferior duodeni, the processus uncinatus of the pancreas and the large abdominal vessels, as well as, on each side, parts of the mm. iliopsoas et quadratus lumborum, the kidney and the ureter. In front and lateralward the small intestine is covered to a variable extent by the great omentum (see Fig. 588) and is separated by this from the peritoneal covering of the m. transversus abdominis and of the mm. recti abdominis.

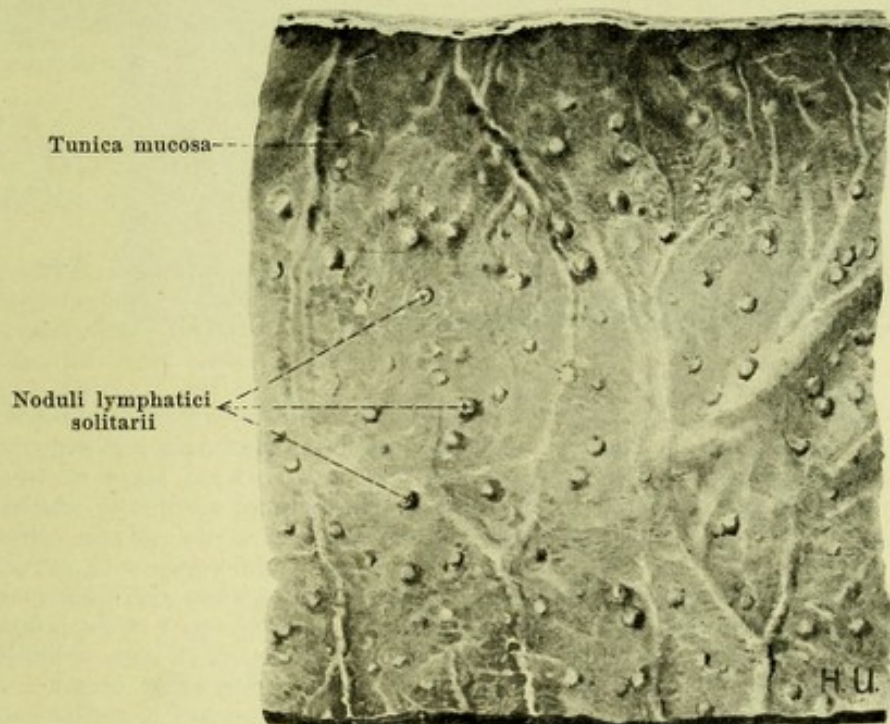
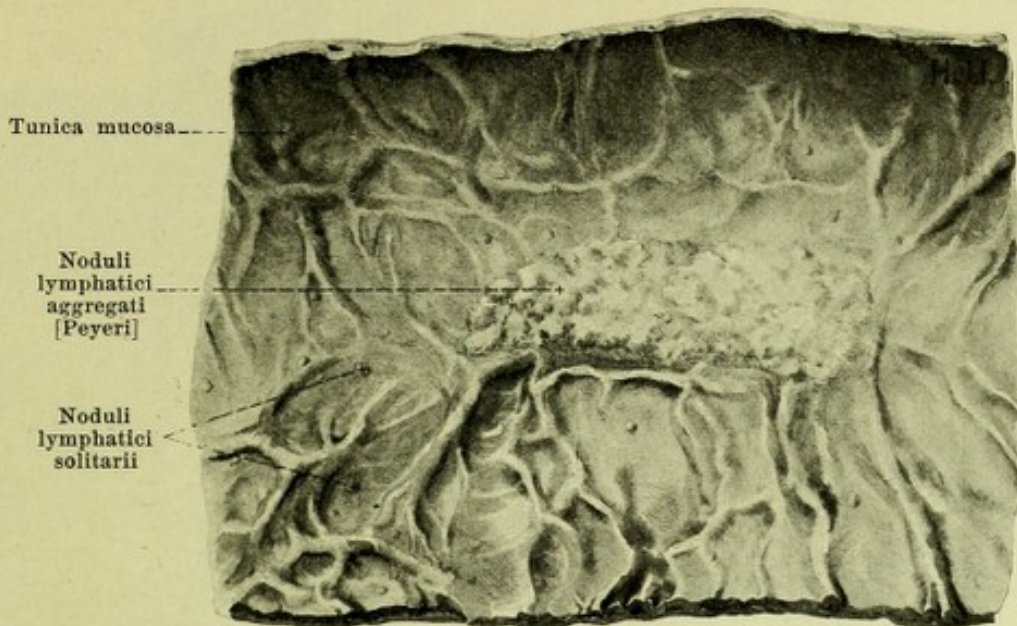


565. Portion of the intestinum jejunum,
in part cut open at the attachment of the mesentery and spread out.

Of the *intestinum tenue mesenteriale* about the upper half is called the *intestinum jejunum* (empty intestine), the lower is called the *intestinum ileum* (convoluted intestine); a sharp limit between the two however exists neither on the external nor on the internal surface. The general arrangement is very frequently as follows (see Figs. 512, 589 and 590): the first portion lies in the regio hypochondriaca sinistra with two groups of loops, which reach above as far as the flexura coli sinistra and are partly covered by the colon transversum; the intestine then passes through the regio umbilicalis turning into the right half of the body, curves around there and runs backward again across the median plane; thereupon it forms several loops in the left fossa iliaca, extends to the right again and finally descends into the small pelvis, where it fills up the excavatio rectovesicalis (in the male, the excavatio rectouterina in the female) with its loops; its terminal portion passes upward again, curves to the right around the margin of the right m. psoas major and passes in the right fossa iliaca into the colon ascendens (see also Fig. 573). Deviations from this course are frequent.

The external covering of the *intestinum tenue mesenteriale* is formed by the delicate *tunica serosa* (peritoneal coat) (see also Fig. 568), which leaves free only a narrow strip where the mesenterium is attached to the intestine. The second layer of the wall consists of the *tunica muscularis*; this is composed of a thinner, external, less complete longitudinal layer, *stratum longitudinale*, and of a thicker internal continuous circular layer, *stratum circulare* (see Fig. 568). The innermost layer, *tunica mucosa* (mucous membrane) is separated from the preceding by the *tela submucosa* (see Fig. 568). In the duodenum the latter contains the glandulae duodenales [Brunneri] (not illustrated) and throughout the whole length of the intestine the bodies of the noduli lymphatici; it sends stripe-like continuations into the plicae circulares [Kerkringi]. The mucous membrane is of a reddish color and presents the following special structures:

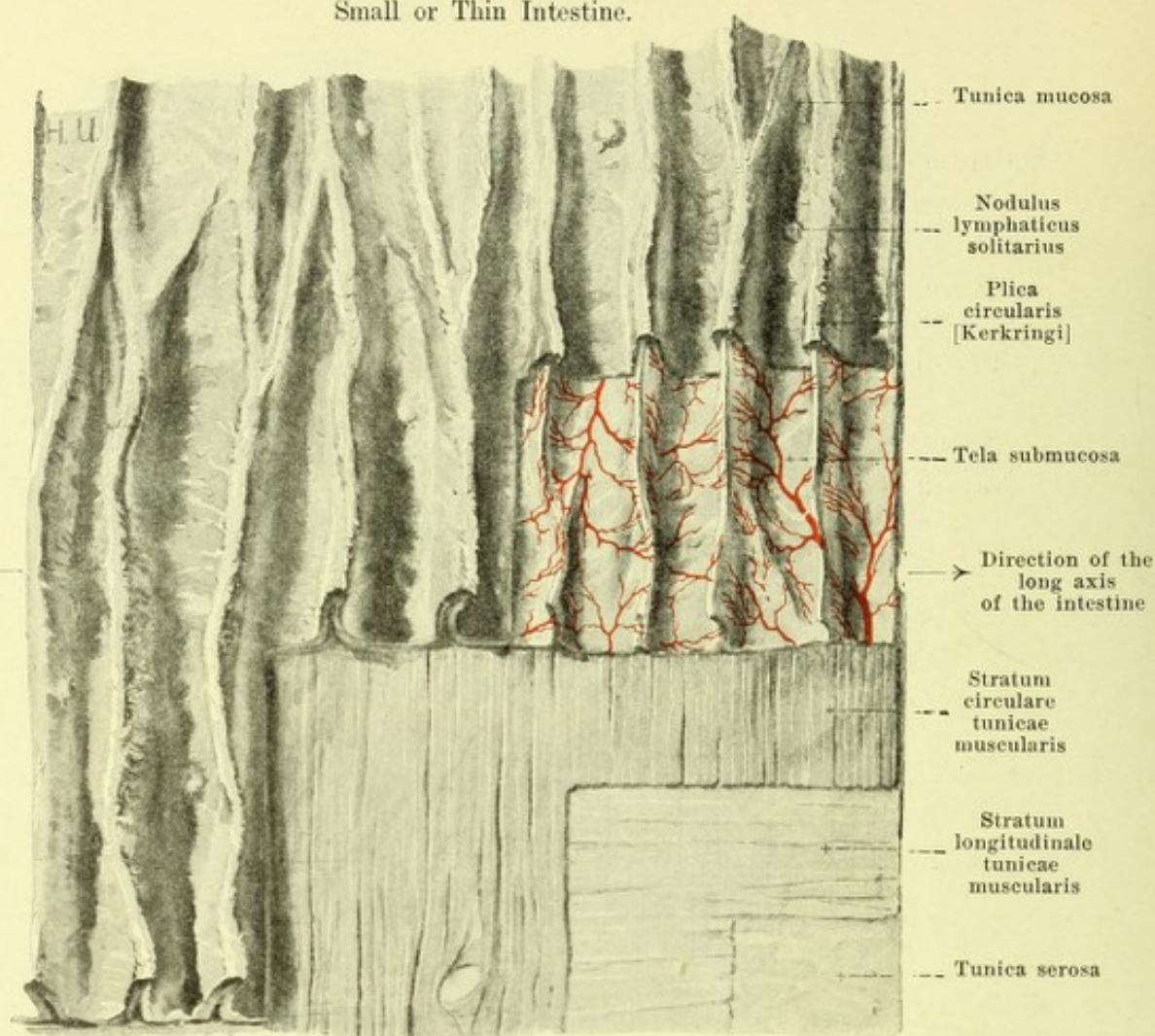
- a) *Plicae circulares [Kerkringi]* (O. T. valvulae conniventes) (see also Fig. 568) are constant folds, which are formed by the mucous membrane and the tela submucosa. They are absent in the pars superior duodeni, appear in the pars descendens duodeni and are especially numerous and large in the pars inferior duodeni and in the upper third of the intestinum jejunum; further on they diminish again and are usually completely absent in the lowermost portion of the intestinum ileum. They run approximately at right angles to the long axis of the intestine and extend usually over only a part of the circumference; a number of folds form complete rings and others encircle the intestine in a spiral turn (more rarely in several). In the upper part of the intestine they are longer and higher than in the lower part. The folds are manifoldly forked; neighboring ones are also frequently united with one another by low slender folds.



566 and 567. Portions of the intestinum ileum,
cut open at the insertion of the mesenterium and spread out.

(The upper figure shows an intestine with many groups of lymph nodules (Peyer's patches), the lower an intestine in which the groups of lymph nodules are only slightly developed and are replaced by an increased number of solitary nodules.)

- b) *Noduli lymphatici (lymph nodules)* (see also Figs. 568—570) are small usually pear-shaped structures, whose thick bodies are situated in the tela submucosa; the blunt wedge-shaped apex of each lies in the tunica mucosa and forms a (non-villous) dome-like elevation of the surface of the mucous membrane. They are usually single in the intestinum jejunum (*noduli lymphatici solitarii*). In the intestinum ileum they are numerous and much higher and in part are crowded together into oblong *Peyer's patches* (*noduli lymphatici aggregati [Peyeri]*); these vary in size but generally contain from twenty to thirty nodules; they lie opposite the insertion of the mesenterium; these patches may be replaced in part by an increased number of solitary nodules.

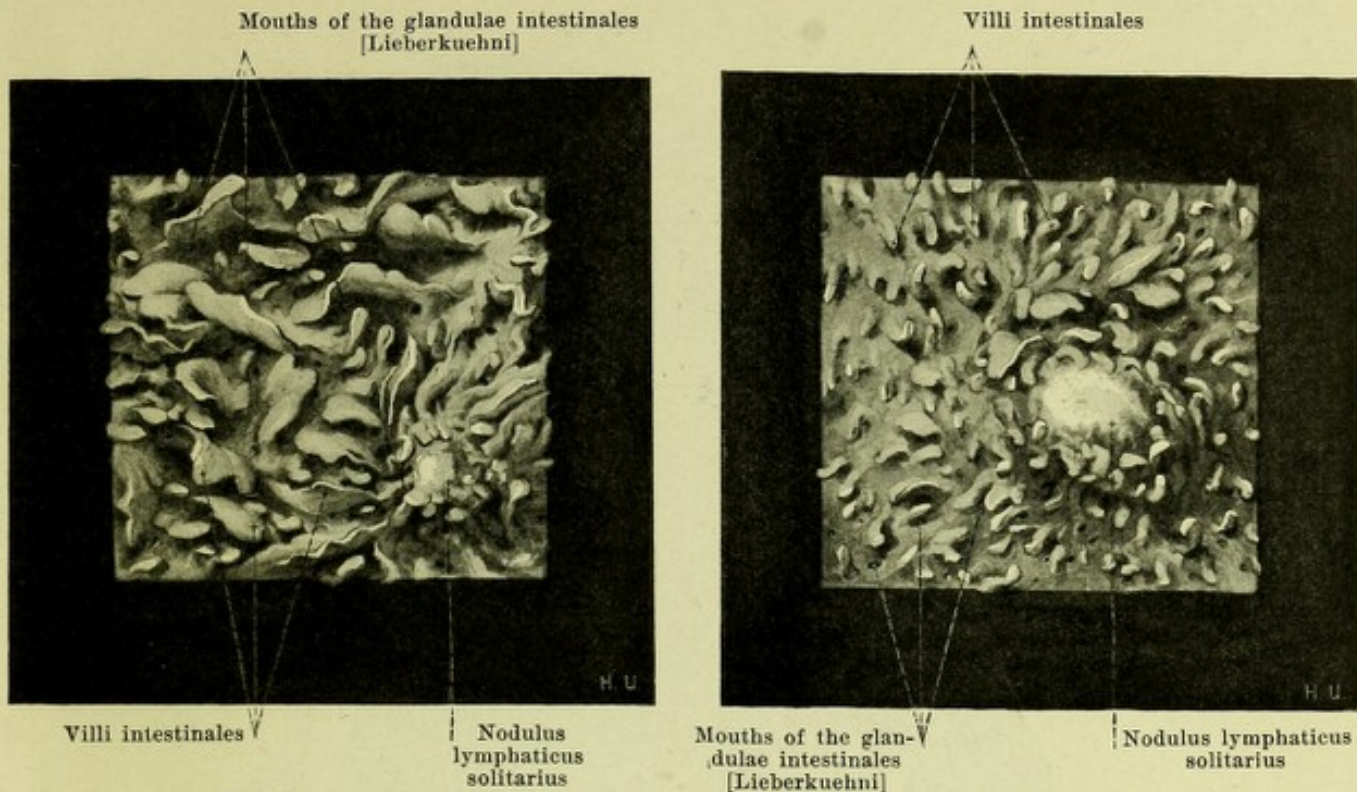


568. The wall of the small intestine. Magnification 3:2.

(Passing from above downward the individual layers have been gradually removed.)

- c) *Villi intestinales* (villi of the intestine) (see Figs. 569 and 570) are small elevations, (the largest being 1 mm long) of the surface of the mucous membrane which are present from the pylorus almost as far as the free margin of the valvula coli and are closely crowded upon the plicae circulares [Kerkringi] and between them. They leave free only the domes of the noduli lymphatici and are somewhat more numerous in the upper than in the lower part of the intestine. In the upper part of the intestine they are also much broader, more leaf-like, in the lower part more slender, cylindrical or flattened; along with these however all possible intermediate forms occur.
- d) *Glandulae intestinales [Lieberkuehni]* (O. T. crypts of Lieberkuehn) (not illustrated) are tube-like glands which are studded over the mucous membrane perpendicularly to the surface throughout the whole extent of the small and large intestines. With the hand lens their mouths are visible as small openings (see Figs. 569, 570 and 577).
- e) *Glandulae duodenales [Brunneri]* (Brunner's glands of the duodenum) (not illustrated) are glands which are found in the duodenum only; the main bodies of the glands are situated in the tela submucosa while the ducts extend between the glandulae intestinales [Lieberkuehni] through the tunica mucosa to its surface. The glands are largest and most numerous in the pars superior duodeni; farther on they gradually become less numerous and vanish entirely at the level of the flexura duodenojejunalis.

The **large or thick intestine** (*intestinum crassum*) (see Figs. 589—591), following upon the small intestine, is the most variable portion of the digestive tube. It begins as the *intestinum caecum*, in the fossa iliaca dextra, surrounds a part of the peritoneal cavity and the small intestine with a large loop, which ends in the fossa iliaca sinistra and in which we distinguish an ascending (*colon ascendens*), a transverse (*colon transversum*) and a descending limb (*colon descendens*). Its terminal portion (*colon sigmoideum*) hangs down as a loop into the cavity of the small pelvis and goes over in front of the sacrum into the rectum. The portion from the caecum to the rectum is called the *colon (gripping intestine)*.



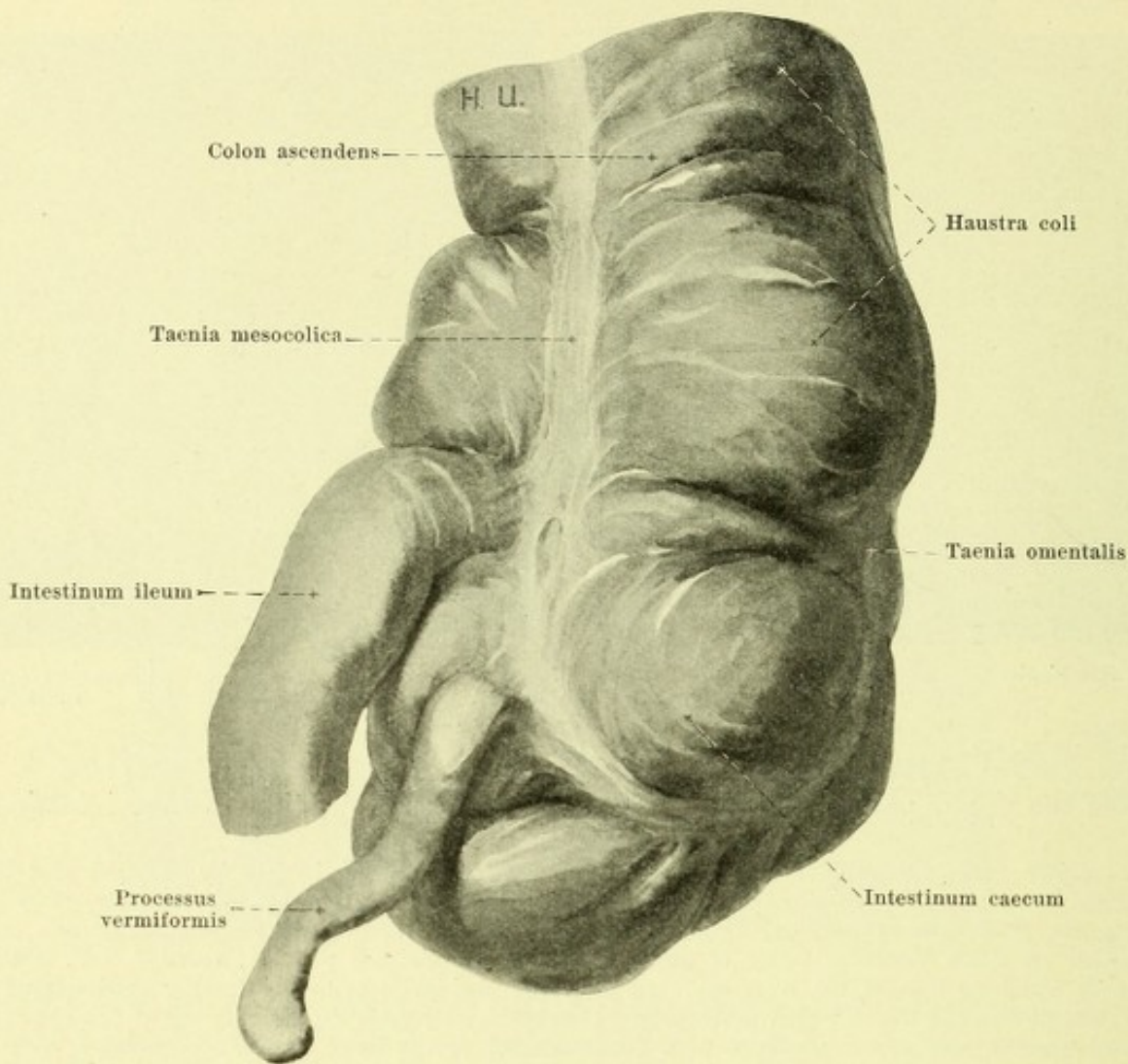
569 and 570. Villi of the small intestine,
 from the upper part of the intestine from the lower part of the intestine.

Magnification 12 : 1.

The large intestine is characterized (see Figs. 571, 572 and 574) by the fact that its surface is not smoothly cylindrical but presents a nodular appearance due to three rows of irregular, flask-like projections, *haustra coli*. These rows of haustra are separated from one another by three band-like strips of the longitudinal muscle (see p. 527), *taeniae coli*, which run in the long axis of the intestine, but they are besides individually further subdivided by furrows of varying depth which correspond to sickle-shaped folds on the surface of the mucous membrane, the *plicae semilunares coli*. The diameter of the large or thick intestine is larger than that of the small or thin intestine, but diminishes gradually towards its termination. The distention of the large intestine with faeces usually diminishes from the caecum toward the rectum, so that the colon descendens is usually empty and collapsed; the colon sigmoideum is, on the contrary, often distended by gas.

The *intestinum caecum* (blind gut) (see Figs. 571—574) is the blind-sac-like portion of the large intestine situated below the opening of the *intestinum ileum* into the large intestine. Its upper boundary is indicated externally by a deep incomplete groove which surrounds the intestine at the level of this opening and to which internally the frenula valvulae coli correspond. The contracted caecum (see Fig. 572) forms a kink in this furrow with the colon ascendens, so that it runs to the left, downward and backward; its haustra are but little marked and it has the shape of a wedge, from the apex of which the *processus vermiformis* goes off with more or less distinct narrowing, at first in the direction of the main tube. The distended caecum (see Figs. 571, 573, 574 and 596) forms a less marked kink with the colon ascendens and is directed downward and a little to the left. It is approximately hemispherical in shape and has well marked haustra. The *processus vermiformis* goes off directly from the medial part of the posterior wall. The three *taeniae coli* extend toward the beginning of the *processus vermiformis*; in the contracted intestine they converge gradually as they approach, in the distended they meet one another in the form of a T.

The *processus vermiformis* (O. T. *vermiform appendix*) (see Figs. 571—574 and 596) is a narrow, generally cylindrical, hollow, blind-ending appendix of the *intestinum caecum*, the length, curvature and position of which vary extraordinarily. From its origin behind and beneath the termination of the small intestine it runs straight or tortuous toward the small pelvis or upward behind the caecum or to the left and upward behind the small intestine, or often in some other direction. Its position varies correspondingly; it is covered in its course partly or entirely by the caecum. It is covered externally by a continuous layer of longitudinal muscle. The *processus vermiformis* often becomes partly or entirely obliterated in the later years of life.



571. Caecum, distended,

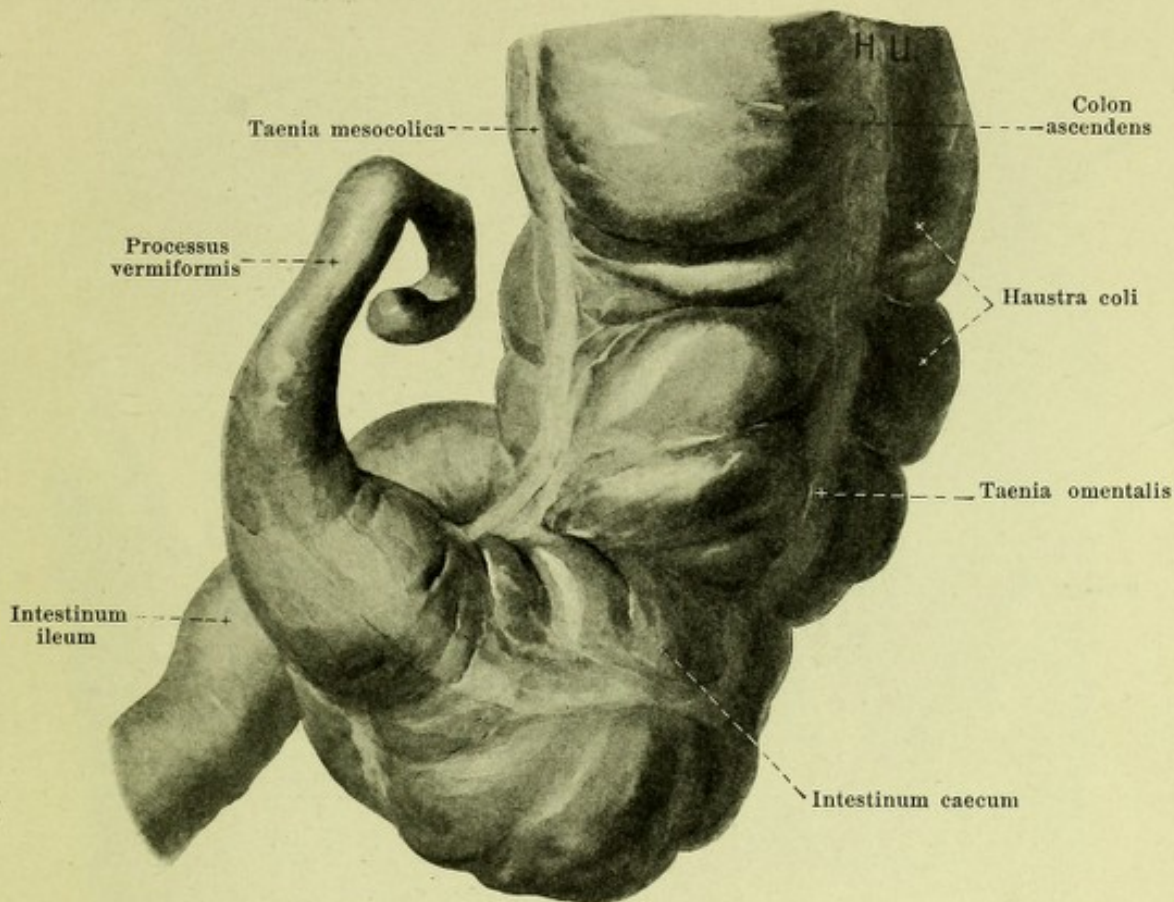
viewed from behind, after removal of the peritoneal coat.

Position of the caecum (see Figs. 589—591). The caecum rests in the fossa iliaca dextra directly upon the fascia iliaca, separated by this from the m. iliopsoas. When it is full its lower end lies just over the lateral half of the ligamentum inguinale; its right wall is in contact with the lateral wall of the abdominal cavity; its anterior wall is overlapped below and to the left by small intestines and is directly in contact above and to the right with the anterior abdominal wall; its left wall may reach the left margin of the m. psoas major and the vasa iliaca externa. In the contracted condition the lower end does not reach so far downward and the anterior wall is completely covered in front by loops of small intestine.

The *wall of the caecum* consists like that of the whole of the large intestine of *tunica serosa*, *tunica muscularis*, *tela submucosa* and *tunica mucosa*.

The *tunica serosa* (*peritoneal coat*) (see Figs. 573 and 596) covers the caecum and the vermiform process almost completely in by far the majority of cases; it leaves free only a narrow strip which extends from the orifice of the small intestine to near the tip of the vermiform process and along this the mesenterium processus vermiformis is attached to the intestine. Sometimes only the inferior portion of the posterior wall is covered by the peritoneum; the upper part then has the same relations as the colon ascendens.

The *tunica muscularis* resembles that of the rest of the large intestine (see p. 527).

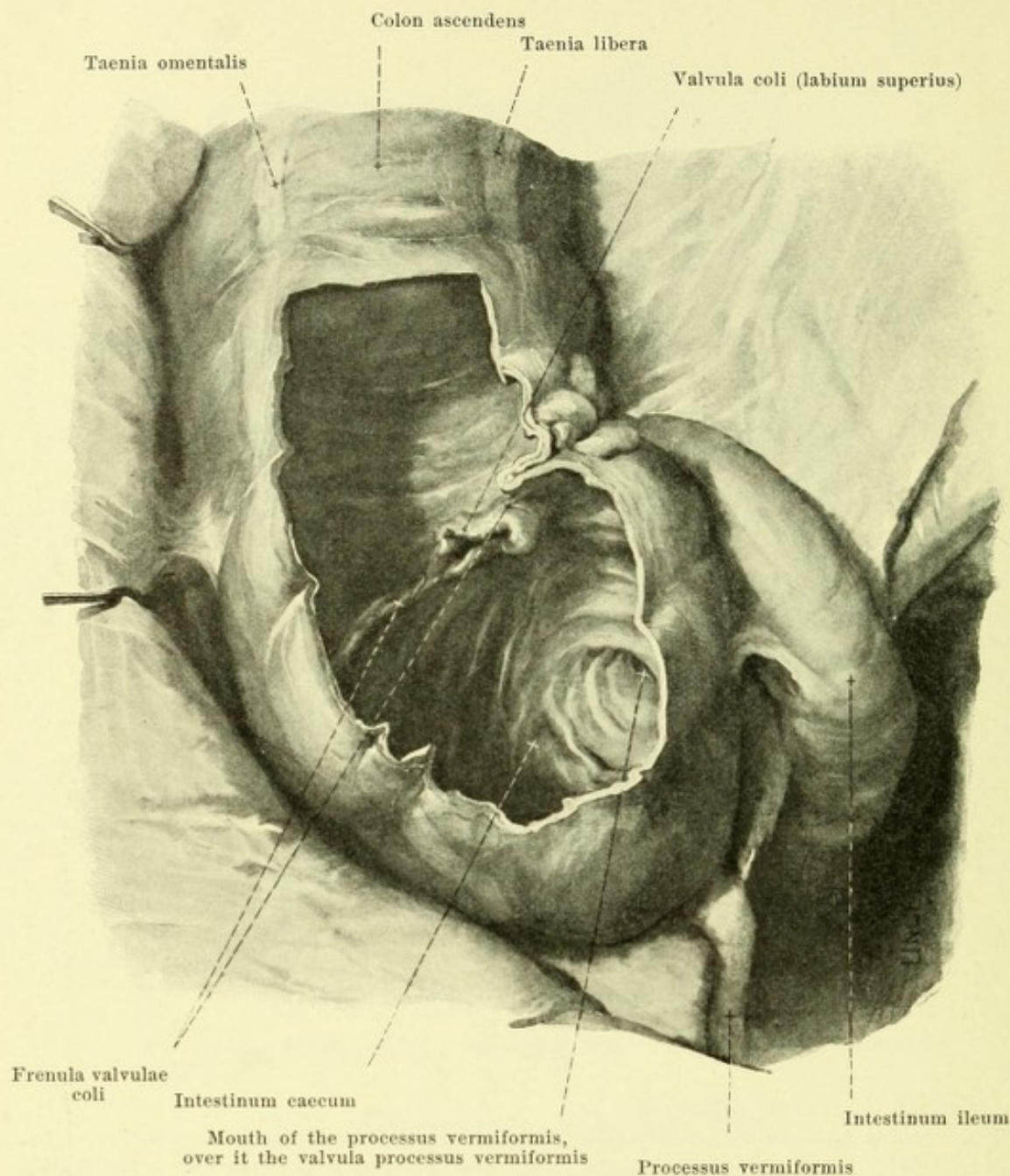


572. Caecum, contracted,

viewed from behind, after removal of the peritoneal coat.

Wall of the caecum (continued):

The *tunica mucosa* (*mucous membrane*) (see Figs. 573 and 574) presents fossa-like depressions which correspond to the haustra, and plicae semilunares which correspond to the constrictions on the external surface. The funnel-shaped opening of the processus vermiformis is sometimes surrounded on the left and above by a sickle-shaped fold of mucous membrane (*valvula processus vermiformis*). At the upper limit of the caecum in the posterior part of the left wall lies the opening of the small intestine within the *valvula coli* (*valve of the large intestine*). In the formation of this the terminal portion of the small intestine is invaginated into the cavity of the large intestine (see Fig. 574), its external wall being fused for a certain distance with that of the large intestine. There thus arise two high folds formed by the walls of the small and large intestines, the *labium superius* and *labium inferius* of the *valvula coli*, of which the lower may be shorter than the upper. Both folds go over into one another at their ends and surround the opening of the small intestine proper by their projecting margins. This opening is slit-shaped and its longitudinal diameter is usually directed from the left and above to the right and downward. From the point of union of the two folds there goes off in front and behind a high fold of mucous membrane of the large intestine, the *frenulum valvulae coli*, the two frenula have in common with the *labium superius* a sickle-like form, run from the left and above to the right and downward and extend over more than half the circumference of the intestine; the posterior fold is the longer and broader. They correspond to the deep furrow on the outer surface at the level where the caecum forms a kink with the large intestine (see p. 521). The valve of the large intestine is said to be always insufficient in the newly born, in children and adults it is normally sufficient. Regarding the membrane see further p. 527.

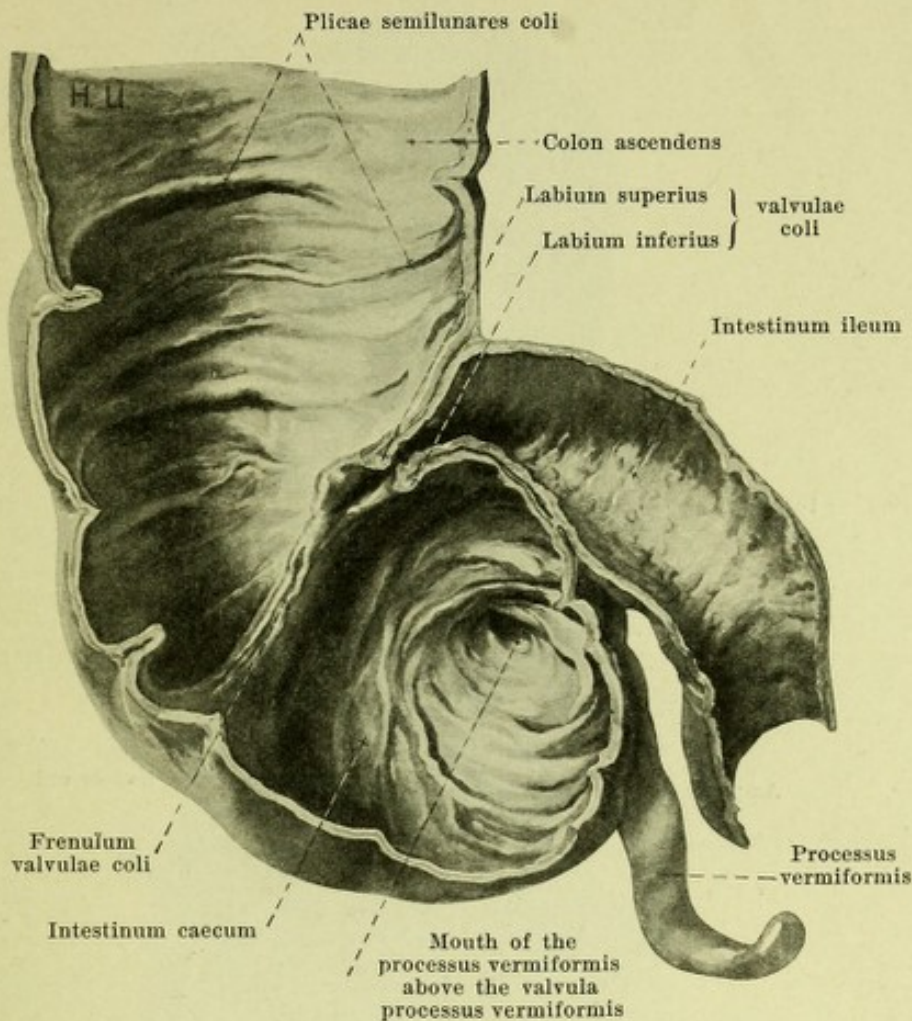


573. Caecum, distended, *in situ*, partly opened from in front.

(The anterior abdominal wall has been reflected to the right and downward; the small intestines have in large part been removed.)

The *colon ascendens* (see also Figs. 589—592) begins at the frenula valvulae coli as the direct continuation of the caecum; it passes upward and somewhat backward from the fossa iliaca dextra in front of the posterior part of the crista iliaca to the anterior surface of the m. quadratus lumborum dexter and then turns again somewhat forward to go over at the inferior pole of the right kidney through the flexura coli dextra into the colon transversum. Its right wall touches the lateral wall of the abdomen; its anterior wall in the contracted condition is completely, in the distended condition only partly, covered by loops of the small intestine and elsewhere is in contact with the anterior abdominal wall; its left wall is bounded partly by the m. psoas major, partly by loops of small intestine.

The *flexura coli dextra* (O. T. hepatic flexure of the colon) (see Figs. 591, 592 and 594) reaches either only from below to the inferior pole of the right kidney or covers the latter for some distance and is in contact in front and above with the impressio colica of the liver.



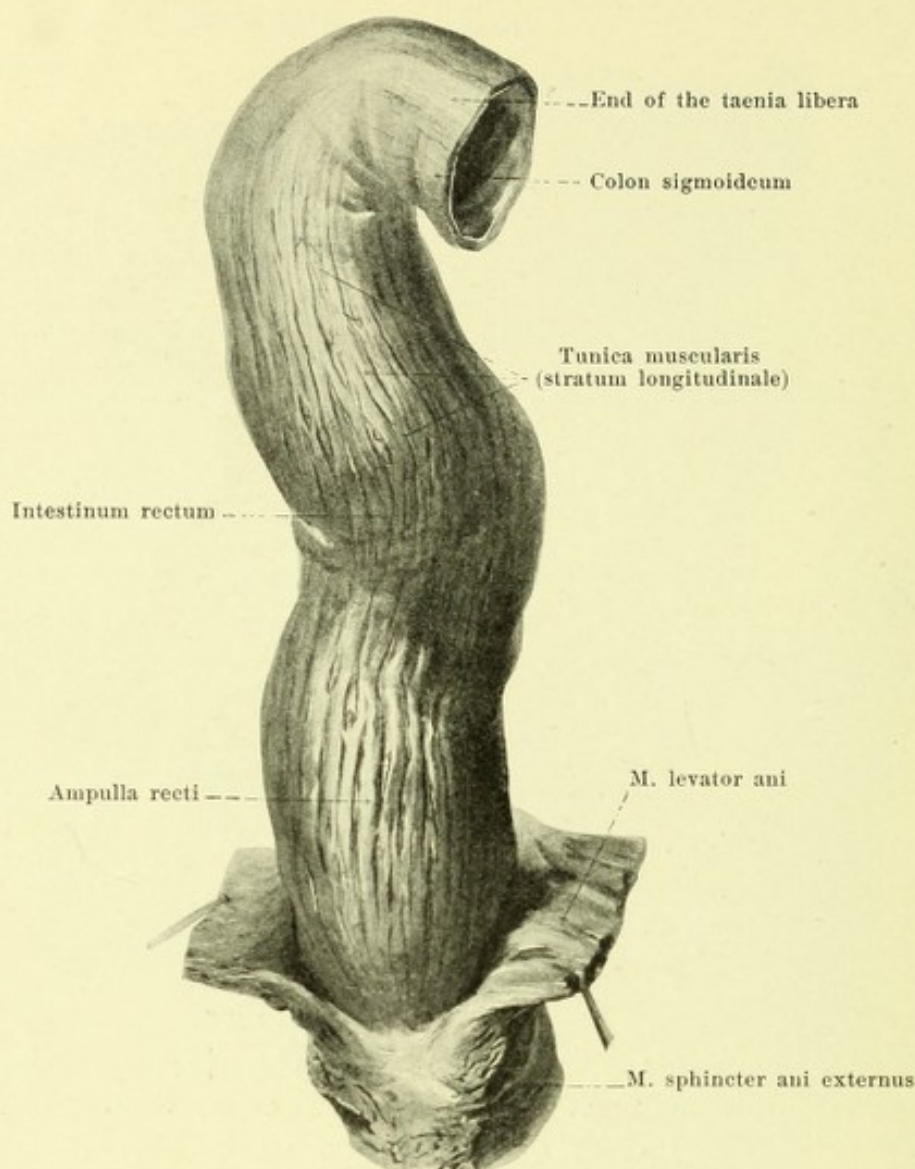
574. Valve of the large intestine (*valvula coli*)

and neighboring pieces of intestine, cut through, viewed from in front.

The *colon transversum* (*transverse colon*) (see Figs. 591 and 594) runs out to the left and somewhat upward from the flexura coli dextra over the median plane in a curve convex forward and at the same time somewhat downward and goes over just at the right of the extremitas inferior of the spleen through a sharp curve (flexura coli sinistra) into the colon descendens (see Fig. 593); it is often markedly curved downward. In its course it is bounded above by the impressio colica of the liver, the body of the gall bladder and the curvatura ventriculi major; it lies in front of the pars descendens duodeni, the pancreas, the pars ascendens duodeni and the upper part of the left kidney; on its inferior surface lie loops of the intestinum jejunum, the latter being also shoved upward to the left of and partly behind it; its anterior surface (see Figs. 589 and 598) is covered by the omentum majus and by this separated from the anterior abdominal wall and (on the left) from the diaphragm.

The *flexura coli sinistra* (O. T. splenic flexure of the colon) makes a sharper bend than the flexura coli dextra and lies in front of the upper part of the lateral margin of the left kidney, regularly higher and farther dorsalward than the right; it reaches as far as the spleen (see p. 536) and may when the stomach is empty reach as far as the left dome of the diaphragm.

The *colon descendens* (see Figs. 590 and 591) runs, in a curve which is slightly convex backward and lateralward, to the inferior pole of the left kidney and then downward and forward on the lateral surface of the m. psoas in front of the m. quadratus lumborum, the posterior part of the crista iliaca and the m. iliacus to the fossa iliaca sinistra; there it bends around and extends parallel to and above the lig. inguinale sinistrum to the right, downward and forward, in front of the m. iliopsoas until it is in front of the vasa iliaca externa and the left ductus deferens (in the male, the ligamentum teres uteri in the female); in that situation it goes over into the colon sigmoideum (see also Fig. 597). It is bounded above and on the left by the lateral wall of the abdomen; below, its anterior wall may lie partly against the anterior abdominal wall, otherwise it is overlapped by loops of small intestine (see Fig. 589).

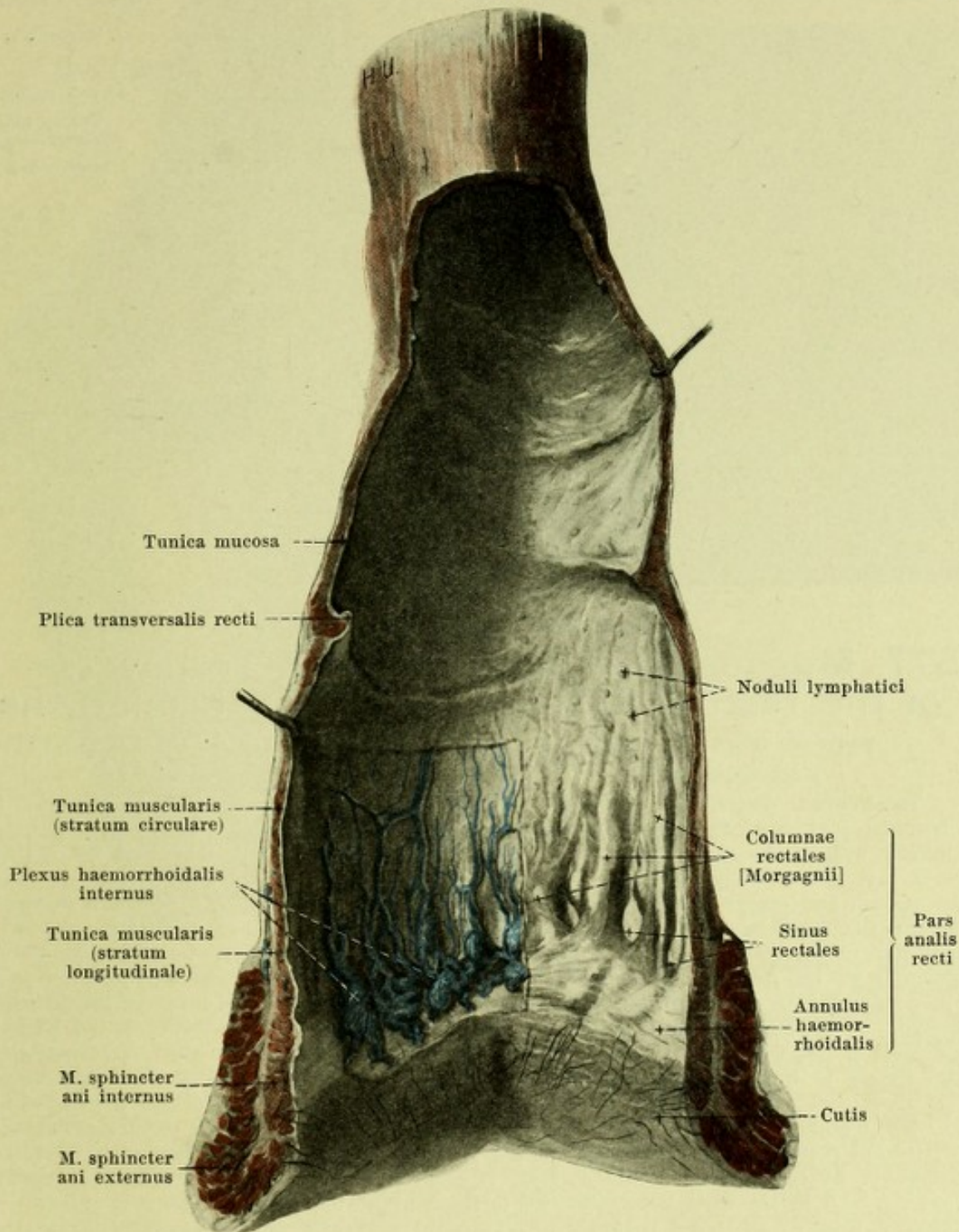


575. Rectum, after removal of the peritoneum, viewed from in front.

The *colon sigmoideum* (O. T. sigmoid flexure of the colon) (see Figs. 591 and 597) forms a moveable loop of variable length consisting of two limbs running nearly parallel to one another. This either hangs down into the small pelvis and lies upon the left and posterior wall of the same and helps to fill up the excavatio rectovesicalis (in the male, rectouterina in the female), or it passes directly upward or obliquely to the right and upward; the latter position is especially frequent in the new-born. The colon sigmoideum is usually overlapped by loops of small intestine. At its termination it goes over, in a curve or straight from the 3rd sacral vertebra, in the median plane into the rectum. The junction is indistinct and only recognizable by the fact that the haustra which are indistinctly marked but still recognizable in the colon sigmoideum stop altogether, and that, of the three taeniae, the omentalis and the libera unite in order to form the anterior strengthening band of the longitudinal muscle of the rectum while the taenia mesocolica goes over into the posterior band.

Wall of the large or thick intestine.

The *tunica serosa* (*peritoneal coat*), after development has been completed, covers only the anterior lateral and medial walls of the colon ascendens and descendens, the posterior wall being left free to a variable extent. The colon transversum is almost completely covered by it, being free from it only along the taenia mesocolica where the mesocolon transversum is attached, and along the taenia omentalis, where the omentum majus goes off. The colon sigmoideum behaves similarly to a loop of small intestine and there remains only a narrow strip uncovered by peritoneum where the mesocolon sigmoideum is attached. Along the whole large intestine are found variably developed lobe-like fatty duplicatures of the tunica serosa, *appendices epiploicae*; they are usually situated near the taeniae (see Figs. 596 and 597).




576. Rectum, opened, viewed from in front.

(A strip has been cut out of the anterior wall. The mucous membrane has been partly dissected off.)

Wall of the large or thick intestine (continued):

Tunica muscularis: the *stratum longitudinale* is limited to three strips which are called the *taeniae coli* (see Figs. 571—573, 590 and 591). On the colon ascendens, colon descendens and colon sigmoideum the *taenia libera* is placed anteriorly, the *taenia mesocolica* posteriorly and medianward and the *taenia omentalis* posteriorly and lateralward; on the colon transversum the *taenia libera* lies below, the *taenia mesocolica* behind, the *taenia omentalis* in front and above. The *stratum circulare* is uninterrupted and is somewhat strengthened at the *plicae sigmoideae*. The thickness of the musculature increases somewhat from above downward.

The *tunica mucosa* is connected with the *tunica muscularis* by the connective tissue of the *tela submucosa* and is elevated into large sickle-shaped folds, *plicae semilunares coli* (see p. 521). Its finer structure agrees with that of the upper part of the rectum (see p. 529).



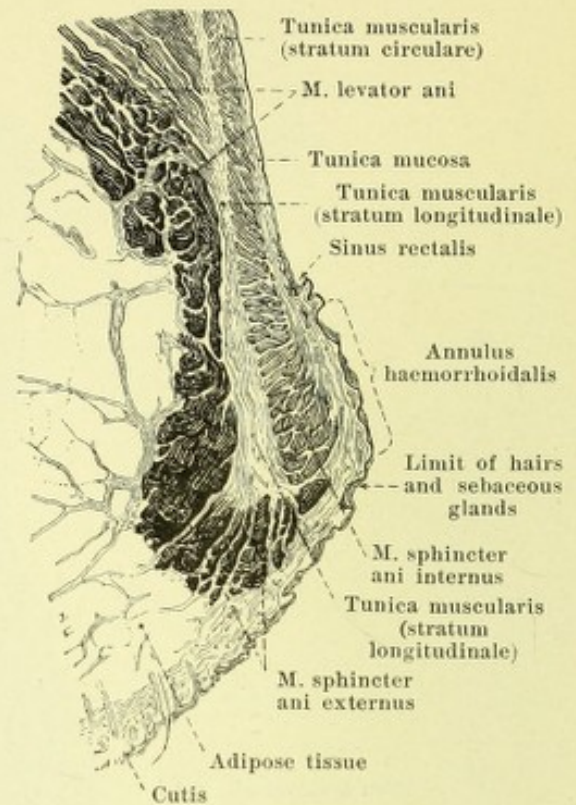
Mouths of the glandulae intestinales [Lieberkuehni]

577. Mucous membrane of the rectum (upper part), viewed from the surface.

Magnification 12:1.

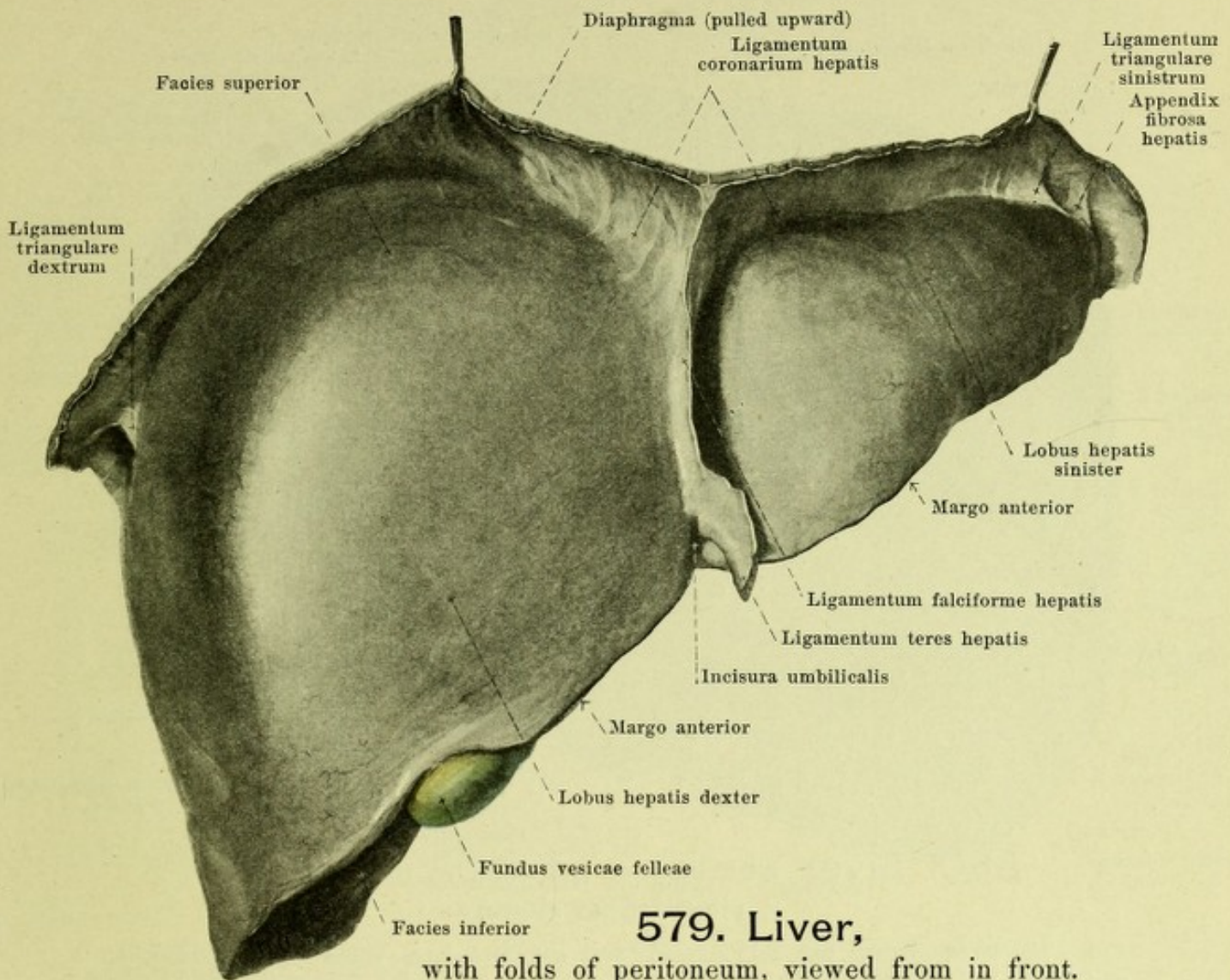
The **rectum** (*intestinum rectum*) (see Figs. 575, 576, 591, 655, 656, 665 and 667) is the terminal portion of the digestive tube which extends from the colon sigmoideum through the inferior wall of the small pelvis to the inferior opening, the *anus*. It runs in the median plane at first downward and backward, and extends forward and downward directly in front of the sacrum and coccyx in a curve which is concave forward and upward, the *flexura sacralis*, as far as the facies posterior of the prostata (in the male, the lower part of the posterior vaginal wall in the female); thence it goes downward and backward in a markedly curved arch convex in front, the *flexura perinealis*. It is covered above in front and laterally by peritoneum; the lines of reflection of the peritoneum then gradually turn forward and leave the lateral walls uncovered. From the anterior wall the peritoneum in the male is reflected upon the bladder at the level of the mouths of the ureters and thus lines a fossa, the *excavatio rectovesicalis*; in the female it turns to the posterior wall of the vagina at the level of the orificium externum uteri and forms the *excavatio rectouterina* [*cavum Douglassi*]. In this portion of its course the rectum is covered above by loops of small intestine or by the colon sigmoideum; below, its anterior wall lies in the male on the posterior surface of the bladder when the latter is distended, in the female on the uterus. Beneath the site of reflection of the peritoneum the anterior wall in the male lies against the fundus vesicae, the ductus deferentes and vesiculae seminales as well as the facies posterior prostatae, in the female against the posterior wall of the vagina. A little above the anus the rectum is surrounded by the fibers of the mm. levatores ani and sphincter ani externus. In the frontal direction also it often presents curves, produced by lateral furrows, which correspond to the plicae transversales recti (see p. 529). The middle portion is rarely entirely empty; it is often on the contrary the site of spindle-shaped distention, the *ampulla recti*. The lowest portion surrounded by the mm. levatores ani and the mm. sphincteres, corresponding to the pars analis recti (see p. 529) is always found empty and contracted, and represents a narrow canal the narrow, slit-like lumen of which lies in the median plane.

Wall of the rectum. *Tunica muscularis* (see also Fig. 575). The *stratum longitudinale* covers the whole surface but forms in front and behind a stronger and shorter band of fibers (see p. 526); only in the lower part of the ampulla is the distribution more even. A band of smooth muscle fibers which arise from the lig. sacrococcygeum anterius, *m. rectococcygeus* (see Figs. 670—672) is mixed with them on the posterior surface. The longitudinal fibers interweave below with the fibers of the mm. levatores ani and go partly to the skin. The *stratum circulare* is emphasized in the base of each plica transversalis; at the inferior end it is concentrated gradually to form the *m. sphincter ani internus* and reaches as far as the junction with the external skin.



578. Transverse section through the orifice of the rectum.

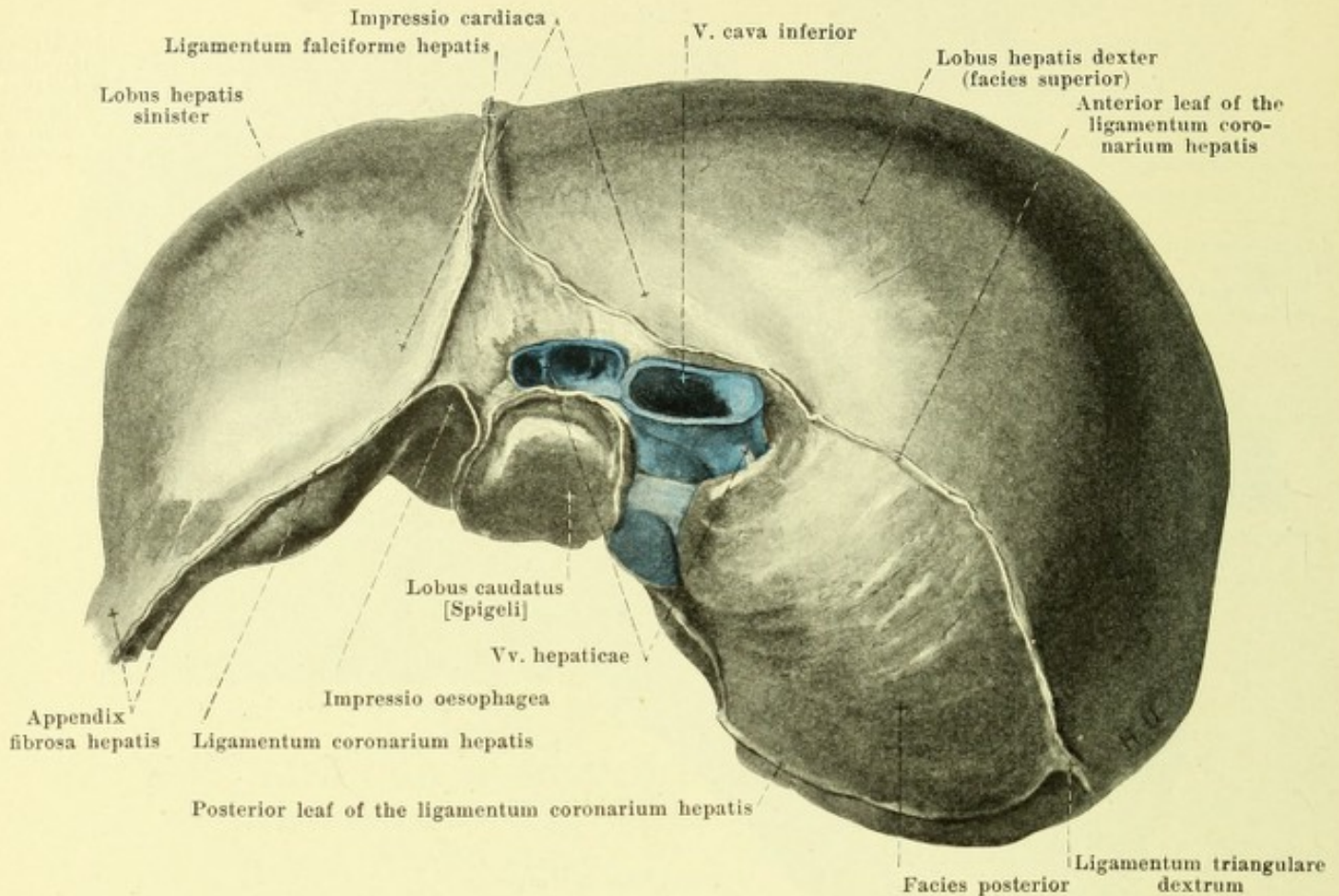
Magnification 2:1.



579. Liver,

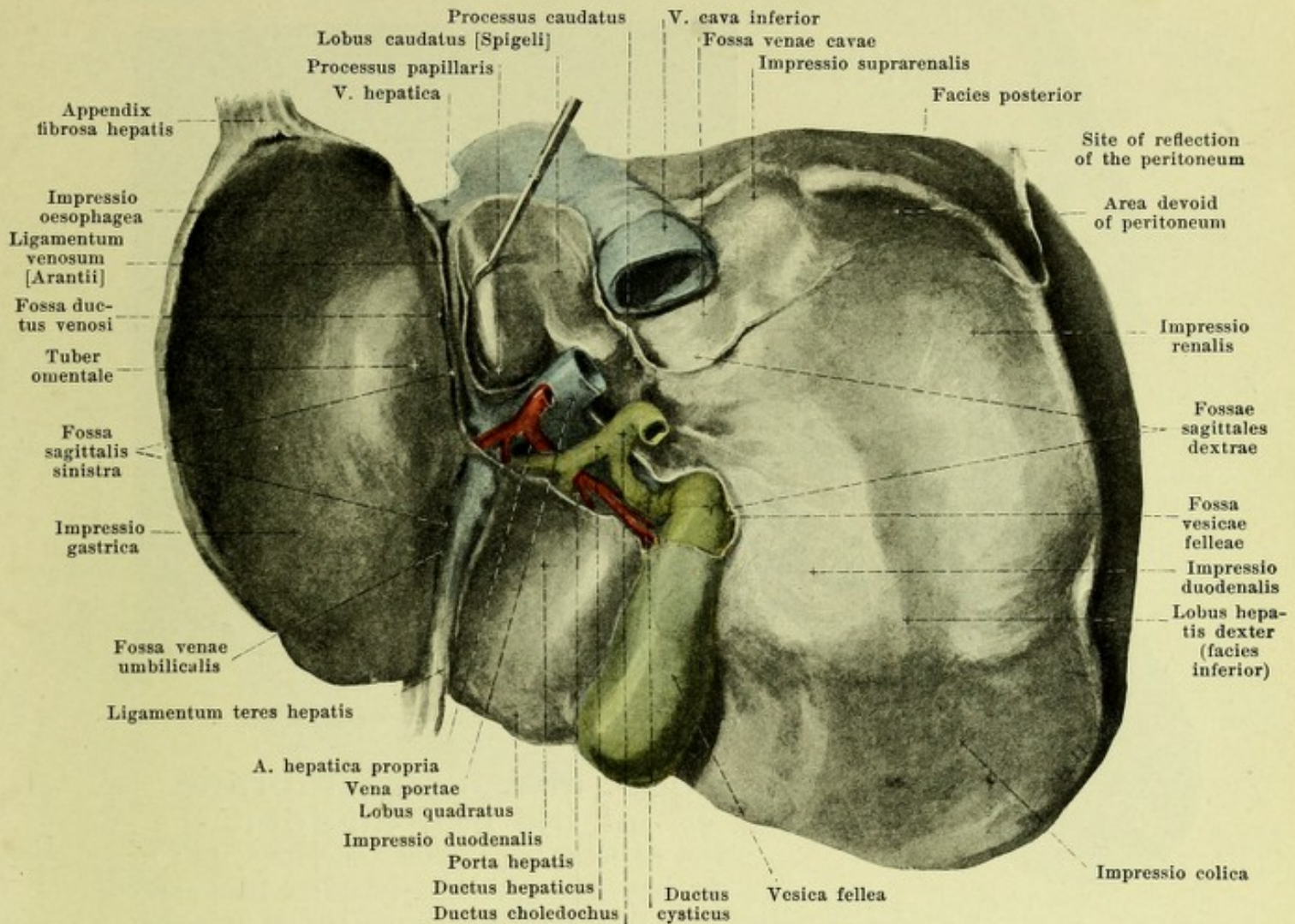
with folds of peritoneum, viewed from in front.

Wall of the rectum (continued). The *tunica mucosa* (mucous membrane) (see Figs. 576 to 578) is separated from the *tunica muscularis* by the connective tissue of the *tela submucosa*. It forms in the distended rectum in common with this (and a band of the circular muscle layer) usually two sickle-shaped transverse folds, *plicae transversales recti*, which surround more than half the circumference of the tube; of these two folds the lower larger one, 6 to 6.5 cm above the anus, lies on the right, the upper one 9–10 cm above the anus on the left; a third is often present on the left about 4 cm above the anus. In the ampulla recti project from five to ten longitudinal folds of the mucous membrane, *columnae rectales* [*Morgagnii*], which contain bundles of longitudinal muscle. They become higher and broader below and each unites with the two neighboring ones by means of arch-like folds of mucous membrane which help to bound fossa-like depressions open above, the *sinus rectales*. The next zone, *annulus haemorrhoidalis*, reaches below as far as the line from which on hairs, sebaceous glands and glandulae circumanales appear; it bounds the *anus*, is fairly smooth when distended but at other times presents a circular ridge due to the bulging of the *m. sphincter ani internus* and indentations corresponding to radial folds streaming out to the skin. At the *annulus haemorrhoidalis* and somewhat above it can often be seen ampulla-like dilatations of the venous plexus *haemorrhoidalis internus* in the form of flask-shaped projections of the mucous membrane. The region of the *columnae rectales*, the *sinus rectales* and the *annulus haemorrhoidalis* is as a whole designated the *pars analis recti*. The mucous membrane in the upper part has the same structure as in the large or thick intestine; it is whitish, contains numerous tube-like *glandulae intestinales* [*Lieberkuehni*] running perpendicularly to the surface, the openings of which are visible as small holes with the aid of the hand-lens (see Fig. 577) and between them are scattered lymph nodules, *noduli lymphatici*, the domes of which project somewhat above the surface (see Fig. 576). The mucous membrane of the *pars analis recti* changes somewhat in structure and mediates the gradual transition to the external skin.



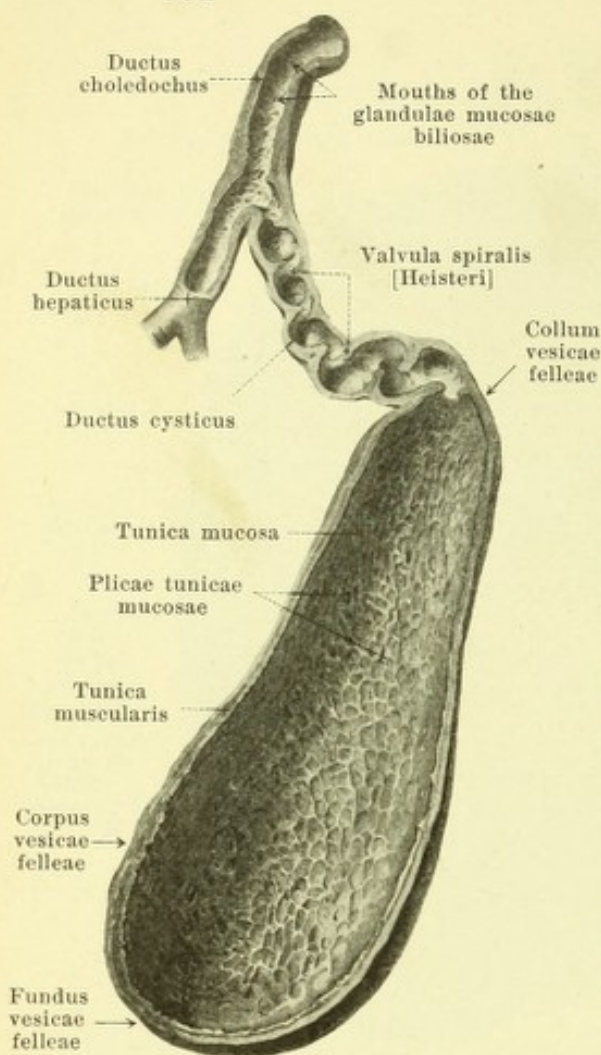
580. Liver with lines of reflection of the peritoneum, viewed from above.

The **liver** (*hepar*) (see also Figs. 579 and 581) is a large reddish-brown gland, approximately wedge-shaped, which is situated for the most part to the right of the median plane in the regio hypochondriaca dextra and in the regio epigastrica, a small part however reaching over into the regio hypochondriaca sinistra. It presents for examination five surfaces, a right, an anterior and a superior which together form the *facies superior*, a posterior, *facies posterior*, and an inferior, *facies inferior*. The facies superior and inferior meet in the sharpened *margo anterior*; on the right side this presents a shallow indentation, in which the fundus of the gall bladder is visible, on the left side a sharper notch, the *incisura umbilicalis*. This notch and a fold of peritoneum running upward from it on the facies superior separate a larger right lobe, *lobus hepatis dexter*, from a smaller, left, variable *lobus hepatis sinister*. On the inferior and posterior surfaces, the left lobe is bounded by the correspondingly directed *fossa sagittalis sinistra*, while a medial region is marked off from the right lobe by the *fossae sagittales dextrae*, approximately parallel to it; this medial region is divided by the transversely placed *porta hepatis* into the *lobus quadratus* and the *lobus caudatus* [Spigeli]. The *right surface* is approximately rectangular and everywhere somewhat convex; it goes over gradually into the anterior, superior and posterior surfaces; with the inferior it helps to form the *margo anterior*. The *anterior surface* is approximately triangular and smooth; it is not sharply limitable from the superior surface and with the inferior surface it forms the *margo anterior*. The *superior surface*, like the right and (for the most part) the anterior, lies directly against the diaphragm and is curved corresponding to the dome of that structure; it reaches somewhat higher up on the right than on the left and between is slightly depressed (*impressio cardiaca*); it meets the posterior surface in a blunt margin. The *facies posterior* is approximately rectangular-triangular, and is uneven. It is curved so as to be convex on the right side where it is formed by the right lobe of the liver; passing to the left there then follows the superior fossa sagittalis dextra as a flat furrow, *fossa venae cavae*, which is filled up by the v. cava inferior; it helps to bound below the triangular fossa situated to the right, namely the *impressio suprarenalis*, for the glandula suprarenalis dextra.



581. Liver with lines of reflection of the peritoneum, from below and behind.

Liver (continued). To the *facies posterior* belongs further the quadrangular, oblong lobus caudatus, the long axis of which is placed vertically and lies upon the right crus mediale diaphragmatis. To the left of this follows the upper part of the fossa sagittalis sinistra, the *fossa ductus venosi*, which extends for a variable distance in front of the lobus caudatus and in its depth contains the cord-like *ligamentum venosum [Arantii]*, the obliterated ductus venosus (see p. 473). Near the upper part of this fossa, on the left lobe of the liver, the groove-like *impressio oesophagea* (for the pars abdominalis oesophagi) runs downward and to the left. The *facies inferior* is very irregular and runs obliquely forward, downward and to the right; it is bounded on the right at the posterior surface by a blunt margin, on the left at the upper by a sharper margin, the continuation of the margo anterior. The right lobe presents in front a flat depression, *impressio colica*, for the flexura coli dextra and the colon transversum; behind it on the right lies the oblong *impressio renalis* for the right kidney and to the left of it the flatter *impressio duodenalis* for the pars descendens duodeni. Thence, in front of the fossa venae cavae and behind the fossa vesicae felleae, a strip of liver substance, the *processus caudatus*, extends to the left to the inferior margin of the lobus caudatus; to the left of it projects downward a flat process of the latter, the *processus papillaris*. Directly in front of these structures lies the porta hepatis and in front of it the lobus quadratus, which is slightly concave, for the pars superior duodeni, *impressio duodenalis*, and the pars pylorica of the stomach. On the right this lobe is bounded by the flat inferior fossa sagittalis dextra, the *fossa vesicae felleae*, which is completely hidden by the gall bladder, on the left by the inferior part of the fossa sagittalis sinistra, the narrow *fossa venae umbilicalis*, in which is situated the cord-like *ligamentum teres hepatis*, the obliterated v. umbilicalis (see p. 473). On the left lobe of the liver near the processus papillaris can be seen a larger projection, the *tuber omentale*, which adjoins the omentum minus; it is surrounded by a deep and broad groove, *impressio gastrica*, in which the stomach comes into contact with the liver.



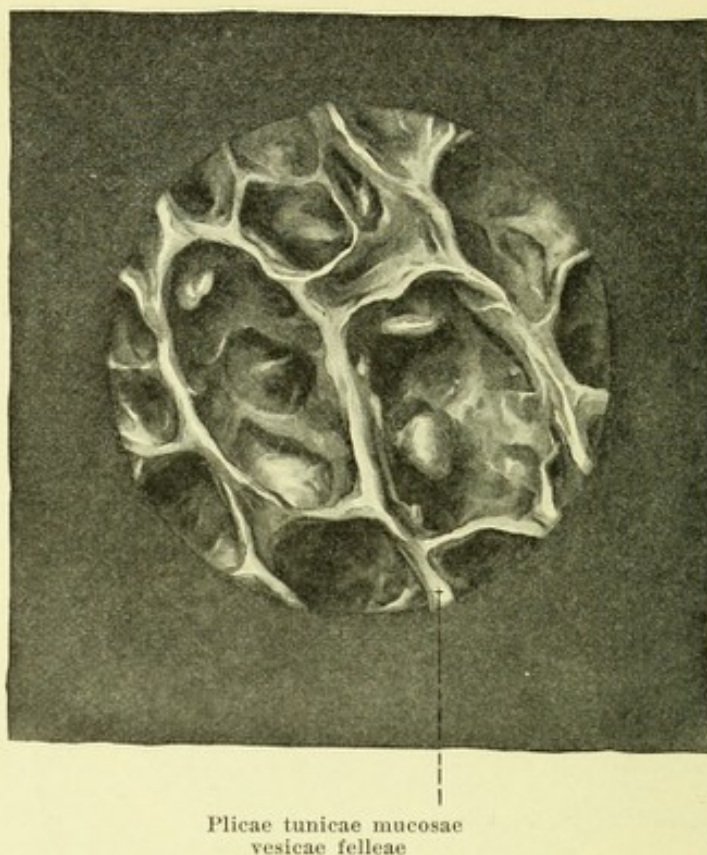
582. Gall bladder and bile ducts, cut through.

The liver completely fills up the dome of the diaphragm on the right side, only partly on the left, and is in contact with this muscle in the largest part of the facies superior and posterior. It is accordingly covered in large extent by the lower ribs; its anterior surface lies directly in contact with the anterior abdominal wall (see Fig. 591) only in the regio epigastrica above a line which extends between the anterior ends of the right 9th or 10th and the left 8th costal cartilage; the incisura umbilicalis is situated somewhat to the right of the median plane. The facies inferior is in close contact with various abdominal organs all of which leave impressions upon it (see these, p. 531). Beneath the processus caudatus is situated the foramen epiploicum [Winslow].

The liver is for the most part covered by the *tunica serosa*. Only the posterior surface of the right lobe, a triangular fold on the upper surface in front of the lobus caudatus, the porta hepatis, the fossae sagittales and two additional narrow strips remain free from it; of the latter one extends from the incisura umbilicalis upward to the triangular area mentioned and is situated at the starting point of the ligamentum falciforme hepatis, while the other runs from the triangular area to the left as far as the appendix fibrosa, and serves as an origin for the left portion of the ligamentum coronarium hepatis and the ligamentum triangulare sinistrum. From the fossa ductus venosi and the porta hepatis goes off the omentum minus.

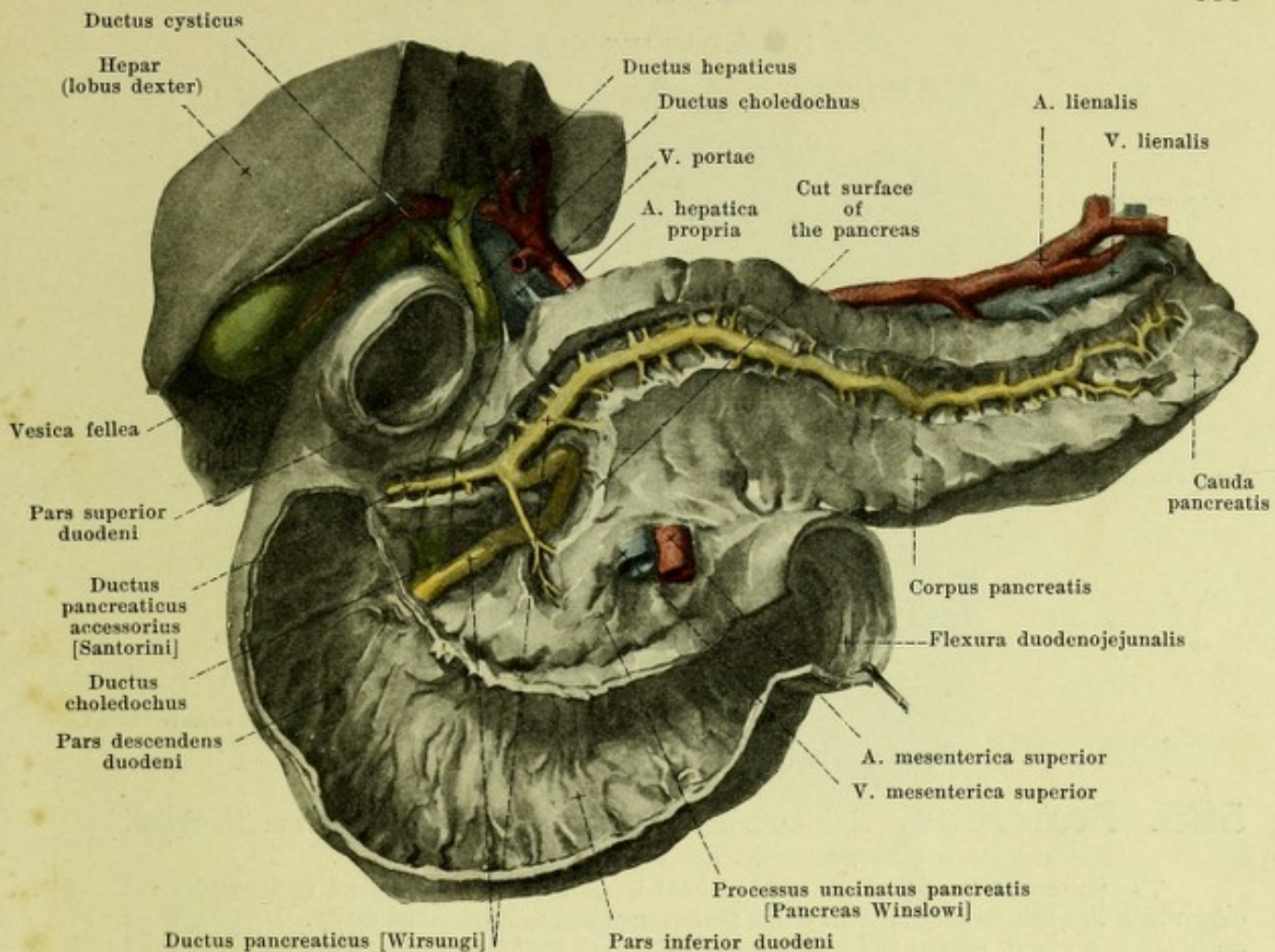
At the porta hepatis the branches of the v. portae and the a. hepatica enter the liver and the branches of the ductus hepaticus leave it, while the vv. hepaticae leave the liver on the upper surface in the neighborhood of the fossa venae cavae.

A sagittal plane passing through the v. cava inferior and the fundus of the gall bladder divides the liver into two parts of almost equal weight and separates fairly exactly the domains of the right and left branches of the v. portae, of the a. hepatica and of the ductus hepaticus.



583. Mucous membrane of the gall bladder, viewed from the surface. Magnific. 14 : 1.

Liver (continued) (see Figs. 579—581). The posterior part of the sharpened edge of the left lobe not infrequently presents a flat appendix of variable size, composed of connective tissue, the *appendix fibrosa hepatis*; it is the remnant of the liver substance present there in the new-born and later still contains parts of the bile ducts, the *vasa aberrantia hepatis* (not illustrated), and blood vessels.



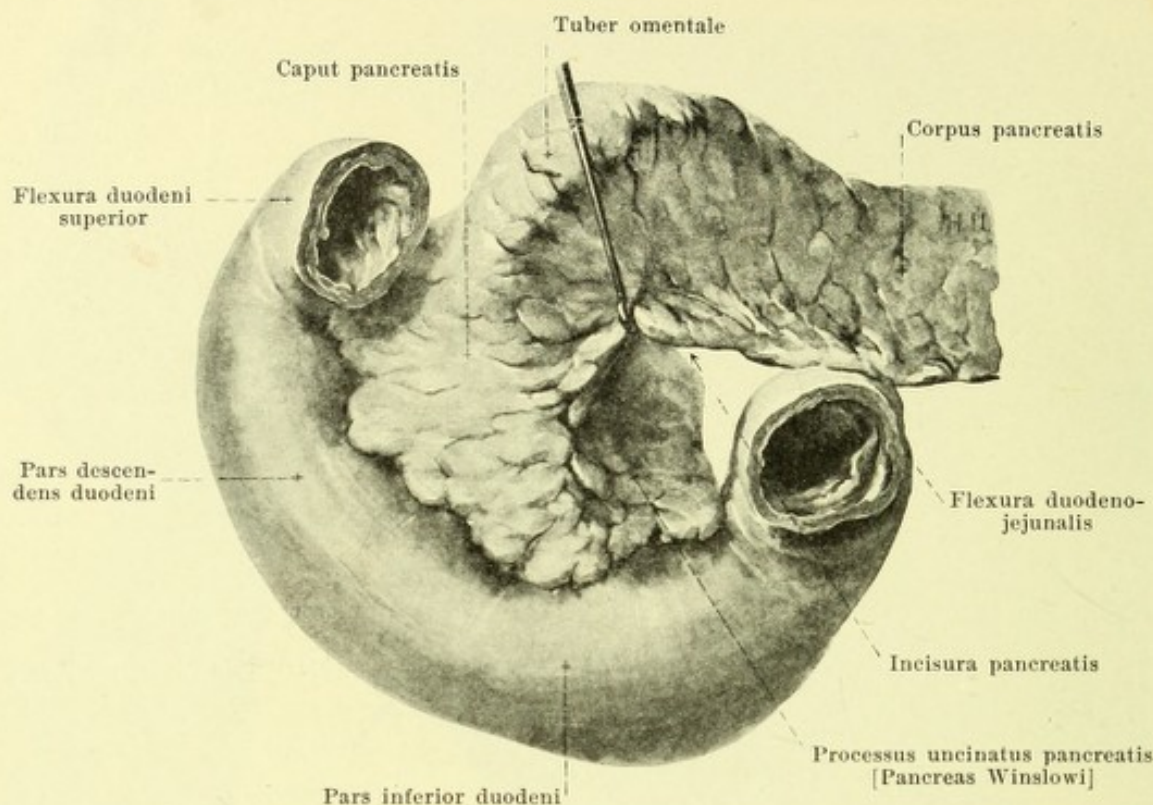
584. Excretory ducts of the liver and pancreas, viewed from in front.

(In the pancreas the ducts have been dissected out; the duodenum has been partly opened; of the liver only the right lobe has been retained and it has been pressed somewhat aside.)

The *ductus hepaticus* (see also Figs. 581 and 582), the excretory duct of the liver, begins in the porta hepatis by the union of a right and a left branch. It runs downward in the ligamentum hepatoduodenale to the right of the a. hepatica propria and in front of the v. portae and soon unites at an acute angle with the ductus cysticus to form the ductus choledochus (*vide infra*).

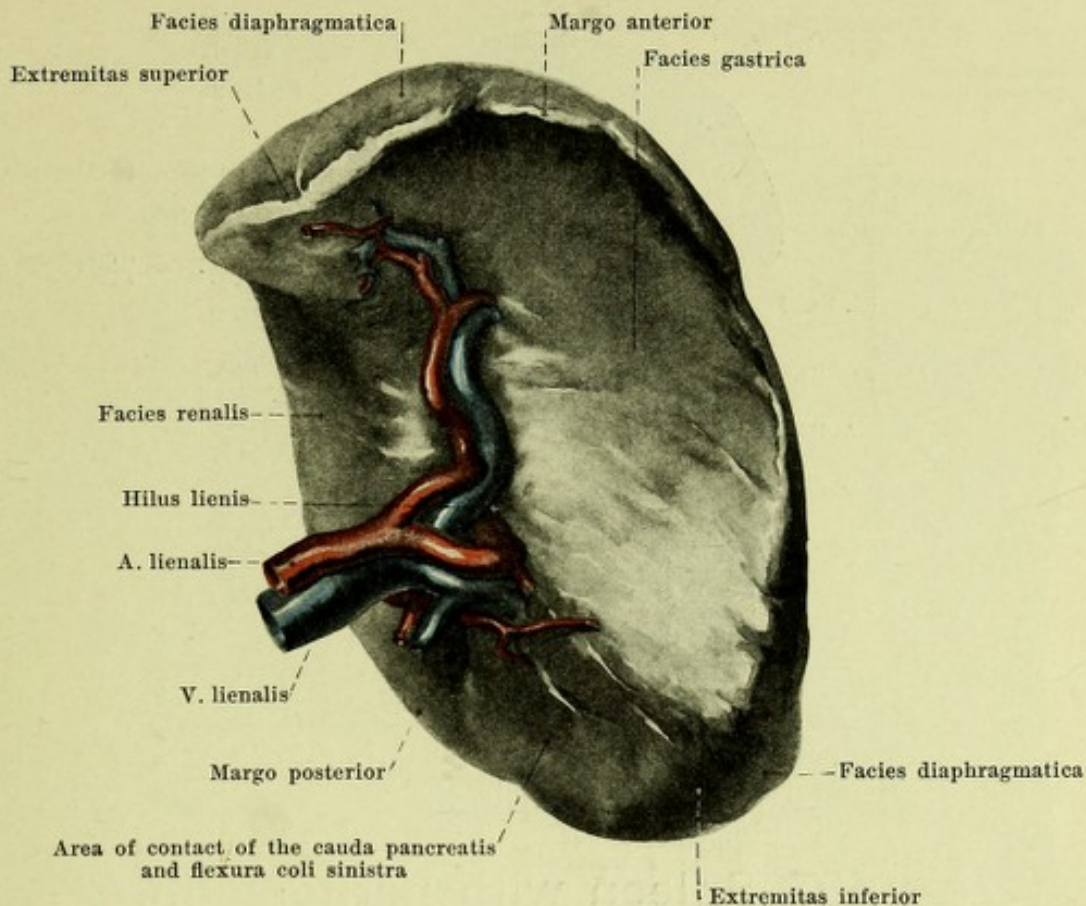
The *gall bladder* (*vesica fellea*) (see also Figs. 581—583, 591—594) is an ablong, pear-shaped sac, which is fastened by connective tissue in the fossa vesicae felleae of the liver. When the bladder is full, its broad, blind and rounded end, *fundus vesicae felleae*, projects somewhat beyond the margo anterior of the liver and comes in contact with the anterior abdominal wall just medianward from the anterior extremity of the 9th costal cartilage of the right side. From the fundus the *corpus vesicae felleae* extends upward, backward and somewhat to the left and narrowing suddenly (*collum vesicae felleae*) goes over at the right side of the porta hepatis into the ductus cysticus. The gall bladder comes into contact below with the colon transversum and behind with the pars descendens duodeni. The fundus and the posterior, inferior surface possess a peritoneal coat, *tunica serosa*. The wall consists of a delicate layer of muscle, *tunica muscularis*, and a mucous membrane, *tunica mucosa*, from which project numerous ridges, *plicae tunicae mucosae*, arranged in the form of a network. The *ductus cysticus* leaves the bladder with a marked downward bend, extends downward and to the left and after a short course joins the ductus hepaticus; its mucous membrane presents a series of folds, which are arranged in the form of a spiral (*valvula spiralis [Heisteri]*), and which correspond to grooves on the external surface.

The *ductus choledochus* runs downward, in the direction of the ductus hepaticus, at first in the ligamentum hepatoduodenale to the right of the v. portae, then in the caput pancreatis at the junction of the left and posterior walls of the pars descendens duodeni. It perforates the tunica muscularis of the same, extends downward in the tela submucosa and opens near the ductus pancreaticus or in common with it at the inferior extremity of the plica longitudinalis duodeni.



585. Pancreas, right portion, drawn apart, viewed from in front.
(The peritoneum has been dissected off.)

The **pancreas** (see also Figs. 563 and 584) is an unpaired, long gland of a grayish red color which lies transversely in front of the posterior wall of the abdominal cavity. It presents for examination a *caput*, *corpus* and *cauda pancreatis*. The *caput pancreatis* fills up the concavity of the *pars descens* and *pars inferior duodeni* and is intimately united with their walls. A notch directed from left to right, *incisura pancreatis*, in which run the a. and v. mesenterica superior, marks off the inferior portion, *processus uncinatus [Winslowi]*; this lies below upon the *pars inferior duodeni*; above it is shoved up behind the upper portion and is hollowed out in the form of a groove on its anterior surface for the a. and v. mesenterica superior. From its upper part and from the beginning of the *corpus* a broad, blunt-wedge-shaped mass, the *tuber omentale*, projects forward and upward, its dome covered by peritoneum coming into contact with the inferior surface of the omentum minus. The anterior surface, *facies anterior*, of the *caput*, is in contact above with a part of the *corpus*, with the *pars pylorica* of the stomach and the *pars superior duodeni*, below with loops of small intestine; between the two it is crossed by the colon transversum. The posterior surface (*facies posterior*) of the *caput* is curved so as to be concave from right to left and is in close contact in front of the 1st and 2nd lumbar vertebra with the *pars lumbalis diaphragmatis*, the aorta abdominalis and the v. cava inferior; above it is in contact with the a. coeliaca, a. and v. mesenterica superior and the beginning of the v. portae as well as the v. renalis sinistra, on the right with the ductus choledochus. The *corpus pancreatis* (body of the pancreas) is curved from right to left so as to be somewhat convex behind and has an approximately triangular prismatic shape. Its *facies anterior* is directed forward and upward and curved so as to be concave, corresponding to the bulging curvature of the *paries posterior ventriculi*, which is in contact with it. The *facies inferior* is narrower and curved slightly in the form of the letter S. It rests to the right upon the *flexura duodenojejunalis*, to the left upon the end of the colon transversum; between lie upon it the loops of the upper part of the small intestine. With the anterior surface it forms a sharp margin, *margo anterior*, directed toward the root of the mesocolon transversum. The *facies posterior* is in direct contact with the v. lienalis, the left suprarenal and kidney and presents a flat depression corresponding to these organs, as well as a groove for the left renal vessels and the v. mesenterica inferior. With the inferior surface it forms the blunter *margo posterior*, with the anterior surface the sharper *margo superior*, which is concave upward. The *cauda pancreatis* (tail of the pancreas) is the blunt end directed to the left and upward; its narrow inferior surface lies upon the *flexura coli sinistra* and its posterior surface comes into contact with the lower part of the spleen.



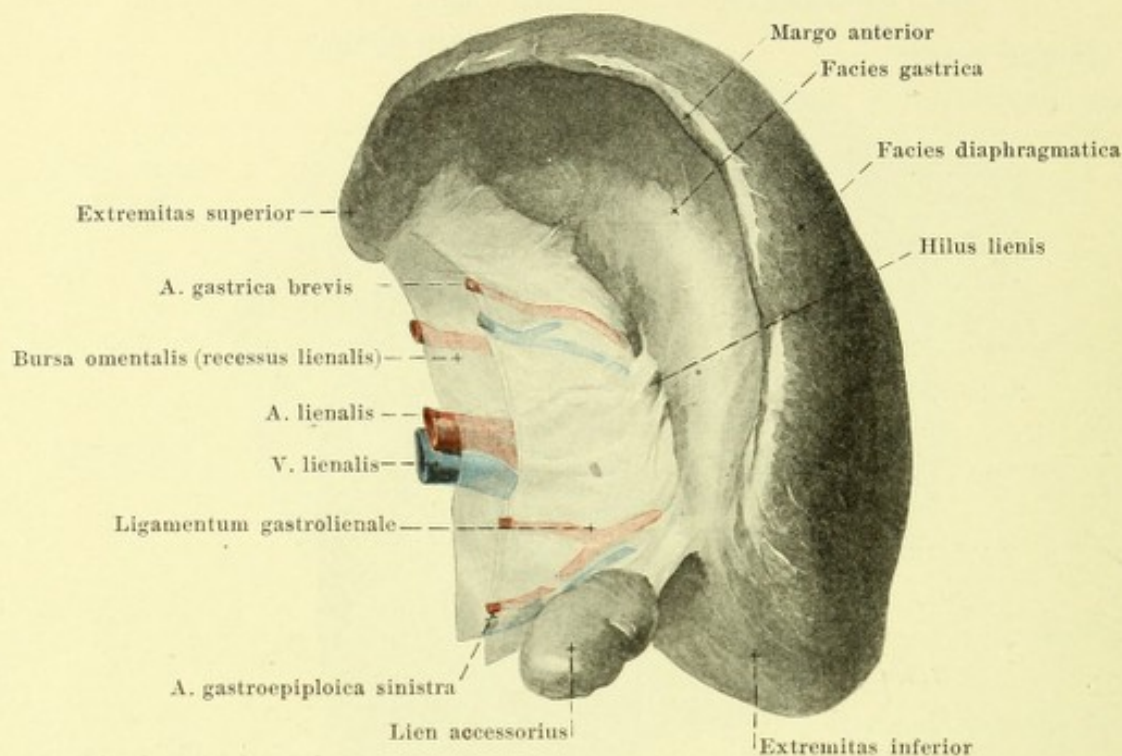
586. Spleen, viewed from in front and somewhat from the right.

(The peritoneum has been dissected off at the hilus lienis.)

Pancreas (continued): The anterior and inferior surfaces are covered by peritoneum (see Fig. 563). The posterior surface is free from it; in addition, transversely in front of the caput and along the margo anterior, is a narrow strip which remains uncovered by peritoneum and to which is turned the root of the mesocolon transversum. The portion lying above this strip belongs to the bursa omentalis. On the portion situated below this strip there is another area free from peritoneum, in which the a. and v. mesenterica superior extend to the root of the mesentery.

The *duct* (*ductus pancreaticus* [*Wirsungi*]) (see Fig. 584) begins as a delicate duct in the cauda, extends within the substance of the gland to the right to the caput and gradually enlarges as it receives numerous narrow branches. In the caput it is markedly tortuous and runs to the right and somewhat downward; near its lower end it lies close to the ductus choledochus and opens at the inferior extremity of the plica longitudinalis duodeni (see also Fig. 564) either after previous union with the former or separately from it. Very often the duct gives off in the caput a lateral branch (*ductus pancreaticus accessorius* [*Santorini*]), which extends in front of the ductus choledochus to the duodenum and there opens upon the papilla duodeni [*Santorini*] (see also Fig. 564); this opening is often absent: sometimes the upper duct is the larger of the two or opens in common with the ductus choledochus.

The **spleen** (*lien*) (see also Fig. 587) is an unpaired, soft, oblong organ, very variable in size, of a dark bluish-red color. Its largest surface, *facies diaphragmatica*, directed to the left, backward and upward, is smooth and convex. It is separated by a blunt margin, *margo posterior*, from the narrow, flat or slightly concave, *facies renalis*, which is directed medianward and downward. The sharper, multiply indented *margo anterior* separates the facies diaphragmatica from the markedly concave *facies gastrica*, which looks forward and to the right. Upon this, near the medial margin and parallel with it, lies a series of depressions or a slit, the *hilus lienis*, in which enter or leave the vessels and nerves. The upper pole of the spleen, *extremitas superior*, is curved medianward, the lower pole, *extremitas inferior*, is directed to the left and downward. The medial surface of the latter goes over usually into an approximately triangular area, well marked off from the facies renalis and gastrica; this area serves above (in the immediate neighborhood of the hilus) for contact with the cauda pancreatis and below for contact with the flexura coli sinistra.

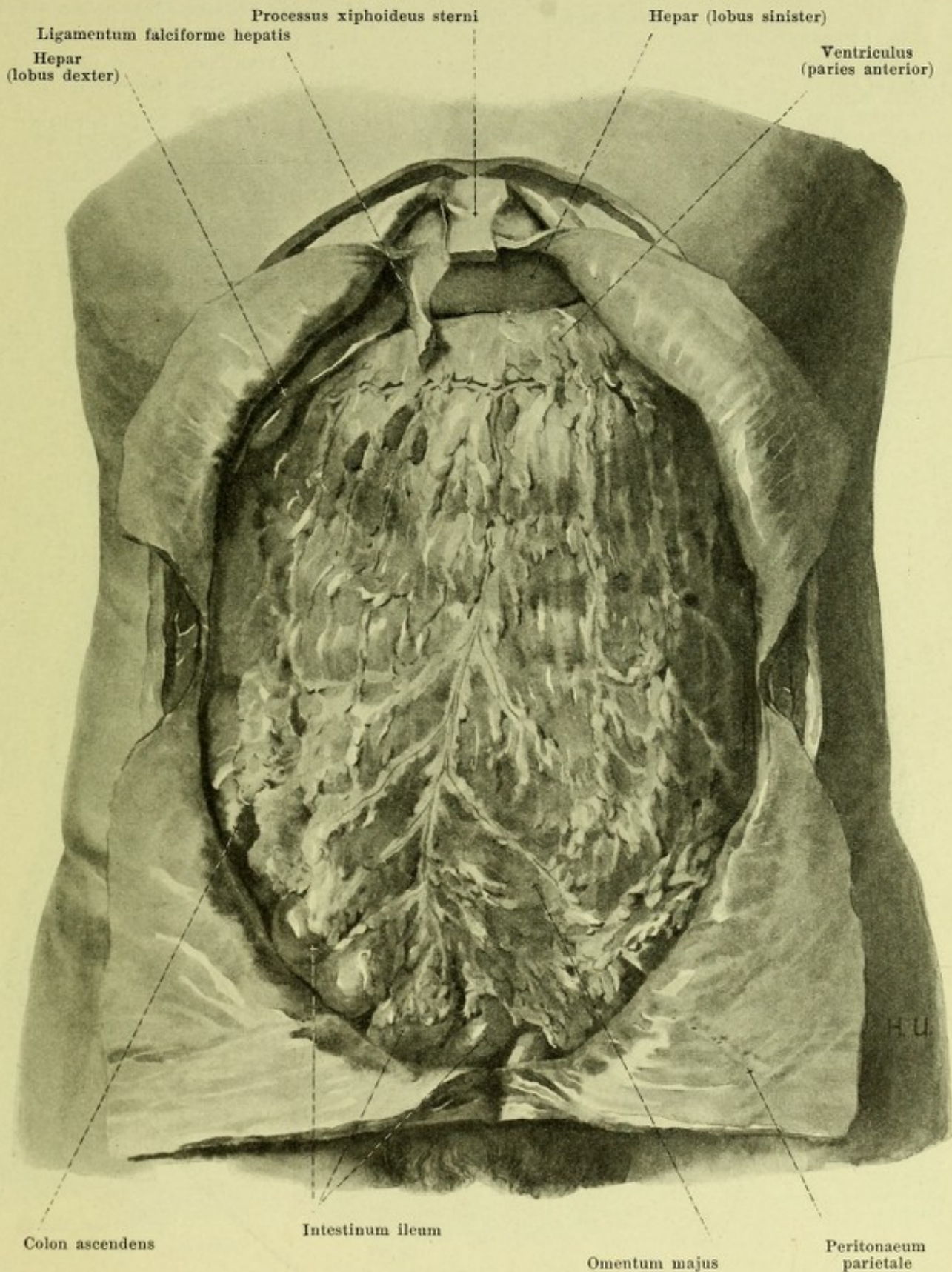


587. Spleen with peritoneum, viewed from in front and somewhat from the right.

Spleen (continued): *Position* (see Figs. 592 and 593). It lies in the posterior part of the left regio hypochondriaca so shoved in between the posterior circumference of the stomach, left kidney and diaphragm that it is not visible from in front. Its facies diaphragmatica is so closely in contact with the concave surface of the diaphragm that it corresponds approximately to the space between the 9th and 11th rib on the left side, and that its long diameter runs approximately parallel to the 10th rib; it is separated from the ribs not only by the peritoneum and diaphragm but partly also by the pleural cavity and the lung. The extremitas superior reaches close to the left side of the body of the 10th or 11th thoracic vertebra. The facies renalis is in contact with the margo superior of the left suprarenal gland and with the upper anterior part of the margo lateralis of the left kidney. The facies gastrica is bounded in front and to the right by the fundus and corpus ventriculi; the triangular area beneath it lies in contact with the cauda pancreatis and the flexura coli sinistra. Near the latter is situated also the extremitas inferior; it rests in a pocket which is bounded in front by the *ligamentum phrenicocolicum* (O. T. sustentaculum lienis) (see Fig. 593). This stretches out membrane-like from the flexura coli sinistra to the region of the origin of the diaphragm and presents a free margin directed upward; originally it is connected with the great omentum.

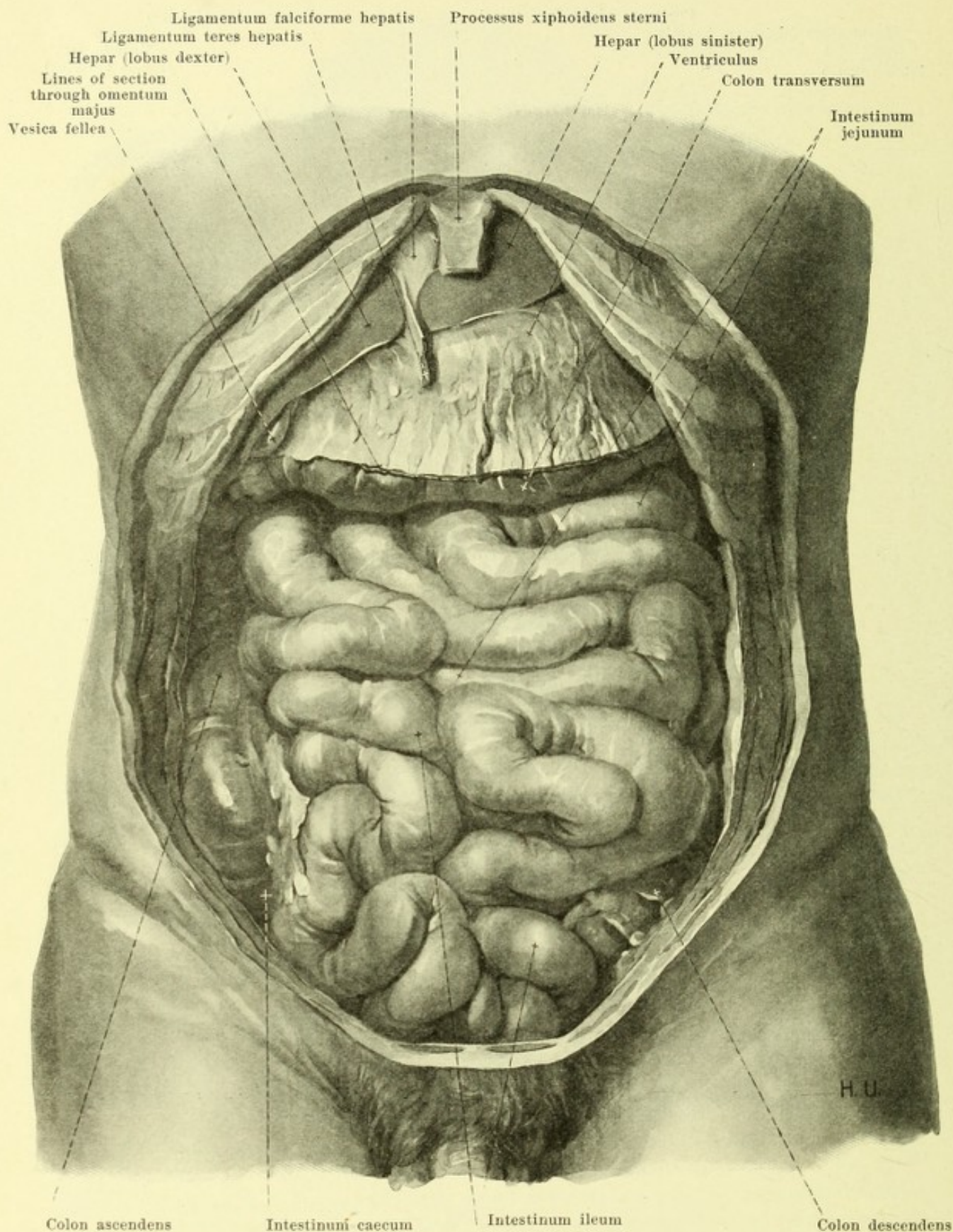
The spleen possesses a complete covering of peritoneum (*tunica serosa*), only the hilus being free from it. Starting from the hilus the peritoneum extends in front as the *ligamentum gastrolienale* to the anterior layer of the great omentum and to the curvatura ventriculi major. Behind starting from the hilus the peritoneum goes to the kidney and the inferior surface of the diaphragm as the *ligamentum phrenicolienale*.

In the ligamentum gastrolienale, in the omentum majus or in the pancreas is to be found occasionally a rounded or oblong *accessory spleen*, *lien accessorius*, of variable size; there may be two or even many of these.



588. Abdominal viscera, viewed from in front.

(Figs. 588—591 are drawn from the same dissection. The skin and muscles of the anterior abdominal wall have been removed; their peritoneal covering has been cut through and reflected backward.)



589. Small intestines, viewed from in front.

(Figs. 588—591 have been drawn from the same dissection. The anterior abdominal wall and the great omentum have been removed. In Figs. 589 and 590 the crosses have been placed upon the portions of small intestine and of the margin of the mesentery which belong to one another. The course of the loops of the intestine is visible in Fig. 590.)

Lines of section of the omentum majus

Taenia omentalis

Bursa omentalis (recessus inferior)

Flexura duodenojejunalis

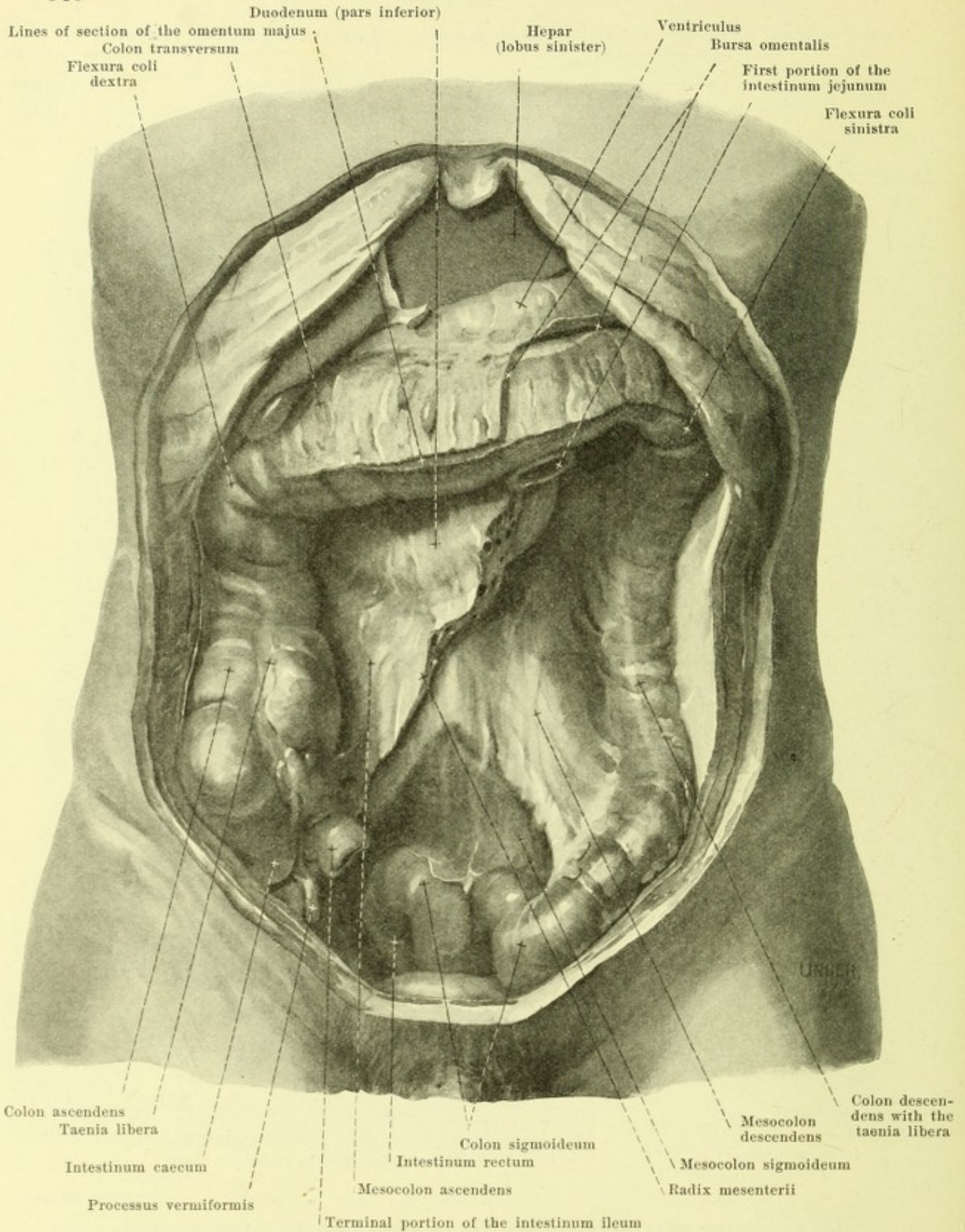
Hepar
(lobus dexter)Mesenterium for
the intestinum
jejunumColon ascendens
with the
taenia liberaIntestinum caecum
Processus vermiformisTerminal
portion of the
intestinum
ileum

Mesenterium for the intestinum ileum

Colon sigmoideum

Colon descendens
with the
taenia libera**590. Convolution of the mesentery, viewed from in front.**

(Figs. 588—591 have been drawn from the same dissection. The colon transversum has been drawn upward. The small intestine has been cut off close to its mesentery and the course of invisible parts of the free margin of the mesentery indicated by dotted lines. For further explanation see Fig. 589.)



591. Large or thick intestine and root of the mesentery, viewed from in front.

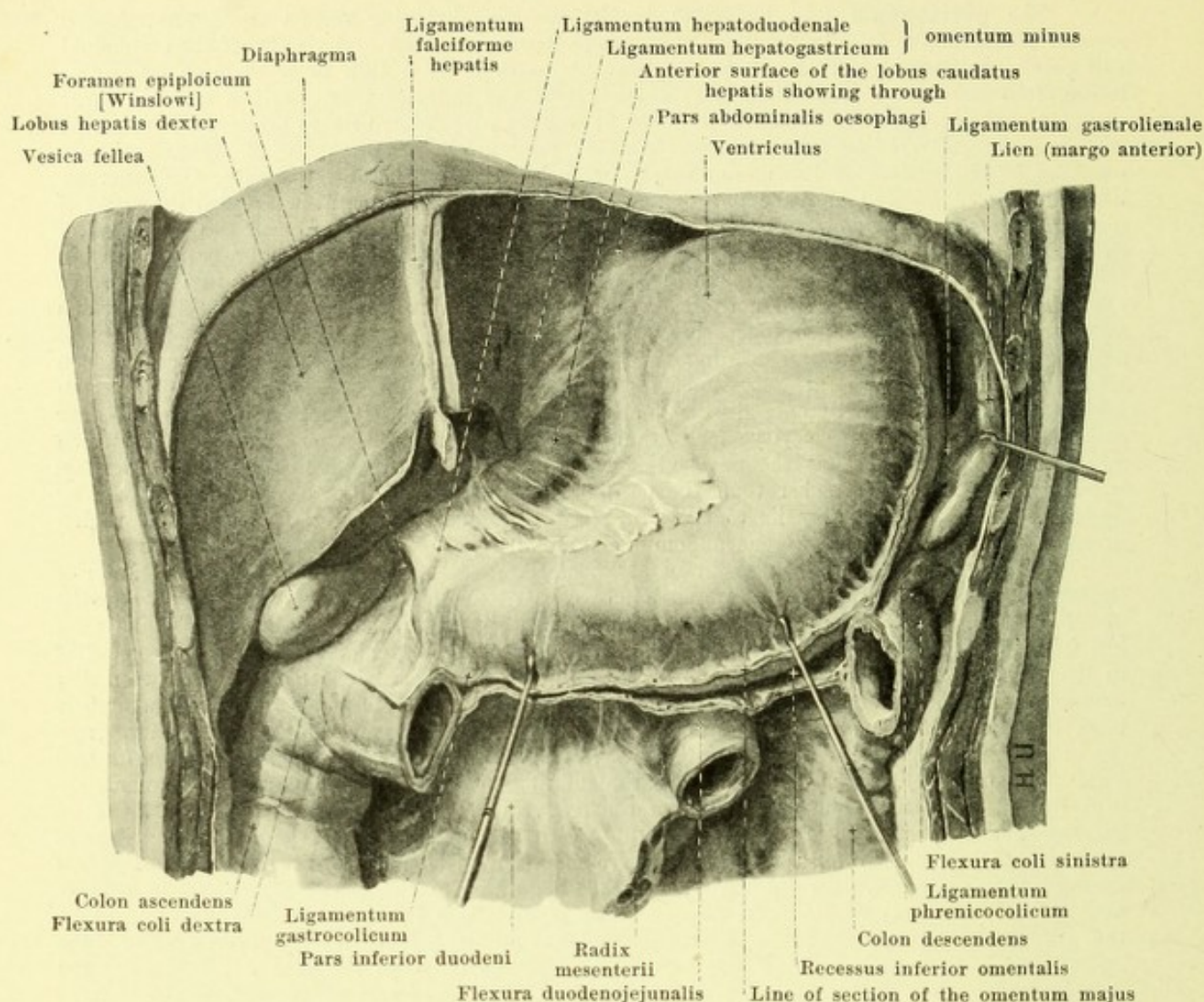
(Figs. 588—591 have been drawn from the same dissection. The mesentery of the small intestine has been cut away at its root.)

The **peritoneum** (see Fig. 598) is the smooth glistening serous membrane, *tunica serosa*, which covers in varying degrees of completeness the walls and viscera of the abdominal and pelvic cavities; it is fastened to the tissue beneath it by a thin layer of loose connective tissue, *tela subserosa*. That part of it which covers the walls of these cavities and the large vascular and nerve trunks attached to them as well as part of the urinary and sexual apparatus is called the *parietal peritoneum* (*peritoneum parietale*). That part of it which is firmly attached to the surface of the more freely moveable portions of the digestive tube, the pancreas, liver and spleen, as well as some parts of the urinary and sexual apparatus is called the *visceral peritoneum* (*peritoneum viscerale*); under the latter term are also grouped the coverings of the membranes which stretch out between the abdominal wall and individual viscera, passing free through the abdominal cavity, and in which the vessels and nerves belonging to these viscera run. The parietal and visceral peritoneum go directly over into one another at their margins and can therefore be grouped together as a great sac, which in the male is completely closed and in the female presents an opening only at the ostium abdominale tubae uterinae on each side. The free surface of the peritoneum surrounds a cavity, the *peritoneal cavity* (*cavum peritonei*), which is really only slit-like, since the viscera lie closely pressed upon one another and upon the walls of the cavity; it contains a very small amount of clear serous fluid which moistens the surface so that the parts glide easily upon one another. The peritoneum parietale is in general somewhat thicker than the peritoneum viscerale and is attached rather loosely by means of the fascia transversalis to the mm. recti abdominis, the posterior layer of the vagina m. recti and to the m. transversus abdominis, more firmly to the diaphragm.

Course of the peritoneum. From the posterior surface of the upper part of the anterior abdominal wall and from the diaphragm a fold of peritoneum, *ligamentum falciforme hepatis* (see Figs. 579, 580, 588 and 589) runs off approximately in the median plane; it begins as a low fold at the umbilicus and gradually increasing in height extends backward and somewhat to the right to the incisura umbilicalis and to the facies superior of the liver; between the umbilicus and the incisura umbilicalis it presents a free margin, in which runs the *ligamentum teres hepatis*. At the impressio cardiaca of the liver the two layers of the fold diverge from one another and go over into the anterior layer of the *ligamentum coronarium hepatis* (see Figs. 579 and 580), which extends from the inferior surface of the diaphragm approximately in a frontal plane to the upper surface of the liver. On the left side this fold consists of an anterior and a posterior plate of peritoneum which are in contact with one another; it runs as far as the appendix fibrosa hepatis and there ends in a sharp concave margin, the *ligamentum triangulare sinistrum*. On the right, the fold is formed of two plates which are in contact with one another only at its right free end, the *ligamentum triangulare dextrum*; elsewhere the posterior plate is considerably separated from the anterior, leaves the posterior surface of the right lobe of the liver uncovered and follows a course partly upon the posterior surface of the diaphragm, partly upon the anterior surface of the right kidney and suprarenal, to run in front of the same as far as the flexura coli dextra. Between the inferior surface of the liver and the kidney a special fold, the *ligamentum hepatorenale* (see Fig. 594), is often stretched out.

The peritoneum covers the superior and inferior surfaces of the liver and extends (see Figs. 592 and 593) from the fossa ductus venosi from the porta hepatis to the inferior surface of the diaphragm, to the right side of the pars abdominalis of the oesophagus, to the curvatura ventriculi minor and to the upper surface of the pars superior duodeni as the anterior layer of the **lesser omentum**, *omentum minus*, and then covers these organs. The omentum minus is a membrane of variable strength, the posterior peritoneal covering of which belongs to the bursa omentalis (see p. 543); the portion going to the oesophagus and stomach is called the *ligamentum hepatogastricum*; in its upper sickle-shaped portion, which goes to the oesophagus and cardia, it is striped and stout, in its lower part attached to the curvatura minor it is very thin and loose. To the latter on the right side without sharp limit is attached the portion of the omentum minus, which extends from the porta hepatis to the duodenum, *ligamentum hepatoduodenale*; this is thick, ends on the right in a free slightly concave margin (see also Fig. 594) and contains within it the a. hepatica propria (to the left and in front), the v. portae (in the middle and behind) and the ductus choledochus (to the right and in front) (see Figs. 497 and 584), as well as the plexus hepaticus s. sympathici and lymph vessels. From the anterior surface of this ligament there often arises a fold, *ligamentum hepatocolicum* (see Fig. 594), which runs from the posterior surface of the gall bladder either only as far as the pars descendens duodeni or even to the colon transversum. From the region where the free margin of the lig. duodenale ends below, a smaller fold, *ligamentum duodenorenale* (see Fig. 594), often extends to the anterior surface of the right kidney.

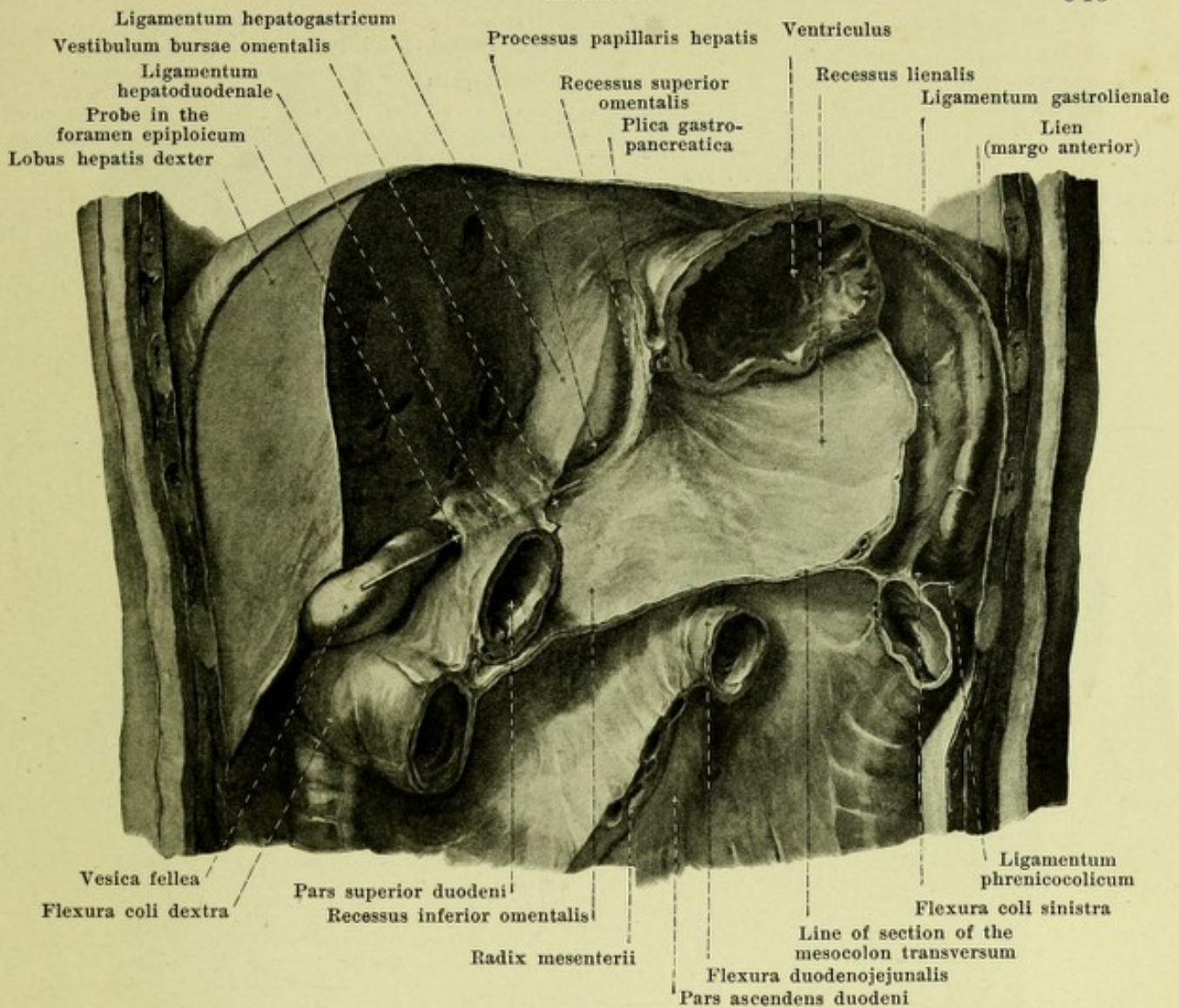
The peritoneum covers the anterior superior surface of the stomach and on the left side at the curvatura major goes backward as the broad *ligamentum gastrolienale* (see Fig. 592) to the facies gastrica of the spleen, covers the spleen and passes from its facies renalis as the *ligamentum phrenicolienale* (not illustrated) around to the left kidney and the diaphragm.



592. Lesser omentum (*omentum minus*), viewed from in front.

(The left lobe of the liver has been completely removed, the colon transversum in largest part; the stomach has been drawn somewhat downward, the spleen somewhat to the left.)

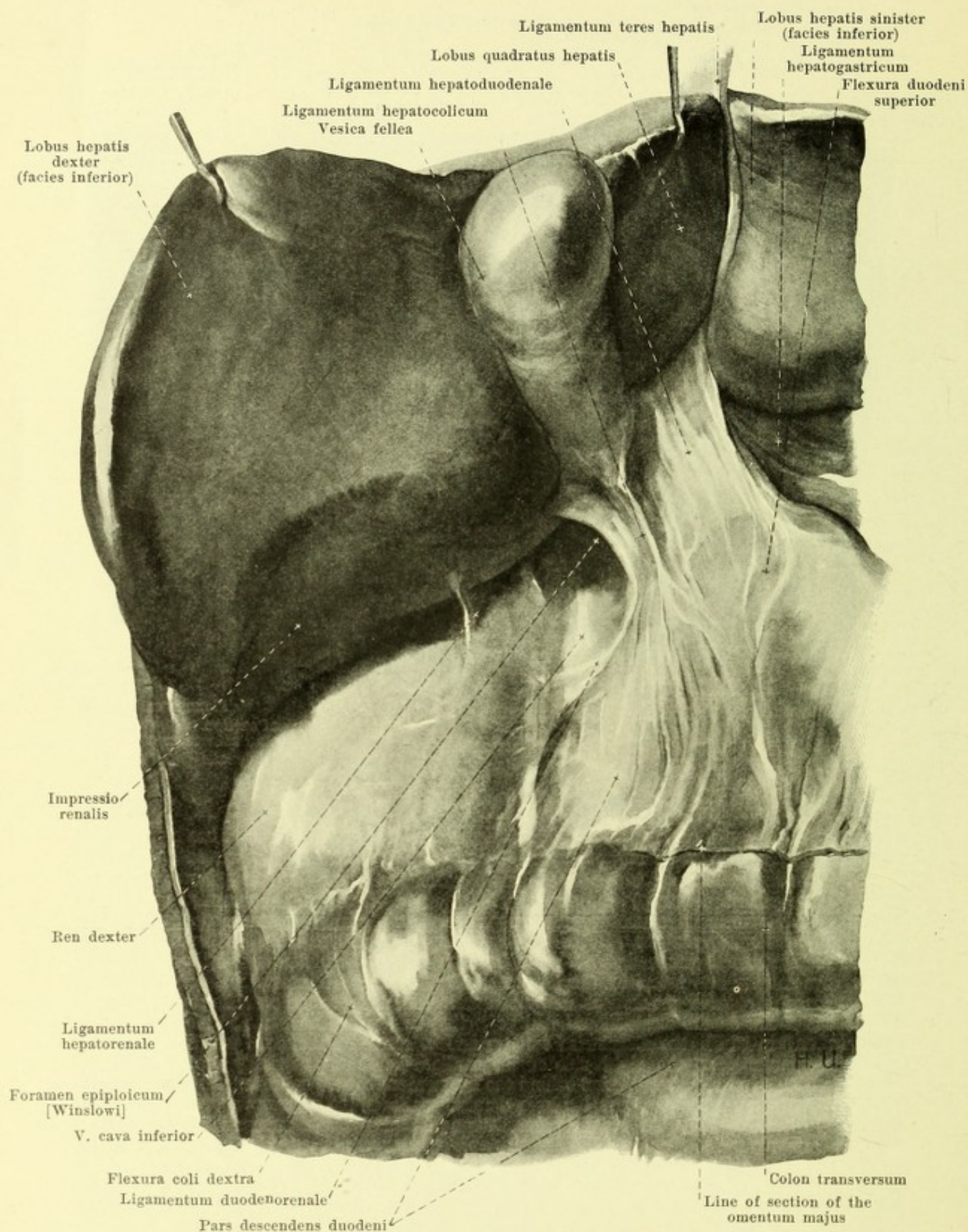
Course of the peritoneum (continued). Hanging downward from the *curvatura major* of the stomach like an apron in front of the colon transversum and in front of the small intestine for a variable distance (see Fig. 588) and ending below in a jagged margin is the great omentum, *omentum majus*. This broad peritoneal appendage is for the most part thin and transparent, but often contains large accumulations of fat along the vessels. In youth it consists of four layers (see also Fig. 598); the two anterior proceed at the *curvatura ventriculi major* directly from the tunica serosa of the paries anterior et posterior ventriculi; the two posterior are continued at the *taenia omentalis* of the colon transversum into the tunica serosa of this portion of the intestine and into the mesocolon transversum; at the free margin the two outer layers and the two inner layers go directly over into one another. In the embryonal period (see Fig. 598) the two posterior layers extend above the colon transversum as far as the posterior abdominal wall; later however the mesocolon transversum and its intestine come into contact from below with this portion of the great omentum and fuse with it. The recessus inferior omentalis (see p. 543) extends originally into the great omentum as far as its free margin, but vanishes in youth or later often more or less completely owing to a fusion of the two middle layers of peritoneum bounding this space. When this fusion has advanced as far as the colon transversum (which happens earlier on the right side than on the left), the two anterior layers of the great omentum extend from the *curvatura ventriculi major* wholly or partly directly to the colon transversum and form a *ligamentum gastrocolicum*. On the left side the two anterior layers go over directly into the *ligamentum gastrolienale* (see p. 541) and are connected with the *ligamentum phrenicocolicum* (see p. 536).



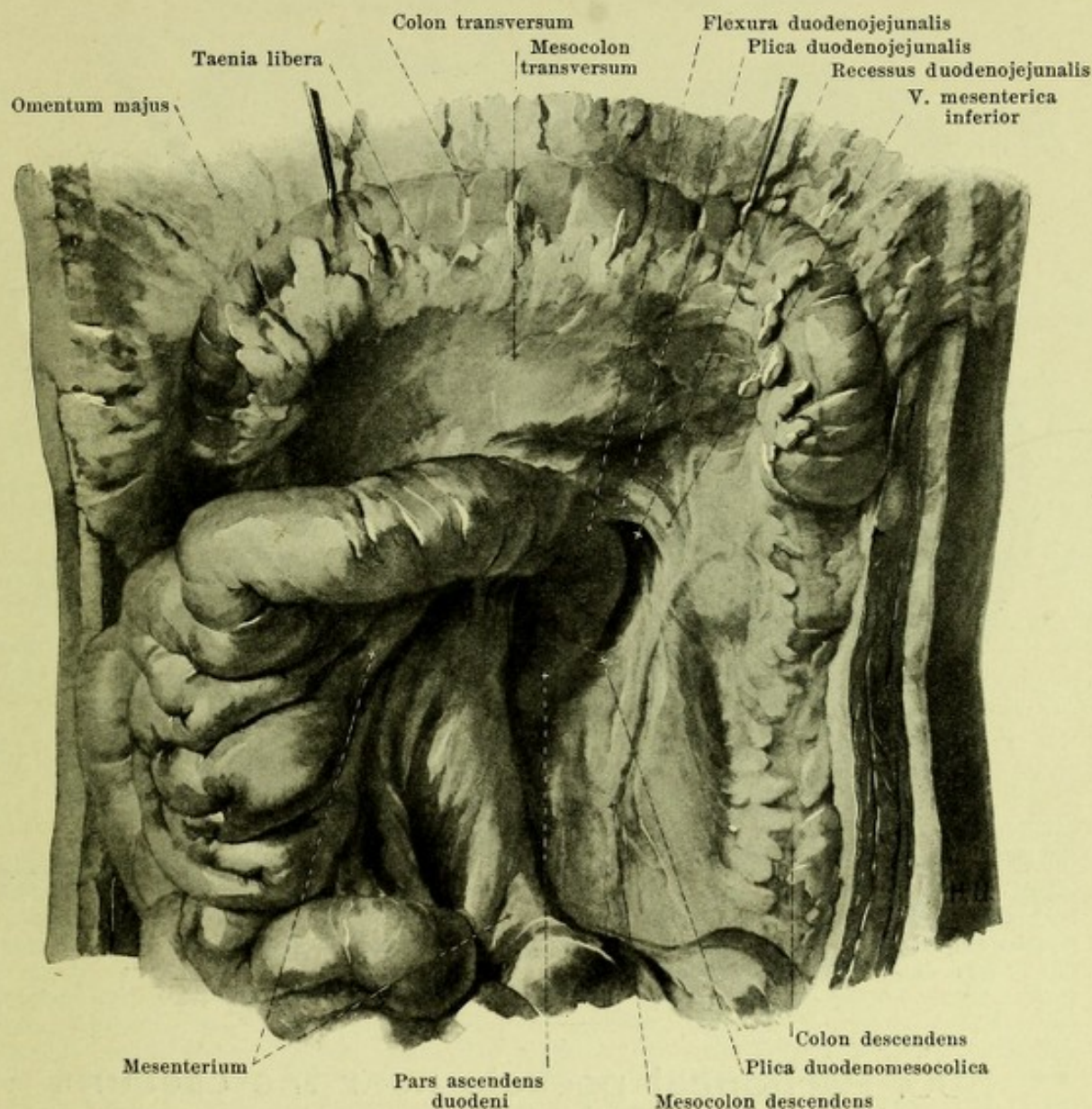
593. Bursa omentalis, opened, viewed from in front.

(From the dissection illustrated in Fig. 592 a piece of the right lobe of the liver has been removed and also the stomach in its largest part; the mesocolon transversum has been cut off shorter.)

Course of the peritoneum (continued). The **omental bursa**, *bursa omentalis* (O. T. lesser peritoneal cavity) (see also Fig. 598) is a slit-like cavity surrounded on all sides by peritoneum, which is connected with the general cavum peritonei at one spot only. This opening, *foramen epiploicum* [Winslow], (see also Figs. 592 and 594) is bounded in front by the ligamentum hepatoduodenale, above by the processus caudatus of the liver, behind by the v. cava inferior and below by the flexura duodeni superior. A narrow passage, *vestibulum bursae omentalis*, leads out from it under the processus caudatus and over the caput pancreatis to the left as far as the sickle-shaped fold projecting in the median plane, the *plica gastropancreatica*, in which the a. gastrica sinistra and v. coronaria ventriculi run from the tuber omentale pancreatis to the right side of the cardia. Ascending vertically upward from the vestibulum as a narrow prolongation behind the ligamentum hepatogastricum and lobus caudatus [Spigeli] and in front of the pars lumbalis diaphragmatis is the *recessus superior omentalis*; it clothes these parts with its peritoneum. Near the plica gastropancreatica is the passage into the main portion which as the *recessus inferior omentalis* extends downward from the cardia into the great omentum; its anterior wall is formed by the paries posterior of the stomach, its posterior by the anterior surface of the left suprarenal, of the upper part of the left kidney and of the pancreas, as well as by the mesocolon transversum and the colon transversum; all of these parts possess a peritoneal covering belonging to the bursa omentalis. Concerning the inferior portion of the recessus inferior situated in the omentum majus see p. 542. On the left side the bursa omentalis extends as the *recessus lienalis* behind the ligamentum gastrolienale almost as far as the hilus of the spleen (see also Fig. 587). The bursa omentalis may be diminished in size in old age by partial fusion of its peritoneal walls.



594. Entrance to the omental bursa,
the liver having been drawn upward.

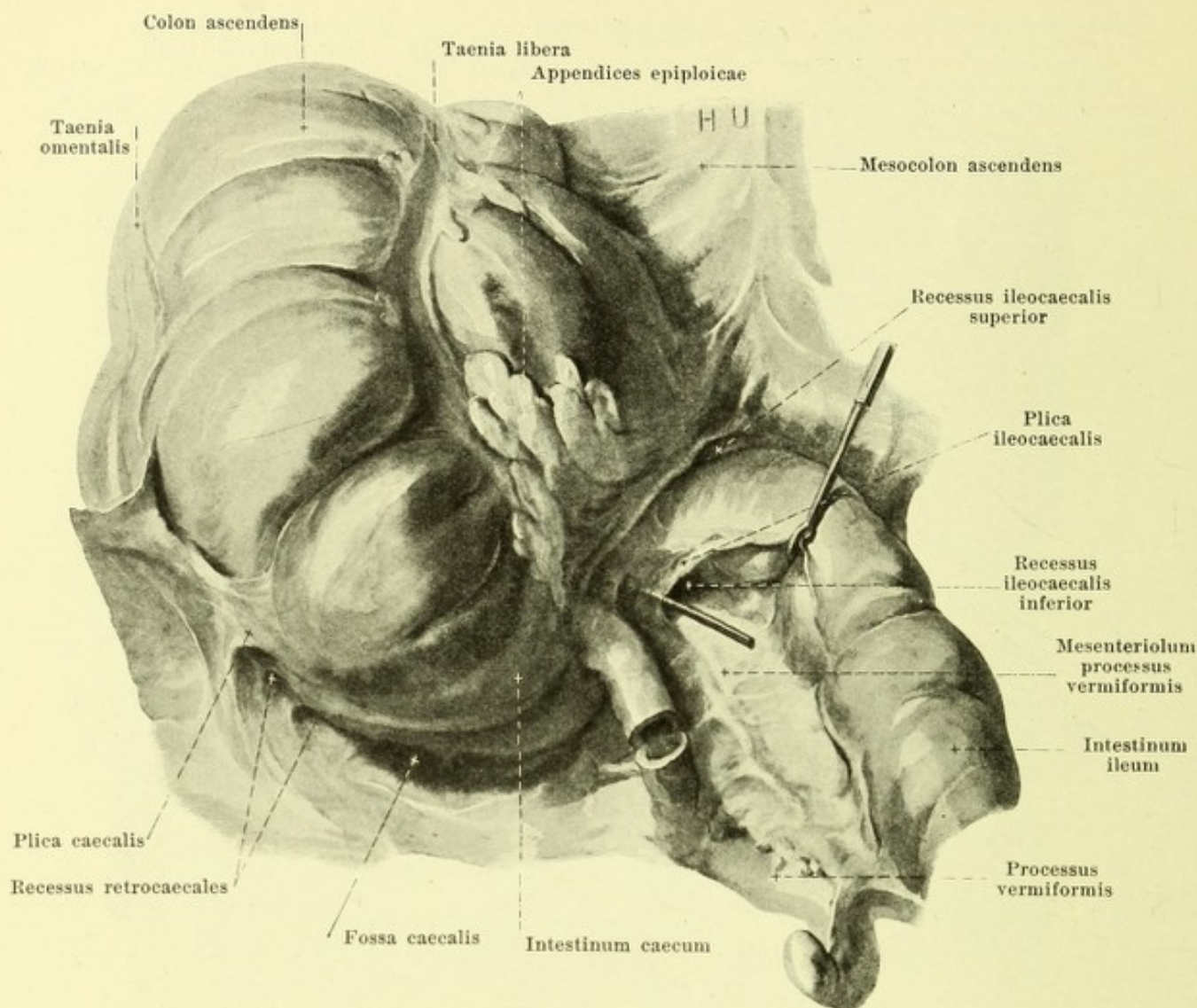


595. Recessus duodenojejunalis, viewed from in front.

(The colon transversum is drawn upward, the small intestine with the mesentery to the right.)

Course of the peritoneum (continued). From the flexura duodeni jejunalis on there arises from the posterior wall of the abdomen a large fold of peritoneum, the *mesenterium* (*mesentery*), the starting point of which, *radix mesenterii* (root of the mesentery) (see Figs. 591 and 593), extends from the left side of the body of the second lumbar vertebra obliquely downward and somewhat to the right in front of the pars ascendens duodeni, the aorta abdominalis and the v. cava inferior and the right ureter to the right articulation sacroiliaca. The mesentery consists of a layer of connective tissue, *lamina mesenterii propria*, in which are situated the vessels, lymph glands, nerves and masses of fat; it is covered on both sides by the tunica serosa. It is narrow at its starting point, then broadens fairly suddenly and presents many markedly zigzag-shaped tortuous folds (see Fig. 590) and is finally attached to the whole extent of the intestinum tenue mesenteriale; its peritoneal covering goes over into the tunica serosa of the intestine (see Fig. 598). The length of the mesentery measured from its starting point to the intestine increases distalward from the flexura duodenojejunalis on, is longest on those loops which descend into the true pelvis (see p. 518), and then again becomes shorter.

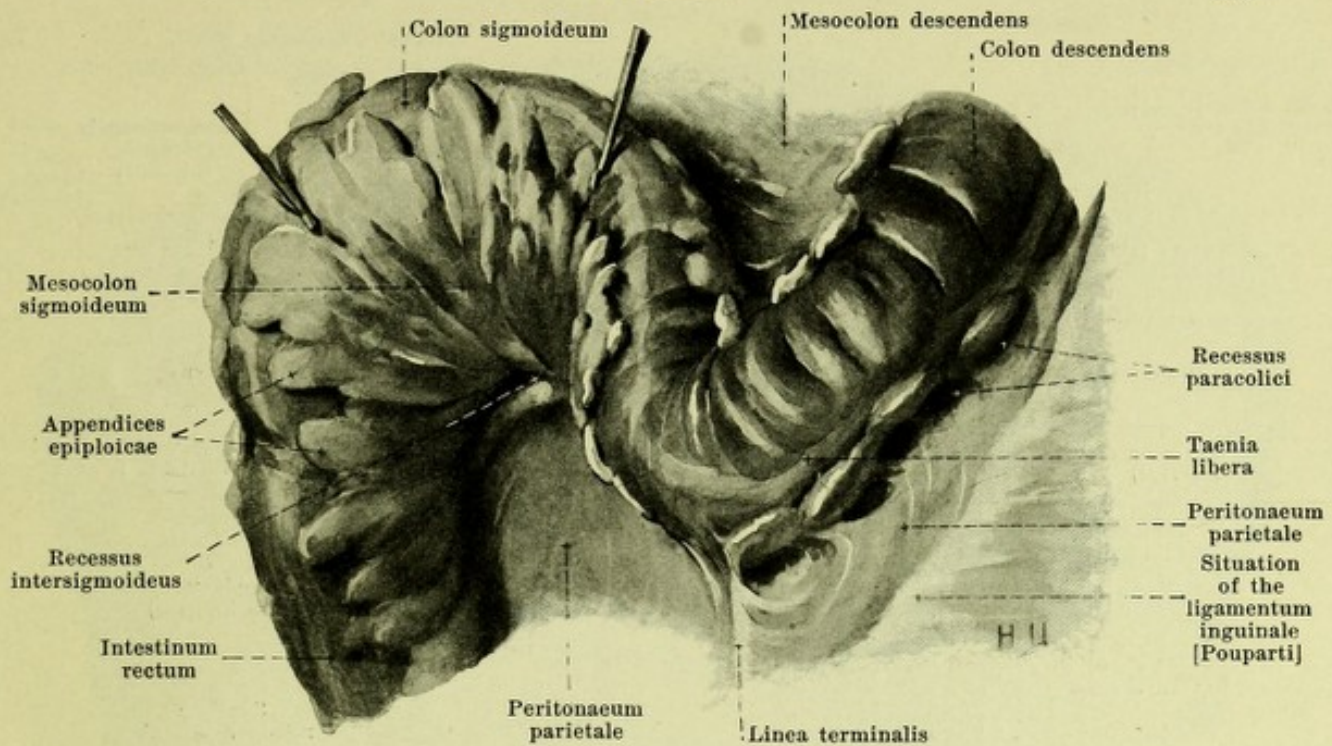
Above, extending to the left from the flexura duodenojejunalis is a variably developed sickle-shaped fold of peritoneum, the *plica duodenojejunalis*, which may contain the v. mesenterica inferior; somewhat deeper there often goes off from the pars ascendens duodeni a narrower, *plica duodenomesocolica*. Their free edges are directed toward one another. These folds bound the *recessus duodenojejunalis*.



596. Peritoneal pockets near the caecum, viewed from in front.

(The small intestine has been drawn to the left, the vermiform process has been cut into.)

Course of the peritoneum (continued). Up to the fourth month of embryonic life the large or thick intestine is moveably hung by its **mesocolon**, a duplicature of the peritoneum, exactly in the way that the small intestine is hung by its mesentery; it is connected with the peritoneum parietale in front of the spinal column only. Originally the inferior portions of both kidneys, the ureter and vasa spermatica interna as well as the mm. quadratus lumborum and iliopsoas on each side are also covered by peritoneum parietale. Subsequently, however, the moveability of the large or thick intestine becomes lost owing to the fact that the mesocolon and large intestine come into relation to neighboring portions of the peritoneum and fuse with them in variable extent. This happens in the following way: the colon ascendens and its fold of peritoneum, *mesocolon ascendens*, becomes attached in the fourth month of the embryo to the posterior abdominal wall to the right of the radix mesenterii and the posterior layer of the mesocolon fuses with the peritoneum parietale originally present there. After this fusion the peritoneum parietale becomes directly continuous with the tunica serosa of the right wall of the colon ascendens, and the posterior wall of the latter no longer possesses a peritoneal covering. The fusion does not extend usually as far as the intestinum caecum (see p. 522). Behind this therefore is found a prolongation of the peritoneal cavity open below, the *fossa caecalis*; it is bounded on the right by the *plica caecalis*, which is stretched out downward from the right inferior extremity of the surface of fusion. From the cupola of the fossa caecalis extend upward not infrequently one or several small depressions, *recessus retrocaecales*, the origin of which is to be explained in irregularities in the fusion of the colon to the peritoneum parietale.



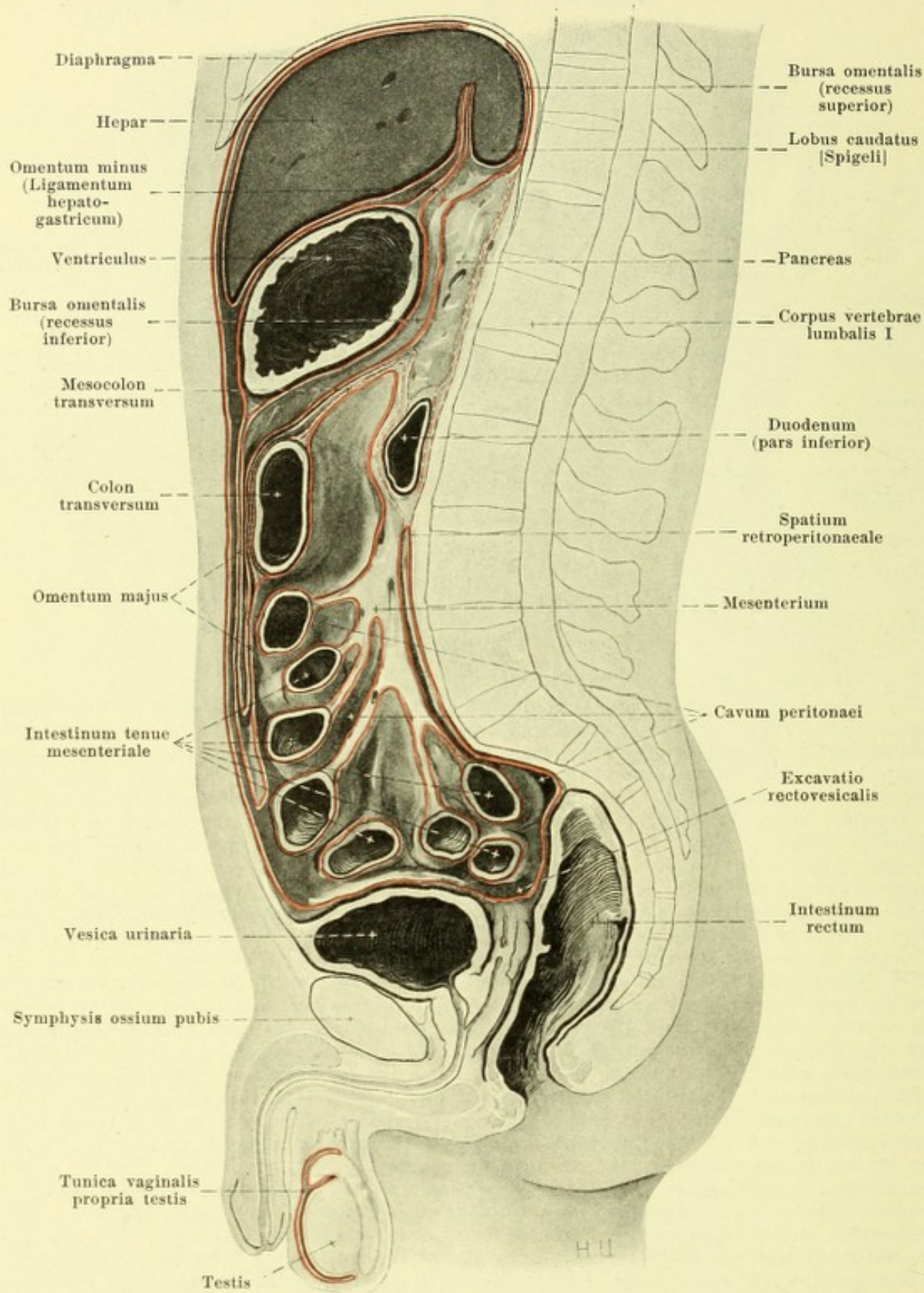
597. Recessus intersigmoideus, viewed from in front and below.

(The colon sigmoideum has been drawn upward.)

Course of the peritoneum (continued). Behind the terminal portion of the intestinum ileum there arises from the posterior wall an approximately quadrangular fold of peritoneum, the *mesenterium processus vermiformis* (see Fig. 596). This is attached to the taenia mesocolica of the caecum and to the upper margin of the processus vermiformis, going over there into its tunica serosa. From the anterior wall of the last piece of small intestine extends a variably developed fold of peritoneum, the *plica ileocaecalis*, to the caecum and to the anterior surface of the mesenterium (see Fig. 596). It contains smooth muscle fibers and bounds from in front the *recessus ileocaecalis inferior*, which is very variable in size and open downward and to the left. Above this portion of the small intestine a narrow triangular fold of peritoneum goes to the right and downward from the anterior surface of the mesentery in front of the small intestine to the large intestine; it forms the anterior wall of the *recessus ileocaecalis superior* (see Fig. 596) which is usually small and open toward the left.

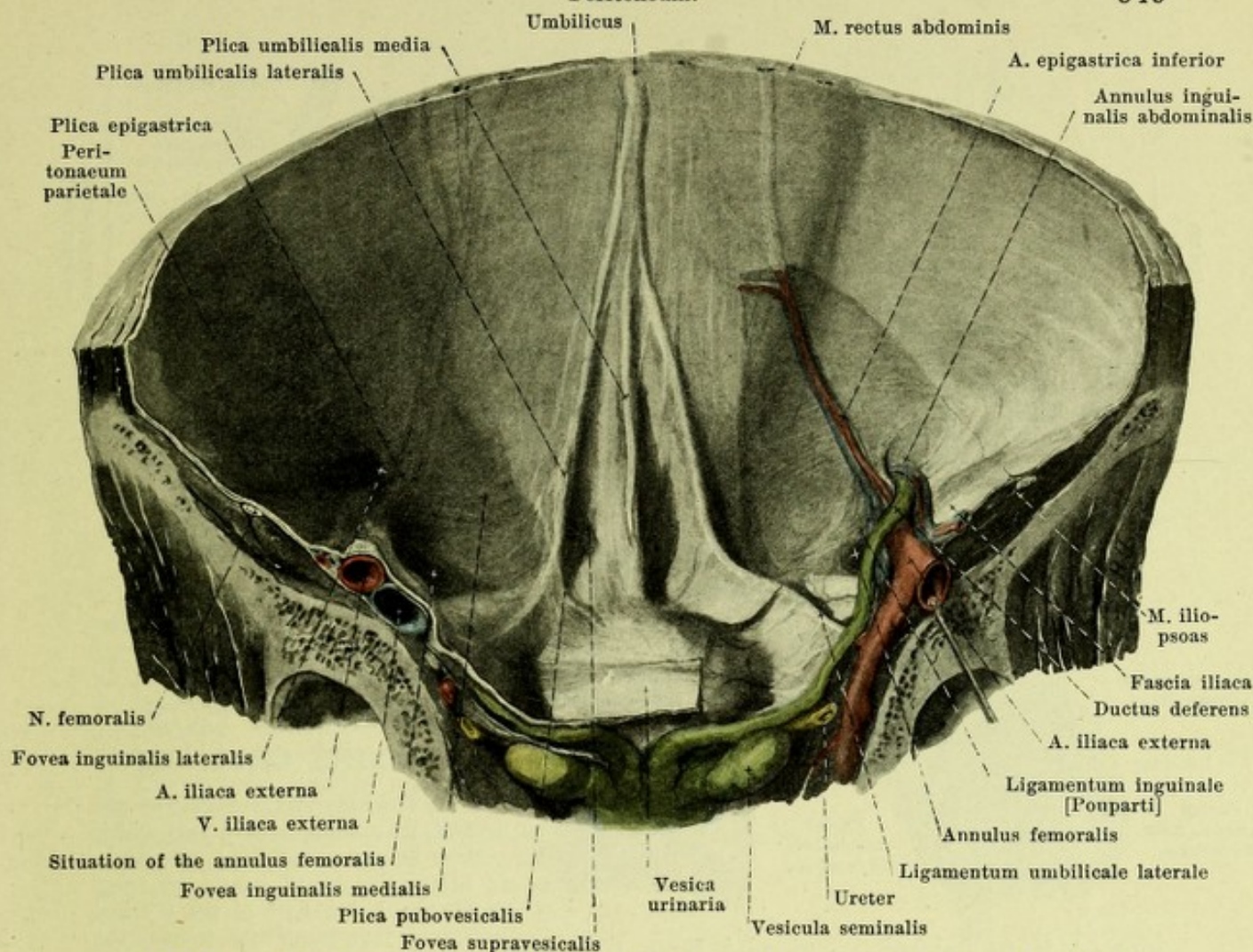
The colon transversum and its duplicature of peritoneum, the *mesocolon transversum*, in the fourth month of the embryo lies on the right side on the peritoneum parietale as well as on the inferior portion of the pars descendens duodeni, on the pars inferior duodeni and on the processus uncinatus pancreatis. The posterior layer of the mesocolon transversum then fuses there with the peritoneum parietale and with the peritoneal covering of the duodenum and pancreas so that later the peritoneum goes over directly from the anterior surface of the right kidney and of the upper part of the pars descendens duodeni to the colon transversum (see pag. 542 and Fig. 594). On the left the mesocolon transversum becomes attached from below to the two posterior layers of the omentum majus (see Fig. 598) which went originally as far as the posterior abdominal wall, and its upper layer, as well as the tunica serosa of the upper surface of the colon transversum, fuses with the most posterior layer of the omentum majus. Later as a result of this the two posterior layers of the omentum majus are directly attached to the colon transversum so that the latter lies as it were between these layers of the great omentum, and the upper layer of the mesocolon transversum looks into the bursa omentalis.

The colon descendens and its fold of peritoneum, *mesocolon descendens*, becomes attached in the fifth month of the embryo on the left of the radix mesenterii to the posterior abdominal wall and fuses there with the peritoneum parietale exactly as does the mesocolon ascendens on the right; this fusion reaches below usually as far as the medial margin of the left m. psoas major (see also Fig. 633), but it may fail to take place to a variable extent in the fossa iliaca. Small fossae on the left side which lead behind the intestine, *recessus paracolici*, arise in very much the same way as do the recessus retrocaecales (see p. 546).



598. Course of the peritoneum, red,
in a median section of a male (after W. Braune), somewhat schematic.

(The dotted red lines refer to the embryonic conditions [see pp. 542 and 547].)



599. Anterior abdominal wall (inferior half).

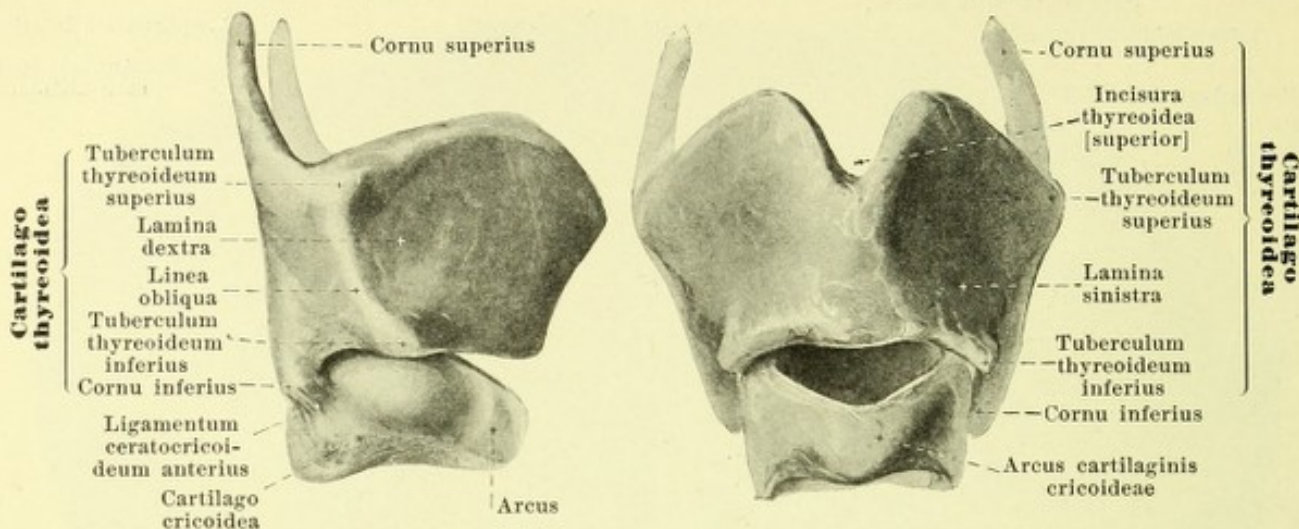
(The posterior part of the pelvis has been removed by a frontal section; the peritoneum has been partly dissected away on the right side. Cf. Fig. 328. The bladder is empty.)

Course of the peritoneum (continued). The colon sigmoideum and its duplicature of peritoneum, *mesocolon sigmoideum*, does not fuse with the peritoneum parietale but remains always freely moveable. The starting point of this mesocolon forms a \wedge (see Fig. 633), the left limb of which corresponds to the inferior extremity of the surface of fusion of the mesocolon descendens (see p. 547), and its right limb extends downward and to the right in front of the promontorium. From the apex of the \wedge a funnel-shaped prolongation, *recessus intersigmoideus*, of varying size extends upward (see Figs. 597 and 633).

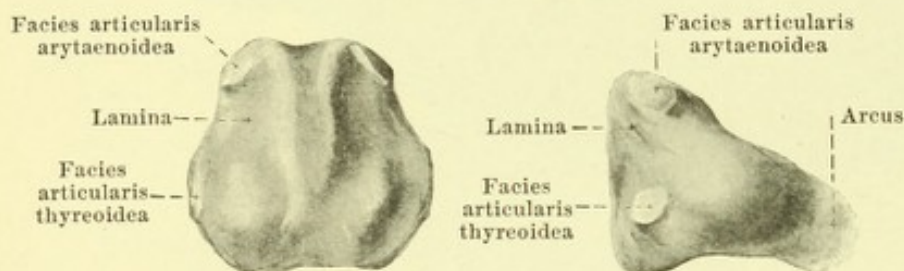
The duodenum with the pancreas are also originally made freely moveable by a plate of peritoneum but later like the colon become firmly attached to the posterior abdominal wall owing to the fact that one surface of the peritoneal plate fuses with the peritoneum parietale.

The space situated behind the primary peritoneum parietale, and which contains the suprarenal glands, the kidneys, the ureters, the large vessels and nerves is called the *spatium retroperitoneale* (*retroperitoneal space*).

The posterior surface of the anterior abdominal wall is covered by the *peritoneum parietale*. From this arise, below the umbilicus, five folds (see also Fig. 328). The *plica umbilicalis media*, which is made to project by the ligamentum umbilicale medium (see p. 581), runs approximately in the median plane; the *plica umbilicalis lateralis*, in which is situated the ligamentum umbilicale laterale (see p. 428) extends downward and lateralward to the pelvic inlet. The plicae umbilicales are sometimes indistinct, usually low above, higher below; they usually fuse somewhat below the navel. Between these folds on each side, above the pubis and behind the m. rectus abdominis, lies the *fovea suprapavesicalis*. Further lateralward is situated the *plica epigastrica* which is caused to project by the a. epigastrica inferior; it is distinct below only. Lateralward from it, behind the annulus inguinalis abdominalis, lies the *fovea inguinalis lateralis*, medianward from it the *fovea inguinalis medialis*; from this, leading in front of the plica umbilicalis lateralis, a pocket very often extends medianward.



600 and 601. Thyroid and cricoid cartilages,
viewed from the right. viewed from in front.



viewed from behind. viewed from the right.

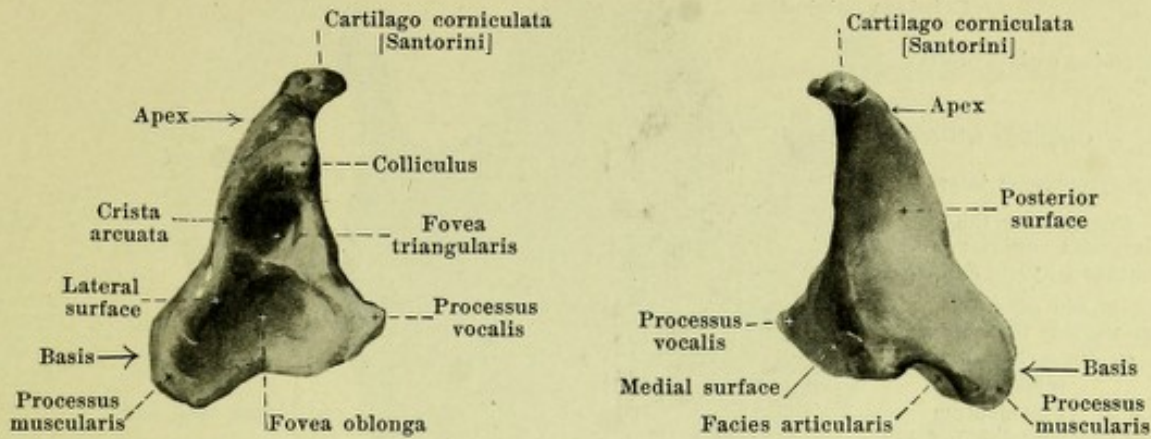
602 and 603. Cricoid cartilage,

The **larynx** (see Figs. 516 and 609) is an oblong hollow body which lies in the middle of the neck, below the hyoid bone, in front of the lower half of the cervical spine. It is bounded in front in the median plane directly by the fascia colli and the skin (bursa [mucosa]

subcutanea prominentiae laryngeae see p. 257), is covered laterally by the thyroid gland and the mm. sternohyoidei, sternothyroidei, thyrohyoidei, omohyoidei and constrictores pharyngis inferiores and is bounded behind by the pars laryngea pharyngis. Above it opens through the aditus laryngis into the pharynx, below it goes over into the trachea. In the male it is absolutely and relatively larger than in the female. It possesses a cartilaginous framework.

Cartilages of the larynx (*cartilagineae laryngis*). They ossify in old age but later in the female than in the male.

Cartilago thyroidea (*thyroid cartilage*) (see also Fig. 612), unpaired, is the largest hyaline cartilage and lies in the anterior superior part of the larynx. It is formed of two quadrangular plates, *laminae* (*dextra et sinistra*), which converge in front and below and in the male meet at an angle (above, about 90°), in the female they go over into one another in the form of an arch. The line of junction in the male runs obliquely backward and downward; its uppermost, most anterior point causes a projection of the skin, *prominentia laryngea* (see Fig. 516), which is scarcely noticeable in the female. The inner surface is smooth; the outer surface frequently presents a flat ridge behind extending from above and behind downward and forward, the *linea obliqua* (for the mm. sternothyroideus, thyrohyoideus and thyropharyngeus); this begins above in a triangular nodule, *tuberculum thyroideum superius*, and ends below in a smaller ridge-like projection of the inferior margin, *tuberculum thyroideum inferius*. Below the tuberculum superius there is frequently an opening, *foramen thyroideum* (see Fig. 609), of variable size. The upper margin is curved so as to be convex on each side; in the middle at the junction of the right and left upper margins is a notch of variable depth, *incisura thyroidea [superior]*. The inferior margin presents on each side two flat depressions of variable development. From the posterior margin which is almost straight on each side projecting upward and a little backward is the *cornu superius*, projecting downward and a little forward the shorter *cornu inferius*. Both are rounded and curved somewhat medianward; the inferior presents on the median declivity of its apex a rounded articular surface (for the facies articularis thyroidea of the cartilago cricoidea).



604 and 605. Right arytaenoid cartilage, viewed from in front and lateralward. viewed from behind and medialward.

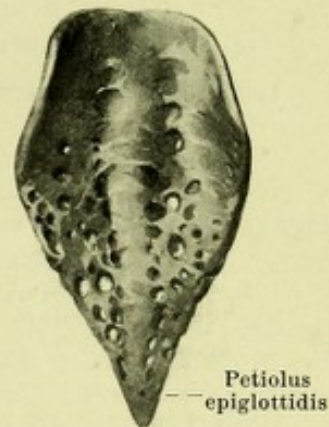
Magnification 3 : 2.

Cartilago cricoidea (ring cartilage or cricoid cartilage) (see Figs. 600—603), unpaired, consists of hyaline cartilage and lies below the thyroid cartilage. It has the shape of a seal ring. The anterior portion, *arcus*, is low in front and becomes gradually higher behind. The posterior portion, *lamina*, is approximately hexagonal and higher; it projects upward between the posterior margins of the thyroid cartilage. Its anterior surface is smooth, its posterior presents two flat fossae (for the mm. cricoarytaenoidei posteriores), separated by a median ridge. Each lateral superior angle of the lamina bears a small articular surface looking upward, forward and lateralward, the *facies articularis arytaenoidea* (for the facies articularis of the cartilago arytaenoidea); this surface is cylindrically curved. Each lateral middle angle of the lamina possesses a small rounded articular surface, *facies articularis thyreoidea* (for the cornu inferius of the cartilago thyreoidea).

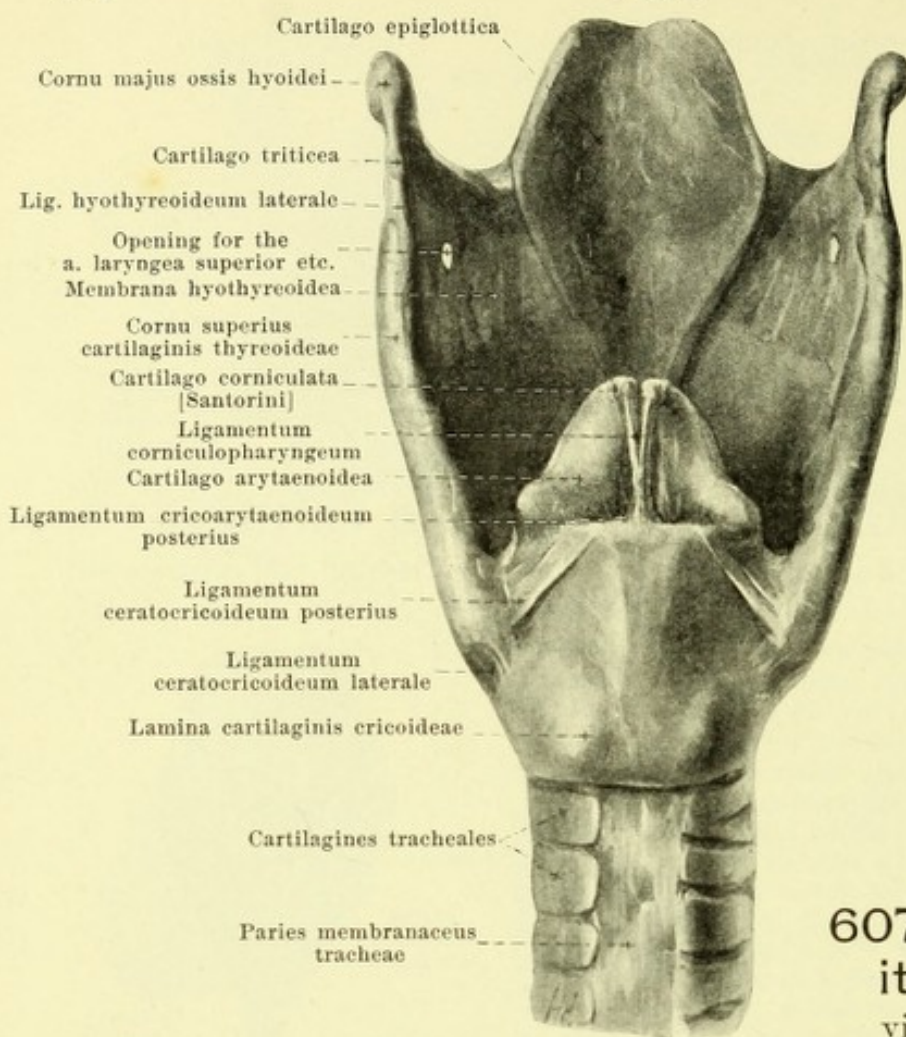
Cartilago arytaenoidea (arytaenoid cartilage) (see also Figs. 607 and 612), paired, lies above the lamina of the cricoid cartilage in the posterior part of the larynx and consists of hyaline cartilage with the exception of the processus vocalis and often the apex which are elastic cartilage. It has approximately the form of a three-sided pyramid. The posterior surface is markedly concave (for the m. arytaenoideus transversus); the medial, narrow surface is flat and stands sagittally. The lateral surface looking at the same time forward presents close below the apex a small nodule, the *colliculus*. From this a ridge, *crista arcuata*, goes first backward then forward and downward to the processus vocalis; it forms the margin of a deep fossa, *fovea triangularis*, and separates it from a larger flatter depression, *fovea oblonga* (for the m. vocalis). The oblong, somewhat obliquely placed *basis* presents behind a rounded, concave *facies articularis* (for the facies articularis arytaenoidea of the cartilago cricoidea); directly above this lies the lateral blunt angle, *processus muscularis*, for the mm. cricoarytaenoidei. The anterior angle of the basis, *processus vocalis*, is longer and tapered. The tip, *apex*, is blunt and curved backward; it carries a short wedge-shaped appendage, the **cartilago corniculata [Santorini]**, which consists of elastic cartilage and is directed backward and medianward.

Cartilago cuneiformis [Wrisbergi], paired, consisting of elastic cartilage, often lies as an oblong rod close in front of the arytaenoid cartilage in the posterior part of the plica aryepiglottica (see Fig. 614 in the projection beneath the tuberculum cuneiforme).

Cartilago epiglottica (cartilage of the epiglottis) (see also Figs. 607, 608 and 614), unpaired, consisting of elastic cartilage, is thin, very flexible, shaped like the ace of hearts, multiply perforated and presents numerous small depressions; it is situated above the thyroid cartilage behind the root of the tongue and the hyoid bone and directed obliquely backward and upward. It presents below a thicker tip, *petiolus epiglottidis*, above frequently a notched margin. Its posterior surface is curved so as to be saddle-shaped, being slightly convex backward in the sagittal direction, markedly concave in transversal direction.



606. Cartilage of the epiglottis, viewed from behind.



607. Larynx with its ligaments, viewed from behind.

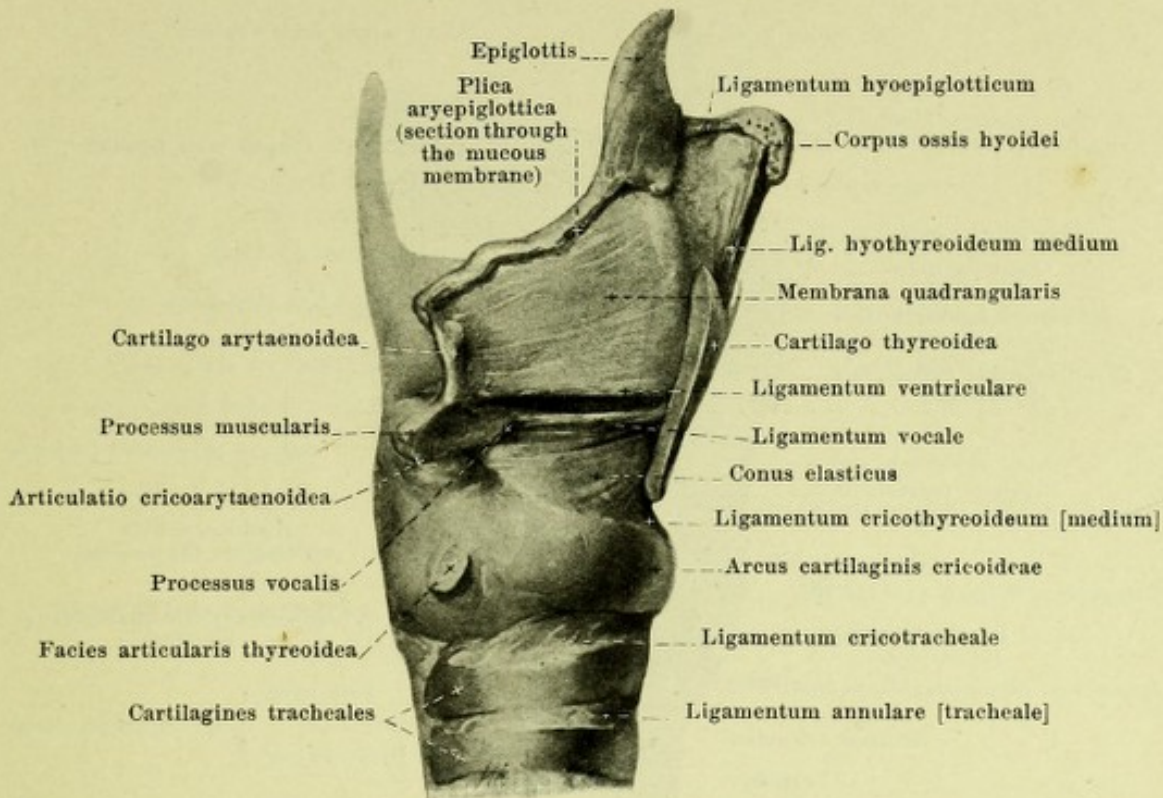Ligaments and joints of the larynx.

Membrana hyothyreoidea (*hyothyroid membrane*) (see also Fig. 609) is the name given to the loose membrane of connective tissue, which goes from the posterior margin of the corpus and from the cornua majora ossis hyoidei (bursa, see p. 257) to the upper margin of the thyroid cartilage. It presents an opening for the passage of the a. and v. laryngea superior and the ramus internus n. laryngei superioris and is strengthened in the middle by elastic fibers which form the *ligamentum hyothyreoideum medium* (see also Fig. 614). Its lateral extremity is thickened on each side by means of elastic fibers between the tips of the cornu majus ossis hyoidei and the cornu superius cartilaginis thyreoideae to form a rounded cord, *ligamentum hyothyreoideum laterale* (see also Fig. 609); this usually contains a small piece of fibrocartilage, *cartilago triticea* (not infrequently ossified).

In the *articulatio cricothyreoidea* on each side the facies articularis thyreoidea of the cricoid cartilage glides upon the cornu inferius of the thyroid cartilage. The *capsula articularis cricothyreoidea* is stretched out between the margins of the articular surfaces; it is very thin and loose. It is strengthened by the *ligamenta ceratocricoidae*, which arise at the cornu inferius of the thyroid cartilage, and of which the *anterior* (see Fig. 600) extends forward and downward, the *laterale* downward, while the *posterius* passes medianward from the inner surface of the cornu inferius to the upper margin of the lamina cartilaginis cricoideae.

In the *articulatio cricoarytaenoidea* on each side the facies articularis of the arytaenoid cartilage moves upon the facies articularis arytaenoidea of the cricoid cartilage. The *capsula articularis cricoarytaenoidea* goes off just outside the margins of the articular surfaces; it is very thin and loose. It is strengthened on the posterior surface by the *ligamentum cricoarytaenoideum posterius*, which, diverging somewhat, extends from the upper margin of the lamina cartilaginis cricoideae to the medial part of the dorsal surface of the arytaenoid cartilage.

Synchondrosis arycorniculata is the name given to the moveable union formed by loose connective tissue bands between the cartilago corniculata [Santorini] and the apex cartilaginis arytaenoideae.



608. Larynx with its ligaments, viewed from the right.

(The lamina dextra of the cartilago thyroidea has been removed.)

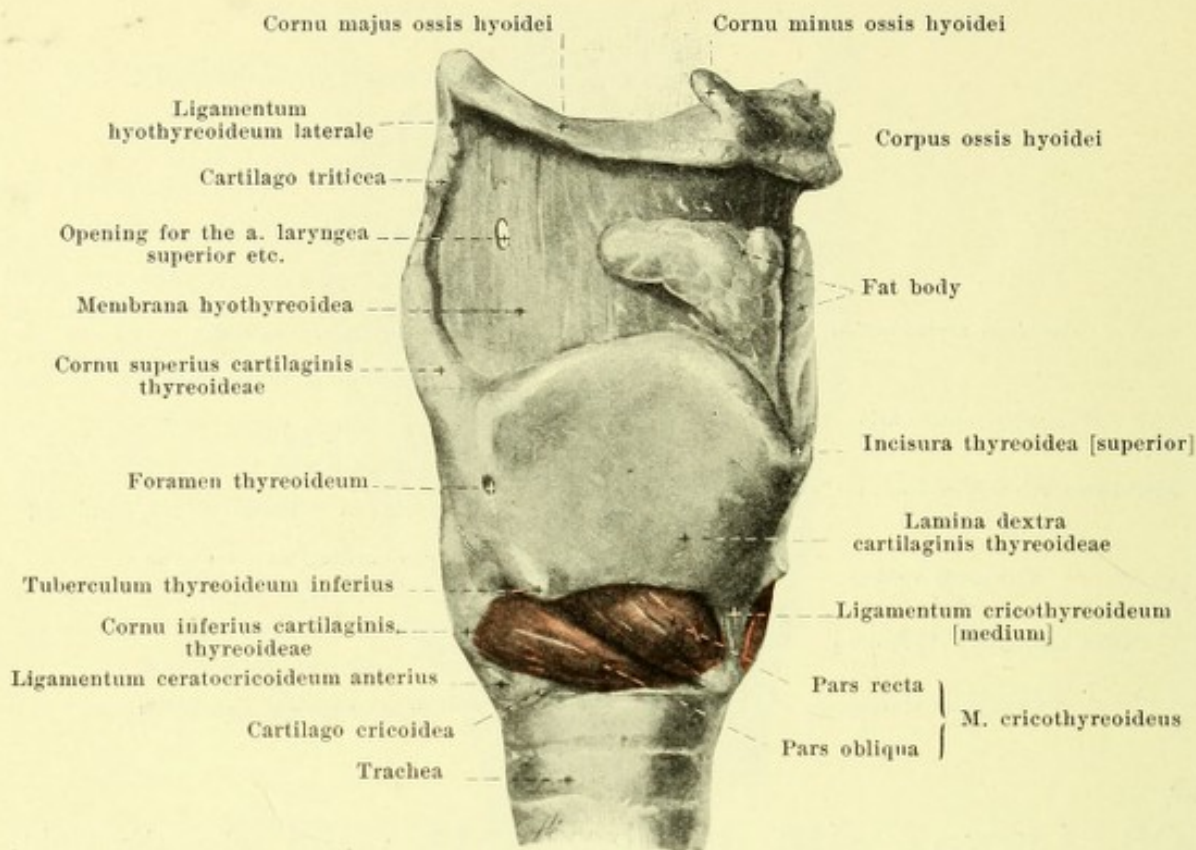
Ligaments and joints of the larynx (continued).

Going downward from the tip of each cartilago corniculata (see Fig. 607) is a thin band of connective tissue, the *ligamentum corniculopharyngeum*, which unites behind the mm. arytaenoidei with that of the other side to form a strip of connective tissue, which extends to the upper margin of the lamina of the cricoid cartilage and to the anterior surface of the mucous membrane of the pharynx; the inferior fibers of this strip are designated the *ligamentum cricopharyngeum* (not illustrated).

The cartilago epiglottica is connected with the other cartilages by ligaments only. At the root of the tongue it is fastened by the *ligamentum glossoepiglotticum* (consisting of elastic fibers (not illustrated), which runs from before backward in the plica glossoepiglottica mediana. The *ligamentum hyoepiglotticum* (see also Fig. 614) extends as a short but broad plate of elastic fibers from the upper margin of the body and the cornua majora of the hyoid bone to the anterior surface of the cartilage of the epiglottis. The apex of the cartilago epiglottica is fastened behind and below the incisura thyroidea superior by means of the powerful *ligamentum thyroepiglotticum* (see Fig. 614) consisting of elastic fibers. The triangular space between the ligamentum hyoepiglotticum, the anterior surface of the cartilage of the epiglottis and the ligamentum hyothyroideum medium contains on each side a mass of fat (see Figs. 609 and 614), which is shoved in lateral from the latter upon the anterior surface of the membrana hyothyroidea.

The *ligamentum cricotracheale* is the name given to the vertical, short bands of connective tissue which run from the inferior margin of the cricoid cartilage to the superior margin of the first cartilago trachealis.

The *conus elasticus* (see also Fig. 616) is a membrane the elastic bands of which radiate fan-like from the lower margin and from the posterior surface of the angle of the cartilago thyroidea to the upper margin of the arch of the cartilago cricoidea and to the processus vocales of the cartilagine arytaenoideae. The two halves of the membrane converge above and medianward and are slightly concave lateralward. The most anterior thick portion consisting of perpendicular fibers, *ligamentum cricothyroideum [medium]* (see also Figs. 609, 610 and 614), is stretched out in the middle from the inferior margin of the thyroid cartilage to the upper margin of the arcus cartilaginis cricoideae; it is perforated by vessels and becomes broader below. The uppermost strengthened bands of fibers of the conus arise on each side as the *ligamentum vocale* (see also Figs. 612, 615 and 616) close to the median plane from the middle of the angle of the cartilago thyroidea and run horizontally to the processus vocalis. They surround in front a small nodule of elastic tissue which may contain cartilage cells, *cartilago sesamoidea* (not illustrated).



609. Larynx with its muscles, viewed from the right.

(The lig. hyothyreoideum medium has been removed.)

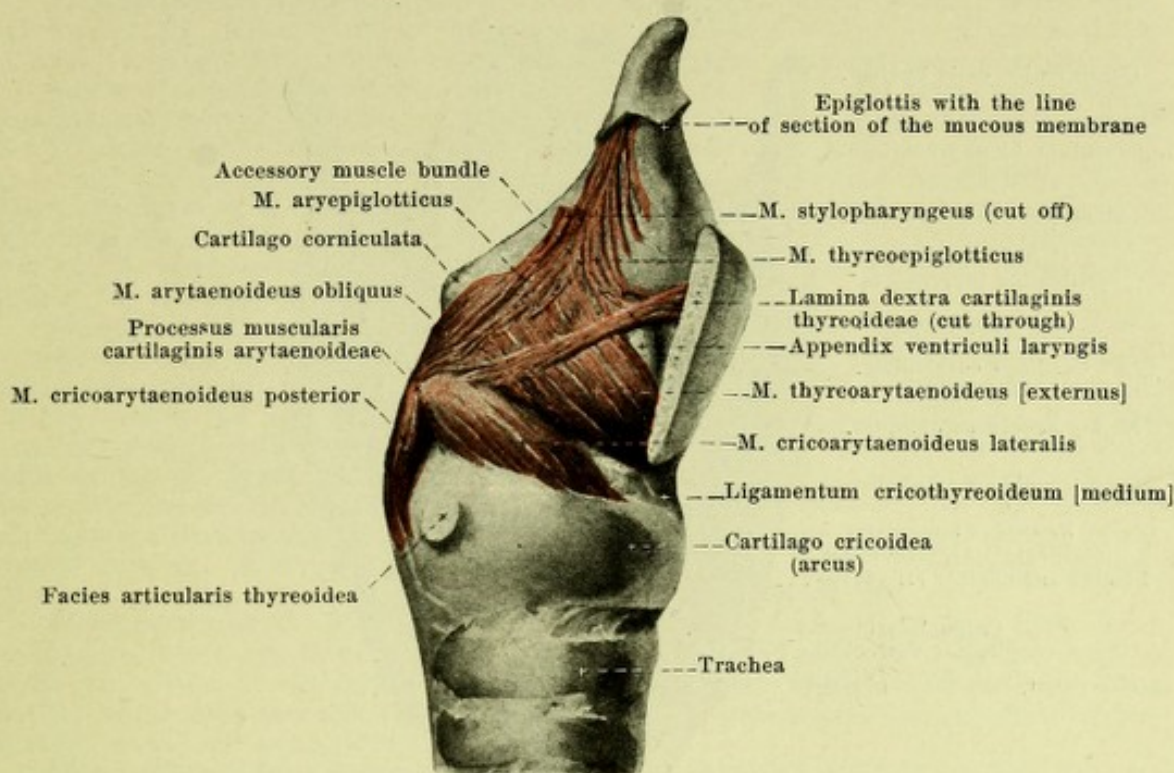
Ligaments and joints of the larynx (continued).

Membrana quadrangularis (see Fig. 608) is a membrane somewhat split up by glands deposited in it; it consists of elastic fibers the bundles of which run downward in the main sagittally, partly also backward and downward. It arises on each side in front and above at the lateral margin of the cartilago epiglottica, below at the posterior surface of the angle of the cartilago thyreoidea and becomes attached behind to the cartilago corniculata [Santorini] and to the medial margin of the arytaenoid cartilage. The membranes of the two sides converge below and medianward. The inferior end is called the *ligamentum ventriculare* and consists of fibers which go off at the thyroid cartilage somewhat above the ligamentum vocale and extend horizontally near the median plane backward to the medial margin of the fovea triangularis of the arytaenoid cartilage. Its upper margin runs obliquely backward, downward and medianward. The membrane above forms the basis of the plica aryepiglottica and there contains posteriorly the cartilago cuneiformis [Wrisbergi].

Conus elasticus and membranae quadrangulares are grouped together as **Membrana elastica laryngis**.

Muscles of the larynx (*musculi laryngis*).

M. cricothyreoideus (see also Figs. 298, 302, 555 and 616), paired. Form: quadrangular, broader and thicker above. Position: on the external surface of the larynx, covered by the glandula thyreoidea, as well as by the mm. sternothyreoideus and sternohyoideus. Those of the two sides leave free between them in the middle a triangular area broader above, in which the ligamentum cricothyreoideum [medium] is visible. Origin: external surface of the arcus cartilaginis cricoideae. Insertion: inferior margin and medial surface of the lamina cartilaginis thyreoideae as far as the apex of the cornu inferius. The fibers radiate upward like a fan so that in the anterior portion, *pars recta*, they extend more vertically, in the posterior portion, *pars obliqua*, more obliquely backward; the two portions are often distinctly separated from one another. Behind, the muscle is usually covered by bundles of origin of the m. constrictor pharyngis inferior and is connected with them. Action: It elevates the arcus, moves the upper margin of the lamina of the cricoid cartilage (and the cartilagine arytaenoidae) dorsalward and makes the ligamenta vocalia tense. Innervation: ramus externus n. laryngei superioris (X).



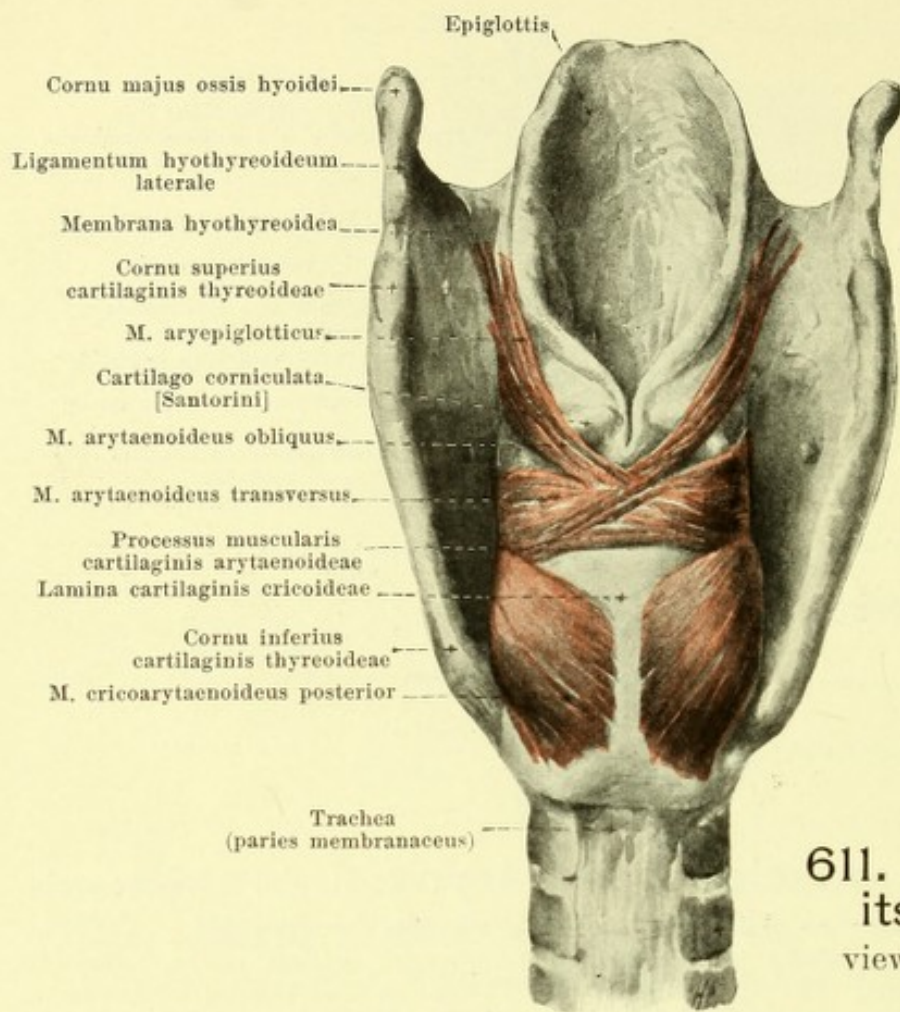
610. Internal muscles of the larynx, viewed from the right.

(The lamina dextra of the cartilago thyroidea has been removed.)

M. cricoarytaenoideus posterior (O. T. cricoarytaenoideus posticus) (see also Figs. 551 and 611), paired. Form: triangular. Position: on the posterior surface of the lamina cartilaginis cricoideae, directly covered behind by the tela submucosa of the pharynx. Origin: medial and inferior part of the posterior surface of the lamina cartilaginis cricoideae. Insertion: the fibers converge upward and lateralward to the posterior surface and to the apex of the processus muscularis cartilaginis arytaenoideae; in their course the lateral fibers run nearly vertically, the upper fibers almost horizontally. Action: it draws the processus muscularis backward and downward, rotates the arytaenoid cartilage so that the processus vocalis is turned lateralward and somewhat upward and the ligamentum vocale is put somewhat upon the stretch. Innervation: ramus posterior n. laryngei inferioris (X).

M. cricoarytaenoideus lateralis, paired. Form: triangular. Position: in the lateral wall of the larynx upon the conus elasticus covered by the lamina cartilaginis thyroideae, the glandula thyroidea and the mm. sternothyroideus, thyrohyoideus, sternohyoideus and thyropharyngeus. Origin: upper margin and external surface of the arcus cartilaginis cricoideae, as well as the conus elasticus. Insertion: by converging fibers backward and upward to the anterior surface of the processus muscularis cartilaginis arytaenoideae. The muscle is very frequently inseparable from the m. thyroarytaenoideus [externus]. Action: it draws the processus muscularis forward and downward so that the processus vocalis is turned medianward and a trifle downward, and the ligamentum vocale is put somewhat upon the stretch. Innervation: ramus anterior n. laryngei inferioris (X).

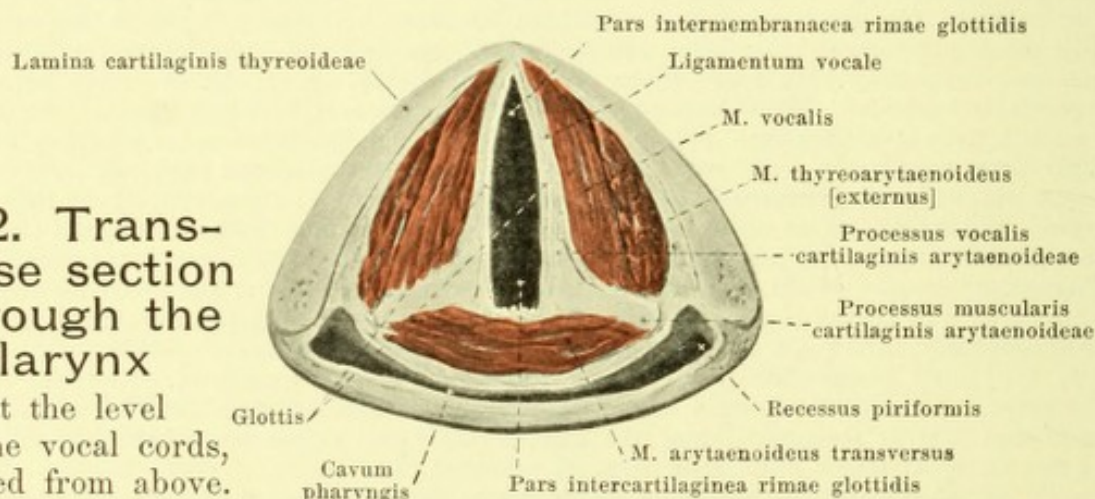
M. thyroarytaenoideus [externus] (see also Figs. 612, 615 and 616), paired, forms with the m. vocalis a common mass of muscle, separable only by artificial means. Form: thin, quadrangular. Position: in the lateral wall of the larynx; medianward it is adjacent above to the appendix ventriculi laryngis, below to the m. vocalis and partly to the conus elasticus; lateralward it is covered by the lamina cartilaginis thyroideae and the mm. thyrohyoideus and sternohyoideus. Origin: posterior surface of the cartilago thyroidea, directly lateralward from the m. vocalis, reaching for a variable distance upward. Insertion: the fibers extend backward and upward to the lateral margin of the arytaenoid cartilage; some bundles go over into the m. arytaenoideus obliquus. The upper fibers vary greatly in their development. Action: it draws the cartilago arytaenoidea forward and rotates it, so that the processus vocalis is turned medianward and somewhat downward and the ligamentum vocale is rendered somewhat flaccid. Innervation: ramus anterior n. laryngei inferioris (X).



611. Larynx with its muscles, viewed from behind.

612. Transverse section through the larynx

at the level of the vocal cords, viewed from above.



M. thyreoepiglotticus (see Fig. 610), paired, very variable. Form: oblong, thin. Position: in the lateral wall of the larynx; it is bounded below directly by the m. thyreoarytaenoideus [externus], medianward and below lies adjacent to the appendix ventriculi laryngis, above to the membrana quadrangularis and is covered lateralward by the lamina cartilaginis thyreoideae and by the mm. thyrohyoideus and sternohyoideus. Origin: medial surface of the lamina cartilaginis thyreoideae, immediately adjacent to the m. thyreoarytaenoideus [externus]. Insertion: the fibers run in arches upward and backward partly toward the margin of the plica aryepiglottica, partly toward the margin of the cartilago epiglottica, interwoven with the m. aryepiglotticus. Action: it widens the aditus and the vestibulum laryngis. Innervation: ramus anterior n. laryngei inferioris (X).

M. arytaenoideus obliquus (see Figs. 610 and 611), paired. Form: narrow, thin. Position: in the posterior wall of the larynx, bounded in front by the m. arytaenoideus transversus, covered behind by the tela submucosa pharyngis. Origin: posterior surface of the processus muscularis cartilaginis arytaenoideae. Insertion: the fibers run obliquely medianward and upward, decussate in the median plane with those of the other side, arrive at the tip of the arytaenoid cartilage of the other side, and there become partially attached; part of them, arising there (*m. aryepiglotticus*), extend forward and upward in arches in the plica aryepiglottica to terminate in the membrana quadrangularis and at the lateral margin of the cartilago epiglottica. Above, it is connected with fibers of the m. stylopharyngeus (see p. 509). Action: it narrows the aditus and the vestibulum laryngis. Innervation: ramus anterior n. laryngei inferioris (X).

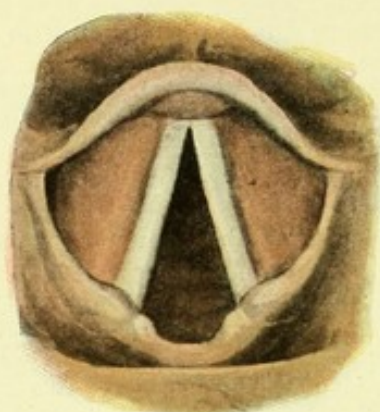M. vocalis (O. T. inner portion of the m. thyreoarytaenoideus), (see Figs. 612, 615 and 616), paired, forms with the m. thyreoarytaenoideus [externus] a common mass of muscle, separable only artificially. Form: triangularly prismatic. Position: in the labium vocale; its medial surface lies adjacent to the ligamentum vocale and the conus elasticus, its upper surface runs close beneath the upper surface of the labium vocale, and its lateral surface is bounded by the m. thyreoarytaenoideus [externus] (see this muscle). Origin: inferior half of the posterior surface of the angle of the cartilago thyreoidea. Insertion: the fibers are parallel and run horizontally backward to the processus vocalis and the fovea oblonga of the arytaenoid cartilage. Action: it draws the processus vocalis forward and relaxes the ligamentum vocale. Innervation: ramus anterior n. laryngei inferioris (X).

M. ventricularis (see Fig. 616) consists of several bundles of muscle, visible under the microscope, which run between the glands in the plica ventricularis in a sagittal direction from the lateral edge of the arytaenoid cartilage to the lateral margin of the cartilage of the epiglottis. In addition the pocket ligament contains also outrunners of the mm. thyreoarytaenoideus [externus] and aryepiglotticus.

M. arytaenoideus transversus (see also Figs. 611, 612 and 614), unpaired. Form: oblong-quadrangular, thick. Position: in the posterior wall of the larynx; its anterior surface is adjacent to the posterior concave surface of the arytaenoid cartilage and between them is covered by the mucous membrane of the larynx; its posterior surface is covered by the mm. arytaenoidei obliqui and by the tela submucosa pharyngis. It reaches below as far as the lamina cartilaginis cricoideae, above not quite as far as the apex of the arytaenoid cartilage. Origin and insertion: on both sides to the posterior surface of the processus muscularis and to the lateral edge of the cartilago arytaenoidea. The fibers run in a frontal direction. Action: it draws the processus musculares backward and upward so that the processus vocales approach one another and are somewhat elevated, and the ligamenta vocalia are put somewhat upon the stretch. Innervation: ramus posterior n. laryngei inferioris (X) of both sides.

Cavum laryngis (cavity of the larynx), (see Figs. 612—616).

The cavity of the larynx is considerably smaller than its outer circumference. It is bounded in front (see Fig. 614) by the posterior surface of the cartilago epiglottica, of the ligamentum thyreoepiglotticum, of the angle of the cartilago thyreoidea, of the ligamentum cricothyreoideum [medium] and of the arcus cartilaginis cricoideae. The lateral wall (see Figs. 614 and 615) is formed on each side by the medial surface of the membrana quadrangularis with the cartilagine cuneiformis [Wrisbergi] et corniculata [Santorini], of the cartilago arytaenoidea, of the conus elasticus and of the arcus cartilaginis cricoideae. The posterior wall (see Fig. 614) is closed by the anterior surface of the m. arytaenoideus transversus and the lamina cartilaginis cricoideae. These walls are all directly covered by the *mucous membrane of the larynx, tunica mucosa laryngis*. It is connected at the *epiglottis* with the mucous membrane of the tongue. At the upper margin of the membrana quadrangularis it is continuous on each side with the tunica mucosa pharyngis and it forms a fold with the latter, *plica aryepiglottica* (see Figs. 613 and 614), which extends medianward, downward and backward from the lateral margin of the epiglottis to the apex of the arytaenoid cartilage, and which contains processes of the mm. stylopharyngeus, thyreoepiglotticus and aryepiglotticus. This fold in the neighborhood of its posterior end presents two small nodules, an anterior, *tuberculum cuneiforme* [Wrisbergi], and a posterior, *tuberculum corniculatum* [Santorini], which are due to the projections of the cartilages of the same name. The anterior wall is broad above (see Fig. 613) and becomes very markedly narrow toward the middle, widening out again below; it presents just above the middle a small transverse projection, *tuberculum epiglotticum* (see Fig. 613), which covers the petiolus epiglottidis and the ligamentum thyreoepiglotticum. The lateral surface (see Fig. 614) presents above a projection which extends obliquely downward and forward from the tuberculum cuneiforme; this projection contains the cartilago cuneiformis and the glandulae laryngeae mediae. Just below, running in a sagittal direction, are two folds, *plica ventricularis* and *plica vocalis* (see Figs. 613^a—616) separated from one another by a deep groove, *ventriculus laryngis* [Morgagni].



613^a. Laryngoscopic view of the larynx

on quiet breathing (after M. Schmidt).

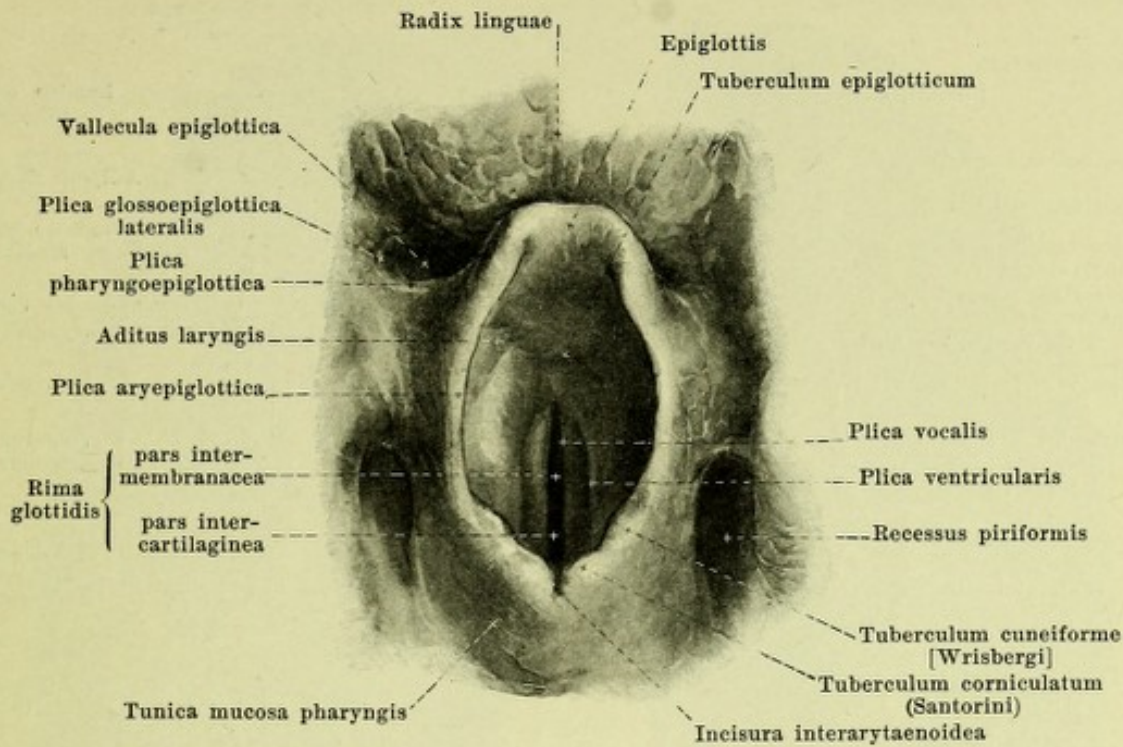
Cavum laryngis (see Figs. 612—616) (continued).

The upper fold, *plica ventricularis* (O. T. false vocal cord) presents a projecting free margin and forms by its broad inferior surface the upper wall of the ventriculus laryngis; its insertions are the same as those of the ligamentum ventriculare (see p. 554). It contains within it the lower part of the membrana quadrangularis with the ligamentum ventriculare, the m. ventricularis and the glandulae laryngeae mediae.

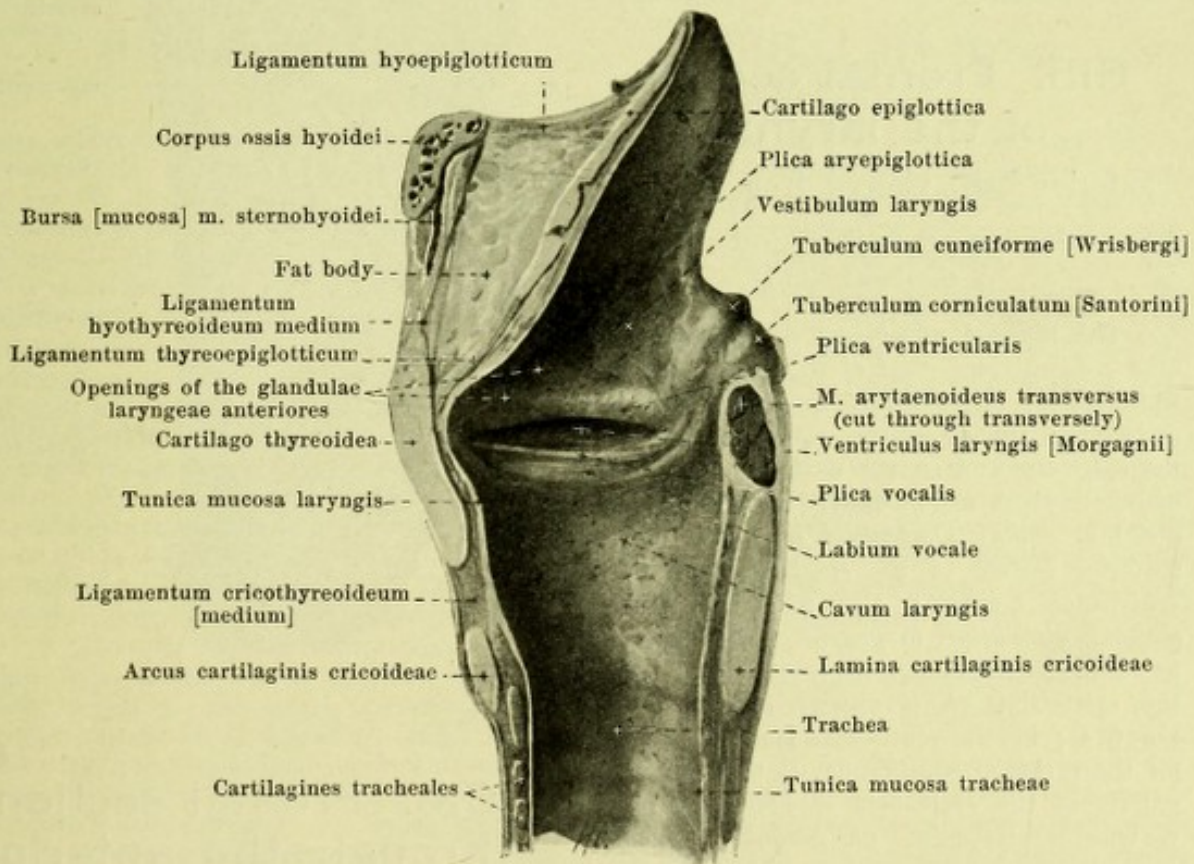
The lower fold, *plica vocalis* (O. T. true vocal cord), is the free margin of the triangular-prismatic projection, *labium vocale*, the upper free surface of which is horizontal, flat or a little concave and forms the inferior wall of the ventriculus laryngis, while its medial, free surface is turned at the same time downward; the projection contains within it the upper part, particularly, of the conus elasticus with the ligamentum vocale, as well as the m. vocalis. The vocal fold projects farther medianward than the ventricular fold. It presents a tolerably sharp free edge which has the same attachment as the ligamentum vocale; near the anterior end the cartilago sesamoidea shows through the mucous membrane as a yellowish spot (*macula flava*). The tone-producing apparatus formed by the two vocal folds is called the *glottis*.

The *ventriculus laryngis* [*Morgagnii*] is a long drawn out pocket-shaped slit which extends lateralward between the ventricular fold and the vocal fold and is deepest in the middle. It gives off usually from anterior half vertically upward a very variable slit-like blind sack, *appendix ventriculi laryngis*, which is shoved in upward between the ventricular fold on one hand, the m. thyreoarytaenoideus [externus] and the lamina cartilaginis thyreoideae on the other (see also Fig. 610) and usually ends beneath the upper margin of the latter; its anterior margin is bounded by the epiglottis; its walls are folded. Very rarely the appendix is absent, or, it may be enlarged. In the new-born it is larger than in the adult.

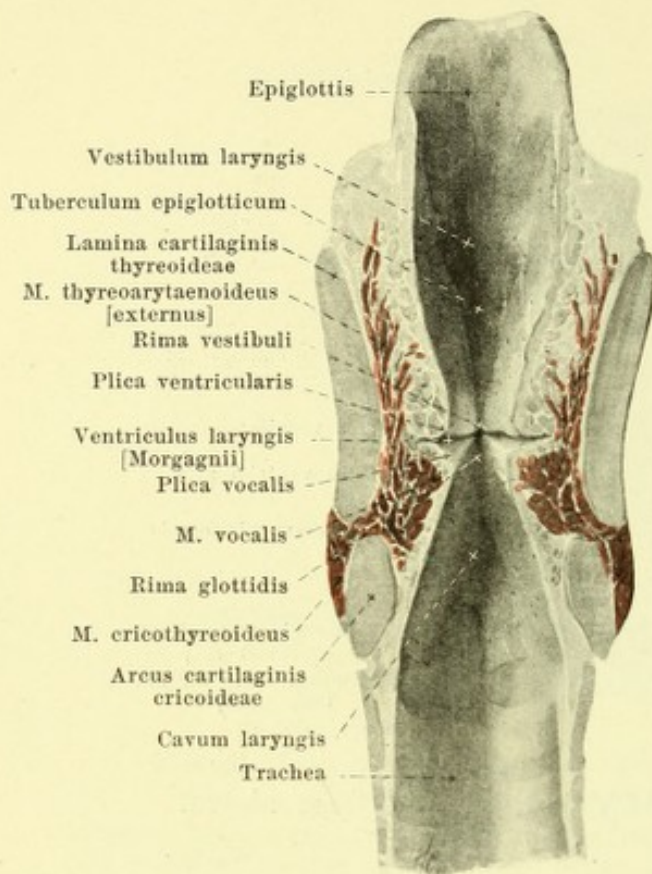
The upper opening of the larynx, *aditus laryngis* (see Fig. 613), looks backward and upward and is triangular and rounded. It is bounded by the posterior surface of the epiglottis and by the plicae aryepiglotticae converging backward; passing for a short distance downward between the cartilagine corniculatae is a small slit, the *incisura interarytaenoidea*. The upper approximately oval part of the cavity, *vestibulum laryngis* (see Figs. 613—615) is higher in front than behind, becomes narrower passing downward and goes over through the *rima vestibuli* (bounded by the two ventricular folds) into the *aditus glottidis superior*, which is bounded lateralward by the ventriculi laryngis. Just beneath it, between the two plicae vocales, lies the *rima glottidis* (see Fig. 612, 613 and 615), the form of which is approximately lancet-shaped in the cadaver, but in life is very variable. In it can be distinguished a longer anterior portion situated between the plicae vocales and called the *pars intermembranacea*, and a shorter posterior portion, bounded lateralward by the medial surfaces of the arytaenoid cartilages, behind by the anterior surface of the m. arytaenoideus transversus, and called the *pars intercartilaginea*. The space situated just beneath the rima glottidis, the *aditus glottidis inferior*, is oval in cross-section; where it goes over into the trachea it is round.



613. Cavity of the larynx, viewed from above.



614. Median section of the larynx, right half, viewed from the left.

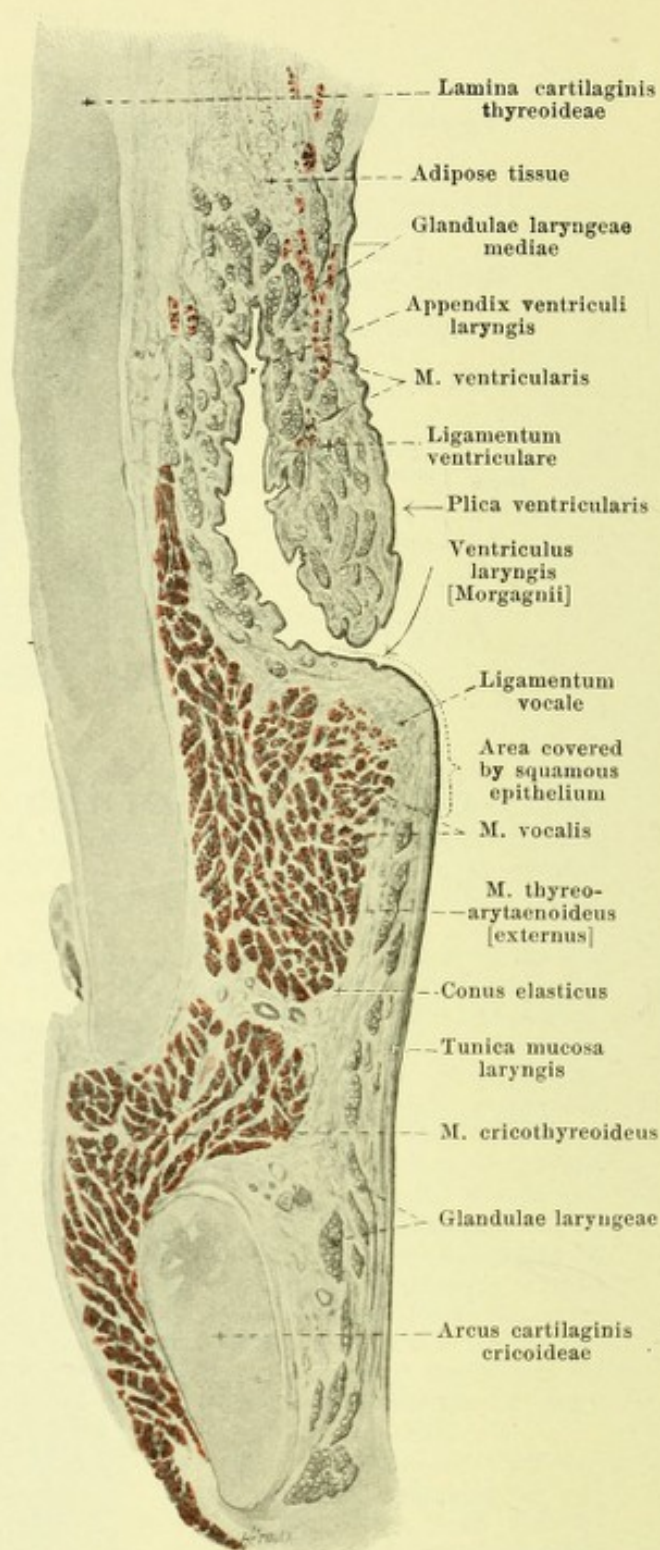


615. Frontal section of the larynx,

anterior half, viewed from behind.

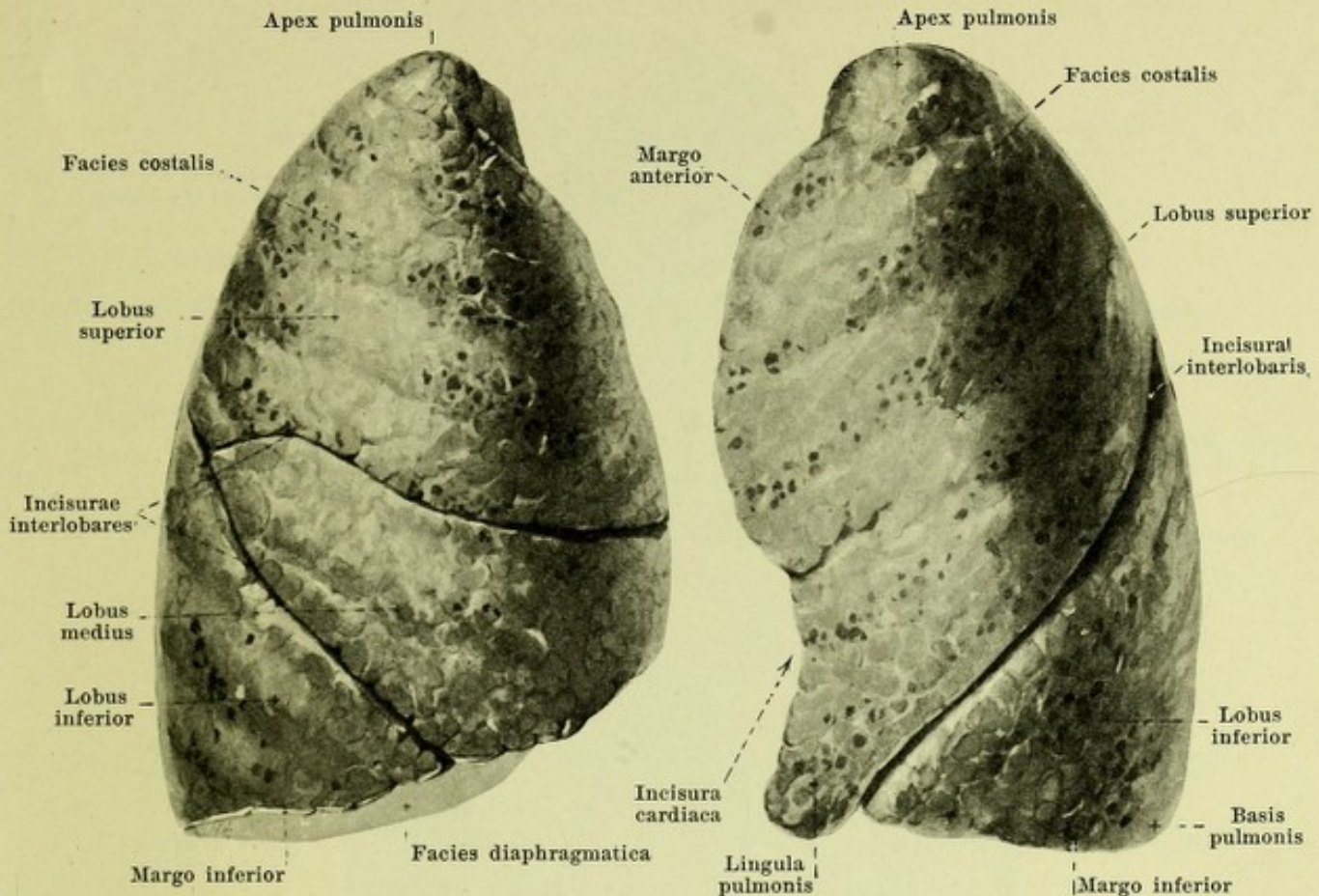
(The section passes through the posterior portion of the vocal fold.)

The *mucous membrane of the larynx* is of a reddish color, that of the vocal folds of a white color; it is firmly connected with the underlying tissue on the posterior surface of the epiglottis and on the ventricular and vocal folds, elsewhere more loosely. It contains lymph nodules, *noduli lymphatici laryngei*, on the posterior surface of the epiglottis and in the ventriculus laryngis; also numerous mucous glands, *glandulae laryngeae*. The latter are found in larger groups in front of and behind the epiglottis, *gl. laryngeae anteriores* (see Fig. 614); in the ventricular fold, as a sheath for the cartilago cuneiformis, in the fovea triangularis of the arytaenoid cartilage and in the ventriculus laryngis, *gl. laryngeae mediae*, as well as before, within and behind the m. arytaenoideus transversus, *gl. laryngeae posteriores*; they are entirely absent from the vocal folds.



616. Frontal section through the anterior part of the larynx.

Magnification 5 : 1.



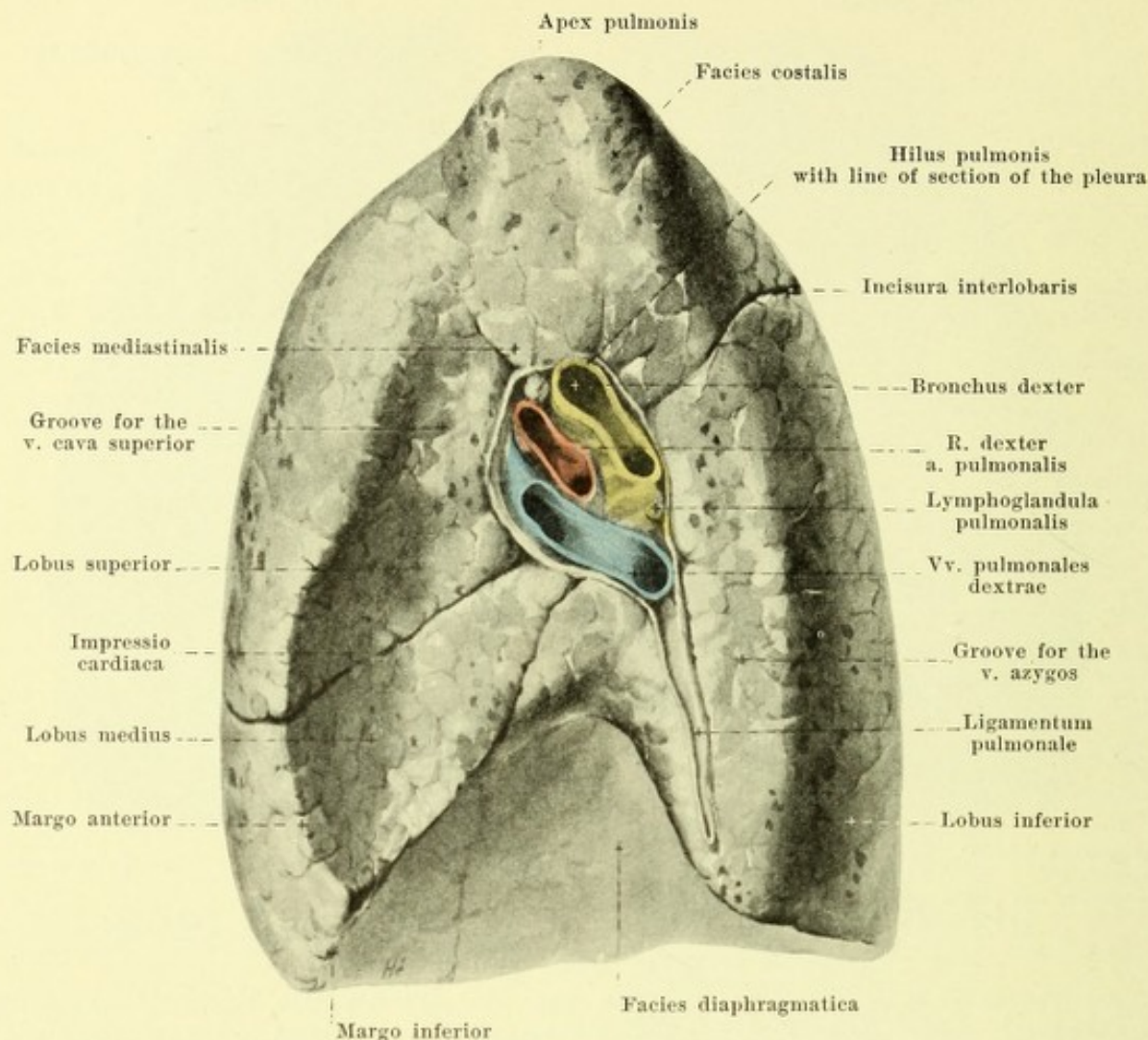
617. Right lung,

618. Left lung,

viewed from in front and lateralward.

The **trachea** (see Figs. 307, 512, 516, 555, 556, 607, 608, 614, 623, 628 and 630), is a cylindrical, hollow, elastic tube. It begins above as the continuation of the larynx in front of the 7th cervical vertebra, passes downward and somewhat backward and divides (*bifurcatio tracheae*) in front of the 4th or 5th thoracic vertebral body, at the level of the processus spinosus of the 4th thoracic vertebra or somewhat below this point, into the two *bronchi*; as it descends it is more deeply situated, lies in the median plane and below only deviates a little to the right. Its posterior wall adjoins the oesophagus. In front it is covered in the neck by the isthmus glandulae thyroideae and by the v. thyroidea ima, in the thoracic cavity by the a. anonyma, a. carotis communis sinistra, arcus aortae, v. anonyma sinistra and by the thymus situated in front of them. Its lateral surfaces lie in the neck in contact with the lobi glandulae thyroideae and the nn. recurrentes (X), in the thoracic cavity on the right side with the n. vagus dexter, the v. azygos and the pleura mediastinalis, on the left side with the n. recurrens sinister (X) and the arcus aortae. It is ensheathed in loose connective tissue, which contains especially on the anterior surface numerous lymph nodules, *lymphoglandulae tracheales*; especially constant is a large group of lymph glands beneath the angle of bifurcation, *lymphoglandulae bronchiales*. The cross-section of the trachea is rounded with its posterior wall flattened. The lumen enlarges from above toward the middle and then again diminishes in size.

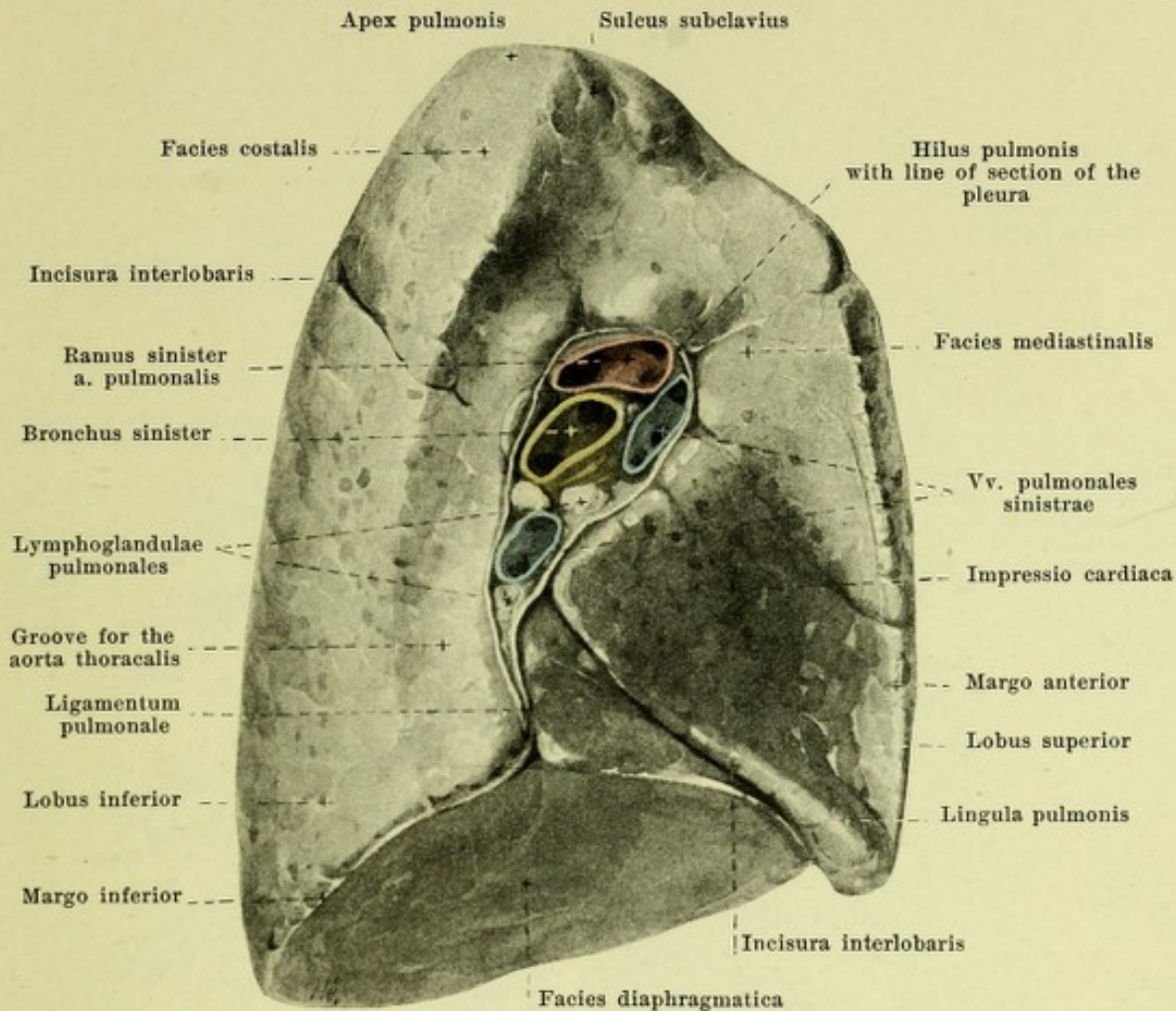
The wall of the trachea contains 16—20 horseshoe-like curved strips of hyaline cartilage, open behind, the *cartilagine tracheales*. They are often split and may be united with their neighbors. The strips of cartilage are connected with one another by means of the *ligamenta annularia [trachealia]*, tough membranes, consisting chiefly of elastic and collagenous fibers running longitudinally; these membranes are continuous with the perichondrium, and with a similarly built but thinner layer of the posterior wall. The posterior wall, *paries membranaceus*, consists besides internally of a layer of smooth muscle fibers, *tunica muscularis*, which is stretched out, especially transversely, between the ends of the cartilages. The mucous membrane, *tunica mucosa*, is pale, and on the posterior wall is thrown up into longitudinal folds. It is connected with the underlying tissue by the *tela submucosa*, which consists of connective tissue, in which are numerous mucous glands, *glandulae tracheales* (not illustrated), especially in the anterior and posterior wall; posteriorly, the largest are found in part between and behind the muscles.



619. Right lung, viewed from the medial surface.

The **lungs** (*pulmones*) (see also Figs. 618, 620, 626, 627, 630 and 631) are paired, approximately wedge-shaped organs, which fill up the lateral halves of the thorax, are connected with the trachea through its two subdivisions, the bronchi, and contain the terminal branches of these bronchi.

Each lung presents above a blunt tip, *apex pulmonis*, and below a broad base, *basis pulmonis*, with the markedly concave *facies diaphragmatica*, which lies upon the diaphragm and is directed downward and medianward. The markedly convex *facies costalis* which looks forward, lateralward and backward is bounded by the ribs; it presents corresponding to the intercostal spaces, flat bulgings, which are characterized by the presence of more marked accumulations of pigment. This surface with the *facies diaphragmatica* helps to form the sharp *margo inferior*. The medial surface, *facies mediastinalis*, is approximately vertical and is directed toward the pericardium and the mediastinal spaces; it forms with the *facies costalis* in front the sharp *margo anterior*, behind a blunt margin, while with the *facies diaphragmatica* it forms a part of the sharp *margo inferior*. This surface presents, nearer its posterior margin than its anterior, a club-shaped fossa, the *hilus pulmonis*, in which lie the bronchi and the vessels and nerves entering and leaving the lung and also several lymph nodules, *lymphoglandulae pulmonales*. The structures lying in the hilus are grouped together as the *root of the lung*, *radix pulmonis* (see also Fig. 631). Behind the hilus on the left runs a deeper and broader furrow for the aorta thoracalis, on the right a flatter and narrower one for the v. azygos perpendicularly upward and then bends around forward. Connected with this toward the apex is a flat groove, the *sulcus subclavius*, for the a. subclavia. In front of and below the hilus lies a fossa, for the heart, *impressio cardiaca*, deeper on the left side and going over on the right side above into a groove for the v. cava superior.

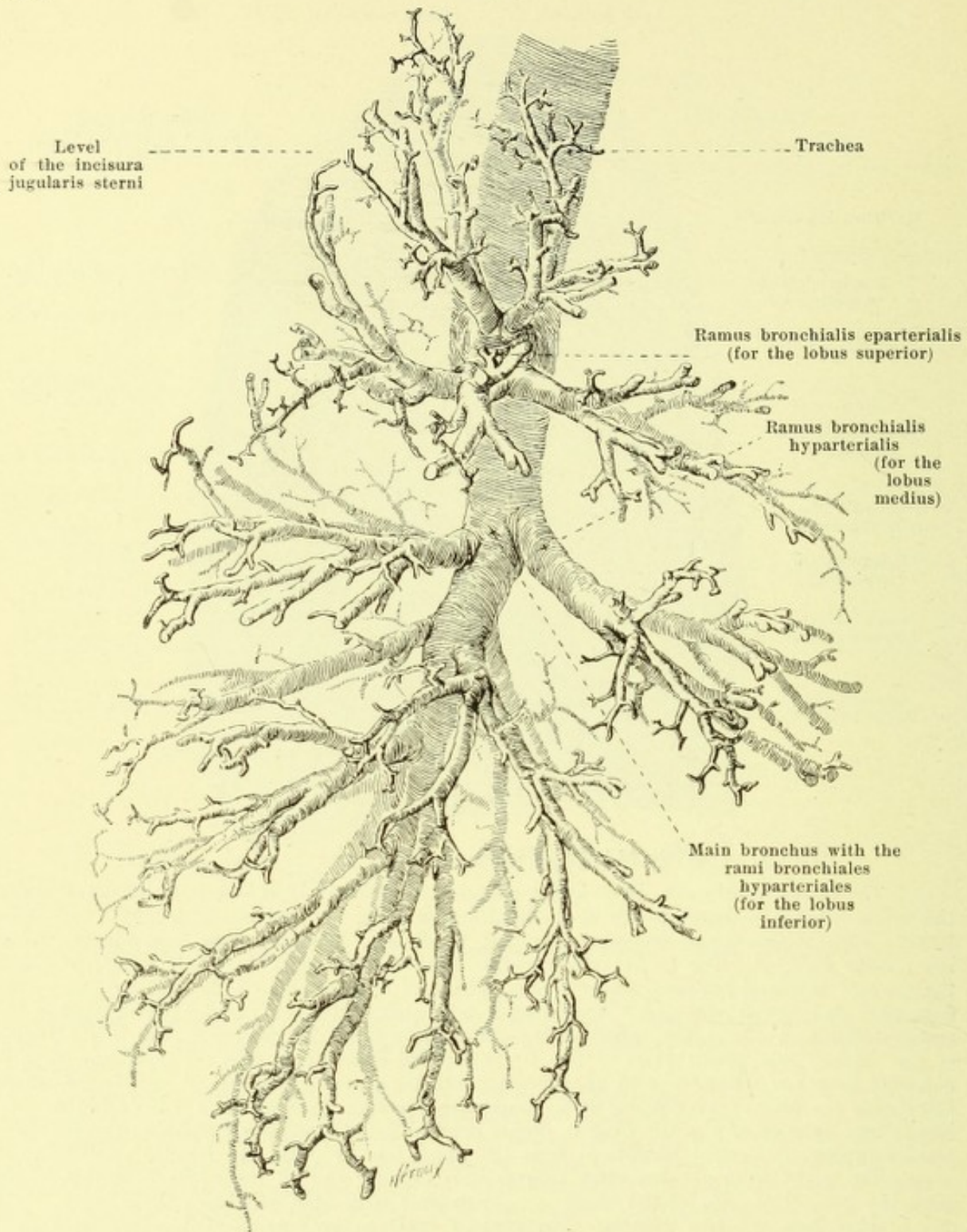


620. Left lung, viewed from the medial surface.

The **lungs** (continued). In each lung a fissure, the *incisura interlobaris*, which cuts through the whole substance almost as far as the hilus (see also Fig. 631) extends from behind and above forward and downward and separates a smaller, upper lobe, *lobus superior*, from a larger, lower lobe, *lobus inferior*. The fissure whose course often varies begins commonly somewhat below the apex at the level between the processus spinosi of the 2nd and 3rd thoracic vertebrae, runs downward and forward (on the left somewhat more steeply than on the right) and reaches the margo inferior in about the region of the mammillary line. In the right lung in the region of the axillary line at the level of the 4th intercostal space there goes off from this incisure a second deep one which runs in an approximately horizontal direction and strikes the margo anterior at the level of the 4th rib; it together with the main incisure bounds the *lobus medius*. The margo anterior of the left lung is deeply notched below, *incisura cardiaca*; the narrower portion projecting forward beneath it from the upper lobe is called the *lingula pulmonis*.

The right lung is somewhat shorter and broader and on the whole somewhat larger than the left. The color of the lungs is reddish grey with blue and black flecks.

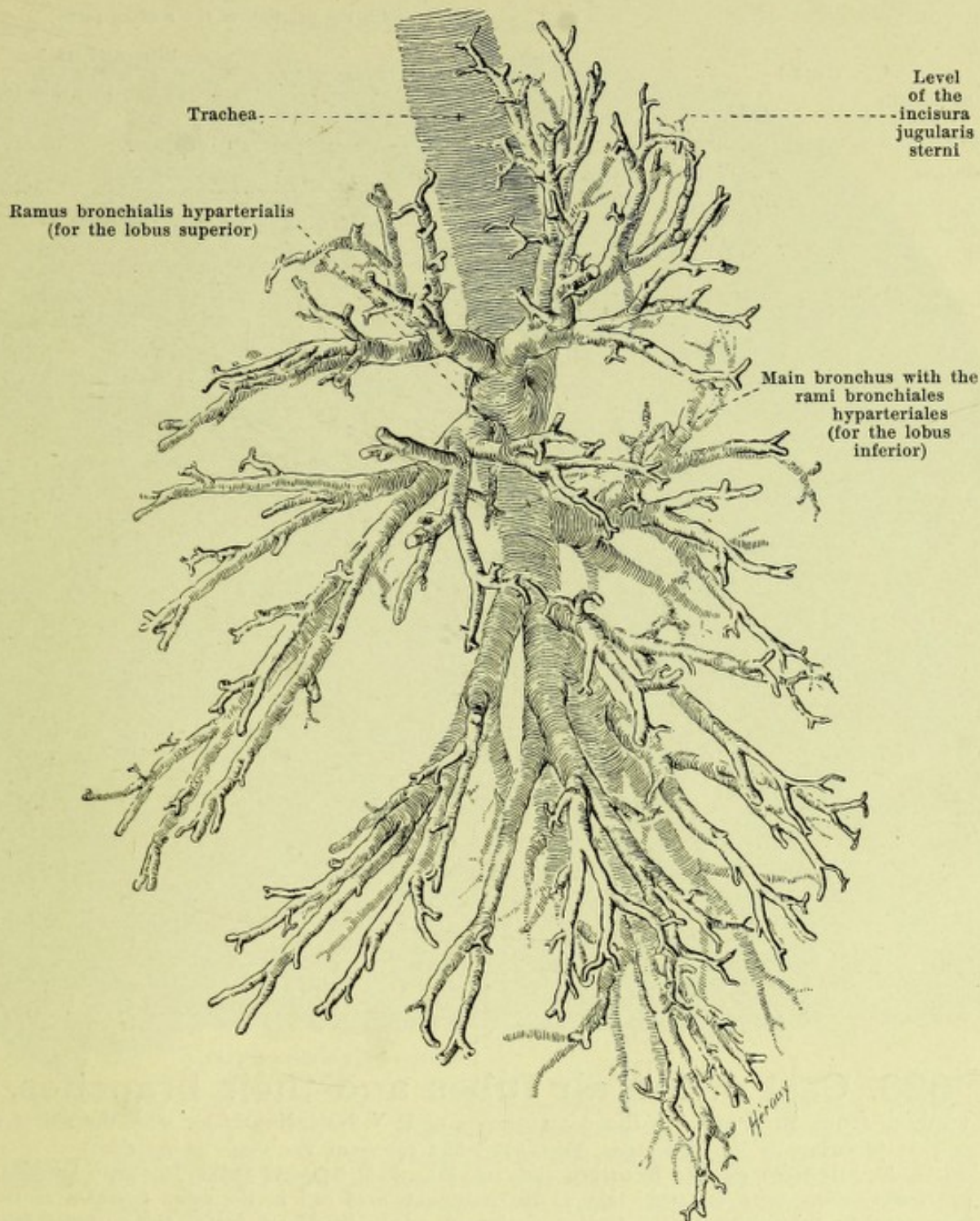
Position of the lungs. The apex of the lung projects upward as far as in front of the neck of the first rib (see Figs. 627—629); it is somewhat higher and somewhat farther forward on the right than on the left and in the ordinary, upright position reaches from one to three cm above the extremitas sternalis claviculae. The margo inferior extends in front, on moderate expiration, first along the lower margin of the 6th rib, cuts the upper margin of the 7th rib in the mammillary line, crosses the 8th rib in the axillary line, the 9th and 10th ribs in the scapular line, and reaches the spine at the level of the processus spinosus of the 11th thoracic vertebra; it thus runs lateralward and backward almost horizontally. The margo anterior begins above on both sides symmetrically behind the articulatio sternoclavicularis, extends thence on the right in a slightly convex curve toward the insertion of the 6th costal cartilage and goes in the middle of its extent a little beyond the median plane. On the left it runs in a corresponding direction as far as the level of the 4th costal cartilage and then curves at the incisura cardiaca first lateralward, then downward and somewhat medianward.



621. Cast of the air tubes and their branches, viewed from the right, semi-schematic.

(After a preparation of F. V. Birch-Hirschfeld, with the aid of a drawing by Dr. M. Lange. Figs. 621—623 represent the same preparation.)

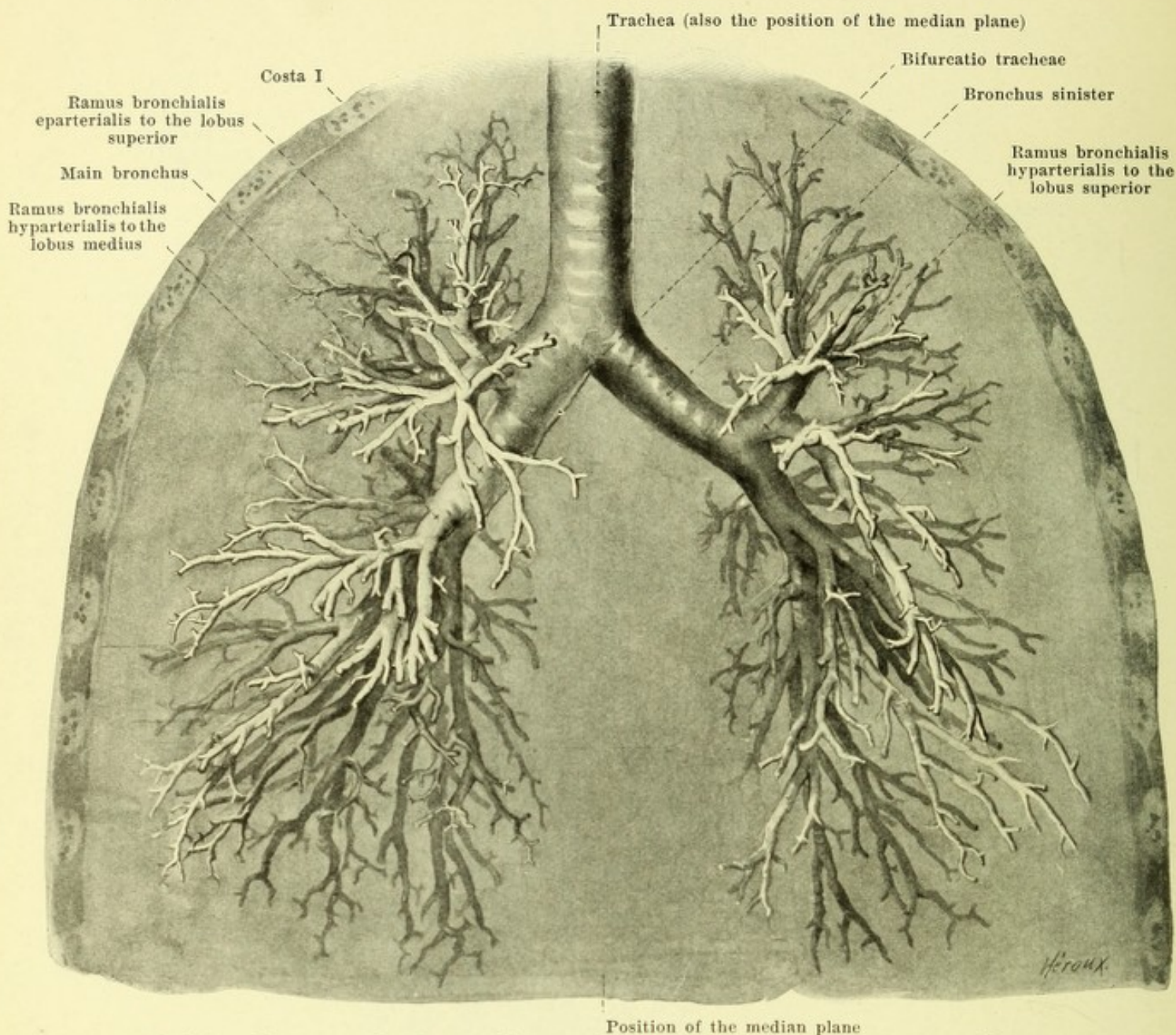
The two **bronchi**, *bronchus dexter* and *bronchus sinister* (see also Figs. 556, 622 and 623) extend out from the bifurcatio tracheae at an angle, usually less than 90° , and pass downward and lateralward to the hilus pulmonis. The non-branched part is steeper, shorter and wider on the right side than on the left. They are constructed exactly as is the trachea and have on the right side 6—8, on the left side 9—12 rings of cartilage which are open behind; they possess numerous mucous glands, *glandulae bronchiales*, and single lymph follicles, *noduli lymphatici bronchiales*.



622. Cast of the air tubes and their branches, viewed from the left, semi-schematic.

(After a preparation of F. V. Birch-Hirschfeld, with the aid of a drawing by Dr. M. Lange.
Figs. 621—623 represent the same preparation.)

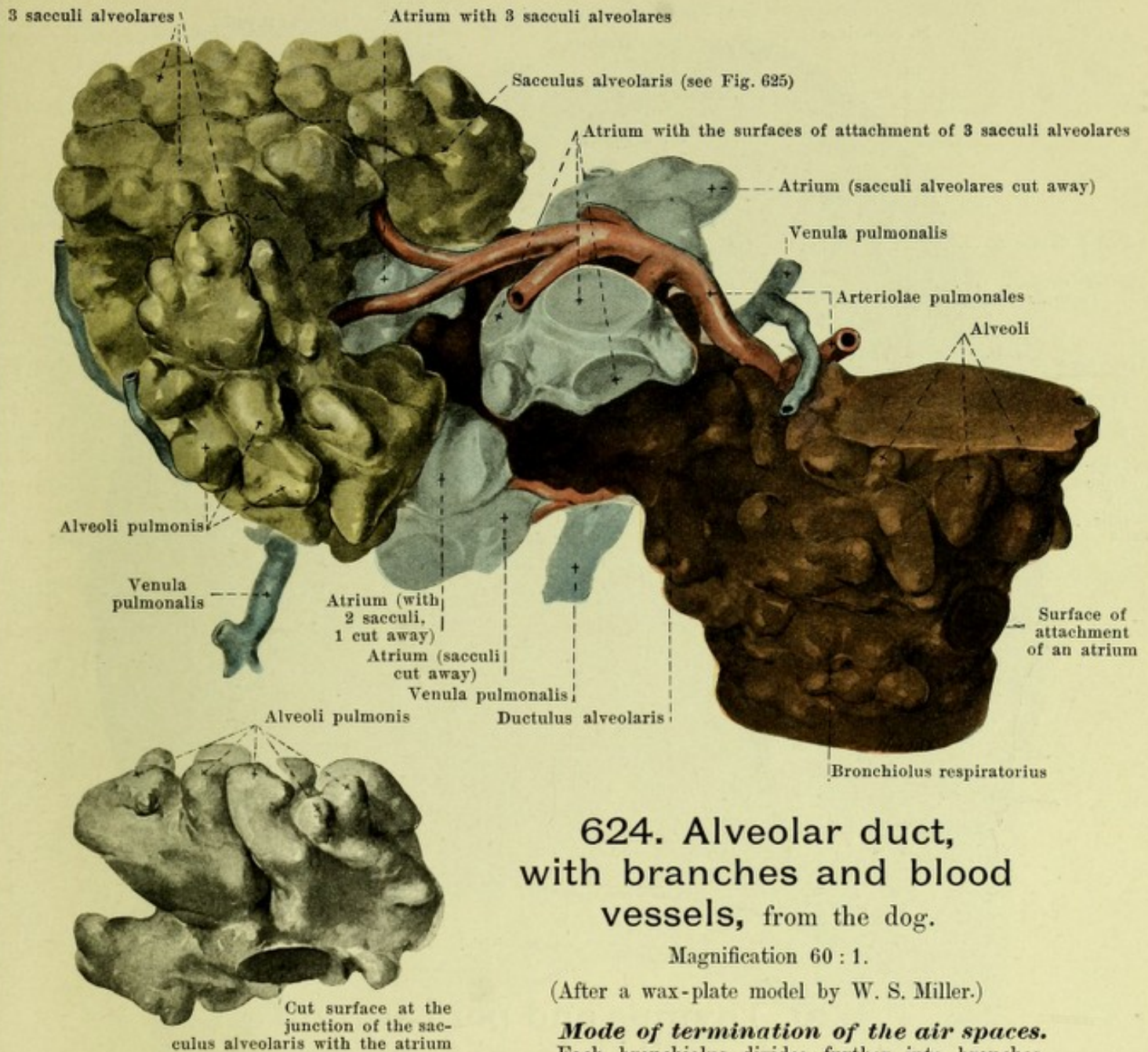
Position of the bronchus (see Figs. 556, 619, 620, 628 and 629). The branch of the a. pulmonalis runs on each side in front of the bronchus to the hilus, there lies on the anterior and upper surface of the same and then curves around it lateralward to run into the lung along its posterior surface. The vv. pulmonales leave the hilus at the anterior and inferior surfaces of the bronchus. The a. bronchialis is situated in the hilus on the posterior surface of the bronchus. Above and behind the bronchus on the right side runs the v. azygos, on the left side the aorta thoracalis, behind it on both sides the n. vagus.



623. Cast of the air tubes and their branches, viewed from in front. (After a preparation of F. V. Birch-Hirschfeld, with the aid of a drawing by Dr. M. Lange. Figs. 621—623 represent the same preparation.)

Branching of the bronchi (see also Figs. 556, 621 and 622). The main bronchus or *stembronchus* runs on each side as the continuation of and in the same direction as the corresponding subdivision of the trachea during its whole length as far as the posterior part of the basis pulmonis; the left one is curved slightly like the letter S. From it go off monopodic *lateral bronchi*, *rami bronchiales*, four ventral and four dorsal arising alternately. The first lateral bronchus supplying the lobus superior goes off on the right side above the place where the bronchus and the branch of the a. pulmonalis cross one another as a (single) *ramus bronchialis eparterialis*; on the left it arises below the place of crossing and belongs accordingly like all the other branches to the *rami bronchiales hyparteriales*. The middle lobe on the right side is supplied by the first ventral lateral bronchus. These lateral bronchi give off numerous branches which go on subdividing so that they become finer and finer and form the *bronchioli*.

The main bronchi and their branches present only irregular cartilaginous plates which are distributed about the whole circumference of the tubes. They are larger at the beginning, where they are also closer together; they disappear in the tubes of 1 mm diameter. Internally from them lies a circular layer of smooth muscle fibers and a mucous membrane. Mucous glands are present wherever the cartilage occurs on the outer surfaces of the muscle; *noduli lymphatici bronchiales* are present down to the finest branches.



624. Alveolar duct, with branches and blood vessels, from the dog.

Magnification 60 : 1.

(After a wax-plate model by W. S. Miller.)

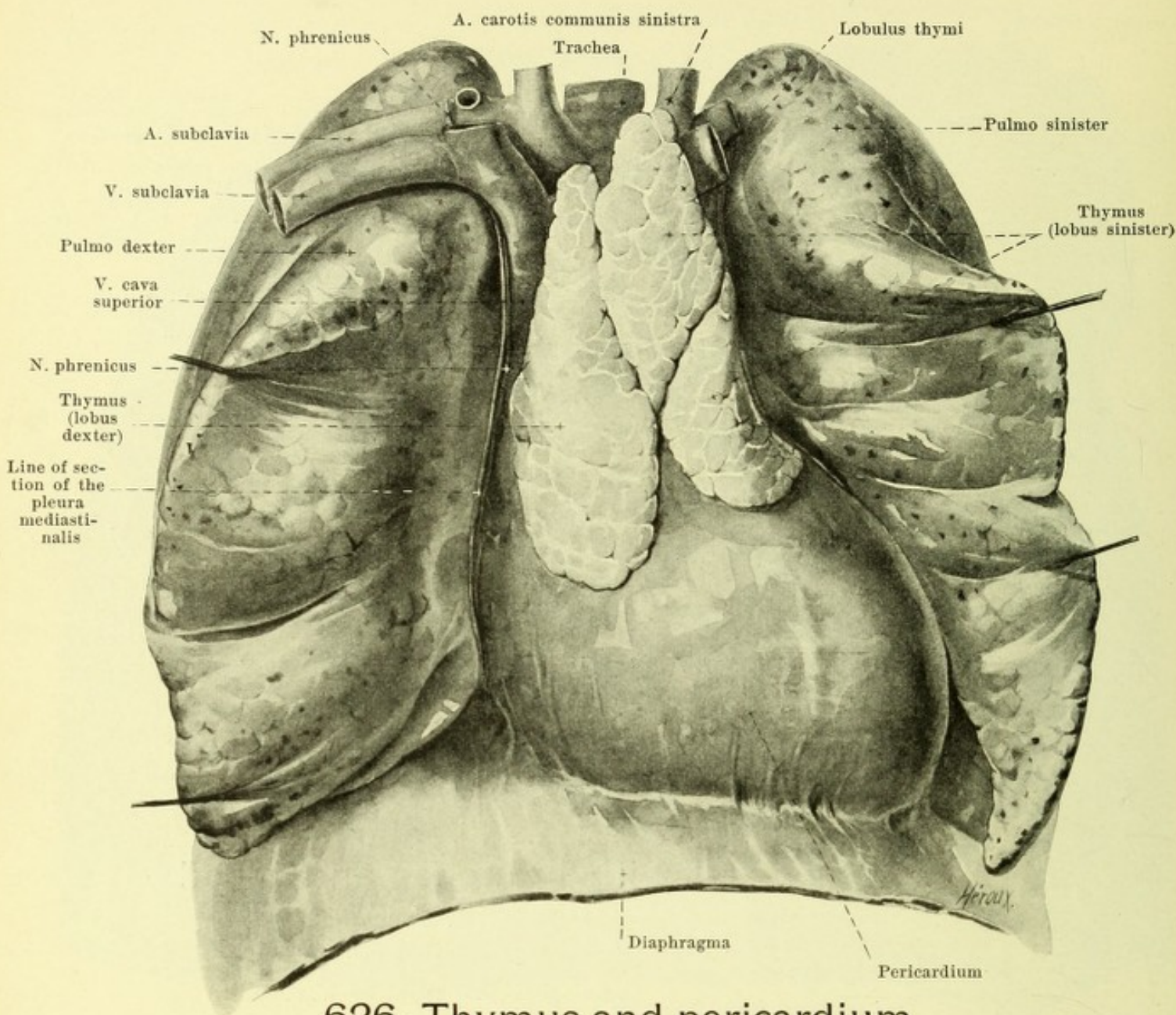
Mode of termination of the air spaces.

Each bronchiolus divides further into branches, *bronchioli respiratorii*, the walls of which are no longer smooth but present small bulgings, *alveoli*. Out of these *bronchioli respiratorii*, as terminal branches, pass the *alveolar ducts*, *ductuli alveolares*, which bear *alveoli* on all sides and lead through openings in their terminal piece into several approximately spherical spaces, *atria*. Each atrium is connected in turn with a number of larger and more irregular cavities, *air sacs*, *sacculi alveolares* (*infundibula*), the whole surface of which is closely set with small cavities, *alveoli pulmonis*. Each alveolar duct together with its branches forms a *lobule of the lung*, *lobulus pulmonis*. The *bronchioli respiratorii* and the *ductuli alveolares* still possess a circular layer of smooth muscle fibers but this is absent from the *atria* and *sacculi alveolares*.

The branches of the *a. pulmonis* accompany the air-conducting tubes as far as the *atria* and break up into capillaries on the *sacculi alveolares*. The smallest veins collect at the periphery of the lobule, receive tributaries from the points of division of the *bronchioli* and run at first between the lobules, separated as far as possible from the *bronchioli* and the arteries; only when the larger branches have been reached in the neighborhood of the hilus do they approach the bronchi.

625. Air saccule, by itself.

Magnification 60 : 1 (see Fig. 624).

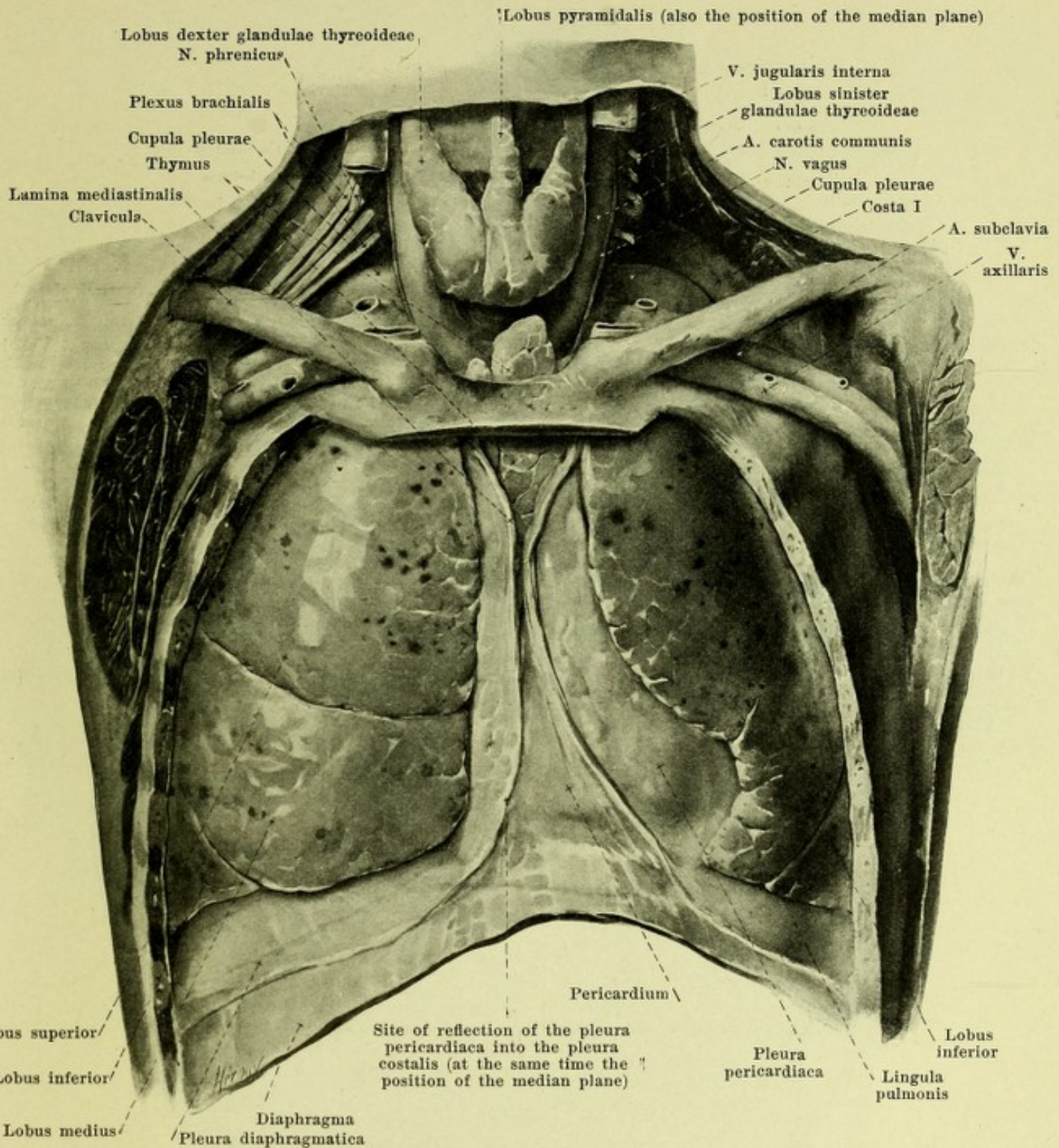


626. Thymus and pericardium of a 12-year-old boy, viewed from in front.

(The lungs have been drawn aside and the thymus and pericardium dissected out after removal of the pleurae mediastinales.)

The **thymus** is an unpaired organ which reaches its greatest weight at the end of the second year of life; then its development ceases and at the time of puberty it is already undergoing distinctly retrogressive changes. Later the tissue of the thymus is gradually replaced by adipose tissue, which still contains remnants of the former structure; the form of the organ is retained. It is of a grayish red color, has an irregular flat-oblong shape and consists of two usually asymmetrical *lobes*, *lobus dexter* and *lobus sinister*, united only by loose connective tissue. Each of these lobes is composed of a large number of small *lobules*, *lobuli thymi*, which are separable from one another, but all are connected by a *medullary cord*, *tractus centralis* (not illustrated), which follows a tortuous course inside the thymus.

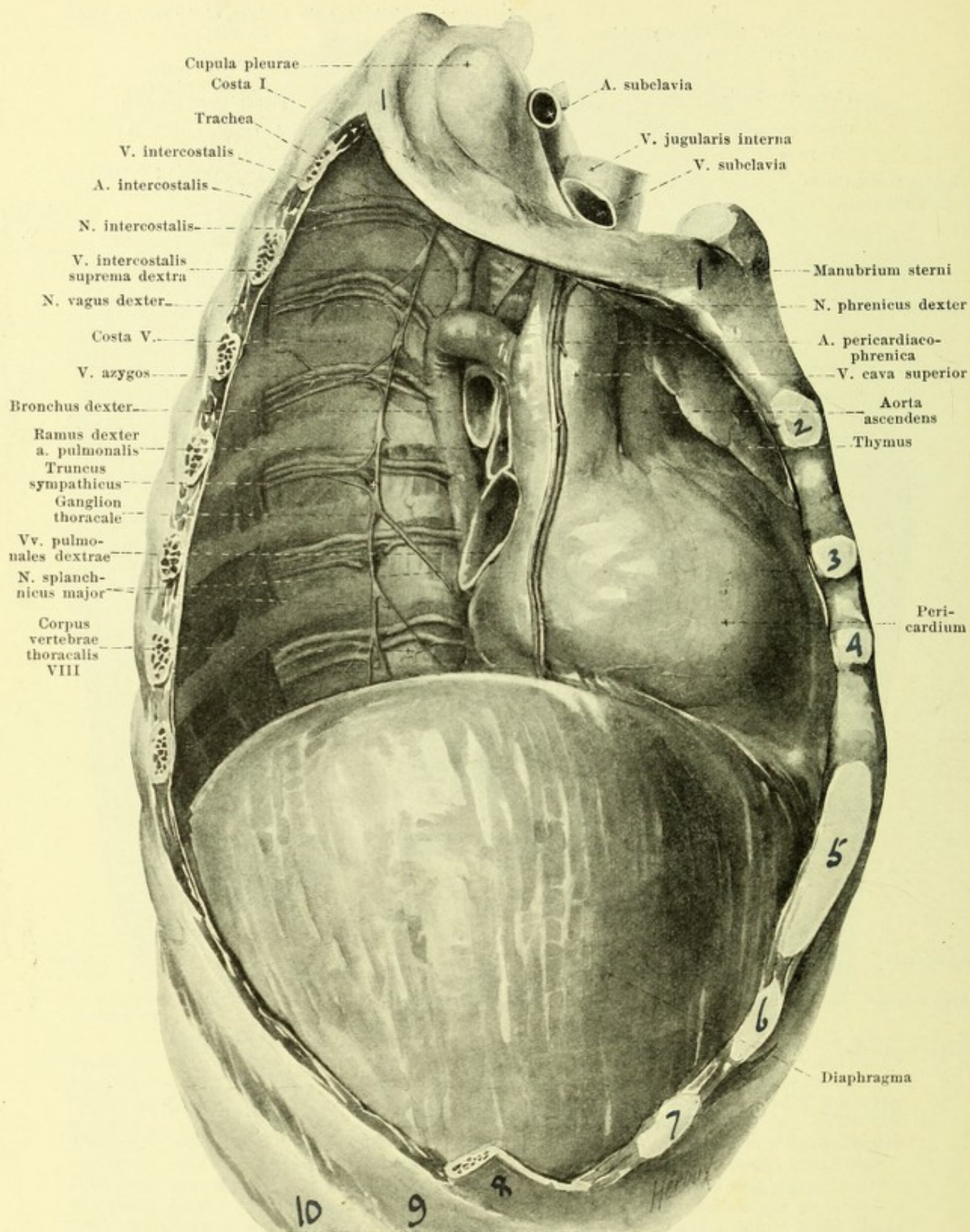
It lies (see also Figs. 627—629) just behind the sternum in the *spatium mediastinale anterius*, is bounded behind by the upper part of the pericardium, the v. cava superior, vv. anonymae, the arcus aortae and its branches, lateralward and partly in front by the pleura mediastinalis. Above it may reach behind the mm. sternothyroidei as far as the glandula thyroidea. Its anterior wall is loosely, the others more firmly connected with the surrounding tissues.



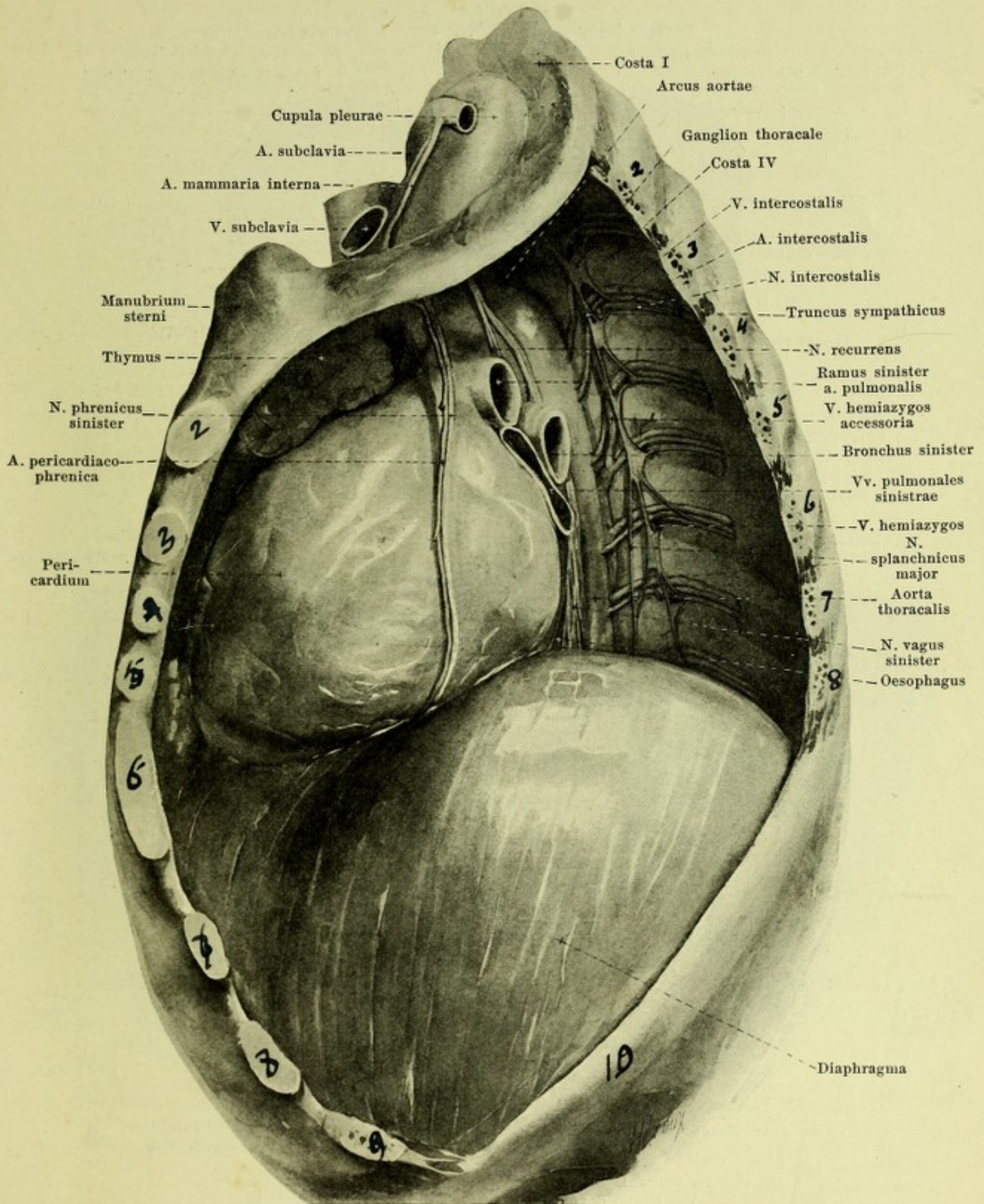
627. Thoracic viscera of a 12-year-old boy, viewed from in front.

(The sternum and ribs have been removed. In the neck the cupulae of the pleura have been exposed. The lungs are somewhat retracted.)

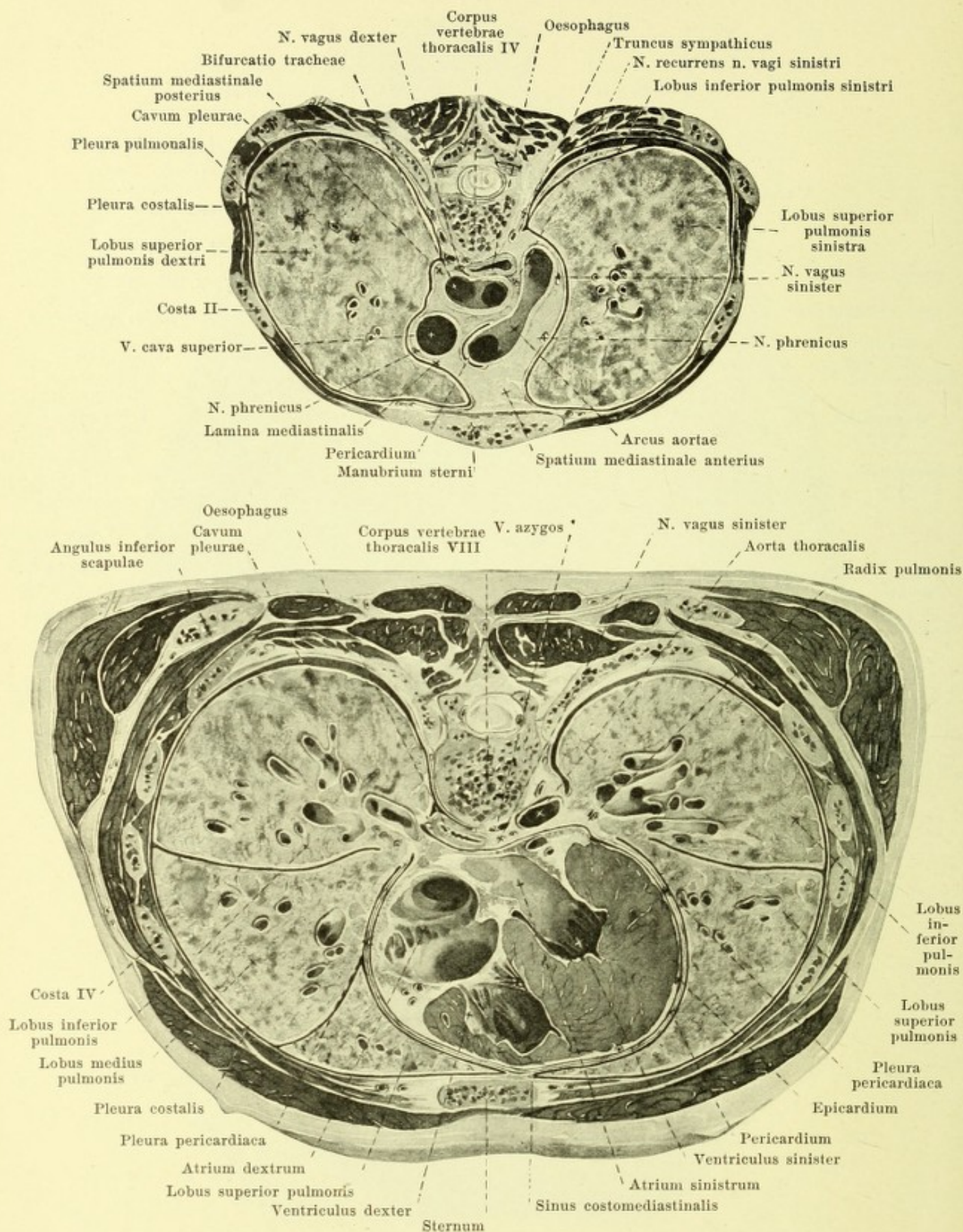
The **pleurae** (see also Figs. 630 and 631) are two smooth glistening serous membranes which cover the walls and viscera of the thoracic cavity (*cavum thoracis*). They form, one in the right and one in the left half of the thoracic cavity, sacs complete in themselves separated from one another by the septum mediastinale; one portion of each sac, *pleura pulmonis*, covers the lung, and the other portion, *pleura parietalis*, the walls of the space occupied by the lung; the two portions go over into one another at the hilus pulmonis and inclose a slit-like space, *cavum pleurae*, which contains a very small amount of clear serous fluid.



628. Right thoracic cavity and septum media-stinale, viewed from the right, after removal of the lungs and pleura.



629. Left thoracic cavity and septum mediastinale, viewed from the left, after removal of the lungs and pleura.



630 and 631. Cross-sections of the thorax, viewed from above (after W. Braune).

Pleura (continued).

The *pleura pulmonalis* is intimately fused with the surface of the lung and follows it even into the depth of the incisura interlobaris (see Fig. 631). At the hilus pulmonis it leaves the surface of the lung, is attached for a short distance to the root of the lung (see Fig. 631) and is then continued into the pleura mediastinalis. In so doing it forms between the hilus and the pleura mediastinalis a triangular duplicature, *ligamentum pulmonale*, the origin of which on the right lung runs in front of the groove for the v. azygos, on the left lung in front of the groove for the aorta thoracalis almost as far as the facies diaphragmatica (see Figs. 619 and 620); below it ends with a free margin or is attached to the pleura diaphragmatica.

The *pleura parietalis* is divisible into *pleura costalis*, *pleura diaphragmatica* and *pleura mediastinalis*. The *pleura costalis* (costal pleura) (see Figs. 630 and 631) covers the inner surface of the ribs, the lateral surface of the bodies of the thoracic vertebrae, partly also the posterior surface of the sternum, the mm. intercostales, subcostales and transversus thoracis, as well as the vessels and nerves running along the inner surface of the thoracic wall. It is connected with these parts by the *fascia endothoracica* (not illustrated), a layer of connective tissue, which is strongest anteriorly behind the cartilages of the ribs and becomes thinner and looser posteriorly. Above the pleura forms a blind-sac-like prolongation, the *cupula pleurae* (see Figs. 627 to 629) which lies exactly at the apex of the lung and which accordingly projects as this does upward as far as the neck of the first rib (see p. 563). The cupula is related (from behind forward) to the lowermost bundles of origin of the plexus brachialis, to the ganglion cervicale inferius, the m. scalenus minimus, the a. subclavia with the first portions of the a. vertebralis and intercostalis suprema, the m. scalenus anterior, the a. mamma interna and the v. subclavia, on the left also the ductus thoracicus; it is attached by the m. scalenus minimus and different bands of connective tissue upwards to the fascia praevertebralis and the fascia colli. The *pleura diaphragmatica* (see Fig. 627) covers the upper surface of the diaphragm very firmly and exactly as far as the neighborhood of the heads of the ribs, where it is reflected into the pleura costalis; this line of reflection begins near the sternum at the lower margin of the 6th rib, cuts the 7th rib at the junction of the cartilage with the bone, the 8th rib behind it and reaches the spine at the lower border of the body of the 12th thoracic vertebra or of the processus transversus of the 1st lumbar vertebra below the attachment of the 12th rib. Between this line of reflection and the lower margin of the lung (see p. 563) the pleura diaphragmatica lies on the pleura costalis for some distance and with it bounds the *sinus phrenicocostalis*. During inspiration the lung passes into the *sinus pleurae* which then becomes smaller, but is not totally obliterated in its most dependent parts since the lung does not pass as far as the line of reflection.

The right and the left cavum pleurae are separated by the *septum mediastinale* which is narrower above and broader below and contains chiefly the heart, the great vessels, the trachea, the oesophagus and the thymus (see Figs. 628—631). This septum is covered right and left by the *pleura mediastinalis*; that portion of this which is very frequently fused with the parietal layer of the pericardium is designated *pleura pericardiaca*, the rest of it as *lamina mediastinalis*. The two pleurae mediastinales are connected in front and behind with the pleura costalis, below with the pleura diaphragmatica. The anterior line of reflection (see Fig. 627) runs on the right as does the anterior margin of the right lung (see p. 563), on the left in a similar curve but so that it usually lies lateralward from the medial end of the 5th left intercostal space; as a result of this the pleura of the two sides may come into contact with one another between the 2nd and 4th costal cartilages but are usually separated, however, especially in younger individuals by a layer of loose tissue. The starting point of the mediastinal pleura behind lies on the lateral surface of the bodies of the vertebrae. Toward the apex the pleura mediastinalis goes over into the medial wall of the pleural cupula; below this it extends almost directly (see Fig. 630) from before backward and in so doing directly covers on both sides the thymus, nn. phrenici and vagus, on the right side (see Fig. 628) the vv. cava superior, anonyma dextra and azygos, as well as the trachea, on the left side (see Fig. 629) the aorta thoracalis and the a. subclavia sinistra. The pleura mediastinalis is curved out lateralward below (see Fig. 631) more markedly on the left than on the right side, but in the neighborhood of its posterior portion it is interrupted by the hilus pulmonis and the ligamentum pulmonale, upon which it becomes reflected; it thus directly covers in front the pericardium, the nn. phrenici and the accompanying vessels, behind the oesophagus (the right in the middle, the left below) as well as on the left the aorta thoracalis. Anteriorly, where the pleura costalis goes over into the pleura mediastinalis, more distinctly visible below than above, is a slit-like space, *sinus costomediastinalis* (see Fig. 631), which on inspiration is, in general, completely filled up by the margo anterior of the lung; only that portion situated in front of the heart and corresponding to the incisura cardiaca (see Fig. 627) remains free from the lung even on deepest inspiration. In the sinus phrenicocostalis and in the groove between the pleura diaphragmatica and the pleura mediastinalis are frequently, situated, lobe-like adipose appendages of the mediastinum, *plica adiposae* (not illustrated), which carry small villous projections, *villi pleurales*.

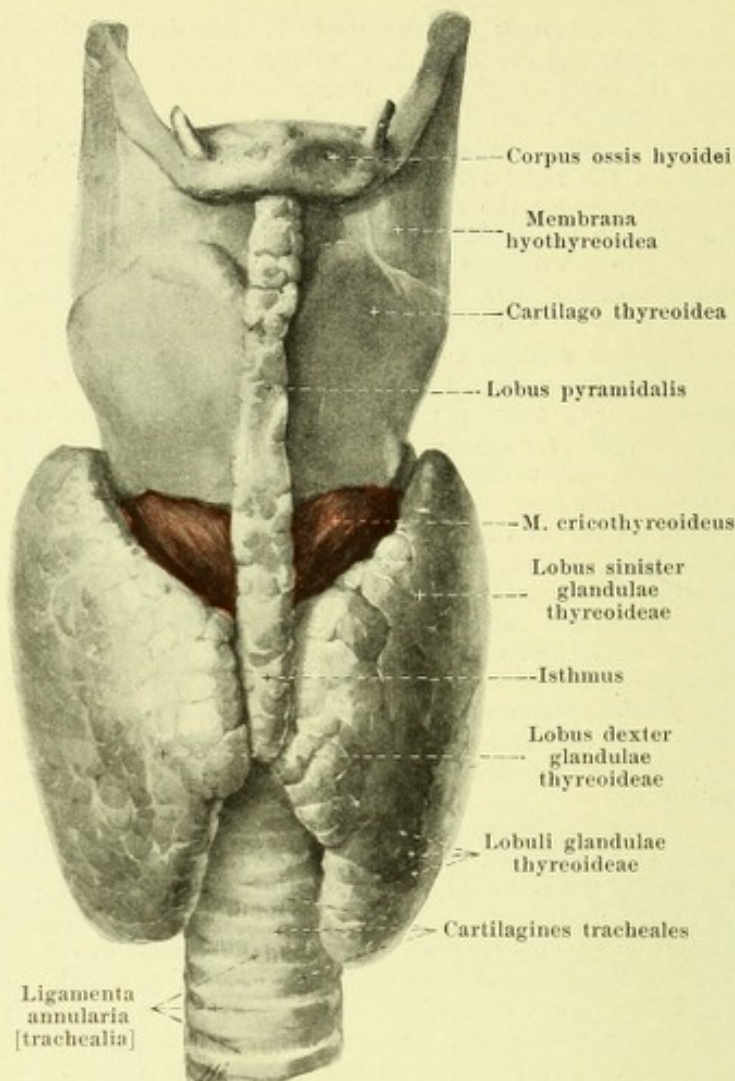
632. Thyroid gland, viewed from in front.

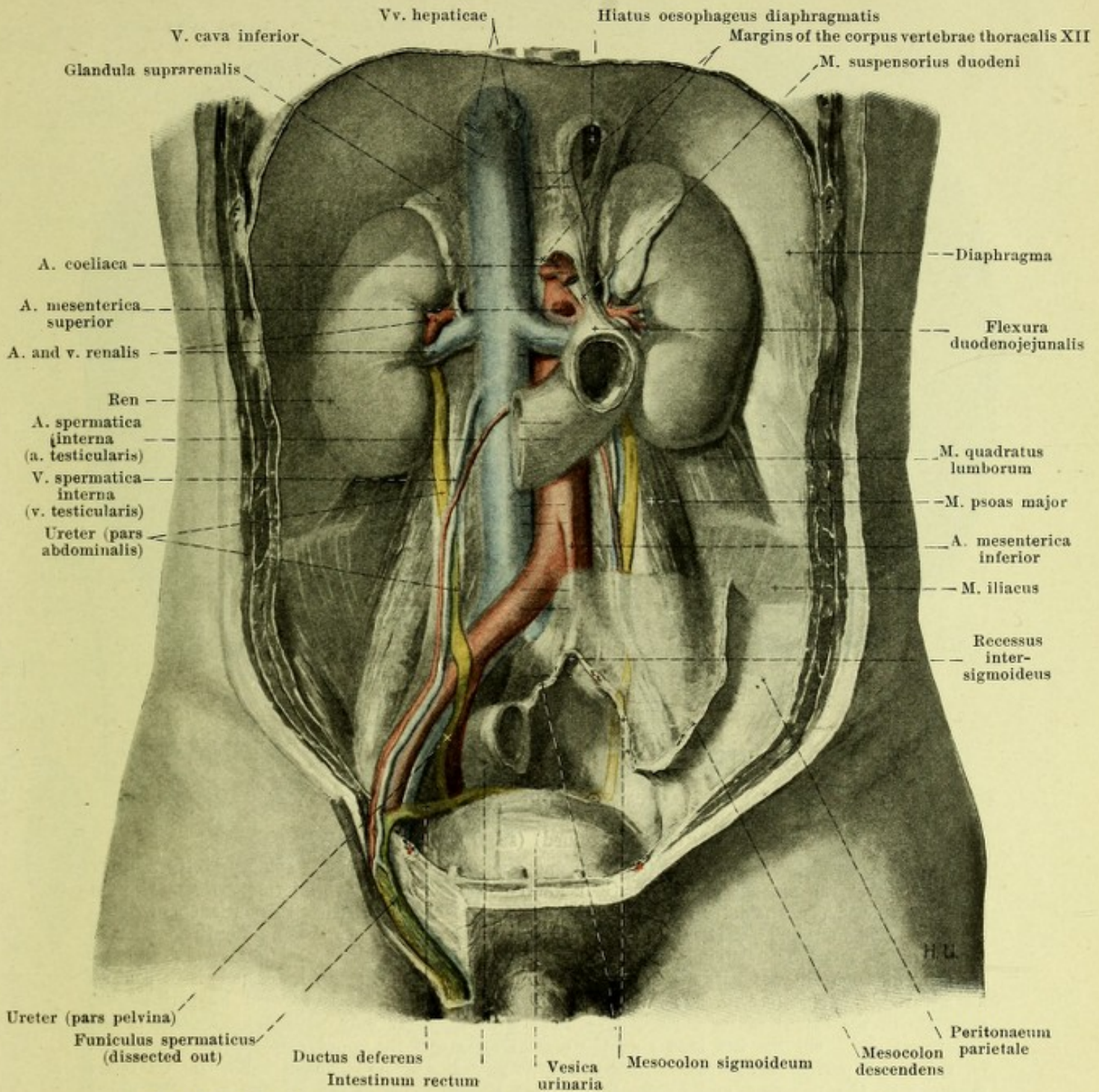
Pleura (continued).

The *septum mediastinale* is divided into two portions of different size, which are separated only indistinctly from one another by the heart with the pericardium, the large vessels, the roots of the lungs and the trachea. The smaller anterior portion, *spatium mediastinale anterius*, contains the aa. and vv. mammae internae, nn. phrenici, thymus and lymph glands; the posterior, *spatium mediastinale posterius*, contains the aorta thoracalis, aa. intercostales dextrae, vv. azygos and hemiazygos, ductus thoracicus, nn. vagi and splanchnici majores, oesophagus and lymph glands (see also Figs. 630 and 631).

The **thyroid gland** (*glandula thyreoidea*) (see also Figs. 307, 516 and 627) is an unpaired, very variable, frequently asymmetrical gland, which opens to the outside by means of a excretory duct, *ductus thyreoglossus* (see p. 489), only in the early embryonal period, later however forming a body completely shut off from the surface. It is of a bluish red or reddish yellow color, lies upon the lateral surface of the larynx as well as upon the lateral and anterior surfaces of the upper end of the trachea and surrounds the latter like a horseshoe. It is covered in front (see Figs. 298 and 302) by the mm. sternothyroidei, omohyoidei, sternohyoidei and sternocleidomastoidei. It presents for examination two *lateral lobes*, *lobus dexter* and *lobus sinister*, which are united with one another in front by means of a middle piece, *isthmus glandulae thyreoideae*. The oblong and thick *lateral lobe* lies on each side on the lateral surface of the trachea and oesophagus as well as on the larynx and pharynx. On the thyroid cartilage it reaches only as far as the insertion of the m. sternothyroideus; from there on it is pressed somewhat backward and becomes drawn out into a pointed process which may extend as far as the hyoid bone. Its medial surface is in contact below also with the n. recurrens (X); its posterior surface is in relation with the a. carotis communis (which usually makes a groove-like impression upon it), the a. thyroidea inferior and the v. jugularis interna, above also with the fascia praevertebralis; the anterior surface, directed at the same time lateralward, is covered by the above-mentioned muscles. The *isthmus* or *middle piece* is essentially shorter and covers the 2nd, 3rd and 4th and often also the 1st cartilago trachealis; going out from it, usually from the left side, is a process, variable in form, the *lobus pyramidalis*, which passes in front of the thyroid cartilage upward toward the middle of the hyoid bone, but does not always reach it. The isthmus varies much in its development and may be absent altogether. The gland consists of connective tissue, *stroma glandulae thyreoideae*, in which lie small gland vesicles, which are arranged in larger groups, *lobuli glandulae thyreoideae*.

The *glandulae thyreoideae accessoriae* (not illustrated) are small masses of thyroid tissue which may occur close above the hyoid bone (*glandula thyreoidea accessoria suprahyoidea*), in the course of the lobus pyramidalis, in the lateral region of the neck, or upon the trachea as far down as the arcus aortae.



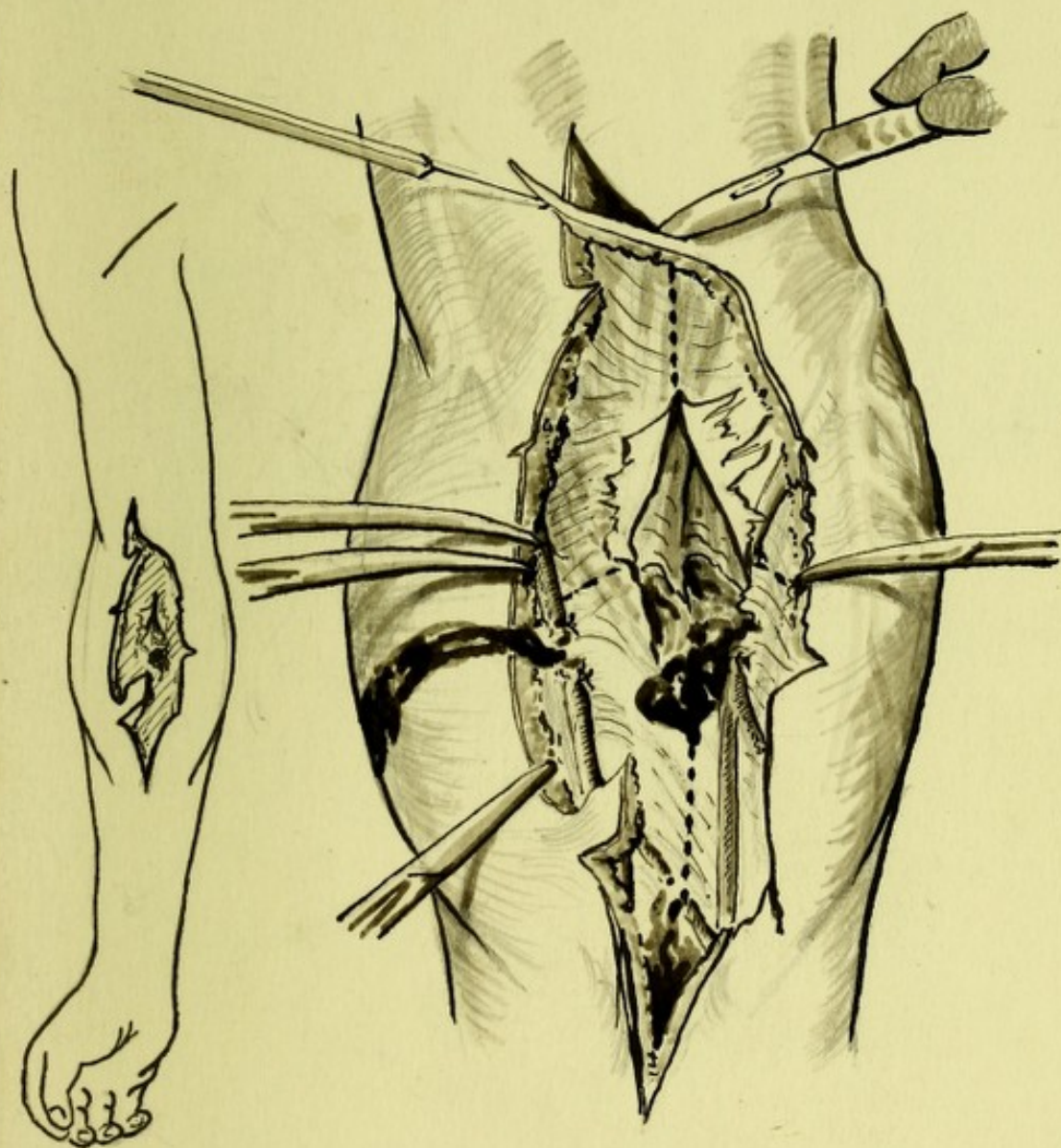



633. Urinary organs in position, viewed from in front.

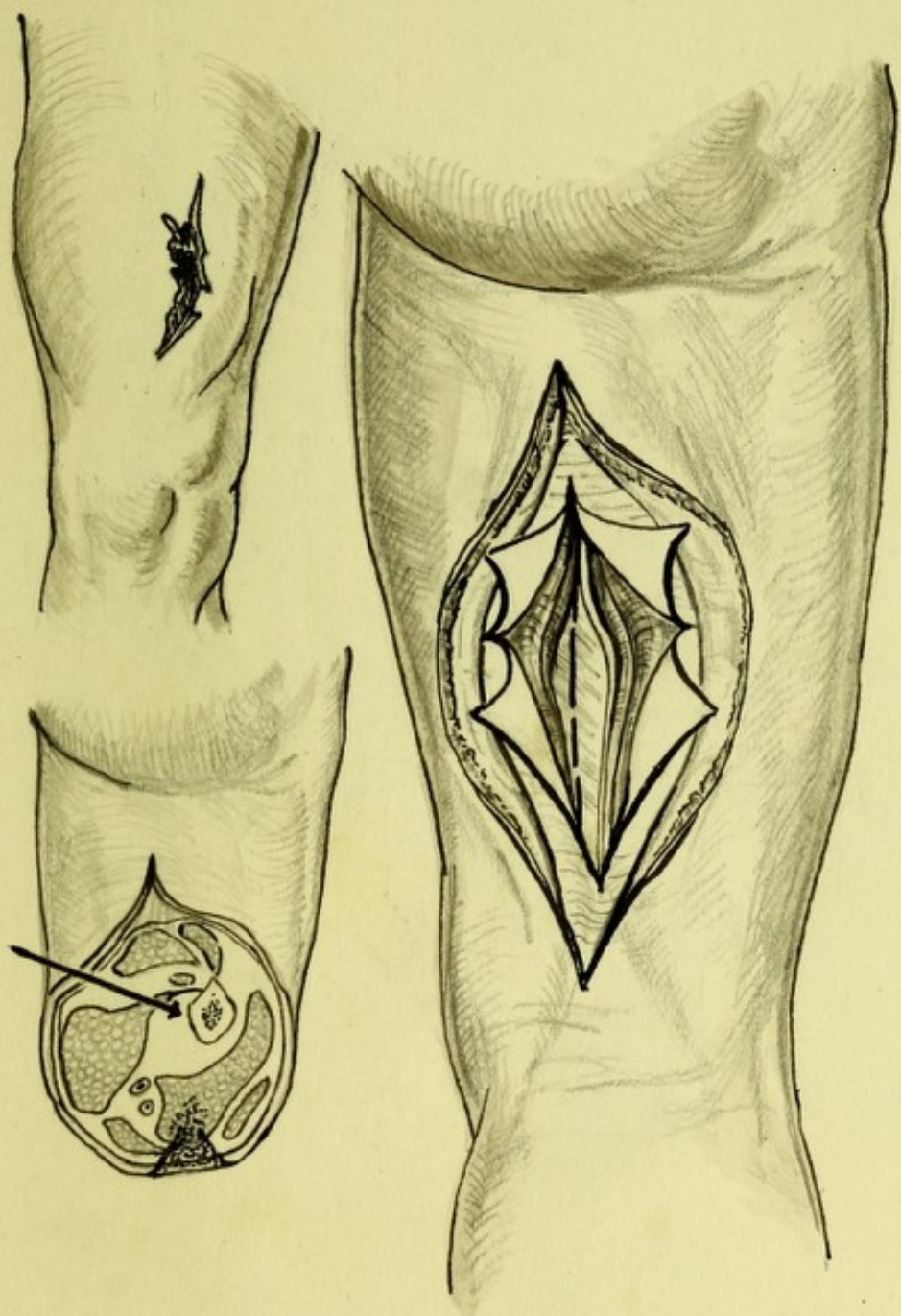
(Of the intestine only the termination of the duodenum has been left; the peritoneum, with the exception of the inferior portion on the left side, has been removed. The margins of the bodies of the vertebrae are indicated by interrupted lines.)

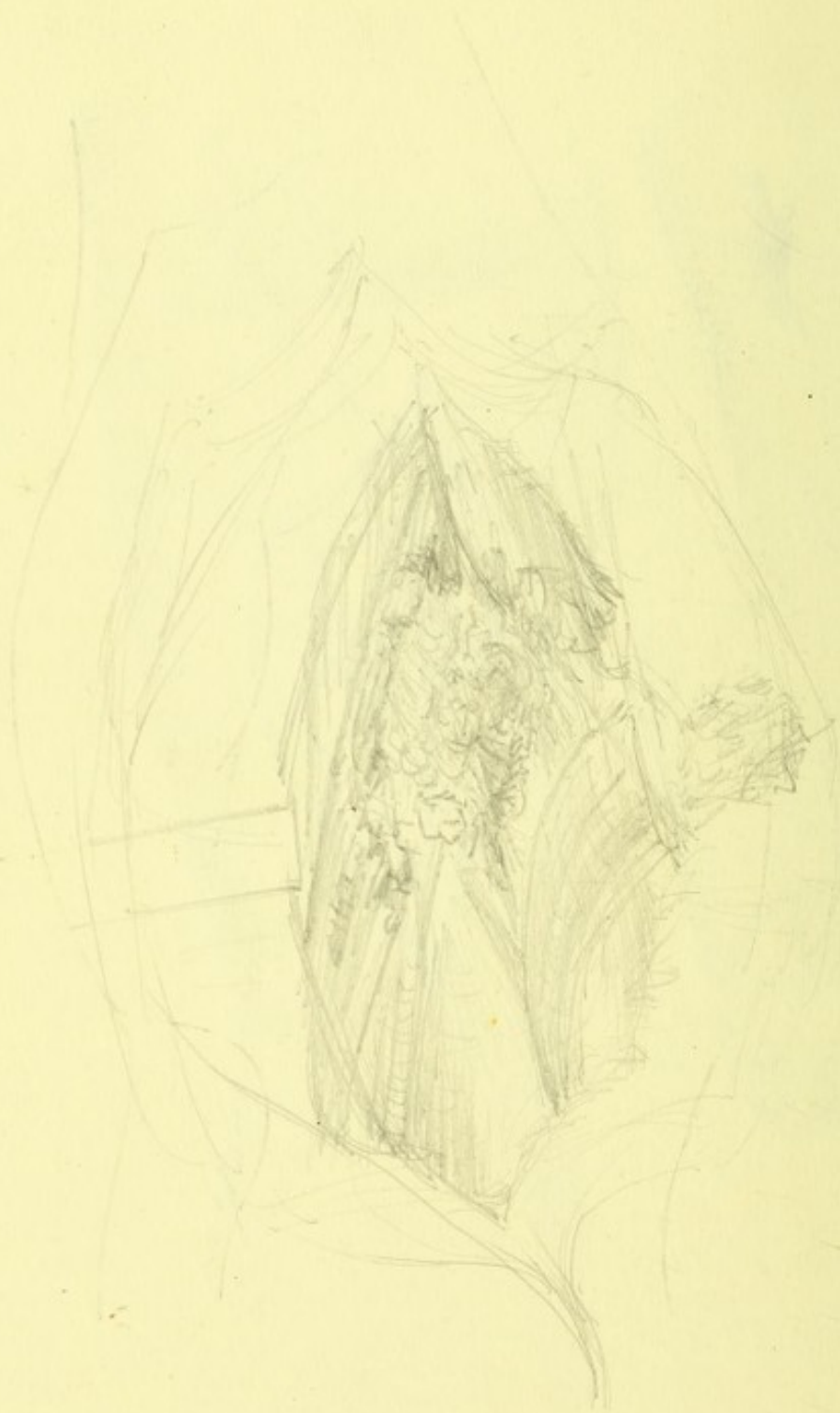The **kidneys** (*renes*) are two large glands, which are situated, one on each side, in the upper part of the posterior wall of the abdominal cavity near the spine. The posterior surface of the kidney, directed at the same time medialward, lies in front of that portion of the diaphragm which arises from the arcus lumbocostales, as well as in front of the mm. psoas major, quadratus lumborum and transversus abdominis and is separated from them by a layer of loose tissue, rich in fat, the *capsula adiposa*. In the male the left kidney reaches usually from the 11th thoracic vertebra as far as the upper border of the third lumbar vertebra; the right lies usually deeper by the distance of from a half to a whole vertebral level. In the female both kidneys are lower down by about one half a vertebra. The twelfth rib runs obliquely downward behind the posterior surface of the kidney. The upper part of the kidney accordingly still remains in the domain of the sinus phrenicocostalis of the pleura.

TOP. I.



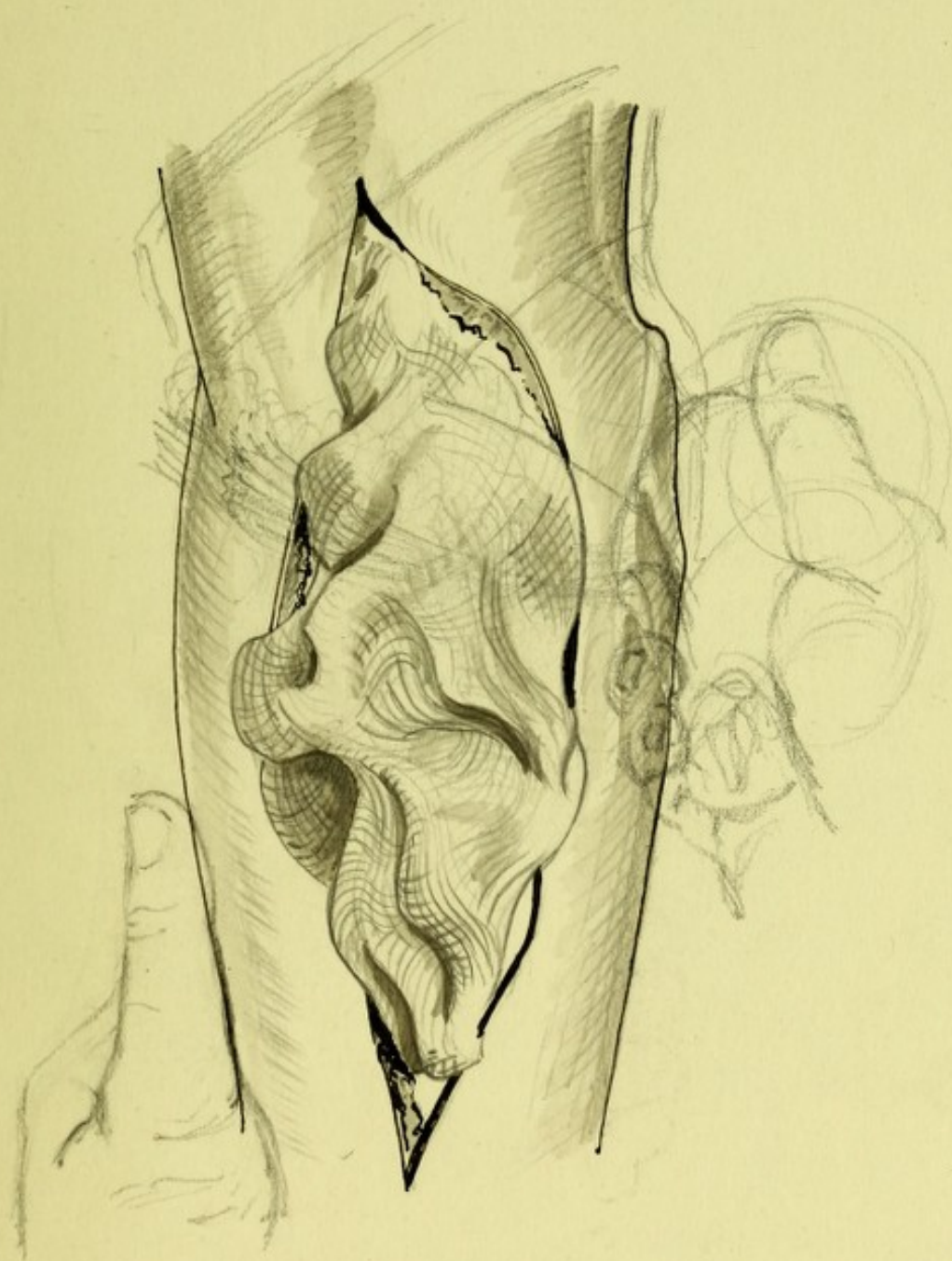


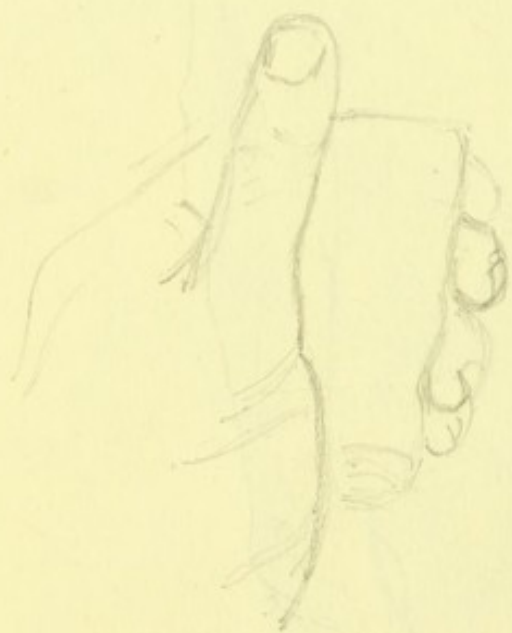
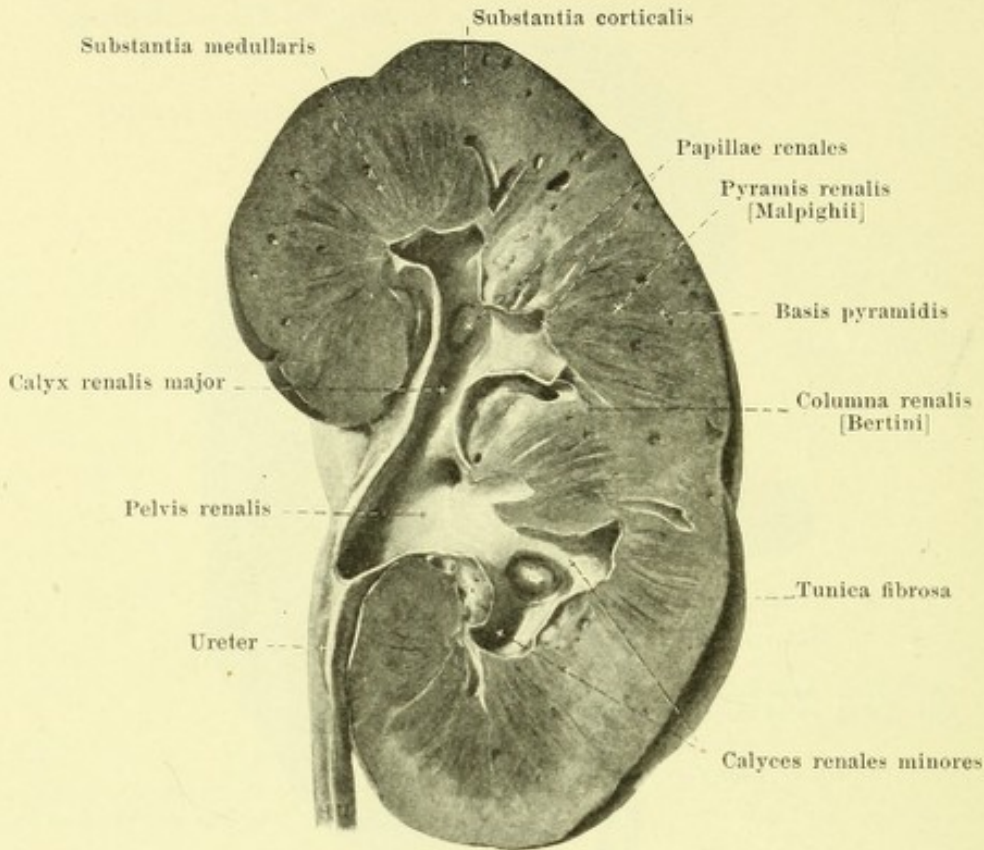


π

TOP. VI







637. Right kidney, cut through, viewed from behind.

Structure of the kidney (continued).

The cortical substance and the columnae renales are of a reddish-brown color, the pyramids are somewhat lighter toward their apices, but elsewhere more violet and dark.

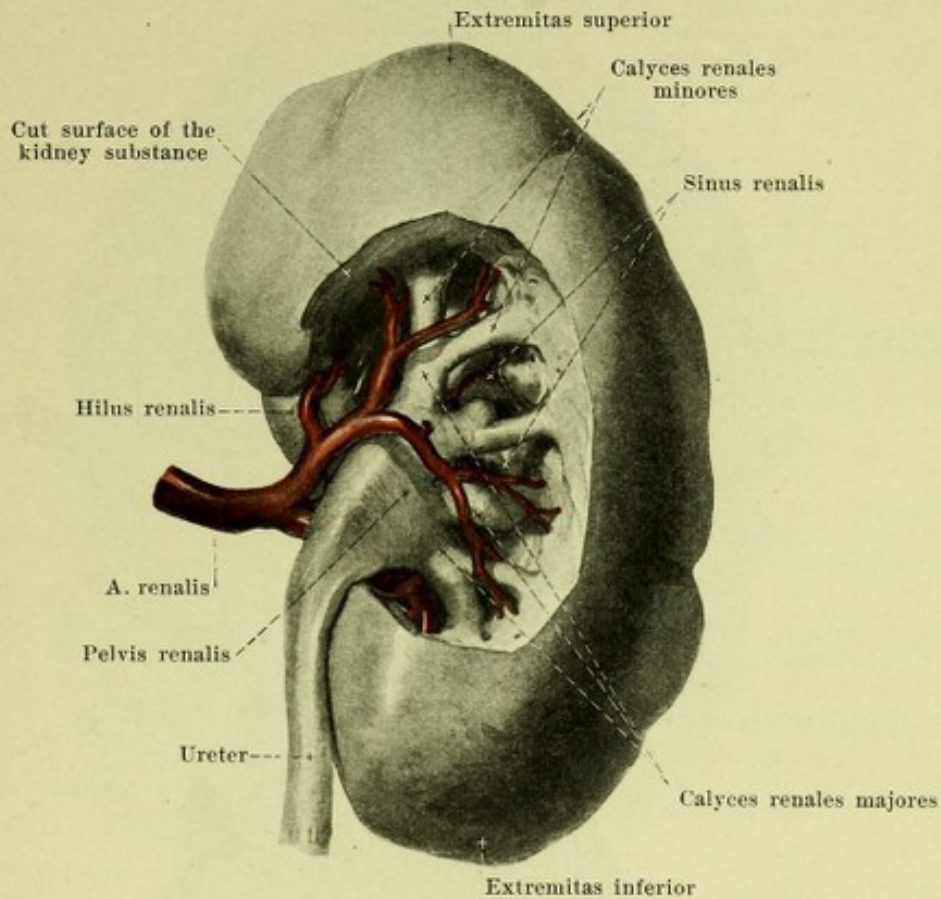
In the embryo and new-born (rarely in the adult) the surface is divided by deep, irregular furrows into 11—21 (averaging 15) areas (see Fig. 639). Each wedge-shaped portion of the cortical and medullary substance reaching as far as the sinus renalis corresponding to one of these areas is called a *lobus renalis*; each renal lobe contains several pyramides renales and is not separable in the depth from its surroundings.

The excretory ducts of the kidney, *urinary tubules*, *tubuli renales* (not illustrated), in the cortex are in their course partly tortuous, *tubuli renales contorti*, partly straight, *tubuli renales recti*, in the pyramids straight only. The cortex consists of an enormous number of very small columnar *cortical lobules*, *lobuli corticales*, all of which extend from the medullary substance to the periphery, lying closely packed together and only incompletely separable from one another; their margins are indicated by the radially directed aa. and vv. *interlobulares renis*. In the axis of each lobule extending peripheralward from the basis pyramidis is a light strip, *pars radiata* [*processus Ferreini*], which is formed of tubuli recti; the rest of the lobule, *pars convoluta*, is of a somewhat darker color and consists of tubuli contorti.

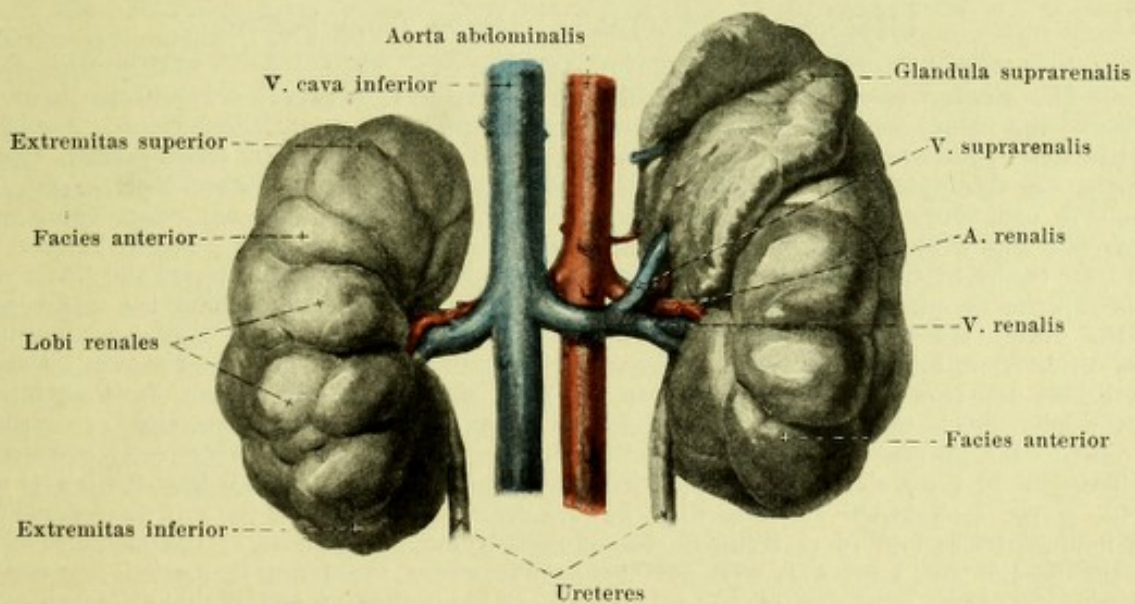
The largest tubuli renales of each pyramid converge toward its apex, open there by *foramina papillaria*, into the calyx of the kidney and thus form the *area cribrosa* of the papilla.

Excretory channels of the kidney (see also Fig. 638).

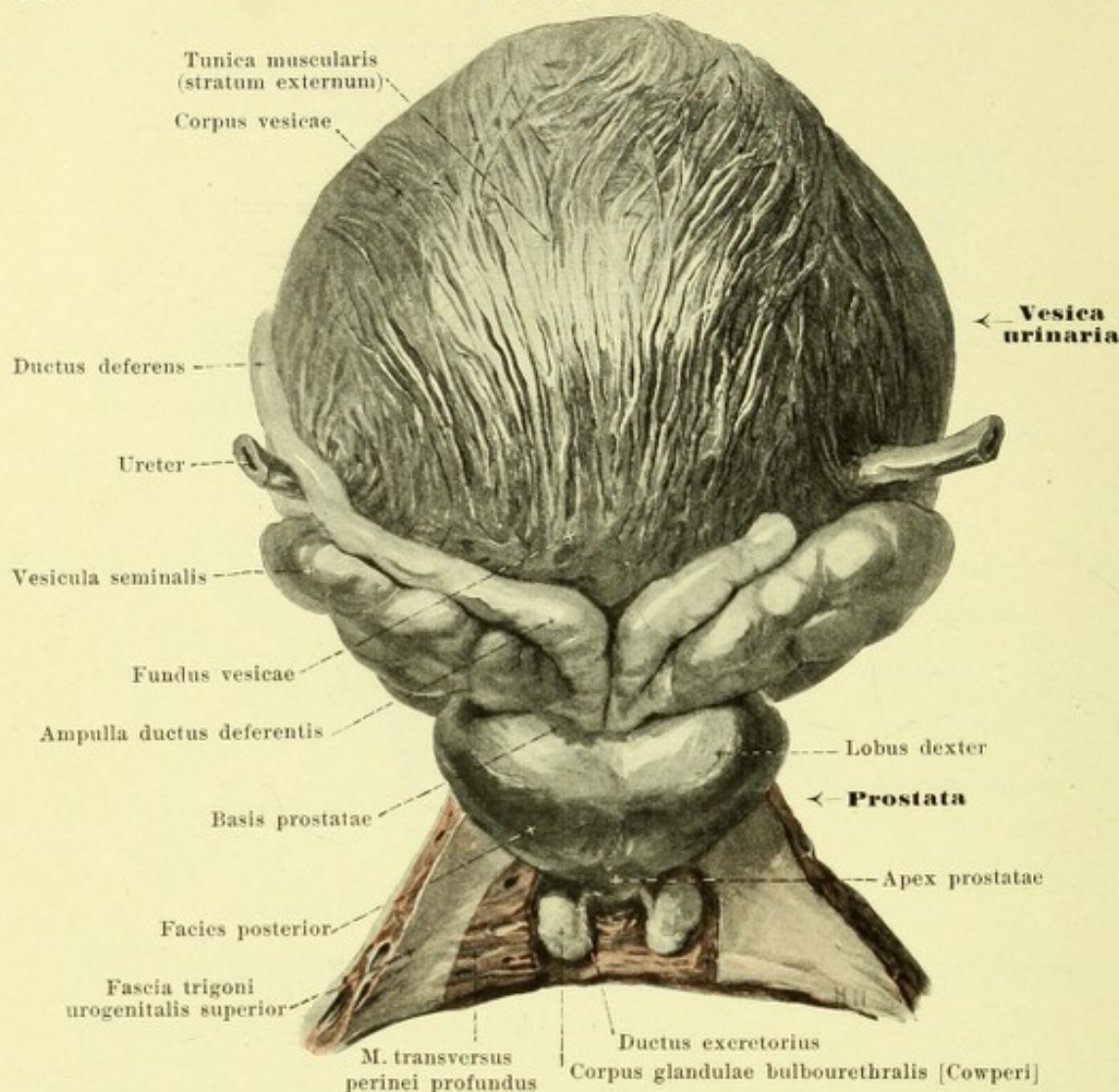
Each papilla renalis projects usually singly into the blind end of a short narrow tube, *calyx of the kidney*, *calyx renalis minor*, and is covered by its mucous membrane. Several calyces minores unite to form one short, broader *calyx renalis major*, of which there are altogether usually 2 or 3; these again combine and form the pelvis of the kidney, *pelvis renalis*, a flattened tube curved downward and narrowed below, which either gradually or by sudden constriction goes over into the ureter. The calyces renales, with the branches of the blood vessels and some fatty tissue, completely fill up the sinus renalis. The pelvis of the kidney in part projects out of the hilus renalis (see also Fig. 636) and there lies behind the blood vessels surrounded by fatty tissue.



638. Right kidney with its pelvis exposed, viewed from behind.



639. Kidneys of a new-born babe, viewed from in front.
(The left suprarenal gland has been left in position, the right has been removed.)

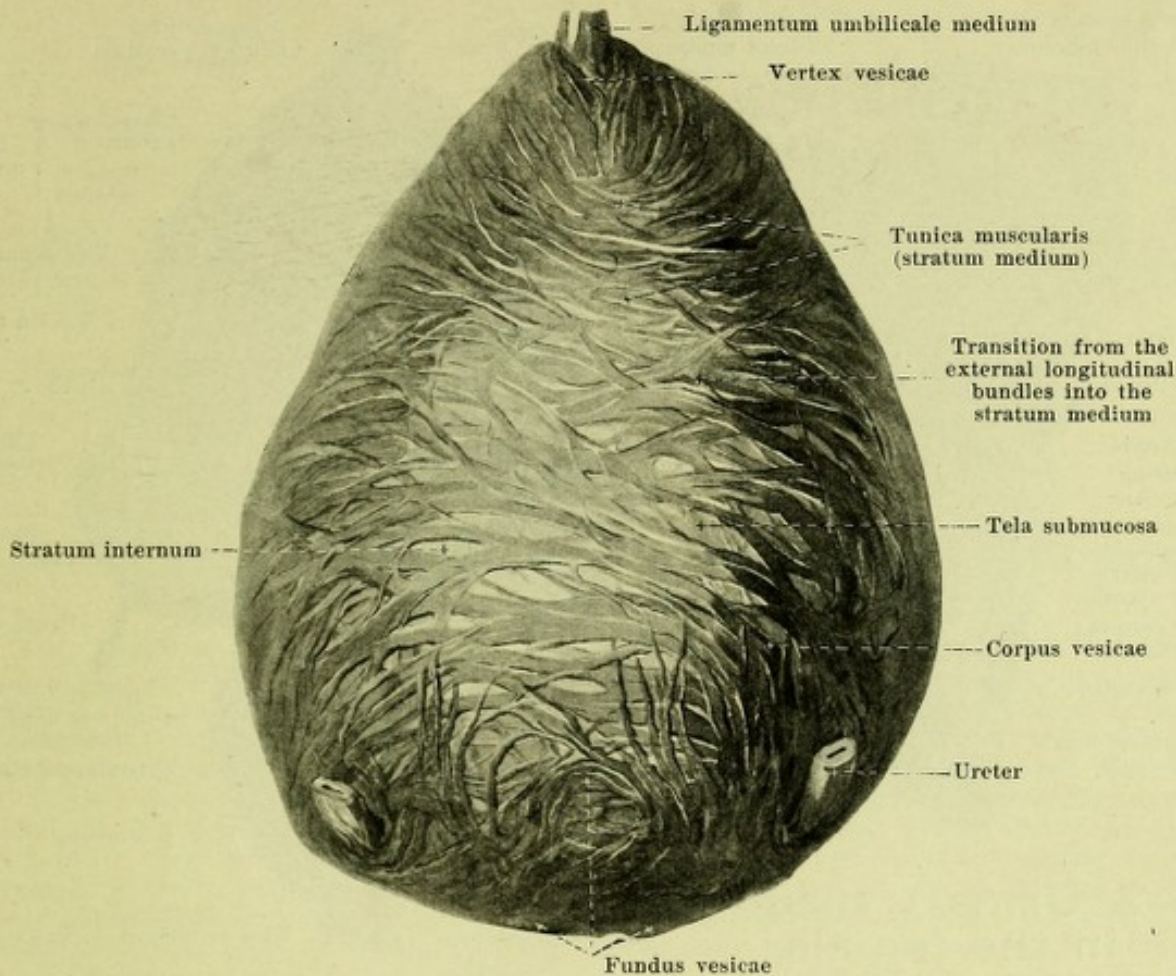


640. Urinary bladder, distended, with surrounding structures, viewed from behind.

(The glandulae bulbourethrales have been exposed in the trigonum urogenitale.)

The **ureter** (see also Figs. 633, 636, 655, 665—667) runs out on each side from the pelvis of the kidney in front of the m. psoas and the fascia iliaca; it is imbedded in loose connective tissue, is curved slightly downward and a little medianward (*pars abdominalis*), crosses usually on the right side the a. and v. iliaca externa immediately after their origin (see Figs. 470 and 500), on the left side the a. and v. iliaca communis and then (*pars pelvina*) (see Fig. 470) extends on the medial surface of the a. hypogastrica, usually further forward on the right than on the left medianward from the a. and n. obturatorius and the a. vesicalis superior (a. umbilicalis) (in the female at the same time directly behind the margo liber of the ovary, see Figs. 665 and 666), downward on the lateral wall of the small pelvis; from there on it behaves somewhat differently in the two sexes. The *pars abdominalis* above lies behind the *pars descendens duodeni* on the right side, behind the *flexura duodenojejunalis* on the left side, is then crossed in front by the a. and v. spermatica interna and is everywhere retroperitoneal in position. The *pars pelvina* is also, for the most part, directly covered by peritoneum. In the male its terminal portion (see Figs. 633 and 655) extends from the lateral wall of the pelvis, medianward and somewhat forward near the upper end of the vesicula seminalis to the fundus vesicae and in so doing is crossed medianward and in front by the ductus deferens. In the female (see Figs. 471, 472, 502, 665—667) where the terminal portion lies on the medial side of the a. uterina on the pelvic wall, it turns forward and medianward below the posterior layer of the ligamentum latum uteri to the base of the urinary bladder; in so doing, it runs through the parametrium, somewhat lateral from the cervix uteri, then comes into direct contact with the anterior and lateral walls of the vagina, being crossed in front by the a. uterina.

The ureter enters the urinary bladder, passing obliquely forward and medianward, runs for some distance in the wall of the same, and then opens at the orificium ureteris (see Figs. 642 and 643).



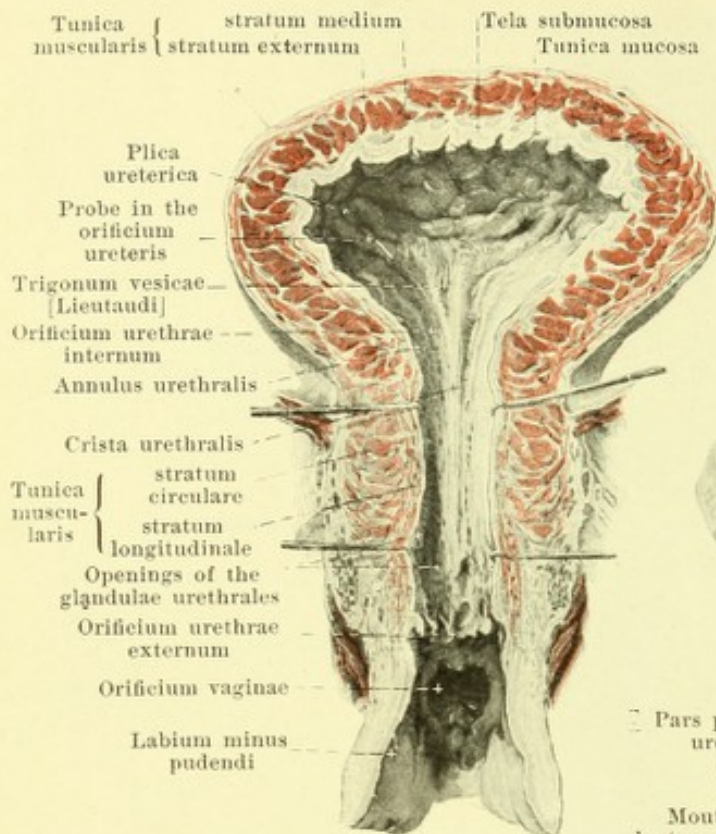
641. Urinary bladder, distended,
after removal of the superficial muscular layer, viewed from behind and above.

Ureter (continued).

The ureter is a tube, flattened from before backward, which, in the lower part of its pars abdominalis, presents a spindle-shaped dilatation of variable length, the lower boundary of which is situated in front of the a. iliaca. The pars pelvina is of approximately even caliber throughout. The *wall of the ureter* (not illustrated) consists of a peripheral *tunica adventicia*, composed of connective tissue, a thick muscular layer, *tunica muscularis*, in which are distinguishable a middle circular layer, *stratum medium*, as well as an external, *stratum externum* (existing only in the lower half), and an internal longitudinal layer, *stratum internum*, and the mucous membrane, *tunica mucosa*.

The **urinary bladder**, *vesica urinaria* (see also Figs. 633, 640, 642, 643, 655, 656, 665, 666 and 677) is an unpaired, musculo-membranous sac, situated in the small pelvis, into which open the right and the left ureter; it communicates with the urethra through the orificium urethrae internum. It presents for examination a *vertex vesicae* or vault of the bladder directed forward and upward; in youth this has the shape of a blunt wedge. Extending upwards from the vertex vesicae to the navel is a cord of connective tissue, *ligamentum umbilicale medium* (see p. 549), the remnant of the obliterated embryonic urachus. The inferior and posterior region turned toward the perineum, which contains the orificium urethrae internum, the trigonum vesicae and the plicae uretericae. The rest is called the body of the bladder, *corpus vesicae*.

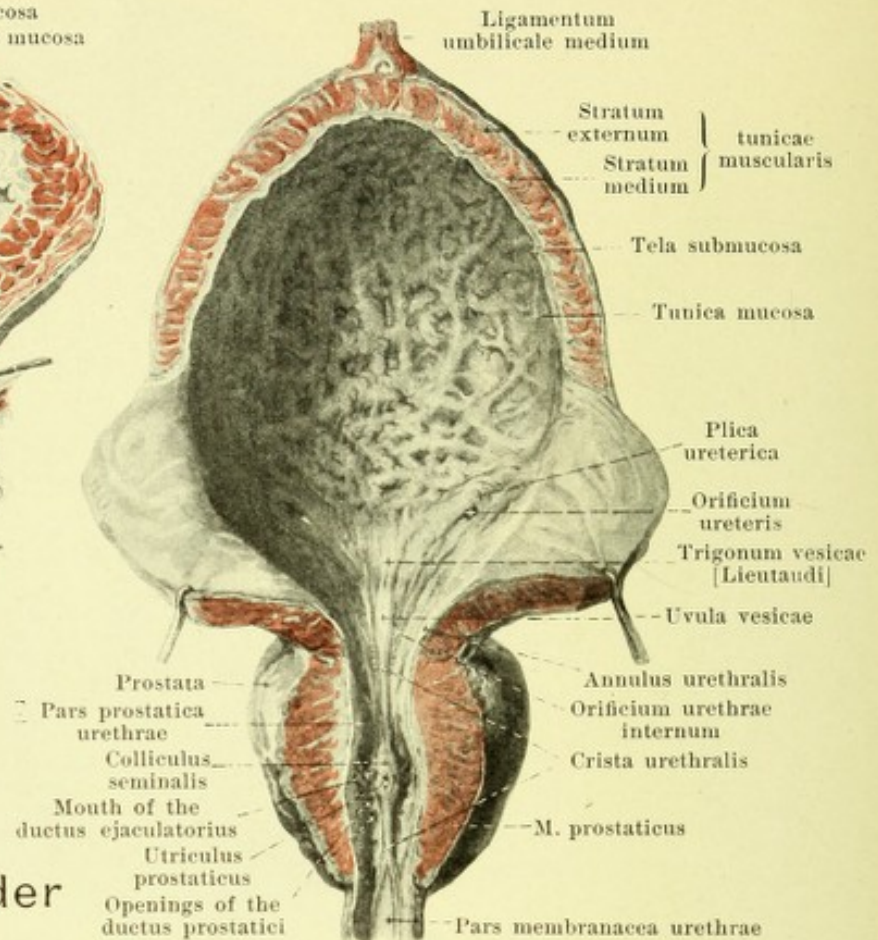
The **form** of the empty bladder (see Figs. 655, 656, 665, 666 and 677) in the male is usually egg-shaped, the small end being directed forward and upward; in the female it is more extended in the transverse direction and is usually flattened from above; the bladder when full is egg-shaped or spherical. Deviations in shape are not unusual. The more tube-like or pear-shaped form met with in childhood may be found even in the adult. In all cases the contracted bladder has a thicker wall than the relaxed bladder, and the wall is thicker in the male than in the female.



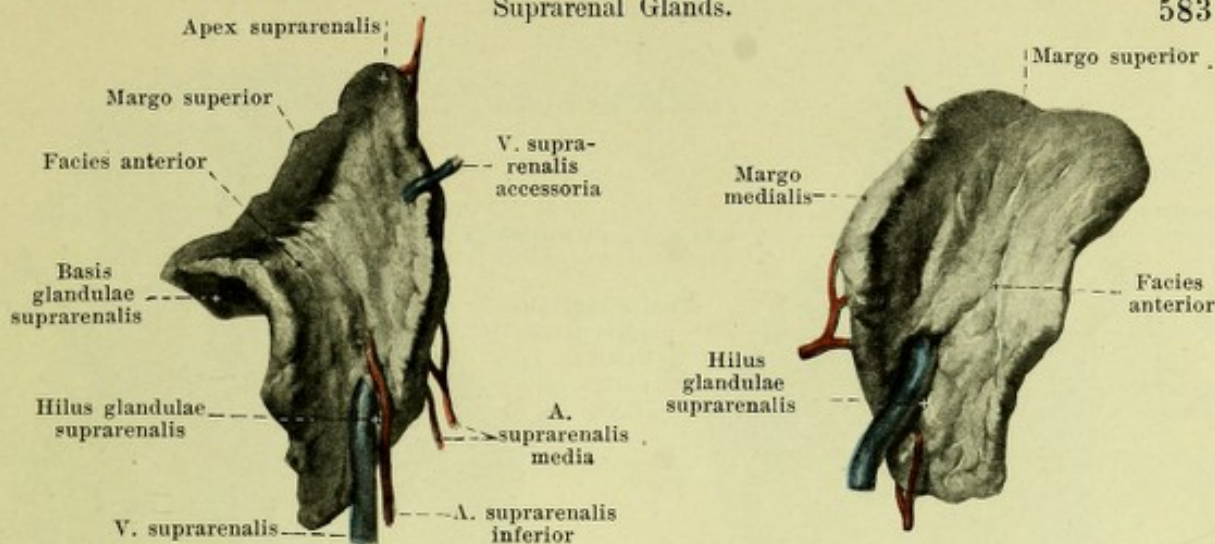
642. Urinary bladder in the female,

contracted, opened from in front.

Wall of the urinary bladder (see also Figs. 640, 641, 655, 656, 665, 666, 676 and 677). It is partly covered by a peritoneal coat, *tunica serosa*. This covers the upper wall and the upper part of the lateral surface (in the male, also in the upper part of the posterior wall, reaching somewhat deeper in the middle); it turns in the female upon the facies vesicalis uteri, in the male upon the anterior surface of the rectum usually somewhat above the basis prostatae. The peritoneum forms a transverse fold, *plica vesicalis transversa* (see p. 595) over the empty bladder. The second layer, *tunica muscularis*, consists of smooth muscle fibers, which are arranged in the form of a network. Its *stratum externum* (see Fig. 640) is formed of bundles which are very narrow-meshed especially in the middle; the bundles run in a longitudinal direction and diverge somewhat toward the vertex; in front they are connected with the *m. pubovesicalis* (see p. 613), behind with the *m. rectovesicalis* (see p. 595). The *stratum medium* (see Fig. 641) is the strongest; its bundles run especially in the transverse direction, form an uninterrupted layer at the fundus and there go over into fibers which surround the urethra in a ring inclined obliquely forward and downward, the *m. sphincter vesicae*, and are connected in front with the *m. prostaticus*. The *stratum internum* is thin and consists of wide meshes somewhat drawn out in the longitudinal direction. All three layers are intimately connected with one another, since bundles from one go over into the others. The tunica muscularis is separated by the vascular *tela submucosa* from the mucous membrane, *tunica mucosa*. The latter, of an intense red color, presents, when the bladder is empty or moderately filled, numerous folds which vanish when the organ is distended. Situated at the fundus vesicae is an approximately triangular smooth area (or when the bladder is empty not quite smooth), *trigonum vesicae* [Lieutaudi]. This is bounded behind on each side by the *plica ureterica*, a flat projection which is bulged forward by the ureter on its passage through the wall of the bladder and which in front contains the obliquely situated *orificium ureteris*. In front the trigonum reaches as far as the sickle-shaped *orificium urethrae internum*, which is convex forward forming a small oblong rounded elevation, *uvula vesicae*. The orificium urethrae internum is surrounded by a circular projection, *annulus urethralis*, which is especially distinctly developed in the male and which surrounds also the initial portion of the urethra.



643. Urinary bladder in the male, moderately distended, opened from in front.



644. Right suprarenal gland, viewed from in front.

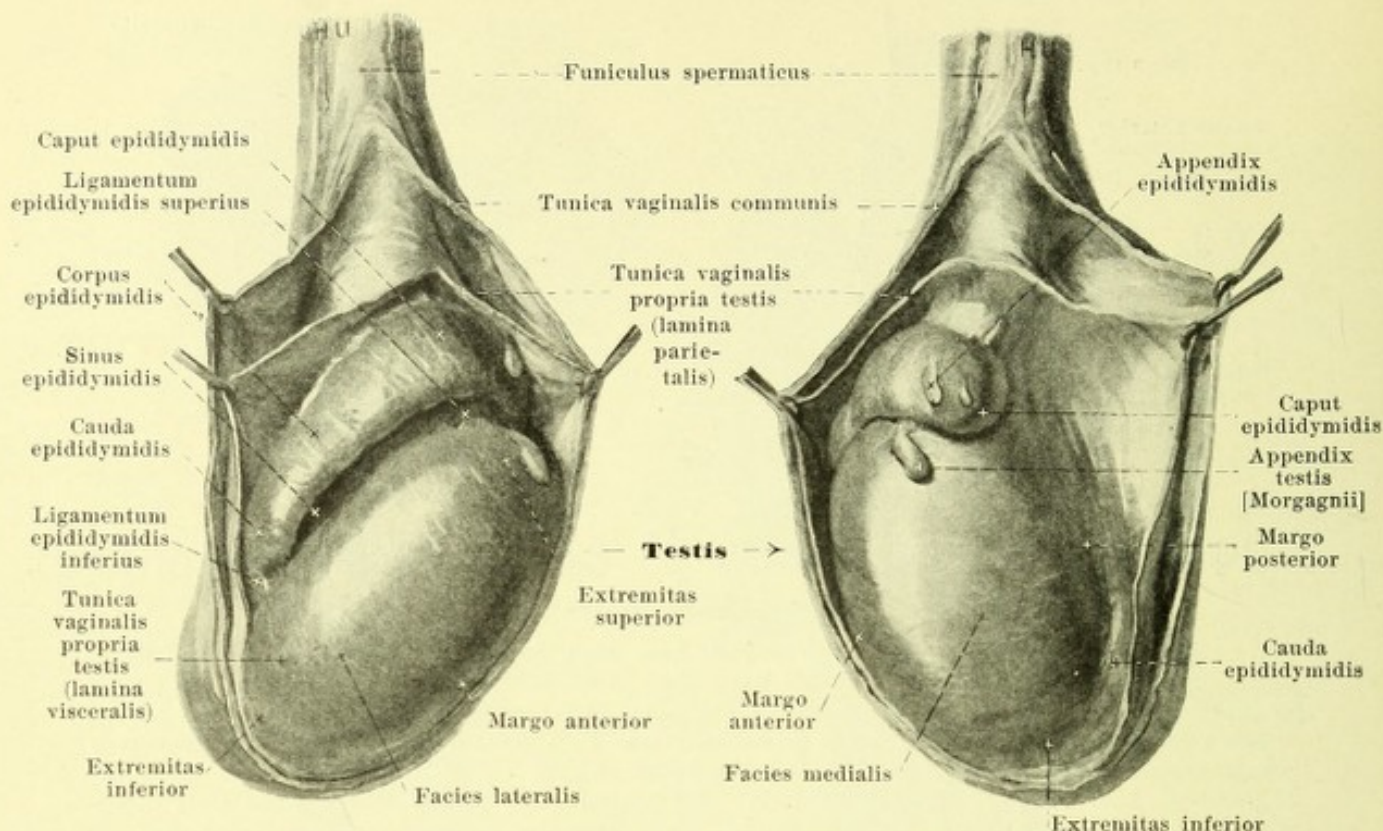
645. Left suprarenal gland,

Position of the urinary bladder (see Figs. 633, 655, 656, 665—667 and 677).

The anterior wall, looking at the same time downward, lies just behind the symphysis ossium pubis and the neighboring parts of the pubic bone, separated from them above by loose tissue only, below also by the plexus pudendalis (see Figs. 500 and 502). When the bladder is empty the vertex does not project beyond the upper margin of the symphysis; when it is full it projects above it for a variable distance. The lateral wall, turned at the same time downward, is very narrow when the bladder is empty and lies against the *m. levator ani* (see Fig. 677); when the bladder is full it passes upward on the *m. obturator internus* and is crossed by the *a. umbilicalis* (ligamentum umbilicale laterale) and the ductus deferens (in the male, ligamentum teres uteri in the female) (see Fig. 655); it is separated from the muscles by loose tissue, the fascia pelvis and the plexus vesicalis (see Figs. 500, 502 and 677). The inferior wall, corresponding to the urinary bladder, adjoins in the male the basis prostatae, in the female the trigonum urogenitale; its deepest point is usually the orificium urethrae internum, which in the male is situated behind the middle of the symphysis ossium pubis or somewhat higher, in the female is situated somewhat deeper. The posterior wall, directed at the same time somewhat downward, is in relation in the male with the seminal vesicles, with the ampullae of the seminal ducts, as well as, between and above these in variable extent and, separated from it by loose tissue, with the rectum; above it is covered by peritoneum. In the female it rests upon the anterior wall of the vagina and is connected with it and the cervix uteri by loose tissue rich in veins. On the upper wall, covered by peritoneum, in the male lie intestinal loops; in the female the facies vesicalis of the uterus lies upon it, separated from it only by the slit-like excavatio vesicouterina. The bladder, when full, projects for a variable distance upward into the peritoneal cavity. By distension of the rectum orificium urethrae internum is pressed forward and upward so that the bladder when it becomes full at the same time lies directly in contact for some distance with the anterior abdominal muscles.

The **suprarenal glands, glandulae suprarenales** (see also Fig. 633 and 639) are two small flat bodies, which lie directly medial from and above the kidneys, one on each side. The right is approximately triangular and sits more upon the upper pole of the kidney, the left approximately sickle-shaped and lies more upon the margo medialis of the kidney. Each presents for examination a posterior surface, *facies posterior*, which lies loosely upon the pars lumbalis diaphragmatis, and a *facies anterior*, which is in relation on the right side with the impressio suprarenalis hepatis (there covered below by peritoneum) and the *v. cava inferior*, on the left side above with the pars cardiaca of the stomach (thus far covered also by the posterior layer of the bursa omentalis), below with the *a. and v. lienalis* and the pancreas; on the anterior surface runs a groove, *hilus glandulae suprarenalis*, from which the principal vein, *v. centralis*, emerges. The concave *basis glandulae suprarenalis* looks lateralward and backward and lies upon the kidney. In addition there can be made out a sharpened *margo medialis* and *margo superior*, which form on the right an obtuse angle, *apex suprarenalis*. The left margo superior is in contact with the facies renalis of the spleen. The suprarenal gland consists of a firmer yellowish *substantia corticalis* and of a softer brownish *substantia medullaris*.

Accessory suprarenal glands, glandulae suprarenales accessoriae (not illustrated), are often found as small round structures in the connective tissue of the neighborhood, sometimes even in the kidney along the vasa spermatica interna and in the neighborhood of the sexual glands.



646 and 647. Right testicle and epididymis

after opening the ensheathing membranes,

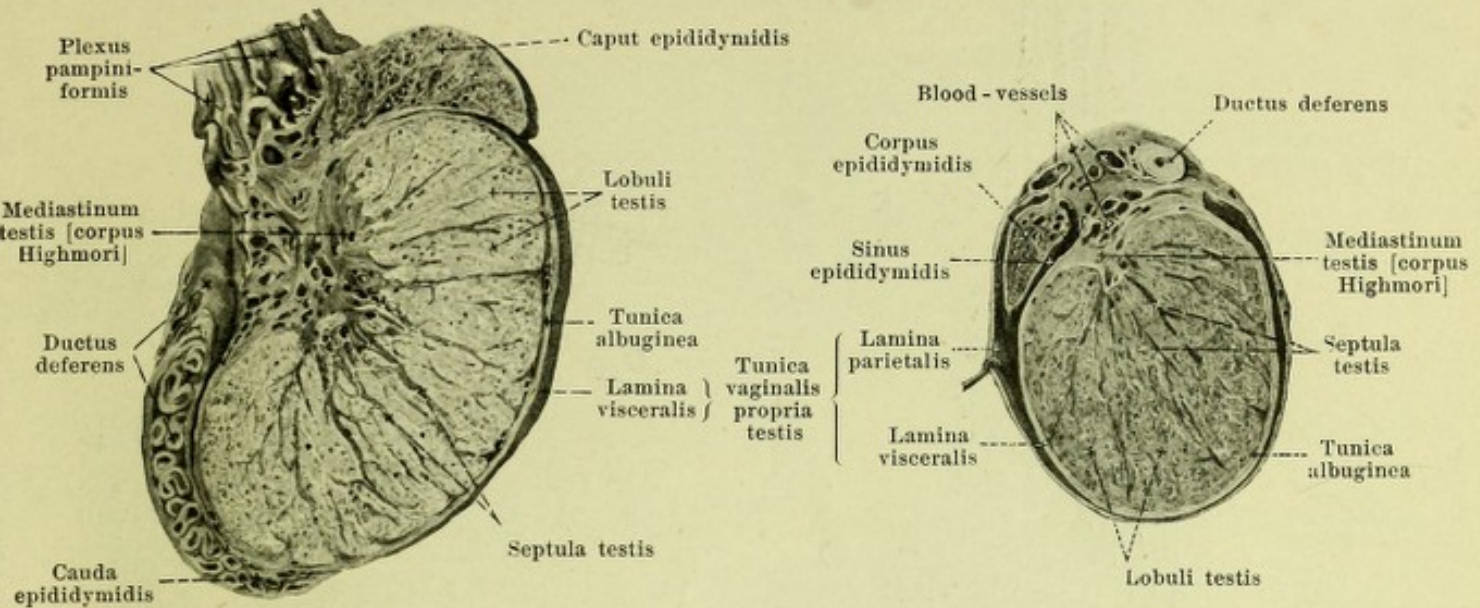
viewed from the lateral surface,

viewed from the medial surface.

The **testicles**, *testes*, are the two male sexual glands which secrete the *sperm* [*semen*]; they lie in the lower portion of the scrotum (see Fig. 652) and each possesses an appendage, the *epididymis*.

The **testicle**, *testis* (see also Figs. 648 and 649) is approximately egg-shaped, flattened somewhat from side to side and presents a convex surface of a bluish-white color. Its upper pole, *extremitas superior*, is directed at the same time somewhat forward and lateralward; its lower pole, *extremitas inferior*, is directed at the same time somewhat backward and medianward. It presents also a slightly convex *facies lateralis*, which looks at the same time somewhat backward, and a more flattened *facies medialis*, which is directed at the same time somewhat forward; these surfaces are connected with one another by a free *margo anterior*, which is directed at the same time a little downward, and the hidden *margo posterior* which looks also upward and at which the vessels and nerves enter and leave the testicle.

Structure of the testicle (see also Figs. 648—651). The surface of the testicle with the exception of the margo posterior is smooth and glistening, being formed by the *lamina visceralis* of the *tunica vaginalis propria testis* (see p. 588). Beneath it, fused with it, lies the *tunica albuginea*. This tough membrane of connective tissue completely ensheaths the substance of the testicle and is thickened at the posterior margin to form a triangular projection of loose sponge-like porous structure which extends into the interior of the testicular substance and is called the *mediastinum testis* [*corpus Highmori*]. Radiating out from this like a fan are thin leaflets of connective tissue, interrupted in spots, *septula testis*; these unite with the peripheral tunica albuginea. In the connective tissue framework lies the *parenchyma testis*. This consists of the approximately wedge-shaped lobules of the testicle, *lobuli testis*, which are separated from one another by the septula; the lobules converge with their apices toward the mediastinum testis. Each lobule contains two or more long, manifoldly twisted, tortuous seminal canals which anastomose with one another, *tubuli seminiferi contorti*. They unite at the apex of the lobule to form short, narrow, straight seminal canals, *tubuli seminiferi recti*, which enter the mediastinum testis and form in it along with the others a fine network, *rete testis* [*Halleri*]. Out of this network proceed about a dozen *ductuli efferentes testis*, which perforate the tunica albuginea at the upper end of the posterior margin and enter the head of the epididymis.



648 and 649. Right testicle and epididymis.

Sagittal section.

Transversal section.

The *epididymis* (see also Figs. 646, 647, 650 and 651) is long, cordlike, and sits upon the posterior margin of each testicle; it is curved so as to be convex backward and at the same time lateralward. Its upper, somewhat thicker portion, *caput epididymidis*, is directed medianward with its rounded end, rests with its lower concave surface upon the upper pole of the testicle and in largest part is there fused with it. The approximately triangular middle piece, *corpus epididymidis*, lies with its concave anterior surface upon the posterior margin and the posterior portion of the lateral surface of the testicle; it is partly separated from it by the sinus epididymidis, otherwise fused with it. The lower, rounded end, *cauda epididymidis*, goes over below with a sharp bend into the beginning of the ductus deferens, which extends upward and backward.

Structure of the epididymis (see also Figs. 646, 647, 650 and 651). The slightly nodular surface is covered on the convex side of the caput, on the lateral and partly also on the anterior surface of the corpus and on the lateral surface of the cauda by the *lamina visceralis* of the *tunica vaginalis propria testis* (see p. 588). Between the testicle and the corpus epididymidis this membrane therefore gives rise to a slit-shaped prolongation of variable length, *sinus epididymidis*, which is bounded above and below by variably developed folds, *ligamentum epididymidis superius* and *ligamentum epididymidis inferius* respectively. The caput epididymidis consists of about a dozen small wedge-shaped lobules, *lobuli epididymidis*; each of these has its base directed toward the free surface and receives at its apex one ductulus efferens testis, which forms a skein and by numerous turns completely fills up the lobule. The ductulus of the uppermost lobule goes from the base of the same, markedly twisted, to the corpus epididymidis, receives the ducts of the other lobules and becomes the *ductus epididymidis*. This completely fills up the corpus and the cauda epididymidis with its numerous short and marked turns and is continued at the end of the cauda directly into the ductus deferens.

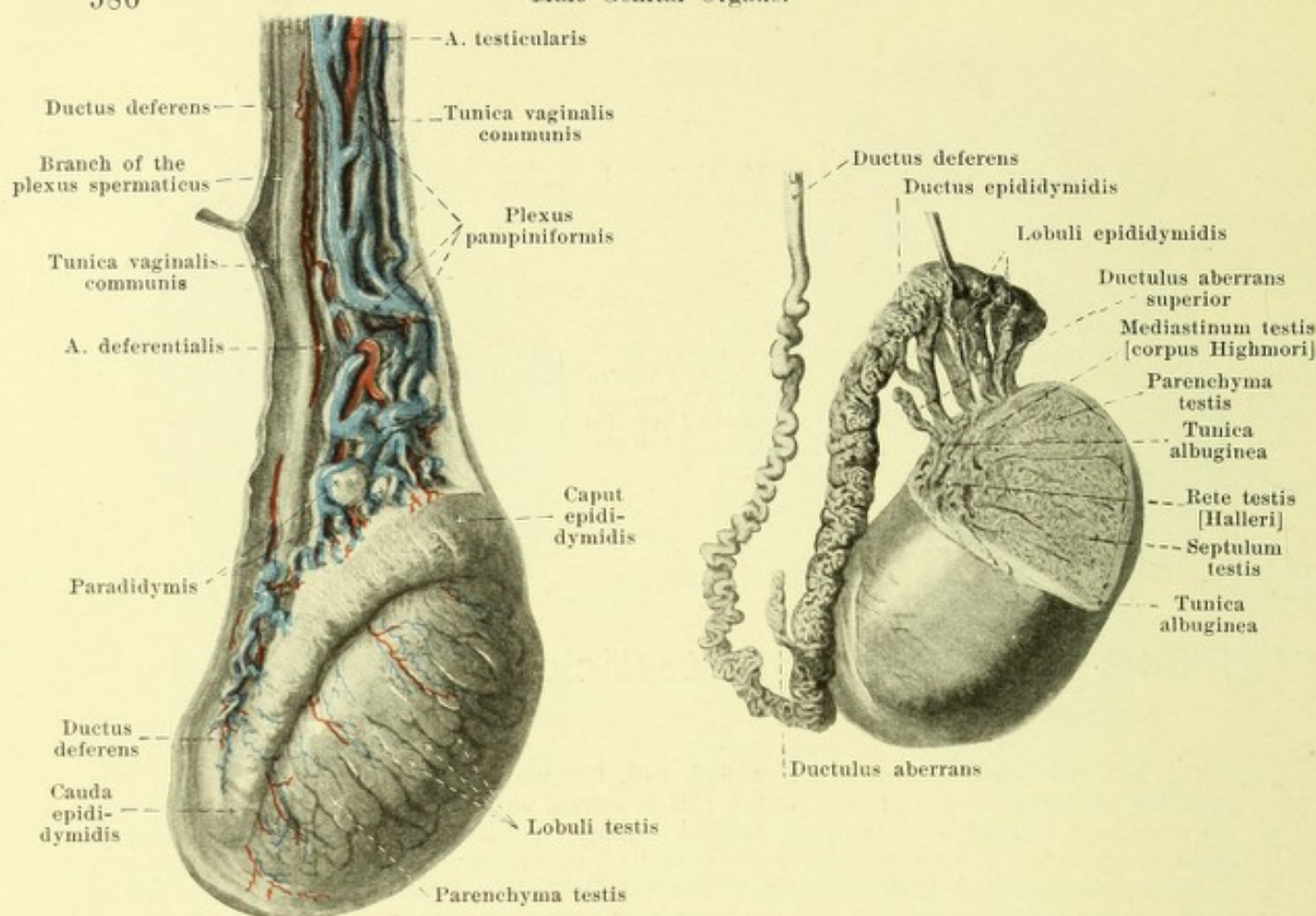
Appendages of the testicle and epididymis, appendices testis (see Figs. 646 and 647).

Appendix testis [Morgagnii], non-pedunculated hydatid, constant, sits as a soft, oblong corpuscle with a broad base upon the upper pole of the testicle, just beneath the caput epididymidis. It is a remnant of the upper end of Müller's duct, homologous with the infundibulum tubae uterinae.

Appendix epididymidis, pedunculated hydatid, single or multiple, connected frequently with the free end of the caput epididymidis as a small pedunculated pear-shaped vesicle. It arises through secondary pinching-off of the ductuli efferentes.

Ductuli aberrantes (see Fig. 651) are tortuous ducts ending blind, in the epididymis. The *ductulus aberrans superior*, in the caput epididymidis, is connected with the rete testis. The other, larger, in the cauda epididymidis, arises from the ductus epididymidis, runs upward for a variable distance; it is a canal of the Wolffian body which has persisted.

Paradidymis (O. T. organ of Giraldés) (see Fig. 650) lies as an oblong body in the lowermost end of the spermatic cord, in front of the vessels. It consists of groups of microscopic vesicles and tubules which are partly remains of the posterior part of the Wolffian body, partly ductuli efferentes which have been pinched off at a later period.



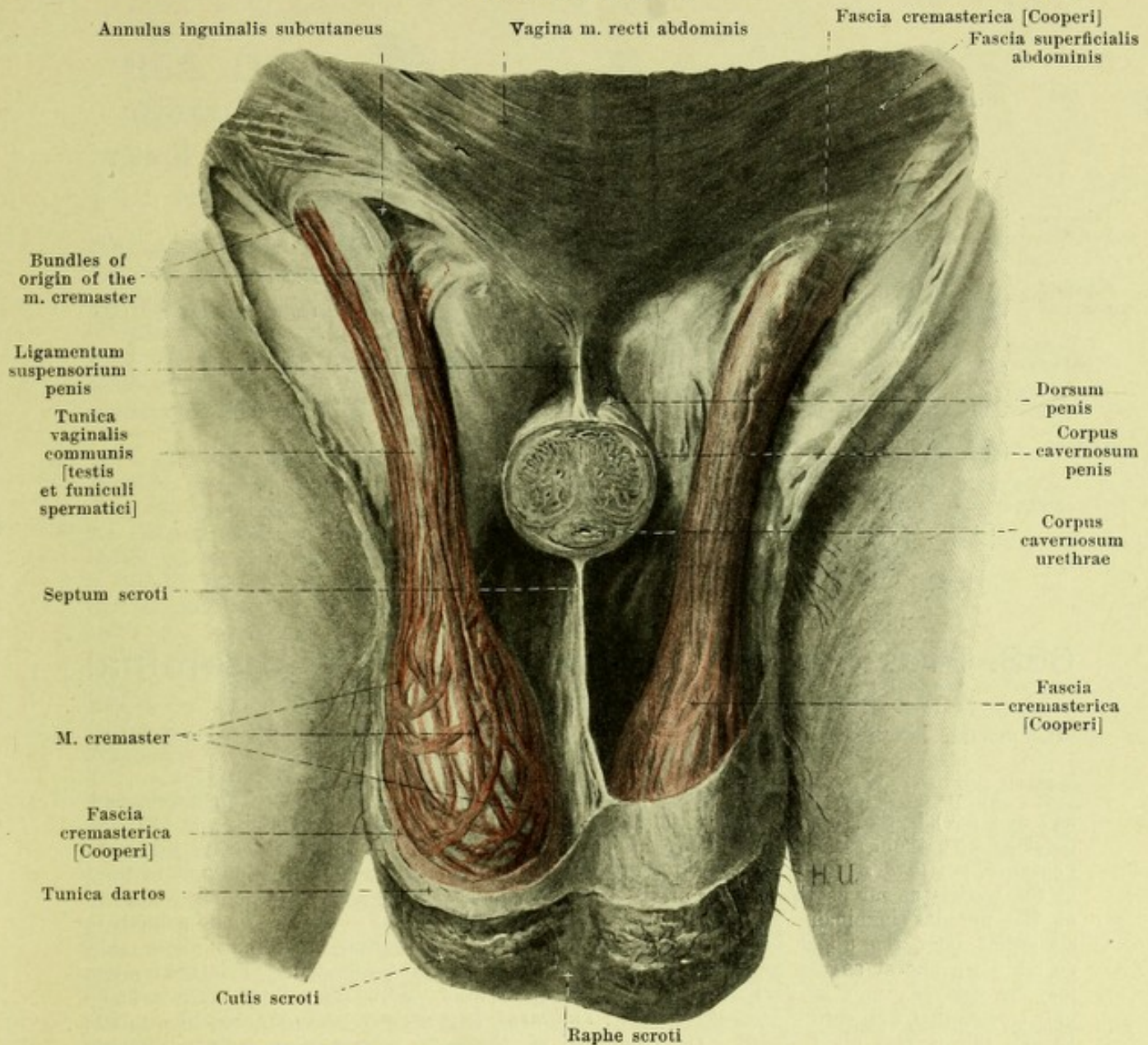
650 and 651. Right testicle and epididymis, viewed from the lateral surface

after removal
of the tunica albuginea and dissection
of the spermatic cord.

after removal of a sector
from the testicle and dissection
of the epididymis.

The **seminal duct, ductus deferens** (see also Figs. 599, 633, 640, 653, 654 and 656) is the excretory duct of the testicle. It begins at the cauda epididymidis as the continuation of the ductus epididymidis and ends by uniting with the ductus excretorius of the seminal vesicle to form the ductus ejaculatorius. It runs upward at first in a markedly tortuous direction, then less tortuously its wall gradually increasing in thickness, on the posterior margin of the testicle and on the medial surface of the epididymis; it then extends as a rounded, thick-walled, hard cord almost straight upward in the posterior medial portion of the spermatic cord and, passing through the canalis inguinalis lying directly on its inferior wall, arrives in the peritoneal cavity. There it loops over the origin of the a. and v. epigastrica inferior (see Figs. 470, 599 and 633) medianward and runs downward and backward on the lateral wall of the small pelvis; the a. and v. iliaca externa, the ligamentum umbilicale laterale, the vessels and nerves of the neighboring pelvic wall and the ureter lie on its lateral surface in this portion of its course. It then turns medianward to the fundus vesicae and extends at first directly over the upper end of the seminal vesicle, then on the medial surface of the same, close behind the wall of the bladder, to the basis prostatae; the ducts of the two sides converge in this part of their course. This last portion situated behind the bladder is often markedly curved and presents a spindle-shaped dilatation, *ampulla ductus deferentis*, the external surface of which is nodular and the internal surface of which shows depressions, the *diverticula ampullae*, separated by projecting ridges. From the annulus inguinalis abdominalis as far as the middle of the ampulla, the duct lies directly beneath the peritoneum.

The wall of the ductus deferens consists of three layers. Externally lies a *tunica adventicia*, which consists of connective tissue. Then follows the *tunica muscularis*, which is composed of a thin, longitudinal *stratum internum*, present only at the beginning, a thick, circular *stratum medium* and a correspondingly thick longitudinal *stratum externum*. Innermost lies the mucous membrane, *tunica mucosa*, partly thrown up in folds.

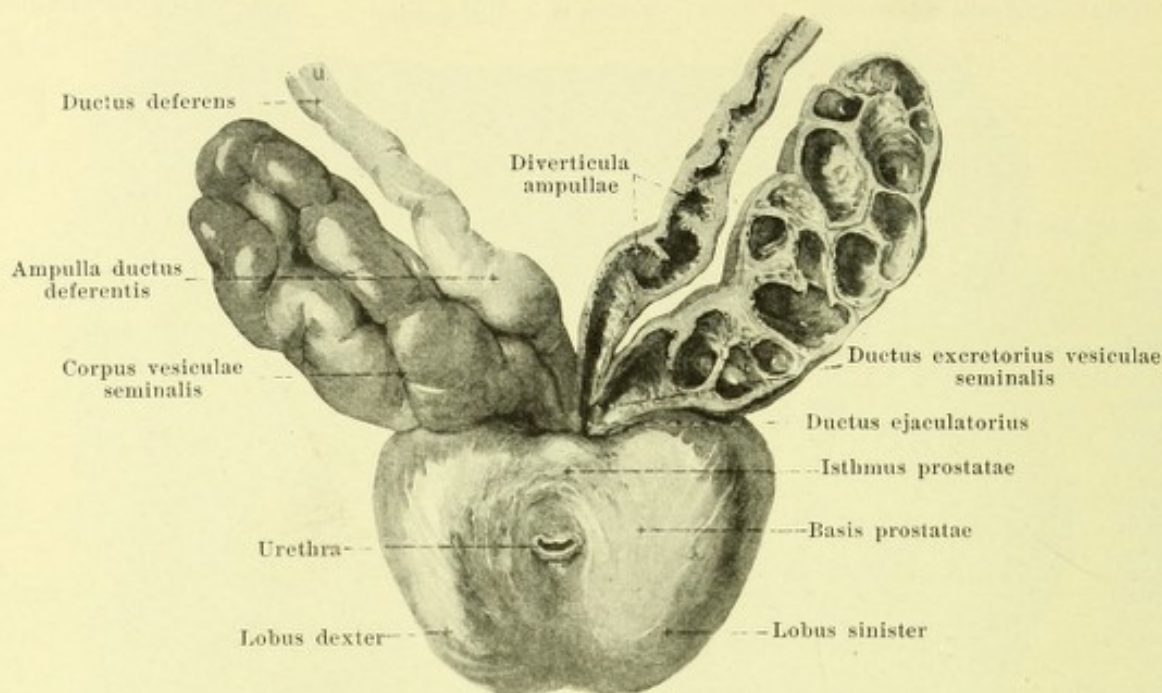


652. Scrotum, opened, viewed from in front.

(On both sides the skin and the tunica dartos have been removed. On the right side the fascia cremasterica [Cooperi] and the fascia superficialis abdominis have also been removed. The penis has been cut through transversely.)

The **spermatic cord**, *funiculus spermaticus* (see also Figs. 633, 646, 650) is a round, smooth, soft cord, which extends from the annulus inguinalis abdominalis to the posterior margin of the testicle.

It contains the ductus deferens, the a. and vv. deferentiales (to the v. epigastrica inferior), the a. testicularis, the plexus pampiniformis, lymph vessels, the plexus sympathici deferentiales and spermaticus, as well as (when present) the rudimentum processus vaginalis (see p. 588), all united by loose connective tissue. These structures are all ensheathed by a common tunic, composed of connective tissue, *tunica vaginalis communis [testis et funiculi spermatici]*, which may be looked upon as a continuation of the fascia transversalis abdominis. It is very loose and cannot be dissected out in the inguinal canal and does not become tougher until the neighborhood of the testicle and epididymis is reached. It also completely encloses the two latter and is firmly fused with the lamina parietalis of the tunica vaginalis propria testis (see p. 588), as well as with the posterior margin of the testicle and epididymis. In the inguinal canal the fibers of the *m. cremaster* (see p. 281) lie upon this sheath and accompany it downward. In the same layer lie also the a. and vv. spermaticae externae (to the v. epigastrica inferior) and the n. spermaticus externus. Around these parts at the annulus inguinalis subcutaneus is situated a continuation of the fascia superficialis abdominis, the *fascia cremasterica [Cooperi]* which is usually distinct above only.



653. Prostate with seminal vesicles and seminal ducts, viewed from in front and above.

(The prostate has been separated from the urinary bladder; on the left side the seminal vesicles and seminal ducts have been cut open.)

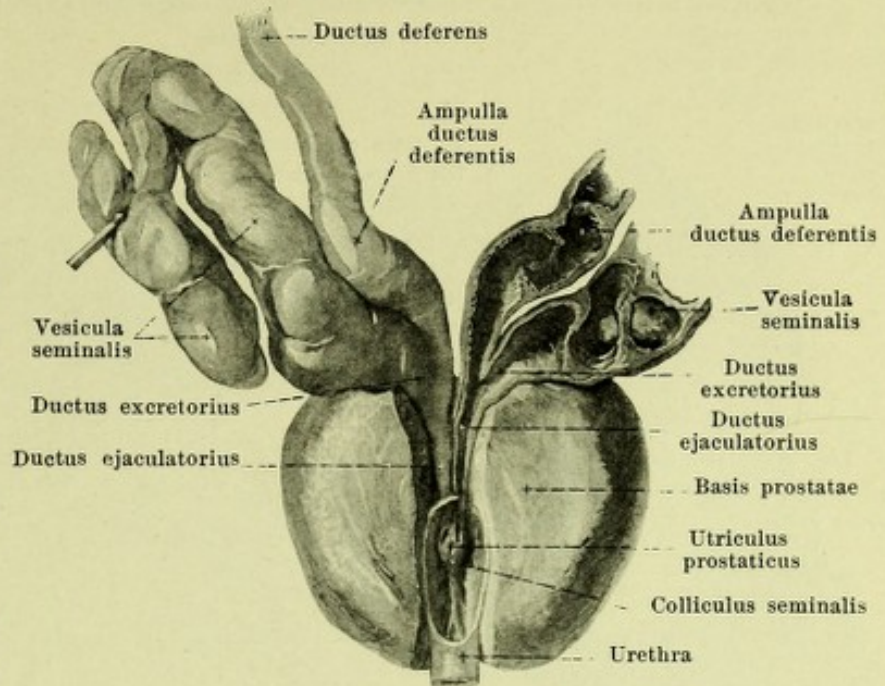
The *proper sheath of the testicle, tunica vaginalis propria testis* (see Figs. 598, 646, 647 and 649) is the serous covering of the testicle and epididymis (see pp. 584 and 585) and develops with the descensus testis as a blind-sac-like prolongation of the peritoneum, *processus vaginalis peritonaei*. This extends in the foetus in front of the ductus deferens and in front of the testicle as far as the bottom of the scrotum and surrounds a cavity which is connected at the annulus inguinalis abdominalis with the peritoneal cavity. At the time of birth or somewhat later the upper longer part of this cavity from the annulus inguinalis abdominalis as far down almost as the caput epididymidis usually becomes obliterated. (This obliteration may be delayed, may be partial, or may not occur at all.) In its place later there is found only a somewhat firm cord of connective tissue, *rudimentum processus vaginalis* (not illustrated), though this is very often absent. The lower end of this foetal peritoneal sac remains throughout life as the tunica vaginalis propria testis. This membranous sheath with its *lamina visceralis* directly covers the surfaces of the testicle (see p. 584) and of the epididymis (see p. 585), as well as in part the lowermost end of the ductus deferens and forms between the testicle and the epididymis the *sinus epididymidis* (see p. 585). Beyond these attachments it is continued into the *lamina parietalis*, which surrounds the testicle and epididymis with the exception of the posterior margin as a wide, loose sac and is separated from the lamina visceralis by a slit-like space containing a little serous fluid.

The **testicular sac** or *scrotum* (see Fig. 652) is a wide, loose, unpaired bag formed by the external skin; it incloses the testicles, epididymis and spermatic cord and their sheaths. Its cutis (see also Figs. 655 and 656) is connected above with that of the penis and the mons pubis, lateralward with that of the thigh, behind with that of the perineum; it is thin, of a dark color, wrinkled and possesses only a few hairs but many sebaceous and sweat glands. In the median plane runs a narrow darker strip, *raphe scroti*, from the under surface of the penis to the perineum. In the tela subcutanea of the skin lies the *tunica dartos*, a layer consisting of smooth muscle fibers interwoven in the form of a network, which is connected above with the fascia penis and fascia superficialis of the abdomen, thigh and perineum. It is continued in the median plane as the *septum scroti* (see also Fig. 656) into the interior of the scrotum, and so separates the two spaces filled up on each side by testicle and spermatic cord; it is connected with the fascia of the penis and perineum. Beneath the tunica dartos follows a very loose subcutaneous tissue, free from fat, which forms the connection with the fascia cremasterica and the m. cremaster.

654. Ductus ejaculatorii,

viewed from in front
and above.

(The same preparation as in Fig. 653. In addition the right seminal vesicle has been further dissected out and a wedge has been cut out of the prostate reaching as far as the ductus ejaculatorii and the urethra.)

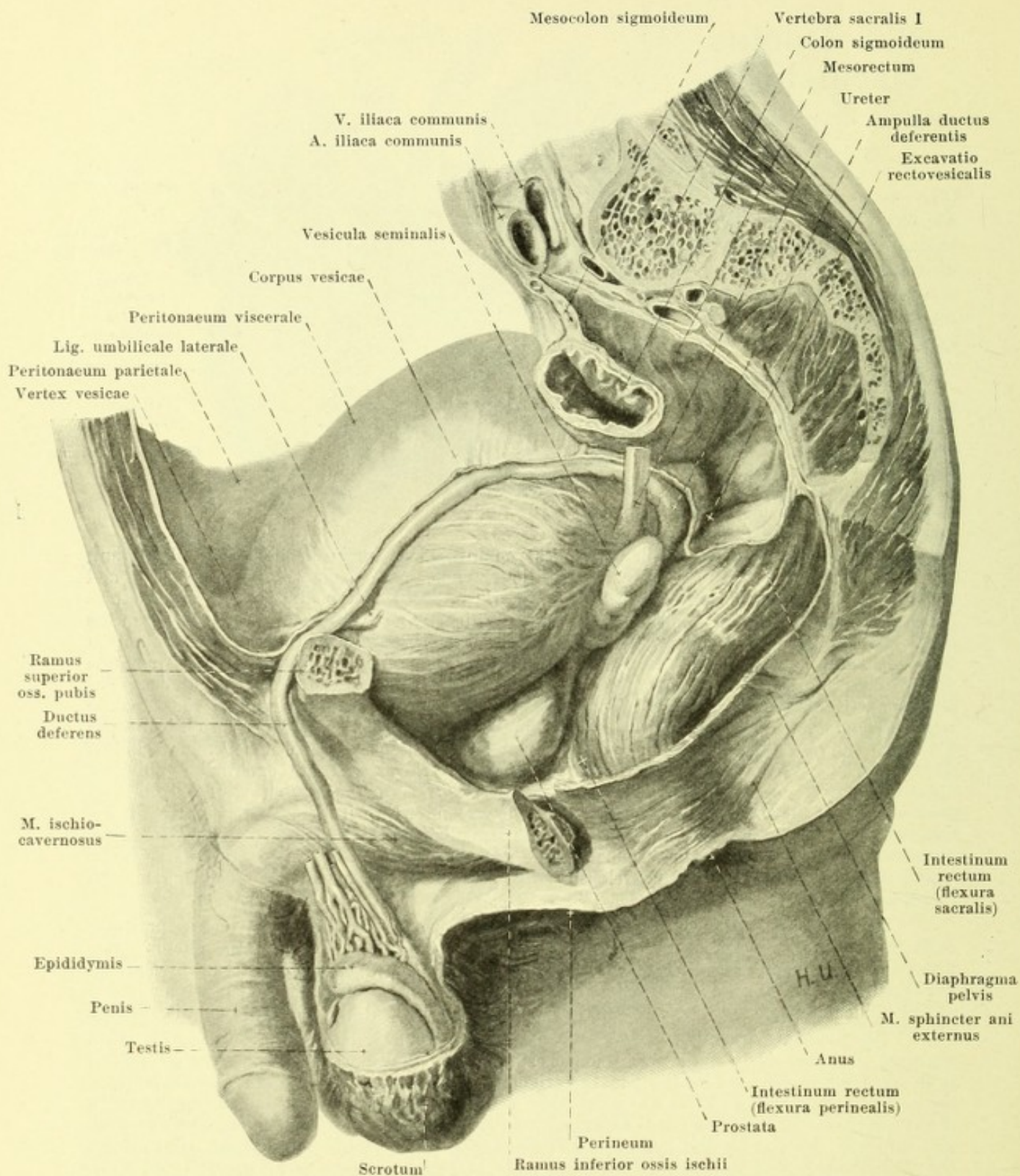


The **seminal vesicles**, *vesiculae seminales* (see also Figs. 599, 640, 653 and 655) are paired, oblong, flattened bodies of variable size, with a nodular surface; the upper end of each is broader, the lower end apical and directed

toward the basis prostatae. Their long axes run in a plane inclined forward and downward, and at the same time they converge at their lower ends. The seminal vesicles lie above and behind the prostate; they are attached in front, when the bladder is full in their whole extent (when the bladder is empty only in their lower portions) to the fundus vesicae, behind in the lower half to the rectum and are separated from the musculature of these organs by only a little connective tissue. The medial margin lies on each side in contact with the ampulla ductus deferentis, and in front of its upper end runs the last portion of the ureter. The posterior surface is covered in its upper third or upper half by the peritoneum of the excavatio rectovesicalis. Each seminal vesicle consists of a large tortuous main duct into which open a variable number of accessory ducts; the main duct is often bent like a hook. In addition all the ducts present inside depressions separated by ridges and are externally united by connective tissue to form a firm continuous mass, *corpus vesiculae seminalis*. The main duct goes over into the *ductus excretorius* at the lower end where it becomes narrower; the excretory duct unites with the lower end of the ampulla ductus deferentis to form the ductus ejaculatorius. The wall of the seminal vesicle consists of an external connective tissue layer, *tunica adventicia*, a middle, well-developed *tunica muscularis* and an internal, secreting mucous membrane, *tunica mucosa*.

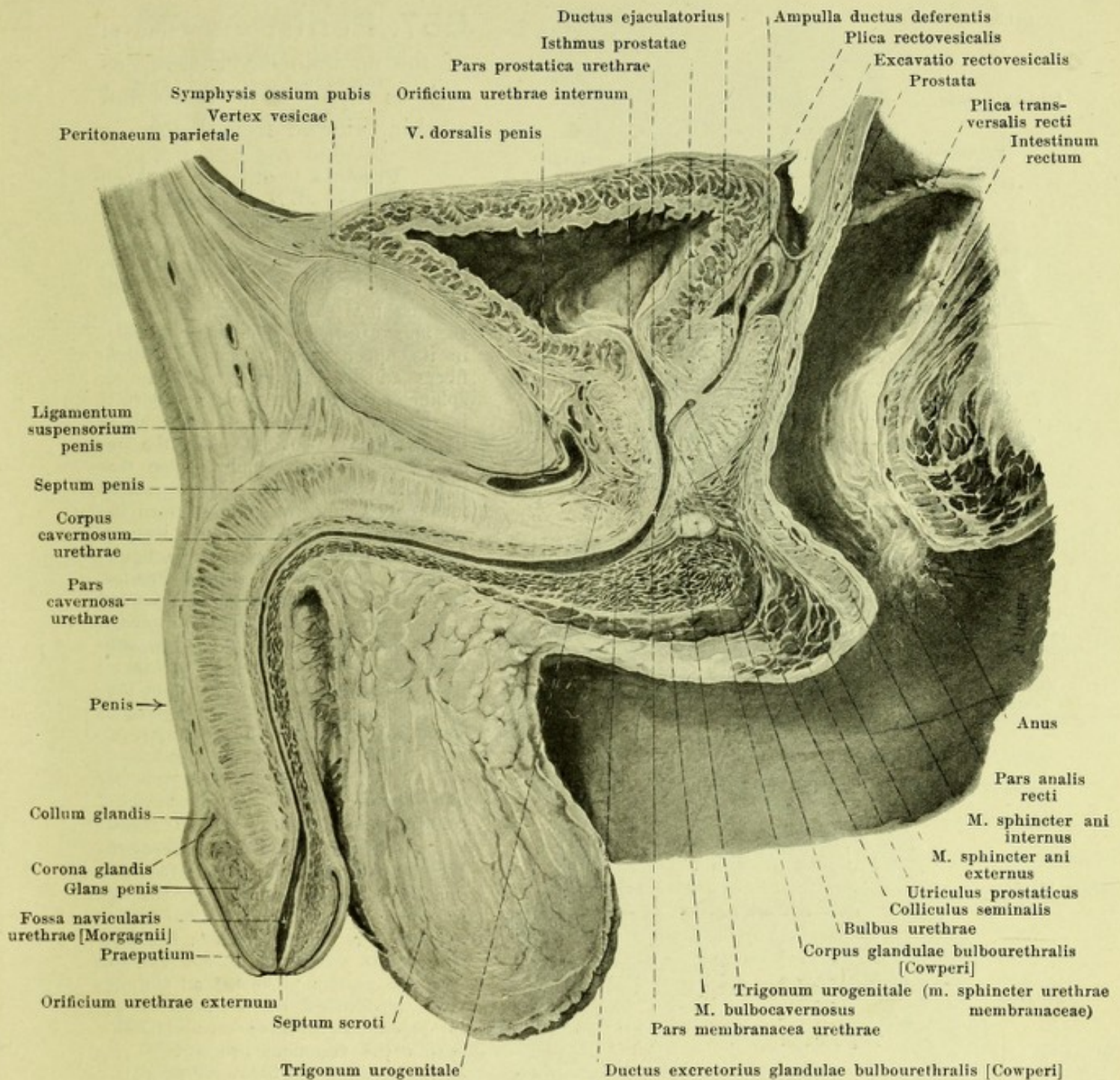
The *ductus ejaculatorii* (see also Fig. 656) arise on each side at the basis prostatae through the union of the lower end of the ampulla ductus deferentis with the ductus excretorius of the seminal vesicle. They are two very narrow canals which run downward and forward into the prostate, lie directly upon the wall of the of the utriculus prostaticus and open at the colliculus seminalis (see also Fig. 643) each by a fine slit-like opening into the urethra.

The **prostate gland**, *prostata* (see also Figs. 640, 643, 653, 655, 656 and 677) is an unpaired glandular body of the form of a chestnut, the rounded tip of which, *apex prostatae*, is directed downward and rests upon the trigonum urogenitale. Its anterior shortest surface, *facies anterior*, which looks at the same time a little downward, lies behind the lower portion of the symphysis ossium pubis; it is separated from it by the plexus pudendalis (see also Fig. 500) and connected with it by the ligamenta puboprostatica. The lateral surfaces are bounded by the medial margins of the mm. levatores ani and the plexus vesicalis (see Figs. 500 and 677), which fills up especially the groove between the basis prostatae and the bladder. The posterior surface, *facies posterior*, is in almost direct contact with the anterior wall of the rectum, being separated from it only by a little loose connective tissue, devoid of fat; it frequently presents a median groove (see Fig. 640) which only imperfectly separates the two lateral halves, *lobus dexter* and *lobus sinister* from one another. The largest, upper surface, *basis prostatae*, is at the same time directed a little obliquely forward and is concave. That portion of it situated behind the urethra presents in the middle a deep short transverse groove for the entrance of the ductus ejaculatorii; this groove separates a posterior from an anterior area. The posterior area lies in loose contact with the ampulla of the seminal ducts and the seminal vesicles.



655. Pelvic organs in the male,
after removal of the left wall of the pelvis, viewed from the left.

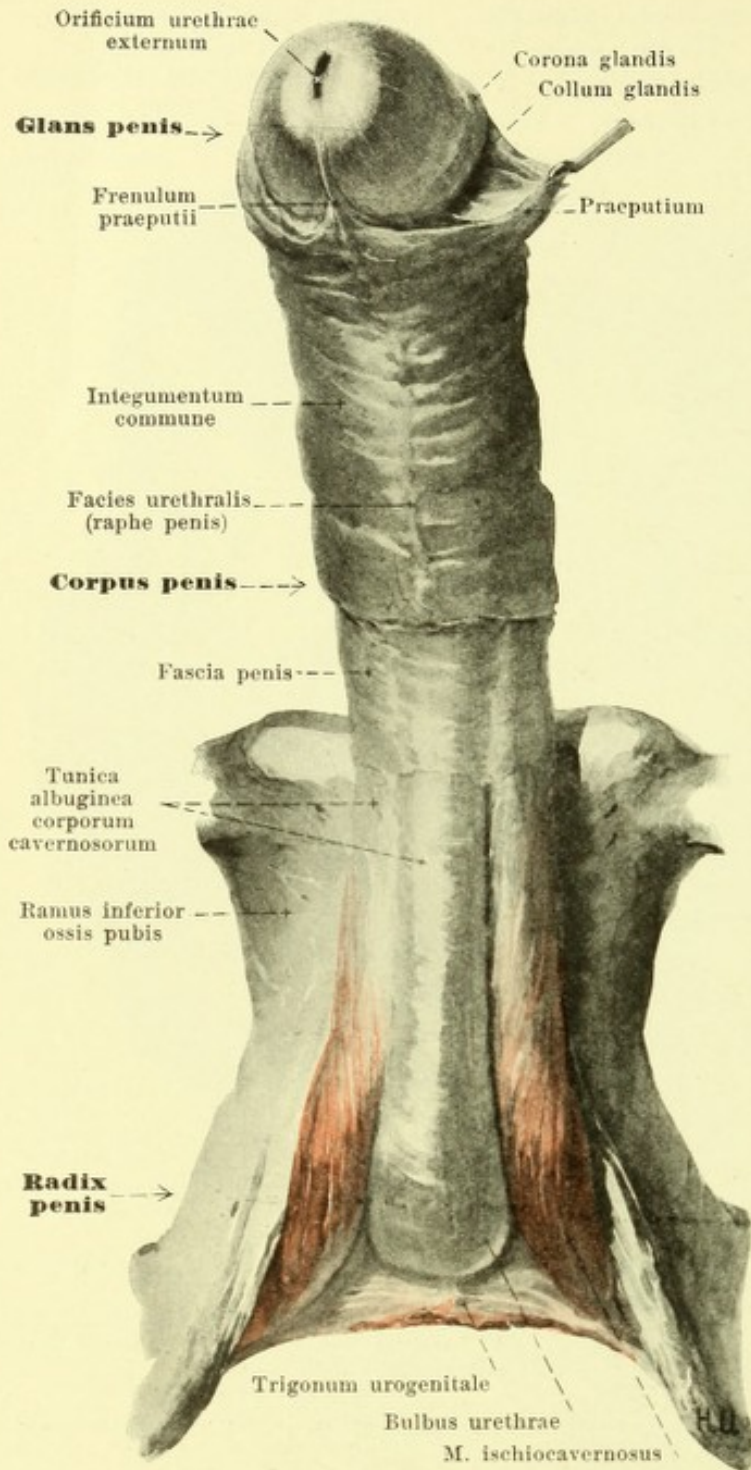
(The urinary bladder is markedly distended.)



656. Median section through the pelvic organs in the male, right half, viewed from the left side (partly after a frozen section by W. Braune).

(The urinary bladder has been only partly filled. The left glandula bulbourethralis [Cowperi] situated laterally from the median plane has been introduced as though projected upon the median plane. The urethra is represented as somewhat dilated.)

Prostata (continued). The area of the basis lying between the urethra and the ductus ejaculatorii, *isthmus prostatae* (see Fig. 653), is with the rest of the basis firmly united to the fundus vesicae; it may project so as to form a rounded module, *lobus medius* (not illustrated), which bulges forward the wall of the trigonum vesicae. The prostate is obliquely perforated in its posterior upper part by the ductus ejaculatorii; through its anterior part from the basis as far as the apex runs the pars prostatica of the urethra.



657. Penis, after removal of the *m. bulbocavernosus*, as well as a part of the fascia and skin, viewed from below.

Prostata (continued) (see Figs. 643, 656 and 677). It consists in largest part of glandular substance which as *corpus glandulare* surrounds the first portion of the urethra in the form of a broad clasp, open in front. This clasp is closed to form a ring by the *m. prostaticus*. The latter consists, in its upper part, of smooth muscle fibers and is connected with the *m. sphincter vesicae*; in the lower part it is formed of striped fibers and is inseparably continuous with the *m. sphincter urethrae membranaceae* (see p. 609). The muscle fibers run especially transversely and radiate out into the glandular substance and upon its surface. The glandular substance consists of many small wedge-shaped lobules, the apices of which are directed toward the urethra; each of them contains a small excretory duct, *ductus prostaticus*; of such ducts there are in all from 20 to 30, they mostly open into the urethra in the two grooves lateralward from the colliculus seminalis.

The surface of the prostate is smooth and is covered on its posterior and lateral surfaces by a sheath of connective tissue, the *fascia prostaticae*.

The **glandulae bulbourethrales** [Cowperi] (see Figs. 640, 656 and 673) are two glands, of the size of a pea; the surfaces of these glands are nodular. Each of them lies with its *corpus glandulae bulbourethralis* near the median plane behind the urethra, ensheathed by the fibers of the *m. sphincter urethrae membranaceae*, within the trigonum urogenitale. Its excretory duct, *ductus excretorius* (see Fig. 656), is very thin, runs forward in the bulbus urethrae and opens by a fine slit in the posterior part of the pars cavernosa urethrae.

The **penis** (see also Figs. 655, 656, 658—661) is a long, triangularly prismatic body, which lies below and in front of the symphysis ossium pubis and surrounds the longest part of the urethra. It presents for examination a posterior, broader end, *radix penis*, and an anterior main portion, *corpus penis*, the free end of which is formed by the *acorn* or *glans penis*. The root and the posterior part of the corpus lie hidden below the skin of the perineum and scrotum and are immoveably fastened (*pars fixa*), by fusion with the trigonum urogenitale, the pubic bones and the symphysis; the rest projects free and is easily moveable (*pars mobilis*); between these two parts when the organ is relaxed is an angle which vanishes during erection. The corpus penis possesses an upper surface, *dorsum penis*, and a lower surface, *facies urethralis*; these are not sharply separated from one another by the rounded lateral surfaces.

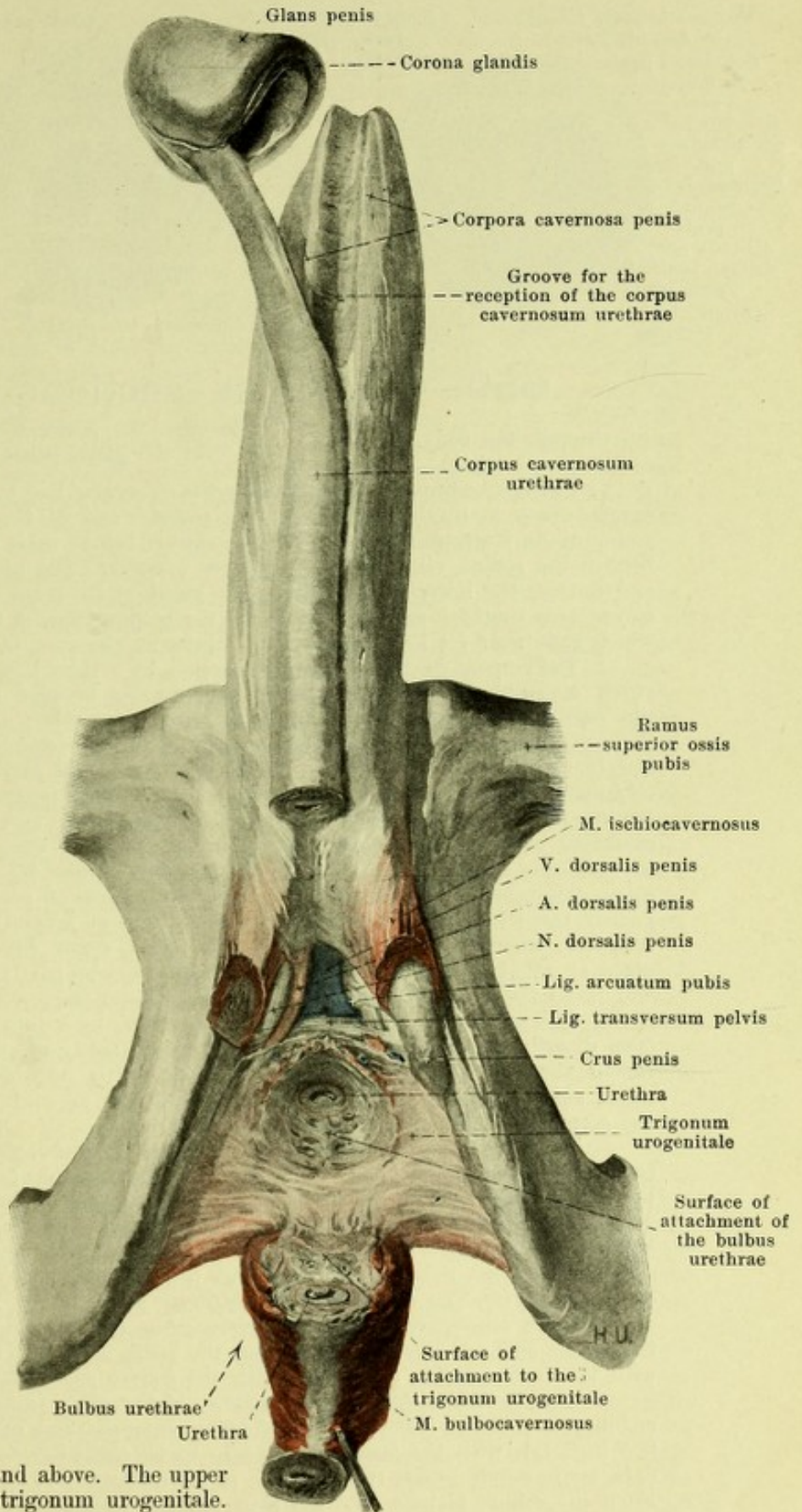
658. Corpora cavernosa penis and trigonum urogenitale, viewed from below.

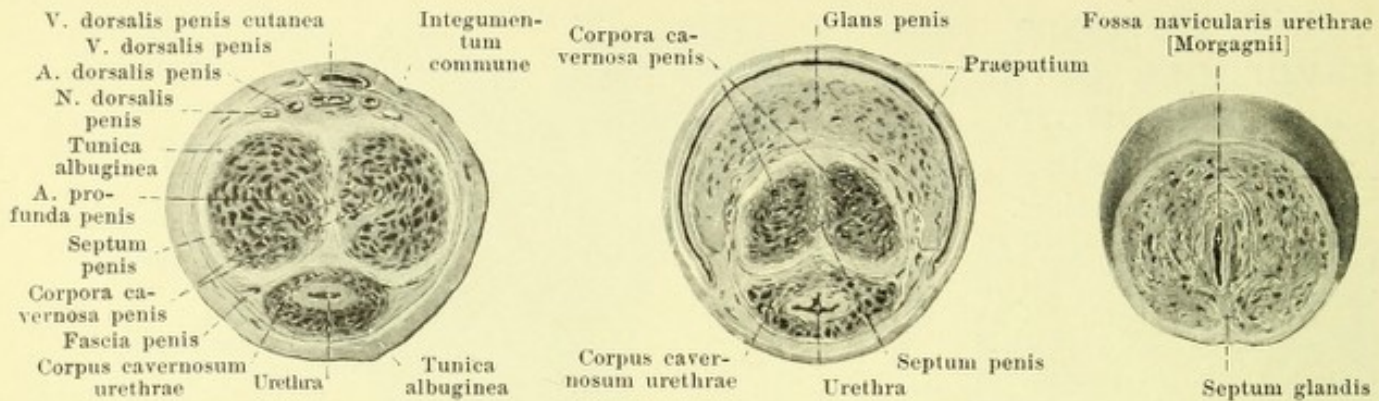
(The bulbus urethrae has been cut off distalward, dissected out and reflected backward. On the left side the m. ischiocavernosus alone has been cut through, on the right side it and also the crus penis have been cut away. The glans penis has been loosened from its position.)

Penis (continued). The penis consists chiefly of the three *erectile bodies*, *corpora cavernosa*.

The two *corpora cavernosa penis* are approximately cylindrical, tube-like structures. Their posterior pointed ends, *crura penis*, run converging along the medial margins of the rami inferiores of the ischium and pubis in front of the symphysis pubis and are firmly attached to the bones by fusion of their tunica albuginea with the periosteum. In front of the lower part of the symphysis the two crura unite at an acute angle to form an unpaired, flat-rounded body, which reaches by its anterior pointed end into the posterior excavation of the glans penis; its upper surface possesses a flat median groove for the v., aa. and nn. dorsales penis, its lower surface a deeper groove for the reception of the corpus cavernosum urethrae.

The *corpus cavernosum urethrae* (O. T. corpus spongiosum) is thinner and longer than the two others. It begins behind in a swelling the size of a hazelnut, the *bulbus urethrae*, which may be divided by a shallow constriction of the posterior margin into two *hemisphaeria bulbi urethrae*; this groove corresponds to a thin median *septum bulbi urethrae* in the interior which consists of connective tissue and projects deep down from behind and above. The upper surface is firmly united with the trigonum urogenitale. The bulbus is perforated in front and above by the urethra so that its main mass lies behind the latter. In front becoming gradually narrower it goes over into the longest narrow-cylindrical part, which is attached to the corpora cavernosa penis in a longitudinal groove on their lower surface and surrounds the urethra on all sides.





659—661. Cross-sections of the penis

through the body.

through the posterior part
of the glans penis.

through the anterior
part of the glans penis.

Penis (continued). The *glans penis* or *acorn* has the form of a blunt wedge. Its excavated base is firmly united with the anterior end of the combined corpora cavernosa penis and projects lateralward and upward somewhat behind these by a swelling, the *corona glandis*; behind the corona runs a groove, *collum glandis*. The upper surface of the glans is longer and convex, the lower is more flat. The glans in its lower part is connected with the corpus cavernosum urethrae and appears to be the continuation of the same; it surrounds the urethra, which runs near its lower surface and opens at the apex of the acorn.

The corpora cavernosa penis is covered by a thick layer of connective tissue, *tunica albuginea corporum cavernosum*, which extends also between the combined corpora cavernosa as the *septum penis*; in front and dorsalward the latter possesses numerous slit-like openings through which the vessels of the two corpora cavernosa communicate with one another. Numerous leaf-like or thread-like columns, *trabeculae corporum cavernosorum*, go off from the tunica albuginea into the interior, where they form a close network; the meshes of the same are smaller in the periphery than they are near the septum and surround spaces filled with blood, *cavernae corporum cavernosorum*. Through this network of trabeculae extending forward on each side near the septum is the a. profunda penis. The arterial branches run in the trabeculae and open directly into the cavities by means of precapillary branches. Part of them, namely these in the crura penis, appear to be bent around tendril-like at the end, *arteriae helicinae*, when the organ is relaxed. The veins, *venae cavernosae*, perforate the tunica albuginea at different spots, surround the penis as they go partly in the form of arches (see Fig. 500) and reach the v. dorsalis penis; the posterior form the vv. profundae penis.

The corpus cavernosum urethrae is covered by a thin tunica albuginea; in it no arteries open directly into venous spaces; it is composed solely of especially well developed submucous venous plexuses; their channels of exit empty partly into the branches of the v. dorsalis penis which surround the penis, partly directly into the vv. pudendae internae. The larger part of the corpus cavernosum lies under the urethra.

The glans penis is covered by a thin tunica albuginea, which sends a median *septum glandis*, composed of connective tissue from the lower surface as far as the urethra. The erectile tissue of the glans has essentially the same construction as that of the urethra and communicates with it.

The penis is attached above by means of two ligaments. The short, triangular, tough *ligamentum suspensorium penis* (see Figs. 652 and 656) goes from the anterior surface of the symphysis ossium pubis on the pars fixa penis to the tunica albuginea of the combined corpora cavernosa penis. The *ligamentum fundiforme penis* (see p. 279) is attached farther distalward.

Loose connective tissue, the *fascia penis* (see also Fig. 657) covers the organ, and also the v., aa. and nn. dorsales penis, from the radix as far as the collum glandis; it is connected with the tunica dartos as well as with the fasciae superficiales perinei and abdominis.

The *skin, integumentum commune*, of the penis (see also Fig. 657) covers only the pars mobilis, is delicate, almost devoid of hairs, extensile and united by loose subcutaneous tissue, free from fat, with the fascia penis so as to be easily moveable. On its lower surface a narrow dark strip, *raphe penis*, runs forward as a continuation of the raphe scroti as far as the prepuce. From the collum glandis on, the skin forms a folded duplicature, the *prepuce, praeputium* (see also Fig. 656), in that it goes forward at first over the apex of the glans, is then reflected, runs backward again as far as the collum glandis and finally, becoming very thinned, covers the surface of the glans directly; it is connected with the lower surface of the glans by a median fold, *frenulum praeputii*.

The **male urethra**, *urethra virilis* (see Fig. 656), is the excretory duct of the bladder and (with the exception of its initial portion) also of the genital organs; it begins at the collum vesicae at the *orificium urethrae internum*, and ends at the apex of the glans penis at the *orificium urethrae externum*. When the penis is relaxed the urethra describes in its course an S-shaped curve which varies individually, and is divided according to the structures perforated by it into a *pars prostatica*, *pars membranacea* and *pars cavernosa*.

The *pars prostatica* (prostatic portion of the urethra) (see Figs. 643 and 656) perforates the prostate from base to apex, surrounded by it on all sides and runs in an almost vertical direction. At the *orificium urethrae internum* and directly beneath it, it is surrounded by the *annulus urethralis vesicae* (see p. 582). In the middle of its posterior wall projects an oblong, rounded elevation, *colliculus seminalis*; this appears as a swelling on a longitudinal ridge of mucous membrane, *crista urethralis*, which reaches from the uvula vesicae on into the *pars membranacea* and even somewhat farther and distalward frequently bifurcates. Above the colliculus and in front of it the urethra is markedly bulged out being deepened at its two sides to form grooves. The colliculus contains the openings of the ductus ejaculatorii, of several ductus prostatici and in the median plane an oblong, slit-like blind sac, the *utricle prostaticus*, which is directed obliquely upward toward the basis prostatae and opens, slit-like, at the level of the colliculus. The utricle is the rudiment of the fused caudal extremities of Müller's ducts.

The *pars membranacea* (see Figs. 656 and 673) perforates the trigonum urogenitale obliquely from behind and above forward and downward and is almost immovably attached to it. It is surrounded by a ring of cavernous tissue and by a layer of cross-striated muscle fibers, *m. sphincter urethrae membranaceae* (see p. 609), which goes over proximalward directly into the *m. prostaticus* and can be followed distalward as far as the anterior half of the penis.

The *pars cavernosa* (cavernous portion of the urethra) (see Figs. 656, 659—661) runs within the corpus cavernosum urethrae and the glans penis. Behind, it is curved so as to be slightly convex downward, then extends forward and somewhat upward and finally if the penis is flaccid bends downward. In the region of the bulbus it is regularly bulged out somewhat backward. In this region open also the glandulae bulbourethrales [Cowperi]. In the glans penis it presents an oblong dilatation, *fossa navicularis urethrae* [Morgagni]; on its upper wall there is frequently a thin fold of mucous membrane, *valvulae fossae navicularis* (not illustrated), which bounds a pocket, open in front.

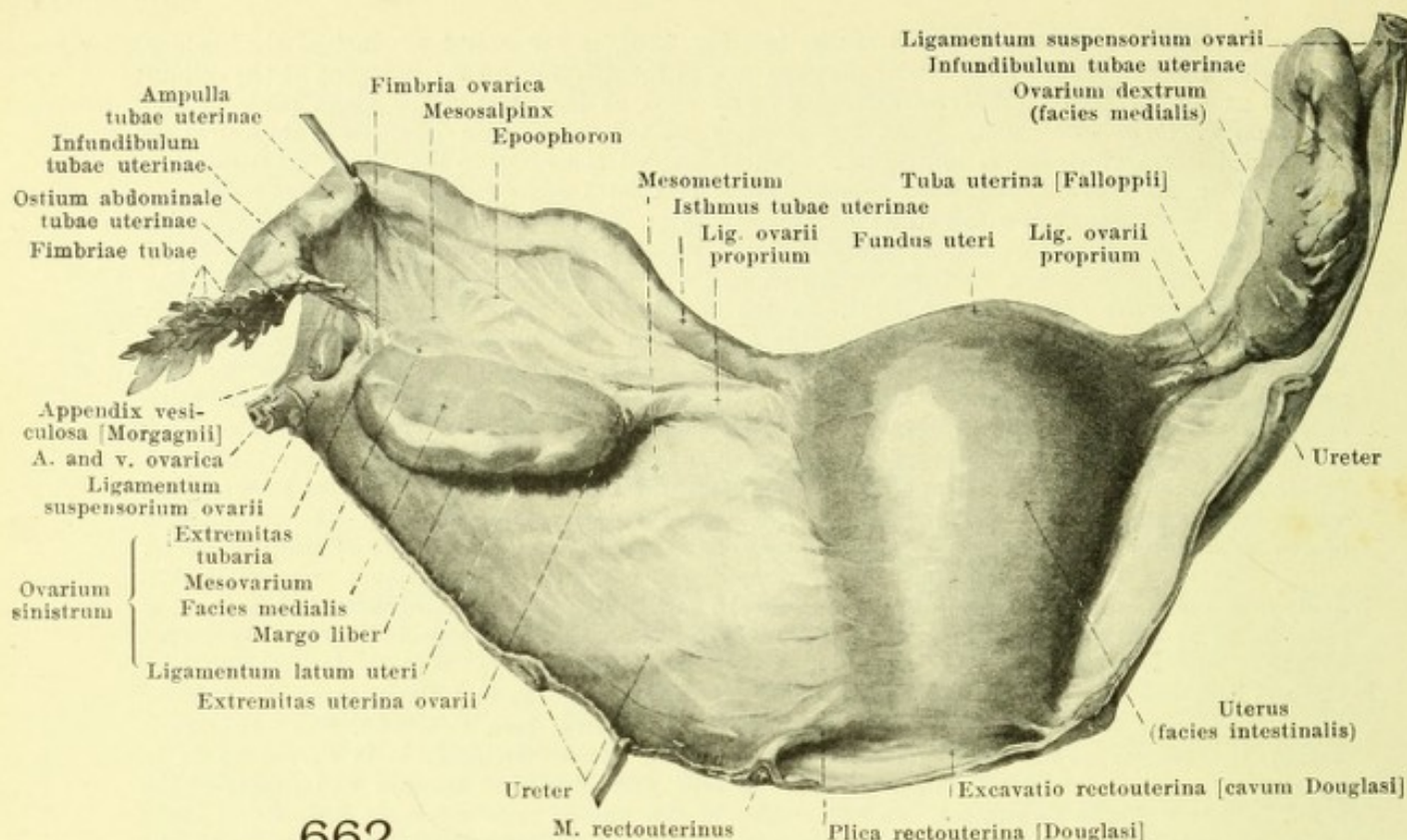
The walls of the empty urethra lie directly in contact with one another. At the *orificium urethrae internum*, in the *pars prostatica* and *pars membranacea* (see Fig. 658) its *lumen* forms a slit which is convex forward, the greatest breadth and depth of which corresponds to the colliculus seminalis; in the most posterior part of the *pars cavernosa* it is a vertical slit, in the larger anterior portion (see Fig. 659) it is a slit which is slightly concave dorsalward; in the base of the glans it is 1-shaped (see Fig. 660), in the *fossa navicularis* and at the *orificium externum* it is vertical (see Fig. 661).

The *caliber* of the urethra is narrowest at the *orificium externum* and becomes dilated in the *fossa navicularis*; then follows the progressively somewhat narrower, long stretch of the *pars cavernosa* as far as the second dilatation in the bulbus urethrae; upon this again follows a marked narrowing in the *pars membranacea*, then a third wider portion in the *pars prostatica*, and finally again a narrowing at the *annulus urethralis*. The two narrowest spots (at the *orificium externum* and in the *pars membranacea*) are also the least extensible.

The whole urethra is lined by a thin, whitish mucous membrane. This possesses, except in the most anterior portion, small mucous glands, *glandulae urethrales* [Littrei]; they open partly into the *lacunae urethrales* [Morgagni] (see Fig. 642), which are small pockets of mucous membrane, open forward, occurring especially in the upper wall of the *pars cavernosa*.

Course of the peritoneum in the male pelvis (see Figs. 598, 599, 655 and 656).

From the posterior surface of the anterior abdominal wall the peritoneum goes directly over upon the upper surface of the urinary bladder; but it covers for a certain distance the lateral surfaces of the small pelvis, that is, the vessels and nerves situated there, the ureters and the seminal ducts, before it is reflected upon the wall of the bladder. This distance is larger when the bladder is empty than when it is full. In addition when the bladder is empty the peritoneum forms a larger fold, *plica vesicalis transversa* (see also Fig. 667), which runs transversely over the upper surface of the bladder toward the origin of the *annulus inguinalis abdominalis*; less constantly present are from two to three smaller folds, *plicae pubovesicales*, which extend from the region of the vertex vesicae toward the *plica umbilicalis lateralis*. Behind, the peritoneum covers a portion of the fundus vesicae, the seminal vesicles and the seminal ducts and then bends around into the tunica serosa of the rectum. Between the bladder and rectum there thus arises a pocket, *excavatio rectovesicalis*. It is deepest in the middle and is bounded above by two folds, *plicae rectovesicales*, which go from the posterior part of the bladder in the form of an arch to the lateral surface of the rectum; the folds contain smooth muscle fibers in their bases, *mm. rectovesicales*.



662.

Uterus, Fallopian tubes and ovaries, viewed from behind.

(On the right the parts have been left in their natural position, on the left the ligamentum latum has been unfolded).

The **ovaries**, *ovaria*, (see also Figs. 663—667) are the two genital glands in the female; they lie in the small pelvis and are attached by a narrow fold of peritoneum, *mesovarium*, to the posterior surface of the ligamentum latum uteri.

Each ovary has the form of a flattened ellipsoid. It presents for examination a *facies medialis* and a *facies lateralis*, a pole directed upward, *extremitas tubaria*, and a somewhat narrower pole looking downward, *extremitas uterina*; its more convex posterior margin, *margo liber*, is free; its more anterior, straight margin, *margo mesovaricus*, is attached to the mesovarium. The latter margin presents also an oblong groove, *hilus ovarii*, for the entrance and exit of vessels and nerves. From the lower pole goes off the ligamentum ovarii proprium and to the upper pole the fimbria ovarica is attached.

The ovary (see also Figs. 664—667) is placed almost exactly sagittally in its largest plane of hemisection, and nearly vertically in its longest diameter (when the body is in the upright position); it is freely moveable and can be easily displaced from its position. Its lateral surface lies directly in contact with the peritoneal covering of the lateral wall of the small pelvis. The area of apposition is sometimes depressed so as to form a pocket, lies below and behind the a. and v. iliaca externa and is bounded in front and above by the a. umbilicalis, behind and above by the a. and v. hypogastrica and by the ureter, which in this situation runs on the anterior margin of the a. hypogastrica; lateralward from this area are situated the n. obturatorius, the a. and v. obturatoria and the m. obturator internus. It is rare that the two ovaries lie exactly symmetrically. If the uterus is displaced to the right, then the left ovary sinks somewhat and its lower pole is turned somewhat medianward and *vice versa*. The ovarium is partly overlain by the tuba uterina, so that only a relatively small part of its medial surface looks free into the pelvic cavity.

The surface of the ovary is grayish red; in childhood it is smooth, later it is uneven on account of nodular projections and scarred depressions. The interior (see Fig. 664) consists of a central medullary layer and a peripheral cortical layer. The latter contains spherical structures, up to the size of a pea, the *egg follicles*, the largest of which project beyond the surface. The smaller are called *primary follicles*, *folliculi oophori primarii*, the larger contain a clear fluid, *liquor folliculi*, and are called *Graafian follicles*, *folliculi oophori vesiculosi* [Graaf]. Each egg follicle contains one egg, *ovulum*; the follicles are separated from one another by firm connective tissue, *stroma ovarii*. After the extrusion of the egg from the follicle a *corpus luteum* develops from the latter; this changes later into a firm mass of connective tissue, *corpus albicans*, and finally vanishes entirely.

663. Right ovary and Fallopian tube,

in their natural position,
cut through transversely.

The **uterine** or Fallopian tubes, *tubae uterinae* [*Fallopii*]. (see also Figs. 662, 664—667) are paired, long, thin, tube-like structures, which run from the ovary to the uterus and are moveably attached to the *ligamentum latum uteri* by means of a thin fold of peritoneum, the *mesosalpinx*.

Each *tuba uterina* (see Figs. 662 and 664) begins at the ovary by a wide, funnel-shaped portion, *infundibulum tubae uterinae*, the margin of which is split up into numerous narrow, very jagged processes, *fimbriae tubae*; one of these, the *fimbria ovarica*, is as a rule longer than the others, is continued along the free edge of the *mesosalpinx* as far as the *extremitas tubaria* of the ovary and forms a groove beside the ovary. The inner surface of the *fimbria* is studded with numerous folds of mucous membrane, which are continued directly into the longitudinal folds of the *ampulla* and in its depth is situated the narrow opening, *ostium abdominale tubae uterinae*. The longer portion following upon the *infundibulum* is called the *ampulla tubae uterinae*; it is tortuous and narrows gradually toward the narrowest part, the *isthmus tubae uterinae*, which is immediately adjacent to the uterus. The short terminal portion of the Fallopian tube, *pars uterina*, lies within the wall of the uterus and opens into the *cavum uteri* by a narrow funnel-shaped opening, *ostium uterinum tubae*.

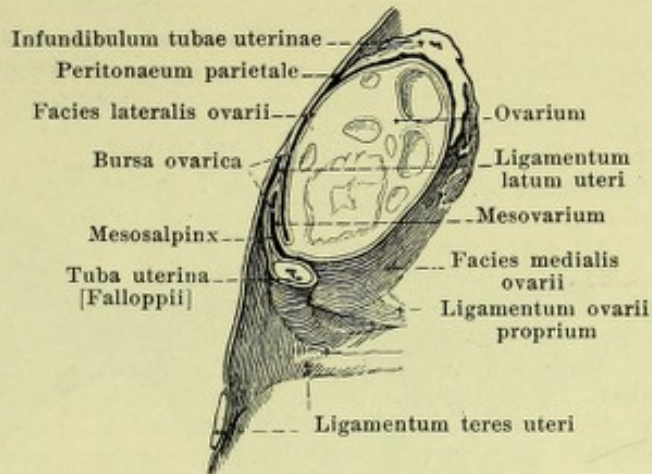
The *isthmus* runs (see also Figs. 662, 664—667), when the body is upright, nearly horizontally in a frontal plane as far as the *extremitas uterina* of the ovary. The Fallopian tube there bends around almost at a right angle and, lying close to the wall of the pelvis, ascends in front of the *margo mesovaricus* as far as the *extremitas tubaria*. Here it turns again abruptly downward and somewhat backward and along with the inner surface of the *infundibulum* lies directly upon the *margo liber* and the posterior portion of the *facies medialis*; the *fimbria ovarica* thus ascends in a recurrent direction to the *extremitas tubaria*. Since the ovary lies against the *peritoneum parietale* of the pelvic wall lateralward and since in front, above, behind and partly also medianward it is overlapped directly by the Fallopian tube and by the *mesosalpinx*, it is enclosed by these parts in a pocket, *bursa ovarica*, the slit-like lumen of which is connected with the *cavum peritonaei* only laterally behind and medianly in front.

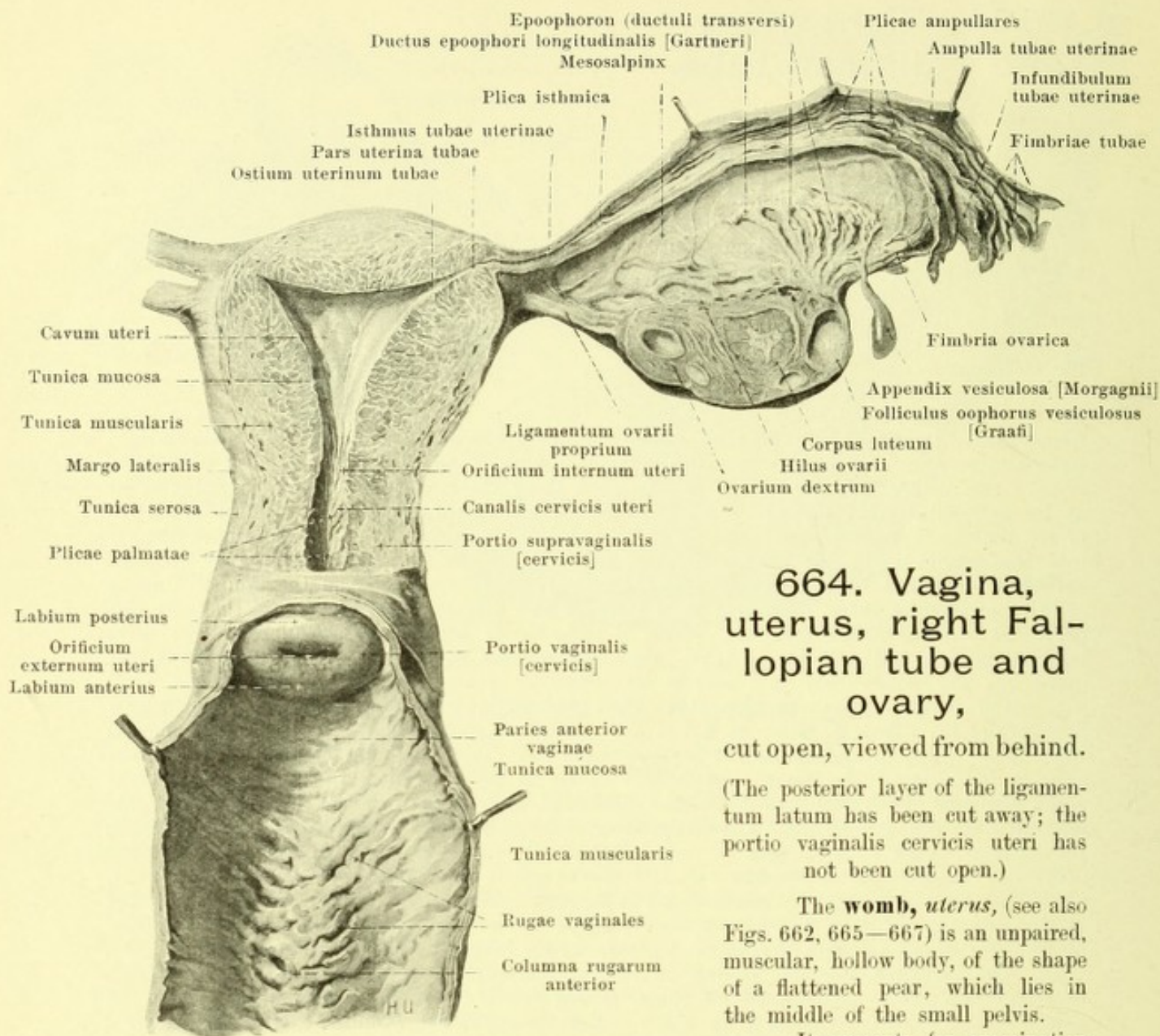
The Fallopian tube is covered on its external surface by peritoneum, *tunica serosa*, beneath which lies a loose connective tissue, *tunica adventicia*. Then follows a layer of smooth muscle fibers, *tunica muscularis*, in which can be distinguished a thinner external longitudinal layer, *stratum longitudinale*, and a thicker internal circular layer, *stratum circulare*. The inner surface is formed by grayish-red mucous membrane, *tunica mucosa*. This everywhere presents very delicate folds, *plicae tubariae* (see Fig. 664), which begin in the *pars uterina* as simple, low, longitudinal folds and become larger in the *isthmus*, *plicae isthmicae*; in the *ampulla* they are highest and form the *plicae ampullares*, and here they are studded with accessory folds. At the free jagged margin of the *infundibulum* the mucous membrane is continued directly into the peritoneum.

The **epoophoron** (see Figs. 662 and 664) is a small flattened body which lies on each side in the lateral portion of the *mesosalpinx* between its peritoneal layers. It consists of several short canals, *ductuli transversi*, which converge toward the *hilus ovarii* and near the Fallopian tube open almost at a right angle into a main canal, *ductus epoophori longitudinalis* [*Gartneri*]. The latter represents the remains of the embryonal Wolffian duct, the *ductuli transversi* being remains of the tubules of the Wolffian body.

Appendices vesiculosae [*Morgagnii*] (see Figs. 662 and 664). (O. T. hydatids of Morgagni.) Hanging down free, almost constantly, from the region of the *epoophoron*, one or several pedunculated vesicles filled with fluid; they have their origin in the Wolffian duct.

Paroophoron (not illustrated) is an aggregation of small usually pigmented canals, usually absent in the adult, visible only by means of a hand lens; it is situated beneath the ovary between the ultimate branches of the *a. ovarica* before their entrance into the *ovarium* just under the anterior peritoneal layer of the *ligamentum latum medianward* from the *epoophoron*, and contains remnants of tubules of the Wolffian body.





664. Vagina, uterus, right Fallopian tube and ovary,

cut open, viewed from behind.

(The posterior layer of the ligamentum latum has been cut away; the portio vaginalis cervicis uteri has not been cut open.)

The **womb, uterus**, (see also Figs. 662, 665—667) is an unpaired, muscular, hollow body, of the shape of a flattened pear, which lies in the middle of the small pelvis.

It presents for examination a larger and thicker *body, corpus uteri*, and a *neck, cervix [uteri]*.

The body possesses an inferior, fairly smooth surface lying upon the urinary bladder, *facies vesicalis*, and an upper surface, turned at the same time somewhat backward, *facies intestinalis*, which is curved above so as to be convex in the frontal and sagittal directions. The anterior, blind end is broad and convex (more markedly convex in women who have borne children than in nulliparae); that portion of it which projects beyond the line between the openings of the Fallopian tubes is called the *fundus uteri*. The body narrows behind, goes over into the cervix and is usually marked off from the latter by a shallow constriction. Lateralward on each side runs a blunt margin, *margo lateralis*, from which the ligamentum latum uteri goes off. The neck in children and nulliparae is spindle-shaped; in women who have borne children it is of a cylindrical shape. Its posterior, inferior third is surrounded by the upper end of the vagina and projects into the cavity of the latter; it is called the *portio vaginalis [cervicis]*. The portio vaginalis is transversely elliptical and divided by the round or transversely oval *orificium uteri externum, external mouth of the womb*, into an upper *labium posterius*, and a more deeply situated *labium anterius*, both of which are smooth and of almost equal thickness; in women who have borne children the orifice is a transverse slit with notched margins.

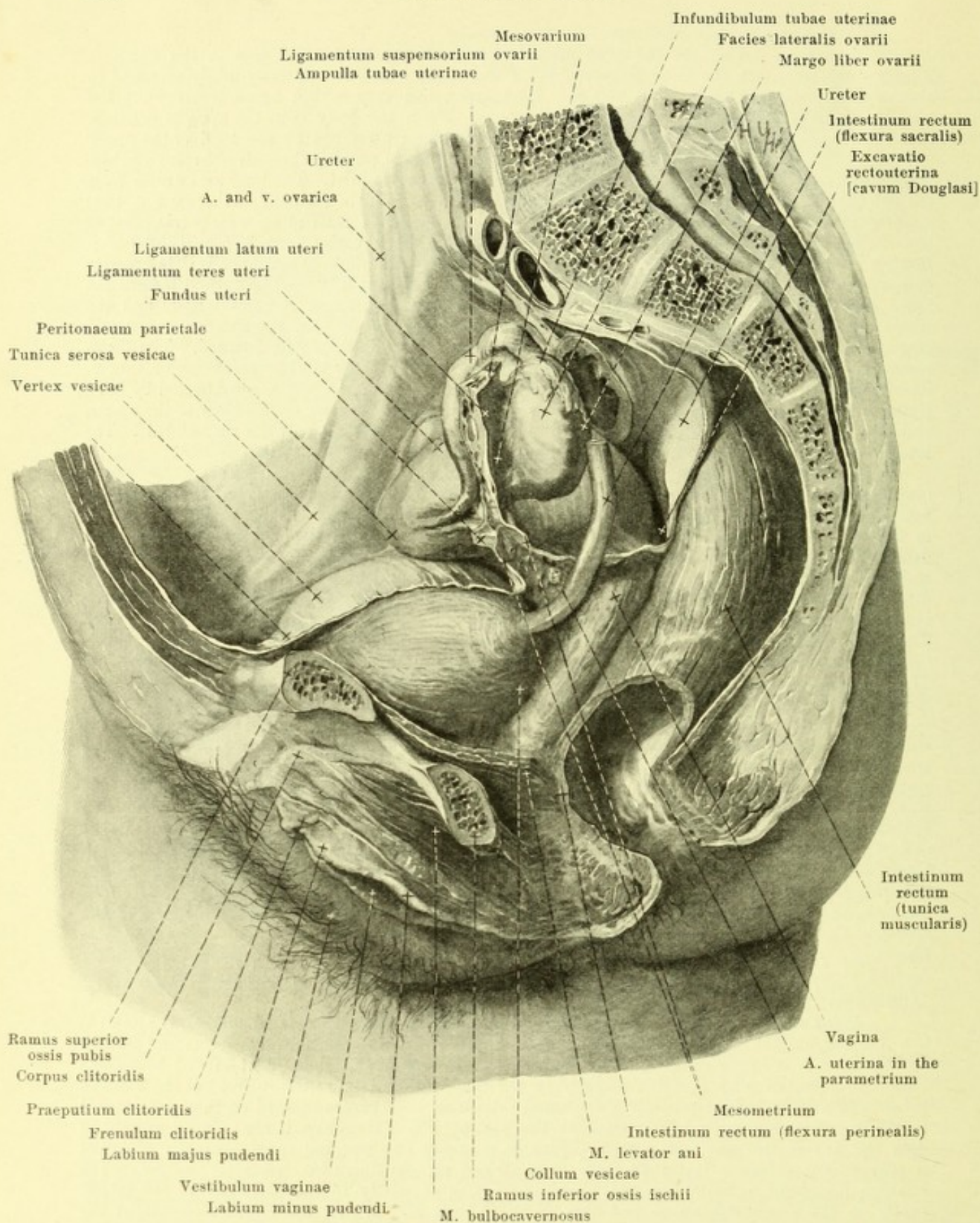
Uterus (continued).

The uterus belongs to the most moveable parts of the body. Not only is the organ as a whole moveable but the body is moveable on the neck, which is relatively firmly attached to the vagina, urinary bladder and vessels. Its position can vary within broad limits, but the typical situation is as follows (see Figs. 665—667). When the body is in the upright position, and the bladder and rectum empty, the orificium externum uteri lies at the level of the upper margin of the symphysis ossium pubis and in a frontal plane passing through the spinae ischiadicae; above, the uterus does not reach the plane of the pelvic inlet. The long axis drawn from the fundus to the external orifice of the uterus lies above in front of the axis pelvis (see Fig. 167) (*anteversion* of the whole uterus). The long axis of the cervix runs in the axis pelvis, that of the corpus almost horizontally; the two form an angle which varies from 70° to 100° (*anteflexion* of the body of the uterus). The uterus lies usually somewhat asymmetrically; its anterior end especially tends to be displaced somewhat toward the right; it may even be turned toward the left. When the bladder fills, the anteflexion is diminished (its angle becomes larger) and the whole organ is displaced backward and upward. When the rectum fills, the anteflexion becomes larger (its angle is diminished in size) and the whole organ is displaced forward. The facies vesicalis of the corpus uteri lies upon the upper surface of the urinary bladder and causes a saucer-like depression in the latter when empty. The anterior wall of the cervix is connected by loose tissue with the posterior wall of the bladder. The facies intestinalis of the body of the uterus and the posterior surface of the neck help to form the floor of the excavatio rectouterina. The lateral surfaces of the corpus and of the cervix adjoin the parametrium (see p. 603).

The uterus possesses in part a visceral peritoneal coat, *tunica serosa* (*perimetrium*) (see Figs. 664—666). This covers the posterior surface of the portio supravaginalis cervicis as well as the facies intestinalis, the fundus and the facies vesicalis of the body and is reflected in front at the junction between the corpus and cervix at the level of the orificium internum uteri upon the urinary bladder. It is attached very firmly to the fundus and the largest part of the body, lateralward more loosely, to the cervix very loosely and at the margo lateralis goes over directly into the ligamentum latum uteri. Beneath the tunica serosa is situated the thick *tunica muscularis*, composed of smooth muscle fibers, and consisting mainly of a middle circular layer. The corresponding layer of the cervix, *tunica muscularis cervicis*, is formed by a thick middle layer of circular fibers as well as of an external and an internal thin layer of longitudinal fibers. The musculature is connected with that of the vagina, of the Fallopian tubes and of the ligamenta teretia and ovarii propria and with the mm. rectouterini. The inner covering is formed by the mucous membrane, *tunica mucosa*. This is of a grayish-red color, is firmly connected with the musculature and contains in the corpus tube-like glands, *glandulae uterinae*, in the cervix markedly dilated, *glandulae cervicales [uteri]*, which secrete mucus. The mucous membrane in the body is smooth and surrounds a cavity (see Figs. 664 and 666). In the corpus this is a triangular slit, *cavum uteri*, the anterior and posterior wall of which usually lie close against one another; the sides project so as to be convex inward in women who have not borne children; the upper two corners go over like funnels into the ostia uterina of the Fallopian tubes, the lower end is separated only imperfectly from the *canalis cervicis uteri* by a canal-like narrowing, *orificium internum uteri*. The cavity situated in the neck, *canalis cervicis uteri*, has a rounded spindle-shaped slit-like lumen, is widest in the middle and opens into the vagina through the *orificium externum uteri* (see p. 598). Its mucous membrane presents a fold-formation, *plicae palmatae*, on its anterior and posterior walls; this consists of a thicker median ridge and finer folds going off obliquely from it lateralward; the formation gradually vanishes at the orificium internum uteri.

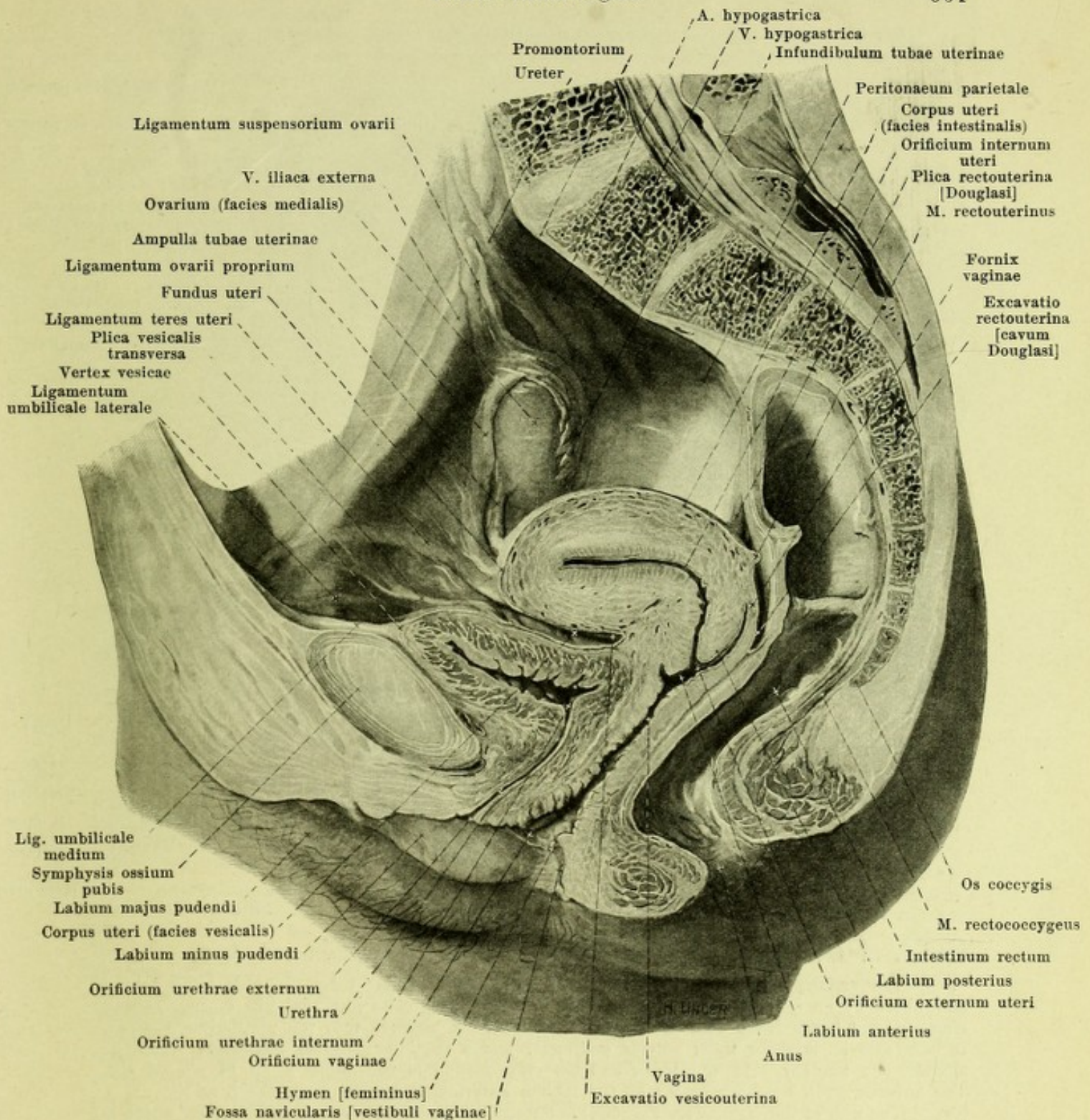
Ligamentum teres uteri (round ligament of the uterus) (see Figs. 665—667 and 675) is a rounded, smooth cord about the size of a goose quill consisting of connective tissue and smooth muscle fibers; it arises on each side from the margo lateralis uteri in front of and below the Fallopian tube, runs at first horizontally in the ligamentum latum uteri in front of the isthmus tubae uterinae to the lateral wall of the small pelvis and then passes upward on this and forward to the annulus inguinalis subdominalis. In this last portion of its course it runs almost exactly as does the ductus deferens (see p. 586). Finally it enters the inguinal canal, extends with the n. spermaticus externus and with some cross-striped muscle fibers (m. cremaster) as far as the annulus inguinalis subcutaneus and, spreading out, goes partly to the periphery of the latter, partly to the connective tissue and skin of the labium majus. At the annulus inguinalis abdominalis, lying in front and over it, is a small sac-like prolongation of the peritoneum, *processus vaginalis peritonaei* (not illustrated) which is longer in foetal life and sometimes persists so.

Ligamentum ovarii proprium (O. T. ligament of the ovary) (see Figs. 662, 664, 666 and 667) consists of connective tissue and smooth muscle fibers; it goes off on each side as a rounded cord from the upper end of the margo lateralis uteri, extends in the ligamentum latum to the extremitas uterina of the ovary and becomes lost in the hilus of the latter.



665. Pelvic organs in the female,
after removal of the left pelvic wall, viewed from the left.

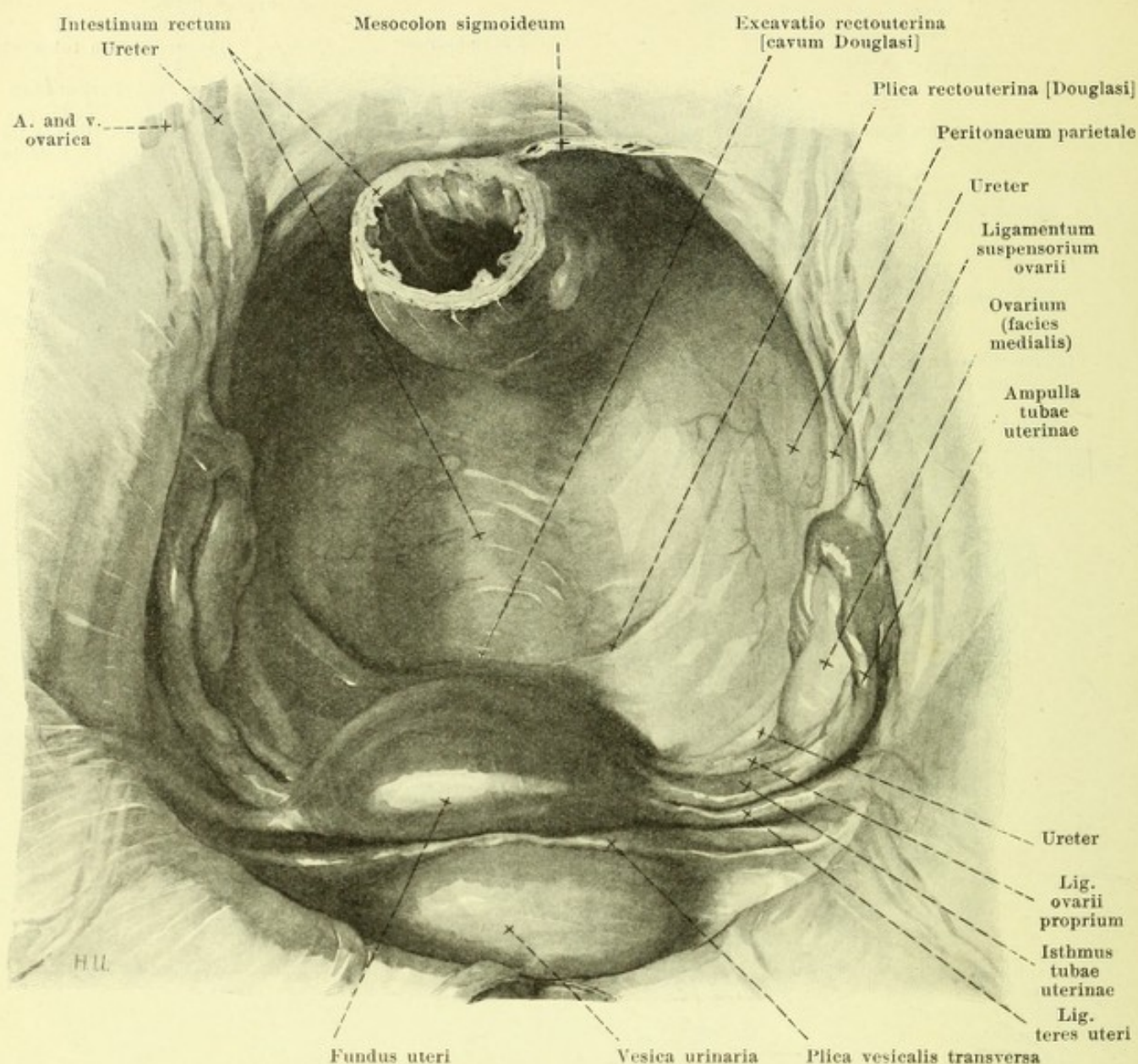
(The urinary bladder is only partially filled. A piece has been cut out of the rectum.)



666. Median section through the pelvic organs in the female,

right half, viewed from the left (partly after a frozen section by W. Braune). (The urinary bladder is empty. The canals lined by mucous membrane and the peritoneal spaces are represented as though somewhat dilated.)

M. rectouterinus (see also Fig. 662) is the name given to the smooth muscle fibers which run in the plica rectouterina [Douglasi] on each side. It arises as a flat, rounded cord from the posterior wall of the neck of the uterus, radiates out near the rectum into the neighborhood of the latter and extends in part to the musculature of the rectum, in part to the anterior surface of the sacrum.



667. Pelvic organs in the female, viewed from above.

The **vagina** (see Figs. 664—666) is a flattened muscular tube. It ends blind behind and above by an extremity which surrounds the portio vaginalis [cervicis] like a ring, *fornice vaginae*, and opens below and in front by the *orificium vaginae* into the vestibulum vaginae. It possesses an anterior wall, *paries anterior*, and a posterior, *paries posterior*, which lie against one another. At the lower end the cross-section of the lumen is an H-shaped slit. The anterior wall, reaching as far as the labium anterius, is shorter than the posterior.

The wall of the vagina (see Fig. 664) is formed externally of a *tunica muscularis*, which is divisible into an external longitudinal and an internal circular layer. It consists above of smooth muscle fibers, in the trigonum urogenitale of cross-striped fibers. It has, lying loosely upon it within, the thick, grayish-red mucous membrane, *tunica mucosa*. In the virgin this presents, especially below, numerous strong transverse folds, *rugae vaginales*, which in the middle of the anterior and posterior walls form a longitudinal projection, *columna rugarum anterior* and *posterior*. The anterior projection is higher below and is continued in the vestibulum vaginae as far as the orificium urethrae externum as the *carina urethralis [vaginae]* (see Fig. 669). In virgins, going off at the orificium vaginae, chiefly from the posterior wall of the vagina, is a fold of mucous membrane, usually sickle-shaped, the *hymen [femininus]* (see Figs. 666 and 669); it extends forward and upward and narrows the opening. Its margin is smooth or slightly jagged. By sexual intercourse the hymen is torn into several lobules, which shrivel up after the first child-birth into small lobe-like or wart-like projections, *carunculae hymenales* (see Fig. 668).

Vagina (continued).

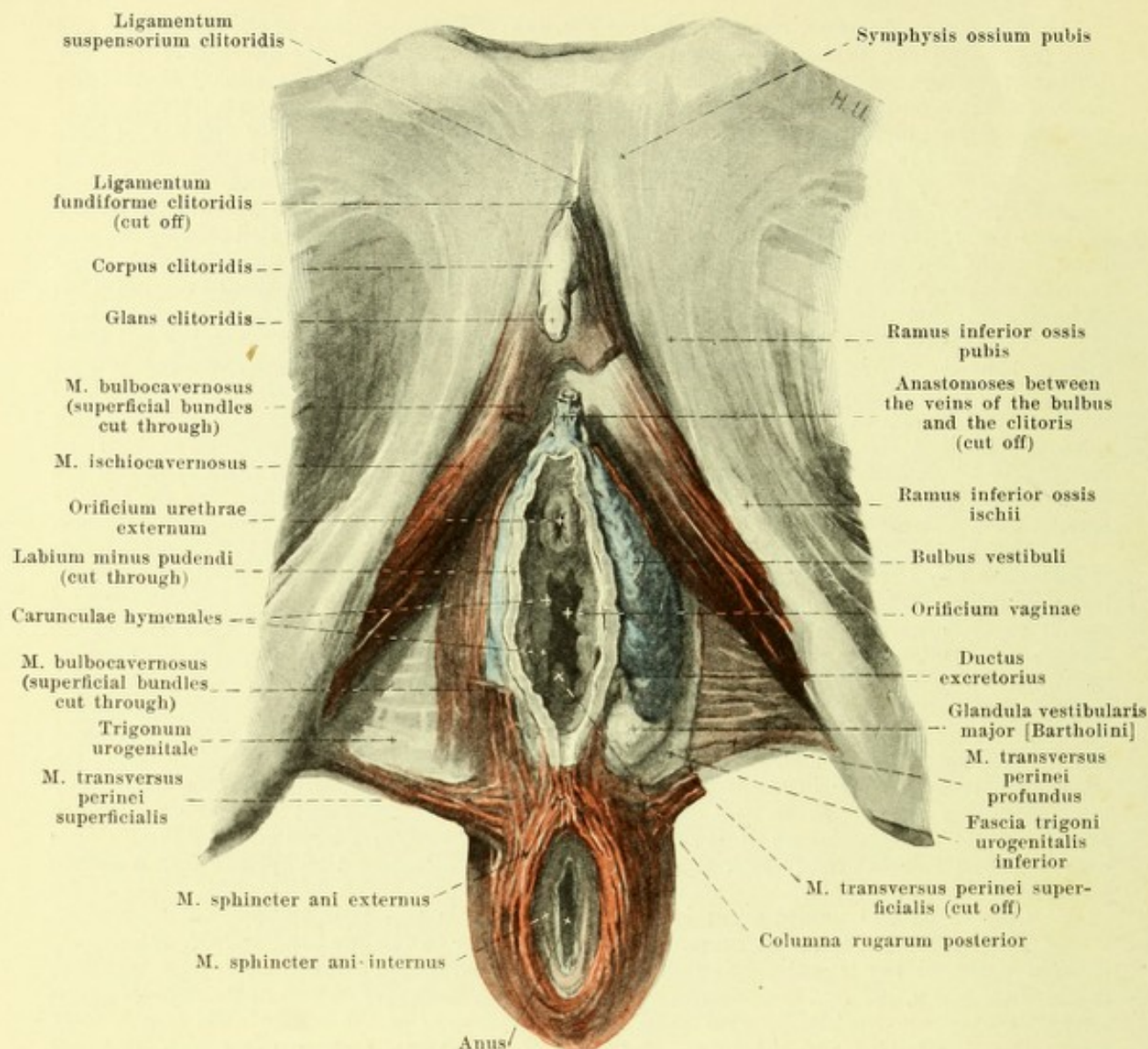
The vagina forms an obtuse angle (see Fig. 666) with the long axis of the cervix uteri and runs from above and behind, downward and forward approximately in the direction of the lower portion of the axis pelvis (see Fig. 167). In front it adjoins the fundus of the urinary bladder and urethra and is connected by loose connective tissue with the bladder, by very firm connective tissue with the urethra; above, the two ureters also lie for some distance on its anterior wall but far more loosely connected (see Fig. 665). Behind, it is covered above as far as the level of the orificium externum uteri by the peritoneum; it then lies on the anterior surface of the rectum and does not become separated from it again until beneath the mm. levatores ani; above, it is separated from the rectum by loose connective tissue; below, the musculature of the peritoneum is situated between the two. Laterally on each side above (see also Figs. 471, 472, 502 and 503) the vagina adjoins the parametrium with the plexus uterovaginalis and the a. uterina, below, it adjoins the medial margin of the m. levator ani; just in front of its opening into the vestibulum it perforates the trigonum urogenitale.

The **female urethra**, *urethra muliebris* (see Figs. 642 and 666) is the channel of exit of the urinary bladder; it begins at the fundus vesicae as the *orificium urethrae internum* (see p. 582) and ends in the vestibulum vaginae upon a small, blunt-wedge-shaped projection as the *orificium urethrae externum*, which as a rule is a sagittal slit. It runs downward and forward in the same way as does the vagina, being curved so as to be somewhat convex behind. In front and laterally it adjoins the plexus pudendalis, the trigonum urogenitale, which it perforates, and the bulbi vestibuli; behind, it is directly united with the anterior wall of the vagina below the bladder scarcely for a distance of 1 cm by means of loose tissue, elsewhere, however, it is very firmly attached.

The wall of the urethra (see Fig. 642) consists externally of a *tunica muscularis*, which is composed of an internal longitudinal layer, *stratum longitudinale*, and of an external circular layer, *stratum circulare*, of smooth muscle fibers; external from it lies a layer of cross-striped muscle fibers, connected with the m. sphincter membranaceae, which form a closed ring near the bladder only. Internally from this follows a thick, loose *tela submucosa*; it contains large venous networks, which are continued between the layers of muscle and give to them a spongy character, *corpus spongiosum urethrae*. The inner surface is covered by the mucous membrane, *tunica mucosa*. Along the posterior surface, extending from the anterior end of the trigonum vesicae, is a marked longitudinal fold, *crista urethralis*, which goes as far as the neighborhood of the orificium externum. The lumen is stellate and capable of marked dilatation. The mucous membrane possesses *lacunae urethrales* as in the male (see p. 595), and small tubular glands, which are considered the homologues of the prostatic glands in the male; a large group of these glands opens on each side externally near the orificium urethrae externum through the narrow *ductus paraurethralis* (see Fig. 669).

Course of the peritoneum in the female pelvis (see Figs. 662 and 665—667).

The relations of the peritoneum, between the bladder on the one hand and the anterior abdominal wall and the lateral pelvic wall on the other, correspond throughout to those met with in the male (see p. 595). The peritoneum is reflected from the upper surface of the bladder at the level of the orificium internum uteri upon the facies vesicalis of the corpus uteri (see p. 599), covers this, the fundus and the facies intestinalis of the uterus, then goes over upon the fornix of the vagina, covers its posterior wall as far as the level of the orificium externum uteri and finally turns to the anterior surface of the rectum. There thus arise two slit-like spaces, the *excavatio vesicouterina* between the bladder and the facies vesicalis uteri, which also extends lateralward under the anterior surface of the ligamentum latum, and the *excavatio rectouterina* [*cavum Douglasi*] between the uterus and rectum. The latter space is closed in front by the cervix uteri and the fornix vaginae, behind by the sacrum and rectum; it ends below in a blind sac at the level of the orificium uteri externum; its upper boundary is formed by two folds of peritoneum, *plica rectouterinae* [*Douglasi*], which run from the posterior surface of the cervix uteri to the lateral wall of the rectum; the two go over into one another in front and possess a free concave margin. Arising at the margo lateralis uteri on each side is a duplicature of the peritoneum, *ligamentum latum uteri* (broad ligament of the uterus); it is stretched out so as to be quadrangularly rounded in form (see Fig. 662) and its two layers lie for the most part close to one another. Lateralward and below they deviate from one another and go over into the peritoneum on the lateral pelvic wall, the bladder (in front), and the rectum (behind). They thus bound in front and behind an approximately quadrilateral space, which is bounded lateralward by the m. levator ani, medianward by the upper, lateral part of the vagina, as well as the neck and body of the uterus. This space contains the a. uterina and the ureter, surrounded by the large plexus uterovaginalis (see Figs. 502 and 503), all ensheathed in loose, fatty, connective tissue, the *parametrium*. The lateral margin of the ligamentum latum reaches above as far as the v. iliaca externa; going off upward from it in that situation is a fold of peritoneum, *ligamentum suspensorium ovarii* which contains the a. and v. ovarica. Passing upward from the posterior surface is the short *mesovarium* (see p. 596); the larger, denser portion lying beneath it is called the *mesometrium*, the other, thinner part the *mesosalpinx* (see p. 597). The ligamentum latum turned forward near the bladder lies close to the parietal layer of the peritoneum.



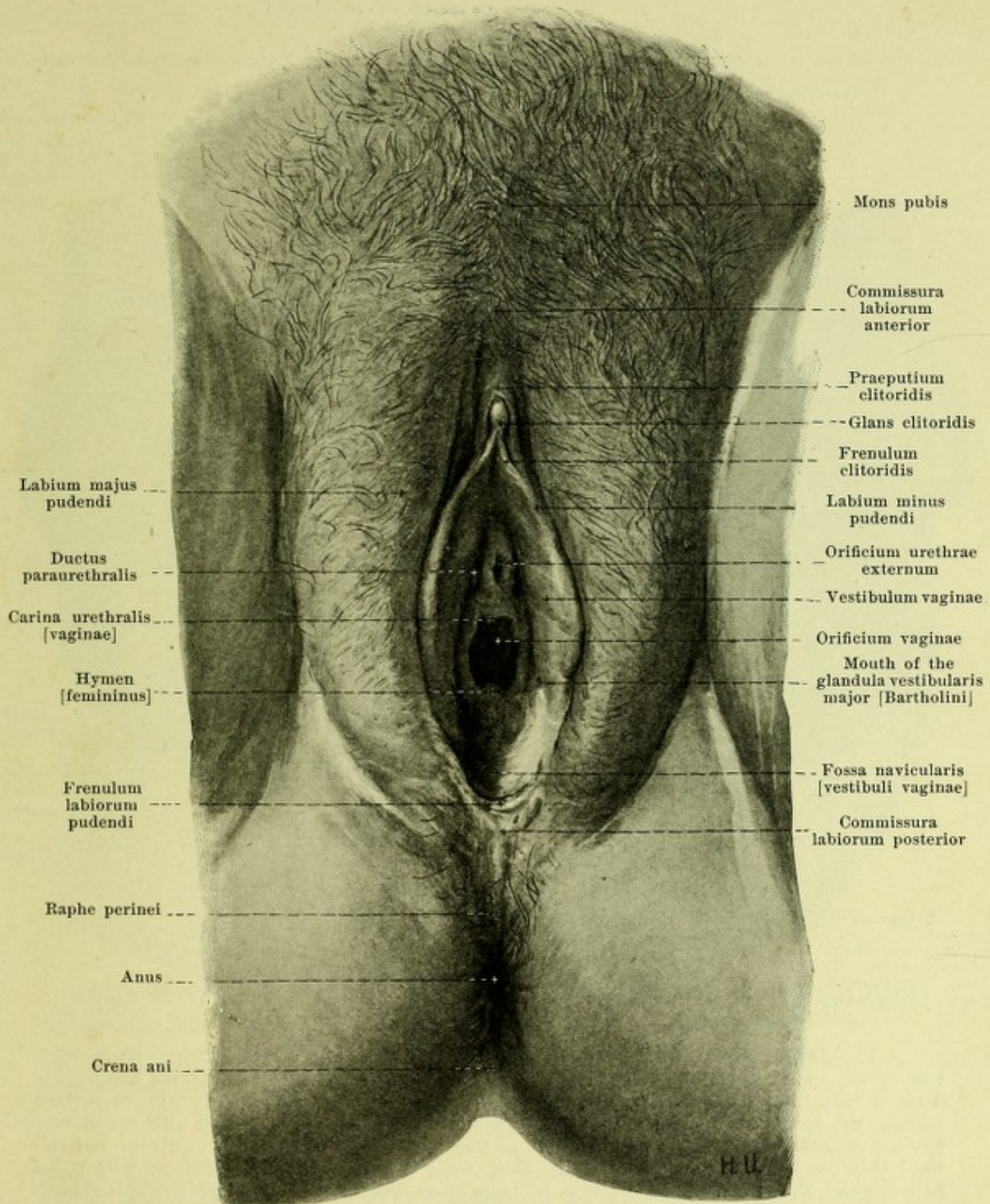
668. Bulbus vestibuli and trigonum urogenitale, viewed from below.

(On the right the superficial layer has been removed; on the left the whole mass of the m. bulbocavernosus and the m. transversus perinei superficialis has been removed. On the left side the m. transversus perinei profundus has been partially exposed.)

The **pudendum muliebre** (O. T. vulva) (see Figs. 665, 666 and 669) lies beneath the trigonum urogenitale and in front of the symphysis ossium pubis; it consists of the labia majora and of the parts which are visible when the vulvar slit is relaxed (see Fig. 669).

The **clitoris** (see also Figs. 503 and 665) corresponds essentially to the corpora cavernosa penis (see pp. 593 and 594), but is much smaller. It consists of two similarly constructed *corpora cavernosa clitoridis*, which, as the *crura clitoridis*, are separated behind, where they exactly resemble the crura penis in position and attachment; they unite in front to form the unpaired, rounded *corpus clitoridis*, which is divided in the median plane by the *septum corporum cavernosorum* and hangs down, even during erection, in a curve in front of the symphysis ossium pubis. The tip of the corpus, *glans clitoridis*, lies free and is covered by external skin. The clitoris is ensheathed by the *fascia clitoridis* and attached by means of the *ligamentum suspensorium clitoridis*; these parts correspond also to those of the penis.

The **bulbus vestibuli** is an oblong body, somewhat pointed in front, somewhat rounded off behind; there is one on each side below the trigonum urogenitale; medianward it adjoins the wall of the vestibulum vaginae and the glandula vestibularis major; lateralward and below it is covered by the m. bulbocavernosus. It corresponds to the bulbus urethrae of the male (see pp. 593 and 594). Beneath the clitoris the two bulbi are connected with one another and with the veins of the clitoris.

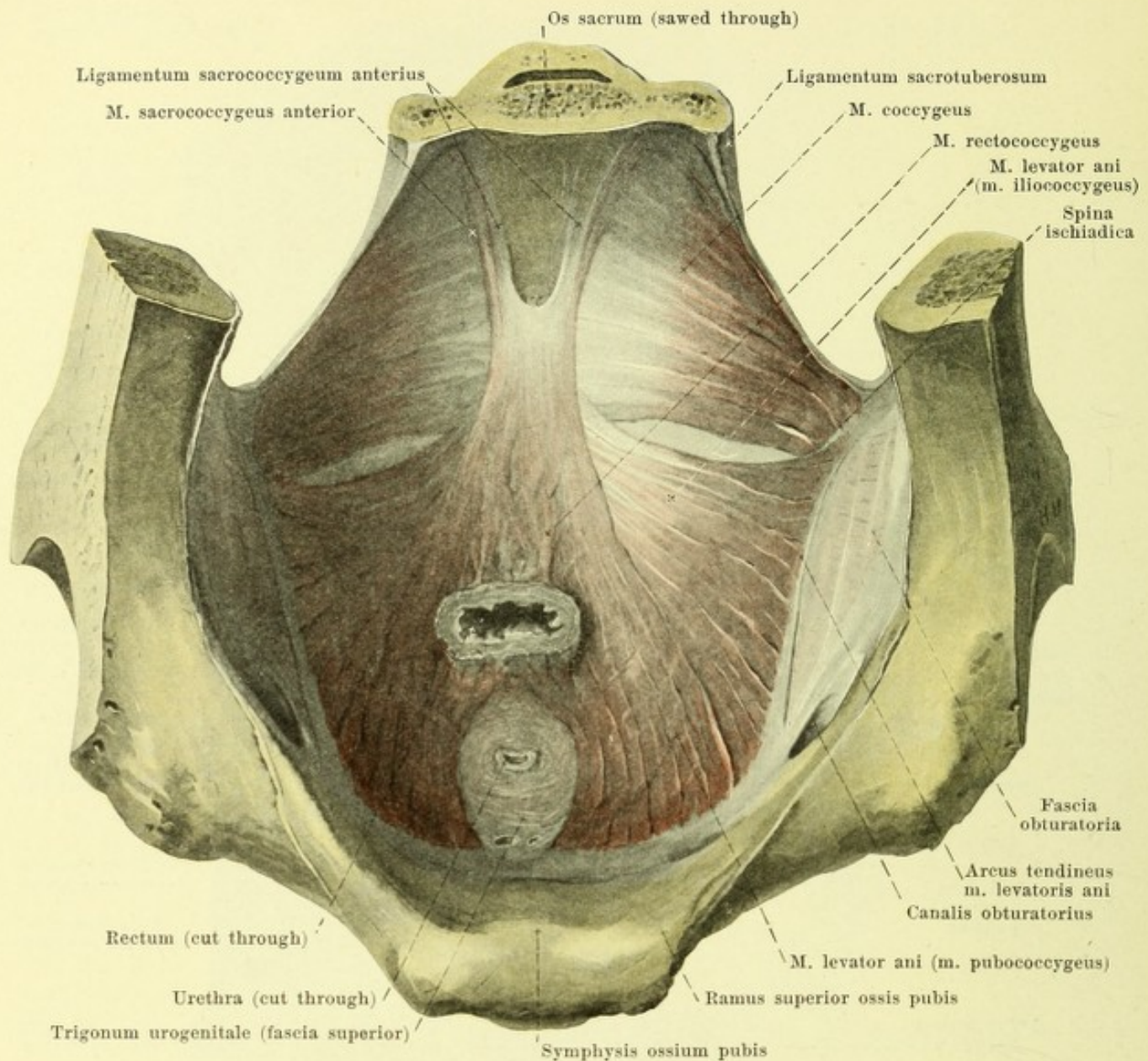


669. External genitals of the female.

(The labia have been drawn apart.)

The *glandula vestibularis major* [Bartholini] (see also Fig. 668) corresponds in structure, form and size to the glandula bulbourethralis [Cowperi] of the male (see p. 592). It lies on each side lateralward from the posterior part of the vestibulum vaginae partly in the trigonum urogenitale and is partly covered by the posterior end of the bulbus vestibuli and by the m. bulbocavernosus. Its duct opens just externally from the hymen at the level of the posterior half of the orificium vaginae.

Spalteholz, Atlas.

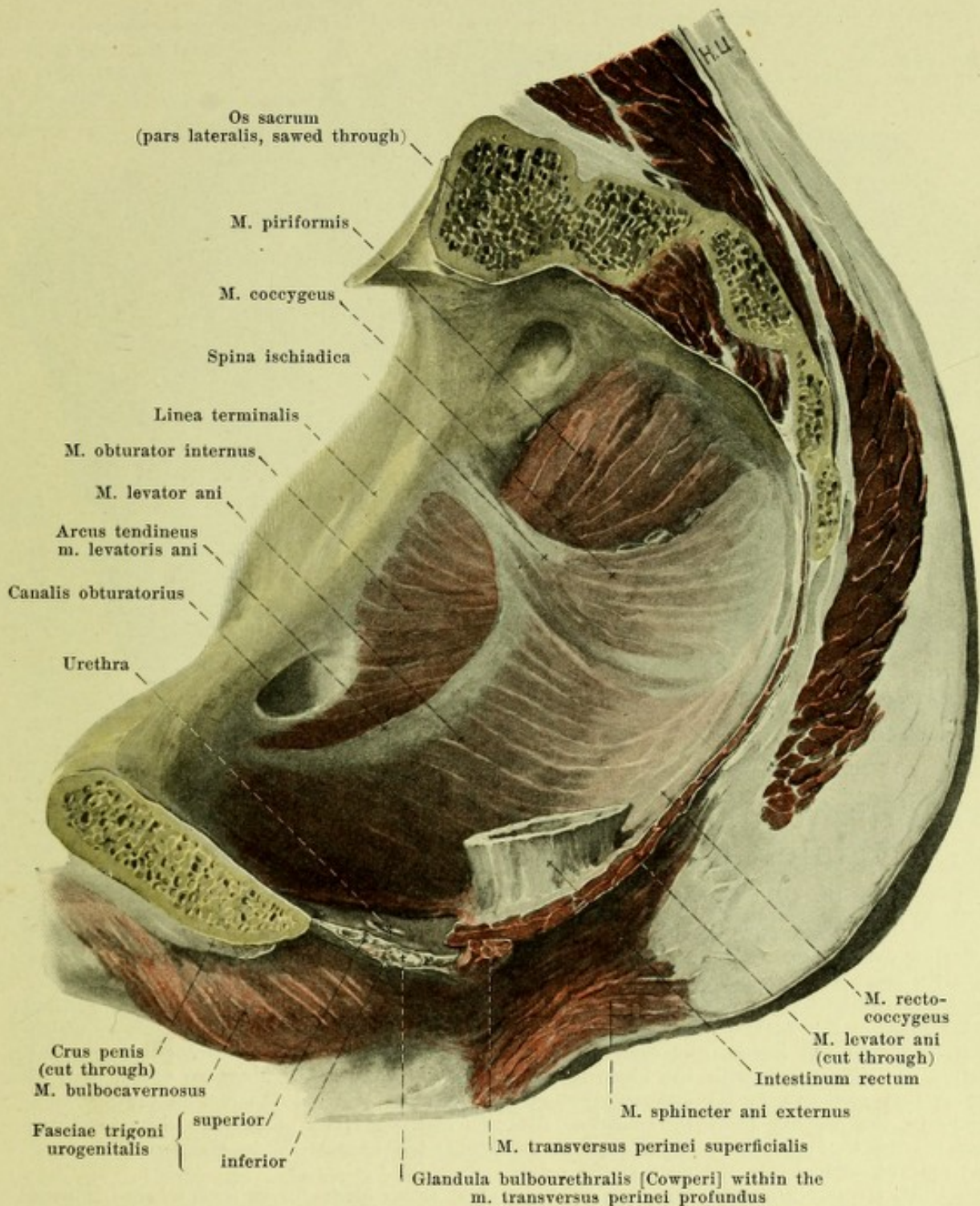


670. Mm. levatores ani of the male, viewed from above.

(The prostate has been removed, the rectum cut off short.)

The **large lips**, *labia majora pudendi*, (see Fig. 669) are two large folds of skin, rich in fat, which extend from the upper margin of the symphysis to the perineum and include between them the *rima pudendi* or *pudendal slit*. In front these folds go over into one another forming the *commissura labiorum anterior*; behind they are either connected with one another forming the *commissura labiorum posterior*, or they may remain separated by a groove. Lateralward they are bounded by furrows in the skin; their anterior surfaces are covered with pubic hairs, *pubes*. The skin of the labia majora contains many sweat glands and large sebaceous glands.

The **small lips**, *labia minora pudendi*, (see Figs. 665, 666 and 669) are two thinner, cockscomb-like, reddish folds which enclose the *vestibulum vaginae* and are ordinarily not visible when the pudendal slit is closed. They are separated from the labia majora by a groove. They unite behind in women who have not borne children, usually forming a delicate fold, *frenulum labiorum pudendi*, behind which lies a fossa, *fossa navicularis [vestibuli vaginae]*. In front they divide into two limbs; the external limbs unite over the glans clitoridis to form the gable-like *praeputium clitoridis*, the internal limbs become attached together to the under surface of the glans clitoridis as the *frenulum clitoridis*. In the vestibulum, especially between the urethral and the vaginal opening, small mucous glands, *glandulae vestibulares minores*, occur.



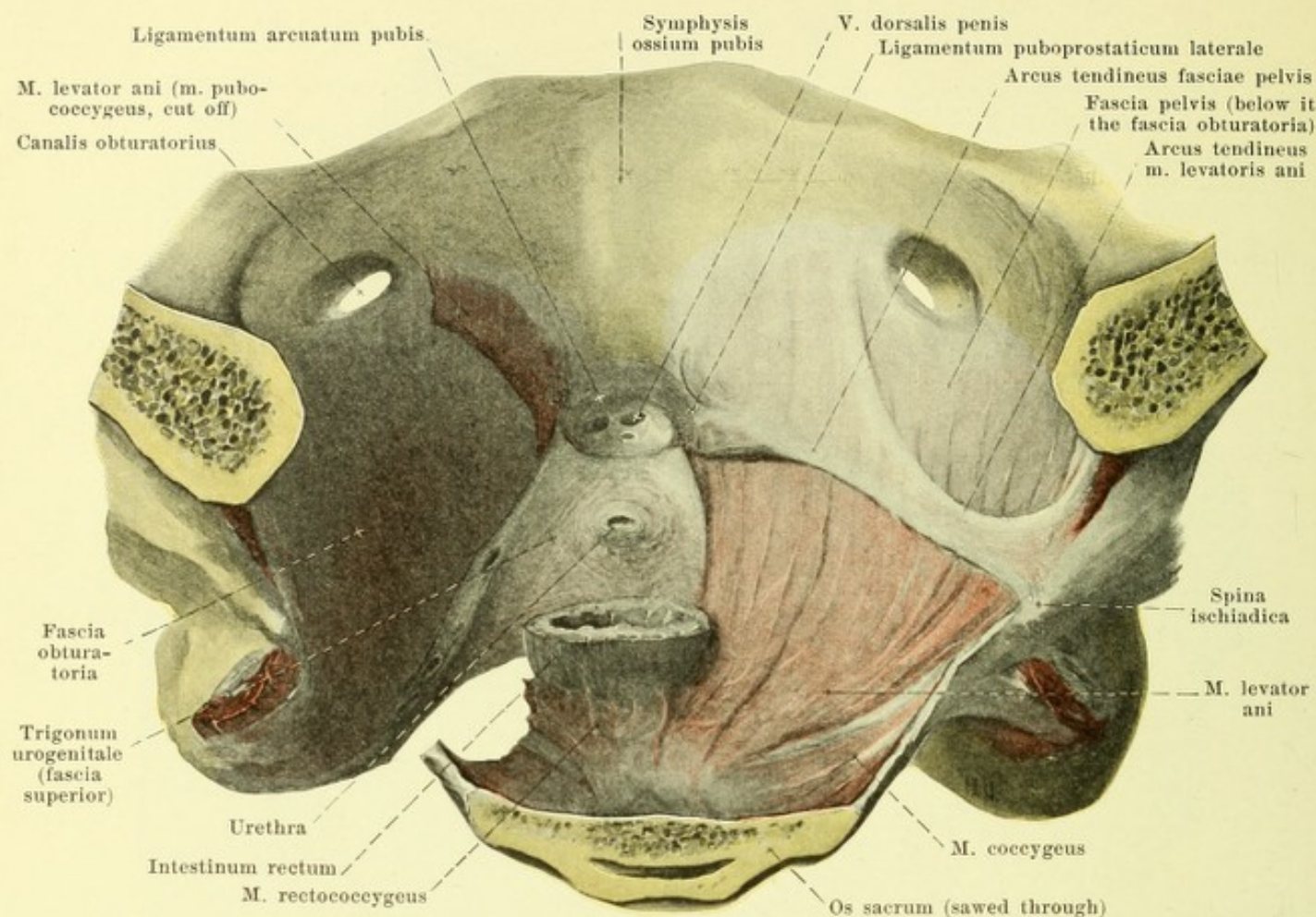
671. Right m. levator ani in the male, viewed from the left.

(The pelvis has been cut through on the left side near the median plane; otherwise as in Fig. 670.)

The floor of the small pelvis is formed chiefly by the **diaphragma pelvis**; this is composed of the two mm. levatores ani and coccygei and has the form of a funnel, the deepest point of which lies below in the pars analis recti.

M. coccygeus (see p. 328).

M. levator ani (see also Figs. 670, 672, 674, 675 and 677), paired. Form: quadrangular, thin, flat, in two portions, *m. pubococcygeus* and *m. iliococcygeus*. Innervation: branches of the plexus pudendus.



672. Right m. levator ani and trigonum urogenitale of the male, viewed from behind and above.

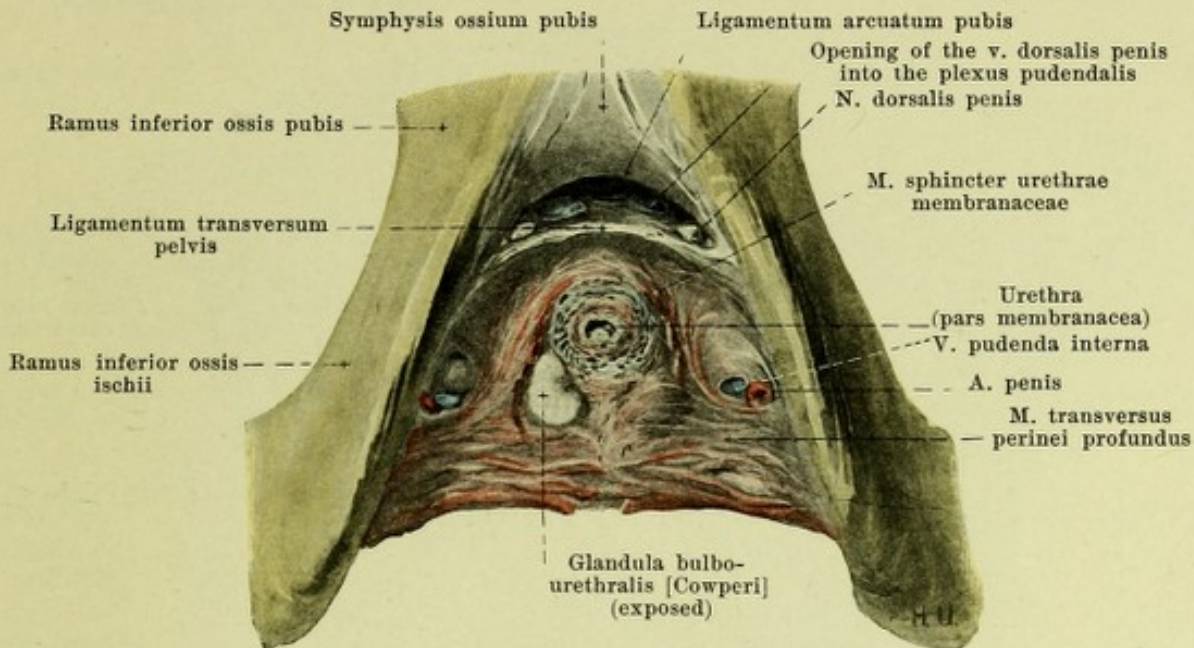
(On the right side the upper part of the fascia pelvis has been retained.)

M. pubococcygeus. Origin: from the posterior surface of the rami ossis pubis in a narrow curved area (which in front surrounds the region of the m. obturator internus) and from the most anterior portion of the arcus tendineus m. levatoris ani (*vide infra*). Insertion: the fibers run backward, downward and medianward near the prostate (in the male, the urethra and vagina in the female) and near the rectum; partly they go to a tendinous plate, which goes over into the ligamentum sacrococcygeum anterius; partly they interweave between the rectum and the coccyx with the fibers of the other side; only a few fibers go to the wall of the rectum and run in its anterior portion to the skin. Behind the rectum the m. rectococcygeus lies directly above this muscle. Action of the muscles of the two sides together: they narrow the pars analis recti (and in the female the vagina), draw the rectum forward and upward, and elevate the floor of the pelvis.

M. iliococcygeus. Origin: From an arch, *arcus tendineus m. levatoris ani*, convex downward, interwoven in the fascia obturatoria; the anterior end of the arch begins on the posterior surface of the ramus superior ossis pubis, and the posterior end can be followed as far as the linea arcuata of the ilium; between these two points it descends for a variable distance but always leaves the canalis obturatorius free. Insertion: the fibers run medianward and downward, pass beneath the posterior portion of the m. pubococcygeus and also often overlap the m. coccygeus from above; the anterior fibers between the anus and the tip of the coccyx form tendinous connections with the fibers of the other side, the posterior fibers go to the margin of the os coccyx. Action of the muscles of the two sides together: they elevate the floor of the pelvis.

M. sacrococcygeus anterior (see Fig. 670), paired, present only at times. Form: narrow, thin. Position: on the upper surface of the m. coccygeus. Origin: anterior surface of the 3rd or 4th sacral vertebra. Insertion: ligamentum sacrococcygeum anterius.

M. sacrococcygeus posterior (not illustrated), paired, rarer than the preceding muscle. Thin muscle bundles upon the posterior surface of the lower sacral and upper coccygeal vertebrae.



673. Muscles of the trigonum urogenitale of the male, viewed from below.

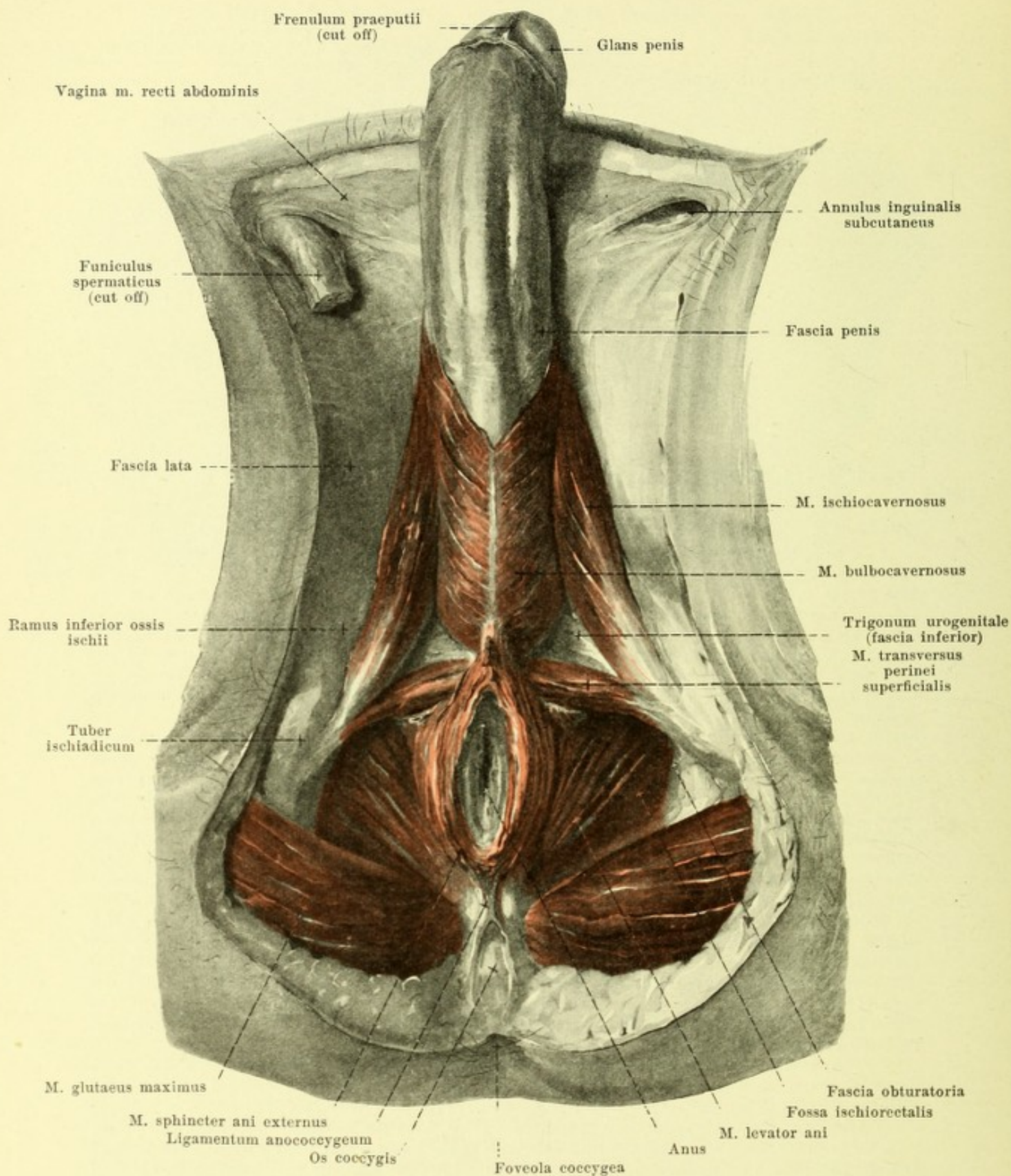
(The fascia inferior has been removed, on the right side the glandula bulbo-urethralis has been exposed.)

The **trigonum (diaphragma) urogenitale** (O. T. triangular ligament) (see Figs. 640, 656—658, 668, 671, 672, 674, 675 and 677) is a firm, trapezoid, musculo-tendinous layer which fills up the space between the rami inferiores of the ischial and pubic bones, beneath the two mm. pubococcygei, so that only a space is left free in front, just beneath the ligamentum arcuatum pubis for the passage of the v. dorsalis penis (clitoridis). It ends behind in a thin slightly concave curved margin, in front in a sharp margin and is perforated perpendicularly by the pars membranacea of the urethra (in the male, the urethra and the vagina in the female).

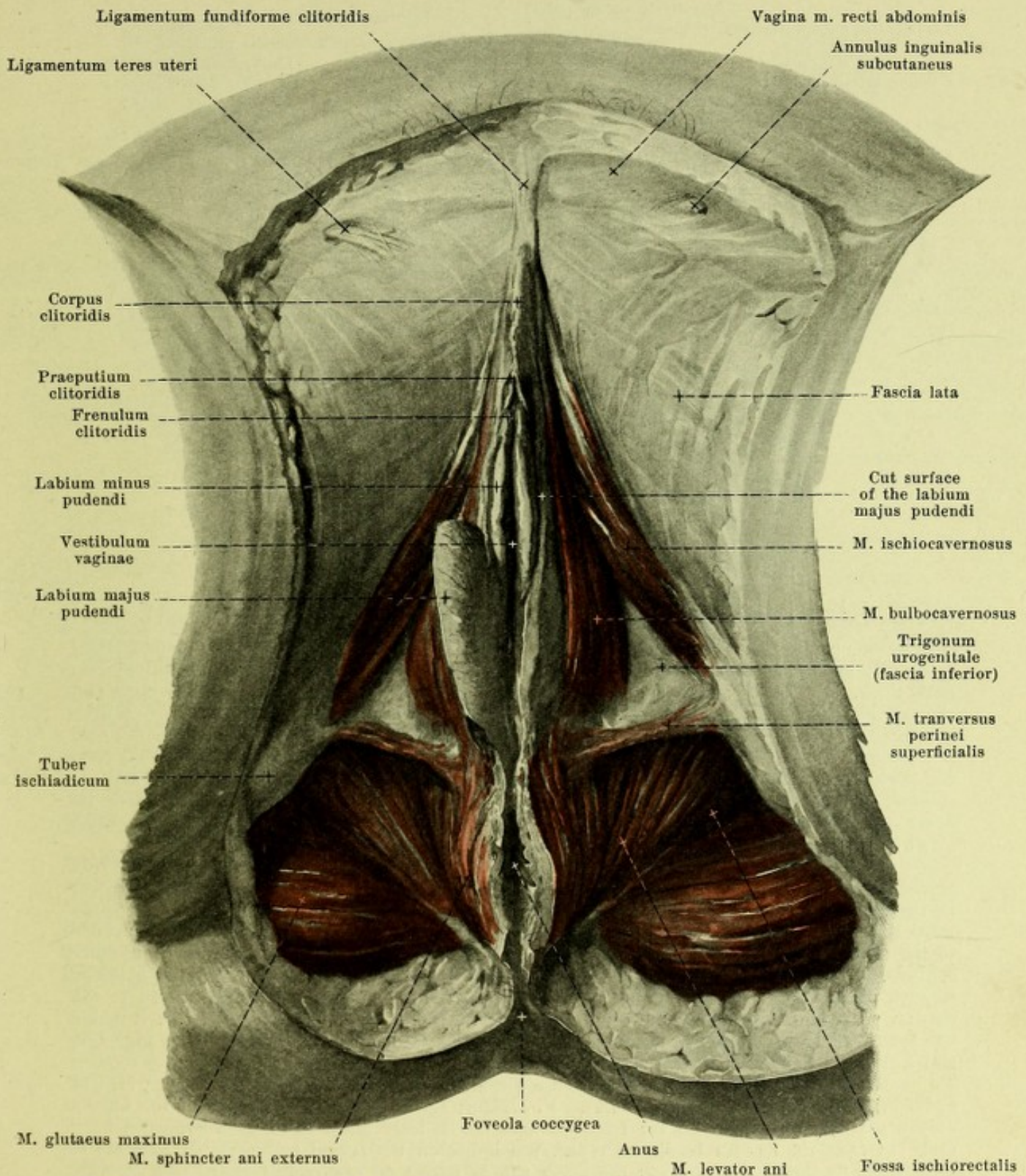
The trigonum urogenitale consists of two strong layers, the *fascia trigoni urogenitalis superior* (O. T. posterior layer of triangular ligament, deep or superior triangular ligament), and *fascia trigoni urogenitalis inferior* (O. T. anterior layer of the triangular ligament, superficial or inferior triangular ligament). These are fused with one another at their anterior and posterior margins and enclose a flat slit-like space. Through the fusion of their anterior margins there is formed a firm cord, *ligamentum transversum pelvis*, which is stretched transversely from one pubic bone to other; the region of fusion of the posterior margins is less pronounced and is covered on its inferior surface by the m. transversus perinei superficialis. The compartment between the two fasciae is filled up by the m. transversus perinei profundus, the m. sphincter urethrae membranaceae, the glandulae bulbo-urethrales (in the male, a part of the glandulae vestibulares majores in the female); in the grooves at the two sides run the aa. penis (clitoridis), vv. pudendae internae and nn. dorsales penis (clitoridis). The two fasciae arise from the lower rami of the ischium and os pubis, are strongest lateralward and are connected medianward with the wall of the urethra (and vagina); the upper is continued also into the fascia prostaticae.

M. transversus perinei profundus. Form: flat. Position: in the posterior part of the trigonum urogenitale. Origin: rami inferiores ossis ischii. Insertion: the fibers run to the median plane and there, becoming tendinous, interweave with one another. Innervation: n. dorsalis penis (clitoridis).

M. sphincter urethrae membranaceae. a) In the *male*. Its innermost fibers surround the urethra as an uninterrupted circular layer and are directly connected proximalward with the m. prostaticus, distalward with circular fibers of the pars cavernosa urethrae. The external fibers arise from the angle of junction of the crura penis, from the ligamentum transversum pelvis, from the fasciae trigoni and from the rami inferiores of the pubic bones, they surround the urethra and the glandulae bulbo-urethrales in arches and, becoming tendinous, unite with one another behind in the median plane. Action: it compresses the urethra and the glandulae bulbo-urethrales. b) In the *female*. The innermost fibers run similar to those in the male, forming a ring around the urethra. The external fibers arise from the ligamentum transversum pelvis, the fasciae trigoni and the pubic bones and extend in arches or straight to the junction between the urethra and the vagina or become attached to the wall of the vagina; they pass through and partly cover over the glandulae vestibulares majores. Innervation: n. dorsalis penis (clitoridis).



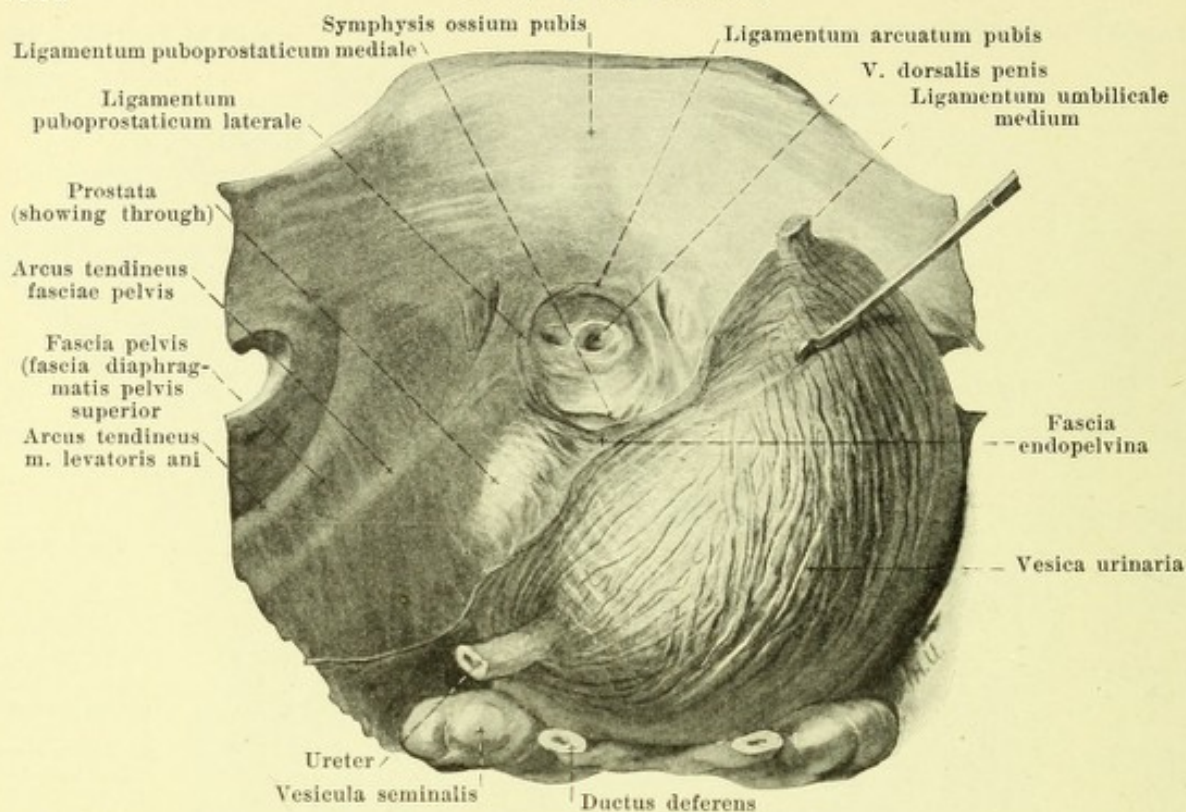
674. Muscles of the male perineum,
viewed from below.



675. Muscles of the female perineum, viewed from below.

(On the right side the posterior part of the labium majus has been left *in situ*.)

M. transversus perinei superficialis (see also Figs. 668 and 674), paired, very variable. Form: narrow, rounded or flattened. Position: below the posterior margin of the trigonum urogenitale. Origin: medial margin of the ramus inferior ossis ischii, above or below the origin of the m. ischiocavernosus. Insertion: the fibers run medianward to the region between the anus and the urogenital canal; there, undergoing partial decussation, they run to the raphe of the m. bulbocavernosus, to the trigonum urogenitale and, in the depth, very often also to the m. sphincter ani externus of the other side. Innervation: n. perinei.



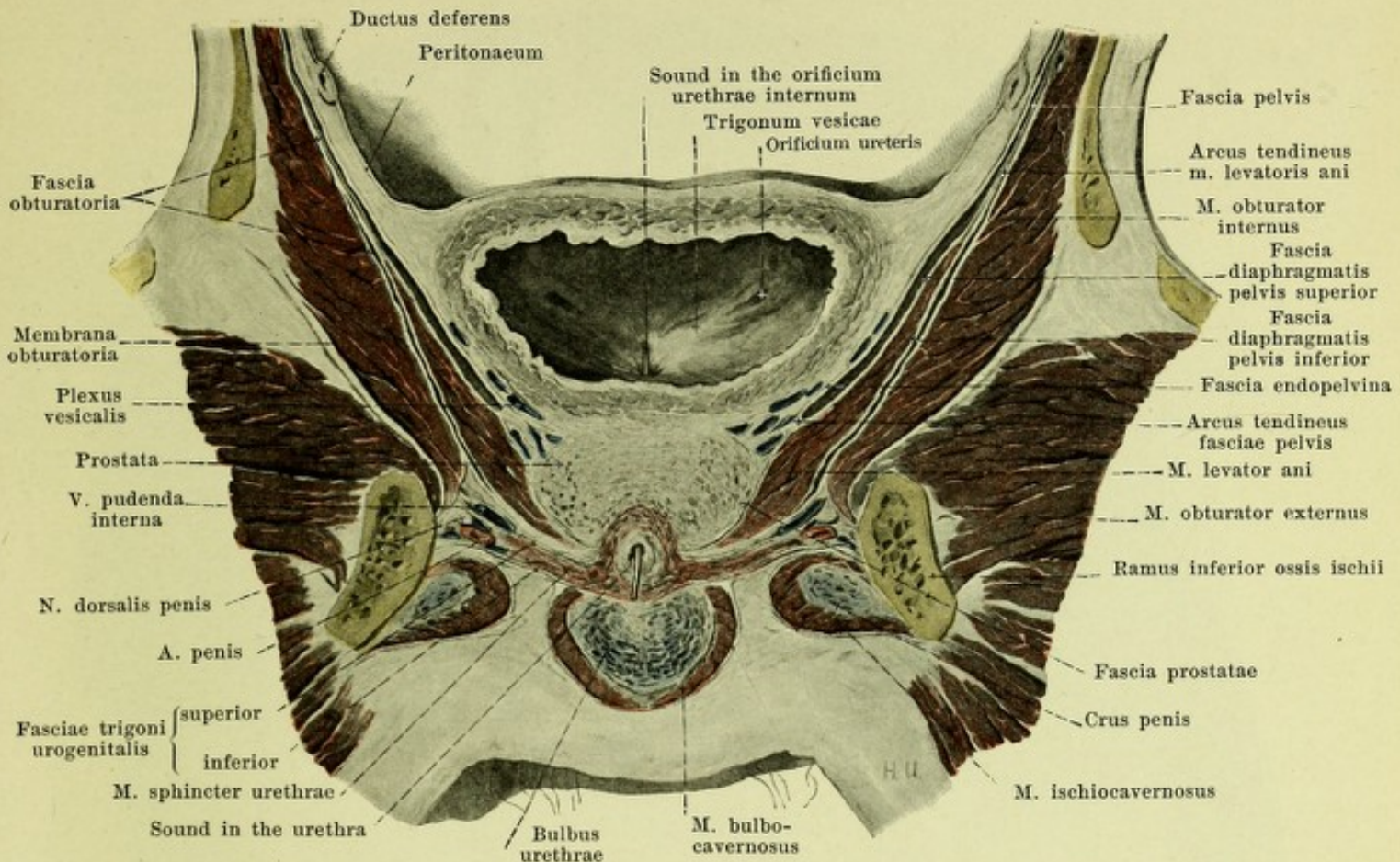
676. Ligamenta puboprostatica, viewed from above and behind.

(The urinary bladder has been drawn to the right, its musculature has for the most part been exposed.)

M. sphincter ani externus (see Figs. 578, 668, 671, 674 and 675), unpaired. Form: oval, thick. Position: external from the m. sphincter ani internus, encircling the anus and the annulus haemorrhoidalis; above it is directly continuous with the mm. pubococcygei. Origin and insertion: the more superficial fibers arise behind the anus, partly crossed, from the skin or, through the mediation of a strand of connective tissue, *ligamentum anococcygeum*, from the posterior surface and the tip of the coccyx, and end in front of the anus, crossed and uncrossed, in the raphe of the m. bulbocavernosus. The deep, thicker fiber mass is circular; its fibers partly decussate in front and behind; see also p. 611. Action: it closes the anus. Innervation: nn. haemorrhoidales inferiores.

M. ischiocavernosus (O. T. erector penis in the male, ischiocavernosus in the female), paired. a) In the *male* (see Figs. 655, 657, 658, 674 and 677). Form: oblong, groove-like, thicker in the middle, where it is fleshy, tendinous in front and behind. Position: below and medianward it embraces the crus penis; it is adjacent above to the trigonum urogenitale, medianward to the m. bulbocavernosus; behind it reaches as far as the posterior margin of the trigonum urogenitale. Origin: medial surface of the ramus inferior ossis ischii. Insertion: the fibers go forward partly to the medial and inferior surfaces of the crus penis, partly lateralward to the dorsum penis and, becoming tendinous, are attached to the tunica albuginea. Action: it makes the tunica albuginea tense and helps in erection and ejaculation. b) In the *female* (see Figs. 668 and 675) it is feebler, but otherwise resembles that of the male. Innervation: n. perinei.

M. bulbocavernosus (O. T. accelerator urinae). a) In the *male* (see Figs. 656, 671, 674 and 677), unpaired. Form: groove-like. Position: ensheaths the free surface of the bulbus urethrae, is adjacent above to the trigonum urogenitale, lateralward to the mm. ischiocavernosus. Origin: from the median tendinous raphe, which lies on the lateral and posterior surfaces of the bulbus urethrae. Insertion: the fibers run in curves on each side forward and upward; the anterior more superficial fibers embrace the corpus penis and end upon its dorsum in the fascia penis; the deeper fibers go partly to the angle of junction of the crura penis, partly to encircle the bulbus (see Fig. 658). b) In the *female* (see Figs. 665 and 675) divided behind into two symmetrical halves. Position: directly on the lateral surface of the bulbus vestibuli and the glandula vestibularis major; otherwise as in the male. Origin: most posterior portion of the trigonum urogenitale. Insertion: the more superficial fibers go to the dorsum clitoridis, the deeper fibers embrace the bulbus vestibuli and go to the angle of junction of the crura clitoridis (see Fig. 668). The muscle is frequently connected, especially in the female, with the m. sphincter ani externus of the same side. Action: it compresses the bulbi (and glandulae vestibulares majores), and helps in erection and ejaculation. Innervation: nn. perinei.



677. Frontal section through the male pelvis.

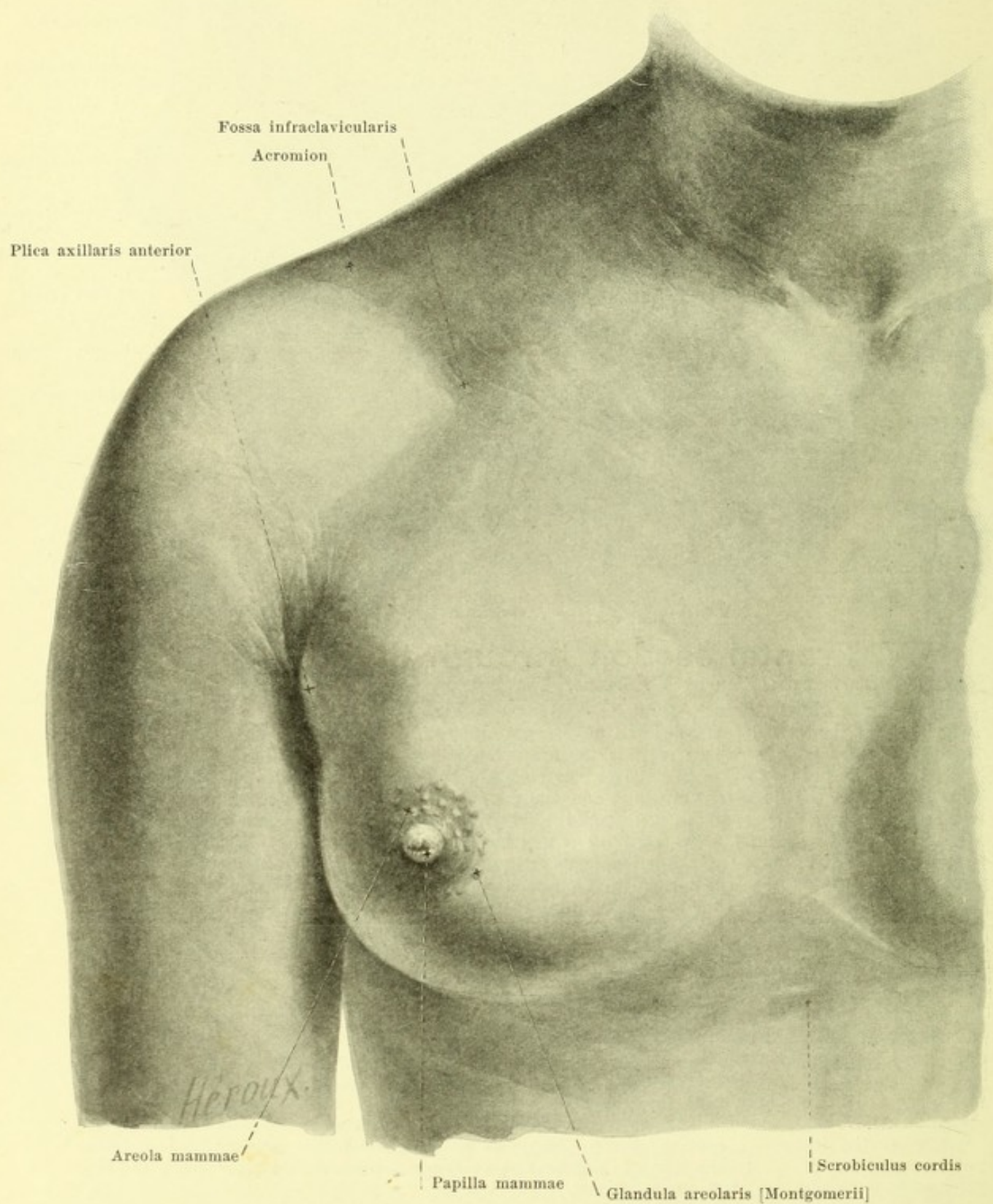
(After a frozen section by W. Braune. The posterior part is viewed from in front.)

Fascia obturatoria (obturator fascia) (see also Figs. 670 and 672) is a very strong fascia which covers the medial surface of the m. obturator internus and is everywhere attached at its border to the bone; interwoven in it is the arcus tendineus m. levatoris ani (see p. 608).

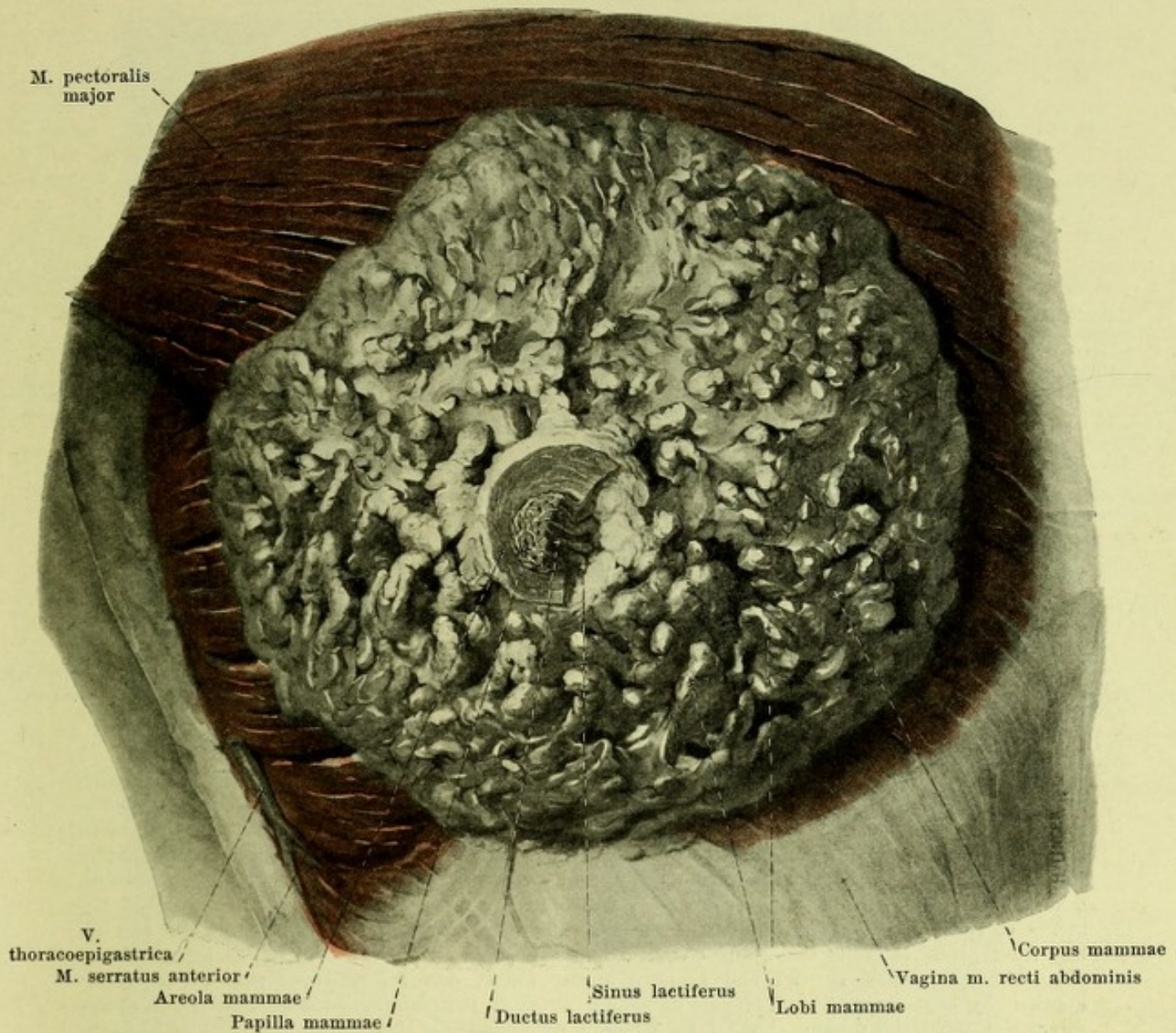
Fascia pelvis (pelvic fascia) (see also Figs. 672 and 676) is connected above at the linea terminalis with the fascia transversalis and the fasciae iliacae. As a thin membrane it covers at first the inner surface of the bone and the fascia obturatoria, then becomes stronger and as the *fascia diaphragmatis pelvis superior* covers the medial, upper surface of the diaphragma pelvis downward as far as a tough tendinous strip of connective tissue, *arcus tendineus fasciae pelvis* (O. T. white line), which runs in it on each side from the lowermost portion of the symphysis ossium pubis backward and lateralward to the spina ischiadica. At this strip the main mass of the fascia goes over upon the pelvic viscera and, as the *fascia endopelvina*, covers the urinary bladder, the vagina and the rectum, along with their venous plexuses, gradually becoming lost above. Other bands of fascia extend from the arcus tendineus fasciae pelvis to the medial surface of the diaphragma pelvis in the male on as far as the tip of the prostate and there go over into the fascia prostatae (in the female they go to the vagina and the urethra). Between the anterior ends of the two arcus tendinei fasciae pelvis, the fascia descends somewhat deeper and thus forms a fossa which is bounded lateralward by two projecting strips, the *ligamenta puboprostatica* (in the female *pubovesicalia*) *lateralia* (O. T. lateral true ligaments of the bladder) and in its depth runs the *ligamentum puboprostaticum* (in the female *pubovesicale*) *medium* (O. T. anterior true ligament of the bladder). The ligaments run out from the posterior surface of the lowermost portion of the symphysis in the male to the urinary bladder and prostate, in the female to the urinary bladder and urethra, and contain in their depth bands of smooth muscle fibers, *mm. pubovesicales*.

The lateral, lower surface of the diaphragma pelvis is covered by the thin *fascia diaphragmatis pelvis inferior*, which is connected with the fascia obturatoria above. The wedge-shaped space (see Figs. 674 and 675) situated between it and the fascia obturatoria is called the *fossa ischiorectalis*.

The *fascia superficialis perinei* (O. T. fascia of Colles) (not illustrated) begins at the posterior margin of the trigonum urogenitale, covers the radix penis and its muscles, is connected lateralward with the bone and goes over in front into the tunica dartos and into the fascia penis.



678. Right breast of a girl, eighteen years old.

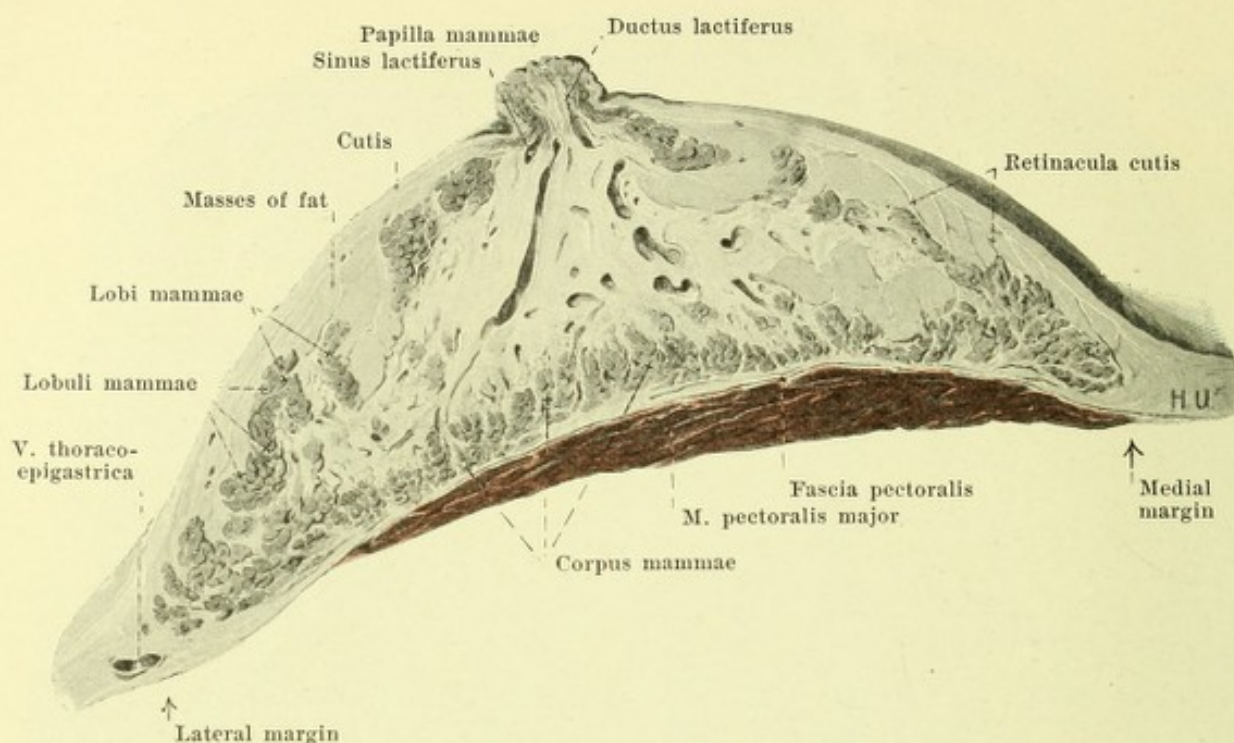


679. Right breast of a woman in advanced pregnancy,

dissected out, in its natural position as regards the thoracic muscles.

The **breasts**, *mammæ*, (see also Figs. 678 and 680) come to full development in the female only; in the male they remain rudimentary throughout life. They are paired, and are very differently developed and formed according to race, individual and the functional condition of the gland.

A well-formed, firm elastic breast represents a segment of a sphere which projects a little less below than above. At about the height of the convexity projects the *nipple of the breast*, *papilla mammae*, variable in height; in nulliparae this is wedge-shaped or cylindrical. Its apex is rough and fissured and contains in its depressions the openings of the milk ducts; its circumference is covered with wrinkles. It is surrounded by a circular area, also wrinkled, the *areola mammae*; this presents, especially during pregnancy, several rounded elevations the size of a head of a pin, which are due to the glandulae areolares. When the breasts are well developed their bases reach from the third to the sixth, rarely as far as the seventh, rib and are separated from one another in the middle by a furrow, the *bosom*, corresponding to the sternum. In nulliparae the breasts are obliquely placed, that is the nipples are directed somewhat lateralward. They project lateralward beyond the margin of the *m. pectoralis major* and beyond the anterior axillary fold corresponding to it, the *plica axillaris anterior*. The nipple, when the breast is firmly seated, is situated at the level of the 5th rib; the level on the right and left side frequently varies and the two nipples vary in their distance from the median plane.



680. Horizontal section through the right breast of a woman in advanced pregnancy, upper half, viewed from below.

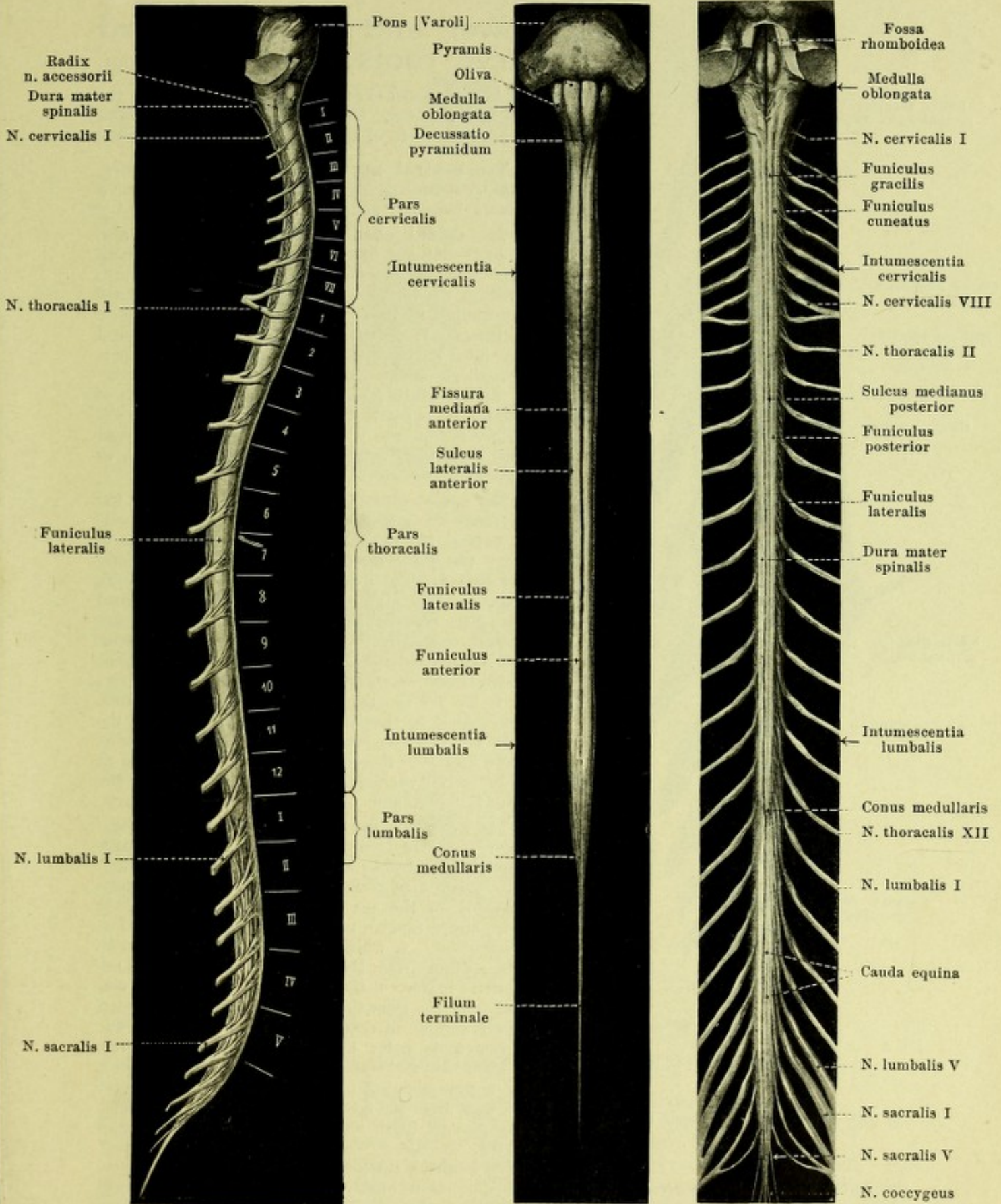
The **glands of the breast**, *corpus mammae*, enclosed by the breast, form a disk with rounded angles, the smooth posterior surface of which lies for the most part upon the *m. pectoralis major*, in a smaller lateral portion upon the *m. serratus anterior*; it is connected with these muscles by the loose connective tissue of the *fascia pectoralis* so as to be moveable upon them. The anterior surface is very uneven and presents, especially below and lateralward, numerous comb-like and jagged processes which leave deep spaces between them. From the apices of these elevations go off connective tissue cords, *retinacula cutis*, to the cutis and all the interspaces between the gland substance, retinacula and cutis are filled up by masses of fat. The gland has 15—27 and more irregular **lobes**, *lobi mammae*, separated from one another by connective tissue; these lobes are broader peripheralward and have their apices directed toward the nipple. Each lobe is again subdivided by the penetrating connective tissue into numerous smaller **lobules**, *lobuli mammae*, and possesses one excretory duct, *ductus lactiferus*, which extends as a whitish cord in the yellowish red glandular tissue to the apex of the lobe, and there bends around into the nipple. Before entrance into the nipple each excretory duct presents a spindle-shaped dilatation, *sinus lactiferus*, which may reach half a centimetre in width. In the nipple itself the ductus lactiferi run parallel to one another and open in the depressions at the apex.

In the region of the nipple and of the areola there are well developed sebaceous glands, *glandulae sebaceae*. In the areola sweat glands, *glandulae sudoriferae*, are found in small number as well as several rudimentary milk glands, *glandulae areolares* [*Montgomerii*], which latter open each with one small milk duct at the level of the elevation caused by it.

The skin over the breast is soft and delicate and is especially thin on the nipple and areola. Its color in the last two places is light red in nulliparae, while in beginning pregnancy it usually becomes dark brown.

The **male breast**, *mamma virilis* (not illustrated), is a small flat structure which consists essentially of connective tissue and usually contains indications of glandular tissue. It possesses a brown *areola mammae* and a *papilla mammae*, but the latter is smaller than in the female. The nipple lies usually in the 4th intercostal space, more rarely upon the 4th or 5th rib, the level frequently varying on the right and left sides; the nipples of the two sides may vary in distance from the median plane.

Supernumerary nipples and breasts, *mammæ accessoriae* (*muliebres et viriles*) occur in very variable development in both sexes in the region of two lines which run down from the attachment of the upper extremities, converging over the normal glands, to the genitalia.



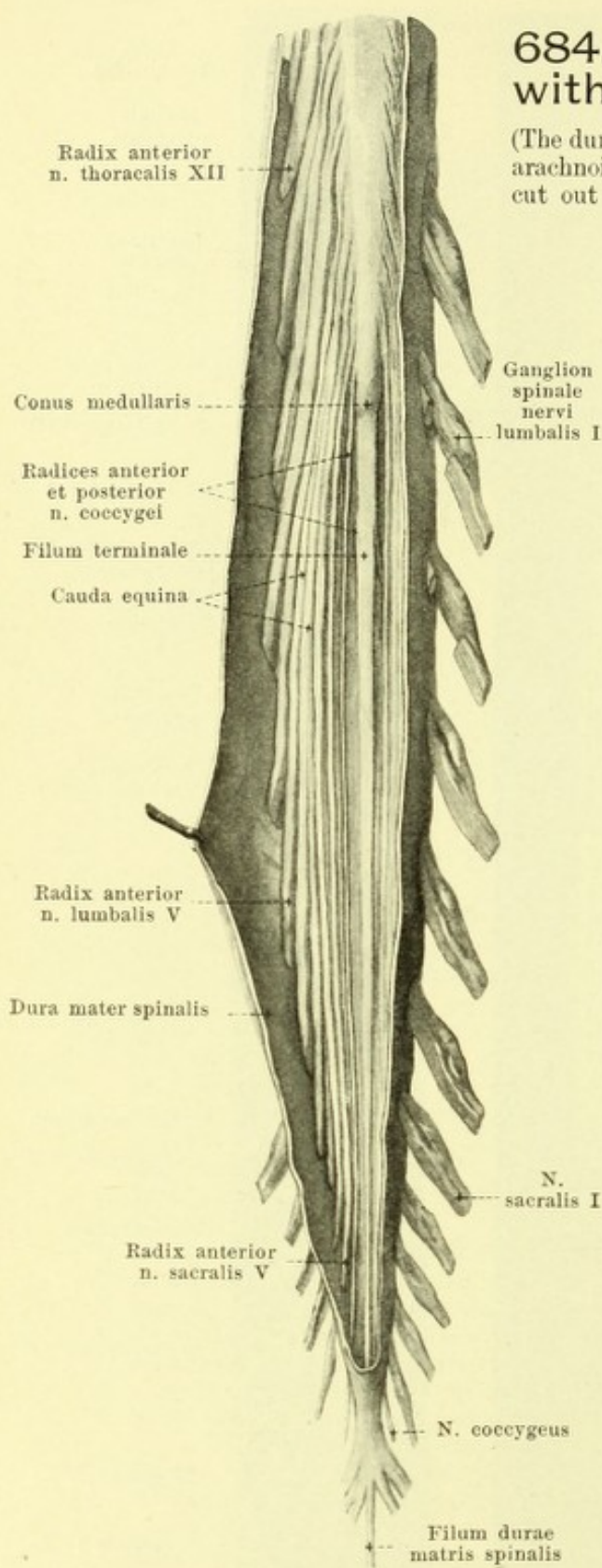
681—683. Spinal Cord.

Viewed from the right.
Spalteholz, Atlas.

Viewed from in front. Viewed from behind.
(Nerve roots not shown.)

684. Lower end of spinal cord with nerve roots, viewed from in front.

(The dura mater has been opened and drawn to the right side; the arachnoidea has been removed. On the left side pieces have been cut out of the anterior roots of the 1st and 2nd lumbar nerves.)



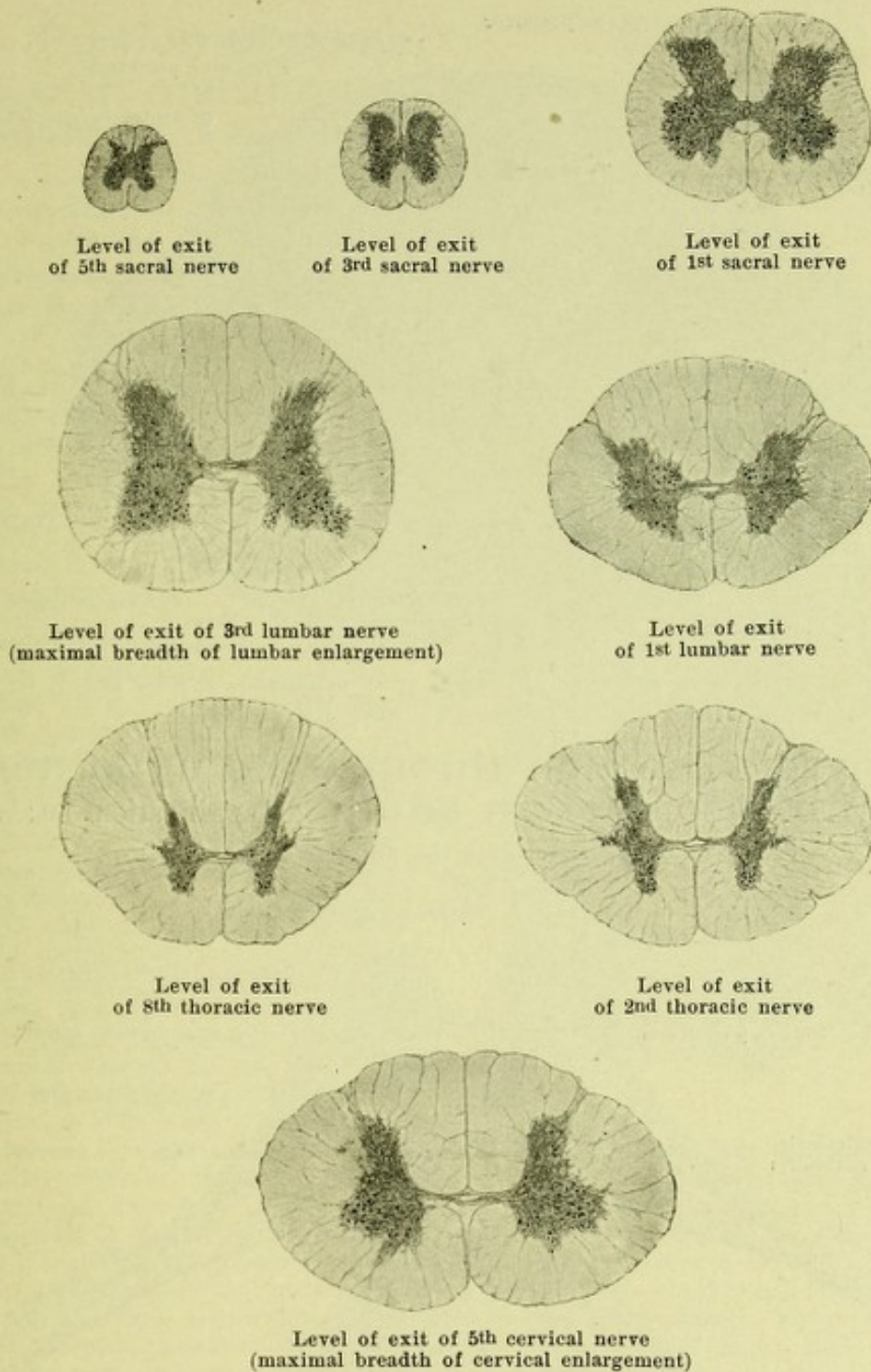
The **central nervous system** (*systema nervorum centrale*) is divisible into the *spinal cord* (*medulla spinalis*) and the *brain* (*encephalon*).

The **spinal cord** (*medulla spinalis*) (see also Figs. 681—683 and 689), an approximately cylindrical strand more or less flattened from before backward, lies within the vertebral canal and presents curvatures corresponding to those of the canal. Above, it goes over insensibly, between the atlas and the occipital bone, into the medulla oblongata; below, it tapers into a short, wedge-like portion (*conus medullaris*) and, in the adult, goes over at the lower margin of the first, or opposite the upper part of the second, lumbar vertebra into a long, delicate terminal thread (*filum terminale*) which can be followed as far as the posterior surface of the coccyx.

The spinal cord is divisible into three parts; the *pars cervicalis* includes the region of exit of the cervical nerves, the *pars thoracalis* that of the thoracic nerves, the *pars lumbalis* that of the lumbar and sacral nerves. The diameters of the spinal cord are not the same at all levels; those portions of the cord which give off the nerves for the extremities are thickened especially in the frontal direction to form spindle-shaped enlargements. The cervical enlargement (*intumescentia cervicalis*) extends from the 3rd cervical to the 2nd thoracic vertebra, its greatest breadth corresponding to the 5th or 6th cervical vertebra; the lumbar enlargement (*intumescentia lumbalis*) begins at the 9th or 10th thoracic vertebra, is most marked at the 11th or 12th thoracic vertebra, and, at the 1st or 2nd lumbar vertebra, goes over into the conus medullaris.

The **surface of the spinal cord** (see Figs. 681—683 and 685—687) is divided into two nearly symmetrical halves by a broad, deep anterior median fissure (*fissura mediana anterior*), which contains a duplicature of the pia mater spinalis rich in blood vessels, and a median posterior sulcus (*sulcus medianus posterior*), to which extends a median connective tissue septum from the interior. On each of these two lateral halves, in the posterior part $2\frac{1}{2}$ — $3\frac{1}{2}$ mm lateral from the sulcus medianus posterior can be seen a groove, *sulcus lateralis posterior*, along which the posterior roots enter the spinal cord; the anterior root fibres leave the spinal cord on its anterior aspect along a zone about 2 mm broad, situated somewhat lateralward from the fissura mediana anterior, running nearly parallel to it, and called the *sulcus lateralis anterior*. In the cervical region there is still another delicate longitudinal groove on the posterior surface,

the *sulcus intermedius posterior* (see Fig. 698); it runs downward from the medulla oblongata about 1 mm lateralward from the sulcus medianus posterior and corresponds to the junction of the fasciculus gracilis with the fasciculus cuneatus. Occasionally an analogous groove, *sulcus intermedius anterior*, can be seen on the anterior surface of the cervical portion, forming the lateral boundary of the fasciculus cerebrospinalis anterior.

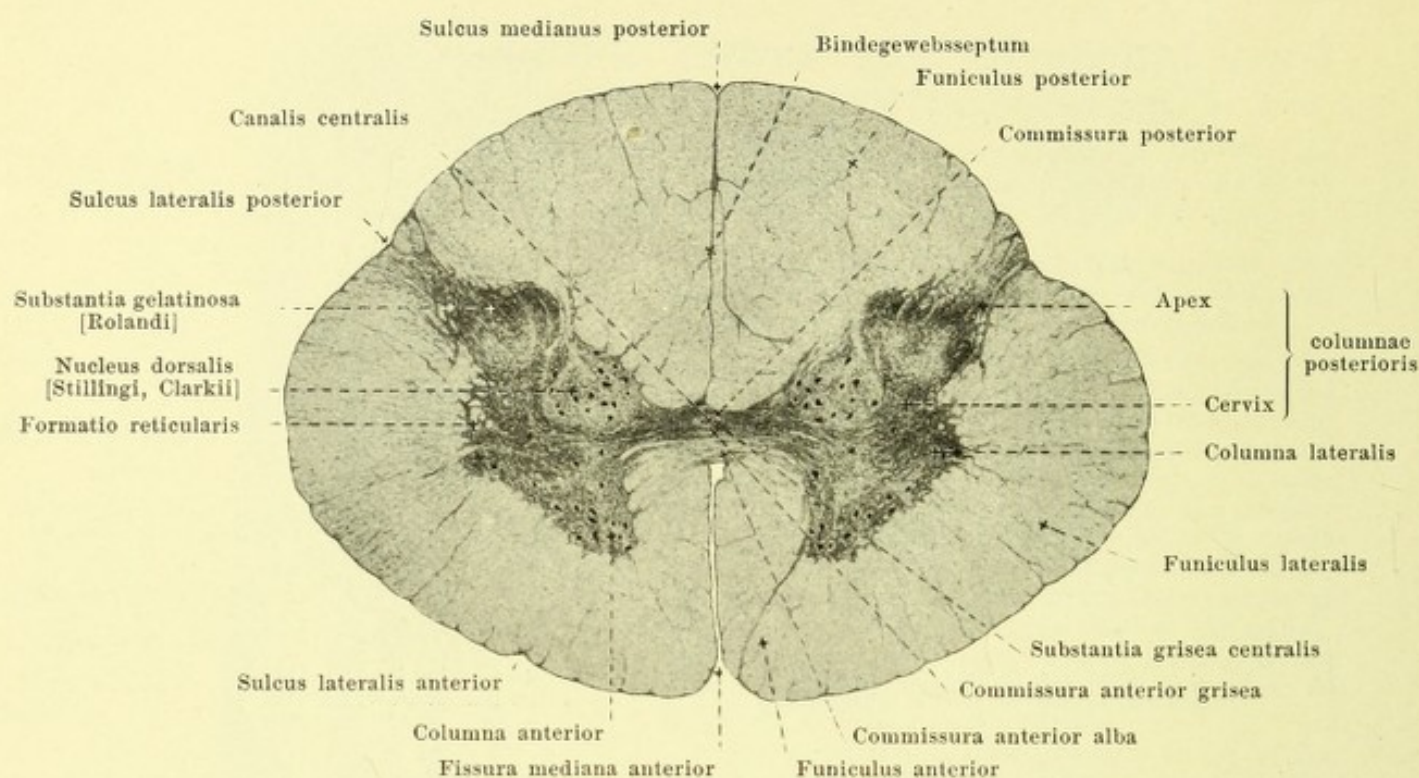


685. Transverse sections through the adult human spinal cord.

Magnification 4:1. (Held.)

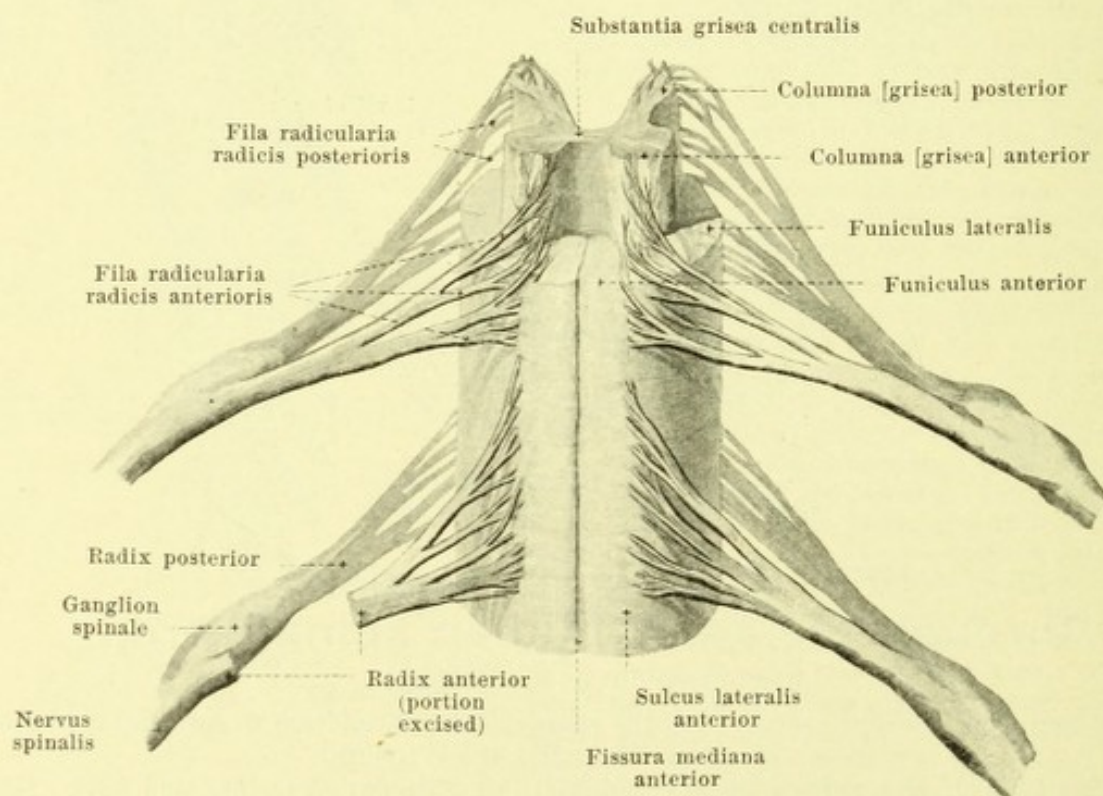
(The sections have all been taken from the same spinal cord and are so arranged that the dorsal margin of the section is uppermost.)

Surface of the spinal cord (continued) (see Figs. 681—683, 686 and 687). The prismatic mass situated on each side between the fissura mediana anterior and the lateral bundles of the anterior root fibres is called the *anterior funiculus* (*funiculus anterior*, O. T. anterior column); the mass which extends from this to the sulcus lateralis posterior is called the *lateral funiculus* (*funiculus lateralis*) and that between the sulcus lateralis posterior and the sulcus medianus posterior, the *posterior funiculus* (*funiculus posterior*).



686. Transverse section through the uppermost part of the lumbar cord of an adult. Magnification 10:1. (Held.)

(The section is the same as the fifth one in Fig. 685.)



687. Portion of the spinal cord with the roots of two nerves, viewed from in front, partly schematic. Magnific. ca. 3:1.

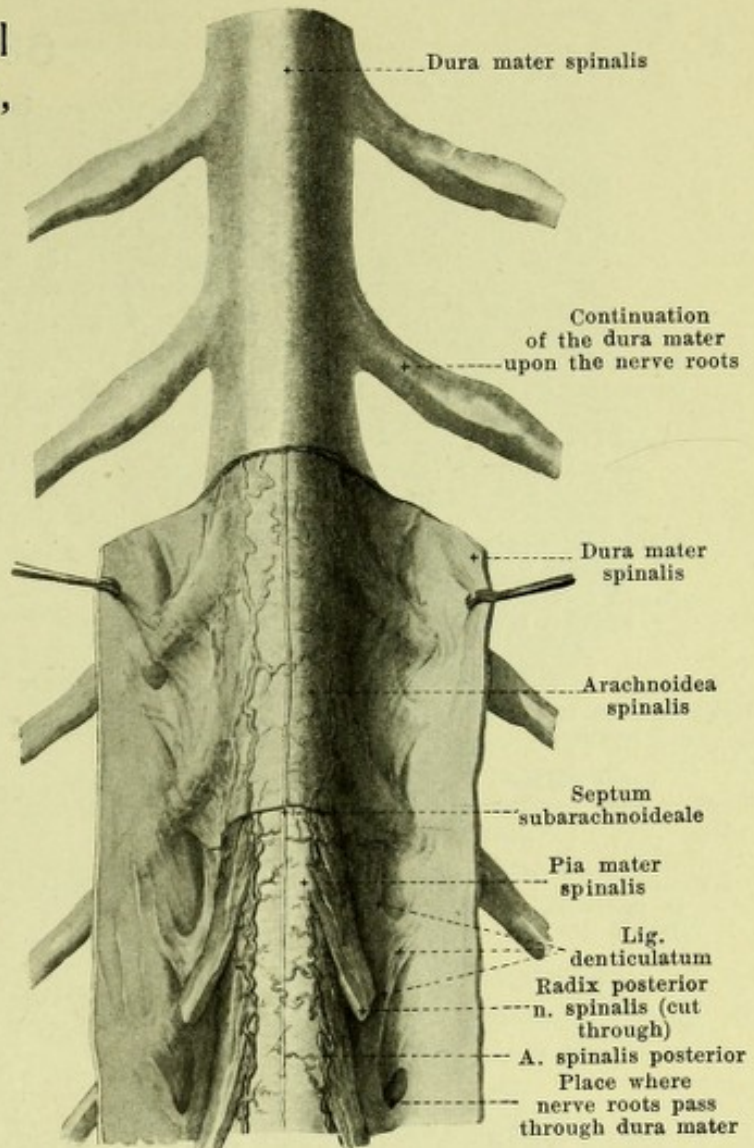
(In the uppermost part the white matter has been removed.)

688. Portion of spinal cord with membranes, viewed from behind.

(The dura mater has been slit up below and turned aside; the arachnoidea has been in part removed.)

The *interior of the spinal cord* (see Figs. 685—687, 749 and 750) consists of *grey matter* (*substantia grisea*) and *white matter* (*substantia alba*), the reciprocal volume-relations of which vary somewhat at different levels (see Fig. 685).

The *grey matter* contains the nerve cells and lies in the interior of the spinal cord, so that it nowhere touches the surface; it consists of two markedly developed lateral parts, one on each side of the cord, and of a bridge connecting the two in the middle so that on cross section an H-like figure is produced. The bridge in the middle usually lies somewhat nearer the anterior surface of the cord than the posterior and surrounds the small rounded or oval *central canal* (*canalis centralis*). This canal is continued above into the medulla oblongata and opens at the inferior angle of the rhomboid fossa, in front of the obex, into the fourth ventricle; in the lower part of the *conus terminalis* it becomes widened to form the elongated, usually three-sided, *ventriculus terminalis* (not illustrated) and then runs as an extremely fine canal for a variable distance far into the *filum terminale*, finally ending blind; it contains a small amount of fluid and is immediately surrounded by the *substantia grisea centralis*. The transverse bar behind it is called the *commissura posterior*, the very narrow band in front of it, the *commissura anterior grisea*, the latter being immediately adjacent to the *commissura anterior alba* which belongs to the white matter. In the lateral parts of the grey matter, the form of which varies somewhat at different levels, two approximately cylindrical *columnae griseae* can be distinguished on each side. The *columna anterior* (*anterior column*, *anterior horn*) is directed forward and a little lateralward, and reaches backward as far as the grey bridge mentioned. The *columna posterior* (*posterior column*, *posterior horn*) extends from here backward and a little lateralward in places going very close to the surface; it is longer and narrower than the *columna anterior*, is constricted somewhat ventralward (*cervix columnae posterioris*) and is somewhat pointed dorsalward (*apex columnae posterioris*); the sickle-shaped area seen in cross section, bounding the posterior horn behind, is called the *substantia gelatinosa* [Rolandi]. The sharply circumscribed group of ganglion cells situated on the medial side of the posterior horn, near the *commissura posterior*, extending from the 3rd lumbar to the 7th cervical nerve, and most markedly developed in the upper lumbar and lower thoracic cord, is called the *nucleus dorsalis* [Stillingsi, Clarkii] (*Clarke's column*); it is round or oval in cross section. In the upper part of the thoracic cord, projecting lateralward from the posterior part of the anterior horn into the white substance, is a triangular process, *columna lateralis* (*lateral column*, *lateral horn*); it gradually vanishes below; in the cervical cord it fuses with the anterior horn to form a common mass. In the angle between it and the posterior horn, the grey matter sends strands out lateralward, arranged in the form of a network, *formatio reticularis*; these are indistinct in the lumbar cord but become progressively more marked toward the upper end of the spinal cord.



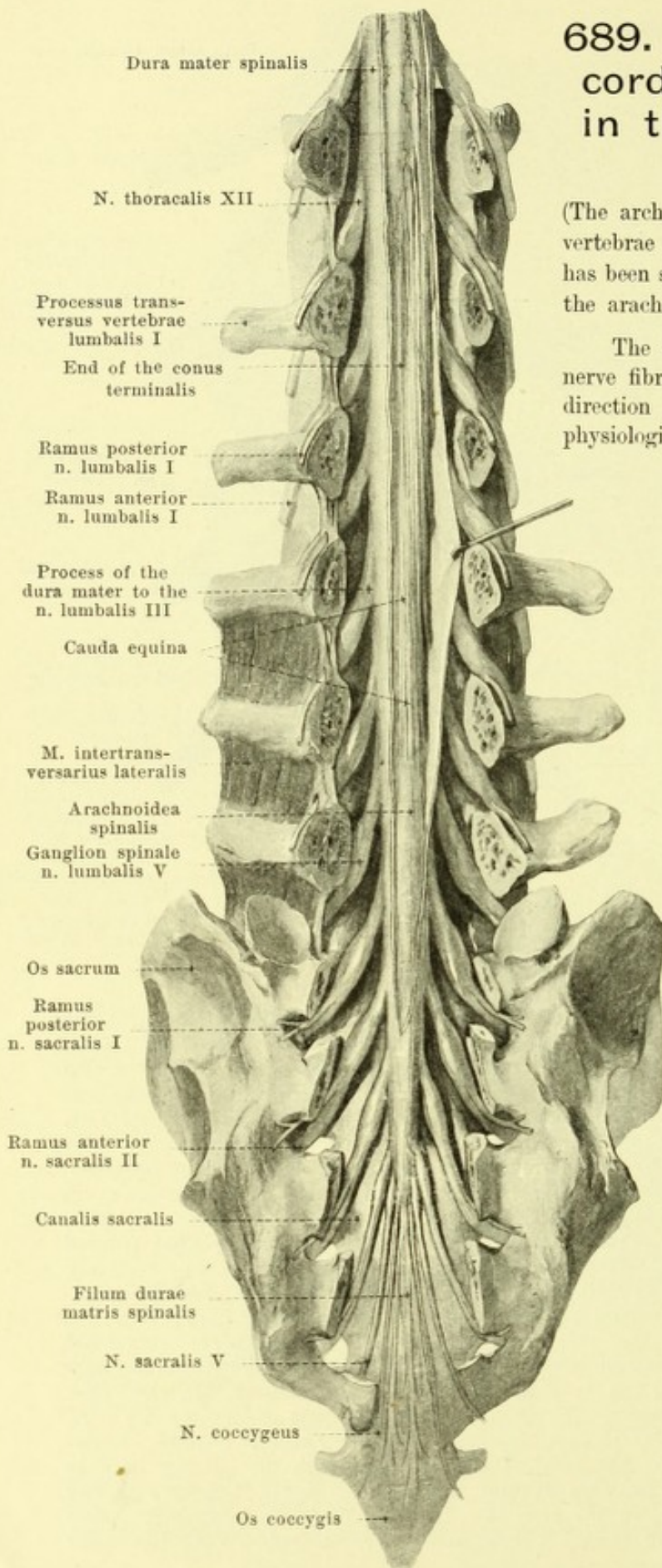
689. Lower end of spinal cord with membranes, in the vertebral canal, viewed from behind.

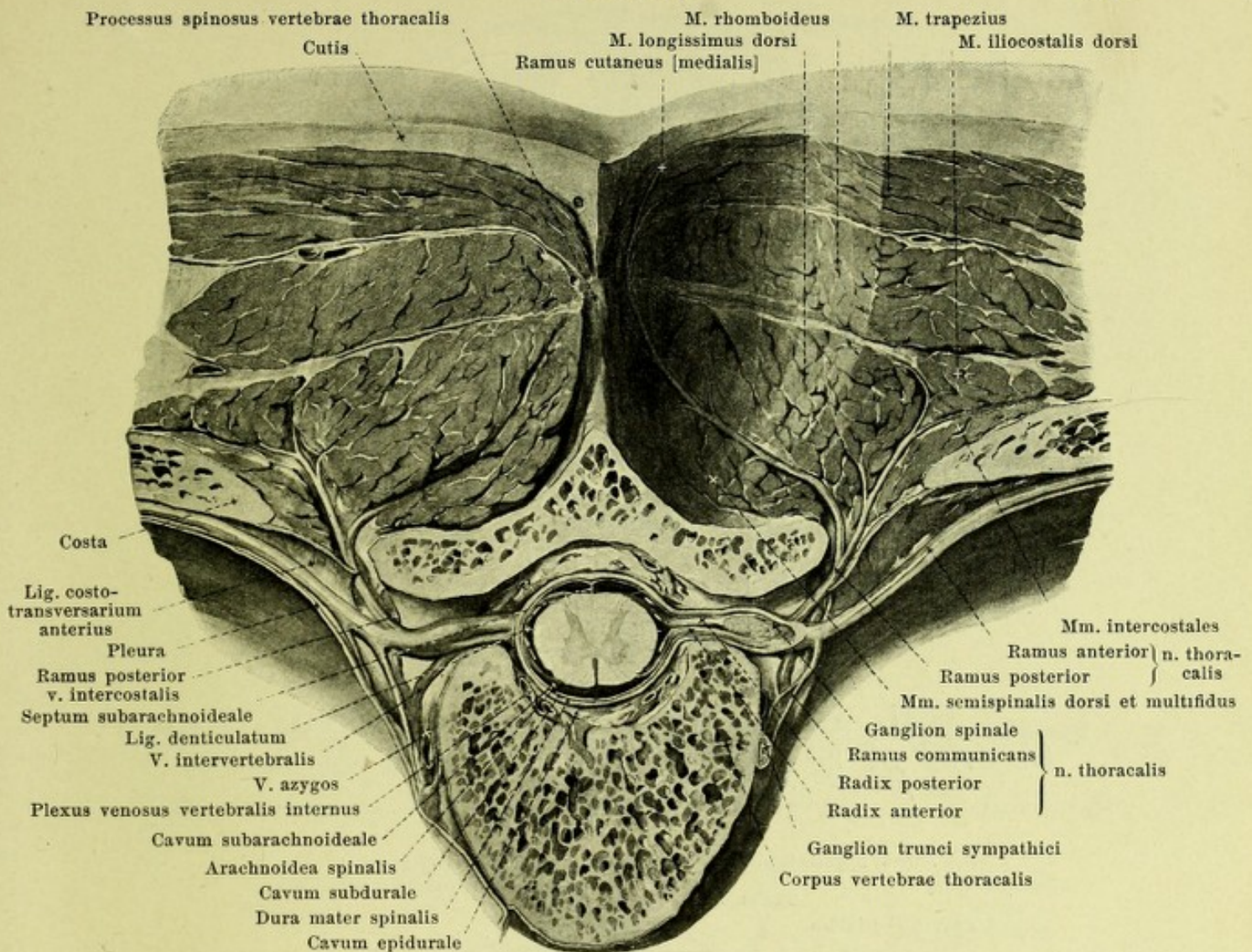
(The arches of the thoracic, lumbar and sacral vertebrae have been removed; the dura mater has been slit open lengthwise and partly reflected; the arachnoidea has been in large part removed.)

The *white matter* contains only medullated nerve fibres; they run chiefly in a longitudinal direction and are divisible into a number of physiologically non-equivalent bundles, the size of which varies at different levels and the areas of which partly overlap. Concerning these bundles and the principal groups of cells of the grey matter and their connections, the reader is referred to Figs. 749 and 750.

In the *conus terminalis* the white matter is relatively much reduced as compared with the grey; the latter has gradually fused to a common mass in which the differentiation of anterior horn and posterior horn is impossible. In the *filum terminale* the grey and the white matter are continued in the same arrangement for 6—8 cm further. Further down, the *filum terminale* consists only of connective tissue, vessels and peripheral nerves.

The spinal cord is surrounded by the **membranes of the cord** (see also Figs. 684, 688 und 690), which are continuous above with the *membranes of the brain*, forming with these the *meninges*. The *pia mater spinalis* (*soft membrane of the cord*) is everywhere closely attached to the spinal cord as a delicate vascular membrane. It sends a duplicature into the *fissura mediana anterior* and numerous blood vessels into the substance of the spinal cord. Below, it surrounds the portion of the *filum terminale* situated in the sac of the *dura mater* and then fuses with the *dura mater*.



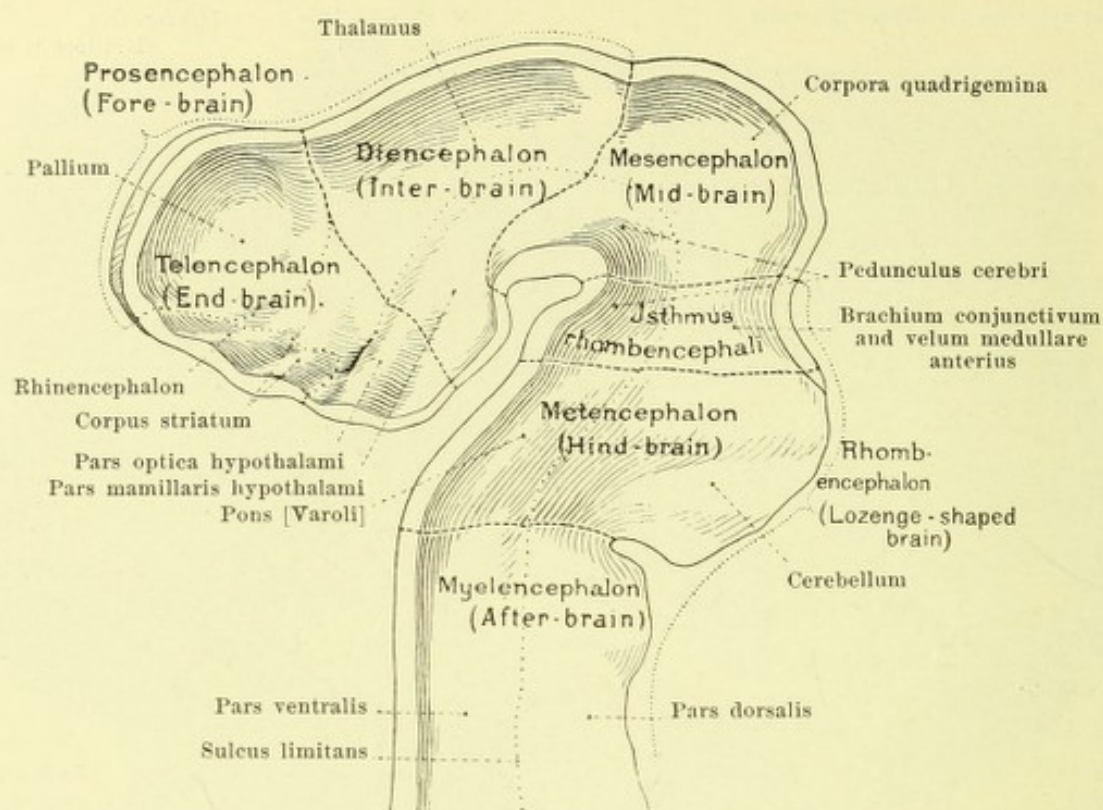


690. Transverse section through the vertebral column and the muscles of the back.

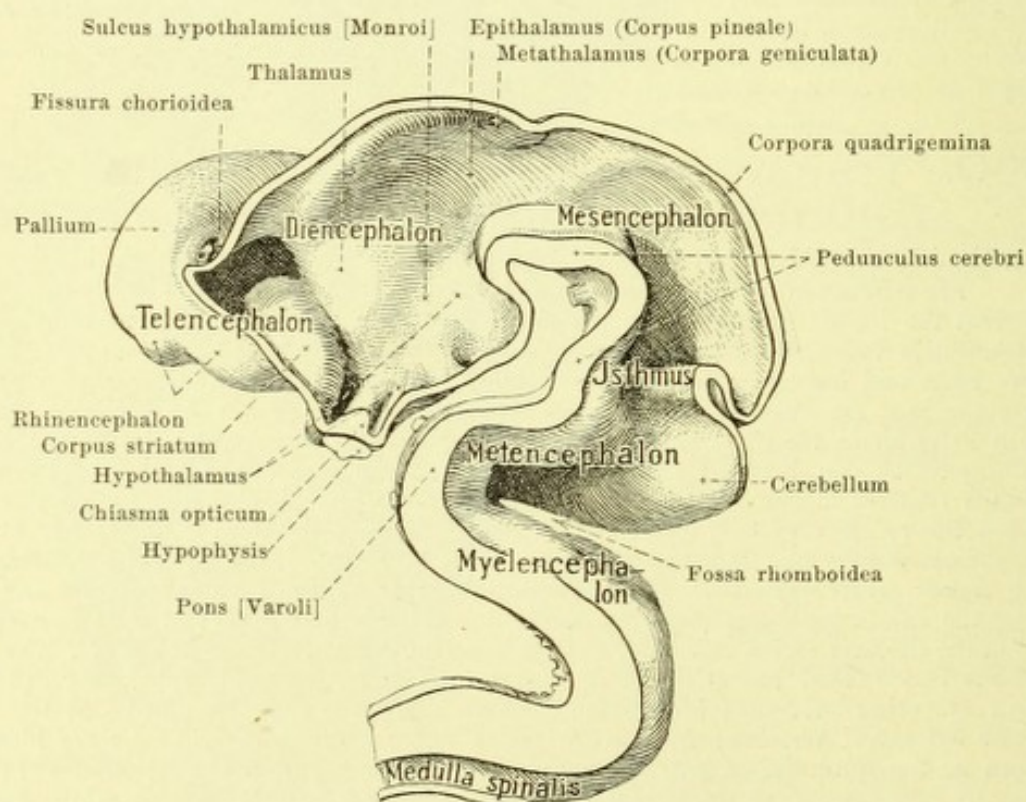
(On the left side the pleura has been drawn aside and a piece of muscle has been cut out.)

Membranes of the spinal cord (continued) (see also Figs. 684, 688 and 689). Going off from the lateral surface of the pia mater spinalis on each side is a frontally placed leaflet of connective tissue, *ligamentum denticulatum*, which runs between the anterior and posterior nerve roots and becomes attached to the inner surface of the dura mater usually by twenty-one jags; the jags are inserted there usually between the points of exit of two nerves, the uppermost one a little above the place where the a. vertebralis passes through the dura mater (see Fig. 775), the lowermost one between the last thoracic and the first lumbar nerve. The *arachnoidea spinalis* (*cobweb membrane*), a very delicate non-vascular membrane, forms a sac which surrounds the spinal cord only loosely; it is separated from the dura mater merely by a capillary slit, *cavum subdurale*, from the pia mater by a large space, *cavum subarachnoideale*, filled with *liquor cerebrospinalis*. The arachnoidea ensheaths the lig. denticulatum and, especially along the sulcus medianus posterior, sends fine threads to the pia; in the lower cervical region and in the thoracic region these fuse to form lamellae, *septum subarachnoideale*. The *dura mater spinalis* (*hard membrane of the cord*) is a tough connective tissue tube, poor in blood vessels, which, tapering out, ends blind some distance below the conus terminalis at the level of the 2nd or 3rd sacral vertebra; from there on it forms a direct covering for the filum terminale known as the *filum durae matris spinalis*. It is separated from the periosteum of the vertebral canal by fat, connective tissue and venous plexuses (see p. 454), among which there exists a system of lymph spaces, *cavum epidurale*; strong bands of connective tissue pass from its anterior surface to the lig. longitudinale posterius, especially in the canalis sacralis.

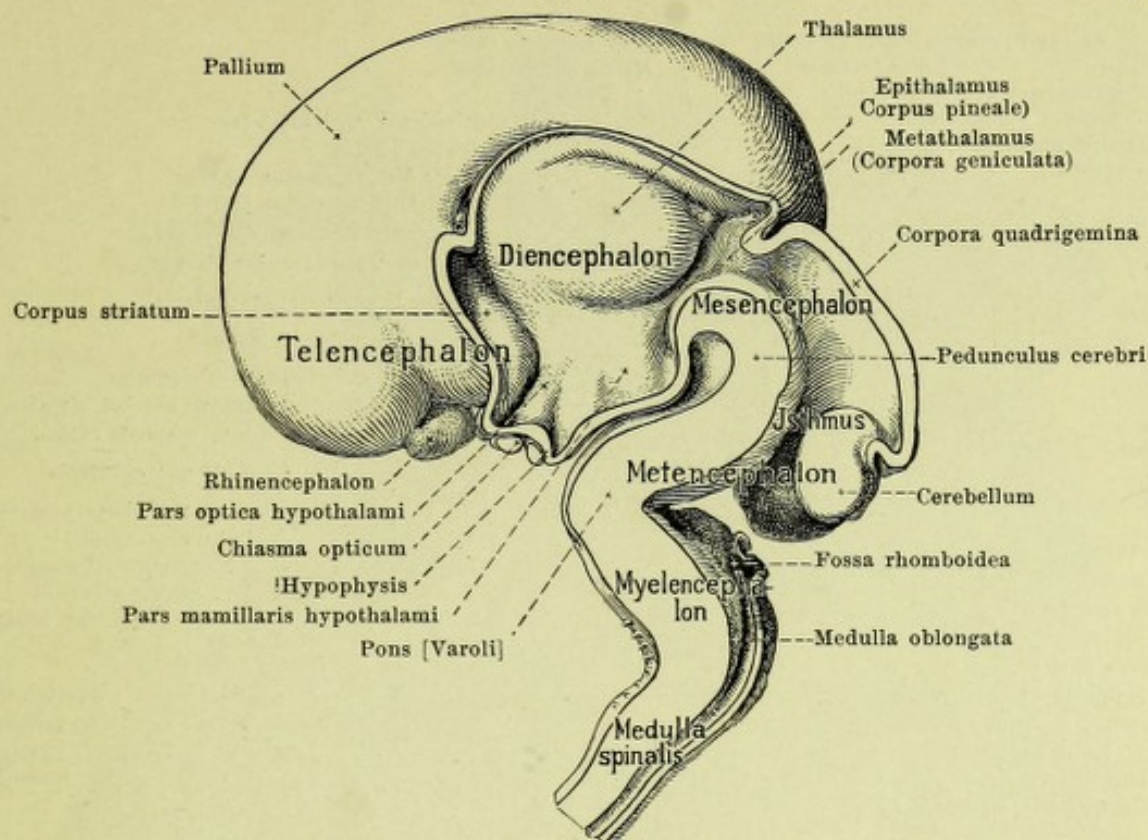
All three membranes are continued upon the nerve roots, fuse near the ganglia, and then go over into the connective tissue sheaths of the nerves.



691. Brain of a human embryo at end of 1st month, right half, viewed from the left.
(After a model by W. His.)

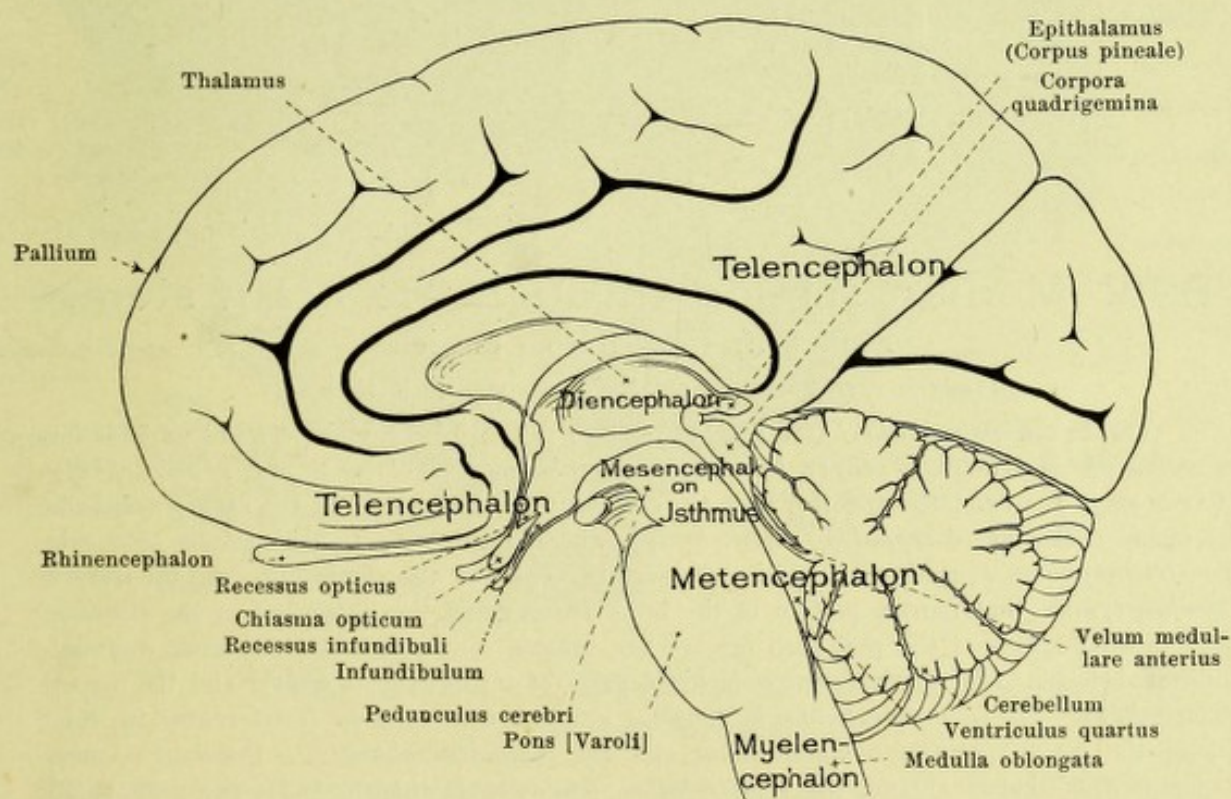


692. Brain of a human embryo five weeks old, right half, viewed from the left. (After a model by W. His.)

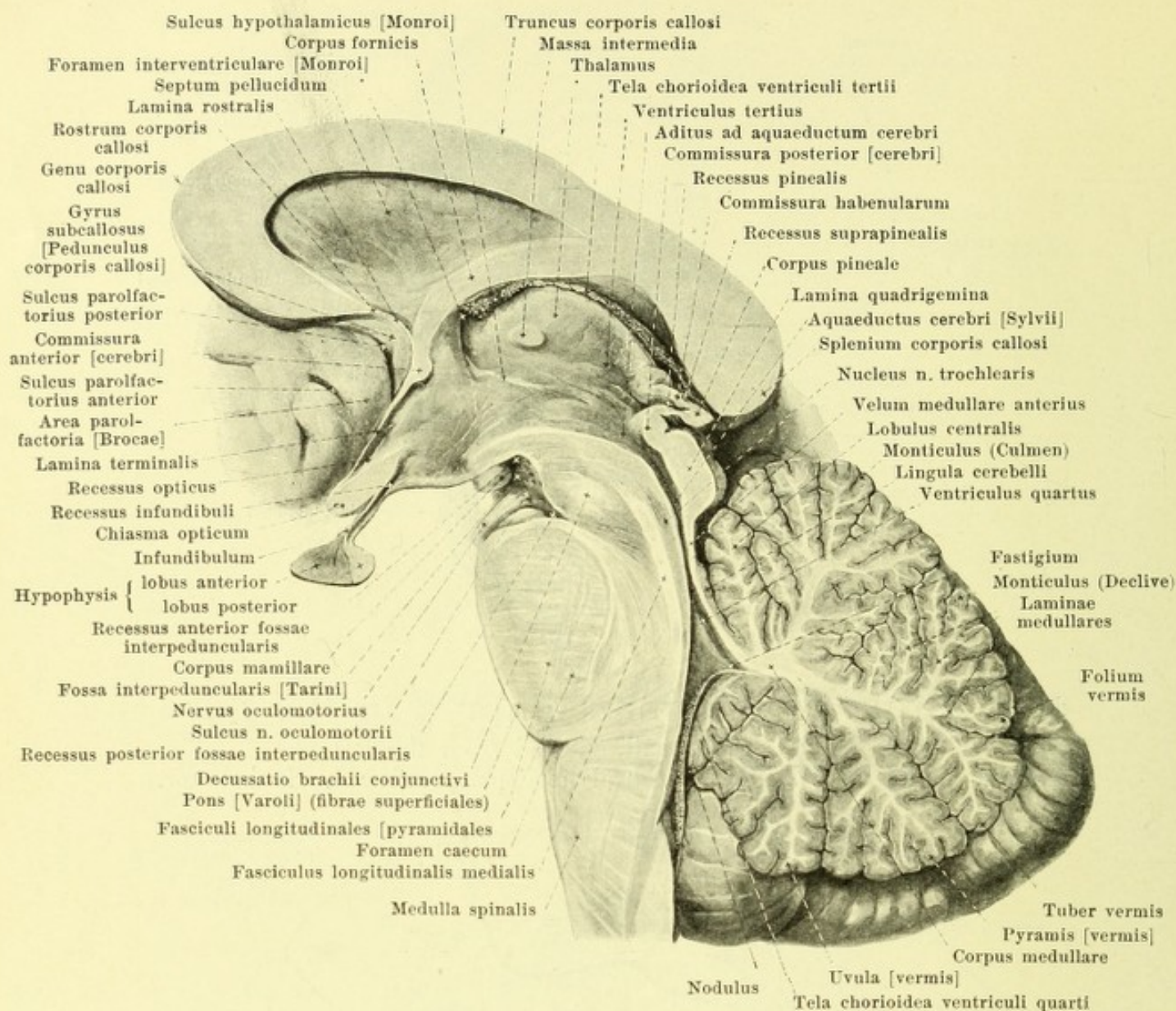


693. Brain of a human embryo in the third month, right half, viewed from the left.

(After a model by W. His; cerebral hemisphere after J. Hochstetter.)



694. Adult human brain, right half, viewed from the left, partly schematic.

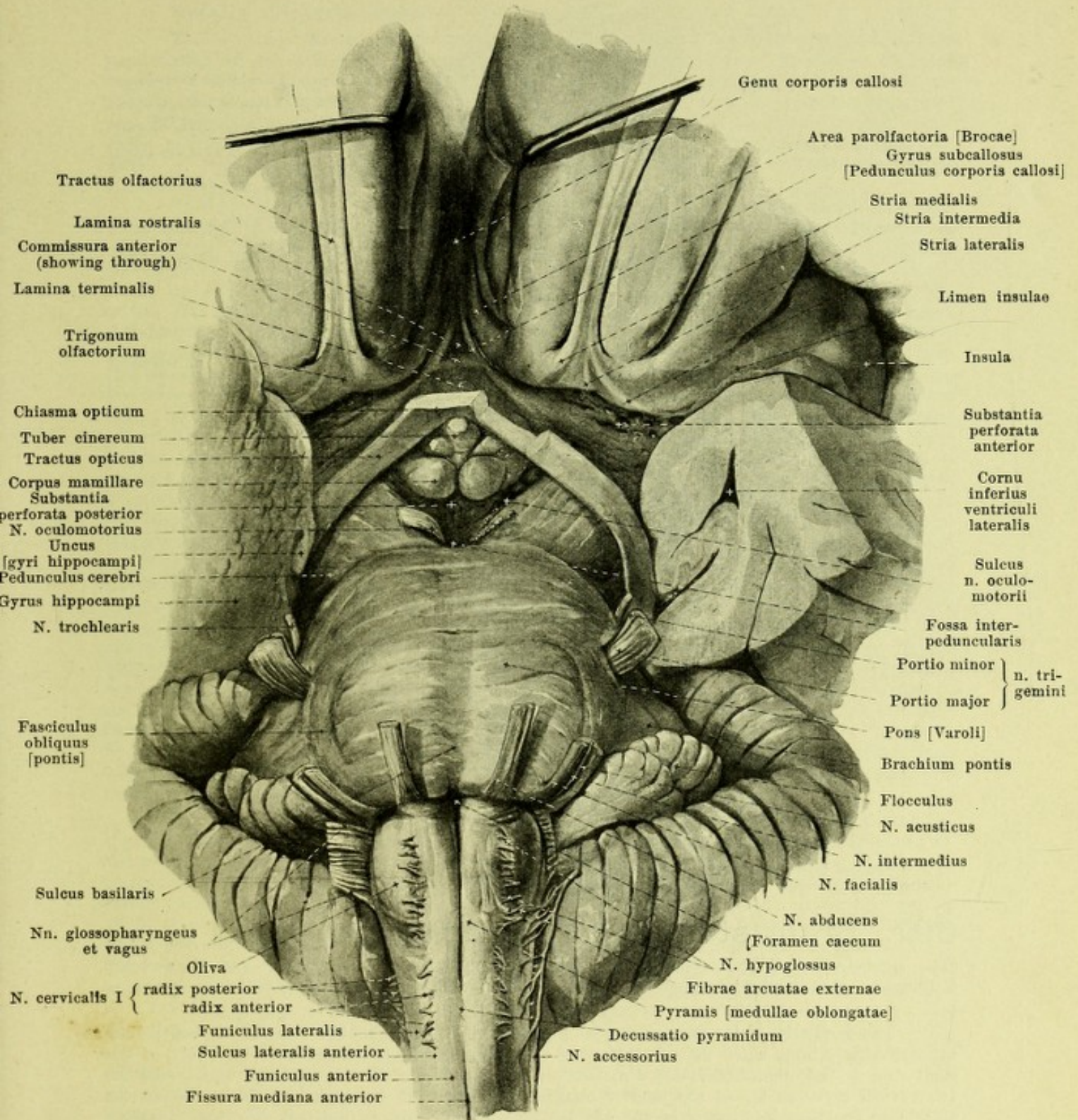


695. Median section through the brain stem, right half, viewed from the left.

(Only a very small part of the brain mantle is shown.)

The **brain** (*encephalon*) (see Figs. 691—694) is divisible on embryological grounds into *rhombencephalon* (lozenge-shaped brain), *mesencephalon* (mid-brain), and *prosencephalon* (fore-brain); the two latter together form the *cerebrum* (large brain). In the *rhombencephalon* are included the *myelencephalon* (after-brain), which corresponds to the medulla oblongata, the *metencephalon* (hind-brain), which includes the pons and the cerebellum, and the *isthmus rhombencephali*, that narrow portion of the brain surrounding the upper end of the rhomboid fossa to which parts of the pedunculi cerebri, the brachia conjunctiva and the velum medullare anterius belong. The *mesencephalon* includes parts of the pedunculi cerebri and the corpora quadrigemina. The *prosencephalon* is divisible into the *diencephalon* (inter-brain) to which belong the *pars mamillaris hypothalami* and the *thalamencephalon* (= thalamus + metathalamus + epithalamus) and the *telencephalon* (end-brain) which includes the *pars optica hypothalami* and the *hemisphaerium* (= corpus striatum + rhinencephalon + pallium).

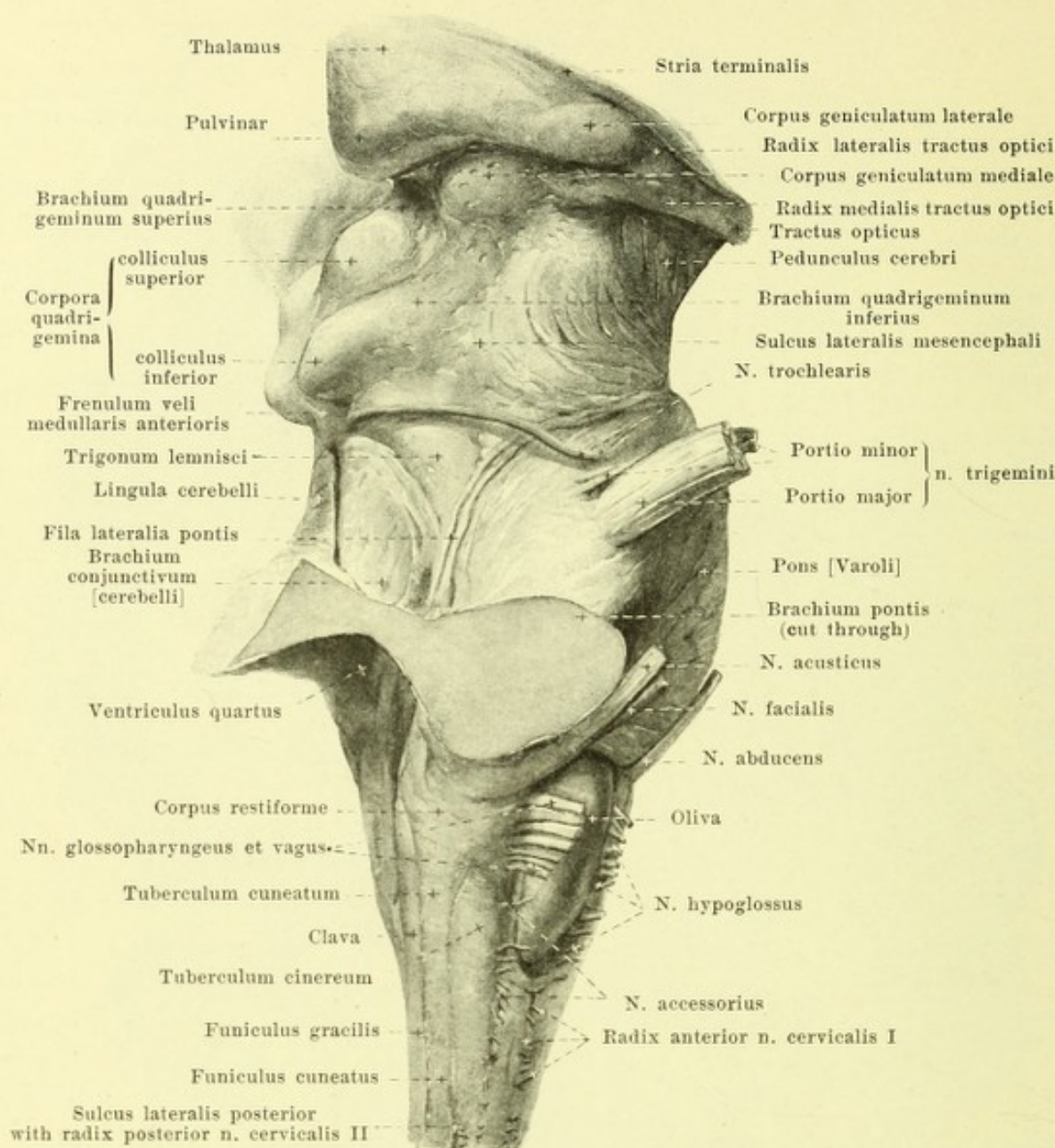
The term *brain-stem* is applied often to the part of the brain left after removal of the pallium.



696. Base of brain, viewed from below.

Magnification circa 4 : 3.

(The cerebellar and cerebral hemispheres are shown only in part. The frontal lobes have been pulled apart. The anterior and medial portions of the left temporal lobe have been cut away and a piece has been excised from the left tractus opticus. On the right the radicular threads of the n. oculomotorius have been cut off short.)



697. Brain stem, viewed from the right. Magnification ca. 3:2.

(The cerebellum has been removed by cutting through the brachia pontis and the brachia conjunctiva; the cerebral hemispheres have also been removed. The taenia ventriculi quarti is not shown.)

The **medulla oblongata** (see also Figs. 695, 696, 698, 699, 702 and 705) is continuous without sharp limit with the upper end of the spinal cord; it lies for the most part in the skull and in an almost vertical direction. It extends from the upper root bundles of the 1st cervical nerve as far as the inferior margin of the pons in front, and as far as the inferior margin of the pars intermedia of the 4th ventricle behind (see p. 629); it becomes expanded above, especially in the frontal direction, somewhat less so in the sagittal direction.

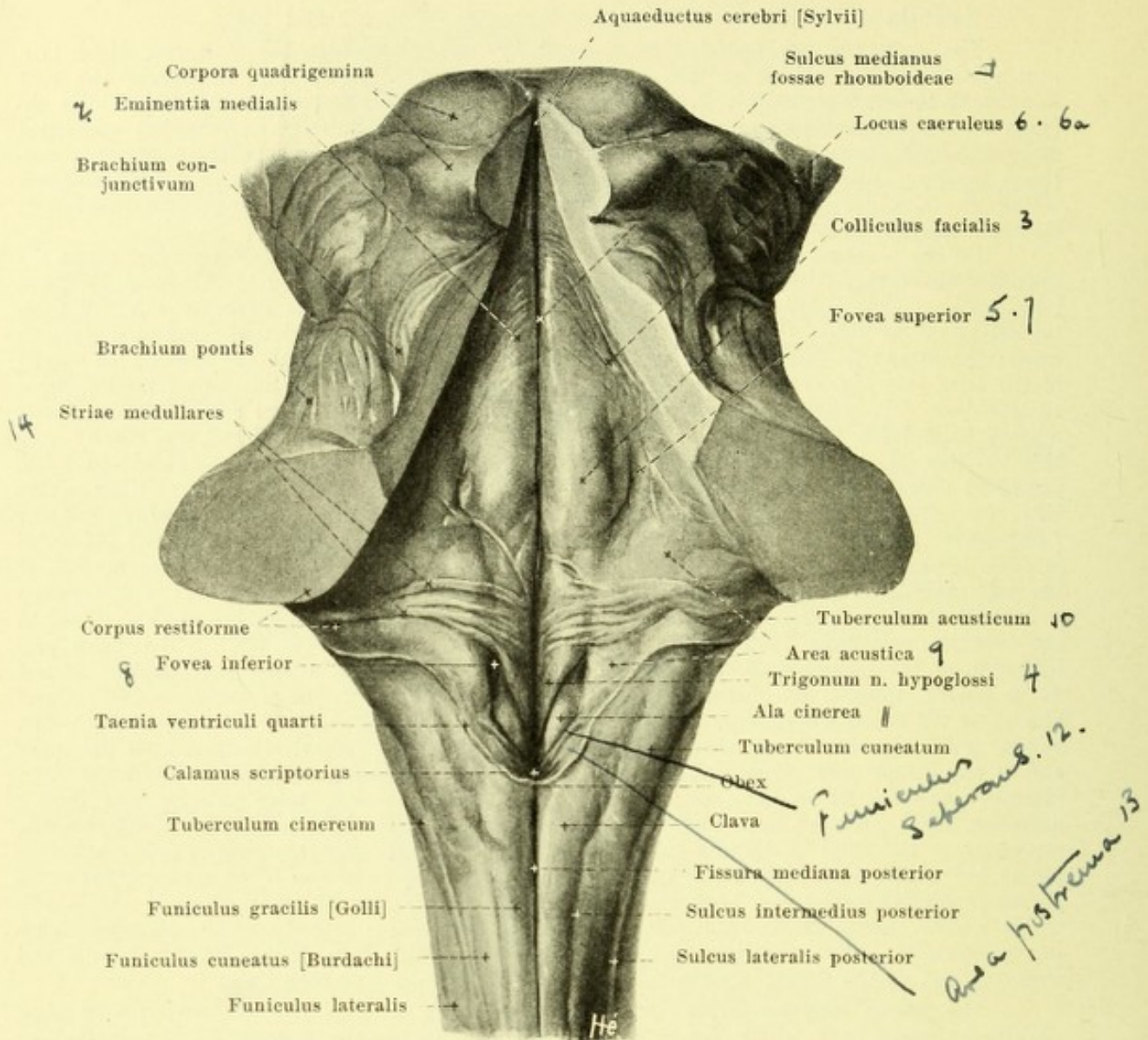
On its anterior surface (see Fig. 696), running in the median plane, is the deep *fissura mediana anterior*; it corresponds to the fissure of the same name in the spinal cord, but is separated from it, about at the level of the root bundles of the 1st cervical nerve, by decussating bundles of nerve fibres, *decussatio pyramidum* (*decussation of the pyramids*); it ends above at the pons in a triangular depression, the *foramen caecum* (see also Fig. 695). The mass of white matter lying on each side of this fissure, the *pyramis [medullae oblongatae]* (*pyramid*), appears at first to be continuous with the anterior funiculus of the spinal cord, but in reality it sends only a small part of its fibre bundles into it to the anterior pyramidal tract, while the larger portion of them go to the lateral funiculus of the opposite side to form the lateral pyramidal tract.

Medulla oblongata (continued) (see Figs. 695—699, 702 and 705).

The pyramids are bounded lateralward by the *sulcus lateralis anterior*, which is a continuation of the sulcus of the same name in the spinal cord; from it emerge the root bundles of the n. hypoglossus. Lateral from this groove in the upper part of the medulla oblongata an oblong, egg-shaped elevation, the *oliva* (*Olive*) appears; it is somewhat broadened and thickened above and extends as far as the pons; its surface is sometimes smooth, sometimes nodular; below, it is frequently crossed by arch-like fibres, *fibrae arcuatae externae*, which go from the surface of the corpus restiforme (vide infra) to the region of the sulcus lateralis anterior, sometimes overlying and obscuring the sulcus.

On the posterior surface (see Figs. 697 and 698) the *fissura mediana posterior* forms the continuation of the sulcus medianus posterior as far as the lower end of the rhomboid fossa (vide infra). The *sulcus lateralis posterior* and *sulcus intermedius posterior* run, as continuations of the sulci of the same names in the spinal cord, upward and somewhat lateralward; the former is frequently indistinct and extends upward as far as the level of the middle of the olive (see Fig. 697), the latter ends at the lower margin of the recessus lateralis fossae rhomboideae. The *funiculus gracilis* [Golli], ascending from the spinal cord, broadens somewhat a little below the rhomboid fossa and presents there a flattened bulging, the *clava*; from this swelling on, the funiculi graciles run along the lower lateral margin of the rhomboid fossa, diverging upward and lateralward; they gradually become narrowed and go over without sharp limit into the medial part of the corpora restiformia (vide infra). The *funiculus cuneatus* [Burdachi] is the continuation of the funiculus of the same name in the spinal cord and above is often bounded very indistinctly lateralward by the sulcus lateralis posterior; the funiculi of the two sides diverge from the clava on, passing upward and lateralward where each presents a variably developed slight projection, the *tuberculum cuneatum*; they become lost above in the corpora restiformia (vide infra). The *funiculus lateralis* (see Fig. 697) is the direct prolongation of the funiculus of the same name in the spinal cord; it becomes somewhat broadened as it passes upward and extends in front as far as the lower end of the olive and behind almost as far as its upper end. A fine groove in which the root-threads of the nn. accessorius, vagus, and glossopharyngeus are situated, runs upward on the lateral funiculus from the upper end of the spinal cord; it is curved slightly forward and, passing somewhat behind the olive, extends almost as far as the pons; below, it separates a broader, more anterior area from a narrower, more posterior area; above, on the contrary, the posterior area is broader and presents, especially in the child, a distinct club-shaped swelling, *tuberculum cinereum* which reaches as far as behind the olive and finally goes over into the corpus restiforme. The name *corpus restiforme* (*rope-like body*) has been given, on account of its external appearance, to the bundle which bends around dorsalward just in front of the recessus lateralis of the rhomboid fossa passes upward to the cerebellum and is the apparent continuation of the funiculi gracilis and cuneatus and of the dorsal portion of the funiculus lateralis just mentioned.

The *fossa rhomboidea* (*lozenge-shaped fossa*) (see Figs. 698 and 699) is a rhombic, slightly depressed area, which lies in a nearly vertical plane; only its lower part, embraced by the corpora restiformia, belongs to the medulla oblongata; the middle part lies in the metencephalon, and the uppermost part belongs to the isthmus. The lower part (*pars inferior fossae rhomboideae*) is approximately triangular and contains at its inferior angle the opening of the canalis centralis; it appears much deepened below and is marked there by several furrows which converge downward and medianward; this peculiar configuration of the surface has led to the further name *calamus scriptorius*. Along its lateral and inferior margin the tela chorioidea ventriculi quarti (see also Fig. 703) is attached; when this is forcibly removed it leaves behind it a fine jagged edge, a part of the *taenia ventriculi quarti*, as a thin triangular plate called the *obex* which covers the lowermost apex of the rhomboid fossa from behind. The taenia, above, bends around sharply lateralward upon the corpus restiforme and there forms the lower boundary of the *pars intermedia fossae rhomboideae*; this pars intermedia on each side, with the *recessus lateralis fossae rhomboideae*, passes far lateralward over the corpus restiforme, but above, between the brachia pontis, becomes considerably narrower and goes over at the upper end of the fovea superior (see p. 630) into the *pars superior fossae rhomboideae*. The pars superior is bounded lateralward by the brachia conjunctiva and covered behind by the velum medullare anterius; it becomes much narrower above and goes over insensibly in front of the lamina quadrigemina into the aquaeductus cerebri. The rhomboid fossa is divided into two symmetrical halves by the *sulcus medianus fossae rhomboideae* which runs in the median plane; the sulcus is deeper below, shallower above. Close to this on each side, extending through the whole length of the fossa, is a ridge, the *eminentia medialis*; in the pars superior it occupies the whole breadth; in the upper part of the pars intermedia it presents an elongated projection, the *colliculus facialis*; from this point on, downward, it tapers, at first gradually, but in the pars inferior rather suddenly, so as to form there a right-angled triangular area, *trigonum n. hypoglossi*.

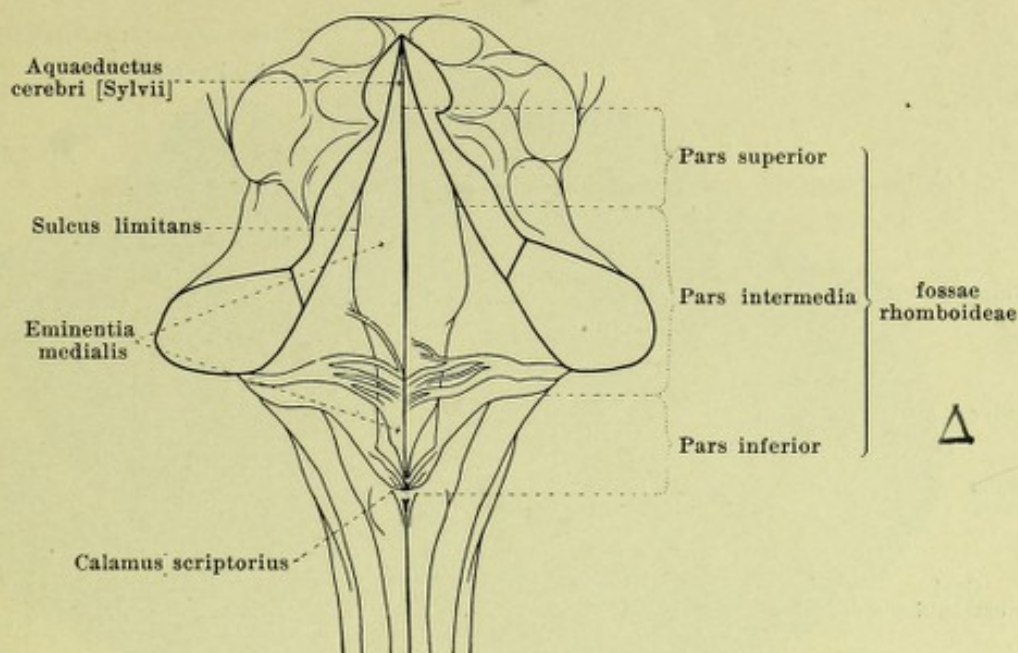


698. Rhomboid fossa, viewed from behind. Magnification 2:1.

(The cerebellum and the chorioid plexus of the fourth ventricle have been completely removed; the brachia conjunctiva with the velum medullare anterius and the lamina quadrigemina have been partly cut away.)

Fossa rhomboidea (continued) (see also Fig. 699).

The eminentia medialis is bounded lateralward by the *sulcus limitans*. This runs, in the pars superior, along the lateral margin and is accompanied there for a considerable distance by a greyish-blue or dark-brown colored area, the *locus caeruleus*. Near the colliculus facialis the *sulcus limitans* broadens out to form a flat fossa, *fovea superior*, which is usually of a bluish color owing to the presence of a superficial vein; the sulcus ends in the uppermost part of the pars inferior in a sharply marked depression, *fovea inferior*. The narrow somewhat depressed triangular area beneath the latter which extends not quite so far as the lower margin of the rhomboid fossa, is of a dark grey color and is called the *ala cinerea*. Lateral the *sulcus limitans* in the pars intermedia and from the *ala cinerea* of the pars inferior is a flattened elevation, the *area acustica*, which, medianward, ends in a convex arch, and lateralward extends into the recessus lateralis to end there in the *tuberculum acusticum* (usually but poorly developed in man). Running transversely over the *area acustica* and over the neighboring part of the eminentia medialis are certain superficial bands of white fibres, *striae medullares*, which arise on the surface of the *tuberculum acusticum* and disappear in the depth in the *sulcus medianus* or before going that far; the striae are very variable in number and size; they run parallel to one another or diverge as they pass medianward.

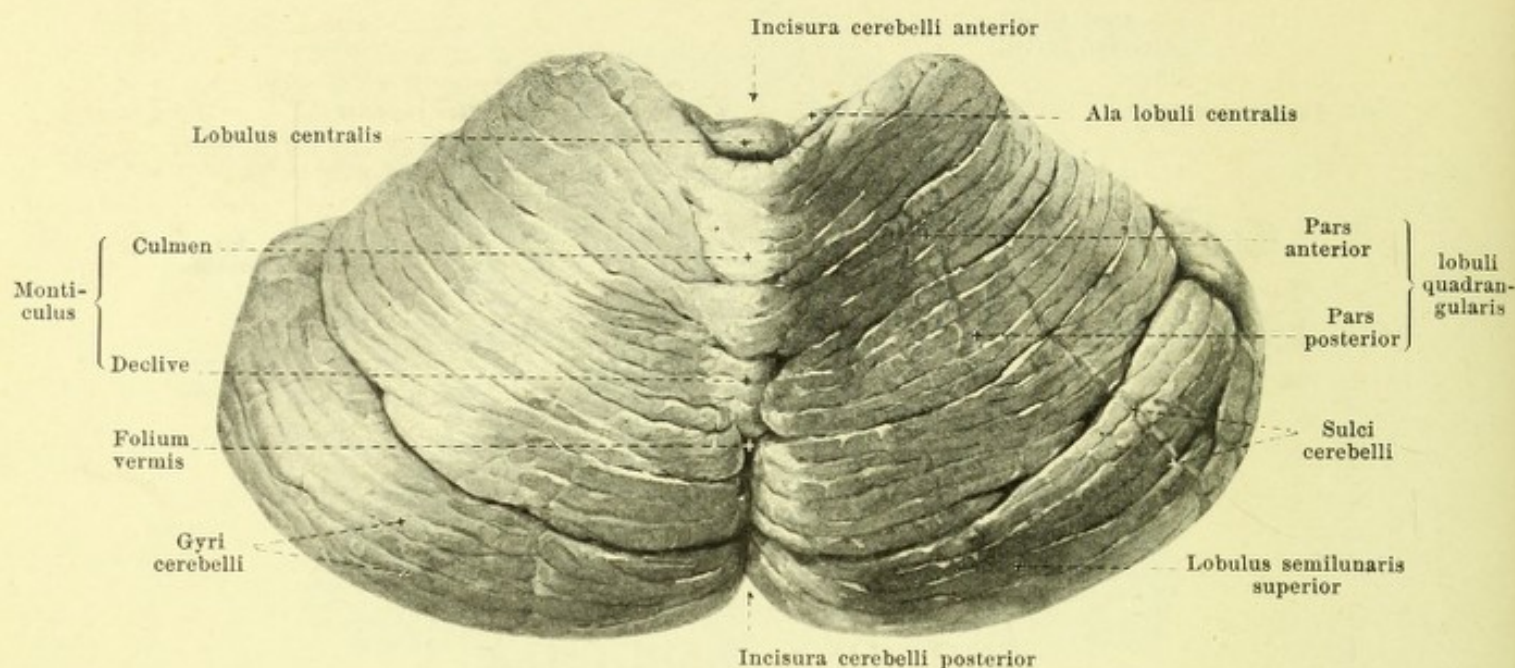


699. Rhomboid fossa,

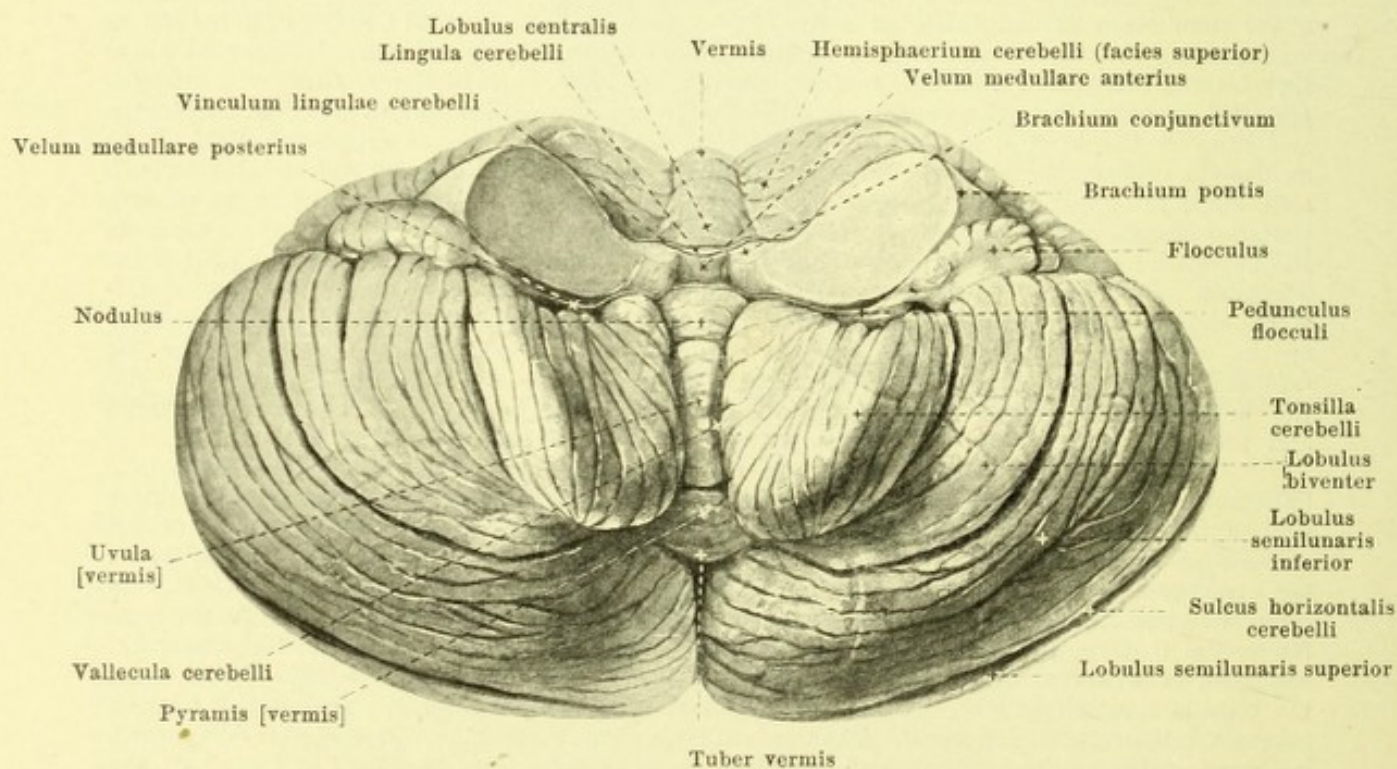
viewed from behind, partly schematic, slightly enlarged.

The **bridge** (*pons* [Varoli]) (see Figs. 685—697, 702 and 705) forms a broad, white mass, running transversely, which is sharply marked off at its lower posterior margin from the medulla oblongata and at its upper anterior margin just as distinctly from the cerebral peduncles which pass through it; it lies upon the clivus and reaches upward as far as the upper margin of the dorsum sellae (see Fig. 757). It is convex forward in both sagittal and transversal directions, but presents in the median plane a flat longitudinal groove, the *sulcus basilaris*, which is broader above than below and in which, as a rule, the a. basilaris runs. Broad bundles of fibres can be seen passing in transversal direction on its surface; they converge somewhat lateralward where they become interwoven with one another; usually one broad band of fibres, *fasciculus obliquus [pontis]*, emerges from the general mass medial from the superficial origin of the n. trigeminus and runs on the surface, in a curve convex lateralward, to the region of superficial origin of the nn. facialis and acusticus. Lateralward from this bundle the pons narrows considerably on each side, since the upper anterior margin curves markedly downward and backward while the inferior posterior margin runs further in the transversal direction. Lateralward from a line which connects the superficial origin of the n. trigeminus with that of the n. facialis the mass is designated the *brachium pontis* (*arm of the pons*) [O. T. middle peduncle of the cerebellum]; it passes lateralward and backward between the flocculus and the lobulus quadrangularis into the substance of the cerebellum. Certain small bundles of nerve fibres, very variable, known as the *fila lateralia pontis* (see Fig. 697), arise in the groove between the brachium conjunctivum and the brachium pontis, and run medianward along the upper boundary of the brachium pontis and the pons to disappear in the fossa interpeduncularis in the cerebral peduncle.

The **cerebellum** (*small brain*) (see Figs. 695, 700—702 and 705) has the shape of a flattened egg with its longest diameter directed transversely; it lies dorsalward from the upper part of the medulla oblongata, from the rhomboid fossa, and from the brachia conjunctiva and corpora quadrigemina, and with the brachia pontis and the pons forms a ring through which the structures lying in the floor of the rhomboid fossa appear to have been thrust. It fills up completely the fossa lying below the sulcus transversus of the occipital bone, extends above as far as the tentorium cerebelli which arises from the angulus superior pyramidis of the temporal bone and is separated by this from the occipital lobes of the cerebrum. Below, on each side, the tonsilla cerebelli and the lobulus biventer very often project slightly through the foramen magnum into the vertebral canal. The upper surface of the cerebellum, directed also dorsalward, is curved in the sagittal and frontal directions so as to be convex backward and upward; the lower surface, looking forward and also ventralward is likewise arched in two directions, and presents in the middle a broad groove, formed by the nodulus, the uvula and the tonsillae, called the *vallecula cerebelli*, in which the medulla oblongata is situated. The anterior margin of the upper surface presents in the middle a flat notch, *incisura cerebelli anterior*, which corresponds to the neighboring corpora quadrigemina; on the posterior margin, in the median plane is a deep, narrow notch, *incisura cerebelli posterior*.

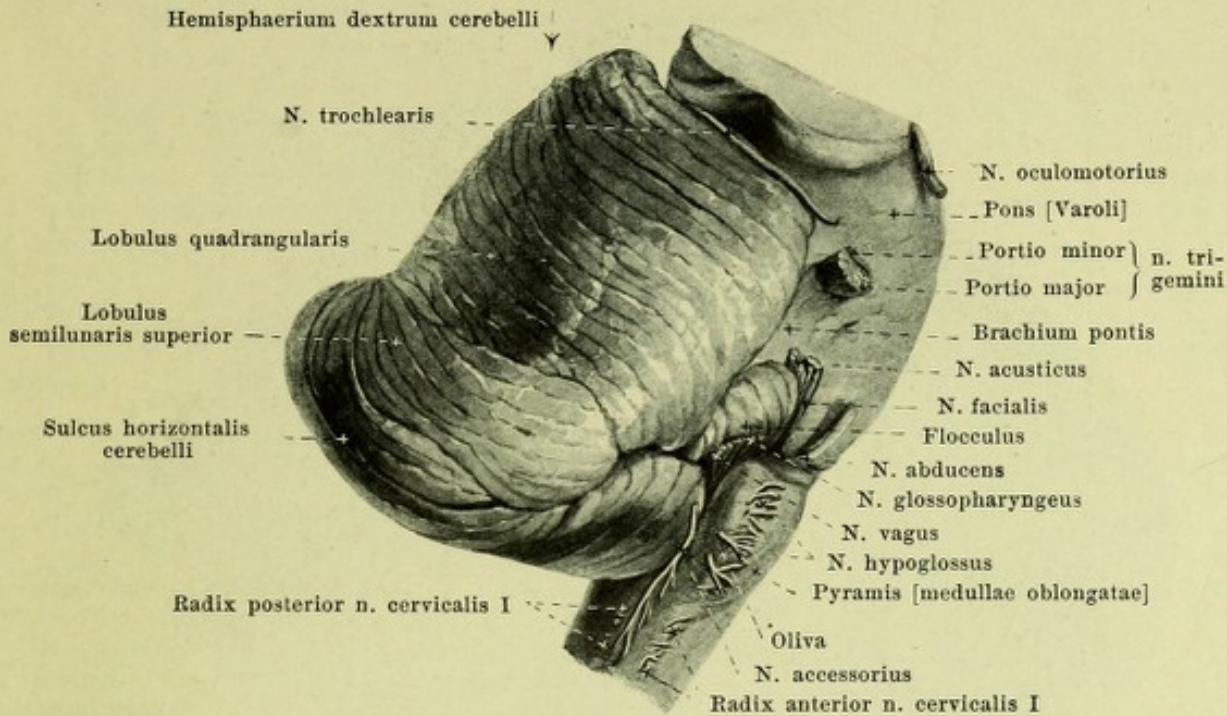


700. Cerebellum, viewed from above and behind.



701. Cerebellum, viewed from below and in front.

(In both figures the cerebellum has been freed by cutting through the brachia pontis, the brachia conjunctiva and the velum medullare anterius.)



702. Rhombencephalon, viewed from the right side.

(The cerebrum has been removed by cutting through the cerebral peduncles and the corpora quadrigemina.)

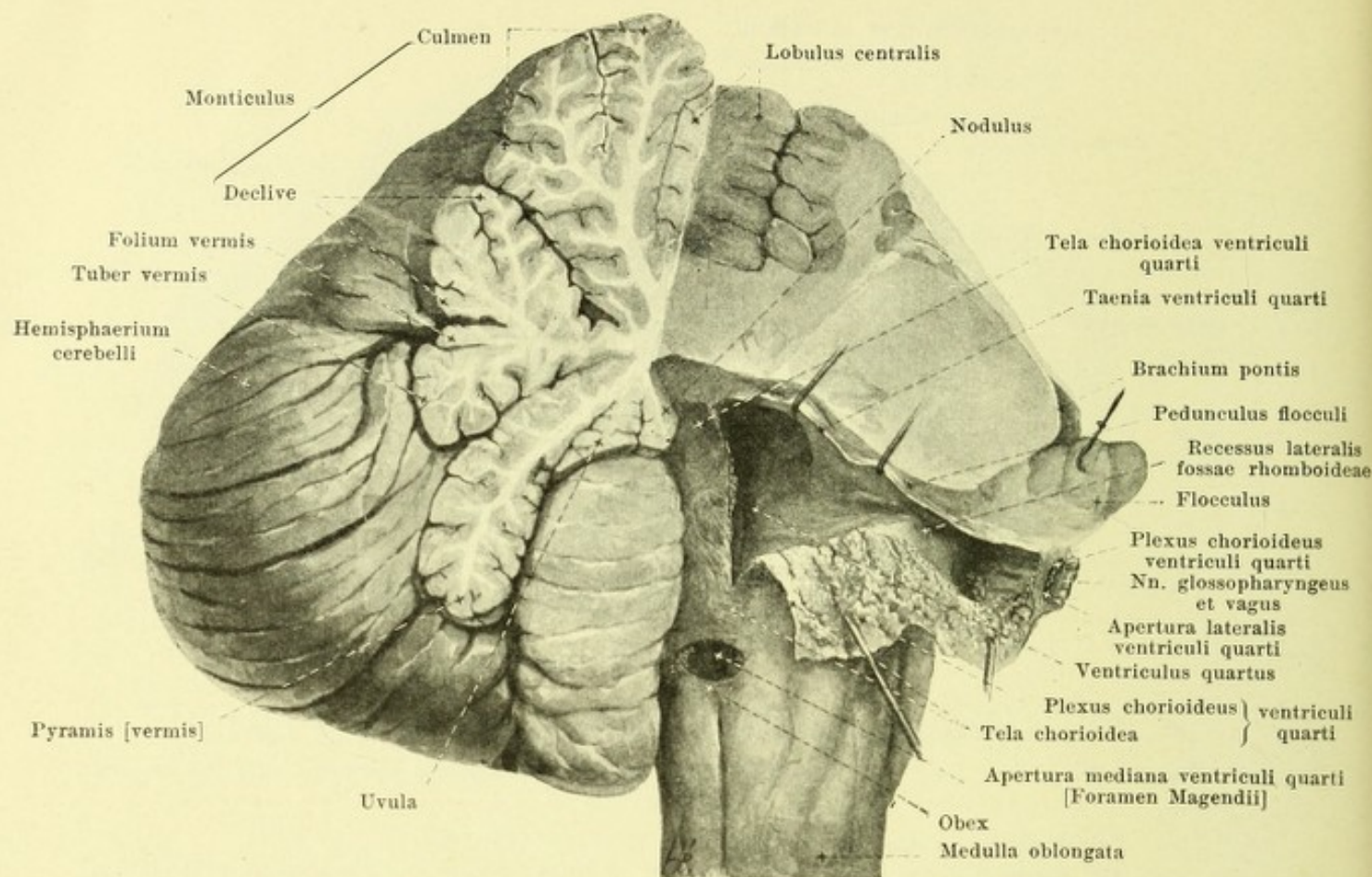
Cerebellum (continued) (see also Figs. 695, 700, 701, 703).

The medial portion, situated between the incisura anterior and the incisura posterior, is called the *worm (vermis)*. It is distinctly separated from the two lateral parts on the inferior surface but very indistinctly on the superior; each of these lateral portions is called a *cerebellar hemisphere (hemisphaerium cerebelli)*. The *convolutions, gyri cerebelli*, are separated from one another by numerous narrow grooves, *sulci cerebelli*, which extend continuously, on the superior surface, over the worm and the hemispheres and run approximately parallel to the posterior margin. A deeper sulcus, *sulcus horizontalis cerebelli*, extends along the posterior margin or rather upon the inferior surface; it divides the surface of the hemispheres into a *facies superior* and a *facies inferior*. Other deep sulci separate individual lobes from one another, each involving both hemispheres and worm so that one lobule of the worm always corresponds to a similar lobule of the hemisphere. On the upper surface of the worm, from before backward, the following structures are met with: *lingula cerebelli* (see p. 635), *lobulus centralis*, *monticulus*, in which are to be distinguished *culmen* and *declive*, and the narrow *folium vermis*; on the hemispheres: the delicate *vincula lingulae cerebelli* (see p. 635), the narrow *ala lobuli centralis*, the *lobulus quadrangularis* which consists of a *pars anterior* and a *pars posterior*, and the *lobulus semilunaris superior*. On the inferior surface of the worm, passing from behind forward, are to be seen the *tuber vermis*, the *pyramis [vermis]*, the *uvula [vermis]* and the *nodulus*; on the hemispheres, the *lobulus semilunaris inferior*, the *lobulus biventer*, and surrounded lateralward by it, the *tonsilla cerebelli* and the *flocculus*. The latter is a club-shaped lobule situated in front of the lobulus biventer and the tonsilla cerebelli and just behind the brachium pontis; it tapers out medianward to the *pedunculus flocculi* and then goes over into a thin leaflet, *velum medullare posterius*, which lies in contact with the front of the nodulus.

The cerebellum is united on each side with the medulla oblongata by means of the corpus restiforme, with the pons by means of the brachium pontis, and with the cerebrum by means of the brachium conjunctivum. These connecting bundles are crowded closely together at the anterior part of the cerebellum.

The **fourth ventricle (ventriculus quartus)** (see Figs. 695 and 703), situated within the rhombencephalon, is a cavity containing a small amount of fluid, continuous below with the central canal of the spinal cord and going, above, directly over into the aquaeductus cerebri. On the whole, it is a transverse slit of the form of the rhomboid fossa, and is nowhere deep except in the middle of its length.

Its anterior wall (*floor of the 4th ventricle*) is formed by the rhomboid fossa (s. p. 629).



703. Fourth ventricle,

partly opened, viewed from behind and from the right.

(The right half of the cerebellum has been in large part removed; the tela chorioidea ventriculi quarti has been cut through on the right side and reflected.)

Fourth ventricle (continued) (see also Fig. 695).

Its posterior wall (*roof of the 4th ventricle*) consists in its upper part of the velum medullare anterius and the brachia conjunctiva; in its lower part it is formed by a thin layer, *tela chorioidea ventriculi quarti*, which extends from the velum medullare posterius, the pedunculus flocculi and the flocculus to the margins of the inferior and middle parts of the rhomboid fossa. This layer is lined on its ventricular surface with epithelium, *lamina chorioidea epithelialis*, which, at the margin, is continuous with the brain substance. On forcibly opening the ventricle the epithelial layer goes with the tela, tearing along the line of transition into brain substance; the fine, jagged border visible along the margin of the tear is called the *taenia ventriculi quarti*; it runs (see Fig. 698) along the margin of the pars inferior fossae rhomboideae (see p. 629), then follows the lower margin of the recessus lateralis as far as the posterior surface of the region of origin of the nn. glossopharyngeus and vagus, and turns, further on, to the anterior surface of the flocculus; finally it passes along the pedunculus flocculi and the velum medullare posterius. The main mass of the tela chorioidea is formed by a lamella of the pia mater encephali, which is united by loose subarachnoideal tissue with the covering (also formed by pia mater) of the under surface of the worm and of the tonsillae cerebelli. The tela chorioidea is provided on its ventricular surface with lobulated, villus-like, reddish processes, known as the *plexus chorioideus ventriculi quarti*; they run as two parallel bands close to the median plane in the lower part of the ventricle; they are united with one another above and then bend around at a right angle into the recessus laterales; the free ends of the plexus project for a variable distance through the three openings of the ventricle (see p. 635) and hang in the subarachnoideal space, so that in the undissected brain the lateral end can be seen on each side, in the angle between the flocculus, nn. facialis and acusticus on the one hand, and the tonsilla cerebelli, nn. glossopharyngeus and vagus on the other (see Fig. 705).

Fourth ventricle (continued) (see Figs. 695 and 703).

The tela chorioidea, completely closed in the embryo, is regularly broken through later in three places; these openings (see Figs. 703 and 757) unite the subarachnoidal spaces with the fourth ventricle; they are of variable size. One unpaired opening, *apertura medialis ventriculi quarti* [*foramen Magendii*], lies just over the obex at the lower end of the posterior wall of the ventricle; the other paired opening, *apertura lateralis ventriculi quarti*, corresponds approximately to the apex of the recessus lateralis and lies upon the posterior surface of the roots of the nn. glossopharyngeus and vagus.

The angle formed by the meeting of the velum medullare anterius and the velum medullare posterius, very distinct in the median section (see Fig. 695), is called the *fastigium*.

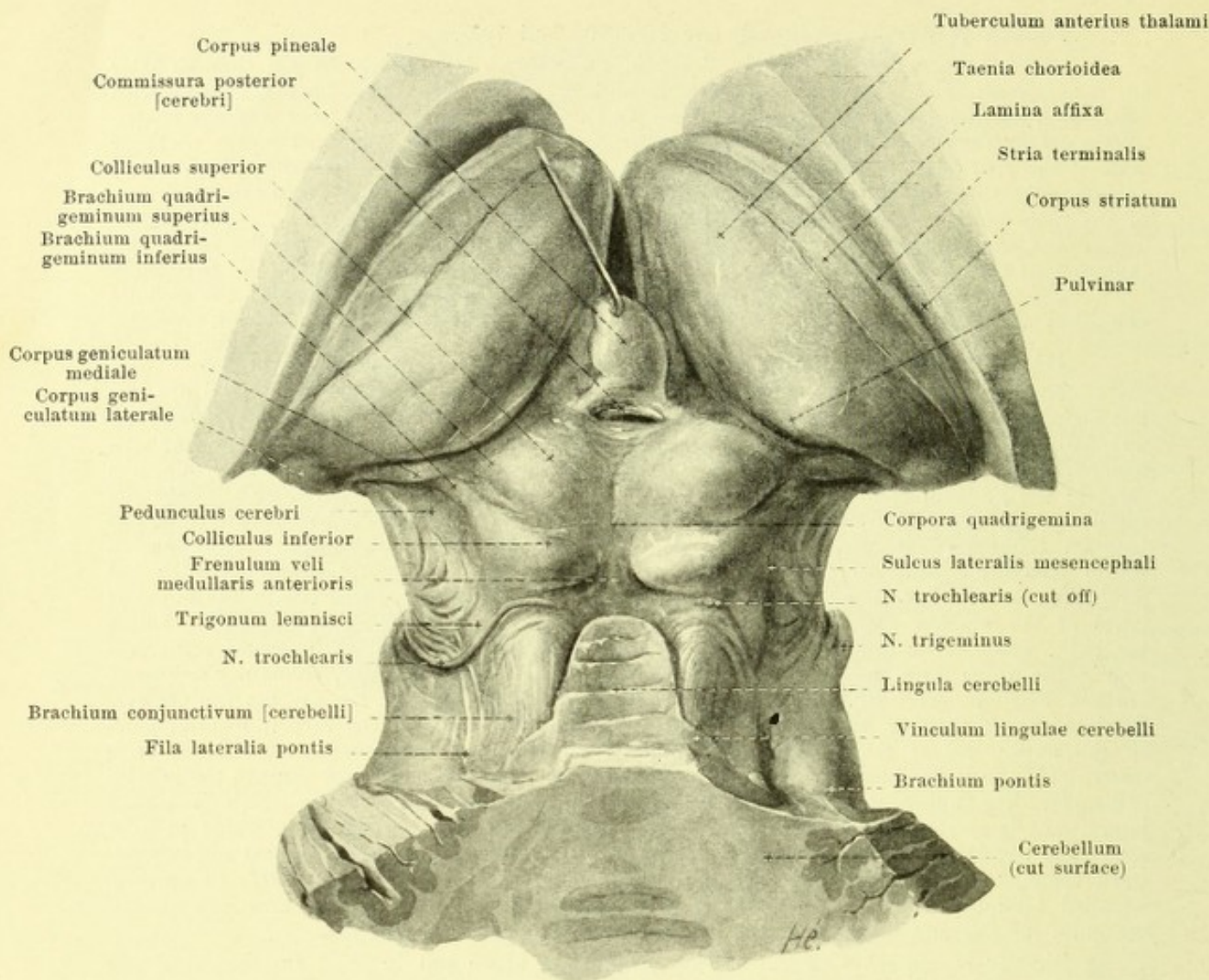
The transverse slit which passes upward between the posterior surface of the medulla oblongata and the anterior surface of the cerebellum is called the *fissura transversa cerebelli*.

Isthmus rhombencephali and mesencephalon.

The *brachia conjunctiva cerebelli* (O. T. superior cerebellar peduncles) are two flat striped white bundles which pass out of the anterior portion of the cerebellum (see Figs. 697, 701 and 704), converge as they pass upward and disappear beneath the lamina quadrigemina. Lateral, each one fuses, below with the brachium pontis, above with the pedunculus cerebri; the junction of these structures is indicated on the surface by a groove, *sulcus lateralis mesencephali*, which is continued upward as far as the medial geniculate body. Stretching out between the medial margins of the brachia conjunctiva is an unpaired, thin, white leaflet, *velum medullare anterius* (see also Figs. 695 and 701); it is directly connected with the cerebellum below, but narrows as it passes upward; its anterior surface, with the adjacent parts of the brachia conjunctiva, forms the upper part of the posterior wall of the fourth ventricle, while its posterior surface (see Figs. 695 and 704) is fused with several transverse grey ridges which form the *lingula cerebelli* of the worm; from the latter, triangular processes, *vincula lingulae cerebelli*, go off below and pass lateralward over the brachia conjunctiva. A white strand running from the lower end of the median sulcus of the corpora quadrigemina to the upper end of the velum medullare anterius is called the *frenulum veli medullaris anterioris*; the n. trochlearis emerges lateralward from it on each side, just beneath the inferior colliculus. The upper part of that surface of the brachium conjunctivum which is turned lateralward is overlapped by a triangular area, *trigonum lemnisci* (see Fig. 697), which projects somewhat but is not always well defined; the fibres directed obliquely lateralward and ventralward belong to the *lemniscus (fillet)* and to the *lemniscus lateralis [acusticus]*; this area is bounded lateralward by the sulcus lateralis mesencephali, in front by the brachium quadrigeminum inferius and contains in the depth the *nucleus lemnisci lateralis*.

Directly in contact with the brachia conjunctiva above and in front are the *corpora quadrigemina* (see Figs. 695, 697 and 704). These are subdivided by a median flat groove and by a transverse groove passing at right angles to the median groove somewhat behind its middle, sharply marked lateralward, into four, whitish hemispherical elevations, so that a *colliculus inferior* and a *colliculus superior* are formed on each side; the anterior colliculi are considerably larger than the posterior, but their convexities are more flattened. In the median groove between the two superior colliculi lies the corpus pineale; it hides them for a variable distance downward (see Fig. 717). The corpora quadrigemina are elevations from a plate, the *lamina quadrigemina* (see Figs. 695 and 734), which goes directly over, on each side, lateralward and in front, into the tegmentum of the pedunculus cerebri; its anterior boundary corresponds to a plane passing through the aqueductus cerebri parallel to the posterior surface. Each colliculus is continuous lateralward with a *quadrigeminal arm* (see also Fig. 697) directed upward and lateralward, each arm being separated by a groove from its neighbor; the *superior quadrigeminal arm (brachium quadrigeminum superius)* proceeds from the colliculus superior and disappears beneath the medial geniculate body and beneath the pulvinar by which it is partly overlapped; the *inferior quadrigeminal arm (brachium quadrigeminum inferius)*, from the colliculus inferior, is longer, passes along the upper margin of the trigonum lemnisci as far as the sulcus lateralis mesencephali, and then disappears beneath the medial geniculate body.

On the anterior inferior surface of the brain-stem (see Figs. 696 and 705) two large, striped, white bundles, *pedunculi cerebri* (O. T. crura cerebri) are to be seen close to one another; they emerge from the upper margin of the pons and diverging almost at a right angle, pass upward and lateralward to disappear beneath the tractus optici. The ventral surface here visible and the lateral free surface as far as the sulcus lateralis mesencephali (see Fig. 607) belong to the *basis pedunculi (foot of the cerebral peduncle)*, while the area between this sulcus and the lamina quadrigemina overlaid by the trigonum lemnisci and the brachium quadrigeminum inferius belongs to the *tegmentum* (see Fig. 734).



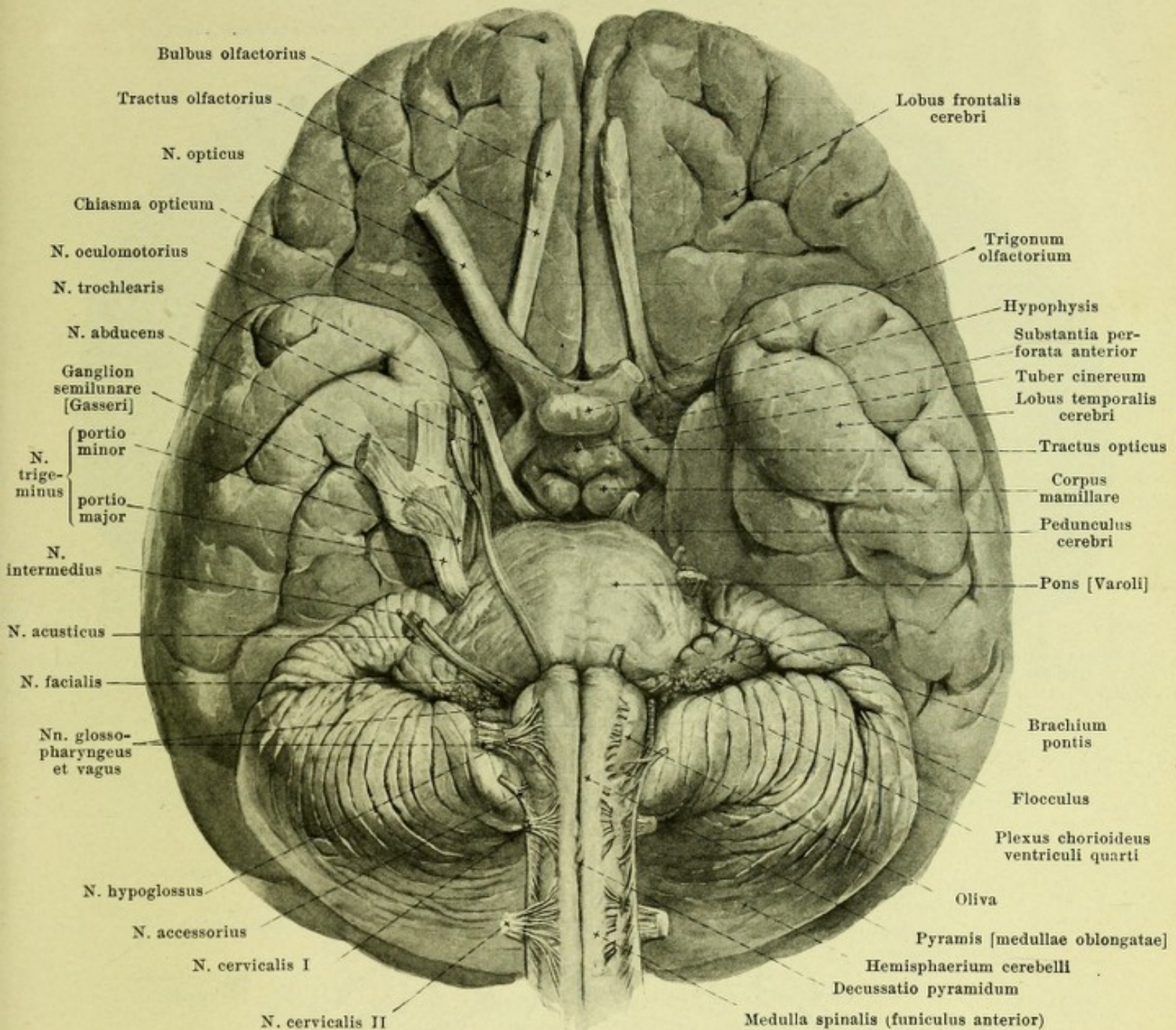
704. Corpora quadrigemina and neighborhood, viewed from behind and above.

(The upper part of the cerebellum has been removed by a cut passing obliquely backward and downward; the cerebral hemispheres have been removed; the corpus pineale has been pulled upward.)

Between the diverging cerebral peduncles is a deep depression, *fossa interpeduncularis* [Tarini] (see Fig. 696); its *recessus posterior* slightly undermines the upper margin of the pons and its *recessus anterior* passes into the depth between the corpora mamillaria (see Fig. 695). The floor of this approximately triangular fossa, which reaches upward as far as the corpora mamillaria, is formed by the *substantia perforata posterior*, the surface of which is subdivided by a median shallow groove, which presents numerous openings for blood vessels; it helps, on each side, to bound the tegmentum medianward (see Fig. 734) and is marked off from the cerebral peduncle by a groove, the *sulcus n. oculomotorii* (see Fig. 696).

The *aqueductus cerebri* [Sylvii] (see Fig. 695) is a narrow canal, 1.5 cm long, which passes from the upper end of the fourth ventricle (see p. 633) through the mesencephalon to the third ventricle. It is covered behind by the lamina quadrigemina and the commissura posterior; it is bounded in front by the tegmentum of the pedunculus cerebri. In cross section it is triangular or T-shaped in its upper and lower parts, while in the middle it has approximately the shape of an ace of hearts, though it deviates sometimes from this shape.

The **cerebrum** (*large brain*) (see p. 626) is approximately egg-shaped. It presents a surface, markedly convex upward in the sagittal and frontal directions, *facies convexa cerebri* (see also Figs. 706, 707 and 710), which corresponds to the inner surface of the roof of the skull, and an inferior surface, *basis cerebri* (see Figs. 712 and 713); the front part of the latter lies in the anterior and middle fossae of the skull, the back part upon the tentorium cerebelli which separates it from the cerebellum; its bulgings correspond to these surfaces.



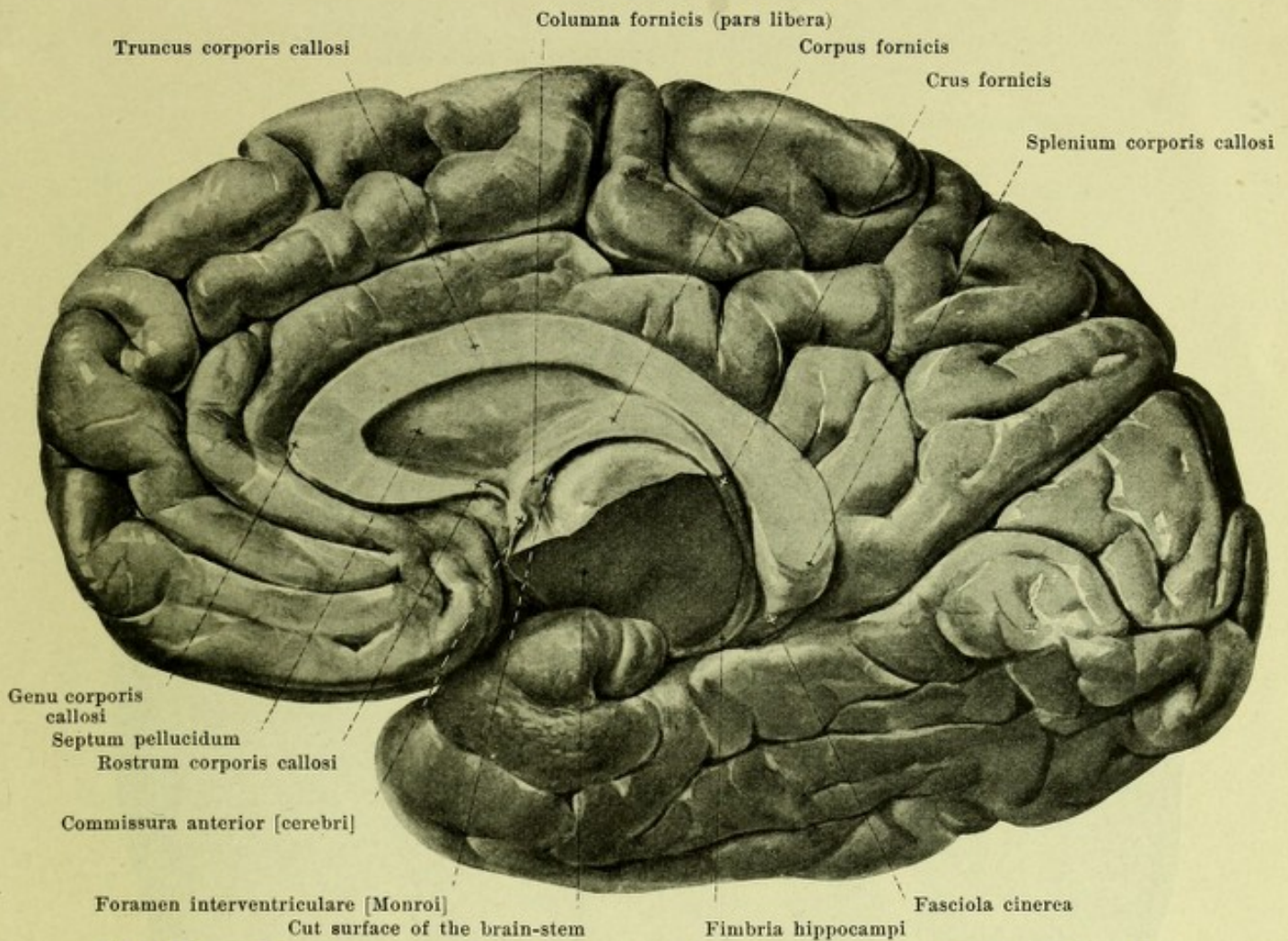
705. Brain, viewed from below and in front.

(The nerves on the left side have been cut off short.)

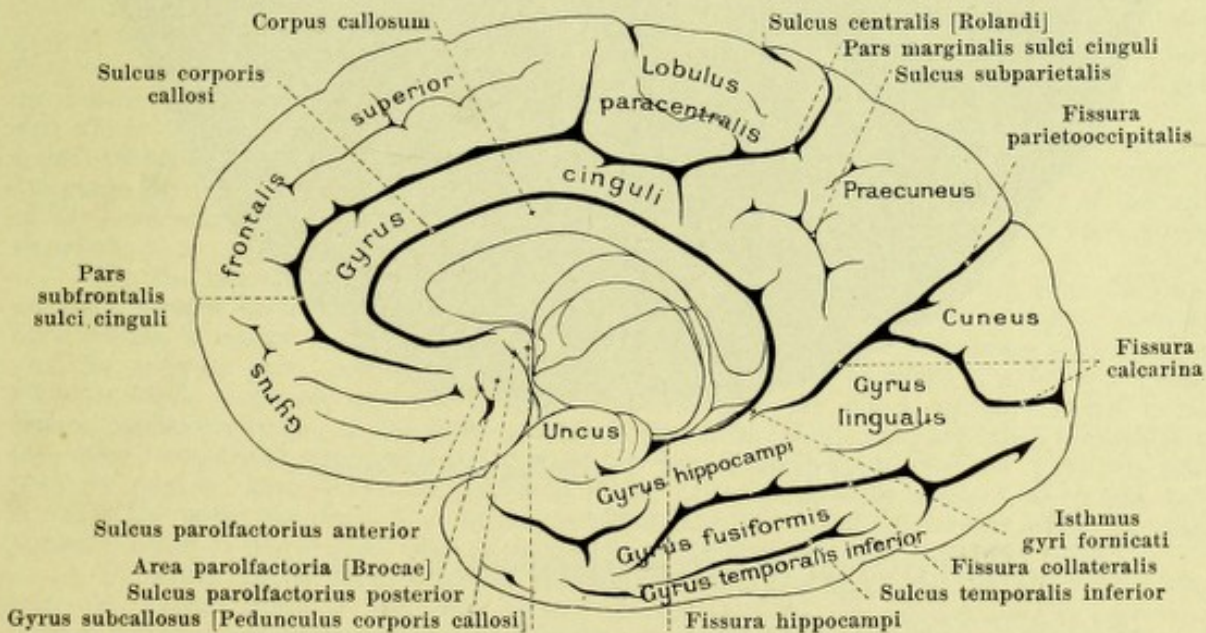
Cerebrum (continued). It is composed of two symmetrical halves, only partly united with one another in the median plane; hence each half presents an approximately flat *facies medialis cerebri* (see Figs. 695, 708 and 709), which belongs partly to the 3rd ventricle, partly to the free surface.

The largest mass of the cerebrum is formed on each side by the **cerebral hemisphere** (*hemisphaerium cerebri*), in which are to be distinguished the *pallium*, the *rhinencephalon* and the (buried) *corpus striatum*.

The *pallium* (brain mantle) is the main mass of the hemisphere, markedly fissured on the surface; that of one hemisphere is separated from that of the other side by a deep median slit, *fissura longitudinalis cerebri* (see Figs. 710 and 712), reaching to the corpus callosum. The deep transverse slit, which passes in from behind, between the pallium on the one hand and the upper surface of the cerebellum, the corpora quadrigemina and the corpus pineale on the other, filled up behind by the tentorium cerebelli and in front by a duplicature of the pia mater, is called the *fissura transversa cerebri* (see Fig. 694, not designated).

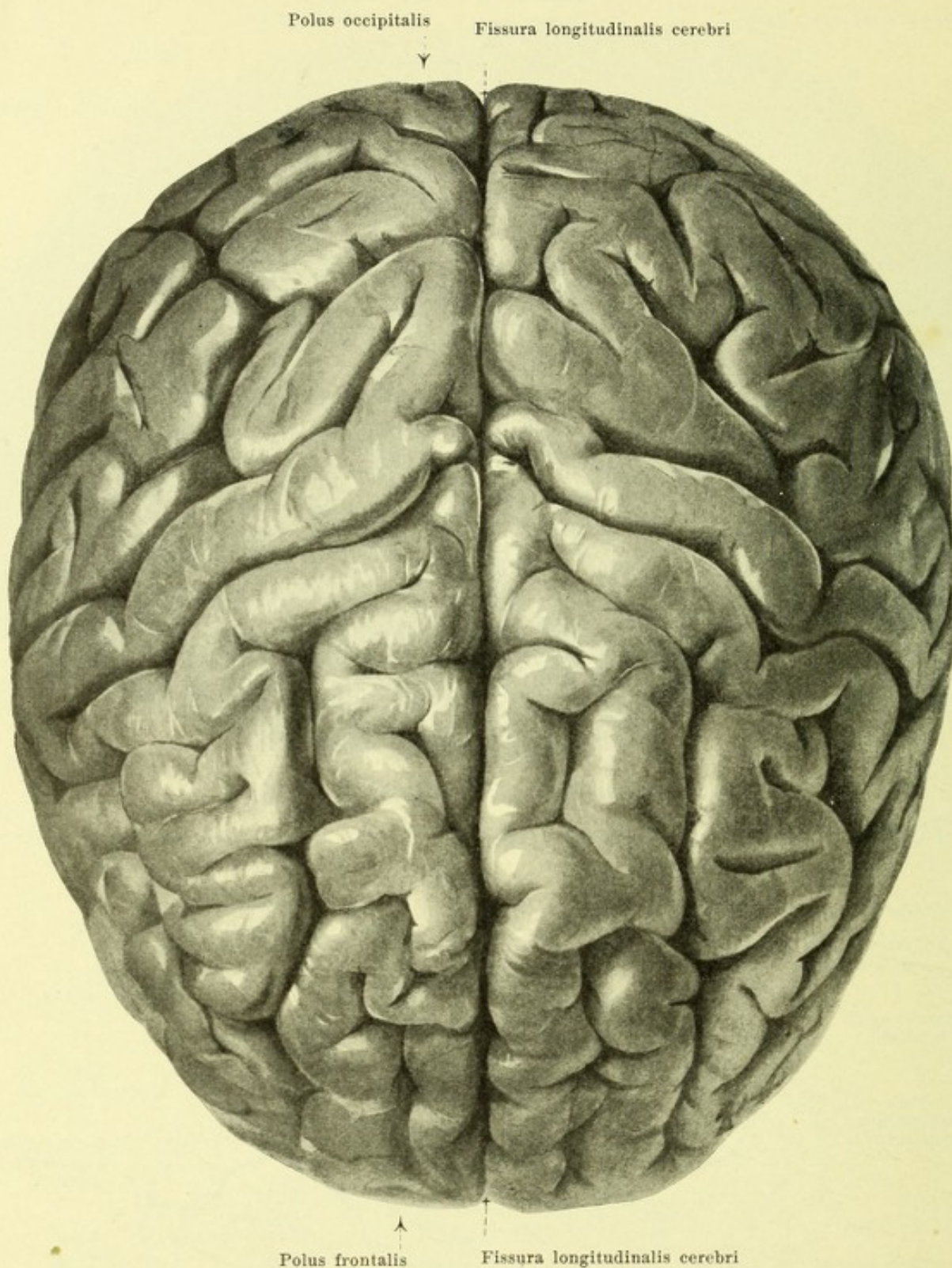


708. Right cerebral hemisphere, viewed from the left.



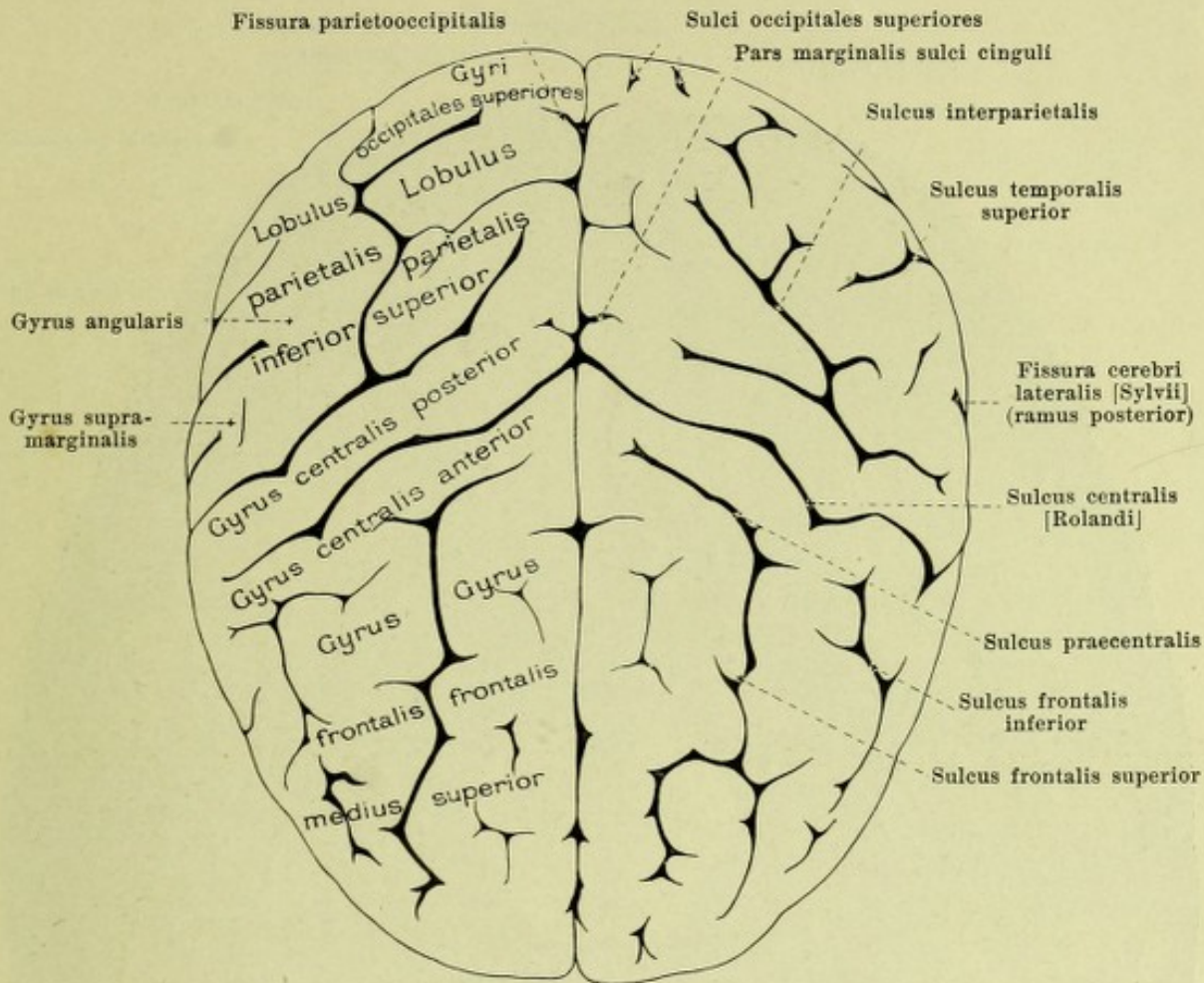
709. Right cerebral hemisphere, viewed from the left, partly schematic.

(The brain has been cut in half; the lower part of the brain-stem has been removed by an oblique cut.)



710. Cerebral hemispheres, viewed from above.

Pallium (continued). What has been said concerning the form of the cerebrum holds for the pallium; on the inferior, basal surface the upper angle of the pyramid of the temporal bone causes a slight depression, *impressio petrosa* (see Fig. 712), which runs obliquely lateralward and dorsalward.

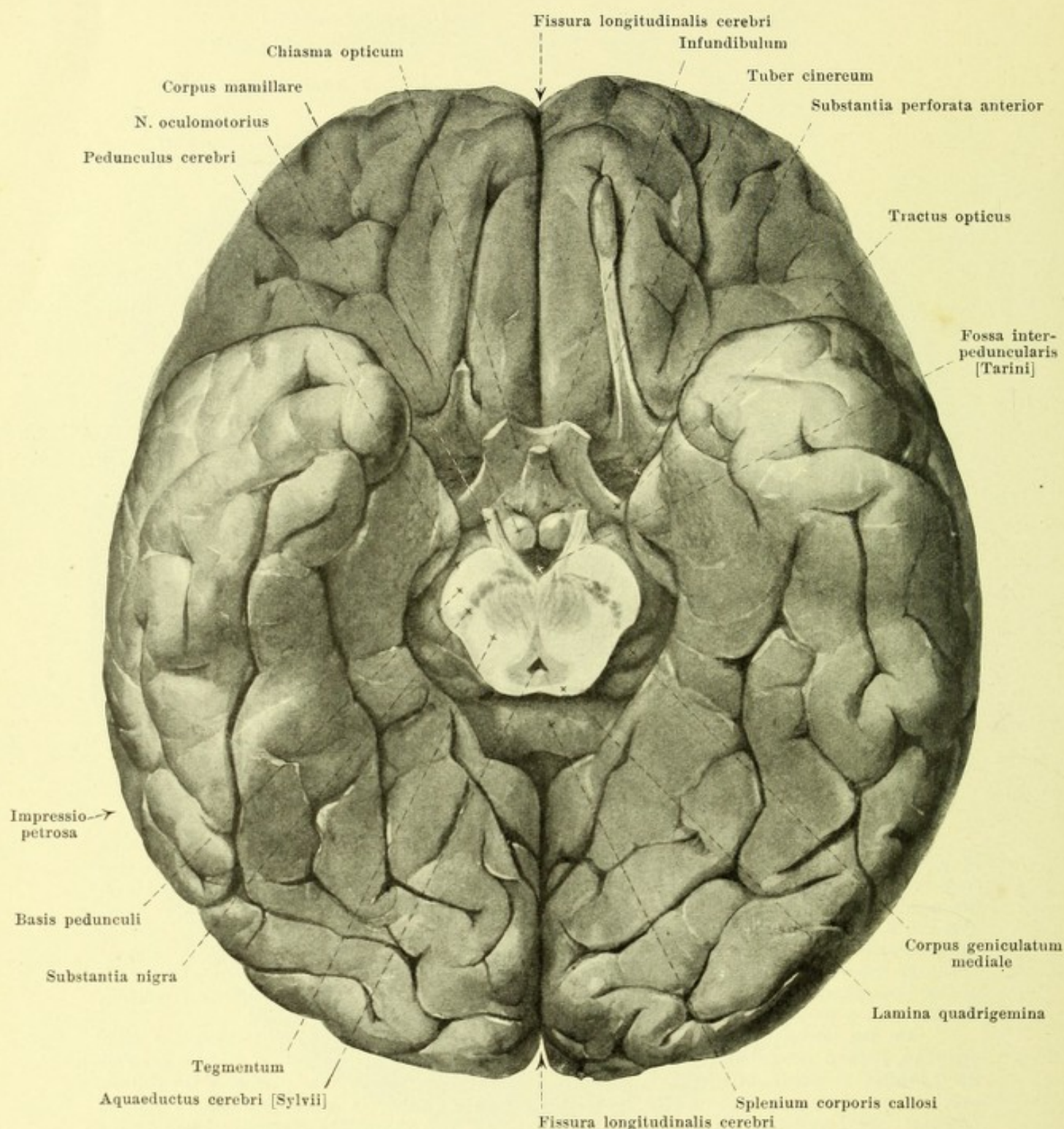


711. Cerebral hemispheres, viewed from above, partly schematic.

Pallium (continued). The surface is studded by numerous convolutions, *gyri cerebri*, in part individually variable; they are shorter or longer, straight or curved elevations, separated from one another by groove-like or slit-like depressions, *sulci cerebri*. These superficial gyri are manifoldly connected in the depth of the sulci by hidden *deep gyri*, *gyri profundi*. Short gyri which, lying superficially or in the depth, make a connection between two longer gyri are called *transitional gyri*, *gyri transitivi* (O. T. annectant gyri). Those sulci which arise as "primary fissures" in the embryo by a total infolding into the ventricular cavity of the wall of the hemisphere, still very thin at this time, are called *fissurae*; each of these corresponds, therefore, to a projection in the wall of the ventricle, usually similarly named.

On the lateral, convex surface of the pallium (see Figs. 706 and 707) runs the deep, arch-like, *fissura cerebri lateralis [Sylvii]* (see also p. 644); it divides into a *ramus anterior horizontalis*, a *ramus anterior ascendens*, and a *ramus posterior*. The portion of the pallium over its anterior part, reaching as far as the sulcus centralis, is called the *lobus frontalis* (*frontal lobe*); that over its posterior part, extending from the sulcus centralis almost to the fissura parietooccipitalis, is the *lobus parietalis* (*parietal lobe*); the part lying beneath it is the *lobus temporalis* (*temporal lobe*) which is very indistinctly marked off from the most posterior portion, *lobus occipitalis* (*occipital lobe*). The most anterior point of the frontal lobe is called the *polus frontalis*, that of the temporal lobe, the *polus temporalis*, while the most posterior point of the occipital lobe is called the *polus occipitalis* (see also Fig. 713).

Upon the convex surface of the *frontal lobe* (see also Figs. 706, 707 and 710) above runs the *sulcus frontalis superior*, below, the *sulcus frontalis inferior*, which goes over behind into the *sulcus praecentralis*; in this way are formed the *gyrus frontalis superior*, the *gyrus frontalis medius*, which is again subdivisible in front into a *pars superior* and a *pars inferior*, the *gyrus frontalis inferior*, divided by the two anterior rami of the fissura cerebri lateralis into a *pars orbitalis*, a *pars triangularis* and a *pars opercularis*, and the *gyrus centralis anterior*.

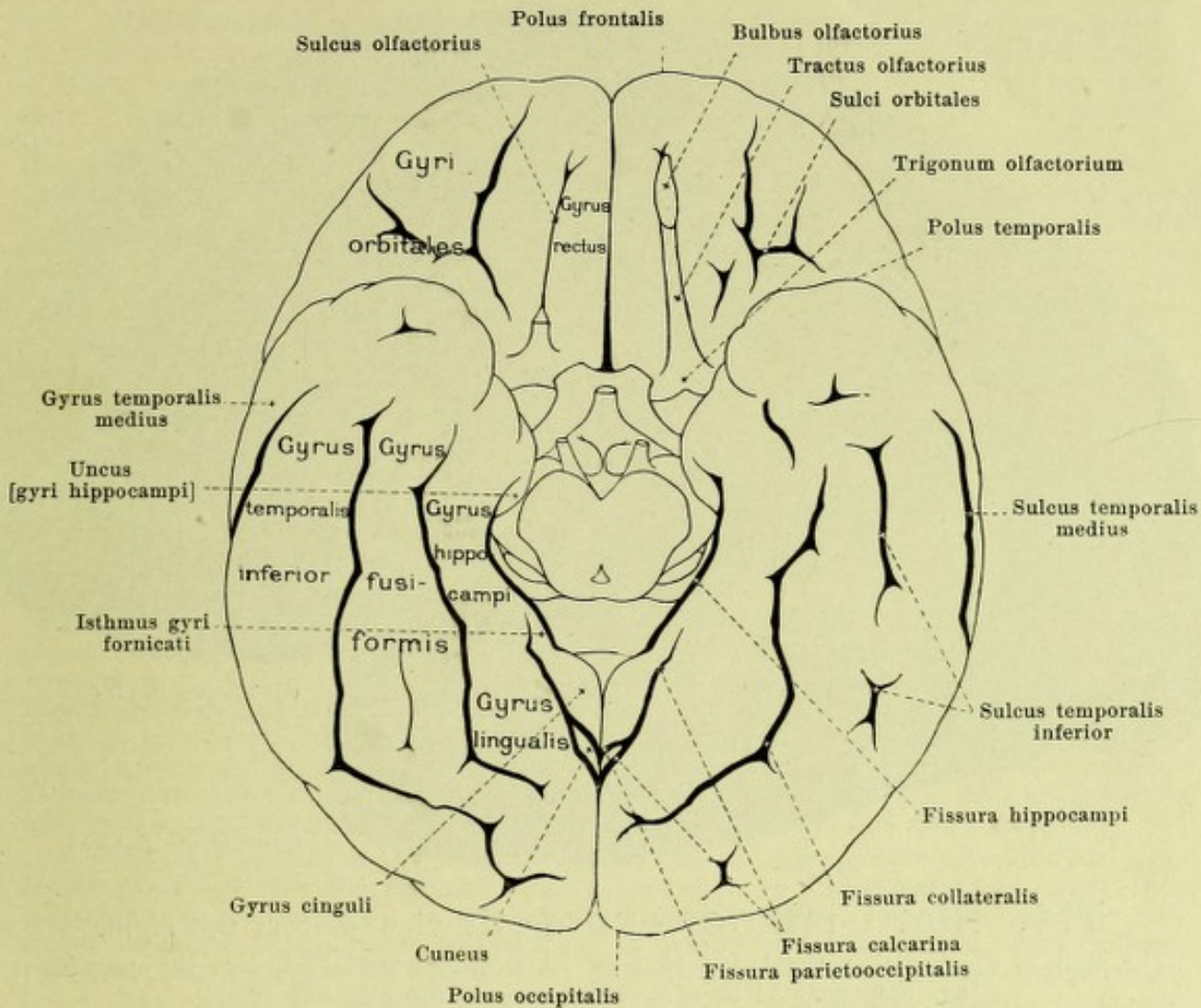


712. Base of cerebrum (*basis cerebri*), viewed from below.

(The rhombencephalon has been cut off transversely, just above the pons. The hypophysis and the right tractus olfactorius have been removed.)

Pallium (continued).

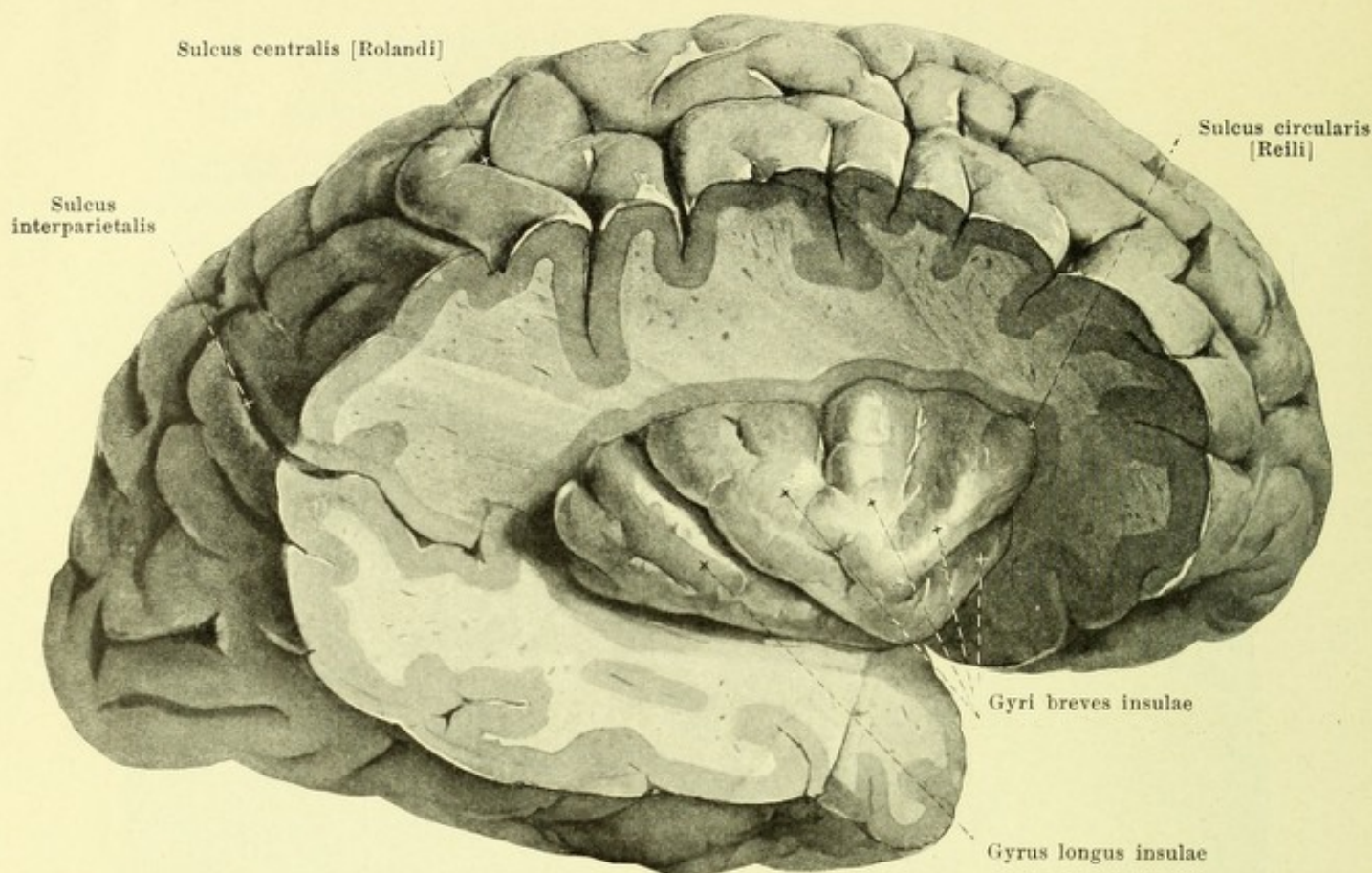
Behind the gyrus centralis anterior, the *sulcus centralis* [Rolandi] (O. T. fissure of Rolando) (see Figs. 706—711) passes obliquely upward and backward, usually as far as the medial surface. On the inferior, basal surface, the *sulci orbitales* and the *sulcus olfactorius* are to be seen; they separate the *gyri orbitales* and the *gyrus rectus* from one another.



713. Base of the cerebrum (*basis cerebri*),

viewed from below, partly schematic. (See legend to Fig. 712.)

Pallium (continued) (see also Figs. 706—712). In the parietal lobe, on the convex surface, the *gyrus centralis posterior* is bounded behind by the *sulcus interparietalis*, which also separates the *lobulus parietalis superior* from the *lobulus parietalis inferior*; in the latter, the curved gyrus surrounding the end of the fissura cerebri lateralis is called the *gyrus supramarginalis*, and the corresponding gyrus at the end of the sulcus temporalis superior, the *gyrus angularis*. The *occipital lobe* is divided, on its convex surface, by the *sulcus occipitalis transversus*, as well as by the *sulci occipitales anterior, laterales, superiores* into the *gyri occipitales laterales et superiores*. In the *temporal lobe*, the *sulci temporales transversi* (see Fig. 715) divide the surface, which is turned partly toward the island, into the *gyri temporales transversi*; on the convex and basal surfaces are to be seen the *sulci temporales superior, medius* and *inferior*; situated beneath, or medianward from the *gyri temporales superior, medius* and *inferior*; next to the latter, on the basal surface, is the *gyrus fusiformis*, then the *fissura collateralis*, and, behind this, the *gyrus lingualis*. On the *facies medialis hemisphaerii* (see Figs. 708 and 709), the *sulcus corporis callosi* runs just above the corpus callosum and goes over, behind, into the *fissura hippocampi*, which is situated between the *gyrus hippocampi* and the fascia dentata. Along these two sulci runs the *gyrus fornicatus*, which is divisible into an upper part, *gyrus cinguli*, a lower part, *gyrus hippocampi*, with the *uncus [gyri hippocampi]* (see also Figs. 721 and 722 and p. 654) and an intermediate portion, *isthmus gyri fornicati*. By means of the rhinencephalon, which connects through the area parolfactoria with the *gyrus cinguli* and through the substantia perforata anterior with the *gyrus hippocampi*, the two ends of the *gyrus fornicatus* are united to form a closed ring. The *gyrus cinguli* is bounded by the *sulcus cinguli*, which in its *pars subfrontalis* belongs to the antero-inferior part of the frontal lobe, and in its *pars marginalis* turns up behind the medial end of the sulcus centralis to the convex surface of the hemisphere.



714. Right island, exposed, viewed from the right.

(The parts of the frontal, parietal, and temporal lobes covering the island, *i. e.*, the operculum, have been removed by a cone-like section. See also Fig. 706.)

Pallium (continued). Following upon the sulcus cinguli (see Figs. 708 and 709) can be seen, in front, the gyrus frontalis superior and behind it, as far as the ramus marginalis, the *lobulus paracentralis*; behind this, again, lies the *praeuncus*, which is bounded, below by the *sulcus subparietalis*, and behind by the *fissura parietooccipitalis*; behind this fissure, extending as far as the *fissura calcarina*, is the *cuneus*.

If the margins of the fissura cerebri lateralis [Sylvii] (see p. 641) be drawn apart, a deep fossa becomes visible, the *fossa cerebri lateralis* [Sylvii]; its floor is formed by a special lobe of the cerebral hemisphere, the *island (insula)* (see also Figs. 715 and 716). During embryonic life this is exposed, but later it becomes overlapped in front and above by part of the frontal lobe, behind and above by a part of the parietal lobe, and below by a part of the temporal lobe. These parts of the hemisphere, which hide the island completely, are spoken of, together, as the *operculum (lid)*; it is divisible into a *pars frontalis*, a *pars parietalis* and a *pars temporalis*. The surface of the island is convex lateralward; it is divided by a crest, gradually rising from before backward, into an upper lateral, a lower lateral and an anterior surface; a narrow inferior surface (see Fig. 695) lies approximately horizontal and goes over medianward into the limen insulae (see p. 645). At the junction of the surface of the island with that of the operculum, running between the two, is a slit-like groove, *sulcus circularis* [Reili]; it is lacking only at the limen insulae. On the surface of the island are a number of gyri, *gyri insulae*. A deep sulcus running from in front and below, backward and upward, separates a larger anterior portion of the island from a smaller posterior portion; in the anterior portion several *gyri breves insulae* can be seen diverging from the apex of the crest; in the posterior, there is a simple, long, arched gyrus, *gyrus longus insulae*.

The **rhinencephalon** (*olfactory brain*) (see Figs. 691—696, 708 and 709) is relatively feebly developed in human beings. It belongs chiefly to the base of the brain, but in part helps also to form the medial surface of the cerebrum, where it is separated, by a short curved sulcus, *sulcus parolfactorius anterior* (see Figs. 695, 708 and 709), from the gyrus frontalis superior and the gyrus cinguli. On embryological grounds a *pars anterior* [rhinencephali] and a *pars posterior* [rhinencephali] can be distinguished.

Rhinencephalon (continued) (see Figs. 696, 705, 712 and 713). The pars anterior, at the base of the brain, is formed by the *lobus olfactorius* which, on each side, passes backward and somewhat lateralward on the inferior surface of the frontal lobe to the brain stem; at its largest anterior part it lies very close to the sulcus olfactorius. It presents, in front, an oval, grey enlargement, *bulbus olfactorius*, which lies upon the lamina cribrosa of the ethmoid bone, and into which the nn. olfactorii enter; connected with the bulb is a whitish, triangular, prismatic band, *tractus olfactorius*, which broadens somewhat behind and goes over into a grey ridge, running transversely and at right angles to it, the *trigonum olfactorium* (see Fig. 696). This is sharply marked off behind from the substantia perforata anterior and presents on its inferior surface three whitish bands of fibres which begin at the tractus and disappear at the anterior boundary of the substantia perforata anterior: the *stria lateralis*, the longest, passes in a curve backward and lateral, the *stria medialis*, goes backward and somewhat medial, while the *stria intermedia*, occasionally present between these two, runs almost straight backward. Running out lateralward and somewhat backward from the trigonum, along the substantia perforata anterior, to the gyrus hippocampi is a gyrus which is directly connected lateralward with the island (see p. 644) and is therefore called, in that situation the *limen insulae* (*threshold of the island*). Medianward, the trigonum goes over into a gyrus, the *area parolfactoria* [*Brocae*] (see Figs. 696, 708, 709), which belongs to the medial surface of the cerebrum; it is bounded in front by the sulcus parolfactorius anterior (see p. 644) and is separated behind from the gyrus subcallosus by the deep *sulcus parolfactorius posterior*.

The pars posterior rhinencephali includes, at the base of the brain, the *substantia perforata anterior* (see Fig. 696), which lies directly behind the trigonum olfactorium; it is an approximately quadrangular area, perforated, especially in front, by numerous openings for blood vessels; laterally it adjoins the uncus, medially and behind, the tractus opticus; medially, in front, it goes over into a whitish ridge, *gyrus subcallosus* [*pedunculus corporis callosi*], which passes above the chiasma opticum to the medial surface of the cerebrum, runs upward in front of the commissura anterior and the lamina rostralis (see Figs. 695, 696, 708 and 709) and, tapering out, becomes fused with the rostrum corporis callosi (see also p. 648).

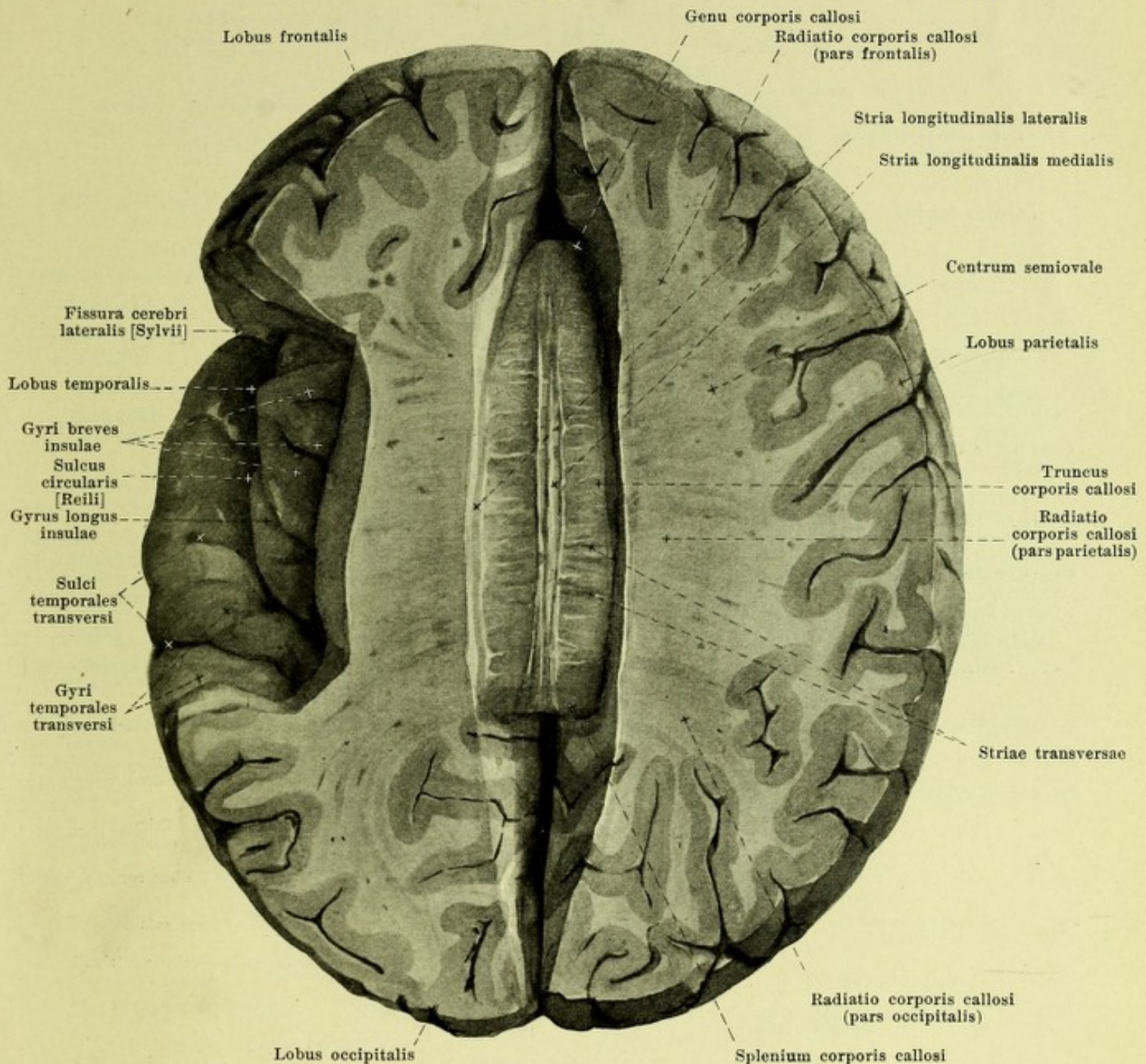
The other portions of the brain, situated at the base in front of the substantia perforata posterior (see Figs. 691—695, 696, 705 and 712), belong to the *hypothalamus*. In it, two parts are to be distinguished; its posterior part, *pars mamillaris*, which is formed by the corpus mamillare, belongs to the diencephalon; its anterior part, *pars optica*, which includes the other parts, belongs to the telencephalon. Just in front of the substantia perforata posterior (see p. 636) project the *corpora mamillaria*, two white, pear-shaped elevations which are crowded close against one another at their thick, medial extremities. In front of them rises an unpaired grey, somewhat irregular hillock, *tuber cinereum*, which, in front, tapers off like a cone to form the *infundibulum* (*funnel*) (see Figs. 695 and 712). Hanging to the latter, as though on a stem, is an egg-shaped grey mass, about the size of a bean, the *hypophysis* (*pituitary body*) (see Figs. 695 and 712), the largest diameter of which is placed frontally. It is situated in the fossa hypophyseos of the sella turcica, and on section is seen to consist of two parts, a larger anterior, *lobus anterior*, which, genetically, does not belong to the brain, but only lies in contact with it, and a smaller posterior, *lobus posterior*, which alone is directly continuous with the infundibulum. Directly attached to the tuber cinereum in front and lateralward is the posterior margin of the unpaired *chiasma opticum*, a white, thick, quadrangular plate, with concave margins, situated somewhat behind the sulcus chiasmatis of the sphenoid bone; at its two anterior corners, it receives the nn. optici; from its two posterior corners go off the two *tractus optici*. Passing upward from the upper anterior surface of the chiasm, is a thin layer, *lamina terminalis* (see Figs. 695 and 696), which is in contact above with the anterior surface of the commissura anterior [cerebri] and then goes over into the lamina rostralis; it forms a part of the anterior wall of the third ventricle.

The *tractus opticus* (see Figs. 696, 697, 705 and 712), a flattened band fused with the subjacent tissue, runs at the posterior margin of the lamina perforata anterior, at first along the tuber cinereum; turning then lateralward and backward approximately at right angles to the direction of the pedunculus cerebri, it goes around the latter in the form of an arch, adjoining the gyrus hippocampi lateralward and below, and finally divides into two limbs which form the transition to the *metathalamus* (see p. 626). The narrower, medial limb, *radix medialis*, passes into the grey *corpus geniculatum mediale* (*medial geniculate body*) (see Figs. 697 and 704), an oblong, oval enlargement, situated at the anterior end of the sulcus lateralis mesencephali and of the brachium quadrigeminum inferius (see p. 635), bounded medianward by the brachium quadrigeminum superius as well as by the overhanging pulvinar and separated by a deep groove from the corpus geniculatum laterale. The thicker and shorter, lateral limb, *radix lateralis*, passes to the greyish-white *corpus geniculatum laterale* (*lateral*

geniculate body), an oblong body projecting only a little from the postero-inferior surface of the thalamus, lateral from the pulvinar.

Just in front of the geniculate bodies and corpora quadrigemina, on each side, lies the *thalamus* (see Figs. 695, 697, 704, 717, 720, 745 and 748), which first becomes visible after removal of the corpus callosum, fornix and chorioid plexus. It is a large ganglionic mass of approximately oval shape, broadening behind. Only its upper and medial surfaces are free, its lateral and its narrow inferior surface are fused with neighboring parts. The upper approximately triangular surface, covered by a layer of white matter (*stratum zonale*), lies approximately horizontally and is curved so as to be slightly convex in the frontal direction, markedly convex in the sagittal direction. In front it presents an oval enlargement, *tuberculum anterius thalami*; behind it goes over into a ridge, protruding dorsalward, the medial portion of which, the *pulvinar*, projects for a greater or less distance over the superior quadrigeminal arm and the medial geniculate body, and the lateral portion of which contains the lateral geniculate body (*vide supra*). The medial grey surface forms approximately a right angle with the superior surface, is placed sagittally and separated from that of the opposite side only by the third ventricle; below, it is separated from the ventricular surface of the hypothalamus by a shallow groove, *sulcus hypothalamicus* [*Monroi*] (see Fig. 695), which runs, curved somewhat like the letter S, from the foramen interventriculare to the aditus ad aquaeductum cerebri. Stretching out between the two thalami, somewhat in front of their middle, is a grey bridge, *massa intermedia*, very variable in thickness and form. At the junction of the medial and superior surfaces, runs a band of white matter, *stria medullaris*, which is situated somewhat deeper behind than in front; this gradually broadens behind to form a nearly horizontal area, *trigonum habenulae*. The stria, at its sharpened margin, is directly continuous with the epithelial lamella, *lamina chorioidea epithelialis*, which covers the *tela chorioidea ventriculi tertii* below, and which, on being removed at its attachment, leaves behind a fine jagged edge, *taenia thalami*; behind, the taenia, corresponding to the region of departure of the epithelial lamella (*vide infra*), turns to the upper surface of the habenula and of the corpus pineale to go over at the latter place into that of the opposite side. Running out medianward from the trigonum habenulae is a white band of fibres, *habenula* (see Fig. 717); in its anterior part, it is continuous with that of the opposite side, thus forming the *commissura habenularum*; behind, on the contrary, it goes over into the *corpus pineale* (O. T. pineal gland). The latter (see Figs. 695, 704 and 717) forms a greyish-red, flattened, oval body, usually nodular on the surface and variable in size; it is narrowed somewhat in front and lies in the groove between the two superior colliculi. The pineal body, the habenula and the trigonum habenulae belong to the *epithalamus* (see p. 626).

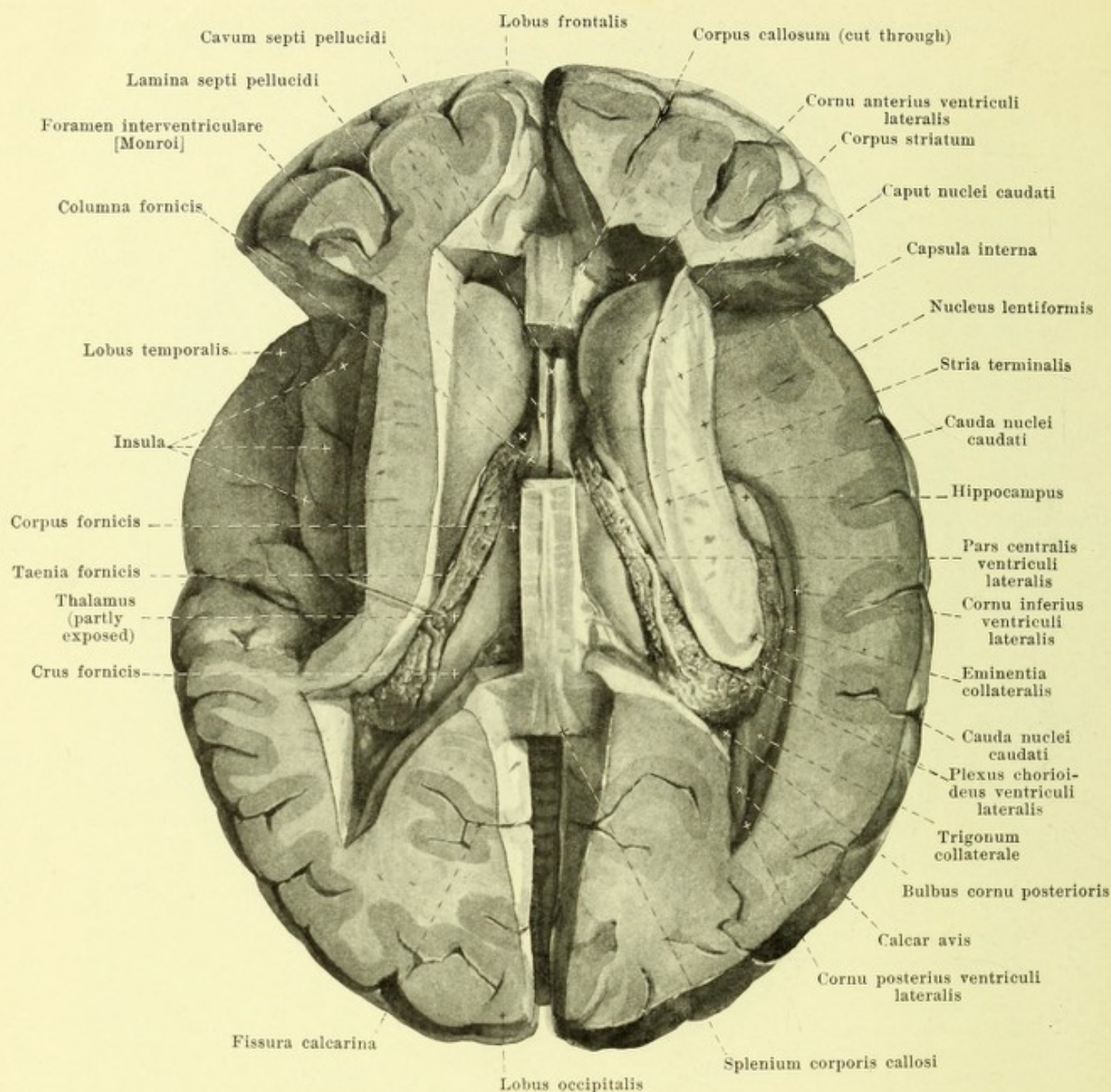
The *third ventricle* (*ventriculus tertius*) (see Figs. 695, 717, 720, 745 and 748) is an unpaired, median, slit-like space which is bounded on each side by the medial surface of the thalamus and of the hypothalamus; in that situation are to be seen the massa intermedia and the sulcus hypothalamicus. The posterior wall is formed above by the corpus pineale, which is penetrated in front by a short slit, *recessus pinealis*; just beneath it runs the *commissura posterior* [*cerebri*], a white band of fibres which bends around in a transverse direction between the two cerebral hemispheres and bulges into the cavity of the third ventricle; it bounds above the *aditus ad aquaeductum cerebri*, a three-sided funnel-shaped opening leading to the fourth ventricle. The narrow inferior wall is bounded behind by the diverging cerebral peduncles and presents two small elevations due to the corpora mamillaria; in front of them it is formed by the thin wall of the tuber cinereum; it becomes narrowed behind the chiasma opticum to form the funnel-like *recessus infundibuli*, from which a fine slit passes into the infundibulum. In front of the chiasma opticum, which projects into the cavity, is situated the *recessus opticus*, bounded in front by the thin *lamina terminalis*. This lamina forms the anterior wall; behind it above lies the *commissura anterior* [*cerebri*], a thick band of white fibers which unites the two cerebral hemispheres with one another and which is visible here, for a short distance, on the surface, but, otherwise, lies hidden in the substance of the brain. Lateral behind this commissure the columnae fornicis (see p. 650) form a part of the lateral wall of the ventricle and, converging, run upward; in this way, with the commissure, they surround the *recessus triangularis* (see Fig. 717). Above, the ventricle is closed by the *lamina chorioidea epithelialis* (*vide supra*). In front, on both sides, this is continued in its greatest extent through the taenia thalami into the stria medullaris, but it is fastened behind to the upper surface of the habenula and of the corpus pineale, and hence forms the upper boundary of the *recessus suprapinealis*, a blind sac like cavity situated above the corpus pineale; in front it goes over into the posterior surface of the columna fornicis (see Fig. 695) and forms the upper boundary of the *foramen interventriculare* [*Monroi*], which is bounded in front by the columna fornicis, behind by the thalamus, and connects the third ventricle with the lateral ventricle on each side.



715. Corpus callosum, exposed, viewed from above.

(The upper part of the cerebral hemispheres has been removed by a horizontal cut; small pieces in front and behind have been removed by wedge-shaped cuts. On the left side a portion of the hemisphere has been cut away to expose the island.)

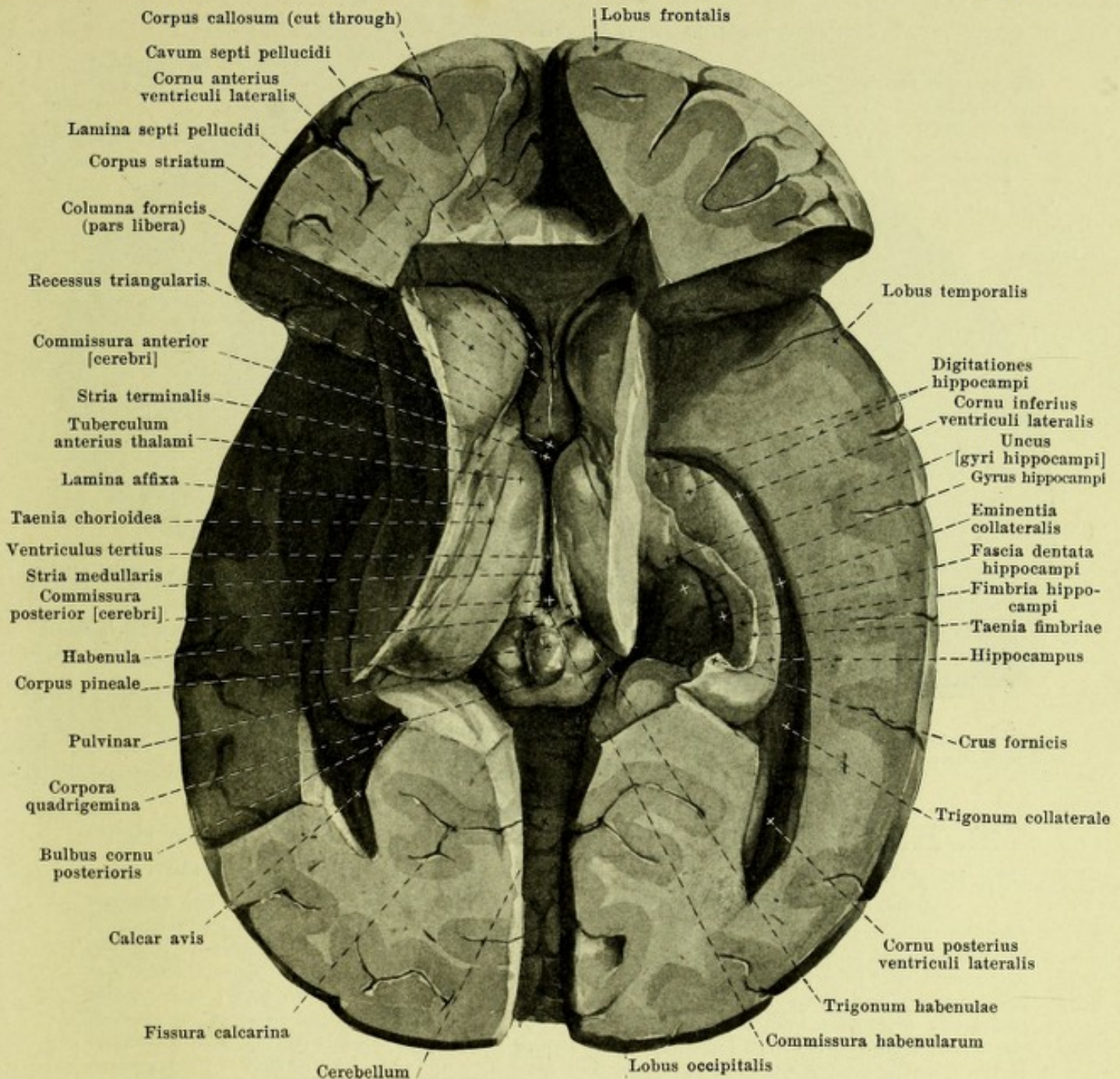
The *corpus callosum* (see also Figs. 695, 708, 716—720, 745 and 748) is a large mass of white fibers which unites the two cerebral hemispheres to each other. Only a smaller, medial portion of the mass lies free in the depth of the fissura longitudinalis cerebri; by far the larger part is concealed in the substance of the hemispheres into which it radiates. It begins in front of and above the commissura anterior (see Figs. 695 and 696), in direct contact with the lamina terminalis, by a short, thin layer, *lamina rostralis*, which runs, in a curve, upward and forward; it then thickens suddenly to form the *rostrum corporis callosi*, extends forward and then bends sharply backward, as the *genu corporis callosi*, to pass backward as the arched *truncus corporis callosi* until over the corpora quadrigemina, where it ends in a thickened margin, *splenium corporis callosi* (see also Fig. 712).



716. Lateral ventricle, opened, viewed from above.

(As in Fig. 715. In addition, the corpus callosum, with the exception of a narrow remnant, has been removed; besides, the posterior horn has been opened on both sides, and, on the right side, the inferior horn has been fully exposed by cutting away the island and the upper part of the temporal lobe.)

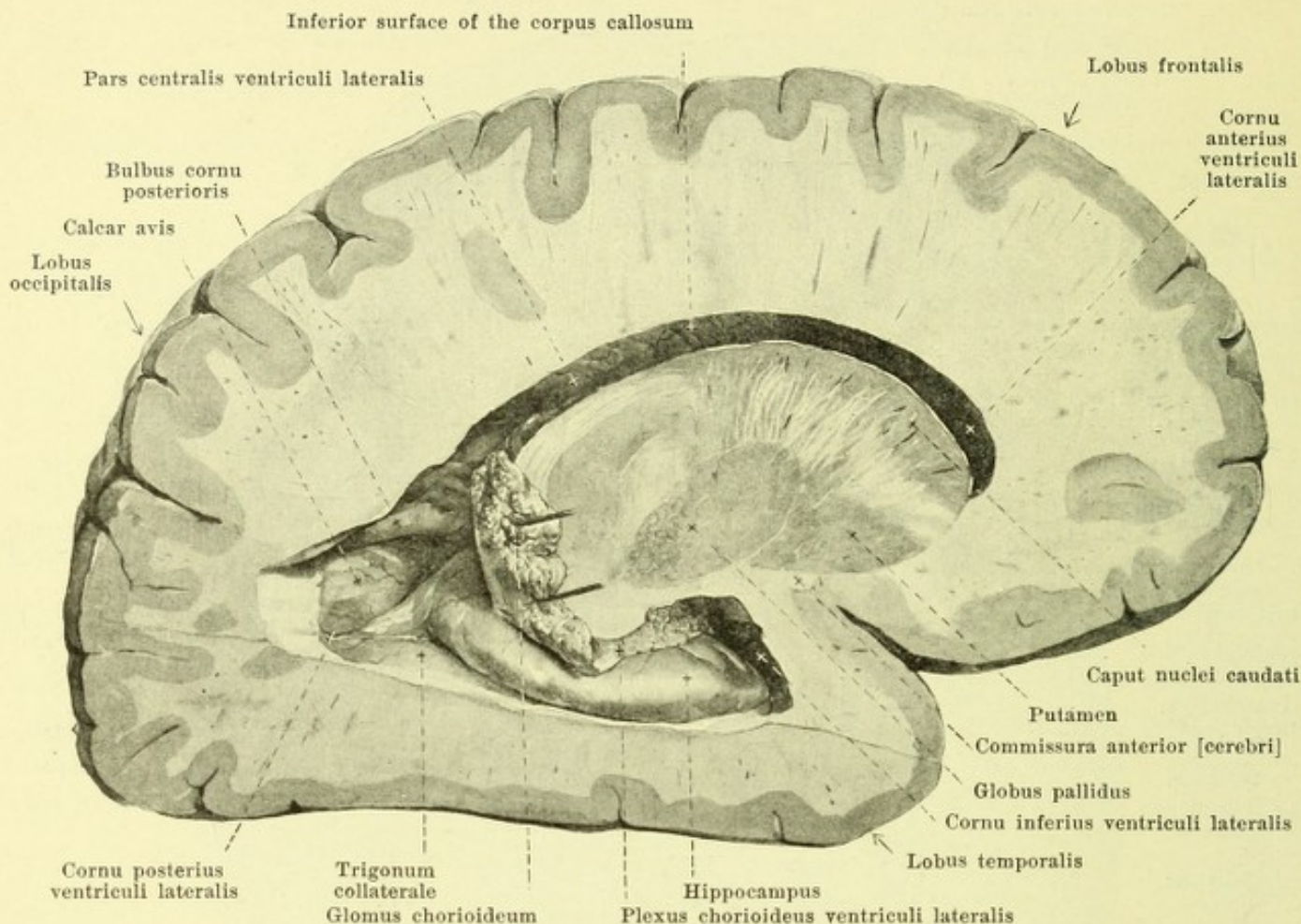
Corpus callosum (continued) (see also Figs. 715 and 720). The surface shows transverse bands, *striae transversae*, due to the fibre bundles. In addition, a delicate, variable, longitudinal band, *stria longitudinalis medialis*, runs, on each side, close to the median plane. This bends around, in front, upon the rostrum and unites with the gyrus subcallosus; behind, it goes over into the *fasciola cinerea* (see Fig. 708), a strip of grey matter which lies directly in contact with the splenium corporis callosi, below and lateralward, and is continued, below and in front, into the fascia dentata hippocampi. A second, still more delicate and more irregular longitudinal band, *stria longitudinalis lateralis*, lies lateralward on the surface of the corpus callosum, in the depth of the sulcus corporis callosi.



717. Third ventricle, opened, viewed from above.

(Same as in Fig. 716. In addition, the corpus callosum and a large part of the fornix have been removed. On the left side the inferior horn has been opened. On the right side more of the basal ganglia has been cut away, so as to expose completely the hippocampus and its neighborhood.)

Beneath the corpus callosum lies the *fornix* (see also Figs. 695, 708, 716, 720, 745, 746 and 748). It consists of two white strips, a right and a left one, often not entirely symmetrical, each being curved almost in the form of a spiral. These run separately in the most anterior part (*columnae fornicis*), are closely approximated in their middle portion to the unpaired *corpus fornicis*, which is joined above to the under surface of the corpus callosum; behind they again become separated (*crura fornicis*), and as they diverge, they pass to the inferior horns of the lateral ventricles, there becoming continuous in the main with the fimbria hippocampi. In the triangular space, bounded by the lamina rostralis, rostrum, genu and truncus corporis callosi on the one side, and by the uppermost part of the columnae and of the corpus fornicis on the other side (see Figs. 695 and 708), the *septum pellucidum* is stretched out as a partition between the anterior cornua of the lateral ventricles; it consists (see also Figs. 716, 746 and 747) of two thin layers, *laminae septi pellucidi*, which enclose a narrow median slit, *cavum septi pellucidi*, closed on all sides.

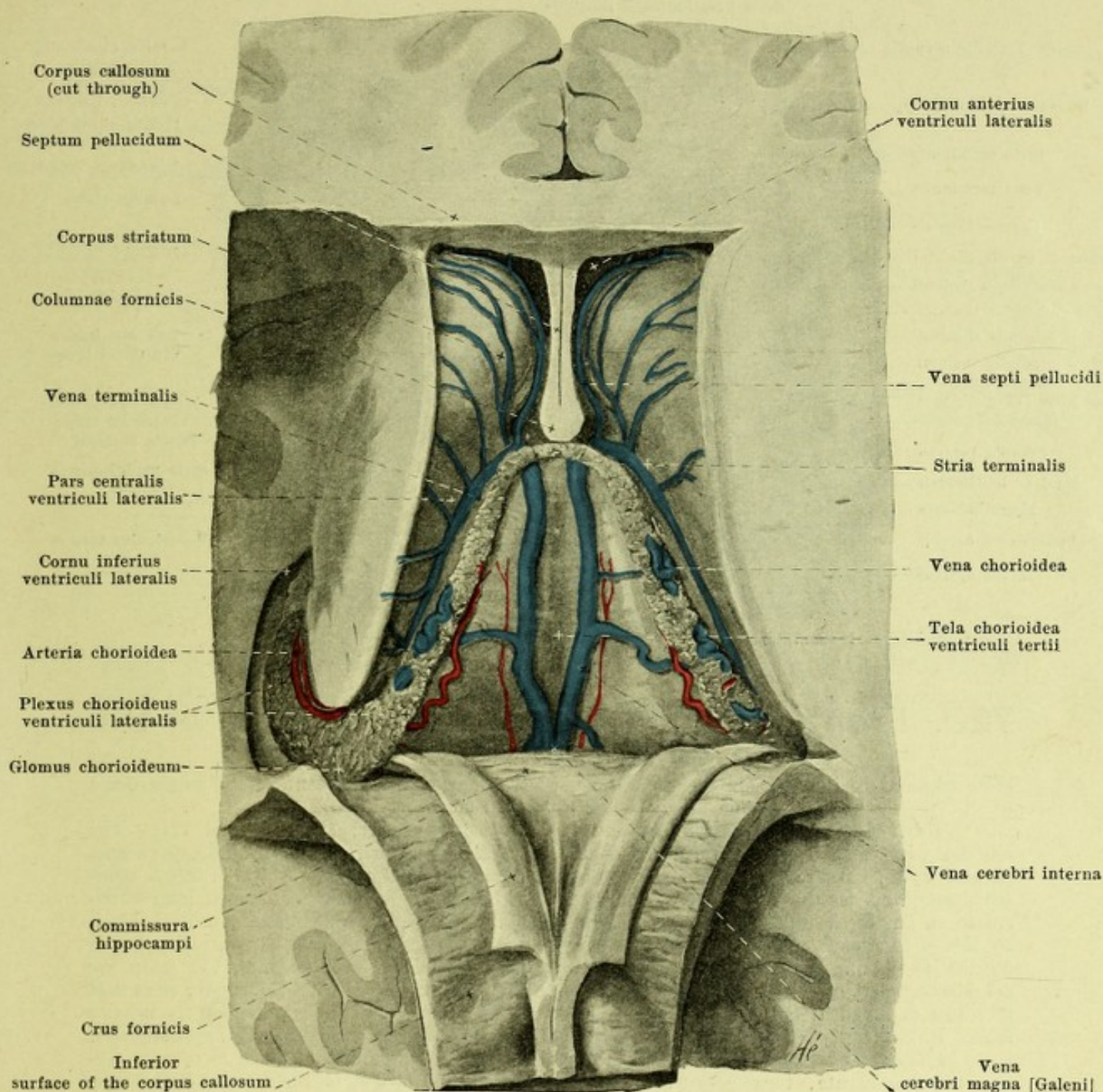


718. Right lateral ventricle, opened, viewed from the right.

(The largest part of the right hemisphere has been removed by two approximately sagittal cuts.)

Fornix (continued) (see Figs. 695, 708, 716, 720, 745, 746 and 748). The *columna fornicis* (bilateral) is a cylindrical bundle of medullated fibers; hidden in the hypothalamus it extends forward and upward from the corpus mamillare as the *pars tecta columnae fornicis*, emerges in part from the lateral wall of the 3rd ventricle just behind the commissura anterior and runs upward and somewhat medianward as the *pars libera columnae fornicis*, soon fusing completely with its fellow of the opposite side; the pars libera forms the anterior boundary of the foramen interventriculare [Monroi] (see p. 646). The *corpus fornicis* reaches from the region of the foramen interventriculare backward and somewhat upward as far as that of the trigonum habenulae; in this course it is separated from the roof of the 3rd ventricle and from the upper surfaces of the thalami by the tela chorioidea ventriculi tertii. It is fused behind with the inferior surface of the corpus callosum; in front it is united with that body by the septum pellucidum. The inferior surface presents a groove-like depression in the middle. Each half is rather rounded in cross-section in front, more triangular behind, and is drawn out laterally into a fine edge, *taenia fornicis*, from which the lamina epithelialis of the plexus chorioideus ventriculi lateralis extends out; the two taeniae fornicis become continuous with each other in front, over the foramen interventriculare. The *crus fornicis* is markedly flattened and directly attached to the inferior surface of the corpus callosum; it runs obliquely backward, lateralward and downward on each side, over the pulvinar, to the inferior horn (see p. 649). The two crura fornicis bound a triangular area, which is closed behind by the splenium corporis callosi, and the floor of which is formed by the inferior surface of the corpus callosum (see Fig. 719); the transverse fibers visible in this area form the *commissura hippocampi*.

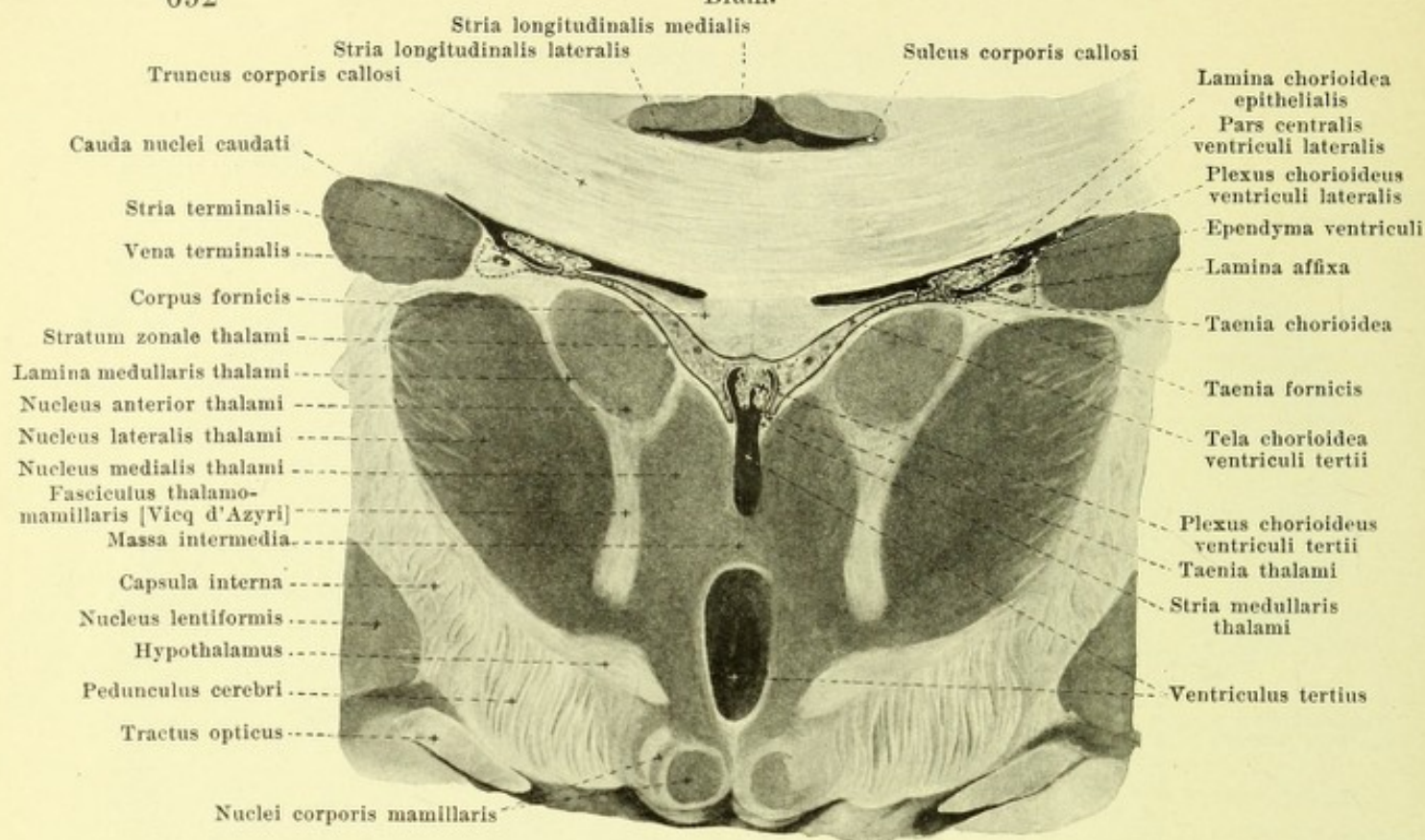
The *ventriculus lateralis* (lateral ventricle) (see also Figs. 716, 719—721) is the paired cavity which is situated symmetrically within each cerebral hemisphere; it is connected by the foramen interventriculare [Monroi] with the 3rd ventricle and through this indirectly also with the lateral ventricle of the other side, but is otherwise completely closed; it contains a small amount of liquor cerebrospinalis.



719. Tela chorioidea ventriculi tertii, laid bare from above.

(The specimen has been prepared in a similar way to that in Fig. 716, except that the corpus callosum, along with the fornix, has been cut through and reflected backward.)

Ventriculus lateralis (continued) (see also Figs. 716, 718, 720 and 721). It resembles on each side, in the main, a horse-shoe, open in front (see Fig. 718), the upper end of which, *cornu anterius*, lies in the frontal lobe and the lower end of which, *cornu inferius*, lies in the temporal lobe; from the posterior convexity, a short process, *cornu posterius*, projects into the occipital lobe; the part between the foramen interventriculare and the cornu posterius is called the *pars centralis*. The lateral ventricle is partly bounded by the grey *corpus striatum* (*striate body*), of which the anterior, flask-like, thickened end forms the lateral inferior wall of the cornu anterius; by means of its long, narrow, posterior part it extends through the pars centralis and, thence, markedly curved, into the roof of the cornu inferius. This forms only the free surface of a correspondingly shaped grey mass, the *nucleus caudatus* (*tailed nucleus*), of which the anterior part is called the *caput nuclei caudati*, the inferior part, the *cauda nuclei caudati*.

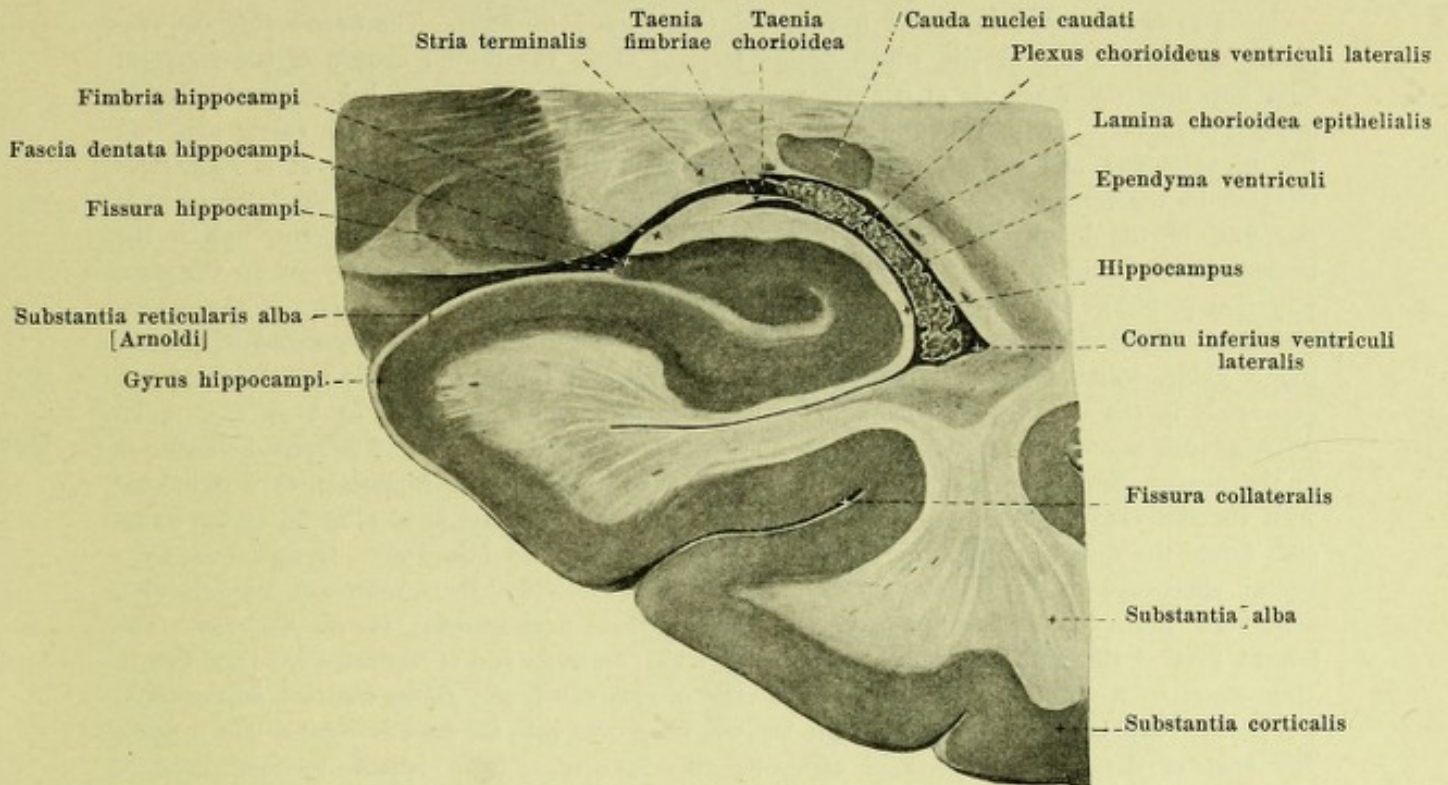


720. Frontal section through the middle of the third ventricle. Magnification 2:1.

(The relations of the chorioid plexus are somewhat schematically represented; the origin of the lamina affixa is indicated by the dotted lines.)

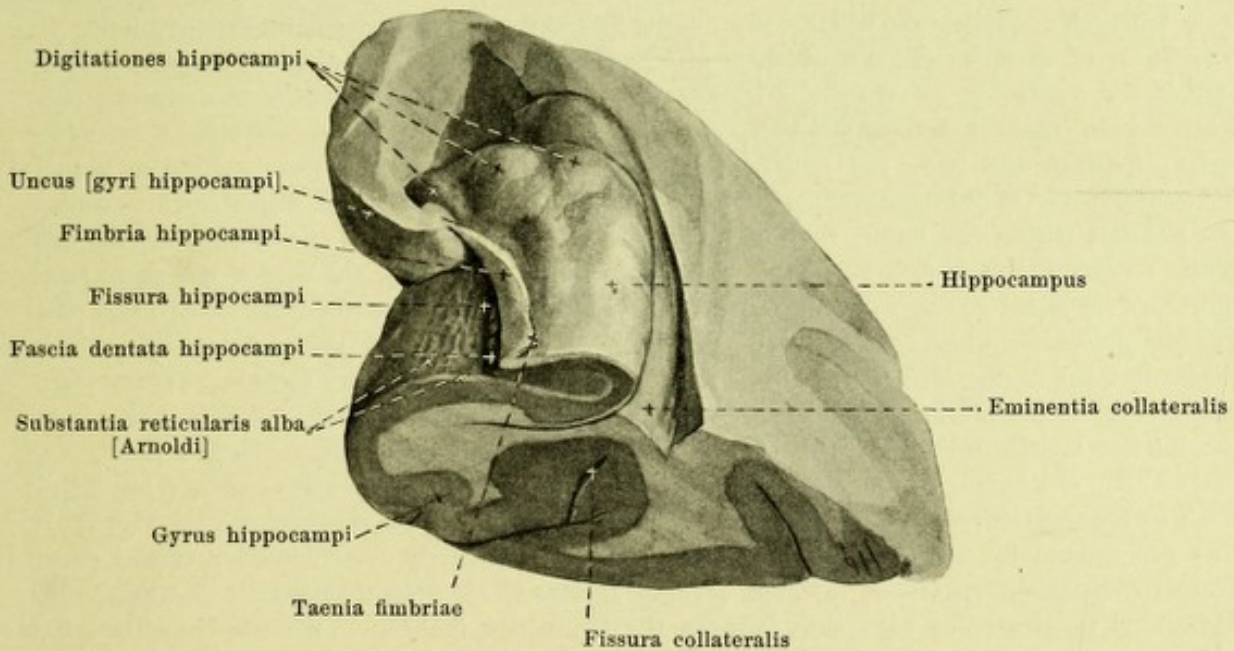
Ventriculus lateralis (continued) (see also Figs. 716, 718, 719 and 721). The anterior part of the corpus striatum rises above the thalamus in front; the middle part runs parallel to its lateral margin. In the latter situation, the stria terminalis (O. T. taenia semicircularis) runs on the surfaces between the two, from the region of the foramen interventriculare as far as the inferior horn; it contains a band of medullated fibers and is colored bluish by the v. terminalis which partly covers it. The layer of substance which covers the v. terminalis is continued as a thin layer, *lamina affixa* (see also Figs. 704 and 717), upon the neighboring part of the thalamus and, even in the embryo, is fused with this body; it at first increases in breadth from before backward, but further on decreases; it is absent in the inferior horn. It is directly continuous with the epithelium of the plexus chorioideus ventriculi lateralis, i. e. the *lamina chorioidea epithelialis*, and on removal of the chorioid plexus is seen to terminate in a delicate, torn margin, *taenia chorioidea*; the latter, in the inferior horn, runs directly medianward from the end of the corpus striatum, is connected at its anterior end with the taenia fimbriae and at the foramen interventriculare with the taenia thalami.

The *cornu anterius* (*anterius horn*) resembles a part of the cavity of a bowl, convex forward, upward and medianward; the arch of the bowl is formed by the most anterior part of the corpus striatum. Above in front, and below, it is bounded by the radiations of the knee of the corpus callosum, medianly by the septum pellucidum, laterally by the corpus striatum. The *pars centralis* is an approximately horizontal slit, the roof of which is formed by the inferior surface of the truncus corporis callosi; its inferior surface (see also Fig. 716) is composed of the middle, narrow part of the corpus striatum, the stria terminalis, the lamina affixa, the lamina chorioidea epithelialis of the plexus chorioideus ventriculi lateralis, as well as the upper surface of the corpus and crura fornicis. The *cornu posterius* (*posterius horn*) is a curved slit of variable length, convex lateralward in the horizontal direction; its posterior apex is curved somewhat medianward. Its lateral, superior, limiting surface is formed by that part of the radiation of the corpus callosum known as the *tapetum*. Two variable longitudinal ridges run out backward upon its medial surface from the end of the pars centralis (see Figs. 716, 718 and 748). The inferior, thicker ridge, *calcar avis*, corresponds to the anterior part of the fissura calcarina, which here shoves the thin wall of the hemisphere into the ventricle. The superior, irregular ridge, *bulbus cornu posterius*, is formed by fibers of the corpus callosum which bend around the deep fissura parietooccipitalis, hooklike, into the occipital lobe.



721. Frontal section through the inferior horn of the right lateral ventricle, viewed from behind. Magnification 2:1.

(The chorioid plexus is somewhat schematically represented.)

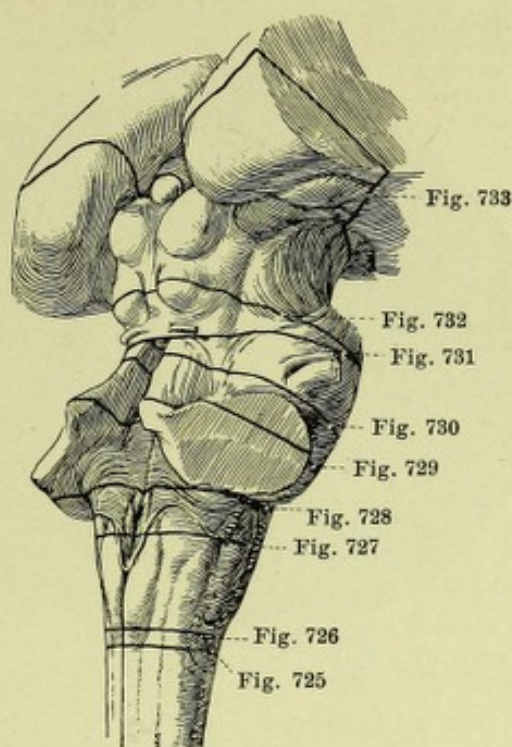


722. Inferior horn of the right lateral ventricle, anterior half, viewed from above and behind.

(The temporal lobe has been removed by a frontal section and the roof of the inferior horn afterwards cut away. See also Figs. 717, 718 and 721.)

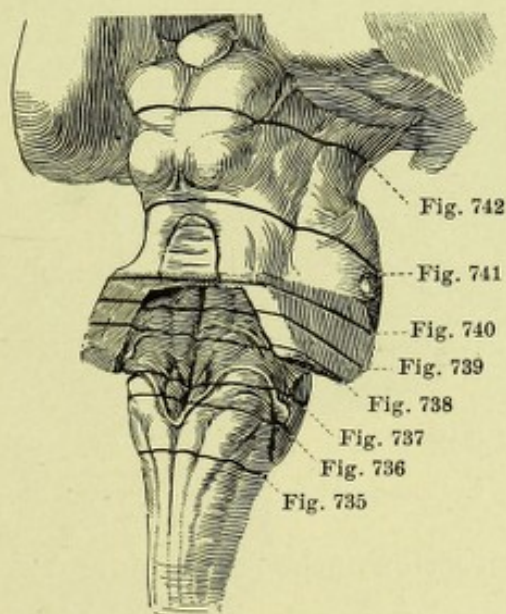
Ventriculus lateralis (continued) (see Figs. 716—722). The *cornu inferius* (*inferior horn*) is a curved slit which passes forward along the medial margin of the temporal lobe but does not reach its apex. Its narrow inferior wall is developed behind from a feebly arched triangular area, *trigonum collaterale*, which is situated between the calcar avis and the hippocampus and extends also into the beginning of the posterior horn. It is sometimes elevated in the form of a longitudinal ridge (*eminentia collateralis*), due to the bulging in of the wall of the hemisphere by the fissura collateralis. The lateral and superior wall is the immediate continuation of the similar surface of the posterior horn and is formed in the same way (see p. 652), but medianward it contains in addition the lowermost end of the corpus striatum. The medial wall is formed by a thick, white, longitudinal ridge, *hippocampus*, curved, like a sickle, which begins gradually behind at the end of the pars centralis and ends in front, expanded, in the uncus gyri hippocampi; its surface is divided, in front, by 2—4 flat, radial grooves, into a number of flattened elevations, *digitationes hippocampi*. The ridge corresponds to the fissura hippocampi and is caused by it. A white covering of the hippocampus is connected with the *fimbria hippocampi*, a triangular white strip which passes forward as far as the uncus and forms the direct continuation of the crus fornicis (see also Fig. 708). It goes over by a lateral sharpened edge into the epithelium of the plexus chorioideus ventriculi lateralis and, when the chorioid plexus is removed, ends in a delicate torn margin, *taenia fimbriae*. The largest part of the fimbria is situated outside of the ventricle and is separated from the fissura hippocampi by a narrow, peculiarly notched strip of grey substance, *fascia dentata hippocampi*, which, in front, ends in the uncus and, behind, goes over into the fasciola cinerea (see p. 648). The part of the gyrus hippocampi adjoining this is covered by a delicate reticular layer of white substance, the *substantia reticularis alba* [Arnoldi], (the relations of which are represented in Figs. 721 and 722).

The *pia mater encephali* (see p. 622) lies everywhere closely in contact with the external surface of the brain and penetrates also into the depths of the cerebral sulci. In addition it penetrates into the fissura cerebelli transversa, forming there the *tela chorioidea ventriculi quarti* (see p. 634); further, it passes into the fissura cerebri transversa as the *tela chorioidea ventriculi tertii* (O. T. velum interpositum) (see Figs. 695, 719 and 720). The latter is a triangular duplicature which ends blind, in front, at the foramen interventriculare. It consists 1. of an upper lamella which is attached to the inferior surface of the corpus callosum and of the fornix, 2. of an inferior lamella which covers the larger part of the superior surface of both thalami and in addition, covered by the lamina chorioidea epithelialis (p. 646), forms, between the two, the roof of the third ventricle, and 3. of loose connective tissue, the continuation of the subarachnoideal connective tissue of the cisterna venae cerebri magnae (see p. 682); within the latter, running from before backward close to one another are the two *venae cerebri internae* (see Fig. 719) which unite in the region of the corpus pineale to form the broad unpaired *v. cerebri magna* [Galen]. Each *v. cerebri interna* receives, in front, the *v. septi pellucidi*, which comes from the septum pellucidum, and the *v. terminalis*, which passes forward in the stria terminalis; one of these two receives the very tortuous *v. chorioidea*, which runs in the plexus chorioideus ventriculi lateralis. Hanging down, on each side, from the inferior lamella into the cavity of the third ventricle, very close to the median plane, is a narrow strip of lobulated, villus-like, reddish processes; those of the two sides together, are called the *plexus chorioideus ventriculi tertii* (*venous plexus of the third ventricle*) (see Fig. 720); they are covered by the lamina chorioidea epithelialis. A similarly constructed but thicker strip, *plexus chorioideus ventriculi lateralis* (*venous plexus of the lateral ventricle*) (see Figs. 716, 718—721) penetrates on each side, between the fornix and fimbria on the one hand, and the stria terminalis on the other hand, into the pars centralis and into the cornu inferius of the lateral ventricle, being especially well developed at the junction between the pars centralis and the inferior horn where it is called the *glomus chorioideum*; the lamina chorioidea epithelialis, which covers it, proceeds from the taenia fornicis and from the taenia fimbriae to the taenia chorioidea. The two strips of the plexus chorioideus ventriculi tertii and the plexus chorioidei of the lateral ventricle are connected with one another at the foramen interventriculare.



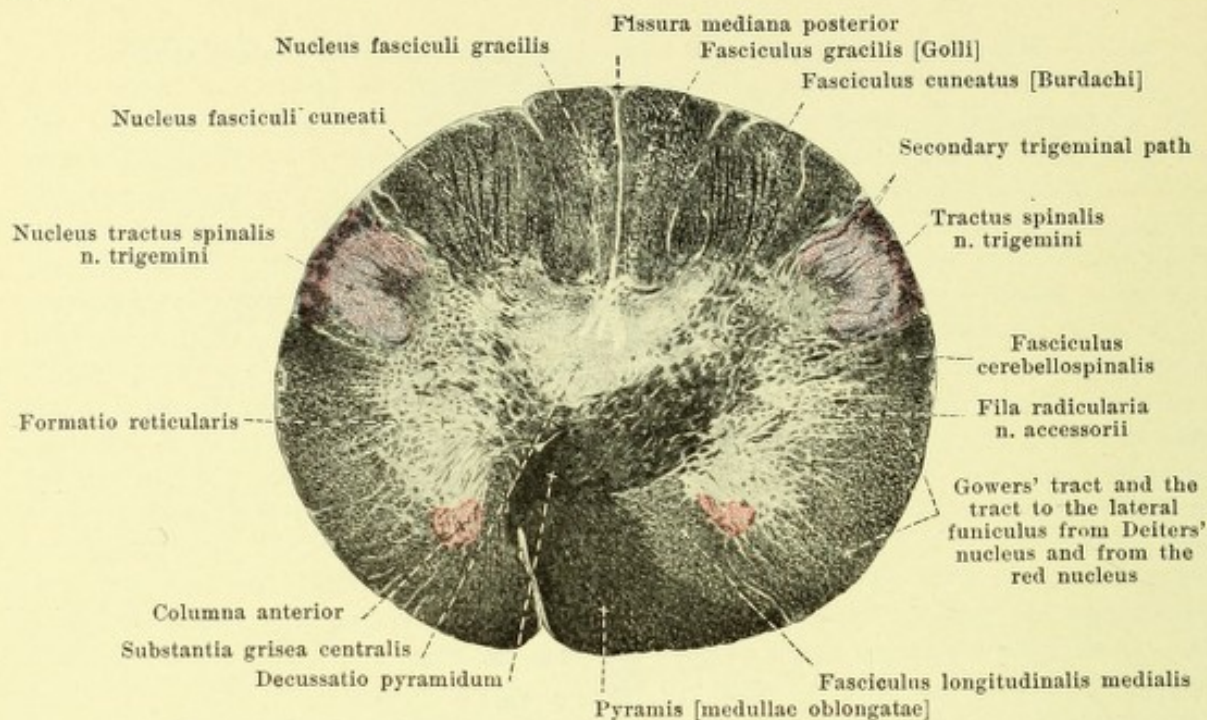
723. Brain-stem of an adult, viewed from the right and showing the directions of the sections represented in Figs. 725—733.

Magnification 6 : 7.

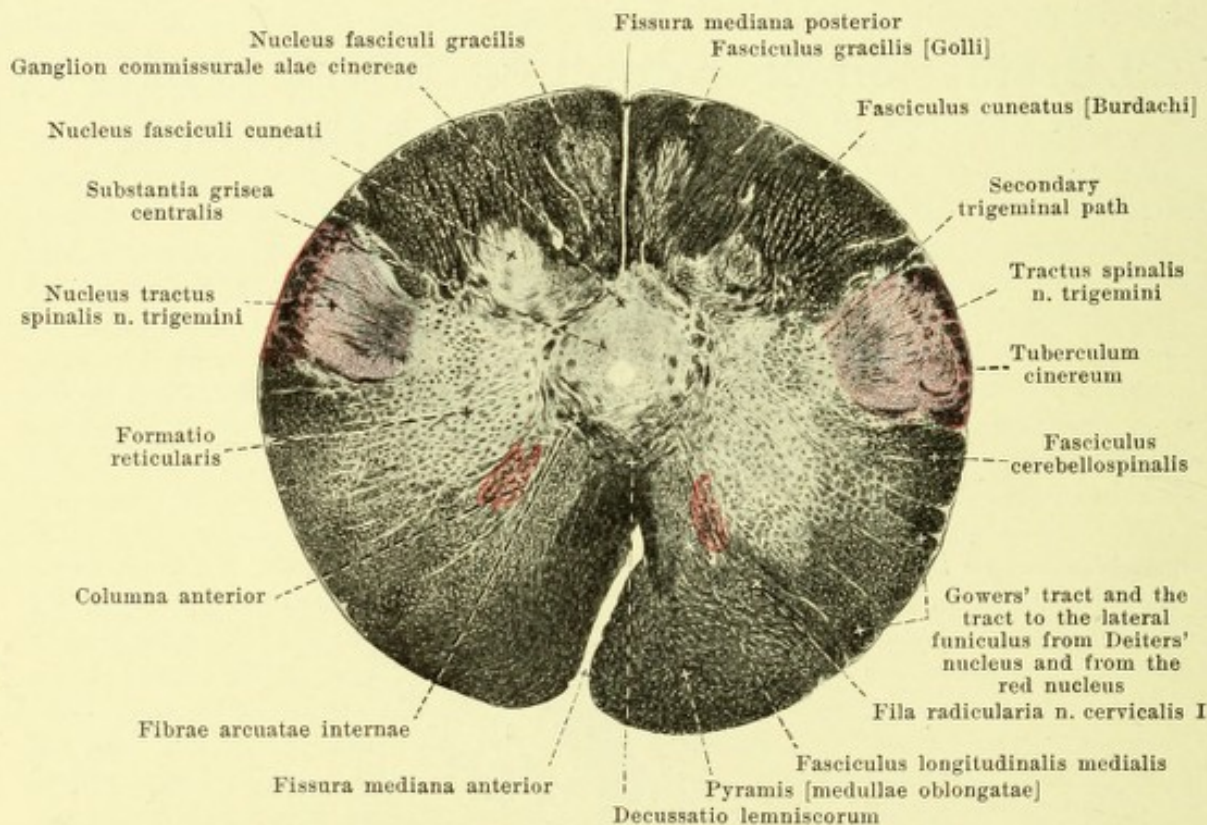


724. Brain-stem of an 8—9 month human foetus, viewed from behind and somewhat from the right, showing the direction of the sections represented in Figs. 735—742.

Magnification 4 : 3.



725. Through the decussation of the pyramids. Magnification 6:1.

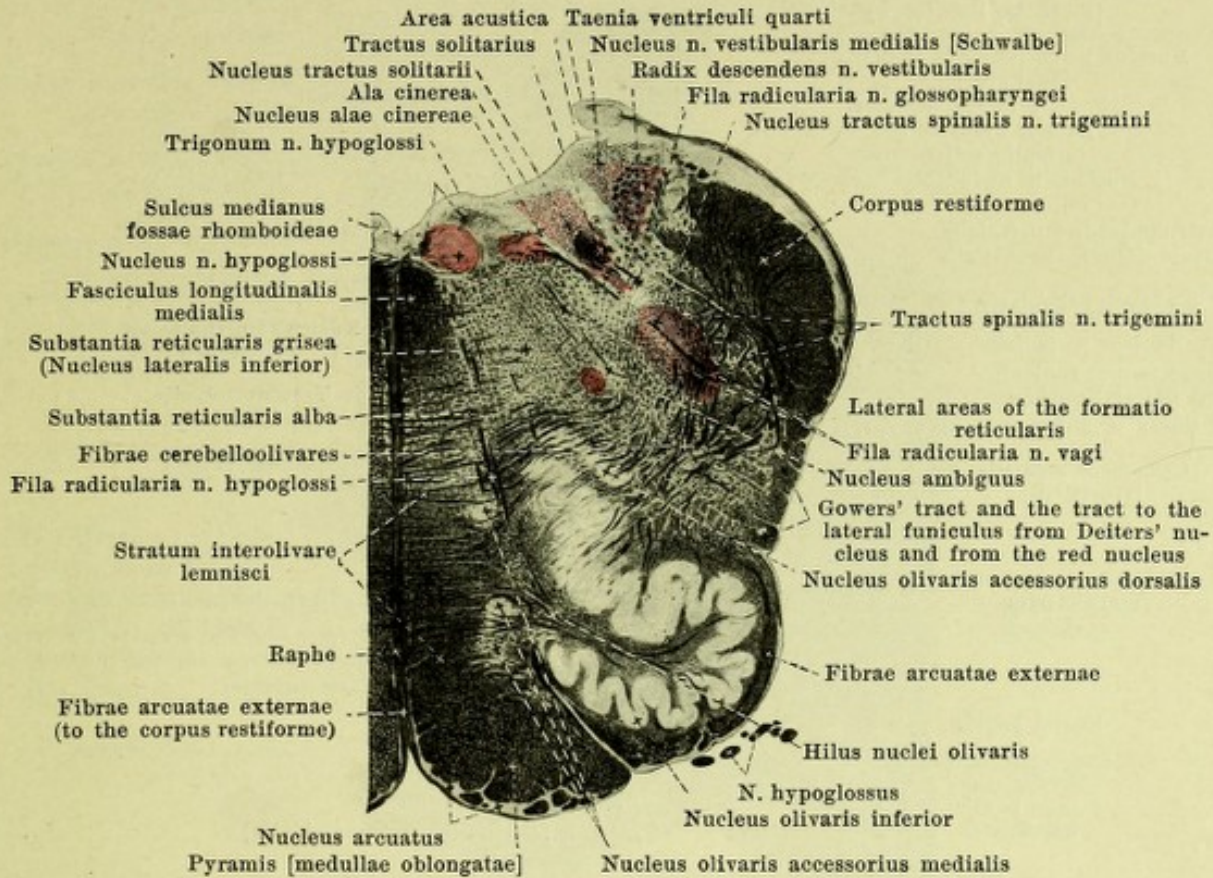


726. Between the decussation of the pyramids and the olives. Magnification 6:1.

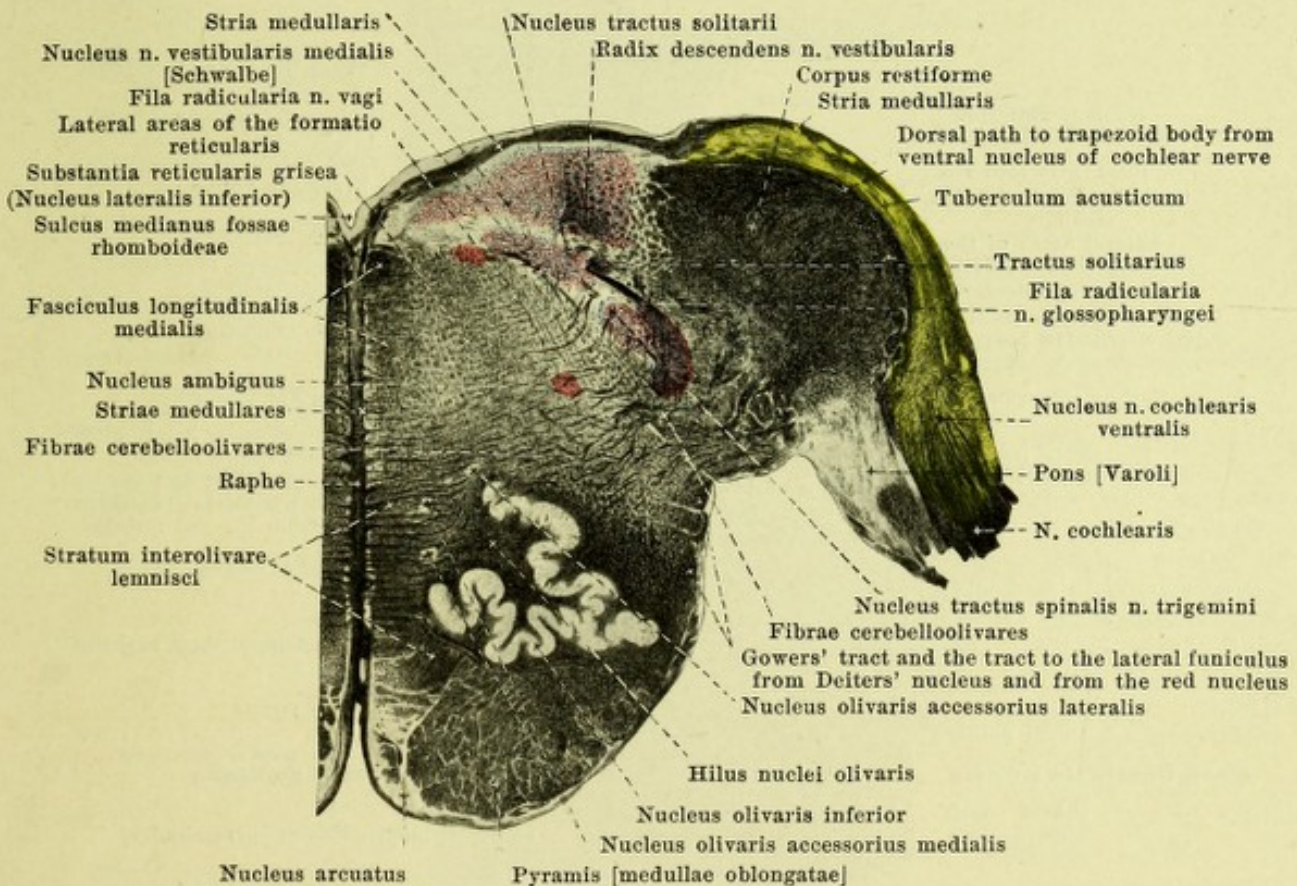
725—733. Transverse sections through the brain-stem of an adult. White substance, black; grey substance, light. Motor nuclei, red. Sensory nuclei of termination colored violet (except the nuclei of the n. cochlearis which are colored yellow). (Held.)

Concerning the level and direction of the sections see Fig. 723.

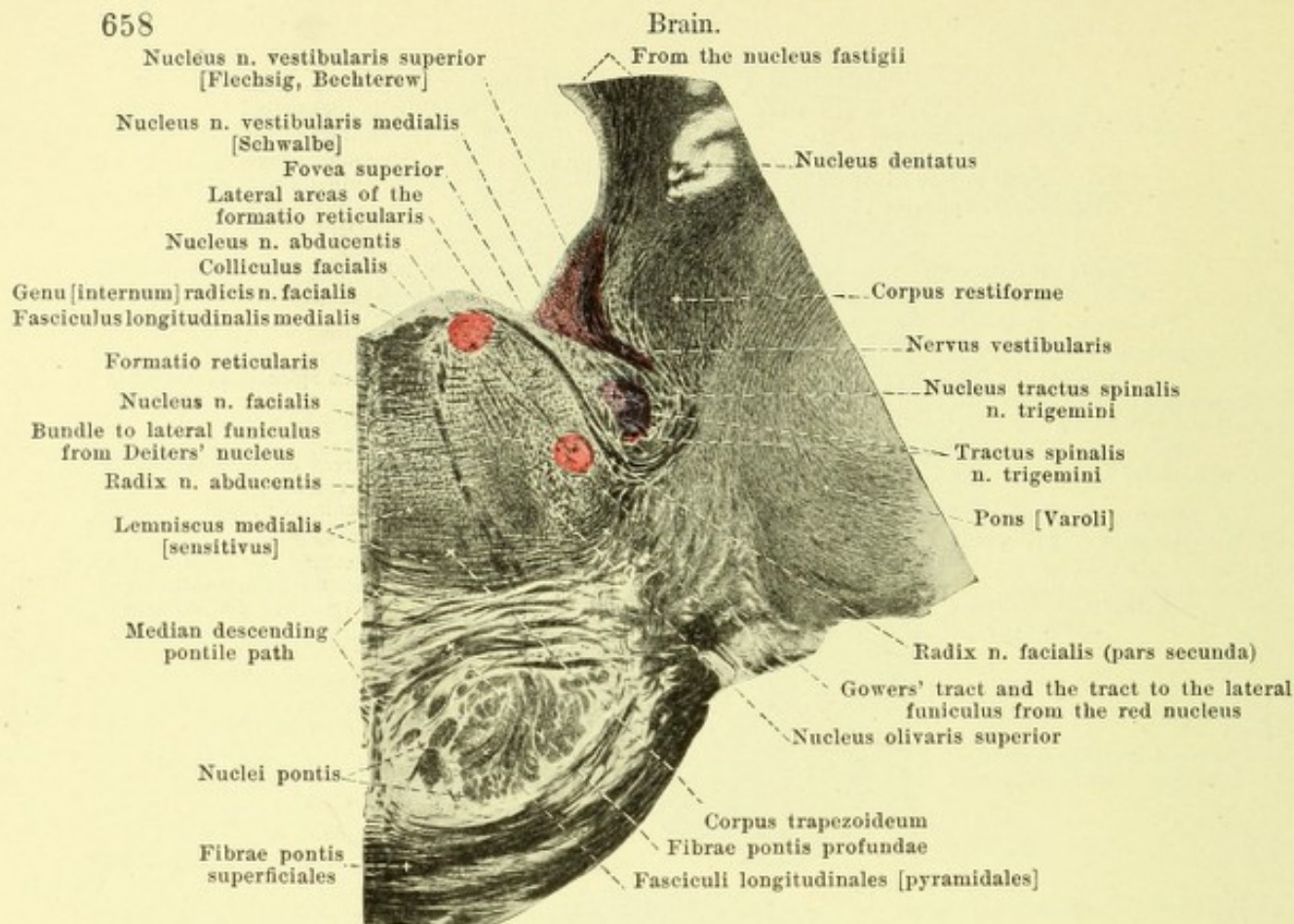
(The sections in Figs. 725—743 have been arranged so that the dorsal margin is upward.)



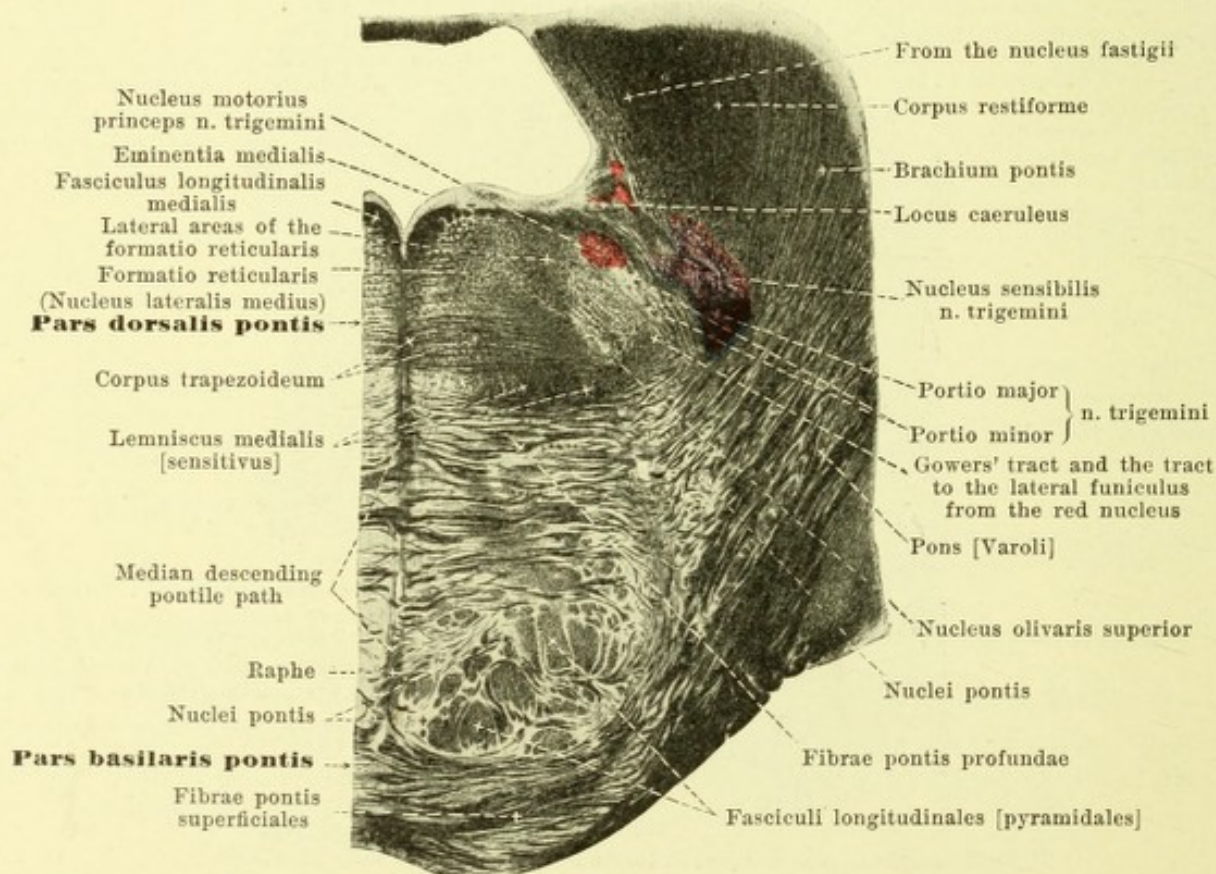
727. Through the middle of the olive. Magnification 4,5:1.



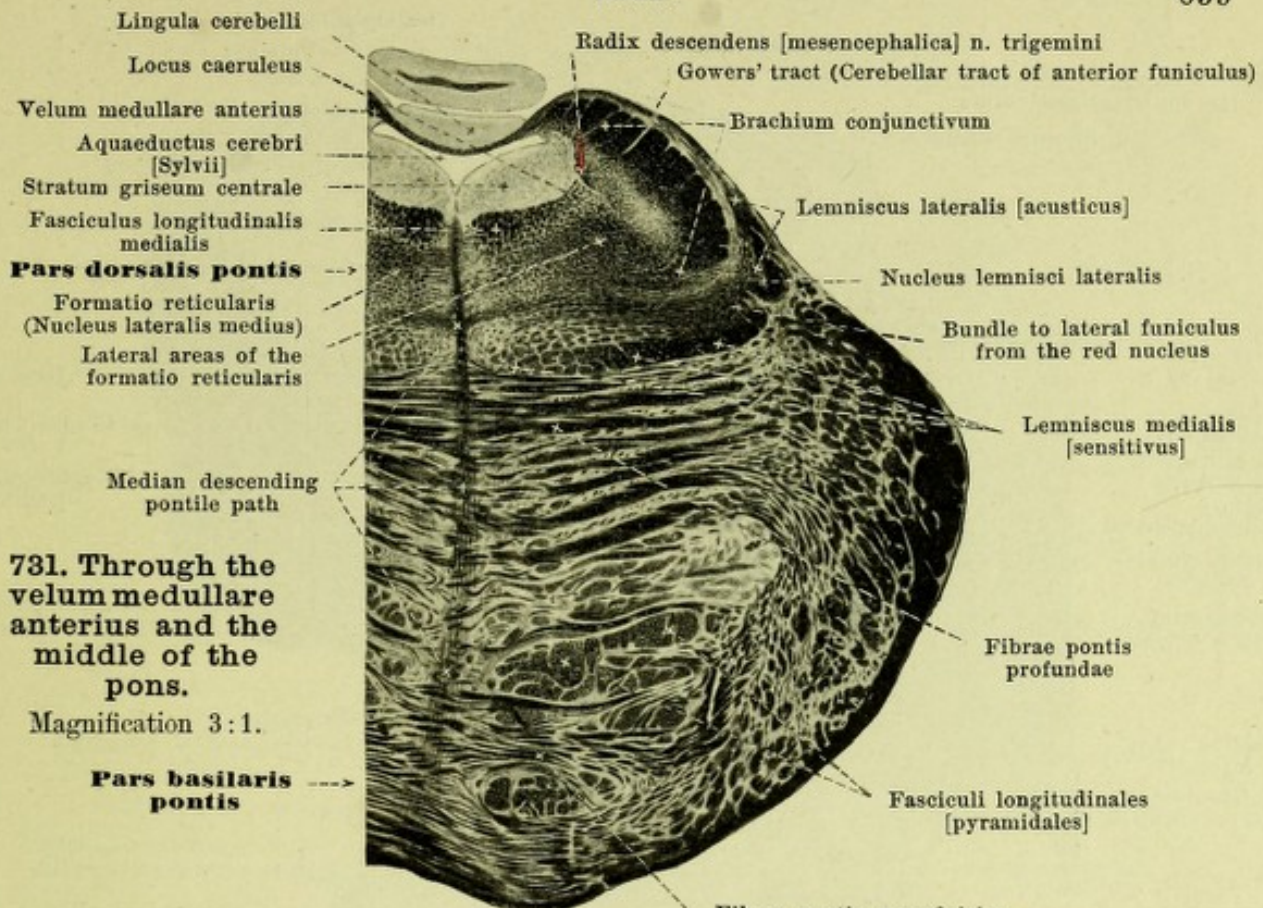
728. Through the level of entrance of the n. acusticus. Magnification 4,5:1.



729. Level of the roots of the n. facialis and n. abducens. Magnification 3:1.

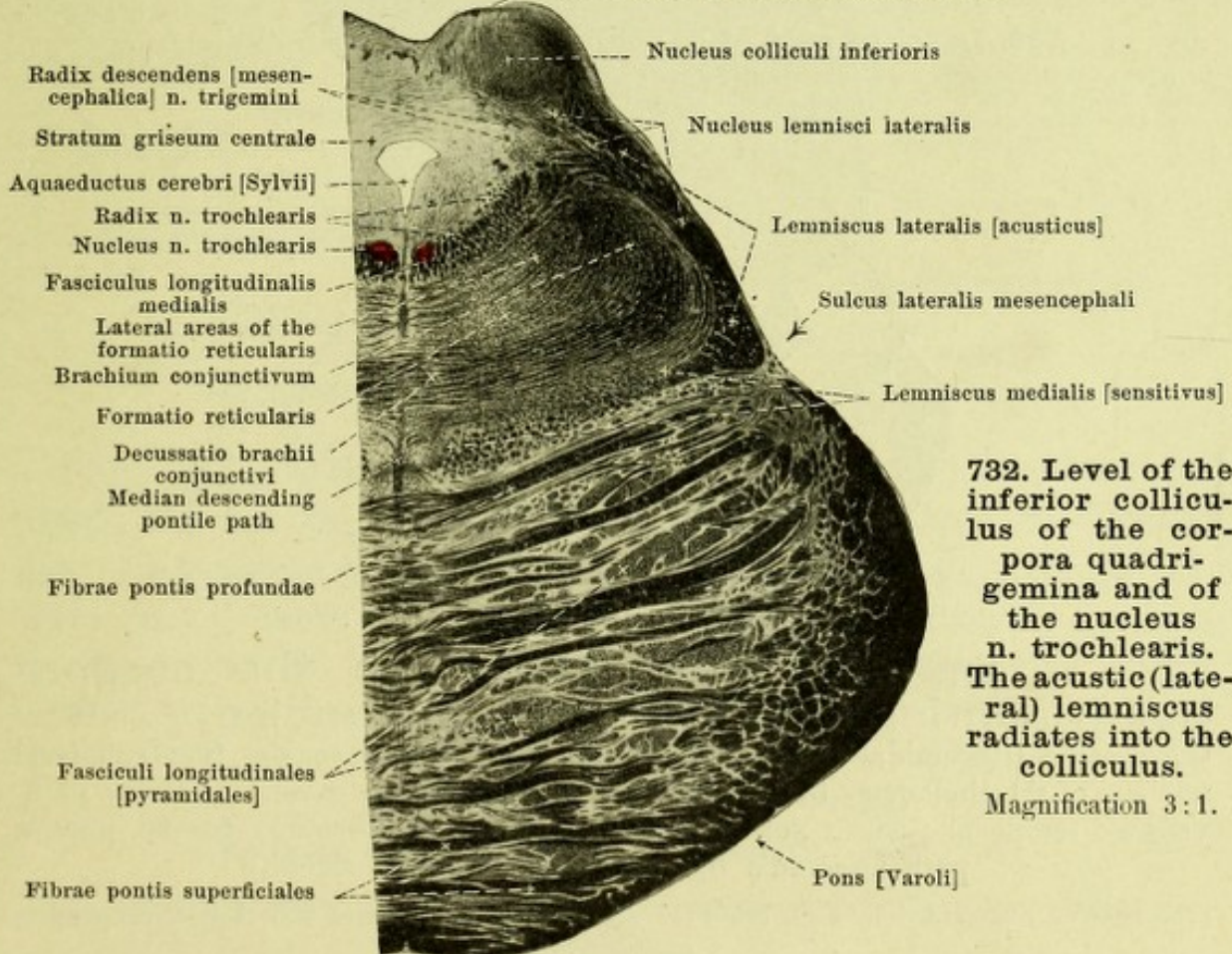


730. Level of the roots of the n. trigeminus. Magnification 3:1.



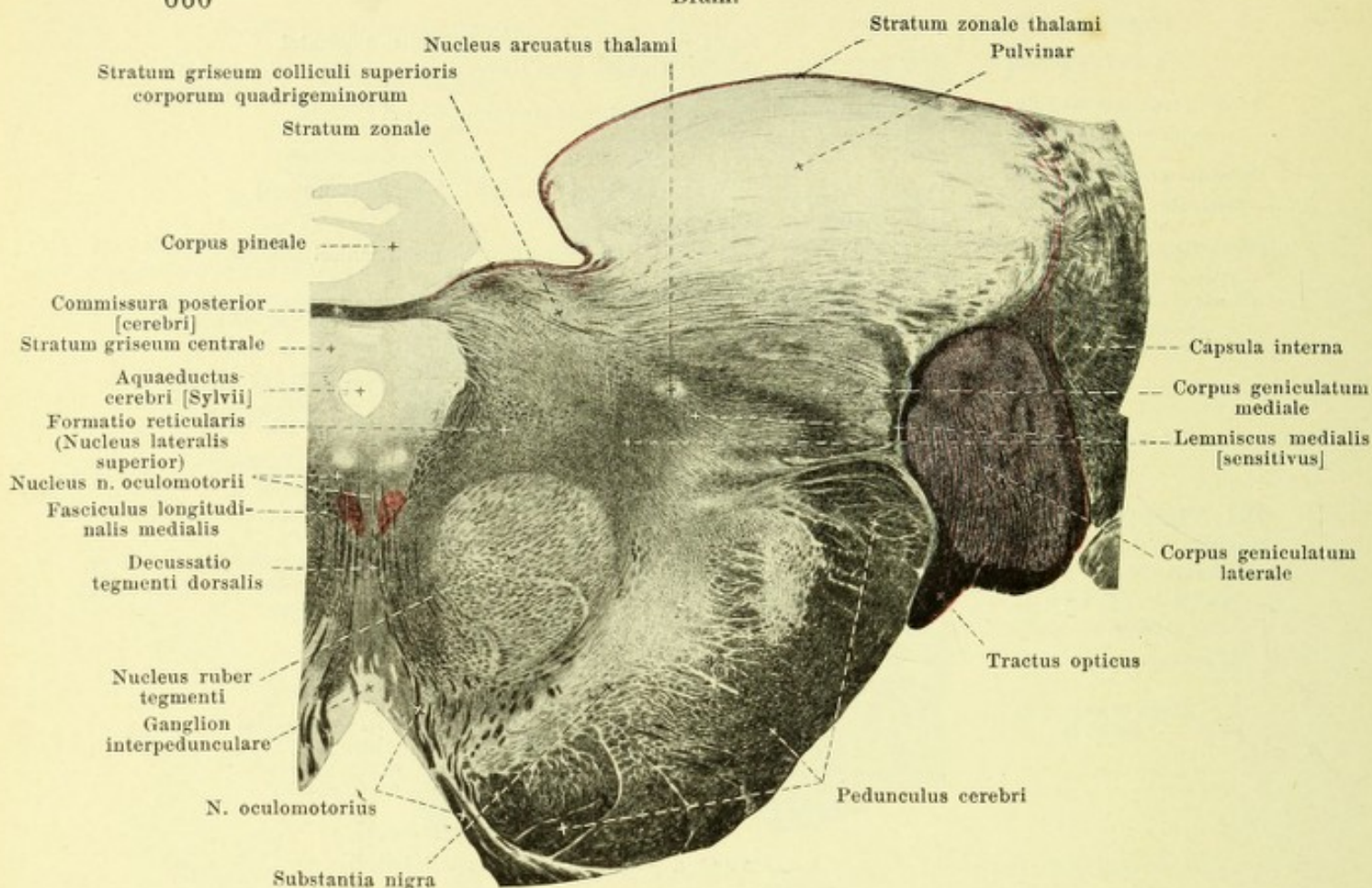
731. Through the velum medullare anterius and the middle of the pons.

Magnification 3:1.

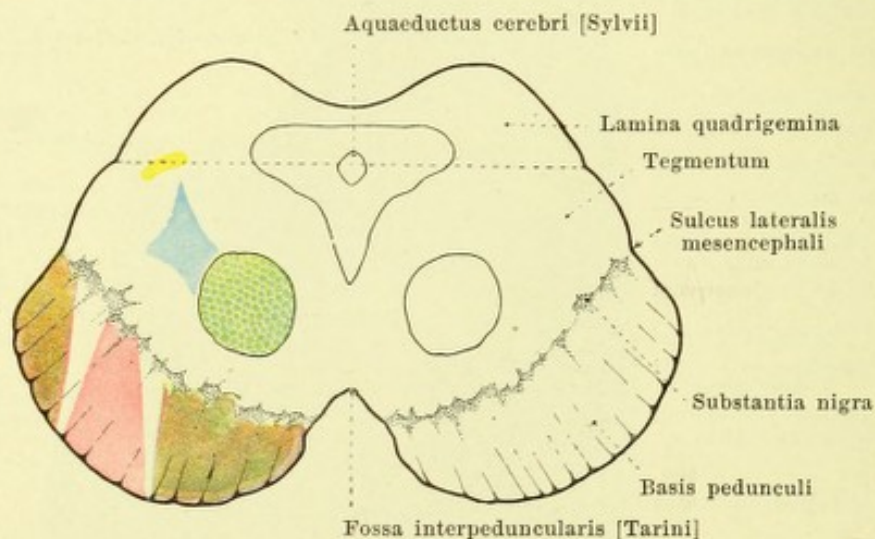


732. Level of the inferior colliculus of the corpora quadrigemina and of the nucleus n. trochlearis. The acoustic (lateral) lemniscus radiates into the colliculus.

Magnification 3:1.

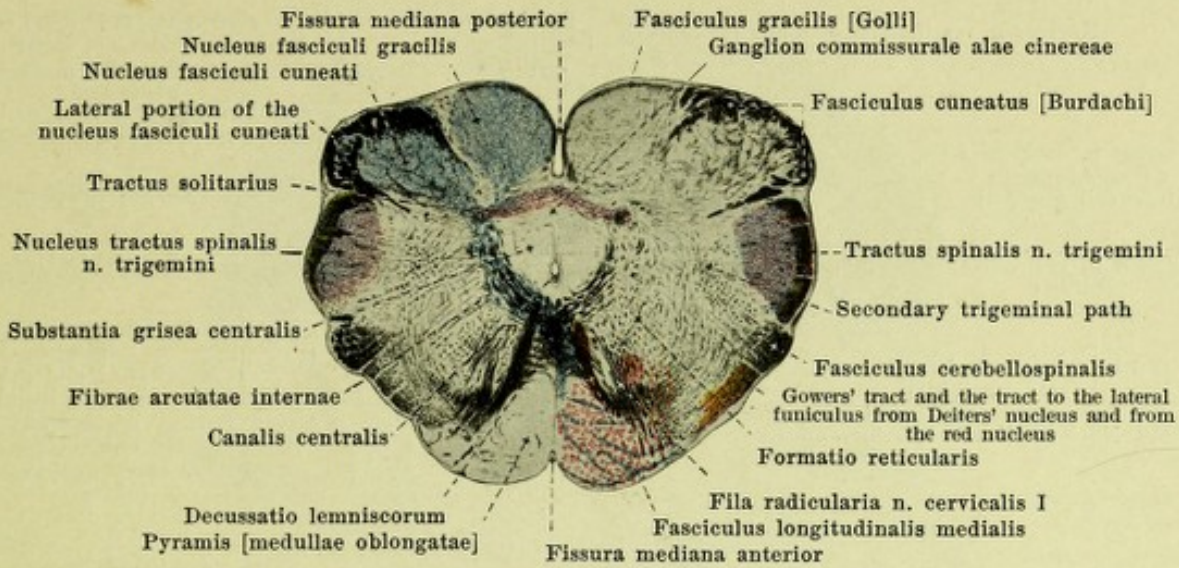


733. Level of root of n. oculomotorius. Magnification 3:1.

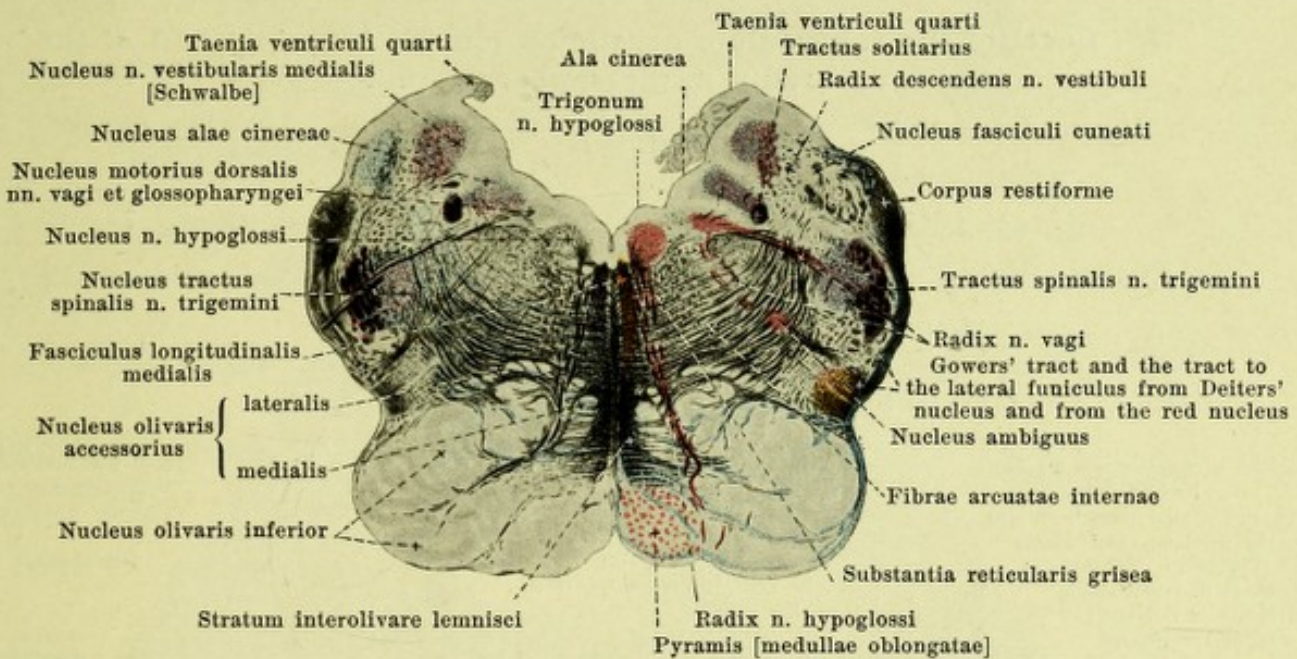


734. Transverse section through the corpora quadrigemina and cerebral peduncles, somewhat schematic. Pyramidal tract, red; medial lemniscus to the [ventro]lateral nucleus of the thalamus, blue; brachium conjunctivum, green; auditory path, yellow; temporal pontile path (Türk's bundle), light brown; frontal pontile path (Arnold's bundle), dark brown. (Held.)

(The sections represented by Figs. 725—743 are regularly so arranged that their dorsal margins are upward.)



735. Level of the sensory decussation (Decussatio lemniscorum).

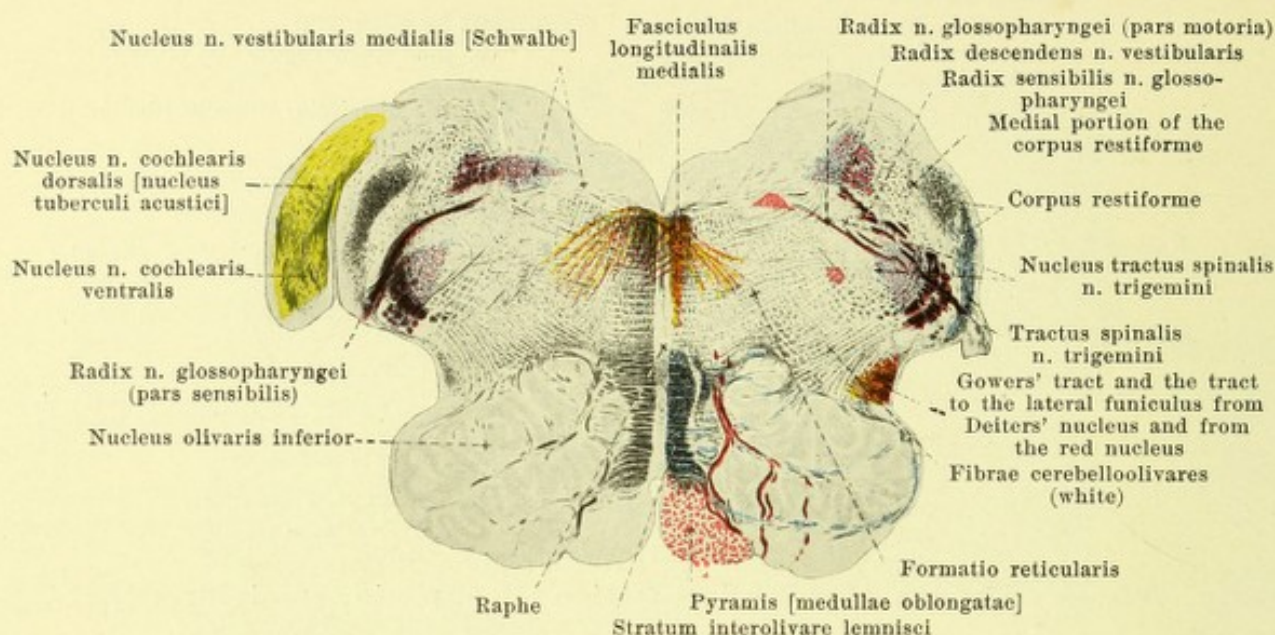


736. Level of radix n. hypoglossi and radix n. vagi.

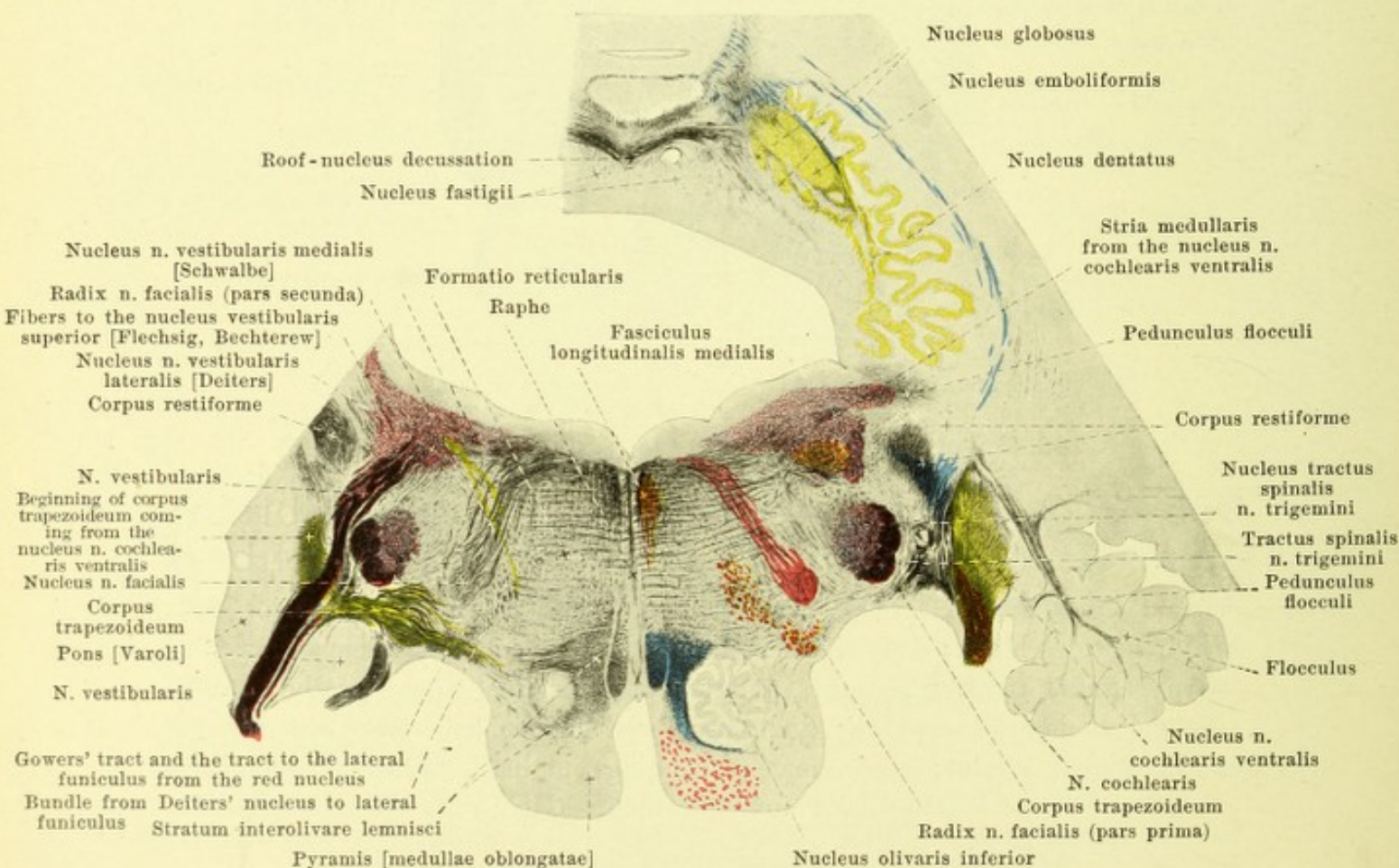
735—742. Transverse sections through the brain-stem of an 8—9 month foetus; the nerve fibres are not yet completely medullated. Magnification 6:1. White matter, black; grey matter, light. Motor roots and nuclei, as well as the pyramidal tract, red; roots and primary terminal nuclei of the sensory cerebral nerves (except the yellow-colored n. cochlearis and its indirect continuations), violet; secondary (ascending) paths from the nuclei of the posterior funiculi, blue. (Held.)

Concerning the level and direction of the sections see Fig. 724.

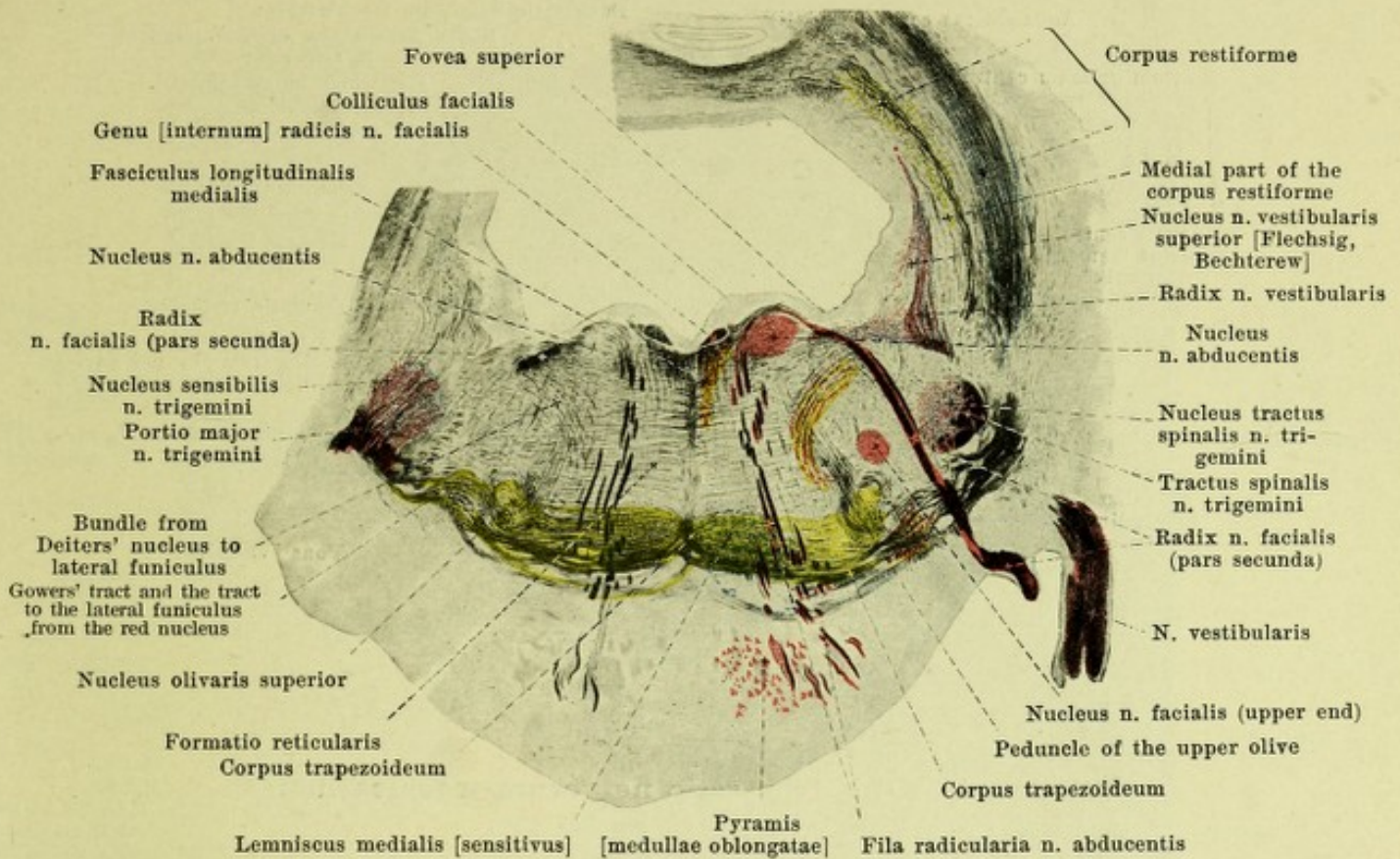
(The sections represented by Figs. 725—743 are so arranged that their dorsal margins are upward.)



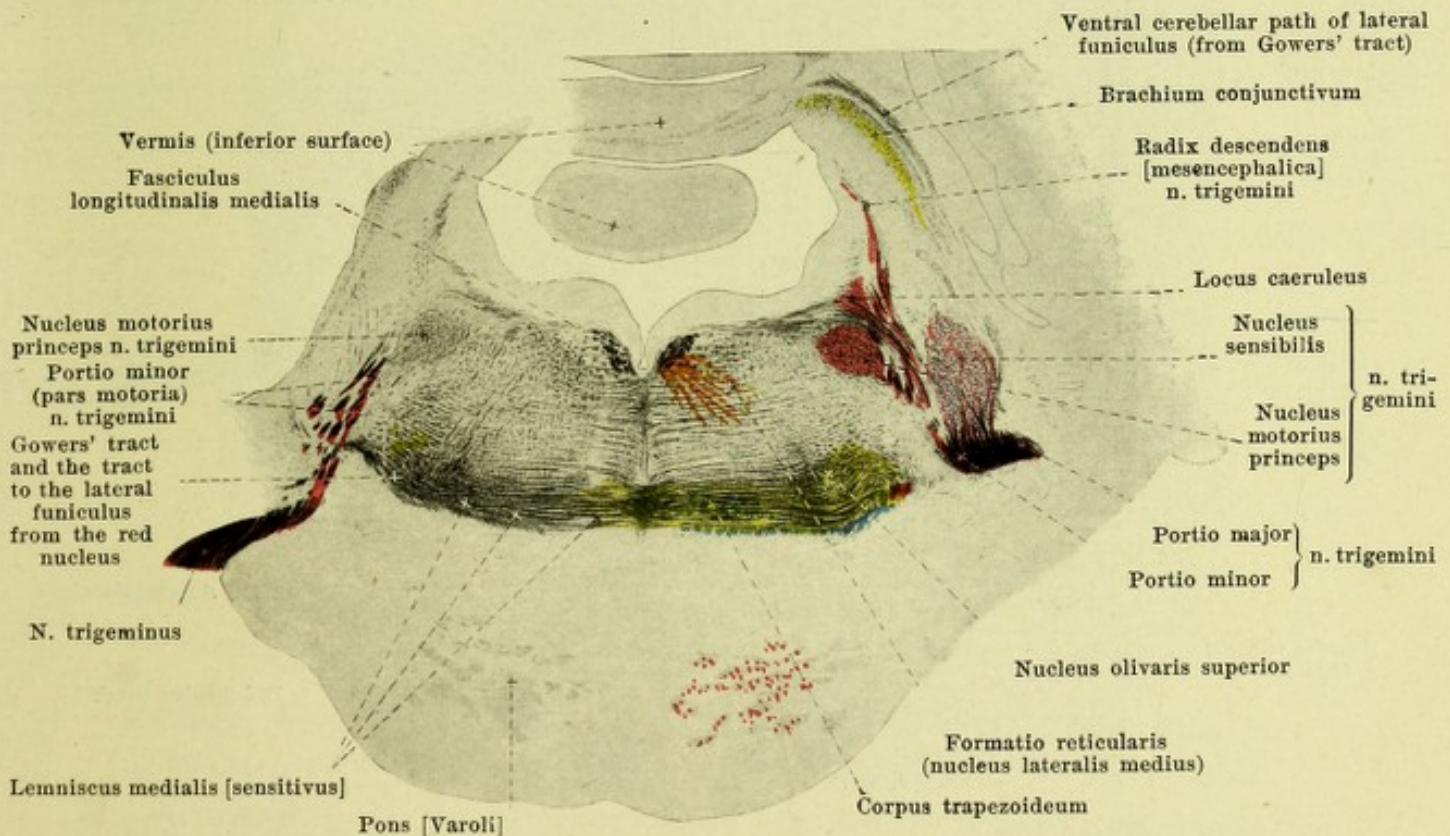
737. Level of the tuberculum acusticum (on the left side) and of the radix n. glossopharyngei.



738. Level of entrance of the n. acusticus (left side: n. vestibularis, right side: n. cochlearis) and, on the left, of the exit of the n. facialis.

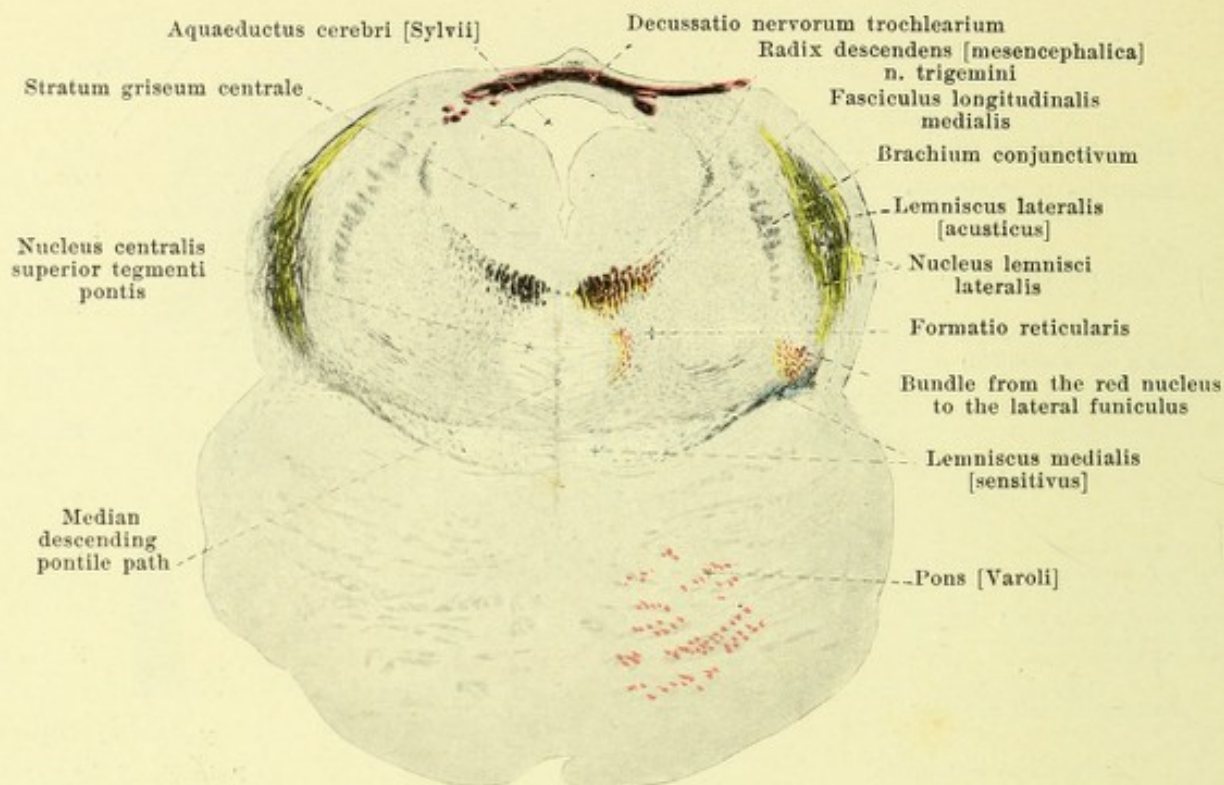


739. Level of exit of the n. facialis and of the nucleus n. abducentis.

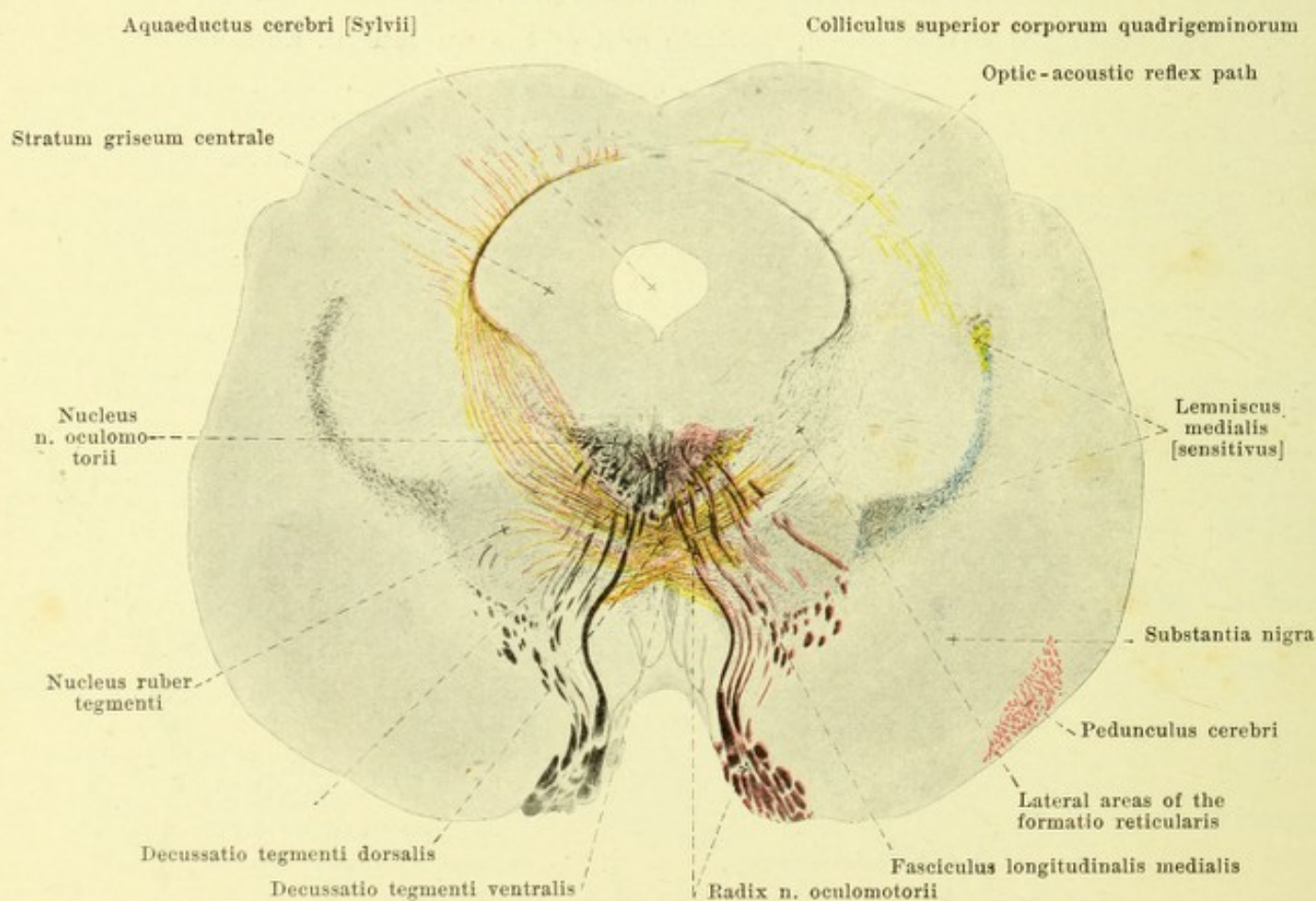


740. Level of roots of n. trigeminus.

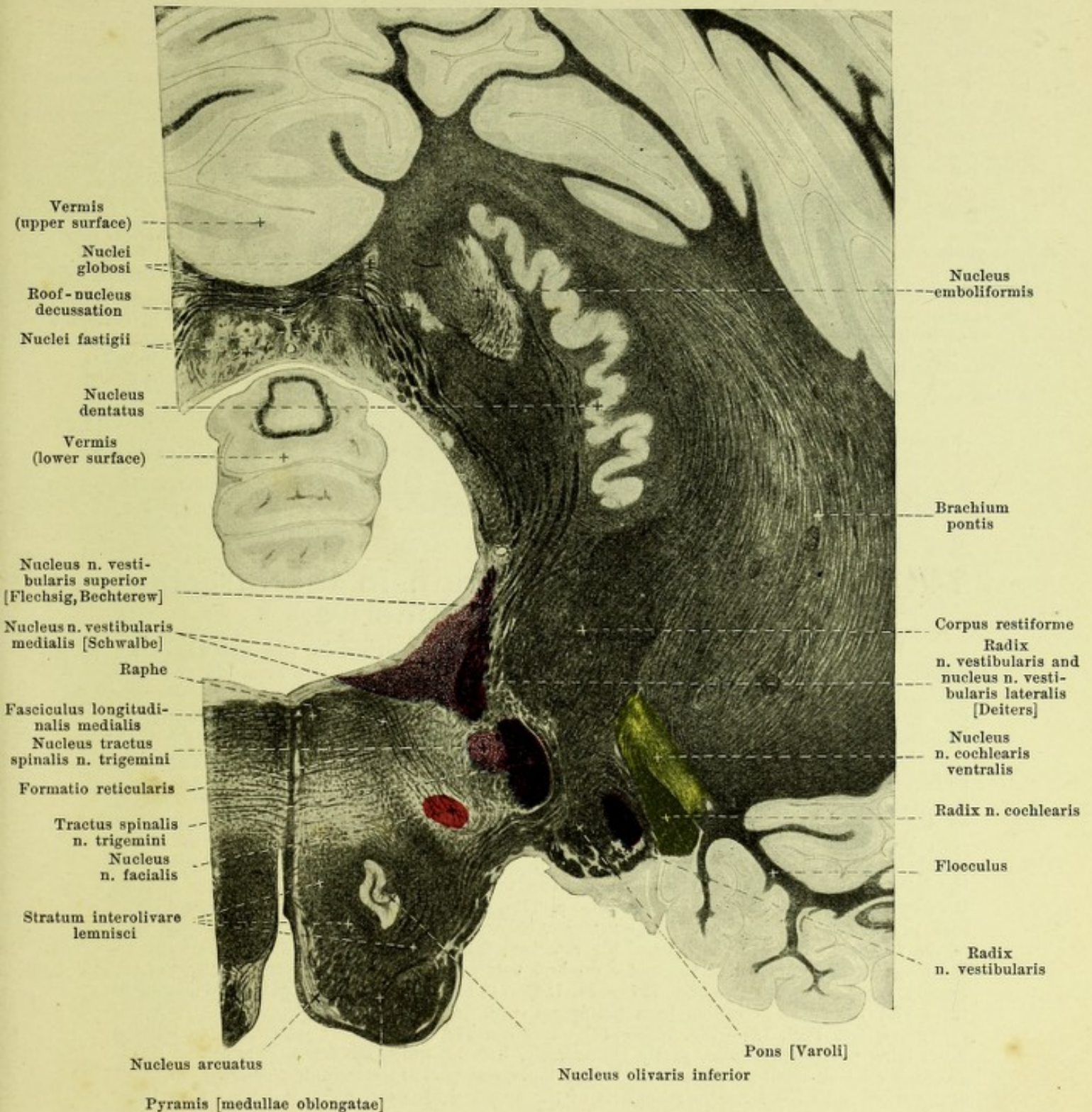
739 and 740. Region of the corpus trapezoideum.



741. Level of the decussatio nervorum trochlearium
(radix n. trochlearis see Fig. 732).



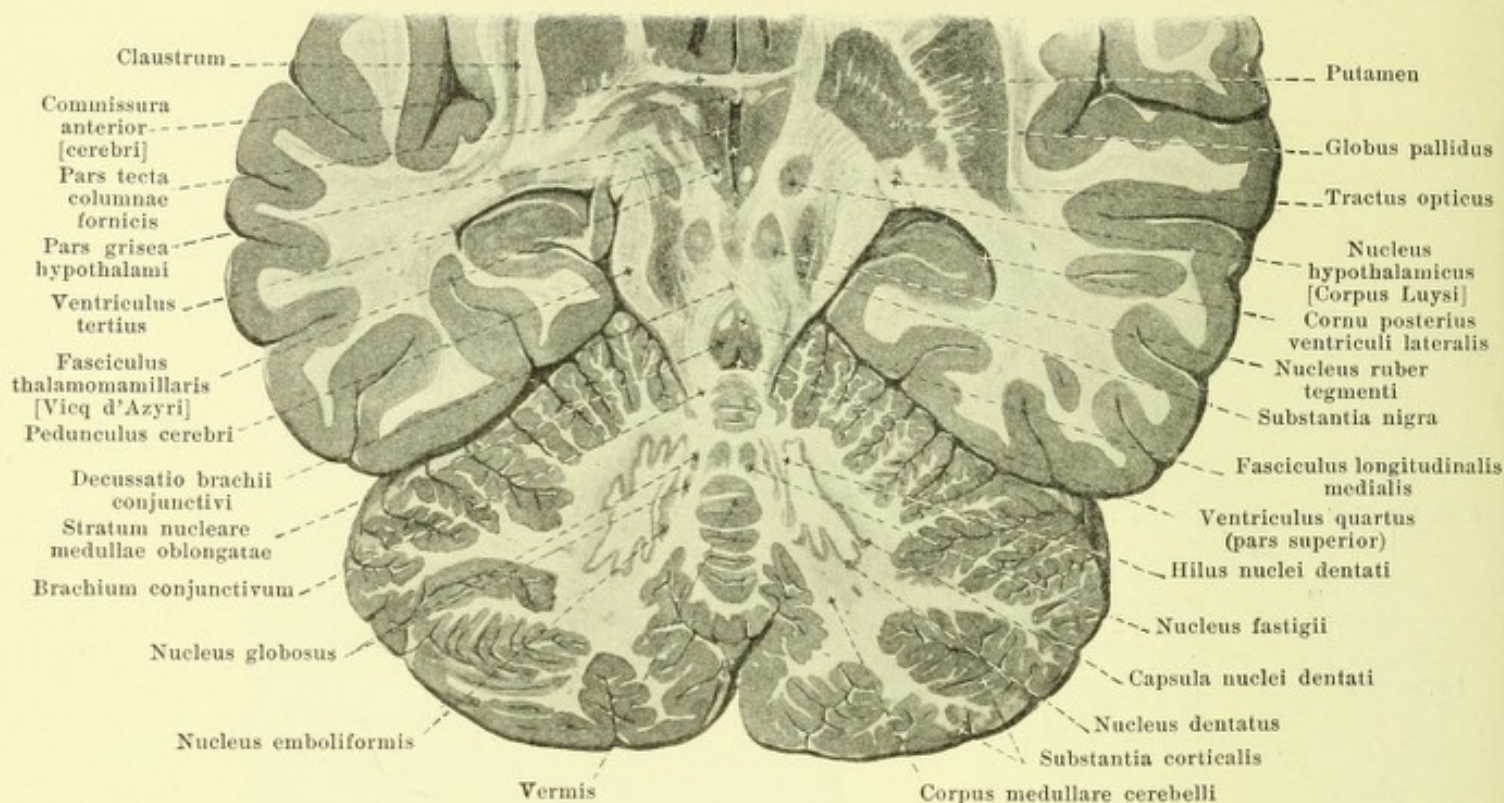
742. Level of exit of the n. oculomotorius.



743. Section through the middle of the cerebellum and through the medulla oblongata.

Approximately in the direction of the radiation of the corpora restiformia (after a preparation by P. Flechsig). Magnification 4:1. (Held.) White substance black; grey substance light.

Motor nuclei red, sensory blue, acoustic yellow.



744. Section through the brain in the direction of the brachia conjunctiva.

Distribution of the principal masses of grey matter in the brain. In the region of transition from the spinal cord to the *medulla oblongata* (see Figs. 725 and 726) a long club-like mass of grey matter, *nucleus fasciculi gracilis*, appears in the fasciculus gracilis causing the clava on the surface; somewhat further cerebralward a similarly formed mass corresponding to the tuberculum cuneatum on the surface and called the *nucleus fasciculi cuneati* appears in the fasciculus cuneatus; both nuclei are connected with the central grey matter. The posterior horn is gradually displaced ventralward and soon vanishes. Near it, lateralward and ventralward, is a large grey mass, *nucleus tractus spinalis n. trigemini*, covered on the surface by the *tractus spinalis n. trigemini* and giving rise there to the tuberculum cinereum which is more distinct in the child than in the adult. At the lower end of the rhomboid fossa the posterior funiculi diverge from each other, become gradually displaced to the lateral surface of the medulla oblongata and with the direct cerebellar tract help to form the *corpus restiforme* on each side (see also p. 678). In the meantime the central canal opens into the fourth ventricle and the grey masses adjacent to it ventralward appear in the floor of the ventricle. Beneath the floor of the rhomboid fossa, in part also further caudalward, lie the majority of the nuclei of the motor cerebral nerves and the primary terminal nuclei of the sensory cerebral nerves (see Figs. 727—731, 736—743 and 751) with the paths pertaining to them and the paths ascending from the spinal cord. A special feature here is the *formatio reticularis* (see Figs. 725—733, 735—742). This consists of manifoldly interwoven medullated fibers lying partly lengthwise, partly transversely, between which are deposited numerous single ganglion cells or small grey masses. In the lowermost part of the medulla oblongata, in direct continuation with the *formatio reticularis* of the spinal cord (see p. 621), it begins with those remains of the anterior and lateral funiculi which are to be seen above the pyramidal decussation and the remains of the anterior horns. Below, it lies between the pyramids and olives on the one hand and the nuclei of the posterior funiculi (*vide supra*) on the other; it then approaches closer to the floor of the rhomboid fossa and is continued through the dorsal portion of the pons (see p. 667) as far forward as the level of the inferior colliculi of the corpora quadrigemina. The medial region bounded lateralward by the root fibers of the *n. hypoglossus* (see Fig. 727), is relatively poor in ganglion cells and is called the *substantia reticularis alba* in contrast with the area situated lateralward from it, the *substantia reticularis grisea*. On the ventral side (see Figs. 727, 728, 736—738 and 745) the *nucleus olivaris inferior* appears in the olive; it is a shell-like much folded grey mass which is open medianward at the *hilus nuclei olivaris*;

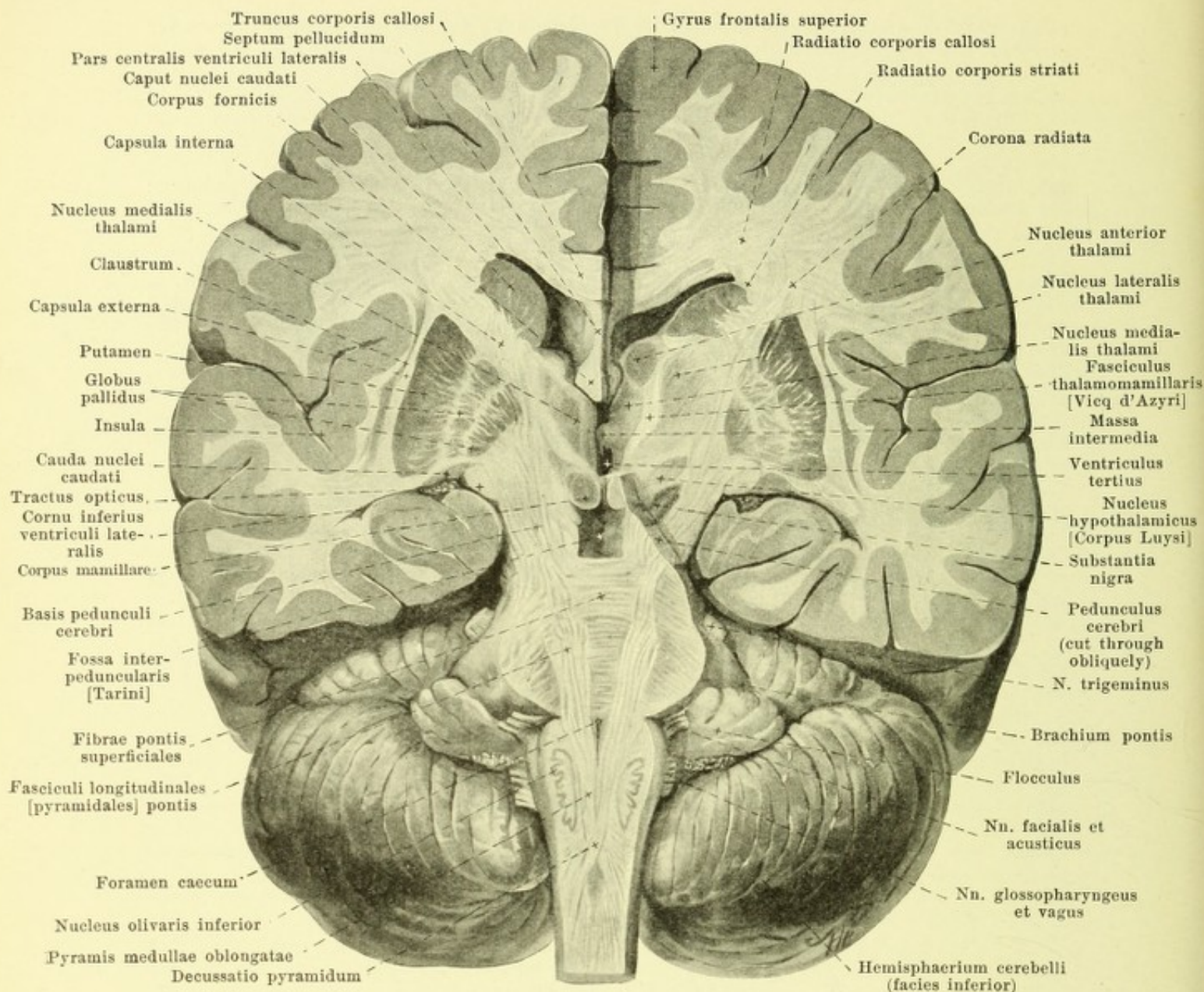
small detached portions of its grey matter are known as the *nucleus olivaris accessorius medialis* and *dorsalis* (*medial* and *dorsal accessory olive*). At the same level the *nuclei arcuati*, flat masses of grey matter, lie in the *fibrae arcuatae externae* (see p. 629) on the ventral and medial surfaces of the pyramids. The region of the *pons* (see Figs. 729—732, 740 and 741) is divisible into two parts. The larger ventral part, *pars basilaris pontis*, consists principally of transverse bands which pass lateralward to the brachia pontis; these bands contain irregular masses of grey matter, *nuclei pontis*, and are traversed by the *fasciculi longitudinales [pyramidales]* passing to the pyramids from the base of the cerebral peduncle: the transverse fibers are thus divisible into *fibrae pontis superficiales* and *profundae*. The dorsal part, *pars dorsalis pontis*, extends to the floor of the ventricle (see p. 666).

The *cerebellum* (see Figs. 695, 743 and 744) consists also of white and grey matter. The latter covers the whole surface as the *cerebellar cortex (substantia corticalis)*; in it, in a fresh or properly hardened preparation, two layers can be made out even with the naked eye, an inner yellowish or reddish brown layer, *stratum granulosum (granular layer)* and an outer grey layer, *stratum cinereum*; between these two lies the narrow *stratum gangliosum (Purkinje's cells)*. In the interior of the cerebellum the white matter forms a continuous mass, *corpus medullare*: this is small in the worm but markedly developed in the hemispheres. From it go off into the interior of the individual lobes *medullary layers, laminae medullares*, which in turn send off secondary and tertiary laminae into the lobules and gyri, so that upon a sagittal median section of the worm (see Fig. 695) a tree-like, much branched figure, *arbor vitae*, is produced. In the corpus medullare lie several grey masses (see Figs. 743 and 744); thus near the worm on each side is the jagged and markedly convoluted *nucleus dentatus*, the *hilus nuclei dentati* of which looks medianward; medial from it is the club-shaped *nucleus emboliformis* (the *cork* or *plug*) and medianward from this one or several *nuclei globosi (spherical nuclei)*; in the worm on each side, close to the ventricular cavity is the *nucleus fastigii (nucleus of the roof)* which is thicker in front and, behind, runs out into several points. The layer of white fibers which passes along the lateral surface of the nucleus dentatus is called the *capsula nuclei dentati*.

In the *mid brain* (see Figs. 732, 733, 741 and 742) the aquaeductus cerebri is completely surrounded by a grey mass, *stratum griseum centrale*, which is the direct continuation of the grey covering of the floor of the rhomboid fossa. In it lie also the nuclei of origin of the nn. trochlearis and oculomotorius and one nucleus of origin of the motor root of the n. trigeminus (see also Fig. 751). In its ventral part, in the interior of the tegmentum pedunculi (see p. 635), lies the spherical grey mass called the *nucleus ruber [tegmenti] (red nucleus of the tegmentum)* (see Figs. 733, 742, 744 and 748), and ventral from this between the medial lemniscus and the base of the cerebral peduncle is a larger area, *substantia nigra* (see Figs. 733, 744 and 745), dark colored even to the naked eye owing to its markedly pigmented ganglion cells, it extends upward into the hypothalamus. Dorsalward in the center of the inferior colliculus is a lenticular grey mass, *nucleus colliculi inferioris* (see Fig. 732) and in the superior colliculus, covered by a layer of white matter, *stratum zonale*, is a manifoldly lamellated grey mass, *stratum griseum colliculi superioris* (see Fig. 733).

In the *inter-brain* (see p. 626) in the region of the *hypothalamus*, lying within the corpus mamillare (see Figs. 720 and 745) are two grey masses, *nuclei corporis mamillaris*. Directly continuous with the stratum griseum centrale of the mid-brain is a layer of grey matter, *pars grisea hypothalami*, which invests the floor of the third ventricle as far forward as the infundibulum, covering also the medial surface of the hypothalamus and thalamus; it also forms the *massa intermedia* (see p. 646). In the depth lies a special lens-shaped grey mass, the *nucleus hypothalamicus [corpus Luysi]* (see Figs. 744, 745 and 748), directly in contact with the dorso-medial surface of the base of the cerebral peduncle; it begins approximately in the middle of the nucleus ruber and extends farther rostralward than this. In the *thalamencephalon*, within the *thalamus* (see p. 646 and Figs. 720 and 745) are several grey nuclei which are partly circumscribed by sharply defined layers of white matter, *laminae medullares thalami*; the largest mass which reaches dorsalward as far as the pulvinar is called the *nucleus lateralis thalami*; besides this there may be distinguished the *nucleus medialis thalami* and, under the tuberculum anterius, the *nucleus anterior thalami*; in addition, another centrally situated mass is especially striking, usually in the posterior part of the thalamus, the *centre median*. The *corpus geniculatum laterale* (see Fig. 733) and *mediale* (see Figs. 733 and 748) each contain a large nucleus, *nucleus corporis geniculi lateralis* and *medialis*; the *trigonum habenulae* (see Fig. 748) contains a small grey mass, *nucleus habenulae*.

The *cerebral hemisphere* is covered on its whole surface by a layer of grey matter, the *cerebral cortex (substantia corticalis)* (see Figs. 744—748). Internally the corpus striatum contains the *nucleus caudatus* (see p. 651). Lateral from the latter and the thalamus, lying buried in the interior, is the wedge-shaped *nucleus lentiformis* (see Figs. 745—748). It does not reach so far forward as the nucleus caudatus nor backward nearly so far as the thalamus; it is divided into three parts by two thin medullary layers, concentric with the convex lateral surface.

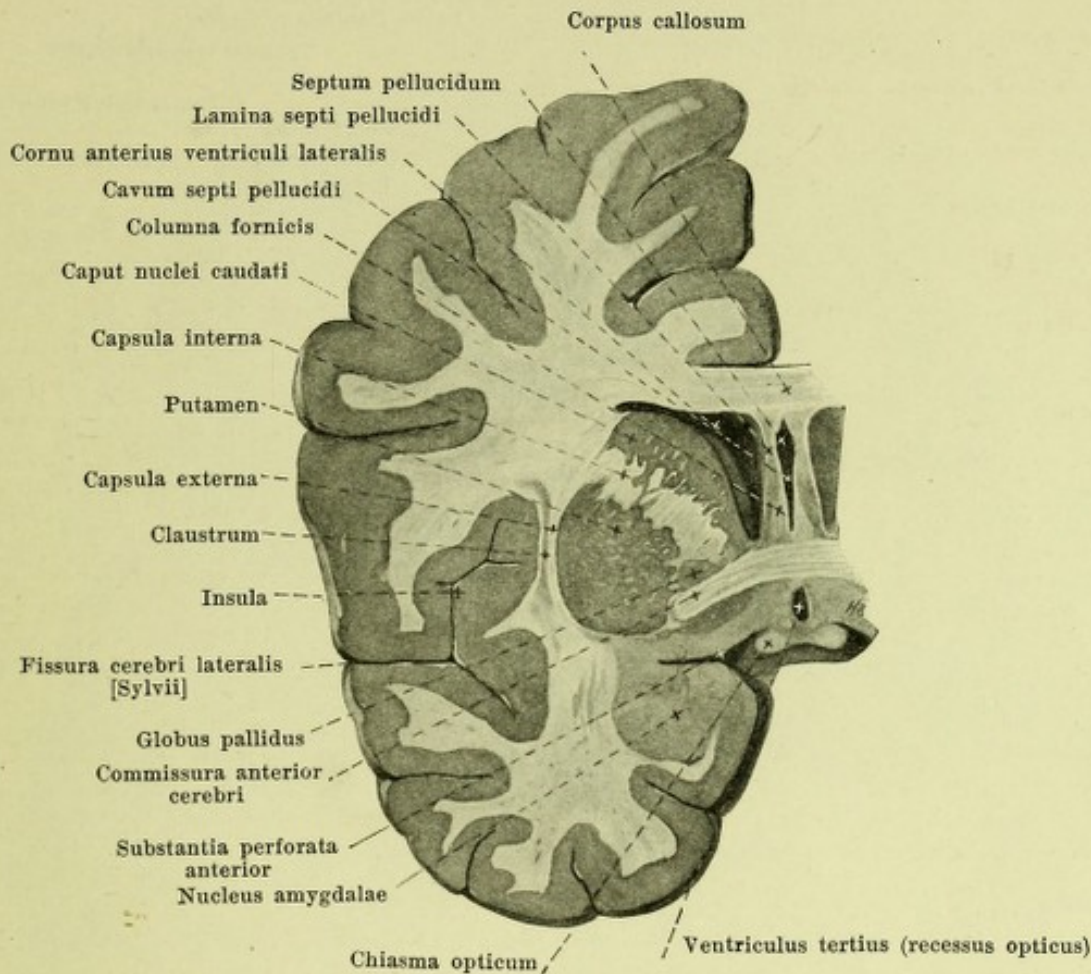


745. Section through the brain in the direction of the cerebral peduncles, viewed from in front.

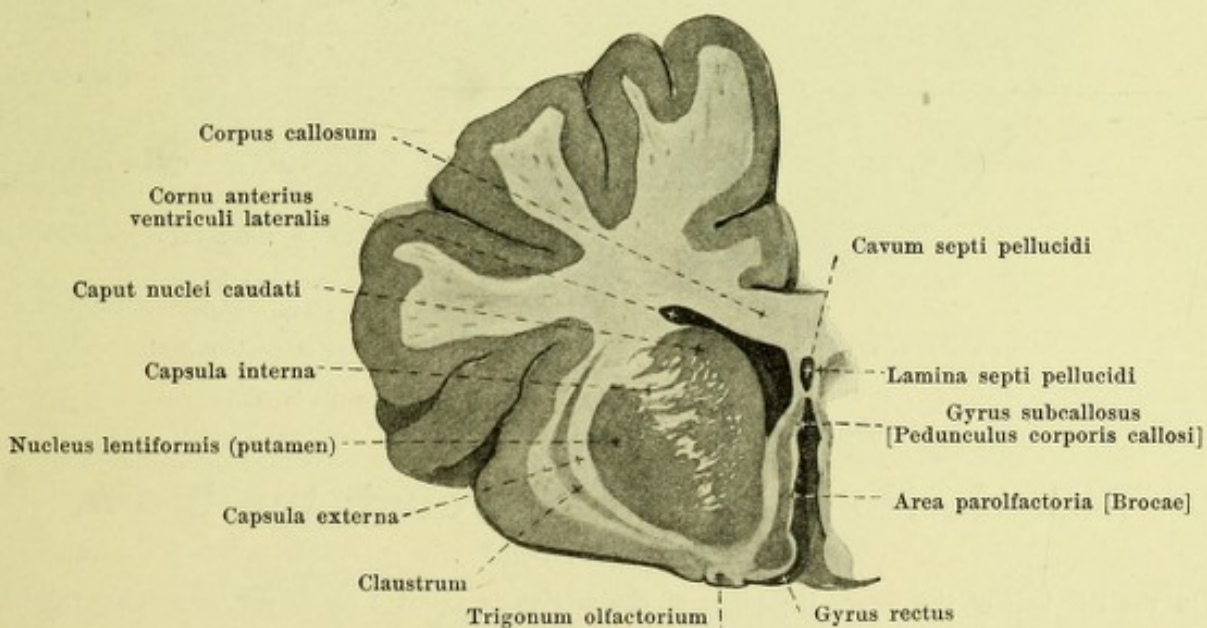
(In the left half of the cerebrum a second cut has been made parallel to the first and a plane situated somewhat further dorsalward represented.)

Distribution of the principal grey masses in the brain (continued).

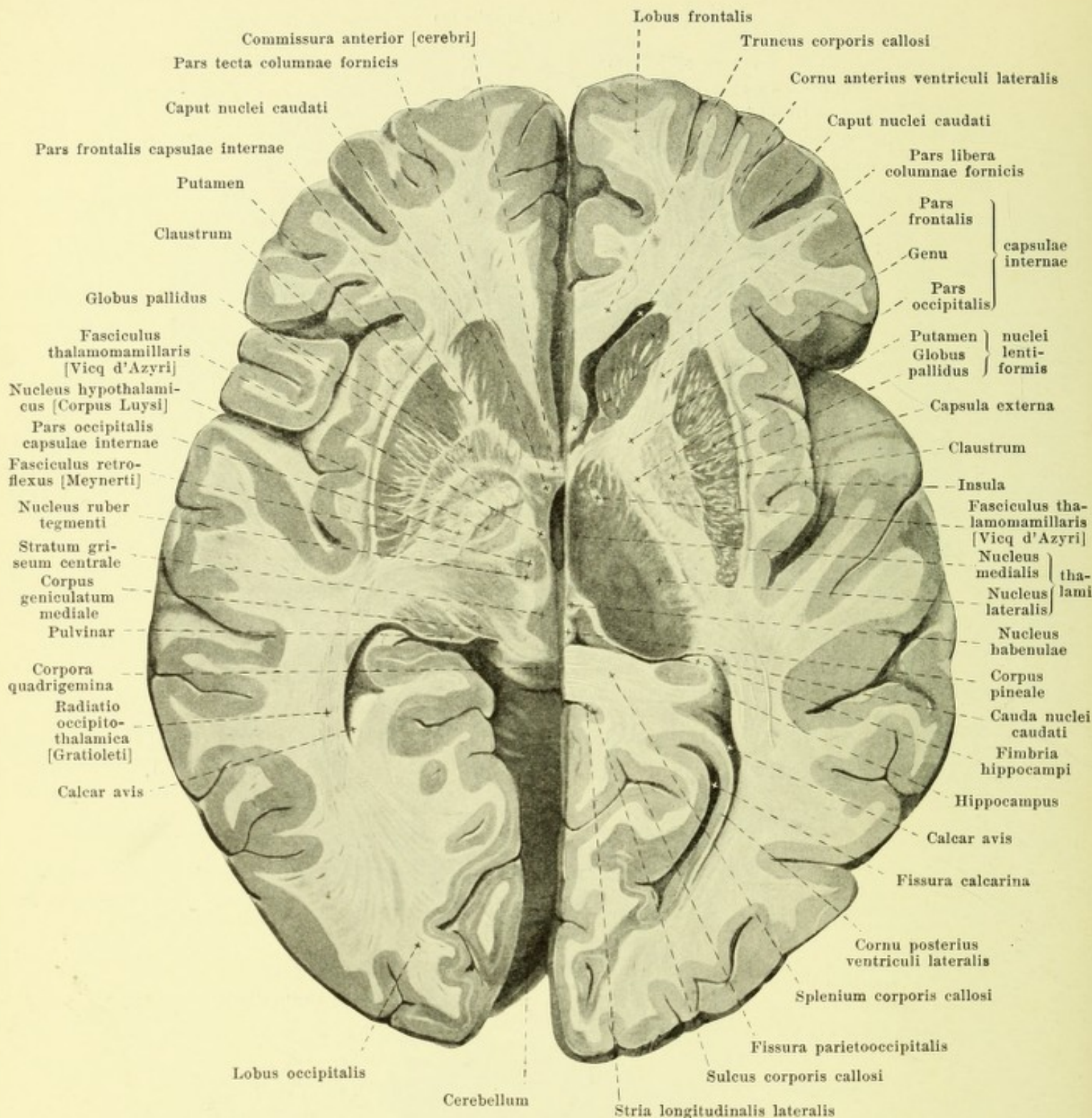
Of the parts of the nucleus lentiformis, the medial and middle portions together, pale and like the adjacent thalamus, are called the *globus pallidus*, while the lateral largest part, *putamen* is colored dark grey like the nucleus caudatus; putamen and nucleus caudatus are partly connected with each other in their frontal portions (see Figs. 718, 746—748). The medial boundary of the lentiform nucleus (see Figs. 745—748) is formed by a broad mass of white matter, *capsula interna*. This is bent at an angle and is subdivisible into a *pars frontalis capsulae internae* between the nucleus caudatus and the lentiform nucleus, a *genu capsulae internae*, and a *pars occipitalis capsulae internae* between the thalamus and the nucleus lentiformis. The lateral surface of the nucleus lentiformis corresponds in its position to the island. It is separated by a thin medullary layer, *capsula externa*, from a narrow layer of grey matter, *claustrum* (*bulwark*); the medial surface of this is smooth but its lateral surface presents small projections corresponding to the gyri of the island. The claustrum is separated from the cortex of the island by a further layer of white matter.



746. Frontal section of the brain passing through the anterior commissure, left half, viewed from behind.



747. Frontal section through the brain in front of the anterior commissure, left half, viewed from behind.

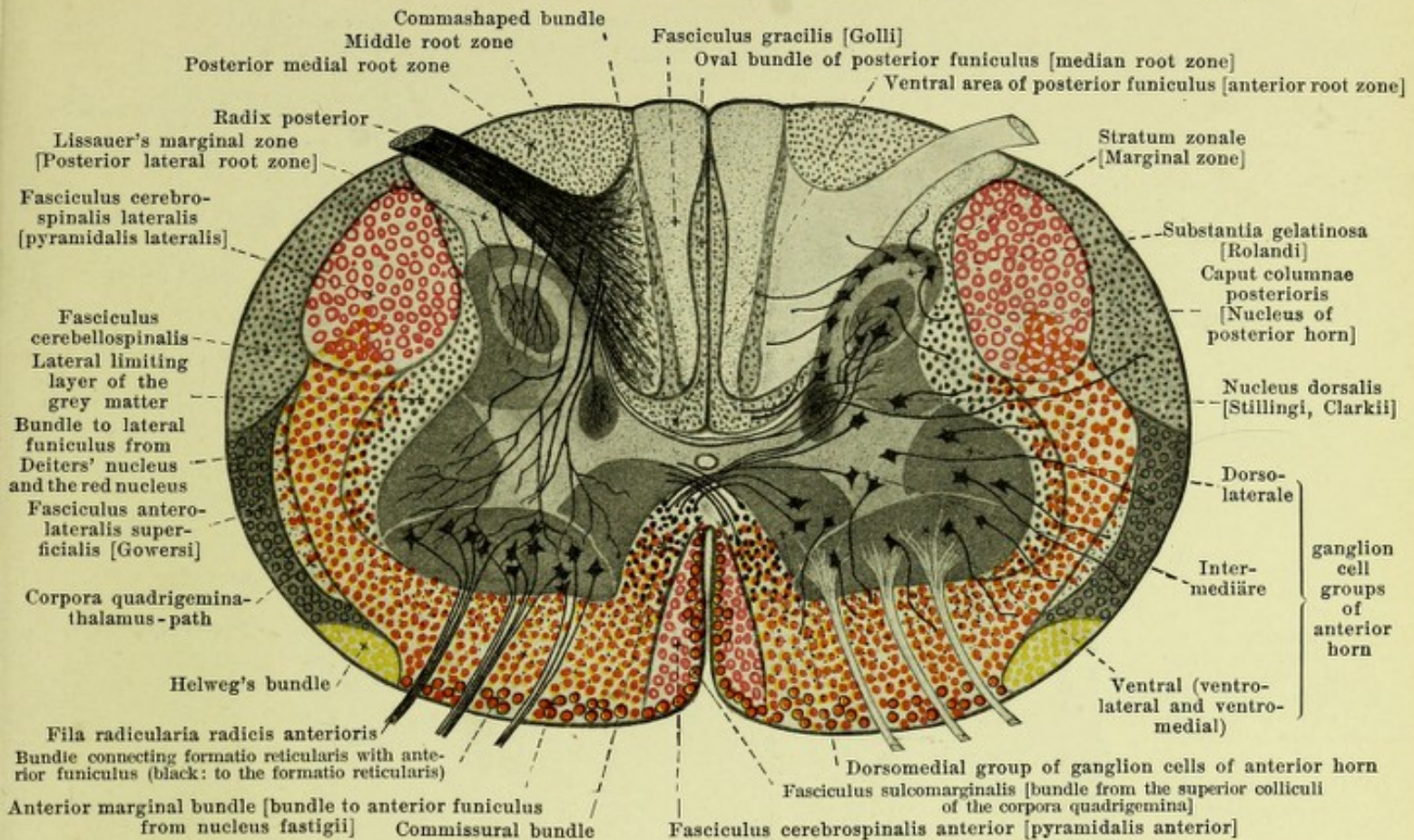


748. Horizontal section through the brain, viewed from above.

(In the left half of the figure the plane of the section is about 1 cm deeper than in the right.)

Distribution of the principal grey masses in the brain (continued).

In the most anterior part of the temporal lobe lies a large grey mass, *nucleus amygdalae*, almond nucleus (see Fig. 746), which is continuous medianward with the cortex of the gyrus hippocampi and dorsalward with the lentiform nucleus.



749. Schematic transverse section of spinal cord with conduction paths and groups of ganglion cells. Magnification circa 12,5:1. (Held.)

(All the paths descending from the brain to the spinal cord are in colors; all other paths in the spinal cord, ascending and descending, are indicated in black.)

Brief resumé of the conduction paths of the spinal cord with synonyms. (Held.)

Funiculus posterior.

Oval bundle of posterior funiculus = median root zone.

Fasciculus gracilis [Golli] = Goll's tract.

Ventral area of posterior funiculus = anterior root zone

Comma-shaped bundle

Middle root zone

Posterior medial root zone

Lissauer's marginal zone = posterior lateral root zone.

Fasciculus cuneatus [Burdachi]
= Burdach's fasciculus.

Funiculus lateralis.

Fasciculus cerebrospinalis lateralis [pyramidalis lateralis] = lateral pyramidal tract.

Fasciculus cerebellospinalis = direct cerebellar tract.

Fasciculus antero-lateralis superficialis [Gowersi] = Gowers' tract = cerebellar tract of antero-lateral funiculi.

Lateral limiting layer of grey matter

Bundle to lateral funiculus from Deiters' nucleus and from the red nucleus

Corpora quadrigemina-thalamus-path

Helweg's bundle

Fasciculus lateralis
proprius [Flechsigi] =
ground bundle of lateral
funiculus.

Funiculus anterior.

Bundle to anterior funiculus from formatio reticularis (partly also to the formatio reticularis)

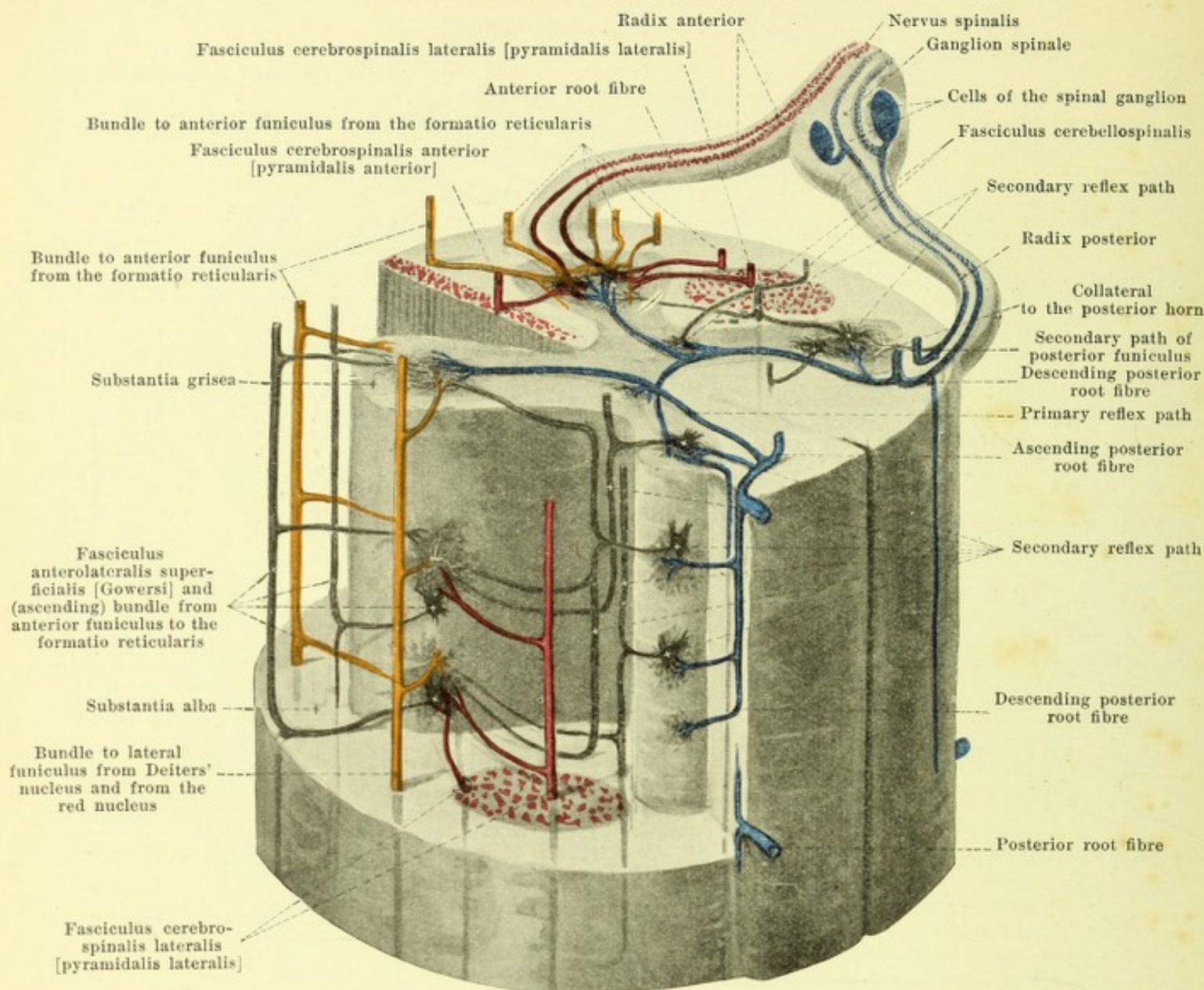
Anterior marginal bundle = bundle to anterior funiculus from the nucleus fastigii [roof-nucleus]

Commissural bundle

Fasciculus cerebrospinalis anterior [pyramidalis anterior] = anterior pyramidal tract.

Fasciculus sulcomarginalis = path from corpora quadrigemina to anterior funiculus.

Fasciculus anterior
proprius [Flechsigi]
= ground bundle of
anterior funiculus.



750. The most important relations of the nerve-elements of the spinal cord in transverse and longitudinal section, schematic. Magnification circa 10:1. (Held.)

(A part of the grey matter has been exposed on the left side in a piece of spinal cord. The nerve fibers have been drawn in as rigid tubes and the cells have been introduced in the grey matter [supposedly transparent]. The spinal cord is viewed from the left and behind.) Motor anterior roots red; posterior roots from the spinal ganglion blue; colors otherwise the same as in Fig. 749.

Conduction paths of the spinal cord (see also Fig. 749). (Held.) **Cross-section relations of the posterior roots:** to the posterior horn of the same and of the opposite side, to Clarke's column and to the anterior horn (*reflex bundle of the sensory roots of the spinal cord*).

The **funiculi of the spinal cord** are derived, aside from the areas of the posterior funiculus which come from the limbs of bifurcation of the posterior roots themselves, from the different funicular cells of the grey matter (see their arrangement also in Fig. 749), or they are the continuations of conduction paths, the origins of which are situated above the spinal cord in the brain-stem, cerebellum or cerebrum.

All funiculi of the spinal cord have, by means of their collaterals, cross-section relations with the grey matter of the spinal cord and its cell groups.

The origin of the conduction paths descending to the spinal cord (indicated in colors in Fig. 749) is as follows: the *pyramidal tract* (red) comes from the anterior and posterior central gyri (of the same and of the opposite side, decussation of pyramids, see Figs. 725 and 753); the *anterior marginal bundle* comes from the roof-nucleus (nucleus fastigii) (see Fig. 743), perhaps also from other grey masses of the cerebellum (of the same and of the opposite side). The *fasciculus sulcomarginalis* arises as the *optic acoustic reflex path* in the middle grey matter of the superior colliculus (see Fig. 742), in largest part crosses in the *dorsal decussation of the tegmentum* (see Figs. 733 and 742) and then passes into the brain stem in the *fasciculus longitudinalis medialis* (O. T. *posterior longitudinal bundle*) (see Figs. 725—732, 735—741) downward to the spinal cord; individual fibers in the more lateral areas of the anterior and lateral funiculi (not designated) have the same origin. The origin of the orange-colored area is in three places: 1. in Deiters' nucleus (nucleus n. vestibularis lateralis) (see Figs. 738 and 751) of the same side; this system passes as the *bundle of the lateral funiculus from Deiters' nucleus* obliquely through the formatio reticularis (see Figs. 729, 738, 739) and runs through the medulla oblongata in the area occupied by Gowers' tract (see Figs. 725—728 and 735—737). 2. In the red nucleus of the tegmentum (nucleus ruber tegmenti) of the opposite side; this bundle goes through the *ventral decussation of the tegmentum* (see Fig. 742) into the lateral lemniscus of the opposite side (see Figs. 731 and 741), then perforates the trapezoid body (corpus trapezoideum) (see Figs. 729, 730, 739 and 740) and as the *bundle of the lateral funiculus from the red nucleus* joins that from Deiters' nucleus (see Figs. 728—730 and 737—740). 3. In the three lateral nuclei of the formatio reticularis (nucleus lateralis inferior see Figs. 727 and 728, medius see Fig. 730, superior see Fig. 733); its fibers lie in large part in the *fasciculus longitudinalis medialis* (O. T. *posterior longitudinal bundle*), in part also in the longitudinal strands of the formatio reticularis (substantia reticularis alba) (see Fig. 725 to 733, 735—742).

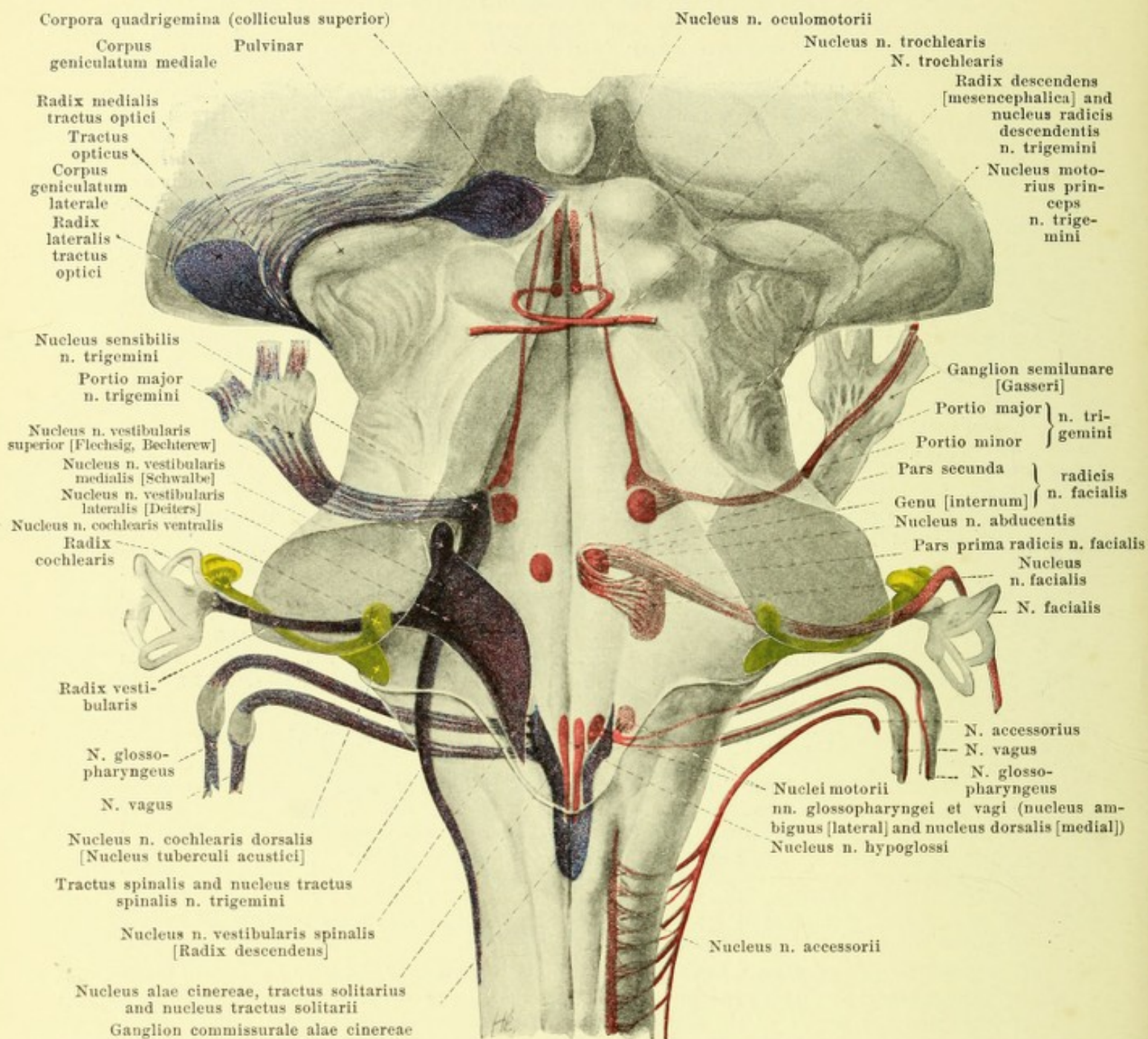
The other descending conduction paths in the spinal cord come from three sources: 1. From the posterior roots (origin: spinal ganglia); these lie partly in Lissauer's marginal zone, partly in the middle root zone. 2. From the cells of the posterior horn (stratum zonale see Fig. 749); these run partly in the *comma-shaped bundle*, in the *ventral area of the posterior funiculus* and in the *lateral limiting layer of the grey matter*, partly also in *Lissauer's marginal zone*. 3. From the cells of the anterior horn; these lie partly in the anterior, partly in the lateral funiculi.

The ascending systems of the spinal cord (see Figs. 749 and 750) are the following three:

1. *Direct continuation of the posterior roots*; these run in the posterior funiculus to the nucleus fasciculi gracilis and nucleus fasciculi cuneati. Their *secondary path* arising here, crosses in the *sensory (fillet) decussation, decussatio lemniscorum* (see Figs. 726 and 735) and goes as the *interolivary layer (stratum interolivare lemnisci)* and *medial fillet (lemniscus medialis [sensitivus])* to the [ventro]lateral nucleus of the thalamus, partly directly to the somaesthetic area (see Figs. 726—733, 736—742, 755 and 756) as well as partly by way of the *fibrae arcuatae externae* and in the path of the corpus restiforme to the nucleus dentatus and worm of the cerebellum (see Figs. 736—739).

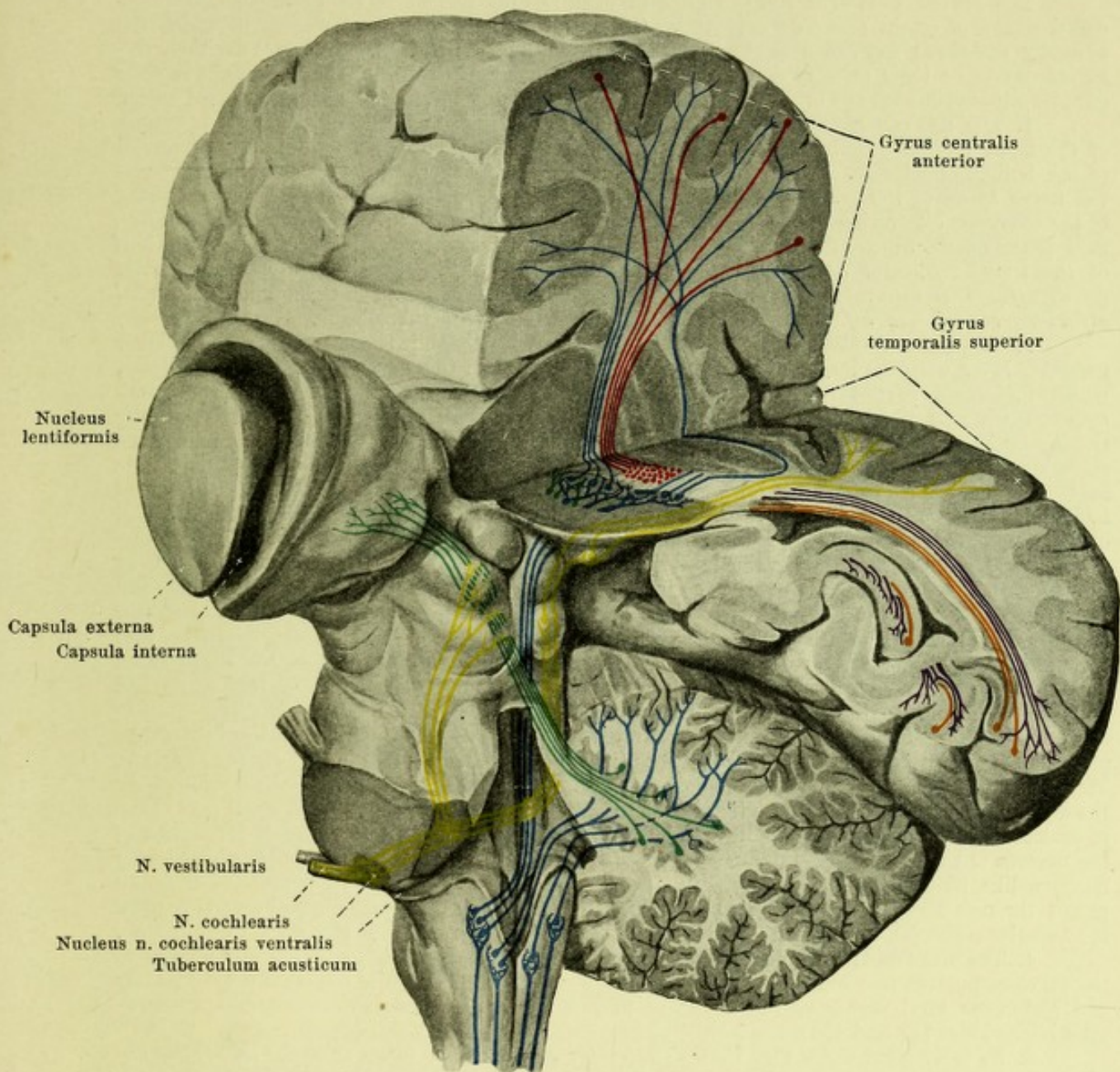
2. The *conduction paths superimposed upon this primary sensory path of the posterior funiculus* are derived from the cells of the posterior horn, of Clarke's column, and also, partly, of the anterior horn, around which collaterals of the posterior roots break up. The conduction paths arising from the posterior horn go partly into the posterior funiculus of the same side and into the lateral funiculus of the same side (*lateral limiting layer of the grey matter*), partly also into the opposite anterior funiculus, (by way of the *anterior white commissure*). The cells of Clarke's nucleus send their axones by way of the *homolateral direct cerebellar tract, fasciculus cerebellospinalis* (contained above in the corpus restiforme) (see Figs. 725—730, 735—739) to the cortex of the upper surface of the worm. The anterior horn cells concerned send their axis cylinder processes probably in the area of the *homolateral Gowers' tract (fasciculus anterolateralis superficialis [Gowersi], cerebellar path of anterior funiculus)* (see Figs. 725—731, 735 to 740) to the inferior surface of the worm and into the *commissural bundle* whence their course and end is unknown.

3. The *conduction paths arising from the anterior horn cells* are partly short, running in the ground bundles of the anterior and lateral funiculi and then back into the grey matter, partly long, extending upward as far as the formatio reticularis to end in an unknown manner.



751. Nuclei of origin of motor, and primary terminal nuclei of sensory cerebral nerves, schematically represented in a supposedly transparent brain stem, viewed from behind (see also Figs. 698 and 704). Magnification 2:1. (Held.)

Nuclei and roots of motor nerves red, of sensory reddish-violet, of the n. cochlearis yellow and of the n. opticus bluish-violet.



752. Course of some of the greater conduction paths in the brain (see also Figs. 753 and 754). (Held.)

On the left side the cerebellum has been completely removed as has the cerebrum with the exception of the large ganglia; on the right side the posterior superior part of the cerebral hemisphere has been removed by a vertical (not exactly frontal) and a horizontal section. The brain is viewed from the left and from behind.

Pyramidal tract red; **path from the [ventro]lateral nucleus of the thalamus to the somaesthetic area** blue; **posterior funiculi, nuclei of posterior funiculi and further portions of the same conduction paths, viz.: 1. medial lemniscus (crossed) to the [ventro]lateral nucleus of the thalamus, 2. part of the corpus restiforme (of the same and of the opposite side) to the nucleus dentatus and to the cortex of the vermis** blue; **cochlear nerve and auditory conduction path** yellow; **primary (corticopetal) optic radiation** violet, **secondary (corticofugal)** orange; **brachium conjunctivum** green.

Origin and central conduction paths of the cerebral nerves. (Held.)

The **motor cerebral nerves** arise in definite gray masses of the brain-stem, their so-called nuclei of origin (*nucleus originis*). On the other hand, the gray masses in which the **sensory cerebral nerves** first enter and branch up (nuclei of the sensory nerves) are their *terminal nuclei* or their primary domains of termination, while their origin must be sought in their ganglia situated outside the brain. The *secondary paths* proceed from the primary terminal nuclei.

1. The **nervus olfactorius** arises in the bipolar olfactory cells of the regio olfactoria of the nasal mucous membrane; its primary domain of termination lies in the olfactory glomeruli of the bulbous olfactorius. From this a secondary path proceeds from the mitral cells and forms the nerve fibers of the *tractus olfactorius* (see p. 645). A part of the latter ends in the cortex of the trigonum olfactorium; a second part, the *lateral olfactory root (stria olfactoria lateralis)*, runs to the uncus, whence further paths go to the hippocampus, the gyrus hippocampi and the half of the gyrus fornicatus adjoining the corpus callosum (see Fig. 756). The *intermediary root (stria olfactoria intermedia)* penetrates into the substantia perforata anterior and the *medial olfactory root (stria olfactoria medialis)* passes to the gyrus subcallosus.

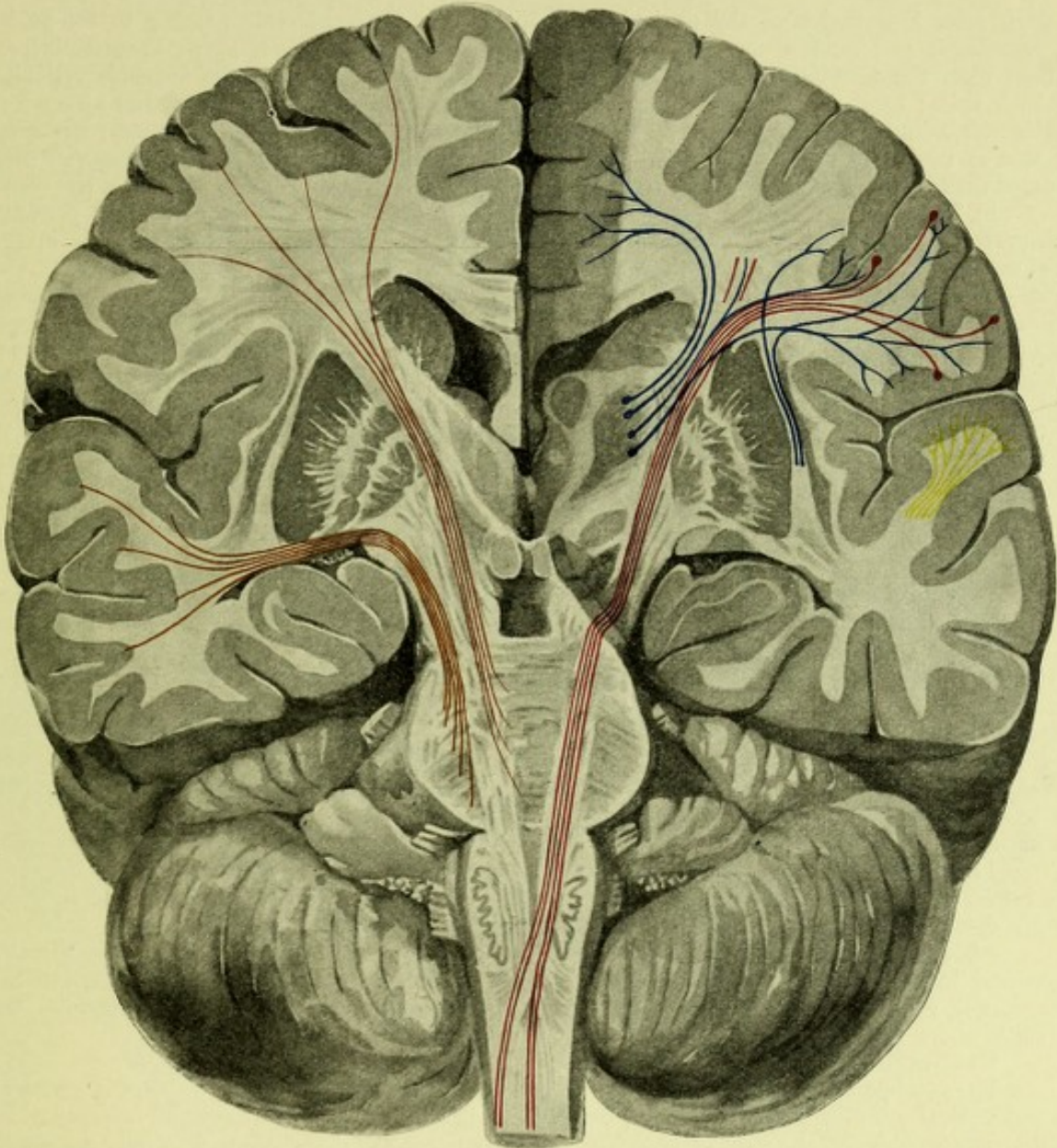
2. The sensory cells of the retina are connected by the bipolar nerve cells of the inner granular layer with the large ganglion cells of the retina; from these arises the **nervus opticus**, which undergoes partial decussation with the optic nerve of the other side in the *chiasma opticum*, whereby the largest part (from the nasal half of the retina) passes into the opposite tractus opticus, a smaller part (from the temporal side of the retina) into the tractus of the same side. The tractus opticus, which therefore contains nerve fibers from both retinae, ends in the corpus geniculatum laterale, and in the pulvinar thalami as well as in the superficial and middle gray matter of the superior colliculus (see Figs. 733 and 751). The cortical visual conduction path runs from the geniculate body and thalamus in the *radiatio occipitalthalamica [Gratioleti]* occipitalward along the posterior horn of the lateral ventricle (separated from it by the tapetum) to the cortex of the occipital lobe lying around the fissura calcarina and characterized by the linea Gennari (see Figs. 748, 752, 754—756). In the middle gray matter of the superior colliculus arises the *optic-acoustic reflex path*, which in largest part goes over through the "fountain-like" or dorsal decussation of the tegmentum into the posterior longitudinal bundle of the other side and, innervating the nuclei of the nn. oculomotorius, trochlearis and abducens, descends to the spinal cord (see Figs. 725—733, 735—742).

3. The **nervus oculomotorius** arises in the *nucleus n. oculomotorii*, which lies in the floor of the substantia grisea centralis at the level of the superior colliculus (see Figs. 733, 742 and 751). The ganglion cell groups lying in the dorsal trough of the fasciculus longitudinalis medialis form the lateral nucleus, which especially innervates the extrinsic muscles of the eye. A small part of the n. oculomotorius crossing the middle line between the two nuclei arises from the distal portion of the nucleus of the other side. From the cortex of the central gyri (see Fig. 755) the oculomotorius nucleus, like that of the n. trochlearis, in all probability receives voluntary innervation: the path passes through the base of the cerebral peduncle. In addition, the cortical visual area acts upon the superior colliculus through the corticofugal "secondary optic radiation" (see Figs. 752 and 754).

4. The **nervus trochlearis** arises from the nucleus n. trochlearis situated just inferior to the previous nucleus (see Fig. 732); it passes dorsalward at the margin of the central gray matter and undergoes total decussation in the velum medullare anterius (*decussatio nervorum trochlearium*) (see Figs. 741 and 751).

5. **N. trigeminus** (see Fig. 751). The motor *portio minor* arises from the *nucleus motorius princeps n. trigemini*, the *locus caeruleus* and the cell column (*nucleus radialis descendens*) accompanying the *radix descendens n. trigemini*, which reaches upward at the margin of the central gray matter almost as far as the level of the commissura posterior (see Figs. 730—732, 740 and 741). The sensory *portio major* arises from the *ganglion semilunare [Gasseri]*, perforates the pons and, bifurcating, ends partly in the *nucleus sensibilis n. trigemini*, partly descending as the *tractus spinalis n. trigemini* in the gray mass (*nucleus tractus spinalis*) adjacent to it (see Figs. 725—730, 736—739 and 743). From the sensory trigeminus nucleus a reflex path passes to the motor trigeminus nucleus of the same and of the opposite sides; upon these also collaterals of the radix descendens impinge. Similarly a path to this motor nucleus of origin arises from the nucleus tractus spinalis n. trigemini by way of the fibrae arcuatae internae at the level of the facial nucleus. In addition secondary cortical paths extend from the terminal nucleus of the tractus spinalis partly in the crossed interolivary layer, partly in fields of the formatio reticularis of the same and of the opposite sides; they finally, through intercalation of the ventrolateral nucleus of the thalamus, become connected with the cortex of the somaesthetic area. The voluntary cortical path for the motor nucleus of the n. trigeminus runs in part in the pyramidal tract; it arises in the inferior third of the anterior central gyrus and in the feet of the frontal gyri in front of it (see Fig. 755).

6. **N. abducens**. It arises from the *nucleus n. abducentis*, which lies just in front of the [inner] knee of the facial on the floor of the fourth ventricle (see Figs. 729, 739 and 751). The cortical path for its voluntary innervation is probably the pyramidal tract.



753. Course of the pyramidal tract (red) and of the cerebropontile paths (temporal: light-brown; frontal: dark-brown); end of auditory conduction path (yellow) and indirect continuation of medial lemniscus and brachium conjunctivum from the [ventro]lateral nucleus of the thalamus (blue), introduced into Fig. 745. (Held.)

7. N. facialis. Its nucleus of origin, *nucleus n. facialis*, lies in the ventral part of the formatio reticularis at about the middle of the dorsoventral diameter of the pons (see Figs. 729, 738, 739 and 751). It is innervated by the lower third of the anterior central gyrus (see Fig. 755) by way of the pyramidal tract, which gives off arcuate fibers, partly to the nucleus of the same side, partly to that of the opposite side, through the raphe.

The central connections of the *n. intermedius* have been insufficiently worked out in man.

8. N. acusticus. It consists of the *n. vestibularis* and the *n. cochlearis* (see Fig. 751).

a) The *n. vestibularis* arises in the *ganglion vestibulare*; its central root ends in the region of the floor of the rhomboid fossa in the *nucleus nervi vestibularis lateralis* [Deiters], *nucleus medialis* [Schwalbe] and *nucleus superior* [Flechsig, Bechterew] (see Figs. 727–729, 738, 739 and 743). Another part passes downward as the *radix descendens* and ends in the gray mass accompanying it (*nucleus n. vestibularis spinalis*) (see Figs. 727, 728, 736 and 737). Reflex paths pass from Deiters' nucleus to the lateral funiculus of the spinal cord, from the medial and superior nuclei to the fasciculus longitudinalis medialis of both sides,

a part, after innervation of the nucleus n. abducentis of the same side passing to the nucleus n. trochlearis and nucleus n. oculomotorii of the opposite side, further, *fibrae arcuatae internae* extend from the terminus of the n. vestibularis to the lateral areas of the *formatio reticularis* of both sides; of these a part acts upon the motor trigeminus nucleus and further up upon the oculomotorius nucleus, arriving finally in the [ventro]lateral nucleus of the thalamus; hence connection is made with the somæsthetic area. Special paths from the lateral and superior nuclei connect with the nucleus fastigii of the cerebellum, the nucleus dentatus and the cortex of the vermis.

b) The *nervus cochlearis* arises from the *ganglion spirale*; its central root perforates the posterior, lateral margin of the pons and ends in the *nucleus n. cochlearis ventralis* and the *nucleus n. cochlearis dorsalis* [*nucleus tuberculi acustici*] (see Figs. 728, 737, 738 and 743). From the latter proceed the *striae medullares*, inconstant in man; from the ventral nucleus arises the corpus trapezoideum, the nerve fibers of which are supplemented by others from the upper olive and the trapezoid nucleus. The upward continuation of the trapezoid body is the lateral lemniscus (*lemniscus lateralis* [*acusticus*]); it carries fibers from the corpus trapezoideum of the same and of the opposite side, also fibers from the *nucleus lemnisci lateralis* and ends in the nucleus of the inferior colliculus of the same and of the opposite side, as well as in the middle gray matter of the superior colliculus. Another part, supplemented by paths from the inferior colliculi, goes to the corpus geniculatum mediale, or directly over into the higher conduction path, extending from this geniculate body to the cortex of the first temporal gyrus (see Figs. 751—754).

9. 10. **N. glossopharyngeus** and **n. vagus** (see Fig. 751). Their motor fibers arise partly in the *nucleus dorsalis nn. glossopharyngei et vagi* (medial from the ala cinerea), partly in the *nucleus ventralis* [*nucleus ambiguus*], which lies in the *formatio reticularis* dorsal from the dorsal accessory olive (see Figs. 727, 728 and 736). Their sensory fibers arise in the *ganglion superius* and *petrosum n. glossopharyngei*, and in the *ganglion jugulare* and *nodosum n. vagi* and pass upward in an oblique direction from the lateral margin of the medulla oblongata to the ala cinerea. Through bifurcation of their nerve fibers the *tractus solitarius* arises. Their primary terminal domain is the *nucleus alae cinereae*, the *nucleus tractus solitarii* and the *ganglion commissurale alae cinereae* (see Figs. 726—728, 735 and 736). Reflex fibers extend to the dorsal vago-glossopharyngeal and to the hypoglossal nucleus. The secondary paths lie in the lateral areas of the *formatio reticularis* of the same and of the opposite side, as well as in the crossed interolivary layer. Fibers from the pyramidal tract pass to the motor nuclei.

11. **N. accessorius**. Its upper bundles arise along with the motor portion of the vagus, the lower spinal bundles, on the other hand, from the dorsolateral group of anterior horn cells as far down as the 5th—7th cervical segment (see Fig. 751).

12. **N. hypoglossus** arises in the *nucleus n. hypoglossi* in the floor of the rhomboid fossa and in the central gray matter at the end of the central canal (see Figs. 727, 736 and 751). The nuclei receive voluntary innervation from the operculum by way of the pyramidal tract through fibers running upward in the raphe which dominate both nuclei.

Connections of the cerebellum. (Held.)

The conduction paths of the cerebellum on each side ending or arising in its gray cortex and its subcortical ganglia lie chiefly in three great bundles, which are distinguished macroscopically as the *restiform body*, the *arm of the pons* and the *connecting arm*. Macroscopically inseparable from the restiform body is a fourth bundle called the *medial part of the corpus restiforme*.

1. The **corpus restiforme** (O. T. inferior cerebellar peduncle) unites the *paths from the spinal cord and the medulla oblongata*. These arise

a) from Clarke's column of the same side (*direct cerebellar tract*) (see p. 673). (A path parallel to the direct sensory cerebellar tract is the *cerebellar path of the anterior funiculus* (Gowers' tract) (see also p. 673), which runs on the more ventral surface of the medulla oblongata, is covered later by the pons, then loops around the lateral lemniscus and the brachium conjunctivum, and, passing along the velum medullare anterius, ends in the vermis) (see Figs. 725—731, 735—740 and 749);

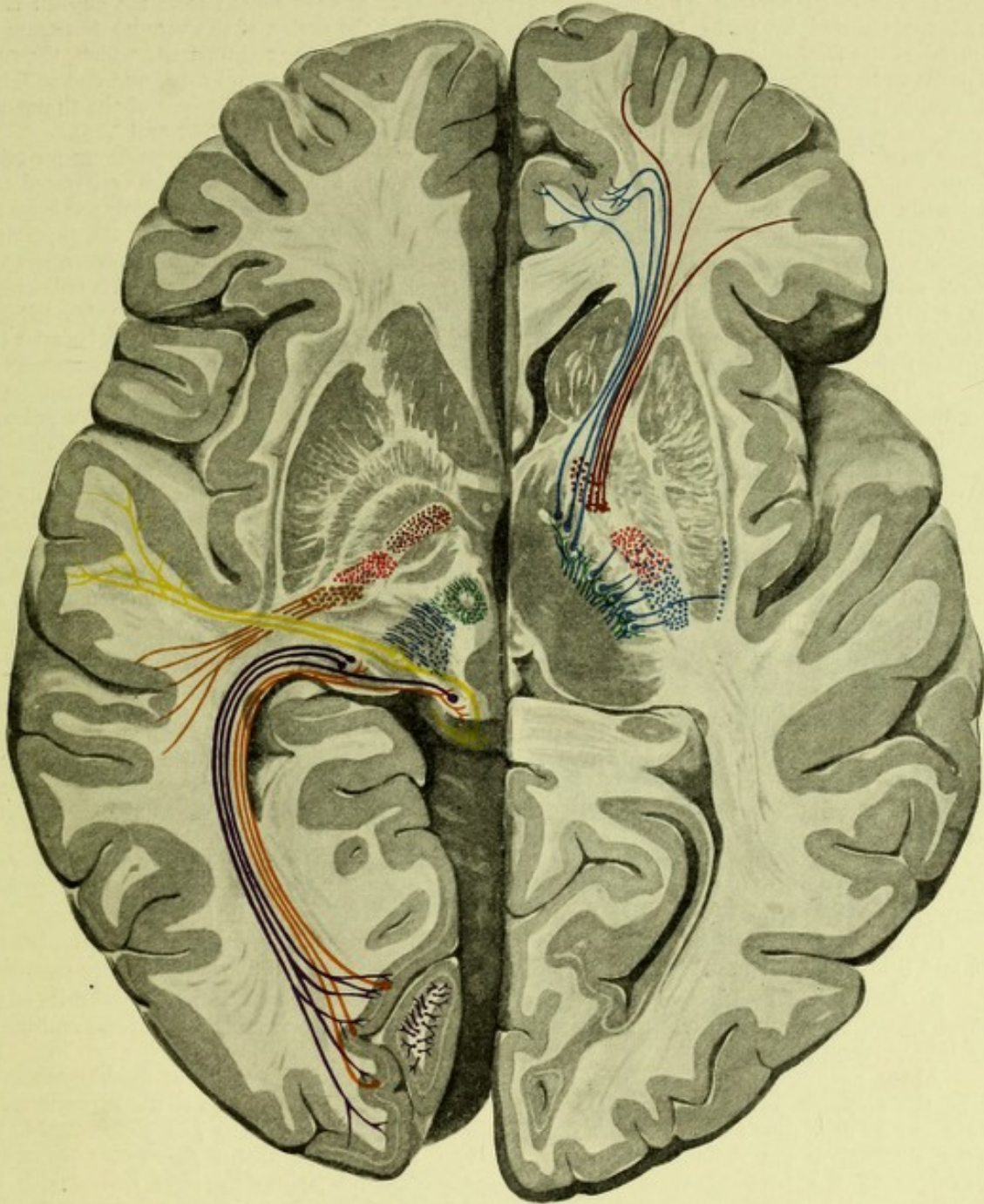
b) from the nuclei of the posterior funiculi of the same and of the opposite side (sensory decussation, *fibrae arcuatae externae*) (see Figs. 726 and 735);

c) from the inferior olives of the same and of the opposite side (*fibrae cerebelloolivares*) (descending paths also run in this *olive-norm-path*) (see Figs. 727, 728, 736 and 737);

d) from the nucleus of the lateral funiculus.

The corpus restiforme ends in the nucleus dentatus, nucleus emboliformis and nucleus globosus (chiefly through collaterals), the nucleus of the roof and in the cortex of the vermis (see Figs. 738, 739, 743 and 752).

2. The **medial part of the corpus restiforme** (see Fig. 739) consists in large part of the *direct sensory cerebellar path*, which passes from the terminal nuclei of the nn. glossopharyngeus, vagus, vestibularis and trigeminus to the nucleus of the roof and the cortex of the vermis. There are also descending paths which go partly directly by way of the *formatio reticularis* into the anterolateral funiculi of the spinal cord, in large part, however, indirectly, ending in Deiters' nucleus, from which a bundle descends to the lateral funiculus.



754. Position of the pyramidal tract (red), secondary optic radiation (orange), frontal pontile path (dark-brown), temporal pontile path (light-brown), auditory conduction path (yellow), primary optic radiation (violet), medial lemniscus (blue), brachium conjunctivum (green), cortical path from the [ventro]-lateral nucleus of the thalamus (blue), introduced into Fig. 748. (Held.)

3. The *arms of the pons*, *brachia pontis*, (O. T. middle cerebellar peduncles) arise in the cortex of the cerebellar hemispheres, and end in the nuclei pontis of the same and of the opposite side; paths in the opposite direction also exist. Further continuations are a) the *median descending pontile path* (see Figs. 729—732), which penetrates the tegmentum of the pons and hence in part descends to the spinal cord, in part ascends toward the corpora quadrigemina, as well as b) the *corticopetal fibers of the cerebropontile paths* (chiefly of the temporal).

4. The *connecting arms, brachia conjunctiva*, proceed chiefly from the nucleus dentatus (supplemented by paths from the nucleus fastigii and the cortex of the vermis) decussate in the raphe of the tegmentum, become connected by collaterals with the red nucleus, which, through its bundle to the lateral funiculus, innervates the opposite half of the spinal cord, and end in large part finally, together with the medial lemniscus, in the [ventro]lateral nucleus of the thalamus, whence the cortical path passes to the somaesthetic area (see Figs. 744, 752 and 754).

Connections of the cerebrum. (Held.) The white substance of the cerebrum contains 1. proper, endogenous conduction paths, the *association fibers*, which unite spatially separated and functionally non-equivalent gyri of the cortex with one another, 2. those which bring the cerebral cortex (or parts homologous with it: nucleus caudatus, putamen) into relation with the thalamus, the so-called corona radiata of the thalamus (*Stabkranz des thalamus*), 3. paths which connect the cerebral cortex with lower regions of the central nervous system (brain-stem, medulla oblongata, spinal cord) and which are contained in the stem bundles. The two latter form the system of *projection fibers* and include the sensory conduction paths as well as the motor paths which transfer the voluntary impulses of the cerebral cortex to the lower nuclei of origin of the individual muscle nerves.

I. The *associations fibers* are intercortical conduction paths, and as such unite either different gyri of the same hemisphere or of the two hemispheres. The latter are contained in the corpus callosum, the anterior commissure and the commissura hippocampi.

II. While the association fibers run more superficially beneath the cortex and follow its surface, the *radiation of the thalamus* presents a fan-like arrangement toward the depth. It is arranged in the gross in the form of the so-called *peduncles of the thalamus*, the anterior, superior, posterior and inferior peduncles converging from the frontal, parietal, occipital and temporal lobes respectively to the thalamus, and there forming, on its outer surface and on that of the nucleus caudatus, the capsula interna. Ascending and descending conduction paths are to be distinguished in this radiation (*Stabkranz*).

1. The *ascending conduction paths* of the radiation carry the different sensory paths to the sense centers of the cerebral cortex (see Figs. 752, 754—756).

a) from the [ventro]lateral nucleus of the thalamus to the cortex of the *somaesthetic area*; these are the continuations of the medial lemniscus, of the lateral areas of the formatio reticularis, and of the brachia conjunctiva (see Fig. 753). (A small part of the first mentioned goes directly through the thalamus without interruption.) They lie in larger part in the posterior third of the capsula interna (see Fig. 754), in smaller part also, after perforating or encircling the nucleus lentiformis from below, in the capsula externa (see Fig. 752).

b) Behind this the *auditory conduction path* emerges from the internal capsule; it runs transversely a little behind the free posterior margin of the nucleus lentiformis and passes directly lateralward to the cortex of the first temporal gyrus and of its insular transverse gyrus.

c) The *visual conduction path* (primary visual conduction path of Flechsig), emerging lateralward and below the pulvinar, runs straight occipitalward to the cortex about the fissura calcarina.

2. *Descending conduction paths.* They arise in general from the pyramidal cells of the cerebral cortex and end in part in the subcortical ganglia of the cerebrum or in the mid-brain. Here belong, among others

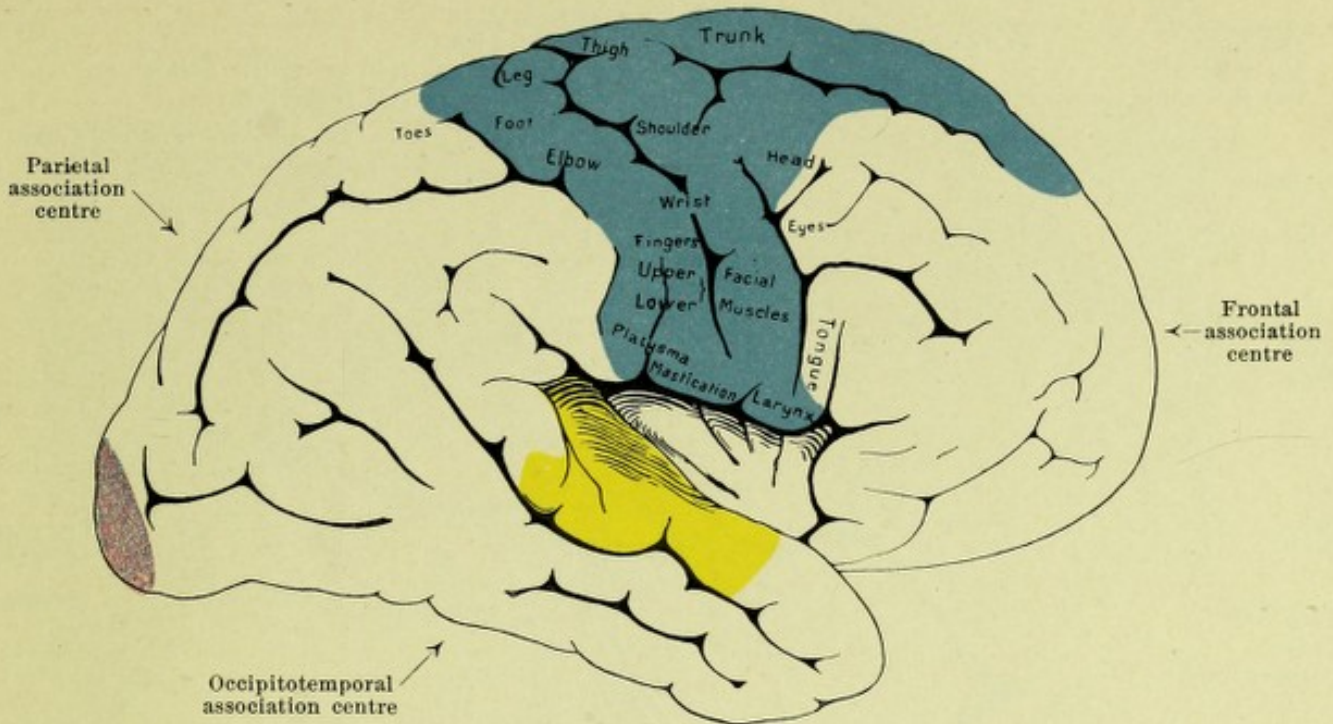
A) the part of the fornix which as the fimbria proceeds from the cortex of the hippocampus, and as the columna fornicis ends in the corpus mamillare of the same and of the opposite sides, whence the path is continued, partly as the *fasciculus thalamomamillaris* [*Vicq d'Azry*] to the anterior nucleus of the thalamus (see Figs. 720 and 745), partly as the *fasciculus tegmento-mamillaris* to the tegmentum of the base of the cerebral peduncle. Here belong also the secondary visual conduction path (see Figs. 752 and 754), which acts upon the superior colliculus.

B) Of the descending conduction paths of the cortex a large part passes through the capsula interna directly into the base of the cerebral peduncle and ends partly in the pons, partly not until the spinal cord is reached (see Figs. 734, 753 and 754).

a) *Frontal [cerebro]pontile path (Arnold's bundle).* It arises from the frontal layers of the somaesthetic area and ends in the gray matter of the pons. On its way it lies in the anterior (frontal) areas of the internal capsule, and farther down in the medial part of the base of the cerebral peduncle. Toward the pyramidal tract lie special motor conduction paths for the nuclei of the motor cerebral nerves (corticobulbar path).

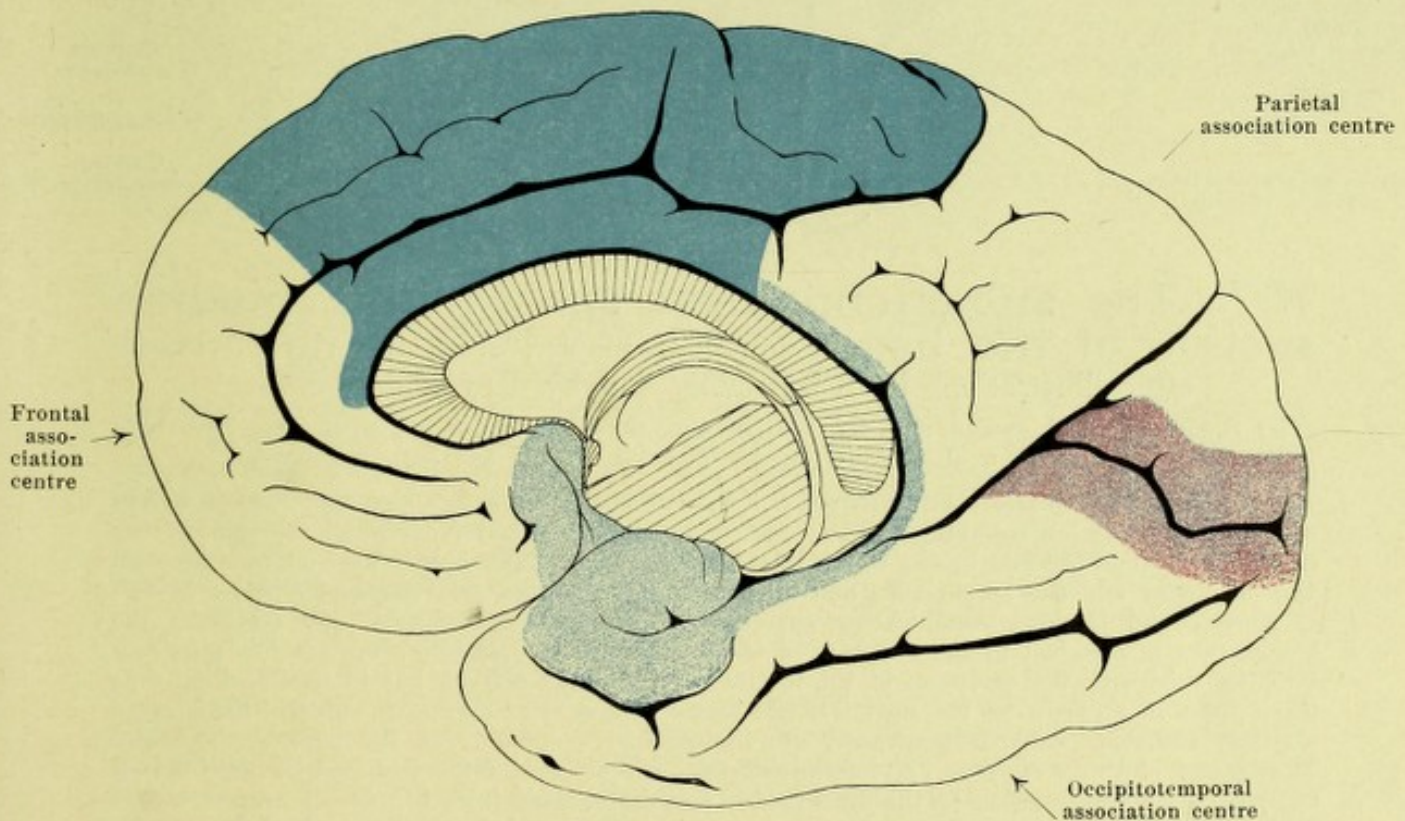
b) *Temporal [cerebro]pontile path (Türk's bundle).* It unites the temporal lobe with the pons. It lies in the most posterior part of the capsule, which it, together with the auditory conduction path, bounds; farther down, in the base of the cerebral peduncle, it lies lateral from the pyramidal tract.

c) *Pyramidal tract.* It arises in the central gyri of the somaesthetic area. Besides the motor fibers for the nuclei of the cerebral nerves, it carries also chiefly fibers for the motor anterior horns of the spinal cord. In the internal capsule the paths for the motor nerves of the upper extremity lie more frontalward and are separate from those for the lower extremity.



755. Convex surface.

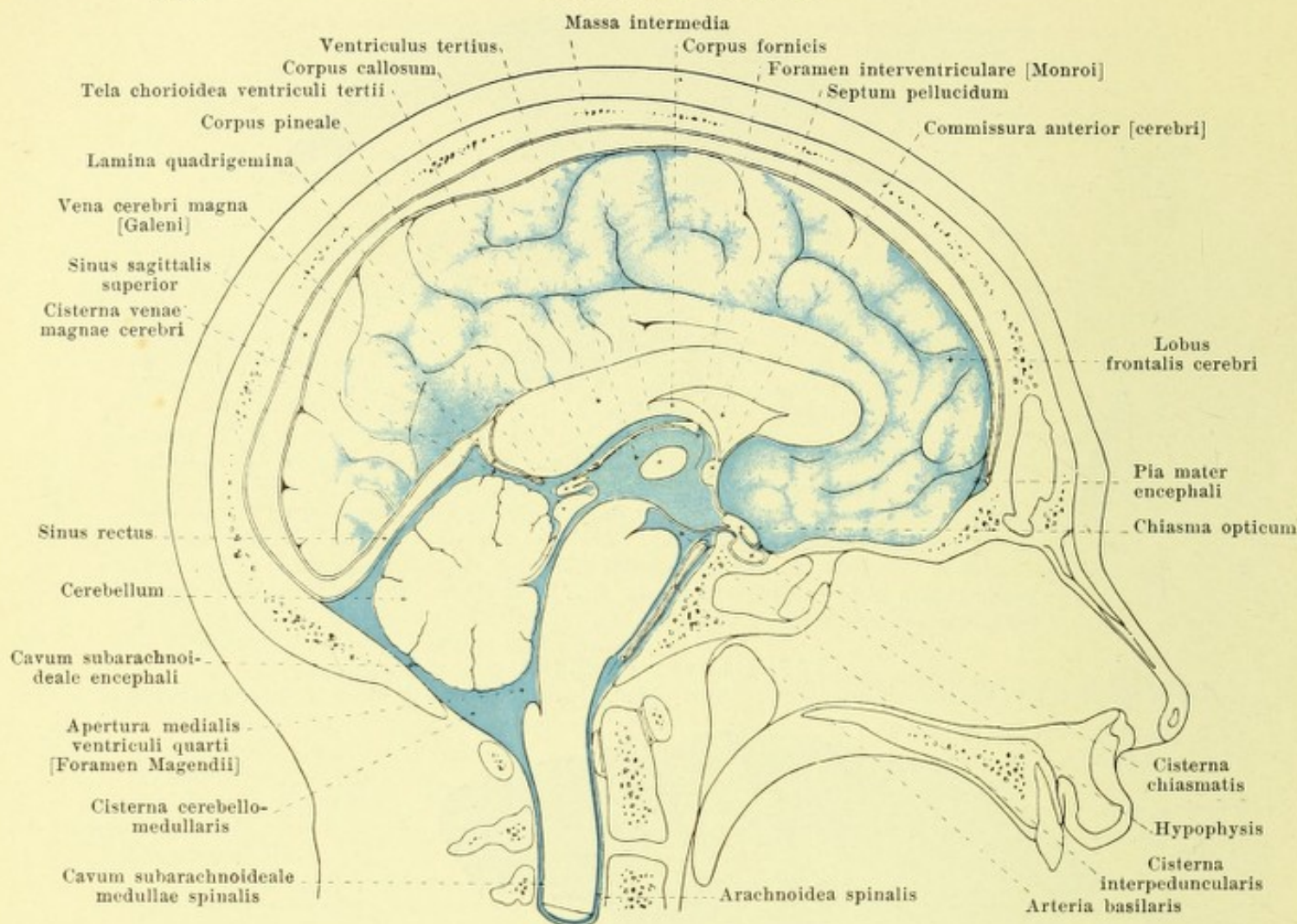
(The temporal lobe has been drawn away from the island, in order to expose its upper transverse gyri.)



756. Medial surface.

755 and 756. Motor and sensory cortical areas of the right cerebral hemisphere.

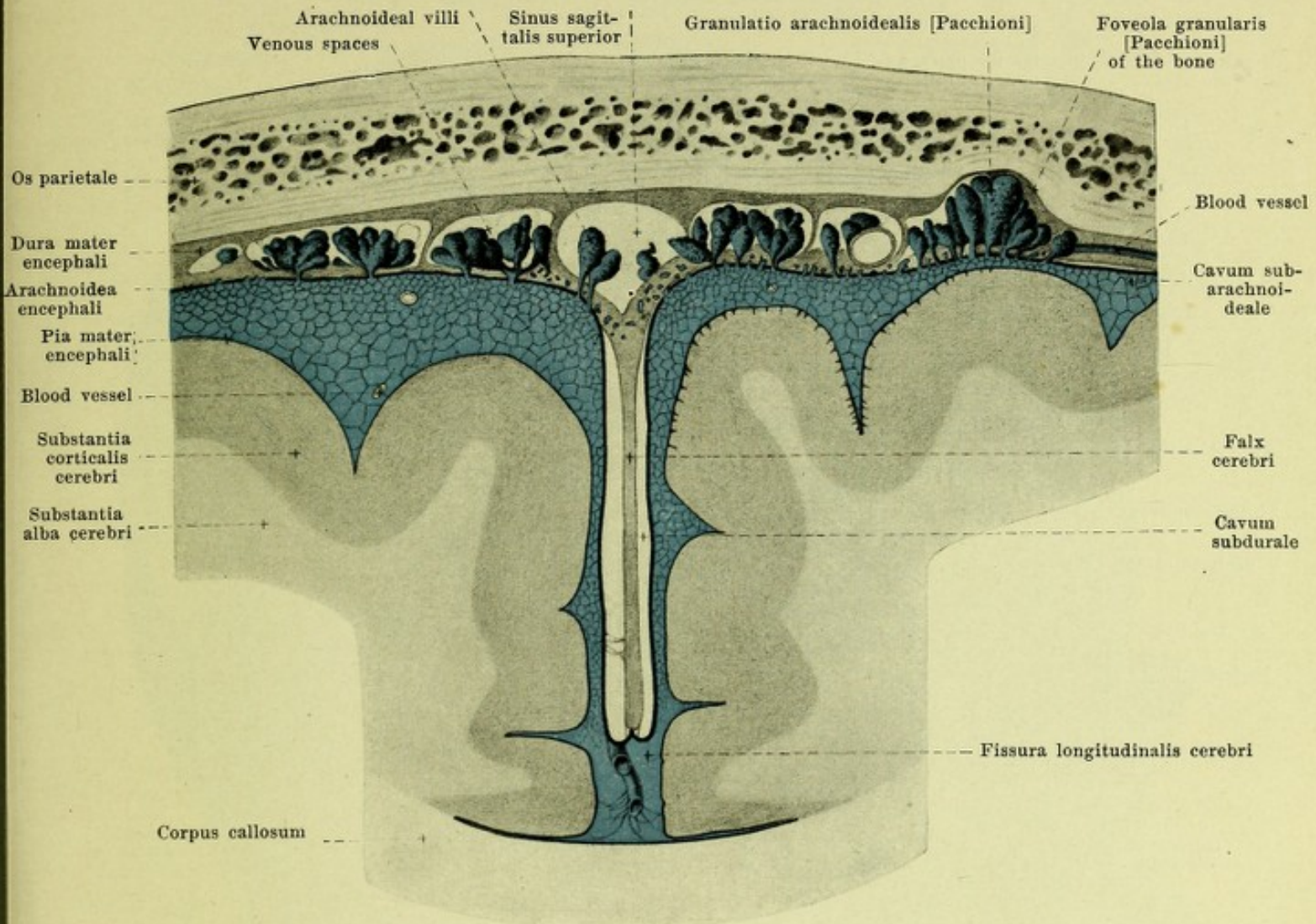
(Sense centres and association centres after P. Flechsig.) (For names of gyri, sulci, etc. see Figs. 706—709.) Somaesthetic area dark-blue, olfactory area light-blue, visual area violet, auditory area yellow, association centres white.



757. The subarachnoideal spaces in a median section of the head, left half viewed from the right. (Partly after illustrations by W. Braune, and by Key and Retzius.)

(The subarachnoideal spaces and the ventricles of the brain connected with them have been injected with a blue-colored mass. The falx cerebri has been removed.)

The *arachnoidea encephali* (*spider-web membrane*) (see also Fig. 758) is a very delicate non-vascular membrane loosely attached to the pia mater encephali (see p. 654) by numerous strands and membranes which transform the *cavum subarachnoideale* situated between the pia mater and the arachnoidea and filled with serous *liquor cerebrospinalis* into a system of smaller and larger communicating spaces. On the convex surface of the cerebrum the arachnoidea is attached to the summits of the gyri by shorter strands; it does not penetrate into the sulci with the exception of the fissura longitudinalis cerebri, but is stretched out over these from one gyrus to the next. Hence larger spaces arise over each sulcus. Still larger cavities, *cisternae subarachnoideales*, are to be found, especially at the base of the brain. The largest of these, *cisterna cerebellomedullaris*, arises through the fact that the arachnoidea encephali as a continuation of the arachnoidea spinalis extends from the dorsal surface of the medulla oblongata over the fissura transversa cerebelli (see p. 635) directly to the lower surface of the cerebellum. The arachnoidea does not even penetrate into the fissura transversa cerebri (see p. 637); hence in the neighborhood of the vena cerebri magna [Galen] arises the *cisterna venae cerebri magnae*, which extends far forward between the layers of the tela chorioidea ventriculi tertii (see p. 654). From the anterior surface of the medulla oblongata the arachnoidea stretches in front of the pons and the brachia pontis lateralward as far as the surface of the cerebellum, then, passing out from the upper margin of the pons bridges over the corpora mamillaria and their neighborhood (see Fig. 705) to reach the temporal lobes lateralward and the frontal lobes forward, in front of the chiasma opticum.

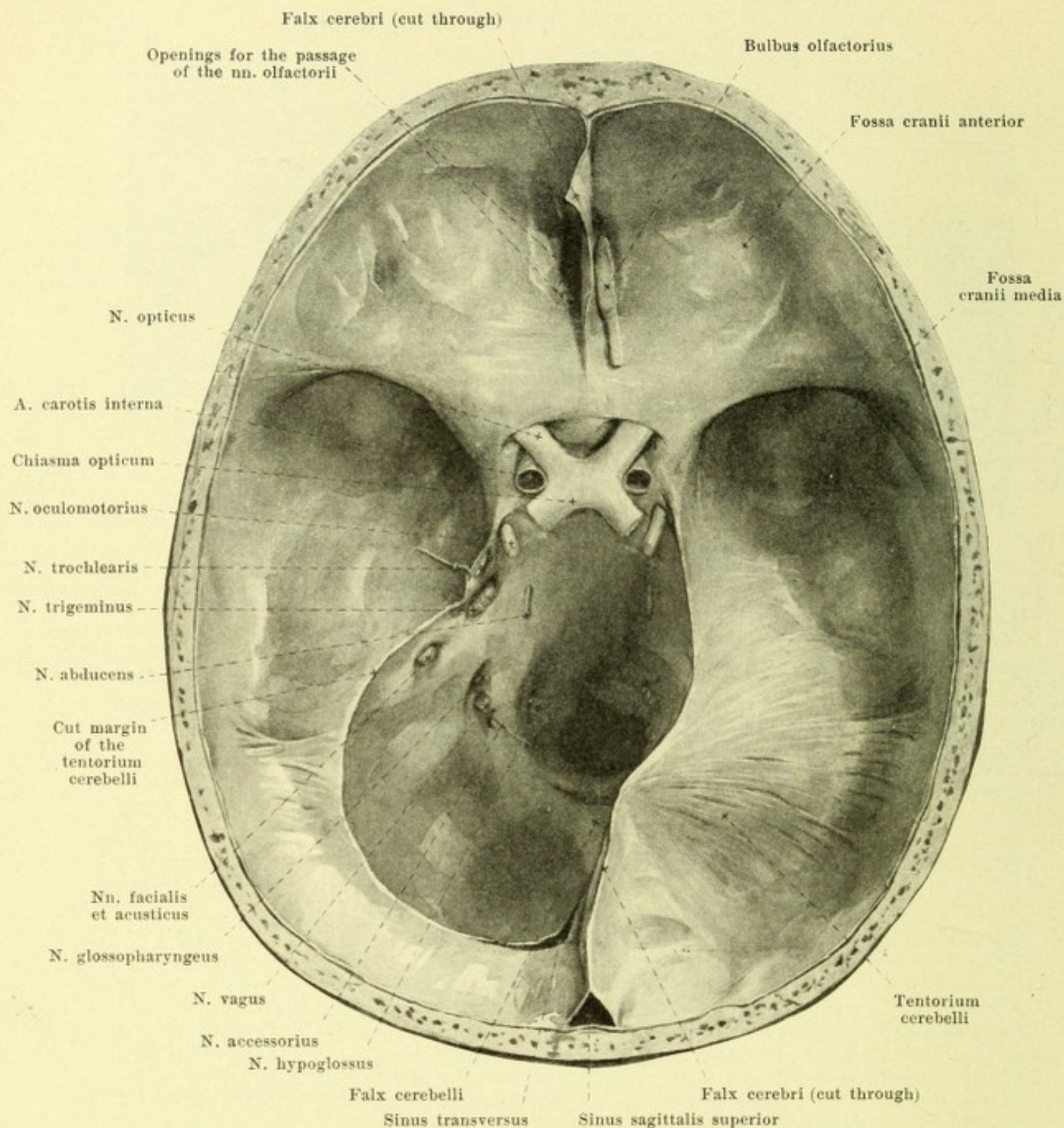


758. Frontal section through the skull, meninges and brain (after Key and Retzius).

(The subarachnoideal spaces have been injected with a blue-colored mass.) Magnification $2\frac{1}{2}:1$.

Arachnoidea encephali (continued) (see also Fig. 757). There thus arises a large subarachnoideal space, through which pass the a. basilaris, the tractus optici and the beginnings of the cerebral nerves; the portion situated behind the infundibulum is called the *cisterna interpeduncularis*, that below and in front of the chiasma opticum the *cisterna chiasmatis* (see Fig. 757). Adjacent to these lateralward on each side is the *cisterna fossae cerebri lateralis* [Sylvii] (not illustrated), which owes its origin to the fact that the arachnoidea does not penetrate into the depth of the fissura cerebri lateralis, but stretches out directly from the surface of the temporal lobe to that of the frontal lobe.

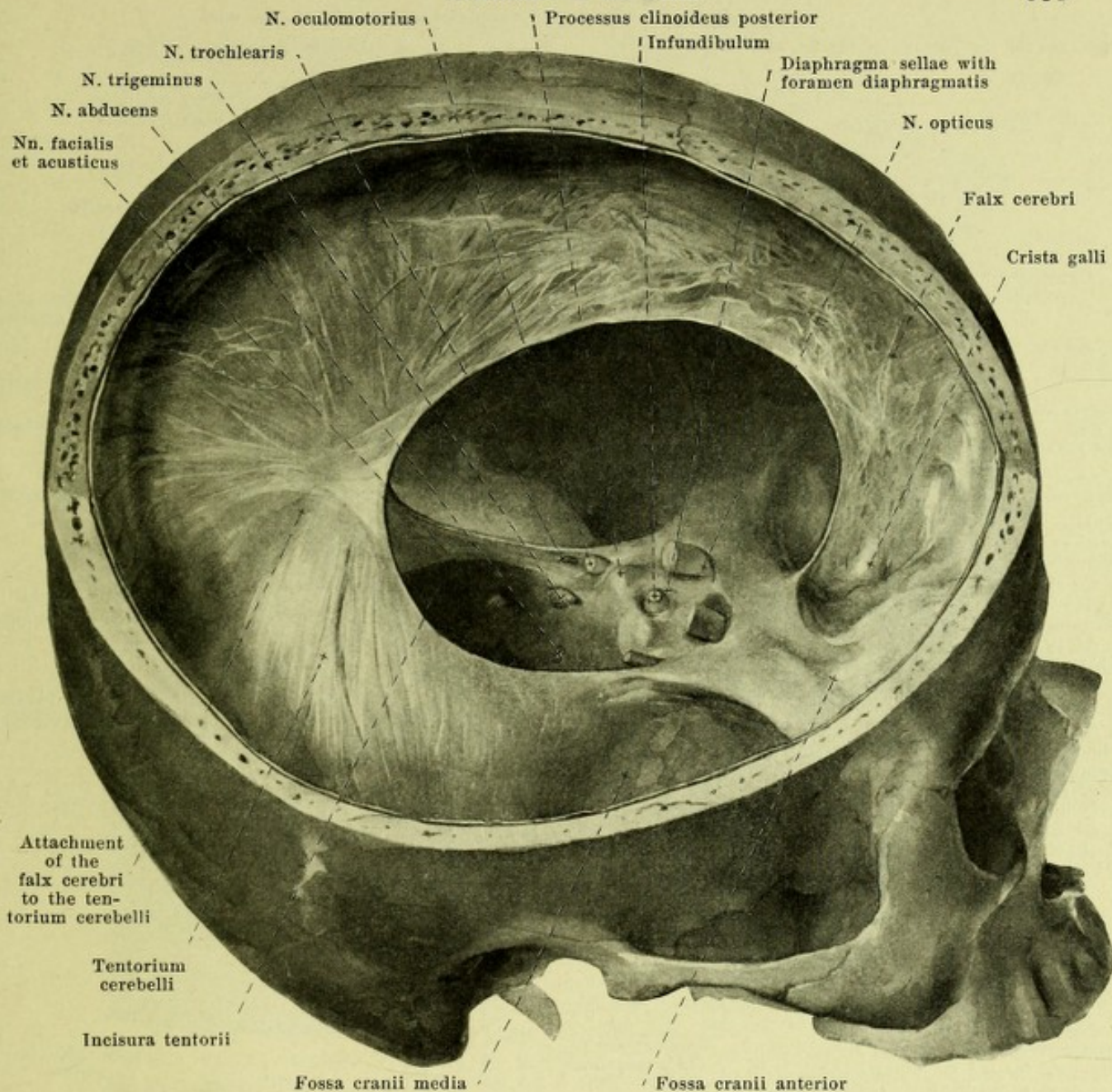
Projecting from the surface of the arachnoidea encephali are numerous grayish-red villus-like appendages (*arachnoideal villi*), varying in size from that of a millet-seed to that of a grain of wheat, which are united as a rule in groups as the *granulationes arachnoideales* [Pacchioni]. They are remarkably variable, are absent in early childhood, usually appear in the tenth year of life, are regularly present in the adult, and especially abundant in old age; they are less developed in woman than in man. They are attached to the arachnoidea by delicate pedicles in the form of flask-like outgrowths, and contain within them a network of connective tissue strands as well as of subarachnoideal spaces. They penetrate the dura mater and project into the sinuses or into venous spaces with which these communicate. They can become so large that the bone opposite them is absorbed and becomes deepened to form a *foveola granularis* [Pacchioni]. They are most numerous and largest in front at the sinus sagittalis superior and in its neighborhood, especially in the middle portion; they are smaller and less numerous at the pole of the temporal lobe, as well as on the cerebellar surface of the sinus rectus, sinus transversus and sinus petrosus superior.



759. Dura mater, viewed from above.

(The falx cerebri has been almost completely removed, the tentorium cerebelli on the left side only.)

The *dura mater encephali* (*hard membrane of the brain*) (see also Figs. 760 and 761), a white, tough, connective tissue membrane, glistening like tendon, lines the cavity of the skull like a periosteum. In children it is everywhere firmly attached to the bone, but in the adult is intimately attached only in the region of the base of the skull and at the cranial sutures, being elsewhere united with it only loosely by means of numerous connective tissue threads; in the latter places a capillary lymph space, *cavum epidurale*, exists between it and the bone. The inner surface of the dura mater is smooth and is separated from the outer, likewise smooth surface of the arachnoidea encephali, by a capillary slit, *cavum subdurale*, which is lined on all sides by endothelium and contains only a very small amount of fluid (see Fig. 758).

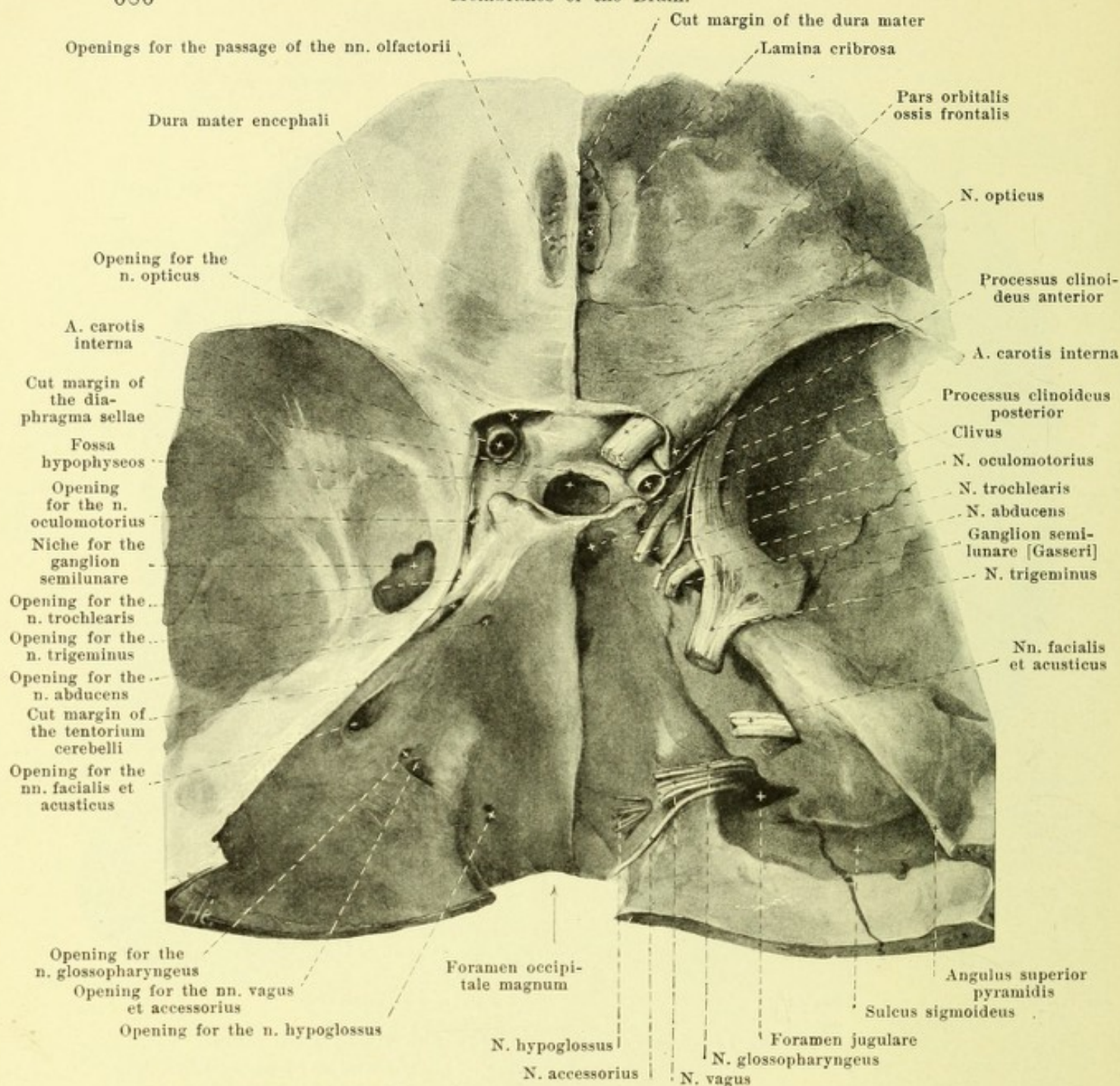


760. Dura mater, viewed from the right and above.

(A sector of the skull has been removed on the right side by a horizontal and a sagittal saw-cut.)

Dura mater encephali (continued) (see also Figs. 759 and 761). The dura mater completely lines the depth of the fossa hypophyseos, spreads out above the same between the tuberculum sellae and the upper margin of the dorsum sellae as *diaphragma sellae*, and there presents only a small opening, *foramen diaphragmatis [sellae]*, for the passage of the infundibulum. It then runs lateralward on each side and stretches out from the processus clinoides anterior and from the processus clinoides posterior to the angulus superior pyramidis (lateral from the impressio trigemini); thence it passes, behind, downward to the clivus and to the facies posterior pyramidis, lateralward, however, obliquely downward to the middle cranial fossa (lateral from the foramen rotundum and foramen ovale), and thus helps to enclose a large space (see Figs. 482 and 761), in which are situated the a. carotis interna, the sinus cavernosus, the n. oculomotorius, n. trochlearis, n. trigeminus along with its ganglion semilunare and its branches, as well as the n. abducens. The dura mater possesses three tough processes:

1. The *tentorium cerebelli (cerebellar tent)* (see also Figs. 484 and 759) goes off on each side in transversal direction from the angulus superior pyramidis and from the horizontal portion of the sulcus transversus, is sickle-shaped and in the middle elevated like the ridge of a roof; by its anterior, deeply notched margin it bounds the *incisura tentorii*. The occipital lobes of the cerebrum rest upon its upper surface.



761. Passage of nerves through the dura mater and the skull.

(On the right side the dura mater has been completely removed, on the left the tentorium cerebelli has been cut away at the temporal bone and the niche for the ganglion semilunare opened.)

Dura mater encephali (continued). 2. The *falx cerebri* (cerebral sickle) (see Figs. 484, 750 and 760), a septum increasing in height from before backward, penetrates from above in the median plane between the two cerebral hemispheres. It is attached to the crista galli, to the crista frontalis and at the sulcus sagittalis as far as the protuberantia occipitalis interna to the bone, fuses behind with the ridge-like edge of the tentorium cerebelli, and possesses below a concave margin which does not reach down as far as the corpus callosum of the brain (see Fig. 758). 3. The *falx cerebelli* (cerebellar sickle) (see Fig. 759) arises behind on the bony ridge which passes from the protuberantia occipitalis interna to the foramen occipitale magnum, is shoved in from behind as a low plate into the incisura cerebelli posterior, and ends in front with a concave margin; above it is united with the under surface of the tentorium cerebelli and below it runs out into two diverging low folds, which grasp the foramen occipitale magnum from behind.

762. Right ganglion semilunare [Gasseri],

viewed from the medial side,

Magnification 2 : 1.

Twelve pairs of **nervi cerebrales, cerebral nerves**, go off from the brain. Of these, three (nn. olfactorii, optici, acustici) are pure sensory nerves, six (nn. oculomotorii, trochleares, abducentes, faciales, accessorii, hypoglossi) pure motor, three (nn. trigemini, glossopharyngei, vagi) mixed in nature.

I. **Nervi olfactorii, olfactory nerves** (see Figs. 767 and 768) are sensory nerves, of which approximately twenty non-medullated threads of different size on each side, leave the inferior surface of the bulbus olfactorius and arrive in the

nasal cavity through the openings of the lamina cribrosa of the ethmoid bone. As they go they become ensheathed with processes of the meninges and of the subarachnoideal spaces, divide into a lateral row which passes to the regio olfactoria of the lateral wall of the nose, and a medial row which goes to that of the nasal septum; they anastomose with one another and multiply in the lower part of their course. Their domain of distribution does not extend lateralward beyond the middle of the upper concha, and medianward it is of similar extent (see Fig. 925).

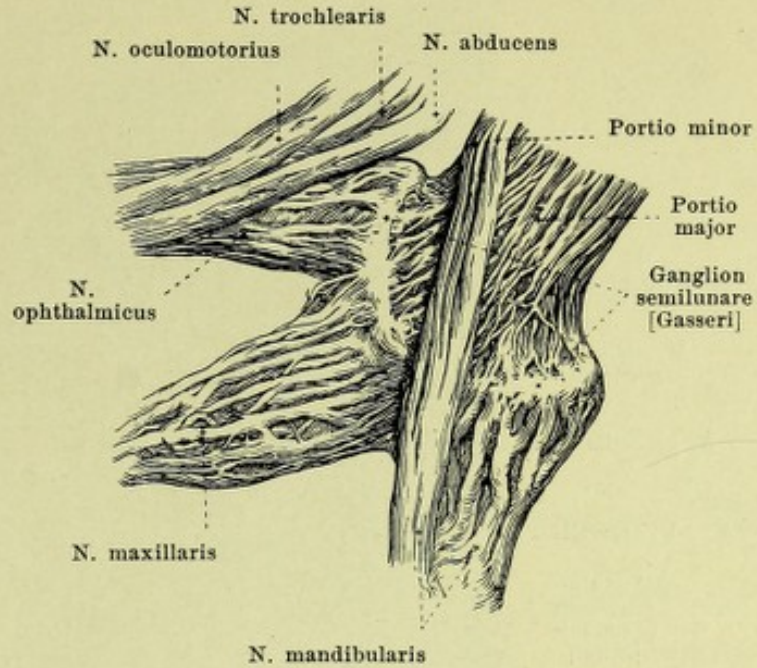
II. **N. opticus, visual nerve** (see Figs. 705, 759, 761, 764, 861 and 866) is a sensory nerve, but it is not comparable with the other cerebral nerves, since from its development and architecture it belongs to the brain and must be looked upon as a central intracerebral cord. It proceeds on each side from the anterior angle of the chiasma opticum (see p. 645) and, somewhat flattened, runs obliquely lateralward and forward to the foramen opticum, passes through this as a round cord along with a. ophthalmica (see p. 397) and then extends obliquely to the posterior surface of the eye-ball (see p. 771). It forms a slightly S-shaped curve in the horizontal direction, so as to be convex behind and lateralward and in front and medianward; it presents a slight bayonet-like curve in the vertical direction and is surrounded by sheet-like processes of the meninges, and of the subdural and subarachnoideal spaces.

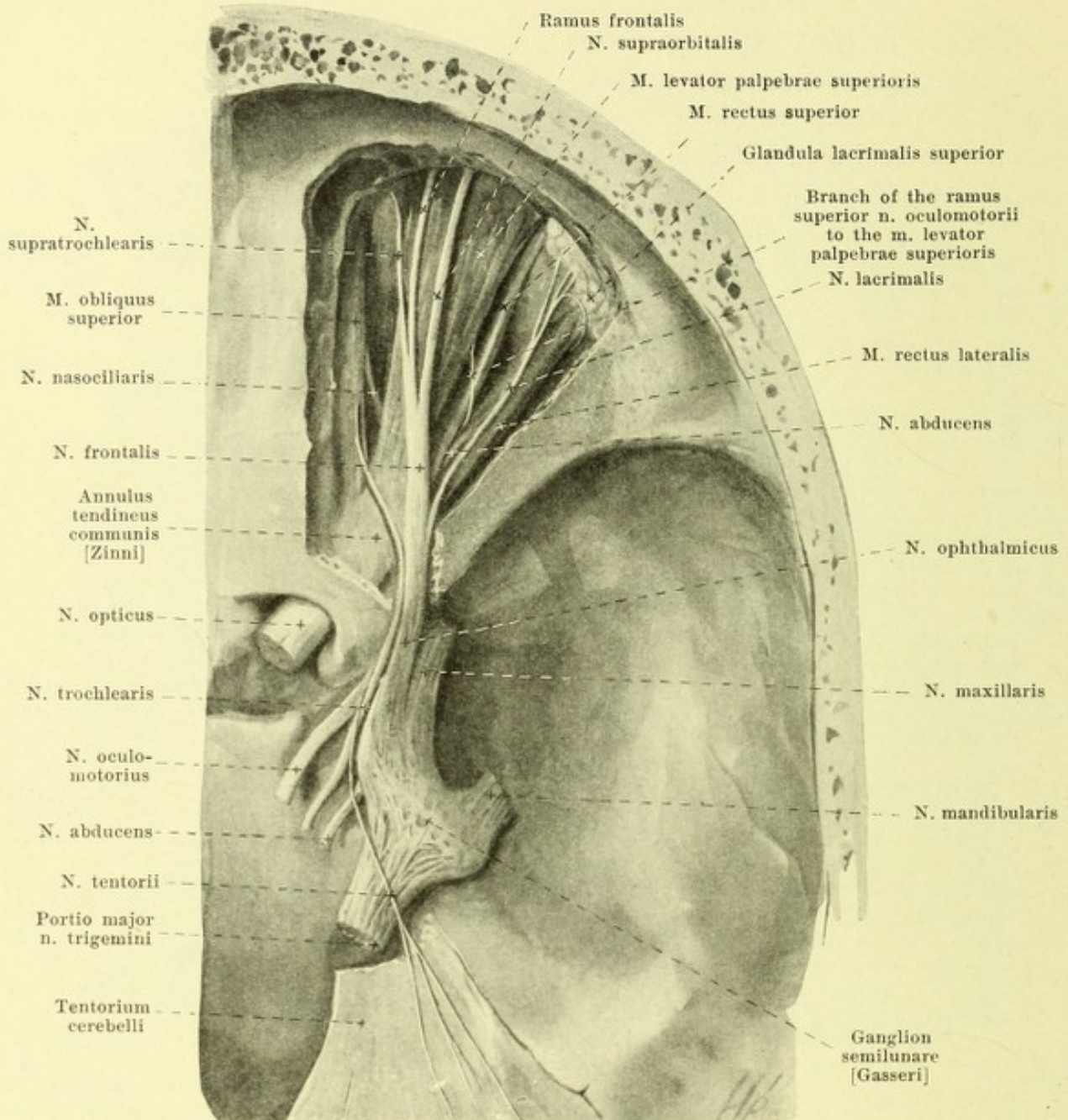
III. **N. oculomotorius** (see Figs. 695, 696, 705, 712, 759—761, 763—765 and Organ of Vision), motor, emerges by a medial group of (on the average) eight flat bundles from the sulcus n. oculomotorii (see p. 636) and by a very variable but approximately as large posterior lateral group, from the ventral surface of the cerebral peduncle (see Figs. 695 and 696). The root bundles converge and form a round cord, which passes forward and lateralward between the a. cerebelli superior and a. cerebri posterior (see Fig. 444), and perforates the dura mater lateral from the processus clinoides posterior (see Figs. 759—761). It then runs forward and a little downward in the lateral wall of the sinus cavernosus (see Fig. 482), lateralward from the a. carotis interna; in this course it lies at first over the n. trochlearis and the n. ophthalmicus and is then crossed on its lateral surface by both of these, so that finally it reaches the fissura orbitalis superior below them, and passes within the annulus tendineus communis [Zinni] (see Figs. 761, 763—765, 857 and 858). There it divides immediately into two branches, a smaller, *ramus superior*, and a larger, *ramus inferior*.

a) *Ramus superior* (see Figs. 763 and 765) passes forward and upward lateral from the a. ophthalmica and from the n. opticus to the mm. rectus superior and levator palpebrae superioris.

b) *Ramus inferior* (see Figs. 764 and 765) divides into a branch which runs under the n. opticus to the m. rectus medialis, a short branch to the m. rectus inferior, and a long branch which passes along the lateral margin of the m. rectus inferior to the m. obliquus inferior. A short, thick thread, *radix brevis ganglii ciliaris*, runs from the latter to the posterior inferior part of the ganglion ciliare (see p. 690).

Anastomoses: in the sinus cavernosus it receives sympathetic fibres from the plexus cavernosus, and sometimes anastomoses in the fissura orbitalis superior with the n. ophthalmicus (V).



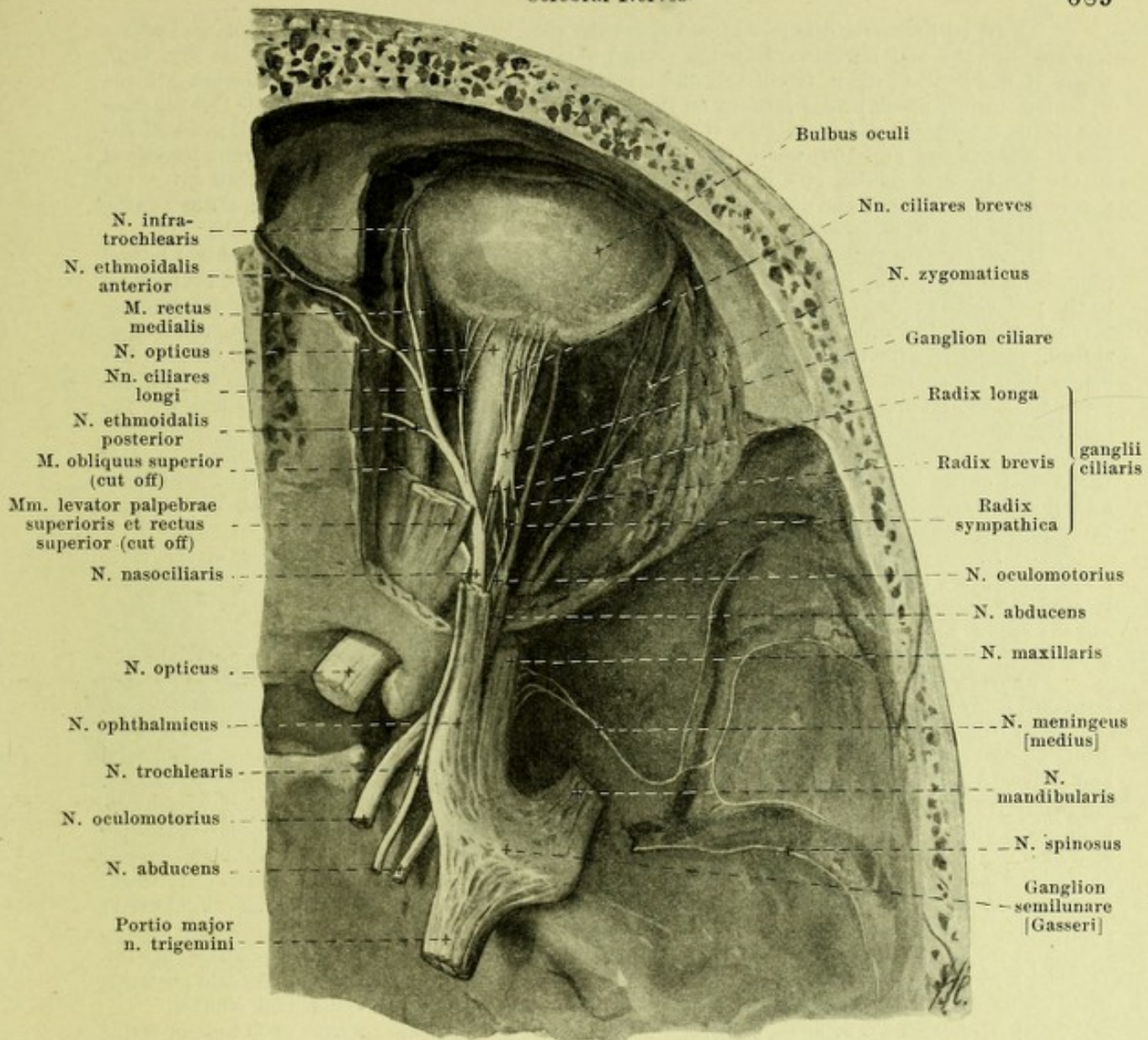


763. Nerves of the right orbital cavity, viewed from above, 1st layer.

(The roof of the orbit has been removed and the fissura orbitalis superior partly exposed. The dura mater and the upper layer of the tentorium cerebelli have been dissected away.)

IV. N. trochlearis (see also Figs. 696, 697, 702, 704, 705, 759—762, 765, 775, 857, 858, 861—863), motor, leaves the brain (see Fig. 704) on each side near the frenulum veli medullaris anterioris (see p. 635), runs (see Figs. 696, 697, 702, 704 and 705) as a delicate, curved cord along the upper margin of the pons, around the pedunculus cerebri, forward and perforates the dura mater lateral from the n. oculomotorius and below the most anterior jag of origin of the tentorium cerebelli (see Figs. 759—761). It then passes forward in the lateral wall of the sinus cavernosus (see also Fig. 444) under the n. oculomotorius and over the n. ophthalmicus, then crosses the former on its lateral side, goes through the fissura orbitalis superior outside the annulus tendineus communis [Zinni] (see also Figs. 857 and 858) and extends over the origin of the m. levator palpebrae superioris obliquely forward and medianward to the m. obliquus superior.

Anastomoses: In the sinus cavernosus it receives sympathetic fibers from the plexus cavernosus and usually anastomoses with the n. ophthalmicus (V).



764. Nerves of the right orbital cavity, viewed from above, 2nd layer.

(Same preparation as in Fig. 763. In addition most of the eye muscles and the lateral wall of the orbit have been removed; the foramen ethmoidale anterius has been opened. The nn. meningeus and spinosus have been introduced according to *F. Arnold*.)

V. N. trigeminus (see also Figs. 696, 697, 702, 705, 759—763, 765—772 and 775), a mixed nerve, makes its appearance on the anterior surface of the pons (see p. 631) with two roots, the thick, sensory *portio major* and the thin, motor *portio minor*; the site of emergence of the round *portio minor* is somewhat rostral and dorsal from that of the flattened *portio major* (see Figs. 696, 697, 702 and 705). The *portio minor* loops around the medial margin of the *portio major* to its under surface; both pass forward and upward and perforate the dura mater beneath the line of departure of the tentorium cerebelli (and beneath the sinus petrosus superior) over the impressio trigemini of the pyramid of the temporal bone (see Figs. 759—761). Immediately in front of this spot, in a blind sack-like protrusion of the dura mater (see Fig. 761) the *portio major* becomes broader and goes over into the flat, sickle-shaped *ganglion semilunare [Gasseri]* (see also Figs. 705, 761—763 and 765); this lies adjacent to the a. carotis interna, lateral from the sinus cavernosus, over the foramen lacerum, or is separated from the artery by a thin layer of bone. On its under surface lie the nn. petrosi superficiales. The *portio minor* runs, on the inferior surface of the ganglion and without forming a nervous connection with it, to the n. mandibularis (see Figs. 705 and 762). The convexity of the ganglion is directed forward and downward, and from it diverge three branches: n. ophthalmicus, n. maxillaris and n. mandibularis.

a) *N. ophthalmicus* (see Figs. 761—765), sensory, the smallest branch, flattened, passes forward, upward and lateralward in the lateral wall of the sinus cavernosus (see also Fig. 482), where it lies beneath the n. trochlearis and lateral from the n. abducens, at first also beneath the n. oculomotorius, which passes forward on its medial side; it receives fine sympathetic threads from the plexus cavernosus and usually anastomoses with the n. trochlearis. In the sinus it gives off the fine *n. tentorii* (see Fig. 763) which passes at first close to the n. trochlearis, then runs backward to the tentorium cerebelli, and in it as far as the sinus. The n. ophthalmicus then enters the fissura orbitalis superior and divides, usually before its entrance, into three branches: *n. lacrimalis*, *n. frontalis* and *n. nasociliaris*.

1. *N. lacrimalis* (see Figs. 763, 766, 857, 858, 861—863), the finest branch, passes lateral from the n. frontalis (and annulus tendineus communis [Zinni]) into the orbital cavity, and runs close to the periorbita and over the m. rectus superior to the upper lacrimal gland, some threads passing through this to the connective tissue and skin at the lateral angle of the eye; a fine connecting thread, *ramus anastomoticus cum n. zygomatico* (see Fig. 766), on the lateral wall of the orbit brings to it the secretory fibers for the lacrimal gland, which are believed to arise from the n. intermedius, to extend from the ganglion geniculi through the n. petrosus superficialis major to the ganglion sphenopalatinum and to pass from this into the n. maxillaris and the n. zygomaticus.

2. *N. frontalis* (see Figs. 763, 765, 774, 857, 858, 861—864), the thickest branch, enters the orbital cavity lateral from the annulus tendineus communis [Zinni] between the n. trochlearis and the n. lacrimalis, runs forward over the m. levator palpebrae superioris and divides into the following branches:

α) *N. supraorbitalis*, the largest of them, goes forward in the direction of the main trunk and passes through the foramen supraorbitale (or the incisura supraorbitalis) to the forehead. It supplies numerous large branches to the skin of the forehead as far back as the vertex and some smaller branches to the skin and connective tissue of the upper eyelid. One branch, running at the upper margin of the orbital cavity, unites with a branch of the n. facialis.

β) *Ramus frontalis*, forward and somewhat medianward to the incisura frontalis (or foramen frontale); it is distributed medial from the n. supraorbitalis and like it, to the forehead and upper eyelid.

γ) *N. supratrochlearis*, the finest branch, extends forward and medianward on the roof of the orbita and over the trochlea m. obliqui superioris to the upper eyelid, the root of the nose and the medial and inferior regions of the forehead. In front of the trochlea it anastomoses with the n. infratrochlearis.

3. *N. nasociliaris* (see Figs. 763—765, 857, 858, 861—863) enters the orbit within the annulus tendineus communis [Zinni] (see also Organ of Vision), runs at first between the m. rectus superior and the n. opticus forward and medianward, then forward between the mm. obliquus superior and rectus medialis and divides into the n. ethmoidalis anterior and n. infratrochlearis. Branches:

α) *Radix longa ganglii ciliaris*, slender, arises usually while still outside the orbital cavity and passes on the lateral side of the n. opticus and of the a. ophthalmica to the ganglion ciliare.

β) *Nn. ciliares longi*, usually two, on the medial side of the n. opticus to the eye-ball (see p. 778).

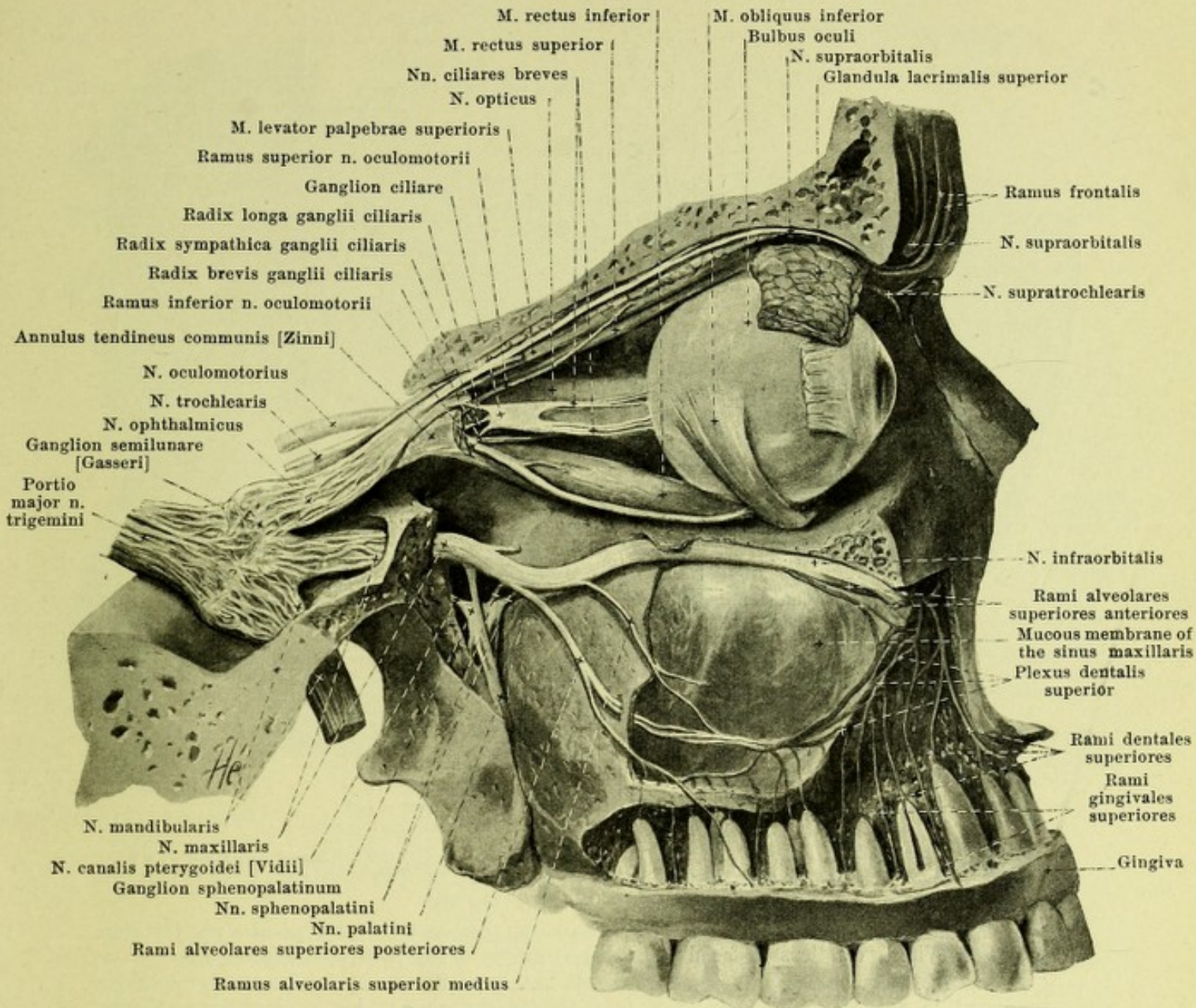
γ) *N. ethmoidalis posterior*, very fine, passes through the foramen ethmoidale posterius to the mucous membrane of the posterior ethmoidal cells and of the sphenoidal sinuses.

δ) *N. ethmoidalis anterior* goes through the foramen ethmoidale anterius upon the upper surface of the lamina cribrosa, then perforates the latter and divides into several *rami nasales anteriores*. Of these, the *rami nasales interni* go to the mucous membrane of the anterior part of the septum (*rami nasales mediales*, see Fig. 768) and to the lateral wall of the nasal cavity (*rami nasales laterales*, see Fig. 797); the *ramus nasalis externus* (see Fig. 797) runs first behind the spina frontalis, then in the sulcus ethmoidalis of the nasal bone, passes outward between the nasal bone and the nasal cartilage, and supplies the skin of the tip of the nose and of the alae nasi (see Fig. 774).

ε) *N. infratrochlearis* passes forward under the m. obliquus superior and divides (see Fig. 774) under its trochlea into a *ramus palpebralis superior*, which helps to supply the eyelids and usually anastomoses with the n. supratrochlearis, and a *ramus palpebralis inferior* to the tear-sac, caruncula lacrimalis, eyelids and nose.

Ganglion ciliare (see Figs. 764 and 765), a sympathetic ganglion, lies as a small, oblong, flattened disc, on the lateral surface of the n. opticus. At its posterior margin it is united 1. at the inferior angle with the n. oculomotorius by means of the short, thick *radix brevis* (see p. 687), 2. at the upper angle with the n. nasociliaris (vide supra) by the long, delicate *radix longa*, and 3. with the plexus cavernosus by the delicate *radices sympathicae*. From its anterior margin 3—6 *nn. ciliares breves* go to the eyeball (see p. 778).

b) *N. maxillaris* (O. T. superior maxillary) (see Figs. 764—768), sensory, flattened, passes forward in the lateral wall of the sinus cavernosus (see also Fig. 482), to the foramen rotundum, runs through this as a round cord, extends obliquely forward, lateralward and downward through the uppermost part of the fossa pterygopalatina over the a. maxillaris interna to the sulcus and canalis infraorbitalis and from there on is known as the *n. infraorbitalis*. Within the skull cavity it gives off the fine *n. meningeus [medius]* (see Fig. 764), which passes lateralward to the anterior branch of the a. meningeus media, breaks up in the dura mater in its neighborhood and anastomoses with the n. spinosus (see p. 695). Outside the skull cavity the following branches are given off:



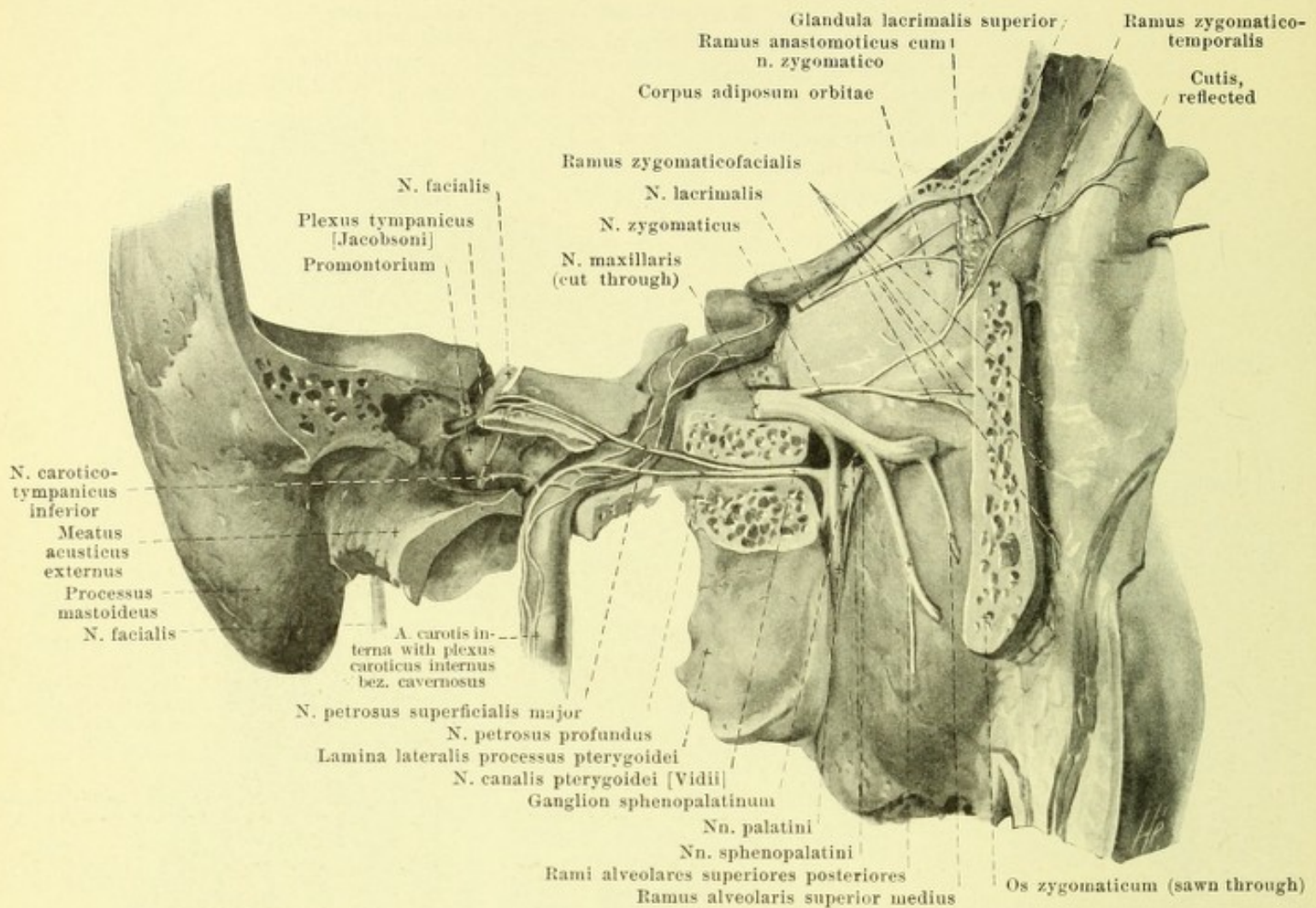
765. Nerves of the right orbital cavity and of the upper jaw, viewed from the right.

(The great wing of the sphenoid and the lateral wall of the orbit have been completely removed; the upper wall of the orbit and the wall of the upper jaw have been partly removed; the m. rectus oculi lateralis has also been removed.)

1. *N. zygomaticus* (see Figs. 764 and 766) arises as a small branch from the upper margin within the fossa pterygopalatina, runs lateralward in the connective tissue closing the fissura orbitalis inferior, as far as its end, then enters the orbital cavity, passes forward along the lateral wall of the same, and divides into two branches:

a) Ramus zygomaticotemporalis, the upper of the two, gives off a fine communicating thread to the n. lacrimalis (see p. 690), passes through a foramen zygomaticoorbitale into the yoke-bone, and leaves this again through the foramen zygomaticotempore; it thus arrives in the temporal fossa, and thence, usually divided into two branches, extends over the upper margin of the yoke-bone, through the fascia temporalis to the skin of the temporal region (see Figs. 766 and 774). It anastomoses manifoldly with its own twigs or with those of neighboring branches and varies much in its distribution.

β) Ramus zygomaticofacialis, sometimes doubled, runs from a foramen zygomaticoorbitale to the foramen zygomaticofaciale through a canaliculus of the yoke-bone to the facies malaris of the latter and spreads out in the skin in the anterior part of the yoke-bone region and at the lateral angle of the eye (see Figs. 766, 770 and 774).



766. Right nervus canalis pterygoidei [Vidii], viewed from the right.

(The lateral wall of the orbit has been for the most part removed; the canales pterygoideus [Vidii], caroticus et facialis and the tympanic cavity have been exposed.)

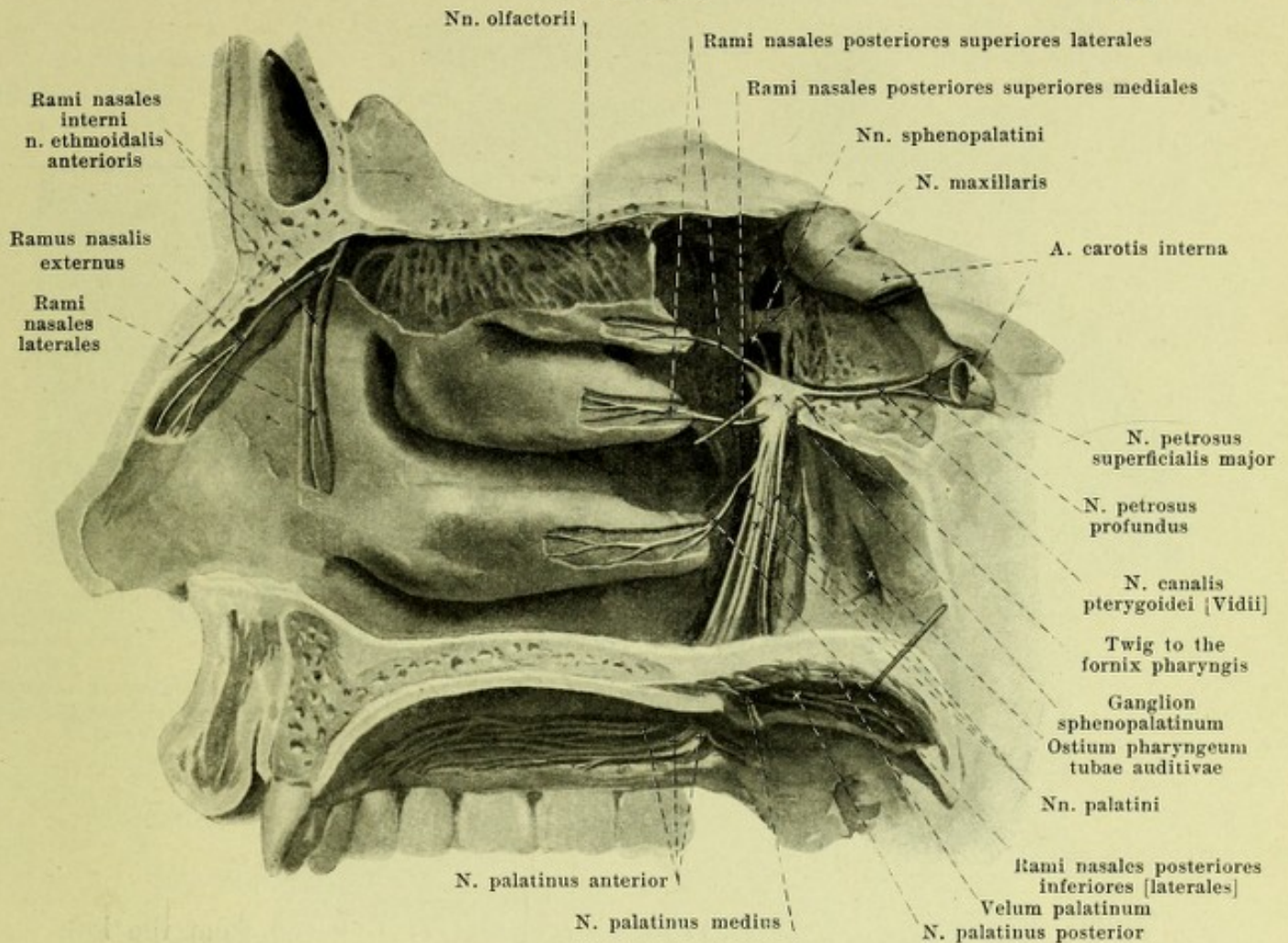
2. *Nn. sphenopalatini* (see also Figs. 765 and 767), two or three, sometimes single, go downward in the fossa pterygopalatina from the lower margin of the n. maxillaris. A very small part of their fibers, sometimes interwoven, enters the ganglion sphenopalatinum; the largest part, however, passes on its lateral surface or in front of it and goes over directly into the rami orbitales, rami nasales posteriores and nn. palatini, which are usually designated as branches of the ganglion (see p. 694).

3. *Nn. alveolares superiores* (see also Fig. 765) arise partly from the n. maxillaris, partly from the n. infraorbitalis (see p. 690).

a) *Rami alveolares superiores posteriores*, usually two, arising a little before the entrance into the orbit, run downward and forward upon the facies infratemporalis maxillae and pass through the foramina alveolaria into the canales alveolares and help to form the plexus dentalis superior (vide infra).

β) *Ramus alveolaris superior medius* is given off from the n. infraorbitalis in the posterior part of the canalis infraorbitalis and passes downward and forward in a special bony canal of the lateral wall of the maxilla to the middle part of the plexus dentalis superior (vide infra).

γ) *Rami alveolares superiores anteriores* given off from the n. infraorbitalis close behind the foramen infraorbitale, run downward in the canales alveolares of the anterior wall of the maxilla. With the other rami alveolares within the canales alveolares they form a plexus, *plexus dentalis superior*, which is curved so as to be convex downward; it anastomoses with that of the other side. From it arise *rami dentales superiores* to the roots of the individual teeth, *rami gingivales superiores* to the gums, as well as branches to the bone and to the mucous membrane of the sinus maxillaris.



767. Nerves of the right lateral wall of the nose.

(The fossa pterygopalatina and the canales palatini have been exposed; the body of the sphenoid bone has been partly removed.)

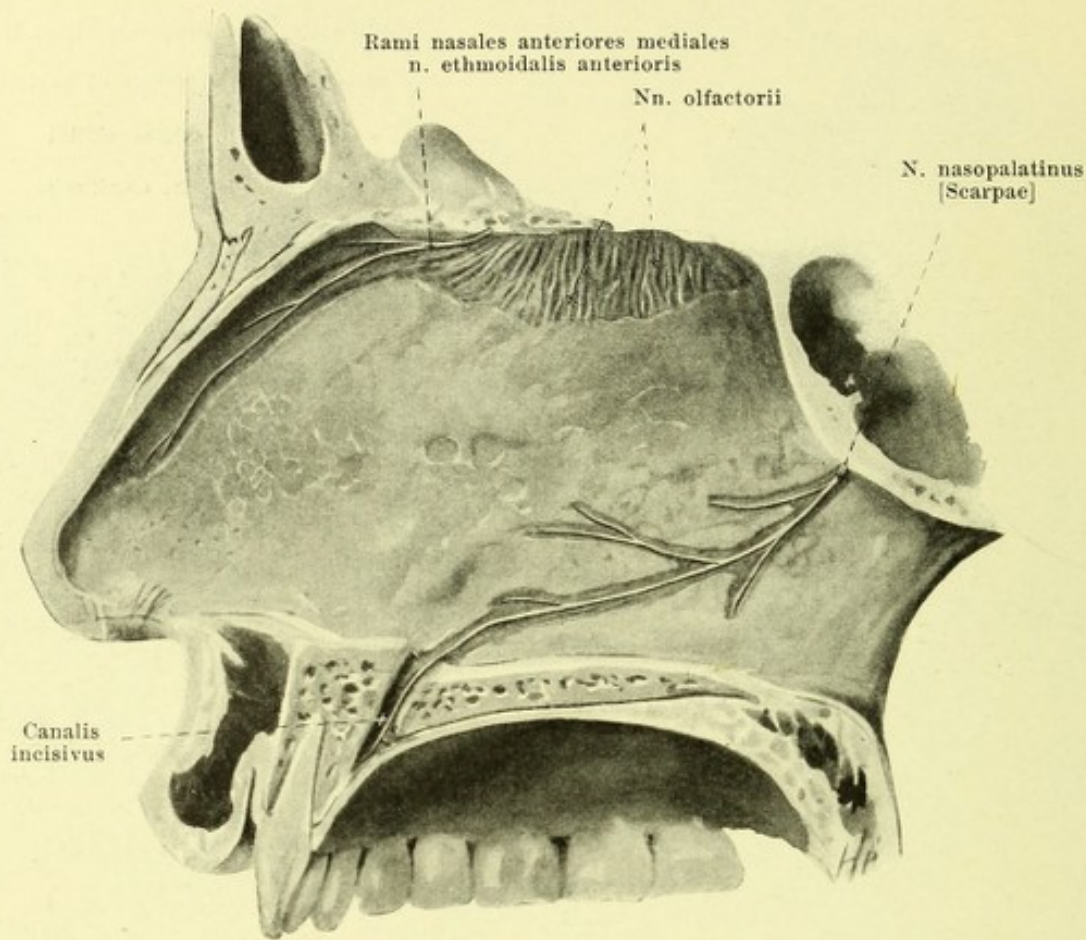
4. The *n. infraorbitalis* (see p. 690), usually a flat plexus, perforated at the beginning of the canalis infraorbitalis by the *a. infraorbitalis*, leaves the canalis infraorbitalis through the foramen infraorbitale and divides there quickly into its terminal branches (see Figs. 770 and 774), which partly unite with branches of the *n. facialis*. The terminal branches are:

- a*) *Rami palpebrales inferiores*, several delicate branches, go through the caput infra-orbitale of the *m. quadratus labii superioris* to the skin of the lower eyelid and of the two angles of the eye.
- β*) *Rami nasales*, 2—3, run upon the *m. nasalis* to the skin of the ala nasi (*rami nasales externi*) and of the septum mobile nasi (*rami nasales interni*).
- γ*) *Rami labiales superiores*, 3—4, pass between the *m. quadratus labii superioris* and the *m. caninus* downward to the skin and mucous membrane of the upper lip and to the gum.

Ganglion sphenopalatinum (see also Figs. 765 and 766) is a sympathetic ganglion and lies as a small, flattened wedge, with its apex behind, in the fossa pterygopalatina, just in front of the anterior opening of the canalis pterygoideus [Vidii], a few millimeters below and medianward from the *n. maxillaris*. The following are usually designated as its roots:

1. *N. canalis pterygoidei* [Vidii], enters the posterior apex of the ganglion, runs in the canalis pterygoideus [Vidii], there arising through the union of two threads:

- a*) *n. petrosus superficialis major* (see also Figs. 766, 771 and 773) comes off from the *n. facialis* at the ganglion geniculi (see p. 700), anastomoses with the *n. petrosus superficialis minor* (see Fig. 773) and arrives through the hiatus canalis facialis in the sulcus *n. petrosi superficialis majoris* of the temporal bone. It then passes lateral from the *a. carotis interna* through the fibrocartilago basalis, filling up the foramen lacerum, to the canalis pterygoideus. In it run certainly the sensory and perhaps also the taste fibers of the anterior two-thirds of the tongue (see p. 699); in addition it carries the secretory fibers for the lachrymal gland (see p. 690).



768. Nerves of the nasal septum, viewed from the left.

Ganglion sphenopalatinum (see Figs. 765—767) (continued):

- β) *n. petrosus profundus* (see Fig. 766) arises from the sympathetic plexus caroticus internus, woven around the a. carotis interna, from the horizontal part of the artery, and goes through the fibrocartilago basalis to the posterior opening of the canalis pterygoideus.
2. Fibers of the *nn. sphenopalatini*, which connect the ganglion with the n. maxillaris (see p. 692).

The following nerves are usually mentioned as branches of the ganglion, although they are, for the most part, direct branches of the *nn. sphenopalatini* (see p. 692), and are only strengthened by a variable number of threads from the ganglion.

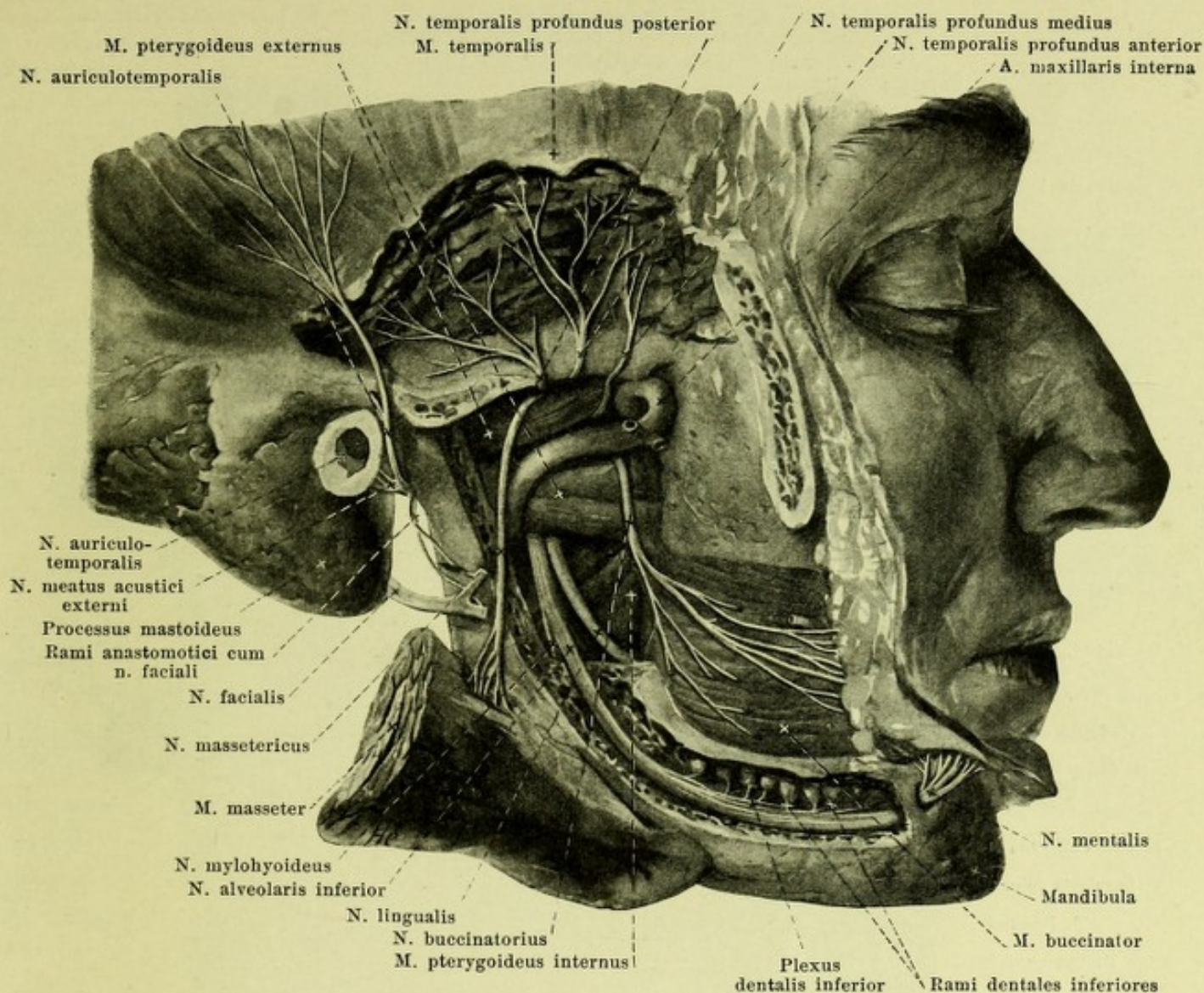
1. *Rami orbitales* (not illustrated), 2—3 extremely fine threads, which pass through the fissura orbitalis inferior into the orbital cavity and through the foramen ethmoidale posterius or a special small opening to the mucous membrane of the ethmoidal cells and sphenoidal sinus.

2. *Rami nasales posteriores superiores* (see also Fig. 767), several fine threads, enter the nasal cavity through the foramen sphenopalatinum, and, as *rami laterales*, arrive in the mucous membrane of the upper and middle nasal conchae (some also through the canales pharyngeus and basipharyngeus to the fornix pharyngis and ostium pharyngeum tubae auditivae), as *rami mediales* on the inferior surface of the body of the sphenoid bone to the nasal septum; of the latter the largest, *n. nasopalatinus [Scarpae]*, extends forward and downward on the septum to the canalis incisivus, anastomoses with that of the other side and ends in the mucous membrane of the hard palate.

3. *Rami nasales posteriores inferiores [laterales]* (see Fig. 767), usually branches of the n. palatinus anterior (vide infra), pass through small openings in the pars perpendicularis oss. palatini into the nasal cavity and to the mucous membrane of the inferior concha.

4. *Nn. palatini* (see Figs. 765—767) run downward through the canalis pterygopalatinus and the canales palatini, dividing into three branches:

- α) *n. palatinus anterior*, the largest, passes through the foramen palatinum majus on the inferior surface of the hard palate, passes forward on it, divided in several branches, and supplies the mucous membrane of the hard and soft palate and the gums.



769. Branches of the right n. mandibularis (V), more superficial layer, viewed from the right.

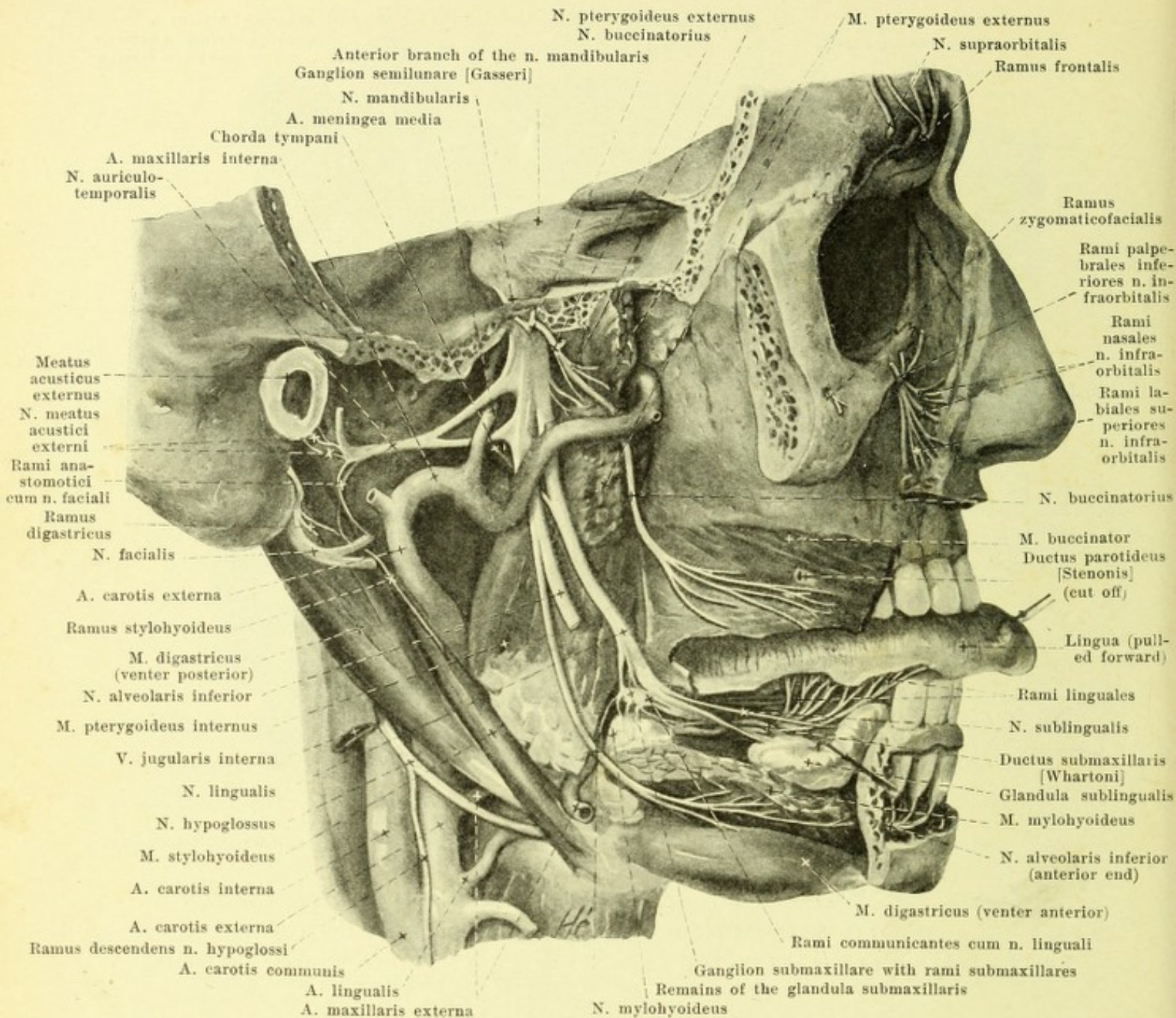
(The arcus zygomaticus and the proc. coronoideus mandibulae have been removed; the canalis mandibulae has been chiseled open; the m. masseter has been reflected lateralward.)

Ganglion sphenopalatinum (see Fig. 767) (continued):

β) *n. palatinus medius*, the smallest, goes through a foramen palatinum minus to the mucous membrane of the soft palate and to the region of the tonsil.

γ) *n. palatinus posterior* goes through a foramen palatinum minus and then passes backward to the mucous membrane of the inferior surface of the soft palate.

c) **N. mandibularis** (O. T. inferior maxillary) (see also Figs. 762, 764, 765, 770, 771 and 776), a mixed nerve, the largest branch, is formed of the (sensory) inferior division of the ganglion semilunare [Gasseri] and of the smaller (motor) portio minor (see p. 689), which are partly interwoven with one another beneath the ganglion. It runs downward through the foramen ovale (surrounded by the venous rete foraminis ovalis) and immediately beneath the same gives off the delicate *n. spinosus* (see Figs. 764 and 771), which receives a strand from the ganglion oticum (see p. 699), goes into the skull cavity through the foramen spinosum with the a. meningea media and arrives along with the branches of the artery in the sphenoid bone and the ethmoid cells. The n. mandibularis divides into a smaller anterior and a larger posterior branch. The anterior branch is chiefly motor; into it almost the whole portio minor goes and is continued into the pure motor *nn. massetericus, temporales profundi, pterygoideus externus* (all these together with the n. pterygoideus internus, being designated as the *n. masticatorius*): it contains only a few fibers which are not motor, viz., the pure sensory *n. buccinatorius*.

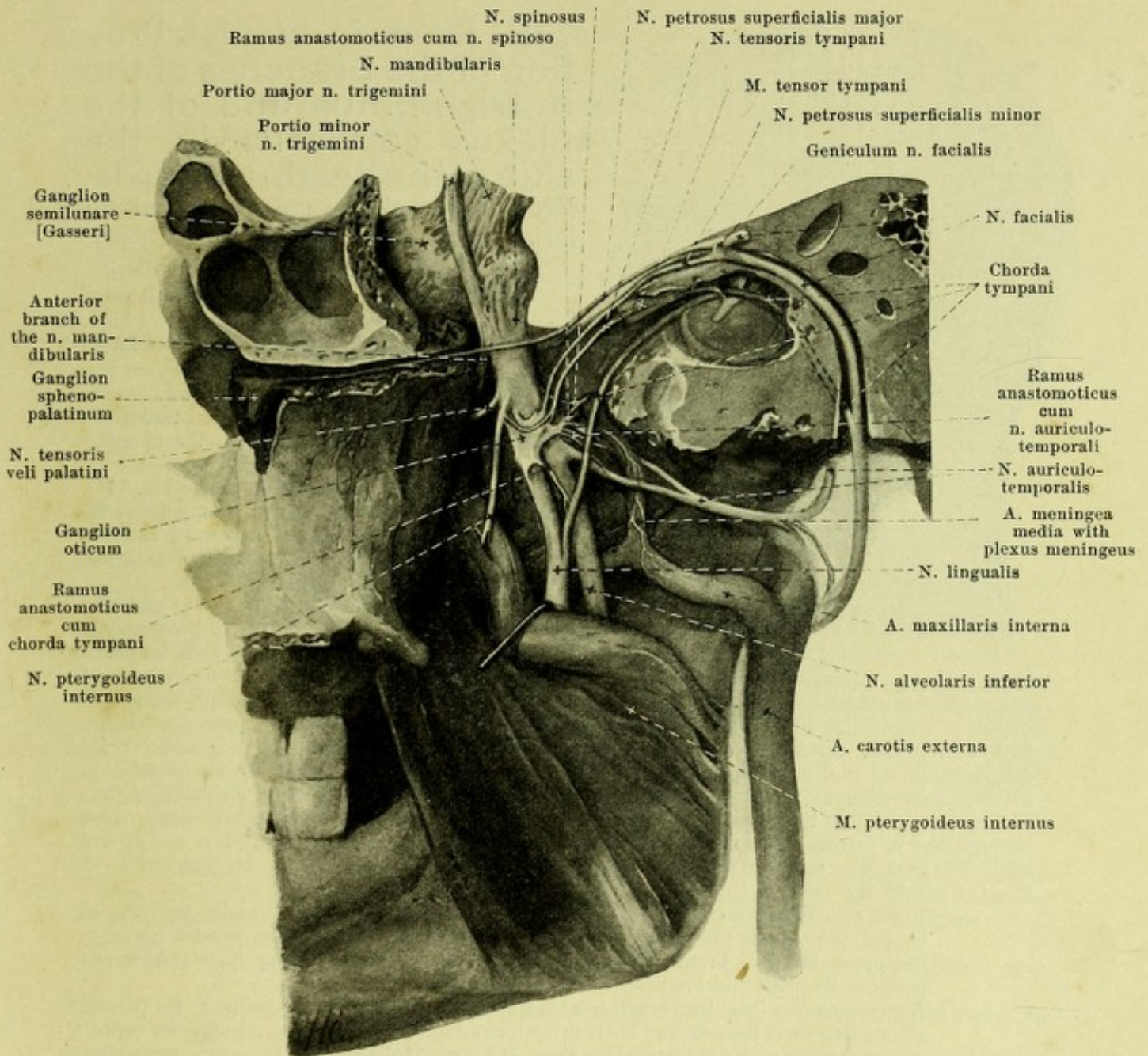


770. Branches of the right n. mandibularis (V), deeper layer, viewed from the right.

(Like Fig. 769, but the lower jaw and masticatory muscles have been almost completely removed; all but a small part of the glandula submaxillaris has been removed.)

c) **N. mandibularis** (see also Figs. 769, 771 and 776) (continued): The posterior branch is almost exclusively sensory; it carries only a few motor fibers to the pure motor *n. pterygoideus internus*, *n. tensoris veli palatini*, *n. tensoris tympani* and *n. mylohyoideus*; the latter is a branch of the *n. alveolaris*, which otherwise contains only sensory fibers, and together with the pure sensory *nn. auriculotemporalis* and *lingualis*, makes up the main mass of sensory fibers of the *n. mandibularis*. The posterior branch is united by (usually two) short, fine threads with the upper margin of the ganglion oticum (see p. 699).

1. *N. massetericus* (see Fig. 769) arises usually with the *n. temporalis profundus posterior*, passes horizontally lateralward on the facies infratemporalis of the sphenoid bone, above the *m. pterygoideus externus*, and then runs lateralward and downward through the incisura mandibulae to the medial surface of the *m. masseter*; it gives off 1—2 threads for the joint of the jaw.



771. Right ganglion oticum, viewed from within.

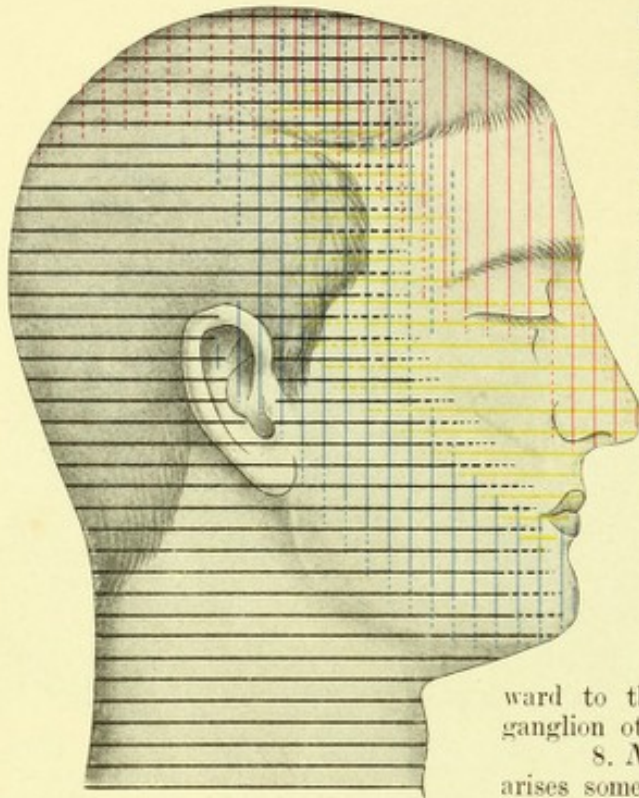
(From one portion of a head cut in half the viscera and spine have been removed; the internal ear and the apex of the pyramid of the temporal bone have been cut away.)

2. *Nn. temporales profundi* (see Fig. 769), usually three, a *posterior*, *medius* and *anterior*, of which the middle one may be absent; the posterior usually arises in common with the n. massetericus, the anterior with the n. buccinatorius. They run at first horizontally lateralward like the n. massetericus (see p. 696) (the anterior often between the two heads of the m. pterygoideus externus), then bend vertically upward and finally break up, anastomosing with one another in the m. temporalis.

3. *N. buccinatorius* (see Figs. 769, 770 and 774) (see also above) passes downward, forward and lateralward, either between the two heads of the m. pterygoideus externus or between the two mm. pterygoidei, arrives upon the lateral surface of the m. buccinator and there anastomoses with branches of the n. facialis. It sends branches through the m. buccinator to the mucous membrane of the cheek, and is distributed also to the skin of the angle of the mouth.

4. *N. pterygoideus externus* (see Fig. 770) arises almost always in common with the n. buccinatorius and runs downward and lateralward to the m. pterygoideus externus.

5. *N. pterygoideus internus* passes near the ganglion oticum or through it, connected with it by fine threads, downward to the medial surface of the m. pterygoideus internus.



772. Domain of distribution of the branches of the n. trigeminus and of the plexus cervicalis in the skin of the head, after R. Zander.

Red: n. ophthalmicus; yellow: n. maxillaris; blue: n. mandibularis; black: branches of the plexus cervicalis.

(The regions which are regularly supplied by the nerves concerned are indicated by solid lines, those not regularly supplied by dotted lines.)

6. *N. tensoris veli palatini* (see Fig. 771), usually a branch of the foregoing, runs forward and downward to the m. tensor veli palatini; it is connected with the ganglion oticum by a fine thread.

7. *N. tensoris tympani* (see Fig. 771), usually a branch of the n. pterygoideus internus, very fine, passes backward and upward to the m. tensor tympani; it is connected with the ganglion oticum by a delicate thread.

8. *N. auriculotemporalis* (see Figs. 769—771 and 774) arises somewhat beneath the foramen ovale from the posterior margin of the n. mandibularis, usually by two roots, which

include the a. meningea media between them and then unite. It runs at first backward and somewhat downward on the medial surface of the m. pterygoideus externus and processus condyloideus mandibulae over the a. maxillaris interna, bends around the collum proc. condyloidei, first lateralward, then upward through the substance of the glandula parotis in front of the cartilaginous external acoustic meatus, to pass finally, behind the a. temporalis superficialis, in a vertical direction to the skin of the temple. It is united by several threads with the ganglion oticum (see p. 699); these lead to it the secretory fibers of the glandula parotis, which come through the n. petrosus superficialis minor (see p. 699) and the n. tympanicus (see p. 706 and Fig. 773) from the n. glossopharyngeus leaving the brain with the latter. It gives off 1—2 fine threads to the joint of the jaw, and in addition:

- a) *Rami anastomotici cum n. faciali* (see Figs. 769, 770 and 774), usually two, go off behind the collum proc. condyloidei and pass forward through the parotid gland to the upper terminal branch of the n. facialis; they contain sensory fibers which run peripherally with the branches of the n. facialis.
- β) *Rami parotidei* (not illustrated) from the main stem or from the preceding to the parotid gland; they carry the secretory fibers to it which arise from the ganglion oticum (vide supra).
- γ) *Nn. meatus acustici externi* (see Figs. 769 and 770), usually two, run backwards, penetrate at the junction between the cartilaginous and bony external acoustic meatus into the latter, supply its skin and send a fine branch, *ramus membranae tympani*, to the ear-drum membrane.
- δ) *Nn. auriculares anteriores* (see Fig. 774) to the skin of the anterior part of the auricle.
- ε) *Rami temporales superficiales* (see Figs. 774), usually two, to the skin of the temple; they anastomose above with branches of the nn. ophthalmicus (V) and occipitalis major and alternate in their distribution with the n. zygomaticotemporalis.

9. *N. alveolaris inferior* (see Figs. 769—771), the largest branch, passes first on the medial surface of the m. pterygoideus externus and of the a. maxillaris interna, then between the ramus mandibulae and the m. pterygoideus internus, slightly curved, downward to the foramen mandibulare and thence forward in the canalis mandibulae with the a. and v. alveolaris. It gives off the following branches:

- a) *N. mylohyoideus* (see Figs. 769 and 770) goes off close above the foramen mandibulare and passes downward and forward in the sulcus mylohyoideus mandibulae, at first lateral from the m. pterygoideus internus, then beneath the m. mylohyoideus; it supplies the latter and the venter anterior m. digastrici.
- β) *Rami dentales inferiores* (see Fig. 769) and *rami gingivales inferiores*, fine branches, which go off in the canalis mandibulae; of the former there is one for each root of a tooth; the latter go to the alveoli and to the gum. They form a plexus, *plexus dentalis inferior*, above the n. mandibularis.

- γ) *N. mentalis* (see Fig. 769), a large branch, leaves the canalis mandibulae by way of the foramen mentale, covered by the m. triangularis. It divides into *rami mentales*, which, perforating this muscle, go to the skin of the chin, and *rami labiales inferiores*, which pass upward to the skin and mucous membrane of the lower lip.

10. *N. lingualis* (see Figs. 769—771 and 776), almost as large as the n. alveolaris inferior, runs in front of the latter nerve and somewhat medianward from it, on the medial side of the m. pterygoideus externus and of the a. maxillaris interna, then between the m. pterygoideus internus and the ramus of the lower jaw, slightly curved, downward and forward, then passes under the m. mylopharyngeus and over the m. styloglossus (see Figs. 555, 770 and 776) on the lateral side of the latter, and, under the mucous membrane of the floor of the mouth, passes forward over the m. mylohyoideus and the glandula submaxillaris, goes around the ductus submaxillaris [Whartoni] lateral and below (see also Fig. 540) and then breaks up.

Upon the m. pterygoideus internus it unites with the chorda tympani (see p. 700), which approaches it at an acute angle from behind and above. This union with the n. facialis carries certainly 1. the secretory fibers for the glandula submaxillaris and sublingualis, which arise from the n. intermedius to the n. lingualis, 2. from the n. lingualis the pure sensory fibers and the taste fibers from the anterior two-thirds of the tongue to the n. facialis. From there on the sensory fibers pass through the n. petrosus superficialis major to the ganglion sphenopalatinum. The further path of the taste fibers is questionable: either they run also through the n. petrosus superficialis major to the ganglion sphenopalatinum, thence to the n. maxillaris (V) and further centralward, or through the ramus anastomoticus cum plexu tympanico to the n. petrosus superficialis minor from the ganglion oticum to the n. mandibularis (V) and further centralward, or they arrive in the brain by way of the n. intermedius.

The n. lingualis is united further by several threads with the ganglion submaxillare (vide infra) and anastomoses upon the lateral surface of the m. hyoglossus with the n. hypoglossus through one or two *rami anastomotici cum n. hypoglossus* (see Fig. 776), by means of which sensory fibers probably pass over into the peripheral part of the n. hypoglossus. Branches:

- α) *Rami isthmi faucium* (see Fig. 776), fine, go between lower jaw and m. pterygoideus internus to the tonsil and to the posterior part of the mucous membrane of the mouth.
- β) *N. sublingualis* (see Figs. 540 and 770), runs forward, lateral from the glandula sublingualis, innervates this gland (vide supra) and the neighboring mucous membrane.
- γ) *Rami linguales* (see Figs. 770 and 776) pass through the musculature of the tongue to the mucous membrane of the back and of the margins of the anterior two-thirds of the tongue (see also above and Fig. 778). They anastomose manifoldly with the same branches of the other side and with those of the n. glossopharyngeus.

Ganglion oticum (see Fig. 771) is a sympathetic ganglion, a grayish-red, flatly rounded body, which lies close under the foramen ovale, immediately adjacent to the medial surface of the n. mandibularis; medianward it lies close to the pars cartilaginea tubae auditivae; close behind it runs the a. meningea media. The so-called roots of the ganglion are:

- α) Communicating thread with the n. mandibularis, usually two, very delicate, from the upper margin.
- β) Communicating threads with the sympathetic plexus meningeus surrounding the a. meningea media.
- γ) Communicating threads through especial canals with the n. canalis pterygoidei [Vidui].
- δ) *N. petrosus superficialis minor* (see Figs. 771 and 773), is in largest part a continuation of the n. tympanicus (IX) (see p. 706), but it also receives a thread of communication from the n. facialis (see p. 700), runs through the upper part of the canaliculus tympanicus, goes through its apertura superior into the sulcus n. petrosi superficialis minoris and then passes either through the fissura sphenopetrosa or through a special canaliculus, medianward forward and downward to the ganglion. In it run secretory fibers for the glandula parotis (see p. 698: n. auriculotemporalis), as well as taste fibers perhaps (vide supra: n. lingualis).

So-called branches of the ganglion (see Fig. 771):

- α) Threads to the nn. pterygoideus internus, tensoris tympani and tensoris veli palatini.
- β) *Ramus anastomoticus cum n. spinoso*, fine thread to the n. spinosus.
- γ) *Ramus anastomoticus cum n. auriculotemporalis*, fine threads to the n. auriculotemporalis, in which the secretory fibers for the parotid gland run (see p. 698).
- δ) *Ramus anastomoticus cum chorda tympani*, one or two fine threads to the chorda tympani.

Ganglion submaxillare (see Figs. 540 and 770) is a sympathetic ganglion, a spindle-shaped body lying directly in front of the m. pterygoideus internus, under the n. lingualis and over the glandula submaxillaris. It communicates with the n. lingualis by means of several *rami communicantes cum n. linguali*; some of them pass upward and are attached in the n. lingualis in centripetal direction, others run forward to the peripheral part of the n. lingualis. It further communicates by means of fine threads with the sympathetic *plexus maxillaris externus*

surrounding the a. maxillaris externa. From the lower margin several threads, *rami submaxillares*, go to the glandula submaxillaris (see p. 699) and to the ductus submaxillaris [Whartoni].

VI. N. abducens (see Figs. 696, 697, 705, 759—764 and Organ of Vision), motor, leaves the brain, on each side, at the lower, posterior margin of the pons in the groove between this and the pyramid, runs between the pons and the clivus upward, lateralward and forward (see Fig. 705) and perforates the dura mater medialward from and beneath the n. trigeminus, somewhat below the apex of the pyramid; it then passes over this into the sinus cavernosus, goes forward in the middle through it (see also Fig. 482), lateral from and below the a. carotis interna, medial from the n. ophthalmicus (V), enters the annulus tendineus communis [Zinni] under the nn. oculomotorius and nasociliaris (V) through the fissura orbitalis superior (see Organ of Vision), becomes applied to the medial surface of the m. rectus lateralis and ends in it.

Anastomoses: In the sinus cavernosus it receives sympathetic fibers from the plexus cavernosus.

VII. N. facialis (see Figs. 696, 697, 705, 759—761, 766, 769—771, 773—775 and 779), motor, appears on each side lateral from the n. abducens, just medial from the nn. intermedius and acusticus, at the inferior, posterior margin of the brachium pontis (see p. 631) above and somewhat lateral from the olive; it passes lateralward along with the nn. intermedius and acusticus at the upper margin of the flocculus in front of the brachium pontis upon the tuberculum jugulare oss. occipitalis and upon the facies posterior pyramidis, and runs upward and forward to the porus acusticus internus (see Figs. 761 and 775) and into the meatus acusticus internus. In this the n. facialis lies over the n. acusticus in a groove of the latter, the n. intermedius between the two; they have a sheath in common formed by continuations of the meninges, and of the cavum subdurale and subarachnoideale, all of which reach as far as the bottom of the meatus. From there on it runs lateralward with the n. intermedius (vide infra) in the canalis facialis (see Figs. 771 and 773) to the geniculum canalis facialis, there bends sharply around, *geniculum n. facialis* (*facial knee*), and extends further, first backward and lateralward and then downward. At the foramen stylomastoideum it enters the substance of the parotid gland and within it runs in an arch concave upward and medianward (see Figs. 769—771), lateral from the posterior belly of the m. digastricus, a. carotis externa and v. facialis posterior upon the lateral surface of the ramus of the lower jaw, there to break up into its terminal branches (see Fig. 774).

N. intermedius (see Figs. 696 and 705), a mixed nerve, leaves the brain just lateral from the n. facialis, between it and the n. acusticus (n. vestibularis), enters the canalis facialis with the n. facialis (vide supra), and is at first loosely and then more intimately united with the n. facialis; its sensory part forms at the geniculum n. facialis the *ganglion geniculi* (see Fig. 773), a conical aggregation of ganglion cells comparable to those of the spinal ganglia, with its apex directed medianward and intimately united with the n. facialis; the ganglion geniculi anastomoses with the ganglion vestibulare by a delicate nerve-thread. The further course of the fibers is only partly known; the secretory fibers in it coming from the brain for the glandulae submaxillaris and sublingualis go over into the chorda tympani (vide infra); the latter is often looked upon as the direct continuation of the n. intermedius; the fibers for the lachrymal gland, all of which are carried by it, enter into the n. petrosus superficialis major (see also p. 690).

A. Branches of the n. facialis within the temporal bone:

1. *N. petrosus superficialis major*, from the geniculum n. facialis to the ganglion sphenopalatinum (see p. 693).

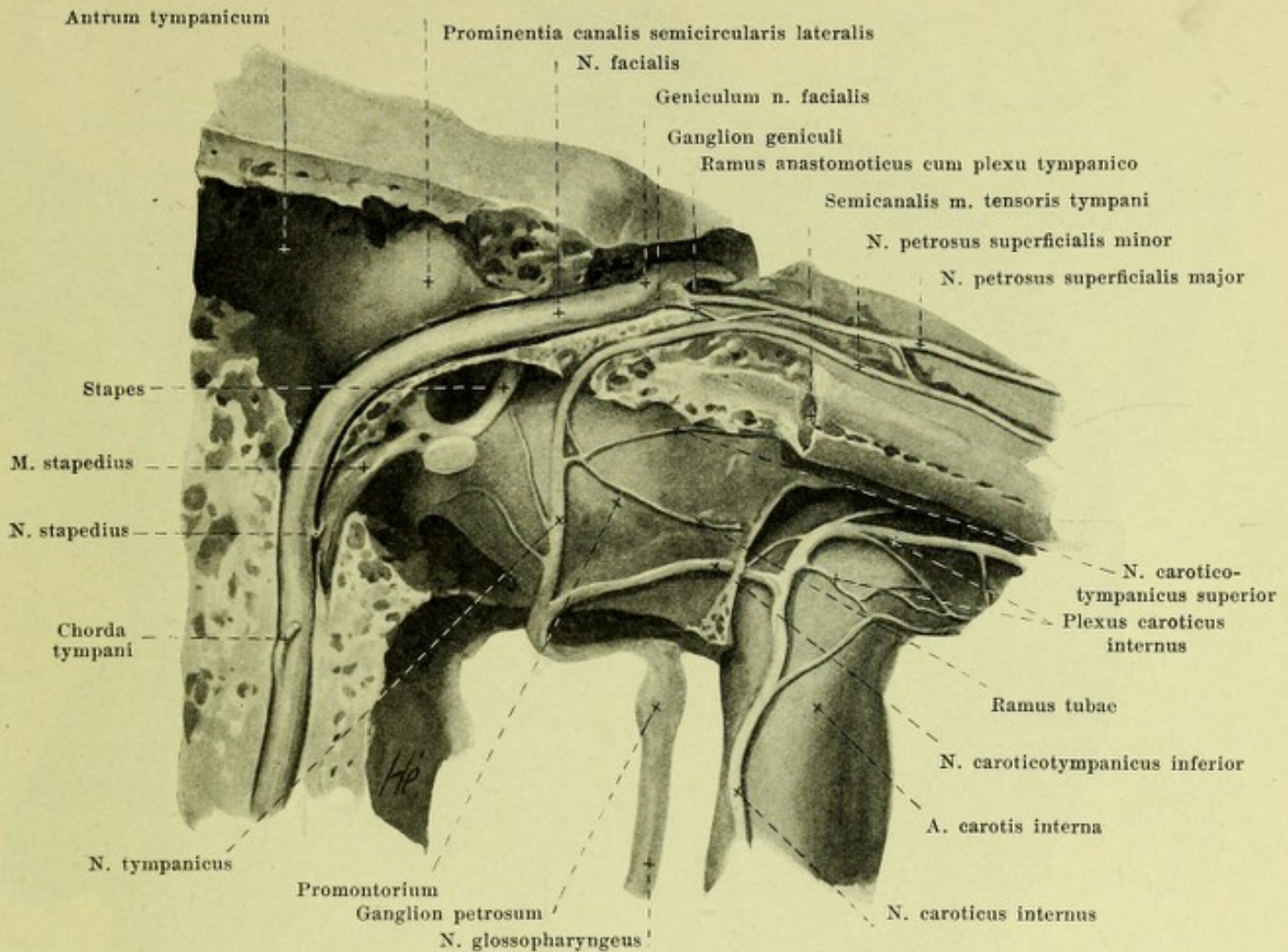
2. *Ramus anastomoticus cum plexu tympanico* (see Fig. 773), a fine thread, from the geniculum n. facialis to the n. petrosus superficialis minor (see p. 699).

3. *N. stapedius* (see Fig. 773) arises in the vertical part of the canalis facialis and passes through a small opening to the m. stapedius, situated within the eminentia pyramidalis.

4. *Chorda tympani* (see Figs. 770, 771, 773, 776, 886, 888 and 889) goes off beneath the preceding, running back in an acute angle open above; it runs at first through the canaliculus chordae tympani to the cavum tympani, then in the plicae malleolares posterior and anterior between the crus longum incudis and manubrium mallei, and finally in the fissura petrotympanica [Glaseri], in order to pass medial from the spina angularis, a. meningea media, and the nn. auriculotemporalis and alveolaris inferior downward to the posterior margin of the n. lingualis (see p. 699). In its course it describes a curve, convex upward and lateralward, and is connected by one or two fine threads with the ganglion oticum (see p. 699). Concerning its fibers see n. lingualis, p. 699.

B. Branches of the n. facialis outside the skull.

1. *N. auricularis posterior* (see Figs. 774, 779 and 787), arises close under the foramen stylomastoideum, runs upward and backward on the anterior surface of the processus mastoideus, between this and the external ear, near the a. auricularis posterior, anastomoses by fine threads with the sensory nn. auricularis magnus and occipitalis minor, and sends an anterior branch upward to the mm. auriculares posterior and superior, as well as to the mm. transversus, obliquus auriculæ and antitragicus, and a posterior branch horizontally, *ramus occipitalis*, to the m. occipitalis.



773. Right n. facialis and plexus tympanicus, viewed from in front. Magnification 4 : 1.

(The canalis facialis, canaliculus tympanicus and canalis caroticus have been opened.)

2. *Ramus digastricus* (see Figs. 770 and 779) arises close under the preceding, and passes downward to the anterior surface of the venter posterior m. digastrici, which it innervates. Branches:

- a) *Ramus stylohyoideus*, a long thread, downward and forward to the m. stylohyoideus.
- β) *Ramus anastomoticus cum n. glossopharyngeus* (see Fig. 779) given off in the m. digastricus or previously, runs medianward in a curve, convex below, to the n. glossopharyngeus, which it reaches below the ganglion petrosum.

C. Terminal branches of the n. facialis (see Figs. 774 and 787), an upper, usually the larger, and a lower; the two usually form an obtuse angle with one another. The upper one passes upward and forward, the lower one to the angulus mandibulae. Their branches form a plexus, *plexus parotideus* (see Fig. 774), often distinct only above. The upper branch communicates by two threads with the n. auriculotemporalis (see p. 698). The terminal branches are subdivisible into:

1. *Rami temporales*, over the zygomatic arch, upward to the mm. helicis major, helicis minor, tragus, mm. auriculares superior and anterior, as well as upward and forward to the mm. frontalis, orbicularis oculi and corrugator.

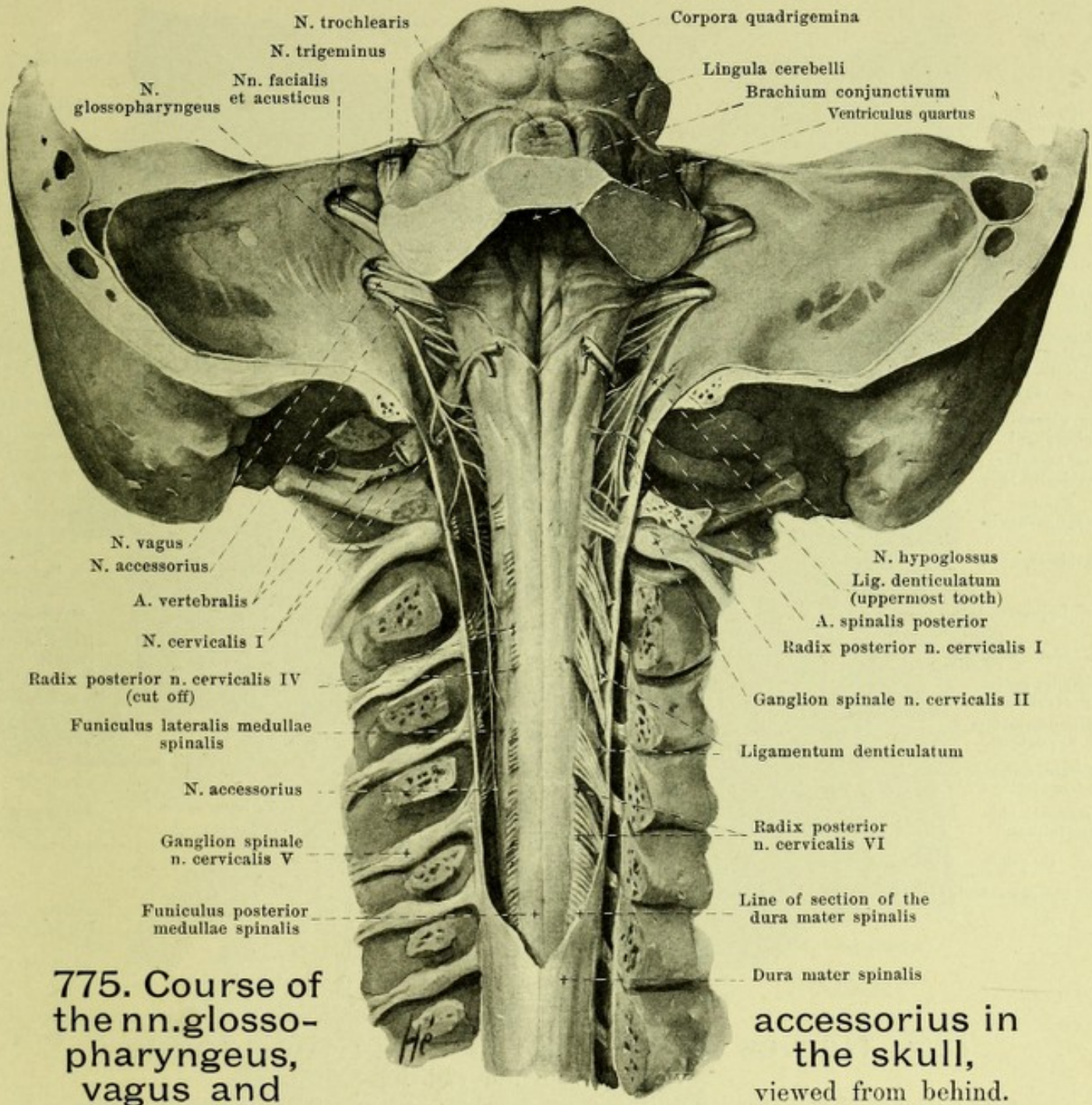
2. *Rami zygomatici*, forward to the mm. orbicularis oculi and zygomaticus.

3. *Rami buccales*, upon the m. masseter, forward to the mm. risorius, zygomaticus, quadratus labii superioris, caninus, buccinator, incisivi, orbicularis oris, triangularis, quadratus labii inferioris and to the muscles of the nose.

4. *Ramus marginalis mandibulae*, runs along the base of the lower jaw to the region of the chin and gives branches to the mm. quadratus labii inferioris and mentalis.

5. *Ramus colli*, from the angle of the lower jaw on the neck forward and downward, covered by the platysma, which it alone innervates. It anastomoses with the (sensory) n. cutaneus colli.

These branches form numerous anastomoses with branches of the n. trigeminus, e. g., the rami temporales with the n. supraorbitalis and the rami buccales with the n. buccinatorius.



775. Course of the nn. glossopharyngeus, vagus and

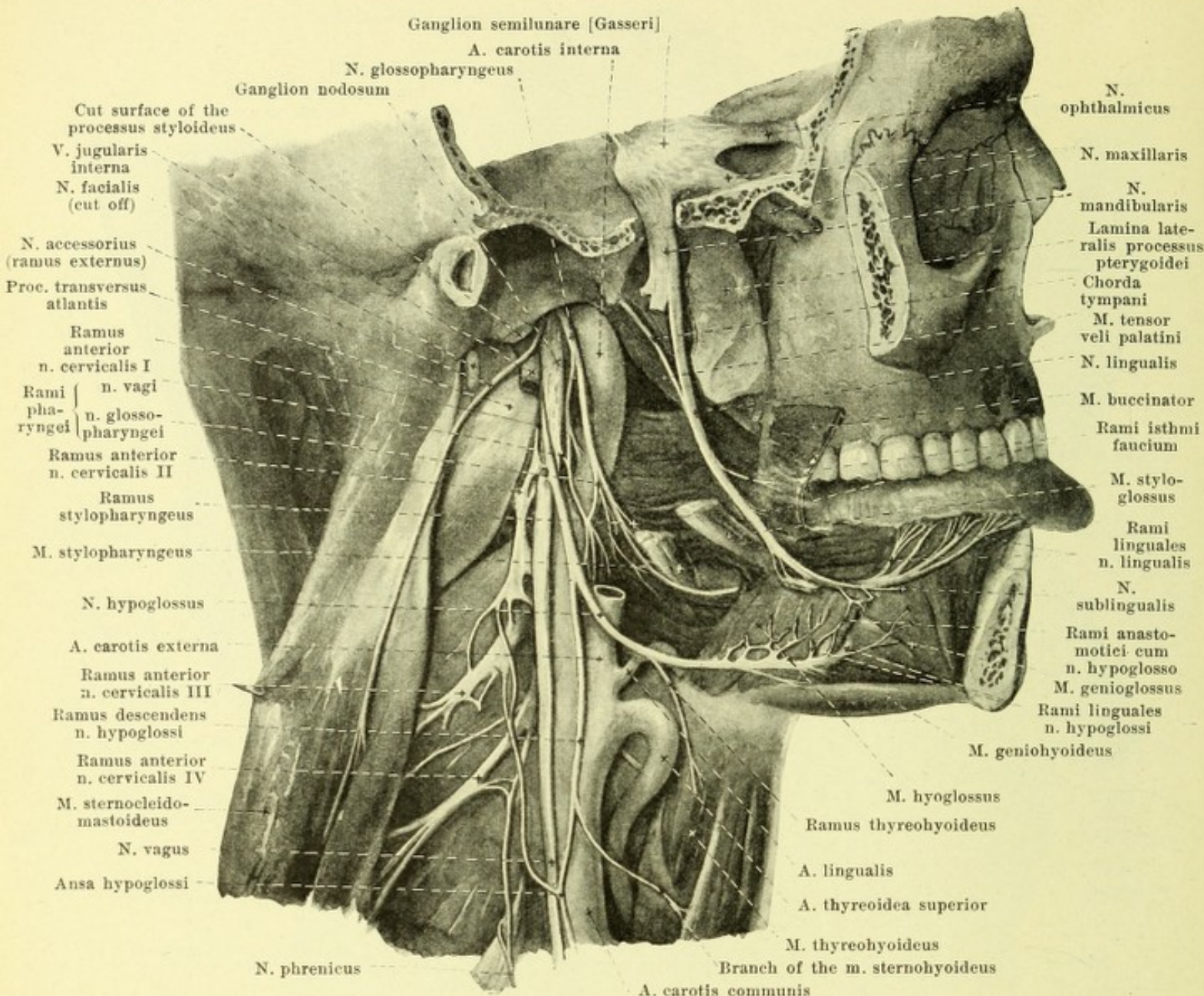
accessorius in the skull, viewed from behind.

(The occipital bone and the vertebral arches have been largely sawn away, the cerebrum and cerebellum cut away; the sac of the dura mater spinalis has been opened. On the left the posterior roots of the cervical nerves have been partly removed, the lig. denticulatum completely.)

VIII. **N. acusticus**, *acoustic nerve* (see also Figs. 696, 697, 702, 705, 759—761, 913 and 914) is a sensory nerve, which appears on each side with two roots at the lower posterior margin of the brachium pontis above and behind the olive. The medial root (*radix n. vestibularis*) appears just lateral from the n. intermedius in front of the corpus restiforme, the lateral (*radix n. cochlearis*) passes around the latter like an arch from the outside. The n. acusticus passes with the nn. facialis and intermedius into the meatus acusticus internus (see p. 700) and there divides into two branches, the *n. vestibularis* and the *n. cochlearis*.

1. The *n. vestibularis* is interrupted at the bottom of the internal acoustic meatus by a ganglion, *ganglion vestibulare* (which anastomoses by a thread with the ganglion geniculi [see p. 700]) and divides into an upper and a lower terminal branch. The former goes from the area vestibularis superior to the macula cribrosa superior vestibuli; its branches run as follows:

- a) *N. utricularis* to the macula acustica utriculi,
- β) *N. ampullaris superior* to the ampulla membranacea superior and
- γ) *N. ampullaris lateralis* to the ampulla membranacea lateralis.

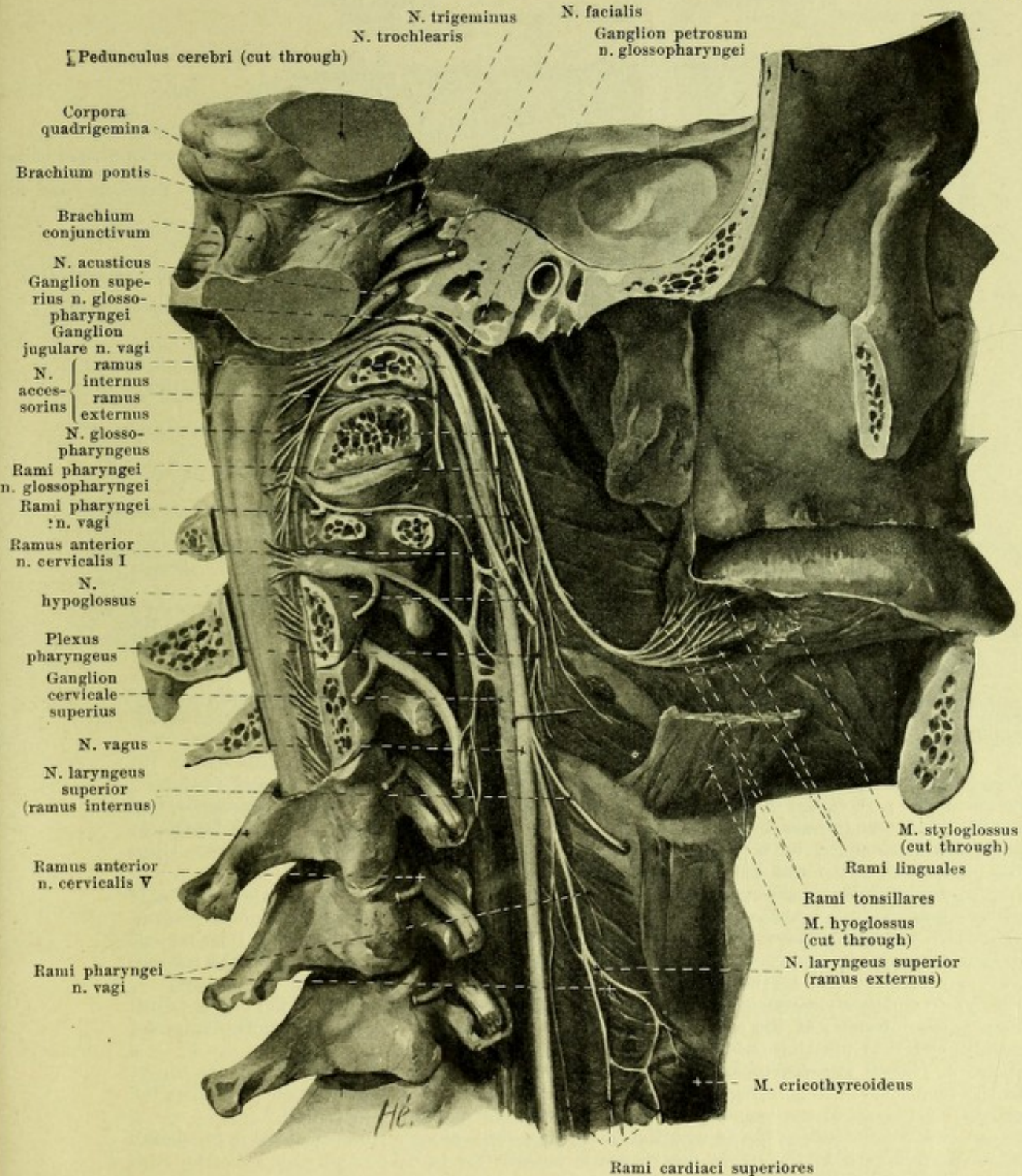


776. Nerves to the right side of the tongue, viewed from the right.

(The right half of the lower jaw with its muscles and the processus styloideus with its muscles have been removed; the foramen ovale has been exposed from the lateral side.)

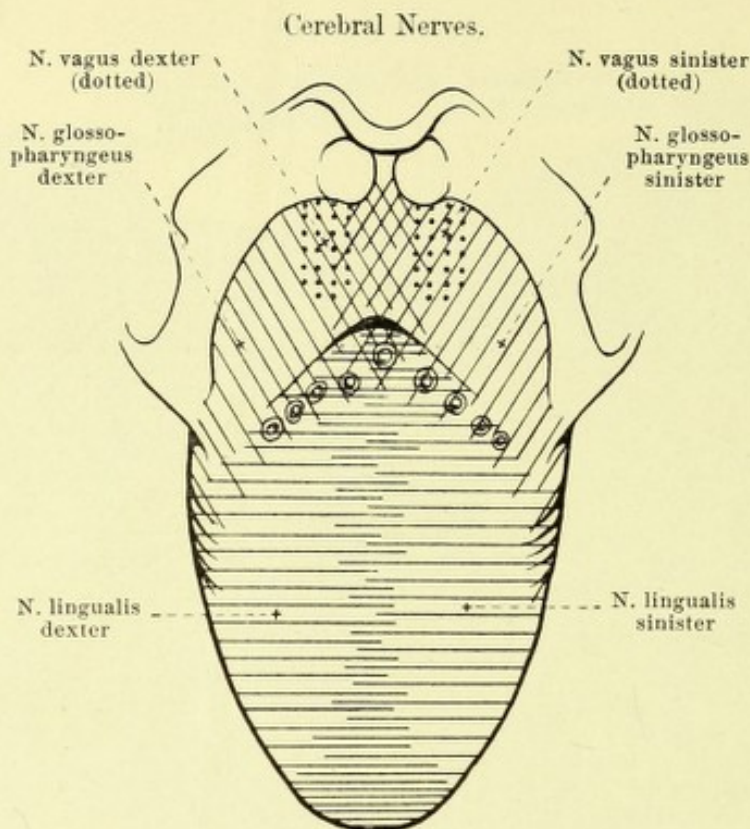
1. *N. vestibularis* (continued) (see Figs. 913 and 914). Its lower terminal branch divides into:
 - δ) *N. saccularis*, which passes out from the area vestibularis inferior through the macula cribrosa media vestibuli to the macula acustica sacculi, and
 - ε) *N. ampullaris posterior*, which passes from the foramen singulare through the macula cribrosa inferior vestibuli to the ampulla membranacea posterior.
2. *N. cochlearis* goes through the tractus spiralis foraminosus into the canales longitudinales modioli and in the canalis spiralis modioli forms the long stretched-out *ganglion spirale*.

IX. *N. glossopharyngeus* (see also Figs. 696, 697, 702, 705, 759, 761, 773, 775, 777 and 779), a mixed nerve, appears with 5—6 threads below the *n. acusticus* in the upper part of the groove of the medulla oblongata running behind the olive (see p. 629); upon the tuberculum jugulare under the flocculus it passes almost horizontally lateralward and forward to the foramen jugulare; it runs through the most anterior medial part of the latter, separated from the vagus and *n. accessorius* by a strip of dura mater (see Figs. 759, 761 and 777), passing in a curve downward and forward. In the foramen jugulare it becomes swollen to form the small *ganglion superius* and beneath this in the fossula petrosa to form the somewhat larger, elongated *ganglion petrosum* (see Figs. 773 and 777).



777. Right glossopharyngeal nerve, viewed from the right and somewhat from behind. (The preparation is similar to that of Fig. 776; in addition the medulla oblongata and the course of the nerve in the bone have been exposed; the muscles of the vertebral column have been completely removed, those of the tongue partly.)

IX. N. glossopharyngeus (continued). The two ganglia may fuse with one another; they are similar in construction to the spinal ganglia and contain the cells of origin of the sensory fibers of the nerve (see p. 678); the motor fibers run by these ganglion cells. Outside the skull the nerve goes downward, at first behind, then lateral from, the a. carotis interna, between it and the m. stylopharyngeus and then bends around the posterior margin of the latter upon its lateral surface (see also Fig. 776).



778. Distribution of sensory nerves in the mucous membrane of the tongue, schematic (after R. Zander).

IX. **N. glossopharyngeus** (see Figs. 776 and 777) (continued). It then passes in a curve, convex downward and backward, on the medial side of the m. styloglossus to the root of the tongue. Branches: A) From the ganglion petrosum:

1. *N. tympanicus* (see Fig. 773) runs upward in the canaliculus tympanicus (see p. 12) first in the cavity of the tympanum, then in the sulcus promontorii, becomes directly continuous in the upper part of the canaliculus tympanicus with the n. petrosus superficialis minor (see p. 699) and communicates by a fine thread with the n. facialis (see p. 700). In the lowermost part it is surrounded by a swelling of vascular tissue, the *intumescencia tympanica*. Upon the promontorium it forms with its branches the *plexus tympanicus*. Branches:

a) *Ramus tubae*, delicate, runs forward to the mucous membrane of the ear trumpet; besides it sends delicate branches backward to the region of the fenestra vestibuli and fenestra cochleae.

β) *N. caroticotympanicus superior*, delicate, runs medianward in the cavum tympani and through a special canal to the plexus caroticus internus surrounding the a. carotis interna, sometimes also to the n. petrosus superficialis major.

γ) *N. caroticotympanicus inferior* connects the plexus tympanicus with the plexus caroticus internus; at the same time it passes through one or two canaliculi caroticotympanici and runs upon or under the promontorium.

2. *Ramus anastomoticus cum ramo auriculari n. vagi* (see Fig. 779), a delicate thread to the ramus auricularis n. vagi; it may be absent. Besides, a delicate thread goes from the ganglion petrosum to the vagus, just below the ganglion jugulare (see p. 709).

3. A communicating thread with the ganglion cervicale superius (branch of the n. jugularis).

4. A branch to the ramus digastricus n. facialis (see p. 701).

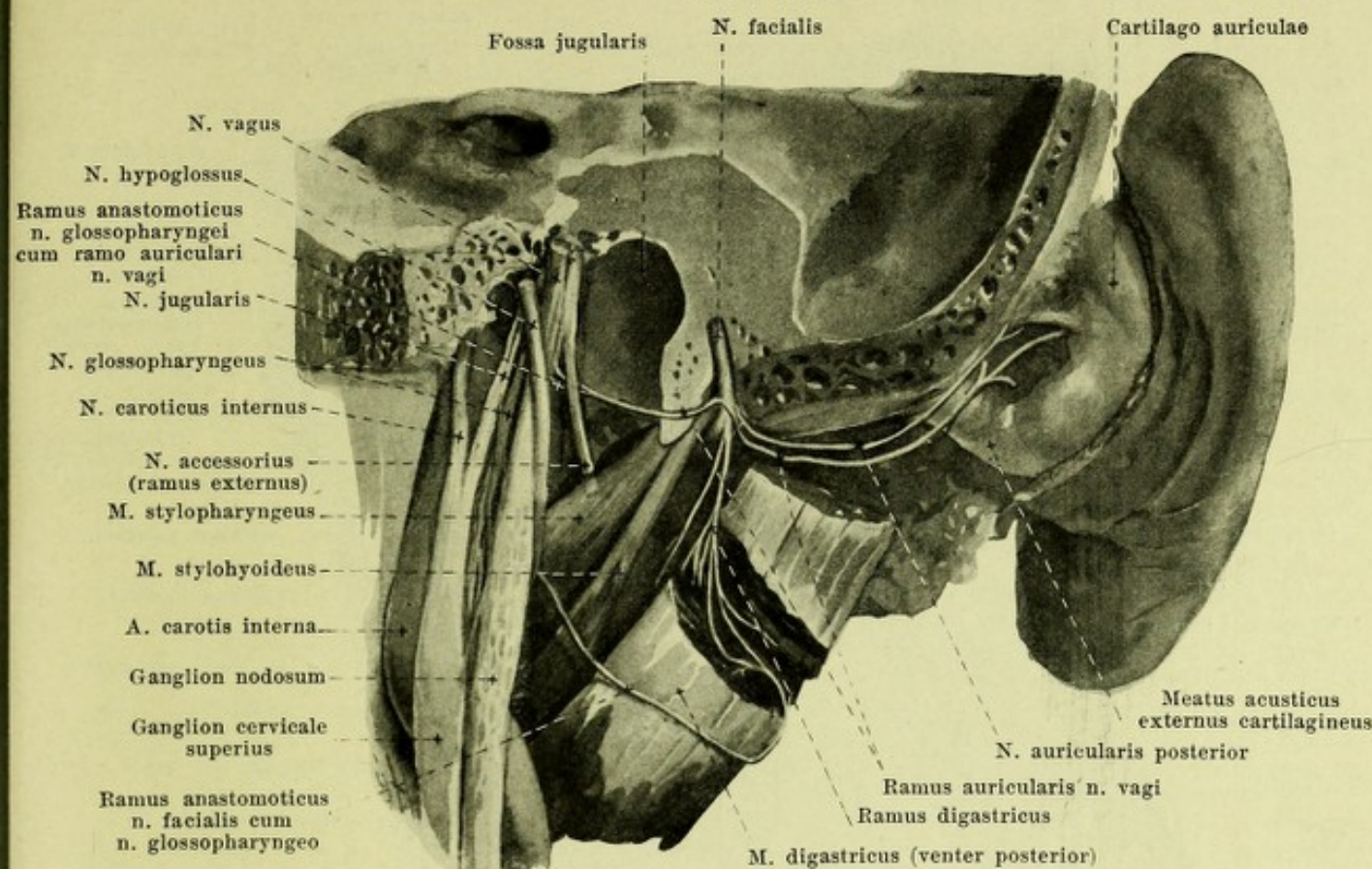
B. Peripheral branches:

5. *Rami pharyngei* (see Figs. 776 and 777), 2 or 3, go off at variable levels on the lateral surface of the a. carotis interna and help to form the plexus pharyngeus (see p. 709).

6. *Ramus stylopharyngeus* (see Fig. 776) goes off behind the m. stylopharyngeus and passes to this muscle (these fibers are said not to be motor, see p. 709: rami pharyngei).

7. *Rami tonsillares* (see Fig. 777) arise close behind the root of the tongue, and pass to the mucous membrane of the tonsil and of the palatine arch.

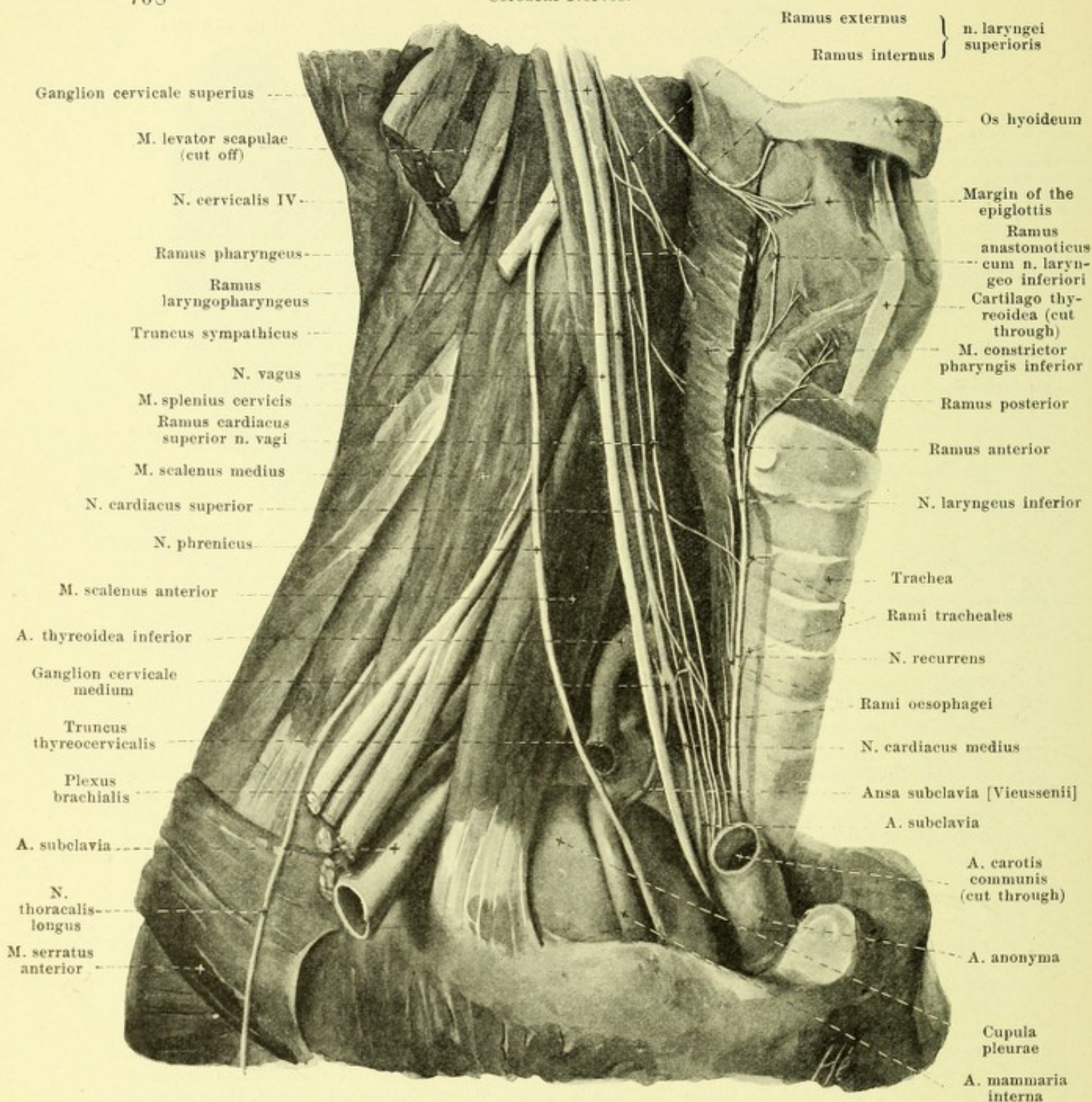
8. *Rami linguales* (see Fig. 777) to the mucous membrane of the posterior third of the tongue (see Fig. 778); they unite manifoldly with one another, and carry chiefly the taste fibers and other sensory fibers for this region. Numerous anastomoses exist between the right and left branches and those of the n. lingualis (V).



779. Right ramus auricularis n. vagi, viewed from behind.

(The head has been removed from the spine by a frontal section; the processus mastoideus with the origin of the m. digastricus has been subsequently removed.)

X. N. vagus (see Figs. 696, 697, 702, 705, 759, 761, 775—781), a mixed nerve, leaves the brain with 10—15 fila radicularia just below the n. glossopharyngeus in a sulcus of the medulla oblongata running behind the olive (see p. 629). The fibers converge to form a round nerve stem which passes lateralward in front of the tonsilla cerebelli on the tuberculum jugulare to the anterior compartment of the foramen jugulare, and downward through this in a curve (see Figs. 759, 761, 775 and 777). It together with the n. accessorius is accompanied there by a process of the dura mater and arachnoidea and is separated by these from the n. glossopharyngeus. In the foramen jugulare it presents a small swelling, *ganglion jugulare* (see Fig. 777); below it receives the ramus internus n. accessorii (see p. 710), and becomes thickened, its bundles loosening up plexus-like, to form the elongated spindle-shaped *ganglion nodosum* (see also Figs. 776 and 777). Both ganglia are similar in structure to the spinal ganglia and contain the cells of origin of the sensory fibers of the nerve (see p. 678); the motor fibers run past the ganglion cells. Just beneath the foramen jugulare (see also Figs. 776 and 777) the n. vagus lies behind the n. glossopharyngeus, in front of the n. accessorius and the v. jugularis interna and lateral from the n. hypoglossus, which then loops around past the posterior surface of the ganglion nodosum to the lateral side of the n. vagus. The n. vagus then lies in the groove between the a. carotis interna or communis and v. jugularis interna (see also Fig. 307) and passes with these vessels down the neck (see Figs. 776, 777 and 780) as far as the upper aperture of the thorax; in its course it lies somewhat lateralward and in front of the ganglion cervicale superius and the truncus sympathicus, which intervene between it and the prevertebral muscles. From there on downward the right and left nerves behave somewhat differently. On the right side (see Figs. 780 and 788) the nerve runs in front of the a. subclavia (medial from the truncus thyrocervicalis) and downward behind the v. subclavia and gives off here the n. recurrens which loops around the inferior surface of the a. subclavia in a curve backward and upward. The nerve then passes downward and backward (see Figs. 628 and 630) on the right side of the trachea to the posterior surface of the bronchus dexter (in front of the v. azygos) and there breaks up into an elongated plexus. From this one or several strands run on the posterior surface of the oesophagus, anastomose with one another there (*plexus oesophageus posterior*) and with the branches of the left n. vagus and finally arrive on the posterior surface of the stomach.



780. Right n. vagus in the neck, viewed from the right.

(The scapula and clavicle with their muscles, the hyoid muscles and the thyroid gland have been completely removed; the large vessels have been partially removed.)

X. N. vagus (continued): The left n. vagus (see Figs. 629—631, 781 and 788) descends between the aa. carotis communis and subclavia sinistra, directly in contact with the pleura mediastinalis to the anterior left surface of the arcus aortae and there sends off the n. recurrens, which runs upward and backward in a curve around the inferior surface of the arcus aortae. The further course of the n. vagus differs from that of the right side only through the fact that it lies upon the anterior surface of the oesophagus (there forming the *plexus oesophagus anterior*) and runs on it to the anterior surface of the stomach.

Branches from A) Cephalic part of the n. vagus (between the brain and the ganglion nodosum):

1. *Ramus meningeus* (not illustrated), from the ganglion jugulare runs upward in a recurrent direction through the foramen jugulare and gives off branches to the dura mater around the latter.

2. Anastomoses with the ganglion cervicale superius (branch of the n. jugularis).
 3. *Ramus auricularis* (see Fig. 779) arises close below the ganglion jugulare, but usually receives a thread from the n. glossopharyngeus (see p. 706), passes in front of the n. accessorius and the bulbus v. jugularis superior in the fossa jugularis to the canaliculus mastoideus and through this to the canalis facialis, and lies in contact with the n. facialis as far as the foramen stylomastoideum, it then runs upward in a curve at the anterior margin of the processus mastoideus near the n. auricularis posterior, perforates the membranous part of the auricula and is distributed to the concave surface of the auricula (see Fig. 774) and to the external acoustic meatus.
 4. *Ramus anastomoticus cum n. glossopharyngeo* (see Fig. 777, not designated), 1—2 fine threads of communication between the ganglion petrosum n. glossopharyngei and the n. vagus.
 5. Communication of the n. vagus with the ramus internus n. accessorii (see pp. 707 and 710).
- B) Cervical part of the n. vagus (as far as the origin of the n. recurrens).
1. Anastomoses between the ganglion nodosum and α) the ganglion cervicale superius (see Fig. 779) and β) the n. hypoglossus (see Fig. 776 and 777).
 2. *Rami pharyngei* (see Figs. 776 and 777), usually two, from the ganglion nodosum, between the a. carotis interna and externa, downward and forward to the pharynx, interweaving upon the m. constrictor pharyngis medius with the rami pharyngei n. glossopharyngei (see p. 706) and the rami laryngopharyngei of the sympathetic to form the *plexus pharyngeus*. From this arise the motor fibers for the mm. constrictores pharyngis, levator veli palatini, uvulae, glosso-palatinus, pharyngopalatinus, which leave the brain in the n. vagus, and for the m. stylopharyngeus, which come from the brain in the n. glossopharyngeus and go into the n. vagus (vide supra) in the foramen jugulare, as well as the sensory fibers for the mucous membrane of the pharynx.
 3. *N. laryngeus superior* (see Figs. 777 and 780), from the inferior extremity of the ganglion nodosum, runs downward and forward upon the m. constrictor pharyngis medius on the medial side of the a. carotis interna and externa; in its course it anastomoses by delicate threads with the plexus pharyngeus and the ganglion cervicale superius and gives off a delicate branch to the a. carotis interna. At the cornu superius oss. hyoidei it divides into two branches:
 - a) *Ramus externus* (see Figs. 777 and 780), the smaller of the two, descends almost vertically upon the external surface of the m. constrictor pharyngis inferior to the m. cricothyroideus, supplies this with motor fibers and gives sensory fibers to the mucous membrane of the larynx. It receives a thread from the ganglion cervicale superius, anastomoses with the plexus pharyngeus and gives off *rami pharyngei* to the m. constrictor pharyngis inferior, often also a ramus cardiacus superior (vide infra).
 - b) *Ramus internus* (see Figs. 777 and 780) runs forward and downward medial from the a. thyroidea inferior and from the m. thyroehyoideus on the membrana hyothyroidea (see also Fig. 776), perforates the latter along with the a. laryngea superior (see also Fig. 609), extends medianward and downward in the plica nervi laryngei (see Figs. 549 and 551) and divides into several branches (see Fig. 780). Some of these go upward near the epiglottis to its mucous membrane and to that of a small part of the root of the tongue (see also Fig. 778), others supply the mucous membrane of the larynx above the glottis and the pharyngeal mucous membrane behind the cartilaginee arytaenoideae and cricoideae; a delicate twig, *ramus anastomoticus cum n. laryngeo inferiori*, passes downward upon the internal muscles of the larynx to the n. laryngeus inferior.
 4. *Rami cardiaci superiores* (see Figs. 777, 780, 781 and 788), 1—3, arise at a variable height between the n. laryngeus superior and n. recurrens, the uppermost often wholly or partly from the n. laryngeus superior; they pass along the a. carotis communis (and, on the right side, the a. anonyma) to the aorta and there help to form the plexus cardiacus (see p. 767). They anastomose even in the neck with the nn. cardiaci of the sympathicus.
 5. *N. recurrens* (see Figs. 780, 781 and 788) (for origin see pp. 707 and 708) bends medianward and upward on the right around the inferior surface of the a. subclavia, on the left around that of the arcus aortae (lateral from the lig. arteriosum), passes from there, close to the trachea, vertically upward, on the right side on the right margin of the oesophagus, on the left side on its anterior surface, and ends above as the *n. laryngeus inferior*. It anastomoses with the ganglion cervicale inferius and the n. cardiacus superior. Branches:
 - a) *Rami cardiaci inferiores* (see Figs. 781 and 788), variable in number, arise partly from the thoracic part of the n. vagus and pass on the right side close to the a. anonyma, on the left side on the arcus aortae to the plexus cardiacus (see p. 767), which they help to form.
 - b) *Rami tracheales* (see Fig. 780) (some also from the thoracic part of the n. vagus) to the musculature and mucous membrane of the trachea.
 - c) *Rami oesophagei* (see Fig. 780) to the wall of the oesophagus and of the pharynx.
 - d) *N. laryngeus inferior* (see Fig. 780) ascends usually between, more rarely behind or in front of the terminal branches of the a. thyroidea inferior, on the medial surface of the lateral lobe of the thyroid gland, passes under the m. cricopharyngeus (see also Fig. 555) on its medial side and divides behind the articulatio cricothyroidea into two branches.

The *ramus anterior* passes upward and forward upon the mm. cricoarytaenoideus lateralis and thyreoarytaenoideus and supplies these, as well as the mm. vocalis, arytaenoideus obliquus, aryepiglotticus and thyreoepiglotticus; the *ramus posterior* runs upward to the mm. cricoarytaenoideus posterior and arytaenoideus transversus, supplies them and anastomoses with the ramus internus n. laryngei superioris (see p. 709).

C) Thoracic part of the n. vagus (downward as far as the hiatus oesophageus):

1. *Rami bronchiales anteriores* (see Fig. 781) go over and under the bronchus to its anterior wall and on it, with branches of the sympathicus, form a plexus, *plexus pulmonalis anterior*, which penetrates with the bronchus into the lung.

2. *Rami bronchiales posteriores* (see Fig. 781), larger and more numerous, form with branches of the sympathicus a narrow-meshed plexus upon the posterior surface of the bronchus, *plexus pulmonalis posterior*, which is manifoldly connected with that of the other side behind the bifurcatio tracheae; it passes forward with the bronchus into the lung.

3. *Rami oesophagei* (see Fig. 781) from the plexus oesophagei to the wall of the oesophagus.

4. *Rami pericardiaci* (not illustrated), several delicate branches from the stem of the n. vagus or from the plexus pulmonales and oesophagei to the anterior and posterior surface of the pericardium.

D) Abdominal part of the n. vagus.

The left n. vagus (see Fig. 781) forms along the anterior surface of the curvatura minor ventriculi the elongated *plexus gastricus anterior*, from which numerous *rami gastrici* pass to the wall of the stomach and several *rami hepatici* in the omentum minus to the liver.

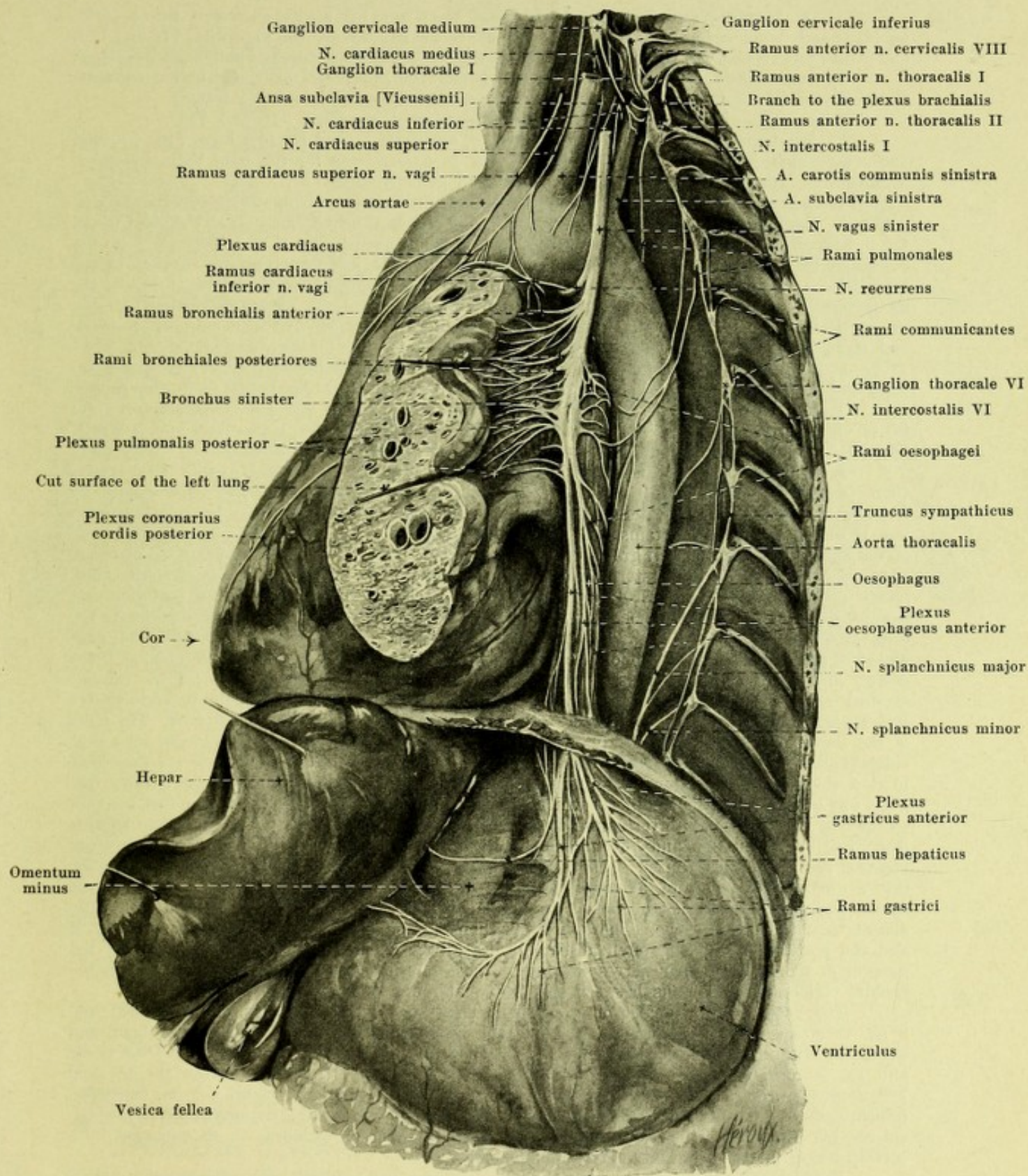
The right n. vagus (see Fig. 833) forms in a corresponding way on the posterior surface of the curvatura minor the *plexus gastricus posterior* and also sends off *rami gastrici*; in addition it passes with the majority of its fibers, *rami coeliaci*, near the a. gastrica sinistra to the ganglia coeliaca and thence with branches of the sympathicus along the vessels to the spleen (*rami lienales*), to the kidneys (*rami renales*) and to other abdominal organs.

XI. **N. accessorius** (see Figs. 696, 697, 702, 705, 759, 761, 775—777, 779 and 787), motor, leaves the central organ by two kinds of root threads, superior and inferior. The 3—6 superior threads appear just below the n. vagus in a sulcus of the medulla oblongata running behind the olive (see p. 629), the inferior are added thereto from the funiculus lateralis of the cervical cord, usually down as far as the exit of the 5th, more rarely of the 7th cervical nerve, so that usually there is a root thread corresponding to each segment (see Figs. 775 and 777). The inferior threads unite to form a small stem which ascends between the posterior roots of the cervical nerves and the lig. denticulatum; it often forms connections with the posterior roots of the first, more rarely of the second cervical nerve (usually only apparent); it then passes behind the a. vertebralis through the foramen occipitale magnum into the skull cavity, unites with the superior root fibers and, passing in front of the tonsilla cerebelli below the n. vagus to the foramen jugulare, goes downward through this in the form of a curve (see p. 707). On emergence from the foramen jugulare the n. accessorius divides into two branches (see Fig. 777):

1. *Ramus internus* (see Fig. 777), the smaller of the two, formed chiefly of the superior root fibers, unites with the n. vagus above the ganglion nodosum (see p. 707).

2. *Ramus externus* (see Figs. 776, 777, 779 and 787) runs behind or in front of the v. jugularis interna, behind the processus styloideus and its muscles and behind the venter posterior m. digastrici upon the proc. transversus atlantis downward and lateralward to the medial surface of the m. sternocleidomastoideus, usually to perforate the deep layer of this muscle, sometimes however to run past it on its medial surface. It gives motor branches to this muscle and anastomoses at the same time with a branch of the n. cervicalis III. At about the middle of the posterior margin of the m. sternocleidomastoideus it enters the regio colli lateralis (see Fig. 787) and goes downward and backward in its fatty layer to the anterior surface of the m. trapezius, in order to supply it in common with branches of the plexus cervicalis (see Figs. 786 and 787) (from the nn. cervicales II and III, or III and IV) with motor fibers.

XII. **N. hypoglossus** (s. Figs. 696, 697, 702, 705, 759, 761, 770, 775—777, 779, 786 and 789), motor, appears with 10—15 threads between the pyramid and the olive from the sulcus lateralis anterior of the medulla oblongata (see p. 629). The threads converge lateralward behind the a. vertebralis (see Fig. 775) to the canalis hypoglossi, enter the canal, usually in two bundles, more rarely as a single stem, through openings in the dura mater and run through it forward and lateralward as a single stem surrounded by the venous rete canalis hypoglossi. On emergence from the canal (see Figs. 777 and 779) the nerve lies medial from and behind the n. vagus, passes in front of the v. jugularis interna, behind the n. vagus, downward upon its lateral side (see Fig. 776, 777 and 779), goes downward and forward on it and on the lateral surface of the a. carotis interna, covered by the m. stylohyoideus and venter posterior m. digastrici, to the lateral side of the a. carotis externa (below the origin of the aa. occipitalis, maxillaris externa and sternocleidomastoidea) (see Figs. 434, 770 and 776) and then runs forward in a curve, convex below and behind, upon the lateral surface of the m. hyoglossus, there to break up into its terminal branches.



781. Left n. vagus in the thoracic and abdominal cavities, viewed from the left.

(The ribs and the left lung have been almost wholly removed, the latter and the liver have been drawn to the right, the stomach to the left and downward; the diaphragm has been partly cut away; the pleura has been dissected off.)

XII. N. hypoglossus (continued). In front it crosses the medial surface of the m. stylohyoideus and venter posterior m. digastrici close above the hyoid bone (see Figs. 434, 770 and 776) and is covered externally by the glandula submaxillaris, v. facialis communis and platysma. Branches:

1. Anastomosis by a delicate thread between the upper end of the ganglion cervicale superius and the n. hypoglossus just under the canalis hypoglossi (not illustrated).

2. Anastomosis with the ganglion nodosum n. vagi (see Figs. 776 and 777).

3. Anastomosis with the ramus anterior n. cervicalis I (and II) (see Figs. 776, 777 and 786), by which motor fibers are brought to the n. hypoglossus for the mm. thyrohyoideus, omohyoideus, sternohyoideus, sternothyroideus and geniohyoideus.

4. Delicate threads in the canalis hypoglossi running back to the bone and the sinus occipitalis.

5. *Ramus descendens* (see Figs. 770, 776, 786 and 789) usually goes off at the point where the n. hypoglossus crosses the a. carotis interna, passes downward upon it and upon the a. carotis communis (see also Figs. 307), often lying against the n. vagus, and communicates through one or several loops, *ansa hypoglossi*, (see Figs. 776, 786 and 789) situated upon the lateral surface of the great vessels (sometimes also between them) with branches of the plexus cervicalis from the nn. cervicales II and III, which bring to it motor fibers for the mm. omohyoideus, sternothyroideus and sternohyoideus. From this loop arise the branches for the muscles named.

6. *Ramus thyrohyoideus* (see Fig. 776) arises at the cornu majus oss. hyoidei and runs downward and forward to the lateral surface of the m. thyrohyoideus (for origin of its fibers vide supra).

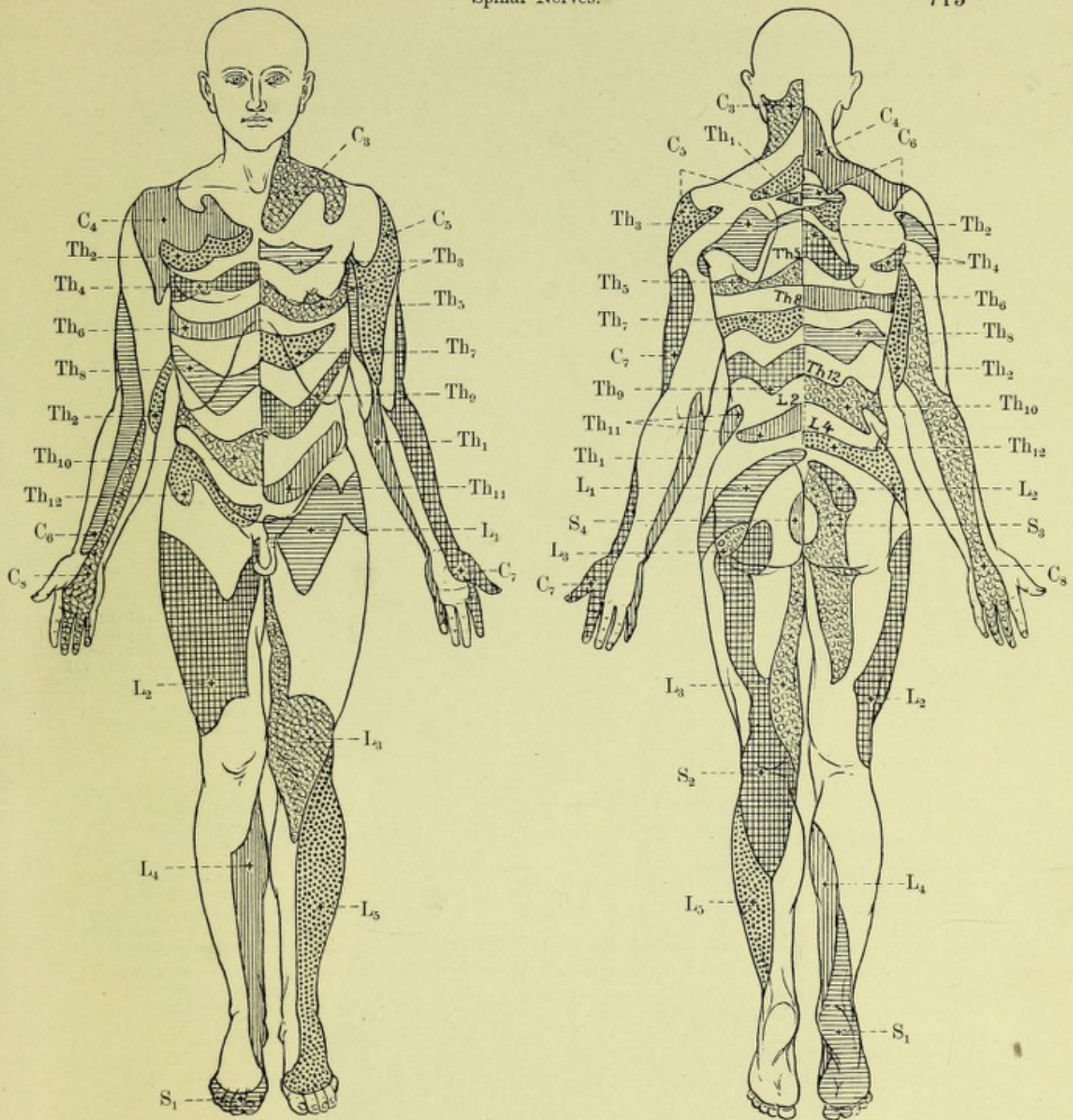
7. *Rami linguales* (see Fig. 776), terminal branches, to the mm. geniohyoideus (origin of fibers, vide supra), hyoglossus, styloglossus, genioglossus, longitudinales, transversus and verticalis linguae. They anastomose upon the m. hyoglossus with the branches of the n. lingualis (V) (see p. 699).

Nervi spinales, spinal nerves, go off from the spinal cord. They appear there (see Figs. 681, 687, 749 and 750) with two rows of *root threads, fila radicularia*, an anterior row at the sulcus lateralis anterior, a posterior row at the sulcus lateralis posterior (see p. 618); the former contains only motor, the latter only sensory fibers. The root threads of the anterior row converge in groups lateralward, each group forming a small stem, an *anterior root, radix anterior*, the posterior row situated at the same level, forming a *posterior root, radix posterior* (see Figs. 681, 687, 705 and 775). Each anterior passes with a posterior root toward the corresponding foramen intervertebrale (see Fig. 690) and the two there perforate the dura mater spinalis (see also p. 623). The direction of the roots (see Figs. 681, 683, 684, 688, 689, 775 and 777) is horizontal for the uppermost cervical nerves, becomes more oblique lower down, and caudalward descends more and more. The foramen intervertebrale for the inferior cervical nerves lies approximately one vertebral level lower, for the 1st—10th thoracic nerves two lower, than the level of emergence of the roots concerned from the spinal cord. The roots of the lowermost thoracic, of the lumbar, sacral and coccygeal nerves run downward for a considerable distance within the sac of the dura mater (see p. 622) before they leave it; they form in it a thick bundle of strands running longitudinally, the *cauda equina (horse's tail)* (see Figs. 684 and 689) in the middle of which lies the filum terminale. Each posterior root becomes swollen in the foramen intervertebrale to form the egg-shaped *spinal ganglion, ganglion spinale* (see Figs. 684, 687, 690 and 750), and lateralward from this fuses with the corresponding anterior root to form a (mixed) *n. spinalis, spinal nerve*, which divides after a short course, into a *ramus posterior* and a *ramus anterior* (see Figs. 689 and 690). The number of the spinal ganglia corresponds to that of the spinal nerves, except that the ganglion is usually absent from the n. coccygeus. The spinal ganglion of the first cervical nerve is very small, it and the posterior root being often absent; it lies in the sulcus a. vertebralis of the atlas; the ganglia of the lower lumbar nerves lie partly, those of the sacral nerves completely, within the canalis vertebralis or sacralis between the dura mater and the bone (see Fig. 689).

There are 31 nn. spinales on each side. They are divided (see Figs. 681 and 683) into 8 *nn. cervicales, cervical nerves*, of which the first emerges between the occipital bone and the atlas, the second between the atlas and the epistropheus, the eighth between the 7th cervical and 1st thoracic vertebra, 12 *nn. thoracales, thoracic nerves*, the first between the 1st and 2nd thoracic vertebrae, the twelfth between the 12th and 1st lumbar vertebrae, 5 *nn. lumbales, lumbar nerves*, 5 *nn. sacrales, sacral nerves* and 1 *n. coccygeus, coccygeal nerve*, which emerge like the thoracic nerves. An increase in the number of vertebrae is accompanied by a corresponding increase in that of the spinal nerves.

In the 1st and 2nd cervical nerves the posterior branches are larger than the anterior, otherwise the reverse is true. Each anterior branch is connected by at least one fine thread, *ramus communicans*, with a ganglion of the sympathicus (see Figs. 690, 777, 781, 832, 873 and 878). Besides, it gives off a *ramus meningeus* (not illustrated), which receives sympathetic threads from the ramus communicans, passes back through the foramen intervertebrale of its nerve into the vertebral canal, anastomoses with others and is distributed to the wall of the canal.

Neighboring nerves anastomose manifoldly with one another through *ansae, loops*, which are regularly present and large in size, on the anterior branches of the cervical, lumbar and sacral nerves.

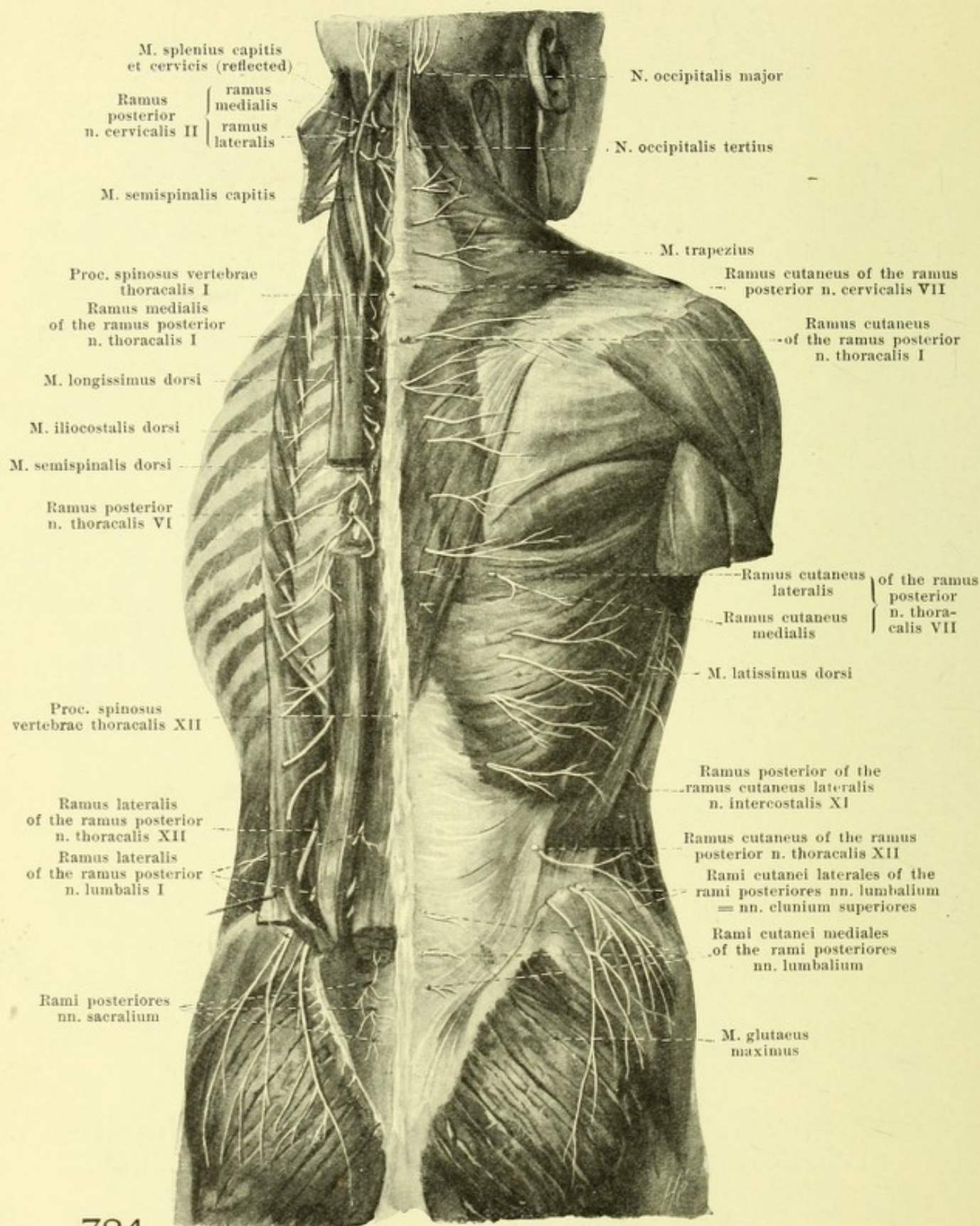


782 and 783. Areas of distribution of the individual spinal nerves in the skin (after H. Head),
 viewed from in front viewed from behind.

In reality the individual areas overlap one another more or less.

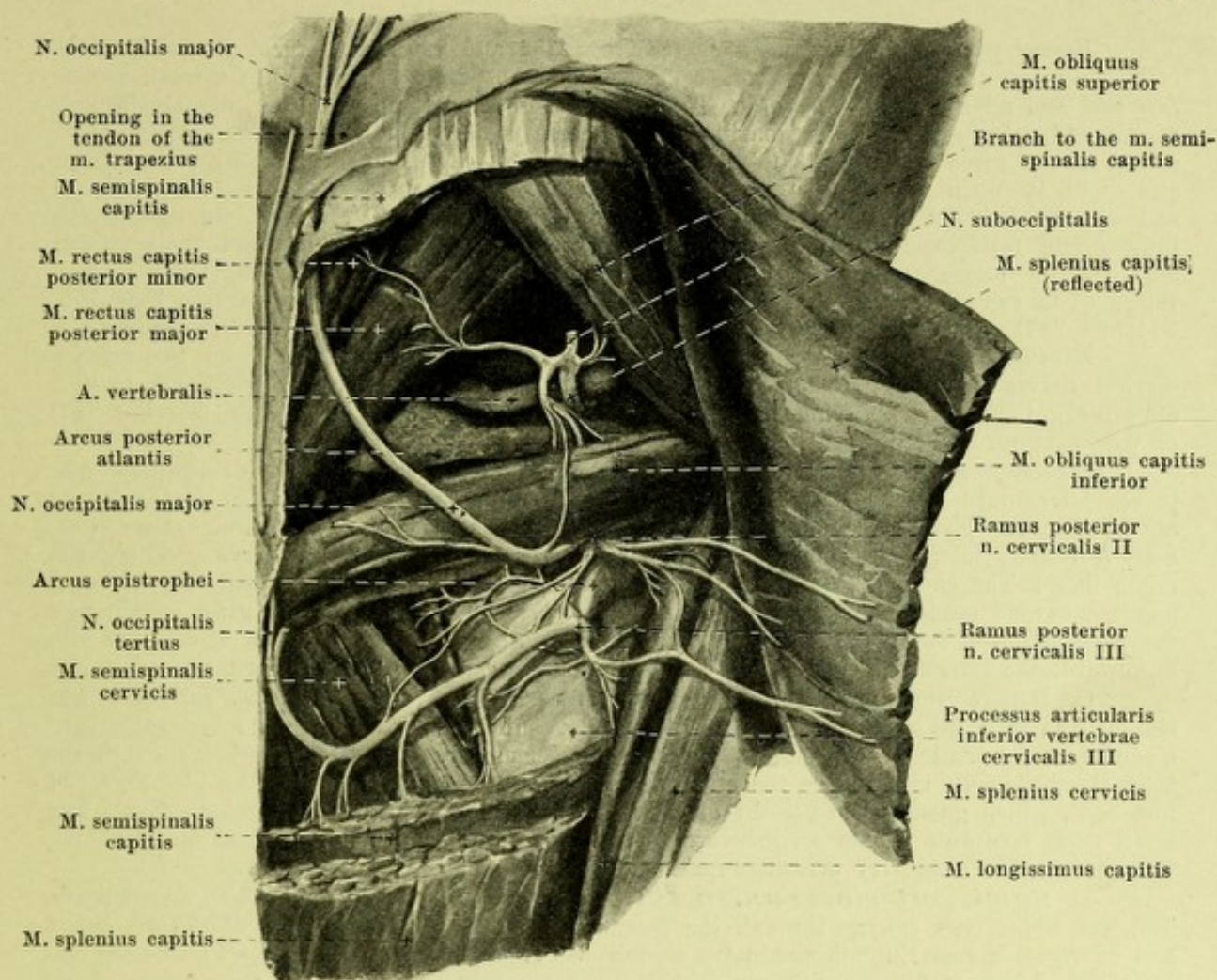
(The designations Th 5, L 2 etc. printed in Fig. 783 indicate the position of the proc. spinosus vertebrae thoracalis V, lumbalis II etc. Concerning the other designations vide infra.)

Note: In the figures and descriptions of the spinal nerves C = n. cervicalis, Th = n. thoracalis, L = n. lumbalis, S = n. sacralis, Co = n. coccygeus; thus C₅ = n. cervicalis V etc. Spalteholz, Atlas.



784.

Posterior rami of the spinal nerves, viewed from behind.
 (On the left the shoulder girdle with its muscles, along with the mm. latissimus dorsi, rhomboidei and the fascia lumbodorsalis have been removed. The long muscles of the back have been isolated [see Figs. 336—338], and pieces have been cut out of them; the posterior surface of the sacrum is exposed.)



785. Posterior rami of the 1st, 2nd and 3rd cervical nerves of the right side, viewed from behind.

(The m. splenius capitis has been reflected lateralward, the m. semispinalis capitis has been for the most part removed, the m. trapezius completely removed.)

The **rami posteriores nn. spinalium** (see also Figs. 690 and 784) with the exception of the three upper cervical nerves are smaller than the anteriores. In a typical nerve (middle thoracic) each ramus posterior passes dorsalward medial from the ligg. costotransversarium anterius and intertransversarium (mm. intertransversarius posterior for the cervical nerves, lateralis for the lumbar nerves), and divides (excepting the first cervical, fourth and fifth sacral and the coccygeal nerves) into *ramus medialis* and *ramus lateralis*, which enter the musculature, and of which usually only one in the upper half the medial, in the lower half the lateral goes to the skin. Almost all the rami run also caudalward, especially the lower ones, so that their distribution in muscle and skin lies below their emergence from the foramen intervertebrale (see Figs. 783 and 784). The rami behave differently at different levels.

A. Rami posteriores nn. cervicalium (see also Figs. 777 and 784). Each *ramus lateralis* passes lateralward around the m. semispinalis capitis and branches on it, on the m. intertransversarius posterior, the mm. iliocostalis, longissimus and splenius. The *ramus medialis* passes medianward between the mm. semispinalis capitis and cervicis, supplies these, as well as the deeper lying and short muscles of the neck, near the proc. spinosus perforates the mm. semispinalis capitis and trapezius (true usually only of the 4th—6th cervical nerve), to bend around lateralward as the *ramus cutaneus* to the skin. The course and distribution of the posterior rami of the first, second and third cervical nerves deviate somewhat.

Ramus posterior n. cervicalis I = *N. suboccipitalis*, considerably larger than the corresponding anterior ramus, purely motor, passes backward under the a. vertebralis in the triangle between the mm. obliqui capitis and rectus capitis posterior major. It supplies these muscles as well as the mm. rectus capitis minor and semispinalis capitis, gives off branches to the articulatio atlantooccipitalis and anastomoses with the posterior limb of the 2nd cervical nerve.

Ramus posterior n. cervicalis II (see Figs. 784 and 785), the largest posterior ramus of all, divides at the inferior margin of the m. obliquus capitis inferior into a small *ramus lateralis* and a large *ramus medialis*. The former sends motor branches to the mm. longissimus capitis and splenius; the latter anastomoses with the posterior branches of the first and third spinal nerves, gives motor fibers to the mm. semispinalis capitis and obliquus capitis inferior and, with its main mass as the sensory *n. occipitalis major*, passes in a curve medianward and upward between the m. semispinalis capitis on the one side, the mm. obliquus capitis inferior and recti capitis posteriores on the other side, perforates the m. semispinalis capitis near the lig. nuchae and goes through an opening in the tendon of the m. trapezius (see Fig. 296) to run under the skin. Its branches go upward as far as the vertex (see Figs. 772, 774 and 787) and anastomose with one another and with branches of neighboring nerves.

Ramus posterior n. cervicalis III (see Figs. 784 and 785) differs from the inferior cervical nerves in that the end of its ramus medialis, as the sensory *n. occipitalis tertius*, after perforation of the m. semispinalis capitis goes either to the adjacent skin (see Fig. 787) or passes upward wholly or in part with the *n. occipitalis major*.

Rami posteriores nn. thoracalium (see Figs. 690 and 784). Each *ramus lateralis* passes lateralward between the mm. longissimus and iliocostalis and usually on the 7th or 8th—12th nerve gives off through the m. latissimus dorsi a branch to the skin, *ramus cutaneus lateralis*, lateralward and somewhat downward, that for the 12th nerve reaching the crista iliaca. The *ramus medialis* goes medianward toward a proc. spinosus between the mm. longissimus and semispinalis dorsi, that for the 1st—7th or 8th nerve usually gives off through the m. trapezius a *ramus cutaneus medialis* lateralward. The rami mediales decrease in size downward, the laterales increase. Both send motor branches to the neighboring muscles.

C. Rami posteriores nn. lumbalium (see Fig. 784). The *rami laterales* pass obliquely lateralward through the m. sacrospinalis, supply it and the mm. intertransversarii mediales and decrease in size below. The three upper usually send skin branches through the fascia lumbodorsalis close above the crista iliaca, the *nn. clunium superiores* (see also Figs. 821 and 828), which go downward to the buttock (lateralward as far as the trochanter major). The small *rami mediales* extend medianward to the m. multifidus and to the short muscles; the three lower ones send very delicate branches to the skin of the sacral region.

D. Rami posteriores nn. sacralium et n. coccygei (see Fig. 784), very delicate. The four upper ones emerge through the foramina sacralia posteriora, those of the 5th sacral and coccygeal nerves through the hiatus sacralis between the ligg. sacrococcygea posteriora (see Fig. 689). They anastomose with one another upon the posterior surface of the sacrum. *Rami laterales* are present on only the three upper sacral nerves; they perforate the origin of the m. gluteus maximus and there go as *nn. clunium medii* to the skin (see Figs. 821 and 828). The *rami mediales* go to the m. sacrolumbalis and send most delicate branches to the skin (like the preceding).

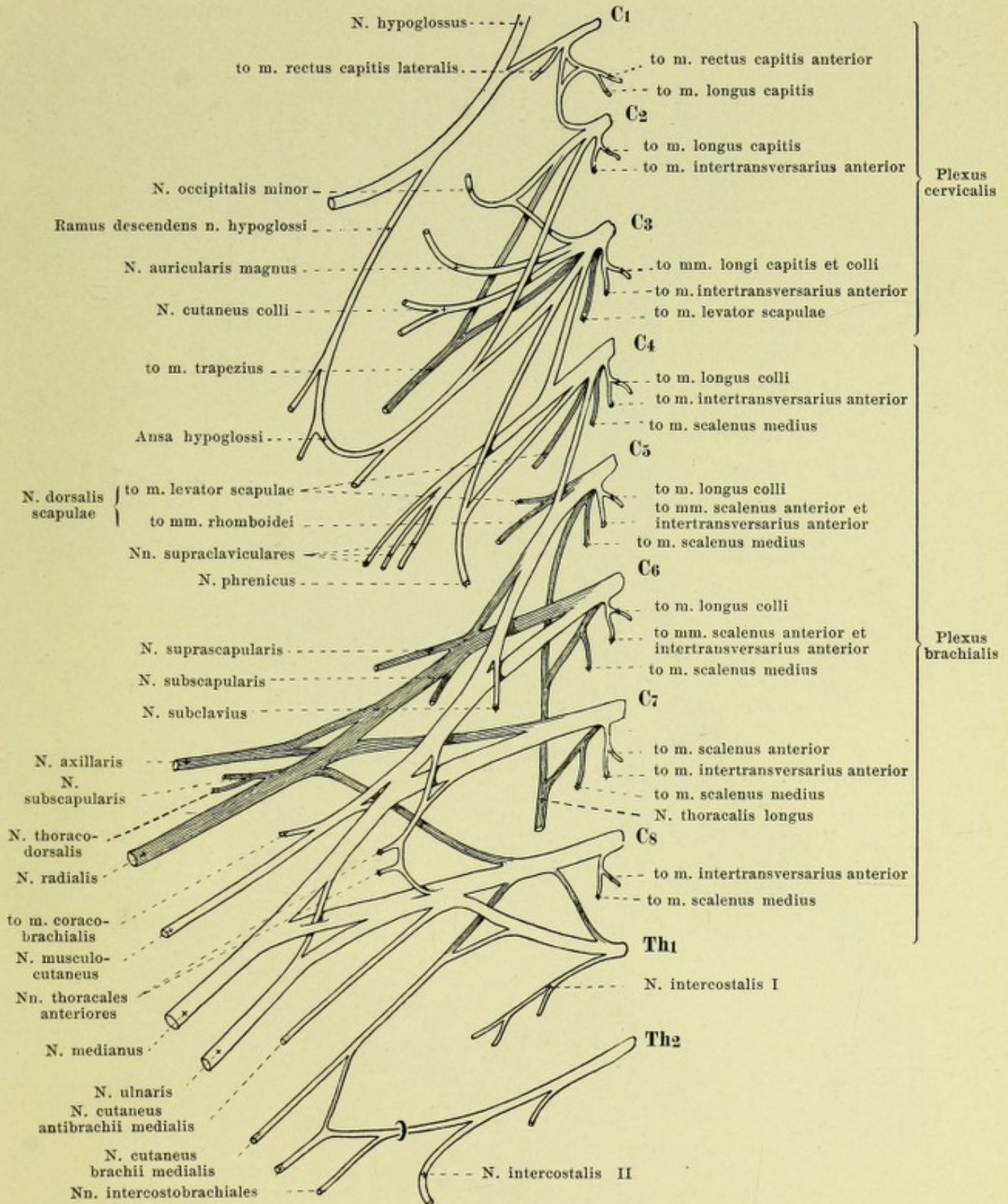
The **rami anteriores nn. spinalium** remain independent in their course only in the region of the thoracic nerves. In the cervical, lumbar and sacral regions they form connections with one another, at the same time dividing, so as to give rise to complicated plexuses, *plexus*, of which there are three on each side, *plexus cervicalis*, *brachialis* and *lumbosacralis*.

Rami anteriores nn. cervicalium. Those for the 3th—8th nerve run lateralward behind the a. vertebralis in the sulcus n. spinalis of the corresponding vertebra (see Fig. 777) between the mm. intertransversarii anterior and posterior; they appear lateral from the mm. longi capitis and colli and the origins of the m. scalenus anterior, medial and in front of the origins of the mm. splenius cervicis, levator scapulae and scalenus medius (see Fig. 776). That of the first goes forward under the a. vertebralis (see Figs. 775 and 777) and appears between the mm. recti capitis anterior and lateralis; that of the second (see Fig. 777) grasps the a. vertebralis from behind and without and turns forward, medial from the m. intertransversarius posterior.

The anterior rami of the 1st—4th cervical nerves anastomose with one another by means of curved loops and thus form the *plexus cervicalis*, *cervical plexus* (see Figs. 776, 777 and 786). This, covered by the m. sternocleidomastoideus, attached to the fascia praevertebralis, lies in front of the origins of the mm. splenius cervicis, levator scapulae and scalenus medius. The plexus communicates with the n. accessorius (see p. 710), the main trunk and ramus descendens of the n. hypoglossus (see p. 712), as well as with the ganglion cervicale superius and the truncus sympathici (see Fig. 777) by rami communicantes, at least one for each cervical nerve. The rami of the plexus are divisible into cutaneous and muscular branches.

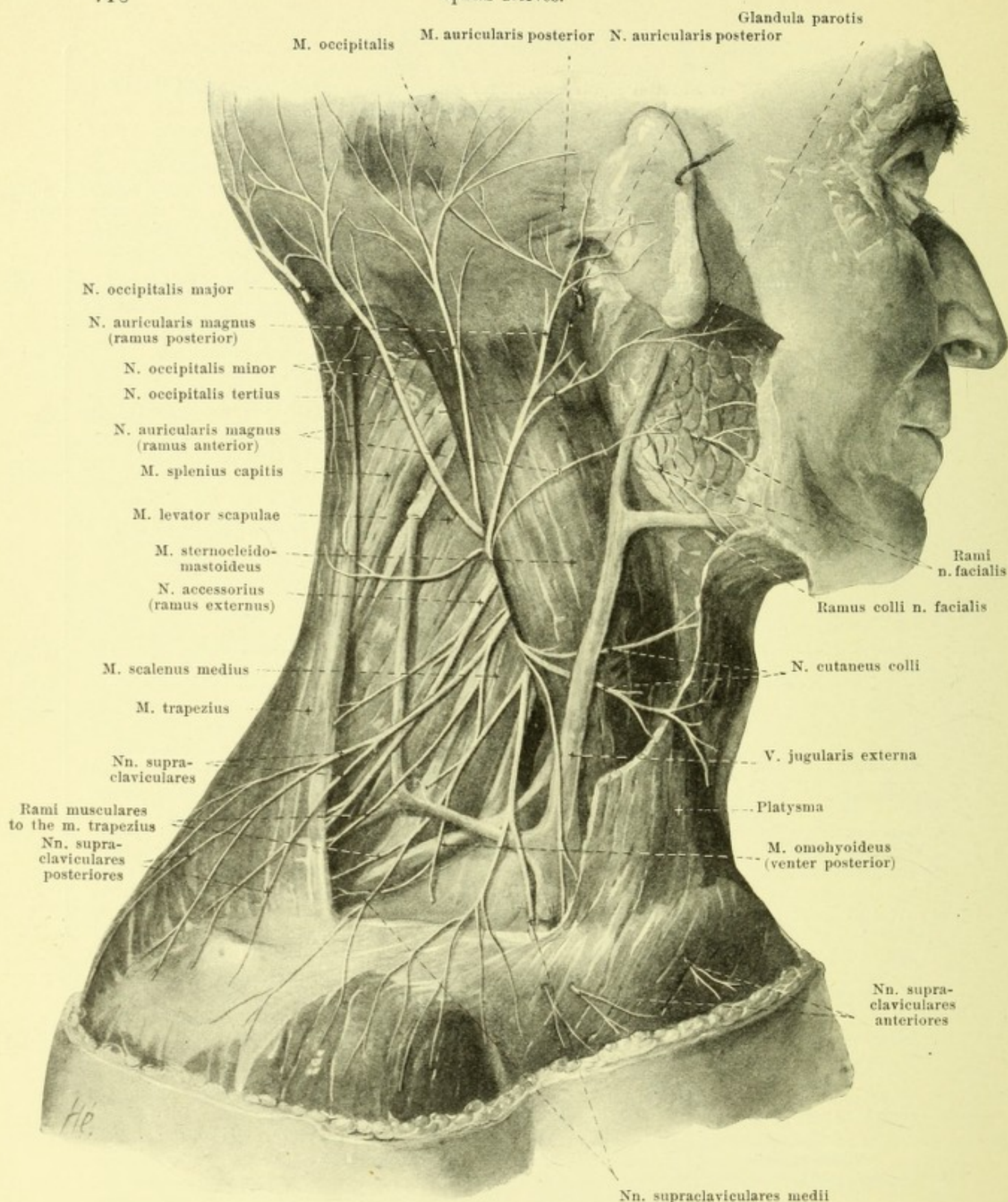
A. Cutaneous branches (see Figs. 772 and 787), appear at the middle of the posterior margin of the m. sternocleidomastoideus:

1. *N. occipitalis minor* (see Figs. 774, 786 and 787), from C₂ and C₃, runs upward at the posterior margin of the m. sternocleidomastoideus upon this and the m. splenius, and sends its terminal branches to the skin of the lateral occipital and the temporal region; it anastomoses with branches of the nn. auricularis posterior, occipitalis major and auricularis magnus.



786. Right plexus cervicalis and brachialis, schematic, viewed from in front (after P. Eisler).

(The darkly shaded strands are derivatives of the dorsal half of the plexus.)



787. Cutaneous branches of the right plexus cervicalis, viewed from the right.

(The platysma has been partially removed.)

2. *N. auricularis magnus* (see Figs. 774, 786 and 787), from C_3 , usually the largest branch, ascends in front of the preceding upon the lateral surface of the m. sternocleidomastoideus behind the v. jugularis externa, vertically to the ear. At the level of the angulus mandibulae it undergoes division. The smaller *ramus anterior* passes forward and upward under the ear, and passes sometimes partly through the parotid gland, to the skin of the lateral inferior half of the face (see Fig. 772), as well as to that of the lobule of the ear and of the concave surface of the auricula. The *ramus posterior* runs behind the ear to the skin on the convex side of the auricula and forward as far as the skin of the temporal region. It anastomoses with branches of the nn. auricularis posterior and occipitalis minor.

3. *N. cutaneus colli* (see Figs. 786 and 787), from C_3 or C_2 and C_3 , passes forward, under the foregoing, upon the lateral surface of the sternocleidomastoideus, covered by the platysma, medial or lateral from the v. jugularis externa. It divides into *rami superiores* of which one unites with the ramus colli n. facialis (see Figs. 774 and p. 701), and *rami inferiores*. They perforate the platysma, are all sensory and go to the skin of the regio sternocleidomastoidea and of the regio colli anterior upward as far as the margin of the lower jaw.

4. *Nn. supraclaviculares* (see Figs. 786, 787, 792, 794, 806 and 807) from C_3 and C_4 , run superficially, covered only by the platysma, through the fossa supraclavicularis major, diverging downward, and divide into three groups:

a) *Nn. supraclaviculares anteriores* pass downward upon the v. jugularis externa and in front of the clavicle and through the platysma to the skin under the medial part of the clavicle.

b) *Nn. supraclaviculares medii* go downward in front of the clavicle to the skin over the clavicle and m. pectoralis major as far as the region of the nipple.

c) *Nn. supraclaviculares posteriores* pass downward and backward upon the m. trapezius to the skin over the m. deltoideus, rarely still farther distalward.

B. Muscular branches, partly directly from the cervical nerves (see Fig. 786):

1. For the mm. rectus capitis lateralis from C_1 , rectus capitis anterior from C_1 and C_2 , longus capitis from (C_1) C_2 and C_3 , longus colli from C_3 — C_6 , scalenus medius from C_4 — C_5 , levator scapulae from C_3 — C_5 and intertransversarii anteriores from C_2 — C_8 .

2. Branch to the ramus descendens hypoglossi (see Figs. 776 and 786), from C_2 and C_3 ; it helps to form the ansa hypoglossi (see p. 712) under the m. sternocleidomastoideus.

3. Branch for the m. trapezius (see Figs. 786 and 787), from C_2 and C_3 or C_3 and C_4 , frequently a branch of the nn. supraclaviculares posteriores; it anastomoses with the n. accessorius.

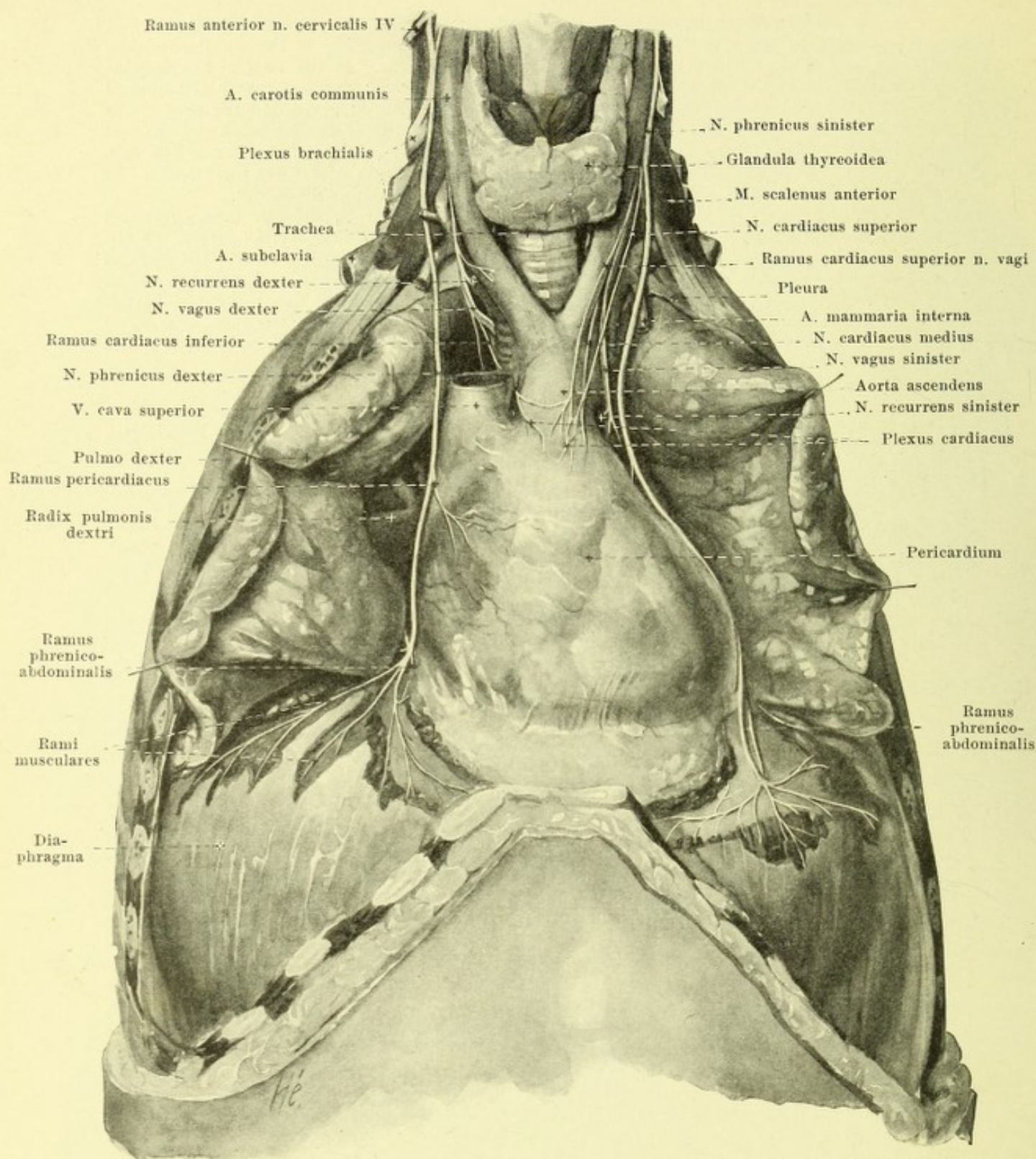
4. *N. phrenicus* (see Figs. 776, 780, 786, 788 and 789) a mixed nerve, from C_3 and C_4 or C_4 and C_5 , with the largest root from C_4 , passes downward and somewhat medianward upon the anterior surface of the m. scalenus anterior (see Fig. 780), lateral from the a. cervicalis ascendens, runs between the a. and v. subclavia, lateral from the truncus thyrocervicalis and n. vagus, in front of or behind the a. mammaria interna, to the anterior medial declivity of the cupula pleurae, and enters the thoracic cavity behind the articulatio sternoclavicularis. There it passes under the pleura mediastinalis along with the a. pericardiophrenica in front of the root of the lung to the pericardium and then between this and the pleura pericardiaca to the diaphragm (see also Figs. 628—630). In its course on the right side it lies on the lateral surface of the v. anonyma dextra and vena cava superior, close in front of the radix pulmonis, and reaches the diaphragm somewhat in front of and lateral from the foramen venae cavae. On the left side it runs lateral from the arcus aortae, lies further ventral from the root of the lung and reaches the diaphragm further lateralward and forward than on the right side. It communicates by delicate threads with the ganglion cervicale inferius of the sympathetic and very often receives a branch from the n. subclavius (see Fig. 789). Branches (see Fig. 788):

a) *Ramus pericardiacus*, usually on the right side only, upon the v. cava superior to the pericardium.

b) Very delicate branches to the pleura (not illustrated).

c) Terminal branches, perforate the diaphragm; as *rami musculares* they innervate the musculature from the concave side; as *rami phrenicoabdominales* they anastomose with the plexus phrenicus of the sympathetic, and send threads to the tunica serosa of the liver and to the suprarenal glands.

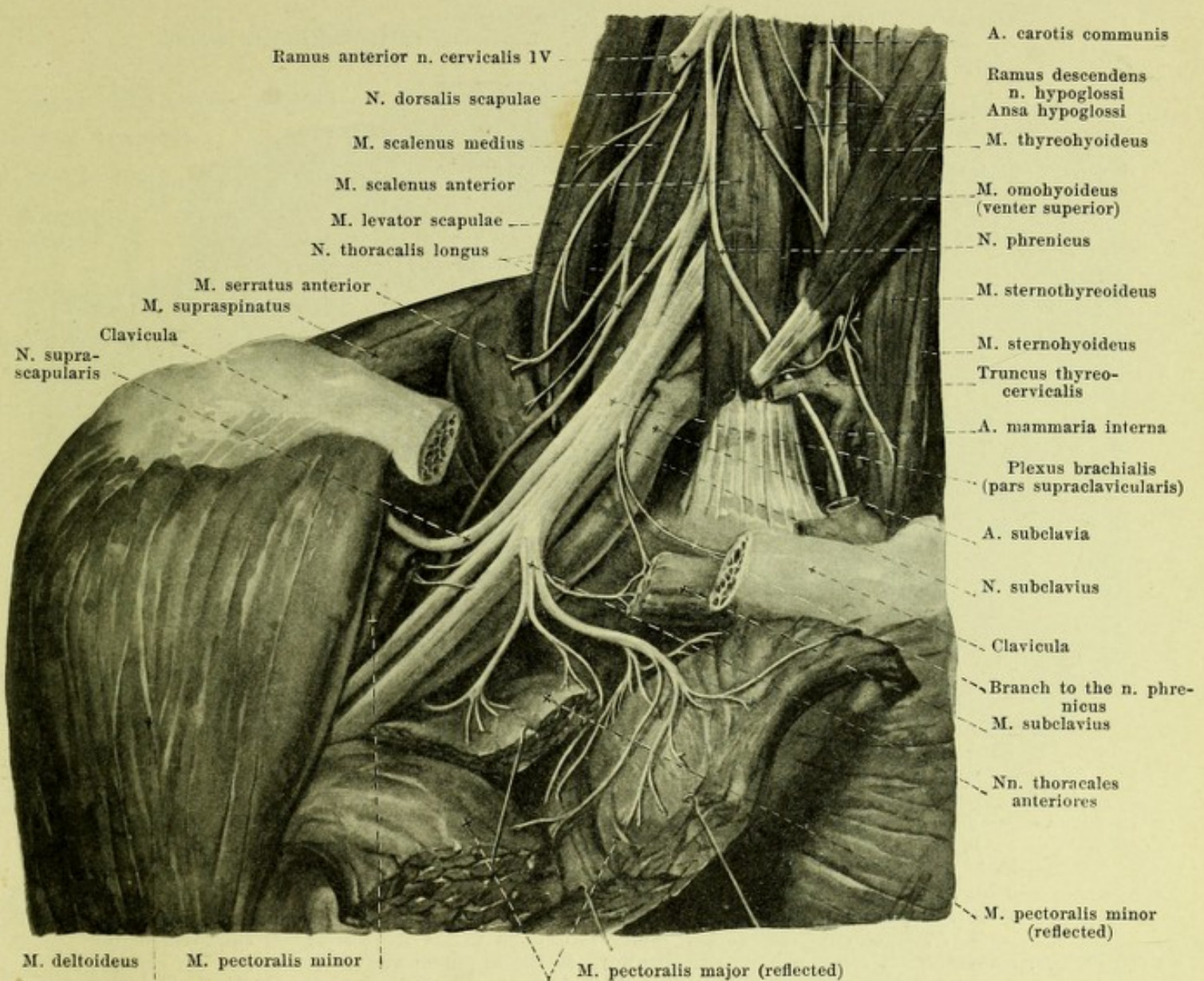
The anterior rami of the 5th—8th cervical nerves together with a small part of the 4th cervical nerve, with the upper, larger part of the 1st thoracic nerve and very often with a delicate branch of the 2nd thoracic nerve form the plexus brachialis, *arm plexus* (see Figs. 780, 781, 786, 789, 791 and Sympathicus). Its roots pass lateralward behind the origins of the m. scalenus anterior, in front of those of the m. scalenus medius; the 5th—7th cervical nerves run at the same time markedly downward, the 8th horizontally, the 1st thoracic nerve upward in front of the neck of the 1st rib. They unite to form an elongated plexus which lies in the space between the mm. scaleni anterior and medius, with its three upper root portions over, and with the two lower behind, the a. subclavia, thence the plexus, narrowed, passes immediately adjacent to the artery, behind the clavicle and the mm. subclavius and pectorales into the axillary fossa.



788. Nn. phrenici, viewed from in front.

(The anterior wall of the thorax has been removed; the thymus has been cut away and the pleura dissected off.)

Plexus brachialis (continued). Each of the nerves composing it sends off a ramus communicans to the ganglion cervicale medium or inferius of the sympathetic, before it enters the plexus (see Fig. 781 and Sympathicus).



789. Right plexus brachialis with its short branches, viewed from in front.

(The mm. sternocleidomastoideus and trapezius have been completely, the mm. omohyoideus and subclavius partially removed; a piece has been sawn out of the clavicle; the mm. pectorales have been incised and reflected.)

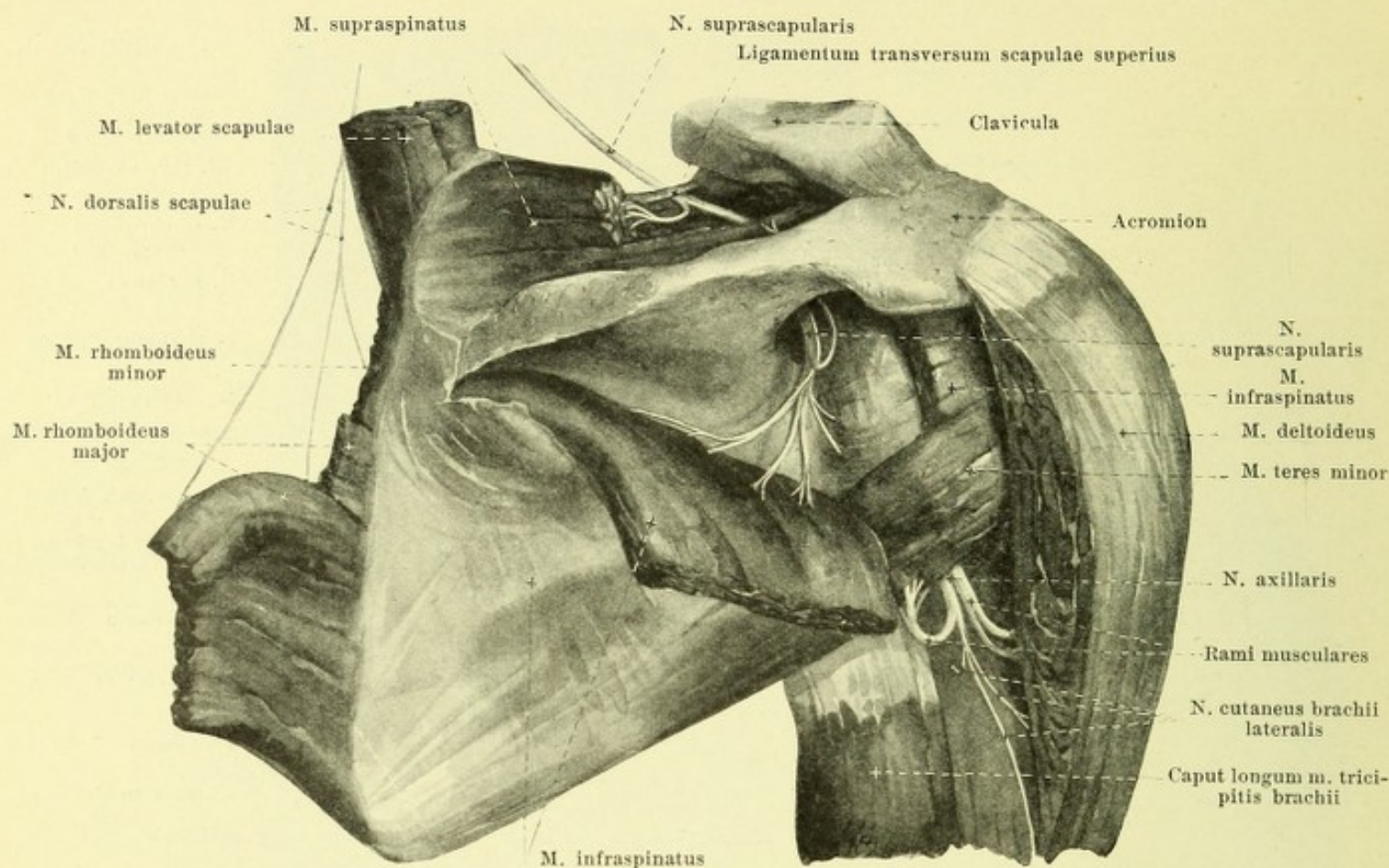
Plexus brachialis (see also Fig. 791) (continued). The plexus is divisible into a *pars supraclavicularis* and a *pars infraclavicularis*. The former reaches distalward as far as the clavicle, adjoins the mm. scalenus medius and serratus anterior dorsalward, is perforated by the a. transversa colli and is crossed in front by the posterior belly of the m. omohyoideus and by the aa. cervicalis superficialis and transversa scapulae; all the short branches are counted as belonging to it, even if they are not given off until the axillary fossa is reached; these branches innervate the deep muscles of the neck and those of the shoulder girdle.

1. Threads (directly from the trunks of the cervical nerves) for the mm. longus colli, intertransversarii and scalenus medius (see p. 719) and a branch to the n. phrenicus (see p. 719).

2. Direct branches (from the trunks of the cervical nerves) to the mm. scalenus anterior from C₅, C₆ and C₇, and scalenus posterior from C₈ (see Fig. 786).

3. *Nn. thoracales posteriores* (see also Figs. 780, 786 and 790) appear through the m. scalenus medius.

a) *N. dorsalis scapulae* (see also Fig. 790), from C₅, runs downward on the anterior surface of the m. levator scapulae, the lowermost tooth of which it supplies (see also p. 719), to the ventral surface of the mm. rhomboidei, in which it ends.



790. Nerves of the right shoulder blade, viewed from behind.

(The mm. supraspinatus and deltoideus have been partially cut away, the infraspinatus reflected.)

b) *N. thoracalis longus* (see Figs. 780, 786, 789, 791 and 811) from C_5 , C_6 and C_7 , the roots of which usually unite first in front of the m. scalenus medius (see Fig. 789), descends behind the plexus brachialis, nearly in the axillary line, upon the lateral surface of the m. serratus anterior giving a branch to each digitation.

4. *N. subclavius* (see Figs. 786 and 789), from C_5 , in front of the a. subclavia to the m. subclavius; it sends a branch medianward to the n. phrenicus (see p. 719).

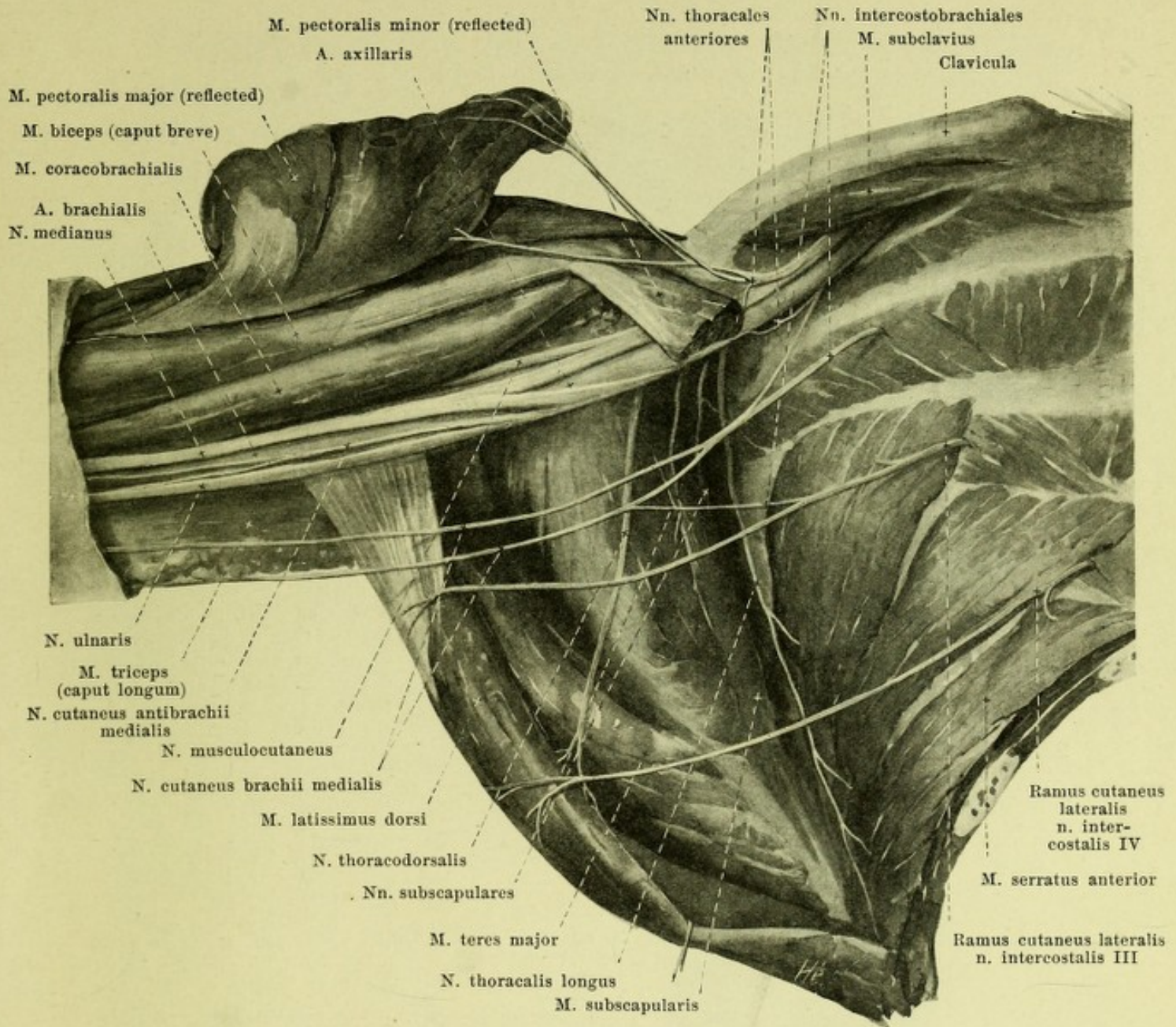
5. *Nn. thoracales anteriores* (see Figs. 786, 789 and 791), from C_5 , C_6 , C_7 , C_8 and Th_1 , usually two, run forward and downward in front of and behind the artery, then between the a. and v. subclavia, anastomosing, to the mm. pectoralis minor and pectoralis major.

6. *N. suprascapularis* (see also Figs. 786 and 789), from C_5 and C_6 , large, passes lateralward near the a. transversa scapulae under the m. trapezius and venter posterior m. omohyoidei and under the clavicula; it then passes beneath the lig. transversum scapulae superius into the fossa supraspinata, and behind the collum scapulae into the fossa infraspinata. It supplies the mm. supraspinatus and infraspinatus and gives off branches to the shoulderjoint.

7. *Nn. subscapulares* (see Figs. 786, 791 and 796), from C_5 , C_6 and C_7 , usually two, from the dorsal surface of the plexus or the n. axillaris; they run downward on the ventral surface of the m. subscapularis to this (from C_5 and C_6) and to the m. teres major (from C_7).

8. *N. thoracodorsalis* (see Figs. 786, 791 and 796), from (C_6) C_7 and C_8 , arises like (7), passes along the margo axillaris scapulae to the anterior surface of the m. latissimus dorsi.

9. *N. axillaris* (see also Figs. 786, 794, 796, 804, 806 and 807) (O. T. circumflex nerve), from C_5 , C_6 (C_7), large, arises in the axillary fossa from the fasciculus posterior of the pars infraclavicularis (see p. 723), runs behind the a. axillaris with the a. circumflexa humeri posterior, at first backward between the humerus, m. teres minor, teres major and caput longum m. tricipitis, then lateralward upon the collum chirurgicum, covered by the m. deltoideus. It sends branches to the shoulderjoint, rami musculares to the mm. teres minor and deltoideus, and gives off also the n. cutaneus brachii lateralis between the m. deltoideus and the caput longum m. tricipitis to the skin over the dorsal part of the m. deltoideus and over the posterior and lateral part of the upper arm. Some of the muscular rami of the m. deltoideus go to the skin. The lower cutaneous branches anastomose with the nn. cutanei brachii posterior and antibrachii dorsalis.



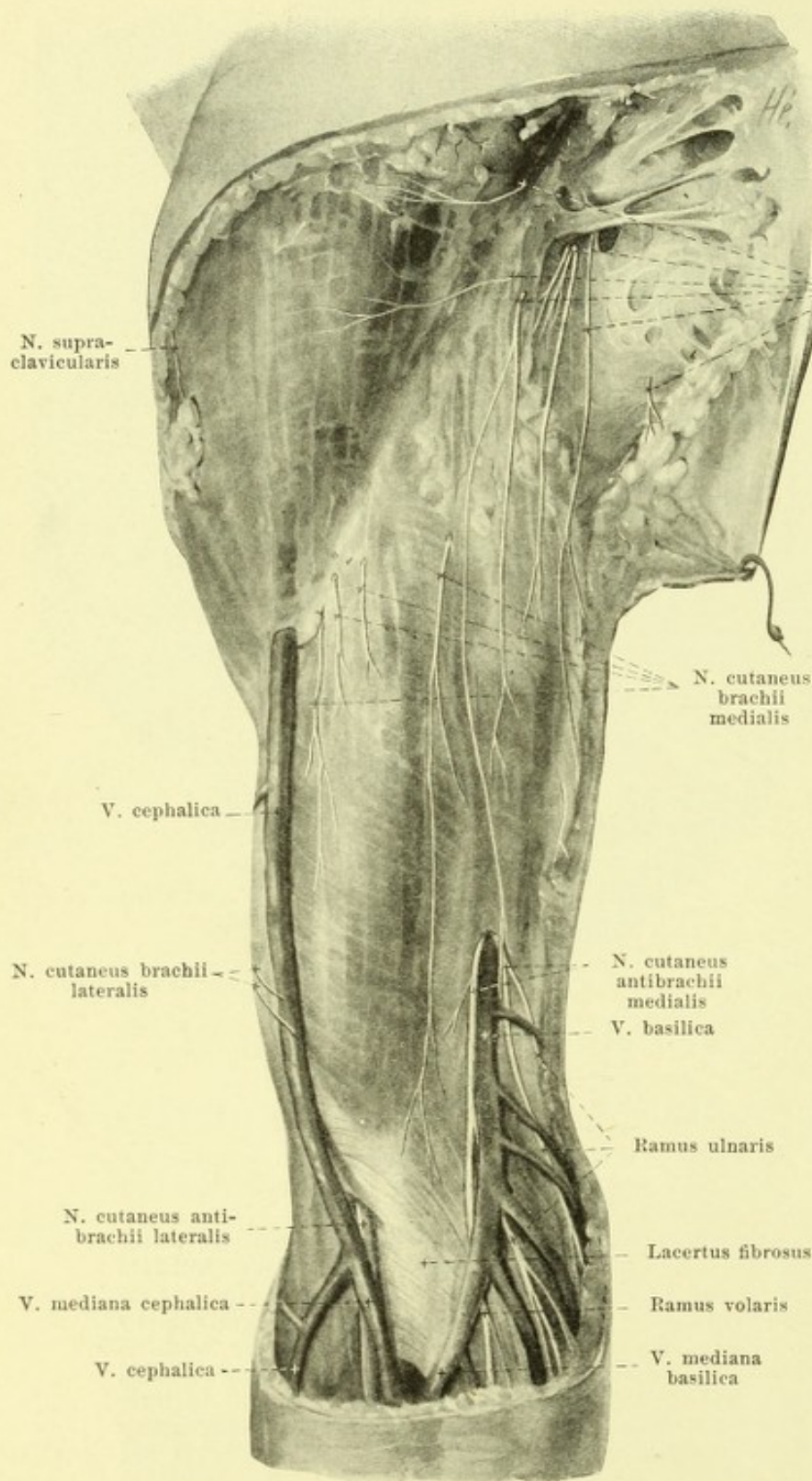
791. Right plexus brachialis (pars infraclavicularis) in the axillary fossa, viewed from below and in front.

(The mm. pectorales major et minor have been in large part removed; their attachments have been reflected.)

The *pars infraclavicularis* of the *plexus brachialis* (see also Figs. 789 and 796), passes distalward from the clavicle through the axillary fossa and breaks up in its lower half into its branches, which may also be designated as the long branches of the plexus; they go exclusively to the arm. It is bounded medianward by the m. serratus anterior, dorsalward by the m. subscapularis, is covered in front by the mm. pectorales and distalward lies, with its branches, in the groove between the mm. subscapularis and latissimus dorsi on the one side and the m. coracobrachialis on the other. The constituents of the plexus are arranged in three cords, which lie in direct contact with the a. axillaris, the *fasciculus posterior* running dorsalward, the *fasciculus lateralis* above and lateralward, and the *fasciculus medialis* below and medianward from the artery. The v. subclavia lies directly in front of and medianward from this bundle of the nerves and artery. From the fasciculus medialis proceed the nn. *cutaneus brachii medialis*, *cutaneus antibrachii medialis*, *ulnaris*, and the inferior root of the n. *medianus*, from the fasciculus lateralis the upper root of the n. *medianus* and the n. *musculocutaneus*, from the fasciculus posterior the nn. *axillaris* (see p. 722) and *radialis*.

792. Cutaneous nerves of the right upper arm,

viewed from in front.



(The arm has been abducted; the fascia has been preserved throughout.)

1. *N. cutaneus brachii medialis* (O. T. lesser internal cutaneous) (see also Figs. 786, 791, 806, 807 and 811), from C_8 and Th_1 , runs downward in the axillary fossa, in front of the *mm. subscapularis* and *latissimus dorsi*, at first dorsal, and then medial from the *v. axillaris*, and unites here in a very variable manner with the *n. intercostobrachialis* of the second, sometimes also with that of the third intercostal nerve. The branches of these stems or their anastomoses perforate the fascia axillaris or brachialis in different places; they supply the skin of the axillary fossa and of the medial surface of the upper arm as far as the elbow joint, in addition to a proximal portion of the anterior surface and a distal portion of the posterior surface.

2. *N. cutaneus anti-brachii medialis* (O. T. internal cutaneous) (see also Figs. 786, 791, 793—796, 806 and 807), from C_8 and Th_1 , lies on the anterior medial side of the *v. axillaris* and passes distalward near it; it perforates the fascia brachii in the middle of the upper arm or somewhat lower, usually at the point where the *v. basilica* vanishes under the fascia into the depth, and then (or previously) divides into two branches, which lie upon the fascia anti-brachii.

793. Cutaneous nerves of the right forearm, volar surface. (The fasciae brachii and antibrachii have been preserved.)

2. *N. cutaneus antibrachii medialis* (continued) (see also Figs. 792, 794, 795, 806 and 807).

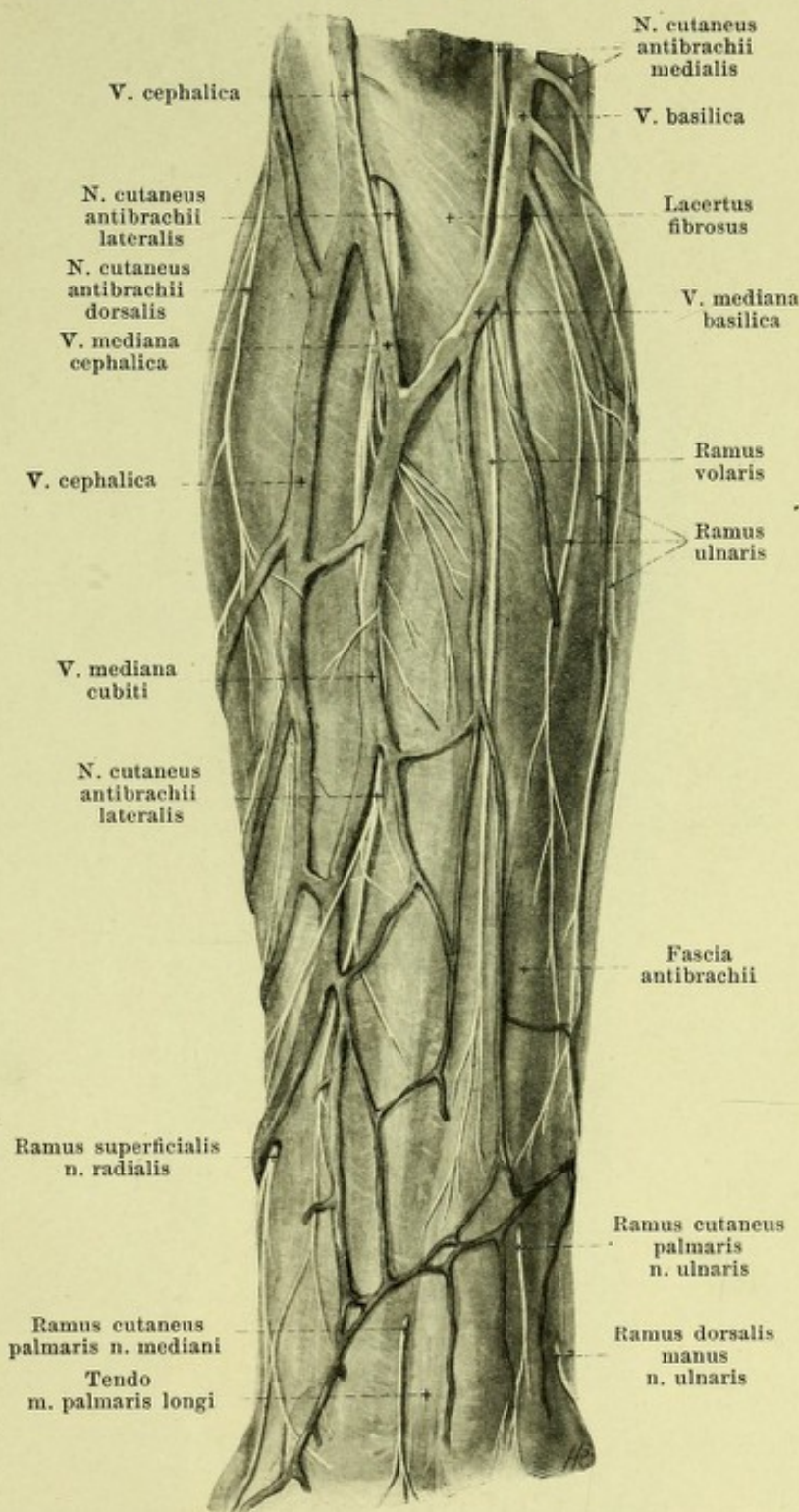
a) Ramus volaris (from Th_1) runs downward at first in front of the *lacertus fibrosus*, lateral from the *v. basilica*, then crosses it, usually on its posterior surface, and is distributed to the ulnar half of the volar surface of the forearm as far as the eminence of the little finger. It anastomoses in the forearm with branches of the *n. cutaneus antibrachii lateralis* and of the *ramus cutaneus palmaris n. ulnaris*.

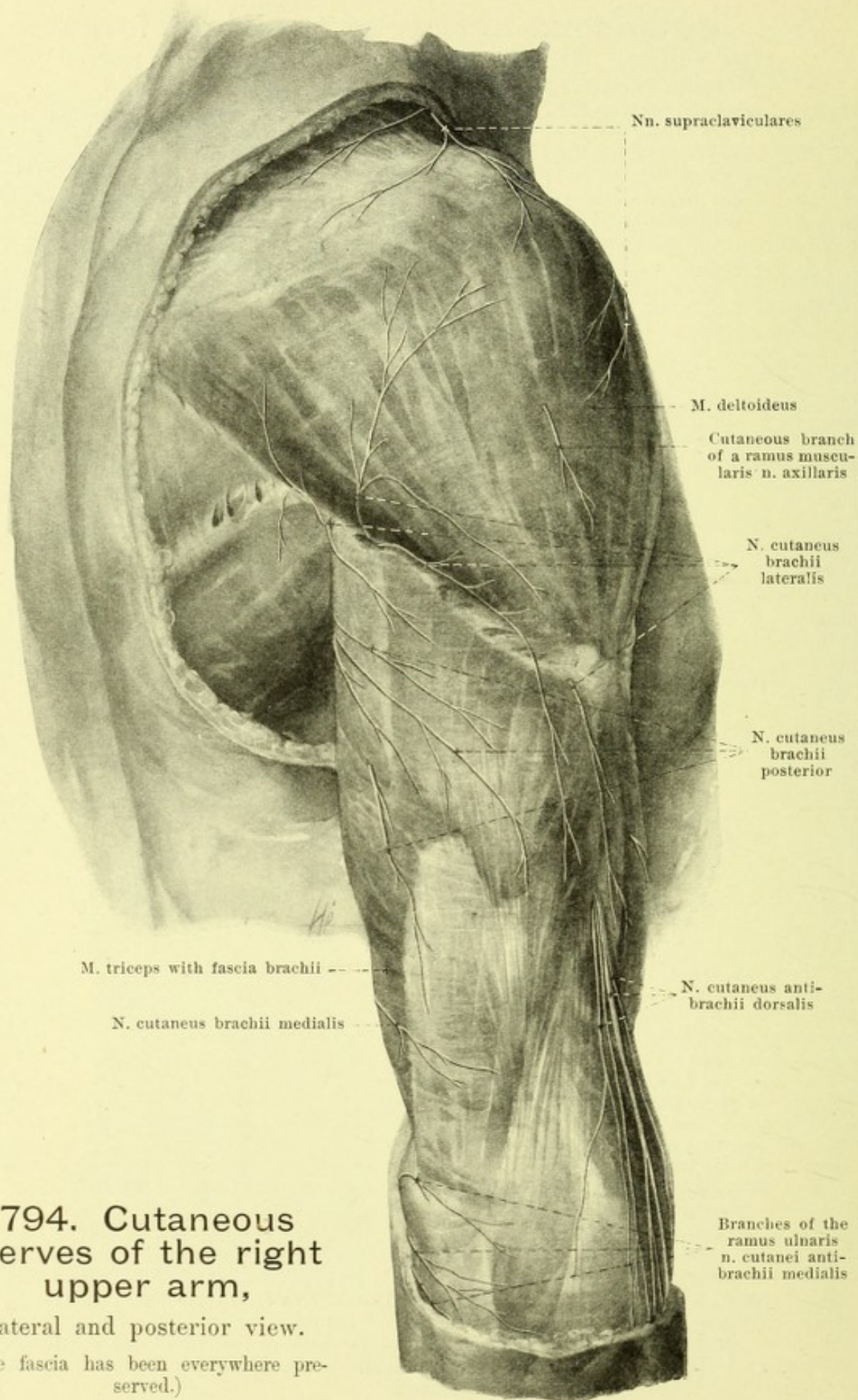
β) Ramus ulnaris (from C_8), smaller, passes over the epicondylus to the ulnar margin of the forearm and along this almost as far as the region of the capitulum ulnae. It sends its branches to the skin of the ulnar half of the dorsal surface of the forearm and anastomoses in the forearm with branches of the *n. cutaneus antibrachii dorsalis* and of the *ramus dorsalis manus n. ulnaris*.

3. *N. musculocutaneus* (see also Figs. 786, 791, 792, 795 to 797, 806—808), from C_5 , C_6 and C_7 , behaves like a branch of the *n. medianus*. It runs distalward, at first lateral and dorsal from the *n. medianus* and from the *a. axillaris*, perforates obliquely the substance of the *m. coracobrachialis*, passes distalward and lateralward between the *m. biceps brachii* and *m. brachialis*, to finally perforate the *fascia brachii* with its terminal branch, the *n. cutaneus antibrachii lateralis*, close above the elbow lateral from the tendon of insertion of the *m. biceps*, medial from and behind the *v. cephalica*. In about one third of the cases it anastomoses in the upper arm (see Fig. 797) with the *n. medianus* by a branch which is usually directed distalward toward the latter. It gives off:

a) Rami musculares (see Fig. 797) to the *mm. coracobrachialis* (from the first part of the nerve), *biceps* and *brachialis*.

b) N. cutaneus antibrachii lateralis (see also Figs. 795, 802, 806—808) passes upon the *fascia antibrachii* near the *v. cephalica* distalward usually as far as the hand; it supplies the skin upon the radial margin and the radial half of the volar surface of the forearm, upon the ball of the thumb and upon the thumb region of the back of the hand, and anastomoses in the forearm with the *n. cutaneus antibrachii medialis*, in the hand with the *ramus superficialis n. radialis* and *ramus dorsalis manus n. ulnaris*.





794. Cutaneous nerves of the right upper arm,

lateral and posterior view.

(The fascia has been everywhere preserved.)

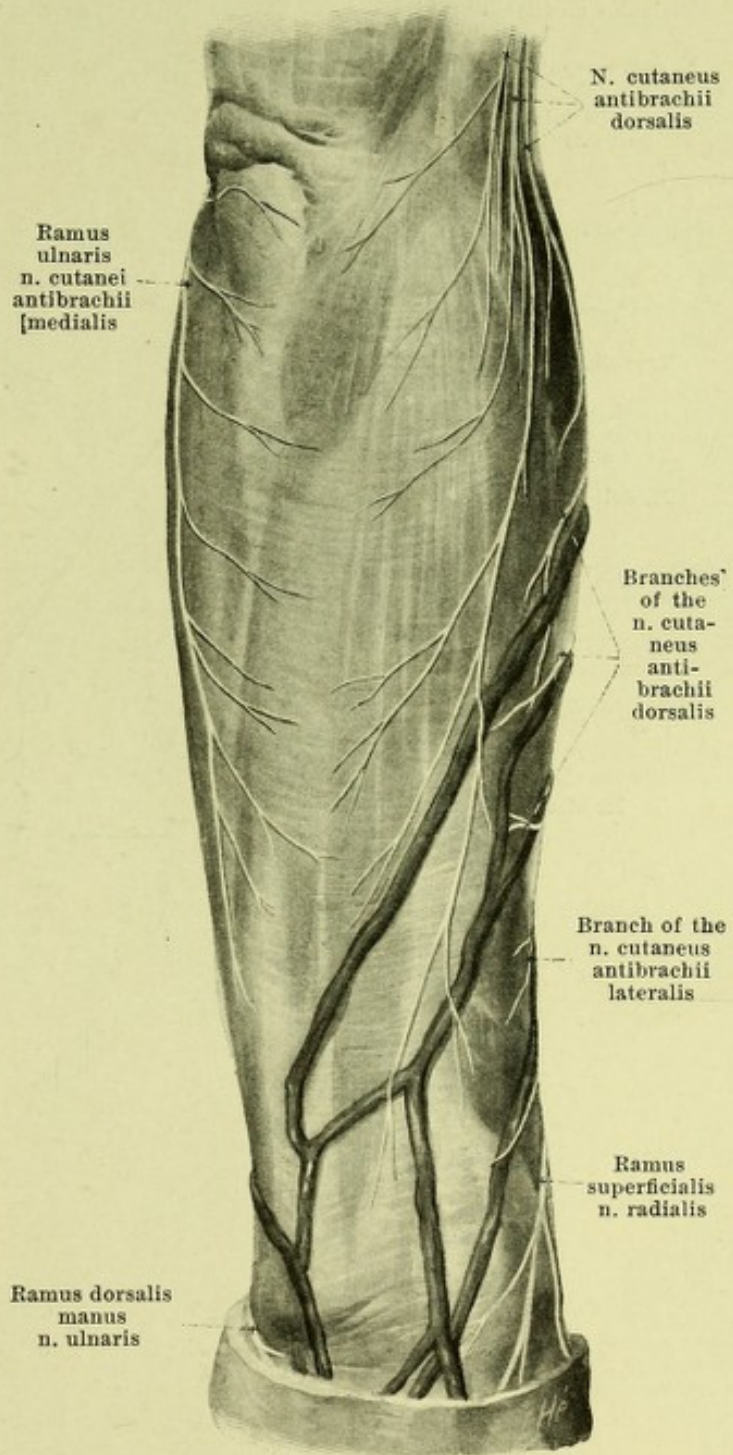
795. Cutaneous nerves of the right forearm, dorsal surface.

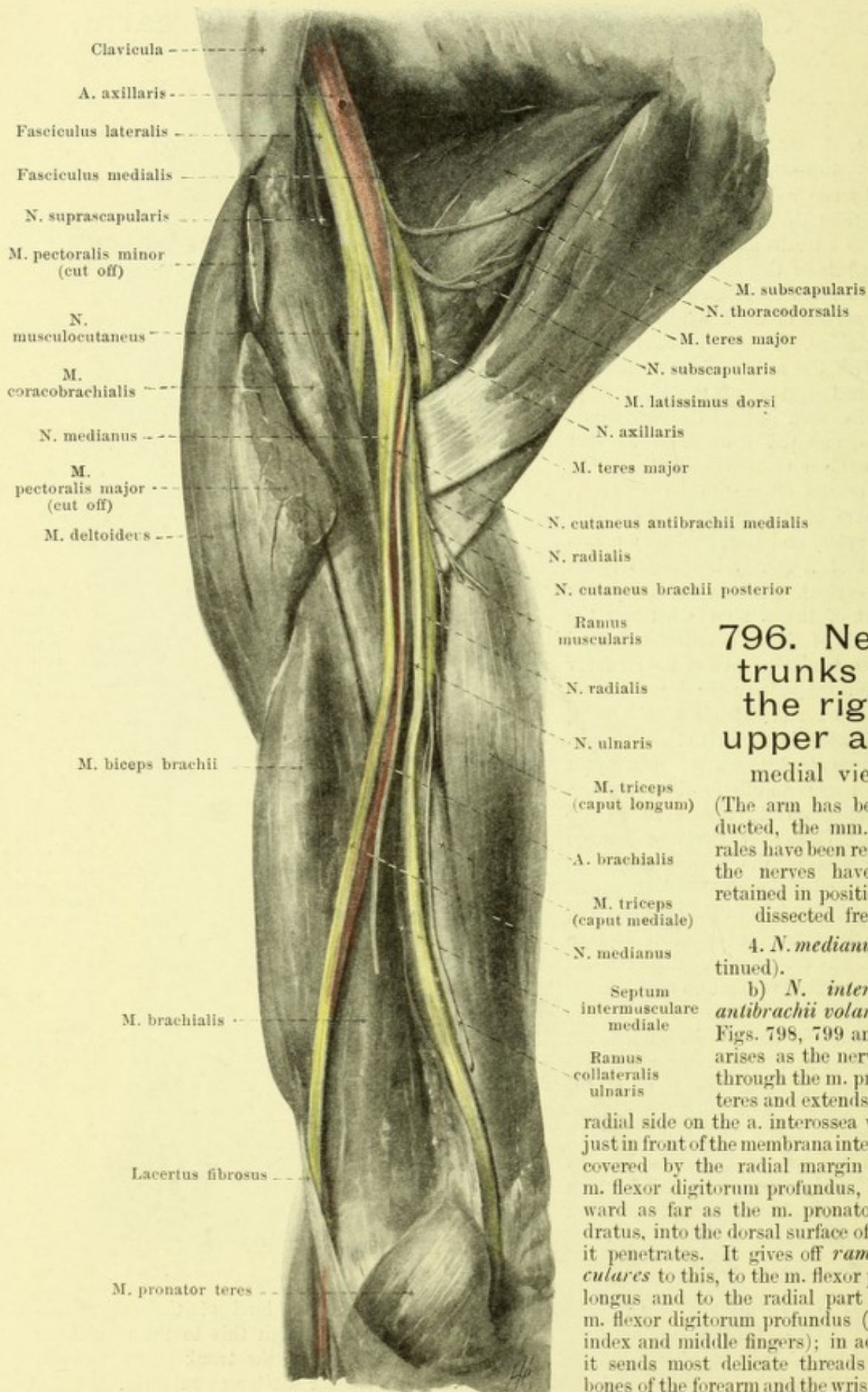
(The fasciae brachii and antibrachii have been preserved.)

4. *N. medianus* (see Figs. 786, 791, 793, 796—801, 803, 806 and 807), arises by two roots from the plexus, an upper (from C_5 , C_6 and C_7) from the fasciculus lateralis and a lower (from C_8 and Th_1) from the fasciculus medialis. The two roots converging pass to the lateral surface of the a. axillaris, where they combine. The nerve runs distalward with the a. brachialis, at first on the dorsal surface of the m. coracobrachialis, then in the sulcus bicipitalis medialis, and passes under the lacertus fibrosus upon the m. brachialis in the depth of the elbow; in its course it lies above on the anterior lateral side of the artery and then gradually passes in front of it (rarely behind it) to its medial surface. In the forearm it passes in front of the a. ulnaris between the two heads of the m. pronator teres and below the tendinous arch of the m. flexor digitorum sublimis on the dorsal surface of the latter and extends to the wrist, approximately in the axis of the forearm in the groove between the mm. flexor pollicis longus and flexor digitorum profundus along with the a. mediana (see also Fig. 455). Close above the latter between the tendons of the mm. flexor carpi radialis and palmaris longi it passes (see Fig. 798) close to the surface again under the fascia antibrachii. It then turns to the volar surface of the tendons of the mm. flexores digitorum and passes with these dorsal from the lig. carpi transversum in the canalis carpi to the hand (see Fig. 799). In the upper arm it receives in about one third of the cases a thick bundle from the n. musculocutaneus (see p. 725 and Fig. 797), and in the forearm it anastomoses by a fine thread with the n. ulnaris between the mm. flexores digitorum. It gives off no branches in the upper arm.

Branches in the forearm:

a) *Rami musculares* (see Figs. 797—799), go off at the level of the epicondylus medialis humeri to the m. pronator teres (usually two) and through this to the mm. flexor carpi radialis, palmaris longus and flexor digitorum sublimis; as the trunk passes through the m. pronator teres still other branches arise for the m. flexor digitorum sublimis.





796. Nerve trunks of the right upper arm, medial view.

(The arm has been abducted, the mm. pectorales have been removed, the nerves have been retained in position and dissected free.)

4. *N. medianus* (continued).

b) *N. interosseus antibrachii volaris* (see Figs. 798, 799 and 801) arises as the nerve goes through the m. pronator teres and extends on the radial side on the a. interossea volaris, just in front of the membrana interossea, covered by the radial margin of the m. flexor digitorum profundus, distalward as far as the m. pronator quadratus, into the dorsal surface of which it penetrates. It gives off *rami musculares* to this, to the m. flexor pollicis longus and to the radial part of the m. flexor digitorum profundus (for the index and middle fingers); in addition it sends most delicate threads to the bones of the forearm and the wrist joint.

797. Muscle nerves of the right upper arm,

viewed from in front.

(The arm has been abducted; the mm. biceps, triceps and brachioradialis have been drawn aside; a piece has been cut out of the m. pronator teres.)

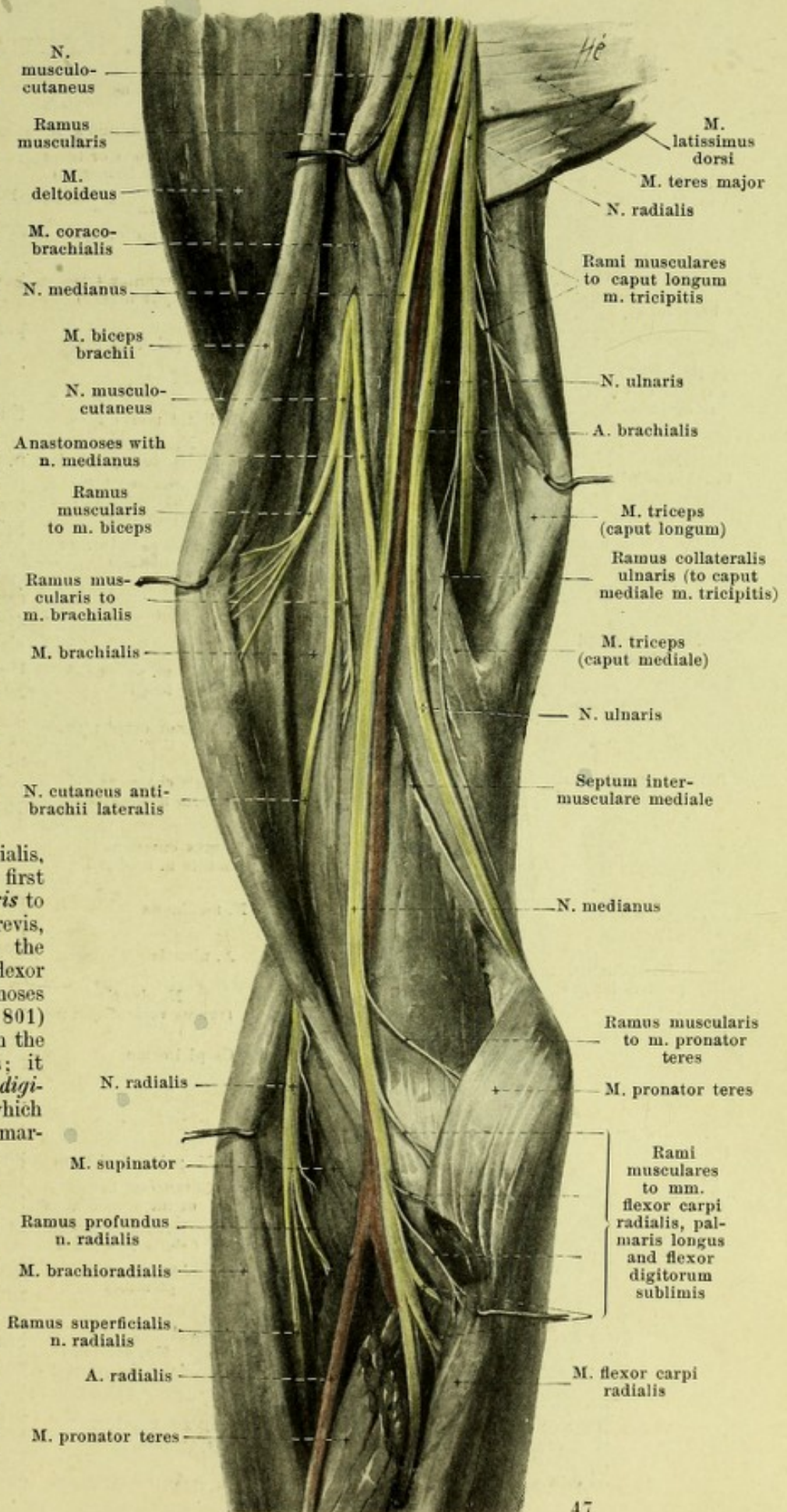
4. *N. medianus* (continued).

c) *Ramus cutaneus palmaris* (see Figs. 793, 798 and 806) arises at a variable level above the wrist, perforates the fascia antibrachii between the mm. flexor carpi radialis and palmaris longus, and passes upon the fascia to the skin of the ball of the thumb and of the hollow of the hand.

Branches in the Hand:

d) *Nn. digitales volares communes* (see Figs. 798—801, 803, 806 to 809), three, pass in the 1st to the 3rd spatium interosseum metacarpi under the aponeurosis palmaris and the arcus volaris superficialis, diverging distalward. The first gives off a *ramus muscularis* to the mm. abductor pollicis brevis, opponens pollicis and to the superficial head of the m. flexor pollicis brevis and anastomoses by a delicate branch (see Fig. 801) passing into the depth with the ramus profundus n. ulnaris; it then divides into three *nn. digitales volares proprii*, which run on the radial and ulnar margins of the volar surface of the thumb and on the radial margin of the volar surface of the index finger as far as the tips of the fingers; the first anastomoses with the branches of the n. radialis (digital), the last usually sends cutaneous branches to the back of the finger (see Figs. 800 and 803) and a muscular branch to the m. lumbricalis I (see Fig. 800).

Spalteholz, Atlas.



798. Nerves of the right forearm,

viewed from in front, more superficial layer.

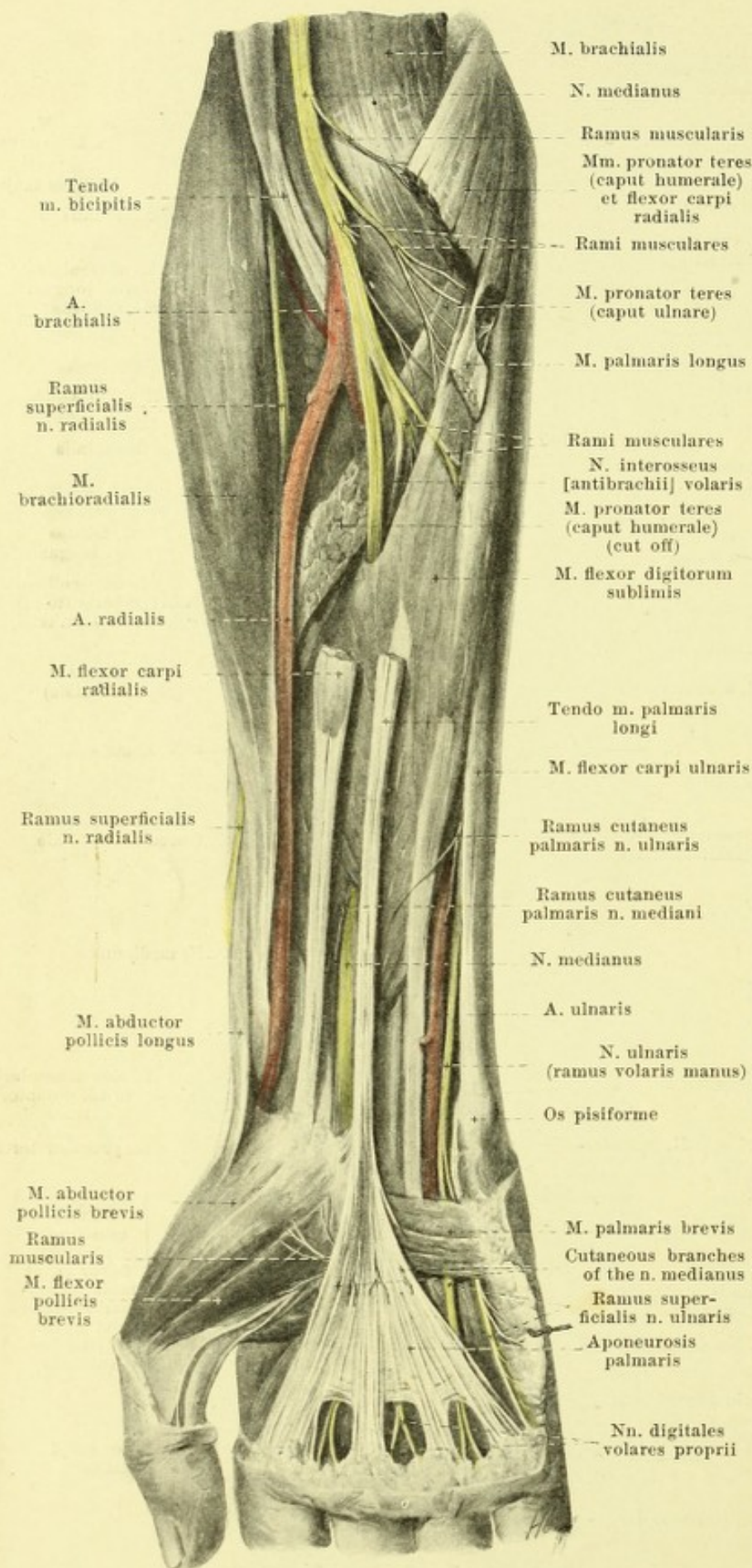
(The caput humerale of the m. pronator teres, as well as the muscular bellies of the mm. flexor carpi radialis and palmaris longus have been in large part removed.)

4. *N. medianus* (continued).

The second and the third n. digitalis volaris communis (see Figs. 799, 800, 806—809) send a twig to the mm. lumbricales II and (often) III; each divides into *nn. digitales volares proprii* for the adjacent margins of the 2nd, 3rd and 4th fingers, which usually supply also the dorsal surfaces of their second and third phalanges. The third unites in a variable manner by means of a ramus anastomoticus cum n. ulnaris with the ramus superficialis n. ulnaris (see Figs. 799 and 800).

The nn. digitales volares communes send delicate branches through the aponeurosis palmaris to the skin of the palm. In the region of the fingers numerous small *corpuscula lamellosa* [Vateri, Pacini] (see Fig. 800) are to be found; they are united with the nerves by small lateral twigs.

5. *N. ulnaris* (see Figs. 786, 791, 793, 796—802, 806, to 809), from C₇, C₈ and Th₁, passes distalward at first on the posterior medial surface of the aa. axillaris and brachialis in front of the n. radialis, m. latissimus dorsi and caput longum m. tricipitis, and then runs superficially downward, covered only by the fascia brachii, on the anterior medial surface of the caput mediale m. tricipitis behind the septum intermusculare mediale, gradually becoming separated from the a. brachialis, to the sulcus n. ulnaris of the humerus.



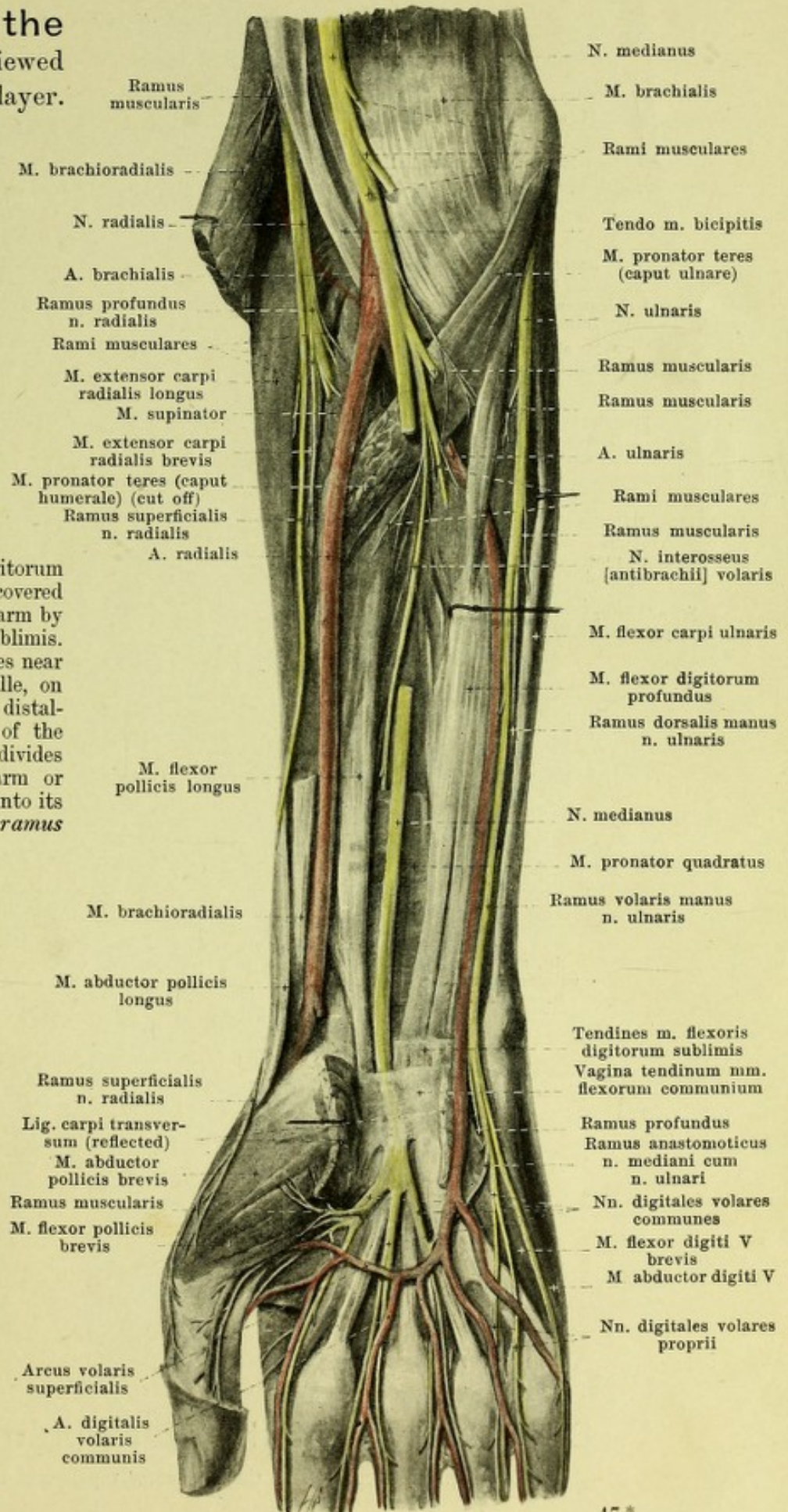
799. Nerves of the right forearm, viewed from in front, deeper layer.

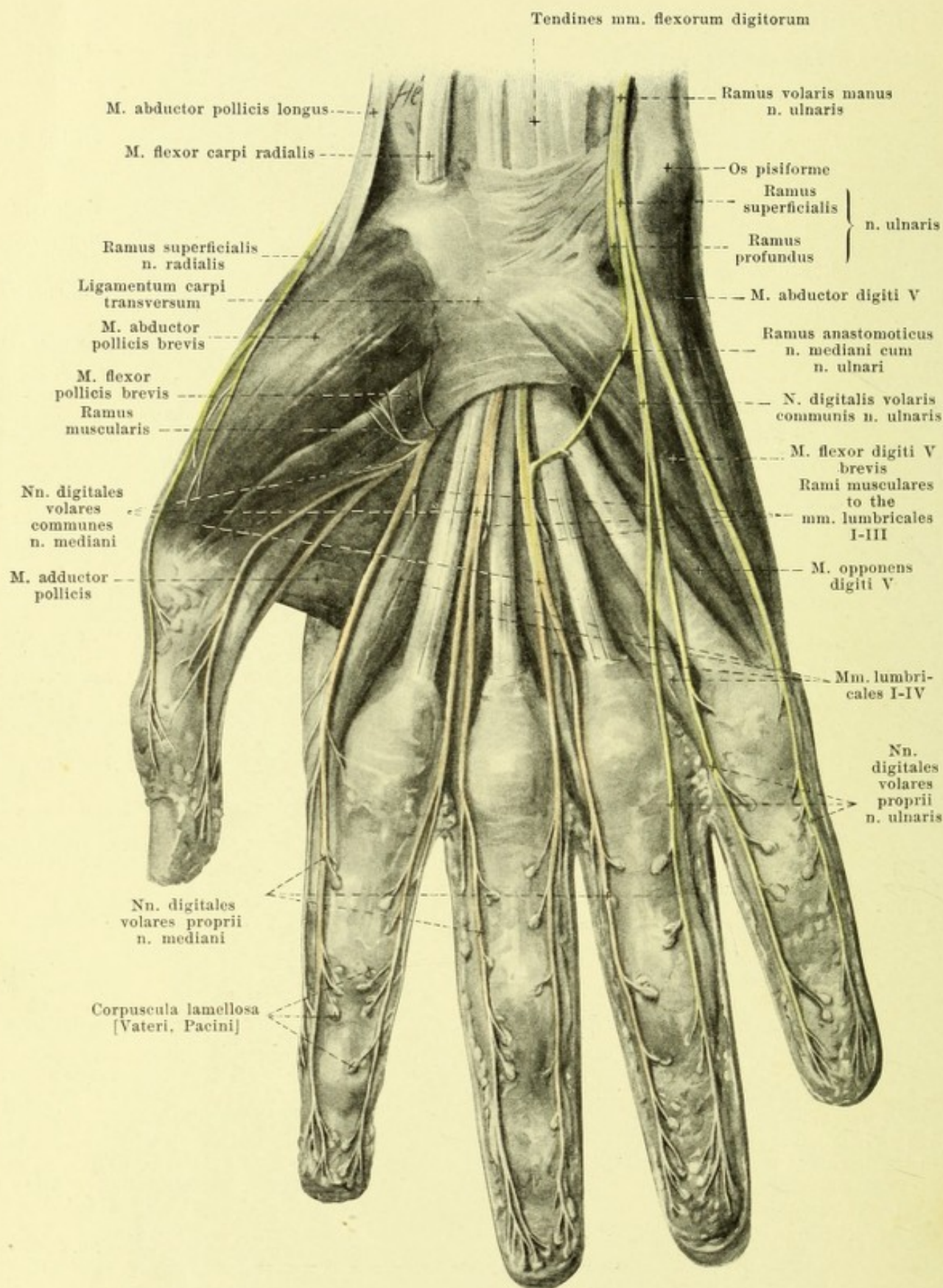
(The caput humerale of the m. pronator teres, as well as the mm. brachioradialis, flexor carpi radialis, palmaris longus and flexor digitorum sublimis have been removed; the lig. carpi transversum has been cut through and reflected.)

5. *N. ulnaris* (see also Figs. 793, 798, 800—802, 806—809) (continued). In the sulcus n. ulnaris of the humerus it lies between the epicondylus medialis humeri and the olecranon ulnae directly upon the bone. Thence it passes between the two heads of the m. flexor carpi ulnaris on its radial surface in front of the m. flexor digitorum profundus and is accordingly covered in the upper half of the forearm by the m. flexor digitorum sublimis. Near the a. ulnaris, which lies near it, somewhat above the middle, on its radial side, it passes next distalward on the radial margin of the m. flexor carpi ulnaris and divides in the middle of the forearm or somewhat farther distalward into its two terminal branches, the *ramus dorsalis manus* and the *ramus volaris manus*. It gives off no branches in the upper arm; in the forearm it anastomoses by a delicate branch with the n. medianus (see p. 727) and sends off the following branches:

a) *Rami musculares* to the m. flexor carpi ulnaris and to the ulnar part of the m. flexor digitorum profundus (to the 4th and 5th finger).

b) *Ramus cutaneus palmaris* (see also Figs. 793, 798 and 806), delicate, arises in the middle of the forearm or more proximalward, accompanies the a. ulnaris as far as the hand and in the forearm sends a twig through the fascia distalward to the skin of the volar surface of the wrist and of the ball of the little finger; this twig anastomoses with the n. cutaneus antibrachii medialis.



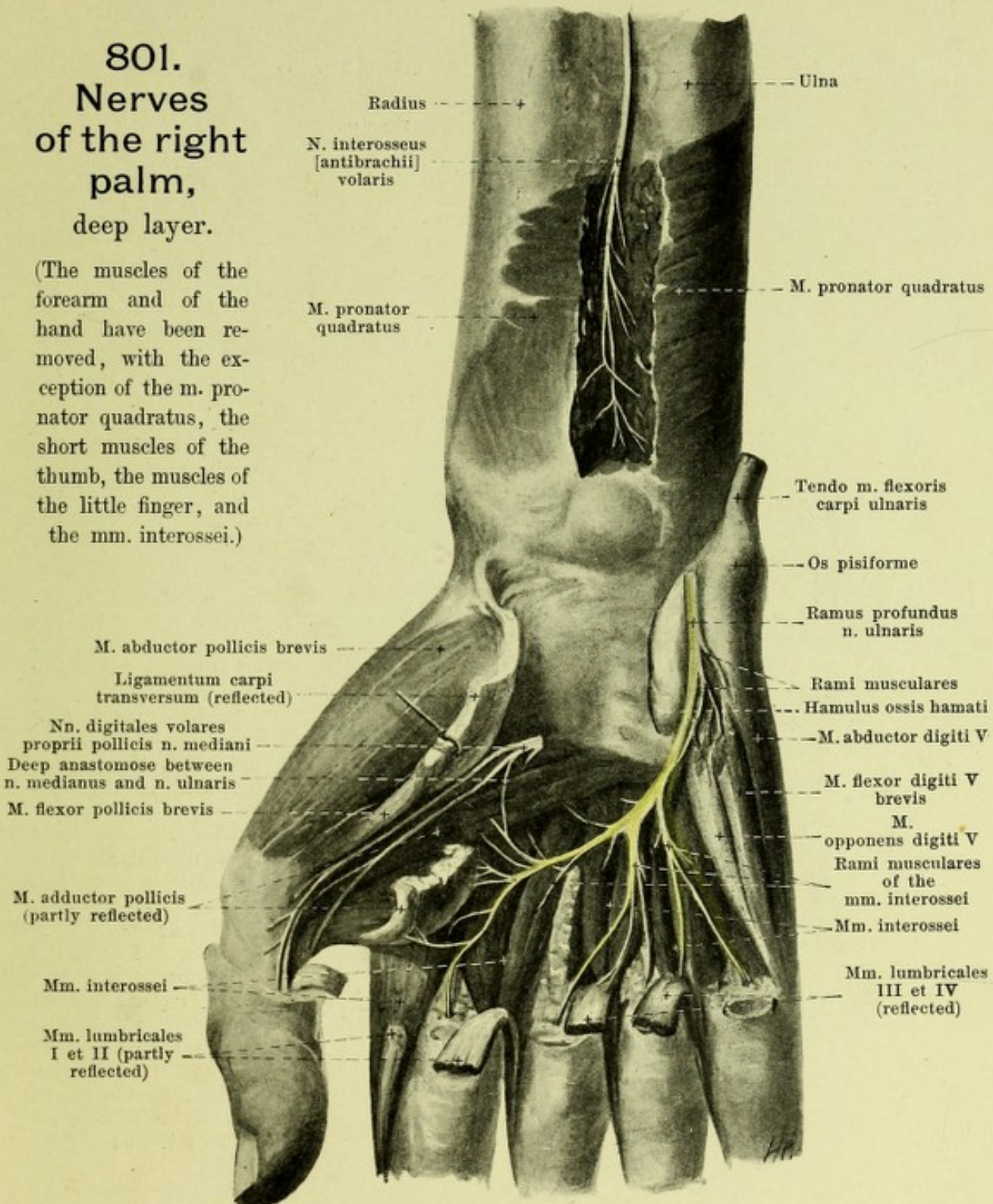


800. Nerves of the right palm, superficial layer.

(The fascia antibrachii and the aponeurosis palmaris have been removed.)

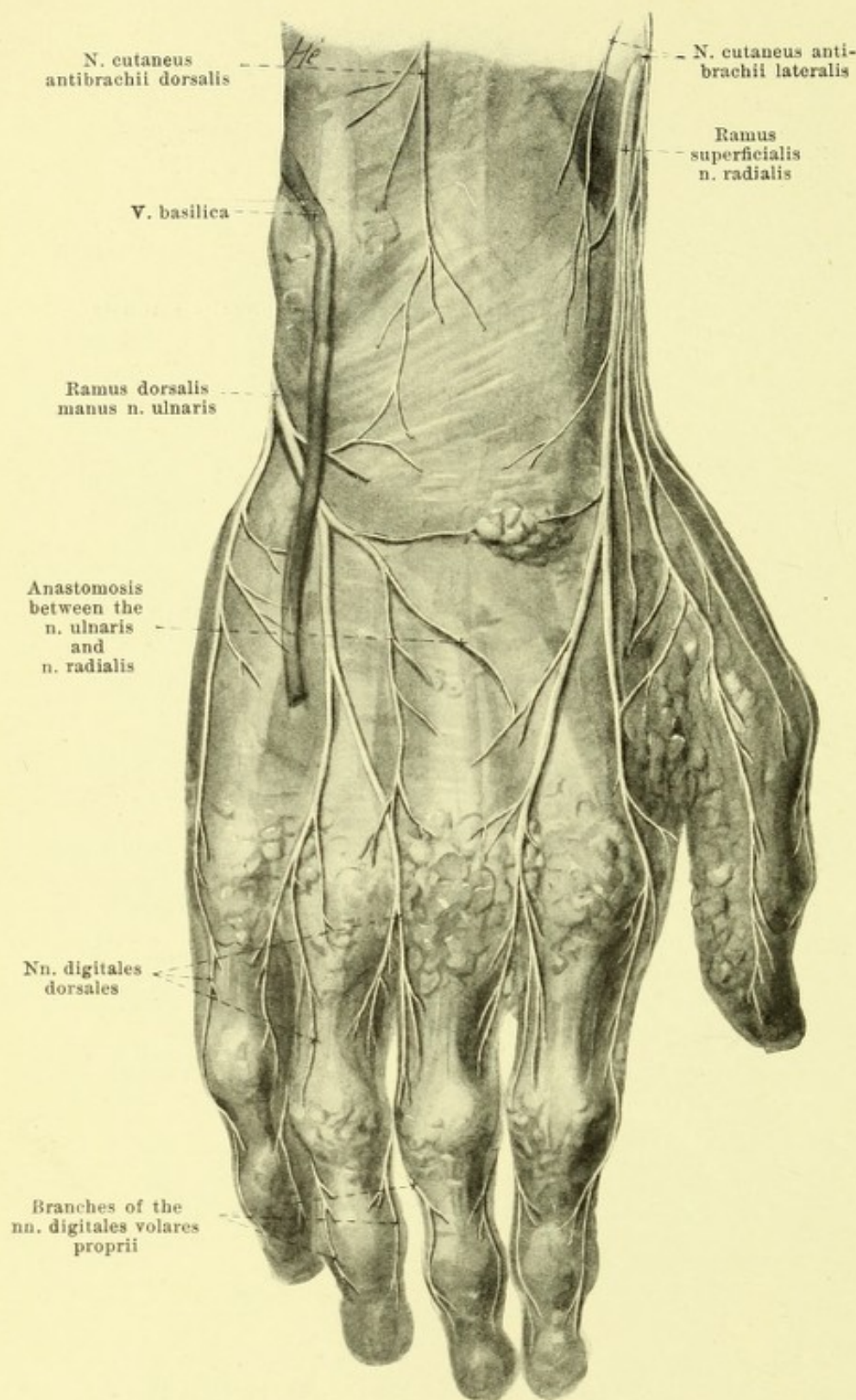
801. Nerves of the right palm, deep layer.

(The muscles of the forearm and of the hand have been removed, with the exception of the m. pronator quadratus, the short muscles of the thumb, the muscles of the little finger, and the mm. interossei.)



5. *N. ulnaris* (continued):

c) *Ramus dorsalis manus* (see Figs. 795, 799, 802, 806—809), one terminal branch, usually the smaller, passes along the ulna, between it and the tendon of the m. flexor carpi ulnaris, distalward upon the dorsal surface of the capitulum ulnae. There it perforates the fascia antibrachii and divides upon the lig. carpi dorsale. It sends delicate branches radialward, which anastomose with branches of the nn. cutanei, antibrachii medialis, dorsalis and lateralis and of the ramus superficialis n. radialis, and 5 *nn. digitales dorsales* distalward, which run along the ulnar margin of the 5th, 4th and 3rd fingers, and the radial margin of the 5th and 4th fingers, reaching constantly to the base of the nail on the 5th finger but on the 4th finger usually and on the 3rd finger almost constantly not going beyond the first phalanx.



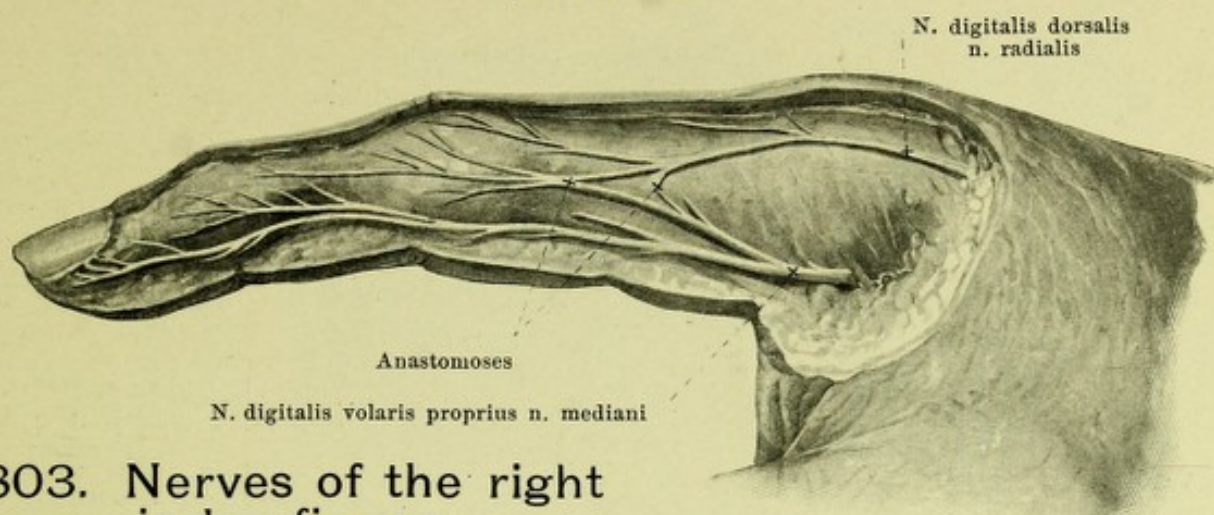
802. Nerves of the dorsum of the right hand.

(The fascia has been everywhere preserved; the veins have been in large part removed.)

5. *N. ulnaris* (continued):

d) *Ramus volaris manus* (see Figs. 798 to 801 and 806), the second terminal branch, runs in the direction of the stem on the ulnar side of the a. ulnaris and at the radial margin of the m. flexor carpi ulnaris, between this and the m. flexor digitorum sublimis, covered only by the fascia antibrachii and the lig. carpi volare, to the hand, and there divides in front of the lig. carpi transversum on the radial side of the os pisiforme into the *ramus superficialis* and *ramus profundus*.

e) *Ramus superficialis* (see Figs. 798 to 800 and 806) gives off at first a fine *ramus muscularis* to the m. palmaris brevis and an anastomosing branch to the n. medianus (see p. 730). It then divides into a *n. digitalis volaris proprius*, which runs distalward upon the muscles of the ball of the little finger to the ulnar margin of the volar surface of the 5th finger, and into a *n. digitalis volaris communis*, which runs distalward just beneath the aponeurosis palmaris, upon the fourth spatium interosseum metacarpi, and divides into two *nn. digitales volares proprii*, for the adjacent margins of the volar surfaces of the 4th and 5th fingers, that for the 4th finger usually supplying also the dorsal surface of the 2nd and 3rd phalanx. They are connected with small *corpuscula lamellosa* [Vateri, Pacini] (see p. 730).



803. Nerves of the right index finger,

viewed from the medial side.

5. *N. ulnaris* (continued): d) *Ramus volaris manus*:

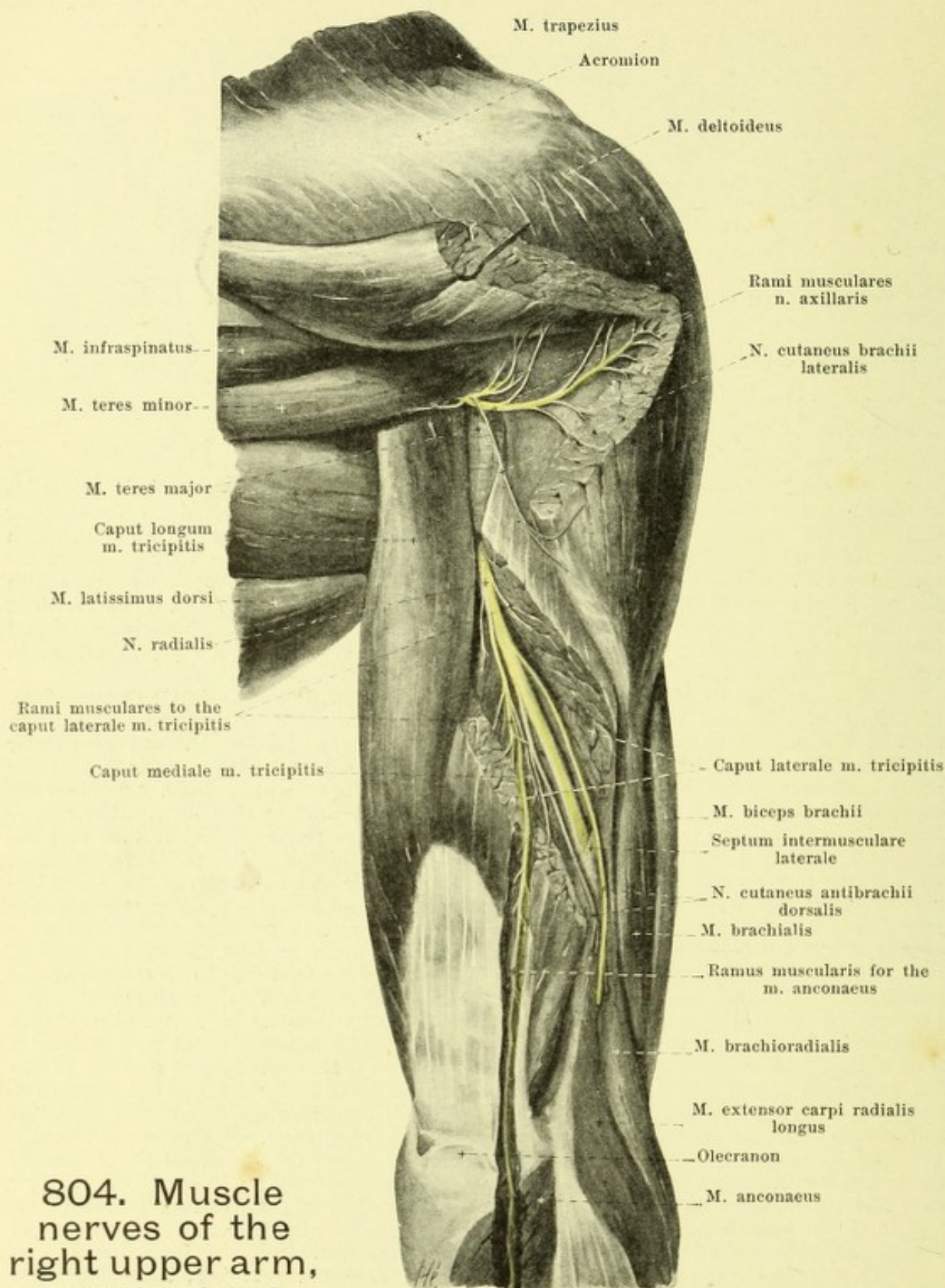
β) *Ramus profundus* (see Figs. 800 and 801), with the *ramus volaris profundus* a. *ulnaris* bends into the depth between the origins of the mm. abductor digiti V and flexor digiti V brevis through the origin of the m. opponens digiti V and at the same time in a curve radialward around the hamulus ossis hamati; it then lies upon the volar surface of the mm. interossei, crosses the arcus volaris profundus and ends in a delicate anastomosis with the n. medianus (see p. 729). It gives off *rami musculares* at its beginning to the short muscles of the little finger, in the depth to the mm. interossei, the mm. lumbricales IV and (often) III, the m. abductor pollicis and the deep head of the m. flexor pollicis brevis; in addition branches to the joints and bones of the hand.

6. *N. radialis* (O. T. musculospiral nerve; see also Figs. 786, 793—800, 802, 804—809), from C₅, C₆, C₇, C₈ (and Th₁), passes distalward behind the n. ulnaris and the a. axillaris in front of the m. subscapularis and the tendons of the mm. latissimus dorsi and teres major (see Figs. 796 and 797) and lateral from the caput longum m. tricipitis bends behind the artery, and then on the dorsal surface of the humerus in its sulcus n. radialis, covered by the caput laterale of the m. triceps, runs distalward and lateralward in a long drawn-out spiral (see Figs. 351 and 804); in its course it lies at first near the a. profunda brachii, then near the a. collateralis radialis (see also Fig. 454). At the junction of the middle and lower thirds of the humerus it perforates the septum intermusculare laterale and the origin of the m. brachioradialis (see Figs. 351, 353 and 804) and on the medial surface of the latter arrives in the groove between the m. brachioradialis and the m. brachialis; in this it lies behind on some bundles of the latter and passes distalward near the a. recurrens radialis, to divide in front of the capitulum radii or somewhat higher up into the *ramus profundus* and *ramus superficialis* (see Figs. 797, 799 and 805). Before dividing it gives off the following branches:

a) *N. cutaneus brachii posterior* (see Figs. 794, 796 and 807) arises, often along with a muscular branch for the caput longum m. tricipitis, at the lower margin of the fossa axillaris in front of the tendon of the m. teres major, then runs in front of the caput longum of the m. triceps and around its medial margin obliquely curved upon its posterior surface, there perforates the fascia brachii and branches in the skin of the back of the upper arm, about over the caput laterale and mediale of the m. triceps. It anastomoses with branches of the n. cutaneus brachii lateralis.

b) *Rami musculares* (see Figs. 796, 797 and 804) to the three heads of the m. triceps; the branch for the caput mediale, *ramus collateralis ulnaris* (see Figs. 796 and 797) runs for some distance superficially, just behind the n. ulnaris distalward, and a long branch passes first in the caput laterale (see Fig. 804), then in the caput mediale between the olecranon and the epicondylus lateralis humeri downward to the m. anconaeus.

c) *N. cutaneus antibrachii dorsalis* (see Figs. 793—795, 802, 804, 806—809) arises (see Fig. 804) in the sulcus n. radialis in front of the caput laterale of the m. triceps, passes in front of it lateralward and downward near the n. radialis and lateral from this muscle perforates the fascia brachii (see Fig. 794), between the insertion of the m. deltoideus and the epicondylus humeri, behind the v. cephalica. There it divides into several branches and passes distalward to the skin of the radial part of the elbow and to the dorsal surface of the forearm as far as the proximal part of the back of the hand. In its course it anastomoses with the branches of the nn. cutanei brachii lateralis and antibrachii medialis, as well as the ramus dorsalis manus n. ulnaris and the ramus superficialis n. radialis.



804. Muscle nerves of the right upper arm, viewed from behind.

(Pieces have been cut out of the m. deltoideus, caput laterale m. tricipitis and m. anconaeus.)

6. *N. radialis* (continued).

d) *Rami musculares*, after perforating the septum intermusculare laterale (see Figs. 797, 799 and 805) go to the mm. brachioradialis, extensor carpi radialis longus; often a delicate thread also to the lateral part of the m. brachialis.

805. Muscle nerves of the right forearm, viewed from behind and lateralward.

(The mm. brachioradialis, extensores carpi radialis and digitorum communis have been cut through and reflected dorsalward and ulnarward. A piece has been cut out of the m. supinator.)

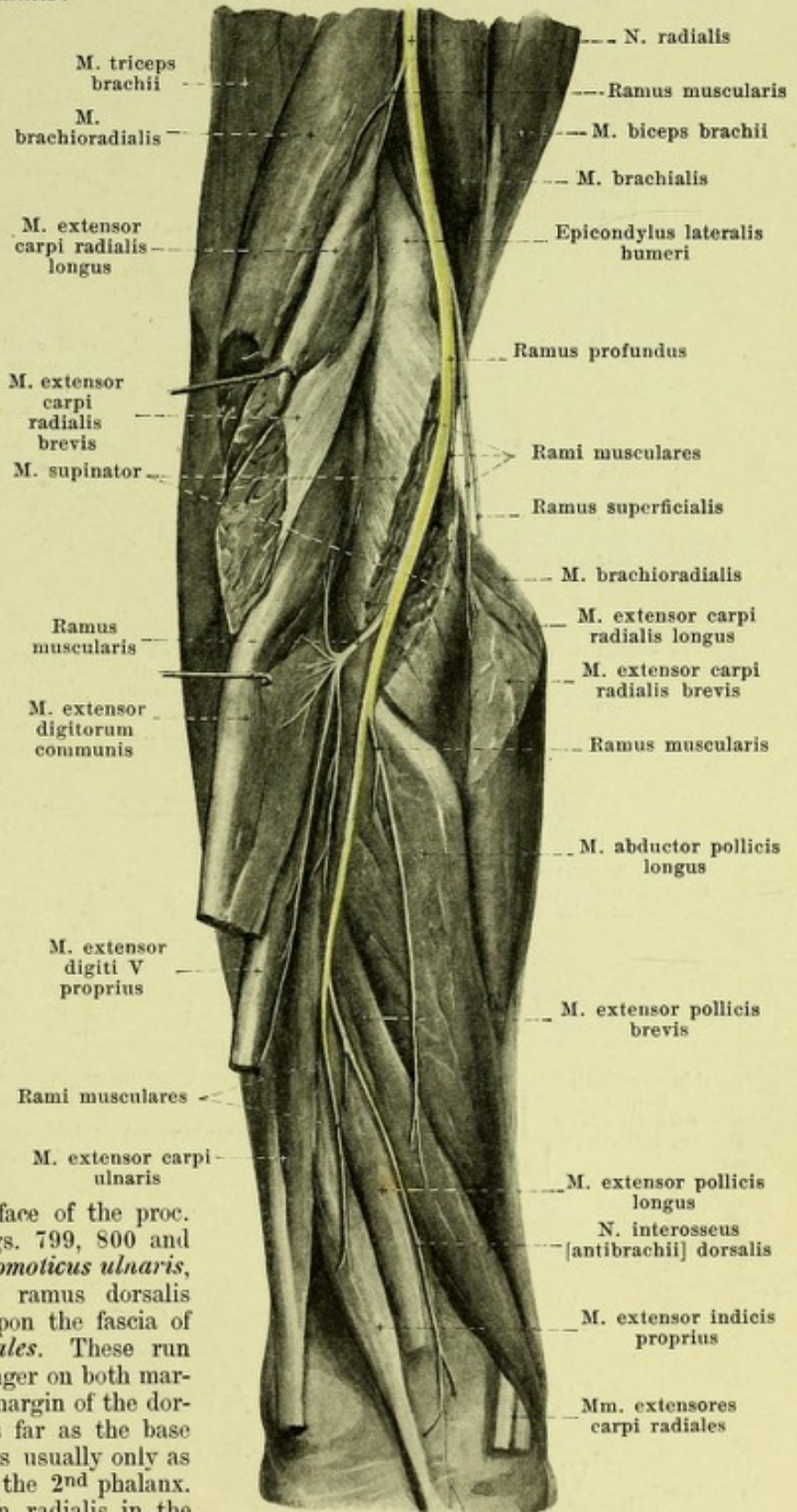
Terminal branches of the n. radialis:

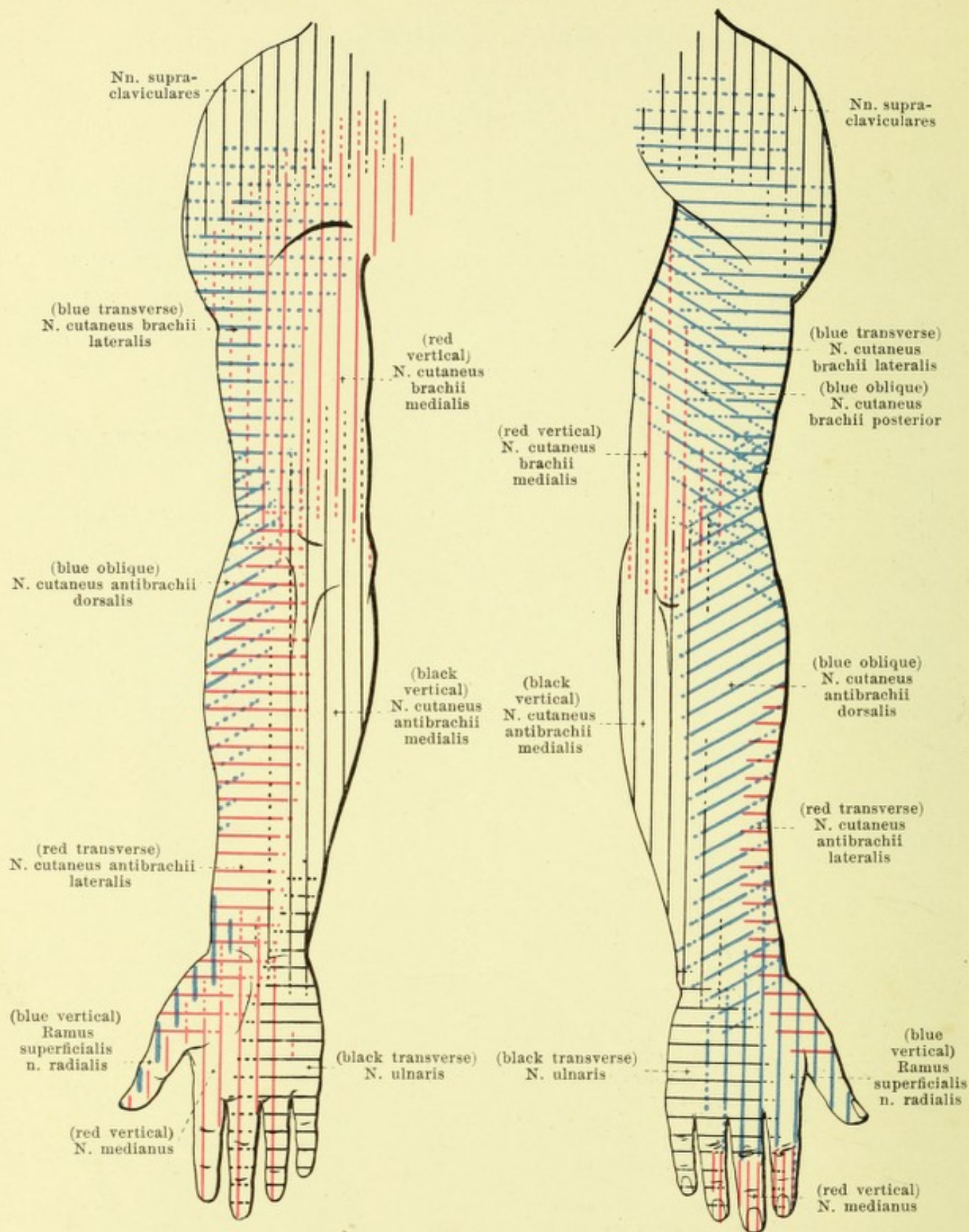
e) *Ramus profundus* (see also Figs. 797 and 799), the larger of the two, penetrates the volar surface of the m. supinator, and passes within this muscle in a long spiral winding around the collum radii to the dorsal surface of the radius, where it runs distalward upon the mm. abductor pollicis longus and extensores pollicis and ends as the *n. interosseus anti-brachii dorsalis*. It gives off:

a) *Rami musculares*, before entrance into the m. supinator, to the mm. extensor carpi radialis brevis and supinator, on the back of the forearm to the mm. extensores digitorum communis, digiti V proprius and carpi ulnaris, abductor pollicis longus, extensores pollicis and extensor indicis proprius.

β) *N. interosseus antibrachii dorsalis* passes in the direction of its trunk in the distal third of the forearm between the mm. extensores pollicis to the membrana interossea and upon it to the bones and ligaments of the forearm and of the hand.

f) *Ramus superficialis* (see also Figs. 797—800, 802, 803, 806—809) runs (see Figs. 798 and 799) distalward in front of the m. supinator behind the ulnar margin of the m. brachioradialis, at first near the a. recurrens radialis, then radialward from the a. radialis; it passes in a long curve between the m. brachioradialis and m. extensor carpi radialis longus gradually to the radial margin of the forearm, and there perforates the fascia antibrachii in the lower third of the forearm. Here it anastomoses with the n. cutaneus antibrachii lateralis and divides into two branches, which pass upon the lig. carpi dorsale over the lateral surface of the proc. styloideus radii to the hand (see Figs. 799, 800 and 802). These give off a *ramus anastomoticus ulnaris*, which unites with branches of the ramus dorsalis manus n. ulnaris, and then divide upon the fascia of the hand into 5 *nn. digitales dorsales*. These run distalward in the thumb and index finger on both margins, in the 3rd finger on the radial margin of the dorsal surface, in the thumb regularly as far as the base of the nail, in the 2nd and 3rd fingers usually only as far as the joint between the 1st and the 2nd phalanx. Variations in the distribution of the n. radialis in the hand are common (see Fig. 809).



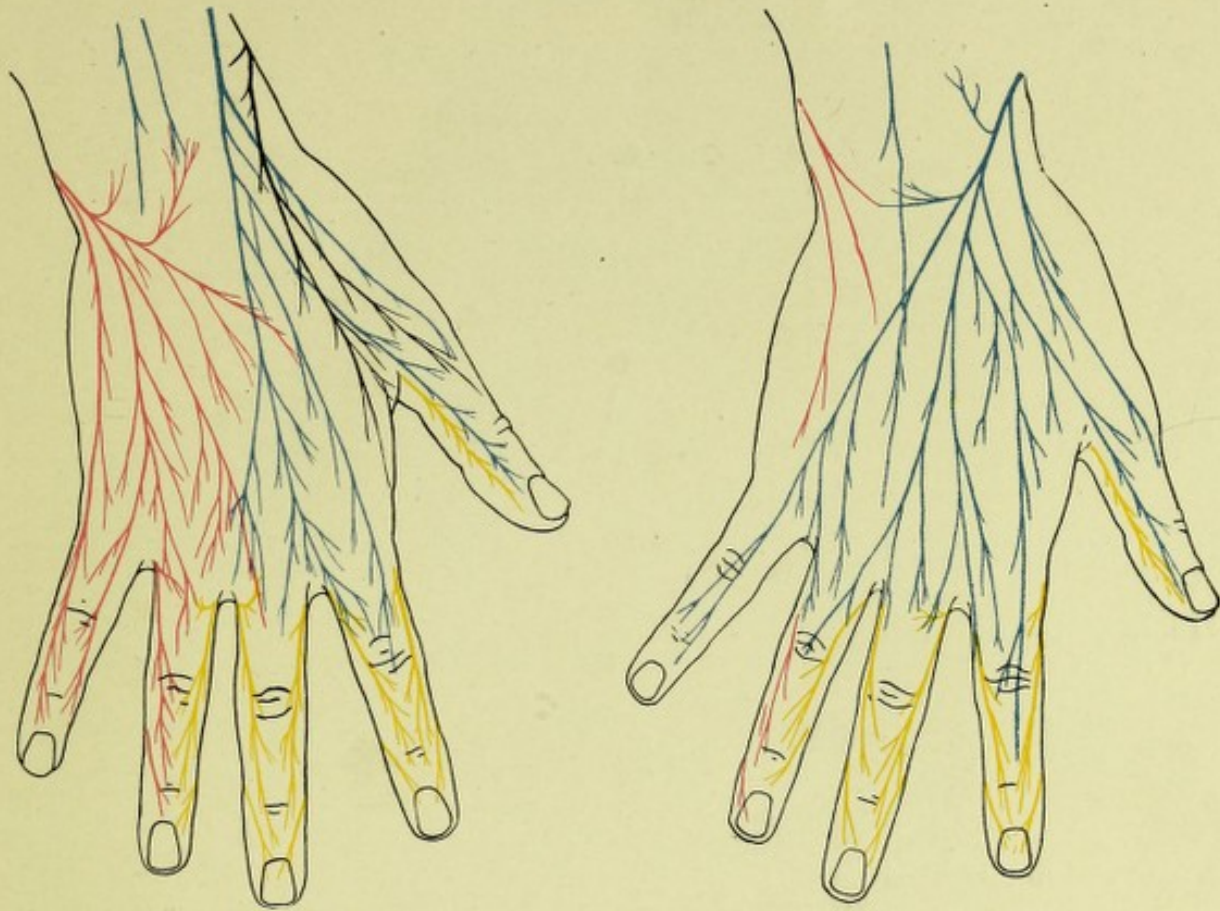


806 and 807. Areas of distribution of the cutaneous nerves of the right arm.

Viewed from in front,

Viewed from behind.

(The areas constantly supplied by the nerves concerned are indicated by solid lines, those inconstantly supplied by dotted lines.)



808 and 809. Branching of the cutaneous nerves on the back of the right hand (after E. Hédon)
(see also Fig. 802).

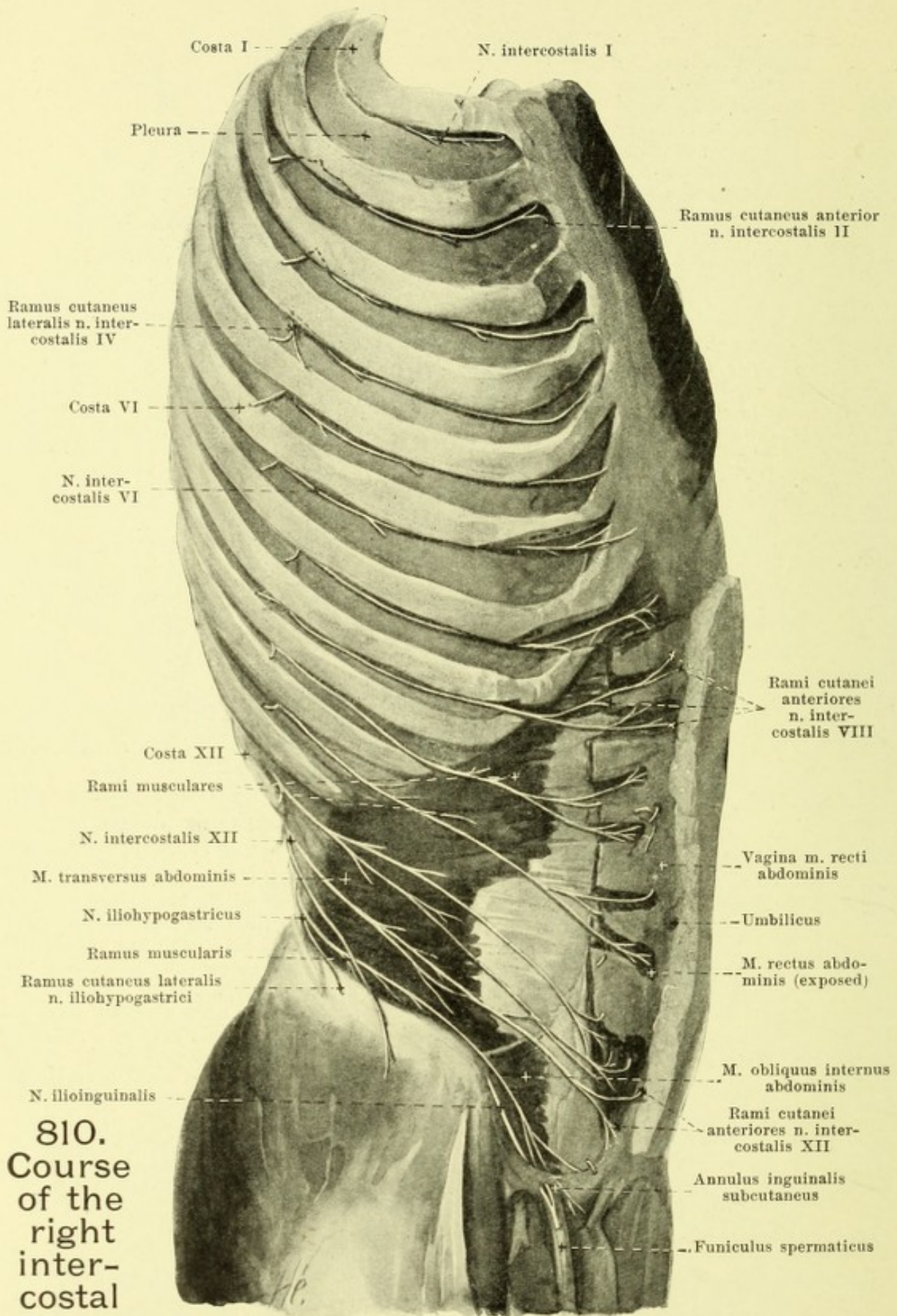
Ordinary arrangement.

Arrangement when the ramus superficialis
n. radialis is markedly developed.

(Black: n. cutaneus antibrachii lateralis; red: n. ulnaris; blue: n. radialis; yellow: n. medianus.)

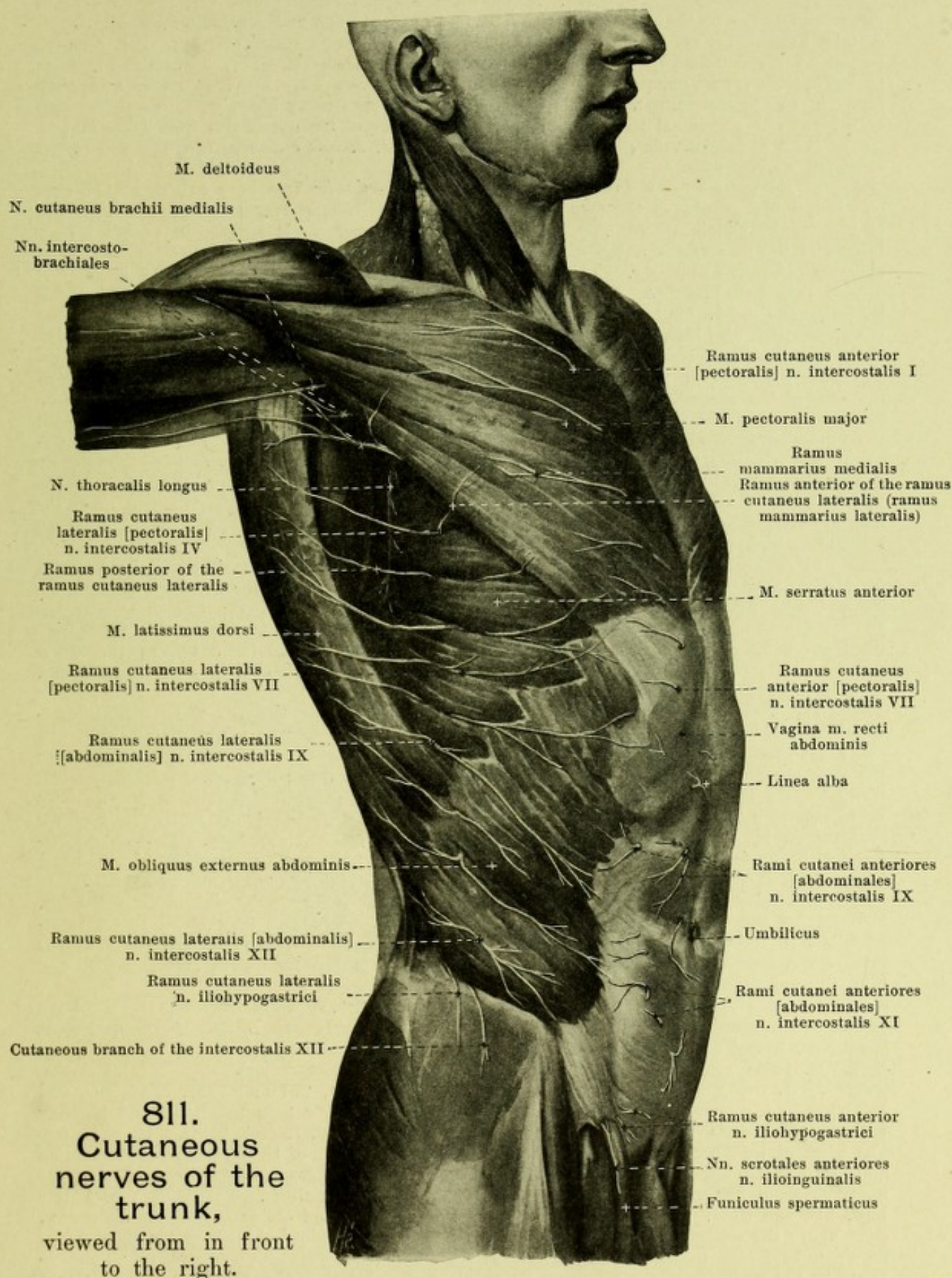
The **rami anteriores of the nn. thoracales** (see Figs. 690, 781, 810, 811, 813 and 832), go forward in a curve in the intercostal spaces (the 12th at the lower margin of the 12th rib), and hence are called the **nn. intercostales**. Each of them (see Figs. 690 and 832) is connected at its beginning by one or several **rami communicantes** with the ganglia or truncus of the sympathicus. Most of the intercostal nerves form an anastomosis only exceptionally with adjacent ones where they begin; such connections are constantly present only between the 1st thoracic and the 8th cervical nerve, since the former sends its main mass to the plexus brachialis (see p. 709) and goes on as the n. intercostalis I, only by a delicate thread, and between the 12th thoracic and 1st lumbar nerves, whereby a part of the former goes over into the tract of the latter; usually also the 2nd thoracic nerve connects with the first and with the plexus brachialis (see p. 719).

Each runs just beneath the a. intercostalis (see also Figs. 312, 628 and 629) lateralward in front of the lig. costotransversarium anterius and internal from the mm. intercostales externi, covered only by the fascia endothoracica and pleura, in the middle of the intercostal space, then at the angulus costae approaches the upper rib and passes along it behind between the mm. intercostales externi and interni in front between the two layers of the latter as far as the anterior extremity of the bones of the ribs, there to pass again to the middle of the intercostal space. It ends in the 1st—6th intercostal space near the sternum in a ramus cutaneus anterior pectoralis. The 7th, 8th and 9th pass behind the anterior ends of the costal cartilages, the 10th, 11th and 12th under the anterior end of the corresponding rib, between the mm. obliquus internus abdominis and transversus abdominis and go medianward between these in the direction of the bony ribs as far as the m. rectus abdominis; the 7th assumes between the abdominal muscles a course ascending somewhat cranialward, the 8th an approximately horizontal, the 9th—12th a course descending more and more caudalward.



810.
Course
of the
right
inter-
costal
nerves,

viewed from the right and in front. (The mm. intercostales and obliqui abdominis have been removed; pieces have been cut out of the m. rectus abdominis.)



(Figs. 810 and 811 have been drawn from the same cadaver.)

Nn. intercostales (continued). In the whole length of their course they give off delicate *rami musculares* to the neighboring muscles (see Figs. 810 and 832), including the mm. intercostales externi, interni (and subcostales) and levatores costarum from Th₁—Th₁₁, mm. serratus posterior superior from Th₁—Th₄, serratus posterior inferior from Th₆—Th₁₁, transversus thoracis from Th₃—Th₆, mm. obliqui and transversus abdominis from Th₇—Th₁₂, m. rectus abdominis from Th₅—Th₁₂, and m. pyramidalis from Th₁₂; in addition, sensory fibers go to the peritoneum of the anterior abdominal wall and to the marginal zone of the diaphragm from Th₇—Th₁₂.

Each n. intercostalis gives off cutaneous branches, *ramus cutaneus lateralis* and *ramus cutaneus anterior*.

a) *Ramus cutaneus lateralis pectoralis et abdominalis* (see Figs. 810 and 811) goes off about midway between the spine and the sternum, is usually larger than the continuation of the trunk, and is absent only on the 1st intercostal nerve. It appears between the digitations of the m. serratus anterior, lower down between those of the mm. latissimus dorsi and obliquus externus abdominis, about midway between the mammillary and axillary lines, and divides into two branches. The *ramus posterior* passes around the lateral margin of the m. latissimus dorsi, approximately horizontal, to the skin, toward the branches of the rami posteriores (see also Fig. 784); the branch of the 2nd and sometimes of the 3rd intercostal nerve unites, as the n. *intercostobrachialis* (see also Fig. 791) with the n. cutaneus brachii medialis, and goes wholly or in part to the skin of the medial surface of the upper arm. The *ramus anterior* of the 2nd—6th intercostal nerves bends around the lateral margin of the m. pectoralis major medianward to the skin over this muscle; in the female branches from the 4th—6th nerves, *rami mammarii laterales*, enter the mammary gland; the anterior ramus of the 7th—11th intercostal nerves passes upon the external surface of the m. obliquus externus abdominis obliquely downward and medianward to almost in front of the sheath of the rectus, that of the 12th usually runs with a large branch over the crista iliaca downward to the skin upon the mm. glutaeus medius and tensor fasciae latae and there alternate with the ramus cutaneus lateralis n. iliohypogastrici (see also Figs. 816, 827, 828 and p. 744).

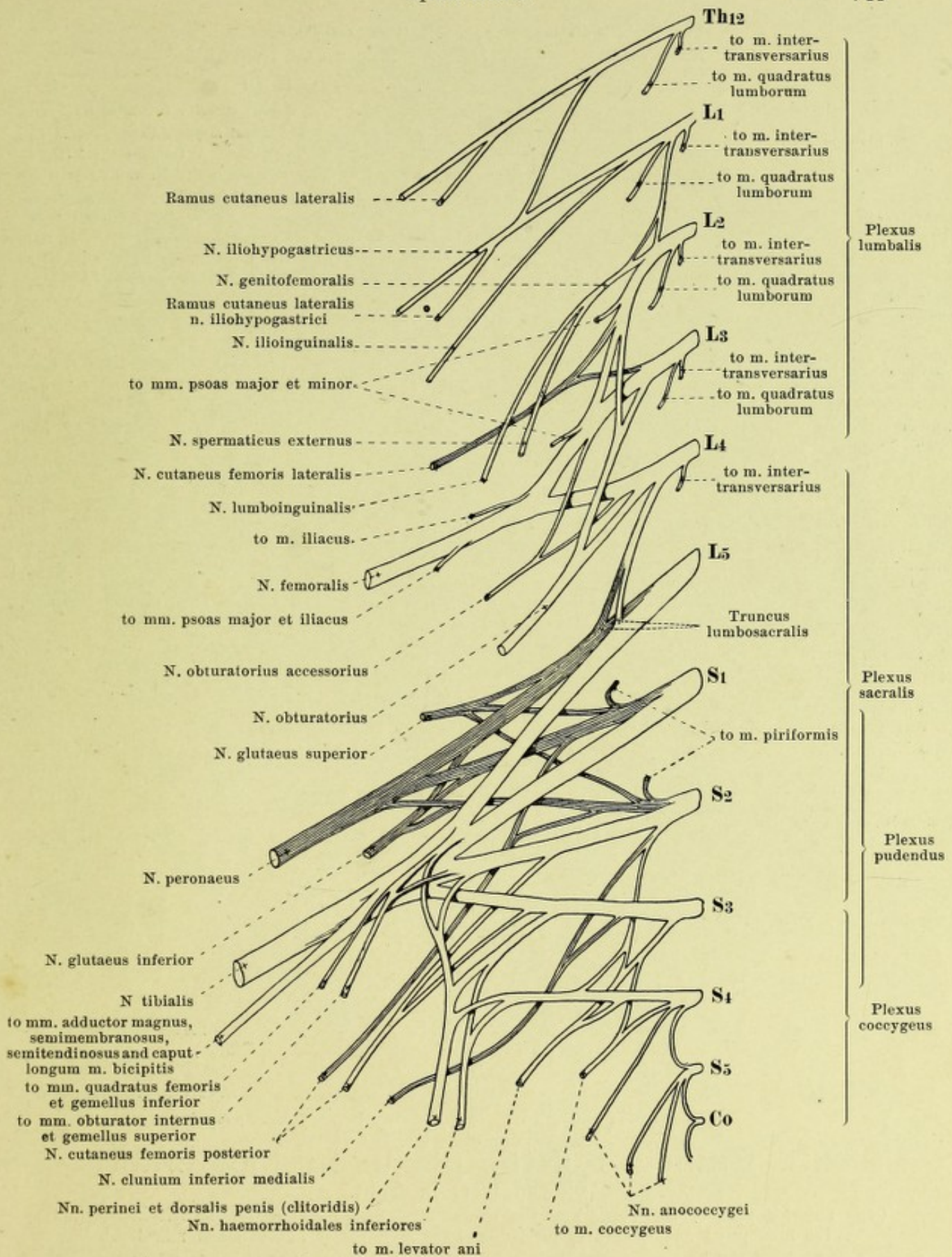
b) *Ramus cutaneus anterior pectoralis et abdominalis* (see Figs. 780 and 781) passes from the upper 6 intercostal nerves close to the lateral margin of the sternum through the m. pectoralis major to the skin of the anterior surface of the chest; branches from the 2nd—4th pass as *rami mammarii mediales* to the mammary gland in the female. Those from the lower 6 intercostal nerves perforate the m. rectus abdominis and the anterior layer of the rectal sheath, often subdivided into several twigs, and go to the skin in front of the same, that of the 10th usually at the level of the umbilicus.

The *rami anteriores of the nn. lumbales* pass through the foramina intervertebralia, those of the *nn. sacrales* through the foramina sacralia anteriora (see Figs. 813 and 818); that of the n. *coccygeus* (see Fig. 689) runs through the hiatus sacralis between the ligg. sacrococcygea posteriora, surrounds the root of the cornu coccygeum from below and perforates the lig. sacrospinosum and the m. coccygeus. In general they increase in size from L₁ to S₁, then quickly decrease; they are all connected with the trunk and ganglia of the sympathicus by one or several rami communicantes (see Figs. 813 and 818). They all anastomose with one another and thus form the large *plexus lumbosacralis* (see Figs. 812, 813 and 818), which is subdivisible into the *plexus lumbalis*, *sacralis*, *pudendus* and *coccygeus*.

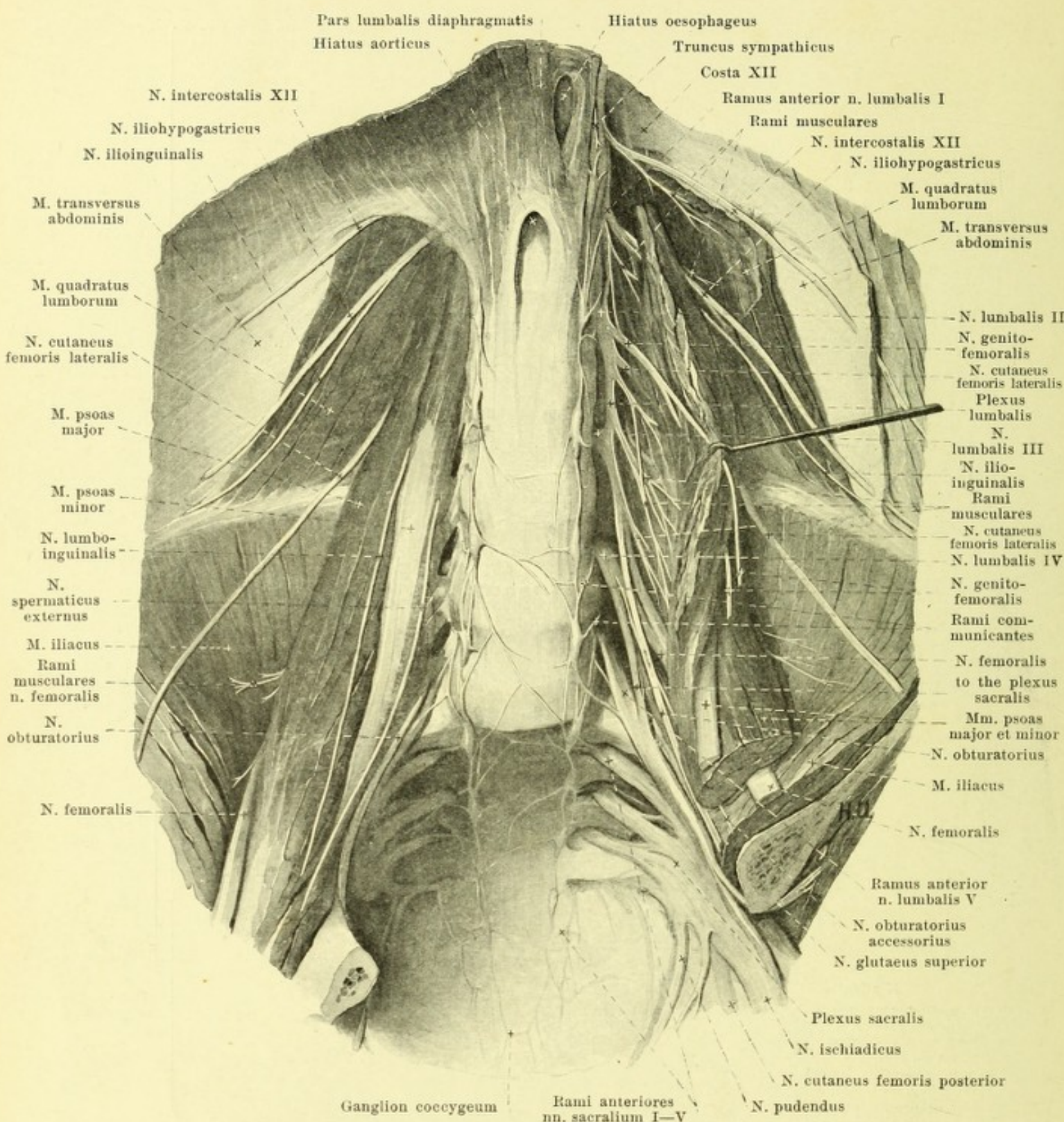
The *plexus lumbalis* (see Figs. 812 and 813) is formed by the whole of the 1st, 2nd and 3rd and a part of the 4th lumbar nerves and receives also fibers from the n. intercostalis XII through one of its branches. It lies in front of the procc. transversi of the lumbar vertebrae within the m. psoas major, between its origins from the vertebral bodies and from the procc. transversi. It gives off:

1. *Rami musculares* (see Figs. 812 and 813), short, directly from the roots of the plexus to the mm. intertransversarii, from the Th₁₂, L₁, L₂, L₃ and L₄ and the m. quadratus lumborum, from Th₁₂, L₁, L₂ and L₃; further to the m. psoas major from L₂, L₃ and L₄ and to the m. psoas minor, from L₁ and L₂ (perforates the m. psoas major).

2. *N. iliohypogastricus* (see Figs. 810—813, 816, 821, 827 and 828), from Th₁₂ and L₁, often in a common stem with the n. ilioinguinalis, is larger than the latter and together with it corresponds in its behavior almost exactly to an intercostal nerve. It runs (see Fig. 813), at first parallel to the 12th intercostal nerve, in front of the m. quadratus lumborum and behind the lower part of the kidney lateralward and downward to the tendon of the m. transversus abdominis which it perforates above the crista iliaca. Thence it passes (see Figs. 810 and 816), at first between the mm. transversus and obliquus internus abdominis, close above the crista iliaca, then between the mm. obliqui abdominis, above the ligamentum inguinale as far as the sheath of the rectus; from this part of its course it gives off an anastomosis to the n. ilioinguinalis. During its entire course between the broad and the straight muscles of the abdomen it gives off *rami musculares* to them, as well as sensory branches to the peritoneum. In addition it gives off:



812. Right plexus lumbosacralis, schematic, viewed from in front (after P. Eisler). (The darkly shaded trunks are derivatives of the dorsal half of the plexus.)



813. Branches of the plexus lumbosacralis, viewed from in front.

(The anterior part of the pelvis and the viscera have been removed; on the left in addition the mm. psoas and quadratus lumborum have been partly loosened and reflected.)

2. *N. iliohypogastricus* (continued) (see also Figs. 810, 811, 821, 827 and 828).

a) *Ramus cutaneus lateralis*, goes downward over the middle of the crista iliaca through the mm. obliqui abdominis to the skin over the mm. gluteus medius and tensor fasciae latae. Its size and area of distribution vary inversely as those of the corresponding branch of the ramus cutaneus lateralis n. intercostalis XII (see p. 742).

814. Muscle nerves of the right thigh, viewed from in front.

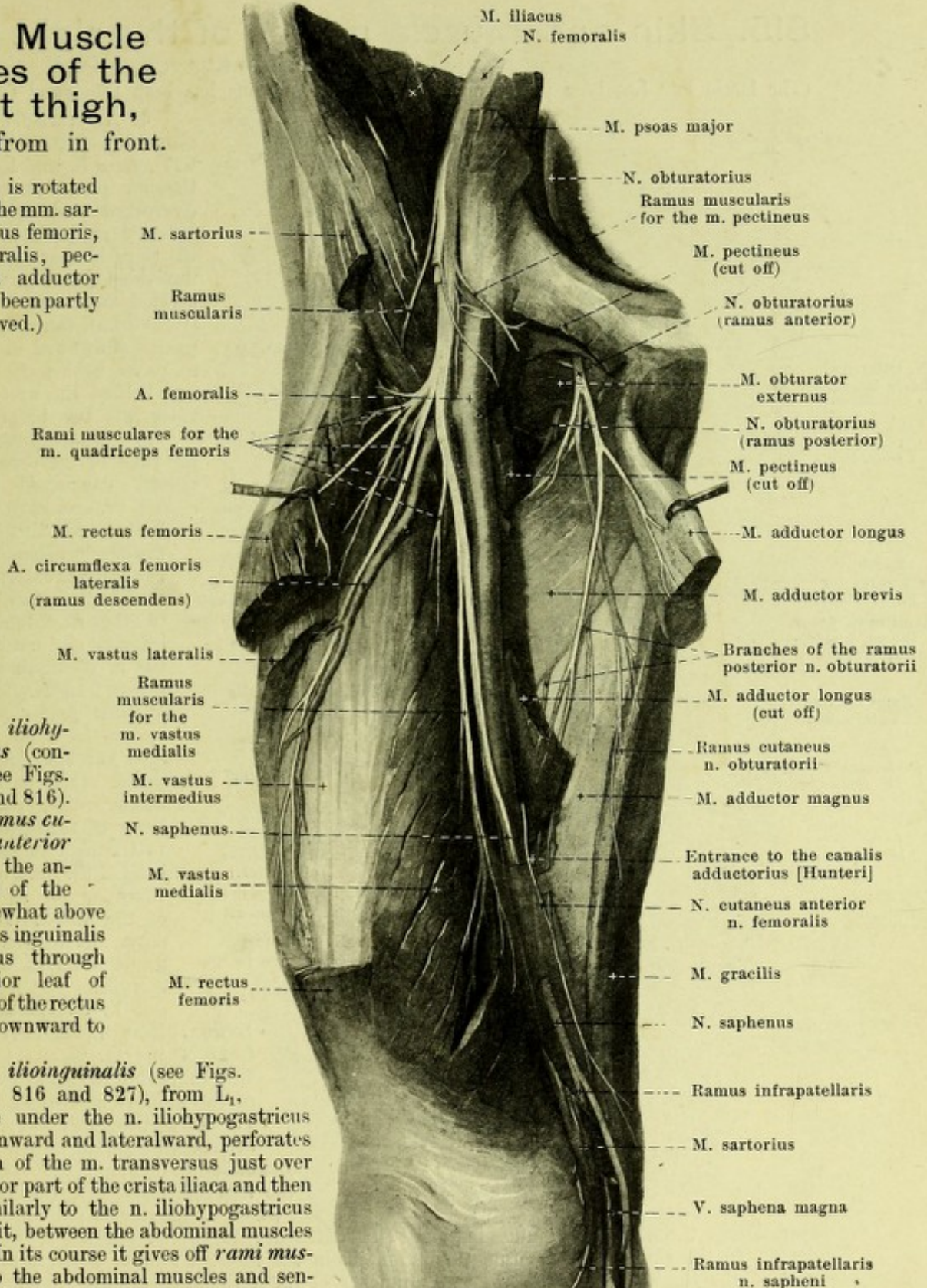
(The thigh is rotated outward. The mm. sartorius, rectus femoris, vastus lateralis, pectineus and adductor longus have been partly removed.)

2. *N. iliohypogastricus* (continued) (see Figs. 810, 811 and 816).

b) *Ramus cutaneus anterior* goes from the anterior end of the nerve somewhat above the annulus inguinalis subcutaneus through the anterior leaf of the sheath of the rectus and then downward to the skin.

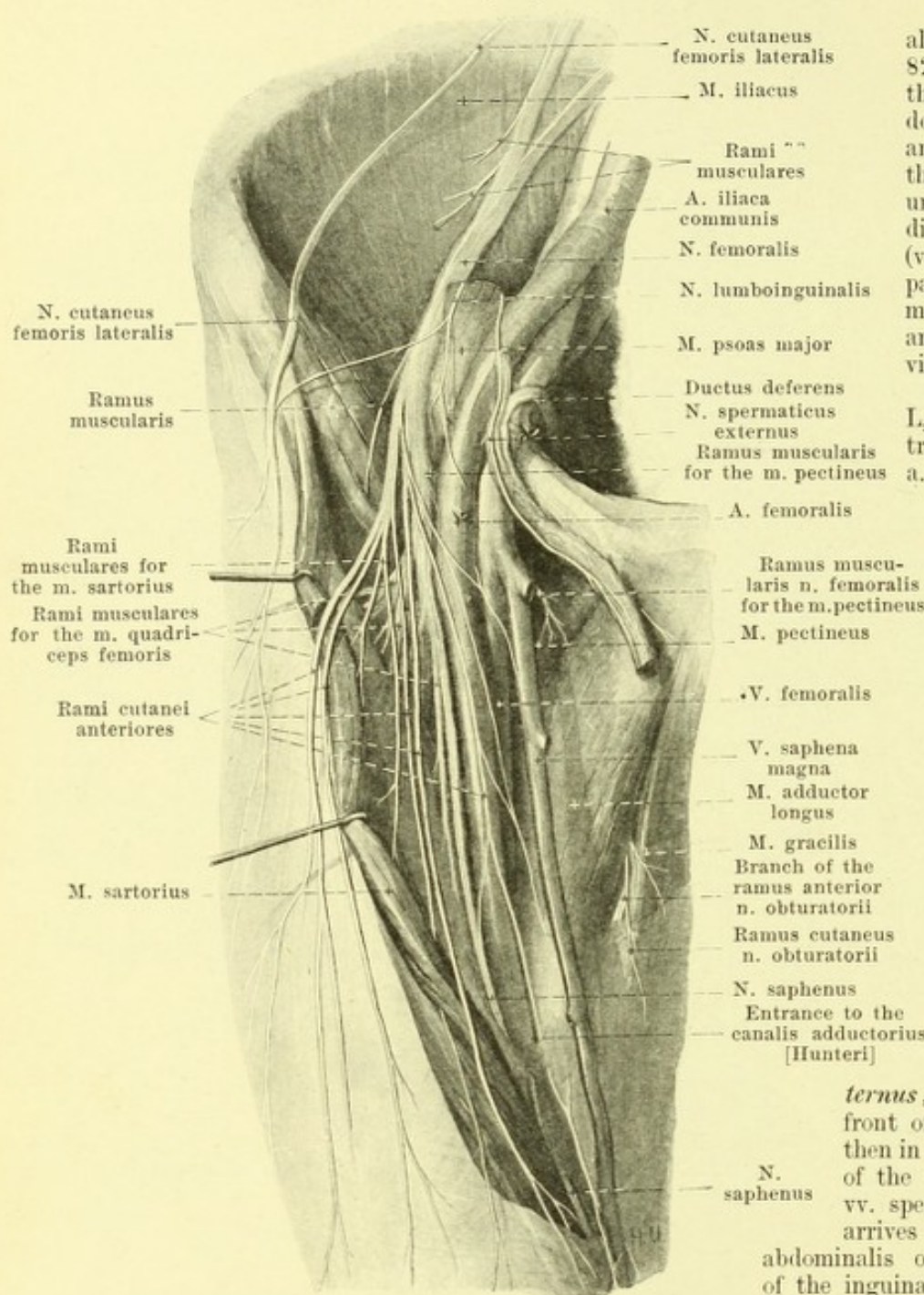
3. *N. ilioinguinalis* (see Figs. 810—813, 816 and 827), from L_1 , runs close under the *n. iliohypogastricus* (q. v.) downward and lateralward, perforates the tendon of the *m. transversus* just over the posterior part of the *crista iliaca* and then passes similarly to the *n. iliohypogastricus* but below it, between the abdominal muscles forward. In its course it gives off *rami musculares* to the abdominal muscles and sensory branches to the peritoneum anastomoses with the *n. iliohypogastricus* (see p. 742) and at the upper anterior side of the *funiculus spermaticus*, passes through the *annulus inguinalis subcutaneus*. There it gives off descending branches to the uppermost, medial part of the thigh, which anastomose with branches of the *n. spermaticus* and may take the place of these, and *rami scrotales (labiales) anteriores* transversely to the lower part of the *mons pubis*, as well as to the anterior, upper part of the *scrotum* (*labium majus* in the female).

Spalteholz, Atlas.



815. Skin and muscle nerves of the right thigh, viewed from in front.

(The fascia lata has been partly removed; the m. sartorius has been lifted and drawn aside.)



4. *N. genitofemoralis* (see also Figs. 812, 813, 816 and 827), from L_1 and L_2 , perforates the m. psoas major obliquely downward and appears on its anterior surface at the level of the third lumbar vertebra, either undivided (see Fig. 816) or subdivided into its two branches (vide infra) (see Fig. 813). It passes downward in front of the m. psoas, behind the peritoneum, and behind the ureter, and divides into two branches:

a) *N. lumboinguinalis*, from L_2 , runs in the direction of the trunk, downward behind the a. and vv. spermaticae internae, first under then in front of the fascia iliaca, lateral from the a. iliaca externa and in its course often gives off a branch to the n. cutaneus femoris lateralis and not rarely one to the n. ilioinguinalis through the m. transversus abdominis. It then passes lateral from, and in front of, the a. femoralis through the lacuna vasorum and partly in the fossa ovalis, partly lateral from it through the fascia to the skin in the neighborhood of the fossa ovalis, sometimes as far as the middle of the thigh. Its branches often anastomose with cutaneous branches of the n. femoralis.

b) *N. spermaticus externus*, from L_1 and L_2 , runs in front of the m. psoas, first behind, then in front of the fascia iliaca, in front of the a. iliaca externa and the a. and vv. spermaticae internae, downward, arrives through the annulus inguinalis abdominalis or through the posterior wall of the inguinal canal into this and goes on the posterior inferior surface of the funiculus

spermaticus through the annulus inguinalis subcutaneus, to the m. cremaster, to the tunica dartos, to the skin of the scrotum (labium majus in the female), and to the uppermost medial part of the thigh. It anastomoses with branches of the n. ilioinguinalis and may take its place.

5. *N. cutaneus femoris lateralis* (O. T. external cutaneous) (see also Figs. 812, 813, 816, 818, 821, 827 and 828), from L_2 and L_3 , passes behind or through the m. psoas major, in front of the m. quadratus lumborum, crista iliaca and the m. iliacus behind the fascia iliaca, downward and lateralward, on the right side behind the caecum, on the left behind the colon descendens, often receiving a branch of the n. lumboinguinalis. It then goes in front of the a. circumflexa ilium profunda medial from the spina iliaca anterior superior beneath the lig. inguinale downward and, in front of the m. sartorius, perforates the fascia lata, usually with two or three separate branches. It may be included in the n. femoralis as far as the lig. inguinale.

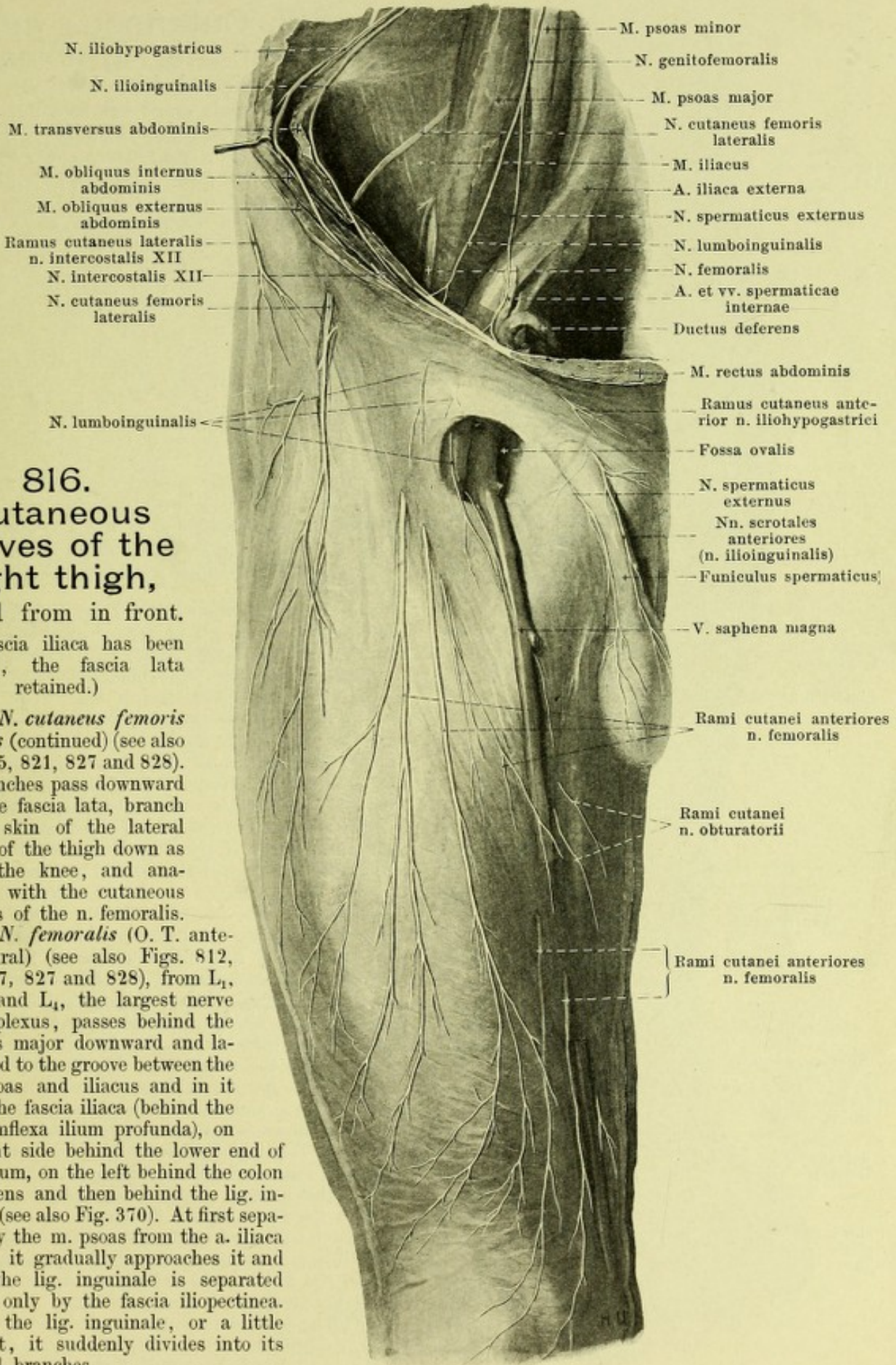
816. Cutaneous nerves of the right thigh,

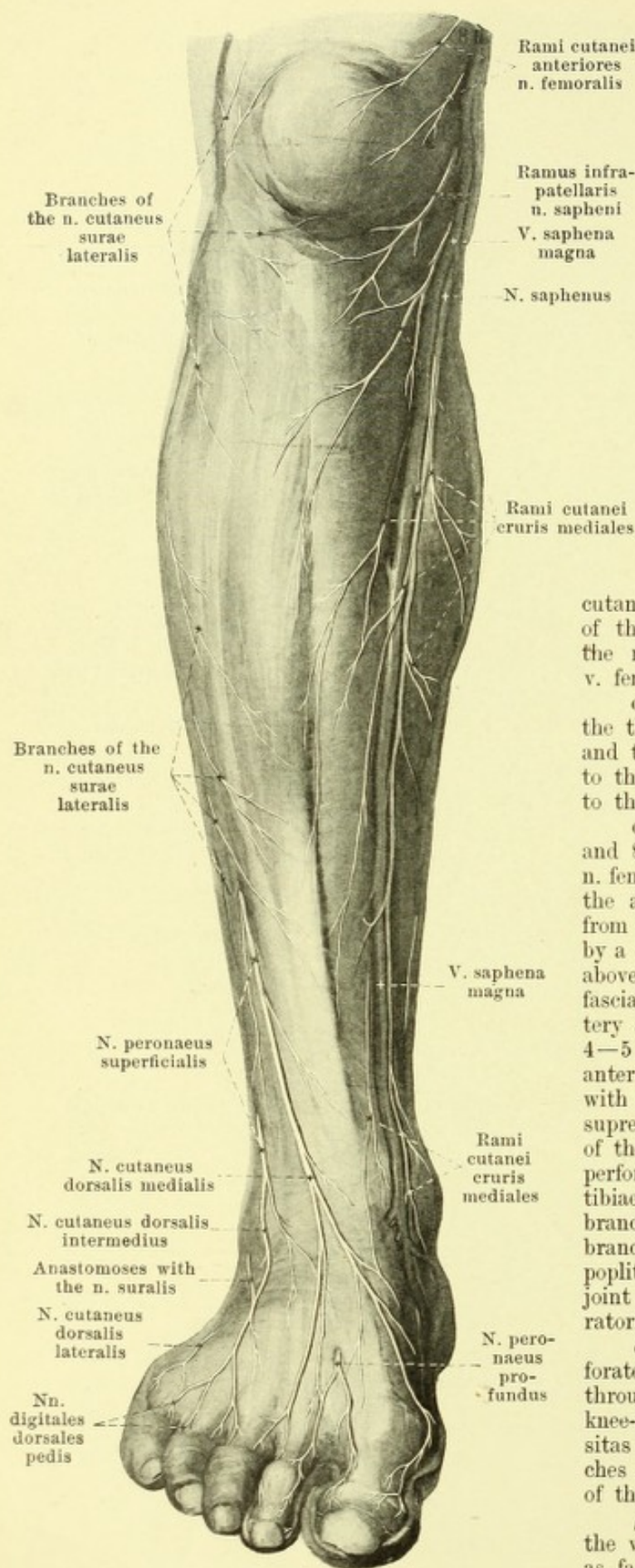
viewed from in front.

(The fascia iliaca has been removed, the fascia lata retained.)

5. *N. cutaneus femoris lateralis* (continued) (see also Figs. 815, 821, 827 and 828). The branches pass downward upon the fascia lata, branch in the skin of the lateral surface of the thigh down as far as the knee, and anastomose with the cutaneous branches of the *n. femoralis*.

6. *N. femoralis* (O. T. anterior crural) (see also Figs. 812, 815, 817, 827 and 828), from *L*₁, *L*₂, *L*₃ and *L*₄, the largest nerve of the plexus, passes behind the *m. psoas major* downward and lateralward to the groove between the *mm. psoas* and *iliacus* and in it under the fascia iliaca (behind the *a. circumflexa ilium profunda*), on the right side behind the lower end of the caecum, on the left behind the colon descendens and then behind the *lig. inguinale* (see also Fig. 370). At first separated by the *m. psoas* from the *a. iliaca externa*, it gradually approaches it and under the *lig. inguinale* is separated from it only by the fascia iliopectinea. Behind the *lig. inguinale*, or a little below it, it suddenly divides into its terminal branches.





817. Cutaneous nerves of the right leg, viewed from in front.

(The fascia cruris has been retained.)

6. *N. femoralis* (continued): Branches:

a) *Rami musculares* (see Figs. 812—815), short, in the fossa iliaca to the m. iliacus and to the distal part of the m. iliopsoas.

b) *Rami cutanei anteriores* (see also Figs. 814—816, 827 and 828), in two groups. One group goes partly through the m. sartorius, at the same time innervating it, partly over its medial margin through the fascia to the skin on the anterior surface of the thigh almost as far as the knee-cap; they anastomose above with branches of the nn. lumbinguinalis and cutaneus femoris lateralis. The others run along the medial margin of the m. sartorius, perforate the fascia at different levels and run, one close to the v. saphena magna, to the skin of the anterior medial surface of the thigh; they anastomose with branches of the ramus cutaneus n. obturatorii and of the n. saphenus; one of these branches gives off a *ramus muscularis* for the m. pectineus which runs behind the a. and v. femoralis.

c) *Rami musculares* (see Figs. 814 and 815) in the thigh to the heads of the m. quadriceps femoris and to the m. articularis genu; they send fine threads to the hip- and knee-joint, and often also a thread to the m. tensor fasciae latae.

d) *N. saphenus* (see also Figs. 814—816, 827 and 828) runs in a way as the continuation of the n. femoralis, covered by the m. sartorius, in front of the a. circumflexa femoris lateralis, at first lateral from the a. femoralis downward, separated from it by a continuation of the fascia iliopectinea; somewhat above the middle of the thigh it passes through this fascia, lies on the anterior medial surface of the artery and with it goes into the canalis adductorius. 4—5 cm below the hiatus tendineus it perforates the anterior wall of the canalis adductorius, usually along with the ramus musculoarticularis of the a. genu suprema, passes downward on the posterior margin of the m. sartorius, behind the epicondylus medialis, perforates the fascia at the level of the tuberositas tibiae and divides immediately into its two terminal branches. In the thigh it gives off in fine cutaneous branch to the medial surface of the thigh and to the popliteal space and an articular branch to the knee-joint and anastomoses with a branch of the n. obturatorius. Terminal branches:

a) *Ramus infrapatellaris*, goes around or perforates the tendon of the m. sartorius and passes through the fascia in the form of a curve under the knee-cap lateralward as far as in front of the tuberositas tibiae; it anastomoses with the cutaneous branches of the n. femoralis and supplies the skin in front of the knee-cap and beneath it.

β) The continuation of the main nerve runs along the v. saphena magna, usually behind it, distalward as far as the medial margin of the foot and anasto-

moses there with branches of the n. peroneus superficialis. It sends *rami cutanei cruris mediales* to the anterior and posterior surfaces of the leg, which anastomose behind with branches of the n. cutaneus surae medialis.

7. *N. obturatorius* (see Figs. 812—816, 821, 827 and 828), from (L_1), L_2 , L_3 and L_4 , goes almost vertically downward at first in the m. psoas major between the n. femoralis and truncus lumbosacralis, then leaves the m. psoas major on its medial surface in front of the articulatio sacroiliaca and then passes forward lateralward and downward somewhat below the linea terminalis and above the a. obturatoria directly upon the fascia pelvis to the canalis obturatorius; in its course it runs at first lateral from the vena, then from the a. hypogastrica, then from the ureter and in the female crosses the lateral surface of the ovarium. In the canalis obturatorius it gives off a branch to the dorsal surface of the m. obturator externus. It then divides into two terminal branches:

a) *Ramus anterior* (see Figs. 814—816, 827 and 828) passes distalward over the upper margin of the m. obturator externus, then behind the mm. pectineus and adductor longus, between the latter and the m. adductor brevis, and gives off motor branches to the mm. adductores longus and brevis, m. gracilis and not rarely to the m. pectineus. It ends as the *ramus cutaneus*, which usually passes between the mm. adductor longus and gracilis in the middle of the thigh through the fascia to the skin and supplies the lower half of the medial surface of the thigh. It anastomoses with the n. saphenus.

b) *Ramus posterior* (see Fig. 814) not infrequently perforates the m. obturator externus and runs downward between the mm. adductores brevis, minimus and magnus; it sends motor branches to the three mm. adductores mentioned and branches to the hip-joint.

8. *N. obturatorius accessorius* (see Figs. 812 and 813), often present, from (L_2), L_3 and L_4 , passes distalward under the fascia iliaca at the medial margin of the m. psoas major, then over the pecten oss. pubis and between the mm. iliopsoas and pectineus into the depth. It gives off branches to the latter and to the hip-joint and finally enters the n. obturatorius. When markedly developed it may partly substitute for the n. obturatorius.

Plexus sacralis (see Figs. 812, 813 and 818) is formed of the anterior branches of the nn. lumbales IV (partly) and V, as well as of the nn. sacrales I—III, all of which converge downward and lateralward. The n. lumbalis IV sends from half to nine-tenths of its fibers to the plexus sacralis; these are separated from the n. lumbalis V by the ramus iliaca a. ilio-lumbalis, and with it form a common stem, *truncus lumbosacralis*, which passes obliquely downward over the basal surface of the pars lateralis oss. sacri into the small pelvis and is separated from the nn. sacrales I by the a. glutea superior. The last root of the plexus arises usually from the n. sacralis III, more rarely II or IV. The plexus sacralis yields exclusively nerves for the pelvic girdle and the lower extremity.

The nerves for the pelvic viscera, for the muscles and for the skin of the perineum come from the *plexus pudendus* (see also p. 762), which is in a way a portion introduced into the plexus sacralis (see Fig. 812), and arises from S_1 , S_2 , S_3 and S_4 .

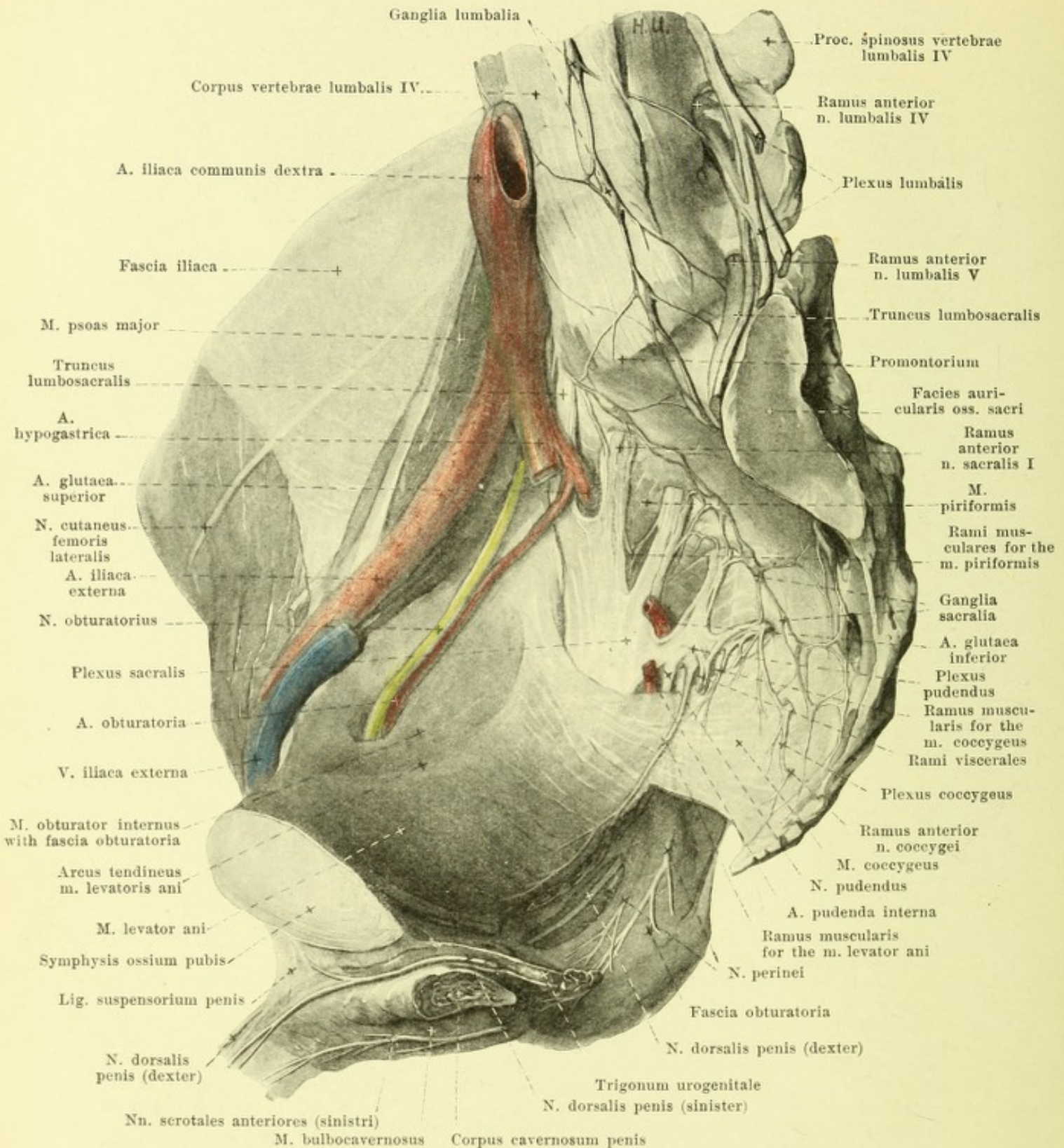
The plexus sacralis lies as a flat, triangular mass on the anterior surface of the m. piriformis as far as the upper margin of the m. coccygeus; its inferior apex is directed toward the lower portion of the foramen ischiadicum majus and goes over into the n. ischiadicus. The plexus is covered in front by the most posterior portion of the fascia pelvis and by peritoneum and lies on the lateral surface of the rectum and the contents of the excavatio rectovesicalis (rectouterina in the female). It sends branches A. to the pelvic girdle and B. to the extremity.

A. Branches to the pelvic girdle:

1. *Rami musculares* a) for the m. piriformis (see Figs. 812 and 818) from S_1 and S_2 , pass directly into the anterior surface of the muscle; b) for the mm. obturator internus, gemelli and quadratus femoris (see Figs. 812 and 819) from L_4 , L_5 , S_1 and S_2 ; they pass through the foramen ischiadicum majus upon the dorsal surface of the spina ischiadica and there divide into two trunks; the medial gives branches to the m. gemellus superior and passes lateral with the a. pudenda interna through the foramen ischiadicum minus to the medial surface of the m. obturator internus; the lateral runs upon the capsule of the hip-joint, to which it gives branches, distalward to the mm. gemellus inferior and quadratus femoris.

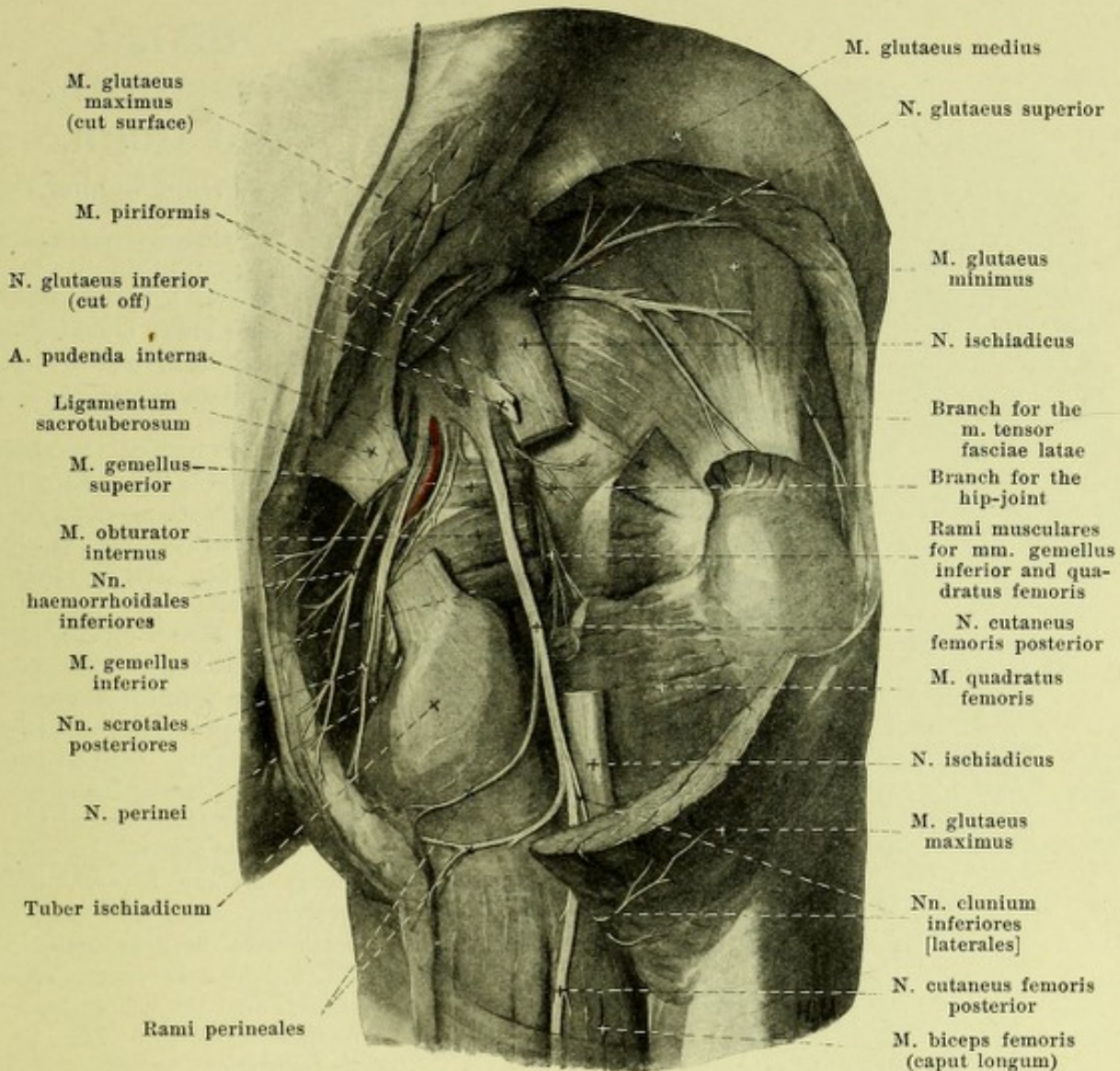
2. *N. gluteus superior* (see Figs. 812, 813, 819 and 820), from L_4 , L_5 , S_1 (S_2), runs lateralward above the m. piriformis (not rarely by one bundle through it) lateral from, then below, the a. glutea superior through the foramen ischiadicum majus and then between the mm. glutei medius and minimus; it supplies these and, usually partly perforating the m. gluteus minimus, sends a twig into the medial surface of the m. tensor fasciae latae.

3. *N. gluteus inferior* (see Figs. 812, 819 and 820), from (L_4), L_5 , S_1 and S_2 , passes in front of the distal margin of the m. piriformis between it and the n. ischiadicus, lateral from the a. glutea inferior through the foramen ischiadicum majus and enters the anterior surface of the m. gluteus maximus.



818. Nerves of the right half of the pelvis, viewed from the left.

(The viscera have been removed, the fascia pelvis has been completely, the fascia iliaca partly, removed. Of the m. levator ani only the lateral part has been preserved; a piece has been cut out of the fascia obturatoria.)



819. Deep nerves of the right buttock, viewed from behind.

(The mm. glutei maximus and medius, piriformis, obturatores and gemelli, as well as the lig. sacrotuberosum have been partially removed; a piece has been cut out of the n. ischiadicus.)

B. Branches to the lower extremity:

4. *N. cutaneus femoris posterior* (O. T., small sciatic) (see also Figs. 812, 813, 820—822, 828—830), from S_1 , S_2 and S_3 , runs through the foramen ischiadicum majus under the distal margin of the m. piriformis, behind the n. ischiadicus, lateral from the a. and v. glutea inferior and goes distalward directly in front of the m. gluteus maximus approximately midway between the tuber ischiadicum and the trochanter major. It then crosses the origin of the caput longum m. bicipitis dorsalward and runs farther in the groove between the mm. semitendinosus and biceps under the fascia lata into the popliteal space. It sends larger medial and smaller lateral branches, which are shorter above, longer below, through the fascia to the skin of the posterior surface of the thigh and of the calf; in addition:

a) *Nn. clunium inferiores [laterales]*, two or three, arise in front of m. gluteus maximus, loop around its distal margin to its dorsal surface and go to the skin over the lateral part of the buttock.

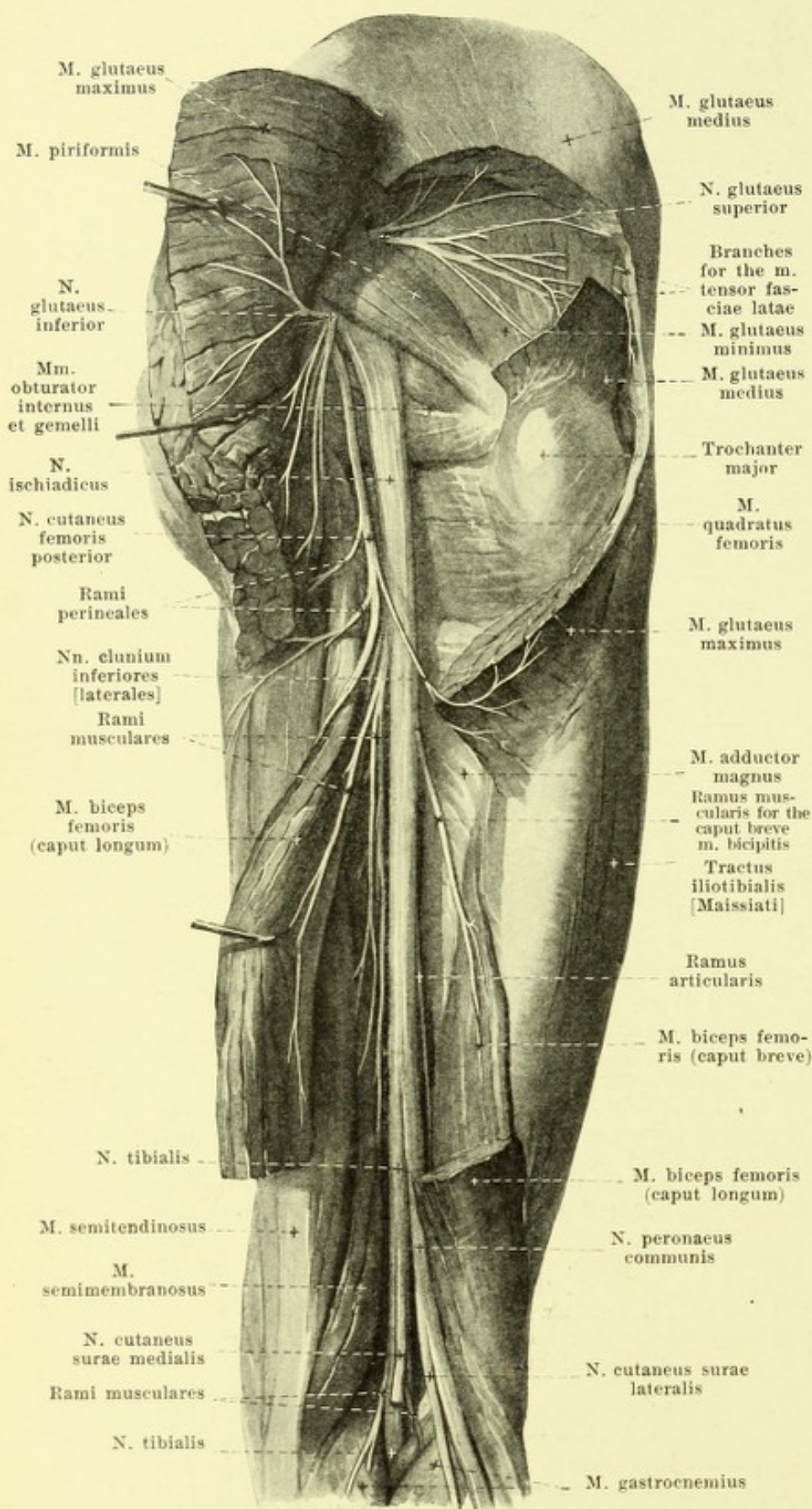
b) *Rami perineales*, usually two, arise at the same level as the preceding, run at first downward in front of the gluteus maximus, then close under the tuber ischiadicum medianward upon the muscles springing from it, and go through the fascia to the skin of the uppermost part of the medial surface of the thigh, of the perineum and to the posterior surface of the scrotum (labium majus in the female); they anastomose there with the nn. scrotales (labiales) posteriores.

820.

Nerves of the right thigh, viewed from behind.

(The m. gluteus maximus and the caput longum m. bicipitis femoris have been cut through and drawn to the side; a piece has been cut out of the m. gluteus medius.)

5. *N. ischiadicus* (see also Figs. 812, 813, 819, 823 and 829), the largest nerve of the body, is a flattened cord which passes under (very rarely through) the m. piriformis lateral from the a. glutea inferior (see also Fig. 477) through the foramen ischiadicum majus and thence passes almost vertically downward behind the mm. gemelli, the tendon of the m. obturator internus and the m. quadratus femoris, approximately midway between the trochanter major and the tuber ischiadicum, in front of the n. cutaneus femoris posterior and the m. gluteus maximus. It then runs on the posterior surface of the m. adductor magnus in front of the caput longum m. bicipitis as far as the upper apex of the popliteal space and there divides into the *n. tibialis* and the *n. peroneus communis*. In about 15% of the cases this division occurs as high up as the plexus itself, in which event the n. peroneus runs through the m. piriformis, the n. tibialis below it. In the other cases this separation can be easily brought about artificially, and thus it is easy to establish whether the branches which go off to the thigh from the n. ischiadicus belong really to the n. tibialis or to the n. peroneus. Branches:



821.

Cutaneous nerves of the right thigh, viewed from behind.

(The fascia lata except for a middle strip has been preserved.)

A. Branches in the thigh:

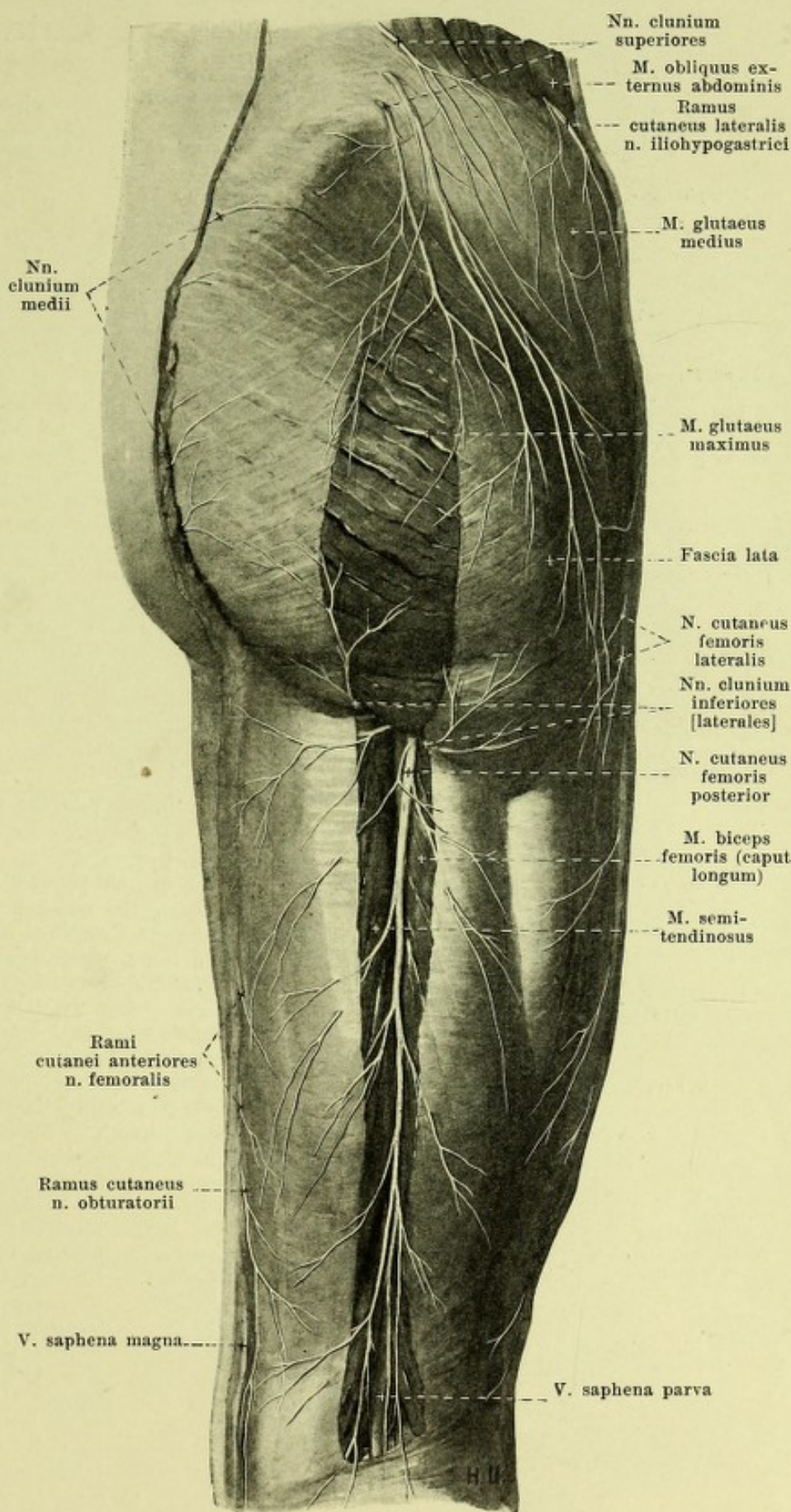
a) Belonging to the n. tibialis (from its ventral surface):

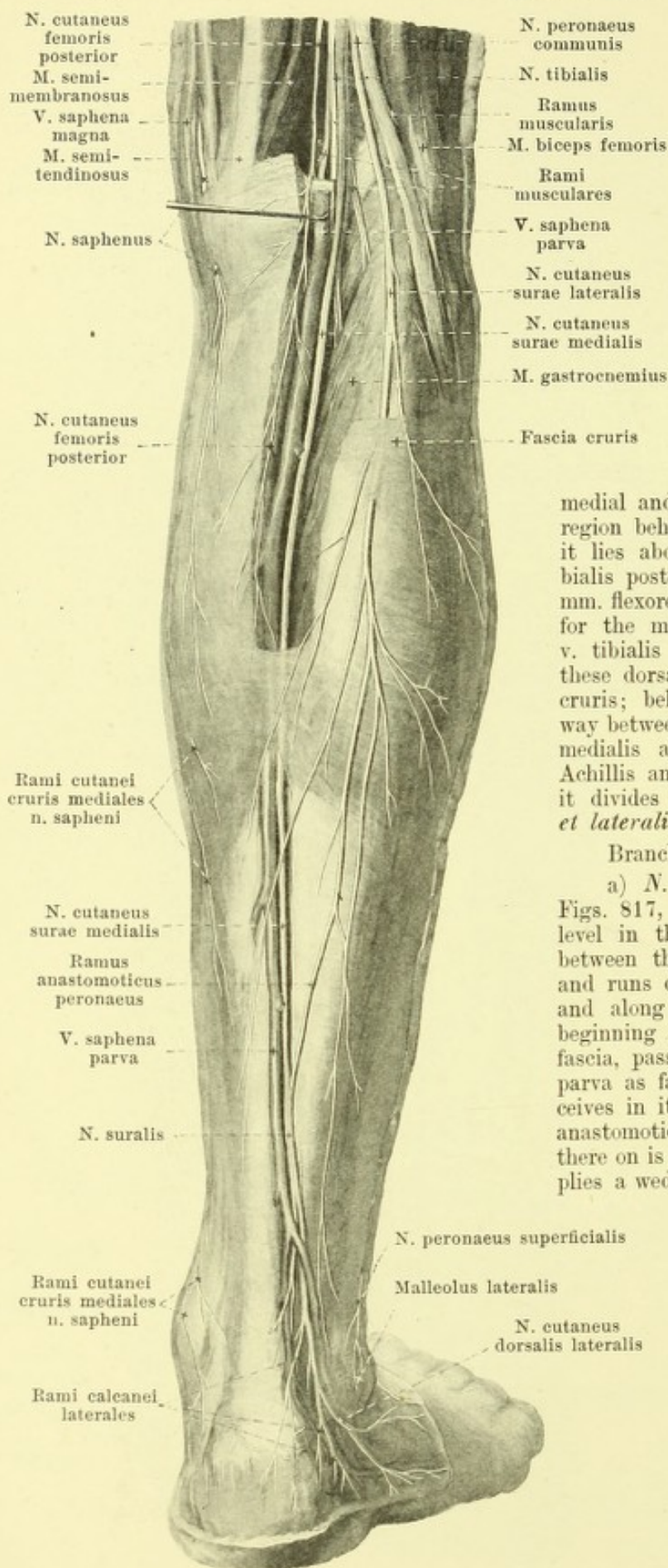
Rami musculares (see Fig. 820), from L₄, L₅, S₁, S₂ and S₃, for the m. semitendinosus (an upper and a lower), for the caput longum m. bicipitis, the m. semimembranosus and for the dorsal part of the m. adductor magnus.

b) Belonging to the n. peroneus:

Ramus muscularis (see Fig. 820), from L₄, L₅ and S₁, for the caput breve m. bicipitis, and *ramus articularis* downward to the capsule of the knee-joint.

B. *N. tibialis* (see Figs. 812, 820, 822—825, 827 and 828), from L₄, L₅, S₁, S₂ and S₃, runs almost perpendicularly from the upper to the lower angle of the popliteal space and passes between the two heads of the m. gastrocnemius into the depth, behind the m. popliteus and in front of the tendinous arch in the origin of the m. soleus.





822.

Cutaneous nerves of the right leg, viewed from behind.

(The fascia has been preserved, except for its upper part.)

B. *N. tibialis* (continued) (see also Figs. 820, 823—825, 827 and 828). In the popliteal space it lies directly beneath the fascia, dorsal and lateral from the v. poplitea, which itself runs dorsal and lateral from the a. poplitea; below it is separated from the m. popliteus by the vessels. In the leg it descends above in front of the middle of the m. soleus, below medial and in front of the tendo Achillis to the region behind the medial malleolus; in this course it lies above on the dorsal surface of the m. tibialis posterior, below in the groove between the mm. flexores digitorum longus and hallucis longus, for the most part lateralward from the a. and v. tibialis posterior, being covered along with these dorsalward by the deep layer of the fascia cruris; below the nerve runs approximately midway between the posterior margin of the malleolus medialis and the medial margin of the tendo Achillis and at the same time behind the vessels; it divides there into the *nn. plantares medialis et lateralis*.

Branches in the popliteal space:

a) *N. cutaneus surae medialis* (see also Figs. 817, 823, 826—828) arises at a variable level in the popliteal space, goes to the groove between the two bellies of the m. gastrocnemius and runs downward in it beneath the fascia cruris and along with the v. saphena parva. At the beginning of the tendo Achillis it perforates the fascia, passes upon it lateral from the v. saphena parva as far as behind the malleolus lateralis, receives in its course at a variable level the ramus anastomoticus peronaeus (see p. 758) and from there on is called the *n. suralis*. In the leg it supplies a wedged-shaped distal portion (see Fig. 828) and gives off *rami calcanei laterales* to the dorsal and lateral portions of the skin of the heel. It then runs forward in front of the v. saphena parva, passing in a curve behind and below the lateral malleolus, anastomoses with the *n. cutaneus dorsalis intermedius* (see Fig. 817) and goes as the *n. cutaneus dorsalis lateralis* (see also Figs. 817 and 826) along the lateral margin of the foot as far as the face of the terminal phalanx of the 5th toe, in order usually to break up on the lateral margin of this toe, more rarely also on the dorsal surfaces of the 4th and half of the 3rd toe.

823. Muscle nerves of the right leg, viewed from behind.

(The mm. semitendinosus, semimembranosus, biceps, gastrocnemius, plantaris, soleus and flexor hallucis have been wholly or partly removed.)

B. *N. tibialis* (continued):

b) *Rami musculares* (see also Figs. 820 and 822) to the two heads of the m. gastrocnemius, to the mm. plantaris, soleus and popliteus.

c) *Rami articulares* to the knee-joint.

d) *N. interosseus cruris* (see also Fig. 826) passes distalward near the a. tibialis anterior inside the membrana interossea cruris and gives branches to the vessels, bones and syndesmosis tibiofibularis.

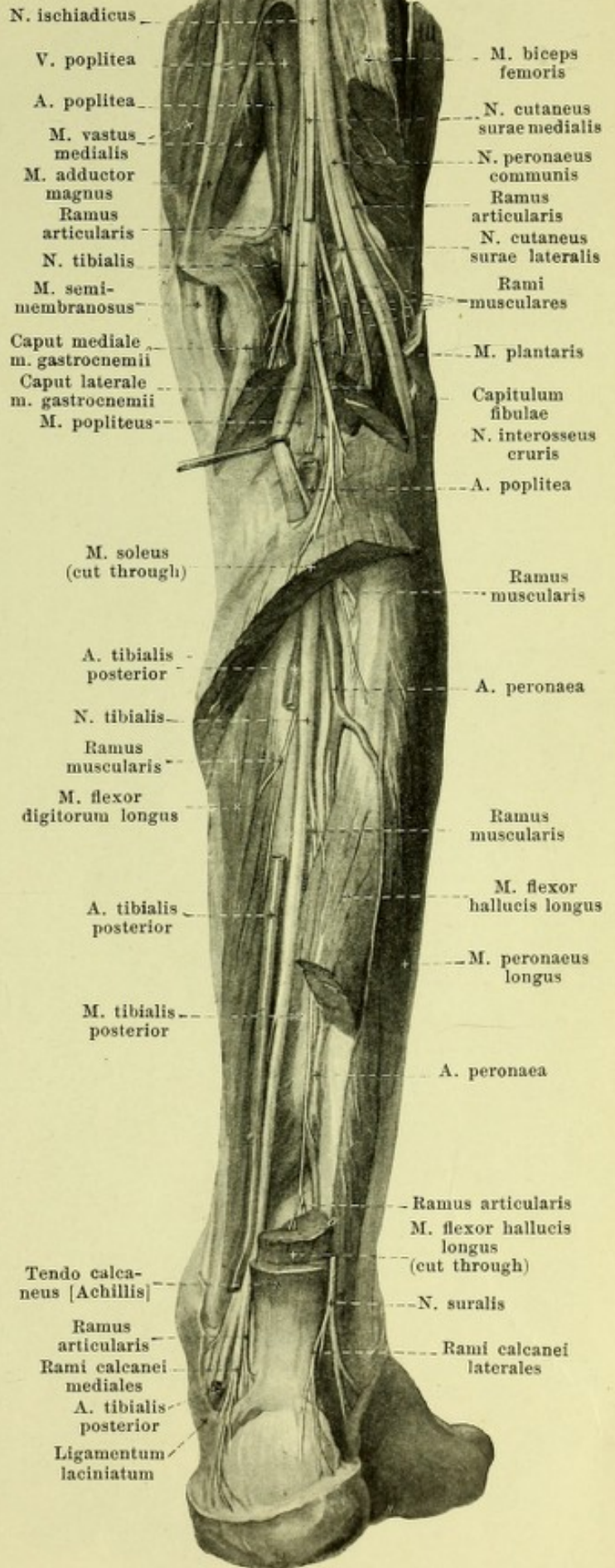
Branches in the leg:

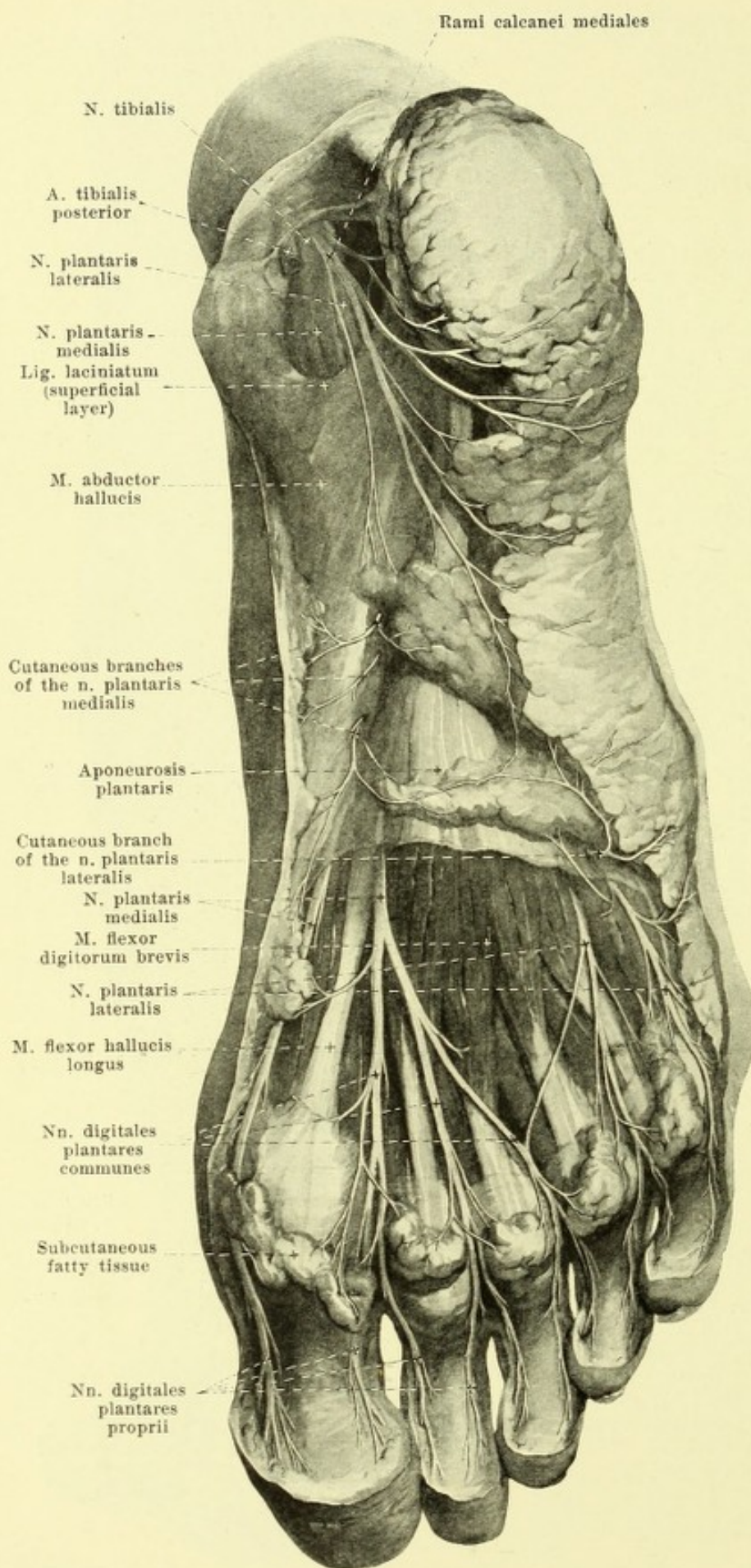
e) *Rami musculares* to the mm. tibialis posterior, flexor digitorum longus and flexor hallucis longus.

f) *Rami articulares*, partly from e) to the ankle joint.

g) *Rami calcanei mediales* (see also Figs. 824, 827 and 828), frequently going off from a trunk in the lower third of the leg, extend to the skin on the posterior medial surface of the heel and on the posterior part of the sole of the foot; they anastomose with branches of the nn. suralis and plantares.

h) *N. plantaris medialis* (see Figs. 824 and 825), the larger terminal branch, runs at first between the two leaves of the lig. laciniatum (in the medial compartment, see p. 360), then on the lateral surface of the m. abductor hallucis and arrives on the lower surface of the tendon of the m. flexor digitorum longus and finally on the medial surface of the m. flexor digitorum brevis, crossed by the vessels more superficially situated. In its course it gives off small branches (see Fig. 824) to the skin of the medial portion of the hollow of the foot, as well as *rami musculares* (see Fig. 825) to the mm. flexor digitorum brevis, abductor hallucis and flexor hallucis brevis. It then sends (see Figs. 824 and 825) a *n. digitalis plantaris proprius* to the medial margin of the plantar surface of the great toe, which also sends a branch to the medial head of the m. flexor hallucis brevis, and divides into three *nn. digitales plantares communes*, which pass distalward between the m. flexor digitorum brevis and the aponeurosis plantaris to the 1st—3rd spatium interosseum and divide at the level of the articulationes metatarsophalangeae, each into two *nn. digitales plantares proprii*. The latter supply the adjacent sides of the volar surfaces of the 1st—4th toe, as well as the dorsal surfaces of the corresponding terminal phalanges. The first n. digitalis plantaris communis sends also a small branch to the m. lumbricalis I, and the third often receives an anastomosis from the n. plantaris lateralis (see p. 757).





824.

Cutaneous nerves of the sole of the right foot,

viewed from below.

(The aponeurosis plantaris has been removed in front.)

B. *N. tibialis* (continued).

i) *N. plantaris lateralis* (see also Fig. 825) lies at first between the two layers of the lig. laciniatum (in the lateral compartment, see p. 360), then runs distalward and lateralward between the mm. flexor digitorum brevis and quadratus plantae, gives off as it goes *rami musculares* to the mm. quadratus plantae and abductor digiti V and divides into a *ramus profundus* and a *ramus superficialis*.

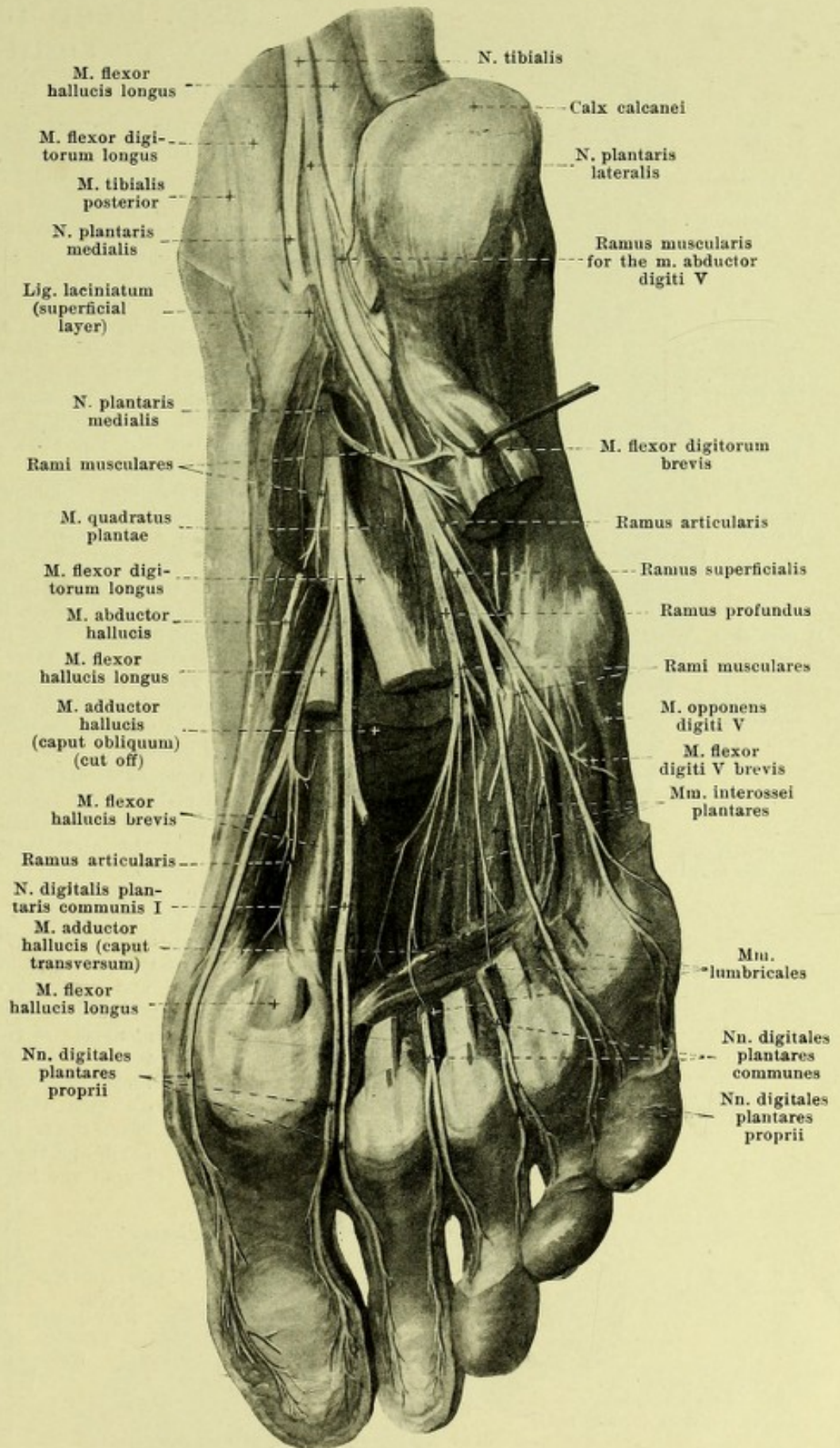
a) *Ramus profundus* goes into the depth with the arcus plantaris and runs medianward on the dorsal surface of the m. quadratus plantae and of the caput obliquum m. adductoris hallucis, between it and the mm. interossei. It gives branches to the joints as well as *rami musculares* to the mm. interossei of the 1st—3rd spatium interosseum, to the mm. lumbricales II—IV, the m. adductor hallucis and rarely to the lateral belly of the m. flexor hallucis brevis.

825. Deep nerves of the sole of the right foot, viewed from below.

(The muscles of the toes have been partially removed.)

i) *N. plantaris lateralis* (continued) (see also Fig. 824).

β) *Ramus superficialis* divides at the lateral margin of the m. flexor digitorum brevis into a medial and a lateral branch. The medial *n. digitalis plantaris communis IV*, runs distalward upon the 4th spatium interosseum, sends an anastomosis to the n. plantaris medialis (see p. 755) and divides into two *nn. digitales plantares proprii* for the adjacent sides of the volar surfaces of the 4th and 5th toes and for the dorsal surfaces of the terminal phalanges. The lateral branch runs as a *n. digitalis plantaris proprius* under the m. flexor digiti V brevis distalward and lateralward to the lateral margin of the 5th toe; in its course it gives off *rami musculares* to the mm. flexor digiti V brevis and opponens digiti V and the mm. interossei of the 4th spatium interosseum.



826. Deep nerves of the right leg,

viewed from in front and lateralward.

(The mm. peroneus longus, extensores digitorum and tibialis anterior have been partly removed and drawn asunder.)

C. *N. peroneus communis* (see also Figs. 812, 820, 822, 823, 827 and 828), from L_4 , L_5 , S_1 and S_2 , runs along the medial margin of the m. biceps femoris upon the dorsal surface of the caput laterale m. gastrocnemii distalward and lateralward, then behind the capitulum fibulae to the lateral margin of the collum fibulae, where it divides into its two terminal branches, both of which pass through the canal located in the origin of the m. peroneus longus (see also Fig. 395). It gives off in the popliteal space:

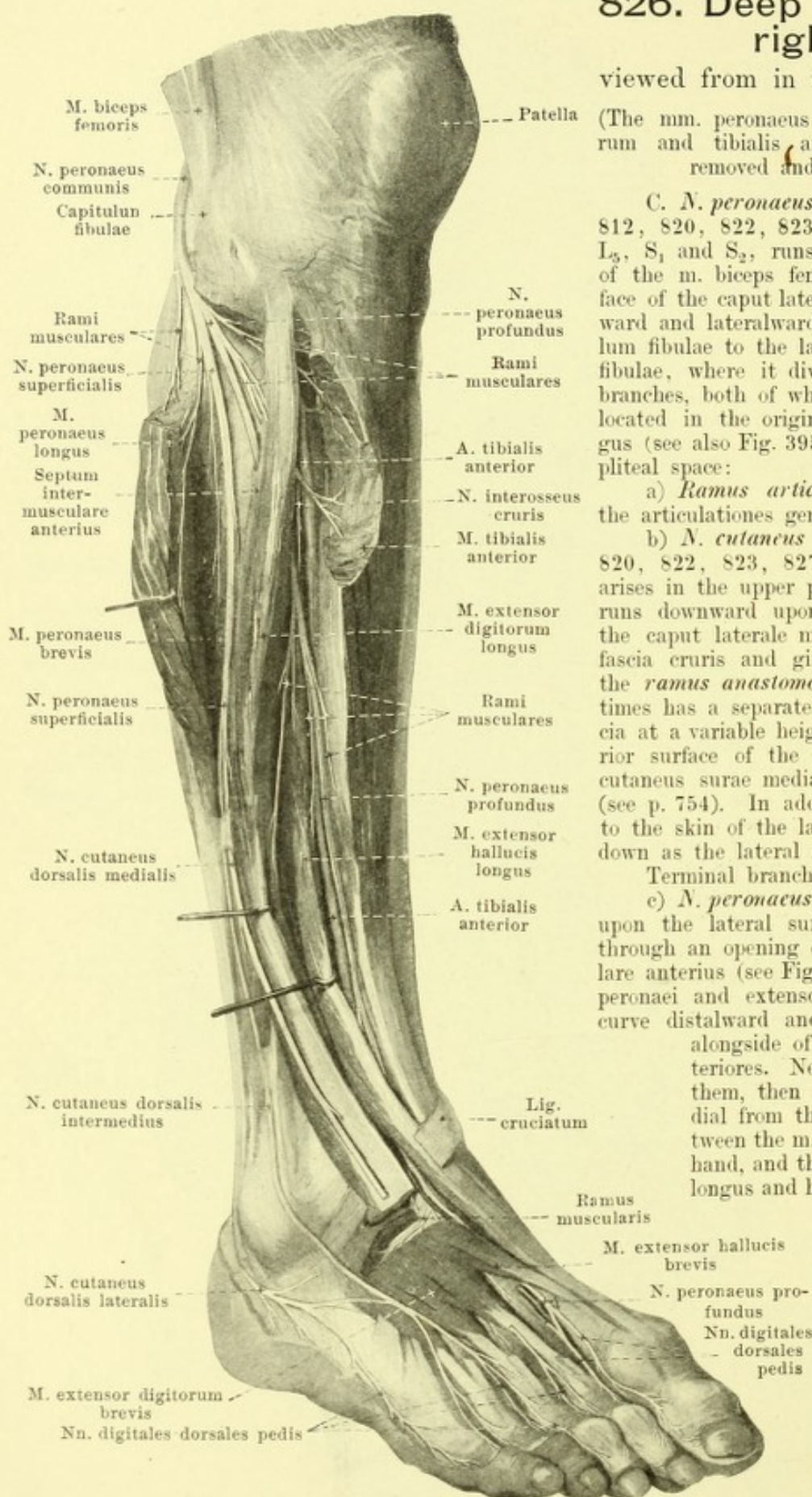
a) *Ramus articulares* (see Fig. 823) to the articulationes genu and tibiofibularis.

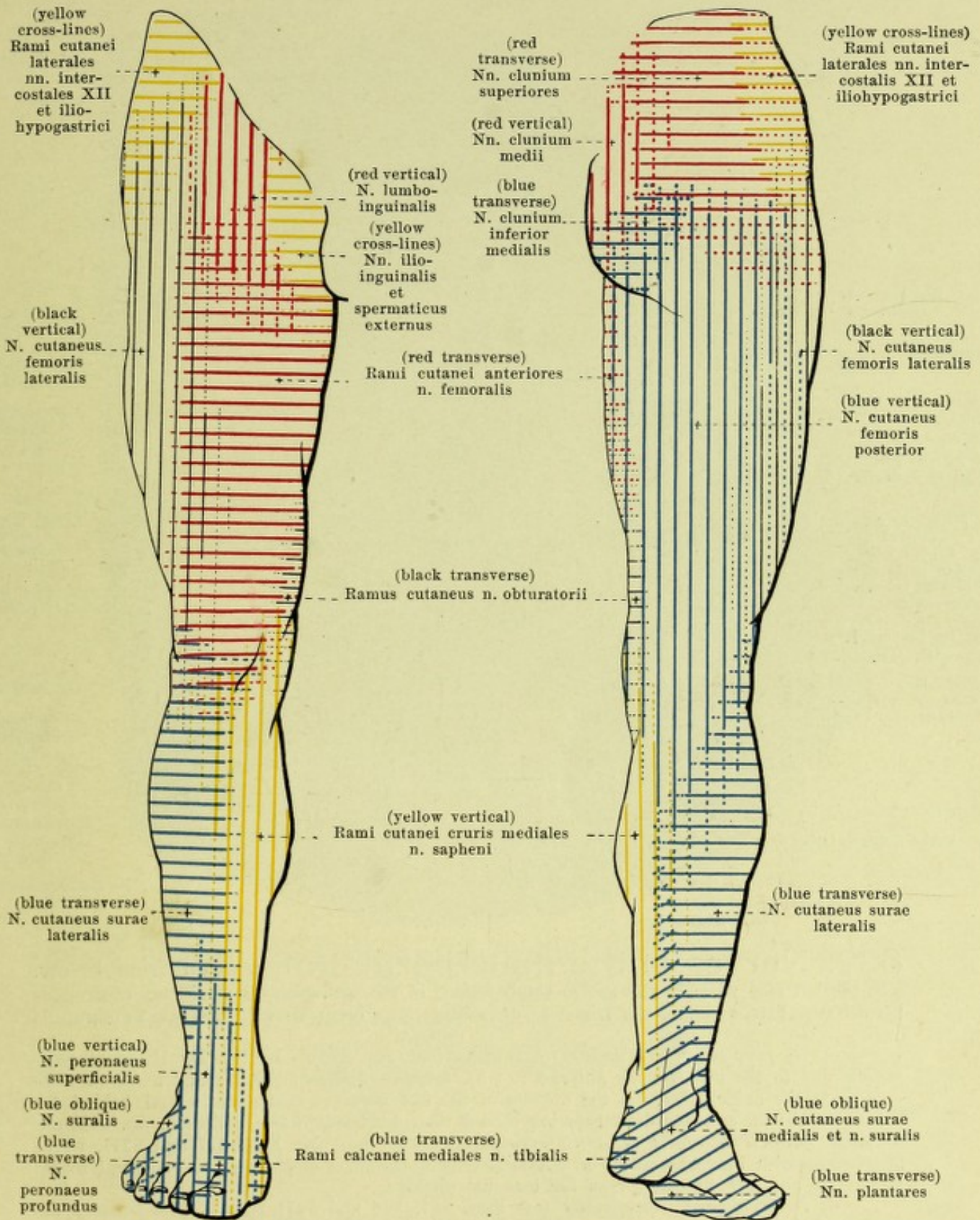
b) *N. cutaneus surae lateralis* (see Figs. 820, 822, 823, 827 and 828), very variable, arises in the upper part of the popliteal space, runs downward upon the posterior surface of the caput laterale m. gastrocnemii, under the fascia cruris and gives off at a variable level the *ramus anastomoticus peroneus* (it sometimes has a separate origin), perforates the fascia at a variable height and unites on the posterior surface of the tendo Achillis with the n. cutaneus surae medialis to form the *n. suralis* (see p. 754). In addition it gives off branches to the skin of the lateral half of the leg as far down as the lateral malleolus.

Terminal branches:

c) *N. peroneus profundus* passes directly upon the lateral surface of the collum fibulae through an opening of the septum intermusculare anterius (see Fig. 392), covered by the mm. peronei and extensor digitorum longus, in a curve distalward and medianward and arrives alongside of the a. and vv. tibiales anteriores. Near these, first lateral from them, then in front of, and finally medial from them, it runs downward between the m. tibialis anterior on the one hand, and the mm. extensores digitorum longus and hallucis longus on the other,

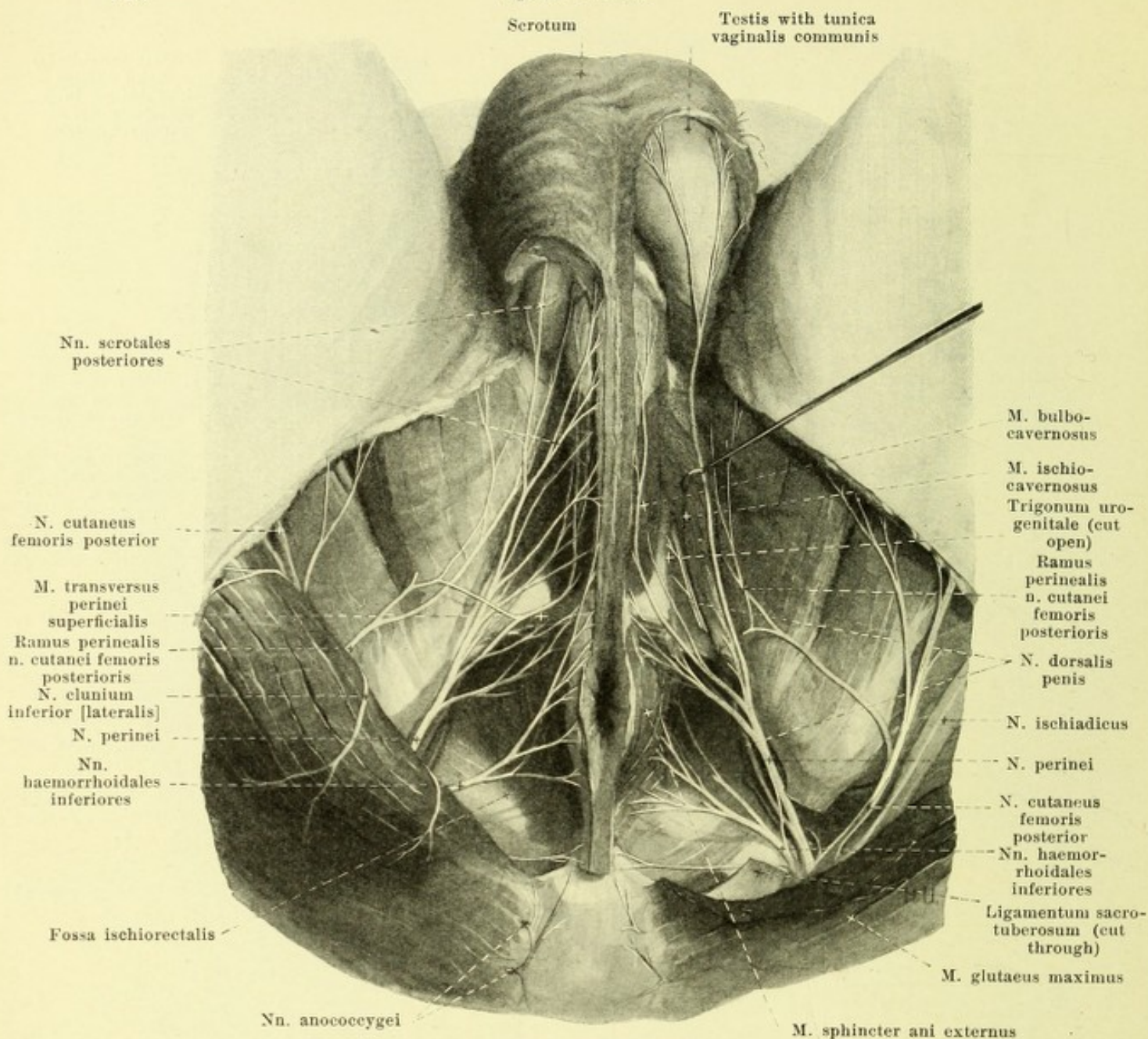
passes behind the ligg. transversum and cruciatum cruris (and behind the tendon of the m. extensor hallucis longus) upon the dorsum of the foot and there passes at first between the mm. extensores hallucis longus and brevis, then behind the tendon of the latter to the first spatium interosseum.





827 and 828. Areas of distribution of the cutaneous nerves in the right lower extremity, viewed from in front. viewed from behind.

(The areas constantly supplied by the nerves concerned are indicated by solid lines, the areas not constantly supplied, by dotted lines.)



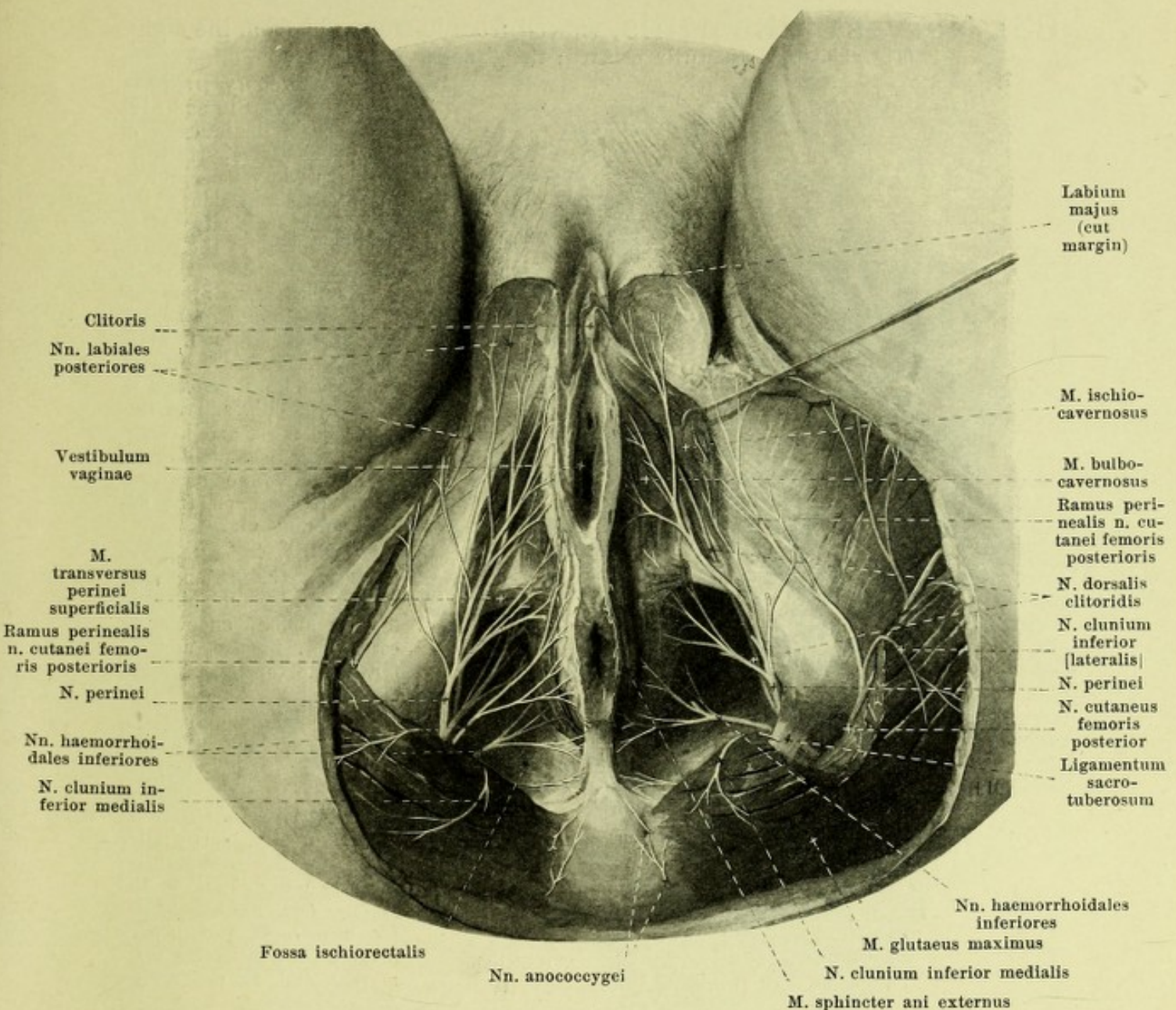
829. Nerves of the male perineum, viewed from below.

(On the left side parts of the lig. sacrotuberosum, of the mm. gluteus maximus, transversus perinei superficialis and of the trigonum urogenitale have been removed. The fascia obturatoria has been removed.)

c) *N. peronaeus profundus* (continued) (see Fig. 826). In the leg it sends *rami musculares* to the mm. tibialis anterior (2—3), extensor digitorum longus and a *ramus articularis* to the ankle-joint, on the dorsum of the foot a ramus muscularis lateral behind the vessels to the m. extensor digitorum brevis and then divides into two branches: *nn. digitales dorsales hallucis lateralis et digiti secundi medialis* (see also Figs. 817 and 827), which anastomose with branches of the n. cutaneus dorsalis medialis and supply the adjacent halves of the 1st and 2nd toes as far as the terminal phalanx.

d) *N. peronaeus superficialis* (see Figs. 817, 826 and 827) runs at first between the fibula and the m. peronaeus longus, then distalward on the lateral anterior surface of the m. peronaeus brevis and as it goes gives off *rami musculares* to the mm. peronaei. It then perforates the fascia cruris in the lower half of the leg and divides into two terminal branches:

a) *N. cutaneus dorsalis intermedius*, the smaller, passes upon the fascia to the base of the 4th toe, sends branches to the skin of the leg and dorsum of the foot, anastomoses with the n. suralis (see p. 754) and finally divides into four *nn. digitales dorsales pedis* for the adjacent halves of the dorsal surfaces of the 3rd—5th toes.



830. Nerves of the female perineum, viewed from below.

(On the left side pieces have been cut out of the mm. gluteus maximus, transversus perinei superficialis and the trigonum urogenitale. The fascia obturatoria has been removed.)

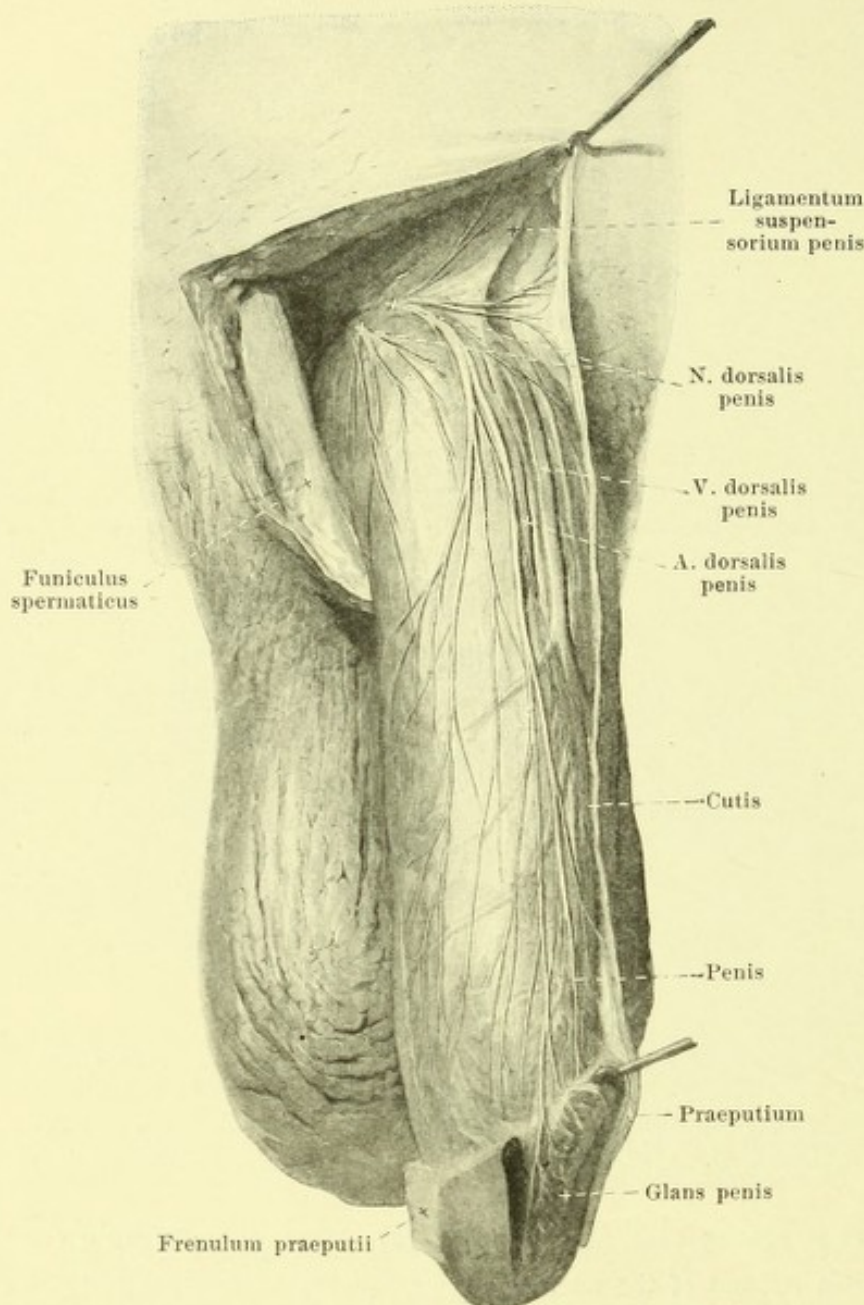
d) *N. peroneus superficialis* (continued) (see Figs. 817, 826 and 827):

N. cutaneus dorsalis medialis, runs upon the fascia cruris distalward and medianward to the dorsum of the foot, gives off branches to the skin of the leg and dorsum of foot and divides into a medial branch, which passes to the medial margin of the foot and of the great toe as far as its terminal phalanx, anastomosing with the n. saphenus and n. peroneus profundus, and a lateral branch, which goes to the 2nd interosseous space, often anastomoses with the n. peroneus profundus and divides into two *nn. digitales dorsales pedis* for the adjacent paths of the dorsal surfaces of the 2nd and 3rd toes.

7. *N. clunium inferior medialis* (see also Figs. 812 and 828) from S_2 and S_3 , goes with the n. pudendus through the foramen ischiadicum majus on the back of the spina ischiadica and thence alone in front of or behind the lig. sacrotuberum, or also through its whole breadth to the inferior margin of the m. gluteus maximus, passes around the latter and goes upward through the fascia to the skin over the medial part of the buttock.

831. Nerves of the penis, viewed from in front and from the right.

(The skin has been partly removed; the glans has been incised.)



The *plexus pudendus* (see Figs. 812 and 818) is formed of the branches of the spinal nerves, which go to the pelvic viscera and to the muscles and skin of the perineum. It is situated in the lower part of the plexus sacralis. Its chief root is S_3 ; besides it receives contributions from (L_5) S_1 , S_2 and S_4 . It lies in front of the lowermost parts of the m. piriformis, is crossed in front by the a. and vv. sacrales laterales, and is separated from the ampulla recti by the excavatio rectovesicalis. It gives off the following branches:

1. *Rami musculares* (see Figs. 812, 818 and 834) for the m. levator ani, from (S_2), S_3 and S_4 , and the m. coccygeus, from S_3 and S_4 , forward to the inner surface of the same.

2. *Rami viscerales*, 4—6, (see Figs. 818 and 834), from (S_2), S_3 and S_4 , run upward on the sides of the pelvic viscera. They go partly directly, partly after union with sympathetic plexuses (see p. 769), to the rectum (*nn. haemorrhoidales medii*), to the urinary bladder (*nn. vesicales inferiores*) and to the vagina (*nn. vaginales*).

3. *N. pudendus* (see also Figs. 812, 813, 818, 819, 829, 830 and 834), the largest nerve of the plexus, from all of its roots, runs

under the m. piriformis near and caudalward from the a. pudenda interna upon the back of the spina ischiadica, then turns downward, forward and medianward between the fascia obturatoria and the m. obturator internus and divides at the tuber ischiadicum into the *n. perinei* and the *n. dorsalis penis (clitoridis)*. Before division it gives off the *nn. haemorrhoidales inferiores*, from S_3 and S_4 , which pass through the fascia obturatoria and medianward and forward through the fossa ischio-rectalis, to supply the m. sphincter ani externus and the skin of the anus and its neighborhood and to anastomose with branches of the *n. perinei*. Terminal branches:

a) *N. perinei*, from S_2 , S_3 and S_4 , passes in a curve forward and downward on the medial surface of the tuber ischiadicum, and with its branches perforates the fascia obturatoria behind the trigonum urogenitale; its superficial branches, *nn. scrotales (labiales) posteriores*, go to the skin of the perineum and of the scrotum (labium majus in the female), its deep branches to the mm. transversus perinei superficialis, bulbocavernosus and ischiocavernosus, as well as into the penis; it anastomoses with the *nn. haemorrhoidales inferiores* and rami perineales n. cutanei femoris posterioris as well as with branches of the *n. dorsalis penis* (see p. 763).

b) *N. dorsalis penis (clitoridis)* (see Figs. 812, 818, 829—831 and 834), from S_1 , S_2 and S_3 , smaller than the n. perinei, passes forward in the trigonum urogenitale (see also Figs. 658 and 673) lateral from the a. penis (clitoridis) between the lig. transversum pelvis and the lig. arcuatum pubis and near the lig. suspensorium penis to the back of the penis (clitoris); on its way it sends fine branches to the mm. transversus perinei profundus and sphincter urethrae membranaceae and anastomoses with the nn. cavernosi penis (see p. 769). Upon the penis its lateral, superficial branches go to the corpus cavernosum penis and to the skin of the lateral and inferior surfaces, anastomosing with terminal branches of the n. perinei; its medial branches run lateral from the a. dorsalis penis as far as the glans. Upon the clitoris the nerve is very delicate; it supplies the skin of the clitoris and gives off twigs to the small and large lips.

Plexus coccygeus (see Figs. 812 and 818) is formed chiefly by the anterior branches of the n. sacralis V and the n. coccygeus (see p. 742), but receives also branches from the nn. sacrales III and IV. It lies in front of the origin of the m. coccygeus from the sacrum and coccyx, unites with the lower end of the truncus sympathicus and sends fibers to the viscera. Besides it gives off the nn. anococcygei (see also Figs. 829 and 830), three to five, which run near the inferior end of the sacrum and coccyx through or below the m. coccygeus, backward to the skin over the coccyx and in its neighborhood.

Systema nervorum sympathicum (*sympathetic nervous system, sympathicus*) is formed 1. by a chain of ganglia lying on each side along the spinal column, the ganglia being united with one another by vertical bundles of nerve fibers to form a longitudinal cord, *truncus sympathicus*, together with the *ganglia trunci sympathici*, 2. by the rami communicantes of the nn. spinales (see p. 712) and communicating rami of the nn. cerebrales, which bring fibers of the spinal and cerebral nerves to the sympathetic ganglia and also reversely bring sympathetic fibers to the branches of the latter, and 3. through peripheral branches, which carry the fibers arising from the cells of the ganglia of the truncus sympathicus, usually accompanying the arteries to the viscera, blood vessels and glands and to the smooth muscle of the whole body and which in so doing are characterized by numerous plexus-like communications of their branches with one another and with those of the cerebral and spinal nerves: in these plexuses, *plexus sympathici*, smaller and larger groups of ganglion cells, *ganglia plexuum sympathicorum* (*peripheral sympathetic ganglia*) are frequently intercalated; the branches contain also sensory fibers, which, however, pass by the sympathetic ganglion cells to go to the cells of the spinal ganglia.

The sympathicus is divisible into a *head and neck portion, pars cephalica et cervicalis*, a *thoracic portion, pars thoracalis*, and an *abdominal and pelvic portion, pars abdominalis et pelvina*; these are, however, only indistinctly separable from one another.

The *truncus sympathicus* (see Figs. 779—781, 813, 818, 832 and 834) extends from the foramen caroticum externum to the coccyx; it sends a continuation (see Figs. 766 and 773) upward into the canalis caroticus, to unite with the ganglia lying upon the branches of the n. trigeminus, and with these to form the head part of the sympathetic trunk. The ganglia of the sympathetic trunk are in general arranged segmentally in the thoracic, abdominal and pelvic portions, i. e., there is a ganglion corresponding to each spinal nerve, though neighboring ganglia may be united with one another; in the cervical portion they are fused with one another to form two or three. They are of oblong, rounded or angular form and according to the region of the body in which they are situated are designated as *ganglia cervicalia, thoracalia, lumbalia, sacralia, coccygeum*.

The *rami communicantes of the nn. spinales* (see Figs. 699, 781, 813, 818, 832 and 834) are single or double, sometimes triple and arise usually from the corresponding n. spinalis, sometimes also by single threads from its anterior and posterior roots. Equivalent to these may be regarded the communicating rami of the cerebral nerves, namely of the V., IX., X. and XII. with the sympathicus.

A. Pars cephalica systematis sympathici. It begins as the *n. caroticus internus* (see Figs. 773 and 779), which proceeds from the upper end of the ganglion cervicale superius (see p. 764), in a way as a continuation of the truncus sympathicus; it lies upon the posterior surface of the a. carotis interna and by continued subdivision and anastomoses forms a wide-meshed plexus, *plexus caroticus internus* (see also Fig. 766), which accompanies the artery as far as its division and in the sinus cavernosus becomes most close meshed as the plexus cavernosus. Delicate plexuses go off from it upon the branches of the a. carotis interna as the *plexus ophthalmicus* (around the a. ophthalmica), *plexus arteriae cerebri anterioris*, *arteriae cerebri mediae* and *arteriae chorioideae*, and most delicate threads pass to the lobus anterior of the hypophysis cerebri. By means of the *radices sympathicae ganglii ciliaris* (see p. 690 and Figs. 764 and 765), which go from the plexus cavernosus through the

fissura orbitalis superior to the ganglion ciliare, it is continued as far as this, and through the *n. petrosus profundus major* (see p. 694 and Fig. 766) it is connected with the ganglion sphenopalatinum. These two ganglia, like the ganglion oticum (see p. 699), which in their structure resemble other sympathetic ganglia, are accordingly to be looked upon as the uppermost head ganglia of the sympathicus. In addition the plexus cavernosus or caroticus internus communicates by fine threads with the nn. oculomotorius (see p. 687), trochlearis (see p. 688), ophthalmicus (V) (see p. 690), abducens (see p. 700), as well as by nn. caroticotympanici (see p. 706) with the n. tympanicus (IX).

B. Pars cervicalis s. sympathici. The trunk here contains only two or three ganglia (see p. 763). The *ganglion cervicale superius* (see Figs. 777, 779 and 780) is a swelling of the trunk, usually spindle-shaped, approximately 2 cm long, and 5—8 mm broad; it lies in front of the transverse processes of the 2nd—4th cervical vertebrae on the fascia praevertebralis and the m. longus capitis, and in front and medialward adjoins the a. carotis interna, in front and lateralward the n. vagus. From its lower end the sympathetic trunk (see Fig. 780) passes in front of the fascia praevertebralis and the mm. longi capitis and colli, behind the a. carotis communis, behind and somewhat medial from the n. vagus downward and presents at about the 6th cervical vertebra on the anterior or posterior surface of the a. thyroidea inferior the very variable (often absent) small *ganglion cervicale medium* (see Figs. 780, 781 and 832). From its lower end go off usually two (or more) fibers, of which one, the shorter and larger descends behind the a. subclavia, while the other passes around the artery from in front and behind like a loop (*ansa subclavia [Vieussensii]*); these go down into the *ganglion cervicale inferius* (see Figs. 780, 782 and 832), a flattened irregular mass situated in front of the transverse process of the 7th cervical vertebra and in front of the neck of the first rib behind the a. subclavia and the origin of the a. vertebralis; it is often wholly or partly fused with the uppermost ganglion thoracale. The ganglion submaxillare (see p. 699) also belongs to the cervical part of the sympathetic system.

The ganglion cervicale superius is united by the delicate *n. jugularis* (see Fig. 799), which passes upward from the upper end close by the n. caroticus internus and bifurcates with the ganglion petrosus n. glossopharyngei and ganglion jugulare n. vagi, also by fine threads with the ganglion nodosum n. vagi and with the n. hypoglossus, as well as by rami communicantes with the 1st—4th (or 3rd) cervical nerves (see Fig. 777). The ganglion cervicale medium (or when this is absent, the corresponding part of the trunk) is united by rami communicantes usually with the (4th), 5th, 6th (and 7th) cervical nerves, the ganglion cervicale inferius with the (7th) 8th cervical and 1st thoracic nerves (see Fig. 832).

The following are designated as peripheral branches:

1. From the ganglion cervicale superius:

a) Vascular branches (as a rule, not illustrated). They are usually as two fine threads, *nn. carotici externi* (not illustrated), which run to the a. carotis externa and downward on it as far as its origin; they form a plexus, *plexus caroticus externus*, around this artery, from which plexus-like twigs are given off to the branches of the artery, namely: *plexus thyroideus superior*, *lingualis*, *maxillaris externus* (from which the *radix sympathica ganglii submaxillaris* for the ganglion submaxillare (see p. 699), similar in structure to other sympathetic ganglia, is derived), *plexus occipitalis*, *auricularis posterior*, *temporalis superficialis*, *maxillaris internus*, *meningeus* (on the a. meningea media, from which go off threads to the ganglion oticum (see p. 699), which belongs to the sympathetic), and *plexus pharyngeus ascendens* on arteries of corresponding name; the main plexus is continued as the *plexus caroticus communis* upon the a. carotis communis.

b) Visceral branches: *Rami laryngopharyngei* (see Fig. 780) go off independently or from one of the branches, pass partly to the n. laryngeus superior and with this to the larynx, partly to the lateral wall of the pharynx, there to form the plexus pharyngeus (see p. 709) with the rami pharyngei of the nn. glossopharyngeus and vagus.

c) *N. cardiacus superior* (see Figs. 780, 781 and 788), larger on the left side, arises simply or by several roots from the lower end of the ganglion or from the trunk, passes medial from the latter behind the a. carotis communis, downward directly in front of the fascia praevertebralis, behind or in front of the a. thyroidea inferior, on the right side along the a. anonyma, on the left side along the a. carotis communis to reach the arch of the aorta and the plexus cardiacus. In the neck it unites repeatedly with the n. laryngeus superior, the rami cardiaci superiores n. vagi and the n. recurrens (see p. 709) and sends fine threads to the plexus thyroideus inferior.

2. From the ganglion cervicale medium:

a) Vascular branches: very fine, partly to the *plexus caroticus communis* (vide supra), partly to the a. thyroidea inferior, around which they form the *plexus thyroideus inferior* (not illustrated), together with branches of the ganglion cervicale inferius and of the nn. cardiaci superior and medius.

832. Right Sympathetic trunk in the thoracic cavity,

viewed from the right and from in front.

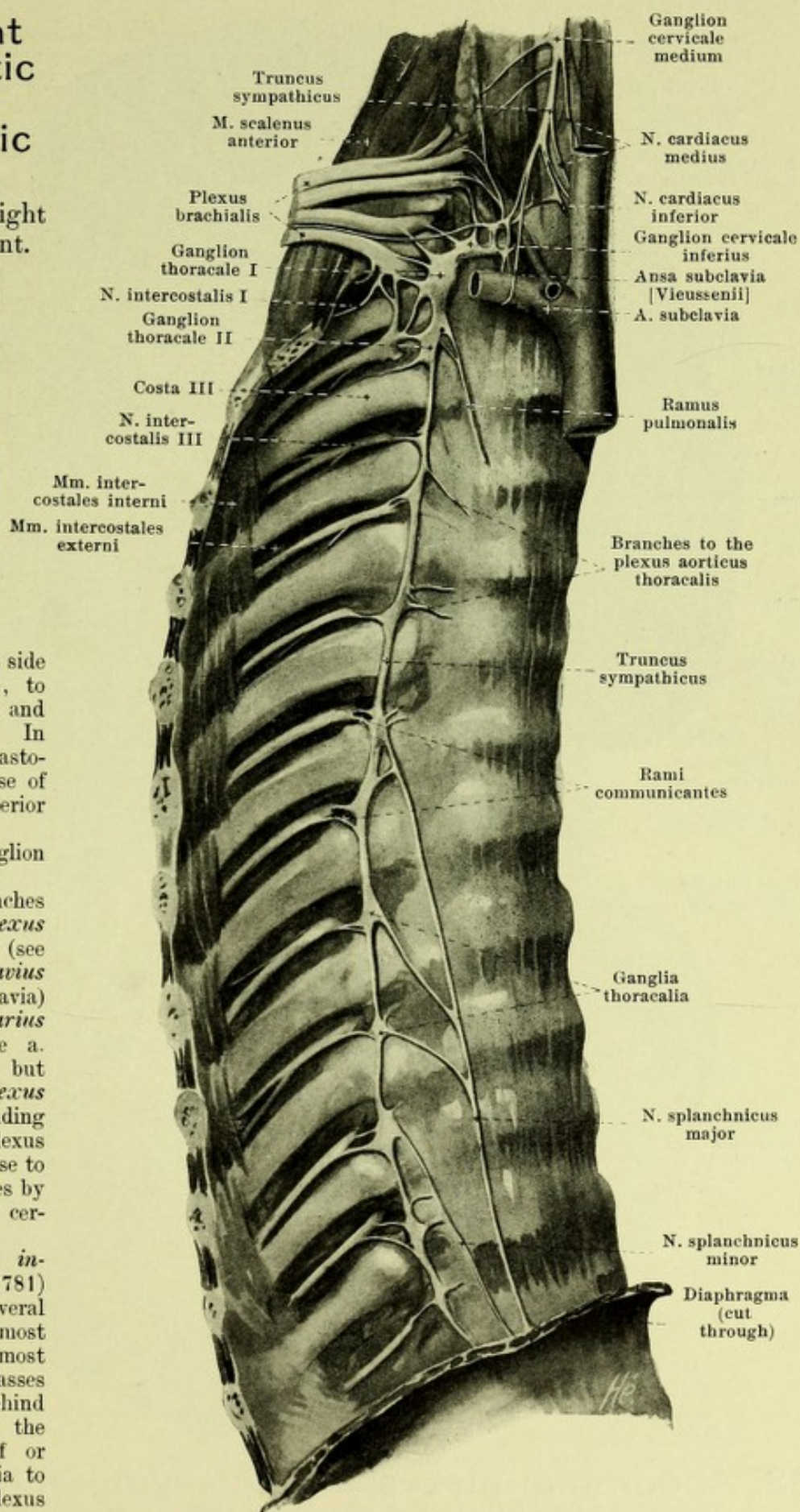
(The pleura and fascia endothoracica have been removed.)

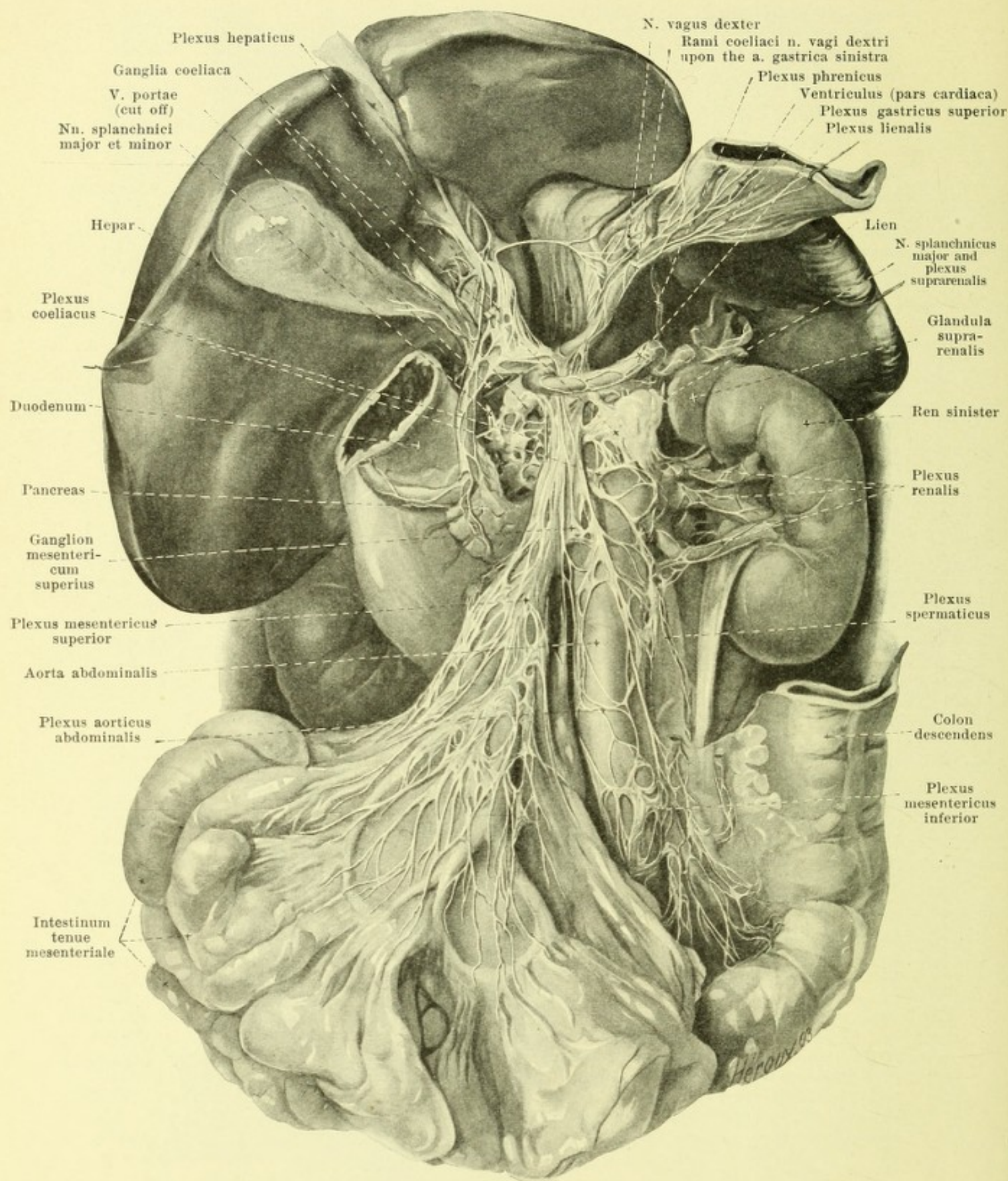
b) *N. cardiacus medius* (see also Figs. 780, 781 and 788), usually larger than the superior, arises simply or by several roots from the ganglion or from the trunk itself and runs behind the a. carotis communis, in front of or behind the a. subclavia, on the right side along the a. anonyma, to the arch of the aorta and the plexus cardiacus. In the neck it forms anastomoses similar to those of the n. cardiacus superior (see p. 764).

3. From the ganglion cervicale inferius:

a) Vascular branches (not shown) to the *plexus thyroideus inferior* (see p. 764), *plexus subclavius* (around the a. subclavia) and *plexus mammarius internus* (around the a. mammaria interna), but especially to the *plexus vertebralis*, surrounding the a. vertebralis, a plexus which during its course to the brain communicates by fine threads with the cervical nerves.

b) *N. cardiacus inferior* (see also Fig. 781) goes off usually by several roots from the lowermost cervical and the uppermost thoracic ganglion, passes on the right side behind the a. anonyma, on the left side in front of or behind the a. subclavia to the arcus aortae and plexus cardiacus.





833. Abdominal plexuses of the sympathicus, viewed from in front.

(Stomach and large intestine have been for the most part removed; the pars ascendens duodeni has been excised. The liver is displaced upward, the stomach and the spleen to the left, the small intestine downward. The peritoneum has been partly dissected off.)

Plexus cardiacus, heart plexus (see Figs. 781 and 788), is formed by the plexus-like anastomoses around the arch of the aorta of the rami cardiaci n. vagi and the nn. cardiaci of the sympathicus of both sides. In it there can be distinguished a feebler, superficial portion, spread out on the left anterior part of the aortic arch, between it and the site of bifurcation of the a. pulmonalis, and formed chiefly by the rami cardiaci of the left n. vagus and by the left n. cardiacus superior, and frequently possessing the *ganglion cardiacum [Wrisbergi]* (not illustrated), as well as a larger, deeper portion; the latter lies on the right, posterior surface of the aortic arch, between it and the bifurcation of the trachea, and is formed by all the other heart-nerves. The heart plexus sends direct branches to the atria, as well as the *plexus coronarius cordis anterior* on the a. coronaria cordis dextra and the *plexus coronarius cordis posterior* on the a. coronaria sinistra, besides others to the plexus pulmonales of the nn. vagi (see p. 710).

C. Pars thoracalis s. sympathici (see Figs. 628—630, 781 and 832). The sympathetic trunk extends downward in front of the heads of the ribs and in front of the aa. and vv. intercostales, covered directly by the pleura and contains 10—12 *ganglia thoracalia*, situated in front of the heads of the ribs or in front of the intercostal vessels or nerves; below it turns somewhat ventralward and passes between the crus intermedium and crus laterale of the diaphragm into the abdominal cavity. Each ganglion is united by one or several rami communicantes with the nn. thoracales. The ganglia give off the following branches:

a) Vascular branches to the aorta thoracalis; these together with outrunners from the plexus cardiacus form the *plexus aorticus thoracalis*, which is connected below with the plexus coeliacus.

b) *Rami pulmonales* to the plexus pulmonales (see p. 710), as well as branches to the plexus oesophagei (see p. 710).

c) *N. splanchnicus major* arises with several roots from the 5th or 6th to the 9th thoracic ganglion, is of a white color like the spinal nerves; its fibers arise chiefly from the spinal cord and go past the sympathetic ganglia. It runs distalward and somewhat medianward upon the bodies of the thoracic vertebrae and possesses in front of the 12th thoracic vertebra, regularly on the right side, and frequently on the left side, a small *ganglion splanchnicum* (not designated); it passes between the crus mediale and the crus intermedium into the abdominal cavity and enters the corresponding ganglion coeliacum (see Fig. 833).

d) *N. splanchnicus minor*, of the same appearance and structure as the foregoing, arises from the 10th—12th thoracic ganglion, extends close to the foregoing nerve, sometimes united with it, downward through the diaphragm, enters the ganglion coeliacum near the a. renalis and sends a ramus renalis (not designated) to the plexus renalis.

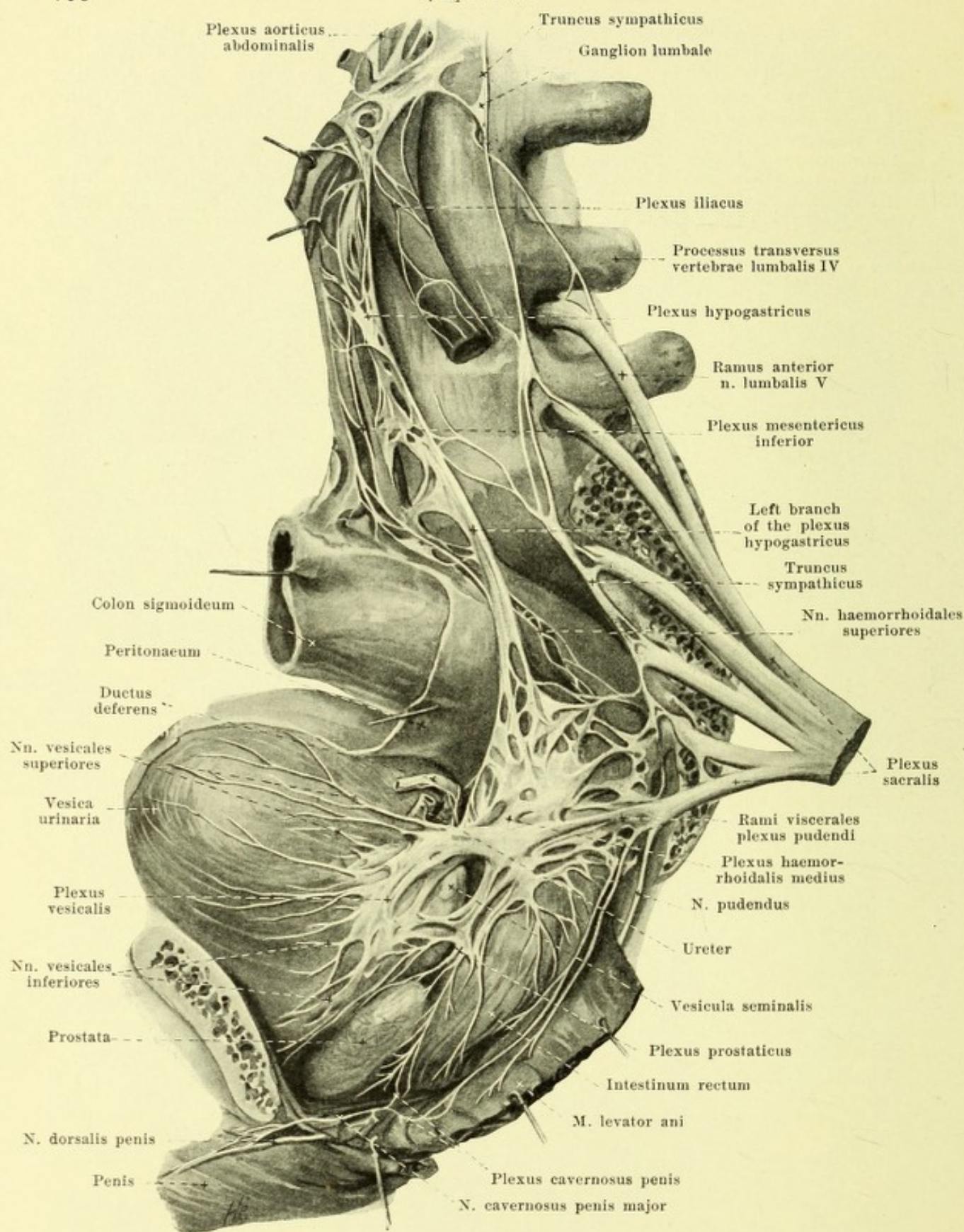
D. Pars abdominalis s. sympathici (see Figs. 813, 818 and 833). The sympathetic trunk runs directly upon the bodies of the lumbar vertebrae, ventral and medianward from the origins of the m. psoas major, on the right side behind the v. cava inferior, on the left behind the aorta abdominalis downward and near the promontorium curves upon the facies pelvina oss. sacri; it contains 5 (or 4) small *ganglia lumbalia*. Its rami communicantes are usually double and run near the aa. lumbales between the bodies of the vertebrae and the tendon arches of the m. psoas.

Its main plexus is the unpaired *plexus coeliacus*, which lies behind the pancreas and the bursa omentalis directly upon the anterior surface of the aorta abdominalis and the crura diaphragmatis, surrounds the origin of the aa. coeliaca and mesenterica superior, lateralward as far as the suprarenals, reaches downward as far as the origin of the aa. renales, and is continuous upward through the hiatus aorticus with the plexus aorticus thoracalis. It is formed by the nn. splanchnici major and minor of both sides, by the rami coeliaci of the right (more rarely also of the left) n. vagus, and threads from the upper lumbar ganglia of the sympathicus. Intercalated in this plexus on each side there is constantly a large, flat, very variable *ganglion coeliacum*, which may be subdivided into several small ones, and often a small *ganglion mesentericum superius* is found beneath the root of the a. mesenterica superior.

The following branch plexuses go off from the plexus coeliacus chiefly with the arteries:

Paired plexuses:

Plexus phrenicus with the a. phrenica inferior, which unites with the rami phrenico-abdominales n. phrenici (see p. 719) and on the right side possesses a small *ganglion phrenicum* (not illustrated) *plexus suprarenalis*, numerous fine threads to the dorsal surface of the suprarenal; *plexus renalis* with threads from the lumbar ganglia around the a. renalis to the kidney, receiving the ramus renalis of the n. splanchnicus minor; *plexus spermaticus* around the a. spermatica interna in the male to the testicle, in the female (*plexus arteriae ovaricae*) to the ovarium and fundus uteri, where it anastomoses with the plexus utero-vaginalis.



834. Pelvic plexuses of the sympathicus, viewed from the left.

(The left half of the pelvis with its muscles has been in large part removed; the plexus sacralis and the m. levator ani have been drawn somewhat aside.)

Unpaired plexuses (see Fig. 833):

Plexus lienalis with the a. lienalis to the spleen, to the pancreas and fundus ventriculi; *plexus hepaticus* near the a. hepatica and the ductus choledochus to the liver (anastomosing with the rami hepatici n. vagi dextri) and gall bladder, to the pylorus and along with the branches of the a. gastroduodenalis to the pancreas, duodenum and to the curvatura major ventriculi (*plexus gastricus inferior*, not designated); *plexus gastricus superior* along with the a. gastrica sinistra to the curvatura minor ventriculi, where it unites with the plexus gastrici anterior et posterior of the nn. vagi; *plexus mesentericus superior*, the largest, accompanies the a. mesenterica superior and its branches to the pancreas, duodenum, small intestines, caecum, colon ascendens and the larger part of the colon transversum and forms within the wall of the small intestine, between the longitudinal and circular walls of muscle, the narrower-meshed *plexus mesentericus*, in the tela submucosa the wider-meshed *plexus submucosus* (not illustrated).

Plexus aorticus abdominalis (see Figs. 833 and 834) consists essentially of two lateral cords uniting by transverse threads which are developed from the plexus coeliacus and receive threads from the lumbar ganglia. Around the a. mesenterica inferior it is continued as the *plexus mesentericus inferior* and thus arrives at the colon transversum, descendens and sigmoideum, and as the nn. haemorrhoidales superiores to the upper part of the rectum, where it anastomoses with the plexus haemorrhoidalis medius; in the wall of the intestine it behaves like the plexus mesentericus superior.

The plexus aorticus is continuous below with the *plexus hypogastricus* (see Fig. 834), which at first runs as an unpaired, flat, broad plexus, as far as the promontorium, there bifurcates and then extends on each side on the medial side of the a. hypogastrica, dorsal and lateral from the rectum, as far as the large pelvic plexus (vide infra); it receives branches from the lumbar and sacral ganglia.

Another continuation of the plexus aorticus is met with in the feebler *plexus iliacus* upon the a. iliaca communis; it again goes over into the delicate *plexus femoralis* upon the a. femoralis and *plexus popliteus* upon the a. poplitea.

E. Pars pelvina s. sympathici (see Figs. 813, 818 and 834). The sympathetic trunk lies directly upon the facies pelvina of the sacrum, medial from the foramina sacralia anteriora, dorsal and lateral from the rectum, and usually presents there 4 ganglia sacralia; the right and left trunks converge somewhat distalward, so that on the anterior surface of the 1st coccygeal vertebra they either unite by simple loop, or both end there (more rarely) in a small unpaired ganglion coccygeum. Each ganglion is united by one or two rami communicantes with the corresponding nerves.

On the lateral surface of the pelvic viscera, between them and the medial upper surface of the diaphragma pelvis is the large pelvic plexus (see Fig. 834), which is only indistinctly separable into the single portions belonging to individual viscera. It is formed of the lower ends of the plexus hypogastrici, of branches of the pelvic ganglia, as well as of the rami viscerales of the plexus pudendus (nn. haemorrhoidales medii, nn. vesicales inferiores and nn. vaginales) (see p. 762). Of the subdivisions of this large plexus the following are common to both sexes:

a) *Plexus haemorrhoidalis medius*, furthest dorsalward, on the lateral surface of the rectum, around the a. haemorrhoidalis media, receives the nn. haemorrhoidales superiores and sends branches to the wall of the rectum.

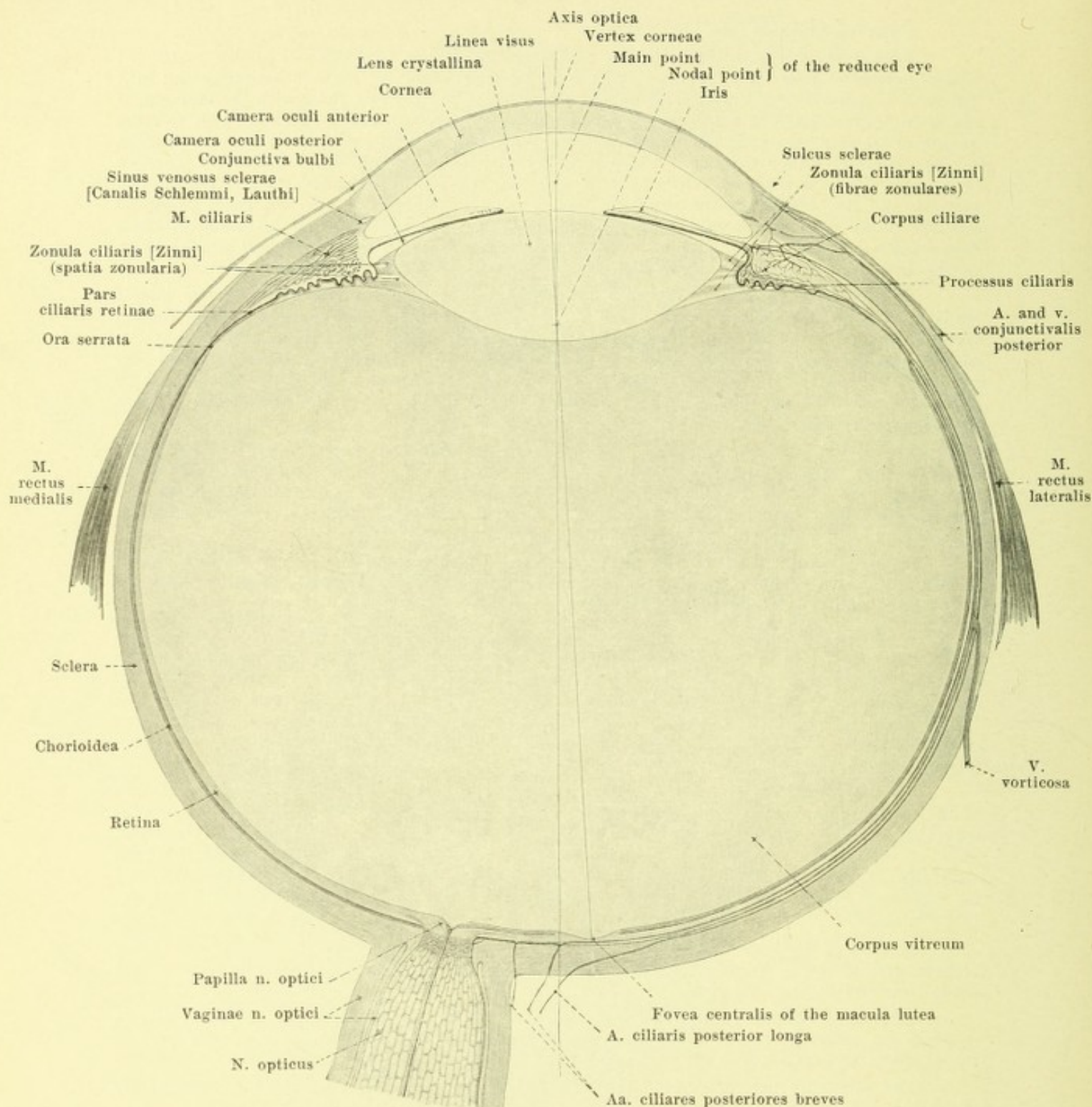
b) *Plexus vesicalis*, situated farther lateralward, on the lateral surface of the bladder; it sends nn. vesicales superiores to the upper, nn. vesicales inferiores to the lower part of the bladder; the former give off branches to the ureter, the latter to the urethra.

The following are present in the male only: c) *Plexus deferentialis* (not designated) about the seminal vesicle and ductus deferens, with branches to these.

d) *Plexus prostaticus*, lateral from and behind the prostata, with branches to it.

e) *Plexus cavernosus*, a continuation of the preceding; it passes lateral and dorsal from the prostata to the trigonum urogenitale, and through this upon the back of the penis, where it anastomoses with branches of the n. dorsalis penis. It gives off branches to the pars membranacea of the urethra, and ends in the nn. cavernosi penis major et minores, which penetrate the corpora cavernosa penis.

In the female: f) *Plexus uterovaginalis* (not illustrated) in the parametrium on the lateral surface of the cervix uteri and of the upper part of the vagina, sends branches with the a. uterina to the uterus (anastomoses with the plexus arteriae ovaricae), as well as to the vagina. From the anterior surface of the vagina, a fine *plexus cavernosus clitoridis* with nn. cavernosi clitoridis major et minores goes to the clitoris.



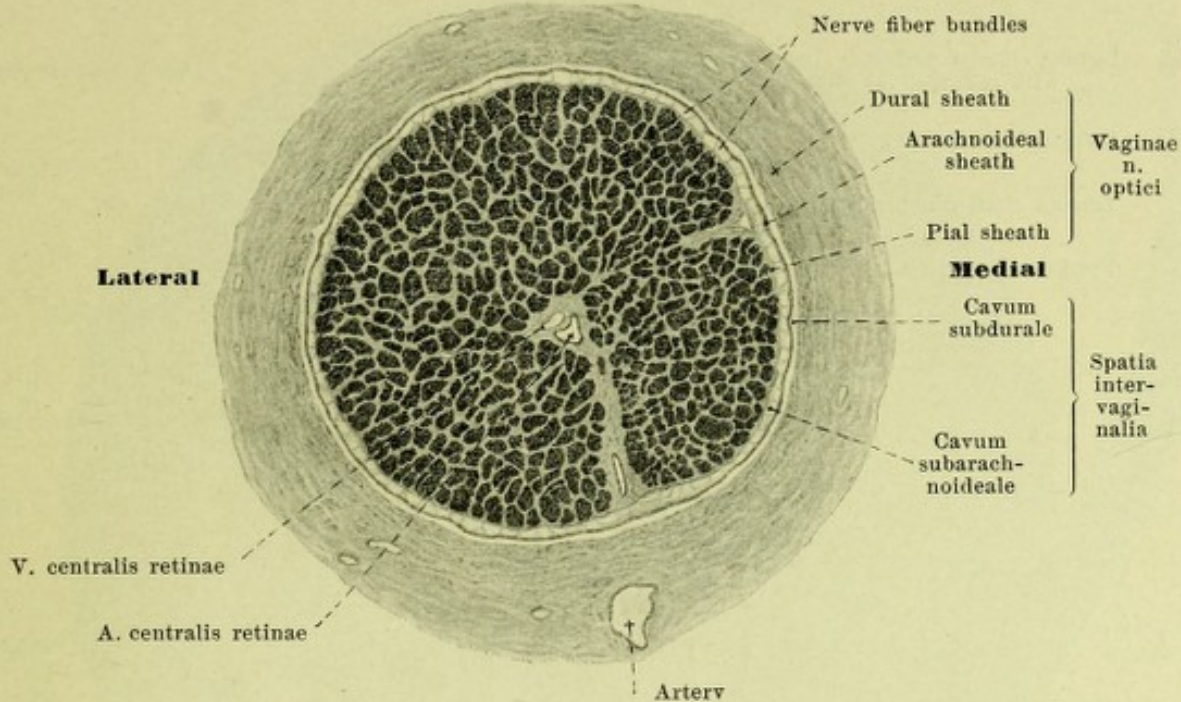
835. Schematic section through the right eye in the horizontal meridian, viewed from above (after H. Sattler).

Magnification 5 : 1.

The **organon visus** (*organ of vision*) consists of the *eye (oculus)* and of the *appendages of the eye (organa oculi accessoria)*.

The *eye* consists of the *n. opticus* (*optic nerve*) and the *bulbus oculi* (*eye-ball*).

The *accessory organs of the eye* include the *musculi oculi* (*eye muscles*), *fasciae orbitales* (*fascia of the orbital cavity*), *palpebrae* (*eye-lids*), *conjunctiva* and the *apparatus lacrimalis* (*tear apparatus*).



836. Cross-section of the optic nerve

a little in front of the entrance of the a. centralis retinae. (After a preparation by H. Sattler.) Magnification 15 : 1.

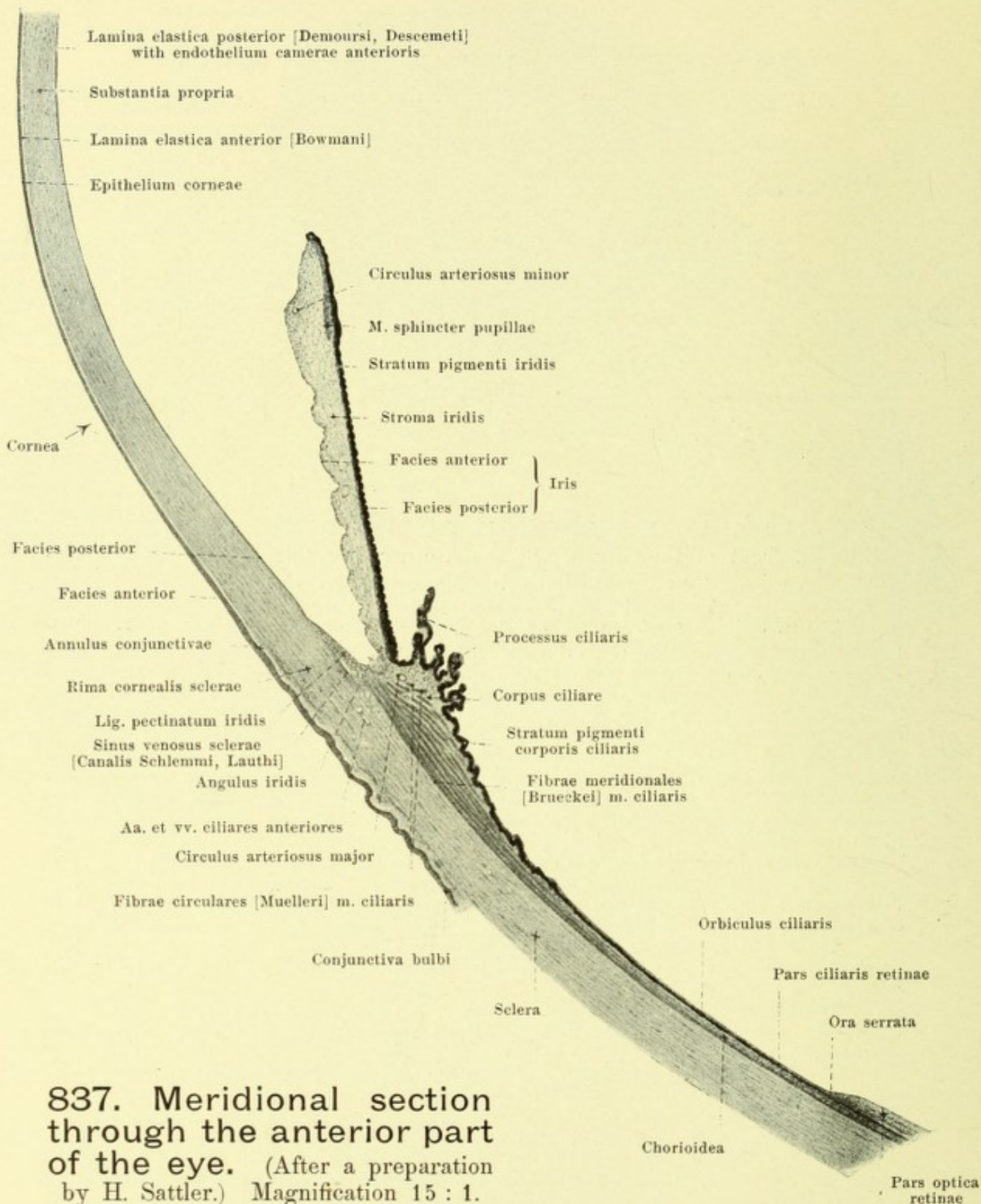
(The bundles of nerve fibers are dark in the drawing.)

The **n. opticus** (*optic nerve*) (see also p. 687 and Figs. 835, 846, 847, 861—866), is variably curved in the orbital cavity; in the vertical direction it is curved so as to be slightly bayonet-shaped, in the horizontal direction slightly S-shaped, behind lateralward, in front medianward convex, and enters into the posterior surface of the eye-ball about 4 mm. medial from, and somewhat below, the posterior end of the optic axis. It is enclosed in its *sheaths*, *vaginae n. optici* (see also Figs. 835, 846 and 847), which are continuations of the brain membranes, and at the eye-ball go over into the sclera. The outer thickest *dural sheath* consisting of tough connective tissue, is derived from the dura mater and forms the periosteum lining the foramen opticum. Following upon this is the delicate *arachnoideal sheath*, a continuation of the arachnoidea, and upon this a continuation of the pia mater, the *pial sheath*, which is connected by fine strands with the arachnoideal sheath and sends septa in between the bundles of nerve fibers. The sheaths are separated from one another by the *spatia intervaginaria*, and between the dural and arachnoideal sheaths is a continuation of the cavum subdurale, between the arachnoideal and pial sheaths a continuation of the cavum subarachnoideale; both of these extend forward as far as the sclera but do not communicate with one another there.

The a. and v. centralis retinae enter the optic nerve about 1 cm. behind the eye-ball, constantly entering in the medial part of its inferior circumference; they then run farther forward in the axis of the nerve.

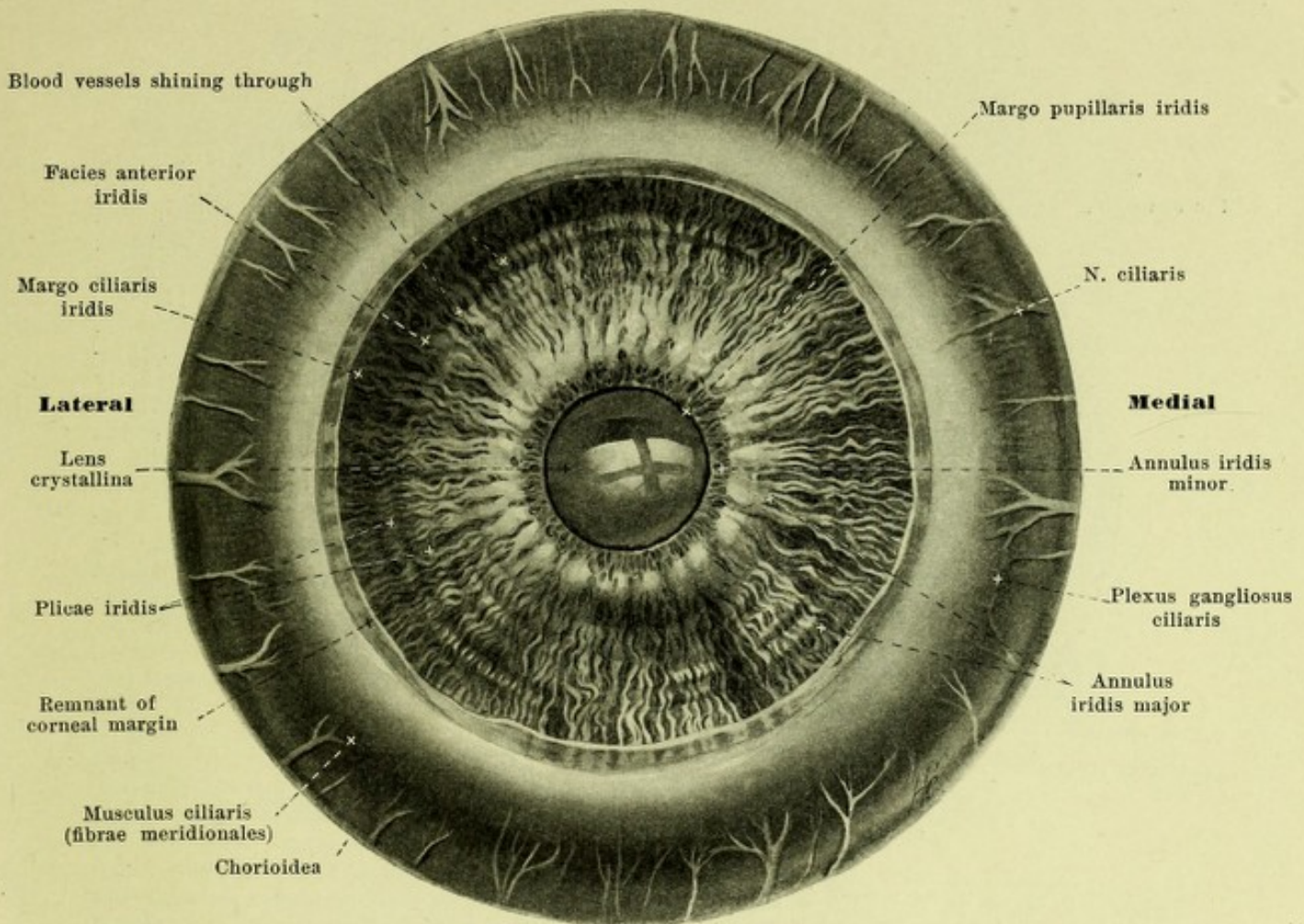
The fibers of the n. opticus are medullated, but lose their myelin sheaths immediately behind the lamina cribrosa sclerae (see p. 773 and Fig. 846); the nerve accordingly narrows on passage through the coats of the bulbus.

The **bulbus oculi** (*eye-ball*), (see Figs. 835 and 842) lies, surrounded by fat, fascia and muscles, in the orbital cavity and presents, roughly speaking, the form of a sphere. In describing it therefore expressions corresponding to those used for the globe are employed, thus an *anterior pole*, *polus anterior*, in the vertex corneae is spoken of, and a *posterior pole*, *polus posterior*, in the middle point of the posterior convexity, somewhat medianward from the spot in the sclera corresponding to the fovea centralis. The line uniting the two poles is called the *axis oculi externa*, the distance measured upon it, between the posterior surface of the cornea, and the anterior surface of the retina, being called the *axis oculi interna*; it coincides with the *optic axis*, *axis optica*, which contains the centers of the different refracting surfaces of the eye. The largest circle, the plane of which stands perpendicular to the optic axis, is called the *aequator*; circles which go through both poles are called *meridiani*; by the two vertical and the horizontal the bulbus is divided into four quadrants. The name *visual line*, *linea visus*, is given to the line which in the reduced eye is drawn from an external object through the nodal point to the fovea centralis.



837. Meridional section through the anterior part of the eye. (After a preparation by H. Sattler.) Magnification 15 : 1.

The **bulbus oculi** resembles a section of a sphere fairly completely only in its posterior half. The anterior half possesses a frontal, shallow, circular indentation, *sulcus sclerae* (see Fig. 835), from which the most anterior part projects as a small segment of a sphere with smaller radius of curvature. This projection belongs to the cornea, the other part of the surface to the sclera, so that the *sulcus sclerae* indicates at the same time the external junction between the cornea and the sclera.



838. Iris of a grayish-blue right eye, along with corpus ciliare and chorioidea, viewed from in front.

Magnification 6 : 1. (The cornea and sclera have been removed.)

The **bulbus oculi** (see Fig. 835) is formed of the *contents (nucleus) of the eye-ball*, in the interior, and of the *coats of the eye* ensheathing these externally. The former, from before backward, consist of 1. the *humor aqueus*, 2. the *lens crystallina*, *lens*, and 3. the *corpus vitreum*, *glass body*. The coats of the eye are concentrically laminated and consist, from the outside in, of 1. the *tunica fibrosa oculi*, 2. the *tunica vasculosa oculi* and 3. the *retina*.

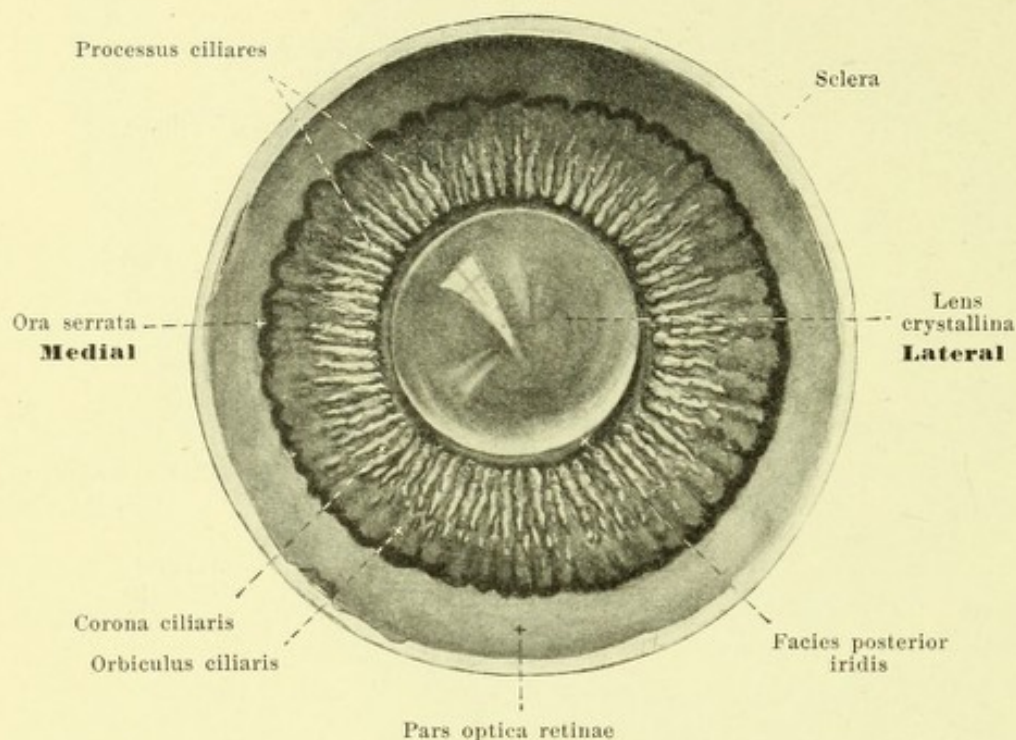
The **tunica fibrosa oculi** (see Figs. 835 and 837) is a tough, thick membrane completely enclosing the eye-ball, and conditioning its form. About five-sixths of it consists of the non-transparent *sclera*, one sixth of the transparent cornea, which surrounds the anterior pole.

The **sclera**, *white or hard coat of the eye* (see Figs. 835, 837, 842, 846, 847, 865 and 866), is a tough connective tissue membrane, usually of a pure white color. It is thickest at the entrance of the optic nerve, the sheaths of which go over directly into it, and passing forward it becomes gradually thinner as far as the attachments of the straight eye-muscles, the tendon bundles of which interweave with it and strengthen it in its most anterior part. It is loosely covered in its anterior part by the conjunctiva bulbi, and is thus far also visible in the lid-slit as the white of the eye (see Figs. 869 and 870). In front the non-transparent bundles of the sclera go over directly into the transparent ones of the cornea; this transition occurs, so that the sclera in a way forms a groove, *rima cornealis*, for the reception of the margin of the cornea, *limbus corneae*. Just behind this transition in a furrow of the sclera, runs a circular blood-vessel, *sinus venosus sclerae* [*canalis Schlemmi*, *Lauthi*] (see p. 778), which is bounded internally by the lig. pectinatum iridis. The sclera is perforated behind by the n. opticus; bundles of connective tissue arranged in the form of a net-work separate the individual bundles of nerve fibers from one another and form a perforated plate, *lamina cribriformis sclerae*, for the passage of the latter. In addition the sclera possesses openings for the passage of the aa., vv. and nn. ciliares.

839. Anterior part of a right eye,

viewed from behind. Magnification 3 : 1.

(The zonula ciliaris [Zinni] has not been represented.)

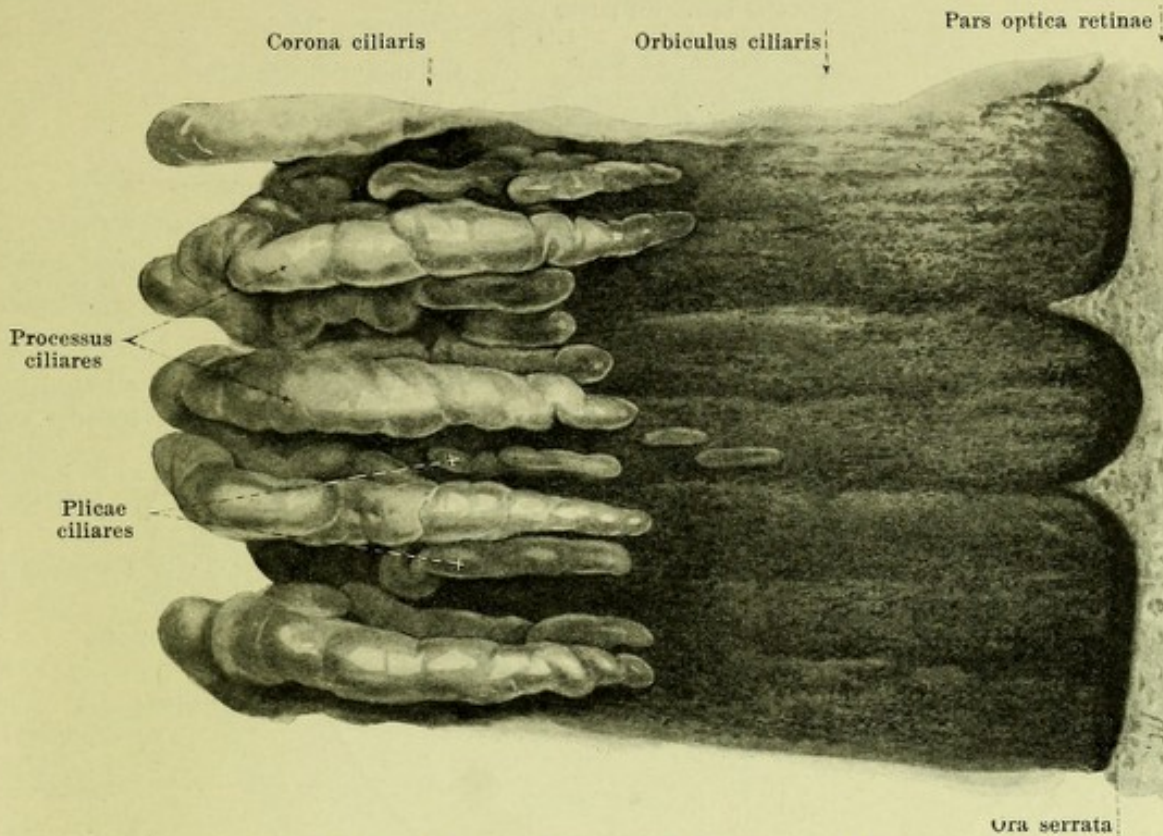


Sclera (continued). On its outer surface it is united by a delicate net-work with the surrounding fascia bulbi [Tenoni] (see p. 792), which, however, does not inhibit the moveability of the eye-ball. Its innermost layer lies everywhere in direct contact with the tunica vasculosa, is colored brownish by numerous pigment cells, and is accordingly called the *lamina fusca sclerae*.

The **Cornea** (see Figs. 835, 837, 866, 869 and 870) is a colorless, transparent and non-vascular connective tissue membrane, and has the shape of a flat, round

bowl curved so as to be convex in front, concave behind. At its margin, *limbus corneae* (see p. 773) the sclera above and below reaches somewhat farther forward than medial and lateral; hence the circumference of the cornea viewed from in front looks like an ellipse with its longest diameter placed transversely; viewed from behind it is circular. The anterior surface of the cornea resembles approximately an ellipsoid of revolution only in the zone of the pole; it is thereby a little more markedly curved in the vertical direction than in the transversal. Its thickness is greater than that of the neighboring sclera, but diminishes gradually from the margin on and is least at the point of greatest convexity, the *vertex corneae*. The convex, anterior surface, *facies anterior*, lies free to view in the lid-slit and is covered by the *epithelium corneae*, a direct continuation of the conjunctiva bulbi, which is attached for the most part loosely on the anterior surface of the sclera and is connected with it firmly only in a narrow, often ridge-like strip, *annulus conjunctivae*, immediately surrounding the cornea, and which then goes over without sharp limit into the anterior layers of the cornea. The epithelium corneae rests upon the narrow, very transparent *lamina elastica anterior* [Bowman], and this goes over behind into the laminated substantia propria, which forms the main mass; then follows the *lamina elastica posterior* [Demoursi, Descemeti], which resembles the anterior but is thinner, and finally the *endothelium camerae anterioris*; this covers the facies posterior of the cornea, forms the anterior boundary of the anterior chamber of the eye filled with aqueous humor, and is continuous lateralward upon the angulus iridis and the anterior surface of the iris.

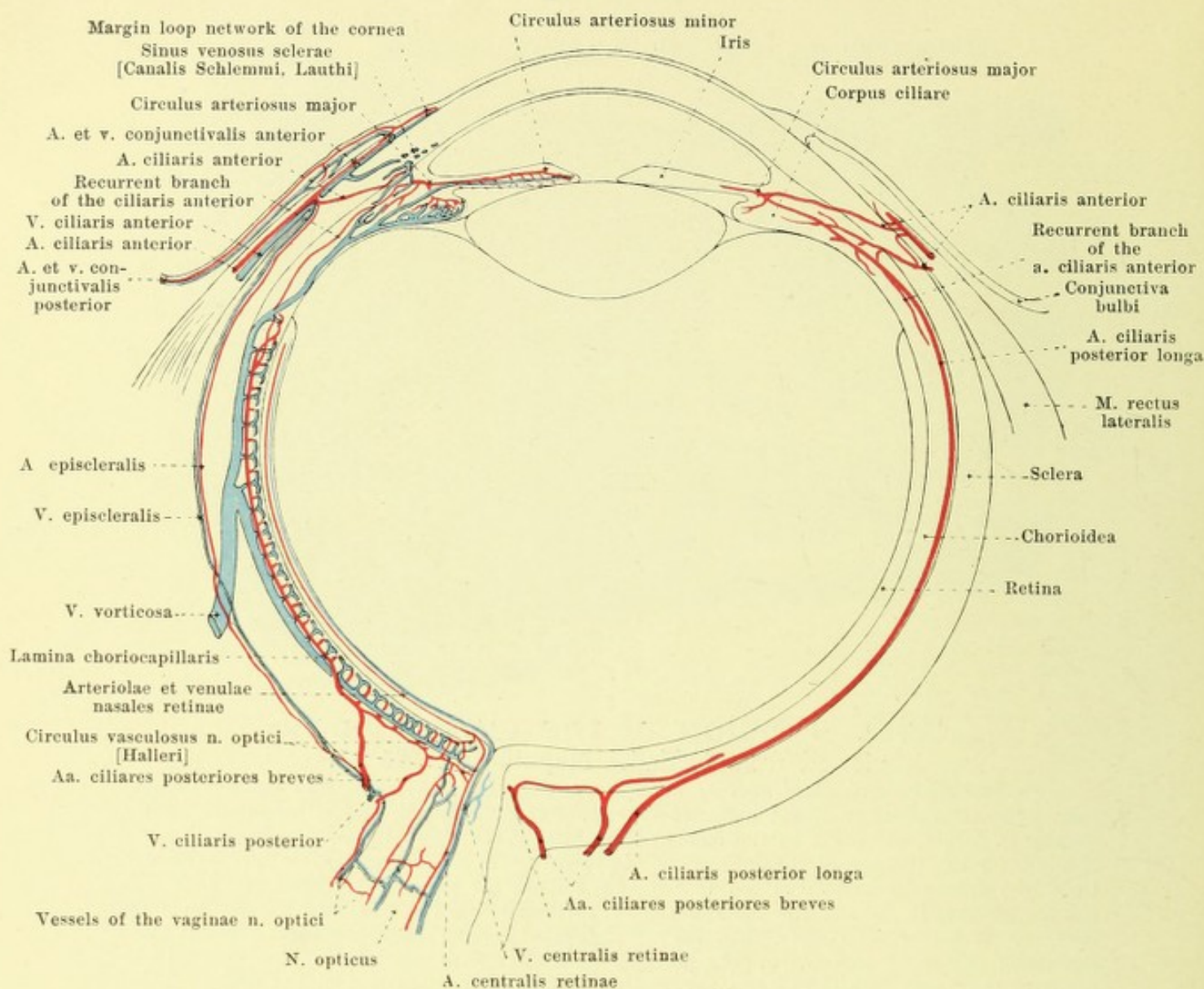
The **tunica vasculosa oculi** (see Fig. 835) with its main mass lies directly on the inner surface of the sclera; only its most anterior portion, the *iris*, projects inward free into the bulbus from the region of the rima cornealis, approximately transversely to the optic axis. The part lying against the sclera is divisible into a larger, posterior, smooth portion, the *chorioidea*, and a narrow, anterior, ridged portion, the *corpus ciliare*; it is firmly fused with the sclera behind only at the entrance of the optic nerve and in front at the rima cornealis, but otherwise is separated from it by a slit-like space, *spatium perichorioideale*, traversed by numerous fine, pigmentholding lamellae, which is bounded externally by the lamina fusca sclerae (vide supra) and internally by the most superficial layer of the chorioidea, the *lamina suprachorioidea*, and is perforated by some vessels and nerves. All portions of it are very delicate and contain an extraordinarily large number of blood vessels, numerous nerves and ganglia; the corpus ciliare and the iris contain muscles in addition.



840. Portion of the ciliary body, viewed from behind. Magnification 25 : 1.

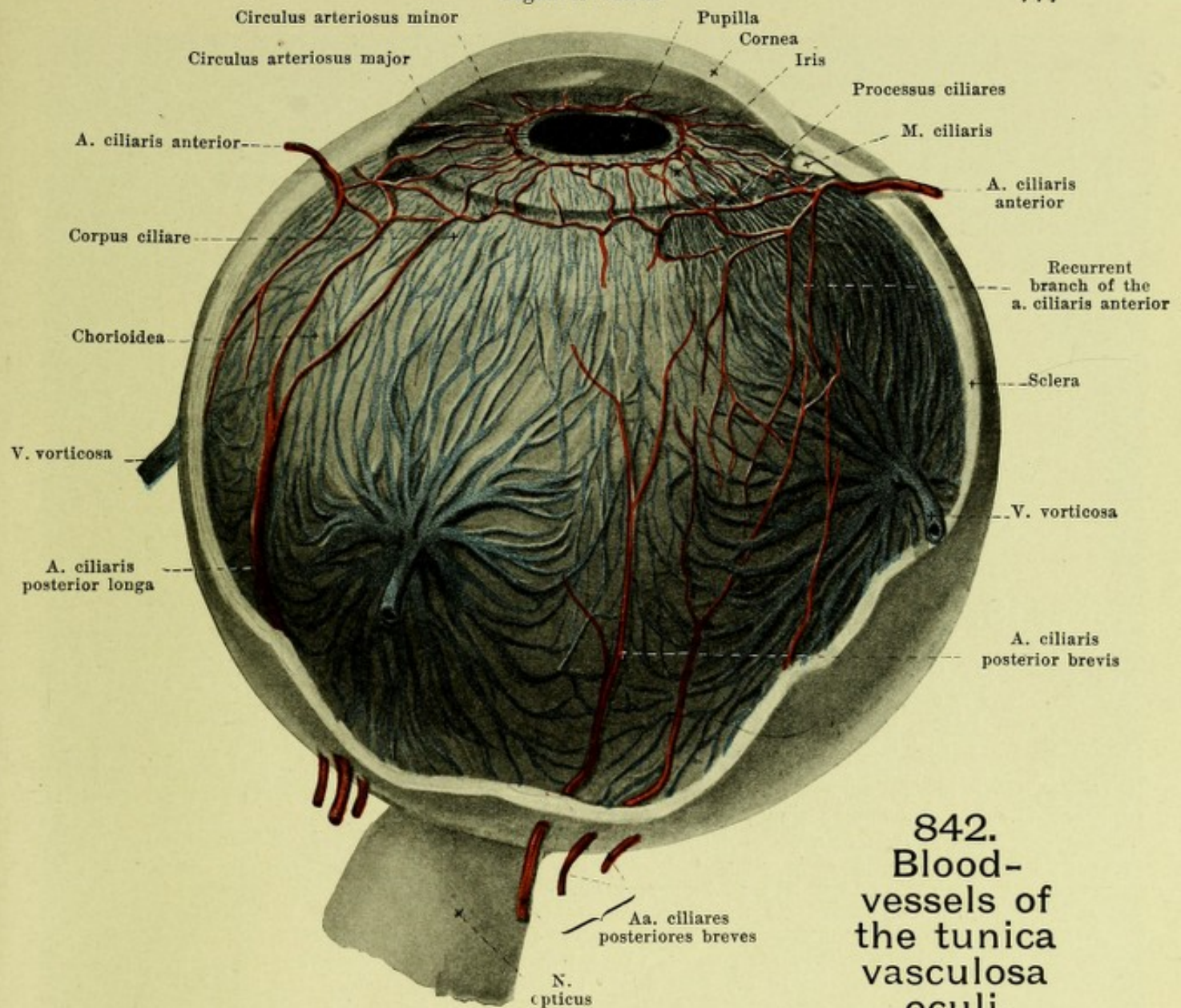
Chorioidea, *chorioid coat of the eye* (see Figs. 835, 837, 838, 846 and 847) is very thin, includes approximately the posterior two-thirds of the eye-ball, and is sometimes lighter, sometimes darker, according to the amount of pigment it contains. It possesses behind a round opening, for the passage of the optic nerve. In it five layers are distinguishable microscopically. Upon the *lamina suprachorioidea* (see p. 774) follows the pigmented lamina vasculosa with the coarser vessels, namely the roots of the vv. vorticosae (see Fig. 842) and nerves; then the layer of medium-sized vessels, then the non-pigmented *lamina choriocapillaris* with the blood capillaries and upon this the *lamina basalis*; in contact with the latter is the stratum pigmenti of the retina, which remains attached to it even after separation of the retina (during life and after death).

Corpus ciliare, *radiating body, ciliary body* (see also Figs. 835, 837—839, 841 and 842) reaches from the ora serrata retinae (see p. 780) to the margo ciliaris of the iris and is lined inside by the *pars ciliaris retinae*. Its posterior portion, *orbiculus ciliaris*, approximately 4 mm. broad, differs from the chorioidea essentially by the absence of the lamina choriocapillaris and by the addition of muscle fibers; the inner surface presents fine, meridionally placed, markedly pigmented grooves which often go out from the tips of the teeth of the ora serrata. The anterior portion of the ciliary body forms a three-sided circular ridge parallel to the equator, and is formed chiefly by the m. ciliaris. Its external anterior surface lies against the sclera; its internal surface is united with the margo ciliaris of the iris and otherwise adjoined to the chambers of the eye; its posterior surface juts on the lens. From the posterior and internal surfaces about seventy narrow, meridionally placed, glistening white, markedly ridged, vascular folds, *processus ciliares*, *ciliary processes*, arise, which are low where they begin laterally and end with a margin projecting internally over the margo ciliaris of the iris (see Fig. 848); in the upper nasal portion they are longer and higher and more widely separated. Between them lie smaller folds, *plicae ciliares*. The totality of folds is called the *corona ciliaris*. The m. ciliaris (see Fig. 837) appears as a triangular, prismatic, light ring of smooth muscle fibers, which arise largely from the internal wall of the sinus venosus sclerae. The fibers adjoining the sclera, *fibrae meridionales* [Bruekei] run in a meridional direction and extend as far as into the chorioidea; connected with them are fibers diverging backward in meridional planes and uniting in the form of net-works with one another and with the others; in addition near the inner posterior angle are fibers which run circularly, *fibrae circulares* [Muelleri]. In the m. ciliaris the nn. ciliares form a circular plexus, *plexus gangliosus ciliaris* (see Fig. 838), with numerous ganglion cells.



841. Scheme of the bloodvessels of the eye, (after Th. Leber) (see Fig. 835). Magnification ca. 4 : 1.

Iris, rainbow coat (see Figs. 835, 837 and 838), is a round disc with a round opening, *pupilla* (*star of the eye, pupil*), which does not lie exactly concentrically, but deviates from it somewhat downward and nasalward. At its lateral attached margin, *margo ciliaris*, it proceeds from the ciliary body, and by its medial, free margin, *margo pupillaris*, it rests on the anterior surface of the lens. Its medial margin lies in front of the plane of the lateral margin (see Fig. 835), so that the whole disc has the form of a very flat funnel. On widening of the pupil it becomes narrower and thicker. Its greatest thickness lies near the margo pupillaris, and corresponds to the junction between the annuli iridis (vide infra); from there on it diminishes toward the thin margo ciliaris, less so toward the margo pupillaris. The anterior surface, *facies anterior* (see Figs. 837 and 838) is visible through the cornea as far as the marginal part and is of variable color according to the pigment it contains. About 1 mm from the margo pupillaris runs a jagged line, which separates a narrow, inner zone, *annulus iridis minor*, from a broader, outer, *annulus iridis major*. In the former, small, anastomosing ridges run to the margo pupillaris, which itself is formed by a fine, notched, dark-brown edge belonging to the stratum pigmenti iridis (see Figs. 837 and 838). In the outer zone run several usually incompletely circular contraction grooves, *plicae iridis*, concentric to the margo pupillaris; in addition when there is little pigment in it the vessels are visible as radiating, tortuous, whitish lines. The posterior surface of the iris, *facies posterior*, is covered by the *stratum pigmenti iridis*, is uniformly black and is studded with very fine radiating folds.



842. Blood- vessels of the tunica vasculosa oculi,

viewed from the outside (with use of figures by Th. Leber). Magnification ca. 4 : 1.

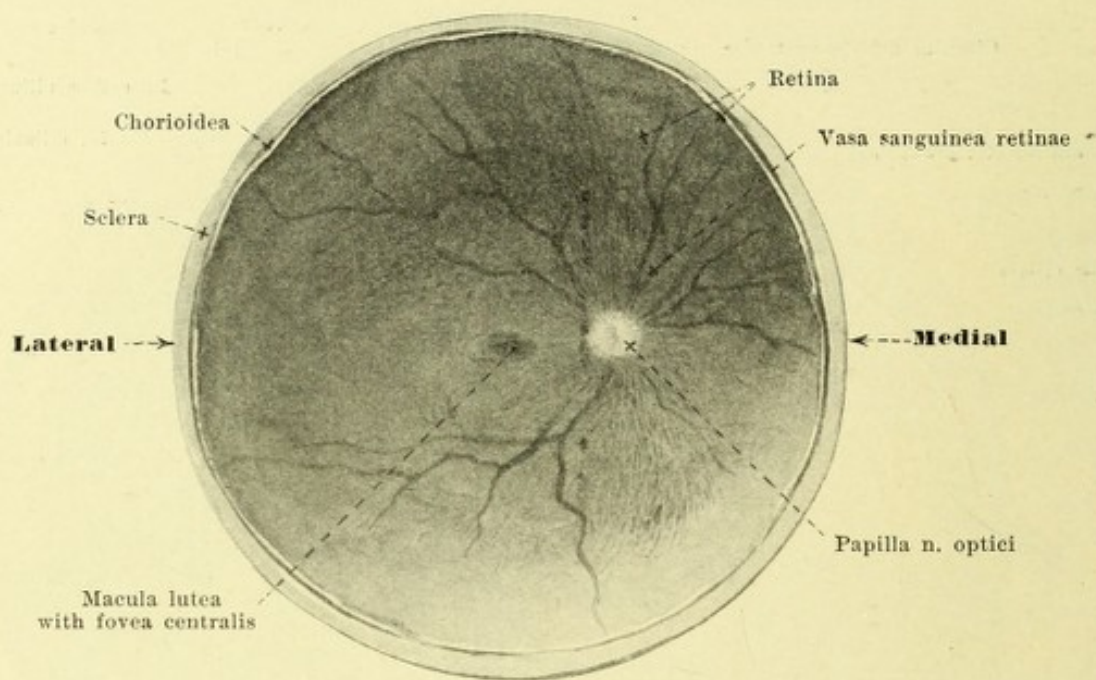
(The sclera, cornea and corpus ciliare have been partially removed.)

Iris (continued) (see Figs. 835 and 837) consists mainly of the soft *stroma iridis* rich in bloodvessels; in its posterior part close to the margo pupillaris it contains a circular muscle, *m. sphincter pupillae*, and the fibers of the *m. dilator pupillae*; diverging from it toward the periphery; the latter lie directly in front of the stratum pigmenti iridis.

The groove in front of the margo ciliaris iridis is called the *angulus iridis* (see Fig. 837 and p. 783). It is bounded externally by a net-work of circular strands covered by epithelium, the *lig. pectinatum iridis*; between the strands are oblong spaces, *spatia anguli iridis* [Fontanae]. This network of strands forms the inner boundary of the sinus venosus sclerae (see pp. 773 and 778), is connected in front with the deepest layer of the cornea, behind with the margo ciliaris iridis and gives origin to a large part of the *m. ciliaris*.

Bloodvessels of the tunica vasculosa oculi. A. *Arteries* (see also Fig. 841).

1. *Aa. ciliares posteriores breves* (see also p. 398) give fine branches to the posterior half of the external surface of the sclera and perforate the sclera by about twenty branches in the neighborhood of the *n. opticus*; they run forward in the lamina vasculosa chorioidea and break up in the close capillary network of the lamina choriocapillaris. In front they unite with fine recurrent branches of the *aa. ciliares posteriores longae* and *ciliares anteriores*. Some branches from these vessels in the sclera close to the exit of the *n. opticus* form a closed, vascular circle, *circulus vasculosus n. optici* [Halleri], from which branches enter into the *n. opticus* and anastomose with branches of the *a. centralis retinae*.



843. Posterior half of a right eye, viewed from in front.

Magnification 4:1.

2. *Aa. ciliares posteriores longae* (see p. 398 and Figs. 841 and 842), two, perforate the sclera very obliquely in the neighborhood of the n. opticus and in the horizontal meridian, one on the lateral, the other on the medial side of the eyeball, pass forward in the lamina supra-chorioidea as far as the corpus. There each divides into two diverging branches, which near the margo ciliaris iridis along with the branches of the other corresponding arteries and with those of the *aa. ciliares anteriores* form a large, circular anastomosis, *circulus arteriosus major* (see also Fig. 837), and which give branches to the m. ciliaris.

3. *Aa. ciliares anteriores* (see p. 398 and Figs. 841 and 842), usually 5—6, give off on the external surface of the sclera 1. backward fine branches *aa. episclerales*, to the anterior half of the same and 2. forward branches, *aa. conjunctivales anteriores*, to the conjunctiva bulbi, which anastomose with the *aa. conjunctivales posteriores* from the *aa. palpebrales mediales* and *laterales* (see pp. 398 and 399) and give off fine branches to the extraordinarily delicate marginal loop network of the cornea, situated in the annulus conjunctivae. They then perforate the sclera with 8—10 branches in the region of the m. ciliaris, send branches to this and enter the *circulus arteriosus major* (vide supra). From this branches pass to the m. ciliaris, to the processus ciliares, as well as recurrently to the union with the *aa. ciliares posteriores breves*; besides, numerous branches pass out of it into the iris and run in its anterior layers toward the margo pupillaris, part of them reaching this, part of them stopping short of it to form by anastomoses a delicate vascular circle, *circulus arteriosus minor*.

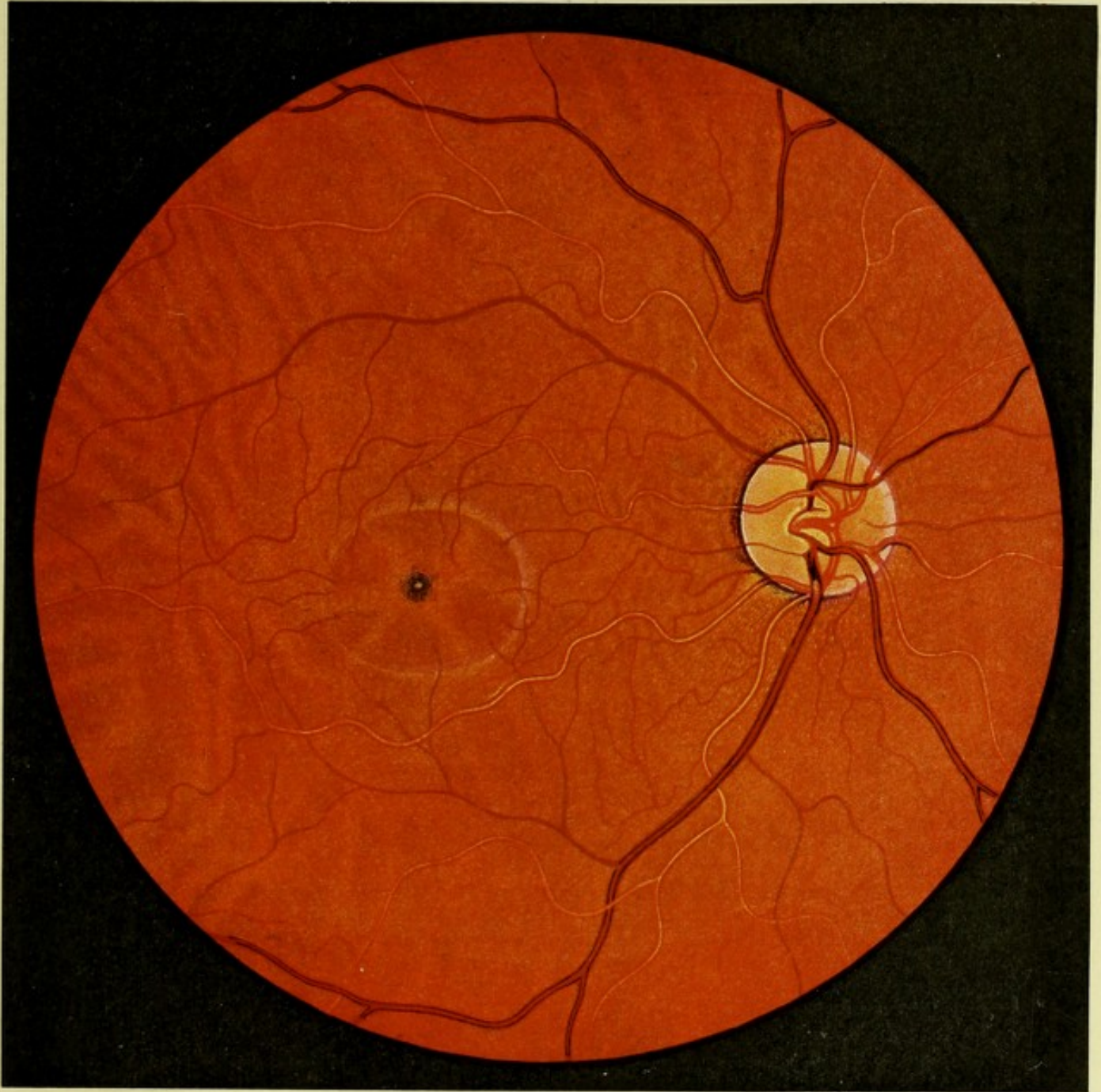
B. *Veins* (see pp. 442 and 443 and Figs. 841 and 842).

1. *Vv. vorticosae*, 4, more rarely 5 or 6, form the chief channels of exit for the blood; they arise by the running together, in groups radially toward 4 (5 or 6) spots on the equator, of the veins proceeding from the capillary network of the lamina choriocapillaris, and of numerous large branches from the corpus ciliare and from the iris in the lamina vasculosa chorioideae; they then perforate the sclera very obliquely and open into a v. ophthalmica.

2. *Vv. ciliares anteriores* perforating the sclera near the *aa. ciliares anteriores*, are numerous derivatives of the *sinus venosus sclerae* [*canalis Schlemmi, Lauthi*] (see also p. 773 and Fig. 837), a circular venous plexus, which receives small branches from the m. ciliaris. Upon the sclera they receive further the *vv. conjunctivales anteriores* and *vv. episclerales*, corresponding to the arteries of the same name. They open into the veins of the rectus muscles of the eye.

3. *Vv. ciliares posteriores* collect the blood near the n. opticus upon the external surface of the sclera from the vessels situated upon the surface of the latter and anastomose in front just as do the *vv. episclerales* with the *vv. vorticosae*. They, therefore do not correspond to the *aa. ciliares posteriores*.

Nerves of the eyeball. The *nn. ciliares longi* and *breves* (see p. 690) perforate the sclera with about 20 branches in the neighborhood of the n. opticus, run forward in the lamina supra-chorioidea, form the *plexus gangliosus ciliaris* (see p. 775 and Fig. 838) in the m. ciliaris, and send branches to the chorioidea, sclera, cornea, corpus ciliare and iris.



844. Background of right eye.

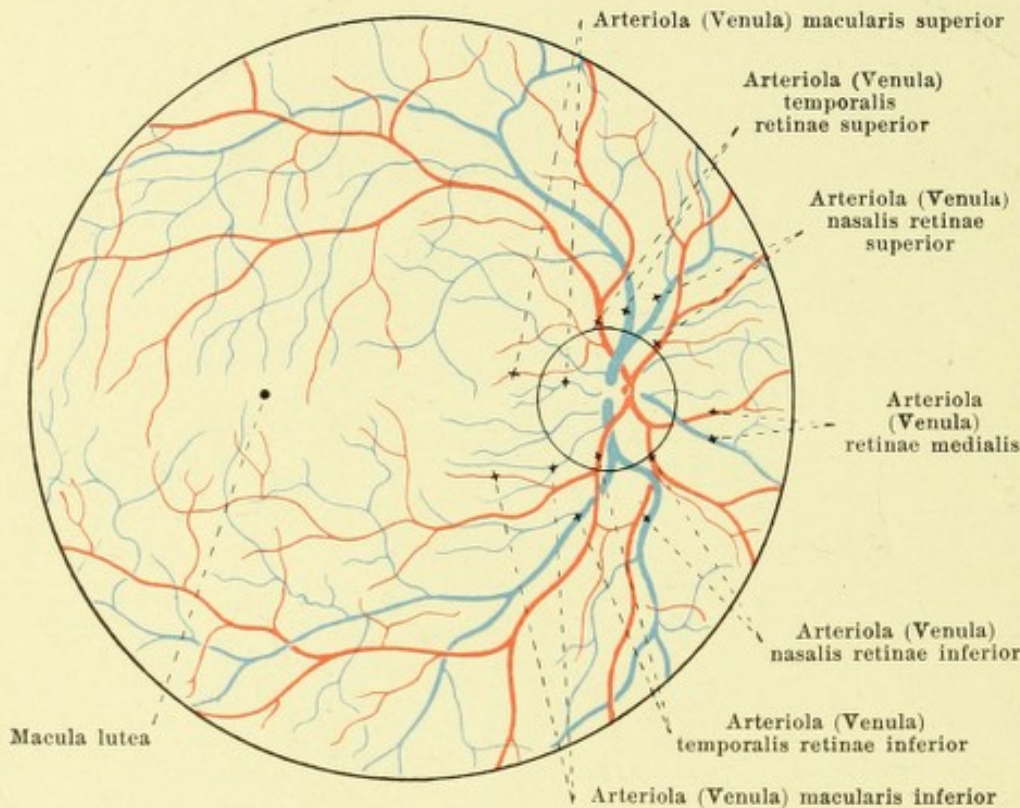
(After J. Oeller.)

(The vv. vorticosae are partially visible as light stripes; the arteries of the retina look lighter than the veins.)

Retina (see also Figs. 835, 837, 839—841, 843, 845—847), lies everywhere directly adjacent internally to the tunica vasculosa oculi, and is divisible into a larger posterior portion, *pars optica retinae*, which contains the expansion of the n. opticus, as well as the sensory epithelium, sensitive to light, and a smaller anterior portion, *pars ciliaris retinae*, which belongs to it embryologically, but which possesses neither nerves nor elements sensitive to light. The junction between the two portions is formed by the *ora serrata* (see p. 780).

The *pars optica retinae* is smooth and transparent like glass in the living eye and permits the stratum pigmenti and the chorioidea lying external to it to appear as dark-red surfaces, their distinctly visible details varying according to the pigmentation; the blood-vessels of the retina lie internally upon it.

845. Blood vessels of the retina of the right eye, viewed from in front (after E. Jäger and Th. Leber).



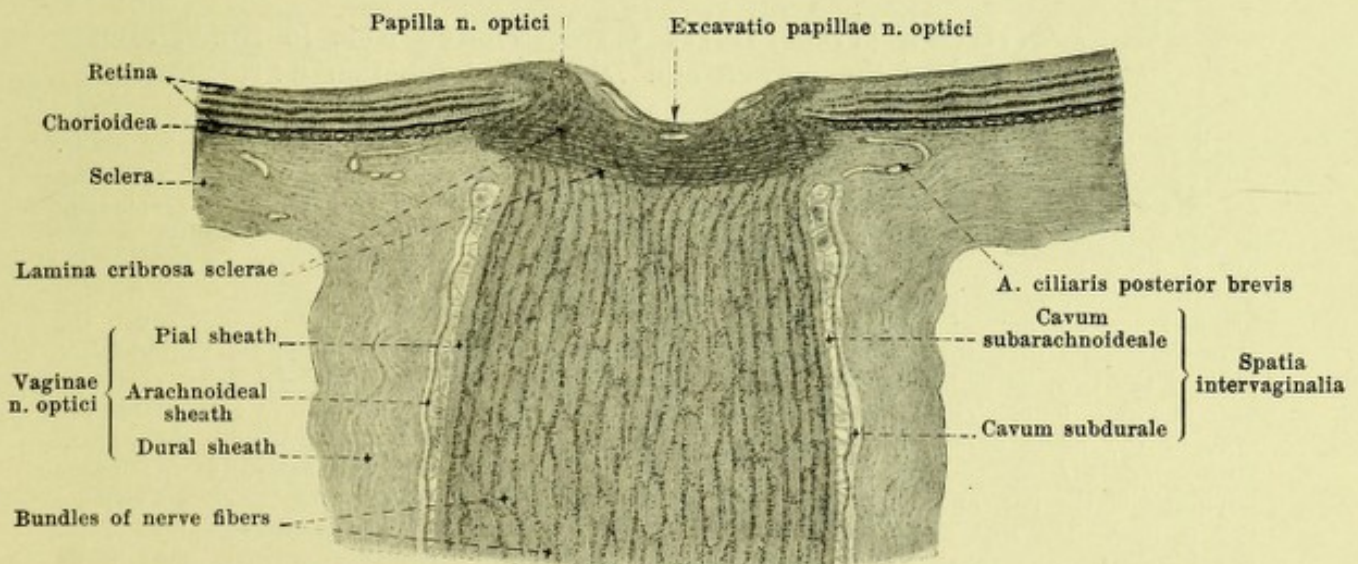
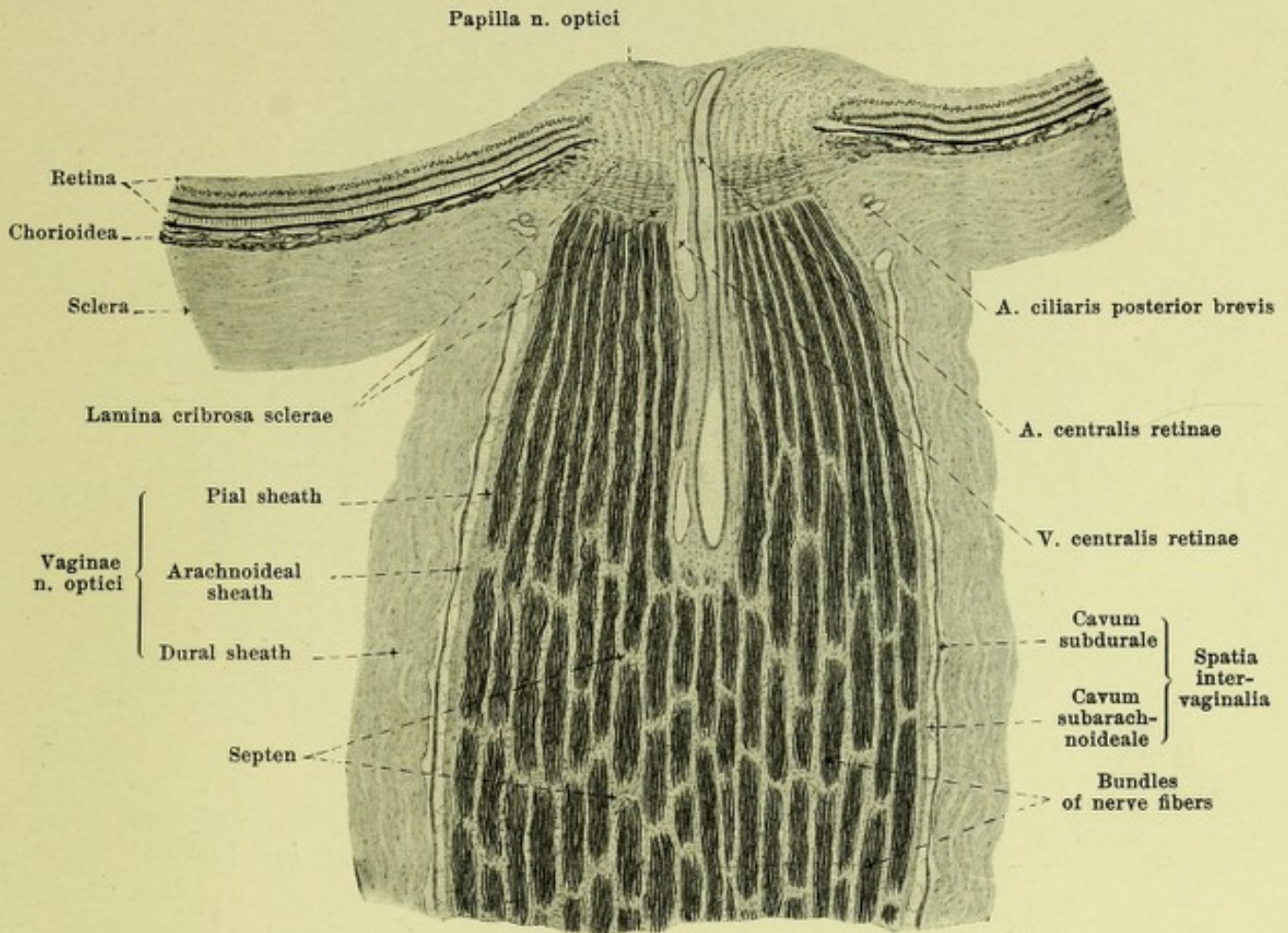
Pars optica retinae (continued) (see Figs. 835, 837, 839, 840, 843, 844, 846 and 847). Its thickness diminishes slowly from the papilla n. optici (vide infra) forward. The n. opticus after perforating the sclera, chorioidea and retina arrives on the inner surface of the retina, whence it spreads out on all sides; the place where it enters, situated somewhat medianward from the posterior end of the axis oculi externa, has the form of a round-

ed hillock, *papilla n. optici* (see Figs. 835, 843, 844, 846 and 847), which is slightly depressed in the middle, or presents a fossalike depression, *excavatio papillae n. optici*, reaching as far as the level of the chorioidea; the papilla appears during life as a circular whitish spot from the middle of which the blood-vessels of the retina emerge. About 4 mm lateralward from the center of the papilla and a little deeper down lies a pin-prick-like depression, the *fovea centralis* (see Figs. 835, 843 and 844), in the middle of the circular or transversely oval, not sharply defined, yellow-colored *macula lutea*, *yellow spot*. The anterior boundary of the *pars optica* is formed by the *ora serrata* (see Figs. 835, 837, 839 and 840). This is a line with minute outward curved projections, which reaches somewhat more forward on the nasal side than on the temporal side, but otherwise varies extraordinarily in its appearance. Its teeth directly toward the corpus ciliare are rarely even in the whole circumference; they are more often better developed nasalward than temporalward and are often directed toward the interspaces between the processus ciliares.

The *pars ciliaris retinae* (see Fig. 837), a microscopically thin layer, covers the posterior surface of the corpus ciliare and of the iris as far as its margo pupillaris; it is formed 1. by the stratum pigmenti corporis ciliaris et iridis (vide infra) and 2. by an inner layer of cells, which is also pigmented on the iris, but is colorless on the corpus ciliare.

The outermost layer of the retina, which lies directly in contact with the tunica vasculosa, consists of a simple layer of pigmented cells, *stratum pigmenti*, which is designated on the *pars optica retinae* as the *stratum pigmenti retinae*, on the *pars ciliaris retinae* as the *stratum pigmenti corporis ciliaris* and *stratum pigmenti iridis*.

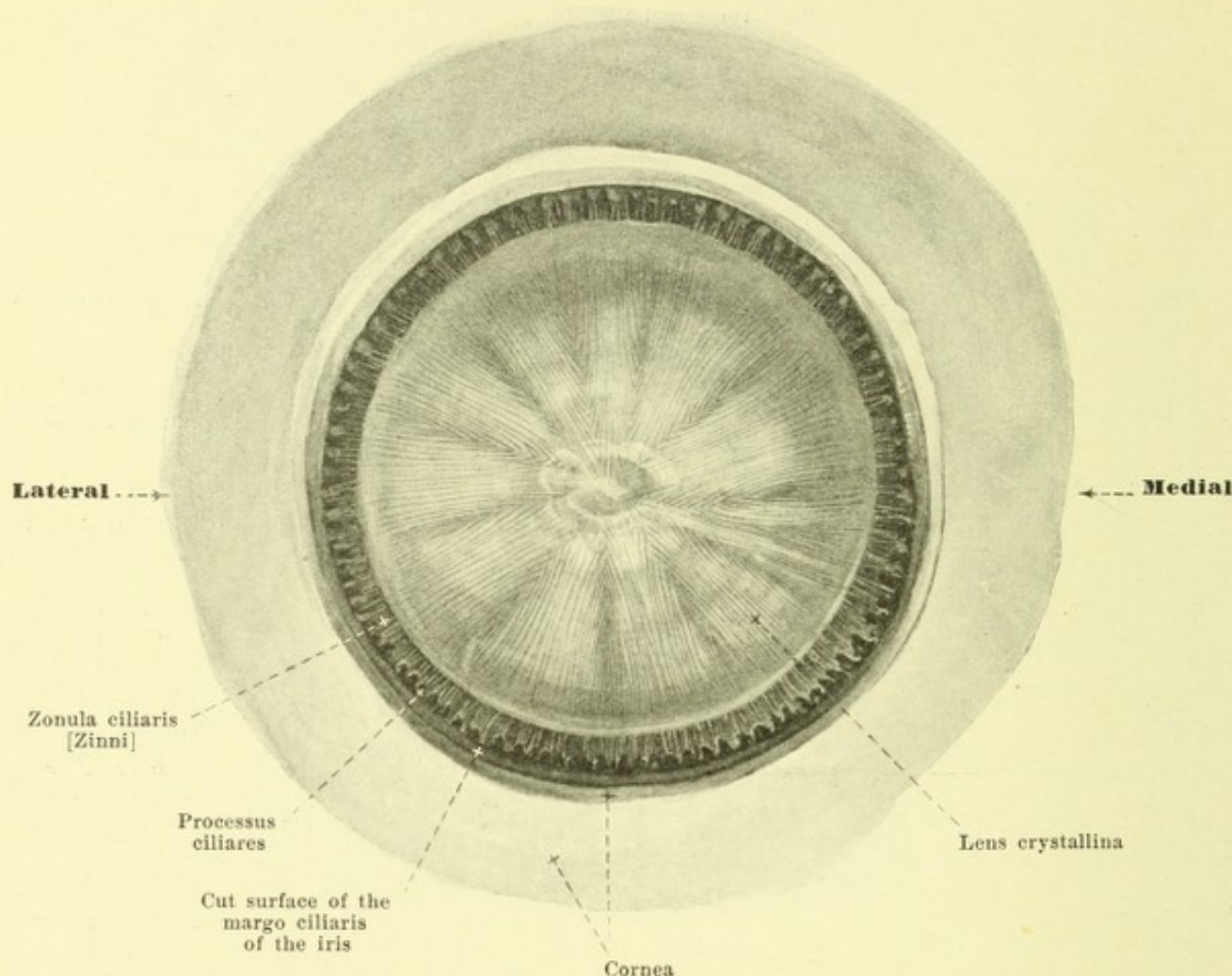
Vasa sanguinea retinae (see also Figs. 841 and 844) are branches of the a. and v. centralis retinae (see pp. 398, 442, 771), the larger branches of which lie in the layer of optic nerve fibers; arteries and veins run almost parallel with one another; the arteries do not anastomose with one another. Aside from the anastomosis with the aa. ciliares posteriores breves mentioned on p. 777 they are completely separate from the vessels of the tunica vasculosa. The a. and v. centralis retinae divide on the surface of the papilla, or somewhat deeper, first into an upper and a lower branch, and each of these divides again into a shorter branch running nasalward, *arteriola (venula) nasalis retinae superior, inferior*, and a lateral, longer, *arteriola (venula) temporalis superior, inferior*. In addition two small vessels run from the papilla lateral to the macula lutea, *arteriola (venula) macularis superior, inferior*, and usually one vessels medianward, *arteriola (venula) retinae medialis*.



846 and 847. Longitudinal sections of the n. opticus and of the papilla n. optici,

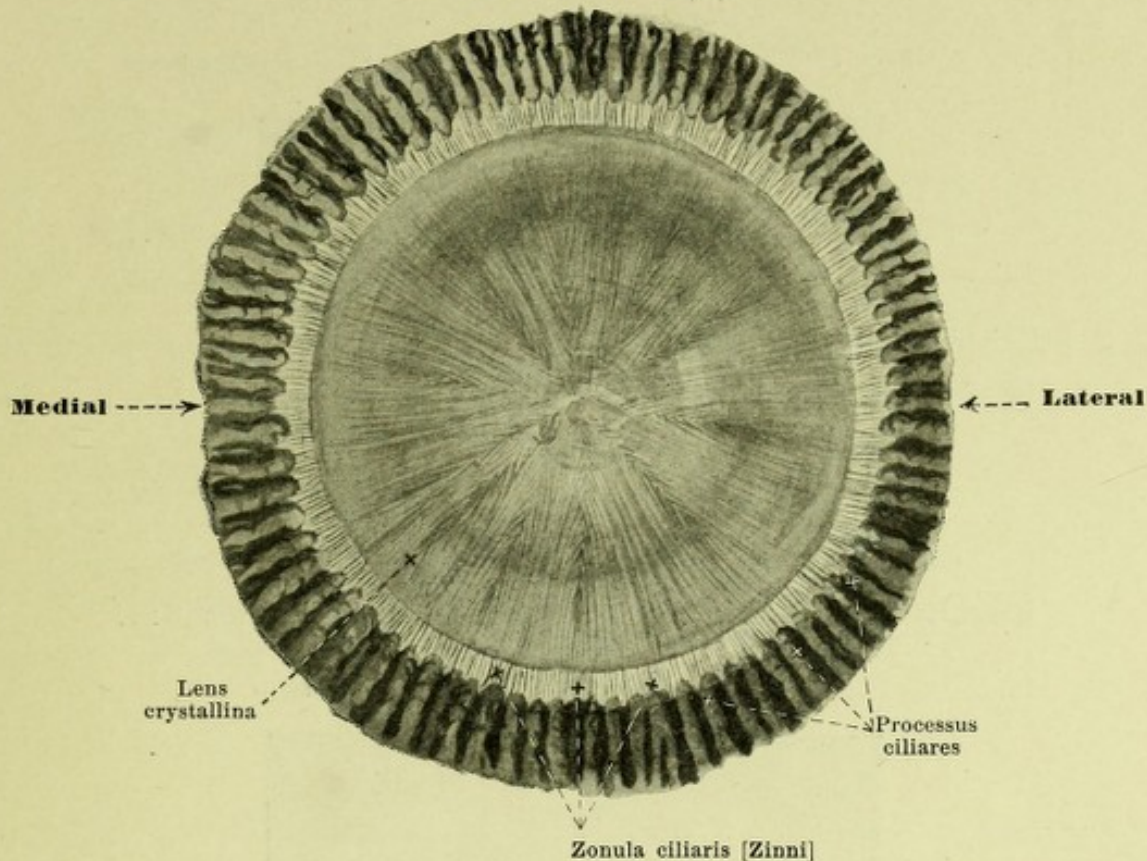
the upper without, the lower with, the excavatio papillae n. optici (after preparations by H. Sattler). Magnification 15:1.

(On the upper figure the medullated portions of the nerve fibers are shown dark; the lower section has not been cut axially.)



848. Lens of the right eye, viewed from in front, after removal of the cornea and iris. Magnification 6:1.

Lens crystallina, lens (see also Figs. 835, 838, 839, 849—852) is a very transparent, colorless, biconvex body, the two surfaces of which meet in a rounded margin, *aequator lentis*. The anterior surface, *facies anterior lentis*, is more feebly curved than the posterior surface, *facies posterior lentis*, neither corresponding, however, exactly to a portion of a spherical surface. Besides, the radius of the middle part of the lens' surfaces differs according as the eye is fixed for near or distant objects; the radius of the anterior surface on fixation for distant objects, is 8,3 mm, for near 5,2 mm, the radius of the posterior surface on fixation for distance 6,0 mm, for near 5,0 mm. The midpoint of the anterior surface is called the *polus anterior lentis*, that of the posterior surface the *polus posterior lentis*, the straight line uniting the two, is called the *axis lentis* and on fixation for distant objects is 3,7 mm, for near 4,4 mm long. The equatorial plane of the lens stands perpendicular to the axis of the eye, in the plane of the corpus ciliare. The lens is there held in position by the *zonula ciliaris [Zinni]* (see p. 783); its anterior surface touches the posterior surface of the margo pupillaris of the iris, and its posterior surface lies in the fossa hyaloidea of the corpus vitreum (see p. 783). The lens substance, *substantia lentis*, is ensheathed by a structureless membrane, *capsula lentis*, and consists of a softer, juicier cortical layer, *substantia corticalis*, and a firmer nucleus, *nucleus lentis*, which gradually go over into one another, their relations varying in different individuals. The lens substance consists of the one-layered cubical *lens epithelium, epithelium lentis*, covering its anterior surface, and the band-like *lens fibres, fibrae lentis*, making up the remaining mass, the two merging at the equator. These fibres run in curves from points in front of the equatorial surface to points behind it, and are attached in front and behind to stellate collections of intercellular substance, which on maceration of the lens, open up as slits. These *lens stars* have three rays, *radii lentis*, in the foetus and new-born, of which one on the anterior surface is directed upward, the others downward and medialward and downward and lateralward; on the posterior surface they diverge by about 60°.



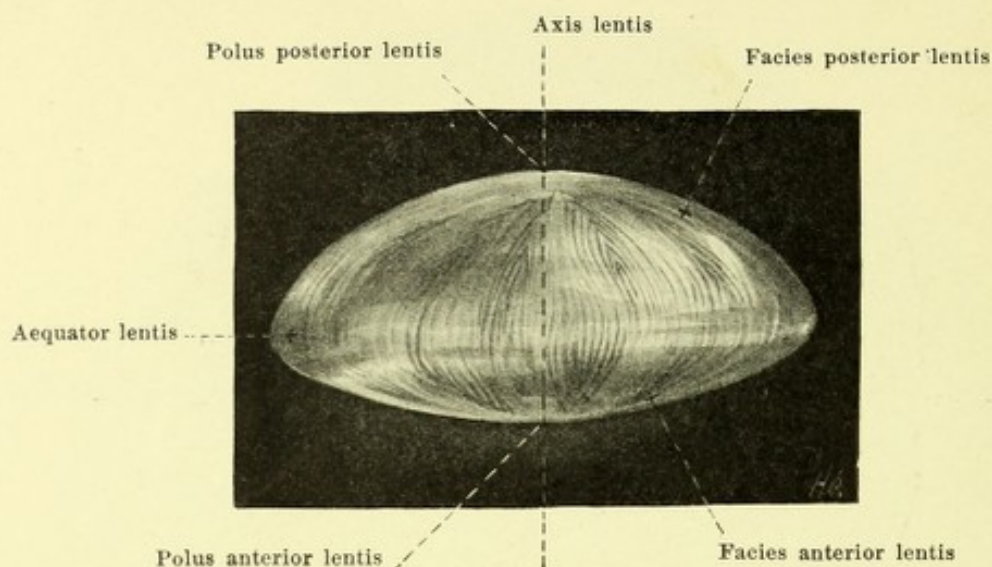
849. Lens of the right eye, viewed from behind, after removal of the cornea and iris. Magnification 6:1.

Lens crystallina (continued) (see also Fig. 848). The *lens star* of the adult usually presents in the nucleus the triradiate type; in the external layers it is six-rayed or more, alternating usually on the anterior and posterior surfaces so that one anterior ray lies in the middle between two posterior and vice versa.

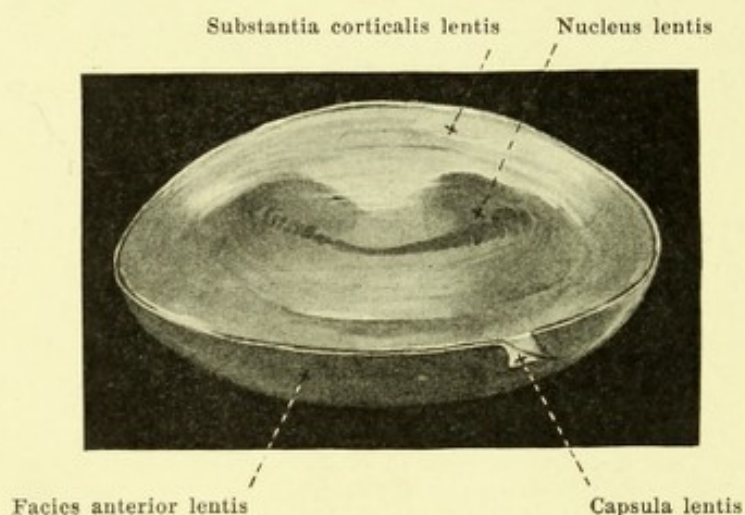
The **zonula ciliaris [Zinni]**, *radiate platelet* (see also Figs. 835 and 848) is the suspensory apparatus of the lens and consists of innumerable extremely fine fibrils, *fibræ zonulares*, which stretch across from the region of the orbiculus ciliaris and corpus ciliare radially to the equator of the lens and there enter the capsula lentis. In so doing they run only in the grooves between the processus ciliares. The fibers arising behind are distributed in several bands over the whole equator, those arising in front reach the lens behind it; accordingly the fibers undergo partial decussation. The large spaces between the fibers, *spatia zonularia*, are filled with aqueous humor and communicate freely among one another and with the part of the posterior chamber of the eye lying in front of them; behind they adjoin the anterior surface of the vitreus.

Humor aqueus, aqueous humor, is a fluid, poor in albumen, which fills up the space between the anterior surface of the lens (and of the vitreus) and the posterior surface of the cornea. It is subject to a slow but steady flow, is probably produced by the processus ciliares and perhaps also by the iris, and is led away by filtration into the sinus venosus sclerae. The space filled with aqueous humor is divided by the iris into two compartments, the *camera oculi posterior* and *camera oculi anterior*, *posterior* and *anterior chambers of the eye* (see Fig. 835). The former includes also the spatia zonularia and is bounded behind by the vitreus, externally by the inner surface of the corpus ciliare and the processus ciliares, in front by the iris and internally by the lens. The anterior chamber of the eye is surrounded in front by the cornea, behind by the iris and by that part of the anterior surface of the lens visible in the pupil; its gutter-like external margin which in front touches the cornea, behind, the iris, and externally the lig. pectinatum iridis, is called the *angulus iridis* (see also p. 77).

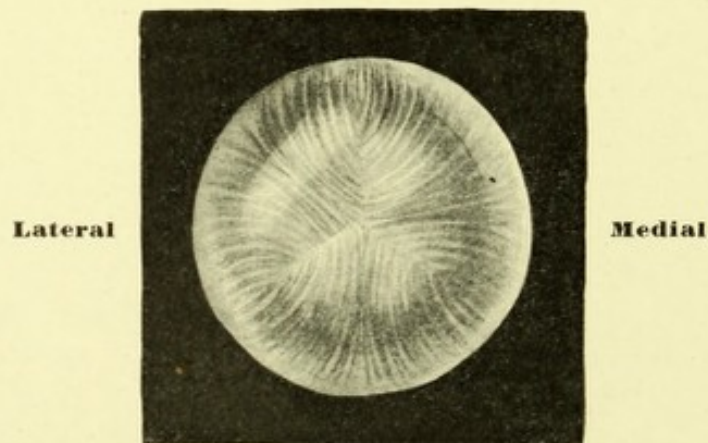
Corpus vitreum, vitreous or glassy body (see Fig. 835), a colorless, transparent, gelatinous body, fills up the space between the retina and the lens, reaches forward as far as the zonula ciliaris and presents a fossa-like depression, *fossa hyaloidea*, for the reception of the posterior surface of the lens. It is enclosed externally by a fibrous membrane, *membrana hyaloidea*, and consists of a frame-work of very fine fibers, *stroma vitreum*, the meshes of which are filled with fluid, *humor vitreus*.



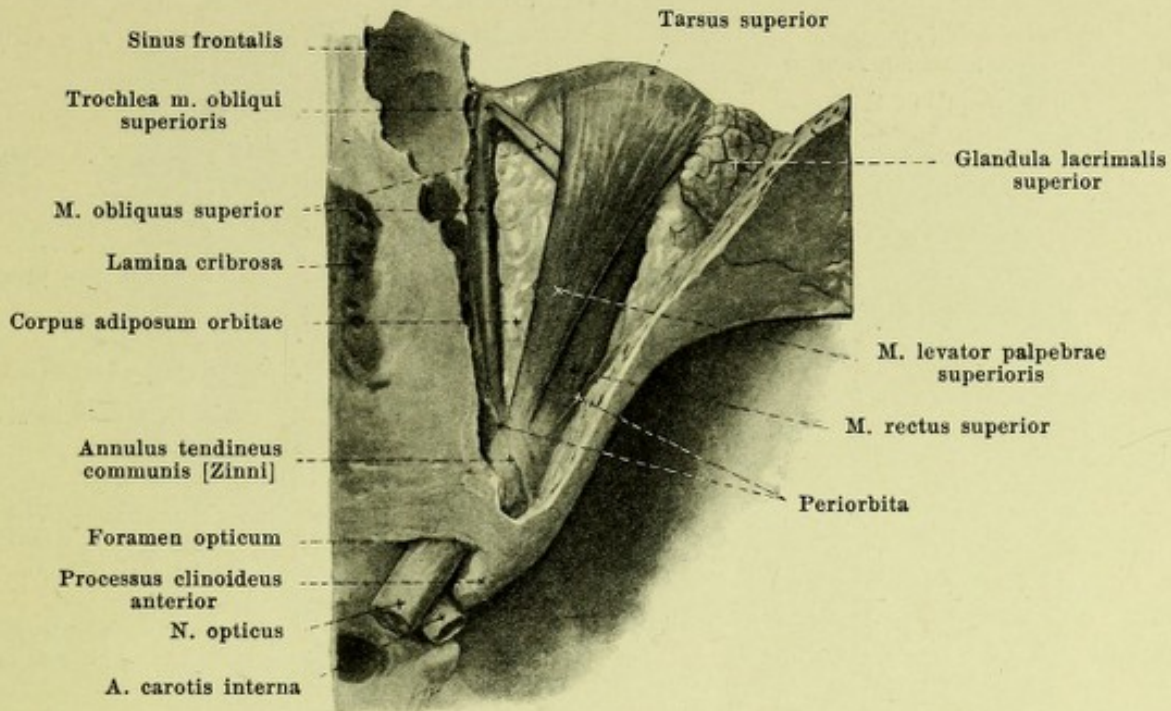
850. Lens, viewed from above. Magnification 6:1.



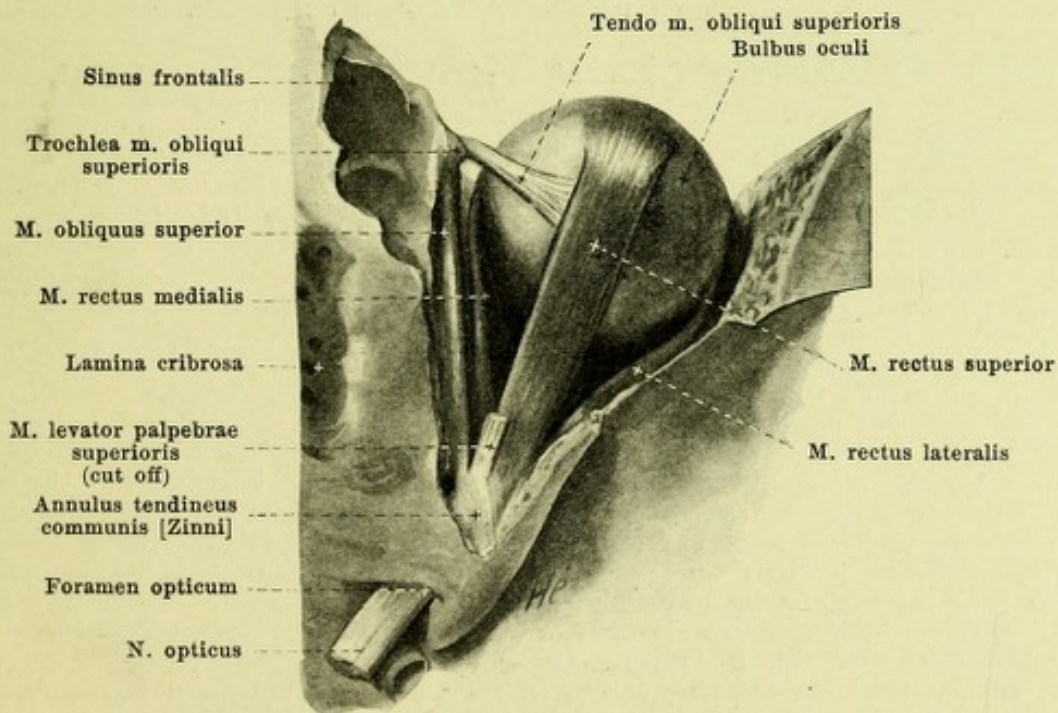
851. Lens cut through horizontally, Magn. 6:1.
(The capsule of the lens has been loosened somewhat.)



852. Lens of a seven months' foetus,
viewed from in front. Magnification 6:1.

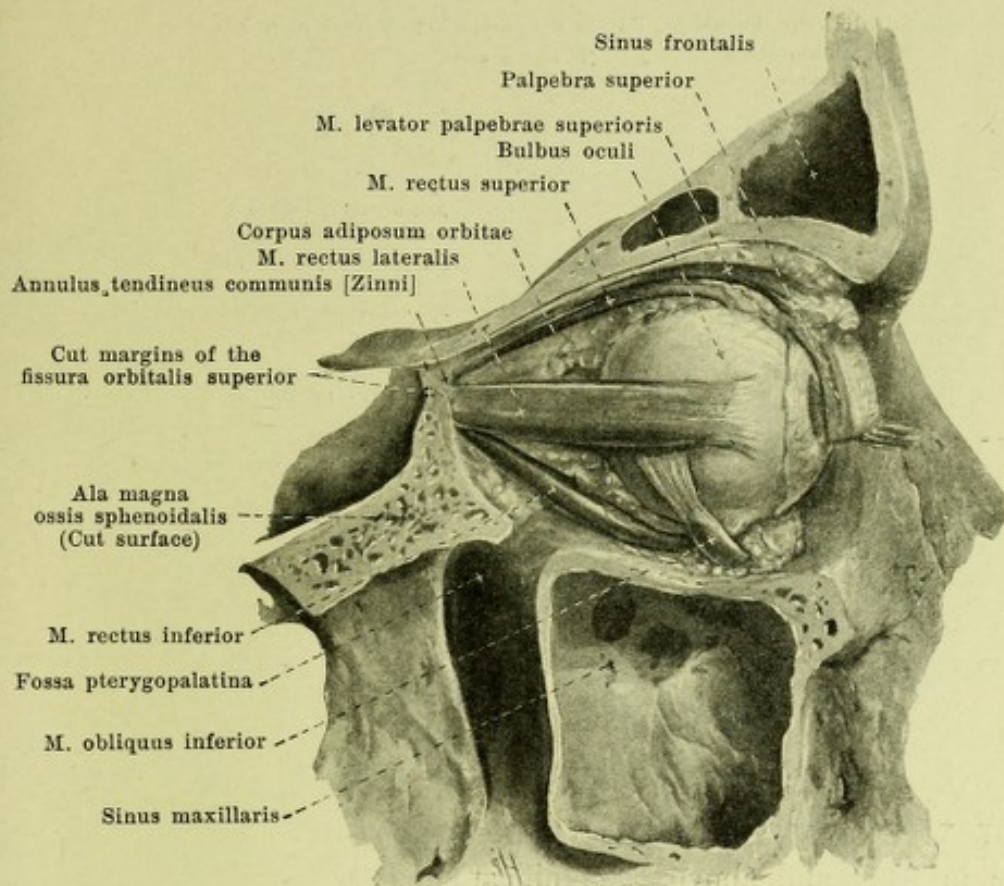


853. Contents of the right orbital cavity, viewed from above.



854. Muscles of the right eye, viewed from above.

(The m. levator palpebrae superioris, the corpus adiposum orbitae, the lachrymal glands and the eyelids have been removed.)



856. Contents of the right orbital cavity,

viewed from
the right.

(The glandulae lacrimales and the lower eyelid have been removed; the muscles are exposed.)

2. *Mm. recti* (see also Figs. 853—855, 857 to 866), are oblong, flat muscles, narrow behind and broad in front which all arise from the annulus tendineus communis [Zinni] (see p. 786); they run forward close to the orbital wall (the upper one separated from it by the *m. levator palpebrae superioris*), pass in its anterior half through the fat body toward the eye-

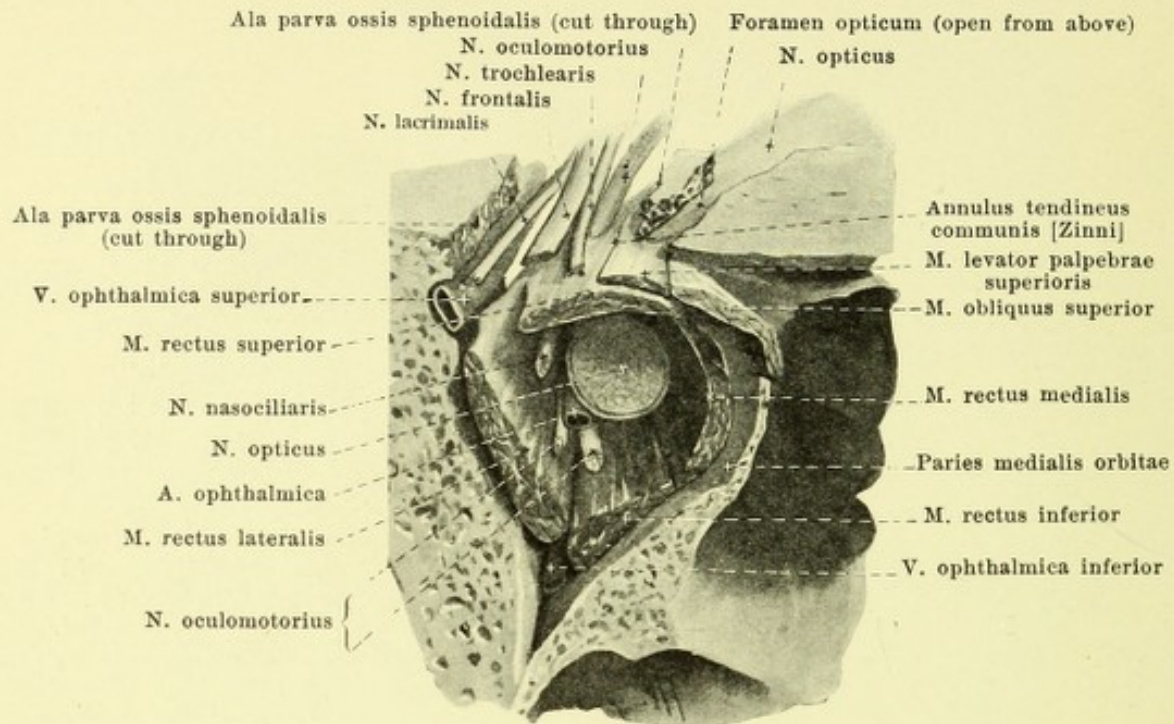
ball, are situated upon it for some distance from the region of the equator on, and go over by broad, thin tendons in front of the equator into the sclera. The longest of them is the superior, next comes the medial, then the lateral, then the inferior. The mode of action of the *mm. recti superior et inferior* and of the *mm. obliqui* depends on the size of the angle between the visual line and the course of the muscle.

a) *M. rectus superior*. Position: just beneath the *m. levator palpebrae superioris*, projecting beyond it behind and lateralward; it passes forward and lateralward and forms an angle of about 25° with the direct visual line. Insertion: on the average 7,75 mm from the margin of the cornea; the line of insertion is 10,8 mm long, curved so as to be slightly convex forward, asymmetrical, oblique. Action: it draws the anterior pole upward and medianward and rolls the superior pole medianward. The influence of the elevating component is greatest on looking lateralward, that of the rotating on looking medianward. Innervation: n. oculomotorius.

b) *M. rectus medialis* (O. T. internal rectus). Position: on the medial wall of the orbital cavity. Insertion: on the average 5,5 mm from the margin of the cornea; the line of insertion is 11 mm long, curved so as to be slightly convex forward, usually symmetrical. Action: turns the anterior pole medianward. Innervation: n. oculomotorius.

c) *M. rectus inferior*. Position: on the inferior wall of the orbital cavity, separated from it in front by the *m. obliquus inferior*; it runs obliquely forward and lateralward and forms an angle of about 25° with the direct visual line. Insertion: on the average 6,6 mm from the margin of the cornea; the line of insertion is 10 mm long, usually curved so as to be markedly convex forward and symmetrical, always somewhat oblique. Action: it turns the anterior pole downward and medianward and rolls the upper pole lateralward. The influence of the depressing component is greatest on looking lateralward, that of the rolling on looking medianward. Innervation: n. oculomotorius.

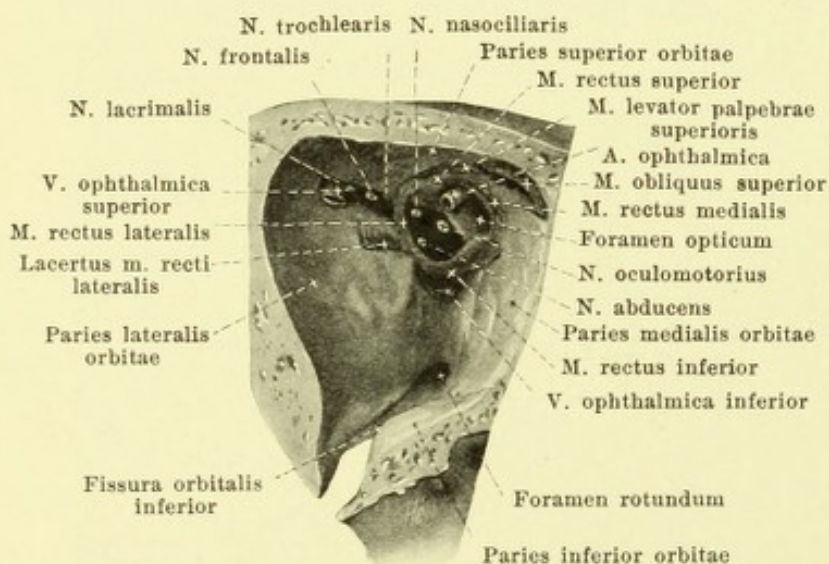
d) *M. rectus lateralis* (O. T. external rectus), with two heads (see p. 786). Position: on the lateral wall of the orbital cavity; it passes obliquely forward and lateralward; insertion: on the average 7 mm from the margin of the cornea; the line of insertion is 10 mm long, curved so as to be slightly convex forward, usually symmetrical. Action: it turns the anterior pole lateralward. Innervation: n. abducens.



857. Muscles, vessels and nerves in the back part of the right orbital cavity,

viewed from in front and above. Magnification 2:1.

(The fissura orbitalis superior and the foramen opticum have been opened from above.)



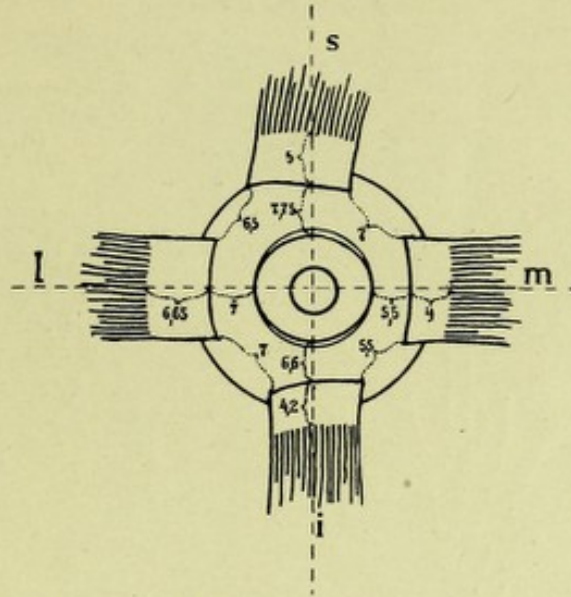
858. Origins of the muscles of the orbital cavity,

viewed from in front.

(The muscles, vessels and nerves have been cut off short.)

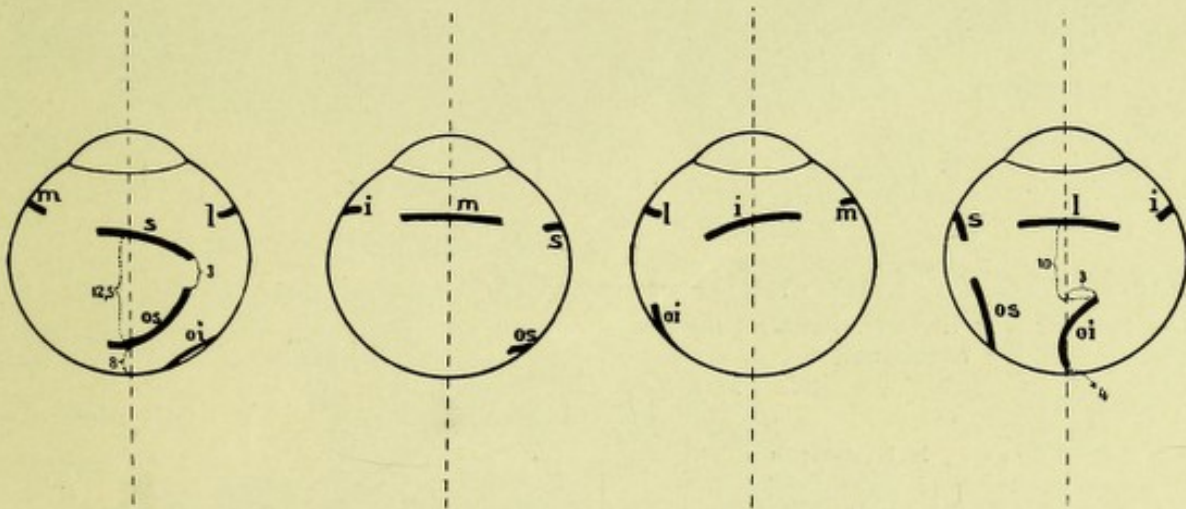
M. obliquus superior (see also Figs. 853—855, 860, 861 to 864, 866), the longest and thinnest eye-muscle. Origin: see p. 786. It lies with its oblong rounded belly at the junction between the upper and medial walls of the orbit, directly on the bone, runs forward with its rounded tendon through a short

fibrocartilaginous tube, *trochlea*, fastened to the fovea or spina *trochlearis* (here is a small bursa, *bursa trochlearis*) and bends at an angle of about 50° lateralward and backward through the fat to the bulbus; on this it passes on directly beneath the m. rectus superior and enters in a very variable manner behind the equator into the sclera by a tendon about 10 mm broad; its line of insertion is curved so as to be convex behind and lateralward, lies asymmetrically and obliquely (see Fig. 860) and is separated from the posterior end of the external axis of the eye by about 8 mm. Action: it turns the anterior pole downward and lateralward and rolls the upper pole medianward. The more the eye is directed medianward, the greater is the influence of the depressing component, the less that of the rolling. Innervation: n. trochlearis.



859. Insertions of the muscles on the right eyeball, viewed from in front.

(The muscles have been pulled off the eyeball.)



860. Insertions of the muscles on the right eyeball,

viewed from above.

viewed from the
medial side.

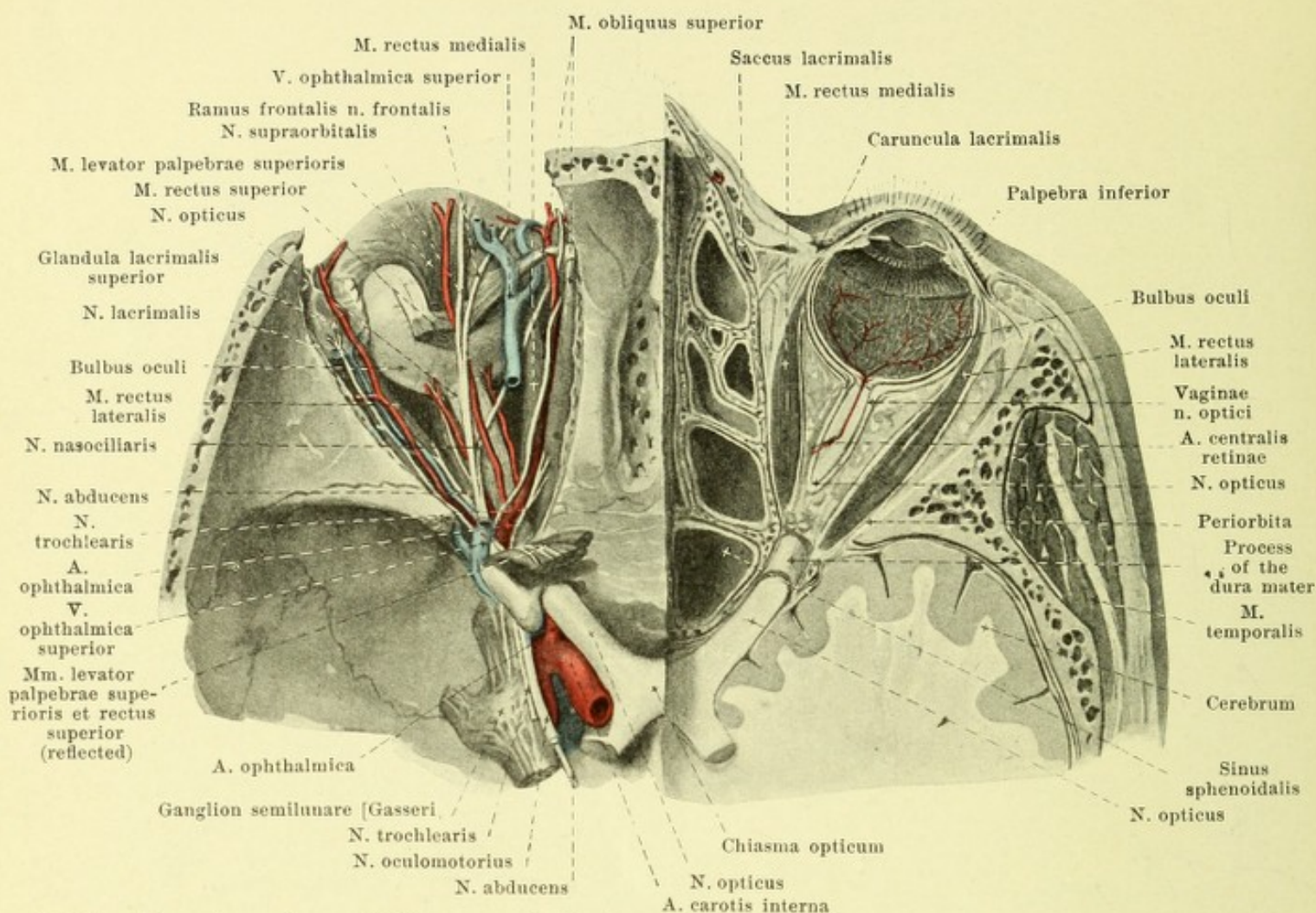
viewed from below.

viewed from the
lateral side.

The Figs. 859 and 860 have been constructed from measurements made by H. Sattler.

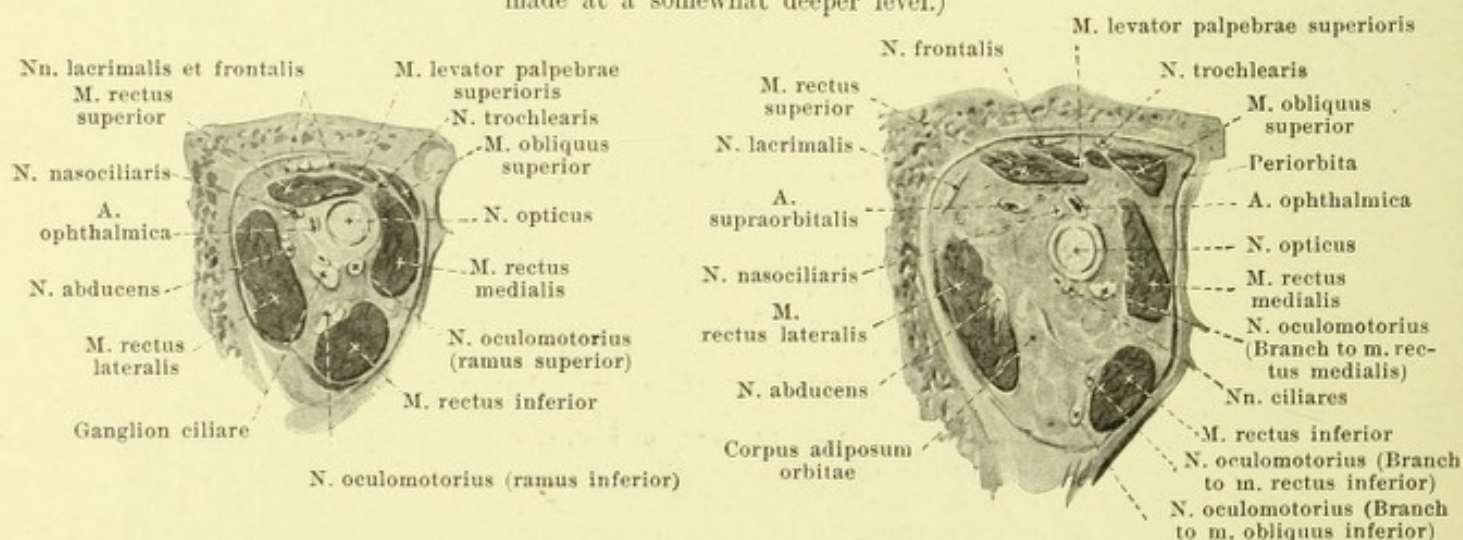
The figures indicate millimeters, s = m. rectus superior, m = m. rectus medialis, i = m. rectus inferior, l = m. rectus lateralis, os = obliquus superior, oi = m. obliquus inferior.

4. *M. obliquus inferior* (see also Figs. 855, 856, 865, 866 and 874), the shortest eye muscle, arises from the anterior part of the inferior wall of the orbit, just lateral from the beginning of the canalis nasolacrimalis, passes through the fat, lateralward upward and backward, beneath the m. rectus inferior, to the posterior half of the eyeball forming an angle of about 50° with the direct visual line, and enters the sclera in a very variable manner by a tendon about 10 mm broad at the horizontal meridian; the line of insertion is curved so as to be slightly convex upward and is separated at its medial end by about 4 mm from the external axis of the eye. Action: it turns the anterior pole upward and lateralward and rolls the upper pole lateralward. The influence of the elevating component is greatest on looking medianward, that of the rolling on looking lateralward. Innervation: n. oculomotorius.



861. Contents of the orbital cavity, viewed from above (after H. Sattler).

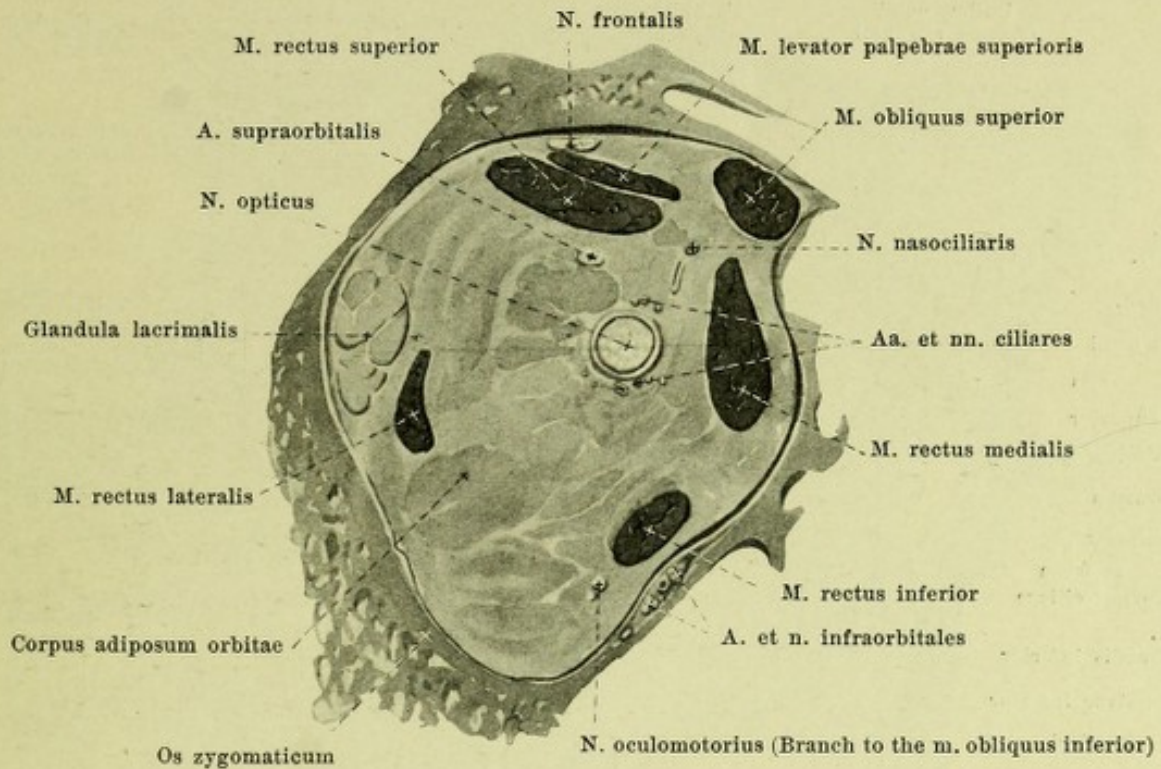
(On the left side the mm. levator palpebrae superioris and rectus superior have been partly removed and the vessels and nerves dissected out; on the right a horizontal section has been made at a somewhat deeper level.)



862 and 863. Frontal section through the right orbital cavity, viewed from in front. Magnification 3:2.

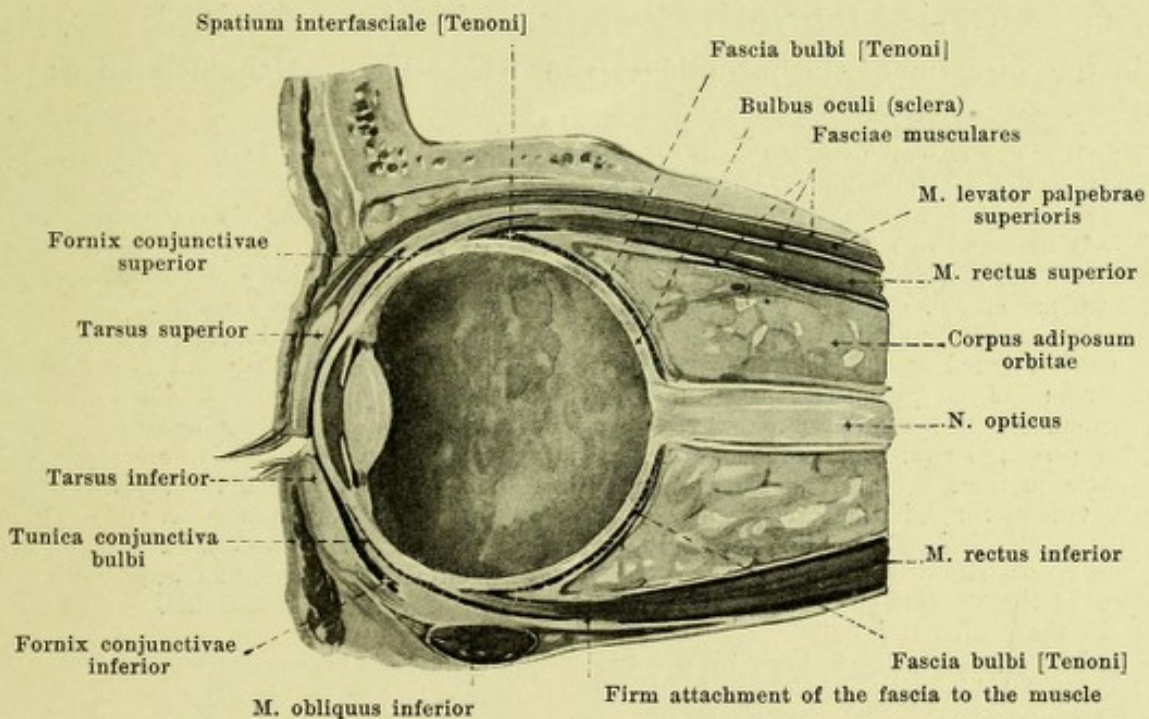
Close in front of the foramen opticum.

Midway between foramen opticum and bulb.



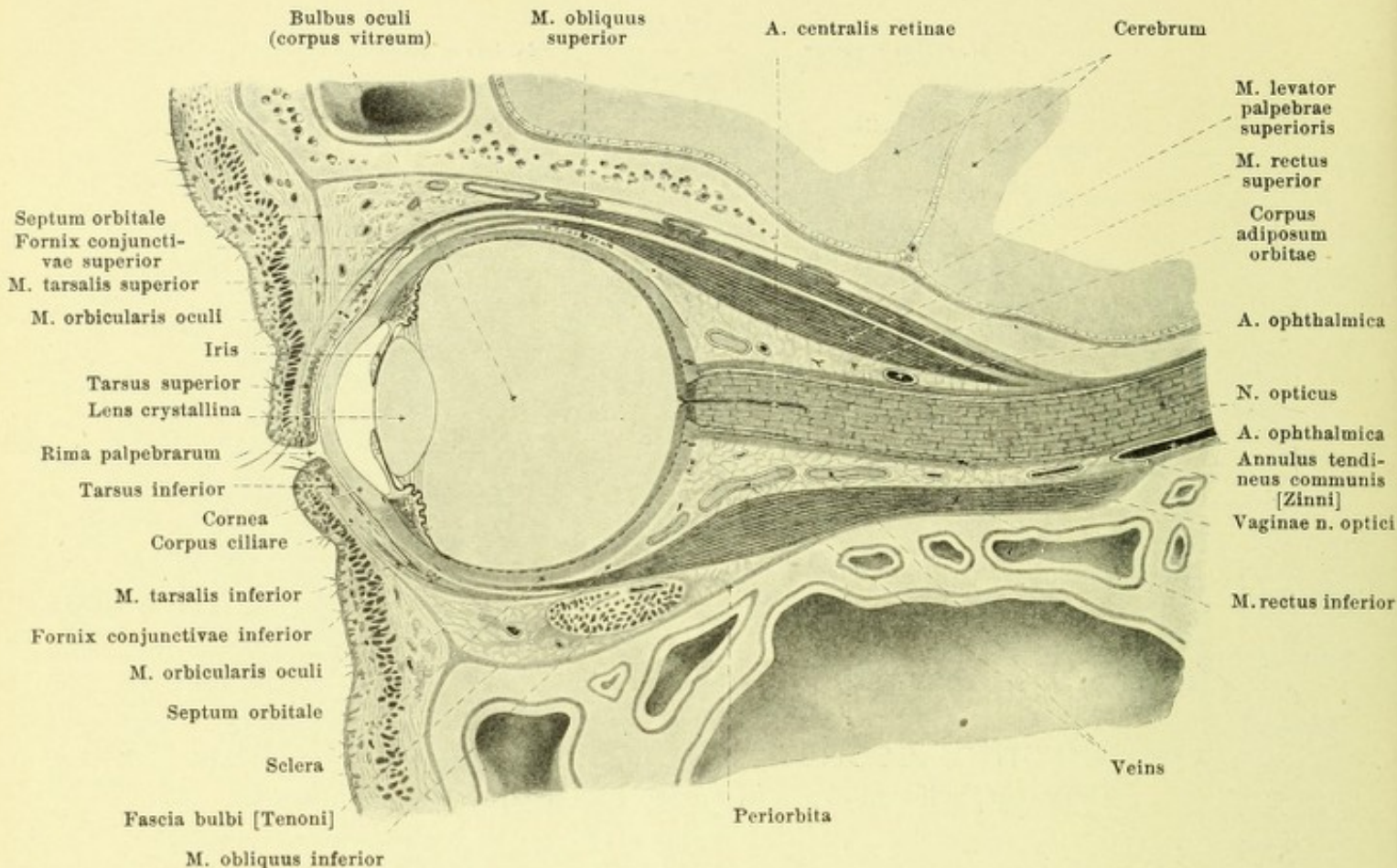
864. Frontal section through the right orbital cavity, viewed from in front close behind the bulb.

Magnification 3:2.



865. Vertical section through the eye-ball, somewhat schematic (with use of a figure by H. Virchow).

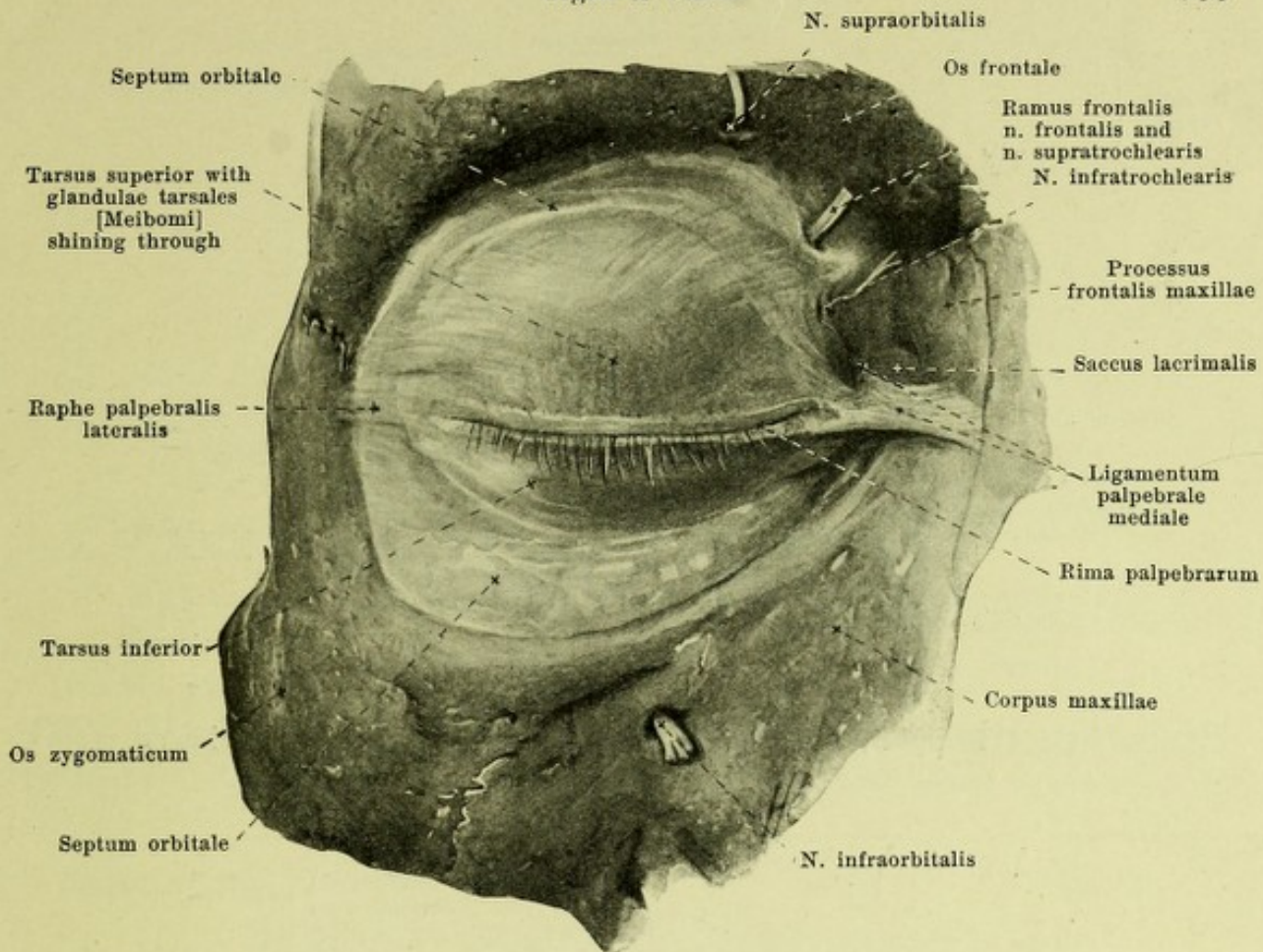
Magnification 3:2.



866. Vertical section through the orbital cavity, in the direction of the n. opticus (after H. Sattler). Magnification 3:2.

Fasciae orbitales, Fascias of the orbital cavity (see also Figs. 853, 855, 856, 861—865 and 867). The eyeball with the exception of the corneal portion, is directly ensheathed by a connective tissue membrane *fascia bulbi* [Tenoni] (*Tenon's capsule*) which in turn is again directly connected with the surrounding fat. This capsule has a lamellar structure and is relatively firm and of somewhat variable thickness. It is united everywhere with the sclera and the tendons of the eye-muscles (vide infra) by delicate reticular tissue, the communicating meshes of which are spoken of as the *spatium interfasciale* [Tenoni] (*Tenon's space*). The capsule is continuous in front with the conjunctiva bulbi and conjunctiva palpebrarum, behind it ends, very much thinned at the point of entrance of the optic nerve (a little removed from it laterally). The tendons of the eye-muscles pass through slits in the capsule to the bulbus. Each eye-muscle is surrounded in the anterior half by a fascia, *fascia muscularis*, which becomes gradually thicker passing forward and which appears as a tubelike process of the fascia bulbi; this fascia ensheaths in front a continuation of Tenon's space, and somewhat behind the point of passage of the tendon through the fascia bulbi, is firmly united with the muscle (see Fig. 865). Tenon's capsule is attached in front by expanding bands lateralward to the lateral orbital wall, medially to the fascia situated behind the pars lacrimalis m. orbicularis oculi and besides near the tendon of the m. obliquus superior to its trochlea. Tenon's space projects in front as far as beneath the conjunctiva bulbi.

The orbital cavity is lined by a tolerably thin periosteum known as the *periorbita*; this is connected behind with the dural sheath of the n. opticus (see p. 771) partly closes the fissurae orbitales and goes over in front into the periosteum of the bones of the face; in the fissura orbitalis inferior it contains the thin m. orbitalis (not illustrated) consisting of smooth muscle fibers and also similar isolated bundles in other places. The space about the eyeball, the optic nerve, the muscles and the lachrymal gland is filled up by fatty connective tissue, *corpus adiposum orbitae*, *fat body of the orbital cavity*, through which the vessels and nerves run.

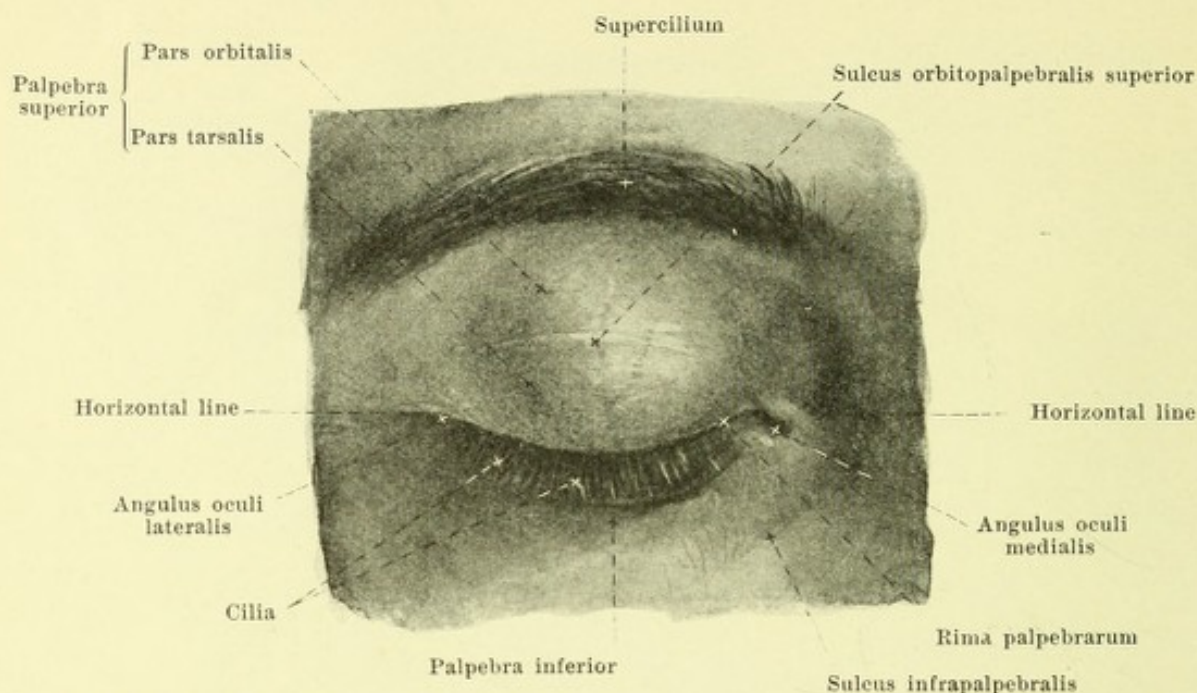


867. Right septum orbitale, viewed from in front. Magn. 4:3.

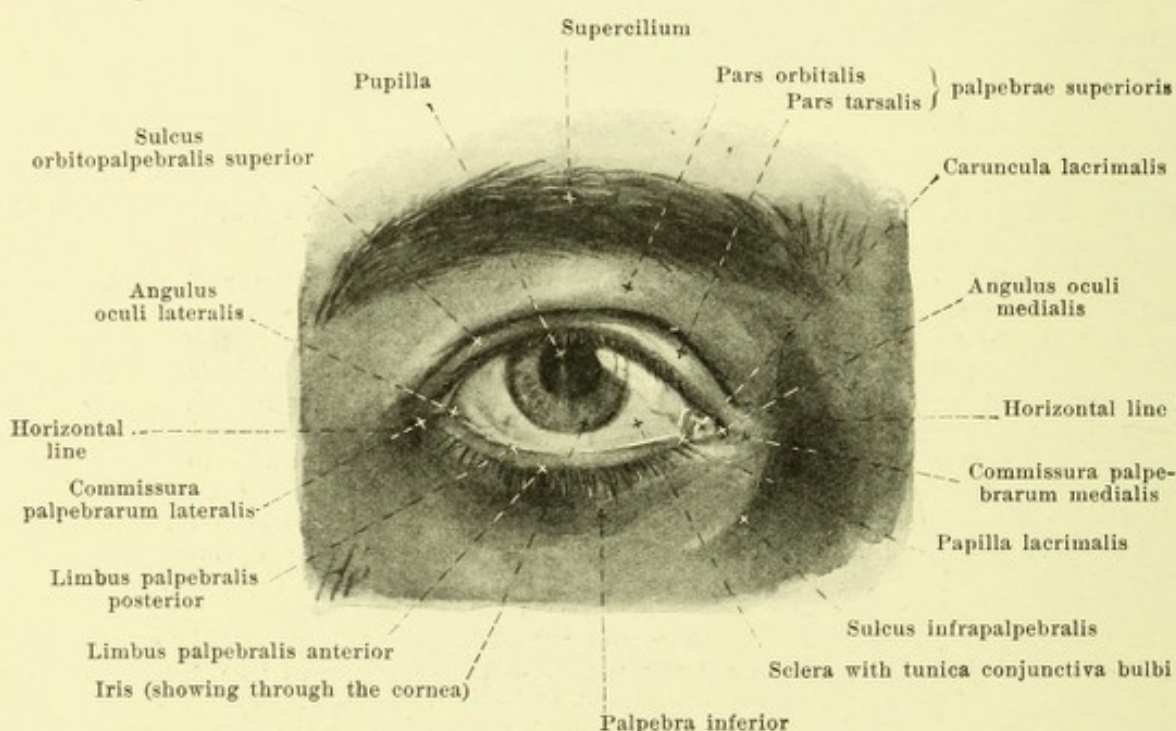
(The m. orbicularis oculi has been dissected off.)

The orbital cavity is bounded in front toward the eyelids by a layer of fascia, *septum orbitale* (see also Figs. 866 and 872) which is fastened to the aditus orbitae and stretches out into the lids. In the upper lid it coincides with the anterior expansion of the m. levator palpebrae superioris and, united with it, passes downward behind the m. orbicularis oculi, being intimately united with the anterior surface of the tarsus; in the lower lid it runs isolated in a corresponding way. The septum therefore lies in front of the conjunctival sac. Above it arises from a narrow tough marginal strip of connective tissue fastened to the margo supraorbitalis which transforms the incisurae supraorbitalis and frontalis into canals; medianward its attachment lies behind the crista lacrimalis posterior (therefore also behind the pars lacrimalis m. orbicularis oculi). The septum is not everywhere of the same thickness, being most powerfully developed at the upper circumference while at the lower it is very delicate and sometimes perforated by fat lobules; it is also very thin upon the tarsi.

Palpebrae, eyelids (see Figs. 865, 866, 868—873), are two folds of the external skin, which are shoved in front of the anterior surface of the eyeball until they touch with their free margins, one from above, *palpebra superior*, and one from below, *palpebra inferior*. The upper eyelid is somewhat larger than the lower. The boundary of the upper eyelid above is to be seen in the *eyebrow, supercilium*; this is a ridge, convex upward, running at the level of the margo supraorbitalis; it is thickly studded with stiff hairs directed in general lateralward; the position and size of the eyebrows varies greatly, and so does the color. The lower eyelid is indistinctly bounded below by a gutter-like groove, *sulcus infrapalpebralis*, which begins medial from the inner angle of the eye, passes lateralward and downward and ends somewhat above the level of the margo infraorbitalis. In old age the groove becomes deeper and there is added to it a furrow ascending to the lateral angle of the eye. The free margins of the eyelids which bound the *lid-slit, rima palpebrarum*, have each an anterior and a posterior sharply or (especially in front) slightly blunted edge, *limbus palpebralis anterior* and *posterior*; at the lateral and medial ends of the lid-slit they go over into one another at the *commissura palpebrarum lateralis* and *medialis* and with these bound the lateral and medial angles of the eye, *angulus oculi lateralis* and *medialis*.

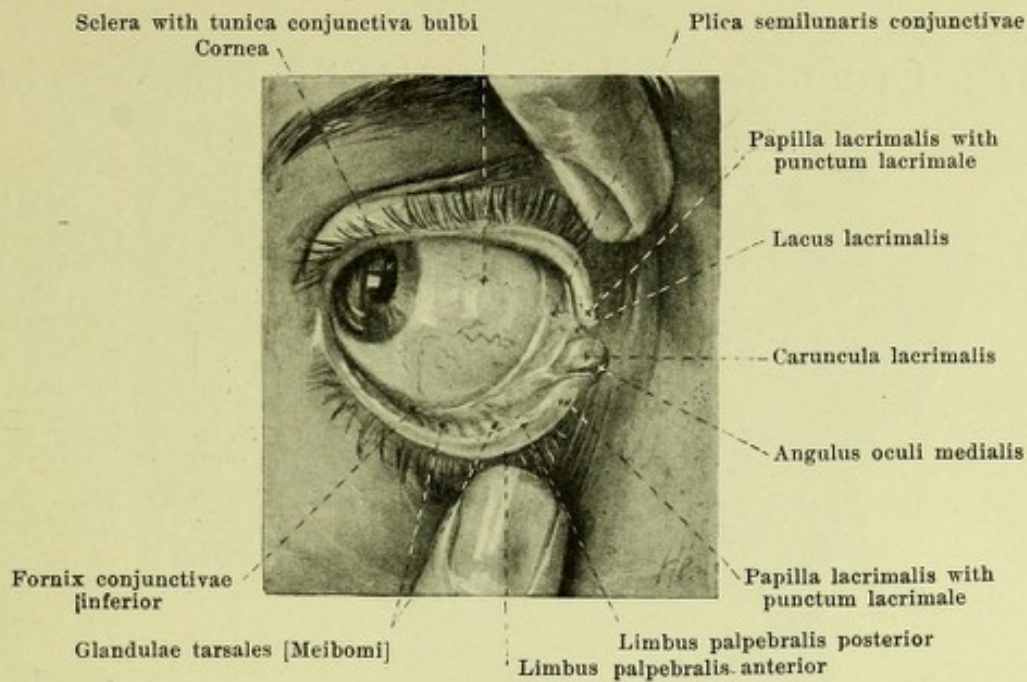


868. Right eye, closed, of a twenty-year old girl, viewed from in front.

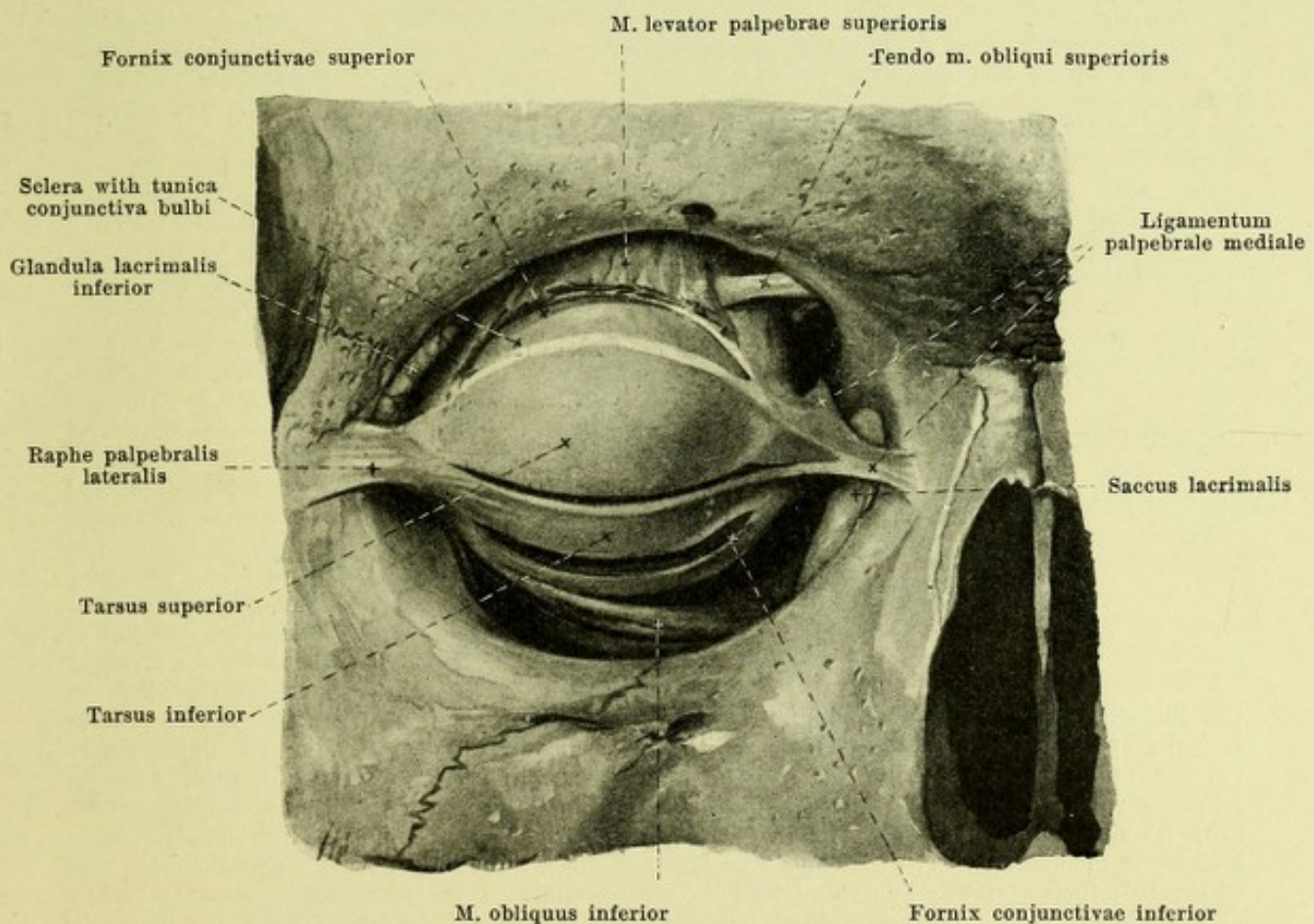


869. Right eye, open, of a twenty-year old girl, viewed from in front.
(The horizontal lines in Figs. 868 and 869 correspond to one another.)

Palpebrae (continued) (see also Figs. 865, 866, 870—874). The *angulus oculi lateralis* is acute; the *angulus oculi medialis* is situated somewhat deeper, is a rounded evagination of the lid-slit and surrounds the *lacrimal lake*, *lacus lacrimalis*. When the lids are open, a small club-shaped elevation of the conjunctiva, *caruncula lacrimalis*, is visible and lateral from it a sickle-shaped fold of the mucous membrane, *plica semilunaris conjunctivae*, concave lateralward, passes from the fornix superior to the fornix inferior of the conjunctiva. The lacrimal lake reaches laterally as far as a small cone-shaped elevation of the eyelid, *papilla lacrimalis*, upon the apex of which is directed somewhat backward, the lacrimal tubule begins as a punctate opening, the *punctum lacrimale*, somewhat larger in the lower lid than in the upper.



870. Right eye, with lids forcibly pulled apart, of a twenty-year old girl, viewed from in front. (The eyeball has been turned to the right.)

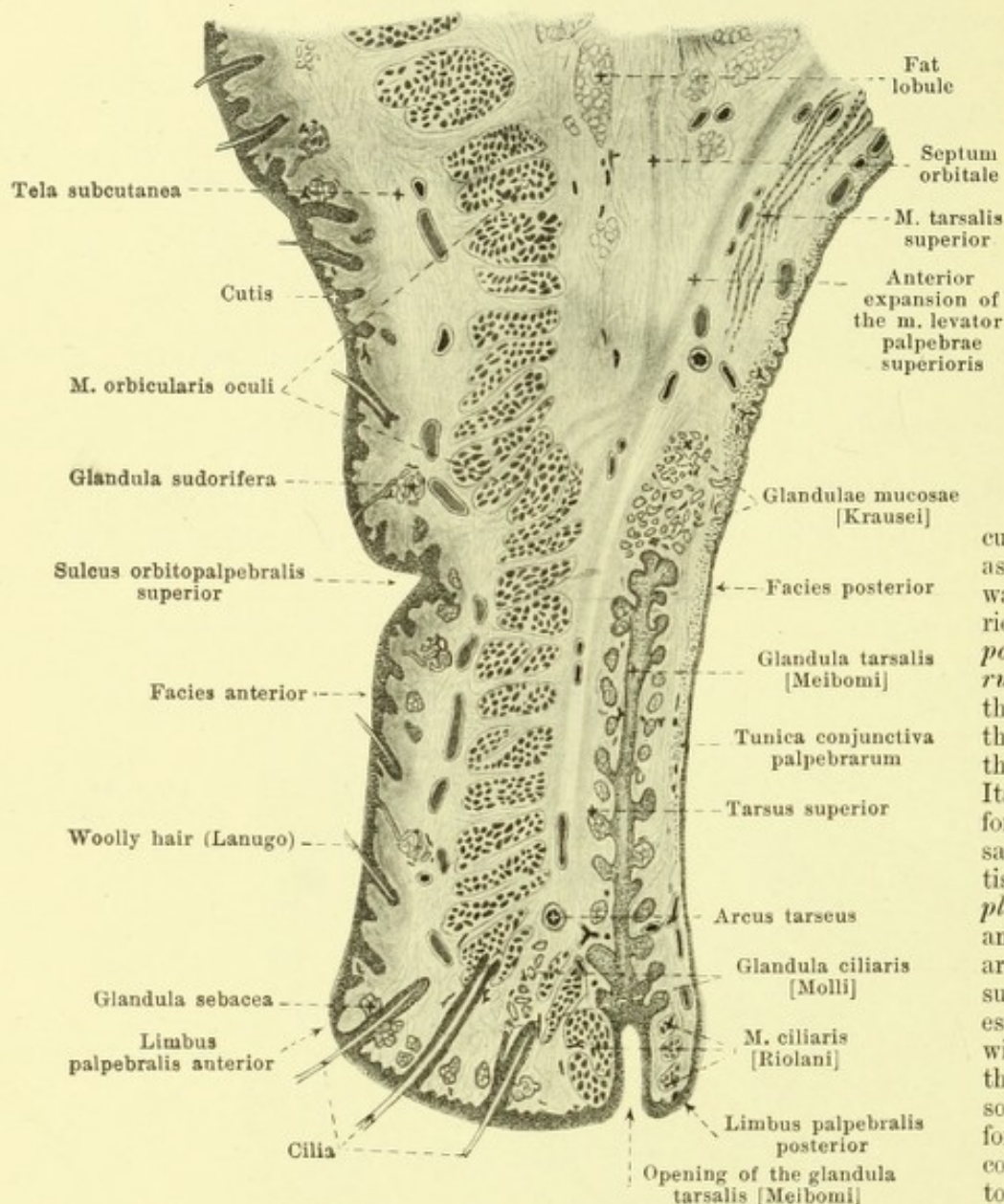


871. Lid plates of the right eye, dissected out, viewed from in front. Magnification 4:3.

(The lid-plates and the eye-muscles have been dissected out; the insertion of the m. levator palpebrae superioris has been removed, and the conjunctival sac has been opened from in front above and below the lid-plates.)

872. Cross section through the upper eyelid

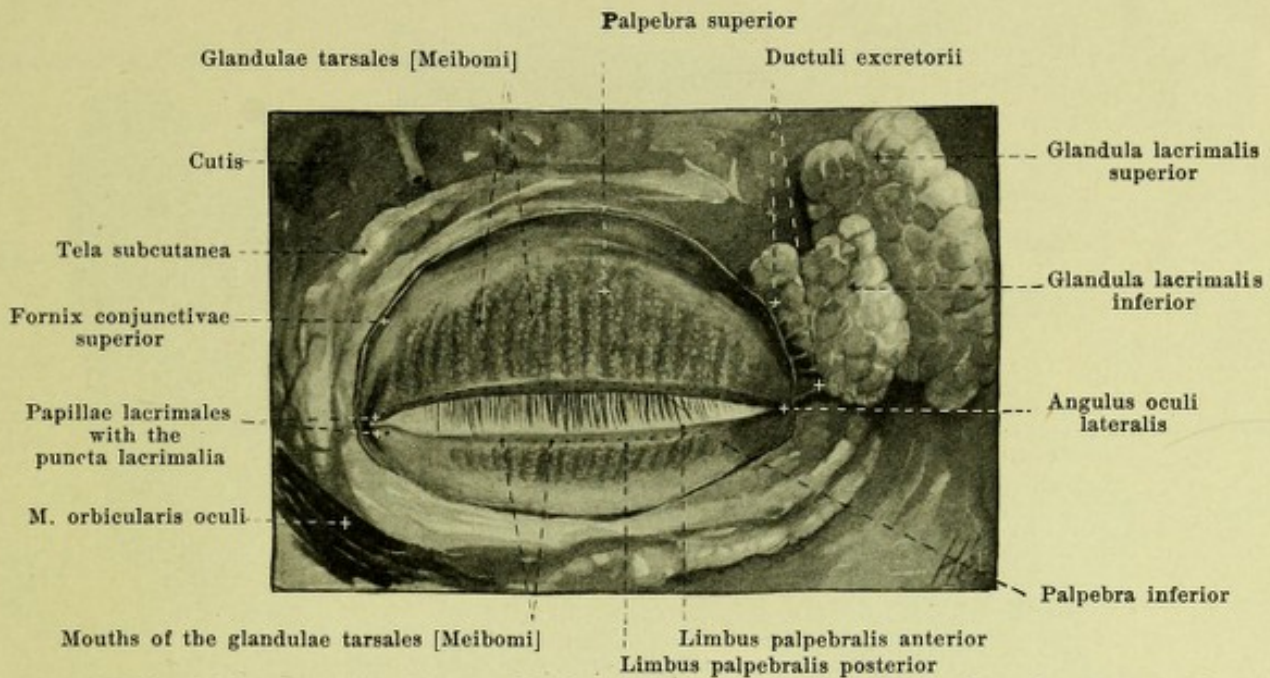
(after H. Sattler). Magnification 14:1.

**Palpebrae**

(continued) (see also Figs. 865, 866, 870, 871 and 873). The *rima palpebrarum* when the lids are open is bi-convex and presents marked individual variations. When the lids are closed, it is a curved slit, convex below, which passes below a horizontal line drawn through the two angles of the eye.

The eyelid is curved saucer-like so as to be convex forward and on its posterior surface, *facies posterior palpebrarum*, is separated from the eyeball only by the slit-like space of the conjunctival sac. Its firm foundation is formed by a tough, saucer-like connective tissue disc, the *lid-plate, tarsus superior and inferior*, which are united with the surrounding tissue and especially intimately with the conjunctiva; these discs are curved so as to be convex forward and present a convex margin turned toward the insertion of the lid and a straight margin reaching to

the lid-slit. At their medial, blunter angles, they are continuous with the *lig. palpebrale mediale*, at their lateral sharper angles, with the *raphe palpebralis lateralis*; the upper disc is twice as high as the lower. In the substance of the lid-plates lie the *glandulae tarsales [Meibomi]*, in the upper lid 30—40, in the lower lid 20—30, usually closely crowded into a row, running approximately vertically through the whole height of the lid-plate (see also Fig. 873); on account of their richness in fat they show through yellowish upon the back side of the lid; their excretory ducts end by punctate openings on the free margin near the *limbus palpebralis posterior*. Their secretion, *sebum palpebrale*, is rich in fat. To the upper margin of the tarsus superior is attached the posterior tendinous expansion of the *m. levator palpebrae superioris* and the *m. tarsalis superior* (see p. 786), to the lower margin of the tarsus inferior, the *m. tarsalis inferior* (see Fig. 866), a bundle of smooth muscle fibers which passes out from the region of the *fornix conjunctivae inferior*.

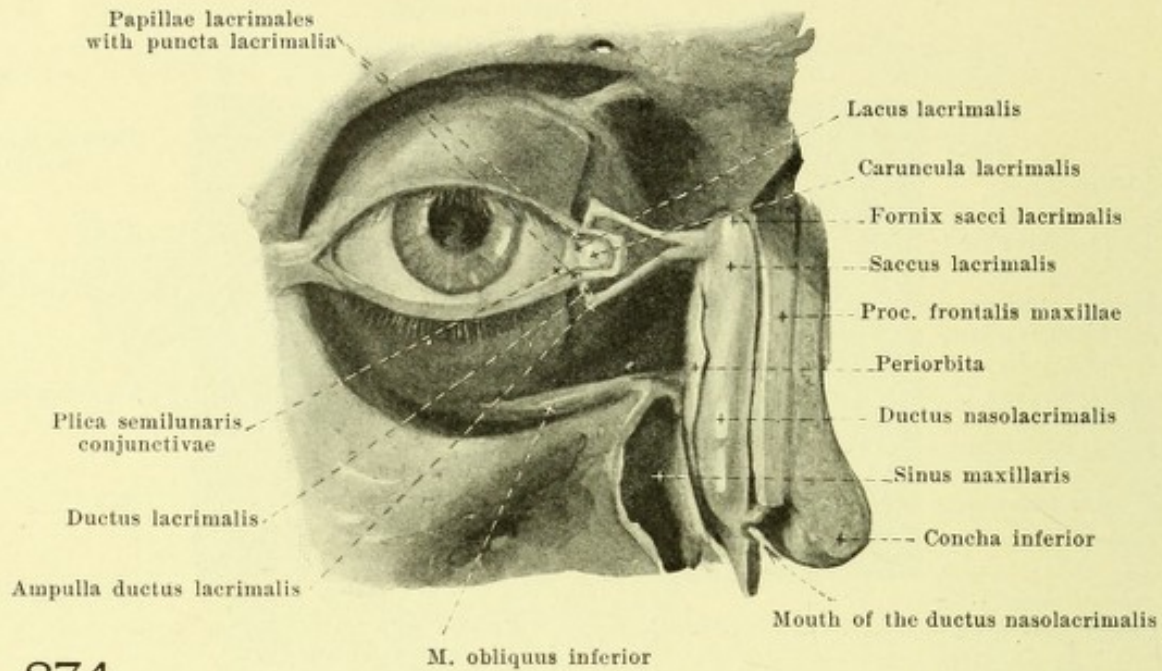


873. Lids of the right eye with the lachrymal glands, viewed from behind.

(The lids have been loosened from the subjacent tissue; the muscle has been for the most part dissected off.)

Palpebrae (continued) (see also Figs. 865, 866, 870—872). The anterior surface of the eyelids, *facies anterior palpebrarum*, is formed by the external skin which goes over at the free margin of the lid, directly into the tunica conjunctiva palpebrarum; it is delicate and devoid of fat, and presents many fine, transverse wrinkles, in middle and advanced age also numerous vertical folds. In the region of the lidplate, *pars tarsalis palpebrae*, it is firmly united with the subjacent tissue, in the other part, *pars orbitalis palpebrae*, more loosely. The junction between these two portions is formed in the upper lid by the *sulcus orbitopalpebralis superior* (see Figs. 868 and 869) a curve which is deep when the lid-slit is open and above which the *pars orbitalis* projects, and to which the tendon fibers of the *m. levator palpebrae superior* are attached; in the lower eyelid a feeble corresponding furrow, *sulcus orbitopalpebralis inferior*, is visible in the medial half only (see Figs. 868 and 869, not designated). Beneath the loose subcutaneous connective tissue the *m. orbicularis oculi* spreads out (see p. 243) bundles of which directly adjacent to the lid-slit (*m. ciliaris [Riolani]*, see Fig. 872) run between the excretory ducts of the glandulae tarsales, the hair follicles of the eyelashes and the glandulae ciliares [Molli]. The *eyelashes, cilia*, appear on the free margin of the lid and behind the limbus palpebralis anterior; they are arranged in three rows and stand closely together and are more numerous (100—150) in the upper lid than they are in the lower (50—75); they are stiff, directed obliquely downward in the upper lid, obliquely upward in the lower lid, and so curved that the convexity of the upper is turned toward that of the lower. The eyelashes possess *glandulae sebaceae, sebaceous glands*, like other hairs and usually receive the mouths of the *glandulae ciliares [Molli]*, modified sweat glands (see Fig. 872). The posterior surface of the lid is covered by the *tunica conjunctiva palpebrarum* (vide infra).

Conjunctiva, connecting membrane, (see also Figs. 835, 837, 855, 866, 869—872) is a mucous-membrane-like continuation of the external skin which lines the posterior surface of the lids as the *tunica conjunctiva palpebrarum*, then, forming the upper and lower transition folds, *fornix conjunctivae superior* and *inferior*, it passes over upon the anterior surface of the sclera and extends on in front of the latter as the *tunica conjunctiva bulbi* (see pp. 773 and 774) as far as the cornea; thus when the lids are closed it forms a closed sac, the *conjunctival sac*, the anterior wall of which is formed by the lids and the posterior wall by the eyeball (see also p. 794). The tunica conjunctiva palpebrarum upon the tarsus is firmly united with the subjacent tissue and studded with minute depressions; above the tarsus it is more loosely attached and when the lid is open, presents coarse concentric folds. Small mucous glands, *glandulae mucosae [Krausci]* which are to be looked upon as accessory lachrymal glands occur on the fornix conjunctiva and in the upper margin of the tarsus superior. Some lymph nodes, *noduli lymphatici conjunctivales*, not always distinctly defined, are also present in the fornix and its neighborhood under normal conditions.



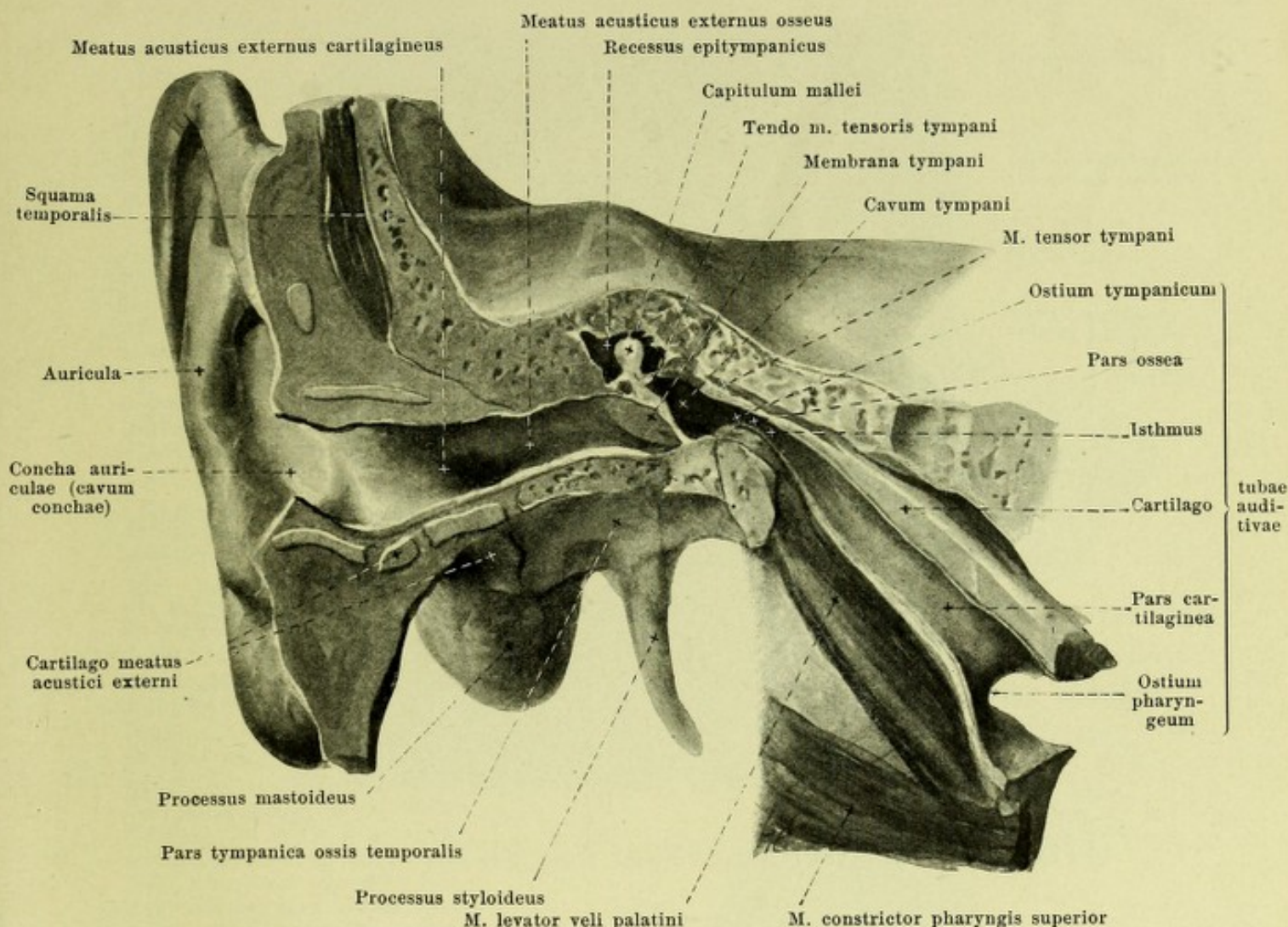
874.

Lachrymal canals of the right eye, viewed from in front.

(The lid-plates have been separated medianward, the lig. palpebrale mediale has been removed, and the canalis nasolacrimalis opened.)

Apparatus lacrimalis, lachrymal apparatus, consists of the *lachrymal gland*, and of the lachrymal canals, namely, *ductus lacrimales*, *saccus lacrimalis* and *ductus nasolacrimalis*. The *lachrymal gland* (see Figs. 853, 855, 861, 864, 871 and 872) is of a reddish grey color and consists of an upper and lower part which are separated from one another by the tendinous expansion of the *m. levator palpebrae superioris*. The upper part, *glandula lacrimalis superior*, is oval in shape and varies somewhat in size; it lies directly under the periorbita, in the fossa glandulae lacrimalis of the frontal bone, and is attached there by laminae of connective tissue; it reaches lateralward as far as the suture between the frontal and zygomatic bones. The lower smaller part, *glandula lacrimalis inferior*, is more loosely constructed and reaches downward as far as the fornix conjunctivae superior and the lateral angle of the eye. Its *excretory ducts*, *ductuli excretorii [glandulae lacrimalis]*, consist of approximately twelve delicate tubules which open in the conjunctival sac, just in front of the fornix, the lowermost and largest at the level of the lateral angle of the eye (see Fig. 873); the ducts of the upper gland perforate the lower gland.

The *tears, lacrimae*, moisten the free surface of the eyeballs and when the lids are closed, can run medianward in a narrow triangular slit, *rivus lacrimalis*, which remains open between the anterior surface of the bulbus and the free margins of the lid. They pass into the lacus lacrimalis and thence through the puncta lacrimalia (see p. 794) into the *ductus lacrimales, lachrymal tubules*. These are two thinwalled canals, about 10 mm long, which run at first for a short distance vertically (and somewhat medially); they then turn medianward and grasp the lig. palpebrale mediale between them, and open, finally, into the tear sac, usually separately, more rarely by a common terminal portion; at the bend of each duct is a small pear-shaped dilatation, *ampulla ductus lacrimalis*. The *tear sac, saccus lacrimalis*, (see also Figs. 867, 871), is a canal, closed above like a blind sac, which goes over below without boundary, into the ductus nasolacrimalis and above receives the lachrymal ducts laterally. It fills up the fossa sacci lacrimalis completely, but projects with its pointed cupola, *fornix sacci lacrimalis*, not at all or only slightly beyond the *lig. palpebrale mediale*, which stretches out as an arch from the crista lacrimalis posterior to the proc. frontalis maxillae and is fused with the wall of the tear sac by means of loose tissue. Laterally the tear sac is also covered by the periorbita which is stretched out between the cristae lacrimales. Its lumen is a sagittally placed slit. The *nasolachrymal duct, ductus nasolacrimalis*, a membranous canal filling up the canalis nasolacrimalis, is narrowest at the upper end of the bony canal and possesses a wider lumen than the tear sac. Its mucous membrane often shows small folds and pockets. It opens in the lower nasal meatus by passing obliquely through the mucous membrane, usually by a longitudinally oval slit; the lip of mucous membrane which guards this opening above, is called the *plica lacrimalis [Hasneri]* (see Fig. 924).



875. General view of the right external ear and middle ear, looked at from in front and externally.

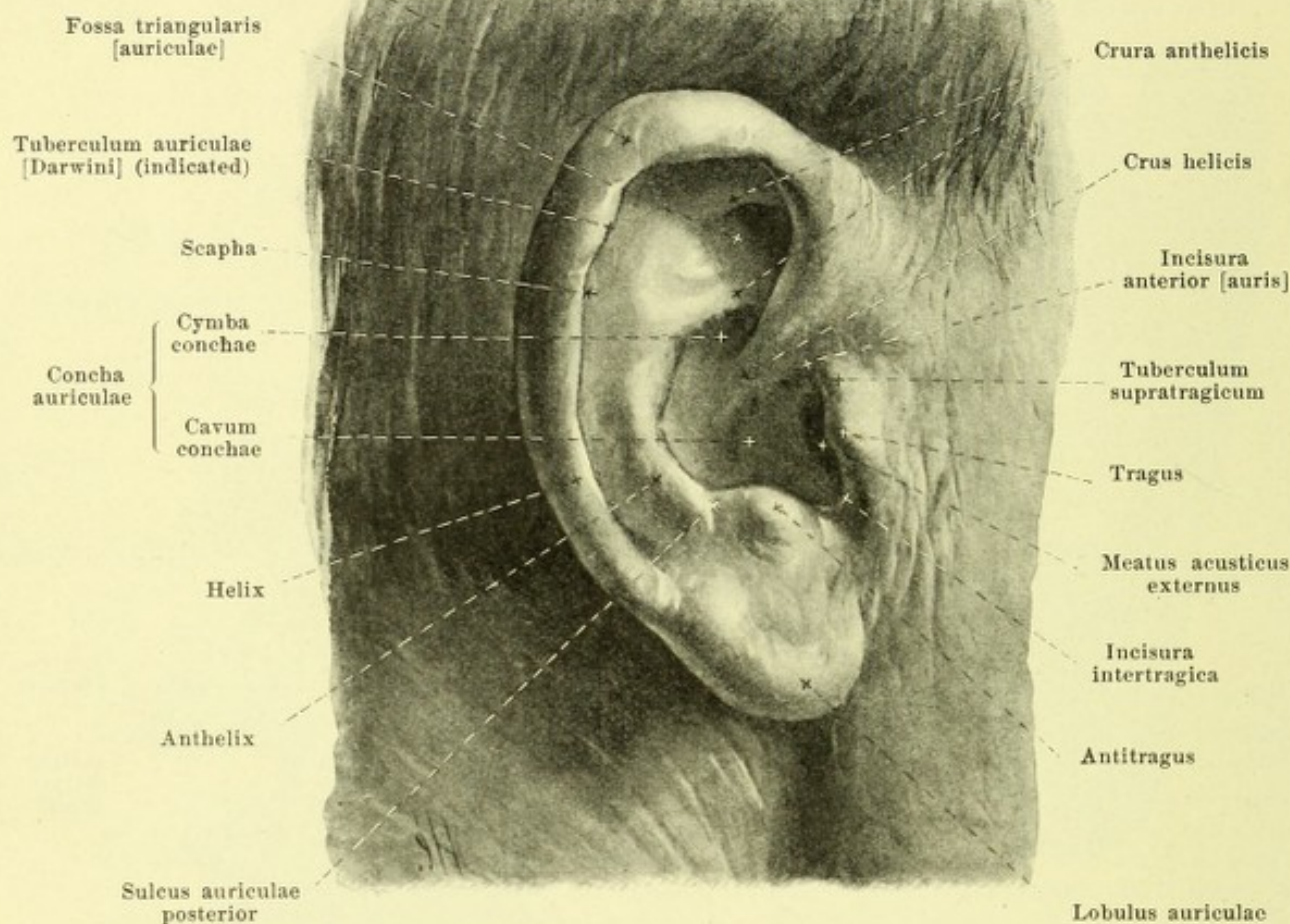
(The external ear has been opened by a frontal section; the tympanic cavity and Eustachian tubes have been opened by a vertical section carried obliquely lateralward and dorsalsward.)

Organon auditus, *organ of hearing*, is divisible into the *external ear*, *auris externa*, the *middle ear*, *auris media*, and the *internal ear*, *auris interna*.

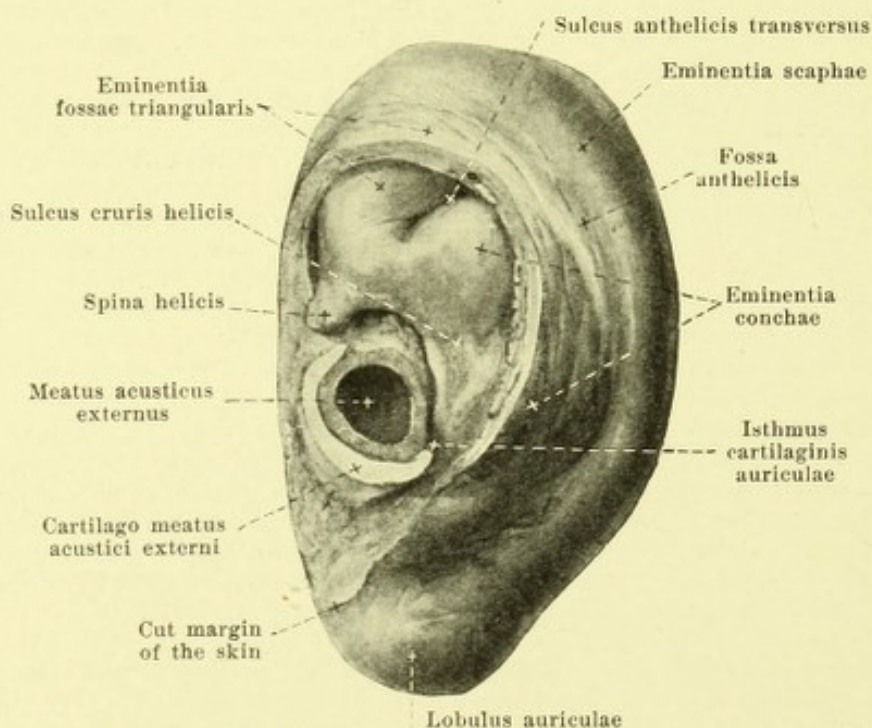
Auris externa, *external ear* (see also Figs. 876—883) is formed of the ear proper, auricle, and the external auditory canal, meatus acusticus externus.

The *auricula*, or *outer ear proper* (see also Figs. 876—883) is an oblong, flat fold of skin, in general irregularly shell-shaped, which surrounds the opening of the external acoustic canal; it is approximately twice as long as broad, and is bent in and out in different directions, but so that its lateral surface is essentially concave while its medial surface, turned toward the skull, is convex. It contains within it the *ear cartilage*, *cartilago auriculi*, consisting of elastic cartilage, which is chiefly covered only by thin skin and so determines the essential form of the auricle, but below it is somewhat shorter than this. The ear cartilage is continued in front and below directly into the cartilago meatus acustici externi (see Figs. 878 and 879) and together with it forms a half tube, open above; the posterior limb of the tube belonging to the ear cartilage is connected with the anterior limb formed by the cartilage of the acoustic canal and of the lamina tragi by a narrow intermediate piece, *isthmus cartilaginis auriculæ*, the lateral margin of which forms the deepest part of the *incisura intertragica* (see p. 805) and the medial margin of which helps to bound the corresponding medial notch between the two limbs, the *incisura terminalis*.

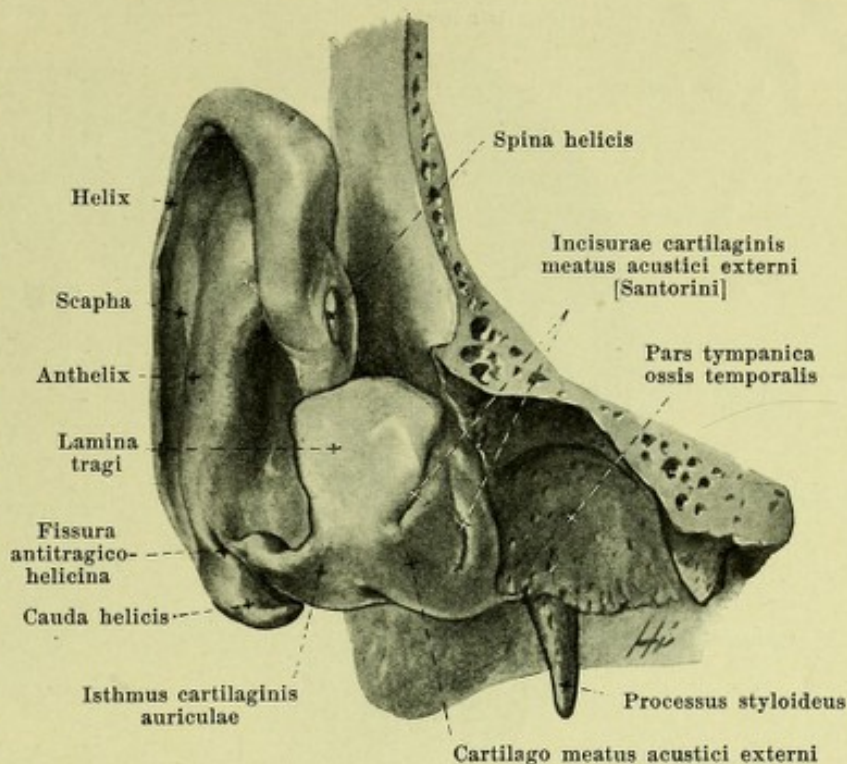
Helix



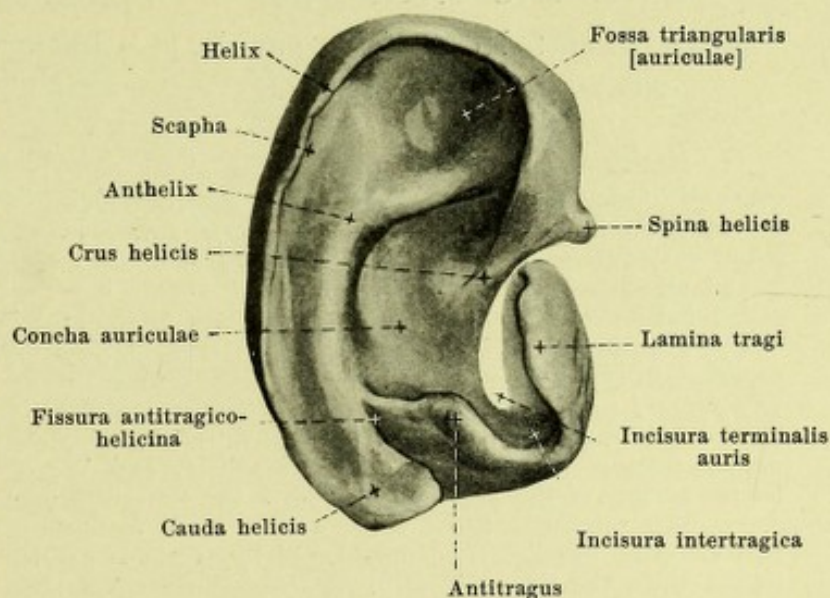
876. Right auricle, viewed from without (drawn from life).

877. Right auricle, viewed from within.
(The auricle has been removed from the head by a clean cut.)

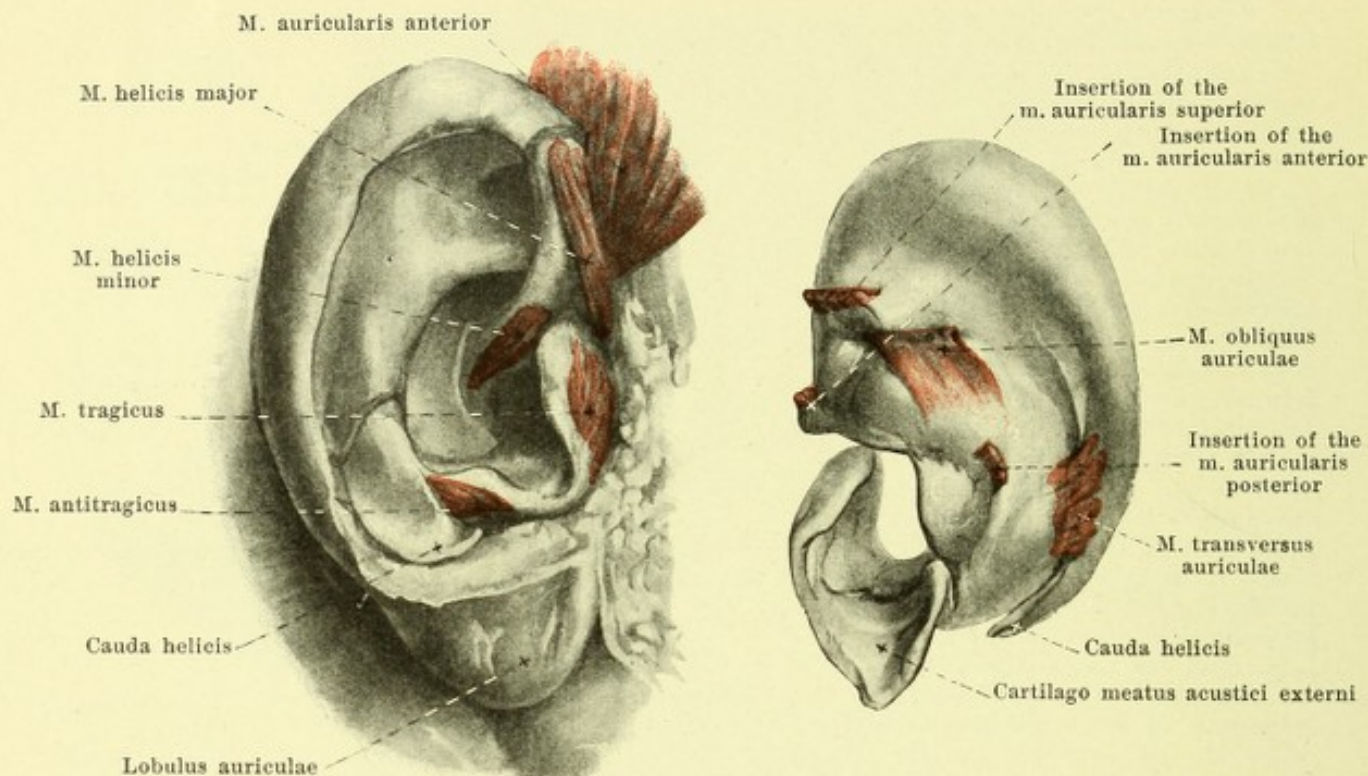
Cartilago auriculæ (continued) (see also Figs. 876, 877, 880—882). Its posterior and superior markedly curved margin, turned up outward, *helix* (ear border), arises from the cavity of the auricle by means of a slightly curved projection, *crus helices*, and at its anterior margin sends a small nodule, *spina helices*, forward and downward; below it ends in a plate, *cauda helices*, curved around forward, which is separated from the neighboring antitragus by a deep notch, *incisura antitragico-helicina*; its free, tolerably sharp edge often possesses, in the upper part of the posterior portion, a small process, *tuberculum auriculæ* [Darwini]. Running approximately parallel to the helix upon the lateral surface is an elongated, ridge *anthelix*; it begins in front and above under the helix by two limbs which converge behind, *crura anthelices*, which include between them a flat depression, *fossa triangularis auriculæ*; behind, it is separated from the helix by an elongated depression, *scapha*, and below it goes over into the antitragus, often insensibly, sometimes separated from it by a depression, *sulcus auriculæ posterior*. The lower part of the ear cartilage turns around near the cauda helices and forms a small triangular plate, projecting free upward, the *antitragus*, which is separated in front by a shallower or deeper notch, *incisura intertragica*, from the *lamina tragi*. This quadrangular disc of cartilage is the lateral part of the *cartilago meatus acustici* (see pp. 799 and 805) and forms the basis of the *tragus* of the auricle; it overlies the opening of the external acoustic canal like a valve in front, and not rarely presents on its upper part a small tubercle, *tuberculum supratragicum*. The deep depression between the anthelix, tragus and antitragus, is called the *concha auriculæ* and is incompletely divided by the *crus helices* into a smaller upper part, *cymba conchæ*, and a larger lower part, *cavum conchæ*, which leads in its anterior portion directly into the *meatus acusticus externus*. The projections present on the convex medial surface of the auricles correspond to the fossa-like depressions of the concave lateral surface, and are correspondingly designated, *eminentia fossæ triangularis*, *eminentia scaphæ* and *eminentia conchæ*.



878. Right ear cartilage, with its attachments to the bone, viewed from in front and externally.



879. Right ear cartilage, isolated, viewed from without.



880. Cartilage of right ear with the muscles,
partly dissected out of the auricle,
viewed from the outside.

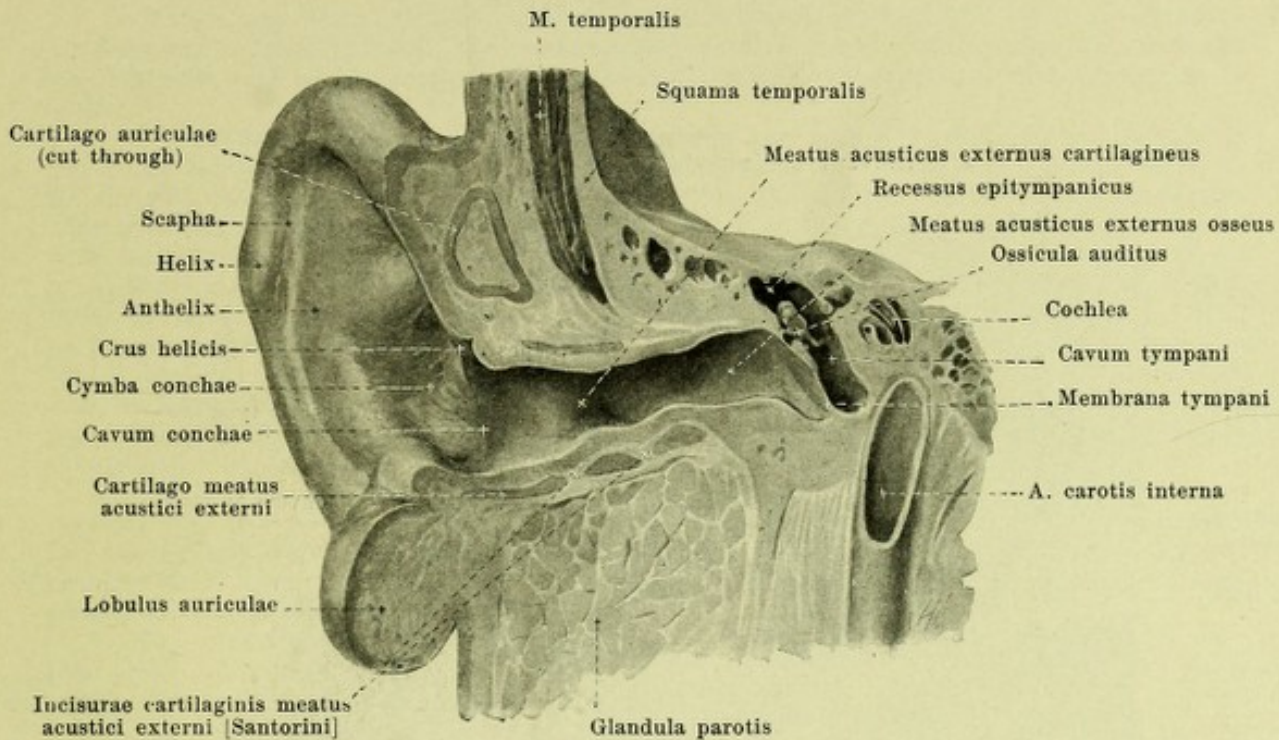
881. Cartilage of right auricle, isolated, with the muscles,
viewed from the inside.

Cartilago auriculae (continued) (see also Figs. 877—879), medial, convex surface. The eminentia fossae triangularis is separated from the eminentia conchae by the *sulcus anthelicis transversus*; it corresponds to the lower crus anthelicis, and goes over arch-like, into the long *fossa anthelicis* which is directed downward and which causes the bulging of the anthelix on the lateral surface. Upon the surface of the eminentia conchae running approximately horizontally is the flat *sulcus cruris helix*, corresponding to the crus helix.

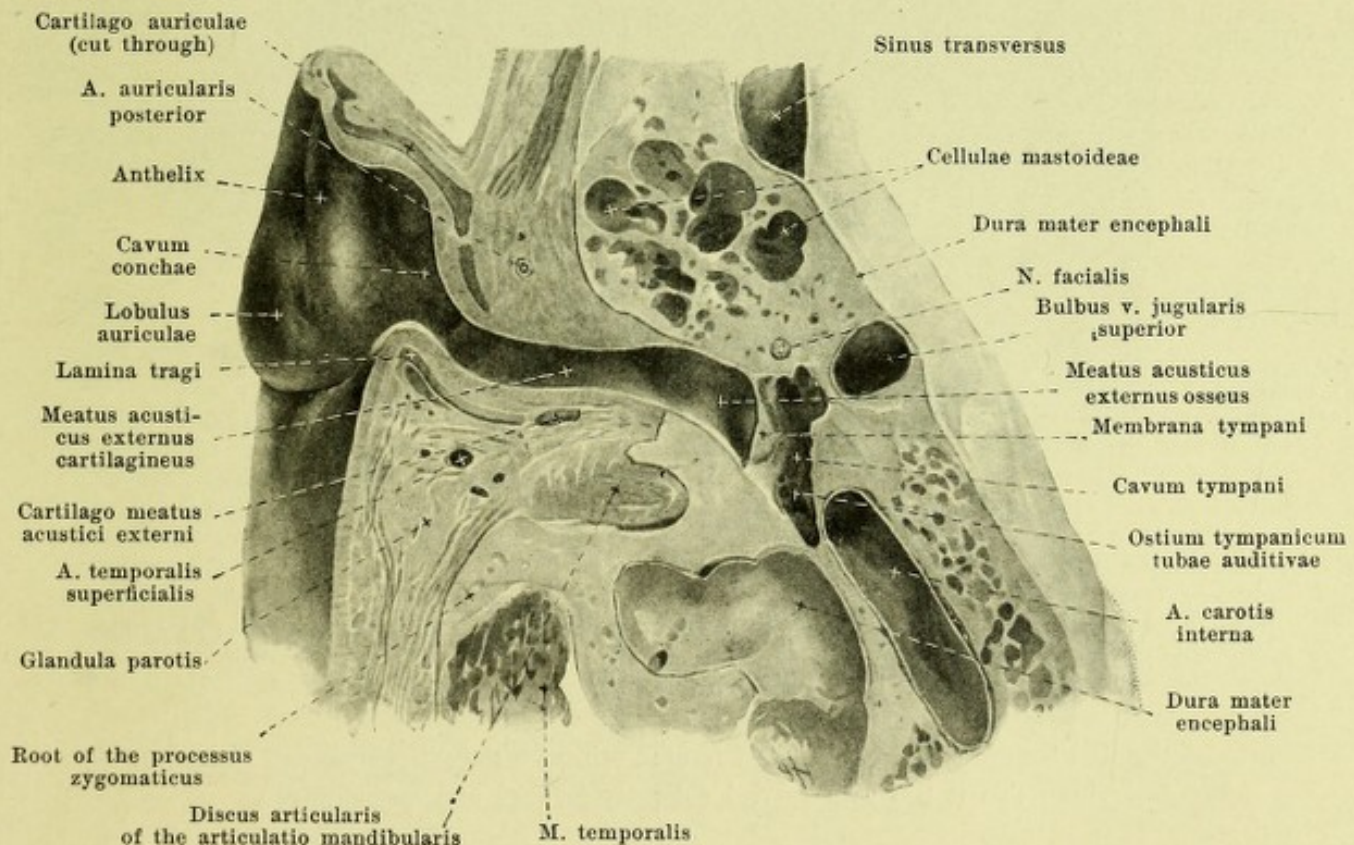
The cartilage of the auricle is fastened to the temporal bone by a more or less connected fiber mass in which are distinguishable three bands of fibers, *ligamenta auricularia* [*Valsalvae*] (not illustrated): the *lig. auriculare anterius* from the root of the zygomatic arch to the helix and lamina tragi, the *lig. auriculare superius*, from the upper margin of the porus acusticus externus to the spina helix, and the *lig. auriculare posterius*, from the lateral surface of the proc. mastoideus to the eminentia conchae.

The cartilage of the ear possesses small intrinsic muscles composed of striped fibers; they are pale, usually six in number, of very variable development, all innervated by the n. facialis. Upon the lateral surface: *m. helix major* from the spina helix upward to the helix; *m. helix minor* upon the crus helix; *m. tragus* upon the lamina tragi; *m. antitragus* upon the antitragus and partly to the cauda helix; these two are said to narrow the entrance to the external acoustic meatus. Upon the medial surface: *m. transversus auriculae*, horizontal, from the eminentia scaphae to the eminentia conchae; *m. obliquus auriculae*, vertical, from the eminentia fossae triangularis to the eminentia conchae.

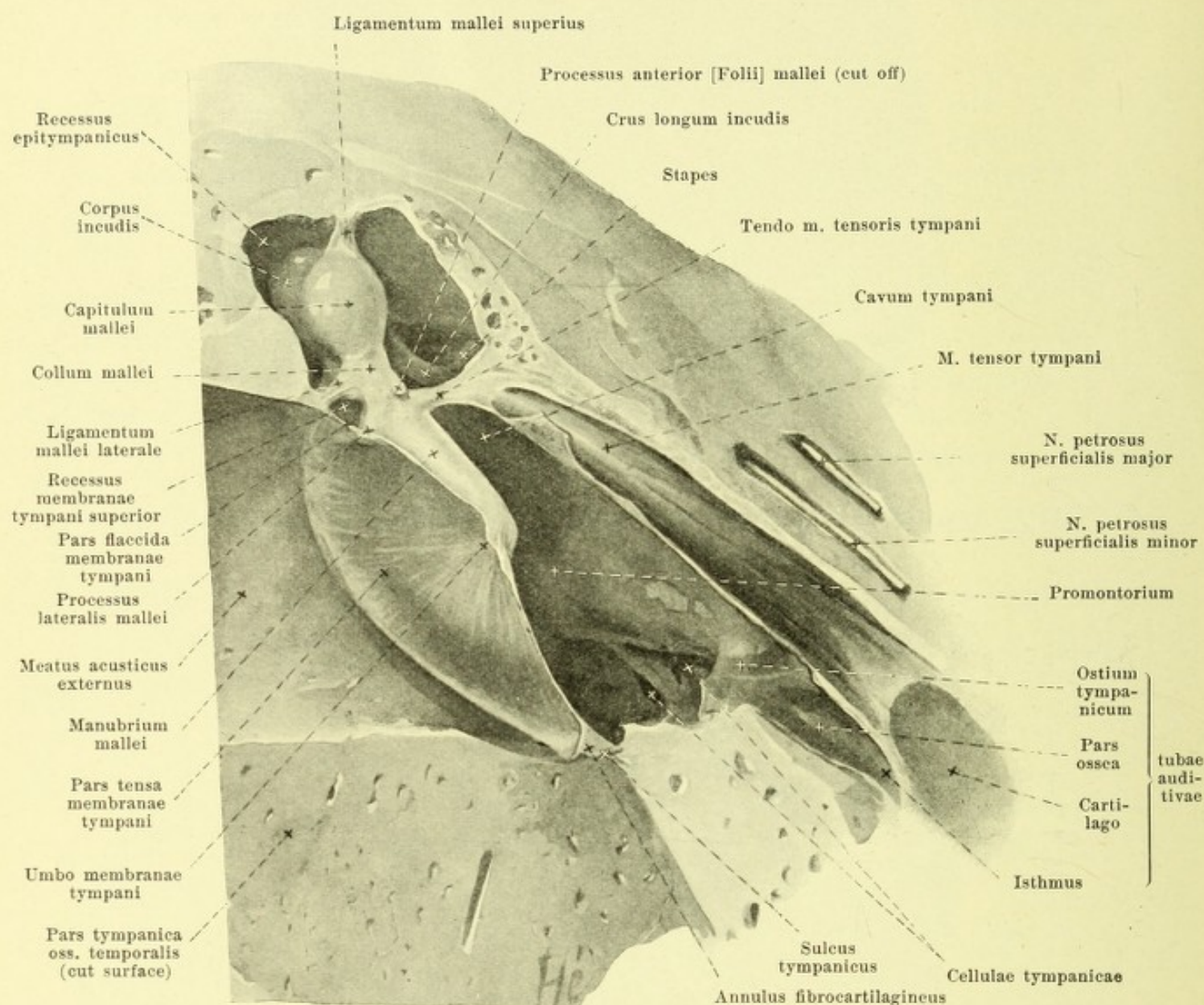
The *auricula*, *auricle* (see also Figs. 876, 877) (O. T. pinna), is completely covered by the skin on its lateral surface which bridges over the notch between the crus helix and lamina tragi and transforms it into a groove, *incisura anterior auris*, and is then continued into the skin of the cheek. On the medial surface the skin covers only the upper and posterior part of the ear cartilage when it curves around into the skin of the head. Below, the skin over the cauda helix and the antitragus forms a flat, rounded, fatty duplicature, *lobulus auriculae*, *lobule of the ear*, which hangs down and is very variable in different individuals.



882. Vertical section through the right external acoustic canal, viewed from in front.



883. Horizontal section through the right external acoustic canal, viewed from above.



884. Vertical section through the right ear-drum,
viewed from in front. Magnification 6:1.

(The section has been carried approximately frontally through the external acoustic canal; medial from this it has been carried obliquely forward and medianward.)

Meatus acusticus externus, external acoustic canal (see Figs. 875—879, 882—883) is divisible into a lateral portion, the *cartilaginous acoustic canal, meatus acusticus externus cartilagineus*, and medial part, the *bony external acoustic canal, meatus acusticus externus osseus*.

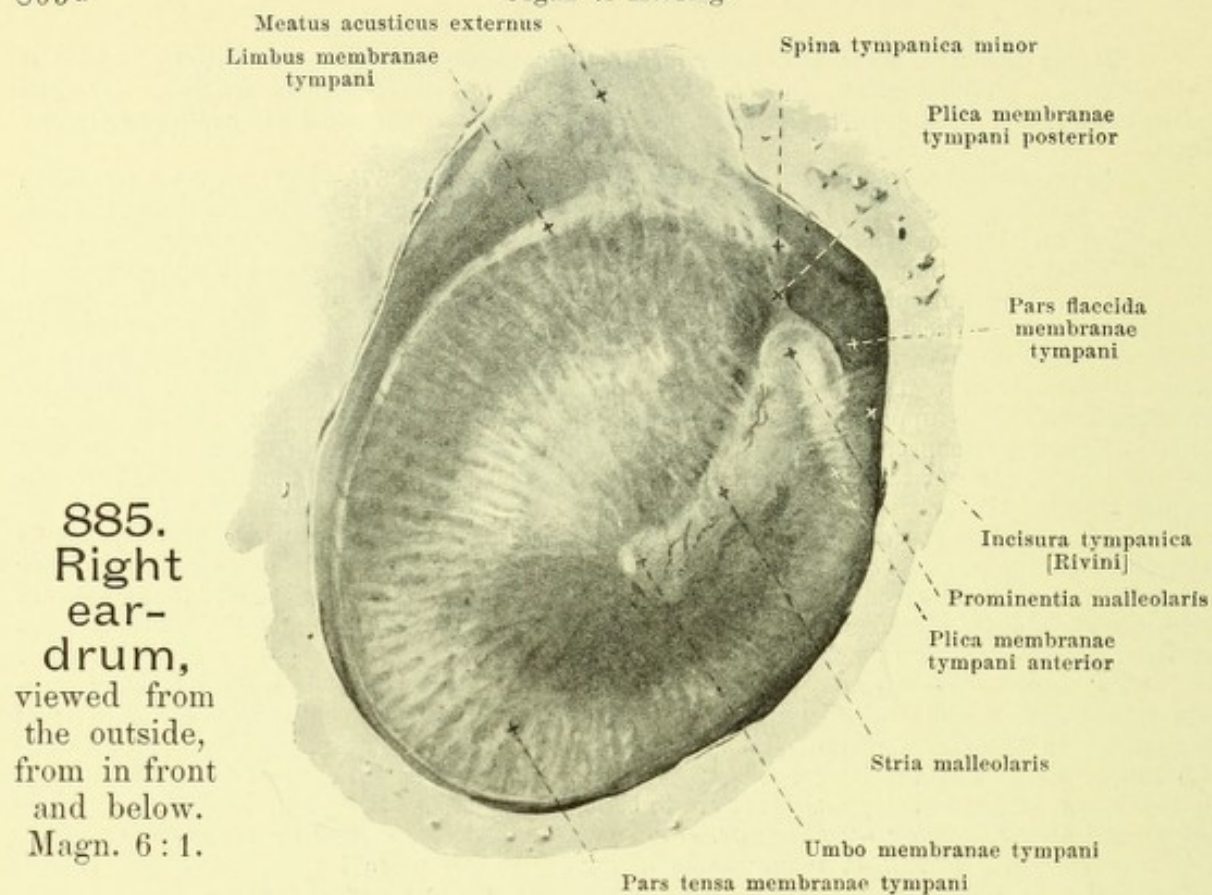
The *meatus acusticus externus cartilagineus* (see Figs. 875—884) begins laterally in the cavum conchae (see p. 801) and reaches medianward as far as the porus acusticus externus. Its anterior and inferior walls are formed by a groove-like cartilage, *cartilago meatus acustici externi*, which is continued laterally into the lamina tragi (see p. 805) and behind is connected with the cartilago auriculæ (see p. 799). This cartilago is usually interrupted in two places by approximately vertical slits, *incisurae cartilaginis meatus acustici externi* [Santorini], which are filled up by connective tissue; it is fastened in front and below firmly (see Fig. 878) to the posterior root of the proc. zygomaticus and to the lateral margin of the pars tympanica oss. temporalis. The upper and posterior somewhat shorter wall of the cartilaginous acoustic canal is formed by connective tissue plate which unites the upper margin of the cartilage with the cartilage of the ear and with the bone and is attached medially to the upper and posterior circumference of the porus acusticus externi (and to the spina suprameatum).

The *meatus acusticus externus osseus* belongs to the temporal bone (see p. 7); it begins laterally with the *porus acusticus externus* and possesses smooth walls of which the anterior and inferior are slightly convex towards the lumen and longer, the superior and inferior slightly concave and shorter. Medianward it ends in the *sulcus tympanicus* and the *incisura tympanica* [Rivini], (see p. 13 and Figs. 906 and 907).

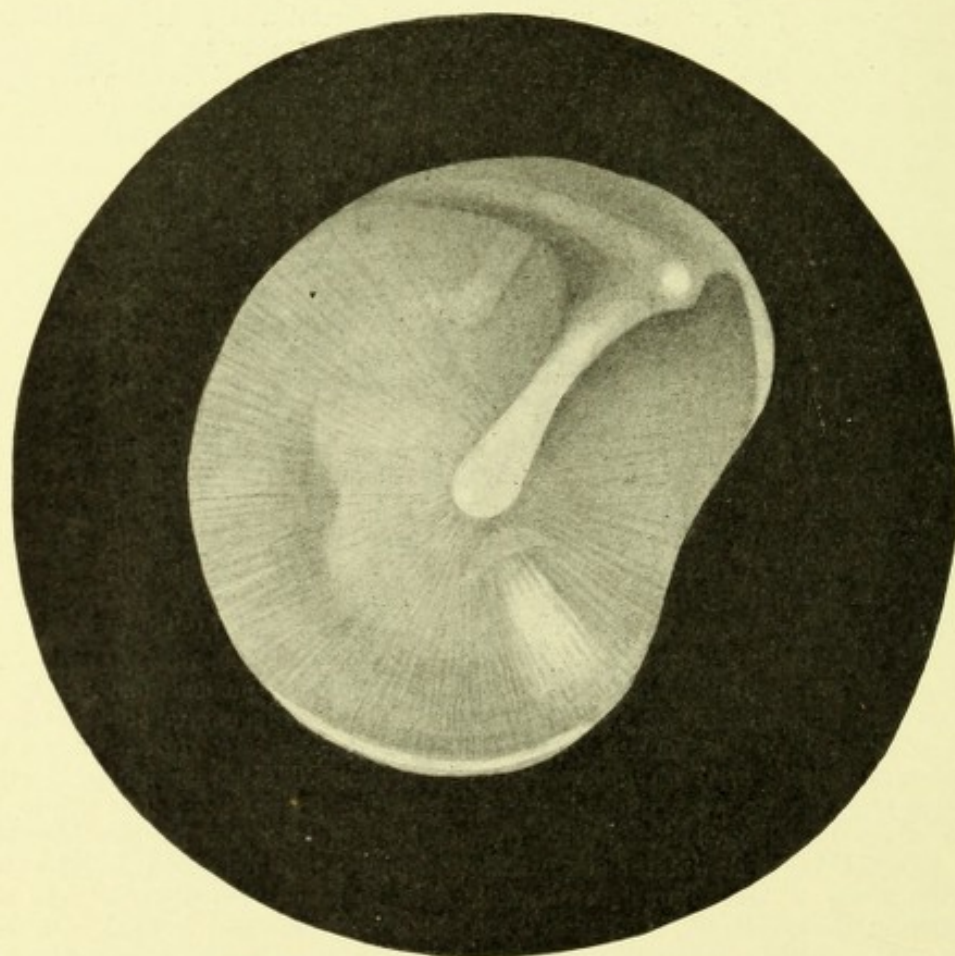
The *meatus acusticus externus* (see Figs. 875, 882 and 883) is lined internally by a thin perichondrium and periosteum and clothed by a blind sac-like continuation of the external skin, which in the region of the pars tympanica is very thin and inseparably united with the periosteum, and covers the lateral surface of the membrana tympani as an especially thin layer. In the region of the cartilaginous part are to be found numerous strong hairs, called *tragi* (ear-hairs) and the *glandulae ceruminosae, ear-wax glands*, which secrete the *cerumen, ear-wax*. The acoustic canal is subject to numerous individual variations in length, lumen and course. In general it is directed horizontally and frontally, but slightly curved like the letter S in a horizontal and vertical plane, so that in the horizontal direction it is curved laterally so as to be convex forward, and medially so as to be convex backward; in the vertical direction it is convex below laterally, and convex above medially. The lateral portion of the curvature belongs to the cartilaginous part and is longer than the medial. The lumen is irregularly oblong elliptical; its long axis stands approximately vertically lateralward and medianward approaches the horizontal; the narrowest part is the junction between the cartilaginous and the bony portion. The medial boundary is formed by the membrana tympani. It is due to the oblique position of the latter that the anterior and inferior walls of the acoustic canal are longer than the posterior and superior.

The *ear-drum membrane, membrana tympani* (see Figs. 875, 882—885, 887—889) is a very thin, smooth membrane, stretched out between the external acoustic canal and the cavity of the tympanum, separating these two from one another completely and thus separating also the outer ear from the middle ear. It is subject to marked individual variations in form, size and obliquity.

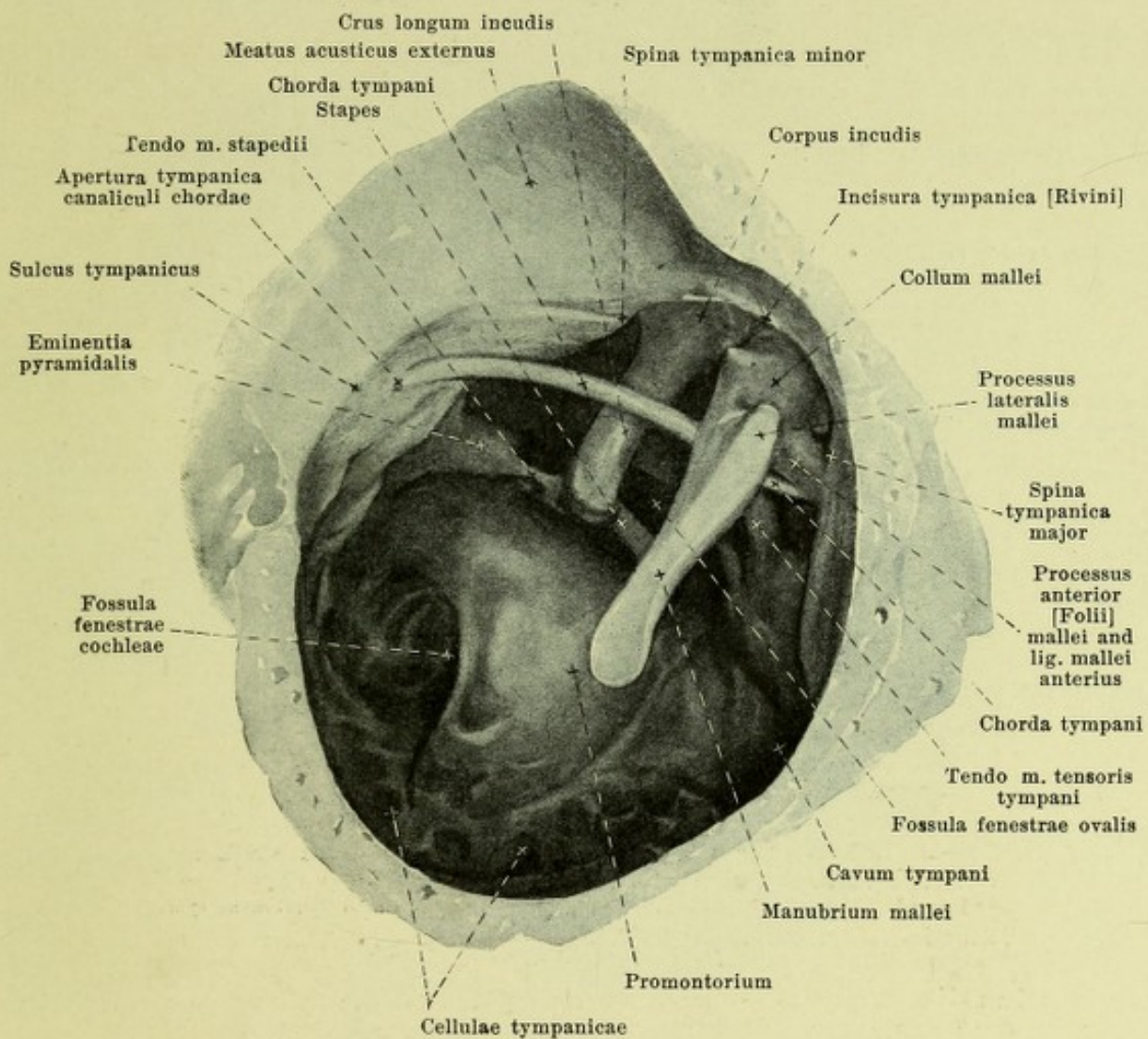
The membrana tympani is usually elliptical, sometimes quite oval and has a longitudinal diameter (obliquely from above and in front downward and backward) from 9—10 mm and a transverse diameter of 8—9 mm. It is stretched out in the sulcus tympanicus and in the incisura tympanica [Rivini] and is so inclined in the body that a plane passing through the sulcus tympanicus looks medianward, backward and upward; corresponding to this is the variable length of the walls of the external acoustic canal (see above). In the new-born, the incline is such that the membrana tympani stands almost horizontal. The small upper portion, situated within the incisura tympanica, is loose and is called the *pars flaccida*; it reaches downward as far as the button-like *prominentia malleolaris* pushed forward by the proc. lateralis mallei, and as far as two folds going out from the spinae tympanicae and converging toward this point, namely the shorter *anterior* and the longer *posterior ear-drum membrane folds, plica membranae tympani anterior* and *posterior*. The larger inferior portion of the membrana tympani is tightly stretched and is called the *pars tensa*; it is drawn in, so as to be funnel-shaped medianward, by the tip of the handle of the hammer imbedded in its substance, so that upon its lateral surface there occurs a flat depression, *umbo membranae tympani*; the walls of this funnel are curved so as to be convex outward. The umbo does not lie exactly in the middle but is displaced somewhat downward and forward. On the external surface one sees a whitish stripe, *stria malleolaris*, passing from the prominentia malleolaris to the umbo, due to the handle of the hammer situated there showing through; it runs obliquely from in front and above backward and downward.



885.
Right
ear-
drum,
viewed from
the outside,
from in front
and below.
Magn. 6:1.



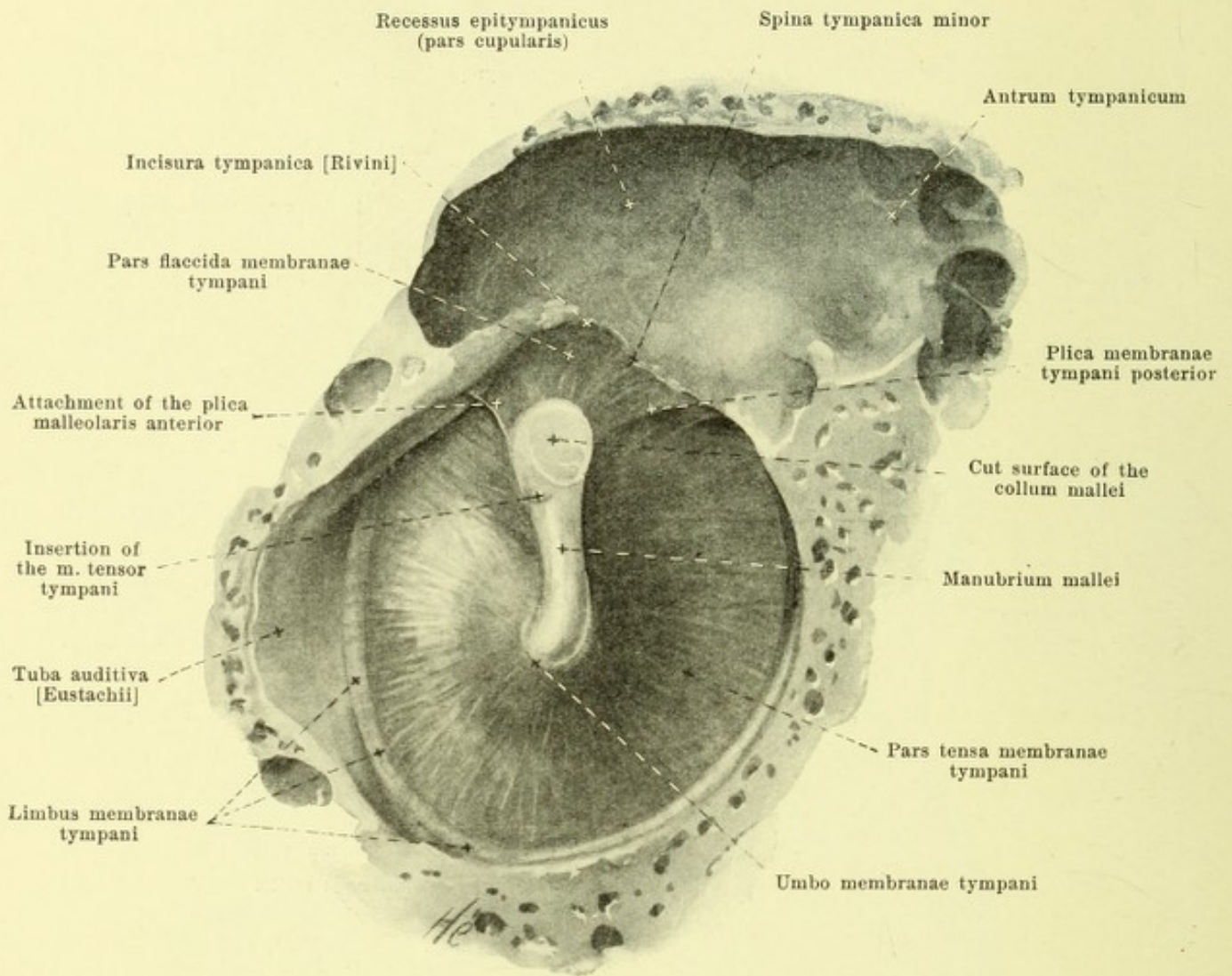
885^a. Right ear-drum
as viewed through speculum; from life (after O. Körner). Magn. ca. 6:1.



886. Small bones of right ear,

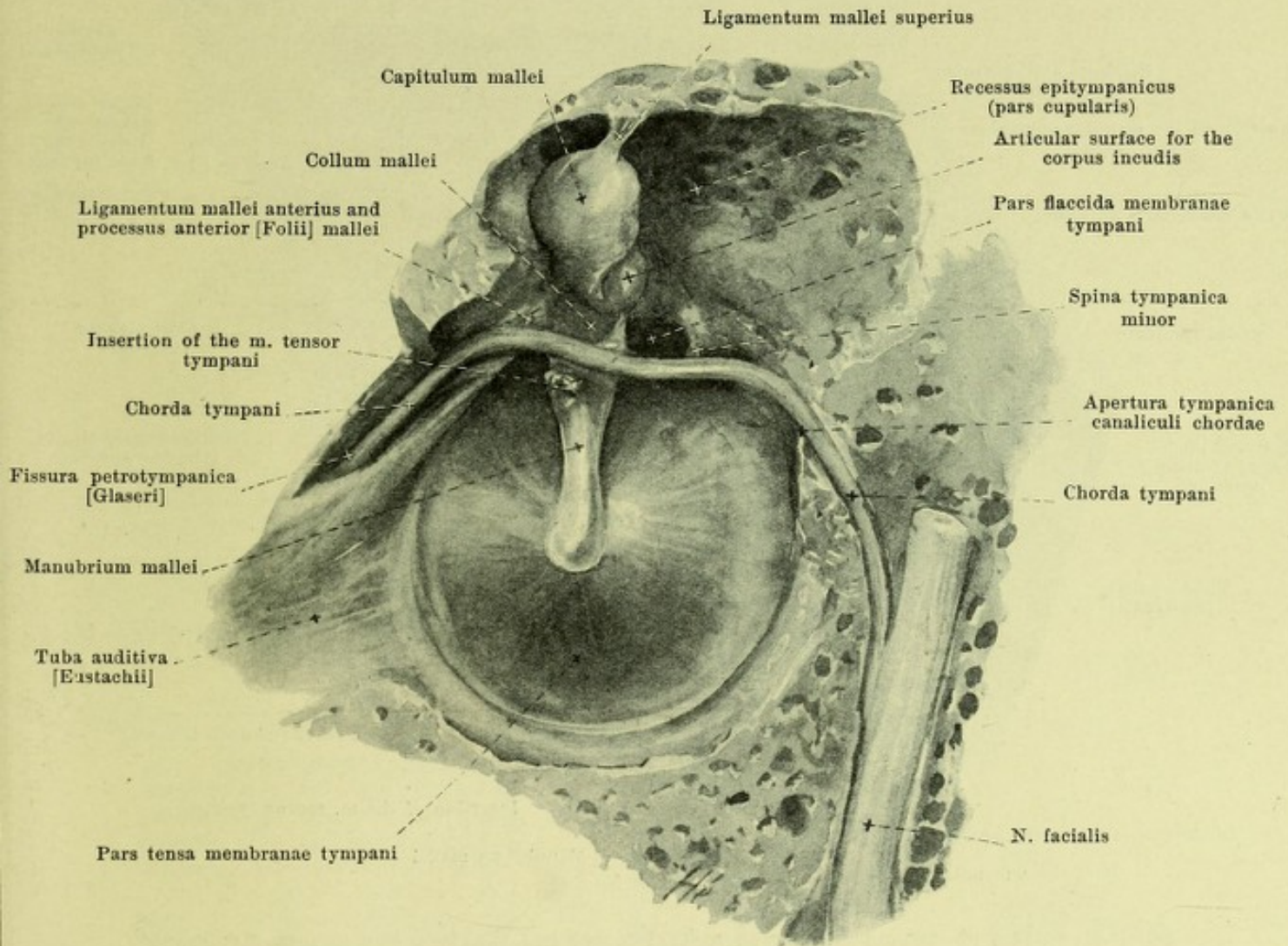
after removal of the ear-drum, viewed from the outside in front and below.

Magnification 6:1.



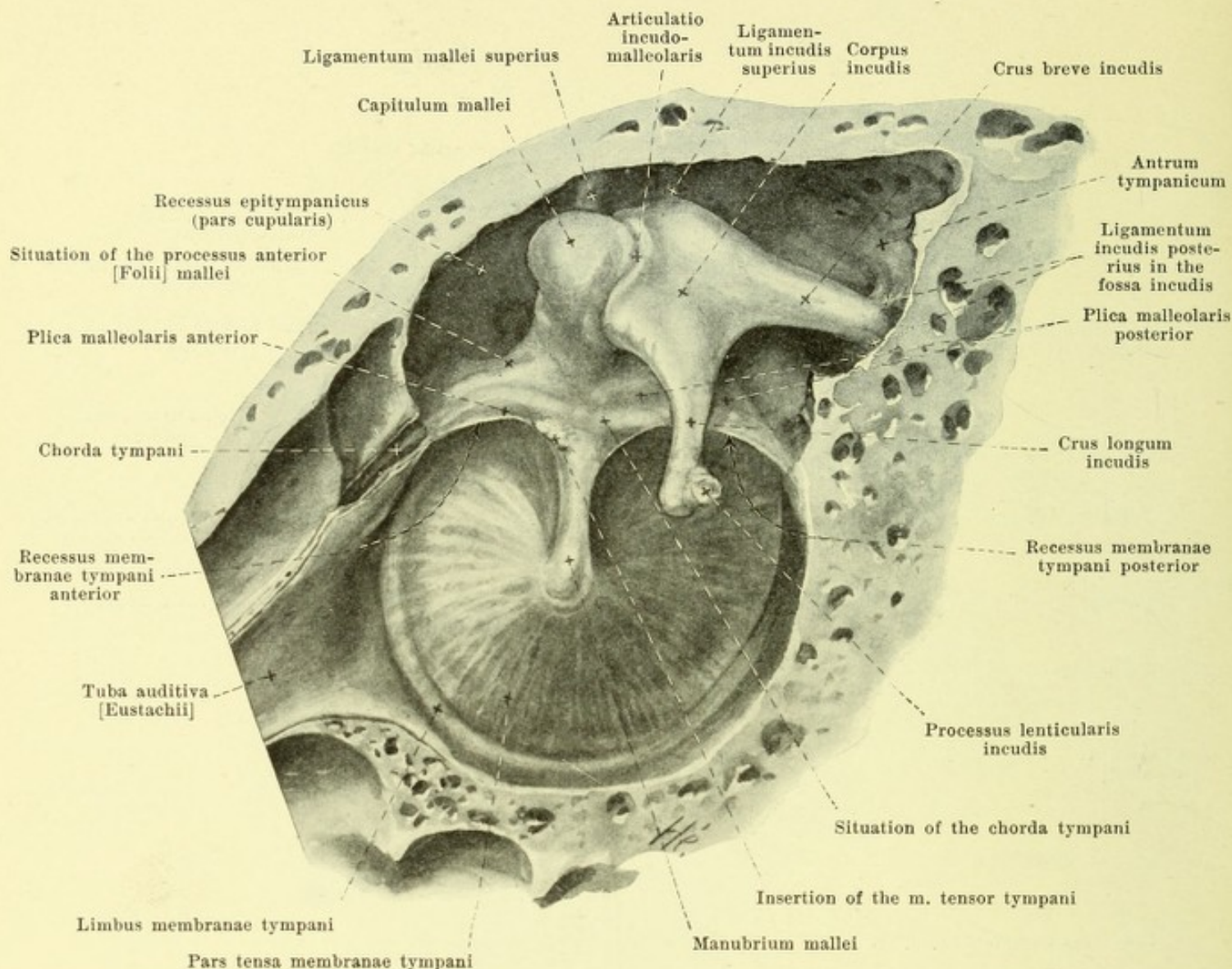
887. Right ear-drum with handle of hammer,
viewed from within behind and above. Magnification 6:1.

(The chorda tympani and the head of the hammer, with the folds of mucous membrane have been removed.)



888. Right membrana tympani with the hammer and the chorda tympani, viewed from within, behind and above. Magnification 6:1.

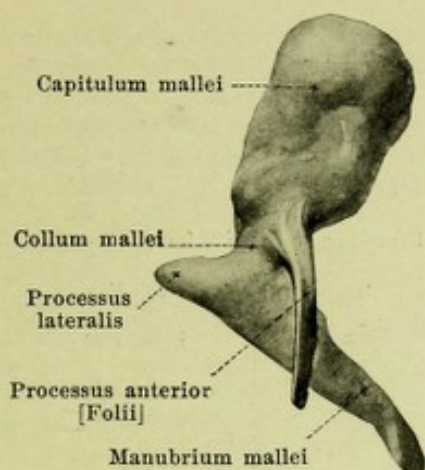
(The folds of mucous membrane have been removed; the course of the chorda tympani and of the n. facialis has been exposed.)



889. Right membrana tympani with hammer and anvil, viewed from within, behind and above. Magnification 6:1.

(The fold of mucous membrane, plica incudis, passing from the anvil upward and the fold running forward from the head of the hammer, the two of which bound the pars cupularis of the recessus epitympanicus medianward, are not shown in the drawing.)

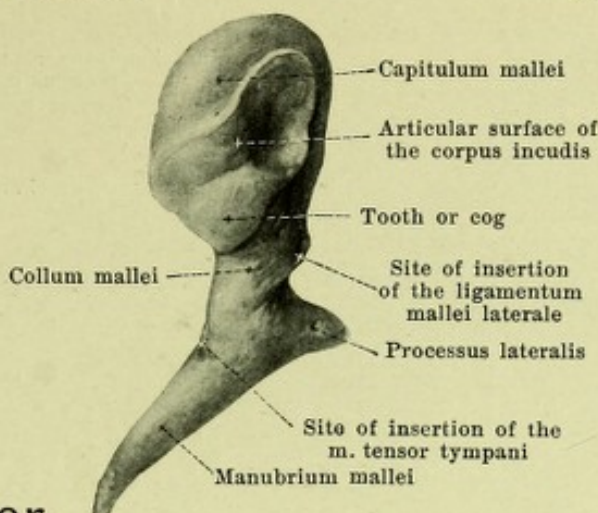
The *membrana tympani* (continued) (see also Figs. 875, 882—885, 887 and 888) is fastened by a somewhat thickened margin, *limbus membranae tympani*, in the sulcus tympanicus by means of the fibrocartilaginous *circular pad*, *annulus fibrocartilagineus*, and is there sharply marked off from its surroundings; in the incisura tympanica [Rivini] the fibrocartilaginous ring is absent and the skin of the acoustic canal goes over gradually and without sharp limit into the membrane. The membrana tympani is covered on its lateral surface by the *stratum cutaneum*, a continuation of the external skin which is somewhat thicker in the region of the stria malleolaris but is elsewhere very thin. Following upon this is a connective tissue membrane, composed of a lateral layer of radial fibers, *stratum radiatum*, in which stiff fibers run approximately radial to the handle of the hammer, and of a medial layer of circular fibers, *stratum circulare*, in which the fibers are arranged in circles closer together at the periphery than near the centre; both layers are connected with the annulus fibrocartilagineus; they are lacking in the pars flaccida. The medial surface is covered by the *stratum mucosum*, a continuation of the mucous membrane of the tympanic cavity.



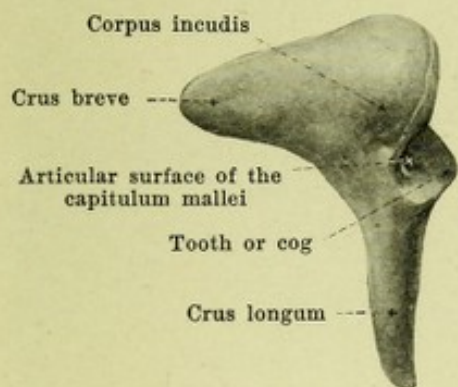
890. Right hammer,

viewed from in front.

Magn. 6:1.



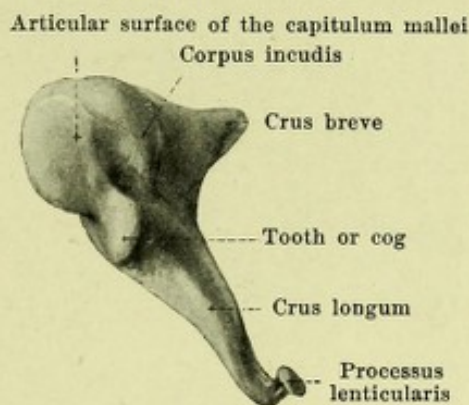
viewed from behind.



lateral view.

891.
Right
anvil,

Magn. 6:1.

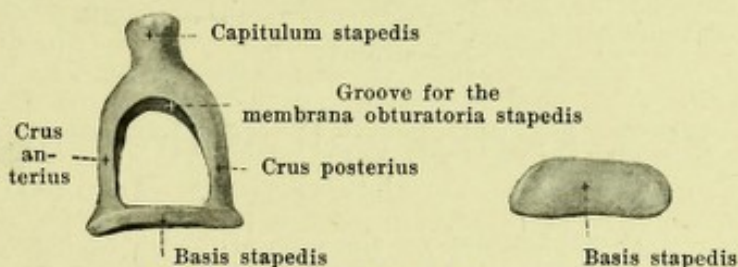


medial and front view.

Auris media, middle ear (see Figs. 875, 882—884, 886—889, 893—898) is formed by the *cavum tympani* with the *ossicula auditus* and by the *tuba auditiva* [Eustachii].

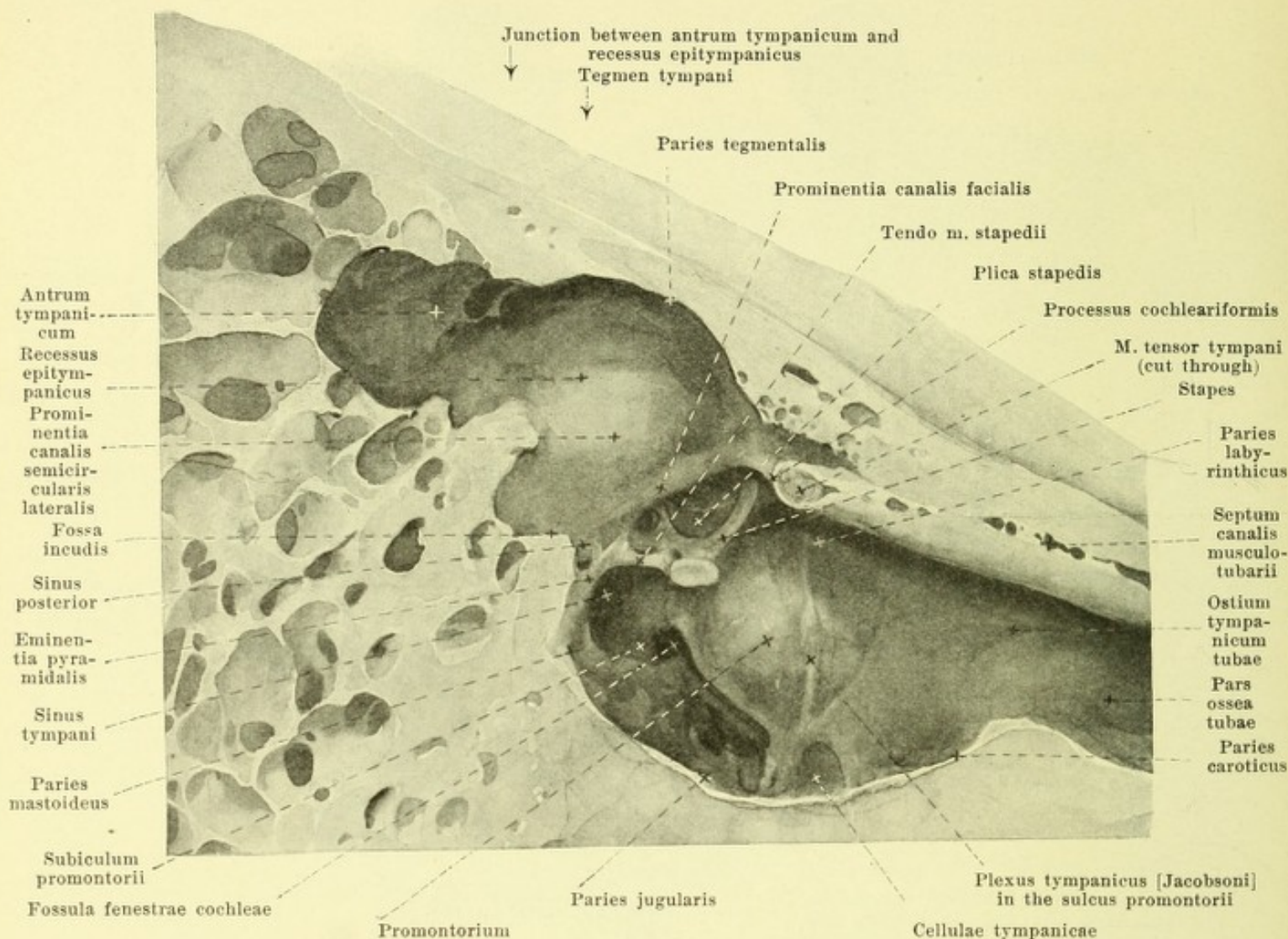
The *cavum tympani*, *tympanic* or *ear-drum cavity* (see Figs. 875, 882—884) is a slit-like air-containing space lined by mucous membrane which is continuous behind and lateralward with the air-containing *cellulae mastoideae*, while in front and medianward it opens into the pharynx through the *tuba auditiva* [Eustachii]; laterally it is completely separated by the *membrana tympani* from the external acoustic meatus and medially by the *basis stapedis* and the *membrana tympani secundaria* from the internal ear. Its slit-like space forms with the median plane an angle of about 45°. Its form is comparable with that of a bi-concave lens, the broad surfaces of which are placed vertically and correspond to the medial and lateral walls and the margin of which forms a narrow anterior, inferior, posterior and superior wall; the distance between the medial and lateral walls varies much in different individuals, but is wider behind and above than in front and below and is least between the umbo and the promontorium.

The lateral wall (see Figs. 882—884, 887—889) is in large part occupied by the *membrana tympani*, and in this far is designated as *paries membranaceus*. It exceeds the limits of the *membrana tympani* a little below and in a very variable manner, considerably on the other hand above; in the latter situation it is formed by a bony plate which extends laterally over the end of the external acoustic canal, belongs to the *squama temporalis* and laterally bounds the *pars cupularis* of the *recessus epitympanicus* (see p. 811). In front the lateral wall goes over into the *tuba auditiva*, immediately above which the *fissura petrotympanica* [Glaseri] can be recognized in a macerated preparation.



892. Right stirrup,

viewed from above. Magn. 6:1. medial view.



893. Medial wall of the right tympanic cavity, lateral view. Magnification 5:1.

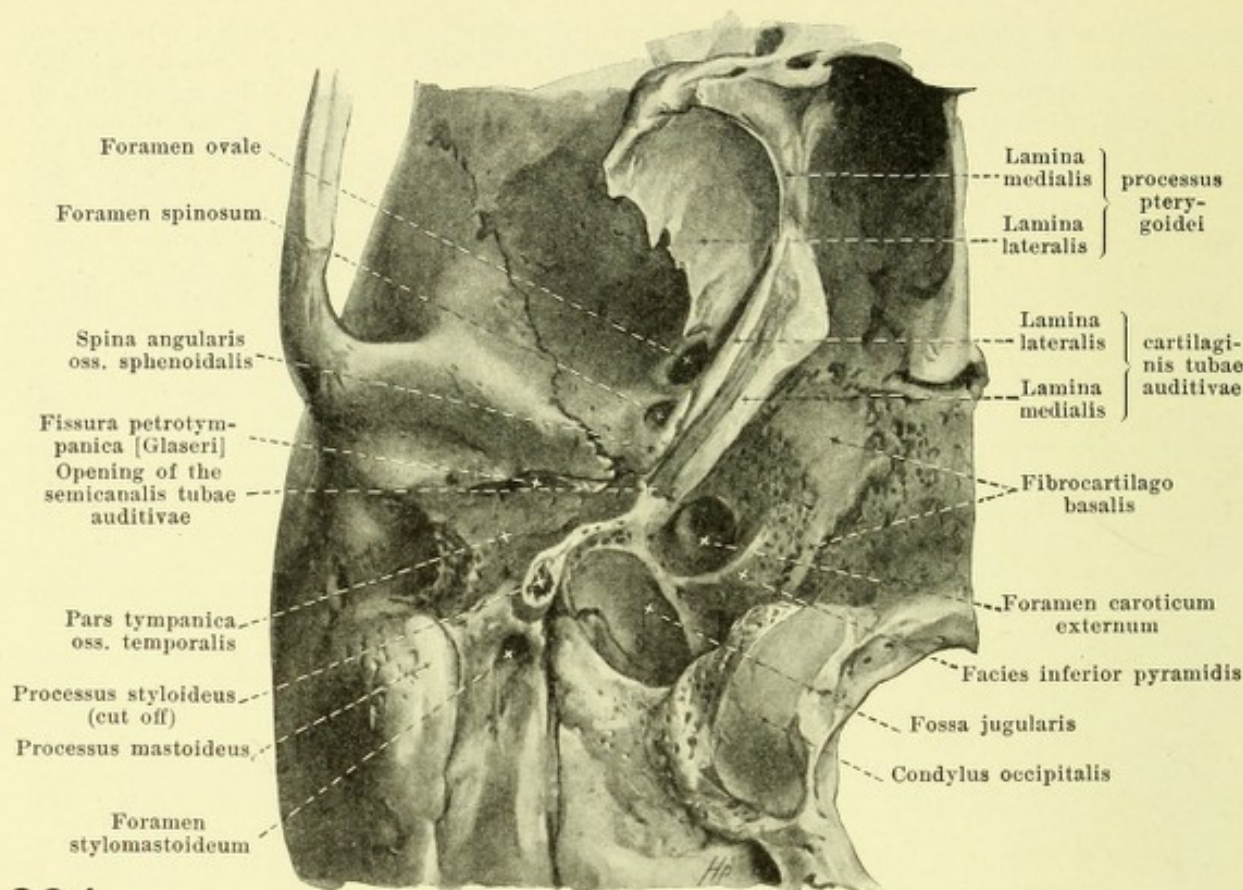
Cavum tympani (see also Figs. 11, 875, 882—884). The medial wall adjoins the labyrinth and is therefore called the *paries labyrinthicus*. In the macerated bone, one notices almost in its middle a transversely oval opening, *fenestra vestibuli*, *vestibular window*, leading into the vestibulum, this opening being situated at the bottom of a fossa, *fossula fenestrae vestibuli* (see also Figs. 906—908). Medial from it, the *canalis musculotubarius* passes forward and the posterior end of its septum bends lateralward and forms the *processus cochleariformis*. Beneath this the *promontorium*, a large projection due to the beginning of the basal turn of the cochlea, goes forward medially without sharp limit, over into the wall of the tuba auditiva; on its surface is a groove, *sulcus promontorii*, for the reception of the plexus tympanicus [Jacobsoni]. On the inferior, posterior, sharply cut-off declivity of the promontorium a triangular fossa, *fossula fenestrae cochleae*, leads forward, upward and medianward, to the *fenestra cochleae*, *cochlear window*, which opens into the beginning of the basal turn of the cochlea (in its *scala tympani*); it is bordered by a narrow bony ridge, *crista fenestrae cochleae*, to which the *membrana tympani secundaria* is attached. The *fossula fenestrae cochleae* is bounded above by a smooth bony projection, *subiculum promontorii*, which passes out dorsalward from the promontorium and forms the inferior boundary of the *sinus tympani*, a deep fossa, going over above into the *fossula fenestrae vestibuli* and bounded behind by the *eminencia pyramidalis* and the *prominentia canalis facialis*. Above and behind the *fenestra vestibuli* is the *canalis facialis*, passing in a curve backward and downward to vanish behind the *eminencia pyramidalis*. It bulges the wall forward in the form of the *prominentia canalis facialis*. Just above it is the broad bulging of the wall due to the lateral semicircular canal and called the *promi-*

nentia canalis semicircularis lateralis. These two bulgings form the medial boundary of the *recessus epitympanicus*. The inferior wall, *paries jugularis*, goes over gradually into the anterior and posterior walls; it is sometimes smooth, sometimes studded with numerous niches, *cellulae tympanicae*, separated by bony spicules, and contains one opening of the canaliculus tympanicus (see p. 12). At the boundary toward the posterior wall, there often projects an irregular nodule, *prominentia styloidea* (see Fig. 906) which corresponds to the upper end of the proc. styloideus. The wall abuts below on the fossa jugularis and varies extraordinarily in thickness. The posterior wall, *paries mastoideus*, possesses below many *cellulae tympanicae* (see p. 810). Just near the sulcus tympanicus one sees in it a fine opening, the *apertura tympanica canaliculae chordae* (see Figs. 886, 888, 906 and 907) and at the same level, further medianward, a small wedge-shaped elevation, *eminentia pyramidalis*, which, at its tip, possesses a small opening and in its interior an elongated cavity (see Fig. 902) for the m. stapedius; a bony spar stretched out between these two forms the lower boundary of a depression, *sinus posterior* (see Figs. 893, 903 and 906); following upon this is a step-like place in the upper deepened surface of which, *fossa incudis* (see Figs. 889, 893, 903 and 906), the crus breve incudis is attached by means of the lig. incudis posterius. The portion of the tympanic cavity lying above this receives the head of the hammer and the largest part of the anvil. It is called the *recessus epitympanicus* (see Figs. 875, 882, 884, 887—889 and 893) and reaches forward and downward as far as the *prominentia canalis facialis*, upward as far as the tegmen tympani; concerning its lateral and median walls see p. 809 and 810. Its uppermost portion, which extends downward between the lateral wall on one side, the capitulum mallei, corpus and crus breve incudis and the folds of mucous membrane stretched out from them to the upper and anterior walls on the other side (see also p. 815) ends below in the form of a blind sac called the *pars cupularis*, over the lig. mallei anterior. The recessus epitympanicus is directly continuous behind with the *antrum tympanicum*, a larger cavity roofed in above by the tegmen tympani; it forms the entrance to the very variable *cellulae mastoideae* (see also p. 9). The upper wall of the tympanic cavity, *paries tegmentalis* (see Figs. 893 and 907), is formed by the tegmen tympani (see p. 11) and is slightly rough. The anterior wall, *paries caroticus* (see Fig. 893), is bony only in its lower portion, where it possesses *cellulae tympanicae* and the openings of the canaliculi caroticotympanici (see p. 13). It is formed by bony leaflets of variable thickness which separate it from the ascending part of the canalis caroticus (see Figs. 773, 882, 883 and 902). Its upper part is occupied by the *ostium tympanicum tubae auditivae*.

Ossicula auditus, small bones of the ear (see Figs. 875, 882—893), lie in the upper part of the tympanic cavity, are articulated with one another and form a chain which begins in the membrana tympani and ends in the fenestra vestibuli. They show considerable individual variations.

1. *Malleus, hammer*, the largest of them, lies furthest lateral and forward. Its upper part, *capitulum mallei, head of hammer*, situated in the recessus epitympanicus, is thick and club-shaped and presents on its posterior and medial surfaces an elongated approximately saddle-shaped articular surface covered with cartilage for the corpus incudis, which encroaches below upon a toothlike process, *tooth or cog of the hammer*. The head is separated by a constriction, *collum mallei, neck of the hammer*, from the *manubrium mallei, handle of the hammer*; the latter is a thin, bony rod, oval in cross-section, which tapers off toward the tip, where it ends like a spatula; its largest cross-section plane is perpendicular to the plane of the membrana tympani with the middle plate of which the handle of the hammer is fixed; on its lateral margin it has a cartilaginous covering; its lateral surface gives rise to the stria malleolaris (see p. 807) and internally it is covered by the mucous membrane of the tympanic cavity. With the head of the hammer, the handle forms an angle varying according to race, age and individual (on the average of about 130°) being always somewhat greater on the right than on the left. Its angle with the horizontal plane varies also, and amounts on the average on the right to about 50°, on the left to 45°. Above and laterally the handle of the hammer is continued into the small, tapered *processus lateralis*, which bulges out the *prominentia malleolaris* of the tympanic membrane. From the anterior surface of the neck, there passes forward the thin *processus anterior [Folii]* which appears longer in the infant.

2. *Incus, anvil*, has approximately the form of a tooth with two roots. To the crown of the tooth corresponds the flattened *body, corpus incudis*; on its free basis it presents an articular surface covered with cartilage which encroaches somewhat upon a ridge on the lateral surface, the *tooth or cog of the anvil*, and serves for the reception of the head of the hammer. To the roots of the tooth correspond the *crus breve* and *crus longum*, *short and long leg*; the short leg is thicker and plumper; both taper out toward their tips and diverge from one another forming an angle of about 100°. The short leg is directed horizontally backward; the long one runs parallel to the manubrium mallei and lies somewhat medially and dorsally from it. On the medial side of the tip of the long leg is a small process, *processus lenticularis*.



894.

Cartilage of the right Eustachian tube, viewed from below.

(The processus styloideus has been cut off at its root.)

3. *Stapes, stirrup* (see Figs. 884, 886, 892 and 893), possesses a *foot-plate, basis stapedis*, two *legs, crus anterior* and *posterior*, and a *small head, capitulum stapedis*. The foot-plate fills up the fenestra vestibuli nearly completely, is flat and possesses an upper convex and a lower straight or slightly concave margin. The two legs are hollowed out groove-like on their concave side, and are of approximately equal length: The anterior is finer than the posterior and less markedly curved; the latter possesses near its capitulum a small rough area for the insertion of the *m. stapedius*. Between the legs and the foot plate is stretched out a thin connective tissue membrane, *membrana obturatoria stapedis* (not illustrated). The capitulum is very variable and presents on its lateral free end a small articular surface covered with cartilage for the *processus lenticularis*. The plane of the stirrup lies approximately horizontally and is laterally inclined somewhat downward (see Fig. 893).

The small bones of the ear are united with one another by joints, *articulationes ossiculorum auditus*, namely by the *articulatio incudomalleolaris* (see Fig. 889) between the head of the hammer and the body of the anvil, the *articulatio incudostapedialis* between the *processus lenticularis* of the anvil and the *capitulum stapedis* and the *syndesmosis tympanostapedialis* between the cartilage-covered margins of the fenestra vestibuli and *basis stapedis*, the interspace of which is filled up by a ligamentous mass, *lig. annulare basis stapedis* (not illustrated).

The small bones of the ear are fastened in the wall of the tympanic cavity so that the manubrium mallei is inserted in the *membrana tympani* and the *basis stapedis* is fastened in the fenestra vestibuli; in addition there are interosseous ligaments, *ligamenta ossiculorum auditus*.

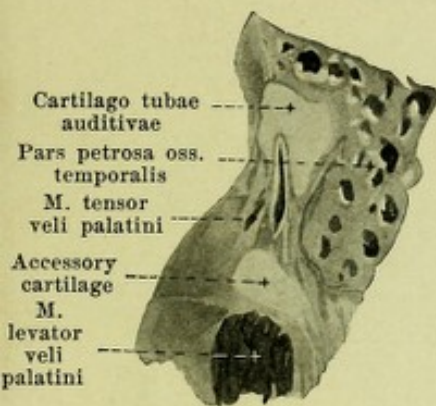
1. *Lig. mallei anterior* (see Figs. 886 and 888) in the *plica malleolaris anterior*, from the *proc. anterior [Folii] mallei*, ensheathing it; it passes into the *fissura petrotympanica [Glaseri]* and goes on as far as the *spina angularis* of the sphenoid bone.

2. *Lig. mallei laterale* (see Fig. 884), diverging from the neck of the hammer to the *spinae tympanicae major* and *minor* and to the margin of the *incisura tympanica [Rivini]*.

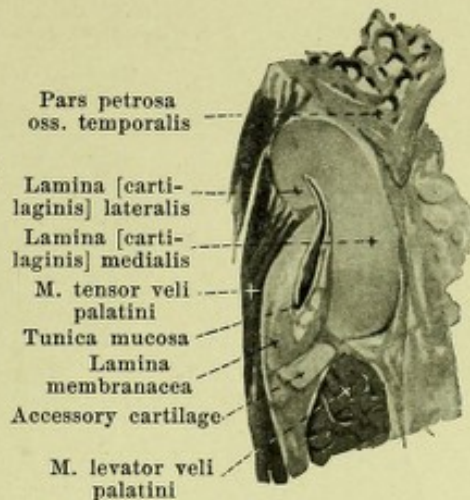
3. *Lig. mallei superius* (see Figs. 884, 888 and 889), variable, from the roof of the *recessus epitympanicus* downward to the upper end of the head of the hammer.

4. *Lig. incudis posterior* (see Fig. 889) passes from the *crus breve incudis* to the posterior wall of the tympanic cavity and fastens the former in the *fossa incudis*.

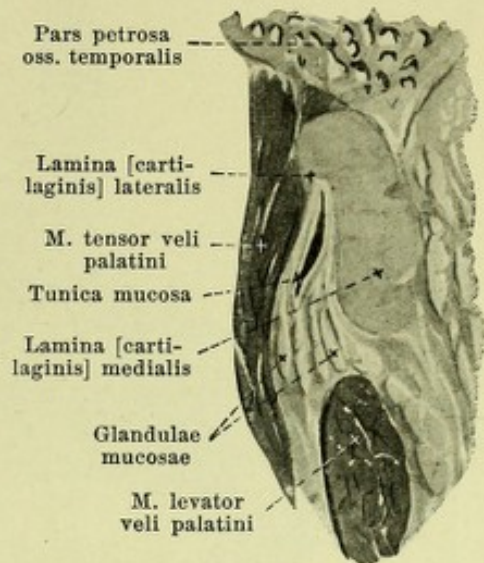
5. *Lig. incudis superius* (see Fig. 889) from the roof of the *recessus epitympanicus* downward to the *corpus incudis*; it is only a bridge of mucous membrane and contains no ligamentous fibers.



895. Near the lateral end of the cartilaginous part.



896. At the junction between the lateral and middle thirds.



897. At the junction between the middle and medial thirds.

895-898. Cross sections through the cartilaginous Eustachian tube of the right side, viewed from the medial side.

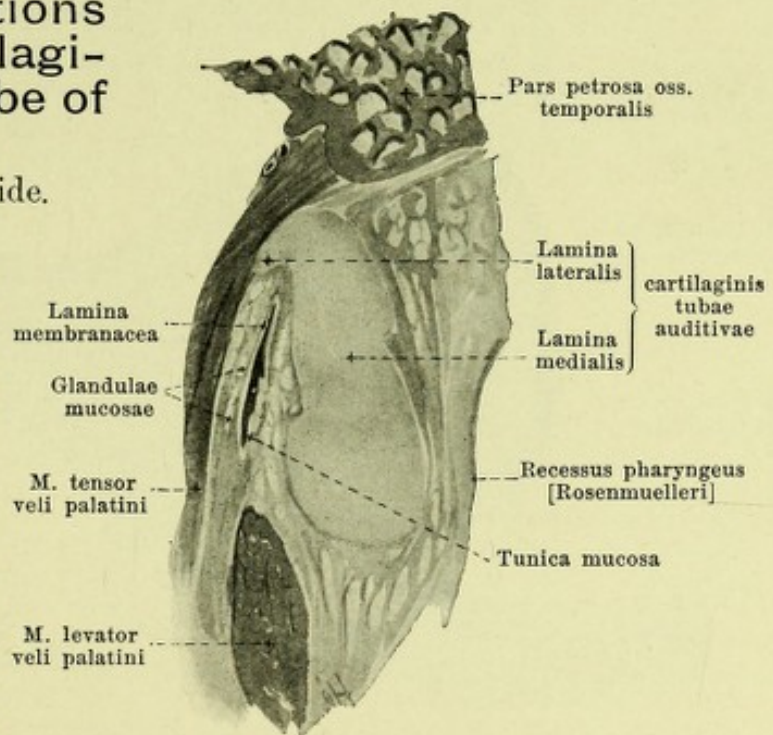
Magnification 3:1.

Musculi ossiculorum auditus.

1. *M. tensor tympani* (see Figs. 875, 884, 886-890 and 893) spindle-shaped, pinnate, lies in the semicanalis m. tensoris tympani (see p. 11) the bony wall of which is completed by tough connective membrane. It arises from the upper surface of the cartilago tubae auditivae and from the walls of the canal (especially the upper). The rounded tendon bends around almost at a right angle at the proc. cochleariformis, passes lateralward through the tympanic cavity, covered by mucous membrane, and becomes attached to the handle of the hammer near the neck of the hammer. It draws the manubrium mallei medianward and stretches the membrana tympani. Innervation: n. tensoris tympani (V).

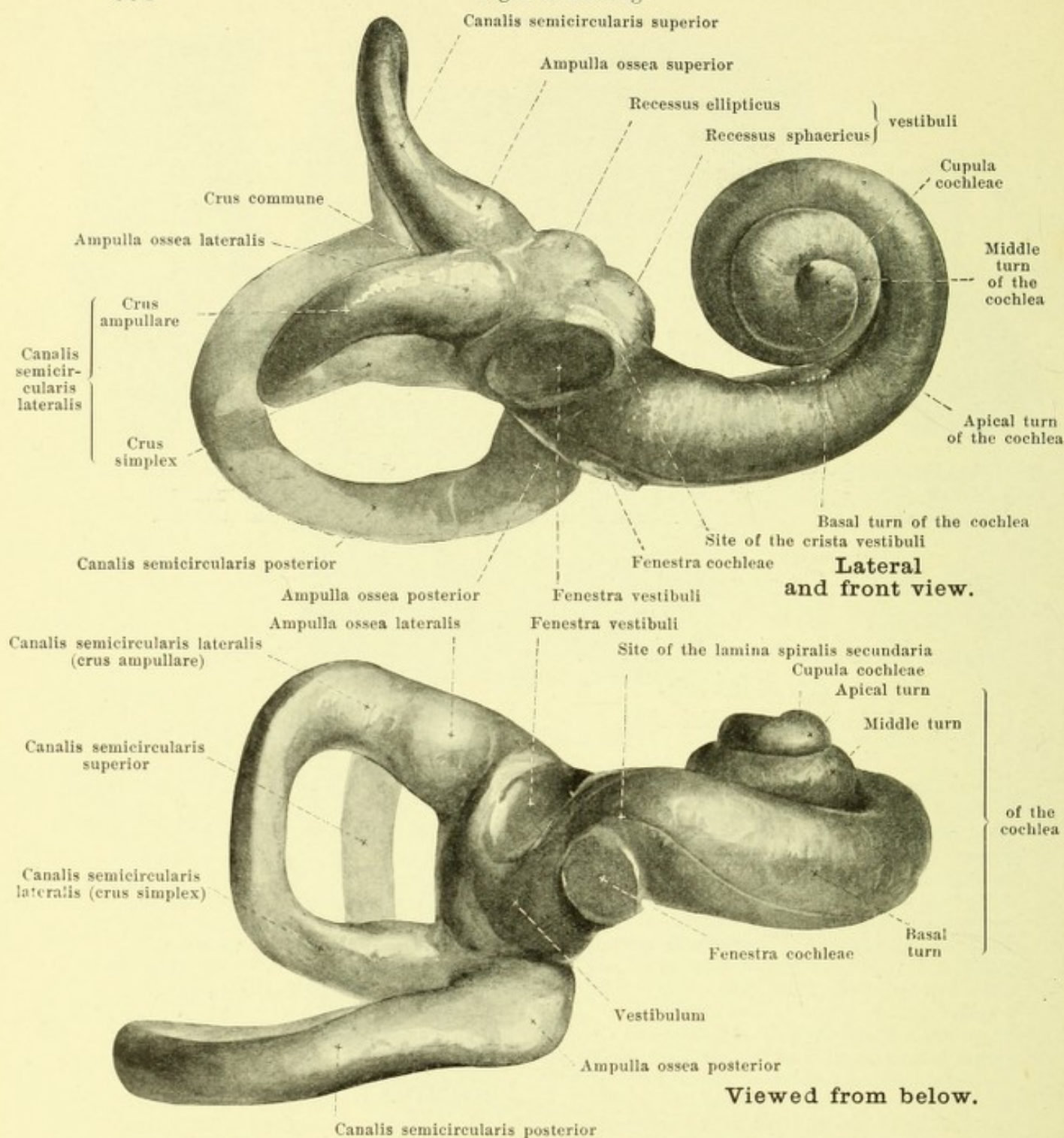
2. *M. stapedius* (see Figs. 773, 886 and 893), pinnate, fills up the cavity situated in the eminentia pyramidalis (see Fig. 902). Its tendon appears at tip of the eminentia pyramidalis, bends somewhat downward at an obtuse angle and, covered by mucous membrane, passes forward and medianward to the posterior margin of the capitulum stapedis. It moves the posterior end of the basis stapedis somewhat inward, the anterior end somewhat outward. Innervation: n. stapedius (VII).

Tunica mucosa tympani, mucous membrane of the tympanic cavity (see Figs. 884, 887, 889 and 893), lines the surface of the whole tympanic cavity, of the cellulae mastoideae, of the small bones of the ear, of the membrana tympani (see p. 808), as well as of the tendons and ligaments, as a thin membrane and is intimately united with the periosteum. In approaching some of these structures duplicatures or folds, *plicae*, are formed, most of which are very variable.



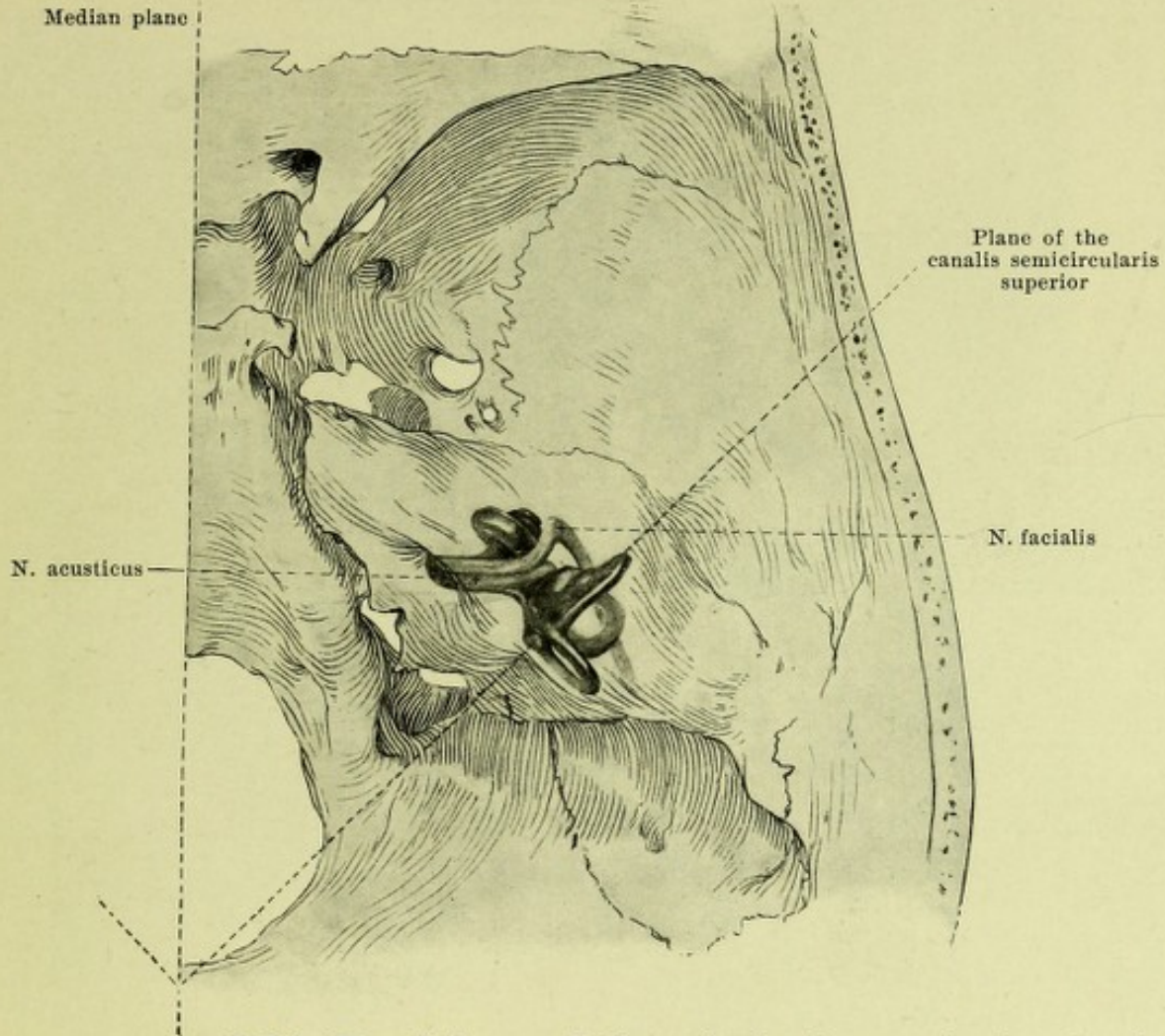
898. Near the ostium pharyngeum tubae auditivae.

Organ of Hearing.



899 and 900. Corrosion preparation of the right bony labyrinth of the ear. Magnification 6:1.

Tunica mucosa tympani (continued) (see Figs. 884, 887, 889 and 893). The most constant folds are the following: the *anterior hammer fold*, *plica malleolaris anterior* (see Figs. 887—889), goes off from the membrana tympani between the spina tympanica major and the manubrium mallei, ensheaths the proc. anterior [Folii] mallei, the lig. mallei anterior, and the anterior part of the chorda tympani, and ends in a free concave margin; the pocket ending blind above, situated between it and the membrana tympani, is called the *anterior pocket of the membrana tympani*, *recessus membranae tympani anterior*. The larger, *posterior hammer fold*, *plica malleolaris posterior* (see Fig. 889) goes off from the membrana tympani between the spina tympanica minor and the manubrium mallei, is fastened behind to the uppermost part of the sulcus tympanicus, encloses below the posterior part of the chorda tympani and ends with a free concave margin.

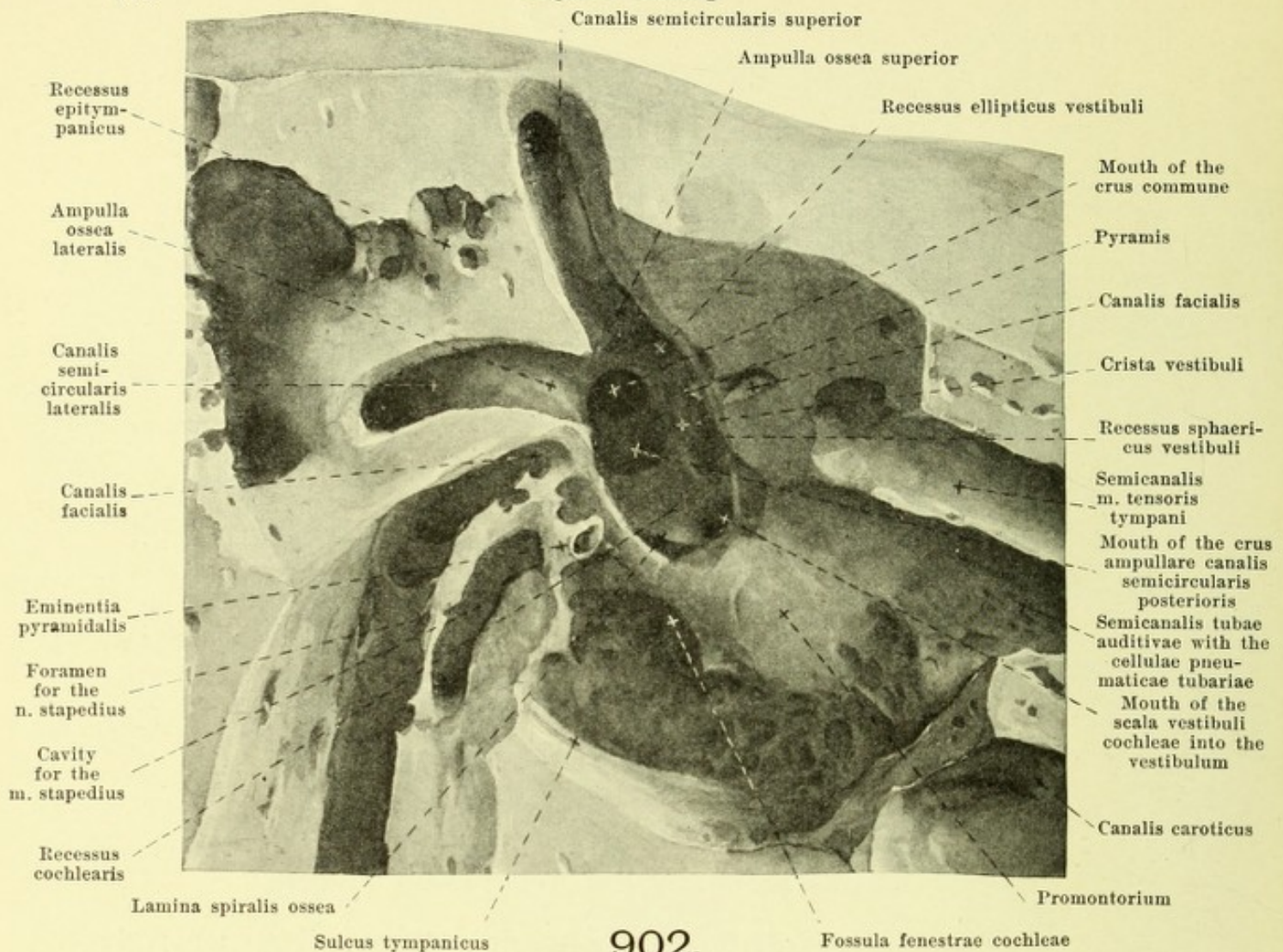


901. Position of the right bony labyrinth of the ear in the skull, viewed from above.

(The temporal bone is considered transparent and the labyrinth drawn in from a corrosion preparation.)

Tunica mucosa tympani (continued) (see Figs. 884, 889 and 893). Between the posterior hammer folds and the membrana tympani lies the *posterior pocket of the membrana tympani, recessus membranae tympani posterior*. It ends blind above or is continued above directly into the *upper pocket of the membrana tympani, recessus membranae tympani superior* (see Fig. 884), enclosed by the pars flaccida of the membrana tympani, the lig. mallei laterale as well as the collum and proc. lateralis mallei; the pocket may also open inward through a special foramen. From the roof of the recessus epitympanicus a vertical fold, *plica incudis* (not illustrated), descends to the corpus and crus breve incudis and a similar fold goes from the head of the hammer to the anterior wall; they help to form the medial wall of the pars cupularis of the recessus epitympanicus (see p. 811). The *plica stapedis* (see Fig. 893) ensheaths the whole stirrup along with the membrana obturatoria stapedis and the tendon of the m. stapedius and often stretches out also to the posterior wall of the tympanic cavity. Over the fenestra cochleae the mucous membrane as it passes forms the *membrana tympani secundaria* (see p. 828).

Tuba auditiva [Eustachii], ear trumpet, Eustachian tube, (see Figs. 545, 549—553, 875, 883, 884, 889, 893—898) unites the tympanic cavity with the pharynx, runs in general obliquely forward medially and downward and divides into a lateral shorter bony part and a medial longer cartilaginous part. These form with one another a large obtuse angle open below, the vertex of which corresponds to the narrowest part of the lumen, the *isthmus tubae auditivae*. The bony part, *pars ossea tubae auditivae*, begins in the anterior wall of the tympanic cavity (see p. 811) in the oblong oval *ostium tympanicum tubae auditivae* and includes the semi-canal of the tubae auditivae (see p. 11). Its lumen narrows medianward and is approximately triangular; the upper wall is formed by the tegmen tympani, the medial wall partly by the septum canalis musculotubarii, and its connective tissue supplement (see p. 813) partly by the medial wall of the tympanic cavity and lies there laterally very close to the canalis caroticus.



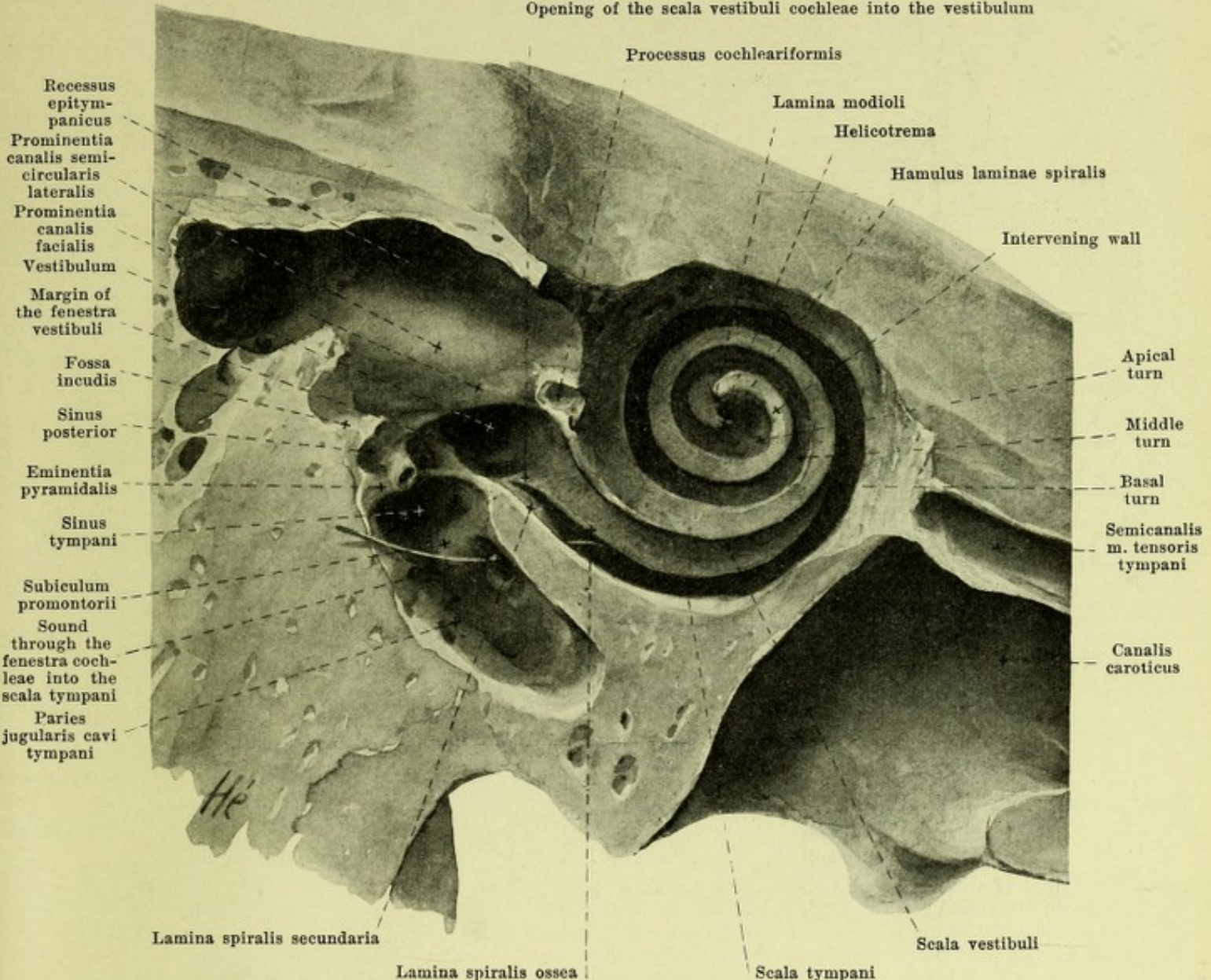
902.

Right vestibule and semicircular canals in the macerated bone, open from the outside. Magn. 5:1.

(In addition the canales caroticus and facialis, as well as the cavity for the m. stapedius have been opened up.)

Tuba auditiva (continued) (see Figs. 545, 549—553, 875, 883, 884, 889, 893—898). The lateral wall of the bony part is shorter than the others and consists of the pars tympanica of the temporal bone, the lower boundary is groove-like and near the tympanic cavity presents several variably developed small evaginations, *cellulae pneumaticae tubarii*. The cartilaginous part, *pars cartilaginea tubae auditivae*, reaches as far as the *ostium pharyngeum tubae auditivae*, (see p. 505) its form being essentially determined by the *cartilago tubae auditivae* which consists partly of hyaline, partly of elastic cartilage. This together with the broad plate, *lamina [cartilaginosa] medialis*, which is somewhat thickened below, forms the whole posterior medial wall, and together with the narrow, upper continuation of the former, bent around sharply downward, the *lamina [cartilaginosa] lateralis*, forms the upper part of the anterior lateral wall; the cartilage directly adjoins the bone of the pars ossea and laterally is somewhat longer, since there the bone stops sooner (vide supra). The upper edge of the cartilage is united firmly along and under the fissura sphenopetrosa with the fibrocartilago basalis, the lateral plate adjoins laterally the sulcus tubae auditivae oss. sphenoidalis and medially the posterior margin of the proc. pterygoideus. The lateral wall is formed beneath the lamina lateralis by the connective tissue *lamina membranacea*. From it and the lamina lateralis arise fibers of the m. tensor veli palatini (see p. 506). The whole inner surface of the Eustachian tube is lined by mucous membrane, *tunica mucosa*. This is very thin in the bony part; in the cartilaginous part it is thicker and contains numerous mucous glands, *glandulae mucosae*, and various lymph nodules, *noduli lymphatici tubarii*. The lumen of the cartilaginous part is slit-like and in the middle of its length is closed when the velum palatinum is loose.

Opening of the scala vestibuli cochleae into the vestibulum

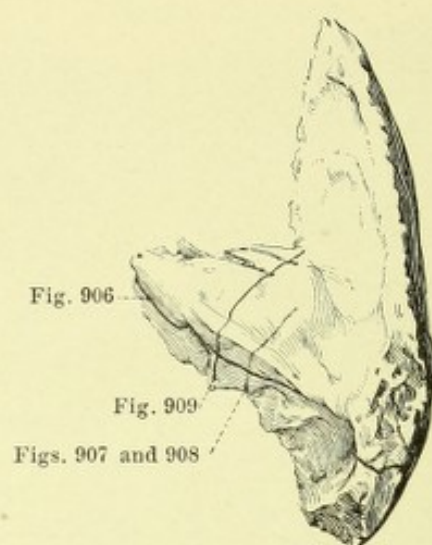
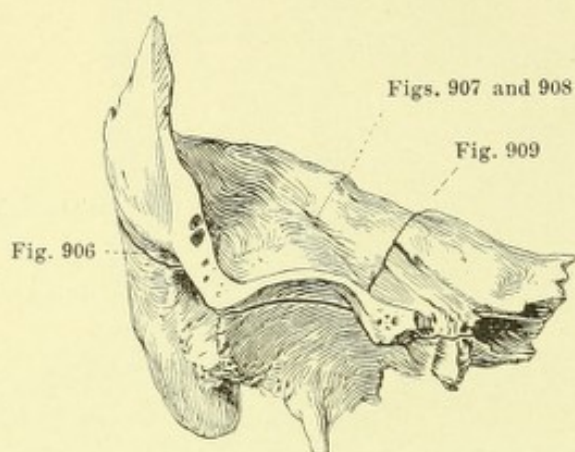


903. Right cochlea in the macerated bone open from the outside. Magnification 5:1.

(The canalis caroticus has been laid open; a fine sound has been passed through the fenestra cochleae.)

Auris interna, internal ear, consists of a bony capsule, the *bony labyrinth*, *labyrinthus osseus*, and the *membranous labyrinth*, *labyrinthus membranaceus*, surrounded by it.

Labyrinthus osseus, *bony labyrinth* (see also Figs. 899—902 and 904—911), lies within the pars petrosa oss. temporalis, lateralward adjoins the paries labyrinthicus of the tympanic cavity, medianward the floor of the meatus acusticus internus, being connected through the latter with the skull cavity. It is surrounded by a very hard layer of bone, 2—3 mm thick, which in the foetus and new-born in many places reaches the surface of the pars petrosa; in others is separated by spongy bony substance distinctly from the rest of the bony mass of the pyramid of the temporal bone, while in the adult it lies more in the interior and is in large part fused with the compact bony substance of the neighborhood. The bony labyrinth is almost as large in the new-born as in the adult. It surrounds a system of cavities in which three parts may be distinguished: a middle, the *vestibule*, a medial anterior, the *cochlea*, and a lateral posterior, the three *semicircular canals*.



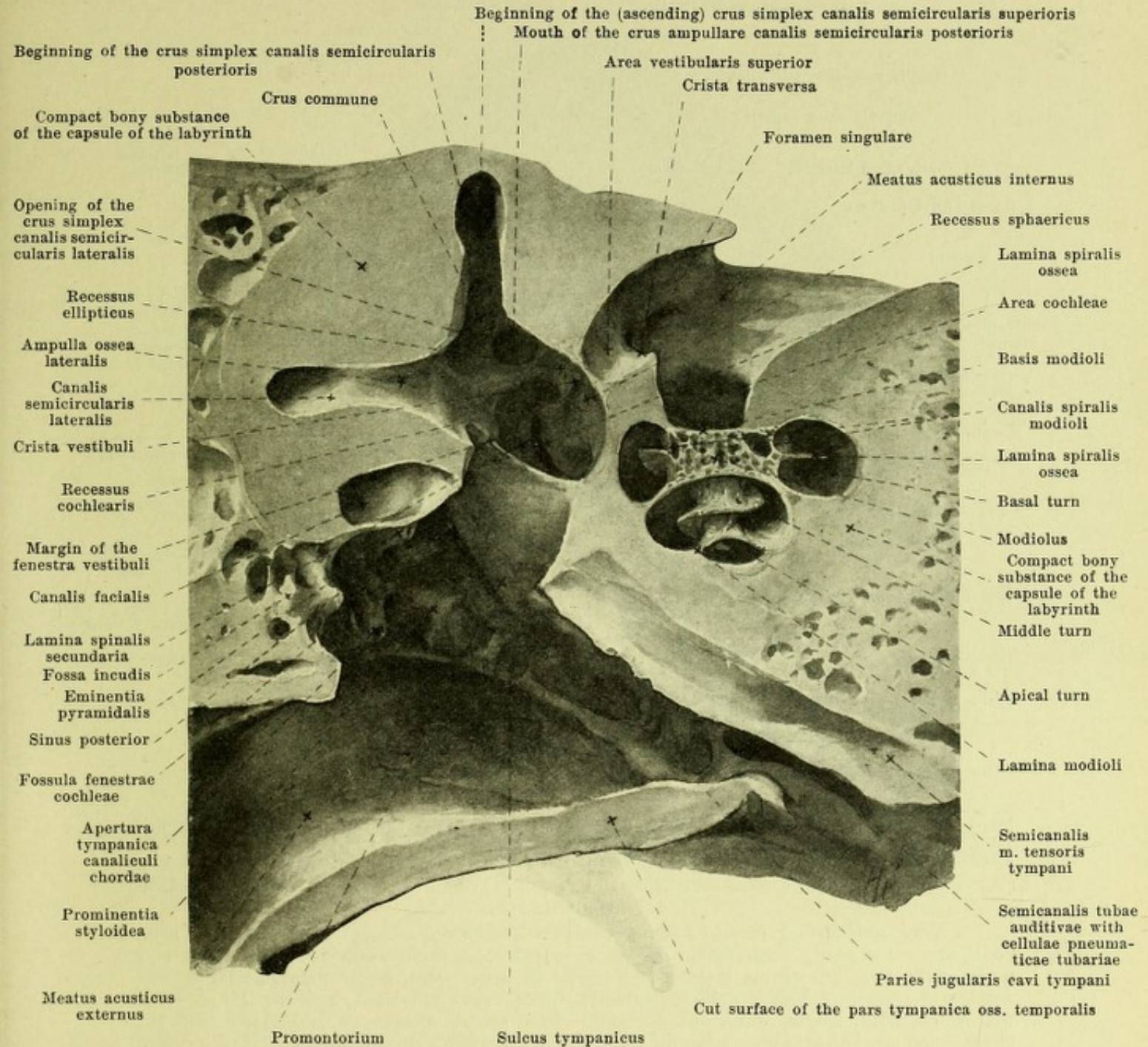
904. Right temporal bone viewed from in front and above, after removal of the anterior part of the squama temporalis

905. Right temporal bone viewed from above and behind

giving the direction of the sections pictured in Figs. 906—909.

The *bony labyrinth* (continued) (see Figs. 899—901) has a maximal length of about 20 mm and lies approximately parallel to the posterior surface of the pyramid of the temporal bone; thus situated the cochlea lies in front medially and below, the semicircular canals behind laterally and above. The basis of the cochlea adjoining the meatus acusticus internus is directed parallel to the plane of the posterior semicircular canal; both run approximately vertically and form an angle of 45° with the median plane, as does the plane of the superior semicircular canal which stands perpendicular to both; the meatus acusticus internus is directed nearly horizontally and frontally.

The *vestibule, vestibulum* (see Figs. 899, 900, 902, 903—908), is a small oval cavity, the wall of which is almost everywhere smooth. Its medial wall (see Figs. 902, 906 and 908) helps in its anterior part at the same time to form the fundus meatus acustici interni, namely the part of the same occupied by the *areae vestibulares*. On it (see Fig. 908) runs a delicate ridge, *crista vestibuli*, which begins laterally over the fenestra vestibuli, runs at first obliquely backward and downward, but then straight downward and marks off from one another two deepened areas of unequal size. The posterior superior elongated oval area, *recessus ellipticus*, serves for the reception of the utricle (see p. 825), and in a small depression contains the *apertura interna aquaeductus vestibuli* (see p. 9). The anterior inferior rounded area, *recessus sphaericus*, receives the sacculus (see p. 825) and in its middle contains a small perforated area, *macula cribrosa media*, in which open the fine foramina of the area vestibularis inferior (see p. 824) and the n. saccularis (see p. 704) arrives in the vestibule. The crista vestibuli close behind and over the fenestra vestibuli presents a variably developed prong, *pyramis vestibuli*. Upon this and in its immediate neighborhood are the minute openings which correspond to the foramina of the area vestibularis superior (see p. 824) and serve for the passage of the upper branch of the n. vestibularis (see p. 703); together they are designated as the *macula cribrosa superior*. Under the posterior end of the crista vestibuli lies a small depressed area, *recessus cochlearis* (see Figs. 906—908); it is separated behind by a ridge from the opening of the crus ampullare canalis semicircularis posterioris, goes forward immediately upon the beginning of the lamina spiralis ossea and lamina spiralis secundaria and receives the caecum vestibulare of the ductus cochlearis (see p. 827). Close behind this area, in the anterior wall of the ampulla ossea posterior (see Fig. 908), a small perforated area, *macula cribrosa inferior*, is visible, which contains the openings of small canals beginning in the foramen singulare (see p. 824) and through which the n. ampullaris posterior (see p. 704) arrives in the vestibulum. The recessus cochlearis leads medianward directly into the vestibular opening of the scala vestibuli cochleae (see p. 823) which occupies the lowermost portion of the medial wall of the vestibule.

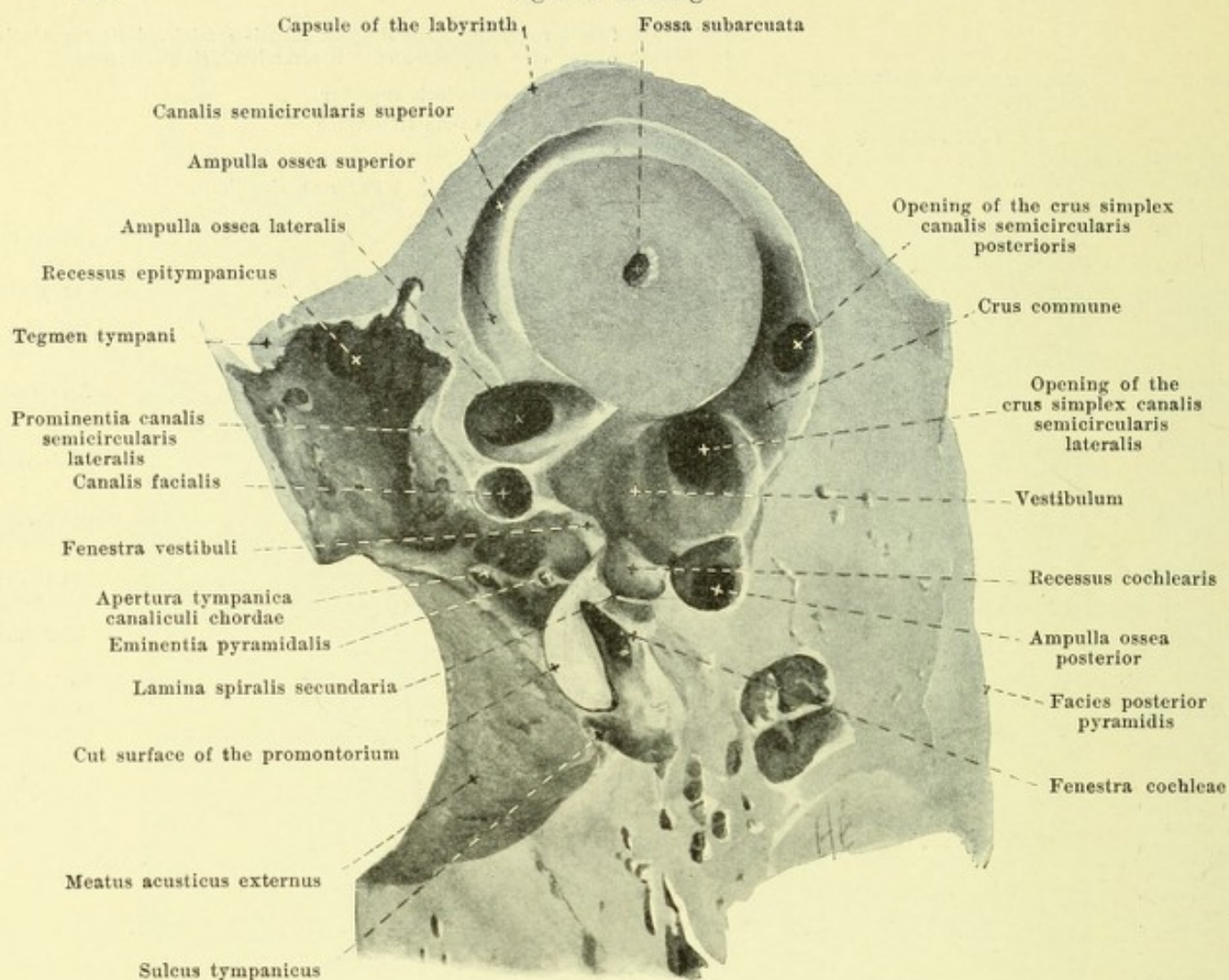


906. Transversal section through the right temporal bone, lower half, viewed from above. Magnification 5:1.

Concerning the direction of the section, see Figs. 904, 905.

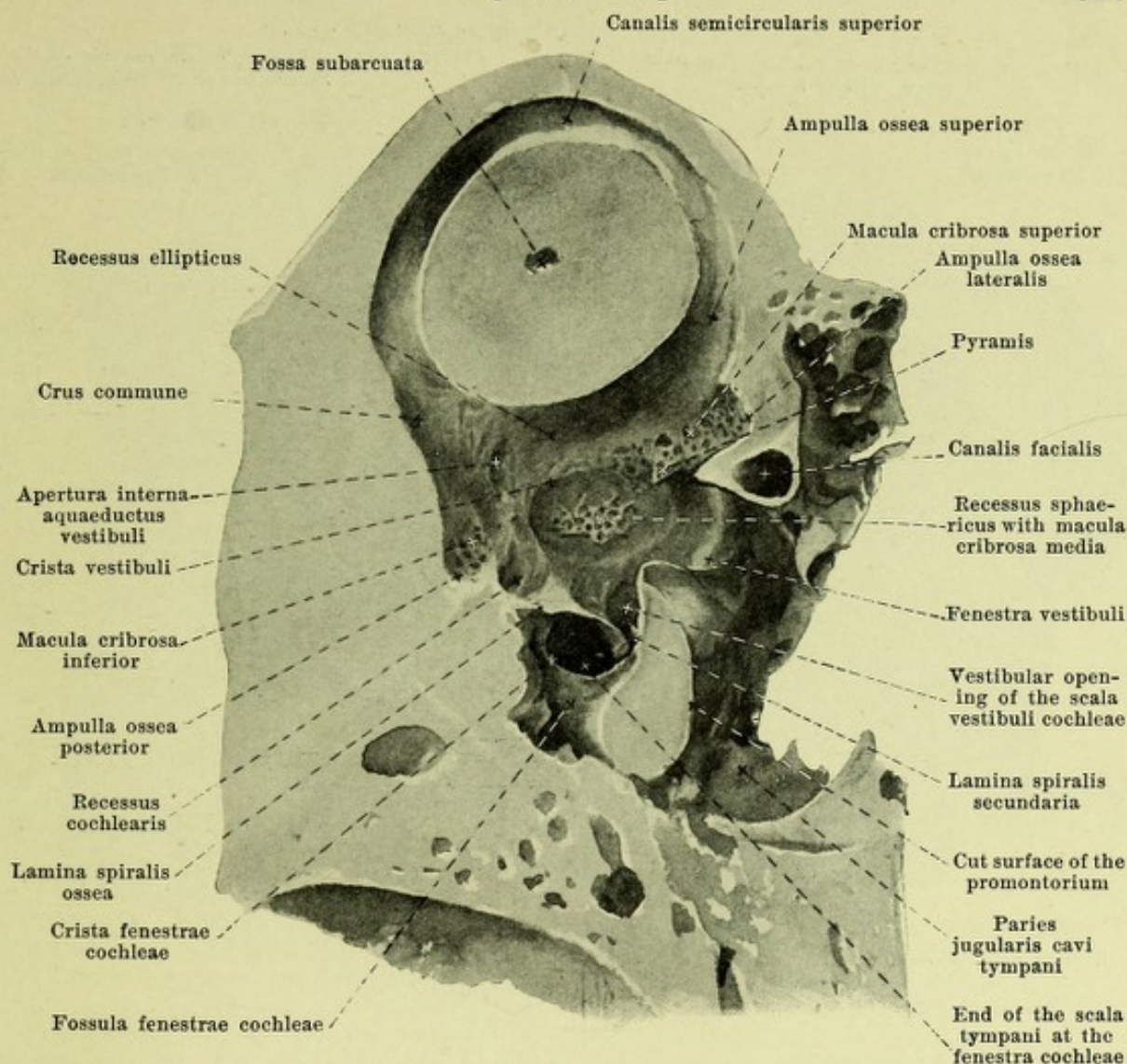
(The crus commune, which was not struck by the section, has been subsequently opened.)

Vestibule (continued) (see also Figs. 902, 903, 907 and 908). It is connected in the macerated bone in front laterally with the tympanic cavity through the *fenestra vestibuli* (see p. 810), in which the foot-plate of the stirrup is fastened by the lig. annulare basis stapedis. Opening into the vestibule besides are the semicircular canals, the five mouths of which are so distributed over the lateral and inferior walls (see Fig. 907) that the crus ampullare of the lateral canal opens over the fenestra vestibuli and over it the crus ampullare of the superior semicircular canal; behind the former lies the opening of its crus simplex and over that that of the crus commune, and in the posterior part of the floor the opening of the crus ampullare of the posterior semicircular canal is to be found.



907. Vertical section through the right temporal bone, lateral portion viewed from the medial side. Magnification 5:1. (For the corresponding medial portion see Fig. 908.) Concerning the direction of the section see Figs. 904, 905.

Bony semicircular canals, canales semicirculares ossei (see also Figs. 899—902, 906, 908), are three nearly semicircular curved bony tubes, each of which is connected at two places with the wall of the vestibule. They lie in three planes nearly perpendicular to one another and together form a right-angle (see Figs. 899—901). In detail, however, this angle as well as the form, length, width and curvature of the semicircular canals are subject to fairly great variations, but are alike on the right and the left side of the same individuals. The shortest of them, *canalis semicircularis lateralis*, is directed lateral and backward, adjoins lateralward and forward the recessus epitympanicus and there causes the prominentia canalis semicircularis lateralis; it does not lie exactly in a (horizontal) plane drawn through the lowest point of both infraorbital margins and the highest point of both ear openings but forms with it an angle of about 24° , open lateralward, dorsalward and downward. The two other semicircular canals run in approximately vertical planes (see p. 818); one of them, *canalis semicircularis superior*, stands at right angles to the axis of the pyramid of the temporal bone, and gives rise on its facies anterior to the projecting eminentia arcuata, the other, the longest of all, *canalis semicircularis posterior*, lies nearly parallel to the facies posterior pyramidis and goes above and below considerably beyond the plane of the lateral semicircular canal. Each of them deviates in part somewhat from its plane and so presents a slight "surface curvature"; the posterior and superior, viewed from the side, appears slightly S-shaped, the horizontal curved so as to be slightly C-shaped. The lumen of each semicircular canal has the form of an ellipse the largest diameter of which falls in the plane of the canal; it is largest (measured at the vertex of the semicircular canal) in the posterior canal, smallest in the superior.

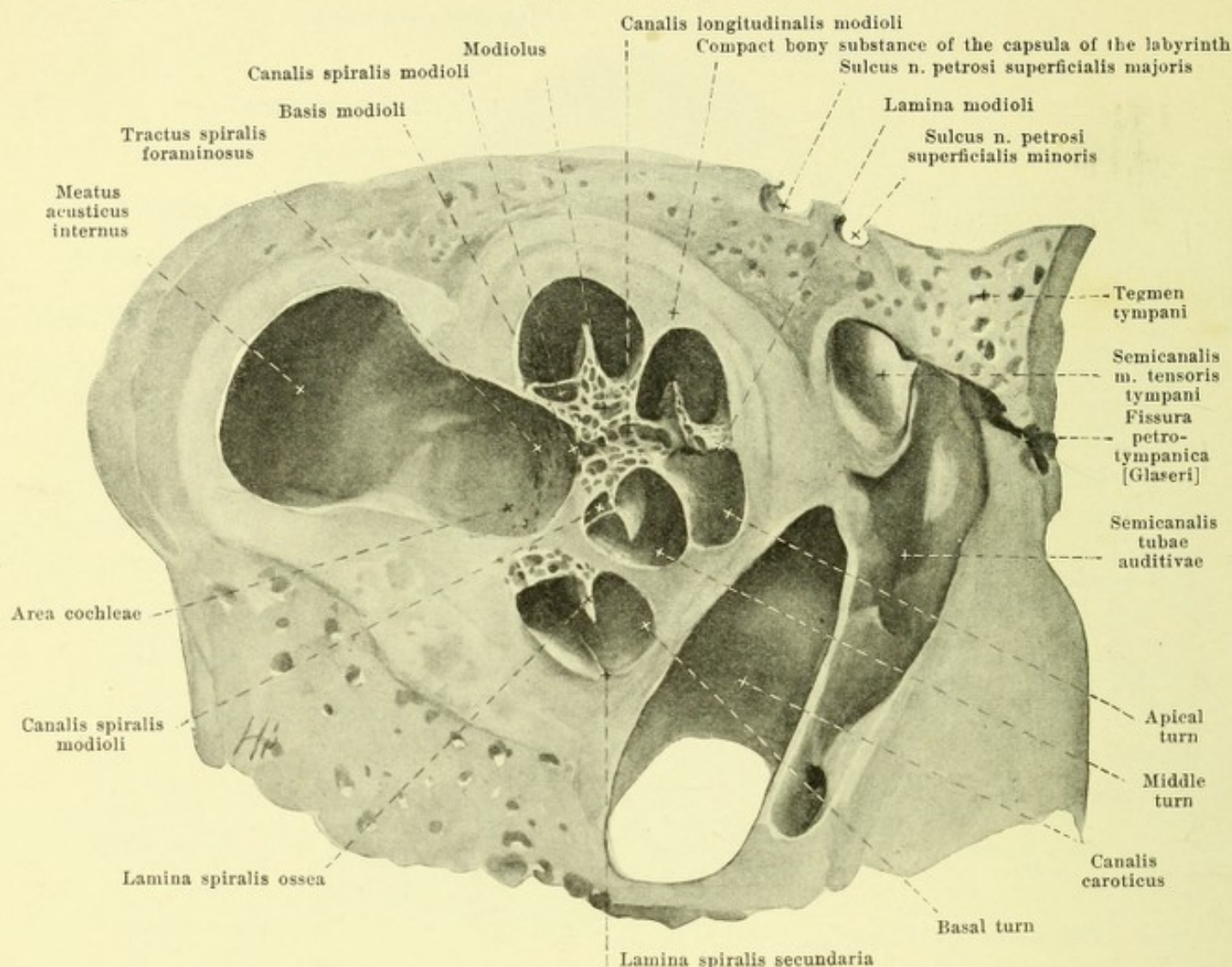


908. Vertical section through the right temporal bone, medial portion, viewed from the lateral side. Magnification 5:1.

(The corresponding lateral portion is shown in Fig. 907.) Concerning the direction of the section see Figs. 904, 905.

Bony semicircular canals (continued) (see also Figs. 899—902, 906, 907). One of the two ends of each semicircular canal presents a flask-like dilatation, *ampulla ossea*; the corresponding limb of the semicircular canal is called the *crus ampullare*, the other non-dilated one, the *crus simplex*. The ampullae osseae vary somewhat in length and width, that of the lateral semicircular canal, *ampulla ossea lateralis*, and that of the superior semicircular canal, *ampulla ossea superior*, lie at their lateral ends, that of the posterior semicircular canal, *ampulla ossea posterior*, at its inferior end. The two ends of the lateral semicircular canal open separately into the vestibule; the same is also true of the crura ampullaria of the superior and of the posterior semicircular canal, the former on the lower wall, the latter close to the upper wall of the vestibulum. The simple limbs of the superior and posterior semicircular canals unite on the contrary to form a common round limb, *crus commune*, $3\frac{1}{2}$ —4 mm long, which forms an angle of 40° — 50° with the horizontal plane (see p. 820) and opens directly behind and over the crus simplex of the lateral semicircular canal into the vestibule.

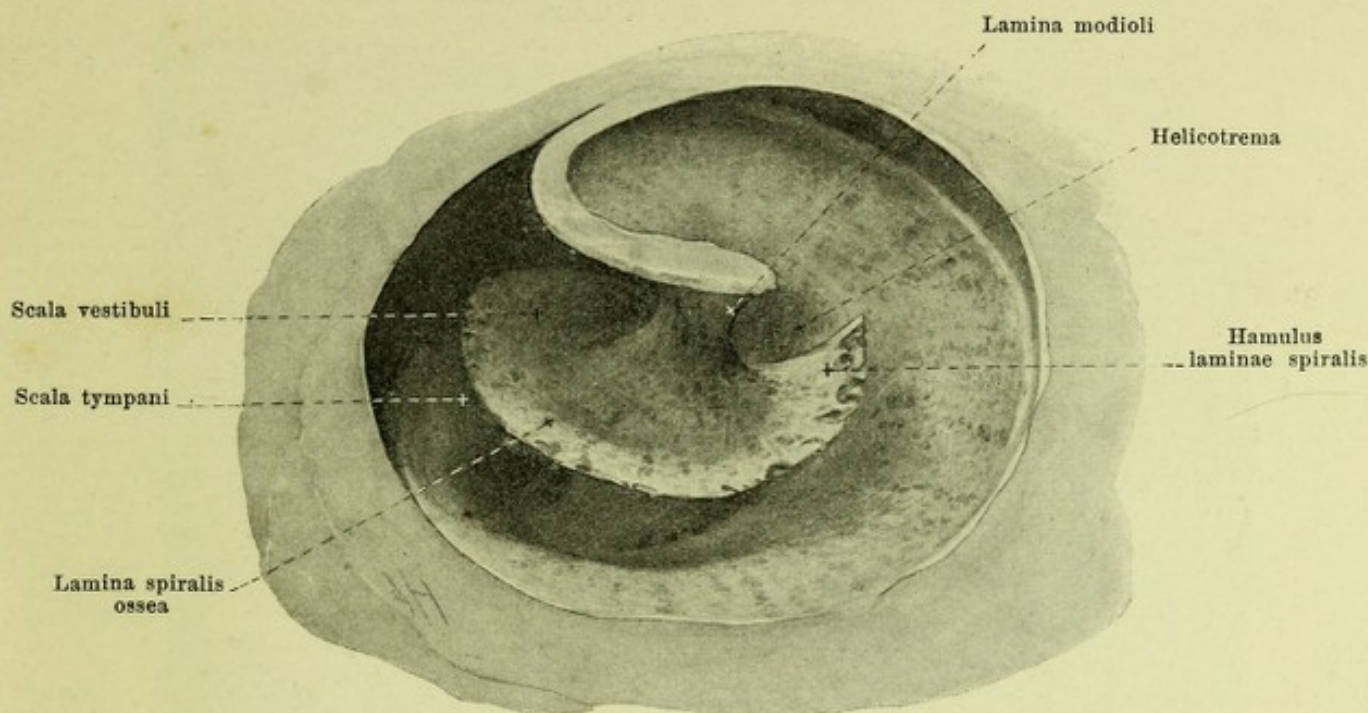
The *snail, cochlea* (see also Figs. 899—903, 906, 907, 909 and 910), is a low cone formed of hard bony substance, its axis being placed horizontally; its base, *basis cochleae*, (see also p. 818) is directed toward the anterior part of the fundus meatus acustici interni, its blunt *apex, cupula*, toward the semicanalis m. tensoris tympani; its inferior anterior wall directly adjoins the rectangular curvature of the canalis caroticus in the temporal bone. In its interior it contains a spirally wound canal, *canalis spiralis cochleae*, which begins in the anterior and lowest portion of the vestibule (see p. 818) and at the fenestra cochleae, and ends blind at the apex.



909. Vertical section through the right cochlea, medial portion viewed from the lateral side. Magnification 6:1.

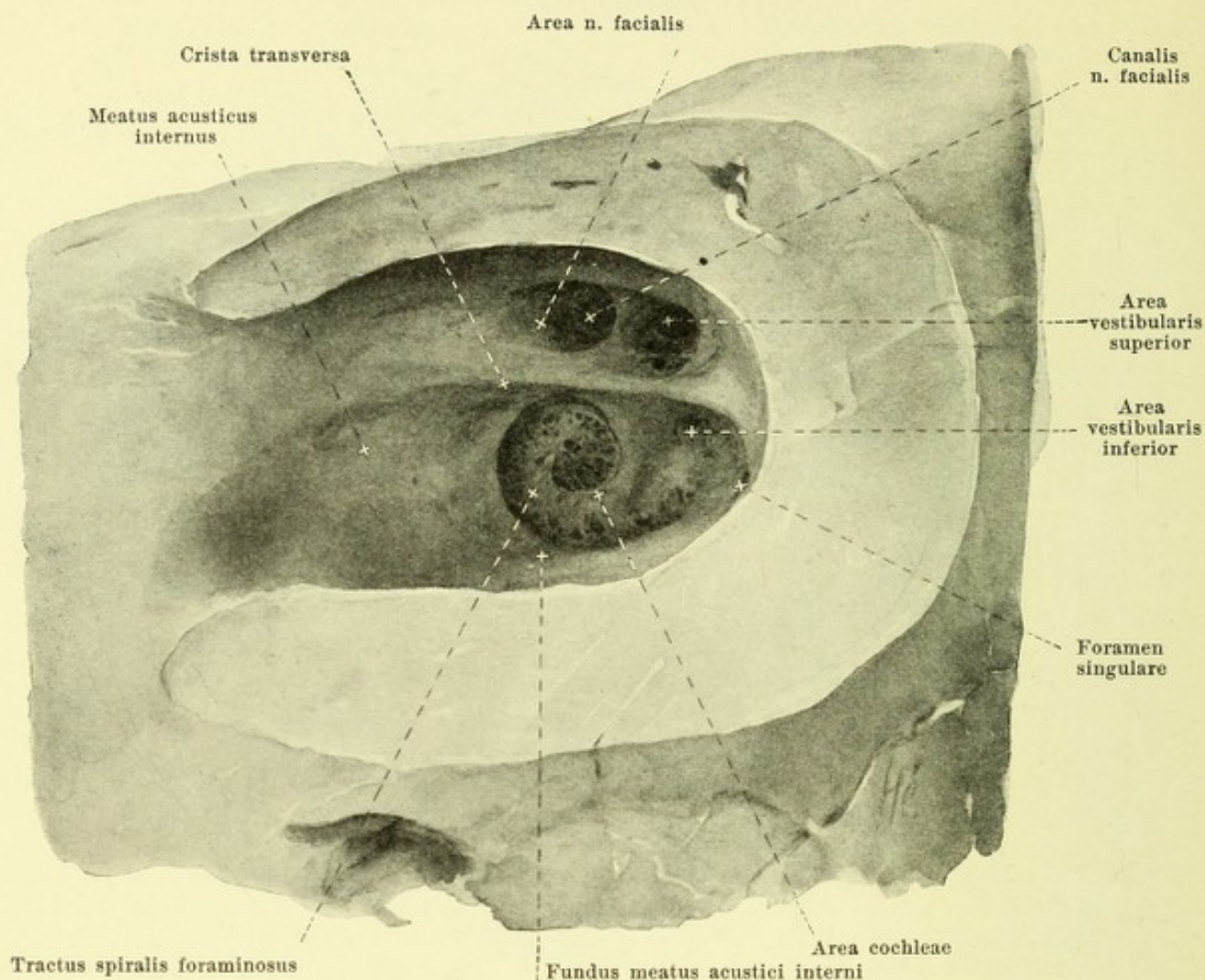
Concerning the direction of the section, see Figs. 904 and 905.

Cochlea (continued) (see also Figs. 899—903, 906—908 and 910). The *canalis spiralis cochleae* (see also p. 821) is on the average 37.5 mm long, runs from its beginning in the vestibule at first curved somewhat downward, medial from the promontorium, forward and medianward as far as the canalis caroticus (see Fig. 903), there bends around upward then curls up on itself first loosely, then more closely, in the form of a spiral, so that usually $2\frac{3}{4}$ turns arise, called the *basal turn*, the *middle turn* and the *apical turn*; these turns do not lie in one plane, but each subsequent one becomes elevated laterally over the preceding and is at the same time more markedly curved than it (see Figs. 899 and 903); the *cupula* (see p. 821) is formed by the blind end and the last portion of the second turn. The axial space of the cochlea around which the canalis spiralis is coiled consists of spongy bone substance and is called the *modiolus (spindle)*; this represents at the same time the inner wall of the canal; the outer wall of the canal is formed by the compact capsule of the labyrinth (see p. 817) and is connected with the spindle by thin lamellae of bone, which at the same time form the septa between the neighboring turns. The modiolus is hollowed out on that surface which is turned toward the fundus meatus acustici interni, *basis modioli*, almost as far as half the height of the first turn and there forms the floor of the area cochleae (see p. 824). The spindle is perforated by one larger or several smaller canals, *canales longitudinales modioli*, running parallel to the axis. At the apex it goes over laterally into a thin compact bony layer, *lamina modioli* (see also Figs. 903, 906 and 910), around which the end of the apical turn curves; the lamina modioli ends by a concave margin, is attached to the cupula and goes over directly into the septum between the second and the third turn.



910. Cupula of the right bony cochlea, opened,
viewed from the outside. Magnification 15:1.

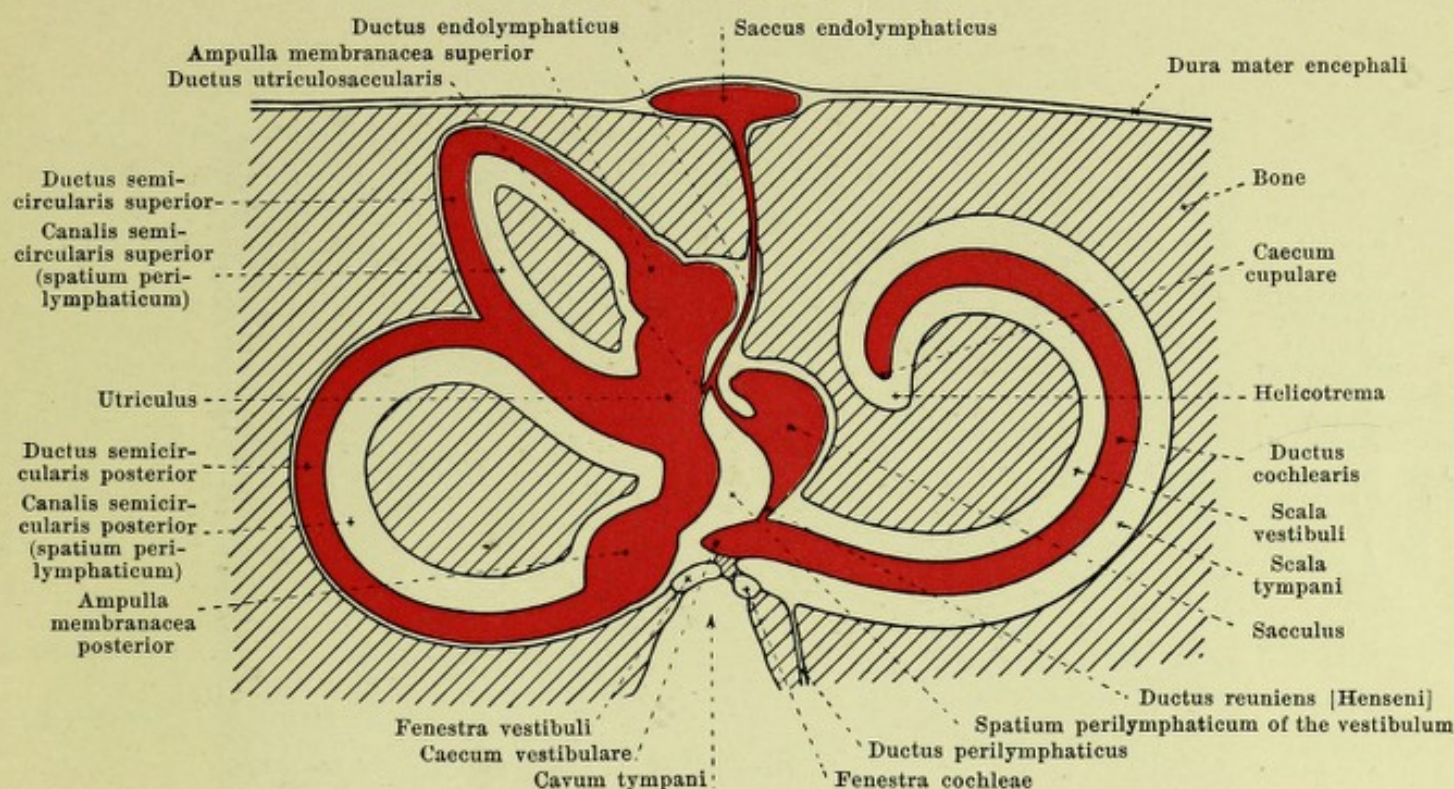
Cochlea (continued) (see also Figs. 899—903, 906—909). The diameters of the lumen of the canalis spiralis cochleae parallel and perpendicular to the axis of the modiolus are almost equal (about 2 mm) in the first half of the basal turn; in the second half of the basal and in the middle turn, the height (parallel to the axis) is 2 mm, the breadth (perpendicular to the axis) 1.5 mm; in the third turn the height quickly diminishes and the breadth exceeds it. Springing out from the spindle is a delicate bony plate, *lamina spiralis ossea*, *bony spiral layer*, midway between two septa, for some distance into the lumen of the canalis spiralis; it divides this incompletely into the *scala vestibuli*, *vestibular staircase*, turned toward the cupula, and the *scala tympani*, *tympanic staircase*, nearer the base of the cochlea, the two becoming completely separated by the interposition of the membranous cochlear canal. The spiral layer and vestibular and tympanic staircases run along the whole canalis spiralis and are therefore also turned in a spiral. In the region of the basal turn the scala tympani is wider than the scala vestibuli; in the middle and apical turn the reverse is true. The breadth of the spiral layer corresponds approximately to half the breadth of the canalis spiralis (vide supra) and accordingly diminishes somewhat from the base toward the apex; at the beginning of the third turn, the spiral layer becomes separated from the modiolus and ends in a free projecting process, *hamulus laminae spiralis*, ending tapered off; between the concave margin of the latter, the lamina modioli and the terminal portion of the ductus cochlearis, a round opening, *helicotrema* (see also Figs. 913 and 915), forms the sole connection between the scala vestibuli and scala tympani which are otherwise separated from one another by the ductus cochlearis. Along the attachment of the lamina spiralis ossea in the modiolus runs a triangular canal, *canalis spiralis modioli*, for the ganglion spiralis n. cochleae. The lamina spiralis ossea begins directly lateral from and in front of the recessus cochlearis of the vestibule (see Figs. 903, 906 and 908) as a broad plate and goes over, there, into a smaller similarly formed bony platelet, *lamina spiralis secundaria*, which runs at first separated from it by a narrow, then by a broader slit, on the inferior surface of the first half of the basal turn (see also Fig. 900), becoming gradually lower as it goes and finally vanishing. Only the space situated lateral from the two laminae spirales, the scala vestibuli, opens at its beginning in the vestibule; the medial of them, the scala tympani, ends there as a blind sac and in the macerated bone communicates with the tympanic cavity through the fenestra cochleae (see p. 810), but is otherwise separated from it by the membrana tympani secundaria; in this latter blind-sac-like portion lies the internal opening of the *canaliculus cochleae* (see p. 9).



911. Right internal acoustic canal, viewed from the medial side. Magnification 6:1.

(The upper, posterior and inferior walls have been in large part removed.)

Meatus acusticus internus, internal acoustic canal (see also p. 9 and Figs. 901, 906 and 909) is a short canal running nearly transversely and frontally, the lumen of which varies individually and which begins medial in a transversely oval opening, *porus acusticus internus*, bounded by a sharp lateral and blunt medial margin; the lateral end, *fundus meatus acustici interni*, floor of the internal acoustic canal, is closed by a bony plate, which is in large part also the medial wall of the vestibule and cochlea. It is divided into an upper and a lower area by a horizontal sharp ridge, *crista transversa*. The upper smaller area, in an anterior depression, *area n. facialis*, contains the internal opening of the canalis facialis Fallopii (see p. 12) and in a posterior funnel-shaped depression, *area vestibularis superior*, contains several delicate openings of small canals which conduct the branches of the upper terminal rami of the n. vestibularis (see p. 703) to the macula cribrosa superior of the vestibule (see p. 818). The lower, larger area presents in front a rounded depression, *area cochleae*, in which begins a broad, spiral band, curved like the cochlea, of variably-sized openings, *tractus spiralis foraminosus*, which ends in the lateral part; these foramina carry the bundles of the n. cochleae directly to the basal turn or through the canales longitudinales modioli to the middle and apical turns. In the posterior part of the inferior area, close below the crista transversa, lies an area with small openings, *area vestibularis inferior*, which conducts the bundles of the n. saccularis (see p. 704) through small canaliculi to the macula cribrosa media of the vestibule (see p. 818), and somewhat medianward and behind it is to be found a single larger foramen, *foramen singulare*, whence the n. ampullaris posterior (see p. 704) passes through a longer delicate canaliculus to the macula cribrosa inferior (see p. 818).



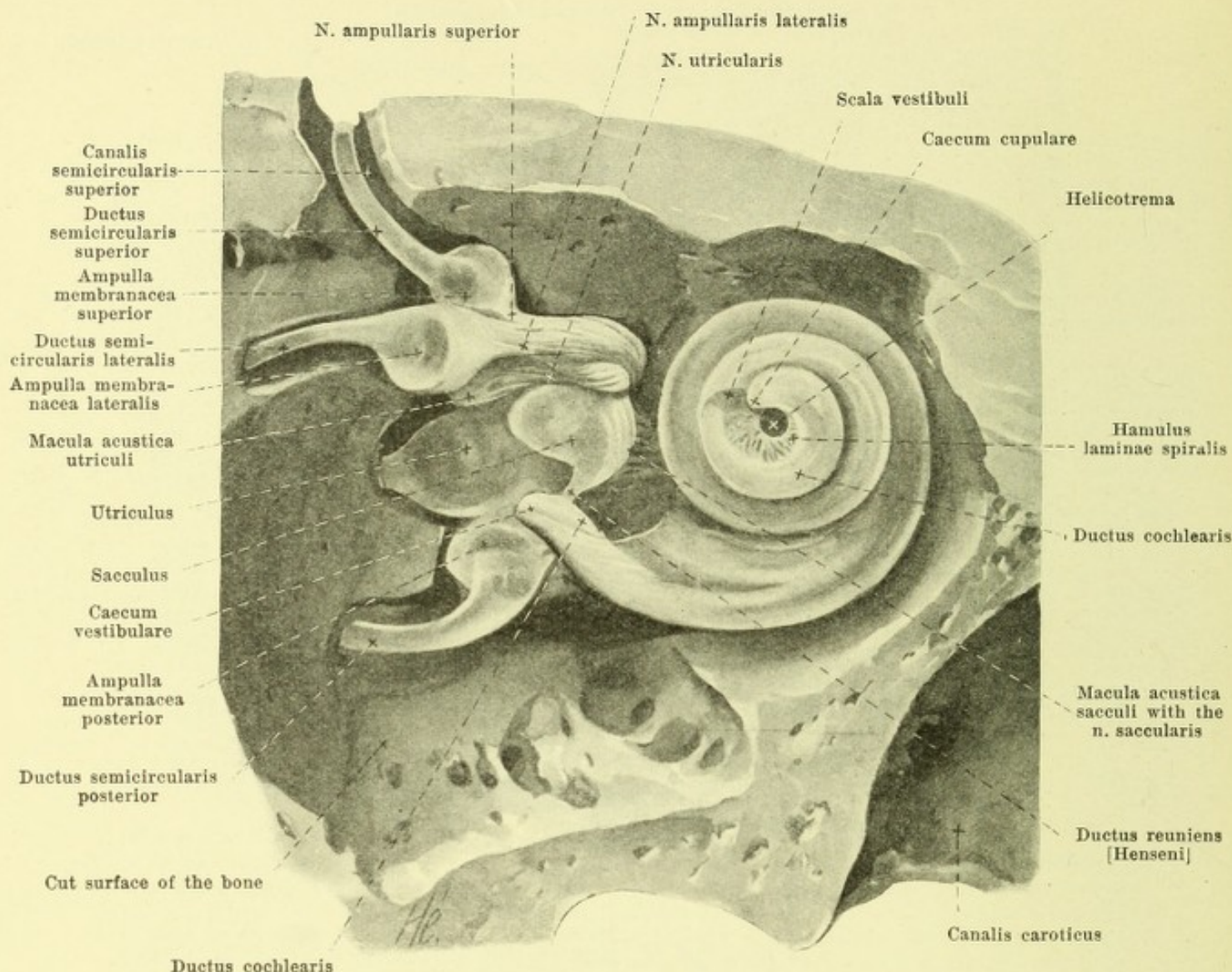
912. Scheme of the right bony and membranous labyrinth. Magnification 5:1.

(The perilymphatic space is shown in white, the endolymphatic in red. The lateral semicircular canal it not shown.)

Labyrinthus membranaceus, membranous labyrinth (see also Figs. 913—919) is a system of cavities which contain the terminations of the n. acusticus, lined by epithelium and filled by a clear fluid, *endolympha*, poor in albumin. These cavities all communicate with one another but are completely shut off from the outside and lie in the spaces of the bony labyrinth, the forms of which they approximately repeat; their transverse diameter is everywhere smaller than that of the bony canals concerned, and there remains between their delicate walls and the bone a system of communicating spaces which are lined with endothelium, contain a clear fluid, *perilympha*, poor in albumin, and together are known as the *spatium perilymphaticum*.

In the vestibulum the membranous labyrinth is formed by the two *vestibular saccules*, the *utricle* and the *sacculus*. The *utricle* (see also Figs. 913, 914 and 917) is an approximately tube-shaped vesicle directed from above and in front downward and backward; it lies in the recessus ellipticus of the vestibule (see p. 818) is there in large part tolerably firmly attached to the bone by connective tissue, and by the bundles of the n. utricularis emerging from the macula cribrosa superior, but otherwise separated by perilymphatic spaces from the wall of the vestibule. The upper slightly constricted part presents on its anterior lateral surface an oval thickened place of a whitish color, *macula acustica utriculi*, in which the fibers of the n. utricularis (see p. 703) terminate.

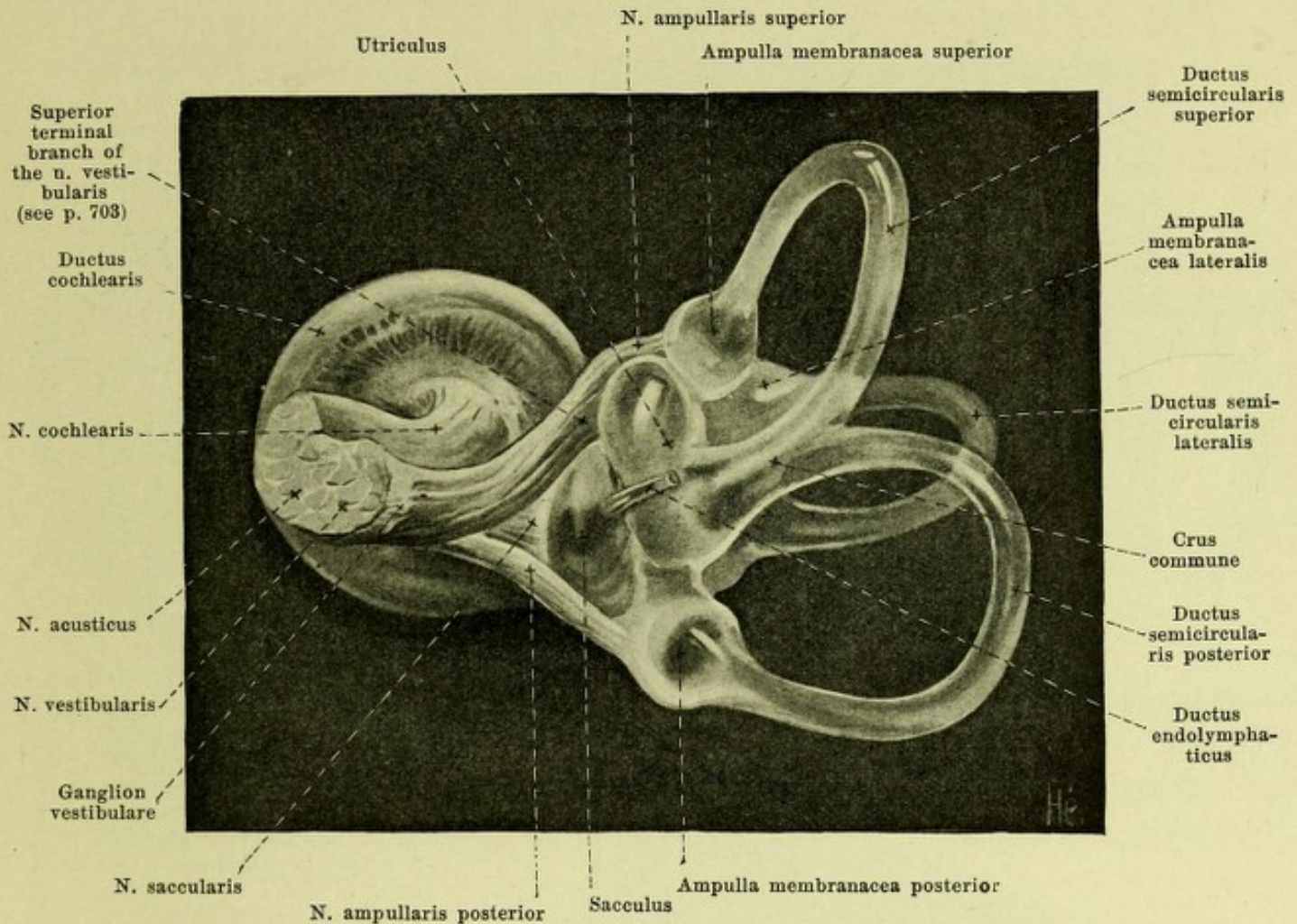
In the utricle open the three *membranous semicircular canals, ductus semicirculares*, which lie in the three bony semicircular canals, correspond to them exactly in arrangement and course, and are distinguished accordingly as *ductus semicircularis lateralis, superior, posterior*; they empty by five openings into the utricle. Each membranous semicircular duct lies eccentrically on the convex side of the bony canal, and its diameter is only one-third of that of the bony canal; the perilymphatic space is also very large here and is crossed by single strands of connective tissue. Corresponding to the three ampullae osseae there are also three *ampullae membranaceae* in the membranous ducts, which analogous to the bony ones are designated *ampulla membranacea lateralis, superior, posterior*; they represent very marked dilatations of the membranous ducts, appear sharp and large on the concave side of the ducts and much more completely fill up their bony space; each of them presents on its surface turned toward the convex side of the semicircular canal a transverse groove, *sulcus ampullaris*, in which the n. ampullaris (see p. 703—704) enters, and a sickle-shaped ridge, *crista ampullaris*, projecting thence into the lumen.



913. Right membranous labyrinth of an adult, partially exposed, lateral and front view. Magnification 5:1.

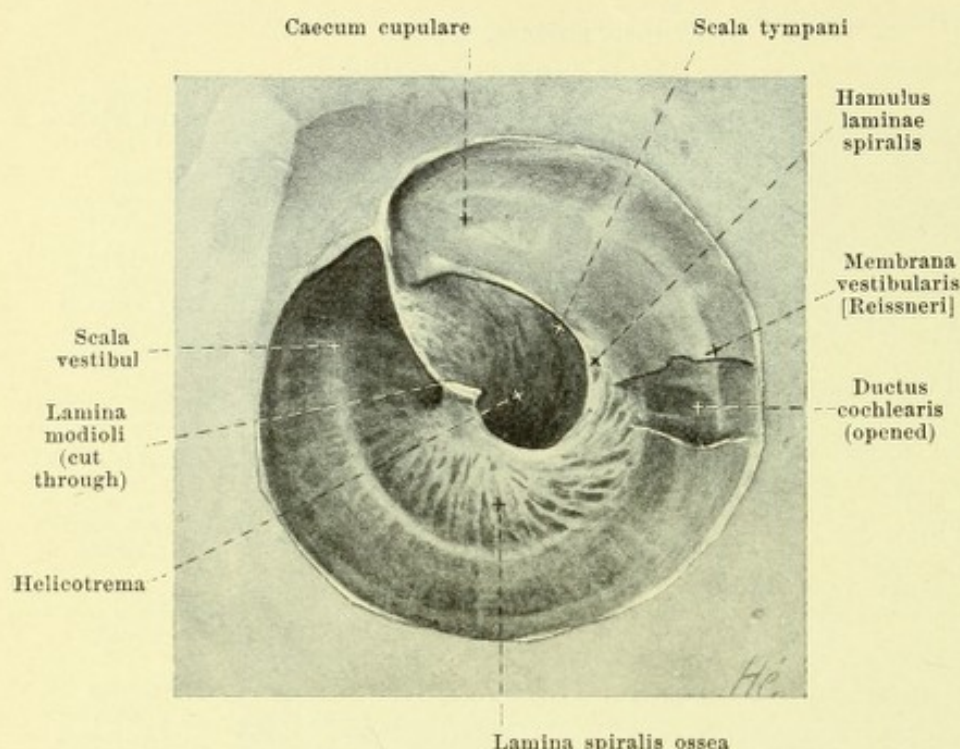
(The lateral and upper portions of the capsule of the labyrinth have been carefully removed in a decalcified temporal bone. The scala vestibuli has been opened only at its beginning and at its end.)

Labyrinthus membranaceus (continued) (see also Figs. 902, 914—918). The *sacculus* is a flattened oval vesicle with its long diameter vertically placed; it lies in the recessus sphaericus of the vestibule (see p. 818), is fairly firmly attached to the bone there by connective tissue and the bundles of the n. saccularis emerging from the macula cribrosa media, but otherwise is separated from the walls of the vestibule by a large perilymphatic space. Its lower end narrows gradually to become the *ductus reuniens* [Henseni], a delicate duct, 0.5 mm wide, 1 mm long, connecting the sacculus with the ductus cochlearis (see p. 827). On the medial anterior surface of the sacculus a thickened area, *macula acustica sacculi*, can be made out in which the fibers of the n. saccularis (see p. 704) terminate. The sacculus is not directly connected with the utricle, but only indirectly through the *ductus endolymphaticus*; this arises as a very fine canal from the posterior wall of the sacculus, receives the short and very fine *ductus utriculosaccularis* which goes off from the anterior medial wall of the utricle, and then passes through the aquaeductus vestibuli to the posterior surface of the pyramid of the temporal bone; it ends there in a flattened caecal dilatation, *sacculus endolymphaticus*, which is situated just below the apertura externa aquaeductus vestibuli in a duplicature of the dura mater encephali and is not connected with the surrounding lymph spaces.

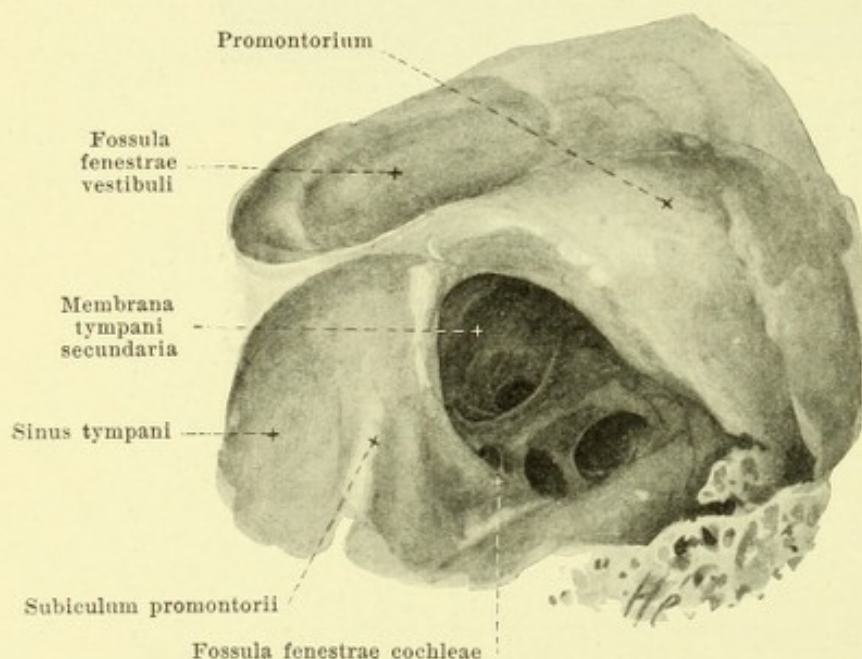


914. Right membranous labyrinth of an adult, isolated, medial and posterior view. Magnification 5:1.

Labyrinthus membranaceus (continued) (see also Figs. 912, 913, 915—918). The cochlear part of the membranous labyrinth is formed by the *ductus cochlearis*. This begins in the recessus cochlearis of the vestibule, extends within the canalis spiralis cochlea as a narrow spirally turned duct as far as the end of the apical turn where it ends blind; near its beginning it is united with the sacculus by the ductus reuniens Henseni. It is in large part triangular in cross-section (see Fig. 918). Its outer wall unites with the thickened periosteum of the inner surface of the cochlear canal. Its wall parallel to the base of the cochlea runs in the direction of the lamina spiralis ossea from its free margin to the *ligamentum spirale cochleae*, a ridge-like projection of the periosteum of the outer wall; it consists of a fibrous plate of connective tissue, *lamina basilaris* and supports the *organon spirale [Corti]*, an epithelial structure which contains the termination of the fibers of the n. cochlearis (see p. 704). The third wall, *membrana vestibularis [Reissneri]* is remarkably thin, arises from the lamina spiralis ossea near its free margin and passes at an angle of approximately 45° to the outer wall. The ductus cochlearis thus separates two perilymphatic spaces from one another, of which that near the membrana vestibularis is called the *scala vestibuli*, that near the lamina basilaris, the *scala tympani*. In the apical turn (see Fig. 915) the somewhat flattened ductus cochlearis projects beyond the hamulus laminae spiralis, its blind end, *caecum cupulare*, being deposited in the cupular cavity of the apical turn and so helping to form the *helicotrema* (see p. 823). The beginning of the ductus cochlearis is also in the form of a blind sack, and projects a little beyond the opening of the ductus reuniens Henseni; this portion is called the *caecum vestibulare* and rests in the recessus cochlearis of the vestibule (see p. 818). The perilymphatic space communicates with the cavum subarachnoideale by a fine canal, *ductus perilymphaticus*, situated in the canaliculus cochleae, near the v. canaliculi cochleae.



915. Cupula of the right cochlea, opened, viewed from the outside. Magnification 15:1.



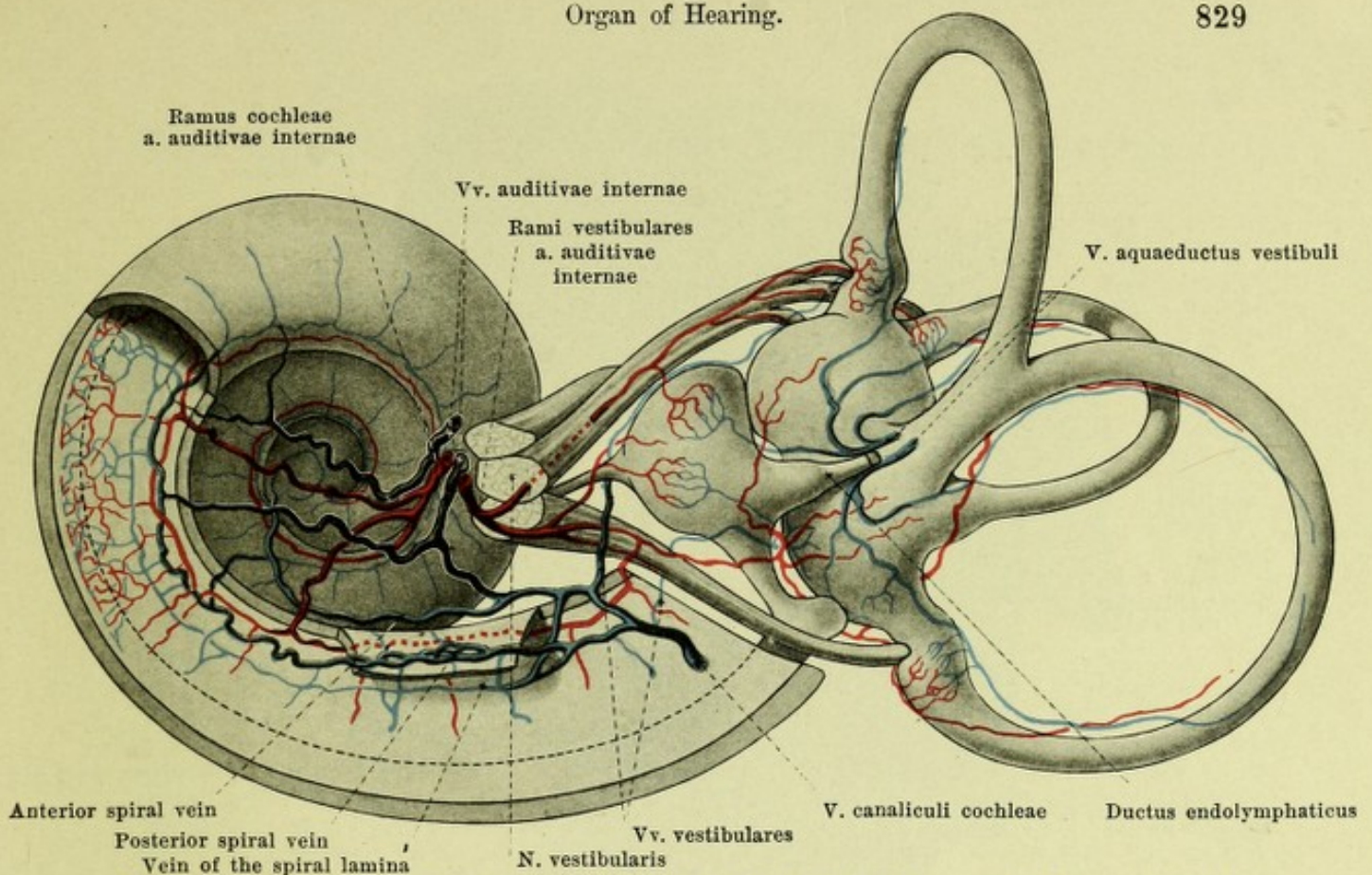
916. Right membrana tympani secundaria, lateral and inferior view. Magnification 12:1.

The fenestra cochleae is closed by a thin connective tissue membrane, *membrana tympani secundaria* (accessory ear-drum membrane) (see Fig. 916) which arises on the crista fenestrae cochleae (see p. 810) and is usually bulged somewhat into the scala tympani; its lateral surface is covered by the mucous membrane of the tympanic cavity which is continued upon it with one or several folds.

Blood vessels of the internal ear, vasa auris internae (see Figs. 917 and 918). The single afferent vessel is the *a. auditiva interna* (see also p. 404) which enters the internal acoustic meatus along with the *n. acusticus*; there it divides into *rami vestibulares* and the *ramus cochleae*, the former pass with the single nerve branches to the saccus, utricle and the membranous semicircular canals, form a rich vascular network on the maculae acusticae and ampullae membranaceae and send branches to the lining of the spatium perilymphaticum; one of these branches goes over to the first third of the basal turn and anastomoses there with a branch of the *ramus cochleae*. The *ramus cochleae* enters the spindle, usually sends two branches to the rest of the basal turn, and by its terminal branch supplies the whole middle and apical turns; these branches run in the modiolus close to the origin of the lamina spiralis ossea and give off terminal branches continuously, 1st to the ganglion spirale cochleae, 2nd into the lamina spiralis ossea as far as the organon spirale Cortii, and 3rd in the wall off the scala vestibuli as far as the lig. spirale cochleae. The *vv. vestibulares* collect

the blood from the capillary domains of the semicircular ducts and the vestibular saccules; they form in largest part the delicate *v. aquaeductus vestibuli*, run in separate canals and empty into the sinus petrosus superior; a part of them open also into the *v. canaliculi cochleae*.

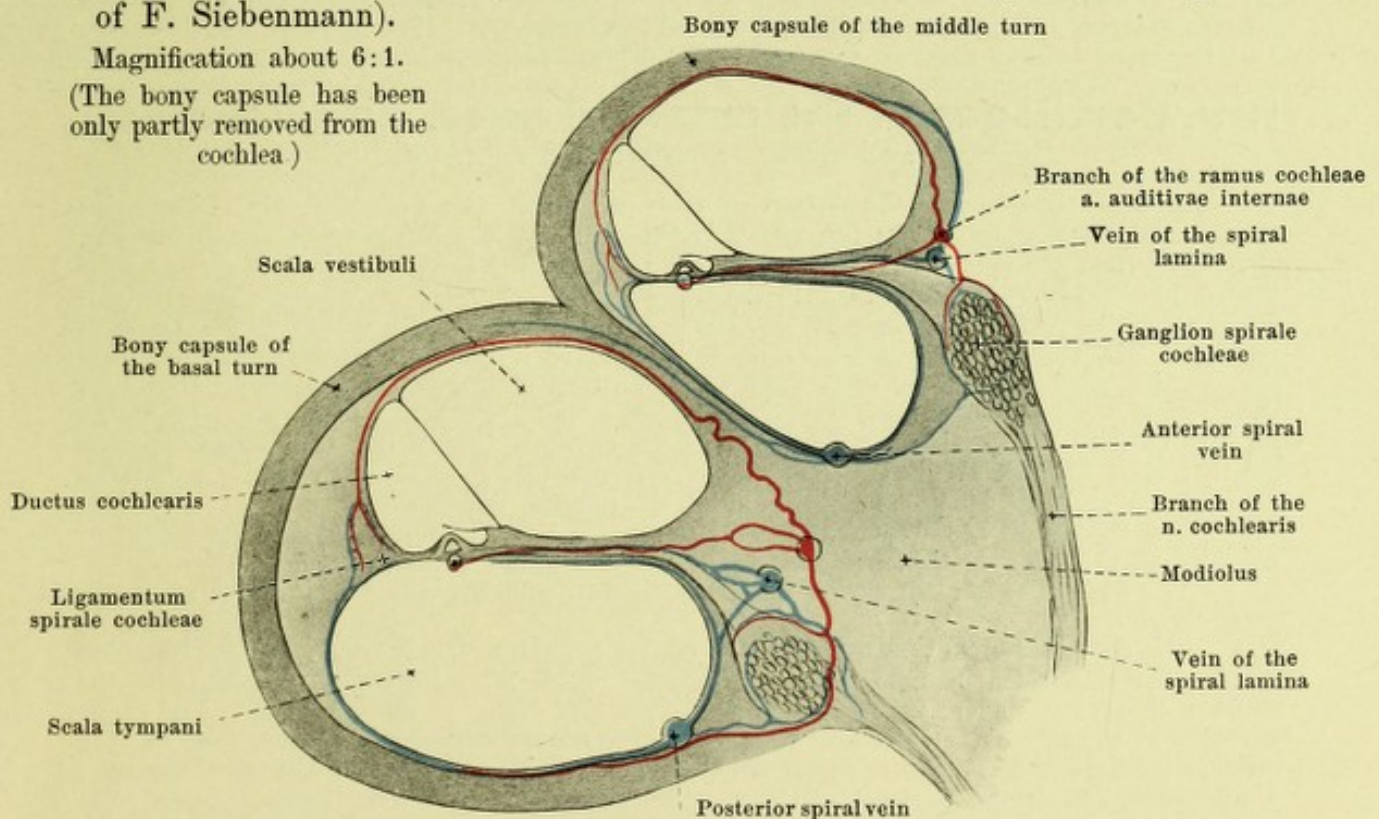
The capillary domain of the lamina spiralis empties its blood through radial vessels in the *vein of the spiral lamina* which runs along the origin of the lamina spiralis and empties into the two spiral veins at the beginning of the basal turn.



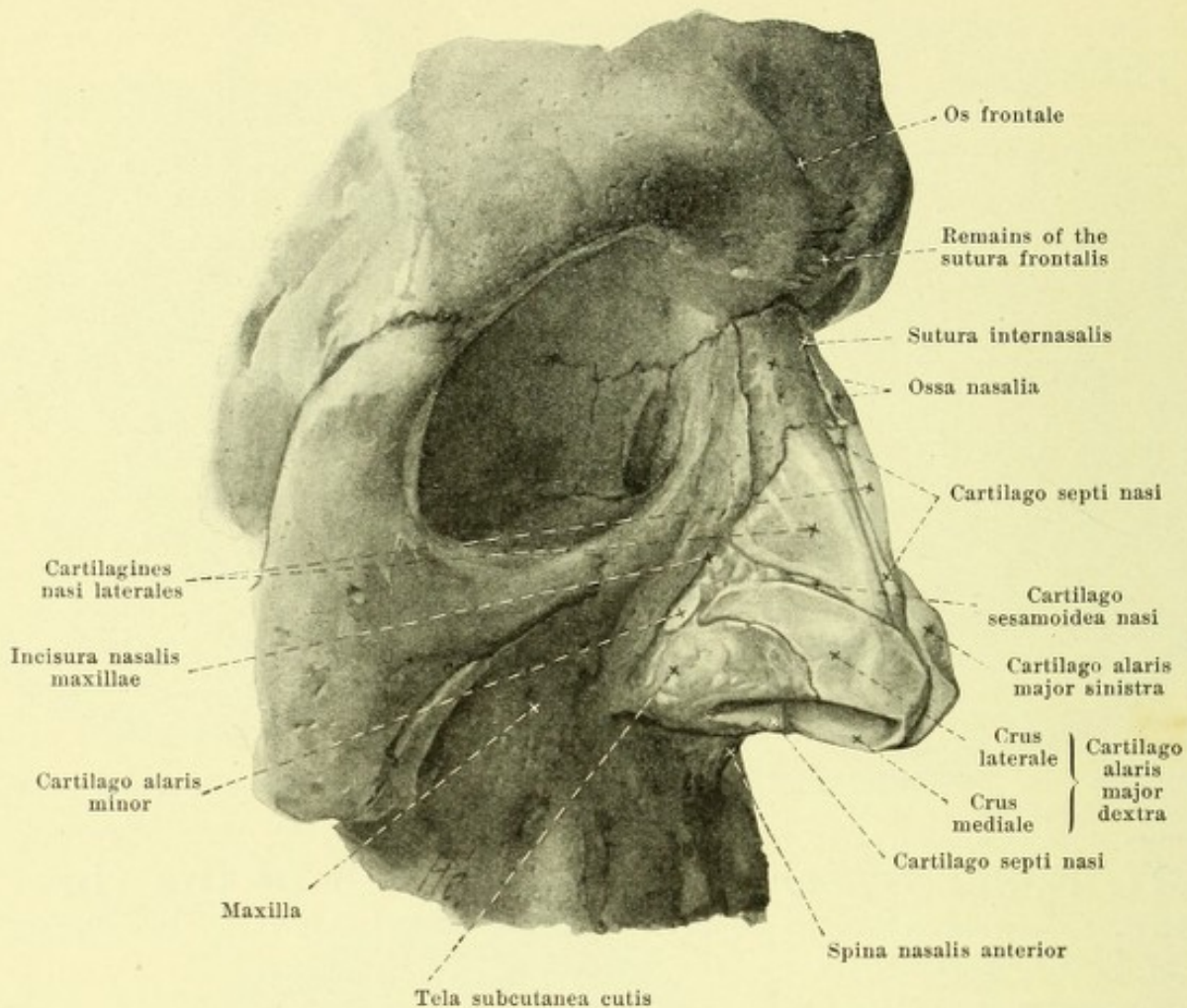
917. Blood vessels of the labyrinth of the right ear, somewhat schematic, viewed from the medial side (after description of F. Siebenmann).

Magnification about 6:1.

(The bony capsule has been only partly removed from the cochlea)



918. Section through the basal and middle turns of the cochlea schematic (after F. Siebenmann). Magnification about 18:1.



919. Cartilages of the external nose, dissected out, viewed from the right and in front.

Blood vessels of the internal ear (continued) (see Figs. 917, 918). The veins from the capillary region of the lig. spirale cochleae, from that of the ganglion spirale cochleae, and partly from the spiral lamina empty in the region of the basal and of a part of the middle turn, into the *posterior*, otherwise into the *anterior, spiral veins*; the afferent branches surround the scala tympani but in part also run along with the arteries in the wall of the scala vestibuli. The spiral veins together are spoken of as the *v. spiralis modioli* and each of them lies on the basal wall of the scala tympani of the turn of the cochlea concerned; they both open into the conspicuous *v. canaliculi cochleae* (see p. 446). From the vein of the spiral lamina as well as from the spiral veins there is given off always a branch into the internal acoustic meatus, there to enter the large *vv. auditivae internae* (see p. 444) which receive tributaries mainly from the n. acusticus and the walls of the internal acoustic meatus.

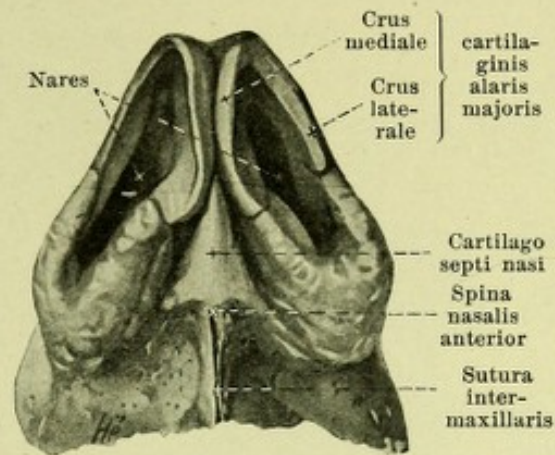
The **Organ of Smell, organon olfactus**, lies in the nose; but this must also be regarded as belonging to the organs of respiration, the initial portion of which it forms.

The **nose, nasus**, consists of the *external nose* and the *nasal cavity* with its *accessory cavities*.

The **external nose, nasus externus** (see also Figs. 513, 920—924) has the shape of an irregular three-sided pyramid which is connected on its basal surface, *basis nasi*, with the skeleton of the face and at its margin projects from the region of the upper jaw. The upper narrow end which joins the forehead is called the *radix nasi, root of the nose*; from this the *dorsum nasi, back of the nose*, passes obliquely downward and forward to the *tip of the nose, apex nasi*. The lateral surfaces of the nose are more markedly curved below, project more and are limited laterally by a sharp groove; this part is movable and corresponds to the *nasal wings, alae nasi*, the lower free margin of which, *margo nasi*, surrounds the *nasal openings, nares*; the latter are separated from one another by the most anterior movable part of the nasal septum, *septum mobile nasi*.

920. Cartilages of the external nose, dissected out, viewed from below.

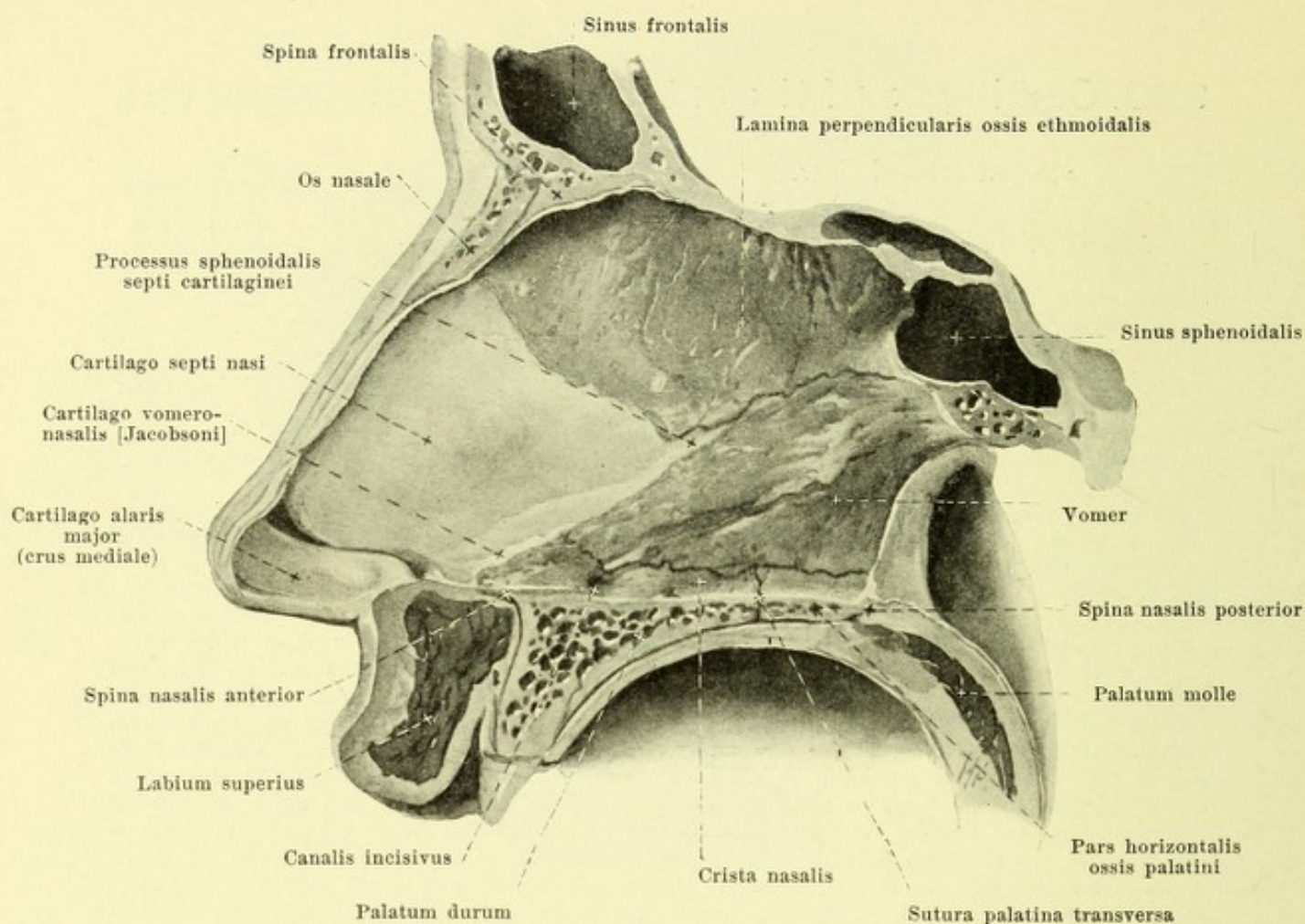
Nasus externus (continued) (see also Figs. 919, 921—924). The framework of the external nose is formed by the nasal bone and by the *nasal cartilages, cartilagine nasi*, which consist of hyaline cartilage. Both are partly covered on the external surface by the nasal muscles, and by the external skin, while the inner surface is clothed by the mucous membrane of the nasal cavity. The nasal bones form only the upper smaller part of the external nose; the cartilaginous and membranous part is attached directly to the apertura piriformis (see p. 62) and closes this completely with the exception of the nares.



The *cartilago nasi lateralis*, paired, is a thin irregular triangular plate, which forms the middle part of the lateral wall. Its upper margin is shoved somewhat behind the nasal bone and the proc. frontalis maxillae and is attached to this by tough connective tissue; its inferior margin reaches partly as far as the cartilago alaris major; its medial margin fuses on the dorsum nasi partly with the anterior margin of the cartilago septi nasi. The *cartilago alaris major*, paired, is especially thin and of uncommonly variable development. It consists of two curved horse-shoe plates which go over into one another in front and which so surround the nares that the broader *crus laterale* helps to form the nasal wing and above is partly in contact with the cartilago lateralis, while the *crus mediale*, along with that of the other side passes for some distance backward in the septum mobile nasi and unites with this and with the cartilago septi loosely. The *cartilagine alares minores* are small, irregular pieces of cartilage which are found separated from the preceding in a variable number on each side in the posterior part of the nasal wing. The name *cartilagine sesamoideae nasi* is given to one or two very small pieces of cartilage which are situated on each side between the cartilago lateralis and the cartilago alaris major. In the posterior inferior portion of the nasal wing is a region of variable size which is free from cartilage; it is formed by a duplicature of the skin only.

The *cartilago septi nasi, septal cartilage* (see also Figs. 919 and 921) is an unpaired median irregular quadrilateral plate of cartilage which forms the anterior inferior part of the nasal septum and is inserted in the angle between the lamina perpendicularis oss. ethmoidalis and the vomer. The posterior superior margin is united with the lamina perpendicularis; the posterior inferior is laid in the groove of the vomer and of the anterior part of the crista nasalis maxillae. The anterior superior margin begins above behind the sutura internasalis and extends forward below as far as the dorsum nasi between the two cartilagine laterales, uniting with both above. The anterior inferior margin forms in front the upper boundary of the septum mobile nasi, reaches behind somewhat deeper and is attached there to the spina nasalis anterior. From the posterior angle a process of variable height, *processus sphenoidalis septi cartilaginei* is inserted backward and upward into the anterior groove of the vomer (see p. 26), between it and the lamina perpendicularis oss. ethmoidalis, sometimes extending close to the sphenoid bone. The cartilage of the septum is, like the bony nasal septum (see p. 62), partly displaced to one side or the other. The *cartilago vomeronasalis Jacobsoni* (see Fig. 921) is a small strip of cartilage which lies close over the spina nasalis anterior on each side of the cartilago septi nasi (see also p. 833).

The external skin of the nose is very thin, is fastened above to the subjacent tissue by looser connective tissue free from fat, and to the nasal wings by tough connective tissue. Its hairs, especially toward the tip, are very fine. Its sebaceous glands, especially on the posterior part of the nasal wing are extraordinarily large. The skin is reflected at the nares upon the inner surface of the nose and at the limen nasi gradually goes over into the mucous membrane; it presents for some distance in the nares sebaceous glands and hairs which are here called the *vibrissae* and which may reach a considerable size.

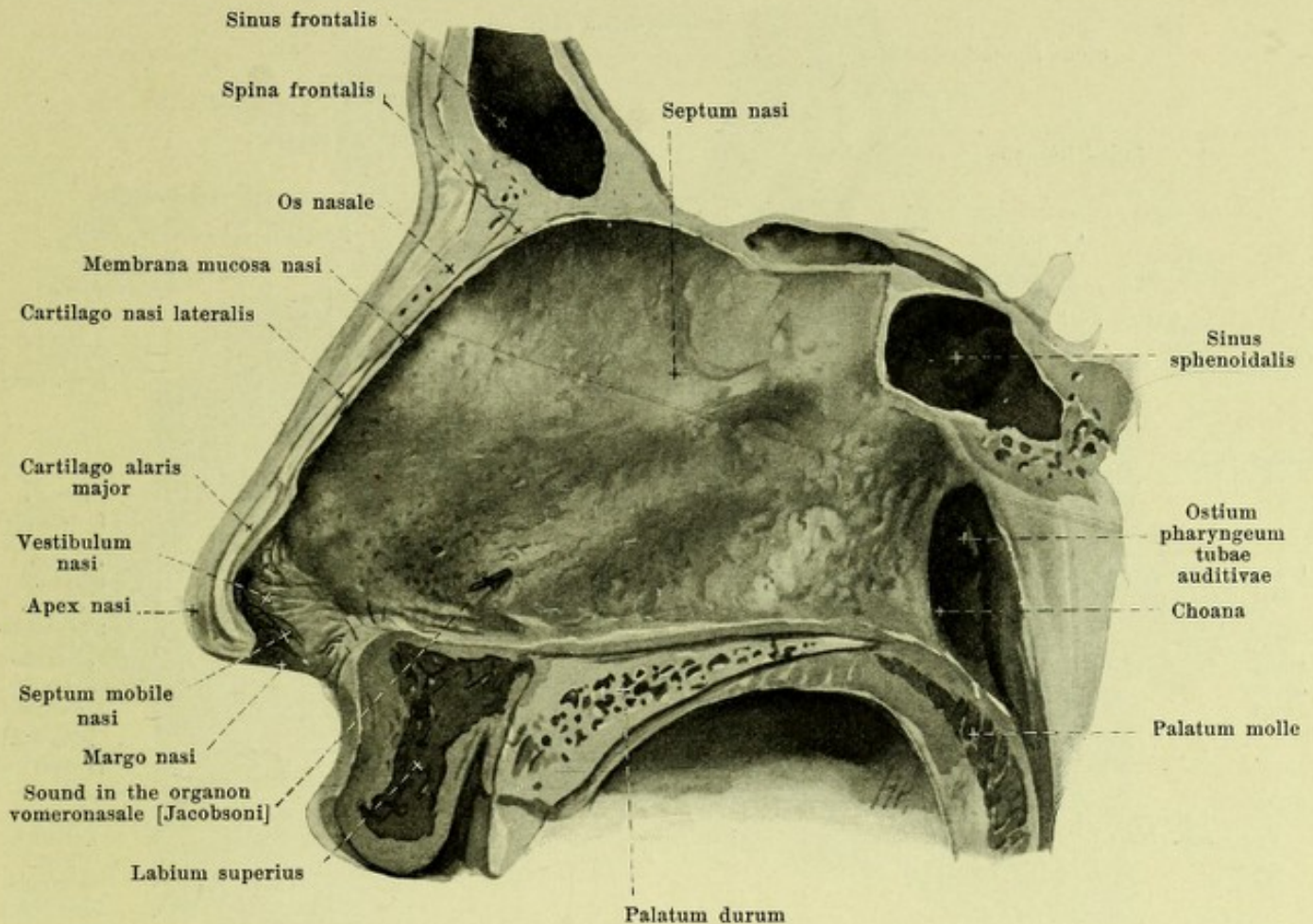


921. Nasal septum without the mucous membrane. Viewed from the left.

(Figs. 921 and 922 come from the same preparation, but are from a different head than Figs. 923 and 924.)

The *nasal cavity*, *cavum nasi* (see also Figs. 73—75, 517, 549, 550, 922—925) is bounded by the inner surface of the external nose and by bone (see pp. 60—62). It opens in front through the *nares*, *nasal openings*, bordered only by skin and situated on the inferior surface of the external nose; they are of very variable form and are somewhat obliquely placed. Behind, the nasal cavity communicates with the pharynx through the two adjacent, quadrilateral, *choanae* (see p. 60). It is divided into two symmetrical halves by the medianly-placed *nasal septum*, *septum nasi*, which usually deviates somewhat to one side; the upper and posterior part of the septum is bony and is called the *septum nasi osseum* (see p. 62); the anterior part is formed by the cartilago septi nasi (see p. 831) and is called the *septum cartilagineum*; attached to this in front and below is the *septum membranaceum* which lies between the two nares, contains the crura medialis of the cartilagine alares majores and is also designated the *septum mobile nasi* (see p. 830).

The walls of the nasal cavity are lined by mucous membrane, *membrana mucosa nasi*. This is of fairly even thickness and is markedly thicker only upon the middle and inferior turbinated bones. It repeats therefore, on the whole the form of the nasal cavity and its (cartilaginous and bony) walls, which have already been exactly described on pp. 60—62, the only difference being that the air-containing inner spaces are more or less narrowed.



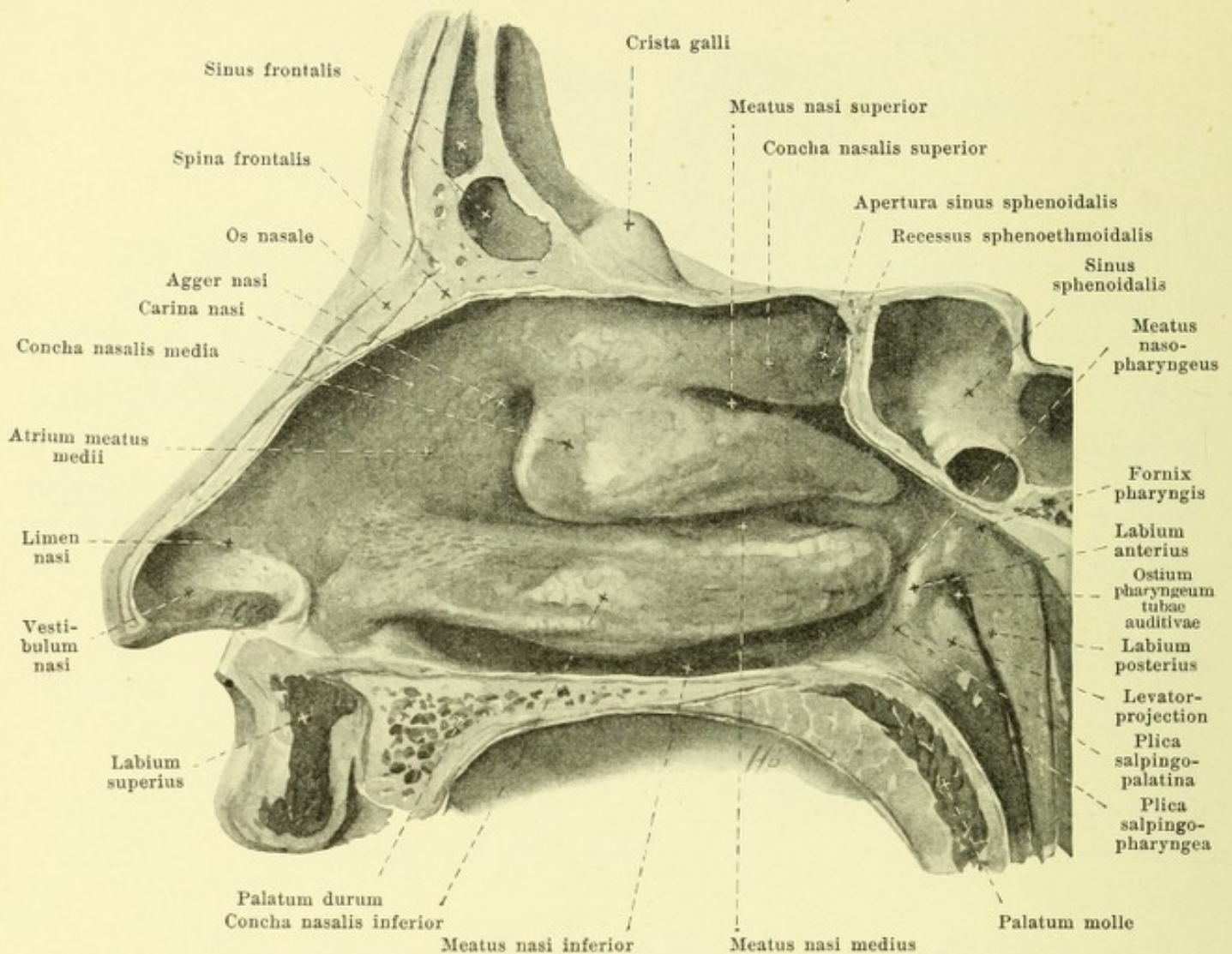
922. Nasal septum with the mucous membrane intact, viewed from the left.

(Figs. 921 and 922 have been taken from the same preparation, though from another head than that used in Figs. 923 and 924.)

Nasal cavity (continued) (see also Figs. 73—75, 517, 549, 550, 923—925). The space, which is enclosed by the movable nasal wings is called the *vestibule*, *vestibulum nasi*; it is marked off above from the nasal cavity proper by a distinct ridge on the lateral wall, *limen nasi*, which projects from the upper margin of the cartilago alaris major.

The *septum nasi* is evenly covered by mucous membrane. A little above the spina nasalis anterior it presents very often a fine opening which leads into a short canal ending blind and passing backward directly upon the cartilago septi, the *organon vomeronasale Jacobsoni*; this with the cartilago vomeronasalis Jacobsoni (see p. 831) forms the homologue of a larger structure constant in a large series of animals to which (in these animals) fibers of the nn. olfactorii can be followed. Below and behind this opening in the floor of the nasal cavity there is often a pinpoint-like opening which leads into a canaliculus, the *ductus incisivus* (not illustrated); this enters the canalis incisivus and usually ends blind, though it may open by a very fine unpaired opening upon the papilla incisiva of the palate (see p. 499); it is the rudiment of *Stenson's passage*, so well developed in many mammals.

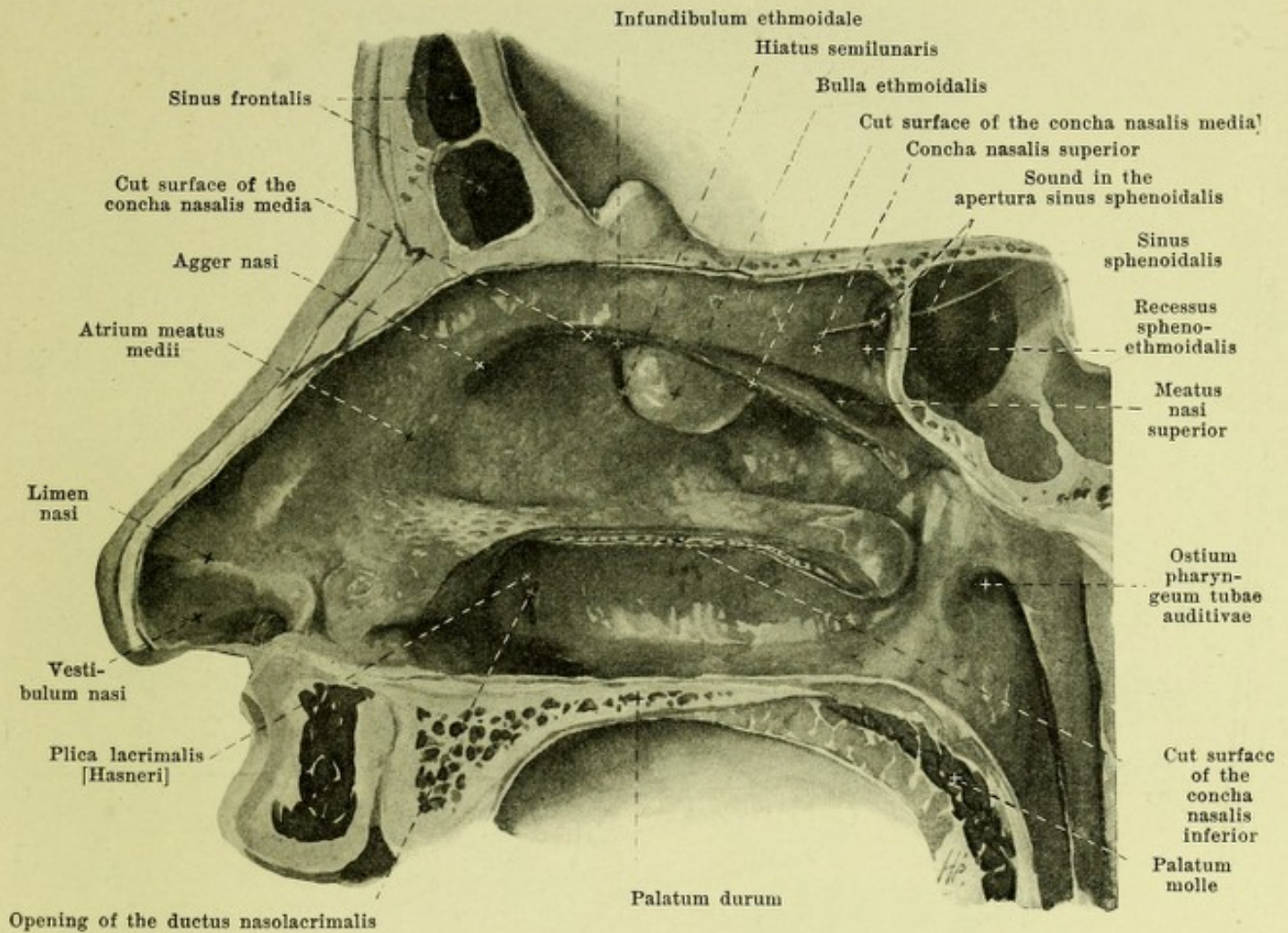
The narrow superior and the broad inferior walls are covered by smooth mucous membrane.



923. Right wall of the nasal cavity with the mucous membrane, viewed from the left.

(Figs. 923 and 924 are from the same preparation though from another head than Figs. 921 and 922.)

Nasal cavity (continued) (see also Figs. 73—75, 615, 549, 550, 921, 922, 924 and 925). The lateral wall presents a free turbinated bone, *nasal mussels*, *concha nasalis superior, media and inferior*, and also below each and lateral from it (see also Fig. 517) the corresponding *nasal meatus*, *meatus nasi superior, medius, inferior* (see pp. 60 and 61). The inferior concha arises in front very gradually from the wall; it and the lower meatus are longest, the upper concha and upper meatus shortest. The middle concha hangs down valve-like in front from its insertion for quite a distance and ends in front in an approximately vertically-placed free margin from the upper end of which extending downward in a curve is a small ridge, *agger nasi*; this bounds from above a slightly depressed area, *atrium meatus medii* which reaches below as far as the upper margin of the inferior nasal concha and gradually goes over backward into the middle meatus. The narrow space situated between the agger nasi and the inner dorsum of the nose and which extends obliquely upward and backward as far as the upper wall of the nasal cavity is called the *carina nasi*. Concerning the *recessus sphenothmoidalis* and *meatus nasi communis* see pp. 60 and 61. The *meatus nasopharyngeus* (see also p. 60) appears lateralward in the nasal cavity, covered by mucous membrane and bounded by a narrow groove situated behind the posterior end of the middle and inferior conchae; dorsalward from this is the labium anterius of the ostium pharyngeum tubae auditivae and an elevation, *plica salpingopalatina*, which passes to the soft palate.

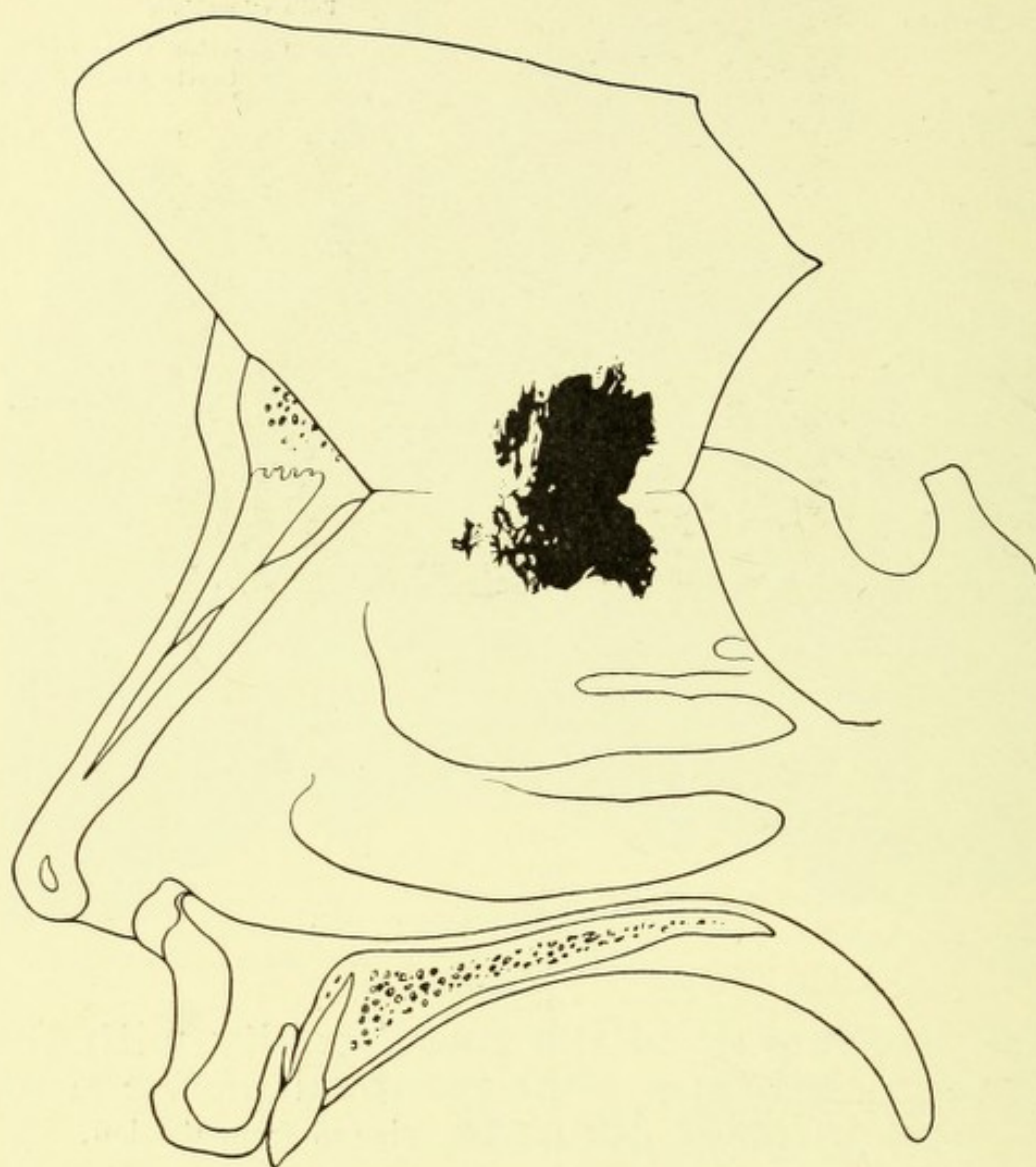


924. Right wall of the nasal cavity with the mucous membrane after removal of the middle and inferior conchae, viewed from the left.

(Figs. 923 and 924 come from the same preparation though from another head than Figs. 921 and 922.)

Nasal cavity (continued) (see also Figs. 73—75, 517, 549, 550, 921—923, and 925). The essentials concerning the *accessory cavities of the nose*, *sinus paranasales*, and their communications with the nasal cavity have been mentioned on pp. 4, 17, 21, 27 and 61. The opening of the sinus frontalis is found in the upper part of the infundibulum ethmoidale. The sinus maxillaris opens also usually in the infundibulum ethmoidale, and through the hiatus semilunaris (see p. 861) in the middle nasal meatus; sometimes behind and below this main opening an accessory opening exists, also in the middle meatus, which corresponds to the spot free from bone, situated behind the proc. uncinatus (see Fig. 74). The ductus nasolacrimalis opens in the inferior nasal meatus.

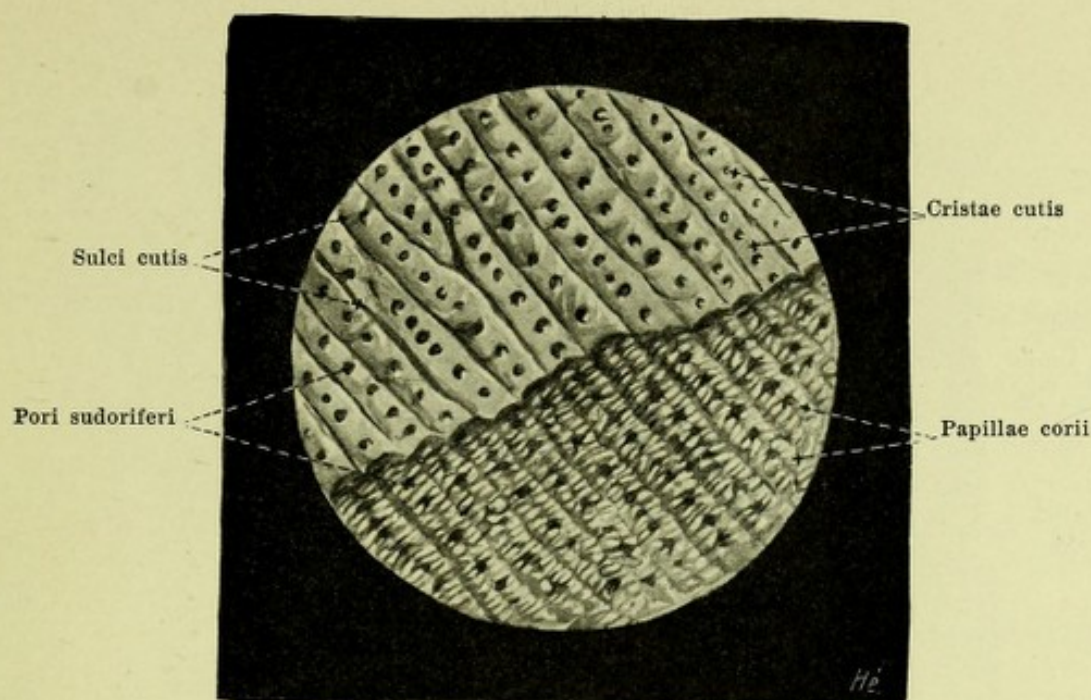
The *nasal mucous membrane*, *membrana mucosa nasi* (see also p. 832) is continuous in front with the skin of the face (see p. 831), at the choanae with the mucous membrane of the palate and of the pharynx. In the nasal cavity proper, it is firmly attached to the periosteum of the bone and to the perichondrium of the cartilage, and is studded with numerous mucous glands, *glandulae nasales*. It presents in its tela submucosa numerous venous networks, which are developed to form very thick erectile tissue plexuses, *plexus cavernosi concharum*, on the middle and inferior conchae and are the cause of the marked thickness of the mucous membrane in these places. The mucous membrane is continued into all the accessory cavities and lines their walls as a very thin membrane, poor in glands.



925. Extent of the true olfactory mucous membrane (after A. v. Brunn).

(The nasal septum has been reflected upward and the regio olfactoria on it and on the lateral wall indicated in black.)

Nasal cavity (continued) (see also Figs. 921—924). The mucous membrane is of a reddish color, of variable shade. A small region in the upper part of the superior concha and in the corresponding portion of the septum is characterized even macroscopically by a brownish color-tone; it is at the same time somewhat thicker, contains the terminations of the nn. olfactorii in an especially constructed epithelium and is called the *regio olfactoria*; it is characterized by long tube-like glands, *glandulae olfactoriae*. This part of the mucous membrane alone can be designated the *olfactory organ*, *organon olfactus*, in the strict sense. The rest of the mucous membrane is distinguished from it as the *regio respiratoria*.



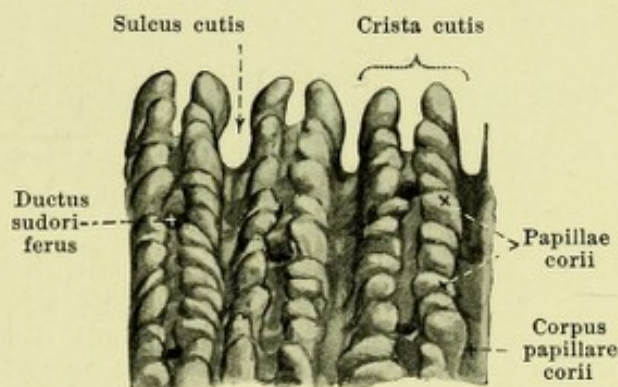
926. Skin ridges and papillae in the sole of the foot. Magnification 8:1.

(In the upper part the epidermis has been partly macerated off, in the lower part completely.)

The **external skin**, *integumentum commune*, an external sheath for the body of about 1,6 sq. meters in extent, covers the whole surface and at the opening of the respiratory, digestive, urinary and sexual passages, goes over uninterruptedly into the mucous membranes. It is divisible into the skin in the stricter sense, *cutis*, and its accessory structures, *hairs, pili*, and *nails, ungues*, which are products of the epidermis just as are the *cutaneous glands, glandulae cutis*, which are situated in the cutis.

The *cutis* (see Fig. 934) consists of two parts sharply separable from one another in their development and in their structure, an epithelial part, the *epidermis, scarf skin*, and a part consisting essentially of connective tissue, which is further subdivisible into the *corium, leather skin*, and the *tela subcutanea, subcutaneous tissue*.

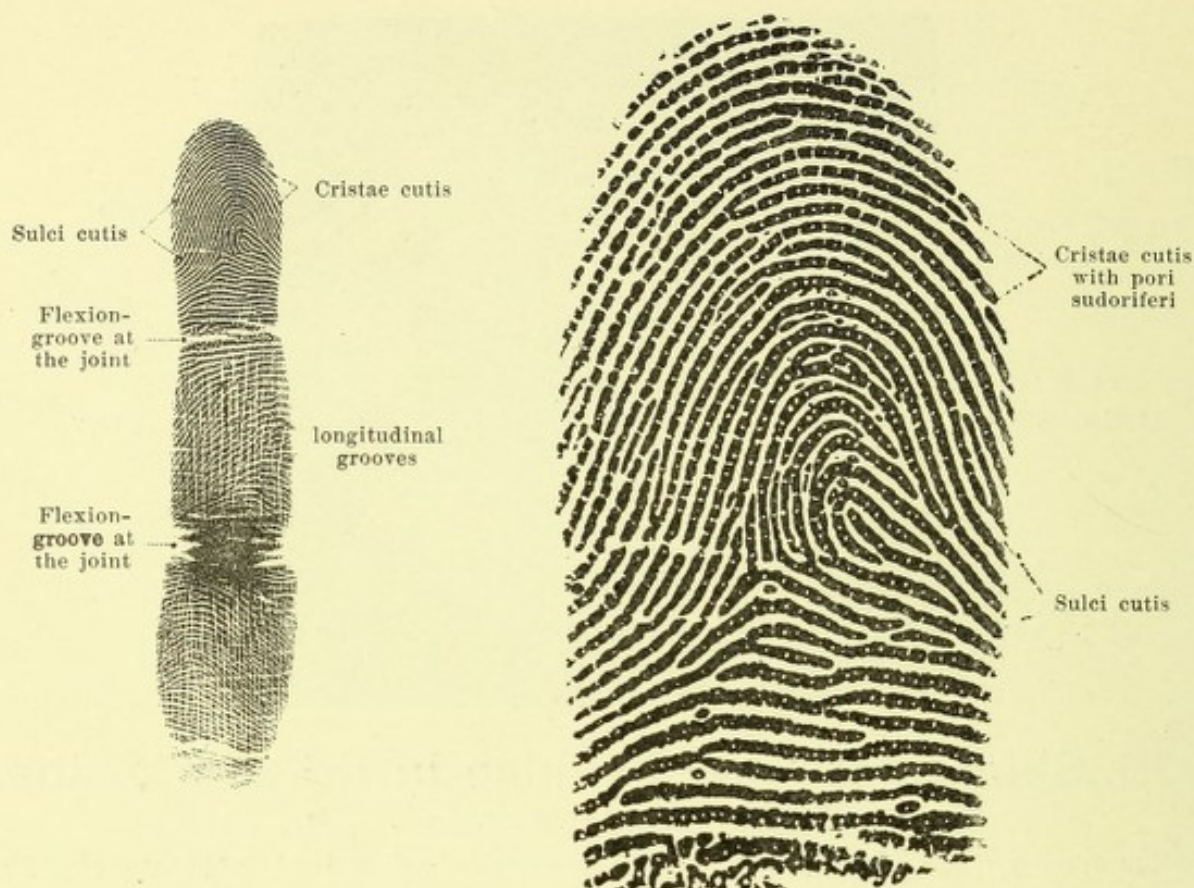The *epidermis, scarf-skin* (see also Fig. 934) consists of a lamellated epithelium and forms the external visible surface of the skin, it covers the corium directly and completely and sinks into its depressions. Its thickness varies in different individuals and is also very variable in the same individual; in the sole of the foot it measures about 2 mm in depth, in the palm of the hand about 1 mm and elsewhere varies between 0,07 and 0,17 mm. In white races the epidermis contains a little pigment (except in the non-pigmented Albinos); in colored races there is much pigment.



927. Papillae of the skin of the sole of the foot.

Magnification 21:1.

(The epidermis has been completely removed.)



928 and 929. Ridges and sulci in the skin of the volar surface of a finger of the right hand, obtained by impression.

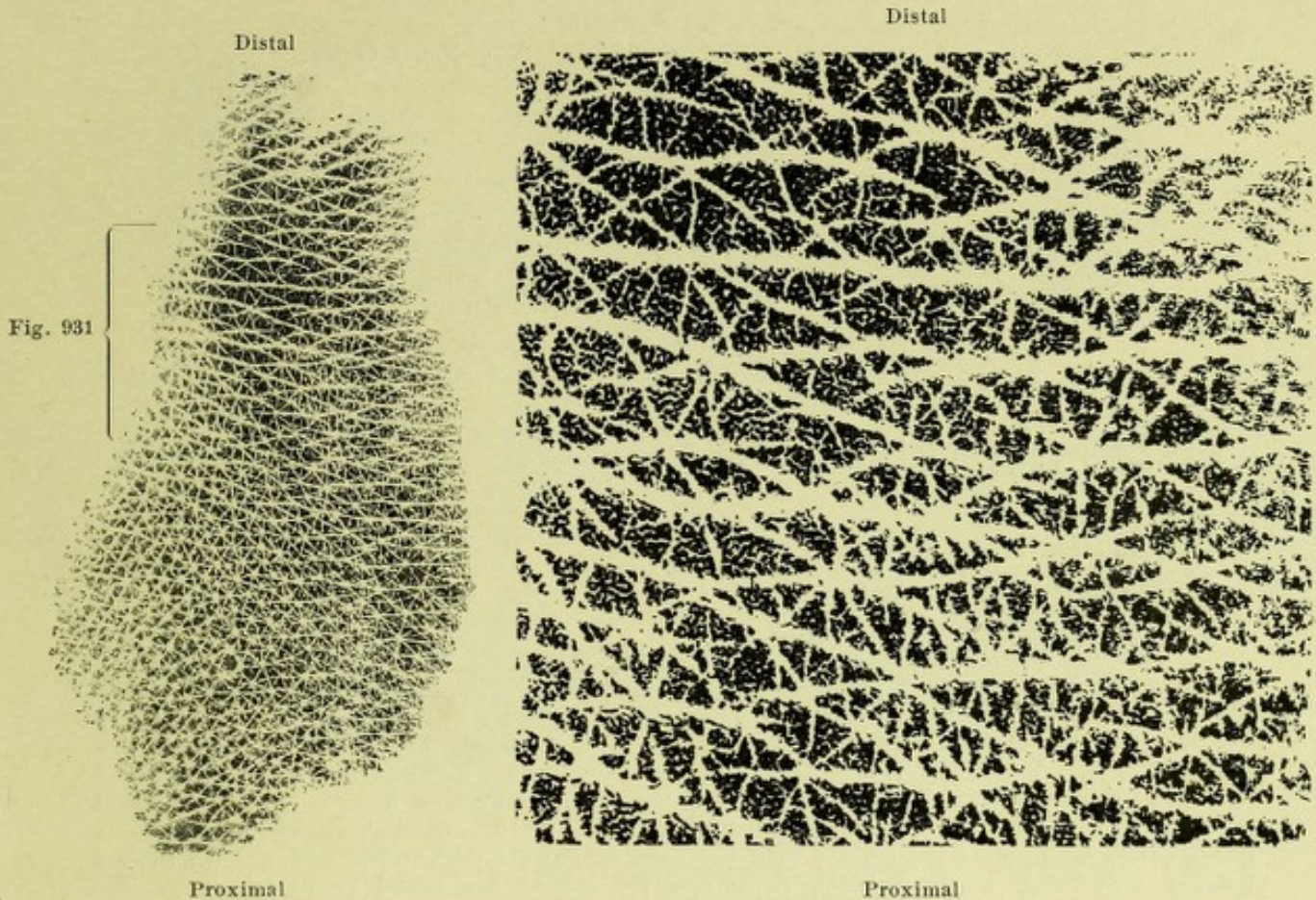
Natural size.

Distal part of Fig. 928, magnified 4 times.

The *corium*, *leather skin* (see Figs. 926, 927, 934 and 935) consists of a close plexus of bundles of connective tissue along with elastic fibers and smooth muscle fibers. The connective tissue bundles, especially in the deeper layers, are usually directed only a little obliquely toward the surface, run nearly parallel to it and as they go are interwoven with one another as in straw-matting; corresponding to the permanent or often repeated tension which usually is exerted upon them from their surroundings, certain particular directions are preferably followed by them and the bundles parallel to these directions are more tightly stretched than those perpendicular to them; accordingly wounds which are situated in the direction of the tighter stretching gape less than those directed perpendicular to it. The smooth muscle is found usually in connection with the hair follicles, but may be spread out in a surface as in the *tunica dartos*; but in the latter case it belongs to the *tela subcutanea*.

The thickness of the *corium* varies according to race, sex (somewhat thicker in the male than in the female), age (much thinner in the child than in the adult) and individual; it also varies in the same body in different places: it is thinnest in the eyelids and in the genitalia (0.3—0.6 mm), thickest on the back, buttock, palm and sole (2—3 mm).

The surface of the *corium* turned toward the epidermis is studded by microscopically small thread-like or ridge-like processes, *papillae*. They, together with the more superficial layer of the *corium* from which they project, are spoken of as the *corpus papillare* and consist of especially closely interwoven fine connective tissue fibers; the other larger part of the *corium* which is more loosely woven of coarser bundles is called the *tunica propria*. The *papillae* in different parts of the body are of different length, form and frequency; they are absent only in a few places (forehead, external ear, perineum, parts of the scrotum and of the axilla); the longest (0.1—0.2 mm) are found in the palm and sole.



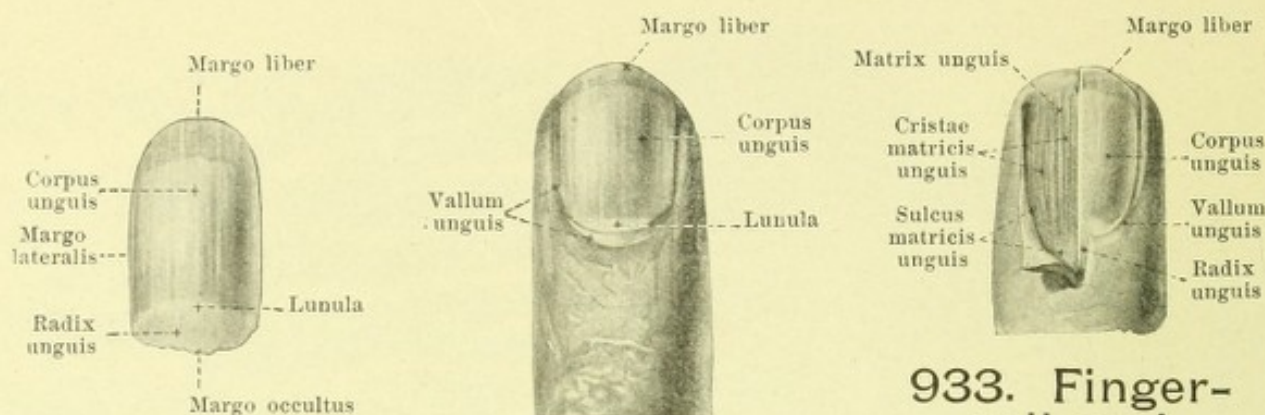
930 and 931. Skin sulci and cutaneous areas on the surface of the back of the left hand (ulnar portion), obtained by impression.

Natural size.

The area in the bracket in Fig. 930 is here shown magnified 4 times.

(The hairs were shaved off before the impression was taken; they emerge in the middle of the stellate white figures distinctly visible in the proximal part of Fig. 930.)

The *papillae* (continued) (see also Figs. 926—929, 934 and 935) project into the lower layers of the epidermis and very often cause corresponding smaller hillock-like projections on the surface of the epidermis. When this is not the case, the surface of the epidermis looks smooth and the presence of the papillae appears first on cross section. In other cases even on the free surface a delicate marking can be seen which depends upon the fine *cutaneous sulci*, *sulci cutis*, and the groups of papillae projecting slightly above the surface situated between them. This marking is very variable in different parts of the body, and in part also shows great individual variation (especially in the fingers). In the palm and the fingers, in the sole of the foot and in the toes the papillae are arranged in rows, but the epidermis does not sink in near each one of them but forms small wall-like *cutaneous ridges*, *cristae cutis*, of which each regularly covers over two rows of papillae and is separated from the next by a groove-like cutaneous sulcus; the sweat glands open at the top of these cutaneous ridges and enter into the corpus papillare in the groove between the two corresponding rows of papillae.



932. Fingernail, viewed from the dorsal surface.

isolated.

in situ.

933. Finger-nail and bed of nail, viewed from the dorsal surface.

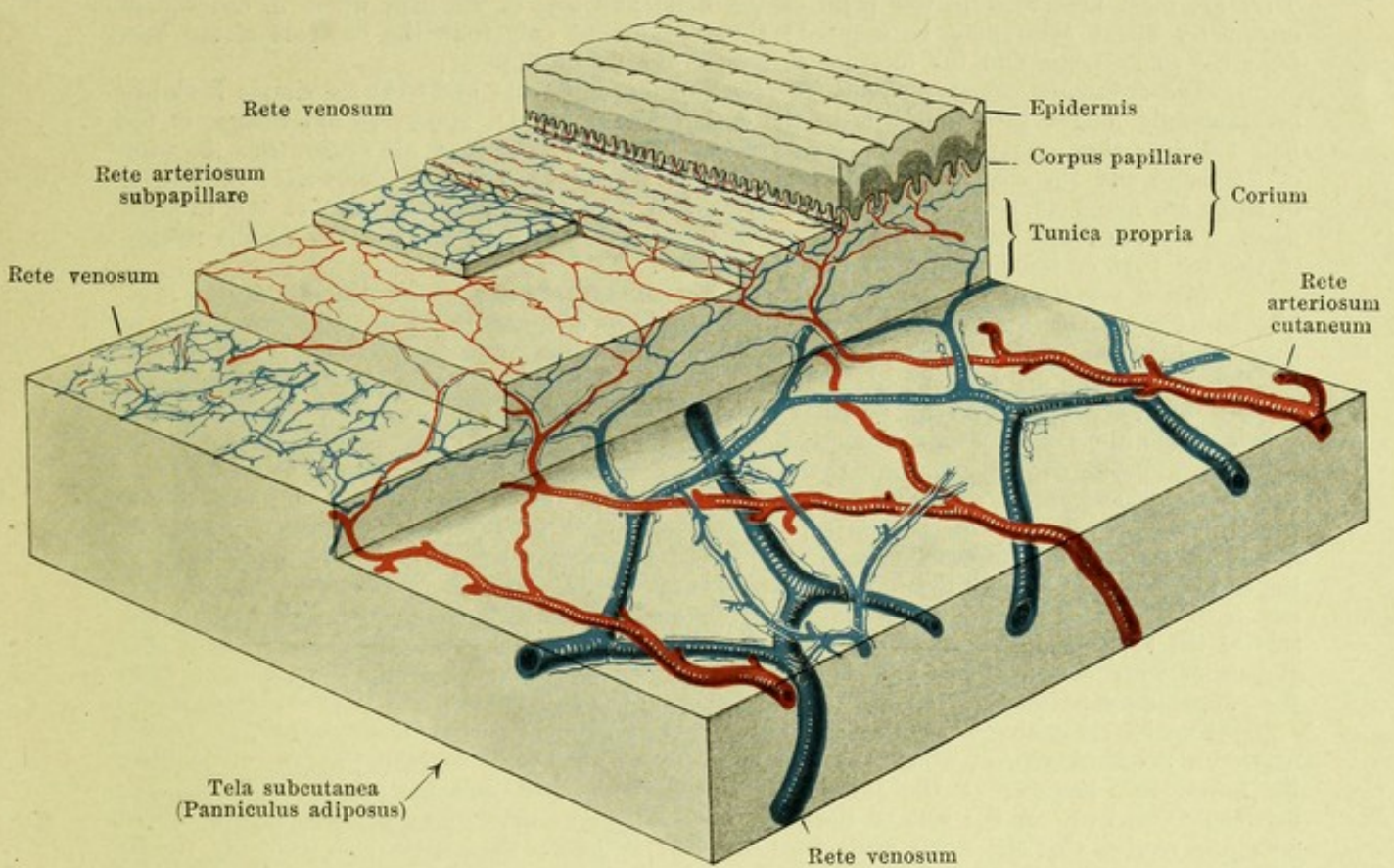
(The left half of the nail has been removed.)

The *tela subcutanea*, *subcutaneous tissue* (see Fig. 872) is not sharply separated from the corium but passes out of it without sharp limit; it is distinguishable from the corium by the greater thickness and looser interweaving of the bundles of connective tissue as well as by the fact that it may contain fatty tissue in a very variable way, arranged in smaller or larger lobules. When the fat is abundant the subcutaneous tissue is called the *panniculus adiposus*; the connective tissue septa between the lobules may then become thickened to form a septal wall, parallel to the surface, which divides the fat into two layers. The subcutaneous tissue everywhere unites the corium with the deeper-lying structures; the more sharply limited tougher connecting bands between these and the corium are called *retinacula cutis* (see also p. 616).

The *hairs*, *pili*, are found upon the whole surface of the body except the red border of the lips, the palms of the hands, the soles of the feet, the dorsal surfaces of the phalanges of the fingers and toes, the nipples of the breast, the glans penis and the inner surface of the praeputium; they are epidermoidal structures and project into the corium or into the subcutaneous tissues. They usually stand obliquely to the surface and in definite directions varying according to the region of the body and thus form *hair-streams*, *flumina pilorum*, and *hair whirlpools*, *vortices pilorum* (not illustrated), which are more distinct in embryos than in adults. The hairs are of very different length and thickness; they include the *capilla* (hairs of the head), *supercilia* (hairs of the eyebrows), *cilia* (eyelashes), *barba* (hairs of the beard), *tragi* (hairs of the ear), *vibrissae* (hairs of the nose), *hirci* (axillary hairs), and *pubes* (pubic hairs); the very fine hairs found on other parts of the body are together spoken of as *lanugo* (woolly hairs).

The *nails*, *ungues*, are quadrilateral curved plates consisting of horny cells of the epidermis which end distalward in the *margo liber*. Their lateral margins, *marginēs laterales*, and their proximal sharpened margin, *margo occultus*, are enclosed in a groove-like depression of the cutis, the *ungual fold*, *sulcus matrixis unguis*, and are overlaid on the surface by the *ungual wall*, *vallum unguis*. The main mass of the nail, *corpus unguis*, rests upon the *bed of the nail*, *matrix unguis*, which is beset with numerous longitudinal ridges, *cristae matrixis unguis*. The regeneration of the nail surface takes place at the proximal part hidden beneath the unguinal wall, which accordingly is called the *root of the nail*, *radix unguis*; this part consists of cells which are not yet hornified and not yet dry, and is recognizable by its whitish color; it often projects beyond the distal end of the unguinal wall as a small sickle-shaped area, the *lunula*.

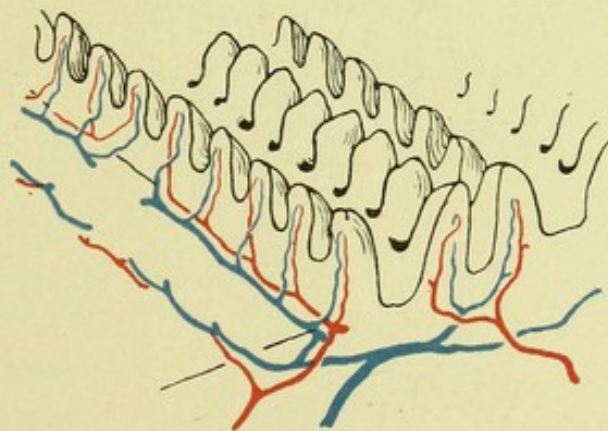
The *glands of the skin*, *glandulae cutis*, occur in two varieties, *glandulae glomiformes*, *coil glands*, and *glandulae sebaceae*, *sebaceous glands*. To the former belong the *glandulae ciliares* (Molli) (see p. 797), the *glandulae ceruminosae* (see p. 806), the *glandulae circumanales* (especially large sweat glands in the immediate neighborhood of the anus) and the *glandulae sudoriferae*, *sweat glands*. The latter (see Fig. 872) consist of a simple tubule, which by a coil-like rolling up of its blind end forms the spherical gland-body, *corpus glandulae sudoriferae*. This lies in the subcutaneous tissue or in the corium and sends its excretory duct, *ductus sudoriferus*, perpendicular to the surface, where it opens by a small rounded opening, *porus sudoriferus*, at the top of the cristae cutis where these are present (see p. 839).



934. Distribution of the blood vessels in the skin of the sole of the foot, in a staircase-like model.

Magnification circa 12 : 1.

(The sweat-glands and their vessels have not been shown; only the uppermost part of the subcutaneous tissue is illustrated.)



935. Distribution of the blood vessels in the corpus papillare of the corium. Magnification circa 40 : 1.

(The epidermis is not shown.)

Glands of the skin (continued). The sweat glands vary greatly in size and number. They are most numerous in the palm of the hand and sole of the foot, where in one square centimeter about 1000 may be counted; they are absent only from the red part of the lips, from the glans penis and the internal surface of the praeputium.

The sebaceous glands, glandulae sebaceae (see Figs. 514 and 872) are simple flask-like or manifoldly bulged sacs which lie in the cutis and, as a rule, appear as appendages of the hair follicles; they secrete the sebum cutaneum. They, like the hair, are absent from the palm of the hand and the sole of the foot. They are everywhere of about the same size; the largest of them are found in connection with the very fine woolly hairs in the skin of the external nose. They are found entirely independent of any connection with hair follicles at the margin of the red part of the lips and on the glans penis.

Blood vessels of the external skin, vasa sanguina integumenti communis (see Figs. 934 and 935). The arteries which enter the skin are destined to supply this exclusively or they are branches of the arteries to the muscle; their number and their diameter are different for the surface unit in different places; they are larger in those places which are frequently exposed to external pressure (e. g. palm of hand, sole of foot, regio glutea). These arteries pass through the subcutaneous connective tissue, anastomose with one another in the lowermost layer of the corium and form there a leaf-like cutaneous network, *rete arteriosum cutaneum*, the concentration of which varies in the same way as do the number and diameter of the tributary branches. The vessels supply the superficial fat layer and the sweat glands by means of finer twigs. From this network proceed branches which form in the upper third of the corium a second laminar network, the *subpapillary network, rete arteriosum subpapillare*, and from this arise minute twigs, which do not anastomose with one another; they run in the sole of the foot, usually a short distance in the direction of the rows of papillae without anastomosing with one another, and finally send off the smallest twigs into the papillae; from the subpapillary network go off also the branches to the hair follicles and the sebaceous glands.

The blood arising from the capillaries of the papillae passes through several venous networks, *retia venosa*, of which the uppermost is situated close beneath the rows of papillae, the lowermost, largest, at the junction between the corium and the subcutaneous tissues; between these two, in the sole of the foot, still two other networks are interpolated. These networks receive also the small veins from the hair follicles, the glands and the fatty tissue. The veins run only partly beside the arteries. From the deepest network larger trunks enter the subcutaneous tissue and open usually into the large veins of the skin (*venae cutaneae*).



Index.

(The numbers always refer to pages; the references to the figures will be found there in the text. Exceptionally a name may not be mentioned in the text, in which event the figure to be found upon the page referred to is meant.)

A.

- | | | |
|--|--|--|
| <p>Abdominal part of Sympathetic 763.
 Abductor minimi digiti 318, 353.
 — pollicis 318.
 Accelerator urinae 612.
 Accessorius or flexor accessorius digitorum pedis 354.
 Accessory muscle to the ilio-costal 291.
 Accessory organs of the eye 770.
 — suprarenals 583.
 Acetabulum 115.
 Acromion 88.
 Acromiothoracic axis, or thoracic axis 406.
 Aditus ad aquaeductum cerebri 646.
 — glottidis 558.
 — laryngis 558.
 — orbitae 56.
 Adminiculum lineae albae 279.
 Aequator bulbi oculi 771.
 — lentis 782.
 After brain 626.
 Agger nasi 834.
 Air sacs 567.
 Ala cinerea 630.
 — ossis ilium 115.
 Alae lobuli centralis 633.
 — magnae oss. sphenoidalis 4.
 — nasi 830.
 — parvae oss. sphenoidalis 6.
 — vomeris 26.
 Almond nucleus 670.
 Alveolar passages 567.
 Alveoli dentales 29, 34.
 — pulmonis 567.
 Ampulla(ae) ductus deferentis 586.</p> | <p>Ampulla(ae) ductus lacrimalis 798.
 — membranaceae 825.
 — osseae 821.
 — recti 528.
 — tubae uterinae 597.
 Anastomotica magna 436.
 — — artery 410.
 Angulus costae 79.
 — frontalis oss. parietalis 18.
 — iridis 777, 783.
 — mandibulae 35.
 — mastoideus oss. parietalis 18.
 — occipitalis oss. parietalis 18.
 — oculi lateralis, medialis 793, 794.
 — parietalis oss. sphenoidalis 5.
 — scapulae 87.
 — sphenoidalis oss. parietalis 18.
 — sterni 83.
 Ankle joint, under 222.
 — — upper 217.
 Annulus(i) conjunctivae 774.
 — femoralis 325.
 — fibrocartilagineus membranae tympani 808.
 — fibrosus 157, 158.
 — fibrosi [cordis] 373.
 — haemorrhoidalis 529.
 — inguinalis abdominalis 280, 283.
 — — subcutaneus 273.
 — iridis major, minor 776.
 — tendineus communis [Zinni] 786.
 — tympanicus 14.
 — urethralis 582, 595.
 Ansa(ae) hypoglossi 712.
 — nn. spinalium 712.
 — subclavia [Vieussensii] 764.</p> | <p>Anterior radial carpal 412.
 Anterior angle (of the shoulder blade) 87.
 — bicipital ridge 94.
 — carpal rete 417.
 — choroid artery 401.
 — circumflex artery 408.
 — costovertebral or stellate ligament 171.
 — dental branch 395.
 — or external crucial ligament 206.
 — fasciculus of external lateral ligament 218.
 — interosseous artery 413.
 — interventricular groove 367.
 — layer of the triangular ligament, superficial or inferior triangular ligament 609.
 — or lesser sacrosciatic ligament 194.
 — ligament 187.
 — nares 62.
 — occipitoatlantal ligaments 163.
 — peroneal artery 438.
 — and posterior chondroster-nal ligaments 175.
 — — — superior tibiofibular ligaments 216.
 — surface 366.
 — terminal branch 390, 392.
 — tibiotarsal ligament 219.
 — ulnar carpal 413.
 Anthelix 801.
 Antitragus 801.
 Antrum of Highmore 27, 28.
 — pyloricum 513.
 — tympanicum 811.
 Anus 528, 529.
 Anvil 811.</p> |
|--|--|--|

- Anvil, crus of 811.
 Aorta 387.
 — abdominalis 420, 421.
 — thoracalis 418.
 Aortic arch 388.
 — spindle 389.
 Apertura externa aquaeductus vestibuli 9.
 — externa canaliculi cochleae 9.
 — inferior canaliculi tympanici 10, 12.
 — interna aquaeductus vestibuli 818.
 — lateralis ventriculi quarti 635.
 — medialis ventriculi quarti 635.
 — piriformis 28, 62.
 — sinus sphenoidalis 4.
 — superior canaliculi tympanici 11, 12.
 — tympanica canaliculi chordae 811.
 Apex capituli fibulae 137.
 — columnae posterioris griseae 621.
 — cordis 365.
 — linguae 489.
 — nasi 478, 830.
 — ossis sacri 72.
 — patellae 135.
 — pulmonis 562.
 — pyramidis 9.
 — radialis dentis 487.
 — suprarenalis 583.
 Aponeurosis palmaris 317.
 — plantaris 352.
 Apparatus digestorius 478.
 — lacrimalis 770, 798.
 Appendages of the testicle 585.
 Appendix(ices) auricularis posterior 376.
 — epididymidis 585.
 — epiploicae 526.
 — fibrosa hepatis 532.
 — testis [Morgagnii] 585.
 — ventriculi laryngis 558.
 Appendices vesiculosae [Morgagnii] 597.
 Aquaeductus cerebri [Sylvii] 636.
 — vestibuli 9, 818.
 Aqueduct of Fallopius 12.
 Aqueous humor 783.
 Arachnoidea encephali 682, 683.
 — spinalis 623.
 Arachnoidealsheath of optic nerve 771.
 — villi 683.
 Arbor vitae 667.
 Arcus anterior atlantis 66.
 — aortae 387, 388.
 — Arcus dentalis 488.
 — glossopalatinus 500.
 — lumbocostales [Halleri] 270.
 — pharyngopalatinus 500.
 — plantaris 440.
 — posterior atlantis 66.
 — superciliares 15.
 — tarseus inferior, superior 399.
 — tendineus fasciae pelvis 613.
 — — m. levatoris ani 608.
 — venosus digitalis 451.
 — — dorsalis pedis [cutaneus] 470.
 — — juguli 450.
 — — plantaris cutaneus 470.
 — — plantaris profundus 469.
 — vertebrae 64.
 — volaris profundus 417.
 — — superficialis 416.
 — — venosus profundus 451.
 — — — superficialis 451.
 — zygomaticus 32.
 Area(ae) acustica 630.
 — cochleae 824.
 — cribrosa 578.
 — gastricae 515.
 — n. facialis 824.
 — parolfactoria [Brocae] 645.
 — vestibularis inferior, superior 824.
 Areola mammae 615, 616.
 Arm of the pons 631, 678, 679.
 Arnold's bundle 680.
 Arteria(ae) acetabuli 428.
 — alveolares superiores 395.
 — alveolaris inferior 393.
 — angularis 390.
 — anonyma 389.
 — appendicularis 424.
 — arcuata 439.
 — auditiva interna 404, 828.
 — auricularis posterior 391.
 — — profunda 393.
 — axillaris 406.
 — basilaris 402, 404.
 — brachialis 409.
 — bronchiales 419.
 — buccinatoria 395.
 — bulbi urethrae 431.
 — — vestibuli [vaginae] 433.
 — canalis pterygoidei [Vidii] 395.
 — carotis communis 389.
 — — externa 389.
 — — interna 397.
 — centralis retinae 398, 771, 780.
 — cerebelli inferiores 403, 404.
 — — superior 404.
 — cerebri anterior 401.
 — — media 400.
 — — posterior 404.
 Arteria(ae) cervicalis ascendens 404.
 — — profunda 406.
 — — superficialis 404.
 — chorioidea 400.
 — ciliares anteriores 398, 778.
 — — posteriores 398, 777, 778.
 — circumflexa femoris lateralis, medialis 436.
 — — humeri anterior, posterior 408.
 — — ilium profunda 435.
 — — — superficialis 435.
 — — scapulae 406.
 — clitoridis 433.
 — coeliaca 421.
 — colica dextra, media, sinistra 424.
 — collaterales 410.
 — comitans nervi ischiadici 428.
 — communicans anterior 400.
 — — posterior 400.
 — conjunctivales anteriores 398, 778.
 — — posteriores 398, 399, 778.
 — coronaria [cordis] dextra 382.
 — — — sinistra 383.
 — cystica 422.
 — deferentialis 429.
 — digitales of the foot 439, 440.
 — — of the hand 414, 416, 417.
 — dorsalis clitoridis 433.
 — — nasi 399.
 — — pedis 439.
 — — penis 433.
 — epigastrica inferior 434.
 — — superficialis 435.
 — — superior 406.
 — episclerales 398, 778.
 — ethmoidales 398, 399.
 — femoralis 435.
 — frontalis 399.
 — gastricae 421, 424.
 — gastroduodenalis 422.
 — gastroepiploicae 422, 424.
 — genu 436, 437.
 — glutaeae 428.
 — haemorrhoidalis inferior 431.
 — — media 429.
 — — superior 424.
 — helicinae 594.
 — hepatica 421.
 — — propria 422.
 — hypogastrica 424.
 — jejunaes 424.
 — ileae 424.
 — ileocolica 424.
 — iliaca communis 424.
 — — externa 433.
 — iliolumbalis 426.
 — infraorbitalis 395.

- Arteriae(a) intercostales 419.
 — intercostalis suprema 406.
 — interossea communis 413, 414.
 — — dorsalis 414.
 — — recurrens 414.
 — — volaris 413.
 — intestinales 424.
 — labiales 390.
 — — anteriores 435.
 — — posteriores 431.
 — lacrimalis 398.
 — laryngea inferior 404.
 — — superior 389.
 — lienalis 422.
 — ligamenti teretis uteri 434.
 — lingualis 389.
 — lumbales I—IV 421.
 — lumbalis ima 421.
 — malleolares 438, 439.
 — mammaria interna 404, 405, 406.
 — masseterica 394.
 — maxillaris externa 389, 390.
 — — interna 393—395.
 — mediana 413.
 — mediastinales anteriores 404.
 — meningea anterior 399.
 — — media 394.
 — — posterior 396.
 — mentalis 393.
 — mesenterica inferior 424.
 — — superior 424.
 — metacarpea dorsalis I 412.
 — metacarpeae dorsales 414.
 — — volares 417.
 — metatarsae 439, 440.
 — musculophrenica 406.
 — nasales 395.
 — nutricia femoris 437.
 — — fibulae 438.
 — — humeri 408, 410.
 — — tibiae 438.
 — obturatoria 427, 428.
 — occipitalis 391.
 — oesophageae 419.
 — ophthalmica 397—399.
 — ovarica 421.
 — palatina ascendens 389.
 — — descendens 395.
 — palatinae, major, minores 395.
 — palpebrales laterales 398.
 — — mediales 399.
 — pancreaticoduodenales 422, 424.
 — penis 431.
 — perforantes 436, 437.
 — pericardiacophrenica 404.
 — perinei 431.
 — peronaea 438.
 — pharyngea ascendens 395.
 — phrenica inferior 421.
- Arteriae(a) phrenicae superiores 419.
 — plantares 440.
 — poplitea 437.
 — profunda brachii 409, 410.
 — — clitoridis 433.
 — — femoris 436.
 — — linguae 389.
 — — penis 432.
 — pudenda interna 431.
 — pudendae externae 435.
 — pulmonalis 380.
 — radialis 411.
 — recurrens radialis 411.
 — — tibialis anterior 438.
 — — — posterior 438.
 — recurrentes ulnares 412.
 — renalis 421.
 — sacralis lateralis 427.
 — — media 421.
 — scrotales anteriores 435.
 — — posteriores 431.
 — sigmoideae 424.
 — spermatica externa 434.
 — — interna 421.
 — sphenopalatina 395.
 — spinales 403.
 — sternocleidomastoidea 391.
 — styломastoidea 392.
 — subclavia 401.
 — sublingualis 389.
 — submentalis 390.
 — subscapularis 406.
 — supraorbitalis 398.
 — suprarenalis inferior 421.
 — — media 421.
 — surales 437.
 — tarseae 439.
 — temporales profundae 395.
 — temporalis media 390.
 — — superficialis 390.
 — testicularis 421.
 — thoracalis lateralis 406.
 — — suprema 406.
 — thoracoacromialis 406.
 — thoracodorsalis 406.
 — thymicae 404.
 — thyreoidea inferior 404.
 — — superior 389.
 — tibialis anterior 438.
 — — posterior 437.
 — transversa colli 406.
 — — faciei 390.
 — — scapulae 404.
 — tympanica anterior 393.
 — — inferior 396.
 — — posterior 392.
 — — superior 394.
 — ulnaris 412.
 — umbilicales 428, 473.
 — urethralis 431.
 — uterina 430.
 — vaginalis 430.
- Arteria(ae) vertebralis 402 to 404.
 — vesicalis inferior 429.
 — vesicales superiores 428.
 — zygomaticoorbitalis 390.
 Arteries of the heart 382, 383.
 Arteriola retinae 780.
 Artery of the bulb 431.
 — — — vas deferens 429.
 Articular branch of the superior profunda 410.
 Articulation of the atlas with the axis 165.
 — — — — occipital bone 163.
 Articulationes 152—228.
 Articulatio(ones) acromioclavicularis 177.
 — atlantoepistropheica 164, 166—169.
 — atlantooccipitalis 164, 169.
 — calcaneocuboidea 227.
 — capitulum costarum 170.
 — carpometacarpeae 188, 189.
 — costotransversaria 170—172.
 — costovertebrales 170—173.
 — coxae 199—203.
 — cricoarytaenoidea 552.
 — cricothyreoidea 552.
 — cubiti 181—185.
 — cuneonavicularis 227.
 — digitorum manus 191.
 — — pedis 227.
 — genu 204—215.
 — humeri 178—180.
 — humeroradialis 181.
 — humeroulnaris 181.
 — incudomalleolaris 812.
 — incudostapedial 812.
 — intercarpea 187—189.
 — interchondrales 175.
 — intermetacarpeae 188, 189.
 — intermetatarsae 221, 225, 227.
 — intertarsae 221.
 — mandibularis 152—155.
 — manus 187—189.
 — metacarpophalangeae 190, 191.
 — metatarsophalangeae 227.
 — ossiculorum auditus 812.
 — ossis pisiformis 187, 189.
 — pedis 217—227.
 — radiocarpea 187—189.
 — radioulnaris 181, 186.
 — sacroiliaca 193—196.
 — sternoclavicularis 176.
 — sternocostalis 175.
 — talocalcanea 222, 227.
 — talocalcaneonavicularis 222, 227.
 — talocruralis 217—219.
 — talonavicularis 222, 227.

Articulatio(ones) tarsi trans-
versa [Chopart] 227.
— tarsometatarsa [Lisfranci]
221, 225, 227.
— tibiofibularis 216.
Articulations of the metatarsal
bones with each other 221.
— — — phalanges 227.
— — — tarsus 221.
Arytaenoid cartilage 551.
Ascending or anterior palatine
artery 389.
— ramus of ischium 117.
Association fibers 680.
Astragalus 140.
Atlanto-epistrophe joint 165.
Atlanto-occipital joint 163.
Atlas 65, 66.
Atrium cordis dextrum 376, 377.
— — sinistrum 379.
— meatus medii (nasi) 834.
Attollens aurem 250.
Attrahens aurem 250.
Auditory canal, external 7, 13,
802—806.
— — bony 802.
— — cartilaginous 802.
— conduction paths 680.
— internal 9, 824.
Auricles 370.
Auricula 798, 802.
— cordis dextra 377.
— — sinistra 379.
Auricular appendices 370.
— appendix 367.
Auriculoventricular groove 367.
Auris externa 798—808.
— interna 817—830.
— media 809—816.
Axillary arch 299.
— cavity 298, 299.
— hairs 840.
Axis lentis 782.
— oculi externa, interna 771.
— optica 771.
— pelvis 127.
Axis (of spine) 66.
Azygos articular artery 437.
— uvulae 506.

B.

Barba 840.
Basis cerebri 636.
— cochleae 822.
— cordis 365.
— cranii externa 46, 47.
— — interna 51.
— mandibulae 34.
— modioli 822.
— nasi 830.
— oss. metacarpalis 109.
— oss. metatarsalis 146.
— ossis sacri 72, 74.

Basis patellae 135.
— pedunculi cerebri 635.
— pulmonis 562.
— stapedis 812.
Beard, hairs of 840.
Bicipital groove 94.
Bicuspid or premolar teeth 483.
Bifurcatio tracheae 561.
Bladder, base of 581.
— neck of 581.
— urinary 581.
— vertex of 581.
Bones of vault 63.
Bosom 615.
Brachia conjunctiva 635, 680.
— pontis 631, 679.
— quadrigemina 635.
Brachial plexus 719.
Brachialis anticus 303.
Brain 626, 638.
— hard membrane of 684—686.
— mantle 637—644.
— membranes of 622.
— soft membrane of 654.
— stem 626, 628, 655.
Breast, areola of 615.
— gland of 616.
Breasts 615.
Broad part of anterior annular
ligament 347.
Bronchi 564—566.
— subdivisions of 564—566.
Bronchioli 566.
— respiratorii 567.
Bronchus dexter, sinister 564.
Buccae 479.
Buccal branch 395.
Bulbus aortae 387.
— cornu posterioris 652.
— oculi 770—773.
— olfactorius 645.
— urethrae 593.
— v. jugularis inferior 446.
— — superior 446.
— vestibuli 604.
Bulla ethmoidalis 61.
Bulwark 668.
Bundle, posterior longitudinal
673.
Bursa(ae) anserina 333.
— bicipitogastrocnemialis 348.
— bicipitoradialis 303.
— cubitalis interossea 303.
— glutaefemorales 343.
— iliaca subtendinea 333.
— iliopectinea 332.
— infrapatellaris profunda 214.
— — subtendinea 331.
— intermetacarpophalangeae
324.
— intermetatarsophalangeae
357.
— intratendinea olecrani 315.

Bursa(ae) ischiadica m. glutaei
maximi 342.
— ligamenti coracoclavicularis
177, 300.
— [mucosa] subcutanea promi-
nentiae laryngeae 257.
— — suprapatellaris 211.
— — m. poplitei 214.
— m. bicipitis femoris inferior
345.
— — — superior 343.
— — coracobrachialis 300.
— — extensoris carpi radialis
brevis 312.
— — flexoris carpi radialis 308.
— — — ulnaris 308.
— — gastrocnemii lateralis
214, 350.
— — — medialis 214, 349.
— — infraspinati 306.
— — latissimi dorsi 300.
— mm. lumbricalium pedis
362.
— m. obturatoris interni 343.
— — pectinei 333.
— — pectoralis majoris 263.
— — piriformis 343.
— — poplitei 214.
— — recti femoris 334.
— — sartorii propria 333.
— — semimembranosi 348.
— — sternohyoidei 255, 257.
— — subscapularis 180, 300.
— — tensoris veli palatini 506.
— — teretis majoris 300.
— — thyreohyoidei 256, 257.
— olecrani 306.
— omentalis 543.
— ovarica 597.
— pharyngea 503.
— praepatellaris subcutanea
214.
— — subfascialis 214.
— — subtendinea 214.
— sinus tarsi 221.
— subacromialis 300.
— subcutanea(ae) acromialis
297.
— — calcanea 348.
— — digitorum dorsales 324.
— — epicondylis lateralis, me-
dialis 315.
— — malleoli lateralis 364.
— — — medialis 361.
— — metacarpophalangeae
dorsales 324.
— — olecrani 315.
— — tendinis calcanei [Achil-
lis] 348.
— — tuberositatis tibiae 331.
— subdeltoidea 300.
— subtendinea m. tibialis an-
terioris 357.

Bursa(ae) subtendinea m. tibialis posterioris 362.
 — — olecrani 315.
 — suprapatellaris 211, 214.
 — tendinis calcanei [Achillis] 351.
 — trochanterica m. glutaе maximi 343.
 — — m. glutaе medii 343.
 — — m. glutaе minimi 335.
 — — subcutanea 338.
 — trochlearis 788.

C.

Caecum 521—523.
 — cupulare, vestibulare 827.
 Calf bone 137—139.
 Calamus scriptorius 629.
 Calcaneus 141, 142.
 Calcar avis 652.
 Calyces renales 578.
 Camera oculi anterior, posterior 783.
 Canal for the Eustachian tube 11.
 — — tensor tympani muscle 11.
 Canaliculi caroticotympanici 10, 13.
 Canaliculus chordae tympani 12.
 — cochleae 824.
 — mastoideus 9, 12.
 — tympanicus 12.
 Canalis(es) adductorius [Hunteri] 336.
 — alveolares 27.
 — basipharyngeus 6.
 — caroticus 10.
 — carpi 107.
 — centralis medullae spiralis 621.
 — cervicis uteri 599.
 — condyloideus 2.
 — diploici [Breschets] 445.
 — facialis [Fallop] 12, 824.
 — femoralis 331.
 — hypoglossi 2.
 — incisivus 29.
 — infraorbitalis 27.
 — inguinalis 280—283.
 — longitudinalis modioli 822.
 — mandibulae 35.
 — musculotubarius 11.
 — nasolacrimalis 23, 28, 61.
 — nutritius femoris 128.
 — — fibulae 137.
 — — humeri 94.
 — — oss. metacarpalis 109.
 — — phalangis 109.
 — — radii 100.
 — — tibiae 136.
 — — ulnae 98.
 — obturatorius 119, 197.

Canales(is) palatini 30, 31.
 — pharyngeus 6.
 — pterygoideus [Vidii] 6.
 — pterygopalatinus 31, 55.
 — radialis dentis 487.
 — sacralis 72, 74.
 — Schlemmi, Lauthi 773, 778.
 — semicirculares ossei 817, 820, 821.
 — spiralis cochleae 821, 822.
 — — modioli 823.
 — vertebralis 64.
 Canine teeth 482.
 Capilli 840.
 Capitellum or radial head (of humerus) 95.
 Capitulum costae 78.
 — — XI—XII 81.
 — humeri 95.
 — fibulae 137.
 — mallei 811.
 — mandibulae 35.
 — oss. metacarpalis 109.
 — — metatarsalis 146.
 — radii 101.
 — stapedis 812.
 — ulnae 99, 102.
 Capsula adiposa 575.
 — articularis cricoarytaenoidea 552.
 — — cricothyreoidea 552.
 — externa 668.
 — interna 668.
 — lentis 782.
 — nuclei dentati 667.
 Capsular ligament 152, 165.
 — ligaments 163.
 Caput femoris 128.
 — humeri 94.
 — nuclei caudati 651.
 — tali 140.
 Cardia 512.
 Carina nasi 834.
 — urethralis [vaginae] 602.
 Carpus 107.
 Cartilagineae laryngis 550.
 — nasi 831.
 — tracheales 561.
 Cartilago alaris major, minor 831.
 — arytaenoidea 551.
 — auriculae 798—802.
 — corniculata [Santorini] 551.
 — costalis 78, 79.
 — cricoidea 551.
 — cuneiformis [Wrisbergi] 551.
 — epiglottica 551.
 — meatus acustici externi 805.
 — nasi lateralis 831.
 — septi nasi 831.
 — sesamoidea 553.
 — — nasi 831.
 — thyreoidea 550.

Cartilago triticea 552.
 — tubae auditivae 816.
 — vomeronasalis [Jacobsoni] 831.
 Caruncula lacrimalis 794.
 — sublingualis 494.
 Carunculae hymenales 602.
 Cauda equina 712.
 — helices 801.
 — nuclei caudati 651.
 Cavernae corporum cavernosorum 594.
 Cavernous groove 4.
 Cavitas glenoidalis scapulae 89.
 Cavum conchae 801.
 — dentis 487.
 — epidurale 623, 684.
 — laryngis 557, 558.
 — nasi 60—62, 832—836.
 — oris 478.
 — peritonaei 541.
 — pharyngis 502.
 — pleurae 569.
 — septi pellucidi 649.
 — subarachnoideale 623, 682.
 — subdurale 623, 684.
 — thoracis 569.
 — tympani 809, 810.
 — uteri 599.
 Cellulae ethmoidales 21, 60.
 — mastoideae 9, 811.
 — pneumaticae tubariae 816.
 — tympanicae 811.
 Cement 487.
 Central canal of the spinal cord 621.
 Centre median 667.
 Centrum tendineum [diaphragmatis] 269.
 Cerebellar path, direct sensory 678.
 — — ventral (Gowers' tract) 678.
 — peduncle, middle 678, 679.
 — peduncles, middle 631.
 — tent 685.
 — tract, direct 673, 678.
 Cerebellum 631—633, 667.
 — cortex of 667.
 — hemisphere of 633.
 — layers of 667.
 — sulci of 633.
 — white matter of 667.
 Cerebral nerves 676, 687—712.
 — — motor, nuclei of origin of 674.
 — — nuclei of origin of 676.
 — peduncle, foot of 635.
 — — tegmentum of 635.
 Cerebro-pontile path, corticopetal fibers of 679.
 — frontal 680.
 — median 680.

- Cerebro-pontile path temporal 680.
 Cerebrum 626, 636—637.
 — connections of the 680.
 — convolutions of 641—644.
 — cortex of 667.
 — deep gyri of 641.
 — hemispheres of 637—641, 667.
 — peduncles of 635.
 — sulci of 641—644.
 Cerumen 805.
 Cervical enlargement of spinal cord 618.
 — nerves 712.
 — plexus 716.
 — rib 65, 67.
 — vertebrae 65—68.
 Cervix columnae posterioris griseae 621.
 — uteri 598.
 Cheek 479.
 Chiasma opticum 4, 645, 676.
 — tendinum 309.
 Choanae 60, 832.
 Chondroxioid ligaments 175.
 Chorda(ae) obliqua 186.
 — tendineae 375.
 — tympani 700.
 Chorioidea 774, 775.
 Choroid coat 775.
 — plexus of the lateral ventricle 654.
 — — of the 3^d ventricle 654.
 Cilia 797, 840.
 Ciliary body 775.
 — processes 775.
 Circle of Willis 404.
 Circulus arteriosus [Willisi] 404.
 — — [iridis] major, minor 778.
 — vasculosus nervi optici [Halleri] 777.
 Circumferentia articularis radii 101.
 — — ulnae 99.
 Circumvalate papillae 493.
 Cisterna(ae) cerebellomedullaris 682.
 — chiasmatis 683.
 — fossae cerebri lateralis [Sylvii] 683.
 — interpeduncularis 683.
 — subarachnoideales 682.
 — venae cerebri magnae 682.
 Clarke's column 621.
 Claustrum 668.
 Clava 629.
 Clavicula 92—93, 177.
 Clitoris 604.
 Clivus 1.
 Coccygeal nerve 712.
 — vertebra 76.
 Coccyx 76.
 Cochlea 817, 821—823.
 — apical turn of 822.
 — basal turn of 822.
 — middle turn of 828.
 Cochlear window 810.
 Cock's comb 20.
 Coeliac axis 421.
 Collateral digital arteries 416, 440.
 Colliculus cartilaginis arytae-noideae 551.
 — facialis 629.
 — inferior, superior of the corpora quadrigemina 635.
 — seminalis 595.
 Collum anatomicum humeri 94.
 — chirurgicum humeri 94.
 — costae 78.
 — dentis 487.
 — femoris 129.
 — glandis 594.
 — mallei 811.
 — mandibulae 35.
 — radii 101.
 — scapulae 89.
 — tali 140.
 — vesicae felleae 533.
 Colon 520.
 — ascendens 524.
 — descendens 525.
 — sigmoideum 526.
 — transversum 525.
 Column, anterior 619.
 Columna(ae) fornicis 649, 650.
 — griseae 621.
 — rectales [Morgagnii] 529.
 — renales [Bertini] 577.
 — rugarum 602.
 — vertebralis 64.
 Comma-shaped bundle of spinal cord 673.
 Commissura (cerebri) ant. 646.
 — — posterior 646.
 — habenularum 646.
 — hippocampi 650.
 — labiorum oris 478.
 — — pudendi 606.
 — medullae spinalis anterior 621.
 — — — posterior 621.
 — palpebrarum lateralis, medialis 793.
 Commissural bundle of spinal cord 673.
 Commissure, anterior white 673.
 Communicating first interosseous perforating or plantar artery 439.
 Complexus 293.
 Concha(ae) auriculae 801.
 — nasales 21, 23, 834.
 — sphenoidales 4.
 Conduction paths, ascending of the corona radiata 680.
 — — descending of the corona radiata 680.
 — — from the spinal cord and medulla oblongata 678.
 — — secondary 676.
 Condyles of femur 130.
 Condylus femoris 130.
 — tibiae 136.
 Condylus occipitalis 2.
 Confluens sinuum 441.
 Conjugatae 127.
 Conjunctiva 770, 797.
 Conjunctival sac 797.
 Connecting arms 635, 678, 680.
 Conus arteriosus 377.
 — elasticus laryngis 553.
 — medullaris 618.
 Cor 365.
 Coracoid process 89.
 Corium 837—839.
 Cork 667.
 Cornea 773, 774.
 Cornu inferius, posterius ventriculi lateralis 651, 652, 654.
 — — superius of the margo falciformis 330.
 Cornua cartilaginis thyreoideae 550.
 — coccygea 76.
 — ossis hyoidei 40.
 — sacralia 73.
 Corona ciliaris 775.
 — dentis 487.
 — glandis 594.
 Coronary valve or valve of Thebesius 376.
 Corpora cavernosa clitoridis 604.
 — — penis 593.
 — mammillaria 645.
 — quadrigemina 635.
 Corpus adiposum orbitae 792.
 — albicans 596.
 — calcanei 141.
 — callosum 647, 648.
 — cavernosum urethrae 593.
 — ciliare 774, 775.
 — costae 79.
 — femoris 128.
 — fornicis 649, 650.
 — geniculatum laterale, mediale 645, 646, 667.
 — glandulae sudoriferae 840.
 — glandulae prostatae 592.
 — Highmori 584.
 — humeri 94.
 — incudis 811.
 — luteum 596.
 — Laysi 667.
 — mammae 616.
 — medullare cerebelli 667.

- Corpus oss. metacarpalis 109.
 — oss. metatarsalis 146.
 — papillare corii 838.
 — pineale 646.
 — radii 100.
 — restiforme 629, 666, 678.
 — —, medial portion 678.
 — spongiosum urethrae 603.
 — sterni 83.
 — striatum 637, 651.
 — tali 140.
 — tibiae 136.
 — trapezoideum 658, 662, 663.
 — ulnae 98.
 — unguis 840.
 — uteri 598.
 — ventriculi 513.
 — vertebrae 64.
 — vesicae felleae 533.
 — — urinariae 581.
 — vitreum 773, 782.
 Corpuscula lamellosa [Vateri] 730, 734.
 Cortical substance 577, 583.
 Costae 78—81.
 — I et II 80.
 — XI et XII 81.
 — verae, spuriae, fluctuantes 78.
 Cotyloid ligament 199.
 Cremasteric branch 434.
 Crest of ilium 115.
 Cricoaerotaenoides posticus 555.
 Crista(ae) ampullaris 825.
 — anterior fibulae 137.
 — — tibiae 136.
 — arcuata 551.
 — buccinatoria 35.
 — capituli costae 78.
 — colli costae 78.
 — conchalis 28, 31.
 — cutis 839.
 — ethmoidalis 28, 31.
 — fenestrae cochleae 810.
 — fibulae 137.
 — frontalis 16.
 — galli 20.
 — iliaca 115.
 — infratemporalis 5.
 — interossea fibulae 137.
 — — radii 100.
 — — tibiae 136.
 — — ulnae 98.
 — intertrochanterica 129.
 — lacrimalis anterior 28.
 — — posterior 24.
 — matricis unguis 840.
 — m. supinatoris 99.
 — nasalis 29, 30.
 — obturatoria 119.
 — occipitalis externa 2, 3.
 — sacrales 73.
 — sphenoidalis 4.
 Crista(ae) supraventricularis 377.
 — terminalis 376.
 — transversa meatus acustici interni 824.
 — tuberculi majoris, minoris 94.
 — urethralis 595, 603.
 — vestibuli 818.
 Cruciform ligament 165.
 Crura ampullaria 821.
 — antheliciis 801.
 — cerebri 635.
 — clitoridis 604.
 — diaphragmatis 270.
 — fornicis 649, 650.
 — incudis 811.
 — penis 593.
 — stapedis 812.
 Crureus 335.
 Crus heliciis 801.
 Crypts of Lieberkuehn 520.
 Cuboid bone 145.
 Culmen 633.
 Cuneiform bone 104.
 Cuneus 644.
 Cupola of cochlea 821.
 Cupula cochleae 821, 822.
 — pleurae 573.
 Curvatura ventriculi major, minor 512.
 Cuspides 375, 377.
 Cutis 837—840.
 Cymba conchae 801.
 D.
 Declive 633.
 Decussatio lemniscorum 673.
 — nervorum trochlearium 676.
 — pyramidum 628.
 Deep branch 436.
 — epigastric artery 434.
 — palmar arch 417.
 — ulnar artery 413.
 Deiters' nucleus 677.
 Deltoid or internal lateral ligament + the anterior and posterior tibiotarsal ligaments 219.
 Demifacet for head of rib 69.
 Dens epistrophei 66.
 Dentes 482—488.
 Dentine 487.
 Depression for Gasserian ganglion 11.
 Diagonal conjugata 127.
 Diameter obliqua 127.
 — recta 127.
 — transversa 127.
 Diaphragm 269, 270.
 Diaphragma 269—270.
 — pelvis 607.
 — sellae 685.
 — urogenitale 609.
 Diencephalon 626.
 Digastric fossa 9.
 Digestive tube 477.
 Digital fossa 129.
 — or plantar digital arteries 440.
 Digitationes hippocampi 654.
 Discus articularis of the articulation sternoclavicularis 176.
 — — radioulnaris distalis 186.
 — — of the jaw joint 152.
 Diverticula ampullae 586.
 Dorsal ligaments (of hand) 188.
 — and palmar ligaments 188.
 — vertebrae 69.
 Dorsalis indicis, or dorsal artery of the first finger 412.
 — scapulae 406.
 Dorsum nasi 830.
 — sellae 4.
 Ductuli aberrantes 585.
 — alveolares 567.
 — efferentes testis 584.
 — excretorii glandulae lacrimales 798.
 — transversarii epoophori 597.
 Ductus arteriosus [Botalli] 473.
 — choledochus 533.
 — cochlearis 827.
 — cysticus 533.
 — deferens 586.
 — ejaculatorii 589.
 — endolymphaticus 826.
 — epididymidis 585.
 — epoophori longitudinalis [Gartneri] 597.
 — excretorius vesiculae seminalis 589, 592.
 — hepaticus 533.
 — incisivus 833.
 — lacrimales 798.
 — lactiferus 616.
 — lingualis 489.
 — nasolacrimalis 798.
 — pancreaticus [Wirsungi] 535.
 — — accessorius [Santorini] 535.
 — paraurethralis 603.
 — parotideus [Stenonis] 497.
 — perilymphaticus 827.
 — prostaticus 592.
 — reuniens [Henseni] 826.
 — semicirculares 825.
 — sublinguales 496.
 — submaxillares [Whartoni] 497.
 — sudoriferus 840.
 — thyroglossus 574.
 — utriculosaccularis 826.
 — venosus [Arantii] 473.

Duodenum 516, 517.
Dura mater encephali 684—686.
— — spinalis 623.

E.

Ear, cartilage of 799.
— external 799, 800, 802.
— hairs of 806, 840.
— helix of 801.
— inner 799, 817—830.
— lobule of 802.
— middle 799, 809—816.
— outer 799.
— small bones of 805, 809, 811, 812.
— wax 806.
— — glands 806.
Ear-drum 805—808.
— cavity 809.
— circular ridge of 808.
Egg 596.
— follicle 596.
Elbow-joint 181—185.
Eminence for superior semi-circular canal 11.
Eminentia(ae) arcuata 11.
— carpi radialis 107.
— — ulnaris 107.
— collateralis 654.
— conchae 801.
— cruciata 3.
— fossae triangularis 801.
— iliopectinea 115, 119.
— intercondyloidea 136.
— medialis of the rhomboid fossa 629.
— pyramidalis 811.
— scaphae 801.
Emissaria 445.
Enamel 487.
Encephalon 626.
End-brain 626.
Endocardium 370.
Endolymph 825.
Endothelium camerae anterioris 774.
Ensiform process 83.
Epicardium 370, 386.
Epicondylus femoris 130.
— humeri 95.
Epidermis 837.
Epididymis 585.
Epiglottis 557.
— cartilage of 551.
Epistropheus 65, 66.
Epithalamus 646.
Epithelium corneae 774.
— lentis 782.
Epoophoron 597.
Erectile bodies 593.
Erector penis 612.
— spinae 291.
Ethmoid bone 20—22.

Ethmoid plate 20.
Ethmoidal cells 21.
— crest 4.
— labyrinth 21.
Eustachian tube 815, 816.
— valve 376.
Excavatio papillae n. optici 780.
— rectouterina [cavum Douglasi] 528, 603.
— rectovesicalis 528, 595.
— vesicouterina 603.
Excretory ducts of the kidney 578.
Extensor carpi radialis longior 311.
— indicis 315.
— minimi digiti 313.
— ossis metacarpi pollicis 314.
— primi internodii pollicis 314.
— proprius hallucis 347.
— secundi internodi pollicis 315.
External calcaneal artery 438.
— calcaneostrageloid ligament 221.
— calcaneonavicular ligament 221.
— circumflex artery 436.
— condyle 95.
— division of erector spinae 291.
— or facial surface 27.
— or inferior haemorrhoidal artery 431.
— intermuscular septum 299.
— lateral ligament 153, 183, 187.
— oblique line (of the jaw) 34.
— parietal or posterior temporal diploic vein 445.
— pillar, internal pillar 280.
— plantar artery 440.
— semilunar fibrocartilage 204.
— surface (of humerus) 94.
— tarsal artery 439.
Extremities acromialis, sternalis claviculae 92.
Eye 770.
— angle of 793.
— cavity 56—59, 785, 790, 791.
— chambers of 783.
— coats of 773.
— hard or white coat 793.
— muscles 770, 785—789.
— poles of 771.
Eyeball 770, 771—773, 791.
Eyebrow hairs 840.
Eyebrows 793.
Eyelids 770, 793—797.

F.

Facet for tubercle of rib 69.
Facial artery 389.

Facial nerve, knee of 700.
Facies articularis(es) acromialis 92.
— — acromii 88.
— — atlantis inferior 66.
— — calcanea tali 140.
— — calcanei 141.
— — capituli costae 78.
— — — fibulae 137.
— — carpea radii 101, 102.
— — cuboidea 141.
— — epistrophei 66.
— — fibularis 136.
— — malleolaris 137.
— — navicularis 140.
— — ossis temporalis 7.
— — patellae 135.
— — sternalis 92.
— — tibiae superior 136.
— — — inferior 137.
— — tuberculi costae 78.
— — vertebrae 64, 65, 69, 71.
— auricularis oss. ilium 115.
— — — sacri 75.
— cerebialis oss. frontalis 16, 17.
— — — parietalis 18, 19.
— — — sphenoidalis 4.
— — — temporalis 7.
— convexa cerebri 636.
— corneae 774.
— costalis scapulae 87.
— dorsalis ossis sacri 72, 73.
— — scapulae 87.
— fibulae 137.
— frontalis oss. frontalis 15.
— humeri 94.
— infratemporalis maxillae 27.
— — oss. sphenoidalis 5.
— iridis 776.
— lentis 782.
— lunata oss. coxae 115.
— malaris oss. zygomatici 32.
— maxillaris oss. palatini 31.
— medialis cerebri 637.
— nasalis maxillae 28.
— — oss. palatini 30, 31.
— orbitalis maxillae 27.
— — oss. frontalis 17.
— — — sphenoidalis 5.
— — — zygomatici 32.
— palatina oss. palatini 30.
— palpebrarum anterior 797.
— — posterior 796.
— parietalis oss. parietalis 18, 19.
— patellaris femoris 130.
— pelvina oss. sacri 72.
— radii 100.
— sphenomaxillaris oss. sphenoidalis 5.
— symphyseos 119.
— tali 140.

- Facies temporalis oss. frontalis 15.
 — — oss. sphenoidalis 5.
 — — temporalis 7, 32.
 — tibiae 136.
 — ulnae 98.
 — urethralis penis 592.
 Falciform ligament 194, 330.
 Fallopian tube 597.
 False vocal cord 558.
 Falx [aponeurotica] inguinalis 282.
 — cerebelli 686.
 — cerebri 686.
 Fascia(ae) axillaris 299.
 — brachii 299.
 — buccopharyngea 247.
 — bulbi [Tenoni] 792.
 — clitoridis 604.
 — colli 261.
 — cremasterica [Cooperi] 587.
 — cribrosa 331.
 — cruris 347.
 — dentata hippocampi 654.
 — diaphragmatis pelvis 613.
 — dorsalis pedis 356.
 — endopelvina 613.
 — endothoracica 573.
 — iliaca 325.
 — iliopectinea 325.
 — infraspinata 305.
 — lata (anterior half) 330, 331.
 — — (posterior half) 338.
 — lumbodorsalis 288.
 — musculares orbitae 792.
 — nuchae 287.
 — obturatoria 613.
 — of orbit 770, 792.
 — orbitales 770, 792.
 — parotideomasseterica 246.
 — pectinea 330.
 — pectoralis 299.
 — pelvis 613.
 — penis 594.
 — pharyngobasilaris 509.
 — praevertebralis 261.
 — prostatae 592.
 — subscapularis 300.
 — superficialis perinei 613.
 — supraspinata 305.
 — temporalis 246.
 — trigoni urogenitalis 609.
 Fasciculus(i) anterior proprius [Flechsigi] 671.
 — anterolateralis superficialis [Gowersi] 673.
 — cerebellospinalis 673.
 — cuneatus [Burdachi] 629.
 — gracilis [Golli] 629.
 — lateralis proprius [Flechsigi] 671.
 — longitudinales [pyramidales] 667.
 Fasciculus(i) longitudinalis medialis 673.
 — obliquus pontis 631.
 — of the pars infraclavicularis plexus brachialis 723.
 — sulcomarginalis 673.
 — tegmentomamillaris 680.
 — thalamomamillaris [Vieq d'Azyri] 680.
 — transversus aponeurosis palmaris 317.
 — — — plantaris 352.
 Fasciola cinerea 648.
 Fastigium 635.
 Fat body of orbit 792.
 Fauces, isthmus of 501.
 Femur 128—134.
 — head of 129.
 — neck of 129.
 — shaft of 128.
 Fenestra cochleae 810.
 — vestibuli 810, 818.
 Fibrae arcuatae externae 629, 678.
 — cerebelloolivares 678.
 — circulares [Muelleri] m. ciliaris 775.
 — intercrurales 280.
 — lentis 782.
 — meridionales [Brueckii] m. ciliaris 775.
 — obliquae of the tunica muscularis of the stomach 515.
 — pontis profundae, superficiales 667.
 — zonulares 783.
 Fibro-cartilage of jaw joint 152.
 Fibrocartilago basalis 9.
 — intervertebralis 156, 157.
 — navicularis 224.
 Fibula 137—139.
 Fila lateralia pontis 631.
 — radicularia n. spinalis 712.
 Fillet of the brain 635.
 — decussation of 673.
 — medial 673.
 Filum durae matris spinalis 623.
 — terminale 618.
 Fimbria(ae) hippocampi 649, 654.
 — ovarica 597.
 — tubae 597.
 Fingers, joints of 191.
 Fissura calcarina 644.
 — cerebri lateralis [Sylvii] 641.
 — collateralis 643.
 — hippocampi 643.
 — longitudinalis cerebri 637.
 — mediana anterior 618, 628.
 — — posterior 629.
 — orbitalis inferior 5, 27, 31, 59.
 — — superior 4, 5, 6, 58.
 — parietooccipitalis 644.
 Fissura petrooccipitalis 1, 2, 9.
 — petrosquamosa 11.
 — petrotympanica [Glaseri] 13.
 — pterygoidea 6.
 — sphenoccipitalis 1.
 — sphenopetrosa 5, 9.
 — transversa cerebelli 635.
 — — cerebri 637.
 — tympanomastoidea 13.
 Fissure of Rolando 642.
 Flexor brevis minimi digiti 318.
 — — — pedis 359.
 Flexura coli dextra 524.
 — — sinistra 525.
 — duodeni inferior, superior 516.
 — duodenojejunalis 516.
 — perinealis recti 528.
 — sacralis recti 528.
 Flocculus cerebelli 633.
 Flock 633.
 Flumina pilorum 840.
 Foetal circulation 473.
 Folium vermis 633.
 Folliculi linguales 493.
 — oophori 596.
 Fontanelles 63.
 Fonticuli 63.
 Foot, bones of 140—151.
 — — — root of 140—145.
 — joints of 217—227.
 — root of 140.
 Foramen(mina) alveolare 27.
 — apicis dentis 487.
 — caecum (basis cranii) 16.
 — — fissurae medianae 628.
 — — linguae [Morgagnii] 489.
 — carotica 10.
 — costotransversarium 77, 173.
 — diaphragmatis sellae 685.
 — epiploicum [Winslowi] 543.
 — ethmoidalia 17, 21.
 — frontale 15.
 — incisivum 29.
 — infraorbitale 27.
 — interventriculare [Monroi] 646.
 — intervertebrale 64, 74.
 — ischiadicum majus, minus 194.
 — jugulare 2, 9.
 — lacerum 9.
 — Magendii 635.
 — magnum 1.
 — mandibulare 35.
 — mastoidea 8.
 — mentale 34.
 — nasalia 25.
 — nutrium femoris 128.
 — — fibulae 137.
 — — humeri 94.
 — — oss. metacarpalis 109.
 — — oss. metatarsalis 146.

- Foramen(mina) nutricium phalangis 109.
 — — radii 100.
 — — tibiae 136.
 — — ulnae 98.
 — obturatum 119.
 — occipitale magnum 1.
 — opticum 4, 6.
 — ovale [cordis] 377.
 — — of the sphenoid bone 4, 5.
 — palatina 30.
 — papillaria 578.
 — parietale 19.
 — posterior condyloid 2.
 — rotundum 4, 5.
 — sacralia 72, 73.
 — singulare 824.
 — sphenopalatinum 31.
 — spinosum 4, 5.
 — supraorbitale 15.
 — stylomastoideum 10, 12, 14.
 — thyroideum 550.
 — transversarium 65.
 — venae cavae 270.
 — venarum minimarum [Thebesii] 385.
 — vertebrale 64, 65, 69, 71.
 — zygomaticofaciale 32.
 — zygomaticoorbitale 32, 57.
 — zygomaticotemporale 32.
 Fore-arm, bones of 102, 103.
 Fore-brain 626.
 Fore-chamber, left, of heart 379.
 — right, of heart 376.
 Formatio reticularis 621, 666.
 Fornix (cerebri) 649—650.
 — conjunctivae 797.
 — pharyngis 503.
 — sacci lacrimalis 798.
 — vaginae 602.
 Fossa(ae) acetabuli 115.
 — antheliciis 802.
 — axillaris 238, 239.
 — caecalis 546.
 — canina 27.
 — carotica 237.
 — cerebri lateralis [Sylvii] 644.
 — condyloidea 2.
 — coronoidea 95.
 — digastrica 35.
 — ductus venosi 531.
 — glandulae lacrimalis 17.
 — hyaloidea 783.
 — hypophyseos 4.
 — iliaca 115.
 — ilipectinea 330.
 — incudis 811.
 — infraclavicularis 237, 238.
 — infraspinata 88.
 — infratemporalis 54.
 — intercondyloidea femoris 130.
 — — tibiae 136.
 Fossa(ae) interpeduncularis 636.
 — ischiorectalis 613.
 — jugularis 9, 237.
 — mandibularis 7.
 — mastoidea 8.
 — navicularis urethrae [Morgagnii] 595.
 — — [vestibuli vaginae] 606.
 — occipitales 3.
 — olecrani 95.
 — ovalis (heart) 376.
 — — (thigh) 280, 331.
 — parietalis 19.
 — pterygoidea 6, 30.
 — pterygopalatina 31, 55.
 — radialis humeri 95.
 — retromandibularis 237.
 — rhomboidea 629—630.
 — sacci lacrimalis 24.
 — sagittalis dextra, sinistra 530.
 — scaphoidea 6.
 — Scarpae major 330.
 — sigmoidea 9.
 — subarcuata 9, 14.
 — subscapularis 87.
 — supraclavicularis major, minor 237.
 — supraspinata 88.
 — supratonsillaris 501.
 — temporalis 54.
 — triangularis auriculae 801.
 — trochanterica 129.
 — venae cavae 530.
 — — umbilicalis 531.
 — vesicae felleae 531.
 Fossula(ae) fenestrae cochleae 810.
 — — vestibuli 810.
 — petrosa 10, 12.
 — tonsillares 501, 503.
 Fourth ventricle, floor of 633.
 Fovea(ae) articularis superior atlantis 66.
 — capitis femoris 129.
 — capituli radii 101.
 — centralis (retinae) 780.
 — costales 67, 69.
 — costalis transversalis 69.
 — dentis 66.
 — inferior fossae rhomboideae 630.
 — inguinales 549.
 — nuchae 239.
 — oblonga 551.
 — pterygoidea processus condyloidei 35.
 — sublingualis 35.
 — submaxillaris 35.
 — superior fossae rhomboideae 630.
 — supravesicalis 549.
 — triangularis 515.
 Fovea trochlearis 17.
 Foveolae gastricae 515.
 Foveolae(a) granulares [Pacchioni] 19, 683.
 — palatina 499.
 Frenulum(a) clitoridis 606.
 — labiorum 478.
 — — pudendi 606.
 — linguae 494.
 — praeputii 594.
 — valvulae coli 523.
 — veli medullaris anterioris 635.
 Frontal bone 15—17.
 — eminence 15.
 — lobe 641.
 — process 32.
 Fundus of internal acoustic meatus 824.
 — meatus acustici interni 824.
 — uteri 598.
 — ventriculi 512.
 — vesicae felleae 533.
 — — urinariae 581.
 Funicular cells of grey matter 672.
 Funiculi medullae spinalis 619.
 Funiculus anterior 629.
 — lateralis 629.
 — posterior 629.
 — spermaticus 587.
 — umbilicalis 473.
 Funnel of brain 645.
- G.**
- Galea aponeurotica 242.
 Gall bladder 533.
 Ganglion(ia) cardiacum [Wrisbergi] 767.
 — cervicalia 764.
 — ciliare 690.
 — — radices brevis, longa, sympathicae 690.
 — coeliaca 767.
 — commissurale alae cinereae 678.
 — geniculi 700.
 — jugulare 678, 707.
 — lumbalia 767.
 — mesentericum superius 767.
 — nodosum n. vagi 678, 707.
 — oticum 699.
 — peripheral sympathetic 763.
 — petrosum n. glossopharyngei 678, 704.
 — phrenicum 767.
 — plexuum sympathicorum 763.
 — sacralia 769.
 — semilunare [Gasseri] 676, 689.
 — sphenopalatinum 693—695.
 — spinale 712.
 — spirale (cochleae) 678, 704.

Ganglion(ia) splanchnicum 767.
 — submaxillare 699.
 — superius n. glossopharyngei 678, 704.
 — thoracalia 767.
 — trunci sympathici 763.
 — vestibulare 677.
 Gaster 512—515.
 Gastric or coronary artery 421.
 Genial tubercles 34.
 Genuiculate bodies 645, 646.
 Geniculum canalis facialis 12, 14.
 — nervi facialis 700.
 Geniohyoglossus 491.
 Genu capsulae internae 668.
 — corporis callosi 647.
 — internum nervi facialis 674.
 Gimbernat's ligament 280.
 Gingiva 481.
 Glabella 15.
 Gladiolus 83.
 Gland of Nuhn 494.
 Glandulae(a) areolares [Montgomerii] 616.
 — bronchiales 564.
 — buccales 479.
 — bulbourethrales [Cowperi] 592.
 — ceruminosae 805, 840.
 — cervicales [uteri] 599.
 — ciliares [Molli] 797, 840.
 — circumanales 840.
 — cutis 837, 840—842.
 — duodenales [Brunneri] 520.
 — gastricae [propriae] 515.
 — glomiformes 840.
 — intestinales [Lieberkuehni] 520, 529.
 — labiales 478.
 — lacrimalis 798.
 — laryngeae 560.
 — linguales 494.
 — lingualis anterior [Blandini, Nuhn] 494.
 — molares 479.
 — mucosae [Krausei] 797.
 — — tubae auditivae 816.
 — nasales 835.
 — oesophageae 512.
 — olfactoriae 836.
 — palatinae 499.
 — parotis 497.
 — — accessoria 497.
 — pharyngeae 505.
 — pyloricae 515.
 — sebaceae 616, 797, 840, 842.
 — sublingualis 496.
 — submaxillaris 497.
 — sudoriferae 616, 840.
 — suprarenales 583.
 — — accessoriae 583.
 — tarsales [Meibomi] 796.
 — thyreoidea 574.

Glandula(ae) thyreoidea accessoria suprahyoidea 574.
 — thyreoideae accessoriae 574.
 — tracheales 561.
 — urethrales [Littrei] 595, 603.
 — uterinae 599.
 — vestibulares minores 606.
 — vestibularis major [Bartholini] 605.
 Glans clitoridis 604.
 — penis 592, 594.
 Glaserian fissure 13.
 Glenoid cavity 7.
 — ligament 178.
 Globus pallidus 668.
 Glomus chorioideum 654.
 — coccygeum 421.
 Glottis 558.
 Gluteal groove 338.
 Gowers' bundle or tract 673.
 Graafian follicle 596.
 Granular layer of cerebellum 667.
 Granulationes arachnoideales [Pachioni] 683.
 Great sacrosciatic foramen 194.
 — — notch 115, 117.
 Greater tuberosity (of humerus) 94.
 Grey matter, distribution of principal masses of 666—670.
 Groove for lateral sinus 19.
 — — nasal nerve 25.
 Gum 481.
 Gyri, annectant 641.
 — of cerebellum 633.
 — of cerebrum 641—644.
 Gyrus(i) angularis 643.
 — breves insulae 644.
 — centrales 641, 643.
 — cerebelli 633.
 — cerebri 641—644.
 — cinguli 643.
 — fornicatus 643.
 — frontales 641.
 — fusiformis 643.
 — hippocampi 643.
 — insulae 644.
 — lingualis 643.
 — longus insulae 644.
 — occipitales laterales, superiores 643.
 — orbitales 642.
 — profundi 641.
 — rectus 642.
 — subcallosus, 645.
 — supramarginalis 643.
 — temporales 643.
 — transitivi 641.

H.

Habenula 646.
 Hair streams 840.
 — vortex 840.
 Hairs 837, 840.
 Hammer 811.
 — folds 814.
 Hamular process 6, 24.
 Hamulus lacrimalis 24.
 — laminae spiralis 823.
 — ossis hamati 105.
 — pterygoideus 6.
 Hand, bones of 110—113.
 — bones of root of 104—107.
 — root of 107.
 Handle of sternum 83.
 Haustra coli 521.
 Head bone of wrist 105.
 — hairs of 840.
 Hearing, nerve of 703.
 — organ of 799—830.
 Heart 365.
 — apex of 365.
 — base of 365.
 — left auricle of 379.
 — — ventricle of 380.
 — muscle 370—371.
 — position of 365.
 — right auricle of 377.
 — — ventricle of 377, 378.
 — serous sac of 386.
 — sympathetic plexus of 767.
 — vessels of 381.
 — vortex of 371.
 Heel-bone 141, 142.
 Helicotrema 823, 827.
 Helix 801.
 Hemisphaeria bulbi urethrae 593.
 — cerebelli 633.
 — cerebri 626, 637.
 Hemispheres, cerebellar 633.
 — cerebral 626, 637.
 Hepar 530—533.
 Hepatic flexure of the colon 524.
 Hiatus aorticus 270.
 — canalis facialis 11, 12.
 — Fallopii 11, 12.
 — maxillaris 27, 28.
 — oesophageus 270.
 — sacralis 73.
 — semilunaris 61.
 — tendineus [adductorius] 336.
 Hilus glandulae suprarenalis 583.
 — lienis 535.
 — nuclei dentati 667.
 — — olivaris 666.
 — ovarii 596.
 — pulmonis 562.
 — renalis 576.
 Hind brain 626.

Hip bone 114—122.
— joint 199—203.
Hippocampus 654.
Hirci 840.
Hook bone 105.
Horizontal plate 30.
Horse tail 712.
Humerus 94—97.
Humor aqueus 773, 783.
— vitreus 783.
Hunter's canal 336.
Hydatids of the testicle 585.
Hymen [femininus] 602.
Hyoid bone 40, 41.
Hypogastric artery 428.
Hypophysis [cerebri] 645.
Hypothalamus 645, 667.
Hypothernar 317.

I.

Ileum 518.
Iliac fossa 115.
Iliolumbar artery 426.
— ligament 193.
Iliotibial band 338.
Ilium 115.
Impressio cardiaca (pulmonis) 562.
— petrosa (cerebri) 640.
— trigemini oss. temporalis 11.
Impression for conoid ligament 92.
— — rhomboid ligament 92.
Impressiones digitatae 3, 5, 11, 16, 17, 19.
— hepatis 530, 531.
— renis 577.
Incisor teeth 482.
Incisura(ae) acetabuli 115.
— anterior auri 802.
— antitragicohelicina 801.
— [apicis] cordis 367.
— cardiaca 563.
— cartilaginis meatus acustici externi [Santorini] 805.
— cerebelli anterior, posterior 631.
— claviculae sterni 83.
— costales sterni 83.
— ethmoidalis 16, 17.
— fibularis 137.
— frontalis 15.
— interarytaenoidea 558.
— interlobaris 563.
— intertragica 799, 801.
— ischiadica major, minor 115, 117.
— jugularis oss. occipitalis 2.
— — oss. temporalis 9.
— — sterni 83.
— lacrimalis 28.
— mandibulae 35.
— mastoidea 9.

Incisura(ae) nasalis 27, 28.
— pancreatis 534.
— parietalis 8.
— radialis 99.
— scapulae 87.
— semilunaris 99.
— sphenopalatina 31.
— supraorbitalis 15.
— tentorii 685.
— terminalis cartilaginis auricularae 799.
— thyroidea [superior] 550.
— tympanica [Rivini] 13, 805.
— ulnaris 101.
— umbilicalis 530.
— vertebralis 64, 74.
Inclination pelvis 127.
Incus 811.
Inferior calcaneonavicular ligament 224.
— coronary artery 390.
— curved line (of ilium) 115.
— dental canal 35.
— dental foramen 35.
— external articular artery 437.
— born 653, 654.
— internal articular artery 437.
— lingual 491.
— longitudinal sinus 441.
— maxillary bone 34.
— profunda artery 410.
— radioulnar articulation 186.
— turbinated crest 31.
Infratemporal fossa 54.
Infundibula(um) pulmonis 645.
— ethmoidale 61.
— tubae uterinae 597.
Inguinal canal 280—283.
— ligament 280.
— ring 280.
Inner condyle (of femur) 130.
— division of erector spinae 293.
— portion of the m. thyroidei-arytaenoideus 557.
— tuberosity 130.
Innominate vein 445.
Inscriptiones tendineae 277.
Insula 644.
Integumentum commune 594, 837—842.
Interarticular fibrocartilage 152, 176.
— ligament 170.
Interauricular septum 376.
Inter-brain 626.
Intercolumnar fascia, external spermatic fascia 280.
Internal abdominal ring 283.
— annular ligament 360.
— auditory artery 404.
— border, external border 94.
— calcaneal branch 438.

Internal calcaneoastrageloid ligament 221.
— calcaneonavicular ligament 221.
— condyle 95.
— cuneiform bone 144.
— and external abdominal ring 280.
— intermuscular septum 299.
— lateral ligament 182, 187, 208.
— malleolar branch 438.
— oblique line (of jaw) 35.
— plantar artery 440.
— pudic vein 463.
— semilunar fibrocartilage 204.
— surface 16.
— — (of humerus) 94.
— tarsal artery 439.
Interolivary layer 673.
Interosseous ligament 221.
— recurrent, or posterior interosseous recurrent 414.
Interpubic disc 197.
Intertransversales 295.
Intertrochanteric line 129.
Intervertebral discs 156, 157.
— foramina 64.
Intestine, large or thick 520.
— villi of 520.
— small or thin 516.
Intestinum caecum 521—523.
— crassum 520.
— ileum 518.
— jejunum 518.
— rectum 528—529.
— tenue 516.
— — mesenteriale 517, 518.
Intumescencia cervicalis, lumbalis 618.
— tympanica 706.
Iris 774, 776, 777.
Ischiocavernosus 612.
Ischium 117.
Island of Reil, threshold of 645.
Isthmus aortae 389.
— cartilaginis auricularae 799.
— faucium 501.
— glandulae thyroideae 574.
— gyri fornicati 643.
— prostatae 591.
— rhombencephali 626, 635.
— tubae auditivae 815.
— — uterinae 597.

J.

Jaw joint 152—155.
Jejunum 518.
Joint capsule 152.
Joints 152—228.
Juga alveolaria 29, 34.
— cerebellaria 3.

Juga cerebralia 3, 5, 7, 11, 16, 17, 19.
Juncturae tendinum 312.

K.

Key-bone 92, 93, 177.
Kidney, calyx of 578.
— cordical lobule of 578.
— pelvis of 578.
Kidneys 575—579.
Knee cap 135.
Knee-joint 204—215.

L.

Labium(a) externum, internum ossis ilium 115.
— laterale, mediale femoris 128.
— majora, minora pudendi 606.
— oris 478.
— uteri 598.
— vocale 558.
Labrum glenoidale articulationis humeri 178.
— — — coxae 199.
Labyrinthus ethmoidalis 20, 21.
— membranaceus 817, 825 to 828.
— osseus 817—823.
Lacertus fibrosus 301.
— musculi recti lateralis 786.
Lachrymal apparatus 770, 798.
— bone 24.
— crest 24.
— gland 798.
— groove 28.
— lake 794.
— tubules 798.
Lachrymo-nasal duct 798.
Lacrimae 798.
Lacuna musculorum, vasorum 325.
Lacunae urethrales [Morgagnii] 595, 603.
Lacus lacrimalis 794.
Lamina(ae) affixa 652.
— basalis 775.
— basilaris cochleae 827.
— cartilaginosa cricoideae 551.
— chorioepithelialis 775.
— chorioidea epithelialis 634, 646, 652.
— cribrosa of the ethmoid bone 20.
— — sclerae 773.
— elastica anterior [Bowmani] 774.
— — posterior [Descemeti, Demoursi] 774.
— fibrocartilaginea interpubica 197, 198.
— fusca (sclerae) 774.

Spalteholz, Atlas.

Lamina(ae) lateralis cartilaginis tubae auditivae 816.
— — processus pterygoidei 6.
— medialis cartilaginis tubae auditivae 816.
— — processus pterygoidei 6.
— mediastinalis 573.
— medullares of the cerebellum 667.
— — thalami 667.
— membranacea tubae auditivae 816.
— mesenterii propria 545.
— modioli 822.
— papyracea 21.
— perpendicularis 20, 22.
— quadrigemina 635.
— rostralis 647.
— septi pellucidi 649.
— spiralis ossea 823.
— — secundaria 823.
— suprachorioidea 774, 775.
— terminalis 645, 646.
— tragi 801.
— vasculosa 775.
Lanugo 840.
Larynx 550.
— cartilage of 550.
Lateral false ligament 428.
— funiculus bundle 673.
— — of the spinal cord 619, 671.
— limiting layer of grey matter of spinal cord 673.
— mass of ethmoid 21.
— sinus 441.
— ventricle 648, 650, 654.
— — anterior horn of 652.
Left auricle 366, 379.
— auricular appendix 379.
— terminal branch 422.
Lemniscus 635.
— lateralis [acusticus] 635, 659, 664, 678.
— medialis [sensitivus] 659, 664, 673.
Lens 773, 782, 783.
— capsule of 782.
— crystallina 773, 782—784.
— epithelium of 782.
— fibers 782.
— stars 782, 783.
Lentiform nucleus 667, 782.
— — segments of 667.
Lesser sacrosclatic foramen 194.
— — notch 117.
— tuberosity 94.
Levator palati 506.
— projection 505.
Lid plates of eye 795, 796.
— slit 793.
Lien 535—536.
— accessorius 536.

Ligament of the ovary 599.
Ligamenta(um) accessoria volaria 191.
— acromioclaviculare 177.
Ligamentum(a) alare dentis 167.
— alaria 211.
— annulare baseos stapedis 812.
— — radii 183.
— annularia 322.
— — [trachealia] 561.
— anococcygeum 612.
— apicis dentis 167.
— arcuatum pubis 197.
— arteriosum 380.
— auricularia [Valsalvae] 802.
— basium [ossium metacarpalium] dorsalia, volaria 188.
— — [ossium metacarpalium] interossea 189.
— — [ossium metatarsalium] dorsalia 221.
— — [ossium metatarsalium] interossea 227.
— — [ossium metatarsalium] plantaria 225.
— bifurcatum 221.
— calcaneocuboideum dorsale 221.
— — plantare 224.
— calcaneofibulare 217, 218.
— calcaneonavicularia dorsale 221.
— — plantare 224.
— calcaneotibiale 219.
— capituli costae interarticulare 170.
— — costae radiatum 171.
— — fibulae 216.
— capitulorum [ossium metacarpalium] transversum 190.
— carpi dorsale 316.
— — radiatum 187.
— — transversum 317.
— — volare 317.
— carpometacarpea 188.
— ceratocricioidea 552.
— collaterale fibulare, tibiale 208.
— — radiale, ulnare 182, 183.
— collateralia carpi 187.
— — digitorum 191.
— colli costae 173.
— columnae vertebralis 156.
— conoideum 177.
— coracoacromiale 177.
— coracoclaviculare 177.
— coracohumerale 179.
— corniculopharyngeum 553.
— coronarium hepatis 541.

Ligamentum(a) costoclaviculare 176.
 — costotransversaria 172.
 — costoxiphoida 175.
 — cricoarytaenoideum posterius 552.
 — cricopharyngeum 553.
 — cricothyreoideum [medium] 553.
 — cricotracheale 553.
 — cruciata digitorum manus 322.
 — — genu 205—207.
 — cruciatum atlantis 166.
 — — cruris 356.
 — cuboideonaviculare dorsale 221.
 — — plantare 225.
 — cuneocuboideum dorsale 221.
 — — interosseum 227.
 — — plantare 225.
 — cuneometatarsea interossea 227.
 — deltoideum 217, 219.
 — denticulatum 623.
 — duodenorenale 541.
 — epididymidis 585.
 — falciforme hepatis 541.
 — flava 156, 159.
 — fundiforme clitoridis 279.
 — — penis 279, 594.
 — gastrocolicum 542.
 — gastrolienale 536, 541.
 — glossoepiglotticum 553.
 — hamatometacarpeum 188.
 — hepatocolicum 541.
 — hepatoduodenale 541.
 — hepatogastricum 541.
 — hepatorenale 541.
 — hyoepiglotticum 553.
 — hyothyreoidea 552.
 — iliofemorale 199.
 — iliolumbale 193.
 — incudis superius, posterius 812.
 — inguinale [Poupart] 280.
 — inguinale reflexum [Collesi] 282.
 — intercarpea interossea 189.
 — — volaria 187, 188.
 — interclaviculare 176.
 — intercostalia externa 267.
 — — interna 267.
 — intercuneiformia dorsalia 221.
 — — interossea 227.
 — — plantaria 225.
 — interfoveolare [Hesselbachi] 283.
 — interspinalia 156, 158.
 — intertransversaria 156, 158.
 — ischiocapsulare 200.

Ligamentum(a) laciniatum 360, 361.
 — lacunare [Gimbernati] 280.
 — latum uteri 603.
 — longitudinalia 156, 160, 161.
 — lumbocostale 288.
 — mallei anterius, laterale, superius 812.
 — malleoli lateralis 216, 217.
 — mucosum 211.
 — navicularicuneiformia dorsalia 221.
 — nuchae 163.
 — — plantaria 225.
 — ossiculorum auditus 812.
 — ovarii proprium 599.
 — palpebrale mediale 798.
 — patellae 213.
 — pectinatum iridis 777.
 — phrenicocolicum 536.
 — phrenicolienale 536, 541.
 — pisohamatum 187.
 — pisometacarpeum 187.
 — plantare longum 223.
 — poplitea 209.
 — pubicum superius 197.
 — pubocapsulare 199.
 — puboprostata 612, 613.
 — pubovesicalia 613.
 — pulmonale 573.
 — pylori 514.
 — radiocarpea 187, 188.
 — sacrococcygea 162.
 — sacroiliaca 193, 194, 196.
 — sacrospinosum 194.
 — sacrotuberosum 194.
 — sphenomandibulare 154.
 — spirale cochleae 827.
 — sternoclaviculare 176.
 — sternocostale interarticulare 175.
 — sternocostalia radiata 175.
 — sternopericardiaca 387.
 — stylohyoideum 40.
 — stylomandibulare 154.
 — suprspinale 156, 161.
 — suspensorium 167.
 — — clitoridis 604.
 — — ovarii 603.
 — — penis 594.
 — talocalcanea 221.
 — talofibularia 217, 218.
 — talonaviculare [dorsale] 221.
 — talotibialia 219.
 — tarsi dorsalia 221.
 — — plantaria 223—227.
 — tarsometatarsea dorsalia 221.
 — — plantaria 225.
 — temporomandibulare 153.
 — teres femoris 202.
 — — hepatis 531.
 — — uteri 599.

Ligamentum(a) thyreoepiglotticum 553.
 — tibionaviculare 219.
 — transversum acetabuli 199.
 — — atlantis 166.
 — — cruris 347.
 — transversum genu 204.
 — — pelvis 609.
 — — scapulae 177.
 — trapezoideum 177.
 — triangularia 541.
 — tuberculi costae 173.
 — umbilicale laterale 428.
 — — medium 581.
 — vaginale 322.
 — venae cavae sinistrae 384.
 — venosum [Arantii] 531.
 — ventriculare 554.
 — vocale 553.
 Limbus alveolaris 29, 34.
 — corneae 773, 774.
 — fossae ovalis [Vieussensii] 376.
 — membranae tympani 808.
 — palpebralis anterior, posterior 793.
 Limen insulae 644, 645.
 — nasi 833.
 Linea(ae) alba 279.
 — arcuata 115.
 — aspera femoris 128.
 — glutaee 115.
 — intercondyloidea 130.
 — intermedia alae oss. ilium 115.
 — intertrochanterica 129.
 — musculares scapulae 87.
 — mylohyoidea 35.
 — nuchae 3.
 — obliqua cartilaginis thyreoideae 550.
 — — mandibulae 34.
 — pectinea 128.
 — poplitea 136.
 — semicircularis [Douglassi] 275, 279.
 — semilunaris [Spigeli] 279.
 — temporales 7, 15, 19.
 — terminalis 119.
 — transversae ossis sacri 72.
 — visus 771.
 Lingua 489.
 Lingual tonsil 493.
 Lingula cerebelli 633, 635.
 — mandibulae 35.
 — pulmonis 563.
 — sphenoidalis 4.
 Lips 478.
 Liquor cerebrospinalis 623, 682.
 — folliculi 596.
 — pericardii 386.
 Lissauer's marginal zone 673.
 Liver 530—533.

- Lobulus(i) auriculæ 802.
 — biventer (cerebelli) 631, 633.
 — centralis 633.
 — corticales renis 578.
 — epididymidis 585.
 Lobulus(i) mammae 616.
 — paracentralis 644.
 — parietalis inferior, superior 643.
 — pulmonis 567.
 — quadrangularis 633.
 — semilunaris inferior, superior 633.
 — testis 584.
 — thymi 568.
 Lobus(i) caudatus [Spigeli] 530.
 — cerebri 641.
 — hepatis 530.
 — hypophyseos 645.
 — mammae 616.
 — olfactorius 645.
 — pyramidalis 574.
 — quadratus hepatis 530.
 — renales 577, 578.
 Locus caeruleus 630, 676.
 Long calcaneocuboid or long plantar ligament 223.
 — externallateral ligament 208.
 — thoracic artery 406.
 Lower jaw, body of 34.
 — — bone 33—39.
 — — ramus of 35.
 — part of anterior annular ligament 356.
 Lumbar arteries 421.
 — enlargement 618.
 — nerves 712.
 — rib 71.
 — vertebra 71.
 Lumbosacral vertebra 75.
 Lung, lobule of 567.
 — root of 562.
 Lungs 562—567.
 Lunula unguis 840.
 — valvulae semilunaris 380.
 Lymph node 529.
 Lymphoglandulae bronchiales 561.
 — pulmonales 562.
 — tracheales 561.

M.
 Macula(ae) acustica sacculi 826.
 — — utriculi 825.
 — cribrosae 818.
 — flava 558.
 — lutea 780.
 Malar bone 32.
 — process 28.
 Malleoli, medial and lateral 137.
 Malleolus lateralis 137.
 — medialis 137.
 Malleus 811.
 Mamma(ae) 615.
 — accessoriae 616.
 — virilis 616.
 Mandibula 33—39.
 Mandibular or inferior dental artery 393.
 Manubrium mallei 811.
 — sterni 83.
 Marginal bundle, anterior 673.
 — loop network of cornea 778.
 — zone, Lissauer's 673.
 Margo(ines) ciliaris iridis 776.
 — falciformis 330.
 — frontalis ossis parietalis 18.
 — — oss. sphenoidalis 5, 6.
 — humeri 94.
 — infraglenoidalis 136.
 — infraorbitalis 27, 32, 56.
 — lacrimalis 28.
 — lambdoideus 1, 3.
 — mastoideus 1—3.
 — nasalis 16.
 — nasi 830.
 — occipitalis oss. parietalis 18.
 — — — temporalis 8.
 — parietalis oss. frontalis 15.
 — — — temporalis 7.
 — pupillaris iridis 776.
 — radii 100.
 — sagittalis oss. parietalis 18.
 — scapulae 87.
 — sphenoidalis oss. temporalis 7.
 — squamosus oss. parietalis 18.
 — — — sphenoidalis 5.
 — supraorbitalis 15, 17, 56.
 — tibiae 136.
 — ulnae 98.
 — unguis 840.
 — zygomaticus 5.
 Massa intermedia 646, 667.
 Massae laterales atlantis 66.
 Mastication, muscles of 249.
 Mastoid process 9.
 Matrix unguis 840.
 Maxilla 27—29.
 Meatus acusticus externus 7, 13, 805.
 — — — cartilagineus 805.
 — — — osseus 805.
 — — internus 9, 824.
 — nasi 21, 60, 834.
 — — communis 60.
 — — inferior 60, 61, 834.
 — — medius 60, 834.
 — — superior 21, 60, 834.
 — nasopharyngeus 60, 834.
 Median artery or arteria comes nervi mediani 413.
 Mediastinum 573.
 — testis 584.
 Medulla oblongata 628-629, 666.
 — spinalis 618.
 Medullary cord 568.
 — laminae 667.
 — substance 577, 583.
 Membranae(a) atlantooccipitales 164.
 — elastica laryngis 554.
 — hyaloidea 783.
 — hyothyreoidea 552.
 — interossea antibrachii 186.
 — — cruris 216.
 — obturatoria 119, 197.
 — — (stapedis) 812.
 — quadrangularis 554.
 — sterni 175.
 — tectoria 168.
 — tympani 805, 808.
 — — secundaria 815, 828.
 — vestibularis [Reissneri] 827.
 Meninges encephali 6.
 — spinales 622.
 Menisci articulares of knee-joint 204.
 Mental process 34.
 Meridiani bulbi oculi 771.
 Mesencephalon 626, 635.
 Mesenterium processus vermiformis 547.
 Mesenterium 545.
 Mesentery of small intestine 545.
 Mesocolon 546, 547, 549.
 Mesometrium 603.
 Mesosalpinx 597.
 Mesovarium 596.
 Metacarpal bones 108, 109.
 Metatarsal artery 439.
 — bones 146.
 Metathalamus 645.
 Metencephalon 626.
 Mid brain 626, 667.
 Middle curved line 115.
 — division of erector spinae 292.
 — ear 809—816.
 — fasciculus of external lateral ligament 218.
 Milk teeth 486, 487.
 Modiolus 822.
 Molar teeth 483, 484.
 Monticulus 633.
 Mouth cavity 478.
 — mucous membrane of 481.
 — slit 478.
 Multangular bone, large, small 105.
 Muscle external rectus 787.
 — internal rectus 787.
 Muscles of pharynx 509.
 Musculospiral groove 94.
 Musculus(li) abductor digiti quinti of the foot 353.
 — — — of the hand 318.
 — — hallucis 360.
 — — pollicis brevis 318.

- Musculus(li) abductor pollicis longus** 314.
 — adductor hallucis 355.
 — — pollicis 320.
 — adductores femoris 333, 334.
 — anconaeus 313.
 — antitragicus 802.
 — articularis genu 335.
 — aryepiglotticus 557.
 — arytaenoideus obliquus 557.
 — — transversus 557.
 — auricularis anterior 250.
 — — posterior 250.
 — — superior 250.
 — biceps brachii 301.
 — — femoris 344.
 — brachialis 303.
 — brachioradialis 307.
 — bronchooesophageus 512.
 — buccinator 248.
 — buccopharyngeus 509.
 — bulbocavernosus 612.
 — caninus 245.
 — ceratopharyngeus 509.
 — cervicalis ascendens 291.
 — chondroglossus 491.
 — chondropharyngeus 509.
 — ciliaris 775.
 — — [Riolani] 797.
 — coccygeus 328.
 — constrictores pharyngis 509.
 — coracobrachialis 302.
 — corrugator 245.
 — cremaster 281.
 — cricoarytaenoideus lateralis 555.
 — — posterior 555.
 — cricopharyngeus 509.
 — cricothyreoideus 554.
 — deltoideus 297.
 — depressor septi 245.
 — digastricus 253.
 — dilatator pupillae 777.
 — epicranii 212.
 — extensor carpi radialis brevis 312.
 — — — longus 311.
 — — — ulnaris 313.
 — — digiti quinti proprius 313.
 — — digitorum brevis 357.
 — — — communis 312.
 — — — longus 346.
 — — hallucis brevis 357.
 — — — longus 347.
 — — indicis proprius 315.
 — — pollicis brevis 314.
 — — — longus 315.
 — flexor carpi radialis 308.
 — — — ulnaris 308.
 — — digiti quinti brevis of the foot 359.
- Musculus(li) flexor digiti quinti brevis of the hand** 318.
 — — digitorum brevis 353.
 — — — longus 350.
 — — — profundus 310.
 — — — sublimis 309.
 — — hallucis brevis 355.
 — — — longus 350.
 — — pollicis brevis 320.
 — — — longus 310.
 — frontalis 242.
 — gastrocnemius 348.
 — gemelli 341.
 — genioglossus 491.
 — geniohyoideus 257.
 — glossopalatinus 506.
 — glossopharyngeus 509.
 — glutaeus maximus 337.
 — — medius 340.
 — — minimus 342.
 — gracilis 332.
 — helcis major, minor 802.
 — hyoglossus 490.
 — iliacus 327.
 — iliococcygeus 608.
 — iliocostales 291.
 — iliopsoas 326.
 — incisivus labii inferioris 245.
 — — — superioris 245.
 — infrapinnatus 304.
 — intercartilaginei 267.
 — intercostales externi 267.
 — — interni 267.
 — interfoveolaris 283.
 — interossei of the foot 358, 359.
 — — of the hand 322, 323.
 — interspinales 295.
 — intertransversarii 295.
 — ischiocavernosus 612.
 — laryngis 554—557.
 — latissimus dorsi 286.
 — levator ani 607.
 — — palpebrae superioris 786.
 — — scapulae 287.
 — — veli palatini 506.
 — levatores costarum 295.
 — linguae 490, 491.
 — longissimus 292.
 — — capitis 292.
 — — cervicis 292.
 — — dorsi 292.
 — longitudinales linguae 491.
 — longus capitis 259.
 — — colli 259.
 — lumbricales of the foot 354.
 — — of the hand 319.
 — masseter 246.
 — mentalis 245.
 — multifidus 294.
 — mylohyoideus 257.
 — mylopharyngeus 509.
 — nasalis 245.
- Musculus(li) obliquus auriculae** 802.
 — — capitis superior, inferior 296.
 — — externus abdominis 273.
 — — inferior oculi 789.
 — — internus abdominis 275.
 — — superior oculi 788.
 — obturator externus 329.
 — — internus 328.
 — occipitalis 242.
 — oculi 770, 785—789.
 — omohyoideus 254.
 — opponens digiti quinti of the foot 359.
 — — — of the hand 320.
 — — pollicis 320.
 — orbicularis oculi 243.
 — — oris 245.
 — orbitalis 792.
 — ossiculorum auditus 813.
 — palmaris brevis 317.
 — — longus 307.
 — papillares 375.
 — pectinati 376.
 — pectineus 332.
 — pectoralis major 262, 263.
 — — minor 264.
 — peroneus brevis 352.
 — — longus 351.
 — — tertius 346.
 — pharyngopalatinus 505.
 — piriformis 329.
 — plantaris 349.
 — pleurooesophageus 512.
 — popliteus 349.
 — procerus 242.
 — pronator quadratus 311.
 — — teres 307.
 — prostaticus 592.
 — psoas major 327.
 — — minor 326.
 — pterygoideus externus 249.
 — — internus 249.
 — pterygopharyngeus 509.
 — pubococcygeus 608.
 — pubovesicales 582, 613.
 — pyramidalis 273.
 — quadratus femoris 342.
 — — labii inferioris 245.
 — — — superioris 242.
 — — lumborum 326.
 — — plantae 354.
 — quadriceps femoris 333.
 — recti oculi 787.
 — rectococcygeus 528.
 — rectouterinus 601.
 — rectovesicalis 582, 595.
 — rectus abdominis 277.
 — — capitis anterior 258.
 — — — lateralis 258.
 — — — posterior major 296.
 — — — minor 296.

Musculus(li) rectus femoris 333.
 — rhomboideus major 286.
 — — minor 286.
 — risorius 245.
 — rotatores 294.
 — sacrococcygei 608.
 — sacrolumbalis 291.
 — sacrospinalis 291.
 — salpingopharyngeus 505.
 — sartorius 331.
 — scalenus anterior 260.
 — — medius 260.
 — — minimus 260.
 — — posterior 260.
 — semimembranosus 339, 340.
 — semispinalis 293.
 — semitendinosus 339.
 — serratus anterior 265, 267.
 — — posterior inferior 289.
 — — — superior 289.
 — soleus 349.
 — sphincter ani externus 612.
 — — — internus 528.
 — — pupillae 777.
 — — pylori 515.
 — — urethrae membranaceae 609.
 — — vesicae 582.
 — spinales 293.
 — splenius capitis 289.
 — — cervicis 289.
 — stapedius 813.
 — sternocleidomastoideus 252.
 — sternohyoideus 255.
 — sternothyreoideus 256.
 — styloglossus 490.
 — stylohyoideus 253.
 — stylopharyngeus 509.
 — subclavius 264.
 — subcostales 267.
 — subscapularis 300.
 — supinator 311.
 — supraspinatus 304.
 — suspensorius duodeni 517.
 — tarsalis inferior 796.
 — — superior 786, 796.
 — temporalis 247.
 — tensor fasciae latae 337.
 — — tympani 813.
 — — veli palatini 506.
 — teres major 300.
 — — minor 305.
 — thyreoarytaenoideus [externus] 555.
 — thyreoepiglotticus 556.
 — thyreohyoideus 256.
 — thyreopharyngeus 509.
 — tibialis anterior 345.
 — — posterior 351.
 — tragicus 802.
 — transversus abdominis 279.
 — — auriculae 802.
 — — linguae 493.

Musculus(li) transversus menti 245.
 — — nuchae 250.
 — — perinei profundus 609.
 — — — superficialis 611.
 — — thoracis 267.
 — trapezius 285.
 — triangularis 245.
 — triceps brachii 305.
 — — surae 348.
 — uvulae 506.
 — vasti 335, 336.
 — ventricularis 557.
 — verticalis linguae 493.
 — vocalis 557.
 — zygomaticus 245.
Myelencephalon 626.
Myocardium 370.

N.

Nail 837, 840.
 — bed of 840.
 — groove 840.
 — root of 840.
 — wall 840.
Nares 830, 832.
Nasal bone 25.
 — branch 399.
 — cavity 60—62, 832—836.
 — conchae 21, 23, 834.
 — opening 830, 832.
 — passages 21, 60, 834.
 — process 28.
 — septum 62, 832.
 — spine 16.
Nasus 830.
 — externus 830, 831.
Navel 279.
Navicular bone of foot 143.
 — — of hand 104.
Nerve, anterior crural 747.
 — external cutaneous 746.
 — internal cutaneous 724.
 — lesser internal cutaneous 724.
 — musculospiral 735.
 — small sciatic 751.
Nervous system, sympathetic 763.
Nervus(i) abducens 676, 700.
 — accessorius 678, 710.
 — acusticus 677, 703.
 — alveolares superiores 692.
 — alveolaris inferior 696, 698.
 — ampullares 703, 704.
 — anococcygei 763.
 — auriculares anteriores 698.
 — auricularis magnus 719.
 — — posterior 700.
 — auriculotemporalis 696, 698.
 — axillaris 722, 723.
 — buccinatorius 695, 697.

Nervus(i) canalis pterygoidei [Vidii] 693.
 — cardiaca 764, 765.
 — carotici externi 764.
 — caroticotympanicus inferior 706.
 — caroticus internus 763.
 — cavernosus penis major, minores 769.
 — cerebrales 687.
 — cervicales 712.
 — ciliares breves 690, 778.
 — — longi 690, 778.
 — clunium inferiores [laterales] 751.
 — — inferior medialis 761.
 — — medii 716.
 — — superiores 716.
 — coccygeus 712.
 — cochlearis 677, 678, 703, 704.
 — cutaneus(ei) antibrachii dorsalis 735.
 — — — lateralis 725.
 — — — medialis 723—725.
 — — brachii lateralis 722.
 — — — medialis 723, 724.
 — — — posterior 735.
 — — colli 719.
 — — [pedis] dorsalis lateralis 754.
 — — — — medialis 761.
 — — femoris lateralis 746, 747.
 — — — posterior 751.
 — — surae lateralis 758.
 — — — medialis 754.
 — digitales dorsales manus 733, 737.
 — — — hallucis lateralis et digiti secundi medialis 760.
 — — — pedis 760, 761.
 — — plantares communes 755, 757.
 — — — proprii 755, 757.
 — — volares communes 729, 734.
 — — — proprii 729, 730, 734.
 — — volaris proprius 755, 757.
 — dorsales penis (clitoridis) 762, 763.
 — dorsalis scapulae 721.
 — ethmoidalis anterior 690.
 — — posterior 690.
 — facialis 677, 700, 701.
 — femoralis 747, 748.
 — frontalis 690.
 — genitofemoralis 746.
 — glossopharyngeus 678, 704, 706.
 — glutaei 749.

- Nervi(us) haemorrhoidales** 762, 769.
- hypoglossus 678, 710—712.
 - iliohypogastricus 742—745.
 - ilioinguinalis 745.
 - infraorbitalis 690, 693.
 - infratrochlearis 690.
 - intercostales 739, 742.
 - intercostobrachiales 742.
 - intermedius 677, 700.
 - interosseus [antibrachii] volaris 728.
 - — — dorsalis 787.
 - — — cruris 755.
 - ischiadicus 752.
 - jugularis 764.
 - labiales posteriores 762.
 - lacrimalis 690.
 - laryngeus inferior 709, 710.
 - — superior 709.
 - lingualis 696, 699.
 - lumbales 712.
 - lumboinguinalis 746.
 - mandibularis 689, 695 to 700.
 - massetericus 695, 696.
 - masticatorius 695.
 - maxillaris 689, 690.
 - meatus acustici externi 698.
 - medianus 723, 727—730.
 - meningeus [medius] 690.
 - mentalis 699.
 - musculocutaneus 723, 725.
 - mylohyoideus 696, 698.
 - nasociliaris 690.
 - nasopalatinus [Scarpae] 694.
 - obturatorius 749.
 - — accessorius 749.
 - occipitalis major 716.
 - — minor 716.
 - — tertius 716.
 - oculomotorius 676, 687.
 - olfactorius 676, 687.
 - ophthalmicus 689, 690.
 - opticus 676, 687, 770, 771.
 - palatini 694.
 - palatinus anterior 694.
 - — medius 695.
 - — posterior 695.
 - perinei 762.
 - peroneus communis 752, 758.
 - — profundus 758, 760.
 - — superficialis 760, 761.
 - petrosus profundus 694.
 - — — major 764.
 - — superficialis major 693, 700.
 - — — minor 699.
 - phrenicus 719.
 - plantares 754, 755, 756.
 - pterygoideus externus 695, 697.
- Nervus(i) pterygoideus internus** 696, 697.
- pudendus 762.
 - radialis 723, 735—737.
 - recurrens 709.
 - saccularis 704.
 - sacrales 712.
 - saphenus 748.
 - scrotales posteriores 762.
 - spermaticus externus 746.
 - sphenopalatini 692, 694.
 - spinales 712.
 - spinosus 695.
 - splachnici 767.
 - stapedius 700, 813.
 - subclavius 722.
 - sublingualis 699.
 - suboccipitalis 715.
 - subscapulares 722.
 - supraclaviculares 719.
 - supraorbitalis 690.
 - suprascapularis 722.
 - supratrochlearis 690.
 - suralis 754, 758.
 - temporales profundi 695, 697.
 - tensoris tympani 696, 698.
 - — veli palatini 696, 698.
 - tentorii 690.
 - thoracales 712.
 - — anteriores 722.
 - — longus 722.
 - — posteriores 721.
 - thoracodorsalis 722.
 - tibialis 752, 753—757.
 - trigeminus 676, 689.
 - trochlearis 676, 688.
 - tympanicus 706.
 - ulnaris 723, 731—735.
 - utricularis 703.
 - vaginales 762.
 - vagus 678, 707—711.
 - vesicales 762, 769.
 - vestibularis 677, 703, 704.
 - zygomatikus 691.
- Nipple** 615.
- Noduli lymphatici** 501, 519, 529.
- — aggregati [Peyeri] 519.
 - — bronchiales 564, 566.
 - — conjunctivales 797.
 - — laryngei 560.
 - — solitarii 519.
 - — tubarii 816.
- Nodulus valvulae semilunaris** [Arantii] 380.
- Nose** 830.
- accessory cavities of 60, 835.
 - back of 830.
 - cartilage of 831.
 - external 830, 831.
 - hairs of 831, 840.
- Nose, root of** 830.
- tip of 830.
 - wings of 830.
- Nucleus(i) alae cinereae** 678.
- ambiguus 678.
 - amygdalae 670.
 - anterior thalami 667.
 - arcuati 667.
 - caudatus 651, 667.
 - of cerebral nerves 676—678.
 - colliculi inferioris of the corpora quadrigemina 667.
 - corporis geniculati lateralis, medialis 667.
 - — — mamillaris 667.
 - dentatus 667.
 - dorsalis [Stillingi, Clarki] 621.
 - — nn. glossopharyngei et vagi 678.
 - emboliformis 667.
 - of eyeball 773.
 - fasciculi cuneati 666.
 - — gracilis 666.
 - fastigii 667.
 - globosus 667.
 - habenulae 667.
 - hypothalamicus [corpus Luyisi] 667.
 - laterales thalami 667.
 - lemnisci lateralis 635, 678.
 - lentiformis 667.
 - lentis 782.
 - motorius princeps n. trigemini 676.
 - n. abducentis 676.
 - — cochlearis dorsalis 678.
 - — — ventralis 678.
 - — facialis 677.
 - — hypoglossi 678.
 - — oculomotorii 676.
 - — trochlearis 676.
 - — vestibularis lateralis [Schwalbe] 677.
 - — — medialis [Deiters] 677.
 - — — spinalis [Flechsig, Bechterew] 677.
 - — — superior 677.
 - olivares accessorii 667.
 - olivaris inferior 666.
 - pontis 667.
 - pulposus 157, 158.
 - radialis descendens n. trigemini 676.
 - ruber tegmenti 667.
 - sensibilis n. trigemini 676.
 - of termination of sensory nerves 676.
 - thalami 667.
 - tractus solitarii 678.
 - — spinalis (n. trigemini) 666, 676.

Nucleus tuberculi acustici 678.
— ventralis n. glossopharyngei 678.

O.

Obex 629.
Oblique ligament 186.
— vein of Marshall 384.
Obturator foramen 119.
Occipital bone 1—3.
— lobe 641.
Occipito-axial ligament 168.
Oculus 770.
Odontoid or checkligaments 167.
— process 66.
Oesophagus 510—512.
Olecranon 99.
Olfactory brain 644, 645.
— lobe 645.
— nerve 687.
— organ 836.
— roots 676.
Olive 629.
— path from to vermis 678.
Olives, accessory 667.
Omental sac or bursa 543.
Omentum, great 542.
— majus 542.
— minus 541.
— small 541.
Opening for smaller petrosal nerve 11.
Operculum 644.
Opponens minimi digiti 320.
Optic groove 4.
— nerve 687, 770, 771.
— — dural sheath of 771.
— nerves, sheaths of 771.
— radiation, secondary 676.
Ora serrata 779, 780.
Orbicular ligament 183.
Orbicular ciliaris 775.
Orbita 56—59.
Organon(a) auditus 799—830.
— oculi accessoria 770.
— olfactus 836.
— spirale [Cortii] 827.
— visus 770—798.
— vomeronasale [Jacobsoni] 833.
Orificium ureteris 582.
— urethrae externum 595.
— — internum 582, 595.
— uteri externum 598.
— — internum 599.
— vaginae 602.
Os (Ossa) calcis 141.
— capitatum 105.
— carpi 104—107.
— coccygis 76.
— costale 78.
— coxae 114—122.
— cuboideum 145.

Ossa(os) cuneiformia 144.
— ethmoidale 20—22.
— frontale 15—17.
— hamatum 105.
— hyoideum 40—41.
— ilium 115.
— incisivum 29.
— inominatum 115.
— ischii 115, 117.
— lacrimale 24.
— lunatum 104.
— magnum 105.
— manus 110—113.
— metacarpalia 109.
— metatarsalia 146.
— multangulum majus 105.
— — minus 105.
— nasalia 25.
— naviculare manus 104.
— — pedis 143.
— occipitale 1—3.
— palatinum 30.
— parietale 18—19.
— pedis 140—151.
— pisiforme 104.
— planum 21.
— pubis 115, 119.
— sacrum 72—75.
— sesamoidea 109, 146.
— sphenoidale 4—6.
— tarsi 140—145.
— temporale 7—14.
— trigonum 140.
— triquetrum 104.
— uteri, external 598.
— — internal 599.
— zygomaticum 32.
Ossicula auditus 809, 811, 812.
Ostium abdominale tubae uterinae 597.
— arteriosum 365, 378, 380.
— pharyngeum tubae auditivae 816.
— tympanicum tubae auditivae 811, 815.
— uterinum tubae uterinae 597.
— venosum 365, 377, 380.
Outer condyle (of femur) 130.
— tuberosity 130.
Ovaria 596.
Ovary 596.
Ovulum 596.

P.

Pacchionian depressions 19.
Palate 498.
— bone 30.
— hard 498.
— mucous membrane of 499.
— sail or veil of 500.
— soft 500.
Palatine arch 500.

Palatine tonsil 501, 503.
Palatoglossus 506.
Palatopharyngeus 505.
Palatum 498.
— durum 498.
— molle 500.
Pallium 637—644.
Palmar digital arteries 416.
— fascia 317.
— interossei 322.
— ligaments 187.
Palpebrae 770, 793—797.
Pancreas 534—535.
Panniculus adiposus 840.
Papillae(a) conicae (of the tongue) 493.
— filiformes (of the tongue) 493.
— foliatae (of the tongue) 493.
— fungiformes (of the tongue) 493.
— lenticulares (of the tongue) 493.
— vallatae (of the tongue) 493.
— corii 838, 839.
— of the corium 838, 839.
— duodeni [Santorini] 517.
— incisiva 499.
— lacrimalis 794.
— linguales 493.
— mammae 615, 616.
— nervi optici 780.
— renalis 577.
Papillary muscles 375.
Paradidymis 585.
Parametrium 603.
Parenchyma testis 584.
Paries caroticus cavi tympani 811.
— inferior orbitae 59.
— jugularis cavi tympani 811.
— labyrinthicus cavi tympani 810.
— lateralis orbitae 58.
— mastoideus cavi tympani 811.
— medialis orbitae 57.
— membranaceus tracheae 561.
— — cavi tympani 809.
— superior orbitae 58.
— tegmentalis cavi tympani 809.
Parietal bone 18, 19.
— lobe 641.
Paroophoron 597.
Parovarium 597.
Pars abdominalis oesophagi 511.
— — s. sympathici 767.
— alveolaris mandibulae 34.
— basilaris ossis occipitalis 1.
— — pontis 667.
— cavernosa urethrae 595.
— centralis ventriculi lateralis 651, 652.

- Pars cephalica s. sympathici 763.
 — cervicalis oesophagi 511.
 Pars cervicalis s. sympathici 764—767.
 — ciliaris retinae 775, 779, 780.
 — cupularis recessus epitympanici 811.
 — dorsalis pontis 667.
 — flaccida membranae tympani 805.
 — frontalis capsulae internae 668.
 — grisea hypothalami 667.
 — horizontalis ossis palatini 30.
 — inferior fossae rhomboideae 629.
 — infraclavicularis plexus brachialis 721, 723.
 — intermedia fossae rhomboideae 629.
 — lacrimalis [Horneri] m. orbicularis oculi 243.
 — laryngea pharyngis 505.
 — libera columnae fornicis 650.
 — lumbalis diaphragmatis 270.
 — mamillaris hypothalami 626.
 — membranacea septi atriorum 376.
 — — urethrae 595.
 — nasalis pharyngis 505.
 — occipitalis capsulae internae 668.
 — optica hypothalami 626.
 — — retinae 779—780.
 — oralis pharyngis 505.
 — pelvina s. sympathici 769.
 — perpendicularis ossis palatini 30, 31.
 — petrosa ossis temporalis 9.
 — prostatica urethrae 595.
 — superior fossae rhomboideae 629.
 — supraclavicularis plexus brachialis 721.
 — tecta columnae fornicis 650.
 — tensa membranae tympani 805.
 — thoracalis oesophagi 511.
 — — s. sympathici 767.
 — tympanica ossis temporalis 13.
 Patella 135.
 Pecten ossis pubis 119.
 Pedicle 64.
 Peduncles, superior cerebellar 635.
 Pedunculus cerebri 635.
 — corporis callosi 645.
 — flocculi 633.
 Pelvic diameter 127.
 — part of sympathetic 763.
 Pelvis 123—127.
 Pelvis, ligaments of 192—198.
 — renalis 578.
 Penis 592—594.
 Pericardium 386.
 Perilympa 825.
 Perimetrium 599.
 Periorbita 57, 792.
 Periosteum alveolare 487.
 Peritoneum 541—549, 595, 603.
 — parietale 541, 549.
 Peritoneal covering 517.
 Perpendicular portion (of jaw) 35.
 Petiolus epiglottidis 551.
 Petrosal branch 394.
 Peyer's patches 519.
 Phalanges digitorum manus 109.
 — — pedis 146.
 — of fingers 109.
 Pharynx 502.
 — constrictors of 509.
 Philtrum 478.
 Pia mater encephali 654.
 — — spinalis 622.
 Pial sheath of optic nerve 771.
 Pili 837, 840.
 Pineal body 646.
 Pinna 802.
 Pisiform bone 104.
 Pituitary body 645.
 — fossa 4.
 Placental circulation 473.
 Planum nuchae 2, 3.
 — occipitale 2, 3.
 — orbitale 27.
 — popliteum 128.
 — sternale 83.
 Platysma 251.
 Pleura, cupula of 573.
 Pleurae 569—574.
 Plexus chorioideus ventriculi lateralis 654.
 — — — quarti 634.
 — — — tertii 654.
 — (nervosus)(i) aorticus abdominalis 769.
 — — — thoracalis 767.
 — — arteriae cerebri anterioris, mediae 763.
 — — — chorioideae 763.
 — — — ovaricae 767.
 — — auricularis posterior 764.
 — — brachialis 716, 719—721.
 — — cardiacus 767.
 — — caroticus communis 764.
 — — — externus 763.
 — — — internus 764.
 — — cavernosus 763.
 — — clitoridis 769.
 — — — penis 769.
 — — cervicalis 716—718.
 — — coccygeus 742, 763.
 — — coeliacus 767.
 Plexus (nervosus)(i) coronarius cordis 767.
 — — deferentialis 769.
 — — dentalis inferior 698.
 — — — superior 692.
 — — femoralis 769.
 — — gangliosis ciliaris 775, 778.
 — — gastricus anterior 710.
 — — — inferior 769.
 — — — posterior 710.
 — — — superior 769.
 — — haemorrhoidalis 769.
 — — hepaticus 769.
 — — hypogastricus 769.
 — — iliacus 769.
 — — lienalis 769.
 — — lingualis 764.
 — — lumbalis 742.
 — — lumbosacralis 716, 742, 743.
 — — mammarius internus 765.
 — — maxillares 764.
 — — meningeus 764.
 — — mesenterici 769.
 — — occipitalis 764.
 — — oesophageus anterior 708.
 — — — posterior 707.
 — — ophthalmicus 763.
 — — parotideus 701.
 — — pharyngeus ascendens 764.
 — — phrenicus 767.
 — — popliteus 769.
 — — prostaticus 769.
 — — pudendus 742, 749.
 — — pulmonalis anterior 710.
 — — — posterior 710.
 — — renalis 767.
 — — sacralis 742, 749.
 — — spermaticus 767.
 — — subclavius 765.
 — — submucosus 769.
 — — suprarenalis 767.
 — — sympathici 763.
 — — temporalis superficialis 764.
 — — thyreoidei 764, 765.
 — — tympanicus [Jakobsoni] 706.
 — — uterovaginalis 769.
 — — vertebralis 765.
 — — vesicalis 769.
 — (venosus)(i) basilaris 444.
 — — caroticus internus 445.
 — — cavernosi concharum 835.
 — — haemorrhoidales 464.
 — — mamillae 466.
 — — pampiniformis 460.
 — — pharyngeus 446.

- Plexus (venosus)(i) pterygoideus 449.
 — — pudendalis 464.
 — — sacralis anterior 463, 466.
 — — thyreoideus impar 445.
 — — uterovaginalis 464.
 — — vertebrales 454, 455.
 — — vesicalis 464.
 Plica(ae) adiposae 573.
 — alares 211.
 — ampullares 597.
 — aryepiglottica 557.
 — axillaris anterior 615.
 — caecalis 546.
 — ciliares 775.
 — circulares [Kerkringi] 518.
 — duodenojejunalis 545.
 — duodenoimesocolica 545.
 — epigastrica 549.
 — fimbriatae 494.
 — gastropancreatica 543.
 — glossoepiglotticae 494.
 — ileocaecalis 547.
 — incudis 815.
 — iridis 776.
 — isthmicae 597.
 — lacrimalis (Hasneri) 798.
 — longitudinalis duodeni 517.
 — malleolares 814.
 — membranae tympani 805.
 — mucosae 515.
 — nervi laryngei 505.
 — palatinae transversae 499.
 — palmatae 599.
 — pharyngoepiglottica 505.
 — pubovesicales 595.
 — rectouterinae [Douglasi] 601, 603.
 — rectovesicales 595.
 — salpingopalatina 834.
 — salpingopharyngea 505.
 — semilunares coli 521.
 — semilunaris conjunctivae 794.
 — stapedis 815.
 — sublingualis 494.
 — synoviales patellares 211.
 — transversales recti 529.
 — triangularis 500.
 — tubariae 597.
 — tunicae mucosae 533.
 — umbilicales 549.
 — ureterica 582.
 — ventricularis 557, 558.
 — vesicalis transversa 582, 595.
 — villosae 515.
 — vocalis 557, 558.
 Plough-share bone 26.
 Polus(i) bulbi oculi 771.
 — frontalis 641.
 — lentis 782.
 — occipitalis 641.
 — temporalis 641.
 Pons [Varoli] 631.
 Pontile path, frontal (Cerebro-) 680.
 — — median descending 679.
 — — temporal (Cerebro-) 680.
 Popliteal space 128.
 Porta hepatis 530.
 Portal vein 457.
 — — anastomoses of 459.
 — veins, accessory 459.
 Portio major n. trigemini 676, 688.
 — minor n. trigemini 676, 688.
 — supravaginalis [cervicis] uteri 598.
 — vaginalis [cervicis] uteri 598.
 Porus acusticus externus 7, 13, 805.
 — — internus 9, 824.
 — sudoriferus 840.
 Posterior annular ligament 316.
 — bicipital ridge 94.
 — calcaneostrageloid ligament 221.
 — carpal rete 414.
 — circumflex artery 408.
 — column of spinal cord 622.
 — common ligament 161.
 — fasciculus of external lateral ligament 218.
 — dental canals 27.
 — or descending palatine branch 395.
 — funiculus of spinal cord 619, 671.
 — —, ventral area of 673.
 — or great sacrosciatic ligament 194.
 — horn of lateral ventricle 652.
 — — of the spinal cord 621.
 — or internal crucial ligament 207.
 — interosseous artery 414.
 — interventricular groove 367.
 — layer of triangular, deep or superior triangular lig. 609.
 — ligament 188, 209.
 — longitudinal bundle 675.
 — nares 60.
 — occipitoatlantal ligament 164.
 — palatine canal 31.
 — radial carpal 412.
 — root, relations in cross-section 672.
 — surface 366.
 — terminal branch 390, 392.
 — tibiotarsal ligament 219.
 — ulnar carpal 413.
 Poupart's ligament 280.
 Praecuneus 644.
 Praeputium clitoridis 606.
 Praeputium penis 594.
 Premolar or bicuspid teeth 483.
 Prepuce 594.
 Presternal notch 83.
 Primary fissures 641.
 — follicle 596.
 Primordialocranium 63.
 Princeps pollicis radialis indicis and palmar interosseous aa. 417.
 Processus accessorius 70, 71.
 — alares 20.
 — alveolaris 27, 29.
 — articulares of the vertebrae 64, 65, 69, 71, 73, 74.
 — caudatus 531.
 — ciliares 775.
 — clinoides 4, 6.
 — cochleariformis 810.
 — condyloideus 35.
 — coracoideus 89.
 — coronoideus mandibulae 35.
 — — ulnae 99.
 — costarius 65, 71.
 — ethmoidalis 23.
 — falciformis 194.
 — Ferreini 578.
 — frontalis 27.
 — frontosphenoidalis 5, 32.
 — inferior tegminis tympani 13.
 — intrajugularis 1, 2, 9.
 — jugularis 2.
 — lacrimalis 23.
 — lateralis tali 140.
 — — medialis tuberis calcanei 141.
 — lenticularis (incudis) 811.
 — mallei anterior [Folii] 811.
 — — lateralis 811.
 — mamillaris 70, 71.
 — mastoideus 8, 9, 14.
 — maxillaris 23.
 — muscularis cartilaginis arytaenoideae 551.
 — orbitalis 31.
 — palatinus 27, 29.
 — papillaris 531.
 — paramastoideus 2.
 — posterior tali 140.
 — pterygoidei 4, 6.
 — pterygospinosus [Civinini] 6.
 — pyramidalis 30.
 — retromandibularis 497.
 — sphenoidalis (of the palate bone) 31.
 — — septi cartilaginei nasi 831.
 — spinosus 64, 65, 69, 71.
 — styloideus ossis temporalis 10, 14.
 — — — metacarpalis III 109.
 — — radii 101, 102.
 — styloideus ulnae 99, 102.

- Processus temporalis 32.
 — transversi 64, 65, 69, 71, 76.
 — trochlearis 141.
 — tuberis calcanei medialis et lateralis 141.
 — uncinatus ossis ethmoidalis 21.
 — — [pancreas Winslowi] 534.
 — vaginalis of the sphenoid bone 6.
 — — peritoneaei 588, 599.
 — vermiformis 521.
 — vocalis 551.
 — xiphoideus 83.
 — zygomaticus 7, 15, 17, 27, 28.
 Profunda or deep femoral artery 436.
 Projection fibers 680.
 Prominentia canalis facialis 12, 810.
 — — semicircularis lateralis 810.
 — laryngea 550.
 — malleolaris 805.
 — styloidea 811.
 Promontorium of middle ear cavity 810.
 — pelvis 74.
 Pronator radii teres 307.
 Prosencephalon 626.
 Prostata 589—592.
 Prostate gland 589—592.
 Protuberantia mentalis 34.
 — occipitalis externa 3.
 — — interna 1, 3.
 Pterygoid ridge 5.
 Pterygo-palatine canal 6.
 — fossa 55.
 Pubes 119, 606, 840.
 — hairs of 606, 840.
 — symphysis of 193, 197, 198.
 Pubofemoral ligament 199.
 Pudendum muliebre 604.
 Pulmonary circulation 380.
 Pulmones 562—567.
 Pulp-cavity 487.
 Pulpa dentis 487.
 Pulvinar 646.
 Punctum lacrimale 794.
 Pupil 776.
 Pupilla 776.
 Purkinje cells 667.
 Putamen 668.
 Pyloric artery 421.
 Pylorus 513.
 Pyramidal decussation 628.
 — tract 673, 680.
 — — anterior 628.
 — — lateral 628.
 Pyramides renales [Malpighi] 577.
 Pyramids of medulla oblongata 628.
 Pyramid [medullae oblongatae] 628.
 — oss. temporalis 9.
 — vermis 633.
 — vestibuli 818.
 Q.
 Quadrigeminal arm 635.
 R.
 Radiatio occipitohalamica [Gratioleti] 676.
 Radii lentis 782.
 Radius 100, 101.
 Radius anterior border 100.
 — bicipital tuberosity 101.
 — external surface 100.
 — internal or interosseous border 100.
 — posterior border 100.
 — sigmoid cavity 101.
 Radix(ices) arcus vertebrae 64.
 — descendens n. trigemini 676.
 — — n. vestibularis 677.
 — ganglii ciliaris 687, 690.
 — mesenterii 545.
 — nasi 830.
 — n. cochlearis 703.
 — n. vestibularis 703.
 — pulmonis 562.
 — sympathica ganglii ciliaris 763.
 — — — submaxillaris 764.
 — unguis 840.
 Rainbow membrane 776.
 Rami(us) alveolares superiores n. maxillaris 692.
 — anastomoticus ganglii otici cum n. auriculotemporalis 699.
 — — — — chorda tympani 699.
 — — — — n. spinoso 699.
 — — n. auriculotemporalis cum n. faciali 698.
 — — n. digitalis proprius cum n. ulnari 730.
 — — n. facialis cum plexu tympanico 700.
 — — n. glossopharyngei cum ramo auriculari n. vagi 706.
 — — n. lacrimalis cum n. zygomatico 690.
 — — n. laryngei superioris cum n. laryngeo inferiori 709.
 — — n. lingualis cum n. hypoglossus 699.
 — — peroneus n. cutanei surae lateralis 758.
 Ramus(i) anastomoticus rami digastrici n. facialis cum n. glossopharyngeo 701.
 — — ulnaris rami superficialis n. radialis 737.
 — — n. vagi cum n. glossopharyngeo 709.
 — anterior(es) of the nn. cervicales 716.
 — — of the n. coccygeus 742.
 — — of the nn. lumbales 742.
 — — — — sacrales 742.
 — — — — thoracales 739.
 — — n. auricularis magni 719.
 — — n. ilioinguinalis 745.
 — — of spinal nerves 714.
 — articularis(es) n. peronei communis 758.
 — — — — profundi 760.
 — — — — tibialis 755.
 — bronchiales bronchi 566.
 — — anteriores, posteriores n. vagi 710.
 — buccales n. facialis 701.
 — calcanei laterales n. tibialis 754.
 — — mediales n. tibialis 755.
 — cardiaci inferiores n. vagi 709.
 — — superiores n. vagi 709.
 — coeliaci n. vagi 710.
 — collateralis ulnaris n. radialis 735.
 — colli n. facialis 701.
 — communicantes ganglii submaxillaris cum n. linguali 699.
 — — nn. cervicalium 716.
 — — — coccygei 742.
 — — — intercostalium 739.
 — — — lumbalium 742.
 — — — sacralium 742.
 — — — spinalium 712, 763.
 — cutaneus(i) anterior n. iliohypogastrici 745.
 — — — n. intercostalis 742.
 — — cruris mediales n. sapheni 748.
 — — lateralis n. iliohypogastrici 744.
 — — — — intercostalis 742.
 — — n. femoralis 748.
 — — — obturatorii 749.
 — — palmaris n. mediani 729.
 — — — ulnaris 731.
 — — of the rami posteriores nn. thoracalium 716.
 — dentales inferiores n. alveolaris inferioris 698.
 — — superiores n. sphenopalatini 692.
 — descendens n. hypoglossi 712.

Ramus(i) digastricus n. facialis 701.
 — **dorsalis manus n. ulnaris** 731, 733.
 — **frontalis n. frontalis** 690.
 — **gastrici n. vagi** 710.
 — **gingivales inferiores n. alveolaris inferioris** 698.
 — — **superiores of the nn. alveolares superiores** 692.
 — **hepatici n. vagi** 710.
 — **infrapatellaris n. sapheni** 748.
 — **isthmi faucium n. lingualis** 699.
 — **labiales inferiores n. mentalis** 699.
 — **laryngopharyngei ganglii cervicalis superioris** 764.
 — **liales n. vagi** 710.
 — **linguales n. glossopharyngei** 706.
 — — — **hypoglossi** 712.
 — — — **lingualis** 699.
 — **mammarii laterales, mediales nn. intercostalium** 742.
 — **mandibulae** 35.
 — **membranae tympani n. auriculotemporalis** 698.
 — **meningeus n. spinalis** 712.
 — — — **vagi** 708.
 — **muscularis(es) manus n. ulnaris** 734.
 — — — **n. axillaris** 722.
 — — — **digitalis volaris communis** 729.
 — — — **femoralis** 748.
 — — — **iliohypogastrici** 742.
 — — — **ilioinguinalis** 745.
 — — — **nn. intercostalium** 742.
 — — — **n. interossei volaris** 728.
 — — — **mediani** 727.
 — — — **musculocutanei** 725.
 — — — **peronaei** 753.
 — — — — **profundi** 760.
 — — — — **superficialis** 760.
 — — — **phrenici** 719.
 — — — **plantaris medialis** 755.
 — — — — **lateralis** 756.
 — — — — **radialis** 735, 736.
 — — — — **tibialis** 753, 755.
 — — — — **ulnaris** 731.
 — — — **plexus lumbalis** 742.
 — — — **pudendi** 762.
 — — — **sacralis** 749.
 — — **rami profundi n. ulnaris** 735, 737.
 — — — **superficialis n. ulnaris** 734.
 — **nasales n. ethmoidalis anteriores** 690.
 — **n. accessorii** 710.

Rami(us) n. auricularis magni 719.
 — — **auriculotemporalis** 698.
 — — **nn. cervicalium** 715, 716.
 — — **n. cutanei colli** 719.
 — — **laryngei** 709.
 — — **obturatorii** 749.
 — — **oculomotorii** 687.
 — — **nn. spinalium** 712, 715, 716.
 — — **thoracalium** 716.
 — **occipitalis n. facialis** 700.
 — **oesophagei n. vagi** 709, 710.
 — **ossis ischii** 117.
 — — **pubis** 119.
 — **palpebrales n. infratrochlearis** 690.
 — **parotidei n. auriculotemporalis** 698.
 — **pericardiacus n. phrenici** 719.
 — **pericardiaci n. vagi** 710.
 — **perineales plexus sacralis** 751.
 — **pharyngei n. glossopharyngei** 706.
 — — — **laryngei superioris** 709.
 — — — **vagi** 709.
 — **phrenicoabdominalis n. phrenici** 719.
 — **posteriores nn. cervicalium** 715, 716.
 — — — **n. coccygei** 716.
 — — — **nn. lumbalium** 716.
 — — — **sacralium** 716.
 — — — **of spinal nerves** 714.
 — — — **spinalium** 715.
 — — — **thoracalium** 716.
 — **profundus n. plantaris lateralis** 756.
 — — — **radialis** 735, 737.
 — — — **ulnaris** 734, 735.
 — **pulmonales gangliorum thoracalium** 767.
 — **renales n. vagi** 710.
 — **renalis n. splanchnici minoris** 767.
 — **scrotales anteriores n. ilioinguinalis** 745.
 — **styloideus rami digastrici n. facialis** 701.
 — **stylopharyngeus n. glossopharyngei** 706.
 — **submaxillaris ganglii submaxillaris** 700.
 — **superficialis n. plantaris lateralis** 756.
 — — — **n. radialis** 735, 737.
 — — — **ulnaris** 734.
 — **temporales n. facialis** 701.
 — — **superficiales n. auriculotemporalis** 698.
 — **thyreohyoideus n. hypoglossi** 712.

Rami(us) tonsillares n. tympanici 706.
 — **tracheales n. vagi** 709.
 — **tubae n. tympanici** 706.
 — **ulnaris n. cutanei antibrachii** 725.
 — **viscerales plexus pudendi** 762.
 — **volaris n. cutanei antibrachii** 725.
 — **zygomatice n. facialis** 701.
 — **zygomaticofacialis** 691.
 — **zygomaticotemporalis** 691.
Raphe palati 499.
 — **palpebralis lateralis** 243, 793.
 — **penis** 594.
 — **pharyngis** 509.
 — **pterygomandibularis** 247.
 — **scroti** 588.
Recessus anterior fossae interpeduncularis 636.
 — **cochlearis** 818.
 — **duodenojejunalis** 545.
 — **ellipticus** 818.
 — **epitympanicus** 809, 811.
 — **ileocaecales** 547.
 — **infundibuli** 646.
 — **intersigmoideus** 549.
 — **laterales fossae rhomboideae** 629.
 — **lienalis** 543.
 — **membranae tympani** 814, 815.
 — **omentalis inferior, superior** 543.
 — **opticus** 646.
 — **paracolici** 547.
 — **pharyngeus [Rosenmuelleri]** 505.
 — **pinealis** 646.
 — **piriformis** 505.
 — **posterior fossae interpeduncularis** 636.
 — **retrocaecales** 546.
 — **sacciformis** 182, 186.
 — **sphaericus** 818.
 — **sphenoethmoidalis** 21, 61.
 — **suprapinealis** 646.
 — **triangularis** 646.
Rectum 528—529.
Rectus capitis anticus major 259.
 — — — **minor** 258.
 — — **posticus major** 296.
 — — — **minor** 296.
 — **sheath of** 279.
Red nucleus of tegmentum 667.
Reflex bundles of sensory roots of spinal nerves 672.
 — **path, optic acoustic** 673, 676.
Regiones corporis 237—240.

- Regio olfactoria 836.
 — respiratoria 836.
 Renes 575—579.
 Restiform body 629, 678.
 Rete acromiale 406.
 — arteriosum cutaneum 842.
 — — subpapillare 842.
 — articulare cubiti 414.
 — — genu 437, 438.
 — calcaneum 438.
 — canalis hypoglossi 445.
 — carpi dorsale 414.
 — — volare 417.
 — dorsale pedis 439.
 — malleolare laterale, mediale 438, 439.
 — patellae 438.
 — testis [Halleri] 584.
 — venosum dorsale manus 451.
 — — — pedis cutaneum 470.
 — — plantare cutaneum 470.
 Retia venosa cutis 842.
 — — vertebrarum 454.
 Retina 773, 779, 780.
 Retinacula cutis 616, 840.
 — mm. peroneorum 345.
 — patellae 336.
 Retinaculum ligamenti arcuati 209.
 Retrahens aurem 250.
 Rhinencephalon 637, 644, 645.
 Rhombencephalon 626.
 Rhomboid brain 626, 633.
 — fossa 629, 630.
 — ligament 176.
 Ribs 78—81.
 — bones of 78.
 — cartilage of 79.
 — connections of the 174.
 — heads of 78.
 Right auricle 376.
 — auricular appendix 377.
 — terminal branch 422.
 Rima cornealis 773.
 — glottidis 558.
 — oris 478.
 — palpebrarum 793, 796.
 — pudendi 606.
 — vestibuli 558.
 Ring cartilage 551.
 Rivus lacrimalis 798.
 Roof bones 63.
 — of 4th ventricle 634.
 — nucleus of 667.
 Root canal 487.
 — foramen 487.
 — intermediary of the n. olfactorius 676.
 — membrane 487.
 — threads of spinal nerves 712.
 — tip of 487.
 Roots of spinal nerves 712.
 Rostrum corporis callosi 647.
 Restrum sphenoidale 4.
 Rudimentum processus vaginalis 588.
 Rugae vaginales 602.
 S.
 Saccule 825.
 Sacci alveolares (infundibula) 567.
 Sacculus (labyrinthi) 825, 826.
 Saccus endolymphaticus 826.
 — lacrimalis 798.
 Sacral nerves 712.
 Sacrovertebral angle 74.
 Sacrum 72—75.
 Saddle, back of 4.
 — pommel of 4.
 Scala tympani 823, 827.
 — vestibuli 823, 827.
 Scalenus anticus 260.
 — posticus 260.
 Scapha 801.
 Scaphoid bone 104.
 Scapula 87—91.
 Scarpa's triangle 330.
 Sclera 773, 774.
 Scrotum 588.
 Sebaceous glands 616, 797, 840, 842.
 Sebum cutaneum 842.
 — palpebrale 796.
 Sella turcica 4.
 Semen 584.
 Semicanalis m. tensoris tympani 11.
 — tubae auditivae 11.
 Semicircular canals, bony 817, 820, 821.
 — — membranous 817, 825.
 Semilunar bone 104.
 — fascia 301.
 Seminal duct 586.
 — vesicle 589.
 Seminiferous tubules 584.
 Semispinalis colli 293.
 Septula testis 584.
 Septum(a) atriorum 376.
 — bulbi urethrae 593.
 — canalis musculotubarii 11.
 — cartilagineum 832.
 — corporum cavernosorum 604.
 — femorale [Cloqueti] 325.
 — glandis 594.
 — interalveolaria 29, 34.
 — intermuscularia femoris 338.
 — — fibularia 347.
 — — humeri 299.
 — linguae 493.
 — mediastinale 573, 574.
 — membranaceum nasi 832.
 — — ventriculorum 374.
 — mobile nasi 830.
 Septum(a) musculare ventriculorum 374.
 — nasi 832, 833.
 — — osseum 62, 832.
 — orbitale 793.
 — pellucidum 649.
 — penis 594.
 — scroti 588.
 — sinuum frontalis 17.
 — — sphenoidalium 4.
 — subarachnoideale 623.
 — ventriculorum 374.
 Sesamoid bones 109, 146.
 Shin-bone 136—139.
 — condyles of 136.
 Short calcaneocuboid or short plantar ligament 224.
 Shoulder, tip of 88.
 Shoulder-blade 87—91, 177.
 Shoulder-joint 178—180.
 Sigmoid flexure of the colon 526.
 — notch 35.
 Sinus aortae [Valsalvae] 387.
 — cavernosus 441.
 — circularis 443.
 — coronarius cordis 384.
 — costomediastinalis 573.
 — durae matris 441.
 — epididymidis 585.
 — frontales 17, 60, 835.
 — intercavernosus anterior, posterior 443.
 — lactiferus 616.
 — maxillaris 27, 28, 60, 835.
 — occipitalis 441.
 — paranasales 60, 835.
 — petrosus inferior 1, 444.
 — — superior 443.
 — phrenicocostalis 573.
 — pleurae 573.
 — posterior cavi tympani 811.
 — rectales 529.
 — rectus 441.
 — renalis 576.
 — reuniens 376, 384.
 — sagittalis inferior 441.
 — — superior 441.
 — sphenoidalis 4, 60.
 — sphenoparietalis 443.
 — tarsi 141.
 — tonsillaris 500.
 — transversus 441.
 — — pericardii 386.
 — tympani 810.
 — venarum [cavarum] 376.
 — venosus sclerae [Canalis Schlemmi, Lauthi] 773, 778.
 — vertebrales longitudinales 454.
 Skin, external 837—842.
 — glands of 837, 840—842.

- Skin, ridges of 839.
 — sulci of 839.
 — upper 837.
 Skull, membranous capsule of 63.
 Smell, organ of 830.
 Snail 817, 821—823.
 Somaesthetic area 680.
 Spatia anguli iridis [Fontanae] 777.
 Spatium(a) intercostale 81.
 — interfasciale [Tenoni] 792.
 — interosseum metacarpi 109.
 — — metatarsi 146.
 — intervaginalia n. optici 771.
 — mediastinalia 574.
 — perichorioideale 774.
 — perilymphaticum 825.
 — retroperitoneale 549.
 — suprasternale 261.
 — zonularia 783.
 Sperma 584.
 Spermatic artery 421.
 — cord 587.
 Sphenoid bone 4—6.
 — — body of 4.
 — — large wing of 5.
 — — small wing of 6.
 Sphenoidal cells 4.
 — fissure or foramen lacerum anterius 58.
 — sinuses 4.
 — turbinated bones 4.
 Sphenomaxillary fissure 59.
 — fossa 55.
 Sphenopalatine or nasopalatine artery 395.
 Spider-web membrane of brain 682, 683.
 — — of spinal cord 623.
 Spina(ae) angularis 5.
 — frontalis 16.
 — heliis 801.
 — iliacae 115.
 — ischiadica 117.
 — mentalis 35.
 — nasalis anterior 29.
 — — posterior 30.
 — palatina 29.
 — scapulae 88.
 — supra meatum 8.
 — trochlearis 17.
 — tympanicae 13, 807.
 Spinal cord 617—623.
 — — anterior column of 621.
 — — — funiculus of 619, 671.
 — — — horn of 621.
 — — conduction paths of the 672.
 — — funiculi of the 672.
 — — ground bundle of anterior funiculus of 671.
 — — interior of the 621.
 — — lower end of 618, 622.
 Spinal cord, membranes of 622, 623.
 — ganglia 712.
 — nerves 712.
 — — cutaneous distribution of 713.
 — — distribution of in the skin 713.
 — — loops of 712.
 Spinalis colli 293.
 Spindle of the cochlea 822.
 Spine of ischium 117.
 — — os pubis 119.
 — of scapula 88.
 Spinous process of the sphenoid 5.
 Spiral lamina, bony 823.
 — — vein of 828.
 — line 129.
 — vein, anterior and posterior 830.
 Spleen 535—536.
 — accessory 536.
 Splenic artery 422.
 Splenium corporis callosi 647.
 Splenius colli 289.
 Spoke-bone 100, 101.
 Squama frontalis 15.
 — occipitalis 1, 3.
 — temporalis 7.
 Stapes 812.
 — capitulum of 812.
 — foot-plate of 812.
 Stem-bronchus 566.
 Stenson's duct 833.
 Sternum 82, 83, 174.
 — body of 83.
 Stirrup 812.
 — crus of 812.
 Stomach 512—515.
 — mucous membrane of 515.
 Stratum cinereum (cerebelli) 667.
 — gangliosum (cerebelli) 667.
 — granulosum (cerebelli) 667.
 — griseum centrale 667.
 — — colliculi superioris 667.
 — interolivare lemnisci 673.
 — pigmenti corporis ciliaris 780.
 — — iridis 776, 780.
 — — retinae 780.
 — zonale 646, 667.
 Stria(ae) longitudinalis lateralis of the corpus callosum 648.
 — — medialis of the corpus callosum 648.
 — malleolaris 805.
 — medullares fossae rhomboideae 630.
 — medullaris thalami 646.
 Stria(ae) olfactoria intermedia 645, 676.
 — — lateralis 645, 676.
 — — medialis 645, 676.
 — terminalis 652.
 Striae transversae 648.
 Stroma glandulae thyreoideae 574.
 — iridis 777.
 — ovarii 596.
 — vitreum 783.
 Styloid process 10.
 Stylo-maxillary ligament 154.
 Subcrureus 335.
 Subcutaneous tissue 837, 840.
 Subiculum promontorii 810.
 Sublingual fossa 35.
 — gland 496.
 Submaxillary fossa 35.
 — gland 497.
 Subpubic ligament 197.
 Substantia adamantina 487.
 — alba of the central nervous system 622.
 — corticalis cerebelli 667.
 — — cerebri 667.
 — — of the kidneys 577.
 — — lentis 782.
 — — of the suprarenal capsule 583.
 — eburnea 487.
 — gelatinosa medullae spinalis [Rolandi] 621.
 — grisea (centralis) 621.
 — lentis 782.
 — medullaris of the kidneys 577.
 — — of the suprarenal capsule 583.
 — nigra 667.
 — ossea (dentis) 487.
 — perforata anterior 645.
 — — posterior 636.
 — propria corneae 774.
 — reticularis alba 666.
 — — [Arnoldi] 654.
 — — grisea 666.
 Sulcus(i) ampullaris 825.
 — anthelialis transversus 802.
 — arteriae occipitalis 9.
 — — temporalis mediae 7.
 — — vertebralis 66.
 — arteriosus 7, 19.
 — auriculae 801.
 — basilaris pontis 631.
 — bicipitales 303.
 — calcanei 141.
 — canaliculi mastoidei 9.
 — caroticus 4.
 — carpi 107.
 — centralis [Rolandi] 642.
 — cerebelli 633.
 — cerebri 641.

- Sulcus(i) chiasmatis 4.
 — cinguli 643.
 — circularis [Reili] 644.
 — coronarius cordis 367.
 — corporis callosi 643.
 — costae 79.
 — cruris antheliciis 802.
 — cutis 839.
 — ethmoidalis 25.
 — frontales 641.
 — glutaeus 338.
 — hamuli pterygoidei 6.
 — horizontalis cerebelli 633.
 — hypothalamicus [Monroi] 646.
 — infraorbitalis 27.
 — infrapalpebralis 793.
 — interparietalis 643.
 — intermedii medullae oblongatae 629.
 — — anterior, posterior medullae spinalis 618.
 — intertubercularis 94.
 — lacrimalis 24, 28.
 — lateralis anterior medullae oblongatae 629.
 — — — spinalis 618.
 — — posterior medullae oblongatae 629.
 — — — spinalis 618.
 — — mesencephali 635.
 — limitans fossae rhomboideae 630.
 — longitudinales cordis 367.
 — malleolaris 137.
 — matricis unguis 840.
 — medianus fossae rhomboideae 629.
 — — linguae 489.
 — — posterior medullae spinalis 618.
 — m. flexoris hallucis longi 140, 141.
 — — peronei [longi] 141, 145.
 — mylohyoideus 35.
 — n. oculomotorii 636.
 — — petrosi superficialis majoris 11.
 — — — minoris 11.
 — — radialis 94.
 — — spinalis 65.
 — — ulnaris 95.
 — obturatorius 119.
 — occipitales 643.
 — olfactorius 642.
 — orbitales 642.
 — orbitopalpebralis 797.
 — palatini 29, 30.
 — paraglenoidalis 115.
 — parolfactorii 644, 645.
 — petrosus inferior 1, 9.
 Sulcus(i) petrosus superior 9.
 — praecentralis 641.
 — promontorii 12, 810.
 — pterygopalatinus 6, 31.
 — sagittalis 1, 3, 16, 19.
 — sclerae 772.
 — sigmoideus 9.
 — subclaviae 80.
 — subclavius 562.
 — subparietalis 644.
 — superior longitudinal 3.
 — tali 140.
 — temporales 643.
 — terminalis 489.
 — — atrii dextri 376.
 — transversus 2, 3, 19.
 — tubae auditivae 6.
 — tympanicus 13, 14, 805.
 Supercilia 840.
 Superciliary ridge 15.
 Supercilium 793.
 Superficial and deep external pubic arteries 435.
 — palmar arch 416.
 — perineal artery 431.
 Superior angle (of the shoulder blade) 87.
 — astragalonavicular ligament 221.
 — coronary artery 39.
 — curved line (of ilium) 115.
 — external articular artery 437.
 — or external calcaneonavicular ligament 221.
 — or first perforating artery 436.
 — internal articular artery 437.
 — lingual 491.
 — longitudinal sinus 441.
 — maxillary bone 27.
 — profunda artery 409.
 — radio-ulnar articulation 186.
 — thoracic artery 406.
 — tibiofibular articulation 216.
 — turbinated crest 31.
 Supinator brevis 311.
 — longus 307.
 Supraglenoidal tubercle 89.
 Suprarenal capsule 583.
 Suprascapular notch 87.
 — or transversalis humeri artery 404.
 Supraspinous ligament 161.
 Suspensory ligament 279.
 Sustentaculum lienis 536.
 Sustentaculum tali 141.
 Sutura coronalis 15, 18, 54.
 — ethmoideomaxillaris 21, 27, 59.
 Sutura frontalis 15.
 — frontoethmoidalis 16, 17, 20—22, 57.
 — frontolacrimalis 17, 24, 57.
 — frontomaxillaris 16, 28.
 — incisiva 29.
 — intermaxillaris 29.
 — internasalis 25.
 — lacrimoconchalis 23, 24.
 — lacrimomaxillaris 24, 27, 28, 57, 59.
 — lambdoidea 3, 18.
 — nasofrontalis 16, 25.
 — nasomaxillaris 25, 28.
 — occipitomastoidea 2, 8.
 — palatina mediana 29, 30.
 — — transversa 29, 30.
 — palatoethmoidalis 21, 31, 59.
 — palatomaxillaris 27, 31, 59.
 — parietomastoidea 8, 18.
 — sagittalis 18.
 — sphenoethmoidalis 4, 20, 21, 22, 57.
 — sphenofrontalis 5, 6, 17, 54, 57, 58.
 — sphenoorbitalis 4, 31, 59.
 — sphenoparietalis 5, 18, 54.
 — sphenosquamosa 5, 7, 54.
 — sphenozygomatica 5, 32, 54, 57, 58.
 — squamosa 7, 18, 54.
 — squamosomastoidea 8.
 — zygomaticofrontalis 15, 32, 54, 57, 58.
 — zygomaticomaxillaris 28, 32, 54, 59.
 — zygomaticotemporalis 32, 54.
 Sweat glands 616, 840.
 Sword process 83.
 Sympathetic, cervical portion of 763.
 — head portion of 763.
 — nervous system 763.
 — trunk 763.
 Sympathicus 763.
 Symphysis ossium pubis 193, 197, 198.
 — pubis 119.
 — sacrococcygea 72, 76, 162.
 Synchondrosis arycorniculata 552.
 — petrooccipitalis 1, 9.
 — sphenooccipitalis 1.
 — sphenopetrosa 5, 9.
 — sternalis 83.
 Syndesmosis tibiofibularis 216.
 — tympanostapedial 812.
 Systema nervorum centrale 618.
 — — sympathicum 763.

T.

- Taenia*(ae) *chorioidea* 652.
 — *coli* 521, 527.
 — *fimbriae* 654.
 — *fornicis* 650.
 — *libera* 527.
 — *mesocolica* 527.
 — *omentalis* 527.
 — *semicircularis* 652.
 — *thalami* 646.
 — *ventriculi quarti* 629, 634.
Tailed nucleus 651.
Talus 140.
Tapetum 652.
Tarsal interosseous artery 439.
Tarsometatarsal articulations 221.
Tarsus 140.
 — inferior, superior of the lids 796.
Tear sac 798.
Tears 798.
Teeth 482—488.
Tegmen tympani 11.
Tegmental decussations 673.
Tegmentum 635.
Tela chorioidea ventriculi quarti 634, 654.
 — — — *tertii* 646, 651, 654.
 — *subcutanea* 837, 840.
 — *subserosa* 541.
Telencephalon 626.
Temporal bone 7—14.
 — — *pyramid of* 9.
 — — *squama of* 7.
 — *fossa* 54.
 — *lobe* 641.
Temporo-malar canals 32.
 — *maxillary articulation* 152.
Tendo calcaneus [Achillis] 348.
Tendon-sheaths of the foot 361 to 364.
 — — of the hand 321—324.
Tenon's capsule 792.
 — *space* 792.
Tensor vaginae femoris 337.
Tentorium cerebelli 631, 685.
Terminal thread of spinal cord 618.
Testicle 584.
 — *lobules of* 584.
Testis 584.
Thalamencephalon 626, 667.
Thalamus 646, 667.
 — *peduncle of* 680.
 — *radiation of* 680.
Thenar 317.
Thigh-bone 128—134.
Thoracic nerves 712.
 — *part of sympathetic* 763.
 — *vertebra* 69.
Thorax 84—86.
Thymus 568.
Thyroid cartilage 550.
 — *gland* 574.
Thyroid axis 404.
Tibia 136—139.
 — *external tuberosity* 136.
 — *internal tuberosity* 136.
 — — *malleolus* 137.
 — *spinous process* 136.
 — *tubercle* 136.
Tibialis anticus 345.
Tongue 489.
 — *mucous membrane of* 493, 494.
 — *papillae of* 493.
Tonsilla cerebelli 631, 633.
 — *lingualis* 493.
 — *palatina* 501.
 — *pharyngea* 503.
Tooth of the anvil 811.
 — — — *epistropheus* 66.
 — — — *hammer* 811.
 — *pulp of* 487.
Torus tubarius 505.
Trabeculae carnae 371, 377.
 — *corporum cavernosorum* 594.
Trachea 561.
Trachelomastoid muscle 292.
Tractus centralis thymi 568.
 — *iliotibialis* [Maissiat] 338.
 — *olfactorius* 645, 676.
 — *opticus* 645.
 — *solitarius* 678.
 — *spinalis n. trigemini* 676.
 — *spiralis foraminosus* 824.
Tragi 805, 840.
Tragus 801.
Transitional gyri 641.
Transverse cervical artery, or transversalis colli 406.
 — *colon* 525.
 — *facial artery* 390.
 — *ligament* 166.
 — *metacarpal ligament* 190.
 — *or pontal artery* 404.
 — *processes of vertebra* 64.
Trapezium 105.
Trapezoid bone 105.
Trigonum(a) collaterale 654.
 — *femorale* [fossa Scarpae major] 330.
 — *fibrosa (cordis)* 373.
 — *habenulae* 646, 667.
 — *lemnisci* 635.
 — *lumbale* [Petiti] 287.
 — *n. hypoglossi* 629.
 — *olfactorius* 645.
 — *omoclaviculare* 237.
 — *urogenitale* 609.
 — *vesicae* [Lientaudi] 582.
Trochanter 129.
Trochanteres 128, 129.
Trochlea humeri 95.
 — *m. obliqui superioris oculi* 788.
 — *phalangis* 109.
 — *tali* 140.
True vocal cord 558.
Truncus corporis callosi 647.
 — *costocervicalis* 406.
 — *lumbosacralis* 749.
 — *sympathicus* 763.
 — *thyrocervicalis* 404.
Tuba auditiva [Eustachii] 809, 815, 816.
 — *uterina* [Fallop] 597.
Tuber calcanei 141.
 — *cinereum* 645.
 — *frontale* 15.
 — *ischadicum* 117.
 — *maxillare* 27.
 — *omentale* 531, 534.
 — *parietale* 19.
 — *vermis* 633.
Tubercle of Lower 376.
Tuberculum(a) acusticum 630.
 — *anterior atlantis* 66.
 — — of the *processus transversus vertebrae cervicalis* 65.
 — — *thalami* 646.
 — *articulare* 7.
 — *auriculae* [Darwini] 801.
 — *carotica* 68.
 — *cinereum* 629.
 — *corniculatum* [Santorini] 557.
 — *costae* 78.
 — *cuneatum* 629.
 — *cuneiforme* [Wrisbergi] 557.
 — *epiglotticum* 557.
 — *intercondyloideum* 136.
 — *intervenosum* [Loweri] 376.
 — *jugulare* 2.
 — *majus humeri* 94.
 — *mentale* 34.
 — *minus humeri* 94.
 — *obturatorium anterius, posterius* 117, 119.
 — *ossis multanguli majoris* 105.
 — — *navicularis* 104.
 — *pharyngeum* 1, 2.
 — *posterius atlantis* 66.
 — — of the *processus transversus vertebrae cervicalis* 65.
 — *pubicum* 119.
 — *scaleni* [Lisfranci] 80.
 — *sellae* 4.
 — *supratragicum* 801.
 — *thyroidea* 550.

- Tuberositas coracoidea 92.
 — costae II 80.
 — costalis 92.
 — deltoidea 94.
 — glutaea 128.
 — iliaca 115.
 — infraglenoidalis 89.
 — oss. cuboidei 145.
 — — metatarsalis I, V 146.
 — — navicularis 143.
 — radii 101.
 — sacralis 75.
 — supraglenoidalis 89.
 — tibiae 136.
 — ulnae 99.
 — unguicularis 109.
 Tuberosity of ischium 117.
 Tubuli renales 578.
 — seminiferi 584.
 Tunica albuginea corporum cavernosorum 594.
 — — testis 584.
 — conjunctiva bulbi 797.
 — — palpebrarum 797.
 — dartos 588.
 — fibrosa oculi 793.
 — — renis 577.
 — vaginalis communis [testis et funiculi spermatici] 587.
 — — propria testis 588.
 — vasculosa oculi 773, 774.
 Türk's bundle 680.
 Turkish saddle 4.
 Tympanic branch 397.
 — fold 807.
 — pockets 814, 815.
 — staircase 823.

U.

- Ulna 98—99.
 Ulnar, anterior border 98.
 — surface 98.
 — external or interosseous border 98.
 — greater sigmoid cavity 99.
 — internal surface 98.
 — lesser sigmoid cavity 99.
 — posterior border 98.
 — surface 98.
 Umbilical vein 473.
 Umbilicus 279.
 Umbo membranae tympani 805.
 Unciform bone 105.
 — process 21, 105.
 Uncus gyri hippocampi 643.
 Undefined space 374.
 Unguis 837, 840.
 Upper jaw 27—29.
 Upper portion of adductor magnus 334.

- Ureter 580, 581.
 Urethra female 603.
 — male 595.
 — muliebris 603.
 — virilis 595.
 Urinary organs 575.
 Uriniferous tubules 578.
 Uterus 598, 599.
 Utricle (labyrinth) 825.
 — prostaticus 595.
 Uvula of palate 500.
 — [palatina] 500.
 — vermis 633.
 — vesicae 582.

V.

- Vagina 602, 603.
 Vagina(ae) mucosa intertubercularis 180, 301.
 — m. recti abdominis 279.
 — nervi optici 771.
 — processus styloidei 10, 13.
 — tendinum of the foot 361 and 364.
 — — of the hand 321—324.
 Vaginal process 10, 13.
 Vallecule cerebelli 631.
 — epiglottica 494.
 Vallum unguis 840.
 Valve, ilio-caecal 523.
 Valvula(ae) bicuspidalis [mitralis] 375.
 — coli 523.
 — conniventes 518.
 — foraminis ovalis 377.
 — fossae navicularis 595.
 — processus vermiformis 523.
 — pylori 515.
 — semilunares 378, 380.
 — sinus coronarii [Thebesii] 376.
 — spiralis [Heisteri] 533.
 — tricuspidalis 375.
 — v. cavae [inferioris, Eustachii] 376.
 Vasa intestini tenuis 424.
 Vasa(vas) aberrantia hepatis 532.
 — auris internae 828, 830.
 — deferens 585.
 — sanguinea integumentum communis 842.
 — — retinae 780.
 Vastus externus 335.
 — internus 336.
 Velum interpositum 654.
 — medullare anterius 635.
 — — posterius 633.
 — palatinum 500.
 Venae(a) alveolares superiores 446.
 — alveolaris inferior 449.
 — angularis 446.
 Venae(a) anonymae 445.
 — aquaeductus vestibuli 828.
 — articulares genu 468.
 — — mandibulae 449.
 — auditivae internae 444, 830.
 — auriculares anteriores 448.
 — auricularis posterior 450.
 — axillaris 453.
 — azygos 456.
 — basilica 452.
 — basivertebrales 454.
 — brachiales 451.
 — bronchiales anteriores 445.
 — — posteriores 456.
 — bulbi urethrae 463.
 — — vestibuli [vaginae] 463.
 — canaliculi cochleae 446, 830.
 — canalis pterygoidei [Vidui] 446.
 — cava inferior 460.
 — — superior 445.
 — cavernosae 594.
 — centralis retinae 442, 780.
 — cephalica 452.
 — — accessoria 452.
 — cerebri interna magna [Galeni] 444, 654.
 — cervicalis profunda 446.
 — chorioidea 654.
 — ciliares 778.
 — circumflexa ilium profunda 466.
 — — — superficialis 466.
 — circumflexae femoris 468.
 — colicae 457.
 — comitans n. hypoglossi 446.
 — conjunctivales 778.
 — cordis (anteriores, magna, media, minimae, parva) 384, 385.
 — coronaria ventriculi 459.
 — costoaxillares 453.
 — cutaneae abdominis et pectoris 466.
 — cystica 459.
 — deferentiales 464.
 — digitales of the foot 469, 470.
 — — of the hand 451, 452.
 — diploicae 444, 445.
 — dorsales linguae 446.
 — dorsalis penis (clitoridis) 464.
 — — — cutanea 466.
 — duodenales 457.
 — epigastricae inferiores 466.
 — — superiores 445.
 — — superficiales 466.
 — episclerales 778.
 — ethmoidales 442.
 — faciales 446, 448.
 — femoralis 466, 468.
 — femoropoplitea 472.

- Vena(ae) frontalis 446.
 — gastricae breves 457.
 — gastroepiploicae 457.
 — glutaee 466.
 — haemorrhoidales inferiores 463, 464.
 — — mediae 464.
 — haemorrhoidalis superior 457, 464.
 — hemiazygos 456.
 — — accessoria 456.
 — hepaticae 460.
 — hypogastrica 463.
 — ileocolica 457.
 — iliaca communis 463.
 — — externa 463, 466.
 — iliolumbalis 466.
 — intercapitulares of the foot 470.
 — — — hand 452.
 — intercostales 455.
 — intercostalis suprema 456.
 — intervertebrales 455.
 — intestinales 457.
 — jugularis anterior 450.
 — — externa 450.
 — — interna 446.
 — labiales 446.
 — — anteriores 466.
 — — posteriores 463.
 — lacrimalis 442.
 — laryngea inferior 445.
 — — superior 446.
 — lienalis 457.
 — lingualis 446.
 — lumbales 460.
 — lumbalis ascendens 460.
 — mammaria interna 445.
 — marginales 470.
 — massetericae 446, 449.
 — mediana antibrachii 453.
 — — basilica 453.
 — — cephalica 453.
 — — colli 450.
 — — cubiti 453.
 — mediastinales anteriores 445.
 — — posteriores 456.
 — meningeae 444, 446.
 — mesentericae 457.
 — metacarpeae 451.
 — metatarseae 469.
 — musculophrenicae 445.
 — nasales 446.
 — nasofrontalis 442, 446.
 — obliqua atrii sinistri [Marshalli] 384.
 — obturatoria 466.
 — occipitalis 450.
 — oesophageae 445, 456.
 — ophthalmica inferior 443.
 — — superior 442.
 — ovarica 460.
- Venae(a) palatinae 446.
 — palpebrales 446.
 — pancreaticae 457.
 — pancreaticoduodenalis 457.
 — parotideae anteriores 446.
 — — posteriores 448.
 — parumbilicales [Sappey] 459.
 — perforantes (femoris) 468.
 — pericardicae 445.
 — peronaeae 469.
 — pharyngeae 446.
 — phrenica inferior 460.
 — phrenicae superiores 445.
 — plantares 469.
 — poplitea 468.
 — portae 457.
 — posterior ventriculi sinistri 385.
 — profunda femoris 468.
 — profundae clitoridis 463.
 — — penis 463.
 — pudenda interna 463.
 — pudendae externae 466.
 — pulmonales 380.
 — pylorica 459.
 — radiales 451.
 — renalis 460.
 — sacrales laterales 466.
 — sacralis media 463.
 — saphena accessoria 471.
 — — magna 471.
 — — parva 472.
 — scrotales anteriores 466.
 — — posteriores 463.
 — septi pellucidi 654.
 — sigmoideae 457.
 — spermaticae externae 466.
 — spermatica interna 460.
 — sphenopalatina 449.
 — spinales 455.
 — spiralis modiolii 830.
 — sternocleidomastoidea 446.
 — stylomastoidea 449.
 — subclavia 454.
 — sublingualis 446.
 — submentalialis 446.
 — supraorbitalis 446.
 — suprarenalis 460.
 — temporales 448, 449.
 — terminalis 654.
 — testicularis 460.
 — thoracalis lateralis 453.
 — thoracoepigastrica 453, 466.
 — thymicae 445.
 — thyreoidea ima 445.
 — thyreoideae inferiores 445.
 — — superiores 446.
 — tibiales 469.
 — tracheales 445.
 — transversa colli 454.
 — — faciei 449.
 — — scapulae 454.
- Venae(a) tympanicae 449.
 — ulnares 451.
 — umbilicalis 473.
 — urethrales 463.
 — uterinae 464.
 — vertebralis 446.
 — vesicales 464.
 — vestibulares 828.
 — vorticosae 778.
 Ventricle(s) of heart 366.
 — left 380.
 — right 377.
 Ventricular fold 558.
 — septum 374.
 Ventriculus 512—515.
 — cordis 366.
 — — dexter 377, 378.
 — — sinister 380.
 — laryngis [Morgagnii] 557, 558.
 — lateralis (cerebri) 650—654.
 — quartus (cerebri) 633, 634.
 — terminalis 621.
 — tertius (cerebri) 646, 649.
 Venulae retinae 780.
 Vermiform appendix 521.
 — process 521.
 Vermis cerebelli 633.
 Vertebra, arch of 64.
 — articular processes of 64.
 — body of 64.
 — prominens 65, 67.
 Vertebrae 64—77.
 — cervicales 68.
 — coccygeae 76.
 — lumbales 71.
 — sacrales 72.
 — thoracales 69.
 — varieties of 77.
 Vertebral canal 64.
 — column 64.
 — — ligaments of 156.
 — foramen 64.
 Vertex corneae 774.
 — vesicae 581.
 Vertical plate 31.
 Vesica fellea 533.
 — urinaria 581.
 Vesiculae seminales 589.
 Vestibular staircase 823.
 Vestibule of labyrinth 817 to 819.
 — of nasal cavity 833.
 Vestibulum bursae omentalis 543.
 — labyrinthi 817—819.
 — laryngis 558.
 — nasi 833.
 — oris 478.
 — vaginae 606.
 Vibrissae 831, 840.
 Vidian canal 6.
 Villi intestinales 520.
 — pleurales 573.

Vinculum linguae cerebelli 633,
635.
Vision, organ of 770—798.
Visual conduction path 680.
— line 771.
Vitreous body 773, 783.
Vocal chord 558.
— lip 558.
Vomer 26.
Vortex cordis 371.
Vortices pilorum 840.
Vulva 604.

Vulva lips of 606.
— slit of 606.

W.

Wedge bones of foot 144.
Wing processes 6.
Wisdom tooth 483.
Woolly hairs 840.
Worm, cerebellar 633.
Wrist joint 187—189.
— rows of bones in 106, 107.

Y.

Yellow spot of retina 780.
Yoke arch 32.
— bone 32.

Z.

Zona orbicularis 201.
Zonula ciliaris [Zinni] 782,
783.
Zygomatic fossa 54.
— surface 27.



